

Graphic methods in heart disease / By John Hay ... ; with an introduction by James Mackenzie.

Contributors

Hay, John.
Mackenzie, James, 1853-1925 (Introduction by)
Royal College of Physicians of London

Publication/Creation

London : Henry Frowde, 1909.

Persistent URL

<https://wellcomecollection.org/works/q3nc4x9x>

Provider

Royal College of Physicians

License and attribution

This material has been provided by This material has been provided by Royal College of Physicians, London. The original may be consulted at Royal College of Physicians, London. where the originals may be consulted. Conditions of use: it is possible this item is protected by copyright and/or related rights. You are free to use this item in any way that is permitted by the copyright and related rights legislation that applies to your use. For other uses you need to obtain permission from the rights-holder(s).



Wellcome Collection
183 Euston Road
London NW1 2BE UK
T +44 (0)20 7611 8722
E library@wellcomecollection.org
<https://wellcomecollection.org>

HEART DISEASE GRAPHIC METHODS

JOHN HAY


OXFORD MEDICAL
PUBLICATIONS

616.12-072.7

Supd

SL

616.12-072.7



Albert Palmerin

Aug '09.

G.R.I.



1/6 net

OXFORD MEDICAL PUBLICATIONS

GRAPHIC METHODS IN
HEART DISEASE



Digitized by the Internet Archive
in 2015

<https://archive.org/details/b24906499>

OXFORD MEDICAL PUBLICATIONS

GRAPHIC METHODS IN HEART DISEASE

BY

JOHN HAY,

M.D., M.R.C.P. ¹

ASSISTANT PHYSICIAN, LIVERPOOL ROYAL INFIRMARY

WITH AN INTRODUCTION BY

JAMES MACKENZIE

M.D., M.R.C.P.

LONDON

HENRY FROWDE

HODDER & STOUGHTON

OXFORD UNIVERSITY PRESS

WARWICK HOUSE, E.C.

1909

51

| | |
|--|----------------------|
| ROYAL COLLEGE OF PHYSICIANS LIBRARY | |
| CLASS | 616.12-072.7 |
| ACCN. | 35161 |
| SOURCE | Univ. Dundee Library |
| DATE | 17/4/66 (don) |

PREFACE

GRAPHIC methods of investigating the disorders and diseases of the heart have opened up numerous avenues of research, and it is now generally recognised that valuable information is obtained by such means, concerning diagnosis, prognosis and treatment.

The value of sphygmographic tracings is slight in the absence of simultaneous records from the apex beat, jugular pulse or the liver, and all who confine themselves to records of the radial pulse very soon realise the limitations and comparative barrenness of this field of investigation.

It is very different, however, when combined records are taken : the vagaries of the heart are then full of meaning and interest ; they can be explained satisfactorily and their full import comprehended. An arrhythmia which was formerly viewed with vague distrust and misgiving is recognised as simple and harmless, while other variations from the normal, slight though they may be, are recognised as ominous and of moment.

As difficulties are sure to be encountered by all

who attempt to obtain graphic records, difficulties not only in the recording of the actual pulsations but also in the analysis and interpretation of the tracings, I have written this book that it may serve as an introduction and a guide to those who wish to follow this line of clinical investigation.

Beginners are apt to be disheartened by the difficulties they experience in their first attempts, but manipulative skill is soon acquired, and good results obtained with ease and rapidity from all except a small percentage of patients.

I have not described the ordinary methods of clinical examination, inspection, palpation, percussion and auscultation, since they are fully and adequately treated in many excellent works: while Dr. Oliver's handbook (*Studies in Blood Pressure*) gives a satisfactory account of the accurate estimation of variations in blood pressure and the inferences which may be drawn from such variations.

The number of illustrations is large, and I look upon these records as perhaps the most valuable portion of the book. I have given a representative series, so that readers may find examples of all the more common variations from the normal rhythm.

Most of the records are my own, but I have not hesitated to avail myself of the kindness of my friends in order to supplement and complete the series.

In the interpretation and description of the records

I have not done more than give that explanation which appeared to me the most reasonable. It would have been inadvisable to overload a small handbook with controversial theories.

My indebtedness is great to my colleagues at the Royal Infirmary for their invariable kindness and courtesy in permitting me to investigate the cases under their care ; also to Dr. Arthur Keith, whose writings on the anatomy of the heart I have used freely ; and, above all, to Dr. James Mackenzie, at whose suggestion I began this book. His brilliant work and kindly sympathy have been a constant stimulus, and I feel that any value which this contribution to the literature may possess is due in a large measure to him.

12, RODNEY STREET,
LIVERPOOL.

JOHN HAY.



CONTENTS

| | PAGE |
|-------------------------------|------|
| INTRODUCTION | xi |
| DEFINITION OF TERMS | xv |

CHAPTER I

| | |
|-------------------------------|---|
| THE MYOGENIC THEORY | 1 |
|-------------------------------|---|

CHAPTER II

| | |
|--|---|
| SOME ANATOMICAL CONSIDERATIONS | 7 |
|--|---|

CHAPTER III

| | |
|-----------------------|----|
| INSTRUMENTS | 17 |
|-----------------------|----|

CHAPTER IV

| | |
|--------------------------|----|
| NORMAL RECORDS | 39 |
|--------------------------|----|

The Normal Sphygmogram. The Cardiogram. The Interpretation of the Cardiogram. Epigastric Records. The Interpretation of the Venous Pulse Tracing.

CHAPTER V

| | |
|--|----|
| THE AURICULAR TYPE OF VENOUS PULSE | 73 |
|--|----|

CONTENTS

| | CHAPTER VI | PAGE |
|--|--------------|------|
| THE EXTRA-SYSTOLE | | 81 |
| (1) Auricular Extra-Systoles. | | |
| (2) Ventricular or Infra-nodal Extra-Systoles. Inter- polated Extra-Systoles. | | |
| (3) Nodal Extra Systoles. | | |
| | CHAPTER VII | |
| THE VENTRICULAR OR NODAL FORM OF VENOUS PULSE | | 105 |
| | CHAPTER VIII | |
| DISTURBANCE OF FUNCTION | | 131 |
| <i>Section</i> 1. Conductivity. | | |
| <i>Section</i> 2. Excitability. | | |
| <i>Section</i> 3. Contractility. | | |
| <i>Section</i> 4. Stimulus Production. | | |
| <i>Section</i> 5. Tonicity. | | |
| | CHAPTER IX | |
| DIFFICULTIES IN INTERPRETATION OF SPHYGMOGRAMS | | 163 |
| | CHAPTER X | |
| ILLUSTRATIVE CASE OF MITRAL STENOSIS | | 169 |
| INDEX | | 177 |

INTRODUCTION

By JAMES MACKENZIE, M.D., M.R.C.P.

IN clinical medicine the recognition of symptoms depends to a very great extent on the senses of the observer. As the acuteness of perception varies in different individuals, and as there are limitations to human powers, and as the symptoms are often elusive and difficult of recognition, many of the phenomena of disease are imperfectly appreciated. To supplement the inadequate power of perception the imagination is often called upon, with the result that statements are made which are supposed to be a true description of the facts, but which are in reality a combination of imperfect observation and possibly erroneous deduction. These limitations and imperfect methods are very evident in the interpretation of the features of the circulation, as carried out at the present day. The movements of the circulation are so distinct that the unaided senses can recognise certain features, and a limited advance has been made in the study of the subject. But this advance has been greatly restricted by an inability to detect the time in a cardiac cycle in

which certain movements occur, and by the consequent inability to assign each movement to its appropriate cause. Too often the imagination has been allowed such free play in the interpretation of these movements that fanciful and incorrect explanations are widely prevalent. The result is that many features of the circulation are misunderstood, while many others have not been recognised. Any method, therefore, that promises a means of more accurate observation will be welcomed by all who realise the great limitation of our present methods.

When care is taken to avoid errors due to defective apparatus the tracing of any movement of the circulation obtained by instrumental means remains as a true and permanent record of an actual event. This alone, apart from any interpretation, is a great gain. When we read the literature bearing upon the movements of the circulatory system we would gladly sacrifice many pages of verbal description for one correct tracing of the events as they actually occurred. The interpretation of tracings should be kept distinct in our minds from the actual record itself. The latter is a true representation, the former but represents the present phase of our knowledge, which may or may not be correct. With our present knowledge much has been brought to light in the interpretation of graphic records of the movements of the circulation, and features which can be recognised but which are at

present inexplicable are the subjects of inquiry by many observers. The employment of these methods of investigation is giving not only a stimulus to further inquiry, but act as guides in directing the inquiry towards a definite aim in the fields of physiology, pathology and pharmacology, as well as in clinical medicine. This is as it ought to be, for these sciences should be handmaidens to clinical medicines, for heretofore clinical medicine has been too long content to follow languidly in the wake of the sister sciences.

A further benefit is derived from the employment of graphic records, in that it compels the clinician to think clearly, to reason with precision, and to observe with accuracy. The interpretation demands a knowledge of every possible factor and requires the measuring of the events with the utmost precision.

While strongly insisting upon the help to be derived from graphic records, it is not pretended that these should always be taken in the routine examination of patients with heart affections. In most cases there are associated phenomena capable of being appreciated by the unaided senses. With the knowledge of what graphic records reveal we can obtain a clear perception of the associated signs by auscultation and palpation, so that with practice and experience we can often tell what is happening in the heart without the assistance of graphic records.

To those who wish to follow some line of inquiry

that will shed new light on the problems of disease, there is no subject in clinical medicine so full of promise as the methods described in this book. Once the manipulative skill is acquired there is no difficulty in finding a line to pursue. In the attempts to acquire this skill subjects of interest will frequently be met which will lead the inquirer to objects worthy investigation. So obscure are the effects of disease upon the heart's action that only a very small proportion of the work has been accomplished, so that there lies before an intelligent investigator a region of indefinite scope, fascinating and full of interest, and withal of the greatest practical importance to suffering humanity.

DEFINITION OF TERMS

THE following are definitions given by Dr. James Mackenzie in his book on Diseases of the Heart, of a number of terms which are more or less new to the literature dealing with this subject.

a-c interval is the time between the beginning of the auricular and carotid waves in tracings of the jugular pulse.

Auricular venous pulse is the form of jugular pulsation where the wave due to the auricle is found preceding the ventricular contraction. Sometimes called also the normal or negative venous pulse.

Auriculo-ventricular node (*a-v* node, Knoten of Tawara) is the enlargement of the remains of the primitive cardiac tissue found in the wall of the right auricle, from which the *a-v* bundle arises.

Auriculo-ventricular bundle (*a-v* bundle, Gaskell's bridge, His' bundle). The remains of the primitive cardiac tissue which passes from the *a-v* node to the right and left ventricles.

Conductivity is the term used by Gaskell to describe that function of the fibres of the heart muscle which conveys the stimulus from fibre to fibre. It is usually studied by observing the time between the systole of the auricles and ventricles.

Contractility is Gaskell's term for the power of contracting possessed by the muscle.

Heart-block is the term used by Gaskell to signify the stoppage or blocking of the stimulus for contraction in its passage from the auricles to the ventricles.

Myogenic theory. The view that the heart muscle-fibres

possess in themselves the power of originating and maintaining the contraction of the heart, as opposed to the neurogenic theory, where it is held that the heart acts only in response to nerve stimulation.

Nodal rhythm. In the majority of cases of continuous irregularity and paroxysmal tachycardia, it is found that the ventricular contraction precedes or is synchronous with the auricular contraction, and hence it is inferred that the heart's contraction in these cases must originate from a point that could affect both auricle and ventricle at or about the same time. It is suggested that the *a-v* node may be this point, and as it is important to recognise the abnormal rhythm, it is provisionally distinguished by the term "nodal rhythm."

Primitive cardiac tissue is the term applied to the tissue in the mammalian heart which represents the cardiac tube of the more primitive vertebrates. It is shown in Fig. 46, page 83, and consists of the *s-a* and *a-v* nodes and *a-v* bundle.

Pulsus alternans means that form of abnormal rhythm where the radial pulse is perfectly regular, but where there is an alternation in the size of the beats, and is an evidence of the failure of the function of contractility.


Sino-auricular node (*s-a* node) the term given by Keith and Flack to a small bundle of tissue representing the remains of the primitive cardiac tube (portion of the sinus venosus) near the mouth of the superior vena cava (1, Fig. 46, page 83).

Tonicity is the term applied to that function of the heart muscle which keeps the heart during diastole in a state of slight contraction. Depression of this function results in dilatation of the heart and of the auriculo-ventricular orifices.

Ventricular rhythm. This term is applied to the ventricular contractions in cases of complete heart-block. As this occurs when a lesion severs the *a-v* bundle, it is assumed that the remaining fibres of the *a-v* bundle in the ventricles start the ventricular contractions—the rate being very slow, rarely above thirty-two beats per minute.

Ventricular venous pulse (or **nodal form of venous pulse**) is

that form of jugular pulsation in which the auricular wave disappears or coincides with the period of ventricular systole, there being no sign of the auricular wave at the normal period of the cardiac cycle. Sometimes called the positive or pathological venous pulse.



CHAPTER I

THE MYOGENIC THEORY

SINCE the publication by Gaskell in 1883 of his work on the contraction of cardiac muscle, the "myogenic" theory of the heart's activity has been steadily gaining ground, and is now accepted by the majority of those competent to form an opinion.

Whether this view be ultimately accepted as correct or not, the investigations to which it has given rise have greatly advanced our knowledge of the manner of the heart's contraction and the meaning and relative importance of the many forms of cardiac arrhythmia.

According to the "myogenic" doctrine, the heart, instead of being a passive instrument played on by the nervous system, possesses the power of originating in its own muscle fibres the stimulus for contraction.

Gaskell showed that the myocardium can originate its own stimulus, that its fibres are excitable and can respond to the stimulus by shortening, that they can conduct that stimulus from one portion of the heart to another, and that in addition the heart muscle possesses the characteristic of tone.

2 GRAPHIC METHODS IN HEART DISEASE

One must also remember that when the heart is excited by a stimulus sufficiently strong to initiate a contraction, it responds with the maximum contraction possible at the time, irrespective of the intensity of the stimulus; its contraction is all or nothing. Again one must not forget that during, and for a short time after systole, the heart is in a refractory condition of varying duration in which no further contraction can be obtained on stimulation.

Immediately after systole all the functions of the myocardium, with the exception of tonicity, are in abeyance. The myocardium is then inexcitable, its conducting power is lost, its contractility has disappeared, and the stimulus matter has been used up by the immediately preceding systole.

With diastole all these functions begin to improve; generally the improvement is uniform, and by the time there is sufficient stimulus matter to excite the muscle to another contraction, the contractility and conductivity are again normal. This period of rest after systole is necessary to enable each function to fully recover itself, and it is easy to understand that under abnormal conditions one or more functions may be depressed and require a longer period for their complete restoration.

Further, these functions of the cardiac muscle are not possessed in an equal degree by all the fibres throughout the heart, but in particular regions of

the myocardium some functions are more highly developed than others ; for example, the function of stimulus production is most marked wherever there are remains of the sinus venosus, as at the opening of the great veins into the auricles and about the orifice of the coronary sinus. Of these sites, the junction of the superior vena cava with the right auricle is most active, and the result is, that the stimuli originating here initiate muscular contractions which spread from this point over the auricles and ventricles.

The function of tonicity, possessed of course by all the fibres, is present in a high degree in the muscular fibres surrounding the valvular openings and the openings of the veins into the auricles ; while contractility is especially developed in the large thick walls of the ventricles.

Thus we see that, though every fibre possesses in some degree all five characteristics, in certain groups of fibres one function is predominant.

The most important fact about the myocardium is its reserve power. If the load of the heart be increased or the resistance to the flow of blood from the ventricles be augmented, the contraction of the muscle fibres becomes greater ; and in spite of the added difficulty, the action of the heart is efficient. The heart is thus enabled, within certain limits, to meet sudden and unusual calls upon its resources.

When the heart fails to cope with the added stress,

4 GRAPHIC METHODS IN HEART DISEASE

and its action becomes inefficient, it is because the reserve power of the myocardium has been unable to overcome the difficulties. Cardiac insufficiency spells muscle insufficiency.

Just as when speaking of the myocardium as a whole we can speak of its reserve power, so also can we speak of the reserve power of any individual function possessed by the myocardium. As a rule, when the reserve power of the myocardium is good and the area of cardiac response is large, each individual function is correspondingly active; but it is essential to remember that one function may be seriously depressed although the others are normal, and that the depression of only one function may seriously interfere with the satisfactory working of the heart.

In considering a case of heart disease, the tendency in the past has been to lay stress rather on the nature and extent of the organic lesion and the character of the murmurs than on the actual power of the heart to do its work.

The most important fact to be determined is, of course, the area of cardiac response, the power of the heart muscle to carry on its work and to meet stress. In the examination of an individual case, after having carefully formed an opinion as to the organic defect, if one be present, the actual amount of hypertrophy and dilatation, and the pathological nature of any lesion, one should estimate any limitation in the area

of cardiac response; having done this, the last step and perhaps the most important, is to investigate the manner of the heart's activity and to endeavour to discover which function or functions of the myocardium are at fault.

In every case of cardiac insufficiency or irregular action of the heart, one or more of these functions is either depressed or exalted; and it is essential that we should know the exact nature of the insufficiency if we are to treat the patient adequately.

The valuable work of Mackenzie enables us to investigate patients in such a way as to form an opinion of the activity of the various functions of the myocardium.

With the data thus obtained the treatment and prognosis of heart disease enters a new phase, based on a more accurate conception and knowledge of the functional activity of the myocardium.



CHAPTER II

SOME ANATOMICAL CONSIDERATIONS

THE study of the jugular pulse is undertaken in order to gain information concerning the movements of the heart, and it is obvious that a short account of the anatomy of certain portions of the heart, and more especially, of those structures directly concerned in the production of the venous pulse, will be helpful.

In the following description I have made free use of a paper¹ written by Dr. Arthur Keith, in which he gives a full "account of the structures concerned in the production of the jugular pulse."

The right jugular bulb is situated about one inch external to the sternal end of the clavicle; the jugular valves which define the upper limit of the bulb and separate it from the rest of the vein are situated about three-quarters of an inch above the clavicle. The

¹ "An Account of the Structures concerned in the Production of the Jugular Pulse," by Arthur Keith, *Journal of Anatomy and Physiology*, vol. xlii. See also *The Lancet*, February 27, 1904; March 5, 1904; March 12, 1904; "The Evolution and Action of Certain Muscular Structures of the Heart."

8 GRAPHIC METHODS IN HEART DISEASE

bulb lies over the first part of the subclavian artery, and when the sterno-mastoid is relaxed can be reached between its sternal and clavicular heads.

These points are well seen in Fig. 1. "The jugular bulb is part of a large venous cistern represented in Fig. 2, and consequently 'tracings obtained from this

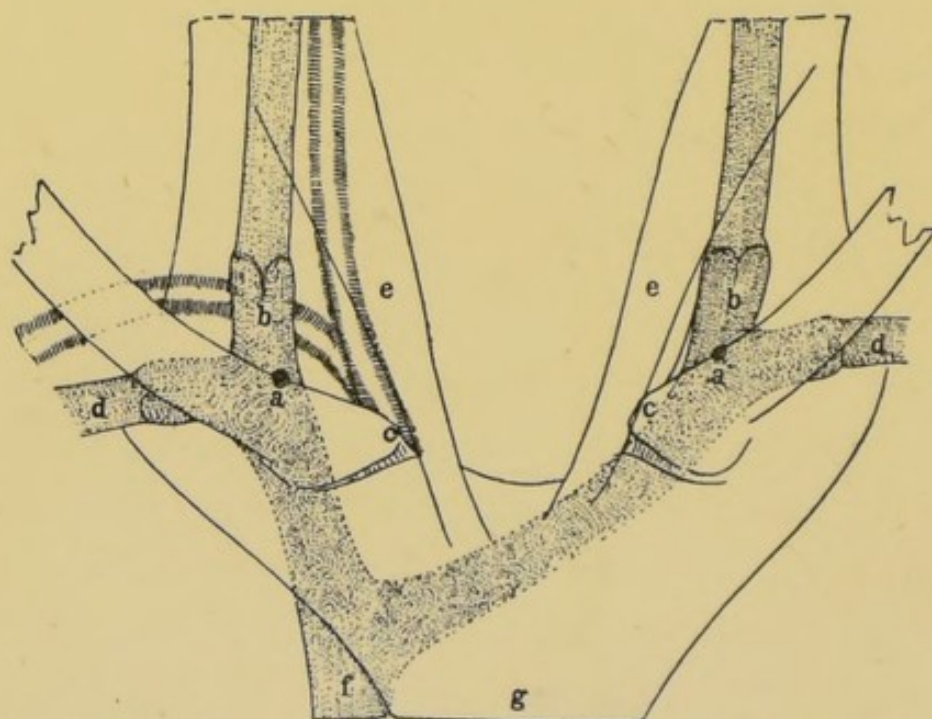


FIG. 1.—Diagram showing the average position of the jugular bulb.

a, the jugular point, 25 mm. from the sternal end of the clavicle (*c*); *b*, jugular bulb, behind sternal head of sterno-mastoid and in front of first stage of subclavian artery; *d*, subclavian vein; *e*, sternal head of sterno-mastoid; *f*, superior vena cava; *g*, manubrium sterni. (Keith.)

bulb' represent the fluctuation in the pressure of blood contained within the cistern. The cistern is formed by the superior vena cava, the innominate, iliac, hepatic and renal veins; it is shut off from the venous system of the lower extremities by strong valves situated in the common femoral veins, from

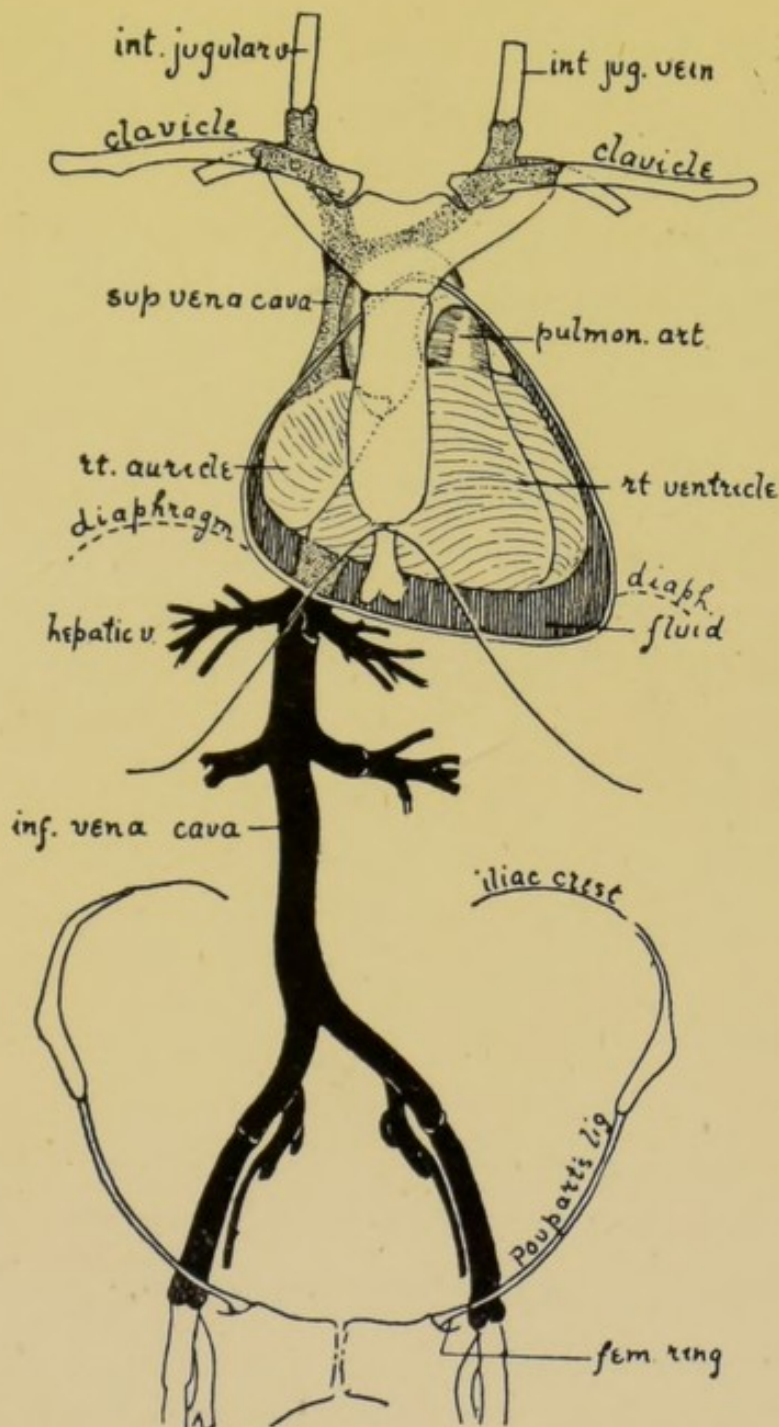


FIG. 2.—Diagram of the venous cistern from which the heart is filled, as seen in a man aged fifty-five, in whom the pericardium was distended and the heart compressed by a large effusion of fluid. The abdominal or infra-diaphragmatic part of the cistern is indicated in black; the thoracic or supra-diaphragmatic is stippled. The heart is compressed upwards and backwards against its attachments. (Keith.)

10 GRAPHIC METHODS IN HEART DISEASE

10 to 25 mm. below Poupart's ligament, from the venous system of the upper extremity by equally strong valves in the terminal part of the subclavian vein; from the venous system of the head and neck by the valves above the jugular bulb." The jugular valves are the weakest, and are the first to give when there is any undue pressure in the venous cistern.

It has been estimated that this cistern contains about 430 c.c. of blood; 30 c.c. in the thoracic portion, 400 c.c. in the abdominal. The pressure in the abdominal portion of the cistern is always positive, and may range from a few mm. of mercury up to 40 or even 60 mm. when the body is bent or when a heavy weight is lifted. It is obvious that such pressure will act directly on the right auricle and ventricle, and especially on the walls of the former, as being the less resistant.

This cistern opens into the heart by the two caval orifices. The abdominal portion by the inferior vena cava, and as the pressure in this portion of the cistern is always positive, the orifice is not efficiently closed during systole of the auricle. It is different, however, with the superior vena cava, for the pressure of the thoracic portion of the cistern is recurringly negative, and accordingly its opening into the heart is guarded by a muscular mechanism which is probably competent at low pressures. When the right auricle becomes distended the muscular mechanism fails in some de-

gree, and during systole of the auricle blood regurgitates into the superior vena cava.

So far as the anatomy of the heart itself is concerned, I think it is only necessary for us to consider the arrangement of the muscular fibres of the right auricle and ventricle. For it is this portion of the heart which is more particularly concerned in the production of the venous pulse.

Broadly speaking, the musculature of the heart is composed of two sets of fibres—the circular and the longitudinal. The circular fibres by their contraction expel the blood and drive it onwards, and if the heart were composed of circular fibres only it would necessarily increase in length during systole. This, however, does not occur, for it is very generally accepted that the apex of the ventricle is approximately a fixed point, and also that during systole and diastole the long diameter of the heart does not vary.

The tendency of the heart to increase in length when the circular fibres contract is counteracted and neutralized by the shortening of the longitudinal fibres.

In order to appreciate fully the action of any group of muscle fibres, it is necessary to know the fixed points from which they act. In the heart the fixed points are three: (1) The venous mesocardium, the site of the passage of the veins through the pericardium on their way to the right and left auricles; this is the commencement of the cardiac tube. (2) The

12 GRAPHIC METHODS IN HEART DISEASE

arterial mesocardium, where the pulmonary artery and the aorta pierce the pericardial sac: this is the end of the cardiac tube. (3) The apex of the heart. The muscle bundles composing the heart must therefore work from these fixed points. It is essential for our purpose to appreciate the manner in which the longitudinal fibres of the right auricle and ventricle act, and the way in which they are interdependent. There is a certain antagonism between them.

The most important muscle fibres in the walls of the right auricle are those of the *musculi pectinati* and the *tænia terminalis*. The right *tænia terminalis* is a thick bundle of muscle fibres which develops in and replaces the right valve of the sinus venosus. It is attached to both the caval orifices and thus to one of the fixed points of the heart—namely, the venous mesocardium. It is an important part of the muscular mechanism which helps to close the orifice of the superior vena cava during systole of the auricle. The pectinate muscle bundles, which are sometimes exceptionally well developed, have their origin in the right *tænia terminalis*, and are inserted in the circular musculature of the auriculo-ventricular septum. When they contract they draw this septum, the auriculo-ventricular groove, and base of the right ventricle towards the venous mesocardium. This movement of the base of the right ventricle, resulting from the systole of the right auricle, is represented in Fig. 3.

A is the position of the auriculo-ventricular groove at the end of auricular systole, *c* is placed over the *tænia terminalis*, *h* are the numerous *musculi pectinati* passing between the *tænia* and the auriculo-

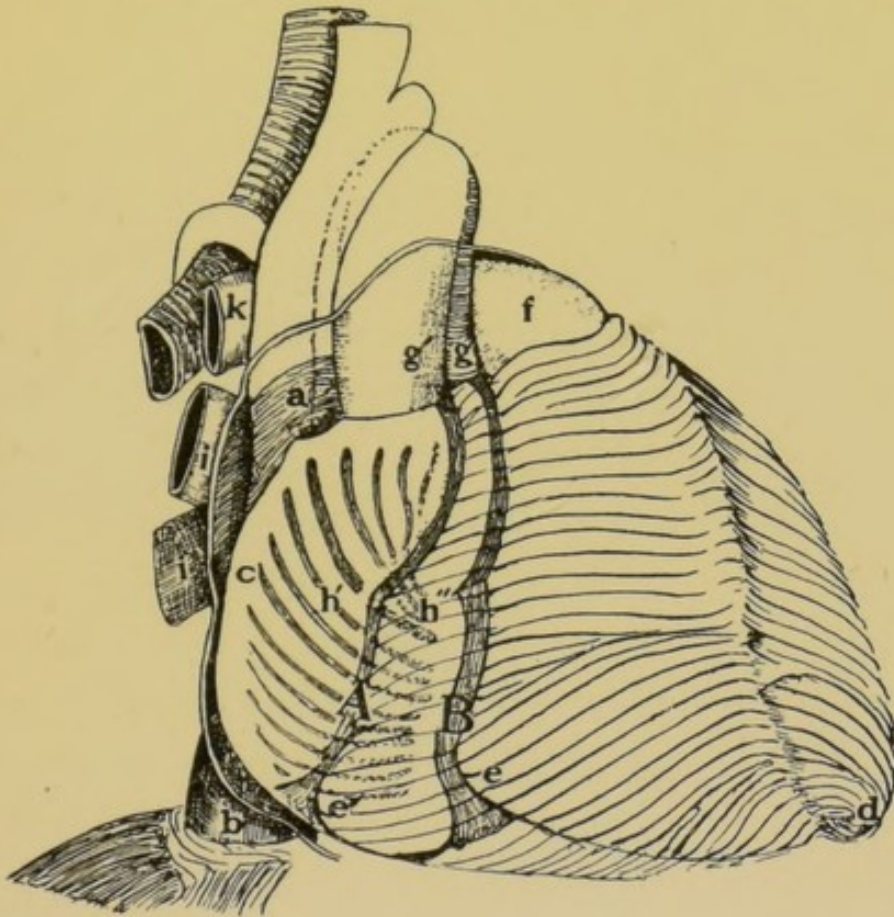


FIG. 3.—Diagram to show the antagonistic action of the musculatures of the right auricle and ventricle.

A, the position of the auriculo-ventricular groove at the end of auricular systole; *B*, its position at the end of ventricular systole. *a*, elliptical fibres round terminal part of superior cava; *b*, inferior vena cava perforating diaphragm and pericardium; *c*, position of the right *tænia terminalis*; *d*, apical vortex; *e*, base of the right ventricle in systole; *e'*, base in auricular systole; *f*, pulmonary artery; *g*, aorta in ventricular systole; *g'*, aorta in auricular systole; *h*, *musculi pectinati* in auricular systole; *h'*, in ventricular systole; *k*, pulmonary artery; *i*, pulmonary veins. (Keith.)

ventricular groove. “The *musculi pectinati* not only expel the blood from the auricle, but also draw the base of the ventricle on to its load of blood.” The

14 GRAPHIC METHODS IN HEART DISEASE

muscle fibres which act in antagonism to these pectinate muscles are found in the right ventricle, and are in two groups, an outer spiral layer and an inner longitudinal. They have their origin in the apex of the heart, which is a fixed point and does not approach the base during systole; on the contrary, the base of the heart approaches the apex. The spiral and longitudinal fibres of the right ventricle are so arranged as to draw the auriculo-ventricular ring towards the apex. In this way the muscoli pectinati are elongated and the auricle itself expanded. The greater the contraction of the ventricle, the nearer does the auriculo-ventricular groove approach the apex of the heart.

In Fig. 3, *B* shows the position of the auriculo-ventricular groove during systole of the ventricle. Such a movement of the auriculo-ventricular ring must obviously cause a marked increase in the capacity of the auricle. With the cessation of ventricular systole the auriculo-ventricular groove swings back to a position midway between *A* and *B*, and there it remains until the next systole of the heart, when it is drawn first to *A* by the contraction of the muscoli pectinati acting from the fixed venous mesocardium, and then to *B* by the contraction of the spiral and longitudinal muscle fibres of the right ventricle acting from the apex of the heart as a fixed point.


In the right heart, which is more particularly in-

volved in the production of the pulse in the jugular vein, we recognize that the distance from the venous mesocardium to the apex of the ventricle remains unaltered, whether the heart is in systole or diastole.

The movable portion is the auriculo-ventricular groove; when the auricle contracts, this groove is drawn towards the venous mesocardium; when the ventricle contracts, the auriculo-ventricular groove approaches the apex, being drawn to this fixed point by the spiral and longitudinal fibres.

When the systole of the heart is over, the auriculo-ventricular groove falls back again to a point about midway between its positions during systole of the auricle and ventricle.

I have not referred to the arrangement of the fibres of the left auricle and ventricle, because they have not the same importance in the production of the venous pulse.



CHAPTER III

INSTRUMENTS

MANY instruments have been devised for recording the movements of the heart and the pulsations in the arteries and veins, but for practical clinical work the two most serviceable are (1) a modification of the Dudgeon sphygmograph named the "clinical polygraph," and (2) the "ink-writing polygraph."

For hospital and laboratory work larger and more elaborate forms of apparatus can be employed, in which several levers attached to tambours record their movements simultaneously on a large drum covered with smoked paper, the drums being driven with electricity or other motive power. Such records are large and in some instances of much value, but to obtain them one or more assistants are necessary; this, together with the fact that these more elaborate instruments are heavy and not adapted for constant removal from patient to patient, makes them unsuitable for ordinary clinical practice.

Throughout this book the records used for illustration, with one or two exceptions, have been taken by

18 GRAPHIC METHODS IN HEART DISEASE

means of the more simple and portable instruments to be described.

Every one interested in the investigation of heart disease by graphic methods must be familiar with the Dudgeon sphygmograph; it is easily applied and is very serviceable, but suffers from two drawbacks: it records nothing more than the radial pulse, and is without a time marker. It is now possible to obtain a Dudgeon's sphygmograph modified by Mackenzie, by means of which the radial pulse is recorded, and at the same time and on the same smoked paper a record of one of the following: the pulse in the carotid artery, the apex beat, the venous pulse, the liver pulse or the respiratory curve. In addition a small time marker is attached which records one-fifth of a second. This time marker is not entirely accurate; for as the clockwork runs down the time marker tends to record slightly more than one-fifth of a second. The clockwork should therefore be wound up before each tracing.

This instrument has been named the "clinical polygraph," see Fig. 4. It carries a broader paper than the Dudgeon's sphygmograph, to provide space for the two simultaneous records in addition to that of the time marker.

To the upright stem of the Dudgeon's sphygmograph a rod can be attached; this rod carries a tambour and lever, see Fig. 5; a light rubber tube is

attached at one end to the tambour, at the other to a small metal cup or "receiver"; this receiver is placed over the pulsations to be recorded, and these are transmitted through the tube to the tambour, converted into movements of the lever, and recorded on the moving black surface. An admirable receiver

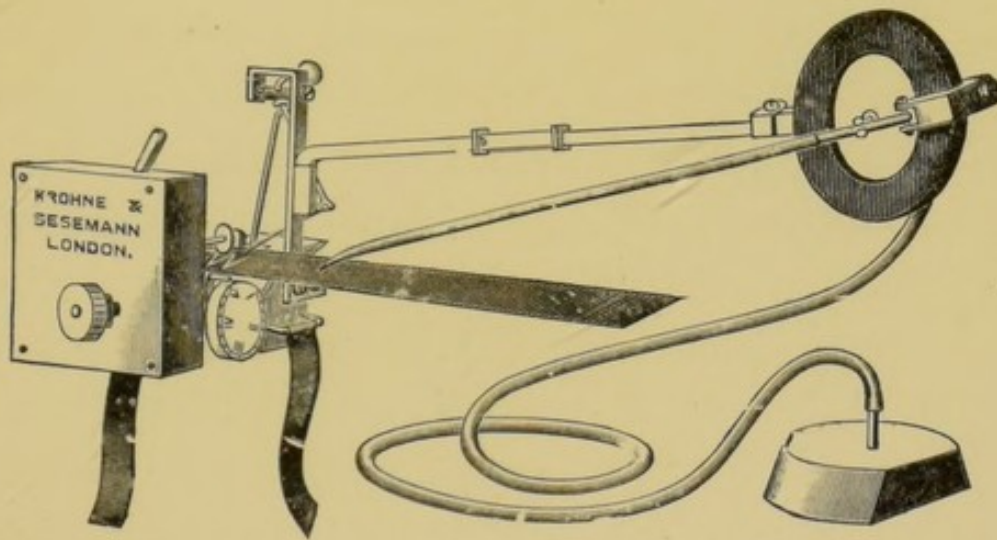
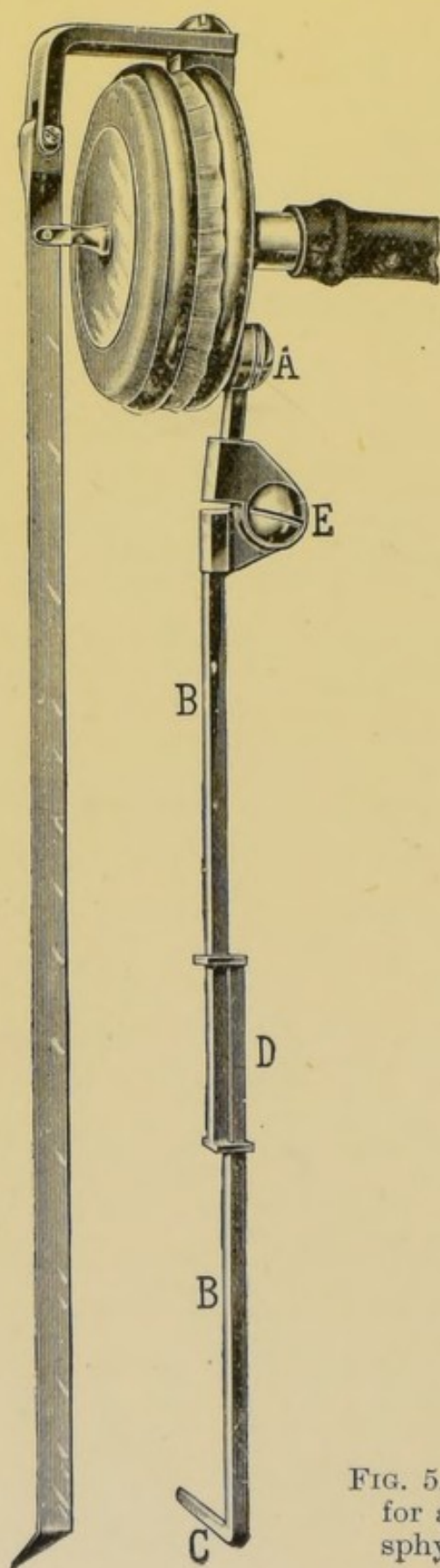


FIG. 4.—Dudgeon's sphygmograph, modified by Mackenzie, and called "The clinical polygraph."

can be improvised by cutting the ball of a Higginson's syringe in two; the edges can then be shaped with a pair of scissors to fit any peculiarity of surface.

In order to adjust the tambour and lever, the bent portion *C* of the metal rod supporting the tambour is inserted firmly into the slot in the upright stem of the Dudgeon's sphygmograph. See Fig. 5, p. 20.

By means of the sliding mechanism at *D* the rod can be made longer or shorter, and the writing point of the lever caused to approach to any given point



on the paper. Again, by moving the tambour on the pivot *E*, adjustment is obtained in the horizontal plane, while by moving the tambour on the pivot *A*, the lever is lifted vertically off the paper. These joints are moderately stiff, so that the tambour remains in the position in which it is placed.

It is essential that the tambour and supporting rod be of as light material as possible; the best lever is one made of aluminium, with a fine wire thread hinged to its end. This hinge movement, which works in a vertical direction, prevents any sticking of the writing point in the event of the lever not running absolutely parallel to the surface of the paper.

FIG. 5.—The tambour with lever and stem for attachment to the Dudgeon or Jacquet sphygmograph.

Care should also be taken that the rubber tubing is not thick and heavy, or its weight will tend to depress the tambour and increase the difficulties of adjusting the polygraph.

Work will be much facilitated by removing the inelastic band and clamp supplied with the polygraph and replacing it by two strips of elastic about half an inch wide.

When about to take a tracing, first make sure that the patient is in a comfortable position, with the head supported by pillows and slightly bent towards the chest; then mark out with a blue pencil the site of the radial artery, just above the level of the styloid process of the radius. Note where the artery is most exposed, and where the pulsation is most definite. For several reasons it is advisable to take the record from the right radial.

Place the sphygmograph on the wrist and forearm, so that the bulging terminal portion of the spring rests on the radial artery, and the spring lies in its long axis. With the instrument in position, tie the elastic bands in a single knot behind the wrist. The sphygmograph is now securely fixed in position, and with a little adjusting the radial pulse should cause a free movement of the small lever. If the patient is in bed it is a good plan to place a roll of flannel or some similar pad under the wrist to steady it. If, however, the patient is on a couch, the wrist can rest

22 GRAPHIC METHODS IN HEART DISEASE

on the knee of the investigator or on the arm of a chair. It is easy to find which is the most convenient method in any particular case. At this point an inch of the smoked paper should be run in and the clock-work stopped. Next adjust the tambour by inserting the bent portion of the rod *C* into the slot in the upright stem, and turn the point of the lever up out of the way by rotating the tambour on the pivot *A*. The weights of the rod and tambour, increased by that of the tubing, will tend to tilt the sphygmograph to one side, and the movements of the small lever recording the radial pulse will probably be diminished, or may even entirely cease. Should this happen, the polygraph must be readjusted with the tambour in position; and we can now appreciate the great advantage of the elastic bands, for they enable us to alter the position of the polygraph without undoing the knot by which it is tied to the wrist. Adjust the polygraph until the radial pulsations are of the desired amplitude, and being recorded either at the upper or the lower half of the paper. The desirability of this is obvious, space is left for the other lever to record, and the two tracings are not hopelessly interwoven.

In varying the amplitude and position of the radial record, the spring regulator graduated in ounces is of considerable assistance.

When satisfied with the movement of the lever

recording the radial pulse, bring the long lever down on to the paper till the tip of the lever is in light contact with the paper, thus avoiding friction. So adjust the tambour that the point of the lever does not trespass on that portion of the paper occupied by the radial tracing.

Next place the receiver over the pulsation you desire to record, and make sure that its entire margin is in contact with the skin. When both levers are moving easily and without encroaching on each other, gently start the clockwork with the hand that is free. One hand is required to apply the receiver, the other to start and stop the clockwork.

As a rule the sphygmograph must depend on the elastic bands to retain it in position; on occasion, however, it may facilitate matters to hold the sphygmograph in position with one hand and requisition the help of some one to start and stop the clockwork.

The radial sphygmogram, except when taken alone, is chiefly of value as an indication of the occurrence of ventricular systoles and for calculating the sphygmic period, see p. 41. A small amplitude in the radial tracing will therefore be sufficient, and if it is thought desirable to record a few full-sized beats this can be done on the last inch or two of the paper.

As a rule it is better to adjust the point of the large lever a little behind that of the small one; if this is not done they collide, and the record is marred.

24 GRAPHIC METHODS IN HEART DISEASE

Before starting the clockwork, and again on stopping it, make certain that both levers record their position by upright lines ; these are of service when analyzing the records. This analysis will be much facilitated if a few beats of the carotid pulse are recorded with the radial either at the beginning or end of the tracing, see Figs. 23 and 34, pp. 56 and 74. To record the carotid pulse the receiver is placed about the level of the thyroid cartilage and to one side of it, or still higher, at the level of the hyoid bone. The pulse in the right carotid is more easily recorded when the head is turned to the left and the chin elevated.

To fail in obtaining a record of the venous pulse is the exception rather than the rule. There are patients, however, in whom it is practically impossible ; a good example is a man with an emphysematous chest suffering from dyspnœa. With each inspiration the sternomastoids stand out, and the variations in the venous blood pressure with each respiratory movement are so great that it is almost impossible to obtain an intelligible record.

When an ordinary individual lies down it is obvious to the naked eye that there is a rhythmical venous pulsation in the neck, and if the receiver is applied to the skin one or one and a half inches from the sternoclavicular joint, just above the clavicle over the site of the internal jugular vein, see Fig. 1, p. 8, the pulsations are transmitted to the lever and can be

recorded. In order to obtain satisfactory results, the right sternomastoid must be in a state of relaxation; to secure this the head must be adequately supported and placed in such a position that the muscle is soft.

If under such circumstances on applying the receiver the excursion of the lever is very limited, it may be augmented by placing the head at a lower level than the body. If, on the other hand, the jugular vein stands out engorged with blood, a better tracing will be obtained if the patient is propped up in bed.

When the respiratory movements cause great variations in the extent of the excursions of the levers, it

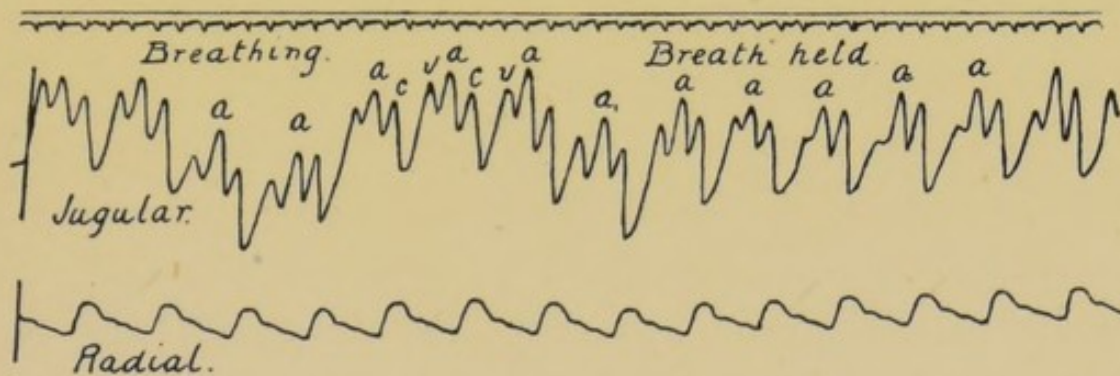


FIG. 6.—Tracing taken by the ink polygraph. The upper tracing is that of the venous pulse in the right internal jugular vein. At first the patient was breathing naturally, but for the latter half of the record the patient ceased to breathe. The lower tracing is from the radial artery.

a=auricular wave; *c*=carotid wave; *v*=the ventricular wave.

is best to take a portion of the record when the breath is held, see Fig. 6. Getting the patient to hold his

breath is also of service when dealing with a very small venous pulse, for it frequently has the effect of definitely increasing the amplitude of the waves. This is well shown in Fig. 32 and Fig. 33, p. 74.

THE APEX BEAT

When recording the apex beat, place the receiver directly over the area of maximum impulse. This may, however, cause too great a swing of the lever, in which case move the receiver a little nearer the axilla; for by so doing less of the forward push of the skin is recorded, and we can be more certain that we are recording the movement produced by the systole of left ventricle. If in order to diminish the excursions of the lever we place the receiver over the inner portion of the impulse, there is a danger of recording the movements due to the systole of the right ventricle, and so obtaining some form of inverted cardiogram.

It is frequently difficult to obtain a satisfactory record of the apex beat; factors such as emphysema, fat, and in women the presence of the soft elastic breast tissue increase the difficulties, but at times even in the absence of such factors failure is unavoidable.

It is hardly necessary to state that any of the various receivers can be used in place of the simple cup described above; especially useful is that cut from a Higginson's syringe.

THE LIVER PULSE

To record the pulsations of the liver, a special form of receiver is required. For this purpose a large metal cup is employed about five inches long, two inches broad, and one inch deep. There is a small air hole towards one end, either in the roof or in one side. The edges of the receiver should be curved so as to adapt themselves to the abdominal walls. Map out the lower edge of the liver, and place the receiver transversely on the right side of the abdomen, so that its lower margin is about one or two inches below the edge of the liver. Next steadily press the receiver into the abdomen backwards and upwards, and then apply its upper margin to the skin. By these means the lower edge of the liver is embraced by the receiver, and on stopping the air hole with a finger the lever will record the variations of pressure within the receiver. These are due in part to the respiratory movements, in part to the pulsatile expansion of the liver. If the patient holds his breath, the liver pulse only is recorded.

RESPIRATORY MOVEMENTS

It is sometimes desirable to record the respiratory movements. These movements are usually indicated in the tracings from the jugular pulse by a rising and falling of the level of the record. They can also be recorded by attaching a small india-rubber bag to

the tube in connexion with the tambour. This rubber bag is lightly bound to the chest by a bandage, and the increase and diminution of the pressure of the air in the bag caused by the respiratory movements is reproduced in the excursions of the lever.

THE PAPER

It is important that the glazed paper on which the tracings are taken should be very accurately cut ; the edges must be smooth and parallel, otherwise the strips will stick in their passage through the machine.

If the paper is of too heavy a make, its weight and rigidity, especially if a long strip is being used, will hamper the regular onward movement and cause temporary delays fatal to a good record.

The length of the strips is usually six or seven inches, but it is useful to have some of fourteen inches or even longer.

The strips are best blackened by passing them through the smoke arising from small pieces of burning camphor ; the paper must be held sufficiently high to prevent any scorching. After blackening the strips allow them to cool on a table or cold slab ; this removes the twisting and curling caused by the blackening process, and which might interfere with the regular movement of the strip through the polygraph. The large strips can be cut down to any size after being blackened.

A small box for holding these smoked papers is

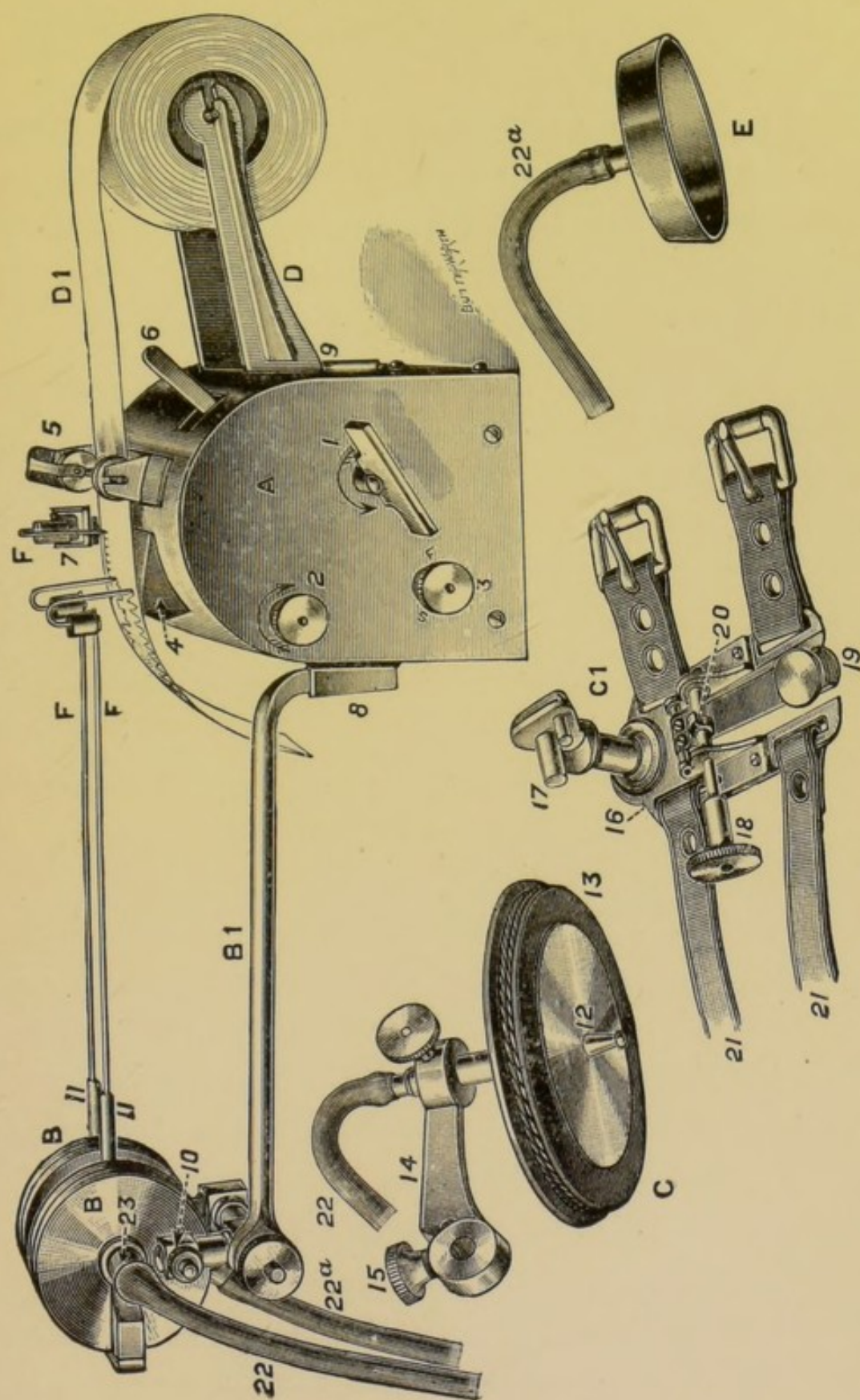


FIG. 7.—The Ink Polygraph.

supplied with the polygraph, and will accommodate six or more strips.

When the record has been taken, the name of the patient, the date, and any other facts worthy of noting should be written on the blackened surface with a pin or other pointed instrument, and the tracing should then be varnished. The following is the formula of a very satisfactory varnish for which I am indebted to Prosper H. Marsden, Esq., F.C.S., Lecturer in Pharmacy to the Liverpool University, and which I have used for some years at the Royal Infirmary :
“ One part of benzoinum is powdered and macerated for a week in five of industrial methylated spirit, and at the end of that time the varnish is either decanted or filtered for use.” This varnish possesses all the necessary requirements, and it has the advantage of drying quickly.

The next instrument to be described is the “ink polygraph.” With it continuous tracings of any length can be obtained, and as the records are in ink on a band of white paper, all the trouble of blackening and varnishing is done away with. This instrument, devised by Dr. Mackenzie, can be obtained from Mr. Shaw, watchmaker, of Padiham, Lancashire. It consists of a body, *A*, Fig. 7, p. 29, containing the paper rolling and time marker movements; a rod, *B*, which can be attached to the body by inserting its bent end into the slot 8. This rod supports two tambours, *B*, each

carrying a pen, *F*, which writes on the ribbon of paper as it is passed on by the clockwork in *A*. The roll of paper is placed on the bracket *D*. Rubber tubing passes from the tambours, *B*, and to these tubes the receivers can be attached.

The wrist tambour requires a more detailed description. It is in two parts. First, the splint (16), which

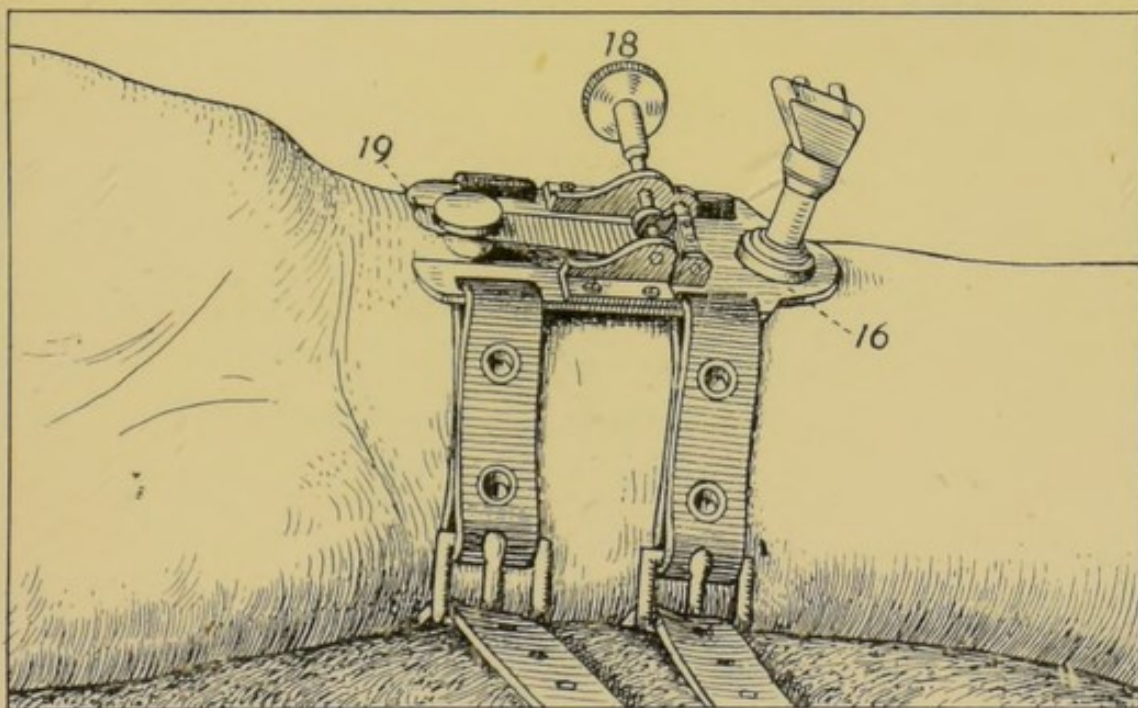


FIG. 8.—The splint of the ink polygraph fixed in position on the right wrist.

is strapped on to the wrist, Fig. 8. This is fitted with a spring tongue and button (19), which is placed on the radial artery and follows its variations in shape. There is also an eccentric and regulating screw (18) for varying the pressure on the artery. Second, the tambour *C*, Fig. 9, with the supporting arm (14) and rubber membrane (13), and compression disc and peg (12), see Fig. 7. The

two parts are held together by the clamping screw (15). When placed in position, the button moves with the variations in pressure in the radial artery; these movements of the button are transmitted to the peg, which is resting lightly on its upper surface. As the

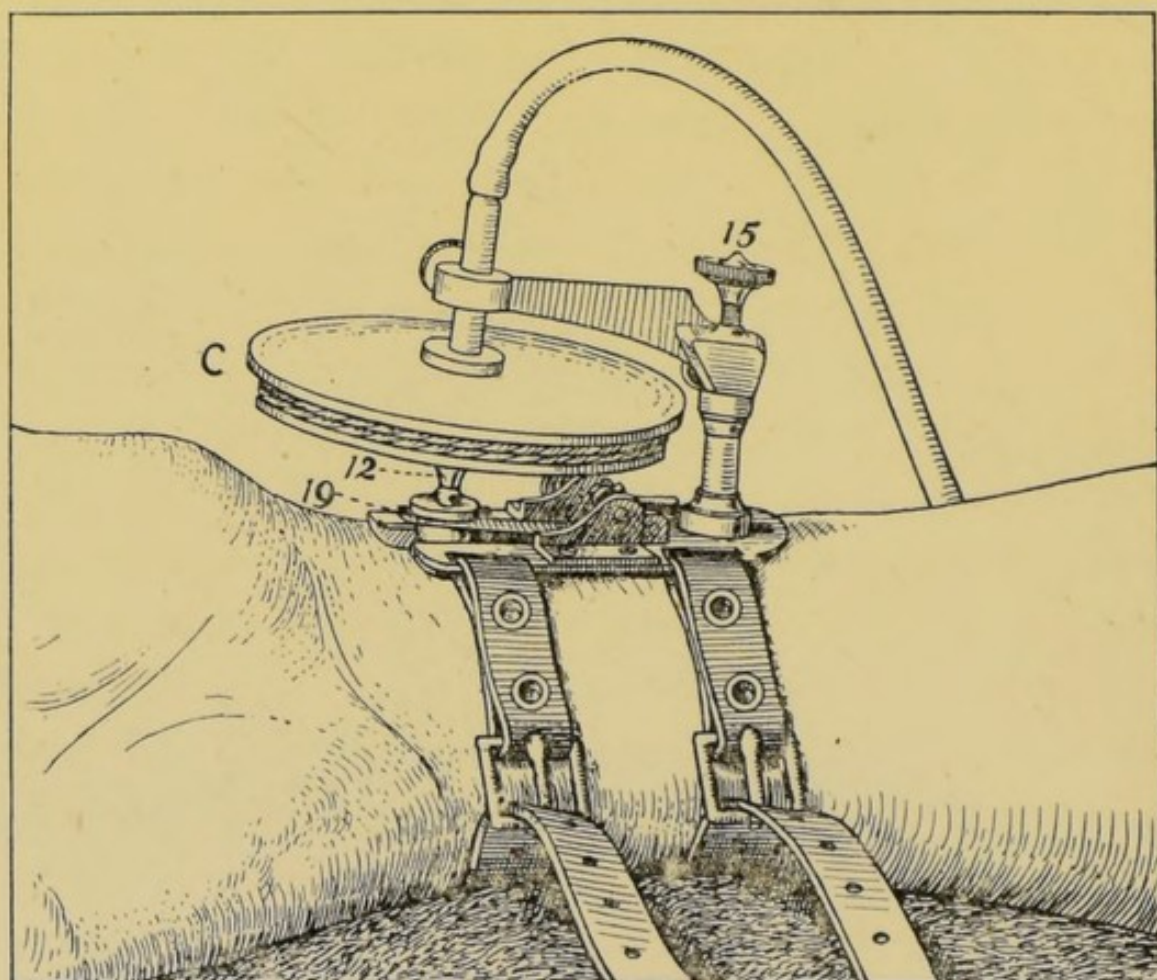


FIG. 9.—The splint and tambour in position.

peg moves up and down its excursions are transmitted to the tambour *C*, and thus by means of the rubber tubing to the pen-bearing tambour *B*.

Behind the friction roller is the start and stop lever (6), and at the other end of the body, in front

of the friction roller is the fork (7), carrying the time marker pen *F*; this fork vibrates at the rate of 300 per minute. See Fig. 7.

At the end of the body *A* there are three keys:—

1. For winding up the clockwork which controls the paper rolling movement.
2. For winding up the time marker.
3. For regulating the rate at which the paper is passed along through the roller, the direction required being indicated by the letters *F.* and *S.* (fast and slow).

On the top are the writing table *A*, the tension rollers, and tension spring (5).

The pens *F* have each small reservoirs and writing pins. These pins are grooved on each side to conduct the ink from the reservoir to the point of the pin.

Various fluids can be used; 2 per cent. aqueous solution of methylene blue or one drachm of methyl blue in sixteen ounces of water have proved satisfactory. "Stephens' blue-black writing fluid," to which a little glycerine has been added, also gives a good record.

It is essential that the pens be kept scrupulously clean and the ink free from dust.

Detailed instructions are sent with the machine. I will only refer to some of the more practical points in the use of the polygraph.

It is best to place the body of the machine on a

34 GRAPHIC METHODS IN HEART DISEASE

table or stand near the head of the patient, a little to the patient's right, then adjust the splint to the right wrist so that the button is placed directly over the radial artery and transmits its pulsations. In order to obtain the maximum movement of the button place a pad under the wrist or lay the wrist across the arm of a chair, so as to extend the hand. The hand must be kept perfectly still, as turning it from one side to the other, or clenching the fist, interferes with the record. It is important, therefore, that the patient be in a comfortable position. The next step is to attach the arm carrying the wrist tambour to the peg on the upright pillar fixed to the splint. Make this secure with the binding screw, and then drop the tambour until the peg attached to the rubber membrane rests on the small plate above the pulse button; then secure this tambour. The two pens can then be inserted into the tambours if this has not already been done, and they may be brought down until they come into the slightest contact with the paper.

It is most important that the pens should be perfectly clean; the smallest quantity of dust or dirt in the ink is sufficient to prevent its flow down the pin. The pens should be rinsed freely in water after they have been used, and it is advisable to brush out the grooves gently in addition.

I find it a good plan, while I am fixing up the apparatus, to place the pens in hot water for a few minutes,

and then before actually attaching them to the tambours to dip them into the methylene blue solution.

Before placing them in the hot water to soak, run a pointed instrument along the grooves of the pen to remove any grit or dust which may have collected.

While taking records the reservoirs must be kept supplied with ink, and this is best accomplished by dipping a small camel-hair pencil into the stock bottle of ink and touching the top of the reservoir with it; a drop or two of ink is thus transferred to the reservoir. When necessary, the weight of the added ink may be utilized to cause the pen to come into contact with the paper.

It is best to connect the wrist tambour with the writing tambour nearest to the supporting bar, the reason being that the pen lever on this tambour is allowed a greater leverage.

Not infrequently it is desired to record two movements, neither of which is the radial pulse, as, for example, the apex beat and the venous pulse, or the apex beat and the carotid pulse, or the left carotid pulse and the right jugular pulse, and so forth. Then, of course the wrist tambour is not used, and the writing tambour nearest the supporting rod is attached to that receiver which is recording the movement having the least amplitude of range.

Sometimes the pens fail to move in quite the same plane as the paper, tending to leave the surface, as

they approach one or other edge of the ribbon. To rectify this, first make sure that, the tambour bar B^1 , is firmly fixed in its socket, and then, if the error still persists, grasp the bar and steadily bend it in the direction necessary to correct the error. This will probably be sufficient.

After using the polygraph for a very short time it becomes obvious that some method must be devised for storing the records. They can be kept in rolls with the date written on the last inch or so of the paper, but this tends towards confusion.

Another method is to have a large book twenty-four to thirty-six inches long and twelve to eighteen inches broad, into which the valuable portions of the tracings can be fixed.

Another plan, and one which I find the most satisfactory, is to get large sheets of tough paper cut to fit a convenient drawer about thirty inches long.

Having taken a record, I decide which portions are worth retaining, and then cut them out in lengths equal to the size of the sheet of paper. I then attach them to the sheets by gumming them at each end. I write the name of the patient, age, date, diagnosis, and any other facts to be noted, on the top of the sheet, and place it in the drawer.

I find this method satisfactory and tidy, and it enables me to refer to the records with ease.

This instrument possesses certain advantages.

With it there is not, as a rule, any difficulty after a little practice in obtaining good records. These records can be of any length, and thus variations which occur infrequently can be recorded with certainty.

It is also a great convenience that the radial pulsations are transmitted through a tambour, for this enables the recording instrument to be placed on a table some little distance from the patient.

To be able to record two movements simultaneously, neither of which is the radial pulse, is a great advance on the modified Dudgeon, where the standard is always the radial. The power to alter the rate at which the paper passes through the machine is also useful. The box containing the ink polygraph can be carried about in a moderately-sized bag.

Von Jacquet's sphygmograph is another useful instrument designed on the same plan as the Dudgeon. It is larger and can be fitted with a tambour and lever, so that two records can be taken simultaneously. It carries a time marker registering one-fifth of a second, and by means of moving a lever the speed of the clockwork can be varied.

It is necessary with the Von Jacquet to use smoked paper as in the Dudgeon. The paper may be of any length up to eighteen or twenty inches; when longer than this it becomes awkward to manage.



CHAPTER IV

NORMAL RECORDS

THE NORMAL SPHYGMOGRAM

It is essential that we should be perfectly familiar with the characteristics and normal variations of the tracings obtained from healthy individuals. I shall therefore consider them first.

The sphygmogram represents the variations in pressure occurring within the vessel wall, magnified in some degree by the mechanism of the sphygmograph. It records the rate and rhythm of the heart, and yields information concerning the heart beat. As we shall find later, it is of great assistance in analysing the tracings of the venous pulse obtained from the veins in the neck.

In Fig. 10 we have a pulse tracing from the radial artery of a healthy individual. The wave *p* is named the percussion wave, and is caused by the first impact of the blood striking the pad of the sphygmograph, placed on the artery; its height is largely instrumental: this wave *p* is followed by the next wave *t*, named the tidal or predicrotic, which ends in the notch *n*,

the dicrotic or aortic notch : this notch indicates the point at which the aortic valves close, and thus de-

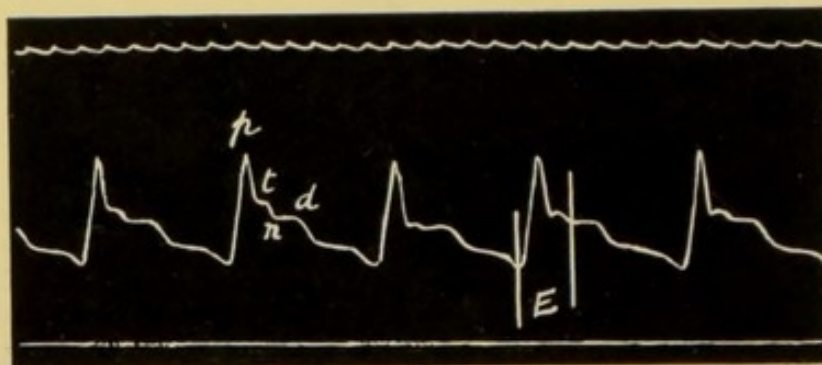


FIG. 10.—Radial sphygmogram from a healthy individual.

p = the percussion wave; *t* = tidal or predicrotic wave; *n* = dicrotic or aortic notch; *d* = dicrotic wave; *E* is the sphygmic period during which the semi-valves are open.

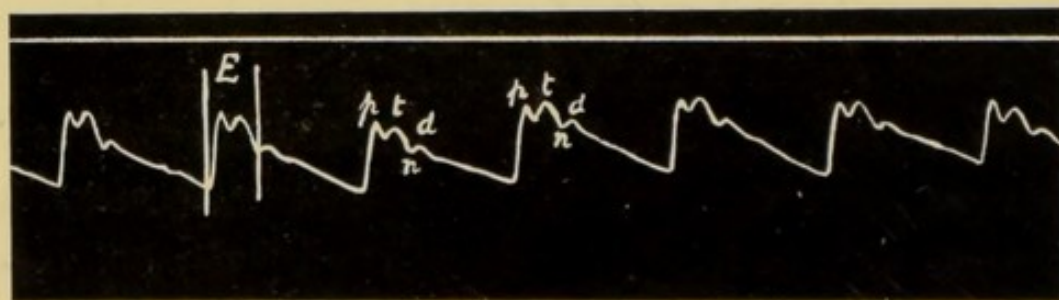


FIG. 11.—Radial sphygmogram, showing hypertension.

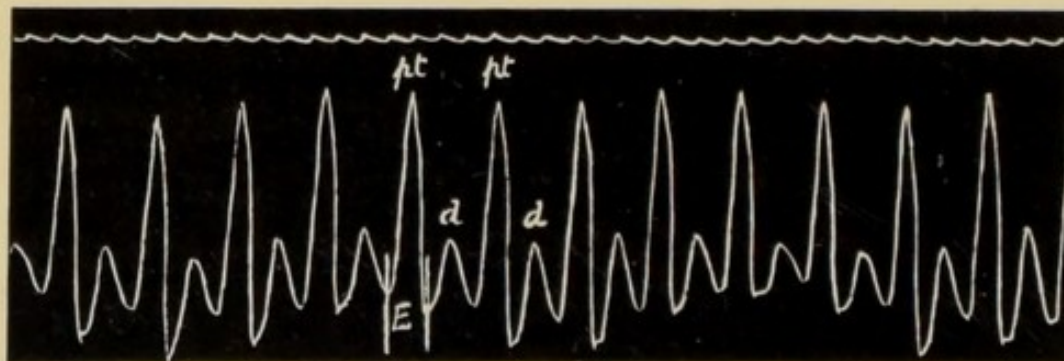


FIG. 12.—Radial sphygmogram, showing hypotension.

finishes the termination of the sphygmic or pulse period of ventricular systole. Following the notch *n* is the dicrotic wave *d*.

The upstroke of the sphygmogram is nearly vertical, though this varies a little in different types of pulse. The downstroke is open to great variations, from the slow fall of hypertension as seen in Fig. 11 to the rapid drop and oscillation in Fig. 12.

For the interpretation of the many and often meaningless variations in the form of the sphygmogram, the works of Mahomed, Marey, Sansom and others should be consulted. I wish here to deal only with those elements in a sphygmogram which can be relied on to yield definite information concerning the movements of the heart.

It is obvious that a tracing of the radial or carotid pulse, when taken with a machine bearing a time marker, will record the frequency and rhythm of the pulse.

From a sphygmogram we can also determine the period during which the aortic and pulmonary valves are open, the sphygmie period; for this begins with the upstroke of the tracing and ends at the dicrotic notch, and throughout all the tracings is labelled *E*.

This period *E* is of considerable value when interpreting the graphic records of the venous pulse, and will be referred to again when describing the cardiogram.

THE CARDIOGRAM

Information concerning the movements of the heart can be obtained by taking graphic records of the apex

beat ; and also from other portions of the praecordium, such as second, third, and fourth interspaces and epigastrium. The records from the apex beat are termed cardiograms, and in some instances are of considerable value, both as standards from which to analyse the phlebogram, though for this purpose the radial pulse is more generally useful, and in giving certain information as to the character of the cardiac systole.

The apex beat in a normal adult is to be found in the fifth left intercostal space, some three or three and a half inches from the middle line. In children it is relatively further to the left, and tends to be higher placed ; in the aged it may be found in the sixth space. The apex beat may be defined as "the lowest and outermost point of the heart's impulse which strikes against the chest wall." In patients with bulky emphysematous lungs the cardiac movements may be neither palpable nor visible ; on the other hand, owing to the retraction of the lungs, so often present in chronic pulmonary disease, the heart may be abnormally uncovered, and its pulsations perceptible not only in the fifth space, but also in the second, third, and fourth. In stout persons and in women with large breasts the apex beat, even when palpable, can rarely be recorded.

Before interpreting the cardiogram it is essential that the nature of the movement which is being re-

corded should be thoroughly comprehended, lest more be read into the tracings than is justifiable.

The cardiogram is simply a record of the mechanical displacement of the heart in relation to the chest wall ; it does not record the ventricular pressure. On inspecting a typical apex beat one sees a thrusting forward of the skin in the fifth space ; this protrusion lasts for a brief interval, and then ceases, the skin remaining undisturbed until the next systole. On placing a hand over this impulse one is conscious of a shock, sudden and short, which initiates the forward thrust. Following on this shock the heart is felt to bulge into the intercostal space for a short period, and then to fall away from the chest wall.

On the occurrence of systole the ventricles which are full of blood contract down on their contents, and some portion of the heart's apex is pressed against the chest wall.

The shock felt on palpation is caused by the sudden hardening of the ventricular muscle ; the thrust is due to the pressure of the apex of the left ventricle against the chest wall. It is essential that one should clearly differentiate between these two features.

THE INTERPRETATION OF THE CARDIOGRAM

(a) The shock caused by the sudden hardening of the ventricular muscle and the slight movement forward of the apex of the left ventricle with commencing systole.

During this period the ventricle is being pressed more and more firmly against the chest wall, and the inter-ventricular pressure is rising. When this pressure has risen above that in the aorta and pulmonary arteries the semilunar valves open, and the ventricles begin to empty themselves.

On comparing a cardiogram with the tracing of the carotid pulse taken simultaneously, Fig. 13, we see that the opening of the aortic valves, as judged by the carotid pulse, takes place about the summit of the ascending limb of the cardiogram, and is indicated by the vertical stroke 3. This point is the beginning of the sphygmic or pulse period *E*.

(*b*) The period *E* during which the heart's apex is pressing against and bulging forwards the soft structures of the chest wall. This period lies between the lines 3 and 5; during it the pressure in the ventricles is above that in the arteries, and the blood continues to flow out of the ventricles into the aorta and pulmonary artery. This period terminates when the pressure in the arteries becomes greater than that in the ventricles. Systole is at an end, the semilunar valves close, the ventricle relaxes and falls away from the chest wall; this is seen in the cardiogram by the sudden drop in the tracing at 5. This point coincides fairly accurately with the dicrotic notch, and the period between 3 and 5 is the sphygmic or pulse period, during which the semilunar valves are open.

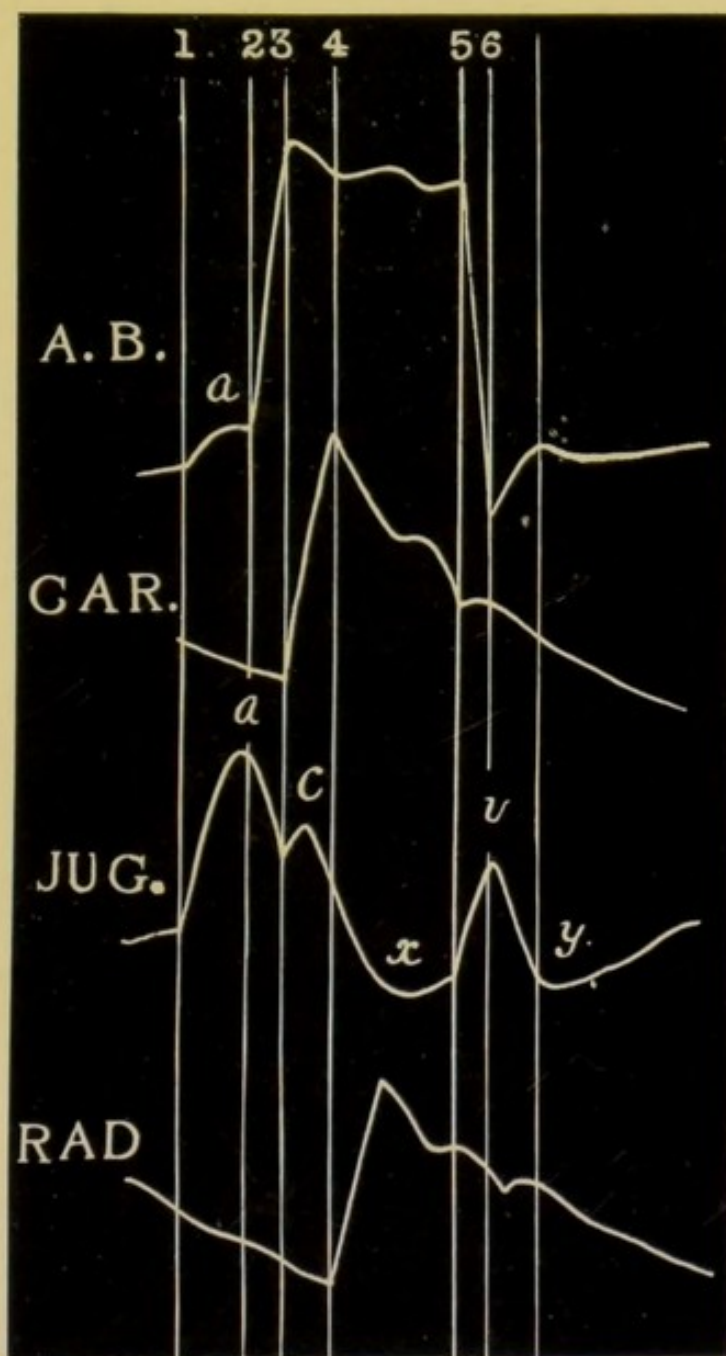


FIG. 13.—Diagram showing the relations of the cardiogram (*A.B.*), the pulse in the carotid (*CAR.*), the jugular pulse (*JUG.*), and the radial pulse (*RAD.*) to each other. The perpendicular lines represent the time of the following events:

1, the beginning of auricular systole; 2, the beginning of ventricular systole; 3, the appearance of the pulse in the carotid; 4, the appearance of the pulse in the radial; 5, the closure of the semilunar valves; 6, the opening of the tricuspid valves. The numbered perpendicular lines in all the tracings indicate the same events as in this diagram.

(c) The falling away of the ventricle from the chest wall. On the cessation of systole at upstroke 5 there is a marked fall in the cardiogram, which indicates that the ventricle is no longer pressed against the chest wall. The point where the record reaches its lowest limit at upstroke 6 is important, for it indicates the opening of the auriculo-ventricular valves and coincides with the apex of the wave *v* in the phlebogram, Fig. 13.

(d) The slow filling and enlargement of the ventricles during diastole. During this period, not fully indicated in the diagram, between the upstroke 6 and the next systole, the ventricles are being slowly filled with blood, and their distension may record itself as a gradual rise in the tracing; more usually, however, the level of the tracing remains fairly constant until the beginning of the next ventricular systole.

(e) The slight alteration in the ventricular wall which may be present just preceding the systole of the ventricle, and which is caused by the auricles discharging their contents into the ventricles. See *A.B.*, Fig. 13, upstroke 1, followed by elevation *a*.

From a typical cardiogram it is therefore possible to determine with some approximation to accuracy the beginning of ventricular systole, the point of time of the opening and closure of the semilunar valves, and the opening of the cuspid valves.

We can ascertain the duration of systole and

diastole, and it is also possible to state whether the apex beat is caused by the right or left ventricle.

To recapitulate briefly—

At 1 the wave due to systole of the auricle begins.

At 2 we have the beginning of ventricular systole.

At 3 the aortic valves open and the carotid pulse appears in the neck.

At 5 the semilunar valves close and the dicrotic notch is seen in the tracing of the carotid pulse.

At 6 the tricuspid and mitral valves open and blood flows into the ventricles from the auricles.

These numbers will be used throughout to indicate the above points of time in the cardiac movements.

Between the beginning of the systole of the ventricles—downstroke 2—and the appearance of the carotid pulse in the neck—downstroke 3—there is a delay of about one-tenth of a second. This delay is chiefly due to the time taken by the ventricles in raising the pressure in their cavities above that in the aortic and pulmonary arteries respectively ; it is the presphygmie time, and when taken together with the very brief time for the transmission of the arterial pulse from the aortic valve to the carotid artery, gives a period of one-tenth of a second.

The pulse wave takes another one-tenth of a second or a trifle less to travel from the carotid artery to the radial at the wrist, so that there is one-fifth of a second between the line 2, the first indication of ven-

48 GRAPHIC METHODS IN HEART DISEASE

tricular systole, and the line 4, the first indication of the radial pulse.

In all the records the time marker indicates fifths

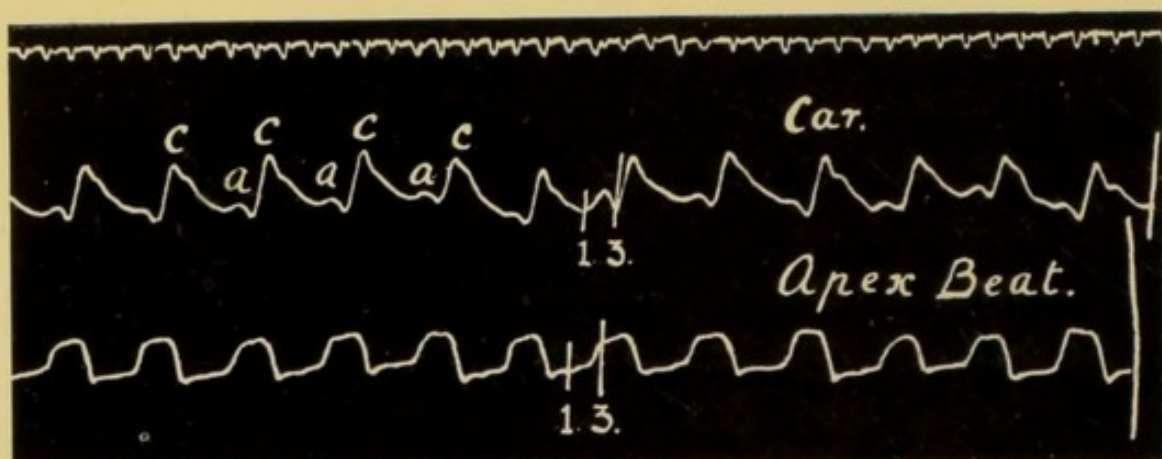


FIG. 14.—Simultaneous tracings of the carotid pulse and the apex beat. *c*, the carotid pulse, *a*, preceding it, is caused by the systole of the auricle distending the jugular vein. The time-marker in this and all subsequent tracings records one-fifths of a second.

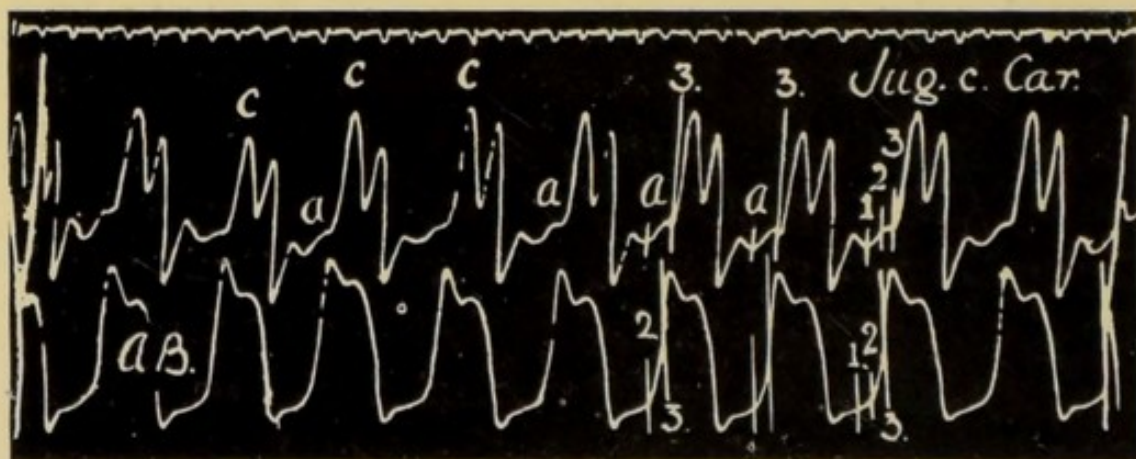


FIG. 15.—Similar record to Fig. 14. In this case, however, the carotid pulse *c* was bisferiens in type. *a*, results from systole of the auricle.

of a second, so that it is easy to find approximately in a radial tracing the point synchronous with the beginning of ventricular systole 2.

In Figs. 14 and 15 we have tracings taken from the carotid artery in the neck compared with the movements of the apex beat. In each there is a wave *a*

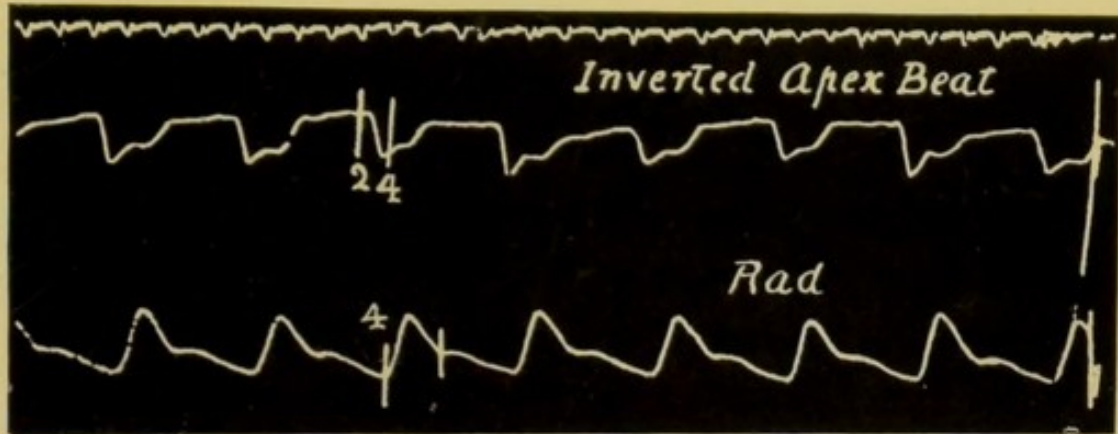


FIG. 16.—Upper tracing shows retraction of the skin over the apex beat with systole. An inverted cardiogram. The upstroke 2 indicates the beginning of ventricular systole; the upstroke 4 the appearance of the pulse in the radial.

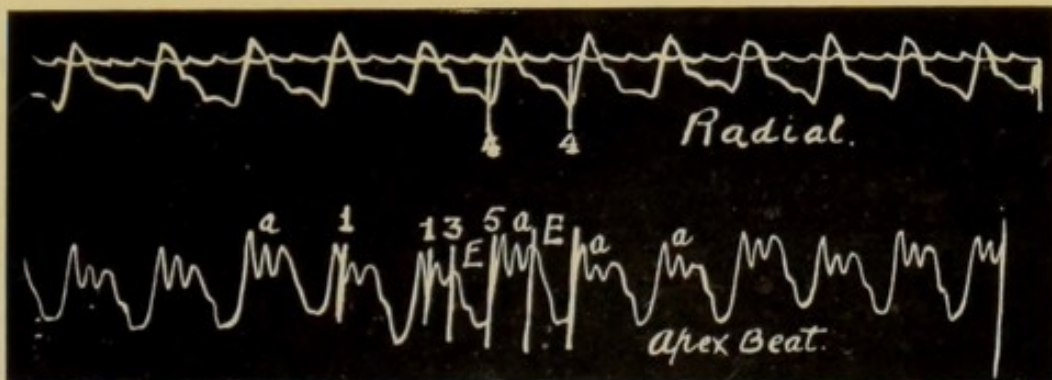


FIG. 17.—The lower tracing from the apex beat shows a wave *a* caused by the auricles forcing blood into the ventricles during auricular systole. The cardiogram is chiefly negative or inverted.

due to the systole of the right auricle causing a distension of the jugular vein. These records demonstrate the point in the cardiogram corresponding to the appearance of the pulse in the carotid artery.

So far, I have described the normal positive cardiogram ; but in many instances the only record to be obtained varies from this type, and it is necessary that one should be familiar with these variations and able to interpret them.

Such records as Figs. 16, 17, 18, and 19 are to be included in this class. Fig. 16 is an inverted or negative cardiogram, and can frequently be obtained by placing the receiver internal to a large forcible apex beat—that is, by recording the movements of the right ventricle. When through enlargement of the right ventricle “the lowermost and outermost portion of the apex beat” is caused by the systole of the right and not by that of the left ventricle, the cardiogram obtained from the actual apex beat is similar to Fig. 16. The upright strokes are numbered as in Fig. 13, and have a similar significance.

In Figs. 18 and 19, examples of the inverted cardiogram, the negative phase is preceded by a short rise, systole of the ventricles beginning with the rise in the tracing marked by the upstroke 2. In Fig. 17 we find a marked elevation due to systole of the auricle ; this is followed by a definite rise coincident with the onset of ventricular systole, but almost at once there is a falling away of the ventricle and the tracing is then a combination of a positive and negative cardiogram, suggesting that the apex beat was largely caused by the right ventricle.

The transition from the positive to the negative cardiogram can be followed in cases of heart disease. When from any cause the right ventricle hypertrophies and dilates and by reason of this increase in its bulk

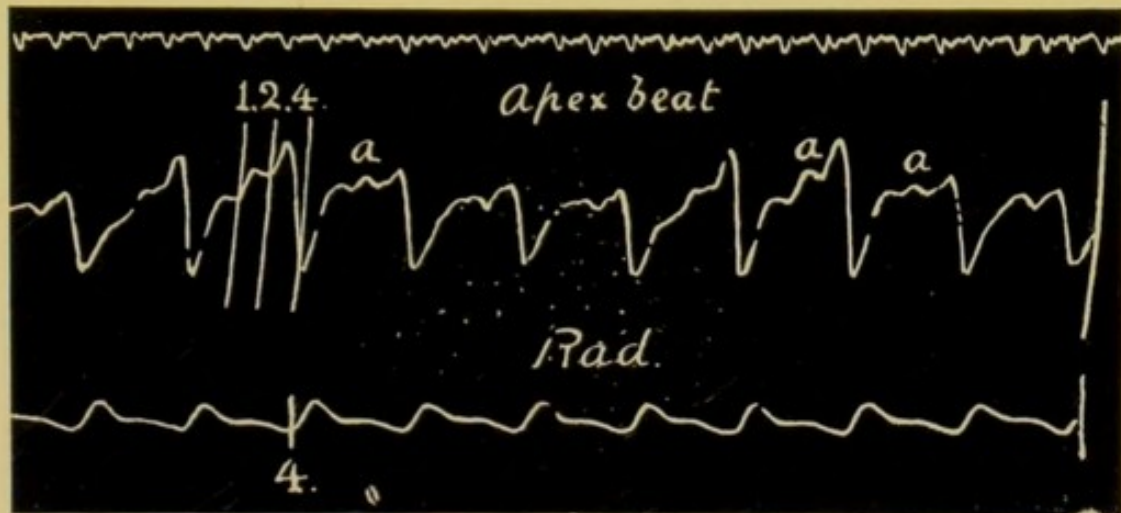


FIG. 18.—The record from the apex beat is a combination of a positive and negative cardiogram.

a, is caused by the systole of the auricles ; at 2 ventricular systole begins.

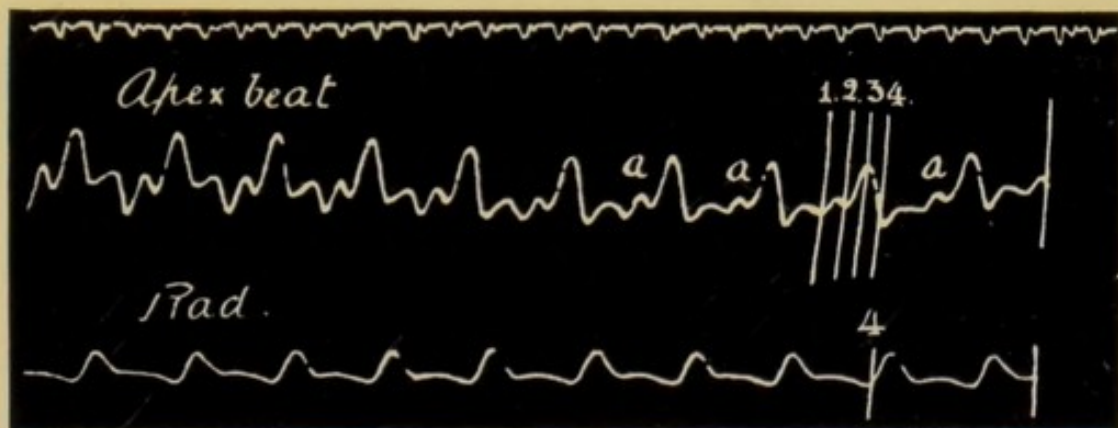


FIG. 19.—Similar record.

pushes the left ventricle away from the chest wall, the cardiogram is then of the inverted type. On palpating in such a case one feels the shock of the heart, which is due to the hardening of the cardiac

muscle; but one does not feel any actual thrust, and the cardiogram shows that the thrust is absent, and that there is rather a withdrawal of the heart from the chest wall during the actual systole.

If the cause of the enlargement of the right side has been temporary it is possible, as the right ventricle diminishes, to observe the gradual return of the cardiogram to the positive type, indicating that the left

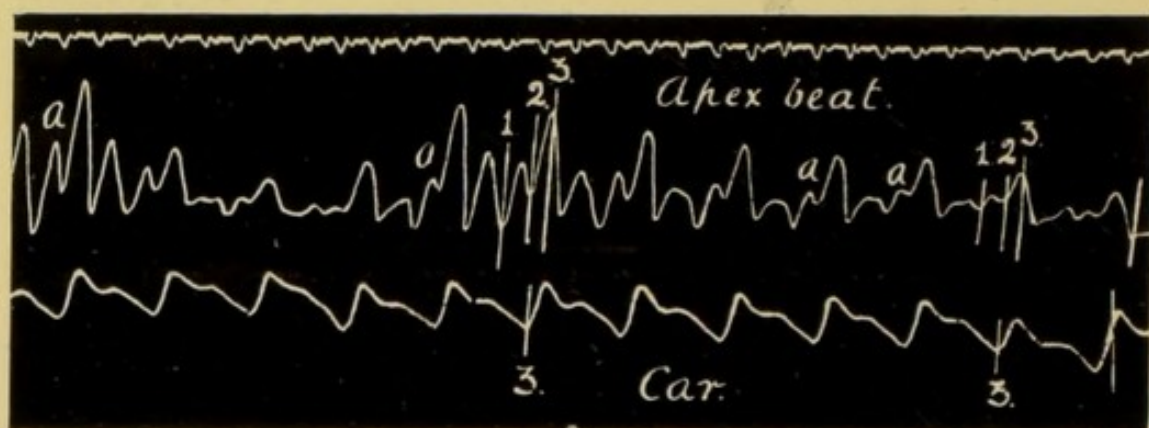


FIG. 20.—Abnormal cardiogram recorded simultaneously with the carotid pulse.

a = wave due to systole of the auricle.

ventricle is taking a larger and larger share in the production of the apex beat. Figs. 18, 19, and 20 are examples of records intermediate between the positive and negative types of cardiogram.

It is important to remember that an inverted cardiogram is of significance only when it is obtained from the "lowest and outermost" portion of the heart's impulse, for it then signifies that the right ventricle forms the apex of the heart. With a strong

apex beat due to the left ventricle such records as Fig. 21 can always be obtained. In this tracing both a positive and a negative cardiogram are shown from the same heart. One receiver was placed over the apex beat in the sixth space, the other in the fifth space within the nipple line.

It must not be forgotten also that the apex beat

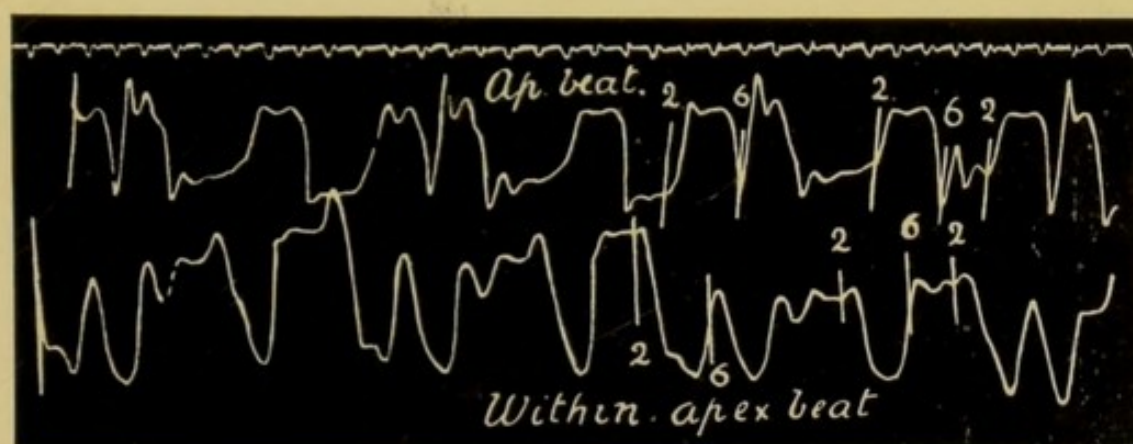


FIG. 21.—The upper record, a positive cardiogram, was obtained from the apex beat of a young man whose heart was very much enlarged. The lower, a negative cardiogram, from the praecordium well within the apex beat. At the upstroke 2 ventricular systole begins, at 6 the tricuspid and mitral valves open.

may change from an inverted to the normal type in patients with a large heart and a bulky lung, in whom the left ventricle is hidden by the lung and the right ventricle only is engaged in producing the apex beat; after a time the pressure of the enlarged heart pushes back the lung, and the left ventricle comes into relation with the chest wall, and a positive apex beat is felt far out.

54 GRAPHIC METHODS IN HEART DISEASE

From the records given above it is obvious that the cardiograms vary greatly and that many of them are difficult to analyse. Much has yet to be done before a decided opinion can be given as to the exact meaning of some of these records. In straightforward cases, however, the apex beat may prove of considerable service, as, for example, when it is impossible to obtain any record from a small and feeble radial pulse.

EPIGASTRIC RECORDS

From the epigastrium one can often obtain a tracing showing the movements of the right ventricle, as in

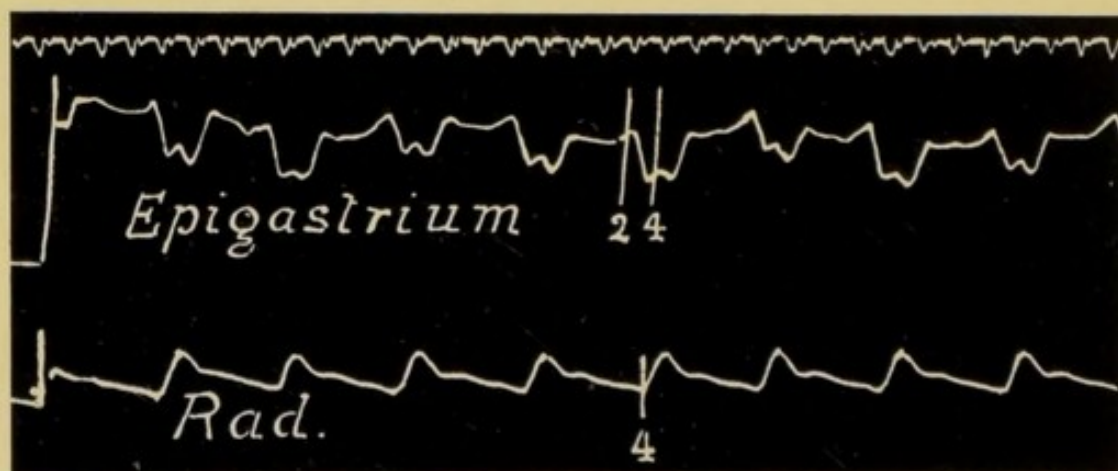


FIG. 22.—Movements of the right ventricle, demonstrated by placing receiver over the epigastrium close to the left costal margin.

Fig. 22. This fact is worth remembering when the apex beat is not sufficiently well marked. In the patient from whom this record was obtained no movement of the lever followed the placing of the receiver over the apex beat or on the epigastrium; but when

he sat upright, the heart came into more definite relationship with the chest wall, the lever moved freely, giving an inverted cardiogram. The receiver was placed in the angle between the left costal margin and the xiphisternum; when placed over the site of the apex beat, even when the patient was upright, no movement of the lever was obtained.

THE INTERPRETATION OF THE VENOUS PULSE TRACING

The sphygmogram is concerned only with the movements of the left side of the heart, the cardiogram records the mechanical displacement of the heart in relation to the chest wall, and the phlebogram represents the variations in pressure in the veins of the neck. The latter affords information concerning the movements and condition of the right auricle and ventricle. So by taking simultaneous tracings of the venous and arterial pulses, or of the venous pulse and apex beat we obtain facts concerning the working of both the right and left sides of the heart.

Having recorded the phlebogram in the manner already described, the next step is to analyse the tracings, and in order to obtain a clear appreciation of their meaning this must be done most carefully.

The value of the records depends on the accuracy of the information gathered from them and this again depends on the manner of analysis employed. Careful measurement is absolutely essential; this being

so we must first find the fixed points from which to make the necessary measurements.

On page 24 it is advised that either at the beginning or towards the end of the combined record of phlebogram and sphygmogram the carotid and radial pulses should be recorded together. Such a record we have in Fig. 23; here the upper tracing is from the jugular pulse, the lower from the radial. Towards the left the

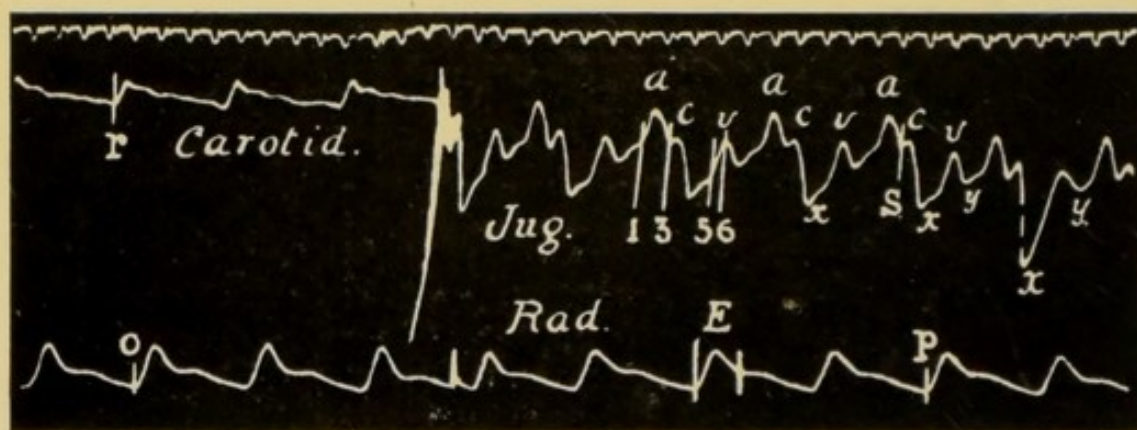


FIG. 23.—Shows tracings of the normal pulsation in the jugular vein. For the first $1\frac{1}{4}$ inches the carotid pulse is recorded, the clockwork was then stopped and the receiver so placed as to transmit the pulsations of the jugular vein.

a, is the auricular wave; *c*, the carotid wave; *v*, the ventricular wave; *x*, the auricular depression; *y*, the ventricular depression; *E*, the sphygmic period. The numbers as in Fig. 13, p. 45.

jugular pulse is replaced by the carotid, the latter having been recorded with the lever used to record the venous pulse. Now take a pair of compasses, and place one point into the tracing just where the beginning of the upstroke of a radial pulse is shown, say at *o*; then measure from this point to the beginning of the upstroke of any other radial pulse, say at *p*. Having obtained this distance place one

point of the compasses on the beginning of the upstroke of that carotid pulse r which was recorded simultaneously with the radial pulse o , and was, therefore, the outcome of the same systole, and measure a distance from r equal to op ; this will give you a point in the venous tracing s where the carotid pulse might be expected to be met with; at any rate you will have indicated the beginning of the sphygmie period. Mark this point on the tracing. As a matter of fact, in this tracing the carotid pulse has affected the lever which was recording the venous pulse, and in addition to the record of the variations in the venous pressure there is the small wave c caused by the impact of the carotid pulse. This is of the greatest value in analysing the phlebogram.

In the absence of the record of the carotid pulse it is still possible to indicate in the phlebogram the beginning of the period E , the position where one would expect to find the small wave c manifesting itself.

Measure from the ordinate of the radial tracing to a point one-tenth of a second in front of any upstroke in this record. The deduction of one-tenth of a second is necessary because the pulsation takes one-tenth of a second to travel from the carotid artery to the wrist. Having obtained this point, measure from the ordinate of the phlebogram a corresponding distance along the tracing, and you will reach the

point at which the sphygmie period begins, in fact where the wave *c* begins.

Having once obtained this point in the phlebogram it is easy to mark out *E* on the tracing. To do this you measure the length of *E* in the radial tracing and then mark off a similar distance from the beginning of *c* in the phlebogram. By this means we divide the phlebogram into two portions: (1) during which the aortic and pulmonary valves are open; (2) that during which they are closed. In Fig. 23 we see that the downstrokes 3 and 5 include within them this sphygmie period. It is questioned by some whether this wave *c* is really due to the pulse in the carotid

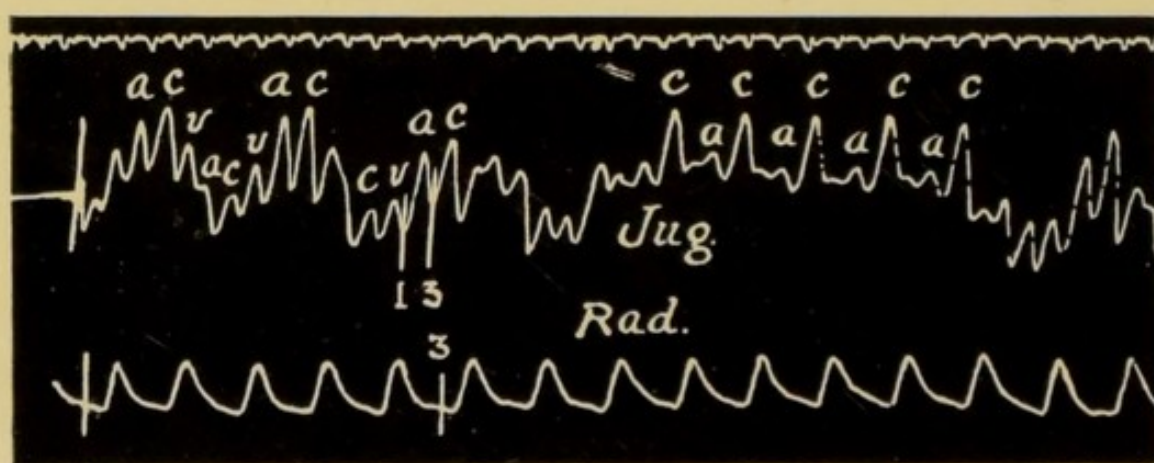


FIG. 24.—Shows variations in the size of the waves *a* and *c*.
a, the auricular wave; *c*, the carotid pulse.

artery. This wave is absent in the venous pulse tracing obtained from the liver, Fig. 26, and in the tracing from the jugular vein when freed from the neck. Also one finds that if greater pressure be applied to the receiver the small wave *c* becomes a typical record

of the carotid pulse, preceded by a small wave *a*. This can be seen in Figs. 14 and 15, p. 48. In Fig. 24 the wave *c* is in some portions of the tracing a strongly marked feature, in others it is no larger than the wave *a*. Again where the function of conductivity is depressed, as in Figs. 88 (p.133), 104, and 105 (p.145) and the wave *a* is more widely separated from the wave *c*, the latter appears synchronously with the carotid pulse.

THE WAVE *a* DUE TO AURICULAR SYSTOLE

On further analysing the tracing we find a wave immediately preceding *c*, indicating that there has been a sudden rise in the pressure in the jugular vein



FIG. 25.—Shows the synchronous appearances in the cardiogram and phlebogram of the wave *a*. This wave begins in each at the downstroke 1. In the apex beat it ceases at the downstroke 2, when ventricular systole begins; in the phlebogram it continues until the appearance of the carotid pulse wave *c* at the downstroke 3.

just antecedent to ventricular systole. It is reasonable to assume that this wave is caused by the systole of the right auricle, whose contraction is synchronous

with the wave *a* in the jugular tracing. In Fig. 13, p. 45, and Fig. 25, p. 59, the downstroke 1 in both the cardiogram and the phlebogram falls exactly at the beginning of the two waves labelled *a*. In fact, there is nothing else which satisfactorily accounts for the sudden rise in the jugular pressure. We are justified, therefore, in considering this wave as the result of the systole of the auricle, and in all the tracings it is labelled *a*. In all probability it is due chiefly to the stronger filling of the jugular vein during auricular systole, for then, in the normal heart, the venous orifices are closed, it is less commonly the result of regurgitation into the veins, and is then usually very large. It may also be very marked when the auricle and ventricle contract simultaneously, and the blood is unable to pass on into the ventricle from the auricle. It is in part due to the sudden impact of blood on to the closed caval orifice, from which a wave is transmitted backwards.

Rarely auricular systole causes a pulsation of the liver. This is admirably shown in Fig. 26, which records the pulsation in the liver of a patient who was probably suffering from tricuspid and mitral stenosis.

The jugular pulse was of the auricular type; there was a wave *a* preceding the small wave *c*. In such a patient it is more than probable that the right auricle actually expelled blood through the inferior vena cava into the liver with every systole.

After recording the wave *a* the lever falls, and the

negative phase *x* is recorded, Figs. 23 and 28. The temporary break in the descent of the lever is due to the impact of the carotid pulse.

If one measures the distance from the beginning of the wave *a* to the beginning of the wave *c*, it will be found to be one-fifth of a second. This interval is almost constant in normally acting hearts. In

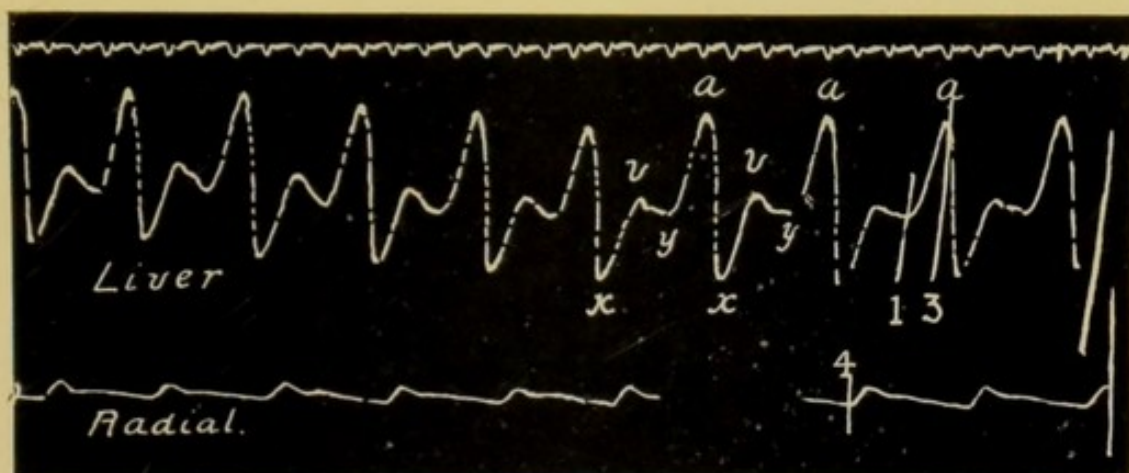


FIG. 26.—Tracing from the liver, shows a large wave *a* immediately preceding ventricular systole and caused by the systole of the right auricle. The wave *a* is followed by the negative phase *x* which is again followed by the wave *v*. The wave *v* is separated from the wave *a* by the second negative phase *y*. Note the entire absence of any wave corresponding to *c*.

x, is the auricular depression; *v*, is the ventricular wave; *y*, is the ventricular depression.

hearts with a high frequency it has been noted that there is a tendency for the *a-c* interval to become shortened. This interval, situated between the downstrokes 1 and 3 represents the time between the beginning of the systole of the auricles and the opening of the aortic valves, and is generally referred to as the *a-c* interval.

x THE FIRST NEGATIVE PHASE

The negative phase *x* represents a sudden diminution in the pressure of the blood in the veins leading to the heart. It occurs during the systole of the ventricles, as is clearly seen in the tracing, Fig. 13, p. 45, and Fig. 23, p. 56. It begins at the highest point of *a*, and in a normal heart persists to the end of the active systole, as indicated by the systolic plateau in the cardiogram.

During this period the tricuspid and mitral valves are closed, and the auricle which was previously contracting, is in diastole and receiving the blood from the veins. Their sudden emptying accounts for the drop in pressure recorded in the phlebogram, and labelled *x*.

The extent to which this factor can be credited with the negative phase *x* can be gauged from Figs. 101, 102, and 103, p. 143, where we see the effect of systoles of the auricle in the absence of ventricular systoles. Another reason advanced in explanation of the negative phase *x* is the following: that with each contraction of the heart there is a distinct movement of the *a-v* septum, Fig. 3, p. 13. With systole of the auricles it is drawn upwards to *A*, while at the beginning of the systole of the ventricles it is drawn suddenly downwards to *B*. As a result of this downward movement of the *a-v* septum at the beginning of ventricular systole, the capacity of the auricles will be definitely augmented

and there will accordingly be an increased flow of blood into the flaccid auricles from the veins of the neck, which become correspondingly emptied.

Yet another factor in the production of x is the diminution of intrathoracic pressure caused by the contraction of the ventricles and the expulsion of their contents. The negative phase x is therefore synchronous with, and largely due to the systole of the ventricles.

THE WAVE v

Towards the end of systole the pressure increases in the jugular veins, and this is recorded in the phlebo-

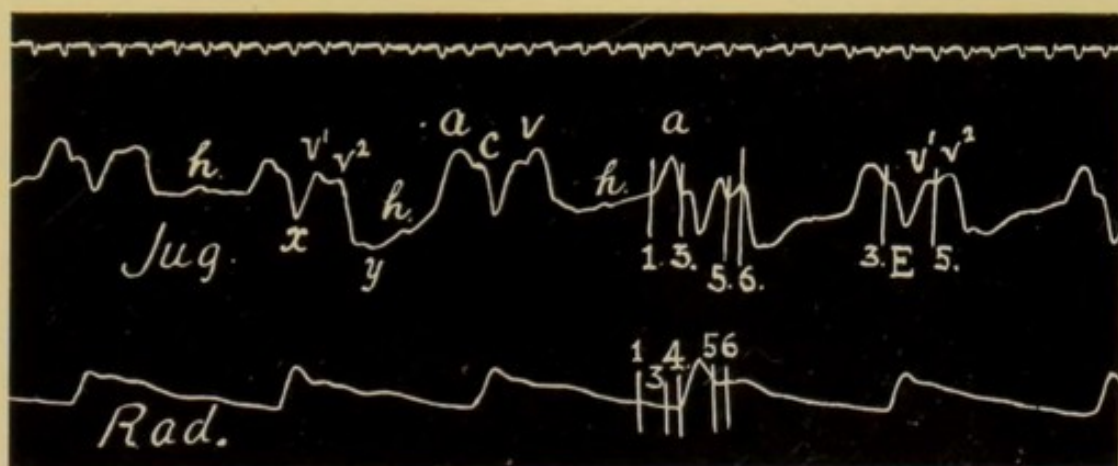


FIG. 27.—Phlebogram from slowly-acting heart. Shows the subdivision of the ventricular wave v into its two component parts v^1 and v^2 . The wave h is also seen in the record.

gram by a rise in the tracing. This wave, which extends beyond the sphygmic period, is named v , and varies greatly in size, sometimes being almost unnoticeable, at others dominating the record and standing alone. It is made up of two portions, v^1 and v^2 . v^1 appears

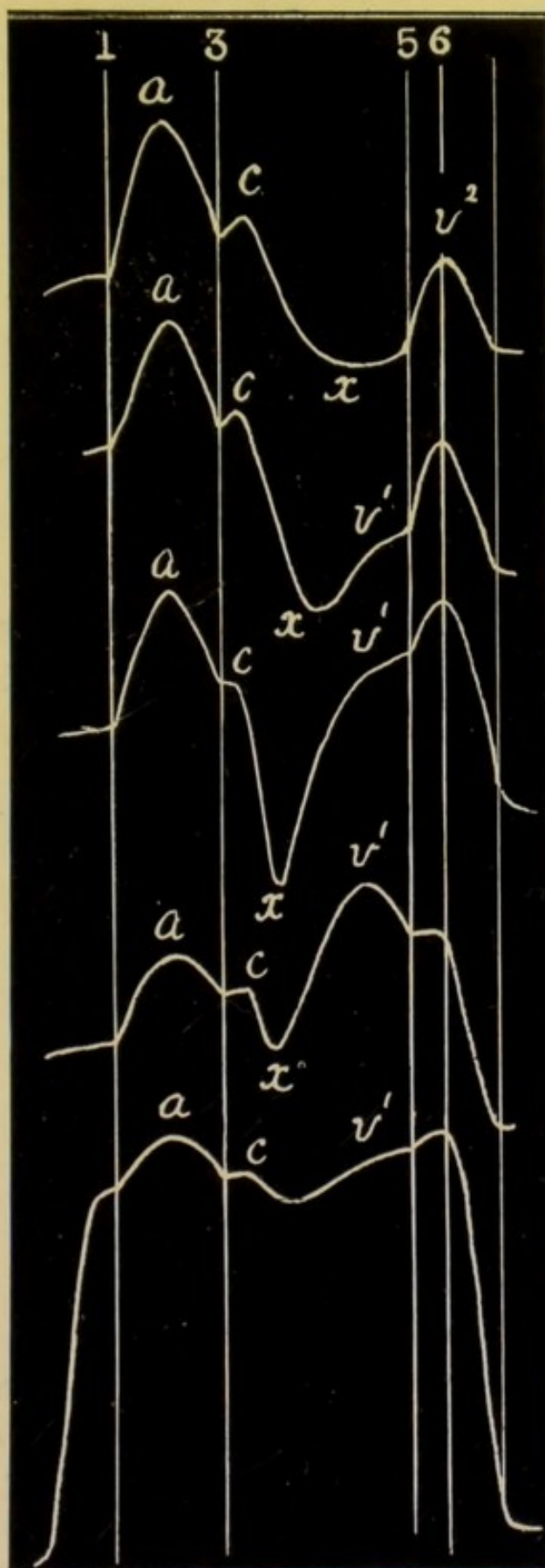
a little before the end of the sphygmic period, and accordingly in the tracing in Fig. 27 is seen antecedent to the downstroke 5; v^2 is the second portion of the wave v ; it begins, as is clear in Fig. 27, with the end of the sphygmic period, and usually rises somewhat abruptly from the gently rising v^1 , Fig. 23. In many cases, therefore, a distinct angle is present at the junction of v^1 and v^2 and this angle coincides with the end of the sphygmic period. Although the size of v^1 and v^2 may and does vary greatly, it is, as a rule, easy to distinguish the notch between them, and an analysis of the phlebogram reveals that its position is a constant one in relation to the cardiac cycle.

The duration of v^2 is usually about one-fifth of a second, and it is important to note that its apex coincides in point of time with the opening of the auriculo-ventricular valves, that is, with the end of systole, indicated in the tracings by the downstroke 6.

The variations in the wave v are marked, both in regard to its duration and to its form. When its duration increases it does so by beginning at an earlier point in the sphygmic period, and therefore at the expense of x , see Fig. 28; but it is never prolonged past the downstroke 6, for it ceases with the beginning of diastole.

Many views are held concerning the factors responsible for the appearance of this wave v . It is very generally accepted that the first portion, v^1 , is the

FIG. 28.—Diagram drawn from actual tracings showing the variations in the records of the auricular type of venous pulse. The upper phlebogram is normal, the lowest shows the marked effect of free tricuspid regurgitation in increasing the engorgement of the right auricle. The lettering and numbering is as in the previous records. Note the gradual increase of the wave *v* at the expense of the auricular depression *x*. The portion *v*¹ of the ventricular wave *v* occurs in the phlebogram before the perpendicular line 5.



result of the accumulation of the blood in the veins after the auricle is filled; no blood can pass on to the ventricles, for they are in systole; it therefore first fills the auricles and then begins to collect in the veins.

This first rise, v is increased by all factors which tend towards the more rapid filling of the right auricle; it is immaterial whether the blood come from the veins or from the right ventricle. High venous pressure with engorged veins causes a rapid filling of the right auricle, and consequently an increase in the amplitude of v^1 at the expense of the phase x . Similarly tricuspid regurgitation must result in a more rapid engorgement of the right auricle, and a correspondingly earlier filling of the jugular veins. We may take it, therefore, that the earlier v^1 begins in the phase x , the greater is the engorgement of the auricle. Increasing tricuspid regurgitation will tend, therefore, to cause the wave v^1 to become more marked and to encroach on the negative phase x .

The second element, v^2 , is not so easily accounted for. It begins simultaneously with the closure of the semilunar valves, and is sometimes a marked and distinct wave when v^1 is hardly appreciable.

The wave v^2 rises between the two downstrokes 5 and 6, and must be the result of causes in operation during this short interval of time, namely, between the closing of the semilunar valves and the opening

of the auriculo-ventricular valves. As possible factors we have then—

1st. The movement of the *a-v* septum. I place this first because I consider that it is probably the most important of the possible factors. During systole, as we have already noted, the septum is drawn towards the apex of the heart, thus increasing the capacity of the auricles. With the relaxation of the ventricular walls which takes place between the closure of the semilunar valves and the opening of the auriculo-ventricular valves, this *a-v* septum swings back to a position of rest and in doing so will diminish the capacity of the auricles, and so cause an alteration of the status of the blood in the veins and a corresponding rise in the phlebogram.

2nd. The alteration of the position of the heart with the cessation of systole. During systole the ventricle is pressed against the chest wall; when systole ceases the heart falls back into the chest, and as the result of this alteration in position there is a sudden and temporary check given to the flow of blood into the right auricle. Indeed, it is not unlikely that, owing to this movement, a little blood may even be squeezed out of the flaccid non-contracting auricle into the veins.

3rd. If there be any tricuspid regurgitation present, this will persist after the closure of the semilunar valves, and be an added factor in the production of v^2 .

Which of these three factors is the most important in the production of v^2 it is impossible to say, indeed the true cause may be one so far not suspected. I simply give these suggestions as the only ones up to now offered in explanation of a wave which is practically always present, and which bears a very definite relation to the terminal events of ventricular systole.

In Fig. 28, p. 65, we have a diagrammatic representation of the gradual disappearance of the negative phase x , and of the increase in the volume of the wave v .

The topmost record is that of a so-called normal phlebogram; in it x is well defined and v is represented by v^2 only. In the second tracing v^1 appears, and in the third and four tracings becomes still more evident. In the lowest v^1 has almost completely taken the place of the negative phase x .

Each record in the diagram was drawn from an actual tracing.

THE SECOND NEGATIVE PHASE y

The negative phase y follows the positive wave v , Fig. 23, p. 56, and Fig. 27, p. 63. It begins when the tricuspid valves open; at this point the tracing suddenly falls, and then slowly ascends to a varying level, at which it remains until the positive wave a appears. This fall y is found to vary greatly in the phlebograms recorded from different patients, and represents the emptying of the veins in the neck associated, in this

instance, with the more free flow of blood into the heart which takes place at the beginning of diastole. The commencement of the fall is coincident with the

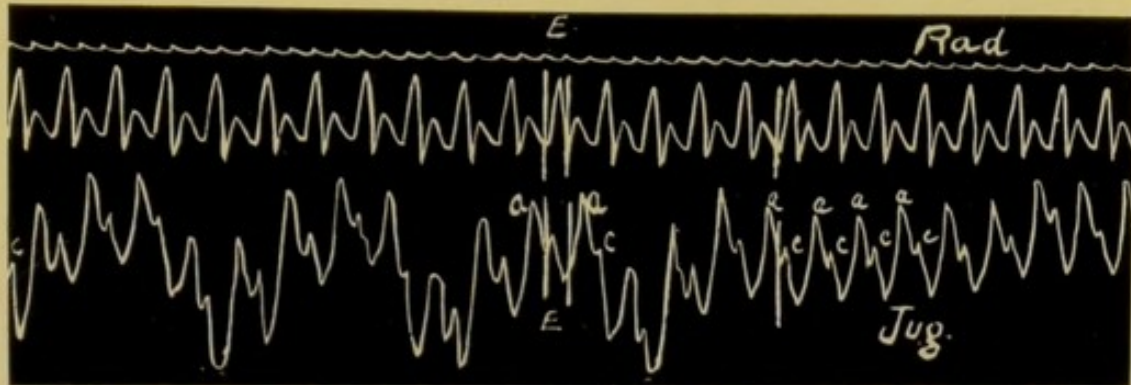


FIG. 29.—Shows the phlebogram in a case of frequently acting heart. The wave *v* has become fused with *a*, the waves *a* and *c* being the only two positive waves in the record.




FIG. 30.—In this phlebogram the wave *v* has become fused with *a* as in Fig. 29. *x*, the auricular depression, is the only negative phase; *E* is the sphygmie period.

opening of the tricuspid valves indicated in the tracing by the downstroke 6.

After the sudden flow of blood into the heart at the commencement of diastole, and the filling of the ventricle and auricles, the veins in the neck begin to

be distended, and accordingly the curve of the tracing rises.

It is clear that *y* is essentially a phenomenon of diastole, and as diastole becomes shortened with an increasing frequency of the heart's action, *y* tends to be less and less distinctly marked. The beginning of the wave *v* accordingly approximates more and more closely to the wave *a*, and in some instances *v* becomes fused therewith, as in Figs. 29 and 30, p. 69. In Fig. 31 the gradual transition of the two waves *v* and *a* to one wave *va* is clearly shown.

When the engorgement of the right side of the heart

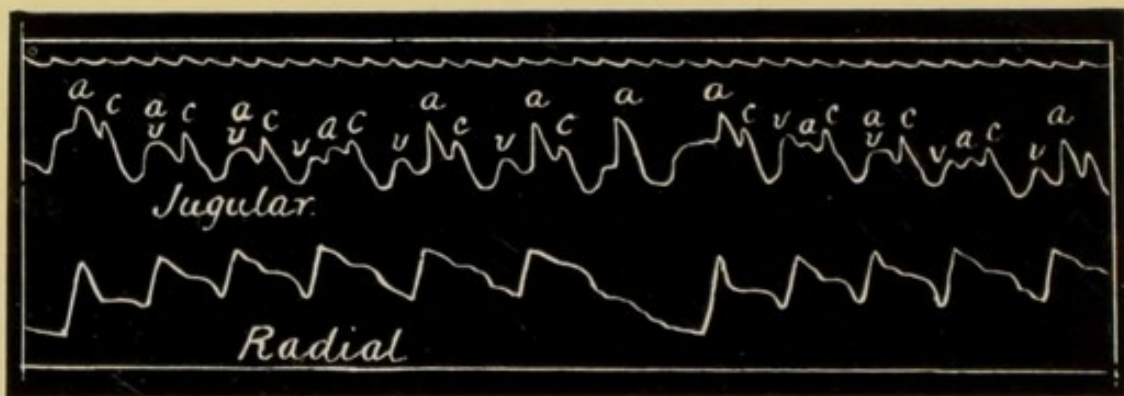


FIG. 31.—Simultaneous record of the jugular and radial pulses. It shows the gradual fusion of the waves *v* and *a*. At the beginning of the tracing *v* and *a* form one wave, *av* preceding *c*, then the two waves *v* and *a* become differentiated.

is pronounced, and the veins of the neck are distended in consequence, we find that the wave *x* has practically disappeared, and the only fall in the tracing is a sharp and sudden one *y* in Fig. 38, p. 76, and Fig. 74, p. 112. It is sudden because of the quick onward rush

of blood into the right ventricle when the tricuspid valves open, and short because the veins are almost immediately filled up again owing to the general engorgement.

Occasionally there is a small rise h in the tracing obtained from a slowly beating heart, Fig. 27, p. 63. This wave h bears a fairly constant relationship to c , and is usually separated from c by an interval of $\cdot 5$ to $\cdot 6$ of a second. This interval may, however, be as long as one second.

Hirschfelder, and Gibson, of Oxford, have both described this wave, and look upon it as due to the floating up and closure of the mitral and tricuspid valves shortly after the beginning of diastole.

In one of the cases recorded by Gibson it was possible to hear a faint, low-pitched, clear sound, synchronous with the appearance with the wave h , that is, during the period of diastole of the heart. This sound was audible over the apex beat and also over the jugular bulb. It was difficult to hear and most audible in the interval between expiration and inspiration.



CHAPTER V

THE AURICULAR TYPE OF VENOUS PULSE

IN the majority of cases a phlebogram can be classed as belonging to one of two types, named respectively the "auricular" and "nodal." The auricular type is that found in ordinary healthy individuals, and also in many cases of functional and organic heart disease. The constant feature in a phlebogram of the auricular type is that the wave *a*, due to the systole of the auricle, is present and begins about a fifth of a second before the wave *c*. This demonstrates that the auricle has contracted before the ventricle, and that the normal sequence of events is sustained. In these cases the stimulus initiating the contraction of the heart arises in some differentiated tissue at the junction of the superior vena cava and the auricle, and the rhythm may with reason be named the sinus rhythm. Figs. 32 and 33, p. 74, are good examples of this rhythm. They also show the effect of holding the breath, on the amplitude of the venous pulse, already referred to on p. 25. Fig. 33 was taken during a period in which the patient held his breath.

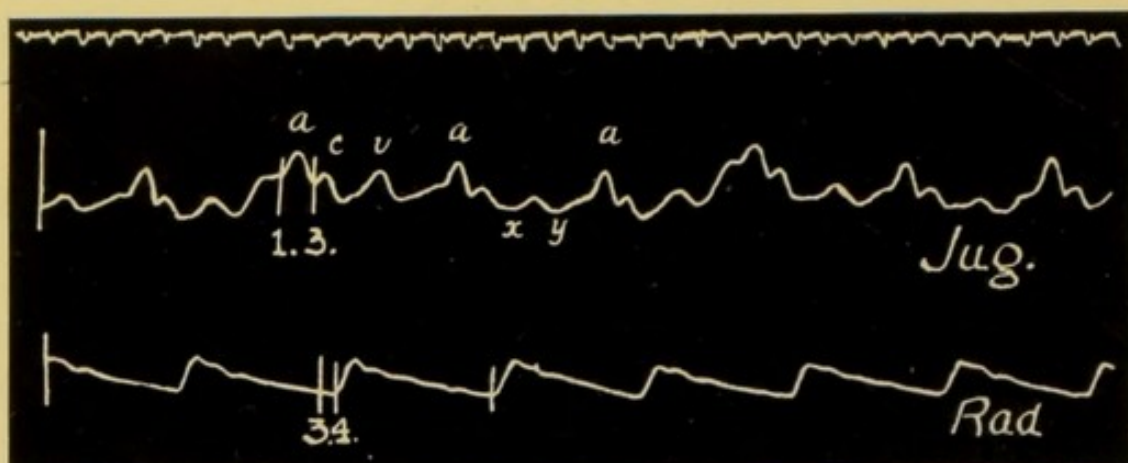


FIG. 32.—The auricular type of venous pulse. *a*, the auricular wave; *c*, the carotid pulse. The *a c* interval is normal in duration, namely one-fifth of a second.

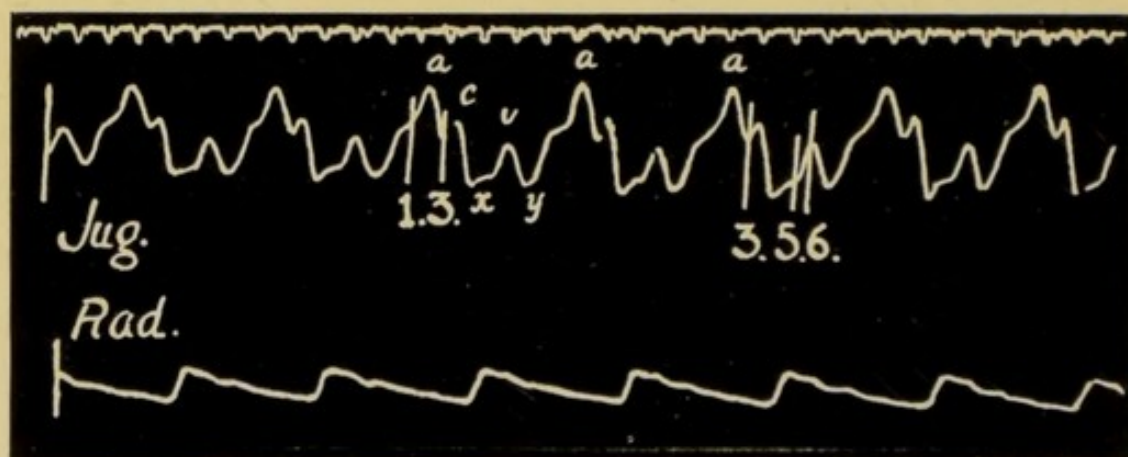


FIG. 33.—Record from the same patient when holding his breath. Note the increased amplitude of the pulsations in the jugular vein.

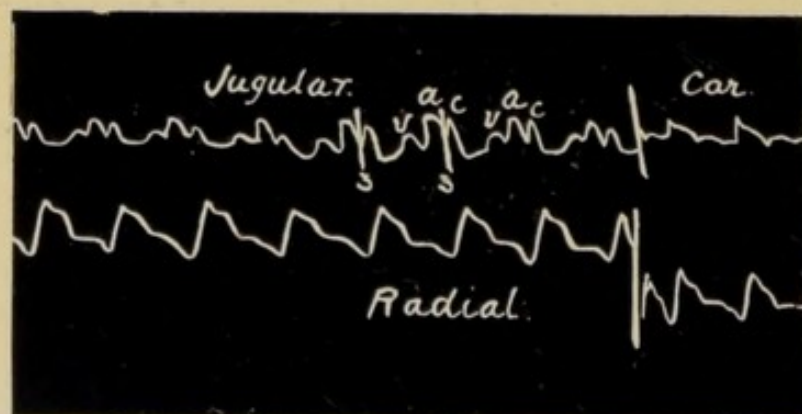


FIG. 34.—Another example of the auricular type of venous pulse.

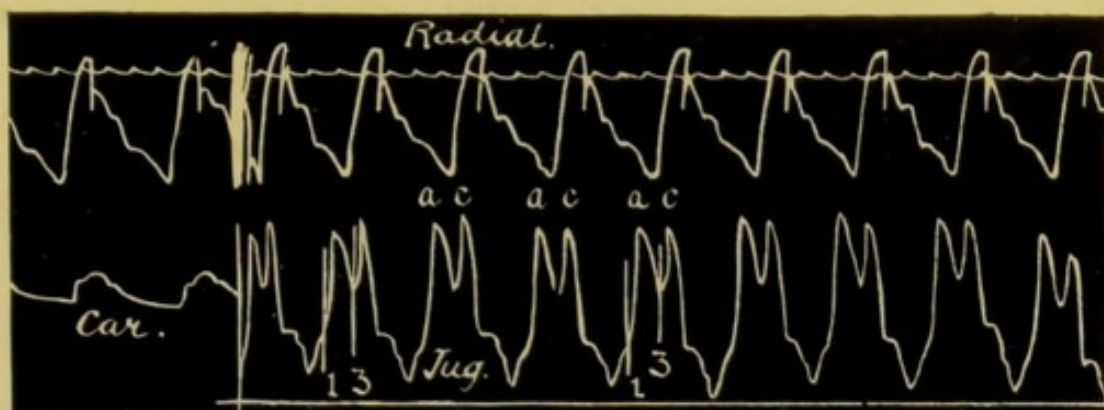


FIG. 35.—Example of the auricular type of venous pulse. The wave *v* is practically absent.

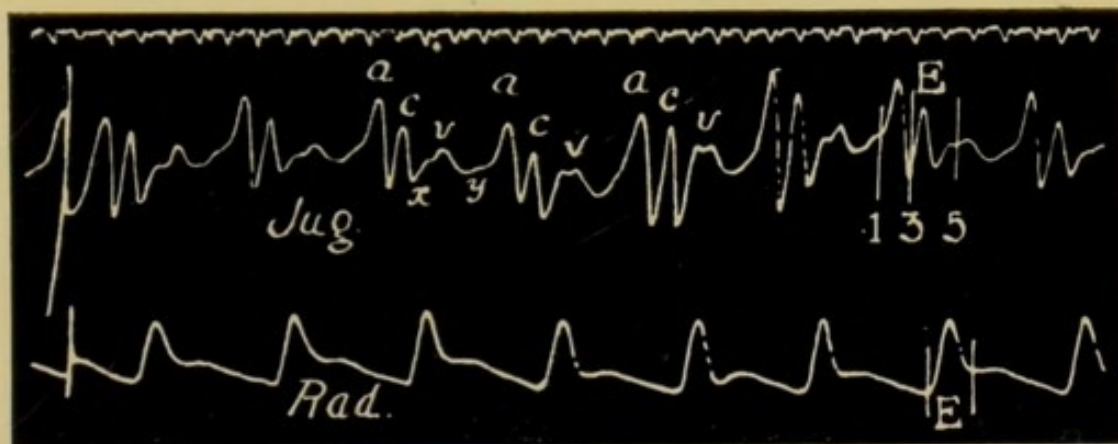


FIG. 36.—Example of the auricular type of venous pulse. Here the waves *a*, *c* and *v* are all well defined.

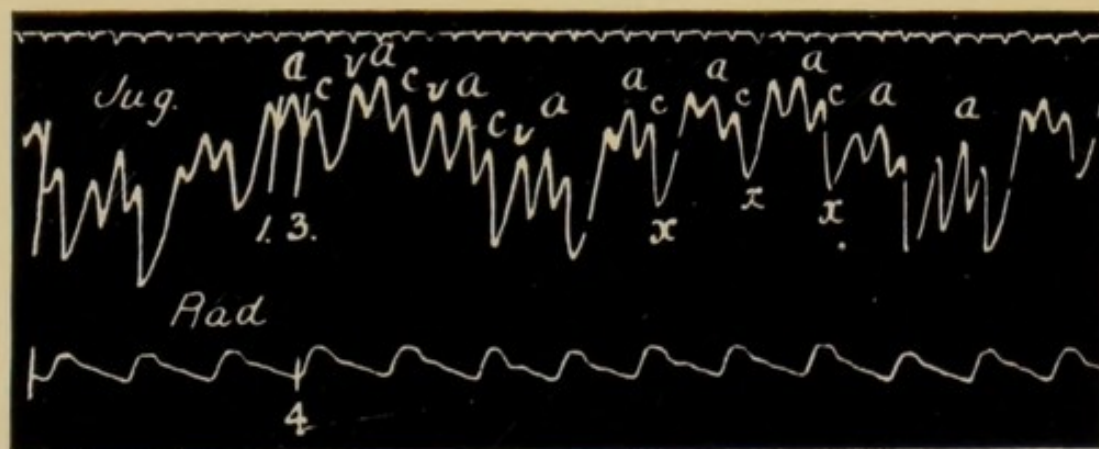


FIG. 37.—Example of the auricular type of venous pulse. Here the waves *a*, *c* and *v* are in evidence.

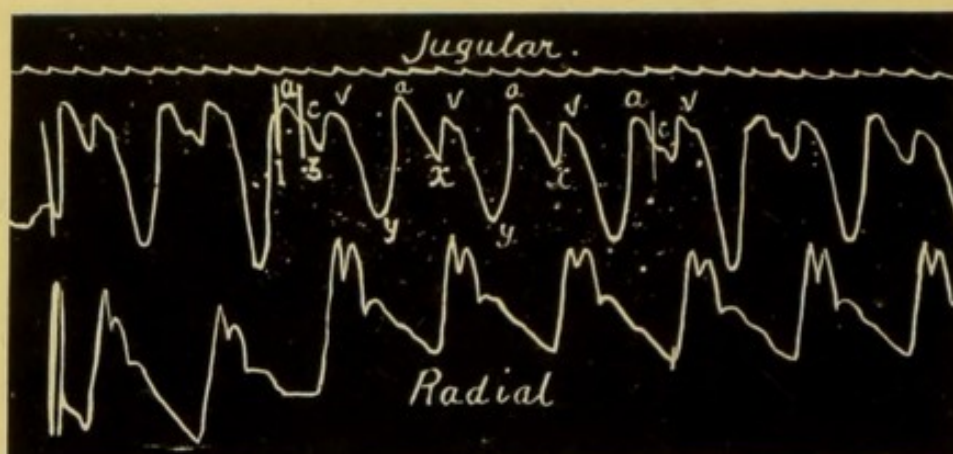


FIG. 38.—An example of the auricular type of venous pulse. The wave *c* is only slightly marked. The ventricular depression *y* is very noticeable. In this patient there was considerable engorgement of the right heart.

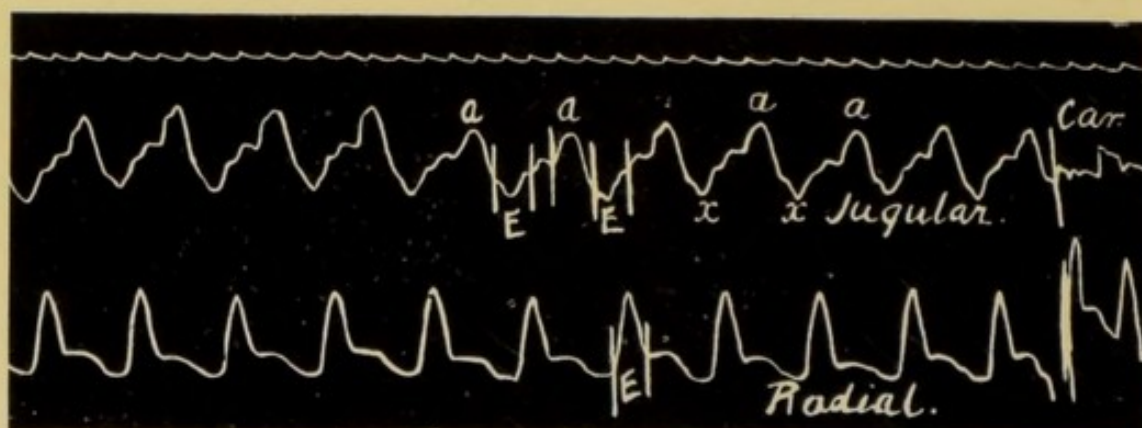


FIG. 39.—A tracing, very different in appearance from Figs. 38 and 35, but still an example of the auricular type of venous pulse.

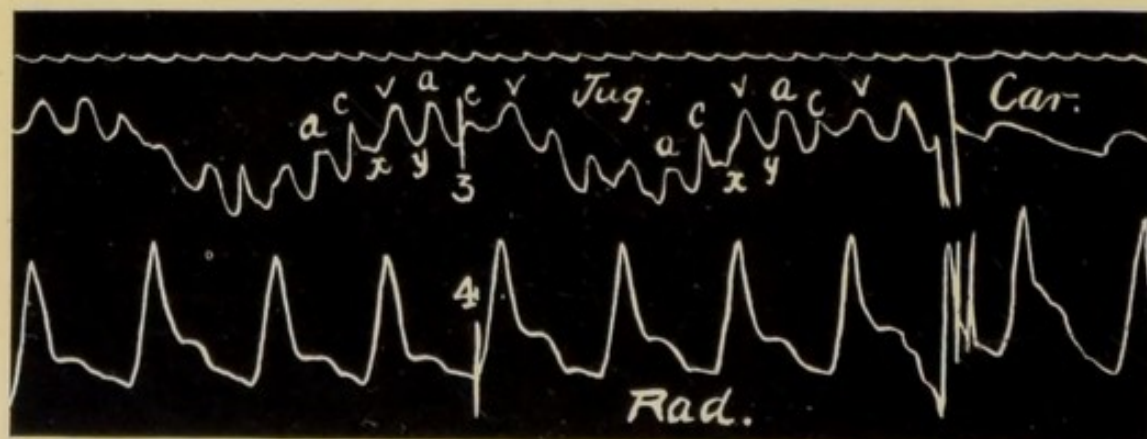


FIG. 40.—Another example of the auricular type of venous pulse.

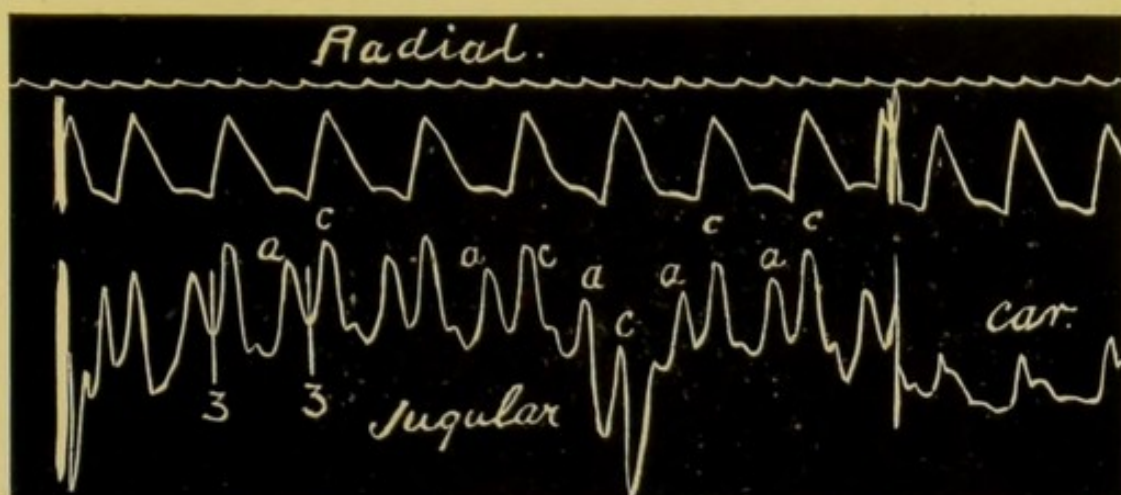


FIG. 41.—Another example of the auricular type of venous pulse. The waves *a* and *c* both well marked.

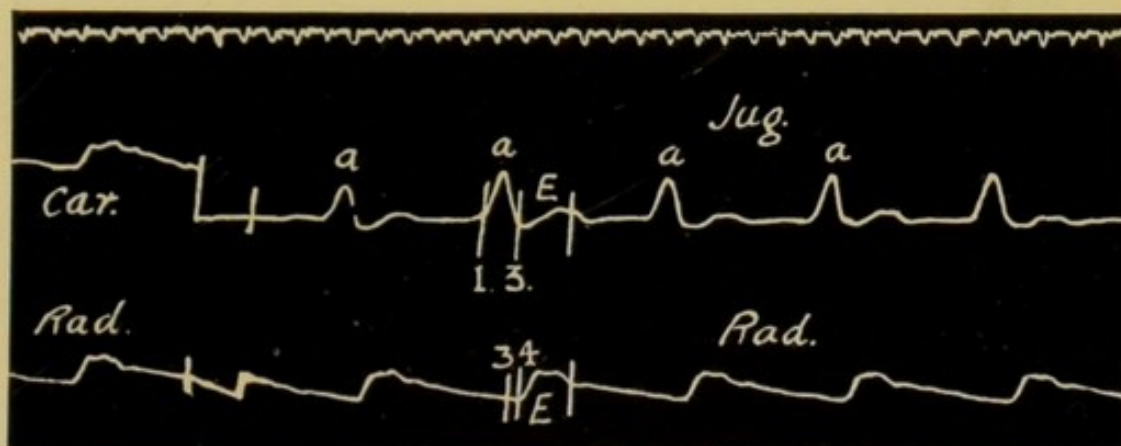


FIG. 42.—This phlebogram of the auricular type shows no wave *c* only the large rise caused by the systole of the auricle followed by an indefinite wave *v*. The *a-c* interval, 1 to 3, is somewhat prolonged.

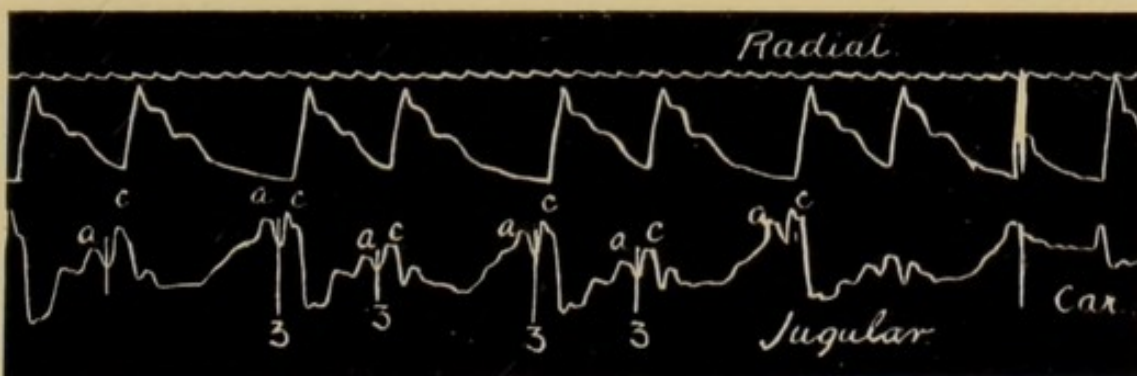


FIG. 43.—An arrhythmia due to irregularity in the origin of the stimulus in the sinus. The phlebogram is auricular in type.

78 GRAPHIC METHODS IN HEART DISEASE

It will be found on analysing a number of phlebograms that many which appear at first sight to be entirely different from each other must be classed in this group. For example, we find in both Fig. 34 and Fig. 35, which are markedly dissimilar, that the wave *a* precedes the sphygmie period *E* by one-fifth of a second. The following examples further bear this out: Figs. 36 to 41. Certain inferences can be drawn from these variations, but the important

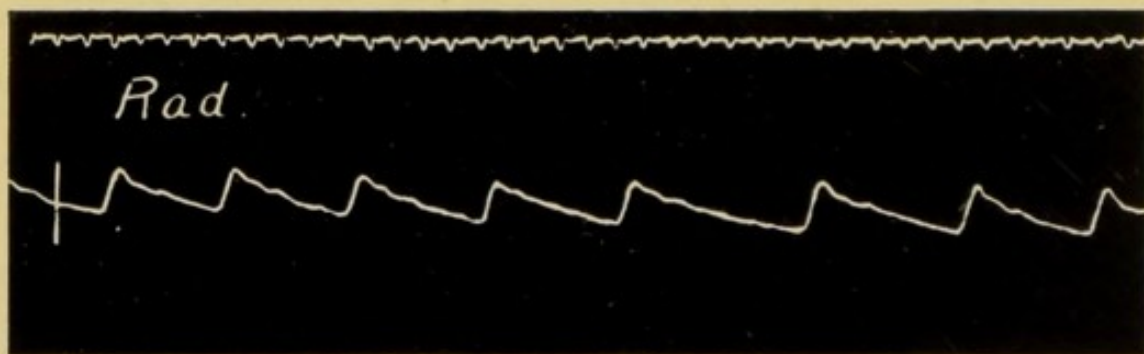


FIG. 44.—The radial tracing from a patient showing a sinus arrhythmia.

point is, that the normal sequence of the waves *a* and *c* is present in them all: each phlebogram is auricular in type. Occasionally the tracing of the jugular pulse shows no wave representing the carotid pulse, as in Fig. 42, where the only marked wave is due to the systole of the auricle.

In every patient suffering from heart disease it is important to know whether this rhythm is present or not, for the prognosis and the treatment depend on such knowledge. It is obvious that in patients

AURICULAR TYPE OF VENOUS PULSE 79

with a venous pulse of the auricular type irregularity in the production of the stimuli at the sinus will cause a corresponding irregularity in the heart's action.

The arrhythmias of childhood are largely of this nature.

Occasionally similar tracings are obtained from adults, Figs. 43 and 44.



CHAPTER VI

THE EXTRA-SYSTOLE

IN this chapter I shall describe in some detail the most common cause of cardiac arrhythmia, namely, the extra-systole, for a thorough comprehension of this variation from the normal will greatly facilitate the description of the other types of venous pulse and cardiac arrhythmia. "An extra-systole is a premature contraction of an auricle or ventricle, or of both, while the fundamental rhythm is maintained at the sinus."

Not unfrequently patients suffering from this form of arrhythmia are quite unaware of its existence, and this is more often found to be the case where the condition tends to be persistent: on the contrary, however, transient sensations of giddiness, a fluttering at the heart or a feeling as if the heart had stopped or rolled over, may be experienced and cause considerable anxiety to the patient. It is also not uncommon to find that associated with the occurrence of an extra-systole the patient is conscious of a thud in the region of the heart.

In a person suffering from the occurrence of extra-systoles, the normal rhythm of the heart is interrupted either occasionally or frequently by a premature beat, which appears in response to a stimulus irregular in its time and in its site of origin. As for example in Fig. 45, where x signifies a premature beat.

The two characteristic features of an extra-systole are—

- (1) Its premature appearance, and

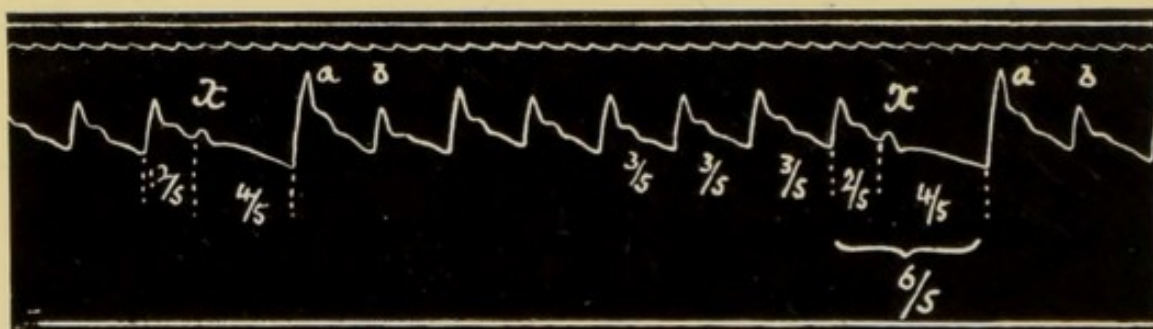


FIG. 45.—Tracing of the radial pulse in a patient suffering from occasional extra-systoles. The extra-systoles occur at x . Note the compensatory pause of four-fifths of a second and the large pulse wave terminating this pause.

- (2) That in most instances it is followed by a prolongation of the diastolic phase.

The earlier it occurs in the diastole the smaller will be the pulse wave sent on into the arteries: this, indeed, may be so insignificant that the extra-systole is not represented by any pulse wave at the wrist, and thus we have the most common form of the "intermittent" pulse.

While it is admitted that the irregular stimuli

initiating the extra-systoles may arise in any portion of the heart, the most usual site is in some portion of the remains of the primitive cardiac tube, namely, the node, the *a-v* bundle, and its many ramifications.

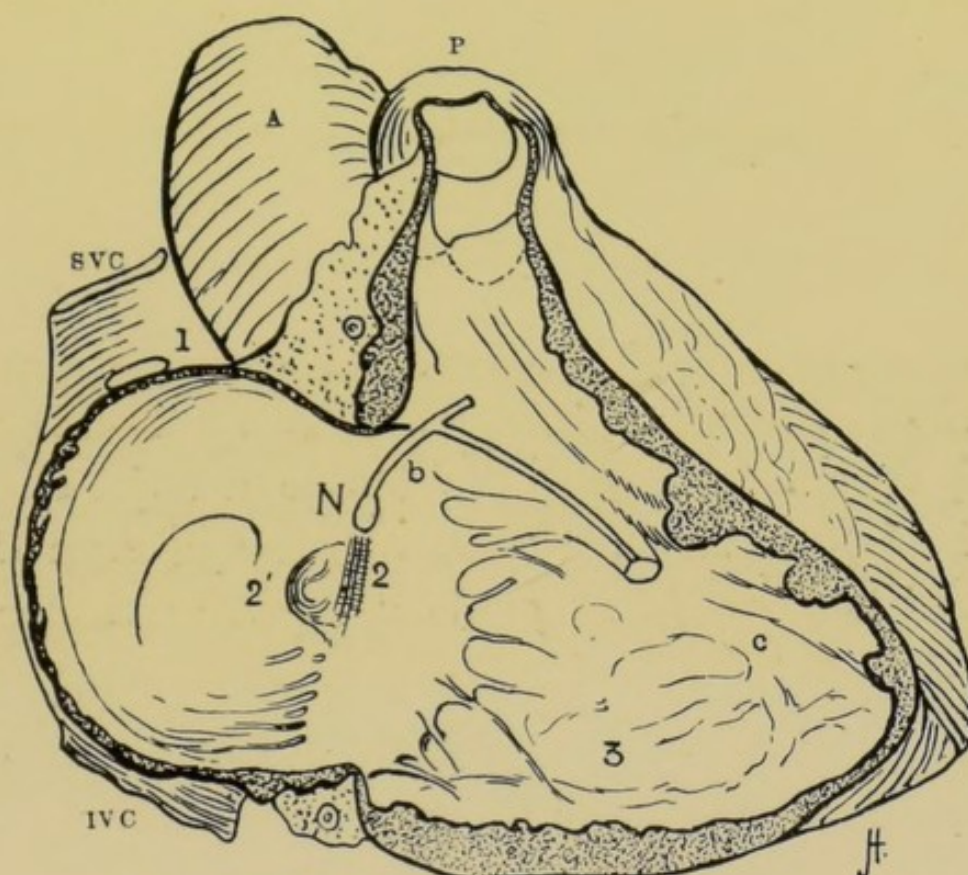


FIG. 46.—Diagram illustrating sites of origin of extra-systoles.

A, the aorta; *P*, the Pulmonary artery; *S.V.C.*, the superior vena cava; *I.V.C.*, the inferior vena cava; *N*, placed above the orifice of the coronary sinus indicates the auriculo-ventricular *node* or *Knoten* from which the *a-v* bundle *b*, arises. 1, the collection of primitive cardiac tissue, the sino-auricular node in which the stimulus usually arises; 2, diagrammatic representation of some of the circular fibres of the auricle terminating in the node; 3, the ventricular muscle fibres.

In addition they may arise in the musculature of the auricle. The site of origin of these stimuli can be determined, with some probability, by a careful analysis of the phlebogram, which varies according to the particular variety of extra-systole present.

Fig. 46 is a diagram constructed to illustrate the possible sites of origin of abnormal stimuli responsible for extra-systoles.

To all intents and purposes the normal physiological stimuli originate at the junction of the superior vena cava and the right auricle, 1 in Fig. 46. A stimulus arising in any other part of the heart or heart muscle may, if strong enough, give rise to a contraction of either the auricle or ventricle, or both, and thus cause cardiac arrhythmia.

For example if the abnormal stimulus originates in the fibres of the auricle as at 2 or at the opening of the coronary sinus 2¹, the auricle contracts prematurely, and its systole is followed by that of the ventricle, which is also premature. Such an extra-systole is recorded in Fig. 56, p. 94, and is termed an auricular extra-systole. It will be considered later. Again, there is reason to believe that abnormal stimuli originate in the node *N* and spread up into the auricle and down into the ventricle, or in the infra-nodal portion *b* of the *a-v* bundle. This is easily understood on referring to the diagram, and it is obvious that the time relationship of the systole of the auricle to that of the ventricle depends in some degree on the site of the stimulus; for example, when the stimulus arises towards the terminations of the Purkinje fibres, as at *c*, or when it arises in the ventricular musculature at 3, the ventricular systole will either precede or




FIG. 47.—In this record an extra-systole, originating in the ventricle, has occurred before the time for the normal systole of the auricle a^1 . Note that in this case there is no ventricular systole resulting from the auricular systole a^1 , the $a-v$ bundle apparently refused to conduct the stimulus. Note absence of the wave v immediately after the extra-systole. The downstrokes in the upper space As of the diagram indicate auricular waves a in the jugular pulse, the downstrokes in the lower space vs indicate the carotid waves c in the jugular tracing, the slanting lines connecting them give the $a-c$ interval. At x note the long compensatory pause.

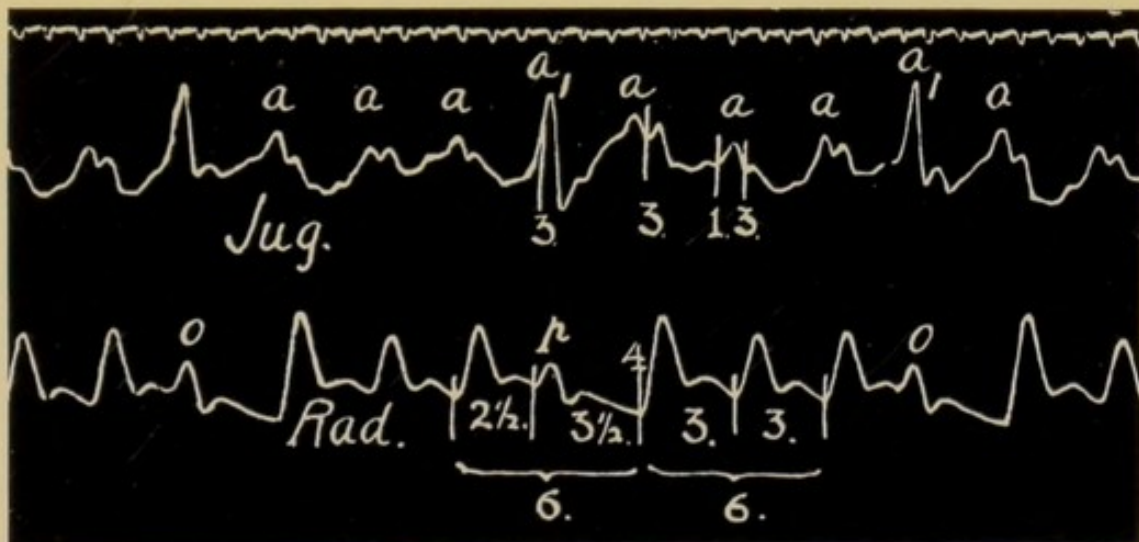


FIG. 48.—Simultaneous record of radial and jugular pulses. Three extra-systoles are recorded at o , p and o in the radial tracing. The rhythm of the auricle is regular but the ventricle contracts prematurely. The post extra-systolic pause is fully compensatory and lasts three and a half fifths of a second.

a , the auricular wave; a^1 , the auricular wave associated with the extra systole.

coincide with the auricular. In Fig. 47 the former has happened, and we find the small wave *c* preceding the wave *a*¹ caused by the systole of the auricle. I shall consider the varieties of extra-systoles later, and will first deal with records illustrating one of the most common forms of extra-systole, an example of which we have in Fig. 48, p. 85.

The chief points to be noted in this tracing are—

- (1) That at *o* and *p* a small wave appears prematurely in the radial pulse, followed by a prolonged diastole.
- (2) That the radial pulse terminating this lengthened diastole is unusually large.
- (3) That the rhythm of the auricle is not interfered with.
- (4) That the wave in the jugular pulse, occurring simultaneously with the extra-systole of the ventricles, is high and pronounced.

That the ventricle contracted prematurely at *o* and *p* is obvious from the radial sphygmogram. A similar state of affairs is seen in Fig. 50, where simultaneous records of the apex beat and radial pulse are shown, and in Fig. 51, where the carotid artery is recorded with the apex beat. The diagram, Fig. 49, constructed from the venous pulse in Fig. 48, makes the sequence of events clearer. The upright strokes in the upper compartment, *As*, represent the systoles of the auricle; those in the lower, *Vs* the systoles of

the ventricle; the slanting line in the middle compartment the conduction of the stimulus along the *a-v* bundle. From a careful examination of this



FIG. 49.—Diagram representing the events in the latter two-thirds of Fig. 48.

diagram we see at once that the auricle has continued to beat with perfect regularity: the rhythmical systole of the auricle is also obvious at a glance in the venous pulse tracing in Fig. 48 and Fig. 52, where

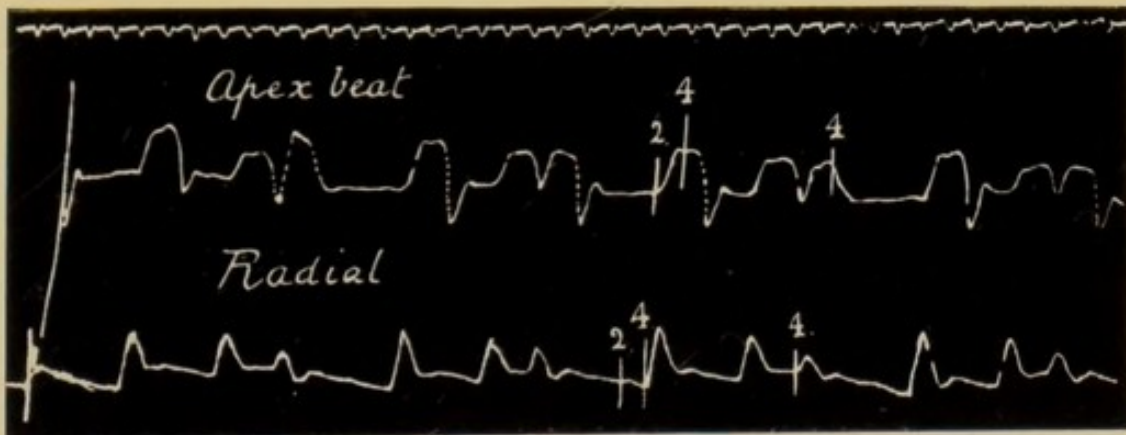


FIG. 50.—Simultaneous record of apex beat and radial pulse showing numerous extra-systoles. The ventricle contracts prematurely every third beat.

we have simultaneous tracings of the jugular pulse and the apex beat.

The explanation of the arrhythmia present in the radial sphygmogram is as follows: The ventricular muscle has contracted prematurely in reponse to a

stimulus originating in the infra-nodal fibres of the $a-v$ system, therefore, when the normal physiological stimulus arrives it finds the ventricles either in a state

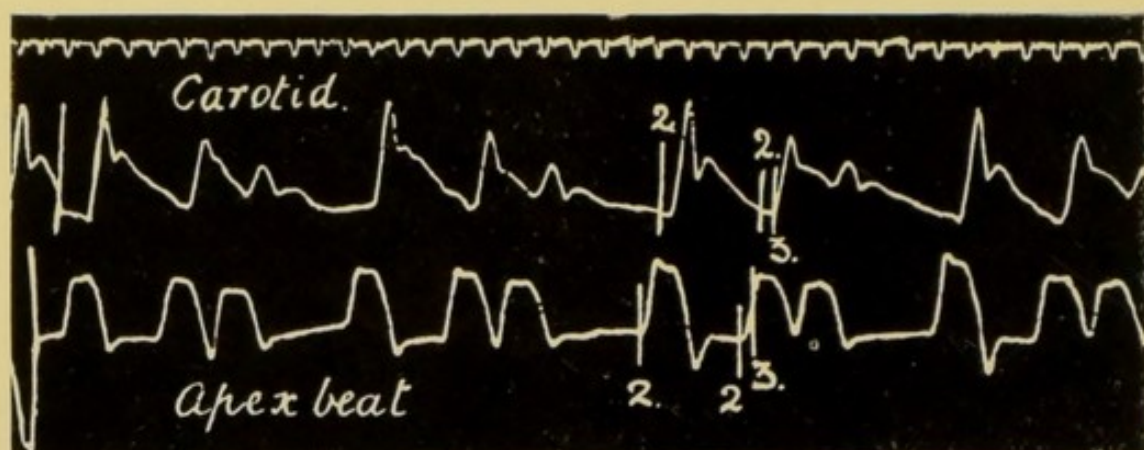


FIG. 51.—Simultaneous record of the carotid pulse and apex beat. It is an example of the "Trigeminal pulse" caused by the premature contraction of the ventricle every third beat. Note the large wave following the compensatory pause.

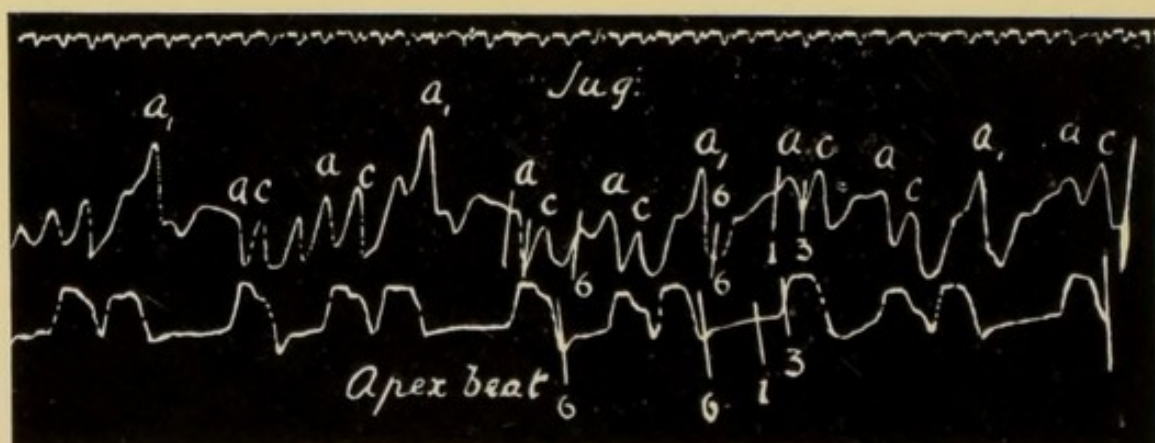


FIG. 52.—Simultaneous record of the jugular pulse and the apex beat. Obtained from the same patient as Figs. 50 and 51. Note large wave a_1 when the ventricle and auricle contract simultaneously. The auricular rhythm is normal.

of active contraction or in the refractory condition which is the necessary sequel to the just completed systole. Before the ventricle can contract again it

must wait until the advent of the next normal stimulus, hence the post extra-systolic delay, or compensatory pause. Note that this prolonged diastole, together with the preceding shortened diastole equal, in time, two normal cardiac cycles: the compensatory pause is therefore in this instance complete. This prolongation of the resting time of the heart affords the explanation of the increased amplitude of the radial pulse following on the extra-systole. During the compensatory pause the ventricle has a longer period than usual in which to recover its contractility and also to become well filled with blood; its systole is therefore stronger and more effectual than usual. In addition to these factors it must be remembered that at the termination of a prolonged diastole the blood pressure in the aorta will be correspondingly diminished, and the resistance to the discharge of the ventricular contents lessened, accordingly, more blood is poured with greater force into the aorta, and the amplitude of the radial pulse increased.

The occurrence of the extra-systole in Fig. 48, p. 85, is characterized by the presence of a large and noticeable wave in the phlebogram. On careful measurement we find that this wave begins at that point in the tracing where the wave due to the auricular systole should normally appear. On analysing still further, we see from the radial pulse tracing that the ventricle also is in systole at this time; in other words, the

auricle and ventricle are contracting simultaneously. Under such circumstances the blood in the auricles cannot be discharged into the ventricles, and in consequence there is a sudden and unusual increase in the pressure of the blood in the veins of the neck, represented by the large wave in the phlebogram.

It is not unusual to find that the wave *v* immediately following the extra-systole is much less distinct

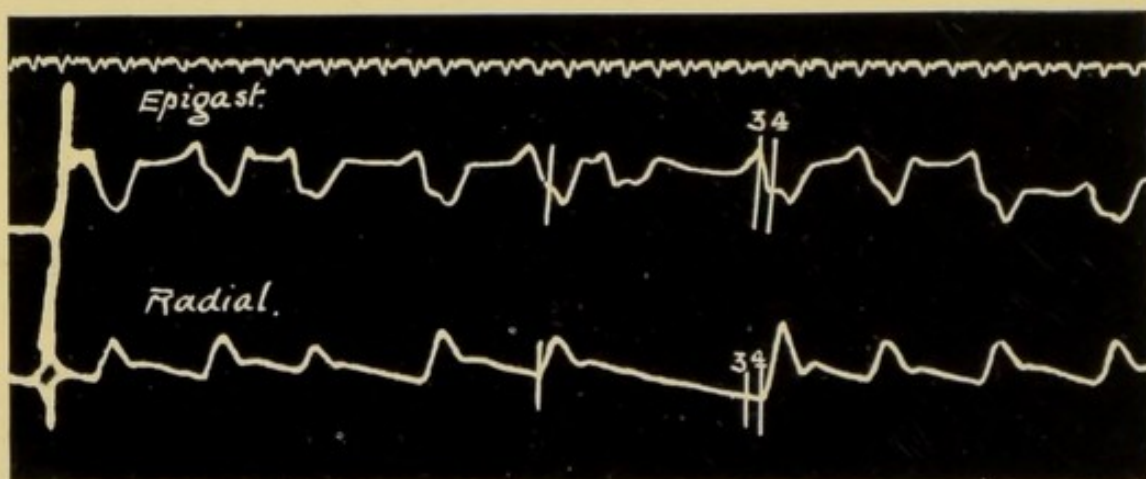


FIG. 53.—Simultaneous records from the epigastrium and the radial artery. Patient was sitting up. Shows the action of the right ventricle in extra systole. With each systole of the right ventricle there is a negative or inverted record.

than usual. In Fig. 47, p. 85, for example this wave *v* is entirely absent whenever an extra-systole occurs. In the type of extra-systole which we have described in some detail, Figs. 48, 50, 51, and 52, the ventricle contracts either at the same time as or in advance of the auricle, and the latter contracts independently of the irregular stimuli to which the ventricle responds: it maintains its normal rhythm and contracts in

response to the physiological stimuli arising at the sino-auricular junction. In Fig. 53 the inverted upper tracing obtained from the epigastrium demonstrates the presence of an extra-systole of the ventricle when there was no evidence of it in the radial pulse. No cardiogram could be obtained from this patient, accordingly the receiver was placed on the epigastrium with successful results.

Abnormal stimuli, causing extra-systoles, may originate—

- (1) In the muscle fibres of the auricles.
 - (2) In the α -v node itself
 - (3) In the α -v bundle below the node
- } in the primitive
cardiac tube.
- (4) Possibly in the muscle fibres of the ventricle.

Clinically, these extra-systoles may be classed as auricular, nodal, and infra-nodal or ventricular, and I propose now to describe them under the above headings.

It is a noteworthy fact that all varieties of extra-systoles are sometimes found occurring in the same patient, and possibly within a few seconds of each other. This strongly suggests that there is a common basis for the three varieties.

(1) AURICULAR EXTRA-SYSTOLES

In these cases the stimulus exciting the extra-systole originates in the muscle fibres of the auricle,

and initiates a contraction before the time for the auricle to respond to its normal stimulus. The auricle is therefore fired off prematurely, and is in turn followed by a premature ventricular systole.

In the tracing from the jugular vein, Figs. 54, 55, the normal systoles of the auricle are indicated by a . In Fig. 54 a^1 indicates the premature contraction of the auricle, and is followed by c^1 the carotid pulse wave. In Fig. 55 there are three extra-systoles

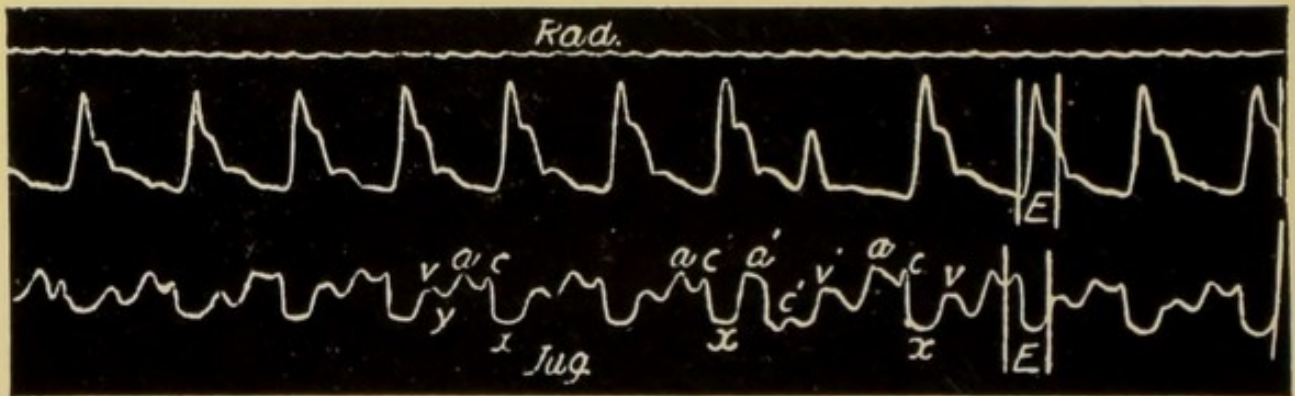


FIG. 54.—Shows an extra-systole of auricular origin at a^1 . This tracing is interpreted in the diagram Fig. 58. (Mackenzie.)

at A , B and C ; at C the extra-systole is auricular, and the $a^1 c^1$ interval is slightly longer than normal. This a^1-c^1 interval is lengthened because the $a-v$ bundle has been called upon to conduct the stimulus from the auricle to the ventricle, before it had completely recovered from the passage of the preceding stimulus. Rarely the stimulus is blocked and no ventricular systole results, because of the depressed conductivity. In these tracings there is a full compensatory pause. Frequently, however, there is no compensatory pause

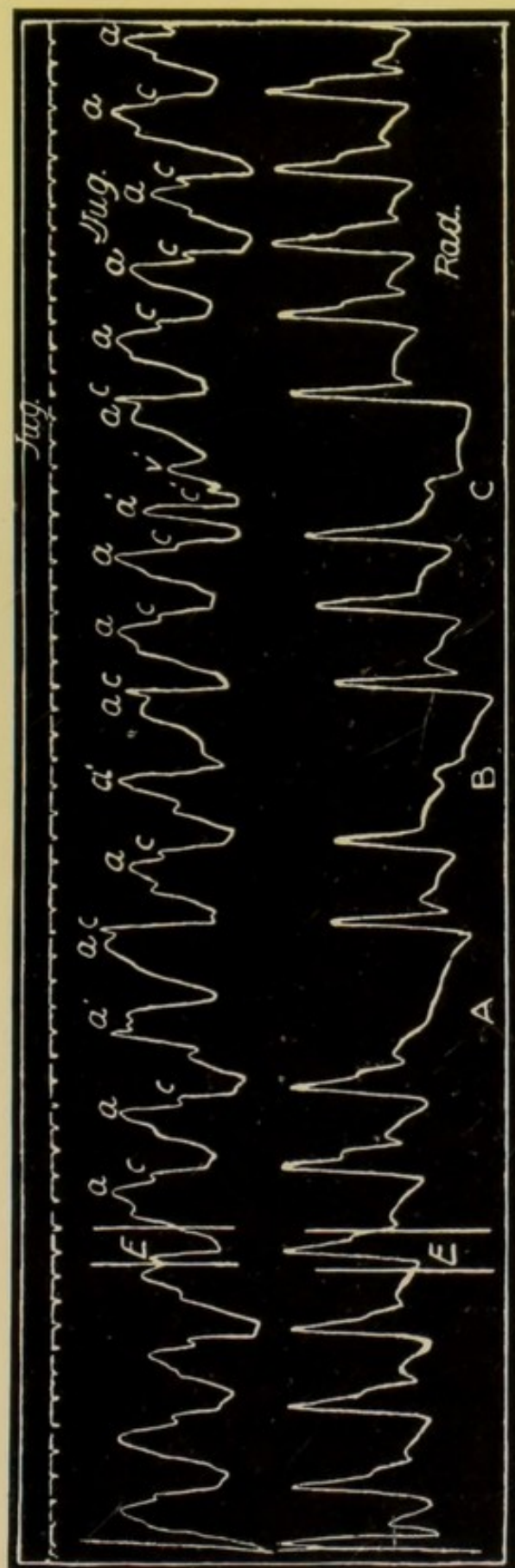


FIG. 55.—Shows three irregular periods due to extra-systoles: an auricular extra-systole at C, a ventricular extra-systole during B, and a nodal extra-systole at A. (Mackenzie.)

after an auricular extra-systole, the distance from a^1 to the following a being equal to the distance between any a and the a following, Figs. 56 and 57.

In the first examples, Figs. 54, 55, the auricular extra-systole has not affected the discharge of the normal stimulus at the sinus. This occurred at the usual time, but was unable to initiate a contraction of the auricle, because it found the auricle refractory

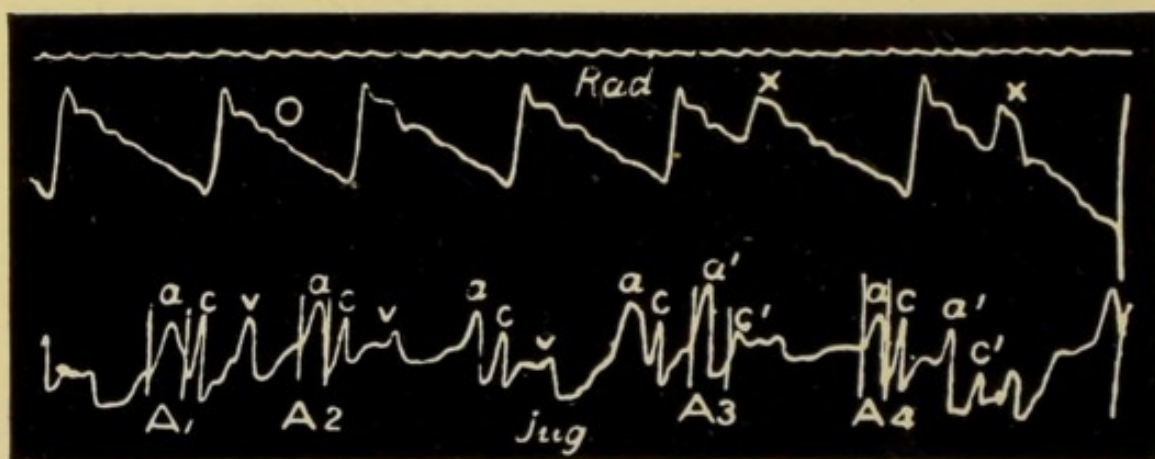


FIG. 56.—Shows two extra-systoles, auricular in origin x . The waves c^1 in the jugular tracing occur at the same time as the small premature beats x in the radial tracing, and are therefore due to the carotid. These are preceded by the premature waves a^1 due to the auricle. The interval a^1-c^1 , space A_3 , is greater than the average $a-c$ interval A_2 and much greater than the following $a-c$ interval A_4 . (Mackenzie.)

from the immediately preceding extra-systole. The auricle therefore remained passive until the discharge of the next physiological stimulus from the sinus, and we therefore find the pause completely compensatory.

In the second tracings, Figs. 56 and 57, the pause following the extra-systole is incompletely compensatory. This is the more common type. The

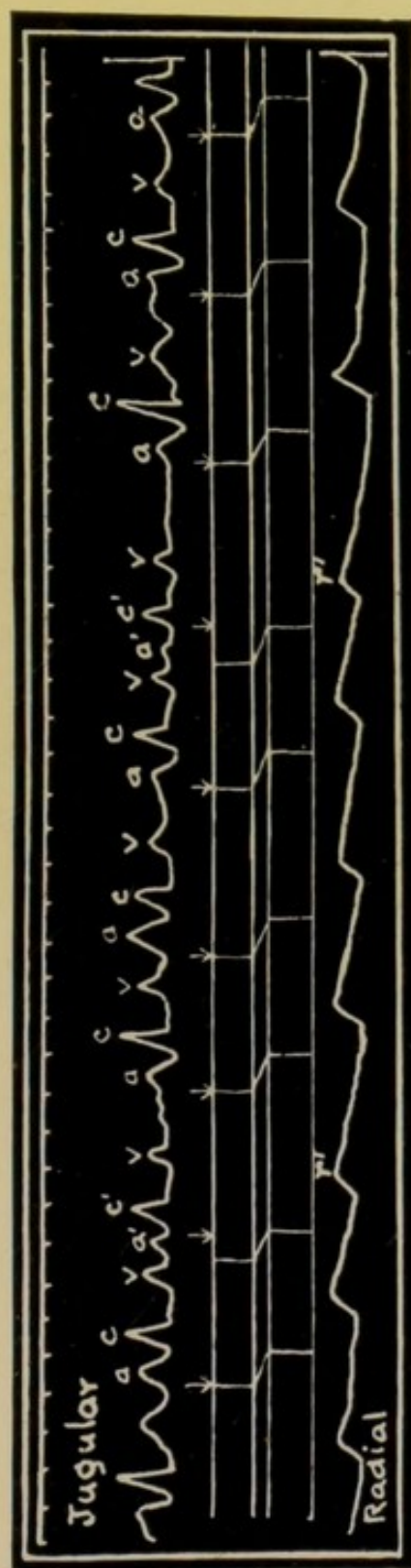


FIG. 57.—Shows auricular extra-systoles a^1 followed by ventricular contractions c^1 , r^1 . The arrows in the diagram represent the sinus stimulation and the long pauses after the extra-systoles are seen to be due to the fact that the auricle did not respond to the sinus stimulation. (Mackenzie.)



FIG. 58.—Diagram representing the events in Fig. 54. The extra stimulation occurred in the auricle at x and passed back to the sinus, disturbing its rhythm. Note the lengthening of the $a-c$ interval after the auricular extra-systole.

stimulus exciting the extra-systole has, in addition, caused a premature discharge of the stimulus matter at the sinus. After a normal period of rest the sinus will again give rise to a physiological stimulus to which the auricle responds.

The diagram intercalated in Fig. 57, and Fig. 58 demonstrate these points.

The points in a tracing by which auricular extra-systole are recognized are—

- (1) The premature appearance of the wave *a* in the jugular pulse.
- (2) The lengthening of the *a-c* interval, when present.
- (3) That in some instances the compensatory pause is incomplete.

(2) VENTRICULAR OR INFRA-NODAL EXTRA-SYSTOLE

In the most common type of extra-systole as described in pp. 86 to 90, the extra-systole is in all probability the result of an abnormal stimulus originating in some portion of the *a-v* bundle below the node, the stimulus occurring at such a time as to cause the ventricle to contract simultaneously with the auricle, the auricular rhythm remaining unaltered.

The extra stimulus may, however, occur so early in diastole as to cause an extra-systole to be interpolated between two ventricular contractions, each of which is the response of the ventricle to the normal

stimulus from the auricle. This has occurred at x in Figs. 59, 60, and 61, and this form of extra-systole is termed "**interpolated.**" The auricular systole a^1 in Fig. 59 is followed by a normal ventricular response, and almost immediately the ventricle contracts again at x , causing the small wave rx in the

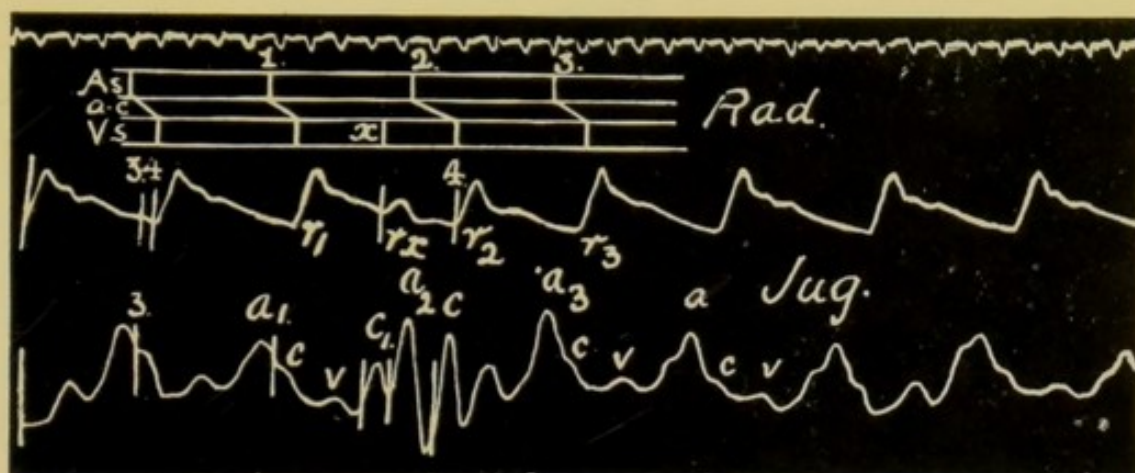


FIG. 59.—Shows an interpolated extra-systole at c_1 and rx . The normal rhythm of the auricle is not interrupted, but between a_1 and a_2 the wave c_1 appears, caused by the extra contraction of the ventricle. Note the lengthening of the $a_2 c$ interval following the extra-systole. The diagram represents the events in the jugular tracing. At x the extra-systole occurred, originating in the ventricle, influencing the $a-v$ bundle, delaying but not preventing the next auricular stimulus from getting through.

radial pulse. The next auricular systoles, a^2 and a^3 , both initiate contractions of the ventricle, with this difference, that the systole following a^2 is delayed in its appearance, the interval a^2-c being longer than normal: the $a-v$ bundle must therefore have been stimulated when the ventricle contracted prematurely at x .

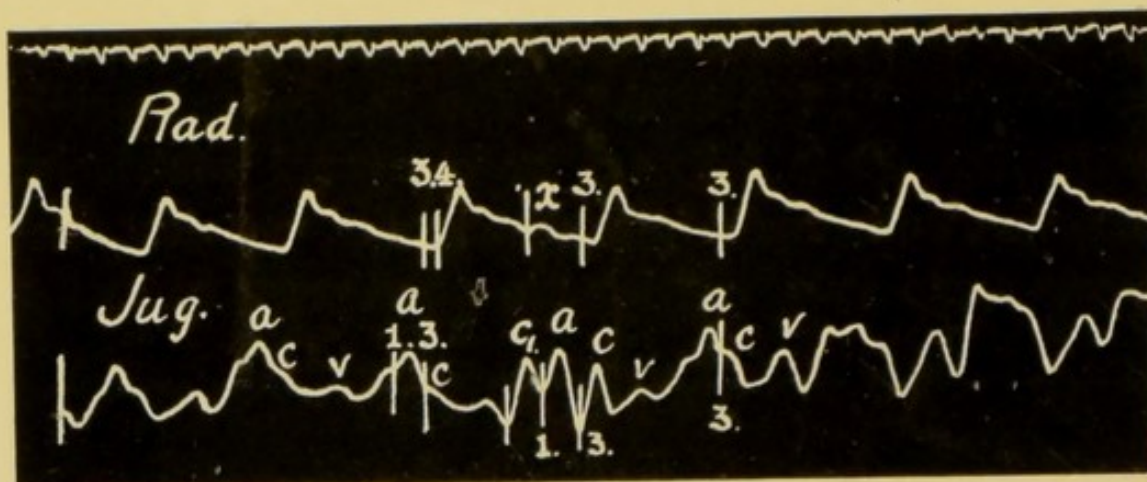


FIG. 60.—Record similar to that in Fig. 59. The interpolated extra-systole occurs at *x* in the radial tracing and *c*₁ in the jugular.

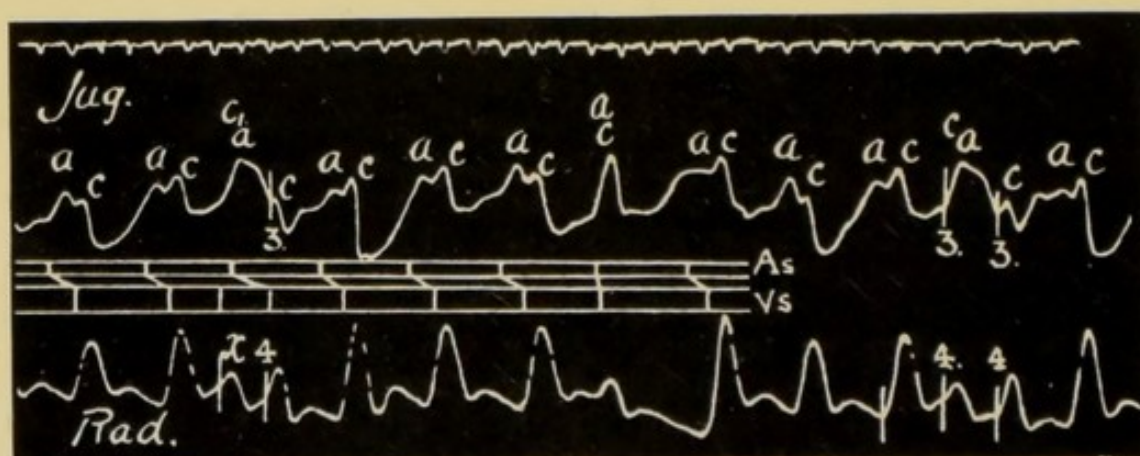


FIG. 61.—Shows two interpolated extra-systoles, one at the beginning, the other towards the end of the tracing. In the middle of the record there is a typical infra-nodal extra-systole. Note (1) the fusion of the wave *c*₁ and *a* in the phlebogram when the interpolated extra-systole occurs. (2) The depression of contractility following the interpolated extra-systole; this is shown by the very small wave in the radial tracing at 4. (3) The recovery of contractility in the compensatory pause after the infra-nodal extra-systole, shown by the large wave immediately following the pause.

The diagram represents an interpolated extra-systole and the infra-nodal extra-systole. The auricular rhythm is uninterrupted.

This interference with the conducting power of the $a-v$ bundle consequent on the interpolated systole may be so marked that the auricular systole immediately following it may fail to reach the ventricle, and accordingly a ventricular systole drops out. This happened at x^1 in Fig. 47, p. 85. Here the auricular systole fails to get through, and the ventricle consequently remains in diastole until the arrival of the next physiological stimulus.

Here the compensatory pause is due not to the refractory condition of the ventricle, following on its systole, but rather to the refractory condition of the $a-v$ bundle and its refusal to transmit the stimulus reaching it from the auricle. Mackenzie suggests that this is perhaps the more correct interpretation of the compensatory pause so frequently found following the appearance of an extra-systole. The fact that the $a-c$ interval following on an interpolated ventricular systole is prolonged, as in Figs. 59, 60, and 61, is of considerable importance, for it proves that the $a-v$ bundle did not escape stimulation, for if the ventricle had been fired off at x independently of the $a-v$ bundle, then there would have been no increase in the duration of the a^2-c interval: its prolongation proves that the bundle was involved.

The characteristics of the ventricular or infra-nodal extra-systole are—

- (1) An unaltered auricular rhythm.

(2) A premature systole of the ventricles either preceding that of the auricle or simultaneous with it.

(3) Complete compensatory pause.

(3) NODAL EXTRA-SYSTOLES

Figs. 62 and 63 are records of a slightly different character to those preceding them. They show a premature contraction of both auricle and ventricle.

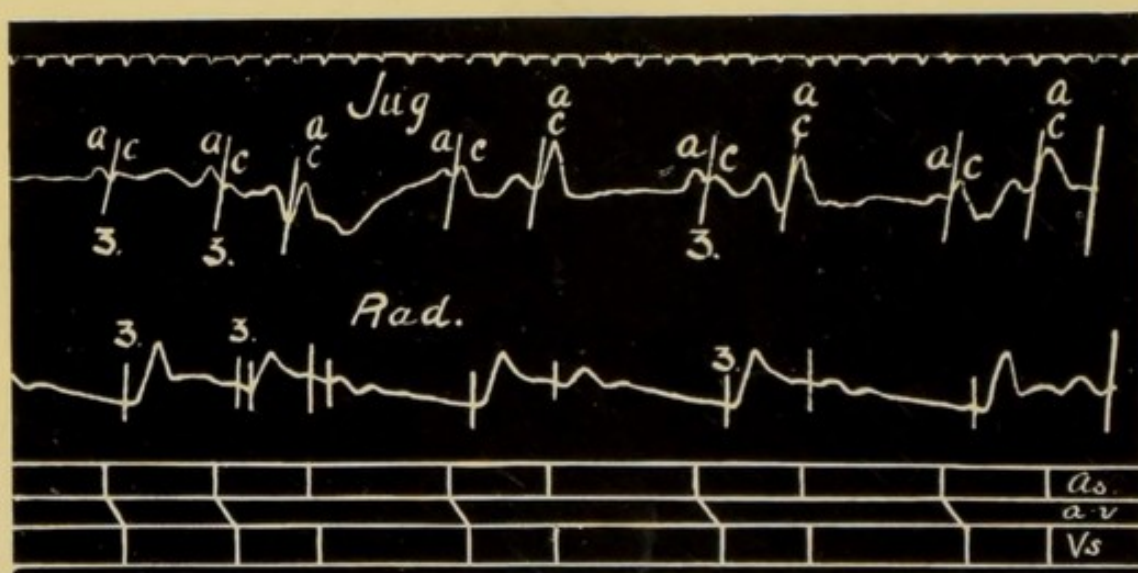


FIG. 62.—Simultaneous records of the jugular and radial pulses. Shows four nodal extra-systoles. The diagram gives the sequence of events as shown in the jugular tracing. Note (1) that both auricle and ventricle contract prematurely; (2) that there is a full compensatory pause; (3) that the wave *v* is greatly diminished after the extra-systoles.

The systole of the auricle occurs in advance of the time at which the normal auricular systole is expected, and the systole of the ventricle is again practically simultaneous with that of the auricle. The carotid pulse must have occurred, as judged by the record of

the radial tracing, a fraction of a second after the wave due to auricular systole: but when allowance is made for the pre-sphygmie delay it is obvious that the ventricle must have passed into systole either synchronously with the auricle or slightly in advance of it. A tracing of a somewhat similar character is seen in Fig. 64. Here again the auricle contracts prematurely at a^1 , but the a^1-c interval A^1 is very much shorter than normal, and when the pre-sphygmie

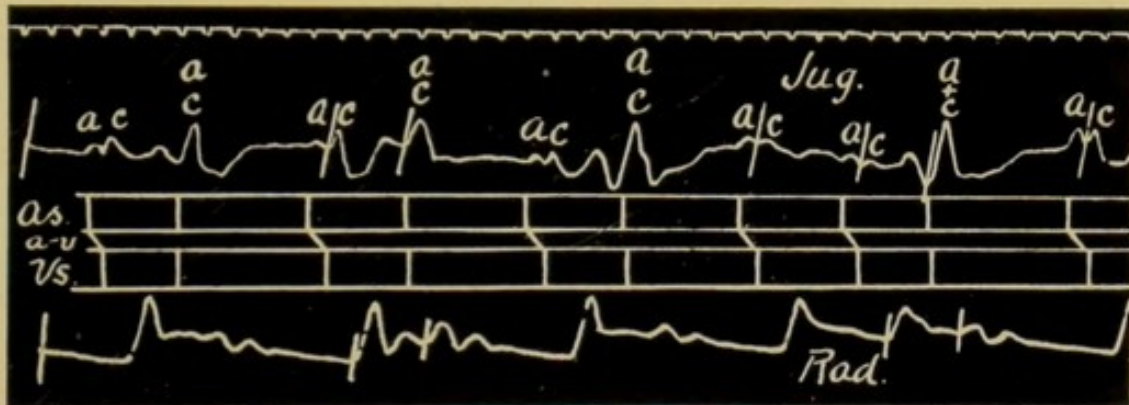


FIG. 63.—Tracing similar to Fig. 62. Shows four characteristic nodal extra-systoles.

time is allowed for we see that the auricle and ventricle must have contracted simultaneously. The diagram in the lower half of Fig. 64 demonstrates these points clearly.

The characteristics of a nodal extra-systole are—

- (1) The premature and simultaneous systole of both auricle and ventricle.
- (2) The full compensatory pause.

It is not possible at present to speak with certainty

as to the site of origin of the stimuli responsible for such premature beats as those in Figs. 62, 63, and 64, but there are many facts which seem to locate the excitable point in the node. It is not advisable here to go into all the reasons for accepting this view, or the experimental work in its favour; but it should

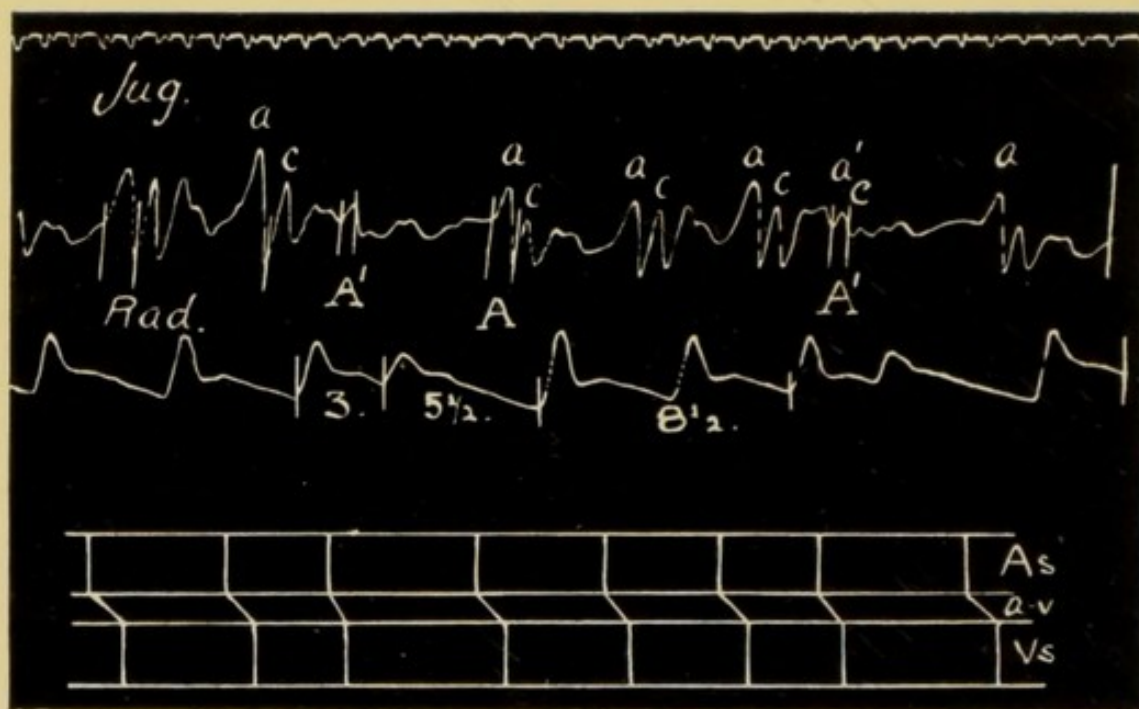


FIG. 64.—Shows two extra-systoles, probably nodal in type. Note the premature contraction of both auricle and ventricle and also the complete post extra-systolic pause, the compensatory pause; there is, however, a distinct though diminished a^1-c interval A^1 , when the extra-systole occurs. At A the $a-c$ interval is normal.

be noted that in the instances quoted above, the auricle and ventricle both contract prematurely, that they begin their systole almost simultaneously and that the $a-c$ interval, when present at all, as in Fig. 64, is one-tenth of a second or even less in duration.

This fact excludes the possibility of the premature beats arising in the auricular fibres, and the fact that the auricle begins its systole at the same time or even a little antecedent to the ventricle is against the view that the stimulus in these patients originated in the muscular fibres of the ventricle, or in the terminal fibres of the *a-v* bundle. It seems reasonable, therefore, to consider that the stimulus originated in the *a-v* system in or near the node.



CHAPTER VII

THE VENTRICULAR OR NODAL FORM OF VENOUS PULSE

THIS form of venous pulse differs essentially from those already described, and is found in a large number of patients suffering from arrhythmia, irrespective of the presence of valvular disease. On the other hand, it is frequent in mitral stenosis, and is the basis of a valuable clinical classification of that trouble; and it is the usual type of venous pulse found in the persistent arrhythmias of the aged associated with arteriosclerosis.

The cardiac arrhythmia associated with this form of venous pulse is usually persistent and continuous, and there is no regularity in the disorderly rhythm. In Fig. 65 we have a tracing showing this form of irregularity; while in Fig. 66, which was taken two years previously, we see that the heart was beating with perfect regularity. In this patient there was no valvular lesion but there was cardio sclerosis.

A recognition of the presence of this form of arrhythmia is important, both when considering treatment

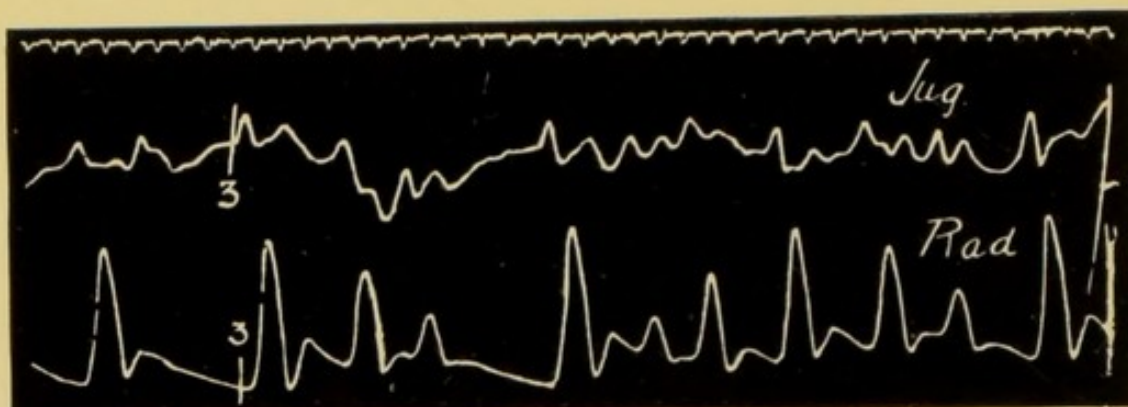


FIG. 65.—Simultaneous tracings of the jugular and radial pulses, from a patient with a persistent disorderly action of the heart (the nodal rhythm). Note the absence in the jugular tracing of any wave *a* preceding ventricular systole. In this patient, a man over eighty, the arrhythmia had come on insidiously and was only discovered accidentally. Is resulted from cardio-sclerosis.

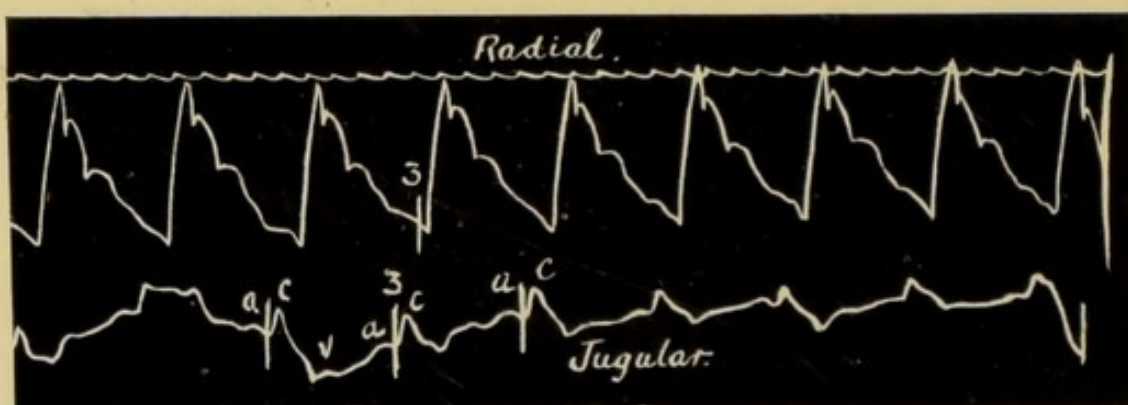


FIG. 66.—Record obtained from the same patient two years before Fig. 65 was taken. Here the rhythm is perfectly regular and the jugular pulse is auricular in type.

and also when weighing the prognosis. On analysis, the tracings taken from these patients differ essentially from the auricular type of phlebogram. The chief obvious characteristic and difference is the absence of the wave *a*. In the tracings of this form of venous pulse there is nothing to indicate that the auricle has contracted before the ventricle. This feature is persistent in all the tracings.

Fig. 67 is a diagram demonstrating the difference between the auricular and the nodal form of venous pulse when the heart is beating tranquilly. 1 represents the nodal type, 2 the auricular, 3 is a tracing of the carotid pulse. In the three portions of the

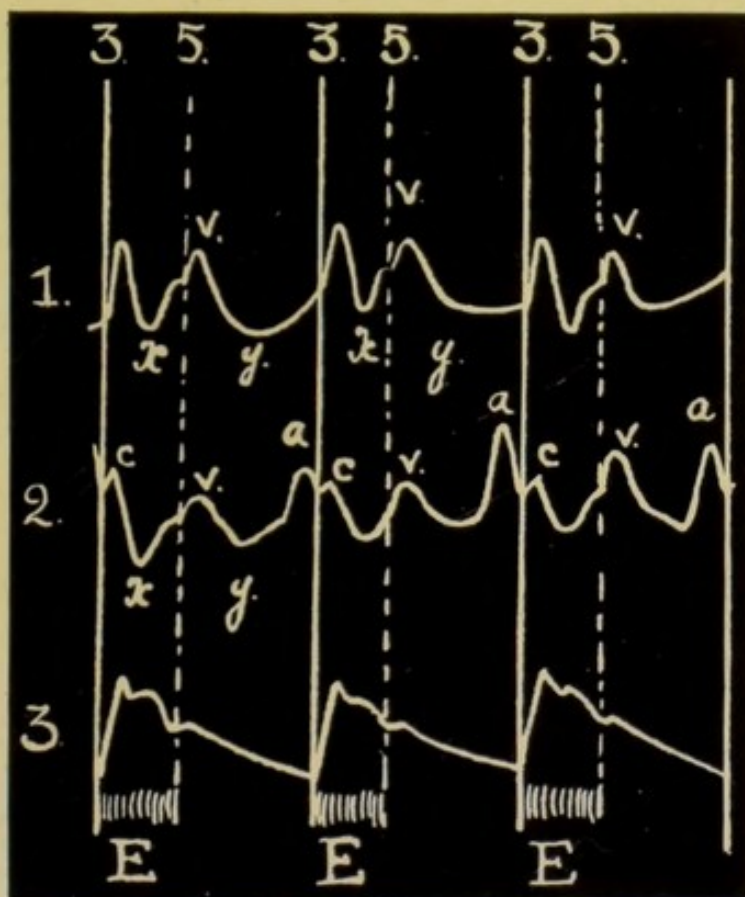


FIG. 67.—Diagram in which the nodal and auricular forms of jugular pulse are compared.

1. Nodal form of venous pulse, heart beating quietly. There is no indication of systole of the auricle preceding that of the ventricle.

2. Auricular form of venous pulse. The *v* wave is similar in both forms of venous pulse.

3. Sphygmogram of the carotid pulse.

diagram the sphygmic period *E*, lying between the lines 3 and 5, is indicated.

Note that in the tracing of the nodal type there is no indication of a wave *a*, and that, on the contrary,

in 2, the tracing of the auricular venous pulse, this wave *a* is a constant and well marked feature, while in both the wave *v* is present and very similar in

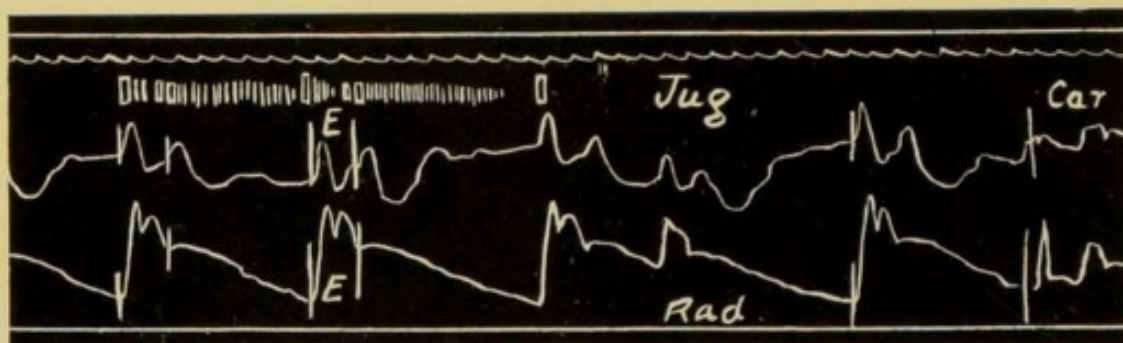


FIG. 68.—Tracing showing the nodal type of jugular pulse obtained from a patient suffering from mitral stenosis. There is no indication of any contraction of the auricle preceding the period *E*. The heart is beating infrequently forty to forty-five beats per minute. The short upright strokes indicate the murmurs and sounds heard in this case. No presystolic murmur was audible.




FIG. 69.—Simultaneous tracings taken from the same patient as Fig. 68 during a paroxysm of frequent heart action. The heart is beating with a frequency of 160 beats per minute. The jugular pulse is of the nodal type; the only wave present is *v*, this wave is synchronous with, and due to, ventricular systole; these waves are separated by the negative phase *y* which is synchronous with, and caused by, ventricular diastole.

character. The above points are well seen in Figs. 68 and 70, both examples of this type of pulse.

As already described, the size and character of *v*

depends on the condition of engorgement of the right auricle; as this increases the wave becomes larger and encroaches on the negative phase x , until at length this is obliterated, and the whole of the sphygmie period is occupied by one large wave, these large waves being separated from each other by the depressions y ; see diagram Fig. 28, p. 65.

Except in patients where the tricuspid regurgitation is free, or where the heart is beating frequently, as in

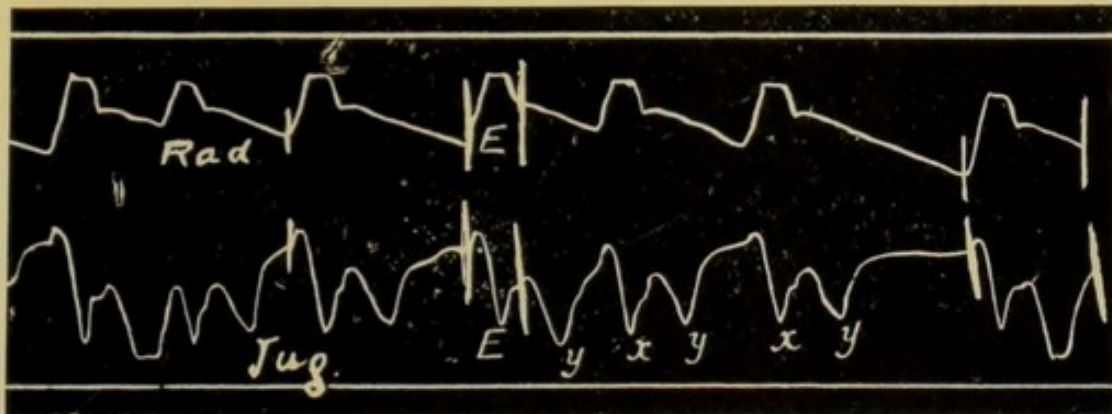


FIG. 70.—An example of the disorderly rhythm showing the nodal form of venous pulse.

Fig. 69, the wave v is divided into two portions separated by the dip x , as in the diagram, Fig. 67, and the tracings Figs. 71 and 72. The first of these portions, which we may call a s , is synchronous in its origin with the sphygmie period, and may be therefore, and probably in some instances is, partially the result of the carotid pulse in the neck. A careful examination of very many tracings has, however, convinced me that this explanation is insufficient.

For in tracings such as Fig. 73, the wave *a s* is larger just at those points in the tracing where the carotid pulse must have been extremely small, as judged by

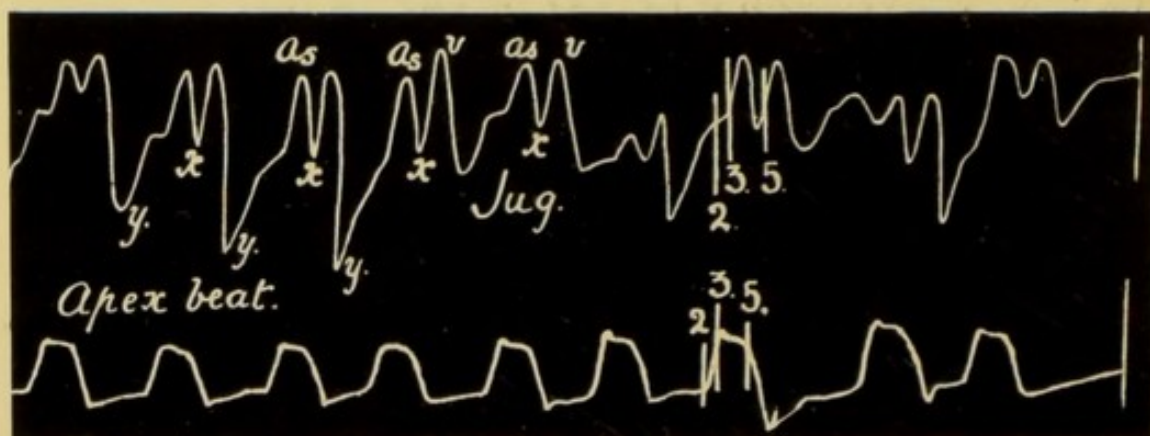


FIG. 71.—Simultaneous tracings of the jugular pulse and the apex beat, from a patient with the nodal rhythm. Note (1) the entire absence of any wave *a* preceding ventricular systole; (2) the wave *A_s* begins at the downstroke 3 and is probably caused by the systole of the auricle; (3) *x*, the auricular depression; (4) *y*, the ventricular depression.

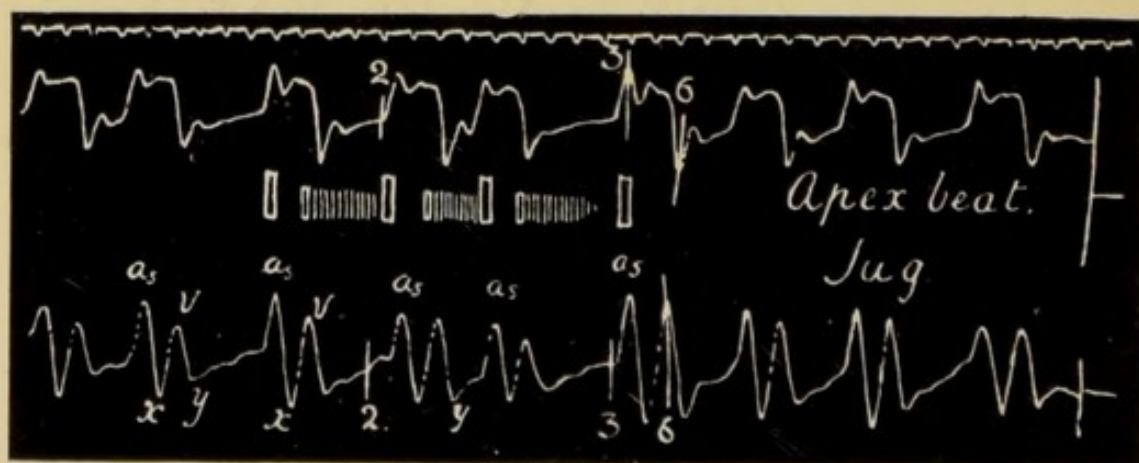


FIG. 72.—Tracings from a patient suffering from mitral stenosis. Shows similar condition to Fig. 71. The heart is acting irregularly. No presystolic murmur was present.

the almost negligible pulse which reached the radial artery.

This wave *a s* is in all probability caused by the

systole of the auricle, which must therefore occur simultaneously with that of the ventricle. This conclusion is partly based on the presence of the depression at x , Fig. 73, where c is small. This depression represents a sudden emptying of the veins in the neck, and is the resultant of several factors, first, diastole of the right auricle, and, second, the

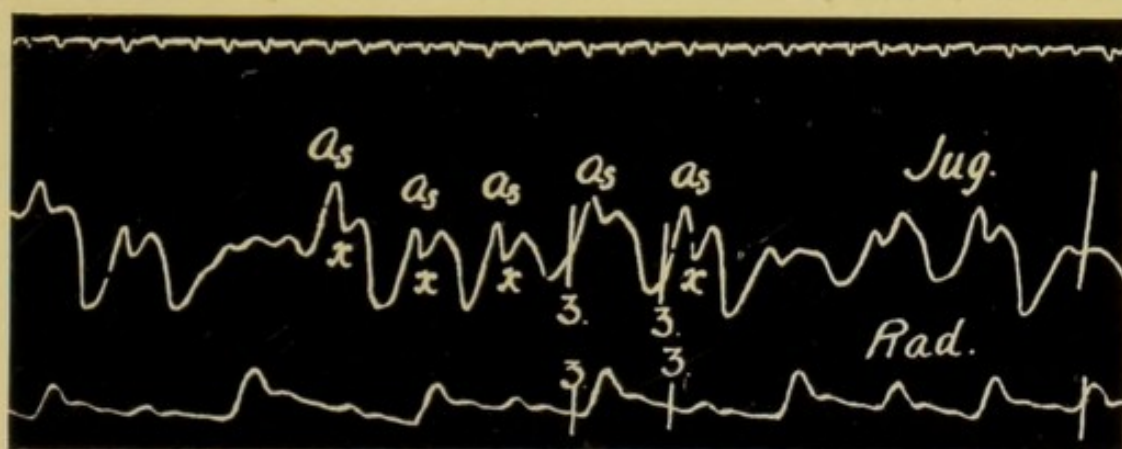


FIG. 73 — Simultaneous tracings of the jugular and radial pulses, from patient with severe mitral lesion. The venous pulse is of the nodal type. Note that the size of the wave As is independent of the size of the arterial pulse. The first wave labelled As in the jugular record is very large, while the corresponding pulse in the radial is hardly perceptible, and the carotid pulse must have been equally insignificant.

systolic depression of the auriculo-ventricular septum. As x occurs during the systole of the ventricle, one is compelled to look upon it as possibly due to both. Keith has shown, however, that in many of these patients with a nodal type of venous pulse the ventricle is compressed by the greatly dilated auricle, and that owing to this the movement of the auriculo-ventricular septum is practically done away with.

The depression x is therefore probably due to the diastole of the right auricle. Diastole of the auricle necessitates a preceding systole, therefore the wave in the tracing preceding x is caused by the systole of the auricle.

As in Fig. 73 so in Fig. 74 the height of as bears no relationship to the size of the carotid pulse. In Fig. 74 the record was taken from the left jugular bulb,

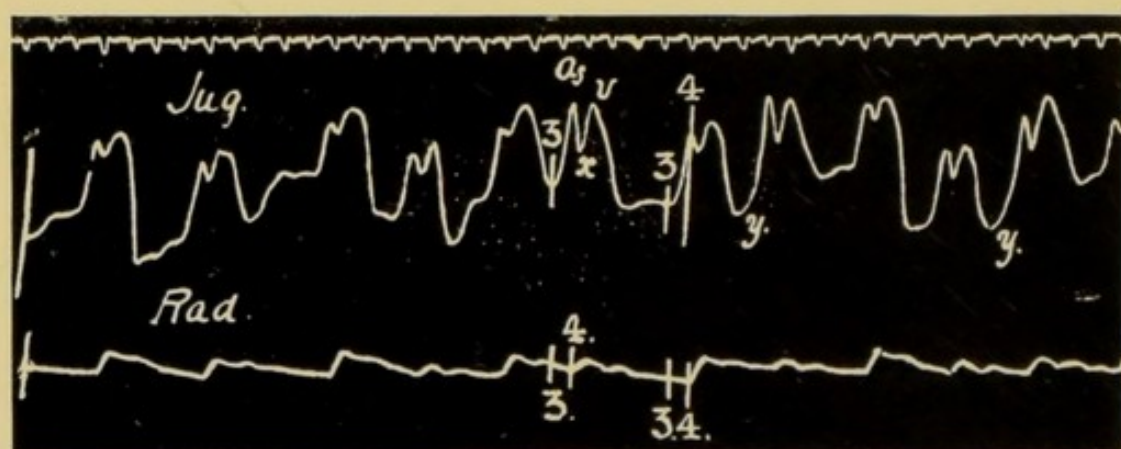


FIG. 74.—Simultaneous tracings of the right jugular and radial pulses. The venous pulse is nodal in type. The two waves As and v were both visible in the distended left jugular bulb. The negative phase y is well marked.

which was distended and obviously beating with a double pulsation.

An interesting fact has been noticed in patients suffering from mitral stenosis, in whom the rhythm has changed from the regular heart action and auricular type of venous pulse to the irregular action and nodal form. Previous to the change there is a pre-systolic bruit audible at the mitral area; after the alteration in the venous pulse and cardiac rhythm

no presystolic murmur can be made out ; this fact, which has been verified repeatedly, is strongly in support of the statement made above that in these cases there is no systole of the auricle preceding that of the ventricle. In Figs. 68 and 72, pp. 108 and 110, the murmurs have been marked on the tracing, and it is noticeable that when the heart is beating infrequently the diastolic murmur ceases before the first sound. When the heart beats more frequently the diastolic murmur may be continued up to the first sound, but it always lacks the presystolic accentuation so typical of the murmur caused by auricular systole. It happens rarely that the auricle does occasionally contract before the ventricle in a patient in whom, with these few exceptions, the venous pulse is of the nodal type. When this does occur there is a wave in the tracing preceding the period of ventricular systole, and there is also a presystolic murmur caused by the systole of the auricle.

It is an interesting fact, and one for which there is at present no adequate explanation, that the venous pulse in patients with this nodal rhythm is often extremely small in volume, even when there is not a condition of cardiac failure. When, however, the heart does fail the venous pulse generally becomes large and obvious, but dwindles away again rapidly and in a remarkable manner as the heart responds to treatment, and tracings of the venous pulse can then only be obtained with difficulty.

In patients with this form of arrhythmia the liver pulse, when present, may consist of one large wave *v*, due to the systole of the ventricle, Fig. 75, or the liver pulse may be similar to the jugular pulse as represented in Figs. 68, 71, 73, and 85, where there are two waves *a s* and *v* with an entire absence of any wave immediately preceding the downstroke 3.

The presence of the wave *a s* in the liver pulse,

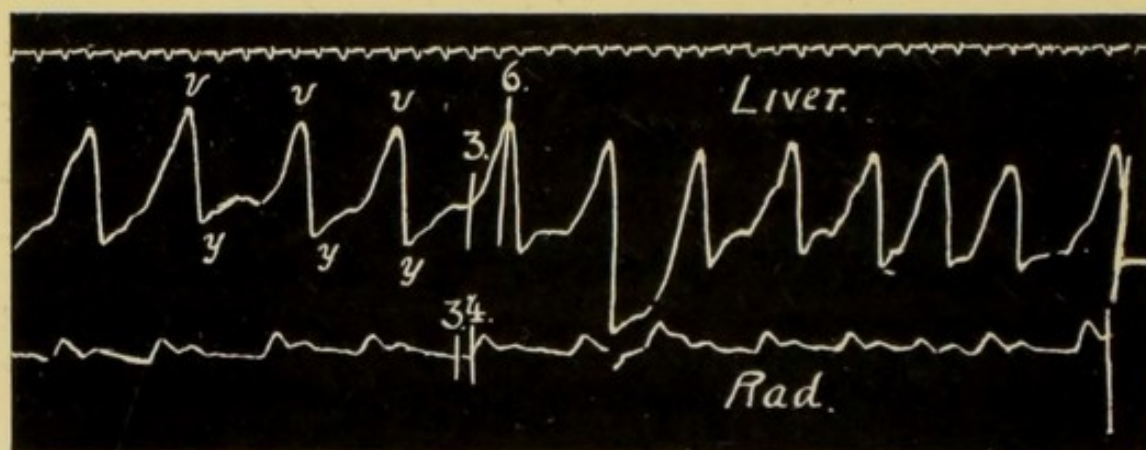


FIG. 75.—Simultaneous tracings of the pulsation in the liver and the radial pulse. In this patient the rhythm of the heart was nodal in type, and with each systole there is a large wave *v*; these *v* waves are separated by negative phases *y*, the ventricular depressions.

Fig 76, supports the view already referred to, that the auricle is responsible for this wave.

As the receiver was held well away from the middle line when the tracing was taken it is most improbable that the abdominal aorta had anything to do with the causation of this wave *a s*. This wave in the tracings obtained from the liver is similar to that in the jugular pulse, in that in each case it terminates with the open-

it was irregular. Sometimes, however, the reverse is the case, the inception of the abnormal rhythm is then accompanied by palpitation and vertigo, with a feeling of lassitude and a sense of anxiety and cardiac distress; the heart dilates and serious cardiac failure may ensue.

Before the abnormal cardiac rhythm has become permanently instituted, the patient probably suffers from temporary attacks of frequent heart action in which the phlebogram is of the nodal type; these attacks tend to become more frequent and to last for longer periods, until finally the disorderly rhythm is persistent.

In Fig. 28, p. 65, we see how the wave *a* may increase in size until the phlebogram shows one large wave to each cardiac cycle, and that wave separated from the next by the short sudden negative phase *y*; note, however, that throughout the diagram the wave *a* is present and invariably precedes the sphygmie period *E*, the phlebogram is therefore persistently of the auricular type. In Fig. 77 the auricular venous pulse I is contrasted with the various forms of the nodal type II, III, IV and V. There is no gradual transition from the auricular to the nodal type. In II, III, IV and V, representing the nodal type, there is no sign of any wave between the lines 1 and 3, that is, there is no evidence of any systole of the auricle antecedent to that of the ventricle.

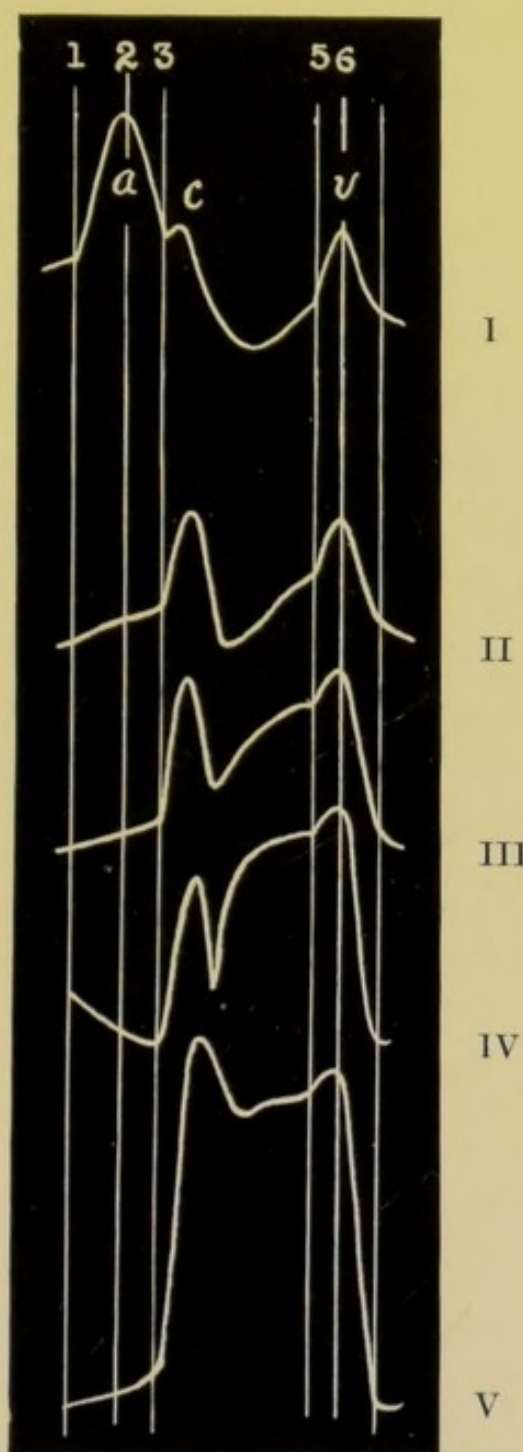


FIG. 77.—Diagram representing the differences between the auricular type of phlebogram and the various varieties of the nodal type.

I is an auricular phlebogram, an example of the so-called negative venous pulse. *a* = wave due to systole of the auricle ; *c* = the small wave caused by the pulse on the carotid artery ; *v* = the second positive wave.

II. A common form of nodal type of venous pulse showing two marked waves between the upstrokes 3 and 6. The wave *v* is absolutely the same as in I.

In II, III, IV, V there is an entire absence of the wave *a* between the lines 1 and 3.

Note that there is no gradual transition between the auricular and nodal types of phlebogram.

In the "nodal" phlebogram the first wave begins invariably at the downstroke 3, Fig. 77, synchronously with the carotid pulse, and therefore follows the beginning of ventricular systole by the duration of the pre-sphygmic interval, represented by the space between the downstrokes 2 and 3; this time relationship holds even when the wave is large and the tricuspid regurgitation is free.

Another point to be noted is that the wave *v* whatever its shape or size, terminates both in the nodal type of phlebogram and in the auricular, with the opening of the tricuspid valves, i.e. at the downstroke 6.

Great help in comprehending the transition from the auricular type to the nodal type of venous pulse can be obtained by carefully analysing tracings obtained from patients presenting a combination of both types. In Fig. 78 we see at once that the venous pulse is almost entirely of the nodal type, but on two occasions the wave *a* is present in the record; the negative phase *x* is practically absent, because of the engorged condition of the auricle and veins, and the more or less permanent depression of the auricular base of the ventricle (see Keith). Fig. 79 is yet more helpful. We see there a series of beats in which the rhythm is normal and the usual sequence of *a*, *c*, *v* present; this is suddenly interrupted by the appearance in the jugular pulse of a number of large *v* waves. In this portion of the record the wave *a* is absent,

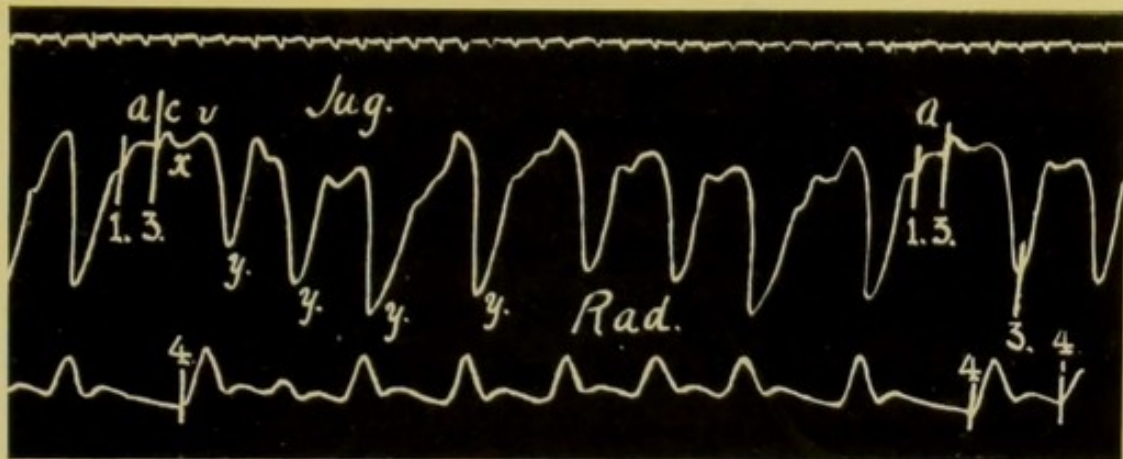


FIG. 78.—Shows a venous pulse of the nodal type similar to *v* in Fig. 77, p. 117. On two occasions, however, the auricle contracts normally before ventricular systole and there appears a wave *a* between the downstrokes 1 and 3. The negative phase *x* is practically absent.

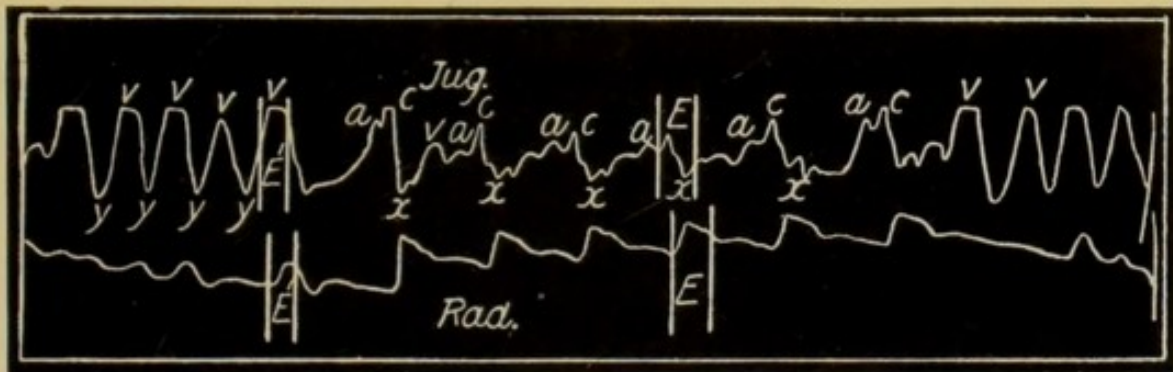


FIG. 79.—A phlebogram showing a combination of both auricular and nodal types of phlebogram. In the middle portion of the record the jugular pulse is normal and shows the typical sequence of *a, c, v* and the negative phase *x* is present. Preceding and following this normal portion of the phlebogram the jugular pulse is nodal in type, there is one large wave *v* and one negative phase *y*; the wave *a* has disappeared. (Mackenzie.)

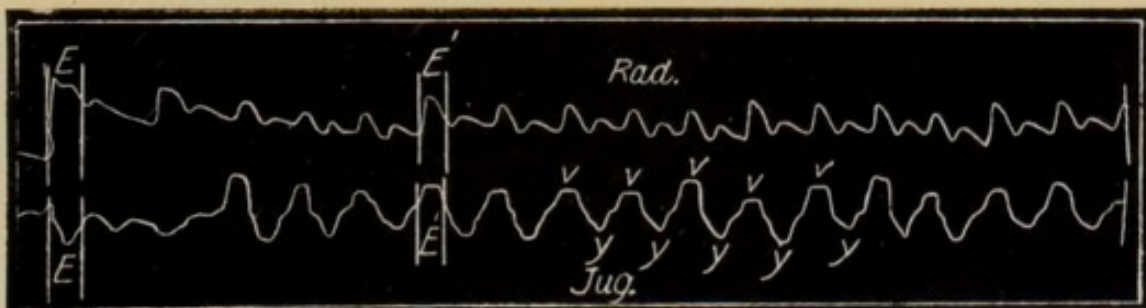


FIG. 80.—A record similar to that in Fig. 79. In this tracing only one normal beat is recorded, after that every contraction is of the nodal type. (Mackenzie.)

and the heart is beating abnormally: the jugular pulse is nodal in type. In Fig. 80 there is only one normal beat, and the rest of the tracing is of the nodal type. The patient from whom Dr. Mackenzie obtained these tracings was under his care for many years, and he had the opportunity of watching the change from the auricular to the nodal type of venous pulse. Previous to the attacks of the disorderly rhythm she suffered occasionally from extra-systoles of various kinds, usually of the type described on p. 86. For some years before her death the venous pulse was persistently of the nodal type.

In two patients suffering from paroxysmal tachycardia I have been able to demonstrate a similar change, and in one of these cases the termination of the attack was characterized by an interesting arrhythmia, illustrating this point.

On examining the tracings taken from this patient some interesting points can be made out.

Fig. 81 was taken during the paroxysm, and shows that the heart was beating with perfect regularity. There is only one definite wave in the jugular vein during each cardiac cycle, and this corresponds to that portion of the wave v termed v^2 , see p. 64. Fig. 82 is an interesting tracing, for during a series of 2, 3, or even 12 small beats the heart contracted in the same manner as at the height of the paroxysm; these groups of abnormal beats are separated by large full

beats. The jugular record demonstrates that when a large pulse wave occurs in the radial artery the action of the heart has been normal, and a wave due to the

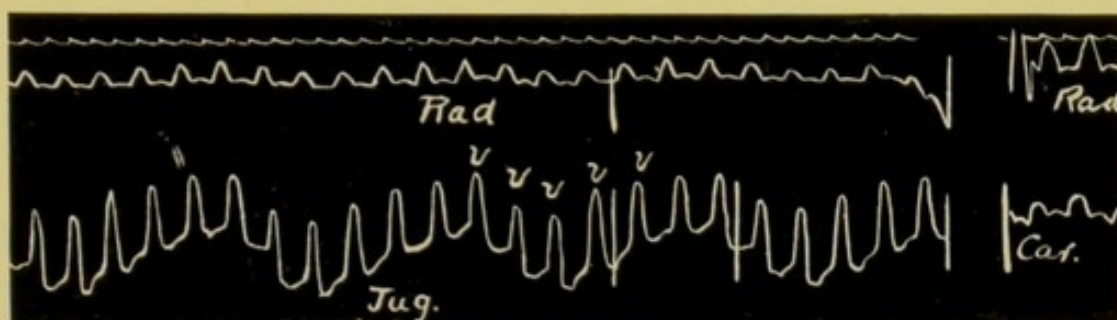


FIG. 81.—Simultaneous tracings of the radial and jugular pulse, taken from a boy of six suffering from an attack of paroxysmal tachycardia. The venous pulse is nodal in type and is composed of a number of large waves *v* separated by depressions *y*.

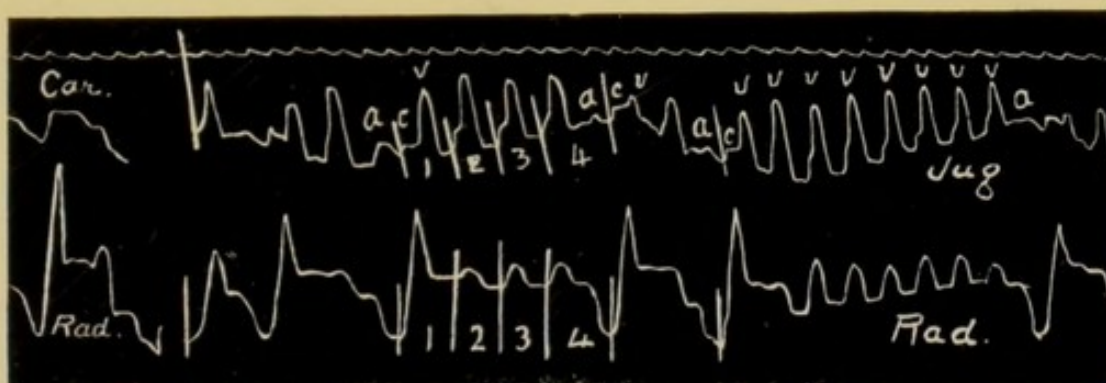


FIG. 82.—Tracing from same patient as Fig. 81, eleven days later. Note the arrhythmia due to the interpolation of a few normal cardiac contractions. When these occur the diastole preceding them is no longer, as at 4, than when the rhythm is nodal as at 2 and 3.

systole of the auricle is present in its normal position in the phlebogram.

In Fig. 82 the longest series of abnormal beats is one of seven, but in some of the tracings the series were much longer. Note that when the normal con-

traction occurs, the preceding diastolic period is distinctly longer than when the nodal rhythm is dominant.

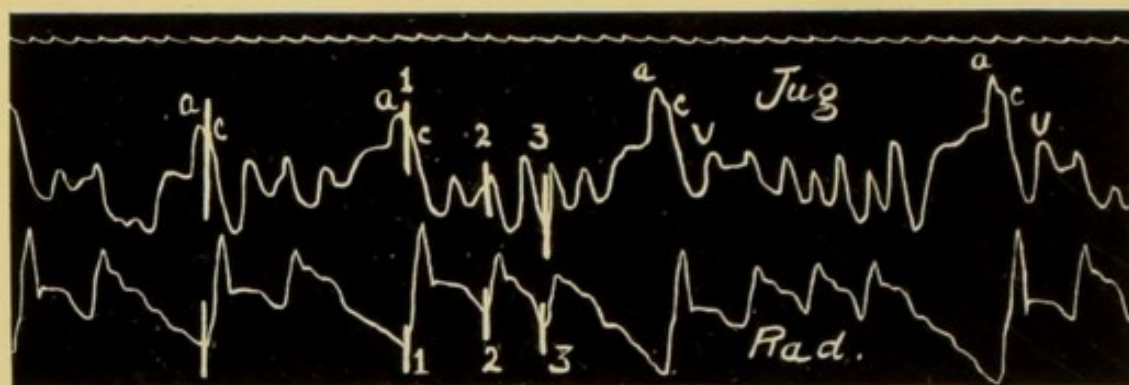


FIG. 83.—From the same patient as Figs. 81 and 82. This tracing shows a great number of interpolated normal contractions. The prolonged diastole preceding the normal contraction is well shown.

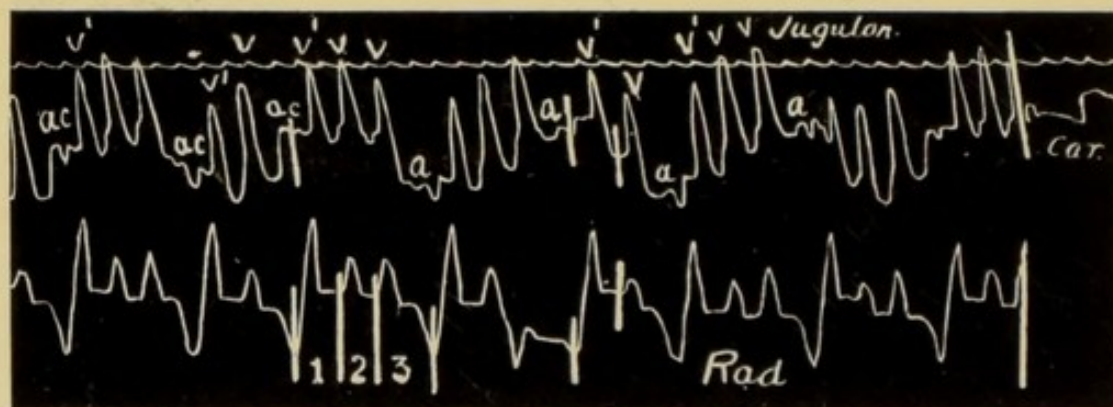


FIG. 84.—Records from the same patient. Shows numerous interpolated normal contractions. Note that the v^1 wave occurring with the normal contraction is exactly similar to the v wave in the nodal portions of the tracing.

In Fig. 84 there are a number of interpolated normal contractions, and it is noteworthy that the wave v , whether occurring with a normal contraction of the heart as at v^1 or with an abnormal contraction as at v , is exactly similar in character.

We see, therefore, that the nodal form of venous pulse is a common condition in advanced life, that it is not unusual in mitral disease, and that it is present in certain cases of paroxysmal tachycardia. One other fact must be noted, that not unfrequently the onset of this form of cardiac activity is preceded by a stage in which extra-systoles are present. This is suggestive, as pointing to a tendency for stimuli to originate in sites other than the normal. In this connexion the question arises as to the site of origin of the stimuli when the heart is contracting in this abnormal manner. As there is no sign in the tracings of any systole of the auricle preceding that of the ventricle, the auricle must either have been paralysed or it did not contract in its normal time relation to the rest of the heart.

In all the hearts examined by Keith in which this form of venous pulse had been present, there was great dilatation of the auricles, and in addition hypertrophy of the *tænia terminalis* and *musculi pectinati*; he also found that the auricular base of the ventricle tended to remain in the position found normally during the systole of the ventricles *B* in Fig. 3, p. 13. This in itself would largely account for a great diminution of the negative phase *x* in the phlebogram.

Tracings such as Figs. 79, 80, 82, 83, and 84 also point to the existence of an auricle perfectly able to contract whenever given an opportunity.

In each of these tracings it is important to note the prolongation of the diastole in relation to the normal beats to which we have already referred. This invariable prolongation of diastole before the normal systoles signifies that temporarily the abnormal stimuli dominating the rhythm had ceased, and the auricle, therefore, freed from their influence is allowed to contract in response to its own normal physiological stimulus, and to initiate a systole of the ventricle in the natural manner. These tracings tend to prove that the auricle has not been paralysed, and support the view that it has been contracting at the same moment as the ventricle, for whenever normal beats occur they do so after a delay greater in duration than the length of the cardiac cycles found during a paroxysm.

The importance of this is as follows : If the auricle had not contracted with every systole of the ventricle, and so used up the stimulus matter in the sinus node, there would be no reason why the wave *a* should not crop up in the tracing at points varying considerably in distance from the last cardiac contraction in the groups of the nodal type ; but instead of this we find that following on the last systole of one of these groups a diastolic pause is always present of sufficient duration to allow the stimulus matter to accumulate at the sinus node, in answer to which stimulus a systole of the auricle is initiated, and is followed in due time by that of the ventricle. The inference from this

prolonged diastole is that during the period of abnormal rhythm the stimulus matter at the sinus must have been used up with each abnormal systole of the heart, and that when the abnormal rhythm ceases sufficient time must be allowed the sinus node to accumulate its stimulus matter before it can initiate a normal contraction.

From a careful consideration of many tracings I find no gradual transition from the auricular to the nodal type of venous pulse. I find also that in the nodal type the venous pulse begins at the downstroke 3, one-tenth of a second or so after the beginning of the systole of the ventricle. With these facts we must attempt to form an opinion as to the site of origin of the stimuli which dominate the rhythm in these cases.

In such a tracing as Fig. 85, p. 126, the second portion of the wave is undoubtedly caused by ventricular systole, but the first portion is not so easily explained: it may be simply the result of the carotid pulse; it may be a wave transmitted to the superior vena cava by the aorta when the latter is suddenly distended with blood at the beginning of systole; or it may be the manifestation of a contraction of the auricle occurring during the period of ventricular systole. The reasons which have led us to accept this latter view have already been stated. If this wave represents an auricular systole, then the stimulus which originated it and

which also stimulated the ventricle must be situated in the ventricle itself or in some portion of the *a-v* system of fibres.

That the auricle and ventricle can and sometimes do contract at the same time has been demonstrated experimentally by both Cushny and Lohmann.

Through the kindness of the former I am enabled to publish the two tracings Fig. 86, and 87. They are

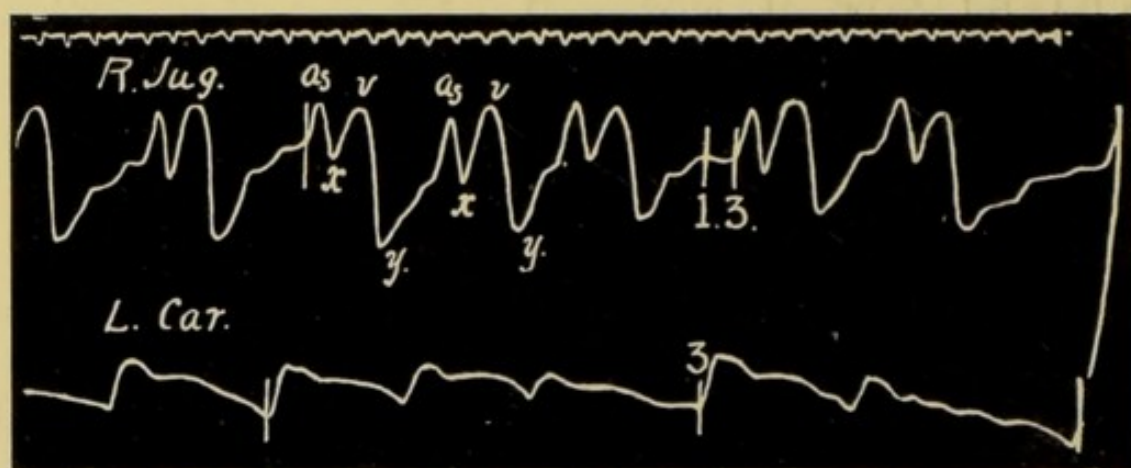


FIG. 85.—Simultaneous tracings of carotid and jugular pulses. The jugular tracing is of the nodal or ventricular type.

As is probably due to the contraction of the auricle occurring at the same time as that of the ventricle; *x* is the auricular depression; *v* is the ventricular wave; *y* is the ventricular depression. Note the entire absence of any wave between 1 and 3 where the wave due to auricular systole ought normally to be found.

records obtained from the auricle and ventricle of a dog's heart. In Fig. 86 the auricle and ventricle are beating normally, the systole of the auricle *As* preceding that of the ventricle *Vs* by about $\frac{1}{10}$ th of a second.

While under the influence of aconitine the mode of contraction altered to that shown in Fig. 87. In this record one sees that the ventricle contracts first and is followed in about $\frac{1}{10}$ th of a second by the auricle.

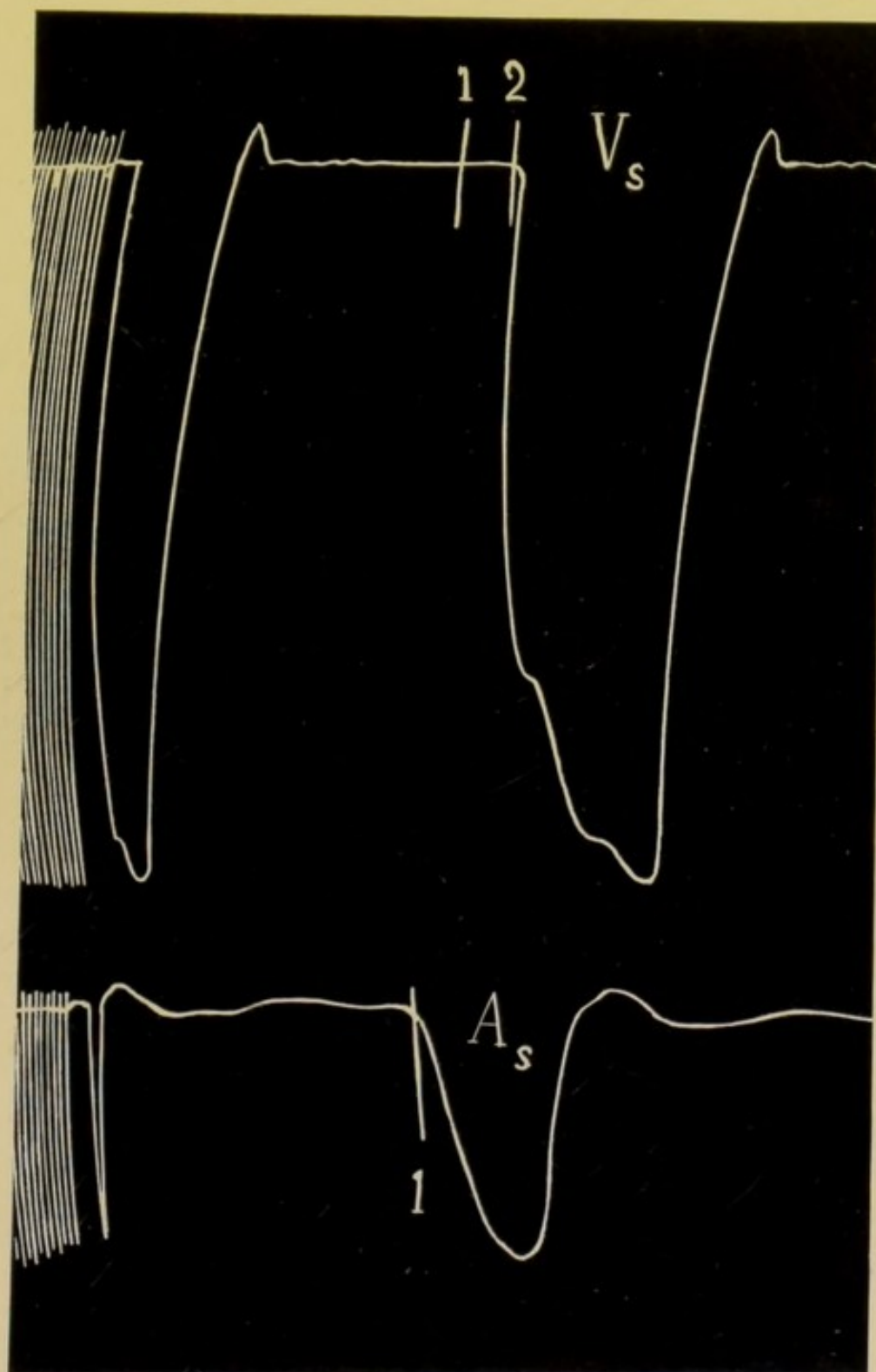


FIG. 86.—Records obtained from the auricles and ventricles of a dog's heart.

A_s represents the systole of the auricle beginning at the downstroke 1; V_s the systole of the ventricle beginning at the downstroke 2. The rhythm is normal; the auricle begins to contract one-tenth of a second before the ventricle. (Cushny.)

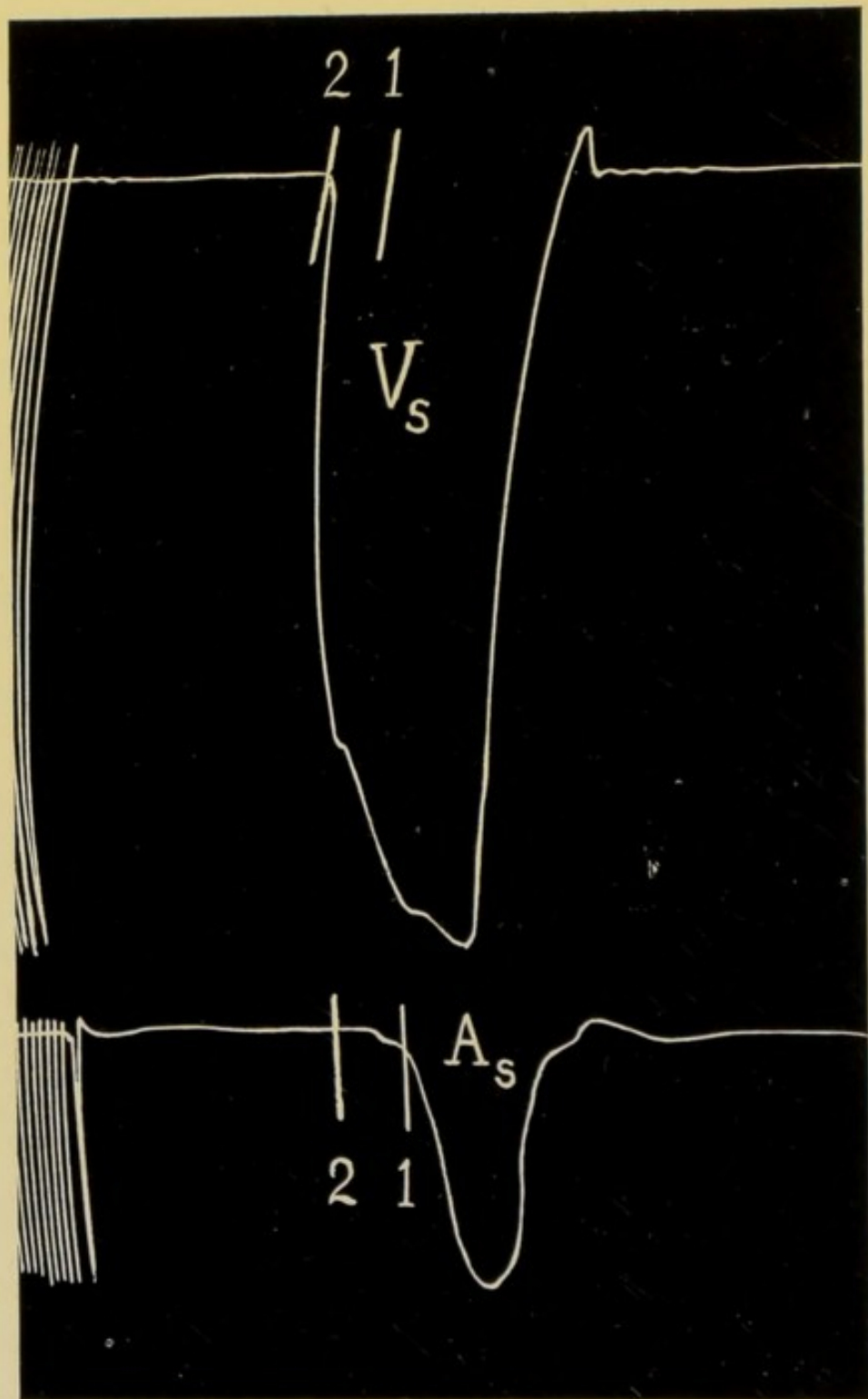


FIG. 87.—Under the influence of aconitine the cardiac rhythm became abnormal. The ventricular systole preceded that of the auricle by about one-tenth of a second and persisted after the auricle had ceased to contract. The auricle and ventricle were therefore contracting simultaneously. (Cushny.)

The tracing shows also that the auricle and ventricle are both in systole together. This is exactly what is represented in such tracings as Fig. 62, p. 100, and Fig. 63, p. 101, at those points where an extrasystole is recorded, and also in Figs. 68, 70, 71, 72, 85, etc., which are all examples of the nodal rhythm.

Professor Cushny hesitates to commit himself as to which portion of the myocardium is responsible for the stimulus causing the abnormal mode of contraction seen in Fig. 87, and I publish these records simply to demonstrate that a more or less continuous rhythm has been noted experimentally in which the auricular systole occurred during the systole of the ventricle.

In Figs. 62 and 63 we have a tracing in which almost every alternate beat of the heart is premature. On careful analysis of the record we find that when ventricular systole is premature, the auricle also beats before its appointed time, and when we reach that portion of the tracing where the wave *a* should be found, there is no indication whatever of any systole of the auricle; both the auricle and ventricle have contracted together, and both have contracted prematurely. The only inference possible is that the stimulus originated in the *a-v* system of fibres, and the probability is that the actual site was the *a-v* node. Hence this type of venous pulse is termed nodal.



CHAPTER VIII

DISTURBANCE OF FUNCTION

SECTION I

CONDUCTIVITY

IN this chapter I will discuss the manner in which information concerning the various functions of the myocardium can be obtained by means of the graphic method. The function which perhaps most easily lends itself to investigation and demonstration is that of conductivity, and I shall therefore deal with it first, and show that variations in conductivity can be recorded with ease and certainty.

The simplest method of estimating conductivity in any case is by measuring, on the tracing of the jugular pulse, the distance between the first indication of systole of the auricle and the appearance of the carotid pulse. This is the *a-c* interval already described at p. 61.

It includes—

- (1) The duration of the systole of the auricle.
- (2) The time taken for transmission of the stimulus

along the *a-v* bundle from the auricle to the ventricle.

(3) The period elapsing between the beginning of ventricular systole and the opening of the aortic valves—the pre-sphygmic period.

(4) The time taken for the pulse to travel from the ventricle to the carotid artery in the neck at the point where the receiver is placed.

(1) (3), and (4) are practically constant : variations in the length of the *a-c* interval must, therefore, denote differences in the rate of the passage of the stimulus from the auricle to the ventricle, that is, variations in the conducting power of the *a-v* bundle.

When conductivity is normal the *a-c* interval remains fairly constantly about one-fifth of a second, even in a frequently acting heart. Sometimes, however, in a rapidly beating heart the *a-c* interval is shortened, the reason being that with the increase of stimulus production there has been a simultaneous increase in the conducting power of the *a-v* bundle. When the conducting power of the bundle becomes depressed, the transmission of the stimulus is correspondingly delayed until the *a-c* interval is double or treble its normal duration. Such a delay is seen in Fig. 88, where the *a-c* interval is more than two-fifths of a second. In Fig. 89, obtained from the same patient, we have a radial tracing recorded simultaneously with the apex beat. The systole of the auricle is clearly

seen in the cardiogram, and the depression of conductivity is well shown.

With increasing depression of the conductivity the

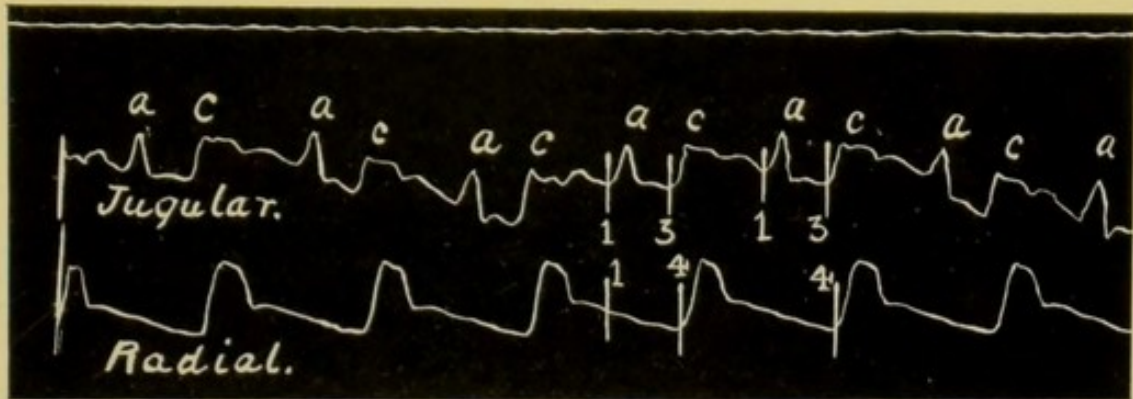


FIG. 88.—Simultaneous records of the jugular and radial pulses. In the jugular pulse we see a marked lengthening in the *a-c* interval. The distance between the downstrokes 1 and 3 represents more than two-fifths of a second. This indicates delay in the passage of the stimulus from the auricle to the ventricle. (Herringham.)

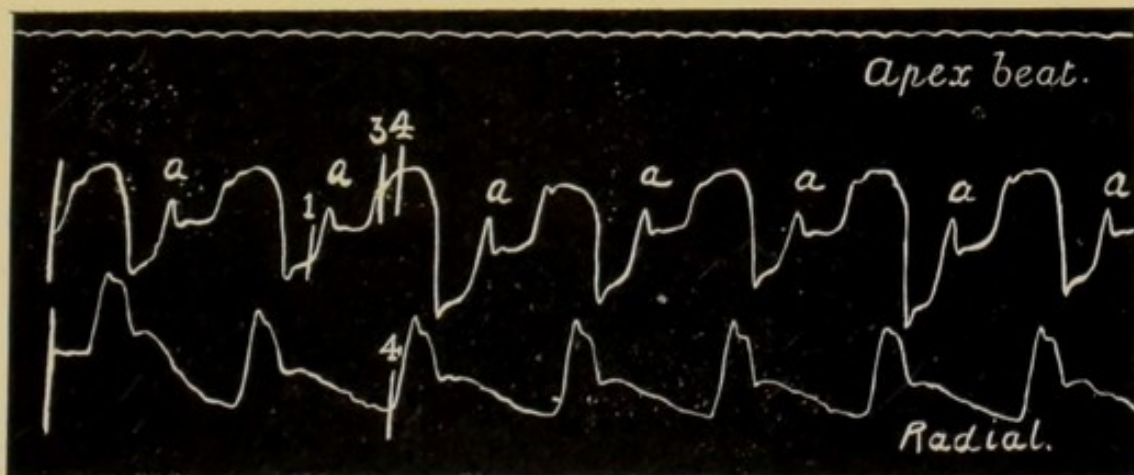


FIG. 89.—From the same patient, showing simultaneous records of the apex beat and the radial pulse. The increased delay between the systole of the auricle *a* and that of the ventricle is clearly seen in the cardiogram.

conducting power may be so impaired that when the stimulus from the auricle reaches the *a-v* bundle the

latter is unable to transmit it to the ventricle, and a systole of the ventricle drops out. The reason for this is, that the time allowed between two systoles of the auricle for the bundle to recover its conducting power has been insufficient. A condition may ensue in which every other auricular systole fails to initiate a systole of the ventricle; such a sequence is termed a 2 : 1 rhythm, Fig. 90. With still greater depression only every third systole of the auricle is able to get

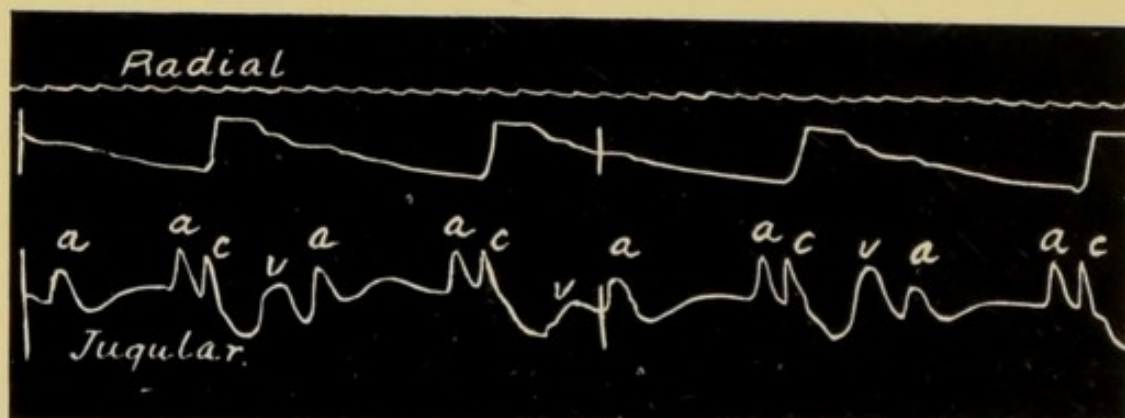


FIG. 90.—In this tracing the ventricle only responds to every other systole of the auricle. The *a-c* interval is normal in length.

through, and accordingly there is a 3 : 1 rhythm. When the block is complete the rhythms of the auricles and ventricles are found to be different and independent, the ventricles beat slowly and infrequently, the auricles at their usual rate.

Every stage between normal conductivity and complete block has been demonstrated in man in tracings of the jugular pulse. Similarly, every stage has been produced experimentally in warm blooded

animals by varying the pressure on the *a-v* bundle : as the pressure was increased the conductivity was diminished, until finally there was complete block.

I will now illustrate the above points and the method

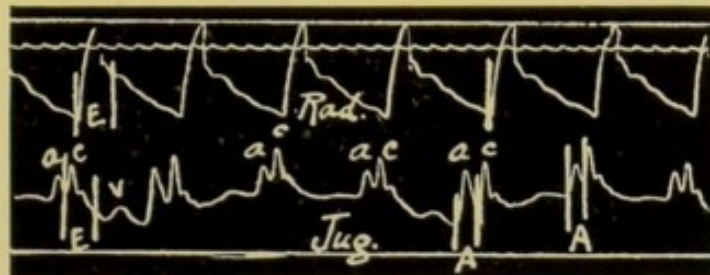


FIG. 91.—The first of a series of records from a patient showing various grades of heart-block. In this tracing the conducting power of the *a-v* bundle is normal ; the *a-c* interval is one-fifth of a second.

of analysing the records so as to obtain information concerning the conductivity, by reference to a number of tracings, the first seven of which were obtained from the same patient, and show all stages between

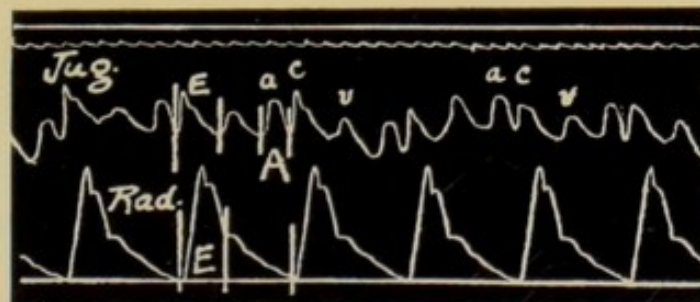


FIG. 92.—Shows some depression of conductivity. The *a-c* interval *A* is abnormally prolonged.

the normal condition and complete block. In Fig. 91 the conductivity is normal : the *a-c* interval is one-fifth of a second.

Fig. 92 represents a tracing taken from the same

man six months later. In it the $a-c$ interval A is more than one-fifth of a second, indicating that there is some delay in the transmission of the stimulus

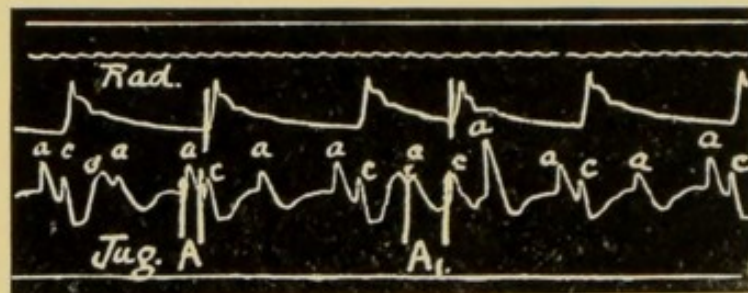


FIG. 93.—Increased depression of conductivity producing an arrhythmia. The wave a occurs perfectly regularly. Note that the $a-v$ bundle requires the whole time of two auricular systoles to recover its conducting power; when this length of time is curtailed as in the middle of the record the $a-c$ interval A_1 is at once lengthened. See the diagram, Fig. 94.

along the $a-v$ bundle. Six months later the tracing shown in Fig. 93 was taken. The conducting power of the bundle is still further depressed, for throughout



FIG. 94.—Diagram representing the condition present in Fig. 93. The downstrokes in the upper compartment As , representing auricular systoles, occur with perfect regularity, with one exception every other systole is blocked. Note the lengthening of the $a-c$ interval when two consecutive stimuli pass down the $a-v$ bundle. The downstrokes in the compartment Vs represent systoles of the ventricle.

the greater part of the tracing only every other systole of the auricle is able to get through to the ventricle,

and start a contraction. The first wave *a* is followed by a ventricular systole, the next auricular systole fails to initiate a ventricular response, because the *a-v* bundle is unable to conduct the stimulus; the third, however, finds the *a-v* bundle so recovered by its prolonged resting time that it is transmitted at the normal rate, the resulting ventricular systole being represented by the *c* wave in the phlebogram and the pulse in the radial artery.

This is an example of the 2:1 rhythm. At one point in the tracing this regular 2:1 rhythm is interfered with, and two consecutive auricular systoles transmit a stimulus to the ventricle. As a result of thus diminishing the time allowed for the recovery of the bundle, the second stimulus passes much more slowly along the *a-v* fibres and the length of the *a-c* interval A_1 is doubled.

Note that the wave *a* following on this long *a-c* interval is very ample, the cause being that at this point the waves *a* and *v* have become superposed. The diagram Fig. 94 still further explains the sequence of events. In the tracing, Fig. 93, the time occupied by two auricular cycles is sufficient to enable the *a-v* bundle to recover itself, and the *a-c* interval is practically normal in length. When conductivity becomes still further depressed the time of two auricular systoles is insufficient to permit the *a-v* bundle to attain its normal, and the *a-c* interval

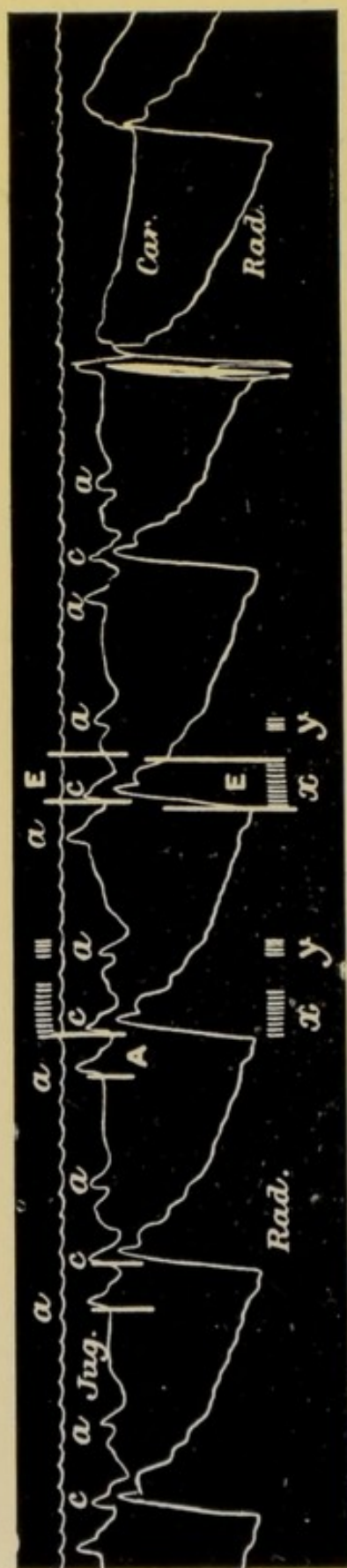


FIG. 95.—From the same patient, showing still further depression of conductivity. The length of time of two auricular systoles is here insufficient to allow the *a-v* bundle to completely recover its functional activity. Note that every other systole is blocked and that the *a-c* interval is two-fifths of a second. *x* represents the murmur due to ventricular systole, mitral regurgitation; *y* represents a short whiffy murmur heard during diastole of the ventricle and synchronous with and caused by systole of the auricle discharging blood into an incompletely filled ventricle.

increases in duration. Fig. 95 is an excellent example of such a condition.

In the tracing Fig. 96 we find conductivity much more depressed than in the previous tracings. An analysis of such a complicated record is almost impossible without the aid of the diagram placed below the tracing which reveals the explanation, namely, that we are here dealing with a combination of a 2 : 1 and a 3 : 1 rhythm.

As a rule the ventricle responds to every third auricular systole, as in the case with the III, IV, VI, VII, VIII, X, and XI ventricular systoles recorded in the tracing. The II, V, and IX, however, are the

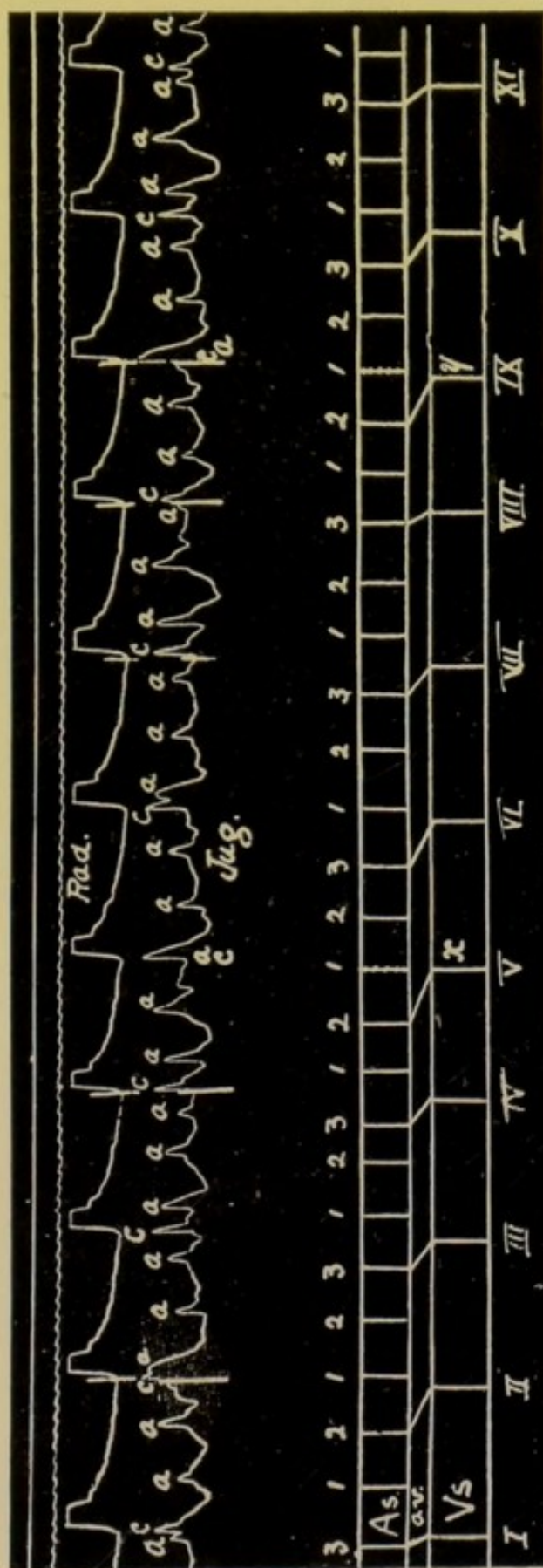


FIG. 96.—From the same patient, showing a combination of a 2:1 and a 3:1 rhythm. The 3:1 rhythm allows the conductivity of the *a-v* bundle to recover, while the 2:1 rhythm causes serious depression. At *x* and *y* the auricles and ventricles contract together, owing to the great prolongation of the *a-c* interval. The chart in the lower part of the figure is constructed from the jugular tracing. The upper numerals refer to auricular systoles, the lower to ventricular systoles.

response of the ventricle to the second auricular systole and it is interesting to note that when the ventricle responds to every third auricular systole, thus allowing the *a-v* fibres time to recover, the *a-c* interval steadily diminishes until it becomes normal, as at I, VIII, XI. Following on this improvement the second auricular systole gets through and a 2 : 1 rhythm starts but the depression of conductivity caused by this is so great that the *a-c* interval is again greatly lengthened and a series of a 3 : 1 rhythm is initiated, which lasts until the conductivity permits a 2 : 1 rhythm, the occurrence of which again so disturbs conduction that a 3 : 1 rhythm is necessary, and so forth.

The next two tracings, Figs. 97 and 98, show a complete block to the passage of the stimulus from the auricle to the ventricle. In Fig. 97 the auricle is contracting 64 times to the minute, the ventricle about 8. On analysing Fig. 98, and constructing the diagram Fig. 99, one sees that the block is complete, and that the auricular and the ventricular rhythms differ and are independent.

In Fig. 98 we have a form of irregular ventricular rhythm not uncommon in complete heart-block. The ventricle is fired off by some stimulus which occurs earlier than that to which it is steadily replying. The result is seen in the tracing. Following on this irregular and premature beat, which has interfered with the slow rhythm of the ventricle, there is a pause

equal to that which has become normal to the ventricle, namely of six-fifths of a second. This is also well shown in Fig. 100.

This series of tracings was obtained at different

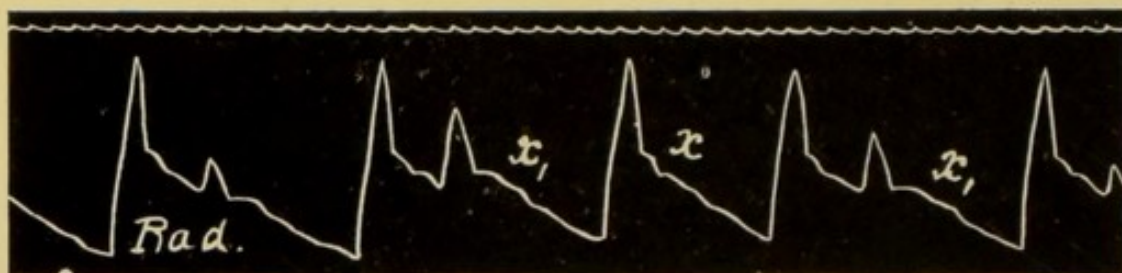


FIG. 100.—Sphygmogram showing the form of bigeminy occurring in complete heart-block, similar to that in Fig. 98.


times from a patient in whom the *a-v* bundle was found post-mortem to be partially obliterated. The bundle was, therefore, both functionally and organically below normal.

The tracings in Figs. 101, 102, and 103 were obtained from a patient of Sir James Barr's suffering from complete heart-block, and in whom also the bundle was found to be diseased.

In Fig. 101 the regular and frequent appearance of the auricular systole contrasts with the infrequent and independent rhythm of the ventricle. The tracings, Figs. 102 and 103, are portions of a continuous record, during which the patient had several seizures of an epileptiform nature. The radial pulse was observed to cease and a few seconds after its cessation, unconsciousness supervened, followed by some twitching and



FIG. 101.—A record from a case of Stokes Adams disease, showing complete heart-block. The rhythm of the auricle differs from and is entirely independent of that of the ventricle. *a*=systole of the auricle. This patient was under the care of Sir James Barr.



FIGS. 102, 103.—Tracings from the same patient, showing periods during which there is no evidence of systole of the ventricle. In Fig. 102 for 70 fifths of a second and in Fig. 103 for 90.5 fifths of a second. During these pauses the auricle continued to beat with perfect regularity.

cyanosis. Fig. 103 records such a seizure and demonstrates that the auricle continued to beat throughout the whole period of asystole of the ventricle which lasted eighteen seconds.

As further examples of arrhythmia due to impaired conductivity, we may take the effect of digitalis on patients in whom the *a-c* interval is found to exceed one-fifth of a second. These show marked susceptibility to the action of this drug, which in them seems to pick out this function of conductivity and to depress it still further. In consequence an arrhythmia may result which would either be unintelligible or ascribed, very probably, to the presence of extra-systoles. Careful analysis of the jugular and radial pulse tracings at once reveals the true nature of the irregularity.

In Figs. 104, 105, and 106 we have good examples of this peculiar action of digitalis. The waves *a* and *a*¹, due to auricular systoles, appear with perfect regularity, but owing to the digitalis the passage of the stimulus is occasionally blocked, and in consequence a ventricular systole drops out and causes an arrhythmia. The failure of the stimulus to affect the *a-v* bundle, owing to the great depression of its conducting power, occurs after the auricular systoles labelled *a*¹, and, as in Figs. 93 and 96, the extra rest thus obtained by the bundle enables it to recover, in some degree, its conducting power. This recovery is recognised by the comparative shortening of the *a-c* interval,

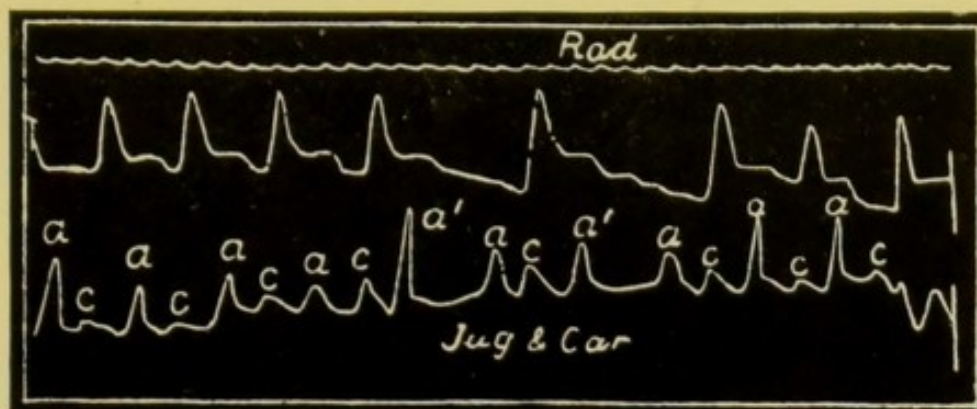


FIG. 104.—Tracings of the radial and jugular pulses, showing one effect of digitalis. The auricle contracts regularly (a and a'), but after each auricular wave a' a ventricular systole is missed; the auricular stimulus has failed to reach the ventricle. Note the variations in the a - c interval. (Mackenzie.)

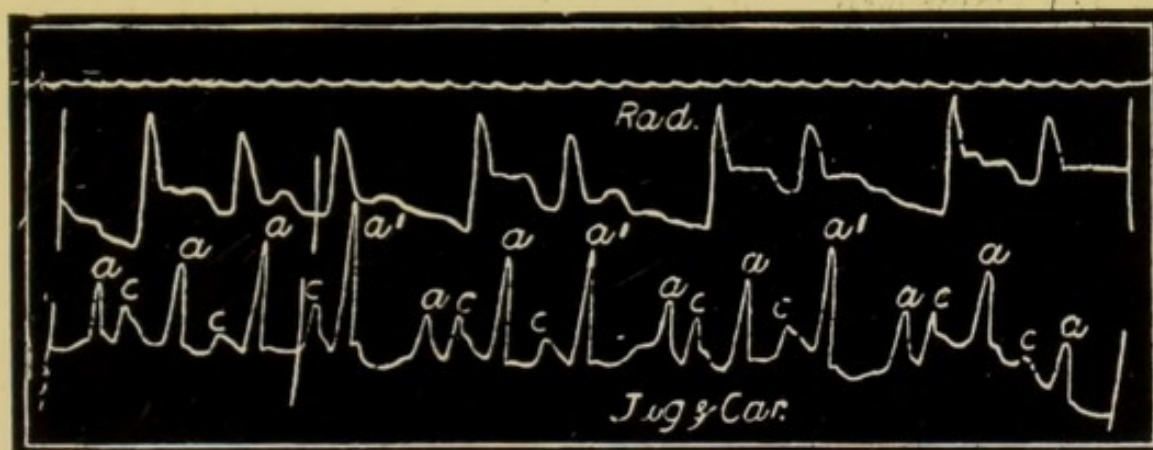


FIG. 105.—Similar record to Fig. 104. It shows a more frequent failure of the auricular stimulus to reach the ventricle, causing the ventricular rhythm to be more irregular. (Mackenzie.)

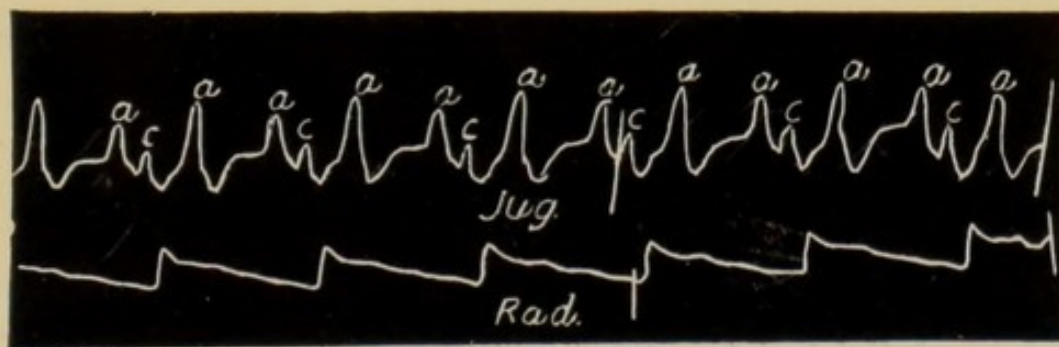


FIG. 106.—Marked slowing of the pulse, caused by digitalis depressing the conducting power of the a - v bundle so that the ventricle responds only to every second stimulus. While the ventricle contracted forty-eight times per minute the auricle contracted ninety-six times. (Mackenzie.)

following each occasion on which a ventricular systole dropped out. In this patient the conductivity became still further depressed by digitalis, and in Fig. 106 we see a 2 : 1 rhythm similar to that in Fig. 90, p. 134, every other stimulus from the auricle being blocked.

Depression of conductivity results in—

- (1) Lengthening of the *a-c* interval.
- (2) Occasional dropping out of ventricular systoles.
- (3) A 2 : 1 rhythm, a 3 : 1 rhythm or a combination of the two, etc.
- (4) Complete block, the auricular rhythm being independent of and differing from the ventricular.

SECTION 2

EXCITABILITY

The excitability of the myocardium is judged experimentally by the smallest stimulus which will initiate a contraction. The greater the excitability the weaker the stimulus required, and the earlier in the refractory period will the heart respond. It is obvious, that clinically, there are no means of estimating the intensity of the stimulus, and in forming an opinion of the excitability of the myocardium fibres we have to be satisfied with other indications.

One result of increased excitability will be increased frequency of heart action, though it must be borne

in mind that increased stimulus production effects a similar change in the frequency.

Another result of increased excitability of the myocardium is that it responds more readily to abnormal or irregular stimuli, and thus extra-systoles are initiated with greater ease. Extra-systoles are to be regarded, therefore, as in some degree an evidence of increased excitability of certain portions of the

FIG. 107.—Shows the occasional dropping out of ventricular systoles with a normal conductivity, the *a-c* interval being about one-fifth of a second irrespective of the frequency of the pulse. The arrhythmia is due to depression of excitability.

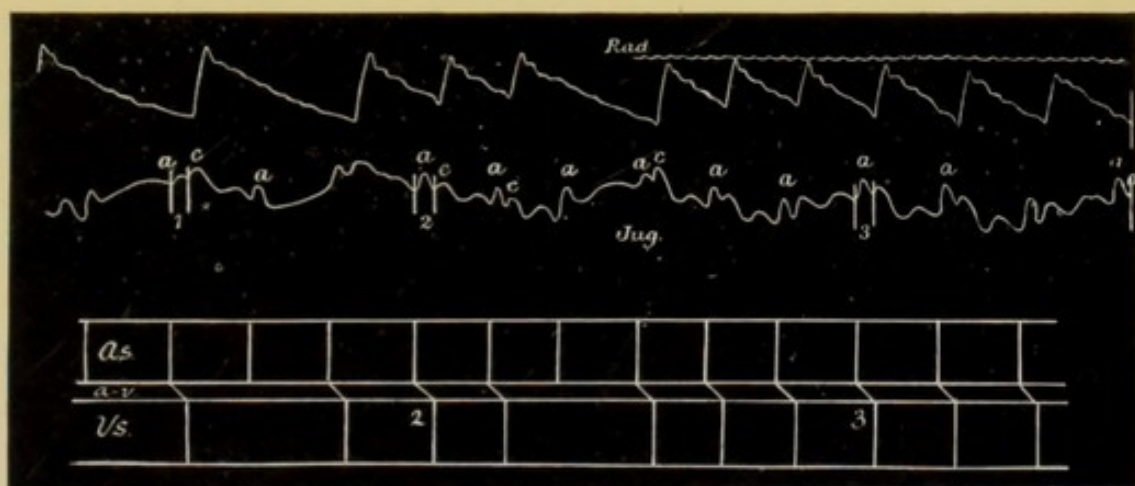


FIG. 108.—Diagram constructed from Fig. 107. Conductivity is seen to be normal and the *a-c* interval is the same throughout.

heart, for all that is required for an extra-systole is that some portion of the heart shall have an excitability greater than that of the sino-auricular node.

Rapid heart action tends to do away with extra-systoles by diminishing the period during which the heart can respond to stimuli. The presence of extra-systoles in a frequently beating heart points, therefore,

to a high grade of excitability and possesses significance in prognosis.

One result of depression of excitability is the dropping out of ventricular systoles. This is rarely seen, and it would be almost impossible to put a correct interpretation on such an arrhythmia if it were not for the information obtained from an analysis of the

FIG. 109.—Shows a sudden halving of the pulse frequency. There is no depression of conductivity; the *a-c* interval is normal throughout. Depression of excitability is shown by the refusal of the ventricle to respond to a stimulus normally conducted.

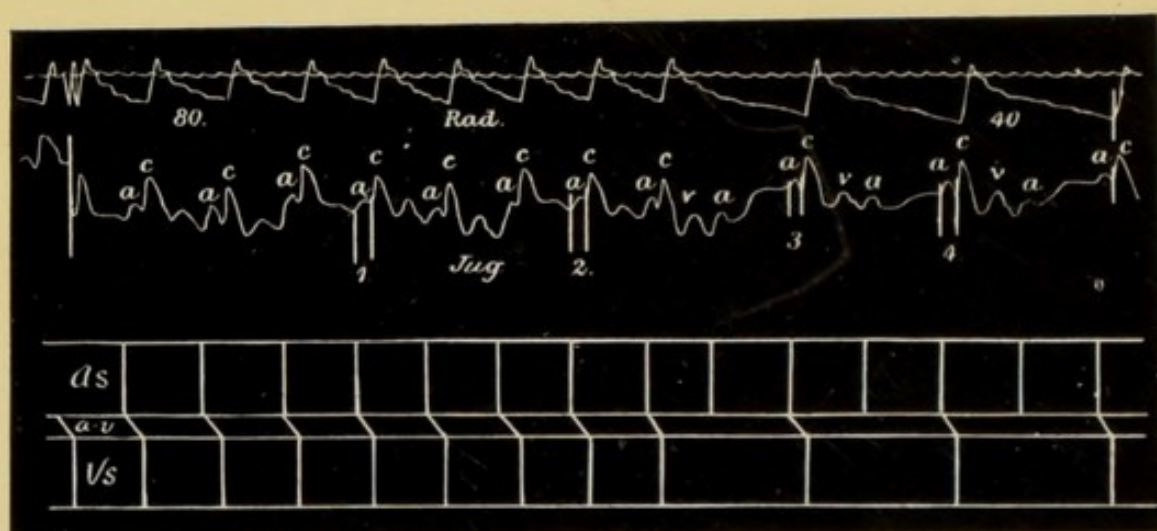


FIG. 110.—Diagram constructed from Fig. 109, representing the events shown in the jugular record.

jugular pulse. Figs. 107 and 109 are examples of this form of arrhythmia, and they demonstrate the manner in which the jugular pulse enables us to unravel the mystery. In Fig. 109 we see a sudden change in the pulse rate from 80 to 40 per minute. On analysing the jugular tracing we find that the *a-c* interval is one-fifth of a second throughout: con-

ductivity is therefore normal, for if it were depressed the *a-c* interval would be more than one-fifth of a second during the first two-thirds of the tracing, when every auricular stimulus reaches the ventricles, and accordingly the *a-v* bundle was stimulated 80 times per minute.

Stimulus production is also normal, for we see in the jugular tracing that the rhythm of the auricle does not alter, but remains throughout at 80 per minute. Again, there is nothing in the record to suggest any failure of contractility on the part of the ventricles. The only other function of the myocardium, variations in which might produce this sudden half frequency in the ventricular rhythm, is that of excitability. In the event of this function being depressed, the stimuli originating in the sino-auricular node would cause the auricle to respond, and then on reaching the *a-v* bundle or the ventricle might find the excitability of the one or the other so impaired that they remain unaffected, and, as a consequence, no ventricular contraction ensues. There can be no intermediate condition: the excitability of the tissue is such that it either responds to the stimulus on its arrival, as in the first nine beats in Fig. 109, or, as is seen to be the case in the latter portion of the tracing, it fails to respond to every other stimulus arriving from the auricle. The slightest depression of excitability below the minimum necessary to enable the

muscle to respond results in a temporary block to the stimulus, and a ventricular systole drops out: by the time the next stimulus arrives, the excitability of the muscle fibres has sufficiently recovered to permit the normal sequence of events to take place.

The same form of arrhythmia is seen in Fig. 107, where the excitability was obviously fluctuating on the borderland of the necessary minimum. Diagrams 108 and 110 are explanatory of Figs. 107 and 109.

The evidence, such as it is, favours the view that the depression of excitability is situated in the musculature of the ventricle. On carefully measuring the *a-c* intervals in Fig. 107, we find that their duration is a little over one-fifth of a second, whether the ventricle beats at 60 or 30 per minute. There is, therefore, a very slight depression of conductivity, not, however, of such a degree as to invalidate in any way the foregoing argument. Now, if through depression of excitability the auriculo-ventricular fibres had failed to respond to the stimulus reaching them, they would certainly have attained the normal speed of conductivity by the time the next auricular stimulus reached them, and the *a-c* interval would have been one-fifth of a second only. Figs. 93 and 96, pp. 136 and 139, show that, given a sufficient length of time, these fibres have the power of complete recovery. The inference is, therefore, that these fibres did respond to every stimulus, that they conducted them to the ventricle, and

that there they failed on occasion to elicit a response. We have, then, a condition of heart-block due to depression of the function of excitability. This function is here in a state of unstable equilibrium; mental excitement, alteration of posture, and deep breathing all tend to alter the extent of the depression and thus to vary the frequency of the ventricular systole.

Increased excitability of the myocardium can be inferred from increased frequency of the heart's action, and from the presence of extra systoles in a frequently beating heart.

Diminished excitability may give rise to infrequent heart action, and to a type of heart block in which ventricular systoles drop out because the excitability of the ventricle is such that the myocardium fails to respond to the stimulus on its arrival.

SECTION 3

CONTRACTILITY

The most obvious and important function possessed by the myocardium is its power to contract. Information as to the condition of this function can be obtained from the records of the radial and jugular pulses. The contractility of the heart is measured by the degree of the contraction, and this is generally dependent on the length of the preceding diastole.

It must not be forgotten, however, that the ampli-

tude of the radial pulse and the height of the ascending limb in the radial tracing are not necessarily correct indications of the contracting power of the ventricle.

As we have already observed, when discussing the wave in the radial artery caused by an extra systole, other factors must be considered above and beyond that of the actual force of the contraction.

Contractility of the heart is dependent on the length of the preceding diastole. The faster the heart beats the greater is the likelihood of cardiac failure.

The condition in which the circulation is most efficient is that where the diastole is of just sufficient duration to allow the heart to recover its full contracting power. A frequency above or below this is disadvantageous.

It has been demonstrated experimentally that when the contractility of the myocardium is depressed there is a tendency for the heart to beat in an alternating manner, large and small beats alternating with perfect regularity. This condition is frequently found in dying hearts. It is also met with in hearts made to beat with great frequency. Drugs such as *antiar* and *digitalis* produce a similar result.

This alternating action of the heart is represented in the radial pulse, and gives rise to the "pulsus alternans," Fig. 111. In this tracing the alternation of large and small beats persists throughout: the length of each cardiac cycle is equal, and is three-

fifths of a second in duration, the only irregularity being in the amplitude of the waves. In this instance the small wave is equidistant from both the preceding and the following wave. When the contractility becomes still further depressed, the weaker of the

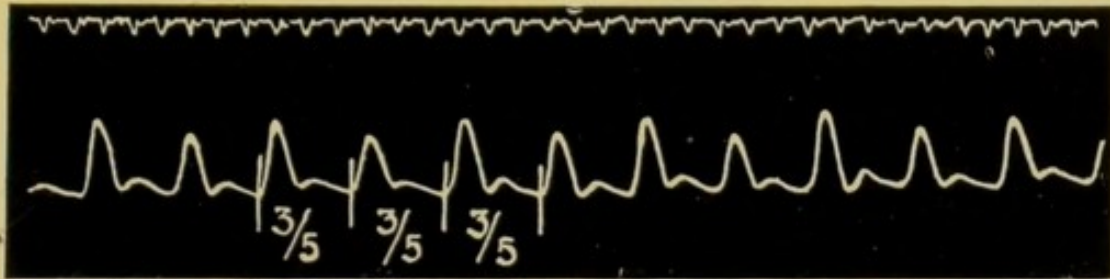


FIG. 111.—Pulsus alternans. Every alternate wave is small, each pulse period is of equal duration.

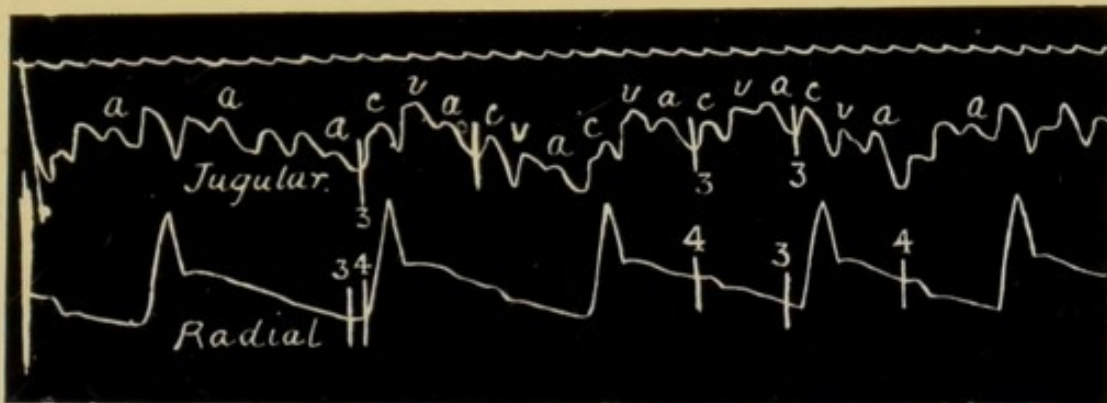


FIG. 112. Pulsus alternans. Simultaneous record of the jugular and radial pulses. The auricle (wave *a*) beats regularly, but every alternate ventricular systole is feeble. At the beginning of the record this alternate feeble contraction is hardly indicated in the radial tracing.

two systoles may be unable to send a pulse wave to the wrist, and, accordingly, every other beat of the heart fails to be represented in the radial artery, and a half frequency ensues. This is the condition recorded in Fig. 112, where the small wave would certainly

not be perceptible to the finger; in fact, it is not even indicated in the record of the first pair of beats. The jugular pulse gives ample evidence of the regular contraction of the auricle, and also demonstrates that the auricle is contracting normally and that conductivity is not interfered with.

Fig. 113 is the record obtained from the radial artery of a patient presenting the *pulsus alternans*,

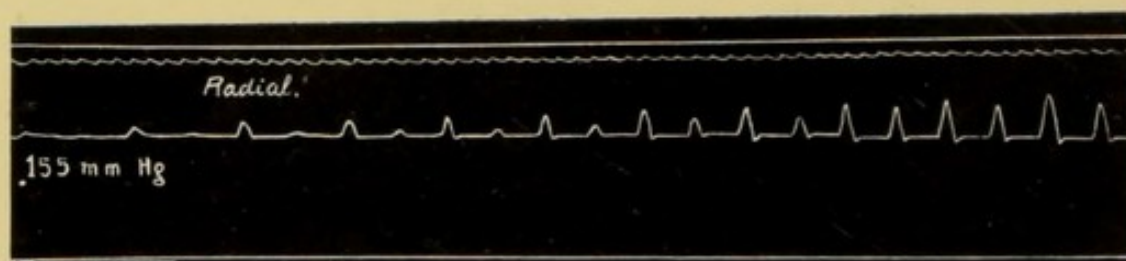


FIG. 113.—*Pulsus alternans*. This record of the radial pulse was taken with the armlet of Oliver's Haemomanometer embracing the brachial artery with a pressure of 155 mm. of mercury. The air was allowed to escape, and as the pressure fell the amplitude of the radial pulse increased, but the alternating quality of the pulse persisted.

in whom the brachial artery was compressed by the armlet of an Oliver's hæmodynamometer while the tracing was being taken. To the left of the tracing the pressure in the armlet was 155 mm. Hg. This pressure just permitted the larger of the two waves to get through to the wrist; the smaller was blocked by the armlet and is not indicated in the record. As the tracing was being taken the air was allowed to escape gradually from the armlet, and accordingly the waves at the wrist are seen to become more and more ample as the obstructing pressure round the arm falls.

It occasionally happens in some patients that digitalis depresses the contractility of the myocardium, and as the result of its administration to these patients an alternating pulse results. This alternating action

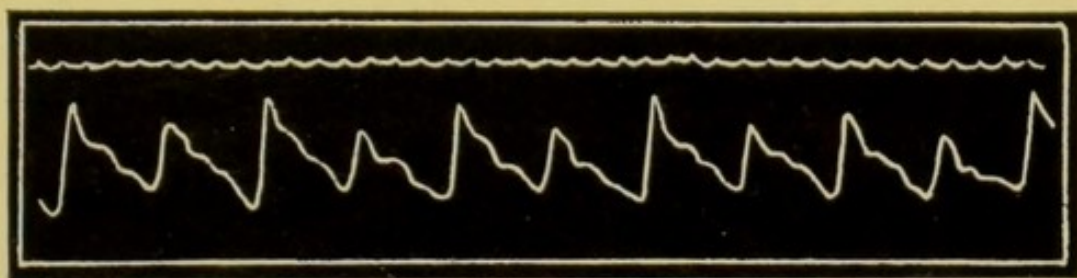


FIG. 114.—Typical pulsus alternans due to digitalis. (Mackenzie.)

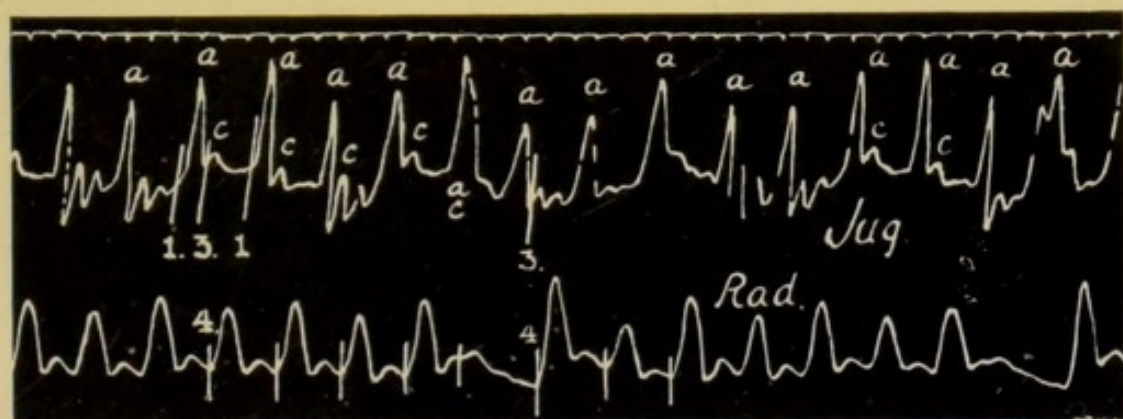


FIG. 115.—Shows an alternating pulse complicated by the occurrence of extra-systoles. Note that the alternation is much more evident after the extra-systole. The extra-systole is of the ventricular type. (Mackenzie.)

of the heart disappears when the drug is stopped. Fig. 114 is an example of the alternating pulse produced by the administration of digitalis.

In Fig. 115 we have a tracing from a patient in whom an alternating pulse is complicated by the presence of extra-systoles. It is worthy of note that after the occurrence of an extra-systole the alternation

is much more pronounced. This characteristic can also be seen in Fig. 45, p. 82, where a distinct though transient alternation is evident subsequent to the extra systole.

In a heart in which the contractility is depressed periods of alternation are frequently initiated by extrasystoles.

It has already been noted that an alternating action

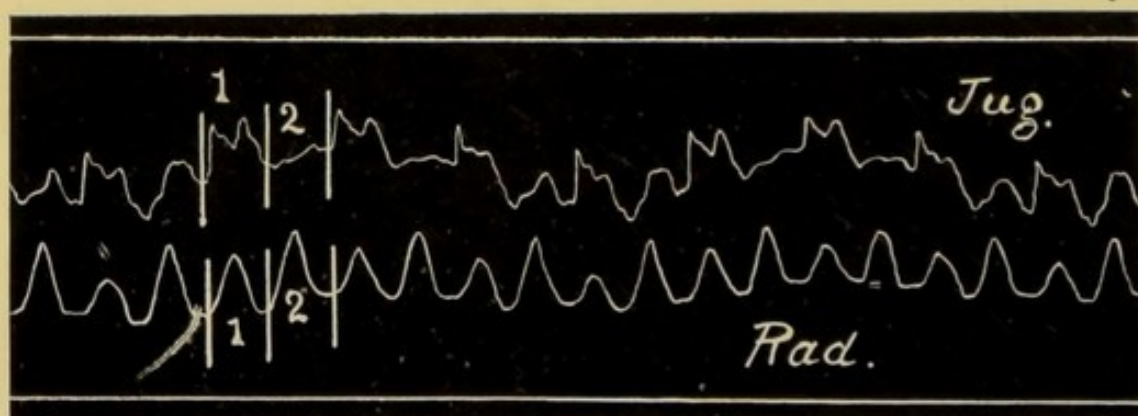


FIG. 116.—Pulsus alternans. Tracing taken during a paroxysm of tachycardia during which the frequency was over 200 beats per minute. The radial pulse is monocrotic and alternating. The jugular pulse is "ventricular" in type and it is also markedly alternating.

of the heart can be produced experimentally by very frequent stimulation of the cardiac muscle. We find a parallel to this in some cases of paroxysmal tachycardia, where the heart is beating so frequently that there is not sufficient time allowed for the contractility to recover itself, which thus becomes depressed. Fig. 116 was taken during an attack of tachycardia, when the heart was beating about 200 times per minute. The radial pulse is monocrotic

and alternating, and it is interesting to note that the venous pulse is also alternating, and that the more ample wave in the radial tracing is coincident with the less ample wave in the jugular, and *vice versa*. Fig. 117 represents diagrammatically the condition present in the jugular and radial pulses, and also the heart sounds which accompanied them.

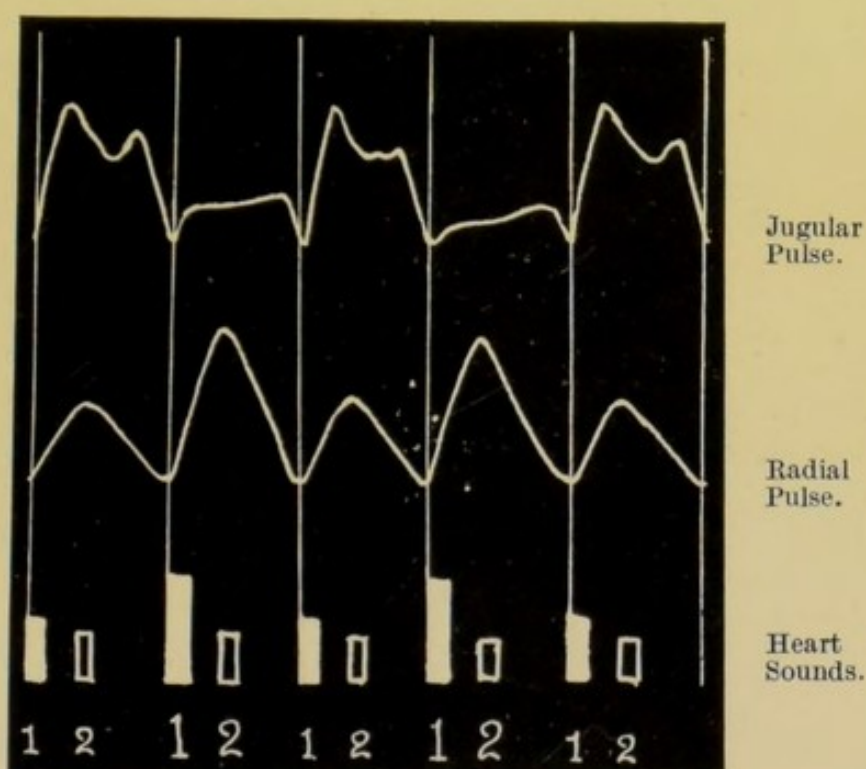


FIG. 117.—Diagram illustrating the alternation in the jugular and radial pulses, and also the character of the heart sounds in relation to this alternation. The louder sounds were only heard in relation to the larger radial pulse waves, and occurred at the commencement of ventricular systole.

The alternating action of the heart at times became so marked that only one-half of the contractions of the heart were able to produce a perceptible radial pulse. A superficial examination of the tracings,

Figs. 116 and 118, might give rise to the idea that the smaller rise was a dicrotic wave, and not a separate pulse beat. Simultaneous tracings taken from the radial and the apex beat, and from the radial and the

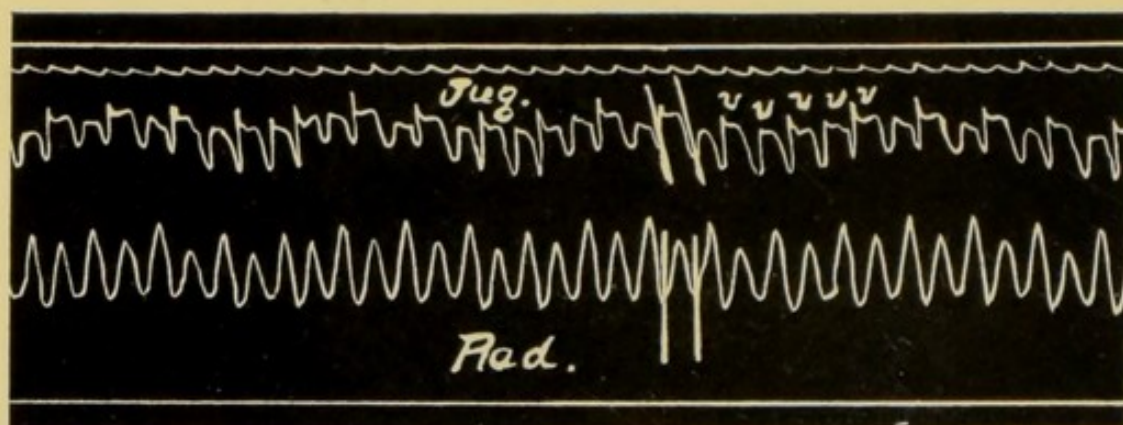


FIG. 118.—Pulsus alternans occurring in a paroxysm of tachycardia. The jugular pulse is "ventricular" in type. With each contraction of the heart there is only one wave *v* and these waves are separated by the negative phase *y*. Note that the radial pulse is monocrotic, not dicrotic.

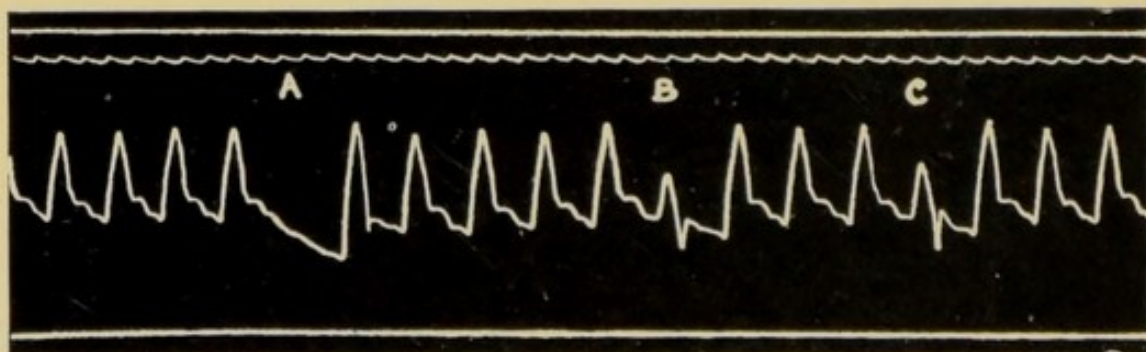


FIG. 119.—Radial sphygmogram, showing a form of arrhythmia due to depression of contractility. At *A* ventricular systole fails to send a pulse wave to the wrist, at *B* and *C* the wave is very small. These smaller waves occur at a point equidistant from the wave preceding and the wave following. They are, therefore, not extra systoles but a temporary alternation.

conus of the right ventricle, proved that the smaller wave was in every case the consequence of a ventricular systole.

Depression of contractility can also be inferred from such tracings as that in Fig. 119. At *B* and *C* the small pulse waves occur exactly at the time when a pulse wave is normally expected; at *A* the wave was so small that it fails to be recorded.

Note that there is no compensatory pause following on the smaller waves, and that each small wave is equidistant from the wave preceding and the wave following.

This form of arrhythmia represented in Fig. 119 occurs in pneumonia, pericarditis, septic and other conditions, and indicates a grave prognosis.

Depression of contractility can be inferred, therefore, when we find an alternating pulse, or a half frequency which is not due to depression of conductivity or excitability, or again where there is an occasional dropped beat not due to an extra-systole, or where a small beat occurs at the normal time, as in Fig. 119.

SECTION 4

STIMULUS PRODUCTION

The activity of the function of stimulus production is constantly varying, and every pulse record demonstrates the existence of such variations. The commonest example is the slight quickening of the heart's action with inspiration, followed by the corresponding

slowing accompanying expiration. In neurasthenic patients this respiratory variation becomes much more distinct, so much so that in some instances, if it were not for the record from the jugular vein, the arrhythmia might be looked upon as due to extrasystoles or depression of conductivity. The phlebogram shows, however, that the arrhythmia originates in the sinus, and that the ventricle is simply following the lead of an irregularly acting auricle.

Marked variations in the frequency are usually due to chronotropic influences, probably of a nervous nature, and it is common to find that positive chronotropic influences are accompanied by those affecting the other functions, the increased frequency being associated, up to a certain point, with increased contractility and increased conductivity.

When attempting to estimate the condition of the function of stimulus production in any case the simultaneous records of the radial and jugular pulses are of value in the following way :—

(1) When there is an arrhythmia due to altered stimulus production, as in Fig. 43, p. 77, an analysis of the jugular tracing demonstrates that the arrhythmia originates in the sinus and that it is not caused by an alteration in any other function.

(2) The phlebogram enables us to differentiate between a bradycardia which is purely the outcome of lowered stimulus production, Fig. 27, p. 63, and a

bradycardia caused by depressed conductivity, Fig. 90, p. 134, or by depressed excitability, Fig. 107, p. 147, or again, by depressed contractility Fig. 112, p. 153.

(3) In patients exhibiting a frequent heart action, the phlebogram informs us as to the site of the stimulus production. It demonstrates whether the inception of the rhythm is in the sinus, as in Fig. 29, p. 69, or whether it is located in the *a-v* system, as in Fig. 69, p. 108, Fig. 81, p. 121, and Fig. 118, p. 158.

SECTION 5

TONICITY

Information as to this function must be obtained by other means than that of recording the arterial and venous pulses.

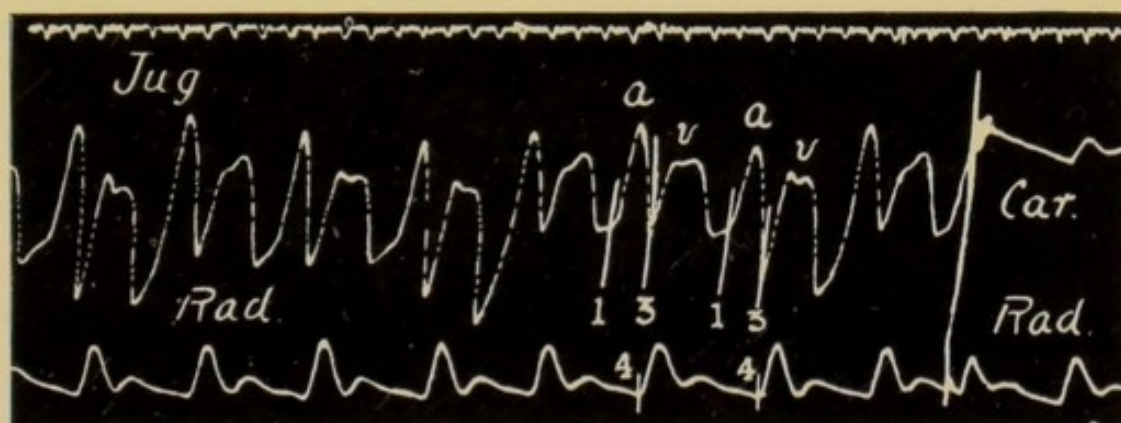


FIG. 120.—Tracings from a patient with extreme anaemia and marked double pulsation in the veins of the neck. She was recovering from pericarditis and endocarditis, rheumatic in origin. The tracing of the jugular pulse suggests that there is loss of tonicities in the muscle fibres guarding the orifice of the superior vena cava, and also that there is some depression of the conducting power of the *a-v* bundle, for the *a-c* interval (1-3) is more than one-fifth of a second.

The only point to be noted here is that depression of tonicity is frequently manifested by dilatation of the heart, and also by large and very distinct pulsations in the jugular veins, the latter resulting from lack of tone in the muscular fibres guarding the caval orifices, Fig. 120. As these muscle bands regain their tone, the caval orifices become efficiently closed during systole, and the jugular pulsations largely disappear.

These two manifestations of depressed tonicity may occur singly or in combination.

CHAPTER IX

DIFFICULTIES IN INTERPRETATION OF SPHYGMOGRAMS

FOR the sake of simplicity variations in each function of the myocardium have been dealt with separately, but it is much more common to find that two or more functions are at fault simultaneously. As an example of this, it is not unusual to find the heart beating with much increased frequency, and at the same time to discover that conductivity is increased simultaneously with stimulus production.

In Fig. 115, p. 155, there is evidence both of an alternating action of the heart and also of the presence of extra-systoles. In this patient the contractility of the myocardium was impaired, and the excitability of the node and *a-v* bundle was increased.

Extra-systoles may occur where the conductivity is depressed, and both these variations from the normal will be evident in the records.

These few examples are enough to demonstrate that in every tracing one must search for indications of a variation from the normal in each function of the myocardium.

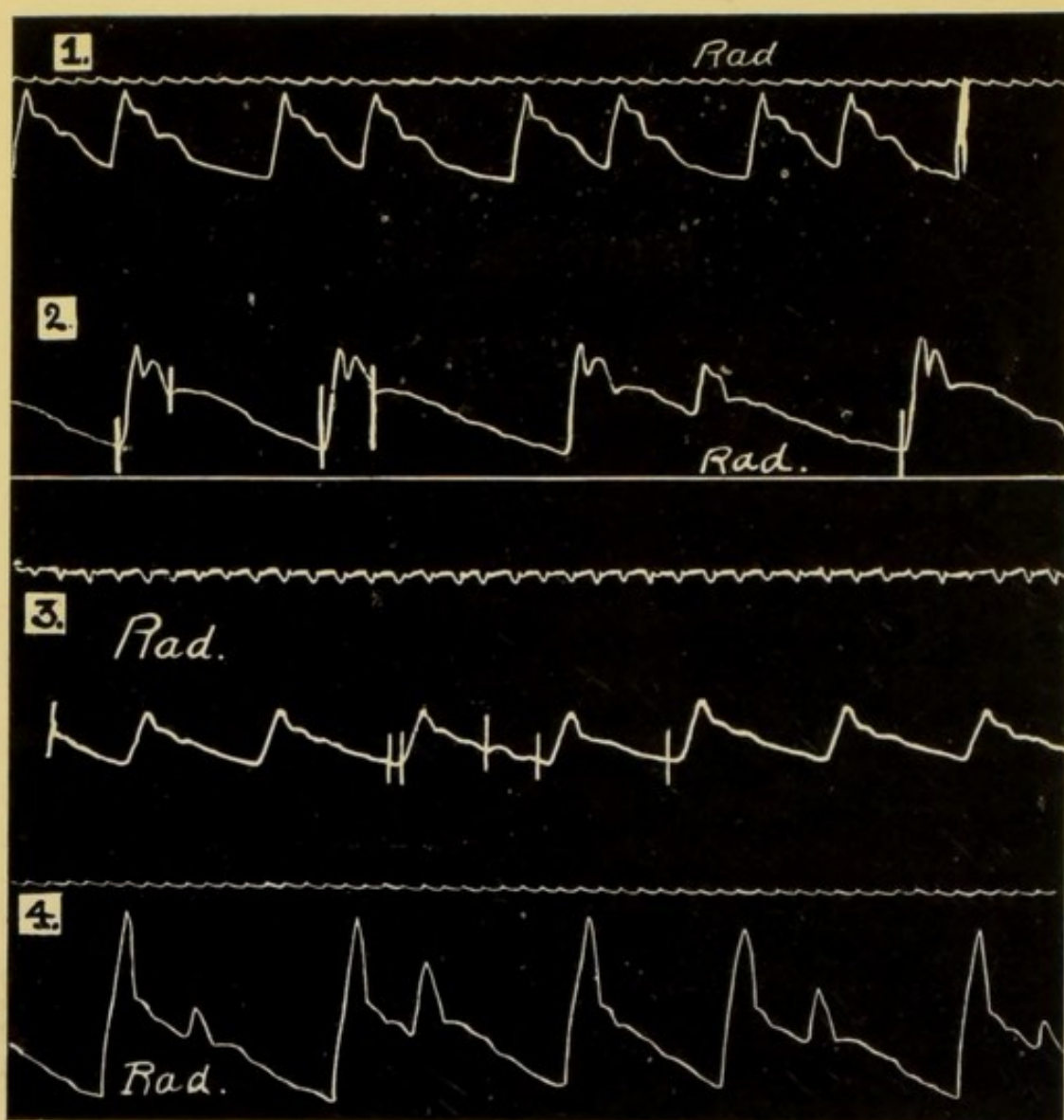


FIG. 121.—Shows four radial tracings reproduced without any accompanying phlebogram or cardiogram. They demonstrate the great difficulties in forming a correct opinion of the cause of any arrhythmia in the absence of some such complementary evidence.

1. A sinus arrhythmia—reproduced with phlebogram in Fig. 43, p. 77.
2. Nodal rhythm. See Fig. 68, p. 108.
3. An interpolated extra systole. See Fig. 60, p. 98.
4. The bigeminy of complete heart block. See Figs. 98 and 100, pp. 140, 142.

In order to demonstrate the difficulty of forming a correct opinion of the manner of the heart's activity, and of any abnormality of function of the myocardium

from the records of the radial pulse alone, I have placed a number of radial tracings one above the other, Figs. 121 and 122. On carefully comparing these records it is clear that if it were not for such information as can be obtained from the phlebograms it would be impossible to differentiate satisfactorily between the various forms of arrhythmia as demonstrated in the tracings of the radial pulse.

The first in Fig. 121 is a simple sinus arrhythmia, see also Fig. 43, p. 77; the second is the record of a radial pulse very similar in rhythm to the first, but where the heart was acting in an entirely different manner, for the stimulus originated in the node, see Fig. 68, p. 108. In the third sphygmogram in Fig. 121 the arrhythmia is due to an extra-systole, see Fig. 60, p. 98; and in the fourth, the condition is one of complete block, see Figs. 98 and 100, pp. 140 and 142.

In each of these patients the correct diagnosis, prognosis and treatment depended on an accurate conception of the manner of the heart's contraction, and this was greatly facilitated by an analysis of the records from the jugular pulse.

In the next series, Fig. 122, the same idea is borne out. The first tracing of the four, see also Fig. 105, p. 145, shows that the slight arrhythmia is the result of depression of conductivity causing the dropping out of ventricular systoles. In the radial tracing

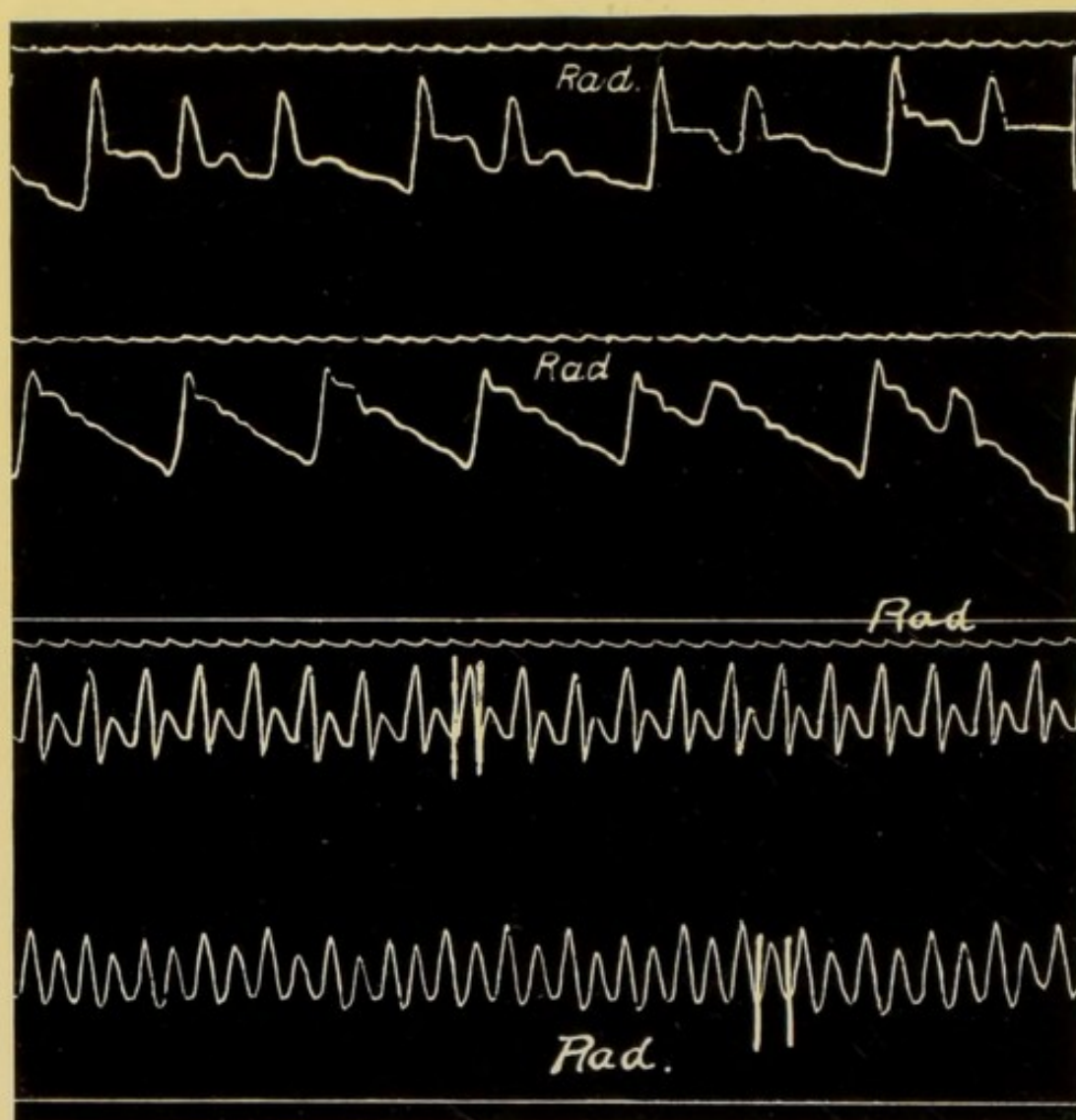


FIG. 122.—Series similar to Fig. 121.

1. An arrhythmia due to the dropping out of ventricular systoles as the result of the exhibition of digitalis. See Fig. 105, p. 145.
2. Two auricular extra systoles. See Fig. 56, p. 94.
3. Frequent heart action. Pulse dicrotic. Stimulus originating at the sinus. See Fig. 29, p. 69.
4. Frequent heart action, pulse alternating and monocrotic. Nodal rhythm. See Fig. 118, p. 158.

of the second example, see also Fig. 56, p. 94, there is a superficial resemblance to that of the first, but the phlebogram proves that the arrhythmia is caused by auricular extra-systoles.

The next record in Fig. 122, see Fig. 29, p. 69, is that of a frequently beating heart in which the stimulus originated in the sinus. This is inferred from the phlebogram because it is auricular in type.

The last sphygmogram in Fig. 122, see Fig. 118, p. 158, is in contrast with the third, and was obtained from a patient suffering from paroxysmal tachycardia. Here the phlebogram is of the nodal type, and demonstrates that the cardiac action differs entirely from that shown in the third tracing, though the radial records are almost identical.

Such tracings could easily be multiplied, but these eight examples are amply sufficient to demonstrate the value of the phlebogram in arriving at a satisfactory opinion of the way in which the heart is contracting, and thus making possible a scientific classification of disorders of the heart.



CHAPTER X

ILLUSTRATIVE CASE OF MITRAL STENOSIS

I HAVE thought it might be of interest to give some tracings illustrating the way in which the changes in the manner of the heart's activity can be followed in an individual case.

The patient was a male, aged 21, and was under observation for some years at the Royal Infirmary, Liverpool, under the care of Dr. T. R. Bradshaw. At the age of ten he suffered from acute rheumatism, and since that attack he has had several relapses.

On admission, September, 1907, the heart was much enlarged and appeared to be anchored; over the apex beat a presystolic thrill was easily palpable, and on listening to the heart at the same area one heard systolic, pre-systolic and diastolic murmurs. Over the aortic area a systolic murmur could be heard conducted up into the neck.

The diagnosis arrived at was adherent pericardium, mitral stenosis and regurgitation with aortic obstruction. So far as it went this was proved to be correct, when in due course an autopsy was made;

there was, however, in addition narrowing of the tricuspid orifice and some chronic peritonitis.

For the last three or four years of his life the reserve power of the heart was very limited, and compensation was frequently disturbed, being restored by rest, laxatives and cardiac tonics.

In March, 1908, the tracing shown in Fig. 123 was

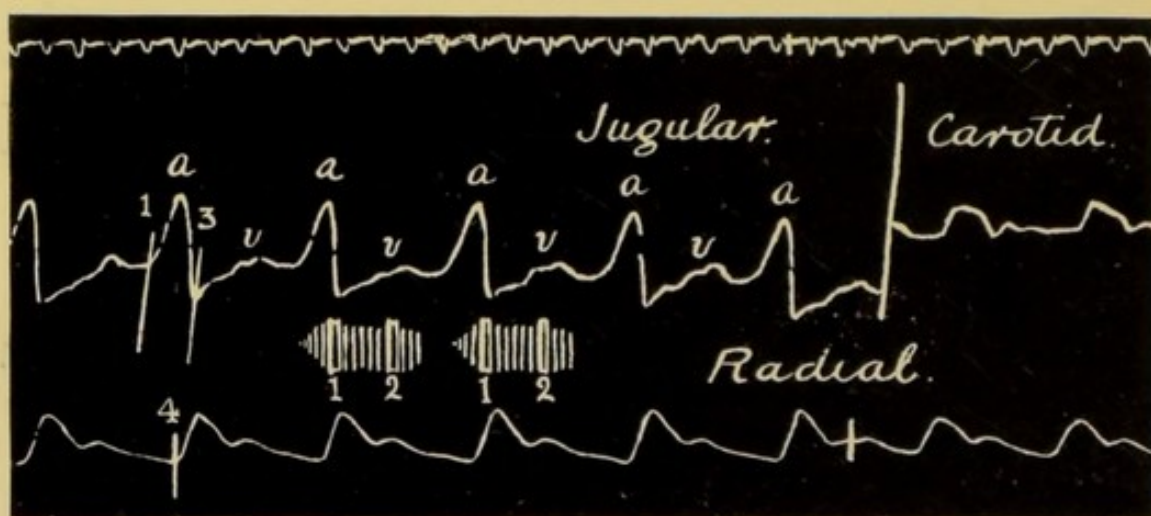


FIG. 123.—The first of a series of six records from the same patient. The jugular pulse is auricular in type, the wave *a* is well marked and occurs regularly. The *a-c* interval 1 to 3 is lengthened, showing some depression of conductivity. The murmurs are indicated on the tracing; presystolic, systolic and diastolic. March 19, 1908.

taken, after he had been in bed for a few days. The points to be noted are (1) the regularity of the cardiac action; (2) the large wave *a* in the jugular tracing, and (3) that this wave occurs before ventricular systole, showing that the stimulus for the inception of the rhythm originated in the sinus. Note also (4) the increased length of the *a-c* interval, the distance from

1 to 3 being more than three-tenths of a second. When this tracing was taken there were presystolic, systolic and early diastolic murmurs at the apex, as

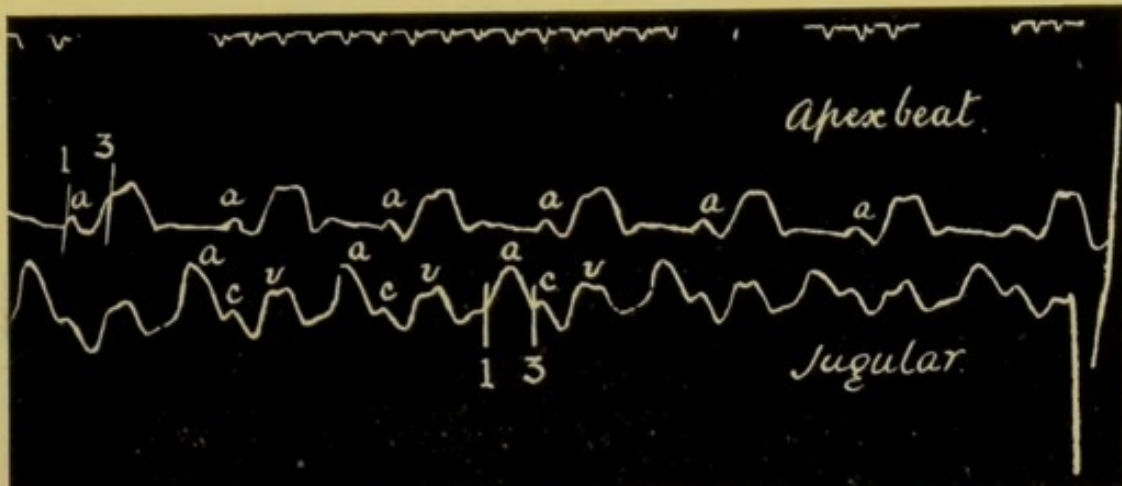


FIG. 124.—Simultaneous tracings from the apex beat and the jugular pulse. Taken on March 19, 1908. Note the regular appearance of the wave *a* in the cardiogram and phlebogram, and also the delay in the transmission of the stimulus from the auricle to the ventricle.

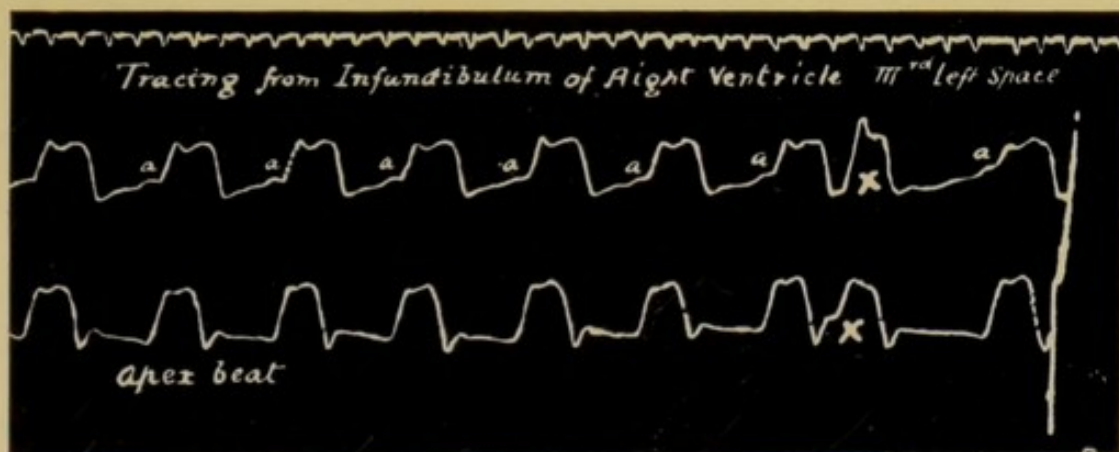


FIG. 125.—Simultaneous tracings from the infundibulum of the right ventricle (third left space) and the apex beat. Shows the occurrence of an extra systole at *x*. March 19, 1908.

indicated on the record. The same features are to be made out in Fig. 124, where we have the record from the apex beat contrasted with that from the jugular vein.

Fig. 125, taken on the same day, shows the records obtained by placing one receiver over the infundibulum of the right ventricle in the third left space, and the other over the apex beat. Towards the right of the tracing an extra-systole occurs.

In all these records the sinus dominates the rhythm. Occasionally extra-systoles became evident, but, as

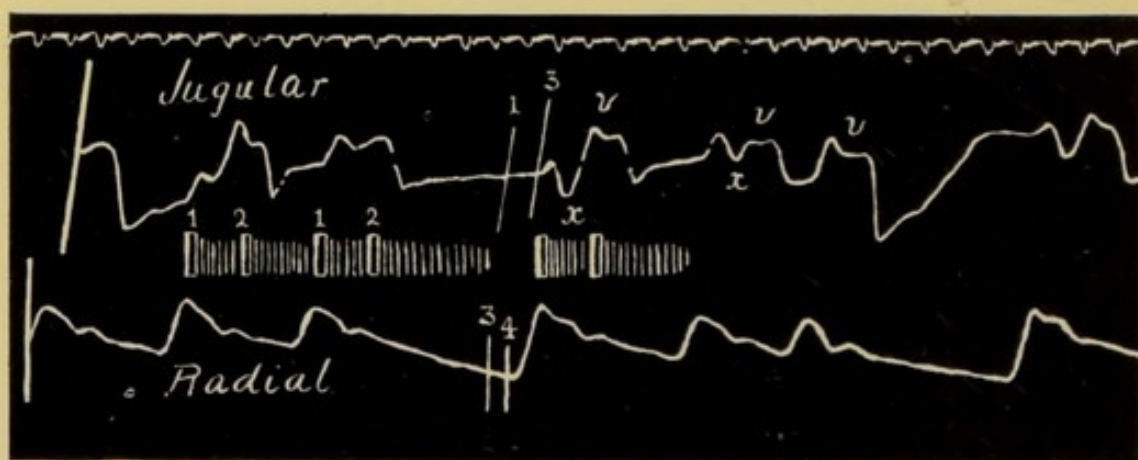


FIG. 126.—Simultaneous tracings of the jugular and radial pulses, showing an entire change in the character of both. The rhythm is now disorderly and the jugular pulse is "ventricular" or "nodal" in type. The wave *a*, present in the three previous tracings, has disappeared. The murmurs are charted on the record. Note that the presystolic murmur has disappeared. July 3, 1908.

a rule, they were infrequent. On June 8, the patient was discharged much improved. He was able to get about with comfort. Shortly after his discharge he began to suffer from attacks of very rapid heart action; these attacks varied in their duration from two or three hours to twenty-four hours—they began suddenly and were equally abrupt in their cessation. Between the attacks the pulse rate was about 80.

He was re-admitted on July 1 very much worse. The heart was more dilated, the liver was engorged, and extended $2\frac{1}{2}$ inches below the costal margin, the slightest exertion precipitated an attack, during which the rate of the heart was over 160 per minute. Fig. 126 was taken only two days after admission, and reveals that the whole character of the heart's action is altered. The heart is beating irregularly, without any rhythm in its irregularity. It is a typical example of a nodal rhythm. There is an entire absence of any wave in the jugular tracing between the upstrokes 1 and 3, that is, just when one would naturally expect the appearance of a wave due to auricular systole. It is also noteworthy that the presystolic murmur which was so prominent a physical sign when the earlier records were taken has now gone, and the only murmurs audible are a systolic and a diastolic. There is no presystolic accentuation of the diastolic murmur, and during the longer pauses the diastolic murmur entirely ceases before the beginning of the next systole, as indicated by the first sound, and there is a silent period antecedent to this sound. The murmurs are charted on the tracing.

Squills was given in efficient doses, and in a few days the typical response was obtained, that is, marked slowing of the heart and the peculiar and characteristic coupling of the heart's beats. This is well shown in Figs. 127 and 128; in Fig. 127 the upper tracing is

from the jugular vein, in 128 from the apex beat. In neither do we find any indication of auricular systole before the systole of the ventricle.

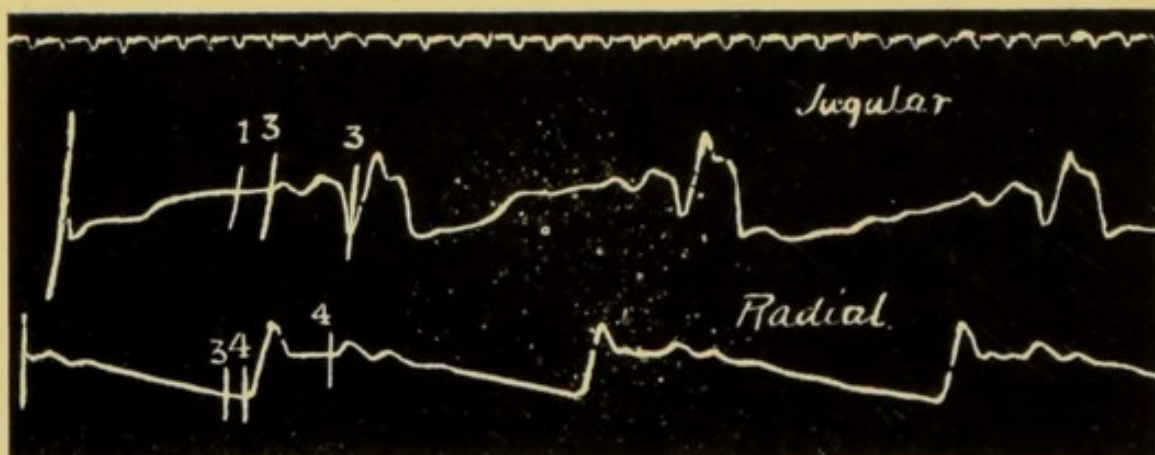


FIG. 127.—Shows the typical response to the digitalis group. There is marked slowing of the heart and the characteristic coupling of the heart's beats. The upper tracing is from the jugular vein and is a good example of the nodal or ventricular type of venous pulse. July 6, 1908.

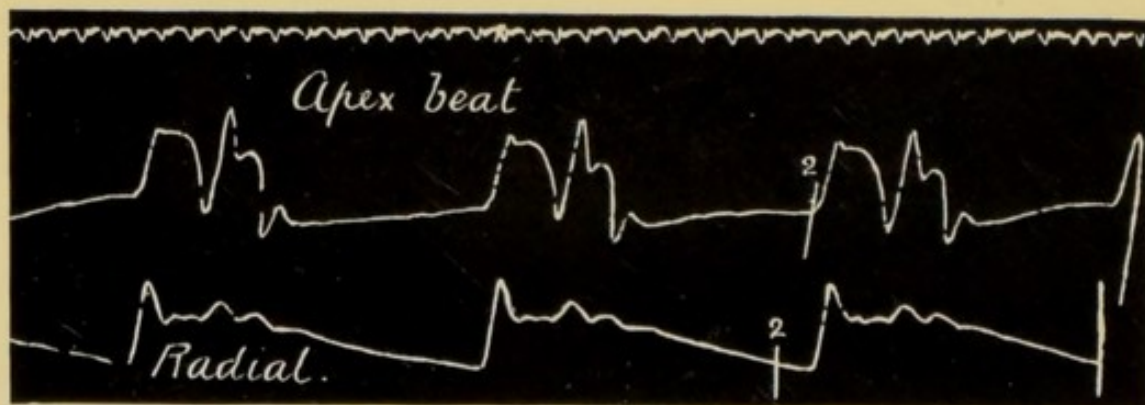



FIG. 128.—This record shows the effect of the digitalis group on this particular form of heart disease. The upper tracing is from the apex beat and shows very beautifully the coupled systoles of the ventricle. July 6, 1908.

The patient had been given squills and digitalis on previous occasions, but they had never brought about this specific arrhythmia which is, so far as I

know, confined to hearts dominated by the nodal rhythm.

This nodal form of rhythm, as shown in Fig. 126, entails of necessity extra strain on the heart. It was too much for the myocardium, and the patient, after rallying a little, became steadily worse, and died on August 24.



INDEX

- Abdominal pressure, 10
- a-c* interval—
 cases showing prolongation
 of, 133, 134, 135, 136, 138,
 139, 145, 170
 definition of, xv
 description of, 61, 131
 duration of, 131
 increased, 132
 in extra-systole, 92, 94, 97,
 98
- Adams Stokes disease, 142, 143
 See "heart-block."
- Adherent pericardium and
 valvular disease, 169
- Anatomical considerations, 7
- Aortic notch, 40
- Apex beat, 26
 caused by left ventricle, 47
 caused by right ventricle,
 50, 47
 definition of, 42
 difficulties in obtaining re-
 cord of, 26
 in children, 42
 in the aged, 42
 position of apex beat, 42
- Apex of heart, 11, 12
- As* wave—
 cause of, 109, 110, 111
- Auricle—
 expansion of, 14
 movements of, 12
 musculi pectinati in right, 12
- Auricular extra systoles, 91
- Auricular liver pulse, 61
- Auricular systole—
 effect on *a-v* septum, 12, 15
 in cardiogram, 46
- Auricular venous pulse, 73, 107
 comparison of nodal and,
 116, 117
 definition of, xv
- Auricular waves—
 absence of wave *a*, 106 et
 seq.
 cause of, in cardiogram, 46
 cause of, in jugular pulse,
 59, 60
 in jugular pulse in heart-
 block, 140
 in the nodal form of venous
 pulse, 110, 111
- Auriculo ventricular (*a-v*)
 bundle—
 definition of, xv
 diseased, 142
- Auriculo-ventricular (*a-v*)
 node, 83
 definition of, xv

- Auriculo-ventricular septum,
12
cause of movements of, 67
movements of, 15, 62
- Cardiac response—
area of, 4
- Cardiogram, 41 et seq.
auricular systole in, 46
characteristics of, 47
comparison with carotid
sphygmogram, 44
during diastole, 46
interpretation of, 43
inverted, 49, 50, 51
inverted, palpation in, 51
inverted, significance of, 52
normal positive, 48, 49
period *E* in, 44
time relationship of, 47
variations from the normal,
49 et seq.
- Cardio-sclerosis, 105
- Carotid pulse—
relation of, to apex beat, 45
relation of, to jugular pulse,
45
relation of, to radial pulse,
45
value in analysing phlebo-
gram, 57
- Carotid wave, *c*—
with jugular pulse, 57
- Caval orifices, 10
- Childhood—
cardiac arrhythmia in, 79
- Circulation—
condition of greatest effi-
ciency, 152
- Clinical polygraph, 17, 18
- Compensatory pause—
value of, 89
- Conductivity—
action of digitalis on, 144, 145
definition of, xv
depression of, 59, 170
depression of, in mitral
stenosis, 170
depression of, results of, 146
depression of, stages of,
136 et seq.
depression of, with inter-
polated extra-systoles, 99
disturbance of, 131
method of estimating, 131
recovery of, 2
- Contractility, 151 et seq.
definition of, xv
depression of, indicated by
pulsus alternans, 152
depression of, indications
of, 159
depression of, measured by,
151
depression of, resulting in
half frequency, 153
recovery of, 2
- Contraction of the heart, 2
- Contraction, simultaneous, of
auricles and ventricles,
60, 90, 96, 100, 128, 129
- Coupled beats—
in response to squills, 173,
174
- Definitions—
apex beat, 42
a-c interval, xv

Definitions—

auricular venous pulse, xv
 auriculo-ventricular bundle,
 xv
 auriculo-ventricular node,
 xv
 conductivity, xv
 contractility, xv
 extra-systole, 81
 heart-block, xv
 myogenic theory, xv
 nodal form of venous pulse,
 xvi
 nodal rhythm, xvi
 primitive cardiac tissue, xvi
 pulsus alternans, xvi
 sino-auricular node, xvi
 tonicity, xvi
 ventricular rhythm, xvi
 ventricular venous pulse,
 xvi

Dicrotic notch, 40

Digitalis, 144

causing dropping out of
 ventricular systoles, 144,
 145
 causing pulsus alternans,
 155
 depressing conductivity,
 144, 145
 depressing contractility, 155
 in nodal rhythm, 174
 in sinus rhythm, 174

Dilatation of the heart, 162

Disappearance of presystolic
 murmur, 112, 113, 173

E period, 41

in cardiogram, 44

Epigastric records, 54

Excitability of myocardium,
 146

depression of, causing heart
 block, 148

depression of, results of, 151

extra-systoles resulting
 from, 147

increased, indications of,
 151

increased, results of, 147

Experimental evidence—

of the nodal rhythm, 126,
 129

Extra-systoles, 81, 171

and primitive cardiac tube,
 91

auricular, 84, 91

auricular, *a-c* interval in, 92

auricular, characteristics of,
 96

auricular, sphygmogram in,
 165, 166

auricular, with compensa-
 tory pause in, 92, 94

auricular, without com-
 pensatory pause in, 94

characteristic features of, 82

definition of, 81

diminution of wave *v* fol-
 lowing, 90

gravity of, in frequently
 acting heart, 147

infranodal, 84, 96

interpolated, 97, 99

nodal, 84

nodal, characteristics of, 101

nodal, site of origin of
 stimuli, 102, 129

Extra-systoles—

post-extra-systolic delay,
82, 89

premature appearance of,
82

relation to nodal rhythm,
123

sites of origin of, 83, 84

subjective sensations of, 81

ventricular—

characteristics of, 99, 100

site of origin, 96

with depression of con-
ductivity, 99

Gaskel, 1

Graphic records—

of apex beat, 41 et seq.

of epigastric movements, 90

of jugular pulse, 55

of liver pulse, 27, 58, 61

of radial pulse, 39, 40

value of combined, 163

Heart—

fixed points of, 11

long diameter of, 11

longitudinal fibres of, 11

Heart-block—

a-v bundle in, 142

complete, 141, 142, 143

definition of, xv

incomplete, 134

Heart irregularity—

due to disturbance of con-
ductivity, 131

due to disturbance of ex-
citability, 146

Heart irregularity—

due to extra-systoles, 81

in complete heart-block, 141

of childhood, 79

originating at the node,
101, 129

originating at the sinus, 77,
78, 79

His' bundle—

See "auriculo-ventricular
bundle."

Holding breath—

effect on tracing of, 25, 26

Inks for ink-writing poly-
graph, 33

Ink-writing polygraph, 17

advantages of, 37

defects of pens for, 34, 35

description of, 29, 30, 31
et seq.

pens for, 34

the splint, 31

the tambour, 31, 32

Instruments, 17

Intermittent pulse, 82

Interpolated extra-systoles,
97, 99

Irregular action of the heart, 5

See also "heart irregular-
ity"

Jugular bulb, right, 7

Jugular pulse—

auricular wave in the, 59, 60

changes in volume of, 113

first negative phase "*x*" in,
61, 62, 111, 112

- Jugular pulse—
 interpretation of records of, 55
 production of, 11
 second negative phase "y" in, 68
 ventricular depression, variations in, 68, 69
 wave "h" in, 71
 wave "v" in, 46
 Jugular valves, 7, 8
- Keith, 7
- Liver pulse, 27, 58, 61
 auricular wave in, 61, 115
 how to record, 27
 ventricular wave in, 114, 115
- Mitral stenosis—
 change in murmurs, 113, 173
 change in rhythm, 112, 172
 depression of conductivity in, 170, 171
 effect of digitalis on, 174
 illustrative case of, 169
 nodal pulse in, 105
- Movements of respiration—
 effect on jugular pulse, 25, 26, 58, 74
 method of recording, 27
- Murmurs—
 disappearance of presystolic, 173
- Muscle fibres—
 circular, 11
 of right auricle, 10
 of right ventricle, 10
 pectinate, 13
- Musculature of the heart—
 circular fibres, 11
- Musculi pectinati, 13
- Myogenic theory, 1
- Neurasthenia—
 sinus arrhythmia in, 160
- Nodal extra-systoles, 101, 103
- Nodal form of venous pulse, 105 et seq.—
 combined with auricular, 119
 definition of, xvi
 in paroxysmal tachycardia, 120 et seq.
- Nodal rhythm, 105
 abrupt onset with distress, 115-116
 characteristics of jugular pulse in, 105, 106
 clinical indications of onset of, 115, 116
 condition of right auricle in, 111, 123, 126
 definition of, xvi
 example of, 172
 explanation of, 126 et seq.
 insidious onset, 115
 liver pulse in, 114, 115
 prognosis in, 105
 site of origin of stimuli in, 125
 sphygmogram in, 164, 165
 transient attacks of, 16
 treatment in, 105
- Normal records, 39
 cardiogram, 41
 epigastric records, 54
 phlebogram, 55
 sphygmogram, 39

- Paper for recording records,
 28
 its length, 28
 varnish for, 30
- Paroxysmal tachycardia, 120, 156
 nodal rhythm in, 120 et seq.
 pulsus alternans in, 156, 157, 158
 sphygmogram in, 166
 termination of attack, 121, 122
 venous pulse in, 120
- Pectinate muscle bundles in right auricle, 12
- Pens, defects of, 34, 35
- Pens for ink polygraph, 34
- Percussion wave in sphygmogram, 39
- Phlebogram, 45
 analysis of, 55
 carotid pulse wave in, 57, 58
 period *E* in, 57, 58
 value of, 163
- Polygraph, clinical, 17, 19
- Position of patient when taking records, 22, 25
- Post extra-systolic delay, 89
- Predicrotic wave in sphygmogram, 39
- Presystolic murmur, disappearance of, 173
- Primitive cardiac tissue—
 definition of, xvi
- Pulse—
 disorderly, in nodal rhythm, 105, 106, 108, 109
 intermission due to depressed conductivity, 145
- Pulse—
 intermission due to depressed excitability, 147
 intermission due to extra-systoles, 81, 82, 93
- Pulse, venous—
 See "jugular pulse."
- Pulsus alternans, 152, 155
 action of digitalis in producing, 152, 155
 complicated by extra-systoles, 155
 definition of, xvi
 indicating depression of contractility, 152
 initiated by extra-systoles, 155
 in paroxysmal tachycardia, 156, 157, 158
 in pericarditis, 158
 in pneumonia, 158
 in prognosis, 158
 in septic infections, 158
- Receiver for transmitting pulsations, 19
 for liver pulse, 27
- Recording pulsations—
 position of patient, 34
- Records—
 method of storing, 36
- Regurgitation into superior vena cava, 10
- Reserve power of myocardium, 3
- Respiratory movements, 25, 27
- Respiratory variations in cardiac rhythm in neurasthenia, 160

- Rhythm—
2 : 1, 136
3 : 1, 138
combination of 2 : 1 and
3 : 1, 138, 139
ventricular rhythm, irregular
action in complete
heart-block, 141, 164, 165
Right heart, effect of engorge-
ment of, 70, 109
Right ventricle—
arrangement of muscle fibre
in, 14

Senile heart, 105
Sensations of the patient with
extra-systole, 81
Septum, *a-v*—
movements of, 12, 14, 15,
62
Sino-auricular node—
definition of, xvi
Sinus rhythm, 73
Sinus venosus—
remains of, 3
right valve of, 12
Sphygmic period—
in phlebogram, 57
in sphygmogram, 40, 41
Sphygmogram—
cause of percussion wave
in, 39
definition of, 39
in complete heart-block,
164, 165
in depression of conducti-
vity, 165, 166
in extra-systoles, 164, 165

Sphygmogram—
information yielded by, 39
in sinus arrhythmia, 164,
165
normal, 39
of hypertension, 41
of hypotension, 41
predicrotic wave in, 39
sphygmic period in, 40,
41
value of radial, 39, 41
Sphygmograph—
Dudgeon's, 18, 19
Von Jacquet's, 37
Splint for ink polygraph, 31
Squills—
typical response to, 173,
174
Starting place—
of heart's contraction, 73
of nodal rhythm, 129
Sternomastoid, right, 25
Stimulus production, 159
increased, 146, 147
respiratory variations in,
159, 160
Superior vena cava, regurgi-
tation into, 10
Systolic period, 40, 44, 45, 47

Tachycardia—
See "paroxysmal tachycar-
dia."
Tænia terminalis, 12
Tambour—
of ink polygraph, 31, 32
Tambour and lever, 18, 20
Tidal wave, 39

- Time marker, 48
- Tonicity, function of, 2, 161
definition of, xvi
depression manifested by, 162
localisation of, 3
- Tracing—
how to take a, 21
- Tricuspid regurgitation—
and wave “v,” 109
effect of, 67
- V wave. *See* “wave v.”
- Varnish—
formula for, 30
- Varnishing records, 30
- Vena cava—
inferior, 10
superior, 10, 12
- Venous cistern, 8, 9, 10
- Venous mesocardium, 11, 12, 15
- Venous pulse—
See “jugular pulse.”
- Ventricle—
condition of, during systole, 44
- Ventricle—
filling during systole, 46
period of systole, 44
- Ventricular extra systole, 96
- Ventricular liver pulse, 114, 115
- Ventricular rhythm—
definition of, xvi
- Ventricular systole—
action on auricle, 14, 15
shock caused by, 43
- Ventricular venous pulse—
definition of, xvi
See “nodal form of venous pulse”
- Wave a, first positive phase—
See “auricular waves.”
- Wave v, second positive phase, 46, 63
cause of, 64
component parts of, 63
size and character of, 108, 109
termination of, 118
variations in, 64



Wm. J. B.
11/24/68



