

The use of the Röntgen ray by the Medical Department of the United States Army in the War with Spain (1898) / prepared under the direction of Surgeon-General George M. Sternberg ... by W.C. Borden.

Contributors

Borden, William Cline, 1858-1934.
Sternberg, George Miller, 1838-1915.
United States. Surgeon-General's Office.

Publication/Creation


Washington : Govt. Print. Off, 1900.

Persistent URL

<https://wellcomecollection.org/works/rjz7sbqc>

License and attribution

Conditions of use: it is possible this item is protected by copyright and/or related rights. You are free to use this item in any way that is permitted by the copyright and related rights legislation that applies to your use. For other uses you need to obtain permission from the rights-holder(s).



DT. 6

X18820



22101262209



Digitized by the Internet Archive
in 2016

<https://archive.org/details/b24877426>

THE USE
OF THE
RÖNTGEN RAY

BY THE
Medical Department of the United States Army

IN THE
WAR WITH SPAIN.

(1898.)

PREPARED UNDER THE DIRECTION OF
Surgeon-General **GEORGE M. STERNBERG**, United States Army,
BY
W. C. BORDEN,
CAPTAIN AND ASSISTANT SURGEON, U. S. ARMY.

WASHINGTON:
GOVERNMENT PRINTING OFFICE.
1900.

V.T. 6



LETTER OF TRANSMITTAL.

U. S. ARMY GENERAL HOSPITAL, WASHINGTON BARRACKS,
Washington, D. C., December 9, 1899.

Brigadier General GEORGE M. STERNBERG,
Surgeon-General, United States Army.

SIR: I have the honor to transmit herewith a report prepared by your direction on the use of the Röntgen ray by the Medical Department of the United States Army in the war with Spain.

In submitting this report, I desire to express my great appreciation of the earnest support you have given its preparation, both personally and by affording me every possible facility for the work.

Very respectfully, your obedient servant,

W. C. BORDEN,
Captain and Assistant Surgeon, United States Army.

TABLE OF CONTENTS.

	Page.
Introduction	11
SECTION I:	
Röntgen ray apparatus	13
Static apparatus	14
Coil apparatus	14
Storage batteries	14
Primary batteries	15
Where Röntgen ray apparatus should be placed for military surgical use ..	18
Röntgen ray apparatus compared	26
SECTION II:	
Lodged missiles	30
Lodged, Mauser bullets deformed by ricochet	33
Lodged, undeformed, Mauser bullets	35
Lodged, shrapnel bullets	37
Lodged, brass-jacketed bullets	39
Injuries to the central nervous system by lodged, Mauser bullets	40
General conclusions relative to lodged missiles	44
SECTION III:	
The localization of lodged missiles	45
The Röntgen ray and wound exploration compared	45
Necessity for the localization and removal of lodged missiles	46
Localization methods	49
By direct observation	49
By multiple observation	51
Photographic apparatus for localization	52
Apparatus for visual localization	60
SECTION IV:	
Gunshot fractures of the diaphyses of long bones	63
Fractures by perforating bullets	63
Fractures by perforating bullets at short range	64
Fractures by perforating bullets striking the bone in the median line	67
Fractures by bullets striking the bone tangentially	69
Fractures by penetrating, undeformed bullets	71
Fractures by penetrating, deformed bullets	72
Clinical conclusions	75

	Page.
SECTION V:	
Gunshot fractures of the extremities of long bones and of the cancellous bones generally	76
Gunshot of the epiphyses	76
Gunshot of the cancellous bones	81
Clinical conclusions	83
SECTION VI:	
Radiographic technic	85
The static machine	85
Crookes tubes	86
Manipulations of the tube to secure maximum radiation	87
The coil machine	88
Radiography	90
Photographic plates	91
Exposure	93
Röntgen ray burns	93
Development	97
Printing	98

LIST OF ILLUSTRATIONS.

PLATES.

	To face page
I. The Edison battery apparatus and the static apparatus	14
II. Lodged, Mauser bullets	30
III. Radiograph of deformed, Mauser bullet lodged in the leg	32
IV. Radiograph of deformed, Mauser bullet lodged superficially in knee	34
V. Radiograph of undeformed, Mauser bullet lodged in the thigh	36
VI. Lodged, shrapnel bullets	36
VII. Radiograph of shrapnel bullet, lodged in the back	38
VIII. Radiograph of shrapnel bullet, lodged in thigh	38
IX. Lodged, brass-jacketed bullets	40
X. Radiograph of Mauser bullet, lodged in the back	40
XI. Radiograph of Mauser bullet, lodged in the brain	42
XII. Radiograph of fragment of missile, lodged in the fibula	48
XIII. Radiograph of Mauser bullet, lodged in the foot	52
XIV. Radiograph of Mauser bullet fracture of metacarpal bones	66
XV. Radiograph of Mauser bullet fracture of radius by "contact"	66
XVI. Radiograph of Mauser bullet fracture of femur	68
XVII. Radiograph of Mauser bullet fracture of femur after union	68
XVIII. Radiograph of Mauser bullet fracture of phalanx	68
XIX. Radiograph of Mauser bullet fracture of metatarsal bones	68
XX. Radiograph of Mauser bullet fracture of humerus	70
XXI. Radiograph of Mauser bullet fracture of radius	70
XXII. Radiograph of Mauser bullet fracture of humerus	70
XXIII. Radiograph of Mauser bullet fracture of femur	70
XXIV. Radiograph of Mauser bullet fracture of humerus	72
XXV. Radiograph of Mauser bullet fracture of ulna	72
XXVI. Radiograph of Mauser bullet fracture of femur by "mushroomed" bullet	72
XXVII. Photograph of bone fragments from a case of fracture of the thigh by a "mushroomed" Mauser bullet	72
XXVIII. Radiograph of gunshot fracture of the femur	74
XXIX. Radiograph of fracture of tibia by brass-jacketed bullet	74
XXX. Radiograph of Mauser bullet, embedded butt-end foremost in the tibia	76
XXXI. Radiograph of shrapnel bullet in the thigh, the bullet having per- forated the femur	76

	To face page
XXXII. Radiograph of Mauser bullet fracture of neck of femur	78
XXXIII. Radiograph of Remington bullet, lodged in upper end of tibia	78
XXXIV. Radiograph of Krag-Jørgensen perforation of upper end of tibia	80
XXXV. Radiograph of separation of olecranon by Mauser bullet	80
XXXVI. Radiograph of fracture of lower end of radius by lodged, Mauser bullet	80
XXXVII. Radiograph of Remington bullet perforation of os calcis	82
XXXVIII. Radiograph of Remington bullet, lodged in the face	82

FIGURES.

1. Edison-Lalande cell	16
2. Edison, break-wheel apparatus	28
3. Diagram of location of ball in case of Private Keene, First United States Volunteer Cavalry	35
4. Diagram of location of bullet in case of Private Cooper, Tenth Cavalry ..	36
5. Diagram explanatory of Plate VII	38
6. Diagram explanatory of Plate VIII	38
7. Diagram showing location of bullet in case of Edward Marshall	41
8. Photograph of Private Gretzer, First Nebraska Volunteers	43
9. Diagram showing location of bullet in case of Major Eskridge	47
10. Diagram showing relative size of umbra and penumbra in foreign bodies lodged in the tissues	50
11. Mackenzie-Davidson exposor	53
12. Mackenzie-Davidson localizer	54
13. Diagram showing method of using localizer	58
14. Diagram showing method of localization	58
15. Harrison portable localizing apparatus	60
16. Dennis fluorometer	60
17. Diagram illustrating lateral transmission of energy by osseous tissue	65
18. Diagram explanatory of Plate XIV	66
19. Diagram explanatory of Plate XVI	67
20. Diagram explanatory of Plate XX	69
21. Diagram explanatory of Plate XXVI	73
22. Diagram explanatory of Plate XXIX	74
23. Diagram explanatory of Plate XXXII	78
24. Diagram explanatory of Plate XXXVI	81
25. Röntgen ray burn, case of Private McKenna	94
26. Röntgen ray burn, case of Private Booth	95

THE USE
OF THE
RÖNTGEN RAY
BY THE
MEDICAL DEPARTMENT OF THE UNITED STATES ARMY
IN THE
WAR WITH SPAIN.
(1898.)

THE USE OF THE RÖNTGEN RAY BY THE MEDICAL DEPARTMENT OF THE UNITED STATES ARMY IN THE WAR WITH SPAIN.

INTRODUCTION.

Soon after the discovery by Professor Röntgen of the new form of radiation and the placing on the market of apparatus for its production, the Surgeon-General of the Army supplied Röntgen-ray apparatus to several of the larger post hospitals. On the outbreak of the war with Spain and the establishment of general hospitals the most prominent and important of these hospitals and the three hospital ships *Relief*, *Missouri*, and *Bay State* were supplied with similar appliances.

In all, seventeen apparatus were available during the war, of which five were static and twelve were coil machines. These apparatus proved to be not only invaluable aids in military surgery, but the use of the two types, coil and static, gave an opportunity for comparison of these two methods for producing the Röntgen ray as adapted to the needs and environments of military hospitals.

The use of the Röntgen ray has marked a distinct advance in military surgery.

It has favored conservatism and promoted the aseptic healing of bullet wounds made by lodged missiles, in that it has done away with the necessity for the exploration of wounds by probes or other means, and by this has obviated the dangers of infection and additional traumatism in this class of injuries.

In gunshot fractures it has been of great scientific value by showing the character of the bone lesions, the form of fracture, and the amount of bone comminution produced by the small-caliber and other bullets—conditions which could not have been otherwise determined in the living body.

In the treatment of these traumatisms it has been of great value in determining the course of treatment to be pursued, as its use, together with the course of the cases under treatment, has shown that aseptic or

septic condition of the wound is of far greater importance than the amount of bone comminution. This is illustrated by those cases of extensive bone comminution which, when connected with aseptic wounds, progress to favorable termination with a minimum of immediate and remote ill effects; while those cases in which the bone traumatism is slight, if complicated by infection of the wound, are much more difficult to treat and serious in their result.

In the sections of this report which are devoted to a consideration of the effects produced by missiles, care has been taken to select the cases and radiographs which are, as far as possible, typical of the conditions treated of.

In making these selections, many case reports and radiographs, which have been submitted to the Surgeon-General, and which are similar to those introduced in the text, have been omitted, as the reproduction of radiographs which only show that which is illustrated by those introduced would add to the bulk of the report without increasing its value. As the scientific value of the plates depends upon their being true representations of the objects as shown by the Röntgen ray, the radiographs and the negatives, from which they were printed, have not in any case been retouched other than to remove some slight defects which may have appeared in the prints or negatives during their preparation. In this connection the writer wishes to express his appreciation of the work done by Dr. W. M. Gray, of the Army Medical Museum, in preparing many of the negatives, and of the preparation of many of the prints by Private Harry Utter, Hospital Corps, United States Army.

In the sections devoted to technic, the theory and physics of Röntgen radiation have been omitted as having no practical bearing upon the use of the Röntgen ray in military surgery, and these sections have been devoted to questions of practical technic, knowledge of which has proved of value in manipulating the apparatus used to produce the new kind of radiation.

I.

RÖNTGEN RAY APPARATUS.

Two types of apparatus—coil and static—were in use in the Medical Department of the United States Army during the Spanish-American war. In both apparatus, Röntgen rays are produced by passing a rapidly interrupted electrical current of high potential through a specially constructed glass bulb (Crookes tube) of high vacuum. In the static machine, the electrical current is produced directly by the machine and carried direct from it to the tube. The electrical energy given out by the static machine is derived from the motor energy used in driving the machine.

In the coil machine, the electrical current is produced in the secondary portions or coils of a special apparatus—Ruhmkorff coil—by induction through the passage of a primary current of low potential through the primary portions or coils of the apparatus.

The primary current is obtained from many forms of electrical sources; either from primary batteries, accumulators, dynamo machines, or from local electrical installations, and is led to the Ruhmkorff coil by means of insulated wires.

In the Ruhmkorff coil, the primary current traverses the primary coil, which is placed within the secondary coil, and in so doing induces a secondary current of high potential in the outer or secondary coil. This secondary current, after being interrupted with high frequency by mechanical means, is carried to the tube and there gives rise to the peculiar form of energy known as Röntgen radiation.

When working properly, both the static and the coil apparatus produce Röntgen rays of practically equal power and working efficiency. The apparatus are, however, so utterly unlike in construction and require such different means for their manipulation that they are not, under all conditions, equally adapted to the requirements of military surgery.

THE STATIC APPARATUS.

The static machines now used for the production of Röntgen radiation are of the Wimshurst-Holtz type, which includes a charger and an induction apparatus, the latter consisting of eight or ten circular glass plates supported on an axle, with intervening oblong plates of glass, combs, connections, etc., all inclosed in a case of glass and wood. The circular plates are revolved by hand or by motor power. With the latter, a motor of one-sixth to one-fourth horsepower is required. The static machines used by the Medical Department were made by Otis Clapp & Son, of Providence, R. I. Their apparatus weighs about 500 pounds, is well constructed and reliable, and, with proper manipulation, gives Röntgen rays of high power.

COIL APPARATUS.

The coil machines used by the Medical Department were of several different patterns. They comprised those made by the Edison Manufacturing Company, the Fessenden Company, and the General Electric Company.

In these apparatus, the primary current is supplied from primary batteries, storage batteries, or dynamos, and all these different means were in use during the war. The Edison machines were the type operated by Edison-Lalande cells. The Fessenden machines, and that of the General Electric Company, were supplied with storage batteries or with current from dynamos. Where a dynamo current can be had it is the best kind of current, as it is always ready for use and can be had in sufficient and constant quantity. It is, however, rarely available for Röntgen ray apparatus used for military purposes, except on hospital ships, as few military hospitals are supplied with electric plants or are situated where current from them can be obtained. In consequence, primary or secondary (storage) batteries, ordinarily have to be used.

STORAGE BATTERIES.



These batteries when in good working order yield excellent results. They are objectionable on account of their bulk and weight, and especially from their being apt to get out of order and yield currents uncertain in quantity unless they are constantly used and carefully attended to. Another disadvantage is, that as they are an intermediary method of supplying electricity, they require a source from which to obtain their charge. Where

PLATE I.

PLATE I.

The Edison Battery Apparatus.

The Static Apparatus.



war ships or electric-light plants are available the problem of their supply is easily solved. But this is rarely the case. The British medical department in the Soudan expedition¹ overcame the difficulty of charging storage batteries by charging them from a dynamo run by means of a tandem bicycle attachment. This method is objectionable in that it requires an extra amount of complex apparatus and time and labor to run the machine, while the resulting output of electricity is no better or greater than that obtained direct from primary batteries.

In the Spanish-American war a storage battery was at first used on the hospital ship *Relief*, but its weight and bulk, and the difficulty experienced in keeping it in order, caused its use to be abandoned.

PRIMARY BATTERIES.

But one type of primary battery has been used by the Medical Department of the United States Army.

These batteries are made up of Edison-Lalande cells in direct series.

The medical department of the British army made use in the Terah campaign of a battery of Grove cells, and with it obtained excellent results.² The Edison-Lalande cell is much more constant and steady in action than the Grove cell, and is undoubtedly the best form of primary battery for Röntgen ray purposes. The cell used is the type W of the Edison Manufacturing Company. It consists of a porcelain jar $7\frac{1}{2}$ by 15 inches, with the contained elements and solution. Ten of these cells are united in direct series to form the battery for Röntgen ray work, and all are inclosed in a metal-lined zinc box.

The elements employed in the Edison-Lalande cell are zinc, which forms the negative pole, and black oxide of copper (CuO), the positive pole of the battery. The exciting liquid is a solution of caustic potash. The oxide of copper is obtained by the process of roasting copper turnings; the oxide is then ground into a fine powder and compressed into solid blocks, from which plates of a suitable size for the different cells are cut. These plates are suspended from the cover of the containing vessel (a porcelain jar), in a grooved copper frame, the sides of which are rigidly bolted to the cover by means of thumb nuts, one of which also serves as the positive pole of the battery. On each side of the copper oxide element

¹Battersby, J. "The present position of the Roentgen rays in military surgery," Archives of the Roentgen Ray, Vol. III, page 74. London, 1899.

²Beevor. "The working of the Röntgen ray in warfare," Journal of the Royal United Service Institution, Vol. XLII, page 1152. London, 1898.

in the cells is suspended a rolled zinc plate. These zinc plates are fastened by a bolt to a knob on the cover. This prevents any movement in the relative position of the elements, and does away with the necessity of using vulcanite separators to prevent any short circuits occurring in the solution. The zines are amalgamated and, as in most batteries, the zinc is attacked more vigorously near the top than at the lower part of the plate, the zines for this cell are made slightly tapering, the thick part being uppermost.

The exciting liquid employed in the battery consists of a 25 per cent solution of caustic potash in water, or in other words, of a solution of 1 pound of caustic potash in 3 pounds of water. When the circuit is closed and the cell is put in action, the water is decomposed, the oxygen forming,

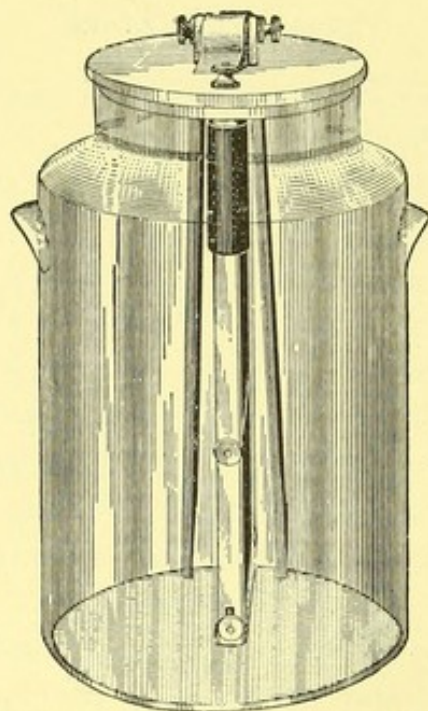


FIG. 1.—Edison-Lelande cell, type W.

with the zinc, oxide of zinc, which, in turn, combines with the potash to form an exceedingly soluble double salt of zinc and potash, which dissolves as rapidly as it is formed; the hydrogen, liberated by the decomposition of the water, reduces the copper oxide to metallic copper. A layer of heavy paraffin oil three-eighths of an inch deep is added to keep out the air and prevent creeping.

The Edison-Lalande battery has an initial electromotor force of 0.95 volt, which drops to 0.7 volt on closed circuit. At first sight it appears that the electro-motive force is low. The internal resistance is, however, correspondingly lower (in the type W cell being only 0.02 ohm), and

consequently it follows that the available electro-motive force (potential difference) is very high.

The efficiency of the Edison-Lalande cell as compared with other primary batteries is shown in Table I.

TABLE I. *Dr. A. E. Kennelly's table showing comparative efficiency tests between the Edison-Lalande cell, type W, and other types of battery on the market, for purposes of driving small electric motors, or for moderate general delivery of power.*

Type of cell.	1. Mean working, E. M. F. volts.	2. Average internal resistance.	3. Maximum delivery current.	4. Capacity in ampere hours.	5. Power valuation.	6. Economic power valuation.
		<i>Ohms.</i>	<i>Amperes.</i>			
Edison-Lalande, type W .	0.67	0.028	33.35	300	22.22	4.58
Fuller bichromate.....	1.8	0.40	4.50	68	8.1	8.1
Western Union carbon, bichromate type	1.8	0.40	4.50	5	8.1	6.48
Partz motor cell.....	1.83	0.51	3.58	65	6.57	1.458
Hussey Eclipse	1.4	0.8	1.75	45	2.45	0.98
Leclanche	1.5 to 0.5	0.5	3.0	1.0	1.0
Gravity Daniell, Western Union type, local.....	1.0	0.5	2.0	2.0	2.22

The third column gives the current that the cells will deliver when placed on short circuit, and the fourth and fifth columns show the great capacity in ampere hours and the high-power valuation of the type W cell compared with other similar sources of electrical energy.

The Edison-Lalande battery has the following advantages for Röntgen ray work:

1. High and constant available electromotive force.
2. Little loss of energy while the cell is idle, the chemical action in the cell being only about 1 per cent a month.
3. Constant and heavy current delivery.
4. No attention or inspection required until the elements are exhausted.
5. Freedom from noxious fumes or chemical deposits. No freezing or influence by temperature changes or differences.
6. Comparatively cheap materials, easily obtained.

The Röntgen ray battery of ten cells, type W, has a life of 600 ampere hours, or about 200 working hours. The cost of renewal of the elements is about \$22, making the hourly running cost only about 11 cents per hour.

The Edison battery apparatus complete, as furnished the Medical Department, is as follows:

- 1 Edison-Ruhmkorff coil, 6-inch spark, with adjustable condenser and vibrator.
- 1 Edison fluoroscope, 6 inches by 8 inches.
- 1 Edison X-ray focus tube, medium size.
- 1 Edison X-ray focus tube, large size.
- 1 adjustable stand for tube.
- 10 Edison-Lalande cells, type W, in metal-lined polished oak box.
- 1 combination rheostat, for using battery for X-ray, cautery, motor, diagnostic, and centrifugal work.
- 1 battery cord, connecting combination rheostat to coil.
- 1 battery cord, connecting battery to combination rheostat.
- 2 insulated wires for connecting tube to coil.

For a battery apparatus, this outfit is quite compact and can be transported without danger of breakage.

WHERE RÖNTGEN RAY APPARATUS SHOULD BE PLACED FOR MILITARY SURGICAL USE.

Before comparing the different types of apparatus it should be determined where the apparatus is to be placed for use.

In the Spanish-American war, apparatus were supplied to general hospitals and hospital ships only. None were used in movable hospitals or in the field. Some advocates of the Röntgen ray in military surgery have advised the use of apparatus in the field hospitals. In the Terah expedition an apparatus was used at the extreme front—so far to the front that the operators were, at one time, under fire when engaged in removing a bullet with its aid.

Experience with its use in the late war and the conditions of military surgery lead to the conclusion, that the use of the apparatus in movable hospitals is not advisable, and that its use should be restricted to permanent base and general hospitals and to hospital ships. This conclusion is reached through a combination of reasons:

First. That lodged bullets only in extremely rare cases require immediate removal.

Second. That the environments of, and conditions incident to movable field hospitals, render asepsis in operating practicably impossible; and, in consequence, in field hospitals noninterference with wounds should be practiced to the utmost extent possible.

Third. That surgical interference with lodged bullets, except where adequate asepsis is available or the necessity urgent, is to be condemned, as the suppuration which follows is much more detrimental to the patient than the presence of the lodged missile.

Fourth. That a Röntgen ray apparatus in the field is an additional incentive to surgeons to operate under conditions not adequately aseptic.

The percentage of the recoveries of the wounded in the war with Spain was high compared with preceding wars, as will be seen by reference to Table II, which shows the comparative mortality of the wounded in recent wars.

In the American civil war, where the larger caliber rifle was used and asepsis and antisepsis were unknown, the mortality was nearly double that of the Spanish-American war (12.96 to 6.64 per cent).

The question naturally arises, how much of the reduction in mortality is due to the use of a smaller caliber rifle firing a small bullet with high velocity and how much is due to modern surgical methods. In an attempt to determine this question, attention is called to Table III, which shows the mortality of regional wounds in the two wars. From this table, it will be seen that the mortality from wounds of the head, face, neck, spine, and abdomen did not materially differ in the two wars. There was, however, a marked difference in the chest wounds (27.8 to 11.4), and a very great difference in wounds of the extremities and flesh wounds of the back. The great difference in mortality from injuries of the pelvis and genital organs is mainly to be ascribed to the fact that these injuries recorded in the Spanish-American war were mostly flesh wounds, while in the civil war many penetrating wounds of the pelvis and severe fractures of the pelvic bones were tabulated.

TABLE II.—*Number of wounded in recent wars who came under treatment and percentage of mortality.*

	Wounded.	Died.	Mortality.
			<i>Per cent.</i>
Crimean, 1854-56—English (Matthew ¹)	12,094	1,840	15.21
French (Chenu ²).....	39,868	4,359	10.90
In Italy, 1859-60—French (Chenu ³)	17,054	2,962	17.36
American civil, 1861-65—Federals (Otis ⁴)	246,712	31,978	12.96
Prussia-Denmark, 1864—Prussians (Loeffler ⁵).....	2,021	316	15.63
Austria-Prussia, 1866—Prussians (Loeffler ⁶).....	13,731	1,455	10.59
France-Germany, 1870-71—Germans (official ⁷).....	99,566	11,023	11.07
Russia-Turkey, 1877-78—Russians (Kosloff ⁸).....	56,652	6,824	12.04
China-Japan, 1894-95—Japanese ; Third Division (Haga ⁹) .	1,105	108	9.77
Indian frontier, 1897-98—English; Terah expedition (Gore ¹⁰)	948	99	10.44
Spanish-American, 1898—Americans (official ¹¹).....	1,594	106	6.64

¹ Matthew. Medical and Surgical History of the British Army in the Crimea, Vol. II, p. 259. London, 1858.

² Chenu. Rapport au Conseil de Santé des Armées sur les résultats du Service Médico-Chirurgical aux Ambulances des Crimée, 1854, 1855, 1856. Paris, 1865.

The number of deaths among the wounded and the mortality of the wounded as here given are much lower than given by most writers for the French forces in this war, the mortality of the wounded usually being stated at about 25 per cent.

As most writers in giving the high mortality of about 25 per cent quote Chenu as authority, it is probable that an original error of computation was made by some writer quoting Chenu and that this has been perpetuated. Chenu himself states that while his figures can not be considered as absolutely accurate that there is probably but slight error. They may, therefore, be considered sufficiently accurate for general deductions.

³ Chenu. Statistique Médico-Chirurgicale de la Campagne d'Italie en 1859 et 1860, Tome II, p. 853.

⁴ Otis. Medical and Surgical History of the War of the Rebellion, Vol. III, pp. 685-691. Washington, 1883. The figures cover wounds made by weapons of war.

⁵ Loeffler (F). General-Bericht über den Gesundheitsdienst im Feldzuge gegen Dänemark, 1864, Erster Theil, pages 36-46. Berlin, 1867.

⁶ Loeffler (F). Das Preussische Militär-Medezinalwesen und seine Reform nach 1866, II, Table I. Berlin, 1868.

⁷ Sanitäts-Bericht über die Deutschen Heere im Kriege gegen Frankreich, 1870-71. Berlin, 1888. II. Bund, II, p. 94.

⁸ Kosloff. Compte-Rendu du Service de Santé Militaire pendant la Guerre de Turquie de 1877-1878 d'après les données officielles. St.-Pétersbourg, 1887.

These figures differ widely from those of Pirogow, which are often quoted and which give the mortality of the wounded at 26.03 per cent. Pirogow's figures are entirely erroneous, being based on estimates only and not on official records.

⁹ Haga. Kriegschirurgische Erfahrungen aus dem Japanisch-Chinesischen Krieg, 1894-95. Archiv für klinische Chirurgie, vol. 55, pp. 256-257. Berlin, 1897.

¹⁰ Gore. Army Medical Department (British) Report, 1897. Appendix No. VI, p. 451. London, 1898.

The figures are the wounded of the Terah expeditionary force only.

¹¹ Report of the Adjutant-General of the Army to the Secretary of War. 1899. Tables facing pp. 10 and 16. Washington, 1899.

TABLE III.—*Number, regional distribution, and mortality of gunshot wounds in cases which came under treatment in the American civil war and the Spanish-American war.*¹

	Seat and character of injury.	Total number of cases.	Per cent of frequency.	Recoveries.	Deaths.	Undetermined results.	Per cent of mortality.
<i>Head.</i>							
Civil war...	Flesh wounds....	7,739	3.14				
	Fractures.....	4,350=12,089	1.76= 4.9	6,573	2,676	2,840	28.9
S.-A. war...	Flesh wounds....	40	2.86				
	Fractures.....	31= 71	2.21= 5.07	51	18	2	26.1
<i>Face.</i>							
Civil war...	Flesh wounds....	4,914	1.99				
	Fractures.....	4,502= 9,416	1.83= 3.82	7,406	462	1,548	5.9
S.-A. war...	Flesh wounds....	43	3.07				
	Fractures.....	16= 59	1.14= 4.21	54	4	1	6.89
<i>Neck.</i>							
Civil war...	Flesh wounds....	4,895= 4,895	1.99= 1.99	3,496	618	781	15.0
S.-A. war...	Flesh wounds....	35= 35	2.50= 2.50	26	7	2	21.2
<i>Spine.</i>							
Civil war...	Injuries of spine..	642= 642	0.26= 0.26	279	349	14	55.57
S.-A. war...	Injuries of spine..	8= 8	0.57= 0.57	3	5	0	62.5
<i>Chest.</i>							
Civil war...	Nonpenetrating ..	11,995	4.87				
	Penetrating.....	8,269=20,264	3.36= 8.23	13,921	5,373	970	27.85
S.-A. war...	Nonpenetrating ..	61	4.36				
	Penetrating.....	53= 114	3.79= 8.15	99	13	2	11.6
<i>Abdomen.</i>							
Civil war...	Nonpenetrating ..	4,748	1.93				
	Penetrating.....	3,690= 8,438	1.50= 3.43	3,455	3,293	1,690	48.80
S.-A. war...	Nonpenetrating ..	20	1.43				
	Penetrating.....	44= 64	3.14= 4.57	35	29	0	45.3
<i>Perineum and genital.</i>							
Civil war...	Injuries of pelvis.	1,494	0.60				
	Flesh wounds of genito-urinary organs.	1,665= 3,159	0.67= 1.27	2,194	930	35	29.77
S.-A. war...	Perineum and genital.	7= 7	0.50= 0.50	7	0	0	00.0
<i>Back.</i>							
Civil war...	Flesh wounds of back.	12,681=12,681	5.15= 5.15	10,883	800	998	6.85
S.-A. war...	Flesh wounds of back and hips.	108= 108	7.72= 7.72	106	2	0	1.9
<i>Upper extremities.</i>							
Civil war...	Flesh wounds....	54,801	22.29				
	Fractures.....	32,992=87,793	13.39=35.68	80,090	5,608	2,095	6.54
S.-A. war...	Flesh wounds....	289	20.66				
	Fractures.....	140= 429	10.00=30.66	426	1	2	0.20
<i>Lower extremities.</i>							
Civil war...	Flesh wounds....	59,139	24.06				
	Fractures.....	27,274=86,413	11.09=35.15	73,665	11,813	935	13.8
S.-A. war...	Flesh wounds....	354	25.30				
	Fractures.....	150= 504	10.72=36.02	490	8	6	1.6

¹The cases from the civil war are compiled from the Surgical History of the War of the Rebellion. The cases from the Spanish-American war are those which occurred in the Regular troops, and which are reported in the Report of the Surgeon-General of the Army for 1899, complete records of the Volunteer troops not yet being available.

The great reduction in mortality in wounds of the extremities is especially noticeable (Table IV).

TABLE IV.—*Number of cases and mortality from gunshot of the extremities in the civil war and United States Regulars in Spanish-American war.*

	Cases.	Died.	Mortality.
Civil war, upper extremities	87, 793	5, 608	6. 5
Spanish-American war, upper extremities	429	1	0. 2
Civil war, lower extremities	86, 413	11, 813	13. 6
Spanish-American war, lower extremities.....	562	9	1. 6

Thus in the civil war, while the mortality of all wounds of the extremities, upper and lower, was 6.5 and 13.6 per cent, similar wounds, in the Spanish-American war, had a total mortality of but 1.0 per cent. The number of deaths in the latter war from wounds of these regions were surprisingly small, being but 10 in 991 cases, and of these 10 cases, 3 died very shortly after the receipt of their injuries, probably from hemorrhage.¹ The difference in treatment adopted in these wars is not less great than the mortality (Table V).

TABLE V.—*Wounds of the extremities treated by excision and amputation, and by conservatism, and the relative mortality of each treatment for two wars (in Spanish-American war, United States Regulars).*

War.	Wounds of extremities.		Amputations and excisions.		Percentage of operations to wounds.	Operative mortality.	Conservative mortality.
	Total.	Deaths.	Total.	Deaths.			
Civil	174, 206	17, 421	12, 193	2, 636	6. 99	21. 6	9. 1
Spanish-American.....	991	10	32	6	3. 20	18. 7	0. 4

This table shows at once (a) the small number of operations done or required to be done in wounds of the extremities since the adoption of the new rifle and modern surgical methods, the proportion having been reduced over one-half (6.99 to 3.20); (b) the great decrease in mortality in these cases, the mortality being reduced over twenty-two times in cases treated conservatively (9.1 to 0.4) and somewhat decreased in those treated by amputation or excision.

¹ Report of the Surgeon-General of the Army, 1899, p. 314. Washington, 1899.

The high mortality in operation cases in the Spanish-American war arose from the fact that only the extremely serious cases were operated on. In the cases reported among the Regulars, the deaths that occurred were all from high amputations (TABLE VI).

TABLE VI.—*Resections, amputations, and deaths from these operations in the Spanish-American war (Regular troops).*

	Resections.	Amputations.	Deaths. ¹
Arm	1	4	1
Forearm.....	1	2	0
In hand		13	0
Hip joint.....		2	2
Thigh.....	1	5	2
Knee.....		1	1
Leg.....		1	0
Ankle.....		1	0
Total.....	3	29	6

¹No deaths from resection.

These tables demonstrate that the lower mortality in gunshot of the extremities in the Spanish-American war was accompanied with increased conservative treatment. That the conservative treatment which was practiced was made possible entirely through a difference in effect produced by the small caliber bullet from that produced by the old lead bullet can not be entertained. The Röntgen ray examinations have shown that in compound fractures the amount of bone comminution is generally as great with the new as with the older bullet, and the writer's observations upon shrapnel bullet wounds have led him to believe that slow-moving lead bullets very frequently produce wounds practically as aseptic as those made by the new bullet.¹ It follows, that conservatism has been made possible mainly through (a) the fact of the recognition of the general aseptic nature of bullet wounds; (b) the maintenance of their asepticity by the use of occlusive dressings; and (c) the treatment of septic wounds by antiseptic methods.

The Röntgen ray has played an important part in allowing the surgeon to preserve the asepticity of bullet wounds by doing away in many cases

¹Borden. Gunshot wounds: A report of gunshot cases in the Spanish-American war. New York Medical Journal, Vol. LXXI, New York, 1900.

with the necessity for immediate wound exploration, especially for lodged bullets.

The many cases of lodged bullets in which the bullets were left undisturbed until the patients reached a general hospital or hospital ship, where the missiles were located by the Röntgen ray and removed under aseptic technic with complete safety to the patient and rapid recovery, prove the nonnecessity for the use of Röntgen ray apparatus in field or other advanced hospitals. Even where the bullet can be readily located without the use of the Röntgen ray, the experience of the late war and the opinion of numerous authorities lead to the conclusion that the zeal of the surgeon should not cause him to remove the missile at the field hospital except in special cases. Infection is almost sure to occur from the almost absolute impossibility of obtaining asepsis under conditions which are present at the front, and the recovery of the patient is delayed and the functions of the wounded part likely to be impaired in consequence of the suppuration which will follow. Von Bergmann, who obtained such brilliant results in the Turko-Russian war by the use of occlusive dressing, and who has since advocated the use of such dressings and noninterference in gunshot wounds,¹ has expressed the opinion that the Röntgen ray will prove a menace in military surgery in that its use will prove an incentive to unnecessary operative interference.

In a recent clinical lecture he said :

After many years' practice in peace and in war I maintain that foreign bodies, the presence of which in the body is not a source of any trouble or danger, ought to be left where they are.

The consciousness of having some extra lead, for instance, in one's body, especially when it causes one no inconvenience whatever, does not in the least counterbalance the danger of an operation necessary for its removal.

This is especially the case in war, when it is often impossible to operate with all aseptic precautions. If special merit was ascribed to me in the Russo-Turkish war I ascribe it partly to the fact that when my colleagues came up with bullet probes of every kind I dissuaded them from their purpose. Even then I had a tough battle to fight—a battle which is not quite ended even yet, and will now, after Röntgen's discovery, begin afresh.

Professor Kuttner,² of Lubingen, who followed the Greek war in connection with the German Red Cross Society, has stated, as a result of his experience with a Röntgen-ray apparatus in that war, that the Röntgen

¹ V. Bergmann. Die Resultate der Gelenkresectionen im Kriege. Giessen, 1874.

V. Bergmann. Die Behandlung der Schusswunden des Kniegelenks im Kriege. Stuttgart, 1877.

² Kuttner (H.). Ueber die Bedeutung der Röntgenstrahlen für die Kriegschirurgie nach Erfahrungen im Griechisch-Türkischen Krieg, 1897.

Beiträge zur Klinischen Chirurgie XX, p. 167. Tübingen, 1898.

rays are of great importance for medical aid in war, but only for fixed hospitals and those installed in fortresses, while for moving field hospitals their application is very limited.

Abbott,¹ in an article in the *London Lancet* of January 14, 1899, on Surgery in the Græco-Turkish war, states that a coil, battery apparatus was used in the base hospital at Phalerum. As a result of his experience in this war, he says:

The use of the Röntgen ray becomes an impossibility at the actual front. Fortunately it is not necessary there, and could very possibly do harm by stimulating the young surgeon to premature operations under bad surroundings. We believe that the X-ray in future wars will be of the greatest use, but not at the actual front.

In closing his article Abbott formulates the following:

The apparatus is of no use on the field where the detection of bullets can only be an incentive to premature exploration.

The less wounds are tampered with before satisfactory surroundings are reached the better.

The modern bullet * * * is practically aseptic, and there is no urgency for its removal.

Surgeon Major-General Jameson, of the medical department of the British army, in discussing the use of the Röntgen ray in warfare and as used by the British medical department, says:

Reference has been made to the necessity of supplying these various apparatuses to the hospitals at the front, but the difficulty of transport must really be considered. It seems to me that from our present knowledge the advantages are not so very great after all in that part. The place, I think, for them is in the line of communication or at the base hospital, because after all nothing except very urgent operations are advised to be performed in advanced places. What the photography really determines is more the position of the bullet or the kind of fracture, but the urgency of operation is determined by other conditions.²

Our experience in the war with Spain was fully in accord with the above opinions, as the use of the Röntgen-ray apparatus at general hospitals and on board hospital ships met all practical requirements.

As to the use of the Röntgen ray in gunshot fractures, the same rules hold as for lodged missiles; i. e., occlusive dressings and noninterference at the field hospitals except where operation is imperatively demanded, and in this connection it may be stated that cases of gunshot fractures are extremely

¹ Abbott, (F. C.). Surgery in the Græco-Turkish War. *Lancet*, Vol. I, pp. 30 and 152. London, 1899.

² Journal of the Royal United Service Institution, Vol. XLII. London, 1898. Jameson discussing Beevor's paper "The working of the Röntgen ray in warfare."

infrequent which can be benefited in any way by the use of Röntgen apparatus at the front.

Also, in considering where Röntgen apparatus are to be placed for use in military surgery in time of war, the fact must be taken into account that these apparatus are all more or less bulky, heavy, somewhat difficult to transport, and that their use requires considerable experience, and at field hospitals necessitates expenditure of time when surgeons are most busy with work incident to active operations. These disadvantages should not be considered were the benefits to be derived from the employment of these apparatus in field hospitals at all in proportion to the difficulties incident to their transportation and use. But, when the benefits to be derived from using them at advanced hospitals is confined to extremely few, if any cases, and is useless in all others, the time, work, and transportation expended on these apparatus under such circumstances can be better employed in other ways.

In view of these facts, it appears that the place for Röntgen-ray apparatus is at base and general hospitals and on hospital ships, and that apparatus so located will meet all requirements compatible with the conditions incident to the practice of military surgery. With apparatus so located, Röntgen-ray examinations can be followed when necessary by proper aseptic or antiseptic operative methods. This plan of locating and using Röntgen-ray apparatus was adopted in the Spanish-American war with the best possible results.

RÖNTGEN-RAY APPARATUS COMPARED.

Premising that these apparatus are to be used at base and general hospitals, it will not be necessary to sacrifice efficiency to too great compactness or convenience for transportation.

At the same time, the apparatus should not only be efficient and not too complex or difficult to operate, but it should not be effected by climatic or atmospheric conditions, and should be fairly portable.

The choice of machines necessarily lies between two types—the static and the coil. When properly managed the two machines are practically equally effective. Their adaptability for use in military surgery rests, therefore, entirely with which best meets the requirements above given. These requirements are undoubtedly usually best met by some form of coil machine.

The static machine is bulky and heavy, glass enters largely into its construction, and consequently it can not ordinarily be as easily or safely

PLATE II.

PLATE II.

Lodged Mauser bullets (natural size), removed from Spanish-American war cases after having been located by the Röntgen ray. All the bullets, except No. 1, show deformity due to ricochet impact.



1



5



2



6



3



7



4



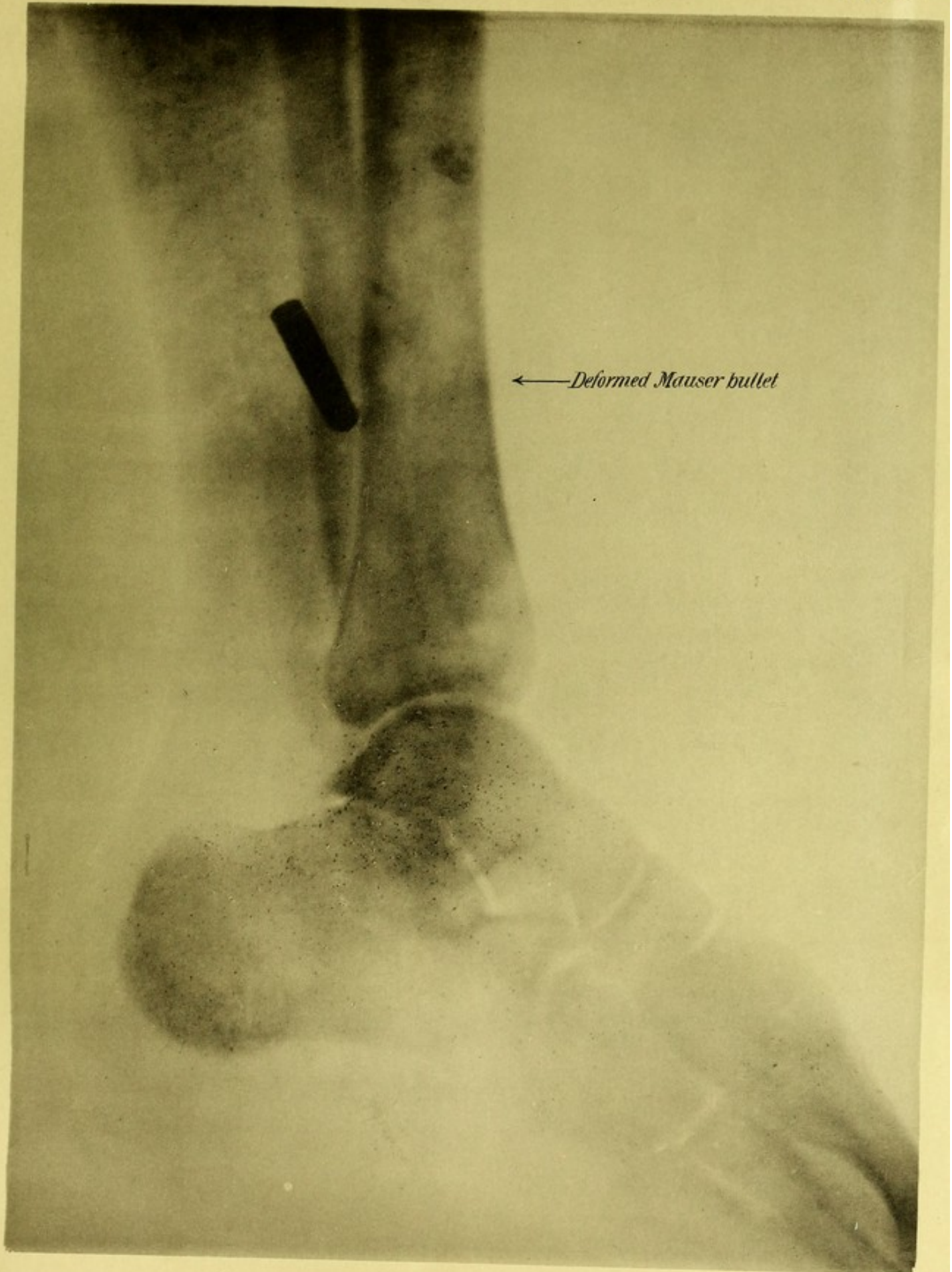
8

PLATE III.

PLATE III.

CASE 1, SECTION II.—Ralph Barkman, private, Company K, Second Massachusetts Volunteer Infantry.

Radiograph of left leg, viewed from the inner side, showing deformed, Mauser bullet lodged behind the tibia.



transported to, or set up at hospitals established for military purposes as can the coil apparatus. It is subject to a certain extent to atmospheric influences, and while these can be largely overcome by proper precautions, they add to the difficulty of obtaining good work. The apparatus can be run by hand power; but, when so run, its output is not equal to that of the same machine when run by motor power at an even rate of speed. To run the static machine by hand for any length of time is exceedingly tiresome, even with a relay of men, while motors add to the expense and trouble of transportation and installation of the apparatus.

The advantages of the static apparatus are that, when properly managed, it gives a constant output which is at any time available and that it is economical in tubes, as tubes do not wear out so rapidly with it as with the coil machine. In permanent military hospitals in dry climates, and especially where motor power is available and a dynamo current is not to be had, the static apparatus will give a constantly available and steady source of Röntgen radiation.

Relative to the coil machines, taking the Edison 6-inch coil machine run with 10 Edison-Lalande cells as a type, this form of apparatus has the advantages over the static machine of less weight, greater portability, less complexity, and nonliability to climatic or atmospheric influences. The battery is easily set up, easily run, lasts for a long time, and the cost of maintaining it in use is not great. Coil apparatus can be transported with comparative ease and with a minimum danger of breakage. These are all decided advantages in times of active operations where apparatus have to be shipped to recently established hospitals and used more or less constantly under disadvantageous conditions. A battery apparatus can be quickly set up, and by having a supply of extra charges on hand for the battery, the apparatus can always be kept in working order. For these reasons, in time of war, where hospitals are being established and equipped, the coil apparatus with primary batteries is best for general hospitals and base hospitals where dynamo currents can not be obtained.

The battery apparatus has the disadvantage of requiring a certain amount of care to keep the battery up to its maximum working efficiency and of not giving currents of absolutely equal strength. With the Edison-Lalande cells these disadvantages are reduced to a minimum, and in time of active operations, when the machines are being used frequently, give rise to no decided trouble. In established hospitals, in time of peace, where an apparatus is used infrequently, and where it can be placed in a good room and well attended to, a static machine is probably to be

preferred to one operated by a battery, particularly where motor power is available.

Where dynamo currents can be had, the coil machines of the "break-wheel" type will give the greatest efficiency. No machine of this type was in use during the war with Spain, as none of the general hospitals were supplied with dynamo currents. Since the war, an apparatus of this type has been placed in the hospital connected with the Soldiers' Home in this city (Washington, D. C.). The writer has carefully examined this

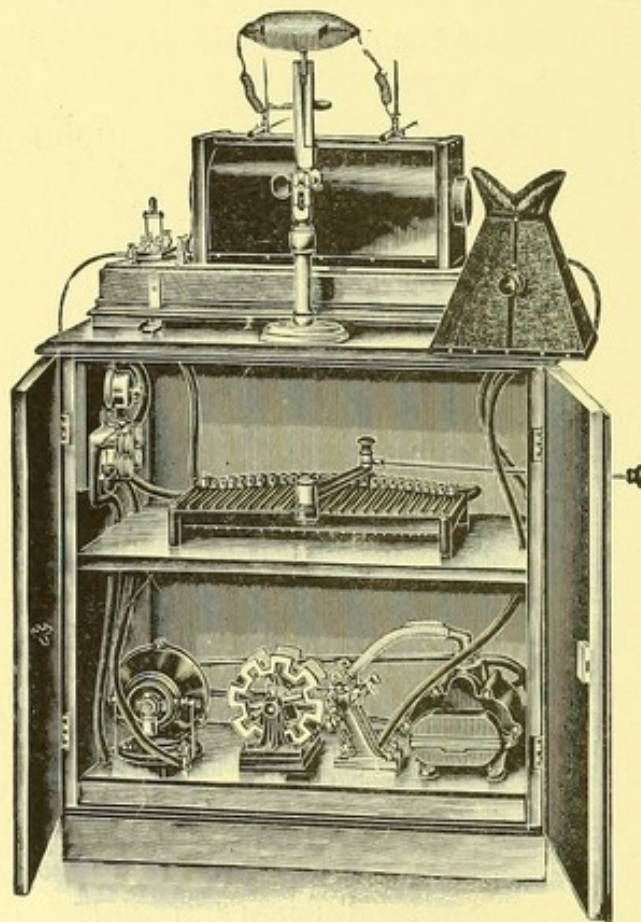


FIG. 2.—Edison break-wheel apparatus.

apparatus and believes that in hospitals where a dynamo current can be had, this apparatus should be supplied to the exclusion of any other.

The distinctive feature of the "break-wheel" apparatus is that there is no vibrator on the induction coil, its place being taken by an instantaneous air break-wheel device. This device consists of two, toothed wheels mounted on the same shaft, the projections or teeth making contact with two flat brushes which bear on the outer peripheries and by which the current is brought in and led out again. These wheels are rotated at very

high speed by a small direct-current motor, which also runs a pressure blower. The air blast from this blower enters a bifurcated tube and is connected with two flat nozzles immediately over the contact brushes. When the device is set in operation by starting the motor and connecting the primary of the coil in series with the binding post, the spark, formed at the contact brushes when the coil is energized, is instantaneously blown out by the air blast at the moment of formation. This greatly increases the rapidity of change in the magnetic circuit, and consequently vastly augments the electric-motor force in the secondary coil. In consequence, Röntgen radiation of higher penetration and efficiency is produced in the tube. The apparatus can be worked only by 110 to 120 volt direct current.

The whole apparatus, with the exception of the coil, is in an oak cabinet. It is extremely compact, strongly made, and not liable to get out of order or be affected by atmospheric conditions. It surpasses all apparatus with which the writer is familiar, both as to ease of operation and quantity and penetration of its Röntgen-ray output. As it requires a direct current of 110 to 120 volts to operate it, it is, of course, only applicable in military surgery in those hospitals and hospital ships which are supplied with this form of electrical current.

The general conclusions reached relative to the kind of Röntgen-ray apparatus best adapted to military surgical use, and the place in which the apparatus should be used, are:

First. The place for the apparatus is at general hospitals, permanent hospitals on the line of communication, and on hospital ships.

Second. That in equipping base and general hospitals for war service, coil apparatus actuated by primary batteries should be supplied.

Third. That in permanently established hospitals, where there is no dynamo current available, the static machine will probably give best satisfaction, especially if motor power can be had.

Fourth. That in permanent base hospitals, or on hospital ships supplied with direct currents of 110 to 120 volts, the "break-wheel" apparatus will give the highest obtainable efficiency.

II.

LODGED MISSILES.

The penetrating and perforating power of a missile depends upon the relation which its velocity, its weight, its sectional density and its form bear to the constitution of the obstacle against which it impinges. With the modern jacketed bullet these proportions are such, relative to animal tissues, that the bullet usually perforates the part against which it impinges unless its velocity is greatly reduced. Reduction in velocity may arise from long range or from the missile having impinged against some other object before striking the body. In the first case, loss of penetrating and perforating power is due entirely to decreased velocity of the ball. In the second case, it may be due to decreased velocity from previous impact or its power may be further lowered by deformation in shape, so decreasing its penetrating or perforating power by altering its form and decreasing its sectional density.

Even with velocity so lowered that perforating power is lost, the jacketed bullet, when undeformed, almost invariably travels in a right line after entering the body. This peculiarity of the bullet is probably due in part to its form, but mainly to its great sectional density. In this it differs markedly from the old lead bullet of large caliber, with which deflections, after entering the body, were extremely common.

The small-caliber bullet is sometimes found lying at an angle to its course of entrance. This slight displacement may be produced by contact of the bullet with some of the more resistant tissues of the body, but in the soft tissues it is probable that slight displacement of the bullet from the line of its course is often due to muscular action or pressure by neighboring tissues after the bullet has come to rest. Thus in Case 14 of this section, where the bullet was embedded in the brain and consequently was not acted upon by such forces, the bullet lies exactly in the line of its course; while in Case 6 of this section, and Case 6, Section V, the bullets have been displaced, probably by pressure from neighboring tissues, notably in the last case by pressure from the overlying flexor tendons of the forearm. In perforating wounds made by the modern bullet, the positions of the entrance and exit wounds and the symptoms, together with experiments upon dead bodies, show that the bullet almost invariably takes a direct course through the part hit, irrespective of the tissues, be they soft parts or bone which may lie in its course.

In bullets which penetrate only, the important fact that they also, almost invariably, pursue a direct course until they come to rest is clearly demonstrated by the position in which they have been located by the Röntgen ray. Thus in Case 11, Section IV, though the bullet entered butt end foremost, it passed in a direct line through the ulna to its place of lodgment beneath the flexor tendons in front of the inner condyle of the humerus. This direct course of the bullet when reversed has been noted in other cases, and it would seem, therefore, that the direct course of the modern bullet through the tissues must be mainly due to its great sectional density rather than the shape of its end. It is this property which gives it relatively great inertia even with lowered velocity and causes it to pass without deflection through the opposing force of the tissues until it comes to rest.

In experimental trials with the jacketed projectile, its tendency to produce perforating rather than penetrating wounds was found to be very great. Arguing from this, it was thought that the number of lodged bullets in warfare where this missile was used would be few. But in these experiments the bullet impinged against the part without previous ricochet, while in warfare, especially where the firing is at long range or where the troops are intrenched or are sheltered in any way, wounds from ricochet missiles are exceedingly common and largely increase the number of lodged bullets. Röntgen-ray examination of cases of lodged Mauser bullets, and the deformed condition of many of these bullets when removed by operation, indicate that lodgment was due in many instances to the velocity of the missiles having been reduced by ricochet.

As stated above, the high velocity of the compound bullet, its small size, and great sectional density cause it to perforate animal tissues rather than penetrate them, unless its velocity is greatly reduced. At the same time, its high velocity gives it great tendency to ricochet for considerable distance and yet retain sufficient momentum to produce penetrating wounds. The compound bullet is very resistant to deforming violence; yet, that it can sustain violent ricochet impact and still retain sufficient velocity to cause penetrating wounds, is shown by the great deformity of some lodged bullets (Plate II).

In determining the cause which has so lowered the velocity of a small caliber projectile that it has lodged in a part, instead of perforating it, evidence is either presumptive or positive. The evidence of having struck some resistant object before entering the body, may be considered positive, when the bullet is deformed, especially if the deformation is marked,

as was the case with many deformed bullets, in cases reported in the late war. It is stated by some observers that the modern bullet may be deformed by impact with bone. The writer is inclined to believe this doubtful, as the bullet is relatively so much more resistant than osseous tissue it hardly seems possible that bone could offer sufficient resistance to deform it. In any event, the deformation would be slight, and the fact should be considered that the bullet might have struck some object before entering the body and that the first obstacle and not bone, had deformed the missile.

When a lodged missile is undeformed, it may or may not have struck some object before producing the penetrating wound. If the wound was received at extremely long range, the evidence is presumptive that the lowered velocity of the ball was due to the length of its flight. When, however, the range is short or unknown, it is impossible to say whether lodgement was caused by decreased velocity from unknown long range, or from the bullet at short range having passed through some obstacle which lowered its velocity without altering its shape. For, while the jacketed bullet is frequently deformed by ricochet, its resistance to deformation is so great that in many cases where it produces penetrating wounds, it is quite reasonable to suppose that it may have impinged against objects not sufficiently dense to deform it, or even may have passed through trees or wooden obstacles, for it is known that the jacketed bullet will pass through many inches of hard wood without becoming deformed. In cases of penetrating wounds, where the lodged bullets are undeformed, it is fair to suppose that quite a percentage of these wounds are due to lowered velocity from causes, such as those given above.

In the Santiago campaign, the large number of lodged missiles was commented on by the surgeons. In 198 Mauser bullet wounds, seen by the writer, there were 21 lodged bullets. This number is unusually high, but serves to show that, under certain conditions, quite a number of lodged missiles may be expected. At Santiago, many wounds were received at long range and in a wooded terrain. It is quite possible that, in some cases, the velocity of the bullets was reduced by passage through the branches of trees, in which event, from the resistance of the bullet to deforming violence, its velocity might be lowered and the bullet not be deformed.

Where the bullet is lodged butt end foremost in the tissues, it is to be concluded that the ball has ricocheted and turned end for end before striking the part. The fact that quite a number of bullets were found lodged butt end foremost, and that so many lodged missiles showed deformation

produced by ricochet, demonstrates the property this bullet has of retaining sufficient momentum to produce penetrating wounds after ricochet impact. While, therefore, under conditions of direct impact, the small size and great sectional density of the small-caliber jacketed bullet cause it to produce perforating wounds, except at extremely long range, so raising the percentage of perforating to penetrating wounds which it is liable to inflict, relative to these percentages compared with similar wounds made by the older lead bullet of large caliber; the ricocheting property of the modern projectile, which is greatly in excess of that of the old bullet, increases the proportionate number of penetrating wounds which it is liable to inflict in actual warfare. This ricocheting property of the compound bullet and its ability to produce penetrating wounds after ricochet, as well as after having its velocity reduced in other ways, accounts for the fact that the number of cases of lodged bullets was greater in the late war than was anticipated from experimental trials of the bullet made previous to its use under actual conditions of warfare.

DEFORMED, LODGED, MAUSER BULLETS.

In the two following cases, the first illustrates the direct course of a bullet which has been blunted at the point by impact with some object before entering the body, but without materially lessening its sectional density, and both cases illustrate the noninfection of wounds by deformed bullets.

Case 1.—Deformed, Mauser bullet lodged in leg; aseptic wound; localization by Röntgen ray; removal.

Ralph Barkman, private, Company K, Second Massachusetts Volunteer Infantry, wounded July 1, 1898, by two bullets, one of which passed through the left arm, shattering the humerus; the other entered the left leg, at the outer surface, upper third, and lodged. The patient was transferred from the field hospital to the *Relief*, where Röntgen examination located the bullet behind the tibia, 3 inches above the ankle joint (Plate III). The bullet was removed and it (No. 4, Plate II) and the radiograph show that the missile had been blunted at the point, from impact with some other object, before entering the leg. The wound of entrance was small and not infected. There was marked discoloration of the skin from the entrance wound downward, by which the course of the bullet could easily be traced.—*Case report compiled from records in Surgeon-General's Office.*

Case 2.—Deformed, Mauser bullet lodged in thigh; aseptic wound; localization by Röntgen ray; removal.

Augustus Snoten, private, Company C, Twenty-fourth United States Infantry, wounded July 1, 1898, by a Mauser bullet, which entered at the anterior and outer

surface, middle third, right thigh. The patient was transferred to the *Relief*, where a much-deformed bullet was located by Röntgen ray, partially behind the femur, some distance lower down the limb. It was removed, when it was found to be greatly deformed from lateral impact, the casing being split and the body of the bullet concaved and flattened (Plate II, No. 5.).

The wound of entrance was small and uninfected and, despite the deformed missile by which it had been made, presented nothing in appearance different from an entrance wound made by an undeformed bullet. — *Case report compiled from records in Surgeon-General's Office.*

It would be supposed that bullets which had struck other objects and had been deformed before entering the body, would, from their jagged and irregular form and lowered velocity, be more likely to carry infection into a wound than undeformed bullets which struck the body without having ricocheted. There are, however, but two cases reported of infection by deformed Mauser bullets, though probably many others occurred. The fact that so few cases of infection were reported, as arising in this way, tends to show that infection so caused, is not as common as would be supposed. In one of the infected cases reported, the large size of the wound and its location in the sole of the foot would make it particularly liable to infection. In the other case, the bullet was greatly deformed and had lodged very superficially.

Case 3.—Deformed, Mauser bullet lodged superficially in knee; wound slightly infected; localization by Röntgen ray; removal.

Samuel Davis, private, Company L, First United States Volunteer Infantry, wounded July 1 by a ricochet ball, which entered and lodged superficially, behind the internal condyle of the left femur. The patient was transferred to the *Relief* and the bullet (No. 7, Plate II), the whole point of which had been carried away by ricochet, was located (Plate IV) by the Röntgen ray and removed. The wound of entrance was infected, but healed readily under antiseptic dressings. — *Case report compiled from records in Surgeon-General's Office.*

Case 4.—Deformed, Mauser bullet lodged in foot; septic wound; localization by Röntgen ray; removal.

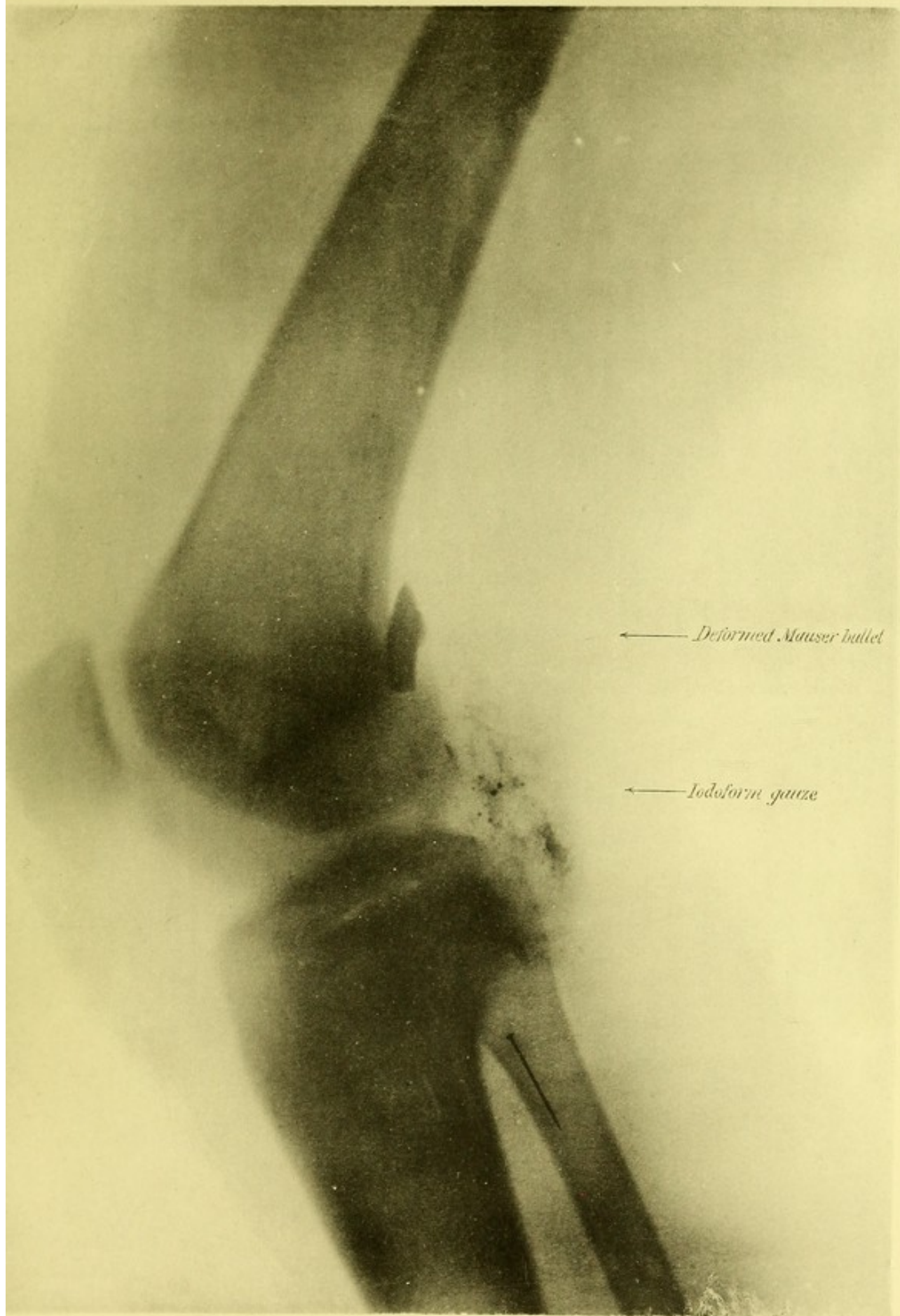
John N. Taylor, private, Company B, Twelfth United States Infantry, was wounded July 1 by a Mauser bullet, which passed through the sole of his shoe and entered the bottom of the left foot, directly below the arch. The wound was quite large and irregular in shape and, on that account, was thought to have been made by a fragment of shell, until the Röntgen ray disclosed a Mauser bullet, with an indentation near the point, lying directly beneath the cuboid bone, in a line with the second metatarsal bone (Plate XIII). The wound was infected and suppuration set in. The patient was transferred to the *Relief* and then to Washington Barracks, D. C., where the bullet was removed December 26, 1898, and the patient returned to duty shortly afterward.

PLATE IV.

· PLATE IV.

CASE 3, SECTION II.—Samuel Davis, private, Company L, First U. S. Volunteer Cavalry.

Radiograph of left knee, viewed from the inner side, showing a Mauser bullet, deformed by ricochet, lodged behind the internal condyle. As the radiograph was taken through the dressings, a pin and the mottling due to the iodoform gauze are also shown.



← *Deformed Mauser bullet*

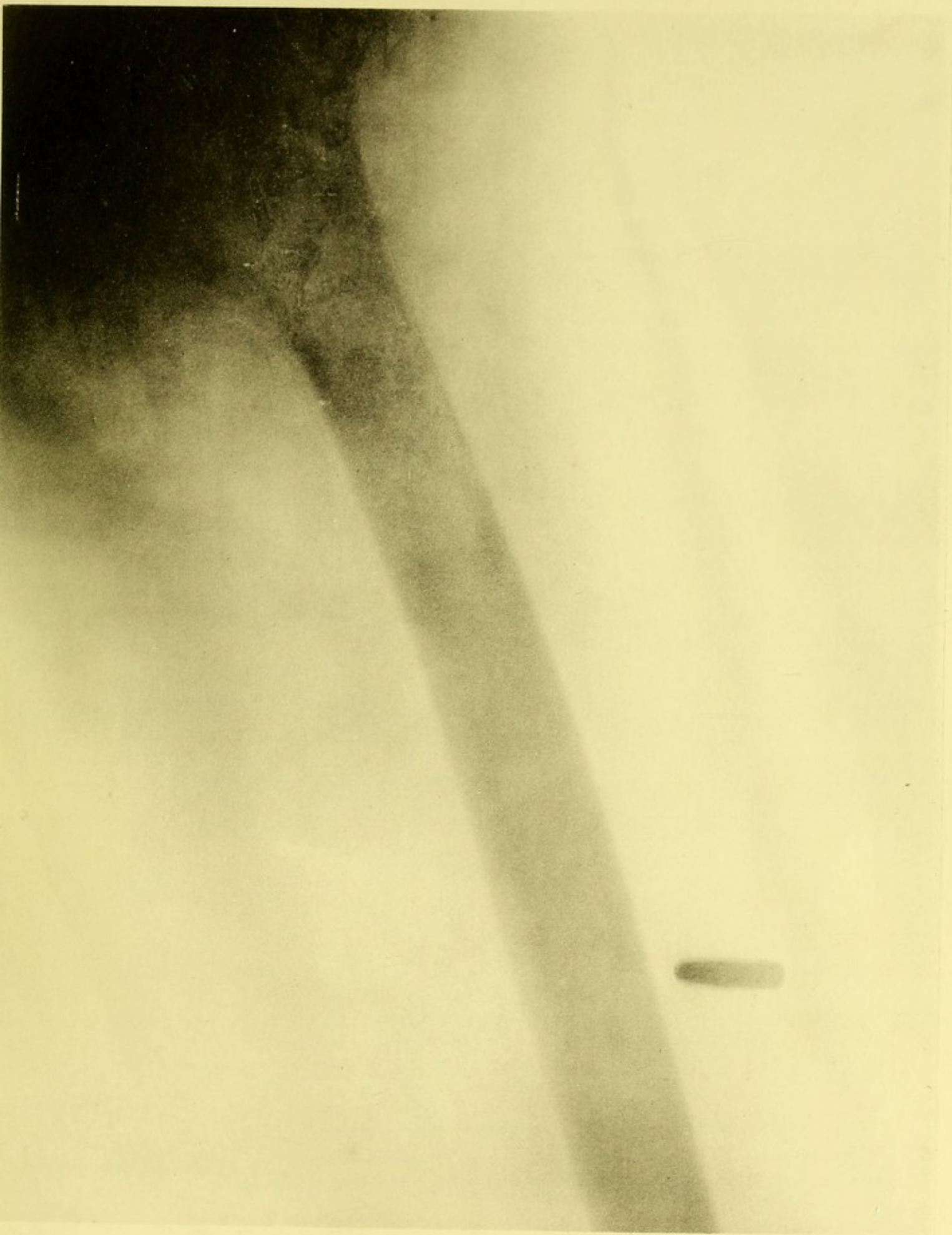
← *Iodoform gauze*

PLATE V.

PLATE V.

CASE 6, SECTION II.—William A. Cooper, private, Company A, Tenth United States Cavalry.

Radiograph showing undeformed Mauser bullet lodged in right thigh. The view is from the posterior surface and the bullet lies at nearly a right angle to its line of entrance.



LODGED, UNDEFORMED, MAUSER BULLETS.

From its resistance to external violence, the compound bullet is probably frequently ricocheted without becoming deformed. In many cases, the bullet, from its irregularity of flight, may produce extremely jagged wounds, as in the case next given, or may enter the body butt end first, and the radiograph or extraction, alone, show that ricochet had occurred.

Case 5.—Mauser bullet lodged in chest; fracture of clavicle; lacerated, septic wound; localization by Röntgen ray; bullet not removed.

John R. Keen, private, Troop L, First United States Volunteer Cavalry, was wounded June 24, by a Mauser bullet, which entered over the clavicle at the junction of its outer and middle thirds. No wound of exit. The entrance wound was about 3 inches long and so lacerated, that it was thought that the injury had been done by a fragment of a shell. The patient was transferred to the general hospital, Key West, Fla., where fluoroscopic examination showed a Mauser bullet just back of the left border of the sternum at the second intercostal space, lying at an angle to the line of entrance (fig. 3).

The large size and laceration of the external wound indicated that the ball had ricocheted and had struck the body while oscillating or while turning on its long axis. As the clavicle was badly shattered and the wound much inflamed and suppurating, the wound was thoroughly cleansed under anæsthesia and all loose fragments of bone removed. The wound healed very slowly and a small sinus still existed when the patient was transferred to New York, August 23. There he was admitted to the Roosevelt Hospital, where Dr. Robert Abbè took a radiograph, which located the bullet. The patient was anæsthetized, the wound thoroughly cleansed, and the bullet searched for with a telephonic probe, passed through the front wall of the thorax, 3 or 4 inches deep, twenty or thirty times in the location of the bullet, as shown by the radiograph, but no result was obtained. In reporting the case, Dr. Abbè gives his opinion, as a result of his trial of the telephonic probe, that it is unreliable, and can not be compared with the Röntgen ray for locating lodged missiles.

The following cases illustrate displacement of the bullet from the line of its course, either from pressure of neighboring tissues, or from muscular action, or from impingement of the missile against some resistant tissue

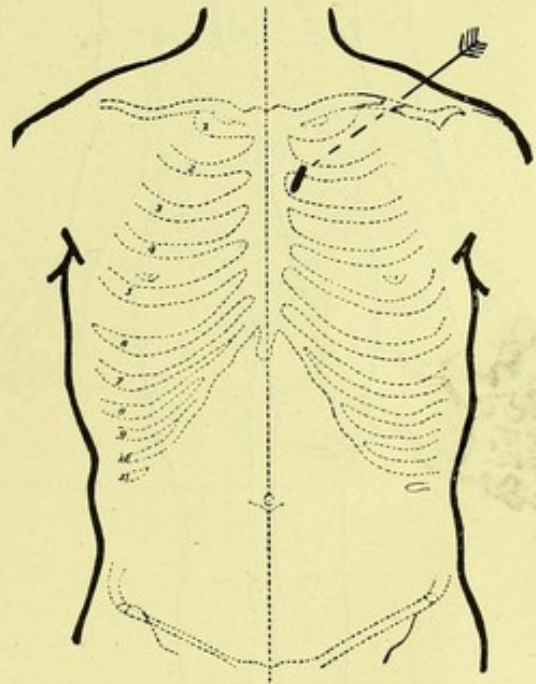


FIG. 3.—Course and location of bullet in case of Private John R. Keen, Troop L, First United States Volunteer Cavalry.

just as the bullet comes to rest. Other similar cases are shown in Plates V, and XXXVII, and case 6, Section V.

Case 6.—Multiple wounds, all aseptic; Mauser bullet lodged in thigh; localization by Röntgen ray; removal.

William A. Cooper, Company A, Tenth United States Cavalry, struck by a Mauser bullet (No. 1, Plate II), which entered the left breast, passed superficially through the anterior thoracic wall, and passed out to the right and 2 inches above the umbilicus, then entered the right thigh at its anterior third and lodged (fig. 4).

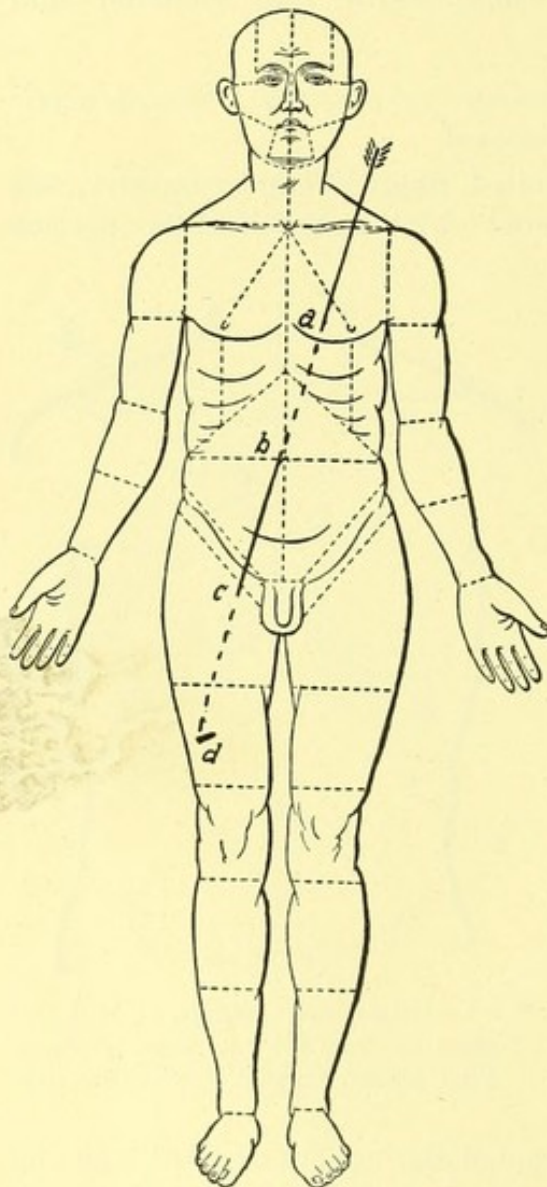


FIG. 4.—Course and position of bullet in case of Private William A. Cooper, Company A, Tenth United States Cavalry. *a*, First wound of entrance; *b*, wound of exit; *c*, second wound of entrance; *d*, position of bullet.

The wounds were all uninfected. The patient was transferred to the *Relief*, where a radiograph was taken (Plate V), which showed the bullet several inches below the entrance wound, lying nearly at a right angle to its course of entrance. The bullet was removed and prompt recovery resulted.—*Case report compiled from records in Surgeon-General's Office.*

The case is interesting not only from the displaced position of the bullet, but from the noninfection of the second wound of entrance by the bullet which had passed not only through the clothing but twice through the skin.

That the Mauser bullet may ricochet, remain undeformed, and, having turned end for end, enter the body butt end foremost, is shown by several cases in which the bullet lay in a reversed position in the part. This reversed position of the bullet has been present in quite a large number of cases seen by the writer, the occurrence being so common as to lead him to believe it an ordinary result of ricochet impact, and consequently, a frequent accompaniment of lowered velocity and lodgment of the ball. In case 13 of this section, the bullet lay butt end foremost in the wound, and the same position was present

in cases 9, and 11, Section IV, and case 1, Section V.

PLATE VI.

PLATE VI.

Lodged shrapnel bullets (natural size), located by the Röntgen ray and removed by operation. These bullets show slight deformation, probably produced at the time of explosion of the case in which they were contained, and not due to ricochet. From the low velocity of the shrapnel ball, it probably seldom ricochets with sufficient force to produce penetrating wounds.



LODGED, SHRAPNEL BULLETS.

The shrapnel bullet, used by the Spaniards, was a round, soft lead bullet, measuring 1.25 centimeters in diameter, and weighing a little over 11 grams. (Plate VI.)

As the velocity of these bullets is only that of the bursting charge of the shrapnel, plus some of the initial velocity of the shell, their velocity is comparatively low, and these missiles belong to the large caliber, low velocity type. Theoretically, wounds produced by these missiles should differ materially from those produced by the small-caliber bullet. Practically, there was not so marked a difference as would have been expected, for, in the reported cases, the wounds which had been given a primary dressing with the first-aid packet generally healed as readily as those made by the Mauser bullet. Also, reported cases show that in many instances, neither by the appearance of the entrance wound or the sensation of the wounded man, could the nature of the missile be determined. In consequence, many cases of penetrating wounds by shrapnel bullets were thought to have been made by Mauser bullets, until the Röntgen ray or removal of the missiles showed them to be shrapnel.

These cases are of special clinical value, as they show that wounds made by the larger lead bullets, when uninterfered with and treated by occlusive dressings, are usually aseptic and run favorable courses.

Case 7.—Shrapnel ball lodged in neck; aseptic wound; localization by Röntgen ray; removal.

George A. Harper, private, Company E, Thirteenth United States Infantry, was wounded July 1, by a shrapnel ball which entered the back of the neck, half an inch to the left of the second cervical spine. The wound was dressed with the first-aid packet and the patient was transferred by the steamer *Iroquois* to the general hospital, Key West, Fla. When admitted to the hospital, the wound of entrance was aseptic and so small that there was nothing to indicate that it had been made by other than a Mauser bullet, and the patient himself believed that he had been wounded by that missile.

The fluoroscope, however, showed that it was a shrapnel ball, and it was removed July 16, from beneath the anterior edge of the sterno-mastoid muscle, 2 inches below the lower end of the mastoid process. Though made by a shrapnel, the wound track was not infected, the wound of operation healed by first intention, and the patient was well when furloughed August 6.

Case 8.—Shrapnel ball lodged in back; aseptic wound; localization by Röntgen ray; removal.

Henry E. Conover, private, Company E, Ninth United States Infantry, was wounded in the left shoulder July 1, the bullet entering 1 inch above the clavicle, at

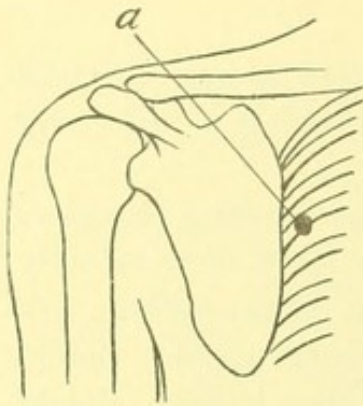


FIG. 5.—Diagram explanatory of Plate VII, showing location of shrapnel bullet, *a*, in the case of Private Henry E. Conover, Company E, Ninth United States Infantry.

the junction of the outer and middle thirds of the bone. The wound was dressed with the first-aid dressing and the patient was transferred to the general hospital, Key West, Fla., where fluoroscopic examination was made, but the bullet could not be located. A static machine was used at Key West, and, owing to the great humidity of the air at that place, the apparatus failed to produce sufficient light to penetrate the thicker parts of the body. For that reason, lodged bullets could not be located in some cases while at that hospital.

On admission to the hospital, the wound was small and aseptic, healed quickly, and from its appearance it was thought to have been made by a small-caliber bullet. The patient complained of pain in the region of the shoulder blade, but had no other symptoms. He was furloughed August 6, but on rejoining his regiment at the expiration of his furlough he found it difficult to handle a gun, and was sent to the general hospital at Washington Barracks, D. C. The bullet was located just beneath the posterior border of the left scapula. The radiograph showed it to be a shrapnel (Plate VII and fig. 5).

The bullet was removed December 3, 1898, the wound healed by first intention, and the patient returned to duty six days later. In this case the wound, though made by a shrapnel, was entirely aseptic and remained so until the bullet was removed, five months after receipt of the injury. At the operation, the tissue about the bullet wound showed no evidence of inflammation, and the bullet was producing trouble only through friction in movements of the shoulder.

The bullet was removed December 3, 1898, the wound healed by first intention, and the patient returned to duty six days later. In this case the wound, though made by a shrapnel, was entirely aseptic and remained so until the bullet was removed, five months after receipt of the injury. At the operation, the tissue about the bullet wound showed no evidence of inflammation, and the bullet was producing trouble only through friction in movements of the shoulder.

Case 9.—Shrapnel bullet wound left groin; aseptic wound; localization by Röntgen ray; removal.

Jeremiah Butler, corporal, Company C, Sixteenth United States Infantry, was wounded July 1, by a bullet, which entered the groin 2 inches to the left of the root of the penis. From the appearance of the wound, the bullet was thought to have been a Mauser and the wound was dressed with the first-aid dressing. The patient was sent from Santiago to Fort McPherson, Ga., where, by examination with the fluoroscope, the bullet was located deep in the left thigh, about 3 inches below the lesser trochanter. As the examination could be made only from before backward, the round shadow thrown by the ball caused the examiner to think the bullet a Mauser lying end on. Afterwards,

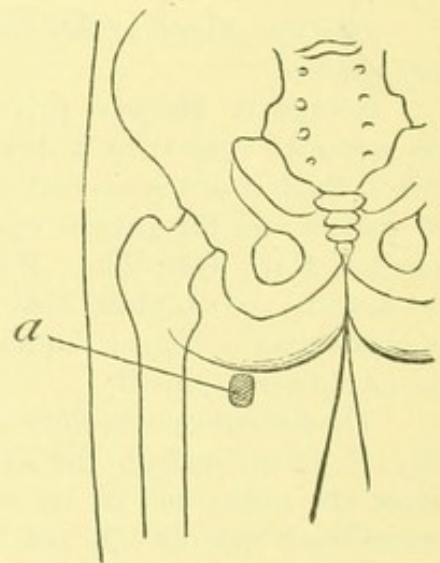


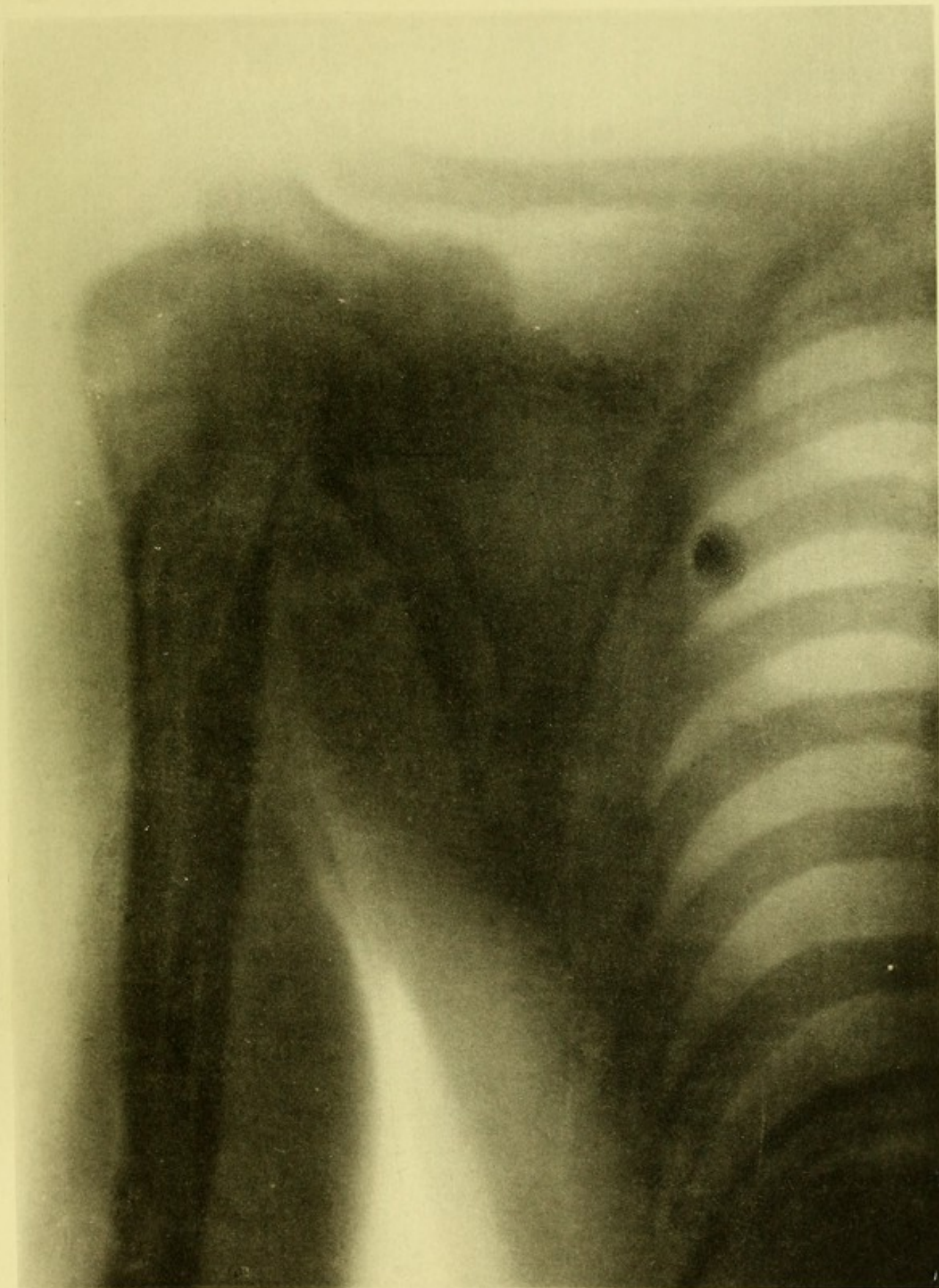
FIG. 6.—Diagram explanatory of Plate VIII, showing location of bullet in the case of Jeremiah Butler, corporal Company C, Sixteenth United States Infantry.

PLATE VII.

PLATE VII.

CASE 8, SECTION II —Henry E. Conover, private, Company E, Ninth United States Infantry.

Radiograph of the left shoulder, viewed from the back, showing shrapnel bullet lodged just behind the internal border of the scapula.



the patient was transferred to the general hospital, Washington Barracks, D. C. On admission, there was no evidence of inflammation, but the patient complained of pain extending down the limb, and he walked with a limp. A radiograph was taken, which showed the bullet to be a shrapnel (Plate VIII and fig. 6).

In the operation for removal the bullet was found embedded in the tissues in close proximity to the sciatic nerve, thus explaining the pain and disability. The patient recovered without event and was returned to duty a few days after operation.

When subjected to operative treatment in the field hospitals under conditions not strictly aseptic, wounds by the shrapnel, like those by other missiles, generally become infected.

Case 10.—Shrapnel ball lodged in axilla; wound explored at field hospital; suppuration; localization by Röntgen ray; removal.

Patrick McDonnell, private, Company F, Sixteenth United States Infantry, was wounded July 1, by a shrapnel bullet which entered 2 inches below the right acromion process. No wound of exit. An unsuccessful attempt was made in the field hospital to remove the bullet. Suppuration occurred, and an incision for drainage was made. The patient was transferred to Fort McPherson, thence to the general hospital, Washington Barracks, D. C. Suppuration ceased and the wound healed. Radiograph disclosed bullet lying in the axilla beneath the neck of the scapula. Operation, under ether, December 7, the bullet removed. Wound healed by first intention and patient returned to duty January 26, 1899.

Case 11.—Shrapnel ball lodged superficially; septic wound; localization by Röntgen ray; removal.

William T. Earle, private, Company G, Sixth United States Cavalry, wounded July 1, by a shrapnel, which entered and lodged just above the superior iliac spine, left side. The wound was dressed and the patient transferred to the *Relief*. Radiograph showed bullet lodged just above point of entrance. The wound was probably infected, for slight suppuration and necrosis of the ilium was noticed at the Long Island College Hospital, where the patient was transferred from the *Relief*. The wound eventually healed and the patient was returned to duty.—*Case report compiled from records of Surgeon-General's Office.*

LODGED, BRASS-JACKETED BULLETS.

The Spanish regular troops were armed exclusively with the Mauser, but some of the irregular troops were armed with the Remington of .41 caliber, carrying a bullet having a brass jacket and soft lead core. This bullet was easily deformed, the jacket being much less resistant to deforming violence than the nickel-steel jacket of the Mauser (Plate IX).

In consequence of its large size and deformability, this missile frequently produced wounds of considerable size—wounds either originally infected or extremely liable to become so.

A sufficient number of Röntgen-ray cases of wounds by this bullet were not reported to enable any general conclusions to be drawn relative to its action when penetrating. The cases reported were infected and their histories are given under Cases 13, and 14, Section IV, and Case 5, Section V.

INJURIES TO THE CENTRAL NERVOUS SYSTEM BY PENETRATING MAUSER BULLETS.

In gunshot injury of the spinal cord or brain, where the bullet is lodged, it becomes important to ascertain whether the symptoms are due to the original traumatism or to pressure from the ball. In the late war, but three cases where the Röntgen ray was used were reported which came under this class, but these cases were of marked clinical interest.

Two of these cases were of injury to the spinal cord, and in one, the brain was wounded. In the cord cases, localization of the embedded bullets by Röntgen ray demonstrated that the symptoms were due to the original traumatism and not to the presence of the bullet. The brain case is of interest from the full history which is given of the patient's condition, the bullet being still embedded in the brain at the time the report was rendered.

Case 12.—Gunshot injury of the cord; Mauser bullet lodged in back; localization by Röntgen ray; removal; discharge for disability.

C. James Edwards, private, Hospital Corps, wounded at Malate, Philippine Islands, July 31, 1898. Bullet entered at a point over the middle of the left deltoid muscle, opposite the surgical neck of the humerus. At the time of the casualty, the arm was deflected from the thorax at an angle of about 60-degrees. There was no wound of exit. Immediately upon receipt of the injury, the patient fell to the ground, and there was complete paralysis, involving both the upper and lower extremities. He was removed to the hospital, soon became unconscious and remained so for two days. There was no discoverable active hemorrhage or fracture. Reflex functions, so far as it is possible to ascertain, were entirely absent below that portion of the spine where the injury was supposed to be. There was rectal and vesicle paralysis. After an interval of three weeks, during which time there was no improvement, he began to regain control of his arms. A progressive change for the better was inaugurated, followed by partial restoration of power of movement. Complete sensibility, both as to pain and temperature, returned to the right half of the body. He was transferred to the division hospital, Presidio, San Francisco, Cal., October 22, 1898. At that time he was able to walk, but with great difficulty. On his arrival at Presidio there was a loss of electro-contractility as to sensibility in the left arm, forearm and hand, left half of the thorax, left half of the abdomen and left leg and foot. There was loss of sense of temperature over this area. Tactile sense, however, was generally present. A partial paralysis of the sphincter ani and vesicæ persisted. Knee jerk increased on right side, feebly present on left side. Motion of the

PLATE VIII.

PLATE VIII.

CASE 9, SECTION II.—Jeremiah Butler, corporal, Company C, Sixteenth United States Infantry.

Radiograph of left thigh, viewed from the posterior surface, showing shrapnel bullet lodged deeply in the thigh about 3 inches below the lesser trochanter. The deep location of the ball is indicated by its dimness of outline and the lack of contrast between it and the surrounding parts.

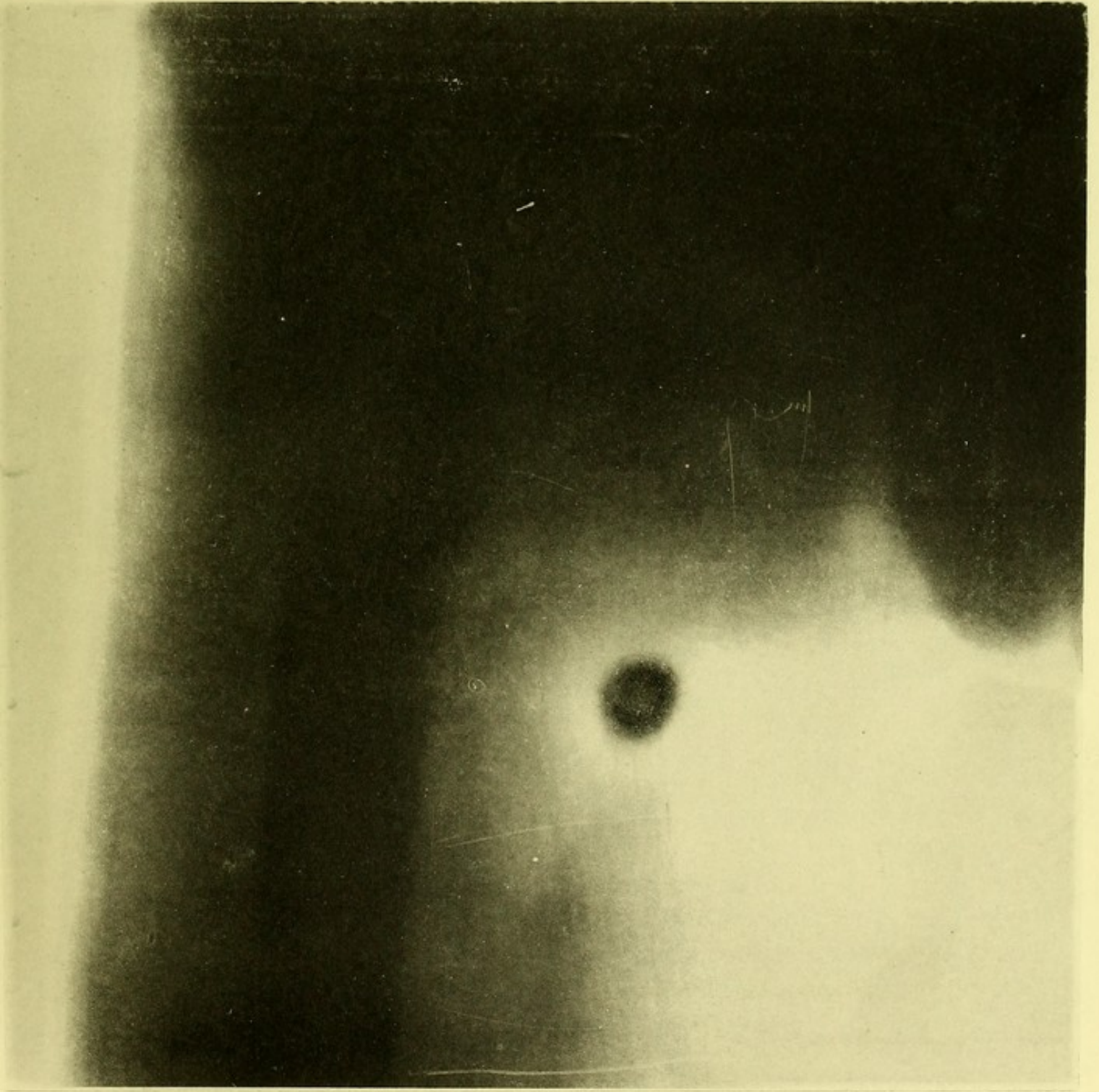


PLATE IX.

PLATE IX.

Lodged, brass-jacketed bullets, natural size. The bullets have been deformed by ricochet, one having the jacket entirely stripped off.


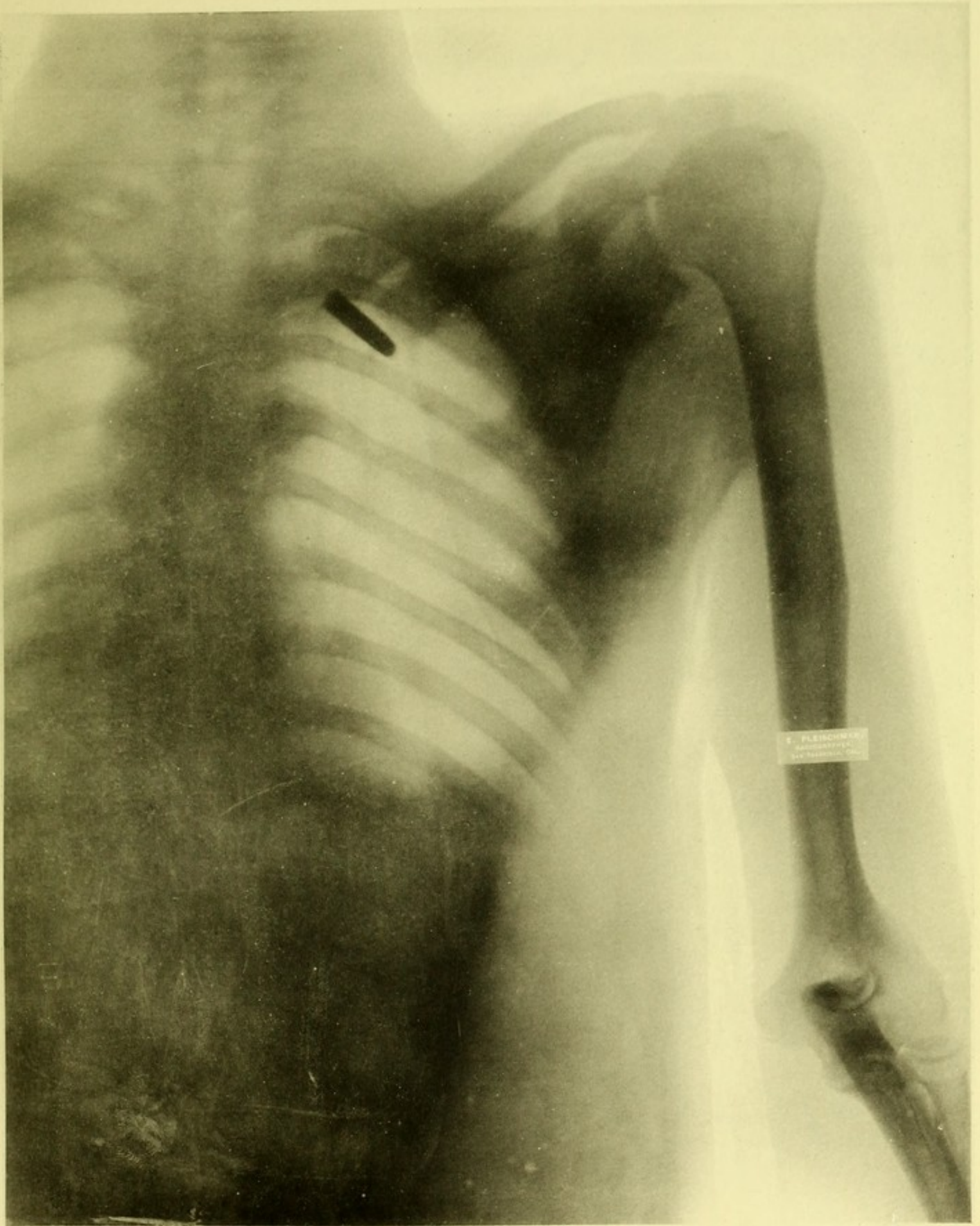


PLATE X.

PLATE X.

CASE 12, SECTION II.—C. James Edwards, private, Hospital Corps.

Radiograph of chest, viewed from the back, showing lodged Mauser bullet, which has passed through the spine, lying 2 inches to the right of the spine over the third intercostal space.



extremities was almost completely restored. Symptoms in reference to the brain, negative. Sexual power and desire almost nil. No ankle clonus. No irregularity in any of the internal organs, but a languid and sluggish condition, lacking the power of vigorous action.

January 2, 1899, motion now only slightly impaired in left upper and left lower extremity. Coordination of muscles virtually normal. Power of muscles is inhibited in right leg. Electro-contractility absent in the left lower extremity, extending from the crest of the ilium to the planter surface of the foot. There is also loss of the sensation of temperature over this area. Sensibility completely absent in the left leg and foot. Mobility absent in the left foot. Micturation and defecation disturbances are still present. Sexual power is diminished, but desire is normal. As far as he can remember there has been a constant dull pain in the back, in the region of the third intercostal space, an inch and one half to the right of the spinous process of the third dorsal vertebra. Radiograph (Plate X) shows a lodged Mauser bullet at the point where the pain above mentioned exists. Bullet was extracted March 7, 1899, and as the patient remained disqualified for military service, he was finally discharged on account of impairment of mobility of right leg and thigh, and loss of sense and contraction of the left leg.—*Case reported by Maj. W. S. H. Matthews, Surgeon, U. S. Vols.*

In the following case, spinal injury was caused by depressed fragments of bone. Localization of the bullet showed that the missile was producing no ill effect in the tissue. Laminectomy was done and recovery followed. The position of the bullet, butt end foremost in the tissues, makes it probable that the missile had ricocheted before entering the body.

Case 13.—Edward Marshall, reporter, wounded at La Quasimas, July 24, by Mauser bullet, which entered the back, 1 inch to the left of the spine at level with the sacro-lumbar articulation. Complete paralysis of the lower extremities and loss of sensation followed the receipt of the injury. Patient was transferred north on the *Olivette*, and entered the Roosevelt Hospital, New York City, where he came under the care of Dr. Robert Abbè. Dr. Abbè took a radiograph of the case, which located the missile lying butt end foremost, 1 inch to the right of the first lumbar vertebra and deeply placed in the neighborhood of the renal vessels (Fig. 7).

The position of the bullet precluded the possibility that the symptoms were due to the pressure from the missile. Dr. Abbè did a laminectomy and removed all

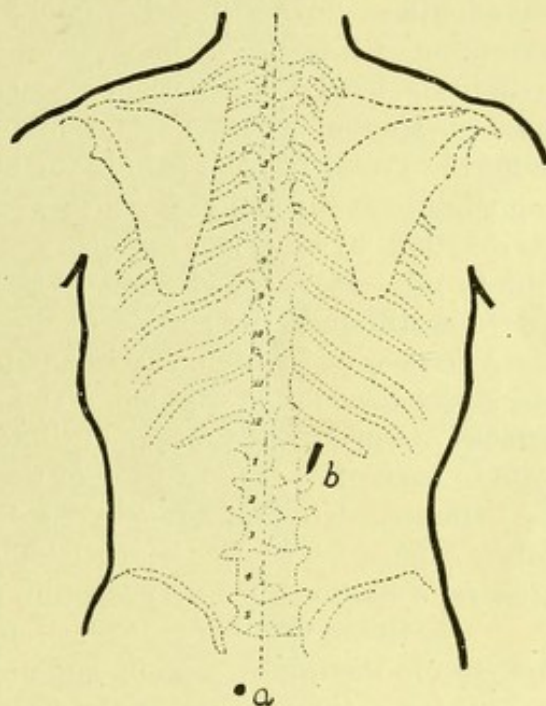


FIG. 7.—Diagram showing wound of entrance, *a*, and position of bullet, *b*, in the case of Edward Marshall.

depressed fragments of bone which were pressing on the spinal cord. The bullet was not removed.

The next case is of interest, in that it shows the result of a gunshot wound of the brain, the bullet being unremoved, and what slight disability and how few important or disturbing symptoms may persist as a result of lodgement of a small-caliber bullet in the brain.

Case 14.—Penetrating, Mauser bullet wound of brain; wound aseptic; bullet not removed.

John Gretzer, jr., private, Company D, First Nebraska Volunteer Infantry, wounded at long range, March 27, 1899, at Mariboa, Philippine Islands, by a Mauser bullet entering cavity of cranium, three-fourths of an inch above the supraorbital ridge and one-fourth of an inch to the left of the median line. There was total loss of consciousness during first few hours following receipt of the traumatism, with the exception of a few short intervals of semiconsciousness, at which time, excruciating pain in the head was experienced. The patient was taken to the First Reserve Hospital at Manila, where he laid in bed for about four weeks. While in bed, he suffered extremely from pain in the head, most severe the first three days, moderating slightly at the end of the fifth week, becoming intermittent, greatly exaggerated on exertion, by heat, and especially direct rays of the sun, exposure to which caused him to reel, stagger, and almost lose consciousness. At the present time (August, 1899), is still quite susceptible to direct rays of the sun. First few days of illness were marked by extreme nausea and persistent vomiting; the slightest thing taken in the stomach would be rejected. The pain in the head increased the severity of these attacks. During early weeks of illness any exertion of the brain, as reading, caused pain in back of eyes and vertex of the head.

Returned to San Francisco with his regiment in August, 1899. Radiograph taken August 20, showed Mauser bullet embedded in left occipital lobe (Plate XI). General condition good, as shown by photograph (Fig. 8).

Condition, October 1, 1899, six months after receipt of the injury: Occasionally has pain in the lumbar region, and describes it as being a "catch," lasting about five minutes at a time. Pain in the head, when present, is located a little anterior to parietal eminence on left side. There is no history of loss of power on either side, but a weakness is appreciated in the right arm and leg, and a slowness in response to mental impulse. This last is demonstrated in the act of writing; though the thought is perfectly clear, there is a slowness in the forming of the words.

Voice: Patient did not, to his knowledge, exercise this function for first two days of illness, but on beginning to do so, noticed a slight confusion of ideas, it being necessary to first clearly fix a thought before giving expression. There was also temporary loss of power to recall past events and names of companions. This returned with full clearness at other times. A slight confusion still remains.

Eye: Pain back of left eye more or less severe, and increased by use, and relieved by closing the lid. During confinement to bed following injury, patient tested vision of left eye by closing right. The vision was clear, but slight weakness and photophobia was noticed. Ptosis of left eye was marked during early weeks of

illness. Aperture is now smaller than that of right eye. A slight diplopia was also present, a line of printing appearing double. Pupils are regular, but left slightly larger. Reaction to light and power of accommodation is noticeably decreased, especially in left eye. Visual field normal. No nystagmus.

Hearing is normal. Sense of smell more acute on right side. Sense of taste more acute on right side, the anterior two-thirds of left showing marked dullness.




FIG. 8.—Photograph of Private John Gretzer, jr., Company D, First Nebraska Volunteer Infantry, taken five months after receipt of injury. Scar of wound of entrance above left eye.

Tactile sense seemingly slightly dull on right side. General sensation of right side not as acute as on opposite side.

Reflexes: Knee reflex very marked on right side, responding to touch above, as well as below the joint; the contact from finger causing a disagreeable tingling throughout the thigh. On left side, reflex is exaggerated, but not to such a marked

extent. Wrist reflex marked on right side, causing a chronic spasmodic contraction of the fingers, and the hands tingling. Reflex absent on left side. Ankle clonus and patellar reflex absent. Chremasteric marked on both sides. Sphincters uninvolved at any period of illness; coordination good, though a slight uncertainty is felt on attempting to walk with the eyes closed. No epileptiform seizures. No disturbance of nutrition or bodily functions. The patient afterwards entered the mail service and returned to Manila on duty.—*Reported by Major A. C. Girard, Surgeon, United States Army.*

GENERAL CONCLUSIONS RELATIVE TO PENETRATING MISSILES.

From the foregoing, it seems reasonable to conclude that the compound bullet of small caliber is not apt to lodge in the tissues unless its velocity has been greatly reduced by long range, by ricochet, or by having passed through some obstacle before entering the body.

Relative to infection of the wound, it would seem probable that missiles which had struck some other object before entering the body would be more liable to be infected and to produce infected wounds than those which had passed through the air only; and that the small caliber bullet, toward the end of its flight, when traveling with low velocity, would be extremely liable to carry foreign matter, shreds of clothing, etc., into the wound and so infect it. In fact, that all bullets which lodge, would be more likely to produce infection of the wound than bullets which have sufficient velocity to pass through the part. It appears, however, that neither ricochet, passage through other objects, or lowered velocity markedly increases the proneness of the jacketed missile to produce infection. This is of clinical importance in that the lodgment of a bullet does not necessitate the treatment of the wound which it has made as though it were an infected one. It appears that such wounds are best treated by occlusive dressings and non-interference, unless manifestly infected or some special condition calls for operation. It further appears that large lead bullets of low velocity are not as apt to make infected wounds as was supposed, and that the same conclusions as to treatment hold with them as with the modern, jacketed projectile.

III.

THE LOCALIZATION OF LODGED MISSILES.

THE RÖNTGEN RAY AND WOUND EXPLORATION.

The superiority of the Röntgen ray over other methods of locating lodged missiles is so great that, when available, it should be used to the exclusion of all others.

It is a most distinct aid to conservative surgery, in that, with it obtainable, disturbance of the wound through immediate attempts to locate missiles is usually unnecessary. Before its introduction, it was frequently thought requisite to follow, or attempt to follow, the track of the bullet before the track was healed, as the only way of locating a missile which might produce subsequent trouble. When the probe, or one of its substitutes, is used, one of the tenets of modern military surgery, namely, noninterference, can not be followed, and septic infection is made possible or probable. With the Röntgen ray at hand, the surgeon can locate a lodged missile at any time when necessity demands, and its track can safely be left undisturbed.

The unreliability of the probe for locating lodged missiles is well known. With the probe it is possible to follow only a small minority of bullet tracks. The contractility of the tissues may interpose obstacles to its passage and a change of position on the part of the patient may cause such a shifting of muscular and fascial structure as to completely obstruct or alter the path made by the projectile. In fact, a great majority of cases, where the bullet has been located by the the Röntgen ray, show clearly how impossible it would have been to determine the position of the missile by means of a probe.

Not only is it difficult to follow the path of the bullet with a probe, but, even having done so, assurance that the missile has been touched is often impossible. The nickel-steel jacket of the modern bullet leaves no mark on the porcelain tip of a Nelaton probe, and sensation of contact as differentiated between a missile and fibrous tissue is not sufficiently definite to enable an examiner to determine that the probe is in apposition with the bullet. Nor can the telephonic probe be relied upon; as is shown in Case 5 of the preceding section.

But not only is the probe unreliable, but it is a source of danger, even when used with all possible aseptic and antiseptic precautions. The experiments of LaGarde, Delorme, Habart, and Faulhaber have shown that in practically all bullet wounds, even those made by the modern compound bullet, some foreign matter and bacteria are carried into the wound. The number of bacteria so carried in are usually not sufficient to produce surgical infection and subsequent inflammation and suppuration, provided, the wounds are protected from further infection and are left undisturbed. For, undoubtedly, the factor of noninterference with the wound is of great importance. No sooner is a traumatism inflicted than natural processes are brought into action for protection and repair. There is a local increase in vascular activity, serum is poured out, leucocytes accumulate, and the defensive factors of phagocytosis and serum bactericidal action are brought into play. That these factors may have best opportunity for action, rest and nondisturbance of the tissue are necessary. Mechanical disturbance of the tissues by probes, by the finger, or by instruments will produce fresh traumatisms and cause disturbance of the defensive action going on, and these traumatisms and disturbances, however slight, will favor growth of the bacteria and add to the defensive labor required of the tissues. So that even aseptic or antiseptic operative or explorative interference may throw the scale on the side of the invading bacteria and lead to troublesome or disastrous consequences. For these reasons, and in consideration of the unreliability and danger of searching for a bullet through the wound, it may be stated that such search is contraindicated, except in cases where the immediate danger from the presence of the bullet is greater than the possible consequences which may arise from interference.

Fortunately, cases requiring immediate removal of lodged missiles are extremely rare, and for all other cases, the uncertainty and danger of exploration through the wound are done away with by the certain and safe action of the Röntgen ray.

NECESSITY FOR THE LOCALIZATION AND REMOVAL OF LODGED MISSILES.

It is well known that lodged missiles frequently become encysted in the tissues and cause no further trouble. In other cases, however, they give trouble through causing suppuration, or by pressure upon some neighboring nerve or organ, or by being so situated as to interfere with, or produce pain during muscular action.

Frequently, also, knowledge of the presence of a foreign body causes mental disquietude, and in other cases it is important to know the exact

location of the missile in order to determine whether the symptoms which sometimes follow its lodgment are due to the lesions incident to the original traumatism or to irritation from the foreign body, or whether or not the symptoms may not be due to something entirely unconnected either with the original traumatism or the presence of the lodged missile. In such cases, accurate localization of the bullet is of the greatest importance and value from a standpoint of diagnosis and treatment.

The following two cases are illustrative of those cases in which, without accurate localization of the bullet, it is impossible to determine whether or not the symptoms are due to the effects of the original traumatism or to irritation set up by the lodged missile. Case 1 is illustrative, also, of the aseptic course of a wound made by a slow-moving lead bullet when left undisturbed.

Case 1. Shrapnel ball lodged in back; traumatic neurasthenia; localization by Röntgen ray; missile not removed.

Richard J. Eskridge, major, Tenth United States Infantry, wounded with shrapnel, July 2, at Santiago and transferred to Massachusetts General Hospital, where following history was noted:

Ball entered back while he was sitting. Immediate shock severe. Intense dyspnoea. Complete temporary paralysis of the left side. After being taken to rear was able to move arm and wiggle toes slightly. Dyspnoea lasted twenty-four hours. Severe constant pain in lower half of left side of trunk and left leg. Wound healed readily. No wound of exit found. Paresis of leg remained same for about three weeks, then began to disappear gradually till he was able to raise his leg from the bed about three weeks later. Since then, improvement less rapid. Pain has continued with about same severity, requiring one-quarter to one-half grain of morphia at night. More severe at night; more severe in damp weather.

August 16. Examination: In left back, $2\frac{1}{2}$ inches from median line, at level of ninth rib, a round scar one-fourth inch in diameter. Marked muscular atrophy of hip, thigh, and leg of left side. Thigh and leg (left) very flabby. Extreme sensitiveness of thigh and leg, most marked just above popliteal space. Knee jeak absent on left side. Able to get around little on crutches and put a little weight on left leg.

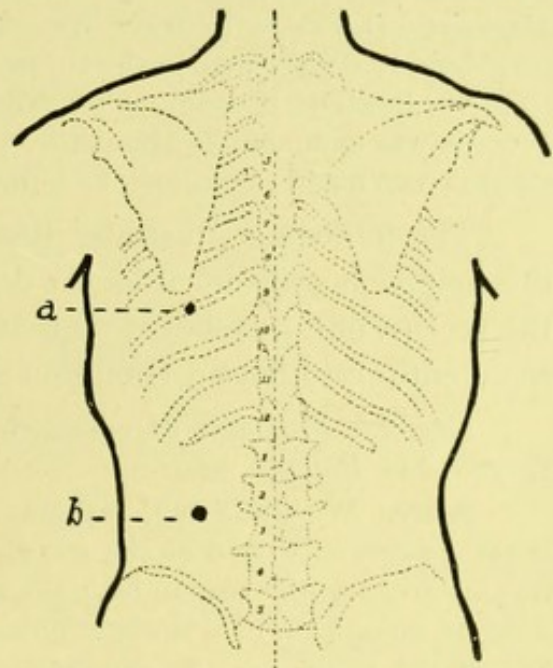


FIG. 9.—Diagram showing location of wound of entrance (*a*) and position of bullet (*b*) in the case of Maj. Richard Eskridge, Tenth United States Infantry.

November 6, X-ray plates taken; bullet found. Three plates then taken, one directly over site of bullet, one on either side at angle of 45° . These located bullet at level of second lumbar intervertebral disk, $1\frac{1}{2}$ inch above level of crests of ilium and about three-fourths inch to 1 inch deep. Removal not advised by neurologists, as no source of irritation.

From the Massachusetts General Hospital the patient was transferred, with a diagnosis of traumatic neuritis, to the Army and Navy General Hospital, Hot Springs, Ark., and thence to the General Hospital at Washington Barracks.

On arrival at the latter hospital the same symptoms of pain and local hyperaesthesia were the same as given above. The motor functions of the left leg had considerably improved. Some doubt existing as to whether the symptoms were due to the original traumatism or to pressure from the bullet, a radiograph was taken, from which it was thought that the bullet (shrapnel) lay as located in the Massachusetts Hospital. The bullet was cut for, but could not be found. The Mackenzie-Davidson localizer was then used and with it, the bullet was located considerably deeper and in the subperitoneal tissue just below the left kidney. As from its location, it could by no possibility be causing any of the symptoms, the neuritis was undoubtedly traumatic, a result of the original lesion, and no further attempt was made to remove the bullet.

The following illustrates those cases in which it is necessary to locate the lodged missile in order to determine whether symptoms which follow the receipt of a gunshot wound are due to the presence of the bullet or to some entirely different condition :

Case 2.—Fragment of missile lodged in the back; neuralgia; localization of fragment by Röntgen ray.

Alfred W. Bjornstad, captain, Thirteenth Minnesota Volunteers, received a slight superficial wound of the left shoulder at Manila, P. I., August 13, 1898. On turning to go to the rear to have the wound dressed, he was struck a second time by what he thought to be a ricochet bullet. The wound of entrance was 3 inches to the left of the spine and midway between the ninth and tenth ribs. The wound was dressed with a first-aid dressing and healed without trouble. After returning to duty, he was troubled with almost constant pain in his right side, especially when marching. This continued until he was returned to the United States with his regiment to be mustered out. After being mustered out, he was appointed captain in the Forty-second United States Volunteer Infantry, and as the pain in the right side still troubled him somewhat, though much less than formerly, he applied for treatment before being returned to the Philippine Islands, with a view to determine whether or not the pain in his right side was due to the presence of a lodged bullet. He was ordered to the general hospital at Washington Barracks, D. C., where a Röntgen ray examination was made and a small, irregular piece of metal, probably a fragment of a bullet, was located in the left side almost directly beneath the wound of entrance. Careful examination showed no other missile and determined the fact that there was no lodged bullet on the right side producing the pain from which the patient was suffering. As the small piece of metal on the left side was producing no trouble, it was not removed, and the patient left the hospital shortly afterwards.

PLATE XI.

PLATE XI.

CASE 14, SECTION II.—John Gretzer, jr., private, Company D, First Nebraska Volunteers.

Radiograph of head viewed from the left side, showing Mauser bullet lodged in the brain.

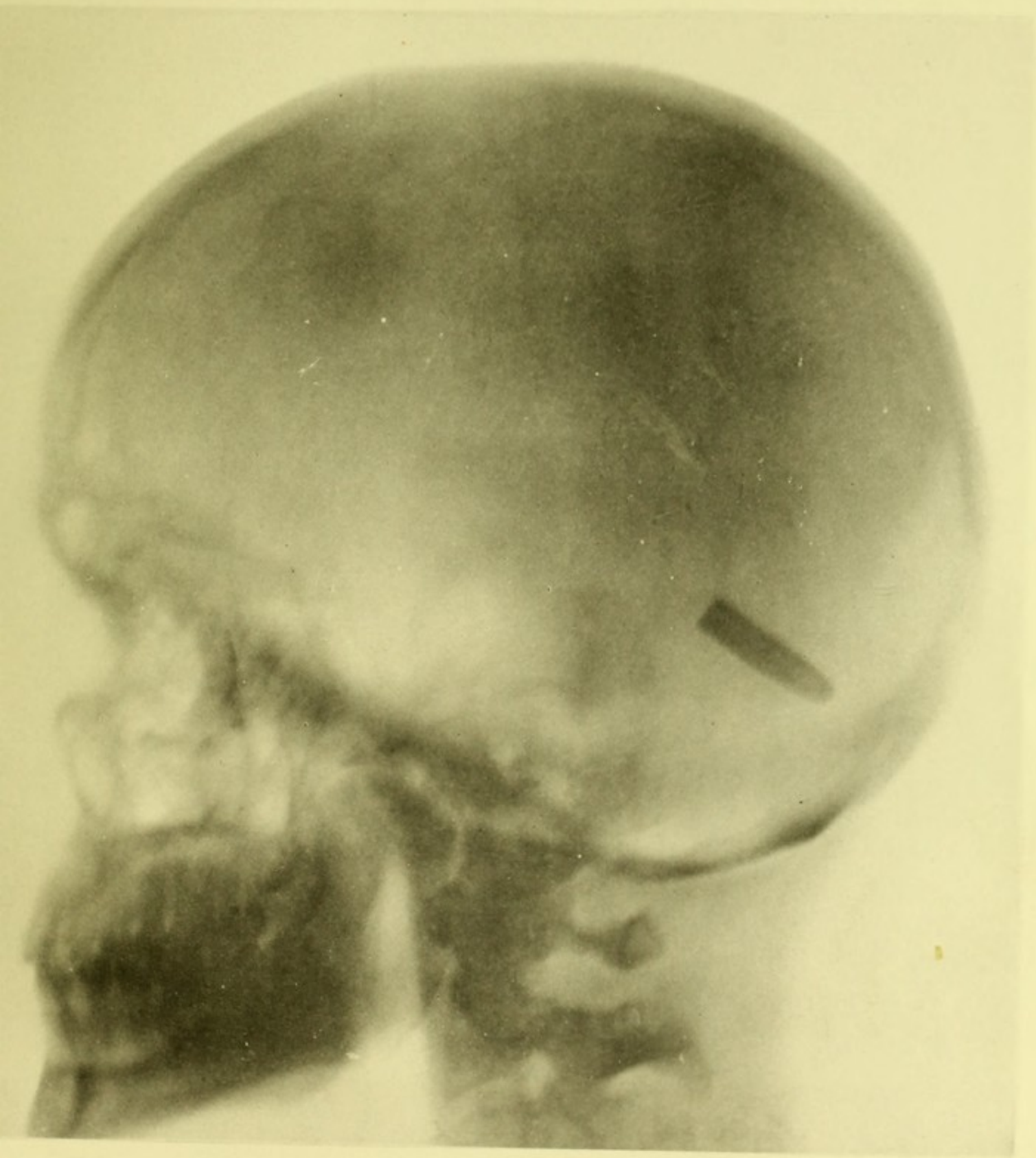
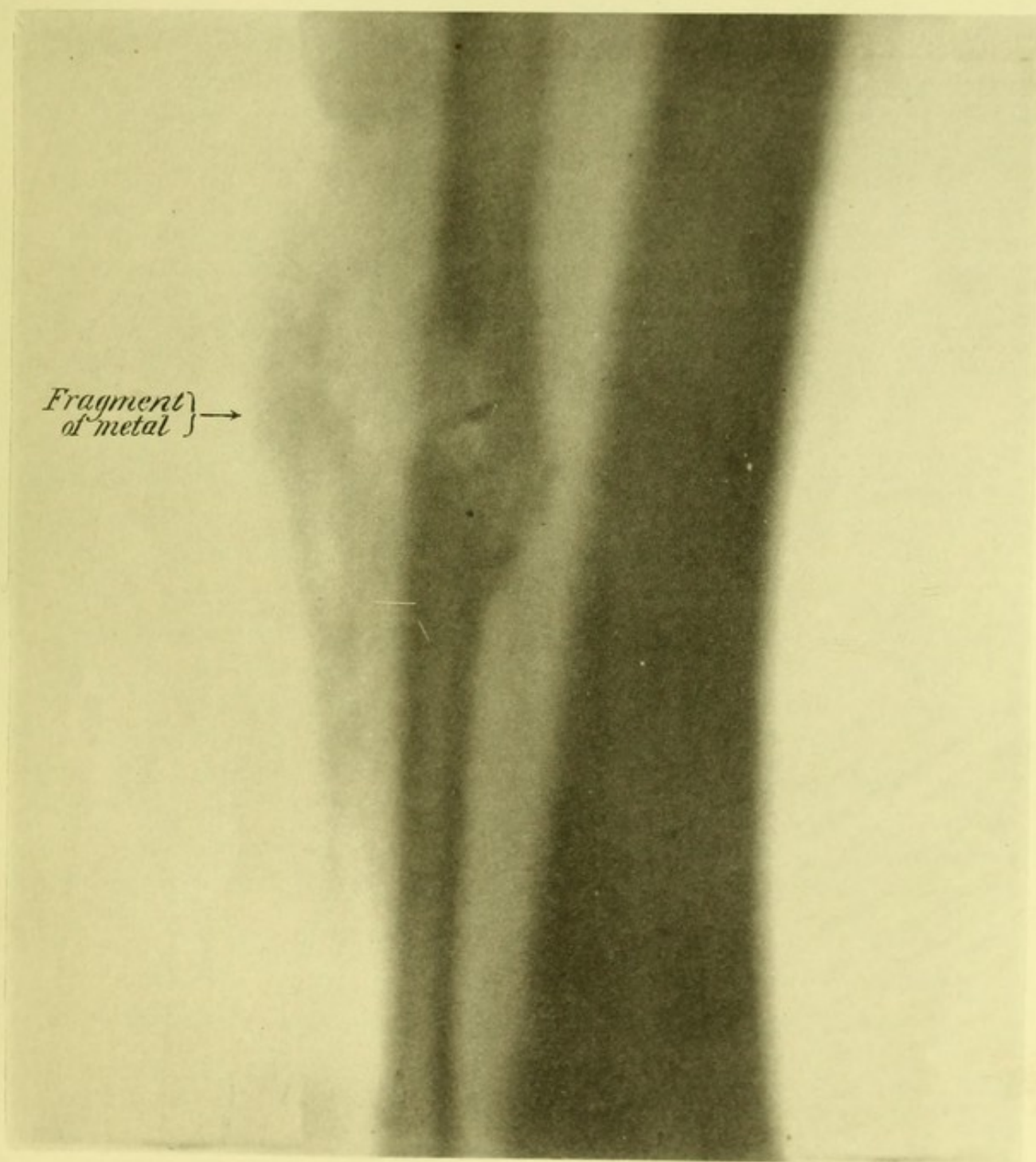


PLATE XII.

PLATE XII.

CASE 3, SECTION 3.—John Watson, private, Troop F, Tenth United States Cavalry.

Radiograph of left leg, viewed from the back, showing fragment of missile embedded in the center of the callus formed at the site of a gunshot fracture of the fibula.



*Fragment
of metal* } →

The value of the Röntgen ray in locating missiles or small fragments of missiles which have infected the wound and cause continued suppuration is shown by the following case:

Case 3.—Fragment of metal lodged in fibula; suppuration; localization by Röntgen ray; removal; recovery.

John Watson, private, Troop F, Tenth Cavalry, was wounded July 1, by a missile, supposed to be a Mauser, which entered the anterior surface upper part of middle third right leg, fractured the fibula, and passed out at the internal lateral surface. The patient was transferred north and finally to the general hospital at Washington Barracks. A suppurating sinus persisted at the site of the original wound of entrance. A radiograph was taken which showed a small fragment of metal embedded in the callus uniting the fractured fibula, (Plate XII). Operation disclosed a small piece of lead at the point indicated. This was removed, the wound promptly healed, and the patient was returned to duty.

LOCALIZATION METHODS.

It is to be noted that Röntgen rays are projected in right lines from the anode of the Crookes tube. As a consequence of this, the observed shadow of an object, the object itself, and the anode are all in line. This direct projection of the observed image is both an advantage and a disadvantage in locating missiles lodged in the body. It is a disadvantage, in that erroneous conclusions may be formed of the location of a missile, unless the position of the anode and the position of the shadow of the object are accurately observed and noted. For, if the position of the anode is not known, the foreign body may lie in any line projected from the position of the observed shadow. The projection of the shadow of an object in a right line is of advantage in that, knowing the position of the anode and the position of the shadow, the object itself must be at some point directly between the two. This fact of the direct projection of the shadow of objects has given rise to two methods of localization of lodged missiles; *a*, by direct observation; *b*, by multiple observation.

LOCALIZATION BY DIRECT OBSERVATION.

Direct observation has to be employed in those cases in which lateral views can not be made through the part in which the foreign body is lodged. Thus, in examinations made for foreign bodies in the chest, abdomen, pelvis, shoulder, and upper part of the thigh, the observation has to be made from before backward, or vice versa. As no lateral views can be obtained by which the depth at which the foreign body lies can be determined, resort

must be had to other means, of which there are two; first, the use of some form of localizer, discussion of which will be taken up later; and, second, critical observation of the image of the foreign body and its relative position. By carefully examining the outline and size of the image of the lodged missile and the movement of its image when the tube is shifted from side to side, the depth of the foreign body in the part can be approximately ascertained.

If a lodged missile is very near the fluoroscopic screen or the photographic plate, the outline of its shadow will be quite sharp. If farther away, the outline of its shadow will be blurred and indistinct and its size increased; the blurring, indistinctness and size, increasing with the distance of the lodged missile from the plane upon which its shadow is cast.

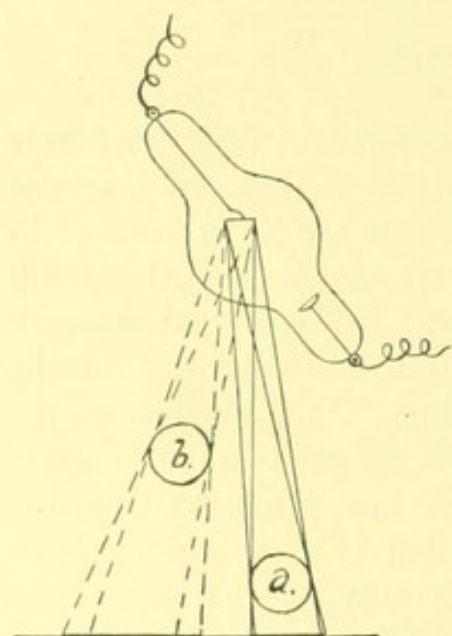


FIG. 10.—Diagram showing the relative size of umbra, penumbra, and shadow in foreign bodies located superficially (*a*) and deeply (*b*) in the tissues.

If the outline of a lodged missile is sharp and distinct in the radiograph, it indicates that the missile is near the surface of the body against which the photographic plate was placed. If, on the other hand, the picture of the lodged missile appears blurred and indistinct in the radiograph or on the screen, it is an evidence that the missile is at a considerable depth in the tissues. The increased size of the image of a deeply placed foreign body is due to the greater dispersion of its shadow the nearer the body lies to the source of light (fig. 10 *b*). Its blurred outline is due to the fact that the Röntgen rays are not projected from a single point on the anode, but from its entire surface. As the rays are not projected from a single point, they cross each other at the edges of an object, forming a penumbra, and, necessarily, the penumbra is wider the greater the

distance between the object and the plane upon which its shadow is cast (fig. 10 *b*).

In making these observations, photography is a much safer guide than visual observations made with a fluoroscope, as the photographic image will show differences of outline more clearly than the eye can determine them. A number of examples of the relative dimness of outline and variations in size of the image of lodged missiles, according to the distance of the missiles from the surface of the body, are given in the radiographs accompanying this report.

In addition to the methods already given for approximating the position of lodged missiles, advantage can be taken of the position of the image of the foreign bodies relative to surface markings and points on the bones. Thus in Case 9, Section II, the position of the observed image of the bullet relative to that of the lesser trochanter and the fold of the buttock was of the greatest assistance in locating the bullet at the time of operation, while the dimness of outline and large size of the image of the ball indicated that it was deep in the part.

A still further means of approximating the depth at which a lodged missile lies in a part is to note by the fluoroscope, the distance which the image of the object moves when the tube is shifted laterally. If when the tube is moved, the image moves but slightly, the missile can not be deep in the part; while, if the image movement is considerable, the foreign body is probably quite deeply placed.

These means of localizing lodged missiles give only inferential results, but by careful observation and by combining all possible factors, foreign bodies can be localized, in a majority of cases, with sufficient exactness for all practical purposes, especially if they are not deeply placed. On account of its size, a bullet is not likely to be missed by a surgeon when it is situated superficially, provided the operator cuts in direct line from its observed shadow toward the point where the anode of the Crookes tube was located. But in pursuing the method of direct incision, the surgeon must be quite certain before operating that the body for which he is searching is situated superficially, or he may have to cut too deeply or through important structures to find it.

Where foreign bodies are deeply placed or in the neighborhood of important structures or organs, it is necessary that they be accurately located before operative interference is adopted, and in such cases one of the methods of localization by multiple observation must be resorted to.

LOCALIZATION BY MULTIPLE OBSERVATION.

Localization by multiple observation covers all the methods of localization in which the location of the foreign body is determined by observations, so made, that the right lines of light from the anode cross each other. As the anode, the observed body and its shadow are always in line; when two observations are made with the anode in different positions at each observation, it must follow, that the observed body must lie at a point where the lines drawn from the anode to the shadow of the body cross each other.

As a consequence of this, if two observations are made with the anode in different positions, and these positions and the points on the surface of the body where the images of the missile are projected are recorded, then the missile can be accurately located at the point where lines cross each other which are drawn from the positions occupied by the anode to the points on the surface of the body where the shadows of the missile were cast.

A number of means have been devised for determining the position of the anode and the shadow of foreign bodies relative to the surface of that part of the body in which the foreign body is located. The most common method is to make an observation and mark upon the skin the point where the shadow of the foreign body is thrown, then to move the anode to a position where it will approximately project the Röntgen rays at right angles to the first observation, and, after marking on the skin the point where the second shadow of the foreign body is cast, the operator can, by angulation, approximately determine the point where the foreign body lies. This method, like the method by single observation, is generally sufficient for cases where the missile lies superficially or in close relation to some bony point. Examples of this method of determining the position of lodged missiles by right-angled observation are given in Plate XIII, and in Plate XXXIII.

But where the bullet is lodged deeply, this method, like the method by direct observation, while sufficient for some cases, can not be depended upon for accuracy, and instruments have been devised for definitely fixing the position of all the points necessary to accurate localization; namely, the positions of the anode, the places on the surface of the body where the projected shadows of the foreign body are thrown, and the position of these points relative to each other.

These instruments are divided into two classes; those in which photography is used, and those in which visual effects are relied upon.

Instruments of each class have been used and have been found of great value in difficult cases arising from the late war.

PHOTOGRAPHIC APPARATUS FOR LOCALIZATION.

Mackenzie-Davidson devised and, in 1898, described a method of localization, since known as the crossed-thread system.¹ This method, either with Mackenzie-Davidson's original apparatus or one of its modifications, is probably the most accurate and reliable means now used for the localization

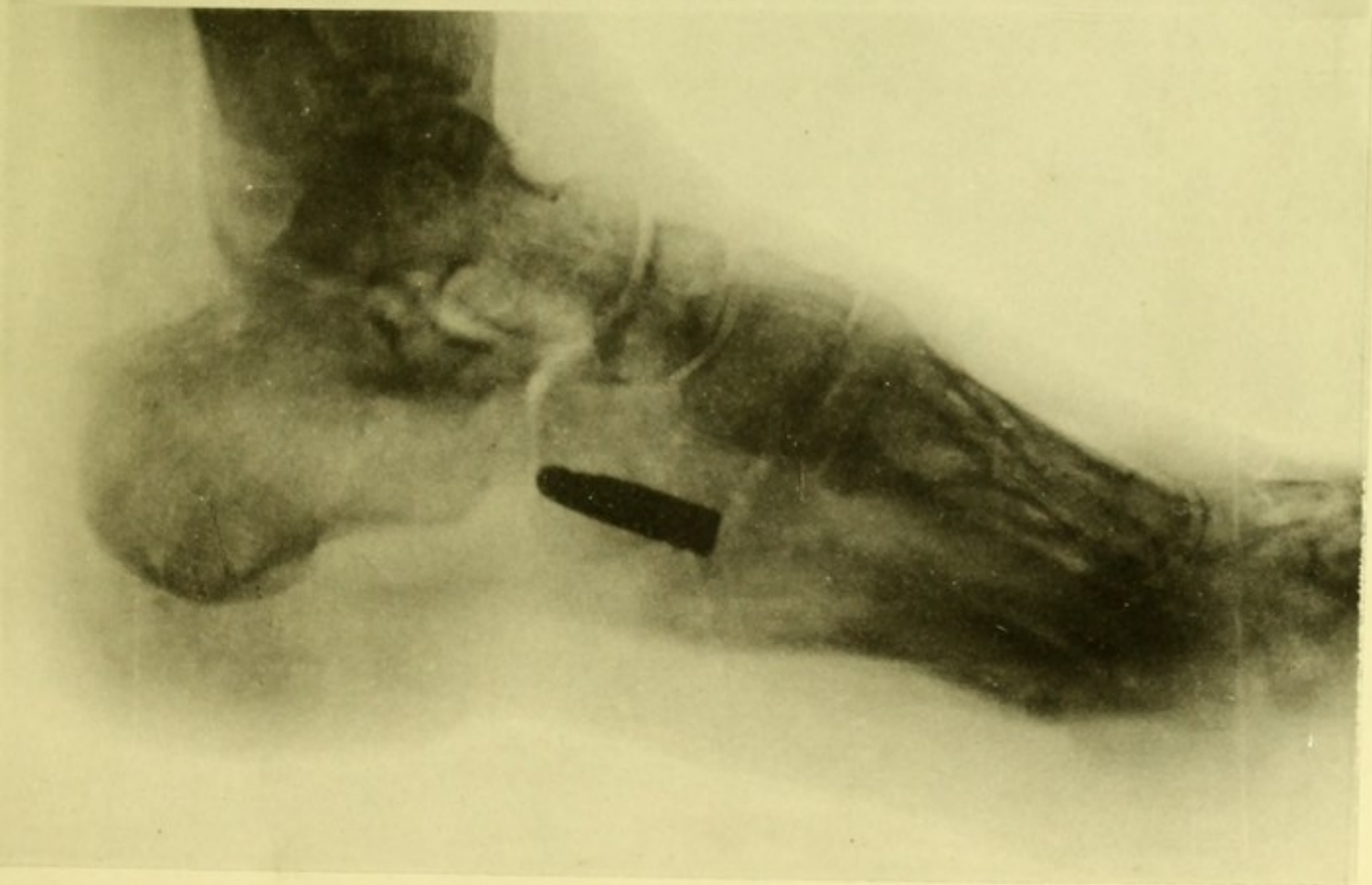
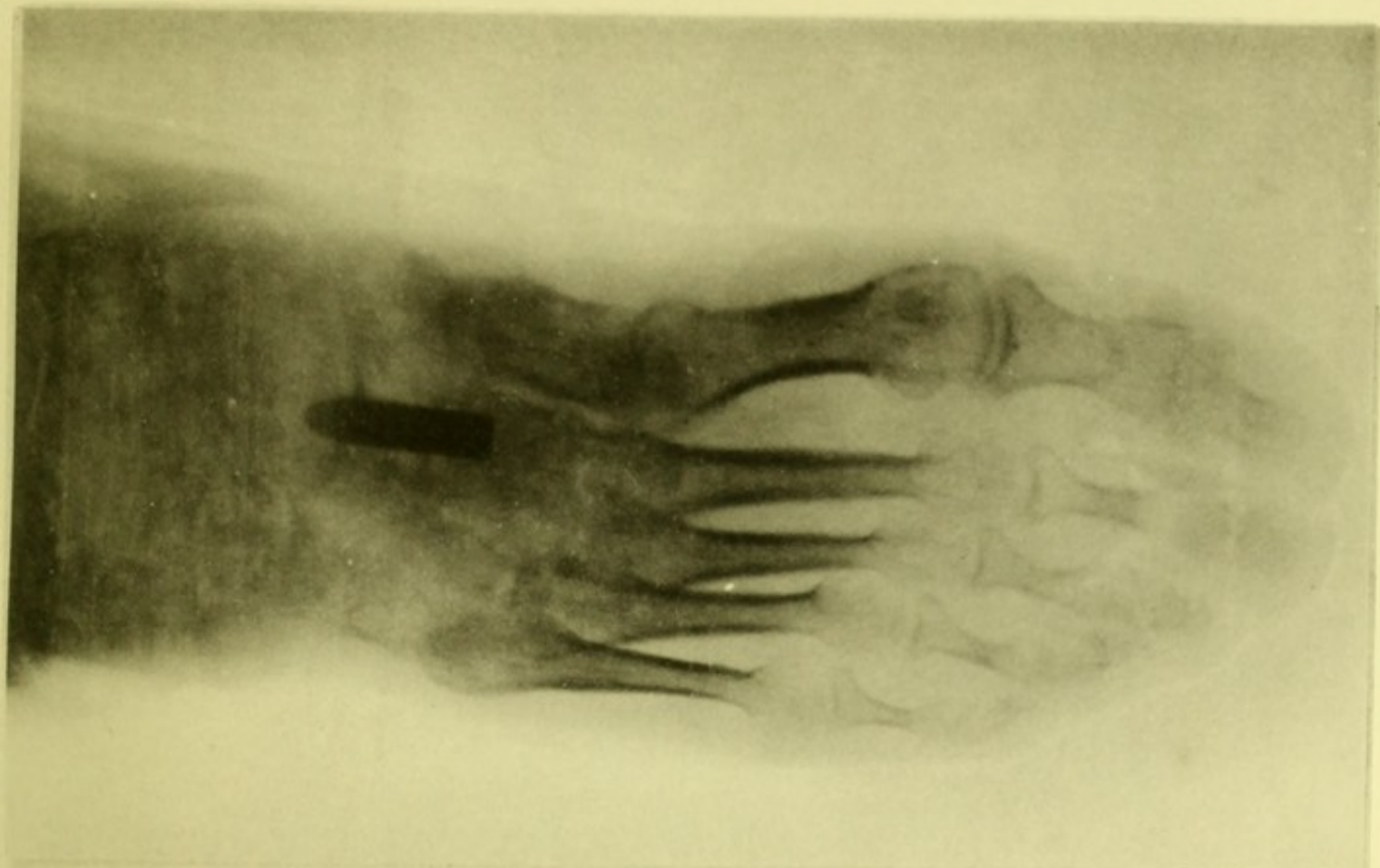¹ Mackenzie Davidson. Röntgen ray and localization, *British Medical Journal*, January 1, 1898.

PLATE XIII.

PLATE XIII.

CASE 4, SECTION II.—John N. Taylor, private, Company B, Twelfth United States Infantry.

Radiographs of the left foot, viewed from the inner, and from the plantar surface, showing a slightly deformed bullet embedded in the sole of the foot, beneath the cuboid bone and in a line with the second metatarsal bone. The two views accurately locate the missile.



of foreign bodies with the Röntgen ray. The Mackenzie-Davidson apparatus consists of two parts, the exposer (fig. 11), and the localizer (fig. 12).

By means of the exposer, that part of the body in which the foreign body is lodged is fixed in a definite position relative to a photographic plate. Two exposures are then made upon the same plate with the anode




FIG. 11.—Mackenzie-Davidson exposer. The photographic plate is placed beneath the crossed wires on the board. The wires are inked and leave marks on the skin of the part and the image of the wires appears on the negative. This gives lines for localization. The tube is suspended vertically above the transverse wire and equidistant at each exposure from a point vertically above where the wires cross.

in different position for each exposure, the position of the anode being by means of the apparatus accurately fixed and determined for each exposure. The plate being then developed, two images of the shadow of the foreign body will appear in the negative.

By placing the negative in the localizer (fig. 12), and stretching threads from corresponding points of the two images on the negative to the positions which, relative to these images, were occupied by the anode at each

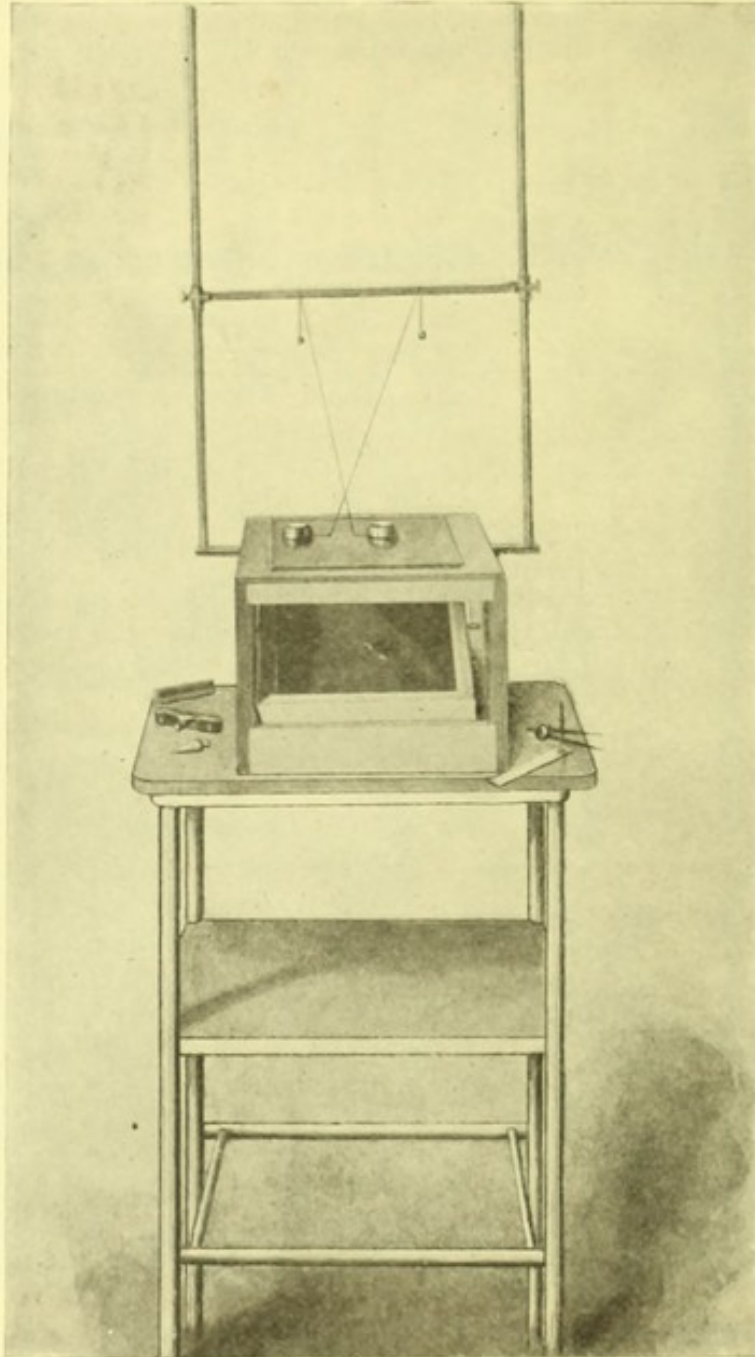


FIG. 12.—Mackenzie-Davidson localizer. The negative is placed on the glass plate in the same position relative to the two points on the crossbar that it occupied relative to the anode when the exposure was made. Weighted threads are then stretched from corresponding points on the image to the points on the crossbar, and their point of crossing indicates the position which the lodged missile occupied relative to the plate when the exposure was made.

exposure, the threads will cross at a distance and position from the negative which the foreign body occupied at the time that the negative was made.

By measuring the location of the point where the threads cross, the position of the foreign body in the tissues is then determined by markings made on the skin at the same time that the negative was taken. In this way, foreign bodies can be located with mathematical exactness.

The method in detail is as follows: Radiographs are taken from two different points of view. In order to carry out the adjustment and movement of the Crookes tube, a horizontal bar is used with a scale upon the front of it, graduated in millimeters, with 0° at the middle point of the bar (fig. 11). This bar slides up and down upon the two rods which rest upon the floor, each with a base similar to those in standard lamps. There is a small holder for the Crookes tube, which slides horizontally along the bar, and there are two sliding checks, which can be fixed by means of a small screw at any desired points on the scale, thus enabling the tube to be quickly and accurately removed from position on one side of 0° to a corresponding point on the other side.

In case it is desired to adjust the Crookes tube to any particular height, there is a small bar which slides vertically up and down and carries the tube with it and acts as a fine adjustment; a small thumbscrew clamps it. There is a small spirit level fixed on the top of the carrier of the Crookes tube.

The method of taking the radiograph is as follows: The first step in the process is to measure, as accurately as possible, the height of the point of origin of the Röntgen rays above the photographic plate or film, and generally for all practical purposes, the middle of the anode plate may be taken as the radiant point. The sliding holder with the tube is placed with one of its edges on 0° of the scale on the horizontal bar. The check clips are adjusted on either side of the 0° to the desired degree of displacement and fixed there, so as to allow of equal displacements of the tube to either side of 0° . The amount of displacement of the tube does not seem to affect the accuracy of the results; a displacement of 7 cm. to each side of zero working well in practice, though other distance may be required in some cases.

On the table below the tube there is a board with two fine wires stretched across it at right angles, and dividing it into four equal parts (see fig. 11). It should be considerably larger than the largest photographic plate or film which is to be used, so that the plate or film covered with black paper in the usual way can be slipped beneath the cross wires. Or, instead of the board, two wires can be tied directly across the covered photographic plate. The adjustments now necessary are as follows: Put the tube holder at 0° , and then with a small plumb line drop a perpendicular

from the middle of the platinum anode. The board is then placed so that the point where the wires upon it cross is just under the plumb-line needle; in fact, vertically below the center of the anode. Further, the board must be so placed that one of the wires is parallel to the plane in which the tube is to be placed; that is, it must be made to lie parallel to the horizontal bar. This can be done by mere inspection by looking along the edge of the horizontal bar and seeing that the wire is parallel to it. Once these adjustments are made, the board can be fixed to the table and the instrument is ready for use at any time without further adjustments being necessary.

The distance of the center of the anode vertically from the plate is carefully measured and recorded. The tube holder is now displaced to the previously fixed check clip on one side. The cross wires are lightly brushed over with some suitable dye (the ink used for rubber stamps is good). The plate, covered as usual, is then slipped beneath the cross wires. The patient now places the part to be photographed on the plate and a small object, opaque to Röntgen rays (a small coin answers well), is placed on one of the corners of the plate, so as to mark a quadrant. The current is turned on and one exposure made. It is then stopped for an instant till the tube is pushed over to the other side of 0° , to where the other check clip had been previously fixed, and then another similar exposure is given on the same plate and without the patient moving. When the patient raises the part from the plate he should carry the mark of the cross wires in ink and it is important to make a small mark on the quadrant of his skin, which corresponds to the quadrant on the plate upon which the opaque object was placed. This is clearly necessary to keep the parts and the negative in register.

The negative is at once developed and fixed in the usual way, when two shadows of the foreign body will appear. If, for example, the foreign body is a bullet, there will be two bullet shadows in the negative.

From the above data and with this negative one can, by means of mathematical formulæ or geometrical drawing to a scale, arrive at a correct knowledge of the position of the bullet. But the requisite knowledge is not always at hand; and the second part of the apparatus is now brought into use. Fig. 12 shows the apparatus called the "localizer."

It resembles a photographer's retouching desk. Upon an iron stand a piece of plate glass is placed horizontally and beneath it, a mirror which can be adjusted so as to reflect the light from a window or lamp up from below. There is a horizontal bar which slides up and down upon two vertical rods. On this bar, there is a millimeter scale with a small notch at each millimeter

mark. The O° is at the middle point of this bar. On the glass plate there are two lines cut with a diamond at right angles to each other (to correspond to the cross wires on the vulcanite plate), and this glass plate, which is movable and can be clamped, is so placed that the point where the lines cross is vertically beneath the O° on the scale above, and the line on the glass running right and left (when facing the scale) is placed parallel to the edge of the scale. In other words, they are in the same vertical plane. The scale is now raised or lowered so as to make the O° on it precisely at the same height vertically above the negative as the anode of the Crookes tube was from the photographic plate or film when the negative was being produced.

The negative being washed after fixing, can be at once placed upon the horizontal stage and easily adjusted, so that the white lines produced by the cross wires, are made to coincide with the cross line on the glass plate, care being taken that the marked quadrant is in the same relative position as it occupied when the photograph was being taken. As a routine practice, it is best to mark the right upper quadrant, as the operator stands facing the scale on the bar.

It is important to remember that the negative should be placed face up on the stage, for if placed on the stage with the gelatin face downward the relations of the parts are reversed.

The negative being thus arranged, it will be seen that it is really placed under exactly the same conditions as it occupied when it was being taken. Under these circumstances, all that is now required is to trace the path of the rays which produced the negative. This is done in a very simple way. The distance on each side of the middle point (O° on the scale) to which the anode was displaced is known. Suppose it was 7 cm., a fine white silk thread is placed in the notch 7 cm. to one side of O° and another silk thread (red) is placed in the notch 7 cm. to the other side of O° . Small weights are attached to one of the ends of each thread to keep them taut, while the other is threaded into a fine needle, which is weighted by being fixed into small lead weights, in shape resembling a mouse (Figs. 12 and 13).

Now, these threads can be used to show the path of the rays which produced the negative. Suppose we are dealing with a bullet in some part of the body. On looking down on the negative we find two bullets, and it is not difficult to see, that as the Crookes tube was displaced horizontally in a line running right and left, that the shadow of the bullet to the left was produced by the tube when displaced to the right, and vice versa.

Thus, if we place one of the threads on the point of the bullet in one shadow, it will indicate the path of the ray that produced the shadow of the bullet point (P, fig. 13.) Now, if the other thread is placed on the correspond-

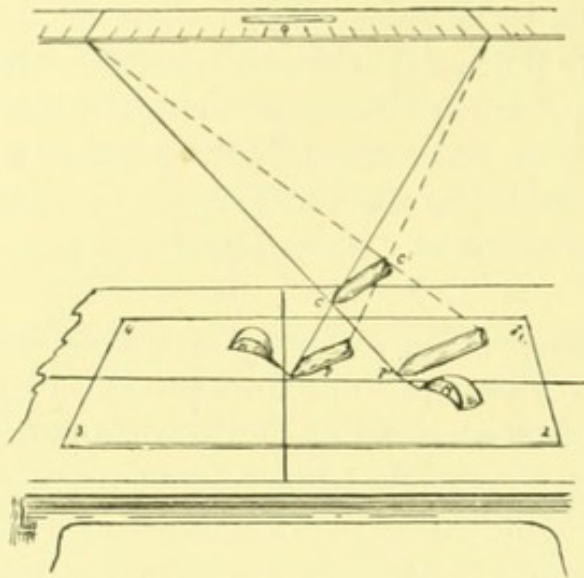


FIG. 13.—Diagram showing method of using the localizer (Mackenzie Davidson).

ing point of the other bullet shadow (P^1 , fig. 13), then it must follow that the position actually occupied by the point of the bullet in question is precisely where the two threads cross at c in fig. 13.

If the perpendicular distance of a point can be measured from three planes which are at right angles to each other—in short, if the x , y , and z can be ascertained—then all will be known about the position of the point in question.

This we can do at once with the point c in fig. 13. First, the vertical distance from the negative to where the threads cross each other is measured. This is the distance of the point of the bullet beneath the skin (of the patient), which rested on the photo-

graphic plate. This can be measured with an ordinary pair of compasses.

The vertical distances are next measured from the two vertical planes represented by the shadows of the cross wires to the point where the

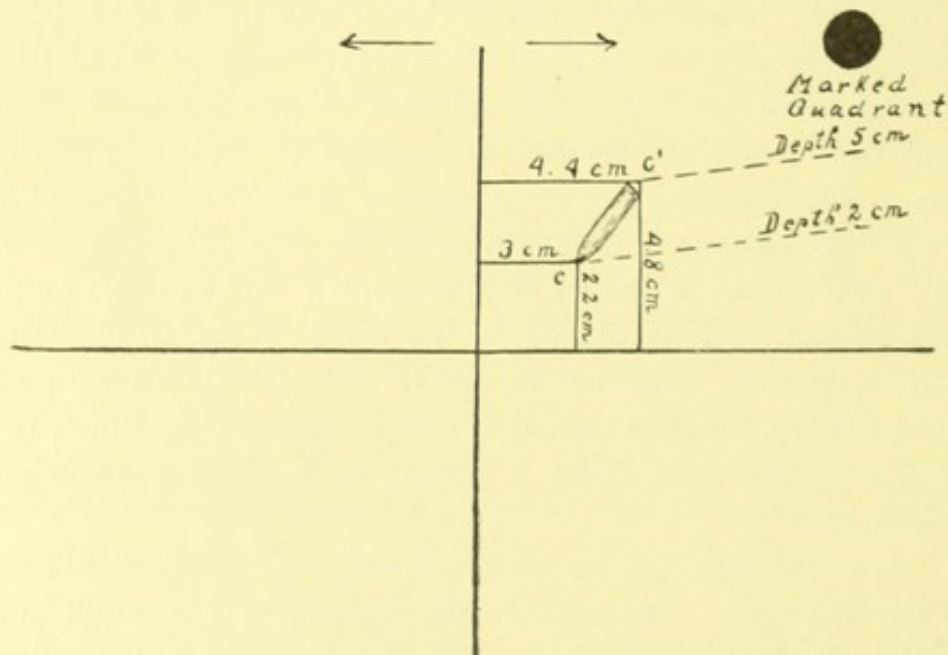


FIG. 14.—Diagram showing method of localization (Mackenzie-Davidson).

graphic plate. This can be measured with an ordinary pair of compasses.

The vertical distances are next measured from the two vertical planes represented by the shadows of the cross wires to the point where the

threads cross. An upright square is placed with its edge coincident with the shadow of one of the wires, and the perpendicular distance is measured with compasses from it to the point where the threads intersect. In this way x , y , and z of the point of the bullet is ascertained and the result noted down, as shown in fig. 14. The arrows in fig. 14 indicate the direction of the displacements of the Crookes tube. We then proceed in a similar manner to ascertain the position of the butt of the bullet c , in fig. 13. And the distance between c and c' in fig. 13 gives the direction and actual length of the bullet.

From the measurements jotted down, as shown in fig. 14, a line can be marked on the patient's skin in the same plane as the bullet, and the surgeon can be given the exact depth at which each of its extremities can be reached by a vertical puncture.

Several pairs of threads might be used, and in this way the shape of the foreign body might be outlined; but it is more convenient to use one pair. The point where they intersect can be fixed by the point of a surface gauge; and, when the threads are moved to another position, the difference between their new point of intersection and their former, where the point of the surface gauge stands, can be measured at once. In fig. 13, the dark lines indicate the position of the threads, the dotted lines show the position they occupy when they are each directed to the butt of the bullet, and the distance from c to c' is the actual length of the bullet. It also indicates the direction in which the bullet lies.

The final result of the process is, that we can draw an outline of the foreign body on the patient's skin and give the depth below the skin of any of its parts, and this enables us to give the direction and depth at which it can be reached from any point the surgeon may select.

The original Mackenzie-Davidson localizer has been modified on the lines of portability and simplicity, but the principle remains the same. In the Harrison portable localizing apparatus, the essential features are retained and the apparatus is made very portable and consequently well adapted to military surgical use.

This apparatus (fig. 15), consists of a baseboard which supports a sliding tube holder. The tube is fixed at a certain height above the surface of the board, and radiographs are taken with the tube at each extremity of the slide. The negative is then developed and placed on the baseboard. Two pillars, which plug into the board, are so arranged that a small notch at the top exactly coincides with the two points from which the radiographs were taken without any measuring or calculations, and silk threads con-

nected to weighted pointers are taken from these pillars to the image on the negative, as in MacKenzie-Davidson's apparatus.

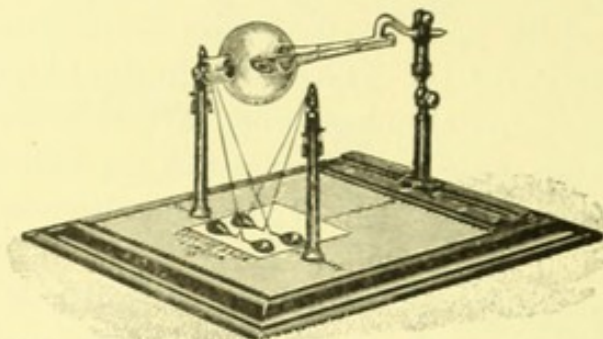


FIG. 15.—Harrison portable localizing apparatus.

The tube holder, pillars, etc., are all removable, and can be packed flat with the board.

APPARATUS FOR LOCALIZATION BY VISUAL OBSERVATION.

But one form of apparatus of this type has been used by the Medical Department of the United States Army. It is known as the Dennis fluorometer (fig. 16).

This is an instrument by means of which the position of the anode,

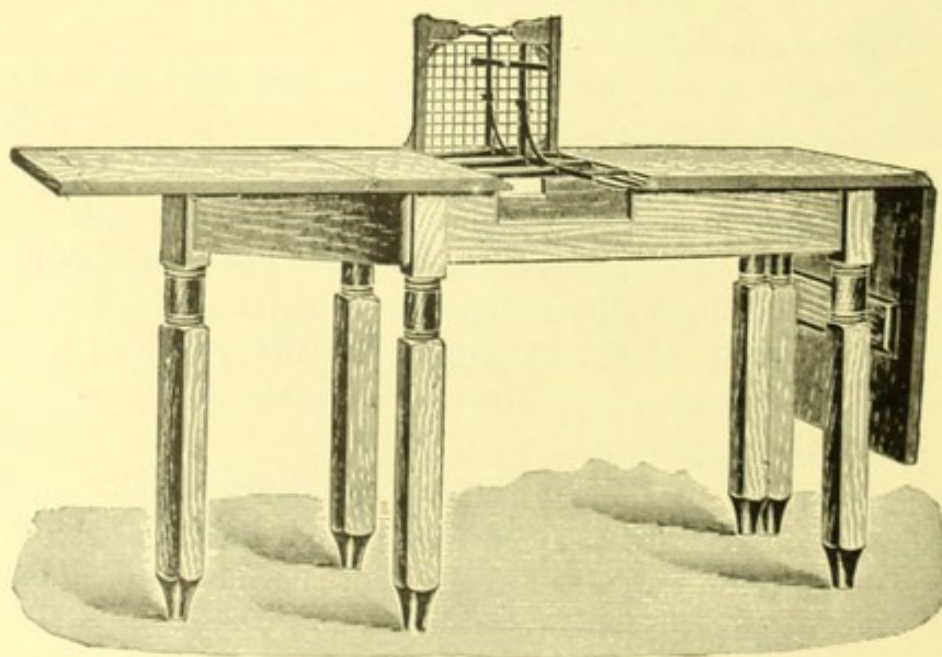


FIG. 16.—The Dennis fluorometer.

the foreign body, and its shadow as projected upon the surface of the body may be noted by visual observation through the fluoroscope. With it,

localization is made by determining the position of the foreign body by two observations made at right angles to each other.

The instrument consists, essentially, in a set of carefully designed metallic angle pieces which conform generally to the shape of the body or limb, and which, in their use in connection with the Röntgen rays, are susceptible of being squared with a simple and conveniently adjustable table. The patient being laid on the table and a fluorometer appliance adjusted, the fluorometer is brought into the parallelism of the rays—that is, when the proper position of the cross section is obtained, the two arms of the fluorometer will present the characteristic single shadow on the field of the fluoroscope.

Attachable to the arms of the fluorometer are two pins or sights. By means of these sights, the foreign object having been brought in line with them and the proper adjustment having been made, a correct line is produced, with the sights and foreign object coincident.

By means of a metallic grating of inch mesh, which is placed adjacent to one side of the body and consequently one side of the fluorometer, exact measurements can be made with the eye from the base line of the fluorometer and from points on the circumference of the body to the foreign object.

Then, without moving the body or the fluorometer, the Crookes tube is placed directly over the subject for the purpose of obtaining the vertical line. By means of an adjustable crosspiece, which is placed over the arms of the fluorometer, exactly the same results in a vertical way are obtained by viewing the subject from beneath, the same condition of parallelism having been produced, another set of pins having been placed in position.

It will be seen at once that while the first operation locates the foreign object on an exact cross section, the second observation shows the exact position occupied by the foreign object in that cross section.

All the elements of distortion having been eliminated, the foreign body will necessarily be at the intersection of the two lines of the right angle.

In practice, the surgeon indicates the first cross section obtained by a line of India ink or iodine on the body, and is thus enabled to establish the position of the object by measurements from points on the exterior of the subject, with as much exactness as if the body or limb were actually severed at the first cross section and presented to view.

The fluorometer is a useful apparatus in many cases. But on account of the difficulty and frequent impossibility of using the fluoroscope where

missiles are lodged in the thicker parts of the body, especially in regions where dense shadows are cast by the contained organs of the abdominal cavity, this apparatus has only limited use and can not compare with the Mackenzie-Davidson or cross-thread apparatus, which are applicable to all cases.

It is, however, only in exceptional cases, and those of considerable rarity, that recourse will have to be made to either form of localization apparatus. In the great majority of cases, visual observation or radiographs will give all necessary information to the surgeon relative to the location of lodged missiles. For this reason, in military surgery, it would not seem necessary to supplement every Röntgen apparatus with one of these apparatus. They should, however, be available for use at a few general hospitals where cases of marked difficulty can be sent for treatment

IV.

GUNSHOT FRACTURES OF THE DIAPHYSES OF LONG BONES.

In gunshot fractures of the shaft of long bones, the extent of the fracture, its form, and the amount of comminution vary considerably according to the conditions which obtain at the time of the receipt of the traumatism. The conditions which influence the bone lesion are the part of the bone struck, the structure of the bone at the place of impact, the velocity and form of the missile, and the angle of incidence. As all these factors can hardly be identical in any two cases, bone lesions are bound to vary within certain limits.

Of great importance in these factors is the part of the bone struck. The physical qualities of the cancellous tissue of the epiphyses are so different from those of the compact tissue of the shaft of the long bones that, under conditions of gunshot impact, different traumatic results occur according to whether one or the other of these parts is struck.

The results of Röntgen-ray examinations made during the late war lead to the conclusion that, minor differences apart, gunshot lesions of the shafts of long bones by small-caliber bullets may be divided into three main classes:

Class 1, fractures by bullets having sufficient velocity to produce perforating wounds.

Class 2, fractures by undeformed bullets having sufficient velocity to penetrate only.

Class 3, fractures by penetrating, deformed bullets.

A possible fourth class, namely, fractures produced by deformed bullets traveling at velocity sufficient to produce perforating wounds, is not recorded and would be extremely difficult to determine. Such bullets pass through the part wounded, and the only evidence that the fracture had been made by a deformed missile would be an atypical appearance of the wounds of entrance and exit, appearances which are not always present, and which if present would lead to inferential conclusions only.

CLASS 1.—FRACTURES BY PERFORATING BULLETS.

Under this class come all fractures produced by bullets traveling with sufficient velocity to pass out of the wounded part after having fractured the bone. So far as observed, fractures by perforating bullets have one

common characteristic: they are all more or less comminuted. The amount of comminution apparently depends mainly on two factors:

First, the velocity of the missile; second, the angle of incidence of impact.

Where the velocity of the bullet is extreme, as at short range, the amount of comminution is considerable, and is greater than at long range, whatever the angle at which the bullet strikes the bone.

With lowered velocity, comminution is great only when the bullet strikes the shaft of the bone in the median line.

Under the condition of extreme velocity, the so-called "explosive" effects are produced.

Under the condition of median impact, comminution of bone is considerable, but not so great as where the effect is explosive, unless the factors of high velocity and perpendicular impact combine. For these reasons, fractures of the first class, namely, those made by perforating bullets, may be divided into three subclasses, in the order of the amount of bone comminution produced:

Subclass 1, fractures by perforating bullets at short range.

Subclass 2, fractures by perforating bullets striking the bone in the median line.

Subclass 3, fractures by bullets striking the bone tangentially.

SUBCLASS 1.—FRACTURES BY PERFORATING BULLETS AT SHORT RANGE.

In this class there is the maximum amount of bone splintering (explosive effect), and the lateral destructive-action of the bullet is so great in some cases that fractures are produced even when the bullet barely grazes the bone (Case 2).

Much has been written of the *explosive effect* produced by the modern bullet, and many theories have been advanced to explain it. In the opinion of the writer, the theory which best explains this effect of the bullet is that the destructive effect is the result of the lateral transmission of energy imparted to the tissues by a rapidly moving missile.¹ If energy were transmitted only in a line directly in front of a bullet, the bullet would make clean-cut perforations in all organs or tissues through which it passed, and immediately fatal results would arise only from direct wounds of blood vessels, perforations of the heart, or impingement of the bullet upon some vital part of the central nervous system.

¹Stephenson: Wounds in War, p. 71. New York, 1898.

Forwood: Warren & Gould's International Text Book of Surgery, Vol. II. Philadelphia, 1900.

The lateral transmission of the energy of the bullet to an extent sufficient to cause extensive solutions of continuity occurs in marked degree only in certain organs and tissues, and in these only when the velocity of the missile is great. As this destructive effect occurs only in certain organs and tissues, it must follow that it is because these organs and tissues best transmit the energy imparted by the bullet; and, as the structures which transmit this energy with traumatic-producing violence are either compact bone, or organs containing fluid, or those practically saturated with fluid, it seems most probable that this energy is transmitted in two ways—either through the transmission of vibration by the closely knit compact bone tissue or through the incompressible fluid in fluid-saturated or fluid-containing organs. In compact bone, with the missile at high velocity, by the suddenness of the shock, the bone is disrupted, and the osseous particles acting as secondary missiles, are forced outward, increasing the disruption and traumatism by lateral transmission of the energy imparted, (Fig. 17).

With the bullet moving at lower velocity the shock in bone or organ is less, the disruption consequently less, and with still lower velocity, the ball may enter and pass through the same tissue or organ with practically no lateral destructive effect. In a broad way, the result may be likened to the difference in effect produced by throwing a bullet into water contained in an open leaden vessel or firing the bullet into it. In the first case, the bullet will enter making slight commotion, and that mainly upon the surface of the water; while, if the bullet is fired into the water, the containing vessel, even though open at the top, will be completely destroyed through the lateral transmission of energy by the incompressible fluid.

When the shaft of a bone is struck at short range, extensive comminution is produced whatever the angle at which the bullet may impinge against the bone. The bullet in these cases produces an explosive effect in accordance with the reasons already given, (Fig. 17).

This effect is not confined to the bone alone; the bone fragments driven out into the surrounding tissues may produce extensive traumatism of the subcutaneous soft parts, and may even be driven out through the

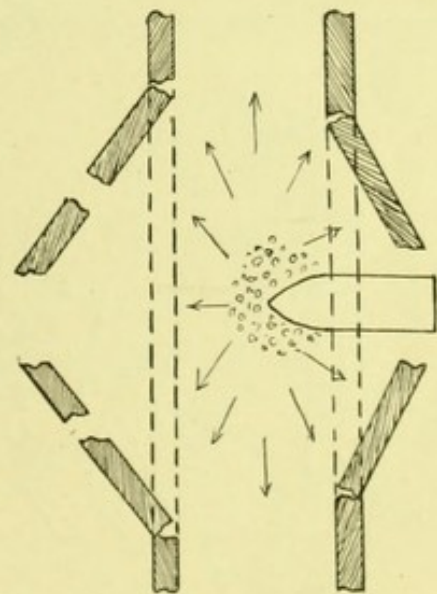


FIG. 17.—Lateral transmission of energy in the shaft of a long bone. Diagrammatic; modified from Reger. A similar effect is produced in fluid-containing and fluid-saturated organs.

wound of exit and into a neighboring part. In a case of this sort which came under the observation of the writer, the shaft of the femur was shattered for five inches of its length and largely reduced to bone sand. The bullet passed through both thigh and leg, and on examining the wound in the latter, bone sand and several fragments of bone were found which had been carried through the first wound of exit and driven into the second wound of entrance by the force of the missile.

In another instance (Plate XIV), the whole of the distal part of a metacarpal bone was blown out through the exit wound, which was but little larger than usual.

Case 1.—Explosive effect and fracture by contact.

John T. Sullivan, private, Company F, Thirteenth United States Infantry, was wounded at 500-yards range by a Mauser bullet, which passed obliquely through the

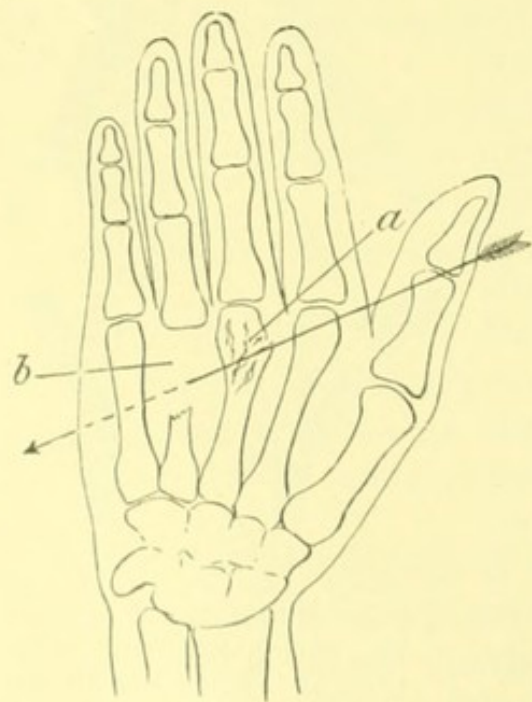


FIG. 18.—Diagram explanatory of Plate XIV. The arrow indicates the course of the bullet.

hand, fractured the third metacarpal bone by contact, completely destroyed the distal end of the fourth metacarpal bone, and carried out all the fragments through the exit wound. Though all the fragments of the fourth metacarpal had been driven out through the exit wound, the wound was little larger than the wound of entrance, and only by use of the Röntgen ray would it have been suspected that the bullet had made a clean resection (Plate XIV).

The hand was dressed with the first-aid dressing and the patient transferred to the general hospital at Key West. On arrival at the hospital the wounds were found aseptic and healed quickly, but some impairment of function resulted, as the soldier writes in November, 1898: "Motion of middle, ring, and little fingers much restricted, especially in flexion."

In the case above given, the radiograph shows that the third metacarpal bone had been shattered by lateral contact of the bullet. The following case further illustrates this interesting form of fracture. In this class of cases, though the ball barely grazes the bone, the energy transmitted laterally from the swiftly moving missile is sufficient to produce marked comminution.

PLATE XIV.

PLATE XIV.

CASE 1, SECTION IV.—John T. Sullivan, private, Company F, Thirteenth United States Infantry.

Radiograph of left hand, viewed from the back, showing gunshot fracture of third, and fourth metacarpal bones. The distal end of the third metacarpal, fractured by contact; the distal end of the fourth metacarpal, entirely destroyed by the missile.

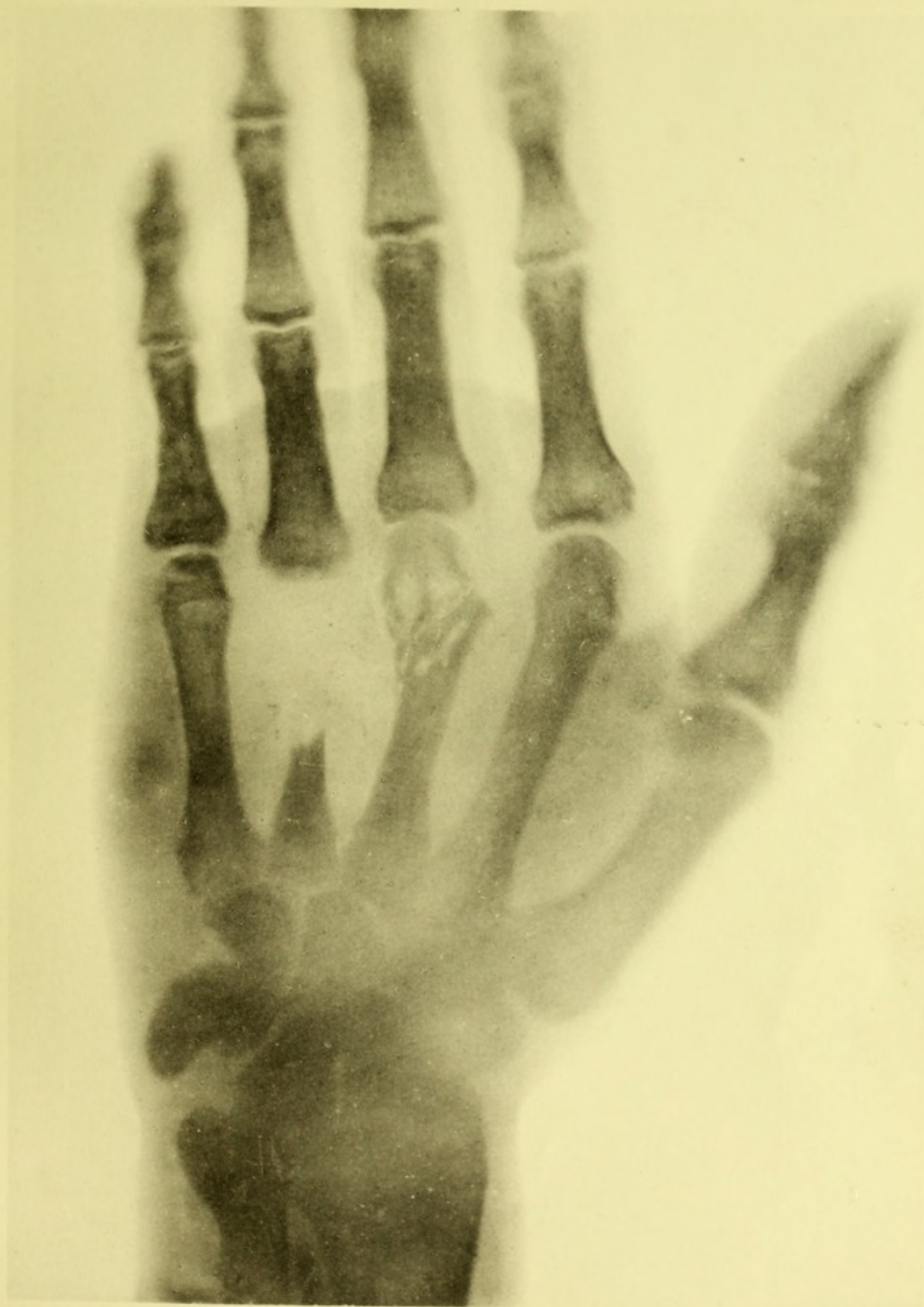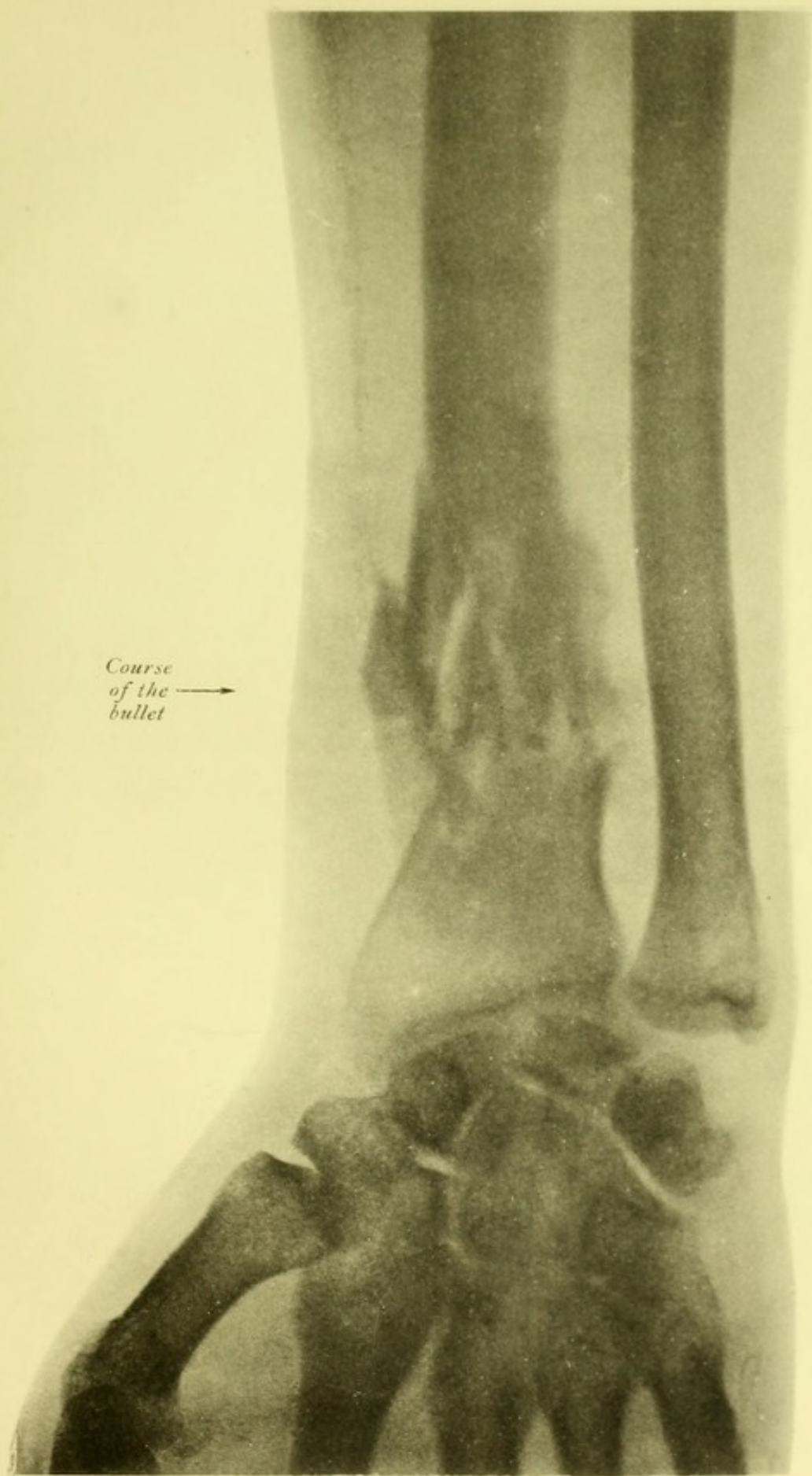


PLATE XV.

PLATE XV.

CASE 2, SECTION IV.—Thomas F. Cavanaugh, sergeant, Troop G,
First United States Volunteer Cavalry.

Radiograph of right forearm, viewed from the front, showing Mauser
bullet fracture "by contact."



Course
of the →
bullet

Case 2.—Fracture by contact; operation at field hospital; suppuration.

Thomas F. Cavanaugh, sergeant, Troop G, First United States Volunteer Cavalry, was wounded at a range estimated at under 400 yards by a Mauser bullet which passed across the front of the right forearm at its lower third, severed the flexor tendons, grazed the periosteum of the radius, and shattered the bone. The track of the bullet was laid open at the field hospital, the tendons sutured and the wound united by silk sutures. The patient was transferred to the General Hospital, Key West. On his arrival there, pus was escaping from between the sutures and the wound was tense, bulging, and much inflamed. The sutures were removed under anæsthesia and the wound carefully cleansed. Owing to extensive inflammation and suppuration, it was found impossible to unite the tendons. A radiograph (Plate XV), was taken which showed excellently the shattered condition of the radius and the longitudinally disposed fissures between the bone splinters. The wound was treated with antiseptic applications, but had not entirely healed when the patient was transferred north, August 22, 1898. In November of the same year, the soldier writes that he has no use of the hand, the fingers remaining stiff. The disability is probably permanent.

SUBCLASS 2.—FRACTURES BY PERFORATING BULLETS STRIKING THE BONE IN THE MEDIAN LINE.

Case 3.—Comminuted fracture of femur due to median impact of ball; aseptic wound; recovery without complications.

John Robertson, second lieutenant, Sixth United States Infantry, wounded July 1, by a Mauser bullet, which entered the anterior surface of the right thigh just below Scarpa's triangle, passed from before backward through the femur, and passed out directly posterior. There was profuse hemorrhage, which was partly controlled by an improvised tourniquet applied by an officer of the line. Lieutenant Robertson was carried to the rear by the men of his command and while thus conveyed, he was shot in the left side, the bullet entering just below the inferior angle of the left scapula, passing beneath the muscles, but not through the thoracic wall, and making exit just below the left nipple. With these wounds of entrance and exit, it was at first thought that the bullet had passed through the chest; that it did not do so was due to the extreme outward displacement of the angles of the scapulæ, from his being, at the time, lifted by the armpits. The first dressing was applied at the

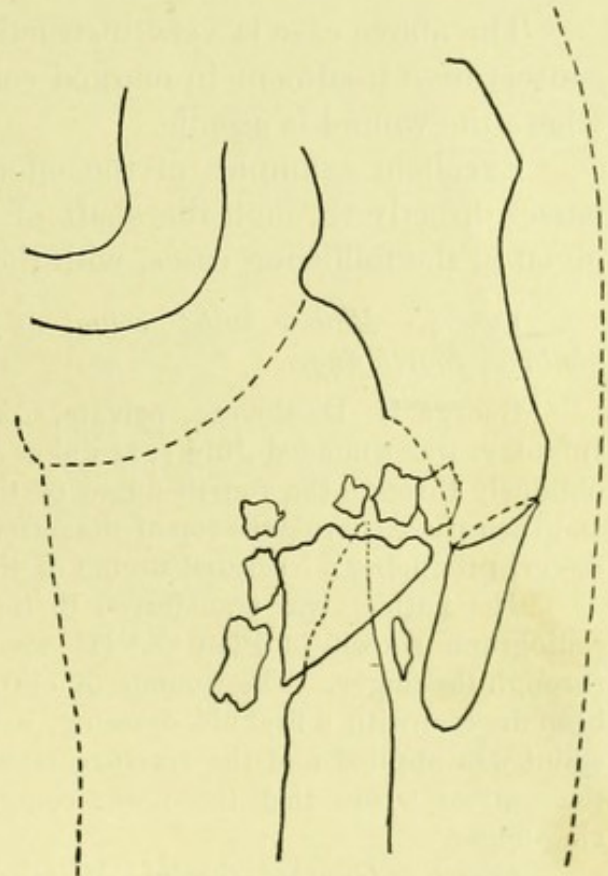


FIG. 19.—Diagram explanatory of Plate XVI.

field hospital. The fracture was dressed by the use of a long splint. Transferred July 9, to Third Division Hospital and two days later to the *Relief*. At this time, both chest wounds were healed. The thigh wounds remained aseptic. A radiograph showed great comminution and displacement of the fragments by overlapping (Plate XVI).

The fracture was then treated by confining the limb upon a double inclined plane, consisting of a hollow posterior splint, made of the sheath of the leaf of the cocoa palm, to which was added an anterior thigh splint of wire gauze. After dressing the limb was placed in a sling. Subsequently a Buck's extension was applied and finally a plaster splint. The final result was excellent, for, though there was $1\frac{1}{2}$ inches shortening, the callus was firm (Plate XVII), and the position and functional use of the limb were excellent.

The above case is very instructive, as it illustrates the possibilities of conservative treatment in marked comminution of the shafts of long bones where the wound is aseptic.

Excellent examples of the effect of the small caliber bullet when it passes directly through the shaft of a small bone of the hand or foot are given in the following cases, with their accompanying radiographs:

Case 4.—Mauser bullet wound of finger, with compound fracture of second phalanx, fourth finger.

George H. De Revere, private, Company L, Second Massachusetts Volunteer Infantry, was wounded July 1, at unknown range, by a Mauser bullet which passed obliquely through the fourth finger of the left hand, shattered the second phalanx, and then passed across the top of the second metacarpo-phalangeal joint of the middle finger, producing a lacerated wound of the joint.

The patient was transferred to the general hospital, Key West, where the radiograph shown in Plate XVIII was taken. The bullet had passed centrally through the finger. The wounds of entrance and exit were very small. They had been dressed with a first aid dressing, were aseptic, and healed quickly. A palmar splint was applied and the fracture treated as a simple one. In November, 1898, the patient wrote that there was complete ankylosis of the second joint of the ring finger.

Case 5.—Gunshot fracture all metatarsal bones of foot; septic wound; anti-septic treatment; recovery without amputation.

Carl F. Meyer, private, Company D, Sixth United States Infantry, was wounded at about 300 yards range by a Mauser bullet, which passed transversely through the foot and metatarsal bones from without inward. First aid dressing was applied directly after receipt of the injury. Wound redressed three days later, at which time foot was much swollen and painful. Patient stated that he was at that time given an anæsthetic and that the "foot was cut." Was transferred to the *Relief*, where the radiograph (Plate XIX) was taken. The wounds were treated with antiseptic dressings and finally healed, but impaired use of the foot led to discharge for disability. Sixteen months after the injury, the second radiograph

PLATE XVI.

PLATE XVI.

CASE 3, SECTION IV.—John Robertson, second lieutenant, Sixth United States Infantry.

Radiograph of right thigh, viewed from the back, showing Mauser bullet fracture with extensive comminution due to vertical, median impact against the shaft of the femur.

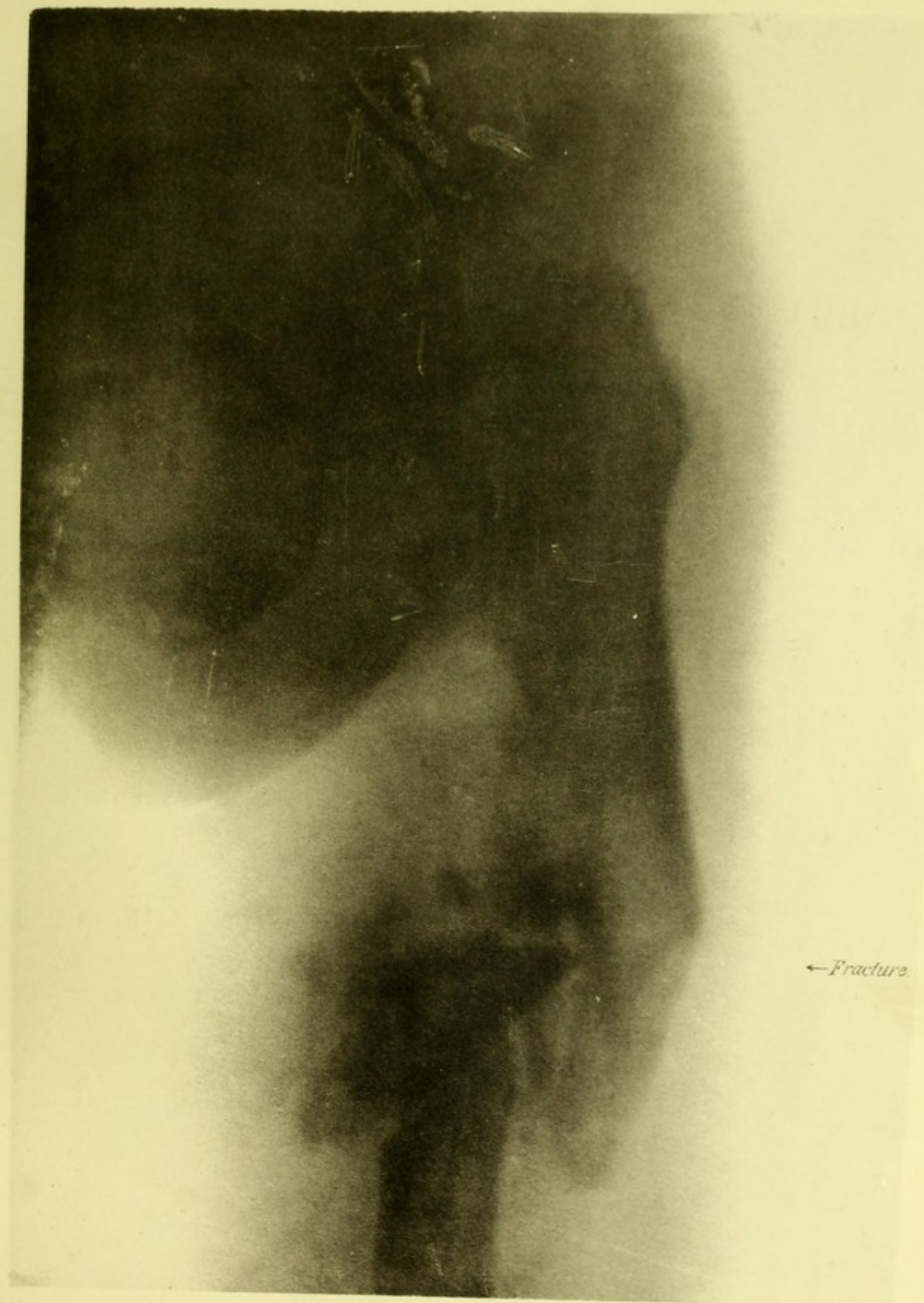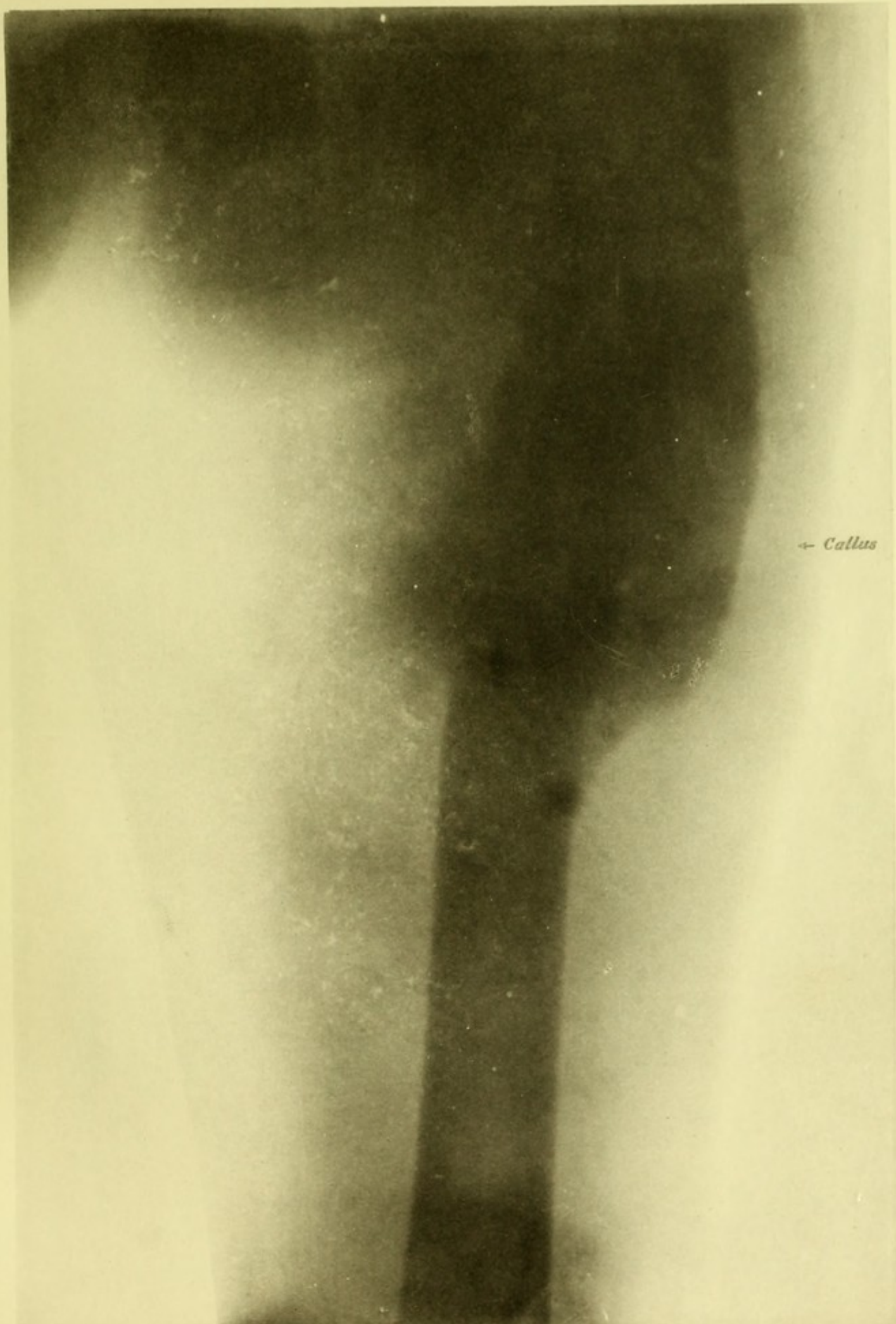


PLATE XVII.

PLATE XVII.

CASE 3, SECTION IV.—John Robertson, second lieutenant, Sixth United States Infantry.

Radiograph of right thigh, viewed from the back, showing condition of the united fracture one year after receipt of the traumatism.



← *Callus*

PLATE XVIII.

PLATE XVIII.

CASE 4, SECTION IV.—George H. De Revere, private, Company L,
Second Massachusetts Volunteer Infantry.

Radiograph of left hand, viewed from the palmar surface, showing
effect of the passage of a Mauser bullet obliquely through a phalanx.

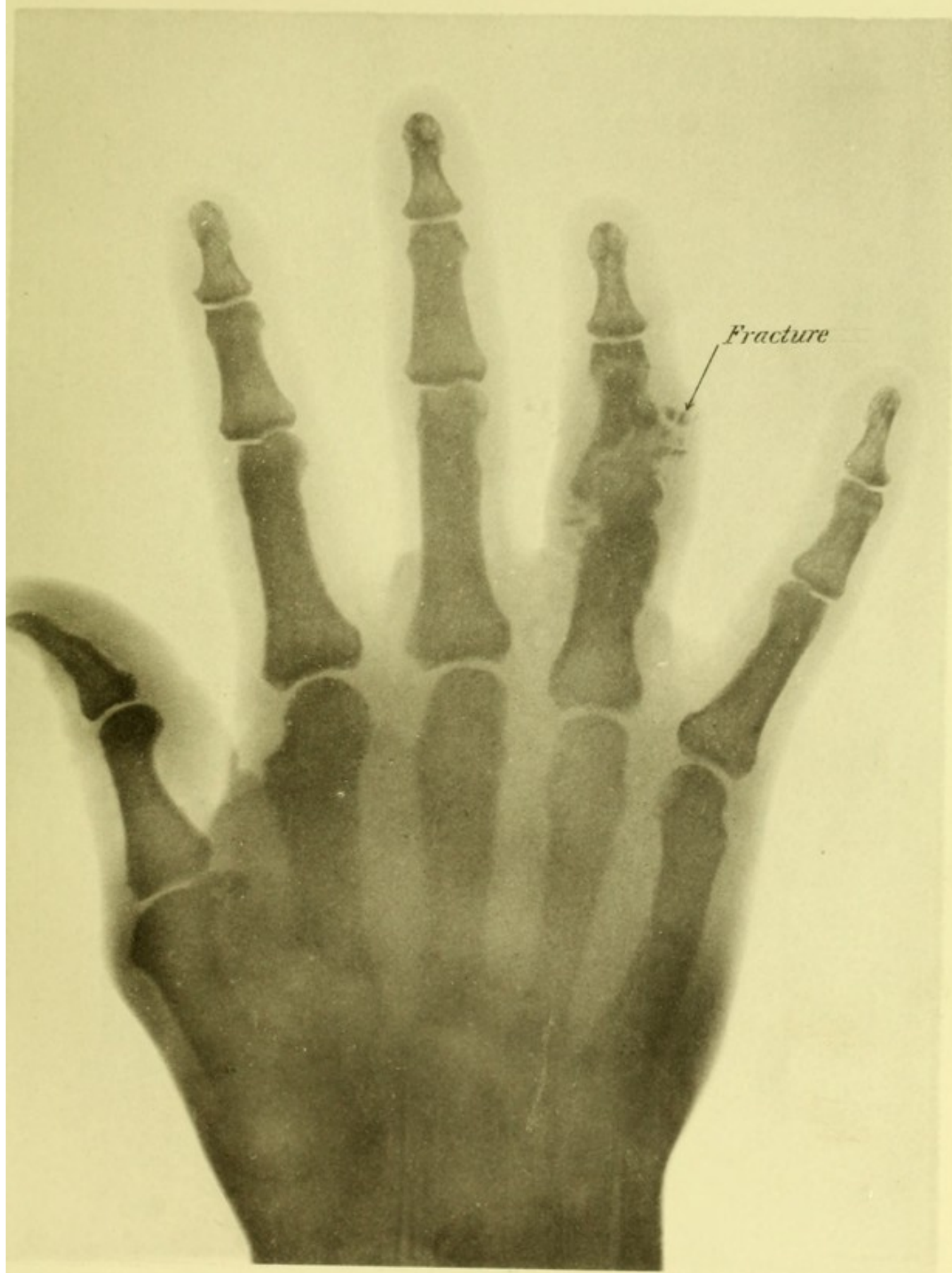
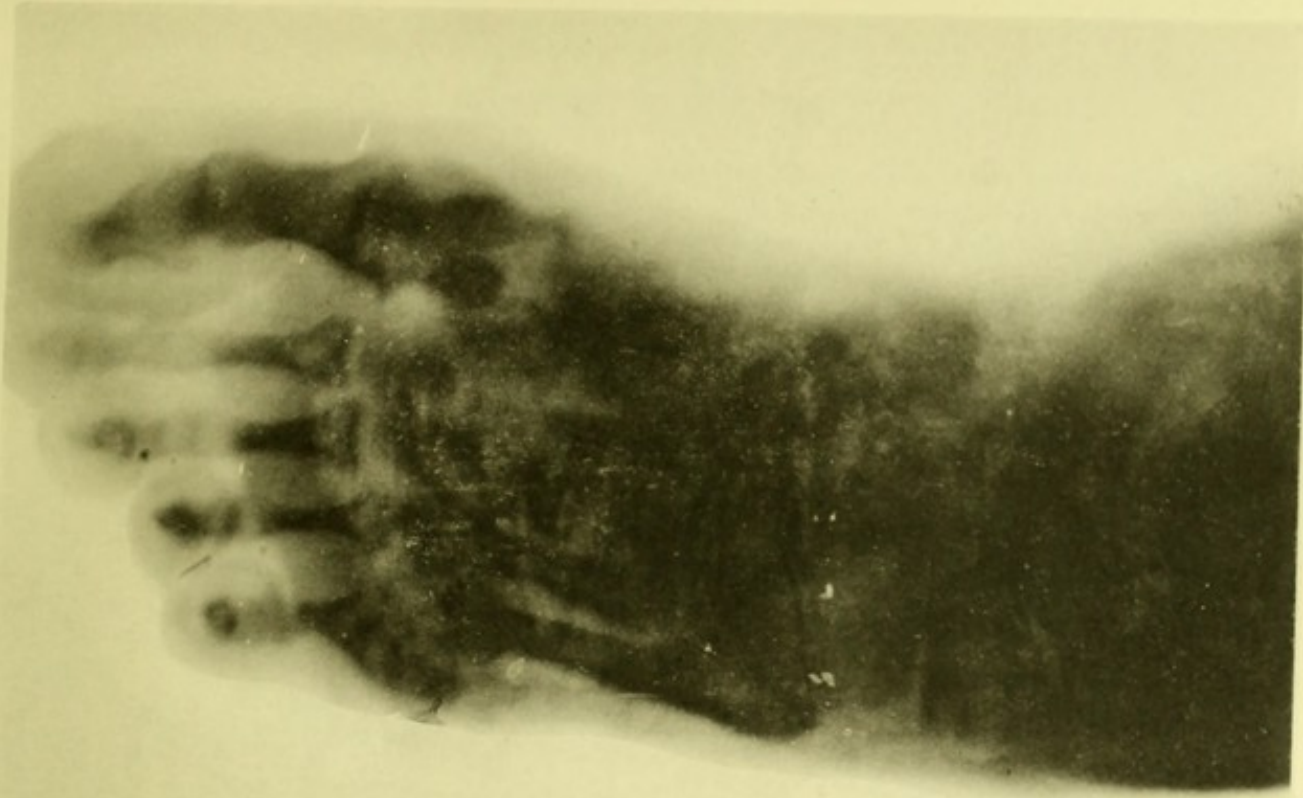
PLATE XIX.

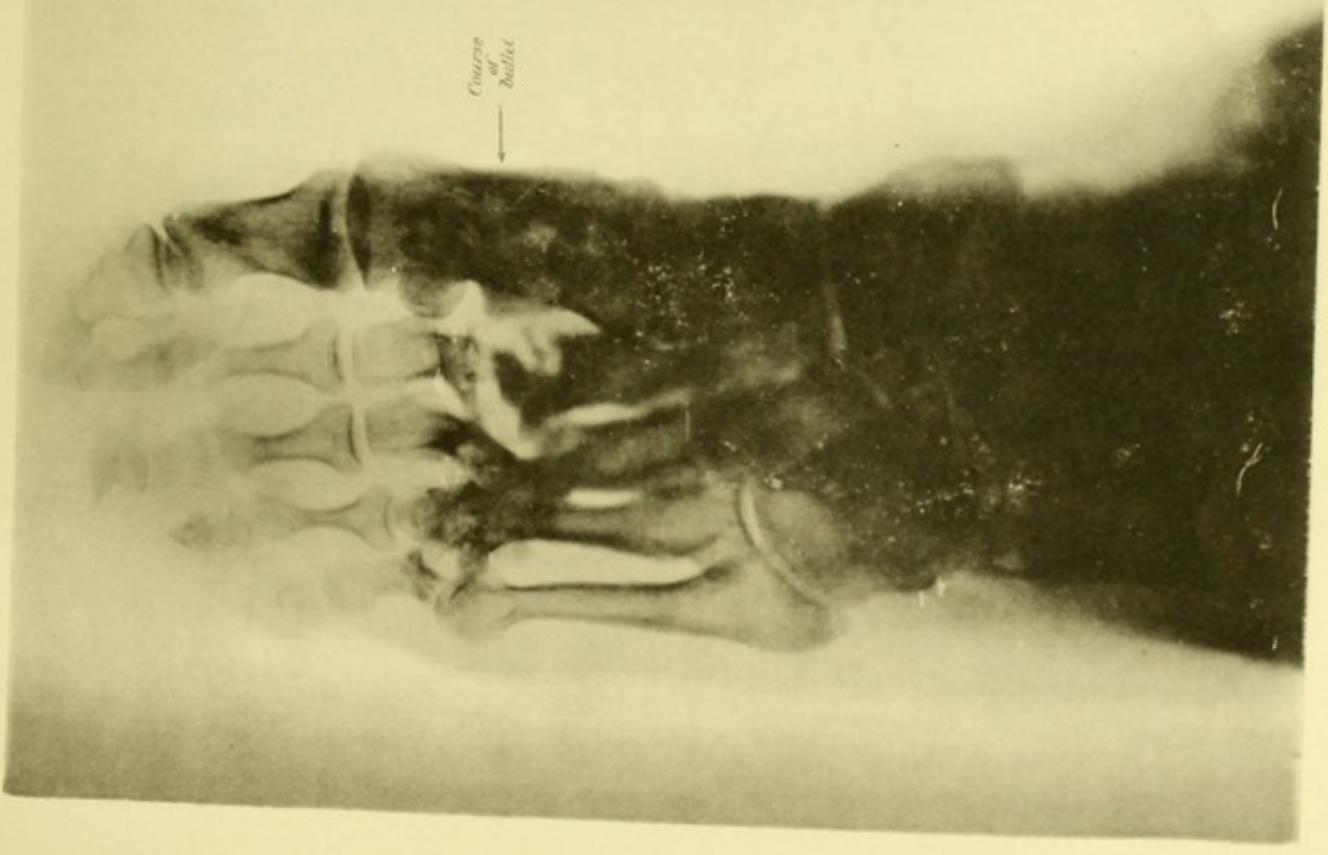
PLATE XIX.

CASE 5, SECTION IV.—Carl F. Meyer, private, Company D, Sixth United States Infantry.

Radiographs of right foot, viewed from the plantar surface, showing recent and remote effects of the passage of a Mauser bullet through the metacarpal bones. The passage of the ball from within outward has projected bone fragments outward, which have united with the neighboring bones and formed a bony bridge locking the bones together.



*Course of
bullet*



(Plate XIX) was taken, and is of interest as showing the condition at that late date. The displaced fragments of bone had all united, forming a solid bony bridge binding the metatarsals together in immovable union. The occurrence of this result would seem to point to the desirability of thoroughly cleaning the wound of all bone fragments in these cases in order to prevent the impaired function which is bound to occur in the hand or foot as a result of the osseous union of the displaced fragments.—*Case reported by Maj. Louis A. LaGarde, surgeon, U. S. A.*

SUBCLASS 3.—FRACTURES BY BULLETS STRIKING THE BONE TANGENTIALLY.

Where the velocity of the bullet is somewhat diminished, and it strikes a bone tangentially, the amount of comminution is not as great as when the ball is at high velocity or the impact is medium and direct.

When the impact is to one side of the median line of the bone, the splintering is greatest on the side struck, and is generally confined to that side.

Case 6.—Oblique fracture of radius; wound explored at field hospital; suppuration; antiseptic treatment; recovery.

John Brown, private, Troop C, Tenth United States Cavalry, was wounded July 1, at 200 yards range, by a Mauser bullet which passed from before backward through the forearm, fracturing the radius.

He was transferred to the general hospital, Key West, where he arrived five days after the receipt of the injury. On examination, the wound of entrance was seen to have been enlarged by incision, and the patient stated that it had been operated on at the field hospital, but did not know what had been done. The wound was suppurating, there was no union, and there was marked tension on the stitches. The wound was laid open under anaesthesia, thoroughly cleansed, a fragment of bone 7 cm. long and 2 cm. wide, was removed, and an iodoform gauze drain was inserted. With the finger in the wound, it was found that best apposition was obtained when the forearm was fully extended and pronated. A long posterior splint was applied to the arm, holding it in that position, after which, examination with the fluoroscope demonstrated that the bones were held in correct position. A radiograph taken at this time shows the position of the bones after the splint was applied, the oblique form of fracture, the loss of bone sustained by removal of the fragment, and that the bullet had passed through the radius at its outer side (Plate XX).

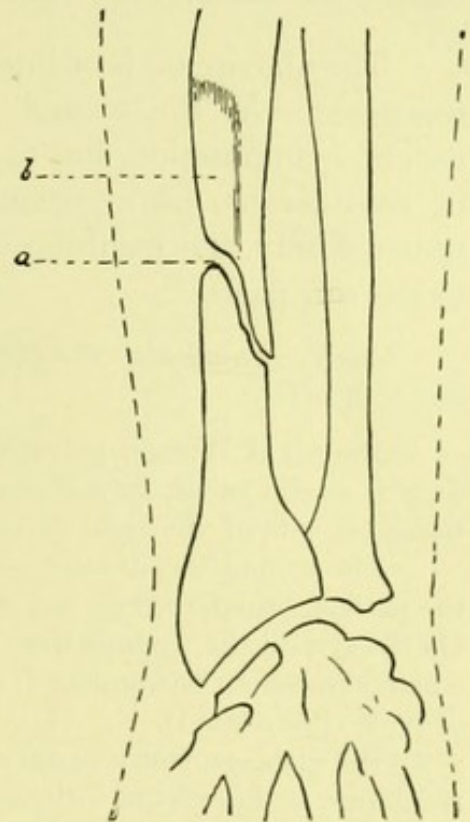


FIG. 20.—Diagram explanatory of Plate XX. *a*, Place of impact of bullet; *b*, site of removed bone fragment.

There was no inflammatory reaction or rise of temperature following the operation. The wound was flushed daily with hydrogen peroxide and normal salt solution, and was entirely closed with firm callus at the seat of the fracture, August 16, when he was transferred to the transport *San Marcus*. January 4, his attending surgeon reports:

“The removed bone seems to have been largely replaced and the hand and forearm present a good form. The joints are freely movable, passively and actively, but all motions are feeble. The hand hangs semiflexed on the wrist. Adduction, abduction, flexion, extension, circumduction, pronation and supination are present on voluntary effort, but all are feeble. Flexion of the fingers is limited to the second and third joints; the grasp is very feeble. The thumb can be approximated to each of the fingers sufficiently to pick up a pencil, but there is little power in it. The hand is relatively of little use, absolutely of considerable.” The patient has since been discharged for disability and admitted to the Soldiers’ Home at Washington, D. C.

The above case is of interest from its excellent progress under antiseptic treatment. As the wound was infected, this case would formerly have required amputation, but as it is, the arm, while disabled, is reported to be of considerable use; certainly better than no arm at all. As the bones united firmly, the resulting disability is probably mainly due to the injury to the soft parts.

Case 7.—Incomplete fracture of radius; aseptic wound; resulting impaired motion due to cicatrix.

Dennis B. Watson, private, Troop C, First United States Cavalry, was wounded July 1, at 800 yards, by a Mauser bullet which passed from behind forward through the outer side of the right forearm, fracturing the radius.

The wound was dressed with the first-aid dressing. Splints were applied and the patient transferred by the steamer *Iroquois* to the general hospital at Key West. On his arrival the wounds were aseptic and quickly healed. A radiograph was taken which showed an incomplete fracture with right-angled displacement of a fragment of bone (Plate XXI).

As the displacement was outward, it was thought that the rotation of the radius would not be interfered with, and that the fragment could be removed later if necessary. The patient was furloughed August 7, at which time, though motion of the forearm was limited, there seemed to be every indication that its full use would be restored. Such did not prove to be the case, as his attending surgeon in November wrote: “Soldier has not full use of the arm and has been recommended for discharge on surgeon’s certificate of disability.”

The patient was afterwards discharged for disability and entered the Soldiers’ Home, Washington, D. C., where recent examination of the case shows that the impaired motion is due to the injury of the soft parts and resulting formation of cicatricial tissue in the track of the ball.

PLATE XX.

PLATE XX.

CASE 6, SECTION IV.—John Brown, private, Troop C, Tenth United States Cavalry.

Radiograph of left forearm, viewed from the posterior surface, forearm supinated, showing effect of the passage of a Mauser bullet through the side of the shaft of the radius. The comminution is not extensive, one fragment of bone only having been separated from the shaft at its outer side.

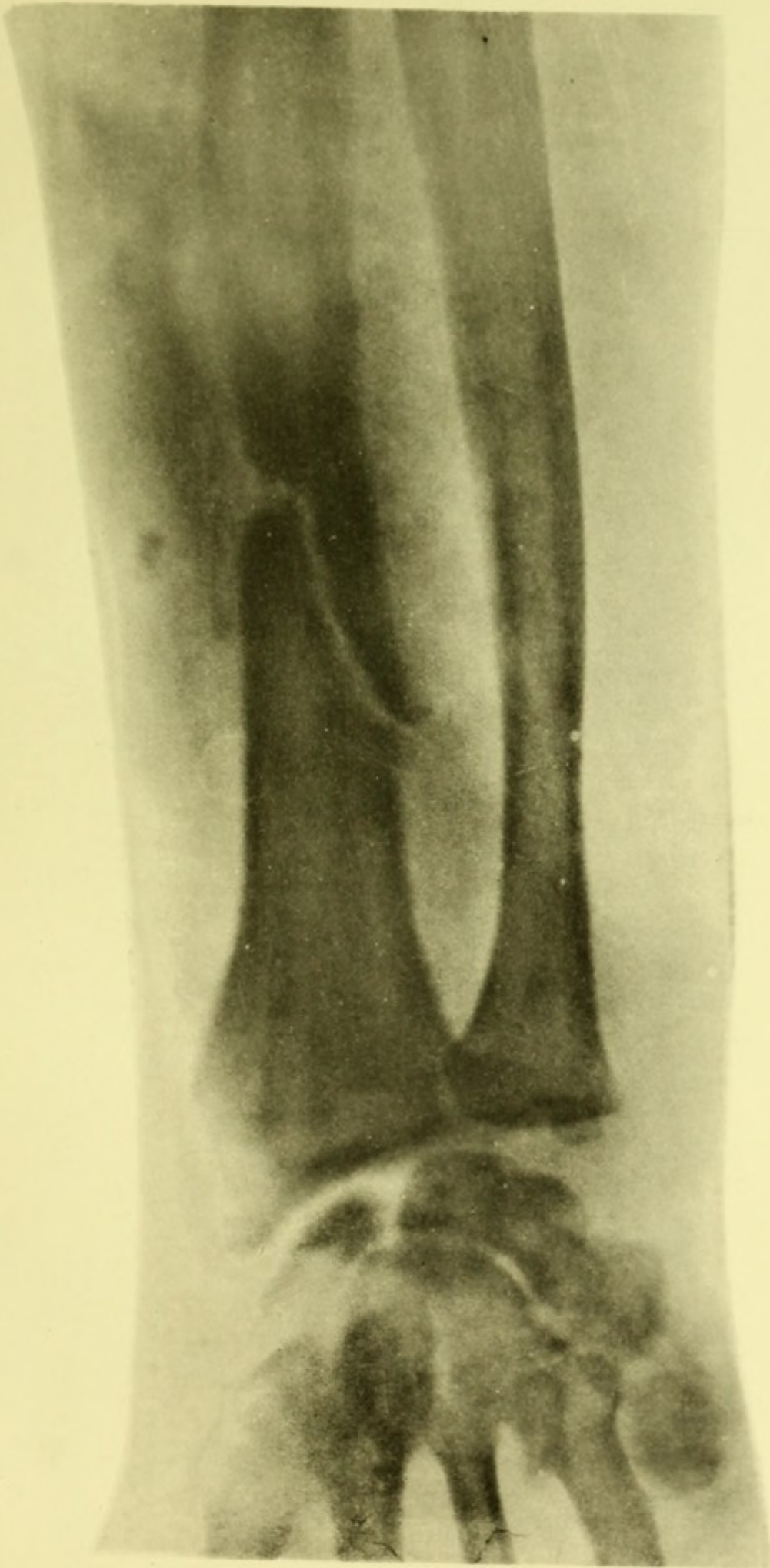


PLATE XXI.

PLATE XXI.

CASE 7, SECTION IV.—Dennis B. Watson, private, Troop C, First United States Cavalry.

Radiograph of right forearm, viewed from the posterior surface, forearm pronated, showing incomplete fracture and right angled displacement of a bone fragment from passage of a Mauser bullet through the outer side of radius.

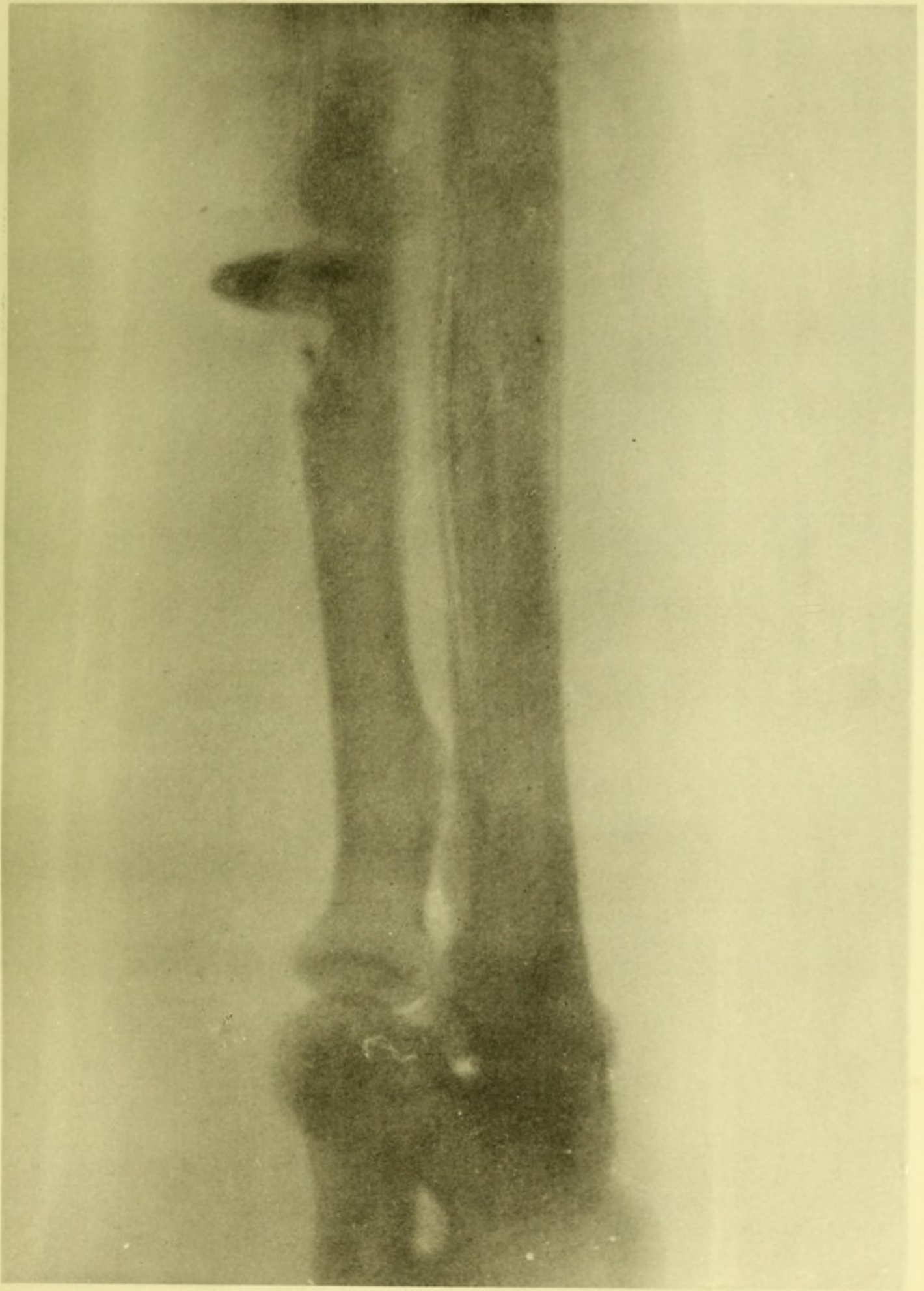


PLATE XXII.

PLATE XXII.

CASE 8, SECTION IV.—Albert B. Swift, private, Company H, Tenth United States Cavalry.

Radiograph of upper part of arm, viewed from the back, showing long, oblique fracture with no comminution, produced by Mauser bullet which struck the shaft of the humerus at its outer side.

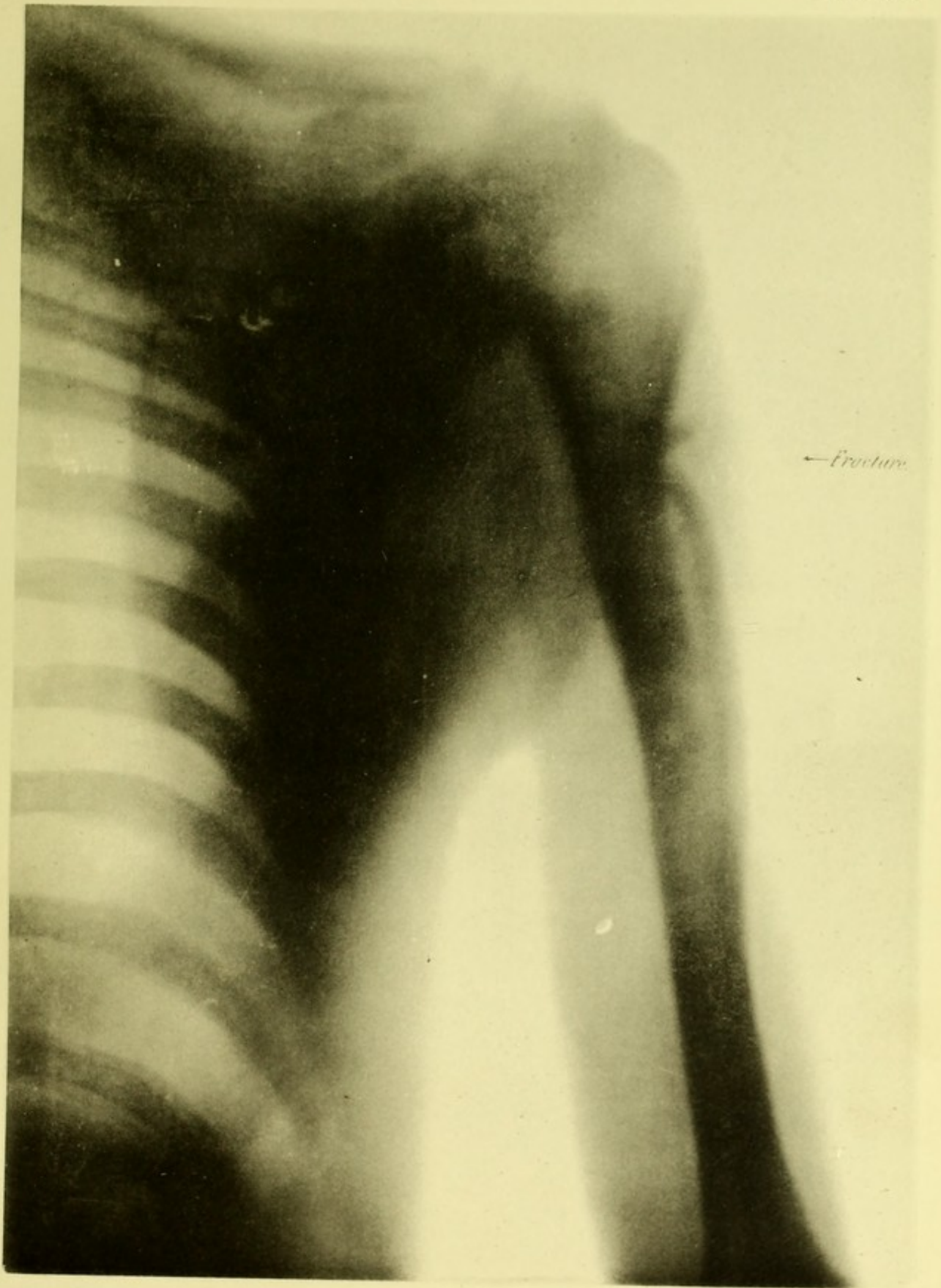
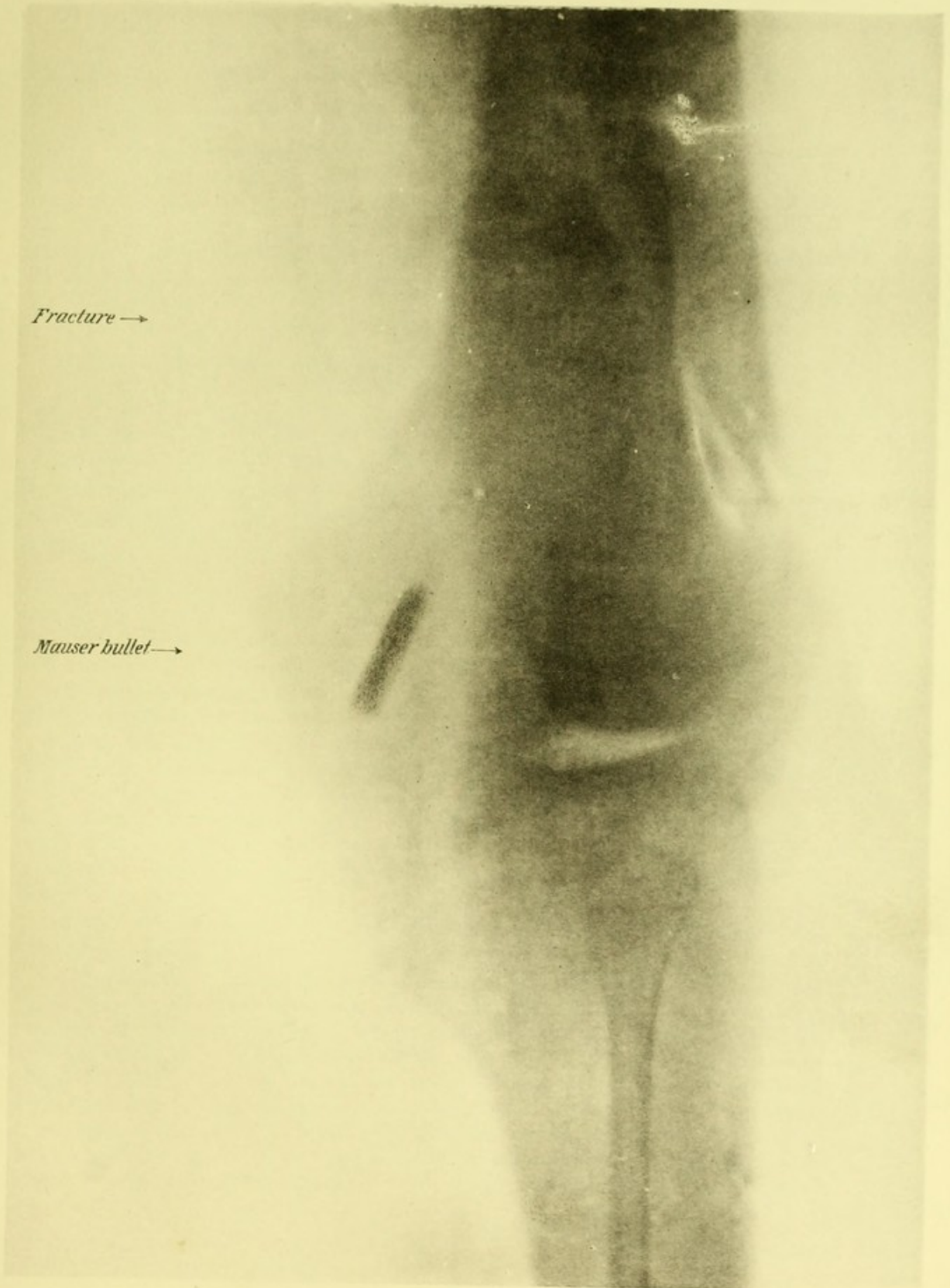


PLATE XXIII.

PLATE XXIII.

CASE 9, SECTION IV.—Frank J. Kraus, private, Company B, Sixteenth United States Infantry.

Radiograph of the lower part of the right thigh, viewed from the posterior surface, showing an oblique fracture of the femur by a penetrating, Mauser bullet. The bullet is seen behind the inner condyle lying butt end foremost.



Fracture →

Mauser bullet →

Case 8.—Oblique fracture of humerus from tangential impact of ball; aseptic wound.

Albert B. Swift, private, Company H, Tenth Cavalry, was twice wounded July 1. One bullet passed through the ulna at lower third, shattering the bone, and a resection was made at the field hospital. The second bullet passed from before backward through the arm at the upper third, striking the humerus at its outer side and producing a long, oblique fracture with no comminution (Plate XXII). The arm was immobilized and union occurred without trouble. Discharge followed for disability resulting from the injury to the ulna.—*Case history compiled from records in Surgeon-General's Office.*

CLASS 2.—FRACTURES BY UNDEFORMED BULLETS HAVING SUFFICIENT VELOCITY TO PENETRATE ONLY.

Fractures by bullets having greatly reduced velocity are usually characterized by small amount of bone splintering. The fractures closely resemble the simpler forms of fracture produced by indirect violence, and this, apparently, whether the bullet passes through the bone or fractures it by impact.

Case 9.—Fracture of femur by ricochet ball, entering butt end foremost; aseptic wound.

Frank J. Kraus, private, Company B, Sixteenth United States Infantry, was wounded July 1, at a supposed range of 500 yards by a Mauser bullet, which entered the body just to the right of the tip of the coccyx. The wound was dressed and the patient transferred to the *Relief*, where a radiograph was taken. The radiograph (Plate XXIII), showed an uncomminuted oblique fracture of the right femur in the lower third, and the bullet lodged, butt end foremost just behind the inner condyle. The line of fracture was from above downward and from behind forward, and had apparently been made by the bullet impinging against the bone. Recovery was uneventful, but the limb was shortened 2 inches, and the soldier was finally discharged for disability.—*Case history compiled from records in Surgeon-General's Office.*

Case 10.—Fracture of humerus by impact of Mauser bullet; aseptic wound; resulting disability.

Clarence Reed, private, Company H, Tenth United States Infantry, July 1, erect position, 500 yards from firing line, received two gunshot wounds. He was transferred to the *Relief*, where the following wounds were found: One, a flesh wound, perforating right arm, producing paralysis of the arm; the other, an entrance wound over third rib, anterior part of thorax, was lacerated, triangular in shape, base toward right side, about 1 inch wide at base and 2 inches long. Left arm showed extravasation from clavicle down to wrist. Oblique fracture of upper part of humerus. Radiograph (Plate XXIV) shows Mauser bullet close to inner side of humerus at point of fracture, entrance evidently right anterior surface of thorax. July 12,

angular splint of palm bark applied, extending from shoulder to wrist. Radiograph showed no other bullets, and position of splint very good. July 23, wounds healed. Considerable callus about fracture and partial union.

November 17, 1899, discharged on surgeon's certificate of disability for "motor and sensory paralysis and trophic changes."—*Case history compiled from hospital records of hospital ship Relief and records of the Surgeon-General's Office.*

In the above case, the bullet must have traversed the anterior thoracic wall and entered the arm behind the axillary folds, struck the humerus on its inner side, and fractured it. The utter impossibility of locating this bullet by means of a probe is evident.

Case 11.—Fracture of ulna with moderate comminution by penetrating Mauser bullet; aseptic wound; bullet located by Röntgen ray and removed.

John Casey, private, Company C, Thirteenth United States Infantry, was wounded July 1, at an estimated range of 400 yards, by a penetrating Mauser bullet, which entered the posterior and outer aspect of the forearm at the lower third. The wound was dressed with a first-aid dressing and the patient transferred to the general hospital at Key West. Examined there July 6; wound small and aseptic. Fracture of ulna at middle third. Examined with the fluoroscope, but the static machine from the excessive dampness of the atmosphere was not working well, and what was thought to be a bullet was dimly seen directly over the fracture. This was cut down upon, July 9, under aseptic precautions, when the supposed bullet was found to be a fragment of bone. This was removed and the wound healed by first intention. Subsequent search, with better light, showed the bullet lodged, butt end foremost, near the internal condyle of the humerus beneath the flexor profundus digitorum. It was removed July 28. The ball had evidently ricocheted, turned end for end, and with reduced velocity entered the arm and passed through the ulna. The ulna was broken transversely and some small fragments of bone separated (Plate XXV).

CLASS 3.—FRACTURES BY PENETRATING, DEFORMED BULLETS.

Penetrating, deformed bullets appear to produce fractures of the shaft of the long bones which are similar in form to those produced by undeformed bullets, unless the deformation of the bullet is excessive. Like the penetrating, undeformed bullets, slightly deformed bullets produce oblique fractures with little splintering, while greatly deformed and mushroomed bullets produce marked comminution of the bone.

CASE 12.—Comminuted fracture of femur by Mauser bullet "mushroomed" by ricochet; bone fragments removed; wound treated antiseptically; recovery without amputation.

Daniel J. Graves, private, Company M, Eleventh United States Infantry, was wounded at Mayaguez, P. R., August 10, 1898. Wound of entrance, inner side, lower third, right thigh. Femur fractured; no wound of exit. Patient was trans-

PLATE XXIV.

PLATE XXIV.

CASE 10, SECTION IV.—Clarence Reed, private, Company H, Tenth United States Infantry.

Radiograph of proximal part of the left humerus, viewed from the back, showing fracture of the humerus produced by impact of a penetrating Mauser bullet against the inner side of the bone. The bullet, which has been turned by the impact, is seen lying against the inner side of the humerus.

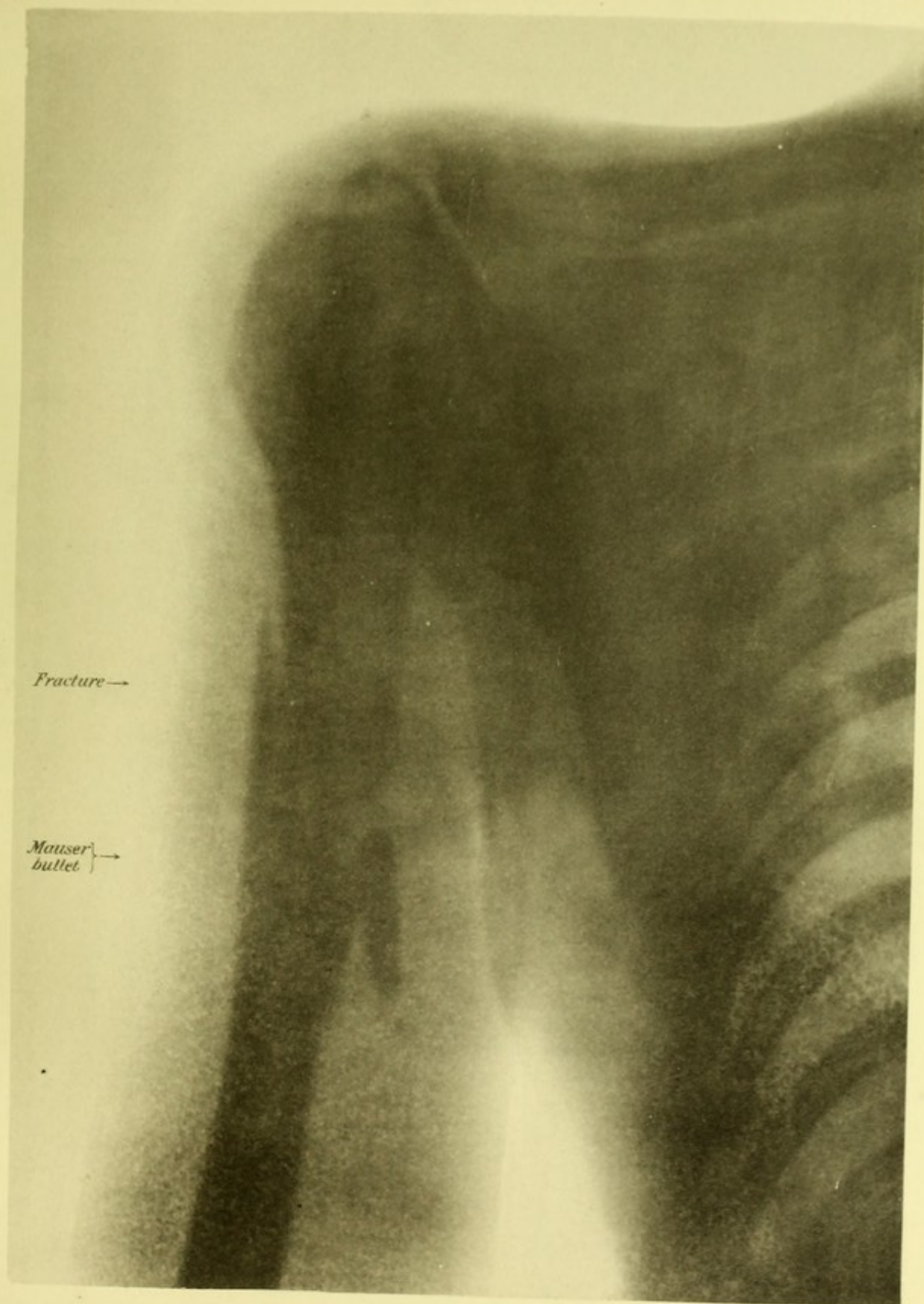
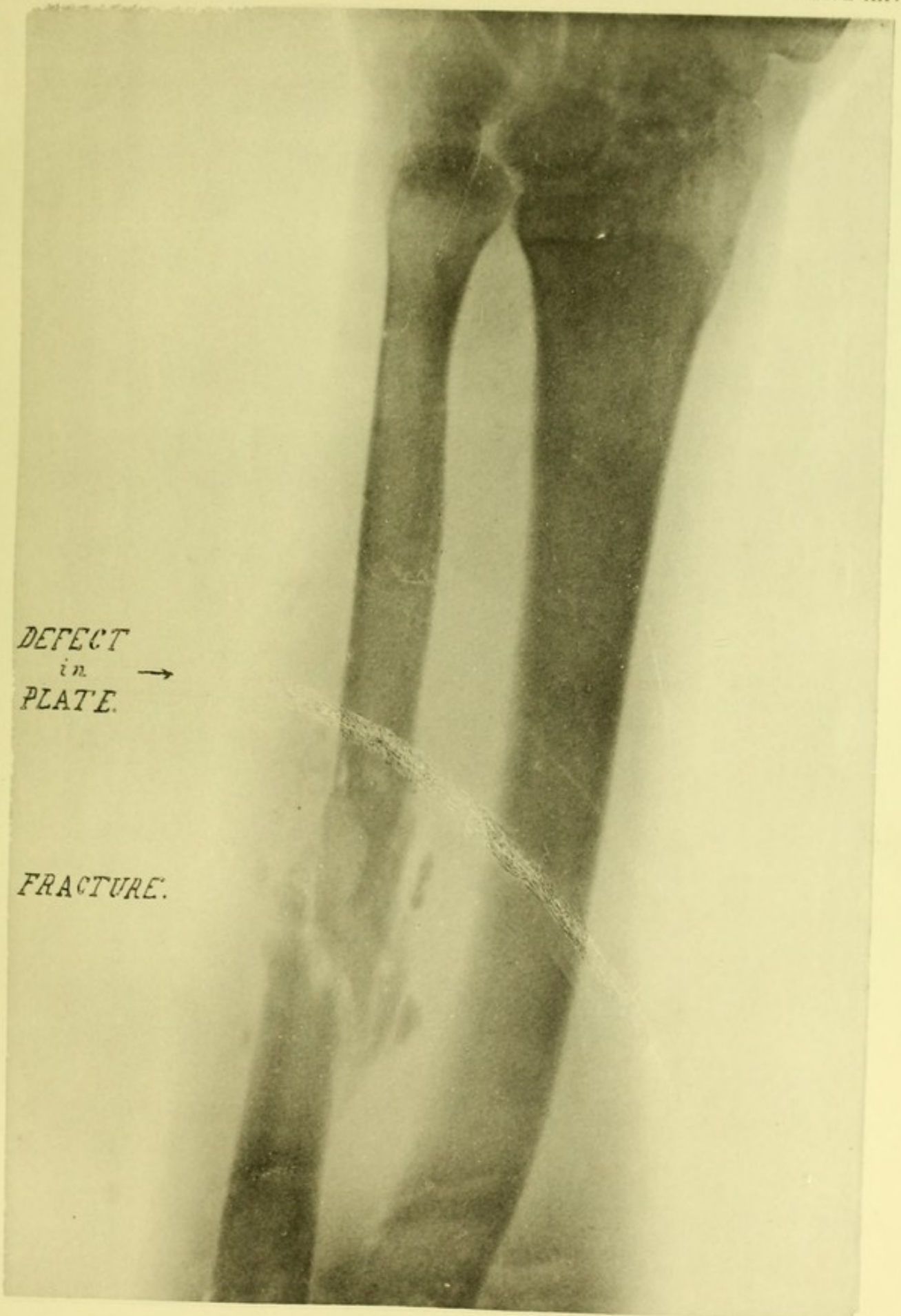


PLATE XXV.

PLATE XXV.

CASE 11, SECTION IV.—John Casey, private, Company C, Thirteenth United States Infantry.

Radiograph of right forearm, viewed from the anterior surface, showing fracture of the ulna by a penetrating, Mauser bullet. The comminution is moderate and does not extend far from the line of fracture.



DEFECT
in →
PLATE.

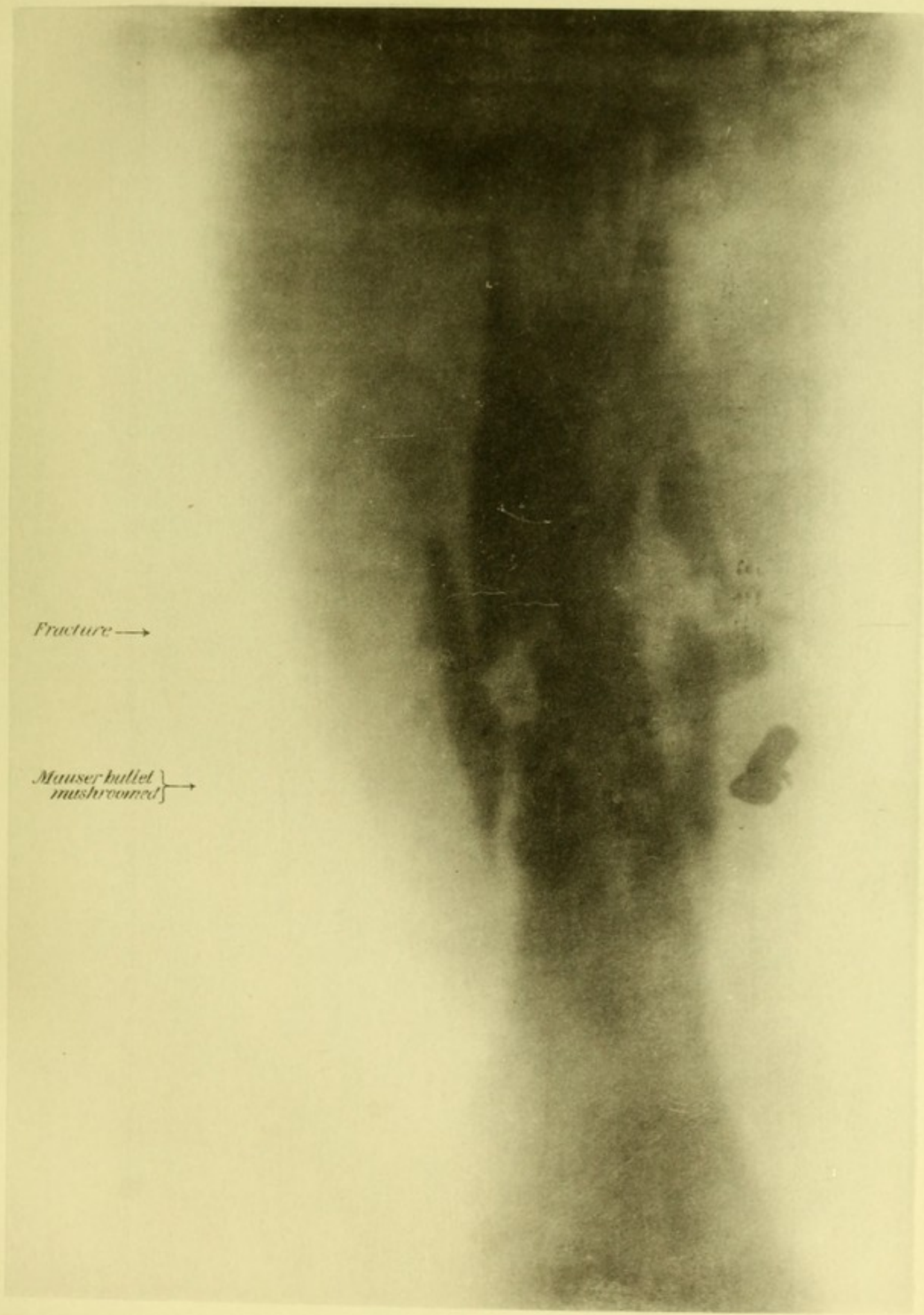
FRACTURE.

PLATE XXVI.

PLATE XXVI.

CASE 12, SECTION IV.—Daniel J. Graves, private, Company M, Eleventh United States Infantry.

Radiograph of right thigh, viewed from the back, showing extensively comminuted fracture of the femur by a penetrating, Mauser bullet mushroomed by ricochet. The bullet is seen lying at the outer side of the bone through which it has passed.




Fracture →

Mauser bullet }
mushroomed } →

PLATE XXVII.

PLATE XXVII.

Photograph of bone fragments, natural size, in the case of Daniel J. Graves, private, Company M, Eleventh United States Infantry.



ferred to *Relief*, where radiograph (Plate XXVI) showed fracture by a mushroomed bullet; comminution great.

The bullet had passed through the bone and lay on the outer side of the femur 13 cm. above condyle. August 18, the bullet (No. 8, Plate II) and several fragments of bone were removed through an incision made on the outer side of the thigh. The fragments removed are shown in Plate XXVII, and this, with the radiograph, shows the great amount of bone splintering which occurs in fracture by a mushroomed bullet. A plaster splint was applied. The patient was transferred from the

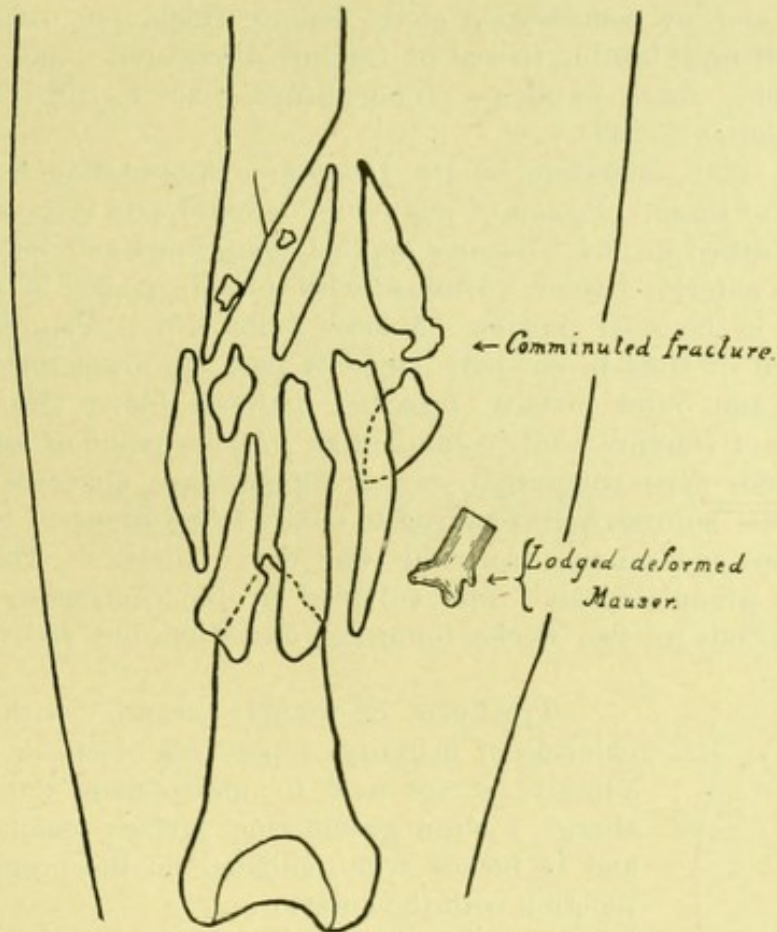


FIG. 21.—Diagram explanatory of Plate XXVI.

Relief to the Long Island College Hospital. He finally recovered with $2\frac{1}{2}$ inches shortening of the limb, and was discharged for disability.—*Case history from records in the Surgeon-General's Office.*

The following case is of interest in that the femur was badly shattered and two deformed bullets were embedded in the limb. One bullet was a Mauser (No. 6, Plate II); the other the lead core of a brass-jacketed bullet from which the jacket had been torn by ricochet. Whether the fracture was made by one or both bullets it was impossible to determine.

Case 13.—Multiple wound of thigh; two bullets lodged; infection; amputation; recovery.

George Parker, corporal, Company E, Twenty-fourth United States Infantry, was wounded July 1. Transferred to the *Relief*, where the radiograph shown in Plate XXVIII was taken, and from the *Relief* was transferred to the Long Island College Hospital.

History at hospital as follows: Two wounds of entrance on outer surface of right thigh at junction of middle and lower thirds; no wound of exit. Wound about the size of a quarter, granulating, but secreting a large quantity of sero-purulent fluid, and by compression along definite track, pus discharged in large quantities; small sinus leading to seat of fracture discovered; knee joint contained considerable fluid; thigh swollen. Temperature, 100° to 102° F. Intellection impaired; circulation feeble.

August 9, 1898, operation by Dr. Delatour. Amputation by transfixing in middle of third of thigh. Pocket of pus found on outer side of posterior flap. All wounds freely bathed in pus. Sutures applied along inner and outer side of flaps and partially on anterior border. Drained with tubes in pocket of pus in posterior flaps and gauze in the other portion. Mauser bullet (No. 6, Plate II), found in leg just behind head of tibia in one-half ounce of pus. In lower third of thigh, just above condyles and outer surface, a second flattened bullet (No. 2, Plate IX). Femur at point of fracture badly comminuted. Above point of amputation, bone apparently sound, flaps congested. Septic temperature appeared soon after the operation and the sutures were removed to secure free drainage. Sinus was found between the flaps and running up beside the femur 5 inches. This closed in few days, the flaps granulated and were enfolded by the contracting cicatrix. The patient was delirious for two weeks following operation, but recovered from this completely.

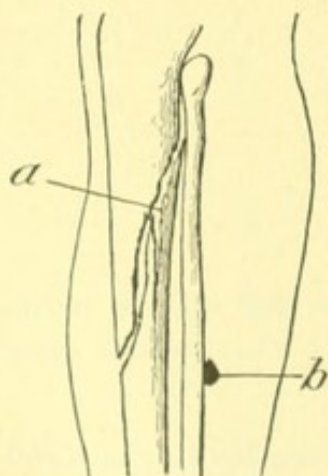


FIG. 22.—Diagram explanatory of Plate XXIX. *a*, Oblique fracture; *b*, fragment of mantle of bullet.

Treatment of wound: Cleansing with solution of bichloride of mercury, application of sterile gauze dressing, adhesive straps used to approximate the flaps. On discharge, a clean granulating surface remains 3 inches long and 1½ inches wide, situated on the posterior flap at its junction with the anterior.

November 25, patient discharged from hospital; general condition, very good.—*Case history from Long Island College Hospital, Brooklyn, N. Y.*

In the following case a brass-jacketed bullet ricocheted, penetrated the leg, and made a long, oblique, fissured fracture of the tibia.

Case 14.—Oblique fracture of tibia by lodged, brass-jacketed bullet; suppuration.

John A. Baronoski, private, Company C, Eighth United States Infantry, wounded at 300 yards range by a brass-jacketed bullet (No. 3, Plate IX).

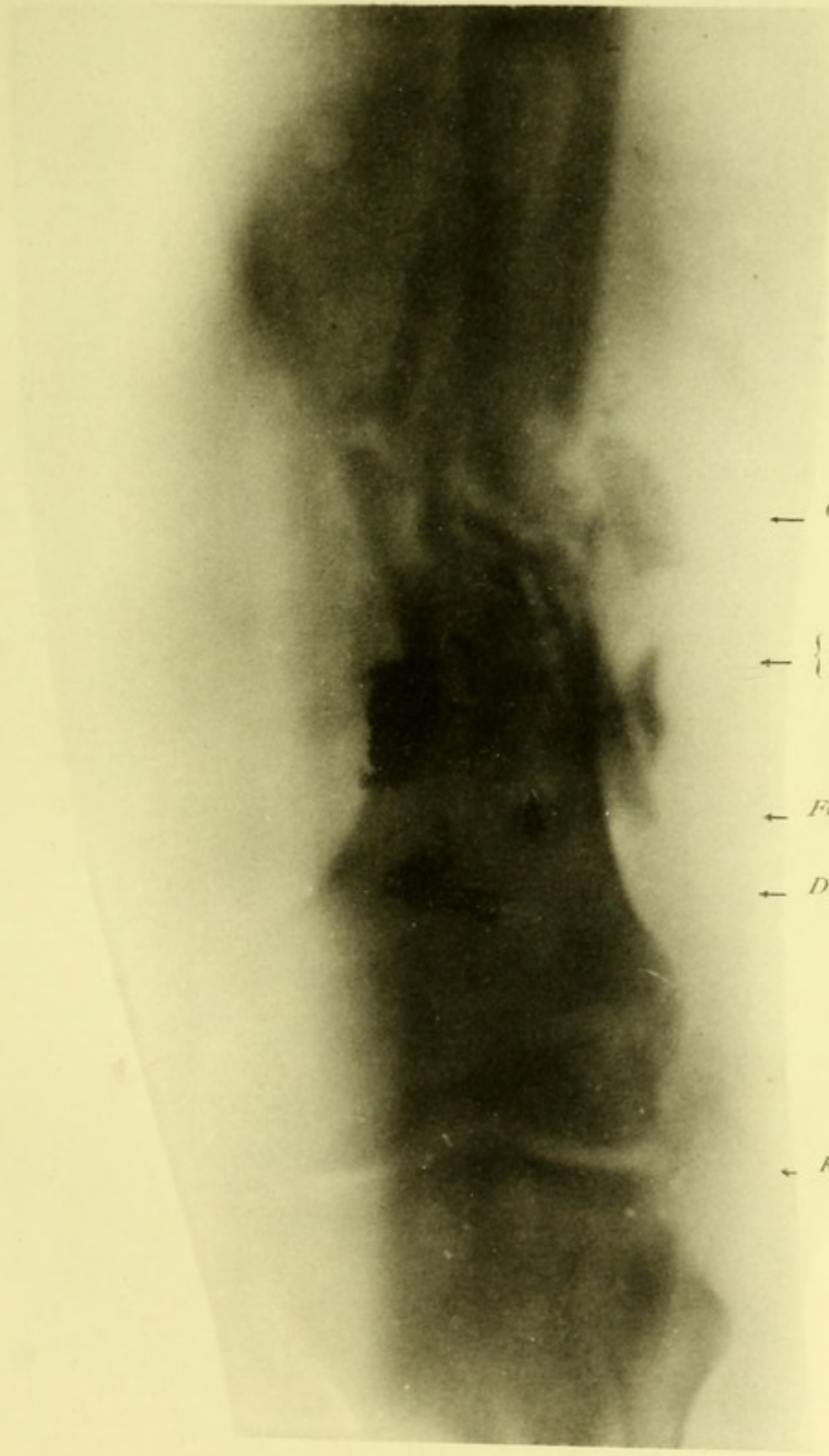
The bullet entered at the internal surface, lower third of the left leg, passed through the bone, and lodged in the tissues on the outer side. The bullet was

PLATE XXVIII.

PLATE XXVIII.

CASE 13, SECTION IV.—George Parker, corporal, Company E, Twenty-fourth United States Infantry.

Radiograph of lower part of right thigh, viewed from the back, showing a much-comminuted fracture, two lodged bullets, and a fragment of metal. One missile is the much-deformed, lead core of a brass-jacketed bullet; the other a deformed, Mauser bullet. It is not known by which missile the fracture was made.



← *Comminuted fracture.*

← { *Lead core of brass jacketed
bullet.*

← *Fragment of metal.*

← *Deformed Mauser bullet.*

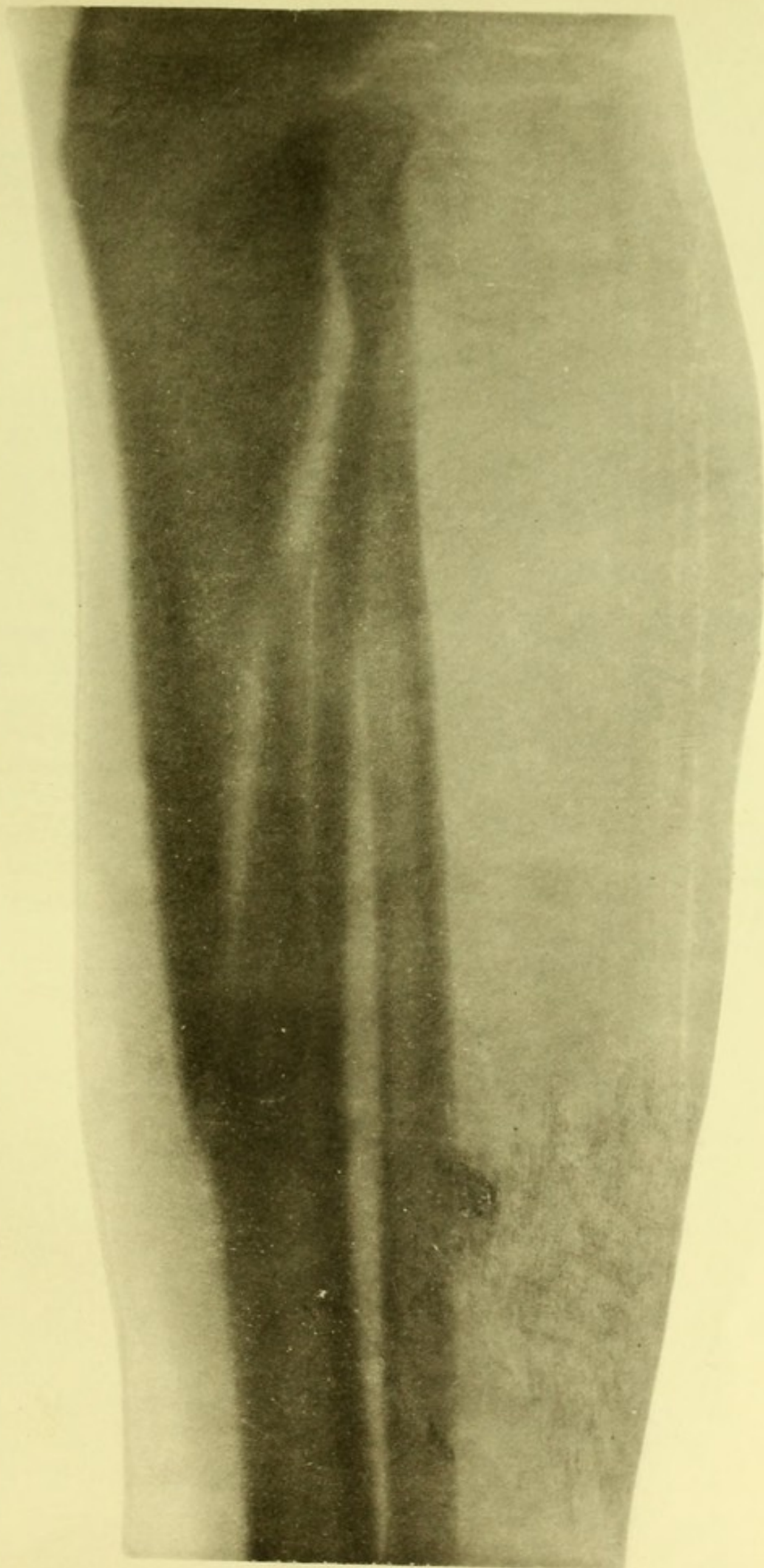
← *Knee joint.*

PLATE XXIX.

PLATE XXIX.

CASE 14, SECTION IV.—John A. Baronoski, private, Company C, Eighth United States Infantry.

Radiograph of left leg, viewed from the front, showing long, oblique fracture of the tibia, made by a brass-jacketed bullet, a fragment of the mantle of which is lying at the side of the fibula.



removed at the field hospital and the leg put up in plaster. Suppuration supervened, and the patient was transferred to the *Relief*, where the Röntgen ray showed a piece of the jacket of the bullet still in the tissues, and that the ball had produced a long, oblique fracture, extending upward from the point of impact of the bullet nearly to the condyles of the tibia (Plate XXIX).—*Case history compiled from records in the Surgeon-General's Office.*

CLINICAL CONCLUSIONS.

Consideration of gunshot traumatism of the shaft of long bones, as shown by the Röntgen ray in connection with the ultimate outcome of the cases, points indubitably to the conclusion, that infection, or noninfection of the wound should influence treatment, rather than the amount or extent of bone comminution.

In noninfected wounds, extensive comminution is not, as a rule, an indication for operative interference of any kind. Occlusive dressings and immobilization give assurance of the best possible results. Where there is considerable comminution, shortening of the limb will probably occur as a result of the comminution and the displacement of the bone fragments. But excellent functional use of the limb may be restored, unless the lesion of the soft parts is extensive and motion is restricted by the formation of cicatricial connective tissue in the traumatic spaces.

Where infection exists, removal of the cause under aseptic or antiseptic precautions is indicated. In such cases, complete cleansing of the wound and removal of all loose bone fragments, followed by drainage and antiseptic dressings and irrigation, will usually suffice, and excision or amputation will only have to be resorted to in extreme cases.

V.

GUNSHOT FRACTURES OF THE EXTREMITIES OF LONG BONES AND OF CANCELLOUS BONES GENERALLY.

GUNSHOT OF THE EPIPHYSES.

Röntgen ray examinations have demonstrated that the effect of the modern small-caliber, jacketed projectile on the extremities of long bones is markedly different from its effect on the shaft. This is undoubtedly due to the difference in the structure of those parts of the bone. In the shaft, compact tissue predominates, and this dense tissue transmits the vibrations produced by the impact of the bullet more readily than the less dense tissue of the extremities, where the loosely knit cancellous tissue forms the main part of the bone. In compact tissue, the vibrations set up by the bullet are transmitted with enough force to cause molecular vibrations sufficient to produce solutions of continuity at some distance from the point of impact of the missile. In cancellous tissue, the forcible vibrations, from the nature of the tissue, are transmitted but a short distance and, in consequence, solutions of continuity take place only within a comparatively short distance from the point of impact. As the amount of destruction in the shaft depends upon the conditions of impact, so in the extremities, the amount of injury done by the ball varies, but to a much less degree than in the shaft. The comminution is never as great and, frequently, the ball simply channels the bone, or, when nearly spent, embeds itself without producing any splintering or comminution.

Case 1.—Mauser bullet lodged butt-end foremost in tibia; bullet located by Röntgen ray and removed.

John J. L. Taylor, private, Company E, Tenth United States Cavalry, July 1, 1898, occupying a prone position about 500 yards from opposite firing line, received perforating wound right ankle, about 3 inches above internal malleolus. Entrance wound punctured. No wound of exit. Considerable œdema and ecchymosis about ankle joint; movement of joint very painful. Röntgen-ray picture (Plate XXX) shows the bullet embedded in the bony part of the internal malleolus, apex protruding, soldier evidently having been exposed to ricochet firing.

July 12: Operation. Incision made 2 inches long directly over internal malleolus; skin and subcutaneous tissue divided and bullet felt distinctly by finger. Soft parts separated by blunt dissection and bullet exposed, firmly embedded in bone. Only with greatest difficulty and by using lion forceps could missile be moved. It proved to be a Mauser. The cavity in the bone was perfectly smooth,

PLATE XXX.

PLATE XXX.

CASE I, SECTION V.—John J. L. Taylor, private, Company E, Tenth United States Cavalry.

Radiograph showing Mauser bullet embedded, butt-end foremost, in the lower end of the tibia, with no splintering of the bone.

Mausser bullet →

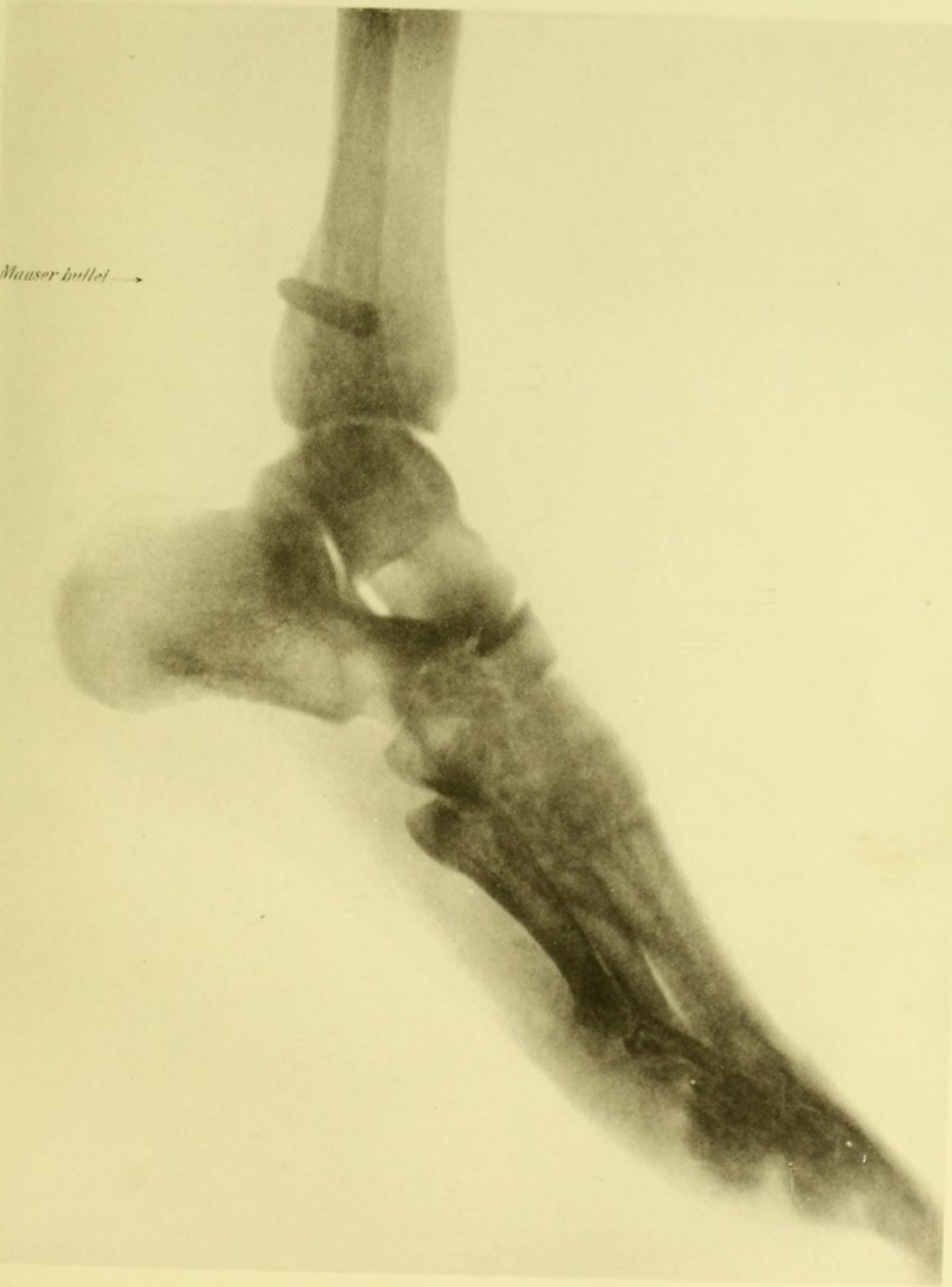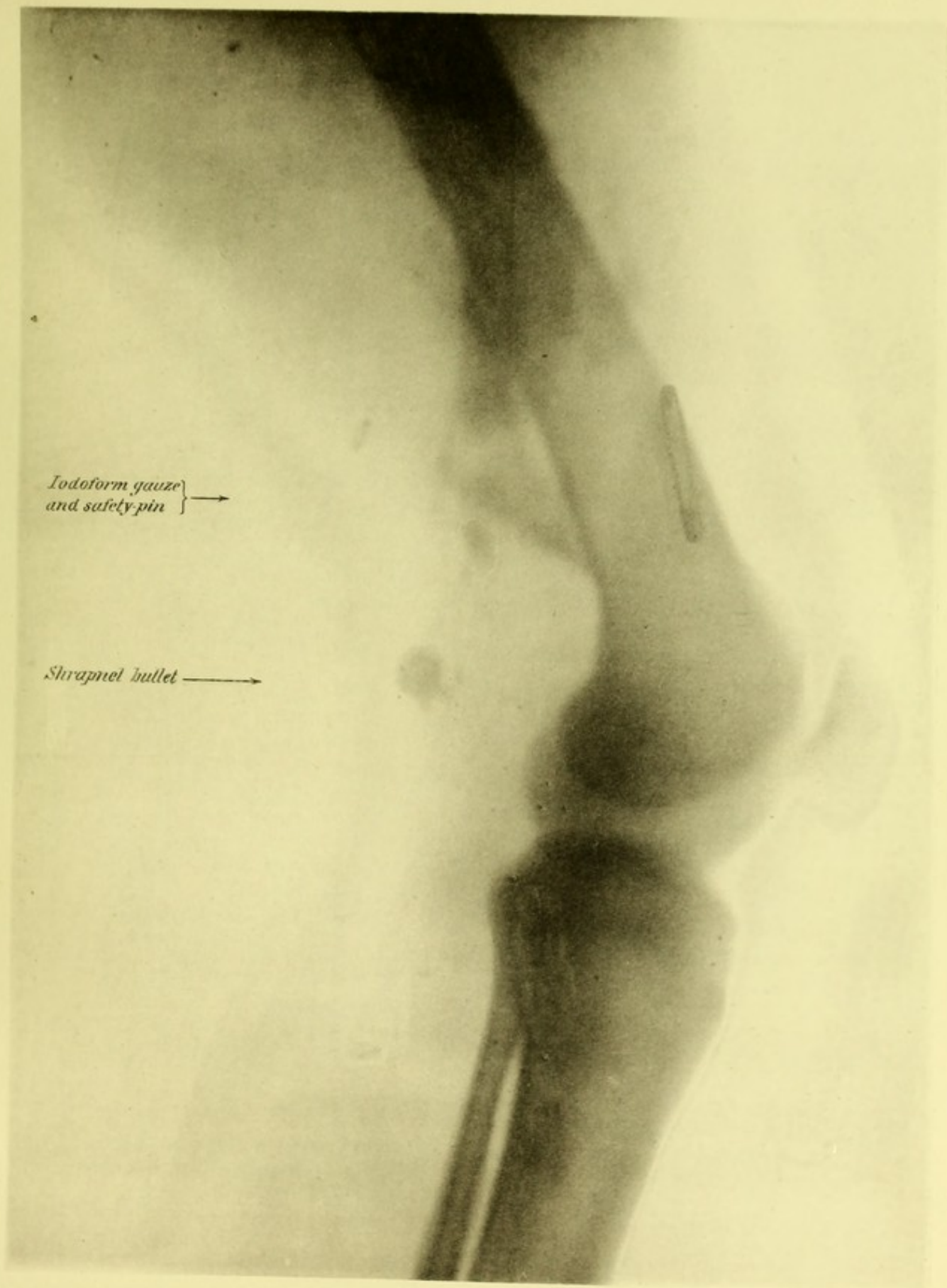


PLATE XXXI.

PLATE XXXI.

CASE 2, SECTION V.—Daniel B. Raymond, private, Company D, Sixteenth United States Infantry.

Radiograph showing shrapnel bullet with small fragments of bone about it, lying in the thigh behind the femur, through which it passed, making a clean-cut hole. The shadows near the femur are from the iodoform dressing. A safety pin in the dressings is outlined on the femur.



*Iodoform gauze
and safety-pin* } →

Shrapnel bullet →

as if drill had been used. No splintering of bone. Wound was cleansed with weak solution of bichloride of mercury and skin brought together by deep silkworm-gut sutures.

July 14, primary union; pain and œdema having disappeared.

July 22, a slight discharge of purulent material. Wound opened at upper part and iodoform gauze introduced. No œdema about ankle. No pain.

July 24, wound clear.

July 26, transferred.—*Case history from hospital ship Relief.*

That the slow-moving, lead bullet can at times produce a clean perforation of the extremity of a bone is shown by the following case:

Case 2.—Perforation of lower end of femur by a shrapnel ball; aseptic wound; missile located by Röntgen ray and removed.

Daniel B. Raymond, private, Company D, Sixteenth Infantry, was wounded July 1. Entrance wound small, dressed with first aid dressing. Transferred to *Relief*, where radiograph was taken which showed that the missile was a shrapnel (Plate XXXI).

Transferred to Long Island College Hospital where the following history is given: The bullet entered the thigh at the lower third, and by Röntgen ray was shown to be located behind the head of the tibia. An incision was made over the point indicated in the picture and the bullet was found with several small fragments of bone it had pushed before it. In the condyle of the femur was a round, clean-cut hole extending completely through the bone. A small amount of turbid fluid was found at the site of the bullet. The wound was closed without drainage. Complete recovery resulted.—*Case history from hospital ship Relief and Long Island College Hospital.*

Cases like the above are probably comparatively uncommon, as the lower end of the shaft of the femur is composed of quite compact tissue and is usually completely fractured or splintered. Perforation of the upper end of the femur, without fracture or comminution, is probably much more common. The following case and radiograph show the small amount of comminution produced by a Mauser bullet passing through the femur in the region of the great trochanter. From the conflicting evidence it is probable that the fracture produced by the ball was not complete at first, but afterwards became so.

Case 3.—Mauser bullet fracture of upper extremity of femur; wound aseptic; recovery without amputation.

Theodore Wint, major Tenth United States Cavalry, July 1, 1898, before Santiago, San Juan Hill, shot in left thigh from before backward, Mauser striking cover of small morocco pocket book, which it pierced; ball did not pass out of trousers behind after having cut through the thigh. Line of flight was at an angle to surface of thigh, so that entrance was larger than exit wound. Direction of

passage through the thigh was from within and below, upward and outward. At time of being struck, felt shock, but was not knocked down. On turning about to pick up a pipestem, fell to the ground and called for assistance, and to be drawn out of line of fire below the hill crest. A surgeon at once dressed the wound temporarily and applied splints from above the hip at the loin to the ankle outside, and inside from the crotch to the ankle. Fracture was diagnosed. After about one hour, a stretcher was improvised and the patient was carried to a dressing station about three-quarters of a mile to the rear. No dressing was done here and the splint was not disturbed. The same night, he was transported on a stretcher to the field hospital, where, about 1 a. m. July 2, the wound was dressed and the leg was again examined and fracture diagnosed by a second surgeon. The splints were reapplied and left on for about two days and the patient given a cot under a tent fly. Then another examination was made and the thigh bone pronounced not fractured by a

third surgeon. The splints were removed. The patient was entirely unable to use or flex the thigh.

July 10, splints were put on and, in an ambulance, the patient was taken about 7 miles over a very rough road to Siboney.

July 11, he was transferred to the *Relief*.

July 12 or 13, splints were removed, plaster strapping applied, bed provided, and July 21, start for the north was made. The wounds were dressed several times at the field hospital and three times on board the vessel. Course of wounds normal, without suppuration or inflammation. Never probed.

Dr. Senn also made an examination of the thigh upon the occasion referred to

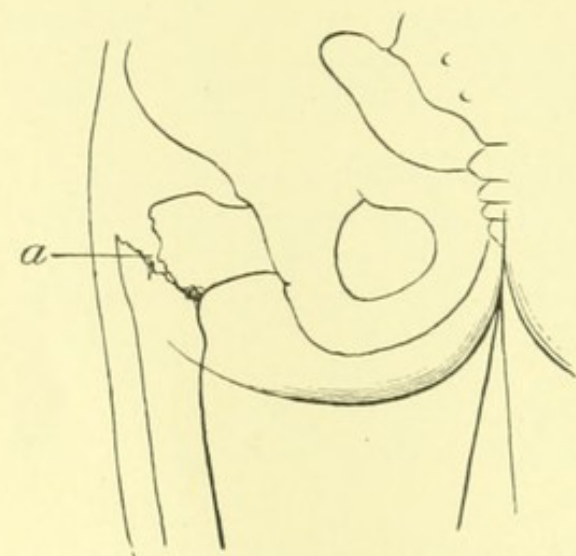


FIG. 23.—Diagram explanatory of Plate XXXII.
a, Place of passage of bullet.

above, at the field hospital, and corroborated the diagnosis of no fracture. On the hospital ship *Relief* a radiograph (Plate XXXII) was taken.

This radiograph plainly shows a fracture with displacement, but the attending surgeon either misinterpreted the picture or from reliance on other symptoms or opinions, corroborated the diagnosis of no fracture. Patient admitted to New York Hospital with no splint; strip of adhesive plaster around body over great trochanter. In this hospital, fluoroscopic examination showed an oblique fracture through the base of the neck and part of the great trochanter, with abundant callus and much displacement.

Physical examination: Leg flexed and everted and shortened about $2\frac{1}{2}$ inches. Wound of exit closed; of entrance, on anterior region of thigh, still suppurating slightly. Movements painful. No crepitation, no false motion. Abrasion at knee. Considerable swelling and tenderness around the joint.

Physical examination on discharge, September 19, 1898: Pressure over great trochanter gives little or no pain. Movement of thigh up to 45 degrees; shortening

PLATE XXXII.

PLATE XXXII.

CASE 5, SECTION V.—Theodore J. Wint, major, Tenth Cavalry.

Radiograph of the upper part of the left thigh, viewed from the back, showing Mauser bullet fracture of the femur in the neighborhood of the intertrochanteric line. There appears to be considerable loss of bone substance in the neighborhood of the great trochanter, and an oblique fracture with no fissuring. It is probable that the ball perforated the bone and so weakened it that it afterwards fractured.

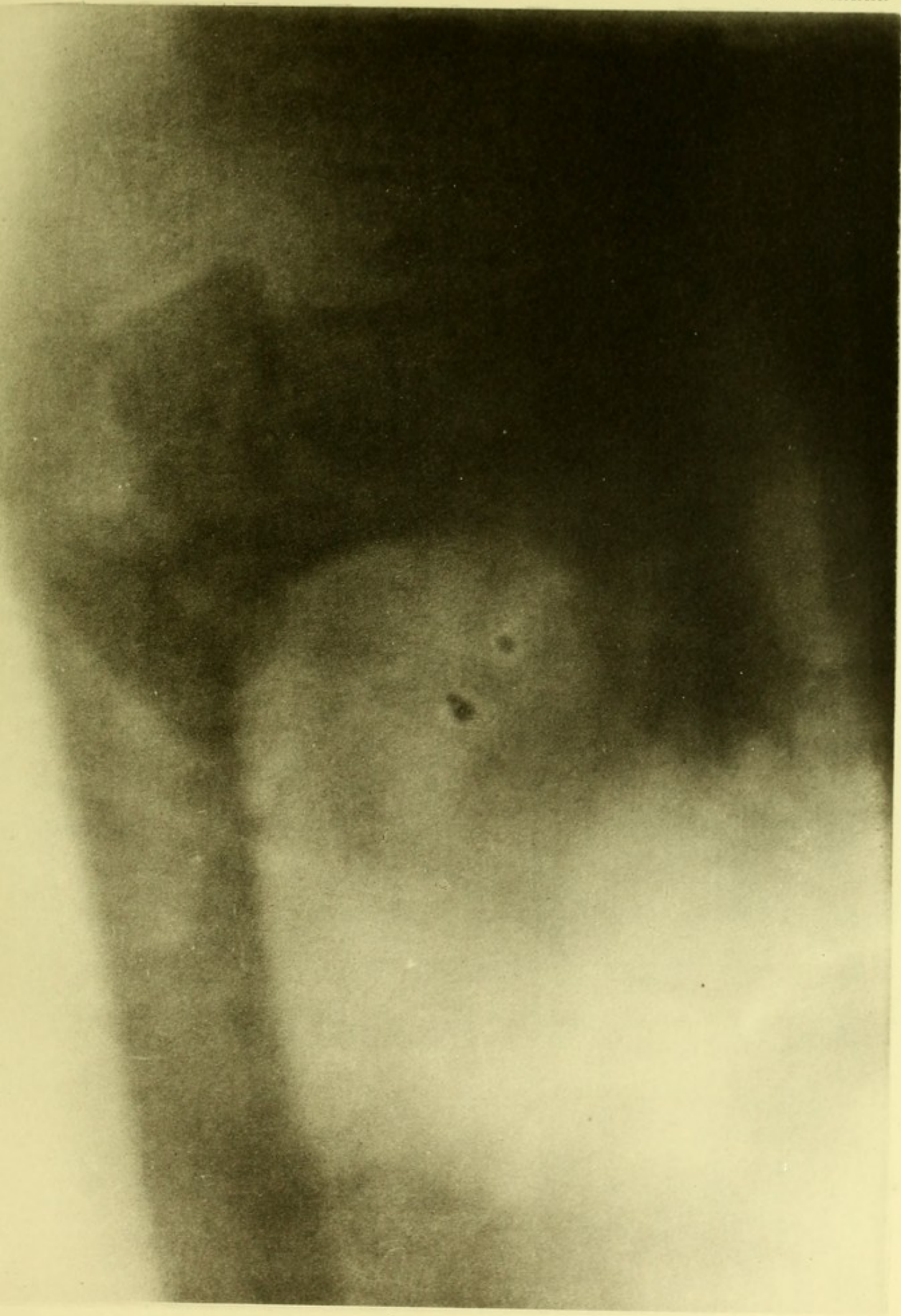
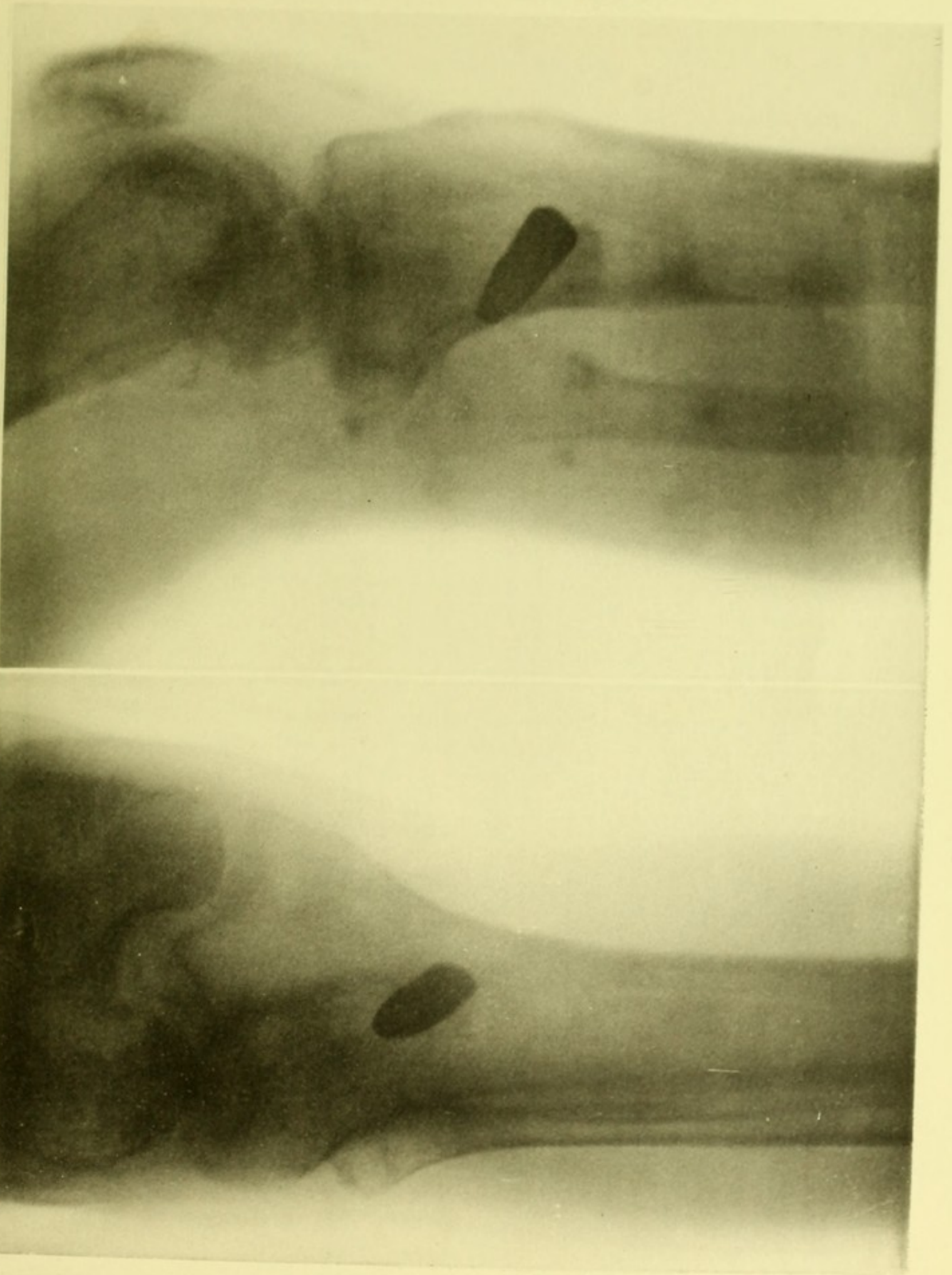


PLATE XXXIII.

PLATE XXXIII.

PLATE XXXIII, SECTION V.—Earnest Knowles, private, Company D, Twenty-first United States Infantry.

Radiographs of left knee, viewed from the inner side, and from the back, showing Remington bullet which has passed downward, backward, and inward and lodged in the upper part of the tibia.



of one-half inch. Knee still slightly swollen, somewhat stiff, but flexion still gradually increasing. Crutches on September 6. Can bear some weight on injured leg.—*Case history compiled from records in Surgeon-General's Office.*

On account of its cancellous structure, the upper end of the tibia is frequently pierced without comminution or complete fracture. The two following cases are of interest in that, in each case, the missile wounded the kneejoint and passed from above downward into the tibia without producing any destruction of bone other than clean penetration.

Case 4.—Wound of kneejoint; perforation of tibia; aseptic wound; recovery without complications.

Lewis Gruner, private, Company E, Sixteenth United States Infantry, wounded by a Mauser bullet at San Juan, July 3, 1898, distance unknown. Projectile entered outer aspect, right kneejoint, between the outer condyle and head of tibia, and ranging downward and inward through the head of the tibia, it emerged at the inner side of the leg 2 cm. below the head of the tibia. The limb was placed on a posterior splint. Was sent to the base hospital at Siboney, July 10.

Examination February 4, 1900: The wound of entrance is marked by a round scar the size of the projectile; the exit wound by a scar a trifle larger. Flexion of knee somewhat impaired. Radiograph shows slight exostosis on inner surface of tibia at site of exit of bullet, probably due to callus formed about small specula of bone displaced outward from exit wound in bone.—*Case history by Maj. Louis A. LaGarde, Surgeon, United States Army.*

The next case illustrates how a bullet of large caliber may penetrate the upper end of the tibia without producing any fracture beyond the direct line of its course. It also shows the good result which may be obtained in gunshot wound of the knee, even when made by a large, ricocheted missile, the good result undoubtedly being due to the continued antiseptic treatment employed.

Case 5.—Gunshot of knee by ricochet Remington, caliber .45, with penetration of tibia.

Earnest Knowles, private, Company D, Twenty-first United States Infantry, was wounded October 23, 1899, at San Cristobal, Calamba, P. I., at about 250 yards range by a Remington bullet. He was kneeling at the time and the bullet struck the ground just in front of his left knee, ricocheted, passed through khaki trousers, apparently without causing loss of substance of the latter, and struck the knee in front of the external condyle of the femur, grazed that bone, passed through the joint and downward, inward, and backward into the upper end of the tibia. A first-aid dressing was immediately applied and the patient transported to hospital. The external wound was so large that two fingers could easily be inserted into it. The wound was cleaned, drained, and irrigated with antiseptic solution. Healing

was complete in about seven weeks. Soldier was discharged for disability on account of impaired motion of the joint, and he entered the Soldiers' Home, Washington, D. C.

Radiograph taken May 14, 1900, shows large bullet lodged in upper and back part of tibia (Plate XXXIII). From this localization, the bullet was subsequently removed from the body of the bone by Maj. Louis A. LaGarde, Surgeon, United States Army.

In the next case, the radiograph, though not taken until six months after the receipt of the injury, clearly shows the perforation made by the bullet (Plate XXXIV). The radiograph indicates that the fracture was not complete, though the patient stated that he could feel the bony fragments move on each other when pressure was made near the wound at the time of the injury. The short range at which the wound was inflicted, 10 feet, would give the maximum of destructive effect in osseous tissue, and that the comminution was not greater must be ascribed to the looseness with which the bony tissue is knit in the upper part of the tibia.

Case 6.—Perforation of tibia by Krag-Jørgensen at short range.

Private Wesley Kibby, Company H, Twenty-fourth Infantry, while on duty at Presidio, Cal., June 25, 1899, was accidentally shot by a comrade. Distance was not over 10 feet. Bullet was a Krag-Jørgensen. Entered left tibia 4 cm. below patella, and emerged from most prominent portion of calf, below bend of knee.

Examination February 4, 1900: Wound of entrance, transverse oval, 1 by $\frac{3}{4}$ cm. Wound of exit, oval, puckered, retracted, 2 by 1 cm. The man says that he could feel the bony fragments move on each other when pressure was made near wound.

Treatment: Dressing and immobilization; wounds healed in three weeks; able to walk in eight weeks with aid of cane; left ankle and foot remained weak, and sole of foot felt numb, with occasional needle-like pains shooting through it. He has weakness of all muscles of posterior aspect of leg; also of extensor hallucis, and loss of sensation over anterior two-thirds of plantar surface of foot. Some stiffness of foot and ankle still present, and he is unable to walk without aid of a cane.—*Case history by Maj. Louis A. LaGarde, surgeon, United States Army.*

The small amount of comminution produced by the Mauser bullet in passing through the extremities of the bones of the arm and forearm is shown in the following cases.

Case 7.—Separation of olecranon by bullet without comminution.

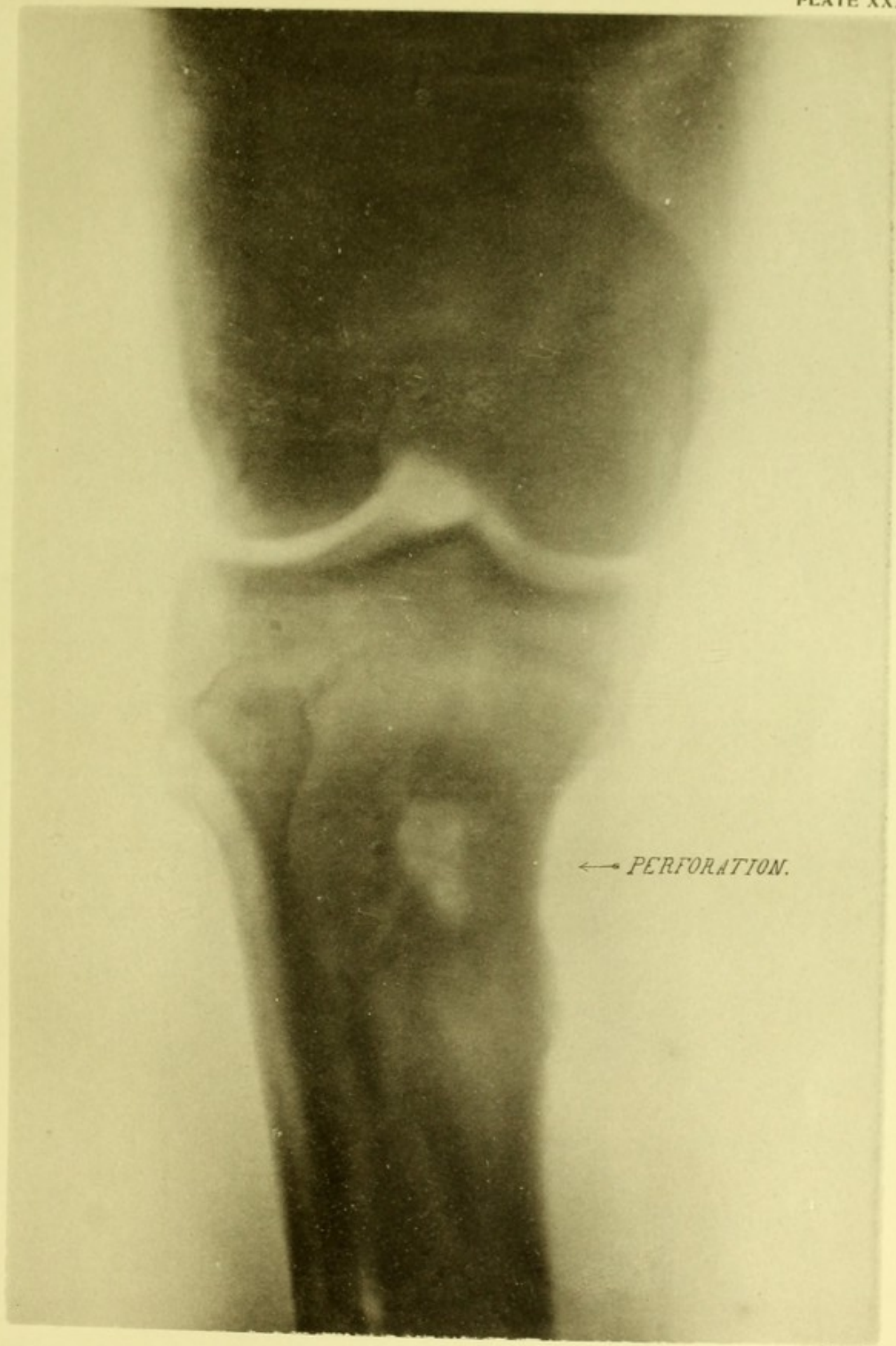
Theodore H. Lubold, private, Company I, Sixteenth Pennsylvania Volunteer Infantry, was shot while retreating during the skirmish near Guayamo, August 9. The bullet entered the right arm above the olecranon process and emerged from the extensor side of the forearm between the radius and the ulna. The Röntgen ray reveals the presence of a fragment of the bullet, or its mantle, lodged in the wound, and that the olecranon was separated from the shaft without comminution (Plate XXXV).—*Case history from records in Surgeon-General's Office.*

PLATE XXXIV.

PLATE XXXIV.

PLATE XXXIV, SECTION V.—Wesley Kibby, private, Company H, Twenty-fourth United States Infantry.

Radiograph of left knee, viewed from the back, showing perforation of upper end of tibia, made by Krag-Jørgensen at short range.



← PERFORATION.

PLATE XXXV.

PLATE XXXV.

CASE 3, SECTION V.—Theodore H. Lubold, Company I, Sixteenth Pennsylvania Volunteer Infantry.

Radiograph of right elbow, viewed from its inner side, showing separation of the olecranon with no fissuring of the fragments, and a small fragment of metal lower down in the forearm.

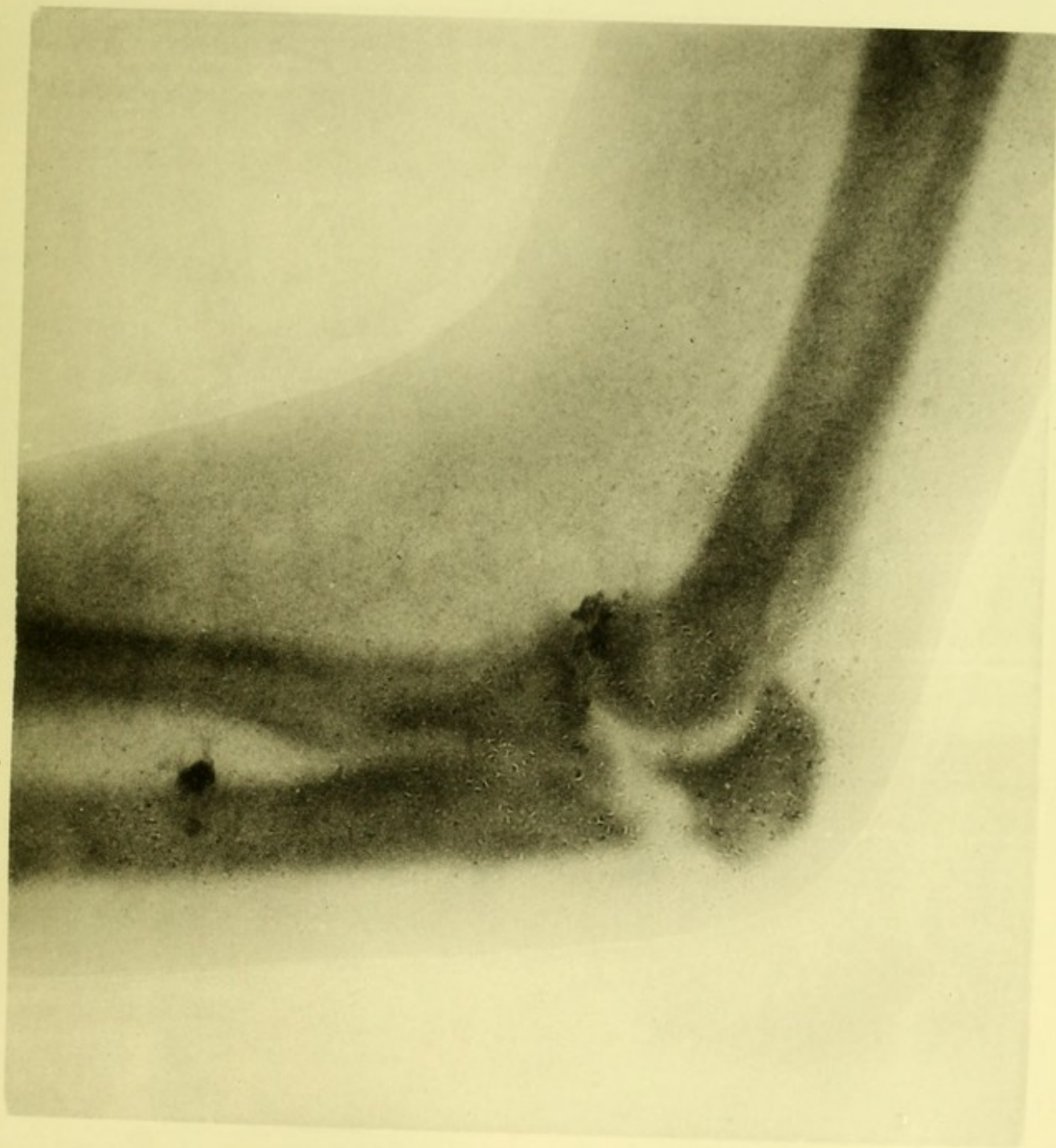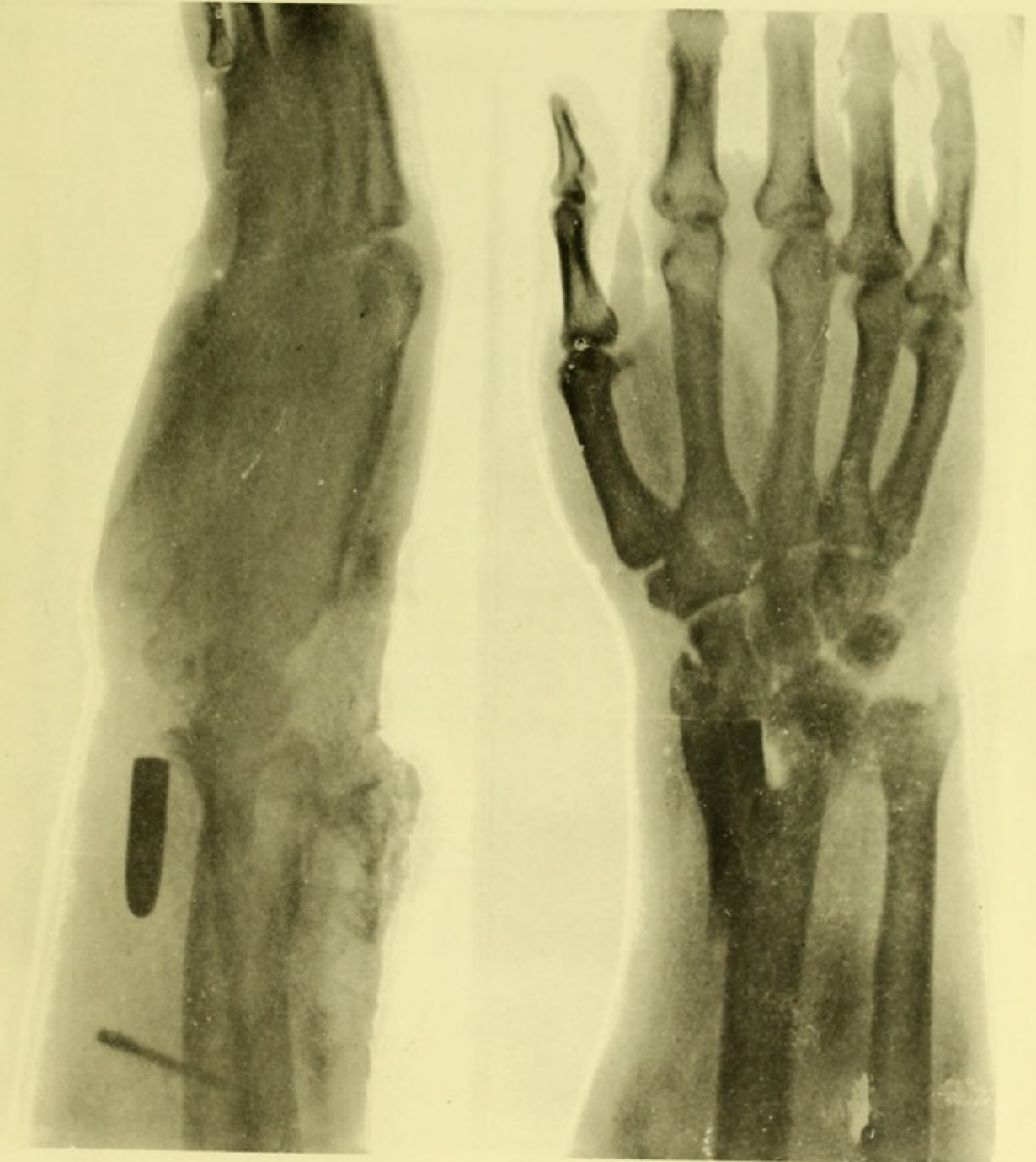


PLATE XXXVI.

PLATE XXXVI.

CASE 6, SECTION V.—Horace K. Devereaux, lieutenant, First United States Cavalry.

Radiographs showing fracture of the lower end of the radius by a lodged Mauser bullet. There is separation of quite a large external fragment, but the comminution does not extend up the shaft. The bullet has been displaced by the flexor tendons and is seen lying point upward in front of the radius. From its position, it is probable that it entered the part butt end foremost.



Case 8.—Mauser bullet fracture of outer condyle of humerus with no extension of fracture of shaft of bone.

Ralph Barkman, private, Company K, Second Massachusetts Volunteer Infantry, was twice wounded at Siboney, Cuba, July 1, 1899. One bullet entered the left leg; the other passed through the lower third of the left arm. The patient was transferred to the *Relief*, where a radiograph was taken which showed that the outer condyle was separated from the shaft, but that there was no splintering of the bone extending up the shaft. The patient was transferred to St. Peter's Hospital, Brooklyn, N. Y., and discharged from there July 29, 1899, "cured."—*Case history from records in Surgeon-General's Office.*

In the following case of fracture of the distal end of the radius, the bullet was probably traveling at low velocity, and entered the part, butt end foremost. The amount of comminution was not great, the fracture being mainly the separation of a rather large external fragment.

Case 9.—Fracture of lower end of radius by Mauser bullet; infection of wound; localization of bullet by Röntgen ray, and removal; antiseptic treatment; recovery without amputation.

Horace K. Devereaux, lieutenant, First United States Volunteer Cavalry, was wounded June 27, at 200 yards, by a Mauser bullet, which entered the dorsal aspect of the left forearm over the ulna. A first-aid dressing was applied twenty minutes after the receipt of the injury. The patient was transferred north on the *Olivette* and entered Roosevelt Hospital, where he came under the care of Dr. Robert Abbè, who radiographed the forearm (Plate XXXVI).

At that time, the forearm was in a condition of diffuse cellulitis and suppuration, the wound having been infected. Dr. Abbè removed the bullet July 18, and the case progressed to excellent recovery with wrist motion about one-fourth and rotation of the forearm about one-half the normal. Though the bullet lodged, the patient believed that it had not ricocheted, but ascribed its low velocity to defective powder. The position of the bullet, however, indicated that it had ricocheted and entered butt end foremost, and that its position—oblique to its line of entrance—was due to pressure from the overlying tendons of the forearm.

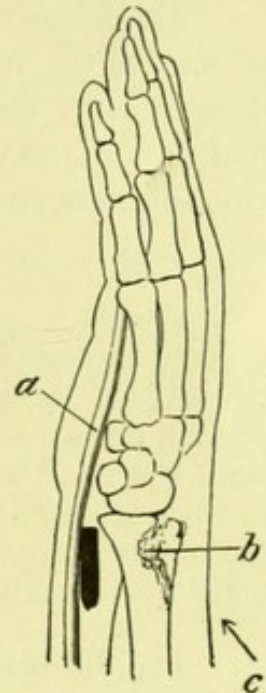


FIG. 24.—Diagram explanatory of Plate XXXVI. *a*, Flexor tendon; *b*, fractured radius; *c*, place of entrance of bullet.

GUNSHOT OF THE CANCELLOUS BONES GENERALLY.

The effect of the modern bullet upon the bones of the wrist and the cancellous bones of the foot and face, is very similar to its effect upon the epiphyseal ends of the long bones; i. e., guttering, or perforation, with small extent of comminution.

Case 10.—Perforation of os calcis by Mauser bullet.

Private John F. Murphy, Company C, Fourth United States Infantry, was wounded at unknown range by a Mauser bullet, which passed from behind forward, and from above downward, through the left os calcis. The wound healed readily, but pain, located beneath the heel, persisted. A radiograph was taken which showed a sharp, bony spur projecting downward from the under surface of the os calcis. This exostosis was undoubtedly a callus, formed about small bone fragments, which had been forced outward from the bone at the place of exit of the bullet. The weight of the body being brought upon this spur when walking, caused the disability. The bullet made so clean a perforation of the bone that there was no evidence of fragmentation of the os calcis with the exception of the small fragments forced out at the wound of exit. The exostosis was removed, November 19, 1898; the wound healed by first intention, and the patient returned to duty.

The following case gives the result of a Krag-Jorgensen bullet fracture of one of the metacarpal bones. It is of interest in that the hand was directly over the muzzle of the gun when it was accidentally discharged, and though the whole charge passed through the hand, the entrance and exit wounds were small and the bone lesion slight.

Case 11.—Perforation of trapezium by Krag-Jorgensen bullet.

Private August Blume, Company C, Twenty-first United States Infantry, accidentally discharged his rifle July 2, the bullet and whole discharge passing through the palm of his hand. Radiograph showed that the bullet had perforated the trapezium, throwing out only a small fragment. The entrance and exit wounds were small and there was nothing in the appearance of the part different from that seen in wounds received at long range. The wound healed by first intention, but full use of the hand was not restored, as cicitrical tissue in the wound caused some limitation of motion.

The following, a case of clean perforation of the os calsis by what was supposed to be a Remington brass-jacketed bullet, like case 5 of this section, shows the clean perforation of cancellous bone by the larger missiles.

Case 12.—Perforation of os calcis by Remington bullet.

Samul S. Wentworth, private, Battery E, First Artillery, wounded June 13, 1899, at Zapote Bridge, near Manila, P. I., presumably by a Remington bullet, as the wounds of entrance and exit were somewhat larger than those made by the Mauser, and the enemy, so far as known, were using Remington rifles. The bullet passed from without inward through the heel, perforating the os calcis. The wound did not heal, and three months after the receipt of the injury, an operation was done and a piece of legging, a piece of stocking, and three small pieces of bone, were removed. Wound has opened twice since and small amount of pus escaped. Was discharged for disability December 29, 1899, and seen by the writer in January, 1900,

PLATE XXXVII.

PLATE XXXVII.

CASE 12, SECTION V.—Samuel S. Wentworth, private, Battery E, First United States Artillery.

Radiograph of left foot, viewed from the inner side, showing bullet (Remington) perforation of the os calcis. Though the radiograph was taken several months after the receipt of the injury, the callus, if it has filled the perforation, is still transparent to the Röntgen rays.

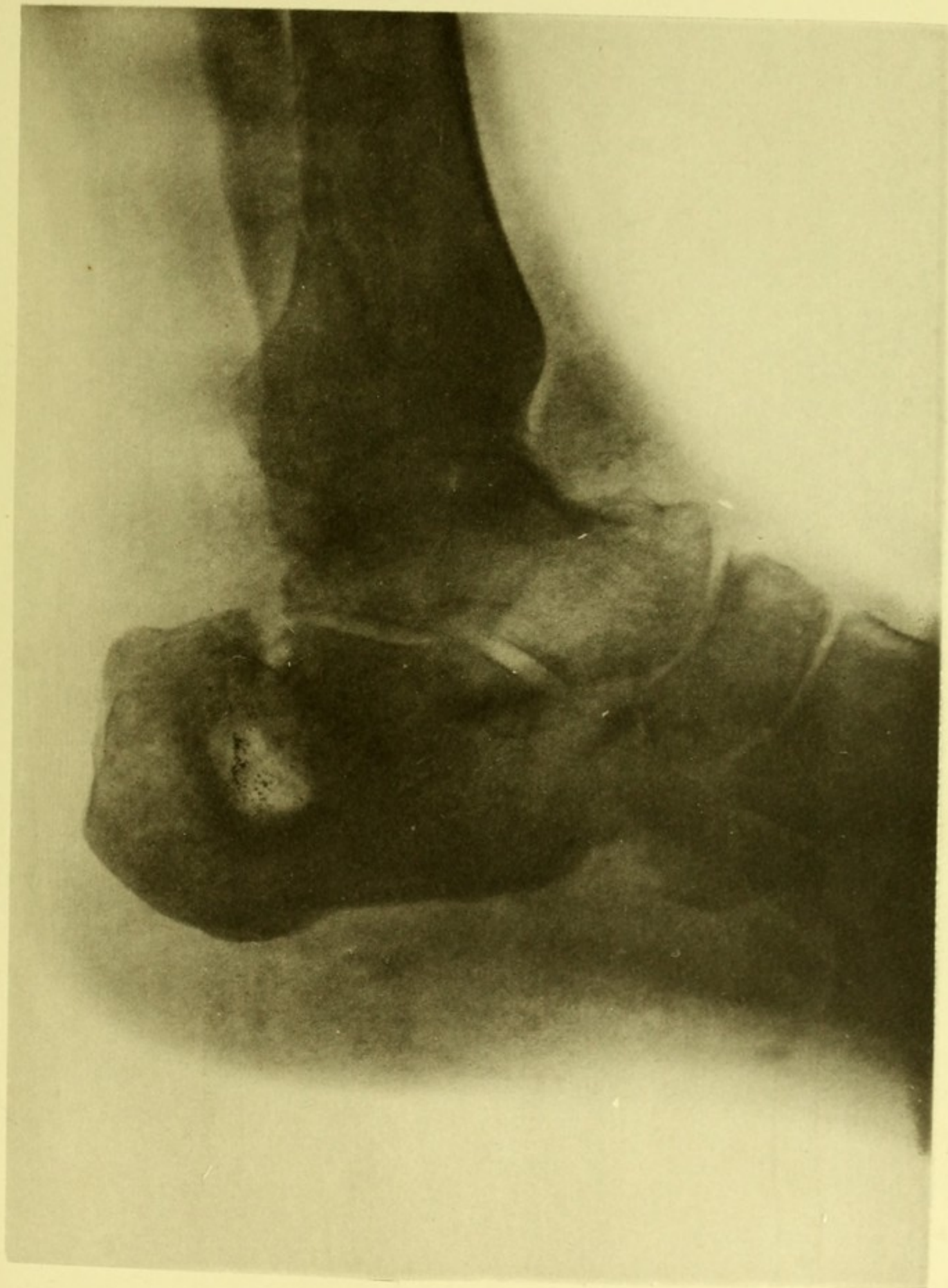
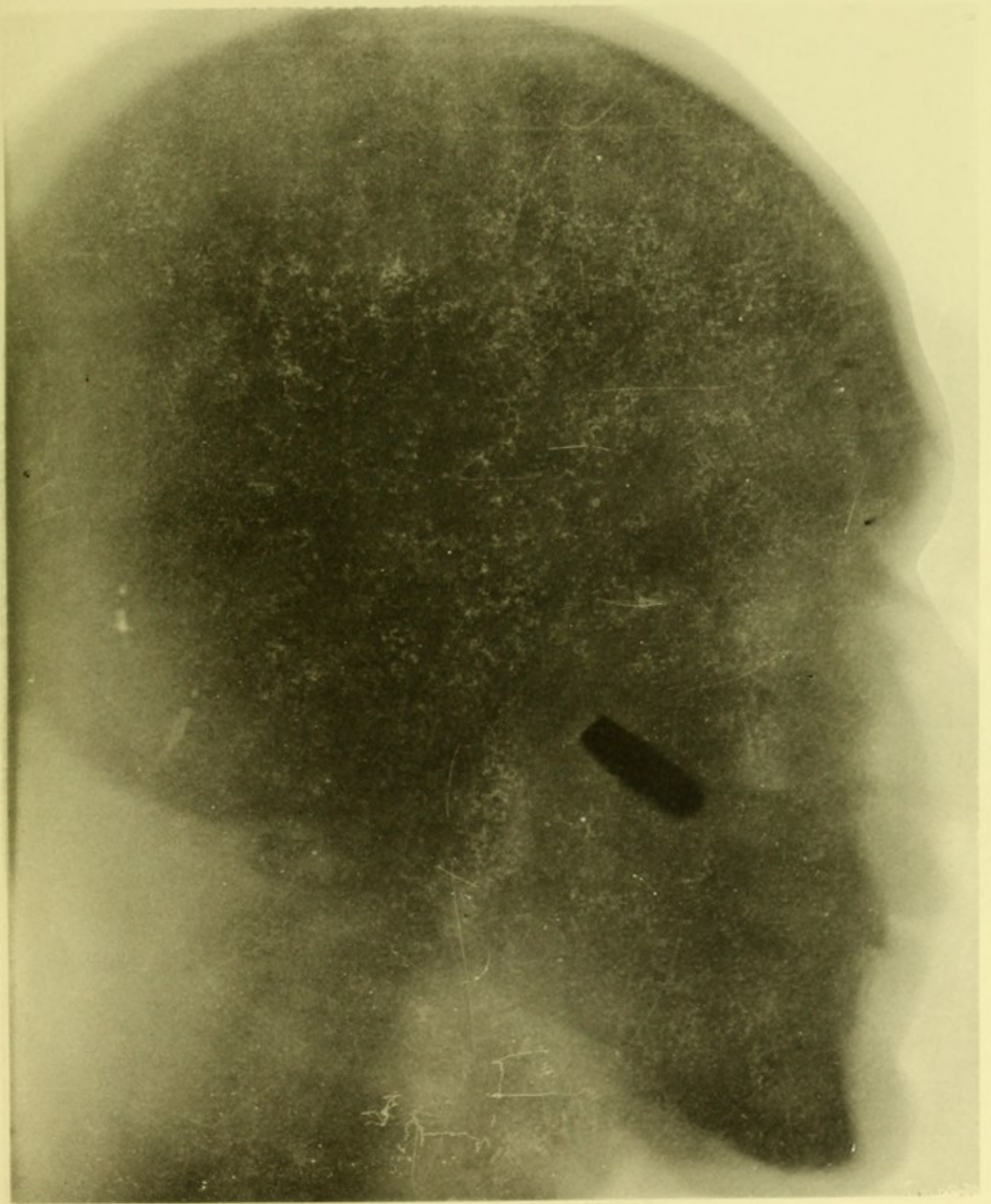

PLATE XXXVIII.

PLATE XXXVIII.

CASE 13, SECTION I.—Conelius L. Eagan, private, Company K, First Nebraska Volunteer Infantry.

Radiograph of face, viewed from the right side, showing Remington bullet in the right antrum of Highmore.





when the radiograph (Plate XXXVII), which shows a clean perforation, was taken. At this time, the wound was healed and the condition of the part and use of the limb appeared to be excellent, though some pain extending up the leg was complained of.

Owing to the cancellous structure of the bones of the face, gunshot traumatism of that region resemble those of the cancellous bones generally.

Case 13.—Penetrating gunshot of face by Remington bullet, caliber .45; localization by Röntgen ray; removal.

Cornelius L. Eagan, private, Company K, First Nebraska Volunteer Infantry. Gunshot wound of right side of face, received February 5, 1899, at Block House No. 7, Philippine Islands. Wound over left eyebrow, one-half inch from inner canthus. No wound of exit.

Symptoms: Partial deafness of right ear and total blindness of right eye.

Ophthalmoscopic examination: Choroiditis and retinitis with atrophy, the sclera showing through large areas in lower portion of field. Left eye normal in appearance. Ankylosis of jaw. Only slight separation of teeth. No pain, and only slight swelling of the right side of the face.

Diagnosis: Foreign body in the right face.

Treatment: Was radiographed in April and again in May (Plate XXXVIII), after which an effort was made to remove the bullet. Operation May 31, by Major Matthews. Incision was made along nose to mouth by median line, and transversely across the face to $1\frac{1}{2}$ inches from the ear. Soft parts retracted and search for bullet was made, but was unsuccessful. Second operation, August 16, 1899, by Maj. A. C. Girard. The same incision was made. The inferior surface of the antrum was chiseled through and the ball, which proved to be a Remington .45, flattened, and somewhat ragged, was removed. The skin incision was closed by subcuticular gut suture and healed excellently.—*Case history by Maj. A. C. Girard, surgeon, U. S. A.*

CLINICAL CONCLUSIONS.

The same conclusions, relative to treatment, obtain in fractures of the extremities of the long bones, as hold in fractures of the shaft. Infection or noninfection of the wound, rather than the amount of comminution, indicates whether, or not, the wound should be treated expectantly or otherwise. From a standpoint of the amount of traumatic destruction done by the ball, expectant and conservative treatment is even more indicated in gunshot injuries of the extremities than in similar injuries of the shaft of the bones. This is due to the fact that observation shows that the amount of comminution is much less and the size of the fragments much smaller, in gunshot fractures of the extremities of the long bones, than in gunshot fractures of the shaft.

Nor does the fact that joints are involved necessitate a divergance from the rule of expectant treatment.

Infection of the wound or extensive destruction of the soft parts may necessitate operative interference. But with ordinary penetrating or perforating wounds, occlusive dressings and immobilization have been followed by best results. When this treatment is supplemented by rapid transportation to base or general hospitals where operation can, if necessary, be done with adequate aseptic or antiseptic technic, the best possible results may be expected.

VI.

RADIOGRAPHIC TECHNIC.

Proper manipulation of the apparatus is most important in Röntgen-ray work; for, with imperfect methods, imperfect or negative results are obtained, and serious injury to the patient by burns may be inflicted. Maximum radiation in the tube depends upon supplying the tube with the current best adapted to its particular condition. To obtain a suitable current, proper adjustment must be made of the different working parts of the apparatus, and knowledge of technical details by which such adjustments are made is essential to success. As the static and the coil machines are entirely different in construction, the means by which radiation is influenced necessarily differs in each, and the method of operating each type of apparatus has to be separately considered.

THE STATIC MACHINE.

In operating the static machine, special attention has to be given to the condition of the machine relative to atmospheric conditions, to the speed of rotation of the plates, and to the adjustment of the spark gaps and the tube.

In the static machine, efficient output is dependent in large measure upon the absence of all dampness and dust from the interior of the case. To keep the plates clean, they must be occasionally carefully wiped. To protect the machine as much as possible from moisture, it should be kept in a well lighted and ventilated room, with windows provided with inside wooden shutters, which can be closed when fluoroscopic examinations are to be made during the daytime. To insure the absence of humidity within the case, it is usually necessary to keep dishes of calcium chloride within it. When this is done, fresh chloride should be placed within the case whenever any moisture accumulates in the dishes holding the old chloride. In very damp climates, the edges of the frame of the case where the glass is inserted should be thickly and carefully covered with thick petrolatum, to insure against passage of the damp exterior air into the interior of the case. As a precaution, to prevent loss of current, the front of the machine should be carefully wiped dry each time before using it.

As sufficient speed and steady rotation of the plates is essential to highest efficiency, the machine is best operated by some kind of motor, the speed of which can be regulated. Regulation of speed is necessary; in that, when a tube is working at its highest efficiency with the anode glowing properly, diminution of speed will decrease the output of rays; and an increase of speed, while not increasing the efficient output, may impair the life of the tube.

To operate an eight or ten plate static machine satisfactorily, a motor of one-fourth horsepower is required.

An electric motor of some reliable make is best for use when an electrical current is available, as such a motor can be easily and quickly adjusted for speed. Unfortunately, electrical currents can not always be obtained in military hospitals.

When electrical current is not available, water motor can be used and will work efficiently, provided the water pressure where the motor is placed is not lower than twenty pounds to the square inch. Such a motor has the advantage of comparatively low original cost and of being free from running expense.

Where motor power is not available, manual power may be used, and with it excellent work can be done; but such labor is extremely tiring, even when relays of men are employed. Where such power has to be depended upon, a tandem bicycle attachment for running the machine would probably be very useful.

CROOKES TUBES

As the electrical currents supplied by the static and the coil machines are quite different; tubes are specially constructed for each type of machine. As a rule, these tubes work best only with the type of machine for which constructed, and can not be used with other types without loss of efficiency or danger to the tube.

Relative to their excitation and radiation, tubes are divided into two classes—low tubes and high tubes.

By a low tube is meant a tube which is readily excited to radiation by a comparatively small current, and which when excited does not produce rays of great penetration. Tubes when first received from the manufacturers are generally in this condition. With such tubes, the bones when viewed by the fluoroscope appear quite dark, and metallic objects can not be seen through them. Such tubes are unfitted for radiography of thick parts. They should be employed for radiography of the thin parts and the

extremities of thin individuals until they become higher. All tubes have a "life." A tube, at first low, by use gradually becomes so resistant to the electric current that it can no longer be illuminated. For this reason, in using a tube, the operator should carefully examine its working with a fluoroscope to determine its condition and to what use it is best adapted. A ready method of determining the condition of a tube, is to see whether or not a coin or cuff button held against the forearm, can be easily seen through the radius. If not, the tube is a low one and should only be used for work for which such a tube is adapted, or it may be raised to a higher vacuum by suitable manipulation.

A low tube may be raised by continued use or by reversing the current; but in reversing the current, care should be taken not to continue the reversal too long a time or the tube may be ruined. This reversal of the current is easily managed in the coil machines by reversing the switch lever; but in the static machine, it is necessary to close the current and reverse the tube.

High tubes are distinguished by requiring a large or maximum current to excite them, and by producing rays of great penetration. With such tubes, the bones appear gray, and metallic objects are readily seen through them. A ready test for such a tube is ability to see with the fluoroscope the shadow of a watch through a man's skull. A tube which will give this result is fitted for chest and body work and for radiography of such deep parts as the pelvis or hip joint.

Eventually, such a tube will become so high as to resist all attempts to illuminate it, even with powerful current and careful adjustment.

When this occurs, the vacuum can be lowered by subjecting the tube to heat, by baking it in a hot-air oven, or carefully heating it over a Bunsen burner or alcohol lamp. When the tube no longer responds to these manipulations, it can be returned to the maker for reexhaustion and will then again work satisfactorily for some time.

MANIPULATION OF THE TUBE TO SECURE ITS MAXIMUM RADIATION.

Maximum radiation of any tube is obtained by supplying it with an electrical current of tension, quantity, and rapidity of oscillation, best adapted to its vacuum. In the static machine, this is arrived at by the use of the spark gaps and the velocity of rotation of the plates. Spark gaps, or current interrupters, are metallic rods attached to, and movable upon, each sliding pole of the machine. By attaching the wires leading to the tube

to these appliances, the current may be carried direct to the tube, or may be interrupted and caused to pass through any desired distance of air space. The spark gaps and their proper manipulation are absolutely necessary to secure proper radiation from most tubes. All tubes, however, do not require their use. Tubes of high vacuum and great penetration frequently work best when the wires are connected direct to the poles of the machine. With low-vacuum tubes, it is necessary to pass the current through an air space; the length of air space depending upon the condition of the tube. The lower the tube, the farther the spark gaps must be separated; so increasing the air space through which the current has to pass. With the tube adjusted and the spark gaps closed, the machine should be started into rapid action and a fluoroscopic examination made. If the bones appear gray and transparent, the tube is probably working at its best and no spark gap is required.

Trial, however, should be made to ascertain if the fluorescence may not be increased. To do this, separate the positive spark gap and observe the result. Then separate the negative gap and adjust the gaps to the distance which gives the best radiation from the tube. This distance may be a very small fraction of an inch, or it may be an inch or more. This can only be determined by a trial, which takes but a few moments. With the spark gaps properly adjusted, the radiation depends, to a certain extent, upon the rapidity of revolution of the plates. Radiation is at its best when the entire anode glows with a dull red color. When this glow is obtained, the revolution of the plates should not be increased; as overheating of the anode and destruction of the tube may result, with no adequate compensation in the way of increased radiation.

THE COIL MACHINE.

In the coil machine, radiation in the tube is regulated by the condenser and vibrator.

The condenser is placed in the mahogany base upon which the coil is placed, and it greatly increases the power of the coil.

The condenser is made in sections, and is connected to a series of four plugs on the top of base, by which it is possible to use any portion or the whole of the condenser at will. It will be found that some focus tubes will work best when only using a few sheets of the condenser, whereas other focus tubes require considerably more condenser, and in some cases it is necessary to plug it all in.

In order to plug in the condenser, the plug should be inserted between the two parallel flat brass strips, in the hole provided for that purpose; whereas, if any part of the condenser is not required for use, that particular plug should be inserted in one of the four holes in the middle of the long brass strip.

The coils furnished with the battery sets are operated by a vibrator which has a special adjustment by which the periodicity of the vibration can be varied at will. As tubes vary in effect relative to the periodicity of the vibrations, these should be regulated by the adjustment made for this purpose, so that the maximum radiation of the tube may be obtained.

A combined switch and pole changer is mounted at the end of the coil for reversing the current and for opening the circuit when desired, and a rheostat is employed for controlling the quantity of current passing to the coil.

When using the coil, close the pole-changing switch and adjust the contact screw of the vibrator (previously loosening the clamping nut of the same), until a steady yellow-green fluorescence occurs in the tube and then retighten the clamping nut. If the discharge is passing through the tube in the right direction, the body of the tube (embracing the space between the flat platinum anode and the concave aluminum cathode) will be filled with a uniform fluorescence and that part of the tube above the flat platinum anode will remain in shadow. If no shadow appears, the pole-changing switch should be reversed. In using a focus tube for the first time, the greatest care should be taken not to allow the flat platinum anode to become red-hot; for if it is allowed to remain at this temperature for any considerable length of time, the inside of the glass tube will blacken through particles of platinum being thrown off against the inner surface of the tube. Also, the high temperature will raise the vacuum in the tube considerably and shorten the working life of the tube, while there is danger of the tube being broken down entirely if the platinum anode is allowed to become bright red-hot.

The best result with the tube can be obtained when the platinum anode is at the temperature of a very dull red (invisible).

When first lighting up a new focus tube, use as little current as possible until it is ascertained that the current is passing in the right direction, as it injures the efficiency of the tube if a heavy current is sent in the wrong direction.

After considerable use, the vacuum in a focus tube rises on account of tendency of the electrodes and glass to absorb the residual gas, until finally

the vacuum becomes too high for the production of the Röntgen rays. In this case the vacuum can be lowered by applying the flame of an alcohol lamp to the surface of the tube so as to warm it, being careful to keep the flame away from the wire terminals and in continual motion so as to prevent breakage of the tube by overheating in one place.

The tube should always be watched most carefully during the whole time that it is in operation, as the vacuum frequently becomes lower, owing to the heat generated by the fluorescence, and this causes the platinum anode to heat up very quickly, which will still further lower the vacuum of the tube and ultimately destroy it, if overheating is not checked by moving the rheostat lever so as to reduce the current.

High vacuum focus tubes require more current to bring them to fluorescence than do low tubes, and consequently the rheostat lever will have to be moved so as to allow more current than when using a new tube. But it should always be remembered that the vacuum decreases, the longer the tube is in continuous operation, and consequently, it should be watched so as not to allow the platinum anode to get hotter than a very dull red. At this temperature, the best results are obtained with a high vacuum tube.

When the vacuum in a focus tube rises very high, the surface of the tube should be cleaned carefully and frequently, as it has a tendency to attract particles of dust from the air, owing to the intense electrification of the glass.

Good alcohol should always be used in the lamp when warming focus tubes, as a poor quality will deposit a thin coating of carbon on the outside surface of the glass, which will cause a leakage around the tube.

The tube should always be kept perfectly clean. This is best accomplished by wiping it with a piece of damp tissue paper.

RADIOGRAPHY.

Photography is an indispensable adjunct to Röntgen ray work, as it is necessary to supplement nearly all fluoroscopic examinations by this agent. This arises from the fact that the visual sense is not sufficiently acute, nor is the outline shown on the fluorescent screen sufficiently distinct, to enable an observer to determine the finer details of most objects through which the Röntgen rays will work. Frequently, in working through the thicker parts of the body, the fluorescence is not sufficient to enable the eye to accurately determine the outlines of an object or to differentiate it from surrounding objects. In such cases, accurate images can only be obtained

by the prolonged action of the Röntgen rays upon a photographic plate. By the prolonged action of the rays, the sensitized surface of the plate stores up the impressions which are received upon it, so allowing the photographic production of images which could not be discerned visually.

Also, by means of photography, a record of the condition which exists in the part examined is made possible, and these may be multiplied indefinitely from a single exposure by means of prints from the negative. For these reasons, Röntgen ray outfits should always be supplemented by sufficient photographic material to enable the operator to resort to photography whenever necessary.

While the technic of the production of photographs by means of the Röntgen ray does not differ materially from that used in ordinary photographic work, still there are certain points, knowledge of which will further the operator's endeavor to obtain good results. Of special importance are the plates used, the length of exposure, and the method of development.

PHOTOGRAPHIC PLATES.

All photographic plates are not equally applicable to radiographic use. Plates for this work should be thickly coated with an emulsion of the highest degree of sensitiveness. Extreme sensitiveness is requisite for the reason, that, compared with ordinary light, the Röntgen rays have but feeble action upon the silver compounds with which photographic plates are coated. Consequently, unless the plates are rapid—i. e., very sensitive—exposure will have to be unduly prolonged in order to produce satisfactory results.

The necessity for a thick coating to the plates arises from the desirability of shortening exposure to the briefest possible time. The Röntgen rays do not work upon the surface of the sensitized emulsion alone, but penetrate it and act equally, or nearly so, throughout its entire thickness. This may be proven by superimposing several, sensitized, celluloid or paper films and then taking a radiograph upon them. When developed, the image upon the lowest film will show no appreciable difference from that upon the upper. If now the developed films are superimposed and viewed by transmitted light, the parts acted upon by the light will appear much more opaque than when each film is viewed separately. From this it follows that a plate coated with a thick emulsion, when exposed and developed, will, by reason of the reduction of the silver salts throughout its

entire thickness, give more contrast and printing density than one with a thin coating.

For these reasons, plates specially made and put on the market for Röntgen ray work are usually thickly coated, and these plates should usually be used in preference to plates made for ordinary photographic purposes. Some ordinary plates, however, give excellent results. Such are the "double-coated" and "nonhalation" plates, all of which are thickly coated. Some rapid plates which are used for ordinary photographic purposes also give excellent results. Notable of these plates are those made by the Cramer Dry Plate Company of St. Louis, Mo., with which results have been obtained equal to the best obtained with special plates.

As photographic plates differ widely in their applicability to Röntgen-ray work, comparative tests should always be made before adopting a new make. In testing plates, the following method is useful: Place four plates in light-tight envelopes, and put them side by side in the form of a square under the Crookes tube. Place on each plate a circular disk of tin, and in the center of the disk a coin. Fix the anode of the Crookes tube directly above the center of the square formed by the plates, so that all the plates will be equally illuminated. Turn on the current so that the tube will be illuminated and the plates exposed. Expose for about three minutes, and then develop all the plates, together, in the same tray, with the same developer. Comparison of the finished negatives will show which plate is the most rapid by the greater density of the shadow where the rays have worked through the tin disk, and the contrast can be judged by the relative density between the shadow and the part of the negative outside of it. Clearness of the negative and absence of chemical fog can be judged from that part of the negative beneath the place where the coin was placed, for as no rays can pass through the coin, this part of the negative should appear perfectly clear. By testing plates in this manner, an operator is able to judge the quality and kind of plates with which he is working.

The keeping quality of plates is a matter of considerable importance in radiography for military surgical purposes. Plates frequently have to be bought in large quantities and shipped to distant points, often to tropical climates, where, unless the plates have exceptionally good keeping qualities, they are liable to spoil. Under such circumstances, if plates deteriorate, it is difficult to replace them without considerable delay. Some kinds of Röntgen-ray plates are put up separately in light-tight envelopes. These plates do not keep well, as the heat and moisture acts in some way upon the paper and cause deterioration in the sensitized surfaces of the plate with

which the paper comes in contact. Plates keep better when packed together in light-tight pasteboard boxes, as they are ordinarily packed for commercial use. For these reasons, plates packed in such boxes, with envelopes separate, should be chosen. Radiographs can be taken upon certain kinds of sensitized paper; such as the Eastman permanent bromide. These papers are, however, much slower than plates, and do not give as clear and well-defined pictures.

EXPOSURE.

The length of exposure depends upon the amount of radiation from the tube, the distance of the tube from the plate, the rapidity of the plate, and the density of the part through which the rays have to work. Some experience is required on the part of an operator, in order to estimate the length of time it is necessary to subject the plate to the action of the rays, to obtain a satisfactory image. Relative to this, it may be said; that, in order to take a satisfactory radiograph through any of the thicker parts of the body, such as the knee, thigh, or head, it is essential that the tube should show the shadow of an object on the fluoroscope through the skull of an adult. With a tube having this radiation, placed at 10 inches from the body, and using a rapid plate, the following lengths of exposure may be considered as the maximum necessary:

Forearm and hand	One to two minutes.
Shoulder and chest.....	Ten minutes.
Knee	Nine minutes.
Hip joint, head, and pelvis	Twenty minutes.

Unless radiographs can be taken of the different parts named, in the time given, the tube is not working properly, either from some defect in the tube or the current by which it is excited, and the attention of the operator should be directed to these defects, and he should correct them rather than attempt to obtain a result by prolonging the exposure.

RÖNTGEN-RAY BURNS.

Röntgen-ray burns are usually produced by prolonged exposure with tubes which are not working properly. There is very little danger if the apparatus is working well; for, with a properly working apparatus, prolonged exposures or close approximation of the tube to the body is not necessary. But two Röntgen-ray burns have been reported as a result of the use of the Röntgen-ray apparatus during the Spanish-American war. One burn was produced by a coil and one by a static machine. In each case, the

exposure was prolonged and frequently repeated, and the apparatus was not working at its maximum. The cases are as follows:

Case 1.—Severe, Röntgen-ray burn by coil machine.

Thomas McKenna, discharged soldier, formerly private, Company C, Sixth United States Infantry, had received a gunshot fracture of the upper third of the right humerus during the Santiago campaign, for which an excision of the upper part of the humerus was made.

December 5, 1898, an attempt was made to radiograph the shoulder in order to ascertain the condition of the bone. An exposure of twenty minutes was made,

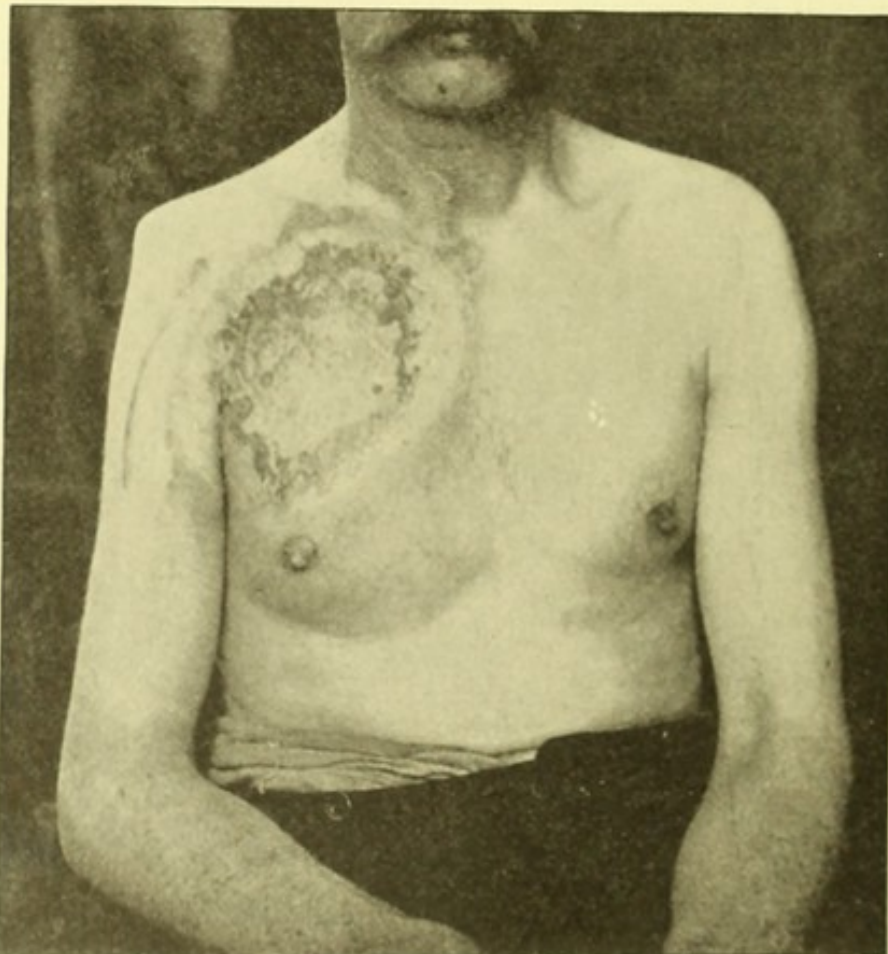


FIG. 25.—Röntgen-ray burn of right breast of Thomas McKenna, formerly private Company C, Sixth United States Infantry. The photograph was taken when the condition was at its worst stage.

using a Fessenden coil machine actuated by a dynamo current, with the tube (a low one) 10 inches from the shoulder. The result was so unsuccessful that a second and third trial on successive days were made, but the tube was working so poorly that no satisfactory radiograph was obtained. Six days after the last exposure, slight redness of the skin appeared on the front of the chest and shoulder. This erythematous condition increased and, two days later, small blebs appeared. These broke and small ulcers formed, which gradually spread and coalesced. The tissue necrosis deepened and extended and was accompanied by marked pain and hyperæsthesia.

The inflammatory action continued until the burn covered nearly the whole right breast (fig. 25).

Treatment of various kinds was tried, but the greatest benefit was derived from continuous application of lead and opium lotion. The burn showed no sign of healing for four months. After that time it gradually grew better, but the healing process was very slow and the burn was not entirely healed until eleven months after its first appearance.

Case 2.—Slight, Röntgen ray burn by static machine.

Walter C. Booth, private, Hospital Corps. Admitted to the Army General Hospital at Washington Barracks, D. C., March 14, 1899, for pyelitis and hydro-

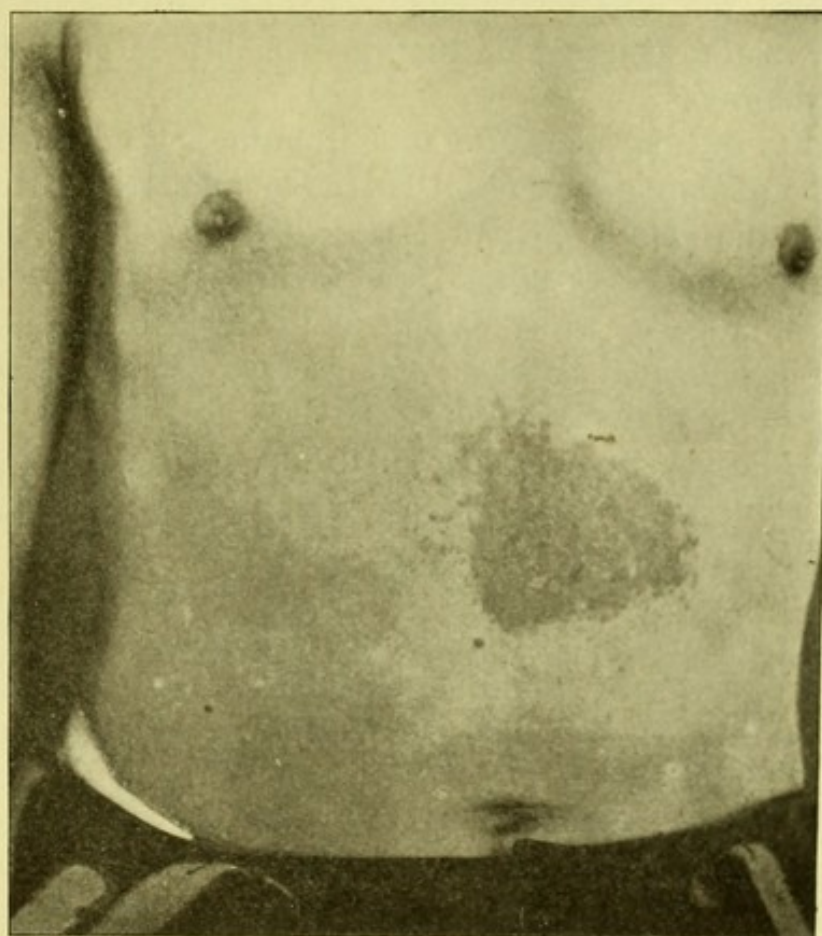


FIG. 26.—Röntgen-ray burn on the abdomen of Walter C. Booth, private, Hospital Corps. The photograph was taken when the erythematous condition was at its height.

nephrosis of the left kidney, supposed to be due to the presence of calculus in the pelvis of that kidney. An attempt was made to determine by radiography whether or not a calculus was present. Exposures of twenty-five minutes each were made every other day for three days with a static machine, but no calculus was found. Five days after the last exposure, an erythematous spot appeared on the left side of the abdomen. This gradually became quite pronounced in color and spread until it reached the size shown in fig. 26. There was hyperesthesia of the part, but no

ulceration occurred, and the irritation disappeared in about ten days, leaving no after effects.

It appears that the factors which influence the production of Röntgen ray burns are: (a) the length of the exposure; (b) the nearness of the tube to the surface of the body; (c) the physical condition of the patient, and (d) individual idiosyncrasy. Relative to the length of exposure; it should not exceed thirty minutes, for with this length of exposure any part of the body may be radiographed, provided the apparatus is working properly and good technic is used. If photographic results are not obtained with a thirty-minute exposure, the operator should look to improving his apparatus or technic rather than to lengthening the time which he exposes the patient to the action of the rays.

In regard to the distance of the tube from the body; ten inches should be taken as the minimum distance. There is no doubt that the nearer the tube is to the surface of the body, the more likelihood there is of producing a burn. A good apparatus, properly adjusted, will work readily through the head, chest, or pelvis with the tube at ten inches; and, in the absence of individual idiosyncrasy, with the tube at that distance, and an exposure not exceeding thirty minutes, there is no danger of a burn.

Personal idiosyncrasy and low vitality have always to be taken into account. The first, fortunately, is very rare, as it can not be determined beforehand; the latter should always be considered. A person in ill health or debilitated in any way is undoubtedly more likely to be burned by the Röntgen rays than one who is strong and vigorous. The well-known fact that weakened tissues easily yield to disturbing forces, holds with the action of the Röntgen rays as with other factors, the action of which, if too long continued, devitalizes the cells. Exposures frequently repeated, with too little interval of time between them, will act in the same way as a single long exposure; the tissues disturbed by one exposure not being able to regain their equilibrium before the second exposure is made. It is to be remembered that the pathological effect of a destructive Röntgen ray exposure is not at once apparent, the first appearance of a burn not showing itself for two or three days. It is quite possible, therefore, to seriously increase a trouble already started, if a second exposure is made within that time. For this reason, it is a good rule, where a thirty-minute exposure has been made, not to repeat the exposure within three days. With exposures of shorter duration, the danger of repetition diminishes *pari passu* with the length of the exposure.

DEVELOPMENT OF RÖNTGEN-RAY NEGATIVES.

The development of Röntgen-ray negatives does not differ from that of ordinary negatives, except that more time is usually required to bring out the details and obtain sufficient contrast. Any developer which will produce good results in ordinary photography, will produce good results in Röntgen-ray work. Of the different developing agents, pyrogallic acid, metol, hydrochinone, and ortol are the best. Pyro is probably the best when properly used, but it has the disadvantage of staining the hands of the operator. This may be overcome by the use of rubber gloves, and where much Röntgen work is to be done, pyrogallic acid is probably the best reducing agent that can be employed. The following formula for its use will be found a good one:

A.		Grams.
Boiled water		500
Potassium bromide		1
Sulphite of soda		125
B.		
Boiled water.....		500
Sodium carbonate.....		125

To develop, take of A, 30 grams; B, 30 grams; water, 200 grams; pyrogallic acid, one-third teaspoonful of dry crystals. By making the developer up as given, and using dry pyrogallic acid, uniform action of the developer is insured, as developers made up with pyrogallic acid in solution are very apt to deteriorate. Metol and hydrochinone, while not having the staining qualities of pyro, do not give negatives with quite as good printing qualities. Developers in which they are used are also somewhat more difficult to make up. But, where there is objection to the use of pyro, the following formula will be found an excellent one:

	Grams.
Boiled water	500
Sodium sulphite	50
Potassium bromide	1
Metol	2
Hydrochinone.....	6
Sodium carbonate, crystallized	50

When great contrast is desired, hydrochinone alone, with a caustic alkali as an accelerator, and some potassium bromide as a restrainer, will give best results. Ortol gives good negatives and has the advantage of being ready mixed, only requiring to be dissolved in water.

For fixing the negative, an acid-fixing bath, with chrome alum, is better than a plain solution of sodium hyposulphite in water. The acid bath removes stains from the negative and hardens the gelatin; an important detail in hot weather or warm climates.

The following formula is a good one:

Water	cubic centimeters..	2,000
Hyposulphite of soda.....	grams..	750
Sulphite of soda.....	do.....	60
Chrome alum	do.....	30
Sulphuric acid.....	cubic centimeters..	4

This solution should be filtered before using. Where chrome alum can not be obtained, ordinary alum may be used, but the solution will require more frequent filtering.

PRINTING.

When prints are to be made from Röntgen-ray negatives, any good printing-out paper may be used. Where it is necessary to retain all the finer details of the negative, Solio, Aristo, or any one of the modern gelatin or collodion papers, will give very good results. For the very best results, however, albumen paper is unequaled. It has the disadvantage of requiring more experience on the part of the photographer and of being more difficult to manipulate than the printing-out papers which have been recently put on the market.

For prints which are to be quickly produced, one of the bromide papers can be used, but these papers do not give as fine detail as do the gellatin, collodion, or albumen printing-out papers.

All the manipulations of Röntgen-ray photography are similar to those of ordinary photography, and anyone who has mastered the technic of the latter will have no difficulty in Röntgen-ray work. Photography is, however, absolutely essential; as the fluoroscope, alone, will show only a minority of the conditions which the Röntgen ray is capable of disclosing. Every Röntgen-ray apparatus should, therefore, be supplemented by a complete outfit for photographic work.

