

Hydatid disease, Vol. II. By the late John Davis Thomas... A collection of papers on hydatid disease / edited and arranged by Alfred Austin London.

Contributors

Thomas, J. Davies 1844-1893.

London, Alfred Austin.

London School of Hygiene and Tropical Medicine

Publication/Creation

Sydney ; London : L. Bruck : Baillière, Tindall & Cox, 1894.

Persistent URL

<https://wellcomecollection.org/works/y6pf5xn2>

Provider

London School of Hygiene and Tropical Medicine

License and attribution

This material has been provided by This material has been provided by London School of Hygiene & Tropical Medicine Library & Archives Service. The original may be consulted at London School of Hygiene & Tropical Medicine Library & Archives Service. where the originals may be consulted. This work has been identified as being free of known restrictions under copyright law, including all related and neighbouring rights and is being made available under the Creative Commons, Public Domain Mark.

You can copy, modify, distribute and perform the work, even for commercial purposes, without asking permission.



Wellcome Collection
183 Euston Road
London NW1 2BE UK
T +44 (0)20 7611 8722
E library@wellcomecollection.org
<https://wellcomecollection.org>







Presented to the Library
by

Dr. T. J. Hackett

Date 11 August 1949

Class Mark ^b MK 1894 Accession No. 35702





HYDATID DISEASE, Vol. II.

BY THE LATE

JOHN DAVIES THOMAS, M.D. (Lond),
F.R.C.S. (Eng.),

FORMERLY PHYSICIAN TO THE ADELAIDE HOSPITAL, AND JOINT LECTURER ON MEDICINE
IN THE UNIVERSITY OF ADELAIDE;

AUTHOR OF "HYDATID DISEASE, WITH SPECIAL REFERENCE TO ITS PREVALENCE
IN AUSTRALIA."

A COLLECTION OF PAPERS ON HYDATID DISEASE.

EDITED AND ARRANGED

BY

ALFRED AUSTIN LENDON, M.D. (Lond.),

LECTURER ON FORENSIC MEDICINE AND ON CLINICAL MEDICINE IN THE UNIVERSITY
OF ADELAIDE; PHYSICIAN TO THE ADELAIDE HOSPITAL; HONORARY
MEDICAL OFFICER, ADELAIDE CHILDREN'S HOSPITAL.

Sydney :

L. BRUCK, MEDICAL PUBLISHER, 13, CASTLEREAGH STREET.

London :

BAILLIERE, TINDALL, & COX, 20, KING WILLIAM STREET, STRAND, W.C.

1894.

35702

Don. 12397



CONTENTS.

	Page.
Editor's Preface	v.
Memoir of the late John Davies Thomas	vii.
<hr style="width: 20%; margin: 10px auto;"/>	
HYDATID DISEASE AFFECTING THE ABDOMINAL ORGANS	1
The Liver	3
The Spleen	21
The Kidneys	23
The Omentum, Mesentery, and Peritoneum	27
The Male Pelvis	28
The Testicle	30
The Female Pelvis	31
The Uterus	32
The Ovary and Broad Ligament	33
Douglas's Pouch	33
HYDATID DISEASE AFFECTING THE THORACIC VISCERA	35
Lungs and Pleuræ	37
The Air Passages	68
The Heart	70
The Pulmonary Vein	75
The Pulmonary Artery	75
HYDATID DISEASE AFFECTING THE NERVOUS SYSTEM	83
The Brain and its Membranes	83
The Spinal Cord	122
HYDATID DISEASE AFFECTING THE BONES, MUSCLES, AND SUPERFICIAL STRUCTURES	123
The Bones and Joints	125
The Muscles and Fasciæ	130
The Female Breast	131
HYDATID DISEASE, THE OPERATIVE TREATMENT OF	133
Classification of the Various Operations and General Considerations	135
Operations which Destroy without Removing the Para- site	139
Puncture and Aspiration	139
Medicated Injections	142
Electricity	143
Radical Operations	143
Caustics (Recamier's method)	144
Canule-à-demeure	145
Incision Operations	146
Abdominal Incisions	148
Simon's Operation	149
Incision in Two Stages	152
Lindemann's Operation	153
Thoracic Incisions	157
Operations involving the Removal of the Fibrous Sac as well as of the Hydatid Cyst	164
Summary	165

Digitized by the Internet Archive
in 2015

<https://archive.org/details/b24764103>

EDITOR'S PREFACE.

THE original intention of the Author was to have brought out a complete work on the subject of Hydatid Disease early in 1890, and the book was nearly ready for publication, when his health unfortunately broke down. After his decease his widow was anxious to carry out this intention, and circumstances pointed to me, his former partner, as the most likely one amongst his intimate medical friends to be able to superintend the publication of the book in accordance with his ideas. When, however, some fasciculi of the work could not be found, the suggestion was made that I should undertake to write the missing portion, which had been compiled from his previous book, and at the same time bring the volume now published up to date. As this course would have involved considerable alterations, I advised against its adoption, and hence the papers now published, or re-published, in Vol. II. may be taken as entirely Dr. THOMAS'S work.

A. A. L.

NORTH TERRACE, ADELAIDE,

January, 1894.

MEMOIR.

JOHN DAVIES THOMAS was born at Swansea in South Wales on the 11th of October, 1844, being the eldest son of the Rev. Thomas Thomas, a Congregational minister of that town.

On his mother's side he was connected with a family of doctors. Two of his great uncles were naval surgeons, and served with Nelson, John Davies (after whom he was named) and Thomas Davies, who lost his life at Trafalgar; two letters received from Lord Nelson by John Davies are still in the possession of the family; three other great-uncles were also surgeons, and practised in different parts of Wales.

He received his early education at Swansea, and at the age of 16, having passed the Matriculation Examination of the University of London, he began his medical course at University College, London. He seems from the first to have applied himself with energy to his studies, and his career was a distinguished one. While at College he gained, in addition to several Certificates of Honour, the first Silver Medal in Physiology, and a Fellowes Silver Medal in Clinical Medicine. In 1866 he became a Licentiate of the Society of Apothecaries of London, and in the following year a Member of the Royal College of Surgeons of England, and a Licentiate of the Royal College of Physicians of London: in this year he also passed his First M.B. Examination with Honors, being first Exhibitioner and taking the first Gold Medal in Organic Chemistry, Materia Medica, and Pharmaceutical Chemistry. At the Second M.B. Examination, in 1869, he gained an University Scholarship and first gold medal in Obstetric Medicine, as well as the Gold Medal in Medicine, with the number of marks qualifying for the Scholarship; he was also sixth in Honors in Forensic Medicine. In 1870 he became a Fellow of the Royal College of Surgeons of England by examination, and in 1871 he took his degree as Doctor of Medicine at the University of London.

During his student days he held several appointments, being for six months Resident Physician's Assistant to Sir William Jenner and Dr. Russell Reynolds, and for another six months Resident Clinical Assistant at the Hospital for Consumption at Brompton. For two years, from 1870 to 1872, he was Resident

Medical Officer at University College Hospital, being selected by the Medical Staff from a large number of candidates to fill this important post. When he resigned, on account of ill-health, he received from the Committee of the Hospital a letter expressing great regret at his retirement and the highest appreciation of the manner in which he had discharged his duties. Letters received at the time from Sir Wm. Jenner, Dr. Russell Reynolds, Dr. Wilson Fox, Sir Henry Thompson, and many others, testify to his professional attainments, his "administrative ability," his "tact and consideration," as well as to his "high moral character," and his "kindness of disposition and gentlemanly feeling."

Change and rest being necessary, he obtained the post of Surgeon in the service of the P. & O. Company, and his first voyage was to India : it was his intention to have remained about six months at sea, and then to have returned to London ; but his vessel was ordered to Australia, and he remained in the service nearly two years. In 1875 he obtained the position of Resident Surgeon at the Clunes Hospital in Victoria : shortly afterwards he was appointed Senior House Surgeon at the Adelaide Hospital, in South Australia and after occupying that position for a year, he entered for a short time into private practice at Glenelg.

In 1878 he joined Dr. Whittell in partnership in Adelaide, and after Dr. Whittell's retirement in the ensuing year he carried on the practice alone till the year 1884, when he took Dr. Lendon into partnership. In 1885 he went to Europe, being away for eighteen months ; this visit was not undertaken for pleasure merely, but to study special subjects—diseases of the eye, throat, and nose, also electricity, and bacteriology. He spent three months in Vienna, working at the Hospital there, and when in London devoted his mornings to study at the Hospitals. On his return to Adelaide he resumed the practice of his profession, and soon afterwards was appointed joint Lecturer with Dr. Verco on Medicine at the University : he was also for many years Honorary Physician to the Adelaide Hospital, as well as a member of the Hospital Board of Management and of the University Council. At Christmas, 1887, his partnership with Dr. Lendon terminated by effluxion of time. Early in 1890, symptoms of general paralysis appeared, and he was forced to retire from active work. After a brief tour in New Zealand, he took up his residence in the Hills—first at Waverley and afterwards at Blackwood, where the remaining years of his life were spent. All that medical skill could suggest, and loving hands accomplish, was done to alleviate his gradually increasing infirmities, always borne most patiently and without complaint. Happily, however, the disease was almost entirely robbed of what is by far its most terrible

accompaniment. He died on the 30th January, 1893, in the 49th year of his age. He married in 1878 Eleanor, fourth daughter of the late Hon. Walter Duffield, M.L.C., of Para Para, near Gawler.

Dr. Thomas was essentially a worker and an enthusiast, carrying on at one and the same time a large practice and an immense amount of literary and scientific work. He wrote many articles for newspapers and magazines on subjects connected with the public health, and while at Clunes he read a paper before the Medical Society of Victoria on "Ether and Chloroform as Anæsthetics," which was afterwards published, with additions, in the *Australian Medical Journal*. In this paper, and throughout his professional career, he strongly advocated the use of ether in preference to chloroform as being a much safer anæsthetic. His studies however were chiefly devoted to the subject of hydatid disease, and the publication, in 1884, of his book "Hydatid Disease, with Special Reference to its Prevalence in Australia" was the result of many years of unceasing labour and research: prior to its publication, and also subsequently, he contributed many papers on the subject to different medical periodicals. He had nearly completed the second portion of his projected work dealing with the clinical aspect of the disease when his health broke down.

Only those who knew him intimately can have any idea of the amount of work he did in order to extend our knowledge of this disease and of the best methods for its prevention and treatment. Many sufferers in the past owe their lives to him, and doubtless many in the future will reap the benefit resulting from his researches, for he ranks high as an authority on the history and treatment of the disease. When in England a paper "On the Experimental Breeding of *Tænia Echinococcus* in the Dog from the *Echinococci* of Man" was read before the Royal Society, and some microscopic slides, prepared by himself, were exhibited by Dr. Cobbold, at a *Conversazione* of the Society.

Dr. Thomas's thorough conscientiousness, sterling character, and undoubted professional ability won for him a high place in the esteem of both the general public and his professional brethren. He made a point of keeping himself *au courant* with all that was going on in the medical world, and spared neither pains to make himself as perfect as possible in every branch of his profession, nor expense in procuring any instrument or appliance that might be useful for his patients. He was scrupulously careful and conscientious in reading up difficult cases, and never undertook a serious operation without much thought and preparation. He had an insatiable thirst for information, and a

tenacious memory, but it would have been impossible for him to have found time, in his busy and active life, for so much reading and scientific research, had he not been extremely methodical, punctual, and industrious.

We cannot more fitly close this slight sketch of Dr. Thomas's professional career than by quoting the sub-leader from the *S.A. Register* of January 31st, 1893 :—

“The death of Dr. Thomas terminates the useful career of a remarkable man, and completes the removal from our midst of one who will long be remembered in South Australia as a true friend of humanity. We say that it completes his removal, because in one sense his death was preceded nearly three years ago by his retirement from that active life which made him a conspicuous figure in the medical circle of Adelaide. The paralysis which then laid him aside was undoubtedly brought on largely through sheer overwork ; and it may be said of the deceased doctor that he literally fell a martyr to his assiduity in his profession and in the cause of medical science. A large practice both as a physician and a surgeon entails of itself very wearing work upon a scrupulously conscientious man like Dr. Thomas. But in addition to this he led a busy and exciting life altogether apart from the ordinary professional routine of a medical man. His investigations into the origin and life history of hydatids, while they enabled him to render signal service to many sufferers from a much-dreaded disease, were yet undertaken more in the interests of medical science and with a view to its world-wide application than for the purpose of extending his own private professional practice. Recognising the scientific and national importance of this work, the University authorities placed a building at his disposal to facilitate his researches, and in addition he had a laboratory on North Terrace. This was the scene of the overwork which finally broke down his health. Visiting patients throughout the day and often far into the night, and then betaking himself with all the ardour of a specialist to his scientific work until but little time remained for sleep—such a life meant serious risk to any constitution however strong, and Dr. Thomas undoubtedly knew and recognised the fact. But in the field of medical science the harvest is so plentiful and the labourers are indeed so few that it is not to be wondered at that the investigator, who is working out important discoveries, should be led to “scorn delights and live laborious days,” as Milton expresses it. Very few men would have had strength to bear the burdens which Dr. Thomas took upon himself in the cause of suffering mankind. The life which he so nobly risked has been forfeited, but

his work in regard to hydatid disease places his name high upon the roll of those who in Australia have made real additions to the sum total of human knowledge. Much of that work, of course, was only fully appreciated by medical scientists, but the recollection of his whole-souled devotion to the cause of humanity and the relief of suffering, places the general public also under an obligation to do honour to his memory."

This was endorsed a few days later, by the following letter from Dr. Dawes, of Gawler, South Australia.

"A TRIBUTE TO THE LATE DR. THOMAS.

"TO THE EDITOR,

"Sir—As one who knew the late Dr. Thomas twenty-five years ago at College, and also as one who has enjoyed the privilege of his friendship in later life, I wish to endorse most fully your appreciative sub-leader in last Tuesday's issue. You have struck the key-note to his character when you speak of the scrupulously conscientious manner in which all his work was done. It was this untiring thoroughness, this unceasing elaboration of intricate detail, which made his life work doubly exhausting, and which undoubtedly hastened his final breakdown. He was not ignorant of the risk he ran, but he deliberately chose to lose sight of his physical welfare in the all-engrossing pursuit of scientific truth. This thoroughness—exaggerated as it must often have seemed to more ordinary men—he carried into his daily round of professional work, and many patients will gratefully remember how the gentle and sympathetic man was never lost sight of in the skilful and busy medical. His intercourse with his professional brethren was characterised by thoughtful consideration, and a punctilious sense of honour. Called away though he was before the work to which he had given his life was completed, Dr. Thomas yet has done yeoman service to the land of his adoption, and his name will long be honoured by her as a pioneer in original research. This tribute to my friend is very brief, but I remember that the heroes of old were better pleased with a simple wreath of laurel or of oak than with an elaborately bejewelled crown of heavy gold.

"I am, Sir, &c.,

"R. ST. MARK DAWES,

"Sutton House, Gawler, February 2."

It is not necessary here to say much of Dr. Thomas's personal character, but a few words cannot be out of place.

By nature, he was gentle and kindly, warm-hearted, generous, and affectionate. He was very honest, straightforward and outspoken, and, perhaps, somewhat over impulsive. He was sympathetic in voice and manner, as well as at heart, and was much beloved by his patients. He was always most kind and considerate to those who served him, and their admiration of, and devotion to him, were quite touching, especially through the illness and trouble of the last three years of his life. His religion was practical and genuine, influencing his daily life, and he was naturally reverent, as his almost boyish veneration for great and good men of all types, and his respect for the ordinances of religion abundantly showed.

In person he was tall, and his face was an indication of his character. He was handsome in feature, and had honest, kindly brown eyes, and a bright and happy expression.

He had often expressed a wish to "die in harness," but this was denied to him, yet though his work was cut short in the meridian of life and apparently ended, we know that it is still carried on here by those whom he taught and influenced, and in the life beyond, we trust that

"Unto him is given
A life that bears immortal fruit,
In such high offices as suit
The full-grown energies of heaven."

HYDATID DISEASE, Vol. II.

PART I.—HYDATID DISEASE AFFECTING THE ABDOMINAL ORGANS, &c.

- A. The Liver.
- B. The Spleen.
- C. The Kidney.
- D. The Peritoneum.
- E. The Male Pelvis.
- F. The Testicle.
- G. The Female Pelvis.

HYDATID DISEASE, Vol. II.

PART II—HYDATID DISEASE AFFECTING THE ABDOMINAL ORGANS, &c.

- A. The Liver.
- B. The Spleen.
- C. The Kidney.
- D. The Peritoneum.
- E. The Male Pelvis.
- F. The Testis.
- G. The Female Pelvis.

PART I.—HYDATID DISEASE AFFECTING THE ABDOMINAL VISCERA, &c.

A. Hydatid Disease of the Liver.

Bibliography.

MURCHISON—Clinical Lectures on Diseases of the Liver. Third Edition, 1885.

BOECKER—Zur Statistik der Echinococcen.

BRIGHT—Clinical Memoirs on Abdominal Tumours. (New Sydenham Society.)

MADLUNG—Beiträge Mecklenburgischer Aerzte. Zur Lehre von der Echinococcen Krankheit, 1877.

DAVAINE—Traité des Entozoaires, 1877.

NEISSER—Der Echinococcen Krankheit, 1877.

VERJEUS—Des Cystes Hydatiques, &c., 1877.

VARIOUS CASES in "Lancet," "British Medical Journal," "Australian Medical Journal," "Australasian Medical Gazette," Transactions of the Pathological Society, London, Guy's Hospital Reports, several Paris Theses, St. Bartholomew's Hospital Reports, St. George's Hospital Reports, Proceedings of the Second Intercolonial Medical Congress, Jahresbericht (Virchow & Hirsch), 1869.

HABRAN—De la Bile et de l'hématoidine dans les Kystes Hydatiques. Paris Thesis, 1869.

SPRINGTHORPE—Bilirubin in a Hydatid Cyst. Australian Medical Journal, June, 1886.

THOMAS, J. DAVIES—Upon the occasional presence of Bilirubin in Hydatid Cysts. Intercolonial Medical Congress, 1889.

Frequency.—In man the liver is by far the most common seat of hydatid disease: for statistics show that this organ is invaded in 57 per cent. of all cases of echinococcus infection, and when multiple hydatids are present, the liver usually harbours one or more of them, for out of 67 cases of multiple hydatids observed in various Australian Hospitals, the liver suffered in 62 instances.*

* For further details, see Thomas, Hydatid Disease, page 121.

Site.—The right lobe of the liver is from five to six times the size of the left lobe under ordinary conditions; it is natural, therefore, that it should be more frequently the seat of an echinococcus embryo; and this is actually the case, for the right lobe is diseased in this way about five times as often as the left.

Right lobe,	279 cases, or about 79·0 per cent.
Left lobe,	58 “ “ 16·5 “
Both lobes,	16 “ “ 4·5 “
	<hr/>
	353 100·0

Symptoms.—In the majority of cases the development of a hydatid cyst in the liver is slow, painless, and imperceptible to the patient, but, as its bulk increases, a sense of distension or weight may be experienced, especially in the right hypochondriac region; in rare cases distinct pain is present, which Murchison suggests may be due to pressure on a nerve.

Not rarely a pain is felt about the right shoulder, and this apparently when the parasite is situated on the convexity of the organ. A similar pain has long been associated with tropical abscess, but it is doubtful whether in either affection the presence of shoulder-pain is suggestive of disease at the upper surface of the liver.

When suppuration of the sac occurs there may be severe local pain, probably due to local peritonitis.

The passage of hydatid membranes through the bile-ducts may cause a violent form of hepatic colic.

The **Physical Signs** vary with the precise situation and the dimensions of the cyst.

A small parasite imbedded deeply in the substance of the organ may produce absolutely no signs, and when centrally situated and of moderate size it may increase the general bulk of the organ without altering its shape, and thus it may escape recognition even after careful examination; but in the case of large hydatids no such difficulty can arise, for in the great majority of them the shape of the organ is so altered that an out-growth may readily be discovered, the form and size of which may vary greatly in different instances.

The tumour may grow in any direction, and it may range in prominence from a mere elevation above the general surface of the organ up to a distinctly pedunculated cyst, the chief bulk of which may be separated from the liver by a distance of several inches.

When small multiple cysts are present, the surface of the enlarged organ may be uneven, and then it may simulate cancer; in rare instances out-growths from a large cyst may produce a similar surface.

When the tumour projects below the margin of the thorax, so as to be felt through the abdominal walls, it usually presents a smooth and somewhat elastic surface, but fluctuation is rare, for the living parasite is too tense to yield this sensation: the amount of elasticity varies with the quantity of liver-tissue interposed, with the density of the fibrous capsule, and the thickness of the abdominal walls.

Briançon, and afterwards Piorry, described under the term "hepatic fremitus," a peculiar vibratile sensation sometimes elicited by percussion over echinococcus cysts of the liver: by some observers it has been maintained that this sign is pathognomonic of hydatids, and it has even been assumed to be caused by the presence of daughter-cysts in the mother-cyst.

With regard to this phenomenon, it has to be stated—

- i. That it is an uncommon sign in hydatid cysts.
- ii. That it has been noticed in other conditions than echinococcus cysts.
- iii. That it is hardly conceivable that daughter-cysts can be concerned in the production of the sign, for when present they are probably not capable of much movement in the tense mother-cyst; moreover, the phenomenon has been observed where no daughter-cysts existed in the fluid of the tumour.

As a physical sign, this symptom possesses no greater diagnostic value than does a "cracked-pot" percussion note in phthisis.

Displacement and Compression of Adjacent Structures are often caused by hydatid cysts: for example, the uninvaded part of *the liver itself may be displaced* by the growth; a cyst on the convexity of the liver may not only displace the diaphragm upwards, but at the same time depress the bulk of the organ downwards, so that the displaced part of the liver may be mistaken for the hydatid cyst itself. Similarly, a large hydatid connected with the right lobe, but not imbedded in it, has been known to displace the greater part of the liver to the left side.* By such compression considerable injury may be inflicted upon the rest of the viscus, as, for example, in a case recorded by Bœcker,† where the left lobe was atrophied to a mere band of fibrous tissue.

* Budd: Lancet, 1859, Vol. I., page 6.

† Zur Statistik der Echinococcen. No. 9.

The parasite destroys the tissue of the organ in proportion to its bulk, but a certain amount of compensatory hypertrophy takes place in most cases, and instances have been recorded in which the left lobe from this cause has attained a large size.

When the parasite is situate on the convexity of the liver it generally grows upwards, and, pushing before it the diaphragm, invades the lung-space of the chest; in this way, without rupture of the diaphragm, the cyst has been known to reach even to the first rib and to compress the right lung to the size of a hen's egg.* Such extreme *compression of the lung*, however, is rare, for rupture of the cyst usually takes place before such portentous dimensions are attained.

The heart may be displaced to the left side by the lateral growth of a cyst on the upper surface of the liver: and not only may it suffer a lateral displacement, but it may also be bodily pushed forward against the chest-wall by the lateral growth of a hydatid of the right lobe, as in a case at the Adelaide Hospital in 1889: evidently, too, a parasite in the left lobe, even of moderate size, might produce a similar displacement: under such circumstances an abnormal amount of visible pulsation over the cardiac area would be present.

More frequently than upwards or laterally, the direction of growth is downwards into the abdominal cavity. When hydatids of the liver grow downwards and forwards, they frequently cause more or less fulness of the lower interspaces, and even eversion of the lower ribs and costal margin.

The size to which a hydatid of the liver may attain in a downward direction is enormous, and is limited only by the capability of distension of the chest, abdomen, and pelvis. I have recorded a case in which a cyst extended from the upper part of the abdomen to the floor of the pelvis; it pushed the stomach, the spleen, and the bulk of the intestines beneath the margin of the thorax, and so fully distended the abdomen and pelvis that when the contents of the fibrous sac had been evacuated by an incision operation, it was a mystery to the bystanders as to where the large intestine and bladder were located; during the early part of the convalescence the lower parts of the abdominal parietes almost touched the posterior wall of the abdomen; ultimately, however, the intestines descended from above, and the patient acquired his normal figure.†

* Tommasini. Cited in Virchow and Hirsch. Jahresbericht, 1869, page 152.

† Transactions South Australian Branch British Medical Association. Australasian Medical Gazette. Vol. ix., p. 72.

In consequence of the yielding character of the gas-containing stomach and intestine, it is rare for these organs to be much disturbed by the slow growth of a hydatid of the liver: but the *stomach* has been seen "forced down by the tumour to the pubes,"* the *duodenum* has been compressed, flattened, and displaced, and fatal acute obstruction caused thereby;† and the *cæcum* with the ascending colon has been pushed to the median line:‡ rarely, however, is the function of these organs impaired, and even in cases of enormous hydatids filling the abdomen, the patency and functional activity of the alimentary canal are maintained.

The right *kidney and ureter* may be so compressed as to cause dilatation of the pelvis and calyces and destruction of the secreting tissue of the kidney; and if multiple cysts are present both kidneys may be destroyed in this manner. §

Pressure on the great venous trunks of the abdomen, viz., the vena cava inferior, the common iliac veins, and the vena portæ is not frequent.

Examples of pressure upon the *cava* by liver hydatids have been observed by Habershon|| and by Hamilton.¶

Pressure on the *vena portæ* is rare, and consequently ascites is seldom an accompaniment of hepatic hydatids; cases have, however, been recorded by Crowther** and Barker.††

Pressure on the gall-bladder or bile-ducts is uncommon in hydatid disease, consequently jaundice is not an usual symptom of it: but the gall-bladder may itself be the seat of an echinococcus cyst, as in a remarkable case recorded by Allen,‡‡ in which "evidently the cyst was formed in the wall of the gall-bladder at the fundus, and had attained a considerable size" before it finally ruptured into the gall-bladder. The gall-bladder may become involved in the growth, may undergo atrophy from its pressure,§§ or may be considerably displaced.|||

* Breech, cited in the "British Medical Journal," 1859, p. 780.

† Bingham Crowther, "Australian Medical Journal," December, 1880, p. 546.

‡ Hyde Salter, Pathological Society's Transactions, Vol. XI., p. 133.

§ The author quotes Murchison and Bright as reporting cases illustrative of these statements; but reference to these writers shows that, although they were describing cases of hepatic hydatids, the renal compression was probably effected by pelvic hydatids.—(A.A.L.).

|| Guy's Hospital Reports, 3rd Series, Vol. VI., p. 182.

¶ British Medical Journal, December 14, 1872.

** Australian Medical Journal, December, 1880.

†† Pathological Society's Transactions, Vol. VII., p. 225.

‡‡ Australian Medical Journal, April 15, 1882.

§§ Gunning: Australian Medical Journal, July, 1875.

||| Dickinson: Pathological Society's Transactions, Vol. XIII., p. 104.

Sometimes the cystic duct is involved, with or without jaundice, according as pressure exists or not upon the common hepatic or common bile-duct : * such pressure may be caused by a cyst occupying or projecting into the portal fissure : † and, owing to their proximity to each other, the bile-duct and the vena portæ may be simultaneously compressed. ‡

The Course of Hepatic Echinococci.—Even if not interfered with by the surgeon, the course of a living hydatid in the liver may be interrupted by numerous accidents, viz.:—

i. It may undergo “spontaneous death and decay,” and in this manner the disease of the “host” may end in “spontaneous cure.” In what proportion of cases this occurs cannot as yet be definitely stated ; but out of 31 cases in which hydatid cysts were found during post-mortem examinations by Murchison § and Ogle, || in only 13 were they concerned in the death of the patient. ¶

ii. The patient may die from the effects of the pressure of the cyst on important organs, from exhaustion, or from the amount of destruction of the liver tissue.

iii. The sac may suppurate and become a focus of septicæmic infection. Its contents may become foetid, and gas may be present in its interior ; sometimes this is due to the establishment of a communication with the alimentary canal, directly or through the bile-ducts, but sometimes apparently to a generation of gas in the sac.

iv. The most frequent termination, however, is rupture of the sac, followed by more or less complete evacuation of its contents.

Rupture of the Cyst.—In the great majority of cases the rupture is to all appearance spontaneous ; but numerous instances of the bursting of the sac in consequence of an injury have been recorded, for falls, and blows upon the abdomen, have often caused rupture of the cyst, followed usually by rapidly fatal peritonitis. ** The rupture may take place in many directions, viz., externally, through the abdominal walls ; internally, into the peritoneal, pleural, or pericardial cavities ; into the bile-ducts, stomach, or intestine ; into the vena cava inferior ;

* Allen ; “Australian Medical Journal,” May, 1881, Nos. 16 and 13.

† Atkinson : Australian Medical Journal, October, 1867, p. 290. Murchison : Pathological Society's Transactions, Vol. XVIII., p. 124. Legg : Pathological Society's Transactions, Vol. XXV., p. 155.

‡ Murchison : Diseases of the Liver, 3rd edition, p. 122, No. 36.

§ Murchison : Lectures on Diseases of the Liver. Page 55.

|| Ogle : British Medical Journal. April 24, 1869.

¶ I find no indication that these cases were instances of spontaneous cure.—(A.A.L.)

** For examples see Madelung, op. cit., No. 24, page 92, and No. 78, page 105.

into the urinary tract; or, after the establishment of adhesions, into the base of the right lung.

As regards the frequency of rupture in different directions, this varies greatly according to the position of the parasite. Neisser* gives the following data from the cases collected by him.

Rupture into the Pleural Sac	16 cases
"	"	Bronchial Tubes	... 31 "
"	"	Peritoneal Cavity	... 16 "
"	"	Stomach and Intestine	45 "
"	"	Urinary Passages	... 7 "
"	through the Abdominal Walls	..	16 "

Rupture into the peritoneal cavity is usually a fatal, but fortunately a rare, event: it may be the result of an injury, such as a fall, blow, or muscular strain, for several instances are cited by Davaine and other writers:† generally, however, the rupture occurs spontaneously, and there is reason to believe that, when the parasite contains normal, clear hydatid fluid, and when the amount that escapes is but small, the patient may recover with no worse effects than a certain degree of shock, temporary pyrexia, and possibly an attack of urticaria. A case apparently of this sort is recorded by Bright:‡ similar cases have been observed by MacGillivray§ and Williams.|| A curious case, apparently of the same kind, occurred at the Hôpital Necker, Paris, in 1877. The patient, who was under the care of M Potain, "while seated quietly, and without any kind of violence or injury, suddenly felt a sensation of liquid running down to the lower part of the abdomen." . . . The next day the abdomen was swollen; two days after he had an attack of urticaria; he was tapped for ascites subsequently, and recovered sufficiently to leave the hospital a month later.¶

It is certain, too, that a small quantity of hydatid fluid often escapes into the peritoneal cavity during and after tapping operations without causing grave symptoms in most cases.

Generally speaking, however, any considerable rupture into the peritoneal cavity is a rapidly fatal accident; and it may take place even

* Op. cit., p. 92.

† Op. cit., page 516.

‡ Clinical Memoirs on Abdominal Tumours. Case XIII, p. 47.

§ Australian Medical Journal, August, 1865.

|| Australian Medical Journal, May 15, 1881, page 217.

¶ The Lancet, January 25, 1879, page 120.

after a partial escape of the hydatid contents by some other channel, such as the bile-ducts.*†

There is reason to believe that fatal peritonitis may be caused by suppurated cysts of the liver without rupture, as in a case under the care of Dr. Page.‡

Rupture into the stomach is not a common occurrence: it takes place principally in connection with hydatids of the left lobe of the liver, and the vomited membranes are sometimes bile stained. It is tolerably certain that in some instances recovery follows rupture into the stomach, and that the cyst contents may be safely and completely expelled by vomiting:§ in other cases, however, death has resulted, and signs of gastric irritation have been met with at the post-mortem examination.

Numerous cases have been observed in which hydatid cysts of the liver have been supposed to *rupture into the intestine*, and yet the patient has recovered completely, but, on the other hand, death may follow. In one remarkable case, mentioned by Jonasson,|| rupture took place both through the abdominal wall and into the intestine: pus, faeces, and gas escaped through the parietal wound.

Rupture into the bile-ducts.—It is probable that rupture into the bile-ducts occurs with some degree of frequency; at any rate numerous cases have been observed, in which shreds of bile-stained membrane have been passed per anum after attacks of hepatic colic, and in which a tumour of the liver has subsequently disappeared; a clear instance of this has come under my notice. In some cases the ducts may become dilated to the calibre of the index finger.¶

In many cases death occurs: this is sometimes due to impaction of membrane in the common bile-duct causing fatal jaundice; the tributary ducts are then often enormously dilated and may even form distinct abscesses:** in one remarkable case†† death resulted from hæmorrhage proceeding from rupture of a large branch of the hepatic artery on the wall of the sac.

The obstruction may be incomplete, so that, though jaundice is

* Wilks; Pathological Society's Transactions, Vol. XI., p. 128.

† George Johnson; Medical Times and Gazette, January 1, 1876, page 2.

‡ Lancet, 1864, Vol. II., p. 572.

§ Verjeus. Des Kystes Hydatiques du Foie ouverts dans quelques organes de la cavité abdominale Paris Thesis, 1877, p. 13.

|| Cited by Neisser. Op. cit., No. 889.

¶ A case by Saussier, cited by Habran, op. cit., p. 22.

** Legg: Bartholomew Hospital Reports. Vol. XII.; also Madelung, op. cit. No. CXIII p. 117; and Bouchut, Gaz. des. Hôpit., 1859.

†† Hillier: Pathological Society's Transactions, Vol. VII., p. 222.

present, a little bile may yet pass into the duodenum;* and I have even known bile to be vomited when there was present obstruction enough to cause jaundice.

Rupture into the bile-ducts may be followed by rupture into the pleura† or peritoneum.‡

In this connection it may be mentioned that biliary calculi have been met with in the interior of ruptured hepatic cysts.§

Rupture into the urinary passages is supposed to have taken place in a few recorded cases, but the evidence as to the original seat of the parasite has always been inconclusive; when it is considered how often echinococcus cysts of the kidney itself rupture into the urinary passages it will be recognized how difficult it would be to prove, at any rate during life, that the original seat of the parasite was the liver.||

In very rare instances hydatids of the liver have ruptured into the great venous trunks.

Seidel¶ has recorded a case where death took place in consequence of a large embolism of the pulmonary artery, probably induced by thrombus found in the veins of the liver, and caused by the pressure of a cyst on its convexity.

Rupture through the abdominal parietes.—This mode of termination is not common nor specially favourable to the patient, for apparently about half the recorded instances have died in consequence of the imperfect evacuation of the cyst-contents.

Rupture into the pericardial sac has been noticed in one case by Chaussier,** the parasite being situated between the liver and the diaphragm.

Rupture into the pleural sac.—Perforation of the diaphragm and consequent rupture into the pleural space is not an uncommon accident of hepatic cysts: it is especially on the right side, and in hydatids on the convexity of the liver, that it is liable to happen.

In nearly all cases a very severe form of pyo-thorax results, and, unless the pleura be soon opened and drained, death is certain; even under the most prompt treatment death occurs in the majority of cases.

* Hardy cited by Verjeus, *op. cit.*, Obs. IX., p. 27.

† Cayla: cited in Virchow and Hirsch, *Jahresbericht*, 1885, Vol. II., p. 202.

‡ Wilks: *Pathological Society's Transactions*, Vol. XI, p. 127.

§ St. George's Hospital Records for 1843 (see *Pathological Society's Transactions*, Vol. XI., p. 299).

|| The kidney is the seat of hydatid infection in nearly 5 per cent. of all cases.—J. D. T.

¶ Cited by Neisser, *op. cit.*, No. 217.

** Cited by Davaine, *op. cit.*, *Observation*, 24, p. 427.

In rare instances, signs of pyo-pneumo-thorax are present: this is sometimes due to rupture, first into the pleura and then through the lung:* sometimes the gas appears to be generated in the pleura, as in a case recorded by Bristowe,† but it is noteworthy that, in the case in point, free communication existed not only with the pleural cavity, but also with the intestine through the right hepatic duct which opened into the hydatid cavity, so that it is probable that the gas was really derived from this source.

Rupture into the lung.—It is, as might be expected, the right lung that is most often involved: a cyst of the convexity of the liver first becomes adherent to the diaphragm, this in turn forms adhesions with the base of the right lung, and by a process of ulceration and erosion the cyst ultimately bursts into the lung. In some cases recovery takes place after prolonged expectoration of pus and shreds of membrane, which, by their bile-stained colour, indicate their source from a hepatic hydatid.

Very frequently death follows rupture into the lung: the fatal issue may be caused by suffocation, due to blockage of the bronchial tubes by cysts and shreds of membrane,‡ the trachea and bronchial tubes of both sides having been found blocked in this manner: or the patient may die from the long-continued cough, foetid expectoration, hectic, and emaciation which simulate pulmonary phthisis: or gangrene may be induced by the irritation of the decomposing cyst contents and sac-walls, as in a case by Peacock: sometimes both lungs become gangrenous by blood-infection or by insufflation from the upper air-passages.

In one case rupture into the lung induced fatal hæmoptysis.§ Rupture into the lung may follow imperfect attempts to cure the disease, *e.g.*, by puncturé or aspiration.||

Rupture into the anterior mediastinum has been known to occur in one case (under Hilton at Guy's Hospital); the parasite was situated in the left lobe of the liver.¶

Suppuration of the Sac.—This is a common and highly important condition; in many cases it precedes and perhaps causes the rupture of

* The case quoted does not bear out these inferences.—A. A. L.

† Pathological Society's Transactions, 1851, p. 341.

‡ Cayley: "Lancet," Vol. II., 1875; also Pathological Society's Transactions, Vol. XXVII., p. 171.

§ Rendu, cited by Verjeus, *op. cit.*, p. 31. Obs. X.

|| Bradbury: British Medical Journal, Vol. II., p. 525, 1874 (aspiration), and Macgilivray: Australian Medical Journal, August, 1865 (repeated tapings).

¶ Lancet, 1851, Vol. I., p. 353.

the sac. Degeneration of the parasite has in many published cases been regarded as suppuration; the resemblance of the contents of some degenerated hydatids to pus is remarkable, and the mistake can be avoided only by microscopic examination, but when suppuration occurs, more or less grave constitutional disturbance results, which is absent in merely degenerated hydatids; pyrexia, rigors, emaciation, quick pulse, thirst, indeed the ordinary symptoms of internal abscess, are well-marked.

As regards the causes of suppuration, the most frequent is probably the treatment by tapping operations, especially when aseptic instruments have not been employed.

Apart from surgical interference, suppuration appears to occur spontaneously from some unknown causes; probably an influx of bile, with or without rupture into a bile-duct, frequently occasions it; or a slight and unperceived mechanical cause.

Suppuration is a very perilous accident of hydatid cysts, for rupture is imminent; and even if this does not happen, death from septicæmic poisoning is sure to follow unless prompt relief is rendered by surgical aid.

In some cases numerous secondary abscesses are present in the liver,* or gangrene of the fibrous sac or of the adjacent hepatic substance may occur.†

Among the rare fatal events of echinococci in the liver may be mentioned: hæmorrhage from the wall of the adventitious sac as in cases mentioned by Hillier,‡ or from the vicinity of the parasite as in Maclean's case.§

Diagnosis.—It is needless to recapitulate the physical signs of this disease in detail: the principal conditions with which it may be confused are—

A. In Hydatids of the upper part of the Liver

1. Sub-phrenic or so-called "Tropical" Abscess.
2. Echinococcus of the base of the right lung.
3. Pleuritic effusion.

B. In Hydatids of the lower part of the Liver

1. Cancer of the Liver.
2. Waxy Liver.
3. Tropical Abscess.

* Murchison: op. cit., cases 36, 121 and 122.

† Murchison: op. cit., case 37.

‡ Pathological Society's Transactions, Vol. VII, p. 222.

§ Australian Medical Journal, October, 1861, p. 265.

4. Enlarged Gall-bladder.
5. Hydronephrosis: renal cyst.
6. Ovarian Cyst.
7. Phantom Tumour.
8. Ascites.
9. Abscess of the Peritoneum.

In the case of Echinococci growing downwards the difficulties of diagnosis, although more numerous, are not usually so great.

A. Diagnosis of Hydatids on the Convexity of the Liver

1. *From Sub-phrenic Abscess.*—If the parasite be in its normal condition, there are no constitutional symptoms save such as are referable to the pressure effects caused by the size of the growth; in abscess, on the other hand, there are marked pain, tenderness, pyrexia, rigors, &c., and in many cases a clear connection with malaria or tropical fever, dysentery, &c.

When the sac has undergone suppuration, however, the similarity of the physical signs is often exact; here the geographical distribution of the two diseases, the history of the patient, and the results of an exploratory puncture, must be called in evidence: a doubt as to the diagnosis is, however, of no practical importance, for the surgical treatment of these diseases is identical. But it must be remembered that even in temperate climates sub-phrenic abscess is occasionally met with; for Coupland has recorded such a case in England,* and I have seen several such in Australia.†

2. *From Echinococcus Cysts of the Base of the Right Lung.*—In many instances it seems to be impossible, during life, to determine by the physical signs present, whether a hydatid cyst at the lower part of the chest is located in the liver or the lung: even a post-mortem examination may not suffice to make this point clear, as, for example, in a case recorded by Neucourt.‡

If a pulmonary hydatid situated near the base is of only moderate size, it may leave a portion of the lung at the base uninvaded, and this may give a clue to the diagnosis.

The occurrence of hæmoptysis, even of small amount or “streaky,” would be a point in favour of a pulmonary cyst; cough, too, is more pronounced in lung implication.

The upward pressure of a large hydatid of the liver may induce

* British Medical Journal, March 23, 1889, p. 636.

† Proceedings of the Second Intercolonial Congress.

‡ Cited by Davaine, Livois, and Hearn.

sufficient compression of the lower part of the lung to cause it to yield a well-marked tympanitic* percussion note.

In either case there may be a considerable downward displacement of the bulk of the liver, which may then be felt below the right costal margin.

3. *From Pleuritic Effusion.*—In both diseases there is abnormal dulness and loss of respiratory murmur at the lower part of the chest. In pleuritic effusion there is usually a history of acute onset with pyrexia and more or less severe pain. As regards the physical signs there is usually more marked displacement of the heart and less of the lower edge of the liver in pleural effusion than in hydatid of the convexity.

Pleuritic effusion is characterized by a curved upper line of dulness which attains its highest level about the right mid-axillary line and falls to a lower level towards the sternum: it also falls posteriorly near the spine. The dulness of a hydatid cyst often follows quite another course.

The dulness may be equally "flat" and toneless in either disease.

Pleural friction may be present in hydatid even without previous rupture into the pleura; it is possible that in some cases a friction sound may be generated between the under surface of the diaphragm and the convexity of the liver; if so, a friction of pleuritic rhythm would be produced.

Loss of vocal fremitus would be present under both conditions, but occasionally in hydatid of the convexity respiratory murmur can be heard a little below the line of deep dulness—an edge of lung being still permeable to the air.

I have never heard an œgophonic vocal resonance with a hydatid.

B. Diagnosis of Hydatids of the Under Surface of the Liver

1. *From Cancer of the Liver.*—The rapid growth, the progressive emaciation, the frequent jaundice, the nodular surface, &c., of cancer generally serve to readily distinguish this disease from hydatid.

The chief difficulty would be from the occurrence of multiple small cysts in the liver, and the accidental concurrence of jaundice.

In the rare cases of multilocular ulcerating hydatid of liver the resemblance to cancer is very great, and I believe that all such cases yet observed have clinically been regarded as cancer.

2. *From Waxy Liver.*—The slow course, with absence of pyrexia,

* The author uses this term where others adopt the word "tubular."—(A.A.L.)

the large size, and smooth surface of the waxy liver offer a certain resemblance to some cases of hydatid imbedded in the liver: an exploratory puncture would readily solve any doubts.

3. *From Tropical Abscess.*—Unless the hydatid has suppurated, but little difficulty is likely to arise, for ordinary hydatid disease is unaccompanied by the constitutional disturbance present in most cases of tropical abscess.

However, a hydatid may suppurate and cause constitutional disturbance, whilst in tropical abscess the disease may lie latent, or pyrexia present may be attributed to the remains of "fever and ague," from which the patient suffered in the tropics.

Echinococcus disease is so rare in most tropical climates, *e.g.*, British India, Ceylon, and the Straits Settlements, that error will rarely happen from this cause.

In cases of doubt an exploratory puncture is indicated.

4. *From Enlargement of the Gall-Bladder.*—A pedunculated hydatid cyst projecting from the under surface or lower edge of the liver closely simulates an enlarged gall-bladder: either may be moveable laterally, and may be elastic or yield obscure fluctuation; an exploratory puncture alone will enable the diagnosis to be made.

The contents of enlarged gall-bladders vary considerably: sometimes consisting of bile or various mixtures containing bile: at other times of colourless serum: or it may be of pus or various mixtures of bile and pus.

Hydatid cysts contain either the normal clear hydatid fluid or, if degenerated, a thick yellow fluid closely resembling pus, but consisting of granular matter, large compound cells, and cholesterin crystals; often, also, hooklets or shreds of hydatid membrane may be discovered.*

5. *From Hydronephrosis and Renal Cysts.*—A thin-walled renal cyst may greatly resemble a hydatid cyst of the kidney or under-surface of the liver; indeed, I have known a renal cyst to be repeatedly tapped and finally to be operated on by abdominal section under the supposition that it was a hydatid cyst; the fluid contained in it was thin, pale, serous-looking, but unfortunately no chemical examination of it was made. The real nature of the case was revealed, partly by the absence of any mother-cyst at the time of operation, partly by the escape by the wound of calculi obviously of renal origin.

* The author does not mention that the hydatid fluid may contain bile and yet remain quite clear and transparent, and that degenerated cyst contents are very often bile stained.—(A.A.L.)

Speaking generally, renal cysts are situated deeper in the abdomen than hydatid cysts of the liver, and the colon is generally placed in front of renal cysts of moderate size.

Renal cysts are less influenced in position by the movements of respiration than hydatids of the liver, or other liver enlargements; but, on the other hand, hydatids may be tied down by adhesions so as to move but little.

The fluid contents of hydro-nephrotic cysts are generally altered urine, urea, and uric acid: earthy and alkaline urinary salts are present in it: albumen is nearly always found, and pus, blood, and colloid material may also be intermixed.

Hydronephrotic cysts are sometimes lobulated, and occasionally a rapid diminution of bulk or even a total disappearance of the tumour occurs, accompanied by a copious discharge of urine: this sign, however, might be simulated by the rupture of a hydatid cyst of the kidney into the urinary passages.

In hydronephrosis, as also in renal hydatid (vide p. 26), there might be a history of renal colic.

6. *From Ovarian Cyst.*—Ovarian cysts grow from below upwards, and are usually of distinctly pelvic origin; hydatids of the liver, on the other hand, grow from above downwards, and only rarely enter the pelvis: an error of diagnosis is more apt to take place in the case of very large cysts than of smaller ones. That such a mistake may occur even to the most experienced is shown by the numerous cases which have been submitted to operation as supposed ovarian cysts, but which have proved to be echinococcus cysts.

7. *From Phantom Tumour.*—In one case, at least, a phantom tumour has been mistaken for a hydatid cyst:* the disappearance of the supposed tumour under the influence of a general anæsthetic would prevent any such mistake.

8. *From Ascites.*—In the majority of cases no difficulty can arise in the diagnosis between ascites and hydatid tumour; but in one case under my care the abdomen was enormously distended by a hydatid cyst which reached from the upper part of the abdomen and filled the pelvis; it resembled a very large abdominal dropsy, where the distension is so great as to conceal the resonance of the intestines, and where so much fluid is present as to fully distend the belly.† The mesentery may be shortened by chronic inflammation, or the intestines may be

* Murchison: op. cit., case VII., p. 61.

† Australasian Medical Gazette, Vol IX., p. 72.

bound down by adhesions ; and thus the front of the abdomen may be dull on percussion : these conditions appeared to be present in the case in point, and an abdominal section was performed which proved that the enormously enlarged abdomen was really caused by a huge hydatid cyst.

9. *From Abscess of the Peritoneum.*—It is not very common for encysted collections of large size to be met with in the abdominal cavity ; but I have had under my care at the Adelaide Hospital a young woman, in whom a large abscess was present in the left hypochondrium ; it presented an exact resemblance to a suppurating hydatid of the left lobe of the liver. Abdominal section performed by one of my surgical colleagues proved the existence of a large abscess, but no hydatid products were discovered either at the time of operation or during the after treatment. Such an error could hardly have been avoided, even by an exploratory puncture ; for in suppurated hydatids definite hydatid products may not happen to come away in the small quantity of fluid removed for examination.

Bile, Hæmatoidin, and Bilirubin in Echinococcus Cysts.

(*The following article "Upon the occasional presence of Bilirubin in Hydatid Cysts" was published in the Transactions of the Second Inter-colonial Medical Congress, held at Melbourne, January, 1889.*)

On October 17, 1888, I operated by abdominal section upon an enormous hydatid of the abdomen in a man aged 25. When the abdomen was opened, it was found that it was nearly filled with a huge echinococcus cyst. The fibrous sac was inseparably adherent to the abdominal wall in front, whilst posteriorly, it seemed to line the abdominal parietes, so that it was a mystery where the intestines lay : it also reached to the bottom of the pelvis, between the rectum and bladder, both of which must have been compressed.

Above, its upper limit could be reached with the finger, at about the margin of the thorax, on the left side of the median line ; but on the right, the sac extended to the under surface of the liver, far beyond the reach of the finger. I felt assured that the parasite had originated at the under surface of the right lobe of the liver, and had grown downwards to the pelvis, almost entirely filling the abdomen. The mother-cyst was dead, and had been ruptured before the operation : it was also stained deep green, apparently from bile. The daughter-cysts, which were present to the number of thousands, were of all sizes, from

that of a large pin's head to that of a medium sized apple. The majority contained clear transparent contents, and were tense and plump; but a great number were flaccid, collapsed, with opaque walls and puriform (not purulent) contents. They were for the most part unruptured. Inside many of these dead, but still entire, daughter-cysts, I found flakes of matter resembling in colour red sealing-wax, but of soft consistence.

Upon microscopic examination, I found that the flakes in question consisted of a collection of ruddy crystals, having the fundamental shape of oblique rhombic prisms. Some were present as isolated crystals, but the majority were accumulated into irregular masses, in which, however, it was easy to recognise the form of the component crystals. Mixed with these coloured crystals were acicular fatty crystals and numerous oil globules of all sizes. The latter were, no doubt, products of the degeneration of the cyst contents.

The quantity of red matter procurable was very small, so that a quantitative analysis was impossible; but it possessed the following chemical characters: insoluble in water and in cold alcohol, soluble in ether, and very readily so in chloroform; from the chloroform solution there were deposited, by the volatilization of the solvent, small oblique rhombic prisms of yellowish-red tint, quite like those found in the original red matter and acicular crystals, apparently of some fatty acid, as well as rhombic plates of cholesterin; both the latter were colourless. The chloroform solution gave the distinctive colours of bile pigment with Gmelin's test, and this was particularly well marked upon the addition of chloroform containing a trace of free chlorine. Spectroscopically examined, the solution was found to extinguish to a great extent the blue end of the spectrum, but there were no absorption bands in the rest of the spectrum. Examination by polarised light showed the crystals to be double refracting.

From the preceding data, it was clear that the matter in question was bilirubin. I must acknowledge with thanks the kind assistance given me by Professors Rennie and Bragg, as well as by Dr. Whittell, in determining this point. The presence of bilirubin has been previously noticed in connection with hydatid cysts. For example, Bristowe* mentions a case of degenerated hydatid in the left lobe of the liver, in every part of which numerous vermilion spots were found. These spots consisted of colourless plates of cholesterin mixed with ruby-coloured, more or less regularly rhomboidal, crystals.

* Pathological Society's Transactions, Vol. IV., p. 166.

In June, 1886, Dr. Springthorpe read a paper before the Medical Society of Victoria upon an interesting case, in which a very large amount of this body was found in an abdominal cyst. It is not clear to me whether this cyst was originally of hepatic origin or not, and this important point does not seem to have presented itself to the writer of the paper. Apparently, however, the cyst in point was not considered to have taken its rise from the liver, for Dr Springthorpe evidently attributes the presence of the bilirubin to altered blood effusion ; but, as he remarks,* it would require about thirty ounces of blood to yield this quantity of pigment, and this loss of blood could hardly fail to assert its occurrence by marked symptoms. In my own case, there could be no doubt that an effusion of bile had taken place into the sac, and had not only killed the mother-cyst, but had also passed by endosmosis into many of the daughter-cysts, destroying them also. In process of time the colouring matter of the bile was precipitated as bilirubin in the interior of the daughter-cysts invaded. I believe that some flakes of bilirubin were present free in the mother-cyst, but of this I cannot be certain, for daughter-cysts may have ruptured during the operation, and so have given rise to what appeared to be flakes in the mother-cyst.

Later Notes by Dr. Davies Thomas.

It is a moot point whether Bilirubin and Hæmatoidin are identical ; the balance of evidence being apparently in favour of their identity.

It has often been noticed in connection with certain hydatid cysts that in their interior more or less of a bright vermilion red material is met with. This never appears to occur unless the parasite is dead, and up to the present time it does not appear to have been seen except in cysts known to be connected with the liver or probably originally arising from this organ. Usually, also, there are present more or less clear indications of bile-staining of the mother or daughter cysts present.

This matter is usually found in very small quantity, but in the case recorded by Springthorpe† it was found in "large quantity."

It possesses the following characters. viz.: it is insoluble in alcohol and water ; slightly soluble in ether, readily so in chloroform ; soluble in potash solution, and this solution, when treated with hydrochloric acid, yields a green precipitate of biliverdin : with sulphuric acid and sugar, it gives a rich purple colouration.

As found in hydatid cysts it is usually associated with fatty matter,

* Australian Medical Journal, June 15, 1886. Page 254.

† Loco cit., page 251.

sometimes in the form of acicular crystals, probably stearine : occasionally cholesterin in the usual tabular crystals is also present.

Microscopically the flakes are seen to consist of collections of oblique rhombic prisms : it is probable that the presence of such crystals is indicative of a former flow of bile into the sac of the parasite.

B. Hydatid Disease of the Spleen.

Bibliography.

LENOEL—Kystes Hydatiques de la Rate. Amiens, 1879.

MOSLER—Ueber Milz-Echinococcus und seine Behandlung. Wiesbaden, 1884.

Frequency.—The Spleen is not a common seat of infection, for it is attacked in only about 2 per cent of the cases. It may be the only organ affected, or it may suffer in company with other organs : these occurrences seem to be about equally common, for in 45 cases the spleen was the only seat of the disease, whilst in 43 other cases it was affected together with other organs. Sometimes multiple cysts have been found in the spleen but generally some other organ is also a seat of the disease, and by far most frequently the liver.

Multiple Cysts affecting the Spleen and other Organs.—

Spleen and Liver	13 cases
“ Liver, and Lung	3 “
“ Liver, and Pelvis	4 “
“ Liver, Uterus, Ovary, and Diaphragm	1 “
“ Liver, and Omentum	6 “
“ Liver, Peritoneum, and Scrotum	1 “
“ Liver, Bladder, Peritoneum, Abdominal Wall, and Anterior Mediastinum	1 “
“ Liver, and Right Ovary	1 “
“ Liver, Diaphragm, Mesentery, and Kidney	1 “
“ Liver, Omentum, and probably Ovary	1 “
“ Liver, Kidney, and Peritoneum	1 “

Spleen, Liver, Diaphragm, Mesentery, and Pelvis	1	case
" Liver, Gall-bladder, and Peritoneum	1	"
" Liver, Peritoneum, Omentum, and Right Kidney	1	"
" Liver, Heart, and Peritoneum ...	1	"
" Brain, and Heart	2	"
" Kidney and Lung	1	"
" and Mesentery	1	"
" Anterior and Posterior Mediastina, and Right Pleura	1	"
" Peritoneum, Omentum, and Pulmonary Artery	1	"
" Liver, Heart, and Peritoneum ...	1	"
		<hr/> 43 cases.

In 37 of these 43 cases the Liver also was attacked.

Sex.—Of 59 cases, 36 were males and 23 females; or males, 61 per cent, females 39 per cent.

Age.—In two cases Vois and Dubone met with hydatid cysts in the spleen, discovered at the post-mortem examinations: the subjects were children under 14 years of age.

1 to 10 years of age	0	cases.
11 to 20 "	"	8	"
21 to 30 "	"	14	"
31 to 40 "	"	11	"
41 to 50 "	"	10	"
51 to 60 "	"	7	"
61 to 70 "	"	1	"
				<hr/> 51	cases.

Symptoms and Physical Signs.—These vary according to the size and the direction of growth of the parasite, and according as to whether suppuration of the sac has taken place or not.

While the cyst is small and not inflamed, or when spontaneous death has occurred, there may be absolutely no symptoms: indeed, in nearly half the published cases of solitary splenic hydatid, the existence of the parasite became known only at the autopsy.

When it reaches a sufficiently large size to cause a local tumour in the left hypochondrium, it may often be definitely diagnosed.

Pain here, as elsewhere, is not a marked feature; but occasionally it has been complained of; and in one case, recorded by Kuhn, it was

believed to have troubled the patient* more or less for twenty years : sometimes pain has been induced by physical exertion.

The hydatid tumour in the spleen shows the same characters as it does in the liver and elsewhere. It is often difficult, and occasionally it is impossible, to distinguish between cysts of the left lobe of the liver and those of the spleen, unless abdominal section or an autopsy decide the question. Friction fremitus over the tumour was noted in one case by Wolff.

Owing to the situation of the organ, hydatid cysts of the spleen must attain a considerable bulk before they produce distinct pressure signs : when they reach a large size and grow upwards they invade the left chest, compressing the left lung and displacing the heart, as in a case by Rombeau : † and when the direction of growth is downward, they may reach into the pelvis and press upon the bladder and rectum. ‡

Several cases of spontaneous cure of hydatid cysts of the spleen are on record. §

The cyst may rupture into neighbouring parts, *e.g.*, into the left lung, || into the intestine, ¶ or through the abdominal walls.

Rupture into the lung is a fatal event, but rupture into the intestine appears in some cases to have led to recovery.

C. Hydatid Disease of the Kidney.

Bibliography.

BERAUD—Des Hydatides des Reins. Paris, Thesis, 1861.

BRAUN—Die Echinococcuscysten der Nieren und des Perirenenalen Bindegewebes. Stuttgart, 1877. (Simon).

ROBERTS—Practical Treatise on Urinary and Renal Diseases. London, 1885.

BARKER—On Cystic Entozoa in the Human Kidney. London, 1846.

CURLING—Medical Times and Gazette, 1863. Vol. II., page 164.

* Berl. Klin. Wochenschr., 1877, No. 43.

† Cited by Mosler : *op. cit.*, No. 22, page 25.

‡ Barret : cited by Mosler ; *op. cit.*, No. 24, page 26.

§ St. Bartholomew Hospital Reports, Vol. VIII., page 180 ; also

Bastian : Pathological Society Transactions, Vol. XVIII., page 257.

¶ Saeller, Duroziez.

¶ Brault : cited by Lenoel : *op. cit.*, Obs. XXXII., page 71.

Frequency.—The kidney is affected in 4·74 per cent. of all cases. Sir William Roberts refers* to seventy or eighty instances in which hydatids existed in the kidney or were passed by the urethra.† I have met with but one case of renal hydatid: the patient, a middle-aged man, produced a ruptured hydatid cyst, which he stated had been passed per urethram. It is very rare for both kidneys to be attacked in the same person, although instances of this are recorded by Cooper‡ and by Richardson,§ but in some of the lower animals, *e.g.*, the sheep, it is common for both kidneys to be affected at the same time.

Site.—Out of 41 cases collected by me the *right* organ was the seat in 17 instances; the *left* in 24.

Sex.—In 60 cases in which this is mentioned there were males, 40; females, 20 cases.

Age. —	From	1	to	10	years of age...	...	0	cases
	"	11	"	20	"	"	5	"
	"	21	"	30	"	"	5	"
	"	31	"	40	"	"	8	"
	"	41	"	50	"	"	5	"
	"	51	"	60	"	"	4	"
	"	61	"	70	"	"	2	"
	Over	70	years of age	2	"

—
31

Course of the Disease.—The parasite may take its rise in the kidney-substance or may merely become attached to this organ in the progress of its growth, which in two instances began in the supra-renal capsule, *viz.*, those recorded by Risdon Bennett || and by Hueter.¶

In the kidney, as in probably every other organ of its human host, a hydatid may undergo spontaneous death and decay, and become converted into an atheromatous mass enclosed in a dense fibrous sac.

Much more frequently, however, the parasite ruptures into the pelvis of the kidney; and this may even take place in the case of echinococcus cysts which are far advanced in spontaneous decay.**

* A practical treatise on Diseases of the Urinary and Renal Organs. London, 1885. Fourth edition. By Robert Maguire, M.D., F.R.S.

† Op. cit., p. 630.

‡ Australian Medical Journal, 1862, pages 122, 279, and 289.

§ Lancet, 1855, Vol. II., page 366.

|| Pathological Society Transactions, Vol. XV., page 224.

¶ Wochenschrift für Klin. Medicin, Vol. V., pages 139 and 140.

** Lancet, September 3, 1854.

Rupture into the Urinary Tract is a very frequent termination of renal hydatids, for out of 79 cases of kidney echinococcus collected by me, 50 ruptured in this direction, and out of 64 cases by Beraud 48 had this termination.

Simultaneously with rupture, not only must the contents of the parasite escape to a greater or less extent, but also urine must obtain access to the cavity which harboured the parasite.*

Possibly too, urine may reach the interior of the parasite without rupture of the mother cyst, by a process of diosmosis^{*}; at any rate crystals of ammoniaco-magnesian phosphate, of uric acid, and of oxalate of lime have been seen in the interior of renal hydatid cysts; indeed in rare instances calculi of the size of a pea or bean have been produced in this manner.†

The complete elimination of the parasite, *per vias naturales*, has, in some instances, extended over several years, with longer or shorter periods of immunity from colic: the rapidity of the process of expulsion depends principally upon the size of the orifice of rupture into the pelvis of the kidney.

Rupture in other directions than into the urinary tract is rare, but it occasionally takes place, *e.g.*, into the bronchi, as in cases recorded by Rayer, Meckel, and Fiaux; into the alimentary canal; into the peritoneal cavity; or even externally.

When the cysts are of large size, and cause great damage to the organs, death may ensue from arrest of the urinary function, as in two cases recorded by Richardson.‡

Symptoms and Physical Signs.—The size of renal hydatids, as of hydatids elsewhere, varies within wide limits, *e.g.*, from a minute size up to that of a foetal head. If the parasite is of small dimensions, and does not rupture into the urinary passages, it may cause no symptoms, and may be discovered only in the event of a post-mortem examination being made: in some instances, however, there are symptoms evidently referable to the urinary organs.

When symptoms are present, there may be a *tumour* in either renal region; but this is often absent even when membranes are passed per urethram.

Pain in the loins has sometimes been observed; but it is curious that frequently it has been impossible for the patient to localise it definitely

* Hence rupture of renal hydatids may be preceded or followed by suppuration.—(A.A.L.)

† Desault, cited in Chopart: *Maladies des Voies Urinaires*.

‡ *Lancet*, 1855. Vol. II., page 366.

in either loin ; it has usually been felt, more or less, in both lumbar regions, and even in the epigastrium, and occasionally this pain has been noticed to be aggravated by physical effort.

When the cyst ruptures into the urinary passages, usually marked symptoms of *renal colic*, precisely resembling those of renal calculus, are experienced, and in some cases the act of rupture has been accompanied by a definite sensation of something bursting in the loin. The violence of the pain has sometimes caused convulsions, and in one case the pains had a bearing down character : * sometimes, on the other hand, the passage of small ruptured cysts has been entirely painless. It is rare for any considerable amount of *hæmorrhage* to accompany the rupture ; but small quantities of blood are often found in the urine under these circumstances. *Pus* is sometimes present in the urine from suppuration of the sac. *Pyrexia* has been occasionally noticed in connection with the spontaneous rupture of renal hydatids.

Whilst the membranes are passing down the ureter into the bladder, more or less severe colic is felt ; as in calculous colic, the pain radiates along the course of the ureter, into the corresponding groin and the perineum, as well as to the inner side of the thigh on the same side ; the testicle may be painful and the cremaster contracted.

Occasionally some difficulty may be experienced in the passage of the membranes of daughter-cysts from the bladder.

Cases.—*Suppuration and pointing in the lumbar region ; incision ; escape of hydatids ; death.*—Dr. Whittell, in 1865, saw, in consultation with a brother practitioner, a patient who was suffering from a swelling in the lumbar region ; he had been ailing and losing flesh for some time past, but the swelling had been observed only for five or six weeks. The urine was found to contain pus, and a hooklet of *echinococcus* was also found in it. Poulticing, followed by incision, was employed ; pus and hydatid cysts were discharged from the loin ; six months later the wound was still discharging, and hydatids were occasionally passed through it ; the patient died a few months afterwards from exhaustion.

Hydatids passed per Urethram.—Private P., aged 35. Pains in the left loin for nine years ; worse for three years. Admitted into the Hospital complaining of intense pain in the lumbar region, shooting down the course of the ureters : this was worse on the left side. During the attack the urine was scanty, the skin hot ; these symptoms were relieved by the passage per urethram of hydatids. Six sub-

* Medical Times and Gazette, February 17, 1855.

sequent attacks so disabled the patient as to necessitate his dismissal from military service. No tumour was discovered in the region, either of the bladder or the kidney.*

D. Hydatid Disease of the Omentum, Mesentery, and Peritoneum.

Frequency—The localities above mentioned are not very common seats of hydatid cysts, for in only 26, out of 1,897 cases of this disease, was it reported that these parts were attacked, *i.e.*, in about 1·37 per cent. In a few instances hydatid cysts have been found free in the peritoneal cavity, *e.g.*, cases recorded by Murchison† and Poland:‡ in most of these cases it is not clear whether the bladder-worm lay nude in the peritoneal cavity, or whether it was enveloped in a fibrous capsule. In Allen's § case, where the cyst was attached to the fundus of the bladder, it appears to be clear that no capsule was present; but in another it is plain that a cyst had descended from the liver and had carried with it a capsule, the peduncle of which had gradually become elongated and attenuated so as to become a mere thread.||

Multiple Cysts.—It is a remarkable circumstance that almost invariably in these cases there are multiple cysts present, and not only are there many cysts in the omentum, mesentery, and peritoneum, but commonly also other parts and organs contain these parasites, *e.g.*, the liver, lung, spleen, and the pelvis. Most of the cases are primarily omental in origin; a few are sub-peritoneal, or situated between the layers of the mesentery.

The frequency with which multiple omental and peritoneal cysts are met with naturally suggests some explanation. There is reason to think that in some cases the multiplicity of cysts is due to the exogenous formation of daughter-cysts: indeed, in some cases I have seen lateral protrusions from cysts, indicative of this process; and often the various cysts are pedunculated, the pedicles being in close proximity at their attachments.

* A. Leith Adams, M B : Lancet, 1864, Vol. II., p. 375.

† Murchison : op. cit., Case XVIII., p. 107.

‡ Thomas : "Hydatid Disease," p. 56.

§ Australian Medical Journal, April, 1882.

|| Medico-Chirurgical Review, July, 1879, p. 229.

Echinococci of the omentum often possess a considerable freedom of movement, both by manipulation and in response to alterations of posture; this may sometimes aid in their diagnosis.

In a remarkable case* of omental hydatids, it is stated—"Behind the umbilicus, in the anterior and lower portion of the mass of cysts, was situated a large irregular cavity of sufficient capacity to contain a child's head. The cavity was apparently formed by the coalescence of several cysts, the interposed partitions having been destroyed." The cavity was lined by a thick layer of "false membrane," but it is not clear whether the "membrane" in question was a mother-cyst or not.

Owing to their frequently multiple character, hydatids of the omentum, &c., are amongst the worst forms of the disease, so far as the prospects of successful operative treatment are concerned.

E. Hydatid Disease of the Male Pelvis.

Frequency.—The pelvis is not a very common seat for hydatid cysts in man; for, out of nearly 2,000 cases of hydatids, the pelvis in both sexes was invaded in only 42 instances. However, this number does not include 29 cases, in which the uterus, or 16 others in which the ovary was reported to have been the seat of the parasite.

It is probable that the pelvis and its contained organs are more frequently attacked in females than in males; at any rate, I have been able to collect only 42 cases of pelvic echinococci in males,† whilst Schatz has‡ tabulated no fewer than 66 recorded instances met with in the female pelvis.

Schatz remarks§ that, although the female pelvic and generative organs appear to be more often the seats of echinococcus cysts than the corresponding parts in males, this is principally due to the alleged fact that women are more liable to infection by this parasite than men: however, there is reason to believe that, throughout the world generally, men and women are attacked in nearly equal numbers.

* St. George's Hospital Reports, Vol II., p. 347.

† The author refers to some tables, which cannot be found. In his previous book he collected 40 cases; but in a later paragraph it will be seen that he accounts for the course of the disease in 42 cases.—(A.A.L.)

‡ In Madelung: op. cit., page 161.

§ Loco cit., page 184.

In the majority of cases the pelvic hydatid was the only one present: this was the case in 25 instances. In 17 instances, however, cysts were present in other parts of the body, and, when multiple hydatids were found, nearly always the liver was invaded.

Pelvis and Liver	1	case
" Liver, and Lung...	1	"
" Liver, and Omentum	6	"
" Liver, Abdominal Wall, and Anterior Mediastinum	1	"
" Liver, and Spleen	1	"
" Liver, Spleen, Pulmonary Artery, and Anterior Mediastinum	1	"
" Liver, Spleen, and Omentum	1	"
" Omentum, and Peritoneum	2	"
" and Supra-renal Capsule	1	"
" and Spleen	1	"
" and attached to the Cæcum	1	"

17

Site.—In the greatest number of cases the parasite was located in the recto-vesical space, and when of large size it caused pressure on the bladder and rectum: in three cases it was of small dimensions, and was attached to the fundus of the bladder; twice it was connected with the prostate gland: in one instance it had apparently originated in the right seminal vesicle.

Course of the Disease.—Of the 42 cases comprised in Tables I and II.* 20 were operated on, in consequence of the serious interference with the function of the pelvic organs caused by the cysts; in the remaining cases no operation was undertaken; in six of the latter cases the pelvic hydatid was clearly the cause of death; but in thirteen others death was not directly attributable to it; in the remaining three the cause of death is not stated.

Symptoms and Physical Signs.—When the hydatid was of small size, and so situated as not to exercise pressure on important organs, no symptoms declared themselves during life, and no tumour could be felt, and the very presence of the parasite in the pelvis was unknown until the autopsy. When of larger size, the tumour sometimes projected upwards in the hypogastric region, where it closely simulated a distended bladder; sometimes downwards in the perinæum, thus frequently causing pressure on the bladder or rectum, or both:

* Vide note, page 28.

hence the most important symptoms were usually those referable to pressure on these organs.

In the case of the rectum, the usual effect was a greater or lesser amount of compression and flattening, causing chronic constipation and occasionally tenesmus.

In the case of the bladder, the pressure effects were very varied; in some instances this viscus was carried upwards and forwards against the abdominal wall in front. In a very remarkable case, recorded by Perrin, the upper part of the bladder had actually become lodged in the left scrotal cavity so as to simulate an inguinal hernia.

In some cases the relations of the urethra were so altered as to cause more or less complete obstruction to the evacuation of the bladder, and to render the passage of a rigid catheter difficult or impossible: and yet it is remarkable that sometimes a cyst large enough to fill the pelvis was present, and yet there was no difficulty in evacuating the bladder.

The relations of the ureters were in many instances disturbed by the growth, the result being that dilatation of their lumen, hypertrophy of their walls, hydronephrosis and more or less destruction of the substance of the kidney followed; in some cases one ureter only was obstructed.

F. Hydatid Disease of the Testicle.

Bergmann* has collected two cases, viz.:—

1. Larrey,† a bipartite hydatid of the spermatic cord, incised and cured.

2. Holscher.‡ Man, aged 31; swelling of the size of the fist in the right testis; puncture showed it to be echinococcus; castration; the sac contained eighteen hydatids, one of the size of a walnut.

* Loco cit, p. 134.

† Memoires de Chirurg. Militaire. Tome I.-III., p. 419.

‡ Schmidt's Jahrbuch. Vol. LL., p. 318.

G. Hydatid Disease of the Female Pelvis.

Bibliography.

SCHATZ—Die Echinococcen der Genitalien und des kleinen Beckens beim Weibe, in Madelung. Beiträge Mecklenburgischer Ärzte zur Lehre von der Echinococcen-Krankheit. Stuttgart, 1885.

Frequency.—The pelvis and its contents appear to be more frequently invaded by echinococcus in women than in men: according to a list prepared by Neisser,* of 35 hydatids found in the true pelvis, 20 were in females and 15 in males. Besides these, there are 27 cases in which the uterus or ovary were considered to have been the seats of the parasite.

In my own statistics, by an unfortunate oversight, no separate entries were made for the male and female pelvis. But "in the true pelvis" there were 40 cases;† the uterus was also credited with 29 cases, and the ovary with 16, so that these two organs of the female pelvis alone gave 45 cases of echinococcus, and probably more than half of those occurring "in the true pelvis" were in females. There can be no doubt that the female pelvis is invaded by this parasite much more often than the male pelvis is.

Schatz‡ explains this by the supposition that hydatid disease in general is far more common in females than in males. This appears to be the case in Mecklenburg, where Schatz practised his profession; but I have elsewhere given reasons for considering that, taking Europe as a whole, hydatid disease is more frequent in the male sex.

Probably the greater liability of women to pelvic cysts is due to the greater bulk and more abundant blood-supply of their pelvic organs; the blood-supply in particular being so enormously increased by the processes of menstruation and pregnancy.

* Die Echinococcen-Krankheit. Berlin, 1877, p. 175-177.

† Vide note, page 28.

‡ In Madelung: op. cit., p. 184.

Site of the Cysts.—

In the uterine walls	14 cases.
In the ovary	8 “
In the broad ligament	7 “
Between the bladder and vagina	3 “
Between the vagina and rectum	5 “
In the connective tissue of the pelvis...	7 “
In Douglas' pouch	11 “
Entering the pelvic inlet	15 “
Rupture per vaginam	1 case.
Filling the pelvis	1 “

 72

Echinococci of the Uterus have been confused with “hydatidiform degeneration of the chorion”; still from the evidence of post-mortem examinations and of operations, a considerable number of genuine examples of this disease are now recorded.

The cysts may be placed beneath the mucous membrane, in the substance of the walls or under the peritoneal investment: probably nearly all originate in the walls, and in process of their growth travel towards one or other surface of the organ.

It has been suggested by Szancer* that when the uterus is infected by this parasite, the ova escape from the intestine into the abdominal cavity, are there seized by the fimbriated ends of the Fallopian tubes, and are through them conveyed into the uterus. This does not appear probable, for the ova do not perforate the intestine, and the six-hooked embryo possesses without doubt an independent activity that soon engages it in the blood-current. Schatz points out also other reasons against this theory.

In the distinction between hydatid mole and echinococcus no serious difficulty can arise. The former is a diseased condition of the villi of the chorion, and is characterized by the presence of a number of pedunculated translucent vesicles forming a mass somewhat resembling a bunch of grapes. There is no striated membrane, and there are no echinococcus heads or hooklets. The fluid also contained in the vesicles is closely allied to ordinary amniotic fluid.

Much greater difficulty exists in the diagnosis of intramural hydatid and myoma: an echinococcus cyst may appear as equally firm and

* Berl. Zeitschr. für Geb. und Gyn. 4, 1879, p. 319.

hard as a myoma: multiple hydatids may exist as well as multiple myomata; but Schatz states that as a rule hydatid cysts of the uterine wall cause but little hypertrophy of the womb, whilst myomata do.

As a rule echinococcus cysts of the uterus, in consequence of their rarity and obscure features, are discovered only by some accidental clue.

Echinococcus Cysts of the Ovary and Broad Ligament.—

When the frequency of cysts in these situations is considered, it is not surprising that the parasitic nature of the few recorded cases of hydatid cysts in these parts should be undetermined except by the information obtained by operation or autopsy: an exploratory puncture might, of course, decide the point, but the information might also be purchased at too high a price.

Echinococci in Douglas' Pouch are in many cases not primarily formed in that cavity, but of sub-peritoneal origin, and they push the peritoneum before them, so as to more or less completely efface the cavity. In other cases hydatids here are immigrants from the upper parts of the abdomen: for example, a huge cyst may descend so as to fill the whole abdomen and pelvis, or a smaller cyst may carry with it a long peduncle, which permits it to occupy the pelvis, while it is still attached to its original home.

In one remarkable case, recorded by Allen,* there was found at the autopsy "a large hydatid cyst, destitute of any adventitia, lying in the pelvic cavity in the pouch between the bladder and the uterus. It is formed simply of a clear transparent gelatinous sac, through which colonies of scolices can be seen growing on the inner surface. The only adhesion to the peritoneum was formed by a soft lymph band which passed towards the fundus of the bladder. The cyst lay on the anterior surface of the uterus, which was thoroughly retroverted."

Another interesting case is reported by Bennie and Allen.†—"Attached to the peritoneum, covering the fundus of the uterus and the bladder,‡ was a somewhat spherical hydatid cyst, four and a quarter inches in diameter, full of small, plump, secondary cysts. This tumour was adherent to and opened into the right Fallopian tube, which was greatly distended and thrown into convolutions, filled with small cysts, some collapsed, some full of fluid."

* Australian Medical Journal, April, 1882, p. 160.

† Australian Medical Journal, October, 1879, p. 478.

‡ In the original reference there is wrong insertion of *gall-bladder*; evidently urinary bladder was meant.—J.D.T.

Symptoms and Signs.—If single or of small size they may cause no symptoms. If of larger size pressure signs may result, and these will vary with the precise situation and the bulk of the cyst. When of large size, and occupying Douglas's Pouch, they may impede labour, as in cases reported by Park,* Blot, and others: or the pressure may bear principally on the bladder and rectum.

The uterus may be displaced from the pelvis, the bladder pushed up to the umbilicus, the outlet of the pelvis blocked, the ureters occluded and dilated, causing pyelonephritis, as in one case witnessed at the Adelaide Hospital in 1883.

In a case recorded by Obre,† a large hydatid situated in the mesorectum had so compressed the rectum as to destroy its walls.

In another ‡ a hydatid cyst, connected with the anterior wall of the uterus, had eroded its wall and projected into the interior of the pregnant uterus, being covered only by a thin layer of womb tissue.

Rupture may take place in various directions, *e.g.*, into the cavity of the uterus, as in cases recorded by Graily Hewitt§ and Szancer,|| or by opening into the Fallopian tube, as in the case already cited, or into the vagina, as in several recorded cases. Once rupture took place through the perinæum ¶ and once into the bladder.**

In many cases the nature of the tumour was discovered by puncture or incision of the cysts: in the great majority, however, the diagnosis was made only at the autopsy.

Treatment.—In consequence of the varied situations of the bladder-worm in the pelvis, and the extreme difficulty of a trustworthy diagnosis in many cases, but little can be definitely formulated by way of treatment.

Of the cases hitherto recorded, 21 were operated on by incision or puncture. *Puncture* was employed in nine cases; in one it was followed by spontaneous rupture into the urinary bladder and recovery; in three others puncture was succeeded by incision. Three were treated by *incision through the vagina*; apparently all recovered. *Abdominal Section* was performed in nine cases.

* Cited by Davaine, *op. cit.*, page 539-540.

† Pathological Society's Transactions, 1854, page 302.

‡ Birch-Hirshfeld, cited by Schatz, *op. cit.*, page 174.

§ Transactions of the Obstetrical Society of London, Vol. XII., p. 135.

|| Cited by Schatz, *op. cit.*, p. 174.

¶ Recorded by Sibille and cited by Schatz, *op. cit.*, p. 178.

** Birnbaum: cited by Schatz, *op. cit.*, table No. 47.

HYDATID DISEASE, Vol. II.

PART II.—HYDATID DISEASE OF THE THORACIC VISCERA.

- A. The Lungs and Pleuræ.
- B. The Heart.
- C. The Great Blood Vessels.

HYDATID DISEASE, Vol. II.

PART II.—HYDATID DISEASE OF THE THORAX.

VI. SCALA

A. The Lungs and Pleura.

B. The Heart.

C. The Great Blood Vessels.

PART II.—HYDATID DISEASE OF THE THORACIC VISCERA.

Cases of intra-thoracic echinococci naturally resolve themselves into two great groups, viz. :—one in which the parasite occupies some organ or structure within the chest as its primary seat : and another in which hydatid cysts, primarily situated in the cavity or in one of the organs of the abdomen, or in some other region outside the thoracic cavity, rupture into the thorax : this latter group has already been considered in another part of this work.*

In the former group are included—

1. Echinococcus Cysts of the Lungs, also those of the Pleuræ, Mediastina, Larynx, and Trachea.
 2. Echinococcus Cysts of the Heart and Great Intra-thoracic Blood-vessels, both without and within the pulmonary parenchyma.
-

A. Hydatid Disease of the Lungs and Pleuræ.

Bibliography.

- VIGLA—Des Hydatides du Poumon et de la cavité thoracique. Archiv. Gen. de Med., Sep. 1855.
- GARREAU—Des Hydatides du Poumon. Paris Thesis, 1856.
- BIRD, DOUGAN—Australian Medical Journal, March, 1871, and October, 1873 ; “On Hydatids of the Lung.” Melbourne, 1874.
- HEARN—Kystes Hydatiques du Poumon et de la Plèvre. Paris Thesis, 1875.
- LURIE—Echinococcus Pulmonum. Inaug. Dissert., Berlin, 1875.
- HUPPERT—Echinococcus Pulmonum. Inaug. Dissert., Jena, 1875.
- BUCHTERKIRCH—Beiträge zur Pathologie und Therapie des Lungenechinococcus. Inaug. Dissert., Greifswald, 1882.
- ROSENTHAL—Ueber einen linkseitigen peripleuritischen Echinococcus. Inaug. Dissert., Berlin, 1881.

* Vide pages 11, 12, 23, 25.

BREITKOPF—Ueber die operative Behandlung eines Lungenechinococcus, Greifswald, 1882.

HARTWIG—Zur Casuistik des Primären Lungenechinococcus. Inaug. Dissert., Halle, 1883.

CHACHEREAU—Un Kyste Hydatique du Poumon ; Urticaire Hydatique. Paris Thesis, 1884.

THOMAS, JOHN DAVIES—Hydatid Disease of the Lungs. Proceedings of the South Australian Branch of the British Medical Association, September, 1884. H. K. Lewis, London.

On the Diagnosis of Pulmonary Hydatids. Australasian Medical Gazette, May, 1888, page 190.

AHLERS—In Madelung. Beiträge Mecklenburgischer Aerzte zur Lehre von der Echinococcen Krankheit. Stuttgart, 1885. Page 196 et seq.

Frequency.—From statistics collected from various parts of the world, and based upon nearly 2,000 cases of echinococcus disease, it appeared that the organs contained in the cavity of the thorax were attacked in the proportion of nearly 15 per cent. of the total number of cases, and that in about 11·5 per cent. the lungs were the seat of the parasite.*

In man the lungs are, next to the liver, the most common seats of hydatid cysts ; but it is curious that in the domestic herbivorous animals, *e.g.* sheep, oxen, and pigs, as well as horses, the lungs are proportionately much more frequently invaded than in man. This circumstance has been observed in India, Europe, and in Australia, and is probably universally the case in these animals.

No plausible explanation of this curious fact can be offered, unless it be connected with the circumstance that the lower animals usually have multiple cysts, and that the variety of echinococcus found in them is the so-called *E. veterinorum*, whilst in man it is the *E. hominis*.

There is reason to believe that the relative frequency of lung infection varies in different parts of the world : thus I found, from the statistics of 800 cases of hydatid disease treated in Australasian Hospitals, that the lungs were attacked in over 16 per cent : and Dr. Dougan Bird has also expressed the opinion that in Australia a disproportionately large number of pulmonary hydatids are met with. On the other hand, in Iceland, Finsen states that the lungs were the seat of the parasite in only 2·7 per cent,† and out of 50 autopsies performed in that country by Jonas Jonassen only once was the disease met with in the lungs.‡

* Thomas : Hydatid Disease, with Special Reference to its Prevalence in Australia : Adelaide, 1884, pages 124-125.

† Lancet, 1869, Vol. 1., p. 92.

‡ Ekinokoksygdommen, 1882, page 41.

This is not so in other parts of Europe, for out of 196 cases of echinococcus in Mecklenburg, collected by Madelung * and his colleagues, 19 were pulmonary and 1 was pleural, *i.e.*, nearly 10 per cent. of all the cases.

From the foregoing data it is clear that in Australia the proportion of pulmonary hydatids is unusually high ; in Iceland, on the other hand, it is equally certain that lung hydatids occur rarely.

Dr. Dougan Bird, of Melbourne, suggests the following explanation, so far as Australia is concerned :—

“The dust of our streets (in Melbourne) is the result of mud from the frequent use of the Yan Yean hydrant, dried by the hot wind, and powdered by the constant traffic of the day. It is notorious that this fine dust does, during respiration, enter into the air-passages, more particularly of women, who are less protected about the mouth and nose by hair than men. Nothing is more likely than that the dried-up ovum, revived by the moisture and steady warmth of the body, should now commence its new career. Anyone who has witnessed the drafting of sheep or cattle on a hot day will readily understand how well this dust-theory applies also for the explanation of the origin of pulmonary hydatid in those engaged in pastoral pursuits ; the readily-dried and pulverised droppings of the sheep-dogs furnishing the materies morbi ready-made on the spot.” †

The chief difficulty in the acceptance of this theory has been to imagine the digestion of the thick shells of the eggs of *Tænia echinococcus* by any means except the action of the gastric juice ; however, recently ‡ there has arisen cause for suspecting that the mucous secretion of inflamed bronchial tubes may acquire a sort of digestive or solvent power equal to this task.

At any rate, the difference in the relative frequency of lung hydatids in Australia (16 per cent.), in Mecklenburg (nearly 10 per cent.), and in Iceland (under 3 per cent.), stands in striking contrast with the average of 15 per cent. for the world in general, and calls for some explanation.

Site.—The two lungs are not attacked with equal frequency, for out of 195 cases the *Right* lung was the seat in 121 cases, and the *Left* lung in 74 cases.

* Op. cit., page 76 et seq.

† On Hydatids of the Lung. Second edition. Melbourne, 1877. Pages 2 and 3.

‡ This was written in 1890.—(A.A.L.)

Moreover, all parts of the lungs are not liable in the same degree to infection, as will be seen by the following table :—

Right lung, upper lobe	16 cases.
Left " " "	14 "
Right " middle part	10 "
Left " " "	2 "
Right " lower "	34 "
Left " " "	24 "
Right lung, entire organ or no part mentioned,				36 "
Left " " " " "				14 "

Speaking generally, the bases are more frequently the seats of hydatid cysts than the apices, and the right middle and lower portions are nearly twice as often invaded as those of the left lung : the former fact is readily explicable by the circumstance that the lungs are larger below than above, but the latter peculiarity is not so plainly understood.

Echinococcus infection thus resembles croupous pneumonia in its proclivity to invade the right base. At present there is no plausible explanation of this curious feature of the right base in regard to croupous pneumonia or echinococcus, for the ratio of bulk of the two lungs is only as 42 of the right to 40 of the left lung : it is possible that some peculiarity of the circulation may be found in order to explain the present anomaly. It might be suggested, with regard to echinococcus, that the apparently greater frequency at the right base might be explained by a mistake in diagnosis between hydatids of the convexity of the liver (which are common), and true pulmonary cysts. However I have ascertained by the unquestionable evidence of post-mortem examinations, that the real frequency of pulmonary hydatids at the right base is at least double that at the left base.

Multiple Cysts.—Multiple cysts, when present, may arise in three different modes.

1st. The patient may have swallowed more than one ripe egg of *Tænia echinococcus*. In some cases where hundreds of separate isolated (mother) cysts have been found in the body, possibly an entire ripe proglottis, containing hundreds of eggs, may have been taken into the stomach ; in this case it is likely that the cysts will be scattered over a great part of the body of the luckless "host."

2nd. Multiple cysts may arise by exogenous development from a single primary cyst : the resulting cysts will then be near each other, perhaps enclosed in a common fibrous capsule. This is a common occurrence in the domestic Herbivora, and is sometimes met with in man ; but then it is usual for the group of cysts to be enclosed in a single common capsule.

3rd. As regards the pulmonary artery, both within and outside the lungs, it is certain that hydatids may rupture into the right cavities of the heart, and give exit to some or all of their contained daughter-cysts, which are then rapidly carried by the blood-current into the pulmonary artery and its branches. If they are not large enough to cause rapidly fatal obstruction to the circulation through the lungs, the transported parasites will settle themselves down to a new lease of life, provided they have not burst in transit. Instances of both living and collapsed hydatid emboli in the pulmonary artery will be recorded later on.

Amongst the cases that I have collected, the distribution of multiple cysts as regards the lungs was as follows—

Cysts in both lungs	16 cases
“ “ pleuræ	1 case
Multiple cysts in right pleura	1 “
“ “ “ lung	2 cases
“ “ left lung	1 case
				—
				21

But when multiple cysts are present it is far more common for other organs to suffer with the lungs. I have met with 55 cases of this description, they are tabulated as follows:—

Lung and liver	24 cases
“ liver and colon	1 case
“ “ “ peritoneal cavity	4 cases
“ “ “ brain	2 “
“ “ spleen and epiploon	1 case
“ “ “ “ abdomen	2 cases
“ “ and kidney	2 “
“ “ heart, spleen, kidney, and psoas and iliacus muscles	1 case
“ “ and heart	1 “
“ and spleen	1 “
“ spleen and kidney	1 “
“ “ “ heart	1 “
“ and heart	6 cases
“ and abdomen	—	2 “
Pleura and liver	5 “
“ lung and heart	1 case

It will be noticed that in 43 out of the 55 cases the liver claimed a share.

Sex.—Pulmonary echinococcus is decidedly more common in men than women :—

Males	168 cases.
Females	109 cases.

Age.—Pulmonary hydatids occur at the average age distribution of the disease, being most common in the third, fourth, and fifth decades of life respectively.

The Course of the Disease.—It is almost certain that whenever a lung hydatid is met with, it took its origin from an embryo conveyed thither through the pulmonary artery,* for it is infinitely more probable, upon anatomical grounds, that the embryo took the shorter and easier course to the lungs through the pulmonary artery, than the (to it) very round-about course through the bronchial arteries.

It would be an extremely unprofitable and futile task to discuss, as some writers have done, the exact element of the lung in which the resting embryo commences its new mode of existence, especially as the point is one of no practical significance.

But what is of far more interest and importance, is the occasional occurrence of hydatid cysts of considerable size in the interior of the blood-vessels themselves, and they have been found both in the pulmonary artery and in the vein.

In the course of its growth, the parasite compresses, and then, to a certain extent, destroys the structure of the lung: in this way nearly the whole of one or even of both lungs may be replaced by the parasite.

A remarkable case of this kind was recorded by Geoffroy and Dupuytren, viz.:—A young man died in a paroxysm of dyspnœa. At the autopsy there was found in the left lobe of the liver a hydatid cyst, and in each pleura there was also a voluminous cyst, which extended on each side from the apex of the chest to the diaphragm: each cyst contained an enormous solitary parasite, filled with about five and a-half pints of clear fluid: the heart was pushed down to the epigastrium, the lungs were compressed, flattened, and pushed towards the front part of the chest. The patient died from the mere loss of breathing space.†

A somewhat similar case of multiple hydatids in the two lungs was reported by Carden.‡

* This is on the assumption that Dr. Dougan Bird's dust inhalation theory is untenable: this statement was written in 1884. Vide note p. 38.

† "Bulletin de l'Ecole de Medicine," 1865.

‡ British Medical Journal, April 3, 1880.

It may happen that a very large hydatid, even of one lung, may induce dyspnœa intense enough to cause sudden death, without rupture, as in a case reported by Allen, of Melbourne.*

"A man, aged 20, under the care of Dr. Cutts at the Melbourne Hospital, died suddenly whilst coughing. At the autopsy there was found a large hydatid of the upper part of the right lung, extending across the middle line and almost down to the base."

The direction of the growth varies, but it generally tends towards the periphery.

In many cases the parasite occupies two-thirds or three-fourths of the lung-space on the side affected. Fortunately, however, a considerable portion of the lung invaded is merely compressed, and consequently a marvellous recovery of lung is often observed after radical operation.

In the space occupied by the cyst, of course, all lung structures have disappeared; the blood vessels are compressed, and for the most part are destroyed and obliterated, but on the wall of the cavity their remains may stand in relief, so that at the time of rupture, when the elastic support of the parasite is lost, the vessels may burst and cause more or less copious hæmorrhage.

The fate of the bronchi is somewhat similar, for most of those formerly located in the invaded part of the lung vanish: some, however, remain and open on the wall of the cavity. When the parasite is intact its tense wall hermetically closes the orifices of these bronchi, but, when rupture occurs, an influx of the watery fluid will at once take place into the bronchial openings, provided the latter are situated at the upper part of the cavity; if, on the other hand, they happen to be placed at the lower part of the cavity, the collapsed mother-cyst may act as a more or less efficient valve, and prevent the rapid escape of the fluid of the mother-cyst. Important acoustic phenomena may result from this cause, and still more grave consequences accrue to the patient.

The Spontaneous Degeneration of Pulmonary Hydatids.

—Apart from surgical interference, the parasite is subject to various vicissitudes, *e.g.*, it may undergo spontaneous death and decay, in the same manner as happens in the liver and other localities: this termination, however, is comparatively uncommon in the human lung, although it often takes place in the domestic herbivora.

When spontaneous degeneration occurs in the human lung the parasite is generally of small size, and an example of this termination has been recorded by Allen:† but on the other hand, it may grow to vast

* Australian Medical Journal, March, 1881.

† Australian Medical Journal Ma 1881 Case XI.

dimensions, as in a case recorded by Garreau.* “A sempstress, aged 30, treated at the Hôpital Necker, Paris, in 1854, presented the usual symptoms and physical signs of pulmonary hydatid, with the unusual feature of a total absence of hæmoptysis: she died of asphyxia. The right lung was almost entirely replaced by one large and a second smaller hydatid cyst; the residual lung tissue was indurated and scarcely permeable to air. The left lung, with the exception of a small portion at the apex, was occupied by an enormous hydatid cyst, containing about 400 grammes of opaque hydatid fluid.”

Chvostek † also mentions the case of a female, aged 31, who had been ill for about six years; the earliest symptoms were those of pleurisy, followed by steadily increasing dyspnœa, etc. During the last few months of her life she suffered from severe bronchial catarrh, fever, marasmus, and dropsy. The local signs were those of pleuritic effusion, and a correct diagnosis was not made during life. *Post-mortem*.—Right lung firmly adherent; upper lobe thickened; in the middle and lower lobes was a large hydatid cyst, containing thick milky fluid but no daughter-cysts.

Rupture of the Cyst.—Far more common than spontaneous cure or than unlimited growth is rupture of the parasite: this may take place in various directions, viz., (1.) into the bronchial tubes: (2.) into the pleural cavity: (3.) into the pericardial cavity: (4.) through the thoracic or even the abdominal parietes: the two last-named are very rare accidents, but both rupture into the bronchial tubes and into the pleura are common.

Rupture into a Bronchus or Bronchial Tube.—This, the most frequent mode of termination of lung hydatids, often occurs spontaneously, and is the almost invariable sequel of puncture of the parasite. Sometimes some slight local injury suffices to determine the rupture of the tense cyst, *e.g.*, pressure on the chest in stooping through a fence, or a playful blow from the fist of a friend, as in two of my cases.

In other instances the bursting appears to be absolutely spontaneous, as in the case of a young lady, who declared to me that she was quietly seated, and “not even thinking,” when she suddenly felt something give way in her chest, and immediately a gush of hydatid fluid and blood poured from her mouth; this was soon followed by the expulsion of a ruptured hydatid, as large as a moderate-sized apple.

At the moment of rupture, a great rush of fluid takes place into the

* Des Hydatides du Poumon. Paris Thesis, 1856, p. 22.

† Cited in Virchow and Hirsch. Jahresbericht, 1866, Vol. II., page 97.

bronchial tubes of the affected lung; and even the opposite lung becomes flooded by the inspiratory efforts induced by the violent dyspnoea caused by the fluid. In one case, recorded by Broadbent * a small hydatid membrane was conveyed by the inspiratory current into the bronchus of the sound lung.

A similar phenomenon has been observed in the case of hydatids of the liver which have ruptured into the lung; in one instance † the trachea and the bronchial tubes on both sides were blocked from this cause, of course with the result of causing death very quickly.

In one patient ‡ who consulted me in 1888, and was found to have a large hydatid at the left posterior base, the cyst ruptured ten weeks later; the patient had merely time enough to utter an exclamation, "I am done for," when he fell down suffocated. The unfortunate man had been urged to submit to operation, but had postponed it in order to make "one more voyage to Mauritius."

The treatment of pulmonary hydatids of a large size by tapping with a small trochar is attended by serious risk from the same cause; for the cyst is ruptured by the puncture, and the instrument is unable in all cases to carry away the fluid fast enough; it then escapes through the bronchial openings on the wall of the cavity, and floods the bronchial tubes: this causes serious dyspnoea, which, in more than one case, has proved fatal. Instances of this termination have been notified by Schede, § and two cases were communicated to me by Dr. Lonsdale Holden, of the Hobart Hospital, one of which died in about five minutes, || the other in about half an hour after the puncture. These cases and others show plainly the danger of suffocation from the flooding of the lungs by a large and sudden outflow from a ruptured hydatid of considerable size.

Even if the danger of being suffocated by the gush of fluid is escaped, the patient has still to encounter a similar and even greater danger from the impaction of membranes.

In some instances death has suddenly supervened from this impediment to respiration, *e.g.*, a case recorded by Schulz. ¶ A woman, aged 20, who had previously expectorated hundreds of small hydatid cysts,

* Lancet, October 26, 1878, page 575.

† Cayley, Lancet, 1875, Vol. II.

‡ Thomas, J. Davies. A full account is reported in The Australasian Medical Gazette, December 15, 1889, page 73.

§ Cited in Madelung, op. cit., page 86.

|| Thomas, J. Davies: Hydatid Disease of the Lungs. Proceedings of S.A. Branch of British Medical Association, September, 1884.

¶ Cited in Madelung. Op. cit., Fall XVI., page 85.

suddenly died during a violent fit of coughing. A cyst removed from the mouth of the deceased by her husband, when spread out, was found to cover the area of a dessert plate.

The rupture of the parasite always causes violent cough and dyspnœa, but fortunately death only occasionally occurs: indeed the most favourable accident of the disease, when not surgically treated, is rupture into a bronchus, for about three-fourths of such cases appear to recover: the results in 102 cases, not operated on, but which had so ruptured, being

Recoveries	63 cases
Deaths	25 "
Result not stated	14 "
				<hr/>
				102

Rupture into a Pleural Cavity.—This is of much less frequent occurrence than rupture into a bronchus, but in the absence of appropriate surgical treatment it is a very fatal accident; indeed, in all the recorded cases where pleural rupture has been positively known to have taken place, the patient died unless relieved by operation: however, in one case reported by Finsen, rupture into the pleura was believed to have occurred, and yet the patient recovered; and once, in an operation case, I have seen the same result: it is probable that a favourable issue can happen only when clear normal hydatid fluid without much air enters the pleural cavity. In some cases an attack of urticaria indicates the nature of the initial lesion.

Rupture into the pleura, as into a bronchus, appears generally to occur spontaneously; but sometimes it is caused by an injury. For example, in a case admitted into St. George's Hospital:—"The patient, a man aged 47, fell off a cab, and the horse fell on him. He died next day, and, at the autopsy, the fifth and sixth ribs were found fractured, one of the ribs had torn a small rent in the sac of a hydatid occupying the left lung, causing evacuation of its contents into the pleural cavity.*

A remarkable case was recorded by Wischer †:—"A healthy soldier, aged 23, who had never complained of any chest troubles, and who was an excellent swimmer, on the occasion of a swimming drill, dived from a height of 18 feet, striking the right side of his chest on the surface of the water: he made two or three strokes, and then sank silently: an hour later he was taken out of the water dead. A *post mortem* exami-

* St. George's Hospital Reports, Vol. IV., pages 272 and 305.

† Madelung: Op. cit., No. 18, p. 85.

nation showed that a hydatid cyst situated in the lower lobe of the right lung had ruptured through an opening eleven centimetres long ($4\frac{1}{2}$ inches): the ruptured cyst partly protruded through the rent: no lesion in any other organ."

The results of rupture into the pleura will vary according to circumstances, viz. :—

The size and position of the orifice of rupture.—If large a copious escape of the contents, solid and fluid, of the parasite must result, and, moreover, air will obtain entry into the pleura; on the other hand there is strong reason for believing that if the opening be small, a slight escape of normal hydatid fluid into the pleura may be followed by no more serious sequelæ than a sharp attack of urticaria, temporary pyrexia, and malaise, the fluid becoming absorbed by the pleural membrane.

If the discharge of fluid be profuse, or still more so if the fluid contents of the parasite be much degenerated or even purulent, then a severe, and often rapidly fatal, pleurisy follows.

In the majority of such cases, a general pleurisy passing quickly into empyema results, but in many instances, where the effusion has been less considerable and not septic, a localised pleuritic effusion is produced, which may naturally be regarded as the parasite itself by the physician. I have repeatedly met with cases where a loculated pleuritic effusion has been found on opening the chest; the lung, still enclosing the parasite, retracting in obedience to the usual law in intra-thoracic effusions. When such cases are operated on, and ample drainage is provided, the lung re-expands and permits the escape of the mother cyst, first into the pleura and then out through the parietal wound. Several instances have come under my observation, one of which is reported.*

If air obtains entry into the pleural space, it follows that pneumothorax will result; under these circumstances the gas contained in the pleura may remain aseptic, as in the following instance :—Herbert S., six years, admitted under my care at the Adelaide Hospital, in November, 1887. No satisfactory history of his case could be procured; but his mother stated that he had suffered from a cough for some time, and that, about ten days before his admission into the hospital, he had a sudden attack of cough and difficulty in breathing, during which he brought up blood through his mouth and nose.

Before he came under my observation he had been seen by Dr. Hayward, who found evidences of pleural effusion; these had vanished when I first examined him.

* The Australasian Medical Gazette, June 1888, page 216.

On admission he had marked dyspnœa but no cyanosis ; the right chest showed bulging and deficient expansion ; the percussion note over the entire right side of the thorax was markedly tympanitic ; and the normal hepatic dulness was entirely absent ; the respiratory murmur was feeble, and the voice sounds had a metallic echo ; the bell sound was well marked ; no signs of fluid in the pleura ; the cardiac apex-beat was felt in the seventh left interspace in the mid-axillary line. Over the left side exaggerated puerile respiration.

Incision in the eighth interspace right scapular line gave exit to a small quantity of spontaneously coagulable fluid, and a slight sound of issuing gas was heard, proving the existence of *plus* tension in the pleural cavity prior to the operation ; the gaseous and liquid contents of the pleura were free from any offensive odour. It was evident that the orifice of rupture in the lung was valvular.

Efficient drainage was maintained, and on the thirty-seventh day after the incision a small hydatid cyst in two fragments escaped. The boy speedily recovered.

In some cases the orifice of rupture is more gaping, and this has very significant consequences, for a greater escape of the contents of the parasite follows, and what is of equal gravity, air conveying bacteria passes into the pleura ; under such circumstances the only hope for the patient lies in a prompt thoracentesis.

I have known a locular pleurisy to be produced by the aspiration of a pulmonary hydatid ; it is needless to insist that a free incision of the pleura should quickly follow such an accident ; this point will be dealt with in connection with the treatment of pulmonary echinococci.

The urgency of the symptoms in pneumo-thorax from rupture of pulmonary hydatids will depend greatly upon—

1. The septic or aseptic condition of the cyst contents.
2. And, probably closely associated with the last factor, the occurrence or not of *plus* tension in the affected pleura.

A good case in point may be here briefly cited :—“ A female, aged 29, was admitted under treatment into the Charité Hospital, Berlin, in December, 1884. She stated, that for about three months she had suffered from cough and pain in the chest. Upon admission, she was noticed to be suffering from extreme orthopnœa, œdema, cyanotic lips and cheeks, and the other usual manifestations of great respiratory trouble. Thoracic respiration was almost abolished, and the thorax was bodily lifted forwards, the intercostal spaces being widened ; the superficial veins of the upper part of the thorax were much distended, especially on

the left side. The percussion note over the front of both the left and right lungs was markedly tympanitic; on the right side there was loud vesicular (*sic*) murmur; on the left, jerking, weakened and accompanied by a rhonchus. The cardiac dulness had almost entirely vanished, being limited to the third intercostal space; the heart sounds were normal but muffled. The left side of the thorax was dilated, and the corresponding shoulder was elevated; there was retraction of the left interspaces during deep inspiration. The percussion note was similar on both sides. At the ninth dorsal spine dulness began, and extended thence to the left base. In the lateral region a metallic tympanitic note could be elicited, and, in addition, an exquisite *bruit-de-pôt-felè*. The lower limit of the liver reached to the umbilicus. The left pleura was punctured with a Pravaz syringe. A second exploratory puncture yielded, besides greenish-yellow serum, gas. The patient's dyspnœa was greatly aggravated after the punctures. A third puncture withdrew much gas, besides 800 cubic centimetres of green offensive pus. The patient died next day.

Autopsy.—On the right the level of the diaphragm was at the fourth rib; on the left it was depressed so that its apex corresponded to the eleventh rib. On opening the left pleura gas issued with a plain hissing. Besides the gas, the pleura contained more than 2,000 cubic centimetres of thin purulent fluid, in which floated a thick fibro-purulent coagulum. Left lung completely collapsed against the spine; pleura greatly thickened; a perforation in the lower lobe of the left lung through which air and foetid masses escaped. The edges of the orifice consisted of gangrenous pleura. Close underneath the spot was found a sac of the size of a fist, which externally was formed of the thickened pleura and a thin, small, slate-coloured envelope of lung-substance. In the cavity lay an echinococcus cyst of the size of an apple."

This case well illustrates the conditions under which a foetid pyopneumo-thorax with *plus* pressure may arise in the chest. It is probable that the earliest portions of fluid effused by the rupture covered the orifice of the sac. During the efforts of respiration putrefactive bacteria were inhaled first into the cavity and then into the pleura; hence arose a generation of putrid gas, supplemented possibly by direct inhalation from the air of the hydatid cavity.*

Usually rupture is spontaneous, and is determined by a process of softening ulceration, or even gangrene,† at the point of rupture. Death follows rupture into the pleura in from 1 to 46 days.

* Lurie; *Echinococcus Pulmonum*. : Inaugural Dissertation, Berlin, 1875; page 14 et seq.

† Huppert's case : Inaug. Dissert., Jena. 1875.

Rupture may take place simultaneously into the pleura and bronchial tract. Indeed, when the parasite collapses, in consequence of rupture into the pleura, air must almost of necessity enter the hydatid cavity through any patent bronchial tubes on its walls.

Rupture through the abdominal parietes near the umbilicus took place in a woman treated by Dupuytren, at the Hotel Dieu, Paris, in 1811. A fistulous channel extended between the external wound and a cavity contained in the lung. At the autopsy the pulmonary cavity still contained a large quantity of hydatid cysts.*

Symptoms.—If the cyst is small or situated centrally in the lung, there may be absolutely no symptoms, and the existence of the parasite may be unknown, until accidentally divulged by a post-mortem examination, more especially when the bladder-worm has undergone spontaneous cure: or the cyst may be coughed up completely at once, and no symptoms may either precede or follow this unexpected event.

When symptoms are present, their character and severity will depend upon the size, and to some extent the situation, of the growth, upon its condition as regards integrity or rupture, upon the direction of rupture when this has occurred, and upon the state of the adjacent lung tissue.

Owing to the slow and latent growth of the echinococcus cyst, it is common for a large area of the lung to be invaded without serious discomfort to the patient; and the first decided intimation of the presence of a lung hydatid is in many instances occasioned by its rupture into the bronchial tract or pleura.

When such a catastrophe has taken place, however, it is usually possible to discover on enquiry that the patient had, for a longer or shorter period, been subject to certain definite, although perhaps fugitive, signs of chronic chest disease.

These are principally *cough*, *hæmoptysis*, *dyspnœa*, and *pain* in the chest.

Cough.—More or less cough is usually present in this disease, but when the cyst is unruptured it may be so slight as to pass unnoticed; less frequently it may be severe, or even exhibit a paroxysmal character, resembling that of whooping-cough.

At the moment of rupture, violent suffocative cough is induced by the escape of hydatid fluid, blood, or even shreds of membrane into the bronchial tract. After rupture, the amount and character of the cough will vary according to circumstances, *e.g.*, the size of the cyst, the

* Cited by Davaine, *op. cit.*, p. 435, Obs., XXXV.

quantity and character of its contents, the presence or absence of putrefaction of the contents, and the size and position of bronchial openings into the cavity. Frequently the expectoration is foetid, and comes up in considerable quantity at longer or shorter intervals of time.

Hæmoptysis is almost as important a symptom in lung hydatid as in phthisis, and it is noticed probably in about the same proportion of cases in both diseases; at any rate, few cases of pulmonary echinococcus run their entire course up to complete expulsion of the parasite without this sign. The amount and character of the bleeding show great variations in different cases, principally in accordance with the stage of the disease.

(1) Hæmorrhages preceding the rupture of the cyst are usually scanty, and consist generally of mere streaks in the mucous expectoration; their principal importance lies in the circumstance that they tend to give rise to an erroneous diagnosis of early phthisis, and several such cases have come under my observation: usually, however, the appearance of general good health and a careful physical examination will prevent the error. These minute bleedings are probably caused by active congestion in the lung adjacent to the bladder-worm. Occasionally, too, a local pneumonia in the vicinity of the cyst gives rise to a scanty rusty sputum.

(2) Hæmorrhages associated with rupture of the cyst are generally much more copious than those just described, but it is by no means universal for decided bleeding to accompany the act of rupture into a bronchus: on the other hand, there may be copious loss of blood. The bleeding under these circumstances is caused by the sudden withdrawal of the support yielded by the unruptured cyst—usually amounting to more than 10 or 12 inches of water—to the blood-vessels left on the walls of the cavity containing the parasite.

(3) Hæmorrhages occurring at a longer or shorter period after rupture of the cyst constitute a class closely comparable with the hæmoptyses of the third stage of phthisis, and indeed have a similar pathogeny, for, owing to the loss of support of the mother-cyst after its rupture, the blood-vessels on the sac-wall tend to degenerate and to become brittle, and also, probably, to develop into aneurysmal dilatations, or, as in Habershon's case,* into varices of the pulmonary veins on the walls. In my opinion, this tendency to degeneration of the blood-vessels of old hydatid cavities forms a strong reason for radical operation at an early date, lest fatal hæmorrhage supervene.

* Vide p. 52.

The liability to bleeding varies greatly in different cases. For example, it was the first symptom noticed in the case of a young man (Dickson), aged 17; in this instance blood-spitting came on in small amount from vigorous exercise, and this was followed next day by a more considerable loss of blood: at the time he first consulted me the physical signs were not sufficiently well-marked to make a radical operation desirable, much of the cyst having been coughed up: shortly afterwards the residue of the parasite was also expectorated, and the patient completely recovered his health. A second case of like character has also come under my care: on the other hand, instances of very large hydatids are not rarely seen in which no bleeding has been observed up to the time of the death of the patient.

Hæmorrhages of the third class are extremely perilous to the patient, and in numerous instances have caused sudden death.

Several cases of this kind have been recorded, *e.g.*, one reported by Habershon,* where death rapidly took place in consequence of the rupture of a varix of the pulmonary vein on the wall of an old hydatid cavity.

Other fatal cases have been noted by Pillon† and by Wolff‡. In the former of these cases, the immediately fatal bleeding was concealed in a huge vomica.

“The case was that of a man, aged 28, who was admitted into the Hospice St. Antoine, in February, 1836. He had suffered from cough and other chest symptoms for some months before his death; there had been some blood-spitting, but not any for a considerable time before his death; nevertheless, at the autopsy, a huge hydatid cyst was found, which replaced the whole of the left lung, excepting a small portion of the anterior edge, the cavity of which was entirely filled with a large mass of coagulated blood, not less than a litre (35 fluid ounces of English measure) in amount.”

Another case was that of a female, aged 42, under the care of Dr. Tatham, at the Consumption Hospital, Brompton.

“She was admitted into that Institution on August 25, and died on December 20, 1884. There was a history of repeated hæmoptyses, of cough, wasting, &c.; total absence of breath sounds, and absolute dullness at left anterior apex down to third rib. She coughed up a piece of membrane, and suddenly died of profuse hæmorrhage. Apparently the cyst came away immediately after rupture. *P.M.*—Besides a degenerated

* Guy's Hospital Reports, Third Series Vol. XVII., p. 374.

† Pillon, Bull. Soc. Anat, Paris, 1836.

‡ Wolff: Vier Fälle von Echinococcus hominis, nebst Bemerkungen ueber das Vorkommen der Echinococcen in Breslau. Inaugural Dissertation, 1869.

hydatid on the under surface of the liver, which pressed slightly on the bile-duct." *

As regards the amount of the hæmoptysis, it varied greatly, being slight in 34 cases; moderate in 54 cases; severe in 26 cases; rapidly fatal in 3 cases out of a total of 117 cases.

Pain in the Chest.—This may be present or absent, and if present it may be severe or slight. The existence and characters of the pain depend upon several conditions, notably upon whether the cyst is ruptured or not, and if ruptured, whether the fluid escapes into the pleural cavity or into a bronchial tube, &c.

When the cyst is unbroken it is usual for no pain at all to be complained of, or if any be present it amounts to little more than a sense of weight or discomfort in the chest; but it occasionally happens that there is a sensation as of the presence of some foreign body in the lung.

Dyspnœa.—More or less shortness of breath is always present when any considerable portion of one or both lungs is invaded by any disease, so that the ærating surface is lessened or impaired.

When a hydatid is small, the area thus rendered useless is so insignificant that the lungs may be equal to any calls made upon them, and then no respiratory trouble results.

Owing to the slow growth and comparatively unirritating character of the unruptured cyst, urgent dyspnœa is not common even in very large pulmonary hydatids. Indeed nothing in the whole range of pulmonary pathology is more curious than the frequent absence of dyspnœa in cases where a considerable area of the lung is replaced by a large cyst.

I have seen cases where fully half, and less frequently where nearly the whole, of one lung has been destroyed in this way, and yet no marked dyspnœa was present except on exertion. Life may be maintained for a considerable period when a large proportion of the entire breathing area of the chest on both sides has been thus lost.

In some of the recorded cases the dyspnœa had a paroxysmal character, but this is rare.

The presence of some intercurrent disease, such as phthisis, bronchitis, pneumonia, or gangrene adds greatly to the difficulty of breathing.

From what has been just stated, it may be concluded, that unless a very large area of lung is invaded, or some intercurrent pulmonary affection is present, the unruptured hydatid cyst causes remarkably little dyspnœa and produces only a shortness of breath chiefly felt upon exertion.

* I have not been able to discover the source from which this case is quoted.—(A. A. L.)

Intense dyspnœa may arise under the following circumstances :— (1) Rupture of the cyst into a bronchial tube. (2) Rupture into the pleural cavity. (3) Perforation of the pericardium. (4) When the circulation through the pulmonary artery or veins is seriously impeded. (5) In rare cases, severe dyspnœa and death may result in consequence of the extensive destruction of lung-tissue by the parasite.

General Symptoms.—As a rule, the general health and physique suffer remarkably little when the cyst is unruptured, and even after rupture an appearance of tolerably good health is usually maintained. This peculiarity is often of great value as an element in the diagnosis between pulmonary hydatid and phthisis, but of course it is not universally so.

Loss of flesh is usually, but not always, noticeable, but it rarely attains to a high degree, even in the ruptured cyst. It is dependent chiefly upon the presence and amount of pyrexia, whether due to the irritation of the parasite, septic poisoning, or concomitant phthisical or other changes in the lungs.

Pyrexia is not usually present in the first stage : it is common after rupture. When found in cases of unruptured hydatid it is probably always due to some intercurrent disease, *e.g.*, pneumonia, pleurisy, phthisis, &c.

In the stage of ruptured cyst, more or less fever is usually present.

The frequent presence of *night sweats*, and of *clubbing of the finger-ends*, increases the resemblance between certain cases of ruptured pulmonary hydatids and the ordinary cases of phthisis.

As improvement occurs, whether it be the result of successful natural efforts to expectorate the mother-cyst, or whether it be produced by surgical treatment, these symptoms disappear entirely.

Decubitus.—When the cyst is small the patient usually lies indifferently on either side : when large, he commonly prefers the affected side. When ruptured, alterations in the position of the collapsed cyst may in certain postures induce coughing, by permitting escape of the fluid contents of the cavity into the bronchial tubes.

As usual when dyspnœa is severe, the patient sits up.

Physical Signs.—Some reference has previously been made to certain physical signs ; it is now necessary to consider the phenomena in question with greater completeness. The phenomena in point vary greatly according to circumstances, particularly according to the size and precise situation of the cyst, its condition as regards integrity or rupture, and the state of the lung-tissue adjacent. It is necessary, therefore, to

study these phenomena as they offer themselves in (1) the unruptured cyst, and (2) the ruptured parasite.

Physical Signs of the Unruptured Cyst.—If the bladder-worm be small and centrally imbedded in the lung, there will probably be no symptoms or physical signs, and, under these circumstances, it may undergo spontaneous death and decay, and be discovered only in the event of a post mortem examination.

If the parasite be of moderate dimensions, say of the size of a large orange, and if it lie near the surface of the lung, a group of distinctive physical signs is found, for the recognition of which we are greatly indebted to Dr. Dougan Bird of Melbourne. These are, in brief, more or less deficiency of expansion of the diseased side; a tolerably sharply-defined area of absolute dulness of limited extent, with absence of respiratory murmur, and loss of vocal fremitus over the dull region: now and then friction is heard over the space affected. Beyond the dull area the normal conditions with regard to percussion and auscultation prevail.*

The percussion note in a typical case is absolutely dull, precisely resembling that found in pleuritic effusion, and, as in the latter, the act of percussion yields a high sense of resistance to the pleximeter finger.

The precise limits of the area of dulness give invaluable aid to diagnosis in many cases, for it frequently happens that some deviation from the type of distribution of dulness in pleuritic effusion points either to hydatid cyst or to loculated pleurisy.

The vocal resonance, too, is usually peculiar in unruptured hydatid, for it is completely lost over the region of absolute dulness, whereas in pleuritic effusion it is often present, but with an ægophonic or bronchophonic character.

When the parasite is of only moderate size and lies deeply embedded in the lung substance, the difficulties of diagnosis increase. However, even under these circumstances, a correct opinion may, in many instances, be arrived at.

The growth of the tumor in the lung causes a certain amount of compression of the parenchyma intervening between the growth and the surface; the result is the production of a percussion-note, varying from full tympanitic to sub-tympanitic. In rare cases I have even heard a well-marked "Skodaic" percussion-note; this may perfectly simulate the note often audible beneath the clavicle in moderate pleural effusion. I

* Dougan Bird, Austr. Med. Jour., March, 1871, page 73.

attribute great diagnostic importance to this note, inasmuch as it is, under due precautions, proof positive of compressed lung.

I have, in several instances, by its means, together with a history of shortness of breath on exertion, cough, pain in the chest, and possibly scanty hæmoptysis, been able to arrive at a correct diagnosis in the absence of the classical physical signs of an unruptured hydatid.*

Pressure Effects of Pulmonary Hydatids.—When the hydatid cyst has attained considerable dimensions it exercises certain pressure effects upon parts outside the normal boundaries of the lung: it will be convenient to group the phenomena of abnormal intra-thoracic pressure into two classes.

The first class embraces those cases in which there are symptoms of pressure exerted upon the central portion of the thoracic cavity within the mediastinum, *i.e.*, about the root of the lung: in such cases the great vessels, the trachea and main bronchi, and the vagi, sympathetic and œsophagus, are involved; these may be termed cases of *centripetal pressure*.

The second class includes those cases where the pressure is exercised chiefly on the walls of the pleural cavity; for example, the bony thoracic wall, the diaphragm below, and the general wall of the mediastinum; these are instances of *centrifugal pressure*.

Of course this classification is one merely of clinical convenience, not anatomical exactness, for I shall regard the collapse of the lung that takes place in pleuritic effusion, pneumo-thorax, &c., as a case of centrifugal pressure. However, I think it will be admitted that the main clinical aspects of cases of intra-thoracic pressure range themselves conveniently in these classes.

Fluid in the pleural cavity, whether it be serum, pus, blood, or gas, causes centrifugal pressure; it presses the mediastinal partition to the opposite side, presses the diaphragm downwards, and tends to bulge the outer wall of the chest outwards: hence result displacement of the heart, liver, and spleen, &c., but not obstruction of the trachea or bronchi, nor interference with the flow of blood through the great vessels, nor pressure effects upon the nerves, œsophagus, &c.

Whilst thoracic aneurysm, cancer, sarcoma, and other mediastinal growths produce signs of centripetal pressure, the pressure effects of pulmonary hydatid are, with few exceptions, centrifugal.

* Dr. Thomas intended to have inserted here an account of the first case in which he noticed this "tympanitic" note, but the record is incomplete: it is rendered in detail in the first paper referred to in the bibliography.—(A.A.L.)

We find the heart, liver, and spleen displaced, according to the size and situation of the cyst; of course a small cyst at the apex can exert no influence upon these organs, but a large one at the base will do so in the same mode as a pleural effusion does, and more or less local bulging of the chest wall may be produced at the same time.

This is the general tendency of the hydatid cyst, and is probably due to its proneness to grow in the direction of least resistance. But the parasite is not a mere collection of fluid, it is rather a slowly growing tumour, the contents of which are fluid, and it may conduct itself as a tumour.

For example, in a case of hydatid of the middle and lower part of the left lung, which I had under my care some years ago, the heart was not displaced to the right, as it would ordinarily have been by an equal amount of fluid free in the left pleural cavity, but it was pushed bodily forwards against the chest-wall, so as to show a very widely diffused beat over the whole left mammary region. This phenomenon disappeared after the evacuation by puncture of the hydatid fluid.

The heart may be twisted on its axis by the pressure of a lung hydatid, and may become permanently fixed by adhesions in that position; thus in one case "the sac was everywhere closely adherent to the thoracic wall adjacent; and was also adherent as far as the median line in front, and behind to the spinal column, forming a sort of wall which, even after the evacuation of the fluid, prevented the heart from returning to its normal situation. Below, the sac adhered to the diaphragm. The lower lobe of the lung was pushed backwards and downwards; the upper lobe had almost entirely disappeared; the heart was not pushed bodily to the right, but it had undergone a sort of torsion on its axis from left to right. In consequence of this the aorta was carried back behind the side of the vertebral column. The pulmonary artery being pulled to the right described almost a complete spiral about the aorta." *

Not only may there be proofs of the displacement of internal organs, but there may be actual bulging of the chest-wall at a spot where cavity-signs exist. Gairdner † noticed in one case a protrusion of the right chest, extending from the second to the fifth rib. However, no sounds indicative of a cavity were heard here, but the signs pointed rather to localized pleurisy; yet at the autopsy a large hydatid was found at the apex of the lung.

* Case recorded by Landouzy and cited in Virchow and Hirsch. *Jahresbericht*, 1883. Vol. ii., p. 163.

† *Edinburgh Medical Journal*, 1857, p. 587. Cited also by Hearn, *Op. cit.*, Obs. XXXVII. p. 140.

In some cases the cyst exerts more or less well-marked centripetal pressure.

Among the cases where venous obstruction was caused by the pressure of pulmonary hydatids may be mentioned a case by Leroux* where œdema of the upper limbs was present; and another by Williams,† where the right hand and arm were œdematous, apparently from the pressure of a huge hydatid of the right lung.

Cases in which the thoracic aorta appears to have been involved have been occasionally alluded to; for example, Federici‡ has related the case of a woman, where certain disturbances of the circulation were referred by him to pressure on the aorta.

Dr. Atkinson§ briefly alludes to a case in which "severe symptoms of aneurysm of the aorta were simulated."

A well-marked case of this kind has been recorded by Allen||—

A woman, aged 50, was admitted into the Melbourne Hospital, on February 19, 1877.

"The left chest was distended and motionless, its measurements larger than those of the right side; the intercostal spaces were slightly tumid; there was absolute dulness all over the left side, with absence of respiratory murmur, and of vocal resonance and fremitus. The right chest was moderately resonant, the breath sounds were roughened, and attended with rather coarse crepitation.

"The heart's beat could be felt, and its sounds heard a little to the right of the sternum, a distinct thrill was very perceptible to the right of the sternum over the upper two intercostal spaces; a loud systolic bruit was heard in the same situation, and could be easily differentiated from the heart's sounds. The superficial veins of the right side of the chest were distended."

The patient died, and at the autopsy:

"The pericardium and its contents were seen to be displaced to the right, but unequally; there was almost universal firm adhesion between the parietal and visceral layers of the pericardium; the heart's apex was retained nearly in its usual position, while the base and great vessels were pushed over to the left (right?); the walls of the heart were very flabby; its cavities were not sensibly dilated; the valves were normal, and there was no aneurysm nor dilatation, nor any trace of atheroma of the aorta or any of its branches. The left pleura was distended by a

* Cited by Davaine and Hearn. Obs. VII., p. 115.

† Australian Medical Journal, 1881, p. 267.

‡ Cited by Hearn. Obs. CXXV., p. 225.

§ Australian Medical Journal, October, 1867, p. 290.

|| Australian Medical Journal, March, 1881, p. 104.

huge hydatid cyst, which was covered above by the collapsed almost airless slate-coloured remains of the left lung. The cyst cavity extended downwards to the diaphragm, displacing the liver downwards and to the right."

In this case, the symptoms to some extent, simulated aortic aneurysm, but the well-marked dulness and absence of respiration all over the left side of the chest were indicative of something more than or different from aortic aneurysm.

It is unusual for pulmonary hydatids to cause erosion of bones.

I have elsewhere alluded to a case where the vertebræ were found eroded, and the vertebral canal was invaded by hydatid disease, but I have raised doubt as to whether this should be regarded as a case of invasion by a hydatid originally of intra-thoracic origin.*

Landau† has recorded a case of hydatid of the right side of the chest where the cyst protruded under the breast, and had eroded the ribs in the parasternal line, causing over an area of about three centimeters square, a defect in the chest wall, with complete destruction of the ribs and intercostal muscles of the part.

Physical Signs of the Ruptured Cyst.—In some cases the cyst may be ruptured and part of its contents be evacuated, and yet it may refill, and the parasite probably still retain its vitality.

That this can occur after a minute puncture made artificially, I am sure, but I have no proof that it can take place after the more extensive tearing of the cyst that occurs in spontaneous rupture.

When a cyst once ruptured refills, it is, as regards physical signs, in the same condition as if it never had been ruptured.

When, however, this does not occur, the local conditions become entirely altered, for the parasite shrinks and occupies the most dependent part of its cavern. The physical signs of fluid tumour are then replaced by those of a cavity of large size.

But it must be remembered that the hydatid cavity is in a very different condition from a vomica, the result of phthisis, gangrene, abscess, or cancer, for in the case of all these diseases the only contents of the excavations are gas, and more or less liquid; in the hydatid cavity there are the extensive remains of the parasite, so that until this has been expectorated or otherwise removed it may, and often does, produce an appreciable influence upon the acoustic properties of the cavity.

* I cannot find this reference.—(A.A.L.)

† Archiv. für Gynækologie viii., Heft. 2.

A few examples of variations of classical physical signs may prove interesting.

(1) *Peculiarities of the Percussion Note.*—The unruptured cyst yields, under ordinary circumstances, an absolutely dull note; when it burst from any cause, and expels its contents, air replaces liquid in the cavity, and we then have a tympanitic, tubular, cavernous, amphoric, or cracked-pot note, according to the local conditions, but in many cases the percussion-note remains as dull as before.

This may occur, because the cyst refills, and the previous physical conditions are restored; but this is not always, probably not even often, the case, and I believe that the cause of dulness then is, that the collapsed mother-cyst, or one of the daughter-cysts, closes the bronchial outlets of the cavity, and thus prevents the development of the usual phenomena.

(2) *Peculiarities of Auscultation Signs.*—The same cause, in my opinion, occasions the unusual auscultatory signs sometimes found, for, when dulness persists, usually also the cavernous respiration and vocal resonance are either ill-marked or wanting, and vocal fremitus is weak or absent; all of which deviations are explicable, it seems to me, by the supposition that air enters and leaves the cavity only sparingly, or not at all.

But if a little air enters, it may do so in small jerks past the valve-like cyst plug, and then we hear a peculiar cog-wheel, rhythmical sound. This was very noticeable in the case of H. P.—, recorded by me* in 1881. In this case, at a certain time in its clinical history, the following signs were present:—

“Posteriorly three fingers’ breadth below the angle of the scapula, there is heard, especially on deep inspiration, amphoric breathing. This sound is interrupted, being split up into several parts or jerks, varying in number with the depth of the inspiration, and not being of cardiac rhythm. This gives a kind of cog-wheel rhythm to inspiration, and to a less degree to expiration also.”

This disappeared after the expectoration of some membrane.

A somewhat similar phenomenon occurred in a patient under the care of Dr. Leared.† The chief physical signs were—

“On the left side, dulness on percussion from beneath a line encircling the chest, and touching the lower angles of the scapulæ. This dulness was very marked posteriorly, somewhat less so at the side, and still more modified anteriorly. The respiratory murmur was found to be impaired

* *Medical Times and Gazette*, January 15, 1881, p. 65.

† *Medical Times and Gazette*, August 15, 1857, p. 162.

in a manner precisely corresponding to the dulness. Bronchial respiration was not noticeable ; but there was a well-marked inspiratory valve-like, or clicking sound, and it was most audible about the lower margin of the axillary space."

Sometimes, when the ordinary respiratory acts are not forcible enough to displace the blocking membrane, cough will do so. Baron* refers to this occurrence in a case under his care, where a somewhat metallic and amphoric sound was heard during coughing efforts only ; he offers no explanation of the phenomenon. Similar allusions are made by other authors, *e.g.*, Pillon† and Bernard.‡

As might be expected, when a copious expectoration of hydatid membrane takes place, a very notable change in the physical signs of the ruptured cyst often occurs ; the usual cavity signs appear, *e.g.*, cavernous or amphoric respiration, with whispered pectoriloquy, &c., and perhaps, but not always, the percussion-note alters from dulness to a tympanitic or amphoric note.

This has been often noticed ; for example, by Greenfield.§

The upper part of a hydatid cavity may give intense cavernous breathing, whilst in the lower half the respiratory sounds, vocal resonance and fremitus, may be annulled. This is evidently due to the presence of the collapsed cyst at the bottom of the cavity.

(3) *Effects of Change of Posture.*—Occasionally mere alterations of the posture of the patient, by producing alterations in the position of the empty mother-cyst, and the fluid present, cause modifications of the physical signs. This was noticed by me in the case of a youth, who had a hydatid in the upper lobe of his right lung.

The same peculiarity was noticed by Fenger and Hollister|| in a case under their care. In this case the observation was perhaps the more significant, because the exact nature of the malady was discovered only at the time of operation. The patient, a man, aged 34, had a suppurating hydatid in the middle lobe of his left lung. In the erect posture there was dulness in the mammary and in the infra-mammary regions ; but "when the patient lies on the back, there is an area of tympanitic percussion sound on the anterior side of the body, namely, in the mammary region." There was a similar variation in the auscultation

* *Mémoires de l' Acad. de Méd.*, 1845. Cited by Hearn. *Obs.* XX., p. 123.

† Cited by Hearn. *Obs.* XXXII., p. 134.

‡ Hearn. *Obs.* CVII., p. 211.

§ *Clinical Society's Trans.*, vol. X., p. 193.

|| *Opening and Drainage of Cavities in the Lungs.* The American Journal of the Medical Sciences, October, 1881, p. 378.

signs. "Over the regions of dull percussion, the respiratory sounds are obscure, when the patient lies down, auscultation over the tympanitic territories gives cavernous respiratory sounds."

The presence of such variations correlative with posture may prove at times of value for purposes of diagnosis, but their absence should in no way influence diagnosis.

Diagnosis.—The principal diseases with which this affection may be confused are—*Phthisis*, *Pleural Effusion*, *Pneumo-Thorax*, *Pyo-pneumo-thorax*, *Cancer*, *Sarcoma*, various *Mediastinal Tumours*, and *Aortic Aneurysm*.

It is often difficult, and sometimes impossible, to decide whether a hydatid located in the lower part of the chest is primarily intra-thoracic, or only apparently so, and in reality connected with the liver or spleen.

In the vast majority of cases, *Phthisis* and *Pleural Effusions* are the lesions to be taken into account.

Diagnosis of the Unruptured Cyst.

(1) *From Early Phthisis.*—Phthisis and pulmonary hydatid may resemble one another in a very puzzling manner, and at all their stages.

Early phthisis and the early condition of an unruptured cyst resemble each other in the slight impairment of health, the short dry cough, the slight, but perhaps repeated, hæmoptyses, the shortness of breath on exertion. But both in this and the more advanced stages the general health is usually far less impaired in hydatid disease than in phthisis, and very extensive lung space may be invaded by echinococcus and yet fairly good general health be maintained.

It is principally when a cyst is present at or near the apex of the lung that confusion with early phthisis is likely to occur; but the general good health, the usual absence of pyrexia, not to mention the sharply defined dulness, the respiratory silence, the usual absence of râles, should enable the differential diagnosis to be made with almost absolute certainty.

Finally an exploratory puncture with a trochar, or a bacteriological examination of the sputum, may absolutely decide the question.

(2) *From Pleural Effusion.*—Perhaps even more frequently than phthisis, collections of fluid in the pleural cavity cause errors of diagnosis, and it is especially circumscribed empyemata that give most trouble in this way. Already references have been made to the physical signs of pleural effusion and pulmonary cyst.*

Of course, it is especially basic hydatids that simulate intra-pleural

* Pages 14, 15.

effusion, but in many cases the history of recent pain, pyrexia, shortness of breath, &c., will give a clue to the nature of the lesion.

In all cases an exploratory puncture will decide the matter, often in a manner alike satisfactory to the doctor and patient.*

Diagnosis of the Ruptured Cyst.†

(1) *From Phthisical Cavities.*—In the advanced stages when a cavity has been produced by the rupture of the cyst, the difficulty of establishing a differential diagnosis is greater. But, apart from the physical signs already described, there are several points that may throw light upon the question.

Hydatid cavities in children, as in adults, may present the usual auscultatory phenomena, and this is a valuable aid towards the differentiation of hydatid and phthisis, for, pneumo-thorax being excluded, cavity signs in childhood are strongly in favour in a doubtful case of hydatid as against phthisis, for children rarely live long enough to exhibit indications of enormous cavities.

In proof of this statement, I may cite Buchanan,‡ who states, that out of 265 cases of phthisis in children that had come under the observation of M.M. Bartnez and Rilliet in Paris in only 28·6 per cent. were there cavities present in the lungs. Almost universally, too, such excavations are of small size and present no typical signs of vomicae.

A second point in the diagnosis between phthisis and pulmonary hydatid is that phthisis is, as concerns the lungs, essentially a bilateral lesion. For example, out of 80 autopsies performed by Flint§ upon phthisical patients, in only 2 were the morbid appearances confined to one lung. To find one lung presenting plain cavity signs, and the opposite one healthy, would, in doubtful cases, give a strong presumption in favour of hydatid. On the other hand, echinococcus of the lungs is rarely bilateral.

Then diarrhoea and laryngeal disease do not form a part of the morbid phenomena of pulmonary hydatid.

Various collateral phenomena may aid in the diagnosis. For example—A boy, aged 9 years, came under my care in November, 1877. He was believed to be dying of phthisis, and his general appearance and symptoms justified the opinion. However, upon examination he was found to have the physical signs of a large cavity about the middle of his right lung. The left one was, as far as could be discovered, perfectly healthy, but his heart was found to be beating half-an-inch to the

* This was written in 1884.—(A.A.L.)

† This was written in 1884.—(A.A.L.)

‡ Lettsomian Lectures, 1868.

§ Phthisis, by Austin Flint, London, 1875, page 20.

left of the left nipple line. These two important points of deviation from the phthisical type of physical signs were conspicuous:—(a) a large cavity in a child's lung, with perfectly normal physical signs in the opposite lung; (b) displacement of the heart away from the lung containing the cavity. Now a phthisical lung containing one or more cavities is a small lung, and the heart, when displaced in phthisis, is displaced towards the most extensively diseased lung. In this case it was plain that a large hydatid in the right lung had pushed the heart to the left, and that before rupture of the cyst the lung had formed adhesions, so that when rupture took place the displacement had been rendered permanent.

Of course, the expectoration of hydatid cysts or membranes is conclusive, but, as Dr. Bird remarks, the physician should never trust a patient's description of the "skins"—he ought to see them for himself.

In my experience, diagnosis has, in the great majority of cases, to be made without any such aid.

There are two directions in which further enquiry needs to be made, viz. :—

(a) As to the frequency of expectoration of shreds of lung tissue and elastic fibres in cases of pulmonary hydatid cavities. (b) Whether the bacillus of tubercle can be depended upon as a means of diagnosis in doubtful cases.

As regards the former, it is quite certain that fragments of lung tissue may be found in the discharge from hydatid cavities. This interesting fact was noticed long ago by Dr. Macgillivray.*

As regards the bacillus of tubercle, I have examined up to the present date about a dozen cases with this object in view. The result was that in no single instance could anything resembling that microbe be found. It affords me great pleasure to acknowledge my obligation to Dr. Whittell for the assistance he has given me in this enquiry. Of course, from the very nature of the case, such negative evidence must be accepted with suspicion, but in my hands it has hitherto proved a valuable piece of proof.

(2) *From Gangrene of the Lung.*—Cavities from gangrene of the lung can generally be distinguished from a hydatid cavity, the wall of which has become gangrenous, by the very acute course of the former.

Both are emphatically cases for the radical operation.

(3) *From Mediastinal Tumour.*—Far less common as sources of error

* Australian Medical Journal, March, 1867, p. 70.

in diagnosis are aneurysm, carcinoma, sarcoma, and various other varieties of mediastinal tumours. *Aortic Aneurysm* has in rare instances been mimicked by hydatid of the lung, but oddly enough this has not been the case when the hydatid was mediastinal.

(4) *From Carcinoma*.—Carcinoma of the chest varies greatly in its distribution. Thus, it may be disseminated, almost like miliary tuberculosis, in which case there may be no physical signs in the lungs except those of general bronchitis. In other instances the disease may be limited to certain parts of the lung; or it may be principally mediastinal, in which case there are usually some centripetal pressure signs.

The cases that may be confused with pulmonary hydatid are those in which extensive infiltration of the lung exists or cavities are formed.

The varieties of phenomena in these cases of cancer of the lungs are so numerous, that it is out of the question to discuss them; but a careful survey of the physical signs, and observation of the progress of the case will generally help to decide the question, and an exploratory puncture may also prove a valuable aid to diagnosis.

When the question is between a ruptured hydatid and carcinoma, the progressive character of the physical signs in the latter is in striking contrast to the non-invading type characteristic of the ruptured parasite.

Finally, it must be born in mind that physical signs simply indicate physical conditions; diagnosis is almost always a matter of judgment of probabilities.

The Diagnosis of the Ruptured Pulmonary Hydatid Cyst.*—In the case of the ruptured cyst we have to deal with two conditions, viz.—(a) when the presence of the parasite is doubtful, (b) when the presence of the cyst is certain, but its locality has to be ascertained.

When shreds of membrane have been expectorated there can of course be no doubt as to the presence of a parasite, either in the lung, or passing through the lung from the liver, or some other primary seat. But it is highly imprudent to trust the mere statements of the patient upon this point, for I have repeatedly had flakes of tough mucus, casts of the bronchial tubes, &c., produced as hydatids or "skins." But when no membranes have been observed, and when the symptoms and physical signs closely simulate phthisis, as is often the case, the difficulties of differential diagnosis may become very great.

1. *The History and General State of the Patient*.—Although in many cases the frequent cough, the night-sweats, the emaciation, the purulent expectoration, and occasional blood-spitting present the precise picture

* This was written in 1889. It could not be conveniently incorporated with the preceding. Vide note, page 63.

of an ordinary case of pulmonary phthisis, yet it may often be noticed that in spite of all this the patient is less ill than might be expected from the general symptoms and physical signs present. Often the colour and complexion of the patient continue good, and a fair amount of flesh is retained.

2. *The Character of the Physical Signs.*—Before the hydatid cyst has ruptured, it is closely applied to the inner wall of its enveloping cavity, in consequence of the elastic tension of its wall; it therefore gives effective support to the blood-vessels that lie on the wall of the cavity, and it hermetically closes the openings of any bronchial tubes that may happen to enter the cavity.

When a pulmonary hydatid attains a considerable size, and is situated at the base of the lung, it closely simulates pleuritic effusion; but even in this situation there is often some erratic feature of the physical signs to arouse suspicion. For example, the heart, instead of being merely laterally displaced as in pleural effusion, may be pushed bodily forwards against the anterior chest wall, or it may be twisted on its own axis, as in a case recorded by Landouzy.* Sometimes, too, the heart may suffer more displacement than the liver when the right base is occupied by an echinococcus cyst. All such phenomena point rather to a tumour than a mere pleural effusion.

This peculiarity of hydatid cysts is of great diagnostic importance in most cases, but I have known all the physical signs of a pulmonary hydatid to be simulated by a sarcoma of the left lung. In this case there was absolute dulness over the lower two-thirds of the left lung, with tympanitic resonance at the apex and at the posterior base; total silence over the dull area; displacement of the heart to the opposite side; no pressure signs affecting the mediastinum; absence of obvious cachexia, and absence of abnormal signs in the right lung.

It is needless to remark that an exploratory puncture usually yields conclusive evidence, but this measure is by no means a trivial one.†

When the cyst ruptures however, this pressure, amounting to ten or twelve inches of water and often more,‡ is suddenly removed, and the fluid contained in the cyst is permitted to escape into the enveloping cavity. If now any bronchial tubes are open, the fluid will rush into them, and thus flood the entire bronchial tract of that lung, and not only will the lung containing the parasite be invaded, but, at each succeeding inspiration, fluid will be sucked back into the healthy lung.

* Virchow and Hirsch's Jahresbericht, 1883, Vol. II., p. 163.

† Compare this remark with the statements on page 45 and 63, with reference to exploration.

‡ Vide Dr. Thomas' Hydatid Disease of the Lungs, 1884.

which may thus become flooded with the watery contents of the cyst: there can be no doubt that occasionally death is caused by drowning in this way.* Fortunately, however, this is rare; but a high degree of dyspnoea is quite common at the moment of rupture. Again, in consequence of the sudden removal of pressure, some of the blood-vessels on the wall of the cavity usually give way, and so a certain amount of hæmoptysis is always present when the cyst bursts. After rupture, not only does the hydatid fluid leave the cavity, but air enters it. The physical signs of the hydatid cavity are greatly modified by the following factors:—

(a) By the position of any bronchial tubes that may open into the cavity, as well as by the size of their orifices.

(b) By the depth from the surface at which the cavity is situated, and by the condition of the intervening lung tissue.

(c) By the existence in the cavity of the ruptured mother-cyst, or of any portions of this structure, or of daughter-cysts that have not been expectorated.

In some cases, after rupture, the usual classical signs of a large cavity may be elicited, *e.g.*, cavernous or amphoric respiration and voice sounds, and possibly even a tympanitic percussion-note or *bruit-de-pôt-felè*, but in my experience this is not the most frequent event. Usually there is remarkably little change in the local physical signs after rupture, for often localised dulness and more or less complete silence and loss of vocal resonance continue. I have no doubt that this anomalous group of phenomena is produced by the peculiar conditions present in many hydatid cavities. In a phthisical vomica there is a larger or smaller excavation in the consolidated lung-substance, and into this one or more bronchial tubes open generally at that part of the wall which lies nearest the root of the lung. In the case of the hydatid cavity, the bronchial openings may be situated at any part of the wall; for the gradually increasing pressure of the growing parasite may produce the most varied effects on both blood-vessels and bronchial tubes.

The depth at which the hydatid cavity is situated must obviously exercise a great influence upon the discoverable physical signs. Practically speaking, however, there is rarely any difficulty in diagnosis from this cause, inasmuch as echinococcus cysts of the lungs, which present themselves for surgical treatment, are generally of large size.

Perhaps the most important factor in connection with the causation of the physical signs of the ruptured pulmonary hydatid is the pre-

* Vide p. 45.

sence of the mother-cyst. It is obvious that a smooth body, such as the ruptured mother-cyst, may be easily moved in accordance with changes of posture of the patient, and such changes must of necessity be accompanied by corresponding alterations of the physical signs.

3. The microscopical examination of the sputa.

In a doubtful case, when the diagnosis lies between phthisis and ruptured pulmonary hydatid, the bacteriological examination of the sputum will yield valuable aid. Up to the present time I have examined the sputum in cases of pulmonary hydatid, but without in any case succeeding in finding bacteria which stain as do those of tuberculosis.

APPENDIX.

Hydatid Cysts in the Air Passages.

Hydatids in the Bronchial Tubes.—It is scarcely possible that a cyst of any material size could long occupy the interior of one of the larger bronchial tubes, for its presence would cause such violent cough and dyspnœa as would probably soon lead to its expectoration.

Indeed it is very rare for the cystic phase of echinococcus to occupy as its primary seat any tube lined by mucous membrane. But Mégnin* has recorded the case of a degenerated echinococcus cyst of the size of a hazel nut, which was found in the substance of the intestine (ileum) of a horse: it lay immediately under the mucous membrane, just above the ileo-cæcal valve. Davaine† cites Reynaud as having seen, in several instances, lungs of the cow, deer, and gazelle, containing "acephalocysts" in the extremities of the bronchial tubes. I have hitherto been unable to find any cases on record where hydatid cysts occupied the larynx, trachea or bronchial tubes as their primary seats in man, but cysts or portions of cysts may rupture into and be arrested, temporarily or until the death of a patient, in the larger air passages, *e.g.*, the larynx or trachea.

Such impaction if of momentary duration, occasions intense dyspnœa, lividity of the face, &c., with sense of dying from suffocation. If of more than very brief duration, the grave obstruction to respiration may without doubt cause death.

* Virchow and Hirsch, Jahresbericht, xiv. Jahrgang, 1879. Part I., p. 355.

† Traité des Entozoaires, deuxième édition. Paris, 1877, p. 352.

Schrötter* records a case in which there was found "in a bronchus of the first order of the left lung a collapsed echinococcus vesicle, surrounded by detritus, and which would have been when full of about the size of a walnut."

Turner† has recorded the case of a woman, 29 years of age, who had many hydatids in the peritoneal cavity, and a large one in the lung, into which many bronchial tubes opened: "in one bronchus a hydatid cyst was found."

In such cases it is probable that the hydatids found in the interior of the bronchial tubes had reached their location not long before the death of the patient.

It is remarkable to observe how extensive a fragment of ruptured cyst, or what large unruptured vesicles, may pass safely through the glottis. Thus, I have known a fragment of mother-cyst, fully as large as a crown piece, to pass through the glottis of a boy aged 9 years, and a piece as large as the top of a tumbler has also been known to be safely expectorated in an adult. Of course in such cases the dyspnœa is for a time very urgent.

Even after the cyst has passed through the glottis the danger of suffocation is not quite over. For example, a case is recorded by Rudall‡ thus—

"One morning the patient was found by his wife on the floor insensible, black in the face and choking: she put her finger into his mouth and hooked up an hydatid cyst, and thus saved his life."

Hydatids of the Larynx.—A man died after presenting for three months the following symptoms:—progressive dyspnœa, hissing breathing, with inspiration more harsh than expiration, and dysphagia.

At the autopsy two transparent vesicles of the size of small nuts were found underneath the epiglottis touching each other and occupying, especially on the right side, a part of the ventricles of the larynx. One of the hydatids adhered by half its surface externally to the neighbouring tissues. §

Hydatid Cyst of the Neck opening into the Trachea. ||—A porter, aged 50, was admitted into the Hôpital de l'Ecole. He had on the right side of his neck a tumour of about the size and shape of a goose's egg: this tumour extended transversely across the lower part of the anterior median line of the neck to the neighbourhood of the

* *Mediz. Jahrbücher.* Wein, 1867, vol. xiv., fasc. 4, p. 31.

† *Bull. de Therap.*, 1848, p. 226.

‡ *Aust. Med. Jour.*, 1877, p. 126.

§ *Davaine. Obs. CCX.*, p. 563.

Davaine. Obs. CCXI., 563.

angle of the jaw. It was regarded by Laennec as a cystic growth. Towards evening it was observed that the patient felt oppression; immediately afterwards he lost consciousness and died asphyxiated. The autopsy showed the condition to have been as follows: the tumour, which was ovoid in shape, and about six inches long, and about four inches at its middle part, covered internally and posteriorly the right side, and to a small extent the anterior part, of the larynx and of the upper cartilages of the trachea, as well as the deep vessels and nerves of the neck. Anteriorly, it was covered by the sterno-mastoid muscle, and to a small extent inferiorly by the sterno-hyoid of the right side; it pushed to the left the right lobe of the thyroid gland, which was slightly elongated. This tumour was formed by an echinococcus cyst of the size of a hen's egg, and a second of the size of a nut, with several smaller ones: the sac which contained these cysts was about two lines in thickness.

At the spot where the tumour covered the larynx and trachea there was found a round perforation into the trachea, so that the cricoid cartilage, the first tracheal ring, and a part of the second, were destroyed and eroded: the fibrous capsule adhered firmly to the contour of this opening. The mucous membrane was inflamed from the glottis down to the bronchi. Death must have occurred from œdema of the larynx.

B. Hydatid Disease of the Heart.

Frequency.—The heart fortunately is a rare seat of hydatid disease, for the ratio of cases in which the "heart and organs of circulation" were invaded in nearly 2,000 cases was only 1·845 per cent.*

From various sources De Welling† collected 30 cases in which the heart was the seat of one or more echinococcus cyst; I have in addition met with 18 cases in the literature accessible to me, consequently there are 48 recorded cases of the existence of this parasite in the human heart.

Sex.—There were 26 males and 18 females; in the remaining 4 cases the sex was not mentioned, the percentage ratio of the sexes being, males 59, females 41.

* Thomas J. Davies, "Hydatid Disease, &c.," page 124.

† Des Kystes Hydatiques du Cœur. Paris Thesis, 1872.

Age:—

From 1 to 10 years old	4 cases
" 11 " 20 " "	11 "
" 21 " 30 " "	7 "
" 31 " 40 " "	7 "
" 41 " 50 " "	1 case
" 51 " 60 " "	2 cases
" 61 " 70 " "	1 case
Age not stated	15 cases
			<hr/>
			48

When the age-distribution of cardiac hydatids is compared with that of echinococcus in general it appears that the heart is especially prone to be invaded in early life.

Site.—In the majority of cases the parasite was imbedded in the muscular wall of the organ, but in some instances it was found free in one of the cavities, and occasionally it was suspended by one or more pedicles from some part of the interior of the heart. In a very remarkable case by Otto* a mass of hydatids—70 to 80 in number—was found attached by pedicles to the free edge of the Eustachian valve: it is possible that these were not really echinococcus cysts.

In the great majority of the recorded cases the only hydatid mentioned in connection with the case is that in the heart, but in 17 instances multiple hydatids were found in other organs, viz.:—

Heart and liver	5 cases
Heart, liver, and peritoneum	1 case
Heart, liver, lungs, omentum, spleen, kidney, psoas, and iliacus muscles	1 "
Heart and pulmonary artery	4 cases
Heart, lung, and spleen	1 case
Heart, lung, kidney, and brain	1 "
Heart, spleen, and brain	1 "
Heart and spleen	1 "
Heart and left ovary	1 "
Heart and left pleura	1 "
			<hr/>
			17

Multiple Cysts.—Most commonly but one mother-cyst was present in the heart, but in Huppert's case† there were several imbedded in

* Cited by De Welling; Obs. IX.

† *Echinococcus pulmonum*, cited by De Welling.

various parts of the heart, and if Otto's case be genuine the number amounted to 70 or 80. Daughter-cysts, of course, were sometimes very numerous.

When the cysts are numerous or large they may produce considerable enlargement of the heart, *e.g.*, in the case recorded by Huppert* where the heart had attained the dimensions of a child's head, or larger.

The size of the cysts varied from that of a millet-seed up to that of a hen's or a duck's egg, or larger; in one case (Budd's) it was of the size of an orange.

The shape of the heart is often greatly altered by the presence of the cysts.

Course of the Disease.—Inasmuch as up to the present time no case of this disease has been recognized during life, it is impossible to describe its natural course; but judging by the *post mortem* appearances, the phenomena differ in different cases.

Spontaneous Cure.—Strange as it may seem, there can be no doubt that spontaneous cure may occur in some instances of cardiac hydatids. For example, in the case of a subject in the dissecting-room of St. Bartholomew's Hospital, Mr. Holmes Cootet found the heart to be greatly enlarged, so as to compress both lungs considerably; the pericardium universally adherent; the wall of the left ventricle occupied by a thick-walled cyst "containing dead acephalocyst hydatids, floating in sero-purulent fluid; the interior of the cyst was rough, probably from the deposit of lymph."

A somewhat similar case, in which the parasite was of the size of a duck's egg, and occupied the posterior and upper part of the ventricular septum, is recorded by Rokitansky.†

Other cases have been recorded in which it is stated that "pus" escaped from a cured hydatid of the heart; there can however be no doubt, from the history of some of these cases, that the supposed pus was really the usual puriform fluid seen in degenerating echinococci, for no inflammatory phenomena were noticed in the neighbourhood of the supposed pus.

A clear instance in point is that recorded by Dr. Goodhart§: another by Habershon|| was equally clearly of this nature: Madelung¶ also has referred to another case.

* *Echinococcus pulmonum*, Inaug. Dissert., Jena, 1875, p. 12.

† *Medical Times and Gazette*, 1854, Vol. I., p. 156.

‡ Cited by De Welling, *op. cit.*, Obs. XVI., p. 20.

§ *Pathological Society Transactions*, Vol. XXVII., p. 72.

|| *Pathological Society's Transactions*, Vol. VI., p. 108.

¶ *Op. cit.*, p. 90.

It therefore cannot be doubted that occasionally even hydatids of the heart may become spontaneously cured.

Rupture.—This is a far more frequent accident of hydatids of the heart than spontaneous cure: and almost always rupture takes place into one of the cavities of the heart. Up to the present time there is no instance of rupture into the pericardium on record: when the maximum growth takes place outwards it would seem that adhesive inflammation of the visceral and parietal pericardium near the parasite is always present.

In one case there was recent pericarditis present,* and it seems probable that the parasite had really suppurated. It is explicitly stated that pus was contained in the cyst, together with daughter-cysts.

The direction of the rupture will, of course, largely depend upon the original situation of the parasite. It occurs more often into the cavities of the right side than into those of the left, for out of 16 cases in which there was clear evidence of rupture into the interior of the heart, 12 were into the right and only 4 into the left side.

Rupture into the Cavities of the Right Heart.—This happened into the auricle four times; into the ventricle eight times. In two cases it is reported that hydatids were found in the right ventricle, but no definite statement is made as to the original site of the parasite.

Hydatid cysts of the septum ventriculorum tend to rupture into the right ventricle, probably because the pressure of blood on this side is much less than on the left side of the septum.

Effects of Rupture into the Right Heart.—The phenomena will vary according to the cavity invaded, and according to the size and number of the cysts liberated.

In one case of rupture into the right auricle recorded by Kelly† a cyst which originally occupied the left auricular appendix ruptured and released a daughter-cyst of the size of a walnut which blocked up the auriculo-ventricular orifice, causing death in twenty minutes.

If the liberated cysts be of a smaller size so as to pass readily through the auriculo-ventricular and pulmonary orifices they will be conveyed into the pulmonary artery; they will then become impacted in one or more branches of the pulmonary artery, and they may even recommence their development in this situation.

In eight cases rupture took place into the right ventricle, and in two

* Peacock: Pathological Society's Transactions, XXIV., p. 37.

† Pathological Society's Transactions Vol. XX., p. 145.

others it is stated that hydatids were found in the right ventricle, but no statement is made as to the original seat of the parasite,

When the parasite is unruptured and of large enough size, it may so fill the right ventricle as to prevent the entry of blood into the pulmonary artery, as in a case by Smith.* Or the cyst may be forced into the conus arteriosus and pulmonary artery so as to completely occlude them, as in a case recorded by Rokitansky. †

If the cysts are of small size or ruptured they may be carried into the branches of the pulmonary artery inside the lungs.

Rupture into the Cavities of the Left Heart is less frequent than into those of the right, but in four cases this is mentioned, viz., once into the left auricle, three times into the ventricle. In the first case‡ the parasite was situated in the posterior wall of the left auricle; it perforated at several places into the auricle, releasing numerous small daughter-cysts; these passed into the systemic circulation and caused blockage of the right common iliac artery, and also of the deep femoral artery, in the latter of which was found a cyst of the size of a hazelnut which contained numerous grand-daughter cysts: two infarcts found in the left kidney were probably of similar origin.

Of the three cases in which the left ventricle was invaded, in one recorded by Wilks§ a hydatid of the size of a billiard ball was found loose in the left ventricle. "The hydatid cyst had in all probability been developed in the apex of the left ventricle, and during the progress of its growth had pushed forward into the cavity of the heart." It would seem that the parasite had carried its fibrous sac with it; had become pedunculated and finally free, the last-named event being followed by sudden death. The other cases are those of Beck|| and of Evans. ¶

In a remarkable case recorded by Huppert** the left renal artery was occluded by an embolic hydatid cyst, but it is not stated clearly whence this appeared to have been derived.

* Lancet, 1837-38, p. 628.

† De Welling, op. cit., Obs. XV.

‡ Oesterlen: cited in Virchow and Hirsch, Jahresbericht, 1868, Vol. II., p. 71.

§ Pathological Society's Transactions, Vol. XI., p. 71.

|| Lancet, Vol. II., 1879, p. 545.

¶ Australian Medical Gazette, 1882, p. 169.

** Echinococcus pulmonum, Inaug. Dissert., Jena, 1875, p. 12.

C. Hydatid Disease of the Great Blood Vessels.

Hydatids in the Pulmonary Vein.—Andral* has recorded an extraordinary case where numerous hydatid cysts of sizes varying from that of a large nut to that of a pea were found enclosed in dilatations of the pulmonary vein.

A man, aged 55 years, had suffered severely from the ordinary signs of heart disease: habitual orthopnœa, œdema of the limbs, face puffed and dusky. Murmurs in the whole extent of the sternum and under the two clavicles: at several points of the thoracic walls moist bronchial râles were heard, whilst at others there was a complete absence of respiration. Respiration became more and more difficult, and the patient died in a state of asphyxia.

Autopsy.—The two lungs were found filled with a large number of hydatids, varying in size from that of a pea to that of a large walnut. At first sight they appeared to be lodged in the lung substance itself, but careful dissection proved that they were contained in dilatations of the pulmonary veins. They existed equally in both lungs, and were found both unruptured and ruptured; in the latter case they occupied elongated narrow channels, which were ramified like the ordinary vessels. Around the cysts, the lung tissue was in many places healthy and crepitant, in others, highly congested and even hepatised. The right cavities of the heart were considerably dilated, and the walls of the right ventricle were somewhat hypertrophied. In the liver was found a hydatid of the size of a large orange. It had cartilaginous walls, and contained eight or ten acephalocysts.

Evidently the dilatation of the cavities of the right heart, and the hypertrophy of the right ventricle were due to the impediment to the circulation through the pulmonary veins.

As far as I have been able to discover, this case is unique in the annals of medicine, and no explanation can be offered to account for the conveyance of the hydatids into the interior of the veins.

Hydatids in the Pulmonary Artery and its Branches.—They have been met with anywhere from the arterial orifice in the right ventricle to the more remote branches inside the lung.

* Clinique Médicale. Paris, 1840. Tome II., p. 392.

For example—Broderibb* has recorded the case of a lady in whom the right ventricle was so largely occupied by a hydatid cyst, as to cause fatal interference with the passage of blood into the pulmonary artery. Death took place three hours after the onset of a sudden severe attack of dyspnoea and cardiac oppression.

In this case the hydatid can scarcely be regarded as being in the pulmonary artery. However, I have from various sources collected and tabulated eleven cases, where hydatids or parts of hydatids actually occupied the interior of this artery or its branches. Five of these occurred in females, six in males. The youngest patient was a boy aged 10; the oldest, a man aged 47. As the most important facts connected with these cases are recorded in the Appendix, it will not be necessary for me to refer at length to them.

However, it is interesting to note that in eight out of the eleven cases, there were present hydatids on the right side of the heart.

In case No. 8, I have not as yet been able to peruse the original record, and the reference to the case in Virchow and Hirsch's *Jahresbericht* is a very brief one.

In case No. 9, no heart hydatid was found, although several cysts were found in the abdomen, one of which, a liver cyst, had ruptured into the pericardium.

Case No. 10 is an example of the rare multilocular variety of echinococcus.

In all the remaining cases there were hydatids in the right side of the heart: once in the right auricle, six times connected with the right ventricle, and once connected with both right auricle and ventricle. In these cases it was either certain or highly probable that, either recently or more remotely, the heart hydatid had ruptured or become detached, and that the hydatids found in the pulmonary artery were really embolic in their origin. This was plainly the case in No. 6.

In some instances the pulmonary circulation was so impeded by the large size of the obstruction that sudden death occurred. In other cases the cysts were smaller or ruptured, and in some instances the unruptured cysts had formed pouches for themselves within the calibre of the blood vessels.

Of course it does not follow of necessity when hydatids are found simultaneously in the right side of the heart and in the lungs, that the latter are secondary to the former. For when a great number of

* *Lancet*, 1837-38, p. 625. Cited also by Davaine and Hearn.

hydatids are scattered all over the body, both the lungs and the heart may receive their shares quite independently of each other.

A very interesting case of this kind was recorded by Dr. Peacock and Mr. Wale Hicks.*

It occurred in a sailor boy aged 18, admitted into St. Thomas Hospital, London, in 1864. He was suffering from cough, dyspnoea and pain in the chest, and he expectorated much blood-stained purulent matter and small hydatid cysts. There were numerous hydatids in the liver, spleen, right kidney, and other parts of the abdomen. Both lungs contained numerous hydatid cysts, most of which were of about the size of a horse-chestnut or somewhat larger, embedded in cavities of the pulmonary tissue. There was a partially collapsed cyst, with thickened walls on the surface of the right ventricle of the heart, apparently partially embedded in the muscular structure, but not projecting into the cavity of the ventricle.

In this case it was evident that the lung and heart hydatids were quite independent of each other.

APPENDIX.

HYDATID CYSTS IN THE PULMONARY ARTERY.

1. REFERENCE.—Griesinger. Archiv für Phys. Heilkunde, 1846, cited by De Welling, Paris Thesis, 1872, p. 18, 19.

Sex and Age.—Female, 37.

Locality.—A hydatid situated in the interventricular septum ruptured into the right ventricle, and passed thence into the pulmonary artery. The cavity that contained the hydatid was of the size of a large walnut.

Symptoms.—Feelings of anxiety and oppression in the chest. Half-an-hour later found dead in bed.

Mode of Death.—Not observed.

2. REFERENCE.—Rokitansky. Cited by Davaine and De Welling.

Sex and Age.—Female, 23

Locality.—Hydatid situated in the interventricular septum. Rupture of the sac, with the escape of the hydatid into the right ventricle. The vesicle, which was of the size of a hen's egg, was forced by the blood current into the conus arteriosus, and as far in the pulmonary artery as

* Pathological Soc. Trans., vol. xv., p. 247.

to reach the left branch of this vessel. There were also three hydatid tumours in the liver.

Symptoms.—None recorded.

Mode of Death.—Death sudden.

3. REFERENCE.—Budd. Path. Soc. Trans., 1859, Vol. X., p. 80.

Sex and Age.—Female, 23.

Locality.—Hydatid of the size of an orange at the apex of the heart projecting into the right ventricle; several hydatids in trunk of pulmonary artery, and clusters of hydatids ruptured and unruptured, in branches of the left pulmonary especially in upper lobe: none in right lung. The pulmonary artery hydatids as well as a ruptured one found under one of the laminae of the tricuspid valve had evidently escaped from the cyst at the apex of the right ventricle.

Symptoms.—Formerly two attacks of pleurisy: cough, dyspnoea especially on exertion: hæmoptysis at first streaky, and afterwards copious: œdema of legs: systolic murmur at the base of the heart, which, however, gradually became less loud, and ultimately disappeared before death; slight albuminuria.

Mode of Death.—Death not abrupt

4. REFERENCE.—Drs. Manson and Barclay. Lancet, 1864, Vol. I., p. 225.

Sex and Age.—Male, 26.

Locality.—In the right ventricle of the heart, near the tricuspid valve, a hydatid of the size of a walnut, containing numerous daughter cysts was found. The pulmonary artery and its branches contained several minute hydatids. Both lungs, but especially the left one, studded with numerous hydatids of various sizes. One of the hydatids in the upper lobe of the left lung, had ruptured into the corresponding pleura, and had caused empyema.

Symptoms.—Hæmoptysis and obscure cardiac and pectoral symptoms, which puzzled his medical advisers.

5. REFERENCE.—Kelly, Path. Soc. Trans., Vol. XX., p. 145.

Sex and Age.—Male, 10.

Locality.—Hydatid in the appendix of the right auricle. It contained many daughter-cysts; the largest, of the size of a walnut, had escaped and blocked up the auriculo-ventricular orifice, causing death. In a main branch of each pulmonary artery at the root of the lungs was an oval hydatid cyst. These cysts had evidently been there for some time, for they had formed adhesions with the coats of the artery, and had made dilated sacs for themselves. Moreover the proximal ends were smaller than their distal ones, and the branches of the pulmonary arteries beyond the obstruction had become narrowed.

Symptoms.—None present, except slight pain in his chest. "He could run about as well as other boys of his age, up to the time of his death."

Mode of Death.—Fell down suddenly, insensible. No dyspnoea, but slight convulsions.

6. REFERENCE.—Stirling and Allen. Aust. Med. Jour., 1879, p. 394.

Sex and Age.—Male, 47.

Locality.—In the substance of the right ventricle of the heart at its apex there was a hydatid of the size of a large hen's egg, full of small daughter-cysts. Rupture in its inner wall, occluded by a pale adherent clot of some standing. Numerous hydatid cysts in both lungs, especially in the right. The cysts were mostly contained in dilatations of the pulmonary arteries. "Some cysts, however, lay in distinct cavities of large size, one being one inch and three-quarters in diameter, lined by fibroid membrane, and one of these larger cavities in the lower lobe of the right lung opened into a bronchial tube." The spleen also contained a large, but partially degenerated cyst.

Symptoms.—Cough, hæmoptysis, expectoration of pieces of membrane. General symptoms of phthisis. Capillary bronchitis and sudden death.

Mode of Death.—Death sudden.

7. REFERENCE.—Bingham Crowther. Aust. Med. Jour., 1880, p. 362.

Sex and Age.—Male, —

Locality.—Hydatid in septum ventriculorum, which had ruptured into the right ventricle, and had permitted the escape of six to eight cysts, varying in size from a pea to a filbert, into that cavity. "Near the origin of the second division of the right pulmonary artery a white collapsed hydatid cyst was found blocking up for two inches this portion of the artery, completely occluding the same."

Symptoms.—Pain in chest, giddiness, and sickness, possibly due to smoking, ("which he had not been accustomed to.")

Mode of Death.—Suddenly became insensible, gave several irregular gasps, and died in a few minutes.

8. REFERENCE.—Maschka. Pragen. Med. Wochenschrift, No. 5. Cited in Virchow & Hirsch's, Jahresbericht, Vol. XV., part 1, p. 665.

Sex and Age.—Female, —

Locality.—Two large echinococcus cysts at the left edge of the heart, one of which had ruptured into the pulmonary artery.

Symptoms.—Suspicion of poisoning in consequence of sudden death.

Mode of Death.—Sudden.

9. REFERENCE.—Wunderlich. Archiv für Physiolog. Heilkunde, 1858. Cited by Davaine and by Hearn.

Sex and Age.—Male, 22.

Locality.—In a branch of the third order, furnished by the right pulmonary artery, and corresponding to the lower lobe of the lung, there was a cylindrical dilatation of the size of a pigeon's egg, completely filled by a hydatid cyst. The branches of the artery beyond this point were filled with debris of hydatids, but the corresponding lung tissue was not altered. No hydatid found in the heart, but a hydatid of the left lobe of the liver had ruptured into the pericardium, and had caused

violent pericarditis. There were several other hydatids in the abdominal cavity including one in the spleen.

Symptoms.—Headache, giddiness, noises in the ears, abdominal pains, diarrhoea, epistaxis. Rigor followed by heat and sweating. Slight albuminuria, &c.

10. REFERENCE.—Schrötter. *Medizin. Jahrbücher.* Wien, Vol. XIV.

Sex and Age.—Male, 29.

Locality.—Tubercles in the peritoneum. Two small ordinary hydatids in the liver, which also contained a small patch of the multilocular form. In both lungs similar and more extensive growths. In a branch of the first order of the pulmonary artery of each lung a hydatid vesicle enclosed in a sort of pouch of the artery. That on the right side was about the size of a nut, that on the left exceeded the size of a bean. In the smaller branches of the pulmonary arteries in both lungs, numerous smaller hydatids, ruptured and entire.

Symptoms.—Cough. Repeated hæmoptysis and expectoration of cysts, pyrexia, emaciation, pain in the chest, physical signs of consolidation, with small cavities in both lungs, elastic fibre in considerable amount found in the expectoration.

11. REFERENCE.—Böcker. *Zur Statistik der Echinococcen.* Berlin, 1868, p. 14.

Sex and Age.—Male, 15.

Locality.—The lumen of the right pulmonary artery contained a sac about the size of a bean, attached to its posterior wall. The artery of the left upper lobe was entirely closed by an echinococcus cyst. Numerous hydatid cysts connected with the heart, which was about the size of a child's head. Right auricle and ventricle dilated. Left renal artery blocked by an embolic echinococcus cyst.

Symptoms.—None recorded.

HYDATID DISEASE, Vol. II.

PART III.—HYDATID DISEASE AFFECTING THE NERVOUS SYSTEM.

- A. The Brain and its Membranes.
- B. The Spinal Cord.

HYDATID DISEASE, Vol. II.

PART III.—HYDATID DISEASE AFFECTING THE

NERVOUS SYSTEM

A. The Brain and its Membranes.

B. The Spinal Cord.

PART III.—HYDATID DISEASE AFFECTING THE NERVOUS SYSTEM.

A. Hydatid Disease of the Brain and its Membranes.*

Bibliography.

RUSSELL REYNOLDS AND BASTIAN—Article, "Adventitious Products in the Brain," Reynolds' System of Medicine. Vol. II., 1868, page 498.

CLEMENCEAUX—Des Entozoaires du Cerveau Humain. Paris Thesis, 1871.

Varieties of Cystic Parasites.—Described by the term "*Hydatids*" at least three, and possibly four, distinct cystic parasites have been known to infest man, viz.:—(1) *Echinococcus*; (2) *Cysticercus cellulosæ*; (3) *Cysticercus acanthotrias*; and (4) *Cœnurus*.

All four species, it is alleged, have been met with in the human brain, and as both *echinococcus* and *cysticercus cellulosæ* are by no means very rare in this situation, it is very desirable that the vague term "*hydatids*" should fall into desuetude, especially in connection with cerebral parasites.

This is of importance, not merely from the standpoint of scientific accuracy, but also on practical clinical grounds; for in some parts of Germany—*e.g.*, in Prussia and Saxony—*cysticercus cellulosæ* is a common parasite: it exhibits moreover a special proclivity to attack the brain in man; for example, Dressel† found that "among the 87 cases of these bladder-worms in Berlin, 72 were in the brain."

Whilst collecting the material upon which this paper is based, I have repeatedly met with cases described as "*hydatids*," which were evidently examples of *cysticercus cellulosæ*.

* This is practically a reprint of Dr. Thomas' paper in the Transactions of the Intercolonial Medical Congress of Australasia; First Session. Page 60 et seq.

† Cited by R. Leuckart, "The Parasites of Man," English translation, 1886, page 549.

It is curious that the only instance of *cysticercus acanthotrias* hitherto placed on record is that observed by Weinland in America. Twelve or fifteen bladder-worms were discovered in the body of a white woman; they were, for the most part, found in the subcutaneous and intermuscular connective tissue, but one "hung freely on the inner surface of the dura mater, near the crista galli."

The occurrence of *cœnurus* in man is denied by Davaine;* nevertheless Clemenceaux† relates a case which certainly appears to be a genuine instance of *cœnurus* in the brain of a woman aged 40. This parasite infests the brain of the sheep, and causes the disease known as the "staggers" or "gid."

Frequency.—The brain is not a common seat of this parasite in man, for out of nearly 2,000 cases of *echinococcus*, collected from various parts of the world, "the brain, its membranes and the cranial cavity" were invaded in only a little over 4 per cent.;‡ whilst out of 800 cases treated in various hospitals in the Australasian colonies, it was found there in only nine cases, or in a little over 1 per cent. It is probable, however, that, especially in private practice, in which post-mortem examinations are infrequent, the presence of the parasite in the brain is sometimes overlooked.

In England it is very rare. For example, out of 100 cases of cerebral tumour collected by Dr. Hale White§ from the post-mortem records of Guy's Hospital during the thirteen years 1872-84, both inclusive, only once was the growth an *echinococcus* cyst. He naturally remarks that "hydatid of the brain is so very unusual that it need not be considered in the group of cerebral tumours." But in Australia, where *echinococcus* infection is so common, we cannot relegate this variety of cerebral tumour to so insignificant a position. Besides, in consequence of the vast strides recently made in the pathology and surgery of brain affections, it becomes a matter of clinical importance to increase, if possible, our knowledge of the diagnosis and possible treatment of this variety of cerebral lesion.

With this end in view I endeavoured during a recent visit to Europe to collect, from all the sources accessible in the library of the Royal College of Surgeons, as many as possible of the recorded cases of *echinococcus* of the brain. After a careful scrutiny I have gathered and tabulated 97 cases, which appear to me to be genuine instances of this

* *Traité des Entozoaires*. Paris, 1877. Pages 696 and 697.

† *Des Entozoaires du Cerveau Humain*. Paris Thesis, 1871, page 30.

‡ Thomas: *Hydatid Disease, with Special Reference to its Prevalence in Australia*. Adelaide, 1884.

§ *Guy's Hospital Reports*, Vol. XLIII., 1886, page 117 and seq.

affection. In some of them the data are very scanty, but in the majority the histories are tolerably complete as far as the then current knowledge of cerebral pathology went. This, it is needless to add, was often very far indeed in arrears of the present state of the question. Still I venture to hope that some light may be thrown upon a confessedly obscure subject

Site.—The cases have been collected into five groups, viz. :—

1. Echinococci occupying the cerebral hemisphere	...	58 cases
2. " " cerebellum	4 "
3. Multiple Echinococci situated in various parts of the brain	15 "
4. Miscellaneous intra-cranial Echinococci	11 "
5. Echinococci specially connected with the base of the brain	9 "
		97

With regard to groups 3 and 4, it is to be feared that but little information either in diagnosis or treatment can be obtained, but as concerns the remaining 71 cases the prospects are more hopeful.

Sex.—In 93 cases the sex of the patient is mentioned, viz. :—males, 62, or 66·65 per cent.; females, 31, or 33·35 per cent., so that there were exactly twice as many males as females attacked. The proportion in which the two sexes suffer from echinococcus infection varies in different parts of the world, partly according to the relative ratio of each sex to the total population, but in a much higher degree dependent upon the chances of infection induced by the mode of life of the two sexes.

Proportion of each Sex to the total Population.—Taking the average of the principal nations of Europe, the proportion of the sexes is, in round numbers*—males, 48·5 per cent.; females, 51·5 per cent. The proportion of the sexes attacked by hydatid disease appears to vary in different parts of Europe. For example in Iceland, according to Finsen,† more than twice as many females as males (2·27 to 1) are the subject of hydatid disease. He attributes the preponderance of women attacked to their occupation in cooking and in washing utensils, this rendering them more liable to swallow the ova of *tænia echinococcus* of the dog than men are, in consequence of Icelandic dogs being permitted to lick the vessels employed in the kitchen. It is certainly not due to the mere preponderance of females in the Icelandic population, for, according to

* Vide Mulhall, Dictionary of Statistics, 1884, p. 404.

† Vide the British and Foreign Medico-Chirurgical Review, No. XXXII., April, 1868, p. 345.

Schleisner,* "in the Icelandic population the proportion of the males to the females is as 1,000 to 1,120," *i.e.*, males, 47·16 per cent.; females, 52·83 per cent. More recent returns—*i.e.*, those for the year 1872—show practically the same proportions of the two sexes in this country, *viz.*, males, 47·49; females, 52·51 per cent.† In Australia the case is different, for in Victoria there is a large preponderance of males among the victims of this parasite. The proportions are, however, nearly in the ratio of the two sexes to the total population.‡ But whether we consider the case of Europe or that of Australia, it is certain that males are greatly more liable to echinococci in the brain than females are, and this shows itself out of all proportion to the population-ratio of the two sexes, and, what is still more curious, in far greater ratio than their liability to echinococcus disease in general. In this respect cysticercus resembles echinococcus, for Kuchenmeister, von Græfe, and Dressel agree that whether located in the brain or elsewhere cysticercus is about twice as common in males as in females. But parasites of the brain are not peculiar in this preference for the male sex; for there can be no doubt that cerebral tumours in general occur far more frequently in males. Obernier§ thinks that the proportion may in general be stated as about ten to six, and out of about 100 cases collected by Dr. Hale White from the Guy's Hospital records, 67 were males and 33 females.

Age.—In 79 cases the age of the patients were mentioned, *viz.*:—

From 1 to 10 years old, 15 cases, or 19·00 per cent.

“ 11 to 20 “ 27 “ 34·17 “

“ 21 to 30 “ 22 “ 27·84 “

“ 31 to 40 “ 8 “ 10·12 “

“ 41 to 50 “ 4 “ 5·07 “

“ 51 to 60 “ 2 “ 2·53 “

Over 60 years old, 1 case, or 1·27 “

79 100·00

The youngest patients were a girl, aged four (Series IV., No. 4), and a boy, aged five (Series III., No. 14). In five cases the patients were seven years old. The eldest was a woman, aged 75 (Series I., No. 57). The average age was 21 years and 10 months. When echinococcus attacks the brain, the patients die, on an average, at a much earlier age than when the parasite invades other parts of the body. From the

* P. A. Schleisner, in the *Journal of the Statistical Society*, Vol. XIV., 1851.

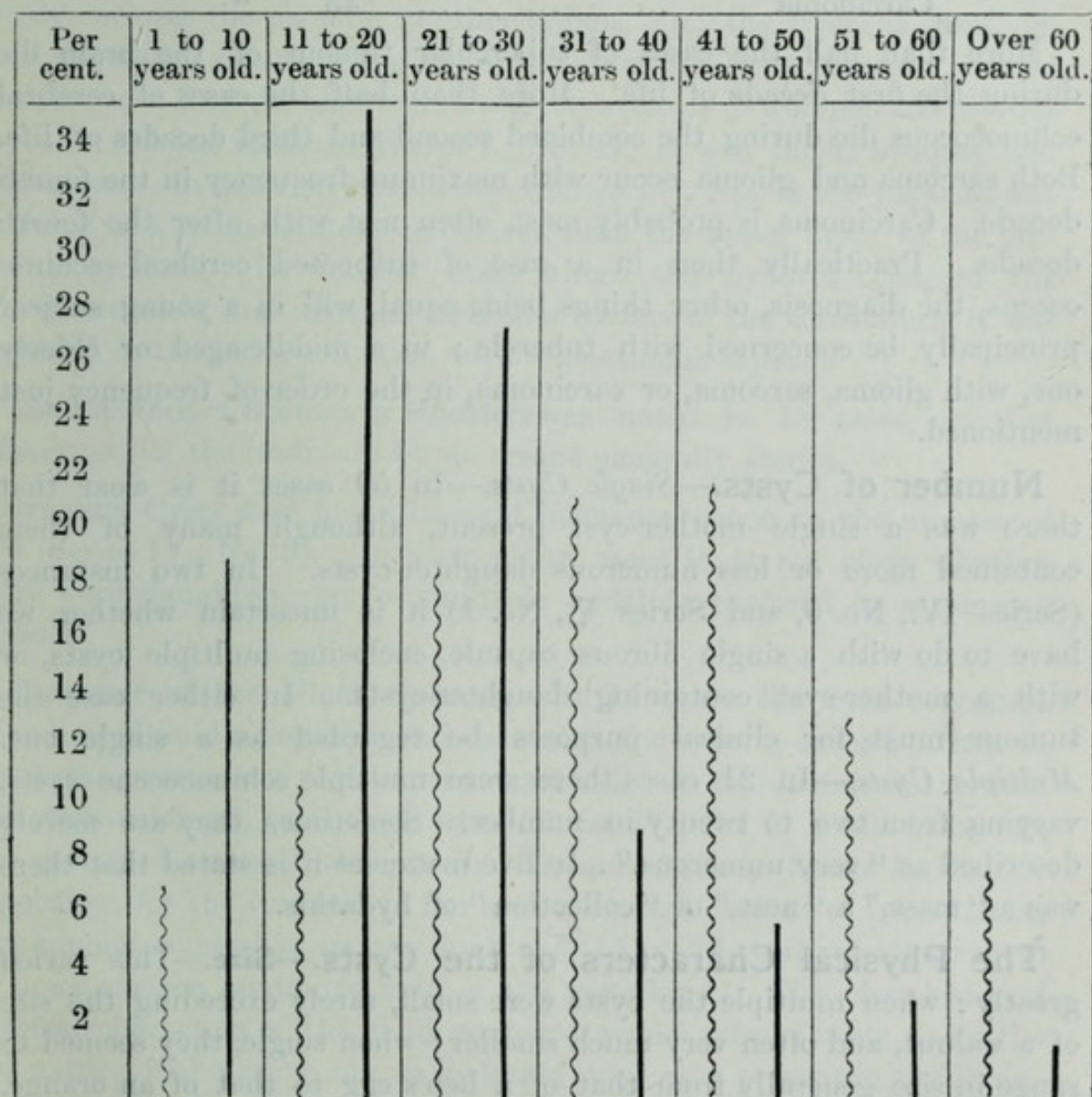
† For the figures from which these percentages have been deduced, see *Ultima Thule, or a Summer in Iceland*, by Richard F. Burton, 1875.

‡ *Hydatid Disease, &c.*, page 151.

§ Ziemssen: *Cyclopædia of Medicine*, Vol. XII., page 232.

accompanying diagram it will be seen that the highest mortality from echinococcus disease in general occurs in the fourth decade of life, at any rate in Australia.* More than 80 per cent. of the cases of cerebral hydatids die below the age of 30, while 80 per cent. of the deaths from hydatid disease in general take place between the ages of 20 and 50.

Diagram showing the distribution, according to age, of the deaths caused by echinococcus in general (wavy line), and by echinococcus of the brain (straight line).



The Age Incidence of Echinococcus compared with that of other Cerebral Tumours.—The principal cerebral tumours in point of frequency are—(1) Tubercle ; (2) Glioma ; (3) Sarcoma ; (4) Carcinoma. According to the statistics of Dr. Hale White already cited, the relative frequency

* For further details see "Hydatid Disease," page 126.

of occurrence is—Tubercular mass, 45 per cent.; Glioma, 24 per cent.; Sarcoma, 10 per cent.; Carcinoma, 5 per cent. The average age incidence of these tumours varies greatly, viz.:—

Disease.				Average Age of Patients.	
Tubercle	12 $\frac{1}{2}$	years old.
Echinococcus	22	"
Glioma	32 $\frac{1}{2}$	"
Sarcoma	37	"
Carcinoma	43	"

More than half the cases of tubercular tumour of the brain die during the first decade of life. More than half the cases of cerebral echinococcus die during the combined second and third decades of life. Both sarcoma and glioma occur with maximum frequency in the fourth decade. Carcinoma is probably most often met with after the fourth decade. Practically then in a case of suspected cerebral echinococcus, the diagnosis, other things being equal, will in a young subject principally be concerned with tubercle; in a middle-aged or elderly one, with glioma, sarcoma, or carcinoma, in the order of frequency just mentioned.

Number of Cysts.—*Single Cysts.*—In 59 cases it is clear that there was a single mother-cyst present, although many of them contained more or less numerous daughter-cysts. In two instances (Series IV., No. 5, and Series V., No. 1) it is uncertain whether we have to do with a single fibrous capsule, enclosing multiple cysts, or with a mother-cyst containing daughter-cysts. In either case the tumour must for clinical purposes be regarded as a single one. *Multiple Cysts.*—In 21 cases there were multiple echinococcus cysts, varying from two to twenty in number. Sometimes they are merely described as "very numerous." In five instances it is stated that there was a "mass," a "nest," or "collection" of hydatids.

The Physical Characters of the Cysts.—**Size.**—This varied greatly: when multiple the cysts were small, rarely exceeding the size of a walnut, and often very much smaller; when single, they seemed to range in size generally from that of a hen's egg to that of an orange. The largest single cysts were—one recorded by Rendtorf (Series I., No. 2), which weighed 2 $\frac{1}{2}$ pounds; Yates' case (Series I., No. 31), where it was of the size of an ostrich's egg; another published by Morgan (Series I., No. 33), which contained about 18 ounces of clear fluid; and a fourth, observed by Headington (Series I., No. 5), which contained 16 ounces of limpid fluid: occasionally they are described as "very large," or

"immense," &c. The largest cysts were found in the cerebral hemispheres.

The Shape of the Cyst.—The prevalent shape is spherical or ovoid. In one instance, the tumour had a lobulated character, probably produced by the superficial veins of the brain acting as ligatures (Series I., No. 23). In some cases the cyst sent prolongations into foramina or into cavities excavated into or through the bones of the cranium.

Fibrous Capsule or Adventitious Sac.—The fibrous envelope that commonly encloses the parasite in other organs, *e.g.*, the liver, is often, indeed generally, absent in the brain, but occasionally its presence is noted—either as a fine cellular membrane or even as a well-marked fibrous capsule. In one instance (Series I., No. 47) it was thick, opaque, and calcareous. In one remarkable case (Series IV., No. 5) the parasite was enclosed in a pedunculated sac derived from the upper layer of the tentorium cerebelli. In another case, where the hydatid occupied the fourth ventricle, and invaded the under surface of the cerebellum, it was provided in the latter situation with a gelatinous capsule.

The Presence of Scolices or Hooklets was noted in 18 cases, so that echinococci of the brain are by no means generally sterile.

Daughter-Cysts were found in eight instances—once to the number of 200 (Series IV., No. 5). In four other cases it is not clear whether there were daughter-cysts or multiple hydatids enclosed in a common capsule.

Character of the Fluid Contents.—In 14 cases the cyst contained clear limpid fluid; probably this was also the case in several others in which the presence of scolices was remarked. In two instances the fluid was straw-coloured, and in one other (Series IV., No. 5) it was brownish, and contained scales of cholesterin. Becquerel's case (Series I., No. 56) is peculiar, for the contents of the cyst were eight ounces of transparent, albuminous, somewhat viscous fluid, and 15 or 20 vesicles, adherent to its inner surface, contained fluid of the same kind. The chemical and physical characters of the fluid contents would raise doubts as to the real nature of the cysts, but as hydatids were also present in the lungs, the liver, and the mesentery, it was doubtless a genuine case of echinococcus in the brain.

Degeneration of the Parasite.—In three cases (Series I., Nos. 17 and 56, and Series V., No. 5) there were some indications of degeneration of the cysts, so that the possibility of spontaneous cure of cerebral echinococci cannot be denied.

Echinococci in other parts of the body.—This was remarked in eleven cases, the distribution being :—

Organ.	Number of Cases.
Liver	5
Liver and pelvis	1
Liver and left kidney	1
Liver, lungs, and mesentery	1
Liver and lungs	1
Heart and spleen	1
Heart and lung	1
	<hr/> 11

Site.—All parts of the brain, even the pineal gland and the choroid plexus, are liable to invasion, but, as might have been expected from their bulk, the cerebral hemispheres are especially so. In more than half of the cases the parasite was situated in one or other hemisphere, viz. :—

In the right hemisphere	30 cases
In the right lateral ventricle	2 “
In the left hemisphere	19 “
In the left lateral ventricle	3 “
	<hr/> 54 “

It is worthy of remark that the right side was involved more frequently than the left, in the ratio of three to two. The cerebellum was the primary seat only four times, the ratio of cerebral to cerebellar echinococci being about fourteen to one. Apparently, the parasite is found in the cerebral hemispheres more frequently than could be expected from the relative weights of the cerebrum and cerebellum, which stand in the proportion of about eight to one.

If we compare the liability of these parts to tubercular growths we find a very different state of things, for Hale White mentions that, in the 100 cases of cerebral tumours collected by him, “the cerebrum was affected 22 times, the cerebellum 20 times ;” so that, considering the small size of the cerebellum, it is affected with tubercular growths much oftener than would be expected. Dr. White concludes that a cerebellar tumour in a child is almost certainly a tubercular mass, and I would add in the absence of other evidence, when the diagnosis lies between tubercle and echinococcus in a young subject, the fact that the cerebellum is affected would be strongly in favour of tubercle as against echinococcus.

Symptoms.—In eight cases there was no history of the symptoms; in seventeen others it was very scanty. Of the remaining 72 cases a tolerably satisfactory record exists, which in about 50 is full. In two cases the patient died of pneumonia, with no symptoms referable to the brain—(Series I., No. 4, and Series III., No. 15); in both the cysts were multiple and small. As might have been expected, the symptoms varied according to the locality and size of the cysts. The symptoms may be divided into general and special, the former including headache, vomiting, vertigo, blindness, optic neuritis and atrophy, convulsions, and coma, the latter paralysis (sensory or motor), and implication of special nerves.

General Symptoms.—*Headache.*—This was by far the most frequent symptom. It was certainly present in 52 cases, and its absence is clearly remarked upon only in two cases. It perhaps was absent in two others. In three cases it is the only symptom mentioned, and in Gee's case (Series I., No. 36), headache of eighteen months' duration was the only brain symptom present up to the moment when the patient suddenly died: the hydatid was of the size of a turkey's egg, and occupied the middle lobe of the left hemisphere. In nearly all the cases, when present at all, the headache was the first or one of the earliest symptoms. In most cases no reference is made to the locality of the pain, but occasionally it was referred to the part of the head corresponding to the seat of the parasite. In character the pain was usually severe and paroxysmal, and in some instances it was greatly aggravated by any movement of the head. Once trigeminal, and once infra-orbital neuralgia, were present.

Vomiting.—This was mentioned as present in 26 cases, and its absence was remarked upon in two instances. In one case (Series IV., No. 5) the patient died during an attack of vomiting.

Vertigo was recorded in 13 cases.

Blindness is mentioned in 36 cases. It was complete or nearly so in both eyes in 19 cases. In two instances (Series I., Nos. 33 and 41) there was total blindness, but of the right eye only. In one case (Series I., No. 23), the patient, a boy aged 14, suddenly fell down senseless: consciousness gradually returned, and it was then discovered that he was blind: in about three weeks time he recovered sufficient vision to distinguish the nurse from others around the bed. Blindness was associated with the presence of echinococcus cysts in almost any part of the brain, but in cases where one eye became blind before the other, or where one eye alone became blind, the parasite occupied the side of the brain corresponding to the blind eye or that first affected.

In one case, where (Series III., No. 7) there was almost complete blindness, an acephalocyst of the size of a small filbert was found in each optic tract.

Optic Neuritis, and Atrophy.—Optic neuritis was noted in seven cases. In two instances optic atrophy was observed. One of the cases of optic atrophy was peculiar, in that while the whole of the right optic disc showed atrophy, only the inner half of the left one was so affected: the result was amaurosis of the right eye and of the outer field of the left one. In most of the cases of blindness it is remarkable that the pupils were dilated and insensible to light. In one case there was photophobia (Series III., No. 1), and in another (Series I., No. 55) there was contraction of the field of vision, &c. It is probable that impairment of vision, optic neuritis, contraction of the field, &c., are present in a large proportion of cases of echinococcus and other tumours in the brain, but that until recently the precise condition of vision has not been observed.

Convulsions.—Convulsions of some kind were noted in 37 cases. In 18 they had the characters of epileptic seizures. In one instance (Series III., No. 4) the patient was "idiotic and epileptic." In another, the epileptic attacks were preceded by chorea, affecting principally the left side of the body, and they were followed by tetanic symptoms, trismus and opisthotonos: in this patient a large hydatid occupied each posterior lobe, and they communicated with one another through the lateral ventricles, whilst that on the right was connected with a subdural hydatid, which in turn opened through the bone into a fourth, situated outside the cranium beneath the scalp. In some cases clonic spasms of the face, arm, and leg, on one side were observed (*e.g.*, Series I., Nos. 30, 38, and 56, and Series V., No. 8). Once the convulsions were limited to the region of the left facial nerve (Series I., No. 46): here the cyst occupied a part of the middle and posterior cerebral lobe on the left side, and reached to the lateral ventricle. In three cases (Series I., Nos. 30, 56, and 57) tonic spasms were present. I have been unable to trace any relation between the occurrence of epileptiform or other convulsions, and the size, number, or situation of the cysts.

Special Symptoms.—*The cranium was enlarged* generally or locally in five cases (*viz.*, Series I., Nos. 5, 43, and 51; Series III., No. 14; and Series V., No. 8). *The cranium was perforated* in five instances (*viz.*, Series III., Nos. 12 and 14; Series IV., No. 8; and Series V. Nos. 8 and 9).

Motor Paralysis.—Hemiplegia.—More or less complete hemiplegic paralysis was noted in 27 cases. It occurred twice as often in the form

of left as of right-sided paralysis, viz.:—left-sided hemiplegia, 18 cases; right-sided hemiplegia, 8 cases; side not mentioned, 1 case. In one instance (Series III., No. 6) of multiple hydatids, scattered over and inside both hemispheres, there was first temporary right hemiplegia and afterwards permanent left hemiplegia. In all the cases of hemiplegia, the parasite either occupied or invaded one or other cerebral hemisphere. But in 26 instances where echinococcus cysts were found in one of the hemispheres, hemiplegia seems to have been entirely absent, and this, too, even when the parasite had attained a great size—*e.g.*, that of an orange or larger; and even in Yates' case (Series I., No. 34), where a huge hydatid of the dimensions of an ostrich's egg occupied the left hemisphere and left ventricle, the patient had only partial paralysis, for "he could grasp with his left (*sic*) hand, but its powers were manifestly impaired, and he could move his left leg about in bed, but could not stand upon it."

Paraplegia is noted in three cases, (viz., Series I., Nos. 33 and 56, and Series IV., No. 1). In one of these cases a large hydatid occupied the right, in another the left cerebral hemisphere, and in the third the fourth ventricle.

Affection of Speech—Aphasia, &c.—The power of speech was affected in various ways and in varied degrees in twelve instances. In some cases there was definite aphasia. In the remarkable case of a patient of Dupuytren and Gendrin (Series V., No. I) a prolongation of the cyst passing through the left anterior condyloid foramen compressed and caused atrophy of the left hypoglossal nerve, with resulting complete atrophy of the left half of the tongue: in consequence the patient lost for a time the power of articulation, but by practice regained it in spite of continued unilateral atrophy of the tongue. In some of the cases it is not clear what the precise nature of the impairment of speech was.

Ataxy—"Staggering" or "Tottering" Gait.—In fourteen instances the gait was affected: in the majority of the cases the cysts appear to have occupied either the posterior lobes of the cerebrum or the cerebellum: in three cases they were connected with the neighbourhood of the pons and once with the third and fourth ventricles.

Prognosis and Duration of Cerebral Echinococci.—Recovery from so formidable a disease as hydatid of the brain could hardly be expected to occur, and yet this was the case in two, if not in three, instances (viz., Series, IV., No. 8, and Series V., No. 9); in another instance (viz., (Series V., No. 8), the ultimate result was not known. A consideration

of these and other cases makes it probable that, in consequence of the continually increasing advances in the localisation of cerebral lesions and in their effective surgical treatment, the day is not far distant when hydatids of the brain will become accurately diagnosed and successfully treated.*

The *duration* of the disease is very uncertain, and no doubt very variable, according to its situation and the rapidity of its growth. In one case (Series I., No. 10) headache and vertigo had been present for five years; in another (Series I., No. 18) the symptoms seem to have existed for four years. On the other hand, in Hankin's case (Series I., No. 52) the illness was ushered in by an epileptiform fit only 27 days before the death of the patient. Probably, judging from 30 cases in which some definite data exist upon this point, the average duration of life after the appearance of the first cerebral symptom is about one year.

Cause of Death.—*Phenomena immediately preceding Death.*—In 18 instances death took place suddenly, and often quite unexpectedly; in one whilst the patient was trying to raise himself in bed, in another while the patient turned in bed. Once death occurred in an attack of vomiting, and once from suffocation caused by the entrance of food into the air-passages. Coma preceded death in 28 cases; in one instance it lasted for five weeks before death, in another for four weeks. In 11 cases death took place during convulsions: twice in a "fit," once with tetanic symptoms. In two death occurred "quietly," twice there was delirium, once exhaustion. In several instances death was due to other diseases, viz., pneumonia twice, pleurisy once, Bright's disease once, erysipelas once, small-pox once

APPENDIX.

SERIES I.

ECHINOCOCCI OF THE CEREBRAL HEMISPHERES.

1. REFERENCE.—Morrah, per Dr. J. Yelloly, in the "Medico-Chirurgical Transactions," Vol. II., p. 260 (1813).

Sex and Age.—Female, 19.

Locality.—Hydatid about three inches long by two inches in breadth,

* This was written of course before Dr. Graham, of Sydney, published his case, in which Dr. Clubbe operated successfully.

embedded in the substance of the right cerebral hemisphere. It projected from the upper surface of the brain, and "to its upper surface a portion of the brain was so firmly attached by the pressure it sustained against the cranium from the increase of the hydatid, that I did not venture to attempt to separate them;" &c. Pia mater injected and elevated by the tumour.

Symptoms.—Headache; vertigo increased by movement, and especially by stooping; repeated fits, during which she had not convulsions, but "apparently merely loss of consciousness." Subsequently nearly complete deafness; loss of sight, first in the right eye, and then in the left; loss of smell, of power of speech, and deglutition much impaired. Later on, left hemiplegia; apoplectic stupor, from which she partially recovered, but soon relapsed and died.

Duration of Illness.—Headache, three years. Fits, eight months.

Mode of Death.—Coma.

Remarks.—No further details supplied.

2. REFERENCE.—Rendtorf, "Dissert. de Hydat. in corpore humano," Berlin, 1822. Cited by Bremser, Livois, Davaine, &c.

Sex and Age.—Female, 8.

Locality.—An enormous mass of hydatids in the right lateral ventricle. Right hemisphere one-third larger than the left. Head enormous; cranium thin. Weight of sac and contents, two and a-half pounds (German).

Symptoms.—Rheumatic pains in the limbs. Intelligence impaired; vomiting; epileptic attacks; paralysis of left side; blindness; loss of smell; death.

Duration of Illness.—About seven months.

Mode of Death.—Convulsions.

Remarks.—Echinococci in the cysts. Evident mother-cyst.

3. REFERENCE.—Martinet, "Revue Médicale" (1824).

Sex and Age.—Male, adult.

Locality.—Hydatid of the size of a hen's egg, in the posterior lobe of the right hemisphere.

Symptoms.—Frequent headache; vertigo.

Mode of Death.—Sudden.

4. REFERENCE.—Tonnelé, "Cas d'hydatides du cerveau, avec lombrics dans le foie" (1829).

Sex and Age.—Male, young.

Locality.—In the anterior lobe of the right hemisphere, at its middle, two acephalocystic hydatids, each of the size of a large nut.

Symptoms.—None referable to the hydatids.

Mode of Death.—Pneumonia.

Remarks.—Lumbrici in the small intestine and in a cavity in the liver.

5. REFERENCE.—Headington, cited by Abercrombie, "Pathological and Practical Researches on Diseases of the Brain," second edition, p. 436, (1829).

Sex and Age.—Male, 11.

Locality.—Immense hydatid in left lateral ventricle. "It contained about

16 ounces of limpid fluid, and, besides this, there were several ounces in the proper cavity of the ventricle." The cyst had nearly advanced to the circumference of the brain at the middle lobe, where the membranes were adherent to the brain.

Symptoms.—Sudden attack of dimness of vision, amounting to blindness; this passed off in a few minutes. The sight became gradually impaired, so as to be nearly lost at the end of a year; then an affection resembling chorea; after a short time an attack in which he was speechless for three days; then right hemiplegia; head enlarged; temporary loss of speech; intellect unimpaired; coma.

Duration of Illness.—Two years. Hemiplegia, one year.

Mode of Death.—Coma for five weeks.

6. REFERENCE.—Abercrombie, op. cit.

Sex and Age.—Female, ?

Locality.—Hydatid three inches long by two wide, in the right hemisphere.

Symptoms.—Dysphagia; loss of sight, of smell, of hearing, of power of speech; headache; vertigo; coma.

Duration of Illness.—Nine months.

Mode of Death.—Apoplexy; coma.

7. REFERENCE.—Guérard, "Bull. de la Soc. Anat." (1835).

Sex and Age.—? ?

Locality.—Hydatid of the size of a hen's egg, in the centre of the middle lobe of the brain, projecting externally and into the lateral ventricle.

Symptoms.—Incomplete hemiplegia, on side opposite to cerebral lesion.

Remarks.—Side of brain affected not mentioned.

8. REFERENCE.—Chomel, "Gaz. des Hôpitaux" (1836).

Sex and Age.—Female, 25.

Locality.—Two hydatids in the right cerebral hemisphere.

Symptoms.—Violent headache. Ten days later, numbness of left leg. Six weeks afterwards, paralysis of left arm. Left hemiplegia. Right pupil dilated and vision enfeebled. Irregular epileptiform attacks. Coma.

Duration of Illness.—About eleven months.

Mode of Death.—Coma.

9. REFERENCE.—Carrère, "Dict. de Médecine, de Chirurgie, et d'Hygiène Vétérinaire" (1839).

Sex and Age.—Male, 24.

Locality.—Hydatid of the size of a turkey's egg, in the posterior and lateral part of the right hemisphere, below the lateral ventricle.

Symptoms.—Headache for four years; dimness of vision; tottering gait; constant agitation of the head; fixed stare; hebetude; delirium requiring use of straight-jacket.

Mode of Death.—Delirium.

10. REFERENCE.—Arndt, in Madelung. "Beitrage zur Lehre von der Echinococcuskrankheit" (1841 ?).

Sex and Age.—Male, 36.

Locality.—In the anterior part of the right cerebral hemisphere, a ruptured

echinococcus cyst of the size of a pigeon's egg. The cavity was filled with clear fluid and a juvenile brood.

Symptoms.—Headache and vertigo for five years. Epileptiform convulsions one year.

Duration of Illness.—Five years.

Mode of Death.—Sudden.

11. REFERENCE.—Sturton, in "Canstatt's Jahresbericht" (1842).

Sex and Age.—Male, 19.

Locality.—Hydatid in the left cerebral hemisphere; partial atrophy of posterior and median lobes. The brain had lost one-fifth of its bulk. Serosity in the left ventricle.

Symptoms.—Headache for a month.

Duration of Illness.—One month.

Mode of Death.—Sudden.

12. REFERENCE.—Milcent, "Bull. de la Soc. Anat. (1843).

Sex and Age.—Male, (?).

Locality.—Hydatid cyst between two convolutions near the upper face of the hemisphere. Near it, traces of an old small pouch. Meningitis.

Symptoms.—The patient was an epileptic, who died in an attack six hours after admission into Hospital.

Remarks.—No details; an exhibit.

13. REFERENCE.—Blache, "Bull. Gen. de Therap." (1847).

Sex and Age.—Male, 34.

Locality.—Hydatid of the size of a walnut, on the convexity of the left hemisphere, between the membranes of the surface of the brain, which was healthy throughout.

Symptoms.—Epileptic attacks since the age of five. These increased in frequency and duration, for the last three months recurring several times daily, at last almost continuous. Coma.

Duration of Illness.—Twenty-nine years.

Mode of Death.—Coma.

14. REFERENCE.—Berncastle, "Lancet" (1846).

Sex and Age.—Male, 10.

Locality.—Hydatid cyst of the size of a large orange, entirely filling up the left posterior lobe of the brain, and "passing out at the inferior portion" of the lobe. Brain congested.

Symptoms.—Headache; amblyopia ending in amaurosis; excruciating pain at back of the head; emaciation. Intellect clear.

Duration of Illness.—One year.

Mode of Death.—Fit.

Remarks.—Contained transparent fluid.

15. REFERENCE.—Barth, "Bull. de la Soc. Anat. de Paris" (1852).

Sex and Age.—Female, 25.

Locality.—Hydatid enclosed in a cavity of the size of a small apple, situated in the left hemisphere above the lateral ventricle, but not connected with it. Convolutions flattened.

Symptoms.—Admitted into hospital in the eighth month of her fourth pregnancy. For four months paralysis of right arm; speech altered;

face discoloured ; sensibility and movement much diminished on the right side, less on the left ; had suffered from headaches on the left side ; drowsy on admission. Patient died suddenly near the end of her pregnancy. Cæsarean section ; removal of a dead fœtus.

Mode of Death.—Sudden.

Remarks.—No capsule ; no echinococci found.

16. REFERENCE. — Gregory, "Observation on Intra-Cranial Hydatids." "Medical Times" (1848-49).

Sex and Age.—Male, (?).

Locality.—Hydatids in the lateral ventricles of the brain.

Symptoms.—Headache ; impairment of sight and hearing ; convulsions, in one of which he died.

Mode of Death.—Convulsions.

17. REFERENCE.—Rigden, "Provincial Medical and Surgical Journal" (1852).

Sex and Age.—Male, 7.

Locality.—The sac, which contained numerous hydatids, occupied the middle and greater part of the anterior portion of the right hemisphere. Convolutions generally were slightly flattened, but more so over the middle of the right hemisphere. Right corpus striatum and optic thalamus extensively damaged. Skull thin, and at its upper part almost diaphanous.

Symptoms.—Admitted with paralysis of the left arm, which resembled paralysis caused by lead. He was able with difficulty to raise the arm to the head. Sensation not impaired. No headache at this time. Repeated epileptic convulsions followed, and continued until death.

Mode of Death.—Convulsions.

Remarks.—Thirty hydatids in various stages of development and decay.

18. REFERENCE.—Faton, "Bull. Soc. Anat. de Paris" (1848).

Sex and Age.—Male, 11.

Locality.—A cyst of the size of the fist, enclosing numerous acephalocysts, situated in the upper and external part of the right hemisphere. It had involved the corpus callosum, the optic thalamus, the fornix, and the septum lucidum. Abundant effusion of serosity in the ventricles and about the brain.

Symptoms.—Severe paroxysmal right-sided headaches. Repeated vomiting. Progressive weakening of the left limbs for two years. About one year later headache returned with increased violence. Intelligence lost, as well as the power of articulation. Power of speech returned in about two months, when loss of vision came on. Partial recovery of sight in the left eye occurred in about two months. Upon admission into hospital, intelligence clear ; almost complete blindness ; pupils dilated ; divergent strabismus on the left ; distortion of mouth ; lowering of left commissure of lips ; tongue deviated to right. Increased cutaneous sensibility of left arm and leg, with muscular weakness of same parts. Involuntary urination and detæcation. Vomiting ; loss of consciousness ; convulsions.

Duration of Illness.—Four years.

Mode of Death.—Coma.

Remarks.—Numerous Cysts. Daughter-cysts (?).

19. REFERENCE.—Charcot and Davaine, "Traité des Entozoaires," second edition, p. 704.

Sex and Age.—Male, 37.

Locality.—A large spheroidal cyst occupying the middle and posterior lobes of the right hemisphere. Apparently it was excavated exclusively in the cerebral substance, so that externally only two mm. of brain substance was left. Below it pushed downwards the roof of the left lateral ventricle, which it did not perforate. Right optic thalamus and corpus striatum slightly compressed and pushed towards the median line.

Symptoms.—For a month before admission, intelligence and memory impaired; right arm enfeebled; headache. Upon admission, marked hebetude; vomiting; slow pulse, 40 per minute; complete paralysis of right arm, very incomplete of right leg, so that patient could walk with much stumbling; no loss of sensation; paralysis slowly progressive, until it became complete right hemiplegia.

Duration of Illness.—About six weeks.

Mode of Death.—Sudden.

Remarks.—A fine cellular membrane lined the cavity, and enclosed three perfectly spherical hydatids, the largest of the size of a hen's egg, the smallest of a pigeon's egg; two hydatid cysts in the heart and eight or ten in the spleen.

20. REFERENCE.—Rodust, Schmidt's Jahrbücher (1862).

Sex and Age.—Male, 9.

Locality.—Hydatid of the size of the fist in right anterior cerebral lobe which had compressed the brain above and below, so as to cause its disappearance at these parts. Apparently originated in anterior cornu of right lateral ventricle. Left anterior cerebral lobe considerably excavated by the cyst; optic thalamus and corpus striatum pressed laterally and downwards; corpus callosum and third ventricle pushed backwards; corpus callosum and fornix much softened; red softening of corpora quadrigemina.

Symptoms.—No history.

Remarks.—Nurse-production; scolices; clear watery fluid.

21. REFERENCE.—Risdon Bennett, Trans. of Path. Soc., Vol. XIII., p. 5 (1862).

Sex and Age.—Female, 13.

Locality.—Two hydatid cysts occupying the middle and posterior lobes of the right cerebral hemisphere. One was of the size of a large lemon. Rest of brain healthy; dura mater slightly thickened in places; right optic nerve smaller than left one. "Of the optic tracts, on the contrary, the left was decidedly the less." Posterior fontanelle open.

Symptoms.—Headache, principally at vertex; fits; sight impaired; pupils dilated and fixed; no vomiting; intelligence, appetite, and nutrition good on admission; occasional epileptic paroxysms; after a time inco-ordination of legs; slight temporary paralysis of left side of face; afterwards loss of control over sphincters; convulsions; drowsiness.

Duration of Illness.—About one year.

Mode of Death.—Prolonged convulsions.

Remarks.—Striated membrane; clear fluid contents; echinococci and hooklets; seven or eight hydatids in the liver.

22. REFERENCE.—Dr. John W. Ogle, Brit. and For. Med.-Chir. Review (1865).

Sex and Age.—Female, 26.

Locality.—Hydatid cyst of the size of a large orange, occupying the anterior lobe of the right cerebral hemisphere.

Symptoms.—"Quite well until three weeks before death, when convulsive attacks came on. She preserved her mental faculties, and was free from paralysis of any kind until the last two weeks of life, when she experienced considerable but not complete loss of vision. She also throughout suffered much from vomiting."

Duration of Illness.—Three weeks.

Remarks.—Striated membrane.

23.—REFERENCE.—Barker, Trans. of Path. Soc. Vol. X., p. 6 (1858).

Sex and Age.—Male, 14.

Locality.—Hydatid, size of a medium-sized orange, occupying the posterior lobe of the right cerebral hemisphere. "It had rendered the lobe irregular and lobulated, and increased its dimensions, but the hydatid was covered everywhere by brain substance, although in many places it was a mere film. The lobulated character seemed to have been produced by the superficial veins acting as ligatures." Convolutions of brain flattened; sulci obliterated; calvaria thinned by pressure of convolutions so as to be transparent in numerous places.

Symptoms.—Suddenly fell down senseless; consciousness gradually returned, and it was then discovered that he was quite blind; headache; pupils moderately dilated and insensible; total blindness of right eye; almost complete also on left side; some improvement in vision of left eye.

Duration of Illness.—About four weeks.

Mode of Death.—Delirium.

Remarks.—The cyst was single, about as large as a middling-sized orange, and contained two hydatids, one nearly as large as the cyst itself, the other the size of a walnut; they contained no secondary cysts." Tubercles at apices of lungs; hydatid of the size of the fist in the liver.

24. REFERENCE.—Duffin, British Medical Journal (1865), Vol. II., p. 467.

Sex and Age.—Female, 10.

Locality.—Hydatid about the size and shape of an orange, in the right anterior lobe of the cerebrum; externally the brain substance only $\frac{1}{2}$ to $\frac{1}{4}$ inch thick; convolutions obliterated; optic chiasma and optic nerves flattened by the pressure of the sac, and their nerve-fibres degenerated.

Symptoms.—Headache; blindness, at first of right eye; pupils dilated; insensible to light; vomiting.

Mode of Death.—"Quiet."

Remarks.—Tubercle in apex of right lung; hypertrophy of left ventricle of heart.

25. REFERENCE.—Flood, Indian Medical Gazette (1866), Vol. I., p. 153.

Sex and Age.—Male, 24.

Locality.—Near the middle of the left hemisphere, somewhat inferiorly and posteriorly. "One large hydatid tumour was found floating in a quantity of straw-coloured fluid, in which was the ruptured sac of a second. The tumour was about the size of a hen's egg. Seven ounces of fluid were removed, and a large cavity with uneven walls exposed; it extended full an inch and a half into the substance of the brain."

Symptoms.—Severe burning headache, referred to the crown of the head; pupils dilated; general and violent convulsions; mental faculties unimpaired to the last.

Mode of Death.—Convulsion.

26. REFERENCE.—Atkinson. Aust. Med. Jour., p. 290 (1867).

Sex and Age.—Female, 10.

Locality.—"A large cyst, single, and holding about half-a-pint of fluid, occupying nearly the whole of one hemisphere."

Symptoms.—"Epileptiform convulsions, recurring two or three times. There was no great peculiarity remarkable in these attacks."

Mode of Death.—Sudden.

27. REFERENCE.—Rasmussen, cited in Brit. and For. Med.-Chir. Review, p. 425, (Oct., 1867).

Sex and Age.—Male, 34.

Locality.—Hydatid rather larger than a duck's egg. Involved the second and third frontal convolutions on the left side.

Symptoms.—Numbness in right arm, and soon afterwards in right leg. Five or six months later violent headache at vertex. Memory impaired. Speech indistinct. Slight facial paralysis on right side. Tongue deviated to right, uvula to left. Complained of dysphagia.

Duration of Illness.—About ten months.

Mode of Death.—Coma.

Remarks.—Scolices abundant. No daughter-cysts.

28. REFERENCE.—Parrot. Archives de Phys. Normal et Pathol, tome I., p. 450 (1868).

Sex and Age.—Female, 7½.

Locality.—In the centre of the left occipital lobe, a hydatid weighing 440 grammes, and 41 (? A.A.L.) centimeters in diameter. Convolutions greatly flattened, especially at posterior part of left hemisphere. The grey commissure, the corpus striatum, and optic thalamus on the left were pushed forwards. The pons, bulb, and cerebellum were pressed upon.

Symptoms.—Headache, drowsiness, vomiting, attacks of epilepsy.

Mode of Death.—Coma.

Remarks.—Echinococci present. Well marked fibrous capsule.

29. REFERENCE.—Magnan. Comptes rendus et Mem. lus à la Société de Biologie" (1868).

Sex and Age.—Female, ?

Locality.—A voluminous cyst occupying almost all the frontal lobe (on the right side (?))—J. D. T.).

Symptoms.—For 20 months violent headaches. Six months afterwards intelligence impaired; then vomiting, dysphagia, incontinence of fæces, retention of urine. For five months incomplete left hemiplegia; towards the end dyspnœa. For some time impairment of vision, at first on the right, and then on the left side.

Remarks.—Hooklets of echinococci found.

30. REFERENCE.—Bettelheim (1868), cited by Wolff, Vier Fälle von Echinococcus hominis, &c., Inaug. Dissert., Breslau (1869).

Sex and Age—Male, 13.

Locality.—Hydatid cyst of the size of an apple, situated in the left anterior cerebral lobe, externally to the ventricle. The cortex of the cerebrum at its lateral aspect had been perforated by the cyst.

Symptoms.—A fall of about nine feet, striking the left side of the head, was followed by temporary loss of consciousness and headache; shortly afterwards loss of vision and of memory; exophthalmos; nystagmus, severe headache, principally frontal; slight paralysis of right arm; vomiting, tonic spasms of muscles at back of neck; clonic contractions of muscles of face, arm, and leg on right side; increasing paralysis while signs of irritation decreased. Coma.

Mode of Death.—Coma.

Remarks.—Well-developed capsule; clear fluid contents; numerous scolices.

31. REFERENCE.—Visconti. Ann. Univers. di. Medic. (1869).

Sex and Age.—Male, 18.

Locality.—An echinococcus cyst, five centimeters in diameter, in the right posterior cerebral lobe.

Symptoms.—Long continued right-sided trigeminal neuralgia.

Remarks.—Numerous scolices.

32. REFERENCE.—Wolff. Vier Fälle von Echinococcus hominis, &c. Inaugural Dissert., Breslau (1869).

Sex and Age.—Male, middle-aged.

Locality.—Hydatid cyst, five centimeters in length, 4.5 cmt. deep, and 4.5 wide, in the posterior part of the right cerebral hemisphere. The cyst projected from the surface of the brain at a point nearly corresponding to the right parietal eminence. Convolutions flattened; sulci nearly obliterated. The cyst lay right over the posterior cornu of the right lateral ventricle, only three or four mm. of brain-substance intervening.

Symptoms.—Admitted into Hospital one week before death; scarcely sensible; staggering gait; no other marked symptoms. Was in this condition for several weeks before his death.

Mode of Death.—Sudden, while raising himself in bed.

Remarks.—Slight loose capsule ; scolices and brood-capsules ; no daughter-cyst.

33. REFERENCE.—Morgan. Brit. Medical Journal (June 18, 1870).

Sex and Age.—Female, 7.

Locality.—Hydatid weighing $18\frac{1}{2}$ ounces, and containing 18 ounces of clear fluid ; occupied the anterior and middle lobe of the right cerebral hemisphere. Externally it projected below the dura mater, internally it reached to the lateral ventricle. A considerable portion of the corpus striatum and part of the optic thalamus were absorbed. No fluid in right lateral ventricle ; about an ounce of clear serum in the left one.

Symptoms.—Ill for nine months before admission into the Manchester Royal Infirmary. Illness commenced with convulsive seizures ; afterwards paralysis of the lower extremities ; pupils dilated ; vision impaired. No strabismus.

Duration of Illness.—One year.

Mode of Death.—Coma ; four weeks' duration.

Remarks.—Echinococci and hooklets present, but apparently no fibrous capsule to the brain hydatid. Hydatids in both lungs and in liver.

34. REFERENCE.—Yates, Medical Times and Gazette, Vol. II., p. 237 (1870).

Sex and Age.—Male, 27.

Locality.—Hydatid of the size of an ostrich's egg in the left hemisphere. It was seen "lying without any other than certain curd-like and perhaps inflammatory attachments within the ventricle, if such it could now be called, the floor of which was entire, while the substance of the brain above had been absorbed by the growing cyst "

Symptoms.—Severe headache ; slight delirium ; occasional discharge of fetid matter from the nostrils ; some ataxia of gait. Later on partial left hemiplegia. (There is probably some mistake in the report of this case, for the hydatid is said to have occupied the left hemisphere, and yet there was left hemiplegia—J.D.T.) He could grasp with his left hand, but its powers were manifestly impaired, and he could move his left leg about in bed, but could not stand upon it."

Duration of Illness.—Two years.

Mode of Death.—Sudden ; apparently as well as usual ; unexpected.

Remarks.—No capsule. It contained sundry echinococci (daughter-cysts (?) J.D.T.)

35. REFERENCE.—Whittell, Lancet, Oct. 15, 1870, page 533.

Sex and Age.—Female, $13\frac{1}{2}$.

Locality.—A hydatid of the size of a small orange, and which contained ten ounces of fluid, was found in the upper part of the right cerebral hemisphere. It replaced almost entirely the white substance of this hemisphere. Cranium thin ; membranes thickened.

Symptoms.—Headache ; a feeling as if something were moving in her head ; vomiting ; pyrexia ; constipation ; right eye blind ; pupils dilated ; optic

neuritis ; slight convulsions ; consciousness perfect ; paresis of left arm and leg.

Remarks.—Echinococci present.

36. REFERENCE.—Gee, St. Bart. Hosp. Reports (1871), Vol. VII., p. 146.

Sex and Age.—Male, 19.

Locality.—Hydatid of the size of a turkey's egg, in the middle lobe of the left cerebral hemisphere ; upper surface of ventricle adherent to lower.

Symptoms.—Headache for eighteen months before death ; not any blindness, or other symptoms of cerebral disease.

Duration of Illness.—Eighteen months.

Mode of Death.—Sudden and unexpected.

Remarks.—A sort of capsule was present.

37. REFERENCE.—Reeb, Observations d'Acephalocystes du Cerveau, Rec. de Mem. de Med. Militaire (1871).

Sex and Age.—Male, 18.

Locality.—The entire right hemisphere was destroyed by a large cyst, filled with acephalocysts.

Symptoms.—Intra-orbital neuralgia radiating to the frontal region on the right side ; vomiting ; hemiplegia, soon followed by coma.

Mode of Death.—Coma.

38. REFERENCE.—Piazza, Gazzetta Clinica della Spedale civiso di Palermo (1872).

Sex and Age.—Male, 28.

Locality.—A globular, transparent hydatid cyst, in the left cerebral hemisphere, near the fissure of Rolando ; five centimeters in diameter, and extended nine centimeters deep ; left hemisphere greatly enlarged and bulged ; convolutions flattened as far as posterior lobe ; dura mater thickened and opaque.

Symptoms.—Severe left-sided headache ; later on, giddiness, buzzing in the ears, and drowsiness ; convulsive tremor of right arm and leg ; mental and general depression.

Duration of Illness.—Several months.

Mode of Death.—Convulsion.

Remarks.—Scolices present.

39. REFERENCE.—Marcks, Ueber Echinococcus im Gehirn. Inaug. Dissert., Halle (1872).

Sex and Age.—Male, 40.

Locality.—A round hydatid cyst of the size of the fist, filled with clear fluid, was found in the left cerebral hemisphere ; it projected on the surface of the outer aspect of the left temporal lobe ; right half of pons much flattened ; adjacent brain-substance somewhat softened.

Symptoms.—Two attacks of giddiness ; right-sided facial paralysis ; complete paralysis of right arm, incomplete of right leg ; sensibility o

whole right side of body reduced ; aphasia ; drowsiness ; incontinence of urine ; death.

Mode of Death.—Coma.

40. REFERENCE.—Bristowe, Path. Soc. Trans., Vol. XXIV., p. 9 (1872).

Sex and Age.—Female, 17.

Locality.—A nearly globular cyst, about two inches in diameter, was found, partly in the anterior, partly in the middle lobe of the left cerebral hemisphere. It seemed to have originated between the corpus striatum and the convolutions of the island of Reil ; the convolutions on the surface of the left hemisphere were flattened ; the falx was displaced half an inch to the right ; optic chiasma somewhat tilted ; third ventricle distended with fluid, and its walls protruded downwards, so that the left third nerve, and possibly also the sixth, were a little displaced by it, but were themselves quite healthy.

Symptoms.—Constant and severe headache ; occasional vomiting ; and double vision. On admission was perfectly rational ; no paralysis of limbs, but right side of face weaker than left ; tongue deviated to right ; pupils dilated, the right one more than the left. "She could see perfectly with both eyes, and could see all objects single at which she looked with both eyes, excepting such as were to the left of the median line, these she saw double." Optic neuritis in each eye ; later on, epileptic fit ; slight ptosis of left eye ; increased double vision.

Duration of Disease.—About twelve weeks.

Mode of Death.—Sudden ; severe convulsion, followed by coma.

41. REFERENCE.—Kotsonopulos, Archiv für Path. Anat. und Physiol. (1873).

Sex and Age.—Male, 14.

Locality.—The entire right cerebral hemisphere was converted into a great cyst. The cavity contained, besides a moderate quantity of fluid (serum), a hydatid of the size of a goose's egg. The interior of the cyst was softened, and a recognition of individual parts of the brain was impossible ; convolutions of right hemisphere flattened.

Symptoms.—For a year and a half, left-sided hemiplegia, which commenced in the left arm, and gradually affected all the left side ; head inclined to left shoulder ; sensation not impaired ; headache severe from the beginning ; hearing and vision on right side defective ; right pupil dilated ; mind clear ; paralysis increased ; pyrexia ; speech impaired, and then lost ; contractions in paralysed limbs. Convulsions and coma.

Duration of Disease.—Two years.

Mode of Death.—Coma.

Remarks.—Echinococci found in the cyst.

42. REFERENCE.—Stocks ; an exhibit at the Manchester Medical Society. Brit. Med. Jour. (Jan. 24, 1874).

Sex and Age.—Male, 22.

Locality.—Hydatid cyst in the left lateral ventricle ; convolutions of left hemisphere obliterated. The hydatid displaced five ounces of water,

and had produced an opening through the brain-substance into the longitudinal fissure.

Symptoms.—A severe blow on the head three months before death. Intense shooting pain in the head, giddiness; irritability of temper; occasional temors, as if he had some "terror on him;" pupils slightly dilated; diplopia; loss of memory; no convulsions. Conversed rationally two hours before death.

Mode of Death.—Quietly from coma.

43. REFERENCE.—Verco. Unpublished case in the Adelaide Hospital (1883).

Sex and Age.—Male, 12.

Locality.—Hydatid cyst about four inches in diameter, located in the right frontal lobe; it sprang principally from the right lateral ventricle, and projected through the fissure of Sylvius; coronal suture widely opened.

Symptoms.—Headache; gradual loss of sight for four months before admission into the Hospital; convulsions followed by left hemiplegia; left side of face paralysed; protrusion of os frontis; white atrophy of optic discs; intelligence retained until towards the end, when he became drowsy and apathetic; epileptiform fits; loss of smell; loss of tactile sensibility on left side; increasing deformity of head; exophthalmos; strabismus; repeated convulsions; coma; death.

Mode of Death.—Convulsions and coma.

Remarks.—No capsule.

44. REFERENCE.—Duffin, at Path. Soc. (May 6, 1873).

Sex and Age.—(?), child.

Locality.—A cyst in the anterior lobe of the right hemisphere.

Symptoms.—Double optic neuritis. "There were no other symptoms pointing to the existence of a tumour."

Mode of Death.—Died in a fit.

Remarks.—No details.

45. REFERENCE.—Russell, Med. Times and Gazette (Feb. 20, 1875).

Sex and Age.—Male, 27.

Locality.—Hydatid of the size of an ordinary orange in the white matter of the left hemisphere, outside the lateral ventricle. Internally it had compressed the corpus striatum and optic thalamus; externally it had flattened the convolutions, coming actually to the surface about the middle of the hemisphere. Pons stretched laterally, but its tissue as well as that of the medulla oblongata was healthy.

Symptoms.—Confused feeling in head; difficulty in choosing his words; partial right facial paralysis; vision imperfect; paralysis of right arm and leg followed; two severe epileptic fits, with increase of paralysis; convulsive movements in right face, arm, and leg; loss of speech; violent headache; stiffness of left cheek; some difficulty in swallowing; bedsores; convulsions; stupor.

Duration of Illness.—Eleven months.

Mode of Death.—Died in a convulsion.

Remarks.—No daughter cysts.

46. REFERENCE.—Ciccimara, Contribuzione alla casuistica dei tumori cerebrali i cisti da Echinococco (1875).

Sex and Age.—Male, 9.

Locality.—In the left cerebral hemisphere was found a hydatid cyst of the size of the fist; it occupied a part of the middle and posterior lobes, and reached to the lateral ventricle.

Symptoms.—Headache; dimness of vision; vomiting; giddiness; in the course of a few weeks total blindness; convulsions in the region of the left facial nerve.

Duration of Illness.—About ten weeks.

Mode of Death.—In convulsions.

47. REFERENCE.—Macnamara, British Med. Jour. (Nov. 11, 1876).

Sex and Age.—Male, 37.

Locality.—“A cyst about the size and shape of a pigeon's egg was found in the substance of the left hemisphere, on the outer side of the corpus striatum.” Capsule thick, opaque, and calcareous.

Symptoms.—Sudden coma; pupils dilated; twitchings of muscles of arms; stiffness of both legs; repeated epileptiform convulsions. Temp. 106.6.

Duration of Illness.—Thirty-six hours after onset of attack.

Mode of Death.—Coma.

Remarks.—No positive evidence of its parasitic nature.

48. REFERENCE.—Cobbold, Parasites, p. 128.

Sex and Age.—Female, girl.

Locality.—Hydatid lodged in right half of cerebrum.

Symptoms.—Partial left hemiplegia.

Remarks.—Specimen in St. Bartholomew's Hospital Museum.

49. REFERENCE.—Cobbold, op. cit., p. 134.

Sex and Age.—? ?

Locality.—Hydatid two inches in diameter, lodged in the anterior horn of the left ventricle.

Remarks.—Specimen in St. Thomas' Hospital Museum.

50. REFERENCE.—Allen. Cited by Cobbold, op. cit., p. 140.

Sex and Age.—Male, 15.

Locality.—A large hydatid, about four inches in diameter, was found on the mid convexity of the right cerebral hemisphere, towards its anterior part. It abutted on the wall of the lateral ventricle.

Symptoms.—Partial left hemiplegia; severe headache. Rapidly became insensible, and died next day.

Mode of Death.—Coma.

51. REFERENCE.—Fricke, Zwei Fälle von Echin., intra-cranialis, Inaug. Dissert., Berlin (1880)—under Professor Westphal's care).

Sex and Age.—Male, 13.

Locality.—An enormous hydatid cyst occupied the right posterior cerebral lobe, which at its external part was entirely replaced by the parasite. Both crura cerebri displaced—the left one flattened. Optic chiasma softened. Left optic tract destroyed; under it and the chiasma and the tuber cinereum a fluctuating collection of fluid. Corpora albicantia wanting. Pons and medulla oblongata displaced to left. Convolutions of both hemispheres flattened. Calvarium thinned. Dura mater adherent to calvarium. Protrusion of right parietal bone.

Symptoms.—After a fall in the gymnasium, on the back of his head, felt discomfort in the head for three-quarters of an hour. Next day vomiting, afterwards headache, giddiness, tendency to fall to left. Occasional double vision; impairment of sight, first in the right and then in the left eye. On admission skull asymmetrical. Intellect clear. Marked impairment of power and smell. Paresis of left abducens oculi. Hemianopsia of left half field of vision, and defect of the upper quadrant of the right field. Double optic neuritis, followed by atrophy. Numerous white patches in both fundi, between optic disc and macula lutea. Epileptiform convulsions; temporary coma; tottering gait.

Duration of Illness.—One year and a half.

Mode of Death.—Shortly before death he felt quite well.

Remarks.—Scolices found in the cyst.

52. REFERENCE.—Hawkins, Australasian Medical Gazette (October 15th, 1882), p. 1.

Sex and Age.—Male, 18.

Locality.—An egg-shaped hydatid, three inches long by two inches wide, situated in the back of the right posterior lobe, from the surface of which it protruded; skull enlarged on right side; calvaria thinned; convolutions closely pressed together.

Symptoms.—Epileptic fit; later on severe occipital headache; sense of fulness about the throat; marked strabismus.

Duration of Illness.—Twenty-seven days.

Mode of Death.—Quietly turned in bed and died.

Remarks.—No fibrous capsule, but apparently scolices and small daughter-cysts.

53. REFERENCE.—L. M. Politzer, cited by Steffen, Jahrbuch für Kinderheilkunde, Band XX., Heft. I. (1883).

Sex and Age.—Female, 7.

Locality.—Hydatid occupying the greater part of the left cerebral hemisphere.

Remarks.—Hydatids also in the liver.

54. REFERENCE.—Mauthner, cited by Steffen, op. cit.

Sex and Age.—Female, 8.

Locality.—In the left cerebral hemisphere.

Remarks.—Hydatids also in the liver.

55. REFERENCE.—Steffen, loco. cit.

Sex and Age.—Female, 10.

Locality.—In the posterior half of the right cerebral hemisphere a hydatid measuring eight centimetres long by six wide ; posteriorly, externally, and superiorly it was surrounded by condensed brain-substance, which generally did not exceed one centimetre in thickness ; it lay on the roof of the left lateral ventricle, which it had compressed, and a very thin layer of brain-substance alone remained here ; membranes vascular ; gyri, especially of the right hemisphere, flattened ; right hemisphere enlarged, and at its posterior half bulged against the left one ; right corpus striatum and optic thalamus pressed forwards ; left lateral ventricle distended with exudation.

Symptoms.—After a fall one year previously, signs of cerebral disturbance and vomiting ; occasional severe headaches ; pains in limbs, with feeling of numbness and visible contractions ; silly conduct, and ataxic gait. On admission, moderate left-sided facial paralysis ; difficult articulation ; some deafness ; pupils dilated ; intelligence weakened ; headaches ; vomiting ; difficulty of standing with eyes closed ; pulse slow and irregular ; optic neuritis ; field of vision contracted ; general convulsions ; contractures of the upper extremities, most marked on left side ; involuntary urination ; stupor ; death.

Duration of Illness.—About a year.

Mode of Death.—Coma.

Remarks.—Echinococci and brood capsules present.

56. REFERENCE.—Becquerel, Gazette Medicale, p. 406, Tome XV. (1837).

Sex and Age.—Female, 13½.

Locality.—At the junction of the anterior with the middle third of the left hemisphere and underneath the membranes a cyst containing eight ounces of *albuminous* somewhat *viscous* transparent fluid was found. Adherent to its inner surface were 15 to 20 hydatid vesicles, containing fluid of the same kind as the parent cyst. The cavity containing the cyst was four inches long by two wide, and occupied the whole of the anterior and half of the middle lobe. The cyst might have compressed the optic chiasma.

Symptoms.—Perfect health until four months before admission ; then headaches, convulsions, gradual loss of sight, failure of intellect ; convulsive attacks, in which the patient cried out, and immediately convulsive movements set in, first in the arms, then contracture of the upper and lower limbs and opisthotonos ; complete loss of consciousness ; headache ; vomiting ; paralysis of lower limbs, rectum, and bladder ; coma ; death.

Mode of Death.—Coma.

Remarks.—Hydatid cysts in lungs, liver and mesentery.

57. REFERENCE.—Potain, Bull. de la Soc. Anat. (1862).

Locality.—"On the convolutions which border posteriorly the fissure of Sylvius on the right side, on one of the convolutions of the posterior lobe, and in the right ventricle, immediately behind the posterior extremity of the optic thalamus and corpus striatum are found three

small tumours of the size of the kernel of a nut; all three exactly alike."

Symptoms.—Weakness of legs for two years; progressive weakening especially of left arm and leg; doubtful external strabismus in right eye; torticollis of head towards right side; retention of urine; involuntary defæcation; increasing prostration; no delirium.

Mode of Death.—Slight convulsion of face preceded death.

Remarks.—Two echinococci were found in one of the cysts.

58. REFERENCE.—Candy, Indian Medical Gazette, p. 155 (1873).

Sex and Age.—Male, 23.

Locality.—Four or five distinct hydatid cysts, varying in size from a large marble to a good-sized walnut, situated in the right hemisphere of the brain and extending into the lateral ventricles.

Symptoms.—Severe frontal headache; impairment of memory; dulness of intellect.

Mode of Death.—Died in slumber.

Remarks.—Contents of brain cysts; clear watery fluid of sp. gr. 1,000; hydatid at apex of right lung, and small cyst (hydatid) in left ventricle of the heart.

SERIES II.

ECHINOCOCCI OF THE CEREBELLUM.

1. REFERENCE.—Bailey, Lancet, p. 770 (1826).

Sex and Age.—Male, 24.

Locality.—A hydatid cyst projected into the fourth ventricle. It occupied the left lobe of the cerebellum, was oval in shape, measured three inches long by two wide. The single cyst, upon partial evacuation of its contents, resolved itself into two others; to one of these a cluster of small cysts (varying in size from a small pea to a small bean) was attached.

Symptoms.—Drowsiness. Severe occipital pain, followed by strabismus and double vision. The slightest concussion of the body greatly aggravated the headache. Occasional rigors; no pyrexia; constipation; Defective sense of smell. Hammering and other noises in the head. The strabismus ceased as amaurosis came on.

Remarks.—Contents of the large cysts pale straw-colored fluid, containing albumen.

2. REFERENCE.—Blin. Bull., Soc. Anat. (1851).

Sex and Age.—Female, 33.

Locality.—A hydatid cyst of the size of a small walnut on the upper surface of the left lobe of the cerebellum.

Symptoms.—Headache for nine months. Walking difficult, but no paralysis. Buzzing in ears. Vomiting.

Mode of Death.—Sudden.

3. REFERENCE.—Evans, British Medical Journal (April 6, 1872); Hull Infirmary.

Sex and Age.—Male, 17.

Locality.—Protruding from the under surface of the cerebellum, on the left side was a mass of hydatids, forming a tumour of about two inches in diameter; most of them collapsed, but some remaining full and transparent.

Symptoms.—Headache; vomiting; confusion of vision; strabismus and facial paralysis; optic neuritis; loud mitral bruit. Diagnosis of embolism. Recovered perfectly. Seven months later readmitted with headache, increased loss of sight, staggering gait.

Mode of Death.—Exhaustion.

4. REFERENCE.—Mignot, Gazette Hebdom. (1875).

Sex and Age.—Male, 25.

Locality.—A cyst, believed to be hydatid, was found in the left lobe of the cerebellum at its posterior surface.

Symptoms.—Severe headache; torticollis; pains in limbs. A little later the gait became uncertain and staggering. Amblyopia. Frequent erections. Pains became severe and general, and rendered all movement impossible. No vomiting or defect of speech. Urination difficult.

Mode of Death.—Sudden.

SERIES III.

MULTIPLE ECHINOCOCCI, SITUATE IN VARIOUS PARTS OF THE BRAIN.

- *1. REFERENCE.—Zeder; cited by Davaine, op. cit., p. 697 (1800).

Sex and Age.—Female, young girl.

Locality.—A dozen vesicles of different sizes (some of the volume of a hen's egg) were contained in the third and fourth ventricles.

Symptoms.—Headache; vertigo; loss of memory; intolerance of light. When she attempted to stand, she knocked herself against surrounding objects.

2. REFERENCE.—Leroux; cited by Davaine, op. cit., p. 710 (1825).

Sex and Age.—Male, 25.

Locality.—A mass of hydatids of the size of a hen's egg, about the posterior lobes of the cerebrum and the cerebellum.

Symptoms.—Headache; vomiting; debility; syncope.

3. REFERENCE.—Leveille; cited by Davaine, p. 712 (1827).

Sex and Age.—Male, 27.

* The anatomical description of the hydatids in this case is so ambiguous that it appears doubtful whether the parasites were *Cœnuri* or *Echinococci*. However, Davaine regards the balance of evidence as in favour of the latter conjecture.

Locality.—Numerous hydatids in the meninges, and on the surface of the brain, in the corpus callosum, the left middle lobe, the right optic thalamus, &c.

Symptoms.—Headache.

Mode of Death.—Sudden.

4. REFERENCE.—Montansey; cited by Davaine, p. 712 (1827).

Sex and Age.—Female, ?.

Locality.—A great number of hydatids on the surface, and in the substance of the cerebrum and cerebellum; a score in the spinal marrow.

Symptoms.—Idiotic and epileptic.

5. REFERENCE.—Calmeil; cited by Davaine, p. 700 (1835).

Sex and Age.—Male, adult.

Locality.—Moderate-sized hydatids in the interval between the cerebral peduncles, in the course of the two chief cerebral fissures; on the pituitary body; the mammillary eminences; the optic chiasma; in the two fissures of Sylvius. The two lateral ventricles were filled with vesicles; others in the substance of the cerebral convolutions, between the folds of the cerebellum, &c.

Symptoms.—Great failure of intellect; headache; increasing dementia; later on, all movements slow; dejections passed involuntarily; drowsiness; febrile pulse; muscular tremors. Coma.

Mode of Death.—Coma.

6. REFERENCE.—Michea, "Gaz. Med. de Paris" (1840).

Sex and Age.—Male, 53.

Locality.—Numerous small hydatids on the surface of the hemispheres near the longitudinal fissure, and in the substance of the brain, especially on the left side and in the anterior lobes; one in each lateral ventricle; one each also in the left optic thalamus and corpus striatum, and in the corpus striatum and the annular protuberance on the right; none in the cerebellum.

Symptoms.—Five months previously, sudden loss of consciousness, with right hemiplegia, which disappeared after a bleeding from the arm. A fortnight before admission into hospital another attack of loss of consciousness, with left hemiplegia, which persisted; no headache; after another bleeding, notable return of sensation and movement in the paralysed limbs; violent delirium, requiring use of straight-jacket; epileptiform convulsions; coma.

Mode of Death.—Coma.

Remarks.—M. Michea remarks that Echinococci of the brain are often mistaken for Polycephali, Cysticerci, and other cysts. Still, this is not a very clear case.—J.D.T.

7. REFERENCE.—Michea, loco. cit. (1840).

Sex and Age.—Male, 23.

Locality.—On the left side, in the fissure which separates the middle from the posterior lobe, was found an acephalocyst of the size of a walnut; another of the size of a small filbert in the left optic tract; another of

nearly similar volume in the right optic tract ; another in the posterior lobe of the right hemisphere ; smaller ones in the right lateral ventricle and the choroid plexus.

Symptoms.—Headache, followed by an epileptiform attack ; loss of memory ; dimness of sight. Upon admission, drowsiness, slow and incoherent replies to questions ; almost complete blindness ; incontinence of urine and fæces ; erysipelas.

Mode of Death.—Erysipelas, apparently.

8. REFERENCE.—Ferrol, cited by Davaine, p. 710 (1842).

Sex and Age.—Male, 23.

Locality.—In the left posterior cerebral lobe, and on the left side of the cerebellum, hydatids of the size of grapes.

Symptoms.—Melancholy ; headache ; delirium.

9. REFERENCE.—Forget, cited by Davaine, p. 712 (1846).

Sex and Age.—Male, 24.

Locality.—Numerous hydatids, varying in size from that of a hemp-seed to that of a filbert, adherent to the pia mater, and situated on the pons, the medulla oblongata, and the under surface of the cerebellum.

Symptoms.—Epileptic attacks ; headache ; imbecile expression of face ; deafness ; dimness of vision ; dilated pupils ; no paralysis ; gait unsteady ; involuntary urination ; diarrhœa.

10. REFERENCE.—Ogle, Brit. and For. Medico-Chir. Review (1865).

Sex and Age.—Male, 46.

Locality.—One cyst of the size of a walnut beneath the arachnoid, about the centre of the right cerebral hemisphere ; another, half the size, at the anterior part of the left cerebral hemisphere. Three or four similar cysts in the substance of both cerebral hemispheres.

Symptoms.—Excepting an epileptic attack, no cerebral symptoms until the end, when convulsions came on ; dropsy from cardiac disease.

Mode of Death.—Convulsions.

11. REFERENCE.—Ogle, loco. cit.

Sex and Age.—Male, 57.

Locality.—In the left Sylvian fissure a small collection of hydatid cysts lying loose, varying in size from a chestnut downwards, the larger ones being shrivelled.

Symptoms.—Signs of bladder trouble ; no calculus ; drowsiness ; delirium ; frequent pulse ; dry tongue ; coma.

Mode of Death.—Coma.

Remarks.—Abscess of kidney.

12. REFERENCE.—Atkinson, Aust. Med. Jour., p. 290 (1867).

Sex and Age.—Male, 19.

Locality.—“ A large collection of hydatids under the calvarium, which was extremely thinned by the pressure, and at one part, about the size of a sixpence, absorbed. The daughter cysts were very numerous, and but

little fluid existed. Both hemispheres were very much encroached upon and deeply hollowed by the super-incumbent cysts."

Symptoms.—Intense headache; vertigo; head bent back; expression dull and stupid.

Mode of Death.—Very sudden.

13. REFERENCE.—Foucalt, "Bull. de la Soc. Anat. de Paris," p. 245 (1870).

Sex and Age.—Female, 12½.

Locality.—A cavity of the size of an orange situated between the thinned-out occipital bone and the dura mater: it was occupied by a large hydatid cyst. In front of this was a second cyst flattened out and attached to the dura mater: it was of the size of a nut. The cyst pushed forwards the posterior cerebral lobes, and compressed the cerebellum and pons.

Symptoms.—For five months dorso-lumbar concavity increased, and head held backwards. For two months, vomiting; for a week, vision impaired; on admission, opisthotonos; no paralysis; severe pain in neck; pupils dilated; optic neuritis; drowsiness; coma.

Duration of Illness.—Five to six months.

Mode of Death.—Coma.

Remarks.—Numerous echinococci.

14. *REFERENCE.—Reeb, "Observations d'Acephalocystes du Cerveau," Rec. de Mém. de Med. Milit. (1871).

Sex and Age.—Male, 5.

Locality.—Under the scalp was found a cyst, which was continued into the interior of the cranial cavity, through an opening situated at the parietal prominence. Inside it communicated with a second one, situated between the bone and the dura mater. This again communicated through a hole in the dura mater with a much larger one, formed at the expense of the posterior lobe of the right hemisphere. The last-named cyst communicated with the lateral and middle ventricles. Another cyst occupied the left posterior lobe, and also communicated with the lateral and middle ventricles.

Symptoms.—For four or five months before admission, chorea, attributed to a fall. On admission, chorea, affecting principally the left side of the body; dimness of vision; pupils dilated; optic atrophy; bulging of skull in right parietal region, where a small, soft tumour appeared; epileptic seizures. Great improvement, so that she returned to her home for six weeks. Upon re-admission much worse. Fever, coma, &c., but again temporary improvement; then pyrexia, tetanic spasms of trunk and limbs; coma; epileptic attacks; external tumour punctured without material relief; trismus; opisthotonos; death.

Duration of Illness.—About 12 months.

Mode of Death.—Tetanic symptoms.

*This case is cited by Davaine, op. cit. p. 701, as one published by Dr. Reer not Reeb. This is incorrect.

Remarks.—Contents of cysts, colourless limpid fluid, and numerous small daughter-cysts. Great temporary improvement under the use of iodide of potassium.

15. REFERENCE.—Espinosa, "Gaz. Hebdom. de Med. et de Chirur.," No. 17, p. 267 (1876).

Sex and Age.—Male, 28.

Locality.—A series of small hydatid cysts on the anterior part of the right frontal lobe. Other similar small cysts scattered between the convolutions; five in the right and three in the left Sylvian fissure. There were 52 in all, and they were covered by the arachnoid.

Symptoms.—No cerebral symptoms. Died of pneumonia.

Mode of Death.—Pneumonia.

Remarks.—No microscopic data.

SERIES IV.

MISCELLANEOUS INTRA-CRANIAL ECHINOCOCCI.

1. REFERENCE.—Keber, "Medicinische Zeitung" (1841).

Sex and Age.—Female, 12.

Locality.—In the fourth ventricle, which was dilated to four times its natural size, was found a semi-transparent vesicle of the size of a walnut, filled with yellowish water. It compressed the left half of the cerebellum and of the pons, as well as the left crus cerebri. A gelatinous capsule surrounded the part of the cyst within the cerebellum.

Symptoms.—Symptoms of two and a-half years' duration; severe paroxysmal headaches; after about a year, gait uncertain; speech and vision affected; giddiness; almost complete paralysis of legs; contraction of flexors of right arm; vomiting, giddiness, headache, stupidity; complete blindness; deglutition difficult; respiration impeded; death.

Duration of Illness.—Two and a half years.

Remarks.—In the vesicle about an ounce of yellowish fluid, but no organic structures; but the structure of the cyst and capsule suggested it to be echinococcus.

2. REFERENCE.—Dalgeish, "Lancet," p. 168 (1831).

Sex and Age.—Male, 27.

Locality.—"On opening the fourth ventricle, which was much enlarged, a hydatid presented itself, equal in size to a pigeon's egg, and containing about two drachms of fluid." Pia mater engorged; arachnoid opaque; upwards of 12 ounces of fluid in the lateral ventricles.

Symptoms.—General symptoms of fever, but pulse of fifty per minute; vomiting; severe headache.

Mode of Death.—Sudden.

3. REFERENCE.—Cazeaux, cited by Davaine, op. cit., p. 711 (1833).

Sex and Age.—(?) (?)

Locality.—Hydatid cyst in choroid plexus.

Symptoms.—Considerable cerebral hæmorrhage.

4. REFERENCE.—Toynbee, Trans. of Path. Soc., Vol. II., p. 21 (1848).

Sex and Age.—Female, 48.

Locality.—Hydatid cyst of the size of a large pea, placed on the inner surface of the squamous part of the temporal bone; it elevated the dura mater, and was partially imbedded in the bone.

Mode of Death.—Bright's disease.

5. REFERENCE.—Erasmus Wilson, "Lancet," Vol. II., p. 143. (1848).

Sex and Age.—Male, 16.

Locality.—Large pedunculated sac growing from the left side of the tentorium cerebelli, and rising by the side of the falx cerebri, to within an inch of the surface of the brain, three and a half inches long by two and a half wide; its principal bulk was lodged in a hollow of the left hemisphere; convolutions of left hemisphere flattened.

Symptoms.—Ailing for 18 months; symptoms attributed to a blow on the head; frequent headaches; slight squint; partial blindness; frequent nausea and vomiting.

Duration of Illness.—Eighteen months.

Mode of Death.—In an attack of vomiting.

Remarks.—The sac was formed by an expansion of the superior layer of the tentorium; contents clear fluid, and about 200 hydatids, varying in size from a millet seed to a pullet's egg.

- . REFERENCE.—Herbert Smith, "Lancet," Vol. I., p. 48 (1871).

Sex and Age.—Male, 17.

Locality.—There was a small clear cyst, in all probability hydatid—though no microscopic examination was made, as the specimen was kept for the Museum—with a few small vessels passing over it (not on its wall) on the pineal gland. The cyst was about twice the size of the gland itself. It did not exercise any pressure on the gland itself.

Symptoms.—Brought in comatose; he gradually recovered consciousness, and moved his limbs; next day he started up in bed, and cried out with pain in the abdomen; soon afterwards he died.

Remarks.—Degenerating hydatid between bladder and rectum. Four degenerating hydatids in the liver.

REFERENCE.—Pullar, reported by Bullock, "Brit. Med. Journal," p. 312 (March 23, 1872).

Sex and Age.—Female, 4.

Locality.—Hydatid cyst of the size of a pigeon's egg lying on the left crus cerebri. Cyst easily separable. No inflammation or softening, but merely absorption of the portion of brain substance with which it came in contact. Congestion of the lungs, with muco-purulent matter in the bronchi.

Symptoms.—Five and a-half months previously, sudden, severe shivering and headache, the latter frequently recurred afterwards; tremors of the

limbs, especially of the left hand and arm; pupils dilated, equal; pyrexia (101° - 103°). Towards the end, the legs rigidly flexed on the abdomen. Pupils dilated, insensible to light; emaciation; loss of control over sphincters.

Duration of Illness.—Five and a half months.

Mode of Death.—Quietly, without convulsions.

8. REFERENCE.—Moulinie, "Gaz. des Hop." (1836), cited by Davaine, *op. cit.*, p. 702.

Sex and Age.—Female, 15.

Locality.—The girl had a perforation of the cranium, covered by a crucial cicatrix, which led to the belief that she had been trephined, but no such history could be obtained. A projection could be felt at the spot, and fluctuation occurred. A small puncture was made; pus, accompanied by about a score of small hydatids of the size of grapes, escaped. The patient left the Hospital in good health.

Symptoms.—Comatose sleep, out of which the patient could be aroused; constant severe headache; squint. After the escape of the pus and hydatids all the symptoms disappeared, and perfect recovery followed.

Remarks.—Recovery.

9. REFERENCE.—Thudichum, "Seventh Report of Medical Officer of Privy Council," p. 33 (1865).

Sex and Age.—Male, adult.

Locality.—Not recorded.

Symptoms.—"Perished from inflammation of the brain, caused by the presence of two echinococcus bladders."

Mode of Death.—Meningitis.

10. REFERENCE.—"St. Barthol. Hosp. Reports," Vol. VII.

Sex and Age.—Female, ?.

Locality.—Not recorded. "Hydatid cyst in brain."

Symptoms.—None recorded.

11. REFERENCE.—J. Davies Thomas, "Hydatid Disease," p. 145 (India).

Sex and Age.—Male, ?.

Locality.—"Hydatid found in brain."

Symptoms.—None recorded. Patient admitted for cataract.

SERIES V.

ECHINOCOCCI SITUATED AT, OR NEAR, THE BASE OF THE BRAIN.

1. REFERENCE.—Gendrin's case, "Lancet" (1832-33), cited by Abercrombie and Davaine.

Sex and Age.—Male, 36 (taken ill at the age of 33).

Locality.—On the left side at the base of the brain a cyst of the size of a turkey's egg, containing a quantity of hydatids; it lay between the left hemisphere of the cerebellum and the upper part of the medulla oblongata, which was somewhat pushed to the right side; a kind of appendix

of the cyst projected into the anterior condyloid foramen, and a second one extended into the anterior portion of the foramen lacerum posterius, where the nerves are situated; traversed this foramen, made its way under the muscles attached to the transverse processes, and formed a projecting tumour near the angle formed by the complexus and sternomastoid muscles; the left hypoglossal nerve, after its passage through the anterior condyloid foramen, was compressed and atrophied, even to its last branches in the tongue; the nerves passing through the left foramen lacerum posterius were compressed, and the glossopharyngeal was atrophied; the muscles of the tongue and of the velum palati on the left side were greatly atrophied; the left vocal cord was atrophied.

Symptoms.—Three years before admission into the Hôtel Dieu, violent left-sided occipital headache, extending to upper and back part of neck [followed a fall, striking back of neck]; difficulty of speaking; passage of air on left side of tongue with a hissing noise; total atrophy of muscles of left side of tongue; by practice he recovered power of articulation, in spite of the continued atrophy of the left half of the tongue; hiccup; vomiting; constipation; evening pyrexia; complete aphonia; loss of memory; deglutition difficult; liquids tended to enter the larynx; intercostal muscles inactive; respiration embarrassed; abundant mucous râles in both lungs; attacks of drowsiness lasting one or two hours; intelligence unimpaired; death.

Duration of Illness.—Three years.

Mode of Death.—Entrance of meat into the larynx, trachea, and bronchi; suffocation.

Remarks.—The hydatid cyst contained two large hydatids.

2. REFERENCE.—Guesnard, 1836; Davaine, op. cit., p. 588; also cited by Odile, "Des Kystes Hydatiques de la Base du Crane," Paris Thesis (1884).

Sex and Age.—Male, 7.

Locality.—In the right middle fossa of the cranium was found a large cyst situated between the dura mater and the temporal and parietal bones. It was twice the size of a hen's egg, occupied the whole of the right middle fossa, projected through the sphenoidal fissure into the orbit, and penetrated into a recess in the body of the sphenoid bone. This cyst was attached to another hydatid, situated in the pituitary fossa. Both cavernous sinuses displaced. Numerous small hydatids in the substance of the body of the sphenoid bone. Right hemisphere excavated by the cyst at the base and sides of the middle lobe. Its convolutions flattened. Floor of right ventricle raised so as to touch its roof. Optic thalamus and corpus striatum slightly flattened. Optic nerves elevated by the tumour, so as to be, as it were, strangled by the upper edge of the optic foramen. The nerves in the outer wall of the cavernous sinus compressed, especially the ophthalmic branch of the fifth.

Symptoms.—Suddenly, and without any precursory symptoms, right ptosis came on. Twelve days later, headache, rigors, vomiting. On admission, ptosis and exophthalmos on the right; pupil dilated; conjunctiva

insensible to touch; blindness of left eye, but tactile and reflex irritability remained. Intelligence perfect. Slight elevation of the angle of the mouth, and of all the features on the right side. Appetite good. Was lively in his talk, and except for his double amaurosis and a slight hemiplegia, he seemed quite well, when he took scarlatina, from which, however, he had hardly recovered before he was attacked with smallpox, of which he soon died.

Mode of Death.—Smallpox.

Remarks.—Hydatid of the size of a walnut in the liver.

3. REFERENCE.—Lagout (1845), "Bull. de la Soc. Anat." (1846), cited by Odile, "Des Kystes Hydatiques de la Base du Crane." Paris Thesis. p. 51 (1884).

Sex and Age.—Female, 45.

Locality.—A hydatid which had developed along the right side of the medulla oblongata and pons. It extended along the fifth nerve, and had destroyed the Gasserian ganglion.

Symptoms.—Right eye altered and softened. Right nostril and right side of buccal cavity insensible. No deviation of tongue.

Mode of Death.—Coma.

4. REFERENCE.—Stewart, cited by Gregory, loco. cit.

Sex and Age.—Male, 24.

Locality.—A nest of hydatids of the size of the closed fist completely filled the middle fossa of the cranium on the left side. It lay between the dura mater and cranium. The adjacent bones were much roughened. Brain pressed to the right.

Symptoms.—Constant headache; epileptic fit, followed by coma; afterwards mental imbecility; vision impaired; slight left ptosis; staggering gait; idiotic expression of face; threatened asphyxia from blockage of œsophagus by a piece of meat; tracheotomy; repeated epileptic fits; coma.

Mode of Death.—Coma.

Remarks.—The cysts varied in size from that of a small pea to that of an orange.

5. REFERENCE.—Roger, "Gaz. des Hop.," p. 345 (1865).

Sex and Age.—Male, 13½.

Locality.—At the base of the brain, behind the optic chiasma, a cyst containing brownish fluid in which scales of cholesterin were floating: the cyst had formed at the side of the cranium, had excavated the bone, and had compressed the optic bands, especially the left one; it entered into and distended the third ventricle, and had penetrated into the lateral ventricle (left). Another group of four or five small degenerating hydatid cysts was found at the level of the middle lobe of the brain (side not mentioned).

Symptoms.—Headache; frequent vomiting; head bent back; pain at nape of neck; general and severe convulsions; amaurosis; coma; pyrexia.

Duration of Illnes.—Several years.

Mode of Death.—Coma.

Remarks.—No microscopic data, but the author regarded the cysts as degenerating hydatids.

6. REFERENCE.—Sunderland, "Lancet," Vol. I. p. 201 (1873). At the Queen's Hospital, Birmingham, under Dr. Sawyer's care.

Sex and Age.—Male, 29.

Locality.—A cyst, with thin opalescent walls lay between the anterior border of the pons behind, the optic chiasma in front, and the middle cerebral lobes laterally. Both right and left third nerves were flattened, the optic commissure pressed upon, the corpora albicantia had disappeared; the fornix was semi-diffuent. The cyst plunged into and formed part of the floor of the third ventricle, and apparently was developed in the posterior subarachnoid space.

Symptoms.—Severe pain at back of head and nape of neck for ten weeks; noises in ears; frequent vomiting; occasional staggering; deafness; loss of memory; speech difficult; hyperæmia of optic discs; ataxia; constipation; coma.

Duration of Illness.—Less than three months.

Mode of Death.—Coma.

Remarks.—Large hydatid cysts in the liver and in the left kidney.

7. REFERENCE.—Kühn, Berlin, Klin. Wochenschrift, No. 41 (1883).

Sex and Age.—Male, 34.

Locality.—At the base of the brain; numerous echinococcus cysts, varying in size from that of a lentil to that of a walnut, in very abundant yellowish fluid. No erosion of brain substance; membranes thickened at the base; lateral ventricle greatly distended with fluid; brain flattened.

Symptoms.—Epileptic attacks; temporary stupor; dementia; uncertain, tottering gait; definite vertiginous movements; dimness of vision; dilated pupils; no paralysis; no affection of speech.

Mode of Death.—From pleurisy.

8. REFERENCE.—Fricke, Zwei Fälle von Echinococcus intracranialis; Inaug. Dissert., Berlin, p. 17 (1880); Westphal's Clinique.

Sex and Age.—Male, 17.

Symptoms.—Right-sided exophthalmos; bulging of right fronto-temporal region; amaurosis of right eye; defect of outer field of left eye; motor paresis of left limbs; white atrophy of right disc, and of inner half of the left one; headache; vomiting; afterwards inflammatory swelling of the eyelids and of frontal, temporal, and vertical regions on the right side; perforation of the bone about ten cm. above the outer angle of the right orbit; fluctuation here; incision gave exit to pus, shreds of membrane, and echinococcus cysts; a second protrusion formed in the line of the coronal suture, incised with similar results. The two openings communicated internally; afterwards cysts were brought away by coughing and hawking, and also through the left nostril; cicatrisation occurred. Great improvement followed, but in a

few months' time clonic spasms of the left arm, leg, and face, without loss of consciousness, but followed by temporary paralysis.

Remarks.—Ultimate result unknown.

9. REFERENCE.—Odile, "Des Kystes Hydatiques de la Base du Crane." Paris Thesis (1884). Patient under the care of Dr. Bucquoy, in the Hôpital Cochin.

Sex and Age.—Male, 43.

Locality.—Hydatid perforating base of skull.

Symptoms.—For three years severe headaches; for two years vision and hearing impaired; for two and a half months a tumour on left side of neck; expectoration of hydatids; left ptosis; imperfect vision on left side; paralysis of left external and inferior rectus muscles; contracture following paralysis of left side of face; anæsthesia of side of face and of the olfactory and buccal mucous membranes, all on the left side; no affection of the limbs; on the left side of the neck a tumour half the size of the fist; it lay below the sterno-mastoid muscle, hard, resistant, not painful, hardly ever tender; it increased rapidly in size, became phlegmonous, and was incised; pus and hydatids escaped, but the patient continued to yield vesicles through the mouth and nose. About six months after admission headache and anæsthesia had disappeared, but the paralysis remained, and the wound had nearly healed; when last seen complete cicatrization had taken place, and no more cysts had been evacuated for a long time; paralysis remained; sensation perfect.

Remarks.—Recovery.

* APPENDIX.

1. REFERENCE.—Arndt-Neustrelitz, in Madelung, op. cit., page 148.

Sex and Age.—Male, 36.

Locality.—A ruptured echinococcus cyst of about the size of a pigeon's egg in the anterior right cerebral hemisphere; the cavity was filled with "lymphatic" fluid and young brood, i.e., daughter-cysts.

Symptoms.—Headache and giddiness, becoming worse as time advanced. Epileptiform convulsions.

Death.—Sudden.

2. REFERENCE.—Subtentorial hydatid tumour, removed by trephining; recovery. H. Widenham Maunsell, pamphlet, Dunedin.

There was no evidence of the parasitic nature of the cyst.

3. REFERENCE.—Dr. Fredet of Royat, cited in the "Lancet," July 3, 1875, page 33.

Sex and Age.—Male 22.

Locality.—A hydatid cyst occupying the upper part of the pons varolii on the right side.

Symptoms.—Headache and neuralgia of the right fifth nerve for some months; some spasm of the muscles on the right side of the face and jerking of the head to the right were noticed just before he fell; this happened as he was walking along the road; he fell to the right and was picked up dead. Very sudden death.

* These cases were not included in the original article, in the Congress Transactions.

B. Hydatid Disease of the Spinal Cord.

Frequency.—The spinal cord is rarely invaded by this disease, for among 1,897 cases of hydatid disease, the spinal cord, its membranes, and the spinal canal were attacked in only 15 instances, or in less than 0·8 per cent.

Site.—In some cases the spinal membranes appear to have been the original seat of the parasite, in others the bones of the spine were probably the original site, and the spinal canal was secondarily invaded.

In a case recorded by Wood* there was found inside the dura mater, at the sacral portion of the cord, a hydatid cyst, which compressed the cord and projected through the second left sacral foramen. "The cyst also extended through the first and second sacral foramina, which were partly thrown into one."

Neisser† collected 13 cases in which the cord was invaded; besides these, cases are recorded by Ricklin,‡ Liouville, and Strauss,|| and Marwood.§ The cases are so few and the phenomena so varied that no general statements of value can be made.

In most of the recorded cases the bones of the spinal column were destroyed to a greater or less extent.

* Australian Medical Journal, May, 1879, pag. 222.

† Op. cit., page 1-79.

‡ Gaz. Med. de Paris, Aug. 15, 1880.

§ Gaz. Hebdom. July 23, 1875.

§ Australasian Med. Gazette, April, 1889, page 182.

HYDATID DISEASE, Vol. II.

PART IV.—HYDATID DISEASE AFFECTING THE BONES, MUSCLES, AND SUPERFICIAL STRUCTURES, &c.

- A. The Bones and Joints.
- B. The Muscles and Fasciæ.
- C. The Breast.

HYDATID DISEASE, Vol. II

PART IV—HYDATID DISEASE AFFECTING THE

BONES, MUSCLES, AND SUPERFICIAL STRUCTURES, &c.

- A. The Bones and Joints.
- B. The Muscles and Fasciæ.
- C. The Breast.

PART IV.—HYDATID DISEASE AFFECTING THE BONES, MUSCLES, AND SUPERFICIAL STRUCTURES, &c.

A. Hydatid Disease of the Bones and Joints.

Bibliography.

- PAUL BONCOUR.—Des Kystes Hydatiques des Membres. Paris Thesis, 1878.
GODEFROY.—Contribution a l'Etude des Kystes des Os. Paris Thesis, 1882.
-

Frequency.—The osseous system was attacked in rather less than two per cent. of the cases, (1·63 per cent. precisely).

Site.—Any bone in the body may be the seat of an echinococcus cyst, even a digital phalanx or a spinal vertebra.

Course.—When a cyst starts inside a bone it usually causes great destruction of the bone ; but it rarely happens that a hydatid cyst, even when of large size, causes much injury of bone from mere pressure externally.

There is reason to believe that exogenous formation of daughter-cysts is more common in the interior of the bones in man than in any other situation.

In most cases the growth of hydatid cysts inside bones is slow ; but in many instances the patients have referred their malady to an accidental injury, received in some cases years before any definite local symptoms have declared themselves.

Cases.—

A. The Skull.—Cysts have been met with in the cranial bones in three cases. When echinococci of the brain reach a large size they cause thinning, and even perforation of the calvaria in rare cases.

(1) *Frontal Bone.*—Female, aged 18. A tumour above the left orbit, about three-fourths of the size of an orange ; of six years' known

duration ; opening of the cavity at first inadequate to permit escape of the cysts ; ultimately cure.*

(2) *Frontal Bone*.—Female, aged 17. History of a violent blow on the right frontal region, followed shortly afterwards by an indolent swelling ; eye displaced downwards and outwards ; soon loss of vision ; no cerebral symptoms ; crucial incision, and trephining of the bone ; mercuric injections caused salivation ; setons passed through the tumour ; apparently cure.†

(3) *Body of the Sphenoid*.—Male, aged 7. Numerous small hydatids in the substance of the sphenoid bone ; cerebral symptoms, but patient died of small-pox.‡

B. Vertebral Column.—(1) Hydatid of the body and spinous process of the 7th cervical vertebra. It projected upon the spinal cord and produced symptoms not unlike those of cancer.||

(2) Male, 52. Hydatid of the 9th and 10th dorsal vertebræ ; destruction of the intervening intervertebral cartilage ; compression of the spinal cord. Between the left lung and the diaphragm a large collection of hydatids, undergoing degeneration. It was inferred from the last named circumstance that the extra spinal lesions were the primary ones, but the circumstance that degeneration was present by no means proves this.—(J.D.T.)§

(3) Cyst attached to the bodies of the 10th and 11th dorsal vertebræ. The case presented all the symptoms and appearance of caries of the lumbar vertebræ. The spinal cord was compressed to the size of a crow-quill.¶

(4) The transverse processes of the 4th and 5th lumbar vertebræ were found to be completely carious, breaking down on the slightest pressure ; hydatid cyst between pia and dura mater compressing the cauda equina.**

C. The Upper Limbs.—(1) *Left Scapula*.—Female, aged 24. A fall on the shoulder was followed by a swelling ; afterwards growth of the cyst ; puncture followed by incision, and finally removal of the lower fourth of the scapula.††

* Keate : *Medico-Chirurg. Trans.*, 1819.

† Langenbeck : cited by Davaine, *op. cit.*, page 584, Obs. CCLI.

‡ Guesnard : cited by Davaine and by Odile. Paris Thesis—vide p. 118, case 2.

§ Ogle : *Path. Soc. Trans.*, Vol. XI., page 299.

¶ Liouville and Strauss : *Gaz. Med.*, 1875. This is probably the case referred to on page 50.—(A.A.L.)

¶ St. George's Hospital Reports, Vol. VIII., page 533 ; also St. George's Hospital Reports, Vol. XIX., p. 430.

** Marwood : *Aust. Med. Gazette*, April, 1889, page 182.

†† Siredey : cited by Paul Boncour. Paris Thesis, page 39.

(2) *Humerus*.—Astley Cooper refers to a case in the Museum of St. Thomas's Hospital, where several hydatid cysts were found in the interior of the humerus.

(3) *Humerus*.—Dupuytren refers to the case of a man, aged 33, who fractured his arm by a muscular effort. No union took place: after a resection of the upper fragment the medullary canal was greatly enlarged, and contained a considerable number of hydatid cysts. The entire medullary canal from end to end was dilated, and its walls perforated in many places; death six weeks after operation.*

(4) *Humerus*.—Male, aged 53. Fracture from muscular effort; medullary canal cleared out, and dressings of lint soaked in permanganate of potash solution inserted; recovery.†

(5) *Humerus*.—Male, aged 30. Fracture by muscular effort; no union in 15 months; resection of the ends of the bone; numerous cysts escaped during the treatment. Three years after the operation there were still fistulae left.‡

(6) *Humerus*.—Kuester. Male, aged 22. In the right humerus was a collection of hydatids; a fibrous capsule was present, but no mother-cyst; it was clearly an instance of exogenous formation of hydatids. Humerus fractured by a fall; no union; amputation at the shoulder-joint; recovery.§

(7) *Digital phalanx*.—Charcot met with a hydatid cyst in the digital phalanx of a man, aged 81. The finger was amputated.||

D. The Lower Limbs.—*Right iliac bone* with exogenous formation of daughter-cysts beneath the gluteus maximus.—(1) Female, aged 23. Pain in region of the right sacro-iliac synchondrosis for three years, then a deep-seated elastic swelling appeared; exploratory puncture yielded clear hydatid fluid; incision and drainage; septicæmic symptoms soon followed, necessitating free incision; this was followed by great improvement, but a third operation was required, when it was found that an hydatid cyst was present in the substance of the iliac bone. This had caused considerable destruction of the bone. The cavity which contained numerous small hydatids was carefully cleared out with the gouge and osteotrite; the patient made a satisfactory recovery, and is still alive (July, 1889, *i.e.*, six years later).¶

* Cited by Davaine, *op. cit.*, page 377.

† Davaine, page 337.

‡ Labbe: cited by Davaine, page 578.

§ Berl. Klin. Wochenschr, 1870, No. 12, page 145.

|| Davaine: *op. cit.*, page 578.

¶ J. Davies Thomas: Proceedings of the South Australian Branch of the British Medical Association, September 1883, page 36.

(2) *Right Iliac Bone* perforating the hip-joint, and perforating into the pelvis. Male, aged 60. History of injury to buttock, followed by a tumour; death from hectic. In the substance of the right iliac bone, and extending through the greater part of the ischium and the horizontal ramus of the pubis, was a large cavity filled with hydatids. Perforation and destruction of the hip-joint and caries of the head of the femur.*

The case was regarded during life as a "cold abscess."

(3) *Right Iliac Bone*.—Male, aged 27. History of a local injury by a fall from a horse, followed by pain and tumour. Hydatid between the two tables of the iliac bone; cotyloid cavity destroyed; sacro-iliac joint invaded; partial destruction also of the two last lumbar and the first two sacral vertebræ. Death in spite of drainage and antiseptic injections.†

(4) *Right Iliac Bone*.—Female, aged 25. Pain in right hip for 13 years; tumour for two years; the body of the os pubis, the whole of the ilium and its cotyloid cavity, as well as the head and neck of the femur, were destroyed by the disease. Punctures followed by "vast incisions." Death.‡

(5) *Left Iliac Bone*.—Male, aged 42. Pain about the hip-joint for four years; on admission, an abscess of the buttock. Incision under antiseptic precautions; still septicæmia followed, and death in about six weeks after the incision. Hydatid of iliac bone, which had destroyed almost completely this bone and the upper part of the femur.§

(6) *Femur*.—Spontaneous fracture of left femur; no union; abscess formation; ankylosis of knee; suppuration and discharge of hydatids; death from septicæmia and exhaustion; perforation of the knee-joint.||

(7) *Femur*.—Amputation; medullary canal dilated; hydatids provided with a double mother-sac, (sic).¶

(8) *Right Femur*.—Male, aged 35. At age of 13, fracture of right femur; very slow repair. At age of 35, second fracture at near the same spot, whilst quietly walking in a room; no union; abscess formation; incision of abscess; disarticulation at hip-joint, no swelling of the bone, but the cortical substance was greatly thinned. Virchow

* Fricke: cited by Davaine, page 586.

† Pihan: cited by Davaine, page 587.

‡ Viertel: cited by Davaine, page 587.

§ Schwartz: Archiv. Gener. de Med., 1884, page 639.

|| Ramè: cited by Davaine, op. cit., page 579.

¶ Boyer and Roussin: cited by Davaine, op. cit., page 580.

regarded this as a genuine case of the rare multilocular form of echinococcus. The patient died 7 hours after the operation.*

(9) *Tibia*.—Male, aged 23. Indolent tumour of leg, of two years' duration; opened by caustic potash and actual cautery; escape of pus and cysts; slow cicatrisation.†

(10) *Tibia*.—Male. Large tumour over upper part of tibia; incision; grave constitutional symptoms; amputation.‡

(11) *Tibia*.—Male, young. Fracture of the tibia; discharge of pus and hydatids; grave symptoms; amputation; death; no union of fracture.§

(12) *Tibia*.—Female. Fracture of the leg from a quick movement. Six years previously she received a blow from a scythe on the leg; a tumour of the size of a hen's egg followed; non-union of the fracture in three months. Incision; resection of the ends of the bone; hydatids in a cavity in the bone; cure.||

(13) *Tibia*.—Female, aged 23. History of an injury to the right tibia followed by a tumour, at first painless, afterwards painful; spontaneous rupture and escape of pus and cysts; free opening. The cavity was lined by a white and shining membrane; (fibrous sac.—J.D.T.); this was cauterised with silver nitrate, and the cavity plugged with lint. About four weeks later a sequestrum was detached, which was covered on both its surfaces with minute hydatids of the size of a pin's head; probably cured.¶

(14) *Tibia*.—A piece of the anterior wall of the caput tibiæ was removed for echinococcus in the bone.**

* Kanzow and Virchow: cited in Virchow and Hirsch, Jahresbericht, Vol. XV., Part I., page 341. See also Kanzow in Virchow's Archiv. fur Path. Anatom. und Physiolog., Berlin, 1880, Vol. LXXIX., Heft. I., page 180.

† Astley Cooper: cited by Davaine, op. cit., page 581.

‡ Cullerier: cited by Davaine, page 580.

§ Webster: cited by Davaine, op. cit., page 584.

¶ Wickham: cited by Davaine op. cit., page 581.

Coulson: cited by Davaine, page 581.

** Virchow and Hirsch: Jahresbericht, 1868, Vol. II., page 412.

B. Hydatid Disease of the Muscles and Fasciæ.

Bibliography.

- BERGMANN.—Zur Diagnose und Operation ausserer Echinococcus-Geschwulste. *Dorpater Medicinische Zeitschrift*, 1870. Erster Band, page 113.
 PAUL-BONCOUR.—Des Kystes Hydatiques des Membres. *Paris Thesis*, 1878.
 TAVEL.—Ueber den Muskel-echinococcus. *Inaug. Dissert.* Berlin, 1880.
-

Hydatids may be situated either in the substance of the muscles or may originate in the inter-muscular connective tissue or fasciæ. The distinction between these is always difficult and sometimes hardly possible; fortunately, it is a matter of no clinical importance. Indeed, Davaine in his classical work includes hydatids connected with the muscles in the same category as those of the subcutaneous tissue and other superficial parts.

Frequency.—Bergmann* collected 102 cases of echinococci of the external parts. Of these 37 were situated in the subcutaneous connective tissue of various parts of the body, 15 were in the female breast, 2 in the testis, and 48 in the muscles or inter-muscular connective tissue.

The muscles appear to be rarely the seats of hydatid cysts, for out of 1,867 cases of echinococcus disease the muscles were only in 13 instances the seat. Tavel,† however, has collected 107 cases from various sources.

Site.—Any muscle in the body may be the seat of an echinococcus cyst, but the greater number of recorded instances have been met with in the muscles of the trunk, head and neck, and limbs. They have been seen in the muscles in the interior of the body, *e.g.*, the heart, diaphragm, psoas, and iliacus, &c.

In 23 cases they were situated in various parts of the head and neck; in 30 the muscles of the trunk were the seat; in 15 they were found in the upper limb, and in 32 in the lower limb.

Tavel remarks that hydatids become far less common the more distant the part from the trunk. For example, in the upper limb, there were 12 cases in the upper arm to 3 in the forearm, and in the lower limb, 23 in the thigh and only 3 in the leg.

Dorpater Medicin. Zeitschrift. Erster. Band, Heft. II. and III., 1870.

† Tavel: *Inaug. Dissert.*

It has been noticed by Hansen,* also by Tavel, that echinococcus cysts are principally found on the sides of the limbs where the principal blood-vessels course. In the neck they affect especially the neighbourhood of the carotid artery. In many cases the first appearance of the tumour was connected by the patients with some injury received. This occurred in so many instances that it could hardly be attributed to merely accidental coincidence. There can be no doubt that in some of these instances a vigorous muscular movement or an injury had displaced the cyst, so as to render it evident; in others, inflammation was induced, and this speedily rendered the previously latent parasite obtrusive.

The diagnosis of echinococcus cysts of the muscles is usually very difficult, unless the cyst be punctured or incised; indeed, in the great majority of cases the real nature of the tumour has been discovered only at the time of operation. They may be mistaken for other kinds of cysts, for abscess, for lipoma, for sarcoma, or cancer.

The treatment should be free incision of the sac, evacuation of its contents, free drainage, and antiseptic dressings.

C. Hydatid Disease of the Female Breast.

Bibliography.

HAUSSMANN.—Die Parasiten der Brustdrüse. Berlin, 1874 (Birkett).

Frequency.—The female breast is not a common seat of this parasite, for it is attacked in less than one per cent. of all cases.

From various sources, Haussmann has collected 16 cases. Exclusive of these, there are instances recorded by several writers.

Cases.—(1) Female, aged 27. Cystic tumour in right breast of nearly four years' known duration, now of the size of a hen's egg. The tumour was punctured, but no fluid escaped; eight or ten days later it was incised and found to be a degenerated hydatid. Cure.†

* Deutsche Zeitschrift für Chirurgie.

† Macgillivray: Aust. Med. Jour., August, 1865, page 249-250

(2) Female, aged 44. Hard lobulated tumour in the right breast, presenting the characters of scirrhus; puncture yielded clear fluid containing echinococci. Next day, tumour excised, with removal of the fibrous capsule; single mother-cyst containing seven or eight daughter-cysts, the largest of the size of a pigeon's egg. Cured.*

(3) Female, aged 34. Hydatid in the left breast, of the size of a hen's egg; extirpated. Cured.†

(4) Female, aged 41. Smooth tumour, of the size of a hen's egg, at the outer edge of the left breast, over the third and fourth ribs; axillary glands not enlarged; afterwards became inflamed and enlarged to the size of a fist; then incised. The fibrous capsule was detached during convalescence. Cured.‡

(5) Marian D——, aged 40, was admitted, under my care, into the "Beatrice" Ward of the Adelaide Hospital, on January 18, 1881. Nine years before received an accidental blow on her right breast; pain followed the injury, and a few weeks later a small tumour appeared; this continued to grow slowly.

On admission, a smooth, moveable tumour, of the size of a large plum, at the upper and outer part of the right breast; elastic, not fluctuant; no retraction of nipple; no enlargement of axillary glands; removal of parasite and sac. Cured 16 days.§

* Macgillivray: loco. cit.

† Jonassen: cited in Virchow and Hirsch, Jahresbericht for 1877, Vol. XII., Part II., page 219.

‡ Hoppener: cited in Virchow and Hirsch, Jahresbericht., for 1881, Vol I., page 397. See also Haussmann: Die Parasiten der Brustdrüse.

§ J. Davies Thomas, (unpublished).

HYDATID DISEASE, Vol. II.

PART V.—THE OPERATIVE TREATMENT OF HYDATID DISEASE.

- A. Operations which destroy without removing the Parasite.
- B. Radical Operations.
- C. Operations involving the removal of the Fibrous Sac as well as of the Hydatid Cyst.

HYDATID DISEASE, Vol. II.

PART I.—THE OPERATIVE TREATMENT OF HYDATID

DISEASE

A. Operations which destroy without removing the

Parasite.

B. Radical Operations.

C. Operations involving the removal of the Fibrous
Sac as well as of the Hydatid Cyst.

THE OPERATIVE TREATMENT OF HYDATID DISEASE.*

Bibliography.

- THOMAS, J. DAVIES.—The Operative Treatment of Echinococcus Cysts of the Liver. Aust. Med. Jour., 1888 and 1889.
- SIMON.—Mittheilungen aus der chirurgischen Station des Krankenhauses zu Rostock. Deutsche Klinik, No. 43, October 27, 1866.
- UTERHART.—Ueber die Incision nach Doppelpunktion zur Heilung der Echinococcencysten des Unterleibes, nebst Beschreibung zweier Operations-fälle, welche in der chirurgischen Klinik des Rostocker Krankenhauses vorkamen. Berliner Klinische Wochenschrift, No. 17, April 27, 1868.
- WOLFF.—Operative Behandlung zweier Unterleibs Echinococcen, nebst einigen Bemerkungen ueber fünf fruher in der hiesigen Klinik operirte Fälle. Berliner-Klinische Wochenschrift, No. 5, January, 31, 1870.
- TRENDELENBURG, in Madelung.—Beiträge Mecklenburgischer Aerzte zur Lehre von der Echinococcen-Krankheit. Stuttgart 1885, page 155, et seq.
- SCENGER.—Zur Operativen Behandlung der Abscesse und Hydatiden der Leber. Berliner Klin. Wochenschrift, 1877.
- KIRCHNER.—Ein Beitrag zur Operation der Echinococcen der Organe der Bauchhöhle. Inaug. Dissert., Berlin, 1879.
- SCHLEGTENDAL.—Die Lindemannsche Einzeitige Operation der Echinococcen der Bauchorgane. Archiv für Klinische Chirurgie, 1886.
- LANDAU.—Zur Operativen Behandlung der Echinococcen in der Bauchhöhle. Berl. Klin. Wochensch., 1880.
- LAWSON TAIT—Four cases of Hepatotomy. Birmingham Medical Review, October, 1881.
-

Classification of the various Operations, and general considerations.—Perhaps among the diseases which afflict mankind, there is no one for the relief of which a greater diversity of treatment has been practised than for "hydatid" disease. But, various as are the surgical procedures which have been followed for this object, they yet may be classified for the purposes of criticism under three headings, viz :—

I.—Those operations by which it is intended that the parasite shall be destroyed, without, however, aiming at its entire removal from the body of its "host." To this group belong—

* This paper was published in the Transactions of the Second Intercolonial Medical Congress (Melbourne, 1889). The alterations since made in it are very few.—(A. A. L.)

- (a) Operations of puncture or "tapping"—aspiratory or simple—by which the fluid contents of the bladder-worm are removed to a greater or less extent.
- (b) The injection through a canula of various bodies supposed to act as parasitocides.
- (c) The destruction of the parasite by electricity.

II.—Those operations, which have as their object the extraction of the entire bladder-worm, with any daughter-cysts that may be present; such may be regarded as "radical" operations. To this class belong cases in which the parasite is removed by an artificial opening into its sac, procured by—

- (a) Caustics.
- (b) Canule-à-demeure.
- (c) Various forms of incision operations.

III.—A third group is constituted by a comparatively few recorded cases of operations, where not only has the parasite been removed, but also, more or less completely, its fibrous sac as well. These operations may be regarded as "ultra-radical," in consequence both of their greater gravity, and of the limited number of cases in which they can be regarded as permissible.

Before proceeding to the discussion of the claims of the different modes of treatment, it is desirable to consider briefly the nature of the conditions present. In its normal state, the echinococcus cyst lies imbedded in some organ, tissue, or closed cavity of its host; almost invariably it is completely enveloped in an adventitious sac, or capsule, which is not an integral part of the parasite, but is a morbid product of the organ or tissue in which the bladder-worm has taken up its abode; it is, nevertheless, a structure of great importance to the parasite, for through it, by a process of diosmosis, the latter obtains its supply of pabulum from the blood of its host; its functional integrity therefore determines whether the parasite shall dwell in plenty, or die of inanition. When the parasite, and consequently also its fibrous sac, is young, the latter is very richly supplied with blood-vessels, which are derived from the neighbouring normal vessels; so that the removal of the fibrous sac entails a very abundant employment of ligatures. But from the very nature of the fibrous capsule, which consists of stratified layers of connective tissue, it tends to contract, and in doing so to impair its own vascular supply; hence follow extreme induration and rigidity of the capsule and calcareous degeneration. This process may result in complete calcification of the entire sac, if it be of small size, but in the case of large cysts it is more or less localised; some portions

of the surface of the cyst being thick, tough, and often infiltrated with calcareous salts, whilst others are much less indurated and rigid. Calcareous degeneration, here as elsewhere, is a necrotic change, and is in this case an indication of impaired blood supply. The effect of this alteration upon the enclosed parasite is fatal, when it has reached an extreme degree, by cutting off its supply of pabulum. When the parasite dies from this cause, as is frequently the case, its fluid contents become more or less opaque, the scolices die and disintegrate, a putty-like matter is found between the parasite and its capsule, and ultimately nothing remains except a tough sac much contracted in size, within which is found a pasty mass, with the remains, if any, of the mother-cyst, variously folded and plaited in a manner resembling the æstivation of certain plants. It is important, clinically speaking, to recognise that the mere death of the parasite does not of necessity mean the cure of the host; for it is quite common to meet with hydatids requiring operation, but in which the parasite is dead and far advanced in spontaneous decay.

In estimating the results of different plans of treatment, certain conditions have to be taken into consideration, viz :—

(1) *The locality of the parasite.*—It is evident that an echinococcus cyst in the female breast may be safely removed, without removal of the mamma itself; whilst a colony of hydatids in the interior of the thigh bone may entail amputation at the hip joint, and so may kill the host indirectly.* Then, again, the cyst may be so placed as to render diagnosis, and consequently treatment, impossible—for example, in the walls of the heart, in the interior of the brain, &c. Speaking generally, the most important cases of hydatid disease, on account of their relative frequency, are those of the interior of the abdomen and thorax, and more particularly those of the liver and lungs. About 72 per cent. of all cases of echinococcus disease in man occur in connection with the abdominal cavity; and as regards individual organs, the liver is most frequently invaded (in 57 per cent.), and the lungs next (in nearly 12 per cent.) Even in the case of the different organs situated in the same cavity, the special local conditions exert a great influence both upon the prognosis and treatment. For example, echinococci of the pericardium and heart must, for the present at least, be regarded as alike beyond the reach of diagnosis and of treatment.

(2) *The rupture of the parasite.*—Echinococci of the lungs are greatly affected in their career by the frequency of their rupture into the bronchial tracts: many cases of this disease in the lungs are spontaneously cured

* Case recorded by Kanzow and Virchow, and cited in Virchow and Hirsch's Jahresbericht, Vol. XV., Part 1, page 341. (Vide ante, p. 128, A.A.L.).

by the elimination of the parasite through the air-passages ; and a considerable proportion of the cases of pulmonary hydatids, reputedly "cured" by tapping operations, really have recovered in consequence of the expulsion of the remains of the parasite by coughing, although the bladder-worm was killed by the puncture. Moreover, in the case of pulmonary hydatids which have ruptured either spontaneously or in consequence of surgical interference, it frequently happens that bacteria are conveyed by the air entering the cavity through the bronchial tubes which open into it, and thus putrefactive changes are induced in the contents of the sac : from this cause, pyrexia, cough, night sweats and emaciation may arise, and the patient often presents precisely the general aspect of a phthisical sufferer. In hydatids of the liver and kidney also, the existence of the natural ducts of these organs often occasions special accidents to befall them. In the case of liver cysts, bile may enter into the sac after the mother-cyst has ruptured, and the remains of the parasite or any daughter-cysts present may pass into or through the bile ducts, or may be arrested in them and cause jaundice. Hydatids of the kidney are particularly liable to rupture spontaneously into the pelvis of the organ, or into some other part of the urinary ducts, for more than two-thirds of the cases collected by Beraud* terminated in this way. On the other hand, the spleen, omentum, mesentery, and the abdominal cavity, which often are the seats of echinococcus cysts, have no natural channels which can serve as outlets for the parasite.

(3) *The condition of the fibrous capsule.*—With advancing age the fibrous capsule becomes thicker, more rigid, and tends to undergo calcareous degeneration ; it also acquires more extensive and closer connection with the adjacent structures, and in consequence it collapses less readily when its contents are removed. I have seen a case of hydatid cyst which projected from the under surface of the liver, and which extended deep into the recto-vesical pouch, where the fibrous capsule was so closely adherent to both the anterior and posterior walls of the abdomen that it was a puzzle to discover where the intestines were placed. It is evident that, under such circumstances, much delay must occur in the process of obliteration of the cavity formerly filled with the bladder-worm, for usually the sac yields readily to the pressure of the stomach, intestines, &c., and thus its opposed walls come in contact and are soon united by membranous adhesions. Again, when the fibrous capsule is extensively degenerated, it may become detached in larger or smaller

* Beraud's *Des Hydatides des Reins*, Paris Thesis, 1861, page 47.

portions during the process of cure; this is especially apt to occur where the sac has undergone calcareous degeneration.

(4) *Suppuration in the sac.*—The occurrence of suppuration in the sac, or of putrefactive changes in its contents, with or without the accumulation of gas, exert a weighty influence upon the prognosis and proper treatment. Usually, such conditions render a radical operation imperatively necessary.

In this essay, I propose to briefly review the modes of treatment more commonly adopted for the relief of hydatid disease, especially as concerns their efficacy and their danger to life; but, as I have elsewhere recently discussed* at length many of the plans of treatment, I shall here only refer to the conclusions arrived at with regard to the following methods, viz., punctures, injections, electricity, caustics, and canule-à-demeure. It is intended, however, that the more modern methods of incision, according to the modifications of Simon, Volkmann, and Lindemann, shall receive further consideration.

A. Operations which destroy without removing the Parasite.

(a) *The Treatment by Puncture, either Aspiratory, or by means of a simple Trochar and Canula.*—Tapping, at first with a common trochar of small calibre, and after its introduction by Dieulafoy, with the aspirator and fine canula, has been a favourite mode of treatment in most parts of the world where hydatid disease is met with. It has been strongly advocated by Murchison in England, by Boinet and Dieulafoy in France, by Hjaltalin in Iceland, and by Hudson, MacGillivray, Bird, and others in Australia.

Until quite recently in Australia puncture has been the recognised regular mode of treatment for all cases of internal hydatids. This fact alone should be proof that sometimes cure results from tapping operations; but, on the other hand, it is certain that in a large proportion of cases it fails to rescue the patient from death. It must also be conceded that the treatment by puncture is attractive on account of its simplicity and of its apparent freedom from risk; moreover, if we accepted without criticism the statements of many of its advocates, it might be concluded that failure to cure by it is exceptional. But a closer scrutiny brings with it much scepticism, for the statistical data based upon the number

* Aust. Med. Journal, 1888.

of reputed "cures" by tapping operations are in the last degree unsatisfactory, inasmuch as it is certain that in many of them the cyst re-fills, and becomes a source of peril to the patient. Such an occurrence has been known to take place even as long as ten years after the patient was believed to have been cured; indeed, it is almost impossible to fix a time at which a hydatid cyst, treated by puncture, may safely be said to be cured. It follows, therefore, that in statistics bearing upon this question, the number of reputed cures must be accepted with very large reservation.

Simple and harmless as puncture with a small trochar generally is, yet it not infrequently happens that alarming symptoms follow it, and in a few cases death has even taken place. I have elsewhere* referred to three cases in which death occurred immediately after puncture of hydatid cysts in the liver, apparently from shock; and in the *Lancet* of August 28, 1875, allusion is made to a case of sudden death resulting from puncture of an hydatid cyst of the liver with a fine trochar. The reference is as follows:—"This misfortune lately happened to M. Martineau, at the Lariboisière Hospital of Paris. The patient was 31 years of age, and presented at the epigastrium an indolent, dull-sounding tumour, with all the symptoms of a hydatid cyst. Tapping was resorted to with a capillary trochar. Very little clear fluid was obtained, and on removing the trochar it was found obstructed by a shred of membrane. The patient in the meantime turned pale and faint; he vomited some wine and threw up much white mucus from the bronchi. In twenty minutes, in spite of the most active means, he breathed his last. Two cysts, the size of fists, were found on the under surface of the liver, one under the right, the other under the left lobe. No peritonitis. M. Martineau considers that the fatal issue was owing to reflex paralysis of the pneumogastric."

I have also seen a patient in imminent danger for hours from shock, after a puncture of a hydatid cyst of the spleen, although a very fine needle was used.† The pathogeny of such cases is obscure at present.

In the case of pulmonary hydatids also death has been known to supervene rapidly after puncture. In two cases kindly communicated to me by Dr. Lonsdale Holden, of Hobart, the patients died, one in about five minutes, the other in about half an hour, after puncture with a fine trochar. Dr. Holden was inclined to regard these as deaths from syncope. It seems to me, however, that, at any rate, in some cases of sudden death after the puncture of large pulmonary cysts, the patient

* *Aust. Med. Journal*, April, 1883.

† *Aust. Med. Gazette*, June, 1887.

has really died of suffocation, in consequence of the flooding of the bronchial tracts of both lungs by the outflow of hydatid fluid from the punctured cyst. That this accident is not more frequent under these circumstances is probably attributable to the fact that the collapsed mother-cyst often occludes the openings of the bronchial tubes on the walls of the cavity.*

In a case recorded by Schede,† a woman aged twenty-three, died from suffocation in the course of a few minutes after an exploratory puncture of a huge hydatid of the right lung. I have witnessed most urgent dyspnœa from the same cause.

When an echinococcus cyst of the kidney is punctured, its contents may escape by the ureter into the bladder, and so become eliminated, as in a case related by Bradbury.‡ In the case of liver cysts, escape of the parasite by the bile ducts after puncture is not very common, probably in consequence of the comparatively small size of the intra-hepatic ducts; jaundice from their blockage is probably more often met with. There is good reason for believing that a large proportion of the cases of lung hydatids cured after puncture recover simply in consequence of the expectoration of the membranes, although it is true that the puncture killed the bladder-worm, and so rendered possible its expulsion by coughing.

The recorded deaths after the puncture of pulmonary hydatids appear to me to be of sufficient interest and importance to merit notice in this paper; they are fully recorded in a table published in the *Australian Medical Journal*, of July, 1889. In four cases death seems to have resulted from rupture into the pleural cavity. In one death was apparently due chiefly to a cyst of the liver that was also present. In four instances death took place very soon after puncture; one of them admittedly died from suffocation, the others possibly from the same cause, or from shock. The remaining cases sank from dyspnœa, pyrexia, and exhaustion.

The general conclusions to be drawn from the statistics of tapping operations, as shown in Table I., are that the death-rate has been about 19 per cent.; that in 46 per cent. it evidently failed to cure the patients; and that, although 54 per cent. were regarded as relieved or cured, still in the majority of them the patients had not been under the

* For a discussion on this point see "Hydatid Disease of the Lungs," Proceedings of the South Australian Branch of the British Medical Association, September, 1884.

† Cited in Madelung, "Beitrage Mecklenburgischer Aerzte zur Lehre von der Echinococcen-Krankheit." Stuttgart, 1885, p. 86.

‡ British Medical Journal, October 6, 1887, p. 471.

observation of the operators for a sufficiently long time after the operation to justify the conclusion that a permanent cure had been effected.

TABLE I.—*Table showing the Results of Tapping Operations upon Echinococcus Cysts in various parts of the body :—*

SITUATION OF CYST.	DEATHS.	NOT RELIEVED	FAILURE OF PUNCTURE. (other operations.	RELIEVED	REPUTED CURES.	RESULT UNKNOWN	TOTAL.
Liver	73	5	92	63	168	10	411
Lung	14	—	20	1	14	4	53
Spleen	2	—	7	4	6	1	20
Kidney	—	—	4	—	2	—	6
Omentum, mesentery, &c. ...	1	—	3	—	3	—	7
"Abdomen" ...	1	—	1	5	1	2	10
Male Pelvis ...	4*	—	4	—	5†	—	13
Total	95	5	131	73	199	17	520

Summary of the Results of Tapping Operations :—

Deaths	18.88 per cent.
Not relieved	0.99 "
Unsuccessful punctures followed by other operations	26.04 "
Total failure of punctures	45.91 "
Relieved	14.51 "
Reputed cures	39.56 "
Total successes of punctures	54.07 "

The results of aspiratory puncture show only about half the ratio of deaths as compared with puncture with an ordinary trochar. The mortality rises with the number of tappings required. The best results are met with in living juvenile echinococci of moderate size, the worst in old degenerated or suppurated cysts.

(b) *The Treatment of Hydatid Cysts by means of Medicated Injections.*—Injections have been extensively employed as adjuncts to various forms of radical operations, *e.g.*, in the course of treatment by

* Once the bladder as well as the cyst was punctured ; twice the cyst was punctured per rectum.

† Three doubtful cures.

caustics and by canule-à-demeure, &c.; their object being partly to evacuate the solid contents of the sac, and partly to correct decomposition; however, they have also had a limited use as direct parasitocides, and also, apparently, with a vague idea that they caused adhesive inflammation in the sac, and thus led to the cure of the disease; in this case puncture forms, of necessity, a part of the treatment.

Out of eighteen cases in which injections were employed in this manner, five died and thirteen recovered. Numerous substances have been used as injections, *e.g.*, iodine, alcohol, carbolic acid, ox-bile, extract of male fern, &c.; the latest modification being that suggested by Professor Bacelli, of Rome; he advises that about ten centigrammes of the contents of the parasite should be removed, and replaced by an equal bulk of a two per 1,000 solution of mercuric chloride. At present, no satisfactory conclusion can be drawn as to the effect of this treatment, but there seems to be no reason to expect better results from it than from the use of iodine or carbolic acid.*

(c) **The Treatment of Hydatid Cysts by Electricity.**—Electromotive force has been tried in various forms for the purpose of destroying this parasite, as faradism, galvanism, and by way of electrolysis. The last-named is the only form of application of electricity worthy of serious consideration. It has been tried principally in cases of liver echinococci. Out of twelve cases, collected from various sources, one died; in one case it distinctly failed to cure, but in the remaining ten cases it was claimed that cure resulted.

In one case of Splenic hydatid recorded by Madelaine (Paris Thesis, 1868), electro-puncture was tried for one minute, but indications of peritonitis followed in a few days, and the patient was then successfully treated by Recamier's method. For the present it seems to me that the successes claimed for electrolysis in the treatment of this disease are probably referable, simply to the puncture which is its necessary accompaniment.†

B. Radical Operations.

We now arrive at the consideration of "radical operations." These include—(a) treatment by caustic; (b) canule-à-demeure operations; and (c) various modifications of incision procedures.

* For a fuller discussion of this mode of treatment see the Australian Medical Journal, June, 1888.

† For a further discussion of this subject, see the Australian Medical Journal, June, 1888.

(a) **Caustics (Recamier's Method).**—The uncertainty of cure, after tapping with a fine trochar, and the danger occasioned by the escape of the cyst contents into the peritoneal cavity when a large instrument is used, led to attempts being made to procure adhesions between the sac and the parietes by various methods. One of the earliest and most important of these, was the use of caustics, applied repeatedly at short intervals of time, until the surface of the sac was reached, or even until an opening in the sac itself was procured; the contents were then removed, and the effects of their decomposition were, as far as possible, corrected by the use of antiseptic injections. The principal chemical agents employed for this purpose were caustic potash, and zinc chloride.

As the process of opening the cyst by caustics was a very tedious one, many operators hastened it by making incisions to a certain depth and then applying caustic to the floor of the wound, and in the majority of cases the sac itself was opened either by an incision or by puncture with a large trochar. The general results of the caustic method appear in Table II.

TABLE II.—*Showing the Results of Treatment by Caustics in Ninety-five cases of Echinococcus Cysts situated in Various Organs.*

ORGAN AFFECTED.	DEATHS.	FAILURES TO CURE.	CURES.	RESULT UNKNOWN.	TOTAL.
Liver	25	2	55	2	84
Kidney	3	—	1	—	4
Spleen	4	—	2	—	6
Abdominal hydatids of uncertain seat	—	—	1	—	1
Total	32	2	59	2	95

Summary of Table II.

Deaths	33·68 per cent.
Cures	62·10 “
Failures to Cure	2·10 “
Result Uncertain	2·10 “
	<hr/>
	99·98 “

It will be seen that about one-third of the cases so treated died.

This method of treatment is to be condemned for the following reasons:—

- (1) Its high mortality, nearly thirty-four per cent.
- (2) Its extreme painfulness; in children it has even been found necessary to discontinue the treatment on account of this.

(3) Its prolonged duration ; probably three or four months on an average are required for convalescence, which can hardly be said to begin until the mother-cyst has escaped.

(4) Its total inapplicability in some localities, *e.g.*, for lung hydatids, or pelvic cysts.

(5) Even when applicable to a given case, it cannot be depended upon to procure efficient adhesions.

For these reasons, Recamier's treatment should forthwith pass into disuse.

(*b*) **Canule-a-demeure.**—The aims of this plan of treatment are identical with those of Recamier's method, viz., to establish a free opening into the sac of the parasite, in order to extract its contents, and at the same time to establish adhesions, in order that none of the cyst contents should escape into the peritoneal cavity ; there can be no doubt that this method represented a great advance upon the treatment by caustics, as is sufficiently proven by its lower death rate, and also by the fact that it can be adopted when the parasite is situated within the limits of the thoracic parietes. In ninety cases in which this treatment was employed for liver hydatids, there were twenty-four deaths, or at the rate of nearly twenty-seven per cent. ; but this is better than the death-rate of the caustic treatment, which amounts to over thirty-three per cent. Three cases of splenic hydatid, however, so treated, all proved fatal. In a large proportion of the fatal cases, death took place from septicæmia, caused principally by imperfect evacuation of the cyst contents, which generally soon become decomposed ; two of the deaths from peritonitis appear to have resulted from escape of the cyst contents into the peritoneum, and in one of them the canula had slipped out of the sac.

The objections to the canule-à-demeure treatment are :—

(1) The uncertainty as to the course of the canula ; in most cases it is not difficult to avoid transfixing the intestine or stomach, but it is common to traverse the omentum ; but in the case, for example, of a pelvic hydatid projecting in the hypogastric region, it may easily happen that the urinary bladder may be carried up by the cyst, and that it may be transfixed by the trochar ; it is needless to comment upon the probable result.

(2) In the case of a deeply-seated cyst, it is quite common for the canula to slip out of the sac, in consequence of the collapse of the parasite, caused by the evacuation of its fluid contents. I have seen fatal pneumo-thorax caused in this way, by an attempt to treat a pulmonary

cyst by canule-à-demeure ; even when a long trochar is used this may happen, and on the other hand, if the instrument be too long, it may wound the distal wall of the capsule.

(3) It is practically impossible to prevent the cyst contents from becoming septic ; the amount of discharge is so great that the usual antiseptic precautions fail ; indeed it is probable that if perfect asepticism could be maintained, adhesions would not form ; this, at any rate, has been the experience of Trendelenberg with regard to Simon's operation of double puncture, in which two canulas are retained in the sac for the sole purpose of causing adhesions

(4) The process is a slow one, for on an average convalescence occupies from two to four months, and it has been known to extend to ten or twelve months ; the reason of this is that a considerable time is occupied in the process of making an opening into the sac of sufficient size to allow the mother-cyst to be extracted ; even then it usually comes away in fragments, and until all the solid constituents of the parasite have been removed the sac rarely closes ; moreover, the presence of any shreds of membrane induces suppuration and decomposition in the sac, and thus tends to cause septicæmia, and to delay convalescence.

(c) **Incision Operations.**—Operations upon hydatid cysts by incisions are influenced in an important manner by the precise locality of the parasite, so that it is necessary to consider separately abdominal and thoracic hydatids. Some hydatid cysts, which have their origin within the abdomen, necessitate operations which invade the thoracic cavity, *e.g.*, echinococci of the convex surface of the liver, and those connected with the upper part of the spleen.

In consequence of their relative frequency, the most important abdominal hydatids are those of the liver, and hence they merit our first and most attentive consideration. The recorded cases of liver echinococci, treated by various modes of incision, compose a motley group. The earlier cases so dealt with were usually operated upon under the impression that they were abscesses pointing on the surface ; but in later instances the incision was made after unsuccessful attempts to cure the disease by other plans of treatment, such as tapping and canule-à-demeure, &c. Very frequently, during the employment of the caustic treatment, the sac was opened by an incision when it was believed that adhesions had been procured ; and, in other instances, preliminary incisions were made into, but not through, the abdominal walls, caustics then being applied to the

bottom of the wound. In a few cases non-suppurated hydatids were rashly cut into, without any precautions being taken to previously procure adhesions, the result generally being that the patient died quickly of peritonitis from escape of the cyst-contents into the peritoneal cavity. The danger of such a procedure soon forced itself upon the notice of operators, and thenceforth it became a recognised principle, that hydatids of the liver should not be incised, unless adhesions were believed to be present. To attain this end, caustics were used by many operators, but others regarded them as unsatisfactory, and various means of procuring adhesions were suggested and practised. For example, Trousseau had recourse to multiple acupuncture for this purpose. Begin's method consisted in reaching the tumour by repeated incisions, the wound being meanwhile plugged with lint; sometimes the first incision was carried down to the peritoneum, and, occasionally, even through that structure. A modification of this procedure, resulting from the introduction of the antiseptic method, has been advocated and successfully practised by Volkmann. Another plan, having a similar aim, is Simon's method of double-puncture, followed by incision. Finally, as a result of the recent advances in abdominal surgery, comes the method of treatment generally associated in Germany with the name of Lindemann, of Hanover, by which the sac is immediately incised, its contents evacuated, the lips of the wound in the fibrous capsule being securely attached by sutures to the edges of the parietal incision.

Before entering into a detailed discussion of these various operations, it is necessary to distinguish between those cases in which the parasite is accessible through the abdominal parietes, and those in which it can be reached only by traversing the pleura, as when the cyst occupies the convexity of the liver; for it is obvious that the invasion of the pleura introduces a new element of difficulty and danger into the treatment.

In order to arrive at trustworthy conclusions it is necessary also to separate those cases in which no precautions against escape of the cyst-contents into the peritoneal and pleural cavities have been taken, from those where such precautions have been taken. Also, it is needful to consider the influence of antiseptic treatment; of complete evacuation of the solid and fluid contents of the sac; of effective drainage, &c.

It follows that a just criticism of the results of the various incision operations is not by any means a simple matter. Operations by incision will be considered under two principal groups, viz., abdominal incisions and thoracic incisions.

Abdominal Incisions.

1. **Simple Abdominal Incisions, without precautions.**—In this class will come simple abdominal incisions in which no special precautions were taken to prevent the escape of the cyst contents into the peritoneal cavity. Many of these were operated upon under the mistaken idea that they were cases of abscess.

GENERAL RESULTS.

	No. of Cases.				Per Cent.
Deaths	23	38.5
Cures	34	56.5
*Recoveries	3	5.0
				<hr/> 60	<hr/> 100.0

Deaths.—It will be seen by the above table that simple incision, without precautions, is a very mortal operation.

CAUSES OF DEATH.

	Cases.
Peritonitis certainly in	7
Peritonitis probably in	4
Septicæmia ,,	7
Exhaustion ,,	1
Pleurisy ,,	1
Uncertain ,,	3
	<hr/> 23

Peritonitis seems to have been the cause of death in about half the fatal cases, and to have been itself occasioned by the escape of the cyst-contents into the abdominal cavity; in one instance, however, the fatal peritonitis was produced by the accidental puncture of the bladder in an attempt to procure drainage. The majority of the remaining deaths were apparently due to imperfect evacuation of the decomposed cyst-contents causing blood-poisoning. Multiple cysts were present in five fatal cases.

Cures.—In 23 of these cases it is clearly set forth that suppuration had taken place in the sac, and, consequently, there is little doubt but that adhesions had formed; indeed, in some instances, it is expressly stated that the tumour was regarded as an abscess. It would profit little to devote much space to the discussion of this form of treatment; it suffices, however, by its appalling mortality, to teach the lesson that the cyst-contents should be jealously excluded from the peritoneal cavity. This vitally important object may be attained, either before the open-

* As regards the distinction between "cure" and "recovery," I imagine that a fistula must have remained when the patient was last seen.—(A. A. L.)

ing of the sac, as by the methods of Simon and Volkmann, or at the time of incising the sac, as by the method of Lindemann.

2. **Simon's Operation of Double Puncture followed by Incision.**—Recognising the dangers of permitting the escape of the cyst-contents into the abdominal cavity, and impressed with the disadvantages of the method of Recamier in the treatment of liver hydatids, Simon devised and practised the method of procedure associated with his name. It must be premised that, both by Simon and by his followers, it was considered that suppuration of the cyst-contents formed an essential feature of the intended process of cure; this is clearly set forth in the contributions both of Uterhart and Simon himself (*loco cit.*)

The plan of operation as described by Uterhart is as follows:—At the most prominent part of the tumour, or where fluctuation is most pronounced, a fine exploratory trochar and canula are introduced to a depth of some inches; the trochar is removed, and the character of the fluid that escapes is observed, in order to establish the diagnosis; if this be satisfactorily determined, a second fine, or a somewhat larger, instrument is inserted at a point two and-a-half or three centimetres (say an inch) distant. After a part of the contained fluid has been permitted to flow away through the canulæ, the latter are plugged with carbolised wax, and a protective dressing is applied; for the next few days the patient must remain very quiet in bed. In two or three days' time a portion of the accumulated fluid is again allowed to escape in order to see whether it contains any admixture of pus, and this inspection is repeated at intervals until the opacity of the fluid, and the penetrating odour, render probable the detachment and commencing decomposition of the mother-cyst. Simon generally allowed the canulæ to remain in the sac until the fluid of the cyst began to escape at the sides of the instruments. Then adhesions are likely to have been established between the sac and the parietes, and now incision into the cyst is performed between the two points of puncture. Unless some urgent symptoms such as high fever with signs of oppression appear, the operator may delay incision until the fourteenth day or later. The solid constituents of the parasite should be removed as completely as possible by means of forceps, &c.

Uterhart compares this method with the caustic treatment, and insists upon the following points in its favour:—

(1) That the diagnosis is safely established, before the commencement of the operation, by the introduction of the first canula.

(2) The great certainty of the production of adhesions between the

sac and the parietes. He states that on one occasion, after the double puncture of a case of hydro-nephrosis, in a person who died soon after the operation from double pneumonia, the post-mortem examination showed that very extensive adhesions had formed within 48 hours. It can also be seen that in two or three days' time after puncture the tumour no longer slides under the abdominal walls synchronously with the movement of respiration. It can hardly be doubted that for the production of adhesions, as compared with the caustic treatment, Simon's method is preferable.

(3) The lesser degree of reaction upon the general health, and the smaller amount of painfulness, as compared with Recamier's plan.

(4) The shorter duration of the treatment prior to the opening of the sac—ten to fourteen days after double puncture the sac may be incised, whilst in some cases under caustic many weeks or even months may elapse before a free exit is procured.

A modification of Simon's procedure was practised in one recorded case by Boinet. A large cyst of the liver was treated by canule-à-demeure, the patient soon showing dangerous symptoms of septicæmic poisoning, apparently due to decomposition of the contents of the sac and imperfect drainage. To relieve the patient Boinet removed the canula, and passed along its track a strongly-curved trochar, so as to make a counter-opening into the sac; through this canula he transmitted an india-rubber drainage-tube, the two projecting ends of which were secured together outside the abdominal wall; in the course of a few days, feeling assured that adhesions had formed, he divided the tissues between the outlets of the drainage tube.

It cannot be denied that Simon's operation represented a decided advance upon Recamier's method, but still it left much to be desired. Simon thought that radical operation was not permissible in recent cases of hydatid disease, and that it should be performed only when the tumour had attained a considerable size, or when suppuration had taken place; he regarded old cysts, with rigid walls, as those particularly suited for his method of treatment. Uterhart, however, considered that all cases of echinococcus cysts that could be satisfactorily diagnosed were fit cases for this operation.

Objections to Simon's Operations.—Suppuration of the cyst-contents, with resulting pyrexia, &c., seems to be an invariable accompaniment of Simon's operation; the temperature usually ranges from 100.4° to 102.4° , and continues till the sac is incised; it has been attributed by Wolff (*loco cit.*) partly to the peritonitis excited by the irritation of the

canulæ, but as it generally subsides soon after incision of the cyst it is more probably due to the retention of suppurated cyst-contents. It is acknowledged by most writers who have advocated this method, that suppuration, if not an essential element of it, at least is its constant accompaniment; occasionally attempts have been made to treat the cases by antiseptic precautions, but usually, if not invariably, this has failed, for the sac has generally suppurated, or adhesions have not formed.

As an example of the extreme difficulty met with in the attempt to carry out Simon's method with Listerian precautions, I may cite briefly a case treated in Volkmann's clinique at Halle, and recorded by Ranke.* In this instance, a hydatid cyst of the liver was first punctured by an exploratory trochar under strict antiseptic precautions, and normal, clear, non-albuminous, hydatid fluid escaped; an attack of urticaria followed; five days later two canulæ were introduced, also with antiseptic measures, after the escape of 1,500 grammes of light-yellowish, clear fluid, containing traces of albumen the canulæ were plugged with carbolised wax; Lister's dressing was applied and continued for six days; the canulæ were then removed and replaced by a silver sound for three days. During the whole of this time the temperature had remained normal; then continuous pyrexia, with increase in size of the tumour, came on. Seventeen days after puncture incision was performed, and it was found that the omentum, which was adherent to the parietal peritoneum had to be divided in order to reach the cyst; although in this case suppuration took place, yet notwithstanding this, when the sac was incised, it was found necessary to stitch it to the abdominal wound. As an indication of the pains taken in the treatment it may be stated that no fewer than four dressings daily were employed for some time; Ranke naturally points out that this would be impracticable in private practice.

Trendelenburg (*loco cit.*), who had enjoyed special opportunities of witnessing and practising Simon's method at Rostock, remarks that it was not found to be satisfactory, because it could not be depended upon to procure adhesions, at any rate to a sufficient extent to make the subsequent incision safe eight days after the insertion of the canulæ. Indeed, he attributes Simon's success in obtaining adhesions to his use of non-disinfected canulæ, in consequence of which a rapid decomposition of the cyst-contents took place, and this evoked adhesive inflammation between the sac and the parietes, and Trendelenburg found that by the strictly antiseptic use of this method, the adhesions were so imperfect at the time of incision that it was found necessary to stitch the sac to the parietes.

* Berl. Klin. Wochen ch., November 9, 1874, page 565.

The Results of Simon's Operations.—I have been able to collect only 24 cases in which this method of treatment was adopted; in 21 of them the parasite was situated in the liver, in 3 in the spleen.

Liver Echinococci treated by Simon's Method.—Out of the 21 cases, there were—cures 10, deaths 10, result not stated, one case. As regards the fatal cases, one died, not from the operation or the parasite, but from dysentery, which was at the time prevalent in the Hospital where the patient was treated. Peritonitis was the immediate cause of death in more than half the cases, *i.e.*, in five instances; in some of them it is expressly stated that when the incision was being performed it was noticed that the adhesions were very imperfect, and it is probable that, in most of the cases in question, the peritonitis was caused by imperfect closure of the peritoneum, and consequent escape of the foetid contents of the cyst into the abdominal cavity. Septicæmia was the cause of death in two cases; in one it was associated with erysipelas, in the other it was largely due to the slow and imperfect evacuation of the putrid cyst contents. In one case, recorded by Fiedler,* the patient died of collapse immediately after injection of the sac.†

Hydatids of the Spleen treated by Simon's Method.—In one case, reported by Uterhart, two fine trochars were inserted into the tumour in the usual manner, but when the bridge of tissues between the puncture was incised, it was discovered that some intervening coils of the intestine had been cut, and that the canulæ had penetrated only one centimetre deep into the sac; the cut intestine was sutured, and the patient recovered both from his hydatid and the operation. Perhaps no case could more clearly demonstrate the drawbacks of Simon's method than this one does. A second case by Wilde‡ recovered, but the fistula did not entirely close for sixteen months. A third case, recorded by Wolff,§ died of pyæmia 25 days after the operation.

The general results of Simon's treatment in the published cases that I have met with are therefore by no means good, as the following summary shows:—deaths, 11; cures, 13 cases. One of the deaths was not due to the parasite or the operation.

3. Incision Operations performed in two or more stages. Methods of Begin, Volkmann and others.—The attempt to produce adhesions between the parietes and the sac or the liver overlying the hydatid has been made by carrying an incision cautiously down to the peritoneum, or even

* Deutsch. Archiv. fur Klin. Medic., 1869.

† See Australian Medical Journal, March, 1889.

Archiv. fur Klin. Medic., von Ziemssen, VIII.

Berlin Klin. Wochenschr., 1870, No. 5, page 56.

through that structure; the resulting wound being then plugged for a few days, until the irritation of the injury and the dressing has caused local peritonitis and adhesions. Begin followed this plan, and plugged the wound with common lint; but after the introduction of the antiseptic method, the dressing consisted of carbolised gauze, &c.—this modification is known in Germany as Volkmann's method. In another modification the surface of the sac is exposed, and is then stitched to the lips of the wound, which is packed with an antiseptic dressing.

I have collected seventeen cases treated by one or other of these procedures, with fourteen recoveries and three deaths.

This operation is decidedly inferior to that of Lindemann, which is next described, and presents no advantages as to safety.

4. Lindemann's Operation.—Schlegtendal (*loco cit.*) has conclusively established the claims of Lindemann to be considered the practical originator of the mode of treatment of hydatid cysts associated with his name in Germany. The first operation of this kind, at any rate of which we have clear details, was performed by Lindemann in 1871; but the earliest account of the method was not published until 1879 by Kirchner (*op. cit.*)

The history of Lindemann's first case, as related by Schlegtendal, is interesting. The patient in question had a tumour of the liver, as regards the nature of which a difference of opinion existed between Lindemann and Stromeyer. The tumour was so tense, and the abdominal wall overlying it so thin, that spontaneous rupture was imminent, and an incision was performed. The opening in the sac was attached to the parietal incision by deep stitches, and the patient recovered rapidly. Although this operation was apparently not premeditated in the form in which it was performed, yet the lesson taught by it was not lost, and in future Lindemann incised the parietes, exposed the sac, opened it and stitched it to the abdominal wound, all under antiseptic precautions; and thus he initiated what is without doubt the most effective and safe form of radical treatment.

Meanwhile, and two years prior to the publication of Kirchner's work, Sænger (*loco cit.*) published a method of operation, which differed but little from Lindemann's plan. The abdominal wall was incised down to the cyst, which was at once secured by stitches to the lips of the external wound, and then was incised. Landau's operation was practically similar. Lawson Tait, in 1881, published an account of four cases, in which virtually the method of Lindemann had been followed. Further allusion to the history of the operation is needless, for any

credit of priority must in fairness be conceded to Lindemaun, of Hanover.

The Mode of Operation.—The usual procedure of antiseptic laparotomy is employed with or without the troublesome adjunct of the steam spray. Before the peritoneum is reached all bleeding is arrested, either by forcipressure, or, if need be, by aseptic ligature (carbolised kangaroo tendon, catgut, or silk); the peritoneum is then carefully incised to the same extent as the rest of the parietal layers, and now usually, if the site of the operation has been well chosen, the surface of the parasite enclosed in its sac appears. Occasionally a piece of omentum, or even a loop of intestine, may intervene, and in some cases (especially if the parasite be very old, or suppuration have taken place) the sac may be adherent to the parietes. When this is not the case, a loop of stout aseptic silk is passed through the sac wall on each side, parallel to the lips of the wound. In order to pass these loops through the tough sac I have found it most convenient to employ a strong well-curved needle, set in a firm handle; the needle may be threaded either before or after having been passed through the sac.

After the passage of the needles and loops, there is usually some escape of the fluid contents of the cyst at the sites of the puncture. This is especially apt to occur in the case of living echinococci in which the fluid is at high pressure. Great care should be taken to prevent the escape of the fluid—especially if it be purulent or fœtid—into the peritoneal cavity; this can be done by drawing the sac firmly up to the parietal wound by means of the loops, and by the use of a sponge. A part of the fluid contents of the cyst may now be removed by means of a trochar, or the sac may be immediately incised. When most of the fluid has been evacuated, the lips of the cut in the sac must be carefully stitched to the corresponding ones in the parietal wound. For this purpose carbolised kangaroo tendon, or silk, or silver wire may be used; the stitches should be applied at intervals of about a quarter of an inch apart, so as to closely unite the sac to the external wound; some operators include the skin; others, such as Trendelenburg, include only the peritoneum, the muscular layers, and tendinous fasciæ. It is claimed that by excluding the skin there is less risk of dragging on the lips of the wound during the contraction of the sac that occurs during the process of cure. It is an open question, however, whether the greater security of hold obtained by including the skin does not compensate for the local irritation often produced by the tension upon the skin. I have seen much redness of the skin around the wound, and even the detachment of a piece of the fibrous capsule, result from this.

cause, but apparently without any untoward influence upon the process of cure ; the irritation of the skin soon subsides after the removal of the deep stitches.

When the sac has been safely stitched, the solid and remaining fluid contents of it should be carefully, and, if possible, completely removed ; for it must be remembered that these are foreign bodies, and until they are completely expelled the sac cannot close. I lay great stress upon this, for the presence in a remote cul-de-sac of even a small shred of cyst is a cause of continued discharge. To attain this object various forms of forceps are useful, but it is desirable that instruments for this purpose should be provided with broad fenestrated jaws, which bite in parallel planes, and so obtain a wide but gentle grasp. Much care is needed to prevent the tearing of the mother-cyst in the process of its removal. In order to remove the daughter-cysts, if any be present, and to get rid of any fragment of the mother-cyst that may remain, it is advisable to wash out the sac with sterilised water, thymol, or carbolic lotion, or some other antiseptic fluid ; a syringe, provided with a long tube, being inserted to the bottom of the sac.

Finally, a long and wide india-rubber drainage tube, with lateral perforations, is inserted into the wound, and the patient is turned on the side, in order to drain the cavity of the injection still left in it. It is also an excellent plan to withdraw, by means of a syringe, to the nozzle of which a long piece of india-rubber tubing is attached, the last traces of fluid from the bottom of the sac ; or the interior of the cavity may be sponged dry.

Antiseptic dressings of some kind should certainly be used. I am in the habit of employing a large pad, the basis of which is a layer of picked oakum about an inch-and-a-half thick ; over this is spread a layer of Hartmann's wood-wool to the depth of half-an-inch or so ; the whole is then enclosed in a layer of alembroth or other antiseptic gauze. The pad is so placed as to provide for the natural gravitation flow of the discharge.

If the sac be thoroughly cleared out at the time of the operation, the amount of the discharge is usually small, but a daily dressing is commonly needed for the first few days. If the case proceed satisfactorily, there is no suppuration from the sac, but there is usually a little pus discharged from the lips of the wound. The stitches may be removed in five or six days.

By Lindemann's operation, unlike Simon's, suppuration of the sac is not a necessary element, but, on the contrary, an accidental and

undesirable one. The normal process of cure was well seen in the case of a child, aged eight, treated in 1886 by my colleague, Dr. Verco. Lindemann's operation was performed, and for four days the progress of the case was satisfactory; on the fifth day, however, convulsions came on, with increased rapidity of pulse and respiration and deepening loss of consciousness, and the patient died, from no evident cause discoverable during life or after death. The condition of the sac was as follows:—"The walls of the cavity had folded together over a considerable area, especially at the outer and back part, so that the opposed surfaces had come together, and here lymph had been poured out, which had united the surfaces by plastic adhesion, and had to this extent obliterated the sac."

Early union of this kind can only take place when the fibrous capsule is not rigid from degeneration; but when the opposite condition exists, the process of cure must, of necessity, be less prompt, for the walls of the cavity do not readily fall together.

When the walls of the cavity collapse after the removal of the mother-cyst, &c., in my opinion it is better not to use injections during the after treatment, but when drainage by collapse of the sac and gravitation is inadequate and pus accumulates, as when the parasite invades or starts in the pelvis, injections may be necessary. I have seen pyrexia result in such a case from no discoverable cause, except that in spite of the use of large drainage tubes, &c., the secretions of the cavity could not freely escape.

In cases where there is a tendency to the accumulation of the secretions of the capsule in the pelvis, probably the employment of aseptic capillary drains, enclosed in indiarubber drainage tubes, would be preferable to injections. I have not yet had the opportunity of trying this mode of drainage in hydatid cysts.

The Results of Lindemann's Operation.—I have collected 68 cases of Liver Hydatids, treated by abdominal section, immediate removal of the mother-cyst, and stitching of the sac to the parietal wound.

GENERAL RESULTS.

Deaths	...	7 or 10·29 per cent.
Recoveries	...	61 or 89·70 per cent

Deaths.—In one case the patient died during the operation from the sudden arrest of the circulation through the heart, by a hydatid cyst in it. In two other cases there were multiple hydatids in the body.

Cures.—These amounted to the extraordinarily high proportion of nearly 90 per cent., and this fact alone establishes the claim of this operation to be regarded as by far the best method of treatment of

liver hydatids now practised, at any rate when the cyst is accessible by an abdominal incision.

Not only are the final results good, but the duration of convalescence is brief, for in 19 cases in which this point is alluded to, the period of convalescence was as follows :—

In 3 weeks	1 case.
In 4 weeks	2 cases.
In 5 weeks	2 cases.
In 6 weeks	1 case.
In 2 months	6 cases.
In 2½ months	4 cases.
In 3½ months	3 cases.

19

Thoracic Incisions.—

Cases of hydatid disease treated by incisions through the chest wall, with or without excision of a portion of one or more ribs, belong to five distinct groups, viz :—

(1) Unruptured hydatids situated on or near the convex surface of the liver, and therefore not accessible by abdominal incision.

(2) Hydatid cysts, usually of the right lobe of the liver, which have ruptured into the pleura, treated by incision and drainage of the pleural cavity.

(3) Pulmonary hydatid cysts which may or may not have ruptured into the bronchial tract.

(4) Pulmonary hydatids which have ruptured into the pleura.

(5) Hydatids of the pleura operated on by incision. These are but few in number, and will not be described in this communication.

(1) **Unruptured Hydatids situated at or near the convex surface of the Liver.**—Echinococcus cysts which have originated near the upper surface of the liver, but still within that organ, usually grow in the direction of least resistance, which then happens to be upwards; they consequently invade the right chest, and often are with difficulty to be distinguished from hydatids of the base of the right lung. Cases have been recorded in which the parasite appeared to have originated between the diaphragm and the upper surface of the liver; and what is perhaps even more curious, hydatid cysts have been met with in the substance of the diaphragm itself. For example, Vital* mentions the case of an Algerian native, aged 35, who died of chronic dysentery, at whose *post-mortem* examination numerous hydatids were found, including one of

* Cited by Lenoel, *Kystes Hydatiques de la Rate*, Paris Thesis, 1879. Obs. XXIX., page 68.

the size of a child's head, which had developed in the substance of the diaphragm, and was covered in part by the peritoneum and in part by the pleura. In the Pathological Museum of the University of Oxford there is also a specimen of this kind. Until quite recently, hydatid cysts in this locality have always been treated by puncture with a fine trochar or aspirator needle; a few, however, have been dealt with by the *canule-à-demeure* method. The results of the treatment of liver cysts by *canule-à-demeure* traversing the thorax, have not been very satisfactory, for in five such cases collected by me, there were three deaths and two recoveries. The main difficulties in this mode of treatment, as applied to cysts in this locality, have been to prevent the canula from slipping out of the collapsed cyst, and to ensure complete evacuation of the cysts contents.

The treatment by direct incision through the thoracic walls of cysts on the convex surface of the liver is certainly one of the boldest innovations of modern surgery. As far as I have been able to discover, the first deliberate operation of this kind was performed by Israel.* In this case, an incision was made in the axillary line, an inch of the sixth rib being removed, and the pleura was opened to a corresponding extent; the wound was then plugged with antiseptic gauze. Seven days later the diaphragm was incised, and the wound was again plugged with gauze. Finally, nine days afterwards the sac itself was freely incised, evacuated, and drained.

An undoubted improvement upon this method is to cut immediately down to the sac, to pass a couple of loops of stout carbolised silk through it, in order that when the sac collapses by the evacuation of its fluid contents it may not retract beyond reach. The sac being securely held by the loops, a trochar is passed into it midway between the loops, and a part of the fluid is permitted to escape in order to reduce the pressure in the sac, and so prevent any escape into the peritoneum; the sac is then freely incised, and the mother-cyst, &c., completely removed. If it is found that the opening made into the sac is not likely to freely drain the cavity, a counter-opening should be made at the time of the operation.

The entire treatment should be carried out under strict antiseptic precautions, and here, if anywhere, the steam spray is useful, for unless adhesions happen to exist, pneumo-thorax is inevitable; however, with careful antiseptic treatment and drainage of the pleura, the results are likely to be satisfactory.

I have collected seventeen cases in which hydatids cysts of the convexity

* Virchow and Hirsch's *Jahresbericht* for 1879, vol. II., p. 412.

of the liver have been treated by thoracic incision* with various precautions against the infection of the pleura; there were 12 recoveries and 5 deaths. In one of the fatal cases, death was not due to operation or to the primary disease, but to hæmorrhage from an ulcer of the stomach. In a second one, the patient was apparently moribund from pneumonia at the time of operation. In another, under the care of Dr. Lendon, the cause of death was obscure, the patient was apparently progressing satisfactorily until the fifth day, when she was seized with abdominal pains, supposed to be due to intestinal colic, and died in about twelve hours. At the post-mortem examination nothing wrong as far as the operation was concerned could be discovered; there was, however, a patch of recent peritonitis on the left lobe of the liver, and old ribbon-like bands of adhesion connected the cyst with the pelvis. It was thought that the stretching of these bands had possibly compressed the intestine, and had thus caused the colic and the fatal result.

2. Liver Hydatids which had previously Ruptured Into the Pleura, operated on by Thoracentesis.—This class of cases presents many points of resemblance to lung hydatids which have ruptured into the pleura. In both cases the effects will depend upon various conditions, the principal of which are:—(a) the characters and quantity of the hydatid fluid entering the pleura; (b) whether the mother-cyst or any daughter-cysts pass into the pleura; (c) whether, in the case of a liver cyst, bile reaches the pleural cavity, or in the case of a ruptured pulmonary hydatid, air passes in, and if so, whether bacteria are also introduced by the air directly or by putrescent fluid from the pulmonary cavity. If only a small quantity of clear normal hydatid fluid enter the pleura, there is reason to think that temporary pyrexia and an eruption of urticaria may be the only ill effects, and that the fluid will be rapidly absorbed. If the quantity be large, absorption will not take place, but the mixture of hydatid fluid and resulting pleuritic effusion may remain serous for a considerable time. If the fluid of the parasite be thick and opaque in consequence of degeneration, or still more so, if it be purulent or foetid it is nearly certain that a severe form of pyothorax will be induced, which, unless promptly treated, will rapidly destroy the patient.

When pulmonary hydatids rupture into the pleura, the probability of pneumo-thorax is very great, but this is not likely to occur from the bursting of a hydatid of the liver. A case, however, has been recorded by Bristowe,† in which it was believed that offensive gas had

* Australian Medical Journal, August and September, 1889.

† Path. Soc. Trans., 1851-52.

been generated in the pleural cavity by a liver cyst which had burst into it. It is worthy of remark, however, that in this case it is stated that there was a very free communication of the dilated right hepatic duct with the cavity of the ruptured hydatid, and so it is possible that the septic condition arose by way of the duodenum and dilated duct, and did not originate *de novo* in the pleural cavity.

The rupture of an echinococcus cyst of the liver into the pleura is an accident of very great gravity to the patient, and even when operative measures are taken the risk of death is very great, for among eight cases treated by thoracentesis, no fewer than six ended fatally; it is probable, however, that an operation performed earlier might have been successful in some of the fatal cases.

3.—**Pulmonary Echinococcus Cysts treated by the establishment of a Free Opening into the Sac, obtained by Incisions or otherwise.**—Hydatid disease of the lungs is without doubt a very grave malady, especially when no surgical treatment is attempted for its relief.

Up to the year 1884 I had collected from various sources 208 cases which had not been operated on, or if operated on, no statement to that effect is made in the reports of the cases. The results were as follows:—

Died	113 cases.
Cured or relieved	71 “
Result uncertain	24 “

If we omit the 24 cases in which the final result was not definitely ascertained, the result stands thus:—

Deaths	61·4 per cent.
Recoveries	38·6 “

It is evident, therefore, that the disease is a formidable one, and even if we exclude all the deaths which cannot fairly be attributed to the direct influence of the parasite in the lungs, there is sound reason yet for believing that more than half the cases of pulmonary hydatid, which are not surgically treated, die*

The most favourable accident of the disease is rupture into the bronchial tract, for about three-fourths of these cases appear to recover; at any rate the following were the results in 133 such cases:—

Deaths	31 cases.
Reputed recoveries	80 “
Result unknown...	22 “

133

I have already alluded to the results of puncture in hydatid cysts of

* For a fuller discussion on this point, see “Hydatid Disease of the Lungs”: Adelaide 1884, page 45

the lungs, but it would lead to a digression of undue length to discuss the question fully on this occasion. I shall therefore content myself with the following statements :—

(a) That the puncture, especially of large lung cysts, is by no means devoid of immediate danger.

(b) That puncture often fails to cure the disease, and that in many cases in which it seems to do so, the cure is really effected by the expectoration of the mother-cyst, a process often accompanied by much danger to the patient from suffocation, hæmoptysis, and hectic.

(c) That even when the cyst has been completely expelled from the sac, the vessels on the walls of the latter have become so degenerate from the long continued suppuration as to readily rupture and cause hæmorrhage: this has proved fatal, as in cases recorded by Habershon.* It is evident, therefore, that it is desirable to reduce to its minimum the period of suppuration.

Less frequently than into the bronchial tracts, pulmonary hydatids rupture into the pleural cavity; generally speaking, such cases prove fatal unless promptly operated upon. In very rare cases rupture has been known to take place externally, or into the pericardium. Occasionally the cyst continues to enlarge, until the long-continued impediment to respiration and the pressure effects of the parasite destroy the patient. The probability that any case of hydatid disease, the presence of which has been ascertained during life, will undergo spontaneous cure by degeneration is virtually *nil*.

Upon the whole, I am convinced that patients suffering from moderate-sized or large pulmonary hydatids are most safely treated by a free opening into the sac, and the immediate removal of the parasite. I have collected 38 cases in which this method was adopted; of these 6 died, and 32 recovered. One of these was operated upon as far back as 1812, but this and all the earlier cases were treated in this manner in consequence of an error of diagnosis; they were generally regarded as cases of empyema, pointing on the surface. There can be no doubt that to Dr. Bird, of Melbourne, Australian physicians are largely indebted for the conviction, that an abscess or suppurating hydatid in the lung should no more be sacred from the knife of the surgeon, than an abscess in the breast. I am disposed to go a step further in this direction, and to operate upon any case of pulmonary hydatid in which there is proof positive of the nature of the disease and its precise locality, with one proviso, namely, that there shall be a distinct, even

though limited area of dulness on some part of the chest-wall; when, on the other hand, the alteration of the percussion note is to the production of a tympanitic note, which seems to me to indicate compression of lung which still contains air, I should feel disposed to puncture with the aspiratory needle.

In the earlier deliberate radical operations upon pulmonary hydatids, the mother-cyst had ruptured, and the operations really were upon abscesses of the lung containing more or less disintegrated hydatid membrane; in such cases adhesions generally existed between the surface of the lung over the cyst and the costal pleura, consequently, no precautions were thought necessary in order to prevent the escape of the cyst-contents into the pleural cavity. However, it was always uncertain whether adhesions were present or not until the sac was actually opened, when, if there were no adhesions, the mischief was done.

I think therefore that in all cases of this operation, the following procedure should be adopted. An incision about three inches long should be made over the central portion of the cyst, and when all the superficial tissues have been divided, and the ribs are exposed, about an inch and a half or two inches of one rib, or if required of two ribs, should be excised, the periosteum being previously stripped off by means of a suitable elevator. The pleura should not be torn, if possible, until the piece of rib has been removed, and until all bleeding has been arrested by the usual measures (it is rarely necessary to use a ligature). A small trochar should now be passed into the cyst through the pleura, and the depth at which fluid is first met with noticed; if at this stage the cyst cannot be found, the wound may be closed without serious injury to the patient, but this, of course, should rarely occur. The exploration being satisfactory, a strong well-curved needle, set in a strong handle, should be passed through the pleura and sac-wall into the interior of the parasite, its point being then brought out so as to include a couple of inches of the wall of the sac, and, unless this has previously been done, the needle now should be threaded with a loop of stout aseptic silk, which is drawn through by the withdrawal of the needle, a second similar loop being passed through the sac, parallel to the first one; in this way the fibrous capsule can be securely held during the next stages of the operation. It is well now to introduce a small trochar midway between the loops, in order to remove a part of the fluid contents of the sac, as this lessens the risk of escape of any of the fluid into the pleural cavity, in case adhesions are absent. The sac should now be freely incised, at least to a sufficient extent to permit two fingers of the operator to pass: the remaining fluid and solid contents of the sac

should then be removed as completely as possible by the use of fingers and suitable forceps : finally, the interior of the empty cavity should be thoroughly sponged out. The wound in the sac should be stitched securely to the lips of the external wound, the sutures being of aseptic material, and stout enough not to cut easily through ; for this purpose carbolised silk, kangaroo tendon, or silver wire are equally well adapted ; a large drainage tube should be inserted, and the usual anti-septic dressings applied. As the contents of the previously ruptured lung hydatids are often already foetid, strict Listerism is neither necessary nor practicable. The employment of injections in the treatment of these cases is undesirable, in consequence of the severe cough caused by the passage of the fluid into the bronchial tubes. The results are usually excellent and immediate, for cough and expectoration cease, pyrexia disappears, and the patient rapidly gains flesh and strength.

Among the 38 cases collected there were 32 recoveries and 6 deaths ; and of 8 cases operated upon by me 7 completely recovered. In one fatal instance, the right lung was so extensively destroyed by the parasite, that recovery was hardly to be expected. It was estimated that in this case the bladder-worm had a superficies of 256 square inches, and the mother-cyst (drained as completely as possible of fluid) weighed ten ounces avoirdupois.

In two cases the operation seems to have failed, principally because the sac was not completely emptied of membranes, and because the drainage was inadequate.

4.—**Pulmonary Hydatids which had previously ruptured into the Pleural Cavity, treated by Thoracentesis.**—The rupture of a pulmonary hydatid into the pleura is a source of very grave peril to the patient ; but the gravity varies according to circumstances, especially according to the condition of the contents of the sac at the moment of rupture. If clear normal hydatid fluid is effused in moderate amount, the resulting symptoms are far less alarming than when the fluid has undergone decomposition. It is probably also of great importance whether or not the mother-cyst or any daughter-cysts present have passed into the pleura. The size of the orifice of rupture, too, must not only affect the extent to which the cyst contents escape into the pleura, but must also influence largely the risk of free passage of air into the pleural cavity by way of the bronchial tubes which open into the sac. It is obvious that a large opening renders more probable the entry of bacteria into the pleura through the sac, and thus septic changes in the former are more readily induced.

It would appear that rupture may occur first into the pleura and then into a bronchial tube, or *vice versâ*, or that both events may take place simultaneously. Usually, these accidents appear to occur spontaneously, but now and then the excitement of a fit of anger, as in a case recorded by Fouquier* ; or an injury to the chest from a blow with the fist, as in a case under my care ; or a fall from a cab ;† or the impact of the chest against the water in diving from a height, as in a case recorded by Wischer,‡ may cause the rupture.

In nearly all the recorded cases, death has resulted from rupture into the pleura, unless surgical measures have been taken to drain that cavity, and permit the remains of the parasite to escape.

I have recorded three cases|| in which cure followed free incision into the pleura for the relief of this condition. In two of the cases there was fœtid pyo-pneumo-thorax, in the third the gaseous contents of the pleural cavity were aseptic at the time of the operation.

C. Operations involving the removal of the Fibrous Sac as well as of the Hydatid Cyst.

Operations upon Abdominal Hydatids in which, besides the Parasite, the Fibrous Sac was removed more or less completely.—In a few recorded cases, the fibrous capsule of the parasite has been removed. Sometimes this kind of operation has been adopted in consequence of an error of diagnosis, in others the procedure has been forced upon the operators by the exigencies of the case.

In one case, operated on by Spiegelberg,§ a woman, aged 42, had a retro-peritoneal echinococcus cyst connected with the omentum, the large and small intestine, and the right kidney, which was mistaken for an ovarian cyst ; the fibrous capsule and a portion of the right kidney were removed. The patient died of collapse twenty-six hours after the operation.

In a second case, operated on by the same surgeon,¶ a woman, aged 30, had a large abdominal hydatid of retro-peritoneal origin. This was treated by abdominal section, partial removal of the fibrous sac, and

* Cited by Hearn. *Kystes Hydatiques du Poupon et de la Plevre*. Paris Thesis, 1875, page 131.

† St. George's Hospital Reports. Vol. IV., pages 272 and 305.

‡ Cited in Madelung. *Beitrage Mecklenburgischer Aerzte zur Lehre von der Echinococcen-Krankheit*. Stuttgart, 1885. No. 18, page 85.

|| Australian Medical Journal, September, 1889.

§ Spiegelberg : *Archiv fur Gynækologie*, 1870.

¶ *Archiv fur Gynæk.*, 1872.

suture of the remnant of that structure to the lips of the parietal wound. After prolonged suppuration of the remains of the sac, the patient recovered.

In 1878, Knowsley Thornton* operated on a pregnant woman, aged 32, for the removal of supposed ovarian tumours, which proved to be hydatids of the omentum and pelvis. Two bunches of cysts were removed, but some were left untouched. The patient recovered.

Fitzgerald,† of Melbourne, in 1880, removed the fibrous capsule, together with the bladder-worm, in the case of a large abdominal hydatid connected with the omentum and liver. The tumour was regarded as an ovarian cyst. The patient recovered.

Whitcombe‡ performed a somewhat similar operation upon a large abdominal hydatid of retro-peritoneal origin. The patient died nine hours after the operation.

Another large abdominal hydatid, connected with the left kidney, was extirpated by Hinckeldeyn, in 1880.|| The patient, a female, aged 42, died of hæmorrhage, caused by the rupture of the left renal artery in the removal of the fibrous sac.

I have assisted Dr. Way, of Adelaide, at an operation in which several hydatids, connected with the peritoneum and omentum, were successfully removed. One large growth closely simulated an ovarian cyst.

In one case, Spiegelberg§ operated upon a hydatid cyst of the spleen by "extirpation." The patient died seventeen hours later.

General Summary.—It is almost impossible, at present, to accurately estimate the real value of those operations for the cure of hydatid disease in which the mother-cyst is not removed, viz., tapping operations, the use of parasiticide injections and electrolysis, inasmuch as the apparent cure, which often follows, is frequently found to be illusory after the lapse of a short time.

As regards tapping operations, there is reason to believe that they fail to cure the patient in fully 40 per cent. of the cases in which they have been tried; indeed it is probable that the actual proportion of failures is much greater than is represented by that number.

Taking aspiratory punctures and ordinary tapping operations

* Medical Times and Gazette, Nov. 16, 1878, page 565.

† Australian Medical Journal, May 15, 1880, page 206.

‡ Australian Medical Journal, October 15, 1885.

|| Cited in Madelung. Beiträge Mecklenburgischer Aerzte zur Lehre von der Echinococcen-Krankheit. Stuttgart, 1885, page 135.

§ Cited by Mosler. Ueber Milz-Echinococcus und seine Behandlung. Weisbaden, 1884, page 24.

together, the deaths amounted to nearly 18 per cent., but the mortality following aspiratory puncture, whether single or multiple, was only about half that of punctures with an ordinary fine trochar.

Speaking generally, the greater the number of punctures required in a given case, the smaller is the probability of the cure of the patient by tapping alone.

Simple puncture, although generally devoid of risk, has been known to cause sudden death, sometimes apparently from shock, sometimes however in the case of pulmonary hydatids, from suffocation by the fluid contents of the bladder-worm. The objection to puncture as the mode of treatment for internal hydatids, however, lies less in the occasional perils of the operation than in its frequent inefficacy.

Of the use of parasiticide injections into the sac, and the employment of electrolysis, it may be asserted that there is at present no evidence in favour of these methods of treatment that does not apply equally forcibly to simple puncture, and, moreover, each possesses drawbacks of its own.

The question of choice between the various forms of radical operation is simple, at any rate for abdominal hydatids, for their mortality is widely different, as a reference to the following table will show :—


Mortality of various Radical Operations.


Caustics	33·68 per cent.
Canule-à-demeure	26·66 “
Simon's method	48·00 “
Volkman's method	19·05 “
Lindemann's method (abdominal sections)					10·29 “
Do				(thoracic incisions)	29·41 “

With regard to hydatids of the liver, or of the lung, which have ruptured into the pleura, thoracentesis is the only resource which offers itself.


Unruptured echinococcus cysts of the convexity of the liver present great difficulties in their successful treatment, for thoracic incisions show a high rate of mortality.


The risks and disadvantages of punctures in cases of pulmonary hydatids have been already discussed, and the results of radical operations are so favourable, that but little difficulty can occur in the choice of treatment in ordinary cases.






W. K. THOMAS & CO., PRINTERS, GRENFELL STREET, ADELAIDE.





6. MK

1894



4

