

A descriptive catalogue of the London Hospital. / Published by the order of the College Board.

Contributors

London Hospital Pathological Museum.
Royal College of Physicians of London

Publication/Creation

London : Taylor & Francis, 1890.

Persistent URL

<https://wellcomecollection.org/works/yk4zgatq>

Provider

Royal College of Physicians

License and attribution

This material has been provided by This material has been provided by Royal College of Physicians, London. The original may be consulted at Royal College of Physicians, London. where the originals may be consulted. This work has been identified as being free of known restrictions under copyright law, including all related and neighbouring rights and is being made available under the Creative Commons, Public Domain Mark.

You can copy, modify, distribute and perform the work, even for commercial purposes, without asking permission.



Wellcome Collection
183 Euston Road
London NW1 2BE UK
T +44 (0)20 7611 8722
E library@wellcomecollection.org
<https://wellcomecollection.org>



LONDON HOSPITAL MEDICAL COLLEGE.

61(069.358)
SL126-1-2-6

SL

The Royal College of Physicians
of London.

~~~~~  
*From the Library of  
Sir Andrew Clark, Bart.*


*Presented by Lady Clark.*

80c












A  
DESCRIPTIVE CATALOGUE  
OF THE  
PATHOLOGICAL MUSEUM  
OF  
THE LONDON HOSPITAL.



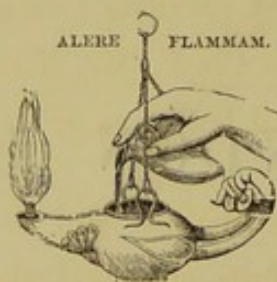
---

PUBLISHED BY ORDER OF THE COLLEGE BOARD.

---

LONDON:  
TAYLOR AND FRANCIS, RED LION COURT, FLEET STREET.





PRINTED BY TAYLOR AND FRANCIS,  
RED LION COURT, FLEET STREET.

|                             |             |
|-----------------------------|-------------|
| ROYAL COLLEGE OF PHYSICIANS |             |
| LIBRARY                     |             |
| CLASS                       | 61(069.538) |
| ACCN.                       | 29096       |
| SOURCE                      |             |
| DATE                        |             |

## P R E F A C E.

THE publication of this Catalogue of the contents of the Pathological Museum of the London Hospital Medical College was rendered necessary by the growth of the Museum and the increasing requirements of the School.

It replaces and embodies a manuscript catalogue which had been gradually built up by previous Curators, among whom may be mentioned Sir Andrew Clark, Mr. Rivington, Mr. McCarthy, Mr. James E. Adams, and Dr. Turner.

Many Members of the Medical and Surgical Staff, and other Officers of the Hospital, have compiled and have assisted in the arrangement of the following Series :—

|                                                                          |                        |
|--------------------------------------------------------------------------|------------------------|
| Plates of Diseases of the Skin . . . .                                   | DR. STEPHEN MACKENZIE. |
| Diseases of the Uterus and Utero-gestation                               | DR. HERMAN.            |
| „ Thyroid Gland and Ear .                                                | DR. WOAKES.            |
| „ Bladder, Prostate, Penis,<br>and Scrotum . . . . .                     | MR. RIVINGTON.         |
| Diseases of the Eye and Skin . . . .                                     | MR. WARREN TAY.        |
| „ Lips, Tongue, Œsophagus,<br>Testis &c. . . . .                         | MR. MCCARTHY.          |
| Diseases of the Joints, Hernia and In-<br>testinal obstruction . . . . . | MR. TREVES.            |
| Diseases of the Bones . . . . .                                          | MR. MANSELL-MOULLIN.   |
| „ Heart . . . . .                                                        | DR. SANSOM.            |
| „ Stomach and Lungs, and<br>General Pathology . . . . .                  | DR. TURNER.            |



|                                                                                                                                                                          |                  |
|--------------------------------------------------------------------------------------------------------------------------------------------------------------------------|------------------|
| Diseases of the Kidney . . . . .                                                                                                                                         | DR. RALFE.       |
| „ Brain and Spinal Cord . . . . .                                                                                                                                        | DR. ANDERSON.    |
| Injuries and diseases of the Spine, diseases<br>of the Breast . . . . .                                                                                                  | MR. EVE.         |
| Injuries of Bones and Joints . . . . .                                                                                                                                   | MR. HUTCHINSON.  |
| Diseases of Ovaries and Fallopian Tubes . . . . .                                                                                                                        | DR. LEWERS.      |
| „ Larynx and Trachea . . . . .                                                                                                                                           | MR. MARK HOVELL. |
| „ Tendons, Muscles, Bursæ,<br>Peritoneum, Intestines, Blood-vessels,<br>and Lymphatics. Entozoa, Malforma-<br>tions, Plaster casts, Wax models,<br>and Calculi . . . . . | MR. OPENSHAW.    |
| Diseases of the Liver, Pancreas, Spleen,<br>Adrenals . . . . .                                                                                                           | DR. F. J. SMITH. |

The general plan of the work has been taken from the catalogue of St. Bartholomew's Hospital museum, while the Classification of the Malformations is in accordance with the nomenclature drawn up by the Royal College of Physicians.

The larger share of the labour of compilation and of editing has fallen upon Mr. T. H. Openshaw, the Curator of the Museum.

|                       |                   |
|-----------------------|-------------------|
| F. CHARLEWOOD TURNER, | } <i>Editors.</i> |
| FREDERIC S. EVE,      |                   |
| T. H. OPENSHAW,       |                   |

*April 1890.*

## TABLE OF CONTENTS.

---

### Section I.—GENERAL PATHOLOGY.

#### SERIES I.—HYPERTROPHY AND HYPERPLASIA.

##### **Simple Hypertrophy from increased Functional Activity.**

Of Muscular Organs impeded in action : 1, 2, 2 A, 3, 4.

Of Glandular Organs, Compensatory or Vicarious : 5, 6.

##### **Hypertrophy or Hyperplasia.**

From irritation : 7, 8, 9, 10.

From collateral afflux of Blood : 10.

From obstruction to Lymphatic or Venous Channels : 11.

From unrecognized causes : 12, 13, 14, 15, 16.

Congenital Hypertrophy : 17.

---

#### SERIES II.—ATROPHY AND DEGENERATION.

##### **Simple or Quantitative Atrophy.**

From disuse : 18, 19.

From impeded Blood-supply : 20, 21, 22.

From defect of General Nutrition : 23.

Atrophy with increased formation of Adipose Tissue, or Fatty Infiltration : 24.

Absorption from constant pressure : 25.

##### **Atrophy with Degeneration of the Tissues.**

Fatty Degeneration : 26, 27.

Pigmental Degeneration : 28.

Calcareous Degeneration : 29.

Lardaceous Degeneration : 30, 31, 32.

Mucoid or Colloid Degeneration : 33, 34.



**Atrophic or Degenerative Changes from Dilatation of Natural Channels or Cavities.**

- Of Mucous Passages: 35, 35 A.
- Of Vascular Channels: 36.
- Of Serous Cavities: 37.

**Atrophy or Degeneration associated with the formation of Cysts.**

- Epithelial or Retention Cysts: 38, 39.
- Endothelial or Exudation Cysts: 40, 41, 42.
  - Proliferous Cyst: 43.
  - Multilocular Cysts: 44.
- Dermoid Cysts: 45.
- Secondary Cysts, formed round foreign bodies, blood, &c.
  - Hydatid Cyst: 46.
  - Hæmorrhagic Cyst: 47.
- Cavities formed by Softening of Tissues: 48.

---

**SERIES III.—INJURIES AND REPAIR.****Wounds.**

- Healing incised Wound: 49.
- Injuries to Vessels: 50, 51.

**Fractures of Bone.**

- Intra-periosteal: 52, 53.
- Callus: 54.
- Bony union: 55.
- Fibrous union: 56.
- Impacted: 57.
- Fracture of Skull: 58.

**Foreign Bodies. Calculi. Entozoa.**

- Foreign Bodies: 59.
- Calculi.
  - Urinary: 60, 61, 62.
  - Biliary: 63, 64, 65.
- Parasites.
  - Hydatids: 65, 66, 67, 68.
  - Tæniæ: 69, 70.
  - Cysticerci: 71, 72.
  - Trichina: 73.

**Displacement or Twisting of Parts.**

- Intussusception: 74, 75, 76.
  - Hernia: 77, 78.
-

**SERIES IV.—NECROSIS AND GANGRENE.****Necrosis.—Coagulative Necrosis, Caseation, Softening.**

Thrombi in Heart or Vessels : 79, 80, 81.

Embolie or Thrombic Necrosis : 82, 83.

Progressive Necrosis (Mycotic) : 84, 85.

**Gangrene.**

Mummification : 86, 94.

Moist Gangrene : 87.

**Removal of Dead parts, and Repair.**

Cicatrization after absorption : 88.

Separation of bony Sequestra : 89, 90.

Encystment : 91, 92.

Detachment of Eschar : 93.

Separation of Mortified parts : 94.

---

**SERIES V.—INFLAMMATION AND ITS RESULTS.****Inflammatory Lesions.**

Exudation.

Fibrinous, Coagulable : 95-99.

Purulent : 100.

Connective Tissue new Growth : 101-103.

Inflammation with Necrosis of Tissues : 104-108.

Abscess : 109-112.

Separation of Sequestrum : 113.

**Reparative Processes and Sclerosis consecutive to Inflammation.**

Adhesion of Parts.

Of Serous surfaces : 114-116.

Ankylosis of Joints : 117, 118.

Valvular Stenosis : 119.

Cirrhosis, Sclerosis, Contraction : 120-123.

After Necrosis and separation of Dead parts.

Encapsulation : 124.

Cavity, sinus, or fistula : 124.

**Degenerative Changes in Inflammatory Products.**

Coagulative Necrosis of Exudation : 125.

Caseation and Cretification of Tissue : 124.

Calcification of Inflammatory growth : 126.

Uratic deposit : 127.

**Changes in Form or Structure of Parts due to Inflammatory Lesions.**

Dilatation or Bulging : 128, 129.

Contraction, with thickening and induration : 130, 131.

Fibrillation in chronic Rheumatic Arthritis : 132.

Ulceration : 133.

---



### SERIES VI.—SPECIFIC DISEASES.

#### Tuberculosis.

Miliary Tubercle: 134, 135.

Tubercular Disease of Lungs: 136, 137.

” ” of the Larynx: 138.

” ” of the Intestines: 139.

” ” of the Genito-Urinary Organs: 140, 141.

” ” of the Brain: 142.

” ” of the Lymphatic Gland and Spleen: 143, 144.

#### Syphilis.

Gummata.

In the Liver: 145.

In the Testis: 146.

Syphilitic Ulceration and Stricture.

Of the Larynx: 147.

Of the Rectum: 148.

Of the Pharynx and Trachea: 149.

Diphtheria: 150, 151.

Typhoid Fever: 152, 153.

### SERIES VII.—MORBID GROWTHS.

#### Connective Tissue Tumours.

Fibroma: 154-157.

Lipoma: 158, 159.

Enchondroma: 160.

Osteoma: 161.

Glioma: 162.

Neuroma: 163, 164.

Myo-fibroma: 165.

Angeioma: 166.

Lymphoma: 167.

Sarcoma.

Myeloid Sarcoma: 168.

Round-celled Sarcoma: 169-177.

Spindle-celled Sarcoma: 178-180.

Osteo-sarcoma: 181.

Melano-sarcoma: 182.

Adeno-sarcoma: 183.

#### Epithelial Tissue Tumours.

Papilloma; villous growth: 184, 185.

Adenoma and Adeno-fibroma: 186-188.

**Carcinoma.**

- Epithelioma; Squamous-celled Carcinoma: 189-193.
- Cylindrical-celled Carcinoma: 194, 195.
- Spheroidal-celled Carcinoma; Scirrhus and Medullary Cancer: 196-200.
- Mucoid or Colloid metamorphism of Carcinoma; Colloid Cancer: 198, 201.

**Section II.—SPECIAL PATHOLOGY.****SERIES I.—INJURIES AND DISEASES OF THE SPINE.****INJURIES.****Fractures:** 204-217.

- Union after Fracture by Fibrous Tissue and Bone: 215, 216.
- Fracture of Ankylosed Vertebrae: 217.
- Separation of Epiphysis: 218.

**Dislocation with or without Fracture:** 219-232.

- Injury to the Spinal Cord from Fractures and Dislocation: 215, 219-222, 229, 231.
- Injury to the Spinal Cord without Displacement of Vertebrae: 233, 234.

**DISEASES OF THE SPINE.**

- Caries, Tuberculous Disease: 235-248.
- Necrosis: 249.
- Destruction of the Intervertebral Discs: 250-252.
- Angular Curvature: 253-254 A, 244, 255, 256.
- Repair after Caries: 255-257.
- Changes in the Spinal Cord and its membranes: 258.
- Formation of New Bone and Ankylosis of Vertebrae: 259-264.
- Morbid Growths implicating the Vertebrae and Spinal Canal: 265, 266.
- Distortions of the Spine: 267-276.
  - Lateral Curvature: 267-274.
  - Antero-posterior Curvature: 275, 276.

**SERIES II.—INJURIES AND DISEASES OF BONES.****FRACTURES.****Fractures of Vault of Skull:** 277-296, 306, 311-313.

- Orbital Roof: 278, 305, 317.
- Fracture with Compression from Hæmorrhage: 293, 295, 318-321.

**Fractures of Base of Skull:** 297-323.



**Fractures of Lower Jaw :** 324, 325.

„ **Hyoid Bone :** 326.

„ **Sternum :** 327-333.

„ **Clavicle :** 334-343.

„ **Ribs :** 344-353.

„ **Scapula :** 354-359.

„ **Humerus :** 360-392.

Separation of Epiphyses : 372, 376, 377, 389.

Fractures involving Elbow-Joint : 385-390, 395, 396.

**Fractures of Radius and Ulna :** 393, 397-409.

“ Elbow-Sprain ” : 394.

Separation of Epiphyses : 400, 404, 404 A, 405.

**Fractures of Pelvis :** 410-413.**Fractures of Femur :** 414-480.

Gunshot Injuries : 537-540.

Fractures of Neck : 414-440.

„ Shaft : 441-474, 477, 479, 480.

„ Lower End : 475, 476, 478, 478 A.

Separation of Epiphyses : 419, 424, 550 A.

**Fractures of Patella :** 481-491.**Fractures of Tibia and Fibula :** 492-536, 542-550.

Separation of Epiphyses : 506, 530, 541.

## DISEASES OF BONES.

**Hypertrophy :** 551.

**Effects of Pressure :** 552.

**Atrophy :** 553-555.

**Mollities Ossium :** 556.

**Rickets :** 557-572.

**Inflammation and its Effects :** 573-634.

Suppurative Periostitis and Osteomyelitis : 597-614.

Caries : 615-619.

Necrosis : 620-634.

**Tuberculous Disease :** 635, 636.

**Syphilis :** 637-656.

**Tumours :** 657-709.

Cyst : 657.

Fibroma : 658, 659.

Fibro-enchondroma : 660, 661.

Enchondroma : 662-664.

Exostosis : 665-670.  
 Sarcoma : 671-707.  
 Secondary Carcinoma : 708, 709.

---

### SERIES III.—INJURIES AND DISEASES OF JOINTS.

#### DISLOCATIONS OF JOINTS.

**Shoulder** : 710, 711.  
**Ankle** : 713.  
**Subastragaloid Joint** : 712, 714, 715.

---

#### DISEASES OF JOINTS.

**Disease probably beginning in the Synovial Membrane** : 716-718.  
 " " **in Bone** : 719-723.  
**Specimens illustrating the Changes in the Structures of Joints, due to Joint Disease.**  
 Separation of Cartilage : 724.  
 Ulceration of Cartilage : 725-729, 716, 718.  
 Ulceration of Articular Ends of Bones : 730-736, 719-724.  
 Separation of Epiphysis : 737.  
 Dislocation of Bones : 738-741 A, 717, 718.  
 Repair after Ulceration of Articular Ends of Bones : 742.  
 Fibrous Ankylosis : 743-745, 734.  
 Bony Ankylosis : 746-760, 731.  
 Atrophy of Bone : 761, 718, 743, 744, 754.  
 Rupture of Tendon : 762.  
 Changes due to Osteo-Arthritis : 762-780.  
 Changes due to Gout : 781-783.  
 Loose Bodies in Joints : 784-786.  
**Excision of Joints** : 787-789.  
 Parts after Excision : 790.  
 Parts removed in Excision : 791-793.

---

### SERIES IV.—INJURIES AND DISEASES OF MUSCLES, TENDONS, AND BURSÆ.

**Avulsion** : 794, 795.  
**Rupture of Muscle** : 796, 797.



- Fatty Degeneration :** 798.  
**Repair of Tendon after Section :** 799.  
**Enlarged Bursæ :** 800, 801, 802, 803.
- 

**SERIES V.—ANATOMY OF STUMPS.**

- Neuromata :** 804, 805.  
**Ankylosis of Bone Ends :** 806.  
**Necrosis :** 807, 808, 809, 810.  
**Absorption of Cartilage :** 811.
- 

**SERIES VI.—INJURIES AND DISEASES OF THE BRAIN AND ITS MEMBRANES.**

**Effects of Injury.**

- Hæmorrhage :** 812, 813, 814.  
**Contusion :** 815.  
**Meningitis :** 816, 817.  
**Abscess :** 818, 819, 820, 821, 822.  
**Hernia cerebri :** 823.

**Atrophy :** 824, 825.

**Calcareous Degeneration :** 826, 827, 828.

**Meningeal Hæmorrhage :** 829, 830, 831.

- Purpura :** 832.

**Cerebral Hæmorrhage :** 833.

- Thrombotic :** 834.

**Hydrocephalus :** 835-837.

**Tubercular Meningitis :** 836.

**Tubercular Tumour :** 837.

**Hydatid :** 838.

**Meningeal Cysts :** 839, 840.

**Apoplectic Cyst :** 841 (?).

**Morbid growths in Dura Mater and Cranium.**

- Fibroma :** 842.  
**Sarcoma :** 843, 844, 845, 846.  
**Carcinoma :** 847.

**Growths in Pia Mater and Brain.**

Psammoma : 848, 849.

Glioma : 850, 851.

Sarcoma : 852, 853, 854, 855, 856.

**Growths in Pituitary Body : 857, 858.****Growth in Pineal Body : 859.****Malformation.**

Encephalocele : 860, 861.

---

**SERIES VII.—INJURIES AND DISEASES OF THE SPINAL  
CORD AND ITS MEMBRANES.****Effects of Injury.**

Contusion and Crushing : 862-869.

Wound : 870.

Meningitis : 871.

**Atrophy from Compression : 872.**

Calcareous Degeneration : 873, 874, 875.

Meningitis : 876, 877, 878.

Myelitis : 879, 880.

**Morbid Growths, &c. :**

In the membranes : 881.

In the cord : 882.

**Hydromyelia : 883.**

---

**SERIES VIII.—INJURIES AND DISEASES OF NERVES.****Atrophy : 884.****Morbid Growths.**

Bulbous ends of nerves in stumps : 885.

See also Series IV. Nos. 804, 805.

General Pathology, No. 165.



# SERIES IX.—INJURIES AND DISEASES OF THE EYE.

## Effects of Injury.

- Wound : 886, 887.
- Intraocular Hæmorrhage : 888.
- Dislocation of Lens : 889, 890.
- Detachment of Retina : 891.
- Shrinking : 892, 893.
- Foreign Body : 894, 895.

|           |                                       |
|-----------|---------------------------------------|
| SUBSERIES | I.—Diseases of the Cornea.            |
|           | Staphyloma : 896-899.                 |
|           | Corneitis : 900.                      |
| "         | II.—Diseases of the Sclerotic.        |
|           | Staphyloma : 901, 902.                |
| "         | III.—Diseases of the Iris.            |
| "         | IV.—Diseases of the Lens.             |
|           | Cataract : 903, 904.                  |
|           | Dislocation : 905.                    |
| "         | V.—Diseases of the Ciliary Region.    |
| "         | VI.—Diseases of the Retina.           |
|           | Detachment : 906, 907.                |
|           | Retinitis pigmentosa : 908, 909, 910. |
| "         | VII.—Diseases of the Choroid.         |
|           | Ossification : 911-914.               |
|           | Inflammation and its Effects.         |
|           | Irido-choroiditis : 915.              |
|           | Choroiditis disseminata : 916.        |
|           | Infective Diseases.                   |
|           | Tuberculosis : 917, 918, 919.         |
| "         | VIII.—Diseases of the Vitreous.       |
|           | Inflammation and its Effects.         |
|           | Detachment of Retina : 920, 921.      |
| "         | IX.—Diseases of the Globe.            |
|           | Inflammation : 922, 923.              |
|           | Glaucoma : 924-929.                   |
|           | Hæmorrhage : 930, 931, 932.           |
|           | Parasites.                            |
|           | Cysticercus : 933.                    |
|           | Morbid Growths.                       |
|           | Sarcoma : 934-939.                    |
|           | Melanotic Sarcoma : 940-954.          |
|           | Epithelioma : 955.                    |

## SERIES X.—INJURIES AND DISEASES OF THE NOSE.

**Necrosis:** 956.

**Polypus:** 957-962.

---

## SERIES XI.—INJURIES AND DISEASES OF THE EAR.

**Foreign Body:** 963.

**Necrosis:** 964, 965.

**Morbid Growth.**

Fibroma: 966.

Myxoma: 967.

Epithelioma: 968.

---

## SERIES XII.—INJURIES AND DISEASES OF THE SKIN.

**Hypertrophy.**

Hypertrichosis: 969.

Ichthyosis: 970.

Othhæmatoma: 971.

**Inflammation and its effects.**

Cuticular Glove: 972.

Ulceration: 973, 974, 975, 976.

Cicatricial Contraction: 977.

**Cysts and Morbid Growths.**

**Cysts.**

Sebaceous Cyst: 978.

**Morbid Growths.**

Fibroma: 979.

Lipoma: 980, 981, 982, 983.

Osteoma: 984.

Angeioma: 985, 986, 987, 988, 989.

Sarcoma: 990, 991, 992, 993, 994, 995, 996.

Round-celled Sarcoma: 991.

Spindle-celled Sarcoma: 992.

Lympho-Sarcoma: 993.

Fungating Sarcoma: 994, 995, 996.

Papilloma: 997.



Adenoma: 998.  
Epithelioma: 999-1005.  
Rodent Ulcer: 1006.

SUBSERIES I.—**Diseases of the Nails.**

Hypertrophy.  
Gryphosis: 1007.

---

SERIES XIII.—**INJURIES AND DISEASES OF THE LIPS  
AND MOUTH.**

**Epithelioma:** 1008, 1009, 1010.

---

SERIES XIV.—**INJURIES AND DISEASES OF THE TONGUE.**

**Inflammation and its Effects:** 1011-1013.

**Specific Inflammation.**

Ulceration: 1014.

**Morbid Growths.**

Sarcoma: 1015.  
Epithelioma: 1016-1020.

---

SERIES XV.—**INJURIES AND DISEASES OF THE TEETH.**

---

SERIES XVI.—**INJURIES AND DISEASES OF THE PALATE,  
FAUCES, AND PHARYNX.**

**Inflammation and its Effects:** 1021, 1022.

**Specific and Infective Diseases:** 1023, 1024.

**Morbid Growths.**

Round-celled Sarcoma: 1025.  
Epithelioma: 1026, 1027.

**Malformation.**

Diverticulum : 1028.

**SUBSERIES I.—Injuries and Diseases of the Tonsil.****Morbid Growths.**

Lympho-Sarcoma : 1029, 1030.

Melano-Sarcoma : 1031.

---

**SERIES XVII.—INJURIES AND DISEASES OF THE  
SALIVARY GLANDS.****Morbid Growths.**

Sarcoma : 1032.

Myxo-Adenoma : 1033.

---

**SERIES XVIII.—INJURIES AND DISEASES OF THE  
ÆSOPHAGUS.**

**Injury :** 1034.

**Corrosive Poisoning :** 1035-1040.

Liquor Ammoniae : 1035.

Caustic Bougies : 1036.

Nitric Acid : 1037, 1038.

Sulphuric Acid : 1039.

**Morbid Growths.**

Epithelioma : 1041-1056.

Stricture : 1048.

Stricture with Perforation : 1049, 1050.

Invasion of the Trachea : 1051, 1052.

Perforation of the Trachea : 1053-1056.

---

**SERIES XIX.—DISEASES OF THE PERITONEUM,  
OMENTUM, AND MESENTERY.**

**Foreign Body :** 1057.

**Peritonitis :** 1058, 1059, 1060, 1066.

**Peritoneal Adhesion :** 1061, 1062, 1064.

Constricting Bowels : 1063, 1069.



**Tuberculosis:** 1064, 1065.

**Morbid Growths.**

Sarcoma: 1066, 1067.

Carcinoma: 1068-1070.

Myxo-Sarcoma: 1071, 1072.

**Cysts:** 1073, 1074.

---

**SERIES XX.—INJURIES AND DISEASES OF THE  
STOMACH AND DUODENUM.**

**Effects of Injury.**

Laceration: 1075.

Effects of Poisons: 1076-1085.

Gastrostomy:

Post-mortem Solution: 1086, 1087.

**Diseases of the Stomach.**

Hypertrophy: 1088-1091.

Dilatation: 1106.

Hæmorrhagic Erosion: 1092.

Perforating Ulcer.

Recent: 1093-1095.

Chronic: 1095-1104.

With Perforation: 1095-1099, 1101, 1103, 1105.

With Erosion of Arteries: 1093, 1094, 1100-1104.

Gastro-colic Fistula: 1105.

Healing Ulcer: 1106.

Perforation from without: 1107.

Stricture of Pylorus: 1108, 1109.

Contraction with Stricture: 1110.

Hour-glass Contraction: 1111.

Necrosis of Mucous Membrane: 1112.

Typhoid Ulceration: 1113.

Polypus: 1110, 1114, 1115.

Lipoma: 1116.

Fibromata: 1117.

Sarcoma: 1118, 1119.

Carcinoma.

Pyloric: 1120-1128.

Of Cardiac end: 1129-1132.

Intermediate: 1133.

Of whole Stomach: 1134, 1135.

Scirrhus Contraction: 1136-1138.

Colloid: 1125-1128, 1132-1134.

Cystic Growth: 1139.

**Diseases of the Duodenum.**

Abnormal conditions of the Mucous Membrane : 1140, 1141.

Ulceration :

After Burns and Scalds : 1142-1144.

With Perforation : 1143-1147.

With Erosion of Arteries : 1151-1153.

Tubercular Ulceration : 1154.

Papillary Growth : 1155.

False Diverticula : Pouching : 1109, 1152, 1153.

## SERIES XXI.—INJURIES AND DISEASES OF THE INTESTINES.

**Laceration and Rupture :**

Of the small intestine : 1156-1161.

Of the colon : 1162.

**Injury from Foreign Body :**

In the Ileum : 1163, 1164.

In the Appendix Cæci : 1165, 1166, 1167.

**Foreign Body passed per Anum :** 1168.

**Artificial Anus :** 1169.

**Pigmentation :** 1170, 1171, 1172.

**Thrombosis :** 1173.

**Gangrene :** 1174, 1175.

**Abnormal condition of Mucous Membrane :** 1176, 1177, 1178.

**Ulceration :** 1179, 1180.

**Dysentery :** 1181-1191.

**Scurvy :** 1192.

**Typhoid Fever :** 1193-1200.

**Tubercular Lesions :** 1201-1218.

**Morbid Growths and Cysts.**

Fibro-Myoma : 1219.

Sarcoma : 1220, 1221.

Melanotic : 1222.

Adenoma : 1223.

Carcinoma : 1224-1231.

Colloid : 1232, 1233, 1234.

Cystic : 1235.

Stricture : 1221, 1224-1233.

**Malformations.**

Diverticulum : 1215, 1236, 1237.

Occlusion : 1238.

Congenital defect : 1239.



## SERIES XXII.—INJURIES AND DISEASES OF THE RECTUM.

### Inflammation and its Effects.

Ulceration: 1241.

Stricture: 1240, 1241.

„ abscess: 1242, 1243.

„ „ perforation: 1244.

**Syphilis:** 1245, 1246, 1247.

**Fistula:** 1252.

Recto-vaginal fistula: 1240, 1244.

**Hæmorrhoids:** 1248, 1249, 1252.

### Morbid Growths.

Adenoma: 1250, 1250 *a*.

Epithelioma: 1251, 1252, 1254, 1256, 1258, 1259.

Stricture: 1253, 1255, 1257, 1261, 1263.

Perforation: 1260.

Colotomy: 1253, 1262.

Recto-vesical fistula: 1253, 1258.

### Malformation.

Imperforate anus: 1264–1274.

Cul de Sac: 1264, 1265, 1266, 1267, 1268, 1269.

Cord to bladder: 1270.

Opening into bladder: 1271.

„ „ urethra: 1272, 1273, 1274.

Artificial anus: 1268.

## SERIES XXIII.—HERNIA AND INTESTINAL OBSTRUCTION.

**Inguinal Hernia:** 1275.

Conditions of the sac.

Relations of the sac to the cord and the testis: 1275–1281.

Relation of the sac to Hydrocele: 1282, 1283.

Double or Intraparietal sac: 1284.

Congenital Inguinal Hernia: 1285.

Hernia into the funicular process: 1286.

Hernia with Hydrocele of the cord: 1287.

Reduction “en masse.” Separation of the neck of the sack: 1288.

Tumour of the sac: 1289.

Carcinoma of the sac: 1290.

**Irreducible Inguinal Hernia:** 1291–1296.

**Strangulated Inguinal Hernia:** 1297, 1298.

**Strangulated Congenital Hernia:** 1299.

**Inguinal Hernia with unusual contents:** 1300, 1301.

**Fatty Hernia:** 1302, 1303, 1304, 1305, 1306, 1307.

**Femoral Hernia:** 1308, 1309, 1310, 1311.

**Littre's or Richter's Hernia.** Partial Enterocele: 1312, 1313.

**Umbilical Hernia:** 1314, 1315, 1316.

    Congenital: 1317, 1318.

**Diaphragmatic Hernia:** 1319.

**Lumbar Hernia:** 1320.

**Intestine contained in Herniæ:** 1321-1330.

**Hernia of the cæcum:** 1321.

**Hernia of the colon:** 1322, 1330.

**Hernia of the appendix vermiformis:** 1300.

**Hernia of a diverticulum:** 1301.

SUBSERIES I.—**Intestinal Obstruction:** 1330 *a*-1348.

---

## SERIES XXIV.—INJURIES AND DISEASES OF THE LIVER.

**Lardaceous degeneration:** 1349.

**Cirrhosis:** 1350-1357.

**Abscess:** 1358-1362.

**Pylephlebitis:** 1359, 1360.

**Pyæmic abscesses:** 1361.

**Dysenteric abscess:** 1362.

**Syphilis:** 1363, 1364.

**Actinomycosis:** 1365.

**Hydatids:** 1366-1380.

    Opening into lung: 1370.

    Opening into the vena cava: 1371.

**Cyst:** 1381.

**Angelioma:** 1382.

**Carcinoma:** 1383-1388.

    Melanotic: 1389-1391.

    Colloid: 1392.

**Cystic Disease:** 1393.



SERIES XXV.—INJURIES AND DISEASES OF THE  
GALL-BLADDER.

Lesions due to Calculi : 1394, 1395.

Calculi : 1396, 1399.

Cystic Adenoma : 1397.

Carcinoma : 1398.

Malformation : 1400.

---

SERIES XXVI.—INJURIES AND DISEASES OF THE  
PANCREAS.

Atrophy : 1401.

Carcinoma : 1402-1404.

Melanotic : 1403.

Medullary : 1404.

---

SERIES XXVII.—INJURIES AND DISEASES OF THE  
HEART AND PERICARDIUM.

Wound : 1405.

Rupture : 1406-1408 *a*, 1414.

Diseases of the Myocardium.

Hypertrophy of heart : 1409-1411.

Atrophy : 1412.

Fatty degeneration : 1407, 1408, 1413, 1414.

Fibroid degeneration : 1415.

with aneurysm : 1416, 1417, 1440, 1441.

Dilatation : 1418.

Myocarditis :

with perforation : 1419.

Syphilis : 1420.

Morbid Growths : 1421-1424.

Diseases of the Endocardium and Valves.

Thrombosis : 1425.

Endocarditis : 1426-1429.

Ulcerative : 1430-1443.

Sclerosis of valves : 1444-1460.

Mitral stenosis : 1445-1450.

Aortic stenosis : 1451.

Mitral and Aortic stenosis : 1452-1455.

Mitral and Tricuspid stenosis : 1456, 1457.

Mitral, Aortic, and Tricuspid stenosis : 1458-1460.

Perforation of mitral valve : 1461.  
 Aneurysm of valve : 1462-1465.  
 Necrosis of the mitral valve : 1466.  
 Growth from valve : 1467.

#### **Diseases of the Pericardium.**

Calcareous plates : 1468.  
 Pericarditis : 1469-1472.  
 Adherent pericardium : 1473-1475.  
 Tuberculosis : 1476.

#### **Malformations of the Heart and Pericardium.**

Heart consisting of two chambers : 1477, 1478.  
 Heart consisting of three chambers : 1479, 1480.  
 Contraction of pulmonary orifice with defect in interventricular septum :  
 1481-1486.  
 Defect in septum ventriculorum : 1487, 1488.  
 Patent foramen ovale : 1444, 1489.  
 Transposition of aorta and pulmonary artery : 1490, 1491.  
 Abnormal pulmonary valve : 1492, 1493.  
 „ aortic valve : 1434, 1494.  
 Persistent Eustachian valve : 1495, 1496.  
 Absence of pericardium : 1497.

### **SERIES XXVIII.—INJURIES AND DISEASES OF ARTERIES.**

#### **INJURIES.**

**Wounds :** 1498-1500.  
**Rupture from Violence :** 1501-1505.  
**Effects of application of Ligature :** 1506-1510.  
 Division of the internal coat : 1506, 1507.  
 Obliteration by clot after ligature : 1508, 1509.  
 No obliteration : 1510.

#### **DISEASES.**

**Arteritis :** 1511.  
**Syphilis :** 1512.  
**Tuberculosis :** 1513.  
**Atheroma :** 1514-1533, 1537, 1540-1544, 1547, 1554, 1555, 1564, 1567, 1569,  
 1578, 1581, 1586, 1590, 1592, 1596, 1598, 1599, 1601, 1602, 1609.  
 Calcareous degeneration : 1518-1523.  
 Calcareous plates.—Exfoliation of inner coat.—Ulceration : 1524-1530.  
 Deposit of fibrin on atheromatous plates : 1531, 1532.  
 Intra-mural cyst : 1533.



**Dilatation of Arteries :** 1534-1536.

**Fusiform Aneurysm :** 1537-1539, 1549, 1551, 1554, 1559-1563, 1582, 1583, 1598, 1601.

**Sacculated Aneurysm :** 1540, 1541, 1548, 1550, 1552, 1553, 1555, 1557, 1558, 1564-1566, 1568-1570, 1572, 1575, 1576, 1579, 1586, 1589-1591, 1593-1597, 1599, 1600, 1602, 1604-1606, 1609-1614.

**Dissecting Aneurysm :** 1542-1544, 1585.

**Diffused Aneurysm :** 1545, 1546, 1571, 1574.

**Aneurysms of particular Arteries.**

Of the Sinus of Valsalva : 1547, 1586.

Of the Aortic Arch : 1537, 1538, 1541, 1542, 1548-1554, 1576, 1578-1580, 1587-1589, 1591, 1593-1595, 1597-1601, 1610-1614.

Of the Thoracic Aorta : 1540, 1543, 1544, 1555, 1585, 1602-1604.

Of the Innominate Artery : 1575, 1577, 1596.

Of the Axillary : 1556.

Of the Ulnar : 1557.

Of the Cerebral arteries : 1558-1562, 1606-1608.

Of the Vertebral : 1563.

Of the Abdominal Aorta : 1543, 1545, 1564-1567, 1581, 1605, 1609.

Of the branches of the Abdominal Aorta : 1568, 1569.

Of the Femoral artery : 1539, 1546, 1570, 1571, 1583.

Of the Popliteal : 1572, 1573, 1574, 1584.

**Specimens illustrating the mode of cure in Aneurysms.**

Spontaneous cure by deposition of laminated fibrin : 1575-1583.

Consolidation after compression of the artery : 1584.

Consolidation after ligature : 1570.

**Specimens illustrating the progress of Aneurysms.**

Rupture into the Pericardium : 1544, 1585-1589.

    "    "    Heart-cavities : 1547, 1590.

    "    "    Superior vena cava : 1591.

    "    "    Pulmonary artery : 1592.

    "    "    Pleural cavity : 1593.

    "    "    Trachea : 1594-1596.

    "    "    Bronchus : 1597-1601.

    "    "    Œsophagus : 1597, 1602-1604.

    "    "    Peritoneal cavity : 1565, 1605.

    "    "    Brain and meninges : 1606-1608.

**Specimens illustrating the pressure-effects of Aneurysm.**

Absorption of bone : 1609.

Pressure on the Trachea : 1551, 1601.

    "    "    Bronchi : 1551, 1611, 1612, 1614.

    "    "    Superior vena cava : 1551, 1587, 1613.

    "    "    Pulmonary artery : 1612, 1614.

    "    "    Nerves : 1552, 1556, 1574.

**Embolism and Thrombosis : 1615-1623.**

Coagula : 1624, 1625.

**SERIES XXIX.—INJURIES AND DISEASES OF VEINS.**

**Varicose dilatation :** 1626.

**Phlebitis :** 1627-1631.

**Thrombosis :** 1632-1634.

**Phleboliths :** 1635, 1636.

---

**SERIES XXX.—INJURIES AND DISEASES OF LYMPHATIC  
VESSELS AND GLANDS.****Degeneration.**

Pigmentary degeneration : 1637.

Fibroid degeneration : 1638.

Calcareous degeneration : 1639.

**Caseation and Tuberculosis :** 1640-1645.

**Morbid Growths.**

Lymphoma : 1646.

Lymphadenoma : 1647, 1648.

Carcinoma : 1649, 1650.

Melanosarcoma : 1649.

Epithelioma : 1650, 1650 *a*.

---

**SERIES XXXI.—INJURIES AND DISEASES OF THE  
LUNGS AND PLEURA.****Effects of Injury.**

Traumatic Emphysema : 1651.

**Diseases of the Lungs.**

Emphysema : 1652-1657.

Fibroid Degeneration : 1658.

      "      "      with dilated Bronchial Tubes : 1659, 1660.

Calcareous Mass in Lung : 1661.

Thrombosis : 1662.

Plastic Bronchitis : 1663.

Pneumonia : 1664-1667.

      Lobular : 1666.

      Interstitial : 1667.

Abscess : 1668-1673.

Miliary Tuberculosis : 1674-1676.

      "      "      with Consolidation : 1677-1680.

Phthisis :

      Acute : 1681.

      Chronic : 1682-1692.

      Cirrhotic : 1693-1695.

Syphilitic Disease : 1696.

**New Growths.**

Enchondroma : 1697.

Medullary Sarcoma : 1698-1700.

Carcinoma : 1701.



**Diseases of the Pleura.**

- Pleuritic Adhesions: 1702.
  - Thickened Pleura: 1703, 1704.
  - Ossification: 1705.
  - Hydatid: 1706.
- 

**SERIES XXXII.—INJURIES AND DISEASES OF THE  
LARYNX AND TRACHEA.****Injury.**

- Foreign body: 1707-1712.
- Tracheotomy: 1707, 1713, 1714, 1717, 1718, 1732, 1734, 1736.
- Cut throat: 1715.

**Diseases.****Effects of Pressure.**

- Compression by gland: 1716.
- „ by abscess: 1717.
- „ by neoplasm: 1718.
- Ulceration: 1719.
- Perforation: 1720-1721.

**Effects of Inflammation.**

- Œdema: 1717, 1722, 1724, 1736, 1750.
- Perichondritis: 1725, 1726, 1746.
- Necrosis: 1718, 1726, 1727, 1739, 1746, 1750.

**Specific Inflammation.**

- Membranous Laryngitis: 1728-1737.
- Syphilis: 1738-1747.
- Tuberculosis: 1748-1753.
- Lupus: 1754.

**Morbid Growths.**

- Sarcoma: 1756.
  - Papilloma: 1757-1759.
  - Epithelioma: 1760.
- 

**SERIES XXXIII.—INJURIES AND DISEASES OF THE  
SPLEEN.**

- Rupture: 1761.
- Lardaceous disease: 1762.
- Calcareous capsule: 1763, 1764.
- Infarction: 1765.
- Leucocythæmia: 1766, 1767.
- Hodgkin's disease: 1768-1770.
- Tuberculosis: 1771.
- Syphilis: 1772.
- Hydatids: 1773, 1774 (?).
- Melanotic Growth: 1775.

SERIES XXXIV.—DISEASES OF THE SUPRARENAL  
BODIES.

Hypertrophy: 1776.  
Fatty degeneration: 1777.  
Lardaceous: 1781-1783.  
Hæmorrhage: 1778.  
Addison's Disease: 1779-1781.  
Syphilis: 1782-1784.  
Sarcoma: 1785-1787.  
Carcinoma: 1788-1790.  
Cystic Growth: 1791.

---

SERIES XXXV.—INJURIES AND DISEASES OF THE  
THYROID AND THYMUS BODIES.

THE THYROID BODY.

**Hypertrophy:** 1792.  
**Goitre:** 1793-1807.  
Fibrous: 1793.  
Cystic: 1794-1807.  
Calcareous: 1799-1801.  
Ossified: 1802, 1803.  
Gelatinous: 1804-1807.

**New Growth.**

Sarcoma: 1808, 1809.  
Carcinoma: 1810.

THE THYMUS BODY.

**Hypertrophy:** 1811.

---

SERIES XXXVI.—INJURIES AND DISEASES OF THE  
KIDNEYS AND URETERS.

**Injury.**

Laceration: 1812.  
Aneurysm: 1813.  
Detached capsule: 1814.



**Hypertrophy:** 1815, 1816.

**Atrophy:** 1816.

**Hæmorrhage:** 1817, 1818.

**Inflammation and its Effects:** 1819-1838.

Parenchymatous nephritis: 1819-1821.

Granular cirrhotic nephritis: 1822-1829.

" " " with Cysts: 1826-1829.

Suppurative nephritis: 1830-1833.

Pyelo-nephritis: 1834-1838.

**Necrosis:** 1839, 1840.

**Tuberculosis:** 1841-1845.

**Changes in the Kidneys and Ureters due to Renal Calculi and Retention of Urine.**

Calculus in the pelvis of the kidney: 1846-1860.

Erosion of Calculi: 1859.

Renal calculi: 1861.

Calculus impacted in the ureter: 1862-1866.

Obstruction to the outflow of urine from the bladder: 1867-1870.

Hydronephrosis: 1856, 1857, 1863, 1864, 1866, 1870-1875.

**Parasites.**

Hydatid: 1876.

**Cysts and Morbid Growths.**

Cysts: 1877-1883.

Retention cyst: 1877, 1878.

Calcification of cyst-wall: 1879.

Congenital cysts: 1880-1883.

Morbid Growths: 1884-1889.

Lympho-sarcoma: 1884, 1885.

Melano-sarcoma: 1886.

Carcinoma: 1887-1889.

**Malformations.**

Supernumerary ureter: 1890, 1891.

Diverticulum from ureter: 1892.

Horseshoe kidney: 1893.

Conjoined kidneys: 1894.

Misplaced kidney: 1895, 1896.

---

## SERIES XXXVII.—INJURIES AND DISEASES OF THE BLADDER.

**Injury.**

Rupture: 1897, 1898.

Operation: 1899, 1900, 1967, 1968.

**Diseases.****Foreign body** : 1901, 1902.**Calculi** : 1865, 1866, 1903-1906, 1938, 1944.

Encysted : 1904.

Effects of : 1865, 1866, 1907, 1908, 1938.

**Hypertrophy** : 3, 4, 109, 1815, 1862, 1865, 1866, 1892, 1903, 1904, 1907-1913, 1934, 1935, 1937, 1938, 1940, 1942, 1948, 1950, 1954, 1955, 1957-1960, 1962-1964.

From Stricture : 1913, 1950, 1954, 1955, 1957-1960, 1962-1964.

From enlarged Prostate : 1909, 1910, 1934, 1935, 1937, 1940, 1942, 1943, 1944, 1945, 1946.

From Calculi : 1903, 1904, 1907, 1908, 1912, 1938.

**Dilatation** : 3, 109, 1859, 1871, 1907, 1913, 1935, 1938, 1940, 1942, 1946, 1951, 1954, 1956, 1958, 1961.**Sacculation** : 4, 1910, 1911, 1913.**Hæmorrhage** : 1914.**Inflammation and its Effects.**

Cystitis : 1903, 1907, 1908, 1910, 1915, 1936, 1945, 1949, 1962-1964.

**Tuberculosis** : 1916, 1917, 1951.**Morbid Growths** : 1918.

Sarcoma : 1918-1921.

Papilloma or Villous : 1922, 1923.

Epithelioma : 1924 1932.

---

**SERIES XXXVIII.—INJURIES AND DISEASES OF THE PROSTATE GLAND.****Injury** : 1933-1936.**Foreign Body** : 1937, 1938.

Calculus : 1937, 1938.

**Hypertrophy** : 3, 1899, 1909, 1910, 1913, 1933, 1934, 1935, 1936, 1937, 1939-1946, 1948.**Inflammation and its Effects** : 3, 102, 1947.

Abscess : 3, 109, 1947-1950, 1960-1962.

**Tuberculosis** : 1951.**Morbid Growth.**

Sarcoma : 1952.



### SERIES XXXIX.—INJURIES AND DISEASES OF THE URETHRA.

STRICTURE: 130, 1953-1955, 1956-1960, 1963, 1965, 1966, 1967, 1968.

**Consequences:**

Dilatation of the urethra: 1954, 1956, 1957, 1958, 1959, 1960, 1961, 1962, 1964.

Ulceration of the urethra: 1958, 1959, 1960, 1961, 1962, 1964.

Abscess: 1961, 1962, 1963.

Perineal fistula: 1962, 1963.

Penile fistula: 1959.

Cysts in the prostate: 1956, 1957.

Abscess in the prostate: 1960, 1961, 1962.

Hypertrophy of the bladder: 1954, 1955, 1957, 1958, 1959, 1960, 1962, 1963, 1964.

Dilatation of the bladder: 1954, 1956, 1958, 1961.

Ulceration of the bladder: 1962, 1963, 1964.

Surgical ureter: 1962, 1964.

Surgical kidney: 1964.

**Effects of the treatment of Stricture:**

Effects of the application of caustic bougies: 1950, 1965.

False passages: 1599, 1966, 1967.

Puncture per rectum: 1967, 1968.

---

### SERIES XL.—INJURIES AND DISEASES OF THE PENIS.

**Morbid Growths.**

Papilloma: 1968 *a*.

Epithelioma: 196, 1969-1975.

**Malformation.**

Epispadias: 1976.

---

### SERIES XLI.—INJURIES AND DISEASES OF THE TESTIS AND TUNICA VAGINALIS.

**Injury.**

Self-castration: 1977.

**Diseases.****Atrophy and Degeneration:** 1978-1987.

Atrophy: 1978-1983.

Fatty degeneration: 1984.

Fibroid degeneration: 1985-1987.

**Inflammation and its Effects:** 1988-1992.

Acute orchitis: 1988.

Abscess of epididymis: 1989.

Fungating growth: 1990-1992.

**Infective Granulomata:** 1993-2015.

Tubercle: 141, 1993-2009.

Syphilis: 146, 2010-2015.

**Cysts and Morbid Growths:** 2016-2061.

Hydrocele of the Tunica Vaginalis: 37, 77, 2016-2023.

Hæmatocele of the Tunica Vaginalis: 47, 2024, 2025.

Encysted Hydrocele of the Tunica Vaginalis: 42, 2026-2034.

Encysted Hydrocele of Spermatic Cord: 40, 41, 2035.

Congenital cyst: 2028, 2035, 2036, 2037.

Laminae of bone from the Tunica Vaginalis: 2038, 2039.

Tumour of the Tunica Vaginalis: 2040, 2041.

Enchondroma: 2042.

Cystic enchondroma: 2043, 2044.

Sarcoma: 2045, 2046.

Fibro-cystic sarcoma: 39, 2047.

Chondro-sarcoma: 2048, 2048 *a*.

Melano-sarcoma: 2049.

Fungating: 69.

Carcinoma: 2050-2061.

Fungating: 2058, 2061.

**Malformation:** 2062, 2063.

Defective development: 2062.

Separation of Epididymis with inversion of Testis: 2063.

---

SERIES XLII.—INJURIES AND DISEASES OF THE  
SCROTUM.

**Hypertrophy.**

Elephantiasis: 2064.

**Morbid Growth.**

Fibroma: 2065.

Lipoma: 2066, 2067.

Melano-sarcoma: 2068.

Epithelioma: 2069, 2070, 2071.

---



## SERIES XLIII.—ENTOZOA.

**Trematoda.**

*Distoma hepaticum* : 2072, 2073.

**Cestoda.**

*Bothriocephalus latus* : 2074.

*Tænia solium* : 2075-2077.

*Cysticercus cellulosæ* : 2078, 2079.

*Tænia medio-canellata* : 2080.

*Tænia elliptica* : 2081.

**Nematoda.**

*Ascaris lumbricoides* : 2082-2084.

*Ascaris mystax* : 2085.

*Dracunculus medinensis* : 2086, 2087.

*Dochmius duodenalis* : 2088.

**Botts** : 2089.

SERIES XLIV.—INJURIES AND DISEASES OF THE  
OVARIES.**Parasites.**

*Hydatid* : 2090.

**Cysts and Morbid Growths.**

Cysts : 2091-2108, 2131, 2134, 2139, 2167.

Simple follicular : 2091-2095.

Congenital : 2096-2099.

Contents : 2100.

Proliferous, with Cystic Growths : 2101-2105.

„ „ Solid Growths : 2106-2108.

Morbid Growths : 2109-2114.

Fibroma : 2109.

Sarcoma : 2110.

Carcinoma : 2111-2113.

Colloid Carcinoma : 2114.

SERIES XLV.—INJURIES AND DISEASES OF THE  
FALLOPIAN TUBES.

**Inflammation and its Effects.**

Hydrosalpinx: 2093, 2115, 2116.

Pyosalpinx: 2117, 2122.

Hæmatosalpinx: 2118, 2183.

**Cysts.**

Congenital: 2119.

---

SERIES XLVI.—INJURIES AND DISEASES OF THE  
UTERUS.

**Inflammation and its Effects:** 2120-2122.

Ulceration: 2120, 2128, 2141.

**Gangrene:** 2123, 2128.

**Displacements:** 2124-2130.

Anteflexion: 2122, 2124.

Inversion: 2125-2128.

Prolapse: 2129, 2130.

**Morbid Growths:** 2131-2180.

Fibromyoma: 2085-2126, 2131-2158.

Undergoing calcification: 2152-2158.

Polypi: 2085, 2107, 2126, 2127, 2130, 2134, 2140, 2147, 2148, 2155, 2159-2162.

Of the body: 2159, 2160.

Of the cervix: 2161, 2162.

Carcinoma: 2163-2180.

Of the body: 2163-2167.

Of the cervix: 2168-2180.

Involving the vagina: 2170-2180.

Involving the bladder: 2175-2180.

Vesico-vaginal fistula: 2176-2180.

**Malformations.**

Uterus unicornis: 2181.

Uterus bicornis: 2181 *a*.

Uterus didelphys: 2182, 2183.



## SERIES XLVII.—INJURIES AND DISEASES OF THE VAGINA AND VULVA.

- Elongation of the Vagina : 2184.  
 Hypertrophy of the Clitoris : 2185-2187.  
 Hypertrophy of the Labia : 2188-2191.  
 Cyst in the Labium : 2192.  
 Carcinoma of the Vagina : 2171-2180.  
 Carcinoma of the Vulva : 2193.  
 Malformation of the Vagina : 2182, 2183.
- 

## SERIES XLVIII.—UTERO-GESTATION.

### Changes in the Ovary consequent upon Ovulation.

- Ruptured Graafian follicle : 2194-2196.

### Changes in the Ovary consequent upon Fecundation.

- Corpus luteum : 2197, 2198, 2258, 2259.

### Specimens showing :—

- The development of the Embryo : 2198-2218, 2245, 2246, 2260, 2276, 2284, 2286-2281.  
 The development of the Placenta : 2198, 2203-2207, 2208 *a*, 2219-2227.  
 The placenta *in situ* : 2228, 2230.  
 The changes in the pregnant uterus before delivery : 2198, 2204, 2205, 2228, 2231, 2232, 2245, 2246, 2257-2260.  
 The changes in the pregnant uterus after delivery : 2233-2241, 2250-2256.

### Utero-gestation in other Vertebrates : 2242-2244.

---

## SERIES XLIX.—ABNORMAL CONDITIONS INCIDENTAL TO GESTATION AND PARTURITION.

### Unusual position of the Child : 2245, 2246.

- Breech presentation : 2245, 2246.

### Abnormal condition of the Cord : 2247, 2248.

### Unusual condition of the Placenta : 2249-2251.

- Triplet placenta : 2249.  
 Placenta prævia : 2250.  
 Adherent placenta : 2251.

### Rupture of the Uterus : 2252, 2255.

### Inversion of the Uterus : 2256.

### Extra-Uterine Gestation : 2257-2265.

**SUBSERIES I.—Diseases of the Ovum and its Membranes.**

- Myxomatous disease of the chorion : 2266-2272.  
Hæmorrhage into the decidua : 2205, 2273-2288.  
Abortion : 2286-2288.  
Compressed foetus : 2289-2292.  
Macerated foetus : 2293.

---

**SERIES L.—DISEASES OF THE MAMMA.****Cysts and Morbid Growths.**

- Galactocoele : 2294.  
Simple Cysts : 2295-2298.  
Proliferous Cysts ; Sero-cystic disease : 2299, 2300.  
Fibro-adenoma : 2301-2304.  
Sarcoma : 2305-2318.  
    Cystic-Sarcoma : 2305-2307.  
    Fibro-sarcoma : 2305, 2308, 2309.  
    Adeno-sarcoma : 2310.  
    Myxo-sarcoma : 2311-2315.  
Carcinoma.  
    Scirrhus, or Hard Cancer : 2319-2326.  
    Infiltrated Axillary Glands : 2320.  
    Infiltrating Cancer : 2321-2324.  
    Of the male breast : 2325, 2326.  
    Medullary or Soft Cancer : 2327-2329.  
    Undergoing fatty degeneration : 2330.  
    Carcinoma myxomatodes : 2331.  
    Infiltration of the Pleura : 2332.  
Mass of Cancer removed by caustic : 2333.

**Malformation.**

- Supernumerary nipple : 2334.

---

**SERIES LI.—MALFORMATIONS.****MALFORMATIONS RESULTING FROM INCOMPLETE DEVELOPMENT.****Of the Head.**

- Acephalous : 2335, 2336.

**Of the Nervous System.**

- Brain absent : 2337-2340.  
Brain rudimentary : 2341, 2342, 2344, 2345, 2368, 2372, 2384.



MALFORMATIONS RESULTING FROM INCOMPLETE DEVELOPMENT (*cont.*).**Of the Organs of Special Sense.**

Eyes absent : 2341, 2344, 2345.  
 Eyelids remaining united : 2346.  
 External ear absent : 2345.  
 Nose absent : 2341, 2342, 2344, 2345.

**Of the Vascular System.**

Abnormal arterial supply of the cord : 2347.

**Of the Respiratory System.**

Lungs absent or rudimentary : 2335, 2336.

**Of the Digestive System.**

Fauces impervious : 2344.  
 Intestine opening abnormally : 2348, 2367.

**Of the Urinary System.**

Kidney absent : 2348.  
 Ureter absent : 2348, 2367.

**Of the Organs of Generation.**

Ovary absent : 2348.  
 Uterus absent : 2348, 2367.  
 Vagina absent : 2348, 2367.  
 External organs absent : 2348, 2349, 2367.  
 External organs rudimentary : 2335, 2365.

**Other similar Malformations.**

Head absent : 2335, 2336.  
 Cranium defective : 2337-2341, 2368, 2372.  
 Lower jaw defective : 2363.  
 Upper and lower extremities absent or rudimentary : 2335, 2350-2352, 2357.  
 One lower extremity absent : 2349, 2353, 2354.  
 Foot articulated to pelvis : 2349.  
 Fingers or toes deficient in number : 2336, 2345, 2352, 2355-2357, 2367.

## MALFORMATIONS RESULTING FROM INCOMPLETE COALESCENCE OF PARTS.

**On the Ventral median plane and Visceral Arches.**

Fissure of the face : 2341, 2344, 2347.  
 Fissure of the lip.  
     Single hare-lip : 2358.  
     Double hare-lip : 2341, 2359.  
 Fissure of the palate.  
     Hard palate : 2357-2359, 2362-2364.  
     Soft palate : 2311, 2357-2359, 2361-2364.  
 Fissure of the chest-wall : 2366, 2367.  
     "     "     diaphragm : 2349, 2367, 2368, 2400.  
     "     "     abdominal walls : 2353, 2354, 2365-2369, 2372, 2389.  
     "     "     symphysis pubis : 2366, 2367.

**Of the Dorsal median plane.**

Fissure of the skull : 2337-2340, 2368, 2370, 2373.

Meningocele : 2371, 2372.

Encephalocele : 2345, 2368, 2373-2375.

Fissure of the spinal column—Spina Bifida.

Cervical : 2337, 2371, 2393.

Dorsal : 2368, 2372.

Lumbar : 2368, 2376-2381, 2389.

Sacral : 2367, 2378-2382.

**MALFORMATIONS RESULTING FROM COALESCENCE OF PARTS.**

Fingers or toes conjoined : 2336, 2345, 2349, 2357.

Cyclops : 2342, 2383, 2384.

**MALFORMATIONS RESULTING FROM COALESCENCE OF TWO FÆTUSES.****Double Fœtus.**

One perfect, the other an appendage : 2385, 2387.

Both more or less perfect.

Upper parts united : 2389-2391.

Middle parts united : 2388, 2392, 2393.

Lower parts united : 2394-2396.

Supernumerary nail : 2397.

**MALFORMATIONS RESULTING FROM DISPROPORTIONATE GROWTH OF PARTS.**

Clitoris : 2398, 2399.

**CONGENITAL DISPLACEMENTS.****Hernia of the Intestines.**

Through the diaphragm : 2349, 2400.

Through the umbilicus : 2354.

**CONGENITAL DISTORTIONS.**

Of the spine : 2401.

Of the thorax : 2335.

Of the limbs : 2372, 2402, 2403.

---

**SERIES LII.—PELVIC DEFORMITIES.**

Flat pelvis : 2404.

Rachitic pelvis : 2405, 2406.

Scolio-rachitic pelvis : 2407.

Osteo-malacic pelvis : 2408-2416.

Oblique pelvis of Nægele : 2417.

Kyphotic pelvis : 254.

Transversely contracted pelvis of Robert : 2418.

Spondylolisthetic pelvis : 2419.

Oblique ovate pelvis : 2420.

Pelvis deformed from dislocation : 2421.

" " fracture : 2422.

" " syphilis : 2423.



# SERIES LIII.—PLASTER CASTS.

## Diseases of Fasciæ, Tendons, and Bursæ.

Dupuytren's contraction of the palmar fascia: 1-7.

Contraction of Tendons: 8.

Talipes: 9-52.

Equinus: 9-11.

Equino-varus: 12-16.

Equino-cavo-varus: 17-34.

Equino-valgus: 35.

Valgus: 36-39.

Calcaneus: 40, 41.

Calcaneo-valgus: 42-47.

Calcaneo-cavus: 48-51.

Calcaneo-cavo-valgus: 52.

Enlarged Bursa: 53.

## Diseases of Bones: 54-80.

Chronic Rheumatic Arthritis: 54-58.

Rickets: 59-75.

Enlarged Epiphyses: 59.

Curvatures: 60-70.

Genu valgum: 71-75.

Morbid Growths: 76-80.

## Injuries of Bones: 81-98.

Fractures of the Skull: 81, 81 a.

" " Clavicle: 82.

" " Humerus: 83-86.

" " Radius: 87-94.

" " Ulna: 95.

" " Fibula: 96-98.

## Deformity from contraction of cicatrices: 99-105.

## Injuries of Joints: 106-124.

Dislocation of the Clavicle: 106-108.

" " Humerus: 109-111.

" " Radius and Ulna: 112-115.

" " Femur: 116, 117.

" " Patella: 118-120.

" " Tibia and Fibula: 121.

" " Foot: 122-124.

## Amputation Stumps: 125-132.

## Diseases of Joints: 133-137.

## Malformations: 138-146.

## Miscellaneous: 147-158.

## Deformity from Empyema: 159-162.

## Lateral Curvature: 163-169.

## Utero-gestation: 170-174.

## Intestinal Obstruction: 175.

## SERIES LIV.—WAX MODELS, ETC.

**Congenital disease or deformity.**

- Foetal caries and curvature: 1.
- Foetal rickets: 2.
- Hydrocephalus: 3-6.
- Anencephalous foetus: 7.
- Parasitic foetus: 8.
- Of the digits: 9-15.
- Of the skin: 16.
- Of the nails: 17, 18.
- Of the lip. Double hare-lip: 19, 20.
- Of the kidney. Cystic disease: 21.

**Calculus:** 22.

**Injury:** 23-26.

**Varices:** 27, 28.

**Skin diseases.**

- Vaccinia: 29.
- Variola: 30-33.
- Scabies: 34.
- Eczema: 35-37.
- Xeroderma: 38.
- Uncertain: 39, 40.
- Syphilis: 41, 42.

**Contraction of cicatrices:** 43-47.

Keloid: 47.

**Bone disease.**

Necrosis: 48-50.

**Joint disease:** 51, 52.

**Fungating Testis:** 53.

**Morbid Growths.**

- Enchondroma: 54.
- Carcinoma: 55-58, 62, 63.
- Sarcoma: 59-61.

**Miscellaneous:** 64-67.

## SERIES LV.—URINARY CALCULI.

SERIES LVI.—CALCULI AND OTHER CONCRETIONS  
FORMED IN THE DIGESTIVE ORGANS.



## SERIES LVII.—PLATES OF DISEASES OF THE SKIN.

### I. Cutaneous affections in specific diseases.

- Cholera : 1.
- Syphilis : 2-11.
  - Early : 2-4.
  - Late : 5-8.
  - Congenital : 9-11.

### II. Inflammatory diseases of the skin.

- Acute.
  - Urticaria : 13, 14.
  - Erythema : 15-21.
  - Erythema vel Herpes : 22.
  - Herpes Zoster : 23-34.
  - Impetigo herpetiformis : 35.
- Chronic.
  - Pemphigus : 37-42.
  - Psooriasis : 43-48.
  - Pityriasis rubra : 49.
  - Lichen : 50-54.
  - Prurigo : 55-57.
  - Strophulus : 58, 59.
  - Eczema : 60-70, 74.
  - Impetigo : 71-73.
- Due to medicines taken internally : 75, 76.

### III. Non-inflammatory diseases of the skin, without destructive tendencies.

- Hypertrophic : 77-87.
  - Tylosis : 77.
  - Ichthyosis : 78, 79.
  - Verruca : 80, 81.
  - Papilloma : 82, 83.
  - Molluscum fibrosum : 84-87.
- Hæmorrhagic : 88.
  - Purpura thrombotica : 88.
- Pigmentary : 89-100.
  - Melasma : 89.
  - Chloasma : 90, 91.
  - Argyria : 92.
  - Melasma supra-renale : 93.
  - Lentigo : 94-96.
  - Leucoderma : 97-100.
- Fatty degeneration :
  - Xanthoma : 101-103.

### IV. Non-inflammatory diseases with profoundly destructive tendencies.

- Lupus : 104-119.
- Morphæa : 120.
- Lepra : 121-124.

- Elephantiasis : 125, 126.
- Rhinoscleroma : 127.
- Keloid : 128, 129.
- Angelioma : 130, 131.
- Sarcoma : 132.
- Carcinoma : 133-138.

**V. Diseases of the appendages of the skin.**

- Of the Hair and of the Hair-follicles.
  - Hypertrichosis : 139, 140.
  - Alopecia : 141, 142.
  - Sycosis : 143-145.
- Of the Sebaceous Glands.
  - Seborrhœa : 140-149.
  - Acne vulgaris : 150-153.
  - Rosacea : 154.
  - Rhinophyma : 156.
  - Miliaria : 157.
  - Medicinal Acne : 157.
  - Molluscum Contagiosum : 158, 159.
- Of the Nails.
  - Onychitis : 160.
  - Psoariasis : 160.

**VI. Parasitic diseases of the skin.**

- Animal Parasites.
  - Scabies, 161-166.
  - Pediculosis : 167-173.
- Vegetable Parasites.
  - Tinea favosa : 174-177.
  - Tinea tonsurans : 178-181.
  - Tinea circinata : 182, 183.
  - Tinea marginata : 184-186.
  - Tinea versicolor : 187-189.

**A tattooed man : 190.**





# CATALOGUE

OF

## PATHOLOGICAL SPECIMENS.

---

### Section I.—GENERAL PATHOLOGY.

#### SERIES I.—HYPERTROPHY AND HYPERPLASIA.

##### **Simple Hypertrophy from increased Functional Activity.**

Of Muscular Organs impeded in action: 1, 2, 2 A, 3, 4.

Of Glandular Organs, Compensatory or Vicarious: 5, 6.

##### **Hypertrophy or Hyperplasia.**

From irritation: 7, 8, 9, 10.

From collateral afflux of Blood: 10.

From obstruction to Lymphatic or Venous Channels: 11.

From unrecognized causes: 12, 13, 14, 15, 16.

Congenital Hypertrophy: 17.

---

#### **Hypertrophy and Hyperplasia.**

1. A heart with the right ventricle and auricle greatly hypertrophied, owing to extreme stenosis of the mitral orifice. The right ventricle is larger than the left, which does not reach the apex of the heart. Its walls are nearly as thick as those of a normal left ventricle.

From a youth aged 17, admitted under Dr. Down, Oct. 29, 1887, with dyspnoea and anasarca from cardiac disease. Symptoms of heart disease for 6 years. There were hæmorrhagic infarcts in the lungs.

Charles Higgins, Reg. no. 1623. Autopsy, Dec. 10, 1887.

2. An hypertrophied heart. The left ventricle is much thickened; its cavity is dilated and rounded, the septum bulging to the right. There is some hypertrophy also of the right ventricle. There is no notable disease of the valves. The aorta is atheromatous. Probably from a case of chronic Bright's disease.

- 2 A. A greatly enlarged heart, with the hypertrophied and dilated left ventricle laid open. The aortic curtains are thickened and retracted; and the greatly hypertrophied and dilated ventricle is evidence of free regurgitation through the valve. The mitral valve is imperfectly seen. The edge of the larger curtain is thin and membranous.



3. An hypertrophied and dilated urinary bladder, with a greatly enlarged prostate consisting of three prominent rounded masses, in the middle lobe of which there is a false passage, through which a piece of glass rod has been passed. The interlacing bundles of muscular fibres in the wall of the bladder are very conspicuous on its inner surface. The mucous membrane is recessed between them.
4. A urinary bladder and commencement of the urethra. The wall of the bladder is greatly thickened. The bands of muscular fibres are thick and prominent on its mucous surface. At the base of the bladder to the left of the trigon a large pouch has been formed by the protrusion of the mucous membrane between the muscular bundles; it is nearly as large as the bladder itself. The left ureter passes over the surface of the pouch, and was apparently compressed by it, being dilated. On the right of the trigon is a smaller pouch. There is a stricture of the urethra.
5. A kidney about twice the normal size, from a man aged 43, whose other kidney was hydronephrotic and converted into a large fibrous sac without any remains of the secretive structure. See No. 35.
6. A uterus with its appendages. The right ovary is converted into a chambered cyst of the size of a goose's egg, in the walls of which the attenuated remains of the ovarian tissues are seen. The left ovary is about twice the normal size. There are two small cysts at its upper and outer surface.
7. Part of the greatly enlarged scrotum of a chimney-sweeper. It is covered with closely-set cauliflower-like papillomatous growths.
8. A labium majus greatly enlarged by overgrowth of the subcutaneous adipose tissue and skin. Its surface is covered with club-shaped outgrowths of varying size, and flattened on the top and laterally by mutual pressure. The skin is thickened and its surface roughened from enlargement of the papillæ.
9. The central part of the shaft of a tibia of a syphilitic subject divided longitudinally in an antero-posterior plane. There has been an extensive formation of osseous tissue, referable to irritation from the syphilitic poison. It is compact at the surface and cancellous beneath, and completely envelopes the original bone, the outline of which is clearly traceable in the transverse section at the upper end of the bone; and in bulk it is greater than the original bone. The medullary canal is occupied by a delicate reticulum of cancellous bone; this is more abundant and of finer spongy character at the lower part, where the periosteal formation has been greater, and forms a node on the surface of the bone.



From a man aged 42, who was admitted in an unconscious state with spasmodic movements, chiefly of the left limbs, and died about two months afterwards. He had softening of the right optic thalamus, a fatty and scarred liver, atrophied testes, and empyema on the right side.

James Bunt, Reg. no. 1317. Admitted Nov. 11, 1880. Autopsy, Feb. 11, 1881. Dr. H. Jackson.

10. The left tibia and fibula, the former greatly enlarged at its upper part and containing an incompletely separated sequestrum in a smooth-walled cavity in the centre of the bone. The tibia has been divided longitudinally in a plane passing from side to side in front of the axis of the bone and exposing the sequestrum. It is seen that the enlargement of the bone is due to the formation of cancellous tissue, which has filled up the medullary cavity. There is only a thin wall of compact bone at the surface, from which there are numerous osteophytic outgrowths. The lower end of the bone is also enlarged, and its medullary cavity is occupied by ingrowth of cancellous tissue. The sequestrum is composed of compact bone, much eroded. It is surrounded by a smooth-walled cavity, excepting at the upper end, where it is still adherent. From the lower end of the cavity there is a sinus, with a funnel-shaped opening on the inner surface of the bone. There is a backward bend in the bone a little above the middle.—The enlargement of this bone was the result of an irritative hypertrophy (chronic osteitis) doubtless of long duration, and referable possibly to the presence of the sequestrum in its centre. It is possible, however, that the sequestrum may have been of secondary occurrence, and resulted from necrosis of a mass of compact bone formed by sclerosing osteitis in the axis of the bone.

The specimen was obtained by Mr. McCarthy from the body of a woman aged 67, who was admitted with concussion of the brain, from which she died shortly afterwards. The enlargement of the left leg attracted attention. There were no abnormal adhesions between the bone and the skin and subcutaneous tissue, and no scar on the former was observed. (See Trans. Path. Soc. vol. xxxv. p. 283.)

11. The lower end of the rectum with the anus, laid open and showing internal and external hæmorrhoids. The former are elongated polypoid projections of the mucous membrane of the intestine, the latter are similar but smaller projections of the mucous membrane at the verge of the anus. They consist of fibrous connective tissue containing dilated and varicose veins.
12. A portion of a greatly thickened cranium. It consists of the outer portion of the left parietal and contiguous parts of the frontal and occipital bones. The enlargement of the bone is due chiefly to great increase of the diplöe. It is greatest towards the vertex, its section measuring about  $\frac{3}{4}$  inch at the thickest part.
13. A cluster of enlarged mesenteric glands with a coil of small intestine



connected with it. Microscopical sections from these glands show no alteration of the type of the structure. Probably from a case of Lymphadenoma or Hodgkin's disease.

14. One half of a greatly enlarged spleen which weighed 29 oz. Its structure appears quite normal, and it was of a natural consistence at the autopsy.

From a youth aged 19, of English parentage, but [born in India, affected with leprosy for twelve years. John Davis, admitted Aug. 20, 1887, under Mr. Tay.

15. A pedunculated tumour from the skin, consisting of an overgrowth of the subcutaneous tissue, the skin over which shows no alteration excepting from the effect of spirit, which has caused the whole specimen to become shrivelled up and much reduced in size (*Molluscum fibrosum*).

16. The radius, ulna, and humerus from an infant affected with rickets, divided longitudinally. There is great enlargement of the articular ends of the bones, excepting those forming the elbow-joints, and enlargement of their shafts from the formation of new persistent bone. The sections of the enlarged articular ends of the bones show broad bands of gelatinous-looking proliferating cartilage, with processes extending into the unchanged articular cartilage on one side, and interdigitating with processes of the medullary tissue of the bone on the other side. The compact tissue of the shaft is for the most part converted into an open network with elongated and compressed meshes. It has still the appearance of compact bone on the outer side of the humerus, and on its inner side except at the upper part. Over the rarefied part of the shaft of this bone and over the bones of the forearm there has been a formation of new bone under the periosteum. It is of close texture and quite distinct from the shaft. There appears to have been an intra-periosteal fracture of radius and ulna about the middle; the medullary cavity is there occluded by osseous tissue. The bones are soft and were cut with a knife.

#### **Congenital Hypertrophy.**

17. A greatly hypertrophied great toe, removed by Mr. James Adams. The soft tissue forming the pad of the toe has grown out beyond the nail, which is hidden from view by the bending backwards of the end of the toe upon the dorsal surface of its upper part. On one side of the toe, and close to the line of amputation, is a flat corn, a local thickening of the epidermis and of the papillary layer of the cutis, due to overgrowth of the latter from irritation by friction and pressure of the boot.



## SERIES II.—ATROPHY AND DEGENERATION.

### Simple or Quantitative Atrophy.

- From disuse : 18, 19.
- From impeded Blood-supply : 20, 21, 22.
- From defect of General Nutrition : 23.
- Atrophy with increased formation of Adipose Tissue, or Fatty Infiltration : 24.
- Absorption from constant pressure : 25.

### Atrophy with Degeneration of the Tissues.

- Fatty Degeneration : 26, 27.
- Pigmental Degeneration : 28.
- Calcareous Degeneration : 29.
- Lardaceous Degeneration : 30, 31, 32.
- Mucoid or Colloid Degeneration : 33, 34.

### Atrophic or Degenerative Changes from Dilatation of Natural Channels or Cavities.

- Of Mucous Passages : 35, 35 A.
- Of Vascular Channels : 36.
- Of Serous Cavities : 37.

### Atrophy or Degeneration associated with the formation of Cysts.

- Epithelial or Retention Cysts : 38, 39.
- Endothelial or Exudation Cysts : 40, 41, 42.
- Proliferous Cyst : 43.
- Multilocular Cysts : 44.
- Dermoid Cysts : 45.
- Secondary Cysts, formed round foreign bodies, blood, &c.
- Hydatid Cyst : 46.
- Hæmorrhagic Cyst : 47.
- Cavities formed by Softening of Tissues : 48.

---

### Atrophy—Simple or Quantitative.

18. The leg of a child much wasted, with ankylosis of the knee. The muscles of the leg are extremely wasted, a thick layer of subcutaneous adipose tissue forming a considerable part of the transverse section of the atrophied limb. There is an adherent cicatrix on the internal surface of the tibia at the upper part, indicative of previous disease of the bone.—The wasting of the muscles is referable to prolonged disuse of the limb from fixation of the knee, which is bent at a right angle. The leg is covered with long hairs, the abnormal growth of which is notable in association with the large amount of subcutaneous adipose tissue in the wasted limb.



19. Parts of the femur, tibia, and fibula of a child, showing the results of long disuse of the bones in consequence of disease of the joint. The patella is ankylosed to the outer condyle, and the limb would appear to have been partially fixed at a right angle. The tibia and femur are so much atrophied that their external lamellæ are not thicker than stout paper, and their cancellous tissue consists of a very delicate framework of bone, enclosing large spaces. The patella is not so much atrophied as the long bones. The fibula is in the same state as the femur and tibia.
20. The testes of a dog, one atrophied in an extreme degree as the result of ligature of the spermatic artery some time before the animal's death, the other showing distention of the epididymis with secretion after ligature of the vas deferens. The upper part of the atrophic testis is cystic. (See Curling, Diseases of the Testis.)
21. A uterus and appendages. The left ovary is atrophic and much smaller than the right. Immediately above the former is a mass of enlarged and tortuous veins which forms a prominent swelling in the broad ligament on that side. The corresponding veins in the right broad ligament are also enlarged.
22. Part of a liver from a case of valvular disease of the heart, atrophic from effect of prolonged congestion. In the section the lobulation of the organ is mapped out in the characteristic nutmeg appearance, the paler and opaque peripheral parts of the lobules contrasting with the dark atrophic central parts about the radicles of the hepatic vein.
- From a youth aged 17, who died from mitral stenosis with symptoms of six years' duration. See No. 1 (the heart of the same patient). Autopsy, Dec. 10, 1887.
23. The atrophic heart of a woman aged 54, who died from malignant cystic disease of the left ovary and very extensive scirrhus carcinoma of the peritoneum. There is a good deal of subpericardial adipose tissue on the surface of the organ, which weighed  $6\frac{1}{4}$  oz. The mitral curtains are thickened and fibrous, and there are some granulations of recent endocarditis upon them.
- Elizabeth Hill, aged 54, admitted Jan. 3, 1888, under Dr. Hughlings Jackson. Autopsy, Feb. 3, 1888.
24. A heart with an excess of subpericardial adipose tissue upon its surface, and wasting of the muscular tissue in the wall of the right ventricle, which appears in one part to be entirely converted into adipose tissue.

From an obese woman aged 42, who died after swallowing some camphor liniment. Autopsy, Dec. 31, 1887.



25. The upper end of the sternum with the contiguous parts of the right clavicle and first rib, and the thoracic aorta, from the first part of which a sacculated aneurism of the size of an orange projects forwards and has led to absorption of the posterior surface of the manubrium sterni at its upper part, and also of the ends of the right clavicle and first rib adjacent. The rib has become separated from the sternum, and the sterno-clavicular joint has been laid open. The surface of the bones has disappeared and their cancellous tissue is exposed. The innominate artery is compressed by the aneurism.

### Atrophy—Qualitative ; Degenerative.

26. Part of a heart from a case of fatal anæmia. In the recent state the innermost layers of the wall of the left ventricle and the muscoli papillares and columnæ carneæ presented the characteristic wavy lines of fatty degeneration of the muscular fibres in a very marked degree. In the preparation some mottling of the muscular tissue in the section of the papillary muscles and fleshy columns is distinguishable.

From a girl aged 15. There were petechiæ over the body and small hæmorrhages studding the surface of the kidneys. Autopsy, Dec. 31, 1887.

27. An aorta laid open longitudinally, showing advanced atheromatous disease. The thickening of the inner coat of the vessel, with softening of its deeper layer, is seen in the section of its wall at the upper part. At some points calcareous plates have been formed. There is much thickening of the inner coat of the aorta about the orifices of the great arterial trunks of the arch and about the intercostals. The vessel is dilated at the upper part, the inner surface being there very uneven from atheromatous swellings and depressions.

From a rigger aged 31, who was admitted with fracture of the skull and other injuries from a fall, and died the following day, after amputation of one leg.

John Mitchell, Reg. no. 216. Autopsy, Feb. 5, 1881. Mr. James Adams.

28. Small portions of a liver and kidney, presenting well-defined black spots of pigmentation of varying size. Thin sections from the former examined by the microscope show much pigmentation of the liver-cells and stroma at the affected spots, but no new growth. The larger melanotic spots are partly softened and disintegrated.
29. A portion of a femoral artery with about 6 inches of the art. profunda femoris. The former and about an inch of the latter from its origin are free from calcareous degeneration. The remainder of the profunda with its branches is converted into a calcareous tube. The calcareous infiltration is marked with transverse lines corresponding with the course of the muscular fibres of the middle coat.



30. A lardaceous spleen. The organ is enlarged and its outline is rounded. It is of firm consistence, the edge of the section being sharp. The enlarged Malpighian bodies, infiltrated with the gelatinous lardaceous substance, are very conspicuous in the section of the organ.
31. Part of a lardaceous liver. Its outline is rounded and it is of firm consistence. In most parts of the section the lobules have been wholly infiltrated with the gelatinous, translucent, lardaceous substance, and appear as dark tracts mapped out by the interlobular lines of connective tissue. A few parts are unaffected and present a uniform opaque and paler colour.

George Gibson, aged 25, labourer, Reg. no. 550, was admitted in June 1880 on the Surgical side for synovitis of the knee, which suppurated and was aspirated twice. He remained an in-patient for about a year with fibroid phthisis, with frequent attacks of hæmoptysis, and lardaceous disease.

The autopsy (May 31, 1881) showed the lungs contracted and fibroid with many cavities, and tubercles in the lower parts; lardaceous liver, spleen, and ileum; ulceration of cæcum and colon; and suppuration of right knee-joint.

32. A lardaceous kidney. The organ is much enlarged. The Malpighian bodies are enlarged, and distinguishable in the section of the organ from the translucence of the lardaceous substance in the walls of the capillary loops.

James G. Knight, 34, cooper, Reg. no. 751, was admitted under Dr. Clark, June 17, 1882, with consolidation of the right lung and great dyspnoea, and died in a few days. He had suffered from cough two years and had lost flesh.

The autopsy, June 20, showed fibroid disease of the right lung with hepatization of the upper lobe, lardaceous liver and kidneys, and a tumour in the right adrenal (? syphilitic), which was also lardaceous. (See Liver, Ser. XXII., and Adrenal, Ser. XXXII.)

33. An enlarged thyroid body, showing well-marked colloid degeneration of its alveolar structure. Globules of brownish gelatinous substance are seen filling up the distended alveoli.
34. Part of a mammary gland with a scirrhus growth in the centre, which has undergone a colloid change.

#### **Dilatation of Channels and Cavities; Cysts and Cystic Degeneration.**

35. The right kidney and ureter with the bladder. The kidney has been converted into a large sac from dilatation of its pelvis and calices. The wall of the sac is fibrous, the renal tissue having wholly



disappeared. The ureter is greatly dilated and thickened, being as large as a piece of small intestine: there is an impermeable obstruction at its lower end. At the autopsy a calculus was found in the hydronephrotic sac. The left kidney was double the normal size and appeared healthy. The left ureter is also thickened and dilated.

From a man aged 43, who was admitted Nov. 17, 1881, under Dr. Sansom, with rheumatic heart disease and a hydronephrotic tumour on the right side. He had incompetence of the aortic valve, with oedema of the legs and ascites, and scanty albuminous urine.

Thomas Thompson, Reg. no. 1358. Autopsy, Dec. 13, 1881.

- 35 A. The lower lobe of a lung (left) laid open longitudinally, in which there are a number of saccular cavities with thin fibrous walls and smooth lining membrane. They communicate with bronchial tubes, of which they appear to form expansions (bronchiectases). The pulmonary tissue around them is vesicular, though condensed, the base of the lung having been firmly adherent and much contracted. The cavities were probably produced by a partial expansion of the completely collapsed base of the lung in the later absorption of a pleuritic exudation, attended with adhesion of the pleura, which is notable in the specimen. They may have been due in part to accumulation of muco-purulent secretion in the bronchial tubes of the damaged lung, the trachea and bronchi having been found filled with such secretion at the autopsy.

William Ford, aged 35, was admitted Jan. 30, 1888, under Dr. Down, and died Feb. 2. He had been intemperate and had suffered from syphilis twelve years previously, and three years ago he had an attack of rheumatic fever. His symptoms dated three weeks. He had general bronchitis with extreme dyspnoea and cyanosis. The heart was hypertrophied (17 oz.), the right side distended. There was slight stenosis of mitral and tricuspid orifices. The lungs were congested and oedematous, and the abdominal viscera venously congested.

Autopsy, Feb. 3, 1888.

36. A testis with spermatic cord, showing great dilatation and tortuosity of the spermatic veins and their branches, which form a convoluted mass above the epididymis.
37. Part of a testis with its tunica vaginalis, from a case of hydrocele. The tunica vaginalis is greatly dilated and forms a large sac, which has been laid open by a longitudinal section passing through the testis. The cavity is occupied by a mass of coagulated albumen, in which the testis is seen imbedded at its lower end.



### Retention Cysts.

38. A kidney affected with cystic disease. The organ is much enlarged and studded throughout with numerous cysts; these are mostly of the size of a hazel-nut and less; one is as large as an orange, and there are a few of intermediate size. The cysts are occupied by masses of coagulated albumen. Many have been emptied of their contents.

From a woman aged 69, admitted under Dr. Mackenzie for chronic renal disease on March 30, 1881. There was general anasarca; urine 10 to 40 oz. per diem, with  $\frac{1}{10}$  albumen. The autopsy (April 12, 1881) showed extreme cystic degeneration of the kidneys and cystic condition of liver; the heart large and fatty; coronary arteries calcareous.

Mary Douglas, Reg. no. 309. 1881.

39. A greatly enlarged cystic testis laid open longitudinally. It is studded with numerous cysts of the size of a bean and less. These are mostly in clusters, and many communicate, forming loculated chambers.

### Exudation Cysts.

40. A bursa patellæ converted into a cyst with greatly thickened fibrous walls.
41. A testis and spermatic cord, with an encysted hydrocele of the latter of the size of a walnut, laid open by the removal of a portion of its anterior wall. It is immediately above the testis, which is exposed by laying open the tunica vaginalis at the lower end of the specimen. Above the cyst is a hernial sac laid open longitudinally.
42. A testis and spermatic cord. There is a cyst of the size of a hen's egg immediately above the testis, connected with the epididymis; it contained spermatozoa. An encysted hydrocele of the testis, or spermatocele. (See Curling, Diseases of the Testis.)
43. A uterus and appendages, showing cystic disease of both ovaries, with extensive papillomatous growth from the inner surface of the cyst. One ovary consists of a cyst as large as a cocoanut, with a smaller bilocular cyst in its wall. The cyst has been turned inside out, and shows the inner surface roughened with small warty growths. The other organ presents an irregularly loculated cavity, with thick fibrous septa springing from its attached surface, from the edges and sides of which massive papillomatous outgrowths of cauliflower appearance project into the cavity. There are small warty growths on other parts of the cyst-wall, but its surface is smooth for the most part. The uterus is enlarged, and there are several myofibromata in its walls of the size of a damson and less. It has been divided longitudinally to show them.



From a woman aged 43, admitted under Dr. Palfrey, with ovarian disease, on Jan. 19, 1883. She was also suffering from pericarditis, with bronchitis and œdema of lungs. The kidneys were granular.

Susan Wood, Reg. no. 19. Post-mortem, Jan. 16, 1883.

44. Part of a large multilocular cystic growth of the ovary, removed by Mr. Treves.

45. A uterus and appendages, showing a loculated dermoid cyst of the right ovary. There are some scattered hairs attached to inner surface of the cyst, and small tufts of them projecting from pits which stud the surface of wart-like elevations on a thick trabecular ridge connected with a thick part of its walls. The cyst was filled with soft fatty substance in which a number of loose hairs were imbedded. The proximal end of the Fallopian tubes are enlarged, giving the uterus a horned appearance. In its cavity is a polypoid growth attached to its posterior wall near the os internum.

From a woman aged 58, who died from erysipelas of the leg. There was also a large cyst in the pia mater in left sylvian fissure, causing great deformity of the brain without evidence of interference with its function. (See Series VI.)

Maria Mansfield. Autopsy, Dec. 31, 1883. Mr. Adams.

### Secondary Cysts.

46. A large cyst from the peritoneum, with portions of the pancreas and duodenum, from a case of hydatids in the liver and peritoneum. It is as large as a cocoanut, and was occupied by a parent hydatid (shown in the preparation), with numerous secondary cysts within it. It was covered with peritoneum over the greater part of its surface. Its inner surface is rough and uneven with the varying thickness of its walls. There are a few smaller cysts on its surface. It was attached to the lower border of the pancreas, and pushed forward the stomach, displacing the liver towards the right side.

From a woman aged 45, who died with multiple hydatids of the peritoneum and in the left lobe of the liver. Several cysts suppurated, and one of these opened through the anterior abdominal wall below the umbilicus while the patient was in the hospital. She had been in pretty good health until about two months before admission; she had then begun to lose flesh, and had noticed a swelling about the navel, and other tumours in the abdomen. But after her last confinement, three years previously, she had been told there was something wrong in her abdomen. When admitted the abdomen was distended by a massive tumour connected with the liver and extending down to within a few inches of the pubes. There was a cluster of small cysts under the skin at the umbilicus, and other nodules to be felt beneath the abdominal parietes, giving the case the aspect of malignant disease.

Mary Ann White, Reg. no. 1670. Autopsy, Dec. 24, 1887. Admitted Nov. 29, 1887, under Dr. Turner.



47. A testis with tunica vaginalis and surrounding tissues, from a case of hæmatocele. The testicle, which has been laid open longitudinally, is seen in the wall of a thick fibrous sac as large as an orange, the inner surface of which is roughened throughout by adherent fragments of blood-clot. At the lower part of the specimen the inner part of the wall of the sac has been separated for some distance, apparently by extravasation of blood into the wall of the sac. The wall of the sac is  $\frac{1}{8}$  inch thick and of a dense fibrous structure.

Case of William Higgins, aged 17. Excised by Mr. McCarthy, Oct. 1, 1887.

#### **Cysts from Disintegration.**

48. A portion of a large enchondromatous tumour from the thigh, showing a cavity in the centre of the growth formed by degeneration with softening of its structure. The characteristic structure of enchondroma is well shown in the specimen.

### SERIES III.—INJURIES AND REPAIR.

#### Wounds.

Healing incised Wound : 49.  
Injuries to Vessels : 50, 51.

#### Fractures of Bone.

Intra-periosteal : 52, 53.  
Callus : 54.  
Bony union : 55.  
Fibrous union : 56.  
Impacted : 57.  
Fracture of Skull : 58.

#### Foreign Bodies. Calculi. Entozoa.

Foreign Bodies : 59.  
Calculi.  
    Urinary : 60, 61, 62.  
    Biliary : 63, 64, 65.  
Parasites.  
    Hydatids : 65, 66, 67, 68.  
    Tæniæ : 69, 70.  
    Cysticerci : 71, 72.  
    Trichina : 73.

#### Displacement or Twisting of Parts.

Intussusception : 74, 75, 76.  
Hernia : 77, 78.

---

#### Wounds and Contusions.

49. Part of the abdominal wall and of the stomach adherent to it, showing union by first intention of a wound made three days before death, in the preliminary operation for gastrostomy in a case of malignant stricture of the œsophagus. The edges of the wound are firmly united, in part to the peritoneal surface of a fold of the stomach, which was drawn into the wound and retained by a loop of silk. The stomach is adherent to the peritoneal surface of the abdominal wall around the wound, with which it was maintained in contact by three quill-sutures. There are some dark red coagula of extravasated blood in the wall of the stomach.

Case of Ellen Collins, Reg. no. 1056. 1887. Mr. Mansell Moullin.



50. The femoral artery and vein, showing the result of contusion of their walls. Both vessels are laid open longitudinally. The artery is contracted in the centre of the specimen, where it is occluded for about an inch by an adherent coagulum. Immediately above and below the occlusion conical coagula are seen attached to the wall of the vessel. The lower one, which is the smaller, is just above the orifice of the deep femoral branch. The larger coagulum is attached to the wall of the vessel about half an inch above the occluding thrombus, with which it appeared to have been connected. The artery elsewhere appears normal. The inner surface of the vein is roughened, but there is no obstructing thrombus.
51. Part of the femoral artery, to which a silken ligature has been applied just above the origin of the profunda. The vessel is laid open on its inner aspect above and below the ligature, exposing two conical coagula, with their broader ends at the seat of ligature, which extend about an inch in each direction. A portion of the sheath of the vessel is also shown. It is adherent to the vessel anteriorly, where it was incised for the passage of the ligature.

### Fractures.

52. Parts of two adjacent ribs connected by the pleural membranes. Both bones have been fractured. In one there has been a transverse fracture without displacement of the fragments and without laceration of the periosteum or extravasation of blood into it or into the soft parts around. The other bone has been fractured obliquely, and there has been displacement of the fragments in the line of fracture with rupture of the periosteum, and thickening of the tissues around with extravasation of blood into them. The displacement is chiefly parallel to the pleura.
53. The femur of an infant, with a marked rickety bend in the upper third, in which there has been an intraperiosteal (or greenstick) fracture about the middle of the shaft. The periosteum by which the fragments are held in position at the seat of the fracture has been preserved; it has been lacerated at one part, possibly in the preparation of the specimen.
54. Part of the left femur of a child divided longitudinally, showing a transverse fracture of the shaft about the middle. There has been slight displacement of the lower fragment outwards, and considerable development of callus about the seat of fracture. The medullary cavity is filled up with new osseous tissue above and below the



fracture. The condition of rickets is seen at the lines of junction of both epiphyses with the shaft of the bone.

55. The lumbar and lower dorsal vertebræ, showing the effect of fracture of the spine after repair by bony union. The last dorsal and first lumbar vertebræ have been fractured obliquely, with displacement of the upper part downwards, forwards, and to the left, and rotation in the same direction. The lower part of the fracture projects backwards, and appears to have compressed the cauda equina; but there has been less lateral displacement of the vertebra posteriorly. The fracture was comminuted. The parts have been firmly united by bone in their abnormal position.
56. One half of the upper end of a femur in longitudinal section, from a case of intracapsular fracture of the neck. The head of the bone has become reunited by fibrous tissue to the upper end of the shaft, the neck of the bone having been wholly removed.
57. The upper end of a femur divided longitudinally in the axis of the neck, from a case of impacted fracture. There has been a fracture in a situation corresponding with the intertrochanteric lines round the base of the neck of the bone, which has been thrust into the cancellous tissue of the upper end of the shaft and great trochanter.
58. The upper half of a cranium, with the corresponding portion of the brain *in situ*, showing the effects of a blow on the right side of the head. On the right side of the brain (to the left in the specimen) is the upper part of an hæmorrhagic extravasation between the dura mater and the skull, the result of laceration of the middle cerebral artery or of one of its branches on this side from a fracture of the base of skull, the upward extension of which is seen in the specimen. Three lines of fracture are to be seen in the squamous bone, with separation of its connexion with the frontal. On the other side of the specimen is a collection of blood on the surface of the brain, beneath the dura mater, from contusion of the surface of the brain on the left side, the effect of *contre-coup* from the blow received on the right side.

#### Foreign Bodies; Calculi; Parasites.

59. A cæcum with the appendix. The appendix, which is adherent to the outer surface of the cæcum, is perforated about  $1\frac{1}{2}$  inch from its tip, having been almost completely divided by the ulcerative process. The surface of the cæcum at this part is roughened with fibrous adhesions, and just above the perforation is what appears to be part



of the wall of an abscess, from which the appendix has become separated.

60. A kidney from a case of calculous disease of the organ. It is converted into an irregularly loculated sac by dilatation of the pelvis and calices, through the formation of a large calculus of an irregular dumb-bell form and semitranslucent crystalline structure superficially, which is seen at the bottom of the jar containing the preparation. The renal tissue has almost disappeared. There is another smaller calculus of rounded form, and consisting of stratified uric acid, which appears to have rested in a depression on the surface of the large calculus near its larger end.
61. A urinary bladder with the left kidney and ureter. The bladder has been laid open longitudinally ; it is hypertrophied and contracted, and there is a nodulated calculus of the size of a damson and of a brown colour at the neck, where there is a large prostatic abscess. The kidney is much atrophied, the calices and pelvis being dilated and portions of some of the pyramids only remaining. The organ is imbedded in a mass of adipose tissue. The ureter is much dilated and thickened. A piece of quill has been introduced into the urethra.
62. Calculi removed from the bladder.

#### **Uric-Acid Calculus.**

At the top of the specimen are portions of three uric-acid calculi. The central specimen is of large size and irregularly nodulated on the surface. The smaller calculi are smooth. All present the regular stratification and the reddish or pale fawn colour of such calculi.

#### **Oxalate-of-Lime Calculus.** Mulberry Calculus.

The two halves of a typical mulberry calculus, with irregular warty surface. The central part of the calculus is composed of uric acid.

#### **Phosphatic Calculus.**

One half of a calculus, showing the white colour and friability of phosphatic calculi. The edge of the section is nowhere entire ; at the lower part the whole of the phosphatic crust has been separated, uncovering a part of a uric-acid calculus upon which it had been deposited. Within this there is a narrow stratum of the phosphates, the centre of the calculus being composed of oxalate of lime.

#### **Oxalate-of-Lime Calculus.**

One half of a spherical calculus, the surface of which is covered with white crystals of pure oxalate of lime. The nucleus of the



calculus is composed of uric acid, and this is surrounded by a brownish deposit of oxalate of lime, like that in the second specimen (*b*).

These specimens of calculi were removed and presented by Mr. James Adams.

### Biliary Calculi.

63. A portion of the under surface of the liver, with the gall-bladder laid open longitudinally, exposing a mass of small calculi completely filling it. The calculi are faceted from mutual attrition.
64. A portion of a gall-bladder with a number of calculi which were found in it. Near the fundus there is an annular constriction, referable to cicatricial contraction of an ulcer caused by the calculi. The calculi are of a pale fawn-colour, consisting of nearly pure cholesterolin.

### Parasites.

65. A liver, the right lobe of which has been almost wholly destroyed by the formation of three hydatid cysts at its lower surface. Two of these cysts are of large size and communicate freely with each other. There is a fourth cyst at the posterior part of the left lobe. In this case suppuration had occurred in the larger cysts, and the pus with daughter-cysts had found its way into the biliary ducts. At the neck of the gall-bladder is seen a rough and warty spherical calculus, composed of carbonate of lime.

From a woman aged 29, who had suffered from biliary colic with jaundice three years and a half before her death. After two and a half years the jaundice returned, and nine months later the hepatic pains. This became severe at the time of her admission to the Hospital. There was then enlargement with tenderness of the liver, and pyrexia with icterus. She died sixteen days after admission.

Elizabeth A. Callow, 29. Autopsy, Jan. 27, 1881.

66. A portion of the diaphragm on the under surface of which are several cysts from which hydatids were removed. They are immediately beneath the peritoneum, and have well-defined fibrous walls which stand out in the specimen.

From a woman aged 45, who had a large number of hydatid cysts in the left lobe of her liver, and beneath the peritoneum in various parts of the abdominal cavity. See also No. 46.

67. A large parent hydatid cyst, collapsed after separation from the wall of the cavity in the liver, which had been formed in its growth.
68. A number of secondary (or daughter) cysts removed from a parent hydatid cyst, from whose walls they had been developed.
69. *Tænia solium*, armed, or pork tænia.—An entire specimen of the entozoon.



70. *Tænia mediocanellata*, unarmed, or beef tænia; also called *Tænia saginata*, the fat or broad tænia.—An entire specimen. The segments are much thicker and broader in proportion to their length than in the previous specimen. In the ripe segments the closely set and numerous branches of the ovary are conspicuous at one end from their coloured contents. The head and adjacent parts are separated and tied to a piece of blue glass. It is shrivelled by the action of spirit.
71. A piece of "measly pork" invaded by *Cysticerci cellulosa*. It is studded with small cavities, in several of which the *Cysticerci* can be seen. They form vesicles of the size of a pea with clear fluid contents.
72. *Cysticerci tenuicollis*, the *Cysticerci* of Sheep. They show the form of the *Cysticerci* (bladder-tails or bladder-worms) on a larger scale than in the previous specimen. In one specimen the head and neck are seen everted, forming a tail-like appendage to the cyst.

This is the larval form of the *Tænia marginata* of the Dog.

73. A portion of the deltoid muscle, in which encapsulated *Trichinae spirales* are seen as minute elongated bodies of chalk-white colour, with their axes parallel to the muscular fibres, scattered through the tissue.

### Displacements ; Intussusception ; Hernia.

74. The cæcum with the adjacent parts of the colon and ileum, from a case of ileo-cæcal intussusception. The colon and cæcum, which form the outer and intermediate folds of the invagination, have been laid open longitudinally to show the extremity of the ileum forming the central fold. The swollen ileo cæcal valve is seen at the apex of the invaginated bowel, and a piece of glass rod has been passed through it into the ileum. Beside it is seen a large appendix cæci, with the folded mesentery of the two inner folds of the intussusception.

From a man aged 20, who died after an illness of some months with gradually increasing symptoms of intestinal obstruction. (See Trans. Path. Soc. vol. vii. p. 193).

75. Two pieces of small intestine which have become invaginated. They have been laid open to show the relation of the three layers of the invagination.
76. A specimen of two-fold invagination of the intestine.—This consists of one half of a portion of the small intestine divided by a median

longitudinal section, and shows an invagination between 2 and 3 inches in length, with a second invagination of its outer layer in the same direction, making five folds of bowel in the middle of the mass.

77. Part of the anterior abdominal wall adjacent to the inguinal canal, with the spermatic cord and testes and their coverings, dissected to show an old and greatly thickened inguinal hernial sac in front of the upper part of the cord. The sac has been laid open to show a coil of intestine within it, which is partially adherent to its wall. A piece of glass rod has been passed through the opening through which the bowel was protruded. Below the hernial sac is a hydrocele of the spermatic cord (figured by Curling). At the lower end of the specimen is the testis, exposed by laying open its tunica vaginalis.
78. Part of right innominate bone with Poupart's ligament and the lower part of the abdominal wall adjacent, and with the right testis and spermatic cord, dissected to show a small femoral hernial sac and its relations to the surrounding structures. The unopened hernial sac is seen emerging below Poupart's ligament with the femoral vessels on its outer side, and separated from the spermatic cord by the spine of the pubes. At the back of the specimen the orifice of the hernial sac is seen. The sac has been filled with horsehair, some of which has been also introduced into a sacculated protrusion of the peritoneum into the inguinal canal.



## SERIES IV.—NECROSIS AND GANGRENE.

### Necrosis.—Coagulative Necrosis, Caseation, Softening.

- Thrombi in Heart or Vessels: 79, 80, 81.
- Embolic or Thrombic Necrosis: 82, 83.
- Progressive Necrosis (Mycotic): 84, 85.

### Gangrene.

- Mummification: 86, 94.
- Moist Gangrene: 87.

### Removal of Dead parts, and Repair.

- Cicatrisation after absorption: 88.
- Separation of bony Sequestra: 89, 90.
- Encystment: 91, 92.
- Detachment of Eschar: 93.
- Separation of Mortified parts: 94.

---

### Coagulative Necrosis; Caseation; Softening; Spreading Necrosis.

79. Part of a heart with several adherent thrombi in the left ventricle. Some of them have become softened and have discharged their contents into the blood-stream. The ventricle is much hypertrophied and dilated. There was regurgitation through the aortic valve, the curtains of which are thickened and contracted. The left auricle is also hypertrophied. Near the apex of the ventricle is a tract of fibroid degeneration in the myocardium.

From a charwoman aged 41, admitted under Dr. Sutton, on Oct. 18, 1887, suffering with cardiac failure from incompetence of both mitral and aortic valves. Her symptoms dated seven years. No history of rheumatism. The heart was greatly dilated and hypertrophied ( $24\frac{1}{2}$  oz.), with mitral and aortic valves thickened, and the orifice of the latter stenosed by cohesion of the anterior and left posterior curtains. There were infarcts in the lungs and in one kidney, the other kidney being scarred.

Sophia Datchelor, Reg. no. 1434. Autopsy, Dec. 15, 1887.

80. The kidneys from a case of valvular disease of the heart, laid open longitudinally. In one of them a large branch of the renal artery has been opened up in the median section, exposing a coagulum of cylindrical form adherent to its walls near the point at which the vessel was cut across in the hilum, when the organ was removed from the body. This thrombotic clot is about  $\frac{1}{4}$  inch long. Its distal end



is rough, and partially disintegrated and crumbled away. It was decolorized in the recent state, contrasting with the deeply stained endarterium. In a branch of the vessel, lower down in the specimen, and cut across by a transverse section of that half of the organ, is a narrow tract of fibrinous deposit on the endarterium, extending nearly  $\frac{1}{2}$  an inch along the vessel. There are extensive well-defined anæmic tracts and areas on the surface of the kidney at this end and about the middle. In the section of the organ these anæmiated (necrotic) tracts are in great part limited to the border of the cortex, but in places extend in wedge-shaped tracts to occluded arterioles near the hilum. Two of the papillæ exposed in the median section are concealed by a thin capsule of coagulated exudation (fibrin). One of these has been cut across in the transverse section, and the papilla forms an anæmiated area in the pyramid, with defined boundary arching outwards from its root. The other, indicated by a piece of thin glass rod, corresponds with an anæmiated area in the middle of the kidney. The other kidney has at one end a large deeply depressed area of cicatricial contraction with radiating processes, beneath which the corresponding calyx is dilated. The organ otherwise appears normal.

From a carman aged 24, admitted under Dr. Sutton on Sept. 16, 1887, with symptoms of cardiac failure with stenosis and incompetence of the mitral valve and aortic stenosis. No history of rheumatic fever. There was great hypertrophy and dilatation of the right ventricle of the heart, with extreme stenosis of mitral valve, and much thickening of the mitral and tricuspid valves, with granulations of recent endocarditis upon them. There were adherent ante-mortem coagula in the auricular appendages, and a slightly adherent coagulum plugging the left common iliac artery. There was a tract of necrosis in the spleen, with a transverse fissure across the convex surface of that organ.

Cornelius Hurley, aged 24, Reg. no. 1890. Autopsy, Nov. 19, 1887.

81. The femoral vein of one side from a case of pyæmia. A large vessel with thickened walls, bifurcating below, is filled to within about an inch of its upper end by an adherent coagulum, which extends into both its branches. The inner surface of the vessel, where exposed by detachment of part of the clot, is roughened.

The patient died in consequence of osteitis of the femur following a wound. The coagulum in the veins was in part decolorized, in part red.

82. Part of a lung from a case of endocarditis with an infarct of old date at the base, which has become softened in part, and has led to inflammation of the pleura. At the upper part of the specimen is a more recent infarct of well-defined wedge-like form. It is distinguished in the section of the lung, and at its surface, by its greater opacity and dense appearance, and by slight prominence. When recent, it was conspicuous by deep congestion and infiltration with



blood, and by its firmness. At the back of the specimen another similar infarct has been exposed by section. The base of the lung is consolidated (hepatised). The pleura over it is thickened and coated with fibrin. At the base of the lung the section has passed through a large vessel going to the softened infarct, which is seen to be plugged by an ante-mortem coagulum.

From a married woman aged 33, admitted livid and moribund, under Dr. Fenwick on Feb. 6, 1882. There was a history of rheumatic fever two years ago. Her symptoms dated a month back. There was great cardiac dilatation with mitral stenosis and incompetence, recent endocarditis of aortic mitral and tricuspid valves, and pericardial adhesions posteriorly. There were loose fibrinous coagula in the auricles, and adherent coagula in the right auricle. Several infarcts in the right lung, a few in the left lung, and one necrotic mass in the spleen.

Emily Painter, Reg. no. 154. Autopsy, Feb. 7, 1882. See the heart in Series XXV.

83. An enlarged spleen of irregular form from a case of valvular disease of the heart, incised to show several wedge-shaped tracts of necrotic tissue, in parts softened, in its substance. On the right is a characteristic encapsulated necrotic mass with its base at the surface of the organ, at the apex of which is a branch of the splenic artery plugged with a coagulum. On the left of the same section of the specimen is a larger partly broken-down wedge of necrotic tissue, in which thickened and contracted arterioles are seen. On the left of the specimen is a depression of the surface of the organ, at the bottom of which an occluded vessel is seen, probably the result of necrosis and subsequent absorption of the tissue supplied by it.

Case of James Barrett, aged 28. Autopsy, Dec. 20, 1880. See the heart of the same patient, No. 102.

84. The cæcum and part of the colon from a case of tropical dysentery. The greater part of the mucous membrane has been destroyed, exposing the submucous tissue, which is rough and shaggy from shreds of necrotic tissue covering it. In most parts of the specimen the remains of the mucous membrane appear as islands with worm-eaten and undermined edges. At the commencement of the colon, where the destruction has not been quite so great, it still surrounds and separates the denuded areas. Round some of these the mucous membrane is not undermined, but superficially eroded for a considerable distance. The pouch of the cæcum, which is much contracted, has been everted and forms a rounded prominence at the upper part of the specimen. It is completely denuded of mucous membrane. The wall of the bowel is much thickened. In places there were extravasations of blood in the submucous tissue, indicating the severity of the destructive process.

From a Lascar coal-trimmer, aged 45, who was admitted under Dr. Sutton, on



Jan. 26, 1882, with dysentery, and died in two days. With the extensive dysenteric ulceration of large intestine there was an area of necrosis, probably embolic, high up in small intestine. The other viscera were normal.

Maryook Ingesof, Reg. no. 109. Autopsy, Jan. 29, 1882.

85. Part of a heart and aorta, with the left ventricle laid open through the aortic orifice to expose the valve. The right anterior curtain, which is covered by partly disintegrated masses of blood-clot and fibrinous coagulum, has been perforated and in part destroyed by the ulcerative lesion. And the ventricular wall adjacent is superficially eroded and roughened with fibrinous deposits, over a defined area with elevated margin corresponding with the range of contact with the vegetations on the valve. The other curtains are thick and fibrous. The left anterior curtain is roughened over its area of contact with the right anterior curtain, and slightly on its aortic surface. There is an opening in the septum below the valve (? congenital), the wall of which is also roughened with fibrinous deposits. The orifice in the right ventricle is surrounded by a projecting ring,  $\frac{1}{3}$  inch high towards the tricuspid valve, in which there is a spot of superficial erosion. In the aorta there is a circumscribed elevated atheromatous area contiguous to the valve, and another similar area of the size of a florin in the arch. On the former there is a small patch of superficial ulceration.

### Gangrene.

86. A foot removed by amputation through the lower end of the leg for gangrene of the toes. The fourth and fifth toes and the corresponding part of the dorsum and outer border of the foot, as far back as the astragalus, are discoloured and slightly shrunken. There is a second gangrenous patch upon the inner side of the heel, which is partially separated at one part. The discoloured areas are well defined, the skin over them is smooth, that around being corrugated. The gangrene is attributable to obstruction of branches of the tibial arteries.
87. The outer portion of the lower lobe of the right lung. The whole of the section, excepting a tract along the base and along the anterior border, is occupied by a large area of gangrene in which the tissue is softened and broken down. The area of gangrene is defined and of rounded outline. Posteriorly it is bounded by the pleura, which is coated with lymph both on the outer and under surface of the lung. The pulmonary tissue is condensed and homogeneous, but not granular.

From a butcher aged 28, a heavy drinker. He had been ill a month when



admitted, with signs of consolidation of the base of the right lung and foetor of breath. Symptoms of delirium tremens appeared, and he died three days after admission.

Francis Crawley, Reg. no. 5. Admitted Jan. 2, 1888. Autopsy, Jan. 6 (Dr. Sutton).

### Removal of Dead Parts, and Repair.

88. A kidney from a case of heart disease with depressed areas of fibroid degeneration, from which deep fissures extend in a radiating manner into the surrounding parts, showing the result of cicatrisation following destruction of tissue by vascular obstruction, probably embolic. The surface of the organ generally is smooth, and the structure normal in appearance.

From a man aged 55, admitted under Sir A. Clark, on Jan. 28, 1881, with symptoms of cardiac failure dating about five weeks. There was a history of rheumatic fever in 1854 and of shortness of breath for ten years. He had irregular cardiac action with systolic mitral bruit, much dyspnoea with hæmoptysis, and oedema of legs. The autopsy showed an hypertrophied heart with button-hole mitral valve fringed with vegetations, and pulmonary apoplexy. Both kidneys were much scarred and fissured.

Wm. Loader, Reg. no. 114. Autopsy, Feb. 8, 1881.

89. Section of the upper third of the tibia of an adult, probably young, showing necrosis of a considerable fragment on the inner side of its head just below the level of its epiphysis. The fragment is an inch and a half long, and at its upper part half an inch in thickness. The specimen is injected, and the vascularity of the parts adjacent to the sequestrum is well shown. A large sinus passes down through the skin and soft parts. The adjacent bone is condensed, and there is considerable subperiosteal deposit in the shaft for 2 inches lower down. It would appear that the abscess extended upwards beneath the periosteum and involved the knee-joint. The disease followed a blow with a stick.
90. A portion of a cranium, apparently part of a parietal bone. On one side the sutural dentations are seen, but over the rest of the circumference the fragment of bone has been completely separated, the edges being eroded and irregular. The outer table has been in greatest part removed, the outer surface of the bone presenting a very uneven worm-eaten appearance. The inner table has been absorbed in places by inflammatory growth from without, but its general surface is quite smooth. The fragment of bone has been trephined, probably to allow of the escape of pus collected beneath the partially detached sequestrum.



91. Two kidneys from the same subject. In one organ the renal tissue has been completely destroyed, and the organ has been converted into a series of sacs corresponding to the component pyramids, which were filled with curdy caseous matter. Most of these had become fused in the form of one loculated cavity laid open by a longitudinal section of the organ. One closed cavity remains unopened. The other kidney is rather larger than normal; its surface is fissured and irregular from numerous depressions, and the pelvis and calices are dilated.

92. Portions of the adrenals of a man aged 56, who died with Addison's disease. Both organs are much enlarged. The normal tissue has been replaced in each organ by a mass of opaque yellowish substance, which is firm and smooth in section, surrounded by a thick fibrous capsule, which indicates the outline of the organs. In one organ the caseous substance is broken down in the centre, and there is a calcareous plate imbedded in it.

From a labourer aged 56, admitted under Dr. Sutton on Oct. 22, 1878, suffering from Addison's disease. He was in a very feeble state, and died the fourth day after admission. There were miliary tubercles in the lungs.

James Hagen, Reg. no. 1164. Autopsy, Oct. 18, 1878.

93. A stomach inverted, and showing a small eroded area of the mucous membrane of the size of a three-penny piece in the lesser curvature. A branch of the coronary artery is exposed in the floor of the ulcer, and a bristle has been introduced into it from the trunk of the vessel and passed through an aperture in its walls where laid bare. There is no thickening of the tissues round the ulcer, which appears to be of quite recent formation, probably by necrosis of mucous membrane from plugging of a small branch of the eroded vessel.

94. A leg and foot amputated in the upper third of the leg for gangrene of the foot and ankle. Nearly the whole of the soft parts have been separated by the natural processes, the soft tissues of the dead part appearing to have been cut through in a horizontal plane about 2 inches from the end of the tibia. The tibia is exposed on its inner and outer aspects at this level, and for an inch above it along the spine. The fibula is also bare on its inner and outer surfaces at the same level. The tendo Achillis was in process of separation about an inch higher up, the line of detachment being indicated by softening and separation of the fibrous bands. The tendon of the extensor longus hallucis, also exposed, was in process of separation at a lower level. The border of the healthy skin is about 3 inches above the dead part on the inner side of the limb, and  $1\frac{1}{2}$  inches above it on



the outer side; and below it the bones with the living soft tissues covering them form a conical stump with granulating surface. The arteries have been dissected out and laid open down to their termination in the cone. In the posterior tibial a plug of fibrin is seen at the closed end of the vessel. The walls of the vessel appear healthy. The leg and foot are denuded of cuticle, with which the nails have disappeared. On the inside of the ankle the cutis is also removed, and it is superficially eroded on the dorsum of the foot at the base of the great toe. The under surface of the great toe is much discoloured, and two lacerated wounds extend across the pulp, in one of which a small piece of glass is partially imbedded.

## SERIES V.—INFLAMMATION AND ITS RESULTS.

### Inflammatory Lesions.

#### Exudation.

Fibrinous, Coagulable: 95-99.

Purulent: 100.

Connective Tissue new Growth: 101-103.

Inflammation with Necrosis of Tissues: 104-108.

Abscess: 109-112.

Separation of Sequestrum: 113.

### Reparative Processes and Sclerosis consecutive to Inflammation.

#### Adhesion of Parts.

Of Serous surfaces: 114-116.

Ankylosis of Joints: 117, 118.

Valvular Stenosis: 119.

Cirrhosis, Sclerosis, Contraction: 120-123.

After Necrosis and separation of Dead parts.

Encapsulation; 124.

Cavity, sinus, or fistula: 124.

### Degenerative Changes in Inflammatory Products.

Coagulative Necrosis of Exudation: 125.

Caseation and Cretification of Tissue: 124.

Calcification of Inflammatory growth: 126.

Uratic deposit: 127.

### Changes in Form or Structure of Parts due to Inflammatory Lesions.

Dilatation of Bulging: 128, 129.

Contraction, with thickening and induration: 130, 131.

Fibrillation in chronic Rheumatic Arthritis: 132.

Ulceration: 133.

---

## Inflammation.

### Inflammatory Exudation.

95. Part of a heart with the pericardium covered with flocculent masses of lymph, some of them club-shaped masses nearly an inch in length. They are most closely-set and longest near the sulcus. The auricular surface is in part thinly coated. The pericardium is seen to be much thickened in the section of the ventricular wall.

From a dairyman aged 18, who was admitted Sept. 28, 1887, under Dr. Sansom, for empyema on left side, with symptoms dating from an acute onset six weeks



before, and died Oct. 14. There was a collection of pus in the anterior mediastinum, as well as in the left pleural cavity, and much effusion in the pericardium. Morgan Jones, Reg. no. 1457. Autopsy, Oct. 15, 1887.

96. Part of a lung from a case of acute lobar pneumonia, with the lower lobe in the condition of red hepatisation. The consolidated tissue is well defined and slightly prominent. It is opaque and dense looking, and granular in section. Coagula are seen plugging several of the vessels, and shreds of mucus project from the bronchioles. There is lymph on the surface of the lung, most abundant at the base. The boundary between the consolidated and still spongy lung-tissue is defined, and follows the lines of interlobular septa.

97. A kidney from a case of intratubular nephritis, or large white kidney. It is enlarged by swelling of its excretory epithelium and by distention of the tubules by coagulated exudation. The cortical tissue is much swelled. The surface is smooth and stippled with points of denser opacity, where the fatty degeneration of epithelial cells and exudation is most advanced.

98. The anterior half of a femur affected with acute osteomyelitis. The cancellous tissue at both extremities is occupied in patches, which have become confluent towards the medullary canal, by opaque material—inflammatory exudation—which quite obscures the structure. The inflammatory lesion is limited above by the epiphysal line, but the lower epiphysis is involved. In the medullary canal is a quantity of opaque coagulated exudation, with spaces in which it has softened down. The compact bone of the shaft and the articular surfaces of the bones appear normal. There are some bony nodules on the surface of the bone along the inner aspect of the shaft.

From a fireman aged 28, who was admitted, under Mr. James Adams, on Sept. 14, 1881, with acute periostitis of the thigh. The limb was incised, and an abscess opened, but he died with symptoms of tetanus. There was suppuration of the knee-joint, and cellulitis of the thigh extending from the knee to the pelvis.

Benjamin Atkinson, Reg. no. 1855. Autopsy, Sept. 20, 1881.

99. The left humerus of a young subject from a case of acute osteomyelitis following compound fracture of the shaft, divided longitudinally. There is a dentated fracture in the middle of the shaft, and the medullary canal for some distance above and below is filled with inflammatory exudation, which has softened down in parts. The periosteum is thickened near the seat of fracture.

100. Part of the dura mater from a case of traumatic erysipelas of the scalp and face with suppuration of the subcutaneous tissue. Over the anterior part of the longitudinal sinus, and just in front of the coronal suture, the outer surface of the dura mater is covered with



puriform lymph for a space of the size of a florin. At this part there was a circumscribed collection of pus between the membrane and the bone, the under surface of which was slightly roughened by adherent shreds of lymph. The longitudinal sinus, which is laid open, was quite pervious. The pia mater was normal.

Case of Charles Mitchell, aged 28. Admitted Jan. 26, 1888. Autopsy, Jan. 31. Mr. Tay.

### **Inflammatory New-formation of Connective Tissue.**

101. The commencement of the aorta with the aortic valve and a portion of the ventricle. On each valvular curtain there is a crescentic ridge of clustered granulations (capped with fibrin) developed from the connective tissue of the valves along the boundary of their lunated borders, the parts which are brought forcibly in contact when the valve is made tense by the impulse of the reflux of the blood-wave in the arch of the aorta.

From a case of recent endocarditis in a girl aged 16.

102. A heart with massive "vegetations," covering the ventricular surface of the aortic curtains and of the contiguous flap of the mitral valve, and the wall of the ventricle between them. The masses, which consist of fibrinous coagula upon outgrowths from the connective tissue of the valves, hang downwards from their attachments. The infective character of the lesion is shown by its limitation to parts into contact with which the thrombotic masses on the aortic valve must have been brought by the blood. It has not assumed the destructive character of the severer forms of endocarditis (v. no. 85), though probably a milder development, or earlier stage, of the same disease. The aortic curtains are thickened from old disease. The mitral curtains are also thickened, and their borders adherent, forming a ring round the valvular opening, but without notable stenosis of it. There has been some hypertrophy and dilatation of the ventricle. The aorta is healthy, excepting at two spots within reach of the diseased valvular curtains.

From a man aged 28, admitted under Mr. Couper on Oct. 27, 1880, with endocarditis and an aneurism of the art. profunda femoris. There was a history of a recent attack of acute rheumatism and of the formation of a swelling in the thigh five weeks before admission. The aneurism was cured by digital compression, but the pyrexia continued, and the popliteal and brachial arteries on the right side became plugged. The patient died Dec. 25. There were infarcts in the spleen and kidneys, and a thrombus also in the left posterior tibial artery.

James Barret, Reg. no. 1953. Autopsy, Dec. 26, 1880. See the spleen, No. 83, and the aneurism, Series XXVI.

103. A portion of a cirrhotic liver with nodulated (hob-nailed) surface.



In the cut surface the lobulation is very distinct, and there are broad tracts of gelatinous-looking interstitial tissue traversing it in many parts. Thin sections show, under the microscope, much fibrous thickening with nuclear infiltration and proliferation of the connective tissue in the portal tracts. (Interstitial hepatitis.)

#### **Inflammation with Necrosis of Tissue.**

104. The knee-joint from a case of suppurative arthritis, laid open from before. (Injected.)—The articular cartilages are extensively eroded, and in places wholly removed. On the outer articular facette of the tibia injected vascular tufts are seen projecting through the eroded cartilage, and the corresponding surface of the outer condyle of the femur is much eroded. On the inner condyle of the femur are two areas of erosion and partial denudation from contact with the tibia and the patella. The injection of the specimen shows the great vascularity of the soft parts, and a transverse incision into them below the patella shows the swelling of the synovial membrane and of the tissues around the joint.
105. Contiguous portions of the tibia, fibula, and femur, with the patella, from a case of suppuration in the knee-joint secondary to necrosis in the tibia in a child. There is extensive erosion of cartilage with denudation of the articular ends of the bones. The femur and tibia have been divided longitudinally. In the upper end of the latter is a cavity with smooth walls communicating with the joint. The cancellous tissue round the cavity is condensed, showing that it was not of recent formation, and that the arthritis was subsequent and secondary to it. The cavity has another opening on the anterior surface of the tibia near the tuberosity. There has been a formation of new bone on the front of the tibia about this opening and extending down the shaft for between two and three inches. The new bone is compact on the surface, cancellous below, showing that this sinus was of old date. There is a shell of similar new bone upon the femur. The periosteum has been separated from both bones, the surfaces of which are bare and rough. On the femur are some bony excrescences. These lesions are evidence of necrosis with chronic periostitis of old date, and recent destructive arthritis with acute periostitis secondary to it.
106. A femur, with the periosteum and tissues connected with it, from a case of acute periostitis. The periosteum has been separated from the shaft throughout by a collection of pus beneath it. The periosteum has been perforated, and collections of pus have been formed in spaces between its outer surface and the muscles.



From a girl aged 14, admitted Jan. 17, 1882, with acute suppurative periostitis of the lower end of the femur, attributed to an injury a week before. Pus was evacuated by an incision into the thigh, but she died two days after admission from pyæmia. Miliary abscesses were found in the lungs, heart, spleen, and kidneys, and extravasation of blood in the pia mater, with softening of the brain-substance. There was recent pericarditis and pleurisy, and suppuration in the knee-joint.

Jenny A. Stafford, Reg. no. 46. Autopsy, Jan. 20, 1882.

107. Part of a liver with several irregular cavities formed by softening of the centres of areas of inflammatory infiltration and necrosis, distinguishable in the section by a greater opacity. At one part several of these have coalesced, and formed a large mass of irregular outline, with a central cavity of corresponding form. Some branches of the portal vein are seen to be occupied by coagula, indicating the cause of necrosis and softening by blocking of small branches of this vessel by infective thrombi detached from a septic phlebitis in some of the chylo-poretic viscera.
108. The urinary organs of a boy the subject of vesical calculus. One kidney is wholly atrophic and contracted to the size of a walnut. The other kidney is enlarged, and shows in section several small areas of softening in clusters at the surface, with tracts of softening running inwards to the pyramids (ascending suppurative nephritis). The calices and pelvis of the kidney are dilated and the mucous membrane thickened, and in places roughened with lymph. The ureters are dilated and thickened. The bladder is much hypertrophied and contracted. The membrane is thickened and rough; at the neck is a large ulcer, caused by a calculus.

#### **Abscess; Separation of Sequestrum.**

109. A urinary bladder with part of the urethra from a case of stricture with prostatic abscess and perineal fistula, laid open from before. There is an ulcer of the mucous membrane of the first part of the urethra extending from the stricture to the neck of the bladder. At the upper end of the ulcer is an opening which communicates with an abscess occupying the left lobe of the prostate. The right lobe is also occupied by an abscess-cavity, which appeared to have no communication with the other or with the urethra. Near the anterior border of the ulcer is another perforation of the wall of the urethra leading into a perineal sinus in front of the prostate. The wall of the urethra and the tissues around are thickened and fibrous at this part. The bladder is greatly hypertrophied.
110. Part of the brain and calvarium, showing an abscess-cavity in the former with thick walls and smooth lining membrane. A hernia



cerebri projects through an opening in the calvarium made by the trephine and removal of a portion of bone. The abscess-cavity is chambered somewhat, and communicated with the ventricle. It contained about 3 ounces of pus.

From a youth aged 18, admitted four days after simple depressed fracture of the skull by a fall from a mast-head. He died three weeks after admission, having become hemiplegic on the right side fourteen days before. Some return of consciousness occurred after trephining.

111. Part of a liver laid open through an abscess-cavity in its substance. The cavity has a well-defined fibrous wall with smooth lining membrane, which is coated with fibrinous deposit. It has pouch-like extension to the upper surface of the liver, where it has perforated the capsule, which is there thickened and rough from fibrous adhesions. There is also much fibrous thickening of the hepatic tissue below the cavity. At the back of the specimen is a smaller cavity with smooth fibrous walls, and fibrous induration of the tissues adjacent: an old and arrested abscess. Probably associated with dysentery.
112. A part of the vertebral column showing caries with angular curvature, about the middle of the dorsal region. In front of the spine there is a large abscess-cavity, round which a thick fibrous wall has been formed. It extends over the whole of the dorsal region, and has been laid open throughout. The body of one vertebra with the cartilage below it has entirely gone, and the bodies of the dorsal vertebræ above and below are all more or less eroded on their surface. The arches of the vertebræ have been removed at the back of the specimen, exposing the spinal canal, which has been perforated at the seat of caries.
113. The upper part of the tibia of a young subject, showing separation of superficial sequestra after inflammation. There has been necrosis of the surface of the upper third of the shaft, portions of which are seen with smooth bare surface and worm-eaten edges, surrounded and in part imbedded in projecting outgrowths of spongy bone of recent formation. Beneath the sequestra portions of the shaft of the bone are seen, with which the dead bone is in parts connected. The compact osseous tissue has become porous, and the upper end of the bone has been changed into a soft sponge-like mass of soft cancellous tissue, traversed by wide sinuous channels in all directions. At the lower part of the specimen the shaft of the bone appears normal.



**Reparative Processes consecutive to Inflammation.****Adhesion ; Cirrhosis ; Sclerosis.**

114. A portion of a heart from a case of rather recent pericarditis. There are adhesions of recent formation between the left auricular appendage and the wall of the left ventricle. The pericardial sac was adherent throughout, but separable without difficulty. The exposed visceral pericardium was deeply injected, but there was no lymph upon it nor any exudation between the surfaces.

Case of George Harris, aged 19. Admitted Jan. 23, 1888. Autopsy, Jan. 28. Dr. Stephen Mackenzie.

115. A piece of lung with part of a rib connected together by loose filamentous adhesions between the pleural surfaces.
116. Two testes, with their tunicae vaginales, laid open longitudinally, showing the result of injection of iodine in the treatment of hydrocele. In one specimen delicate fibrous adhesions have been formed between the serous surfaces, and are seen drawn out by a partial separation of them. In the other specimen the effect of severe and more prolonged irritation of the structures is seen. A broad tract of cicatricial fibrous tissue separates the two surfaces of the tunica throughout, and forms a larger mass above the testis. The tunica albuginea is much thickened, and the testis is smaller than the other, probably atrophied from compression. Both testes appear healthy in structure.
117. A knee-joint divided longitudinally in an antero-posterior plane. The bones are united at an obtuse angle by fibrous tissue, the synovial sac being closed and the contiguous parts of the articular cartilages absorbed. The osseous tissue has a spongy appearance, and was readily cut with a knife. Above is the lower end of the shaft of the femur, which was fractured immediately above the condyle in straightening the limb after death. It consists of spongy cancellous tissue with a thin shell of compact bone.
- From a youth aged 16, who had ankylosis of both hips and knees, said to have resulted from an attack of acute rheumatism.
118. The os calcis and astragalus divided in a median antero-posterior plane. There is bony union between them at the anterior and posterior parts of the articular surfaces. In the middle the articular lamellæ of both bones are entire. At the anterior part the medium of ankylosis is of ivory density. There is a less degree of the same change at the posterior end of the articulation and at other parts of the bones. The osseous trabeculæ are thickened throughout, and the structure coarse. In the centre of each bone is a tract in which the



alveolar spaces are occupied by a residuum of fat from imperfect maceration.

119. A heart showing fibrous thickening with stenosis of the mitral, tricuspid, and aortic valves. The tricuspid orifice is of the "button-hole" form, an aperture in the flat membrane formed by the adherent curtains. The mitral valve is of a conical form. The aortic curtains are much thickened and adherent, the orifice being little larger than a cedar pencil and of a rounded triangular shape. Both auricles are dilated.

From a nursemaid aged 29, admitted, under Dr. Fenwick, Feb. 19, 1880, suffering from dyspnoea and palpitation due to valvular heart-disease. She had had three attacks of acute rheumatism.

At the autopsy the aortic, mitral, and tricuspid valves were all found to be incompetent. There were no infarcts in the viscera.

Emma Cole, Reg. no. 187. Autopsy, March 5, 1880.

120. A pair of granular and contracted kidneys. Both organs are much reduced in size. One is only an inch and a half in length. In the longitudinal sections of the organs the cortical tissue is seen to be very narrow. The larger kidney is irregularly contracted. In parts there is extreme atrophy with depression of the surface. In the more prominent parts the contraction of the cortex is less considerable.

121. A cirrhotic liver with an unevenly nodulated and granular surface. The organ is much contracted, and its anterior edge is thickened and rounded. In a section of the organ, made at the upper surface, the interlobular tracts of connective tissue appear as a semi-translucent network.

From a shoemaker aged 65, with a history of alcoholism, admitted into hospital Oct. 5, 1880, with ascites and oedema of legs, and a purpuric eruption. He had also bronchitis and emphysema, and atheroma of the valves of heart.

James Butler, Reg. no. 1111. Autopsy, Feb. 19, 1881.

122. Part of a lung showing contraction with fibrous induration of the apex, and tracts of pigmented fibrous tissue in other parts. The apex is traversed by strands of fibrous tissue. In another portion of it, also shown in the preparation, two cavities are seen surrounded by deeply pigmented fibrous tissue. The pleura is much thickened, especially at the apex of the lung and rough from old fibrous adhesions. The lung is emphysematous.

From a man aged 54, who was admitted after being run over, and died next day from faecal extravasation through rupture of the bowel in the floor of an ulcer with rounded margin. There were other similar ulcers in the duodenum not perforated. The lower ribs on the left side were fractured (eighth to twelfth), and the pleura lacerated.

Joseph Colls, Reg. no. 2464. Autopsy, Dec. 2, 1881.



123. Part of a heart with the commencement of the aorta, showing fibrous thickening and contraction of the valvular curtains. The wall of the aorta contiguous to the valve is also much thickened, the area of thickening being bounded by a well-defined crescentic line about an inch from the valve. The opening into the sinuses of Valsalva are much narrowed, and these cavities are contracted. The orifices of the coronary arteries are narrowed, as was especially noticeable in the recent state; and this seemed to account for the condition of fatty degeneration of the myocardium, which was indicated by the characteristic marking of the subendocardial layers of the muscular fibres in both ventricles.

Julia Leigh, aged 40, was admitted under Dr. Gilbert Smith on Jan. 4, 1888, with aortic and mitral regurgitation, and died Jan. 12. There was a history of an attack of rheumatic fever at the age of 14, two years after scarlatina, and two attacks of "rheumatics" since. When 15 she had an attack of shingles, and two years ago symptoms of gastric ulcer. Symptoms of cardiac failure had been complained of for only two months. She had repeated anginose attacks, in one of which she died.

Julia Leigh, Reg. no. 18. Autopsy, Jan. 13, 1888.

#### **After Separation of Necrosed Tissue.**

124. Part of a lung with a large cavity with thick fibrous walls lined by a smooth membrane, into which a large bronchial tube opens directly. The cavity is in part enclosed by greatly thickened pleura, which was adherent to the chest-wall. At the back of the specimen there are some caseous and cretaceous masses enclosed in fibrous capsules. At the root of the lung are some enlarged and much pigmented glands, in part caseous.

#### **Degeneration of Inflammatory Products.**

125. Melon-seed bodies from an inflamed bursa or tendon-sheath. The specimen shows a number of detached masses of coagulated and degenerated fibrin moulded into smooth irregularly oval or rounded disks by mutual attrition and compression in an enclosed space. Sections from one of them examined under the microscope present the cloudy reticulated structure of coagulated fibrinous exudation without any appearance of organization.
126. A heart showing the aortic orifice closed by two curtains adherent together at their ends. Both curtains are much thickened, and nodulated from calcareous deposit in the fibrous tissue. The posterior curtain is the larger, and takes the place of both right and left posterior segments of the valve. There is no ridge to indicate their fusion.

Case of Lehman. Autopsy, April 14, 1882.



127. The metatarso-phalangeal joint of the great toe with the surrounding tissues, from a gouty subject. There is a uratic deposit of the size of a walnut on the inner side of the joint, and smaller deposits of the same kind in the tissues below and to the outer side of it. The articular cartilage does not show evidence of infiltration, the urate having been probably dissolved out by the spirit. A portion of it has been removed for examination.

#### **Changes in Form and Structure due to Inflammatory Lesions.**

128. The first part of the aorta, with part of the arch, laid open along the concavity. There is general dilatation of the vessel, with thickening and rugosity of the inner coat, especially near the aortic valve. Behind the anterior curtain there is an aneurysmal bulging of the sinus of Valsalva, forming a projection of the pericardial surface to the right of the pulmonary artery, at the upper part of which there is a small perforation of the wall of the aneurysm. The descending thoracic aorta is shown at the back of the preparation. It is atheromatous above, but normal in appearance at its lower end.

From a well-developed man aged 42, who was brought to the hospital dead from extravasation of blood into the pericardium. There were no indications of syphilis.

James Butler. Autopsy, Jan. 3, 1888.

129. A heart with an aneurysmal bulging of the wall of the left ventricle close to the left anterior curtain of the aorta, into the sinus above which it has opened. The aneurysm has been laid open by a longitudinal section of the left ventricle parallel to the septum. Its wall is fibrous, and is lined with a thick layer of laminated fibrin with a smooth inner surface. It separates the myocardium from the aorta, having apparently resulted from yielding of the fibrous tissue connecting them, and it has extended upwards between the aorta and its pericardial sheath. (Chronic aneurysm of the heart.)

From a married woman aged 32, who was admitted under Dr. Warner on June 1, 1883, with indications of incompetence and obstruction of both mitral and aortic valves, and died suddenly while getting out of bed. There was no evidence of syphilis, gout, or scrofula. The heart weighed 15 oz. The kidneys were granular, but not contracted.

Emma Spurdon, Reg. no. 703. Autopsy, June 6, 1883.

130. A penis with a portion of the bladder, laid open from before along the urethra, showing a stricture of the urethra with much fibrous thickening of the tissues around, at the posterior end of the corpora cavernosa.

131. The pyloric end of the stomach with part of the duodenum laid



open, showing great fibrous thickening of the walls of the former in the immediate neighbourhood of the orifice, which is much contracted. There is great thickening both of the mucous and of the muscular coat. Microscopic examination of sections from the part shows great fibrous thickening of the gastric wall, with hypertrophy of the muscular layer, but no evidence of malignant growth. The anatomical lesion thus appears to be the result of cicatricial fibrosis of irritative connective-tissue growth from chronic irritation of the mucous membrane at this part, as in cases of chronic ulceration.

132. A knee affected with chronic rheumatic arthritis, laid open, with the patella turned down. The articular surfaces of the condyles of the femur are denuded of cartilage over the areas of contact with the tibia and patella. The corresponding surface of the patella is covered with a velvety layer of abraded and altered cartilage, and a similar degeneration of the cartilage is seen at the margins of the denuded area of the femur. A ridge (or "lip") of new bone has been formed along the outer border of the articular surface of both condyles. On the articular surface of the tibia are three rounded nodules of bone covered with cartilage attached to the upper surface of the internal inter-articular cartilage. Two of these are near the median line, and are about  $\frac{1}{2}$  inch across. The third is on the inner side of the joint, and resembles a small pea.

#### Ulceration.

133. A stomach with a large chronic ulcer in the lesser curvature contiguous to the pylorus. There is much thickening of the gastric wall round the ulcer, the sharply cut edge of which forms an abrupt and in part overhanging wall to it, except towards the pylorus, in which direction there has been extension of the ulceration of recent date. The outline of the ulcer on this side is indented, in the line of the lesser curvature. The wall of the stomach has been completely perforated in the floor of the ulcer. There is much fibrous thickening around the pylorus, with narrowing of the orifice and flexion of the extremity of the stomach, which is adherent to the contiguous part of the lesser curvature.



## SERIES VI.—SPECIFIC DISEASES.

### Tuberculosis.

Miliary tubercle: 134, 135.

Tubercular Disease of Lungs: 136, 137.

    "    "    of the Larynx: 138.

    "    "    of the Intestines: 139.

    "    "    of the Genito-Urinary Organs: 140, 141.

    "    "    of the Brain: 142.

    "    "    of the Lymphatic Gland and Spleen: 143, 144.

### Syphilis.

Gummata.

    In the Liver: 145.

    In the Testis: 146.

Syphilitic Ulceration and Stricture.

    Of the Larynx: 147.

    Of the Rectum: 148.

    Of the Pharynx and Trachea: 149.

Diphtheria: 150, 151.

Typhoid Fever: 152, 153.

### Tuberculosis.

134. Two pieces of a lung (injected) showing disseminated grey tubercle in the section of the tissue and under the pleura. They are larger and more abundant in the section of the smaller piece of lung, where also some of them are seen to be connected with smaller branches of the pulmonary veins. Some of the small bronchioles are much thickened.

135. A lung infiltrated with greyish-white opaque nodules, mostly broncho-pneumonic granulations, in part miliary tubercles. At the surface of the lower lobe is a wedge-shaped caseous nodule at the end of a bronchial tube with thickened walls and softened mucous membrane (caseous). A small pulmonary arteriole beside it is studded with miliary tubercles. At the root of the lung are a number of enlarged and caseous glands, in part softened, which seem to have compressed the descending branch of the main bronchus, but have not caused ulceration of it.

From a servant maid aged 21, who was admitted with albuminaria consecutive to scarlatina, and died 6 weeks later from tubercular meningitis. There were tubercles also on the surface of the liver and spleen, and disseminated through the



latter. Her brother was stated to have died of consumption, and two sisters of cerebral disease. This specimen illustrates the observed association between acute miliary tuberculosis and older caseous deposit in some part, and the occurrence of tuberculosis after a specific fever in those predisposed to the disease, or in whom its seeds are present in a latent state.

Ellen Wheeler. Autopsy, Nov. 10, 1883. Dr. Fenwick.

(See Path. Soc. Trans. vol. xxxv. p. 101.)

136. A portion of the upper part of a lung in section, showing areas of consolidation with caseous degeneration and excavation, and isolated miliary nodules studding the intervening lung-tissue (red in the injected specimen). The smaller caseous areas are seen to be made up of clusters of miliary nodules united by consolidation of the tissue between them. The larger areas are formed by union of these smaller masses, and small cavities have been formed by softening of the caseous tissue. At the apex of the lung (at the bottom of the specimen) there is an extensive tract of consolidation of similar character, surrounding two older cavities with well-defined fibrous walls. These cavities have communications with the bronchial tubes, into which pieces of glass rod have been introduced.

137. The outer half of a right lung divided in a vertical plane, from a case of phthisis of rapid course attended with much destruction of the pulmonary tissue. There are numerous cavities throughout the lung, except at the base posteriorly. Some of them appear to be of older date with well-defined fibrous walls, others contain masses of necrotic tissue or softened caseous matter. In most of these, however, an encapsulating fibrous wall is distinguishable, completely or partially surrounding the necrotic tissue. There are also areas of consolidation at the base of the lung posteriorly, and small isolated nodules the size of a hemp-seed and less, studding the intervening vesicular tissue of the lung, similar to those in last specimen. At the apex is a cluster of lobules, contiguous to two small cavities at the surface of the lung, which are consolidated by fibrinous exudation and granular on section. There is another similarly consolidated lobule contiguous to a larger cavity at its anterior surface, over which the pleura has been perforated. The surface of the lung is covered with a thick layer of lymph, readily separable from it. Several cavities immediately beneath the pleura form elevations upon its surface: one of these has been laid open, exposing a large sinuous cavity with rough necrotic walls.

From a labourer aged 23, admitted under Sir A. Clark, Sept. 10, 1881. His illness dating from 10 weeks before.

Benj. Divers, Reg. no. 1055. Autopsy, Nov. 1, 1881.

138. The larynx with the upper part of the trachea, and the tongue and



fauces, from an adult affected with tubercular ulceration. The vocal cords and the surface of the mucous membrane for half an inch below them are roughened by fibrinous deposit, and at their anterior extremities there has been ulceration with destruction of the mucous membrane. At their posterior ends there has been more extensive destruction, and the arytenoid cartilages have been laid bare, and to a great extent separated from the perichondrium. There has been also some superficial erosion of the mucous membrane on the posterior surface of the epiglottis at its upper part, and some fibrinous deposit lower down.

139. The lower part of the ileum, with the cæcum and part of the colon, showing several ulcers with sharply defined, steeply sloping, elevated edges, and of oval outline, with the long axis transverse to the bowel and surrounding it to a greater or less extent. The ulceration is most extensive at the end of the ileum, and is there seen to have spread over the valve into the cæcum. There are several ulcers also in the ascending colon. The destruction of the intestinal wall has laid bare the peritoneal coat in most of the ulcers, and in two of those near the ileo-cæcal valve perforation has occurred. Where the ulcers have approached the line of attachment of the mesentery, the destruction has been less, and there has been much thickening of the intestinal wall. At two places the thickened bowel has bulged in this line. In the colon the ulcers are some of them circular, and others irregular in form from fusion of two or more. They are less deep than in the ileum, and have not exposed the peritoneum.

From a labourer's wife aged 25, admitted under Sir A. Clark, Dec. 2, 1880, with phthisis. She had been wasting 5 months with diarrhœa. There was no history of phthisis in her family.

Mary Thomas, Reg. no. 1202. Autopsy, Dec. 25, 1880.

140. Tubercular Pyelitis and Nephritis; Nephrophthisis.—One half of a kidney divided longitudinally, with the upper end of the ureter. The mucous membrane of the ureter and pelvis of the kidney is much thickened, and at its surface is a thick layer of friable caseous matter. In most parts the pyramids of the kidney have also been destroyed, excavations with similar thick caseous walls taking their place. At one part of the section the lesion has extended only to the margin of the papilla, the pyramid remaining intact.

141. One half of a testicle affected by tubercular disease, with the tunica vaginalis (injected). The organ has been divided longitudinally, and shows tracts and areas of caseous degeneration throughout the body of the testis and epididymis. In the lower part of the epidid-



dymis the centre of the affected area has been broken down. There is lymph on the serous membrane, which is highly coloured by the injection.

142. Tubercular Tumours in the Brain and Dura Mater.—The dura mater from the calvarium, and a portion of the brain from the surface of one hemisphere. On the inner surface of the dura mater are two sessile tumours of rounded outline and finely nodulated surface. The tumours are both situated posteriorly, one on each side of the falx, that in the left being the further back. At the back of the specimen is one half of a third and larger tumour of similar form, which seems to have been removed from another part of the dura mater. The section of this tumour shows it to be caseous with a crescentic tract of softening. In the piece of brain is another smaller tumour immediately under the surface of the pia mater. An incision has been made into the brain through it. It is seen to have a reniform section, with its outer surface flattened by contact with the calvarium. It is caseous and softened in the centre. It appears to have no connection with the brain-substance, but to be a tumour of the membranes like those above described.

143. The mesentery with part of the ileum from a tubercular child. There is great enlargement with caseous degeneration of the mesenteric glands, shown in the section of one which has been laid open at the back of the specimen. The intestine is also laid open, showing several ulcers of the mucous membrane extending in a transverse direction, and having the character of tubercular ulcers.

From a puny wasted child aged 4, admitted with symptoms of "Tabes Mesenterica."

Emily J. Green, Reg. no. 152. Autopsy, Feb. 25, 1883. Dr. Jackson.

144. An enlarged spleen from a case of tuberculosis in a child aged  $3\frac{1}{2}$ , divided transversely. The surface of the organ, and of an attached spleniculus, is studded with small nodules from the size of a pin's head to that of a hemp-seed. The section of the organ is seen to be studded with similar but larger opaque nodules, and at the left of the section is a large tract of caseous tubercular infiltration.

From a wasted anæmic child aged  $3\frac{1}{2}$ , admitted for empyema under Dr. Hughling Jackson, Aug. 12, 1885. The lungs were studded with firm tubercular nodules. Miliary tubercles were scattered over the surface of the right lung, with some lymph. There was pyo-pneumothorax on the left side. There were some enlarged caseous glands in the mediastinum and behind the pancreas. There were caseous nodules in the kidneys, and a nodule in one adrenal. The skin was dark. (See Kidney, Series XXXIV.)

Matthew Allen, Reg. no. 1090. Autopsy, Aug. 18, 1885.



**Syphilis.**

145. The liver of a woman aged 44, affected with syphilis. It is reduced in size and greatly deformed by contraction of its anterior part, which is seamed by deep fissures, giving the anterior border an irregularly lobulated outline. The left lobe is much contracted. Sections made into the organ show tracts of fibrous tissue extending into its substance from the bottom of the fissures, with masses of caseous tissue imbedded in them. At one part a portion of the surface is converted into a fibrous mass, with similar degenerated areas in it.

Mary A. Smith, aged 44, admitted under Dr. Fenwick, on March 30, 1882, with a nodulated liver and ascites, her illness dating 5 months before admission. A probable history of syphilis 12 years ago was given.

Mary A. Smith, Reg. no. 381. Autopsy, Nov. 30, 1882.

146. Syphilitic Disease of the Testis (injected).—One half of a testicle with the tunica vaginalis divided longitudinally. The section of the organ is in great part occupied by an opaque yellowish caseous mass of firm consistence and of triangular outline, extending backward from a broad base at its free surface to the epididymis. The outline of the mass, into which the injection has not extended, is well-defined, being marked by a line of fuller injection. From the upper and lower borders of the caseous mass processes extend, which have united and enclosed areas of injected testicular tissue. There is slight adhesion between the surfaces of the tunica vaginalis above, and firm fibrous union over a limited area lower down. The epididymis is much thickened and fibrous, but there are no caseous masses in it. The tunica vaginalis is also much thickened and fibrous.

147. A larynx laid open from behind, showing extensive destruction of the left vocal cord and of the tissues adjacent by syphilitic ulceration. The wall of the larynx is deeply excavated, and the cricoid cartilage is exposed. The edges of the ulcerated area, which extends from the upper margin of the sinus to about an inch below the cords, are sharply cut, and in parts everted, but there is little or no thickening of the mucous membrane adjacent. The epiglottis is stunted, and its margin deformed.

148. The rectum with the end of the sigmoid flexure of the colon laid open longitudinally, and showing the result of syphilitic ulceration with stricture of the bowel. The mucous membrane of the rectum has been destroyed by ulceration, excepting an irregular tract extending transversely across the upper part of the denuded area, above



which it is much elevated with sharply cut and partly overhanging borders. On the smooth denuded surface of the rectum are depressions, which are numerous and deeply recessed at the lower part, where the surrounding tissues are much thickened, and the inner surface is traversed by many thick fibrous bands. Around the anus are masses of cutaneous warty growth, and hæmorrhoidal tumours at its margin. The anal orifice is narrow, and the rectum dilated.

149. The trachea and larynx with pharynx, fauces, and part of the tongue of a syphilitic subject. There is much cicatricial fibrous thickening and contraction of the soft palate and fauces, and of the upper part of the pharynx. The passage of the fauces is a tunnel with low arched roof, and the passage from the pharynx to the posterior nares is reduced to an aperture of the size of a goose-quill. The epiglottis is stunted from previous ulceration. The trachea is laid open anteriorly, and shows a wide tract of destructive ulceration extending along its posterior wall from an inch above its bifurcation to the rima glottidis. The edges of the ulcer are sharply defined and everted, and the ends of several rings are exposed in its floor. There is a second ulcer above the mouth of the left bronchus and extending into it.

#### **Diphtheria.**

150. The larynx, trachea, and fauces of a child who died from diphtheria, with membranous bronchitis and broncho-pneumonia. The trachea and vocal cords are covered by membrane, which is partially detached at the lower part. There is membrane also upon the tonsils and uvula. The epiglottis and aryteno-epiglottidean folds are swelled but free from membrane.
151. A portion of one lung from the same case as the last specimen, showing membranous exudation lining the larger bronchi, and traceable into some of their finer ramifications. The section of the lung shows, at the lower part, a patch of consolidation surrounding a part of a bronchial tube, which is filled with coagulated exudation. It is surrounded by spongy lung-tissue, but is irregular in outline and not sharply defined. Other small areas of consolidation are seen in the section, some of them sharply defined by the interlobular septa. At the back of the preparation is a smaller piece of the lung, with a section made in the course of a bronchial tube, showing the gradual disappearance of the membranous exudation in its finer branches.

#### **Typhoid Fever.**

152. The lower part of the ileum and commencement of the colon from a case of typhoid fever, showing swelling of Peyer's patches and



solitary follicles with necrosis and sloughing of the mucous membrane in different stages and varying extent. There are numerous well-defined flat elevations of the mucous membrane, in a few of which no ulceration has occurred; in some a small part only has become necrosed, but in nearly all necrosis of all but a narrow border has occurred, the necrotic area being marked off by a line of ulceration. Many of the necrotic masses are discoloured. In one affected area the slough is in part removed, exposing the serous membrane, and there perforation has occurred. The appearances correspond to the end of the second or beginning of the third week of a severe case of enteric fever.

From a female aged 21, who was admitted Oct. 24, 1883, under Sir A. Clark, with typhoid fever, and died Oct. 29. She had been ailing a fortnight, and six days before admission she had been taken seriously ill, and took to her bed with fever and delirium.

Harriet E. Coates, Reg. no. 1332. Autopsy, Oct. 31, 1883.

153. The last few inches of the ileum, from a case of typhoid fever, showing four defined areas of the mucous membrane in Peyer's patches, which have become necrotic. The mucous membrane at the edges of the necrosed patches is elevated and slightly overhanging, but the swelling of the mucous membrane is less notable than in the previous specimen. The sloughs are becoming separated at their edges. In one area the dead tissue has been in greatest part removed. This specimen shows a later stage of the disease than No. 152.

## SERIES VII.—MORBID GROWTHS.

### Connective-Tissue Tumours.

- Fibroma: 154-157.
- Lipoma: 158, 159.
- Enchondroma: 160.
- Osteoma: 161.
- Glioma: 162.
- Neuroma: 163, 164.
- Myo-fibroma: 165.
- Angeioma: 166.
- Lympho-sarcoma: 167.
- Sarcoma.
  - Myeloid Sarcoma: 168.
  - Round-celled Sarcoma: 169-177.
  - Spindle-celled Sarcoma: 178-180.
  - Ossifying Sarcoma: 181.
  - Melano-sarcoma: 182.
  - Adeno-sarcoma: 183.

### Epithelial Tissue Tumours.

- Papilloma; villous growth: 184, 185.
- Adenoma and Adeno-fibroma: 186-188.
- Carcinoma.
  - Epithelioma; Squamous-celled Carcinoma: 189-193.
  - Cylindrical-celled Carcinoma: 194-196.
  - Spheroidal-celled Carcinoma; Scirrhus and Medullary Cancer: 197-200.
  - Mucoid or Colloid metamorphosis of Carcinoma; Colloid Cancer: 198, 201.

---

### Connective-Tissue Tumours.

#### Fibroma.

154. The specimen shows a cluster of fibrous tumours connected together by fibrous bands, from the labium majus. Some have been cut across to show their structure, consisting of interlacing strands of dense and compact fibrous tissue. They are of very various size, the largest being about the size of a plover's egg. They are rounded in outline and ovoid, some lobulated, and in places indented by mutual pressure.
155. A slightly lobulated tumour somewhat larger than a fist, dense and fibrous in structure. It is well circumscribed and has a fibrous capsule. Sections of the growth show a dense fibrous structure with interwoven strands, with some elongated fusiform nuclei amongst the



fibrous bands, more numerous in parts of the section.—A fibromatous or fibro-sarcomatous growth.

Removed from the umbilicus of a lady aged 85, on account of the rapidity of its increase. The peritoneum was opened in the operation, and the patient died from peritonitis. (Old Catalogue.)

156. A portion of a lung with a dendritic outgrowth from its serous surface (near its lower border), having the appearance and the firmness and elasticity of cartilage. Thin sections show a compact laminated structure of dense, fibrous tissue.—Lamellar fibroma.

157. One half of a spherical body of similar structure, from a serous cavity; the centre is calcified.

#### **Lipoma.**

158. A large lipoma from the subcutaneous tissue of the back. The specimen has been dissected to show the lobulated character of the growth.

159. A lobulated fatty tumour of elongated form, and as large as a child's fist. The interest of the specimen consists in the fact that it was placed directly over the inguinal ring and simulated a hernia.

The patient was a young woman. It was excised by Mr. Maunder. See London Hospital Reports, vol. ii.

#### **Enchondroma.**

160. A finger with the second phalanx expanded into a globular mass of cartilaginous tissue. It has been divided longitudinally in an antero-posterior plane passing through the distal, but to one side of the proximal phalangeal joint. The distal articular cartilage is entire, and for half an inch the outline of the shaft of the bone is distinguishable in the axis of the growth with the periosteum covering it. The remainder of the shaft has been invaded and in greatest part destroyed by the growth. The section passes through the head of the metacarpal bone, and the medullary cavity is seen to be filled by the growth, which has also pierced the wall of the shaft posteriorly just above the joint and has formed an elevation on the surface of the bone there.

#### **Osteoma.**

161. An exostosis which grew from the inner border of the right tibia about 2 inches below the knee-joint.

Removed from a boy, aged 16, by Mr. Rivington. It had been first noticed four years previously, when it was about as big as a marble. It had grown more rapidly during the last six months.

Case of John Devial. Operation May 11, 1886.

#### **Glioma.**

162. A cerebellum with pons varolii and medulla oblongata. There is



a growth in the cerebellum, which has developed in the inferior part of the right lobe near its internal border, and projects into the median fissure. The left lobe has been compressed and displaced to the left. A section through the growth shows that it has no definite limitation, but seems to form a part of the white matter. The anterior part of the growth projects into the fourth ventricle, and probably pressed upon the medulla oblongata. It is at this part free and nodulated; posteriorly it is covered by nerve-tissue. Thin sections of the growth show a gliomatous structure.

### **Neuroma; Pseudo-Neuroma.**

163. Three nodulated tumours removed from the arm in the course of the ulnar nerve. The largest is of elongated form and rounded outline, resembling a good-sized potato, with a longitudinal groove down one side. At the lower part a bundle of enlarged nerve-trunks emerge from the mass. A much smaller fasciculus of nerves is seen entering the mass in the upper part of the longitudinal groove. The second tumour is about one fourth the size of the first, and of very irregular form and much nodulated: a cluster of four thick nerves are seen entering the upper end of it. The third tumour is no larger than a nut, and of an irregularly triangular form, one nerve entering above and two emerging below. Thin sections from one of the growths exhibit a fasciculated sarcomatous structure.

164. Amputational Neuromata.—A stump after amputation of the leg in the upper third, with the vessels and nerves dissected out. There are fusiform enlargements at the extremities of several branches of both internal and external popliteal nerves where divided in the operation. A part of the largest, which is of the size of an almond, has been removed for microscopical examination. Sections of this have a dense fibrous structure in which no nerve elements are distinguishable, showing it to be a fibroma or pseudo-neuroma.

### **Myo-fibroma.**

165. A uterus with its appendages. On the anterior wall of the uterus is a fibro-myomatous tumour as large as an orange, with its centre at the level of the cervix. Above it is a smaller growth of the size of a walnut. Both have been divided in half to show the structure of the growth. There are some other smaller nodular growths projecting under the peritoneum.

See also No. 32.

### **Angeioma.**

166. The finger of a child (injected) with the epidermis and nail removed, showing an extensive subcutaneous vascular nævus occupying the two distal divisions of the finger.



**Lympho.-Sarcoma.**

167. Lympho-sarcomatous growth in the forearm (injected).—The right forearm and hand with the muscles and tendons dissected. On the radial side of the forearm, and extending over the lower half of it, is a defined lobulated growth, forming a projection of the size of half an orange just above the wrist, and extending deeply amongst the muscles and tendons, which it surrounds and along some of which it has extended. The external surface of the growth is nodulated. It is of firm consistence. Sections of it show round cells in a reticulum supported by interlacing fibrous strands.

**Sarcoma: Myeloid Sarcoma.**

168. The outer half of the upper end of a tibia. The head of the bone is expanded, and the cancellous tissue entirely absorbed by a soft myeloid sarcomatous growth, the compact tissue of the wall of the bone being reduced to a thin shell, in great part membranous. The articular cartilage has not been invaded. The external wall of the compact bone of the shaft below is entire, but the inner wall has been eroded by the growth for a short distance. The growth was of a highly vascular character, and of a deep claret-colour when recent. It has shrunk in the spirit.

It was removed by Mr. McCarthy from a young woman aged 25. She had complained of pain in the knee for four months. There was a fluctuating and pulsating swelling of the head of the bone, and myeloid cells were seen in blood withdrawn from it. At the operation the growth was found to have extended along the crucial ligaments to the femur, part of which was removed. She died twelve days after the operation, apparently from exhaustion. No secondary growths were found in the viscera at the autopsy. (See *Trans. Path. Soc.* vol. xxxii. p. 208.)

**Round-celled Sarcoma.**

169. The upper arm of a young subject greatly enlarged by a subperiosteal sarcomatous growth around the humerus. It has been laid open longitudinally on its inner side through the growth, which consists of two different structures—the inner part surrounding the bone very soft and highly vascular, as shown by the injection of the specimen, and the outer part, in or external to the periosteum, of firmer consistence, the two being separated by a fibrous membrane, which appears to be the displaced periosteum. The periosteum has been separated from the shaft of the bone throughout its whole extent by the soft growth, in which the bone is seen imbedded with its surface roughened by erosion. There has been a transverse fracture about the middle of the shaft without displacement of the fragments. The growth from the outer surface of the periosteum is thickest at the lower part of the section; it ceases above about  $1\frac{1}{2}$  inches from the neck of the bone.



170. One half of the upper end of a femur divided longitudinally through the axis of the neck of the bone. The upper part of the shaft is involved in a mass of malignant growth, in which its outline is lost. Isolated crescentic tracts of bony tissue with defined outline on their convex side are seen imbedded in the mass, and these form a continuous tract along the inner border of the section for a short distance, in continuity with the shaft of the bone. The growth has invaded the cancellous tissue of the trochanter major and head of bone without altering the natural outline of the latter, but the trochanter is expanded. It has also extended down the central canal of the shaft below the expanded part, where the natural form of the bone is still maintained. The compact osseous tissue of the shaft at this part has a normal appearance, and is of natural thickness in part, but has been extensively excavated by the growth within, especially at the lower end of the specimen. At this part, which is about the juncture of the upper and middle third of the shaft, there has been fracture with bowing outwards, the inner edge of the lower fragment pushing into the mass of growth above. Around the end of the lower fragment there is a downward extension of the growth of a more fibrous structure, in the form of a callus, with a shell of osseous tissue on its surface.

171. Part of an encapsulated growth of ovoid form and of the size of a cocoanut, with a portion of skin and subcutaneous tissues and muscles removed from the axilla. The section of the growth presents a dense structure traversed by intersecting strands of fibrous tissue. At one part there is a cavity where the growth has become degenerated and disintegrated. Thin sections of the growth present the character of small round-celled sarcoma, in places highly corpuscular, in places atrophic with much fibrous tissue.

Removed from J. B. aged 30, a labourer at a distillery. The tumour had commenced in the axilla a year previously to its removal by the formation of a small swelling like a kernel, which had gradually increased in size under every kind of treatment that had been adopted. It had acquired considerable magnitude, and filled up the axillary space from the anterior costa of the scapula, to the under edge of the clavicle, and pushed forward the pectoral muscle to a great extent. It was movable, but slightly adherent, and connected with the axillary vessels and nerves. Its surface was discoloured at the lower part, and unequally soft and elastic over its whole extent; it was also attended with much pain when the arm was moved. After a consultation, Mr. Luke removed it by dissecting it out of the axilla, and the man recovered and was discharged in about a month. Three months after this, the glands above the clavicle became enlarged, and shortly afterwards he complained of difficulty of deglutition and breathing, which continued to increase, and in a few months he died. At the autopsy other growths were found developed in the lungs and stomach.



172. The greater part of the leg, with the knee, of a young subject laid open from before, through a mass of soft sarcomatous growth in the subcutaneous tissue. The tumour, which extends about 5 inches along the limb from near the tuberosity, has involved the skin over its most prominent central part, but is quite separate from it above and below, and encapsulated, having apparently developed from the periosteum as in no. 141. The growth is very soft, its cut surface being flocculent in places. Thin sections present the structure of small round-celled sarcoma, with delicate supporting network of fibrous tissue.

173. The heel and posterior part of the foot cut off by a transverse vertical section dividing the os calcis behind the ankle-joint and passing through a sarcomatous growth in the sole and outer side of the foot. The portion of the growth shown in the specimen is as big as half a large orange. It projects through the skin, forming a fungous mass with constricted base and denuded surface, to which portions of blood-clot still adhere. The section of the growth has a homogeneous appearance, with some puckering from contraction of its fibrous framework. Thin sections show the structure of a round-celled sarcoma.

The following is the note of the specimen in the old Catalogue:—

“Fungus Hæmatodes. A gentleman in Whitechapel applied to Mr. T. Blizard for advice in consequence of a tumour in the heel. In a short time the part ulcerated, and a fungous growth arose which manifested the character of Fungus Hæmatodes; it continued to increase, although arsenic and other applications were employed. Mr. Cline was consulted, and the disease gaining ground, amputation was submitted to. The stump healed in about three weeks. About four months after the operation, the inguinal glands put on a similar disposition and enlarged considerably. The eye became similarly affected, and the patient died in consequence of the fungus making its way into the cranium and pressing upon the brain. The preparation shows a section of the original disease in the heel.”

174. The foot of an adult with a lobulated medullary growth, of the size of a cricket-ball, occupying the sole. The growth is connected with the periosteum of the metatarsal bone of the great toe, the proximal end of which is involved. Thin sections show a small round-celled sarcomatous growth with strands of fibrous tissue, much degenerated and obscured by long preservation in spirit.

175. Part of a lung with a mass of malignant growth at its root, and a contiguous mass of greatly enlarged mediastinal glands. Probably a round-celled sarcoma.

176. A cystic round-celled sarcoma from the region of the left adrenal, with one testis and a piece of lung. The large growth (on the surface of which, but separable from it, is a part of the left adrenal) is of



the size of a man's fist. It is of a soft and highly vascular structure, in part fibrous, and contains several cavities which contained dark red curdy matter, softened blood-clot or highly vascular sarcomatous tissue. The testis is enlarged, and measured  $2\frac{1}{2}$  inches in length. It is hard and fibrous, with a cavity at the upper part. In the lung there are several nodules of soft and friable medullary growth, partly softened and broken-down in the larger masses. Sections from these organs examined under the microscope all show a small round-celled sarcomatous growth; with fibrous tissue in greater or less amount in the larger tumour and testis. In sections from the last small tracts only of the corpuscular growth are to be seen, imbedded in dense fibrous tissue.

There were several nodules of growth in the brain, which had the appearance of coagulated blood. Nodules of secondary growth were scattered through both lungs. There were several at the surface of the right lobe of the liver, and one in one of the kidneys.

### **Spindle-celled Sarcoma.**

177. A portion of a lung (imperfectly injected) with numerous well-defined rounded nodules of soft medullary growth of varying size imbedded in it. Several form rounded projections on the surface of the lung, and over many of these the pleura is lacerated and more or less completely removed, exposing the degenerated and softened growth.

178. A well-defined lobulated growth of rounded outline and ovoid shape, of the size of a turkey's egg, developed in the subcutaneous tissue. It forms a rounded projection with a constricted base on the surface of the skin, which is tightly stretched over its projecting surface and closely united with it, but separated from it at the base, where the tumour projects into the subcutaneous tissue. The skin round the base of the tumour is puckered and corrugated, and there are warty outgrowths on its surface, probably due to irritation of retained secretion and dirt in the folds of the skin. The section of the growth has a homogeneous appearance, with lobulation from separation of soft masses of growth by fibrous septa. The growth has the structure of a spindle-cell sarcoma.

It was removed by Mr. McCarthy from the shoulder, July 1884.

179. Part of the calf, muscles, and skin, divided vertically through a sarcomatous growth of the size of a small orange, which has developed in the subcutaneous connective tissue, apparently from the aponeurosis of the muscles. It has perforated the skin and formed a fungating mass of growth projecting from it. It does not appear to



have invaded the muscles beneath it. Thin sections examined under the microscope show the structure of spindle-cell sarcoma, with cells of medium size.

180. The right forearm with part of the hand (injected). The lower part of the forearm is greatly expanded by a mass of soft growth containing numerous cysts with defined walls and of varying size from a plum downwards. The growth is mostly in front and on the radial side of the limb, and appears to have had a deep origin. It has invaded and perforated the skin, both on the radial and ulnar side. On the radial aspect of the limb, and on both anterior and posterior surfaces contiguous, there is a great elevation of the skin, with overhanging of the projecting masses, from which fungous excrescences project through the broken skin. On the ulnar side there are similar projections where the growth is exposed by abrasion of the skin. Thin sections of the growth show nodules of sarcomatous growth, consisting of small fusiform cells, separated by tracts of fibrous tissue with elongated nuclei, which they appear to have been invading and absorbing.

#### **Ossifying Sarcoma.**

181. The anterior part of a rib, with part of the costal cartilage connected with it, divided longitudinally. The end of the rib is expanded into an elongated ovoid tumour about 4 inches long by  $1\frac{1}{2}$  across, which consists of sarcomatous growth in a cancellous bony framework. There is no shell of compact bone at the surface of the tumour. The anterior extremity of the tumour is indented by the end of the costal cartilage. On one side of the section it has extended a short distance along the perichondrium, but has not invaded the cartilage.

#### **Melano-Sarcoma.**

182. Part of a thumb, with a mass of enlarged glands from the axilla and other glands, invaded by a growth which is in parts melanotic. The thumb is laid open on its palmar surface, showing a mass of melanotic growth in the pulp. The growth appears at the surface beneath the nail, which has been elevated by it and has been in great part cut away. The growth at this part is not pigmented. A mass of enlarged glands, of the size of half an orange, is shown above, with a piece of skin connected with them. One of these is much pigmented, others are slightly pigmented in a few points. Some other isolated glands are also shown, in which there are nodules of growth in part degenerated and softened, but without any appearance of pigmentation.



**Adeno-Sarcoma.**

183. An adeno-sarcoma of the breast removed by operation, with the nipple and a flap of skin contiguous to it. The tumour is circumscribed and does not invade the surrounding adipose tissue, and the nipple is not retracted. The growth is firm, and has a fibrous appearance in section. On microscopical examination it is found to be a spindle-cell sarcoma with glandular acini and ducts imbedded in the sarcomatous mass.

**Epithelial Tissue Tumours.****Papilloma; Villous Growth.**

184. A cluster of papillomatous growths removed from the anus.
185. Part of a urinary bladder with the prostatic urethra laid open from before, showing two rounded masses of villous growth, contiguous to the orifice of the left ureter. The upper and larger growth is about the size of a small cherry. The other is of the size of a large pea. The wall of the bladder is thick, and is recessed in the situation of the growths.

**Adenoma; Adeno-fibroma.**

186. One half of a rectal polypus of the size of a cherry with a narrow pedicle. The surface is slightly lobulated and studded with minute fissures, amongst which are some larger orifices of glandular crypts. The section of the tumour shows numerous cysts, mostly of minute size, several as large as hemp-seed, and one is as big as a pea, all being of the nature of retention cysts.
187. Simple Adenoma of the Breast (Adenocoele).—A small tumour of the size of a hazel-nut and of slightly irregular lobulated form, removed from the breast of a young woman by Mr. McCarthy. It was loosely connected with surrounding parts and shelled out readily.
188. A portion of an adeno-fibromatous mammary tumour consisting of a number of lobules separated by tracts of rather loose connective tissue, and flattened by pressure against one another. The lobules consist of compact tissue containing cysts of varying size, from that of a hemp-seed downwards. Sections of the growth examined under the microscope show glandular acini in a compact fibrous stroma.

**Epithelioma.**

189. A V-shaped portion of a lip excised for the removal of an epithelioma upon its border. The growth is about the size of a shilling,



and presents a typical appearance, a well-defined elevated ridge surrounding a depressed central area which is superficially ulcerated. Anteriorly the ulceration has penetrated more deeply, tunnelling the ridge of growth and appearing on the front of the lip.

190. A tongue with the hyoid bone, showing an extensive excavation of its base on the right side bounded by a well-defined elevated ridge of epitheliomatous growth in front. The greater part of the row of circumvallate papillæ on that side have disappeared, and the growth has extended inwards to within one third of an inch of the raphe.

191. A portion of the œsophagus with the lower part of the trachea attached to it. The œsophagus has been laid open from behind to show an epitheliomatous growth in its wall at the part where it passes over the bifurcation of the trachea. The growth extends all round the œsophagus and has involved the trachea, forming an elevation of mucous membrane at its bifurcation. The walls of the œsophagus are much thickened at the part and its channel much constricted. The growth has been extensively ulcerated, especially at the lower part, where some papillary outgrowths of the mucous membrane project from the borders of the ulcerated area. Above the stricture the muscular wall of the œsophagus is much thickened.

192. A larynx with upper part of the trachea and tongue. The larynx and trachea are laid open from behind to show an extensively ulcerated malignant growth of the former. The vocal cords and wall of larynx below them have been invaded and ulcerated, and the disease has extended downward between the trachea and œsophagus with the formation of a pouch into which masses of growth project from the walls. There is a mass of growth between the larynx and œsophagus which extends around the former, expanding the false vocal cords and invading the thyroid cartilage. The cricoid cartilage, the anterior part of the ring of which is exposed in the ulcerated area, has been invaded and in great part destroyed by the growth. Portions of it are seen exposed in the pouch between the œsophagus and trachea, which appears to have been formed by expansion of its perichondrial sac. The trachea has been opened by operation a short distance below the growth. Thin sections of the growth exhibit the character of epithelial carcinoma.

193. The end of a penis with the glans much enlarged and covered by a warty growth involving its whole surface. About the situation of the frænum there is a depressed and superficially ulcerated area.



**Cylindrical-celled Carcinoma.**

194. A rectum with part of the bladder. The bowel has been laid open from behind to show an extensively ulcerated malignant growth involving its whole circumference, and commencing rather more than an inch from the anus. The growth forms an elevated ridge in the mucous membrane above and below the ulcer. This is most conspicuous above, where the section of the margin of the ulcer shows thickening of the mucous membrane to be the first stage of the lesion, with subsequent invasion of the muscular coat. The ulceration has destroyed the whole thickness of the intestinal wall, and a recto-vesical fistula has been produced. The outer coat above and below the ulcer is much thickened and fibrous looking. At the edge of the ulcer all the coats became fused together in this tissue. Sections from this growth present the character of cylindrical-celled carcinoma.

Wm. Millar, aged 60, was admitted under Mr. Couper, Jan. 23, 1883, for malignant stricture of the rectum. He had been in good health until 7 months previously, and had then begun to have pain in defæcation, and to pass blood with his motions, which were loose and frequent. He had lost flesh and become anæmic. Colotomy was performed. The liver was studded with nodules of secondary growth (see No. 197), and the lungs were studded with caseous nodules. Autopsy, Feb. 2, 1883.

195. Part of the liver from the same case as the last specimen. There are several nodules of secondary growth which form flattened elevations with depressed centres at the surface of the organ. A section through the largest of them shows the great extent of the mass of growth below the surface. The outline of the growth is clearly marked off from the surrounding liver-tissue. Sections of the growth show the same structure as in the last specimen.
196. A stomach laid open along its greater curvature, showing an extensive carcinomatous growth, which surrounds the pyloric orifice and extends along the greater part of the lesser curvature, spreading downwards over both the anterior and posterior walls of the organ for a considerable distance and in a symmetrical manner. The margin of the growth is elevated and rounded, and somewhat overhanging. It is abruptly limited at the pylorus. Its surface is extensively ulcerated. At the back of the specimen are some enlarged glands contiguous to the portal vein. This vessel has been laid open, and in it is seen a coagulum projecting from the mouth of a small tributary coming from the glandular mass. Thin sections from the margin of the growth show spaces lined with cylindrical



epithelium in much fibrous stroma. The muscular coat of the organ has been invaded by the growth.

From a man aged 47, admitted under Dr. Fenwick, November 4, 1880. His symptoms dated 2 years. He had been a spirit drinker, taking neat gin. Jas. Bates. Autopsy, Jan. 28, 1881.

### **Spheroidal-celled Carcinoma.**

197. Part of a mammary tumour removed with the nipple and the skin covering it. The deep surface of the specimen, where part of the growth has been removed, shows the fibrous structure of the growth and its connection with surrounding adipose tissue by spreading processes of the same structure. There has been softening of the central part of the growth, and the tissue there has a reticulated appearance, with a cavity of the size of a filbert at the lower part. The nipple, which is at the upper part of the specimen, is retracted and drawn down towards the growth.
198. A stomach laid open along the greater curvature. It is extensively invaded by malignant growth which surrounds the pyloric orifice, and has spread along the lesser curvature to the cardiac orifice. Over the anterior wall in the pyloric region are fungating masses of soft growth. Over the posterior wall, and at the cardiac end of the organ, the surface is roughened by papillary outgrowth, the sub-mucous tissue being much thickened and indurated (scirrhus). In parts the mucous membrane has been superficially eroded. At the pyloric end of the stomach, where the growth is ulcerated, there is evidence of colloid degeneration with pitting of its surface. The sections from this situation show an alveolated carcinomatous structure with spaces in part distended by colloid substance.
199. A testis greatly enlarged by malignant growth of its glandular structure. The soft growth is in rounded masses separated by fibrous septa. The organ also contains several cysts. A section at the back of the specimen has laid open a large sacculated cavity with loculi in part occupied by soft flocculent matter, which seems to be soft growth from the walls.
200. A kidney removed by operation. One end of the organ is greatly enlarged by a mass of growth of rounded outline. At the other end the organ retains its natural form, and the structure presents a normal appearance on section. Sections of the growth show a carcinomatous structure.

The specimen was removed on March 10, 1882, by Mr. James Adams from a man aged 29. There had been dull pain in the right loin extending down the thigh, but not to testis, and clots of blood had been passed. The urine was passed



frequently. It contained blood and epithelial cells from bladder and kidneys, with triple phosphate crystals, and a little albumen ( $\frac{1}{4}$ ). The patient progressed favourably after the operation until April 15. Pneumonia then appeared at the base of the left lung, and subsequently also in the right lung, causing patient's death on April 18.

### **Colloid Carcinoma.**

201. A portion of the omentum greatly thickened and converted into an irregularly lobulated mass. This is seen on section to consist of a fibrous stroma of alveolar structure, with cysts of varying size with smooth lining membrane, and filled with opaque, finely granular coagulum. A portion of the spleen is also shown with cysts of a similar character in its capsule and invading its substance. In thin sections from this specimen, when examined under the microscope, a fibrous network is seen with a coarser or finer areolar formation, the spaces being empty or occupied by a hyaline substance. In some round nuclei are seen, which appear to be the remains of cells which have undergone colloid degeneration.

From a middle-aged woman, who had been supposed to be the subject of ovarian disease for about two years, and was still in very fair health when she was admitted, and ovariectomy was attempted. The peritoneal cavity was full of colloid material and there was colloid matter in the subperitoneal tissue in various parts. The body of the uterus was destroyed and the ovaries could not be distinguished. The omentum was everywhere adherent to the parietal peritoneum.



## Section II.—SPECIAL PATHOLOGY.

### SERIES I.—INJURIES AND DISEASES OF THE SPINE.

#### INJURIES.

**Fractures :** 204 to 217.

Union after Fracture by Fibrous Tissue and Bone : 215, 216.

Fracture of Ankylosed Vertebrae : 217.

Separation of Epiphysis : 218.

**Dislocation with or without Fracture :** 219 to 232.

Injury to the Spinal Cord from Fractures and Dislocation : 215, 219–222, 229, 231.

Injury to the Spinal Cord without Displacement of Vertebrae : 233, 234.

---

#### Fractures.

204. An atlas and axis. The central part of the anterior lamina of the atlas is separated by a fracture on each side of the tubercle. The posterior lamina is also severed by a fracture just behind the articular facets on each side. The odontoid process has been broken through at its base, and remains connected with the atlas.

205. The upper part of the spinal column and part of the occipital bone. In its present condition there is no displacement although fractures are seen at two different parts. The lower margin of the body of the fifth vertebra is crushed in such a manner as to make it clear that the fracture was caused by bending forwards of the spine. It has also been split vertically. But the most interesting lesion is that of the first vertebra. This bone shows a vertical fracture through its posterior tubercle. On its anterior aspect there are two fractures, which gape slightly, and have occurred almost symmetrically in front of the condyles.

No history has been preserved with this specimen.

206. The upper cervical vertebrae, showing an old separation of the odontoid process with the formation of a false joint between it and the body of the axis. The specimen was thus described by Mr. Curling:—"The odontoid process was connected as usual to the occipital bone by the perpendicular and moderator ligaments, but was attached to the second vertebra by means of two slender ligaments which passed from it to their insertion near the superior articu-



lating processes of the latter. The transverse ligaments, larger than usual, flattened horizontally and polished above and below, formed a distinct interarticular ligament between the odontoid process and the body of the second vertebra. There was a communication between the two articulations in front, where there was also a slight spinous projection of the processus dentatus. Behind this projection the surface of bone which rested on the transverse ligament was flattened, smooth, and tipped with thin cartilage. The corresponding part of the second vertebra likewise presented a distinct articular surface. At this spot the theca vertebralis was much thickened. There were no appearances in the medulla of injury or disease—no rupture of ligament nor extravasation of blood. No opportunity was afforded for obtaining any previous history of this remarkable case.”

From a man aged 38 who walked into the Hospital having just met with an accident. While descending a ladder he slipped and fell a few feet backwards, striking the hind part of his head and neck. There was no external mark of injury. He died suddenly on the third day afterwards, having in the interval suffered with delirium and at times unconsciousness, but without any symptoms of pressure on the medulla. The condition of the odontoid process may be viewed as the result either of an original malformation, or of accidental violence before the third year, at which period the odontoid process becomes united to the body of the second vertebra. See London Hospital Reports, vol. i. page 142.

*Presented by Mr. Curling.*

207. The first four cervical vertebræ. The atlas and the odontoid process are dislocated forwards, to the extent of half an inch, and a little to the left side. The odontoid process has been broken through at its base and is firmly attached to the atlas and to the front of the axis. The lower articular facets of the atlas, displaced forwards and downwards, are ankylosed to the front of the axis; and the axis and the third vertebra have also coalesced. There is no evidence of caries of the bones, and excepting the ankyloses they are free alike from erosion and deposit of new bone. The displacement of the atlas forwards is such that its posterior arch crosses the spinal canal, leaving an aperture which measures a third of an inch from behind forwards, and three quarters of an inch from side to side.

The history of the case renders it probable that in the first instance a fracture without much displacement occurred, the dislocation forwards being brought about gradually with increasing compression of the cord. Thus it was not till three weeks after the accident that any symptoms came on, and after this they passed off sufficiently to allow the man to walk about.

*Presented by Mr. Debenham.*

- 207 A. The specimen consists of the second, third, fourth, fifth, and sixth cervical vertebræ. The odontoid process has been sawn off at its base. The laminae of the second vertebra have been detached from the body



by a vertical fracture which on each side passes through the articular process, leaving the anterior three fourths in connection with the body. This fracture gapes on each side to the extent of a quarter of an inch, the laminae being lower than the body. The laminae of the third vertebra are detached from its body by a vertical fracture on each side, exactly resembling that just described, excepting that there is scarcely any displacement. In this instance the fracture passes through the pedicles close to the body. The intervertebral substance between the third and fourth is ruptured, and the third appears to be bent a little backwards. The pedicle of the fourth vertebra is broken through close to the body on the right side. On the left side, a vertical fracture passes through the middle of the lamina. The fifth vertebra is uninjured.

It is difficult to conceive of any form of violence likely to have caused such a remarkable fracture, and unfortunately no history has been preserved. The conjecture that the neck had been run over, or received severe direct violence in some other manner, is perhaps the most probable supposition.

208. Fracture of the fifth cervical vertebra with displacement. The body of the fifth is extensively comminuted and the fourth is dislocated forwards. The displacement has been considerable, and there is a longitudinal rent, an inch long, in the posterior common ligament, caused by a sharp edge of bone. The laminae of the fourth and fifth are fractured on the right side. The movement permitted is very free, and consequently the displacement was not permanent.

*Presented by Mr. Hutchinson.*

209. Portion of the cervical region, consisting of the five lower cervical vertebrae. There is a lateral vertical fracture with comminution of the body of the fifth. The spine was probably bent violently forwards, and the body of the fifth crushed between the fourth and sixth. The anterior and posterior common ligaments were not torn through but the anterior appeared somewhat lacerated. The cord was crushed at the seat of the injury.

210. A portion of a spinal column showing dislocation with fracture of the sixth cervical vertebra. The lower part of the body of this vertebra has been crushed by being driven on the anterior edge of that below it. A vertical fracture also passes antero-posteriorly through its body. The pedicle of the lamina is broken through on the left side. The right transverse processes of the fourth and fifth vertebrae are broken off, the fracture in each instance passing into the vertebral foramen. It is probable that the sixth cervical was driven forwards, and that the cord was crushed against the upper edge of the seventh vertebra.



211. Portion of a spinal column showing a horizontal fracture through the body of the sixth dorsal vertebra. Neither the anterior nor the posterior common ligaments were torn, and there was no permanent displacement. The cord was uninjured.

There were no symptoms of fracture of the spine during life, death being due to a fracture of the skull. The sternum was also fractured.

*Presented by Mr. Maunder.*

212. The lower dorsal and upper lumbar vertebræ. The upper surface of the first lumbar is extensively crushed, and there is a partial displacement between it and the last dorsal. The upper part of the column is slightly inclined forwards but there is no separation between the articular processes, and the spinal canal is not encroached upon.

213. Part of a spinal column showing separation between the twelfth dorsal and first lumbar vertebræ, and extensive comminution of the upper and anterior part of the body of the latter. All the ligaments are torn through except a shred of the posterior common ligament. The last dorsal vertebra is much displaced forwards; and the posterior margin of the body of the first lumbar forms a prominent angular projection into the spinal canal. *Presented by Mr. Hutchinson.*

214. Portions of four lumbar vertebræ from a case of fracture. The body of the vertebra above the seat of fracture has slipped forwards crushing that of the one below. The upper and posterior edge of the latter projects into the vertebral canal; but this, where most narrowed, is sufficiently large to admit the little finger.

It is probable from the callus thrown out around the fracture that the patient lived some weeks.

#### **Union after Fracture by Fibrous Tissue and Bone.**

215. Part of the dorsal region of the spinal column. The body of one of the lower dorsal vertebræ has been divided by a horizontal fracture, and the upper part of the column is displaced forwards to a considerable extent. The spinal cord has been completely severed, the solution of continuity being about half an inch above its termination. The meninges are lifted up by a prominent angle formed by the projection backwards of the lower portion of the column. The fractured surfaces are firmly united by fibrous tissue which admits of considerable movement between them.

The patient evidently lived for some considerable period after the injury.

216. Three lumbar vertebræ. The upper vertebra has been separated from the second with crushing of the upper and anterior part of the



latter. The bodies of vertebræ are now firmly united by bridges of bone connecting them on each side, and by callus thrown out around the articular processes and laminæ.

### **Fracture of Ankylosed Vertebræ.**

217. A portion of a spinal column comprising the sixth to the twelfth dorsal vertebræ, showing fracture of the uniting medium between ankylosed vertebræ. The bodies are united by a layer of bone which bridges over the intervertebral discs. Opposite the discs between the sixth and seventh, seventh and eighth, and eighth and ninth vertebræ this layer has been broken. The ninth vertebra is divided by a fracture which passes obliquely from side to side.

From a middle-aged man, who was able to walk to the Hospital. During life there was neither displacement nor symptoms of injury to the spinal cord. The fracture was only discovered at the post-mortem.

### **Separation of Epiphysis of Body.**

218. Part of the spinal column of a young child. The upper epiphysis of the fourth dorsal vertebra has been torn off and the third dorsal, to which it is attached, is displaced backwards.

The child was brought to the Hospital dead, having sustained fracture of several ribs and laceration of the left lung by being run over.

### **Dislocation of Vertebræ with or without Fracture.**

219. The upper part of a spinal column, showing dislocation of the fourth vertebra forwards, the separation from the fifth being greatest on the right side. The right inferior articular process of the fourth is fractured; and the anterior common ligament is partially torn through. The cord, which is exposed, does not show externally any trace of injury; but, if cut into, would probably be found to have been crushed.

From a man aged 60, who fell down some stairs, and was admitted to Hospital with complete paralysis of the lower and paresis of the upper extremities. He died twenty-four hours afterwards. His sternum was fractured, probably by thrusting of the chin against it.

220. Several cervical vertebræ showing a dislocation between the fourth and fifth vertebræ, the upper part of the column being displaced forwards. The right transverse and articular processes of the fourth have been separated by a fracture; and the anterior common and inter-articular ligaments are torn through. A line of fracture also passes through the right superior articular facet of the atlas. The odontoid process is absent, and the history of the specimen being wanting, it cannot be stated whether it was broken off or removed after death. A longitudinal section through the spinal cord shows laceration of its central part opposite the seat of displacement.



221. Complete separation of the fifth cervical vertebra from the sixth, without fracture. The intervertebral substance, ligaments, and spinal cord have been completely torn across, and the only connecting bond between the two parts of the spinal column is formed by the two vertebral arteries, which are seen drawn out for about an inch and a half.

The specimen was taken from a child.

*Presented by Mr. Hutchinson, 1869.*

222. The upper part of a spinal column showing dislocation of the sixth from the seventh cervical vertebra, with displacement of the upper vertebræ forwards. The articular processes of the sixth are separated by fractures which pass through the pedicles. The spinal cord, laid open by a vertical incision, shows a complete solution of continuity opposite the separation between the vertebræ, but the membranes are entire.

223. A similar specimen to the preceding, showing dislocation between the fifth and sixth cervical vertebræ. The ligaments connecting the vertebræ are torn through. The bodies are now restored to their natural position, but from the mobility at the seat of displacement it may be presumed that a complete dislocation forwards had occurred. With the exception of a fissure passing through the right pedicle of the sixth vertebra, there is no fracture.

224. The upper part of a spinal column exhibiting complete separation between the fifth and sixth cervical vertebræ. All the ligaments, with the exception of the posterior common, are completely torn through.

225. The fourth, fifth, and sixth cervical vertebræ, showing complete dislocation forwards of the fifth from the sixth, without fracture.—The patient, a middle-aged man, received the injury in a fall from a loaded waggon upon his head. The trunk and lower extremities were completely, and the arms partially, paralysed. His respiration was diaphragmatic. His head was pushed somewhat forwards, and could not be moved without intense pain. An irregularity was felt over the spinous processes, and an attempt at reduction was made, but was discontinued on account of the pain it caused. He died the next day. There was a separation of the manubrium from the body of the sternum, and a large bruise of the scalp over the occiput. The vertebræ were found displaced as seen in the specimen, the intervertebral substance being completely torn through. This is an instance of a complete and unreduced dislocation. The body of the displaced vertebra is more than half an inch in front of the other.

*Presented by Mr. Adams.*



226. Dislocation of the sixth cervical vertebra forwards on the seventh. The intervertebral substance is torn across; but there does not appear to have been any fracture, except of the edges of the articular facets. The articular ligaments, ligamenta subflava, and the interspinous ligaments have all been torn completely through. Free motion is permitted, and there is no permanent displacement. The spinal canal has not been opened.

*Presented by Mr. Hutchinson.*

227. The first two dorsal and two lower cervical vertebræ. A fracture passes through the laminae of the seventh cervical, quite detaching the spinous process. The body of the same vertebra is split vertically; and the intervertebral substance between the sixth and seventh is torn through. The body of the sixth could be moved forwards very readily on the seventh; and, probably, this was the way in which the crushing of the cord occurred, for it was opposite the sixth. The paralysis during life had been carefully noted. From the first the lad had no sensation below the level of the nipples. The arms were paralysed with the exception of the deltoid and biceps; thus he could raise the arm from the side, and bend his elbow, but as soon as the elbow was bent to a certain point the hand fell by its own weight and struck him in the face, as he had no power of steadying it by the biceps or other muscles. This he did repeatedly on the day after his admission. He had but little pain and was quite conscious. He died within twenty-four hours of his admission to Hospital.

*Presented by Mr. Curling.*

228. Dislocation of the seventh cervical vertebra with fracture. Two lower cervical and four upper dorsal vertebræ, showing displacement forwards of the last cervical on the first dorsal vertebra. Neither anterior nor posterior common ligaments have been torn. The displacement in the specimen is about a quarter of an inch, and there is no very material intrusion into the calibre of the vertebral canal. The body of the vertebra has been somewhat crushed.

*Presented by Mr. Hutchinson.*

229. The upper part of a spinal column exhibiting dislocation between the last cervical and upper dorsal vertebræ, with extreme lateral displacement of the upper part of the column. The seventh cervical vertebra is displaced to the right, its body resting upon the head of the first rib. The left transverse and articular processes have been separated from the body by a fracture through the pedicle. Owing to the displacement of the sixth and seventh vertebræ the spinal cord is inclined towards the right side, and its interior is disintegrated, probably as the result of pressure from the extreme displace-



ment of the upper part of the column to the left at the time of the accident.  
*Presented by Mr. Luke.*

230. Portion of a spinal column in the dorso-lumbar region, divided by a vertical section. The body of the tenth dorsal vertebra is displaced backwards and tilted forwards. The intervertebral substance between it and the eleventh has been torn through, but the relations between the ninth and tenth vertebræ have not been altered. The posterior and inferior margin of the tenth vertebra projects as a prominent angle into the vertebral canal.

231. Dislocation of the third lumbar vertebra from the fourth, with slight splintering of the edges of the bones themselves. The third vertebra is displaced forwards nearly half an inch, and the cauda equina is elevated on a bridge formed by the projection backwards of the body of the fourth. There was no laceration of the theca, nor any extravasation of blood. The cauda equina was not crushed, but only somewhat contused and stretched. The paraplegia, from which the man suffered, was at first incomplete. He died of pyæmia. The articular processes of the two vertebræ were completely separated from one another.  
*Presented by Mr. Curling.*

232. The laminae of the lumbar vertebræ from the same case as the preceding specimen. The articular processes of the third lumbar vertebra have completely left those of the fourth, and are displaced forwards a third of an inch. The ligaments connecting the laminae and spinous processes have been very much stretched and elongated, but not materially torn. There is no fracture, except chipping of the edges of the articular processes by pressure against each other, and an incomplete fracture, without displacement, through the spinous process of the fifth.  
*Presented by Mr. Curling.*

#### **Injury to Spinal Cord without Displacement of Vertebræ.**

233. Several cervical vertebræ with the cord which is laid open by a longitudinal incision. Opposite the body of the fifth vertebra the anterior and central portions of the cord are softened and broken down. No displacement of the vertebræ exists, but on firm pressure an undue amount of movement can be obtained between the fifth and sixth vertebræ, and the ligaments connecting the articular processes appear to have been lacerated.  
*Presented by Mr. Hutchinson.*

234. Part of the cervical region of a spinal column. The vertebræ, when removed, were so exactly in place that some examination was



necessary to find the seat of injury. The anterior common ligament was torn through at three places, namely in front of the third, fourth, and fifth vertebræ. The only motion practicable was bending backwards, and with force this could be done until the upper three vertebræ were almost at right angles with the lower one. When bent, gaping was produced at the intervals between the third and fourth, fourth and fifth, and sixth and seventh. In each of these situations the intervertebral substance had given way with detachment of some small fragments of bone above and below. The laminae, transverse and spinous processes were all entire with the exception of the transverse process of the third. Very little lateral motion was practicable at any place, and the bones could not be bent forwards. The intervertebral substance between the second and third was also partially ruptured, but the external ligaments had not given way, so that it did not gape.

It might have been supposed quite possible, judging from the amount of displacement producible after removal, that the cord would have escaped any material damage. But the patient during life had complete paralysis of all the extremities and all the muscles of respiration excepting the diaphragm. The skin of the chest was without sensation below the level of the nipples. Between the nipples and the clavicles the skin was tender. He had also priapism and a slow full pulse; his pupils were moderately small and remained so in the shade. He died about thirty hours after admission.

## DISEASES OF THE SPINE.

- Caries, Tuberculous Disease: 235 to 248.  
 Necrosis: 249.  
 Destruction of the Intervertebral Discs: 250 to 252.  
 Angular Curvature: 253 to 254 A, 244, 255, 256.  
 Repair after Caries: 255 to 257.  
 Changes in the Spinal Cord and its membranes: 258.  
 Formation of New Bone and Ankylosis of Vertebrae: 259 to 264.  
 Morbid Growths implicating the Vertebrae and Spinal Canal: 265, 266.  
 Distortions of the Spine: 267 to 276.  
     Lateral Curvature: 267 to 274.  
     Antero-posterior Curvature: 275, 276.

---

**Caries, Tuberculous Disease.**

235. Part of the occipital bone with the three upper cervical vertebrae showing tuberculous disease of the articulation between the atlas and the occipital bone, and between the odontoid process and the former. The ligaments have been extensively destroyed and the odontoid process so completely liberated, that on the slightest movement of the head forwards it presses back on the medulla. The odontoid process itself and the adjacent part of the occipital bone are eroded by caries.
236. The four upper cervical vertebrae, dry. The odontoid process has, apparently, been destroyed by caries, and the opposed right articular facets of the first and second vertebrae are carious.
237. A portion of the dorsal region of a spine, showing the almost complete destruction of the body of one vertebra by caries. The remains of the walls of an abscess which had formed in front of the spine are observable.
238. Portion of the dorsal region of the spine of an infant, showing two contiguous vertebrae which are completely destroyed by caries. The child died of tuberculous meningitis.

The case of Wm. Collins, aged 18 months. 19. 6. 83. Mr. Hutchinson.

239. Part of a spinal column showing destruction by caries of the larger portions of the bodies of two dorsal vertebrae, with a slight degree of



angular displacement. The intervertebral discs above and below the affected vertebræ are in part destroyed; they were, probably, attacked subsequent to the disease of the bodies.

240. A portion of a spinal column from the dorsal region, divided longitudinally. The bodies of two vertebræ have been in great part destroyed by caries. The cancellous tissue of those vertebræ below them, and in a lesser degree those above, appear softened and infiltrated with caseous material.
241. Eight upper dorsal vertebræ. The bodies of four vertebræ have been almost destroyed by caries, and those of the vertebra above and below them are superficially eroded. The intervertebral discs between the carious vertebræ have been scarcely touched by the disease, and stand out as thin partitions. At one or two places the adjacent ribs are carious. No displacement of the vertebræ has occurred.
242. Part of the spinal column of a young child, showing complete destruction of the bodies of two of the mid-dorsal vertebræ together with their intervertebral substances. The theca of the cord is exposed. A circumscribed abscess-cavity, as large as a hen's egg and with a dense wall, is seen in front of the diseased portion of the column. Although the destruction of the bodies is complete, so that a gap an inch and a half long is left, yet there does not appear to have been any angular displacement.
243. Part of the dorsal region of a spine with the cord *in situ*. The walls of a large abscess which occupied the front of the spine are preserved. The bodies of the vertebræ forming its posterior wall are denuded of periosteum. The lower part of one of the middle vertebræ and the adjacent intervertebral disc are destroyed, and the lowest vertebra but one presents two deep perforations; otherwise the bodies are only superficially eroded.
244. Part of a spinal column showing almost complete destruction from caries of the bodies of three dorsal vertebræ, with marked angular curvature. The intact vertebra above has been displaced forwards and rests in front of the body of the one below, and almost at right angles with it. The cord is compressed. The patient had permanent flexion of the lower extremities.
245. Part of a spinal column from the dorsal region, exhibiting almost complete destruction of the body of one vertebra and partial of those above and below it. A very considerable angular projection has been produced. The cord is compressed and softened. In the



body of the lowest vertebra involved is an isolated cavity containing caseous material; and a collection of the same material may be observed in the front of the column.

The specimen was removed from a man, aged 39, who died of secondary hæmorrhage after amputation of the leg by Mr. Luke, on account of disease of the tarsal bones and ankle-joint. Two years previously an issue had been made in his back on account of disease of the spine, and this was believed to have been arrested. A quantity of caseous deposit was found at the post-mortem around the seat of the disease, and a small fragment of dead bone was detached. From the notes it seems clear that no abscess had ever burst externally, and that no collection of fluid pus was found at the post-mortem. See 723 of Old Catalogue.

246. Four lower dorsal vertebræ, after maceration. The bodies of the tenth and eleventh are completely, and those of the ninth and twelfth partially destroyed by caries.

247. The third, fourth, and fifth lumbar vertebræ, with a part of the sacrum of an adult. The contiguous surfaces of the fourth and fifth lumbar vertebræ are extensively eroded by caries, and no trace of the intervertebral substance remains. The intervertebral disc between the fifth lumbar and first sacral vertebræ is also destroyed, but the adjacent bone is unaffected. There are some bony outgrowths from the sacrum.

248. Seven dorsal vertebræ divided longitudinally. The cancellous tissue of the bodies is extremely rarefied, in some the cancellous tissue being almost completely removed so that only the compact walls are left. The cancellous tissue of the laminae and spinous processes is similarly altered. There is no evidence of suppuration having occurred.

#### **Necrosis.**

249. A portion of a spine in the dorso-lumbar region, showing disease of the body of one vertebra with necrosis and detachment of a large fragment of bone. There is an abscess-cavity in front of the spinal column.

#### **Destruction of Intervertebral Discs.**

250. A portion of a spinal column, showing complete destruction of all the intervertebral discs with one exception. Repair has taken place by, in one instance complete, and in another partial, ankylosis of the contiguous surfaces of the vertebræ. Their cancellous tissue is in some places sclerosed, in others rarefied, but otherwise is unaffected. A large abscess appears to have extended along the front of the column.

251. The second and third lumbar vertebræ, divided transversely. An abscess-cavity occupies the centre of the intervertebral substance



between them. This cavity communicated by two sinuses with the sheaths of both psoas muscles, thus producing double psoas abscess. The adjacent surfaces of both vertebræ are rarefied and infiltrated with inflammatory products.

The specimen was obtained from the body of a middle-aged man, who, about a year before admission into the Hospital, had sprained his back while shunting some trucks. The man was dying when admitted, and the nature of the lesion was only discovered on the post-mortem table. There was no evidence superficially of disease of the vertebræ.

252. Part of the lumbar region of a spinal column divided longitudinally. One of the intervertebral discs is occupied by a large abscess-cavity.

A. Sawing, admitted February 4, 1885. Mr. McCarthy.

### **Angular Curvature.**

253. Part of a spinal column showing extreme angular curvature in the lower part of the dorsal region. The bodies of two vertebræ together with the intervertebral substances have been entirely removed, and two others are extensively destroyed. Reparative processes appear to have been in progress.

254. A spinal column with the thorax and pelvis, showing changes in the thoracic walls associated with an acute angular curvature in the lower dorsal region. The thorax is much elongated from before backwards, and narrowed from side to side. The eleventh rib on each side rests upon the crest of the ilium. The upper aperture of the thorax is extremely narrowed, the border of the manubrium sterni being only separated from the cervical vertebræ by an interval of about one inch. The sternum is pressed forward, and its anterior surface is convex.

- 254 A. A similar specimen. The upper part of the column inclines to the left side, and there is lateral displacement of the thorax towards the same side.

### **Repair after Caries.**

255. A portion of a spinal column showing extreme angular curvature in the dorso-lumbar region. The vertebræ are firmly united together by bone.

256. Part of the spinal column divided by a vertical section. In the mid-dorsal region is an acute angular curvature due to the destruction of the bodies of several vertebræ by caries. The deformity is so great, that an acute angle is formed by the anterior surfaces of



the vertebræ above and below the curve. Complete repair had taken place, the remains of the diseased vertebræ being welded together by bone. The spinal canal is not obviously encroached upon opposite the angle.

257. A spinal column with the thorax; in the lower dorsal region is a slight angular curvature, probably the result of disease involving the two lower dorsal vertebræ. This has been perfectly repaired by osseous ankylosis.

#### **Changes in Spinal Cord and Membranes.**

258. A longitudinal section of the spinal cord and of its membranes at a part opposite to a deficiency in the bodies of the vertebræ from caries, showing considerable thickening of dura mater.

*Presented by Mr. McCarthy.*

#### **Formation of New Bone and Ankylosis of Vertebræ.**

259. An atlas with a portion of occipital bone. There is complete bony ankylosis between the left superior articular process of the atlas and the corresponding occipital condyle; also of the transverse process of the former with the latter bone. The union of the posterior laminae of the atlas is incomplete.
260. A skull with the cervical vertebræ. The atlas is firmly ankylosed to the occipital bone; and all the cervical vertebræ are welded together, owing to ossification of the anterior common ligament.
261. The cervical portion of a spinal column. All the bodies of the vertebræ are smoothly ankylosed by bone formed apparently by ossification of the anterior ligament. The intervals between the vertebræ are obliterated.
262. Five lower dorsal and the upper lumbar vertebræ showing on the right side of the bodies of the tenth and eleventh dorsal two lips of bone, one projecting downwards from the upper, the other upwards from the lower one, and fitting together. The edges of the bodies of the other vertebræ are at several places a little more prominent than normal.

*Presented by Mr. Curling.*

263. Four lumbar vertebræ, showing similar but more marked "lip-ping" of the margins of the vertebræ. These changes are sometimes associated with osteo-arthritis of the joints, but are also observed without it.



264. Five vertebræ from the spinal column of a Horse. On the right side a large splint-like mass of porous bone overlies the vertebræ and firmly unites them together. On the left side the upper three vertebræ only are united by bridges of bone which have coalesced over the intervertebral discs.

See London Hosp. Rep., vol. ii. p. 371.

*Presented by Mr. Rivington.*

#### **Morbid Growths implicating the Vertebræ and Spinal Canal.**

265. Portion of a vertebral column from a case of tetanus. On the anterior surface of the spinal canal, at a point corresponding to an intervertebral disc, a flattened ovoidal tumour projects into it. The tumour appears to have compressed the cord, which was at that part softened and vascular.

*Presented by Mr. Curling.*

266. Part of the dorso-lumbar region of a spinal column divided longitudinally. Surrounding the spinous processes and projecting from its posterior aspect is a smooth oval tumour about six inches in length. It has the appearance of a sarcoma. The morbid growth has infiltrated and extended between the spinous processes and laminae, so that its inner surface is in contact with the lower part of the spinal cord and cauda equina.

#### **Distortions of the Spine.**

##### **Lateral Curvature.**

267. Spinal column with the pelvis, showing lateral curvature. In the lumbar region is a slight curve with the convexity to the left; whilst the dorsal vertebræ form a slight compensatory curve towards the right side.
268. A similar specimen in which the curvature to the left in the lumbar region is somewhat more marked. The bodies entering into the formation of the lumbar curve are rotated so that their anterior surfaces look towards the convexity of the curve. The bodies of the vertebræ forming the concavity of the curve are slightly narrowed and their margins project as prominent lips.
269. A similar specimen with the skull, apparently from an old person. In the dorso-lumbar region is an acute lateral curvature to the left; while in the mid and upper dorsal region is a slighter compensatory curve towards the right. The rotation of the bodies of the vertebræ entering into the lower curve is so extreme that the transverse processes project directly backwards. The posterior extremities of the lower ribs on the left side are closely applied to the convexity of the curve



and form a prominent mass externally. The thorax is widened below and otherwise malformed. The skull is elongated antero-posteriorly, and the sagittal and lambdoid sutures are obliterated.

270. A spinal column with the pelvis, showing a similar deformity.
271. The spinal column and the pelvis, showing an acute lateral curvature to the left in the mid-dorsal region with slight compensatory curves in the opposite direction in the lumbar and cervical regions.
272. A spinal column with the thorax, showing a slight lateral curvature in the dorsal region towards the right side, with compensatory curves in the cervico-dorsal and dorso-lumbar regions. The lateral margins of some of the dorsal vertebræ are united by prominent masses of bone which bridge over the intervertebral discs; and the margins of other vertebræ are "lipped."
273. A similar specimen, showing a more acute lateral curvature in the dorsal region towards the right with considerable rotation of the vertebræ.
274. A similar specimen. The injected aorta has been left attached to the spine to show that it follows its curve.

#### **Antero-Posterior Curvature.**

275. A spinal column with the thorax and pelvis, showing a well-marked antero-posterior curvature in the dorsal region. The dorsal vertebræ project backwards to form an even curve, the centre of which is opposite the seventh. The vertebræ above the centre of the curve are slightly inclined towards the left. The thorax is extremely compressed laterally, owing to the sudden bending of the ribs forwards at their angles. The sternum is thrown prominently forwards. The pelvis presents the deformities usually observed in *mollities ossium*. The brim of the pelvis is cordiform and nearly horizontal. The promontory of the sacrum is thrown forwards and the pubes projects in a beak-like manner, owing to bending inwards of its rami; the horizontal ramus of the pubes on the right side has been fractured. The outlet of the pelvis is narrowed by the approximation of the descending rami of the pubes, and of the tuberosities of the ischium. The deformities apparently resulted from *mollities ossium*.
276. A spinal column showing an even posterior curvature of the spine in the dorsal region, probably the result of rickets. The anterior surfaces of the bodies forming the centre of the curve are slightly compressed, and their margins "lipped."



## SERIES II.—INJURIES AND DISEASES OF BONES.

### FRACTURES.

**Fractures of Vault of Skull:** 277 to 296, 306, 311 to 313.

Orbital Roof: 278, 305, 317.

Fracture with Compression from Hæmorrhage: 293, 295, 318 to 321.

**Fractures of Base of Skull:** 297 to 323.

**Fractures of Lower Jaw:** 324, 325.

„ **Hyoid Bone:** 326.

„ **Sternum:** 327 to 333.

„ **Clavicle:** 324 to 343.

„ **Ribs:** 344 to 353.

„ **Scapula:** 354 to 359.

„ **Humerus:** 360 to 392.

Separation of Epiphyses: 372, 376, 377, 389.

Fractures involving Elbow-Joint: 385 to 390, 395, 396.

**Fractures of Radius and Ulna:** 393, 397 to 409.

“Elbow-Sprain”: 394.

Separation of Epiphyses: 400, 404, 404 A, 405.

**Fractures of Pelvis:** 410 to 413.

**Fractures of Femur:** 414 to 480.

Gunshot Injuries: 537 to 540.

Fractures of Neck: 414 to 440.

„ Shaft: 441 to 474, 477, 479, 480.

„ Lower End: 475, 476, 478, 478 A.

Separation of Epiphyses: 419, 424, 550 A.

**Fractures of Patella:** 481 to 491.

**Fractures of Tibia and Fibula:** 492 to 536, 542 to 550.

Separation of Epiphyses: 506, 530, 541.

---

### Vault of Skull.

277. Vault of the skull showing a fissured fracture, running from the temporal bone through the parietal to end in the sagittal suture.

278. A calvaria with part of the left orbit.

The patient, who when admitted was quite sensible, had received a compound fracture in the left frontal region. Although the left eye did not appear to be injured it was found to be quite blind. The dura mater was lacerated at one point, and the man died of acute arachnitis. At the post-mortem lines of fracture



were found passing into the orbit so as to detach the whole of its upper margin and roof. The apex of the detached fragment included the optic foramen, and the fragment being considerably depressed, the optic nerve had been dragged on.

*Presented by Mr. Hutchinson.*

279. A calvaria showing a fissured fracture of external table with slight depression of the internal table of the left parietal bone. Although the line of fracture traverses some of the grooves for the middle meningeal artery no extravasation occurred.

The injury was caused by a fall of about 40 feet. There was incomplete paralysis of left arm and leg. Death two days after the accident, complete coma having existed throughout. At the post-mortem no important lesions were discovered in the brain; the spine was examined and found uninjured, and death was considered to be due to concussion.

280. This specimen shows the results of a punctured fracture of the posterior part of the left parietal bone.

The history of the case is as follows:—A man about 25 years of age walked into the out-patients' room, and when it became his turn to be examined said that his head was bad. On being questioned he gave rambling answers and said that everything went round. His face was flushed and his manner excited as though he had been drinking. His wife being sent for, stated that four days before, he had been at work and that another workman, quarrelling with a boy, flung a pair of pliers which struck her husband on the head; he was knocked down and, according to her account, was at first stunned, but soon recovered so far as to pull the pliers out of his head, where they had been sticking! When taken to a surgeon his head was bandaged and he was told that it was only a lacerated scalp. On examination Mr. McCarthy discovered a small scalp-wound, with a depression in the bone below.

281. A portion of a calvaria, showing the depression of both tables produced by blows from a small instrument.

282. Part of a calvaria of a child who died from a punctured fracture caused by a fall on a file. The child lived three weeks, and the cut edges have become smooth. The file had pierced the lateral ventricle.

283. The opening in this calvaria was produced by a wound from a small poker, inflicted by the patient's husband, who snatched the poker from the fire, and is described as having "planted" it in her skull, where it remained three or four minutes. The chief point of interest in this specimen is the resemblance which this opening bears to a bullet-hole in the skull. The area of the opening on the inner side is very nearly twice that on the outer side. This increased area of the inner opening is due to the radiation of force.



**284. A punctured fracture of a calvaria from a knife.**

The patient from whom this specimen was taken was a sailor, who, in a drunken brawl, was stabbed in the head by a comrade with a common clasp-knife. The blade broke off and the assailant escaped with the remainder of the knife and was never caught. The man was brought to the hospital, being quite sensible and moderately excited by drink. The projecting piece of the knife was seized by the house-surgeon with a strong pair of forceps, but it was found impossible to move it. When Mr. Maunder saw the case, he chipped away a small piece of the external table by the side of the knife, and then the foreign body came away easily. On seeing the length of the portion of the blade, there could be little doubt that the wound must have extended to the dura mater and probably the brain. Symptoms of encephalitis came on very soon, and the man died in a few days. The dura mater and brain were found to have been wounded. The pushing-in of the inner table, which is so common in punctured fractures, is well shown.

**285. Starred fracture in the right temporal fossa. The skull is remarkably asymmetrical.****286. Fracture through the right parietal bone.**

The patient has been trephined.

**287. Fracture through posterior part of right parietal bone, the internal table alone being involved. A large Wormian bone is present.****288. Comminuted fracture of right parietal, showing a trephine-hole through which the depressed fragments were elevated.****289. Large cleanly-cut fracture through right parietal, probably the result of a fall on some sharp projection.****290. Lines of fracture crossing the frontal and right parietal bones; the upper one involves only the outer table, just as, in 287, the inner one alone is fractured.****291. A fracture of a calvaria, probably produced by a sabre-cut or some similar injury. The inner table may be seen to be extensively detached. There is a groove around the fractured part pointing to the commencing necrosis of the outer table, and proving that the patient must have lived some weeks after the accident.****292. A calvaria with holes in it, the result of at least three applications of the trephine, and the marks of a saw, evidently made either after or immediately before death. The inner table presents a worm-eaten appearance, and is commencing to exfoliate for some distance around the trephine opening on the right side. Possibly trephining was undertaken to let out pus between the dura mater and the bone.**



293. A fracture extending right across the cranial vault, wounding both middle meningeal arteries, causing extensive effusion of blood between the dura mater and the bone, for which trephining has been done on both sides. It is interesting to note that on the right side three attempts were made to secure the meningeal artery by means of ligatures passed through the dura mater.
294. An extensive fracture of the cranial vault, with depression of the bone and laceration of dura mater.
295. Another extensive fracture of the vault, with laceration of the meningeal artery and effusion of blood. The extravasation has pushed inwards the dura mater as high as the sagittal suture.
296. This specimen is described as "punctured fracture, abscess and trephining," "expansion of the skull." The expansion is probably due to chronic hydrocephalus existing for some long time before the accident.

#### **Fractures of the Base of Skull.**

297. Fracture through the right petrous bone, opening up the middle ear and aqueduct of Fallopius, and causing deafness, facial paralysis, and bleeding from the ear.
- 298, 299, 300, 301, 302, 303. Specimens of fractures of base of skull.
304. Fragments removed by trephining.
305. Part of skull and face, showing fracture of the outer wall of the orbit and grooving of the upper part of temporal fossa. The internal table of skull is splintered close to junction of frontal with great wing of sphenoid. There was a small collection of pus between the dura mater and the bone. During life there had been paralysis of right third and of both facial nerves. At the P.M. there were no changes to be found accounting for this. (See No. 322.)
306. An extensive fracture, involving the malar bone, the greater wing of the sphenoid, squamous portion of temporal, and parietal bones.
307. Fracture of cranium, from a case in which hernia cerebri and abscess followed compound fracture of the left frontal bone.

Case reported in 'Brain' (1883). Mr. McCarthy.



308 (in bottle). The anterior part of the skull of a man who died of arachnitis after the removal of an ivory exostosis from the frontal sinus. About 18 months before, a similar exostosis had been removed from the frontal sinus of the left side without ill results. A similar growth having developed on the right side, the operation was repeated; but the dura mater being injured, fatal arachnitis followed. The exostosis was lobulated, and appeared to spring from the nasal processes of the frontal bone. The frontal sinuses were much enlarged, and, in parts, their bony walls were deficient. The specimen shows a small portion of the exostosis still *in situ*. The dura mater has been preserved, and the small laceration which proved fatal is seen. On the arachnoid lining there were numerous flakes of lymph.

Mr. Hutchinson.

309 (in bottle). A right temporal bone, showing fracture across the petrous portion just external to the meatus internus. Passing forwards, the fissure describes a right angle, and crossing the posterior part of the squamous bone vertically, tails off in the lower part of the parietal. There was blood in the internal ear and rupture of the membrana tympani. The bone is thin.

310 (in bottle). A fracture of the petrous portion of the temporal bone immediately above the glenoid fossa; it was caused by the articular process of the lower jaw being forcibly driven upwards. Several small fragments of bone are seen projecting into the skull. In the recent condition the dura mater was not torn; it has been removed in the specimen. Several fissures pass up into the squamous portion of the temporal. One fissure passed obliquely upwards and crosses the sagittal suture ending at the contused spot. The extremity of this fissure is crossed at right angles by another very minute one about an inch in length. There is no splintering of the inner table. The bone in the recent state was discoloured at the seat of inflammation, and there was a thrombus in the superior longitudinal sinus. The case is published in Mr. Hutchinson's work on 'Injuries to the Head.' The specimen shows small exostoses on the inner table of the frontal bone.

Mr. Couper.

311 (in bottle). Compound depressed fracture of skull.

The dura mater was lacerated and some brain substance escaped. The depressed bone was elevated, but the patient sank rapidly. Mr. Tay.

312 (in bottle). Depressed fracture of skull. There is a large aperture in the dura mater extending close to the superior longitudinal sinus.



- 313 (in bottle). A portion of a child's skull from the left parietal region, showing a punctured fracture.

The child was 2 years old, and fell on the spike of a garden rake. There were no cerebral symptoms on admission; on the third day the child was seized with convulsions and died a few hours afterwards. The spike had passed through the bone and dura mater and penetrated the brain-substance to a considerable depth. There was no collection of pus outside the dura mater, nor between it and the arachnoid. The specimen shows an oblique aperture through the bone, of the size of a pea. The inner table projects inwards towards the brain to the extent of an eighth of an inch.

- 314 (in bottle). Petrous portion of temporal bone, showing a fracture which passed through the tympanum and left the fragment connected solely by periosteum. The membrana tympani and the ossicles of the ear may be seen in the outer portion.

- 315 (in bottle). Fracture of the ethmoid bone, the cribriform plate being perforated, a pointed instrument entering through the left nostril.

Case of Jas. Roberts, æt. 35. Dr. Fenwick, June 9, 1883.

- 316 (in bottle). Pistol-shot fracture of skull. A calvaria showing the circular aperture of entrance of a bullet in the right parietal bone, above and behind right ear; and in the left parietal, directly above the squamous part of the temporal, a much larger aperture where the bullet struck this side of the skull after passing through the brain. This aperture is as large as a half-crown on its outer aspect, but smaller in the inner table. The aperture of entrance is larger in the inner table. Near the latter is suspended a small irregularly rounded piece of bone carried before it by the bullet and found within the skull. It is larger on its inner surface. Near the aperture on the left side is suspended the portion of bone there separated. It is broken into five pieces, and exactly corresponds with the aperture in the cranium. The dura mater has been perforated at a point corresponding to that at which the four principal lines of fracture in the separated fragment meet. The bullet had not passed out of the cranial cavity, but was found in contact with the dura mater at this point. There are extensive fractures of the cranium leading from both apertures, chiefly horizontal. The most extensive starts from the aperture of entrance and extends forwards across the temple and thence across the forehead.

Case of Fred Lamey, 58. Autopsy, Dec. 29, 1883.

- 317 (in bottle). The anterior half of the skull of a boy aged 11, who died in consequence of gun-shot injury to left orbit. He was fired at by another boy, who stood almost close to him. The pistol



contained wadding, but no bullet. He was admitted with the eyeball smashed and with extensive laceration of the soft parts in and about the orbit. The finger detected a compound fracture in the roof of the orbit and some portions of brain-matter escaped. No operation was performed. He died of arachnitis, with the usual symptoms, on the sixth day. The specimen shows the inner two thirds of the roof of the orbit lifted upwards and inwards, like the lid of a box. The dura mater is torn over the whole extent of the fracture (an inch and a half). There is a linear fracture, without displacement and without laceration of the dura mater, at the outer part of the orbit. The left brain was covered with lymph, especially at its anterior part. Portions of lymph may still be seen adhering to the arachnoid. The anterior lobe of the left hemisphere was contused and lacerated, and was softened to the depth of half an inch, but without injury to the ventricle. No foreign body was found within the skull.

Mr. Hutchinson.

318 (in bottle). The base of the skull of an adult, showing fracture of the left temporal bone and a large extravasation of blood between the dura mater and bone. On the side of the skull the clot is about half an inch in thickness and in extent as large as the hand. It extends into the sphenoidal fossa up to the root of the clinoid process, bulging as a rounded swelling which nearly fills the fossa. The fracture passes downwards and backwards to the root of the zygoma, and downwards and forwards in front of the pterygoid processes. There are also irregular lines of fracture in the outer wall of the orbit.

Mr. Hutchinson.

319 (in bottle). The skull of a boy, showing fracture of the left temporal bone with a large extravasation of blood between the dura mater and bone. The clot is three quarters of an inch in thickness in most parts, and covers a surface as large as an outspread hand; it dips into the sphenoidal fossa, more than half filling it. The specimen consists of the two halves of the skull; in the upper one the hemispheres have been left in position, and the left shows well the flattening produced by compression. The line of fracture extends in the calvaria across the coronal suture forwards into the left side of the frontal bone. At the base of the skull the fracture tails off just in front of the root of the zygoma. The cerebellum has been left in position.

*Presented by Mr. Hutchinson.*

320 (in bottle). Fracture crossing the temporal fossa in a vertical



direction and involving the anterior inferior angle of the parietal bone. The middle meningeal artery has been ruptured and several ounces of blood have been extravasated between bone and dura mater. This hæmorrhage extends down to the base of the skull, but is limited to the region of the middle fossa and presents an unusually convex surface towards the brain.

- 321 (in bottle). The skull of a boy divided horizontally. There is a fracture of the base of the skull crossing the posterior part of the body of the sphenoid, and extending forwards and upwards on each side into the squamous portion of the temporal, just in front of the root of the zygoma. On the right side the greater wing of the sphenoid is irregularly fractured; on each side the fracture involves the glenoid fossa. The suture between the greater wing of the sphenoid and the frontal bone has started in its whole length, the lines of separation, passing upwards, on neither side go higher than the suture between the squamous and parietal bones. There is no fissure in the calvaria. Between the dura mater and the bone on the right side there is a large clot of blood three quarters of an inch in thickness and three inches in width; it passes forwards into the sphenoidal fossa, which it nearly fills. In the recent state the clot appeared to consist of two parts, one layer more recent than the other. In the calvaria the hemispheres have been retained and the right hemisphere shows very well the results of compression.

The patient was a boy, aged 14, who died on the day following an injury. He had been partially conscious until within half an hour of his death, which occurred suddenly, and without the usual symptoms of coma. The case is recorded in detail in Lond. Hosp. Rep. vol. iv. Mr. Hutchinson.

- 322 (in bottle). The calvaria from the same patient as specimen 305, showing a broad shallow furrow on the surface of the right parietal bone. On the inner surface the bone is fissured and presents a sharp edge; the dura mater in apposition with it shows several patches of pus and lymph; there are slight traces of a lymph-membrane on the arachnoid lining of the dura mater. This specimen is important in reference to the question of primary trephining.

The patient was aged 16. His head had been crushed between a wire rope and the drum on which it was wound. He sustained a severe compound fracture of the left temporal and orbital regions and a compound fracture of the right humerus; the arm inflamed and incisions were made into it. Paralysis of the right third, of both facial, and of the fifth nerves was more or less evident before death, but no cause for it could be found after death. There was no paralysis of arm or of leg. Tetanus came on on the 17th day, and death occurred on the 21st day after admission. Mr. Hutchinson.

- 323 (in bottle). Fracture crossing petrous portion of right temporal bone, breaking into glenoid fossa and tympanum, finally turning over apex of petrous bone so as to reach the foramen lacerum posticum.



### Fractures of Lower Jaw.

324. Specimen of a nearly vertical fracture of the lower jaw obtained from the body of an old man, the subject of chronic rheumatic arthritis and gout. The line of fracture is nearly vertical and unusually close to the symphysis, being a little to the left of the middle line. It was, in all probability, due to direct violence.
325. Lower jaw of an adult which has sustained a double fracture. On the right side an oblique fracture passing downwards and backward from the middle of the sigmoid notch has completely detached the right condyle. On the left side an oblique fracture passing downward and backwards has detached the ascending from the horizontal ramus. The last molar tooth is lodged in the posterior fragment.

### Fractures of Hyoid Bone.

- 326 (in bottle). The larynx and adjacent parts, showing a fracture of the hyoid just to the right of the body of the bone. The central end of the lesser cornu remains as a small nodule of bone connected with, but movable on the body. There has been suppuration about the seat of fracture, where an abscess of the size of a walnut has been formed. This communicates in front of the thyroid with an extensive suppurating and sloughing cavity in the left anterior triangle of the neck which had opened into the floor of the mouth. The fracture was caused by a blow from a spade which did not wound the skin.

Case of Joseph Cooper, 52; admitted Dec. 6, 1884; p.m. Dec. 16. Mr. Couper.

### Fractures of Sternum.

327. The manubrium of a sternum, presenting anteriorly a fracture, but without any trace of injury posteriorly. The fracture passes obliquely across the bone.
328. Separation of the manubrium sterni from the gladiolus; it can hardly be termed a fracture, since the bones were not previously united by osseous tissue.
- 329 (in bottle). Separation between manubrium and body of sternum. The upper fragment lay in an abscess cavity, suppuration having proceeded both in front of and behind the bone.

Obtained from a woman aged 25 who fell out of a window whilst drunk; she



survived seven weeks, dying of pyæmia. An abscess had formed over the manubrium, and it was after this had been opened that the fracture-dislocation was detected.

- 330 (in bottle). Double fracture of sternum with displacement and overlapping. There is separation at the junction of the manubrium with the body, and the manubrium is displaced behind the body, with half an inch overlapping. There is a second fracture through the body of the bone about half an inch lower down, which would appear to have been produced by pressure of the lower part of the manubrium against it. The ligamentous structures are entire both in front and behind, the fractures being wholly intra-periosteal. The extremities both of upper and lower fragments are capped with cartilage. Ossification is in progress, a strong bridge of new bone having been developed in connexion with the periosteum, which has been detached behind the bone.

From a case of fractured spine.

- 331 (in bottle). Fracture of sternum on posterior aspect. A sternum showing transverse fracture just above the level of the third ribs. The ligamentous structures in front of the bone are entire; those behind it are torn completely through, allowing the fracture to gape widely towards the mediastinum. The fracture was no doubt caused by the patient's chin.

- 332 (in bottle). Fracture of sternum on anterior aspect. A sternum showing transverse fracture just below the third ribs. The ligamentous structures behind the bone are entire; those in front are torn completely through, allowing the fracture to gape widely in front. This fracture has clearly been caused by a bending of the bone with the convexity forwards. *Presented by Mr. Little.*

333. A portion of the gladiolus showing a fracture involving the posterior part of the bone only. It is possibly from the same subject as 327, but no history is obtainable.

### Fractures of Clavicle.

334. A recent specimen of fracture of the clavicle, probably by indirect violence. The bone shows an oblique fracture exactly at its middle, which commences on its posterior surface two inches from its sternal end and passes forwards and outwards for a length of two inches and terminates in front exactly two inches from the acromial end.



335. A right clavicle much shortened by union of a fracture with overlapping. The curves of the bone are lost and it is almost straight; the sternal fragment measures three inches and a half, the acromial fragment exactly the same; they overlap rather more than an inch and a half, the acromial fragment being in front, and on a little lower level than the sternal one.
336. A right clavicle, showing the results of comminuted fracture near its middle, the outer fragment is behind and below the inner ones and they overlap to the extent of nearly one inch. A detached fragment nearly one inch long stands nearly vertically on the front surface of the outer fragment, and its sharp point must have projected immediately beneath the skin.
337. A transverse fracture of the left clavicle, two inches from its sternal end, the result of direct violence.
338. Fracture of the right clavicle at its acromial end, through the attachment of the trapezoid ligament and outside that of the conoid. The outer fragment is overlapped by the inner one, and forms with it a very obtuse angle which is filled up with exuberant callus, traversed by one or two channels. The specimen was obtained from the post-mortem room. The left clavicle is kept for purposes of comparison.
339. An oblique fracture of the clavicle at the junction of middle and outer thirds.
340. (in bottle). A specimen of fractured clavicle showing the usual displacement and callus deposited between and around the ends of the fragments.
- The patient from whom it was obtained presented himself as an out-patient at the London Hospital with a painful tumour on the right clavicle. As he denied having met with an accident, he was at first treated on the supposition that it might be of syphilitic origin. There being no improvement he was admitted as an in-patient. Crepitus was discovered and the possibility of ordinary fracture from violence having been excluded by the persistent statement of the patient, it was after consultation decided to remove the clavicle as probably the seat of malignant disease. The operation was performed by Mr. John Couper in 1866, and section of the bone disclosed the true character of the tumour. The man returned to the Hospital in 1872 and had quite as good use of the right as of the left upper extremity.
341. Two clavicles having their acromial extremity broken off. The fracture passing in each case across the attachment of the trapezoid ligament, there would have been but slight displacement of the outer fragment during life.



342. An oblique fracture in the middle of the shaft of a clavicle with the usual displacement. At the outer third is a sudden bend of the bone with the convexity backwards. This was probably due to rickets and quite independent of the fracture.

343. Fracture of the outer end of the right clavicle. The outer fragment, about an inch long, has been displaced forwards and is united at an angle with the shaft. A buttress of bone supports the union.

### Fractures of Ribs.

344. First rib of left side and portion of manubrium of the sternum completely united together by ossification of the cartilage. From its great irregularity it seems probable that this may have resulted from an injury.

345. A portion of a rib well united by bone, and with but little formation of callus.

346. A fracture of the first rib midway between the tubercle and angle, with moderate development of callus. The section passes through the seat of fracture.

347. The first rib of an adult, showing a fracture at its middle. He died from extensive injuries to the chest caused by the wheel of a vehicle, by which he was run over. Several other ribs were fractured.

348 (in bottle). A seventh rib cut cleanly through by a suicidal stab. The incision was made with a shoemaker's knife. The wound in the skin was only an inch in length. The soft tissues and the intercostal spaces above and below were scarcely affected.

From the same case as the specimen of wounded diaphragm. The part cut through is not the cartilage, but is bony throughout.

*Presented by Mr. Curling.*

349 (in bottle). This specimen, probably from the eighth rib of the left side, shows a transverse fracture through the costal cartilage about half an inch from the end of the rib. The costal extremity has been displaced in front of the sternal one, which it overlaps for a third of an inch. The displaced portions are firmly bound together by fibrous bands; and a sort of false joint has been formed, which, however, permits of but little motion. No bone has been deposited, and there has been no absorption of the cartilage.



- 350 (in bottle). A portion of the fifth rib and the sternum, showing an ununited fracture of the costal cartilage very near to the sternum. The outer portion of the cartilage is displaced forwards. The cartilage appears to have undergone atrophy, and is only about half its width from above downwards. Free motion is permitted at the false joint.

The fracture resulted from an accident ten years before the man's death.

*Presented by Mr. Hutchinson.*

- 351 (in bottle). Specimen of old fracture of costal cartilage with considerable displacement, the angle between the displaced fragments is filled with osseous material. Obtained from the body of a man who died from extensive injuries, the results of having been run over.

352. A first rib fractured obliquely at the junction of the anterior third with the posterior two thirds of the bone.

From a case of extensive injury to the chest, obtained from the Post-Mortem Room by Mr. McCarthy.

353. Portions of two ribs which have been fractured transversely about two inches from the sternum. Both are well united by bone with a certain amount of thickening. The two bones are three quarters of an inch apart; but at the site of fracture a strong ridge of bone a quarter of an inch thick passes obliquely from one to the other and joins them both most firmly together.

### **Fractures of Scapula.**

354. The left scapula, showing a line of fracture commencing at the middle of its axillary costa, crossing obliquely upwards to the posterior third of the spine, and thus quite detaching the lower and posterior half of the bone. A portion of the posterior part of the acromion has been broken off; also another portion from the upper border of the bone.

355. A right scapula, fracture extending irregularly through the middle of its body. The fracture begins about the middle of the axillary costa, and passes upwards to the spine, near the middle of the bone, where it divides like the letter Y, one line passing directly backwards, and thus leaving the lower third of the bone completely detached, the other a mere linear crack passing upwards to the angle.

356. Left scapula of a man who had been run over. The outer end of the acromion process has been obliquely broken off; the coracoid process has been completely detached along with a broad piece of bone



which comprises the upper third of the glenoid cavity, the upper border of the neck, and part of the superior costa of the bone with the notch (in this case a foramen) for the supraspinous nerve. The tip of the coracoid process is also smashed. In the remaining portion of the glenoid cavity is an incomplete fracture passing downwards and backward.

357. An extensively comminuted fracture of the scapula, in which the stronger processes of bone, viz. the spine and axillary processes, have given way as well as the thinner portions.

358. Upper part of right scapula, showing a curiously arranged fracture separating the base of the spine, and another detaching the acromion process. There was probably extensive comminution of the lower part.

359 (in bottle). Scapula, showing fracture of coracoid and neck of bone.

The patient, a man aged 35, fell off a cart, and one wheel was supposed to have passed over him. He suffered considerably from the shock, and his abdomen, pelvis, and chest were found to be injured. He died the next day: various injuries were found to the chest, abdomen, and pelvis; and this specimen was obtained from the left shoulder. No doubt the fracture was caused by direct crushing of the wheel, which broke off the tip of the coracoid and next fractured the neck. The fracture does not take the usual direction across the neck of the scapula; but runs into the glenoid cavity, so as partly to separate the upper third of the latter, the biceps tendon and glenoid ligament still maintaining the two to some extent in apposition. Compare No. 356.

### Fractures of Humerus.

360. A specimen of T-fracture into the elbow-joint, with a comminuted fracture of the surgical neck. The former is complicated, as is usually the case, with several other lines of fracture.

361. Right adult humerus.—Comminuted fracture three inches and a half above the elbow. There is also an irregularly vertical split of the articular end of the bone, commencing in the middle of the trochlea, passing upwards through the olecranon fossa, and obliquely inwards so as almost to detach the whole of the inner condyle.

The history of the accident has not been preserved. It is probable that the injury was the result of direct violence. There is also an appearance of fracture without detachment of the greater tuberosity.

362. A left humerus, showing the result of an oblique fracture commencing a little below the middle of the bone behind and passing



downwards and forwards for about two inches. The lower fragment is drawn up behind the upper one and its upper pointed extremity projects backwards. The bone is probably shortened to the extent of an inch and a half, perhaps more. There is a large amount of new bone deposited between the fragments.

363. The left humerus of an adult, twelve inches and a half in length, showing an united fracture in the lower third of the bone. The bone has been shortened a full inch by the overlapping of the fragments, the lower fragment having been drawn upwards, forwards, and outwards in front of the upper one. There is a large amount of new bone, not only connecting the fragments but completely ensheathing the lower end of the upper fragment and concealing its shape. The upper end of the lower fragment has no new bone on its front surface. Probably the fracture was a comminuted one.

364. The left humerus of an adult, showing a united fracture a little above its middle; the line of fracture has been very oblique and the lower fragment is behind the upper one. Owing to the obliquity of the line of fracture, it is difficult to estimate the amount of shortening. Almost the whole of the upper fragment is roughened on its surface by the deposit of new bone, whilst the lower fragment is almost smooth.

365. The left humerus of an adult, showing a united fracture at the commencement of the lower third. The fracture has been oblique and probably comminuted; the lower fragment has been drawn up behind the upper one. The bone is shortened by overlapping to the extent probably of an inch, and its axis is bent, the convexity being outwards.

366. The left humerus of an adult, showing the result of a fracture in two places. The first fracture is at the junction of the upper and the middle third, and the second at the junction of the middle with the lower. In each instance the fracture would appear to have passed obliquely downwards and inwards. Union is firm and the bone much thickened; its medullary canal near the middle is almost obliterated.

367. An adult left humerus, showing a recent fracture through the middle of the shaft. The fracture is dentated and slightly oblique. The obliquity does not involve more than a third of an inch. It may be noted that with this kind and position of fracture non-union occurs not very infrequently.

368. The left humerus of a young woman who committed suicide by



throwing herself under a railway-train. Both legs were crushed. There was no injury to the skin of the arm. The humerus is broken in its lower third; the line of fracture is very oblique, almost spiral. A fragment from the back of the bone has been lost. Traces of the line of epiphysial junction are still evident at the upper end, none whatever at the lower.

369. A right humerus broken with comminution a little below its middle.

The fracture was caused by the arm being wound round a revolving shaft. The great pectoral muscle was torn across. Primary amputation ten hours after accident. The brachial artery opposite the site of fracture was contused and occluded for one inch of its length. From a middle-aged man. Mr. J. Hutchinson, April 11th, 1868.

370. The lower half of a left humerus, showing comminuted fracture of internal and external condyles. That of the external condyle separates the capitellum from the trochlea. On the inner side only the epicondyle has been broken off.

The injury was caused by a wheel passing over the elbow. Secondary amputation became necessary on the tenth day, owing to sloughing of skin and acute inflammation of the joint.

371. The upper third of a left humerus with an oblique fracture of the neck. The lowest end of the upper fragment is in the inner lip of the bicipital groove. The bone has been broken away at the base of the greater tuberosity or behind it, and the fragments have been lost. The head shows evidences of there having been some permanent displacement. The posterior edge of the lower fragment has apparently rested on the outer side of that of the upper one. The shaft must have been shortened to the extent of half an inch.

372. The upper end of a right humerus of a young subject. The epiphysis of the head has been torn off, and a vertical line of fracture separates the greater tuberosity, the bicipital groove, and a portion of the lesser tuberosity from the head of the bone. The shaft of the bone has clearly been crushed, its upper end is wanting, and there are the marks of spikes on its surface. It is about 2 inches long, and the lower extremity is irregular, as if fractured.

373. A plaster cast of the upper half of a humerus, showing appearances as if the articular surface of the head had been driven into the neck. Everywhere a rim of projecting bone encircles the head; union would appear to have been complete and of long standing.



374. A plaster cast of a left humerus, showing a united fracture at the lower part of the surgical neck. The lower fragment has been drawn upwards on the anterior and outer side of the upper one; the overlapping is probably to the extent of half an inch. The fracture has been slightly oblique.

375. The upper part of a left humerus. It shows an oblique comminuted fracture of the shaft a little below the surgical neck of the bone. From this fracture four fissures pass up nearly to the head of the bone, dividing this portion of the shaft into four tolerably equal segments.

From direct violence.

376. A left humerus of a young adult, with separation of the upper epiphysis. The epiphyses for the head and tuberosities are united together, and that for the inner condyle is becoming attached to the shaft.

377. Separation of the epiphysis of the humeral head; probably from a child four or five years old. The line of separation passes below the tuberosities.

378. A left humerus, showing a dentated transverse fracture a little below the middle.

The man died from very severe injuries to the chest, kidney, &c. On the post-mortem table it was found that mere extension did not put the fragments into position, the brachialis anticus, contracted by rigor mortis, preventing it. When the forearm was turned into complete supination, extension being kept up, the fragments fitted accurately. Mr. Hutchinson.

379. The lower half of a left humerus, showing a comminuted fracture in the lower third of the bone passing irregularly through the shaft. The external condyle, and the capitellum for the radius, have been broken off and lost.

From a woman killed by being run over by a railway-train. Mr. Hutchinson.

380. A fracture at the junction of the middle and upper thirds of left humerus, with extreme displacement. The lower end of the upper fragment, which is  $5\frac{1}{2}$  inches from the top of the great tuberosity, is tilted forwards and outwards, and the upper extremity of the lower fragment, distant  $8\frac{7}{8}$  inches from the inner condyle, projects inwards. The broken ends are firmly held together by a large amount of provisional callus.

There is no history to this specimen; but it is evident that the fracture must have occurred a long while before death, and, in all probability, was allowed to unite with little or no treatment.



381. Vertical section of a right humerus, with a transverse fracture at its centre, which has united with an anterior convexity, so that the posterior wall of the bone projects into the medullary canal of the upper fragment. There is considerable amount of ensheathing callus.

382. Fractured humerus through junction of lower third with upper two thirds of the shaft.

This specimen was obtained from a case which survived five weeks, and died eventually from effects of other injuries. The fracture is oblique. A good deal of ossifying callus has been thrown out, chiefly, however, on the upper fragment. On each fragment a portion of bone at the margin of the fracture is dead and distinguishable from the rest of the bone by its much greater whiteness. Any union that had taken place had completely broken down before death.

383. A transverse fracture of the middle of the shaft of a humerus. Two long fissures (about an inch and a quarter long) run down the shaft from the seat of fracture, nearly parallel with one another; and one short one runs upwards in the upper fragment. Probably from indirect violence.

384. An oblique fracture through the middle of the shaft of the right humerus, firmly united in a very faulty position, the upper end of the lower fragment being drawn upwards and outwards.

385. A specimen, without history, of united fracture of the lower part of the left humerus. It would appear that the fracture passed transversely across the outer condyle and the olecranon fossa at a level about half an inch from the articular surface. From the olecranon fossa it extended obliquely upwards, thus detaching the whole of the inner condyle, together with its base of attachment, making a fragment an inch and a half long. A vertical split through the trochlea has divided the lower fragment into two portions. The bones of the forearm, with the lower fragment, have been displaced backwards and inwards, and have then become united by very fine wedges of bone. The lower extremity of the upper fragment is close above the head of the radius, and projects also at least half an inch external to it. Thus there must, during life, have been a considerable projection to be felt in front of the elbow-joint. Flexion beyond a right angle must have been impossible.

386. Parts of humerus, radius, and ulna after fracture of the lower part of the humerus and subsequently chronic rheumatic arthritis.

No history. All the three bones show evidence of chronic arthritis in thickening of their articular margins and irregular bony excrescences. A very dense spur projects from the front of the inner part of the coronoid. These deposits render it



a little difficult to determine the results of the fracture; but it seems pretty clear that there has been, at some long distant period, a fracture passing almost transversely across the lower part of the humerus close above the articular cartilage and implicating the elbow-joint at one or more places. The lower fragment appears to have been twisted backwards and outwards, and its inner extremity projects into the olecranon fossa. The internal epicondyle is wanting, and from the lower aspect of the lower condyle for about half an inch the articular lamellæ is also wanting, the bone being rough. Flexion and extension may have been almost perfect.

387. Parts of the humerus, radius, and ulna from a left arm (adult), showing recent fracture across the base of the olecranon and the neck of the radius. The fractures are at the same level in the two bones. In each there is some splintering. The head of the radius, completely separated from the shaft, is further broken into three fragments.

388. Portions of bone from a case of compound fracture into the elbow-joint.

Primary excision was performed by Mr. Little. The elbow had been crushed by the pole of a van against a wall. There was but a small external wound. The radius and ulna were not injured; but the humerus was broken across obliquely just above the condyles, and the lower fragment smashed into seven pieces. The man recovered from the operation after severe inflammation of the parts.

389 (in bottle). A portion of the humerus of a boy, aged about twelve, who was admitted with compound fracture near to the line of the lower epiphysis on the right side. The lower end of the upper fragment projected into the wound, and was accordingly sawn off. The line of junction of the epiphysis was pretty nearly followed.

The patient recovered well with a stiff elbow.

390 (in bottle). Transverse fracture of humerus passing through olecranon and coracoid fossæ.

391 (in bottle). Upper part of right humerus of an adult man who had been struck by the buffer of a locomotive engine on the shoulder, in consequence of which he was knocked down, and sustained a comminuted compound fracture of the skull and laceration of the brain.

Death within seventy-two hours of admission to the Hospital. No external evidence of injury to the shoulder. The line of fracture roughly corresponds to the line of epiphysis of upper extremity of humerus, traversing the base of the great tuberosity and then following the line of the anatomical neck. This specimen is not one of true epiphysial separation; the line of fracture seems to be a little lower than the normal epiphysial line.



## 392 (in bottle). Fracture through the anatomical neck of each humerus.

The patient was a man, aged 50, who had fallen from the roof of a house upon his hands and head. He lived three days, and during this time crepitus was noticed in each shoulder; but there was neither pain nor deformity, so that the diagnosis was doubtful. He had phthisis, and death was apparently due to dyspnoea. The case is very remarkable for its symmetry, and is perhaps unique. On the right side the great tuberosity is broken off in addition to the fracture through the neck. Mr. McCarthy.

## 393 (in bottle). Right elbow-joint, showing fracture of the head of the radius alone. About one half of the articular portion is split into two fragments, one of which is still kept in position by its continuation with the neck being intact, the other only adhering by the periosteum. The orbicular ligament is still intact. The fracture is evidently recent, and is probably due to the radius being driven against the capitellum.

## 394 (in bottle). Arm of an infant, to illustrate the pathology of the common "elbow-sprain" in children under the age of five or six. The orbicular ligament has slipped off the head of the radius and lies between it and the capitellum. No deformity can be recognized during life; but on flexing and then pronating the forearm, the radial head slips again into its place with an audible "click."

See 'Annals of Surgery,' August, 1885.

*Presented by Mr. J. Hutchinson, Jun.*

## 395 (in bottle). The bones from a fracture above the right elbow-joint.

The patient was admitted with a compound fracture of the humerus about two inches above the elbow-joint; but the joint was not supposed to be injured. He also had injuries to the lower extremity on the same side, which necessitated amputation and led to his death. He was so ill during the whole of the time of treatment, that but little could be done to remedy the displacement of his arm. The specimen shows the lower end of the upper fragment placed behind the lower one, and so low that it almost touches the tip of the olecranon; the two are united by intervening bridges of bone. The lower fragment is two inches in length, and is divided by an almost vertical fissure near its middle. This fissure opens the joint. The joint has been the seat of destructive disease and the cartilage has been almost everywhere removed. Suppuration was still profuse at the time of the man's death, and, had he lived, it is evident that a portion of bone would have exfoliated. The tip of the olecranon is united to the lower end of the upper fragment by fibrous bands. Mr. Little.

## 396. The lower end of the humerus and upper part of the ulna, showing a fracture of the shaft of the humerus immediately above the lower extremity, with a vertical fracture of the latter separating the trochlea from the capitellum. The olecranon process has been broken off transversely, dividing the greater sigmoid cavity into two nearly equal portions.



**Fractures of Radius.**

397. The upper half of an adult radius broken by being crushed by a toothed wheel. The fracture of the shaft is slightly oblique and dentated, its head and neck show several perforations by the teeth of the machine. Primary amputation was necessary. *Mr. Hutchinson.*

398. The left radius of an adult. A fracture extends obliquely through its carpal extremity, commencing on its outer side nearly three quarters of an inch from the tip of its styloid process. The line of fracture runs obliquely downwards and enters the joint near the inner side of the bone. The fragment thus separated is divided into two by a vertical fissure but without displacement. Some small portions have been detached from the posterior edge of the upper fragment and are lost.

399 (in bottle). The lower part of a radius of a woman who died about ten days after an accident. She had fallen from a window, and was said to have come down straight upon her feet, and afterwards fallen forwards. She had sustained fractures of the os calcis in both feet, (compound) fracture of the spine, and fracture of the sternum. Her left wrist showed all the usual symptoms of Colles's fracture, the hand being displaced backwards. On account of the other injuries no treatment was adopted for the wrist. On the post-mortem table it was found impracticable by extension to remove the deformity, the impediment being the contracted muscles, chiefly the supinator longus. On dissection an oblique comminuted fracture of the lower part of the radius was found. The fracture through the shaft was about an inch and a quarter above the articular surface, at some parts only an inch, at others one and three quarters. The lower fragments were displaced behind the extremity of the upper one. Owing to the obliquity and comminution, the lower end of the upper fragment consisted for a third of an inch of the anterior part of the bone only, thus the bones overlapped without the overlapping involving their entire thickness. The lower fragment is splintered into five or six separate portions, two of these being small. A longitudinal fissure, passing through the lower fragment into the wrist-joint divides it into two portions. It is the outer one of these which is comminuted. There has been no penetration of the lower fragment by the posterior edge of the upper, because this posterior edge has been broken completely off and constitutes a separate fragment about three quarters of an inch long.

400 (in bottle). Vertical section of carpal bones and carpal extremities of ulna and radius from a case in which the radius was dwarfed owing to



an injury to the epiphysis in early life. The radius is three quarters of an inch shorter than the ulna. The cartilage of the radius is deficient or much thinned on that part of the bone nearest the ulna and there are some strong bands of adhesion between it and the carpal bones.

The accident had occurred in boyhood and the man was between forty and fifty at the time of his death. There is nothing in the section of the bone to indicate the line of fracture, reparation having been complete, and the alteration in form being the chief remaining peculiarity. The increased thickness of the compact tissue on the ulna border of the radius is deceptive, and results from the section having passed close to its surface. The specimen has been described in detail in the *Path. Trans.*, vol. xvii. p. 237.

*Presented by Mr. Hutchinson.*

**400 A** (in bottle). Colles's fracture of the right radius, the line of fracture passing through the level of the supinator longus insertion.

The patient was an elderly man and the accident was a fall from a height, death ensuing a few days afterwards from other injuries. Some impaction was present of the posterior wall of the radius into the cancellous lower fragment, but it could have been disengaged without much difficulty. The sharp end of the upper fragment is seen to pierce the pronator quadratus. The extensors of the thumb were not specially tense, but the common extensor of the fingers and the short radial extensor were tight. The wrist-joint and the styloid process of the ulna were unhurt, and it is particularly to be noticed that the periosteum on the back of the radius is still intact. Mr. J. Hutchinson, Jun.

**401** (in bottle). Lower extremities of bones of the forearm from a case in which amputation was performed by Mr. McCarthy on account of very severe injury to the hand. On subsequent examination Mr. McCarthy discovered the fracture of the lower end of the radius which is seen in this specimen, and of which in the recent condition there was no symptom. It corresponds in position and direction to a Colles's fracture.

The mode in which the accident occurred (the hand had been caught in a revolving cogwheel) probably accounts for the absence of the usual deformity. It will be noticed that in this, as in most specimens of Colles's fracture, the inter-articular fibro-cartilage and the periosteum on the back of the radius remain intact.

**402.** The lower third of the radius and ulna with carpal bones. There is an almost transverse fracture across the lower extremity of the radius about three quarters of an inch from its articular surface and rather more than an inch from the tip of the styloid process. The distal fragment keeps its normal relations with the ulna and carpal bones. To judge from the specimen in its present state it would appear that there has not been much displacement.



403 (in bottle). The carpal extremities of a left radius and ulna showing a fracture of the former into the wrist-joint. A portion constituting perhaps a fifth of the carpal surface and about three quarters of an inch in length has been split off backwards and to the ulnar side. The detachment is incomplete, neither the periosteal fibres nor the synovial membrane being torn through at all parts; one or two small portions of bone on its posterior surface have been detached. The accident was not diagnosed during life. The patient died of pyæmia after an injury to the head.

404. The right radius and carpus of a young subject showing detachment of the carpal epiphysis of the radius. With the exception that a very small portion of bone is broken off from the posterior part of the shaft, the injury is a clean detachment of the epiphysis without fracture. This specimen has been described and figured by Mr. Hutchinson in the *Trans. Path. Soc.* vol. xiii. p. 182, and in the *London Hosp. Reports*, vol. i. p. 89.

404 A (in bottle). The right elbow-joint, showing detachment of the upper epiphysis of the radius. The outer side has evidently borne the weight of the injury, as the capitellum is partially divided by a line of fracture passing downwards and inwards, in addition to the small epiphysis of the outer epicondyle and the adjoining part of the capitellum being torn off. The upper epiphysis of the radius is cleanly detached at the epiphysial line and remains partly within the grasp of the orbicular ligament, the diaphysis projecting somewhat behind it. The end of the diaphysis is perfectly free from cartilage; in other words, the epiphysial disc has remained with the epiphysis. The periosteum is only slightly detached at the anterior margin of the end of the shaft; in this the specimen is an exception to the rule in complete separation of the epiphyses, there being then nearly always extensive stripping of the bone.

The patient was a lad aged 13 years who fell between the train and platform, tearing off the skin of the forearm and lacerating the muscles. Primary amputation was performed and he rapidly recovered.

Case reported in *Path. Trans.* for 1888.

*Presented by Mr. M. Moullin.*

405. The radius and ulna of a young subject, whose left arm was removed by primary amputation. The carpal epiphysis of the radius has been detached. Almost the whole of the epiphysial cartilage has gone with the epiphysis, but two small patches remain on the extremity of the shaft. The end of the shaft at its margins is a little splintered, but there is no material fracture. On the palmar aspect, about a quarter of an inch from the outer border, is a linear fracture about an inch long, the upper end of which looks as if a tooth of



some machine had entered the bone. The linear fracture does not involve the whole thickness of the bone and consequently does not permit of motion; possibly it is only a scratch, and if so the epiphysis was probably pulled off by the tooth which inflicted it; unfortunately, the carpal end has not been kept. The ulna presents a dentated, almost transverse fracture an inch and a quarter from the extremity of its styloid process.

405 A (in bottle). Radius and ulna of an infant, showing "greenstick" fractures of both bones.

406. The radius and ulna of a left arm, showing union with great displacement after fracture of both bones. The ulna has been broken about its middle and the radius about an inch and a half higher up. Both are firmly united, but with a considerable bend backwards and outwards.

407. The right ulna of an adult, showing a firmly united fracture at its middle. The fracture would appear to have been slightly oblique, and its union has occurred with slight displacement of the lower fragment inwards.

408 (in bottle). Fracture of the olecranon three weeks before death. No union has taken place and the parts are not displaced. The fracture is at the usual site, opposite the lateral notch of the olecranon.

See fracture of neck of femur No. 418. Case of E. Sandown. Post mortem May 31, 1884. Mr. McCarthy.

409. Both bones of the right forearm broken across the middle. The fracture was compound, and was caused by the arm being twisted round a revolving shaft. Removed by primary amputation at the shoulder-joint.

Mr. Hutchinson, April 1, 1868.

### Fractures of Pelvis.

410. The entire pelvis of a female child. The child had been run over in the street; the third, fourth, fifth, and sixth ribs were broken at their angles, and the liver was superficially lacerated. The pelvis shows a fracture through the right pubic bone just internal to the acetabulum, and directly beneath this a corresponding fracture through the ischium just internal to its tuberosity. The whole bone is loosened at the sacro-iliac synchondrosis, but without any material displacement.

Mr. Hutchinson.



411. Part of the left os innominatum of an adult, showing united fractures of the os pubis and ischium. The fracture of the pubis passes through the bone just on the inner side of the acetabulum and the inner fragment has been displaced a third of an inch downwards. The ramus of the ischium has been broken close to its junction with that of the pubis, and three quarters of an inch higher up the ramus of the pubis is again broken. The lines of the fracture are somewhat oblique. The inner fragment is displaced downwards and outwards.
412. A left os innominatum with fractures running in the following directions, one through the ramus of the ischium and another through the ramus of the pubes. There are fractures extending through the body of the pubes dividing it into three portions, of which the posterior, comprising the ilio-pectineal eminence and the greater part of the horizontal ramus of the pubes and a portion of the acetabulum, is the largest. At the upper and posterior part of the acetabulum a portion of the inner surface about the size of a sixpence is depressed into the compact tissue.
413. Comminuted fracture of the right os innominatum. The femur has probably been driven against the bone, splitting it in all directions.

#### Fractures of Femur.

414. A purely intra-capsular fracture of the femoral neck. There is some separation in front, but behind the fragments are held in apposition by the retinacula of Weitbrecht (the bands reflected from the capsule). It is obvious that there could be no shortening in such a case, and slight rotation outwards of the limb with tenderness over the neck of the femur in front with perhaps some swelling would be the chief symptoms, together with loss of power.
415. A similar specimen to 414. In front the fragments gape at the line of fracture, behind there is some splintering of the posterior lamina, the apposition being maintained by the reflected layer of the capsule.
- 416 (in bottle). An intra-capsular fracture of the neck of the femur firmly united by ligament.
- 417 (in bottle). Intra-capsular fracture of neck of femur, the head being still held firmly in place by the reflection of the capsule (retinacula of Weitbrecht). It would have required considerable force in this specimen to have separated the fragments.



417<sup>A</sup> (in bottle). Intra-capsular fracture of the right femur from a woman aged 51. The neck of the bone is much atrophied. The line of fracture passes just beneath the margin of the cartilage and the head is still kept somewhat in position by the reflected part of the capsule (retinacula of Weitbrecht), which is torn through in front but not behind. During life there were the usual symptoms (about 1" shortening, eversion of the limb, laxity of the ilio-tibial band).

Compare Nos. 414, 415, and 417. Mr. J. Hutchinson, Jun.

418 (in bottle). Fracture of neck of left femur (intra-capsular) three weeks before death. The fracture is comminuted, and no union has taken place. Capsule is thickened. Line of fracture parallel to shaft, just within capsule.

See fracture of olecranon No. 408. Case of E. Sandown. Post mortem May 31, 1884. Mr. McCarthy.

419 (in bottle). Pelvis and upper part of each femur, together with the sacral vertebræ of a rabbit. The epiphysis of the head of each femur is separated from the shaft, and the contiguous surfaces of the epiphysis and shaft have become partly smoothed by friction.

The specimen was obtained from a doe rabbit which had never thriven well. The separation of the epiphysis was attributed to the amorous violence of a buck rabbit.

*Presented by Mr. Nettleship.*

420 (in bottle). Impacted fracture of neck of femur. This specimen is a good example of the form of impaction often present in fractures of this region from direct injury. The neck is driven into the trochanteric portion, and its lower border rests on a sort of bony shelf, so that no great shortening would be possible.

421 (in bottle). Fracture of right femur, the line of fracture having followed, both in front and behind, the inter-trochanteric ridges. Both trochanters are also detached.

422 (in bottle). Extra-capsular fracture of neck of femur with impaction.

423 (in bottle). Fracture of upper part of right femur. The section has been made through the acetabulum, head, neck, and shaft of femur. The neck and head have been displaced in relation to the shaft by the injury. The great trochanter is in immediate contact with the articular surface of the head of the femur by its upper border; its



inner surface corresponds to the displaced upper border of the neck of the bone. The part of the neck which has been separated from the trochanter is turned downwards and outwards. Beneath this there is some coagulated blood and attempt at repair. The fractured junction of the neck with the shaft is directed downwards and inwards. The reflection of the capsule along the hinder part of the neck is well shown.

The man had been struck on the side of the hip by a horse's hoof and survived five weeks.

424 (in bottle). Separation of epiphysis of left great trochanter from a small child aged ten, admitted into the London Hospital dying from pyæmia. The separation was caused by a fall on the left hip, ten days before death. Beyond pain and an abscess which formed over the back of the hip nothing was noticed by the parents of the child, who was able to walk about for the three days immediately succeeding the accident. She was after that kept in bed and on the tenth day was brought to the Hospital dying from pyæmic pericarditis and pleurisy. She was even then able to walk with some help. No attempt at diagnosis was made nor was there any definite local injury. The separation was discovered by Mr. McCarthy on the post-mortem table while tracing the course of an abscess which extended from the pelvis through the great sacro sciatic notch to the back of the hip-joint. The fragment is held in position by the reflected part of the capsular ligament and by a band of periosteum in front, which was partially cut away in cleaning the specimen.

Mr. McCarthy.

425. A firmly united impacted fracture with comminution. The neck has been driven into the great trochanter, which also has been broken off and is now welded to the shaft at an obtuse angle. The amount of ossification of provisional callus is excessive, there being numerous bridges and processes of new bone.

426. A firmly united impacted fracture of the neck of the left femur. The line of fracture is just above the trochanters and was probably all extra-capsular. The lower end of the neck is driven into the great trochanter and the upper part of the medullary cavity is completely shut off by a thick process of bone. It is impossible to say, without further section, whether this process is a detached fragment, or a mere thickening of the cancellous texture.

427. A comminuted extra-capsular fracture of left femur. The lesser



trochanter together with a large piece of the great trochanter is splintered off, and the neck is separated from the shaft by a jagged line of fracture below the intertrochanteric line in front and crossing it below.

428. A somewhat similar specimen to 427, but there is more comminution. The lines of fracture in these two specimens would lead to the conclusion that the result was produced by the neck being driven into the trochanters, but the comminution was so extensive as to prevent impaction.
429. An oblique fracture through the neck of the femur of an old person. The bone is much thinned. The fracture must have crossed the line of attachment of the capsule. The head shows many osteophytes, the result of "chronic rheumatic arthritis."
430. The anterior half of the upper third of a left femur, showing the results of an extra-capsular fracture, complicated with a fracture across the shaft, at the level of the lesser trochanter, and probably with splitting-off of the great trochanter. The shaft has been so much drawn upwards, that the neck of the femur, now again united to it, is directed obliquely upwards. Union is firm, with large masses of provisional callus. The neck of the bone has penetrated the shaft for a short distance, but for the most part is displaced in front of it.
431. Posterior half of the upper part of the head, neck, and great trochanter of a right femur. The neck is broken through at a position close to the articular border at the upper part and half an inch from it below. There has been some splintering of the exterior of the bone, and a small fragment, which appears to have been split off, is now firmly united to the head. The neck of the bone is wanting, and there is no evidence as to the condition of parts as regards union; probably it was quite ununited.
432. The left femur divided vertically, showing a comminuted extra-capsular fracture, the neck being driven into the cancellous tissue of the great trochanter, part of which is detached. The fragments would have been retained in position by the interlocking, and, in all probability, osseous union, with upwards of one inch shortening, would have resulted if the patient had lived.
433. Head, neck, and upper third of a right femur, showing an extra-capsular fracture of the cervix, with splitting of the great trochanter, so that almost the whole of it, together with the lesser trochanter, are separate both from the shaft and cervix and displaced obliquely.



The shaft of the bone on its inner aspect has penetrated the cancellous tissue of the neck for a distance of about half an inch. Union is nearly complete.

434. The head, neck, and upper fourth of a left femur, showing an extra-capsular fracture of the cervix, with splitting of the great trochanter and penetration of the neck to the depth of a full inch between the fragments. A part of the great trochanter is wanting; but it would appear as if the posterior two thirds of this apophysis, together with the whole of the lesser trochanter, had been wholly separated from the shaft and displaced backwards by the wedge-like action of the impacted cervix. Union complete in most parts.
435. Head, neck, and upper fourth of a left femur, broken into many fragments, several of which are probably wanting. The fracture would appear to have been extra-capsular, with splitting of the great trochanter and penetration of it by the cervix.
436. Vertical section of the upper third of a right femur, showing the result of an extra-capsular fracture of the cervix close to its base. The shaft has been drawn upwards for nearly two inches, and the cervix is now united to its inner side. Union appears to be firm, and there are strong buttresses of bone at its side. The deformity must have been very great, since not only must there have been very considerable shortening, but the great trochanter must have projected upwards and outwards.
437. The upper third of a left femur. A line of fracture commences externally about an inch from the great trochanter, passes obliquely downwards and inwards to about an inch below the lesser trochanter, thus detaching head, neck, the lesser trochanter, and almost the whole of the great trochanter from the shaft. The lesser trochanter is again broken off from this fragment, to which, however, it has been reunited by bone. It may be seen that there has been but very slight displacement. That which exists is of the upper fragment forwards. There is no shortening.
438. Upper third of a left femur, showing an extra-capsular fracture, with splitting off of the great trochanter. The specimen has been macerated and the fragments are now loose.

No history. The great trochanter has been split off by an oblique line of fracture from before backwards. The fragment is three inches and a half long, and includes the whole of the extremity of the trochanter and the posterior part of its base. The cervix has been broken low down through its shoulder. The lesser trochanter has been detached by the junction of two lines of fracture and is lost.



439. A fracture extending from the summit of the great trochanter about four inches downwards and inwards, running about half an inch below the anterior intertrochanteric line. The lesser trochanter has been broken off and become united to the upper fragment. It appears that before union took place one of two things must have occurred, viz. either the upper fragment must have been displaced forwards and outwards, or the shaft must have been rotated inwards, as the lower part of the upper fragment is firmly united to the anterior aspect of the shaft.
440. The upper half of a left femur, showing a recent comminuted fracture through the cervix and through the base of the great trochanter. The whole of the great trochanter, with the whole of the upper half of the cervix, constitute one fragment, which is quite detached from the rest of the bone.
441. Portion of a femur, showing union of a fracture with displacement. The fracture is probably at the commencement of the lower third. The lower fragment is displaced upwards for an inch and a half behind the upper one. Union is quite firm, but accomplished chiefly by the bridge of bone crossing from one fragment to the other. The medullary cavities at the end of both fragments are closed in. The cancellous tissue has been scraped away. The walls of the lower fragment are very thin.
- 442, 443, 444, 445, 446, 447, 448, and 449. These specimens are all examples of united fractures in the shaft of the femur at various levels. They all show what may be called the usual displacement of the fragments, viz. the lower fragment drawn up behind the upper to a greater or less extent. Nos. 442 and 447 present remarkable spur-like projections of bone. Several of them show also slight rotation of the lower fragment outwards. The shortening in the case of 443 must have amounted to at least 4 inches.
450. A left femur, unusually strong and heavy. It shows a united fracture at its middle, with displacement of the lower fragment behind the upper, and of the upper fragments forwards and outwards, so that a strong convexity outwards is produced. Shortening an inch and a half.
451. Fracture of the left femur at its lower third. There is firm union, but the lower fragment is displaced behind the upper, and so much everted that the inner condyle looks almost directly forwards. Shortening to the extent of two inches and a half.



452. The two halves of a right femur, showing firm osseous union after fracture of the lower part of the upper third. The fragments are united at an angle with two inches of overlapping. The lower fragment is on the outer side and behind the upper one. The upper one would appear to have been adducted. The whole bone is much thickened and roughened.
453. The outer longitudinal half of a left femur, showing union with displacement after a fracture a little below its middle. The lower fragment is drawn up behind the upper one. Shortening to the extent of nearly three inches. The bones are in almost close apposition and the union very firm. There is a little convexity outwards.
454. Probably an imperfectly-united compound fracture of a femur. The specimen is remarkable for the excessive deposit of new bone.
455. The posterior vertical half of a left femur, showing a united fracture just below the level of the lesser trochanter. The lower fragment would appear to have been displaced behind the upper one and to its inner side, but only to a slight extent. There is a curious smooth-walled cavity capable of containing half a walnut, probably an abscess. The union is firm and there is no evidence of disease on the exterior of the bone.
456. A right femur in vertical section, showing a united fracture a little above the commencement of the middle third. Union is complete, with a strong convexity outwards, the upper fragment having clearly been much everted and thrown forwards. The upper end of the lower fragment is displaced behind the extremity of the upper one. The fracture was probably oblique, and the shortening to the extent of an inch.
457. A right femur considerably bent and much atrophied, showing the results of a fracture, probably compound, from two to three inches above the articular surface of the knee-joint. The lower fragment has been displaced backwards and outwards, with much eversion. Shortening to the extent of three inches and a half; the end of the upper fragment is consequently in front of the knee-joint and on its inner side. The lower fragment and leg must have been much everted and adducted.
458. The lower two thirds of a left femur. An oblique and comminuted fracture has passed from without inwards and downwards, at the



junction of its middle with its lower third. The fragments are at present in good position, but no union between the main portions had occurred. Several detached fragments are firmly united to the adjacent bone. Among the rest one fragment, an inch and a half long from the front of the bone, has been driven into the medulla and has there united. In all probability this fracture was by direct violence, and possibly compound.

459. The lower half of a femur after comminuted fracture about five inches above the knee-joint, with displacement of the lower fragment in front of the upper one. The fracture appears to have been oblique from above downwards and backwards. A detached fragment three inches long and irregular in shape is lodged behind the fracture in the popliteal space, and about this there appears to have been an abscess-cavity opening through a cloaca in the lower fragment just above the joint. Both bones are encrusted with porous deposit of new bone. They are not united. No doubt the fracture was compound.
460. The upper two thirds of a left femur, showing the results of an oblique and comminuted fracture in its upper third. Possibly it was a compound one. The upper fragment would appear to have been everted and abducted, and the lower fragment is drawn up on its inner side. Large irregular bridges of bone connect the two, but the process of union would appear to be incomplete. From the lower end of the upper fragment on the outer side a fragment six inches long has been broken off, but is now firmly united.
461. A comminuted fracture of the shaft of the femur near its middle, united with overlapping to the extent of two inches. The consolidation is imperfect; probably not more than two months old.
462. A fracture of the femur at the commencement of its lower third, slightly comminuted and oblique from within outwards and downwards. During life the lower fragment was displaced behind the upper one, and from the shortening the fracture was supposed to be much nearer to the knee-joint than it really is. On the post-mortem table the effect of bending the knee was tried and it was found quite impossible to effect reduction with the limb in this position, as the lower fragment pressed against the upper and tilted it forwards. The more the knee was bent the greater was the difficulty of counteracting the tendency to shortening, probably owing to the quadriceps extensor.
463. A right femur, showing union of a fracture at its middle. The bones



overlap for nearly two inches, the lower fragment being carried behind the upper one. The fracture is, however, somewhat oblique, so that probably the shortening was not more than an inch. Union has occurred, making an obtuse angle outwards. There is a remarkably long spur of new bone projecting upwards and inwards from the callus.

Dissecting-room specimen.

464. The left femur of an adult, showing a recent fracture in its lower half. The lines of fracture are exceedingly oblique and one of them passes in a spiral direction completely round the bone, its upper and lower extremities, which are four inches apart, being joined by one which is almost vertical.

Fracture caused probably by direct violence, the patient being killed by the fall of a house.

465. A right femur, showing a recent fracture at the junction of the middle and lower thirds. The fracture is much dentated and a fragment an inch in length from the posterior part has been detached and lost.

Cause of fracture not known, but believed to have been due to a fall from a house. Mr. Hutchinson.

466. A right femur, showing a recent fracture at the junction of the middle and lower thirds. The fracture has been much comminuted and several fragments are lost.

467. A right femur, showing a recent fracture in the lower third. The fracture is very oblique, commencing on the outer side of the bone at the junction of the middle with the lower third; it passes downwards towards the condyles posteriorly and into the knee-joint. In front the line of fracture passes spirally round the bone and runs into the posterior fracture above the inner condyle; thus the condyles are not completely separate, they were, however, sufficiently loosened to allow of the line of fracture being made to gape on the slightest pressure. The bone is exceedingly light and its walls very thin.

The patient was an old man who broke his femur in a fall from his bench, his leg being fixed. There was much displacement at the time of admission, but it was easily reduced. He died of exhaustion three days after the accident. Mr. Hutchinson.

468. A recent transverse fracture at the middle of the shaft of the femur.

469. A left femur, showing extensive recent fractures. The great



trochanter has been comminuted. A large posterior fragment includes the lesser trochanter also. The shaft is again broken through at the junction of the upper with the middle third, and at this part also the fragments are comminuted and the upper one shows a half spiral fissure passing upwards to the fracture of the trochanter.

Amputation at the hip-joint was performed, but the patient sank. Mr. Little.

470. A left femur, showing a recent fracture in the upper third. The fracture is dentated and comminuted; a large fragment quite detached includes the lesser trochanter, together with part of the posterior surface of the bone.

471. Oblique fracture of the femur at the junction of the lower fourth with upper three fourths. Some fragments have been lost.

472. The lower half of a femur of a young patient. The epiphysis is not yet united. There is an irregular fracture somewhat oblique from behind forwards and much dentated at the junction of the middle with the lower third.

A recent specimen, probably obtained by primary amputation and without history as to the character of the displacement.

473. A left adult femur, showing a broad shallow trough on its anterior surface extending upwards an inch and a half from the trochlea between the condyles. The outer condyle especially shows the effects of attrition, being rather deeply grooved. At its upper part a ridge of new bone has been deposited.

No history attaches to this specimen, but there can no doubt its possessor had an ununited fracture of the patella and that the trough shown is the result of the movement up and down of the upper fragment.

474 (in bottle). The right femur of a rickety child aged 3, with an intra-periosteal fracture in its lower third.

The child died a fortnight after the accident, of malignant scarlet fever. There had never been any separation of the fragments, but motion could be easily produced. The periosteum is seen to be torn at a few points, but for the most part is entire. Just above the fracture the bone is much bent. Mr. Curling.

475 (in bottle). The lower half of a left femur, showing a recent fracture into the knee-joint. The shaft is broken across just above the condyles, and the latter are separated from each other by a vertical split. The lines of fracture thus correspond in shape to the letter Y. The



periosteum was extensively stripped from the lower part of the upper fragment. The crucial ligaments are entire. The condyles can be separated rather widely in front, but not posteriorly. The lower end of the upper fragment projected in front of the condyles, and it is possible that the condyles had been split by its action as a wedge. The line of fracture is dentated and several small fragments have been detached and are lost.

The man, aged 37, died of cellular inflammation of the limb nine days after admission. There was much effused blood in the knee-joint, which had suppurated. The accident was caused by falling with a ladder, but he could not give a clear account. Mr. Hutchinson.

476 (in bottle). The lower end of a femur from a case of compound fracture. The patient, a middle-aged woman, fell out of a chaise and broke her left femur a little above the knee. Amputation was performed by Mr. Tay, but death ensued on the fifth day with gangrene of the flaps. The specimen shows a vertical fracture extending between the condyles into the knee-joint. Mr. Tay suggests that this may have been caused by the patella being driven against the condyles like a wedge. Whether this be the cause or whether it result from the lower fragment being split by the sharp end of the upper fragment, the form of fracture appears to be not unusual.

Compare 475 and 478. A similar fracture of lower end of femur with vertical fracture between the condyles was in the Hospital in November 1872, under Mr. Rivington. The case was treated antiseptically, but the patient died with extensive suppuration between the various layers of muscles round the thigh, by which the greater part of the upper fragment was stripped of muscular attachments. The specimen was not preserved, but the condition of fracture was precisely similar to the two last described.

477 (in bottle). A recent fracture of the femur a little above its middle, from a young subject. The fracture is irregularly transverse. The upper portion presents a very sharp point. A small fragment of the outer lamella has been pressed into the medullary cavity.

The patient died within a day or two of the injury.

478 (in bottle). A T-fracture of the lower end of a femur, the condyles being completely separated, but held in position by the lateral and crucial ligaments. The cartilage on the outer condyle is slightly eroded; probably this was done at the time of accident (a fall down a ship's hold).

On admission a small wound was present on the front of the thigh, through which the pointed end of the femur protruded; this was sawn off and the displacement reduced. The patient died of pyæmia a few days later. At the P.M. the synovial sac was found to be entire, but full of blood and pus, which had entered through the fracture between the condyles. Mr. McCarthy.



- 478 A. The lower end of the left femur from a lad, aged 15, showing an united oblique fracture about 6 inches above the knee, the upper fragment having been displaced downwards and backwards, so as to project into the popliteal space. In addition there is a vertical fracture of the lower epiphysis, which separated the two condyles and passed a short distance up into the diaphysis. Firm bony union without displacement has resulted; the separation of the whole epiphysis is due simply to maceration.

The patient had his left thigh run over in June 1886; the fracture was treated at another Hospital. In December a tumour formed in the popliteal space, which doubtfully pulsated, and which was suspected to be a diffuse aneurism. At the operation Mr. Moullin found a linear rent in the popliteal artery, caused by the projecting fragment of bone. The vessel was ligatured and the patient did well for a time. Subsequently disorganization of the knee-joint rendered amputation necessary, and from this he recovered. Mr. Mansell Moullin, 1888.

- 479 (in bottle). Section of a recently-united fracture of the shaft of the femur. The fragments overlap for the length of two inches and the deformity must have been considerable. It is the duplicate half of specimen No. 461.

- 480 (in bottle). The lower two thirds of a right femur, showing union of an oblique fracture. The fracture has been very oblique, passing downwards and forwards for a length of three inches and a half. The lower fragment is displaced upwards and backwards, the shortening being to the extent of two inches and a half. The lower end of the upper fragment projects forwards within an inch of the knee-joint. The bones are united together by partially ossified fibrous tissue.

No history attaches to this specimen. It probably shows the state of things at six weeks or two months after the injury.

### Fractures of Patella.

- 481 (in bottle). A right patella, showing the results of transverse fracture in the lower part of the bone. The lower fragment is triangular in shape and is not more than one fifth of the whole bone. There is firm union by ligament. At the posterior surface the interval between the fragments cannot be stretched to more than a line. The interval, however, increases rapidly as we approach the front of the bone, owing to the oblique position of the lower fragment, thus leaving a triangular gap between the fragments with its apex backwards. The length between the two fragments in the front aspect of the bone is half an inch, and in the flexed condition may be stretched to considerably more.

- 482 (in bottle). Old specimen of fractured patella, the lower fragment



being, as is so frequently the case, considerably the smaller. Close fibrous union has occurred. The cartilage on both fragments is worn away to some extent.

- 483 (in bottle). A transverse fracture of the right patella, dividing the bone into almost equal halves. There is no comminution. The cartilage of the lower portion appears to have been somewhat damaged by pressure.

The following description is copied from the old Catalogue:—

"Elizabeth Huddart was admitted into the London Hospital under the care of Mr. Scott and died on the following day, having fractured the right patella transversely.

"*P.-M. Appearances.* The right inferior extremity much swollen, with numerous vesications on the cutaneous surface. Subcutaneous cellular structure infiltrated with sero-sanguineous fluid, a quantity of which was contained in the knee-joint. Synovial membrane inflamed, being unusually vascular and softened. A quantity of coagulated blood adherent to the fractured edges of the patella, which were separated about an inch. Cartilage lining the patella softened, its fibrous structure being remarkably distinct."

- 484 (in bottle). A left patella, showing transverse fracture detaching the lower third.

The injury had been caused by a very severe crush of the joint and was attended with a great effusion of blood into it. The joint suppurated, and after long treatment, the man's health giving way, amputation became necessary. The fracture had therefore practically been a compound one. The specimen shows union of the fragments at their articular edges by strong ligamentous tissue, with about the eighth of an inch separation. Excepting at this part, the fragments are not in the least united, whilst the broken surfaces are covered in by new tissue. At the inner angle of the upper fragment there is a small portion of bone in process of necrosis. The lower fragment is considerably thickened by the deposit of new bone; weeks had elapsed between the accident and the amputation. Mr. Hutchinson.

- 485 (in bottle). Transverse fracture of patella, the two chief fragments being united by a firm fibrous band two inches in length. In this, near the upper end, is a smaller fragment.

- 486 (in bottle). Knee-joint &c. from a negro who died four years after a transverse fracture of his patella. The fragments, when on the stretch, are four inches apart. The medium between them consists of a strong membranous ligament. The synovial membrane of the knee-joint is drawn upwards into a large pouch and presents internally many irregular folds or rugæ. The connecting medium is attached only to the front of the upper fragment, not in the least to its fractured surface, which latter is perfectly smooth and covered by an adhering membrane; the angles of this fragment are still quite abrupt



as at the time of fracture. The lower fragment, on the contrary, appears to have been much altered in shape; it is increased in size in all its dimensions, especially in thickness. The uniting medium connects itself with the whole of its upper surface and with its articular rather than its anterior edge. Probably its fractured surface has been somewhat thrown forwards, so that the membrane passing from its anterior edge came in contact with its fractured surface and adhered to it.

- 487 (in bottle). A specimen of transverse fracture of the patella united by a long ligament.

No history was obtained, as nothing was known of the condition of things till after the man's death; it was then noticed that one thigh was much thinner than the other, and on examination this was explained by the discovery of a wide separation between the fragments of the patella; the fragments are five inches apart and are united by strong membrane which adhered to the fascia and to the skin. The fractured surfaces of the bone are thin and have apparently been bevelled off. The uniting medium has been very firmly united to them. The upper fragment is considerably larger than the lower one, and close to its edge there is a thick plate of bone in the substance of the uniting medium. The cartilage on the surface of the upper fragment has been worn away by attrition, but the bone is not actually bare. On the lower fragment there is a patch where the bone is completely denuded and polished. The patient was an old man and probably the injury had occurred many years before his death. The quadriceps extensor was much wasted in size, but its muscular structure appeared healthy. Mr. Waren Tay.

488. Fracture of a patella with fibrous union. The union is so close and firm that it was just as good as osseous, being at no part more than 1 mm. in thickness.

489. The front half of a patella, showing bony ankylosis after a transverse fracture through its middle. In addition to the chief fracture, a small portion is broken off on the outer side. There is a deep furrow in the line of the fracture across the front of the bone, evidently caused by gaping of the fragments.

The patient was a man of middle age who died about nine months after the accident, immediately after which there was considerable separation of the fragments. He was treated by back splint and bands of strapping. After removal of the bone, and before it was divided vertically, not the least movement could be obtained between the two halves. There is no question that the uniting medium was in part bony, and it would probably have increased with the lapse of time.

490. Fracture of patella united by ligament. The upper fragment is very much the smallest and around it in the fibrous tissue is some irregular ossific deposit. In front the periosteum appears to have dipped down into the interval.



490 A (in bottle). Vertical sections of the two patellæ from a dissecting-room subject, a man about whom no history could be obtained. The left patella has been fractured transversely, the upper fragment being considerably smaller than the lower one. Union has occurred by ligament, but the fragments are not separated more than a third of an inch. The aponeurosis of the quadriceps dips down into the interval and covers the surfaces of the broken bone. The right patella has been broken transversely, more nearly in the middle than on the left side, and firm bony union has occurred. The bone uniting the fragments is singularly dense, and more than half an inch in depth. In the depression opposite the union there has evidently been a firm band of adhesion to the femur.

*Presented by Mr. M. Moullin, 1888.*

491. Transverse fracture of patella, from a young subject.

#### **Fractures of the Tibia and Fibula.**

492. A right tibia, probably a grave-yard specimen, with fracture a little above the commencement of the lower third. The axis of the bone is almost straight, but the lower fragment has been drawn upwards behind and to the outer side of the upper one, which consequently projects forwards and inwards. The fracture has probably had an obliquity of about three-quarters of an inch from behind downwards and forwards. There are appearances which suggest that the sharp spine of the upper fragment was in process of absorption. Usual displacement.

493. A right tibia, showing the results of an oblique fracture in the middle of the lower third. The obliquity would appear to have had a length of two inches. The lower fragment appears to have been drawn upwards, behind but chiefly to the outer side of the upper one. The lower point of the upper fragment projects to the height of a third of an inch, at a level of an inch and a half above the level of the tip of the inner malleolus. There is an appearance of projection at the middle of the bone at its anterior edge, as if the fracture had been comminuted.

494. A left tibia, showing the results of fracture at the commencement of the lower third; the fracture has been very oblique, its course being nearly three inches in length. The lower fragment has been displaced to the outer side and behind the upper one, and the tip of the upper fragment consequently projects on the inner surface. Usual displacement.



495. A right tibia, showing the results of fracture at the commencement of the lower third. The lower fragment has, as usual, been displaced upwards, behind and to the outer side of the upper one. The tip of the upper one projects considerably inwards at a distance of 3 inches above the internal malleolus. The fragments have united at an angle of  $135^{\circ}$ , and a dense mass of bone has been formed in the concavity to prevent further yielding. In front of the fracture is a broad shallow groove formed by the pressure of the *tibialis anticus*.
496. Cast of a tibia, showing the result of fracture a little above the commencement of the lower third. The fracture has an obliquity of three inches. The displacement is the usual one, the lower fragment having been drawn upwards, behind and to the outer side of the upper one. The lower extremity of the upper one projects on the inner side.
497. A fracture in the upper part of the lower third of a left tibia. The displacement is of the usual kind as far as the relative position of the upper and lower fragments is concerned, but the bone appears to have been bent after union had commenced, and before it was firm; on the convex surface of the tibia two grooves are visible over the seat of the fracture, one for the *tibialis anticus* and the other for the *flexor longus pollicis*.
498. The lower two thirds of a right tibia and fibula. The tibia alone has been fractured at the junction of lower and middle thirds and is now firmly united. The fracture has been oblique, the obliquity having a length of more than  $1\frac{1}{2}$  inch. The upper extremity of the lower fragment is displaced outwards and perhaps a little upwards. It is firmly united to the inner aspect of the fibula. It is possible that the fibula may have been broken in its upper third. There is a somewhat doubtful appearance of a united fracture in its lower third.
499. The lower third of a left tibia and fibula, showing the state six weeks after a comminuted fracture through both bones about 2 inches above the ankle-joint. The line of fracture is oblique from above downwards and forwards, its length being about 2 inches. The lower fragments have been displaced upwards behind the upper ones, and the foot twisted inwards. The lower extremity of the upper fragment of the tibia appears to have been crushed outwards against the fibula, and the two bones now lie close together and are united. The lower ends of the upper fragments both of the tibia and fibula must have been prominent beneath the skin.

500. A right tibia and fibula, showing a united fracture of both bones



at the middle at a somewhat obtuse angle. The fracture of the tibia is oblique, its length being an inch and a half. The lower fragment is behind and to the outer side of the upper one. The fibula has been broken at two places, the middle fragment being an inch and a quarter in length. The upper extremity of the lower fragment of the tibia projecting upwards and outwards has touched the fibula and is firmly united to the upper fracture in the latter bone.

501. Fracture of left tibia and fibula.—The tibia has been broken a little below the junction of the upper with the middle third. The fracture would appear to have been almost transverse, and the displacement has been complete. The lower extremity has been drawn upwards and outwards, in front and to the outer side of the upper one, and has there united with a full  $1\frac{1}{2}$ " of shortening. The fibula has been broken at two places, first at the junction of the upper and middle thirds, secondly at the junction of the middle with the lower. Both fractures have united with overlapping, especially the lower one. The head of the fibula shows large outgrowths of new bone, and possibly there has been a fracture of its anterior part.
502. A left tibia and fibula from an adult, showing a recent comminuted fracture a little below the middle of the bone. The fracture is oblique from the outer side and behind downwards and inwards. The fibula is broken into three fragments of great length. All the fractures are dentated and more or less oblique, all are also slightly comminuted.
503. Cast of the lower half of a right tibia, showing the results of a comminuted fracture at the junction of the lower and middle thirds. The lower fragment has been drawn upwards in front of the upper one, and has there united with overlapping to the extent of half an inch. No reduction has ever been effected. Probably this fracture was from direct violence.
504. The lower half of a right tibia showing union with great displacement after an oblique fracture, about 4 inches above the ankle-joint. The obliquity is from before downwards, backwards, and inwards, and probably about  $\frac{3}{4}$  of an inch in length. The lower fragment is displaced in front of the upper one, and overlaps it for a full inch. The lower fragment is also somewhat rotated inwards, and slants obliquely outwards. Compare with 521.
505. May be regarded as a typical example of the most common fracture of the tibia, in which the line of fracture passes downwards and forwards, and the lower fragment has slid up slightly behind the upper.



Very little deformity has resulted, but the site of fracture might have been detected by a little projecting spine on the anterior border or crest of the bone.

506. Section of the lower third of a right tibia of a young person with part of the fibula attached. The fibula has been broken across, and shows a dentated transverse fracture 4 inches above outer malleolus. The tibia has been broken almost transversely 1 inch above the articular surface, and  $\frac{1}{2}$  an inch above the junction of the epiphysis. The cartilage of the latter is still very apparent. The portion of bone between the epiphysial line and the fracture shows a vertical split about  $\frac{1}{2}$  an inch from the anterior surface. This split extends down, though less distinctly, through the epiphysis itself to the articular cartilage. The foot and lower fragment have been displaced forwards to a slight extent, and the upper fragment has crushed the cancellous tissue of the lower one backwards so as to permit of this displacement. The periosteum appears to have been everywhere entire. On account of the displacement of the lower fragment forwards it has been detached from the lowest inch of the end of the upper fragment, and the periosteum and the front wall of the bone are  $\frac{1}{4}$  of an inch apart. This preparation is an instance of intra-periosteal fracture, of fracture with impaction, and is further of interest as showing that in young persons fractures near to the extremities of bones do not always follow the line of the epiphysis. It would appear that union was in process, but not complete, at the time that the preparation was obtained.

507. A compound fracture of the tibia and fibula removed some weeks after the injury. There is a considerable quantity of new porous bone thrown out, and several portions of the outer layer of compact bone about the ends were evidently dead at the time of the removal of the bones, and would in due course have exfoliated.

508. A portion of the shaft of the tibia, about 4 inches long, probably removed about a week after compound fracture. The lowest  $\frac{1}{2}$  inch is quite smooth and bare, and there is a shallow line of ulceration marking it out for detachment. At other parts the periosteum was thickened.

509. The tibia and fibula from the right leg of a woman who was killed by the fall of a house. Both bones are broken almost transversely, but with considerable dentations. The fracture of the fibula is about 4 inches and a half above its lower extremity, that of the tibia an inch and a half higher up.



510. The left tibia and fibula from a man, whose limb was amputated about five weeks after a compound fracture of the tibia in the lower third. At the time of his admission the lower end of the upper fragment, shaped like a pen-point, projected into the wound, and about an inch of it was sawn off by Mr. Little. Subsequently the whole limb inflamed, the skin was extensively destroyed, and amputation above the knee became necessary. During the treatment it was found impossible to keep the ends of the bone in good position, the lower end of the upper fragment projected into the wound, and as it rested against the lower fragment it could not be replaced by pressure, whilst the inflamed condition of the limb prevented adequate extension. The fibula is fractured obliquely and with comminution an inch below its upper end.

511. A right tibia and fibula showing union after fracture. The tibia has been broken obliquely just above the commencement of the lower third, and the usual displacement of the lower fragment upwards and outwards has occurred. The tip of the upper fragment projects almost half an inch inwards. It is well rounded off. The fibula has been broken in its upper third, the line of fracture being oblique. Firm union with considerable overlapping has occurred. The specimen was obtained after amputation at the knee-joint by Mr. Little. Amputation was performed at the man's most urgent request fourteen months after the accident. He had been treated in St. Bartholomew's Hospital for a compound fracture, and had been discharged with the fracture well united. Owing to his long confinement to bed, and the inflammation of the limb in the early stage, the nutrition of the limb seems to have been damaged. Although the skin was soundly healed, his foot and leg remained swollen, cold, and liable to such severe aching pain, that not only could he make no use of it, but he was most anxious for its removal.

512. Cast of a left tibia showing similar results of fracture of the bone.

513. The right tibia and fibula of a young subject, showing dentated fractures of both bones at the junction of the middle with the lower third. There is no evidence of attempted repair. The specimen was probably obtained by primary amputation. The transverse line of fracture and the fact that both bones are broken at the same level point to direct violence; very likely the child was run over.

514. A right tibia and fibula showing union after fracture a little below their middles. In each bone the lower fragment has passed behind and internal to the upper one. Reduction has not been accomplished, and the bones overlap for a good inch. In each instance the ends are



united by intervening callus without any on the parts which are not in apposition. The medullary canal in each instance has been sealed up. The end of the distal fragment in each instance has undergone less change than the proximal. There must have been very considerable deformity during life. The fibula is broken about an inch below the fracture of the tibia. Probably the fracture was caused by direct violence.

515. A left tibia and fibula showing recent fracture. The tibia is broken transversely, with dentations, at its middle. A fissure-fracture extends upwards two inches above the transverse one. The fibula is broken in three places, close to its upper articulation, a little below the junction of the upper and middle thirds, and a little above the junction of the middle with the lower third.

516. The tibia and fibula of a young subject, showing union after a compound fracture. There is no history with this specimen, but the fact that the fracture was compound is made certain by the large quantity of soft cancellous new bone which has been deposited around the fragments. The surface of the tibia in almost all its extent is rough with subperiosteal formation. The epiphyses of both bones have been lost in maceration.

517. A left tibia and fibula, showing recent fractures. That of the tibia was transverse with dentations. The fibula is broken at two places, a little below its middle, and about two inches above the tip of the malleolus.

518. A left tibia removed by amputation twenty-five days after a compound fracture. The fracture is a little above the commencement of the lower third and passes obliquely from the outer side downwards and inwards. The bone is encrusted with new deposit over almost its entire surface. Near to the fracture portions of the bone remain smooth and clean and are marked out for exfoliation by a line of demarcation.

519, 520. Specimens of united fracture of the tibia showing the usual displacement. Compare Nos. 512, 514, and 518.

It may be noticed that the bone is stronger at the fractured part than anywhere else.

521. Cast of a fracture of the lower third of a tibia in which the lower fragment is displaced so far forwards as to completely override the lower end of the upper fragment.

Most probably from direct violence.



522. A most extensively comminuted fracture of the tibia.
523. A recent transverse serrated fracture of the tibia at its lower third.
524. Fibula, showing a double fracture united with excessive callus. That about the upper fracture is of ivory consistence.
525. The lower ends of two fibulæ showing bony union, with some displacement, of fractures in the lower third of the bone.
526. The lower two thirds of the left tibia and fibula removed by secondary amputation after a compound fracture involving the ankle-joint. The inner malleolus is broken off at its base. The fibula is broken at two places, first at the junction of its lower and middle thirds, and again an inch below.
527. The lower two thirds of a left tibia removed by amputation a month after a compound fracture involving the ankle-joint. The tip of the inner malleolus is broken off. There is a fracture passing transversely from side to side across the articular surface. This fracture splits off the posterior half of the articular extremity of the bone, as a fragment about an inch and a half in length. At the time of amputation there was an interval between the fragments at their anterior aspect, a third of an inch in width.
528. The lower end of a tibia and fibula with fracture of the internal malleolus. There has been also an oblique fracture of the fibula commencing about half an inch above the malleolus. At the posterior part of the tibia a portion of the compact wall about the size of a sixpence is wanting; probably it was torn away by its attachment to the posterior inferior tibio-peroneal ligament.
529. Separation of inner malleolus from tibia, probably from indirect violence.
530. A fracture of the lower end of the fibula in which the separation follows partly the line of the epiphysis; the specimen is, however, from an adult subject.
532. Fracture of the left tibia and fibula at about the junction of the lower and middle thirds, union having occurred with a strong anterior convexity, and with fusion of the tibia and fibula. The tendons in front of the leg have worn a remarkable groove in the tibia.
533. Oblique fractures at various parts of the fibula, with bony repair and great displacement.



535. Comminuted fracture of the tibia and fibula, with splintering of the bones.

536. Comminuted fracture of the lower end of tibia, with fracture of the fibula.

537, 538. Lower ends of femora, showing gun-shot fractures.

539, 540. Femora, showing gun-shot fractures.

541 (in bottle). The leg and part of the femur of a girl aged 3 years. The upper epiphysis of the tibia has been completely and evenly detached, taking with it also the tubercle. The epiphysial cartilage goes with the epiphysis, as also a thick sleeve of periosteum detached from the upper end of the shaft; on the inner side a flap of the periosteum was found doubled in so as to cover the under surface of the epiphysis and prevent its coming in contact with the shaft. The external lateral ligament is entire, and the fibula being uninjured and still connected with the epiphysis, no great displacement can be effected at this part. On abducting the foot the line of separation gapes widely at the inner side, where all periosteal fibres, &c. have been torn through. No doubt the direction of the original violence was such as to force the leg outwards.

The injury was compound and was attended with great damage to the soft parts, requiring primary amputation. A waggon had run over the limb in the street. The left fore arm was also so injured as to require amputation. Mr. Hutchinson.

542 (in bottle). Fractured tibia and fibula.

Richard Harrison, 75, commercial traveller, was admitted into the London Hospital on the 20th December, 1872, under the care of Mr. Rivington. He was coming down some railway steps when he tripped and fell on his back—he did not fall on his leg—so that the bones were broken by indirect violence, and exhibit the ordinary form of fracture from this cause. On admission the right tibia was found very obliquely fractured, the fracture extending from a point on the outer side of the bone some inches from the ankle-joint, to a point about half an inch above the base of the internal malleolus. The fibula was broken apparently in the upper third. There was considerable displacement of the fragments, the lower end of the upper piece projecting sharply against the skin, which was very tense and almost broken through. There was much contusion, with abrasion of the skin and swelling. Extension could not be maintained so as to counteract the action of the gastrocnemius and soleus on the lower fragment. The patient went on well for four weeks. On January 20th he had a shivering fit, and an erysipelatous blush appeared on the skin. He then sank into a comatose state attended with delirium, and died on the 23rd of January, 1873. It is interesting to notice that the interosseous membrane has resisted the strain thrown upon it by the displacement of the tibia. Mr. Rivington.

543 (in bottle). The lower part of the tibia and fibula with some of the



tarsal bones, from a case of fracture of the fibula, with partial dislocation of the tibia. At the time of the man's admission there was considerable deformity, the foot being twisted outwards and the tibia projecting on the dorsum. It was replaced with considerable difficulty.

The man died suddenly a fortnight after the accident. The specimen shows an almost transverse fracture of the fibula at a level with the ankle-joint, with rupture of the ligaments connecting the tibia and fibula and of the outer two thirds of the anterior ligament of the ankle-joint. The posterior ligaments and the inner lateral are entire. It is easy by twisting the foot to rotate the tibia on the inner malleolus, and displace its outer part in front of the astragalus. This specimen illustrates what is known as Dupuytren's fracture. Mr. Hutchinson.

544 (in bottle). Compound fracture of the tibia and fibula, with periostitis and osteomyelitis of the ends of tibia. Great displacement. End of fragment of fibula covered with fibrous tissue. No repair of fracture of tibia.

545. United fracture of the tibia and fibula. Bony union, with slight displacement of the bones. Fracture of tibia about junction of middle and lower third. That of fibula lower down about 3" above tip of malleolus.

546. Bony union after comminuted fracture of the tibia and fibula at the lower part. There has also been a transverse fracture of the tibia and fibula a short distance below the knee. There is great displacement of fragments in lower fracture.

547. The right tibia and fibula of a pig, showing an ununited fracture of both bones. No history was obtained with the specimen, but it may be conjectured that the injury was received a month or more before the animal's death. Both bones have been broken about three quarters of an inch above their lower ends, and the lower fragments with the tarsus have been displaced backwards to a considerable extent. Excepting some loose bands of areolar tissue, there is no uniting medium between the broken surfaces themselves. The parts around are, however, very much thickened, and beneath the periosteum of the upper fragment of the tibia a layer of new ossifying material has been deposited, which extends upwards to the middle of the shaft. The lower end of the upper fragment has undergone but little change, excepting that the medullary canal is closed by soft fibrinous material. The broken surface of the lower fragment is covered by a tolerably firm layer of new material, upon which the upper fragment appears to have moved. Both at the upper and lower ends of the bone, the lines of epiphysial cartilage can easily be traced; the fracture in the tibia has passed about a quarter of an



inch above the lower one, and does not implicate it. The induration of the cellular tissue around the fracture is so great that the specimen was at first supposed to be one of tumour, the whole constituting an ovoid swelling as large as a small orange. The specimen is probably a good illustration of the early stage of the formation of a false joint.

*Presented by Mr. M. Mackenzie.*

548. Comminuted vertical fracture of tibia opening into knee-joint, from a case of amputation of the thigh by Mr. James Adams in 1871. There was an old united fracture in the fibula of the same limb.

549. Fracture in the lower third of the fibula, with detachment of both malleoli, and oblique splitting of the lower end of tibia, the line of fracture passing downwards and inwards. There has been upward displacement of nearly one inch, and the ankle would have been increased in width to about the same extent. The lesion bears some resemblance to what is known as Dupuytren's fracture.

550 (in bottle). Dupuytren's fracture of left foot, from a man aged 30. The internal and external malleoli have been broken, as well as the fibula, 4 inches above the ankle. This lower fragment of the fibula was forced outwards and had detached a piece of the tibia (the attachment of the inferior tibio-fibular ligament), and the astragalus was displaced upwards in the gap between the two bones.

The accident was produced by a fall of a weight on to the outer side of the foot. Amputation was necessary, on account of the extensive injuries to the soft parts. *Pathol. Trans.* 1888 (J. Hutchinson, Jun.).

550 A (in bottle). Fracture of a femur a short distance above the inferior epiphysial line. There was also a separation of the lower epiphysis of the humerus, and other injuries.

They were caused by the parents, who whilst drunk dragged the child about by its limbs. The child's age is not stated, but it was probably about two years.



## DISEASES OF BONES.

**Hypertrophy:** 551.

**Effects of Pressure:** 552.

**Atrophy:** 553 to 555.

**Mollities Ossium:** 556.

**Rickets:** 557 to 572.

**Inflammation and its Effects:** 573 to 634.

Suppurative Periostitis and Osteomyelitis: 597 to 614.

Caries: 615 to 619.

Necrosis: 620 to 634.

**Tuberculous Disease:** 635, 636.

**Syphilis:** 637 to 656.

**Tumours:** 657 to 709.

Cyst: 657.

Fibroma: 658, 659.

Fibro-enchondroma: 660, 661.

Enchondroma: 662 to 664.

Exostosis: 665 to 670.

Sarcoma: 671 to 707.

Secondary Carcinoma: 708, 709.

**Hypertrophy.**

551. Vault of cranium.—Enormously thickened, very heavy, dense, and hard: the diploe quite gone, and the whole of the bone of ivory polish, probably osteitis deformans.

**Effects of Pressure.**

552. Manubrium and part of gladiolus of sternum.—On the posterior surface is an excavation due to the prolonged pressure of a tumour, probably aneurysmal. The remaining shell has bulged considerably forwards.

**Atrophy.**

553. Os calcis.—The compact tissue is perforated in all directions, and hollowed out so that only a shell is left. The cancellous part has almost disappeared.

554. Os calcis.—Bone divided into two, to show the effects of atrophy.



555. Portions of bone, showing large concretions of adipocere in the cancellous tissue.

### **Mollities Ossium.**

556. Humerus, with oblique fracture in middle third, united. Femur, with recent fracture. Femur, with partially united fracture. Tibia and fibula, with recent fracture at lower third. The bones are loaded with fat, and so atrophied that the outer lamellæ are scarcely thicker than paper.

From an old woman who fractured her thigh when turning in bed: she had been paralysed for several years.

### **Rickets.**

557. Femur, right.—Antero-posterior curve without rotation at junction of upper and middle thirds.
558. Femur, left.—From same subject, showing the increase in the thickness of the compact tissue.
559. Femur, rickets.
560. Femur: arrest of growth due to premature consolidation of epiphyses.
561. Tibia.—Bone much flattened, and curved antero-posteriorly.
562. Tibia.—Same as last, but in addition there is some curvature outwards with rotation.
563. Tibia and fibula, showing the flattening from side to side.
564. Fibula, right.—Showing flattening and moderate curvature.
565. Tibia.—Slightly curved from rickets, but in addition showing the effects of chronic periostitis.
566. Clavicles and ribs, with costal cartilages from a child æt. 2, who was admitted in consequence of severe burns. Abnormal curving of clavicles and the bulging at the costo-cartilaginous junction are well seen.

Mr. McCarthy.

567. Radius and ulna.—Showing enlargement of ends due to rickets.

Mr. McCarthy.



568. Tibia and fibula. From a foetus.—There is a marked curve, with flattening and enlargement of the ends of the bones.

569. Thorax.—From a case of rickets. The sternum projects, and there is a furrow, narrow above and wide below, between the swollen and prominent ends of the ribs and the vertical line, about half an inch from the border of the sternum, where the costal cartilages are bent backwards.

570. Ribs.—Showing marked beading. There has been recent subperiosteal extravasation of blood in the soft tissue between the bone and the cartilage, which has extended along the bone for a short distance, separating the periosteum from it. This is seen in the lower specimen, which is laid open by a median longitudinal incision on its inner aspect. The upper specimen presents externally the same appearance.

Dr. S. Mackenzie.

571. Ribs.—Three last on right side showing extreme bending of the bones. At the lower end of the deep groove, which winds downwards and backwards over the chest wall in these cases, there is a sharp bend forming an angle projecting into the thoracic cavity. The part of the rib behind this forms a rounded curve in the opposite (outward) direction.

Evelina Perkins, 7 months, post-mortem, Reg. No. 752, 1883. Dr. Mackenzie.

572. Rickety skeleton, showing extreme lateral curvature, with rotation and deformity of pelvis. Bending and arrested growth of the bones of the extremities, especially the lower.

### **Inflammation and its Effects.**

573. Section through a parietal bone. The bone is thickened and the diploe has become compact: the dura mater was adherent, and presented a smooth elevation towards the brain. On detaching it there were some soft gelatinous masses adherent to it. No history of syphilis or injury.

574. Calvaria, showing process of exfoliation after injury. There is an oval patch of bone on the right side of the sagittal suture, surrounded by a shallow groove and a vascular circle. A fissured fracture extends across the suture into this patch, and is crossed by another at right angles. From a case of pyæmia.



The patient was admitted with a scalp wound exposing the bone, but no fracture was diagnosed. Post-mortem. The bone was bare and discoloured, and there was a thrombus in the sup. longit. sinus. Mr. Couper. Published by Mr. Hutchinson in his work on injuries to the head.

575. Humerus, longitudinal section, from a boy *æt.* 15. Upper epiphysis not yet united to the shaft: the head and tuberosities are somewhat stunted and irregular in shape. The lower extremity is normal, the internal condyle not yet united. The bicipital groove is nearly obliterated; the shaft is rough and irregular; the centre is thickened, and there is a small medullary cavity; the weight is considerably increased.

Patient had been the subject of strumous disease for years, and finally died at Margate with lardaceous degeneration. The greater part of the shaft had been removed by Mr. Curling with Hoffman's cutting forceps about ten months before death.

576. Left humerus from an adult, in three pieces. Entire surface worm-eaten from periostitis, but nowhere is there any deposit of new bone or any line of demarcation.

577. Humerus, radius, and ulna from a child. *Spina ventosa*. Whole of lower part of humerus roughened by deposit of new bone, and the articular surface in great measure destroyed. The olecranon and upper part of ulna are much enlarged, and present a considerable cavity with large openings externally. The shaft of the radius for its entire length is increased to five or six times its natural dimensions, and is everywhere roughened by deposits of new bone. There is a cavity in the centre and several cloacæ, but there does not appear to be any sequestrum.

578. Radius and ulna.—The lower end of the former is covered with an irregular deposit of soft new bone. The lower articular surface is extensively destroyed, and the deep cavity on it may represent a lost sequestrum.

579. Carpus.—The hand has been injected and laid open on the dorsal surface. The whole of the wrist and hand is much swollen, and there are numerous sinuses leading down to carious bone.

From a lady who at the siege of Valenciennes was struck in the wrist by a fragment of a bomb. The limb was amputated ten years afterwards.

580. Femur, left.—Upper two thirds. Periostitis and necrosis following operation. Lower end of the bone is thin, porous, and very



irregular. For about three inches below the lesser trochanter it is much thickened by subperiosteal deposits of new bone.

From a man 40 years of age, who was admitted with compound fracture of the leg. Suppuration set in, and amputation above the knee was performed. Ten months after a large sequestrum was removed. The patient recovered, and died four years later.

581. Femur, right. Periostitis.—Irregular growths of new bone from the linea aspera and the shaft below the lesser trochanter.

582. Femur, middle third.—There is a rough, irregular growth of bone from the linea aspera, nearly three inches long.

583. Femur, right.—A thin plate of bone developed from the middle of the linea aspera, being an ossification in the intermuscular septum.

584. Femur, left.—An oval mass of bone developed in connection with the linea aspera. It is three inches long: the wall is hard, the interior cancellous; there are two peduncles, one longer than the other, of very dense bone. It may have grown from the small one, and subsequently have become welded to the bone lower down. The linea aspera both above and below is much thickened, and shows in one or two spots a tendency to the formation of spur-like growths.

585. Femur, lower half. Chronic osteitis.—Medullary canal wholly obliterated at the seat of section, the bone being solid. The surface is everywhere rough, and posteriorly is a series of cloacæ leading into the interior, but there does not seem to have been any sequestrum. The articular surface is not involved.

586. Femur, left, vertical half.—There is a small sequestrum in the medullary cavity; the middle two thirds are much increased in thickness and roughened on the surface. The chief increase is within the outer wall: there is little, if any, subperiosteal deposit. The thickening is especially marked on the posterior surface, and the central cavity is closed immediately below the sequestrum. A sinus lined with smooth walls opens on to inner surface. There is another partially detached fragment of bone in the anterior wall of the shaft, a little below the other.

587. Tibia and fibula, part of, from a stump.—The two bones are united at their extremities, and the tibia is covered over with a new deposit.

588. Tibia and fibula, right.—Overgrowths of new bone over whole



surface, uniting the two together below. The articular surfaces are not ankylosed, though there is much new bone round. In the case of the fibula the deposit is especially marked at its angles. On the tibia there is an oval depression, the seat of an ulcer, and a smaller one on fibula.

589. Tibia, left. Chronic periostitis.—The deposit is light, porous, and spongy.

590. Tibia, left.—Surface roughened by new bone: the lower part worm-eaten and carious. A small part of original shaft can be seen in process of exfoliation.

591. Tibia, left. Periostitis.—Bone much bowed forwards. Rough irregular outgrowths from surface: two large cloacæ. The axis of the bone is twisted as well.

592. Tibia, right.—Shaft double natural size. New deposit eburnated and bone exceedingly heavy: the distinction between new and old cannot easily be made out.

593. Tibia, right.—Carious cavity in lower end, the articular lamella being quite destroyed. Two inches above there is an oval depression from recent periostitis.

594. Fibula.—Various forms of bony outgrowth from periostitis.

595. Tibia, right.—Lower two thirds much curved forwards from past rickets. There is a rough outgrowth on anterior and inner surfaces from periostitis, but it is remarkable for the production of processes like exostoses. One very large one, two inches above the malleolus, is perforated for the passage of a vessel or nerve.

596. Tibia. Periostitis.—Bone much roughened, but unusually light.

#### **Suppurative Periostitis and Osteomyelitis.**

597. Costal cartilages, pyæmic ulceration of.—The necrosed ends of the ribs (2nd to 6th) protruded through button-holes in the skin. No trace left of cartilages. Pleura much thickened.

Mr. Hutchinson.

598. Calvaria from a boy æt. 15.—There was a lacerated wound of the



scalp, and this was followed by necrosis and an abscess in left hemisphere.

599. Femur, left.—Shaft much thickened by the deposit of new bone on the outside. In the middle is an irregular worm-eaten sequestrum, four inches long.

600. Femur.—Line of compact tissue corresponding to outer layer of shaft can still be traced under deposit of new bone. Probably osteomyelitis, the periostitis being secondary.

601. Femur.—Lesser trochanter and part of shaft nearly denuded of periosteum. Great trochanter partly separated by ulceration.

From a case of periostitis and pyæmia. No bare bone could be felt when the abscess was opened first.

602. Femur.—Suppuration between end of shaft and epiphysis.

Case of G. Curry, Dec. 19, 1882. Mr. Tay.

603. Femur.—Carious cavity in great trochanter. Periostitis of shaft with extensive exposure of bone. Destruction of cartilage and caries of articular surface.

604. Tibia, right, from a patient æt. 15.—Periosteum stripped from upper two thirds of shaft; near the epiphysis it is roughened. The knee-joint was involved by extension upwards under periosteum, not by perforation of epiphysis.

Amputated by Mr. Little.

605. Tibula and fibula, right.—Whole of shaft of tibia necrosed and enclosed in shell of new bone with numerous cloacæ. Both ankle and knee involved.

606. Tibia and fibula.—Necrosis of shaft of tibia, with perforation into knee-joint. Shell of new bone formed in parts.

607. Tibia. Necrosis of upper third.—Bone much thickened and roughened on surface: cloaca on inner side three inches below knee, with sequestrum inside.

608. Tibia. Shaft roughened by deposit of new bone.—Considerable exfoliation seems to have taken place. Fragment of necrosed bone in cavity just above ankle.

609. Tibia and fibula, left.—Necrosis of nearly whole shaft of former



and shell of porous new bone. Numerous cloacæ, but most of the sequestra removed. Disease did not spread beyond epiphysial line or involve fibula.

610. Tibia, head laid open from before.—A portion of the epiphysial cartilage has been destroyed posteriorly, and the epiphysis is carious at that part. There is a smooth cavity in the upper end.

From a case of periostitis of humerus and tibia. Tibia involved first: free incisions made, letting out pus and laying bone bare. Humerus inflamed and an incision was made, but no pus found. The wound healed, but the arm remained swollen, and child died. A portion of the tibia comprising its entire thickness was found loose. Right humerus was much thicker than its fellow, though there were no other signs of inflammation. The whole shaft is evenly enlarged to more than four times its natural thickness, owing to the deposit of new bone in concentric laminæ round the shaft. Six separate ones can be counted as distinct as those in a young fir-tree: they can only be traced in the anterior and lateral aspects. Posteriorly they are too thin. Part of the opposite humerus is preserved for comparison.

611. Tibia and fibula. Osteomyelitis.—Whole thickness of bones involved; the articulation obliterated, and replaced by fibrous tissue. The centre of the articular lamella of lower end of tibia has been invaded by same process. Over the malleolus it seems to have been perforated at one point.

612. Femur. Osteomyelitis. Probably after amputation.—There is a central sequestrum extending a long way up the shaft; outside a large quantity of new bone has been thrown out by the periosteum, the amount diminishing gradually upwards as the inflammation became less intense.

613. Necrosis. Sequestrum from a similar case.—The exterior is worm-eaten, showing the way in which it has been thrown off by the living bone.

614. Sequestra after amputation.

### **Caries.**

615. Caries of petrous bone.

616. Sternum perforated by an abscess. Manubrium is rough on both sides, and also on its upper surface. Immediately below the right sterno-clavicular joint is a perforation.

617. Femur from a child.—Showing extensive destruction from



disease of knee-joint. Head of tibia was also deeply ulcerated.

Mr. Hutchinson.

618. Femur, right, lower half.—Caries causing spontaneous fracture. The patient was a man æt. 35. While apparently in good health an abscess suddenly formed on the outer side of right thigh. He kept his bed for this, and a month later, while turning, a spontaneous fracture occurred at the seat of the abscess. Amputation was performed three weeks later. He was very feeble at the time, and died with gangrene of the flaps three days later. The two portions of bone show extensive caries at the seat of fracture, and a white sequestrum, only partially loosened, lies in the middle. The bone is deeply eroded in various directions. Considerable portions of a new shell have been formed above and below. Four inches above the seat of fracture the medullary canal is almost obliterated, and the bone is solid and dense. A very curious feature is the presence of a deep hollow in the popliteal aspect of the bone, just above the condyles. It would contain a small walnut, has dense, hard walls, and shows no sign of recent disease. From its upper extremity it communicates with the medulla of the bone, and in the recent state it was lined by a dense fibrous membrane, and contained pus. The man himself always denied having had any previous injury to his limb; but, on questioning his wife after the discovery of the cavity, an obscure history of some previous ailment many years ago was obtained. The arteries were examined, but no trace of old aneurysm could be discovered. On section of the bone the canal leading to the medulla is seen to have a dense smooth wall, and is evidently of old standing. It leads to a small cavity in the shaft six inches above the joint. No foreign body was discovered. He had been an Exciseman in Ireland.

Mr. Hutchinson.

619. Tibula and fibula.—There is a carious cavity immediately above the ankle-joint. From this there are sinuses running backwards and forwards. A fragment of the tibia appears to have been split off by a vertical fracture referable to concussion from the astragalus. Caries probably secondary to this. There was fibrous ankylosis of the ankle-joint, and no evidence of recent disease when the limb was removed.

Mr. McCarthy.



**Necrosis.**

620. Femur, left.—Sequestrum in a cavity above the condyle; several cloacæ, one large one passing into the popliteal space and another forwards; external surface much roughened. Two inches higher up is another sinus; the bone here is much thickened and condensed; medullary canal is narrowed, and there is an irregular and uneven growth of spongy bone.

621. Femur, showing process of necrosis.—On anterior aspect the periosteum is still adherent and much new bone is formed; a line of demarcation is being developed round the sequestrum. The knee-joint was involved.

Mr. Curling.

622. Sequestra exfoliated from cranium after fracture.

623. Inferior maxilla: phosphorus necrosis.—The spongy new bone and eroded dead bone are well seen.

Alf. Rayner, aged 35. Operation Nov. 19, 1884: Mr. McCarthy.

624. Inferior maxilla: necrosis, probably phosphorus.

625. Inferior maxilla: phosphorus necrosis.

Removed by Mr. John Adams. Severe hæmorrhage followed the operation; the carotid was tied by Mr. Gowlland. Sufficient new bone was thrown out to enable him to eat and articulate well.

626. Inferior maxilla.—A similar specimen.

627. Clavicle from a child.—Almost the whole bone was exfoliated after periostitis. No roughening of the surface anywhere. The ends are irregular and worm-eaten.

628. Metacarpal bone of thumb, necrosis.

629. Femur.—Necrosis of shaft and shell of new bone: much overgrowth at lower end.

After amputation.

630. Shaft of long bone.—Necrosis of entire thickness; new casing formed by periosteum.

631. Tibia.—Necrosis of almost the entire shaft, cut through in the middle.



632. Pubes.—Bodies of both pubic bones with parts of rami; the epiphyses are joined. The necrosis is quite symmetrical. The anterior surface is rough and worm-eaten.

The specimen was obtained from a man whose penis and scrotum had sloughed away. For many years after he enjoyed very good health. No cause assigned.

633. Femur.—Sequestrum from a child.

634. Tibia.—Sequestrum.

#### **Osteitis deformans.**

635. Femur, left.—Deposit of new bone on middle third of shaft, very dense but porous.

636. Femur, left.—From the dissecting-room; no other bones diseased. Whole shaft so thickened by a deposit of new bone that it is nearly three times the normal size. The surface is rough but hard. No evidence of necrosis; nor is the deposit uneven, as usual in syphilitic periostitis. The parts near the joints have escaped. The trochanters are free, though the deposit runs as high as the base and the same applies to the condyles. The substance is cancellous and the weight not great.

S. Strange, aged 77.

637. Femur, left.—Shaft thickened and rough from periostitis and ostitis. The new deposit so incorporated with old bone that the line of division is scarcely to be seen.

638. Femur, lower third.—Shaft increased to almost double normal size by formation of new bone. The new bone is very dense, but the line of separation can be seen in most places.

#### **Tuberculous Disease.**

639. Femur, left: Strumous periostitis.—At the junction of the upper and middle thirds the compact tissue is so increased as to fill the medullary canal. Rough new bone is deposited on the external surface of the shaft to correspond.

640. Tarsus.—From a case of strumous caries. The whole mass is light, vascular and porous, filled here and there with soft chalk-like material. The os calcis has almost disappeared; there is a deep abscess-cavity on the upper part of the astragalus; no compact tissue is left anywhere; and there is scarcely any trace of repair.

#### **Syphilis.**

641. Calvaria.—Symmetrical patches of bone on the inner surface of the frontal, very dense, and upwards of one third of an inch thick.



They extend as far back as the coronal suture and almost meet in the middle line, leaving the superior longitudinal sinus free. The rest of the skull shows no change.

642. Calvaria.—Thin and rough over the entire inner surface and also over the exterior except at the lower part of the right parietal region. The right half is extensively eaten away by the pressure of a tumour; the left half presents several islands of new bone separated by deep channels, which are almost transparent in parts. The sagittal suture is very open. In the right frontal region was a pulsating tumour. A little to the left of the median line was a recently healed cicatrix due to the kick of a horse some time before. The pulsation was synchronous with the radial, and the tumour was bounded by the perforation. During life it was a question between deep-seated abscess and solid tumour. Post mortem it proved to be the latter situated in the anterior part of the right cerebral hemisphere.

There was a history of syphilis. Dr. Jackson.

643. Calvaria.—Found while excavating the East Wing of the Hospital in the site of the old burying-ground. There is an exostosis (syphilitic) on the inner surface of the right frontal immediately in front of the middle meningeal.

644. Calvaria.—Symmetrical exostoses on inner surface of vertical plate of frontal bone.

Mr. Curling.

645. Calvaria.—Node about centre of right parietal bone, growing apparently mainly from the diploe. Internal surface unaltered. The outer table is raised so as to form the margin of a deep crater. At the anterior and inferior angle of the bone is a similar growth, which has been sawn through in removing the skull-cap, and here the separation of the two tables can be well seen. The thickness contrasts well with that of the opposite side.

646. Calvaria.—Very thin and pitted all over as if worm-eaten.

Probably syphilitic.

647. Skull, section of.—The whole bone is very dense, the diploe has almost disappeared, and the groove for the middle meningeal artery is deeply channelled. On the vertex is a thick dense mass of vascular bone, rough and irregular on the inner surface, smoother on the outside.



648. Femur, right.—Soft porous bone deposited round the lower third of shaft a third of an inch in depth.

Probably syphilitic.

649. Femur, right.—Line of epiphysis still apparent. The inner and front part of the lower third is covered by a deposit of new bone nearly half an inch thick.

Probably, from the age, inherited syphilis.

650. Femur, left.—Deposit of new bone from below the great trochanter, a quarter of an inch thick. The middle is free, but the lower third presents a larger deposit posteriorly.

651. Femur, left.—In section. Spindle-shaped thickening at junction of middle and upper thirds.

Probably syphilitic.

652. Femur, right.—Very light and porous. There is a deposit of new bone over whole of shaft from below the lesser trochanter.,

653. Tibia, left.—Upper half in section. There is a great projection commencing at the tubercle and passing down to the middle of the bone. The surface is smooth and new deposit very dense.

654. Fibula, right.—Irregular, dense outgrowths of new bone from its borders for about middle two thirds of shaft.

655. Tibia and fibula, left.—Middle third of former encrusted with rough porous new bone. The lower two thirds of fibula shows the same but to an even greater extent. In the middle of the shaft, on the inner side, is a sequestrum lying in the bottom of a depression the sides of which are formed by a deposit of new bone, showing how sequestra are enclosed and cloacæ formed.

Probably syphilitic.

656. Tibia and fibula.—There is an excavated ulcer on the tibia which has eaten through three fourths of the bone. It is covered with granulations through which bone could be felt. The tibia and fibula are ankylosed at the seat of fracture.

From a man æt. 30, who had suffered from syphilis for about two years. He first had an ulcerated node about three inches above the ankle; this was gouged by Mr. Curling but it did not heal. A year later he came under Mr. Hutchinson with a deep ulcer at the bottom of which was rough discoloured bone which exfoliated. The ulcer would not heal. Two months later he returned with a compound fracture of tibia into the ulcer; this united, but the sore would not heal. Finally it was amputated.



**Tumours.****Cyst.**

657. In pelvis, attached to the anterior surface of coccyx.

**Fibroma.**

658. Epulis from lower jaw.

659. Epulis.

**Fibro-chondroma.**

660. From lower jaw.

661. From first phalanx of index finger of child; nearly as large as a walnut.

Mr. Luke.

**Enchondroma.**

662. Of upper end of tibia and lower end of femur.

Mr. McCarthy.

664. Tumour removed from tip of finger of an infant; partly exostosis, partly cystic, with plates of cartilage in wall.

Mr. Hutchinson.

**Exostosis.**

665. Ungual phalanx of great toe.

666. Rib, growing from internal surface. It passed through the edge of the lung and the left ventricle of the heart. The lungs were tubercular, and some of the tubercles had ossific matter deposited in their substance.

The patient (female) appeared to die of phthisis.

667. Lower end of femur.—Exostosis growing from the internal condyle.

668. Femur, right.—Irregular exostosis with enlargement of the whole shaft of the bone at the upper and lower ends, close to the joints, but not apparently involving them. The whole bone is light and porous. The form of the neck and trochanter is altogether lost; the middle of shaft is healthy; a little below the lesser trochanter a porous and somewhat pedunculated exostosis nearly as large as an egg is seen.



669. From inner side of femur a little above base; peduncle very narrow.

Patient aged 18. Tumour growing four years. Severe inflammation followed operation, and abscesses had to be opened in several directions. Recovery was complete and knee-joint was not involved. The operation was undertaken as a precaution against future growth; it is doubtful if it would not have been better to leave it alone. Mr. Hutchinson.

670. Numerous irregular ones from femur and upper part of tibia.

### **Sarcoma.**

671. Myeloid epulis of lower jaw.

672. Sarcoma of antrum.

673. Sarcoma of superior maxilla.

674. Sarcoma of superior maxilla.

675. Sarcoma of superior maxilla invading orbit and adjacent part of cranium.

676. Sarcoma of superior maxilla.

677. Fragments of bone from medullary growth in antrum.

678. Skull.—Anterior portion of skull of child with malignant disease. The bones are divided transversely. The growth is of a semilunar shape, and is crossed from before backwards by vertical plates of thin bone attached at their thickest part to the outer table of the frontal bone and gradually becoming thinner, ending at the circumference of the tumour in a fibrous membrane. Between the plates was a quantity of soft, brain-like, very vascular substance. The front boundary consisted of thickened pericranium. The lamellæ can be broken easily from the bones of the skull, which appear to be normal. Within the skull the spiculæ were smaller and shorter. The soft growth involved the anterior part of the right hemisphere of the brain to within a quarter of an inch of the lateral ventricle. The dura mater was adherent to the arachnoid and pia mater. On the under surface of both anterior lobes, and between it and the corresponding part of the base of the cranium, is a layer of the soft growth about a quarter of an inch thick. In the preparation the left-hand part is the anterior portion of the tumour resting on its side and showing the section through both orbits and the root of the nose, with spiculæ springing from the roof of the orbit and also radiating from the outer surface



of the frontal bone. The right-hand portion shows in the posterior aspect the remainder of the tumour, and, anteriorly, the cranial surface of the roof of the orbit with the growth springing from it.

The patient, aged 3, was admitted July 25, 1867. There was a tumour the size of an almond in the middle of the forehead, about an inch above the root of the nose. It was first noticed in May. It increased rapidly to the size of an adult fist, was dusky-looking, firmly fixed, and with the skin freely movable over it. There was no glandular enlargement, and the child's health was good. The child died on Oct. 3 in an epileptiform fit.—'L. H. Reports,' vol. iv. p. 309. Procured by Mr. F. M. Mackenzie. Under the care of Mr. Curling.

679. Tumour of parietal bone—probably sarcoma. Growing on both surfaces under pericranium and under dura mater.

680. Medullary sarcoma of parietal bone.—A large soft mass beneath pericranium on the one side and dura mater on the other, spreading through the substance of the bone.

681. Piece of rib showing thickening of periosteum by similar growth.

682. Calvaria, with masses of medullary growth involving both surfaces of bones of vertex.

683. Sarcoma growing from scapula.

684. Humerus, right.—The two halves much enlarged by a tumour of mixed myeloid and medullary growth. At the back is a depression where the tumour had overlapped the articular portion of the scapula.

From a woman of middle age. The tumour had been growing several years, and the axillary glands were involved. The upper fourth of the bone and the glands were excised, as she declined amputation. She recovered and could use her arm; but the disease returned, and she died with deposits in her lungs. Mr. Hutchinson. Path. Trans. vol. viii. p. 346.

685. Sarcoma from internal condyle of humerus. It is firm and fibrous in section, with small colloid deposits and cysts. The joint became inflamed, and the cartilage is wholly absorbed from the trochlear surface of the humerus, thus illustrating the effect of pressure in locating disease.

686. Carpus.—Osseous framework only. The little finger and a tumour springing from it were removed by John Hunter. Six years after it returned and the part was removed as seen. Seventeen years later it returned in the metacarpus and ulna.



687. Radial half of the hand with the fingers greatly displaced. In the middle is a large cavity, the walls of which are bony in part and seem to have been developed in connection with the metacarpal bone of the index finger; the proximal phalanx of the thumb and the metacarpal bone are involved.

Mr. Curling.

688. Sarcoma from phalanx of finger.

Mr. Little.

689. Springing from radius, the lower part of which is wholly destroyed.

690. Sarcoma of os innominatum.—Large globular growth surrounding acetabulum and involving both surfaces of the os innominatum.

691. Femur, lower third.—Bone rough, carious and widely destroyed, with above the inner condyle a great porous outgrowth (osteosarcoma).

Mr. Scott.

692. Femur, central.—Central growths in both ends, destroying the compact wall and advancing along the subperiosteal tissue, as seen in the section of the lower end. At the upper end the absorption has led to fracture. The head of the tibia and fibula were invaded by a similar growth.

From a child, aged 6.

W. G. Wren, admitted Feb. 20, 1883. Mr. Tay.

693. Sarcoma, myeloid, of lower end of femur.—Condyles enormously expanded. On section the growth was partly solid, partly cystic; the colours varied from greenish yellow to reddish brown.

From a young woman. Mr. Borlase Childs.

694. Myeloid of femur.

695. Femur.—Surrounded by malignant growth; bone not expanded, but the medullary cavity is filled with growth and the shaft is broken just above condyles.

696. Femur.—The bone is somewhat expanded and indurated; the periosteum is split off and in parts a new shell is formed at some little distance from the original one. At other parts bony spiculæ, arranged in a similar manner, pass from the bone into the tumour. The growth is mainly on inner side.

Mr. Hutchinson.



**696 A. Ossifying sarcoma of the femur.**

Emma Holdsworth, aged 64, was admitted Sept. 3, 1885, with a sarcomatous tumour of the lower third of the right femur. A painful swelling of the right knee had been observed five months before, and had steadily increased, being  $6\frac{1}{2}$  inches more in girth than the left knee at the date of admission. There were enlarged glands in the groin. Amputation was performed by Mr. Fenwick. There were nodules of secondary growth in the lungs.

Autopsy, Oct. 6, 1885. Mr. Tay.

- 697. Femur, lower fourth of right.**—Myeloid and cystic sarcoma growing chiefly from beneath the periosteum and bulging externally instead of expanding it. The solid material is partly fibroid, partly myeloid, but the giant cells were very sparingly found.

From a young woman. Mr. Hutchinson.

- 698. Sarcoma growing from periosteum of femur into popliteal space.** There are two smaller tumours as well.

- 699. Tibia.**—The disease appears to have originated in the upper part of the bone below the epiphysis. There is a large mass projecting downwards into the middle of the calf.

- 700. Myeloid sarcoma of head of fibula, leaving the cartilaginous surface intact.**

- 701. Great toe.**—The bones surrounded by nodular masses of soft, malignant growth. They are described as having originated in connection with soft corns.

- 702. Myeloid sarcoma of lower end of femur, with numerous cysts.** The bone is broken about three inches above the knee.

- 703. Medullary growth of upper part of femur, with spontaneous fracture.**

**Chondro-sarcoma.**

- 704. Femur.**—The bone is broken about the middle, the medullary canal filled up on either side of the fracture, and the whole surrounded by a mass of soft cartilaginous material.

Reg. no. 707. Mr. Eve. 1887.

- 705. Sarcoma of leg, in old scar, either invading the tibia or springing from it.**

H. Brewer, 38. Autopsy, May 24, 1887. Mr. Tay.



**706. Sarcoma of femur.**

Emma Holdsworth, 64. Autopsy, Oct. 6, 1885.

**707. Femur (dry specimen), upper end of.—Probably from a case of central sarcoma, expanding the bone and causing fracture.****Carcinoma.****708. Section of a tibia, showing a firm growth filling up the medullary canal of the bone and cutting like scirrhus.**

From a man, aged 55, who had had an ulcer of the leg for two years. Six months before the ulcer began to sprout without growing at the margin. Chloride of zinc was tried, but it only grew more rapidly. The man died of pyæmia before amputation could be performed.

**Epithelioma.****709. Tibia and fibula.—The interosseous membrane is converted into bone. On the front of the leg is a large ulcer with masses of sprouting granulations springing from the cancellous tissue of the tibia. The cancelli are obliterated above and below, and the bone is remarkably dense.**

History of gun-shot wound with subsequent exfoliation and of the persistence of an ulcer for fifteen years, portions of bone frequently coming away. Old scars visible higher up.



## SERIES III.—INJURIES AND DISEASES OF JOINTS.

## DISLOCATIONS OF JOINTS.

Shoulder : 710, 711.

Ankle : 713.

Subastragaloid Joint : 712, 714, 715.

---

**Shoulder-Joint.**

710. An old case of subcoracoid dislocation of the right humerus. The original glenoid cavity is almost obliterated, and an imperfect new one is formed below and to the inner side of the base of the coracoid process. The head of the humerus has become altered ; it is abnormally small and is much worn down. The changes met with in chronic rheumatic arthritis are also present to some extent.

711. Right scapula and humerus, from a case of old unreduced subcoracoid dislocation.—The head of the humerus has rested below the coracoid process, at the base of which is a small spur of bone. The glenoid cavity is much encroached upon, and the posterior one fourth of the head of the humerus has been worn away by pressure. The posterior part of the great tuberosity rests upon the remains of the glenoid fossa.

**Astragalus.**

712. "A dislocation outwards and forwards of the astragalus." The head and neck and anterior half of body project on the upper and outer part of the tarsus, the foot is bent inwards, and the inner malleolus rests on the small process of the os calcis. There was no fracture.

The accident was caused by the patient, a heavy man, jumping from his chaise. Pronation could not be effected, and the soft parts sloughed. Secondary amputation three weeks after the accident was performed, and the patient died three weeks later. See Path. Soc. Trans. vol. x. p. 224.

*Presented by Mr. N. Ward.*

The astragalus itself is but little displaced from its normal position in regard to the tibia and fibula, and hence the dislocation should, perhaps, be termed a subastragaloid one ; but since its upper and outer articular facets are somewhat moved forwards, the original wording of the description has been left ("dislocation of the astragalus").



**Ankle-Joint.**

713. The foot and lower half of the bones of the leg, from a case of compound dislocation of the ankle-joint, with fracture of the internal malleolus and separation of the lower epiphysis of the fibula. The separation of the epiphysis of the fibula is complete, and there is no splintering of the shaft of the bone. The epiphysial cartilage is left adhering to the epiphysis, and is fissured by crushing at the posterior part. The ligaments connecting the external malleolus to the tarsus are entire. The lower end of the fibula on its outer surface is stripped of periosteum, the latter remaining with the malleolus. The cartilage on the surface of the astragalus has been grazed by pressure. The internal malleolus has been broken off by an obliquely vertical fracture passing upwards and inwards through its base. It is left in position as regards the tarsus; its ligaments are entire, and a thick broad strip of periosteum from the lower end of the tibia adheres to it. The patient was a child aged 5 under the care of Mr. Couper. The injury necessitated primary amputation.

**Subastragaloid Joint.**

714. An example of subastragaloid dislocation of the right foot. The displacement is only partial.

715. Right foot. From a case of partial subastragaloid dislocation of the foot inwards.—The head of the astragalus, just as in the previous specimen (No. 714), has risen out of its cavity and projects on the dorsum. The foot is strongly inverted. No ligaments appear to have been ruptured. The relations of the os calcis to the astragalus have not been greatly disturbed.



## DISEASES OF JOINTS.

**Disease probably beginning in the Synovial Membrane:** 716 to 718.  
 „ „ **in Bone:** 719 to 723.

**Specimens illustrating the Changes in the Structures of Joints, due to Joint Disease.**

Separation of Cartilage: 724.  
 Ulceration of Cartilage: 725 to 729, 716, 718.  
 Ulceration of Articular Ends of Bones: 730 to 736, 719 to 724.  
 Separation of Epiphysis: 737.  
 Dislocation of Bones: 738 to 741A, 717, 718.  
 Repair after Ulceration of Articular Ends of Bones: 742.  
 Fibrous Ankylosis: 743 to 745, 734.  
 Bony Ankylosis: 746 to 760, 731.  
 Atrophy of Bone: 761, 718, 743, 744, 754.  
 Rupture of Tendon: 762.  
 Changes due to Osteo-Arthritis: 762 to 780.  
 Changes due to Gout: 781 to 783.  
 Loose Bodies in Joints: 784 to 786.

**Excision of Joints:** 787 to 789.  
 Parts after Excision: 790.  
 Parts Removed in Excision: 791 to 793.

---

**Specimens of Joint Disease probably beginning in the Synovial Membrane.**

716. A knee-joint showing the effects of acute synovitis. There is an even absorption of the cartilage from the femur and from the patella. The underlying bones are not affected.
717. The knee-joint of a young subject, showing the results of acute synovitis.—The tibia is somewhat displaced backwards, and there is a large irregular abscess cavity in the popliteal space communicating by a sinus with the back of the knee-joint. The cartilage does not appear to be ulcerated. The epiphyses are beautifully distinct.
718. Advanced suppurative disease of the knee-joint, with almost universal destruction of cartilage, displacement of the tibia backwards, and atrophy of the bones.



**Specimens of Joint Disease probably beginning in the  
Articular Ends of the Bones.**

719. A right scapula, showing a small carious cavity in the glenoid fossa.

From a case of early joint disease.

720. The humerus corresponding to the last specimen. The articular lamella of bone is not entirely destroyed and presents one or two patches of eburnation. The surface is rough and worm-eaten. A small cavity (large enough to hold a pea) exists in the lower part of the head of the humerus. The disease probably commenced here, and all the changes in the scapular articular surface may be regarded as the result of suppuration.

721. A hip-joint showing the os innominatum and the upper part of the femur. There is entire absorption of the cartilage of the acetabulum, and a deepening of that cavity from destructive bone disease. A like destruction has affected the head of the femur.

722. Suppurative disease of the knee-joint, with caries of one side of the head of the tibia and partial ankylosis.

723. Lower end of the tibia and fibula, with the astragalus. The specimen was obtained by Mr. McCarthy from a subject in the post-mortem room.

The patient had been under Mr. Couper's care for stricture of the urethra and cystitis. There was no evidence obtainable as to the state of the ankle during life nor as to the patient having complained of it. The lower ends of the bones of the leg appeared to be enlarged, and on the parts being removed, it was found that there was fibrous ankylosis between the astragalus and tibia. Vertical sections made in various directions revealed a small cavity in the cancellous tissue at the lower end of the tibia which seemed to communicate by a small sinus with a much smaller cavity in the upper part of the astragalus. It is distinctly circumscribed and presents some indications of a lining membrane. There appears to be some commencement of a similar condition in the tibia close to the root of the internal malleolus.

724. The lower half of a tibia and fibula. The articular ends of both bones are roughened by a deposit of new bone. There is a carious cavity in the articular surface of the tibia. This had led to suppurative disease of the ankle-joint.



**Specimens illustrating the Changes in the Structures of Joints,  
due to Joint Disease.**

**Separation of Cartilage.**

725. Destructive suppurative disease of the knee-joint of a young subject. The specimen shows ulceration and separation of cartilage. The underlying bone is but slightly involved. Sections of the epiphyses are shown.

**Ulceration of Cartilage.**

726. Disease of the hip-joint, showing extensive absorption of the cartilage in irregular patches, both from the head of the femur and from the acetabulum. The acetabulum is perforated, the perforation being only protected by the thickened periosteum. There is a hole through the latter; this probably is post-mortem. The ligamentum teres is not destroyed.

727. A portion of the condyles of the femur, with the patella, of a boy who died in consequence of a wound of the knee-joint. The chief interest of the specimen consists in the very irregular manner in which the cartilage has been absorbed. Both on the surface of the femur and on that of the patella the cartilage has been eaten away so as to leave abruptly defined patches still standing. On the part of the femur which would come in contact with the tibia the cartilage is wholly removed. By comparing the surface of the patella with that of the anterior part of the femur which it would touch, it is pretty evident that the standing portions of cartilage on the one bone would fit into the spaces where the cartilage has been wholly absorbed from the other.

The patient was 13 years of age and died seven weeks after the incised wound into the knee-joint. Amputation had been refused.

728. A knee-joint from a subject of suppurative synovitis, showing extensive absorption of the cartilages from the condyles of the femur and from the patella.
729. Right half of the sacrum with posterior part of the right innominate bone.—The right sacro-iliac synchondrosis is laid open. It shows on the sacrum ulceration of the circumference of the auricular cartilage, with exposure of the bone: the anterior ligament of the joint is much thickened, and has evidently been distended in a forward direction.



The iliac bone is irregularly eroded on the auricular surface, and is bare over the remainder of the articular surface. There is some inflammatory exudation upon the back part of the sacral articular surface.

From Julia Bucks, who died Nov. 9, 1886, under Mr. McCarthy's care.

### **Ulceration of Articular Ends of Bones.**

730. A left scapula. The articular lamella of the glenoid fossa is almost entirely destroyed, as the result of prolonged suppuration in the joint.
731. The right os innominatum and upper fourth of the femur of a young adult. The head of the femur has been partially absorbed, and its remains are incompletely ankylosed to the acetabulum. The axis of the limb has clearly been across that of its fellow. The surface of the ilium, both internally and externally, as also that of the femur, is rough from the deposit of new bone.
732. The left femur of a young subject. The head of the bone has been destroyed by caries, and from the remaining part of the cervix numerous bony outgrowths have originated. These growths may be contrasted with those occurring in chronic rheumatic arthritis.
733. Section of the right femur of a young subject, showing the epiphyses of the great and small trochanters and of the articular head. There has been acute suppurative arthritis, with destruction of cartilage, and superficial caries of the head and neck of the femur.
734. The knee-joint of a young subject, showing the results of synovitis. The cartilage and articular layer of bone on the head of the tibia are very extensively absorbed, the tibia is displaced backwards, and the patella united by fibrous ankylosis to the femur.
735. The knee-joint of an adult, showing extensive destruction of the cartilage on all the bones, and large sinuses communicating with the interior of the joint.
736. An astragalus (from a case of suppurative synovitis of the ankle-joint), showing removal of the cartilage from almost the whole of its upper articular surface. Small patches of cartilage still remain at the sides of the bone where exempt from contact with others. The articular lamella is extensively ulcerated, and the specimen



being injected, the vascularity of the adjacent cancellous bone is well seen.

- 736 A. An astragalus from a young subject, showing caries of the head of the bone from disease of the astragalo-scaphoid joint. The articular surface of the head has been removed. A narrow rim of cartilage at the lower border of it alone remains, which is detached from the bone beneath; the anterior border of the upper (tibial) articular surface is eroded.

### **Separation of Epiphysis.**

737. Parts of the femur, tibia, and fibula of a young subject, from a case of disease of the knee-joint. The cartilage of the femur and tibia would appear to have been destroyed, and the bones themselves somewhat eroded. The epiphysis of the femur is detached, and is twisted forwards on the outer side. On the inner side it is still in apposition with the femur. The outer condyle of the femur above the spot where the epiphysis is detached was found quite bare of periosteum, and is marked out by a line of demarcation for subsequent exfoliation.

### **Dislocation of Bones.**

738. Ankylosis of tibia, patella, and femur, from a case of amputation by Mr. Curling, April 7, 1869.—The left half of the section shows the patella ankylosed by a small surface to the front of the condyle of the femur. At the upper and front part of patella is a cavity capable of holding two or three peas. The head of tibia is displaced backwards and outwards. There is a well-marked margin of cartilage remaining between the patella and the tibia, and on the femur. In the cancellous tissue of femur inside this is a cavity similar to that in the patella. In the head of the tibia is a third cavity, which contained a sequestrum. This cavity communicates with a sinus on inner wall, and below the patella. There were numerous sinuses leading to it from the back of the leg.
739. A knee-joint, showing ulceration of cartilages and abscesses communicating with the joint, with partial dislocation of tibia and fibula backwards.
740. Right knee-joint, showing dislocation of the tibia and fibula outwards and backwards. The back part of the external condyle



rests upon the internal tuberosity, which has been partially destroyed, the cancellous tissue is exposed. The joint is firmly ankylosed by dense fibrous tissue, the result of old arthritis. The patella is firmly fixed upon the front of the external condyle.

741. This specimen is described in the old Catalogue as one of "compound dislocation of the knee-joint from disease." The knee is bent at an acute angle, and in the middle of a very extensive ulcer the condyles of the femur, denuded of cartilage and in part of periosteum, are exposed to view. The specimen is injected.

741 A. Femur and os innominatum.—Head of femur lies in acetabulum; has been separated from neck by early disease. Acetabulum shows evidence of old joint disease. The rest of femur has been dislocated on to the dorsum, a new joint-cavity having been formed there. The boundaries of this false joint are shown. The femur is minus the head, and shows the worn neck; the worn neck must have articulated with dorsum. To it are still attached the ligaments of the false joint.

From a case of tabes dorsalis. Wm. Bruce, æt. 59.

#### **Repair after Ulceration of Articular Ends of Bones.**

742. The right os innominatum and upper third of the femur of a young adult. The head of the femur has been extensively absorbed, and there is bony ankylosis of its neck to the borders of the acetabulum. The limb has clearly been drawn across its fellow. See also the specimens of Ankylosis.

#### **Fibrous Ankylosis.**

743. Section through a knee-joint, showing extreme atrophy of femur and tibia with fibrous ankylosis at an acute angle. Both in front and behind the tibia are abscess-cavities in which probes are placed, and the ankylosis is therefore most probably the result of acute suppurative inflammation of the joint. The synovial membrane appears to have been entirely destroyed.

744. Fibrous ankylosis of the knee, with atrophy of bones: fractured femur. The joint is flexed at a right angle. The synovial membrane is destroyed. The cartilages are sound.

745. This specimen is described in the old Catalogue as follows:—Union by false membrane of the opposed surfaces of the tibia and astragalus,



taken from a boy whose leg was amputated for extensive suppuration succeeding compound fracture. The specimen is an injected one, and shows very beautifully fibrous union of two opposed cartilaginous surfaces. The cartilage covering the astragalus has been detached artificially and left in apposition with the tibia and fibula, to which it adheres. The adhesions are vascular and have received the injection. They do not appear to have obliterated the whole of the articular cavity, but only to have united the cartilages in certain places. The cartilages, where united, are thick and do not appear to have suffered any absorption; but on the astragalus, at the margins of its cartilage, there is a border of ulceration. There is no evidence of fracture or displacement in the specimen.

### **Bony Ankylosis.**

746. The left humerus and ulna of an adult. There is a complete bony ankylosis at an obtuse angle.
747. Part of the right humerus of an adult. Complete bony ankylosis at right angles. The cancellous tissue is directly continuous.
748. The right elbow-joint of an adult, showing complete bony ankylosis of both bones. The radius is displaced from the ulna to a distance of half an inch outwards, and its shaft crosses the ulna in a state of pronation. The articular ends of the bones are enlarged, and ankylosis has taken place with little loss of more than cartilage.
749. The radius and ulna of an adult right arm. Ankylosis of the radius at the lesser sigmoid notch in a position of pronation. The head of the radius is much enlarged and is placed almost in front of the ulna, where it is firmly united by bone. The cancellous tissue of the two bones is continuous, and no doubt the ankylosis was of long standing. It does not appear that there was any disease of the elbow-joint itself. The bones are atrophied from non-use.
750. Ankylosis at the wrist-joint and of all the carpal and carpo-metacarpal joints. The ankylosis is osseous and welds the radius, carpus, and metacarpus into one mass. The pisiform is not involved, nor is the head of the ulna united either to the radius or carpus.
751. Ankylosis of the wrist-joint. This specimen shows attempts at



repair after suppurative inflammation of the wrist-joint with caries of bones. Most of the carpal bones have been destroyed, but the trapezium and part of the unciform are still left. The metacarpal bone of the thumb is ankylosed to the trapezium, which is united to the anterior part of the radius by bridges of bone. The metacarpal bone of the index-finger appears to be united directly to the radius, and another metacarpal bone, probably that of the ring-finger, is also united to the radius and to the remains of the unciform. The ulna shows scarcely any trace of having participated in the disease.

752. A similar specimen to 753, but with the axis of the femur in a better position. Very little beyond the cartilages on the articular surfaces of the femur and acetabulum have been destroyed, the line of separation of the two bones being distinctly seen. The cancellous tissue of the two bones is not so directly continuous as in the next specimen.

From a young adult, the epiphysial line of union is not yet obliterated.

753. A beautiful specimen of complete bony ankylosis of the left hip-joint. The limb would appear to have been placed across the opposite thigh. There is a considerable cavity in front of the acetabulum just external to the outer lip of the thyroid foramen. The cancellous tissue of the femur and os innominatum is, in most places, directly continuous. The bones are those of an adult.

754. Bony ankylosis of tibia, femur, and patella. The shafts of the femur and tibia are much atrophied, the compact tissue being reduced to a mere shell.

755. Left tibia, femur, and patella of an adult, showing complete ankylosis between the three bones. The lower part of the femur is rotated inwards, and the tibia appears to have been displaced backwards and inwards, instead of backwards and outwards, as is usually the case; so that the internal condyle of the femur and internal tuberosity of the tibia are on a plane posterior to the external condyle and tuberosity.

756. Another specimen of bony ankylosis at the knee-joint at a right angle. There appears to be no trace of the patella. The femur is atrophied. The bone has been extensively destroyed.

757. A right femur, with the patella ankylosed to the external condyle by bone. The condyles of the femur are atrophied.



758. Complete bony ankylosis at the inferior tibio-fibular articulation. The cancellous tissue is more dense than normal.
759. Sections of the tibia, os calcis, and astragalus, showing firm bony ankylosis between them.
760. Ankylosis of the phalanges of the great toe.

### **Atrophy of Bone.**

761. The front half of the upper third of a right humerus. The head of the bone is flattened and expanded, and its articular surface is roughened (not eburnated), its lower margin presents a prominent overhanging lip. The section of a healthy humerus is mounted with this by way of contrast. See List of Specimens, page 143.

Represented in Mr. Curling's paper "On Atrophy of Bone," *Med.-Chir. Trans.* vol. xx. pl. v.

### **Chronic Rheumatoid Arthritis.**

762. Shoulder-joint laid open showing early signs of chronic rheumatic arthritis with rupture of the biceps tendon.
763. A right knee-joint laid open, presenting signs of chronic rheumatic arthritis. Along the edge of the internal condyle there is a well-marked lip. On the surface of the condyle is a longitudinal groove in the cartilage, which corresponds with a bare projecting nodule along the inner border on the patella. The cartilage on the patella and on the corresponding surface of the femoral condyles is thinned and fibrillated.
764. Lower part of femur and patella showing the articular surface of the outer condyle bare of cartilage over a space as large as a shilling. On the corresponding surface of the patella the cartilage is removed to a similar extent. The edges of both patches are bevelled off.
765. A plaster cast of the upper half of a right humerus and neck of a scapula. The articular surface of the humerus is enlarged, flattened, and altered in shape. There is a margin of new bone.
766. The upper fourth of a left humerus showing the results of chronic rheumatic disease of the shoulder-joint. There are growths of new bone around the margins of the articular head, and at one spot on its



upper surface the bone is eburnated and polished. The changes are slight.

767. A similar specimen.

768. Another specimen of chronic rheumatic arthritis of the humerus. The lips of bone and the eburnation of the articular lamella are very well shown. There is a smooth polished eburnated patch on the articular surface, which is contracted by bony deposit round its circumference, showing that movement must have been impaired.

769. An extreme example of chronic rheumatic arthritis at the elbow-joint. There is extreme lipping, especially of the head of the radius and of the coronoid process.

770. A right ulna showing the results of chronic rheumatic arthritis about the edge of its articular surface, more especially about the coronoid process. *Presented by Mr. Frederick Mackenzie.*

771. Parts of the humerus, radius, and ulna of the left arm. The ends of all the bones show deposit around their margins, presenting overhanging lips and irregular outgrowths. The surfaces are much eburnated and the determination of the direction of eburnation by friction is plainly visible; where the bones have been pressed in contact the surfaces are beautifully polished, whereas in parts where there was little or no friction the surfaces are rough. Inasmuch as the lesser sigmoid notch is rough, it might be inferred that rotation at the radio-ulnar joint had been lost; but the fact that the lines on the polished head of the radius are circular proves that this movement must have remained. These circular markings on the head of the radius contrast with those on the trochlear surface of the humerus, which are all longitudinal.

772. Three trapezia, a scaphoid, and a trapezoid bone, showing the effects of chronic rheumatic arthritis.

773. A portion of the ilium of an old woman of 80, showing the effect of chronic rheumatic arthritis on the crest of the bone. The condition was symmetrical. The outer edge of the crest was chiefly affected, an irregular overhanging lip of bone having been produced.



774. Greater portion of the left os innominatum and upper part of femur, showing well-marked changes due to chronic rheumatic arthritis. The upper part of the head of the femur is eburnated, the head is expanded. The anterior surface of the neck is covered with osseous outgrowths, which are distinctly limited by the upper part of the spiral line. The lines of muscular attachment are well marked. The acetabulum presents similar signs. At the lower and anterior part is a large bony outgrowth.

This specimen was taken from a man under the care of Mr. Adams. He had suffered from considerable pain in the left lower extremity. No pulsation could be felt in the femoral below Scarpa's triangle. The man was anxious to have the limb removed, but the cause and locality of the obstruction prevented this course being adopted. Ultimately, to relieve the excruciating pain, neurotomy of the anterior and posterior tibial nerves was performed, pyæmia resulted and death. At the post-mortem the knees and great toe-joints were found to be similarly diseased. The arteries were atheromatous.

775. Posterior half of the great trochanter, cervix, and head of the left femur. The articular surface is irregularly eroded, the cancellous tissue is dense, and in parts sclerosed. There are no distinct lips and no well-marked eburnation. The neck is very short, and at right angles to the shaft.

776. The head of the right femur, showing wasting and deformity of the bone, with eburnation and lipping.

777. A right femur.—The head is considerably enlarged, chiefly by overgrowths from its margins, constituting overhanging prominent lips. The articular surface is polished and eburnated. The cervix is short, horizontal, and almost lost. From the lower part of the head of the bone there are specially large overgrowths. The great trochanter shows no sign of disease, nor does the shaft of the bone on its lower extremity.

778. Cast of the upper fourth of a right femur.—The articular head is expanded and flattened out to a surface as large as the palm of the hand, and presents a smooth surface and overhanging edges. The neck is much shortened.

779. The lower articular end of the left femur, from the same patient, showing the typical changes of chronic arthritis.



780. Dry specimen of the right knee-joint, showing eburnation and lipping, with rotation of the tibia outwards.

#### **Changes in Joints due to Gout.**

781. Gouty deposit in the knee-joint, occupying both the femur and the patella. Gouty deposit upon the head of the metatarsal bone of the great toe.
782. Bones of a right foot, showing the whitish deposit of urate of soda on the cartilage of the articular surfaces of the astragalus, os calcis, and scaphoid.
783. The articular surface of the condyles of a femur covered with a layer of white deposit, dry, and looking as if it would easily scale off. It is nowhere thicker than paper, and looks granular. No history attaches to the specimen. In the old Catalogue it is described as arthritic deposit on the condyles of the femur. It is probably a dissecting-room specimen, and the deposit urate of soda.

#### **Loose Bodies in Joints.**

784. A knee-joint laid open in front, and the patella turned down. Two discs of loose cartilage, one the size of a shilling, but oval and the eighth of an inch in thickness, and the other about a quarter that size, are suspended in front of the joint and were quite loose. No description of the case has been preserved. The cartilage on the inner condyle of the femur is wanting over an area as large as a half-crown, and it is possible that the loose cartilages are fragments detached from this surface. On the surface of the outer condyle there are two shallow grooves caused by the friction of the loose bodies.
785. A loose cartilage of irregular shape, excised from the knee-joint. It is more than an inch in length, and half an inch broad. The patient died in consequence of the operation, and a portion of one condyle of the femur shows an irregular patch of bare and eroded bone, probably the result of "quiet necrosis" and the cause of the exfoliation of the loose cartilage.



786. Melon-seed bodies, from a large ganglion in front of the ankle-joint of a young man (John Young, æt. 20) under Mr. Hutchinson's care. On February, 1871, they were evacuated by a free incision. The ganglion contained little fluid and was almost full of these bodies, some of which were lost. They have shrunk much in the spirit. A piece of synovial membrane, with one or two of the bodies still attached, is preserved also.

P.S.—Mr. Hutchinson removed the foot by Syme's operation several months later. The patient had never got well enough to walk more than a few steps after the first operation. There was disease, chiefly of the astragalo-scaphoid joints. Probably this disease existed at the time that the ganglion-cyst in front of the ankle was opened.

### Excision of Joints.

787. Specimen to illustrate excision of the knee-joint. The parts were removed by amputation from a young man who had suffered from disease of the joint for several years. Excision was attempted, but both tibia and fibula were found so deeply diseased that amputation was the only resource. Deep cavities from carious softening are seen in the ends of both bones.

See Path. Soc. Trans. Mr. Hutchinson.

788. Specimen from a case seven months after excision of the knee-joint by Mr. Couper.

Excision was performed for extensive strumous disease of the joint in a lad. The boy recovered soon and well, and could walk as easily as before the commencement of the disease. Seven months after he was again admitted for acute rheumatism, and died with extensive pleurisy and pericarditis. The osseous union of the epiphysis is perfect, and there is no trace whatever of any line of union. The cancellous tissue, however, of the diaphysis of the femur and tibia is extremely soft and filled with fat. It yielded like butter to the pressure of the finger.

789. Portions of the left femur and tibia after excision of the knee. The excision had been performed by Mr. Partridge. The limb was amputated at Margate on account of the persistence of sinuses. The limb was in good position. In the specimen the end of the femur rests in the front part of the anterior surface of the tibia and projects over its edge. The posterior half of the tibial surface is behind the femur. The bones move on each other, and between their surfaces only a soft gelatinous structure is found. They are, however, fixed to a considerable extent by the deposit of layers of new bone on the



front surfaces of each. The new bone in front of the tibia is nearly half an inch in thickness and is external to the layer of unossified cartilage which originally constituted the outermost surface. In front of the femur there are two distinct new layers with a very thin lamella of dense tissue intervening. The cartilaginous layer is in front of both these, as if the outer layer had been split up by the intervening bony growth. The patella rests on the outer part of the outer condyle and is fixed. Both bones are very soft and loaded with oil. At the lower ends of both there are considerable portions which are of grey colour and comparatively destitute of vessels. Around these discoloured portions the bone is very vascular. At several parts on the posterior surfaces of both there are spots of caries, no doubt the causes of the persistent sinuses.

Patient aged 16. Two years' interval between the operations.

*Presented by Mr. McCarthy.*

790. A vertical section through the right knee-joint, exposing the medulla and cancellous tissue of the femur and head of the tibia. The condyles of the femur, the patella, and articular surface of the tibia have been removed by excision. The line of incision can be seen and the skin has united except at the ends, where the openings of sinuses are seen. There is no union of the ends of the bones. The cavity of the knee-joint is continued up behind the end of the femur for about half an inch. The walls of this pouch are seen to be thickened, and the compact tissue of the shaft ends suddenly at the upper end of the pouch. The medullary substance of the femur is the seat of osteomyelitis.

#### **Parts removed in Excision.**

791. Parts of the humerus, radius, and ulna removed in excision of the left elbow.

792. Part of the olecranon removed in an excision of the elbow-joint, showing extensive caries. Almost the entire shaft of the ulna, including its lower articular extremity, was removed about two months after the excision.

The patient, a middle-aged man, recovered with a useful arm, but with ankylosis at the wrist and elbow. Mr. Hutchinson.



**793. Complete osseous ankylosis of the humerus, radius, and ulna.**

The specimen was removed by resection from a lad aged 16, under Mr. Hutchinson's care at the Metropolitan Free Hospital. The limb was ankylosed in a straight position, and was comparatively useless. About two months after the resection it was found necessary to cut away another portion of the humerus in order to allow the wound to heal. The lad ultimately recovered with a very useful arm, with fair motion at the elbow and with the forearm at right angles to the humerus.



SERIES IV.—INJURIES AND DISEASES OF MUSCLES,  
TENDONS, AND BURSÆ.

**Avulsion:** 794, 795.

**Rupture of Muscle:** 796, 797.

**Fatty Degeneration:** 798.

**Repair of Tendon after Section:** 799.

**Enlarged Bursæ:** 800, 801, 802, 803.

---

**Avulsion.**

794. A thumb torn off by machinery. Separation has taken place at the junction of the epiphysis of the first phalanx. The tendons of the long flexor and of the extensor secundi internodii have been pulled out at their junction with the muscular portions. Some of the muscular fibres have been torn through. The separation was complete, and the youth brought his thumb with him wrapped up in paper. The patient was 17 years of age.

Mr. Hutchinson.

795. The terminal phalanx of the thumb, and part of the second, with the tendons attached. It would appear to have been torn off by violence, and has been preserved in order to show that the tendons have been detached where the muscular fibres were inserted into them.

**Rupture.**

796. Rectus abdominis muscle, showing complete transverse rupture probably the result of tetanus. There is no evidence of repair; therefore death quickly followed the injury.

797. Portion of rectus abdominis ruptured by tetanic spasm.

**Fatty Degeneration.**

798. Fatty degeneration of the gastrocnemius muscle.



**Repair of Tendon after Section.**

799. An os calcis and tendo Achillis preserved in order to show repair of the latter after section.

Mr. Curling.

**Enlarged Bursæ.**

800. A bursal tumour as large as an egg, thick-walled cavity of considerable size and without solid growths.
801. Two enlarged bursæ patellæ, probably removed from the same patient. One of them has its cavity entirely obliterated by solid deposit. The walls of the other are also very dense.
802. An enlarged bursa patellæ removed by Mr. Ward. The bursa is as large as a small orange, and its cavity is quite obliterated by soft fibrous deposit.
803. Enlarged bursa patellæ, removed from a post-mortem room subject.



## SERIES V.—ANATOMY OF STUMPS.

**Neuromata :** 804, 805.

**Ankylosis of Bone Ends :** 806.

**Necrosis :** 807, 808, 809, 810.

**Absorption of Cartilage :** 811.

---

**Neuromata.**

804. A portion of the left humerus, from a stump after amputation in the lower part. All the principal nerves are bulbous near their extremities.

805. The stump of an amputation through the forearm, some years after the amputation. The arteries have been injected and show their gradual diminution downwards to the end of the stump. The enlargements at the end of some of the nerves are also seen.

**Ankylosis of Ends of Bones.**

806. Ankylosis between the lower ends of the tibia and fibula. From the rounded shapes of the ends of these bones it may be inferred that their articular ends had been removed during life.

**Necrosis.**

807. Vertical section of a stump after amputation through the condyles of the femur. The end of the bone is almost covered by adherent flap, but at one point there is a necrosed part of the shaft bare of periosteum and in process of separation. The shaft immediately above this sequestrum is sclerosed. The cancellous tissue is infiltrated in parts by exudation.

808. A piece of femur from a man aged 41, for whom amputation at middle third of femur had been performed on account of disease of the knee-joint. Twelve days after the operation the flaps had not united and the bone projected from the bottom of the wound, covered thickly with granulations and with the periosteum stripped off. The granulations spring from the medullary cavity and spread from thence over the cut end of the compact tissue, nearly to the circumference.



809. Vertical median section of a portion of a femur, showing the lower end of the medullary cavity infiltrated by exudation. The specimen, at its lower part, presents a ring of bone uncovered by periosteum and in process of exfoliation. The periosteum is much thickened immediately above this.

810. The specimen shows the condition of the bone on the eighth day after amputation through the femur in a child aged three years and a half. The amputation was performed on account of disease of the knee-joint; the child was very feeble at the time and sank on the eighth day. The specimen shows the end of the bone for a length varying from an eighth of an inch to half an inch quite bare and in progress of exfoliation, above this the periosteum is much thickened and very loosely adherent to the bone. On the surface of the latter is a thin layer of new bone; this layer is thickest at the lowest part where the periosteum adheres; it commences here by an abrupt margin and diminishes in thickness as you pass up the shaft.

Mr. Hutchinson.

### Absorption of Cartilage.

811. A metacarpal bone from a finger which had been amputated some years before this specimen was obtained. The amputation had been performed at the metacarpo-phalangeal articulation, and the condition of the ends of the bone is illustrated by the specimen. The cartilage over the most prominent part of the bone is removed, but in other parts it still remains in irregular patches. The soft tissues do not adhere to the end of the bone anywhere, but a smooth lined capsule has been formed, in which, as in a synovial membrane, it is contained.



## SERIES VI.—INJURIES AND DISEASES OF THE BRAIN AND ITS MEMBRANES.

### Effects of Injury.

Hæmorrhage: 812, 813, 814.

Contusion: 815.

Meningitis: 816, 817.

Abscess: 818, 819, 820, 821, 822.

Hernia cerebri: 823.

Atrophy: 824, 825.

Calcareous Degeneration: 826, 827, 828.

Meningeal Hæmorrhage: 829, 830, 831.

Purpura: 832.

Cerebral Hæmorrhage: 833.

Thrombotic: 834.

Hydrocephalus: 835-837.

Tubercular Meningitis: 836.

Tubercular Tumour: 837.

Hydatid: 838.

Meningeal Cysts: 839, 840.

Apoplectic Cyst: 841 (?).

### Morbid growths in Dura Mater and Cranium.

Fibroma: 842.

Sarcoma: 843, 844, 845, 846.

Carcinoma: 847.

### Growths in Pia Mater and Brain.

Psammoma: 848, 849.

Glioma: 850, 851.

Sarcoma: 852, 853, 854, 855, 856.

Growths in Pituitary Body: 857, 858.

Growth in Pineal Body: 859.

### Malformation.

Encephalocele: 860, 861.

---

## EFFECTS OF INJURY.

### Hæmorrhage.

812. The upper parts of both cerebral hemispheres, with a portion of dura mater. The dura mater shows on its outer surface a large oval subcranial clot, thin and membranous at its margins, half an inch



thick at the centre. The left hemisphere is indented in the region of the fissure of Rolando, *i. e.* in the region of the middle meningeal artery.

Removed from the body of an old woman, who died between two and three weeks after an injury to the head. She never had any positive symptoms of pressure, and there was no paralysis.

813. The cerebellum, pons, and medulla oblongata from a case of injury to the head. The specimen shows the traces of a hæmorrhage in the pons almost exactly in the middle line under the sylvian aqueduct, and affecting the tegmental fibres of both crura. There were also small extravasations on the surface. *Presented by Mr. Hutchinson.*

814. A brain with the upper parts of the hemispheres removed, from a case of injury to the head. At the base there is evidence of extravasation of blood into the pia mater on the under surface of the pons, and of the cerebellum adjacent. Projecting from the section of the right hemisphere, apparently penetrating deeply into its substance, is a large dark mass of blood-coagulum. Sections of this show no new growth.

#### **Contusion.**

815. Portion of the left hemisphere of the brain from a case of fracture of the skull, showing numerous patches of extravasated blood under the arachnoid, and also lymph effused on the surface of the arachnoid.

#### **Traumatic Meningitis.**

816. Portion of dura mater, with its inner surface in the left frontal and parietal regions covered with a continuous adherent layer of vascular lymph. There is an oval patch of lymph situated on the external surface in the left frontal region, probably at the seat of injury (? fracture).

817. A cerebellum with pons and medulla oblongata from a case of fracture through the petrous bone. The two latter are encased in a thick layer of lymph which extends on to the under surface of the cerebellum. There has been laceration of the right lobe of the cerebellum. *Presented by Mr. Hutchinson.*

#### **Traumatic Abscess.**

818. Portion of brain with membrane covering it, showing an abscess half the size of a walnut in the substance of the brain, and commencing fungus cerebri where the trephine had been used. There is lymph on the outer surface of the dura mater.



819. Part of a brain showing an abscess-cavity the size of a walnut near the surface of the hemisphere. The position cannot now be defined. It lay in the left hemisphere under a trephine aperture.

The patient, a man aged 57, was admitted unconscious, since having fallen into a ship's hold two days before. Treated by venesection and calomel, he became able to speak after a few days. Pericranium was found stripped from the bone, and a slight fracture was discovered. He was trephined by Sir William Blizard, but without relief. He had right hemiplegia with deviation of the face to the left, and was unconscious for a week before his death, which took place three weeks after the accident.

820. Part of a frontal bone and of the subjacent brain, showing a large ill-defined abscess in the latter, the walls of which, in the recent state, were green and contained offensive pus. There is a fissured fracture passing from the left orbit to a depressed fracture near the left frontal eminence. A piece of bone there is detached and depressed about  $\frac{1}{4}$  of an inch.

From a boy, aged 11, admitted unconscious after being trampled on by a horse. He did very well at first, a piece of exposed bone being in process of exfoliation. He was suddenly seized with vomiting, quick pulse, and furred tongue. He was bled to 10 oz., but he died the following day.

821. The calvarium with the upper part of the brain and the cerebellum of a child who died from abscess of the brain following a compound fracture of the frontal bone. There is a large chambered abscess-cavity in the anterior part of the right hemisphere, which has compressed the corpus striatum and pushed it backwards and inwards. It has a channel of communication with the lateral ventricle, which is much dilated to the outer side of the central ganglia. The left lateral ventricle is also much dilated, and the central ganglia compressed and atrophied. The cerebellum shows dilatation of the fourth ventricle and iter. The falx is bulged to the left, and the left hemisphere compressed. Over the anterior part of the abscess-cavity there is a projection of the dura mater through an opening to the outer side of the right frontal eminence.

The patient was a little girl, admitted with a compound fracture of the frontal bone on the right side, caused by the fall of a flower-pot. No symptoms were present, but as the fracture was compound, and as a considerable portion was depressed, primary trephining was performed. The child did well at first; a few weeks later, however, she lost appetite, had frequent sickness, was frequently chilly without any decided sign, and became thin and pale. After this the child improved sufficiently to be able to leave the hospital. Some small portions of bone had meanwhile exfoliated. She was readmitted a fortnight later without definite symptoms, but fretful and ailing. In this condition she remained in the hospital, able to eat and to converse, and having no paralysis or twitching whatever. Suddenly one night she was seized with epileptic convulsions which lasted with moderate severity for several hours, and left her insensible. In this condition



she died about eight hours later. The wound had been covered by a thin cicatrix beneath which the brain bulged somewhat, and its pulsations were easily seen. There had never been any evidence of perforation of dura mater.

The autopsy showed a large collection of thin pus distending both lateral ventricles and passing into the third and fourth; the fourth ventricle was large enough to admit the tip of the little finger. The valve of Vieussens had been ruptured, and the parts at the base of the brain, the medulla &c., were bathed in pus. It seemed probable that the escape of pus in this position had been coincident with the occurrence of fatal symptoms. There was no lymph at the base of the brain, and the pus found there was exactly like that in the distended ventricles. The brain-substance beneath the scar had been thinned away, probably by the formation of an abscess which had subsequently broken into the anterior cornu. In the specimen the hollowing-out of this part of the hemisphere is well shown. The abscess could have been punctured with the greatest ease through the thin scar. Entire absence throughout both of spasms and of paralysis had, however, prevented a correct diagnosis. It should be stated that the bulging scar always pulsated freely.

*Presented by Mr. Hutchinson.*

822. Cerebellum and pons showing an abscess-cavity of the size of a walnut in the anterior part of the left lobe. It has been exposed by removal of the under surface of the lobe.

### **Hernia cerebri.**

823. A calvaria with the upper part of the brain (much shrunk) from a case of compound fracture, showing an abscess-cavity in the right posterior lobe, which has opened externally through an aperture in the parietal bone, and has been followed by hernia cerebri.

From a middle-aged man named Warner, admitted under Mr. Little's care with a severe compound fracture of the right parietal bone. He was trephined, and a portion of bone removed. He lived many weeks and during the last two months of his life he had a large fungus cerebri over the seat of injury. His symptoms had varied much. During the latter part of the time he had been perfectly conscious, and excepting considerable weakness of the left arm had had no paralysis. On two occasions the paralysis of the left arm and leg had been almost complete, but had afterwards passed off. There had been throughout profuse discharge of pus from the fungus, and the attacks of paralysis had been supposed to be dependent on temporary occlusion of the sinus. For a long time it seemed likely that the man would recover. The immediate cause of his death was obscure; he had seemed in his usual health, when one morning he got out of bed, suddenly fell as if in a fit, and died in ten minutes.

The autopsy did not explain his sudden death. There was a fungus the size of a child's fist over the wound; into the middle of this the little finger might easily be passed and made to enter an abscess-cavity the size of an egg. The cavity was in the upper part of the posterior lobe of the right hemisphere. It was separated by a very thin layer from the posterior cornu. The adjacent portions of the brain and the ventricle showed no signs of disease. The arachnoid surfaces at the seat of injury were firmly adherent, but only over a limited area. There had been no diffuse arachnitis.

*Presented by Mr. Little.*



## DISEASES OF THE BRAIN.

**Atrophy.**

824. Portion of brain with the upper parts removed showing atrophy of left corpus striatum and optic thalamus. Those of the right side measure antero-posteriorly  $2\frac{1}{2}$  inches, those of the left side only  $1\frac{3}{4}$ , but the difference in size is much greater than these measurements imply.

Case of Florence E. H., aged 6, an intelligent and well-nourished child, who had had loss of power in the right arm and leg from infancy. The limbs did not appear to be wasted. She got diphtheria a few days after admission and died.

Autopsy, March 22, 1886. Dr. Sutton.

825. Portion of brain with the anterior part of the frontal lobes removed by vertical section through the anterior part of the corpora striata. The section of the right corpus striatum and of the white matter external to it presents the appearance of Gruyère cheese, from numerous well-defined holes in the tissue. There are a few small holes in the corresponding section of the left hemisphere. They are not observable in the cut surfaces of the anterior portions of the frontal lobes, *i. e.* about  $\frac{1}{2}$  an inch from the others. The right lateral ventricle is sealed up at this part by adhesion of its surface over the corpus striatum about the plane of the section. Under the microscope sections of the brain show some of the smaller holes occupied by arterioles in much loose perivascular tissue.

Case of Amelia B., aged 45, married, with a history of miscarriages, but no children, who was admitted with loss of power in left arm and leg and left side of tongue and in right arm. She had been attending as an out patient for three months with pains in the limbs aggravated at night. The paralytic symptoms improved under treatment with iodide of potassium. She was intelligent, but dull and slow in speech. She had cystitis and albuminuria, with suppurative nephritis, and an atrophied heart with fatty infiltration of the right ventricle, and died with œdema of the lungs. There was a well-defined rounded nodule of growth of the size of a cherry at the surface of one kidney, sections of which show a closely felted fibro-nuclear structure, in the middle of which two arteries with thickened walls are imbedded.

Autopsy, July 6, 1888. Dr. Langdon Down.

**Calcareous Degeneration.**

826. Portion of brain from the surface of one hemisphere showing bony plates in the pia mater. The plates are as large as a sixpence, and seem to pass somewhat into the brain-tissue.

From a man who committed suicide by cutting his throat. Mr. Adams has recorded this and a precisely similar case which occurred at the same time.



827. Part of the dura mater from the vertex of the cranium with partially detached membrane hanging down from its inner surface. In the latter there are three bony plates of irregular outline.

There were no head-symptoms during life.

*Presented by Dr. Sutton.*

828. Dried portions of dura mater with bony plates at the inner surface.

### **Meningeal Hæmorrhage.**

829. Piece of dura mater lined on its inner surface with a thin uniform blood-stained false-membrane, which is readily separable.

830. Dura mater of vertex including falx cerebri, lined on its inner surface on both sides with a thin, blood-stained false-membrane, readily separable.

831. Dura mater of left vertex, including falx cerebri. There has been a layer of blood on the inner surface of the dura mater, enclosed by a membrane which has been largely detached and partly removed. Portions of blood-clot are seen still attached to the dura mater and to the false-membrane.

832. The dura mater of the vertex of the cranium, showing numerous hæmorrhages beneath its lining membrane, mostly in the parietal region, and more abundant on the right side, where the inner surface of the dura mater is roughened over the most elevated hæmorrhagic areas.

Case of Florence P., aged 7, admitted with a general purpuric eruption and great debility. There was no ulceration of the gums, and no arthritic symptoms. Autopsy, April 2, 1887.

See Trans. Path. Soc. vol. xxxviii. p. 189. See Bladder, Series XXXVII. and Kidney, Series XXXVI.

### **Cerebral Hæmorrhage.**

833. The basal part of a brain with upper portion of right hemisphere, showing a large hæmorrhagic cavity in the white matter of the right hemisphere, between the central ganglia and the fissure of Rolando with the cortex on both sides of it. In the upper part of this hemisphere a well-defined blood-clot of rounded shape, and of the size of a plum, is seen attached to the inner surface of the cortex, from which nearly the whole of the white matter has been removed by the crushing force of the extravasation.



Case of R. G. G., aged 69, admitted one hour after an attack of left hemiplegia, involving the face. He became unconscious three hours later, and remained so until his death, five days afterwards. The kidneys were granular with contracted and cystic cortex, and the left ventricle of the heart hypertrophied. The aorta and cerebral arteries were atheromatous.

Autopsy, Nov. 7, 1885.

### **Thrombosis.**

834. Part of cerebellum and pons Varolii with the medulla oblongata. The right side of the pons has been removed by an oblique antero-posterior section passing near the basilar artery, and showing numerous punctate extravasations of blood into its substance over an area bounded by a zone of discoloration in the section, the result of arterial occlusion. In the anterior section of the pons the same hæmorrhagic tract is exposed. It is mostly on the right side, but extends across the median line at the lower part of the section, approaching the locus niger.

### **Hydrocephalus.**

835. A brain with the upper part of the hemispheres removed, showing dilatation of all the ventricles with great thickening of the ependyma, which appeared as a grey translucent membrane with finely granular surface. The pia mater was thickened over the diamond-shaped space and over the opening of the fourth ventricle, the thickening extending over a defined area of the surface of the cerebellum around. There was no notable thickening at the apex of the cerebellum. The convolutions of the hemispheres were flattened. The velum is contracted up and forms two prominent rolls encircling the crura cerebri at the posterior border of the thalami. At the extremity of each posterior cornu was a collection of healthy-looking pus (about 3j).

Case of Robert F., aged 8. Admitted with headache and occasional vomiting attributed to an injury ten days before, which had been followed by a "fit" the next day. He was dull and much wasted. He continued in much the same state until his death five months later, which was preceded by a rise of temperature and convulsions. There was a caseous nodule at the surface of one lung. No tuberculosis of the brain or other organs.

Autopsy, Jan. 31, 1886. Dr. Sansom.

### **Tubercular Meningitis.**

836. The upper parts of the hemispheres of the brain from a case of tubercular meningitis, showing thickening and roughening, from a deposit of lymph, of the pia mater at the vertex, over a defined area on the upper and inner surfaces of the right hemisphere equal to



a crown piece. There are similar appearances of less extent and less degree at the corresponding part of the other hemisphere.

Case of Thomas J. F., aged 17. Admitted May 19, 1882, with loss of power and muscular rigidity and tremor in left arm and leg without loss of sensation. The reflexes were exaggerated. On May 29 he got an attack of facial erysipelas, and died June 6. The duration of symptoms was a month. He had tuberculosis of lungs and kidneys and caseous mediastinal glands.

Autopsy, June 7, 1882. Dr. Turner.

### **Tubercular Tumour in the Brain.**

837. The brain of a boy æt. 6, showing a tumour of the size of a plum in the posterior part of the middle lobe of the cerebellum, and extending more to the left than to the right. It caused a projection upwards of the tentorium cerebelli, with compression of the under surface of the posterior lobes of the brain. The outline of the mass is well defined. The lateral ventricles are considerably dilated.

Sections of the tumour show it to consist of a caseous mass with a border of freely corpusculated connective tissue growth, and the pia mater adjacent thickened with similar growth, in which are cloudy areas of necrotic tissue. Sections of the cord show dilatation of the central canal without alteration of the lining epithelium. The dilatation is less in the lumbar than in the cervical and dorsal regions.

Case of Benjamin J., aged 6. Admitted August 20, 1883, for vertigo, with unsteadiness in walking, and headache and occasional vomiting. He was intelligent, but rather dull. The symptoms had been observed about ten days, and were comparatively slight at first. After admission he gradually became more dull and irritable, with loss of power in the limbs, so that he could not sit up. The head became enlarged, and the sutures ultimately separated. There was loss of control over the evacuations and rigidity of limbs. He died April 18, 1884, with diphtheria. The temperature, which had been normal with slight temporary elevation, rose during the last thirteen days of his life. He had double optic neuritis. *Post-mortem*, membrane was found in the larynx and trachea and extending into the bronchial tubes, and the upper lobe of the right lung was consolidated. No miliary tuberculosis or caseous nodules.

Autopsy, April 19, 1884. Dr. Sutton.

### **Hydatid.**

838. The left cerebral hemisphere viewed from its inner aspect, showing a large cavity in the posterior part of the parietal lobe, in which are portions of a parent hydatid cyst adherent to its walls and collapsed secondary cysts within it. The cyst has pushed forward the lateral ventricle, which is dilated, and has compressed the occipital lobe. There is a large opening in the wall of the cavity at the surface of the hemisphere.

From a boy aged 11. Two years before death he began to lose his sight, and became quite blind in twelve months. He then had an apoplectic attack followed



by right hemiplegia and was speechless for three days. He subsequently complained much of his head, and sometimes lost his speech for two or three days. But his intelligence was not affected. He died comatose, after having been in that state five weeks. At the autopsy the membranes were found adherent to the surface of the left middle lobe of the brain. On raising them at this place fluid escaped in great quantity, which was found to have been discharged from the cyst of a large hydatid which had invaded the left lateral ventricle, and had gradually extended to the surface of the brain. It contained about 16 drachms of limpid fluid, and besides this there were several ounces in the proper cavity of the ventricle.

For a report of the case see Dr. Abercrombie, "On Organic Diseases of the Brain," Edinburgh Medical and Surgical Journal, vol. xv. p. 504.

*Presented by Mr. Headington.*

### **Meningeal Cysts.**

839. A brain in which there was a large meningeal cyst in the situation of the left Sylvian fissure. The insula is exposed by separation of the anterior and temporo-sphenoidal lobes, and the third frontal convolution with the lower parts of the ascending frontal convolution is depressed: these convolutions have been somewhat flattened by the pressure of the cyst. Portions of the membrane which enclosed the cyst below and externally, where it was in contact with the cranium, are still attached to the convolutions at its borders. On the right of the brain there are two small cysts in the pia mater immediately in front of the ascending frontal convolution; one is between the second and third frontal convolutions, the other is at the summit of the hemisphere. An extension of the former in a downward direction would produce a cyst in a similar situation to the large cyst on the left side of the brain.

Case of Maria M., aged 58, who died from phlegmonous erysipelas of the left leg. There was no clinical indication of cerebral defect. She had a dermoid cyst in the right ovary, and the commencement of each Fallopian tube was enlarged, forming a horn-like projection from the fundus uteri on either side. There was a polypus in the cavity of the uterus.

Autopsy, Jan. 1, 1884. Mr. Waren Tay.

See Ovaries, Series XLIII.

840. A cerebellum with a large smooth-walled cyst occupying the greater part of the left lobe, extending upwards from the posterior part of its under surface. The wall of the cyst is membranous at this part, and was ruptured at the autopsy. At the under surface of the opposite lobe, about the middle, is the mouth of a smaller cyst, which is about the size of a nut. It is also smooth-walled with rounded outline, and divided into two chambers by a membrane with smooth rounded edge, which is seen projecting from the mouth of the cyst and transfixed by a pin.



Case of E. G., aged 26, who was admitted with hysterical anorexia and other neurotic symptoms. She died unexpectedly in an epileptiform attack. There had been no previous indication of disease of the nerve-centres.

Autopsy, March 15, 1887. Dr. Sutton.

### **Apoplectic Cyst.**

841. A cerebellum with a cavity the size of half a walnut occupying the inferior vermiform process, opened from below. It is described as an "apoplectic cyst."

### **Morbid Growths in the Dura Mater.**

#### **Fibroma.**

842. Portion of dura mater from the left hemisphere, showing a cluster of fibrous tumours developed in its substance and projecting on its inner surface. They are all smooth and rounded, the largest the size of a couple of almonds. Sections from one of these growths show closely interwoven strands of compact fibrous tissue.

#### **Sarcoma.**

843. Part of sphenoid and adjacent bones, showing a mass of morbid growth, which probably commenced in body of sphenoid, and has passed upward into the skull and downward into the nares. The left Gasserian ganglion is imbedded in a mass of growth, which extends on the posterior aspect of the petrous bone, and involved the fourth, sixth, and eighth nerves on that side. The right Gasserian ganglion is invaded by a smaller mass, which involves also the third nerve on that side.

The patient had paralysis of the nerves involved in the growth. At an early stage of his illness he had enlargement of the cervical glands, which led to a correct conjecture as to the seat of the primary disease.

*Presented by Mr. Hutchinson.*

844. Portion of left side of base of skull, showing a cancerous mass in the body of the sphenoid bone, in which the Gasserian ganglion is involved. Patches of lymph were adherent to the base of the cranial cavity at several places.

*Presented by Mr. Hutchinson.*

845. Portion of dura mater and of the calvaria showing a sarcomatous growth of the former, which has perforated the latter by its extension outwards. The tumour, as preserved, is about the size of half an



orange, and looks not unlike a sea-anemone. It is connected with the dura mater only by the centre of the base, and the corresponding part of the deep surface of that membrane is puckered. The tumour on section showed a homogeneous, firm appearance. The parietal bone has been extensively eroded on the inner surface, more than the external aperture would correspond to, and on the margins of the unabsorbed bone are vertically arranged laminae of new growth of bone, about 3''' in length, and suggesting in some degree the appearance seen in the specimen of osteoid cancer in specimen No. 678, Series II.

Sections of the growth show a densely felted fibrous structure, in which fusiform cells with elongated nuclei are imbedded, with thick-walled vessels. The patient from whom this was obtained after death was an apparently healthy man, who applied as an out-patient under Mr. McCarthy, on account of a tumour in the right temporal region. It was somewhat lobulated, and situated beneath the temporal fascia. It seemed freely movable, did not pulsate, nor cause him any pain on pressure or handling. He had never had syphilis. Mr. McCarthy proceeded to remove the growth at his request, but found that it was firmly adherent at the base, and on passing his finger to the bottom of the wound, detected the ragged aperture in the parietal bone. This was undiscoverable before, as the entire growth was somewhat of an hour-glass shape, the portion outside the calvaria being similar in size and shape to that seen on the dura mater, the two portions being connected by a narrower part passing through the bone. The patient died some days after with symptoms of meningitis; but, as a post-mortem examination was forbidden, the condition of the viscera generally could not be ascertained.

*Presented by Mr. McCarthy.*

846. Piece of dura mater with a pedunculated tumour the size of a bean projecting on its surface.

Sections of this growth show a finely reticulated fibrous structure, with tracts of more recent growth in which fusiform and stellate nucleated cells are irregularly mingled.

### **Carcinoma.**

847. Part of the vertex of the skull with the dura mater, showing irregular thickening of the latter from secondary cancerous growth. The surface of the bone is roughened, and softened and eroded on both sides. The pericranium is thick and prominent in places.

The specimen was removed from a woman whose breast had been excised for cancer eighteen months previously, and who died comatose.



**Morbid Growths in Pia Mater and Brain.****Psammoma.**

848. Portions of the velum interpositum, in which are two oval psammomatous tumours of the size of almonds, which were situated in the descending cornua of the lateral ventricles.
849. Portions of the velum interpositum, in which are numerous chalky-looking nodules of varying size, which on section showed a fibrous structure studded with concentrically stratified concretions of spherical form.

From an obese female, aged 60, affected with glycosuria, who died with gangrene of the foot due to arterial thrombosis. There was also necrosis of the pyramids of one kidney.

Eliz. B., Autopsy, Feb. 21, 1888. Mr. Tay. See Kidney, Series XXXVI.

**Glioma.**

850. A brain with the upper part removed just above the corpus callosum, showing a soft sarcomatous growth occupying the centre of the white substance of left hemisphere, and extending further forwards than backwards. The growth extended upwards to the upper part of the fissure of Rolando, at which part the grey substance had been invaded and destroyed over a limited extent about 1" from the longitudinal fissure. The lateral sinus did not appear to have been invaded. In the horizontal section of the brain the growth extends up to and in some degree embraces the bottom of the fissure of Rolando, but has not reached the grey cortex. When recent, the tumour was of a soft gelatinous, almost diffuent consistence, traversed by vessels. This structure is now shrunk and opaque. Sections show it to have been of gliomatous nature.

Case of G. J., aged 31. His symptoms, which dated from three months before his death, were spasmodic contractions of the right arm and leg, with "pricking sensations" in them, and subsequently loss of power and wasting of the limbs; occipital headache, vertigo, and nausea; and double optic neuritis. There was facial and lingual paralysis of the same side. He became suddenly comatose, and died the same day. There was a large medullary sarcomatous growth at the root of the left lung, but no secondary nodules of growth, and no notable lesions of other organs.

Autopsy, Dec. 12, 1885. Dr. Langdon Down.

See Trans. Path. Soc. vol. xxxvii. p. 29.

851. A brain divided horizontally below the corpus callosum, the section passing through a firm nodule of growth in the right parietal lobe, and showing an extension inwards from it of a softer form of growth to the wall of the lateral ventricle, where it has invaded and destroyed the outer part of the optic thalamus and the posterior and outer part of the corpus striatum. The growth extends forwards in the white matter of the section of the brain as far as the fissure of



Rolando, posteriorly to the anterior wall of the descending cornu of the lateral ventricle.

Sections of the growth show a gliomatous structure with round nuclei, traversed by bands resembling strands of medullated nerve-fibres.

Case of Jas. S., 55. About eight months before his death he suffered from headache and occasional vomiting. Fourteen weeks before his death he fell down unconscious in the street, after which he gradually lost power and sensibility in his left arm and leg, and in the face on that side. He had double optic neuritis with hæmorrhages and dimness of vision. He died comatose three weeks after the appearance of symptoms of cerebral disturbance. There was thickening and atheroma of the arteries at the base of the brain and enlargement of the heart. No other notable lesions of the viscera were found.

Autopsy, Jan. 29, 1886. Dr. Langdon Down.

See Trans. Path. Soc. vol. xxxvii. p. 32.

### Sarcoma.

852. The cerebellum, pons, and medulla oblongata, and posterior and lower portions of both cerebral hemispheres. Lying on the upper surface of the left crus, and grooving both it and the neighbouring anterior corpus quadrigeminum, is a rounded bilobed growth in the pia mater, now shrunk to the size of a bean. In the white matter of the right hemisphere near the longitudinal fissure, and just anterior to the parieto-occipital fissure in the horizontal section of the brain is another growth of circular outline, and about five eighths of an inch in diameter.

Sections of this latter growth show fusiform cells with large nuclei, irregularly arranged in a fine reticulum. Owing to the softness of the growth sections of its borders only could be obtained.

Case of Ellen W., aged 7. Her symptoms dated twelve months before her death. They commenced with tremors in one arm and leg, subsequently extending to the other limbs, and followed by loss of vision. When admitted, two months before her death, she was quite blind and unable to stand, and in a torpid state. She said little, but spoke in a syllabic manner. There were irregular movements and twitchings of the eyeballs, with divergence. The back became arched and head retracted, and the limbs rigid. She became unconscious, swallowing with difficulty, and died from respiratory obstruction. The optic and 3rd nerves were swelled and gelatinous, the latter being fusiform, as seen in the specimen.

Autopsy, Jan. 5, 1885. Dr. Turner.

853. Cerebellum and pons, showing a tumour, probably the size of a walnut originally, growing from the pia mater. It lies just to the left of the pons, and had compressed the middle crus cerebelli.

Sections of the growth show, in parts, fusiform cells in strands, freely infiltrated with leucocytes. In other parts a delicate reticulum in which nucleated cells lie

854. Cerebellum with a rounded tumour about the size of an egg in the lower part of the right lobe, immediately under the pia mater. It occupies the posterior and external part of the lobe, and



the notes state that the dura mater was thinned and the adjacent bone partially absorbed.

Sections of the growth show a small round-celled sarcomatous structure.

Patient, a girl *æt.* 17, died in London Hospital under care of Dr. Cooke. She had been subject to fits and had suffered from headache, vomiting, and much impairment of vision, with widely dilated pupils. Her intellect was impaired. Pulse small and weak. She became quite blind, and had much vomiting, and died rather suddenly.

855. The pons Varolii and posterior part of the brain, showing the fourth ventricle occupied by a growth, which has invaded and compressed the medulla oblongata and cerebellum. There were numerous secondary growths in the meninges of the cord on its posterior aspect all the way down. Sections through one of these showed that the growth was a small round-celled sarcoma, and that the posterior white columns of the cord were invaded by it at their surface.

Case of Rosina W., aged 15, admitted under Sir A. Clark on Nov. 22, 1882, with double optic neuritis, and amaurosis dating two months back. She had had vertigo and vomiting at intervals for nine months. She complained of pains in the eyes and down the left side of the body, and loss of power in the limbs on that side. The knee-jerks were absent. She left the hospital in March, 1883, was readmitted in August, and on October 5 she became comatose and died. Autopsy, October 6, 1883.

See *Trans. Path. Soc.* vol. xxxvi. p. 21.

### Cystic Sarcoma.

856. The cerebellum with pons Varolii and medulla oblongata. At the outer border of the right lobe of the cerebellum is a cyst of the size of a damson, surrounded by a wall of new growth except on its outer surface. It is lined by a smooth membrane, and contained clear serous fluid. It appears to be separated from the nerve-structures, but microscopical sections show continuity of the growth with the medullary tissue. At the upper surface of the cerebellum is a smaller tumour of rounded form about 1 inch in diameter. It is contiguous to the central lobe, which it has indented on the right side anteriorly. This tumour has been laid open by an obliquely transverse section, and is seen to contain several cysts, one as large as an almond. Sections of the first tumour showed a highly vascular sarcomatous growth with greatly dilated vessels.

Case of George P., aged 44. His symptoms dated from twenty-two months before his death. These were headache, mostly frontal and occipital, and latterly very severe and accompanied by vomiting, tinnitus, deafness, and dimness of sight. He had incoordination of muscular action in walking, and a tendency to fall to the right side. The knee-jerks were not lost. Latterly there was general enfeeblement of muscular power and apathy, and ultimately coma. He had been a policeman ten years, and had had a good deal of knocking about.



Eight years before admission he was hit on the forehead by a brick. He attributed his illness to want of rest and anxiety. There was a large cystic growth of the right adrenal, several cysts in the left kidney, and a cyst in the liver containing cholesterine. In the gall-bladder were several fawn-coloured calculi of the same material.

Autopsy, April 4, 1887. Dr. Langdon Down. See Trans. Path. Soc. vol. xxxix. p. 9. See Adrenal, Series XXXII. No. .

### **Growths in the Pituitary Body.**

857. Portions of the base of the skull and of the brain, which show an evenly rounded tumour, the size of half a walnut, projecting from the sella turcica. It is said to have caused amaurosis by pressure on the optic nerves.

Sections of this growth show compact cell-masses in the areolæ of a fibrous network more or less abundant, with areas from which the cell-masses seem to have disappeared, and; in places, the meshes of a thicker fibrous reticulum occupied by a loose and open fibrous tissue in which a few epithelial cells appear.

858. An hæmorrhagic tumour of the size of a pigeon's egg, which was found occupying the sella turcica and extending above it, so as to have pushed the corpora albicantia and optic nerves an inch and a half from the posterior clinoid processes. It has the appearance of a mass of laminated blood-clot and was described as having been contained in a spurious aneurysm at the base of the brain; but no communication with an arterial trunk could be traced. The microscope shows tracts of a highly vascular round-celled sarcomatous growth at the surface of a mass of recent blood-clot.

The growth is itself infiltrated with blood of older formation, excepting in parts close to the membrane at the surface of the tumour. The cells consist of nuclei in defined protoplasmic masses. Some are large and multinuclear. There is no alveolar formation.

The patient, a woman aged 39, had suffered from paroxysms of severe headache for six months before her death, lasting from half an hour to two or three hours. Her sight failed, and she became ultimately quite blind. Several times she fell down unconscious, and her death occurred about 24 hours after she had become suddenly comatose. About half an ounce of blood was found extravasated in the pia mater at the surface of the left hemisphere (parietal), none at the base of the brain. The case was published by Mr. Chevalier in *London. Med. and Physiolog. Journ.* Dec. 1827, p. 498.

### **Growth in the Pineal Body.**

859. A brain with a portion of the hemispheres removed exposing a centrally situated nodulated growth of oval outline and flattened shape. It projects from the left lateral ventricle, which it has distended. The tumour has flattened and depressed the upper surface of the left optic thalamus, but has no structural connection with it, nor with other parts of the brain, excepting by membranes. The



absence of any structural continuity between the growth and the cerebral tissue, its situation, and its histological structure, indicate its origin in the pineal body.

Sections from the under surface of the growth show a spindle-celled sarcomatous structure of peculiar character, traversed by tracts of adenomatous growth and by isolated glandular tubules, and columns of epithelioid cells. In the sarcomatous growth are numerous large rounded spindle-cells, and globular cells with processes abruptly given off. In parts the large globular cells are clustered in tracts in a rich capillary network. Other cells have one end greatly enlarged, and resemble large monopolar nerve-cells. In the adenomatous tracts there are tubules lined with regularly arranged columnar and cubical epithelium, others showing active proliferation of the epithelial elements and disturbance of their order. Amongst them are also seen collections of large cells of epithelial or endothelial character, in columns with encapsulating sheath, apparently in lymphatic channels. The tumour presents a lobulated structure, the separating strands consisting of fibrous tissue of loose structure containing small elongated and angular nuclei.

An old museum specimen, of which no history has been preserved. See Trans. Path. Soc. vol. xxxvi. p. 27.

### Malformation.

#### Meningo-encephalocele.

860. The occipital part of the cranium of an infant with the atlas and axis, and medulla oblongata with a portion of the brain, showing a large cyst connected with the occipital bone, and communicating with the cranial cavity by an opening in the bone immediately behind the foramen magnum. The cyst has been laid open in a median vertical plane. Its wall is membranous posteriorly, consisting of a thin scar, evidently from intra-uterine ulceration. It is thick above and below, where it is in three layers—a thick outer layer consisting of skin and subcutaneous tissues, and two thin layers. The inmost layer is separated into three near the opening in the bone (? laminated blood-clot). The aperture through which the meningocele passes is separated from the foramen magnum only by ligament. It is large enough to admit a child's finger. The foramen magnum is very large. Nothing that can be recognized distinctly as part of the cerebellum occupies the cyst-cavity.

861. The cyst of a large occipital meningocele with its cutaneous covering. It is of the size of a small orange. The opening in the skin where the cyst was cut off through its constricted base is about the size of a crown piece, the opening through the membranes being only half that size. The skin over the summit of the cyst is much thinned and rough, and devoid of hair.



## SERIES VII.—INJURIES AND DISEASES OF THE SPINAL CORD AND ITS MEMBRANES.

### Effects of Injury.

Contusion and Crushing: 862-869.

Wound: 870.

Meningitis: 871.

### Atrophy from Compression: 872.

Calcareous Degeneration: 873, 874, 875.

Meningitis: 876, 877, 878.

Myelitis: 879, 880.

### Morbid Growths, &c.:

In the membranes: 881.

In the cord: 882.

### Hydromyelia: 883.

---

## EFFECTS OF INJURY.

### Contusion and Crushing.

862. Part of a spinal cord which has been crushed in fracture of the spine in the cervical region. The cord is completely disorganized and infiltrated with blood-clot for an extent of about  $\frac{3}{4}$  inch. Above and below it appeared quite normal. The theca was uninjured, and there was no blood in the arachnoid sac.

Mr. Hutchinson.

863. A similar specimen to the last. The cord is laid open by a vertical incision. Although there was but little external evidence of injury, it is seen to be disorganized for upwards of an inch.

Mr. Hutchinson.

864. Part of a spinal cord showing a contusion in the lumbar region from fracture of the spine.

865. A similar specimen.

366. A similar specimen.

867. A similar specimen.



868. A specimen in which the contusion is higher up, regarding which it is stated that there was fracture of the spine with displacement, and that the patient died within 24 hours of the accident.

869. Part of the spinal cord from a case of fracture of the spine. The cord was completely divided, and the sheath collapsed at the seat of fracture. The specimen is shrivelled by the action of spirit.

Mr. Couper.

### **Wound.**

870. Spinal cord almost cut across by a stab in the mid-dorsal region. The patient had been stabbed in the back with a narrow knife. She was admitted with incomplete paralysis of the lower extremities and died nearly a fortnight later. The knife had entered obliquely beneath the lamina of one of the dorsal vertebræ, and had crossed the spinal canal from left to right, cutting through the greater part of the cord. The vertebra is preserved, and a piece of wood indicates the direction of the puncture.

Mr. Maunder.

### **Traumatic Meningitis.**

871. Spinal cord, with the dura mater laid open in its whole length, and the arachnoid also laid open at the upper part. The sub-dural space is comparatively free, but there is much lymph effused in the sub-arachnoid space. The amount of lymph is less in the cervical region than elsewhere, and it was less adherent at this part. There is said to have been much effusion of lymph beneath the arachnoid at the base of the brain extending into the lateral ventricles.

Patient was a young man under the care of Mr. Adams, suffering from fracture of the base of the skull, in whom cervical opisthotonos developed towards the end of his illness.

## **ATROPHY AND DEGENERATION.**

### **Atrophy from Compression.**

872. Portion of the spinal cord from a child aged  $3\frac{1}{2}$  years, who had angular curvature of the spine in the mid-dorsal region. The thickness of the spinal cord is reduced by one half in the middle of the part compressed.

Case of Lucy C., aged  $3\frac{1}{2}$ , admitted Sept. 12, 1887, with paraplegia of 8 days' duration. Six days before she had complained of pain round her body at the level of the epigastrium. There was some rigidity of the limbs and loss of



control over the evacuations. She died from measles. The cord was compressed in the mid-dorsal region by a collection of caseous matter outside the theca. There was much bronchitis with pulmonary collapse. Some of the mesenteric glands were cretaceous.

Autopsy, Feb. 14, 1888. Dr. Langdon Down.

### **Calcareous Plates in Pia Mater.**

873. Numerous pearly white flakes of calcareous matter scattered in the arachnoid, varying from a minute point to a quarter of an inch in diameter.

874. A similar specimen.

875. A similar specimen.

## **INFLAMMATION AND ITS EFFECTS.**

### **Meningitis.**

876. The lower portion of the spinal cord, from a case of cerebro-spinal meningitis, showing a layer of lymph in the meshes of the pia mater covering the posterior surface of the lumbar region, and extending along the nerves of the cauda equina.

Case of Joseph B., aged 19, admitted March 7, 1882. He was brought to the hospital by his friends, with the statement that he had been in a fit some hours. He had the appearance of being drunk, but seemed to have pain in his back. His temperature was 100°. He became delirious and ultimately comatose, and died on March 16.

Autopsy, March 17, 1882. Dr. Fenwick.

877. The spinal cord and membranes from a similar case, showing a thick layer of lymph on the posterior aspect of the cord.

Patient, a black sailor, Thos. C., æt. 19, was admitted March 6, 1884, and died March 9, 1884. He had been taken suddenly ill the previous evening with abdominal pain and vomiting, quickly followed by noisy delirium, opisthotonos and loss of power and sensation in left leg. He remained unconscious till death. Collections of puriform lymph were found in several of the sulci between the cerebral convolutions, notably in the right fissure of Rolando, and over the posterior surface of the medulla oblongata. The spleen was enlarged and softened.

Autopsy, March 11, 1884. Dr. Turner.

878. A similar specimen.

Patient, a workman, æt. circa 35, unknown, was admitted March 16, 1884, and died March 20. He had been taken into custody as "drunk and incapable," and was sent the following day to the hospital. After death puriform lymph was found in the sulci of the cerebral hemispheres, and collections of the same in the pia mater over the posterior surface of the cord.

Autopsy, March 22, 1884. Dr. Fenwick.



For reports of this and the previous specimen, and of two other cases of cerebro-spinal meningitis contemporaneously admitted into the Seamen's Hospital at Greenwich under Dr. Carrington, see Path. Soc. Trans. vol. xxxv. pp. 51 *et seq.*

### **Acute Polio-myelitis.**

879. A portion of the lumbar enlargement of the cord of a child aged  $2\frac{1}{2}$  years, showing a circumscribed area of softening and disorganization of the left anterior cornu and of the central grey matter at its base. A narrow strip along the inner border of the cornu remains.

Under the microscope thin sections from the part showed that the structure of the whole of the anterior cornu and also of the posterior cornu on this side were profoundly altered, and that structural lesions were present also in the right anterior cornu. Similar changes were seen in less degree in sections from the cervical enlargement.

Case of Alice A., aged  $2\frac{1}{2}$ , who died from measles six weeks after the onset of symptoms of paralysis. The legs became completely paralyzed thirteen days after a fall on the back. Paralysis of the arms appeared three days later and was not complete.

Autopsy, Dec. 26, 1877. Mr. Hutchinson. See Trans. Path. Soc. vol. xxx. p. 202.

880. Sections of the spinal cord at successive levels from a case of recent acute anterior polio-myelitis in a child aged three years. The sections from the cervical enlargement show a well-defined area of disorganization in the left anterior cornu, leaving only narrow strips of grey matter along its inner and anterior borders, and extending backwards to the base of the posterior cornu, which has been displaced or destroyed by the lesion. Below the middle of the cervical enlargement the softened area was red from extravasation of blood. At the lowest part of the enlargement the softening is limited to the external process of the grey matter. Thin sections show a lesion similar to that in the last specimen.

Case of Thomas P., aged 3, admitted Feb. 20, 1888. He had paralysis of the left arm dating from a convulsive attack affecting that limb, and attended with loss of consciousness four days before, and about ten days after a fall off a chair. There was slight pyrexia up to March 6. The limb wasted. The child died with broncho-pneumonia on April 20. There were several caseous mesenteric glands. Brain and cord firm and apparently normal, excepting in the cervical region of the latter.

Autopsy, April 20, 1888. Dr. Stephen Mackenzie.

### **MORBID GROWTHS, &c.**

#### **Meningeal Growth.**

881. Spinal cord and cauda equina with the dura mater laid open, showing a tumour half the size of a cherry, rounded and firm, within the sheath of the cord. It is loose and rests on one of the dorsal



nerves, probably the fourth or fifth. The cord is slightly flattened opposite the tumour, but there is no evidence of inflammation in the neighbourhood.

Thin sections of this growth show a compact reticulated fibrous structure, in the larger spaces of which are corpuscles, some deeply stained, some pale. There are several vessels with thick walls.

### **Growth in the Spinal Cord.**

882. A spinal cord with a tumour of elongated ovoid form, and of the size of a large filbert nut, occupying its whole thickness in the middle of the dorsal region. It forms an expansion of the cord covered by its sheath of pia mater, and having no adhesion to the theca. Above the tumour the cord appears normal. Below it is softened and has almost disappeared (? crushed in removal). A portion of the tumour has been removed for microscopical examination. In transverse section it appears to the naked eye to consist of a mass of adipose tissue with the cord pushed to the right and altered in shape.

Microscopical examination shows fatty infiltration of the whole section of the tumour, remains of nerve-structures, in the form of bundles of fibres, being seen in tracts of fibro-nuclear (sarcomatous) tissue separating the collections of adipose tissue. There is no evidence of central canal or grey substance.

From an obese woman aged 54, who had had gradually increasing paralysis of the lower limbs for twelve years. She died from the effects of a fracture of the left femur, with bed-sores.

Case of Jessie H., æt. 54. Autopsy, Feb. 25, 1886.

See Trans. Path. Soc. vol. xxxix. p. 25.

### **Syringo-myelia.**

883. A spinal cord traversed by a tubular canal, formed in its grey substance. The channel is of large size and central in the cervical region, and of smaller calibre below. It is more on the right side in the upper dorsal region, and in the mid-dorsal region it is, for a short distance, divided into two separate channels, the larger on the right side invading both anterior and posterior columns, and the smaller the left posterior cornu. In the inferior dorsal region the channel is again symmetrical. In the upper lumbar region the section of the cord appears normal except for a narrow fissure in each posterior cornu. In the lower lumbar region there is a channel of triangular section in the right posterior cornu, which extends down to the conus. This smaller cavity has no communication with the other. The larger cavity commences in the lower part of the medulla oblongata, a little above the upper end of the specimen. Examination of sections from various parts show that the cavity



has been formed in the grey matter behind the central canal, and probably in the grey cornua, the channel where central and symmetrical being divided by a median antero-posterior membranous septum.

The specimen was obtained from a female aged 23, in whom there had been gradual wasting of the upper limbs during twelve months. She was subject to epileptic attacks, and died from a severe burn caused by falling into the fire. There was dilatation of both lateral ventricles of the brain, but rather more on the left side.

Case of Eliza T., aged 23, who was admitted March 18, and died April 1, 1887. Mr. Waren Tay. See Trans. Path. Soc. vol. xxxix. p. 14.



## SERIES VIII.—INJURIES AND DISEASES OF NERVES.

**Atrophy:** 884.

**Morbid Growths.**

Bulbous ends of nerves in stumps: 885.

See also Series IV. Nos. 804, 805.

General Pathology, No. 165.

**Atrophy.**

884. A portion of the basis cranii, including the sella Turcica, with the corresponding part of the base of the brain. Both optic nerves are seen to be greatly atrophied from compression by the greatly dilated extremities of the internal carotid arteries, the walls of which are very atheromatous.

**Bulbous ends of Nerves in Stump.**

885. The soft parts removed from the back of a stump of a man whose thigh had been amputated some years previously. The sciatic nerve is seen in the centre: its lower end is bulbous and is adherent to the scar-tissue.



## SERIES IX.—INJURIES AND DISEASES OF THE EYE.

### Effects of Injury.

Wound: 886, 887.

Intraocular Hæmorrhage: 888.

Dislocation of Lens: 889, 890.

Detachment of Retina: 891.

Shrinking: 892, 893.

Foreign Body: 894, 895.

### Subseries I.—Diseases of the Cornea.

Staphyloma: 896-899.

Corneitis: 900.

### " II.—Diseases of the Sclerotic.

Staphyloma: 901, 902.

### " III.—Diseases of the Iris.

### " IV.—Diseases of the Lens.

Cataract: 903, 904.

Dislocation: 905.

### " V.—Diseases of the Ciliary Region.

### " VI.—Diseases of the Retina.

Detachment: 906, 907.

Retinitis pigmentosa: 908, 909, 910.

### " VII.—Diseases of the Choroid.

Ossification: 911-914.

Inflammation and its Effects.

Irido-choroiditis: 915.

Choroiditis disseminata: 916.

Infective Diseases.

Tuberculosis: 917, 918, 919.

### " VIII.—Diseases of the Vitreous.

Inflammation and its Effects.

Detachment of Retina: 920, 921.

### " IX.—Diseases of the Globe.

Inflammation: 922, 923.

Glaucoma: 924-929.

Hæmorrhage: 930, 931, 932.

Parasites.

Cysticercus: 933.

Morbid Growths.

Sarcoma: 934-939.

Melanotic Sarcoma: 940-954.

Epithelioma: 955.

---

## EFFECTS OF INJURY.

### Wound.

886. The lateral half of an eyeball lost in consequence of a perforating wound. There is a scar in the cornea to which the lens-capsule and



vitreous are adherent. One limb of the iris is adherent to the band which stretches from the cornea backwards : a small portion of the opaque lens is visible behind the cornea. The vitreous contains blood-clot (now nearly decolorized). The retina is adherent to the vitreous, and is separated from the choroid by a shallow space. The cornea is thickened and a little flattened at the site of the wound. The section passes through the edge of the optic disc.

887. A lateral half of a globe, the section passing through the middle of the optic disc. The cornea is flattened on its surface and thickened about its centre: behind this point there is an adhesion to the remains of the lens-capsule. The lens has escaped through the corneal wound. The vitreous contains a quantity of yellowish-white inflammatory deposit, and a more translucent layer of similar exudation is seen between the retina and choroid. The iris is partly adherent to the back of the cornea.

#### **Intraocular Hæmorrhage.**

888. An equatorial section of an eyeball, showing hæmorrhage filling the globe and detaching the choroid (with the retina) from the sclerotic. The eye was lost in consequence of an injury received many years previously. The hæmorrhage, however, was presumably recent.

#### **Dislocation of Lens.**

889. Rupture of the connecting fibres between the lens-capsule and ciliary body, and complete separation of ciliary part of retina from the ciliary processes, so that the vitreous and lens were floating loose in a serous fluid. The lens and vitreous are held back by a pin, to show that the separation was complete. The actual position during life was different, being like that of one sphere within another, as seen in articles known as "Chinese balls."

Mr. Jas. E. Adams.

890. Dislocation of the lens into the anterior chamber. The eye was not removed till twenty years after the injury which produced the dislocation. The calcareous nucleus can be seen lying in the capsule which is almost transparent; the capsule and contents occupy the pupil.

#### **Detached Retina.**

891. A horizontal section of a globe, showing a very unusual detachment of the retina, with partial absorption of the lens subsequent to



a wound by a piece of steel. The large cavity, in the fore part of which all that remains of the lens is seen, probably represents the vitreous cavity, which was filled with clear fluid at the time the section was made. The lens-capsule is much thickened and is firmly held by the suspensory ligament. The ciliary processes are not disturbed. In all probability there has been a serous exudation on each side of the retina, by which the vitreous has been displaced from the retina and the retina from the choroid.

### **Shrinking.**

892. The lateral half of a shrunken globe. The cornea is bulged forwards. The lens is absent. The choroid is thrown into a fold opposite the seat of a rupture. The sclerotic is irregularly thickened. At the lower edge there is a gap, the edges of which are inverted. Here there has probably been an old rupture.

893. Half of an eyeball, showing concentric shrinking and thickening of all the coats. The retina is folded, but not much displaced. The lens is absent from this half of the eye; it was hard, calcareous, and much shrunken.

From a boy aged 16 years, whose eye was wounded fifteen years before excision.

### **Foreign Body.**

894. A portion of a gun-cap embedded in the vitreous. There was a wound of the lens and subsequent absorption, serous exudation between the retina and choroid, producing detachment and supuration in the remains of the vitreous.

Mr. J. E. Adams.

895. The lateral half of the globe, showing degeneration and inflammatory changes of the vitreous, with secondary cataract, due to the presence of a foreign body about a quarter of an inch long, which has passed across the globe and has become fixed in the posterior part of the sclerotic. The wound of entrance cannot be seen.

## **SUBSERIES I.—DISEASES OF THE CORNEA.**

### **Staphyloma.**

896. The lateral half of an eye, lost after ulceration of the cornea. The cornea is staphylomatous. The iris is adherent to the cornea. The lens was *in situ*, but has become a little displaced in the



manipulation of mounting. The vitreous is slightly shrunken and is detached from the retina posteriorly.

897. The cornea is bulged forwards: anterior staphyloma. The iris is thinned out and adherent universally to the back of the cornea. These changes probably resulted from ophthalmia neonatorum.
898. The specimen shows a staphylomatous bulging in the equatorial region. The iris is adherent to the posterior surface of the cornea, the result of perforating ulcer of the cornea. There is also pannus, from trichiasis produced by granular lids.
899. The inner half of the eye of a girl aged  $2\frac{1}{2}$  years, lost by purulent ophthalmia at the age of six months. There is staphyloma and great thickening of the cornea. The iris is in contact with the cornea. The lens is absent, its capsule is thickened and opaque. The other tissues are healthy.

#### **Corneitis.**

900. A lateral section of a small globe much collapsed. There is old inflammatory thickening of the cornea and sclerotic, no doubt due to ulcer. The way in which the iris, lens-capsule, and cornea are blended suggests a perforating ulcer of the cornea, through which the lens escaped.

### **SUBSERIES II.—DISEASES OF THE SCLEROTIC.**

#### **Posterior Staphyloma.**

901. The outer lateral half of a very large eye, probably myopic. There is bulging of the thinned sclerotic (posterior staphyloma), commencing about half an inch from the centre of the disc, and extending forwards over an area of half an inch in diameter. The choroid is thin and of very light colour. Both it and the retina project into the staphyloma. There appear to be pigmentary changes near the disc (yellow spots).
902. Staphyloma at the lower part of the equatorial region of an eye, with displacement of the lower part of the lens into the anterior chamber. The lens has become changed in shape, and is nearly spherical.

From a man aged 45, who sustained a blow on the eye twenty-two years before.



## SUBSERIES III.—DISEASES OF THE IRIS.

## SUBSERIES IV.—DISEASES OF THE LENS.

**Cataract.**

903. A lens in a state of cataract enclosed in its capsule. It escaped with the capsule entire in an operation for extraction. The nucleus was dense and the circumference fluid. "Morgagnian cataract."

904. A shrunken ossified lens.

**Dislocated Lens.**

905. The anterior part of an eye, with an opaque shrunken lens dislocated through the pupil into the anterior chamber. It rests against the iris, which it bulges backwards.

## SUBSERIES V.—DISEASES OF THE CILIARY REGION.

## SUBSERIES VI.—DISEASES OF THE RETINA.

**Detached Retina.**

906. Lateral half of an eyeball, the section passing to one side of the disc (which is not in this half) and through the lens on one side of the middle line and to one side of the pupil. There is a large detachment of the retina from the choroid below (to the left in the specimen) and of the vitreous from the retina above (to the right in the specimen). The vitreous is shrunken and too fibrous in appearance, and contains a small quantity of blood at the lower and anterior part. The iris-angle is blocked, owing to adhesion of the iris and cornea at the periphery. The lens looks small because the section does not pass through its centre.

907. Specimen shows detachment of the retina and a shrunken globe. The lens is absent, and the cornea is adherent to the anterior part of the vitreous and retina.

**Retinitis pigmentosa.**

908. Half a globe, showing pigmentation of the retina in the equatorial region; possibly retinitis pigmentosa.



909. The posterior half of an eye, showing pigmentation of the retina. The pigment is arranged in an almost complete circle around, but at some little distance from the optic disc. The optic disc shows very indistinctly. There is a shallow detachment of the retina from the choroid at one part.
910. The posterior half of the globe everted, showing lines of dark pigment towards the periphery overlying and crossing the choroidal vessels; no doubt retinitis pigmentosa. The disc appears shrunken and is probably atrophied.

#### SUBSERIES VII.—DISEASES OF THE CHOROID.

##### **Atrophy.**

##### **Ossification.**

911. A good specimen of bone in the eye. The globe is much shrunken, without any lens and with scarcely any cornea. The retina is represented by a conical, yellowish cord passing from the optic nerve forwards. The choroid is easily recognizable. The retina with the cord above mentioned is ossified, and the large space between the retina and the choroid is filled by a thick mass of bone excepting a space round the anterior end of the cord, which forms a shallow cup with a smooth surface lined with a rough membrane (corresponding to periosteum), which cannot be seen in the specimen.
912. Bone from the interior of an eye, dried and separated from all the other structures. It is a similar specimen to the preceding, but the bony cup is much deeper, because much thinner at the bottom, which shows one half of a somewhat irregular hole through which the retina passed.
913. A similar specimen. The whole cup is preserved and mounted with its mouth uppermost. The rim of the cup corresponds in position with the front part. Below is seen the irregular hole through which the retina passed.
914. A deposit of bone is found between the retina and choroid; the globe was shrunken and the lens was opaque. The specimen was removed from a subject in the dissecting-room.

##### **Inflammation and its Effects.**

##### **Irido-choroiditis.**

915. A lateral section of a misshapen globe, showing inflammatory



deposit between the retina and sclerotic. The iris is degenerated. There is thickening of the ciliary body. The retina is thrown into folds. The lens is absent. Chronic irido-choroiditis, probably traumatic or sympathetic.

#### **Choroiditis disseminata.**

916. The lateral half of an eye, showing disseminated choroiditis. Scattered about the choroid, especially at some distance from the disc, are patches of black pigment of very various sizes and shape. There is one long streak of pigment which passes forwards for more than half an inch. Interspersed and in some places surrounded with pigment are many small patches of atrophied choroid. The optic nerve, cornea, and iris are apparently normal.

### **Infective Diseases.**

#### **Tuberculosis.**

917. The posterior half of the globe, showing miliary tubercles in the choroid.

The eye was removed from a man named White, aged 40, under the care of Dr. Ramskill, admitted for acute tuberculosis. At the post-mortem on May 29, 1871, immense numbers of miliary tubercles were found in the lungs, kidneys, peritoneum, tunicae vaginales, and a few in the pia mater at the base of the brain. The patient had not complained of amblyopia during life, so the ophthalmoscope was not used.

918. The anterior half of a bisected globe, showing a soft yellowish-white layer of new growth of about 4 millim. in thickness between the sclerotic and choroid, extending from the ciliary region backwards. A similar but more flocculent deposit is seen on the inner surface of the ciliary body and retina. The cornea, lens, and iris appear normal. This growth simulates glioma, but the sclerotic is not infiltrated, nor does the retina itself appear involved.

919. The posterior part of the same globe, showing the backward prolongation of the neoplasm nearly as far as the yellow spot. It is but slightly adherent to the sclerotic, and this points strongly to its being of inflammatory origin. There is in addition extensive deposit of lymph on the inner surface of the retina.

### **SUBSERIES VIII.—DISEASES OF THE VITREOUS.**

#### **Inflammation and its Effects.**

#### **Detachment of Retina.**

920. A lateral section of a globe, showing the results of old hyalitis.



There are thick whitish masses of lymph in the vitreous, whose contraction has produced detachment of the retina and choroid, and dragged backwards the iris, so making the anterior chamber of unusual depth; probably of traumatic origin.

921. A lateral half of the globe, showing detachment and cystic degeneration of the retina. This forms an irregular opaque mass in the centre of the globe and adherent to the back of the lens. The choroid has also become separated from the sclerotic at the front, owing to shrinking of the vitreous, probably inflammatory. The cornea and lens are apparently normal. There is a tough membrane occluding the pupil.

#### SUBSERIES IX.—DISEASES OF THE GLOBE.

##### **Inflammation and its Effects.**

922. A lateral section through a globe showing the effects of panophthalmia; it is somewhat bulged on either side. In the anterior chamber and also between the sclerotic and choroid is a greyish deposit of a uniform consistence. The pupil is obliterated. The ciliary body is involved in the exudation. The lens suggests cataract. The whole of the vitreous cavity is filled with similar greyish exudation, the centre of which glistens and probably contains cholesterine. The disc is invisible.

923. A similar specimen.

##### **Glaucoma.**

924. The anterior half of an eye divided into two lateral halves, showing blocking of the iris-angle by adhesion of the iris and cornea at their periphery. The ciliary processes are rather flattened and pressed forwards. The anterior chamber is shallow. The lens is *in situ* and of normal shape and appearance.
925. The posterior half of an eye, showing glaucomatous excavation of the optic disc. The macula lutea also shows indistinctly; with focal light some of the retinal vessels and a few small hæmorrhages are visible.
926. The posterior half of an eye with hæmorrhagic glaucoma. There are large and numerous retinal hæmorrhages, of a brown colour. The optic disc is deeply excavated. The retinal vessels near the optic disc are visible with focal light.



927. The specimen shows a glaucomatous cup. The optic disc is hollowed out into a deep cavity with overhanging edges; the retinal vessels are nearly empty, but two or three may be seen passing over the brim of the cup.
928. The posterior half of a globe, showing a deep cup involving the whole optic disc. The retinal vessels can be traced as far as the edge of the cup.
929. The lateral half of an eye, showing extensive hæmorrhage between the choroid and sclerotic. Iridectomy for glaucoma had been performed, and the iris is prolapsing at the seat of the incision at the sclero-corneal margin on the right of the specimen. The lens is absent. The retina and choroid can be seen in the middle line of the specimen, passing forwards from the optic disc behind to the seat of the incision (noticed above) in front.

#### **Hæmorrhage.**

930. A lateral half of the globe, showing a very large subretinal hæmorrhage. The retina is detached completely, and is seen running from the optic disc to the ciliary processes. The cornea is flattened, and the lens absent. Such a hæmorrhage sometimes occurs after operation for glaucoma and extraction of cataract, and is then due to escape of the vitreous and the sudden decrease of tension consequent thereon.
931. The other half of the same globe, the section having passed to one side of the middle line, so that only a portion of the anterior part of the retina is seen.
932. A lateral half of a globe, showing detachment of the retina. The space between it and the choroid is lenticular in shape and half an inch in length, and extends from close to the disc to the ciliary region. From its dark colour there has probably been an extensive hæmorrhage into the vitreous cavity. The cornea is normal, the lens lost.

#### **PARASITES.**

##### **Cysticercus.**

933. A globe which was removed after having been entirely destroyed by pressure from behind. During the operation the cyst, which is at the bottom of the bottle, dropped out. It is a large hydatid.



## MORBID GROWTHS.

**Sarcoma.**

934. Part of an eye, with a new growth in the anterior part of the globe; probably sarcoma growing from the ciliary region.
935. An eyeball with adjacent parts. The globe is completely filled with medullary growth. A much larger growth occupies the orbit behind the globe. There is no history.
936. A large, somewhat pedunculated growth of "medullary cancer," from a patient in whom the disease had commenced in the eye and subsequently extended to the brain.
937. Two tumours, symmetrically placed in the orbits, pressing upon the eyes and completely destroying them. They are described as consisting of a substance resembling liver, and were continuous with each other across the forehead, the skin being involved. No history of the case is given. One of the eyes seen in section shows, very beautifully, a complete "umbrella" detachment of the retina.
938. Left orbit and adjacent bones of skull, showing a soft tumour which had commenced in the sphenoidal sinus, and passed forwards into the orbit, displacing the eyeball. The optic nerve can be seen passing through the growth.

Lond. Hosp. Rep. Vol. I. p. 199. First symptom was anæsthesia of upper lip, then loss of power and wasting of temporal muscle, then loss of taste and common sensation in half the tongue. Frontal branch of ophthalmic not affected at death.

*Presented by Mr. Hutchinson.*

939. A section showing the posterior half of a globe, with a tumour growing from the choroid towards the equator and projecting forwards into the vitreous. It has a wide base, 12 millim. in diameter. The centre of it is contracted. Beyond this the growth is rounded and globular, and about the size of a pea. Choroidal pigment is seen both outside its base and in parts over the tumour, so that evidently the origin of the tumour is from the substance of the choroid coat. It is, no doubt, an example of non-pigmented sarcoma.

**Melanotic Sarcoma.**

940. Sarcoma of choroid pigmented on the surface.



941. An eyeball cut vertically into lateral halves and opened out, to show a large melanotic neoplasm situated in the lower segment of the globe. The growth is a quarter of an inch in thickness, and extends from the ciliary processes backwards nearly to the optic disc; it evidently has grown from the choroid, and has distended and thinned the sclerotic, which in other parts of the globe appears healthy. The retina appears healthy, but is detached over a large area. The cornea is healthy. The lens appears calcareous.
942. A globe almost filled with a melanotic growth, which projects through the sclerotic at the posterior and outer part.
943. Portion of an eyeball distended by a melanotic growth.
944. The anterior half of a globe, showing a firm lobulated mass in the anterior chamber, and also passing backwards. It has pushed the iris forwards against the cornea, and at the sclero-corneal junction forms a rounded projection beneath the conjunctiva. There is no trace of the lens. The growth is of a dark brown colour with a lighter centre, and probably is a sarcoma growing from the ciliary region.
945. A lateral section of the globe passing through the disc. A melanotic sarcoma growing from the choroid fills half the globe—touches the lens in front and optic disc behind. It has perforated the sclerotic a quarter of an inch outside the optic disc. The cornea, lens, and iris are apparent. The retina has been detached and pushed forward by the growth. The sclerotic is thinned and bulged. The colour of the tumour is of a nearly uniform brown, with a few streaks of lighter tissue.
946. A large melanotic sarcoma filling nearly half the vitreous cavity, and pushing forwards the retina. It had evidently grown from the choroid towards the posterior pole of the eye, and has, in one place, passed through the sclerotic.
947. An eyeball, with the walls of the orbit, &c., *in situ*. The orbit is filled by a growth of sarcoma partly melanotic, partly medullary, presenting, in section, mottled patches of black and white. There is a growth of melanotic sarcoma within the cranium. Microscopical examination of this section shows the growth to be composed of masses of sarcomatous structure, separated by fibrous strands. This growth consists of large cells of various forms. In parts, a fasciculated



arrangement of spindle-cells is seen. There appears to be very little intercellular substance—the cells being moulded upon each other. The cell-masses are traversed by delicate vessels with proper walls. The larger vessels run in the fibrous trabeculæ. The cells of the growth and the trabeculæ are pigmented in varying degree in many parts. Some tracts of the growth are degenerated, with evidence of blood-extravasation and obstruction of vessels by blood-clot.—(Thrombotic necrosis.)

948. This specimen shows a small melanotic growth excised from the outer part of the sclerotic conjunctiva by Mr. Scott.

949. A large mass of soft sarcomatous growth projecting from the orbit. The greater part of the growth is free from pigment, but some parts are pigmented. Six months after the excision of this tumour there was a recurrence in the eyelid, and two years later the patient died from extension of the disease to the brain and internal viscera.

It was obtained, post-mortem, from the same person as the one from whom the preceding specimen was removed.

950. An eyeball presenting a large melanotic growth, partly external and partly within the eyeball.

951. A portion of a disintegrated melanotic sarcoma developed within the cranium, secondary to disease of the eye.

The patient was a lady, æt. 40, who had suffered from tumour in the eye for five or six years before her death. No operation was performed, and she ultimately died in a state of coma induced by the extension of the disease to the brain. Mr. Ward. For an account of the case, see *Med. and Phys. Journal*, Dec. 1872, p. 502.

952. A portion of an eyeball showing a large sarcomatous growth, partly melanotic, external to the sclerotic.

953. There is a deeply pigmented tumour the size of a small cherry-stone just behind the ciliary body, growing from the choroid. The retina has been displaced in front of the tumour and towards the centre of the eyeball. The anterior chamber is shallow.

954. Melanotic sarcoma of choroid. "The minute structure of this tumour was difficult to make out when the specimen was examined in a recent state; but after soaking in Müller's solution for about six weeks it revealed a structure almost wholly composed of spindle-shaped cells containing pigment."

Mr. Jas. E. Adams.



**Epithelioma.**

955. A section of part of a globe, showing a small globular tumour about the size of a horse-bean (probably epithelioma) growing from the front of, and almost entirely overlapping, the cornea. It is even and rounded on its surface, with one projection which encroaches on the sclerotic. The lens and iris are pressed up against the posterior surface of the cornea, no doubt as a result of previous perforation.

The globe was excised by Mr. Tay, on Aug. 23, 1888, from a man, Alfred Stafford, aged 67. A year before the operation he had been treated with relief in the Hospital for ulcer at the corneal margin. In January 1888 he returned with a small growth in the site of the old ulcer, which was scraped. In August there was a small growth on the outer side of the left globe close to the sclero-corneal junction. The growth encroached upon the pupil to half its extent. The pupil reacted to light and accommodation. Vision was good. Fundus was normal.



## SERIES X.—INJURIES AND DISEASES OF THE NOSE.

**Necrosis:** 956.

**Polypus:** 957 to 962.

---

**Necrosis.**

956. A portion of bone from a case of fistula lachrymalis. The specimen shows the nasal duct laid open and a bristle introduced into it. It appears to be narrowed at its upper part, being possibly carious.

**Polypus.**

957. A very large many-lobed nasal polypus. The lobes are all attached to a common pedicle. The mass altogether is as large as a child's fist. No history has been preserved. From its size and unbroken character it is probable that it was removed after death.
958. A large nasal polypus with a broad thin membranous pedicle.
959. Portions of nasal polypus, with fragments of bone attached.
960. A shrivelled nasal polypus, with long pedicle.
961. A nasal polypus showing ecchymosis and ulceration at its extremity. Probably it had been extruded at the nostril and strangulated.
962. The middle third of a lateral half of the base of the skull, showing a growth from the sphenoidal cells. Anteriorly the section has passed through the posterior ethmoidal cells and the posterior part of the orbital cavity, which is seen to be lined with dura mater. Nearly an inch of the optic nerve is seen hanging down from the optic foramen. The floor of the orbit is wanting. The roof of the nasal cavity has been removed, exposing the sphenoidal cells. The bone forming the inner wall of the nasal cavity, the edges of the sphenoidal cells, and the orbital cavity are bare. Projecting from the inner wall of the sphenoidal cells is a firm lobulated mass about 1 inch long. It is about  $\frac{1}{2}$  inch broad at its centre and gradually tapers downwards to a point. It is attached to the bone by a firm pedicle  $\frac{1}{4}$  inch broad.



The growth has also spread upwards and to the right into the right cavernous sinus. The sella Turcica is not implicated. The growth is probably a fibro-sarcomatous polypus growing from the periosteum lining the sphenoidal cells.

Below the bone is a large, firm, lobulated mass composed of many nodules, which are firm and fibrillated on section. The mass measures about  $2\frac{1}{2}$  inches in its greatest diameter. About its centre is seen a scale of bone about half an inch in width and length, from whose periosteum the tumour appears to grow. At the centre of this bone is an oval depression which probably formed part of the orbital cavity.

At the lower part of the bottle is a portion of the left superior maxilla, showing softer but similar growth on the inferior turbinated bone, which is still *in situ*. Both bones are bare of periosteum.



## SERIES XI.—INJURIES AND DISEASES OF THE EAR.

**Foreign Body :** 963.

**Necrosis :** 964, 965.

**Morbid Growth.**

Fibroma : 966.

Myxoma : 967.

Epithelioma : 968.

---

**Foreign Body.**

963. Part of a temporal bone (dry), showing, originally, a small stone impacted in the middle ear, but now lying loose in the bottle. In the specimen, as now seen, the incus is altogether absent, though the rami of the stapes are *in situ*. The specimen is valuable as evidence of the consequences of indiscreet attempts to extract a foreign body of this kind from the ear ; for to these attempts must be referred the destructive damage inflicted upon the organ. It is, moreover, of historical interest, inasmuch as it marks the point of departure towards an amended method of removing foreign bodies impacted in the ears.

From a girl aged 8 years, who was admitted under Mr. Andrew's care in August 1835, in order to have a stone which she had introduced into her ear removed. Repeated attempts to extract it failed, cerebral symptoms supervened, and the child died comatose.—*Post-mortem Examination.* The vessels of the cerebral membranes were congested, but there was no serous effusion (no mention of lymph). On laying open the tympanum, a small irregularly shaped pebble rather larger than a pea was found in that cavity. The membrana tympani was completely destroyed, the malleus very considerably displaced, the handle being situated at the entrance of the Eustachian tube ; it still retained its attachment to the tendon of tensor tympani muscle. In the Eustachian canal and also in the cavity of the tympanum there was a small quantity of yellowish lymph.

**Necrosis.**

964. Necrosis of the petrous portion of the right temporal bone. A portion of the base of the cranium from a child, showing destruction of the petrous portion of the temporal bone including the whole of the parts enclosing the internal and middle ear. A sequestrum was found lying loose in a smooth-walled cavity.



965. Necrosed petrosal process removed from the right ear of a female patient by Dr. Woakes, Oct. 1888. Making due allowance for erosion, the specimen is very small in all its details, being relatively that of a child.

The patient, Susan Sheard (R. N. 1208), who was 36 years old at the time of its removal, had scarlet fever, with discharge from the ear, at the age of 8, at which time the necrosis probably occurred; its complete detachment probably did not take place till she reached the age of 32 years, when the facial paralysis was first noted. This latter was complete for motion when first seen, but not for sensation. There had been offensive discharge from the ear all this time. The cochlea, or smaller end, presented at the external meatus. Complete cicatrisation and cessation of discharge occurred a week after admission. The anterior and posterior semi-circular canals are incomplete, the horizontal one being most perfect. The cochlea is open at the apex.

### **Morbid Growth.**

#### **Fibroma.**

966. A polypus from the ear: microscopical sections showed a fibrillated tissue with small round cells.

#### **Myxoma.**

967. A lobulated mucous polypus, from the ear.

#### **Epithelioma of External Ear.**

968. The disease has invaded the tragus, antetragus, root of lobule, and floor of the meatus, at the external orifice; passing backwards it forms a projecting mass which occupies the angle between the mastoid process and the auricle upwards, and at its lowest point sending backwards a strongly marked projection which occupies the soft tissues down to the bone. At the inner aspect of the section, where the external canal is divided, the disease is seen to occupy completely the lumen of the canal.

It was removed by Mr. Treves from a woman, Emily H—, aged 45, on May 22, 1885.



## SERIES XII.—INJURIES AND DISEASES OF THE SKIN.

### Hypertrophy.

Hypertrichosis : 969.

Ichthyosis : 970.

Othhæmatoma : 971.

### Inflammation and its effects.

Cuticular Glove : 972.

Ulceration : 973, 974, 975, 976.

Cicatricial Contraction : 977.

### Cysts and Morbid Growths.

#### Cysts.

Sebaceous Cyst : 978.

#### Morbid Growths.

Fibroma : 979.

Lipoma : 980, 981, 982, 983.

Osteoma : 984.

Angeioma : 985, 986, 987, 988, 989.

Sarcoma : 990, 991, 992, 993, 994, 995, 996.

Round-celled Sarcoma : 991.

Spindle-celled Sarcoma : 992.

Lympho-Sarcoma : 993.

Fungating Sarcoma : 994, 995, 996.

Papilloma : 997.

Adenoma : 998.

Epithelioma : 999 to 1005.

Rodent Ulcer : 1006.

### SUBSERIES I.—Diseases of the Nails.

#### Hypertrophy.

Gryphosis : 1007.

## Hypertrophy.

### Hypertrichosis.

969. Some masses of very long hair matted together in the condition known as "plique en queue." It is stated to have reached to the woman's feet. Full of pediculi.

### Congenital Ichthyosis.

970. A foetus showing well-marked congenital hypertrophy of the skin. "Harlequin foetus." The skin is thick and has become cracked in the course of growth of the bones, owing to its unyielding nature.



The fissured edges are widely separated in some positions. The mucous membrane of the mouth has been everted by drawing up of the lips. The eyelids are also everted. Over the proximal phalanx of each thumb there is a nodular tumour of the size of a pea. The ears and nose are undeveloped.

#### **Othhæmatoma.**

971. Hypertrophy of the external ear, due chiefly to extravasation of blood. The cartilage has been separated into two layers, and fibrous tissue subsequently developed between them. Some parts of the cartilage have become ossified. The cavity seen in the specimen contains brown matter which, when microscopically examined, was found to contain blood-disks.

### INFLAMMATION AND ITS EFFECTS.

#### **Cuticular Glove.**

972. A very perfect cuticular glove.

Presented by Mr. Gooch, of Shottesham, in September, 1769, and the case is recorded in the third volume of Gooch's Med. Chir. Observations. It was obtained from the hand of a gentleman, æt. 50, who had had many attacks of a febrile ailment followed by exfoliation; he had frequently turned the cuticle off from the hands and fingers as he would a glove. These attacks would occur as often as twice in the year, and he has been liable to them for ten years. With the attacks there was great itching of skin, especially at the joints; many small red spots would appear, and there was some swelling. The feet as well as the hands were usually affected.

#### **Ulceration.**

973. A portion of the skin covered with the "limpet-shell" crusts and ulcers of rupia. In all probability syphilitic.
974. A chronic glassy ulcer injected, dried, and preserved in oil of turpentine, to exhibit deficiency in true granulations.
975. A similar specimen.
976. The head of a man with a very large irregular cavity on the left side of the face. The cavity is due to ulceration, and is described in the old catalogue as having been caused by "extension from cancer of the gums." The whole of the left lower jaw and part of the cheek, floor of the mouth, and submaxillary region have been destroyed.



**Cicatricial Contraction.**

977. The arm of a child which has been amputated through the middle of the humerus by the circular method. The muscles are atrophied; the fingers bound together; the wrist and elbow are acutely flexed by contracted scar-tissue, most probably the result of a burn.

**CYSTS AND MORBID GROWTHS.****Cysts.****Sebaceous Cyst.**

978. A very large thick-walled cyst, capable of containing two fists. It appears to have a smooth lining-membrane, and to be a simple sebaceous cyst. It was dissected from the back, and a large elliptical portion of skin was removed with it, and is still upon it.

**Morbid Growths.****Fibroma.**

979. A globular tumour (*molluscum pendulum*), the size of a Tangerine orange, covered with shrivelled skin (from spirit). The pedicle is half an inch in diameter and an inch long.

**Lipoma.**

980. The tumour is the size of an orange, and is pedunculated. It has been cut open, and shows a fibrillated structure. The skin over the tumour presents numerous small papillomata.
981. A large lobulated fatty tumour of unusual thickness removed from the back of the neck.
982. A large lobulated lipoma, showing a patch of ulceration of the skin from pressure.
983. A tumour, the size of two walnuts, having a rounded outline, and consisting apparently of white fat with cellular membrane. It has no lobules. It is described in the old catalogue as fatty tumour removed from the scalp.

**Osteoma.**

984. A hard bony tumour the size of a small apple, subcutaneous and adherent to the skin at one spot. It has apparently commenced as a small nodule, and has grown in a circular fashion, expanding gradually.



The wider free end is convex and covered over with smaller prominences, which fitted into corresponding depressions in the subcutaneous tissue. Microscopic examination shows irregularly-placed Haversian canals with concentric rings.

Removed from Sarah S., a midwife, aged 44, by Mr. Mansell-Moullin. It had been growing four years, and was attributed to injury.

### **Angeioma.**

985. Part of the vertebral column of an infant, showing a section of a large subcutaneous nævus.

986. A portion of skin from the previous specimen. These specimens are mentioned merely as "nævi of the back" in the old catalogue.

987. An irregularly-shaped tumour about the size of a walnut, of a dark red colour. It has been bisected. It consists entirely of dilated tortuous veins, with but little connective tissue. There are no cysts.

The tumour was removed by Mr. McCarthy from the right scrotum of a man, Thomas M., aged 45, who gave the following history:—"Twenty-three years ago, whilst playing, he struck the scrotum against a stake of wood. A small lump soon formed in the dependent portion, which enlarged very slowly: a few days ago it had reached the size of a walnut. It then began to swell and increase rapidly." On admission the swelling was irregular on the surface, nodular to the feel, bluish in colour. It was hard, very slightly painful on pressure. There was no pulsation. The skin around it was not cedematous; it was adherent to the tumour over its centre. The tumour was in no way connected with the epididymis and testis; but seemed to lie in the scrotal tissue itself. The glands in the groin were not implicated. The tumour was easily dissected out from the subcutaneous tissue, without much bleeding. The patient made a good recovery.

988. The leg of a child, in the subcutaneous tissue of which a large erectile growth has been developed. As seen in section, the erectile tissue is an inch and a half in thickness. The skin appears to have been sound, the whole limb being, however, much swollen. Probably the specimen was removed by amputation, but no history has been preserved. Thin sections show adipose tissue traversed by numerous large vessels. In the fatty tissues there is a good deal of corpuscular infiltration in places, the cells being round and of the size of leucocytes, but regularly arranged, as in growth, not massed in foci, as in exudation.

989. Described in old catalogue as a specimen of congenital nævus. In its present state there is but little evidence of vascularity. There is thickening of the hair-sheaths and follicles.



**Sarcoma.**

990. A portion of the skin showing the cicatrix of a former operation, and by its side large nodules of new growth, It is described in the old catalogue as "cancer of the skin," and was removed by Mr. Luke from the thigh of a man who had had a similar operation some years before, and who was in the hospital in May 1830.

**Round-celled Sarcoma.**

991. Recurrent tumour from the outer and back part of thigh, removed by Mr. Hutchinson. It recurred in a cicatrix, the result of an operation by Mr. Hutchinson three years before. The patient states that the first tumour was called fatty. The present tumour adhered to both cicatrix and deep fascia; was circumscribed, oval, and on section was firm, yellowish white, semitransparent at the circumference and softened at the centre.

Thin sections of the growth show round-celled sarcomatous structure, tracts of cellular growth being supported by fibrous network.

**Spindle-celled Sarcoma.**

992. A large, soft, somewhat lobulated tumour the size of two fists. The following is the description in the old catalogue:—"Anomalous tumour presenting very much the appearance of medullary sarcoma, removed from the hip of a lady. It was 47 $\frac{1}{4}$  years in growing to its size."

Thin sections from the growth present the structure of spindle-celled sarcoma, the cells being of small size, and the intercellular substance abundant in parts.

**Lympho-Sarcoma.**

993. A tumour the size of a small fist growing from the subcutaneous tissue, with a fungating ulcer through the skin over it. The tumour appears to be well circumscribed, but adherent to the adjacent parts. It is described as follows:—"Tumour from the thigh, consisting of a number of cysts partly cartilaginous, and partly osseous with extravasated blood."

Thin sections present the structure of lympho-sarcoma, the cellular elements being of circular outline, and lying in a reticulum in the meshes of a fibrous meshwork. This structure is degenerated in parts, with disappearance of the cellular elements.

**Fungating Sarcoma.**

994. The specimen shows a cavity in the sole of the foot capable of containing a large walnut, the lining-membrane of which is very



delicate, and crossed in various directions by fibrous trabeculæ. In most parts it is distinct and, with the exception of these trabeculæ, smooth. Entangled among these bands was a soft cerebriform structure. In the recent state the whole of the cavity was filled with a homogeneous soft mass, which scarcely adhered to the walls of the cavity in which it grew. In parts it was ecchymosed. The structure consisted of delicate fibres, spindle-cells, and oval and small round cells.

The tumour had existed almost the whole of the patient's life, and had been operated on by Mr. Ward in the London, and by Sir J. Paget in St. Bartholomew's Hospital. On each occasion it grew again, and the child had never been able to walk; latterly it had bled very profusely, and at the time of her admission the child was emaciated and very pale from hæmorrhage. Firm pressure was requisite in order to prevent its bleeding during the time the child was in the hospital prior to the amputation.

Thin sections recently made show no evidence of morbid growth.

995. A small fungating tumour from the integument of the chest. The tumour was the size of a small walnut, and was attached by a small peduncle as thick as the little finger. It was ulcerated on the surface, from which there had been frequent hæmorrhage; the skin round it was quite healthy.

The patient was an old man who had been sent up from Maidenhead to Mr. Luke. The tumour was excised, together with a portion of skin at least half an inch in width around its peduncle, and, although the wound left was quite healthy, chloride of zinc was very freely applied, in the belief that the tumour would prove recurrent. No attempt was made to close the wound, and it healed slowly. No recurrence two years afterwards.

996. A finger, on the dorsal aspect of which, near the root of the nail, is a pedunculated fungoid growth the size of a hazel-nut. The peduncle passing through the skin is quite narrow, and the surrounding skin appears quite healthy. The tumour appears to grow from the subcutaneous structures.

Thin sections show in parts a highly vascular (cavernous) structure with a meshwork of thick strands of fibrous tissues and a cellular structure in parts, the nature of which is obscured by degeneration of the tissue from prolonged preservation in spirit.

#### **Papilloma.**

997. Described in old catalogue as an unusually large papillary wart of skin of face.

#### **Adenoma.**

998. Lobulated solid tumour, removed from the scalp. Unfortunately no history has been preserved.



Thin sections show a glandular structure, the alveoli being filled with degenerated epithelium.

### **Epithelioma.**

999. Warty growth in an old scar, from extensive ulceration over front of leg. The tibia is exposed and carious. The growth has chiefly developed round the margins of the ulceration. At its inner margin there is a prominent cauliflower excrescence, which has the appearance of an epithelioma. A portion of the growth taken from the outer margin and examined with the microscope showed a papillomatous structure.

1000. The specimen shows an ulcer as large as the palm of the hand, on the side of the leg a little above the middle. The ulcer is covered with fungating granulations.

Thin sections showed nests of epithelial cells with cylindrical downgrowths of epithelium.

1001. A large warty epitheliomatous growth on an old ulcer of the leg.

From a man whose leg, at the age of twelve, was incised for periostitis. In the scar left the ulcer developed. The ulcer, on admission, was 6 by 4 inches, and was situated over the internal surface of the tibia at the junction of middle and lower thirds. It had existed eight months. The edge was raised and hard, the inguinal glands enlarged. The leg was amputated March 20, 1885, at the seat of election by Chauvell's method (outside flap). On March 23 the anterior flap was sloughing, but ultimately the parts healed up completely, and the patient recovered.

1002. A foot, on the dorsum of which is a dense, warty growth, in some places an inch thick. There is no superficial ulceration of the growth. The smaller toes appear to be ulcerated. There are papillary nodules scattered over the sole. Along the inner side of the foot there is a circular ulcer.

1003. The foot and lower third of the leg of a man. On each side of the leg is an irregularly-shaped ulcer as large as the palm: the base is smooth, devoid of granulations, and extends to the periosteum; the edge is abrupt, irregular, and nodular. The surrounding tissues are œdematous and indurated, the epidermis being much thickened and in a papular condition. The section of the leg has been made through the upper part of the ulcer, and the soft parts cut away to show the great hypertrophy of the tibia and fibula from long-standing congestion; the interosseous membrane is ossified. Completely surrounded by bone, a large patent artery is seen, which is probably the anterior tibial; the posterior tibial vessels are seen at the back



with pieces of glass inserted. Microscopic sections of the edge of the ulcer showed cell-nests and papillary downgrowths of epithelial cells.

From Charles J., aged 45, who had suffered from ulcer of the leg for twenty years. For the greater part of this time he had been unable to work. The leg was amputated by Mr. Waren Tay at the seat of election. There was extreme difficulty in controlling the hæmorrhage, which seemed to come from the bone. An ivory peg had to be used for this purpose. Osteo-myelitis followed, and he suddenly died from some obscure cause, probably exhaustion.

1004. Vertical median section of right leg through the tibia, showing a circular, epitheliomatous ulcer which has involved the tibia.

1005. A flat epitheliomatous growth removed from the back of the hand. There is a well-defined elevated area of the size of a crown piece, with flattened top. The borders are slightly sloping, at one part overhanging. The section of the growth shows that there has been much thickening of the cutaneous tissue.

#### **Rodent Ulcer.**

1006. The specimen shows the extent to which rodent ulcer will eat away every structure in succession, even bone. The floor of the right orbit, the greater part of the superior maxillary bone, of the nasal bones and part of the lower jaw, and the whole of the soft parts which cover these bones have been destroyed; the posterior wall of the right antrum, part of the malar bone, the part of the right superior dental alveolus carrying the last molar tooth, the posterior part of the hard palate, the posterior nares, the right middle turbinated bone, the left middle and inferior turbinated bones with part of the left superior maxillary bone carrying the last two molars, the tongue and lower jaw, all lie exposed on the floor of the ulcer. The disease probably commenced in the usual situation, namely, above the mouth and either on the side of the nose or at the inner angle of the orbit.

### SUBSERIES I.—DISEASES OF THE NAILS.

#### **Hypertrophy.**

##### **Gryphosis.**

1007. Enormous hypertrophy of the nails, probably from the great toe.



### SERIES XIII.—INJURIES AND DISEASES OF THE LIPS AND MOUTH.

**Epithelioma** 1008, 1009, 1010.

---

#### **Epithelioma.**

1008. Epithelioma of the lower lip. The growth involves almost the whole border of the lip, and has considerably infiltrated the sub-mucous tissue.
1009. Epithelioma of the lower lip, with characteristic ulceration and papillary growth. An attempt has been made apparently to inject the vessels of this specimen.
1010. Epithelioma of the lower lip. A portion of the growth has been destroyed by ulceration, and the surrounding parts exhibit the characteristic rough, fissured, and cauliflower appearance of advanced specimens of this disease.



## SERIES XIV.—INJURIES AND DISEASES OF THE TONGUE.

**Inflammation and its Effects:** 1011–1013.

**Specific Inflammation.**

Ulceration: 1014.

**Morbid Growths.**

Sarcoma: 1015.

Epithelioma: 1016–1020.

### INFLAMMATION AND ITS EFFECTS.

#### **Glossitis (Angina Ludovici)?**

1011. Tongue, part of submaxillary glands, pharynx, œsophagus, and larynx. Enlargement of tongue and submaxillary glands from inflammation and infiltration (seen in microscopic section). (Edema of mucous membrane of epiglottis and larynx.
1012. Fauces, root of tongue, and larynx. Tracheotomy was required on account of œdema of the glottis. In the recent state the tonsils were discoloured and sloughing, with a line of discoloration in front of the epiglottis along the base of the tongue.

From a man, Alec Soutar, aged 30, admitted under Dr. Sutton on April 12, 1882, with chronic renal disease and dropsy. He had been ill two months before admission with œdema of the legs, loins, and eyelids, headache, morning vomiting, dimness of sight (for three weeks), shortness of breath, and anæmia. (Edema of the glottis supervened, from which he died March 3, 1883. The autopsy showed hypertrophied left heart and granular contracted kidneys with thickened capsules, and enormous œdema of the glottis and larynx.

#### **Ulceration of Tongue.**

1013. A deeply excavated ulcer at base of tongue, extending along right anterior surface of epiglottis. Orifices of follicles in neighbourhood of the ulcer unusually distinct.

### SPECIFIC INFLAMMATION.

#### **Syphilitic Ulceration of Tongue and Fauces.**

1014. A tongue with palatal arches and larynx. Ulceration extends from the median line of soft palate over left oral surface. The left tonsil is represented by a number of irregular excavations (old). On



left side of tongue at the junction of vertical and horizontal part is a ragged and deep ulcer. On the dorsum, close to left side of raphe and near base of tongue, is a growth covered by shreds of ulcerated mucous membrane (gumma); there are old syphilitic cicatrices of mucous membrane of left anterior surface of tongue.

### MORBID GROWTHS.

#### **Spindle-celled Sarcoma.**

1015. The tumour is about the size of a large grape, and was situated in the submucous tissue of the tongue, with a nipple-like projection protruding through an ulcer in the mucous membrane of the tongue.

#### **Epithelioma.**

1016. The left half of a tongue, showing a nodular growth at the side, with hard elevated everted edges and ulcerated surface. The filiform papillæ are everywhere enlarged (ichthyosis).

Removed from a man, John L., aged 47, by Mr. McCarthy on June 13, 1888. The patient had been addicted to smoking, but denied any history of syphilis. He attributed the commencement of the ulcer to the irritation of a sharp tooth. The disease was of about five months' duration, and had already produced glandular enlargement.

1017. A large excavated ulcer at base of the tongue, which has extended backward so as to destroy the greater part of the epiglottis and the left upper border of the larynx. The left true vocal chord is much enlarged from submucous growth.

1018. Ulceration at base of tongue, with warty growths in neighbourhood.

1019. The disease has commenced at the apex of the tongue and by ulceration reduced it to a filamentous condition.

1020. Secondary results of epithelioma of the tongue. The specimen shows the hyoid bone and larynx. On the right side of the larynx is a cancerous growth, which has caused a considerable diminution of the cavity of the larynx. The mucous membrane for some distance above and below the right vocal chord is ulcerated superficially.



## SERIES XV.—INJURIES AND DISEASES OF THE TEETH.

---

1020 a. A soft round nodulated reddish tumour, resembling a raspberry in size, shape, and colour. The tumour is fixed to the neck of the lateral incisor tooth. During life it presented very visible pulsation and could be made to disappear on pressure.

From a woman, aged 29, admitted with a pulsating tumour growing from the periosteum of the right upper lateral incisor tooth. The front teeth were perfect, but all the back teeth had been lost during pregnancies. She had had 5 children, and enjoyed good health. The tumour began two months before as a small tag, felt with the tongue, and situated at the neck of the tooth where it emerged from the gum. It grew rapidly and soon began to bleed; the blood which escaped was arterial. It now bleeds some four times a day. She became anæmic. There was no pain or tenderness on pressing the tumour. The central right incisor was quite loose.

Removed by Mr. Treves. See Path. Soc. Trans. vol. xxxix. p. 100.



## SERIES XVI.—INJURIES AND DISEASES OF THE PALATE, FAUCES, AND PHARYNX.

**Inflammation and its Effects :** 1021, 1022.

**Specific and Infective Diseases :** 1023, 1024.

**Morbid Growths.**

Round-celled Sarcoma : 1025.

Epithelioma : 1026, 1027.

**Malformation.**

Diverticulum : 1028.

**SUBSERIES I.—Injuries and Diseases of the Tonsil.**

**Morbid Growths.**

Lympho-Sarcoma : 1029, 1030.

Melano-Sarcoma : 1031.

### INFLAMMATION AND ITS EFFECTS.

1021. Pharynx showing the results of inflammation (tuberculous?).—The submucous tissue of pharynx and larynx is thickened and causes a projection, about the size of a florin, of the mucous membrane over the anterior wall of the pharynx. This has been laid open on the left side, and in the recent state contained a cheesy substance, which is no longer present. A similar incision has been made higher up on the left side with similar result.

#### **Ulceration of the Pharynx and Epiglottis.**

1022. The mucous membrane of the pharynx and tonsils is deeply ulcerated, particularly on the left side. The epiglottis is almost entirely destroyed, and its remains indurated and altered in shape. The mucous membrane of the pharynx where it is ulcerated is thickened.

History unknown : ? syphilitic.

### SPECIFIC AND INFECTIVE DISEASES.

#### **Scarlatina.**

##### **Ulceration.**

1023. Soft palate, fauces, larynx, and trachea, with base of tongue showing sloughing of tonsils.

From a case of scarlatina.



**Syphilis.**

1024. Cicatricial results of extensive syphilitic ulceration of soft palate and pharynx, producing stricture of the pharynx. The nasal portion of the pharynx has been separated from the rest by adhesions of the shrivelled and contracted soft palate. Leading into this part is a small opening in the median line from the mouth through the soft palate large enough to admit a No. 10 catheter, and indicated in the specimen by the blue glass rod. A little below this opening is the passage from the mouth to the œsophagus and larynx, represented by a narrow tortuous channel about two thirds of an inch in length and only large enough to admit a No. 6 catheter. This is indicated in the specimen by the colourless glass rod.

The patient, a woman, had been under observation about ten years before her death, from which time the commencement of this condition dates. About four years before her death tracheotomy was performed, with alleged temporary (?) relief to respiration. Dilatation, by bougies, of the stricture was made from time to time, and finally an attempt was made to divide it with a bistoury, which resulted in hæmorrhage that proved fatal in her exhausted condition. Immediately below the stricture the pharynx is normal.

*Presented by Mr. Hutchinson*

**MORBID GROWTHS.****Round-celled Sarcoma.**

1025. The growth surrounds the pharynx posteriorly and laterally, but does not extend beyond the posterior pillar of the fauces. Microscopically it proved to be round-celled sarcoma.

The patient, a boy, was admitted with extreme dyspnœa. On examining the mouth the soft palate appeared very red and œdematous, and bulged markedly downwards on the right side. In the absence of any history or information as to the onset, it was supposed to be an abscess, and an incision was accordingly made in the projecting part of the soft palate, with, of course, no benefit, and the patient died the same evening. 31. 9. 81.

**Epithelioma.**

1026. On the right side and posterior wall of the pharynx is an epitheliomatous ulcer extending from a level with the right aryteno-epiglottic fold to the lower border of the cricoid cartilage. The right ala of the thyroid cartilage is extensively exposed.

From a man, W. W., aged 60, admitted under Mr. Adams, on June 3, 1884, for cancerous stricture of the œsophagus. He had suffered from copious expectoration of fetid discharge tinged with blood for two months. He had gradually become unable to swallow solid food, and for the last three days prior to admission had been unable to swallow even liquids. On June 7th an incision was made through the abdominal wall, the stomach was exposed and stitched to the edges of the wound. It was not opened. The patient died from exhaustion next day. The autopsy recorded a healthy wound without peritonitis.



1027. The mucous membrane of the right aryteno-epiglottic fold, and of the contiguous part of the pharynx down to a level with the lower border of the cricoid cartilage, is replaced by an ulcerated surface, irregular, flocculent, and at the upper part with a somewhat cauliflower appearance, being an epithelial cancer in advanced stage.

Mr. Headington.

## MALFORMATION.

### **Diverticulum.**

1028. The specimen shows a well-defined pouch of the pharynx on the left side and on a level with the arytenoid cartilages. Of this form of congenital malformation no explanation has yet been discovered. The perichondrium has been separated from the cricoid cartilage, which is calcified and rough (perichondritis and necrosis?).

---

## SUBSERIES I.—INJURIES AND DISEASES OF THE TONSIL.

### **Lympho-Sarcoma.**

1029. Sarcoma of right tonsil involving adjacent parts of pharynx and larynx. Large nodular masses have grown in towards median line, so as to largely occupy the upper part of the pharynx, and almost completely block the inlet of the larynx. Laryngotomy appears to have been performed.
1030. The specimen shows a mass removed by operation by Mr. McCarthy, March 2nd, 1887, from a man aged 35. It almost blocked the isthmus of the fauces and caused trouble in deglutition. The lymphatic glands below the jaw were also involved. The growth had spread from the right tonsil into the soft palate and for some distance down the right side of pharynx. There was a history of three previous partial removals, but with rapid return of growth. The soft structures of right side of face were everted at the operation and a portion of the vertical ramus of the lower jaw removed. The tumour was readily shelled out, but fatal secondary hæmorrhage occurred on the fifth day. Microscopic structure is that of lympho-sarcoma.

### **Melano-Sarcoma.**

1031. Tongue with palatal arches. A brownish lobulated growth occupies the position of the left tonsil and projects into the pharynx on a level with the uvula.

*Presented by Mr. Luke.*



SERIES XVII.—INJURIES AND DISEASES OF THE  
SALIVARY GLANDS.**Morbid Growths.**

Sarcoma: 1032.

Myxo-Adenoma: 1033.

## MORBID GROWTHS.

**Sarcoma.**

1032. A very large solid tumour, stated to have been removed from the parotid region. The tumour is as large as two fists; a portion of skin has been removed with it. Microscopical examination shows it to be composed of large spindle-cells.

**Myxo-Adenoma.**

1033. A lobulated glandular tumour somewhat larger than a walnut. It has been cut open, and is seen to contain neither cartilage nor cysts.

The specimen is the largest of seven tumours removed by Mr. Moullin from the parotid gland of a young woman aged 18. They were all encapsuled, and shelled out easily. The wound suppurated and healed by granulations. They had been slowly increasing in size for two years, without pain; they were freely movable, elastic to the feel, distinctly circumscribed, and not adherent to the skin. Microscopical section reveals adenomatous structure.



## SERIES XVIII.—INJURIES AND DISEASES OF THE ŒSOPHAGUS.

**Injury:** 1034.

**Corrosive Poisoning:** 1035-1040.

Liquor Ammoniae: 1035.

Caustic Bougies: 1036.

Nitric Acid: 1037, 1038.

Sulphuric Acid: 1039.

**Morbid Growths.**

Epithelioma: 1041-1056.

Stricture: 1048.

Stricture with Perforation: 1049, 1050.

Invasion of the Trachea: 1051, 1052.

Perforation of the Trachea: 1053-1056.

### INJURY.

**1034.** Œsophagus transfixed by a piece of wood.—About half an inch below the lower border of the cricoid cartilage the œsophagus is completely pierced from side to side by a splinter of wood pointed at both extremities, and about an inch and a half in length. The splinter is exactly horizontal, and the mucous membrane of the œsophagus is extensively ulcerated in the neighbourhood of the right-hand perforation. The ulceration is somewhat oval in shape, with vertical diameter about an inch, and the transverse about a third of an inch.

### CORROSIVE POISONING.

**1035.** An œsophagus showing fibrous thickening and stricture, the result of having swallowed ammonia. The œsophagus has been laid open from behind, and shows considerable thickening of its walls from opposite the bifurcation of the trachea to the cardiac orifice of the stomach. The thickening is not uniform, but is most marked posteriorly and on the right side, and especially about an inch below the bifurcation of the trachea. The submucous and muscular coats are especially affected. The cardiac orifice of the stomach (through which a piece of blue glass rod has been passed) is narrowed from thickening of the tissues around it, which also extends for some distance along the coats of the stomach.



From Charles M., who was admitted under Sir Andrew Clark on Feb. 7, 1880, half an hour after taking an unknown quantity of liquor ammoniæ in mistake for lemonade. His lips, tongue, and pharynx were raw, sputa copious and tinged with blood. A dilute solution of ferri perchloride taken through the day, with opium in a mixture, was the treatment. He was discharged in ten days. In the following August (6 months) he was treated for subacute gastritis, there being no stricture at this date. In December (19 months) he was readmitted suffering from dysphagia and obstruction. The gullet was gradually dilated with bougies, with relief to symptoms. He subsequently died in hospital from hæmorrhagic variola. Post-mortem:—Epidermis generally peeling: blood dark and fluid: heart flaccid: numerous subpericardial, subpleural, and submucous extravasations.

1036. Ulceration of the Œsophagus, produced by caustic bougies. About three inches below the bifurcation of the trachea the Œsophagus is considerably diminished in calibre, with corresponding thickening of the coats, but no structural change (congenital stenosis). Above this, for about two inches, the mucous membrane is destroyed and the muscular coat laid bare, the result of introduction of caustic bougies.

1037. Œsophagus with pharynx and tongue, from a case of nitric-acid poisoning. A girl had swallowed half an ounce of nitric acid, and died eight hours afterwards. The mucous membrane is of yellow colour and thickened. The papillæ of the tongue and the follicles of the Œsophagus are unusually distinct. See also Stomach.

1038. The detached mucous membrane of the Œsophagus, the result of nitric-acid poisoning. This specimen presents a complete tube, corresponding in extent to the whole of the Œsophagus and lower part of the pharynx. Its inner surface is mucous membrane, in parts destroyed, leaving the submucous tissue bare. The outer surface is shreddy, and contains many of the circular and longitudinal muscular fibres.

Mary Lamb, aged 35, admitted Nov. 16 (year not given), having three hours previously swallowed half an ounce of nitric acid. Chalk and magnesia, an emulsion of castor oil, bleeding, and leeches were the treatment. Patient complained of pain in throat and at pit of stomach. Nine days later, while vomiting violently, she brought up this membranous tube, and died 24 hours later. Post-mortem:—Œsophagus and stomach were found denuded of mucous membrane. Larynx and trachea much inflamed.

1039. Base of the tongue, the larynx, and Œsophagus, from a case of poisoning by sulphuric acid. The mucous membrane of the Œsophagus, from its commencement nearly to its termination, has been burnt away and is replaced by a sloughing, exceedingly irregular layer of granulations. The calibre is much narrowed, the walls thickened, and the surrounding tissues adherent from long-standing inflammation. The tongue, the epiglottis, and the back of the larynx show no



change: the ulceration begins suddenly, reaches its worst at once, and gradually becomes less and less marked. The patient lived some time after swallowing the acid. A catgut bougie could be passed during life, and gradual continuous dilatation was tried with slight improvement. Electrolysis, with a constant current as strong as the patient could stand, effected no change of any kind. Finally gastrotomy was performed, and the stomach stitched to the abdominal wall (see General Pathology, No. 49). There was no reaction or peritonitis; the temperature continued normal; but on the third day the patient suddenly became collapsed and died.

Ellen C., Reg. No. 1056, 1887.

Mr. Mansell-Moullin.

1040. Sloughing ulceration of the œsophagus from corrosive poison. Close to the cricoid attachment of the œsophagus, the mucous membrane presents for about two inches a shreddy appearance from ulceration, said to be from irritant poisoning.

#### MORBID GROWTHS.

##### **Epithelioma.**

1041. The disease is situated about an inch below the level of the bifurcation of the trachea. It is annular, and forms a considerable projection forwards.
1042. Immediately below the level of the bifurcation of the trachea is an annular mass of epithelial cancer in the wall of the œsophagus for about two inches vertically. The mucous membrane corresponding to this has been completely destroyed. The descending portion of the thoracic aorta is in close relation with the disease, and is very atheromatous. The arch of the aorta is also very atheromatous and dilated.
1043. About three inches from the cardiac orifice of the stomach the lumen of the œsophagus is much diminished by a growth in the walls of the tube. The mucous surface is ulcerated in part, and the growth has completely replaced the other structures in the wall of the tube, and presents in section a wax-like appearance.
1044. A little below the level of the bifurcation of the trachea the normal structure of the œsophagus ceases, and is replaced by an ulcerating mass.

The patient was admitted into the hospital in 1804, having suffered from dysphagia for a year. On admission solids could not be swallowed, and fluids



only with difficulty. A probang was passed so readily that the disease was supposed to be at the pylorus. The patient had a sort of a fit and a sense of suffocation, and died five days after.

1045. The wall of the tube has been completely destroyed for about two thirds of the circumference, and for about two inches in length. The one third that remains presents towards what should be the lumen of the tube an irregular ulcerated surface, and the external fibrous coat is thick and cicatricial in appearance. Above and below the disease terminates abruptly in nodular masses, which considerably diminish the lumen.

1046. The specimen represents the residue of the middle of the œsophagus. The disease is limited superiorly at a level corresponding to about one inch below the arch of the aorta. From thence downward for about four inches scarcely a trace of œsophageal structure remains. A cancerous mass replaces it, which on the inner surface presents a number of shreds and recesses of various sizes. In the original catalogue it is described as epithelial cancer mixed with colloid and encephaloid. At the back of the specimen is the aorta seen in longitudinal section, presenting patches of atheroma.

1047. The mucous membrane of the œsophagus, for about the upper sixth of the tube, is replaced by a flocculent ulcerated surface. The disease has spread upward into anterior wall of pharynx, but is not so far advanced there, presenting on the right side small patches of ulceration and irregular nodules in the submucous tissue, and on the left side a warty ulcerated surface with everted margin, extending to the level of left aryteno-epiglottic fold.

#### **Stricture.**

1048. Immediately opposite the bifurcation of the trachea the œsophagus is the seat of annular epithelioma (apertures have been cut in anterior and posterior walls of trachea to show relation). Above the cancer the lumen of the œsophagus is diminished, so that in life only a small probe could be passed through it. External to the œsophagus and to the right a mass of cancer has grown round the right common carotid artery, through which a quill has been passed. This mass seems to have been partly the cause of the stricture, as the mucous membrane of the œsophagus is said to be healthy at the seat of stricture.

Mr. Hutchinson.

#### **Stricture with Perforation.**

1049. Immediately below the level of the bifurcation of the trachea



there is a slight stricture of the œsophagus from epithelial cancer (a piece of glass rod has been passed through the stricture). Immediately above the stricture the growth perforated into and led to the formation of a cavity in the apex of the right lung.

From a man, W. Watson, aged 61, admitted Jan. 14. Postmortem Jan. 18, 1884. His illness commenced with dysphagia three months before admission.  
Dr. Stephen Mackenzie.

1050. Immediately below the level of the bifurcation of the trachea the lumen of the tube is diminished to the size of a lead-pencil for about two inches vertically. The mucous surface corresponding to the growth is ulcerated, and the normal structure of the wall replaced by the cancerous growth. Immediately above is an opening with smooth walls leading under the left bronchus, and communicating with the pleural cavity. This was caused by a probang having been thrust through the wall of the œsophagus and the parietal pleura with a fatal result.

#### **Invasion of the Trachea.**

1051. Epithelioma of the œsophagus and trachea.—An obstruction of the œsophagus is caused by a growth on the anterior wall at the very commencement of the tube. The growth has extended backward from the trachea, and forms a bulging backward. The mucous membrane and subjacent growth have been incised vertically. The posterior wall of the trachea shows a somewhat papillated growth and some cicatricial puckering of the surface.

1052. The disease has involved the trachea, thyroid gland, and diaphragm. The mucous membrane of the œsophagus is extensively ulcerated, and presents numerous pedunculated growths. A little above the diaphragm the muscular fibres of the tube are exposed for a space measuring  $1\frac{1}{4}$ " vertically and  $\frac{3}{4}$ " transversely. At the cardiac orifice of stomach is a nodular mass the size of an orange, which has invaded muscular fibres of the diaphragm, but not the walls of the stomach.

This patient was ill for six weeks only. His chief symptom at first was epigastric pain, and subsequently dysphagia and regurgitation of food. There was obstruction to the passage of bougies at the level of the manubrium. He rapidly emaciated, and died of exhaustion.

Wm. Hall, June 6, 1882. Dr. Fenwick.

#### **Perforation of the Trachea.**

1053. Opposite the bifurcation of the trachea the posterior wall of that tube has been perforated by the extension of ulceration from the



œsophagus. The posterior wall of the œsophagus has been destroyed for about two inches above and for as many below this level, and the cancer has extended to the approximate dorsal vertebræ, which are also partially destroyed.

1054. The upper part of the œsophagus is almost completely blocked by an epitheliomatous growth, which projects in nodules on the outer wall of the tube, especially on the right side. The mucous membrane is ulcerated, and about the centre of the growth the ulceration extends into the posterior wall of the trachea by an irregular elongated opening, below which is a papillated ulcer extending vertically for about an inch.

1055. The œsophagus has its lumen greatly diminished at the very beginning of the tube by a growth with ulcerated surface. The ulceration extends for a small extent into the pharynx, and terminates inferiorly in an everted irregular border. The ulceration is deepest where the tube is most constricted, and has at this part penetrated into the trachea, on the posterior wall of which is an oval opening about one third of an inch in the vertical and slightly less in the transverse diameter, and bounded by an irregular thick and everted margin.

1056. The upper two inches of the œsophagus is the seat of epithelial cancer, which has reduced the lumen of the tube so as to barely admit a crow-quill. The mucous membrane is ulcerated, and the growth forms irregular nodular projections at both sides, but especially the right. The growth has extended into the trachea, on the posterior wall of which is an opening from the œsophagus.

*History.*—The patient, a woman, came under observation April 14, 1803. She had suffered from dysphagia for a year, and latterly from dyspnoea, especially when lying down. Both these symptoms were much increased about seven weeks before the above date. Liquids only could be swallowed, which gave rise to a gurgling sound on deglutition. She was vigorously treated with calomel and blisters, and said that she felt better, but died from suffocation, April 26, 1803.

Published in Bradley's Journal, June 1, 1803.



## SERIES XIX.—DISEASES OF THE PERITONEUM, OMENTUM, AND MESENTERY.

**Foreign Body:** 1057.

**Peritonitis:** 1058, 1059, 1060, 1066.

**Peritoneal Adhesion:** 1661, 1662, 1664.

Constricting Bowels: 1063, 1069.

**Tuberculosis:** 1064, 1065.

**Morbid Growths.**

Sarcoma: 1066, 1007.

Carcinoma: 1068-1070.

Myxo-Sarcoma: 1071, 1072.

**Cysts:** 1073, 1074.

### Foreign Body.

1057. A loop of small intestine, with a portion of the omentum to which it has become adherent. In the latter there is an abscess-cavity formed around a bend in the adherent intestine, from which a plum-stone had escaped through an opening at the point of the angle, indicated by a piece of wood in the specimen. The abscess measures about 2 inches by 1, and 1 inch deep. The plum-stone is shown *in situ* in it.

From a patient aged 54.

### Peritonitis.

1058. A portion of intestine, from a case of acute peritonitis. The vessels have been injected to show the dilatation of the arterioles and capillaries. The peritoneal surface is coated with recent lymph.

1059. Portion of colon, with thickish layers of lymph on its peritoneal surface.

1060. Coils of intestine, adherent to each other by recent lymph.

### Peritoneal Adhesion.

1061. A portion of the liver and of the diaphragm above it. There are innumerable fibrous bands, forming a loose connection between the opposing surfaces.

1062. Portion of abdominal wall, with a piece of omentum adherent to the peritoneal surface at the umbilicus.

The patient died of hæmorrhage after paracentesis.



1063. Portion of a cæcum and ascending colon partially laid open, showing a narrowing of its channel from peritoneal adhesions. There is a thick strong band uniting the wall of the gut above and below, and causing a sharp bend in the channel. The cæcum is dilated and its wall atrophied. Its mucous membrane is stippled with points of pigmentation.

### **Tuberculosis.**

1064. Coils of ileum, from a case of tubercular peritonitis. The peritoneal surfaces are adherent at places. Contiguous to one of these adhesions opaque white spots are visible in the peritoneal coat of the bowel (miliary tubercle).
1065. A loop of intestine with mesentery attached, injected, showing enlarged caseous mesenteric glands. The glands vary from a quarter, to one inch in diameter, and are spherical. The lacteals leading from the gut to glands are distended with caseous matter.

## **MORBID GROWTHS.**

### **Sarcoma.**

1066. Coils of intestine, showing sarcoma (spindle-celled) of mesentery and omentum, with recent peritonitis. The coils of intestine are seen matted together, with lymph on the surface. At the upper part of the specimen a part of the colon is cut across, and shows thickening and contraction of the omentum and mesentery by malignant growth. The intestine has been contracted by the growth, but the mucous membrane does not appear to have been invaded by it.

From a woman aged 25, admitted Nov. 25, 1882. The symptoms dated three months, and began with abdominal pains. Three weeks before admission the abdomen became swelled, and she began to vomit. The vomiting became constant and uncontrollable, and she wasted rapidly. There was some peritoneal effusion, which became absorbed. She died from hæmorrhage from a nodule of growth in the stomach.

Pauline P.: autopsy, December 9, 1882.

See Stomach from this case, Series XIX, No. 1119.

1067. A portion of transverse colon with omentum, in which numerous pedunculated nodules of sarcomatous growth have been developed, varying in size from a pin's head to a pea. Most of them are coloured more or less of a deep brown.

Sections show a sarcomatous structure consisting of corpuscles of rounded outline and of varying size and form, in a delicate reticulum traversed by thin-walled vessels.



**Carcinoma.**

1068. Omentum and stomach, with structures contiguous to the posterior surface and smaller curvature of the latter. The stomach is adherent to a mass of carcinomatous growth, which appears to have originated in or around the head of the pancreas, and a portion of which is seen projecting beneath the pylorus. The wall of the stomach is thickened and contracted, and its mucous membrane is adherent and thickened and nodular, but not apparently ulcerated. The growth has extended into the omentum, in which a well-defined nodule is seen at the back of the specimen to the left.

Sections from the omentum show much connective-tissue growth of fibrous structure, with regularly arranged elongated nuclei and tracts of large epithelioid cells in columns.

Case of Charlotte A., aged 49, who was admitted September 22, 1882. She had suffered from epigastric pain and vomiting, with some dysphagia, for three months, and had wasted much. There were nodules of growth on the small intestine and sigmoid flexure. No secondary growths in the liver.

Autopsy, November 7, 1882. Dr. Fenwick.

1069. A portion of the colon, showing adhesion of the appendices epiploicæ by cancerous growth, causing constriction of the gut.

Case of Henry M., aged 64. Admitted April 13, 1884, with intestinal obstruction dating from April 6. He had previously appeared quite well. He had diffused carcinoma of the peritoneum secondary to carcinoma of the pylorus and of the stomach. There was a perforation of the anterior gastric wall, closed by the upturned and adherent omentum. The cancerous growth was abundant on both surfaces of the diaphragm, and in hernial sacs at the umbilicus and left side of scrotum. There were vegetations of the aortic valve.

Autopsy, April 23, 1884. Mr. James Adams.

See also Preparation of hernial sacs from the same case, No. 1290, Series XXII.

1070. A portion of the peritoneum, showing great thickening and nodulation from carcinomatous growth. The increase of thickness in some parts is nearly half an inch.

Microscopical examination of sections of the growth shows masses of carcinomatous growth in the meshes of a network, in part fibrous, in part fibro-corpuseular. The cell-masses within the alveoli are separated by a fine reticulum, which is, in places, abundant.

**Colloid Disease.**

1071. A portion of the large intestine with omentum attached, which is converted into a flocculent, gelatinous mass of cancer, which has undergone colloid degeneration.

1072. A piece of omentum infiltrated with colloid cancer, and thereby increased in thickness to half an inch.



Under the microscope degenerated epithelial cells are seen in some loculi. The stroma is fibrous, in parts very thick; in places it is seen to be traversed by large connective-tissue cells, fusiform and irregular in shape.

### Cysts.

1073. A piece of omentum presenting a small, solid, spherical tumour, the size of a small cherry. It appears to be composed of a cyst enclosing a cretaceous nodule, and is possibly a degenerated hydatid.
1074. The posterior surface of the stomach of a rabbit with the great omentum attached, showing many small hydatid cysts about the size of cherry-stones.



## SERIES XX.—INJURIES AND DISEASES OF THE STOMACH AND DUODENUM.

### Effects of Injury.

- Laceration: 1075.
- Effects of Poisons: 1076 to 1085.
- Gastrostomy:
- Post-mortem Solution: 1086, 1087.

### Diseases of the Stomach.

- Hypertrophy: 1088 to 1091.
- Dilatation: 1106.
- Hæmorrhagic Erosion: 1092.
- Perforating Ulcer.
  - Recent: 1093 to 1095.
  - Chronic: 1095 to 1104.
  - With Perforation: 1095 to 1099, 1101, 1103, 1105.
  - With Erosion of Arteries: 1093, 1094, 1100 to 1104.
- Gastro-colic Fistula: 1105.
- Healing Ulcer: 1106.
- Perforation from without: 1107.
- Stricture of Pylorus: 1108, 1109.
- Contraction with Stricture: 1110.
- Hour-glass Contraction: 1111.
- Necrosis of Mucous Membrane: 1112.
- Typhoid Ulceration: 1113.
- Polypus: 1110, 1114, 1115.
- Lipoma: 1116.
- Fibromata: 1117.
- Sarcoma: 1118, 1119.
- Carcinoma.
  - Pyloric: 1120 to 1128.
  - Of Cardiac end: 1129 to 1132.
  - Intermediate: 1133.
  - Of whole Stomach: 1134, 1135.
  - Scirrhus Contraction: 1136 to 1138.
  - Colloid: 1125 to 1128, 1132 to 1134.
- Cystic Growth: 1139.

### Diseases of the Duodenum.

- Abnormal conditions of the Mucous Membrane: 1140, 1141.
- Ulceration:
  - After Burns and Scalds: 1142 to 1144.
  - With Perforation: 1143 to 1147.
  - With Erosion of Arteries: 1151 to 1153.



Tubercular Ulceration: 1154.

Papillary Growth: 1155.

False Diverticula: Pouching: 1109, 1152, 1153.

## EFFECTS OF INJURY.

### Laceration.

1075. Stomach of a man, æt. 23, who had been struck in the abdomen by the handle of a winch. The body at the post-mortem examination was decomposed, and emphysematous everywhere except the lower extremities. In right hypochondriac space the integuments were bruised, and the muscular wall was there ruptured, so that the hand could be introduced into the peritoneal cavity. There was general acute peritonitis. In the inferior and posterior aspect of the stomach are two circular jagged holes, through which the glass rod has been passed, near the greater curvature. The aperture near the pylorus has much more sharply-defined edges than the other, which is near the cardia, and the mucous membrane in the neighbourhood of which is ragged and softened. The peritoneal coat has been torn in several places.

Mr. Rivington.

### Arsenical Poisoning.

1076. The stomach of a man who died from arsenical poisoning. The muscular coat is somewhat contracted, and the mucous membrane corrugated. Its surface is coated with coagulated exudation or mucus.

The patient from whom this was taken was brought into the hospital in a comatose state, and was reported to have swallowed half an ounce of arsenic. He died in a few hours. The stomach was found much inflamed, and the mucous membrane elevated in places from extravasations of blood into the submucous tissue. Arsenic was also found adhering to the surface.

### Carbolic Acid Poisoning.

1077. A stomach from a case of carbolic acid poisoning. The organ has been laid open along the greater curvature and everted. Its cavity is dilated and its walls rigid. The mucous surface is covered with an opaque membrane of coagulated exudation or altered epithelium.

From a woman, aged 64, who died some hours after her admission to the hospital. The mouth, fauces, and œsophagus were denuded of epithelium. The walls of the stomach were leathery, and the under surface of the liver was in a similar condition. The stomach was greatly dilated, and contained much fluid smelling of carbolic acid. The effects of the acid were noticeable as far as the transverse part of the duodenum. Below that the mucous membrane was injected, but appeared normal. The heart was contracted.

Case of Jessie S. Autopsy, Sept. 1, 1882.



1078. Œsophagus and stomach of a patient æt. 37, who died from swallowing carbolic acid. The mucous membrane of the Œsophagus is stiffened and detached in large shreds from the subjacent tissues. In the stomach the mucous surface, except close to pylorus, is also covered with shreds of membrane.

In this case the tongue was pale, fauces and larynx congested, lungs œdematous, heart firmly contracted, kidneys congested, bladder full of normal-looking urine. The contents of the stomach smelt strongly of carbolic acid.

Case of Joseph C., aged 37. Autopsy, July 3, 1876. Dr. Hughlings Jackson.

### **Hydrochloric Acid Poisoning.**

1079. A stomach and Œsophagus from a case of suicide from swallowing hydrochloric acid. The mucous membrane of the stomach has been extensively destroyed, and its surface is flocculent. It is much blackened, especially about the middle of the larger curvature. In the wall of the stomach and in the omentum are massive blood-clots and much congestion. The extravasations form a ridge along the attached border of the omentum. The mucous membrane of the Œsophagus is corrugated, and its epithelial surface is opaque.

From a man, aged 49, who was admitted three hours after swallowing between 1 and 2 oz. of "spirits of salts," and died four hours later. The Œsophagus, stomach, duodenum, and about a foot of the jejunum were much charred, and also the walls of the lesser omentum. The liver was discoloured and shrunken, the heart firmly contracted.

Case of John R. Autopsy, March 18, 1882.

1080. The stomach and Œsophagus of a boy aged 7, who died from the effects of swallowing half an ounce of hydrochloric acid. There has been extensive destruction of the mucous membrane of the stomach about the greater curvature towards the pyloric end, where there are two large perforations of the gastric wall. The mucous membrane adjacent is blackened. Near the cardiac orifice are a number of glandular (?) elevations with crater-like excavations at their summit. The mucous membrane of the Œsophagus is corrugated and opaque.

Case of Richd. B. Autopsy, Nov. 14, 1880.

### **Nitric Acid Poisoning.**

1081. A stomach showing corrosion by nitric acid. The interior has a woolly appearance, and is covered with small yellow shreds, which are the remains of mucous membrane.

From a young woman who took half an ounce of nitric acid, and died in eight hours.

See the pharynx and Œsophagus of the same patient, No. 1037, Series XVII.

1082. Stomach and Œsophagus of a person who died from taking nitric



acid. The free surface of the œsophagus is rough and covered with shreds of detached mucous membrane; the muscular tissue is exposed at some parts, the destruction being greatest at the cardiac end. The effect of the acid on the stomach is not so universal, but the mucous and cellular coats have been destroyed over a considerable surface along the greater curvature.

### **Sulphuric Acid Poisoning.**

1083. A stomach showing the effects of swallowing sulphuric acid. The mucous membrane is corrugated and thickened, and roughened on the surface; in places it is thinned. The corrugated parts are discoloured, partly yellow, mostly black, giving the surface of the stomach a mottled appearance. The pyloric end appears unaffected.

The epithelium of the lining membrane of the mouth was disorganized, and of a yellowish-brown appearance; uvula and soft palate were swollen, and the mucous membrane of pharynx denuded of epithelium for about four inches. The peritoneal coat of the stomach was slightly injected, and a black discoloration visible through it; there was a little dark thin fluid in it. In the duodenum the prominent parts of the valvulæ conniventes were blackened and charred.

### **Irritant Poisoning.**

1084. A stomach laid open and everted. The mucous membrane is corrugated and the summits of the folds are discoloured. At the fundus the mucous membrane is coated with a layer of coagulated mucus or lymph.

From a case of irritant poisoning (? by antimony).

1085. A stomach with the œsophagus and duodenum from a severe case of corrosive poisoning. The wall of the stomach has been destroyed along nearly the whole extent of the greater curvature, leaving a rent with shreddy edges. The mucous and peritoneal surfaces of the stomach are flocculent and shreddy, and much discoloured by black blood-pigment. The duodenum is coated with opaque membrane, but not discoloured. It is perforated about two inches from the pylorus. In the œsophagus the mucous membrane is corrugated and coated with an opaque epithelial membrane above; below it is denuded of epithelium.

### **Post-mortem Solution.**

1086. The stomach of a child, aged 9, showing the effects of post-mortem solution of its walls by the action of the gastric juice. The walls have given way along nearly the whole of the greater curvature,



the edges of the aperture being shreddy and flocculent. The mucous membrane is eroded, and its surface is rough and flocculent except near the pylorus.

"The patient from whom this specimen was taken died from chronic abscess. On gently handling the stomach it accidentally ruptured near its great curvature; its under surface (as the body was recumbent) was destroyed to a considerable extent so as to allow the escape of its contents. The edges of the opening were irregular and pultaceous. The mucous membrane of the whole of the great curvature was soft and transparent; in some places the muscular coat was softened, and in others the whole of the coats were destroyed."

1087. The stomach and part of the liver of a rabbit, in which there is a large irregular opening at the cardiac end, caused by the action of the gastric juice after death. The capsule of the liver is eaten through at several parts, and the texture somewhat destroyed, by the same agent.

### DISEASES OF THE STOMACH.

#### **Hypertrophy.**

1088. An hypertrophied stomach laid open along the greater curvature. The organ is enlarged, and all the coats are thickened.
1089. A very large stomach. The muscular wall is very thick, and the mucous membrane is thrown into rugæ half an inch in elevation. The hypertrophy is greatest near the pylorus.
1090. A portion of an hypertrophied stomach.
1091. Part of an hypertrophied stomach from a case of carcinoma of the pylorus. The mucous membrane has been dissected off from the thickened strands of the muscular coat.

#### **Hæmorrhagic Erosion.**

1092. A stomach and part of duodenum showing numerous small superficial ulcerations of the mucous membrane, and, at the cardiac end, a deeper ulcer the size of a fourpenny piece, which is covered by an adherent blood-clot. Adjacent to this ulcer is a smaller one of similar appearance.

Case of Jessie T., aged 35, who was admitted Jan. 12, 1889, with mitral stenosis, and died Feb. 13, from hæmorrhage from the stomach. There were a few small translucent granulations on the edge of the mitral valve, but no evidence of recent endocarditis. There were areas of infarction and necrosis in the spleen and in one kidney. There was much blood in the intestines. The lower limbs were very œdematous, and there was serous exudation in the peritoneal, and in both pleural, cavities.

Autopsy, Feb. 13, 1889. Dr. Hughlings Jackson.



**Perforating Ulcer.**

1093. A stomach with three ulcers situated in the smaller curvature, one being about the middle of it and the others nearer the cardiac orifice. They are each about the size of a sixpence, the middle one round, the others oval. They are all sharply defined with steep edges, and expose the outer coat. There is little or no thickening of the gastric wall around them. The ulcer nearest the cardiac orifice has exposed and eroded a small branch of the coronary artery, from which hæmorrhage occurred.

John D., 47, an omnibus-driver and an intemperate man, was admitted Feb. 3, 1885, with mitral stenosis. For two years his breath had been short. His last illness dated three weeks. Hæmatemesis occurred two days before his death. He had pericarditis and right pleuro-pneumonia, and granular atrophied kidneys. In the heart there were recent vegetations on the sclerosed and thickened mitral valve.

Autopsy, March 6, 1885. Dr. Down.

1094. A stomach showing several ulcers of recent formation near the smaller curvature, and on both sides of it. On the anterior wall are several ulcers varying in size from a threepenny piece to a shilling, in a cluster about 3 inches long, and extending from 1 to  $2\frac{1}{2}$  inches from the smaller curvature. In the floor of one of these a branch of the coronary artery has been exposed and eroded, and is indicated by a glass rod. In the floor of another ulcer the peritoneum is exposed as a diaphanous membrane. In the floor of a third there is a perforation, which was made after death. On the posterior wall there is an ulcer of the size of a shilling, in a position corresponding with the last. There is no thickening of the mucous membrane about the ulcers, and no lymph on the peritoneum at their base.

Cyrus S., aged 38, a butcher, was admitted Dec. 2, 1886, under Mr. Tay. He had cellulitis of the left wrist and forearm, following Colles's fracture. There was much blood in the stomach and intestines. For a few days before his death there had been some hæmatemesis and melæna. He died in sudden syncope.

Autopsy, Dec. 14, 1886.

1095. A stomach laid open along the greater curvature, showing four ulcers contiguous to the pylorus. On the anterior wall there is a sharp-cut chronic ulcer, of oval outline and of the size of a large plum-stone, with a sharply defined perforation in its floor, also of oval outline, but in a direction nearly transverse to the ulcer. At a point on the other side of the smaller curvature, corresponding to the end of this ulcer which is nearest to it, is a sharply defined, "punched-out" perforation of the whole thickness of the gastric wall, apparently quite recent at the time of death. The other two ulcers are well defined, but superficial and of small size. One is about midway



between those above described, the other further from the smaller curvature, at a point corresponding with the further end of the chronic ulcer; it is at the bottom of a depression between folds of the mucous membrane. There is much lymph on the peritoneal surface of the stomach. There is much fibrous thickening of the submucous and muscular tissue of the wall of the stomach at the pylorus.

Case of John P., 52, who was admitted Nov. 24, 1884, and died the same day.

1096. Part of a stomach with a sharply defined chronic ulcer of triangular outline, in the floor of which is a circular perforation of the size of a threepenny piece. The mucous membrane is puckered near the ulcer, and drawn down over its edges. There is a deposit of recent lymph on the peritoneal surface of the stomach round the perforation.

1097. Part of a stomach showing ulcers of the mucous surface, one of old date, with a perforation in its floor. Both the ulcer and the perforation in its floor are of a rounded triangular (or kite) shape, but with their long axes widely divergent. There is a second ulcer, superficial and no larger than a split pea, near the pylorus, which is to the left of the specimen.

From a patient of Dr. Clark, who, when admitted to the Hospital, complained of pain in the epigastrium, but not of sensitiveness to pressure. On the second day peritonitis set in, and he died on the third day.

See Lond. Hosp. Rep. vol. 3.

1098. A stomach, with part of the duodenum, laid open along the smaller curvature. On the anterior wall, near the middle of the smaller curvature, is a chronic ulcer rather larger than a sixpence with a perforation in its floor, which is formed by the outer coat alone. In a corresponding situation on the posterior wall is a cicatrix, around which there is much puckering of the mucous membrane. There is lymph on the peritoneal surface of the stomach around the perforation, and evidence of fibrous adhesion in the situation of the cicatrix in the posterior wall.

From a woman, aged 42, who was admitted into the Hospital with acute peritonitis, and died the following day. There was extravasation of the contents of the stomach into the peritoneal cavity.

Case of Jane C. Autopsy, September 1, 1882.

1099. Part of a stomach laid open along its smaller curvature, showing a chronic ulcer of irregular quadrilateral outline, about three quarters of an inch from the line of section, in the floor of which is a perforation of the size of a quill pen.

1100. A stomach, with parts of the œsophagus and duodenum, laid open



along the greater curvature and everted, showing a deeply recessed, or pouched, ulcer of the size of a florin on the anterior wall close to the smaller curvature, with a perforation of its floor. In the floor of the ulcer, near its margin, are wart-like projections formed by fibrous thickening around the truncated ends of branches of the coronary artery, which are closed by organized coagula. Through one of these a fine glass rod has been thrust from the coronary artery.

There is great fibrous thickening of the omentum where it is connected with the smaller curvature of the stomach, forming a massive ridge of fibrous tissue, in which some lymphatic glands are imbedded along the gastric wall. The pouching of the floor of the ulcer has been formed by excavation and bulging of this tissue, and perforation occurred through the wall of the pouch so formed.

Case of Geo. B., aged 56, who died shortly after admission to the Hospital. Autopsy, June 5, 1884. Dr. Down.

1101. A portion of a stomach, with part of the pancreas attached, showing a circular ulcer of unusual depth. The mucous and muscular coats have been destroyed, and the floor of the ulcer is formed by the fibrous and peritoneal coats, and the body of the pancreas, which has become adherent to the posterior wall of the stomach. There is considerable thickening of the mucous membrane in the neighbourhood of the ulcer. There is lymph on the peritoneal surface about an oval perforation of the floor of the ulcer. At the back, the adhesions of the pancreas also have given way, so that the ulcer communicates with the peritoneal cavity by two apertures.

From a spinster, Martha S., aged 46, a sempstress. For about a year before her death she had suffered with gastric trouble, flatulence, acid eructations, severe pain after taking food. She vomited occasionally at first, and with relief to the pain, but latterly the vomiting was persistent. There was no hæmatemesis. She died of asthenia from want of food.

1102. Part of a stomach with a large chronic ulcer involving nearly the whole of the smaller curvature, and extending over both the posterior and anterior walls. The gastric wall has been wholly removed, the floor of the ulcer being formed by the connective tissue of adjacent parts, to which the stomach is firmly adherent. The ulcer is reniform, embracing the pylorus on one side. The wall of the stomach around it is thickened and fibrous.
1103. Part of a stomach with a chronic ulcer of the size of a crown-piece, in the floor of which the pancreas is exposed, and there is a perforation at its border. At the lower part of the specimen there has been a more superficial and more recent extension of the ulceration, and another perforation has occurred there.
1104. Part of a stomach, showing a chronic ulcer of crescentic form, which embraces the cardiac orifice on one side. It is  $3\frac{1}{2}$  inches long,



with a maximum breadth of  $\frac{3}{4}$  inch. Its base is formed in part by the liver, and in part by a mass of omental fat. It has exposed and ulcerated a branch of the coronary artery, from which a fatal hæmorrhage occurred.

#### **Gastro-colic Fistula.**

1105. A stomach and part of the transverse colon. At the lower part of the large end of the stomach is an opening, the result of chronic ulceration into the colon, which had become adherent.

"Symptoms commenced with dyspepsia, followed by faecal vomiting at intervals, which was more frequent when the bowels were confined, and lasted two years and a quarter; he followed his occupation till within three months of his death."

#### **Healing Ulcer.**

1106. A portion of the stomach adjacent to the cardiac orifice, showing ulcerations of the mucous membrane in process of healing. The gastric wall is much thinned at the seats of ulceration, and the peritoneal surface between and around them is rough from formation of adhesions to adjacent structures.

#### **Perforation from without.**

1107. A stomach laid open along its smaller curvature and everted showing two perforations near the middle of the greater curvature. The mucous membrane around them is ragged, but unchanged in appearance. On the peritoneal surface there is evidence of the formation of an abscess, which had opened into the stomach.

From a case of (?) actinomycosis of the liver, which led to suppurative peritonitis with formation of collections of pus in several places.

See Liver, Series XXIV.

#### **Stricture of Pylorus.**

1108. A greatly dilated stomach laid open along the great curvature and everted, viewed from behind. On the right is the pylorus with the commencement of the duodenum (unopened). The orifice is much contracted, and there is fibrous thickening of the tissues around it. There is some fibrous thickening also about the cardiac orifice of the stomach and about the lower end of the œsophagus, which is included in the specimen.

Sections from the cardiac orifice show fibrous thickening without evidence of cancerous growth.

From a man, aged 60, who died in collapse two hours after admission to the Hospital. He had suffered four years from gastric symptoms. Impacted calculi



were found in the gall-bladder, and fibrous enlargement of the prostate. The heart was fatty, and the arteries very atheromatous.

Case of John P. Autopsy, September 27, 1881.

1109. The pyloric end of the stomach with the commencement of the duodenum. There is great thickening of all the coats of the stomach near the pylorus, with contraction of the orifice. The pyloric fold of mucous membrane is eroded and in great part destroyed. In the duodenum, contiguous to the valve, is a pouch of the mucous membrane in the submucous tissue. It formed a narrow sac, the end of which has been cut off in laying open the specimen, and has been removed. A glass rod has been passed through what remains of the pouch.

Sections from the pylorus show no evidences of carcinomatous growth.

Aquila P., aged 50, had had epigastric pains and pyrosis for about five months. He died with rheumatic arthritis, and acute pleuro-pneumonia. There was no affection of the lymphatic glands near the pylorus, nor growths in other organs.

Autopsy, April 19, 1881. Dr. Sutton.

### **Contraction with Stricture.**

1110. A contracted stomach laid open along its greater curvature to within an inch of a tight annular stricture, situated about two inches from the pylorus. The wall of the stomach on the cardiac side of the stricture is much thickened. Along the smaller curvature, and in its whole circumference contiguous to the constriction, it is fibrous and rigid and greatly thickened, especially in the former situation. The mucous membrane is united to the outer coats in the smaller curvature, and on either side it is traversed by tracts of fibrous thickening similarly adherent, the cardiac pouch alone being unaffected. On the anterior wall of the stomach close to the stricture is an ulcer with sharply-cut walls and thick edges, from which superficial ulceration extends along the smaller curvature nearly to the cardiac orifice. The peritoneal surface of this part of the stomach is roughened with shreds of fibrous adhesions. It is deeply puckered in the greater curvature at the seat of constriction. The organ is much contracted. The pyloric end of the organ beyond the stricture is greatly thickened, especially in the muscular coat. The channel is contracted and the mucous membrane thrown into deep folds, the end of one of which projects into the duodenum like a hæmorrhoid at the anus. A polypoid growth, of the size of a small pea, stands up from the mucous membrane about an inch from the orifice.

Microscopic sections show fibrous thickening and muscular hypertrophy without cancerous growth. It seems probable that pyloric obstruction may have given rise to extensive ulceration, and that this may have been followed by cicatricial stricture and the fibrous thickening and contraction of the stomach behind the obstruction.



From a man, aged 60, who complained of dysphagia and regurgitation of food. A bougie passed readily into the stomach. Latterly he suffered from persistent vomiting, and wasted. There were no other notable lesions of the abdominal viscera. The aorta was atheromatous, the arch calcareous. There was a depression of a portion of the upper part of the frontal bone to the right of the middle line, dating since from a blow from a beam 20 years before. He had had occasional epileptic fits since that time, for one of which he was admitted. The pia mater over the anterior parts of the hemispheres was opaque.

Case of Ed. G. Gilbert. Autopsy, May 27, 1886. Dr. Sutton. See Trans. Path. Soc. vol. xxxviii. p. 138.

### **Hour-glass Contraction.**

1111. A stomach of hour-glass form from a transverse constriction rather nearer to the pylorus than to the cardiac orifice. No evidence of ulceration was apparent.

From Jane K., aged 50, who died from morbus cordis with button-hole mitral orifice.

Autopsy, March 18, 1882.

### **Necrosis of Mucous Membrane.**

1112. A portion of a stomach, showing a circumscribed superficial slough of the mucous membrane of the size of a three-penny piece. In the fresh state it was of a black colour; it is now decolorized. The specimen appears to show the first stage in the formation of a gastric ulcer.

From a man, aged 60, who was admitted into the Hospital with fracture of the left tibia and fibula. The fracture became reunited; but he got erysipelas, and died with pyæmia four months after admission.

Case of Geo. H. Autopsy, Jan. 19, 1884.

### **Ulceration in Typhoid Fever.**

1113. The pyloric portion of the stomach from a case of typhoid fever. Close to the pylorus, on the left of the specimen, is a well-defined elevated area with central slough, exactly resembling the smaller areas of infiltration in the ileum in such cases. Above it are two or three sharply-cut ulcers of the mucous membrane, resembling such patches in process of healing after separation of the sloughs.

Case of Emma Dodd, 22. Autopsy, March 11, 1884. Dr. Sutton. See preparation of Ileum in Section of GENERAL PATHOLOGY, No. 152.

## **MORBID GROWTHS.**

### **Polypus.**

1114. Part of a stomach with a pedunculated polypus connected with the mucous membrane. The tumour is of the size of a small hazel-



nut, and has a slender stalk  $\frac{1}{4}$  inch long. The surface is smooth and velvety.

1115. A similar specimen. The polypus is elongated and club-shaped, and about  $1\frac{1}{2}$  inches in length.

### **Lipoma.**

1116. Part of a stomach showing a lipoma of the submucous tissue. An incision has been made through the middle of the tumour and the mucous membrane covering it, and the growth, having but slight connection with the surrounding structure, projects through the opening in the mucous membrane. It is composed of yellowish adipose tissue, and is of the size of a cherry.

### **Fibroma.**

1117. A stomach laid open along its greater curvature, showing areas of thickening of its walls, which form defined elevations of its mucous surface and slighter prominences on its serous surface. These bossy elevations of the mucous membrane occupy the greater part of the surface of the stomach. In the smaller curvature there is an area of thickening as large as a man's hand. Between the bossy elevations the gastric wall is thin. In the section of the gastric wall at the edge of the specimen the thickening is seen to be due to increase of the submucous and subperitoneal connective tissue, with corresponding localized increase of the intermediate muscular coat. At one part of the section (to the right of the specimen), where the whole thickness of the wall is not much more than  $\frac{1}{2}$  inch, the muscular coat is fully  $\frac{1}{4}$  inch thick. At this part the limitation of the affected area is well shown. The gastric wall adjacent appears thinned and atrophic.

Sections from a thickened part of the stomach show a fibrous structure under the microscope.

### **Sarcoma.**

1118. A stomach (injected) with the posterior wall greatly thickened by a sarcomatous growth, which is as much as  $1\frac{1}{2}$  inches thick near the pylorus, where an incision has been made into it. The gastric wall, where involved in the growth, is ulcerated on its mucous surface, which there presents a ragged appearance. The anterior gastric wall appears normal. There is a mass of enlarged glands adherent to the posterior surface of the stomach.

Sections of this growth show a network of interlacing strands of fibrous tissue with much corpuscular infiltration, enclosing spaces traversed by a finer reticulum similarly infiltrated. Lympho-sarcoma.



1119. A stomach showing an umbilicated nodule of growth in a case of spindle-celled sarcoma of the omentum and mesentery. The growth is in the outer wall of the stomach, the mucous membrane being free, and is situated in the cardiac portion. It is about the size of a florin.

Pauline A. Giltys, aged 25, was admitted Nov. 25, 1882, with malignant disease of the peritoneum, and died with hæmatemesis. Autopsy, Dec. 12, 1882. Dr. Sutton. See also No. 1066, Series XVIII.

### **Carcinoma of Pylorus.**

1120. Part of a stomach showing an annular scirrhus growth of the pyloric portion. This end of the stomach is contracted into a tubular channel for about three inches, expanding in a funnel-shape at its proximal end. The channel is greatly obstructed by the thickening of the mucous coat, which presents a prominent rounded ring at the commencement of the duodenum. The growth has invaded the middle and outer coats of the stomach, to which a piece of the liver is seen to be adherent.

1121. Part of a stomach showing an annular carcinomatous growth of the pyloric end. About two inches of this extremity of the organ is contracted into a tubular channel obstructed by the growth in the mucous wall. The contiguous part of the gastric wall is rigid and thickened by the morbid growth, especially along the smaller curvature. The mucous surface is elevated and roughened. The peritoneal surface is smooth near the pylorus, but deeply puckered in the greater curvature about an inch from that orifice. The distal end of the growth projects into the duodenum like a thick ring, covered by normal mucous membrane.

1122. A stomach with an annular carcinomatous growth at the pyloric end, extending for about 3 inches from the orifice and bounded by a thick ridge on the mucous surface, near which, at the posterior part, is a rounded nodule of growth of the size of a pigeon's egg. The pyloric orifice is greatly stenosed. There is a large cluster of enlarged glands in the smaller curvature of the stomach, the largest of which is as big as a billiard-ball. They are of a very soft structure.

Sections of the growth show a nucleated fibrous stroma with alveoli filled with epithelioid cells.

1123. Part of a stomach, showing an annular growth at the pyloric extremity, which extends for 4 or 5 inches towards the fundus. Both the mucous and peritoneal coats are invaded, the former being as much as  $\frac{1}{2}$  inch thick. On the anterior wall the growth is bounded by an elevated, overhanging ridge. Posteriorly and along the greater



curvature it has extended to a greater distance in the form of nodules of varying size, with larger masses of lobulated or clustered growth. On the peritoneal surface there are disseminated nodules of growth, some projecting, most of them slightly raised spots.

Sections show a partly fibrous and partly reticulated and nucleated structure in both submucous and subperitoneal growth. It was described in the old Catalogue as consisting of fibro-nucleated tissue. Obtained from a female subject in the dissecting-room.

1124. Part of a stomach showing an annular scirrhus growth of the pyloric end, which extends for about 4 inches from the orifice, and is bounded by a thick elevated ridge on the mucous surface. Within this the mucous surface is ulcerated. The gastric wall is much thickened and rigid. The muscular wall, which is outside the growth, is very greatly thickened. There is great thickening and contraction of the peritoneal surface about the smaller curvature at this part, which has drawn up the pylorus so as to increase the bend at the commencement of the duodenum.

Sections show much fibrous thickening with corpuscular infiltration of the gastric walls.

1125. The pyloric end of a stomach with an extensive, ulcerated, colloid growth in the smaller curvature, extending halfway round the orifice and for about 2 inches from it. The ulcerated area has an elevated border with undermined edges. This growth contains spaces filled with mucoid or colloid substance, which projects from the open mouths of crypts at the margin of the ulcer. The growth has involved the subperitoneal tissue, in which clusters of cysts filled with the same substance form projections on the surface. At the upper part of the specimen there is an isolated nodule of growth on the mucous surface, about an inch from the margin of the ulcer.

Case of Geo. P., aged 50, who was admitted in an exhausted state, and died two days afterwards. There was a history of continuous vomiting and wasting for several weeks. The abdomen was retracted and the tumour could be felt. Secondary deposits were found in the liver.

Autopsy, May 19, 1884.

1126. A stomach laid open along the greater curvature, showing an annular scirrhus growth of the pyloric end, which has converted about an inch of it into a tubular stricture with walls  $\frac{1}{2}$  inch thick, and 3 inches more into a rigid funnel-shaped channel; and has extended along the smaller curvature to within  $1\frac{1}{2}$  inches of the cardiac orifice. In the funnel-shaped part of the growth the muscular wall is greatly thickened. Near the pylorus it is invaded by the growth and indistinguishable.

Sections of the growth show a carcinomatous structure in advanced colloid degeneration, with fibro-nuclear growth of the connective tissue.



Case of Henry S. W., aged 50. Duration of symptoms about 6 months. Admitted with an epigastric tumour. Temporary relief from washing out the stomach and rectal feeding.

Autopsy, March 18, 1882.

1127. The pyloric end of a stomach, with part of the pancreas, showing a colloid growth with ulcerated surface in the smaller curvature, extending for about 2 inches from the pyloric orifice, which it nearly surrounds, and for about an inch into the duodenum, the two parts being separated by the fibrous ring of the pylorus. The mucous surface of the growth is extensively ulcerated. The growth has invaded the peritoneal coat of the stomach, on which are seen tracts and clusters of projecting colloid cyst. The peritoneal surface is contracted in the smaller curvature at the pylorus. The head of the pancreas is invaded.

1128. The pyloric portion of a stomach with part of the duodenum, showing an annular scirrhus, and partly cystic, growth of the former, commencing at the pylorus and extending about 2 inches from it. The mucous surface is ulcerated in the centre of this growth. Beyond it, the mucous membrane of the stomach is roughened with thickly clustered warty outgrowths. In the substance of the growth are clusters of small cysts with smooth walls. The peritoneal surface is irregularly nodulated by the growth, which has invaded the whole thickness of the gastric wall.

#### **Carcinoma of the Cardiac End.**

1129. Part of a stomach with a carcinomatous growth encircling its cardiac end. Towards the centre of the stomach the growth is bounded by a thick and overhanging ridge. In the œsophagus there are a number of cauliflower-like polypoid nodules of growth, of irregular form, connected with the mucous membrane at the border of the affected area. There is a mass of growth as large as half an orange on the outer wall of the stomach at the affected part. The growth is ulcerated on its mucous surface. Sections of the growth show much nucleated fibrous tissue, with some spaces lined by cylindrical epithelial cells.

1130. A stomach laid open along the smaller curvature. Two thirds of it, including the cardiac end, are invaded by carcinomatous growth, which is bounded by an irregular line encircling the organ and cutting off the pyloric portion. Beyond this line are two well-defined elevated areas with overhanging borders, and ulcerated on their summit. Over the affected area the mucous membrane is in great part destroyed, parts projecting as bossy elevations.



1131. Part of a stomach with a scirrhus growth surrounding the cardiac orifice and extending for about an inch along the œsophagus, and downwards along the greater curvature over the cardiac pouch of the stomach, which is contracted. The growth has been divided about the plane of the cardiac orifice. The section shows thickening both of the mucous and peritoneal coats by tracts of scirrhus growth separated by the muscular coat, which is also thick with increase of interfascicular septa. In the œsophagus the mucous membrane is projected in longitudinal folds, but the growth has not extended on the outer surface of the muscular wall. In the greater curvature of the stomach, towards the middle, is a pedunculated, polypoid growth as large as a cherry, of irregular cauliflower-appearance. The gastric wall is drawn in and the peritoneal surface puckered at this point.

Sections of this growth show great fibrous thickening of the connective tissue of the gastric wall, but no appearance of carcinomatous growth.

1132. A stomach with the lower part of the œsophagus, and a part of the anterior abdominal wall to which the former was ligatured in the operation of gastrostomy, showing a mass of ulcerated and partly broken-down growth at the cardiac orifice. In the section of the gastric wall the growth has a defined border, beyond which the sub-mucous tissue is thickened. In the œsophagus the mucous membrane is thickened and everted at the border of the ulceration, which extends along it for two inches. The stomach has been ligatured to the abdominal wall and opened near the middle of the greater curvature. There is lymph on the surface of the peritoneum about the opening.

Sections of this growth show an open alveolar structure with large spaces, occupied by masses of cells which have undergone a mucoid, or colloid, degeneration, and have become fused together. Mr. Tay.

### **Carcinoma of an intermediate part of the Stomach.**

1133. The pyloric part of a stomach, showing an annular carcinomatous growth causing constriction of the organ about 2 inches from the orifice. The peritoneal surface is much puckered at that part.

Sections of the growth show much profusely nucleated fibrous tissue traversed by tubular channels lined with cylindrical epithelium, and by columns of epithelioid cells of indefinite character.

From a woman, aged 63, who was admitted with pneumonia, and died the same day. She had sclerosis of the valves of the heart and recent endocarditis.

Case of Alice B. Autopsy, March 22, 1884.

### **Carcinoma of the whole Stomach.**

1134. A stomach laid open along its anterior wall. The pyloric end is infiltrated and greatly thickened and stenosed by an annular scirrhus growth, which has extended along the smaller curvature nearly to



the cardiac orifice and over both the anterior and posterior walls, encircling the organ and contracting its cavity. The growth has undergone much colloid degeneration, crypts appearing on the mucous surface from which the colloid matter has escaped. The peritoneal surface is in part smooth, in part roughened from adhesions. Near the attachment of the omentum it is studded with nodules of growth. The omentum contains much adipose tissue with nodules of growth.

Wm. Ashley, 63, was admitted April 13, 1884, under Dr. Sutton. Since the preceding August he had suffered from dyspepsia and epigastric pain, subsequently from vomiting with anorexia and hæmatemesis, and rapid wasting.

Autopsy, April 30, 1884.

1135. A stomach with its entire wall, excepting the pyloric end, greatly thickened by scirrhus carcinomatous growth, in which there are numerous cavities filled with tenacious mucous or colloid matter. From the surface of the growth on the anterior wall of the stomach fungating masses project, which are most developed at the cardiac end. The thickening of the stomach is greatest about the middle, where it measures about three quarters of an inch. The peritoneal surface is smooth and rounded in outline, and the organ, with its thick and rigid walls, resembles a thick leather or india-rubber bottle. It was adherent to the liver, a portion of which is seen invaded by the growth.

Sections show much colloid degeneration of a carcinomatous growth, with fibro-nuclear thickening of the connective tissue.

From a woman, aged 53, whose symptoms dated from 10 months before death. She then had pain after food, relieved by vomiting, with loss of flesh and colour, and an epigastric tumour was discovered. The symptoms were gradually progressive, with some hæmatemesis latterly. She had been dyspeptic since the menopause at 43, when her husband died, and became weak and languid. No history of malignant disease in the family could be obtained.

Case of Jane P. Autopsy, May 20, 1882. Sir A. Clark.

### **Scirrhus Contraction of the Stomach.**

1136. A contracted stomach, with part of the posterior wall removed. There is great fibrous thickening of its wall with hypertrophy of the muscle, especially at the pyloric end and along the smaller curvature. The cardiac end is contracted to a rounded pouch. The mucous membrane is closely adherent to the submucous growth.

Sections show a more or less compact fibrous tissue infiltrated with nuclei, with tracts of open reticular tissue about the vessels. The arteries are greatly thickened. The fibrous growth is defined towards the mucous surface, the mucous membrane covering it being thin and villous.



1137. A greatly thickened and contracted stomach laid open along the smaller curvature. The peritoneal surface is thrown into deep folds along the greater curvature, especially at the cardiac end, and the fundus is drawn up towards the smaller curvature, reducing the cavity to a fusiform expansion of the alimentary canal. The mucous surface is eroded, and in places more deeply ulcerated, along the greater curvature, but its inequalities are obliterated by great thickening of the submucous tissue, which is  $\frac{1}{2}$  inch thick in part of the section. The length of the stomach from the termination of the longitudinal corrugations of the œsophagus to the pylorus is less than 4 inches. The pyloric end of the stomach is not notably affected.

Sections from the thickened gastric wall show fibrous tissue with some nuclear infiltration. No carcinomatous structure could be seen.

Case of John F., aged 41, a cook. His illness dated 18 months, wasting, anorexia and epigastric pain after food. Dysphagia 12 months. Occasional vomiting. No history of syphilis was elicited. There were cicatrizations on the surface of the liver, and the results of chronic orchitis in both testes. The kidneys were granular and contracted.

Autopsy, October 1, 1881. Dr. Gilbert Smith.

1138. A contracted stomach, with the greater part of the œsophagus. There is great fibrous thickening of the submucous tissue of the whole of the stomach, excepting a small and sharply defined portion at the pyloric end. The stomach is so contracted by the drawing-up of its greater curvature as to form little more than a fusiform expansion of the alimentary tract. On its peritoneal surface there is a deep fissure, which appears as a ridge on the mucous surface, marking off the cardiac pouch. The mucous membrane appears to have been removed from this part of the stomach and from the œsophagus, where also there is a thickening of the submucous tissue, which at one point, at the upper part of the specimen, forms a projecting nodule of the size of a pea. The muscular coat of the œsophagus and stomach is thickened, but has otherwise a normal appearance in section. The peritoneal surface of the stomach is smooth, excepting posteriorly, where there is a mass of dense fibrous tissue adherent to it, with portions of the spleen and of the left adrenal imbedded.

Sections of the thickened gastric wall show a dense fibrous structure with much corpuscular infiltration, uniting the mucous membrane to the muscularis and invading all the coats. In a few places the growth has an open structure of lymphomatous character. The arteries in the submucous tissue are greatly thickened. Sections of the portion of adrenal show expansion of the organ, apparently due to distention of the vascular spaces in the medullary substance by cloudy coagula more or less freely infiltrated with leucocytes.



**Cystic Growth.**

1139. The pyloric portion of a stomach affected with a cystic growth of its wall. On the peritoneal surface of the posterior wall, about 2 inches from the pylorus, are the remains of a large cyst, the greater part of which was removed during life. This cyst, which has a smooth lining-membrane, is separated from the gastric wall by a smaller cyst, of the size of a turkey's egg, which forms a peduncle to it. The cavity of the smaller cyst, which communicates by a wide aperture with the larger one, is partly occupied with a fibrous trabecular structure. Close to the pylorus, and in the smaller curvature, are two cysts similar to the last, connected with the serous surface; one is about the size of a pigeon's egg, and the other twice as big. "They contained serous fluid and some very dark, almost black, semi-solid substance." At this part also are some irregularly lobulated prominences on the mucous surface of the stomach, one as large as half an orange, and somewhat further from the pylorus, on the posterior wall, is a second projection of the mucous surface, similar to the first, but smaller, the two being separated by a level space where the large cyst is connected with the gastric wall. In the smaller elevation there is an opening at one point, where the wall of a cavity has been opened by ulceration, through which part of a delicate and open-meshed fibrous reticulum of degenerated growth projects. Arising from the peritoneal surface at this part is what looks like a mass of adipose tissue, of the size of an egg. Sections from it show spaces of varying size in a fibrous reticulum, resembling a lymphangioma, and some larger cysts. The structure is hazy and indistinct from long preservation. The peritoneal surface of the cysts is rough from fibrous adhesions.

From a woman, aged 22, who was supposed to be suffering from ovarian disease. An operation was performed, and the greater part of the great cyst, which came down from under the greater curvature of the stomach, was removed. The patient died subsequently of peritonitis. "Some glands along the smaller curvature were enlarged and soft, but did not present any characteristic of cancer. The lymphatic glands in the omentum and round the duodenum were also enlarged, soft, and elastic, but not the seat of any deposition. The other viscera were healthy. The microscope revealed numerous free nuclei of various shapes and sizes and some fibrous stroma. The pulpy substance in the cyst also contained variously shaped free nuclei, some granular matter, and fat."—(Description in the Old Catalogue.)

---

**DISEASES OF THE DUODENUM.****Abnormal Condition of Mucous Membrane.**

1140. A part of the duodenum laid open, with the head of the pancreas attached. The specimen shows thickening of the mucous membrane



and enlargement of the valvulae conniventes. The mucous surface is everywhere studded with bead-like projections, which vary in size from a pin's head to a split pea; some of them are sessile, some pedunculated. A probe is inserted in the common bile-duct.

From a case of hydrochloric-acid poisoning.

1141. A duodenum injected and everted, showing enlarged solitary glands. The mucous membrane is much congested and the seat of numerous small, more or less polypoid, projections; some are mere elevations, some are pedunculated.

This swelling of the glands is the result of catarrhal inflammation, and resembles the condition shown in the previous specimen.

### **Ulceration after Burns and Scalds.**

1142. The pyloric end of the stomach and part of the duodenum laid open, showing an ulcer of the latter about half an inch from the pylorus. The ulcer is irregularly circular in form and  $\frac{3}{8}$  inch in diameter. It has perforated the mucous and submucous coats, and the base is formed by the serous coat, which is transparent. Attached to the duodenum is a piece of the pancreas, and above this the serous coat of the duodenum forms the base of the ulcer and is coated with lymph.

From a patient, aged  $3\frac{1}{2}$  years, who died on the eleventh day from extensive burns.

*Presented by Mr. Curling.*

1143. The pyloric end of the stomach, the pylorus, and part of the duodenum, laid open, showing ulceration of the latter. About half an inch below the pylorus there is an ulcer in the mucous membrane of the size of a sixpence, but somewhat irregular in shape. It looks as if a slough had recently separated, and the edges, which are bevelled off, appear to be already cicatrising. In the mucous membrane of the stomach, about an inch and a half above the pylorus, there is a small oval superficial ulceration which is abruptly defined.

From a woman, aged 70, who died on the tenth day from burns.

*Presented by Mr. Hutchinson.*

1144. A piece of the duodenum with the pylorus, opened, showing ulceration in a case of scalding. At the upper part, about  $1\frac{1}{2}$  inch from the pylorus, are seen two areas of superficial ulceration, circular in form and one fourth of an inch in diameter.

From a patient who died from extensive scalds.



**Perforating Ulcer of the Duodenum.**

1145. The specimen shows portions of the stomach and duodenum, with the pylorus, laid open. Attached to the duodenum is a part of the head of the pancreas. About half an inch from the pylorus is an irregular ulcer with edges clean cut and in part undermined. The substance of the pancreas is visible in the lower half of the floor of the ulcer, and at the upper part the ulcer has perforated the peritoneum, the opening being oval in shape.
1146. A similar specimen. The ulcer is situated near the pylorus. It is of a crater-like form, with defined and thickened borders. The perforation at its base is sharply defined and its margins are rounded. Peritoneal adhesions have been formed at the seat of the ulcer.
1147. A similar specimen.
1148. A similar specimen. There has been extensive superficial ulceration of the mucous membrane immediately below the pylorus, and at one place is a sharply defined perforation of the outer coat, oval in form and about quarter of an inch in length. There is no evidence of adhesive peritonitis and no thickening of the surrounding parts.
1149. A similar specimen. Immediately contiguous to the pylorus is an extensive ulcer of the duodenum with sharply cut steep edges, exposing the pancreas, to which the intestine has become adherent. The ulcer is about  $1\frac{1}{4}$  inch in its long diameter, and about half an inch in a direction transversely to the bowel. There is a perforation close to the pylorus. On a level with the lower end of this ulcer, and directly opposite to it in the circumference of the gut, is a smaller ulcer of more recent formation with sharply cut, crater-like margins. The floor of this ulcer has given way, leaving an opening with thin edges. The outer surface of the gut presents flakes of adhesive lymph at this spot. There has been a recent superficial extension of the older ulcer in the direction of the more recently formed one.
1150. A similar specimen, with extensive perforation. The ulcer commences at the pylorus. It is of an oval outline, with longer diameter running rather obliquely down the intestine; the floor of the ulcer has been separated and is now attached only by one margin.

**Ulceration with Erosion of Arteries.**

1151. Part of the duodenum with the pyloric end of the stomach, laid open. Close to the pylorus is seen an old ulcer the size of a shilling, with raised edges and incurved mucous membrane. The pancreas is exposed in the base of the ulcer, and a branch of the pancreatico-



duodenal artery has been opened. The ulcer is quadrilateral in form. At its lower end there has been a more recent superficial extension of the ulceration to the apparent right. At the upper part there has been a separation to the adhesion between the pancreas and pylorus, making an opening in the floor of the ulcer at this spot (? post mortem).

1152. Portions of the duodenum and stomach from a case of duodenal ulcer fatal by hæmorrhage. The ulcer is immediately contiguous to the pylorus and is about the size of a florin, its edges are sharply cut, the mucous membrane being folded over them. To the left of the specimen the ulcer is deeply excavated, the base there being formed by the pancreas. In it is a perforated branch of the pancreatico-duodenal artery, into which a glass rod has been introduced, and from which fatal hæmorrhage occurred. Adjacent to the ulcer and immediately contiguous to the pylorus is a pouching of the duodenum.

1153. A similar specimen. In the duodenum immediately contiguous to the pylorus is a deeply recessed ulcer, which forms a pouch about three quarters of an inch deep, and extending in a downward direction behind the wall of the duodenum into the pancreas. It is also overhung at its right-hand margin (lower border in specimen). In the floor of the ulcer is an aneurysmal dilatation of a branch of the pancreatico-duodenal artery, which is seen in a section of the pancreas, and into which a glass rod has been introduced. About two inches from the pylorus is a pouch of the duodenum as large as a walnut, with thin walls and lined with villous mucous membrane. Adjacent to the ulcer, and also immediately contiguous to the pylorus, is a small conical pouch in the mucous membrane.

From a female aged 52, under care of Dr. Sutton. For two years she had suffered from pain in her left side and shoulder, which became continuous and was attended by vomiting during the last six weeks of her life. Blood appeared in the vomit for the first time the day before her death. The following night she awoke with profuse hæmatemesis, which was fatal in a few minutes.

#### **Tubercular Ulceration.**

1154. A portion of the duodenum showing tubercular ulceration. The ulcer is irregularly oval, one inch long by a quarter broad, with the long axis running transversely to the gut. The base is uneven, and the peritoneal surface at that part is infiltrated with small nodules.

#### **Papillary Growth.**

1155. Pyloric end of stomach and commencement of duodenum laid open, showing a papillary growth of the latter contiguous to the pylorus and extending over the lower surface of the pyloric fold.



## SERIES XXI.—INJURIES AND DISEASES OF THE INTESTINES.

### Laceration and Rupture:

Of the small intestine: 1156 to 1161.

Of the colon: 1162.

### Injury from Foreign Body:

In the Ileum: 1163, 1164.

In the Appendix Cæci: 1165, 1166, 1167.

Foreign Body passed per Anum: 1168.

Artificial Anus: 1169.

Pigmentation: 1170, 1171, 1172.

Thrombosis: 1173.

Gangrene: 1174, 1175.

Abnormal condition of Mucous Membrane: 1176, 1177, 1178.

Ulceration: 1179, 1180.

Dysentery: 1181 to 1191.

Scurvy: 1192.

Typhoid Fever: 1193 to 1200.

Tubercular Lesions: 1201 to 1218.

### Morbid Growths and Cysts.

Fibro-Myoma: 1219.

Sarcoma: 1220, 1221.

Melanotic: 1222.

Adenoma: 1223.

Carcinoma: 1224 to 1231.

Colloid: 1232, 1233, 1234.

Cystic: 1235.

Stricture: 1221, 1224 to 1233.

### Malformations.

Diverticulum: 1215, 1236, 1237.

Occlusion: 1238.

Congenital defect: 1239.

---

## EFFECTS OF INJURY.

### Laceration and Rupture.

1156. A portion of the small intestine and mesentery showing a transverse laceration of the whole calibre of the gut. The laceration



extends into the mesentery for half an inch. At one extremity of the torn gut the mucous membrane is everted like a turn-up cuff. At the other extremity the serous and muscular coats appear to have been partially and irregularly stripped off from the mucous membrane.

The rupture was caused by a cart passing over the abdomen. From a boy aged 10 years. He lived 3 days.

1157. Portion of the jejunum and mesentery showing a transverse rupture situated at the unattached border of the gut. The opening in the serous coat is oval and about the size of a shilling; this is closed for two thirds of its extent by the everted and projecting mucous membrane. The peritoneal surface of the gut is dull and covered with thin flakes of lymph.

From a patient who had been run over by a cart, immediately after a full meal. He died in 24 hours.

1158. A portion of the small intestine showing a rupture through which the mucous membrane is everted. The edges of the opening appear smooth from the inside, externally they are ragged, though partially concealed by a deposit of lymph. The laceration is about  $\frac{3}{8}$  of an inch long.

At the post-mortem fæces were found extravasated into the peritoneal cavity, and the intestines were glued together with lymph.

The specimen was obtained from a child, who had been run over in the street and who died two days later with symptoms of acute peritonitis.

1159. Portion of small intestine, the seat of a longitudinal rupture of all the coats of the bowel. The serous coat shows a clear rent with even edges, the other coats are torn irregularly, and project through the opening.

From a boy aged 14, who died 24 hours after he had been struck in the abdomen by the handle of a truck. Extreme pain, constant vomiting, and rapid pulse, were his chief symptoms.

1160. A portion of the small intestine partly laid open, with mesentery attached. The specimen shows a laceration of the mesentery about  $\frac{3}{4}$  of an inch in length, and of the attached border of the gut; there is an opening into the intestine large enough to admit a quill, and in order to show it the intestine has been laid open. The peritoneal surface is coated near the rupture with recent lymph.

From a man aged 39, who had been violently kicked in the groin over the sac of a reducible hernia. He died of peritonitis on the fourth day. At the post-mortem the intestine was found still in the sac, but covered with recent lymph; there was no evidence of fecal extravasation. See Path. Trans. vol. v. p. 152.

*Presented by Mr. Ward.*



1161. A portion of the jejunum, laid open along the attachment of the mesentery. This specimen shows a transverse laceration of all the coats of the gut, with an aperture measuring 1 inch by  $\frac{1}{2}$  an inch. The serous coat is torn irregularly and over a greater extent than the mucous membrane, the edges of which project outwards. The serous coat alone is lacerated in two places near the aperture.

From a man, aged 35, who died of acute peritonitis, Feb. 20, 1872. The man walked into the hospital on Feb. 19, stating that he had been squeezed between a brewer's dray and a post, and complaining of pain in his chest. No fracture was detected, and he was made an out-patient. Three hours later he came back still complaining of his chest, and now also of pain in the pit of his stomach, and that he had vomited. His belly was distended and tympanitic, his face livid, pulse quick and weak. Skin bathed in cold perspiration, pupils dilated, breathing laboured and thoracic. He vomited dark bilious-looking fluid.

At the post-mortem there was no external evidence of abdominal injury. On pressure over the sternum a creaking sensation was distinctly felt, and it was evidently depressed at the upper part. The sternum was found to be fractured, and the cartilages of the 5th, 6th, and 7th ribs were separated from it. In the peritoneal cavity was a quantity of flaky lymph, and faecal matter was escaping from the laceration, which was in the free anterior border of the jejunum. *Vide* P. M. record, 1872, pp. 126, 127.

1162. A portion of the large intestine, distended, showing a rupture of the serous coat with longitudinal and circular muscular fibres. Many of the circular muscular fibres, together with the mucous membrane, have escaped.

From a man who was run over, and died of other injuries.

### Foreign Body.

1163. A portion of the ileum showing the stone of a damson lodged in an oval ulcer, by which the intestinal coats have been perforated. There is lymph deposited upon the peritoneal surface of the bowel.

*Presented by Mr. Ward.*

1164. A portion of the ileum with attached mesentery showing a large perforation, one inch by half an inch, the result of an ulcer, which was caused by an impacted cherry-stone. The ulceration does not appear to have extended beyond the perforation.

*Presented by Mr. Ward.*

1165. A portion of the cæcum with the appendix, showing ulceration and perforation of the latter about an inch and a quarter from its extremity, where nearly the whole circumference of the appendix is destroyed. The proximal end of the distal half presents a shallow cup, which would accurately fit a small cherry-stone. A small aperture, which corresponds with the lumen of the tube, is seen at the bottom of the cup-shaped depression.



1166. The cæcum and appendix, with contiguous parts of the intestine, showing ulceration and perforation of the latter, which had led to the formation of an abscess enclosed by peritoneal adhesions. The last inch of the appendix is entire; above that, its peritoneal and muscular coats have been destroyed for some distance, exposing the mucous coat, which projects as a thin sac of membrane. At the upper end of this is a perforation through which a piece of glass rod, passed into the appendix, is visible. The appendix contained some nodules of inspissated fæces.

This specimen was obtained from the body of a woman, aged 43, who was admitted on account of a mammary tumour, and died with acute peritonitis not long after its removal. A collection of pus was enclosed by adherent coils of intestine about the vermiform appendix. One of these was a coil of jejunum, which was much distended above the point of adhesion, but retracted below, having been obstructed at that point. The adhesions were not very firm, and were probably disturbed by the action of the obstructed coil. Case of Maria K. Autopsy, Jan. 18, 1884. Mr. Adams.

1167. The cæcum with adjacent parts, and the rectum, both laid open. This specimen shows a perforation of the tip of the vermiform appendix opening into a small abscess-cavity, which has another opening into the rectum.

This specimen was obtained by Mr. McCarthy from the body of a patient who had died from other causes.

#### **Foreign Body passed per Anum.**

1168. Silver plate carrying two upper central incisors, with two sharp curved hooks, which was passed per anum.

#### **Artificial Anus.**

1169. A coil of the small intestine attached to a portion of the abdominal wall, in which is seen an artificial anus.

The man from whom the specimen was obtained had been subject to constipation for some time, and had had complete obstruction for a fortnight before admission into the London Hospital. Mr. McCarthy, after consultation with Mr. Maunder and Dr. Sutton, opened the small intestine. There was no peritonitis, and the man recovered perfectly. Eight weeks later he died suddenly, while getting into bed. The cause of the obstruction was malignant growth involving the walls of the stomach and transverse colon. The peritoneum was everywhere studded with miliary nodules of cancer. There was fatty degeneration of the heart.



## DISEASES OF THE INTESTINE.

**Pigmentation.**

1170. Piece of ileum four inches in length, laid open, showing pigmentary degeneration of the mucous membrane. The mucous membrane is thinned and varies in colour from yellow to dark brown, it is everywhere traversed by fine, brown, pigmented lines, which in some parts are thickened and aggregated so as to form dark brown patches.

Dr. Clark examined the specimen, and records that the pigment-matter is in the mucous membrane beneath the basement-membrane and between the glands, that it is free and not in the cells.

This specimen is designated in the old Catalogue as blackened mucous membrane or spurious melanosis.

1171. The cæcum opened, showing pigmentation of mucous membrane.

From a female, aged 40, employed in lead-works.

1172. A portion of the colon everted, showing pigmentary deposit in the mucous membrane, staining it everywhere a deep brown tinge.

From a patient who died of typhus fever.

**Thrombosis.**

1173. Portion of the upper part of the jejunum with numerous small perivascular hæmorrhages about small vessels in the submucous tissue. These are seen as opaque nodules in the wall of the bowel when viewed against the light.

From a female, aged 40, who died with suppurative phlebitis after delivery, and pyæmia.

Case of Clara W., aged 40. Admitted Dec. 2, 1885. Autopsy, Dec. 15, 1885. Dr. Fenwick.

See Trans. of Path. Soc. vol. xxxvii. p. 242.

**Gangrene.**

1174. Two coils of small intestine. The upper one is everted and shows gangrenous patches of the mucous membrane. The gangrenous areas are not distinguished by their colour in the preserved specimen, but by their flaccidity and thinness, and by flattening of the valvulæ conniventes. One patch is perforated, the aperture being at the upper border of the specimen. On the peritoneal surface of the lower coil there is lymph.

Case of Chas. J. Hill, aged 23, admitted Jan. 3, 1881. He had sclerosis of mitral and aortic valves, and stenosis of the former. There were no infarcts in the spleen or kidney, and no plugging of the superior mesenteric artery. The peritoneal cavity contained much fluid and lymph.

Autopsy, Jan. 28, 1881. Dr. Sansom.



1175. The cæcum with part of the ascending colon everted, and showing extensive superficial necrosis of the mucous membrane. There is a nearly continuous tract of necrosed and blackened mucous membrane, of very irregular form, extending for about six inches along the ascending colon, and there are several smaller isolated sloughs, and denuded areas from which sloughs have separated. The sloughs are separated at their borders.

From a patient who died of typhus fever.

#### **Abnormal condition of the Mucous Membrane.**

1176. A portion of the ileum opened, showing enlargement of the solitary glands and of Peyer's patches.

From a patient who suffered from "worms," one of which, an *ascaris lumbricoides*, is enclosed.

1177. A portion of the ileum slit open, showing great enlargement of Peyer's patches and of the solitary follicles.

1178. The lower end of the ileum everted, showing great enlargement of Peyer's patches and of the solitary glands. Part of the cæcum, the cæcal appendix, and the ileo-cæcal valve, are seen at the upper part of the specimen.

#### **Ulceration.**

1179. A portion of the ileum opened, showing ulceration and perforation. The ulcer is oval in form, about half an inch in diameter, and has destroyed all the coats of the intestine. The base is partly formed by thickened peritoneum and presents a perforation a quarter of an inch long. The peritoneal surface of the gut is everywhere covered with recent lymph. The rest of the mucous membrane appears healthy.

From a man who died shortly after admission of acute peritonitis, the result of perforation. There were several other ulcers of the ileum.

Case of Thos. P., aged 19. Autopsy, Dec. 11, 1882. Mr. Adams.

1180. The cæcum and part of the colon, showing very extensive ulceration of dysenteric type and of recent and severe character. The cæcum and commencement of the ascending colon are most severely affected, and a part a few inches lower down. At these parts the greater portion of the mucous membrane is destroyed. The mucous membrane at the borders of the ulcers is shreddy and eroded.

Case of George C., aged 39, admitted with suppuration between liver and diaphragm, with excavation of liver, following a fall a month previously. A



fortnight after the accident diarrhoea came on, but ceased after admission. A week before his death profuse diarrhoea came on, the day after two pints of pus had been removed by aspiration from the right hypochondrium. He had been much abroad, but had not suffered from dysentery.

See Liver of this case, Series XXIV., and Path. Soc. Trans. vol. xxxiii. p. 177. Autopsy, July 16, 1881. Dr. Sutton.

## SPECIFIC DISEASES.

### Dysentery.

1181. Portion of colon, with the cæcum and end of ileum, laid open and extended, showing severe dysenteric ulceration. The mucous membrane of the colon has been extensively destroyed in well-defined areas, the margins of which are irregular and have a worm-eaten appearance. The exposed submucous tissue is flocculent, and shreds of necrosed tissue are adherent to the floor and edges of the ulcers. In places the mucous membrane is swelled round the orifices of smaller ulcers of recent formation. In the ileum the mucous membrane is roughened by granular exudation.

Case of Jas. Cooper, aged 34, who was admitted Jan. 1, 1884, and died Jan. 3. His symptoms dated 7 weeks, 4 days out from Singapore. They began with pains in the right side and vomiting, diarrhoea of dysenteric type coming on gradually. At Port Said he was greatly relieved by removal of five oz. of pus by paracentesis. But the symptoms returned with great severity soon after leaving for London. He became collapsed on getting up to stool, and after death was found to have acute peritonitis with fæcal extravasation from the colon, in which several rents appeared. There were two abscesses in the liver, with well-defined walls and numerous small areas of suppuration.

See Liver of this case, Series XXIV.

Autopsy, Jan. 4, 1884. Dr. Fenwick.

1182. Portion of colon, with the cæcum and extremity of the ileum, everted and showing severe dysenteric ulceration. The ulcers are of irregular form with undermined and shreddy margins, exposing the muscular, and in places the serous, coat. There are also defined elevations of the mucous membrane with crater-like openings of smaller ulcers of more recent formation. The end of the ileum is the seat of severe ulceration of the same character.

1183. Portion of colon laid open showing similar ulceration.

1184. Lower end of ileum, cæcum, and part of colon from a case of dysentery, showing numerous irregularly shaped, sharply defined ulcers in the mucous membrane. The mucous membrane is extensively undermined, and the submucous tissue has in many parts completely sloughed, so as to leave the mucous membrane in the form of bridges over the ulcerated areas.



1185. Portion of the large intestine from a case of dysentery, laid open and showing numerous small follicular ulcers in the mucous membrane. The ulcers are mostly clustered, and in places united.
1186. Portion of colon everted showing very extensive ulceration. The denuded area forms a continuous tract along the bowel with well-defined outline. It is of whitish colour in which the injected vessels are clearly seen. The edges are bevelled as in process of healing.
1187. Portion of large intestine from a case of dysentery. The mucous membrane has been in greatest part removed. What remains of it stands out in irregular tracts and islands, the edges of which are steep, but smooth and rounded, indicating commencement of the process of repair.
1188. Part of the colon with the cæcum and appendix, and the extremity of the ileum, from a case of dysentery. Showing ulceration with much thickening and corrugation of the mucous membrane, which is roughened by small polypoid excrescences.
1189. A similar specimen. There is thickening of the submucous tissue with fixation of the mucous membrane. The surface of the latter is uneven and studded with small ulcers.
1190. A similar specimen, showing ragged ulceration and thickening of mucous membrane.
1191. A similar specimen. In the commencement of the ascending colon, which is everted, there has been ulceration with thickening of the mucous membrane. In the cæcum the mucous surface is roughened with nodular excrescences.

### **Scurvy.**

1192. A portion of the colon from a case of scurvy, laid open, showing numerous ulcers, some black in the centre as if from coagulated blood. This was, in the recent state, surrounded by an elevated reddish-grey zone half an inch in width, and this again by a dark red border, as if blood were effused beneath the mucous membrane. The edges of the ulcers are irregular, and the surrounding area is now of a dark colour, wrinkled and raised. In some parts, where the mucous membrane has not been destroyed, are spots of a greyish-yellow colour surrounded by extravasated blood.

From a patient who was admitted for acute scurvy. She dated her illness 14 days before admission. Her symptoms were flooding, abdominal pain, headache,



nausea (but no vomiting), thirst, swelling of face and glands under right maxilla, purple spots, not disappearing on pressure, over chest and upper and lower extremities, slight epistaxis, and ulcers on gums. Her temperature ranged from 102° to 104° Fahr. The post-mortem condition was acute pleurisy and peritonitis, acute pneumonia, thrombosis in spleen, hemorrhagic effusion into kidneys and brain. The broad ligaments were completely occupied by cysts formed by dilated Fallopian tubes and degenerate ovaries, which contained grumous blood.

See Post Mortem Record, 1869, p. 240. Dr. Sutton.

### **Typhoid Fever.**

1193. Lower end of ileum with the ileo-cæcal valve and cæcum, open and extended, showing great swelling of the solitary follicles and of Peyer's patches in an early stage of typhoid fever. The back of the specimen shows the cæcum, the mucous membrane of which appears healthy. There is no evidence of ulceration.

Case of Sarah A., aged 12. Her symptoms dated from 11 days before death. The lower lobes of the lungs were condensed and airless, and the bronchial tubes were filled with mucous secretion.

Autopsy, May 5, 1885. Dr. Sutton.

1194. A similar specimen from a case of typhoid fever fatal in the early stage. There has been no sloughing or ulceration. The mucous membrane is duller and more opaque, and more generally inflamed, than in the last specimen. At the back are two large Peyer's patches swollen, elevated, and very conspicuous.

Case of Harriet E. Coats, aged 23. Admitted October 24, 1883. She had been ailing for a fortnight before admission with pain in the abdomen, delirium, and retention of urine. The temperature was 104° F., and there were signs of congestion of the bases of both lungs.

Autopsy, Oct. 29, 1883. Sir A. Clark.

1195. The lower end of ileum open and extended, showing infiltration and commencing ulceration of Peyer's patches. A large Peyer's patch is seen much elevated by infiltration into its substance. Its surface has a cribriform appearance from minute ulcerations, and at its lower end in the specimen is an ulcer of the size of a fourpenny piece.

1196. The lower end of the ileum and cæcum from a case of typhoid fever. There has been extensive infiltration of Peyer's patches, which have become necrotic and partly separated. There are several ulcers from which the sloughs have been removed. A small ulcer is seen in the cæcum at the back of the specimen.

Case of Alice Cornell, aged 18, admitted Sept. 22, 1883. The disease commenced a fortnight before admission with severe cold and diarrhœa. The temperature was frequently over 105°, sponging and large doses of quinine having no effect in reducing the temperature. She died in the fourth week of the disease. The



autopsy showed pneumonia of both bases, with ulceration of lower end of the ileum and of the colon.

Autopsy, October 6, 1883. Dr. Hughling Jackson.

1197. Portion of the ileum, open and extended, from a case of typhoid fever (25th day) showing ulceration. The larger ulcers are irregular in shape, covered with a reddish-yellow or brownish slough, and without any swelling around them. Other smaller ulcers have a similar slough in the centre and raised edges, which, in the recent state, were of a reddish-grey colour.

From a man aged 25, who died on the 25th day of the disease, with pneumonia of the right lung and peritonitis.

1198. Lower end of ileum opened, showing in front a large Peyer's patch, extensively infiltrated and necrosed. The sloughs are in process of separation, the muscular tissue being exposed in several spots. At the back of the specimen there is an irregular perforation, about half an inch in diameter, in the centre of a Peyer's patch, which is in a similar condition.

1199. The lower end of the ileum showing enteric ulcers in process of repair, with recent extension and perforation. The mucous membrane at the borders of the ulcers is adherent and their floors clean. The borders of the larger ulcers, one of which has caused perforation, are thickened and rounded, and in part overhanging. At the left border of the lowest ulcer is a superficial extension of ulceration, and the surface of the mucous membrane adjacent to others is roughened and eroded. The mucous membrane appears natural at the borders of the smaller ulcers.

This specimen was taken from the body of a man aged 22, who died with peritonitis from perforation of the ileum after typhoid fever. Dr. Sutton in the post mortem record states that it would be impossible, from the appearance of the ulcers, to say that they were the result of typhoid fever, owing to the absence of any infiltration of the mucous membrane at their borders. Two similar ulcers were found in the cæcum. At the posterior part of each vocal chord was a superficial ulcer, but without thickening or deposit. The spleen and other viscera were natural.

See Post Mortem Record, vol. xiv. 1871-72, p. 103.

1200. The cæcum and part of the ascending colon, and the lower end of the ileum, from a case of typhoid fever. In the colon are numerous well-defined ulcers from the size of a hemp-seed to a shilling, with raised borders. From most of them the necrosed mucous membrane has been removed wholly, or remains attached only at the centre; from some it is detached only at the edges. In one large ulcer the outer coat of the bowel is exposed. In the ileum the ulcers are less



numerous, but deeper. In one just above the valve there is a perforation of the size of a threepenny piece, and there is a large perforation of an ulcer higher up.

Case of Geo. G., aged 39, admitted Oct. 8, 1883.

### **Tubercular Lesions.**

1201. A portion of the small intestine, open and extended, showing enlargement of the solitary glands. These are to be seen as minute dots about the size of pins' heads.

From a girl who died of phthisis.

*Presented by Sir Andrew Clark.*

1202. A portion of the ileum, opened and extended, showing enlargement of the solitary glands and small Peyer's patches. The patches are half an inch in diameter, raised above the level of, and of a deeper yellow colour than, the surrounding mucous membrane.

From a case of phthisis.

1203. A portion of the ileum, open and extended, showing early tubercular ulceration. At the upper part of the specimen are seen a few small circular ulcers formed by the sloughing of solitary glands. At the lower part is a large Peyer's patch, the seat of ulceration which has commenced at many points, forming ulcers of irregular shape in the glandular tissue swelled by tubercular infiltration.

1204. A portion of the ileum showing a large Peyer's patch in which ulceration has occurred at several points. These ulcers are typically tubercular. They are oval, with their long axes transverse to the gut, and sharply defined, with borders thickened from tubercular infiltration.

1205. A portion of the ileum, open and extended, showing tubercular ulceration of a Peyer's patch. This specimen is more advanced than the last, the whole of the patch having ulcerated, and the base of the ulcer being thickened and nodulated from deposit.

*Presented by Dr. Little.*

1206. A portion of the small intestine, everted, showing extensive tubercular thickening and ulceration of the mucous membrane. Some of the ulcers are irregular in shape and superficial, others are oval with indurated edges and of variable depth; the bases are uneven and infiltrated.



1207. A portion of the small intestine, everted, showing annular ulceration. This specimen resembles the last, but the ulceration is more limited, the greatest part of the mucous membrane being apparently healthy. The edges of the ulcers are markedly undermined, the mucous membrane being drawn in under their overhanging borders.
1208. A portion of the small intestine, opened, showing similar tubercular ulceration. The ulceration in this specimen has in parts destroyed the submucous and muscular coats; the base of each ulcer at these spots is translucent and is formed by the thickened serous coat, which is coated with recent lymph.
1209. A portion of the ileum, everted, showing still further advanced tubercular ulceration. In some parts of the specimen are reddish knobs,  $\frac{1}{4}$  of an inch in diameter, the seat of tubercular growth not yet ulcerated. The ulcers vary in size from  $\frac{1}{4}$  to  $1\frac{1}{2}$  inches in the longest diameter. The base of each ulcer presents a flat regular surface formed by the circular muscular tissue, all the submucous areolar tissue having been destroyed with the tubercular deposit. The submucous tissue and the mucous membrane, at the edge of each ulcer, are infiltrated and thickened.
1210. A portion of the jejunum, everted, showing tubercular ulceration and contraction. Two ulcers are seen, half an inch in diameter; the upper one nearly, and the lower one entirely surrounds the gut. The base of each is formed chiefly, as in the last specimen, of circular muscular fibre and partly of submucous tissue. The edge of each is even and shelves towards the base as if undergoing repair. The lower ulcer has caused considerable contraction of the gut.
- From a patient who died of diarrhœa.
1211. A portion of ileum, opened, showing ulceration and perforation from tubercular disease. A large Peyer's patch is ulcerated, exposing the submucous, muscular, and serous coats, and in the centre there are two perforations of irregularly oval shape. In other parts are seen ulcerated solitary glands and smaller Peyer's patches.
1212. A similar specimen. There are several deep ulcers with excavated ragged margins. One has perforated, the aperture being oval and the edges smooth. The peritoneal surface is everywhere covered with lymph.
1213. A similar specimen. Many ulcers are seen, of varying size and depth. In all there is well-marked infiltration of the margins. In



one large ulcer there is a perforation of the peritoneal coat of the size of a fourpenny piece. There were no adhesions formed on the peritoneal surface nor other attempt at repair.

From a case of phthisis.

1214. Portion of jejunum showing annular ulcers of the mucous membrane with perforation of the intestine. The annular ulcers are of uniform width all round the intestine. There are other ulcers having a transverse course, but extending only a part of the way round. The ulcers have sharply defined, raised borders and thickened bases. On the peritoneal surface of the bowel at the seat of ulceration miliary tubercles are visible, and there are evidences of adhesion and some lymph. In the line of attachment of the mesentery are some enlarged glands.

Case of Herbert H., *æt.* 35, admitted Jan. 12, 1889, with pulmonary tuberculosis and emaciation. His illness dated 2 years, and had been attended with frequent epigastric pain. Death occurred from perforation of the bowel. Extensive ulceration was found at several parts of the jejunum and at the end of the ileum. At the affected parts the jejunum was drawn into folds by peritoneal adhesions, and adherent to adjacent parts. Several rents were found in the bowels after removal, from one of which *faeces* had escaped and were found in the peritoneal cavity when opened.

Autopsy, Feb. 26, 1889. Dr. Down.

1215. The lower end of the ileum with the *cæcum* and part of the ascending colon from a case of tuberculosis, laid open and showing extensive ulceration of dysenteric type. The ileum is most severely affected, the mucous membrane being in shreds and in great part removed in transverse tracts of ulceration, and the *cæcum* also is extensively ulcerated. The mucous membrane about the ileo-*cæcal* valve is swelled and prominent, as though prolapsed. In the colon are some well-defined ulcers of the same dysenteric type. The ulceration has extended along the appendix *cæci*, at the extremity of which is a perforation of the size of a threepenny piece, and along a diverticulum in the ileum, the tip of which is perforated. Low down in the ileum there is a perforation of the size of a sixpence, and there are small perforations in two smaller ulcers. The peritoneal surface of the intestines is roughened from old adhesion and lymph. The peritoneum is studded with miliary tubercles over the greatly enlarged and caseous glands, but without lymph upon it. Section of one of the enlarged glands shows the areas of caseous degeneration in its substance.

Case of Benjamin C., aged 25, R.N. 328. He was admitted with signs of broncho-pneumonia on the right side, and history of three weeks' illness. The physical signs were those of rapidly advancing phthisis. He suffered much



latterly from abdominal pain. The post mortem showed consolidation and excavation at the apices of both lungs, and extensive ulceration with perforation of the ileum and colon.

Autopsy, Dec. 5, 1882. Dr. Sutton.

1216. A portion of the descending colon and rectum laid open, showing three ulcerated areas of circular outline nearly surrounding the gut, and one (the highest) which is annular. The former are about the size of a halfcrown. The centre of two is in the line of attachment of the mesocolon. That in the rectum is situated at the free border of the gut.

Case of Emily G., aged 4. There were ulcers of tubercular type in the ileum. The mesenteric, mediastinal, and bronchial glands were enlarged and caseous.

Autopsy, Feb. 28, 1883. See Mesenteric glands, Series XXX.

1217. The lower end of the ileum, cæcum, and ascending and transverse colon of a child laid open. The ileum shows a typical annular ulcer two inches from the valve. The cæcum, which is contracted, and the extremity of the ileum present a continuous ulcerated surface; a piece of glass is seen in the orifice of the vermiform appendix. In the colon, about three inches above the cæcum, is an irregular ulcer which has perforated the wall of the gut; a piece of glass marks this spot. About ten inches above the cæcum is a tight stricture, which will only admit a large quill, due to contraction of an annular ulcer with puckering of the peritoneal surface.

- 1217 a. A portion of the large intestine laid open to show a stricture of the gut formed by a hard, rigid, circular ring, which on post mortem would just admit the tip of the little finger. The edges of the scar are raised, rounded, and clearly defined. There is no evidence of recent ulceration. The cicatricial tissue is undermined and in some twenty places is fenestrated with cloacæ.

From a lad aged 15, admitted under Dr. Stephen Mackenzie, March 7, 1887, with symptoms of chronic intestinal obstruction, which had commenced some six months before, viz. diarrhoea, then constipation, colic, nausea, and vomiting. Mr. Treves performed enterotomy, but with no benefit; the patient sank from exhaustion. During his stay in the hospital some phthisical changes developed in the left apex. He came of a phthisical family.

The autopsy revealed general peritonitis; enormous dilatation of the lower end of the ileum; a contracted cæcum and a stricture at the commencement of the ascending colon. Caseous masses were found in the apex of the left lung.

1218. Portion of large intestine, partially laid open, showing ulceration of the mucous membrane; the ulcer is as large as the palm of the hand, its edges are ragged and undermined. The wall of the gut



corresponding to the ulcer is in many places  $\frac{1}{2}$  inch thick, the muscular coat is exposed in the base of the ulcer and at one part is destroyed. At the border of the ulcer the thickening is seen chiefly in the submucous layer, within there is great thickening of the subperitoneal and muscular coats.

Microscopical examination of the specimens shows circumscribed areas of corpuscular infiltration, in which are nucleated lymph-coagula as in tuberculosis, studding the section of the thickened wall of the bowel. There is much fibrous thickening of the connective tissue.

It was removed from a subject in the dissecting-room.

## MORBID GROWTHS.

### Fibro-Myoma.

1219. Portion of ileum with a sharply defined tumour of the size of a bean projecting from both surfaces. It appears to have arisen in the submucous areolar tissue, and projects into the gut as a smooth, firm, hemispherical mass, covered by mucous membrane. Externally it is conical, with its summit turned to one side.

It was firm on section, and found to contain non-striated muscular fibres with fibrous tissue.

### Sarcoma.

1220. Portion of small intestine connected with a tumour of the size of a man's head. Part of the growth has been removed, exposing a large chamber in continuity with the intestinal canal, and with walls in parts over an inch in thickness, in which the structures of the intestinal wall are not distinguishable. At the parts where the entering and emerging coils are continuous with the growth, it is seen extending along them as a thickening of the submucous tissue.

Microscopical examination of sections of this growth show that it consists of a small, round-celled, sarcomatous structure developed in the submucous tissue, the muscular and peritoneal coats, and the mucous membrane extending over the surface of the growth at its margin, with little structural change.

1221. Portion of ascending colon with the cæcum and extremity of the ileum, showing a sarcomatous growth which has surrounded and contracted the colon just below the ileo-cæcal valves. The growth forms a thick mass external to the colon on one side, where the cæcal appendix is buried in it. The ileo-cæcal valve is narrowed by what appears to be a prolapse of the mucous membrane of the ileum through



it. A thick quill is held in it. A piece of wood is passed into the vermiform appendix.

Sections of this growth show small nucleated cells of various forms in a delicate reticulum supported by a fibrous network.

This specimen was removed from the body of a man, aged 60, in whom a hard tumour had been felt just above Poupart's ligament on the right side. He suffered from constipation for some weeks before his death. The coats of the small intestine were much thickened.

### **Melanotic Sarcoma.**

1222. A portion of the ileum with a melanotic growth, oval in form, an eighth of an inch in thickness, and as large as a halfcrown, projecting on its mucous surface. A section has been made through it showing its brown-black texture and accurate limitation. There are two spots of pigmentation of the mucous membrane without elevation of its surface.

The following is Mr. Adams's note as to the history of the case:—"This preparation was taken from a woman, who was admitted into the London Hospital for a supposed hernia. She had a rounded tumour situated near the femoral ring, and as every symptom of strangulated hernia existed, an operation was performed. The tumour, however, turned out to be a lymphatic gland affected with melanosis. She died, and on a post-mortem examination it was discovered that a portion of the small intestine was in a state of invagination. On slitting it open the tumour, as seen in the preparation, was observed."

### **Glandular Polypus.**

1223. Portion of the jejunum laid open, showing a pedunculated polypus composed of lobes of glandular tissue. It is of the size of a damson and of globular form. The peduncle, which is thick and twisted spirally, is an inch and a half long. The mucous membrane is raised in places by gas in the submucous tissue, a result (? post mortem) of intense enteritis, attributed to poisoning by "tinned lobster."

Case of Sarah B., aged 35, who was admitted August 10, 1885, having been seized the day before with persistent vomiting. On the previous day she had eaten some tinned lobster, but it was stated that others had partaken of the same without ill effects. She died the day after admission, after an exploratory abdominal section had been performed to relieve what appeared to be a case of acute intestinal obstruction.

Post mortem:—Intense enteritis was found affecting the upper part of the small intestine. The mucous membrane was grey and opaque, and in places superficially eroded. In patches it was elevated by gas, and had a frothy appearance. It was deeply congested, and in places coated with blood. The peritoneal surface was injected, with patches of lymph upon it. There was blood in the colon. The polypus was about 3 feet from the pylorus.

Autopsy, August 11, 1885.



**Cylindrical-celled Epithelioma: Stricture.**

1224. A portion of the colon, presenting a stricture from a papillary growth from its walls, which entirely encircles the bowel at the part. The growth is of a cauliflower character, and projects into the channel of the gut to a considerable extent. The stricture appears to have been mainly due to the formation of a fold in the intestinal wall and mucous membrane, by the adhesion and contraction of its outer coat at the part.

Sections of this growth show the structure of cylindrical-celled epithelioma.

1225. Portion of colon, showing a tight stricture from an annular growth. Above the stricture are several villous growths from the mucous membrane, which extend for about an inch from the stricture. The mucous membrane between them is corrugated and contracted: above, the intestinal wall is distended and thinned.

Sections of the growth show the structure of a cylindrical-celled epithelioma.

**Scirrhou carcinoma: Stricture.**

1226. Portion of colon laid open, showing a stricture from a carcinomatous growth, which is a third of an inch in thickness, and is limited to about an inch and a half of intestine. The gut would appear to have been almost closed by the stricture. The growth presents a papillary character, with formation of cysts.

Sections of this growth show a carcinomatous structure.

1227. Portion of colon, showing a stricture from an annular scirrhou growth affecting an inch and a half of the gut. The growth forms a dense fibrous mass from two to three inches in diameter. A portion has been cut out of the back of the specimen to show the structure of the growth. Above the stricture the colon is dilated and thinned, and the mucous membrane is superficially ulcerated. On its peritoneal surface is recent lymph.

1228. Portion of colon laid open, showing narrowing of the gut to about half an inch in diameter by a scirrhou growth, which almost completely surrounds it. On one side of the bowel there is a mass of growth an inch thick just above the stricture. This is deeply excavated by ulceration from the mucous surface.

**Stricture from Cicatrising Growth.**

1229. Portion of colon laid open, showing an annular contraction of the gut, narrowing the lumen to a quarter of an inch across. The



mucous membrane appears healthy, except at the seat of stricture, where it is ulcerated, and perforated, apparently from separation of adhesions there. The peritoneal surface is much puckered at the seat of stricture, and above and below it, with thickening of the mesocolon.

1230. A portion of the large intestine partially laid open and showing an annular stricture of the gut, contracting the lumen to the size of a penholder. There is some thickening of the mucous membrane at the point of stricture, and contraction without apparent thickening of the peritoneal coat. The colon above the stricture is dilated.

1231. A similar specimen. Portion of large intestine laid open, showing an annular contraction of the gut to a diameter of half an inch, with ulceration of the mucous membrane and thickening of the walls of the gut at the stricture, and with dilatation and thinning of the wall of the gut above the stricture.

#### **Colloid Growth.**

1232. A loop of the jejunum and part of the attached mesentery, with the anterior wall of the bowel in part removed. The specimen shows the walls of the gut infiltrated with soft colloid material, and thickened to the extent of half an inch in many parts. The lumen of the gut is much narrowed by the thickening of the mucous membrane, the surface of which presents an irregular sponge-like surface. The peritoneum is thinly coated with lymph, and is raised by subjacent small globular nodules of the growth. The growth occupies about six inches of the length of the gut. In the mesentery are several large glands, which are infiltrated with the new growth.

Microscopical examination of sections of one of the glands invaded by this growth shows masses of carcinomatous growth and columns of epithelioid cells with large nuclei in a fibro-nuclear stroma, in which degenerated glandular structure is seen. The nuclei of the large cells are of various forms, probably shrunk from preservation. In the masses of growth occupying the alveoli of the stroma they are mingled with the fusiform cells of vessels and supporting reticulum. The peritoneal coat of the bowel is separated from the growth by a layer of adipose tissue. Some cells appear cloudy and fused together.

The patient was a labourer, aged 50, who died in 1844. He had a tumour of the left elbow, and another beneath the ensiform cartilage, and smaller ones underneath the axilla and on the forehead. The tumour on the elbow was believed to have been the original one. Post mortem, all the growths were found to consist of soft cancer with colloid degeneration.

1233. Part of the ascending colon and omentum with the cæcum, showing a cylindrical colloid growth of the intestinal walls, which



commences about six inches from the ileo-cæcal valve and extends about five inches along the gut, and thickening of the omentum by similar growth. The intestinal canal is closed by the growth, which fills the lumen as a thick ring at both ends of the affected part.

Case of Mary E. Enever, aged 26. Admitted Jan. 15, 1884. R. N. 1873. She had been ill for about a year before admission, and had suffered from dropsy for two months. Her abdomen was aspirated in hospital, and 293 ounces of fluid drawn off; large nodular masses could then be felt in the abdomen. Intestinal obstruction set in later, and left lumbar colotomy was performed. The autopsy showed colloid growth of both ovaries, the right being the larger, and of the omentum and peritoneum generally, with hæmorrhage, and obstruction of the colon by similar growth in its outer coat.

Autopsy, Feb. 29, 1884.

1234. Portion of large intestine laid open, showing on its mucous surface an elevated growth of circular outline and an inch and a half in diameter. The edges of the growth are thick and everted, and its surface is ulcerated and presents a honeycomb appearance of colloid degeneration. There is thickening of the peritoneal coat, but no contraction of it.

### **Cystic Disease.**

1235. The cæcum and extremity of the ileum with an appendix about five inches in length, the end of which is bulbous and nodulated. The appendix is laid open, and the enlargement of its extremity is seen to be due in part to fibrous thickening of the connective tissue, but chiefly to the formation of a number of cysts in its walls and to dilatation of its cavity. The cavity of one cyst, which has been laid open by the section at the commencement of the enlargement, is seen to communicate with the central channel.

## **MALFORMATION.**

### **Diverticulum of Ileum.**

1236. A portion of the ileum distended, showing a conical pouch an inch and a half long and of the thickness of a man's thumb, arising from the mesenteric border of the gut.

Obtained from the dissecting-room.

1237. A dried specimen of a portion of the ileum, showing a conical diverticulum about two inches long and broad at the base, projecting from the unattached surface of the gut.



**Congenital Occlusion of Jejunum.**

1238. The intestinal tract of an infant which died on the fourth day after birth. About the middle of the jejunum is a portion of the canal, an inch in length, which is shut off from the parts above and below by membranous diaphragms. It contains a small quantity of secretion, which could not be pushed past either boundary. The bowel above is much dilated; below it is contracted.

**Congenital Defect of Colon.**

1239. This specimen consists of the lower end of ileum, cæcum, cæcal appendix, and rudimentary ascending colon. The cæcum and appendix are very large and greatly dilated, as is also the end of the ileum. Just beyond the ileo-cæcal valve the colon is constricted. Beyond this constriction is the rudiment of the ascending colon in the form of an elongated blind sac about an inch and a half long, and three quarters of an inch in diameter in the centre.

Case of Henry Watson, aged 4 days. Autopsy, July 22, 1882. Mr. Rivington.



## SERIES XXII.—INJURIES AND DISEASES OF THE RECTUM.

### Inflammation and its Effects.

Ulceration: 1241.

Stricture: 1240, 1241.

„ abscess: 1242, 1243.

„ „ perforation: 1244.

Syphilis: 1245, 1246, 1247.

Fistula: 1252.

Recto-vaginal fistula: 1240, 1244.

Hæmorrhoids: 1248, 1249, 1252.

### Morbid Growths.

Adenoma: 1250, 1250 a.

Epithelioma: 1251, 1252, 1254, 1256, 1258, 1259.

Stricture: 1253, 1255, 1257, 1261, 1263.

Perforation: 1260.

Colotomy: 1253, 1262.

Recto-vesical fistula: 1253, 1258.

### Malformation.

Imperforate anus: 1264 to 1274.

Cul de Sac: 1264, 1265, 1266, 1267, 1268, 1269.

Cord to bladder: 1270.

Opening into bladder: 1271.

„ „ urethra: 1272 to 1273, 1274.

Artificial anus: 1268.

## INFLAMMATION AND ITS EFFECTS.

### Non-malignant Stricture.

1240. Cicatricial stricture of the rectum. The specimen shows the complete removal of mucous membrane and replacement by fibrous tissue for the lower four inches of the bowel. The sinuous line of healthy mucous membrane is well marked. There is considerable thickening of the surrounding tissues, and a fistula passing forward into the vagina.

### Ulceration; Stricture.

1241. Cicatricial stricture of the rectum about three inches above the



anal orifice. The mucous membrane shows cicatrization below the stricture, ulceration above it. The condition is supposed to have resulted from syphilis.

**Stricture : abscess.**

1242. Cicatricial stricture of the rectum from a female subject ; there are two perforations of the mucous membrane, believed to have been occasioned by the forcible use of the bougie, but possibly resulting only from ulceration. They are above the stricture.

The patient died of peritonitis. An abscess-cavity occupies the space between the rectum and the uterus.

1243. Non-malignant stricture of the rectum with a fistulous abscess above and behind it.

The patient was a married woman aged 38, who was in the Hospital, under the care of Mr. Curling, in 1856. She had then suffered for about six months. A stricture was found three inches above the anus, and it was partially divided on a director introduced into the gut. She died ten days after the operation. The post mortem showed recent peritonitis and a large abscess behind the rectum. Two and a half inches of gut were involved in the stricture.

**Stricture : abscess ; perforation.**

1244. Non-malignant stricture of the rectum. A large abscess-cavity occupies the Douglas pouch. This abscess opens by a fistulous passage into the rectum, and also into the vagina and into the pelvic connective tissue. Pelvic peritonitis exists. The uterus is left attached to the specimen.

**SYPHILIS.**

1245. Syphilitic ulceration of the rectum. The uterus is attached to the specimen. Both ovaries are the seat of cystic disease.
1246. Destructive syphilitic ulceration of the rectum. A rectum and uterus with an abscess-cavity in the situation of the right ovary, which communicates with Douglas's pouch and with the rectum, and has also fistulous channels extending in an outward and downward direction. The lower end of the rectum is entirely denuded of mucous membrane from the point where the abscess opens into it. The upper border of the denuded area is well defined, the mucous membrane above appearing normal. The cervix uteri is pushed to the left.
1247. Rectum laid open, showing an extensive cicatricial surface with much thickening of the coats of the bowel, producing stricture. The



strictured part covers several inches vertically, and the whole surface of the lining of the tube is evenly involved. The mucous membrane has been destroyed. The bowel above is dilated. The stricture was due to syphilitic ulceration. Some internal piles occupy the margin of the anus.

### **Hæmorrhoids.**

1248. The mucous membrane is abraded, the lower end of the rectum showing two pedunculated hæmorrhoidal tumours.

1249. The lower end of the rectum showing large external and internal piles. One of the latter has been laid open.

## **MORBID GROWTHS.**

### **Adenoma.**

1250. A polypus of the rectum, the size of a walnut. The polypus represents the usual adenoid growth.

The patient, a healthy boy of 10 years old, had never experienced the slightest symptom with reference to the rectum, until one morning, on going to stool, the mass protruded and could not be returned. Mr. Hutchinson was consulted six hours later, the case being supposed to be one of prolapse. A smaller congested mass was found between the nates, which at first sight looked exceedingly like the mucous membrane of the bowels. On examination, however, a long pedicle was discovered, and the true nature of the disease became apparent. The pedicle, having been tied, was cut through, and the mass removed. No further symptoms occurred. Mr. Hutchinson.

1250 a. A small lobulated adenoma of globular outline about the size of a large raspberry. It has been attached by a small pedicle, which has been cut off close to the tumour.

From a woman, Kate D., aged 21, admitted under Mr. McCarthy's care, R. N. 1302. Since the age of 18 she had passed blood with her motions. Several globular polypi were found, one was ligatured and others cut away. She continued to pass blood per rectum.

### **Epithelioma.**

1251. A portion of the wall of the upper part of the rectum, showing several small simple polypi. Lower down certain of these polypi have become invaded by a malignant growth and form large prominent rigid masses. Nearer the anus the malignant mass was sufficiently extensive to produce a stricture. The descending colon presented a great number of simple polypi. The piece preserved shows the spot where the non-malignant disease is passing into the malignant.

From a woman aged 56.

*Presented by Mr. Treves.*



1252. Extensive ulceration of the rectum, probably epitheliomatous, associated with several fistulæ. Below the ulcerated area are several large piles.

1253. The rectum and part of the descending colon. There is an epithelioma of the rectum producing stricture of the bowel and a large opening into the bladder. Lumbar colotomy has been performed and the artificial anus is shown. The gut between the artificial opening and the cancerous growth is much narrowed.

1254. Epithelioma of the rectum. The specimen shows a well-defined ulcer with raised and thickened border, extending nearly the whole way round the bowel, a few inches from the anus. Section through the base of the ulcer shows great thickening of the coats, and especially of the subperitoneal tissue. The section shows also some destruction of the muscular layer.

1255. Malignant stricture (epithelioma) of the rectum. The mucus membrane and submucous tissues are much thickened. There is deposit also in the cellular tissue external to the muscular coat.

1256. Epithelioma of the rectum. The mucous membrane is thrown into irregular indurated folds. The coats of the intestine are from an inch to an inch and a half in thickness.

The specimen was described in the Old Catalogue as an example of colloid cancer.

1257. Epithelioma of the rectum. All the coats are involved, and are increased to the thickness of from half an inch to an inch. The mucous membrane is thrown into large indurated folds.

1258. Epithelioma of the rectum and bladder. There is extensive ulceration of the entire circumference of the rectum, bordered above by a thickened and overhanging ring of malignant growth. Above this there has been some submucous suppuration. The bladder has also been invaded in the region of the trigone. The prostate appears to have been invaded throughout, and may have been the primary seat of the disease. Between the left ureter and the rectum is a vein with its branches filled with the growth.

Case of H. Parkinson, aged 26. Died June 14, 1883.

Patient came to the Hospital, April 12, complaining of loss of power to hold his motions, which, he said, were always more or less stained with blood, and had



been so for the past 12 months. He had never suffered from dyspepsia, never had constipation, nor any pain on defæcation.

On May 1st, Mr. Adams performed left lumbar colotomy. The patient passed fæces by both passages until his death, which occurred from exhaustion. He suffered from retention and cystitis after the operation.

*Post-mortem notes.*—Body generally emaciated. Peritoneum containing a small amount of sanguineous fluid. There was a malignant growth, involving rectum and neck of bladder with communication between them, and an ulcerated surface in both. Both ureters dilated, this dilatation extending up to the calices of the kidneys. Left kidney small, and cortical substance absorbed from pressure of the dilated pelvis and calices. Calices of right kidney filled with pus, and gland-substance breaking down into abscess-cavities.

**1259. Epithelioma of the rectum, showing extensive ulceration. The bladder is left attached to the specimen.**

From a man aged 36.

The post-mortem note is as follows:—Carcinoma of the rectum and anus invading the bladder. Perforation of the rectum at the bottom of the rectovesical pouch. Acute peritonitis. Lymph on intestines and turbid fluid in peritoneal cavity. Enlargement of inguinal and lumbar glands, also of bronchial glands; growth extending along bronchi into lungs. Many miliary nodules of growth in lungs, which were very oedematous. Heart contracted; muscle relaxed; recent vegetations on thickened mitral valve. Other organs normal. Body much wasted. Bed-sore over sacrum and great trochanter. Old wound of left lumbar colotomy. Legs oedematous and flaccid.

**1260. A rectum laid open. There is a large somewhat circular ulcer, at the base of which is a perforation of all the coats, with jagged irregular edges and about the size of a shilling. The mucous membrane and submucous tissue surrounding the ulcer is infiltrated with a papillary new growth, especially at the lower edge.**

From a man, Robert F., admitted April 7, 1888. Reg. No. 798, under Mr. McCarthy. He had had increasing difficulty in passing his motions for five weeks, with alternating attacks of diarrhoea and constipation. Lumbar colotomy was performed, but the patient sank. The autopsy revealed a little peritonitis, the coils of the intestines being congested at the points of contact; some sero-purulent fluid was present in the lower part of the pelvis. The descending colon was adherent to the abdominal wall at the site of the lumbar incision. The stricture was situated about  $4\frac{1}{2}$  inches from the anus. Cancerous nodules were found in the left lung.

**1261. Malignant stricture (epithelioma) of the rectum, with a considerable amount of deposit.**

Mr. Curling.

**1262. Portion of the rectum and sigmoid flexure from a case in which left lumbar colotomy was performed by Mr. John Adams for malignant disease at the lower part of the rectum. The patient survived**



the operation two years. The specimen shows the artificial opening, the contracted condition of the bowel immediately below, and the lower end of rectum thickened with malignant growth.

1263. Stricture of the rectum due to a malignant growth. The growth is very extensive and is, in places, cystic on section. Ulceration has taken place at the narrowest point.

## MALFORMATION.

### Imperforate Rectum.

#### Cul-de-sac.

1264. An imperforate rectum removed from a female child who lived two weeks. Nothing but the cul-de-sac of the bowel has been preserved. It is very much distended, and would contain a child's fist.
1265. Bladder and rectum of a male child, showing the rectum ending in a cul-de-sac at the upper part of the prostate. The child was under the care of Sir William Blizard. The attempt to find the rectum through the perineum failed.
1266. Imperforate anus from a male child. The rectum terminates just above the prostate.

See Mr. Curling's memoir. Possible communication with urethra.

*Presented by Mr. Harkness.*

1267. The bladder, uterus, and rectum of an infant born with imperforate anus. All the external parts have been cleared away. The distended intestine is seen bulging behind the vagina, and at its extremity is a small opening, which was caused by the trochar used during life.
1268. Side view of the pelvis of a child born with an imperforate anus and hypertrophied coccyx.

The child was brought to the Hospital on the third day after birth, very wasted, and with a history of vomiting immediately after taking food. There was no indication of an anus. Mr. McCarthy, exploring in the middle line, found that the coccyx reached almost to the symphysis pubis. Finding no indication of the rectum, he opened the sigmoid flexure in the left inguinal region. The operation was successful, and the child did well at first, but died on the sixteenth day after the operation.



At the post-mortem examination the rectum was found to terminate in a cul-de-sac above the recto-vesical fascia.

**1269. The pelvis and pelvic organs of a female child showing congenital absence of the rectum.**

The specimen was taken from a child, who died three days after an unsuccessful operation for imperforate anus. Mr. Couper saw the child about 46 hours after its birth. The anal cul-de-sac was a mere shallow dimple, into which a probe hardly entered. A mesial skin-incision was made about three quarters of an inch in length from the anus towards the coccyx. When the subcutaneous fat had been divided, Mr. Couper could feel a bulging downwards of the floor of the wound when the child cried, and on separating the edges of the incision there appeared what was taken for the cul-de-sac of the rectum. It lay immediately above the apex of the coccyx. Mr. Couper readily dragged this to the surface, and on opening it was able to pass his finger into an empty mucous canal corresponding in position and dimension to the rectum. Having by inspection ascertained that the canal opened was lined by mucous membrane, and that it was closely applied to the hollow of the sacrum, Mr. Couper entertained no doubt that he had found the rectum; its emptiness was well explained, as he thought, by the presence of a second interruption of the intestine, felt when the finger had reached the level of the promontory of the sacrum. After a long and ineffectual search for a communication with the colon, Mr. Couper was obliged to abandon the attempt to relieve the child by that operation. As the parents refused their sanction to a further attempt to reach the colon from the left loin, the child died unrelieved after surviving three days. On dissection it appeared that a much dilated upper portion of the vagina had taken the place of the absent rectum, and had filled the hollow of the sacrum. It descended sufficiently low to be readily reached between the anus and coccyx when the skin and fat had been divided. Mr. Couper had opened it in that situation, believing it to be the rectum, which in fact ended in a cul-de-sac at the brim of the pelvis. While searching during the child's life for a communication with the colon, Mr. Couper felt the os uteri, and mistook it for an invagination of the gut, which it somewhat resembled; he was unable to pass his finger into it; even the escape of a little blood from the vulva did not enlighten him at the moment, and he at first took this to mean that the gut terminated by a narrow outlet in the vagina; but as no fæces escaped, evidently such was not the case.

The preparation shows the sigmoid flexure suddenly tapering to an imperforate fibrous cord, which is adherent to the promontory of the sacrum. The vagina has its usual small dimensions at the lower end, but quickly expands into a wide diverticulum, which fills the hollow of the sacrum and replaces the rectum. The removal of a portion of the lower end of the sacrum in the preparation shows this arrangement. No opportunity had been given for post-mortem dissection. In Mr. Couper's opinion a double interruption of the gut was present, *i. e.* that the rectum was isolated from the colon above and the anus below, and was shut at both extremities.

Mr. Couper.

**Cord to Bladder.**

**1270. Bladder, rectum, and part of descending lobe of an infant. The rectum ends in a cul-de-sac, the apex of which is connected with the bladder by a band of fibrous tissue. The sigmoid flexure was opened**



in the left loin by Mr. McCarthy, and an artificial anus formed, which is shown in the specimen. The child lived about three weeks after the operation. It was also the subject of talipes in both feet. It was a puny child and ill-nourished.

The child was admitted when aged four days. An incision was at once made in the anal region, and prolonged search for bowel was made, but without success. No further operation was allowed; and the child was taken out of the Hospital by the friends, who returned with him two days afterwards. Mr. McCarthy then performed Littre's operation; the gut was stitched to the abdominal wall and then opened; there was no more vomiting after the operation; faeces escaped freely and regularly by the wound; patient took the bottle well. Some three weeks after there was a contraction of the rectum, which it was found necessary to dilate; child died a week later from inanition.

### Opening into Bladder.

1271. A case of imperforate anus from a child, who died unrelieved. An attempt was made to reach the rectum, which failed. Post-mortem examination proved that the rectum terminated in a cul-de-sac; but above and in front was a small opening into the bladder, through which a black probe has been passed. This opening was situated exactly at the neck of the bladder.

### Opening into Urethra.

1272. Bladder and part of the rectum from a male infant; the bladder has been laid open; two bristles mark the openings of the two ureters; -a transverse glass rod is placed at the commencement of the urethra. The rectum opens into the anterior part of the prostatic urethra in front of the veru montanum. The bowel terminates as a large cul-de-sac, with thin smooth cyst-like walls; there is no anal orifice. An artificial anus has been made in the groin in the descending colon. A part of the skin of the groin is preserved to show the artificial opening. *Presented by Mr. Mansell-Moullin.*

1273. The rectum and bladder of a child laid open. The rectum is dilated, and ends in a narrow tube which opens into the urethra; glass rods have been passed from the rectum and bladder along the urethra.

From James W., admitted, with obstruction and passage of wind and faecal matter by the urethra, four days after birth. Mr. Reeves performed inguinal colotomy, but the child died of inanition a week subsequently.

1274. The bladder and rectum, from a case of imperforate anus. The specimen shows communication between the rectum and the prostatic



urethra, the orifice being large enough to admit a quill. The bladder was small and did not contain any trace of fæces, the rectum was very much distended.

The patient, a boy, passed fæces by the urethra from the day of his birth; he lived four months, and died rather suddenly without any clear explanation of the cause. He was the subject of congenital syphilis. During the first three months the abdomen had not been distended, and there had been no symptoms of obstruction; but during the last month he had emaciated, the abdomen had become somewhat fuller, and he was occasionally sick; still, however, the fæces came away freely. At the anus there was only a little dimple. During the child's life the propriety of an operation was repeatedly discussed; but his feeble condition, taken with the fact that the fæces came away freely, seemed to discourage its performance.

Mr. Hutchinson.



## SERIES XXIII.—HERNIA AND INTESTINAL OBSTRUCTION.

### **Inguinal Hernia : 1275.**

#### *Conditions of the sac.*

Relation of the sac to the cord and the testis : 1275 to 1281.

Relation of the sac to Hydrocele : 1282, 1283.

Double or Intraparietal sac : 1284.

Congenital Inguinal Hernia : 1285.

Hernia into the funicular process : 1286.

Hernia with Hydrocele of the cord : 1287.

Reduction "en masse." Separation of the neck of the sac : 1288.

Tumour of the sac : 1289.

Carcinoma of the sac : 1290.

**Irreducible Inguinal Hernia : 1291 to 1296.**

**Strangulated Inguinal Hernia : 1297, 1298.**

**Strangulated Congenital Hernia : 1299.**

**Inguinal Hernia with unusual contents : 1300, 1301.**

**Fatty Hernia : 1302, 1303, 1304, 1305, 1306, 1307.**

**Femoral Hernia : 1308, 1309, 1310, 1311.**

**Littre's or Richter's Hernia.** Partial Enterocele : 1312, 1313.

**Umbilical Hernia : 1314, 1315, 1316.**

Congenital : 1317, 1318.

**Diaphragmatic Hernia : 1319.**

**Lumbar Hernia : 1320.**

**Intestine contained in Herniæ : 1321 to 1330.**

**Hernia of the cæcum : 1321.**

**Hernia of the colon : 1322, 1330.**

**Hernia of the appendix vermiformis : 1300.**

**Hernia of a diverticulum : 1301.**

**SUBSERIES I.—Intestinal Obstruction : 1330 a to 1348.**

---

### **Inguinal Hernia.**

#### *Conditions of the Sac.*

#### **Relation of the sac to the cord and the testis.**

1275. The sac of a small inguinal hernia dissected and laid open to show its various coverings. The testis and cord are also preserved with it. The contents of the sac have been removed. The hernia is seen descending in front of the cord. The plications of the peritoneum forming the neck of the sac are well shown.



1276. Inguinal hernial sac with testis and spermatic cord. The sac is laid open and the contents have been removed. The hernia is, as is usual, descending in front of the cord.

Mr. McCarthy. Autopsy, Nov. 26, 1881.

1277. Sac of an inguinal hernia to show the internal ring.

1278. The sac of a scrotal hernia laid open. The contents have been removed. The sac is thickened and plicated. The testis lies below the sac.

Taken from a subject in the post-mortem room, who had been subject of hernia for many years.

Mr. McCarthy.

1279. A large scrotal hernia with the sac laid open. The contents have been removed. The testis has been exposed and is seen to lie below the sac. The specimen illustrates the usual relation of the sac to the testis.

1280. The sac of a large scrotal hernia. The sac has not been opened; it is in close contact with the tunica vaginalis and testis, which lie below it. The tunica vaginalis has been laid open. The specimen illustrates the ordinary relation of scrotal hernia to the testis. At the posterior part of the sac the structures of the cord are to be seen.

1281. A small inguinal hernia containing omentum, which has become adherent to the walls of the sac. The testicle and cord have been preserved.

#### **Relation of the sac to Hydrocele.**

1282. A dried specimen of inguinal hernia with hydrocele. The bowel contained in the sac has been tensely distended with air. Quite below it is the sac of a hydrocele of considerable size. This sac has been opened. The structures of the cord lie behind the hernia.

1283. A large scrotal hernia containing small intestine and omentum still *in situ*. Beneath the hernial tumour is a hydrocele of considerable size, the sac of which is laid open. The testicle is shown. The hernial sac is laid open and has been separated from its coverings.

#### **Double or Intraparietal sac.**

1284. Inguinal hernia with intraparietal sac. In front is seen the aponeurosis of the external oblique muscle and behind the peritoneum. The neck of the sac is at the internal ring. The main or



larger sac extends down the inguinal canal. The small or intra-parietal sac extends upwards and outwards towards the anterior superior iliac spine, between the tissues of the abdominal parietes.

#### **Congenital Inguinal Hernia.**

1285. Sac of a congenital inguinal hernia from a man who had been the subject of inguinal hernia for years. Obtained from the post-mortem room.

#### **Hernia into the funicular process.**

1286. A testis and cord to show a patent funicular process of the peritoneum. The process is unopened, is tubular, is not much larger than a quill, although it is dilated into a pouch at its lower extremity. It lies among the tissues of the cord. The vas deferens winds behind it. The tunica vaginalis has been opened, but is entirely separated from the funicular process.

#### **Hernia with Hydrocele of the cord.**

1287. Left inguinal hernia with encysted hydrocele of the cord. The hydrocele sac is entirely laid open and was large enough to contain a walnut. The hernial sac is much smaller and has been partly opened up. It has not passed much below the external ring, and is above, in front and to the outer side of the hydrocele. The testis has been removed.

#### **Reduction "en masse." Separation of the neck of the sac.**

1288. The sac of an inguinal hernia of the right side, with the detached neck of the sac. The patient was a man aged 61, admitted with a strangulated hernia. The hernia had been reduced "en masse." The patient declined operation until too late, and died of peritonitis. The hernial sac was found to consist of two portions. The part lodged in the scrotum was empty and normal; above this was a constriction corresponding to the very short inguinal canal; above this the remainder of the sac projected into the abdominal cavity, and in shape resembled the bowl of an egg-cup. The margin was rough and irregular. Within the abdomen was found a gangrenous loop of intestine one foot in length and tightly constricted by a fibrous ring (shown in the specimen), which was evidently the detached margin of the neck of the sac.

Mr. McCarthy. Path. Soc. Trans, vol. xxxii. p. 80.



**Tumour of the sac.**

1289. "Encysted tumour removed from an inguinal hernial sac" (Old Catalogue). The tumour has been cut open. It has a fine tough wall and has all the appearances of a dermoid cyst.

**Carcinoma of the sac.**

1290. An old inguinal hernial sac laid open to show cancerous nodules thickly covering its inner surface. At the back of the specimen a portion of the anterior abdominal wall is seen showing nodules of growth about the umbilicus and over the surface of a ventral hernia. The growth has not spread over the parietal peritoneum except in the part indicated.

**Irreducible Inguinal Hernia.**

1291. An irreducible congenital inguinal hernia from an adult. A portion of the colon is involved in the stricture. The hernial sac is continuous below with the tunica vaginalis.
1292. A large inguinal hernia containing omentum alone. The omentum contains much fat, and the mass at the bottom of the sac is as large as a fist. The hernia had been long irreducible.
1293. An inguinal hernia containing omentum. The internal ring is large. The sac is laid open; to the fundus of it the omentum is extensively adherent. The testis lies below the sac and the tunica vaginalis has been laid open.
1294. The sac of an inguinal hernia containing omentum. The sac is laid open. The omentum is adherent to the bottom of the sac. Below the sac is the testis, which has been cut into.
1295. The sac of a large scrotal hernia containing a large mass of omentum and a single coil of small intestine.
1296. "A small inguinal hernia from a patient who died without any operation having been performed. The sac contains a small knuckle of small intestine which is adherent to it. The intestine is tense and its coats smooth. The patient was a young man who died of peritonitis."

**Strangulated Inguinal Hernia.**

1297. A strangulated inguinal hernia with the sac laid open and its contents (small intestine) exposed.



1298. A scrotal hernia showing strangulated omentum and small intestine *in situ* within the sac.

### Strangulated Congenital Hernia.

1299. Portion of anterior abdominal wall with hernial sac and testis. There is a large congenital inguinal hernia, the sac of which is opened and the testicle exposed. A piece of small intestine is strangulated.

The patient was admitted dying and died unrelieved. He was 30 years of age, and the hernia had never before given trouble.

*Presented by Mr. Treves.*

### Inguinal Hernia with unusual contents.

1300. Inguinal hernia, presenting hernia of the appendix vermiformis, with perforation. The specimen shows the cæcum laid open, the end of the ileum, the ileo-cæcal valve, the testis and the cord.

The history of the case is as follows:—

An old man was admitted with a large abscess in the right scrotum and with a history of hernia on the same side. He was exceedingly ill. The abscess was opened and very foetid pus escaped; he lived for about a month and finally sank with pyæmic symptoms. There had been throughout no symptoms of strangulated bowel, nor had either fæces or air ever escaped from the abscess-cavity. The post mortem showed the structures about the cord to be much thickened by old adhesions. At the back of the abscess-cavity lay the appendix vermiformis inseparably united behind to an old hernial sac, the lowest inch of the appendix was free. About two inches from its extremity there was a small perforation in its walls. In the abdomen the cæcum was found firmly adherent around the neck of the hernial sac. The abscess was evidently in connection with the ulcer of the appendix and the escape of a small quantity of flatus.

*Presented by Mr. Hutchinson.*

1301. The sac of an inguinal hernia laid open. The sac is small; close to its neck lies a portion of the colon. There is no meso-colon. The peritoneum covering the colon is continuous with that forming the sac. The gut is healthy. From its wall extends a little diverticulum. This has made its way into an appendix epiploica, and the whole mass is protruded into the hernia and adherent to the sac. Below the sac lie the cord and testis.

### Fatty Hernia.

1302. The specimen shows a portion of the anterior abdominal wall and a large sac that extends far down into the scrotum. A wasted testis lies in the sac, and by the side of it some masses of fat derived from the subperitoneal fatty layer. Into a congenital hernial sac a wasted and probably long-retained testis has been apparently protruded. The end is much thickened by fatty tissue, and is, together with the



testis, surrounded by peritoneum. Certain "fatty herniæ" have protruded into the sac at the same time. These protrusions are also covered by peritoneum and lie free in the great sac.

The patient was admitted with a considerable scrotal tumour and with some symptoms of peritonitis. Paracentesis of the tumour was first performed, but as a considerable mass remained it was thought better to explore; some embarrassment was encountered in the operation, owing to the greatly thickened condition of the tissues composing the cord. The testis itself was small, flabby, and misshapen; the structures of the cord are completely surrounded by peritoneum, and constitute a fleshy mass as large as two thumbs. At the time of the operation the sac contained only testis and cord, but it seemed probable that the man had formerly had a hernia also. The neck of the sac easily admitted the finger. The man died of peritonitis, from which he was suffering at the time of the operation. Mr. Little.

1303. "Fatty tumour connected with the spermatic cord simulating omental hernia. In this preparation the vas deferens is ossified, though it cannot be seen. The tunica vaginalis has been opened to display the testes."

The specimen is so described in the Old Catalogue and is figured in Mr. Curling's work on the testis. The fatty mass appears to be continuous with the subperitoneal fat, and the specimen is probably one of "fatty hernia."

1304. The right inguinal canal of a male, showing a small fatty hernia projecting through the external ring and hanging down in front of the cord. The fat of which it is composed can be traced up and is continuous with the subperitoneal fatty tissue.

1305. Dissection of a fatty hernia in the tissues of the right spermatic cord and projecting through the internal ring. The fat is continuous above with the subperitoneal layer and has descended halfway towards the testicle, enclosed in the coverings of the cord, which are turned aside to expose it. Such a case would most readily be mistaken for an omental hernia.

1306. Large lobulated lipoma from the left groin of a man, aged 37. During life it had been regarded as an omental hernia, the patient giving the history of its sudden descent. The lobulated portion below the abdominal wall (which can be made out with the spermatic cord in the specimen) projects to the outer side and in front of the femoral vessels. It is connected by a narrow neck passing under Poupart's ligament with a second mass of fat, which raises up the peritoneum in the iliac fossa.

See Path. Soc. Trans. 1886. Mr. J. Hutchinson, Jun.



1307. A similar specimen to the preceding one, only in this case the fat, which is clearly continuous above with the subperitoneal layer, has descended so low as nearly to touch the testicle. The rounded lobules of which it is composed would closely simulate omentum. There is, of course, no peritoneal sac round them.

### **Femoral Hernia.**

1308. Femoral hernia, containing adherent omentum and a small knuckle of small intestine.
1309. A small strangulated femoral hernia; the sac, as large as a damson-plum, is seen close to the femoral vein. It has been opened in front. The patient was a man, in whom during life the presence of the hernia was not suspected. He was treated for enteritis. No details are given as to his symptoms. The sac appears to contain omentum only.
1310. Femoral hernia containing omentum.
1311. Portion of small intestine from a strangulated femoral hernia. The symptoms had been mistaken for those of colic. The patient was a healthy woman of middle age. The intestine, although deeply congested, was not gangrenous, and though there were a few shreds of lymph near the neck of the sac there was not a trace of peritonitis within the cavity of the abdomen. The specimen shows only the intestinal coils and the parts immediately surrounding the constricting femoral ring.

*Presented by Mr. Hutchinson.*

### **Littre's or Richter's Hernia.**

#### **Partial Enterocoele.**

1312. The sac of a femoral hernia separated from its surrounding. The bowel involved is shown. Only a part of the circumference of the gut had been involved (Littre's or Richter's hernia). The gut above the involved segment is dilated; that below is shrunken. The herniated piece of bowel was strangulated and gangrenous. Extensive cancerous disease of the uterus.
1313. Strangulated femoral hernia. The sac is shown together with the femoral artery and vein. A coil of small intestine is involved. The portion above the stricture is ulcerated and in many places perforated by sloughing. The notes state that considerably less than half the calibre of the bowel was included in the stricture, so that the canal remained pervious. An example of Littre's or Richter's hernia.



**Umbilical Hernia.**

1314. An umbilical hernia, containing intestine in a state of strangulation; the sac is not open.
1315. Umbilical hernia, containing irreducible omentum.  
Removed from a subject in the dissecting-room.
1316. A large umbilical hernia. The sac contains both omentum and large intestines. The former had been long irreducible and was adherent; only a part of the lumen of the colon is involved in the sac.

**Congenital.**

1317. A congenital umbilical hernia from an infant. The sac probably occupied the umbilical cord. The sac and its contents are wanting, probably from sloughing after strangulation; two sections of small intestine occupy the omental aperture; they were evidently continuous in the sac; the upper coil is greatly distended, the lower empty and shrunken.
1318. Part of the anterior abdominal wall of an infant, showing a congenital umbilical hernia. The bowel involved is small intestine; the gut above the hernia is enormously dilated, that below is shrunken. The sac and contained intestine were accidentally included in the ligature applied to the cord by the midwife.

**Diaphragmatic Hernia.**

1319. A portion of the diaphragm showing an incised wound with hernia of the omentum through it. The wound (suicidal) had been inflicted by a stab from a shoemaker's knife. Death occurred on the eighth day, and the pleural cavity was found full of blood and fluid. The lung was not wounded.

Mr. Curling.

**Lumbar Hernia.**

1320. A mass of fat the size of a hen's egg is seen to protrude between the last rib (on the left side) and the crest of the ilium. It is directly continuous with the subperitoneal fat through an aperture which, during life, admitted two fingers. The opening is situated above and to the inner side of Petit's triangle, which is well seen in the specimen. The fat had worked its way through the transversalis aponeurosis, the internal oblique, and the latissimus dorsi, and was thus immediately beneath the skin. The peritoneum is shown on the



other side, with the descending colon internal to the aperture ; during life intestine could readily be made to protrude through the aperture, and could be reduced with a gurgling sound.

The patient was a man aged 65, under the care of Dr. S. Mackenzie for nervous disease, and the hernia gave him very little trouble, as it could easily be returned. The peritoneal sac must have been protruded into the centre of the "fatty hernia" and returned with the intestine; this could be effected at the post-mortem examination.

Path. Soc. Trans. for 1889. Mr. J. Hutchinson, Jun.

### **Intestine contained in Herniæ.**

1321. Cæcum and adjacent parts from a case of hernia. There is some lymph on the peritoneal surface of the cæcum, and its mucous membrane is ulcerated superficially in places.

Case of a female aged 40. Post-mortem, June 6, 1875.

1322. Coils of small intestine matted together by old and dense peritoneal adhesions. The coils were in the sac of a strangulated hernia.

1323. A similar specimen.

1324. A portion of small intestine from a case of strangulated hernia. The strangulated portion is collapsed and flabby, its peritoneal surface is roughened. A perforation of the gut was found at the time of the operation, through which fæculent matter escaped. A ligature was applied and the man survived the operation two days. The ligature is to be seen still attached.

1325. Portion of intestine from a case of strangulated hernia. The effects of the strangulation are well seen. The portion involved is about five inches long, at one end it is ecchymosed and exhibits some grey patches, it is coated in most parts with lymph. The limits of the strangulation can easily be made out by the constriction of the intestine, which is still evident.

1326. A portion of small intestine from a case of strangulated hernia. The intestine has given way at several distinct places ; at one spot a portion as large as a halfercrown is ragged and sloughing.

1327. A portion of the small intestine, partially laid open, showing a rupture of the gut. The perforation is oval in shape and about a quarter of an inch in length. On the outer surface of the gut there is no evidence of adhesive peritonitis. The mucous membrane shows



patches of atrophy. Here the valvulae conniventes have disappeared, and at the upper part of the specimen and in one of these patches there is a second rupture.

From a widow, aged 33, in whom symptoms of strangulation of femoral hernia had been present for 32 hours.

See Mr. Ward's work on Hernia, p. 30.

1328. A portion of the small intestine, partially laid open, showing a ragged perforation the size of a shilling. The whole of the coats are everted, and the peritoneal surface of the gut is covered with very thin flakes of lymph. The mucous surface around the edges of the perforation shows ulceration, which is abruptly limited by a groove.

From a labourer, aged 36, in whom a strangulated femoral hernia had been reduced by taxis after forty-seven hours strangulation. An operation was subsequently performed, and yellowish fluid mixed with air-bubbles escaped. Death occurred forty-eight hours later. Probably a sloughing patch gave way at the time of reduction by taxis.

See Path. Soc. Trans. vol. v. p. 199.

1329. A portion of the small intestine with attached mesentery. The specimen shows a clean valvular rent in the serous coat an inch in length and placed along the free border of the gut. Supposed to be from the abuse of taxis in strangulated hernia. The mucous and muscular coats are seen bulging into the laceration, and both of them have ultimately given way and now present a circular opening a quarter of an inch in diameter.

From a man who was operated upon for strangulated hernia and who died the third day.

See Path. Soc. Trans. 1848, p. 59.

*Presented by Mr. Ward.*

1330. Part of transverse colon and omentum from a case of omental femoral hernia.

The patient was admitted with a very small femoral hernia. It had been down three days, and the patient was in a most exhausted state, with small pulse, furred tongue, abdominal fulness and tenderness, and intense pain, when any examination of the tumour was made. Ice applied to the part not having caused any relief, the patient was operated upon by Mr. McCarthy. The sac was opened, only a very small portion of the contents was visible, and as that was so congested as to appear almost gangrenous, the stricture having been divided, the parts were not disturbed, with the view of leaving the patient in the most favourable condition if what was thought to be bowel should give way. The patient was much relieved, but died of low peritonitis three days after. On post-mortem examination it was found that almost all the great omentum had been gathered into a curiously shaped mass which bears the traces of having formed hernial protrusions at different times and to varying extents. On the last occasion only the extreme tip of the mass was protruding and had been constricted by the neck of the sac and Gimbernat's ligament.

Mr. McCarthy.



SUBSERIES I.—INTESTINAL OBSTRUCTION.

**Obstruction from Peritoneal Adhesions:** 1330 *a*.

**Occlusion by Kinking:** 1331.

**Strangulation by Bands:** 1332–1334.

**Strangulation by Meckel's Diverticulum:** 1335–1339.

**Strangulation through an aperture in the Mesentery:** 1340.

**Intussusception:** 1341–1348.

Enteric Intussusception: 1342, 1343.

Colic Intussusception: 1344, 1345.

Ileo-cæcal Intussusception: 1346–1348.

**Obstruction from Peritoneal Adhesions.**

1330 *a*. Adhesion of several coils of small intestine by close and extensive adhesions, the result of diffuse peritonitis.

**Occlusion by Kinking.**

1331. A portion of the colon and small intestine. The colon is bent upon itself and is occluded by kinking, the active agent being a band of dense peritoneal adhesions passing between small intestine and the colon, exercising traction upon the latter.

**Strangulation by Bands.**

1332. A flattened band, evidently due to peritoneal adhesion, is seen extending between two coils of small intestine. It is half an inch in width, and of considerable strength. A large knuckle of intestine has passed behind it and become strangulated.

1333. A loop of the ileum, three inches of which have passed behind a membranous band and become strangulated. A portion of the strangulated gut is gangrenous at several places. The band is connected with the mesentery and is well isolated.

1334. A portion of small intestine strangulated by a strong fibrous band connected with the mesentery.



The patient was a girl aged 6, under Mr. R. Wilson's care. Death occurred on the fourth day, after the usual symptoms of intestinal obstruction.

See Path. Soc. Trans. 1851-52, p. 362.

### **Strangulation by Meckel's Diverticulum.**

1335. The specimen shows several coils of the lower ileum strangulated by Meckel's diverticulum. The diverticulum comes off from the ileum below the strangulated coils: the process exists as an open tube for about 1 inch and is the size of the fore finger; it tapers off to a tough band, which is attached by its extremity to the adjacent mesentery.

1336. There is a large globular Meckel's diverticulum arising from the ileum at the usual situation: the process is club-shaped and much dilated; from its apex arises a fibrous cord three inches in length, this goes to be attached to the mesentery of a neighbouring part of the small intestine. The piece of bowel near this attachment has been constricted by the band which passes over it. The diverticulum has been twisted on its own axis, and is also constricted by the band.

*Presented by Mr. Treves.*

1337. Strangulation of a coil of ileum by an adherent Meckel's diverticulum. The diverticulum is almost wholly converted into a fibrous cord; it is wound twice round the pedicle of the strangulated loop, and ends by becoming adherent to the mesentery.

1338. Strangulation of coils of ileum which had slipped behind a diverticulum, the end of which was attached to the umbilicus. The bowel had become obstructed by impaction of a plum-stone at the point of origin of the diverticulum, at which point it was sharply bent owing to displacement of coils immediately above. These had passed from left to right behind the duct, and had become strangulated, apparently by being pushed downward and to the left in front of the duct, by effect of distention of the coils of ileum and jejunum in the upper part of the abdomen, resulting from the obstruction caused by the impacted fruit-stone.

The diverticulum is about 18 inches above the ileo-cæcal valve.

Case of Alf. T. Haywood, 10½. Post mortem, March 23, 1881. Dr. Sutton.

1339. A specimen showing occlusion by knotting of Meckel's diverticulum. From the free border there arises a diverticular process, at its commencement about the thickness of a No. 12 catheter. It ends in a bulbous and almost solid extremity. The greater portion of the diverticulum is cord-like; the process has wound itself round a loop of small intestine and has become tied in a knot.



**Strangulation through an aperture in the Mesentery.**

1340. Internal strangulation of a loop of small intestine, through an aperture in the mesentery. The bowel is adherent to the margin of the aperture. The strangulated bowel is much thickened and has been opened.

**Intussusception.**

1341. The specimen shows the intussusception laid open by vertical section. The curving of the invaginated part is well shown, and the thickening of the coats. A glass rod occupies the apex or orifice of the intussusception. The receiving layer or intussusciens has been removed.

**Enteric Intussusception.**

1342. Specimen from an adult. The termination of the ileum and the cæcum are opened up. The appendix and the ileo-cæcal valve can be seen. A portion of the ileum has been invaginated. The intussusception has hardly reached so far as the cæcum. It is greatly thickened.
1343. Intussusception of small intestine with a polypoid tumour at the end of the intussusception. All three folds have been laid open. The outer (receiving) coil is thrown back; it is a little thickened. The middle and inner folds are much thickened to within about 2 inches of the free end. Over the thickened part they were adherent by recently formed lymph.

**Colic Intussusception.**

1344. Intussusception of transverse and descending colon. Much more had been invaginated, but was reduced. The lower part of the bowel has been slit up so as to allow the protruding part above to be seen.
1345. A good specimen of intussusception of the colon from an adult. The invaginated portion is 6 inches in length.  
The intussusciens is but little changed. It has been opened up to show the greatly swollen end of the intussusception.

**Ileo-cæcal Intussusception.**

1346. The cæcum has become invaginated. The ileo-cæcal valve forms the apex of the intussusception.

From an infant.



1347. Specimen of ileo-cæcal intussusception from a child. Six inches of the gut are involved. The apex or end of the intussusception is formed by the ileo-cæcal valve.
1348. Intussusception of ileum into colon. The ileo-cæcal valve forms the apex of the intussusception. The intussusceptum is much contorted. No adhesions.



## SERIES XXIV.—INJURIES AND DISEASES OF THE LIVER.

**Lardaceous degeneration:** 1349.

**Cirrhosis:** 1350–1357.

**Abscess:** 1358–1362.

**Pylephlebitis:** 1359, 1359 *a*, 1360.

**Pyæmic abscesses:** 1361.

**Dysenteric abscess:** 1362.

**Syphilis:** 1363, 1364.

**Actinomycosis:** 1365.

**Hydatids:** 1366–1380.

Opening into lung: 1370.

Opening into the vena cava: 1371.

**Cyst:** 1381.

**Angeioma:** 1382.

**Carcinoma:** 1383–1388.

Melanotic: 1389–1391

Colloid: 1392.

**Cystic disease:** 1393.

### Lardaceous degeneration.

1349. Part of an enlarged liver showing lardaceous degeneration irregularly distributed through its substance, giving the appearance of a cirrhotic condition.

From a man who died from pneumonia. There was a history of syphilis 10 years before, and a growth (? syphilitic) was found in the right adrenal, which was also lardaceous. The kidneys were also lardaceous.

Case of Jas. Knight, aged 34. Autopsy June 16, 1882.

See Adrenal, Series XXXIV., and Trans. Path. Soc. vol. xxxv. p. 393.

### Cirrhosis.

1350. A cirrhotic liver. The organ is much diminished in size and granular on the surface, in parts coarsely nodulated. The right lobe is especially affected. The section of the organ shows very well the



great increase in the connective tissue stroma surrounding and separating the lobules.

Case of Charles V., aged 54. Admitted with ascites and oedema of the legs. The duration of symptoms was 2 months. Paracentesis was performed on abdomen and thorax.

Autopsy, November 17, 1881.

1351. Two portions of a cirrhotic and contracted liver, injected. One shows the extremely contracted border of one lobe, with fissured and nodulated surface. The section of this part shows little more than connective tissue and vessels. The other is a section from a more central part of the organ, showing nodules of liver-tissue surrounded by tracts of connective tissue, which are very wide in places. In this piece of the liver there is a small encapsulated collection of mortar-like substance (? hydatid).

1352. The right lobe of an enlarged and cirrhotic liver, which weighed 7 lbs. 3 oz. The surface is granular, and the thickened interlobular connective tissue is conspicuous in the section of the organ.

Sections showed great fibrous thickening with nuclear infiltration of the interlobular connective tissue, the lobules themselves not being invaded except at their periphery.

Case of William Dobble, aged 40, who was admitted for fracture of the skull with laceration of the scalp, and died with erysipelas.

Autopsy, Dec. 12, 1882. Mr. Rivington.

1353. A cirrhotic, or hobnailed, liver. The bundles of glistening connective tissue, enclosing small masses of liver-substance in their meshes, are well shown.

1354. An irregularly contracted and nodulated liver, with (? compensatory) enlargement of the spigelian lobe. The anterior parts of both right and left lobes are contracted and form rounded nodular masses marked off by depressions above and below. The quadrate lobe is very small, the portal vein being brought within an inch of the anterior edge of the liver by the great enlargement of the spigelian lobe. The surface of the organ is smooth, and to the naked eye there is no appearance of cirrhosis in the cut surface. But sections show great increase of connective tissue throughout the liver.

Case of Eliza S. Roberts, aged 45, admitted May 8, 1882. Her abdomen had been swelled for two years. Paracentesis was frequently performed. The peritoneum was much thickened. There was much turbid fluid in the cavity and lymph on the intestines. The liver weighed 58 oz. No history of alcoholism.

Autopsy, March 7, 1883.



1355. A granular and contracted, and much deformed, liver. The organ is nearly divided into two by contraction of the central part, where there is a deep fissure above, and a deep wide notch in front and behind. The lobus spigelii is scarcely larger than a sugared almond, and the lobus quadratus is reduced to a small nodule of the size of a nut at the inner border of the left lobe. Portions of the left lobe are marked off by deep fissures, both on its upper and under surfaces. The organ is nodulated throughout, and in parts finely granular. The weight of the organ after being in spirit was thirty ounces.

It was removed from a man who was admitted to hospital for hernia, and while under treatment began to suffer from ascites. He asserted that he had enjoyed good health up to the time of his admission. He had been a free drinker, but not remarkably intemperate; he died in 6 weeks from the commencement of the symptoms.

1356. An irregularly contracted and nodulated liver, with thickened capsule. The anterior edge is retracted so that the anterior border of the organ is rounded like the posterior border, the fundus of the gall-bladder being drawn up on the upper surface, where it lies in a deep depression. The organ is deformed by many fissures, and a section shows a thick tract of fibrous tissue extending from the portal fissure to the bottom of one of them. The liver is not granular, but covered with a thick capsule.

Case of Chas. Davies, aged 46, an intemperate man, who was admitted for ascites and hæmatemesis, with symptoms dating 6 months. The peritoneum was thickened throughout, and there was recent peritonitis. The liver weighed 45 oz. Autopsy, Jan. 13, 1885. Dr. Jackson.

1357. A irregularly contracted and nodulated liver. The organ is much diminished in size and shows extreme cirrhotic degeneration in tracts, leaving portions of apparently unaltered liver-tissue projecting as bosses and nodules on the surface. The cirrhotic tracts appear to consist of little else than fibrous tissue. In the gall-bladder is a small rough black biliary calculus.

Sections through the border of one of the cirrhotic tracts show them to consist of nucleated fibrous tissue, in which biliary ducts are numerous and conspicuous, with many wide vessels. At their borders are lobules of liver-tissue surrounded and invaded by the connective-tissue growth. The capsule is much thickened.

Case of Alice Smith, aged 16, admitted May 29, 1884, with ascites and jaundice, and contracted liver. Her symptoms dated from an attack of jaundice in March 1882, subsequent to which she had several attacks of jaundice and abdominal pain, with increasing ascites. Ten weeks before her death she had epileptiform convulsions. She died comatose. The liver weighed 26 oz. The right kidney was extremely atrophic and nodular; the left weighed 8 oz. The spleen weighed 17 oz. There was no history of alcoholism or syphilis.

Autopsy, August 20, 1884. Dr. Sutton.



**Abscess.**

1358. A liver with a ragged-walled abscess-cavity at the upper surface of each lobe. There has been extensive destruction of the left lobe extending to the upper surface; and a smaller excavation is seen in the upper surface of the right lobe, in the centre of a large area of superficial erosion, formed by an abscess extending between the liver and diaphragm. The latter was adherent over both lobes.

Case of George Chapman, a ship's painter, æt. 39. He had had "fever and ague" 16 years before, but no other illness until an accident in April 1881. His back was then hurt by a fall, but he could get about the next day. A fortnight later the pain again became very severe, and was attended by troublesome "dysentery." He then had medical advice and was admitted under Mr. Adams on May 24. He was transferred to Dr. Sutton on June 20th with symptoms of hepatic abscess, and Oij of pus were removed by aspiration on July 7. Profuse diarrhœa set in, and he died on July 15.

See Colon, Series XXI. No. 1180. See Trans. Path. Soc. vol. xxxiii. p. 177.

**Pylephlebitis.**

1359. Part of a liver with numerous cavities of varying size and irregular form, formed by breaking down of necrotic areas, which have resulted from thrombotic occlusion of branches of the portal vein. On the left of the specimen a necrotic area is seen, which has not broken down. At the back of the specimen the portal vein, where it enters the liver, is seen to be lined with an adherent coating of lymph. This extended down the trunk of the vessel to a thrombus in one of its divisions in the mesentery.

Case of Henry Evans, æt. 17, who was admitted May 5, 1883. He had been ill a week before admission with weakness and diarrhœa. There was irregular pyrexia till death.

Autopsy, May 25, 1883.

1360. A liver showing numerous small abscesses, which are clustered in correspondence with the distribution of branches of the portal vein. At the back of the specimen the portal vein is seen to be coated with a fibrinous deposit on its inner surface.

Case of Henry G., aged 34, admitted April 17, 1882. He died with pyæmic symptoms, which followed reduction of a hernia by taxis.

Autopsy, May 15, 1882.

**Pyæmic abscesses.**

1361. Piece of liver with multiple pyæmic abscesses.

The patient died of cellulitis with pyæmia in 1835, under the care of Mr. Scott. At the post-mortem examination there was found acute pneumonia and numerous abscesses in the liver.



**Dysenteric abscess.**

1362. A liver showing two large abscess-cavities with thick fibrous walls and smooth lining-membrane, at the upper surface of the left lobe, the larger of which reaches to and occupies the situation of the quadrate lobe; and many disseminated abscesses and necrotic areas of small size throughout the right lobe. Depressions of the surface indicative of small abscesses are to be seen on the left lobe.

Case of Jas. Cooper, aged 34, a sailor, admitted Jan. 1, 1834. He had had symptoms of dysentery 7 weeks, and died with perforation of colon two days after admission.

See Colon, Series XXI. No. 1181, with further note of the case.

**Syphilis.**

1363. Portion of liver, from the upper surface, showing a tract of fibrous tissue, in which several caseous nodules are imbedded. The nodules project from the cut surface. One is of the size of a shilling and of rounded outline, the others small and irregular in shape. The affected area is surrounded by portal tracts, and is contiguous to the vena cava inferior. It has not caused depression of the surface.

1364. A portion of a liver showing a nodule of syphilitic growth projecting from the under surface near the anterior edge. The mass, which is about an inch in diameter and apparently encapsulated, is limited by cicatricial depression of the surface. Towards the edge of the liver its outline in section is rounded, posteriorly it is reniform. On its deep surface it is bounded by diverging portal tracts.

From a lad, æt. 16, who was in hospital in 1868 with ulceration of the larynx, and who died from dyspnoea arising from the laryngeal trouble. His soft palate had been destroyed by phagedœnic ulceration two years previously.—*Post-mortem*: large ragged ulcerations of the mucous membrane were found in the larynx and trachea. The liver was enlarged and nodular on the surface, and contained numerous opaque yellow masses. The history of congenital syphilis was not definite.

**Actinomycosis.**

1365. Two portions of the right lobe of a liver showing appearances seen in cases of actinomycosis affecting that organ. On the cut surface of either portion are to be seen three masses of tissue honey-combed with small irregular holes with smooth walls. The affected areas are bounded by a capsule of fibrous tissue, and the septa by which the cavities are separated are wholly fibrous. The affected areas are all in contact with the under surface of the liver, which is roughened by adhesions and lymph, and some of the cavities communicate with the peritoneal cavity through perforations in the



capsule. No fungus-masses were discoverable in sections from the neighbourhood of one of the diseased parts; but in the turbid grumous fluid which filled the cavities granules were seen, which presented, under the microscope, a radiate structure resembling that of actinomycotic masses.

This specimen was obtained from a man, aged 30, who was admitted on Oct. 14, 1884, having been seized a few days before with sudden abdominal pain, with vomiting and relaxation of bowels. His abdomen was distended and tympanitic, and tender, especially in the right iliac region, but not painful. He was slightly jaundiced. His symptoms improved, but he had continued pyrexia of slight grade, and lost weight. On Jan. 4, 1885, there was a rise of temperature, and on Jan. 12 he became suddenly collapsed and died. In the spring of 1884 he had attended as an out-patient with pulmonary phthisis. In addition to the lesion of the liver, connected with which was a large collection of pus extending down to the right iliac region, there was extensive ulceration of the colon, and to less extent in the ileum, with several perforations of the former. There was a collection of pus in the left hypochondrium, and a good deal in the general cavity of the peritoneum. The stomach was perforated in two places in the greater curvature and communicated with the collection of pus in the right hypochondrium. In the apices of the lungs were some old cavities and fibroid tracts, and in the upper parts of the lungs were some disseminated miliary granulations.

Case of William A. Autopsy, Jan. 13, 1885. Sir A. Clark.

### **Hydatids in the Liver.**

1366. The left and part of the right lobes of a liver with two hydatid cysts, the walls of which have been incised and retracted to expose the parent hydatids filling the cavities. The larger cyst occupies nearly the whole of the left lobe. The smaller cyst projects on the upper surface of the organ above the round ligament. The lining membrane of the containing cavities is quite smooth, and the hydatid cysts are thin and membranous.

From a youth, aged 19, who was admitted under Mr. Luke for a slight accident, and died with obscure nervous symptoms, for which no cause was discovered at the autopsy.

1367. Portion of liver with a cavity of irregular form, in which is a shrivelled hydatid cyst of corresponding form still adherent to the cavity. At the upper part of the hydatid is a smaller projecting part of rounded outline, looking like a head upon the shoulders of the main portion. It corresponds with a recess in the wall of the containing cavity above, from which it has become detached. The inner surface of the cavity is rough as from suppuration, and there is much calcareous matter in its wall. It forms a prominence on the surface of the liver.

1368. Portions of a liver with an hydatid cyst presenting on the surface. The parent cyst has been laid open and a number of collapsed daughter cysts are seen within it.



1369. Portion of a liver showing an old hydatid cyst of the size of a hen's egg with thick fibrous wall, projecting on its surface. Within the cavity is a collapsed and folded hydatid.

1370. A liver, with part of the diaphragm and of the right lung and part of the anterior abdominal wall adherent to it, showing three hydatid cavities in the right lobe, one of which has opened into the lung and another externally through the abdominal wall. Both these cavities have thick fibrous walls and are rough and flocculent on their inner surface. There is a larger cyst occupying the greater portion of the anterior part of the right lobe, and projecting into the portal fissure, where its wall is thin. The inner surface of this cavity also is roughened. The upper surface of the liver is in greatest part adherent to the diaphragm and abdominal wall.

Hydatids had been coughed up during life.

1371. Part of a liver showing a large hydatid cyst in the right lobe, which has opened into the vena cava inferior. The contents of the cyst are rust-coloured from admixture of blood. The vena cava has been laid open at the back of the specimen to show the aperture in the cyst-wall opening into it. The cavity has advanced to the upper surface of the liver in two places—(1) in front of, and to the right of, the vena cava, where it had become adherent to the diaphragm and had nearly perforated the floor of the right pleural cavity; (2) more anteriorly and to the left, where a corrugated fibrous area is seen on the upper surface of the liver. The collapsed and thickened parent hydatid is seen in the cavity, the walls of which are rough and shaggy. In front of the opening in the vena cava is a bony plate (1" by  $\frac{1}{3}$ "), which has become detached excepting at one end.

#### **Multiple Hydatids.**

1372. A portion of a liver with numerous thick-walled cavities varying in size from a pea to a small cherry, and of irregular form from intercommunication. In several of them membranous cysts are seen, one of which presented the characters of hydatid membrane on microscopical examination.

#### **Old Hydatid Cysts.**

1373. Part of a liver with a fibrous and calcareous (hydatid) cyst projecting from the anterior edge of the organ. The cyst is of the size of a hen's egg and rough internally.

1374. Portion of liver with a cyst of the size of a hen's egg projecting on the surface of the organ. The cyst-wall is thick and fibrous, and in part calcareous, and rough on its inner surface. Probably of hydatid origin.



1375. Part of a liver with a thick-walled cyst of the size of a hen's egg at the anterior border of the left lobe. The walls of the cyst are fibrous, thick, and rigid from calcareous infiltration, and rough on the inner surface. It was filled with mucoid matter, and was probably an hydatid cyst. Dependent from the edge of the liver is a mass of omentum, which had become adherent to it. In it is a smaller cyst filled with putty-like matter of grey colour, which may have had a similar origin.

From a man, aged 59, admitted April 8, 1885, under Mr. Couper, with calculous disease of bladder and right kidney.

Case of John W. Autopsy, June 23, 1885.

1376. Two portions of a liver each presenting a cavity with thick fibrous walls and rough internally, projecting from the surface. The cavities are of the size of small oranges. That in the lower specimen projects on the under surface of the anterior edge of the liver, which it has notched.

1377. Portion of liver with a smooth-walled cavity of very irregular, chambered form. The walls are fibrous and coated with lymph on the inner surface in places. It is said to have contained an hydatid.

1378. Part of the diaphragm and of the lung adherent to it, with a cyst nearly as large as a foetal head, with thick fibrous walls and rough inner surface, adherent to the under surface of the former. It was situated between the diaphragm and the liver, and appears to have been formed in the latter organ, portions of which are adherent to its surface.

It was lined by calcareous deposit and contained a mortary substance, and was supposed to have been of hydatid origin.

#### **Hydatids from the Liver.**

1379. A large number of free hydatids from a tumour in the liver.
1380. Two degenerated hydatid cysts with calcareous matter in their walls. The lower cyst contains a smaller translucent cyst within it.

From an hydatid cyst in the liver.

### **MORBID GROWTHS AND CYSTS.**

#### **Cyst.**

1381. Portion of liver showing a smooth-walled cyst of the size of a small nut. At one side, where the cavity reached the surface of the liver, the cyst-wall is membranous: it contained clear serous fluid



in which were square tabular crystals of cholesterine, about  $\frac{1}{16}$  of an inch each way and about half as thick.

From a man, aged 44, who had cystic growths in the cerebellum and right adrenal, and several cysts in the left kidney. There were several fawn-coloured calculi in the gall-bladder.

Case of George P. Autopsy, April 16, 1887. Dr. Down.

See Cerebellum, Series VI. No. 856. Adrenal, Series XXXIV.

### **Angeioma.**

1332. Portion of liver showing two contiguous nodules of nævoid growth in the cut surface. One is dark in colour and spongy in texture throughout; the other is fibrous and slightly depressed, remains of dark nævoid tissue appearing in its deeper parts. Both are situated at the surface of the liver.

### **Carcinoma.**

1333. The anterior part of a greatly enlarged liver, which has been divided through the portal fissure, showing extensive masses and smaller nodules of secondary carcinomatous growth. The section of the left lobe is wholly carcinomatous. There are some enlarged glands in the portal fissure. The portal vein and some of its branches are plugged, and some of the latter are seen to enter nodules of growth.

Case of Thomas Woodard, aged 43, admitted Dec. 12, 1887. His symptoms dated from Christmas 1880, commencing with pain in the right side. There was a rapidly-growing tumour in the epigastrium and right hypochondrium. The liver weighed 12 lbs. There was also carcinoma of the pancreas, left adrenal, right lung, and one kidney, and a mass in the left supraclavicular region compressing the thoracic duct.

Autopsy, May 27, 1882. Dr. Fenwick.

See lung from the same case, Series XXXI.

- 1384, 1385. Portions of a liver with masses of secondary carcinomatous growth of firm texture. The nodules of growth are of circular outlines and surrounded by compressed hepatic tissue. At the borders the growth appears to have a cystic character.

Sections show masses of epithelioid cells in a fibrous network. At the borders of the growth are many vacant spaces. The liver-tissue is very fatty.

1386. An injected specimen of a piece of liver containing nodules of scirrhus growth, into which the injection has penetrated to a certain extent.

1387. Portion of liver extensively infiltrated with carcinomatous growth of medullary character. But little of the liver-tissue is visible in the section.



1388. A small portion of liver, injected, showing nodules of partly softened medullary growth, unpenetrated by the injection, and conspicuous by their white colour in the brightly injected liver-tissue.

#### **Melanotic Carcinoma.**

1389. A portion of liver in which there are several well-defined masses of secondary melanotic growth, with circular outline in section.
1390. A portion of a liver, from the surface of the organ, studded with nodules of secondary melanotic growth of the size of a pea and less. The nodules are well-defined and of rounded outline, most of them but slightly pigmented, some unpigmented.
1391. A portion of a liver consisting in greatest part of a circumscribed mass of cancerous growth, which appears slightly pigmented in parts. There are also small nodules of similar growth which have no appearance of pigmentation, and pigmented areas of compacter structure, contiguous to which, and within some of which, are smaller nodules of unpigmented growth.

#### **Colloid Carcinoma.**

1392. Portion of liver with nodules of carcinomatous growth, which have undergone colloid degeneration in part. The specimen is injected, and the nodules of growth are conspicuous from the coloured injection not having penetrated their substance.

#### **Cystic disease.**

1393. A portion of liver the border of which is converted into a collection of cysts in a fibrous framework. The cysts vary in size from that of a pea and less. The border of the hepatic tissue is irregularly scalloped by the cysts. At the upper part of the specimen there is a considerable thickness of the cystic structure; along the side there is only a narrow tract of it. In the section of the liver are two isolated tracts of the same structure in the course of branches of the portal vein.

Sections of the growth at the surface of the liver show it to consist of a dense fibrous structure enclosing spaces in which there appear to be some degenerated cells. The section of the contiguous part of the liver shows tracts of connective-tissue growth along the vessels, which is less compact than that at the surface; but its nature is indistinguishable, from long preservation of the specimen.



## SERIES XXV.—INJURIES AND DISEASES OF THE GALL-BLADDER.

Lesions due to Calculi: 1394, 1395.

Calculi: 1396, 1399.

Cystic Adenoma: 1397.

Carcinoma: 1398.

Malformation: 1400.

---

### Calculus disease.

1394. Part of the duodenum with gall-bladder and ducts connected with it. The gall-bladder is thickened and contracted, with smooth lining-membrane. The cystic, hepatic, and common ducts are also thickened. The cystic duct appears to have been closed. The hepatic and common ducts are large channels. There is a second duct entering the duodenum, probably from the pancreas.

The specimen was obtained from a dissecting-room subject. A gall-stone, which had caused ulceration and perforation of the duct, lay in contact with the duodenum.

1395. Portion of a liver with gall-bladder and ducts attached. The gall-bladder is contracted, and its walls greatly thickened and rough on the outer surface. It is connected with the capsule of the liver by thick fibrous bands. The hepatic and common ducts are thick and large channels, and rough externally.

The condition was probably brought about by the presence of gall-stones.

### Calculus.

1396. An ovoid calculus of the size of a damson, consisting of pure cholesterine. It is covered with a dark and opaque coating of pigment at each end. In the central zone, which is translucent, the calculus appears to be made up of a number of portions of columns of superimposed cholesterine plates, united together in irregular arrangement.

Case of Marie S., aged 45, admitted Dec. 25, 1885, Autopsy, Jan. 26, 1886, Dr. Fenwick.



**Cystic Adenoma.**

1397. Part of a gall-bladder, showing a nodule of growth of cystic structure at the fundus. It is marked off by a constriction from the sac of the gall-bladder.

Sections of the growth showed an adeno-fibromatous structure, with spaces to the walls of which fragments of a lining of columnar epithelium remained attached.

Case of Mary Ann A., aged 67. Autopsy, May 24, 1887. Dr. Jackson.

**Carcinoma.**

1398. The right lobe and part of the left lobe of a liver with the gall-bladder. At the anterior edge of the organ, immediately at the left of the gall-bladder, and involving its wall at the fundus and to the left, is a rounded mass of growth of the size of an orange, which forms a projection on the under surface of the liver. The gall-bladder, which is dilated, is laid open longitudinally, showing elevation and roughening of its mucous surface near the fundus, where it is connected with the mass of growth, and thickening of the wall of the gall-bladder by the growth in that part. Except at the fundus the gall-bladder is thin. The section of the left lobe shows several nodules of secondary growth in the liver-substance, and there are some enlarged glands in the portal fissure.

Case of Eliz. P., aged 61. She stated that she had had a lump in the right hypochondrium for 20 years, and had been losing flesh for 5 years. She complained of weakness and pain at the heart. She was slightly jaundiced, much constipated.

Autopsy, Nov. 16, 1886.

1399. Biliary calculi removed from the gall-bladder shown in the last specimen.

**Malformation.**

1400. The liver and part of the duodenum from a child, with the biliary ducts dissected. The gall-bladder is absent, and the bile was discharged directly into the duodenum by several ducts.

No special symptoms were presented during life.



SERIES XXVI.—INJURIES AND DISEASES OF  
THE PANCREAS.

**Atrophy:** 1401.

**Carcinoma:** 1402-1404.

Melanotic: 1403.

Medullary: 1404.

---

**Atrophy.**

1401. An atrophic pancreas from a case of diabetes mellitus.

Case of Eliza W., aged 22. Admitted Jan. 22, 1888.

Dr. Stephen Mackenzie.

**Carcinoma.**

1402. Part of a pancreas invaded by cancerous growth, and of the duodenum connected with it. The mucous membrane is invaded at one spot and retracted. An injected specimen.

Section of the growth showed it to be scirrhus carcinoma. The head of the pancreas appeared to be the seat of the primary growth, and many secondary nodules were scattered through the liver. The patient died jaundiced, with the gall-bladder so distended as to form a distinct tumour. Case of a woman, aged 38, in 1834.

**Melanotic growth.**

1403. A pancreas studded throughout with small isolated melanotic spots. At the back of the specimen are some larger nodules. The greater portion of the organ is healthy.

Owing to the softness of the tissue from long preservation thin sections for microscopic examination could not be obtained.

**Medullary growth.**

1404. A pancreas surrounded by the pyloric end of the stomach and duodenum, which are laid open. The head of the pancreas is much enlarged by a soft friable neoplasm, which has in parts become disintegrated, leaving innumerable shreds of gland-capsule. The floor of the duodenum presents, at the commencement of the descending portion, a circular ulceration with smooth rounded edges, and an inch in diameter, through which a mass of infiltrated disorganized pancreatic tissue projects.



## SERIES XXVII.—INJURIES AND DISEASES OF THE HEART AND PERICARDIUM.

**Wound:** 1405.

**Rupture:** 1406-1408*a*, 1414.

### **Diseases of the Myocardium.**

Hypertrophy of heart: 1409-1411.

Atrophy: 1412.

Fatty degeneration: 1407, 1408, 1413, 1414.

Fibroid degeneration: 1415.

    with aneurysm: 1416, 1417, 1440, 1441.

Dilatation: 1418.

Myocarditis:

    with perforation: 1419.

Syphilis: 1420.

Morbid growths: 1421-1424.

### **Diseases of the Endocardium and Valves.**

Thrombosis: 1425.

Endocarditis: 1426-1429.

    Ulcerative: 1430-1443.

Sclerosis of valves: 1444-1460.

    Mitral stenosis: 1445-1450.

    Aortic stenosis: 1451.

    Mitral and Aortic Stenosis: 1452-1455.

    Mitral and Tricuspid Stenosis: 1456, 1457.

    Mitral, Aortic, and Tricuspid Stenosis: 1458-1460.

Perforation of mitral valve: 1461.

Aneurysm of valve: 1462-1465.

Necrosis of the mitral valve: 1466.

Growth from valve: 1467.

### **Diseases of the Pericardium.**

Calcareous plates: 1468.

Pericarditis: 1469-1472.

Adherent pericardium: 1473-1475.

Tuberculosis: 1476.

### **Malformations of the Heart and Pericardium.**

Heart consisting of two chambers: 1477, 1478.

Heart consisting of three chambers: 1479, 1480.

Contraction of pulmonary orifice with defect in interventricular septum:  
1481-1486.

Defect in septum ventriculorum: 1487, 1488.

Patent foramen ovale: 1444, 1489.

Transposition of aorta and pulmonary artery: 1490, 1491.

Abnormal pulmonary valve: 1492, 1493.

    "    aortic valve: 1434, 1494.

Persistent Eustachian valve: 1495, 1496.

Absence of pericardium: 1497.



## EFFECTS OF INJURY.

**Wound.**

1405. A heart showing a punctured wound at the apex of the left ventricle.

From a young adult who was stabbed in the sixth interspace with a knife. On his admission there was free hæmorrhage from the external wound, but no collapse. Half an hour after admission symptoms of profound collapse suddenly supervened, the pulse becoming exceedingly weak. A director was at once passed into the wound by Mr. Mansell-Moullin. One of the costal cartilages was divided, and the finger introduced through the pericardium down to the heart, but no pulsation could be felt, though the patient breathed three or four times at very long intervals afterwards.

Mr. Mansell-Moullin.

**Rupture.**

1406. A heart showing extensive laceration at the apex of the right ventricle on its anterior and outer aspect. The opening is of irregular outline and extends halfway to the base, in the direction of the pulmonary valve. Some of the superficial muscular fibres of the interventricular septum near the apex are also lacerated. The wall of the ventricle is thin.

"The subject had fallen from the top window of a warehouse, fracturing the skull and ribs in the right axilla, thus lacerating the right lung. Probably the right ventricle was distended at the time the body touched the ground, and the chest-walls being driven in, the laceration was effected just as an air-bag is burst by compression."

1407. A heart much loaded with subpericardial fat, showing an extensive laceration of the anterior wall of the right ventricle near the septum. The laceration is linear, bifid towards the apex, and extends to within about an inch of the apex and of the pulmonary valve. There has been laceration also of some of the muscular fibres of the septum within the ventricle. The ventricular wall thin.

Believed to be from a man who had been run over.

1408. A heart with much adipose tissue on its surface, showing rupture of both ventricles and of the interventricular septum at the apex. The edges of the lacerated opening are ragged and irregular.

- 1408a. The heart of a man who had been run over by a brewer's dray. It was found at the autopsy lying loose in the pericardial sac, the aorta and pulmonary artery having been torn completely across. The liver, spleen, and diaphragm were also ruptured, and there were comminuted fractures of the vertebral column, ribs, and pelvis.

Case of John Geary. Autopsy, Oct. 9, 1889.  
Mr. McCarthy.



## DISEASES OF THE MYOCARDIUM.

**Hypertrophy.**

1409. A greatly enlarged heart with both ventricles laid open anteriorly parallel to the septum. Both cavities are greatly dilated and hypertrophied. The auricles are hypertrophied, but not notably dilated, being covered by greatly thickened and adherent pericardium. The aortic curtains are thick and their edges rounded, and the mitral curtains are also thick. The surface of the heart is rough from fibrous adhesions, and the pericardium is thick. The aorta is small and its wall thin, as from a young subject.

1410. A large heart with the hypertrophied and dilated left ventricle laid open along its outer border. The valvular curtains are thick, not retracted. The left auricle is dilated. The aorta is also dilated, and there is a good deal of atheroma at its root; one patch is seen just above the anterior aortic curtain, over the orifice of the right coronary artery. The right ventricle presents no notable abnormality, but its moderate size is in striking contrast with the exaggerated dimensions of the left.

1411. An enlarged heart with hypertrophied and dilated left ventricle. The aortic curtains are thickened and their edges rounded. The mitral valve is slightly thickened. There is extensive atheroma of the aorta. The specimen shows also a reticulated Eustachian valve.

**Atrophy.**

1412. The atrophic heart of an adult who died from cancer.

**Fatty degeneration.**

1413. A small heart, having much subpericardial fat upon the surface, with the right coronary artery dissected. The septal branch of the vessel, which is laid open, is thickened and dilated and very atheromatous. Its left branch is plugged with a thrombus.

1414. A heart, with an irregular laceration of the left ventricle at the apex, and a smaller linear laceration of the anterior wall of the right ventricle near the septum, about the middle of it. The ventricular walls are thin, and the organ is much loaded with fat.

This specimen was obtained from a man 76 years of age. He had enjoyed good health until the day of his death, when he complained of pain in the left



side and cough. His lower extremities were œdematous. While sitting over the fire smoking a pipe he died suddenly. The pericardium was enormously distended with blood, and had greatly displaced the lungs, which are stated to have been congested. The muscular fibre of the heart was very fatty.

*Presented by Mr. Elsom.*

### **Fibroid degeneration.**

1415. Part of an enlarged heart, which weighed 17 oz., showing fibroid degeneration with thinning of the anterior wall and apex of the left ventricle. The posterior wall is notably hypertrophied, and its section is nearly three times as thick as that of the anterior wall. The fibrous change of the myocardium is seen to extend through the whole thickness of the ventricular wall in the section at the apex; in the section of the anterior wall it is seen to affect the subendocardial layers, the endocardium being thick and opaque at that part and over the septum. The pericardium is thick, especially about the apex, where its surface is roughened by a cluster of warty outgrowths.

Case of R. Buckley, aged 50, admitted with suppuration in the thigh. He had atheroma of the aorta and coronary arteries, and an enlarged and cirrhotic liver, weighing 5 lbs.

Autopsy, April 17, 1885. Mr. Couper.

### **Chronic aneurysm.**

1416. An enlarged heart, with hypertrophied left ventricle laid open, showing a circumscribed area of fibroid degeneration of the whole thickness of the wall of the left ventricle near the apex, which forms a slight bulging on the posterior aspect of the organ. The endocardium is thickened and opaque at this part. There is no adherent clot.

Case of H. Deville, aged 45, admitted Oct. 14, 1884. There was a history of intemperance, and of syphilis 25 years previously. Three years ago right hemiplegia. His illness dated one month: shortness of breath with œdema of right leg and arm. Autopsy showed atrophy of the left corpus striatum and insula with much atheroma of the cerebral arteries; depressions on surface of liver and kidneys, these organs being indurated, and the liver small but not fissured; ulceration of the stomach; and infarction in the right lung, with pleuritic effusion on that side. The aorta and coronary arteries were atheromatous.

Autopsy, Oct. 21, 1884. Sir A. Clark.

1417. Part of a heart showing an aneurysmal bulging of the wall of the left ventricle in the infundibular region, at the summit of which there is an irregular laceration of the ventricular wall. The perforation is near the septum and about  $1\frac{1}{2}$  inches from the pulmonary valve, part of which is included in the specimen. The ventricular wall is extremely attenuated round the seat of rupture, and the pericardium



is rough from adhesion. Within the aneurysm are portions of blood-clot adherent to the ventricular wall.

### **Dilatation.**

1418. A heart with the left ventricle laid open longitudinally, showing great dilatation of the cavity with thinning of its walls. The columnæ carneæ are much atrophied, many being fibrous. The right ventricle is also atrophied, but in less degree. The mitral and aortic valves are slightly thickened.

### **Myocarditis with perforation of heart-wall.**

1419. A heart with the left ventricle laid open along its border, and extended, showing a well-defined perforation of its wall of the size of a quill. The endocardium around the opening is coated with a layer of fibrin, and several of the columnæ carneæ have been ulcerated and ruptured. The endocardium elsewhere appears normal. There is no lymph on the pericardium.

Probably the result of pyæmic myocarditis with suppuration, perforating the endocardium, and leading to rupture of the ventricular wall.

### **Syphilis.**

1420. A heart with the left ventricle and auricle laid open. Immediately beneath the endocardium, and infiltrating the muscle of the anterior wall of the left ventricle, is a soft, homogeneous, lobulated, new growth, of a greyish-white colour. Both the aortic and mitral valves are somewhat thickened.

Microscopic sections of the growth show gummatous structure.

From a man with a distinct history of syphilis, who suddenly dropped dead after singing a song. Until that moment he was to all appearance in good health.

*Presented by Dr. Sargent.*

### **Sarcoma.**

1421. An enlarged heart, laid open by a transverse section near the apex and by a longitudinal section of the left ventricle passing through the aortic orifice, showing great thickening of the heart-wall by a growth in the pericardium and outer layers of the myocardium. In the transverse section of the apex of the right ventricle the outer wall is about  $\frac{3}{4}$  inch thick at one part, the growth appearing there to be in greatest part subpericardial, this part being marked off from what appears to correspond with the myocardium beneath by a fibrous tract. In the longitudinal section of the left ventricle also subpericardial and myocardial growth appear to be similarly defined, the inner muscular layers only appearing to be free from invasion by the growth.



At the base of the ventricle, contiguous to the aortic valve and commencement of the aorta, is a cavity formed by softening of the growth, and there is a second cavity near the apex formed by breaking down of the growth in the outer layers of the myocardium. The surface of the heart is rough from fibrous adhesion of the thickened pericardium.

Sections of the growth show a small-celled infiltrating growth in meshes of a fibrous stroma, more or less abundant in different parts. There are no muscular fibres visible excepting at the innermost border of the sections. To the naked eye there appears to be a line of demarcation between the thickened subpericardial tissue ( $\frac{1}{8}$  inch) and the muscular wall of the ventricle ( $\frac{3}{8}$  inch thick). The deeper part of the former is of a much more fibrous and looser structure. The latter is compact and profusely infiltrated with corpuscles, which are collected in cloudy masses in places; and some of these are extensive and are broken down in the centre. Towards the pericardial surface the growth has a similar compact and infiltrated structure.

*See plate by Burgess, presented by Mr. McCarthy.*

1422. A heart laid open, with the right ventricle and auricle extended, showing several nodules of growth in its walls. The largest is seen projecting into the right auricle near the auriculo-ventricular orifice. The same nodule of growth, which is of the size of a walnut, projects also into the left auricle immediately above the right angle of the mitral slit. The central part of the growth projects into the infundibular part of the left ventricle contiguous to the aortic valve, infiltrating the upper part of the interventricular septum, the surface of which is made uneven by it. At the autopsy it was distinguished from the muscular tissue by its yellowish-white colour, and several other nodules of growth were visible under endocardium and pericardium. Well-defined nodules are seen in the section of the wall of the left ventricle.

Thin sections of the growth near the apex have the characters of lympho-sarcoma.

Case of Geo. Cook, aged 33, painter, who was admitted in a state of collapse Jan. 19, 1885, and died the same day. He had been working as a painter 8 months, formerly a soldier. Four months before his death he had complained of palpitation, and was relieved by a plaster. Two days before admission he had an attack of palpitation, and the next day he was worse, with vomiting and abdominal pain, supposed to be lead colic. Both sides of the heart were found distended by soft black coagula. The heart weighed 13 oz.

Autopsy, Jan. 20, 1885. Dr. Sutton.

### **Carcinoma.**

1423. A heart with the right ventricle and auricle extended, showing nodules of secondary growth in the Eustachian valve and in the ventricular walls. That in the valve forms a conspicuous nodular



swelling of the membrane, above the sinus venosus. There is much adipose tissue on the surface of the heart.

Case of Eliz. Parrot, aged 57, admitted April 14, 1885. She had scirrhus carcinoma of the pylorus and omentum and pancreas, and the right ovary was converted into a semi-gelatinous spherical mass of softer growth. Six nodules of secondary growth were seen in the heart-wall. There was a large calculus in the gall-bladder, but no growth in biliary passages or liver. Her symptoms dated about 2 months: persistent vomiting, with epigastric pain and wasting.

Autopsy, April 25, 1885. Dr. Down.

1424. A heart with a nodule of carcinomatous growth as large as a damson, forming a bossy projection at the apex of the right ventricle. The summit of the nodule has been nearly cut off and hangs down, exposing a section of the growth.

From a patient who died from cancer of the kidney, &c.

## DISEASES OF THE ENDOCARDIUM AND VALVES.

### Thrombosis.

1425. The heart and part of the right lung of a boy aged 14, with the right auricle and ventricle and pulmonary artery laid open, showing several ante-mortem thrombi adherent to the wall of the auricle, and one plugging a branch of the pulmonary artery in the right lung. In the auricle one thrombus, of the size of a large cherry, is adherent to the Eustachian valve above the opening of the coronary sinus. When first seen the mass was of globular form, with a fold in its surface where attached. There is a smaller mass near the mouth of the auricular appendix, which is plugged by a recent blood coagulum, and there are several small ante-mortem coagula amongst the *musculi pectinati*.

At the autopsy there was seen attached to the end of the thrombus in the pulmonary artery an expanded membrane, which seemed to be a portion of the outer wall of the smaller auricular thrombus, which was defective at one part. The wedge of lung corresponding with the occluded vessel was consolidated, and there was lymph upon the pleura covering it. The muscle of the right ventricle showed the "tabby" markings of fatty degeneration very characteristically. The lungs were fibrous throughout.

Case of Ed. Spong, aged 14, admitted December 13, 1884, with dyspnoea, anasarca, and ascites. He had been always short of breath, his health failing 6 months with disappearance of an eczema which dated from infancy.

Autopsy, Jan. 3, 1885. Sir A. Clark.

### Endocarditis.

1426. Part of a heart with the left ventricle laid open through the aortic and mitral orifices, showing an elevated ridge of granulations along the line of impact of the aortic curtains, and a similar less developed



fringe of granulations along the corresponding line on the mitral curtains. The valvular curtains are thickened. The mitral orifice contracted. There is much lymph on the pericardium.

Case of J. Lennox, aged 20, who was admitted with acute rheumatism of apparently mild character. A few days later his breathing became greatly embarrassed, with pericarditis, and subsequently with fluid in the right pleural cavity. After death the heart was found to weigh 18oz., the left ventricle being hypertrophied and dilated and filled with a mass of soft black clot. There was serous effusion in both pleural cavities and in the peritoneum, not in the pericardium, where the surfaces were becoming adherent. There were minute granulations on one curtain of the tricuspid valve.

Autopsy, Jan. 12, 1884. Dr. Turner.

1427. The heart of a child who died with acute endo-pericarditis, showing lines of granulations fringing the mitral and aortic curtains or their auricular and ventricular surfaces respectively. The pericardium is covered with lymph.

Case of Hy. Folwell, aged 3½, admitted July 12, 1885, with acute rheumatism dating a fortnight. There were signs of pericarditis and a mitral-systolic bruit. After death the heart was found greatly enlarged, and coated with much lymph in a little fluid exudation. The lungs were also coated with lymph, gluing them to the chest wall. A few minute granulations were seen on one curtain of the tricuspid valve.

Autopsy, July 21, 1885. Dr. Sutton.

1428. The basal part of the heart of a young subject with the mitral valve sclerosed, and a rounded and pedunculated vegetation of the size of a dried pea on the auricular surface of the greater curtain. The auricular surface of the smaller curtain is studded with minute vegetations. The valvular curtains are thickened, and the chordæ tendineæ much contracted. There is a slight erosion of one aortic curtain.

The vegetations, on microscopical examination, were found to be crowded with micrococci. The disease was, no doubt, of septic origin, and was associated with pneumonia.

The case is described by Dr. Sansom in the 'Practitioner,' August 1886 and January 1888.

1429. A heart laid open through the aortic valve, showing the ventricular surface of the greater mitral flap and of the right posterior aortic curtain, with the ventricular wall between them, covered with elongated club-shaped vegetations. To the mitral curtain an elongated fibrinous mass was attached, the tip of which could reach the cluster of vegetations seen on the wall of the auricle above the lesser flap. Both valves are thickened.

Case of W. S. Appleton, aged 22. There was a rheumatic history dating 10 years, and of heart-disease for 7 years. Death occurred from hemiplegia due to embolism.

Autopsy, Jan. 6, 1885. Dr. Sutton.



**Ulcerative Endocarditis.**

1430. A heart with left ventricle open, showing the mitral curtains thickened and covered with vegetations, which extend over the surface of the auricle above the posterior curtain. The edge of the larger curtain is much thickened, and the chordæ tendineæ are separated from it, their ends being enlarged and covered with fibrinous deposit.

Case of Eliza Biddle, aged 19, who was an in-patient from May to September 1881, under Dr. Sutton.

She was admitted, during her second attack of acute rheumatism, with a mitral regurgitant bruit, irritable heart's action, pyrexia, and arthritis. On July 29th retinal hæmorrhages were noticed. Towards the end of her illness she suffered from abdominal pain and splenic enlargement. She died with double basic pneumonia, and splenic, renal, and retinal embolisms.

1431. Heart with left ventricle laid open, showing a thrombotic mass of the size of a filbert covering the auricular surface of the larger mitral curtain. It is smooth above, where it encroaches upon the auricle, but has a rough and broken surface over the border of the valve. The smaller curtain is roughened with small granulations and fibrinous deposits.

1432. A heart laid open with the greater curtain of the mitral valve extended, showing great swelling and hæmorrhagic infiltration, with necrotic softening and perforation, of the attached border of the valvular curtain, the free border being entire. The hæmorrhagic infiltration and softening extend into the heart-wall at the base of the valve to a necrosed and softened (? thrombotic) mass, exposed on the surface of the heart by separation of the aorta and left auricle. The endocardium over the affected part is dull and discoloured and coated with lymph, more extensively on the ventricular aspect of the valve. The aortic curtains are thickened and fibrous, and the aperture is narrowed by cohesion at the cusps, but there are no granulations upon them.

Case of Wm. Johnson, aged 15, who died six hours after admission to the hospital on October 23, 1888. His illness dated only three days, during which time he had been delirious, off and on. He was unconscious when admitted and died in coma. There was a history of a fall, but no evidence of injury. He had a petechial eruption about the wrists and ankles, and had had some epistaxis.

*Post-mortem*:—The pericardium was much injected and ecchymosed and coated with lymph, and the cavity contained thin puriform exudation tinged with blood. The myocardium was softened at the point shown in the specimen, and at other spots. In the kidneys were a few wedges of necrosis with zones of injection, and lines of suppuration extending through cortex and pyramids, and ecchymoses studding the surface. In the small intestines were numerous spots of suppuration with surrounding congestion, and ecchymoses. In the left optic thalamus was a black blood-clot of the size of a pea.

Autopsy, October 24, 1888. Mr. Couper.



1433. A heart with left ventricle laid open longitudinally, showing a mass of fibrinous deposit upon the auricular surface of the greatly thickened and contracted mitral valve, where the flaps have become adherent at the posterior angle of the mitral slit. A portion of the coagulum has been removed, and the valvular structure covered by it is there seen to be necrotic and becoming separated from the surrounding tissues. At the autopsy this fibrinous mass and the valvular structure beneath it were of an ashy grey colour, and on its ventricular surface this and the contiguous parts of the valve were of a similar tint, and coated with a rough fibrinous deposit of the same character. The aortic curtains are also thickened.

From the body of a Swedish sailor, aged 22, who was brought to the Hospital from a sailors' home after a few days' illness, and died the second day after admission. There were evidences of septic blood-poisoning, and a collection of pus was found in the right epididymis, and basilar meningitis.

Case of Chas. Lindstedt. Autopsy, May 6, 1887. Dr. Jackson.

1434. The basal part of a heart with the commencement of the aorta, showing extensive destruction of contiguous parts of the anterior and left posterior curtains of the aortic valve, and lesions of the contiguous parts of the ventricular wall, and of the aorta, apparently secondary to the valvulitis. There are massive vegetations on the ulcerated parts. One of these was about an inch in length, its tip reaching upwards to the depression in the aorta above the elevated atheromatous area contiguous to the valve, over which it had played during life, and backwards to the cup-like excavation of the ventricular wall seen below the valve. The aortic curtains are much thickened. Two of them are united to form a single curtain with a thickening of the centre of the free border, like the corpus Arantii of a normal segment.

Case of Richard Hemming, aged 34, intemperate, who was admitted Oct. 30, 1884, and died the next day. His breath was greatly embarrassed and his legs oedematous. His illness was attributed to having caught cold three weeks before. His urine contained much albumen. The aorta was healthy, except near the valve.

Autopsy, Nov. 1, 1884. Dr. Sansom.

1435. Part of a heart including the aortic valve and adjacent parts of ventricle and aorta. The edges of all the curtains on their ventricular surfaces are covered with ragged thrombotic masses of brownish colour, by which they are in great part concealed. The anterior curtain is much thickened and eroded. The right posterior curtain is perforated.
1436. A heart with the infundibulum and commencement of aorta opened out, showing ulceration with much destruction of the anterior and left posterior curtains of the aortic valve, and erosion with



fibrinous deposit, of the ventricular surface of the right posterior curtain and of the contiguous mitral curtain along its right margin, and of the chordæ tendineæ connected with it. On the wall of the aorta immediately above the junction of the ulcerated valves is a roughened area, in which are seen several pin-hole perforations leading into a cavity between the aorta and its pericardial sheath. This pouch, which formed a projection on the pericardial surface of the vessel, has been laid open. There is a similar but smaller projection of the pericardial sheath of the vessel where it covers the right posterior sinus of Valsalva. This is caused by a pouch behind a perforation of the wall of the aorta at a point opposite to a perforation in the middle of the corresponding valvular curtain.

Case of John Collins, aged 25, admitted Nov. 11, 1884, under Dr. Fenwick. He had had a slight attack of rheumatism twelve months before, but no other illness. His symptoms dated from four months before his death.

Autopsy, Feb. 20, 1885.

1437. A heart laid open, showing extensive destruction of the aortic curtains, more particularly of the contiguous portions of the anterior and right posterior flaps. There are massive vegetations attached to these curtains and to the ventricular wall, from which they have been separated about their point of junction. The ventricular wall also between the mitral and aortic valves, and the ventricular surface of the large mitral flap, are covered with soft coagula, which extend also to the chordæ tendineæ. In the left auricle a rounded mass connected with the smaller mitral curtain is seen projecting into and filling up the greatest part of the valvular passage.

Case of Elizabeth Faint, aged 35. Admitted in a moribund state three weeks after confinment. There were infarcts in spleen and kidneys, and ecchymoses on pericardium, in pelves of kidneys, in bladder, stomach, and intestines. There was hæmorrhage from mouth and vagina before death.

Autopsy, August 1, 1884. Dr. Sansom.

1438. A heart with the left ventricle laid open through the aortic orifice, and the valve exposed. The curtains are extensively destroyed by ulceration, and projecting from the right, and from the continuous half of the left, posterior segments, and from the ventricular wall adjacent, is a ragged thrombotic mass as large as the end of the thumb. The anterior curtain is roughened by lymph on the side contiguous to the mass.

1439. A heart with the left ventricle and aorta laid open to show almost complete destruction of the aortic valve from ulceration. The ventricular surface of the mitral valve is covered in part with large vegetations, and the substance of the valve is thickened. The aorta is healthy. The ventricle is dilated and hypertrophied.



Case of David I., aged 11, admitted November 27, 1888, for dyspepsia, cough, dyspnoea, together with double aortic murmurs. He was extremely anemic. The autopsy revealed ulcerative endocarditis, infarcts in both kidneys, and pneumonia of the base of the left lung. Dr. Sutton.

1440. A heart with left ventricle laid open, showing extensive destruction of the aortic valve. One curtain has nearly gone, and in its situation is an aneurysmal pouch with fibrous walls extending upwards from the ventricle between the aorta and pulmonary artery for about an inch. The mitral orifice is slightly contracted, the curtains thickened and fringed with vegetations. Directly above the middle of the great mitral flap, in the angle between two semilunar curtains, is a well-defined excavation of the ventricular wall with rough surface and about half an inch deep. In the opposite sinus of Valsalva is a similar excavation of the aorta.

From Mary A. E., admitted on March 24, 1887, under Dr. Ralfe for palpitation, and oedema of the feet and legs, and with a history of rheumatism. She died four days after admission. At the post-mortem the lungs were oedematous and infarcts were found in one kidney.

1441. A heart with both ventricles laid open and extended. An ulcerated opening is apparent below the anterior and right posterior segments of the aortic semilunar valve, the edges being fringed with vegetations. The overhanging valvular curtains are thickened and extensively eroded. This irregularly circular opening leads into an aneurysmal pouch of about the size of a walnut, with fibrous walls and smooth lining-membrane, which bulges into the infundibulum of the right ventricle contiguous to the tricuspid orifice.

#### **Endocarditis affecting the Tricuspid Valve.**

1442. A heart with both sides laid open and right ventricle and auricle extended, showing massive vegetations on two curtains of the tricuspid valve, the septal segment being unaffected. One curtain has been perforated—indicated by a piece of glass rod passed through it.

Case of William Duffey, aged 55, admitted with physical signs of fibroid phthisis on the right side, with a temperature of 105° F., delirium, and subsultus. He rapidly became comatose and died. At the autopsy there was old fibroid thickening of the right pleura, with consolidation of the lung. There was a history of fractured ribs three months before.

Autopsy, Feb. 2, 1882.

1443. The basal part of a heart laid open through the right ventricle and auricle, with the tricuspid valve extended, showing irregular thrombotic masses, broken down on the surface and in part removed, on the auricular surface of two of its segments. The third segment, which is folded over, is concealed by a similar mass of fibrinous



deposit on its ventricular surface. There is a perforation of one segment. The mitral and aortic curtains, which can be with difficulty seen, are free from vegetations.

The right side of the heart was dilated and the organ weighed 15 oz. The pericardium was adherent. The subject from which it was obtained had been a patient under the care of Dr. Down and died with bronchopneumonia, fibroid induration of lungs and dilated bronchi, cystic kidneys, and atrophied brain.

Autopsy, Dec. 23, 1871.

### Mitral Sclerosis.

1444. The heart of a child, aged 11, with thickened and coherent mitral curtains, open foramen ovale, and great hypertrophy of the right auricle and ventricle. The mitral curtains are much thickened and coherent posteriorly, and drawn down towards the papillary muscles by the contraction of the chordæ tendineæ. At the other angle of the mitral slit they are separated by a small valvular curtain, which is not thickened, and the orifice is not apparently narrowed. The ventricles are distended, the right much larger than the left. The auricles are not dilated; but the right is greatly hypertrophied, its walls being firm and muscular throughout. The left auricle is not hypertrophied and its walls are flaccid. The pulmonary artery is nearly twice the size of the aorta.

From a child, aged 11, who had suffered much from the age of 3 years from difficulty of breathing, increased on the least exertion. A bruit could be heard even by bystanders, and the pulsation of the heart was exceedingly strong. Before her death she had ascites and anasarca. On opening the thorax the heart and pericardium almost concealed the lungs; about half a pint of fluid was contained in the pericardium. The right ventricle and auricle were much dilated, and their parietes were nearly twice as thick as those of the left cavities. The foramen ovale was open and as large as a section of the aorta.

### Mitral Stenosis.

1445. The basal part of the heart, with the mitral and aortic valves extended. The mitral curtains are united together, the orifice admitting the tips of two fingers; the edges of the valve are thickened; the chordæ tendineæ are also thickened.

The specimen illustrates the occurrence of mitral stenosis in a slight or moderate degree. No presystolic murmur was heard during life, but a murmur which was considered diastolic, with a systolic murmur rightly ascribed to mitral regurgitation. A thrill, which was considered systolic, was felt at the apex.

Case of Ada W., aged 24. R. N. 1340. She was admitted Sept. 29, 1887, during the eighth attack of acute rheumatism, with mitral systolic and aortic diastolic murmurs, congestion of the lungs and of the right side of the heart. At the post-mortem, Oct. 14, 1887, there was fluid in both pleural cavities, with congestion of lungs and liver. Dr. Sansom.



1446. A heart with thickened mitral valve and stenosed orifice of 'button-hole' form. The left auricle and cavities on the right side are much dilated and hypertrophied.

1447. The basal part of an hypertrophied heart, with sclerosed and calcareous mitral valve. The mitral curtains are much thickened, especially at their contiguous borders, where they have become fused together. At these parts there are calcareous nodules in the tissue, over and around which the surfaces have been eroded, apparently by attrition of the parts. The abraded surfaces were covered with an adherent layer of fibrin, parts of which remain. They are of diamond-shape, corresponding to areas of contact of the calcareous masses in the contiguous parts of the curtains. There is also a line of granulations along the line of impact of the curtains.

Case of Wm. Franklin, aged 29, who was admitted with erysipelas of one arm and delirium tremens, and died the following day. The heart weighed  $20\frac{3}{4}$  oz. The aorta was free from atheroma.

Autopsy, Oct. 31, 1884. Mr. Treves.

1448. A heart with the left ventricle laid open through the aortic valve and extended, showing extreme stenosis of mitral orifice, which is surrounded by a thick fibrous ring united to the papillary muscles. The aortic curtains are thickened and there are vegetations on their ventricular surface. Two of them are united at the cusp.

1449. A dried preparation of the mitral valve, with a very extensive deposit of calcareous matter in both curtains, nearly encircling the orifice and projecting on both surfaces of the valve.

1450. A dried preparation of a mitral valve with a calcareous mass in its substance.

#### **Aortic Stenosis.**

1451. A dried preparation of the aortic valve, showing rough and nodular masses of calcareous deposit in the curtains and cohesion of them at the cusps.

#### **Mitral and Aortic Stenosis.**

1452. An enlarged heart with hypertrophy and dilatation of all the cavities, showing stenosis of the mitral orifice with vegetations especially at its anterior angle, and extending over the auricular wall. The aortic valve is also sclerosed and stenosed. The pericardium is rough from fibrous adhesions.



1453. A similar specimen. There is ulceration of the auricle above the anterior angle of the mitral valve, and extending on to the curtains.

From Chas. J. H., who was admitted into the Hospital on January 3, 1881, with a history of several attacks of acute rheumatism. He was suffering from severe dyspnoea and abdominal pain, and had a mitral regurgitant murmur.

At the autopsy, January 28, the body was oedematous and jaundiced, and the abdomen was filled with fluid and lymph. The bowel was found to be sloughing in patches; there was no plugging of the superior mesenteric artery. The mitral valve was contracted and roughened. The lungs and spleen were congested. Dr. Sansom.

See also Series XXI. No. 1174.

1454. Part of a heart with extreme stenosis of mitral and aortic valves. The flaps of the mitral valve are adherent to each other, and the orifice would only admit the little finger. The aortic semilunars are also united at their margins and the orifice much contracted and triangular. The wall of the left auricle is hypertrophied.

1455. Part of a heart, showing both mitral and aortic valves much thickened and stenosed, and rigid from calcareous masses in their substance. There is ulceration along the lines of union of the mitral curtains and on the smaller flap, the ulcerated surface being roughened with fibrinous deposit. The anterior and right posterior aortic curtains are united for nearly half their length. The left posterior curtain is ulcerated.

#### **Mitral and Tricuspid Stenosis.**

1456. A heart with stenosis of the mitral and tricuspid valves. The former is much stenosed, and thickened and calcareous, and there are vegetations upon it and upon the adjacent surface of the auricle, and upon the aortic valve. Suspended above it is a sacculated fibrous coagulum with smooth surface, of ovoid form, and about the size of a hen's egg, which was found loose in the left auricle, resting on the mitral valve. At one end is a large opening through which its softened contents had escaped. There is an adherent thrombus filling up the auricular appendix, the exposed surface of which is rough and broken, and from which the loose body may have been detached.

Case of Emily Painter, aged 34, who died shortly after admission into Hospital. There were infarcts in lungs, one of which was softened and had set up pleurisy, and in the spleen; and scars in the kidneys. The heart was much enlarged and weighed 20 oz. There was a history of acute rheumatism two or three years before. She had been in bed for a month, her illness having come on acutely with shivering.

Autopsy, Feb. 7, 1852. Dr. Fenwick.



1457. A heart with stenosis of both mitral and tricuspid valves, the mitral orifice being reduced to a mere slit-like, or "button-hole," opening. The edges of the mitral valve are greatly thickened and the chordæ tendineæ of the posterior segment of the valve are as thick as a piece of whip-cord. The left auricle is very much dilated, its lining-membrane thickened, and its walls about an eighth of an inch thick. The left ventricle is small. The right ventricle is much dilated and hypertrophied. The walls of the pulmonary artery are nearly as thick as those of the aorta. The tricuspid valve is thickened and considerably stenosed.

### Mitral, Aortic, and Tricuspid Stenosis.

1458. An enlarged heart, to which the pericardium is universally and firmly adherent, showing sclerosis with great stenosis of the mitral valve. The left auricle is much thickened and the cavity is dilated, and its wall is in part coated with a thin adherent coagulum. Above it in the specimen are suspended two rounded bodies which were found loose in the cavity, and are seen on section to be formed of folded fibrinous membrane, probably formed on the wall of the auricle and detached in its movement. The aortic valve is also thickened, and narrowed by adhesions between the right posterior and the adjacent curtains. There is thickening with some contraction of the tricuspid valve.

Case of Esther T., aged 39, who was admitted under Dr. Fenwick on October 9th, 1884, with the following history:—She had been ailing since a miscarriage, 18 years ago. She had "rheumatism" 10 years ago and "deadness" of the left leg 3 years ago. Four days before admission she experienced sudden cramp in both legs, followed by swelling, especially of the left. There were, on admission, systolic and presystolic murmurs at the apex and a systolic at the base. The legs and feet rapidly became gangrenous, from which she died. There was some numbness of the right hand, but no gangrene.

*Post-mortem.*—In addition to the cardiac lesion, the aorta and its branches below the inferior mesenteric artery were found thrombosed. The clot in the left iliac seemed older than that in the right.

Autopsy, December 7, 1884.

1459. An enlarged heart, with adherent pericardium and with hypertrophy and dilatation of all the cavities, especially of the right auricle and left ventricle, showing sclerosis with stenosis (rheumatic) of the mitral, tricuspid, and aortic valves. The tricuspid orifice is extremely stenosed, and the valve funnel-shaped. The mitral valve is more thickened and rigid, with button-hole aperture. The coherent aortic curtains form a triangular aperture.



1460. A similar specimen. The mitral orifice is extremely stenosed. The tricuspid would admit a finger. The pericardium is rough from adhesions.

Rheumatic endocarditis and pericarditis. Dr. Fenwick.

#### **Sclerosis with Perforation of the Mitral Valve.**

1461. A heart showing sclerosis and stenosis of the mitral valve, and a large perforation of the greater curtain by which the greater part of its anterior border (about  $\frac{3}{4}$  of an inch) is separated from the attached border. The edges of the aperture are smooth and cicatrised. The edges of the thickened valve, and of the rent in it, are studded with granulations of recent endocarditis, which also festoon the ventricular surface of the aortic curtains. The pericardium is coated with a thick layer of lymph.

#### **Aneurysm of the Cardiac Valves.**

1462. A heart showing stenosis of the mitral orifice, with an aneurysmal pouch on the auricular surface of the greater curtain. It has a smooth fibrous wall, roughened by vegetations on its inner surface, and on its outer surface, about a perforation near the margin of the curtain. The aneurysmal sac covers the whole of the freely-projecting part of the valvular curtain. The tricuspid valve is thickened.
1463. Part of a heart showing a sac with smooth fibrous wall, and of the size of a broad-bean, connected by a somewhat constricted base with the larger mitral curtain, about the centre of its auricular surface. The auricular surface of the valve and sac are smooth, but the ventricular surface of the flap, of the aortic valve, and of the endocardium contiguous to them, is roughened with fibrinous deposit. In the floor of the sac, which has been laid open above, there is a small perforation of the valve, through which a piece of glass rod has been passed. The foramen ovale is incompletely closed.
1464. Portion of a heart with the commencement of the aorta. On the auricular surface of the larger curtain of the mitral valve, near the border contiguous to the aorta, is a membranous pouch of the size of a large pea. It is of spherical form, with a constricted base of connection with the valve, in which it has an opening in the ventricular surface of the valve. At the free edge of one aortic curtain is a small pouch. The aortic curtains are sclerosed; the aorta is atheromatous, with many calcareous plates.



1465. A heart with dilated and hypertrophied left ventricle laid open through the smaller mitral curtain, and with the larger curtain divided in the middle from its free edge to its attached border to expose an aneurysmal bulging of the attached border of the left posterior aortic curtain, projecting into the cavity of the ventricle from the bottom of the sinus of Valsalva. The aneurysmal sac is filled with a firm mass of coagulated blood, which is of a red-brown colour in the section made through the middle of it, and had the appearance of a solid growth of melanotic character until incised.

This specimen was removed from the body of a West Indian negro, who died in the hospital from gangrene of the feet. He was not known to have had any cardiac symptoms.

#### **Necrosis of the Mitral Valve.**

1466. A heart laid open through the sclerosed and stenosed mitral valve, and extended, showing a portion of the greater curtain necrosed, and separated from its connections with the papillary muscles and smaller curtain. The necrosed portion of the valve is well defined on the auricular surface of the valve, being corrugated and dull. At the posterior angle of the mitral slit there is an ulcerated area, extending up to the attached border of the valve, where the sequestrum has become detached. On the auricular wall above the anterior angle is a smaller area over which also the endocardium has become necrotic. On the ventricular aspect of the great mitral flap, the endocardium is bounded by an arched border with smooth sharply-defined edge, beneath which the necrotic valve hangs down for half an inch. The edges of the ulcerated areas were fringed with minute gelatinous granulations. There is advanced fibroid degeneration at the apex of the left ventricle.

From a man aged 42, who had suffered from acute rheumatism 6 years before and from symptoms of cardiac failure for 3 months previous to his decease.

Case of Edwin Rossiter. Autopsy, March 28, 1884. Dr. Fenwick.

#### **Growth from Valve.**

1467. A heart with hypertrophied left ventricle, with the right ventricle laid open through the pulmonary valve and extended, showing nodular growths on contiguous parts of its posterior and left anterior curtains. A projecting and somewhat pedunculated outgrowth arises from the anterior curtain; a flat sessile growth extends along the attached border of the other. The surface of the growths is smooth, with irregularity from depressions.



## DISEASES OF PERICARDIUM.

**Calcareous Degeneration.**

1468. A dried preparation of the basal part of a heart with large plates of calcareous deposit in the pericardium in the auriculo-ventricular sulcus at each side of the organ. That on the right side is the larger, and has a rough projecting portion within the auricle immediately contiguous to the valve.

**Pericarditis.**

1469. The heart and pericardium from a case of acute pericarditis. The pericardial sac is laid open and reflected, showing the serous surfaces coated with lymph, more abundant at the base, and roughened with tufts and fringes of the fibrinous coagulum.

1470. A similar specimen, with a thick deposit of fibrin at the apex of the heart, where it is collected in ridges transverse to the axis of the ventricle.

From a female aged 30, who was admitted a patient of the Hospital with excessive dyspnoea, and pain in the region of the heart, and died shortly after admission.

1471. A similar specimen, but with a much thicker deposit of fibrin, which forms ragged flocculent masses half an inch high, covering the surface of the left ventricle.

1472. Part of a heart from a case of pericarditis with the vessel injected, showing tufts of vascular and villous processes, in clusters and larger tracts, projecting from the surface of the pericardium amongst the lymph with which it is coated.

**Pericardial adhesions.**

1473. A heart with part of the pericardial sac. The pericardium is much thickened, and its surfaces are firmly adherent together at the base of the heart. A part of the pericardial new growth, or "false membrane," has been dissected off the surface of the heart, which appears little changed beneath. The surface of the thickened pericardium has a flocculent velvety appearance; in a fold near the right auricular appendix there is a deposit of lymph.

1474. A heart with the pericardium closely adherent throughout. The left ventricle is cut into, and its walls separated. The parietal pericardium, which is slightly thickened, is separated from the visceral, and pulled back to the extent of a quarter of an inch.



1475. A heart with adherent pericardium. The pericardial sac is partly reflected, showing the surface of the heart rough from fibrous adhesion of the surfaces, and the fibrous bands uniting them.

#### **Tuberculosis.**

1476. The heart of a child with a portion of the pericardial sac, showing a deposit of recent lymph on both surfaces, and scattered miliary nodules over both visceral and parietal pericardium.

Case under Dr. Barlow. Post-mortem, December 19, 1877.

### **MALFORMATION OF THE HEART AND PERICARDIUM.**

*Malformations of the Heart from arrest of development at an early period of life.*

#### **Heart consisting of two chambers.**

1477. A heart consisting of one auricle and one ventricle. The ventricle is very thick with small cavity. The infundibular portion is separated by a constriction from the rest of the ventricle. The endocardium of this part is thickened and rugose; at its commencement are fenestrated folds of endocardium having the form of rudimentary valves. The aortic curtains are thick. There is no appearance of a pulmonary artery.

"The child from whom this was taken was about 6 months old. The heart was turned towards the right side; right auricle and vena cava inferior large; pulmonary vein of left lung terminated in left subclavian vein, that of right lung passed through the diaphragm and terminated in the vena portarum. There is only one auricle and one ventricle. The lungs were supplied by the ductus arteriosus; they were large, but the left was the larger of the two. There appeared to be no attempt to form a pulmonary artery and vein. The heart, vena cava, and pulmonary veins were loaded with blood. The valves appeared so circumstanced that they could not have answered their intention. The aorta is large till the giving off of the ductus arteriosus, the reverse to what is found in that of the foetus naturally formed. There was no spleen." (*Old Catalogue.*)

*Presented by Mr. Thomas Blizard.*

1478. A heart consisting of one auricle with two appendages and one ventricle with one vessel arising from it. The separation of right and left auricle is indicated by a cord stretching across the auriculo-ventricular orifice, and by a median fold of the auricular endocardium continuous with it. The venæ cavæ superior and inferior, and two pulmonary veins, open into the auricle. The auriculo-ventricular valve is of tricuspid form. In front of the aorta is what appears to



be a rudiment of the infundibulum of the right ventricle with blind extremity, without any evidence of pulmonary artery.

**Heart consisting of three chambers.**

1479. A heart consisting of one ventricle and two auricles. The right auricle, which is smaller than the other, communicates with the ventricle by a funnel-shaped membranous valve, behind what appears to be a very thick and contracted larger mitral curtain. There is no other evidence of an auriculo-ventricular valve beyond a fold of endocardium surrounding the orifice. There is no trace of papillary muscles or chordæ tendineæ. The walls of all the cavities are very thick and muscular, except parts of the anterior walls of the auricles, which are membranous. The larger (left) auricle is divided by a membranous fold between the auriculo-ventricular orifice and the foramen ovale (now closed) below and the vessels entering the auricle above. Two vessels open into each auricle, which are indicated by blue and white glass on the left and right respectively. They all enter in the thin anterior walls of the cavities, the muscular masses representing the auricular appendages. At the back of the specimen five arterial trunks arise from the ventricle by two orifices, separated by a fold of membrane only, one behind the other, and just behind the auriculo-ventricular orifice, each being provided with two semilunar valvular curtains. With the anterior orifice two of the arterial trunks communicate—one, representing the aorta, having no branches, the other dividing into four large branches representing the branches of the arch. The other three arterial trunks communicate with the posterior orifice, two of them united at their commencement.

1480. A heart consisting of an auricle with two appendages, and a full-sized and thick-walled right ventricle with a rudimentary left ventricle. The aorta arises from the right ventricle and gives off the coronary arteries in the usual manner, and supplies the pulmonary arteries through an open ductus arteriosus. Behind it is a cord which runs from the roof of the ventricle to the pulmonary arterial branches, and probably represents the pulmonary artery. The vena cava inferior and a right and a left vena cava superior open into the auricle; the latter vessel receives the blood of the pulmonary veins by a branch which passes backwards over the root of the left lung to the point of junction of these vessels behind the bifurcation of the trachea.

From an infant, aged 15 months, a patient at the North-Eastern Hospital for Children, who died from bronchitis with cyanosis. The cyanosis had not been noticed previous to the illness.

*Presented by Dr. Turner, Curator.*



*Malformations of the Heart from arrest of development at a more advanced period of fœtal life.*

**Constriction of pulmonary orifice with defect in interventricular septum.**

1481. A heart from an infant, with extreme contraction of the pulmonary valve, which will only admit a fine bristle, and imperfect interventricular septum, the aorta communicating with both ventricles. The ductus arteriosus is open. The right ventricle is small, its cavity being contracted. Its walls are half an inch thick, and twice the thickness of the walls of the left ventricle. The right auricle is dilated; a bristle is passed from the termination of the inferior vena cava through a small opening in the foramen ovale into the left auricle.

1482. A heart with contracted pulmonary orifice and artery, and incomplete interventricular septum, the aorta arising from the right ventricle. The aperture in the septum, which is immediately below the aortic orifice, is large enough to admit the tip of the little finger. In front of it is the contracted pulmonary artery, into which a piece of glass has been passed from the right ventricle.

1483. The heart of a girl, aged 16, with imperfect interventricular septum, and aorta arising from both ventricles. In front of the root of the aorta is the commencement of the small pulmonary artery, which has been divided close to its origin. It has a small pin-hole opening into the contracted infundibular part of the right ventricle. The separated trunk of the vessel bifurcates, one branch being seen to go to the root of the right lung. The pulmonary blood-supply was afforded by branches of the descending aorta; to the left lung by a large arterial branch contiguous to the ductus arteriosus; to the right lung by the ductus, and an anterior branch lower down. The right ventricle is enlarged and hypertrophied.

At the autopsy made July 2, 1823, the following appearances presented themselves:—

“The upper part of the chest on the right side was a little larger than the left, and formed a projection in front. The lungs were adherent to the side, firm, and dark-coloured, and studded with tubercles of various sizes. On opening the pericardium we remarked that there was no pulmonary artery; the heart itself was of its usual size, but the proportions of its ventricles were reversed; the right was the larger and somewhat the thicker of the two. The aorta was situated anteriorly. The auricles were natural, both in size and thickness. The valves also around the ostia were healthy. The ventricles had an opening of communication between them, at that part from which the pulmonary artery usually springs. It was sufficiently large to admit a forefinger, and over it was the origin of the aorta, which had a part of its area in either ventricle; the valves were perfect,



but its course was irregular—ascending as far as the arch as usual, or, if there was any deviation, it was in its passing more to the right side than natural, from this it took its course to the right of the trachea, winding around the right bronchus to its usual destination in the posterior mediastinum, having passed between the œsophagus and vertebræ. There were the usual number of bronchial arteries, but they were much enlarged, as if to compensate for the deficiency of the pulmonary branches; a branch was sent to each lung shortly after the arrival of the aorta in the mediastinum, the right branch being much the largest; a third artery was given off a little lower down, which divided into two branches, one going to each lung. Here the left branch is the largest. The branches are of such magnitude as to equal in their united area the usual area of a pulmonary artery. All the history that can be obtained is that the child was of a livid blue colour, was unable to take any violent exercise, and through life was subject to considerable difficulty of breathing, especially for the few weeks immediately preceding her death. She arrived at the age of 16 years, but was rather small of stature." (*Report in Old Catalogue.*)

1484. The heart of a very young child, with imperfect interventricular septum and small pulmonary artery, the aorta arising from the right ventricle, coming between the pulmonary and tricuspid orifices. The pulmonary artery and infundibulum are small, the former about a quarter of an inch in diameter. The right ventricle is much larger and thicker than the left. The foramen ovale is open, the ductus arteriosus does not appear to be pervious. Pieces of glass rod are passed into the aorta from each ventricle, and from the right ventricle into the pulmonary artery.

1485. A malformed heart with contracted pulmonary orifice and incomplete interventricular septum, the aorta arising from both ventricles. The aperture in the septum ventriculorum would admit the tip of the forefinger. The pulmonary artery is about a third of the size of the aorta. The foramen ovale is open; the ductus arteriosus closed. The right ventricle is hypertrophied and larger than the left. The great vessels from the arch of the aorta are irregular, and are stated to have been given off in the following order:—(1) the left common carotid, (2) the right common carotid, (3) the left, and (4) the right subclavian.

From a case of "morbus cæruleus" under the care of Mr. Skey. Shortly before death, about the age of 9, general dropsy appeared, and the child died somewhat suddenly.

1486. A heart with stenosed pulmonary orifice and incomplete interventricular septum, the aorta opening into both ventricles. The foramen ovale and the ductus arteriosus are closed. The wall of the right ventricle is as thick as that of the left, but its cavity is small. Its infundibular portion is contracted, and the endocardium lining it is thick and fibrous. There are some vegetations on the ventricular surface of the pulmonary valve.



**Defect in Interventricular Septum.**

1487. A heart with imperfect septum ventriculorum, and both aorta and pulmonary artery arising from the right ventricle. The aortic valve is behind and to the right of the pulmonary valve, intervening between the pulmonary and tricuspid orifices. The wall of the right ventricle is thicker than normal, but not so thick as the left ventricle. There is much thickening of the endocardium about the interventricular opening, especially in the right ventricle, where it forms a protruding fibrous ring, adherent to the tricuspid valve. The mitral valve is thickened, and there are some fibrinous vegetations on its surface. Some of its chordæ tendineæ are ruptured, and their loose ends are swelled and coated with fibrine. The foramen ovale is open, the ductus arteriosus closed.

1488. Portion of an adult heart showing a communication between the two ventricles. The aperture is just below the aortic valves, and would admit the tip of the little finger. In the right ventricle the channel of communication is prolonged by a short fibrous tube, upon the upper part of which a small pouch is developed. This fibrous tube is adherent to the much thickened curtain of the tricuspid valve contiguous to it above, by which it seems to have been formed in part. The endocardium around the opening in the left ventricle is thickened and rough, and on the opposite endocardial surface, on and above the larger mitral curtain, is an oval area of corresponding size, which is slightly elevated and roughened by fibrinous deposit. There is some fibrinous deposit also on one segment of the tricuspid valve, which covers the opening into the right ventricle.

**Patent foramen ovale.**

1489. The heart of an adult with unclosed foramen ovale. The aperture would admit the little finger. The heart is enlarged, and the auricles are dilated.

*Irregularities of the Primary Vessels and Valves.***Transposition of Aorta and Pulmonary Artery.**

1490. A heart with the aorta arising from the right ventricle, which is the larger, and the pulmonary artery from the smaller left ventricle. The pulmonary artery, which is in front, goes to the right side, and the aorta directed at its commencement to the left arches to the right in front of the trachea, and descends on the right side of the



œsophagus behind. The septa are entire. The superior vena cava descends to the left auricle on the right side of the trachea.

Autopsy, May 3, 1878. Dr. Mackenzie.

1491. The heart and lungs of a child with the aorta and pulmonary artery transposed. The right ventricle from which the aorta arises is much thicker than the left, from which the pulmonary artery springs. The ductus arteriosus and the foramen ovale are both open. The lungs are infiltrated with miliary tubercles.

#### **Abnormal Pulmonary Valves.**

1492. A heart with the pulmonary valve formed by two curtains, and the orifice stenosed by cohesion of their edges in the form of a cone, the aperture of which is not more than a third of an inch across. The right ventricle is hypertrophied. The septa are entire.

From a man, aged 21, the subject of congenital heart disease. The patient was a seven-months' child, and suffered from convulsions in infancy. He was also "blue" when crying. He had complained of palpitation and hacking cough since he received a blow from a cricket-ball in 1877. He then presented no signs of cyanosis, but the physical signs led to the diagnosis of stenosis of the pulmonary artery, and the probability of the case terminating in tubercular phthisis was noted. In August 1881 he brought up some blood (half a pint), and signs of phthisis were then found at apex of right lung. He died from phthisis in 1883. There was no family history of phthisis.

*Presented by Dr. Sansom.*

1493. A heart with four segments to the pulmonary valve, two of them being small, as if formed by division of one segment of normal size. The aorta is atheromatous, and the aortic and mitral valves are thickened.

From a man, aged 51, who had also malformation of the testes, the epididymis being separated from the body of the organ. The right kidney was rudimentary, the ureter being dilated and impervious at the lower end. The left kidney weighed 12 oz.

Case of Albert Forman. Autopsy, November 4, 1884. Mr. Treves.

#### **Abnormal Aortic Valve.**

1494. A portion of the left ventricle with the commencement of the aorta laid open, and showing the aortic valve with only two segments, one, formed by fusion of the anterior and left posterior segments, being nearly twice the size of the other, and having a ridge upon its aortic surface where the two segments are united. The aorta is of full size.



**Persistent Eustachian Valve.**

1495. Portion of the right auricle of an adult heart, showing the remains of the Eustachian valve, finely fenestrated, attached to the auricle and to the outer portion of the vena cava inferior.
1496. A similar preparation to the above, but the remains of the valve are more membranous.

**Absence of Pericardium.**

1497. A heart, left lung, part of diaphragm, &c. from a case in which the pericardium was believed to be absent. There are flakes of lymph on the surface of the heart.



## SERIES XXVIII.—INJURIES AND DISEASES OF ARTERIES.

### INJURIES.

**Wounds:** 1498 to 1500.

**Rupture from Violence:** 1501 to 1505.

**Effects of application of Ligature** 1506 to 1510.

Division of the internal coat: 1506, 1507.

Obliteration by clot after ligature: 1508, 1509.

No obliteration: 1510.

### DISEASES.

**Arteritis:** 1511.

**Syphilis:** 1512.

**Tuberculosis:** 1513.

**Atheroma:** 1514 to 1533, 1537, 1540 to 1544, 1547, 1554, 1555, 1564, 1567, 1569, 1578, 1581, 1586, 1590, 1592, 1596, 1598, 1599, 1601, 1602, 1609.

Calcareous degeneration: 1518 to 1523.

Calcareous plates.—Exfoliation of inner coat.—Ulceration: 1524 to 1530.

Deposit of fibrin on atheromatous plates: 1531, 1532.

Intra-mural cyst: 1533.

**Dilatation of Arteries:** 1534 to 1536.

**Fusiform Aneurysm:** 1537 to 1539, 1549, 1551, 1554, 1559 to 1563, 1582, 1583, 1598, 1601.

**Sacculated Aneurysm:** 1540, 1541, 1548, 1550, 1552, 1553, 1555, 1557, 1558, 1564 to 1566, 1568 to 1570, 1572, 1575, 1576, 1579, 1586, 1589 to 1591, 1593 to 1597, 1599, 1600, 1602, 1604 to 1606, 1609 to 1614.

**Dissecting Aneurysm:** 1542 to 1544, 1585.

**Diffused Aneurysm:** 1545, 1546, 1571, 1574.

**Aneurysms of particular Arteries.**

Of the Sinus of Valsalva: 1547, 1586.

Of the Aortic Arch: 1537, 1538, 1541, 1542, 1548 to 1554, 1576, 1578 to 1580, 1587 to 1589, 1591, 1593 to 1595, 1597 to 1601, 1610 to 1614.

Of the Thoracic Aorta: 1540, 1543, 1544, 1555, 1585, 1602 to 1604.

Of the Innominate Artery: 1575, 1577, 1596.

Of the Axillary: 1556.

Of the Ulnar: 1557.

Of the Cerebral arteries: 1558 to 1562, 1606 to 1608.

Of the Vertebral: 1563.

Of the Abdominal Aorta: 1543, 1545, 1564 to 1567, 1581, 1605, 1609.

Of the branches of the Abdominal Aorta: 1568, 1569.

Of the Femoral artery: 1539, 1546, 1570, 1571, 1583.

Of the Popliteal: 1572, 1573, 1574, 1584.



**Specimens illustrating the mode of cure in Aneurysms.**

Spontaneous cure by deposition of laminated fibrin: 1575 to 1583.  
 Consolidation after compression of the artery: 1584.  
 Consolidation after ligature: 1570.

**Specimens illustrating the progress of Aneurysms.**

Rupture into the Pericardium: 1544, 1585 to 1589.  
 " " Heart-cavities: 1547, 1590.  
 " " Superior vena cava: 1591.  
 " " Pulmonary artery: 1592.  
 " " Pleural cavity: 1593.  
 " " Trachea: 1594 to 1596.  
 " " Bronchus: 1597 to 1601.  
 " " Œsophagus: 1597, 1602 to 1604.  
 " " Peritoneal cavity: 1565, 1605.  
 " " Brain and meninges: 1606 to 1608.

**Specimens illustrating the pressure-effects of Aneurysm.**

Absorption of bone: 1609.  
 Pressure on the Trachea: 1551, 1601.  
 " " Bronchi: 1551, 1611, 1612, 1614.  
 " " Superior vena cava: 1551, 1587, 1613.  
 " " Pulmonary artery: 1612, 1614.  
 " " Nerves: 1552, 1556, 1574.

**Embolism and Thrombosis: 1615 to 1623.**

Coagula: 1624, 1625.

**INJURIES.****Wounds.**

1498. A punctured wound.—The aortic arch with the origin of the great vessels. The anterior wall has been laid open, and shows an irregular opening in the posterior wall opposite the origin of the left subclavian artery, about half an inch in length. In this aperture there is a glass tube which is also passed through two apertures in the walls of the œsophagus, which is seen at the back of the specimen.

1499. A specimen showing perforation of the superficial femoral and profunda arteries and of the companion veins, caused by a stab in the groin. A glass tube is passed through the wounds.

The patient sank from uncontrollable hæmorrhage. Mr. J. Adams.

1500. A wound of the left internal mammary artery.—A sternum, with part of the anterior thoracic wall, from a man who died from hæmothorax, due to hæmorrhage from the left internal mammary artery, wounded by a stab in the chest. At the upper border of the third



costal cartilage an expansion of the vessel is seen, with thickening of its coats. There are some adherent coagula around it.

Case of James Welch, aged 45, admitted under Mr. Couper, April 24th, and died on the 27th of April, 1883.

### **Rupture from violence.**

1501. The arch of the aorta, from a child who was run over and killed. About half an inch below the origin of the left subclavian is a cleanly-cut transverse rent in the wall of the artery, through which a glass tube has been passed. It is nearly in a line with the origins of the great vessels and is about a third of an inch in length.

1501 a. Two portions of the arch of an aorta torn completely across. The heart was found lying loose in the pericardial sac. The arch has been ruptured at the origin of the innominate artery.

See Series XXVII. No. 1408 a.  
Mr. McCarthy.

1502. A portion of the left ventricle, with the commencement of the aorta, showing a transverse laceration of the middle and internal coats of the aorta near its origin and rupture of the external into the pericardium. The coats have been separated over a considerable area. Bristles are seen in the coronary arteries.

1503. A left ventricle of a youth, with the origin of the aorta laid open. About half an inch above the aortic valves is seen a large irregular rupture, chiefly of the internal and middle coats. At the lower part the external coat is perforated by a small aperture about a quarter of an inch in length.

1504. A portion of the subclavian and axillary arteries after rupture of the latter. The preparation shows constriction of the artery at a spot where the internal and middle coats are torn completely through. These coats have retracted so as to leave more than an eighth of an inch of the vessel protected by the external coat alone. The edges of the laceration are ragged. Below the laceration the vessel is empty, but above it there is a firm plug an inch in length which at the seat of laceration adheres closely to the coats, but higher up only loosely. From the apex of this plug a thin fibrinous coagulum tails off for several inches within the vessel.

The patient, an elderly man, had been run over. His pectoralis major on the right side was torn across; the clavicle and scapula broken. The arm was found to be pulseless, and on passing the finger into a small wound in the axilla the arrest of pulsation at a definite spot in the artery was easily distinguished. The arm became gangrenous and the man died on the third day.

*Presented by Mr. Hutchinson, Nov. 15th, 1866.*



1505. A knee-joint showing complete rupture of the popliteal artery and vein, from a case in which partial luxation of the knee-joint had occurred. Secondary amputation was performed on account of gangrene, but the patient did not recover.

Mr. Hutchinson.

### **Effects of application of Ligature.**

#### **Division of the internal coat.**

1506. Part of the aorta, with the left innominate, the origin of the left subclavian and common carotid arteries, after ligature of the latter. The ligature has been removed and the artery laid open. The effect of the ligature in cutting through the internal and middle coats is beautifully seen. On the proximal side of the ligature the lining membrane is quite normal, and there is no trace of coagulum. On the distal side all the coats are discoloured and of a purple hue from blood-staining. For the first inch the artery is open, but higher up it is plugged with coagulum. No doubt the patient died before the ligature had separated.

Mr. Critchett.

1507. A portion of the carotid artery after ligature. The specimen shows division of the internal coat. From a case of necrosis of the petrous portion of the temporal bone in a child.

Case of Lewis Danlon. Mr. Treves.

#### **Obliteration by clot after ligature in continuity.**

1508. This specimen is from a patient who died seven years after ligature of the femoral for popliteal aneurysm. He died suddenly, and at the post-mortem a rupture of the aorta into the pericardium was found. The preparation shows the vessel occluded for about two inches and a half. Above and below this it is quite free and of healthy appearance. It becomes again occluded just above what remains of the aneurysmal sac, which latter is to be recognized only by general thickening of the parts about the vessel.
1509. A femoral artery and vein from a case in which the superficial femoral was tied for popliteal aneurysm. The ligature had not separated. The artery, which is laid open, shows a plug an inch and three quarters below the ligature and one inch in length above. The whole length of the vein is inflamed and in parts plugged with coagula. The patient died one week after the operation.



**No obliteration after ligature.**

1510. This specimen shows the condition of the femoral artery ten days after an amputation above the knee. The artery has been laid open down to its ligatured end, and is quite patent, being empty of coagula throughout. There are a few small shreds of lymph above the ligature, but no plugging.

The patient was an old man, for whom amputation had been performed in consequence of sloughing after compound fracture of the tibia.

## DISEASES OF ARTERIES.

**Arteritis.**

1511. This specimen consists of about two inches of a vessel the size of the femoral, with its sheath thickened and adherent. The interior of the vessel shows thin flakes of fibrinous lymph. Both internally and externally every part of the vessel had a dark red blood-stained appearance when first obtained.

**Syphilis.**

1512. Perforation of the aorta, arteritis, syphilitic.—The heart and thoracic aorta, showing extensive destruction of the inner surface of the arch of the aorta, with erosion of its deeper layer and bulging of its wall at several points. At the largest and most prominent of these bulging areas, on the convexity of the arch just within the pericardium, perforation has occurred, which caused sudden death by hæmorrhagic extravasation into that cavity. The aorta has been laid open longitudinally and is viewed from the right side. On this side of the vessel, about the commencement of the arch, is an excavated pit of the size of a pea, more than a quarter of an inch deep. Beyond the left subclavian artery there are many smooth elevations of the endarterium, but no erosion of it or bulging of the vessel. The arch of the aorta is dilated throughout. The aortic valves appear normal. The left ventricle of the heart is dilated. The wall of the right ventricle is much wasted and invaded by adipose tissue, which is in excess over the surface of the organ.

From a woman, a prostitute, aged about 30, who died suddenly while at breakfast. No previous symptoms. "The liver and kidneys showed the usual signs of alcoholism."

*Presented by Dr. H. S. Sargent.*



**Tuberculosis.**

1513. A portion of lung from a case of tuberculosis, with the pulmonary artery and its primary branches laid open, showing in four divisions of the vessel clusters of minute granulations which are surrounded by, and more or less adherent to, enlarged and indurated caseous bronchial glands.

Case of J. Mahoney, 14, who had tubercular disease of the mesenteric, retro-peritoneal, mediastinal, and bronchial glands, with extensive tuberculosis of the peritoneum and ulceration of the ileum. There was fibrous induration and excavation of the apices of the lungs, and masses of caseous consolidation, clustered grey granulations, and isolated miliary tubercles throughout the organs, together with tubercles on the pleuræ. There were a few miliary tubercles in the liver, spleen, and kidneys.

Autopsy, March 24, 1885. Dr. Down.

See Path. Soc. Trans. vol. xxxvii. p. 139.

**Atheroma.**

1514. A portion of the aorta, showing small atheromatous patches. The internal coat is raised over small areas owing to yellowish deposit beneath.
1515. A portion of the aorta, showing well-marked oval patches of atheromatous deposit.
1516. Portions of the femoral artery, showing still more marked patches of atheroma.
1517. A portion of the aorta, the internal coat of which has been stripped up to expose opaque raised patches of atheroma. Similar patches are seen in the middle coat; the two have evidently been morbidly adherent to each other. The external coat appears healthy.

**Calcareous degeneration.**

1518. A dry specimen, showing plates of calcareous matter.
1519. A portion of the abdominal aorta, with its bifurcation, showing calcareous deposits in its coats.
1520. A similar specimen.
1521. A portion of the aorta laid open, showing calcareous plates projecting inwards towards the lumen.



1522. An aorta, everted, showing dense calcareous plates.

1523. A portion of the axillary, with the entire length of the brachial artery. All parts of the vessels preserved in this specimen show a rigid calcareous tube.

**Calcareous plates.—Exfoliation of inner coat.—Ulceration.**

1524. A heart and thoracic aorta showing extreme calcareous degeneration of the arch of the aorta as far as the origin of the left subclavian artery, the descending part of the vessel being little affected. The aortic curtains are thickened; the mitral much so with stenosis. There are calcareous nodules in the valvular curtains and some ulceration with fibrinous deposit at the anterior angle of the mitral slit, and in a slighter degree at the other angle.

Case of Eliza Filer, 68 (R.N. 2), who was admitted under Mr. Tay on Jan. 7, 1885, and died on Jan. 27 from exhaustion consequent upon suppuration about a simple fracture of the neck of the femur.

1525. The abdominal aorta laid open showing nodules of calcareous growth at the orifices of the great branches at the upper part of the vessel. A large warty-looking nodule greatly obstructs the mouth of the celiac axis. There are smaller nodules at the orifices of the renal arteries. Lower down and in the iliac arteries are many small calcareous patches.

The specimen was obtained from the same patient as the preceding.

1526. A portion of the abdominal aorta showing very extensive atheromatous changes. In almost all parts patches of yellow calcareous deposit are seen, with numerous superficial ulcerations. The vessel itself and all its branches appear to be enlarged.

1527. The heart and commencement of the aorta of a man aged 49, who was brought in dead. The orifices of the coronary arteries are stenosed from atheromatous disease of the aorta. At the time of the autopsy there was only a pin-hole opening into the left coronary artery, which was found with difficulty.

Case of James Mahoney, who was taken suddenly in the street with pain in the left arm and side, and died in a shop to which he was taken. The body was well-developed and well nourished; the heart-muscle was flaccid, but showed no appearance of fatty degeneration on microscopical examination.

Autopsy, November 19, 1883.

1528. The lower portion of the abdominal aorta with the iliac arteries, from an old woman. It shows extensive calcification of the arterial



coats. For nearly two inches the whole of the arterial tube is involved and rendered quite rigid. At many other parts there are large plates. The common iliacs are much less extensively diseased than the aorta, and the external and internal iliac arteries appear free from disease. The patient died in consequence of a fracture of the neck of the femur.

1529. Portions of the aorta showing calcareous atheromatous deposit, with patches of ulceration of every degree of depth and size.

1530. The heart and thoracic aorta of a female aged 62, showing extensive and destructive ulceration of the inner coat of the latter. There are several large ulcers of irregular form, with sharply cut edges and the detached endarterium still connected with them in part. There are smaller ulcers, some denuded, some still covered by the undermined superficial layers. The ulcers occur in the arch and descending thoracic aorta. There was only one ulcer in the abdominal aorta, this was just below the diaphragm. The vessel is exceedingly degenerated, with many calcareous plates. The aortic curtains are thickened, the heart hypertrophied. Sections from one of the ulcers showed clusters of micrococci in the deepest layers of the intima in its floor and in its edges.

Case of Hannah Smith, 62 (R. N. 319), who died on April 9, 1885, from cardiac failure with valvular disease and granular kidneys. She had suffered many years with her chest.

Dr. Sansom.

#### **Deposit of fibrin on atheromatous plates.**

1531. The heart and arch of the aorta from the same case as 1500. On the aorta are some raised atheromatous patches, just above the valve is a soft vegetation, and further on are a few smaller nodules of a similar kind.

1532. The arch of an aorta laid open, showing polypoid masses of fibrinous material at the upper part of the arch. At the origin of the great vessels, between the two masses, the endocardium is raised, probably by atheromatous deposit.

#### **Intra-mural cyst in Sinus of Valsalva.**

1533. A heart and commencement of the aorta showing a cyst of the size of an almond with smooth walls, situated behind the right posterior sinus of Valsalva, and communicating with it by a narrow aperture near the junction of the right posterior and anterior curtains.



The long axis of the cavity is transverse, and on a level with the free border of the valvular curtain. There is some thickening of the aortic valve. The aorta is very atheromatous, its surface much roughened. The cyst seems to be between inner and middle coats. The right coronary artery is very large, and gives off a large branch, which runs backwards, and supplies the place of the posterior branch of the left coronary artery, which is undeveloped. The orifice of the left coronary artery was found with some difficulty at the autopsy, being nearly closed by atheromatous swelling of the aorta.

From a man, Alex. S., aged about 60, brought in dead.  
Autopsy, April 22, 1884.

For other specimens of Atheroma, *vide* Nos. 1537, 1540, 1541, 1542, 1544, 1547, 1554, 1555, 1564, 1567, 1569, 1578, 1581, 1586, 1590, 1592, 1596, 1598, 1599, 1601, 1602, 1609.

### Dilatation of Arteries.

1534. Part of a common carotid artery, showing regular fusiform dilatation. The artery is turned inside out in the specimen.

1535. The pons and medulla oblongata, with the basilar and vertebral arteries, showing remarkable thickening and dilatation with atheroma of the lower portion of the latter. The dilated parts of the vessel are abruptly limited at a level corresponding with the foramen magnum. The specimen shows the effects of the strain to which the vessels were exposed outside as compared with the inside of the cranial cavity.

Case of John Potter, aged 52. Died from perforating ulcer of stomach and purulent peritonitis, November 24, 1884.

Mr. Rivington.

1536. An aorta and pulmonary artery. The aorta is atheromatous. The pulmonary artery is dilated owing to obstruction to the passage of blood through the lungs, which were extremely cirrhotic.

From a labourer, Henry M., aged 60, admitted April 9, and died on the 29th, 1869. He had had a winter cough for 8 years. No history of rheumatism. There was much dilation of the right side of the heart, with general anasarca and congestion of liver and intestines. He died somewhat suddenly of heart-failure.



## VARIETIES OF ANEURYSM.

**Fusiform Aneurysm.**

1537. A heart and aorta showing fusiform dilatation of the ascending part of the arch, with very extensive atheromatous disease of the coats. The dilatation involves chiefly the large sinus. The heart has been dissected to show the visceral pericardium, coronary arteries, muscular structure, &c.

1538. Aneurysmal dilatation of the aorta. The ascending part of the arch shows general tubular dilatation; the transverse part is dilated to a slight extent, and the descending part, which has been slit open, is very much distended.

1539. Aneurysm of the femoral artery. This specimen presents a fusiform aneurysm of the lower part of the femoral artery, where it is contained in Hunter's canal. A portion of the sartorius has been left to mark the position. There is another fusiform aneurysm of the popliteal artery, which was not distinguished as a separate dilatation during life. The sciatic nerve has also been left, and shows a tortuous and somewhat dilated condition of the *comes nervi ischiadici* artery; a branch from this passes into the lower part of the upper sac.

The patient was a man over sixty. The femoral artery was ligatured by Mr. Couper at the apex of Scarpa's triangle. Death resulted from gangrene of the extremity and exhaustion.

For other specimens of fusiform aneurysm *vide* Nos. 1549, 1551, 1554, 1559, 1560, 1561, 1562, 1563, 1582, 1583, 1598, 1601.

**Sacculated Aneurysm.**

1540. A portion of the descending aorta, showing an extensive atheroma of the coats, and an aneurysmal pouch which would admit the end of the little finger. At the extremity of this pouch there is a laceration an eighth of an inch long.

It was obtained from a man who died suddenly. No disease was suspected during life.

1541. This specimen is described in the Old Catalogue as aneurysm of the descending aorta. It has been dried and varnished, and is now exceedingly difficult to identify. It shows a tube as thick as a wrist, the coats of which consist almost entirely of bony plates. From this tube three pouches protrude, the largest the size of a child's fist, the two others each the size of an egg.

For other specimens of sacculated aneurysm *vide* Nos. 1548, 1550, 1552, 1553, 1555, 1557, 1558, 1564, 1565, 1566, 1568, 1569, 1570, 1571, 1572, 1575, 1576, 1579, 1586, 1589, 1590, 1591, 1593, 1594, 1595, 1596, 1597, 1599, 1600, 1602, 1604, 1605, 1606, 1609, 1610, 1611, 1612, 1613, 1614.



**Dissecting Aneurysm.**

1542. Portion of the heart and great vessels, showing a dissecting aneurysm of the first part of the arch of the aorta. The middle and external coats are separated (or possibly the middle coat is split) over an extent of almost three inches in length. The layer of blood between them is at the thickest part nearly half an inch across. The coats of the vessel show large patches of atheroma, and a ragged laceration an inch in length.

1543. The thoracic and abdominal aorta, showing a dissecting aneurysm, which commences above beyond the origin of the great vessels, and involves the whole of the descending thoracic and abdominal aorta. At the lower part just above the bifurcation the latter is dilated into two large sacs, which are separated by a septum composed of the internal and part of the middle coats, and are partially filled with clot.

The patient had also an aneurysm of the internal carotid in the cavernous sinus.

*Presented by Mr. Hutchinson.*

1544. Rupture of aorta. Dissecting aneurysm opening into pericardium.

A heart and thoracic aorta, showing a longitudinal laceration of the latter, of older date, commencing immediately above the junction of the two posterior curtains, and running upwards for about  $1\frac{1}{2}$  inch; and an apparently quite recent transverse laceration starting from its upper end, and running all round the vessel to within  $\frac{1}{4}$  inch of its starting-point. Above this transverse rupture the outer coat, with a few layers of the middle coat, has been extensively separated from the middle and inner coats, all over the convexity of the ascending arch and over the innominate artery. At the lower (proximal) part of the longitudinal laceration, the inner coat and inner layers of the middle coat have alone given way, and these coats had become separated rather extensively from the deeper layers of the arterial wall along the left border of longitudinal rent, and had been lacerated also transversely for some distance (about an inch) in the line of the recent transverse rent. These two initial ruptures of the internal layers do not quite meet. This detached flap of the innermost layers, retracted and corrugated both longitudinally and transversely, has become again attached to the outer layers in their displaced position, the free border above remaining free. The middle coat, excepting a thin shell of its outermost layer, has given way at this part in the line of the longitudinal rent, and has been pushed outwards into the cavity of a dissecting aneurysm formed at this part. It is separated by a transverse rupture from  $\frac{1}{2}$  to  $\frac{3}{4}$  inch in extent from the unruptured part.

Behind this upper part of the longitudinal rent is seen a recessed



dissecting aneurysm, lined with a smooth membrane. It has extended upwards in the concavity of the arch for about an inch, and presents two recesses, one above and one below the line of transverse laceration. It is seen in the specimen that the point at which the middle coat has given way corresponds to the point of reflection of the pericardium from the aorta to the left auricle. The dissecting aneurysm bulges out over the arch which the reflection of the pericardium forms at this part. The broad ridge separating the upper and lower recesses of the aneurysm corresponds with the right pulmonary artery.

In the lower recess the pericardium has been perforated in front of the arch above mentioned. Through this aperture extravasation has taken place into the connective tissues of the part, and has spread extensively not only over the concavity of the arch of the aorta, but over the convexity of its first portion from the valve to a short distance above the transverse rent, over the parietal pericardium, into the mediastinum, upwards about the roots of the great arterial trunk in the neck, and downwards along the œsophagus.

There are atheromatous changes in the aorta, not of an advanced degree, and not notable in the first part of the aorta and of the arch. The aortic curtains are slightly thickened. The left ventricle is hypertrophied and dilated.

Case of Charles Thurston, a labourer aged 64, who was admitted into the Hospital on February 18, 1884, in a collapsed and extremely anæmic condition. Brandy was administered and he rallied, but suddenly became faint the following day and died. He had been unwell for some time, complaining of thoracic pain and shortness of breath; he was at work, however, when suddenly taken ill.

Sir Andrew Clark.

*Vide* also No. 1585.

### **Diffused Aneurysm.**

1545. Part of the walls of a very large aneurysm of the abdominal aorta. The opening into it is the size of a shilling, with smooth well-defined edges. The walls of the vessel below the aneurysmal opening show patches of disease of the internal coat, but above it the artery appears healthy. A portion of the lung and diaphragm are seen in the wall of the aneurysm.

1546. A diffused aneurysm of the femoral artery. The aneurysmal sac is as large as a fist, and contains layers of laminated fibrin of irregular thickness. The sac is covered partly by iliacus and psoas muscles. The opening into it is as large as half a crown.

*Vide* also Nos. 1571, 1574.



## ANEURYSM OF PARTICULAR ARTERIES.

### Aneurysm of the Sinus of Valsalva.

1547. The left ventricle and aorta laid open to show an aneurysmal bulging of the right anterior sinus of Valsalva. The aneurysmal sac would contain a walnut. The valve and ventricular wall below it present a globular bulging with a rough ulcerated surface, near the centre of which is an irregular laceration about half an inch in its longest diameter. The aorta is extremely atheromatous.

From a seaman, George E., aged 40, who died on Nov. 23, 1888, a week after admission to the hospital. He had been ill some 4 or 5 months with much pain in the chest, much vomiting, and paroxysmal dyspnoea. There were double aortic and apical bruits audible.

Dr. Gilbert Smith.

*Vide* also No. 1586.

### The Arch of the Aorta.

1548. Aneurysm of the arch of the aorta. A dried specimen. The aneurysmal sac is as large as a cricket-ball, and is situated at the commencement of the transverse part of the arch, close to the root of the innominate, which is pushed over to the left. It bulges chiefly upwards and to the right; the right innominate vein is seen behind the sac.

1549. A foetal heart and aorta, showing a rounded aneurysmal dilatation of the latter. The aneurysmal sac is about as large as a marble and its coats dense. It bulges chiefly to the left, but involves the whole calibre of the artery. It contains little or no fibrin. It is placed just at the commencement of the descending part of the arch, and involves a length of about three quarters of an inch.

1550. A sacculated aneurysm, globular in shape and as large as an orange, springing from the right side of the ascending part of the arch of the aorta. Its communication with the aorta is by means of an oval aperture with smooth edges. The aorta is dilated and extensively atheromatous, the aortic cusps thickened and rigid. The pericardium is closely adherent to the aneurysmal sac, which is partially filled with laminated clot.

Case of Thomas Ward, admitted under Dr. Down on May 23, 1888, suffering from thoracic pain of 4 years' duration. He had had syphilis. He died from exhaustion on July 1, 1889.

1551. An aneurysmal dilatation, as large as a cocoa-nut, of the transverse part of the arch of the aorta. The aneurysm seems to have originated in the posterior and lower walls of the arch, the origins of the great vessels being little dilated. The trachea and left pulmonary artery



and superior vena cava are stretched over the back of the sac. The sac is intimately adherent to these structures and to part of the left lung.

Case of Emma Hawkins, aged 54, who was admitted on Jan. 15, 1889, in a state of profound collapse and died in a few hours.

At the autopsy the left lung was found displaced and the aneurysm in contact with the trachea. The left pleural cavity contained 34 ounces of coagulated blood from a rupture of the aneurysm. The heart and subcutaneous tissues were loaded with fat.

1552. An aorta with the great vessels, left vagus nerve, and trachea, showing a large globular sacculated aneurysm of the third part of the arch bulging backwards and outwards. There is an aperture in the posterior wall which was most probably a rupture. The stretched left vagus and its recurrent branch are well seen.

1553. An aneurysmal pouch as large as an egg, between the aorta and the pulmonary artery. The opening into the aneurysmal pouch is the size of a fourpenny-piece, and is placed about an eighth of an inch below the left coronary artery. The sac does not contain any coagulum. It has displaced the pulmonary artery and the auricles, and bulges into the upper part of the cavity of the left ventricle. In the specimen the trunk of the pulmonary artery and the sac of the aneurysm are seen in section both on right and left.

1554. A very large aneurysmal dilatation of the arch of the aorta. The commencement of each of the great vessels is very slightly dilated. There is no fibrin deposited upon the walls of the aneurysm. The descending aorta has been laid open, and shows extensive patches of atheroma. The superior vena cava is seen in part at the back, and the pulmonary artery in front of the tumour.

For other specimens *vide* Nos. 1537, 1538, 1541, 1542, 1576, 1578, 1579, 1580, 1587, 1588, 1589, 1591, 1593, 1594, 1595, 1597, 1598, 1599, 1600, 1601, 1610, 1611, 1612, 1613, 1614.

### **The Thoracic Aorta.**

1555. An aneurysm of the descending aorta, with numerous smaller dilatations immediately above. The aneurysm is sacculated, but there is not much laminated fibrin. The artery is very atheromatous. The specimen was obtained from the body of a sailor named Peter Clarkson.

For other specimens *vide* Nos. 1540, 1543, 1544, 1585, 1602, 1603, 1604.

### **Innominate Artery.**

*Vide* Nos. 1575, 1577, 1596.



**Axillary.**

1556. Aneurysm of the left axillary artery. The tumour is about the size of an orange. The lesser pectoral muscle is partly adherent to it, and the cords of the brachial plexus are strained over it, more particularly the inner head of the median nerve. The cephalic and some smaller veins pass over it.

The specimen was obtained from a case in which Mr. Maunder ligatured the third part of the subclavian artery. The patient died of pericarditis resulting from purulent infiltration along the anterior mediastinum.

**Ulnar.**

1557. A small globular aneurysm on the ulnar artery, about two inches below the bend of the elbow. It is the size of a small marble. The walls are thin and no laminated fibrin is seen.

**Cerebral Arteries.**

1558. Aneurysm of the basilar artery. The arteries from the base of the brain showing an aneurysm of the size of a nut at the distal end of the basilar artery, viewed from above. The aneurysm projected upwards between the crura cerebri and optic tracts, portions of which are seen adherent to its walls.

From a man named Oswald, aged 52, admitted April 24, 1884, R. N. 591, who fell down insensible at his work. He was brought to the hospital and died about half an hour afterwards. There was divergence of the eyes.

1559. The arteries from the base of the brain, showing a small aneurysm on the anterior communicating artery close to its junction with left anterior cerebral artery. It was rather larger than a hempseed.

1560. Several small aneurysmal dilatations in the trunk of a cerebral artery, laid open.

1561. Branches of one of the smaller cerebral arteries, showing numerous fusiform aneurysmal dilatations.

From a woman named Rebecca Wood, who died of cerebral hæmorrhage.

1562. Aneurysmal dilatation of cerebral arterioles from a case of cerebral hæmorrhage.

For other specimens *vide* Nos. 1606, 1607, 1608.

**Vertebral.**

1563. The two vertebral arteries with the commencement of the basilar artery. There is a fusiform dilatation of the commencement of each vertebral, extending along the artery for half an inch.



**Abdominal Aorta.**

1564. The abdominal aorta laid open from behind, showing a large sacculated aneurysm above the origin of the cœliac axis and renal vessels, which have been cut off short. The aneurysm is nearly filled with dense laminated fibrin. The aorta is very atheromatous, especially at the lower part.
1565. A large sacculated aneurysm which has been laid open. It arises from the abdominal aorta near the origin of the cœliac axis. The hepatic artery arises from the front of the aneurysm, the two renal are given off just below the lower end of the sac. The aneurysm involves about an inch of the lumen of the aorta and has spread forwards, and then to the right, as far as the under surface of the right lobe of the liver, a portion of which, together with the crura of the diaphragm and inferior vena cava, are closely incorporated with the sac. There is little or no clot in the aneurysmal sac, the wall is thin and presents at the upper part a jagged laceration, evidently the seat of rupture.

Case of Charles Jenkins, baker, aged 25, admitted on March 7, 1889, with pulsating swelling immediately below cartilaginous border of right false ribs, which was slightly everted. He declared that he had only noticed it that morning and felt no inconvenience from it; subsequently it transpired that he had had some difficulty in swallowing for the last five weeks. There was no lateral expansion, but a harsh bruit audible also over the spine. On compression from before backward it disappeared, and did not reappear for some seconds, and then gradually. The diagnosis was aortic aneurysm or vascular growth in liver. He died suddenly on March 14th, shortly after eating his dinner. At the post-mortem there was found copious hæmorrhage into the peritoneum from a very large thin-walled aneurysm of abdominal aorta, which was adherent to the liver (hence the absence of lateral expansion) and also to the stomach (hence the dysphagia).

Mr. McCarthy.

1566. The abdominal aorta dividing into the two common iliacs. There is an irregular opening into the lower part of the aorta which presents a sacculated aneurysm, whose walls vary in thickness. The commencement of the common iliacs, especially the right, is dilated.
1567. A dried specimen of an aneurysm said to be at the root of the cœliac axis, with deposit of calcareous matter in the walls of the aneurysm and in the arterial coats adjacent.

For other specimens *vide* Nos. 1543, 1545, 1581, 1605, 1609.

**Branches of the Abdominal Aorta.**

1568. The specimen shows the back of the pancreas, with a small aneurysm on the splenic artery. The aneurysm is somewhat smaller than a horse-bean. It has thin coats and is somewhat sacculated.



1569. Aneurysm of the splenic artery. There is a sacculated aneurysm as large as an orange situated about two inches from the commencement of the vessel. The distal part of the splenic artery and the splenic vein are seen upon the wall of the aneurysm, as is also the left supra-renal body. The lower end of the aorta about the bifurcation is atheromatous, but not the part above, from which the large arterial trunks arise.

Case of John Knight, aged 37, a carpenter, brought in dead. At the autopsy on July 21, 1883, a large effusion of blood was found in the peritoneal cavity. There were no nodes; the liver and testes were normal.

### Femoral.

1570. This specimen is a continuation of No. 1566. The left common iliac artery has been divided. There is a ligature on the artery which was applied for the cure of a large globular sacculated aneurysm below involving the common femoral and profunda arteries.
1571. A femoral artery laid open showing the origin of the profunda femoris. Behind the artery is a sac the size of an orange, with two circular apertures in it each rather larger than a shilling. There is a considerable amount of laminated fibrin within the aneurysm. The sac seems chiefly composed of the adjacent muscular tissues. On the outer side of the sac is seen an artery, probably a branch of the profunda and in which is a red glass rod.

From a man named James B. B., aged 28, admitted Oct. 27, 1880, under Mr. Couper, and died Dec. 27, 1880. There was a history of rheumatic fever before admission and of the gradual formation of a small aneurysm in the thigh which had been noticed for some five weeks. This was easily cured by digital compression. Subsequently, however, there was a persistent high temperature, rapid emaciation, pain in the left flank, evidence of plugging of the popliteal and brachial arteries; delirium; exhaustion. At the autopsy enormous vegetations were found on the aortic valves, with emboli in the spleen, liver, and kidneys, and in the right brachial, popliteal, and left posterior tibial arteries.

For other specimens *vide* Nos. 1539, 1546, 1583.

### Popliteal.

1572. A portion of a knee-joint with the popliteal artery and vein: connected with the artery is an aneurysm globular in shape and as large as an orange, partially filled with laminated coagulum.

Case of Thomas C., aged 35, a seaman, admitted under Mr. Waren Tay on Aug. 8, 1889. He complained of swelling in the right ankle of six weeks' duration, accompanied by some twitching pains which steadily increased in severity. There was on admission a pulsating tumour filling the whole popliteal space, the edges of which could not clearly be defined; a distinct thrill could be felt over the tumour, which was expansile, and a systolic bruit could be heard. Esmarck's bandage was applied to the leg from the foot to the thigh, and a tourniquet



above the bandage for 1 hour, then digital compression for some hours was tried with the effect that pulsation ceased in the tumour. Anæsthesia of the foot, with a zone of hyperæsthesia, supervened, gradually passing on into dry gangrene which necessitated amputation above the knee. The patient made a good recovery.

Mr. Waren Tay.

1573. Part of the sac of a popliteal aneurysm. The opening into the artery involves one half its calibre and is an inch in length.

"A man with popliteal aneurysm was admitted into the London Hospital under the care of Mr. T. Blizard; the operation was performed according to Mr. Hunter's method, with the improvement of Mr. Abernethy. A few days after the operation mortification commenced in the lower part of the leg, and gradually extended as far as the ham. In consequence of this, amputation was performed above the knee, the ligatures of the first operation having already separated. The chief hæmorrhage in the amputation was from the popliteal artery. The aneurysm being examined, it was found that the artery above the disease, though contracted, was not obliterated."

1574. A right knee-joint, presenting a huge diffuse aneurysm of the popliteal artery. A catheter is placed in the artery and is seen to be exposed on the inner side of the posterior wall of the tumour for a distance of over an inch. There is some laminated fibrin within the sac. The lower end of the femur lies partially exposed over a large extent within the sac. The sac is chiefly composed of the surrounding tissues. The sciatic nerve is seen stretched over the back of the tumour.

"This specimen was removed by amputation from an Irishman of middle age under Mr. Hutchinson's care in 1871. The tumour was very large and had ceased to pulsate at the time of the man's admission. The foot was also without sensation and the leg much swollen. There was much difference of opinion as to whether the tumour was a malignant one or an aneurysm, its large size, the paralysis of the foot, and the disorganization of adjacent parts led to the decision in favour of amputation: the man recovered after the operation. The cyst extended from the middle of the thigh to a little below the knee, and contained coagulum in part laminated and in part soft. The vessels ran in its outer wall just beneath the lower edge of the sartorius muscle. There was an opening in the artery of about half an inch in length."

*Presented by Mr. Hutchinson.*

For another specimen *vide* No. 1584.



## SPECIMENS ILLUSTRATING THE MODE OF CURE IN ANEURYSMS.

### **Spontaneous cure by deposition of laminated fibrin.**

1575. The heart, great vessels, and part of the sternum, showing an aneurysm of the innominate artery bulging forwards over the upper border of the latter. The aneurysmal pouch is as large as an egg, and quite filled by fibrinous coagula. It is shaped somewhat like an egg placed with its end on the innominate artery. It communicates with the front of the artery by an orifice the size of a sixpence.

"The patient was a shoemaker, aged 40, who in Nov. 1823 was, after using some exertion, seized suddenly with a pain in his right collar-bone. In June 1824 he had an increase of pain and applied to Mr. Porter. He had experienced the pain at intervals during the whole of the period. At this time he complained of violent pain and beating in his head. For several weeks he was unable to lie down; a swelling had now appeared in his neck, and was increasing. It is stated that for a time he lost his recollection, and everything for a time appeared black. In Oct. 1824 he came under the care of Mr. Luke, treatment by purgation and bleeding was adopted. Between Oct. 20, 1824, and June 14, 1827, he was bled 42 times, in quantities varying from 6 to 16 ounces. The notes state that the tumour, which at first extended some way up the neck, began to diminish immediately on the commencement of the treatment, and continued to do so steadily until all external evidence of its existence was removed, and the man appeared quite well. He died a considerable time after the conclusion of the treatment, from some cerebral disease attended with violent delirium."

1576. An aneurysm, the sac of which is as large as a full-sized orange, and is completely filled with laminated fibrin. The outer layers of the coagula are dense, the inner ones are softer. At the aneurysmal orifice a rounded mass of coagulum is seen bulging into the artery. The orifice itself is as large as a halfcrown, with very definite margins.

1577. An aneurysm of the first part of the arch of the aorta involving the origin of the innominate artery. The aneurysm has been cut across, and is seen divided into two parts by a septum. Each half is almost filled by concentric layers of fibrin, the central layers being redder, softer, and more flocculent.

1578. An aneurysm of the ascending part of the arch of the aorta as large as an orange, completely occupied by a fibrinous clot, which presents a smooth, prominent surface in the mouth of the sac. The aneurysm has pushed its way into the pleural cavity, and compressed the root of the right lung and the bifurcation of the trachæa. At the lower end of the arch is a second smaller aneurysmal pouch, also filled with clot, which has a rough surface. Both aneurysms are on the posterior aspect of the aorta. The aorta is very atheromatous.



1579. A circumscribed and almost solidified aneurysm of the ascending aorta. The opening into the sac would contain a sixpence, and is as if punched out. The sac is as large as a small apple, its coats are thin, and consist probably of stretched external coat and cellular tissue. They are protected by dense and thick layers of laminated fibrin, by which the cavity of the aneurysm is so much diminished that it would barely contain the end of the thumb. The aneurysm rises directly upwards and to the right, and is adherent to the innominate artery through the whole of its length.
1580. An aneurysm of the arch of the aorta about the size of a fist. It appears to commence close to the orifice of the innominate artery. Its cavity contains thick laminæ of firm fibrin.
1581. An abdominal aorta laid open showing near the origin of the cœliac axis a large sacculated aneurysm about the size of an orange, completely filled with laminated clot. The coats of the vessel in the neighbourhood present patches of atheroma. The opening into the aneurysm is about the size of half-a-crown with smooth, well-defined margins.
1582. A fusiform aneurysm of the lowest third of the abdominal aorta, and first inch of right common iliac. The dilatation involves all the coats, thick layers of fibrin are seen occupying the cavity and would appear to have almost closed the tube.  
Taken from a patient in the dissecting-room.
1583. An aneurysm (probably fusiform) of the femoral artery. The sac is almost completely filled with irregular fibrinous laminæ. A thickened nerve-trunk is in contact with the sac.

#### **Consolidation after compression.**

1584. A small globular aneurysm of the popliteal artery, completely consolidated after treatment by digital compression of the femoral artery.

From a man, John Fowler, aged 28, under Dr. Sutton's care, suffering from endocarditis.

#### **Consolidation after ligature.**

*Vide* No. 1570.



SPECIMENS ILLUSTRATING THE PROGRESS  
OF ANEURYSMS.**Rupture into the Pericardium.**

1585. Rupture of a dissecting aneurysm of the thoracic aorta. It was ruptured through two thirds of the circumference posteriorly, and the external coat separated to a considerable extent from the middle and internal. The vessel is dilated and degenerate.

It was presented by Mr. Pope, and obtained from the body of an aged woman who was seen to stumble and fall over a log of wood. She got up, walked a few yards and again fell. There is no history as to her previous condition. The pericardium was found full of blood.

1586. A small aneurysm situated at the very origin of the aorta, resting on the left auricle and projecting between the left auricular appendix and the pulmonary artery. The walls are extremely thin, and at the summit is a small aperture where it had burst into the pericardium. The aortic valves are much diseased. The anterior valve has been replaced by a mass of calcareous substance which encroaches upon the anterior portions of the two lateral valves, particularly the left, thus converting the entrance of the aortic channel into a small triangular opening roughly resembling the dilated rima glottidis. This calcareous deposit extends in tongue-shaped processes upwards on the aortic wall and downwards to a less extent on the mitral valve. On the upper surface of the deposit is a cleft in some degree concealed by fibrinous vegetations through which a probe can be passed for about half an inch between the walls of the aorta. On the lower surface is a fissure with rounded edges extending from the aortic border to within a little of the channel left for the passage of blood. At the aortic border was a small opening through which a probe could be passed into the aneurysmal tumour.

This case was admitted, under the care of Sir A. Clark, into the London Hospital with a history of sudden collapse. The diagnosis was rupture of one of the aortic semilunar valves. A dissecting aneurysm of the aorta was suggested by Mr. Hutchinson. The patient rallied; but a few days after, having, contrary to orders, left his bed to go to the closet, there died from effusion of blood into the pericardium.

1587. Aneurysm of the aorta close to the valves; rupture into the pericardium. The heart and ascending aorta, laid open from the left side. Immediately above the junction of the posterior valves is a vertical rent (half an inch long) in the wall of the aorta with a rough jagged edge, looking like a recent rupture of it. It opens into a cavity as large as a good-sized plum and of rounded outline, which had compressed the superior vena cava, and root of the right lung, and is seen bulging into the left auricle. It



ruptured into the pericardium and caused sudden death. There is great swelling of the wall of the aorta contiguous to the valve, and some pouching of it above the anterior valve. It is swelled at the lower end of the rent, but not about its upper end. The aortic curtains are thick and contracted. The left ventricle is dilated and hypertrophied.

Case of J. Montgomery, aged 31, R. N. 1576, admitted Dec. 17, 1883, under Dr. Fenwick. He was said to have had palpitation ever since an accident 2 years before admission. There were signs of aortic obstruction and regurgitation, mitral regurgitation with extreme hypertrophy and dilation of the ventricles, but no increased dulness over the upper part of the sternum. He had had syphilis. He died quite suddenly.

1588. A small aneurysm of the first part of the aorta opening into the pericardium. The internal aperture is situated just above the left sinus of Valsalva. It presents the appearance of a transverse slit with eroded margins. A vertical incision has been made, probably by accident, at the post-mortem. Externally the sac is thin and the opening large.

The specimen was obtained from a middle-aged woman who dropped dead suddenly without any previous history of heart-disease.

*Presented by Mr. Kibbler.*

1589. Sacculated aneurysm of the commencement of the aorta opening into the pericardium. A heart showing a small sacculated aneurysm of the aorta arising immediately above the valve, to the left of the right coronary artery and just above the valvular cusp. The sac is of the size of a cherry. It is situated behind the pulmonary artery and has opened into the pericardium. *Presented by Dr. Sargent.*

*Vide also No. 1544.*

#### **Rupture into the heart-cavities.**

1590. A larger aneurysm than the preceding specimen, but in a similar situation, immediately above the aortic valves. A small circular opening (rupture) about a quarter of an inch in diameter into the right auricular cavity is seen. The aorta is atheromatous.

*Vide also No. 1545.*

#### **Rupture into the superior vena cava.**

1591. Sacculated aneurysm of the first part of the aorta.—Communication of the superior vena cava with the aneurysmal cavity. The heart and thoracic aorta of a man. The aorta is laid open longitudinally, and shows a large aneurysmal bulging of the convex surface of the



ascending aorta with wide aperture (between 2 and 3 inches in a longitudinal direction), separated from the channel of the aorta by a crescentic ridge from half to three quarters of an inch high at the proximal and gradually lost upon its lateral borders. The superior vena cava has been closed and completely divided by the aneurysm. The central end of it is flattened upon the wall of the sac, with which it has become fused. The peripheral end appears as a short trunk with large branches arising from the surface of the sac near its upper margin. But for their thinness these vessels might be mistaken for abnormal arterial trunks to the neck. Between this part of the vena cava and the aneurysmal cavity is a thin fibrous membrane in which there are two openings, through one of which a glass rod has been introduced. There is much atheroma of the arch of the aorta, less of the descending aorta. The aortic orifice is stenosed. There is much fibrous thickening of the aortic and mitral curtains, with calcareous nodules in their substance. The left coronary artery is seen at the bottom of a longitudinal fissure in the inner layers of the wall of the aorta, probably from a rupture of it at some previous time. The examination of the specimen suggests that the aneurysm may have arisen from a transverse rent of the inner coats of the vessel, and that it is of the nature of a fully formed dissecting aneurysm as described by Dr. Peacock (Path. Soc. Trans. vol. xiv.). The aneurysm is lined with a smooth membrane continuous with the endarterium.

Case of Jas. S. Hale, aged 50, R. N. 1575. Admitted Oct. 28, 1884, died Feb. 17, 1885. He had suffered from headache and cough for seven weeks with gradually increasing œdema of the upper limbs and cyanosis of neck and face. There was a double aortic bruit with a heaving heart's impulse, and dulness over and on each side of the manubrium; inspiration on the right side was imperfect. The right pupil was contracted. General anasarca with hydrothorax supervened. Dr. Sutton.

#### **Rupture into the pulmonary artery.**

1592. An aneurysmal dilatation of the aortic arch. The aorta is extensively atheromatous, patches of ulceration being visible with deposits of fibrinous lymph. Towards the right there is a large sacculated dilatation partially filled with clot. At the back of this aneurysm is seen the pulmonary artery extensively ruptured in an irregularly transverse direction. Through this rent the clot which fills the aneurysm is seen.

#### **Rupture into the pleural cavity.**

1593. A large sacculated aneurysm of the descending portion of the arch of the aorta which has burst into the left pleural cavity. Lower



down is another smaller aneurysm of the aorta. The phrenic nerve is seen to be stretched by the larger aneurysm, to the front of which it is adherent. "One of the most prominent symptoms during life, pain in the left shoulder, is thus accounted for."

### **Rupture into the trachea.**

1594. An aneurysm of the arch of the aorta opening into the trachea. The aneurysm is of the sacculated form, and is situated at the junction of the ascending and transverse portions of the arch. The opening of the sac from the artery is ragged from erosion of the internal coats; that into the trachea is very small, and a glass rod has been passed through it.

The specimen was obtained from the body of a cabman, aged 50, who was brought into the hospital dead. The larynx, trachea, bronchi, and some air-vesicles were found full of coagulated blood. There was also much coagulated blood in the stomach.

1595. Part of the arch of the aorta, trachea, and root of the lung, showing an aneurysmal pouch, springing from the posterior surface of the ascending part of the arch, close to the orifice of the innominate artery. The margins of the orifice are very definite, as if punched out, and the sac of the aneurysm appears to have consisted, in some parts, of cellular tissue only, in others the thinned coats of the artery may be made out. The greater part of the sac has unavoidably been removed in the dissection. The trachea appears to have constituted its left boundary for about two inches in extent. About an inch above its bifurcation ulceration has occurred. One of the rings is laid bare, and a ragged opening large enough to admit a quill has been formed. It was from this rupture into the trachea that the patient died.

1596. Part of the heart, aortic arch, great vessels, trachea, and root of right lung. The aorta shows atheromatous patches and is dilated. There is a sacculated aneurysm of the innominate artery, which has perforated the trachea. A glass tube is passed through the opening into the trachea, which is oval and transverse. There has been some ulceration round the opening, which has exposed two of the tracheal cartilaginous rings.

### **Opening into the bronchus.**

1597. This specimen shows a large sacculated aneurysm of the first part of the aortic arch, almost completely filled with laminated clot; it has been bisected, and is kept open by means of a glass rod. Just above



the mouth of this aneurysm is the origin of the innominate, in which are two glass rods, one passing into the carotid and one into the right subclavian arteries. To the right the descending aorta is seen laid open. From the posterior surface of the transverse arch is seen the opening of another aneurysm, also partially filled with clot. This aneurysm communicates with the left bronchus by a small hole, through which a glass rod has been passed. There is also a small aperture of communication with the œsophagus, which is also laid open.

1598. Aneurysmal dilatation of the aortic arch, together with the trachea and bronchi, and a portion of the lung. The aorta presents atheromatous patches. The aneurysm has ulcerated through the anterior wall of the left bronchus by two small irregular openings, through one of which a blue glass rod has been passed.

1599. An arch of the aorta, œsophagus, trachea and bronchi, and root of the left lung, from a case in which the patient died of rupture of an aneurysmal sac into the left bronchus. The aneurysm is placed beneath the transverse part of the arch. The opening into the sac is as large as a shilling, and the sac itself about as large as a bantam's egg. The coats of the artery are extensively atheromatous.

1600. Part of the heart, aortic arch, roots of lung and bronchi laid open. There is a large sacculated aneurysm of the third part of the arch, arising by an orifice as large as half a crown from the inner and posterior wall of the aorta. The aneurysm is partially filled with clot. There is a small circular perforation through the anterior wall of the left bronchus, through which a glass rod has been passed.

1601. The arch of an aorta, trachea, bronchi, and part of the root of the lung, showing a large aneurysmal dilatation of the descending part of the arch, with a communication between it and one of the first divisions of the left bronchus. The aneurysmal pouch contains no clot, and involves all the coats of the artery. It is somewhat roughened by patches of adherent lymph. The coats of the artery at this and at other parts are most extensively diseased.

#### **Rupture into the œsophagus.**

1602. Part of a heart with thoracic aorta and œsophagus laid open. It shows a small aneurysm of the aorta, apparently at the origin of the left superior intercostal artery, which has opened into the œsophagus. The aneurysm is about the size of a walnut, and has smooth lining membrane. It is situated behind the left bronchus. The aorta is in-



filtrated with atheromatous patches both at the orifice of the aneurysm and in the first part of the arch. There is some fibrous thickening of the aortic curtains, and some gelatinous-looking granulations upon them. Some hypertrophy of left ventricle.

From a waterman, George R., aged 30, brought in dead, June 13, 1884, having died in the street. There was a scar on his penis, but no evidence of syphilis existed in the viscera.

1603. An aneurysm of the descending aorta which has burst into the œsophagus. The walls of the sac and the œsophagus are firmly adherent together, and a large clot is seen projecting into the latter. The aneurysm is situated a little below the level of the bronchi.

The specimen was obtained from the body of a young man who was brought to the London Hospital, and who was said to have vomited a quantity of blood. He died almost immediately after admission, and at the post-mortem examination the stomach and much of the small intestine were found filled with blood.

1604. The œsophagus and aorta laid open from behind, showing a large aneurysmal sac, developed in connection with the descending aorta, and pressing upon the œsophagus, into which it has opened. The orifice of commencement of the aneurysm is round, as if punched, and the size of a shilling. The aneurysmal sac is the size of an orange, but somewhat flattened. The left half of it is filled with fibrin. The opening into the œsophagus is a third of an inch in length.

*Vide* also No. 1597.

#### **Rupture into the peritoneal cavity.**

1605. A sacculated aneurysm springing from the front of the abdominal aorta. The sac and the aorta have been laid open from behind. The vena cava and a portion of the liver are seen behind the right half of the specimen, and part of the œsophagus behind the left. The specimen shows dense, thick, and firm layers of laminated fibrin within the sac. The sac is as large as a fist. The laceration is said to have taken place behind the coagulum, but no definite point of rupture can now be seen.

The disease was recognized some three years before the patient's death, and it was thought that its growth had been retarded by the free use of laudanum. The patient died from rupture of the aneurysm into the peritoneal cavity, and lived half an hour after the first onset of symptoms.

*Vide* also No. 1565.

#### **Rupture into the brain and membranes.**

1606. An aneurysm of the middle cerebral artery.

"A soldier, aged 22, whilst stooping down was suddenly seized with great pain in his head and giddiness. He lived 56 hours after this attack, during



which time he had frequent fits. During the last 24 hours of his life he was completely comatose." At the autopsy an effusion of blood was found between the cerebral membranes to the amount of eight ounces; upon clearing this away it was found to have arisen from the bursting of an aneurysmal sac about the size of a walnut, of "that branch of the carotid artery (internal) which passes between the anterior and middle lobes of the brain."

*Presented by Mr. Lawrence.*

1607. The arteries of the brain. The left internal carotid, middle cerebral artery and branches, from a case of cerebral hæmorrhage, showing, on the branches to the central ganglia, (1) irregular thickenings of the larger arterioles, (2) several miliary aneurysmal dilatations on some of the finest branches. On the right of the specimen are two similar vessels, to the extremities of which are attached coagula of the size of peas and of rounded form. They were found in the wall of the hæmorrhagic cavity, and are probably the vessels from which extravasation occurred. The thickening of the vessel on the left of the specimen is due to hæmorrhagic extravasation between the layers of the outer tunic, and to infiltration of its whole thickness with blood and fibrin. The end of a fusiform dilatation of one vessel so affected was removed and examined microscopically. Several miliary aneurysms were also seen in microscopic preparations of the fine arterial branches.

1608. The arteries of the brain, from a case of cerebral hæmorrhage, showing perivascular hæmorrhage, forming nodules on the branches of the right middle cerebral artery. A large clot attached to one of these indicates the source of the hæmorrhage.

#### SPECIMENS ILLUSTRATING THE PRESSURE EFFECTS OF ANEURYSM.

##### **Absorption of bone.**

1609. Portions of the lumbar vertebræ with part of the abdominal aorta laid open. At the upper part is an oval depression with somewhat smooth edges leading into an aneurysmal sac large enough to hold a filbert-nut. This aneurysm has burrowed in a backward direction towards the bodies of the vertebræ, a portion of whose substance has been absorbed by pressure. The sac of the aneurysm appears to be composed of all three coats. The arterial lining is everywhere the seat of atheromatous patches and plates. The renal vessels have been dissected out in order to mark the exact seat of the aneurysm, which



is an inch above the origin of these vessels, and between the two crura of the diaphragm, which are also to be seen. It has originated at the commencement of the second lumbar arteries, the small size of which may be compared with that of the first on the left side.

Case of Wm. Garfield, aged 50, a labourer, admitted January 12, 1889, with a history of increasing dyspnoea and oedema of a year's duration. No history of acute rheumatism or syphilis. He died on the 30th of January from heart-failure. The post-mortem notes state that in addition to the aneurysm of the abdominal aorta the aortic valves were incompetent, one curtain being deformed. The heart was hypertrophied and dilated on both sides. In the right auricle were ante-mortem thrombi. Lungs very oedematous with hæmorrhagic infarcts from thrombosed vessels. Infarcts in spleen, liver nutmeg, much oedema and congestion of abdominal viscera and lower extremities.

Dr. Stephen Mackenzie.

#### **Pressure on the trachea.**

1610. An aneurysm of the arch of the aorta compressing the pulmonary veins and trachea. The middle and internal coats appear to have been destroyed. The aneurysmal sac is larger than a fist, and is partly filled with coagulum.

*Vide* also No. 1551.

#### **Pressure on the bronchi.**

1611. A larynx, trachea, and bronchi, laid open from behind. The aortic arch shows a thin-walled sacculated aneurysm springing from its convexity, and just involving the origin of the innominate artery. The aneurysm is about the size of an orange, and has evidently ruptured on the right side. There is no clot within the sac. The right bronchus is seen to be compressed and flattened by the aneurysm.

1612. The heart, lungs, and great vessels. The right ventricle is laid open. A strip of the posterior and upper surface of the aortic arch extending from the ventricle to the left subclavian artery has been turned upwards and to the left, exposing the opening into a large sacculated aneurysm and the continuation of the aorta. The opening into the sac has smooth abrupt margins and is as large as a crown-piece. The sac itself is as large as a good-sized orange, and is partially filled with firm decolorized clot. It has pressed upon the root of the left lung and on the pulmonary artery. The left lung, in consequence, is seen to be collapsed and very small; it is everywhere covered with shreds of lymph. The opposite lung is also smaller than normal, possibly from pressure on the trachea.

*Vide* also Nos. 1551, 1614.



**Pressure on the superior vena cava.**

1613. A small sacculated aneurysm of the ascending aorta bulging backwards and to the right. It commences by an abrupt orifice, which would admit a shilling in the posterior wall of the great sinus of the aorta about half an inch below the origin of the innominate. The sac probably consists of thickened external coat and condensed areolar tissue. The aneurysm appears to have contained fluid blood, there being scarcely any coagulum visible. The superior vena cava runs along the back of the aneurysm and was compressed by it.

*Vide also Nos. 1551, 1587.*

**Pressure on the pulmonary artery.**

1614. A large sacculated aneurysm involving the whole of the aortic arch. It is partially filled with laminated clot. The roots of the lungs are pressed upon, and especially the pulmonary arteries, in which glass rods are placed.

*Vide also No. 1612.*

**Pressure on nerves.**

*Vide Nos. 1552, 1556, 1574.*

**Embolism and Thrombosis.**

1615. Thrombosis of the lower end of the aorta and of both iliac arteries. The conical terminations of the thrombus in the internal and external iliac arteries are seen. From a case of endocarditis, in which coagula were found in the left auricle (mitral stenosis).

Case of Esther T., aged 39, admitted on October 9, 1884, with a history that four days before she experienced sudden cramp in both legs, followed by swelling, especially of the left. She stated she had been ailing since a miscarriage 18 years before. She had "rheumatism" 10 years ago. There had been numbness in the left leg for 3 years.

On admission there were systolic and presystolic murmurs to be heard at the apex, and a systolic at the base. The swelling of the extremities gradually passed on into gangrene. At the autopsy the aortic valves were found incompetent, ante-mortem clots were found in the left auricle, together with thrombosis of the aorta and its branches below the inferior mesenteric artery.

1616. A femoral artery and vein completely plugged by old coagula, from a case in which gangrene of the lower extremity occurred.
1617. A portion of the femoral artery, showing two inches and a half in length of its tube completely occluded by an adherent coagulum. The cellular tissue of the sheath appears to be thickened and adherent to the vessel. It is described in the old Catalogue as extensive obliteration of the femoral artery from spontaneous inflammation of its coats.



1618. A portion of the femoral artery, showing a plug of coagulum for the most part not adherent to the coats.

1619. Calcareous degeneration with thrombosis of the left popliteal and tibial arteries. There is much thickening of the walls of the vessels. In some parts they have become converted into calcareous tubes, and here they are enlarged. They have been subsequently occluded by thrombosis.

Case of James Boyd, aged 57, admitted under Mr. Rivington with senile gangrene of the left foot and leg on December 28, 1884. He stated that his illness commenced 9 weeks before, with pain and swelling in the left great toe, which became black in 5 weeks. He had syphilis 20 years ago, and rheumatic fever at the age of 17.

His arteries generally were tortuous and thickened. He suffered from bedsores over the sacrum, right great trochanter, and patella. Amputation was declined. The temperature rose, he became delirious and lost control over sphincters. The inflammation spread up the leg, and he died of pyæmia on January 16, 1885.

At the autopsy general atheroma and abscesses in the lungs were found.

1620. A lung, showing the primary divisions of the pulmonary artery obstructed by thrombi adherent to their walls. The thrombi are covered with a smooth membrane contiguous with that lining the walls of the vessel.

Case of Jane E. Davies, aged 27, who was admitted with valvular disease and sloughing of the integuments of the right foot, due to thrombosis of the iliac and femoral veins.

Autopsy, May 17, 1884. Dr. Sansom.

1621. The root of the other lung from the same case as the last specimen, showing the end of the pulmonary artery of that side and most of its primary branches plugged with adherent thrombi. The smooth rounded central end of one of these is seen above.

1622. The lungs of a woman aged 37, who died after removal of the uterus with a suppurating uterine fibroid tumour adherent to it. In the right lung (in front of the preparation) two fibrinous coagula are seen, which are adherent at their peripheral extremities, at points of division of the vessel, from which they have been extended centripetally, being joined by branches corresponding to the collateral vessels passed by. The central ends of the thrombi are rounded. The thrombi are free from connections except at their periphery. In the left lung (at the back of the preparation) there is great thickening of the ridge between two secondary branches of the pulmonary artery by fibrinous deposit extending some distance along the vessels. Upon



the free edges of the ridge is a small pedunculated nodule, and on the wall of the main vessel is another pedunculated body, such as are seen on the valves of the heart.

Case of Jane M. McCarthy, 37. Autopsy, February 8, 1884. Mr. Adams.

1623. A lung with the pulmonary artery filled with a firm and adherent decolorized thrombus, which terminates abruptly with a smooth rounded surface towards the heart. It has blocked up all the branches of the vessel more or less completely. At the base of the lung is a large cavity with rough shaggy walls as if from sloughing or gangrene of the tissue. The tissue around is hepatized. In opening out the specimen in a line of incision through the cavity and root of lung, the adherent thrombus has been lacerated. There is another cavity in the base of the lung posteriorly.

### Coagula.

1624. Coagula from the pulmonary artery accurately fitting even minute subdivisions of the vessels.
1625. A large fibrinous coagulum from the right side of the heart and from the pulmonary vessels.



## SERIES XXIX.—INJURIES AND DISEASES OF VEINS.

**Varicose dilatation :** 1626.

**Phlebitis :** 1627–1631.

**Thrombosis :** 1632–1634.

**Phleboliths :** 1635, 1636.

---

**Varicose dilatation.**

1626. The upper part of the leg with the soleus divided to expose the popliteal and posterior tibial vessels and nerve. There is a varicose dilatation of the vein which lies among the fibres of the soleus. The fibres have been cut away to show it. The varicosity is an inch and a half in length and a third in thickness, it affects both venæ comites; the accompanying artery was small; there was no communication between the vein and artery (arterio-venous aneurysm).

Obtained from a dissecting-room subject; the knee-joint had been dislocated from old disease, and the posterior border of the tibia pressed upon the popliteal vein.

**Phlebitis.**

1627. A vein laid open; the internal coat presents a rough shaggy appearance due to the presence of soft fibrinous coagula. The vein is occluded at one spot. The coagulum is everywhere closely adherent to the wall of the vein, and is of a deep yellow colour.

From a case of phlebitis following amputation of the leg for disease of the knee-joint; in this case a ligature was applied to the femoral vein as well as to the artery.

1628. Portions of the femoral artery and vein showing the latter extensively destroyed by ulceration. There are several ligatures on the artery.

The disease followed a wound. On the second day after the injury, the foot passed into a condition of pale dry gangrene. See 'Med. Chir. Trans.' vol. xiii. p. 17.



- 1628 a. The preparation shows a long tract of vein laid open, and its lining-membrane rough with flakes of adherent lymph. The coats of the vessel seem much thickened. There is no thrombosis.

The patient died in the Westminster Hospital from inflammation of the arm after venesection.

1629. A portion of the femoral artery and vein, and the origin of the profunda femoris opened up. The vein is nearly filled with shaggy fibrin, adherent to its inner coat. The inner coat of the artery also is roughened by the deposit on it of tags of fibrinous material.

1630. Thrombosis of the inferior vena cava and iliac veins. The lower part of the inferior vena cava with the iliac vein laid open longitudinally, showing an ante-mortem coagulum adherent at the lower end of the vessel, free and terminating in a cone above. The interior of the clot was softened down into a creamy substance in which were two masses of fibrinous coagulum which are shown in the specimen. Both common iliac veins are seen to be plugged with coagulum, the left more completely. The thrombus in the vena cava terminates about opposite to the renal veins.

Case of Geo. W., aged 48, a painter, who had suffered from gout, lead-colic, and a chancre. He was admitted for debility, dyspnoea, and palpitation. His arteries were rigid, and there was a mitral systolic murmur. The post-mortem showed contracted granular kidneys, hypertrophied left ventricle, atheroma of the aorta, gelatinous consolidation of the right upper lobe, a cavity in the right lower lobe of the lung, and this specimen of thrombosis of the vena cava.

1631. A femoral vein showing the results of suppurative phlebitis.

From a case in which the patient died of pyæmia after the ligature of piles. The patient was an elderly man under the care of Mr. Curling. The symptoms of pyæmia followed soon after the operation, and there was a succession of abscesses in various parts. The man lived ten months after the operation, and at one time it was hoped he would recover. The symptoms of plugging of the femoral vein only occurred a week or two before his death, his left lower extremity then began to swell. The post-mortem showed the iliac and femoral veins with their entire lengths plugged by thrombus.

Mr. Curling.

### Thrombosis.

1632. A vena portæ completely plugged with fibrine.

From a patient aged 35, who died with a soft pulpy tumour the size of an orange in his stomach. The notes state that the trunk of the vena portæ was filled with a similar tumour, and that there were others of a caseous or cheesy consistence in the liver.

1633. A vena cava completely plugged by a mass of laminated coagulum, which does not appear to be adherent to the inner coat of the vein. This appears healthy at the part exposed.



1634. This specimen shows portions of the iliac and femoral veins, long tracts of which are distended and plugged by fibrinous clots, which for the most part do not adhere to the coats.

### Phleboliths.

1635. Phleboliths from the pelvic veins. They are as large as small peas, almost round, and of a yellowish-white colour.

They were removed from a woman aged 74, who died of cancer of the ribs, lung, broad ligament, &c.

1636. Phleboliths adherent to the interior of a vein. The vessel is laid open.



### SERIES XXX.—INJURIES AND DISEASES OF LYMPHATIC VESSELS AND GLANDS.

#### Degeneration.

- Pigmentary degeneration: 1637.
- Fibroid degeneration: 1638.
- Calcareous degeneration: 1639.

#### Caseation and Tuberculosis: 1640-1645.

#### Morbid Growths.

- Lymphoma: 1646.
- Lymphadenoma: 1647, 1648.
- Carcinoma: 1649, 1650.
- Melanosarcoma: 1649.
- Epithelioma: 1650, 1650 *a*.

---

#### Degeneration.

##### Pigmentary.

1637. Two axillary glands bisected and stained with minute dots of tattoo pigment. The pigment lies in the cortical part of the gland only, the central part being free.

##### Fibroid.

1638. A bronchial gland the size of a walnut, showing a considerable increase in the interstitial connective tissue.

##### Calcareous.

1639. A small lymphatic gland, showing caseation with a patch of calcification in the centre.

#### Caseation and Tuberculosis.

1640. A gland from the axilla, enlarged and caseous.
1641. Greatly enlarged and caseous bronchial, mediastinal, mesenteric,



and lumbar glands from a case of phthisis with tuberculosis. The roots of the lung, the trachea, and arterial trunks in the neck have been greatly compressed. The upper part of the abdominal aorta is also compressed by a mass of enlarged glands which surrounds the branches it gives off.

Case of Alice M. Silk, aged 16, who came in and died before a history could be obtained.

1642. A greatly enlarged and partly caseous gland enclosed within the mesentery.

From a boy, aged 9, W. H., who was admitted on May 27, 1884, for epileptiform seizures of ten days' duration, which were chiefly right-sided. There was no other history. He had no optic neuritis. He died in a fit on the fifth day after admission.

At the autopsy the brain was normal to the naked eye; there was evidence of bronchitis, old pleurisy, ulceration of the large and small intestine, and chronic peritonitis. The cervical, post-mediastinal, and mesenteric glands were much enlarged.

Dr. Jackson.

1643. Sections of enlarged cervical gland showing many small well-defined patches of caseating deposit.

Removed by Mr. McCarthy.

1644. The open lumen of the aorta, the trachea, bronchi, and part of the lungs of a child, showing masses of enlarged glands infiltrated by numerous irregular nodules of caseating material. On the right, one gland as large as a hen's egg has been bisected and shows, in addition to caseation, some bluish pigmentary deposit. At the back of the specimen is an enlarged thymus gland entirely caseous; above it are the great vessels of the neck. Between the left carotid and subclavian arteries is another enlarged caseous gland the size of a small apple; a section of it shows it to be caseous also.

1645. A portion of a mesentery with many enlarged glands, some of which have been cut open and are seen to be caseous.

### Morbid Growths.

#### Lymphoma.

1646. A tumour of the groin removed by Mr. Curling. This tumour is of nearly spherical shape and measures two and a half inches in its greatest diameter; its surface is well defined and separated from the



surrounding fat by a fibrous capsule. The skin anteriorly is adherent to the tumour, is thinned and discoloured. On section the cut surface was smooth and glistening and of a straw-colour. In the centre was a small patch of extravasated blood which had in part lost its colour, as if undergoing gradual absorption; in other parts it was bright red. Towards the circumference the tumour was more vascular and had a slightly purple tint. There was no juice on pressure. Microscopical examination — "Areolar fibrous tissue with intervening and intermixed cell-elements similar to those of a lymphatic gland. This tumour appears to bear the same relation to a lymphatic gland that a chronic mammary tumour does to the mamma."

### **Lymphadenoma.**

1647. The tongue, larynx, and trachea with enormous lobulated masses of hypertrophied lymphatic glands on each side. The masses are fairly symmetrical. Some glands have been cut open, but no distinct caseation is visible. Microscopic section shows a fine connective tissue with enormous increase of small round lymphoid cells. There has been compression of the trachea, for which most probably the tracheotomy was required.

1648. The heart, pericardium, part of the lung, and other thoracic contents. On each side of the trachea and œsophagus are large oblong lobular masses of enlarged glands which occupied the whole of the posterior part of the chest; the masses are about eight inches long; above each turns forwards into the anterior mediastinum surrounding the origin of the great vessels, and below each mass is continued forwards over the pericardial bag, which is thickened by the attachment of these flattened oval glands. A portion of the right lung is seen to be collapsed. It has been incised to show the new growth spreading from the root into the lung-tissue. It has a homogeneously yellow appearance.

From a youth, aged 18, a carman named F. E. P., admitted under Dr. Langdon. Down with a history of cough and swelling of the glands on the left side of the neck for six months. He had been better and worse from time to time. On admission there was dulness over both lungs posteriorly, with tubular breathing at the apices, albuminuria, and persistent diarrhœa.

At the autopsy, Oct. 13, 1885, the body was anæmic and emaciated. There were enlarged glands in the anterior mediastinum pressing upon the superior vena cava and on the pericardium. There were similar growths of gland-tissue in liver and spleen. The lumbar glands were much enlarged, weighing  $1\frac{1}{2}$  lb. The pericardium was filled with fluid. The heart was atrophied. The kidneys were unaffected.



**Carcinoma.****Melanosarcoma.**

1649. A section of several melanotic glands from inguinal region.

From a patient who died of malignant disease of the liver.

See Series XXIV., No. 1389.

**Epithelioma.**

1650. An enlarged gland infiltrated with epithelial cells.

Removed from the axilla by Mr. Adams, July 1857.

- 1650 a. An enlarged gland with the several tributary lymphatic vessels thickened by cancerous infiltration.

Obtained from the axilla of a dissecting-room subject with scirrhus of both breasts.



## SERIES XXXI.—INJURIES AND DISEASES OF THE LUNGS AND PLEURA.

### Effects of Injury.

Traumatic Emphysema: 1651.

### Diseases of the Lungs.

Emphysema: 1652-1657.

Fibroid Degeneration: 1658.

      "      "      with dilated Bronchial Tubes: 1659, 1660.

Calcareous Mass in Lung: 1661.

Thrombosis: 1662.

Plastic Bronchitis: 1663.

Pneumonia: 1664 to 1667.

      Lobular: 1666.

      Interstitial: 1667.

Abscess: 1668-1673.

Miliary Tuberculosis: 1674-1676.

      "      "      with Consolidation: 1677-1680.

Phthisis:

      Acute: 1681.

      Chronic: 1682-1692.

      Cirrhotic: 1693-1695.

Syphilitic Disease: 1696.

### New Growths.

Enchondroma: 1697.

Medullary Sarcoma: 1698-1700.

Carcinoma: 1701.

### Diseases of the Pleura.

Pleuritic Adhesions: 1702.

Thickened Pleura: 1703, 1704.

Ossification: 1705.

Hydatid: 1706.

## EFFECTS OF INJURY.

### Traumatic Emphysema.

1651. The right lung of a girl aged 8, who was run over, and died from hæmorrhage from rupture of the liver, shortly after admission. Along the anterior part of inferior edge of the lower lobe is a fringe of emphysematous vesicles, reaching the size of a pea and more. They appear to be formed by the dilatation and intercommunication of vesicles.

Case of Mary Ann Briddle, aged 8. Autopsy, July 14, 1885.



## DISEASES OF THE LUNGS.

**Emphysema.**

1652. A portion of a lung, very emphysematous and much pigmented with thickening of its fibrous stromas. There are some loose membranes on the pleura from old adhesions, and nodules of fibrous thickening with puckering of the surface of the lung.
1653. Part of an emphysematous lung with a large subpleural air-sac projecting from its surface. The sac is divided by a constriction in the middle. The larger, proximal, part is of the size of a cherry.
1654. Part of an emphysematous lung, including a portion of its border, with scarred and puckered surface, from which a highly inflated and sacculated portion of the pulmonary tissue projects. It is as large as a child's fist, with a somewhat contracted basis. It has been laid open to show the framework of rarefied pulmonary tissue traversing it from its base to the thickened pleura covering it, over which the interlobular network and the fine capillary network within it are distinctly traceable.
1655. Part of a lung showing extreme emphysematous expansion of the pulmonary tissue at its border. The tissue behind is pigmented and fibrous with thickening and puckering of the pleura. Along the proximal border of the emphysematous area is a line of subpleural air-sacs as large as marbles.
1656. Part of a lung with a cavity of the size of a large hen's egg with fibrous walls, of old date. The pleura over the lung on that side is greatly thickened and its surface rough from fibrous adhesions to the chest-wall. The lung-tissue adjacent is hepatized, and the pleura opaque and coated with lymph. Below, and connected with the lung by a narrow pedicle, is a large saccular expansion of a portion of the lung, capable of containing a man's fist. The lung-tissue generally is emphysematous. The general and localized expansions of the pulmonary tissue are attributable to contraction about the cavity.
1657. Part of the base of a lung (partially injected) with an emphysematous sac of the size of half an orange. Its boundaries are sharply defined on one side of the edge of the lung. The lung-tissue is consolidated by exudation.



### **Fibroid Degeneration.**

1658. Part of an emphysematous lung showing extensive induration of the upper part, in the form of areas of dense and deeply pigmented fibrous tissue extending inwards from the surface. The greater part of the section of this part is thickly studded with firm fibrous nodules, and the apex, which was firmly adherent, is covered with greatly thickened pleura, with a portion of the thickened parietal membrane connected with it. The lower part of the lung is hepaticized, fibrous tracts infiltrated with grey nodules resembling miliary tubercles being seen in the section.

On microscopical examination of sections from this specimen the grey miliary nodules were seen to have a compact fibro-nucleated structure, with polynucleated coagula in dilated lymphatics as in tuberculosis, and haziness of the centre of the large nodules as in commencing caseous necrosis; a few nodules appeared to be wholly fibrous and pigmented.

Case of John Porter, aged 53, who died from erysipelas. Autopsy, March 1, 1882. Mr. Rivington.

### **Dilated bronchial tubes.**

1659. Right lung with the lower and middle lobes contracted and the bronchial tubes dilated. The bronchial tubes are much thickened, and the pulmonary tissue is condensed and fibrous. The upper lobe is expanded and emphysematous. The pleura is greatly thickened over the contracted lobes, and over the upper lobe posteriorly.

Case of Joseph J., aged 54, a musician, but a temperate man. He had suffered from gout and winter cough. He was admitted with shortness of breath and cough with fetid sputum, and albuminuria. He had granular kidneys weighing 14 oz., and some hypertrophy of the left ventricle of the heart.

Autopsy, October 11, 1884. Dr. Turner.

1660. The anterior part of a lung showing fibroid degeneration and contraction of the pulmonary tissue, and dilatation of the bronchial tubes. There is much fibrous tissue about the bronchial tubes and vessels, and along the interlobular septa. Several bronchioles are much dilated, and beneath the pleura at the upper part of the specimen is what appears to be a saccular dilatation of the termination of one of them. The pleura is thick and rough with fibrous adhesions.

The lesion probably resulted from prolonged compression of the lungs by pleuritic exudation.

### **Calcareous Mass in Lung.**

1661. A portion of a lung with an encapsulated calcareous nodule as large as a horse-bean immediately under the pleura, the result of an obsolete caseating broncho-pneumonia, probably tubercular. The lung-tissue is emphysematous.



**Multiple Thrombosis.**

1662. A lung, with a large cavity at the apex with thick fibrous walls, which occupies the greater part of the upper lobe, and showing at the anterior part of the inferior lobe, where the surface of the lung has been removed and the branches of the pulmonary artery and vein dissected out, a number of varicose dilatations of their minute branches, which are filled with firm thrombi and form a cluster of round or irregularly nodulated bodies, which, in the recent state, felt like a collection of firm shotty bodies in the lung-tissue. One which has been laid open is seen to contain an old thrombus, white in the centre and greenish-yellow at the periphery, the whole section being stippled with dots and dotted lines of black pigment. The lung is fibrous throughout and emphysematous. The tissue between the large cavity and the root of the lung is wholly fibrous and dense. The section made through it has divided longitudinally two branches of the pulmonary artery, which had supplied the apex of the lung, and had been cut off and sealed up in the wall of the cavity, up to which they were still patent. The mouth of another vessel similarly cut off is to be seen in the wall of the cavity.

**INFLAMMATION.****Plastic Bronchitis.**

1663. A good specimen of a fibrous cast from the smaller divisions of one of the bronchial tubes.

**Pneumonia.**

1664. Part of a lung which was in the condition of red hepatization. The section is finely granular. In places it has a more uniform appearance.

1665. Part of a lung from a case of pneumonia in the "third stage," of purulent infiltration. The section has a more coarsely granular appearance; and the trabecular framework of the lung is apparent from partial disintegration of the exudation.

**Lobular Pneumonia.**

1666. Part of an emphysematous and pigmented lung, with patches of hepatization in which branches of the pulmonary artery are seen distended and plugged with coagula.



**Interstitial Pneumonia.**

1667. The upper lobe of a lung, divided longitudinally, showing at the lower extremity of the lobe, and extending along its anterior border, a defined tract of uniform consolidation with homogeneous-looking section. The tissue immediately behind and above it is in a state of granular consolidation. The upper part of the lobe is spongy and emphysematous. At the back of the specimen is a cavity of the size of a nut formed immediately under the pleura in the consolidated part of the lung.

Microscopical examination of sections of the consolidated lung-tissue shows much thickening of the walls of the alveoli, with exudation within them.

Case of Robert D., aged 29, a sailor. Admitted under Sir Andrew Clark on April 25, 1889, with a history of having been ill for three weeks with severe dyspnoea. On admission there was evidence of scattered consolidation with bronchitis. He developed pericarditis and died a week after admission. At the autopsy, on May 1, fibrous degeneration of both lungs was found, with gelatinous consolidation of the left; pericarditis with hypertrophied left ventricle; kidneys contracted and granular; skull thickened.

**Abscess.**

1668. Part of a lung with a cup-shaped abscess-cavity of the size of a walnut at the surface, over which the pleura has been removed, and around which it is coated with lymph and thickened, with evidence of older adhesions. The wall of the cavity is in part fibrous, and in part ill defined and shreddy.

Probably the result of the lodgment of some foreign substance in a bronchial tube.

1669. The lower lobe of a lung with a wedge-shaped mass of consolidation at its surface, surrounding a cavity of the size of a hazel-nut just below the pleura. The area of consolidation is exposed by an incision into the lung, and is seen to correspond to a bronchial tube which opens into the cavity. The mucous membrane of this bronchial tube is thickened, and roughened by superficial ulceration.

Case of Esther Field, aged 14. Admitted June 27, 1883, with paralysis and muscular atrophy, and contraction of the limbs. She became extremely emaciated and had numerous bed-sores.

Autopsy, March 26, 1884. Dr. Fenwick.

1670. A portion of the base of a lung showing an abscess-cavity, which would contain a walnut, at the surface. It is covered in only by the pleura, in which there is a large aperture. It is lined by a well-defined membrane, shreddy on its inner surface. Upon the walls of the cavity are seen branches of the pulmonary artery plugged with



coagulum and completely dissected out. The pleural surface, on the side of the specimen on which the perforation has occurred, is covered with a thick layer of lymph; on the other surface the pleura is thickened and opaque and has a little lymph adhering to it.

"The patient, a man aged 74, was admitted under the care of Mr. Andrews, in June 1835, suffering from fractured ribs. He had emphysema and great distress in breathing. For a time he appeared to be doing well, but was suddenly seized with the symptoms of acute pleurisy and died in a few days. The abscess-cavity was found to have opened into the pleura. It was large enough to contain half an ounce of pus. The 8th and 9th ribs on the left side had been fractured, but at the time of death were pretty firmly united."

1671. Part of the lung of a child consolidated by broncho-pneumonia, with a sloughy-looking cavity at the surface, over which the pleura has been removed. There is no lymph on the pleura adjacent.

1672. The left lung of a child, with a ragged cavity at the base, extending to the pleura. The walls of the cavity are shreddy from sloughing of its surface. Numerous nodules of consolidation are seen beneath the pleura over the surface of the lung. At the root of the lung are several caseous bronchial glands, some of which are softening. There was no softening in the lungs except that seen in the preparation. The pleura is thick and coated with lymph.

1673. Part of a right lung with diaphragm and part of the liver adherent to its base. The lung has been laid open to show a large abscess occupying the greater part of the organ and communicating with an abscess in the liver, the upper part of which is shown. The upper part of the lung has been compressed by the abscess. The pleura is thickened, and in parts rough from adhesion.

The patient was a man aged 25, who was under Dr. Billing's care in November 1835. At the autopsy, nearly the whole of the right lung was found converted into one large cavity, without partitions, and lined by a soft false membrane. It contained more than a quart of purulent matter. At its lowest part it communicated with an abscess in the liver; the opening through the diaphragm was as large as a halfcrown. There was no trace of tubercle at any part. There were small patches of ulceration in the colon.

#### INFECTIVE GRANULOMATA.

##### **Miliary Tuberculosis.**

1674. A portion of the injected lung of a child, showing numerous isolated miliary tubercles disseminated through the pulmonary tissue. The tubercles are seen as minute grey dots in the injected tissue.

1675. A lung infiltrated with miliary tubercles, which are in part isolated, in part aggregated in areas of consolidation. These are extensive in



the upper lobe and in the upper part of the lower lobe. The surface of the pleura is studded with tubercles and coated with lymph, which is most abundant in the interlobular fissure. The vesicular tissue has a honeycombed condition at the upper part of the lung, from dilatation of infundibula and bronchioles.

Case of Alfred Goodwin, aged 20, admitted under Dr. Fenwick, for acute tuberculosis. His illness commenced 6 months before with symptoms of right pleurisy. The dyspnoea and weakness gradually increased since that date. He died 10 days after admission. At the post-mortem on April 10, 1882, abundantly-disseminated miliary tubercles were found, in lungs, liver, spleen, kidneys, and adrenals.

1676. The lungs of a child studded over the surface with miliary tubercles. In the anterior part of the upper lobe, and especially at the apex of the middle lobe of the right lung, are lines of emphysematous vesicles along the interlobular tracts. In the line of junction of the middle and upper lobes of the right lung, and in a corresponding situation in the left lung, are some larger vesicles, and at the edge of the middle lobe of the right lung is a large chambered vesicle with thick walls, apparently of older date. The lungs are emphysematous throughout, and there are many conspicuous vesicles over their surface, some of which have been formed under miliary tubercles in the pleura. At the root of the lungs are some caseous glands.

This specimen may be compared with No. 1651, which shows interstitial and vesicular emphysema resulting from compression of the thorax by an external force.

#### **Tuberculosis with Consolidation.**

1677. The left lung of an infant, studded throughout with well-defined nodules of consolidation of varying size in the spongy, somewhat emphysematous, lung-tissue. In one section a large nodule is seen of wedge shape, corresponding with the area of distribution of the bronchiole and pulmonary arteriole directed to it in the plane of the section. The nodules are of more or less irregular form and are evidently formed by fusion of smaller nodules, many of which are seen still isolated. There are tubercular nodules on the pleura, especially at the upper part of the lung.

From a case of *tabes mesenterica*, Evelina Perkins, aged 7 months. Autopsy, December 11, 1883. Dr. Stephen Mackenzie.

See also Rickety ribs from the same case, Series II. No. 571.

1678. Part of the lung of a child aged 2, showing numerous isolated nodules of consolidation of varying size up to that of a pea, the larger irregular in outline and limited by interlobular septa, the others of rounded outline. In the larger nodules spots of caseation are visible.



In the section many vessels are seen distended and occupied by coagula.

1679. A lobe of one lung of a child aged 2, who died of meningitis. The lung shows numerous isolated yellowish opaque nodules of consolidation, similar to those in the last specimen, studding its surface. The pleura appears thickened, but there is no lymph upon it. There is an enlarged and caseous gland at the root of the lung.
1680. A portion of injected lung, showing extensive areas of tubercular infiltration, with some small cavities.

### Phthisis.

#### Acute.

1681. Part of the lower lobe of a lung with masses of hepatisation breaking down into cavities, by which its substance is extensively traversed. One of these had communicated with the pleural cavity and produced pneumothorax. The surface of the pleura is coated with lymph.

Dr. Davies.

#### Chronic.

1682. Part of a lung showing fibroid condensation, with much pigmentation of the tissue and thickened pleura. At the upper part there is great fibroid induration about an old cavity of irregular form, over which the pleura is greatly thickened, and rough from fibrous adhesions. Below are smaller cavities of more recent formation, one of which has perforated the pleura, and the section of the lung is mottled with grey nodules of consolidation and dotted with scattered tubercles. The surface of the pleura over this part is covered with lymph. In the wall of the cavities vessels are conspicuous, more or less dissected out by the destructive lesion. They are mostly plugged by coagula; some are still pervious.
1683. Portion of lung, in part fibrous and condensed about some old cavities and encysted caseous concretions, and in part emphysematous, with tracts of caseous pneumonia extending from the root of the lung to the upper and lower parts of the specimen, and with isolated nodules and larger masses of consolidation of the same kind. There are some enlarged and caseous glands at the root of the lung. The pleura is thickened, and rough from adhesions.
1684. A portion of a lung showing a large cavity of rounded outline with recesses in its walls, and communicating with a large bronchial



tube. The cavity has a well-defined lining membrane. The pleura is much thickened and rough with fibrous adhesions. There is a narrow layer of compressed pulmonary tissue between it and the cavity. There are some smaller cavities of a similar character.

Described as an old tubercular cavity in the lung lined by a secreting membrane.

1685. Part of a lung and of a rib connected with it, showing fibrous thickening of the pulmonary tissue and several old cavities with fibrous walls, and, at one part, caseous consolidation with softening of the tissue. The pleura is  $\frac{1}{4}$  inch thick at one part.

From a case of chronic phthisis.

1686. Part of a much pigmented and fibroid lung riddled with cavities, the walls of which are covered with flocculent shreds of tissue, as from sloughing of the lining membrane. Thick strands of fibrous tissue are seen in the walls of the cavities and between them. The pleura is much thickened and roughened by adhesions.

1687. Part of a lung with portions of two ribs connected with it. The lung-tissue is hepatised and superficially excavated over an extended area, and the destructive process has penetrated deeply in places, forming sinuous cavities of irregular outline. Over the excavated area the pleura has been removed; contiguous to its margin it is much thickened and rough from fibrous adhesions to the chest-wall. The edge with a considerable part of the outer surface of one rib is exposed and bare of periosteum over an opening into the pleural cavity.

The specimen is described as a tubercular cavity in the lung communicating with the pleural cavity and the external surface. Pulmonary fistula.

1688. Part of a lung showing several cavities with fibrous walls, having free communications with the bronchial tubes. To the left of the specimen is a bronchial tube with the accompanying branch of the pulmonary artery laid open longitudinally. In the former are two rough chalky nodules of spherical form in close contact, and apparently blocking the mouth of two branches into which it divides at that point. In the latter there is a similar nodule which blocked up the mouth of a branch of the vessel, through which a piece of thin blue glass rod has been passed, the introduction of which required the partial separation of the nodule from its adhesions to the intima; and contiguous to this nodule is a slightly depressed area of the arterial wall, from which a similar nodule would appear to have been dislodged. Some pieces of glass have been passed through another (larger) branch of the pulmonary artery into the largest cavity.



But there is no appearance of aneurysmal formation in the cavity, and the plugs closing the vessels appear to have been forcibly displaced.

1689. A portion of a lung showing large irregular cavities with fibrous walls, and areas of pneumonic consolidation, in part opaque and caseous. The pleura is much thickened and fibrous.

1690. Portion of lung showing fibrous contraction of the tissue about an old cavity, with smooth lining membrane and thick wall. The cavity is of hour-glass form, the outer part, which is at the surface of the lung, being separated by a deep annular puckering of the pleura at its neck. The pleura is a quarter of an inch thick over this projecting sac, and thickened in less degree around it.

1691. A lung from a case of chronic phthisis. The upper lobe is contracted and excavated. The lower lobe fibroid and infiltrated with miliary tubercle, with a cavity at the upper part of it. The pleura is adherent throughout, and greatly thickened over the upper lobe.

#### **Chronic Phthisis.—Aneurysm of the Pulmonary Artery.**

1692. The right lung of a child with a large cavity of old date occupying the apex, projecting from the fibrous wall of which, near the root of the lung, is an aneurysmal sac of the size of a large pea on a branch of the pulmonary artery. The whole of the pulmonary tissue is fibrous and contracted, and the pleura thickened and rough from fibrous adhesions.

Catherine M., aged 6, a patient in the North-Eastern Hospital for Children, under Dr. Turner, in 1882. Her pulmonary symptoms dated from an attack of measles 2½ years before her death. She had repeated coughs, often bringing up blood with phlegm. Latterly she lost flesh, with fever and sweating. She died from sudden and profuse hæmorrhage.

*Presented by Dr. Turner.*

#### **Cirrhotic Phthisis.**

1693. Portions of the lungs from a case of chronic phthisis. The right lung is cirrhotic and contracted throughout, with a few cavities at the upper part, and the pleura covering it is much thickened. The apex of the left lung is also fibroid and contracted, with old cavities; the remainder of this lung is studded with clustered tubercles and broncho-pneumonic granulations, with several small cavities, and tracts of fibrous induration.

Case of George Gibson, aged 25, a labourer, who was admitted in 1880 (R.N. 1075), for synovitis of the right knee and with signs of broncho-pneumonic phthisis. His knee was aspirated, but continued to suppurate. He was transferred to the



medical side, where he remained until he died with lardaceous disease of the liver, spleen, and ileum. There was ulceration of the cæcum and colon, and suppuration of the right knee-joint.

Autopsy, June 1, 1881. Dr. Jackson.

1694. Portion of a lung from the surface of the organ, showing fibroid degeneration and pigmentation of the tissue with old cavities, and recent tuberculosis with nodules of broncho-pneumonic consolidation. The pleura is much thickened and rough, and perforated over one of the cavities.

1695. A lung showing fibroid consolidation throughout, with excavation at the apex. The pulmonary tissue is much pigmented, contracted, and condensed. There is much fibrous tissue around the vessels and bronchial tubes, and in the interlobular septa. The pleura is greatly thickened, especially over the upper lobe and under surface. The bronchial glands are enlarged and much pigmented.

In the other (right) lung from same subject there were some disseminated tubercles, but no other evidence of disease.

Autopsy, Feb. 14, 1868. Dr. Sutton.

### Syphilis.

1696. The upper lobes of the lungs of a man aged 42, showing symmetrical fibrous induration and contraction of the central parts of both, with extensive puckering of the surfaces. The pulmonary tissue is emphysematous.

Case of Charles B., 42, gardener, previously a soldier for 28 years, with a history of gonorrhœa and "chancre," but having no scar on the penis or other evidence of syphilis. In the kidneys there were depressed areas of fibrous atrophy with finely granular surface, over which the capsules were firmly adherent. He died with great aneurysmal dilatation of the arch of the aorta, and incompetence of the aortic valve.

Autopsy, November 30, 1886. Dr. Fenwick.

See Aorta, Series XXVI. No. 1554.

### NEW GROWTHS.

#### Enchondroma.

1697. Part of a lung showing numerous enchondromatous tumours scattered through it. The tumours are circumscribed and exhibit a cartilaginous structure exceedingly well.

The specimen was presented to the Museum by Sir James Paget, and is from the case published by him in the *Med. Chir. Trans.* The tumours were secondary to enchondroma of the testis.



**Sarcoma.**

1698. Left lung laid open from behind, showing a sarcomatous growth which has invaded it from the mediastinum. It surrounds the commencement of the bronchus and projects into its channel in long elevations of the mucous membrane. The lung is studded with soft masses of secondary growth. The right bronchus is also surrounded and penetrated by the growth. There are several greatly enlarged mediastinal glands which are infiltrated by the growth.

Microscopical examination of sections from a bronchial gland invaded by the growth show it to be a round-celled sarcoma.

Case of Patrick Barry, aged 25, admitted May 3, 1884. His first symptoms, about 4 months before his death, were those of bronchitis. There were subsequently signs of consolidation of the left lung, with loss of flesh and strength. Both adrenals were affected with medullary growth, and formed rounded tumours situated at the extremities of a horse-shoe kidney with the convexity downwards. No other organs were found to be affected.

Autopsy, July 17, 1884. Dr. Down.

See adrenals and kidney, Series XXXIV. No. 1786.

1699. A right lung invaded at the root by a sarcomatous growth, which has also extended along the pleura and invaded it from the surface. The superior vena cava is closed by the growth.

Case of L. Maney, aged 35. Autopsy, Nov. 15, 1889. Dr. Fenwick.

1700. A portion of a lung showing large isolated masses of encephaloid malignant growth, of varying size, invading its tissue.

**Carcinoma.**

1701. Two portions of a right lung showing carcinomatous infiltration of the pulmonary tissue and great thickening of the pleura by the same growth. The larger piece of lung includes the root of the organ, where a large mass of growth is seen surrounding the bronchi, along which tracts of it extend into the lung. In the section of the smaller specimen the growth is seen extending along the bronchial tubes. At the surface of the lung the pleura is greatly thickened, to nearly half an inch in places. In parts the pleural growth is sharply defined, in parts it appears to have extended into the lung. The pulmonary tissue is deeply pigmented, making the dead-white growth very conspicuous.

Sections of the growth show channels lined with cylindrical epithelium in an abundant fibrous stroma with elongated nuclei. Some of the spaces are occupied by masses of cells with large nuclei.

Case of Wm. Woodard, aged 46. On admission his symptoms simulated those of pneumonia, but no clinical notes have been preserved. At the autopsy the liver, pancreas, kidneys, left adrenal, and peritoneum were found affected by the disease, the liver weighing 12 lbs. There was also a mass of growth in the left supraclavicular triangle blocking the thoracic duct.

Autopsy, May 27, 1882. Dr. Fenwick.



## DISEASES OF THE PLEURA.

**Pleuritic Adhesions.**

1702. Portion of a lung and a piece of rib connected together by loose filamentous adhesions between the pleural surfaces, permitting of free motion.

**Thickened Pleura.**

1703. A piece of greatly thickened pleural membrane, which appears to consist of the two surfaces of the pleura much thickened and fibrous, and adherent together, with an incompletely absorbed layer of fibrine between them. The two membranes have been separated at one part of the specimen. The membrane is tough and fibrous and nearly  $\frac{1}{8}$  inch thick.

It was dissected from the lung by Dr. Clark, who found it to consist of fibrous tissue with elastic fibres and blood-vessels.

1704. A specimen of thickened pleura. In parts the adventitious structure is nearly half an inch in thickness.

Sections show dense fibrous tissue without evidence of morbid growth.

**Ossified Pleura.**

1705. Portions of bone from thickened pleura.

**Hydatid.**

1706. Part of a lung with a large hydatid cyst at the base, enclosed by thickened pleura. The cyst has been laid open, and the parent hydatid cyst is seen curled up within it. The pleura covering the cyst is smooth; near the root of the lung it is roughened by old adhesions.

The patient had hydatids in the liver also. The case was under the care of Dr. Clark and Mr. Banks of Stratford.



## SERIES XXXII.—INJURIES AND DISEASES OF THE LARYNX AND TRACHEA.

### Injury.

Foreign body: 1707-1712.

Tracheotomy: 1707, 1713, 1714, 1717, 1718, 1732, 1734, 1736.

Cut throat: 1715.

### Diseases.

#### Effects of Pressure.

Compression by gland: 1716.

„ by abscess: 1717.

„ by neoplasm: 1718.

Ulceration: 1719.

Perforation: 1720-1721.

#### Effects of Inflammation.

Edema: 1717, 1722, 1724, 1736, 1750.

Perichondritis: 1725, 1726, 1746.

Necrosis: 1718, 1726, 1727, 1739, 1746, 1750.

#### Specific Inflammation.

Membranous Laryngitis: 1728-1737.

Syphilis: 1738-1747.

Tuberculosis: 1748-1753.

Lupus: 1754.

#### Morbid Growths.

Sarcoma: 1756.

Papilloma: 1757-1759.

Epithelioma: 1760.

---

## INJURY.

### Foreign Body.

1707. A stone removed by tracheotomy from the trachea of a boy aged 9. The operation was performed by Mr. Luke one month after the accident. Attempts had been made without success (by inverting the body &c.) to remove it. A free opening having been made into the trachea, the stone was ejected with considerable force by a sudden cough. The boy recovered perfectly, and his case is recorded in the 'Medical Gazette' for May 1838.

1708. A portion of bone removed on October 19th, 1889, from the larynx of a woman, aged 33, who came to the Out-Patient Department with the following history:—



About two months previously, whilst eating some sheep's head, a piece of bone stuck in her throat. She pushed it down with her finger to relieve the feeling of suffocation, but felt that it had lodged at a lower level. Since the accident her breathing had been interfered with, and she had gone to several hospitals to endeavour to obtain relief.

When seen by Mr. Hovell she had slight dyspnœa accompanied with a little stridor on deep inspiration, and the cough, which came on occasionally, had a sound similar to that produced by laryngeal obstruction. On examination the larynx was seen to be normal, with the exception of being congested, but about a quarter of an inch below the level of the vocal cords the upper border of the foreign body was visible, passing from before backwards a little to the right of the middle line. The larynx having been sprayed with a 10 per cent. solution of cocaine, Mr. Hovell removed the piece of bone through the mouth with a pair of forceps. Until after removal the two pieces were held together by fibrous tissue.

1709. A larynx and upper part of the trachea from a young child, who had an orange-pip impacted in the glottis. An operation was proposed, but the parents would not consent. The orange-pip can be seen from below effectually blocking up the rima glottidis.

*Presented by Mr. Hutchinson.*

1710. A portion of the trachea and bronchial tubes, showing two fragments of bone impacted in the left bronchus.

The patient was under the care of Dr. Hovell and Mr. Critchett. There was no history as to the entrance of the foreign bodies.

1711. A larynx, in which a large mass of meat is plugged. No history has been preserved, but no doubt the accident caused immediate death.

1712. The larynx of a young child admitted under Mr. Couper in 1874, who died of suffocation at the moment of admission. The post-mortem disclosed the cause in the form of some fish-bones which had become fixed in the larynx by perforating the mucous membrane.

Mr. Couper.

### **Tracheotomy.**

1713. A larynx and upper part of the trachea of a child who was admitted with urgent dyspnœa. Tracheotomy was performed by the house-surgeon on duty, but the child died some hours after



the operation. At the post-mortem it was found that the end of the tracheotomy-tube had perforated the anterior wall of the windpipe by chafing against it. The child was the subject of acute tuberculosis of the lungs and membranes of the brain. The cervical glands are seen to be much enlarged, and on the right side the subclavian has been drawn towards the middle line and the right recurrent laryngeal nerve drawn out to show how it had been liable to compression from the enlarged glands surrounding it.

1714. The larynx and trachea of a child for whom tracheotomy had been performed on account of dyspnœa.

The child recovered from the operation, but was subject to attacks of dyspnœa whenever the tube was removed. After death the cause was found to have been considerable thickening of the mucous membrane, caused by the irritation of the lower end of the tracheotomy-tube, and granulations, which had grown up round the margins of the wound so as, in the abnormal condition of the trachea, to block up its calibre.

For other specimens illustrating tracheotomy *vide* Nos. 1707, 1717, 1718, 1732, 1734, 1736.

### Cut Throat.

1715. The larynx and trachea from a case of cut throat. The wound has been made between the thyroid and cricoid cartilages. There is commencing repair.

## DISEASES OF THE LARYNX AND TRACHEA.

### Effects of Pressure.

#### Compression by gland.

1716. The lower end of the trachea compressed by an encapsulated cretaceous mass of the size of a walnut. The cretaceous mass, which is the residue of tubercular destruction of a bronchial gland, and is enclosed in a thick capsule, pressed upon the bifurcation of the trachea and the commencement of the right bronchus.

#### Compression by abscess.

1717. This specimen shows a large abscess-cavity lying behind the lower part of the pharynx and the upper part of the œsophagus. The abscess caused considerable pressure on the trachea, to relieve which tracheotomy was performed. The heart and great vessels have been left attached to the specimen, and the carotid and subclavian vessels have been filled with horsehair.



**Compression by neoplasm.**

1718. The larynx and the upper part of trachea where tracheotomy had been performed in an adult. On the right side is to be seen an enlarged indurated mass, in the middle of which is manifest the ossified and necrosed border of the thyroid cartilage. The indurated mass caused dyspnœa, by pressure on the trachea. The tracheotomy gave no relief.

**Ulceration.**

1719. A portion of the trachea eroded by the pressure of an aneurysm.

**Perforation.**

1720. A portion of a bronchus laid open, showing a cretaceous mass projecting into it through a perforation in its wall. The mass has been formed in an adjacent gland. There is a similar calcareous mass in another bronchial gland attached to the specimen. These are probably the result of the curative absorption of tubercular suppuration.

1721. The thoracic organs of a child, with the trachea and right bronchus laid open from behind, to show perforation of the latter by an abscess situated in front of the root of the lung. The abscess-cavity has also a communication with the œsophagus. At the surface of the lower lobe of the right lung, which is hepatised and coated with lymph, is a cavity at the extremity of a bronchial tube, laid open by an incision into the lung. The pleura over the upper lobe is thickened and was adherent to the chest-wall. There are nodules of consolidation in the upper lobe of the left lung, and lymph over its surface.

It appeared that in this case an abscess had formed at the root of the lung, probably from suppuration of a gland, and opened both into œsophagus and bronchus, and that thus septic matters had entered the lungs.

**Effects of Inflammation.****Œdema of the Glottis.**

1722. The larynx and adjacent parts, from a female aged 30, showing great œdematous swelling of the epiglottis and aryteno-epiglottidean folds. There had been sloughing of the right tonsil and contiguous part of the back of the tongue.

Case of Eliza Garrett, aged 30, who was admitted suffering from such urgent dyspnœa that tracheotomy was performed at once. She died during the operation. No history could be obtained.



1723. A tongue, larynx, and pharynx &c. The mucous membrane of the epiglottis and aryteno-epiglottidean fold is greatly swelled by œdema of the submucous tissue, as is also that covering the cricoid cartilage and adjacent parts.

1724. A larynx and adjacent parts showing great œdematous swelling of the mucous folds about the epiglottis, arytenoid cartilages, base of the tongue, and back of the larynx.

For other specimens of œdema *vide* Nos. 1717, 1736, 1751.

### **Perichondritis.**

1725. A larynx and trachea laid open in front, with the pharynx open behind. The epiglottis is very much thickened, and there is considerable swelling over both arytenoid cartilages. At the anterior and lower part of the wall of the pharynx is an opening about half an inch from above down, and rather less than that width across, communicating with a cavity left by the necrosed cricoid cartilage. At the upper and anterior part of this cavity is a small irregular opening through which pus was discharged from the neck during life.

Case of James Mason, aged 51, admitted on May 17, 1882, with laryngeal obstruction. There was no history of syphilis. He had been ailing for eight weeks with considerable inspiratory dyspnoea, stridor, and paralysis of the cords. Tracheotomy was performed a week after admission, but without much relief. He gradually sank. At the autopsy, in addition to the specimen, he was found to have granular kidneys and congested lungs.

Sir Andrew Clark.

1726. A larynx and trachea showing a perichondritic abscess with necrosis of the cricoid cartilage.

From a man, aged 22, admitted into the hospital with a history of laryngeal obstruction of 12 days' duration. He had had smallpox 11 weeks before and then had slight trouble until the dyspnoea for which he was admitted began. He was relieved by tracheotomy, but subsequently died from asphyxia before the tube, which he himself had removed, could be replaced.

For another specimen showing perichondritis *vide* No. 1746.

### **Necrosis.**

1727. A cricoid and thyroid cartilage, ossified and necrosed.

For other specimens *vide* Nos. 1718, 1726, 1739, 1746, 1750.

### **Specific Inflammation.**

#### **Membranous Laryngitis.**

1728. The larynx and trachea of a child from a case of croup. A



coherent lymph-membrane is seen lining the epiglottis, larynx, and trachea. The mucous membrane about the epiglottis and arytenoid cartilages is œdematous.

1729. A similar specimen; the membranous cast being detached at the lower part.
1730. The larynx of a young child, showing a croupal membrane extending from the epiglottis to an inch below the cricoid cartilage.
1731. A larynx, trachea, and bronchi of a child, laid open behind, containing a membranous cast extending from the upper border of the epiglottis, and apparently beyond the end of the bronchi. The cast is adherent along its anterior surface to the tracheal mucous membrane.
1732. The larynx and trachea from a child aged 4, upon whom tracheotomy was performed for croup. The child survived the operation some days. The specimen shows the false membrane in the trachea and also œdema of the soft parts in front of the larynx, owing to the presence of which the surface is about an inch in front of the trachea.
1733. The larynx and trachea from a child who died of croup. The false membrane is to be seen in abundance filling up the larynx and upper part of the trachea and extending over the epiglottis, tonsils, and uvula. The considerable swelling of the tonsils and of the glands at the root of the tongue is also noticeable.
1734. A larynx and trachea, showing diphtheritic disease. From a young woman who was admitted for dyspnœa. Tracheotomy was performed by the house-surgeon. She was temporarily relieved, but soon died.
1735. A membranous cast of the trachea and bronchial tubes which was coughed up by the patient from whom the preceding specimen was obtained, as soon as the trachea was opened.
1736. The larynx of a child upon whom tracheotomy was performed for croup. At the very lowest part of the specimen the results of the chafing of the tube may be seen in the exposure of the tracheal cartilage. Also the trachea appears to have been perforated twice before the successful incision was made through which the tube was eventually inserted. This specimen shows œdema of the tissues in front of the larynx. The child survived the operation 4 days.



1737. Larynx &c. from a case of croup, showing patches of false membrane.

**Syphilitic ulceration.**

1738. Ulceration of the larynx. The ulceration involves the chordæ vocales and adjacent parts, and extends deeply. Probably syphilitic.
1739. Ulceration of the larynx. The cricoid cartilage at the posterior part and on the left side is laid bare over a considerable extent, and was probably about to exfoliate. The margins of the ulcer are abrupt and undermined.
1740. Extensive ulceration of the mucous membrane of the larynx and trachea, with destruction of epiglottis and scarring of the mucous membrane; probably syphilitic.
1741. Extensive ulceration of the mucous membrane of the larynx and trachea. The mucous membrane above the chordæ vocales is much thickened and warty-looking. Possibly malignant.
1742. A larynx and trachea, the mucous membrane of the latter being everywhere thickened and showing patches of flocculent lymph. About an inch below the vocal cords there is a long patch of ulceration, the margins of which are very definite, and which involves the whole thickness of the mucous membrane; it is more than an inch long and half an inch broad. Probably syphilitic.
1743. Syphilitic disease of the larynx. A deep ulcer with sharply defined borders, situated immediately below the left true vocal cord, and opening into the left ventricle of the larynx. Water, when injected, passed freely into the ventricle, distending it but not escaping from it, proving that the ulceration had not extended through it. There is much fibrous thickening from the left superior vocal cord to the epiglottis.
- The specimen is from the same subject as No. 2015, Series XLI.
1744. The trachea and bronchi with the adjacent structures and base of the heart, showing syphilitic ulceration of the trachea with perforation of superior vena cava. The trachea and bronchi are laid open from behind, showing a large sharply cut ulcer, of the size of a shilling, at the bifurcation directly above the mouth of the right bronchus. The wall of the trachea has been perforated, the eroded rings appearing in the wall of the ulcer. The floor of the ulcer is occupied by a



rounded body, apparently an enlarged gland, which projects into its cavity. About  $1\frac{1}{2}$  inch above this ulcer is a smaller one with similar sharply cut edges, which has also extended through the whole thickness of the wall of the trachea. It has a smooth fibrous floor, and is almost the size of a sixpenny piece. At the back of the specimen a longitudinal rent in the wall of the superior vena cava is seen at the part where it is adherent to the rounded (? glandular) mass before mentioned. A probe passed from the trachea into the vessel.

From the body of a man aged 40, well developed and fairly nourished, who died suddenly from profuse hæmorrhage from the chest shortly after admission to the hospital. He had been attending as an out-patient and was admitted with urgent dyspnoea, which had come on suddenly. He was said to have had an ulcerated sore throat, in which part of his soft palate was lost. No other evidence of syphilis.

Case of Charles Spickett, 40, carman. Autopsy, June 20, 1885. Sir A. Clark.

1745. Larynx and trachea of a man who died with syphilitic changes in testicles, liver, and lungs. The mucous membrane is extensively ulcerated, and in parts the cartilage exposed. The epiglottis has been completely eaten away.
1746. Syphilitic ulceration of the larynx and perichondritis with necrosis, with a fistulous communication with the œsophagus on the right side.
1747. Syphilitic ulceration of larynx &c. There is extensive ulceration of mucous membrane over the larynx, epiglottis, trachea, and base of tongue. The epiglottis is in part destroyed.

### **Tuberculosis.**

1748. A larynx and trachea laid open behind. The epiglottis and mucous membrane of the trachea present numerous small oval pits with raised edges. These small tubercular ulcers are most numerous just below the true vocal cords.
1749. An adult larynx, showing œdema of the tissues over the epiglottis and arytenoid cartilages, and extensive ulceration of the left ventricular band and posterior surface of the epiglottis, as well as of adjoining parts. On the ulcerated surface, and surrounding it, many small miliary tubercles are seen. Below the vocal cords the mucous membrane of the larynx is similarly infiltrated. Laryngotomy has been performed, and an oval aperture remains.
750. Ulceration of larynx with necrosis of arytenoid cartilages, from a case of phthisis. The vocal cords are destroyed by ulceration in



the posterior part, and in the recent state appeared for the rest of their extent thickened and very white. Immediately above the true vocal cords on each side are symmetrical ulcers, deep, with irregular surface and, in the recent state, very prominent granulations. Between the upper cords and the epiglottis in the mucous membrane were a number of small gelatinous bodies projecting very little above the surface. These do not show well now.

The patient had fibroid consolidation of the lungs with acute pleurisy; cirrhosis of liver, and enlargement of spleen: no ulceration of intestines. *Vide* P.M. Records, 1872, pp. 85-87.

1751. Larynx and trachea, from a case of phthisis. There is swelling of epiglottis and of aryteno-epiglottidean folds, and ulceration of the inner surface of the left fold and at posterior ends of vocal cords. There has been more extensive and deeper ulceration in the trachea, which has exposed several of the rings. There are areas of ulceration also at the orifices of both bronchi.

From a man, aged 44, George P., admitted under Sir Andrew Clark's care on May 15, 1883, with cough, expectoration, wasting, and extreme dyspnoea, and other signs indicative of chronic phthisis.

At the autopsy there was tubercular infiltration throughout both lungs, with fibroid condensation and puckering of the apices. There were a few tubercles on the kidneys and liver. The ileum and cæcum were free from ulceration.

1752. The larynx of a man, showing phthisical changes. The mucous membrane of the oral and laryngeal surfaces of the epiglottis, and that covering the posterior aspect of the arytenoid cartilages, have been completely destroyed by ulceration.

From a sailor, aged 39, who died of broncho-pneumonic phthisis, with extensive disease of both lungs, more particularly the right, and ulceration of the ileum and cæcum. His chief trouble in hospital was almost complete inability to swallow.

1753. Extensive ulceration of the mucous membrane of the larynx and trachea, from a middle-aged man who died of broncho-pneumonic phthisis. There is extensive ulceration and loss of substance at the root of the epiglottis. The left true vocal cord is almost covered by fleshy granulations. The upper part of the trachea is extensively ulcerated, and the tracheal cartilages exposed in places. At the lower part are some deep circumscribed ulcers.

### **Lupus.**

1754. Larynx and trachea of a girl aged 13, who had been for 2 years under treatment in the hospital for lupus of the throat, internal and external. The disease appeared to have commenced simultaneously



in the skin and mucous membrane. That in the skin was completely healed by application of solid chloride of zinc. That in the mucous membrane made steady progress. Some weeks before the child's death an opening formed by ulceration from the larynx to the skin, through which she breathed with great relief. The epiglottis is almost entirely destroyed. The aryteno-epiglottidean folds are puckered with cicatrices. The vocal cords are gone, and the mucous membrane ulcerated for about  $1\frac{1}{2}$  inch. The thyroid gland was the seat of lardaceous disease. The lower end of femur and patella were also diseased.

1755. Ulceration of the epiglottis and of mucous membrane of the larynx. The chordæ vocales at their anterior insertion have been deeply destroyed; the mucous membrane of the trachea exhibits numerous minute pits of ulceration.

### Morbid Growth.

#### Sarcoma.

1756. The half of a firm globular tumour, which was removed from the epiglottis. The section is greyish in colour and homogeneous. Microscopic sections were made, and proved it a lympho-sarcoma.

It was removed by Mr. McCarthy from a man who had been sent up from Poplar Hospital with dyspnoea and dysphagia. When the mouth was opened and his tongue was held and he was told to swallow, a tumour sprang out of the pharynx into the posterior part of the mouth. With the finger one could feel its connection with the epiglottis. It was the size of a hen's egg. When he lay in a horizontal position he was suffocated. It was removed without an anaesthetic. He was told to make a swallowing effort, and the moment the tumour protruded, its anterior end was caught with forceps, and so held until an écraseur was passed round its base. The tumour was removed without hæmorrhage. It sprang from the upper and left half of the epiglottis; its anterior part was superficially ulcerated as if from constant friction. The patient has been several times communicated with, but there has been no recurrence.

#### Papilloma.

1757. Warty growths in the larynx, from a child who was the subject of inherited syphilis. *Presented by Mr. Little.*
1758. Warty growths in the larynx. A larynx showing a row of small warty growths on the left vocal cord, or on the mucous membrane immediately below it. They protrude from a slight fissure-like depression of the mucous membrane. They are situated about the middle of the cord.

Case of Arthur Ridgwell, aged 35, who died from "surgical" kidneys, cystitis, perineal fistula, and stricture. There was no history of laryngeal obstruction. Autopsy, Oct. 10, 1881. Mr. Couper.



1759. The larynx of a child, opened behind, showing swelling and discoloration of the mucous membrane over the arytenoid cartilages and epiglottis. There appears to be a small papillary growth at the mouth of the left ventricle.

### **Epithelioma.**

1760. The tongue, larynx, and pharynx of an adult. The posterior pharyngeal wall has been laid open. The epiglottis is much thickened and indurated, and on its posterior aspect is a circular irregular ulcer with raised everted edge. The arytenoid and cricoid cartilages have been destroyed by ulceration, so that the interior of the larynx is exposed. There is also extensive destruction, with a large perforation, of the right wall of the pharynx. At this point, on the outside, there is great induration of the surrounding tissues. The front of the trachea has been laid open. At the upper part is seen a ring of thick indurated and nodular tissue surrounding a passage into the trachea made by tracheotomy. The walls of this passage and the tracheal mucous membrane are also infiltrated with new growth. The upper part of the trachea is seen to be almost completely blocked. Sections of the growth show epithelial nests and columns.



### SERIES XXXIII.—INJURIES AND DISEASES OF THE SPLEEN.

- Rupture: 1761.
- Lardaceous disease: 1762.
- Calcareous capsule: 1763, 1764.
- Infarction: 1765.
- Leucocythæmia: 1766, 1767.
- Hodgkin's disease: 1768–1770.
- Tuberculosis: 1771.
- Syphilis: 1772.
- Hydatids: 1773, 1774 (?).
- Melanotic Growth: 1775.

---

#### **Rupture.**

1761. Spleen showing three or four lacerations in the lower and posterior surfaces.

It was removed from a youth who had been run over, and was brought into the hospital dead from extravasation in the peritoneal cavity; there was also an extensive laceration in the liver.

#### **Lardaceous degeneration.**

1762. An enlarged spleen, which weighed 11 oz., in the sections of which the enlarged and gelatinous-looking Malpighian bodies are conspicuous from their darker semi-translucent appearance.

From an omnibus-conductor, aged 28, who was admitted with a popliteal aneurysm, which was cured by digital compression, and who subsequently died from ulcerative endocarditis and pleurisy, with large white kidneys. There was no history or evidence of syphilis.

Case of John Fowler. Autopsy, August 6, 1885. Dr. Sutton. See preparation of aneurysm, No. 1584, Series XXVIII.

#### **Calcareous degeneration.**

1763. A portion of the capsule of a spleen, showing calcareous deposit scattered through it.



1764. A dried preparation of a portion of the capsule of a spleen, showing thick calcareous plates in its substance.

Microscopic examination of some of these showed that they consisted of true bone, with lacunæ.

### **Infarction.**

1765. A spleen laid open by longitudinal incisions to show two extensive wedge-shaped necrotic tracts, the bases of which are slightly prominent on the surface of the organ, and marked off by shallow sulci. The upper, and more extensive of the two, extends across the organ transversely, and is seen in the section to be disintegrated at its periphery, and separated from the adjacent splenic tissue and from the capsule, which is thickened at its base.

Case of Samuel Bidmead, aged 43. Admitted June 1, 1889, for morbus cordis with mitral regurgitation.

Autopsy, Dec. 8, 1889. Dr. Down.

### **Leucocythæmia.**

1766. A greatly enlarged spleen, which weighed 10 lbs., laid open longitudinally from the convex surface. Near the upper glass rod placed between the cut surfaces is a circumscribed area of the size of a damson, which is of lighter colour than the rest of the section. The splenic tissue generally appears normal.

Case of Chas. Watts, aged 26. His blood was pinkish. He had a large liver, but no glandular enlargement. His symptoms dated 18 months, and he died from cerebral hæmorrhage.

Autopsy, Dec. 24, 1883. Dr. Sutton.

1767. A greatly enlarged spleen, which weighed 38 oz., divided longitudinally. The section appears fibrous, and shows numerous paler and more opaque areas in the less changed splenic tissue. The capsule is thickened, and the surface of the organ is rough from shreds of peritoneal adhesions.

Sections of the spleen show great increase of the connective tissue throughout, with areas, corresponding with paler nodules seen in the section of the organ, in which it is converted into a compact fibro-nuclear tissue with few leucocytes. Sections of the liver showed great thickening of the fibrous tissue with disappearance of liver-cells.

Case of Rosina Lambert, 24, admitted June 8, 1885. She had been getting weak for 2 or 3 years, with frequent epistaxis, from which she eventually died. Four or five colourless corpuscles to one red one were found in the blood. The spleen and liver were greatly enlarged and indurated, the latter weighing 10½ lbs.

Autopsy, August 4, 1885. Dr. Sutton.

### **Lymphadenoma.**

1768. The two halves of an enlarged spleen divided longitudinally



through the hilum. The cut surfaces show nodules of lymphadenomatous growth, varying in size from that of a cherry to a pin's head, thickly scattered through the tissue. The capsule is smooth, with some shreds of adhesions on the concave surface.

Thin sections of this specimen show great thickening of the connective tissue stroma throughout. In areas corresponding to the nodules, which appear pale in the stained sections from the paucity of nuclei, the tissue is changed into a compact fibro-nuclear structure. Sections of the liver show nodules of similar character, without necrosis or softening. And sections of an indurated gland show similar fibrous condensation.

Case of Wm. Sussex, aged 27, admitted May 13, 1885, with illness dating four months. He had pains in the back and chest, with pyrexia, and enlarged glands and jaundice dating a week, and tumid abdomen with enlarged spleen. Enlarged glands were found in various situations, in the portal fissure and in the hilum of the spleen. There were nodules of growth in the liver.

Autopsy, June 12, 1885. Dr. Hughlings Jackson.

1769, 1770. The two halves of an enlarged spleen, divided longitudinally, studded with numerous firm nodules of growth, varying in size from a pea to a pin's head, which at one part of the section have become fused in a wedge-shaped tract of infiltration with its base at the surface of the organ. In the hilum is a mass of enlarged and firm glands with thickened capsules, and bound down to the splenic capsule by compact connective tissue.

Microscopic examination of sections of one of the specimens shows much thickening of the connective tissue, parts being changed into a fibrous stroma containing cells in its meshes, in which there are numerous cloudy necrotic tracts, in parts softened. In some of these are nucleated lymph-coagula, as in tuberculosis, but no zone of corpusecular infiltration.

### **Tuberculosis.**

1771. A spleen, of about the normal size, with its tissues studded thickly with caseous nodules, many of them softened, and varying in size from a pea to a pin's head. The surface of the organ is nodulated by the projection of the caseous nodules situated just beneath the capsule. The capsule is roughened over the summits of the projecting nodules, and there are some shreds of peritoneal adhesions in places.

### **Syphilis.**

1772. An enlarged spleen, much increased in thickness, with a caseous mass, of the size of a billiard ball, enclosed in a dense fibrous capsule in parts  $\frac{1}{3}$  inch thick, and extending from the hilum to within  $\frac{1}{4}$  inch of the convex surface. The capsule is thickened and has become



adherent to the liver and diaphragm, portions of which are seen upon its surface. The splenic tissue appears normal.

Case of Thos. Whiffen, aged 35, admitted for albuminuria, with ascites and anasarca and pleurisy. The liver and right adrenal showed syphilitic lesions, the kidneys and left adrenal were lardaceous.

Autopsy, October 2, 1869. Dr. Ramskill.

See Adrenals, Nos. 1782, 1783, Series XXXIV.

### **Hydatid Cysts.**

1773. A spleen of rounded outline, with a cavity with smooth fibrous walls, containing a portion of a collapsed hydatid, laid open on the convex surface of the organ.

1774. A spleen, with a cyst of similar character, and as large as a hen's egg, forming a projection on the convex surface at one end of the organ. It has been laid open, and is now empty of its contents. In the capsule of the gland are many calcareous nodules.

### **Melanotic Growth.**

1775. Portions of an injected spleen, with areas of pigmentation of circular outline in section, sharply defined by the pigmentation. There is little appearance of disturbance of the adjacent tissue, the fibrous trabeculae of the splenic tissue passing into the melanotic areas, and traversing them in a normal manner, though less conspicuous than outside in the natural splenic tissue.

Sections show that the melanotic nodules consist of a pigmented fibrous network in which deeply pigmented cells are scattered; these are massed at the borders of the nodules, where they appear to have been invading the splenic tissues. Throughout the section are numerous slightly pigmented cells.



## SERIES XXXIV.—DISEASES OF THE SUPRARENAL BODIES.

Hypertrophy: 1776.

Fatty degeneration: 1777.

Lardaceous: 1781-3.

Hæmorrhage: 1778.

Addison's Disease: 1779-1781.

Syphilis: 1782-4.

Sarcoma: 1785-7.

Carcinoma: 1788-1790.

Cystic Growth: 1791.

---

### Hypertrophy.

1776. The right and left suprarenal capsules. The former is greatly enlarged at one end, the enlarged part of the organ forming a well-defined tumour of rounded outline and ovoid form, about an inch and a half in its longest diameter, and marked off from the rest of the organ; at the back is a spur-like process of the mass. In front is a nodular elevation of the surface of the organ which is probably of the same nature. In the left adrenal is a rounded nodule about the size of a large currant, projecting equally on both faces of the organ.

Microscopical examination of sections from the right adrenal shows the enlargement of it to consist of cortical adrenal tissue in a condition of advanced fatty infiltration.

Case of Sarah Body, aged 62. Autopsy, February 7, 1885. Sir A. Clark.

### Fatty degeneration.

1777. Adrenals, right and left, enlarged from increased thickness. In the sections of the organs the medullary and cortical tissues are distinguishable in their normal relations, but much increased in thickness and both of opaque yellowish colour.

Sections show fatty degeneration of the tissue, with some thickening of the fibrous stroma.

Case of Wm. Watson, aged 61, who died from malignant stricture of the œsophagus.

Autopsy, Jan. 18, 1884. Dr. Stephen Mackenzie.



**Hæmorrhagic infiltration.**

1778. Adrenals enlarged to more than twice their natural size, with the upper parts of the kidneys, with which they are connected by loose areolar tissue. The section of one of the organs, from which a portion has been removed, shows tracts of reddish-brown discoloration from hæmorrhagic infiltration, and a circumscribed area closely stippled with black hæmorrhagic points, indicative of a vascular thrombus. Above this organ is a slightly enlarged and pigmented gland.

Sections show great swelling up of the tissue from infiltration by blood and by exudation, partly in the form of deeply stained masses, mostly unstained and diffused through the tissue. The glandular spaces are greatly distended with blood-coagulum over large areas. In part of the section the tissue has a cloudy necrotic appearance with separation of the tubules by wide interspaces with dilated capillaries. There is thickening of the stroma by fibres with elongated nuclei. There is no evidence of new growth.

**Addison's disease.**

1779. Adrenals, both enlarged from increased thickness, and having a rounded outline in transverse section and nodular surface, with thickened capsules. The transverse sections of the organs show that they have been converted into fibrous tissue with caseous nodules imbedded in it. The left semilunar ganglion, which is enclosed in a thick fibrous capsule, is seen connected with the adrenal from that side by thick strands of nerve-fibres.

Case of Wm. B. Evans, aged 51, who died from Addison's disease. Admitted in a lethargic condition, with shortness of breath, constant vomiting, and pain in the head and back. Considerable pigmentation of skin and mouth. The right kidney was converted into a sac filled with putty-like matter, and there was a cyst in the right epididymis containing caseous and cretaceous matter; no miliary tubercles.

Autopsy, August 15, 1885. Dr. Hughlings Jackson.

- 1780: Adrenals, showing the changes characteristic of Addison's disease in a less advanced stage than the preceding specimen. The organs are nodulated, but have not lost their natural form and are only slightly enlarged. The section of the left adrenal shows opaque caseous nodules in a fibrous stroma; in the right adrenal the caseous nodules are imbedded in some semi-gelatinous structure within the thickened capsule of the organ.

Case of W. Sawyer, aged 36. His chief symptoms were lassitude, vomiting, pain in loins and abdomen, and shortness of breath. The nipples, axilla, and penis and scrotum were deeply pigmented. He died rather suddenly a few days after admission. There was an old cavity in the apex of the right lung, and fibrous nodules in both apices. No miliary tuberculosis. His mother and one brother had died from phthisis.

Autopsy, August 26, 1884. Dr. Hughlings Jackson.



1781. The adrenals from a case of chronic phthisis with lardaceous disease and chronic nephritis. One organ (the left) shows a caseous mass at one end in the lardaceously degenerated tissue. The other is in an advanced state of lardaceous degeneration throughout. Both are enlarged and firm from the lardaceous infiltration.

Case of Geo. J. Jones, aged 28. Symptoms of phthisis dated three years. Dropsy appeared five months before his death. He had old cavities in the lungs with broncho-pneumonic consolidation, lardaceous liver, spleen, and kidney. The kidneys were large white organs. The nipples and penis and scrotum were deeply pigmented.

Autopsy, January 13, 1885. Sir A. Clark.

### **Syphilitic disease.**

1782. A right adrenal with an enlargement of its inner portion, which forms a pyriform tumour, with the narrow end anteriorly, projecting on the under surface of the organ. A transverse section of the organ has been made through the thickest part of the tumour, which is seen to involve the whole of the affected part, but to be separated from the rest by a fibrous capsule. The unaffected part is lardaceous, having a homogenous semi-translucent appearance in section.

Thin sections of the tumour show a central thick tract of fibro-nuclear tissue with ramifying branches forming an open reticular structure, supporting thick-walled vessels, and in great part cloudy and degenerated. Immediately under the capsule are remnants of adrenal tissue in a state of lardaceous degeneration. Sections of the unaffected part of the organ show advanced lardaceous degeneration of its structure.

Case of J. Knight, aged 34, who died from pneumonia, with lardaceous disease of liver and kidneys. There was a history of syphilitic infection 10 years before.

Autopsy, June 16, 1882. See Liver, No. 1349, Series XXIV.

1783. Right adrenal enlarged by syphilitic lesion of the medullary tissue. The section of the organ, which has been divided into two in its thicker part, shows at the lower and broader end a nodule of growth with rounded outline, of the size of a hazel-nut, surrounded by a fibrous capsule; above is an elongated tract of growth surrounded by a darker semi-translucent zone of adrenal tissue, like that of a fold of the organ unaffected by the growth, which is separated from this part of the affected area by the inflected fibrous capsule. The capsule is greatly thickened, and the organ is imbedded in a mass of dense connective tissue and fat.

Sections of this organ show that the nodules of growth, which are opaque and caseous, commenced in the medullary tissue in immediate relation with the larger vessels by which it is traversed. In the medullary and cortical adrenal tissue, which is displaced by this central growth, there is great increase of connective tissue in the deeper parts, and in the periphery the septa are thickened and cloudy, as in the uninvaded part of the organ.

Case of Thos. Whiffen. See above, No. 1772, Series XXXIII.



1784. Adrenals, in one of which (the left) is a nodule of (?) syphilitic growth of the size of a large pea projecting on both surfaces and shown by a transverse section through the organ.

Sections through the growth show fibrous thickening of the apparently normal adrenal tissue, which is compressed at its borders, and in the tumour itself a great development of the glandular structure, at the periphery with swelling of the stroma, more centrally with little stroma between the masses of epithelioid cells.

Case of Thos. Murphy, aged 42, a seaman and a hard drinker, who died from pneumonia. There was a history of syphilitic infection 16 years before admission. The liver was much fissured with fibrous tracts extending inwards; there were fibrous tracts in the testes, and symmetrical nodes on the tibiae, but no gummata.

Autopsy, August 4, 1885. Dr. Langdon Down.

### **Lympho-sarcoma.**

1785. Adrenals of a man, aged 74, who died from gangrene of the left foot. In one (the right) there is a nodule of growth of the size of a filbert, sections from which, in the recent state, showed a lympho-sarcomatous structure.

At the root of the left lung was a growth of similar character, of small extent. There was much atheroma of the aorta with ulceration, and atheromatous and calcareous degeneration of the left iliac and femoral arteries.

Case of John Pattenden, 74. Autopsy, October 26, 1888. Mr. Treves.

### **Medullary Sarcoma.**

1786. Adrenals, greatly enlarged and of rounded outline, and horse-shoe kidney with upturned ends, on which the adrenals rest symmetrically. Both organs are greatly enlarged and rounded in outline, being invaded and destroyed by a soft sarcomatous growth, secondary to a mediastinal growth of the same character.

Sections from a bronchial gland invaded by the growth showed it to be a round-celled sarcoma.

Case of Patrick Barry, aged 25. The left lung was much consolidated, it contained nodules of soft growth and several cavities.

Autopsy, July 18, 1884. Dr. Langdon Down.

1787. Right and left kidneys, with the adrenals invaded by a sarcomatous growth and greatly enlarged and firmly adherent to their upper ends, laid open by median incisions from the convex surface to the hilum. Both adrenals are invaded throughout by growth consisting of lobules separated by strands of fibrous tissue and all disintegrated in greater or less degree; some wholly, most in spaces enclosed in a delicate reticulum. The upper end of the right kidney is flattened by the growth



which rested directly upon it. The upper end of the left kidney does not appear altered in shape, the left adrenal lying more on its inner aspect. The capsules of the organs are much thickened, and each is firmly united to the kidney beneath it, but the growth has not traversed the fibrous septum between them.

Sections show a round-celled sarcomatous growth in the adrenal tissue, in which there has been a great fibrous thickening of the connective-tissue stroma. The sarcomatous growth has invaded the organ in extensive continuous masses, and in narrower tracts between the tubules.

### **Carcinoma.**

1788. A similar preparation to the last, from a case in which the adrenals were invaded by a carcinomatous growth. They are not adherent to the kidneys, but connected with them by loose connective tissue. The right adrenal tumour is a good deal the larger, and the upper end of the right kidney appears to have been somewhat flattened by it.

Sections of the growth show a carcinomatous structure with much fibro-nuclear stroma, and there is much fibrous thickening of the adrenal tissue.

Case of George Cavender, aged 35. Admitted with abdominal and sciatic pains, with anaemia and irregular pyrexia. There was extensive invasion of the liver by secondary carcinomatous growth; similar growth in the costal pleura; and enlarged glands in the mediastinum, about the head of the pancreas and in the mesentery, and in the axilla.

Autopsy, November 27, 1882. Dr. Down.

1789. Adrenals, with the pancreas and portions of the aorta and inferior vena cava, and lumbar glands connected with them. The left adrenal and the lumbar glands are invaded by carcinomatous growth and much enlarged. The former is four times as thick and twice as broad as the healthy right adrenal, but maintains somewhat of its natural form. A transverse section of the organ shows it to be infiltrated by a rather soft growth, of brownish colour from hæmorrhagic infiltration. The enlarged glands form a scirrhus mass adherent to the aorta anteriorly and on its left side, with the left renal artery imbedded in it.

Sections of the adrenal growth show an abundant fibro-nuclear stroma of open structure with spaces occupied by epithelioid, or endothelial, cells, and remains of adrenal tissue. Sections from one of the lumbar glands show a more compact fibro-nuclear structure, profusely infiltrated with small round cells, in places traversed by columns of epithelioid cells, and enclosing larger spaces occupied by an open reticular structure, apparently remains of gland-tissue.

Case of Wm. Carpenter, aged 37. Admitted August 5, 1884, with sacral and sciatic pains. He wasted rapidly without any discoverable organic disease to account for it, but probably from compression of the thoracic duct by the scirrhus glandular growth. He died comatose.

Autopsy, August 28, 1884. Dr. Sutton.



1790. An adrenal occupied by a mass of secondary scirrhus carcinomatous growth, by which it is greatly enlarged. At the upper part of the specimen a portion of the edge of the organ remains unaffected.

Case of Wm. Woodard, aged 43. Autopsy, May 27, 1882.

See Liver, Series XXIV. No. 1383, and Lung, Series XXXI. No. 1701.

### Cystic Growth.

1791. A right adrenal converted into a spherical tumour of the size of a fist, consisting of a large cyst, divided unequally by a rigid septum of fibro-cartilaginous appearance, and with a wall of growth about half an inch thick, in which there are numerous cavities, some as large as hemp seeds, and many with pin-hole openings in their walls showing that they are dilated vessels. In one part the cyst-wall is wholly fibrous, and not more than  $\frac{1}{4}$  inch thick. The cavity is lined with a fibrous membrane covered with much granular coagulum. It contained a quantity of gelatinous matter and coagulum when laid open at the autopsy.

Sections of the growth show a hyaline structure with cells imbedded, traversed by numerous capillary vessels and by many larger vessels with fibrous walls. In parts the tissue is swelled by cloudy exudation, and in parts fibrous and degenerated.

Case of George Pobgee, aged 44. Autopsy, April 12, 1887.

See cystic growth of cerebellum, No. 856, Series VI.



## SERIES XXXV.—INJURIES AND DISEASES OF THE THYROID AND THYMUS BODIES.

### THE THYROID BODY.

**Hypertrophy:** 1792.

**Goitre:** 1793–1807.

Fibrous: 1793.

Cystic: 1794–1807.

Calcareous: 1799–1801.

Ossified: 1802, 1803.

Gelatinous: 1804–1807.

**New Growth.**

Sarcoma: 1808–1809.

Carcinoma: 1810.

### THE THYMUS BODY.

**Hypertrophy:** 1811.

---

### THE THYROID BODY.

#### **Hypertrophy.**

1792. A thyroid body in which one lobe has become greatly hypertrophied. The microscope reveals many large circular spaces filled with yellow deposit and accompanied by an infiltration of small round cells in the surrounding connective tissue.

#### **Goitre.**

##### **Fibrous.**

1793. Solid enlargement of the thyroid body compressing the trachea and œsophagus, which are pushed over to the left side. A section of the right lobe has been made, and numerous small cysts are seen. The connective tissue is extremely dense. Microscopically the structure consists of fibroid degeneration of the tissue with a few scattered cysts.

##### **Cystic.**

1794. Symmetrical enlargement of the thyroid body, the lateral lobes being as large as small oranges and compressing the trachea.



The structure is in part cystic and in part solid. The right lobe has been cut open, and the section shows several loculated cysts with coagulated contents surrounding a solid central axis. The microscope reveals a fibrous stroma enclosing spaces, some of which are lined with flattened epithelium, and are filled with small round cells, other spaces are empty,—fibro-cystic disease.

1795. The anterior part of the right lobe from the same specimen.

1796. A specimen of an inflamed thyroid cyst. It is lined with shreds of flocculent lymph and contained pus when opened. The specimen shows the accustomed association of much gland-tissue with the cyst. There is no evidence to show what was the cause of the inflammation of the cyst. Microscopical examination of the cyst-wall reveals wavy bundles of fibrous tissue infiltrated with small round cells, and enclosing dilated vessels and vascular spaces.

1797. A thyroid body, enlarged, with an enlarged and cystic right lobe, which has pushed the œsophagus to the left side and compressed it. The enlarged right lobe of the thyroid body forms a globular mass about two inches in diameter. There is an opening in the anterior wall of the œsophagus, which leads into a cyst, at the upper part of the tumour. The mucous membrane is ulcerated for some distance round the aperture. There are two other cavities in lower part of the lobe, suggesting the probability that the communication between the œsophagus and the upper cyst was the result of thinning and yielding of the cyst-wall where it met with least resistance, and consequent ulceration from compression. The calibre of the œsophagus at the part compressed was reduced to that of an ordinary pencil, and the patient died of inanition.

1798. A thyroid gland showing fibrous and cystic degeneration. The organ, which is somewhat enlarged, is converted into a loculated fibrous cyst, and contained colloid matter. Its walls are much thickened, and the thick septal ridges and processes are of cartilaginous hardness. The microscope shows it to be composed of wavy bundles of fibrous tissue enclosing many circular spaces.

#### **Calcareous.**

1799. An old cyst in the thyroid body, showing calcareous degeneration of its wall and the remains of an old clot within it.

Case of Thos. Richardson, aged 62, who was admitted with a sinus in front of the neck, leading down to some calcareous plates in the gland. Portions were removed on several occasions. Rigors came on and he sank from septic pneumonia.

Autopsy, July, 26, 1882. Mr. Hutchinson.



1800. A portion of a thyroid body showing fibroid enlargements with numerous cysts, in some of which calcareous matter has been deposited in considerable quantities. The microscope reveals dense bundles of fibrous tissue with small round cells in a state of degeneration.

1801. An enlarged lobulated thyroid tumour surrounding, displacing, and compressing the trachea. It consists of three globular masses. A section has been made of the tumour, and shows fibro-cystic disease, undergoing in places calcareous degeneration. The microscope shows old dense fibrous tissue with degeneration of the glandular follicles.

#### **Ossified.**

1802. A thyroid body, in the lower part of one lobe of which is an encysted mass as large as half a walnut, and tuberculated on its surface, made up of fibrous tissue with nodules of true bone. The fibrous element is small in proportion to the osseous. This specimen is exceptional, such deposits being generally calcareous.

1803. A cystic thyroid body, in which the cyst-walls contain true bone. This specimen corresponds with the last.

#### **Gelatinous.**

1804. A specimen of a fairly symmetrical bronchocele. Each lateral lobe is enlarged to the size of a bantam's egg, and the isthmus is three quarters of an inch in depth and a third in thickness. The enlarged lobes show a solid structure with minute cysts. The upper rings of the trachea are closely surrounded by the growth, and its tube is somewhat narrowed. This specimen also shows that it is possible to get compression of the trachea from posterior enlargement of the lobes. The hypertrophy is chiefly in the connective tissue.

Microscopical examination of sections of the organ shows that the structure consists of many spaces of more or less circular outline with gelatinous contents, surrounded by a little fibrous stroma with small round cells in it.

1805. A thyroid body with both lobes and the isthmus enlarged. A section has been made which shows that the structure consists of a dense fibrous stroma enclosing alveolar spaces filled with gelatinous material. The microscope reveals a fibrous stroma with spaces and dilated vessels and degenerated small round cells.

1806. An enlarged thyroid body, the section of which shows very numerous small cysts containing a gelatinous material.



1807. A specimen of enlarged thyroid body from an old woman. The larynx and upper three inches of the trachea are completely encased by lobes of the organ which meet in the middle line behind, and extend upwards a third of an inch higher than the top of the thyroid cartilage, the right lobe being the larger one. In the middle line a pendulous mass the size of an egg hangs by a very slender connection from the isthmus; it did not compress the trachea, the patient having had no symptoms in connection with the bronchocele.

### Morbid Growth.

#### Sarcoma.

1808. A remarkable specimen of one-sided enlargement of the thyroid body. On the right side the mass is nearly as large as a child's head. It consists of large lobules, amongst which the common carotid artery is seen to be imbedded; there is slight enlargement of the left lobe also, and the trachea and œsophagus were compressed, the latter so much so that death from inanition resulted.

1809. Round-celled fibro-sarcomatous growth of the thyroid body as large as a cocoanut, with extravasations of blood into its structure.

The patient, a woman aged 52, under the care of Mr. Adams, died of asphyxia. Secondary deposits were found in the lungs.

#### Carcinoma.

1810. A thyroid body with enlargement of both lobes and isthmus. At the lower part of the right lobe there is a spherical mass of a denser and paler structure than the rest of the organ. Microscopical examination of this reveals large round cells in a fibrous connective-tissue stroma; (?) scirrhus.

### THE THYMUS BODY.

#### Hypertrophy.

1811. The trachea, lungs, heart, and thymus gland from a boy aged 1 year and 9 months. It is preserved to show some enlargement of the thymus, and its position and relations. It shows also how deep the trachea is at the lower part of the neck of a child, and that the upper end of the gland may be injured in tracheotomy.

*Presented by Mr. Waren Tay.*



## SERIES XXXVI.—INJURIES AND DISEASES OF THE KIDNEYS AND URETERS.

### **Injury.**

Laceration : 1812.  
Aneurysm : 1813.  
Detached capsule : 1814.

**Hypertrophy** : 1815, 1816.

**Atrophy** : 1816.

**Hæmorrhage** : 1817, 1818.

**Inflammation and its Effects** : 1819-1838.

Parenchymatous nephritis : 1819-1821.  
Granular cirrhotic nephritis : 1822-1829.  
" " " with Cysts : 1826-1829.  
Suppurative nephritis : 1830-1833.  
Pyelo-nephritis : 1834-1838.

**Necrosis** : 1839, 1840.

**Tuberculosis** : 1841-1845.

### **Changes in the Kidneys and Ureters due to Renal Calculi and Retention of Urine.**

Calculus in the pelvis of the kidney : 1846-1860.  
Erosion of calculi : 1859.  
Renal calculi : 1861.  
Calculus impacted in the ureter : 1862-1866.  
Obstruction to the outflow of urine from the bladder : 1867-1870.  
Hydronephrosis : 1856, 1857, 1863, 1864, 1866, 1870-1875.

### **Parasites.**

Hydatid : 1876.

### **Cysts and Morbid Growths.**

Cysts : 1877-1883.  
Retention cyst : 1877, 1878.  
Calcification of cyst-wall : 1879.  
Congenital cysts : 1880-1883.  
Morbid Growths : 1884-1889.  
Lympho-sarcoma : 1884, 1885.  
Melano-sarcoma : 1886.  
Carcinoma : 1887-1889.



**Malformations: 1890-1896.**

Supernumerary ureter: 1890, 1891.

Diverticulum from ureter: 1892.

Horseshoe kidney: 1893.

Conjoined kidneys: 1894.

Misplaced kidney: 1895, 1896.

---

**INJURY.****Laceration.**

1812. A left kidney, showing a laceration which extends into the cortex for a depth of a quarter of an inch.

The specimen was obtained from a man who died 18 hours after a severe crush between a dray and a wall. After admission he passed bloody urine once. He died from injuries to the chest.

**Traumatic Aneurysm.**

1813. The right kidney, much disorganized at the upper part, in the hilum of which is an aneurysm of the size of a large cherry, occupied by a firm clot from which the wall of the aneurysm has been in part detached, exposing the lining membrane of the cavity. A bristle has been introduced into the branch of the renal artery with which the aneurysm is connected, and a piece of blue glass rod shows the distal part of the vessel entering the renal tissue.

Case of J. Thos. White, aged 19, who was admitted with the statement that he had been struck on the right side of his chest by the wheel of a cart. On admission he was found to have a fracture of the 7th and 8th rib on the right side, together with severe dyspnoea, surgical emphysema, severe vomiting, and hæmaturia, which was persistent at first and afterwards intermittent. He suffered subsequently from cystitis and finally tenderness and fulness in the right loin.

At the autopsy, June 14, 1884, the right kidney was found disorganized and surrounded by decomposing clot, and the left in a state of acute suppuration spreading along the ureter to the bladder, which was acutely inflamed and contained clots. There was no laceration of lung or other viscus. Mr. Rivington.

**Detached Capsule.**

1814. A kidney with its capsule, which is completely detached. The inner surface of the capsule is smooth, the external is rough and thickened; the surface of the kidney shows irregular depressions. There was a collection of fluid beneath the capsule.



## DISEASES OF THE KIDNEYS AND URETERS.

**Hypertrophy.**

1815. The kidneys, ureters, and bladder of an adult showing a rudimentary condition of the right kidney and compensatory hypertrophy of the left. This organ is greatly enlarged; its surface is granular and puckered at the upper end, and the cortex is there much contracted and contains numerous small cysts; the calyces are moderately dilated. At the lower part of the organ there is also some dilatation of the calyces, and in one of them a small rough black calculus is seen. The pelvis of the kidney and the ureter are dilated, and their walls are thickened. The right kidney is represented by a small flattened body at the extremity of the ureter, apparently consisting only of a number of tubes connected with it and bound together by fibrous tissue, which seem to be the altered calyces of the organ. The ureter is of large size, with thick walls and wide channel; at its lower end it is tortuous. No communication between it and the bladder could be detected. The bladder is dilated and hypertrophied.

Case of Albert Foreman, who was brought to hospital in an unconscious state with abrasion of the occiput after having been thrown out of a cart, which he had driven against the curb; and died four days after admission. At the autopsy the left corpus striatum and optic thalami were found softened, and the left internal carotid and middle meningeal arteries plugged. The aorta was atheromatous. The left kidney weighed  $14\frac{1}{4}$  oz.; the heart  $14\frac{3}{4}$  oz.

Autopsy, November 14, 1884. Mr. Treves.

**Atrophy.**

1816. Two kidneys of unequal size, the larger having two ureters; this is the size of a fist and somewhat lobulated; the other is not larger than a hen's egg.

**Hæmorrhage.**

1817. A kidney from a case of purpura, showing numerous small hæmorrhagic extravasations beneath the capsule.

Case of Margaret Millaine, aged 15, admitted on December 27, 1887, with a purpuric eruption and a history of increasing weakness for three months. At the autopsy, December 30th, there were old and recent petechiæ over the whole body, and ecchymoses over kidneys with some wedge-shaped tracts of hæmorrhage extending in from the surface. The body was wasted; the heart fatty; the aorta stained.

Autopsy, December 30, 1887. Dr. Warner.

1818. One kidney of a girl, aged 7, who died of purpura, laid open and showing hæmorrhage under the mucous membrane of the pelvis and calyces. With it is an oval, flattened, blood-clot, which was found loose in the pelvis of the organ.



The child was admitted with a purpuric eruption and bleeding gums. She had been getting weak and thin for 6 months. The day before her death she passed claret-coloured urine. Extensive extravasation of blood was found behind the peritoneum, under the mucous membrane of the bladder, and in and upon the durarachnoid.

Case of Florence Pepper, aged 7. See Dura Mater, Series VI. No. 832. Autopsy, April 2, 1887. Dr. Sutton.

### **Inflammation and its Effects.**

#### **Parenchymatous Nephritis.**

1819. A thin section of a large white kidney (injected) showing the swollen cortex and other results of chronic parenchymatous nephritis.
1820. A large pale granular kidney, the result of chronic tubal, with interstitial, nephritis.
1821. A somewhat granular kidney about the normal size, from a similar case.

#### **Granular Cirrhotic Nephritis.**

1822. A small pale contracted granular kidney (injected).
1823. Half a kidney showing similar changes, with the vessels dissected.  
*Presented by Mr. Eve.*
1824. A small granular kidney with numerous cysts, and thickened vessels.
1825. An injected specimen of contracted granular kidney, showing opaque white uninjected areas in the pyramids.
1826. A small kidney, the upper end of which is puckered and contracted, and contains several cysts. The surface of the organ is granular at this part, and studded with minute cysts, amongst which a few larger ones are seen. The surface of the organ over the atrophic area is depressed and finely granular, the outline of the depression being well defined but irregular. The remainder of the organ is smooth, presenting a few cysts only.

Case of Hy. Middleton, aged 64, who died from cancer of the pylorus on April 23, 1884. He had suffered from constipation eight days, and persistent coffee-ground vomiting. At the autopsy, there was a large mass of growth between the stomach and liver with infiltration of the omentum and peritoneum.

Mr. Adams.



1827. One half of a granular kidney with cysts.

From a case of phthisis.

1828. A contracted granular kidney, containing cysts (injected).

1829. Half of a granular and contracted kidney (injected) showing numerous cysts.

*Presented by Dr. Letheby.*

### **Suppurative Nephritis.**

1830. Half a kidney showing numerous small hæmorrhagic infarcts in the cortical portion, in which were points of suppuration.

From a case of pyæmia following the passage of a catheter, which made a false passage through the bulbous part of the urethra. Acute suppurative fever followed, and the patient died exhausted on the third day.

1831. Halves of two kidneys, showing minute abscesses in the cones of the pyramids, in radiating lines through the cortex, and in elevated clusters on the surfaces.

Case of Fred. Ziegenbein, aged 16, admitted March 10, 1887, with symptoms of pyæmia following a carbuncle on the back. At the autopsy, a week after admission, in addition to the specimen, septic pneumonia and pleurisy were found. Autopsy, March 19, 1887. Dr. Stephen Mackenzie.

1832. A kidney studded with small abscesses.

From a patient from whom Mr. Luke removed a large cystic-oxide calculus.

1833. A kidney laid open longitudinally, showing breaking down of the cortical tissue at the borders of many of the pyramids, the lesion extending down towards, and in some cases up to, the papillæ. One papilla, indicated by a glass rod, appears to have been completely separated from the mucous membrane covering it. The areas of softening in contiguous lobules are separated by fibrous septa, which have been perforated in places. The pyramids are to a greater or less extent involved in the destructive process, and some are necrosed throughout. The renal artery and its branches are thickened and rigid; the renal vein is also thickened. The capsule of the kidney is thick and fibrous, and firmly adherent. The mucous membrane of the pelvis was thickened and injected. There was some purulent fluid in the ureter, and cystitis. The other kidney (the right) was slightly granular.

Case of Mary Ann Ainsworth (R.N. 470), aged 67, who died about 6 weeks after an attack of left hemiplegia from cerebral hæmorrhage, with intense cystitis and bed-sores.

Autopsy, May 24, 1887. Dr. Hughling Jackson.



**Pyelo-nephritis.**

1834. A kidney converted into a large sac of irregular shape and with several loculi, in which no remains of renal tissue are apparent; the other (right) kidney was the seat of acute suppurative nephritis.

There were two dilated ureters on the left side with a single opening into the bladder, which was diseased. The case was admitted into the hospital for dysentery.

Case of Geo. Bruce, a sailor. Autopsy, July 28, 1869. Dr. Clarke.

1835. A sacculated and loculated kidney, with thinned cortex and nodulated surface. The pelvis of the kidney is dilated, its walls are thickened, and the mucous membrane lining the pelvis and the cysts is covered with minute papillæ.

Case of Robert H., aged 36, admitted on March 17, 1888 (R.N. 636), with a history of pain and hæmaturia for a fortnight. Bladder was examined by cystoscope, but nothing found. There was a large cystic tumour in the right loin, which was opened, and foetid pus and urine escaped; the sinus continued to discharge till Jan. 1889, when the organ was removed, and the man made a good recovery.

Mr. Hurry Fenwick.

1836. A kidney showing the results of chronic pyelitis. The pelvis is much thickened and there is a deposit of calcareous and phosphatic matter upon its mucous membrane. The apices of the pyramids are destroyed.

From a patient who died five months after a fracture of the spine, having suffered from cystitis &c.

1837. An injected kidney from a case of pyelo-nephritis. The pelvis is lined by false membrane into which some vessels pass.

1838. A portion of a kidney with dilated pelvis and calyces, showing chronic thickening of the mucous membrane of the pelvis, and destruction of the renal tissue.

The patient was a woman who had suffered from incontinence of urine. There was no calculus.

**Necrosis.**

1839. A kidney, incised, showing necrosis and discoloration of the tips and immediately contiguous central parts of every one of the papillæ. The sloughs, which are of a black-brown colour, are sharply defined and have become separated in greater or less degree. Some have been removed, leaving cup-shaped excavations on the top of the truncated pyramids.

From a case of phthisis, fatal by empyema and lardaceous disease.

Case of Peter McDonell, aged 38. Autopsy, May 28, 1884. Dr. Gilbert-Smith. See Trans. Path. Soc. vol. xxxvi. p. 268.



1840. Portions of one kidney from a case of endocarditis, showing necrosis with partial separation, of the central parts of some of the pyramids. In the other kidney (the left) were two smaller areas of softening in the centres of contiguous pyramids, the lesions in both organs having been probably due to arterial thrombosis.

From a girl, aged 13, who died with endocarditis; the heart was hypertrophied and dilated; the mitral valve was thickened, and both it and the aortic valve were fringed with granulations; the lungs, liver, spleen, and kidneys were venously congested.

Case of Ada F. Davis. Autopsy, March 23rd, 1886. Dr. Fenwick.  
See Path. Soc. Trans. vol. xxxvii. p. 290.

### **Infective Granulomata.**

#### **Tuberculosis.**

1841. Part of the kidney of an infant showing dilated calyces with thickened walls, and mucous membrane infiltrated with breaking-down tubercular matter. The cortex is thickened and homogeneous, and presents minute abscesses at several points. The walls of the ureter are thickened.

Case of Annie Smith, aged 1, admitted for emaciation, with a history of recurrent diarrhoea. A few miliary tubercles were seen in the liver and over the lungs, which were emphysematous. The mediastinal glands were caseous; not the mesenteric. The left kidney and ureter were normal.

Autopsy, April 24, 1885. Dr. Fenwick.

For the bladder of this case see Series XXXVII. No. 1917.

1842. A kidney and ureter showing similar changes.

From a child two years old, who died of scrofulous disease of the urinary organs. "Both ureters were dilated, and their mucous linings thickened and inflamed. The mucous membrane of the bladder was in the same condition, as also that of the pelves of the kidneys. The mesenteric glands were enlarged and had suppurated."

1843. Two portions of kidney, one showing a cavity with loculi corresponding to adjacent pyramids, and with its walls covered with caseous material similar to that filling a smaller cavity in the lower specimen.

1844. An irregularly lobulated kidney converted into a collection of loculated cavities with fibrous walls, upon which are remains of their caseous contents. The cortex is wholly atrophied.

1845. A sacculated kidney, in which the renal tissue has been entirely destroyed by tubercular disease, the organ being converted into a fibrous sac with loculi corresponding to the several calyces.

The kidney was removed by Mr. Couper from a healthy-looking girl, aged 16, who made a good recovery after the operation.



**Changes in the Kidneys  
due to Calculi and Retention of Urine.**

**Calculus in the Kidney.**

1846. A kidney with a small calculus impacted in the lowest calyx. As the calculus did not obstruct the outflow of urine from the pelvis, there is little or no dilatation.

From a child who had caries of the vertebræ in the dorsal region.

1847. A contracted and sacculated kidney with three calculi occupying cysts in connection with its pelvis. One of the calculi shows a long spur-like projection passing downwards towards the pelvis of the kidney. The calculi consist chiefly of uric acid.

1848. A kidney, atrophied and converted into a series of cysts; no true renal structure remaining. In the pelvis is a phosphatic calculus as large as the last joint of the thumb, but irregularly lobulated, some of its branches extending into the cysts. Several smaller calculi were also present.

From a man, aged 30, under the care of Mr. Adams, who died after lithotomy.

1849. A sacculated kidney with the surface of the dilated pelvis and calyces rough and shaggy. There is a small calculus in its pelvis.

1850. The sacculated and atrophied kidney of a horse, with large phosphatic calculi in two adjacent loculi.

1851. A sacculated and atrophied kidney with several large lithic-acid calculi in its dilated calyces. Each calculus rests in a pouch which surrounds it.

1852. The remains of a kidney with a large calculus of irregular shape encysted in it. The renal structure is completely destroyed, a dense fibrous capsule only remaining, which embraces the stone.

It was removed from the body of an old woman who died of cerebral disease; she had not of late years suffered from any renal symptoms. The other kidney was healthy.

*Presented by Mr. Dyte.*

1853. A contracted and sacculated kidney with several uric-acid calculi lodged in the pouches. The proper structure of the organ is almost wholly destroyed. The ureter is dilated and thickened.

1854. A similar specimen.



1855. Two kidneys extensively disorganized and sacculated consequent on the presence of a large branched phosphate calculus in the pelvis of each. The calculus in each is of the same size and shape, the symmetry in this respect being very remarkable. The stones are as large as magnum bonum plums. The one which is most exposed has a thick foot-stalk, where it projects into the pelvis and had received the most recent additions.

1856. A left kidney removed by nephrectomy. It is greatly expanded by numerous large smooth-walled cavities, which communicate with each other and with the pelvis of the kidney; wedged within, and completely filling the pelvis, is a smooth dark calculus, of the size of a walnut. The walls of the cavities are fibrous, and thin in some parts, no renal substance remaining.

The patient, Alfred Williamson, a butcher, aged 25, was transferred from Dr. Mackenzie's wards on December 2nd, 1886, with a large tumour in the left side of the abdomen. His urine was normal in quantity and constitution. The next day the kidney was excised by Mr. Treves through incisions in the left linea semilunaris and left side of the mesocolon; no drainage-tube was used. He subsequently suffered from severe abdominal pain on the left side, became restless and at length delirious, and died three days after the operation. There was but slight vomiting, and the temperature did not rise. The average amount of urine passed per diem after the operation was 24 oz.

At the autopsy the right kidney was found to be also sacculated, and its ureter was nearly plugged by a calculus (see next specimen); there was a small calculus in one calyx.

Autopsy, December 6, 1886.

1857. A right kidney, laid open along the convex margin, showing great distention of the pelvis with loculi, the walls of which vary in thickness according to the degree of atrophy of the renal tissue. In the centre is seen a dark smooth globular calculus, plugging the commencement of the ureter.

Obtained post mortem from the preceding case.

1858. A greatly expanded and sacculated, and wholly atrophic, kidney. The two halves of a calculus are seen at the lower part of the kidney occupying one of the calyces. It is composed of oxalate of lime upon a uric-acid centre.

#### **Erosion of Calculi.**

1859. The kidneys, ureters, and bladder of a woman, aged 25. In the right kidney, which is enlarged, the calyces are dilated and occupied by calculi, some of which are united in the pelvis. At the upper part of the organ some of the segments are entirely atrophied and con-



verted into cysts. The calculi are much eroded, and present a sponge-like porous surface. The left kidney is wholly fibrous and contracted, and is imbedded in a mass of adipose tissue. A rough discoloured calculus is seen in its contracted pelvis, and in the calyces, exposed by a median section through it, are small collections of calcareous detritus. The upper end of the left ureter is much thickened. The right ureter is also thickened.

The cavities in the upper part of the right kidney contained no calculi and appear to have had no communication with the pelvis. There was no appearance of cystitis.

Case of Harriet Green, aged 25, who had suffered for eight years from gnawing pain on the right side, and had constantly passed pus in the urine. On admission there was a diffused and tender swelling in the right lumbar region. The liver and spleen were lardaceous.

Autopsy, July 12, 1884. Dr. Warner.

1860. A dried specimen of a small kidney, converted into a collection of membranous cysts as a consequence of the impaction of calculi.

### **Renal Calculi.**

1861. Calculi mounted dry on cardboard; they are small chalk-white rounded discs, with smaller concretions of irregular shape, some of which are semitransparent.

They were removed from the walls of a cyst in the kidney, the result of obstruction by calculus. The whole kidney was occupied by large irregular calculi.

### **Calculus impacted in the Ureter.**

1862. A kidney, ureter, and bladder of a patient who proved to have only one kidney, in the ureter of which a calculus has become impacted so as to cause symptoms of suppression of urine.

The upper part of the ureter has been injected with plaster of Paris to show the dilatation. A little lower down may be seen the bulging caused by the impacted calculus. The kidney is enlarged from saccululation.

The history given was that the patient, a middle-aged man, in walking along the street was knocked down and fell against the curbstone; that he got up and went home; passed a little urine; but in the night woke up in pain with a desire, but inability, to pass water. Mr. Hutchinson was sent for, examined the case, and decided that it was probably a case of impacted calculus, and incompetence from disease or absence of the opposite kidney.

*Presented by Mr. Hutchinson.*

1863. The kidney of a child consisting of a fibrous sac formed by the dilated pelvis and calyces. In the ureter is an impacted calculus, the



upper end of which is visible. The secreting renal tissue is completely atrophied.

See 'London Hospital Reports,' vol. iii.

1864. An enlarged kidney with the pelvis and calyces much distended, forming a loculated chamber in the centre of the organ. In the ureter, near its commencement, is a rough black calculus of elongated form, impacted with its long diameter in the direction of the passage. The kidney structure is much wasted, especially in the middle and at the lower end of the organ, where it has entirely disappeared over parts of the most expanded calyces. At the upper end of the kidney there is a considerable mass of renal tissue remaining, which is swelled and studded on the surface with points of suppurative nephritis.

Case of Wm. Clark, aged 23, who was admitted with enteric fever on February 28, 1884, and died from perforation of the bowel. The other kidney was normal. Autopsy, March 15, 1884. Dr. Fenwick.

1865. The kidneys, ureters, and bladder of an adult, the subject of renal and vesical calculi, showing the result of chronic obstruction. The bladder is small, and its wall much hypertrophied; its cavity is nearly filled by a mulberry calculus covered with phosphates. This calculus fits into a pouch behind the prostate. The left ureter is dilated, especially at the lower part, and the pelvis of the corresponding kidney is a little large; the kidney itself is hypertrophied. The right ureter is dilated and sacculated, and has much thickened walls; it contains three calculi at the lower part, and windows have been cut in the ureter to show them. They apparently consist of oxalate of lime, covered with a thin layer of phosphate, and are moulded somewhat by the wall of the ureter and roughly faceted. The pelvis of the right kidney is much dilated, and contains a sharp mulberry calculus about half an inch in its longest diameter. Much of the kidney is hollowed out into four large cavities with smooth walls. There is, however, considerable thickness of cortical substance in various parts.

1866. A kidney, ureter, and bladder. The kidney is converted into one large thin-walled cyst as large as an emu's egg. The ureter is dilated and its wall hypertrophied. Near its lower end a portion of its wall has been cut out to expose an impacted calculus the size of a plum; below the calculus the ureter is of nearly normal size. The bladder is hypertrophied.

Mr. Mansell-Moullin.



**Obstruction to the Outflow of Urine from the Bladder.**

1867. Large pale granular kidneys, with dilatation of pelves and calyces. One organ (the left) is much more affected than the other, and contains numerous large cysts.

Post-mortem: the bladder was found hypertrophied and dilated, with acute cystitis; and there was a cyst in the prostate.

Case of F. Moreas, aged 62, who was admitted with dilatation and hypertrophy of the heart and dropsy.

Autopsy, November 16, 1883. Sir Andrew Clark.

1868. The kidneys of a child laid open to show distended pelves and calyces, the result of pressure on the urethra by a distended imperforate rectum.

Mr. McCarthy.

1869. The right and left kidneys with dilated pelves and calyces, extreme in the right kidney, which is atrophied. Both kidneys are irregularly contracted and nodulated and contain cysts. The right kidney is injected.

1870. A kidney extensively sacculated, with thickened fibrous septa.

From a case of stricture.

**Hydronephrosis.**

1871. A dried specimen of kidneys, ureter, and bladder, showing an extreme degree of hydronephrosis on both sides. The ureters are of the size of small intestine, and the kidneys are converted into thin-walled cysts, all the renal tissue seeming to have gone. The bladder is dilated.

1872. A right kidney, with extreme dilatation of the pelvis. Attached to the upper part of the hilum is a large thin-walled cyst, the size of a foetal head.

It was removed by Mr. Treves from Rose Smith, aged 26, admitted Jan. 27, 1886. At the operation both ovaries were found to be cystic, and were removed. The patient made a good recovery. There was no history of stone.

1873. An enlarged sacculated kidney, the dilatation of pelvis and calyces being consequent on impacted calculi. It shows an earlier stage than in the succeeding specimen.

1874. A sacculated hydronephrotic kidney, from which almost the whole



of the renal structure has disappeared. It shows extreme results of prolonged ischuria. There is no record of the cause of the obstruction.

**1875.** A similar specimen.

It was taken from a man the subject of cystitis, the result of stone.

For other specimens, *vide* 1856, 1857, 1863, 1864-1866.

## PARASITES.

### **Hydatid.**

1876. An hydatid cyst of the kidney, the size of a child's head ; this has pressed against the surface of the kidney, and caused almost complete absorption of the renal substance ; there now remains only a small portion of the original kidney-tissue at the upper part of the specimen.

## CYSTS AND MORBID GROWTHS.

### **Cysts.**

#### **Retention Cyst.**

1877. A kidney, the section of which shows numerous spherical and tubular cysts. Most of them are filled with granular coagulum ; they are probably dilatations of the tubules.
1878. A kidney studded with cysts varying in size from a marble to a pin's head.

#### **Calcification of Cyst-wall.**

1879. A dried specimen of cyst from the kidney, with calcareous masses and ridges projecting from its membranous wall.

#### **Congenital Cysts.**

1880. General cystic disease of the kidneys from a fœtus of seven months. One kidney has been opened in the usual manner, and shows that the whole of the organ has undergone cystic transformation.



1881. A kidney from a full-time foetus, abnormally large and cystic. The opposite kidney was very small and undeveloped.

*Presented by Dr. Hughlings Jackson.*

1882. A kidney entirely converted into a collection of cysts.

From Susan Loder, aged 46, who was admitted into the hospital in 1884 with menstrual trouble; a mass was felt in Douglas's pouch, which was believed to be a cancerous ovary. The liver was also much enlarged and nodular, and she had frequent attacks of hæmaturia. She improved after a time and went out, but returned again in November 1888, and died two days after admission.

At the autopsy the liver and both kidneys were found full of cysts, and the left kidney was fixed at the sacral prominence and was the mass felt in Douglas's pouch.

Autopsy, November 4, 1888. Dr. Sutton.

1883. The kidney of a sheep, showing extreme cystic degeneration, and consisting of a congeries of thin-walled cysts, some of them very small, and others as large as a fist. The whole mass is as large as an adult head.

### **Morbid Growths.**

#### **Lympho-sarcoma.**

1884. A kidney converted into a flattened ovoid mass somewhat lobulated in parts. It measures six inches in its longest diameter, and is three inches in thickness. It presents a homogeneous appearance on section, with indistinct traces of renal tissue; at the back of the specimen is the much-thickened ureter. At the upper part on the right side is the other kidney, with the ureter and bladder attached. The kidney is infiltrated with small yellowish-white homogeneous masses. The ureter is half the size of small intestine. The vesiculæ seminales are enlarged. Sections of the growth show a lympho-sarcomatous structure.

Case of A. G. Osman, aged 38, admitted July 22, 1881, under care of Dr. Sutton. His symptoms, lumbar pain, cough, anorexia, and wasting, dated from three months before admission, and were attributed to an injury. A mass was felt in the left loin, and nodular enlargement of the left spermatic cord. His urine was alkaline; no albumen was found in it. At the autopsy, October 1, 1881, the malignant disease was found to involve the kidneys, left spermatic cord and testis, liver, and lungs.

1885. An enlarged and very irregularly nodulated right kidney, with a portion of the liver laid open longitudinally down to the hilum, showing its lower half entirely destroyed by a lympho-sarcomatous growth. At the upper end the renal tissue remains, but is reduced to a thin shell towards the centre of the organ, where it has been compressed by the growth in the hilum. The growth is traversed by fibrous strands, and contains encapsulated softer masses, more or less



discoloured, which are sections of the growth in greatly dilated veins. The renal vein and its primary branches, and the vena cava above, are greatly expanded by the growth, rounded nodules of which are seen projecting in the upper end of the vena cava behind the liver and in the supra-renal vein. The inferior vena cava and its branches are greatly thickened below the obstruction and resemble arteries. The lobulus Spigelii has been compressed and excavated by the growth in the vena cava, and forms a cap over its upper part.

Sections of the growth showed a lympho-sarcomatous structure, the compressed renal tissue adjacent being fibrous.

Case of Wm. Read, aged 44, who died after amputation of the left leg at the hip-joint for a sarcomatous growth of the femur.

Autopsy, January 16, 1884. Mr. Rivington.

### **Melano-sarcoma.**

1883. A kidney showing numerous small abruptly-defined deposits of melanosis in its cortical structure. None of them are larger than swan-shots.

Sections showed nodules of a round-celled lympho-sarcomatous perivascular growth.

### **Carcinoma.**

1887. One half of a large renal tumour removed by Mr. McCarthy. It is of rounded outline with a nodular surface, and consists of a carcinomatous growth which developed in the hilum of the kidney, that organ being seen flattened out upon its surface. The renal tissue is invaded by nodules of growth, but its outline is clearly traceable. The section has passed through the expanded extremity of one of the calyces of the kidney, which is surrounded by the growth, and occupied by a polypoid outgrowth from the mucous membrane. In the other half of the tumour, which was presented to the Royal College of Surgeons, massive growths were seen projecting into the dilated pelvis of the kidney, and an elongated process extended into the ureter.

Sections of the growth showed a carcinomatous structure, in part degenerated and fatty.

Case of Wm. Bailey, aged 37, who was admitted March 3, 1885. He had been suffering for seven months from hæmaturia and sickness, with pain in the left loin, and first noticed a tumour shortly before admission. He had latterly lost flesh and had become anæmic. There was no family history of tumour. The urine was acid, and contained a fifth albumen and phosphates, and hydatid-like shreds, but no hooklets. On March 18 Mr. McCarthy removed the tumour, which weighed 2 lbs. 4 oz., from within the capsule of the left kidney, and ligatured the pedicle. The



patient made a good recovery, but had a persistently high temperature; it was 101° when he left the hospital. The urine contained no albumen after the operation.

*Presented by Mr. McCarthy.*

1888. Portion of a kidney, showing large well-defined masses of encephaloid growth in its structure.

It was taken from the body of a man whose testis had been removed for medullary cancer under the care of Mr. Curling.

1889. A kidney enormously enlarged by a carcinomatous growth, in part medullary, in part scirrhus, which weighed 9 lbs. A large cavity has been formed in the centre of it, into which nodules of growth project. Nodules of growth are also seen in the section projecting into the pelvis and some of the calyces. At the back of the specimen some calyces are laid open, which are not invaded by the growth. The renal vein and vena cava are thrombosed. The ureter is thickened and dilated.

Sections showed a carcinomatous growth.

Case of John Briggs, aged 27, who was admitted in December 1881, and again in March 1882, for great and increasing abdominal swelling with enlargement of the liver, which weighed 16 lbs. after death, and was greatly deformed by massive growths of carcinoma. The other kidney was hypertrophied, weighing 9 oz.

Autopsy, May 12, 1882. Dr. Warner.

## MALFORMATIONS.

### **Supernumerary Ureter.**

1890. A kidney with two ureters, one of which has a dilated hydro-nephrotic pelvis. The renal artery is injected.
1891. The right kidney and bladder with two ureters from the former opening separately into the latter. Small glass rods have been introduced into the ureters at their lower end. The bladder is small and its walls hypertrophied.

### **Diverticulum from Ureter.**

1892. A right kidney and ureter with the bladder, showing a diverticulum from the ureter. Its orifice is about two inches above the lower end of the ureter, and it forms a tubular pouch, which runs upwards for about three inches, in contact with the ureter to which it is attached. It is slightly enlarged at the end. A piece of glass rod has been introduced into it.

Obtained from the body of a boy aged 11, who was admitted with hip-disease, dating 12 months, and tubercular peritonitis, with a fæcal fistula at the umbilicus.



There was a history of the recent formation of an abscess there after severe abdominal pain. At the autopsy, September 14, 1881, the bladder was found adherent to the abdominal wall at the umbilicus, which had prevented its being emptied, and the ureters were dilated. There was tubercular ulceration of the intestines, and a few scattered tubercles in the lungs.

Case of Frank Treves, R.N. 1784.

### **Horseshoe Kidney.**

1893. A horseshoe kidney. The two kidneys are joined at the lower part; the renal substance is deficient behind and at the lower part, thus exposing the division of the ureters. The kidneys are somewhat smaller than normal.

From a man, J. J. Stone, admitted February 2, 1882, and who died from cedema of the lungs and general anasarca. The heart was found small and flaccid, and the liver and spleen wasted.

Dr. Fenwick.

### **Conjoined Kidneys.**

1894. Conjoined kidneys. The left kidney, which was transposed, is united by its upper end to the lower end of the right kidney. It rested upon the spinal column, by which its surface has been grooved, its hilum looking to the right and downwards, as though the organ had been moved downwards and to the right on to the spine, and then rotated so as to bring its upper end in contact with the lower end of the right kidney.

Case of Ellen Pyke, aged 18 (R.N. 1098), who died from valvular disease of the heart and pericarditis. Autopsy, August 27, 1885.

See also unicorn uterus, with right fallopian tube and ovary from the same subject, Series XLVI. No. 2181.

### **Misplaced Kidney.**

1895. The right kidney from the brim of the pelvis, with the hilum anteriorly, and the surface fissured by the ureter running down, and by vessels entering hilum on both sides from above: on the right, an artery from the extremity of aorta at commencement of right, common iliac, with a vein from vena cava; on the left, an artery from the bifurcation of aorta posteriorly, with a vein from commencement of the left common iliac vein (or vena cava), hooking round the left common iliac artery.

Obtained from John Williams, (R.N. 810), who was admitted with a compound fracture of the occipital bone and laceration of the brain, and died the same day.

Autopsy, April 7, 1885. Mr. Treves.



1896. A left kidney removed from the pelvic cavity. An atrophied kidney with the hilum anteriorly, and the pelvis distended by a calculus. Blood-vessels enter the hilum on both sides from above; on the right an artery from the commencement of the right common iliac artery, with a vein from the end of the vena cava in front; on the left an artery from the left common iliac, with a vein ascending to the left renal, and connected by a cross branch with the left common iliac vein.

Case of Emma Ayres, aged 37, admitted with severe dyspnoea and general anasarca from chronic bronchitis. She died two days after admission.

Autopsy, April 25, 1885. Dr. Hughlings Jackson.



## SERIES XXXVII.—INJURIES AND DISEASES OF THE BLADDER.

### Injury.

Rupture: 1897, 1898.

Operation: 1899, 1900, 1967, 1968.

### Diseases.

**Foreign body:** 1901, 1902.

**Calculi:** 1865, 1866, 1903-1906, 1938, 1944.

Encysted: 1904.

Effects of: 1865, 1866, 1907, 1908, 1938.

**Hypertrophy:** 3, 4, 109, 1815, 1862, 1835, 1866, 1892, 1903, 1904, 1907-1913, 1934, 1935, 1937, 1938, 1940, 1942, 1948, 1950, 1954, 1955, 1957-1960, 1962-1964.

From Stricture: 1913, 1950, 1954, 1955, 1957-1960, 1962-1964.

From enlarged Prostate: 1909, 1910, 1934, 1935, 1937, 1940, 1942, 1943, 1944, 1945, 1946.

From Calculi: 1903, 1904, 1907, 1908, 1912, 1938.

**Dilatation:** 3, 109, 1859, 1871, 1907, 1913, 1935, 1938, 1940, 1942, 1946, 1951, 1954, 1956, 1958, 1961.

**Sacculation:** 4, 1910, 1911, 1913.

**Hæmorrhage:** 1914.

**Inflammation and its Effects.**

Cystitis: 1903, 1907, 1908, 1910, 1915, 1936, 1945, 1949, 1962-1964.

**Tuberculosis:** 1916, 1917, 1951.

**Morbid Growths:** 1918.

Sarcoma: 1918-1921.

Papilloma or Villous: 1922, 1923.

Epithelioma: 1924-1932.

## INJURY.

### Rupture.

1397. The bladder of a male, showing an extensive longitudinal rupture of the posterior wall near the apex. There is lymph on the surface of the peritoneum adjacent. In the contracted condition of the bladder the rent is about an inch in length. The edges are uneven and ragged.

1898. This specimen shows a rupture of the superior fundus of the bladder, which, now that the viscus is contracted, would still admit three or four fingers.



Thomas Walters, aged 27, a creole, admitted Wednesday, Dec. 13th, 1843. He was barely able to support himself, being in a state of partial collapse. He complained of pain in the abdomen and inability to void his urine. On pressure on the hypogastrium, which was tense, he suffered considerable pain. The catheter was introduced, and about fifty-two ounces of fluid drawn off; it was of a brownish colour unmixed with blood, and having the odour of urine. Diffusible stimuli were exhibited, but he did not rally, and the only additional symptoms that supervened before death, which occurred eighteen hours after admission, was intense pain on the left of the epigastrium. Post-mortem.—Viscera agglutinated by thin films of false membrane; in the abdominal cavity there was one quart and a half of sanguineous fluid smelling of urine, which had escaped from a rupture in the upper part of the bladder, of about the size to admit a halfpenny, and all the visceral vessels were much congested. The accident happened three days before admission, he was fighting, and fell with opponent upon his abdomen.

### Operation.

1899. The bladder and prostate of Samuel St. Pier, from whom a small calculus (uric acid) was removed by operation. The prostate was so much enlarged that it was impossible to introduce the finger into the bladder.

The patient was cut for stone by Mr. Hutchinson on February 15, 1871, but died of pyæmia on the fifth day; at the post-mortem examination two other calculi were found behind the prostate gland.

1900. The bladder of a child, with the anterior wall and roof of the prostatic urethra removed. The aperture to the left of the middle line is the incision made in lateral lithotomy—a thin red glass has been placed in the utricle to show that the incision does not involve the seminal ducts.

*Presented by Mr. McCarthy.*

For other specimens showing operations on the bladder, see Nos. 1906–1908.

## DISEASES.

### Foreign Body.

1901. A number-eight flexible catheter removed by lithotomy from a male adult.

The patient had been in the habit of using the catheter himself, and on one occasion whilst intoxicated lost it. After a while symptoms of irritation in the bladder came on, and six weeks later he sought admission into the Hospital, the catheter was removed by lithotomy, and he recovered quickly.

Mr. Hutchinson.

1902. A female catheter, the last two inches of which are coated over with a deposit of phosphate of lime; it shows the result of too long retention within the bladder.



**Calculi.**

1903. A contracted and hypertrophied bladder with a large calculus *in situ*. The mucous membrane of the bladder is thickened and furred over with lymph. The calculus is spherical in outline, smooth on the surface, and as large as a duck's egg. It weighs four ounces and is said to consist of lithic acid.

The patient was a lad, aged 19, who died in 1839. He was too ill when admitted to permit of operation, and died within a month. His urine sometimes passed involuntarily, and his bladder would never contain more than three or four ounces. At the autopsy the kidneys were found much enlarged, inflamed, and with abscesses in their structure.

Mr. Scott.

**Encysted.**

1904. A bladder, on the left side of which, about an inch behind the opening of the urethra, the end of a calculus is seen.

The calculus is about the size of the end of one's thumb, and is soft and eroded. At about a third of an inch from its extremity it is much constricted in passing through the walls of the bladder into a cyst. This cyst bulges backwards and to the left, and is covered by the vesical fold of peritoneum. It is thick-walled, and is completely filled by a calculus, which is moulded in deep furrows like the articular end of a bone. The encysted portion of the stone is about as large as a plum. The neck which connects the two parts is not as thick as the little finger.

From an old man who died in the hospital on December 10th, 1869. The presence of a calculus had never been suspected, and he had never been sounded. It will be seen that it would have been difficult and impracticable, except by the suprapubic operation, to have extracted the encysted part of this stone.

Mr. Hutchinson.

1905. A nodulated oxalate of lime (mulberry) calculus, an inch and a half in diameter, which has been varnished.

Removed from the bladder by lateral lithotomy.

Mr. James Adams.

1906. A calculus bisected; it is globular in form, measures three inches in diameter, weighed seven ounces, and is composed of a central nucleus of uric acid, round which are more or less concentric rings of phosphatic deposit.

It was removed in June 1865, through a limited opening in the prostate; the patient recovered.

Mr. John Adams.

For other specimens of calculus see Nos. 1865, 1866, 1933, 1944.



**Effects of Calculi.**

1907. A bladder showing dilatation and ulceration with thickening of the neck of the bladder, and secondary dilatation of the ureters. There is muscular hypertrophy and fibrous thickening of the walls of the bladder. The walls of the ureters also are much thickened.

From a case of calculus of the bladder removed by lateral lithotomy by Mr. McCarthy. The calyces of the right kidney were distended. The left kidney was reduced to the condition of a loculated sac, and the ureter was impervious.

Case of John Nash, aged 34. Autopsy, July 28, 1873.

1908. A bladder contracted, and extremely hypertrophied; at its base and neck, and in the prostatic urethra, the mucous membrane is ulcerated, and presents papular elevations, the result of prolonged irritation.

From a child, who was admitted with vesical calculus, but in too feeble a condition to admit of an operation. He died about a week after admission.

Both kidneys were found at the autopsy to be extensively diseased. The left was a little larger than a walnut and consisted almost wholly of cysts; the right was dilated and contained numerous abscesses and cysts.

*Presented by Mr. Hutchinson.*

For other specimens showing the effects of calculi, see Nos. 1865, 1866, 1903, 1904, 1912, 1938.

**Hypertrophy.**

1909. A bladder, laid open along the median line in front. The wall of the bladder is greatly hypertrophied, being in some parts an inch in thickness. On the posterior wall are smooth, rounded elevations of the mucous membrane caused by enlargement of the subjacent muscular bundles (fasciculation). The viscus is also a little dilated. At the lower part is the prostate gland, all three lobes of which are enormously enlarged; this enlargement, by obstructing the free passage of urine from the bladder, has caused the hypertrophy.

1910. A bladder, showing hypertrophy and minute sacculations consequent upon enlargement of the prostate with slight projection of the third lobe. The structures about the vesiculæ seminales also are much indurated. Scattered about are small circular ulcers and commencing sacculations.

1911. A male bladder laid open in front to show hypertrophy of the muscular wall, with correspondingly well-marked fasciculation on the mucous surface. The fasciculation is more marked than in No. 1909;



between the muscular elevations are small circular pits or sacculations. On the left side of the posterior surface and on the anterior wall are excavated ulcers of various sizes with uneven bases and abrupt margins. The prostate gland has been cut through to expose an abscess in each lateral lobe.

1912. The bladder of an adult, much thickened and contracted in consequence of calculus. The coats of the bladder in one part exceed an inch in thickness. *Presented by Mr. Luke.*

For other specimens of Hypertrophy, see Nos. 3, 4, 109, 1815, 1862, 1865, 1866, 1892, 1903, 1904, 1907, 1908, 1934, 1935, 1937, 1938, 1940, 1942-1948, 1950, 1954, 1955, 1957-1960, 1962-1964.

For specimens of Dilatation see Nos. 3, 109, 1859, 1871, 1907, 1913, 1935, 1938, 1940, 1942, 1946, 1951, 1954, 1956, 1958, 1961.

### **Sacculation.**

1913. A bladder with two small pouches, one on either side of the posterior wall of the viscus. The right pouch, which is the larger and would contain a pigeon's egg, is higher than the left. The left is near the entrance of the ureter. The opening into the right pouch would admit the forefinger. The prostate is enlarged, and the bladder slightly thickened and dilated.

The specimen was removed from a man, aged 50, who had been treated for stricture of the urethra, and who ultimately died from abscess and exhaustion.

Mr. John Adams.

For other specimens of sacculation, see Nos. 4, 1910, 1911.

### **Hæmorrhage.**

1914. A bladder, the cavity of which was filled by a solid mass nearly as large as a fist, consisting apparently of a decolorized and contracted blood-clot. This mass was very firm, rounded on its exterior, somewhat shreddy and fibrinous-looking in section. It looked, at first sight, like a solid growth rather than the remains of blood. At the back of the bladder is a large irregular cavity, with roughened walls, measuring two inches in diameter, which, in the recent state, was also filled with blood-clot. A glass rod has been passed along the ureter to show it opening into the upper part of the cavity, and the continuation of the ureter is seen at the lower part.

The floor of the penile urethra has been opened just in front of the bulb. A red glass rod is seen, which has been passed along the passage made by a perineal section. The hæmorrhage was probably caused by a wire.

The specimen was removed from a man, aged 37, who had suffered from stricture fifteen years, and had been under much treatment. On the morning of his



admission he had himself passed a thick wire into the bladder, on withdrawing which a stream of blood had followed without any urine. When admitted no instrument could be introduced, and a false passage was found between the bladder and the rectum. It being found impossible to relieve his bladder, the catheter puncture by the perineum was practised. He died, however, on the 25th day. At the post-mortem a large cyst was found behind the bladder, into which the left ureter opened, and which itself communicated with the bladder by a small opening. In the cavity of the bladder was a very large blood-clot.

### **Inflammation and its Effects.**

#### **Chronic Cystitis.**

1915. A portion of a bladder showing chronic cystitis; the submucous tissue is thickened by inflammatory deposit, and upon the surface of the mucous membrane are minute filaments of fibrin with patches of ulceration.

From the same case as specimen No. 1838.

For other specimens showing the effects of inflammation see Nos. 1903, 1907, 1908, 1910, 1936, 1945, 1949, 1962, 1963, 1964.

### **Tuberculosis.**

1916. A bladder and prostatic urethra laid open. In the left half of the trigone is a circular patch of superficial ulceration with raised uneven base. On the posterior wall of the bladder are several smaller ulcers. At the back of the specimen are the vasa deferentia and vesiculæ seminales and prostate incised to show similar tubercular deposit.

From a man who died of phthisis. It had been observed during life that he had enlargement of one testicle, but there were no bladder-symptoms; probably the condition of the vesiculæ seminales was not inquired into.

For the testes of this subject see specimen No. 1895.

1917. The bladder, ureters, and vesiculæ seminales of an infant. The mucous membrane of the bladder is thickened and irregular and superficially ulcerated on the surface. The vesicula on the right side has been laid open; it shows spaces containing caseous plugs.

For the kidney and history of this case see No. 1839.

For another specimen see No. 1951.

### **MORBID GROWTHS.**

#### **Sarcoma.**

1918. The bladder of a female child, laid open along the anterior surface and showing a mass of new growth the size of an orange, completely



surrounding the neck of the bladder. The growth is firm, indistinctly lobulated, and fibrillated on section, and is closely incorporated with the bladder-wall, evidently arising from the submucous tissue; it projects into the cavity as a rounded mass. Sections of this growth show a mass of small spindle-cells.

At the back of the specimen is the vagina laid open.

1919. The left half of a vertical median section of a small bladder. Springing from the anterior wall is a large globular mass of new growth, smooth on the surface, firm and fibrillated on section, and attached by a broad base to the bladder-wall. Sections of this tumour prove it to be a spindle-celled fibro-sarcoma. The bladder is hypertrophied.

1920. A pedunculated mass of soft sarcoma projecting into the cavity of the bladder. The mass is lobulated but not villous. No malignant disease was found in other organs. Sections show masses of large round and spindle-cells with large conspicuous nuclei.

Mr. Luke.

1921. A round-celled sarcoma (described formerly as a medullary cancer) of the female bladder. Large fungating masses project into the interior of the viscus. Its walls generally are much thickened. The ureters, much enlarged, are indicated by portions of bougie. The uterus and vagina are laid open behind and appear to be quite healthy.

#### **Villous Tumour.**

1922. Part of a bladder showing a pedunculated villous growth the size of a walnut, projecting into its interior. It is attached to the bladder-wall by a narrow pedicle close to the orifice of the left ureter.

Mr. Ward.

1923. A bladder, on the mucous surface of which are numerous sessile growths. These growths are shreddy on the surface, and covered in parts with phosphatic deposit, at their attachment there is some thickening of the subcutaneous tissue; the orifices of the ureters are indicated by bristles. The orifice of the right ureter is quite free, the left being completely surrounded by the growth. The bladder is somewhat dilated.



**Epithelioma.**

1924. A bladder of a female laid open along the median line, and its walls turned back. On the left side of the specimen is a mass of new growth extending from the orifice of the left ureter along the left side of the trigone to the floor and left side of the urethra. The upper part of the growth is polypoid, with small villous projections upon its surface, the base is indurated, it has been cut across to show the ureter passing through the centre of it. The lower part of the growth is irregular and ulcerated on the surface with a raised everted edge.

At the back of the specimen is the uterus with the vagina opened up; although there is some thickening on the exterior of the bladder corresponding with the ulcer, internally the vaginal mucous membrane is healthy.

It was removed from the body of a woman, aged 67, who had for some time suffered from symptoms which had been referred to stone. She ultimately died of cholera. No cancer was found in any other viscus. There was no calculus in the bladder.

*Presented by Mr. Welsh.*

1925. The bladder of a woman laid open in front. On the posterior wall and fundus is a papular nodulated new growth, which in some parts is superficially ulcerated. On the anterior wall immediately opposite the former growth is a somewhat circular ulcer with raised everted edges and shreddy irregular base. It illustrates the occasional occurrence of carcinoma from contact.

1926. A bladder showing great thickening from carcinomatous growth of the posterior wall, which extends towards the floor. The mucous membrane is much swelled and uneven from bossy elevations covered with phosphatic deposit, the effects of cystitis.

Case of John Feary, aged 73, admitted August 20th, 1884, for hæmaturia of six months' duration, of increasing severity latterly. On passing a catheter a roughened surface was felt in the bladder. He died on August 25th of asthenia and low muttering delirium.

At the autopsy there were found secondary deposits in the lumbar glands, right kidney, liver, and on the surface of the lungs.

Mr. McCarthy.

1927. The bladder of a female, aged 61, laid open longitudinally from behind, and showing an irregular nodulated growth chiefly affecting the anterior and lateral walls. The dilated urethra is seen. The uterus is hanging below and behind the bladder; it is the seat of a fibromyomatous tumour as large as a nut.

Case of Jane Patrick, aged 61, admitted into the hospital on April 17, 1883, with a history that for three weeks she had been passing phosphatic concretions



with blood. The urine was generally alkaline. The urethra was dilated by the surgeon, and this operation was followed by acute peritonitis with secondary pleurisy and death within three days.

1928. Part of a bladder with walls thickened by infiltrating new growth, which involves the lower segment and trigone. The growth is irregularly excavated by ulceration, and has a raised everted nodular edge. Microscopic examination shows tubular masses of degenerated epithelial cells.

1929. A bladder with a large mass of fungating soft cancer involving its wall on the right side, just above and behind the prostate. The cancerous mass has broken down and presents a shreddy surface in the bladder.

The patient a man, aged 65, had for three or four years suffered from hæmaturia and great pain in the bladder. The pain was chiefly felt after emptying the bladder. The man had been suspected to suffer from stone, his urine had usually contained blood and pus, and he had often passed blood in a pure state.

Mr. John Adams.

1930. A bladder, at the fundus of which is a large obscurely lobulated mass of soft cancer. The growth arises from the posterior part of the trigone and floor of the bladder.

It was removed from the body of a man, aged 32, who died exhausted after a two years' illness. His symptoms had been great irritability of bladder, pain after micturition, blood in urine, &c. When instruments were introduced they appeared to pass further than usual before the urine was reached. His case was for some suspected to be one of stone, but after careful sounding its true nature was detected. The ureters were dilated and the kidneys sacculated.

*Presented by Mr. Boor.*

1931. A portion of a bladder showing a soft pedunculated nodular growth from the lower segment. The wall of the bladder is infiltrated with new growth, and is half an inch in thickness.

Thin sections of this tumour under the microscope show masses of large spherical cells with large and often multiple nuclei, embedded in a scanty matrix of degenerated muscular bundles. Glandular epithelioma.

1932. A bladder, with part of the anterior wall removed; it shows an irregular, nodular, cancerous mass, filling almost the whole interior of the viscus. It is ulcerated upon the surface, and springs from the posterior part of the trigone. The outer surface of the viscus is not infiltrated. Microscopic sections show epithelioma.

It was removed post mortem; three months before death the growth was seen by the endoscope to be quite small.

Mr. Fenwick.



SERIES XXXVIII.—INJURIES AND DISEASES OF  
THE PROSTATE GLAND.

**Injury:** 1933-1936.

**Foreign Body:** 1937, 1938.

Calculus: 1937, 1938.

**Hypertrophy:** 3, 1899, 1909, 1910, 1913, 1933, 1934, 1935, 1936, 1937, 1939-1946, 1948.

**Inflammation and its Effects:** 3, 109, 1947.

Abscess: 3, 109, 1947-1950, 1960-1962.

**Tuberculosis:** 1951.

**Morbid Growth.**

Sarcoma: 1952.

---

**Injury.**

1933. A bladder and urethra laid open to show a false passage in the floor of the prostatic urethra and neck of the bladder; there is some visible enlargement of the lateral lobes of the prostate, and over the third lobe there is a thin bar of tissue half an inch thick.

It was described in the Old Catalogue as transverse septum of the bladder perforated by an instrument.

1934. The left half of a vertical median section of the bladder, showing great enlargement of the whole of the prostate, and in particular of its middle lobe, which projects into the neck of the bladder. Through this middle lobe there is a tract in which a bougie is now placed, no doubt made by attempts at catheterism. The bladder is hypertrophied.

1935. A bladder and prostate laid open along the anterior median line. The prostate is much enlarged in all three lobes. Passed through the middle lobe and base of the bladder is a glass tube, the upper end of which issues close to the orifice of the left ureter; this is probably a false passage made by catheterization. The bladder is hypertrophied, dilated, and fasciculated.

1936. The bladder and urethra laid open to show a false passage about an inch and a half long, commencing in the floor of the membranous



urethra, and passing into the fundus of the bladder. The tunnelling of the prostate in this specimen is very similar to the preceding, but the edges of the wound and adjacent mucous membrane of the bladder are coated with lymph, and there is a large abscess between the bladder and the rectum. There is no evidence of the existence of stricture or of other impediment to the exit of the urine.

### Foreign Body.

#### Calculus.

1937. Irregular enlargement of different parts of the prostate, especially about the third lobe. In the anterior part of the prostate a number of calcareous concretions are impacted in its follicles. In the specimen these are well seen *in situ*. The ureters are connected by a bar of hypertrophied muscle, behind which is a deep pouch. The bladder is hypertrophied. *Presented by Mr. Adams.*

1938. A vertical section passing a little to the left of the middle line through the bladder, prostate, urethra, pubes, and adductor muscles, showing prolapse of the ureter, an irregularly shaped prostatic calculus, and portions of a vesical calculus. The vesical calculus was fixed during life in the ante-prostatic pouch, and consists of almost pure bone-earth phosphate; the difference in colour of the two portions of this calculus disappears as soon as it is dried. The prostatic calculus is phosphate of lime, some animal matter, and a small percentage of carbonate of lime. The bladder is hypertrophied and dilated.

From a case of extravasation of urine from unknown cause, probably connected with the prostatic calculus. The man died of exhaustion three days after admission.

Mr. Mansell-Moullin.

### Hypertrophy.

1939. Slight enlargement of the prostate and very decided projection of the third lobe. An abscess, probably in consequence of the use of the catheter, had formed and opened in the perineum; its cavity has been laid open, and a bristle is passed into it from the prostatic urethra.
1940. Enlargement of the middle lobe of the prostate, which projects exactly in the middle line, and constitutes a mass as large as the end of the thumb, which must have acted as a sort of valve in closing the urethra. The bladder itself is dilated and somewhat hypertrophied.
1941. An enlarged middle lobe of the prostate seen from behind. The posterior wall of the bladder, which is dilated, has been removed. A



glass rod has been passed along the urethra into the bladder; it indents the centre of, and so is partially surrounded by, the enlarged globular middle lobe. The rest of the prostate seems of normal size. The entrance of the ureters is marked by pieces of glass.

Case of Wm. Harris, a dock-labourer, aged 47, admitted with fracture of the cervical spine, and who lived three days.

1942. A bladder opened from behind to show projection of the third lobe of the prostate as a somewhat pedunculated growth as large as a damson, which forms a perfect valve to the neck of the bladder. The rest of the prostate is only moderately enlarged. The ureters have been cut off short; their openings are seen. The bladder is dilated and fasciculated.

Mr. Adams.

1943. The left half of a vertical median section of the bladder, prostate, and urethra, showing very well the relations of the enlarged third lobe to the neck of the bladder and the urethra. The bladder is much hypertrophied. A piece of glass indicates the orifices of the seminal ducts.

1944. A male bladder laid open along the anterior surface, showing considerable enlargement of the lateral, and especially of the third lobe of the prostate. The prostatic urethra is nearly double its usual length. In the post-prostatic pouch is a small phosphatic calculus the size of a bean. The bladder is hypertrophied and contracted.

1945. The specimen shows great enlargement of all parts of the prostate gland, which is as large as the closed fist and projects in all directions. The bladder is hypertrophied, and has a deep pouch behind the third lobe of the prostate; its mucous membrane is superficially ulcerated.

1946. A specimen showing still greater enlargement of the prostate. The prostate is as large as an orange. The bladder is hypertrophied and dilated. The description states that there were calculi in the prostate, but none are exposed in the specimen.

For other specimens of enlarged prostate see Nos. 3, 1899, 1909, 1910, 1913, 1934-1937, 1948.

### **Inflammation and its Effects.**

#### **Abscess.**

1947. There is an abscess in the prostate gland opening by a ragged aperture close to the left of the veru montanum. The cavity is as large as a walnut. The prostate is not enlarged. The bladder is somewhat hypertrophied.



1948. A hypertrophied and fasciculated bladder, with enlargement of the prostate gland, and an abscess in the prostate close to the rectum. The prostate and the abscess have been incised.
1949. The neck of the bladder, prostatic urethra, and penis laid open. A large abscess appears to involve the prostate and the vesiculæ seminales, and opens by a ragged aperture close to the neck of the bladder. The mucous membrane of the bladder near to the opening is ulcerated and is everywhere covered with flakes of lymph. The submucous tissue of the bladder-wall is infiltrated with inflammatory deposit.
1950. A bladder and part of the penile urethra, laid open along the anterior surface. At the back of the specimen there is laid open a large loculated abscess-cavity with irregular walls, and situated in the substance of the prostate gland. Within the prostatic urethra on each side of the veru montanum are seen the dilated prostatic ducts which open directly into the aforesaid abscess-cavity. The bladder is fasciculated and hypertrophied.

The abscess in the prostate followed the use of caustic bougies for the cure of stricture; the man died of pyæmia.

For other specimens of abscess see Nos. 3, 109, 1960-1962.

### **Tuberculosis.**

1951. A bladder and prostate laid open anteriorly. In the prostate is a cavity large enough to hold a walnut, and opening in the floor of the prostatic urethra by an aperture half an inch in diameter; its walls are roughened by small miliary deposits. The bladder is dilated; its mucous membrane is everywhere coated with flakes of lymph.

Case of Edwin Abbott, aged 25, a sailor, admitted on April 25th, 1887, with a history of cough, wasting, and incontinence of urine for three months. The disease commenced whilst the patient was at sea. On admission, phthisical changes in both lungs were noticed. The urine contained pus and some albumen. He died of exhaustion. At the autopsy, April 28th, extensive tubercular changes in both kidneys, lungs, bladder, and left epididymis. Both testes were found atrophic. Tubercular nodules were found in the pia mater at the base of the brain and over the vertex.

Mr. McCarthy.

### **Morbid Growth.**

#### **Sarcoma.**

1952. A bladder and prostate showing considerable irregular enlargement of the latter. The left lateral lobe is enlarged to the size of a small orange, and pushes the prostatic urethra and neck of bladder over to the right. The section of the enlargement shows a somewhat fibrillated structure with soft homogeneous masses. The bladder is dilated.

Microscopic sections show a round and small spindle-celled growth, with large nuclei.



## SERIES XXXIX.—INJURIES AND DISEASES OF THE URETHRA.

STRICTURE: 130, 1953–1955, 1956–1960, 1963, 1965, 1966, 1967, 1968.

### Consequences:

Dilatation of the urethra: 1954, 1956, 1957, 1958, 1959, 1960, 1961, 1962, 1964.

Ulceration of the urethra: 1958, 1959, 1960, 1961, 1962, 1964.

Abscess: 1961, 1962, 1963.

Perineal fistula: 1962, 1963.

Penile fistula: 1959.

Cysts in the prostate: 1956, 1957.

Abscess in the prostate: 1960, 1961, 1962.

Hypertrophy of the bladder: 1954, 1955, 1957, 1958, 1959, 1960, 1962, 1963, 1964.

Dilatation of the bladder: 1954, 1956, 1958, 1961.

Ulceration of the bladder: 1962, 1963, 1964.

Surgical ureter: 1962, 1964.

Surgical kidney: 1964.

### Effects of the treatment of Stricture:

Effects of the application of caustic bougies: 1950, 1965.

False passages: 1959, 1966, 1967.

Puncture per rectum: 1967, 1968.

## STRICTURE.

1953. A portion of the penis and urethra laid open along the floor to show a stricture of the urethra near the membranous part. Stretching across the urethra is a thick dense band half an inch in length, a glass rod has been placed in the urethral canal.

1954. A bladder and urethra laid open along the anterior surface of the former and roof of the latter. There are several strictures within two inches of the external meatus. The rest of the canal is dilated; the bladder is somewhat hypertrophied and dilated.



1955. A bladder and part of the penile urethra laid open to show a short, thick band constricting the urethra, at a point a little in front of the bulbous portion. This band is composed of thickened mucous and submucous tissue, which has been left exposed by the division of the corpus spongiosum. The bladder is hypertrophied.

For other specimens of stricture see Nos. 130, 1956-1960, 1963, 1965-1968.

### **Consequences of Stricture.**

#### **Dilatation of Urethra.**

1956. A bladder, with a portion of the urethra. The urethra has been laid open along the floor to show an almost complete closure of the canal for half an inch in length, just in front of the membranous part; a bristle has been passed through and fits closely the stricture. The membranous and prostatic portions of the urethra are widely dilated. A deep cyst has been formed in the substance of the prostate gland by dilatation of its ducts. The anterior wall of the bladder has been cut open to show great dilatation of its cavity.
1957. A bladder and a part of the urethra, laid open along the floor and posterior surface. About an inch in front of the membranous portion is a slight narrowing of the urethra an inch in length. Behind this stricture the urethra is somewhat dilated; bristles have been placed in the patent orifices of some gland-ducts. In the centre of the prostate is a long tubular cystic cavity. There is much thickening of the penile tissue near the stricture. The bladder is hypertrophied.

For other specimens of dilatation of the urethra see Nos. 1954, 1958-1964.

#### **Ulceration of the Urethra.**

1958. A bladder and part of the urethra, exhibiting a long slight stricture of the bulbous urethra. There is dilatation and ulceration of the canal extending for an inch behind the stricture. The bladder is hypertrophied and dilated. The stricture would now admit a no. 3 catheter. The openings of dilated prostatic glands are seen.
1959. A bladder and penis laid open along the anterior surface and dorsum. The penile urethra presents strictures at several spots with dilatations and irregular ulcerations at others. The chief stricture is placed about two inches from the meatus; at this point the submucous tissue is half an inch in thickness; in front of this there is a false passage in which a piece of blue glass has been placed. Near the membranous urethra is a second narrowing; behind this the floor of



the urethra is deeply ulcerated. On each side of the veru montanum the orifices of dilated prostatic glands are seen. The bladder is hypertrophied and fasciculated.

For other specimens of ulceration of the urethra see Nos. 1960, 1961, 1962, 1964.

For specimens of urethral abscess see Nos. 1961, 1962, 1963.

### **Abscess in the Prostate.**

1960. A bladder, prostate, and part of the penile urethra laid open from above. At the end of the portion of the penile urethra exhibited is a slight stricture. Behind this the canal is extremely dilated, and the mucous membrane ulcerated over a large area. At some spots the floor of the urethra has been nearly perforated by the ulceration. The prostate presents a large excavated space, the walls of which are fairly smooth; the orifice of this space is large and irregular, occupying almost the whole of the floor of the prostatic urethra; it is crossed by the veru montanum and some other strands of hypertrophied mucous membrane. The bladder is hypertrophied, its mucous membrane is thickened but presents no ulceration.

From a man who died of lung disease.

1961. A portion of the bladder, prostate, and penis laid open along the anterior surfaces to expose the urethra. The penile urethra is dilated, and its mucous membrane thickened. The membranous and prostatic urethra presents the extreme effects of ulceration, the surrounding tissues are indurated and are riddled with small abscess-cavities. At the back of the specimen a portion of the prostate has been cut open to show these small abscesses, and below this is shown the abscess in the perineum. The bladder is dilated.

1962. A portion of the urethra, with the bladder and adjacent parts. The urethra is dilated, and at the membranous part the mucous membrane presents numerous circular pits of ulceration. The surrounding tissues are extremely indurated. The prostate at the apex and front part of the lateral lobes lies in a periprostatic abscess-cavity, the walls of which are thick; this cavity opens internally on the right side of the membranous urethra by an oval aperture a third of an inch in its long diameter, and externally by a circular orifice in the perineum. The bladder is hypertrophied and contracted; its mucous lining presents numerous circular ulcers of various depths. The orifices of both ureters are large and patent.



**Perineal fistula.**

1963. A bladder and urethra laid open along the anterior surface. In the bulbous part is a slight stricture. The floor of the membranous and prostatic urethra presents a huge abscess-cavity with uneven irregular walls; the mucous membrane is in many parts represented by flocculent shreds only. The abscess has opened in the perineum, and the aperture of the sinus can be seen at the back of the specimen. The bladder is contracted and hypertrophied, and its mucous lining is everywhere covered with lymph; at several spots are small circular ulcers.

**Surgical Kidney and Ureter, and Bladder.**

1964. A kidney, ureter, bladder, and part of the urethra laid open. The urethra is dilated, and on its floor is a small ulcer. The bladder is hypertrophied, and its mucous membrane ulcerated. The ureter is dilated, its walls thickened, and on its mucous lining are numerous small pits of ulceration. The kidney is hollowed out into many large sacculi, the walls of which are covered with soft lymph.

**Effects of the treatment of Stricture.****Effects of the application of caustic bougies.**

1965. A bladder and penis laid open. There is a stricture of the bulbous urethra, with a perineal fistula. A piece of blue glass has been passed through the fistulous passage. This fistula is the result of treatment by caustic bougies. The prostate is enlarged. The bladder is hypertrophied, and upon its interior are several small circular ulcers.

The patient died of exhaustion consequent upon cystitis.  
For another specimen see No. 1950.

**False passage.**

1966. A bladder and urethra, showing a stricture about three inches from the meatus. A long false passage extends by the side of the urethra and enters the bladder to the right of the prostate by two separate openings. The bladder itself is hypertrophied. There are fistulae and abscess-sacs along the course of the urethra. The specimen also shows the orifice of a puncture per rectum.

**Puncture per rectum.**

1967. A bladder and penile urethra laid open. There is a stricture at the anterior part, with a false passage in the floor of the urethra,



about three inches from the meatus. The bladder is hypertrophied and dilated. The orifices of the ureters are indicated; midway between them is a peg which has been passed through the aperture made by puncture per rectum. The rectum is seen at the back of the specimen.

1968. A bladder and urethra, showing numerous strictures at various parts of the canal, the lowest one involving the membranous urethra. Near the spot is a small abscess-cavity which opens externally by a circular aperture. The bladder had been punctured per rectum; a quill shows the seat of puncture.

The patient had suffered from stricture for many years



## SERIES XL.—INJURIES AND DISEASES OF THE PENIS.

### Morbid Growths.

Papilloma: 1968 a.

Epithelioma: 196, 1969-1975.

### Malformation.

Epispadias: 1976.

---

### Papilloma.

1968 a. The prepuce of a healthy boy, aged 18, presenting a complete ring of small irregular warty growths on its outer surface. There is no induration of the subcutaneous tissues. The prepuce was long.

He had noticed these warts for three months. Had never suffered from gonorrhœa.

*Presented by Mr. Wingrave.*

### Epithelioma.

1969. The anterior two inches of a penis, showing an epitheliomatous mass surrounding the glans penis, and deeply infiltrating the adjacent tissues; it is superficially ulcerated.

1970. The last two inches of the penis, showing a cauliflower ulceration of the glans penis. The ulceration chiefly affects the lower part of the glans and urethra, along which it has spread. There is little infiltration of the corpora cavernosa.

1971. A portion of a penis, showing extensive destruction of prepuce and glans by epithelial carcinoma. The whole surface is covered by warty growths and nodular masses. *Presented by Mr. Ward.*

1972. A section showing extensive destruction of the glands and prepuce by ulceration of new growth with infiltration of adjacent tissues.

1973. A penis, showing epithelial cancer commencing at the corona,



and passing in a deep ragged channel beneath the skin on the dorsum. The disease appears to have extended widely. There appears to be suppuration in several places in one corpus cavernosum, which is much thickened by infiltration.

1974. A penis, with part of the scrotal and abdominal integuments. The penis consists of a tuberculated mass of tissue three inches in length and the same in breadth. The skin of the dorsum is normal for a breadth of an inch, but the glans, prepuce, and skin of the under surface present a nodular irregular outline, with pits of ulceration of various depths.

1975. A large fungating epithelioma of the penis, ulcerated on the surface, the size of the two fists; a portion of the scrotal integument is left attached to the growth: the structure of a corpus cavernosum can be indistinctly made out at the back of the specimen, but otherwise all trace of penile structure is destroyed.

It was removed from a Pole, aged 51, on September 25th, 1889. It had been growing for four months only. The growth recurred, and was rapidly fatal.

Mr. Reeves.

For another specimen see No. 196.

### Malformation.

#### Epispadias.

1976. This specimen consists of parts of the pubic bones, the penis, and part of the bladder. The penis in its whole length shows a deficiency on its dorsal surface, the urethra being exposed. The urethral tube commences by a wide opening large enough to admit the end of the little finger just in front of the symphysis, and is consequently not more than an inch and a half in length. The tract of the urethra on the dorsum of the penis is marked by a shallow groove in which numerous mucous follicles enter. The glans penis is perfect, with the exception of the dorsal cleft, and the cleft prepuce hangs in folds on each side. The vesical extremity of the urethra appears to be normal.



## SERIES XLI.—INJURIES AND DISEASES OF THE TESTIS AND TUNICA VAGINALIS.

### Injury.

Self-castration: 1977.

### Diseases.

#### Atrophy and Degeneration: 1978–1987.

Atrophy: 1978–1983.

Fatty degeneration: 1984.

Fibroid degeneration: 1985–1987.

#### Inflammation and its Effects: 1988–1992.

Acute orchitis: 1988.

Abscess of epididymis: 1989.

Fungating growth: 1990–1992.

#### Infective Granulomata: 1993–2015.

Tubercle: 141, 1993–2009.

Syphilis: 146, 2010–2015.

#### Cysts and Morbid Growths: 2016–2061.

Hydrocele of the Tunica Vaginalis: 37, 77, 2016–2023.

Hæmatocele of the Tunica Vaginalis: 47, 2024, 2025.

Encysted hydrocele of the Tunica Vaginalis: 42, 2026–2034.

Encysted hydrocele of Spermatic Cord: 40, 41, 2035.

Congenital cyst: 2028, 2035, 2036, 2037.

Laminæ of bone from the Tunica Vaginalis: 2038, 2039.

Tumour of the Tunica Vaginalis: 2040, 2041.

Enchondroma: 2042.

Cystic enchondroma: 2043, 2044.

Sarcoma: 2045, 2046.

Fibro-cystic sarcoma: 39, 2047.

Chondro-sarcoma: 2048, 2048 a.

Melano-sarcoma: 2049.

Fungating: 69.

Carcinoma: 2050–2061.

Fungating: 2058, 2061.

#### Malformation: 2062, 2063.

Defective development: 2062.

Separation of Epididymis with inversion of Testis: 2063.

## INJURY.

### Self-Castration.

1977. Healthy testicles from a boy, aged 16, who castrated himself near the Hospital in 1832.



## DISEASES.

**Atrophy and Degeneration.****Arrested development.**

1978. The testicle of normal structure, but not containing any spermatozoa, weighed in the recent state 110 grains. It was a retained testicle, having been found near the brim of the pelvis, half an inch from the internal ring on the right side. The other testicle weighed 7 drachms 15 grains, and was quite healthy.

The patient died of cancer of the penis.

1979. The right testis (the smaller of the two) was retained in the abdomen. The left had descended into the scrotum, but both are undeveloped.

From an epileptic idiot who died of tuberculosis.

1980. Two testicles. The smaller of the two consists of fibrous tissue, the epididymis and vas deferens being normal. This was retained in the inguinal canal. The other gland is normal in structure, and had descended to the normal position.

1981. Testicles from an old man who died from the effects of accident. The smaller gland was retained in the inguinal canal and is undeveloped. The other gland is normal in structure as it was in position also.

1982. Similar to the above. The retained testicle was in the abdomen, and the gubernaculum extending from it to the bottom of the scrotum has been preserved with it.

1983. Two testicles removed from the body of a man, aged 25. The left was normal in position, size, and structure, and weighed 295.5 grs. The right normal in structure, weighed only 132.2 grs., and was retained at the external ring. Both vesiculæ seminales were distended with fluid, but the left alone contained spermatozoa.

**Fatty degeneration.**

1984. The left testicle from a man, aged 46, who died of dropsy from renal disease. The gland is one fifth the normal size. Beneath the



visceral layer of the tunica vaginalis above the testicle is some adipose tissue. In the recent state there was also some yellow substance of a fatty nature irregularly disposed between the wasted tubuli. Described and figured in 'Curling on the Testis.'

### **Fibroid degeneration.**

1985. The testicle, reduced in size, has been laid open. The normal structure has been altogether replaced by fibrous tissue. The tunica vaginalis has been obliterated by adhesion of the opposed layers. It is probably the result of acute orchitis.

1986. In both testes the trabecular structure is increased and thickened at the expense of the tubular part of the gland.

1987. A testis and epididymis bisected. The testis is somewhat enlarged and everywhere intersected by strands of dense fibrous tissue, between which are minute areas of homogeneous substance of cartilaginous appearance.

### **Inflammation and its Effects.**

#### **Acute Orchitis.**

1988. The section of the testicle appears to consist of lymph and blood-clot.

#### **Abscess of Epididymis.**

1989. The testicle appears healthy, but of a very dark colour. The globus minor and commencement of the epididymis are the seat of a large abscess-cavity. There is no distinct limiting membrane, but there are many trabeculae stretching across the cavity.

#### **Fungating Growth.**

1990. The specimen shows a ring of scrotal structure through which almost the entire testicle has protruded. A section of the protruded mass shows an apparently homogeneous solid structure with some irregular smooth-walled cavities. The surface of the specimen is very dark. Microscopically, it shows only fibrous tissue with small cells and nuclei, viz. irritative growth of connective tissue.

The specimen is said to be from a strumous subject.

1991. Fungating growth of the testicle, the result of chronic orchitis. The testicle and epididymis are considerably enlarged from fibrous



thickening, the result of chronic inflammation. The anterior part of the testis protrudes through the scrotum. The protruding part is covered with warty vascular granulations. The specimen has been injected.

1992. A section of a testicle and epididymis enlarged from chronic inflammation. Nearly the entire body of the testicle protrudes from an opening in the scrotum. The exposed surface is covered with warty granulations. The blood-vessels have been injected.

### **Infective Granulomata.**

#### **Tubercle.**

1993. A left testis, epididymis, and cord injected and bisected. The testis presents healthy tubular structure. The epididymis is much thickened by numerous small nodules of firm tubercular matter. The vas deferens is similarly thickened.

The patient, Albert Beaven, aged 45, was admitted into the hospital with strumous disease of the ankle-joint two years ago. The leg was amputated, and on his recovery from the operation the right testis was found diseased and it was removed. On September 3, 1888, he returned with recurrence in the left testis.

Mr. Mansell-Moullin.

This and the following specimens of tubercular disease are arranged in order of severity. Thus in this specimen and the next the testis is healthy, the epididymis only being involved. In No. 1996 the testis is also studded with small miliary tubercles. In No. 1998 these tubercles are no longer discrete. In No. 2003 the tubercular matter has undergone caseation; and in No. 2009 it has caused the testis to fungate.

1994. A testis and cord bisected. The testis is healthy. The epididymis is infiltrated with miliary tubercles.

Case of Wm. Bagnall, aged 59, admitted Feb. 18, 1889, with signs of tubercle in lungs, prostate, and testis. The testis had only been affected for a few weeks. It was removed with a good result.

Mr. McCarthy.

1995. A testis laid open to show a few scattered miliary tubercles amongst apparently normal tubular structure. There is a small abscess-cavity in the globus minor. The globus major is not thickened, but no definite tubercles can be seen.

From the same case as the tubercular disease of bladder and epididymis No. 1916.

1996. A sagittal section of an enlarged testicle the blood-vessels of which have been injected. Isolated masses of tubercle are imbedded in healthy structure. More numerous towards the rete testis, where they coalesce to form close-set yellow lines (see next specimen). Suppuration has occurred in the upper part of the epididymis, while a mass of caseous matter occupies the lower part. Described and figured in 'Curling on the Testis.'



1997. A section of the above.

1998. A sagittal section of a testicle and epididymis. The testicle is but little enlarged and the tubes are the seat of tubercular deposit. The epididymis is very much enlarged from tubercular deposit softened at many points.

1999. A testis and epididymis bisected. The testis is enlarged and studded throughout with miliary tubercles. The epididymis is much thickened and is pitted with numerous minute abscess-cavities, evidently the result of the caseation of similar tubercles.

Case of T. E. Guest, aged 45 (R.N. 1670), admitted into the hospital on July 19, 1889, with tubercular disease of the left testis. He stated that six weeks ago he noticed a fairly large lump at the back of the scrotum, which was not painful except on movement. The epididymis was enlarged and hard to the touch and distinct from the testis. The testis was excised and the patient made a good recovery.

Mr. Waren Tay.

2000. The right and left testicles injected with Prussian blue by Mr. McCarthy. They are both the seat of tubercular deposit alike in the body of the gland and in the epididymis. The lower gland is much enlarged, and in the upper the caseous substance is breaking down.

2001. A sagittal section of a testicle, the body of which is described as normal when fresh, although it now appears unusually homogeneous. The epididymis is enlarged and three times its normal size, and the tubular structure is replaced by tubercular matter.

2002. The disease seems to have primarily affected the epididymis and spread from thence to the testicle. The epididymis is much enlarged, and at the globus minor there are indications of a sinus leading to broken-down caseous matter. The healthy portion of the gland forms a sort of investing capsule for the caseous mass.

Case of Pierre Neilson, aged 28, who was admitted Nov. 10, 1884, in an unconscious state from cerebro-spinal meningitis. At the autopsy two days after admission, in addition to the specimen there were found strumous caries of the cervical vertebræ, and destruction of the left kidney with formation of cysts.

2003. A sagittal section of a testicle, the body of which, slightly enlarged, contains numerous masses of pale homogeneous tubercular matter. Some are small and isolated; but others are large and lobulated, as if formed by the coalescence of smaller masses. The epididymis, much enlarged, is occupied to a great extent by similar deposits.



The specimen has been injected, which marks off very distinctly the sound from the tubercular substance.

The patient died of phthisis.

2004. A section of the last.

2005. In the body of the slightly enlarged gland is a mass of firm homogeneous tubercular matter nearly 1 inch in diameter. There are also several similar but smaller deposits surrounded by portions of healthy tissue. The deposits are partly corpuscular, partly fibroid, the latter around the former within the tubules. There are also similar deposits in the globus major of the epididymis.

Sir Andrew Clark.

2006. Tubercle of the testicle.

The description of the preceding specimen exactly applies.

2007. The gland is of normal size, but the greater part of the normal structure has been replaced by a mass of caseous matter which has softened in places and broken down into numerous minute cavities containing fluid *débris*. A sinus from one of these opened on the surface of the scrotum, a portion of which has been retained on the specimen to show the relation. The very scanty remnant of normal structure forms an investment for this mass immediately beneath the tunica albuginea.

2008. This specimen shows atrophy of the testicle from tubercle. The epididymis is thickened from tubercular deposit. The testicle is atrophied and microscopically consists of fibrous tissue. At one point is some degenerated tubercular deposit. The other testicle was larger than normal.

The patient died of dropsy.

2009. An enlarged fungating testis bisected. The testis is three times the normal size and presents but faint trace of tubular structure; almost everywhere it consists of homogeneous caseous material. At the lower part is a small abscess-cavity with irregular walls. The epididymis is also in the same condition. The outer surface of the testis is nodular. The tunica vaginalis has been laid open; its walls are much thickened by infiltration of similar caseous matter, especially at the lower and back part.

For another specimen see No. 141.

### **Syphilis.**

2010. The whole testis and epididymis has been replaced by a homo-



geneous fibrous-looking material breaking down in some parts (probably syphilitic).

This testicle was removed post-mortem from a boy the subject of inherited syphilis. The central upper incisors were also preserved as characteristic Hutchinson's teeth.

2011. A section of a testicle described in the old Catalogue as chronic orchitis. The whole of the enlarged gland has been transformed into a "wash-leather" mass, which is breaking down in the centre into a pseudo-abscess.

2012. A section of an enlarged syphilitic testicle, the normal tissue being almost entirely replaced by "wash-leather" deposit.

2013. Another part of the last specimen.

2014. A syphilitic testis. The blood-vessels have been injected, and the gland is described as having been cut across transversely. In the centre of the gland is a mass of "wash-leather" substance into which the injection has not penetrated. This presses upon the neighbouring seminal tubules and infiltrates the tissue between them. Peripherally the tissue is healthy. In the old Catalogue this is described as chronic orchitis.

2015. A specimen showing syphilitic disease of the testis. It is similar to the last, but in a more advanced stage.

For another specimen see No. 146.

#### CYSTS AND MORBID GROWTHS.

##### Cysts.

##### **Hydrocele of the Tunica Vaginalis.**

2016. A hydrocele of the tunica vaginalis. The sac is distended, and shows the pyriform shape and well-developed cremaster muscle.

2017. The testicle was retained in the inguinal canal and is in the infantile condition. The sac of the tunica vaginalis was greatly distended, and not merely extended up to the internal ring, but protruded as a sacculated cyst through the external ring. Suggesting, during life, an inguinal hernia.

2018. A hydrocele of the tunica vaginalis and of the spermatic cord. The specimen shows the testis enclosed in the ordinary sac of the distended tunica vaginalis, but extending for about 2 inches along the



cord. Immediately above this is another cyst lined by serous membrane and situated in front of the constituents of the cord.

2019. A hydrocele of the tunica vaginalis, showing the results of injection with iodine. The blood-vessels have been injected. The sac is very vascular, and adhesion of opposed surfaces of the sac has taken place in part. Where adhesion has not occurred, the parietal layer is coated with vascularized lymph, and the visceral similarly, but to a less extent.

2020. The sac in this specimen has thick walls and some flocculent lymph on the inner surface.

2021. The lower smaller sac is that of the tunica vaginalis. The walls are thicker than usual, and the visceral layer is coated with flocculent lymph, as if it had been injected with iodine. Above and in front of the cord is the lower part of another sac of an inguinal hernia.

2022. The sac of a large hydrocele of the tunica vaginalis which had recently been injected with iodine. The inner surface of the parietal layer is thickly coated with lymph. The visceral layer is similarly coated at the borders of the testicle, and where not so coated is irregularly thickened, as if from old chronic inflammation. The parietal layer is also much thicker than usual, probably from chronic inflammation.

2023. A hydrocele of the tunica vaginalis treated by injection. The specimen shows universal firm adhesion of the opposed surfaces of the sac, resulting from injection.

For other specimens of hydrocele of the tunica vaginalis, see Nos. 37, 77.

#### **Hæmatocele of the Tunica Vaginalis.**

2024. An encysted hæmatocele of the tunica vaginalis. The tunica vaginalis, in relation with the testis, is thicker than normal. Above it is distended by a large cyst in connection with the epididymis. The interior of this cyst is rough from papillary growths, and contained in the recent state an unctuous fluid consisting of cholesterine and blood.

2025. The sac of a hæmatocele which had existed for many years. The parietal layer with part of the scrotum adherent to it has been laid open, so as to disclose the interior of the sac. The wall is thick and fibrous, and lined with granular fibres. The testicle, healthy in



structure, has also been incised, so as to show the thickness of the visceral layer, which is rough and nodular on the surface.

For another specimen of hæmatocele, see No. 47.

### **Encysted Hydrocele of the Tunica Vaginalis.**

2026. In this specimen the tunica vaginalis was distended with a small amount of fluid. The globus minor is thicker than normal, and near it is some discoloured lymph. At the globus major is a loculated cyst, said in the recent state to have been of the size of a small hen's egg, by which the testis was displaced, so that the anterior border was directed downwards.

Figured in 'Curling on the Testis.'

2027. The tunica vaginalis is normal as regards the testicle, but is distended by a large multilocular cyst in connection with the globus major of the epididymis.

Figured in 'Curling on the Testis.'

2028. A testicle with part of a cyst, said to have developed in the parietal layer of the tunica vaginalis. It is situated at the posterior border of the gland, extends the whole length of the epididymis, and probably arose from some vas aberrans.

2029. A cyst connected with the globus major of the epididymis. It is unilocular, and on the external surface is a small pedunculated body (hydatid of Morgagni); a similar body is near the attachment of the cyst.

2030. A similar specimen. The cyst has been distended with spirit to show its relation to the globus major of the epididymis.

2031. A large inflated and dried cyst, described in the old Catalogue as a hydrocele of the epididymis. It is about  $4\frac{1}{2}$  inches in its longest diameter, and has the remains of blood-vessels at one part.

2032. The testicle is normal. The globus major of the epididymis is the seat of a number of cysts with smooth thin walls, and communicating with one another. When distended the cysts were twice the size of the testicle.

2033. A similar specimen. The cyst is described as situated on the front of the testis between the visceral layer of the tunica vaginalis and the tunica albuginea. The other half of this specimen is in the Hunterian Museum.

Figured in 'Curling on the Testis.'



2034. An encysted hydrocele of the tunica vaginalis. The cyst is beneath the visceral layer of the tunica vaginalis, possibly in the tunica albuginea. The walls are very thick. It is sacculated. It contained a greyish-brown fluid and some spicula of bone.

From a patient, aged 63, who had been tapped for an ordinary hydrocele six years previously. *Vide* Path. Soc. Trans. vol. vii.

For another specimen, see No. 42.

### **Encysted Hydrocele of Spermatic Cord.**

2035. A small encysted hydrocele on the spermatic cord about 3 inches from the testicle. The testis, which is healthy, presents an hydatid of Morgagni.

For other specimens, see Nos. 40, 41.

### **Congenital Cysts of the Epididymis.**

2036. A testicle with epididymis and cord perfectly healthy, but at the globus major are two small pedunculated cysts, and at some little distance from these are two smaller sessile cysts, all probably remains of the Wolffian body.

2037. A testicle, showing congenital cysts of the epididymis. Similar to the last specimen.

For other specimens, see Nos. 2028, 2035.

### **Morbid Growths.**

#### **Laminæ of bone from the Tunica Vaginalis.**

2038. A number of plates of bone with irregular borders varying in size from that of a shilling to a pin's head. They consist of true osseous tissue with lacunæ.

They were discharged by suppuration from the tunica vaginalis of an old man, who ultimately recovered with an atrophied testicle.

2039. Two small masses of cartilage with a central nucleus of bone from the tunica vaginalis of a man aged 70, with healthy testicles.

#### **Tumour of the Tunica Vaginalis.**

2040. A small tumour about the size of a pea, consisting of fat and calcareous salts covered by a thin smooth membrane.

2041. A similar specimen to the last. It contained cholesterine and calcareous salts.

#### **Enchondroma.**

2042. A section of an enlarged testicle, the normal structure of which is replaced by irregular masses of hyaline cartilage embedded in



fibrous tissue. There are a few cysts from which the cartilage has disappeared.

*Presented by Sir James Paget.*

### **Cystic Enchondroma.**

2043. A section of an enlarged testicle in which the normal structure has been replaced by fibrous tissue enclosing a number of cysts of irregular shape and varying in diameter from an inch to a line. They are smooth-walled and sometimes compound. Some are empty, others contain calcareous matter, epithelium or cartilage.

2044. A similar specimen.

### **Sarcoma.**

2045. Sarcoma of a testicle. The tumour has been bisected. It is as large as a melon and homogeneous on section; all trace of healthy testicular structure is lost.

2046. A section of a sarcomatous testicle removed by Mr. Curling. The specimen was described in the old Catalogue as carcinoma.

The patient was in good health nine years after operation.

### **Cystic Sarcoma.**

2047. An enlarged testicle consisting of fibrous tissue containing cysts of varying size. Some of these contain osseous tissue, others colloid matter or blood.

For another specimen, see No. 39.

### **Chondro-sarcoma.**

2048. Two portions of an enlarged testicle removed by Mr. Henry Thompson, and reported upon in Path. Soc. Trans. vol. vi. by Mr. Curling and Sir Andrew Clark; described in old Catalogue as exhibiting "the combined action of cholesteatoma, enchondroma, and encephaloma." The upper smaller part is studded with nodules of cartilage in connecting stroma. In the larger portion are nodules of cartilage in smooth-walled cysts and some sarcomatous growths.

2048 a. A testis bisected. It is globular in shape, and the size of the two fists. At no part can any normal structure be seen, the whole testis being infiltrated with a soft medullary growth; the inter-tubular connective tissue is everywhere much thickened; scattered throughout the lower half of the organ are spaces irregular in size and shape, the result of degeneration of the new growth. The tunica vaginalis is hypertrophied and covered with flakes of organized lymph.



Case of G. H. Polley, aged 25, admitted on June 14, 1889, R. N. 1274, with a history of gradual swelling of the right testis for eighteen months. On admission it was as large as a cocoanut. It was punctured, and a few drops of blood-stained fluid drawn off. It was excised, and the wound healed quickly under iodoform. There was no recurrence a year after the operation. Microscopic section of the growth revealed a mixed sarcomatous structure with some islets of cartilage scattered throughout its substance.

#### **Melano-sarcoma.**

2049. A testicle showing brownish-black masses separated by wavy fibrous septa. The testis is much larger than normal; no healthy structure remains. The sac of the tunica vaginalis is obliterated, and part of the mass protruded as a fungus testis through the scrotum.

#### **Fungating Sarcoma.**

See specimen No. 69.

#### **Carcinoma.**

2050. A testicle, in which the normal structure has been completely replaced by a mass of medullary cancer. The mass measures three by four inches, and is subdivided by fibrous bands. The tunica vaginalis is in part adherent, in part free.
2051. Medullary cancer of the testicle. A similar specimen to the last.
2052. A section of a testicle four inches in diameter. There is no normal structure remaining. Imperfect septa are seen bounding cavities filled with medullary cancer.
2053. A greatly enlarged testicle, the blood-vessels of which have been injected. The normal structure has been in many parts replaced by the new growth, which microscopically proved to be carcinoma with large epithelial cells and very active growth of the connective tissue.
2054. A section of a testicle with the membranes and a part of the scrotum adherent. The normal structure of the gland has been replaced by a growth described as medullary cancer.
- It had been of two years' duration, and was removed by operation, but the disease recurred in the cord.
2055. A sagittal section of a greatly enlarged testicle. The normal structure is replaced by a homogeneous substance which is in parts flocculent. It is described as encephaloid cancer.
2056. The specimen shows an increase of fibrous tissue, the meshes of which enclose thin layers of granular substance, the residue of the gland substance and rapidly growing encephaloid cancer. There



are also numerous cysts, varying from the size of a pin's head to that of a large pea, with smooth walls, and in the recent state filled with clear, and in some cysts with viscid fluid. There were also numerous recent extravasations of blood.

2057. The testicle is much enlarged. The tunica vaginalis is thick and with its cavity to a large extent obliterated by adhesions. The gland-structure is replaced by a mass of encephaloid cancer, which is posteriorly breaking down into a pseudo-abscess.

The patient was in good health 10 years after its removal.

#### **Fungating.**

2058. A testicle, the normal structure of which is replaced by a new growth of varying consistence. At the upper part it has perforated the visceral layer of the tunica vaginalis.

2059. The gland-substance is entirely replaced by new growth. Some lymphatic glands similarly affected are stitched to the top of the specimen.

2060. A medullary cancer of the testicle with colloid degeneration. A testicle with membranes and part of scrotum. The membranes are thickened and indurated. A section of the mass shows irregular fibrous septa filled with medullary growths. Anteriorly the growth protrudes through the scrotum and presents a flocculent appearance.

2061. A cauliflower-like mass, part of which protruded from the scrotum, consisting of medullary cancer and extravasated blood.

#### **Malformation.**

2062. Defective development of testes. The specimen shows a prostate gland with two well-developed vesiculæ seminales and distal portions of the vasa deferentia, but the duct on the left side terminated in a fibrous cord, which could not be traced beyond the external inguinal ring, and that on the right side terminated as a fine band in some fibrous tissue lodged in the rudimentary scrotum. Of the testes themselves there was no trace.

#### **Separation of Epididymis with inversion of Testis.**

2063. A small left testis with dilated tunica vaginalis and Poupart's ligament with portions of the abdominal muscles and large vessels connected with it. The globus minor of the epididymis with the end of the vas deferens, which diverges from the vessels in the spermatic cord to reach it, is separated from the testis by an attenuated portion



of its body, about an inch in length, at the border of a membranous expansion of the spermatic cord within the tunica vaginalis, at one end of which the globus minor hangs free in the cavity. The extended epididymis passes over the top of the inverted testis, with which it has a firm fibrous connection, and down the side of it remote from the vas, with which it has a membranous connection about half an inch wide, and is united to the lower end of the organ. At this part the small "hydatids of Morgagni" are attached to the end of the epididymis and of the body of the testis respectively, and in the pouched membrane in the digital fossa a similar body is embedded. There is no enlargement in the situation of the globus major of the epididymis. At the upper part of the specimen there is a small hernial sac, to the inner side, and in front, of the spermatic cord; and there is a bulging of the abdominal wall above the inner part of Poupart's ligament. The right testis is also shown; it is a large and apparently healthy organ.



## SERIES XLII.—INJURIES AND DISEASES OF THE SCROTUM.

### Hypertrophy.

Elephantiasis: 2064.

### Morbid Growth.

Fibroma: 2065.

Lipoma: 2066, 2067.

Melano-sarcoma: 2068.

Epithelioma: 2069, 2070, 2071.

---

## DISEASES.

### Hypertrophy.

2064. A portion of the scrotum, showing extreme hypertrophy of the skin and subcutaneous tissues; the mass weighs one and a quarter pounds and measures 8 inches by 4.

It was excised by Mr. Curling from a gentleman, aged 23, born in Surinam, affected with elephantiasis scroti.

### New Growth.

#### Fibroma.

2065. A lobulated fibrous tumour of scrotum; the size of a small fist.

*Vide* Trans. Path. Soc. 1858-9.

*Presented by Mr. Curling, F.R.S.*

#### Lipoma.

2066. A section of a fatty tumour removed from the scrotum. This portion is nine inches long by three deep, and consists of lobules of adipose tissue separated by fine strands of fibrous connective tissue.

*Presented by Mr. Kiernan.*

2067. A globular tumour, the size of a child's head, laid open. The sections show lobules of adipose tissue of various sizes.

It was removed from the scrotum of a man, Wm. Bright, aged 73, who was also the subject of an oblique inguinal hernia.

Mr. Treves.



**Melano-sarcoma.**

2068. A pedunculated mass, about the size of the end of the thumb, which was excised from the scrotum. It appears to consist in part of melanotic, and in part of medullary cancer.

**Epithelioma.**

2069. A portion of scrotum excised from a chimney-sweep, showing an ulcerated surface the size of a crown piece, with irregular, warty, fungating and everted edges. The section shows that the papillæ of the skin are hypertrophied, the subcutaneous tissues infiltrated, and the surrounding skin thickened and indurated. "About half an inch below this ulcer are two good examples of what is known as the soot-wart, the earliest stage of cancer."
2070. A portion of the scrotum removed from a chimney-sweep. It shows a circular excavated ulcer, with thick irregular edges and nodular uneven base devoid of granulations.
2071. A portion of the scrotum excised by Mr. Curling on account of epithelial cancer. It is about the size of a crown piece; the feature of chief interest in the case is, the man had not been exposed to soot. The specimen was examined microscopically by Mr. J. Adams, who reports that the edges did not show any evidence of cancerous disease, which was present only in the centre of the ulcer.

Mr. Curling.



## SERIES XLIII.—ENTOZOA.

**Trematoda.**

*Distoma hepaticum* : 2072, 2073.

**Cestoda.**

*Bothriocephalus latus* : 2074.

*Tænia solium* : 2075-2077.

*Cysticercus cellulosæ* : 2078, 2079.

*Tænia medio-canellata* : 2080.

*Tænia elliptica* : 2081.

**Nematoda.**

*Ascaris lumbricoides* : 2082-2084.

*Ascaris mystax* : 2085.

*Dracunculus medinensis* : 2086, 2087.

*Dochmius duodenalis* : 2088.

*Botts* : 2089.

---

**Trematoda.*****Distoma hepaticum.***

2072. Specimens of *distoma hepaticum* obtained from the liver of a sheep. The head end projects like a beak, and bears a small suckorial disc in which the orifice of the mouth is visible. Immediately behind this on the ventral surface is another suckorial disc. The genital orifice opens between these two discs, but cannot be distinctly seen.

2073. A specimen of *distoma hepaticum*, showing the uterus and intestinal canal injected with mercury.

**Cestoda.*****Bothriocephalus latus.***

2074. A specimen of *bothriocephalus latus*; it shows in a typical manner the middle of the worm, but the two ends are absent. Along the centre is a dark line, which runs the full length of the animal, and indicates the position of the reproductive organs.



**Tænia solium.**

2075. The specimen shows the centre of the worm. The segments are nearly square, with the corners rounded; they measure 10 mm. in length by 8 mm. in width. These segments are fully developed, and the genital opening is placed at the side, a little behind the middle. Running along the borders of each segment are somewhat dark lines, visible on holding the specimen up to the light, which mark the excretory apparatus, or water vascular canal. On the right of the specimen is a string of shorter segments.

2076. A few segments of *tænia solium* injected with mercury to show two tubes running along the borders of each segment and continued across the joints with similar tubes in the adjacent segments; these are the excretory water vascular canals, and lie in the cortical part of the worm. Within the central parenchyma lying close together are the sexual organs; they are best seen in the lower segment of the specimen. Along the centre is the straight uterine tube with numerous lateral branches of the ovary, these branches having dendritic ramifications; below the uterus is the testis, which consists of a clear convoluted tube with vesicles. The genital orifices open into a cloaca.

2077. A similar specimen.

**Cysticercus cellulosæ.**

2078. A portion of the muscle of a pig, showing innumerable minute spherical dots or minute vesicles. These vesicles are the partially developed scolex of the tape-worm, and spring from the embryos which have been lodged within the intestine of the animal; the albuminous envelope having been dissolved, the liberated embryo bores its way through the stomach-wall into the adjacent muscle, where it develops into the cysts seen in this specimen.

2079. A similar specimen; here the cysts are larger, and the head of the tape-worm can be distinctly seen through the thin transparent cyst-wall. The scolex or head springs from the inner wall of the cyst, and has already developed a circlet of hooks, sucking-discs, and water vascular system. If these vesicles reach the stomach of man, the cyst-wall is dissolved and the scolex within grows into a mature tape-worm.



**Tænia medio-canellata.**

2080. The segments are broader and thicker than in *tænia solium*. The head is wanting. The genital opening lies below the middle of the lateral margin, as is the case with *tænia solium*.

**Tænia elliptica.**

2081. It consists of a number of elliptical segments. The head of the worm has a circlet of hooks and a rostellum, but is not present in this specimen. This worm is rarely seen in man.

*Presented by Dr. Turner.*

**Nematoda.****Ascaris lumbricoides.**

2082. A slender, elongated, cylindrical body, with tapering extremities devoid of segments. The cuticle is very elastic. The mouth is at the anterior extremity. The genital orifices are placed along the ventral surface.

2083. A portion of the small intestine distended with *ascaris lumbricoides*; some of these worms lie on the floor of the glass.

2084. A similar specimen.

On the 8th of February, 1889, L. E. R., aged 2, whilst her mother was at needlework, put her hand into the workbox and abstracted some of the contents, putting them into her mouth; the mother at once noticed what the child had done and struck her hand, and hearing something drop thought no more about it. Three days afterwards the mother on emptying the stool after it had been used by the child noticed the specimen, which was quite dead. It is seen to be wedged in one of the rings of the hook; there were a number of hooks in the work-box.

*Presented by Mr. Peskett.*

**Ascaris mystax.**

2085. A round-worm found in the cat, very rarely met with in man. It is considerably smaller than the common round-worm.

**Dracunculus medinensis.**

2086. Portions of a fine thread-like worm. It measures about 2 feet in length.

2087. A similar specimen.

From a Lascar, aged 20, who was admitted with a history of having had a similar worm removed from an abscess over the wrist. When admitted there was on the outer side of the left foot a swelling which resembled a boil; this burst and from



within it the specimen was extracted; the worm was broken in half whilst being removed, but the sore healed well: some short time later a second similar sore appeared a little higher up the same leg, from within which a second worm was removed; it also broke in half during removal, part remaining behind, but this sore also quickly healed up.

Mr. McCarthy.

**Dochmius duodenalis.**

2088. A portion of the duodenum opened and spread out; on the mucous surface are seen numerous pieces of copper upon which are small thread-worms (*anchylostoma duodenalis*). *Presented by Mr. Eve.*

**Botts.**

2089. A portion of the stomach of a horse, to the mucous lining of which 17 botts are adhering.



## SERIES XLIV.—INJURIES AND DISEASES OF THE OVARIES.

### Parasites.

Hydatid: 2090.

### Cysts and Morbid Growths.

Cysts: 2091-2108, 2131, 2134, 2139, 2167.

Simple follicular: 2091-2095.

Congenital: 2096-2099.

Contents: 2100.

Proliferous, with Cystic Growths: 2101-2105.

„ „ Solid Growths: 2103-2108.

Morbid Growths: 2109-2114.

Fibroma: 2109.

Sarcoma: 2110.

Carcinoma: 2111-2113.

Colloid Carcinoma: 2114.

## PARASITES.

### Hydatid.

2090. A true hydatid cyst developed in connection with the broad ligament. No part of the ovary is seen in the specimen. It has perhaps been destroyed by the pressure of the cyst; the enclosing cyst has been laid open and a very large hydatid is seen folded up within it.

## CYSTS AND MORBID GROWTHS.

### Cysts.

#### Simple follicular.

2091. Part of the uterus with Fallopian tube and ovary, showing a small simple ovarian cyst the size of a marble.

2092. An ovarian cyst the size of a walnut, its surface is somewhat irregular, and it is probably polycystic. A bristle has been passed



from the uterus some distance along the Fallopian tube. The fimbriated extremity of the tube is open. A membranous adhesion runs from the surface of the ovarian cyst to the outer part of the Fallopian tube.

2093. The ovaries, uterus, and appendages. In both ovaries there are small cysts. In the body of the uterus there is an encapsuled fibroid tumour as large as a damson-plum, and within its cavity there is a small, smooth, pedunculated growth the size of a pea.

Dr. Ramsbotham.

2094. Portions of a very large cyst of the broad ligament.

The patient, a woman aged 46, presented all the symptoms of ovarian dropsy. The abdominal parietes were exceedingly thin, and fluctuation so distinct that the existence of ascites was suspected. All the other symptoms were, however, in favour of its being ovarian, and the operation of ovariectomy was accordingly attempted. The cyst having been laid bare, a few slender adhesions required detachment in front. It was then tapped, and its anterior part drawn out. At this stage of the operation it was found that the posterior part of the cyst was under the peritoneum, and that there was no true pedicle. The ovary, in a perfectly healthy condition, was attached to the lower surface of the cyst, and clearly had nothing to do with the disease. It was now determined to remove as much of the cyst as could be got away, and to apply the clamp around the part where cut across. This was accordingly done, the anterior five-sixths of the cyst being removed. Acute peritonitis followed, and the patient died.

At the autopsy, in addition to general peritonitis, the lining membrane of the remaining portion of the cyst was found to be intensely inflamed. On attempting to enucleate the cyst-wall from the peritoneum under which it lay, it was found that this could be done without much difficulty. The specimen preserved consists of the anterior part of the cyst removed at the operation, and which comprises both cyst-wall and peritoneal investment, and of the posterior part of the cyst removed at the post-mortem, and which consists of cyst-wall only. The cyst is a simple one, its walls remarkably thin, and everywhere without much difficulty separable from the peritoneum. The cyst contained many pints of thin clear fluid.

*Presented by Mr. Hutchinson.*

2095. A very large simple ovarian cyst, with the remains of adhesions upon its outer surface. The inner surface is somewhat fasciculated, but is free from either secondary cystic or solid growth.

Case of Eliza Beagle, aged 27, who was admitted with a history of abdominal pain for the last 15 months, with distention during the last three months. On admission there was distinct fluctuation with dulness on percussion over the anterior part of the abdomen, the flanks being resonant. At the operation the cyst was found universally adherent; it was emptied by trochar (240 oz. of fluid being drawn off), and numerous adhesions broken down. The patient made a good recovery. Mr. Rivington.

For other specimens of simple cyst see Nos. 2131, 2134, 2139, 2167.



**Congenital.**

2096. The left half of a uterus and its appendages, taken from the body of a woman, aged 50, who died from a burn. The ovary has undergone cystic degeneration, and forms a tumour the size of a fist. The cyst, when recent, was filled with a substance of an amber colour, and of the consistence of wax, with which a quantity of hair was mixed (dermoid cyst). On exposure this substance set like tallow. There are papillary outgrowths from the inner surface of the cyst.
2097. A dermoid cyst as large as a child's fist. Growing from its inner surface are brown hairs an inch long. Within it is covered by true skin. The coagulated contents are seen at the bottom of the bottle.
2098. A dermoid cyst of the right ovary, the size of a hen's egg. It has been laid open. Growing from its inner wall are a solid papular tumour and a piece of hair seven inches in length. The rest of the cyst was filled with coagulated sebaceous matter and short hairs.
2099. Part of a multilocular ovarian cyst, in one chamber of which three or four teeth are seen growing.

**Contents.**

2100. Fœtal structures from a dermoid cyst, consisting of a ring of bone somewhat resembling a lower jaw, with many molar teeth embedded in it. Attached to it are three mammillary processes covered with skin and hair; a portion of the inner surface of this bone is covered with hairy skin.

**Proliferous with Cystic Growths.**

2101. A uterus and its appendages, showing small multilocular cysts in both ovaries. There is a cyst the size of a small grape in the right broad ligament a little below and internal to the fimbriated end of the Fallopian tube.
2102. A portion of the cyst-wall of an ovarian tumour with congeries of secondary cysts developed on its inner surface. These are exceedingly delicate and transparent, resembling clusters of small grapes.
2103. The sac of an ovarian cyst, measuring in the recent state a foot in diameter. The walls are an eighth of an inch in thickness; on its outer surface it is smooth and presents no evidence of old adhesions. Part of the Fallopian tube with its fimbriated extremity, and the pedicle containing the enlarged ovarian artery and veins, are seen. Within the cyst, developed from its walls, is a mass as large as an orange, com-



posed of secondary and tertiary cysts with some solid growth between them. Scattered over the inner surface are numerous sessile and polypoid papillomata.

Case of Adelaide Hillier, aged 34 (R. N. 603), admitted on April 6th, 1889, with abdominal swelling, the girth of the abdomen at the umbilicus being 35 inches. The cyst was excised, and the patient made a good recovery. There were no adhesions.

Mr. McCarthy.

2104. A multilocular ovarian cyst. There is one principal cyst of large size. The smaller cysts are seen projecting into its cavity and clustered in masses in its walls at certain parts. The Fallopian tube is dilated.

2105. A small portion of a multilocular ovarian tumour. The cysts shown in the specimen vary from the size of peas to that of a goose's egg.

#### **Proliferous with Solid Growths.**

2106. Part of an ovarian cyst laid open. Internally it is furred over with flocculent papillary growths. Its walls differ much in thickness at different parts. The fimbriated extremity and the adjoining  $1\frac{1}{2}$  inch of one of the Fallopian tubes is seen hanging by a broad attachment from the upper part of the specimen.

2107. A portion of the wall of an ovarian cyst with secondary solid growths upon its inner surface. The largest of these growths is the size of a fist, and is lobulated on the surface; the others vary in size from a pea upwards.

2108. Part of a polycystic ovarian tumour, the cysts of which contain large masses of papillary growth. It was thus referred to by Sir A. Clark in 1860:—"The warty vegetations are hollow villi formed of tessellated epithelium."

2108 a. A large thin-walled ovarian cyst, with many adhesions on its outer surface. Projecting into and almost filling the cavity of the cyst is a semi-solid, nodular mass, measuring 7 inches in length by 5 inches in width; this has been bisected. It is composed almost entirely of cysts, which vary in size from a pin's head to a walnut; their walls are thin, smooth, and are filled with yellow gelatinous material. At the lower and back part of the section the tumour is more solid. Thin sections of this tumour show numerous thin-walled cysts enclosed by columns of small spindle-cells.

Case of Sarah Vesey, aged 35, admitted on July 4th, 1889. She had been married 17 years, and had had five children, the last  $8\frac{1}{2}$  years ago. Her illness



dated from Christmas 1888, when the abdominal swelling was first noticed. She was under medical treatment in March 1889, for sickness and pain in the abdomen with increasing enlargement; the diagnosis seems to have been chronic dyspepsia with faecal accumulation, and a tumour was mapped out which was thought to be in close connection with the liver. She was quite regular up to Christmas 1888, and since that date till the removal of the tumour she suffered from menorrhagia and constant abdominal pain.

It was removed on August 29, 1889, by abdominal section; the incision had to be extended for four inches above the umbilicus in order to get the tumour out. A glass drainage-tube was left in for 36 hours. Three days after the operation the wound measured  $7\frac{1}{4}$  inches. The patient made a good recovery. (See also 'Lancet,' Dec. 7th, 1889.)

Dr. Lewers.

### Morbid Growths.

#### Fibroma.

2109. A uterus and its appendages, showing in connection with each ovary a rounded fibrous tumour as large as a walnut. These tumours are pedunculated, and project from the ovaries to which they are attached, the greater part of the structure of each organ being still sound.

#### Sarcoma.

2110. An ovary bisected, showing a sarcoma. The cut surface has a distinct fibrous appearance, the surface is smooth and regular. The tumour is the size of an orange.

#### Carcinoma.

2111. A uterus with both ovaries attached. Each ovary is much enlarged by a mass of carcinomatous growth which appears to spring from its outer tunic. The growth is nodular on the surface, as large as a melon, and on section presents a surface intersected by fibrous strands with intervening homogeneous material; the orifices of many vessels are seen. The globular cavity seen in each mass is the ovarian capsule from which the softened ovarian substance escaped when the section was made.

From a woman, aged 30, who had noticed an enlargement within the abdomen for two years.

*Presented by Dr. Tregelles Fox.*

2112. A left ovary, weighing in the recent state 19 ounces, presenting an almost similar appearance to the preceding specimen.

It was removed by laparotomy from the body of a nurse, aged 28, who had noticed that she had been losing flesh for about a year.

Mr. Treves.



2113. The right ovary of the same patient as the preceding; it presents a similar appearance. There is in this case no smooth-walled cavity. The growth in the recent state weighed 3 lb. 14 oz. It measures 6 by 8 inches.

### **Colloid Carcinoma.**

2114. The specimen shows the uterus and appendages with the rectum. Both ovaries are enlarged by malignant growth of colloid character. The right ovary is much enlarged and has become pedunculated. The left ovary is not larger than a hen's egg, and has its normal relation to the broad ligament. The left Fallopian tube is much thickened by infiltration with the same growth. The uterus is not much enlarged. The peritoneum is studded with nodules of the growth, which are especially abundant and conspicuous on the intestine, the appendices epiploicæ being infiltrated and contracted into the form of rounded knobs upon its surface.

Case of M. E. Enever, aged 26, admitted with carcinoma of the peritoneum, omentum, and ovaries. She had been ailing for 18 months before admission, during the last two months of which there had been dropsy of the peritoneum. After 293 oz. of fluid had been drawn off by aspiration, masses were still felt in the abdomen. She died after colotomy, rendered necessary by continued obstruction.

Dr. Fenwick.



## SERIES XLV.—INJURIES AND DISEASES OF THE FALLOPIAN TUBES.

### **Inflammation and its Effects.**

Hydrosalpinx : 2096, 2115, 2116.

Pyosalpinx : 2117, 2122.

Hæmatosalpinx : 2118, 2183.

### **Cysts.**

Congenital : 2119.

---

### **Inflammation and its Effects.**

#### **Hydrosalpinx.**

2115. Uterus and its appendages, from the body of a woman aged 40. The outer end of each Fallopian tube is adherent to the corresponding ovary, and the fimbriated extremity cannot be distinguished. The right Fallopian tube is considerably dilated. The uterus has been opened from behind, and a polypus is seen on the anterior wall.

2116. The specimen was taken from the body of a young woman. Both Fallopian tubes are dilated, the right to a greater extent than the left. The fimbriated ends cannot be distinguished, as the outer ends of the tubes are adherent to the ovaries, both of which are easily recognizable.

For another specimen, see No. 2096.

#### **Pyosalpinx.**

2117. A uterus with appendages. Both Fallopian tubes are laid open, and are distended with yellow caseous matter.

Case of M. A. Cavanagh, aged 32, admitted on July 9th, 1885, with vomiting and epigastric pain of several weeks' duration. She suddenly developed paraplegia whilst in the hospital, and died in four days. At the autopsy, tubercular softening of the cord in the cervical region was found, together with tubercular salpingitis. Tubercles were also found in the lungs and kidneys.

Dr. Sutton.

For another specimen, see No. 2122.



**Hæmatosalpinx.**

2118. A uterus and its appendages. Both Fallopian tubes are dilated, the right more than the left. On the right side the dilated tube is adherent to what appears to be an ovarian cyst. The part of the tube on this side that is most dilated has been cut open, showing yellowish-brown contents of cheesy consistence, probably altered blood, and therefore hæmatosalpinx. On the left side no trace of the ovary can be seen.

For another specimen see No. 2183.

**Cysts.****Congenital.**

2119. A pedunculated thin-walled cyst attached to the Fallopian tube near its fimbriated extremity. The cyst is almost transparent. It appears to contain a small solid body.



## SERIES XLVI.—INJURIES AND DISEASES OF THE UTERUS.

### **Inflammation and its Effects:** 2120-2122.

Ulceration : 2120, 2128, 2141.

### **Gangrene:** 2123, 2128.

### **Displacements:** 2124.

Anteflexion : 2122, 2124.

Inversion : 2125-2128.

Prolapse : 2129, 2130.

### **Morbid Growths:** 2131-2180.

Fibromyoma : 2085-2126, 2131-2158.

Undergoing calcification : 2152-2158.

Polypi : 2085, 2107, 2126, 2127, 2130, 2134, 2140, 2147, 2148, 2155, 2159-2162.

Of the body : 2159, 2160.

Of the cervix : 2161, 2162.

Carcinoma : 2163-2180.

Of the body : 2163-2167.

Of the cervix : 2168-2180.

Involving the vagina : 2170-2180.

Involving the bladder : 2175-2180.

Vesico-vaginal fistula : 2176-2180.

### **Malformations.**

Uterus unicornis : 2181.

Uterus bicornis : 2181 *a*.

Uterus didelphys : 2182, 2183.

## **Inflammation and its Effects.**

### **Ulceration.**

2120. A uterus showing granulations upon and erosion around the external os, and pearl-like bodies projecting from the uterine follicles.

From a young woman who died of phthisis.

For other specimens, see Nos. 2128, 2141.

2121. Dysmenorrhœal membrane.

*Presented by Dr. Herman.*

2122. A uterus with appendages. The body of the uterus has been laid open, and it is seen to be bent forwards at the internal os. The uterine wall is thickened by inflammatory deposit, and there are the remains of peritoneal adhesions scattered over its exterior. The left Fallopian tube is distended with pus.



**Gangrene.**

2123. A black gangrenous mass, consisting of the upper two inches of the vagina, and the lower two-thirds of an inch of the cervix uteri.

From a patient whose illness began with acute febrile symptoms, high temperature, quick pulse, &c. ; after the first few days diarrhoea and delirium were added to these symptoms. The motions at first resembled those of enteric fever, but subsequently became exceedingly offensive and bloody. Two days later the specimen was found hanging out of the vagina and was cut off. After this the patient's condition much improved. Two days later there was a copious vaginal hæmorrhage which ceased spontaneously. At this time the upper part of the vagina was covered with granulations, and was soft and velvety to the touch. The patient was apparently doing well, there being no febrile symptoms, no hæmorrhage, and slight, but not offensive, vaginal discharge. A few days after this the urine began to run away continually, and for this she was admitted into the London Hospital.

Her last child was born eight years before. Her husband had never suffered from venereal disease.

Dr. Herman.

For another specimen, see No. 2128.

**Displacements.****Anteflexion.**

2124. A specimen of anteflexion of the uterus. The body is bent forwards so completely that its upper part is almost on a level with the external os. There is no thinning at the point of flexion, no angle in the uterine canal, and no dilatation of the uterine cavity. The organ is small.

It was removed from a woman who had died of other disease, and was not known to have had any uterine symptoms. She had not borne children.

*Presented by Mr. T. M. Mackenzie.*

For another specimen, see No. 2122.

**Inversion.**

2125. This specimen shows chronic inversion of the uterus. On each side is an ovary with its Fallopian tube. The uterine extremity of each Fallopian tube lies within the inverted uterus.
2126. A bladder, uterus, and external genitals, showing complete prolapse of a large polypus, which has dragged down and inverted the uterus. The polypus is as large as a small fist, and is incorporated with the uterine wall at the fundus. A smaller and pedunculated polypus is attached to one side of the uterus.
2127. The body of an inverted uterus in a gangrenous condition, with a fibroid attached, which was probably the cause of the inversion.



2128. The specimen consists of the inverted vagina and uterus, within which are seen the tubes and ligaments of the ovaries running down to the bottom of the sac which the inverted parts form. The fundus of the inverted uterus is seen to be eaten away over a space as big as a crown-piece; and in the middle of this spot the wall is scarcely thicker than paper.

The inversion was caused by a fibroid, which subsequently became gangrenous. The tumour was removed, and an attempt made to reduce the inverted uterus by the continuous pressure of Aveling's repositior. But the gangrene progressed, destroying the uterine tissue in the way seen, and the patient died from exhaustion before reposition was effected. (See *Obst. Trans.* vol. xxx. 1888, p. 226.)

*Presented by Dr. Herman.*

### **Prolapse.**

2129. A prolapsus of the uterus and vagina. A mass as large as a child's fist projects from the external parts, in the centre of the extremity of which the os uteri may be seen. Probably the bladder is partially prolapsed also. On turning to the back of the specimen we see the fundus uteri just behind and below the symphysis pubis. The body of the uterus is elongated and bent.

Dr. Ramsbotham.

2130. A tumour of the vagina as large as two kidneys. The vulva and the pubic bones have been removed; the urethra and bladder are in their normal situation. There is a protrusion from the vaginal orifice. This consists of the inverted and greatly-thickened vagina, part of which on the left side has been removed to show the alterations in it. At the lower part (behind) the vagina measures an inch in thickness, anteriorly the vagina measures  $\frac{3}{4}$  inch in thickness. At the lower part of the inverted vagina is seen the uterus, which is atrophied from old age, being two inches long. The right ovary and fimbriated extremities of both tubes are seen at the top of the sac formed by the inverted vagina. Attached by a pedicle  $\frac{5}{8}$  of an inch thick to the right side of the vagina close to the cervix uteri is a tumour measuring 7 inches from above downwards, 7 inches from side to side, and  $1\frac{7}{8}$  inch in thickness. To the naked eye it resembles uterine fibroid in structure.

The specimen is interesting because vaginal fibroid tumours are rare, and when found they seldom reach such a size as this one, and they are seldom pedunculated. The specimen also shows the production of prolapse of the vagina by the traction of the tumour, and the thickening of the vagina in consequence of long-standing venous congestion due to the vagina being outside the vulva, the return of blood from it being hindered by the constriction of the vulval orifice.



## MORBID GROWTHS.

**Fibromyoma.**

2131. A uterus and appendages. The body of the uterus is much enlarged, owing to the presence of several fibromyomata. It measures three inches from side to side. These tumours are seen on section to be composed of concentric rings of fibrous tissue and to be distinctly encapsuled. There are several small cystic tumours in each ovary.

From an old woman, aged 70, who died in consequence of severe burns.

*Presented by Mr. Hutchinson.*

2132. Encapsuled fibromyomata as large as walnuts within the substance of the uterine wall.

2133. A uterus with numerous fibroids embedded in its walls. The cut surfaces of the tumours show beautifully the wavy arrangement of the fibrous bands. One of the tumours is pedunculated and projects in the peritoneal surface. This specimen is spotted over with small masses of black.

Dr. Ramsbotham.

2134. A uterus and its appendages. There is a fibroid tumour the size of an egg in the posterior wall of the body of the uterus. Within the cervix are seen two small pedunculated bodies the size of peas. The right ovary and both Fallopian tubes are normal, but there is a cyst as large as a walnut in connection with the left ovary.

2135. A uterus with a portion of the anterior wall removed to expose two spherical fibromyomata. These tumours are as large as apples, distinctly encapsuled, and on section are seen to be composed of a dense fibrous structure. They project somewhat into the uterine cavity.

2136. An enlarged uterus of a pyriform shape, measuring 7 inches by 5, to the outer surface of which are attached its appendages. The uterus has been laid open to show an oval lobulated fibromyoma as large as a cocoanut completely filling the cavity; it is incorporated with the uterine wall at the upper part, but below it is free. The lower half of the uterine wall is hypertrophied.

It was removed by abdominal section from Mary F., aged 44, on June 28, 1889. She was admitted on June 24, 1889, R.N. 666, with a history of a tumour in lower part of the abdomen, noticed for eight years. The only symptom complained of, in addition to the discomfort caused by the bulk of the tumour, was an



offensive vaginal discharge. The patient was discharged from the hospital perfectly well in six weeks.

Mr. Treves.

2137. Three small sessile fibroids of the uterus. The largest is the size of a small cherry. They project on the peritoneal surface of the organ.

2138. The rectum, uterus, ovaries, and bladder. A large fibroid projects from the back of the fundus uteri. The ovaries are as large as hen's eggs, nodular on the surface, and converted into dense fibroid masses.

Dr. Ramsbotham.

2139. A uterus, beneath whose peritoneal covering are two fibromyomata, each about the size of a cherry, encapsuled and very slightly pedunculated. In the right ovary there is a small simple cyst.

From a woman aged 30, who died of epilepsy.

2140. A uterus laid open to show a globular fibroid projecting into the cavity; it is partially encapsuled. Projecting from the posterior part of the body of the organ is a large mass the size of a fist, and from its surface numerous pedunculated growths arise like the knobs on a potato.

Dr. Ramsbotham.

2141. Numerous fibroid tumours in connection with the walls of the uterus; several of them are pedunculated and project from its surface. The os uteri appears to have been ulcerated and is shreddy. There is a cyst the size of a marble at the end of one of the Fallopian tubes.

2142. Two subperitoneal fibroids projecting from the surface of the uterus. The portion of the uterus to which they are attached is evidently that of a woman recently delivered.

Dr. Ramsbotham.

2143. A beautiful specimen of fibroids developed in various positions in connection with the uterine wall. Some of the tumours are displayed in section. Two large growths project from the peritoneal surface and are pedunculated.

Dr. Ramsbotham.

2144. The external genitals with urethra, bladder, and uterus. A fibromyomatous tumour, the size of a fist, projects from the uterus. It



is attached to the uterus by a broad peduncle. The ovaries and their ligaments are not implicated.

Dr. Ramsbotham.

2145. A fibromyoma almost loose in the peritoneal cavity. The tumour is as large as a walnut, and its pedicle of attachment to the walls of the uterus is not thicker than a quill.

Dr. Ramsbotham.

2146. Two fibromyomata, each as large as a foetal head, projecting one from the anterior and the other from the posterior surface of the uterus. Within the uterine wall are several similar but smaller tumours. The tumours together constitute a mass as large as an adult head. It is roughly divided into lobes.

During life it projected so high up in the abdomen that it was mistaken for disease of the liver.

Dr. Ramsbotham.

2147. A uterus enlarged to the size of a foetal head by the presence of large fibromyomata within its walls. Some of them project as polypoid growths into its cavity.

2148. A uterus with numerous large fibroid tumours. Most of them project on its surface, where some have very narrow peduncles. One of them is seen projecting in polypoid form into the cavity of the uterus.

2149. A uterine fibroid as large as a head; the tumour is ovoid, and distends the uterus much as in pregnancy.

2150. A fibromyoma of the uterus. The tumour is round and as large as two adult heads. Its texture is firm on the exterior, but somewhat softened and broken down into irregular cavities in the middle.

2151. A uterus with appendages. The uterine cavity has been laid open; it is seen at the lower and left corner of the specimen. Growing in the left uterine wall is an enormous spherical mass of fibromyomatous structure. It has been bisected; the cut surface measures 13 inches by 7 inches. Attached to the surface of the tumour is the left uterine appendage.

Case of Emily Nesbitt, aged 28, who said she had noticed a lump in her abdomen for 6 years, and had suffered from menorrhagia and painful menstruation for three or four years. The tumour was removed by abdominal section on July 13, 1888 and the patient made a good recovery.

Mr. Treves.



**Undergoing calcification.**

2152. A fibroid tumour of the uterus, as large as an adult head. The body of the uterus is involved in the tumour. One ovary is perfect and not attached; the other cannot be identified. Two or three fibromuscular tumours as large as beans may be identified in the structure of the cervix uteri. The main tumour was very heavy and dense; it consists of fine fibrous tissue, with numerous nodules of bone interspersed. Some of these nodules are as large as the tip of the forefinger, others the size of peas.

The tumour was removed from the body of an old woman; it had been present during the latter part of her life.

2153. A uterus with numerous fibromyomata. The largest one, which is situated in the anterior wall, has undergone calcareous degeneration. It is seen in section. A saw had to be used to divide it. A portion of the bladder is seen: the orifices of the ureters have become prolapsed; they are indicated by pieces of glass rod.

2154. A virgin uterus laid open, projecting from the walls of which are numerous small fibroids. There are so many that the surface of the uterus is everywhere nodular; the largest is as large as a pigeon's egg, and they are nearly all calcareous.

2155. A uterus with its appendages. The uterus has been laid open along its anterior wall. Projecting from the left side is a large globular tumour, the size of a small orange, presenting typical fibromyomatous structure on section; and scattered within it are a few calcareous nodules. Projecting from the anterior wall are two small tumours, also calcareous in the centre. Attached to the middle of the posterior wall of the uterus is a pedunculated soft polypus, moulded to some extent to the cavity.

2156. "This specimen is described in the old Catalogue as a bony tumour from the uterus. It consists of an irregular mass of bone, to which is attached by a short narrow peduncle another ovoid mass of bone much like an ovary. The upper part of the mass probably consists of two uterine fibroids which have undergone calcareous degeneration and the lower part may possibly have been a polypus. Whether the pedunculated mass is an ovary or a uterine fibroid, it is impossible to say."

2157. This specimen consists of a mass of hard bone as large as a child's fist. It has been cut vertically in two. Both on its surface and in



its interior numerous irregular cavities are seen. It was described by Dr. Ramsbotham as an "ossified ovarian removed from a patient in whom both ovaries were in a similar condition, and the os uteri also was commencing to ossify."

**2158.** A similar specimen.

For other specimens of fibromyoma, see Nos. 2035, 2126.

### **Polypus.**

**2159.** A uterus with the cavity laid open, showing a small polypus pedunculated in its fundus.

Dr. Ramsbotham.

**2160.** An excellent specimen of uterine polypus. The growth is the size of a damson plum, pyriform, and attached to the fundus uteri by a peduncle somewhat thicker than a quill.

**2161.** A polypus the size of a small fist, with a pedicle as thick as the little finger, attached to the anterior lip of the cervix uteri. The polypus has been cut into, and, although chiefly solid, shows a large blood-cyst where the incision has been made.

**2162.** A large fibroid growing from the posterior lip of the cervix uteri.

For other specimens, see Nos. 2085, 2107, 2126, 2127, 2130, 2134, 2140, 2147, 2148, 2155.

### **Carcinoma.**

#### **Body.**

**2163.** A uterus with large firm-looking tumours attached. The fundus of the organ appears to be occupied by an infiltrating deposit, in the structure of which cysts have formed. Sir Andrew Clark in the old Catalogue described the projecting tumours as fibro-muscular, and the growth developed in the uterine wall as consisting of cancer with cysts and fibrous stroma, the latter containing multinuclear cells.

**2164.** A uterus laid open to show a warty epitheliomatous growth of the mucous membrane of the body. The cervix is healthy.

It was removed by vaginal hysterectomy from Eliza Griffiths, aged 51, on Feb. 22, 1889. Six months previously she was in hospital with a slight brown discharge, and the growth was then scraped away and diagnosed as carcinoma of the body, but renewed growth took place. The discharge became continuous, was always dark brown, never contained unchanged blood, and was not foetid. She made a good recovery, and has no recurrence at this date, Nov. 18, 1889.

Dr. Herman.



2165. A uterus laid open showing cancer of the body extending downwards to the external os. The uterine wall is thickened by infiltration.

Case of Emma Lamb, aged 60, admitted with continuous foetid discharge of a year's duration, together with uterine pain and emaciation. There was much pain and frequency of micturition, and she had been treated for cystitis. The specimen was removed per vaginam, and she recovered well.

Dr. Herman.

2166. A uterus perforated at its fundus by disease. Its mucous membrane appears to have been everywhere destroyed, and at its fundus there is an aperture the size of a shilling. Dr. Ramsbotham thus refers to the specimen:—"Ulceration having commenced in the whole lining membrane of the uterus has almost destroyed the uterine texture and has formed an aperture into the peritoneal cavity. The uterus in this preparation is turned inside out. Epithelial carcinoma of the internal uterine membranes. I have only seen one other such case."

2167. A uterus laid open, showing in its interior a large irregular patch of ulceration with raised edges and a slightly fungating surface, probably cancerous. There is a multilocular cyst in the left ovary.

### Cervix.

2168. The lower part of a uterus, the lips of which have been destroyed by malignant ulceration. There is much induration of the surrounding tissues.

Dr. Ramsbotham.

### Involving the Vagina.

2169. A specimen showing cancer of the cervix uteri. There is ulceration, which has eaten out a cavity in the cervical canal, but very little disease apparent on the vaginal portion of the cervix. The disease extends a little way above the internal os. The cervix was so friable that in removal it was broken away from the uterus.

Case of Elizabeth Trustam, aged 46, admitted Sept. 10 with a history of foetid hæmorrhagic discharge for 18 months. The uterus was removed per vaginam. The woman was discharged in good health on Oct. 8, 1887, but died a year afterwards.

Dr. Herman.

2170. Malignant disease of the cervix uteri; the posterior lip was extensively involved in a growth of soft cancer, which broke up during removal. A soft shreddy mass is seen hanging from the mucous membrane. The adjacent structures are not yet involved.



2171. The uterus and adjacent parts from a married woman, æt. 51. The posterior lip of the uterus is extensively destroyed by ulceration, and the anterior lip to a small extent. The ulcer is well defined and the adjacent uterine tissue is indurated but not infiltrated to any material depth. The whole surface of the ulcer is covered by flocculent shreds of tissue, some of them an inch long. The disease involves also the adjacent parts of the vagina. The body of the uterus is sound.

This specimen is probably the other half of the preceding.

2172. A uterus with its appendages. The uterus has been laid open from before to show an epitheliomatous growth of the vaginal portion spreading downwards on to the vagina.

Case of Bertha S., aged 21, admitted February 3.

At the autopsy, Feb. 13, 1885, the lumbar glands were enlarged and contained white nodules of growth, having the characters of epithelioma when examined in section under the microscope.

2173. A section of a uterus, showing fungating and sloughing cancer of the cervix and the adjacent part of the vagina.

2174. Extensive cancerous disease of the cervix uteri and vagina. The malignant deposit constitutes a large mass growing from the posterior lip of the cervix. The bladder has been displaced and the rectum surrounded by this mass. There are secondary nodules on the posterior vaginal wall.

#### **Involving the Bladder.**

2175. A uterus laid open from behind to show the lips and lower part of cervix and posterior vaginal wall involved in cancerous ulceration. The septum between the uterus and bladder is involved, and a small fungating growth projects into the latter cavity. The ovary is also diseased.

#### **Vesico-vaginal Fistula.**

2176. A bladder, uterus, and part of rectum, showing soft cancer of the cervix uteri, of the vagina, and all the adjacent parts. The whole of the vagina is involved in a sloughing and fungating ulcer, the coats of the bladder and rectum are greatly thickened by cancerous deposit. There is a fistulous communication between the bladder and vagina. The body of the uterus is quite healthy. The cancerous growth is most abundant in the anterior vaginal wall, where it would seem to have begun.



2177. Cancer of the uterus in an advanced stage. The vagina, bladder, and rectum are all involved. The disease probably began in the anterior vaginal wall. This specimen is probably the other half of the preceding.
2178. Extensive cancerous disease of the uterus, vagina, and adjacent parts. There is a communication with the interior of the bladder. The vaginal portion of the cervix uteri is completely destroyed.
2179. Cancer of the uterus and vagina, involving the posterior wall of the bladder.
2180. Extensive cancerous destruction of the cervix uteri and vagina. The disease would appear to have opened into the bladder by a large ragged ulcer.

### MALFORMATIONS.

#### **Uterus unicornis.**

2181. A uterus with the left appendages, ovary, and left uterine horn only developed. The body of the uterus and the vagina have been laid open in front and appear to be normal at first sight, but the right horn of the uterus and the right appendages are absent. Behind the uterus is a portion of the rectum. The left ovary is large and is situated on the right side of the uterus, the left Fallopian tube being bent over to the right.

Ellen Fyke, May 7, 1885.

#### **Uterus bicornis.**

- 2181 a. A double uterus. The bodies are quite distinct, but the cervical canal is broad and common to both uteri. The vagina is single and has been laid open. The ovaries are small.

#### **Uterus didelphys.**

2182. The uteri are quite distinct, and although the cervixes are adherent along the median line, the cervical canals are quite separate. The septum in the vagina extends almost to the vulva. The left channel was the larger, a finger passed in through the vulva readily entered into the left passage, and nothing abnormal was detected by the touch.

From the body of a healthy woman, aged 35, who committed suicide by throwing herself under an omnibus. She was the mother of two children, and nothing abnormal had been noticed about her. The abnormality was discovered on the p.m. table. Her husband was a collector of curiosities.

Mr. McCarthy.



2183. A vertical antero-posterior section of the pelvic organs of a female.

In the centre is a patent vagina, measuring  $3\frac{1}{2}$  inches in length; this is the right vagina, and attached to it above is a small right uterus with its appendage; a glass rod has been passed along its interior to show a patent cervical canal. Behind this vagina is the rectum, contracted above and widely dilated below, the folds of Houston being lost; it opens below into the posterior wall of the vagina about an inch within the vulva by a circular smooth-edged orifice,  $\frac{3}{4}$  of an inch in diameter. In front of the uterus is a small bladder, whose urethra opens into the anterior wall of the vagina at a point almost opposite to the rectal opening, that is about an inch from the vulva. In front of the bladder the cut surface of the symphysis pubis is seen with the external genitals attached. There is no trace of the left vaginal orifice to be found within the cloaca. On the exterior of the left half of the specimen a small spherical cavity is seen with part of its outer wall removed; it measures  $1\frac{1}{2}$  inch in length by 1 inch in diameter, and is imperfectly subdivided by several smooth crescentic septa; in the recent state it was filled with thick fluid the consistence of treacle and of a chocolate colour. This cavity is the left vagina. No opening into the cloaca can be found. Above and behind this vagina is a small left uterus, whose small cavity, measuring about an inch in length, has been laid open; a glass rod cannot be passed along the cervical canal, which has become obliterated probably by adhesion after suppuration. The left Fallopian tube is dilated at its extremity to the size of an orange; this cyst has calcareous walls, and was filled with thick grumous chocolate-coloured matter, precisely similar to that filling the left vagina—evidently old partly decolorized concentrated menstrual fluid. The interior of the cyst is smooth, except at the outer part, where the cyst-wall is transformed into a hard calcareous plate with a roughened internal surface. A glass rod indicates the orifice, but cannot be passed for more than an inch along the Fallopian tube, this being probably obliterated like the cervical canal.

Case of Sarah Marlton, aged 56, who was admitted for bronchitis and general asthenia. She had borne two healthy children, and did not know that she was abnormally made. She had been an in-patient at St. Bartholomew's, where they diagnosed the rectal deformity, and wished to operate, but the husband indignantly repudiated the idea that his wife was malformed. About a week after admission an enema was ordered, her bowels not having acted, and the absence of an anal orifice was noticed by the nurse. The house physician explored, and found the anal and urethral deformity, but the didelphic uterus was not diagnosed during life. A distinct sphincter to the anal orifice could be felt by the finger. There was the faintest possible depression at a point representing the normal anal orifice. She died a fortnight later of asthenia.

Autopsy. Dr. Sutton.



## SERIES XLVII.—INJURIES AND DISEASES OF THE VAGINA AND VULVA.

- Elongation of the Vagina : 2184.  
Hypertrophy of the Clitoris : 2185-2187.  
Hypertrophy of the Labia : 2188-2191.  
Cyst in the Labium : 2192.  
Carcinoma of the Vagina : 2171-2180.  
Carcinoma of the Vulva : 2193.  
Malformation of the Vagina : 2182, 2183.
- 

### **Elongation of the Vagina.**

2184. Vagina and uterus showing elongation of the former.

Dr. Ramsbotham.

### **Hypertrophy of the Clitoris.**

2185. An enlarged clitoris, probably removed during life. It is irregular in form, and altogether as large as a duck's egg; its surface is covered with papillary growths, and its section shows hypertrophy of the subcutaneous tissue.

2186. The external genitals of an adult woman, showing enlargement of the clitoris to the size of a child's fist. The organ is in a condition of elephantiasis with large papillary growths; the labia are also somewhat hypertrophied.

Dr. Ramsbotham.

2187. A similar specimen. The organ is as thick as a wrist, and about three inches in length. It is in the condition of elephantiasis. The labia are hypertrophied; the perineum appears to have been lacerated. There are projecting folds of skin around the anus, probably from old hæmorrhoids.

Dr. Ramsbotham.



**Hypertrophy of the Labia.**

2188. Two labia majora much thickened and hypertrophied.

2189. A similar specimen, showing a still greater degree of hypertrophy; the mass measures  $4\frac{1}{2}$  inches in length and 3 in breadth. Its surface is covered over with round-topped warty growths.

2190. The labia majora in a condition of elephantiasis, probably excised during life. The papillary growths are unusually large and definite.

2191. A similar specimen.

**Cyst.**

2192. A cyst in the left labium the size of a small cherry. It contained blood-discs, cholestearine, and serum. *Presented by Dr. Barnes.*

**Carcinoma.**

2193. Epithelial cancer of the labium minus.

Mr. Curling.

For other specimens see Nos. 2171-2180.

**Malformation.**

See Nos. 2182, 2183.



### SERIES XLVIII.—UTERO-GESTATION.

#### Changes in the Ovary consequent upon Ovulation.

Ruptured Graafian follicle: 2194-2196.

#### Changes in the Ovary consequent upon Fecundation.

Corpus luteum: 2197, 2198, 2258, 2259.

#### Specimens showing:—

The development of the Embryo: 2198-2218, 2245, 2246, 2260, 2276, 2284, 2286-2288.

The development of the Placenta: 2198, 2203-2207, 2208 *a*, 2219-2227.

The placenta *in situ*: 2228, 2230.

The changes in the pregnant uterus before delivery: 2198, 2204, 2205, 2228, 2231, 2232, 2245, 2246, 2257-2260.

The changes in the pregnant uterus after delivery: 2233-2241, 2250-2256.

Utero-gestation in other Vertebrates: 2242-2244.

#### Changes in the Ovary consequent upon Ovulation.

##### Ruptured Graafian follicle.

2194. The uterus and ovaries of a single woman who died in the hospital whilst menstruating. The left ovary has been cut open to show the turgid Graafian follicle from which an ovule had recently escaped.

The case was reported by Dr. Letheby in a paper read before the Royal Society on May 1st, 1851.

2195. A uterus and appendages. In the right ovary there is an apoplectic clot and in the left are false corpora lutea.

From a woman who had never conceived.

2196. A similar specimen.

From a single woman who died whilst menstruating. See Trans. Royal Society.

*Presented by Dr. Letheby.*



### **Changes in the Ovary consequent upon Fecundation.**

#### **Corpus luteum.**

2197. Half the uterus with the left appendage. The ovary has been bisected to show a corpus luteum.

The patient was a married woman, aged 40, who died of typhus fever in a very early stage of pregnancy.

2198. A uterus which contained twins ; it is probably about the fourth month of pregnancy. The body of the organ is laid open (from behind) so as to expose the membranes. The placentæ seem to be united. The separating amnions are seen. The cords are long and the embryos are attached. In the right ovary is seen a corpus luteum.

For other specimens see Nos. 2258, 2259.

#### **Specimens showing the development of the Embryo.**

2199. A very early ovum within its membranes, probably 2 to 3 weeks intra-uterine age.

2199 a. A similar specimen.

2199 b. An embryo of 19 days enclosed in membranes.

2200. This specimen was thus described by Dr. Ramsbotham :—"Ovum 32 days old. The umbilical vesicle is seen detached from between the membranes and floating loosely in the spirit, being connected with the ovum only by the omphalo-mesenteric duct. The only preparation of the kind I ever saw."

2200 a. The villous membranes enclosing an embryo 4 weeks old.

2200 b. A similar specimen ; the membranes have been opened to expose an embryo a third of an inch in length attached by the umbilical cord.

2201. The chorion of an ovum aged 6 weeks covered with elongated villous processes. The embryo can be indistinctly seen, on holding the specimen to the light, as an opaque body about half an inch in length.

Dr. Ramsbotham.

2202. An ovum of 7 weeks. The umbilical vesicle is seen as an opaque round spot at the lower part of the membranes. The foetus is half



an inch in length and lies at the bottom of the bottle. Its arms are one-eighth of an inch in length and arise near the centre of the whole length.

2203. The membranes intact enclosing an embryo of some 7 weeks intra-uterine age. The embryo is seen within hanging head downwards. The head is as large as a dried pea.

2203 a. An embryo somewhat older; the placenta is more developed.

2204. A uterus laid open, showing the ovum and membranes *in situ*, at an early period of pregnancy.

From the body of a woman who died in consequence of an accident.

*Presented by Mr. Adams.*

2205. A uterus laid open to show an embryo enclosed in amnion and chorion. A portion of the membranes has been removed in front to show a large clot a quarter of an inch in thickness between the amnion and chorion. The embryo is an inch in length and about 8 weeks old; the branchial clefts are well-marked, the arms are about a quarter of an inch in length, and the fingers are differentiated; the legs are situated close to the posterior extremity of the embryo.

2205 a. An embryo about 8 weeks old, measuring nearly an inch in length, with large head and distinct upper and lower extremities enclosed in amniotic and chorionic membranes; the placenta is large and well-formed.

2205 b. A very similar specimen, with long umbilical cord and foetus of 12 weeks old.

2206. A foetus in its membranes, of 4 months. The mouth and eyelids are open; the placenta is fully formed; the chorion much broken away, the foetus being enclosed by the amnion alone over the greater part of the surface.

2207. A similar specimen, the embryo being 4 to 5 months of age. In both these specimens the chorionic villi are seen much enlarged at the placental site and completely atrophied over the rest of the membranes, which are smooth in consequence.

2208. A foetus of 5 months within its amnion, which is entire; there is no placenta.

It was passed by a maid-servant, who it is supposed took medicine to procure the abortion by which she was destroyed.



- 2208 a. A similar specimen, with well-developed placenta.
2209. An embryo 8 weeks old. The head is distinct from the thorax, the face from the cranium; the apertures of the eyes and mouth are visible; the hands and forearms are near the middle of the length, the legs near the anus.
2210. A fœtus of 3 months without membranes. The length is 2 inches; the head larger than the body; eyelids and lips in contact; toes and fingers separate, and the parts of generation are prominent.
2211. A fœtus of 3 months with the cord attached. The eyelids are closed, the nostrils and mouth open and perfectly formed, the nails are appearing; the fingers, toes and limbs, and genital organs (male) are fully formed.
2212. A fœtus of 4 months without membranes. The eyelids and the mouth are open, the nails appearing; the sex (female) distinct.
2213. A similar specimen.
- 2213 a. A fœtus of  $4\frac{1}{2}$  months.
2214. A fœtus about 5 months old without membranes.
2215. A similar specimen  $5\frac{1}{2}$  months old.
2216. A female fœtus of 6 months.
2217. A male fœtus 6 months and 1 week of age.
2218. A male fœtus of 7 months.

For other specimens see Nos. 2198, 2245, 2246, 2260, 2276, 2284, 2286-2288.

**Specimens showing the development of the Membranes  
and Placenta.**

2219. A piece of chorion of an early pregnancy showing the villi.
2220. A piece of chorion showing villi with part of the amnion and umbilical cord, early in pregnancy.
- 2220 a. A similar specimen.
2221. A similar specimen, 8 weeks old, with an embryo enclosed.

Figured in Dr. Ramsbotham's work. See plate xxiii. fig. 3.



2222. An ovum entire about 8 weeks of age. The embryo within cannot be seen, it is enclosed in a flocculent mass of fimbriated chorionic villi.
2223. Membranes of a fœtus, probably in the second month; the amnion and chorion are present, but the embryo has escaped. The continued development of the chorionic villi at one part and their atrophy at others is well seen.
2224. Amnion and injected chorion, showing the vascularity of the villi.
2225. An injected portion of placenta.
2226. A portion of placenta not injected.
2227. An injected still further developed placenta with the amnion attached.

Dr. Ramsbotham.

For other specimens see Nos. 2198, 2203-2207, 2208 a.

#### **The Placenta in situ.**

2228. A uterus at about the sixth month everted to show the placenta still *in situ*. Arising from its centre is the cord, to which is attached the fœtus.
2229. Part of a uterus with the placenta still attached. Separation of the placenta has begun at its edge, but as the placenta is attached over the greater part of its extent, it is probable this was manually effected.

Dr. Ramsbotham.

2230. A similar specimen.

#### **The Gravid Uterus before delivery.**

2231. A portion of the wall of a gravid uterus showing great hypertrophy of the muscular coat; many dilated venous sinuses have been cut across.
2232. A uterus at the 8th month of pregnancy with an enclosed fœtus. Portions of the uterine parietes have been removed anteriorly to show the membranes, and posteriorly to show the attachment of the placenta.

The woman from whom this specimen was obtained died suddenly of convulsions consequent upon an injury to the head.

- 2232 a. A uterus at term with the anterior wall removed to expose a fœtus with the vertex presenting.

For other specimens see Nos. 2198, 2204, 2205, 2228, 2232, 2245, 2246, 2257-2260.



**Changes in the Uterus subsequent to delivery.**

2233. A portion of the wall of a uterus after delivery (injected). The mass measures six inches in length and is fan-shaped, being one inch broad below and four inches broad above; in thickness it varies from  $\frac{3}{8}$  to one inch; the thicker part is situated about two inches above the upper end of the cervical canal. The mucous membrane of the cervix is smooth and is devoid of decidua, which is abruptly limited to the body of the uterus, the point of its reflection being distinctly marked; the whole of the interior of the body of the uterus is covered with shreds of disintegrating decidua. Within the uterine wall are many enlarged vessels.

2234. An injected uterus from a patient soon after delivery. Thinning of the lower segment is apparent. Bristles are inserted into the orifices of the Fallopian tubes. A large piece has been cut out of the anterior surface of the uterus and cervix. The cervix measures an inch and a half long. The difference between the mucous membrane of the body and that of the cervix is distinct.

Dr. Ramsbotham.

2235. A similar specimen, but with more of the decidua still adherent. The cervix is two inches in length and is somewhat thinner than the body, but no abrupt line of demarkation in the relative thicknesses of the body and cervix is perceivable.

Dr. Ramsbotham.

2236. A uterus immediately after delivery. The walls are in some parts more than an inch in thickness and contain sinuses, some empty, some filled with dark clot. The cavity is large and the mucous membrane is everywhere covered with shreds of disintegrating decidua stained and mixed with blood-clot.

2237. The right half of a uterus soon after delivery. The cavity measures  $6\frac{1}{2}$  inches in length and is lined with irregular nodules of disintegrating decidua. The uterine wall is  $1\frac{1}{3}$  inches thick, and at the upper and anterior part of it numerous black spots (coagulated blood) are seen on section, and probably indicate the part where the placenta was attached.

2238. A uterus and appendages undergoing retrogressive changes after delivery. The uterus is contracted, its wall being  $1\frac{1}{2}$  inches in thickness and its cavity, which is everywhere covered with decidua, will now only hold a small apple.



2239. A similar specimen, but with a longer cavity.

Dr. Ramsbotham.

2240. A uterus after delivery laid open along the anterior median line. The cavity measures 7 inches in length. The uterine wall is an inch in thickness at the upper part, and gradually diminishes in thickness to the end of the cervix. The decidua has been completely removed except at the upper angles. There is a simple cyst the size of an orange in the right ovary.

2241. A uterus after delivery partially contracted; it has been opened along the middle of the anterior wall. The cavity measures about four inches in length, and the wall measures half an inch in thickness at the thickest part. The mucous membrane is more smooth than in the preceding specimen; all the decidua appears to have been exfoliated except some within the cornua.

For other specimens see Nos. 2250-2256.

#### **Utero-gestation in other Vertebrates.**

2242. One of the cornua of the uterus of a cow, in an early stage of impregnation; showing the spherical sponge-like cotyledons.

Dr. Ramsbotham.

2243. The uterus of a sheep showing the cotyledons, the horns of the uterus, and lengthened cervix uteri, with a foetus enclosed in membranes, at an early period of gestation, probably about four months.

2244. The uterus of a cow pregnant with twins injected, showing the structure of the cotyledons with the foetal portion of the placenta attached, the foetus, and the cornua of the uterus. At the upper part the cervix uteri is seen cut across.



SERIES XLIX.—ABNORMAL CONDITIONS INCIDENTAL  
TO GESTATION AND PARTURITION.

**Unusual position of the Child :** 2245, 2246.

Breech presentation : 2245, 2246.

**Abnormal condition of the Cord :** 2247, 2248.

**Unusual condition of the Placenta :** 2249-2251.

Triplet placenta : 2249.

Placenta prævia : 2250.

Adherent placenta : 2251.

**Rupture of the Uterus :** 2252, 2255.

**Inversion of the Uterus :** 2256.

**Extra-uterine Gestation :** 2257-2265.

---

**Unusual position of the Child.**

**Breech presentation.**

2245. A uterus at the fourth month of pregnancy, with part of the anterior wall removed to show the edge of the placenta; part of the amniotic bag and the left side of a foetus with the breech presenting.

2246. A uterus at full time with placenta and foetus *in situ*. The left side of the foetus is towards the anterior wall of the uterus and the breech presents.

**Abnormal condition of the Cord.**

2247. Umbilical cord tied in a knot, about 5 inches from umbilicus. The cord was very long. The child lived.

Mr. Leapingwell.

2248. An ovum in the fourth month, with the funis umbilicalis twisted several times round the neck of the foetus.



### Unusual condition of the Placenta.

#### Triplet placenta.

2249. A triplet placenta, injected with wax. Two of the placentæ are united at the edge; the third is separate. The membranes of the two united ones are adherent, but there is no vascular connection perceivable between them.

Dr. Ramsbotham.

#### Placenta prævia.

2250. A uterus bisected to show a placenta prævia. The cervical canal is seen to take no share whatever in the attachment of the placenta, which stops at the internal os. The thin expanded character of the prævia placenta is also well shown. The implantation of the placenta on the anterior wall extends for four inches above the internal os; that on the posterior wall eight inches. The anterior part of the placenta is detached for two inches above the internal os, and here it only measures  $\frac{3}{8}$  of an inch in thickness. The thickest part of the placenta, opposite the implantation of the cord, is half an inch. The presenting part of the placenta has been torn.

#### Adherent placenta.

2251. A uterus about two hours after delivery, with the placenta and membranes still partially adherent. The separation of the placenta has begun at the upper part and is incomplete at the lower. The uterine wall is exceptionally thin.

### Rupture of the Uterus.

2252. A uterus ruptured during labour. A long laceration extends up the left side from the cervix nearly to the Fallopian tube. There is no distinct contraction-ring visible. A piece of retained membrane hangs down into the cervical canal. On the right side there is a contracted part of the canal at a point  $2\frac{1}{2}$  inches above the external os. The greatest thickness of the uterine wall is about 2 inches above this ring, the anterior wall being  $1\frac{1}{8}$  inches, and the posterior, to which the placenta seems to have been attached, is  $1\frac{1}{4}$  inches. The wall of the cervical canal is half an inch thick. In front of the laceration there is a loose piece of separated peritoneum, which would seem to indicate that the rupture had at first been partial only.

2253. A uterus ruptured during labour. The laceration has occurred in one side and extends from the os halfway to the fundus.



2254. A uterus with a rupture beginning on the posterior wall of the cervix at the right side and extending first transversely and then upwards on the left side. There is an abrupt change in thickness  $1\frac{5}{8}$  inches above the external os. No other ring is seen higher up. The anterior wall of the cervix is  $\frac{3}{8}$  inch in thickness. Half an inch above the ring described, the uterine wall is  $\frac{3}{4}$  inch thick. The greatest thickness of the uterine wall is  $4\frac{1}{2}$  inches above the internal os, where the posterior wall is  $1\frac{1}{4}$  inches in thickness. The placental attachment seems to have been fundal.

2255. A uterus and vagina in section. A transverse rupture across the anterior wall of the cervix has taken place. For an inch above the place of rupture the uterine wall is nowhere more than a quarter of an inch thick. The greatest thickness of the uterus is  $3\frac{1}{2}$  inches above the place of rupture, and from this point it gradually thins off to a spot 1 inch above the rupture. At the thickest part the wall of the uterus is an inch thick; the peritoneum can be easily stripped off the uterus up to this point, the ring of the greatest thickness being the point where the peritoneum becomes firmly attached. At this level a circular ridge can be seen projecting into the uterine cavity; it is the so-called contraction-ring or ring of Bandl. The upper part of the uterus is contracted, and its wall is an inch thick. The specimen was shrunk from the action of spirit before these measurements were taken. The posterior uterine wall measures  $4\frac{1}{2}$  inches in length below the point of greatest thickness.

#### **Inversion of the Uterus.**

2256. A uterus inverted immediately after delivery; the anterior wall has been laid open, it is an inch in thickness. Quite concealed within the space formed by the inverted uterus are the uterine appendages. The exposed mucous surface near the fundus is blackened by numerous small blood-clots at the site of placental attachment; some small masses of placenta are still adherent. Nearer the external os, the thin amniotic membrane is seen reflected along a line placed about three inches from the end of the cervical canal.

From a woman whose uterus became inverted immediately after delivery, probably in consequence of traction upon the placenta by the cord, the cord being rendered relatively short by encircling the child's body. She rapidly bled to death before the medical man in charge could replace the organ. Dr. Herman was sent for, but too late.

See Trans. Obs. Soc. Lond. vol. xxvii. 1885, p. 83.

*Presented by Dr. Herman.*

#### **Extra-uterine Gestation.**

2257. A uterus and appendages. The extremity of the left Fallopian



tube is expanded and encloses a semi-solid spherical mass measuring  $1\frac{1}{2}$  inches by 1 inch. The posterior wall of this sac has ruptured. The villous chorion, and amnion enclosing an embryo about  $\frac{1}{3}$  of an inch in length, project through the rupture.

It was removed post mortem from a woman who was supposed to be pregnant and who died with symptoms of sudden severe internal hæmorrhage; the abdominal cavity was full of blood.

*Presented by Mr. Clegg.*

2258. A uterus containing membrana decidua. The right Fallopian tube has been ruptured by an ovum, part of whose membranes still remain within the tube. The ovary of that side contains a corpus luteum still filled with dark coagulum.

2259. A uterus and appendages showing a tubular conception and ruptured Fallopian tube. The corpus luteum,  $\frac{3}{4}$  of an inch wide, is seen in the opposite ovary. There is decidua in utero.

From a woman who died very suddenly and was supposed to have been poisoned.

2260. A foetus in the fourth month lodged in a sac formed by the outer part of the left Fallopian tube. The uterus is enlarged, and a thick soft decidua is present. The left ovary is internal to the gestation-sac.

2261. A uterus with appendages. The uterus is small and lined with villous-looking mucous membrane. The left tube and ovary are healthy. A cyst containing the placenta seems to lie under the right tube. The parts seem to have been adherent, to have been torn in taking out and then sewn up again, so that it is difficult to identify their precise relations; probably a tubal gestation which had burst first into the broad ligament and then again into the peritoneal cavity.

2262. An extra-uterine foetation. The bones of a foetus, probably near full time, are seen lodged in a sac behind the uterus; they are as clean as if macerated.

Dr. Ramsbotham.

2263. An incomplete abdominal cyst, containing the bones of a dis-integrated full-timed foetus, from a case of extra-uterine gestation. A glass rod is passed into a sinus which opened at the umbilicus.

2264. A foetus from a ruptured tubal gestation, removed per vaginam through an opening into Douglas's pouch.

2265. A decidua passed from the uterus in a case of tubal gestation.

*Presented by Dr. Herman.*



## SUBSERIES I.—DISEASES OF THE OVUM AND ITS MEMBRANES.

Myxomatous disease of the chorion: 2266-2272.

Hæmorrhage into the decidua: 2205, 2273-2288.

Abortion: 2286-2288.

Compressed foetus: 2289-2292.

Macerated foetus: 2293.

---

**Myxomatous disease of the Chorion.**

2266. A beautiful specimen of "hydatid" placenta, *i. e.* myxomatous degeneration of the chorion at an early period of gestation. The foetus and its membranes are attached.

Dr. Ramsbotham.

2267. A similar specimen.

Dr. Barnes.

2268. A similar specimen.

Dr. Ramsbotham.

2269. A similar specimen.

Dr. Ramsbotham.

2270. Broken fragments of cystic placenta.

Dr. Ramsbotham.

2271. A specimen of "hydatid" from so-called cystic degeneration of the placenta—*i. e.* myxomatous degeneration of the chorion.

Dr. Ramsbotham.

2272. A similar specimen of so-called "uterine hydatids." The cysts are innumerable and vary in size from a pin's head to a small grape; they are arranged in clusters round the smaller subdivisions of a central fibrous stalk.



**Hæmorrhage.**

2273. The chorionic and amniotic membranes enclosing a fœtus of very early age, probably 3 to 4 weeks. It measures only a quarter of an inch in length, the upper extremities being represented by almost invisible projections situated about the centre of the trunk. About the centre of the chorion is a small dark-coloured clot which has been bisected.

2274. An embryo of about 5 weeks, in its membranes; the membranes are laid open and are thickened by layers of coagulated fibrin, which have destroyed the chorionic villi. The size of the bag of membranes corresponds to about three months' pregnancy; the membranes continued to grow, and the liquor amnii to be secreted after the death of the fœtus.

2275. Fœtal membranes, amnion and chorion, of a 5-weeks' pregnancy. There has been old hæmorrhage into the chorion.

A case in which the fœtus has died and the chorionic villi have become atrophied.

2276. An embryo with its membranes, which are thickened by layers of coagulated fibrin of different dates. The growth of the fœtus was probably arrested by the hæmorrhage into the membranes. The size and development of the fœtus correspond to about six weeks.

2277. An amnion and chorion: a layer of decolorized clot, the result of hæmorrhage which has broken down and destroyed the villi over part of the chorionic surface; the rest of the chorion seems healthy.

2278. A similar specimen. The effusions are old and decolorized and situated outside the amnion.

2279. A specimen of blighted ovum, with clotted extravasations into the ovular membranes.

2280. Membranes of an ovum, with organized and decolorized clot external to the amnion.

2281. A similar specimen. There are clots of different date showing different degrees of decolorization. The hæmorrhage is here into the chorion or between the chorion and amnion. The fœtus is wanting.



2282. A similar specimen. The umbilical cord is seen. There are blood-clots outside the amnion in several layers of different dates.

2283. "Mole, ovum solidified in uterus." An embryo enclosed in membranes; beneath the amnion is an old decolorized clot.

2284. An ovum of about 8 weeks, enclosed in membranes which are thickened to the extent of nearly an inch by extravasation. The foetal surface of the placenta presents nodules as large as a nut, in consequence of the extravasation within.

Dr. Ramsbotham.

2285. A similar specimen.

For other specimens see Nos. 2205, 2286-2288.

### **Abortion.**

2286. A shrivelled foetus of 5 months' intra-uterine age, with membranes and placenta attached. The placenta is solid, with clots of various dates and in various stages of decolorization.

2287. A foetus of 5 months, with a long umbilical cord and placenta. On the foetal surface of the placenta are two small areas of extravasation; they have been cut across.

2288. A foetus of about 5 months, with umbilical cord and placenta. At several points along the margin the placenta is solid and appears to have been the seat of hæmorrhagic extravasation.

### **Compressed foetus.**

2289. A secondary foetus of about five months' intra-uterine age, much compressed.

2290. A similar specimen.

2291. A secondary foetus of about five months, shrivelled and with the abdomen compressed as if by some hard substance.

2292. A similar specimen, so much compressed as to present a flattened cake of skin enclosing a compressed skeleton.



**Macerated foetus.**

2293. A foetus which had been retained for six weeks after its death in utero; it has undergone spontaneous maceration.

*Presented by F. M. Mackenzie, Esq.*



## SERIES L.—DISEASES OF THE MAMMA.

**Cysts and Morbid Growths.**

Galactocoele : 2294.

Simple Cysts : 2295-2298.

Proliferous Cysts ; Sero-cystic disease : 2299, 2300.

Fibro-adenoma : 2301-2304.

Sarcoma : 2305-2318.

Cystic Sarcoma : 2305-2307.

Fibro-sarcoma : 2305, 2308, 2309.

Adeno-sarcoma : 2310.

Myxo-sarcoma : 2311-2315.

Carcinoma.

Scirrhus, or Hard Cancer : 2319-2326.

Infiltrated Axillary Glands : 2320.

Infiltrating Cancer : 2321-2324.

Of the male breast : 2325, 2326.

Medullary or Soft Cancer : 2327-2329.

Undergoing fatty degeneration : 2330.

Carcinoma myxomatodes : 2331.

Infiltration of the Pleura : 2332.

Mass of Cancer removed by caustic : 2333.

**Malformation.**

Supernumerary nipple : 2334.

## CYSTS AND MORBID GROWTHS.

**Galactocoele.**

2294. A portion of a breast enclosing a cyst the size of a broad bean, surrounded by indurated tissue, and into which ducts open. The cyst contained curdled milk. From the ducts, cylinders of curdy matter could be squeezed.

The specimen was excised in the belief that it was scirrhus.

**Simple Cysts.**

2295. A portion of a mammary gland showing a single large retention-cyst of a lactiferous duct which lies beneath the nipple.

It was removed from a lady, aged 40, in whom it had been noticed for a few months only. The operator considered that near to the cyst there was a portion of a scirrhous tumour, but this may have been merely fibroid induration of the tissues of the breast. The sequel of the case is not recorded.



2296. A portion of a mammary gland containing numerous tubular, rounded and intercommunicating channels and cysts, which evidently originated by dilatation of the lactiferous ducts. The intervening stroma is dense, as if it had undergone fibroid induration.

2297. A mammary gland showing several large cysts. It is described in the old Catalogue as scirrhus with cysts; but is probably an example of fibrous induration of the gland with the formation of cysts.

2298. A firm solid tumour the size of a small orange, containing a cyst as large as a cherry; the interior of the cyst is irregular, but has a smooth lining; the solid part is partly fibrous and partly homogeneous, and contains gland-tissue. The microscope showed inflammatory induration of the stroma of the breast with dilatation of some of the ducts.

Case of Florence Tomlinson, a childless widow, aged 37, admitted Sept. 26, 1888, R.N. 1146. She had only noticed a swelling of the left breast for 4 weeks. On admission the tumour was oval, as large as an egg and fairly well defined. It was dissected out and the wound healed well.

#### **Proliferous Cysts; Sero-cystic Disease.**

2299. A portion of a mammary gland exhibiting a duct-cyst, which contains a solid intra-cystic growth. The cyst lies immediately beneath the nipple and is about one inch in diameter. Springing from one side is a sessile lobulated growth, which probably has a gland-like structure, with papillæ on the surface.

2300. A mammary gland with numerous cysts varying in size from marbles to peas, interspersed in its structure. Many of the cysts communicate with each other, and one or more contain soft rounded intra-cystic growths.

#### **Fibro-adenoma.**

2301. A fibro-adenoma of the mammary gland. The tumour, which is 3 inches in diameter, is well defined and encapsuled. Its section is divided into well-defined lobules and exhibits a gland-like surface dotted with a few minute cysts.

2302. A fibro-adenoma of the breast, which after removal weighed 15 lbs. Its surface is well defined, lobulated, and bounded by a distinct capsule. The section is firm, gland-like in appearance, and exhibits small lobules separated by bands of connective tissue. There



are two or three cysts filled with minute lobulated intra-cystic growths. Other gland-tubules may be seen in process of dilatation to form cysts.

The tumour was removed from a woman who was admitted to the London Hospital in 1802. She recovered after the operation. The specimen was originally described as "clusters of hydatids in the breast."

The tumour was microscopically examined in 1889 by Mr. Eve. It is composed of dense fibrous tissue with a few widely scattered gland-tubules. There was no trace of sarcomatous growth.

2303. A firm globular, somewhat encapsuled lobulated adenoma the size of a fist. On section it is seen to be composed of lobules of gland-tissue. The microscope shows a fibrillar matrix studded with round cells, and enclosing numerous gland-tubules and acini.

Case of Ellen Thompson, a childless woman, aged 31, admitted July 24, 1888, R.N. 863. A lump had been noticed for some years, which had recently grown more rapidly, but without pain. It was situated at the lower and inner part of the left breast. The tumour shelled out on an incision being made, and the wound healed by first intention.

Mr. Reeves.

2304. A firm lobulated fibro-adenoma the size of a small orange. The section shows a dense fibrous stroma enclosing lobules of soft somewhat gelatinous gland-tissue. Under the microscope it is composed of much fibrous tissue with irregular gland-tubules.

Case of Elizabeth Naish, aged 31, a married woman with two children, admitted on January 4th, 1889, with a history of having noticed a lump in the outer part of the right breast for two years. When first noticed the tumour was as large as a nut, and it had gradually increased in size since. She suffered occasionally with sharp shooting pains in the breast. On admission a hard tolerably well-defined lobulated tumour was felt; it was freely movable over the pectoral muscles and not attached to the skin. The nipple was not retracted, nor was there any glandular enlargement. The tumour was excised on January 6th; it was encapsuled, but adherent to the surrounding breast-tissue at one spot.

The patient made an excellent recovery.

Mr. McCarthy.

## Sarcoma.

### Cystic Sarcoma.

2305. A portion of a breast with a cystic sarcoma, which is divided in a direction parallel to the integuments. The greater portion of the tumour is composed of a cyst which is nearly filled by soft intra-cystic growths. The solid portion is distributed more or less uniformly around the cyst; it is soft, homogeneous, and, like the intra-cystic growths, composed of sarcomatous material. The nipple is retracted. At a point about an inch from it a small ulceration in the skin communicates with the cyst-cavity.



The growth was microscopically examined by Mr. Eve in 1889, and was found to be a spindle-celled sarcoma.

2306. A large cystic sarcoma of the mamma; its outline is well defined and lobulated. A section shows a homogenous, and, in parts, indistinctly fibrous material in which gland-tubules and very small cysts are imbedded.

2307. A breast bisected to show a large proliferating cystic tumour. The cysts are three in number, and the upper one, the largest, would contain a fist: the inner surface of this cyst is covered with small polypoid cauliflower-like growths, which vary in size from a pea to a marble. The wall of the two lower cysts is irregular and shows the remains of blood-clot still adherent. The cysts are separated by firm solid new growth, half an inch to an inch in thickness. In front the cysts are subcutaneous, the cyst-wall at this part being not more than a line in thickness.

Case of Jane Treves, aged 40, admitted July 2, 1889, R.N. 713. She had a large cystic tumour which had gradually increased in size during the past seven years. The axillary glands were affected. The breast and glands were excised on July 5. The wound healed rapidly, and in January 1890 there had been no recurrence.

Mr. Treves.

#### **Fibro-sarcoma.**

2308. A very large tumour of the mammary gland. It is very firm and fibrous in texture, and its section does not exhibit the gland-like aspect of a fibro-adenoma. The surface appears to have been well defined, but is only faintly lobulated.

Microscopically it was probably composed in great part of fibrous tissue with sarcomatous elements (fibro-sarcoma).

2309. A section of a large sarcoma of the mammary gland. The tumour is well defined and lobulated on the surface. Its section is composed of homogeneous material, intersected by numerous bands of glistening fibrous tissue.

It is probably composed of spindle-cells intermingled with a considerable amount of fibrous tissue (fibro-sarcoma).

#### **Adeno-sarcoma.**

2310. A soft flattened indistinctly lobulated growth the size of a large fig, situated in the centre of the mammary gland. On section it



appears to be made up of fine fibres and irregular lobules. The microscope shows a small spindle-celled sarcoma with gland-tubules imbedded in it.

Case of Jane Long, aged 47, who was admitted on November 29, 1888, R.N. 1388, with a circumscribed mass in the breast. In March 1887 she came with a small nodule, which was excised. This recurrent tumour, together with the remainder of the breast, was excised December 2nd, the wound healing by first intention.

Mr. McCarthy.

### **Myxo-sarcoma.**

2311. A section of a myxo-sarcoma of the breast. The tumour is well defined, surrounded by a distinct capsule, and is composed of soft, glistening, homogeneous material. Slit-like cavities may be observed in places between the surface of the tumour and its capsule.

2312. A section of a myxo-sarcoma of the breast. The tumour is well defined and encapsuled. The section is in some parts pale and translucent and in others fibrous. At each end is a small group of cysts probably formed by dilatation of gland-tubules.

*Presented by Mr. Eve.*

2313. A lobulated, encapsuled, myxo-sarcomatous tumour the size of a fist; in the recent state it was very soft, and when cut across it was found to be composed of cysts filled with mucus which is now coagulated. The cut surface is convex, smooth and glistening, and is intersected by bands of fibrous tissue. Microscopic sections showed homogeneous connective tissue, studded with spindle-shaped and a few branched cells (myxo-sarcoma).

Case of Miss C., aged 40, a single lady, who said the tumour commenced as a small movable lump in the left breast twelve years ago, and had very slowly enlarged with pain during that time. During the last three months its growth became rapid, but she never had pain either in the breast or elsewhere. The tumour before removal was freely movable and the skin was not adherent; there was no glandular enlargement. The patient's general health was markedly affected; she was asthenic, anæmic, and emaciated. She made a rapid recovery and had no return twelve months afterwards.

*Presented by Mr. Collier.*

2314. A soft myxo-sarcoma with cysts, some of which contain proliferous growth. The microscope shows the tumour to be composed for the most part of imperfectly formed fibrous tissue containing numerous elongated nuclei. It is intersected by trabeculæ of spindle-cells and clusters of round cells.



Case of Charlotte Funnell, aged 40, admitted October 23, 1888, R.N. 1246, with a very large and distinctly defined tumour, hard in some parts and fluctuating in others, in the right breast. She gave a history of an injury 9 years ago, and said she had been losing flesh of late. There were no enlarged glands. The breast was excised. The wound suppurated, but slowly healed.

Mr. Treves.

2315. A soft lobulated, partially encapsuled myxo-sarcoma. It contains gland-ducts and lacunæ into which lobulated masses of the stroma project. It is as large as a hen's egg. Alongside it are some small hard infiltrated glands.

The specimens were excised on January 3rd, 1889, from the same patient as the preceding specimen. She first noticed a small nodule in the scar of the former operation some three months ago, and since then it has gradually increased in size without pain. The patient is a fat woman, and no enlarged axillary glands could be felt before operation.

### Sarcoma.

2316. A breast removed and incised. At one corner is a small globular non-encapsuled tumour, firm to the touch, an inch in diameter. The section presents a finely fibrillated appearance, with numerous cysts of microscopic size. The microscope shows numerous small round cells, some bundles of spindle-cells, and small cysts.

Case of Ellen Hill, aged 37, admitted June 26, 1889, R.N. 672, with a hard ill-defined mass the size of a small apple, which she had noticed for 6 months. There were no enlarged glands in the axillæ. The whole breast was excised, and the wound healed rapidly without rise of temperature.

Mr. Treves.

2317. A circumscribed largely lobulated tumour of a mamma, probably a sarcoma. The section shows rounded masses of pale translucent material apparently produced by myxomatous degeneration.

2318. An oval portion of a breast, with the skin covering it. Lying beneath the nipple is a cyst as large as an orange, with walls  $\frac{1}{8}$  inch in thickness; it appears to have been formed by the dilatation of a lactiferous duct. Attached to its wall is a semisolid lobulated nodule an inch in diameter, which contains many small cysts. Microscopically the nodule was composed of round nuclei arranged in ill-defined groups. The nature of the growth could not be determined with certainty; it was either a round-celled alveolar sarcoma or a form of duct-cancer, probably the latter.

Case of Sarah Weedon, aged 84, admitted on June 8th, 1888, R.N. 665. She had noticed the tumour for 18 months. It was excised. The cysts contained grumous fluid.

Mr. McCarthy.



**Carcinoma.****Scirrhus, or Hard Cancer.**

2319. The tumour is firm and fibrous in texture, and its outline is ill-defined. The nipple is deeply indrawn.

The tumour had existed for 15 years (?) and was growing very rapidly at the time of its removal. The patient died fifteen months afterwards.

Mr. Scott.

**Infiltrated Glands.**

2320. Some of the axillary glands from the same case as the preceding. They are infiltrated with cancer, and radiating lines of fibrous tissue are seen connecting the glands with the adjacent textures.

**Infiltrating Scirrhus.**

2321. A section of a mammary gland showing a uniform infiltration of its substance with scirrhus cancer. Bands of fibrous tissue may be observed extending from the surface of the tumour to the integuments. Some enlarged axillary glands are connected with the axillary margin of the tumour.

In connection with this specimen Mr. Scott remarked :—"It is an example of a most malignant variety of true carcinoma, in which the nipple, however, is not drawn in, the tumour presenting an even surface not even lobulated. In such a case as this, how dangerous must it be to look for the retraction of the nipple as the pathognomonic local symptom of the disease."

2322. A section of a breast exhibiting general cancerous infiltration of the whole substance of the gland. The nipple is retracted, and the skin adherent to the tumour.

*Presented by Mr. Eve.*

2323. A portion of a breast with a scirrhus cancer. The integument over the tumour is bulged forward, smooth, and firmly adherent to its surface. An enlarged axillary gland, infiltrated with cancer, is attached to the lower part of the specimen.

2324. This specimen shows a small nodule of scirrhus the size of a bean, lying in the periphery of an atrophied breast.

*Presented by Mr. Eve.*

**Scirrhus of the male breast.**

2325. A section of a male breast, showing a tumour involving the whole gland and forming a swelling beneath the nipple. The growth is



firm, well defined and without fibrous prolongations into the surrounding fat.

The specimen was submitted to the Morbid Growths Committee of the Pathological Society, who were of opinion that it was probably carcinoma.

See Trans. Path. Soc. vol. xxvii. p. 252.

Mr. Maunder.

2326. A similar specimen of scirrhus cancer of the male breast. The tumour appears more fibrous in texture than the preceding.

### **Medullary, or soft Cancer.**

2327. A breast divided in a direction parallel to the surface of the skin. It contains a rounded mass of soft or medullary cancer of indistinctly fibrous aspect. The tumour is fairly well defined; it protrudes, and is adherent to the skin over it. The nipple is not retracted.

2328. A section of a cancer of a female breast which was described as encephaloid. It is softish in texture and contains little fibrous tissue. Eighteen months after removal no recurrence of the disease had taken place.

Mr. Adams.

2329. A breast exhibiting a rounded tumour prominently projecting from the skin immediately above the nipple, which is retracted. The tumour is soft in texture, shows minute alveolation, and is probably a medullary cancer.

Mr. Adams.

### **Undergoing fatty Degeneration.**

2330. A mammary gland showing a scirrhus cancer, near the centre of which softening has taken place in several parts, and small cavities filled with fatty material have been formed.

### **Carcinoma myxomatodes.**

2331. A section of a tumour of the breast, probably an example of carcinoma myxomatodes (so-called colloid cancer). It shows a yellowish-white glistening gelatinous substance intersected by narrow bands of fibrous tissue.

This condition is produced by mucoid metamorphosis of the connective-tissue stroma of the cancer.



**Infiltration of Pleura.**

2332. A specimen showing infiltration of the chest-wall with cancer, which had extended from the breast. The pleura is involved, and the lung adherent.

The patient was a woman, aged 50, who died in 1835 under the care of Mr. Andrews. Both breasts were affected, and the right was ulcerated. The axillary glands and those above the clavicle were diseased.

**Mass of Cancer removed by caustic.**

2333. A mass of cancer together with adjacent textures which was removed from the female breast by the application of zinc paste. The mass is as large as a fist. Notwithstanding the size of the slough the disease persisted at its base, and the wound never healed. Six months later the patient had an enormous ulcer, involving the whole pectoral region.

*Presented by Mr. Kibbler.*

**MALFORMATION.****Supernumerary nipple.**

2334. A portion of skin removed from the pectoral region of a man. There are two nipples, which are an inch and a quarter apart. One is rather larger than its fellow, but both of them are quite distinct, and both are surrounded by well-developed sebaceous follicles. The subjacent parts are not shown.



## SERIES LI.—MALFORMATIONS.

## MALFORMATIONS RESULTING FROM INCOMPLETE DEVELOPMENT.

**Of the Head.**

Acephalous : 2335, 2336.

**Of the Nervous System.**

Brain absent : 2337-2340.

Brain rudimentary : 2341, 2342, 2344, 2345, 2368, 2372, 2384.

**Of the Organs of Special Sense.**

Eyes absent : 2341, 2344, 2345.

Eyelids remaining united : 2346.

External ear absent : 2345.

Nose absent : 2341, 2342, 2344, 2345.

**Of the Vascular System.**

Abnormal arterial supply of the cord : 2347.

**Of the Respiratory System.**

Lungs absent or rudimentary : 2335, 2336.

**Of the Digestive System.**

Fauces impervious : 2344.

Intestine opening abnormally : 2348, 2367.

**Of the Urinary System.**

Kidney absent : 2348.

Ureter absent : 2348, 2367.

**Of the Organs of Generation.**

Ovary absent : 2348.

Uterus absent : 2348, 2367.

Vagina absent : 2348, 2367.

External organs absent : 2348, 2349, 2367.

External organs rudimentary : 2335, 2365.

**Other similar Malformations.**

Head absent : 2335, 2336.

Cranium defective : 2337-2341, 2368, 2372.

Lower jaw defective : 2363.

Upper and lower extremities absent or rudimentary : 2335, 2350-2352, 2357.

One lower extremity absent : 2349, 2353, 2354.

Foot articulated to pelvis : 2349.

Fingers or toes deficient in number : 2336, 2345, 2352, 2355-2357, 2367.

## MALFORMATIONS RESULTING FROM INCOMPLETE COALESCENCE OF PARTS.

**On the Ventral median plane and Visceral Arches.**

Fissure of the face : 2341, 2344, 2347.

Fissure of the lip.

Single hare-lip : 2358.

Double hare-lip : 2341, 2359.



**Fissure of the palate.**

Hard palate: 2357-2359, 2362-2364.

Soft palate: 2311, 2357-2359, 2361-2364.

**Fissure of the chest-wall: 2366, 2367.**

" " diaphragm: 2349, 2367, 2368, 2400.

" " abdominal walls: 2353, 2354, 2365-2369, 2372, 2389.

" " symphysis pubis: 2366, 2367.

**Of the Dorsal median plane.**

Fissure of the skull: 2337-2340, 2368, 2370, 2373.

Meningocele: 2371, 2372.

Encephalocele: 2345, 2368, 2373-2375.

**Fissure of the spinal column—Spina Bifida.**

Cervical: 2337, 2371, 2393.

Dorsal: 2368, 2372.

Lumbar: 2368, 2376-2381, 2389.

Sacral: 2367, 2378-2382.

**MALFORMATIONS RESULTING FROM COALESCENCE OF PARTS.**

Fingers or toes conjoined: 2336, 2345, 2349, 2357.

Cyclops: 2342, 2383, 2384.

**MALFORMATIONS RESULTING FROM COALESCENCE OF TWO FÆTUSES.****Double Fœtus.**

One perfect, the other an appendage: 2385, 2387.

Both more or less perfect.

Upper parts united: 2389-2391.

Middle parts united: 2388, 2392, 2393.

Lower parts united: 2394-2396.

Supernumerary nail: 2397.

**MALFORMATIONS RESULTING FROM DISPROPORTIONATE GROWTH OF PARTS.**

Clitoris: 2398, 2399.

**CONGENITAL DISPLACEMENTS.****Hernia of the Intestines.**

Through the diaphragm: 2349, 2400.

Through the umbilicus: 2354.

**CONGENITAL DISTORTIONS.**

Of the spine: 2401.

Of the thorax: 2335.

Of the limbs: 2372, 2402, 2403.



## MALFORMATIONS RESULTING FROM INCOMPLETE DEVELOPMENT.

**Of the Head.****Acephalous.**

2335. An acephalic foetus. The upper extremities are represented by tags of integument half an inch in length. The umbilical cord is attached near the left groin. The lower extremities were apparently normal, but have been mutilated in removal; they appear to belong to a foetus of about 5 months. The external genitals are undeveloped.

A dorsal median incision has been made through the integuments, which over the upper part are half an inch in thickness and consist of reddish, homogeneous, elastic, subcutaneous tissue. This incision exposes a small thorax with ribs flattened on the right side and expanded on the left side. The dorsal vertebræ are well developed, the spines and neural arches being complete; the dorsal spine is extremely kyphotic. There is no trace of cervical or cranial vertebræ.

2336. An acephalous foetus, whose thoracic and abdominal cavities have been laid open. The head and neck are absent, being represented by a loose pendulous mass of skin and subcutaneous tissue. The chest and thoracic viscera are too rudimentary to identify by dissection. The right upper extremity is represented by a small bony mass attached to the upper part of the thoracic wall, and the left by a small boneless tag of cutaneous tissue with a minute thumb at the end of it; this tag is about an inch in length. The abdomen presents two kidneys of large size, with the lobes of an undeveloped liver in front of them. Between the kidneys are the intestines, which lie in the centre of the abdominal cavity. The cæcum is rudimentary and the rectum is straight and is placed to the right of the vertebral column. There is no trace of a stomach. The hypogastric arteries are seen. The testes lie within the abdomen close to the internal inguinal ring. The penis and scrotum are normal. The lower extremities are normal, except that there are only four toes on the left foot. On the right foot there are five, but the two smallest toes are webbed, and the cleft between the third and fourth is incomplete.

**Of the Nervous System.****Brain absent, anencephalous.**

2337. A foetus with brain and skull undeveloped. The head is small and is joined to the trunk without intervening neck. On the posterior



aspect of the head is a large patch of somewhat circular outline, 2 inches in diameter, covered by membrane only.

On dissection the posterior expanded part of the occipital bone and laminae of all the cervical vertebrae are absent. The dorsal vertebrae and ribs are normal. The long subscapular nerve is seen passing to the latissimus dorsi muscle; it may be traced upwards over the first rib, which lies close to the mastoid process.

The eyes, nose, and mouth are perfect; the limbs are well and normally developed.

2338. A female foetus with undeveloped brain and skull. Over the occipital region is a large raw patch uncovered by skin. On dissection it is seen that there is no brain-case, the bones (frontal, parietal, and occipital) forming the vault of the skull being absent. There is a foramen magnum formed in the occipital bone. The base of the skull is exposed, namely, the basilar processes of the sphenoid and occipital bones. On each side are the petrous portions of the temporal bones with the internal auditory and posterior lacerated foramina with their respective nerves. The neck has been cut open to show the laminae of the cervical vertebrae intact. The limbs are normal except that the feet show talipes calcaneus.

2339. The head and shoulders of an anencephalic foetus with the spinal cord laid bare in the cervical region; it shows the abrupt termination of the cord at the level of the foramen magnum and absence of the brain; several nerves are given off from the upper end of the cord and run upwards and outwards. The spinal meninges are healthy, but at the foramen magnum they are widely expanded and are uncovered with either skin or cranium.

2340. An anencephalic foetus with very large trunk and limbs. The eyes, nose, and external ears are apparently normally developed. At the top of the head there is a large cranial cleft uncovered by skin. The forehead may be said to be absent owing to deficient development of the frontal region of the skull.

#### **Brain rudimentary.**

2341. The head of a foetus over whose frontal and parietal region there is a globular enlargement which is found to consist of skin and membrane; the frontal and parietal bones being undeveloped. The expanded posterior part of the occipital bone is well formed. A portion of the skull has been excised to expose the ossified base of the skull (sphenoid and basilar process and petrous portion of the temporal bone), and the nerves passing through the various foramina.



The eyes and nasal organs are completely undeveloped. The truncated ends of the superior maxillary bones project on each side in the wide facial cleft. The two papillæ seen in the upper edge of the facial cleft are most probably the unattached anterior pillars of the fauces—from them the posterior pillars are seen running backwards to the posterior wall of the pharynx. The hard and soft palates are absent.

2342. The head and bust of a fœtus with undeveloped nose and with a single imperfectly formed eye, which is situated in the middle of the forehead. The upper part of the cranium has been removed to show the brain, in which there is neither longitudinal median fissure nor convolutions on the surface. The central ganglia are conjoined. The cerebellum and the corpora quadrigemina are not covered by the cerebrum, the tentorium extending upwards and backwards to the vault of the cranium.

2343. The posterior part of the vault of the skull, removed from the preceding specimen.

### The Organs of Special Sense.

#### Eyes absent.

2344. The anterior vertical half of the head of a fœtus without eyes and nose. There is a palpebral fissure about  $\frac{3}{4}$  inch in length, situated in the middle of the face; the inferior puncta lachrymalia are seen symmetrically placed upon the border of this fissure, a bristle has been passed into that of the right side. Above the centre of this fissure there projects forwards from the forehead a tubular proboscis an inch in length and a third in diameter. The mouth is well formed. Both pinnæ are notched at the upper and back part of the helix.

At the back of the specimen the basisphenoid, basioccipital, and cervical vertebral column have been bisected to expose the pharynx. The nasal cavity is seen to be shut off from the pharynx by a thin vertical membranous septum. The soft palate, the pharynx, and fauces are normal. On the base of the skull the two optic nerves and anterior clinoid processes are approximate owing to defective development of the presphenoid and ethmoid bones. There is no trace of an orbital cavity, and the anterior fossæ of the skull are quite rudimentary.

2345. The head, bust, and upper extremities of an infant, born at full time with various malformations. The left side of the face is larger than the right, and the left ear is well formed, whilst the right is



small and ill developed. There is an eye on the left side, but only a small puckered depression on the right to mark the palpebral fissure. The alæ nasi are deficient to a considerable extent; the forehead is so small as to be almost level with the root of the nose, the left eye looking upwards and being nearly on the same level as the parietal eminence.

There is a large occipital encephalocele over part of which the skin is wanting; from its left side a long portion of membrane, six inches in length (arachnoid), hangs. The upper extremities are well formed, except that the thumb, fore finger, and middle finger of the right hand are deficient at the metacarpo-phalangeal joint. The last joint of the little finger is also wanting, and its stump is webbed with the adjacent side of the ring-finger.

*Presented by Mr. Rees Llewellyn.*

#### **Eyelids remaining united.**

2346. A fœtus of about 7 months. It presents nothing abnormal beyond permanent closure of the eyelids.

#### **Of the Vascular System.**

##### **Abnormal arterial supply of the Cord.**

2347. A placenta with funis attached. There is but one artery to the funis, which, instead of coming from the internal iliac, was a continuation of the aorta, which did not divide as usual into the two common iliaes. The right common iliac artery was given off from the aorta at the place where it usually divides, the left external iliac artery arising more than an inch lower. The right internal iliac was normal, coming off from the right common iliac; the left internal iliac was given off by the aorta. The child was a male and lived a week; it was attached to the funis, but has been lost.

#### **Of the Organs of Generation.**

2348. The labia, nymphae, &c. of a child born without any of the internal organs of generation. There is a complete absence of uterus and vagina. There is no anus, the rectum as well as the meatus urinarius terminating within the labia. There was only one ureter, which is very large, connected with the underpart of the bladder and a very large kidney. On the left side there was a very small kidney unconnected with the bladder or opposite kidney; it has been lost.



2349. A fœtus without external parts of generation, opened and injected; the heart lies on the right side, the greater portion of the liver on the left; the spleen is in the thoracic cavity, the diaphragm being imperfect on the left side. The right thigh and leg are wanting, the foot being attached to the hip, the great and second toes being webbed.

#### Of the Limbs.

2350. A male fœtus with short limbs. The tips of the fingers would not reach to the umbilicus.

2351. A female fœtus with uniformly dwarfed arms and legs. The upper extremities are each about an inch long, flattened and fin-like. The lower extremities are still less developed.

2352. A hydrocephalic fœtus with truncated limbs. There are only short stumps in the arms, and in the right leg the upper segment only. In the left foot the great toe and two others only are present. At the extremities of the truncated limbs nipple-like bodies are seen, apparently the rudiments of the undeveloped parts.

The spinal cord has been exposed. The dura mater is much thickened in the cervical region, its outer layers at this part are swelled and discoloured, apparently from infiltration with blood; outside the dura mater at this part was found a collection of brown substance like altered blood-clot. It does not seem likely that this had anything to do with the deformity of the upper extremities, it was more probably the result of an injury at or shortly before birth.

2353. A fœtus with the head, thorax, and upper extremities well formed. There is complete absence of the right lower extremity, with imperfectly developed pelvis and deficient abdominal parietes. The liver and intestines are exposed. A well-formed placenta is still attached; the umbilical arteries are very short. The left lower extremity is well formed, but is flexed at the hip, so that the foot, which is flattened, rests against the left parietal bone.

2354. A fœtus of about three months, with the right lower extremity absent. The umbilical opening is on the right side, just where the limb should have been placed, and the liver, intestines, &c. have prolapsed through it.

2355. Congenital absence of the radius and of the thumb of the left hand. Imperfect development of the radius and a rudimentary thumb of right hand.



2356. The upper limbs of a fœtus in which the radii have not been developed. The thumbs also are wanting. In the left hand the ring-finger is as large as the middle finger, and the little finger is larger than the fore finger. In the right hand the fore finger is bent up, but appears to be no longer than the little finger. In both limbs the hands are drawn up on the radial side and form an acute angle with the forearm, the extremity of the ulna projecting beyond the carpus.

In one limb which has been dissected the radial nerve is absent, and in the carpus the scaphoid and trapezium also appear to be absent; the distal row consists of three cartilages and the proximal of one bone only, the os maguum.

#### MALFORMATIONS RESULTING FROM INCOMPLETE COALESCENCE OF PARTS WHICH SHOULD HAVE BECOME CONJOINED.

##### On the Ventral median plane and Visceral arches.

##### Fissure of the face.

2357. A fœtus with cleft face and palate, absence of the left upper extremity, and deformity of three inner toes of each foot.

The centre of the face is occupied by a pentagonal chasm, the upper angles of which extend on the right side to within  $\frac{1}{3}$  of an inch of the inner canthus of the right eye, and on the left to within  $\frac{1}{8}$  of an inch of the canthus. On the left side the chasm extends higher up, and is bordered laterally at the upper part by the inner third of the lower eyelid and the wall of the orbit behind it. The retraction of the left border of the chasm has exposed the rounded anterior extremity of the alveolar process of the left superior maxillary bone. The right superior maxillary bone lies behind the border of the chasm on that side.

The upper margin of the chasm is formed by the lateral extremities of the alæ nasi, which have been displaced upwards and outwards towards the orbits. From the tip of the flattened and expanded nose, which forms a forward and downward projection over the chasm, a further projection overhangs the centre of the chasm, is formed by the anterior extremity of the intermaxillary bone. This intermaxillary process is a triangular body, with the apex upwards. The upper part is covered by the central part of the upper lip, and at the lower part two incisor tooth-sacs are conspicuous imbedded in the gum. The hard palate is absent.

There is a rounded eminence at the left shoulder without any trace of the upper limb.



On the right foot there are only four toes; the three inner toes are webbed, and the first and third have no nails.

On the left foot the two outer toes appear naturally developed. The three inner toes are imperfectly developed and connected together. They are drawn downwards apparently by a tendinous band, which is seen lying in a longitudinal fold of the skin of the sole of the foot, and which is connected separately with each of the digits referred to, and posteriorly with the apex of an elevated fold of the skin, which expands behind to full width of the foot at the heel; this band is probably the flexor brevis digitorum muscle.

#### **Fissure of the lip.**

2358. A fœtus of three months, showing a single hare-lip. There is a cleft also in both the hard and soft palates.

#### **Fissure of the lip and palate.**

2359. A typical double hare-lip with cleft of the hard and soft palates. The lower jaw has been divided and separated in order to allow the deformity to be well displayed. The lateral halves of the soft palate are seen at the back of the mouth as small papillæ  $\frac{1}{4}$  inch in length; each lateral half of the hard palate is narrow, and its free edge is curled upwards towards the lower turbinated bones. The two lower turbinated bones are seen on each side of the thickened rounded lower border of the vomer, which is centrally placed. Anteriorly the vomer is continuous with the premaxillary bone. This bone is attached above to the nasal process, it is rotated forwards and carries the four incisor teeth, the two lateral incisors are to be seen; on its anterior surface is a small portion of cutaneous tissue.

The back of the specimen presents nothing of particular note, the fossæ and cribriform plate of the ethmoid being well developed.

2360. The premaxillary bone of an infant the subject of hare-lip. The premaxillary bone projected nearly an inch, and was cut away. The portion of skin united with it was made to constitute the columna nasi.

Mr. Hutchinson.

#### **Fissure of the palate.**

2361. Cleft of soft palate.

2362. Deficiency of the hard and soft palates without hare-lip.

2363. The anterior part of skull, lower jaw, &c. from an infant, showing



a cleft of the whole of the soft palate and posterior part of the hard. The lower jaw is ill developed and small. During life the want of projection of the chin was very conspicuous.

2364. The upper jaw of a child, showing a cleft in the hard and soft palates. The two halves of the uvula are apparent. At the edge of the cleft in the hard palate the mucous membrane is thick and rounded.

**Fissure of the abdominal walls.**

2365. "A fœtus at full time, with the head and upper part of the body perfect, but wanting the abdominal muscles, and having the viscera covered with and enclosed in the peritoneum. The external organs of generation are imperfect." In its present condition the abdominal viscera are free.

2366. A fœtus of about eight months, with deficient abdominal parietes. The liver and intestines were enclosed in a bag of thickened peritoneum; it has been drawn aside, and is now attached to the left side of the fœtus. The upper end of the cleft seems to have been enlarged so as to open the thoracic cavity, in which the lower edge of the left lung and the pericardial bag are exposed. The sternum is undeveloped. The liver is apparent with the umbilical vein attached, this can be traced forwards along the left side towards the umbilicus. Below the liver are the intestines, with the two kidneys and ureters passing down to the bladder. In the lower part of the abdomen, on each side, is an ovary, parovarium, and rudimentary horn of a uterus. A glass rod has been passed into the anus, and this passes into the lower part of the cleft in the abdominal walls at a point about half an inch in front of the anal orifice. This open space is situated below the line of attachment of the peritoneal bag, and in it are seen the opening into the intestine, the rugose bladder-wall, the partially developed right horn of the uterus, into the orifice of whose Fallopian tube a glass has been passed.

2367. A deformed fœtus of eight months. The head, shoulders, and arms present nothing peculiar. The trunk is twisted over towards the left side. The walls of the abdomen are extensively deficient, and on the left side many of the ribs are very short. A cleft can be felt in the parietes of the chest extending backwards almost to the axilla and upwards to the third rib on the left side.

The abdominal viscera are protected only by parietal peritoneum, which constitutes a large bag capable of holding an adult fist, in addition to the viscera. The viscera hang forwards from the abdo-



minal cavity. Through the transparent peritoneal sac the liver, intestines, spleen, lower two thirds of the heart (piece of glass in it), and lowest portion of the left lung (piece of glass) can be seen. The peritoneal cyst has been ruptured at the lowest part; it contained fluid, and was very probably ruptured during parturition.

There appears to be a cleft in the diaphragm and a deficiency in the pleura on the left side, by which the unexpanded left lung is exposed. The spleen, stomach, and pancreas were in normal position, but have been detached and hang downwards in the bottle. In the lower part of the abdomen the small intestine ends in the cæcum, which is dilated and contained meconium. It is firmly adherent to the abdominal parietes and to the peritoneal sac. From the cæcum the gut passed directly to the left iliac fossa, and so down towards the anus.

The right kidney is very large and lobulated, and presents a few small cysts upon the surface. Its pelvis is extremely dilated, with thin and transparent walls. The ureter is narrowed at its junction with the pelvis, it then dilates and becomes tortuous and joins below a small empty bladder, which is inseparably united to the right Müller's duct. There is no trace either of internal or external genitals or of the anus, but in the right groin is a small cul-de-sac in the skin, which will just admit a probe about the eighth of an inch.

The pelvis appears to be very imperfectly developed, the right femur is loosely attached, probably without an acetabulum, it is bent up on the abdomen. The right foot is much deformed, the cleft between the great and second toes is an inch in length, and there is some appearance of a cicatrix at its bottom. The cleft extends up to the tarsus. The os calcis is depressed (*talipes calcaneus*), and is fixed or nearly so. The foot has only three toes—two appear to represent the fourth and fifth, and the other the great toe.

The left lower extremity is normally formed, with the single exception that its little toe is larger than any of the others except the great one.

There is a cyst at the back of the right hip which contained about a couple of drams of perfectly clear fluid, and appears to communicate with the spinal canal (*spina bifida*).

The foetus was born on Sept. 12, 1867, and was within a month of full term. The mother had borne a healthy family previously, and had no hypothesis by which to explain the peculiarities presented in the present case. It was a case of *placenta prævia*. The child was born after the placenta. It is not known whether it breathed.

*Presented by Dr. Garrett.*



2368. A fœtus with deficiency of the abdominal wall and with undeveloped brain and vertebræ. Projecting from the front of the abdomen is a large peritoneal bag as large as a fist, which contains the abdominal viscera still *in situ*. The liver with its suspensory ligament, the stomach, and the spleen lie contiguously. The intestines are distended with meconium. The cæcum lies high up and to the left, and has a large vermiform appendix. Above the liver there lies exposed about two thirds of the heart, and on its left the expanded base of the left lung, which rests upon the stomach and spleen, being separated from them by peritoneum only. There is no trace of a diaphragm. The anterior thoracic wall seems undeveloped, especially on the left side, but there is no fissure in the ribs. The extremities and genital organs are well developed. The trunk is very short; the shoulders are raised, there is no neck, the sides of the head join with the shoulders; the head is retracted so that the chin, shoulders, and ears are on the same level. The vault of the cranium, all the cervical vertebræ, and the upper dorsal vertebræ are wanting; the laminae of the lower dorsal and lumbar vertebræ are undeveloped; the sacrum and last lumbar vertebra are normal. The meninges are expanded into a cyst, which contained some brain-matter. The cord is seen stretched over the posterior surface of the bodies of the lower dorsal vertebræ, which have an exaggerated dorsal curve.

*Presented by Mr. J. Page Cooper.*

2369. A chick with imperfect abdominal wall.

#### **On the Dorsal median plane.**

##### **Fissure of the skull.**

2370. Portion of the skull from a case of occipital encephalocele, to show the opening through which the tumour had passed and the position of the tentorium. The bones are very imperfectly ossified.

*Presented by Mr. Hutchinson.*

##### **Meningocele.**

2371. A fœtus of about three months, with large folds of pendulous skin over the occipital, cervical, and upper part of the dorsal regions. This fold of skin has been laid open along its whole length. Over the cervical region, where it is most abundant, it encloses a multilocular cyst with thin smooth walls and filled with a clear fluid. Attached to the median ridge on the outer surface of the occipital bone, along the middle line, are two thin narrow sheets of whitish membranous material; these pass outwards towards the skin, one



being placed on each side. On cutting open the one on the right side it is seen to be a similar cyst to those met with below. It would seem that there had been an occipital meningocele which had been shut off by subsequent development of the cranial plates. The whole length of the vertebral laminae has been exposed, but no other defect is demonstrated.

2372. A foetus of three months, with undeveloped brain and cranium, and with deficiency of the laminae of all the dorsal vertebrae. The frontal and parietal bones seem wanting, and there is a cranial meningocele, which during life was probably as large as the head itself; it has been incised, and the small size of the empty brain-case can be seen; the walls are thin, and it does not now appear to have contained brain-matter. In the dorsal region the spinal meninges are exposed, and nerves are visible.

On the front of the specimen there is a deficiency in the abdominal wall near the umbilicus, and prolapse of the liver and small intestines into an enlarged and thickened peritoneal sac.

The limbs are well formed; the right foot presents a talipes calcaneus.

### **Encephalocele.**

2373. The head of a child with a large occipital encephalocele. The tumour is as large as the child's head, and probably contained cerebellum and a large part of the cerebrum. The sac is now apparently empty, but a small quantity of degenerated brain-matter still lines the inner surface of the cyst-wall. The opening into the cranium is circular, an inch in diameter, has smooth rounded edges, and is placed over the vertical part of the occipital bone.

2374. Part of the brain and calvaria from another case similar to the above. The specimen is one of an occipital encephalocele with hydrocephalus. The tumour at the back of the neck was as large as a small fist, and the child's head was twice its natural size. The encephalocele has passed through a large opening just above the foramen magnum. The tumour consisted chiefly of a meningeal cyst with portions of cerebellum adherent to it. The cortical substance of the cerebellum appears to be expanded in the cyst till so thinned out as not to be recognized in many parts. The lateral ventricles were distended with fluid, and were lined throughout by a tolerably strong membrane of uniform thickness, smooth and glistening. This membrane adhered but loosely to the soft cerebral structure, and in the specimen it has been extensively detached; it lined the third ventricle and covered the commissures, appearing to



be everywhere continuous, and it is everywhere of exactly the same appearance. The parts preserved consist of the posterior lobes of the brain cut vertically, the occipital bone, and the encephalocele, together with the cerebellum, medulla, &c.

Mr. Hutchinson.

2375. The body of a female foetus, with an occipital encephalocele as large as a melon. The outer surface of the cyst is smooth, and is apparently composed of greatly expanded and thinned skin, the healthy skin of the scalp shading off gradually. A portion of the cyst-wall has been excised; its inner surface is also smooth over the greater part of its extent, but attached to it here and there, and especially near its attachments to the occipital bone, are strands of yellowish brain-matter. In the centre is a large, irregular, ragged membranous mass of meninges and brain-matter, which probably encloses a diverticulum from the lateral ventricles.

**Fissure of the spinal column—Spina bifida.**

2376. The lower half of a full-grown foetus, showing a spina bifida, which is globular in shape, as large as an orange, and placed over the lowest part of the lumbar region. The tumour is pedunculated, the skin over it is deficient, and the membranes so thin as to be nearly transparent; the surface is marked by whitish lines which correspond with the attachment of nerve-bundles within. From each side an oval piece of the cyst-wall has been cut to expose the nerve-bundles passing backwards to be attached to the cyst-wall; the nerves vary in size, and are surrounded by the smooth meningeal membranes, which are much dilated to form the sac of the meningo-myelocele. The opening into the spinal canal, through which the nerves issue, is circular and a quarter of an inch in diameter.

*Presented by Dr. Ramsbotham.*

2377. A spina bifida, as large as an egg, in the lowest part of the lumbar region. The cyst is opened and the nerve-trunks are adherent to the distended meninges. The bodies of the lumbar and sacral vertebræ have been cut away to expose the spinal canal, but nothing beyond thickened meninges can be seen.
2378. The sacrum, pelvis, and the last three lumbar vertebræ of a foetus of about eight months. At the back of the specimen it is seen that the posterior neural arches of the last two lumbar and sacral vertebræ are incomplete.
2379. Spina bifida from an infant. The arches of the sacral and lower



lumbar vertebræ are absent, the lower end of the spinal cord lying in a large cyst formed by expansion of its sheath. A bent piece of glass rod has been introduced into the part of this cyst on the left of the cord. Outside this cyst on this side (left) is a second cyst apparently formed in the dura mater, or between it and its arachnoid lining. A thin membrane separates the two cysts, between which there seemed to be no communication. A third cystic space is seen between the lower end of these two cysts and the vertebræ. This has a smooth lining-membrane, and ends in a cul-de-sac above. It is held open by a piece of bent glass rod attached to the bodies of the vertebræ.

Case of Robert Carson. Autopsy, April 25, 1884.

*Presented by Mr. McCarthy.*

2380. The sacrum and last two lumbar vertebræ of a child the subject of spina bifida. The laminae of the fourth lumbar vertebra are normal, but those of the succeeding vertebræ are undeveloped. Over the back of the sacrum is a large globular sac the size of an orange, covered with skin. It has been laid open and shows a large cavity with smooth lining intersected by nervous cords of various sizes, which pass directly backwards from the opening of the spina bifida to the middle of the inner wall of the sac; glass rods have been placed under these cords.

2381. The last two lumbar vertebræ and sacrum. The fourth lumbar vertebra is complete, but the posterior neural arches of the last lumbar and of the sacrum have incompletely coalesced.

2382. The sacrum and last three lumbar vertebræ of a fœtus with a small spina bifida the size of a walnut attached to them. The laminae of the lumbar vertebræ have been removed to expose the thickened dura mater and the enclosed cauda equina. The laminae of the sacrum are congenitally deficient, hence the spina bifida. The sac is covered with skin; it has been laid open, and the nerves are seen passing to the back of the sac. The central canal of the cord is dilated and has been opened up. The space at the lower part of the sac and around the nerves is the dilated arachnoid cavity.

MALFORMATIONS RESULTING FROM THE COALESCENCE OF PARTS WHICH  
SHOULD REMAIN DISTINCT.

**Cyclops.**

2383. A one-eyed puppy.



2384. The skull of a cyclops monster. The following points appear probable:—That the ethmoid bone is wanting, its position being occupied by membrane; upon this membrane there rests a mass of cerebral substance about quarter of an inch in thickness and as large as a shilling, which is all that represents the hemispheres; this mass is connected with the pons by a thin isthmus of cerebral structure, the whole resembling a broad-handled battledore in shape. The first and second nerves are wholly wanting; more or less slender filaments may be made out for the third, fourth, fifth, sixth, and seventh; the tentorium is to a large extent deficient; the cerebellum is small but of normal form, and six times as large as all the rest of the cerebral structures put together. The temporal bones are very small, the parietal and occipital large and expanded. The pons corresponds in size with the cerebellum; a canal, probably the iter, is seen opening into the arachnoid cavity; there is no trace of superior or inferior longitudinal sinus, nor of the falx; on each side a sort of falx passes up vertically from the base of the petrous bone up the middle of the parietals, and in this a sinus is present. There are no lateral sinuses.

The foetus was a fully developed female. The limbs and trunk were perfect. The head was large, the fontanelles large, and the bones loose. There was a single small palpebral fissure in the middle line presenting a slight vertical notch in the middle. The mouth, chin, &c. were perfect. The skull contained a large quantity of clear watery fluid apparently in the arachnoid sac and surrounded with several layers of delicate membrane.

*Presented by Mr. Taylor.*

#### MALFORMATIONS RESULTING FROM COALESCENCE OF TWO FŒTUSES OR FROM EXCESS IN NUMBER OF THE PARTS OF ONE FŒTUS.

##### **Double Fœtus.**

##### **One perfect; the other an appendage.**

2385. Monstrosity in a kitten, having the imperfect parts of another joined to its abdomen.

2386. Monstrosity in a kitten, having the hinder extremities of another attached to its abdomen, with some of the intestinal tube external.

2387. A chick, with the body and legs of another attached to its breast.

##### **Both more or less perfect.**

2388. Two foetuses with perfect heads and limbs, but with their thoracic and abdominal cavities in common. The right flank of the left



fœtus and the left flank of the right are absent. The two hearts, diaphragms, and livers are united. The lungs, spleens, and kidneys are separate. The intestines are united, but their exact relationship to each other cannot be ascertained.

2389. The specimen is thus described by Dr. Ramsbotham :—" A double fœtus at nine months, with the faces united ; a mouth and one eye on each side, Janus-like ; each has a proboscis above the eye in lieu of a nose. There is one neck, and all below is double. One appears to have a spina bifida, and to be very deficient in the lower part of the spine." There is a deficiency of the abdominal wall, and the liver is seen hanging down amongst the legs.

2390. " Monstrosity in a chicken, single in its head, double from its neck."

2391. " Monstrosity in a kitten, single in its head and fore parts, double from the thorax downwards."

2392. Two kittens, with distinct upper and lower extremities, a single head, and thoraces coalesced.

2393. A monstrosity in which two bodies are joined from the thoraces upwards, and have a single head with a single face. All the limbs appear to be perfect. Over the back of each side of the head are large pendulous folds of skin, as in No. 2371 ; a section of the fold on the right side has been made, and demonstrates an enclosed multilocular cyst similar in character.

2394. Two fœtuses of apparently full time, with heads, shoulders, and upper extremities well and perfectly developed. They have coalesced by the apposition of their anterior surfaces at the lower part of the chest. Below this point there is only one trunk, which is complete, having one pair of well-developed legs (right and left) and normal male genital organs. At the back of this trunk, over the lumbar region, are two small tags of integument which may be the undeveloped limbs of the opposite fœtus.

2395. Monstrosity in a kitten. The body is single, but two heads are joined in one ; there are two mouths and faces, two single eyes laterally placed, and one in the centre consisting of two globes conjoined.

2396. A double-faced three-eyed chick.



**Supernumerary thumb-nail.**

2397. The hand of an infant, the thumb of which is flattened and has a double nail.

## MALFORMATION RESULTING FROM DISPROPORTIONATE GROWTH OF PARTS.

**Enlarged Clitoris.**

2398. The lower parts of a female foetus about the fifth month, with an enlarged clitoris. Below the clitoris is the vagina with a glass rod in it.
2399. The pelvis and lower part of the trunk of a female infant with an enlarged clitoris.

The child was born in Brownlow Street Infirmary, and the old Catalogue says "that having the appearance of a penis the matron was induced to have it christened for a boy, but that after death it was dissected and the perfect female generative organs were found."

CONGENITAL DISPLACEMENT AND UNUSUAL POSITION OF PARTS OF THE  
FŒTUS.**Hernia of the Intestines.****Through the diaphragm.**

2400. A foetus with perfect head, limbs, and genital organs. The abdominal and thoracic cavities have been laid open, exposing the liver, which is of large size and lies in the centre of the abdomen, with a knuckle of small intestine to its left side. In the thoracic cavity on the left side are other coils of intestine which have passed through a congenital aperture in the diaphragm, situated close to the left crus. The diaphragm is complete in front, and a bent glass rod has been passed through the foramen. The lungs cannot be seen, being concealed by the coils of intestine. The heart is placed on the right side.

## CONGENITAL DISTORTIONS.

**Of the Spine.**

2401. The trunk of an infant with the viscera removed to show the lateral curvature existing. The curve in the bodies of the vertebrae is convex to the left, and is much greater than would appear from



examination of the back; the left ribs are carried bodily backwards, their angle is rendered more acute, the anterior part of the rib is flattened, and is nearly in apposition with the vertebral bodies. In consequence of the rotation of the vertebræ and the ribs being carried backwards, the scapula of that side projects and the shoulder is elevated. On the opposite side the shoulder is depressed and the ribs are flattened out, so that the angle is, to a certain extent, lost. There is no compensatory lumbar curve.

#### **Of the Limbs.**

2402. A hydrocephalic fœtus showing talipes calcaneo-cavo-varus in both feet.

2403. The leg of a full-timed fœtus showing talipes equino-varus.



SERIES LII.—PELVIC DEFORMITIES.

- Flat pelvis : 2404.  
 Rachitic pelvis : 2405, 2406.  
 Scolio-rachitic pelvis : 2407.  
 Osteo-malacic pelvis : 2408-2416.  
 Oblique pelvis of Nægele : 2417.  
 Kyphotic pelvis : 254.  
 Transversely contracted pelvis of Robert : 2418.  
 Spondylolisthetic pelvis : 2419.  
 Oblique ovate pelvis : 2420.  
 Pelvis deformed from dislocation : 2421.  
       "              "          fracture : 2422.  
       "              "          syphilis : 2423.
- 

**Flat pelvis.**

2404. A flat pelvis without evidence of rickets; the sacrum is sunk downwards between the ossa innominata, thereby diminishing the antero-posterior (conjugate) and relatively lengthening the transverse diameter of the pelvic brim.

It has the following dimensions:—At the inlet: conjugate 3 in., transverse  $5\frac{3}{4}$  in., left oblique  $4\frac{1}{2}$  in., right oblique  $4\frac{3}{4}$  in. At the outlet: antero-posterior diameter  $4\frac{3}{8}$  in., transverse  $4\frac{3}{4}$  in. Intercristal diameter  $9\frac{1}{2}$  in., interspinous  $8\frac{3}{4}$  in., posterior interspinous  $3\frac{1}{4}$  in.

**Rachitis.**

2405. A flat rachitic pelvis showing slight deformity. The conjugate diameter is lessened, the sacrum more concave, the arches of the pubes everted, the subpubic angle increased, the alæ of the ilium are expanded, the distance between the two anterior superior spines is increased relatively to that between the two posterior, which is diminished.

It has the following dimensions:—At the inlet: conjugate  $2\frac{5}{8}$  in., transverse 5 in., left oblique 4 in., right oblique  $4\frac{1}{8}$  in. At the outlet: antero-posterior diameter  $4\frac{1}{8}$  in., transverse  $4\frac{3}{4}$  in. Intercristal diameter  $9\frac{3}{4}$  in., interspinous  $9\frac{1}{4}$  in., posterior interspinous  $2\frac{1}{2}$  in.

2406. A plaster cast of a pelvis, showing deformity from rickets in an extreme degree. The pelvis is shallow, the brim contracted, the



outlet widened by separation of the tuber ischii and everted pubic arches; the iliac bones are flattened and approaching horizontal; the anterior superior spines more widely separated than any other part of the crest; the sacral promontory projects; the vertical concavity of the sacrum is increased, the transverse concavity is lost.

It has the following dimensions:—At the inlet: conjugate  $1\frac{1}{8}$  in., transverse  $5\frac{3}{4}$  in. Intercrestal  $9\frac{5}{8}$  in., posterior interspinous  $2\frac{1}{8}$  in. At the outlet: transverse  $5\frac{1}{4}$  in., antero-posterior  $2\frac{7}{8}$  in.

### **Scolio-rachitis.**

2407. A plaster cast of a scolio-rachitic pelvis; it is remarkable in the straightness of the sacrum. The lateral curvature is convex (to the left) in the lumbar region; the sacral promontory is tilted towards the convexity of the curve; the acetabulum on the same (left) side is pushed upwards, inwards, and backwards, owing to the increased pressure upon the left leg. The left lateral mass of the sacrum is narrowed; the left iliac crest is on a higher level than the right; the distance from the promontory of the sacrum to the acetabulum is lessened on the left side.

### **Osteomalacia.**

2408. A pelvis extremely deformed by osteomalacia. The sacrum is displaced downwards, its lateral masses being narrow and its tip and promontory are approximated, thus increasing the vertical concavity. The alæ of the iliac bones are more vertical than normal; the crests are more curved; the anterior superior spines are approximated; the iliac fossæ are deep. The tuber ischii and acetabula are approximated by the inward pressure of the heads of the femora. The horizontal rami of the pubes are parallel with each other, being pushed forwards so as to form a beak (rostrate), and the subpubic arch is partially obliterated. The pelvic brim is Y-shaped.

2409. A pelvis presenting similar deformity.

2410. A plaster cast of a similar pelvis.

2411. A similar specimen.

2412. }  
2413. } Two casts of the same pelvis deformed by osteomalacia.

2414. }  
2415. }  
2416. } Three casts of the same pelvis similarly deformed.



### Nægele's pelvis.

2417. A papier-mâché model of an oblique pelvis of Nægele. There is sacro-iliac ankylosis on the right side, with defective development of the lateral half of the sacrum and os innominatum on that side; the sacrum is turned towards the diseased side; the sound half of the pelvis is changed in shape, being more circular; the true conjugate diameter is increased, the transverse is shortened more and more as the floor of the pelvis is reached. The distances between the promontory of the sacrum and the acetabulum and between the tip of the sacrum and tip of the ischial spine are greater on the sound than on the diseased side.

It has the following dimensions:—At the inlet: conjugate 4 in., transverse  $4\frac{1}{4}$  in., left oblique  $3\frac{3}{8}$  in., right oblique  $4\frac{3}{4}$  in., right sacro-cotyloid  $1\frac{3}{4}$  in., left sacro-cotyloid  $3\frac{3}{4}$  in.

### Kyphotic pelvis.

See No. 254.

The sacrum is rotated about a transverse axis, so that the base is carried upwards and backwards, elongating the antero-posterior diameter at the brim and shortening that at the outlet, the apex being advanced forwards. The tubera ischii are slightly approximated, the ossa innominata being slightly rotated about an antero-posterior axis, so as to throw outwards the iliac fossæ and approximate the tubera ischii.

It has the following dimensions:—Antero-posterior diameter, at the inlet  $5\frac{1}{4}$  in., at the outlet  $3\frac{3}{4}$  in.; the transverse at the inlet  $4\frac{7}{8}$  in., at the outlet 4 in. At the inlet: left oblique  $4\frac{3}{4}$  in., right oblique  $4\frac{3}{4}$  in., right sacro-cotyloid  $4\frac{1}{4}$  in., left sacro-cotyloid  $4\frac{1}{4}$  in. Interspinous  $8\frac{1}{2}$  in., intercrystal  $9\frac{1}{4}$  in.

### Robert's pelvis.

2418. A papier-mâché model of a transversely contracted pelvis of Robert. There has been bilateral sacro-iliac ankylosis and deficient development of the sacral lateral masses. The sacrum is pressed in between the iliac bones, which are approximated; the transverse diameters of the brim, cavity, and pelvic outlet become shorter and shorter; the posterior superior spines are approximated; the venters of the ilia are expanded.

It has the following dimensions:—At the inlet: antero-posterior  $3\frac{5}{8}$  in., transverse  $2\frac{3}{4}$  in. At the outlet: transverse  $2\frac{1}{4}$  in.

### Spondylolisthesis.

2419. A papier-mâché model of a pelvis with spondylo-listhesis. The



lumbar spine is extremely convex forwards and has been partially dislocated forwards from the sacrum, thus the available conjugate diameter is reduced to  $3\frac{1}{4}$  inches. The weight upon the anterior part of the sacrum tends to tilt the sacrum backwards and to diminish the antero-posterior diameter of the outlet; all the transverse diameters are diminished.

Its measurements are as follows:—At the inlet: transverse  $4\frac{7}{8}$  in., right sacro-cotyloid  $2\frac{1}{2}$  in., left sacro-cotyloid  $2\frac{1}{2}$  in. At the outlet: antero-posterior 4 in., transverse  $3\frac{5}{8}$  in.

### **Oblique ovate pelvis.**

2420. A pelvis with old disease of the head of the femur and acetabulum on the right side, and deficient development of the right os innominatum. There is also some new bone connecting the last lumbar vertebra and the sacrum on the left side.

The following are the dimensions:—At the inlet: conjugate  $3\frac{1}{4}$  in., transverse  $5\frac{1}{4}$  in., right oblique  $4\frac{1}{8}$  in., left oblique  $4\frac{1}{2}$  in., right sacro-cotyloid  $3\frac{1}{4}$  in., left sacro-cotyloid  $2\frac{3}{8}$  in. Of the right os innominatum, the vertical height is  $7\frac{1}{4}$  in., of the left 9 in.; the distance from the anterior to the posterior iliac spines on the right side is  $5\frac{1}{4}$  in., on the left side  $6\frac{1}{4}$  in.; the distance from the pectineal eminence to the tuber ischii on the right side is  $3\frac{1}{4}$  in., on the left  $4\frac{1}{2}$  in.; the interspinous diameter measures  $8\frac{1}{4}$  in.

### **Pelvis with congenital dislocation of femora.**

2421. A papier-mâché model of a pelvis deformed owing to congenital dislocation of both femora. The wideness of the pubic arch, the eversion of the tubera ischii, and the steepness of the iliac fossæ are characteristic.

The dimensions are as follows:—At the brim: conjugate  $4\frac{1}{8}$  in., transverse  $5\frac{7}{8}$  in., right oblique  $5\frac{1}{8}$  in., left oblique  $5\frac{1}{8}$  in. Intercristal diameter  $10\frac{1}{4}$  in., interspinous  $9\frac{1}{8}$  in. At the outlet: antero-posterior diameter  $4\frac{1}{2}$  in., transverse  $6\frac{1}{4}$  in.

### **Deformity from fracture.**

2422. A pelvis showing on the right side a vertical fracture of the body of the pubes, and of the ascending ramus of the ischium. Both fractures have united, but the upper one in a deformed position, the inner end of the ramus of the pubis projecting backward for nearly an inch, and producing a narrowing of the right half of the pelvic brim and cavity in consequence.



**Congenital syphilis.**

2423. A pelvis about the age of puberty. The bones are everywhere thick and spongy. The greatest change is observed in the left innominate bone, where the floor of the acetabulum has been destroyed over an area of more than an inch square; its margins are wanting at some parts and tuberculated at others; its walls are roughened and penetrated by several cloacæ. The iliac bone is an inch in thickness near the centre of the iliac fossa, both surfaces being riddled with foramina of various sizes. The secondary epiphysial cartilages are still evident, on the crest, tuber ischii, symphysis, and near the right ileo-pectineal eminence. There has been suppurative arthritis of the right hip and of the left sacro-iliac synchondrosis. The pelvic brim, cavity, and outlet are transversely contracted; the ischial spines are approximated, the coccyx turned forwards and ankylosed. The pelvis resembles the transversely contracted pelvis of Robert.



## SERIES LIII.—PLASTER CASTS.

### Diseases of Fasciæ, Tendons, and Bursæ.

Dupuytren's contraction of the palmar fascia: 1-7.

Contraction of Tendons: 8.

Talipes: 9-52.

Equinus: 9-11.

Equino-varus: 12-16.

Equino-cavo-varus: 17-34.

Equino-valgus: 35.

Valgus: 36-39.

Calcaneus: 40, 41.

Calcaneo-valgus: 42-47.

Calcaneo-cavus: 48-51.

Calcaneo-cavo-valgus: 52.

Enlarged Bursa: 53.

### Diseases of Bones: 54-80.

Chronic Rheumatic Arthritis: 54-58.

Rickets: 59-75.

Enlarged Epiphyses: 59.

Curvatures: 60-70.

Genu valgum: 71-75.

Morbid Growths: 76-80.

### Injuries of Bones: 81-98.

Fractures of the Skull: 81, 81 *a*.

" " Clavicle: 82.

" " Humerus: 83-86.

" " Radius: 87-94.

" " Ulna: 95.

" " Fibula: 96-98.

Deformity from contraction of cicatrices: 99-105.

### Injuries of Joints: 106-124.

Dislocation of the Clavicle: 106-108.

" " Humerus: 109-111.

" " Radius and Ulna: 112-115.

" " Femur: 116, 117.

" " Patella: 118-120.

" " Tibia and Fibula: 121.

" " Foot: 122-124.

Amputation Stumps: 125-132.

Diseases of Joints: 133-137.



**Malformations:** 138-146.

**Miscellaneous:** 147-158.

**Deformity from Empyema:** 159-162.

**Lateral Curvature:** 163-169.

**Utero-gestation:** 170-174.

**Intestinal Obstruction:** 175.

---

### DISEASES OF FASCIAE, TENDONS, AND BURSÆ.

#### **Dupuytren's contraction of the palmar fascia.**

1. A hand, the three inner fingers of which are a little flexed; in the centre of the palm there is very slight thickening along the line of the sheaths of the flexor tendons.
2. A similar case, with more marked contraction in the palm and slight flexion of the little finger only.
3. A specimen showing similar disease, in which all four fingers are flexed.
4. A similar specimen. The ridges caused by contraction of the palmar fascia are more marked; the middle finger is especially affected, and is flexed at the metacarpo-phalangeal joint.
5. A similar specimen.
6. Another specimen, with more flexion of the same fingers, the little finger being the one most flexed.
7. A hand with the ring and little finger completely flexed upon the palm, in which evidence of contraction of the palmar fascia is seen.

#### **Contraction of Tendons.**

8. A hand with the three inner fingers evenly flexed, and without ridges on the palm. The contraction most probably has resulted from tenosynovitis and adherence of the tendons to their sheaths, whilst the fingers were flexed.



**Talipes.****Equinus.**

9. The right foot of a child. The heel is slightly drawn up and the toes pointed, the angle made by the dorsum of the foot with the front of the tibia is more obtuse than normal. The tendo Achillis is contracted and makes prominent the skin over it.
10. A similar specimen from an older subject. The dorsum of the foot and the anterior surface of the leg are in a straight line. The heel is very much drawn up, and the toes are extended. The person evidently walked only upon his toes.
11. Another specimen presenting similar signs. The muscles of the calf are extremely wasted.

**Equino-varus.**

12. A right foot, the heel of which is but slightly drawn up by a contracted tendo Achillis. The inner border of the sole of the foot near the position of the internal cuneiform bone is pulled slightly upwards, probably by contraction of the tibialis anticus muscle. The heads of the metatarsal bones would rest flat upon the ground, the foot as a whole not being inverted.
13. A similar specimen, but with more marked notching of the inner border of the foot, which is somewhat drawn up so that the ball of the great toe would not rest upon the ground when the tibia was perpendicular. It will be noticed that the inner border of the foot is shortened and the outer rendered more convex; the whole of the metatarsus being pulled inwards and turned slightly upwards.
14. The left foot of the same person. It shows on the dorsum the prominence of the astragalus, which is squeezed outwards and forwards in this deformity.
15. A similar specimen, but with somewhat more equinus.
16. The left leg and foot of an infant, showing a similar deformity; in this specimen the inversion of the foot is greater than in those preceding.

**Equino-cavo-varus.**

17. A plaster cast of the right foot, showing extreme contraction of the tendo Achillis, with consequent drawing up of the heel and extension of the ankle-joint. The inner border of the foot is drawn up, but in addition the hollow of the sole is deepened and its length is diminished by contraction of the plantar fascia (cavus).



18. A cast of the right foot of a child, showing similar deformity. The foot is bodily inverted so that the sole looks inwards, and the outer border would rest upon the ground.
19. A similar specimen, with more shortening of the inner border of the foot.
20. A similar specimen.
21. A similar specimen. The sole is shown and is seen to be very concave, and the os calcis is much drawn up.
22. A plaster cast of the foot of an adult, showing similar but more marked deformity. The inner border of the foot is deeply concave and is turned upwards, the sole looking inwards; over the cuboid, which becomes the lowest bone in the tarsus and rests therefore upon the ground, there is a large oval pad of hypertrophied skin and subcutaneous tissue upon which the person walked. Similarly pads are seen in many of the subsequent specimens.
23. A cast of the right foot from the same case. It shows the dorsal surface of the foot and the prominent astragalus and cuboid.
24. A cast of a left foot showing still greater deformity.
25. A cast of a child's right foot similarly deformed.
26. A cast of a thigh, leg, and foot of a child where the inversion of the foot is complete.
27. Plaster casts of the feet of an adult, showing extreme talipes equino-cavo-varus and of long standing, as evidenced by the large size, density, and flattening upon the surface of the pad covering the region of the cuboid bone. The inner border of the foot, which is dislocated from the astragalus, forms an angle less than a right angle with the inner border of the shaft of the tibia.
28. A cast of an adult left foot and leg similarly deformed. The prominence of the astragalus on the dorsum of the foot is well seen.
- 29, 30. Plaster casts of the same feet as No. 27, four years after the operation of tenotomy had been performed upon them. The sole now rests flat upon the ground, and the inner border of the foot is normal in length and appearance.



31. A plaster cast of the right foot of an adult, showing talipes equino-cavo-varus. There is no history attached to this cast, but it seems to have been one taken of a foot which was in process of cure.
32. A plaster cast of the left foot showing extreme varus; the great toe is so pulled backwards and upwards by the flexors and tibialis anticus muscles that its tip looks upwards.
33. Plaster casts of the feet of an infant, showing still more deformity.
34. A cast of an infant's leg where the foot is so inverted that the sole looks almost directly upwards. There is little equinus or cavus in this case.

#### **Equino-valgus.**

35. A plaster cast of the left leg of an infant, showing equino-valgus. The heel is drawn up, the toes are pointed, and the foot is everted. There is also a rickety bend in the tibia. There are only four toes on the foot.

#### **Valgus.**

36. A plaster cast of the right foot of a child at or soon after birth, showing congenital talipes valgus. The inner border of the foot is lengthened and is rounded, the outer border is drawn upwards, the whole foot being somewhat everted.
37. A plaster cast of a right adult foot, showing acquired valgus. The sole is flattened, the plantar arch is obliterated by the descent of the astragalus, which is seen projecting below the internal condyle of the tibia.
38. A cast of a right foot showing similar but more marked deformity.
39. A similar cast with still greater deformity. The inner border of the foot is convex; the astragalus is very prominent, is placed at the centre of the convexity of the curve, and evidently rested upon the ground in walking.

#### **Calcaneus.**

40. A plaster cast of the right foot of a child soon after birth, showing talipes calcaneus in a mild degree. The heel points downwards, and the anterior part of the foot is drawn upwards by the extensor muscles.



41. A plaster cast of the right foot of a subject about 12 years of age, showing similar but increased deformity.

**Calcaneo-valgus.**

42. Plaster casts of the feet of an infant. The heel is drawn down, the anterior part of the foot is drawn upwards; the outer border of the foot is drawn upwards and the foot everted by the peronei; the inner border of the foot is convex.
43. A plaster cast of the left foot of a young subject, showing pointing of the heel and slight eversion of the foot as a whole.
44. A similar specimen.
45. A similar cast, showing slightly increased eversion.
46. A similar specimen.
47. A cast of the right foot of a child showing extreme deformity from calcaneo-valgus; the eversion of the foot is so great that the sole looks almost directly outwards; the astragalus projects on the inner side, just below the malleolus. The dropping of the os calcis is slight.

**Calcaneo-cavus.**

48. A plaster cast of the right foot of an adult; it shows an os calcis vertically placed, with obliteration of the depression above the heel and an increase of the plantar arch. The sole of the foot is crossed in an antero-posterior direction by a prominent ridge which marks the contracted bundles of the palmar fascia.
49. A similar cast showing increased deformity.
50. A similar cast showing a still greater degree of deformity. In this specimen the outermost band of plantar fascia covering the muscles of the little toe is much contracted, and consequently the outer border of the foot is shortened; the outer toes are considerably approximated to the heel, and the outer part of the sole of the foot presents a deep hollow.
51. A plaster cast of a right foot, showing extreme deformity from talipes calcaneo-cavus. The os calcis is so drawn down and rotated forwards that the heel is anterior to the external and internal malleoli.



**Calcaneo-cavo-valgus.**

52. A plaster cast of a right foot of a young adult, showing the os calcis pointing downwards, an increase in the plantar arch, and eversion of the anterior half of the foot.

**Enlarged Bursa.**

53. A plaster cast of the parts forming the right knee-joint, showing a large, smooth, globular tumour four inches in diameter placed over the front of the patella,—an enlarged bursa.

**DISEASES OF BONES.****Chronic Rheumatic Arthritis.**

54. A plaster cast of the left hand of a woman showing enlargement of heads of the metacarpal bones and contraction of the fingers.
55. A similar specimen.
56. A similar specimen ; the ring-finger has been amputated.
57. A plaster cast of a right hand showing extreme enlargement of the heads of the metacarpal bones and of all the phalanges.
58. A specimen showing similar enlargement of the joints with partial dislocation of the fingers to the ulnar side of the hand.

**Rickets.****Enlarged Epiphyses.**

59. A plaster cast of the lower part of the right forearm and hand of a child, showing enlargement of the lower epiphyses of the radius and ulna.

**Curvatures.**

60. A plaster cast of the anterior surface of the thorax of an adult. There is flattening of the chest, with projection forwards of the lower end of the sternum, and a shallow lateral groove.
61. A similar specimen with still greater deformity ; the lateral groove is deeper, and there is marked constriction of the lower part of the thoracic cavity, corresponding to the line of attachment and due to the contraction of the diaphragm.
62. A similar specimen.



63. A plaster cast of the right leg and foot of a child about five years of age, showing a slight forward curve in the tibia and fibula at a point about an inch above the ankle-joint.
64. A similar cast with a still more pronounced forward and outward curve in the leg-bones.
65. A plaster cast of the right leg of a subject about 12 years of age, whose tibia and fibula are curved at a right angle at a point situated near the middle of the leg; the antero-posterior measurement of the leg at this point is  $3\frac{1}{2}$  inches, that through the knee being  $2\frac{1}{2}$  inches. The tibia at the point of flexion has a sharp rounded edge.
66. A plaster cast of the legs and lower part of the trunk of a youth, showing forward curvature of the femur and tibia in each leg. The curvature in the right femur is extreme, and the leg appears to be shorter than the left, but this is only apparent, being in reality due to the tilting of the pelvis. The right anterior superior spine is on a higher level than the left. Most probably there was some lateral curvature of the spine. The legs are of nearly equal length, the greater curvature of the right femur being compensated by the diminished curve in the right tibia as compared with the corresponding bones in the left leg.
67. A similar specimen, but with still more marked curvature in the femora and tibiæ; in this specimen also the right side of the pelvis is elevated.
68. A plaster cast of the right leg of a youth, showing a rickety curve in the tibia; at the centre of the curve the bone is broken, and its point projects through the skin; an ineffectual attempt has probably been made after osteotomy to straighten the leg.
69. A plaster cast of the left leg of a child with marked curvature of the tibia and fibula.
70. A cast of the same leg after osteotomy by Mr. McCarthy.

#### **Genu valgum.**

71. A plaster cast of the lower part of the right thigh, knee, and upper part of the leg of a youth, showing an extreme degree of genu valgum, with overgrowth and projection inwards of the internal condyle of the femur. There is also a rickety forward curve in the tibia.



72. A similar specimen.
73. A plaster cast of the lower extremities, showing well-marked genu valgum ; the knees being together, the ankles are separated by a distance of 8 inches. The right femur is curved.
74. A plaster cast of the legs of a young child, showing similar but slight deformity. There is a curve in the left tibia with some acquired talipes valgus of the left foot.
75. A plaster cast of the leg of a young adult, showing genu valgum ; the ridge formed by the contracted biceps tendon is apparent.

### Morbid Growths.

76. A plaster cast of the right hand of an adult, showing a nodular growth the size of the fist with smooth surface, involving the ring and little fingers and the corresponding metacarpal bones. All trace of the little finger is lost ; the ring-finger is displaced backwards as a whole, and rotated so that its dorsal surface rests against the ulnar surface of the middle finger.
77. A plaster cast of the right tibia, showing a large globular new growth the size of a large melon, springing from the posterior surface of the shaft of the tibia. The tibial shaft itself is hypertrophied. The growth most probably is a periosteal sarcoma.
78. A plaster cast of the left half of a young adult head, with a prominent globular swelling over the malar bone.
79. A plaster cast of a right axilla, with a large irregular fungating mass of new growth, probably melano-sarcoma of the axillary glands.
80. A plaster cast of the left lower extremity and part of the trunk of an adult ; the upper part of the thigh is enormously enlarged, probably by a periosteal sarcoma. The thigh at the part enlarged is  $11\frac{1}{2}$  inches in diameter and 13 inches in length. On the anterior surface the tumour has perforated the skin in two places ; the foot is swollen from œdema.



## INJURIES OF BONES.

**Fractures.****Skull.**

81. A plaster cast of the neck and occipital region of an adult cranium, exhibiting a depressed fracture at the apex of the vertical plate of the occipital bone.
- 81 a. A plaster cast of the head of a man with a depressed parietal bone, probably the result of fracture.

**Clavicle.**

82. A plaster cast of the left shoulder and arm of an adult ; it shows a fracture of the clavicle at the junction of the inner two thirds and outer third, with elevation of the inner fragment and depression of the shoulder and outer fragment. There is a conical stump to the arm.

**Humerus.**

83. A plaster cast of the right shoulder of a youth, showing a rounded projection over the region of the great tuberosity of the humerus ; it is most probably a separated epiphysis.
84. A plaster cast of the right elbow of a child. There has most probably been either a T-shaped fracture into the elbow-joint or a separation of the lower humeral epiphysis. There is distinct projection above the olecranon caused by the displacement of the lower fragment backwards, and the condyles seem somewhat too widely separated.
85. A plaster cast of the left elbow of a child, showing two projections over the internal condyle, with some swelling of the parts adjacent. There was probably a separation of the epiphysis for the internal condyle.
86. A plaster cast of a left adult elbow ; there has probably been an oblique fracture of the lower end of the humerus, with backward and inward displacement of both bones of the forearm ; the projecting knob is probably the head of the radius, with the capitellum displaced backwards.

**Radius.**

87. A plaster cast of the right forearm and hand of a woman, showing outward rotation of the hand, a depression on the radial side of the



forearm about two inches above the wrist, a well-marked projection of the styloid process of the ulna, and increase in the antero-posterior thickness of the lower end of the radius.

88. A similar specimen, with a distinct projection over the back of the lower end of the radius.

89. A similar specimen, but with an extreme depression over the seat of fracture.

90. A specimen showing a similar depression, but without external rotation of the hand; there is displacement backward of the lower end of the radius, with consequent dorsal prominence and palmar hollow.

91. }  
92. } Plaster casts showing slight degrees of similar deformity.  
93. }  
94. }

#### **Ulna.**

95. A plaster cast of the pronated right hand of a child, showing extreme prominence of the lower end of the ulna; there has probably been a separation of the epiphysis.

#### **Pott's Fracture.**

96. A plaster cast of the right foot of an adult, showing prominence of internal malleolus and slight displacement of the foot outwards.

97. A similar plaster cast, showing extreme prominence of the internal malleolus, and much outward displacement of the foot.

98. A plaster cast of an adult right foot, probably taken some little time after the injury was received; it shows much swelling around the ankle, especially on the outer side. There has probably been a fracture of the fibula; there is no displacement of the foot; the internal condyle is obscured by swelling.

#### **DEFORMITY FROM CONTRACTION OF CICATRICES.**

99. A plaster cast of the left side of head, neck, and shoulder of a young subject, showing several narrow raised bands of cicatricial tissue passing vertically down the side of the neck, and causing the approximation of the head to the shoulder.



100. A plaster cast of the same parts from the same subject, taken some months after the bands had been divided by operation.
101. A plaster cast of a left arm, showing flexion of the elbow and wrist and fixation of the fingers with adhesion of their adjacent surfaces, by cicatricial tissue following burns.
102. A plaster cast of a right arm, presenting similar cicatrices. The elbow is somewhat flexed. The hand is dislocated backwards and to the ulnar side, the dorsum and ulnar side of the hand being securely united to the lower part of the extensor surface of the forearm. The thumb and forefinger are not much involved; the other fingers are almost completely buried in the cicatrix.
103. A plaster cast of the hand of a child, showing the thumb and fingers flexed and firmly fixed by dense cicatricial bands.
104. A plaster cast of the right lower extremity of a child. The knee-joint is firmly flexed; the tibia partially dislocated backward and rotated outwards. There are cicatrices over the lower third of the outer surface of the thigh and at many points on the leg. The foot is enlarged from œdema.
105. A plaster cast of the same leg taken some months after division of the band, by which the tibia was displaced. The leg is now straight, and the foot of normal size; there are still numerous small cicatrices scattered over the leg.

#### INJURIES OF JOINTS.

##### **Dislocation.**

##### **Clavicle.**

106. A plaster cast of the left clavicular region of an adult, showing a projection forwards and upwards of the sternal end of the clavicle.
107. A plaster cast of the left shoulder of an adult, showing a dislocation and consequent projection upwards of the acromial end of the clavicle. The acromion process with the arm is slightly displaced downwards and rotated forwards and inwards.
108. A similar specimen.



**Humerus.**

109. A plaster cast of the left shoulder of an adult. The head of the humerus is dislocated from the glenoid fossa and projects below the centre of the clavicle. The cephalic vein is engorged, probably owing to compression of it by the head of the humerus. The acromion process is very prominent and the deltoid flattened.
110. A plaster cast of similar parts, showing the deformity resulting from a subcoracoid dislocation of the shoulder-joint. The arm is abducted, the deltoid flattened, the acromion process prominent, the head projects anteriorly below the coracoid process; the shoulder-girdle is raised.
111. A plaster bust showing flattening of the left deltoid muscle with prominence of the acromion; probably the result of dislocation, a fulness being evident below the coracoid process.

**Radius and Ulna.**

112. A plaster cast of the left elbow of a young subject, showing dislocation of the radius and ulna backwards and outwards; the tip of the olecranon is far behind the internal condyle.
113. A plaster cast of similar parts, showing a dislocation of the head of the radius backwards.
114. A similar specimen.
115. A plaster cast of a child's arm hyper-extended. It shows the head of the radius dislocated forwards and forming a rounded projection on the anterior surface.

**Femur.**

116. A plaster cast of the right hip of an adult, showing flexion and adduction of the femur and a fulness in the gluteal region, probably due to the presence of the head of the femur on the dorsum ilii, the result of dislocation.
117. A plaster cast of the lower extremities of an adult, showing some adduction and extreme rotation inwards of the right thigh, probably due to a dislocation into the sciatic notch.

**Patella.**

118. A plaster cast of the front of the right knee, showing a patella dislocated so that it rests upon its inner edge; the outer edge forms a sharp projection beneath the skin.



119. A plaster cast showing similar deformity.
120. A plaster cast of a man's knee, showing lateral dislocation of the patella outwards. *Presented by Mr. Hutchinson.*

#### **Tibia and Fibula.**

121. A plaster cast of the lower half of the thigh and leg of an adult, showing partial dislocation of the tibia and fibula forwards. The patella is very prominent, the hamstrings and ilio-tibial band are stretched.

#### **Foot.**

122. A plaster cast of a right foot, showing a subastragaloid dislocation of the foot inwards; the external malleolus and astragalus form prominent projections.
123. A similar dislocation of a left foot.
124. A plaster cast showing a similar lesion but with less displacement.

#### **Amputation Stumps.**

125. A plaster cast of a conical stump of a right humerus.
126. A plaster cast of the left forearm of a child after amputation by equal flaps through the lower third of the forearm.
127. A plaster cast of the stump left after amputation at the wrist-joint.
128. A similar specimen; it shows a cicatrix over the middle of the end of the stump.
129. A plaster cast of a stump of a hand, the metacarpal bone of the thumb only remaining.
130. A plaster cast of a stump where the three inner fingers and the terminal phalanx of the thumb and index have been removed.
131. A plaster cast of the stump left after Syme's amputation.
132. A plaster cast of the stump left after Chopart's amputation; it shows the heel much drawn up by the unopposed tendo Achillis, and the consequent liability for the cicatrix to become the lowest part of the stump.



## DISEASES OF JOINTS.

133. A plaster cast of the bones of the right hip-joint, showing destruction of the margins of the acetabulum; the neck of the femur would appear to have been fractured.
134. A plaster cast of the thighs of a young adult. The right femur is flexed and adducted; over the great trochanter there is a large ulcerated surface.
135. A plaster cast of the right leg of a youth; the knee-joint is flexed at a right angle, and was evidently fixed. On the front of the joint is the mark of an old sinus.
136. A plaster cast of a left foot, showing distention of the ankle-joint with fluid; the hollow along each side of the tendo Achillis is obliterated.
137. A cast of a similar part with evidence of an old sinus.

## MALFORMATIONS.

**Rudimentary digits.**

138. A plaster cast of an infant's left hand with undeveloped terminal phalanges of thumb and fingers.
139. A plaster cast of an infant's right hand with all the phalanges rudimentary.
140. A plaster cast of an adult left hand, with a rudimentary little finger, webbed index, middle, and ring fingers, and a bifid webbed terminal phalanx to the thumb; there is one nail between the index and middle fingers.
141. A plaster cast of an infant's right hand, with rudimentary middle, ring, and little fingers.

**Webbed digits.**

142. The left hand of an infant, with ring and little fingers absent, the index and middle being webbed.
143. A plaster cast of the left foot of an infant, with the second and third toes hypertrophied and webbed.



**Absence of parts.**

144. A plaster cast of the right foot of a youth, with absence of the outer half of the foot and three outer toes. The great toe and second are webbed; the foot is everted so that the sole looks directly outwards; the person walked upon the inner side of the foot; the os calcis is drawn upwards.

**Supernumerary digit.**

145. A plaster cast of an infant's right foot, with a supernumerary great toe projecting from the inner side near the base of the first metatarsal bone.

**Genu retroversion.**

146. A plaster cast of the lower extremities of an infant, showing a hyper-extended left knee with valgus of the left foot.

## MISCELLANEOUS.

**Hydropericardium.**

147. A plaster cast of the front of a youth's chest, with great bulging of the thoracic wall in the præcordial region, probably due to hypertrophy and dilatation of the heart with excessive distention of the pericardium.

**Extroversion of the bladder.**

148. A plaster cast of the anterior surface of the lower abdomen of a young male subject, showing a congenital deficiency of the roof of the penis, pubes, and abdominal wall, with prolapse of the mucous membrane of the bladder through the opening; the scrotum is normal.

**Arterio-venous Aneurysm.**

149. A plaster cast of the left elbow of an adult, with a smooth, trilobulated swelling the size of an orange situated over the median basilic vein.

**Distended Stomach.**

150. A plaster cast of the epigastric region, showing a pyriform projection of the abdominal walls, probably due to a stomach distended owing to pyloric obstruction.

**Hemiatrophia facialis.**

151. A plaster cast of the face of a woman, with hemiatrophy of the right lower jaw and superjacent muscles.



**Hydrocephalus.**

152. A plaster cast of a hydrocephalic head, having the following measurements:—fronto-occipital  $11\frac{1}{2}$  inches, biparietal 10 inches, mento-occipital 12 inches, mento-parietal  $11\frac{1}{2}$  inches.

From James Cardinal, born at Coggeshall, Essex, died in 1822, aged 27.

**Microcephalus.**

153. A plaster cast of the head of an adult microcephalic idiot, with the following measurements:—fronto-occipital 6 inches, biparietal  $4\frac{1}{2}$  inches, mento-occipital  $7\frac{1}{2}$  inches, mento-parietal  $7\frac{3}{4}$  inches.

**Encephalocele.**

154. A plaster cast of the head of an infant, with a smooth, bilobate, globular tumour the size of an orange, projecting from the occipital region.

From an infant, who was born in 1845 with talipes calcaneus.  
Mr. Hutchinson.

**Cyclops.**

155. A plaster cast of the head of a child, with a single palpebral fissure, but without eyes or nose; the head is flattened from before back, and has the following measurements:—fronto-occipital  $4\frac{1}{4}$  inches, biparietal  $5\frac{1}{4}$  inches, mento-parietal  $6\frac{1}{2}$  inches.

**Aneurysm.**

156. A plaster bust, showing a very large, globular, indefinitely lobulated tumour occupying the supra and infra-clavicular and right pectoral regions; it measures 10 inches from side to side and  $8\frac{1}{4}$  inches from above down. The skin over it is intact. The tumour is probably an aneurysm of the arch of the aorta or innominate artery.

**Depressed Sternum.**

157. A plaster bust of an adult, showing a shoemaker's sternum, which is depressed to such an extent that the external antero-posterior diameter of the chest at the tip of the ensiform cartilage is only  $5\frac{1}{8}$  inches.

**Enlarged Spleen.**

158. A plaster cast of a wasted child's trunk, showing a large globular bulging of the abdominal integuments in the splenic region.

**Deformity from Empyema.**

159. A plaster cast of a child's trunk, showing flattening of the left half of the chest as compared with the right.



160. A plaster cast of similar parts, with distinct retraction of the left chest and depression of the shoulder.
161. A similar specimen with increased deformity.
162. A similar specimen, where the depression of the left shoulder is extreme, and there is curvature of the dorsal spine to the left.

**Lateral curvature of the Spine.**

163. A plaster cast of an adult trunk, with convexity of the dorsal spine to the right, rotation of the ribs backwards, prominence of their angles, and elevation of the right shoulder. There is very marked symmetrical atrophy of the scapular muscles.
164. A plaster cast of the back of a young adult, showing left lateral convexity of the dorsal spine.
165. A plaster cast of the trunk, showing slight lateral curvature to the right in the dorsal region.
166. A plaster cast showing similar but exaggerated curvature, rotation of the ribs, prominence of their angles, and elevation of the right shoulder.
167. A similar but more marked specimen.
168. A similar specimen, but with increased deformity ; when the tuber ischii rest upon the ground, the right shoulder points directly upwards, the arm being horizontal ; the left side is curved at a right angle.
169. A similar specimen, showing so great an amount of lateral curvature that the left scapula rests upon the innominate bone and outer surface of the left thigh ; with the neck vertical, the right side of the pelvis and loin is horizontal, and rests upon the floor.

**Female Pelvic Viscera.**

170. A plaster cast, showing the pelvic viscera and intestines of an unimpregnated female.

**Utero-gestation.**

171. A plaster cast of the abdominal contents of a female in the last months of pregnancy ; it shows the viscera pushed upwards by the enlarged uterus, which occupies the lower two thirds of the abdominal cavity.



172. A plaster cast of similar parts; the anterior uterine wall has been removed to show a full-timed fœtus *in situ*, with the vertex presenting in the first cranial position.
173. A plaster cast of similar parts, showing a fœtus at term with the breech presenting; the cord is coiled round the neck.
174. A plaster cast of similar parts; it shows the interior of a uterus at term immediately after the expulsion of the fœtus; the placenta is *in situ*.

#### **Intestinal Obstruction.**

175. A plaster cast of the abdominal contents of a youth. Three immensely distended coils of large intestine are alone seen; they measure  $4\frac{1}{4}$  and  $5\frac{1}{2}$  inches in diameter, and 13 inches in length; the sacculi and appendices epiploicæ are very distinct.



## SERIES LIV.—WAX MODELS, ETC.

### **Congenital disease or deformity.**

- Fœtal caries and curvature: 1.
- Fœtal rickets: 2.
- Hydrocephalus: 3-6.
- Anencephalous fœtus: 7.
- Parasitic fœtus: 8.
- Of the digits: 9-15.
- Of the skin: 16.
- Of the nails: 17, 18.
- Of the lip. Double hare-lip: 19, 20.
- Of the kidney. Cystic disease: 21.

**Calculus:** 22.

**Injury:** 23-26.

**Varices:** 27, 28.

### **Skin diseases.**

- Vaccinia: 29.
- Variola: 30-33.
- Scabies: 34.
- Eczema: 35-37.
- Xeroderma: 38.
- Uncertain: 39, 40.
- Syphilis: 41, 42.

**Contraction of cicatrices:** 43-47.

Keloid: 47.

### **Bone disease.**

Necrosis: 48-50.

**Joint disease:** 51, 52.

**Fungating Testis:** 53.

### **Morbid Growths.**

- Enchondroma: 54.
- Carcinoma: 55-58, 62, 63.
- Sarcoma: 59-61.

**Miscellaneous:** 64-67.

### **Congenital disease or deformity.**

#### **Fœtal caries and curvature.**

1. A skeleton at or soon after birth; the head is small, and the bones of the skull are thick and well ossified. The spinal column is extremely convex forwards and to the right in the lumbar and lower



part of the dorsal region; on the right side there is an aperture large enough to admit the tip of the little finger, leading into a cavity in the vertebræ, most probably produced by caries. The right side of the chest is contracted, the ribs lying close together; the two lowest ribs seem to have been destroyed; on the left side the chest is expanded and the ribs widely separated.

#### **Fœtal rickets.**

2. A fœtal skeleton, showing rickets; the ends of the ribs and of all the long bones are enlarged.

#### **Hydrocephalus.**

3. The skeleton of a rickety infant with hydrocephalus; the head is flat, the fontanelles wide, the forehead large and square, the facial bones small, and the ends of the bones are enlarged. The skull has the following measurements:—fronto-occipital  $5\frac{3}{4}$  inches, mento-occipital  $5\frac{3}{4}$ , mento-parietal 5, biparietal 6.
4. A hydrocephalic child's head; its measurements are as follows:—fronto-occipital  $6\frac{1}{2}$  inches, mento-occipital 7, mento-parietal  $5\frac{3}{4}$ , biparietal  $6\frac{1}{4}$ .
5. A similar specimen; it measures in the fronto-occipital diameter  $6\frac{1}{4}$  inches, and in the biparietal  $6\frac{3}{4}$ .
6. The upper part of the vertex of a hydrocephalic cranium, in which, at the autopsy, the brain was found collapsed and lying at the base of the skull, and surrounded by a large quantity of cerebro-spinal fluid occupying the subdural space.

Mr. McCarthy.

#### **Anencephalous fœtus.**

7. A wax model of an anencephalous fœtus, showing the head retracted, the frontal region undeveloped, and a large circular exposed surface over the parietal, occipital, and cervical regions; it is probably a wax cast of No. 2338.

#### **Parasitic fœtus.**

8. A model of a Chinaman, with a parasitic fœtus projecting in the sternal region. The mass appears to be attached by the neck, and to consist of well-formed arms, a trunk, and much enlarged buttocks with truncated thighs.



**Of the digits.**

9. A wax model of an adult left hand ; the thumb is bifid at the extremity, and the nail is double ; the index, middle, and ring fingers are webbed, the index and middle having one nail between them ; the little finger is truncated, the last two phalanges being absent.
10. A wax model of a left hand, showing tolerably symmetrical overgrowth of the thumb, next two digits, and radial side of the hand. The middle finger is bent laterally to the ulnar side.
11. A wax model of a right hand ; the index, middle, and ring fingers are hypertrophied. The middle is double the length of the little finger ; it measures 6 inches in length and  $1\frac{1}{3}$  in diameter.
12. A plaster cast of a hand with the radial side hypertrophied ; it shows enormous enlargement of the middle finger.
13. A wax model of a right hand, showing overgrowth of the ulnar side of the hand, with enlargement of the ring and little fingers.
14. A wax model of a foot, showing enormous overgrowth of the second and third toes and the corresponding part of the metatarsus and tarsus. These toes are webbed and project vertically upwards, and measure 3 inches in length and  $2\frac{1}{2}$  in diameter.
15. A wax model of a malformed club-shaped toe removed by operation.

**Of the skin.**

16. A wax model of the right arm of an adult ; along the radial half of the flexor surface are loose pendulous folds of skin and subcutaneous tissue, extending from a few inches above the elbow to the wrist.

**Onychogryphosis.**

17. A hypertrophied nail removed from a great toe.
18. A similar specimen.

**Double hare-lip.**

19. A wax model of the face of a young adult with double hare-lip. On the left side the cleft is complete, the left nostril being opened up ; on the right the cleft is incomplete. The premaxillary bone is large, and upon it are the two central incisors.
20. The face of an infant, showing a quadrilateral cleft in the centre of the upper lip, with a similar deficiency of the hard palate.



**Cystic Kidney.**

21. A wax model of a kidney wholly converted into cysts, which vary in size from a pin's head to a large grape. The whole organ measures  $7\frac{1}{2}$  inches by  $4\frac{1}{2}$ .

**Calculus.**

22. A plaster cast of a stone removed by Mr. Rivington by supra-pubic lithotomy, a hammer and chisel, in 1886.

**Injury.**

23. A wax model of the skull of an infant, showing a circular saucer-like depression two inches in diameter and half an inch deep, situated over the posterior part of the right parietal bone; it is probably a depressed fracture of the skull.
24. Two wax models, the lower one showing the joint surface of a patella partially united by bone after a transverse fracture; the upper one, a section through the line of union made parallel with the joint surface.
25. A wax model of the left hand of an adult, showing the deformity produced by dislocation of the proximal phalanx of the thumb on to the dorsum of the metacarpal bone. The head of the metacarpal bone projects on the palmar aspect.
26. A wax model of the interior of a stomach, showing the effects of corrosive poisoning.

**Varices.**

27. A wax model of the front of the knee and upper two thirds of the leg, showing numerous spherical elevations of the skin; some are grouped into masses as large as a walnut, and are most abundant over and follow the line of the internal saphenous vein. The skin over them is of a dark colour.
28. A wax model of the inner and anterior surface of the thigh; over the region of the saphenous opening and over the lower third are many spherical raised nodules of a dark colour, evidently meant to represent varices of the long saphenous vein and its branches.

**Skin disease.****Vaccinia.**

29. A wax model of the left deltoid region of a child, showing five vaccinia vesicles about a week after inoculation.



**Variola.**

30. A wax model of a face covered with confluent pustules.
31. A kidney bisected; it is enlarged, the cortical part is much swollen, and there is hæmorrhage into the pyramidal portion. It is believed to be the kidney from the same patient as No. 30.
32. The left arm of a young adult covered with variolous pustules; they are discrete at the upper part, but confluent over the back of the hand.
33. A left arm covered with confluent pustules.

**Scabies.**

34. A wax model of the sole of a foot showing the dark, dirty, heaped-up epidermis of "Scabies Norvegica."

**Eczema.**

35. Two wax models of a hand, showing an eczematous condition of the palmar and dorsal surface, in all probability due to local irritation.
36. A wax model of the right hand of an adult, showing eczema of the back of the hand and wrist; the characteristic features are well shown—vesicles, crusts formed of epidermis infiltrated with serum, dried up crusts, glistening areas of effused serum, and crusts infiltrated with blood, also dried up. There are no or at least very few vesicles represented between the fingers.
37. A wax model of a child's forehead, showing a condition commonly seen when eczema is subsiding. Upon the reddened infiltrated skin there are very numerous small spots, now looking dry, but which have most probably contained fluid.

**Xeroderma.**

38. A wax model of a child's arm and shoulder, showing hypertrophy of hair-follicles common in the condition known as xeroderma. A number of follicles show little plugs of epidermis, and would have given a rough sensation to the finger often compared to the outside of a nutmeg-grater.

**Uncertain.**

39. A wax model of the face of a woman, presenting numerous elevations of the skin, varying in size from a pin's head to a pea, but whether papular, vesicular, or pustular is not now apparent; it may be acne, variola, or iodide-of-potassium eruption.



40. A wax model of the arm of a child with a raised condition of the skin, probably scleroderma.

### **Syphilis.**

41. A wax model of a right shoulder, showing over the deltoid muscle two small circular ulcerations with bossy surface, and one ulcer covered with brown crust, most probably syphilitic in origin.
42. A wax model of the back, showing the characteristic dirty-brown, heaped-up, limpet-shell scabs of rupia. The surrounding skin is not infiltrated or inflamed.

### **Contracted Cicatrix.**

43. A wax model of the right arm of a child, with a dense thick band fixing the elbow in a flexed position. In the centre of the band is another cicatrix, which is probably the result of operation.
44. A wax model of the left arm of a child. The elbow is flexed and firmly fixed, the thumb and little finger are approximated, and the hand is flexed and fixed by bands of cicatricial tissue.
45. A wax model of the head and neck of a woman, exhibiting a contracting cicatrix of the side of the neck, most probably the result of a burn. The angle of the mouth, the head, and the lower eyelid are drawn downwards by the cicatrix. There is palpebral conjunctivitis from exposure. At the lower part of the cicatrix is an indolent ulcer, circular in outline and devoid of granulations.
46. A wax model of the left side of the neck of a woman, showing a thickened band of cicatricial tissue running from the angle of the jaw to the acromion process.

### **Keloid.**

47. A wax model of the upper part of the chest, showing a flattened patch of elevated skin of irregular margin and smooth surface; it is keloid induration in the scar of a burn (Alibert's keloid): it is raised half an inch above the surrounding skin.

### **Bone Disease.**

#### **Necrosis.**

48. A wax model of the front of a young leg, showing a large ulcerated surface, much depressed in the centre, and with dark, rough, spiculated masses of necrosed bone above and below.



49. Portions of exfoliated dead bone from the outer table of the skull.
50. Circular portions of bone removed by the trephine. Portions of the parietal bone removed by the saw, probably from a case of compound depressed fracture of the skull. A portion of the shaft of the femur necrosed and exfoliated after amputation. A sequestrum three inches long with ragged ends, removed from a case of necrosis of the tibia; it is probably a portion of the shaft.

#### **Joint Disease.**

51. A wax model of the knee of a young adult, presenting a depressed cicatrix just above the internal condyle of the femur. The joint is semiflexed, the patella prominent, the tibia rotated inwards and backwards, and partially dislocated inwards; probably the result of old disease of the joint.
52. A wax model of a right knee-joint, completely disorganized by supuration. The joint is acutely flexed. The condyles of the femur, covered with reddened and softened synovial membrane, have been exposed by the complete destruction of the skin and quadriceps muscle. Below the internal tuberosity of the tibia, below the head of the fibula, and above the internal condyle of the femur are red, smooth ulcerated surfaces, probably marking the orifices of sinuses.

Compare specimen No. 741.

#### **Fungating Testis.**

53. Two wax models of the same penis and scrotum. The left cast presents a circular ulcer in the scrotum on the left side, exposing an enlarged fungating testis; the cast on the right was probably taken after a cure had been effected; it presents a cicatrix in a similar situation.

#### **Morbid Growth.**

##### **Enchondroma.**

54. A wax model of the dorsal surface of a child, showing three rounded projections as large as marbles, situated alongside the second, third, and fifth metacarpal bones; the body of the proximal phalanx, and the base of the second phalanx of the ring-finger present similar smooth rounded eminences.

##### **Carcinoma.**

55. A wax model of an oval portion of skin and breast-tissue presenting a fungating hæmorrhagic mass of circular outline near the nipple;



- close to the ulcer is a smooth rounded elevation of the skin; the nipple is depressed.
56. A model of the same breast after bisection; it shows a spherical, partially encapsuled growth as large as a tangerine orange, situated in the centre of the gland, and to the outer surface of which is attached another smaller nodule which is ulcerated upon the surface.
57. A wax model of similar parts, with extensive fungating ulceration of the surface of a large globular tumour.
58. A wax model of the chest of a woman. Over the right breast is an ulcerated surface of irregular outline and nodular base, depressed in the centre; the nipple seems to have been destroyed. The skin over the lower part of the chest is infiltrated with small round nodules, probably enlarged cancerous lymphatics. The left breast is prominent, and appears nodular on the surface, probably owing to infiltration with similar new growth.

### **Sarcoma.**

59. A wax model of the face of a woman, from whose left orbit there is growing a nodular mass as large as a man's fist; it is ulcerated and very irregular on the surface, and is probably a rapidly-growing sarcoma.
60. The lower end of the femur, tibia, and fibula. The tibia is healthy, the femur atrophied. The head and upper half of the shaft of the fibula is represented by an irregular, spiculated, honeycombed mass of bone the size of an adult head. It is probable that the tumour was an ossifying sarcoma, and that the leg was amputated and the bones macerated.
61. A wax model of the head of a woman, showing a large globular protrusion forward of the right cheek, as if from a growth in the antrum of Highmore. The nose is tilted over towards the left side, and the right orbit seems to be encroached upon from below, the eyeball being raised and the palpebral fissure being narrowed on the right side.
62. Wax models, showing a stomach laid open along the greater curvature; its walls are thickened, and its mucous surface infiltrated with carcinomatous growth, which probably originated near the cardiac orifice. The heart on the right is possibly from the same subject, and, if so, is probably intended to show nodules of carcinoma scattered over the surface of the pericardium.



**Rodent ulcer.**

63. A wax model of a man's head and face; in the centre of the face is a huge irregular ulcerated cavity, most probably the result of rodent carcinoma. The whole of the right and part of the left superior maxillary bones, with the soft parts covering them, have been destroyed. The cancer has also eaten away both cheeks, gums, and the integuments over the right lower jaw. The following structures are exposed to view:—The right eyeball with structures along the floor of the orbit, the posterior nares, the right superior turbinated bone, and the right coronoid process of the lower jaw.

Compare specimen No. 1006.

**Miscellaneous.**

64. A painted gelatine cast of a heart, pericardium, lungs, and liver, exhibiting general sarcoma. The lungs are studded with masses of soft growth, yellowish colour, and irregular shape and size. The growth appears to have invaded the lung from the surface, and to have spread along the bronchi. The pericardium is thickened to the extent of half an inch by similar deposit. Over the surface of the heart are nodules of similar deposit arranged linearly.

Case of Laurence A. Maresy, aged 35, admitted with symptoms of hæmoptysis, loss of power, and pain in legs of 11 weeks' duration only. There was much œdema of the left side of the face, neck, and arm. At the autopsy, Nov. 15, 1889, enlarged glands were found on the right side of the neck, and the superior vena cava was distended by growth.

Dr. Stephen Mackenzie.

65. A painted gelatine cast, showing an enormous pyæmic abscess of the spleen. The abscess-cavity measures 7 inches in diameter, and contains dirty yellow nodular masses of disintegrating splenic substance; its wall is irregular; in the recent state the cavity held 2 pints and the spleen weighed 5 lbs. 10 oz.; other smaller collections of pus are seen nearer the surface; upon the surface of the organs adhesions are represented. The splenic tissue is darker and softer than normal.

Case of Fred. T., aged 28, a labourer, who died comatose in the Receiving-Room.

At the autopsy, Oct. 30, 1889, the cerebellum was disorganized by a large hæmorrhage which had spread into the lateral ventricles. The liver was fatty, weighing 10 lbs. The glans penis showed old phagedœna, but no cause for the abscess was found.

66. A painted gelatine cast of a section of a lung, showing great thickening of the pleura, fibroid induration and contraction of the lung, and a large irregular ulcerative cavity, whose walls are stained with recent blood-clot



and which contains a sacculated aneurysm of one of the branches of the pulmonary artery, the rupture of which caused death. The aneurysm is as large as a walnut and has thin walls.

Case of Fred. Morris, aged 35, a labourer who in 1879 contracted primary syphilis, and was an in-patient under Mr. Hutchinson for severe secondaries in that year. He had been frequently in the hospital since (in 1881, 1883, 1884, and 1887) with tertiary disease of liver, and indefinitely of the lungs and nervous system. In March 1889 he was admitted with liver-symptoms, and improved, being sent to a convalescent home in Brighton on July 15. In October 1889 he was readmitted, stating that after his discharge he improved till a week ago, when severe hæmoptysis came on, and death resulted from exhaustion, following a second attack of hæmoptysis.

Autopsy, Nov. 15, 1889. Dr. Stephen Mackenzie.

67. A coloured gelatine cast, showing a portion of a liver containing two gummata. Both are circular in outline, distinctly circumscribed, of a greyish-white colour; the larger measures 2 inches in diameter.

From the same patient as the preceding.



## SERIES LV.—URINARY CALCULI\*.

CALCULI OF WHICH THE NUCLEUS, OR CENTRAL  
PORTION, CONSISTS OF URIC ACID.

## CALCULI CONSISTING MAINLY OF URIC ACID.

1. Fragments of a Calculus, which consists of nearly pure Uric Acid.
2. Fragments of a Calculus. Uric Acid only.
3. Sections of a Calculus, elliptical in shape. Concentric rings of Uric Acid of various shades, with some granular deposit of Phosphates on the outside.
4. Sections of a Calculus, elliptical. Size  $1\frac{3}{8}$  by 1 inch. Uric Acid only.
5. Section of a Calculus, almost spherical. 1 inch in diameter. Uric Acid only.
6. Sections of a pure Uric Acid Calculus. Size  $1\frac{1}{2}$  by  $1\frac{1}{8}$  inch. On the exterior are nodules of Oxalate of Lime.
7. Sections of a similar Calculus. Size  $1\frac{3}{4}$  by  $1\frac{3}{8}$  inch. On the exterior is seen a thin mammillated layer of oxalate. Weight 6 drms. 52 grs.
8. Sections of a Calculus, consisting of concentric rings of various shades of pure Uric Acid. Size  $2\frac{3}{8}$  by  $1\frac{7}{8}$  by  $1\frac{1}{2}$  inch. Weight 3 oz. 74 grs.
9. Sections of a pure Uric Acid Calculus, in shape resembling a cottage-loaf.

\* The whole of these Calculi, 179 in number, have been analysed by F. J. M. Page, Esq., B.Sc., and Mr. Openshaw, during January, February, and March 1890.



10. Sections of an egg-shaped Calculus, measuring  $1\frac{5}{8}$  by  $1\frac{1}{8}$  inch, and composed throughout of Uric Acid.
11. Sections of a similar Calculus. Size  $1\frac{5}{8}$  by  $1\frac{3}{8}$  by 1 inch. On the exterior is a thin shell of Phosphates.
12. Section of a Calculus. Size  $1\frac{3}{4}$  by  $1\frac{1}{2}$  inch. Uric Acid only; though pale in colour there is no Phosphate or Urate.
13. Section of a Calculus of similar composition and appearance. Size  $1\frac{5}{8}$  by  $1\frac{1}{8}$  inch.
14. Section of a Calculus, nearly circular in section,  $1\frac{1}{4}$  by  $1\frac{1}{8}$  inch. An oval nucleus surrounded by concentric rings. Uric Acid.
15. Sections of a Calculus, very flat and circular in shape, with a diameter of  $1\frac{1}{8}$  inch. Uric Acid only.
16. Fragment of a Calculus, measuring  $1\frac{3}{8}$  by 1 inch. Nucleus oval, pure Uric Acid. Periphery consists of a loose-textured layer of similar Uric Acid with organic matter.
17. Sections of a very similar Calculus. Size  $1\frac{1}{8}$  by 1 inch.
18. Sections of a Calculus. Size  $2\frac{1}{4}$  by  $1\frac{3}{4}$  by  $1\frac{1}{2}$  inch. Centre consists of Uric Acid in close texture, surrounded by a mixture of Uric Acid and organic matter, the periphery consisting of concentric layers in appearance and composition to the centre.
19. The other half of the same Calculus.
20. Three calculi, smooth on the surface, oval in shape, measuring  $1\frac{1}{4}$  by  $\frac{3}{4}$  by  $\frac{5}{8}$  inch, and consisting of pure Uric Acid concentrically arranged. They were most probably removed from the same bladder.
21. Sections of an oval Calculus, measuring  $1\frac{3}{8}$  by 1 by  $\frac{3}{4}$  inch, consisting of concentric rings of Uric Acid. Although light-coloured, there is neither Phosphate nor Urate of Ammonia present.

#### CALCULI HAVING TWO LAYERS.

##### **Uric Acid. Urate of Ammonia.**

22. Sections of a Calculus. Size  $1\frac{3}{4}$  by  $\frac{7}{8}$  inch. Nucleus Uric Acid surrounded by loose rings of Urate of Ammonia.



**Uric Acid. Oxalate of Lime.**

23. Sections of a Calculus, showing two nuclei, each surrounded by incomplete rings forming in shape a figure of eight. Size  $1\frac{1}{4}$  by  $\frac{7}{8}$  inch. Constituents: Uric Acid internally with nodules of Oxalate of Lime on the exterior.

**Uric Acid. Earthy Phosphates.**

24. Sections of a flattened circular Calculus. Size  $1\frac{1}{8}$  by  $1\frac{1}{8}$  by  $\frac{3}{4}$  inch. Uric Acid mainly with a thin cake of Phosphate of Lime on the outside.

25. A small flat stone measuring  $1\frac{1}{4}$  by 1 inch. Composed of Uric Acid, with a small deposit of Phosphates externally.

Removed by lateral lithotomy from the bladder of a boy aged 10.  
Mr. Rivington.

26. Sections of a Calculus, in shape triangular with rounded angles. Size  $1\frac{5}{8}$  inch from each angle to the corresponding base. Uric Acid mainly, with several layers of mixed Phosphates externally. Weight  $12\frac{1}{2}$  drams.

27. Section of a Calculus. Size  $1\frac{1}{2}$  by  $1\frac{1}{4}$  inch. Nucleus and concentric rings of Uric Acid; the whole coated externally by mixed Phosphates.

28. Sections of a Calculus, showing an oval nucleus of Uric Acid eccentrically placed in the midst of a mass of mixed Phosphates. Size  $1\frac{1}{4}$  by 1 by 1 inch.

29. Section of a Calculus. Nucleus Uric Acid, in which there is a trace of Urate of Ammonia surrounded by a fenestrated mass of mixed Phosphates. Size  $1\frac{3}{8}$  by 1 inch.

30. Sections of a Calculus, composed of Uric Acid encased in Phosphate of Lime. Size  $1\frac{1}{2}$  by  $1\frac{1}{8}$  by  $1\frac{1}{8}$  inch.

**CALCULI HAVING THREE LAYERS.****Uric Acid. Urate of Ammonia. Earthy Phosphates.**

31. A number of small smooth Calculi, varying in size from a bean to a small egg. Composition: Nucleus Uric Acid, succeeded by Urate of Ammonia, thinly coated with Phosphates.



**Uric Acid. Oxalate of Lime. Uric Acid.**

32. Sections of a Calculus, measuring  $1\frac{3}{8}$  by  $1\frac{5}{8}$  by  $1\frac{1}{4}$  inch. Nucleus Uric Acid, surrounded by a dark ring of Oxalate of Lime with a deposit of Uric Acid on the exterior.

**Uric Acid. Oxalate of Lime. Earthy Phosphates.**

33. Sections of a Calculus, resembling externally the carapace of an echinoderm. Size 2 by  $1\frac{3}{4}$  by 1 inch. It consists almost entirely of Uric Acid, with externally a deposit of crystals of Oxalate of Lime thinly coated with Phosphate. It weighs 12 drams 20 grains.
34. Sections of a Calculus. Size  $1\frac{1}{2}$  by  $1\frac{1}{4}$  by 1 inch. Composition almost solely Uric Acid, with a narrow dark ring of Oxalate of Lime at the extreme periphery, and coated with Phosphates.
35. Sections of an oval Calculus. Size  $1\frac{1}{2}$  by  $1\frac{1}{8}$  by 1. Nucleus oval,  $\frac{1}{2}$  by  $\frac{3}{8}$  inch, Uric Acid; then ring of loose Oxalate of Lime mixed with organic matter; then deposit of mixed Phosphates.

**Uric Acid. Earthy Phosphates. Uric Acid.**

36. Sections of a small elongated Calculus, measuring  $1\frac{1}{4}$  by  $\frac{1}{2}$  inch.

**Uric Acid. Earthy Phosphates. Oxalate of Lime.**

37. A small black flattened oval Calculus, composed of Uric Acid, then of Phosphates and Oxalates.

The Calculus is one of two which were removed from the bladder of a man aged 60, by median lithotomy. Mr. Rivington.

**Uric Acid, succeeded by four or more layers.**

38. Section of an oval Calculus. Size  $2\frac{3}{8}$  by  $1\frac{3}{4}$  inch. Nucleus Uric Acid succeeded by alternating rings of Uric Acid and Urate of Ammonia, with a trace of Phosphates near the centre.
39. Sections of a flattened oval Calculus of similar composition. Size  $1\frac{3}{8}$  by  $\frac{7}{8}$  by  $\frac{5}{8}$  inch.
40. Sections of a Calculus of irregular shape. Nucleus circular, Uric Acid; succeeded by alternating layers of Uric Acid and Oxalate of Lime. The Calculus contains neither Phosphates nor Urate of Ammonia.



41. Sections of a Calculus, quadrilateral in shape, measuring  $1\frac{1}{2}$  inch in its longest diameter. Nucleus Uric Acid, then Urate of Ammonia, then narrow ring of Uric Acid, then Urate of Ammonia, then alternating layers of Urate of Ammonia and Phosphate of Lime.
42. Sections of a Calculus, of quadrilateral shape, longest diameter  $1\frac{3}{8}$  inch. In composition exactly similar to preceding, and probably removed from the same patient.
43. Sections of a similar Calculus.
44. Sections of a similar Calculus.
45. Section of an oval Calculus. Size  $1\frac{1}{4}$  by 1 by  $1\frac{3}{4}$  inch. Nucleus Uric Acid with a trace of Phosphates, then thick layer of Urate of Ammonia succeeded by alternating layers of Urate of Ammonia and Phosphate of Lime.
46. Section of a Calculus. Size 1 by  $\frac{7}{8}$  inch. Composed in the centre of Uric Acid mixed with Phosphates, then two narrow rings of Oxalate, then Urate of Ammonia mixed with Calcic Phosphate.

*Presented by Mr. Treves.*
47. Sections of a Calculus. Measuring  $1\frac{3}{8}$  by  $1\frac{1}{4}$  inch. A small nucleus of Uric Acid, then a layer of Urate of Ammonia, then a layer which contains Oxalate and Phosphate, and lastly Phosphates and Urate of Ammonia.
48. Sections of an elongated tuberculated Calculus. Size  $2\frac{1}{2}$  by  $1\frac{1}{2}$  by 1 inch. Nucleus Uric Acid, then a dark mass of mixed Oxalate of Lime, Uric Acid, blood and organic matter, then loose rings of Urate of Ammonia, and more externally alternating rings of Uric Acid and Urate of Ammonia, with a very thin layer of Oxalate of Lime and Phosphates superficially.
49. Sections of a Calculus, in shape flattened and spherical, tuberculated externally. Size 1 by  $\frac{7}{8}$  inch. Nucleus Uric Acid, then many rings of Urate of Ammonia, Uric Acid, and Oxalate of Lime, with a thin coating of Phosphates externally.
50. Section of a small, oval, flat Calculus. Size  $\frac{3}{4}$  by  $\frac{1}{2}$  inch. Nucleus Uric Acid with some Phosphates, then Urate of Ammonia, then loose layer of Oxalate of Lime, then a thin layer of mixed Phosphates.



Case of John Pedder, aged 4 years. Admitted Jan. 25, 1886, R.N. 204, with a history of having scarcely any symptoms when at rest. Uric Acid crystals were found in the urine. The stone was easily detected by the sound, and could also be found per rectum, it was thought to be large and fixed, and the suprapubic operation was contemplated. It was easily removed, however, by the lateral operation on Feb. 6, 1886. The lithotomy tube was left in for one day. The urine continued to pass through the wound at intervals till March 12th, six weeks after the operation. Mr. McCarthy.

51. Section of a Calculus, in shape oblong with rounded spiculated ends. Size 2 by  $1\frac{1}{8}$  inch. Nucleus Uric Acid mixed with a little Urate of Ammonia, then Oxalate of Lime with organic matter, then a layer  $\frac{1}{4}$  inch thick of Uric Acid and Phosphates, then a ring of Urate of Ammonia, and lastly a mixture of Oxalates and Phosphates.
52. Section of a Calculus. Size  $1\frac{1}{2}$  by  $1\frac{1}{4}$  by 1 inch. Nucleus oval, Uric Acid with a trace of Phosphate, then Uric Acid, then a thin ring of Phosphate, then a layer of Uric Acid, then thin rings of Phosphate and Uric Acid, and externally a deposit of Oxalates succeeded by Calcic Phosphate.

#### CALCULI OF WHICH THE NUCLEUS CONSISTS OF URATE OF AMMONIA.

##### CALCULI CONSISTING MAINLY OF URATE OF AMMONIA.

53. Sections of several small Calculi, almost entirely composed of Urate of Ammonia; the surface of some of the stones is roughened by the deposit of a thin layer of crystals of Oxalate of Lime; the cut surface is smooth, uniform, and yellowish brown in colour.

##### CALCULI HAVING TWO LAYERS.

##### **Urate of Ammonia. Uric Acid.**

54. Sections of a Calculus of a light brown colour, and vacuolated on the cut surface. Size  $1\frac{3}{4}$  by  $1\frac{1}{4}$  inch. Weight 309 grs. Mixture of Urate of Ammonia and Uric Acid.
55. Sections of a Calculus. Nucleus composed of Urate of Ammonia, and surrounded by a mixture of Urate of Ammonia and Uric Acid. Size 2 by  $1\frac{1}{2}$  by  $\frac{7}{8}$  inch.
56. Sections of a Calculus. Nucleus composed of Urate of Ammonia with a little Phosphate, and the periphery principally Uric Acid with a little Urate of Ammonia.



57. A section of a Calculus, the nucleus of which has been lost. Mixture of Urate of Ammonia and Uric Acid. On the surface is a thin layer of Oxalates and Phosphates.

**Urate of Ammonia. Oxalate of Lime.**

58. Half a small Urate of Ammonia Calculus, with a thin villous coating of Oxalates.

Mr. Treves.

59. Sections of a Calculus, tuberculated externally. Size  $\frac{7}{8}$  by  $\frac{3}{4}$  inch. Nucleus a mixture of Urate of Ammonia and Phosphates coated with Oxalate of Lime.

60. Sections of a small Calculus. Size  $\frac{3}{4}$  by  $\frac{1}{2}$  inch. Urate of Ammonia with a thin layer of Oxalate of Lime.

61. Section of a similar Calculus. Size  $\frac{3}{4}$  by  $\frac{3}{4}$  inch. Urate of Ammonia with a thicker peripheral layer of Oxalate of Lime.

62. Section of a Calculus. Nucleus spherical, Urate of Ammonia with some Phosphate of Lime, externally a compact layer of Oxalates.

63. Two small tuberculated Calculi; the one which has been cut across consists of Oxalate of Lime upon a nucleus of Urate of Ammonia.

Mr. Rivington.

64. Section of a mulberry Calculus. Urate of Ammonia and Oxalate of Lime with some animal matter. Size  $1\frac{1}{4}$  by 1 inch.

65. Sections of a mulberry Calculus, with a small oval nucleus of Urate of Ammonia, within a thick, dense, light-coloured tuberculated layer of almost pure Oxalate of Lime. It measures  $1\frac{3}{8}$  inch in its longest diameter.

66. Sections of a similar Calculus. A small nucleus of Urate of Ammonia, with Oxalate of Lime externally.

67. Section of a similar Calculus. The nucleus, Urate of Ammonia, with traces of Phosphates, is still smaller.

68. Section of a Calculus, measuring  $\frac{3}{4}$  by  $\frac{1}{2}$  inch. Composed of Urate of Ammonia in the centre and Oxalate of Lime externally.

69. Section of a small flattened spherical Calculus,  $\frac{3}{4}$  inch in diameter. Urate of Ammonia and Oxalate of Lime.



**Urate of Ammonia. Earthy Phosphates.**

70. Sections of a Calculus. Size  $2\frac{1}{2}$  by  $1\frac{5}{8}$  inch. Composition, Urate of Ammonia, with some Phosphates externally. The Calculus is vacuolated, and it has been saturated with varnish.
71. A number of small smooth Calculi, as large as beans, composed of Urate of Ammonia thinly coated with Phosphates.
72. Sections of a Calculus. Size 1 by  $\frac{3}{4}$  inch. Flattened spherical. Nucleus Urate of Ammonia, surrounded by thick layer of Calcic Phosphate.
73. Sections of a Calculus. Size  $1\frac{1}{4}$  by 1 inch. Flattened oval. Nucleus oval and laminated, principally Urate of Ammonia, with narrow rings of Uric Acid and a trace of Phosphates. The periphery a thick layer of Calcic Phosphate.
74. Sections of a Calculus. Size  $1\frac{1}{2}$  by 1 inch. Flattened oval. Spherical nucleus, Urate of Ammonia, with traces of Oxalates, surrounded by a mixture of Calcic Carbonate and Calcic Phosphate.
75. Sections of a Calculus. Size  $\frac{7}{8}$  by  $\frac{1}{2}$  inch. Oval. Urate of Ammonia with a trace of Phosphates, surrounded by Phosphates with Urate of Ammonia.
76. Fragments of a Calculus the size of a bean. Urate of Ammonia and Ammonio-magnesian Phosphate.
77. Fragments of an elongated oval Calculus, in size 2 by 1 inch. An oval nucleus of Urate of Ammonia surrounded by a thick vacuolated layer of Urate of Ammonia combined with mixed Phosphates.
78. Sections of an egg-shaped Calculus. Size  $2\frac{1}{2}$  by  $1\frac{1}{2}$  inch. Nucleus large, spherical, of Urate of Ammonia, surrounded by the mixed Phosphates. The appearance of the nucleus would suggest oxalate, but analysis proves the absence of this salt.
79. Fragments of a Calculus. An oval nucleus, Urate of Ammonia, with mixed Phosphates, in which is a narrow ring of Urate of Ammonia.
80. Sections of an elongated Calculus, with an oval nucleus of Urate of Ammonia surrounded by mixed Phosphates.



## CALCULI HAVING THREE LAYERS.

**Urate of Ammonia. Oxalate of Lime. Uric Acid.**

81. Sections of a Calculus. Size  $1\frac{5}{8}$  by  $1\frac{1}{4}$  inch. Weight 7 drams 2 grains. Nucleus Urate of Ammonia, then Oxalate of Lime surrounded by Uric Acid.

**Urate of Ammonia. Oxalate of Lime. Urate of Ammonia.**

82. Sections of a Calculus. Size  $1\frac{1}{2}$  by  $1\frac{1}{4}$  inch. Nucleus Urate of Ammonia, then a thin black ring of Oxalate of Lime, then Urate of Ammonia.

83. Sections of a Calculus, composed mainly of Urate of Ammonia upon a nucleus of a mixture of Phosphates, Urate of Ammonia, and a trace of Oxalates. The vacuolation of outer layer is well shown. Size  $1\frac{3}{8}$  by  $1\frac{1}{4}$  inch. *Presented by Mr. Rivington.*

84. Sections of a Calculus. Size  $1\frac{3}{8}$  by  $1\frac{1}{4}$  inch. An oval nucleus of Urate of Ammonia, surrounded by a mixture of Urate of Ammonia and Oxalate, and externally a layer of Urate of Ammonia.

**Urate of Ammonia. Oxalate of Lime. Earthy Phosphates.**

85. Section of a Calculus. Nucleus oval, Urate of Ammonia, with narrow ring of Oxalate of Lime, and thinnest possible layer of Phosphates. Size  $\frac{3}{4}$  by  $\frac{1}{2}$  inch.
86. Sections of a Calculus. Nucleus circular, of Urate of Ammonia, then ring of Oxalates succeeded by thin layer of Phosphates. Crystals of Oxalate of Lime are seen on the exterior. Size  $\frac{7}{8}$  by  $\frac{7}{8}$  inch.
87. Section of a Calculus. Urate of Ammonia, then Oxalate of Lime, then distinct layer of mixed Phosphate. Size  $\frac{7}{8}$  by  $\frac{7}{8}$  inch.
88. Sections of a Calculus, with a small oval Nucleus of Urate of Ammonia combined with Phosphate of Lime, succeeded by tuberculated Oxalates and then a layer of mixed Phosphates. Size  $\frac{3}{4}$  by  $\frac{3}{4}$  inch.
89. Sections of a mulberry Calculus. Nucleus extremely small, Urate of Ammonia, succeeded by pure Oxalate of Lime, with a thin layer of Phosphates outside. Size  $1\frac{3}{8}$  by  $1\frac{1}{4}$  inch.



90. Section of a mulberry Calculus. Internal portion Urate of Ammonia with Phosphates, surrounded by black rings of Oxalate of Lime, a small quantity of Calcic Phosphate on the exterior. Size  $1\frac{1}{2}$  by  $1\frac{1}{4}$  inch.
91. Sections of a Calculus. An oval nucleus, Urate of Ammonia, measuring  $\frac{1}{2}$  by  $\frac{3}{8}$  inch, then Oxalates, then a ring of Phosphates of Lime. Size  $1\frac{3}{8}$  by  $1\frac{1}{4}$  inch.
92. Sections of a Calculus. Nucleus,  $\frac{7}{8}$  by  $\frac{3}{8}$  inch, Urate of Ammonia, Oxalate of Lime  $\frac{1}{4}$  inch, Phosphates 1 millim. Size  $1\frac{1}{4}$  by 1 inch.
93. Section of a Calculus. Nucleus oval,  $\frac{3}{8}$  by  $\frac{1}{4}$  inch, Urate of Ammonia, then Oxalate of Lime  $\frac{1}{2}$  inch wide, then mixed Phosphates  $\frac{1}{8}$  inch wide. Size  $1\frac{1}{8}$  by  $1\frac{1}{8}$  inch.
94. Sections of a Calculus. Nucleus oval,  $\frac{3}{4}$  by  $\frac{1}{2}$  inch, Urate of Ammonia with a trace of Phosphates, thin dark ring of Oxalate of Lime, succeeded by mixed Phosphates. Size  $\frac{7}{8}$  by  $\frac{3}{4}$  inch.
95. Sections of a Calculus. Nucleus  $\frac{1}{4}$  by  $\frac{1}{4}$  inch, Urate of Ammonia, succeeded by layer of Oxalates with some Urate of Ammonia, and externally a thick layer of fusible Phosphates mixed with organic matter. Size  $2\frac{3}{4}$  by  $1\frac{3}{4}$  inch. Weight 22 drams 9 grains.
96. Sections of a Calculus. Nucleus  $\frac{1}{2}$  by  $\frac{1}{4}$ , Urate of Ammonia in alternate layers with Phosphates, then Oxalate of Lime, coated externally by mixed Phosphates. Size  $1\frac{1}{4}$  by  $\frac{7}{8}$  inch.
97. Fragments of an oval Calculus. Size  $\frac{3}{4}$  by  $\frac{1}{2}$  inch. Oval nucleus of Urate of Ammonia, then mixture of Oxalates and Phosphates, then Calcic Phosphate.
98. Sections of a Calculus. Nucleus circular,  $\frac{1}{4}$  by  $\frac{1}{4}$  inch, Urate of Ammonia, succeeded by a mixture of Oxalate of Lime and Urate of Ammonia, and mixed Phosphates externally. Size  $1\frac{1}{2}$  by 1 inch.
99. Sections of a Calculus. Nucleus  $\frac{1}{2}$  by  $\frac{3}{8}$  inch, concentric rings of Urate of Ammonia and Phosphate of Lime; then Phosphate of Lime the central layers of which are mixed with Oxalate of Lime. Size  $1\frac{3}{8}$  by  $1\frac{1}{8}$  inch.
100. Section of a Calculus. The interior composed of rings of Urate of Ammonia, Oxalate of Lime, and Phosphates, with an irregular layer of mixed Phosphates on the exterior. Size  $1\frac{1}{4}$  by  $\frac{3}{4}$  inch.



101. Fragments of a Calculus. Nucleus large and irregular. Composition: Urate of Ammonia with Phosphates, Oxalates of Lime as a narrow black ring, Mixed Phosphates and animal matter, and ring of Calcic Phosphate externally. Size  $1\frac{3}{4}$  by  $1\frac{1}{4}$  inch.
102. Sections of a Calculus. Nucleus, spherical areas of Uric Acid and Urate of Ammonia, then dark ring of Oxalates with mixed Phosphates externally. Size  $1\frac{1}{4}$  by  $\frac{3}{4}$  inch.
103. Sections of a Calculus. An oval nucleus,  $\frac{3}{4}$  by  $\frac{1}{2}$  inch, layers of Urate of Ammonia and Uric Acid, with Phosphates; then a narrow ring of Oxalate, coated externally with Calcic Phosphate containing animal matter and Urate of Ammonia. Size 2 by  $1\frac{3}{8}$  inch.
104. Sections of a Calculus. Urate of Ammonia with some Phosphates, then Oxalate of Lime, then Calcic Phosphate. Size  $1\frac{1}{2}$  by  $1\frac{1}{8}$  inch.

**Urate of Ammonia. Phosphate of Lime. Oxalate of Lime.**

105. Section of a Calculus. Nucleus double, oval,  $\frac{3}{8}$  by  $\frac{1}{8}$  inch, Urate of Ammonia, then Calcic Phosphate with two narrow rings of Urate of Ammonia, the whole with a thin coating of Oxalate of Lime. Size  $1\frac{3}{8}$  by  $1\frac{1}{8}$  inch.

**Urate of Ammonia succeeded by four or more layers.**

106. Sections of a Calculus, oval in shape. Size 1 by  $\frac{3}{4}$  by  $\frac{5}{8}$  in. Nucleus Urate of Ammonia, then a little Phosphate, then Urate of Ammonia, alternating with three narrow rings of Uric Acid.
107. Sections of a spherical Calculus. Size  $1\frac{3}{8}$  by 1 by  $\frac{5}{8}$  inch. Nucleus Urate of Ammonia, succeeded by alternating layers of Uric Acid and Urate of Ammonia.
108. Section of an oval Calculus, measuring  $1\frac{1}{2}$  by  $1\frac{1}{4}$  inch. A nucleus of Urate of Ammonia, with a considerable amount of Phosphate, succeeded by Uric Acid loosely arranged in rings with Phosphates intervening.
109. Sections of a Calculus, consisting of rings of Urate of Ammonia loosely arranged and separated by animal matter, the whole coated externally by narrow rings of Phosphates, then Oxalates, then Phosphates. Size  $1\frac{1}{2}$  by  $1\frac{3}{8}$  inch.
110. Section of a Calculus, measuring  $1\frac{3}{4}$  inch in its longest diameter, composed of innumerable alternating rings of Urate of Ammonia and fusible Phosphate upon a Urate of Ammonia nucleus.



111. Fragments of a Calculus. Size 1 by  $\frac{7}{8}$  by  $\frac{1}{2}$  inch. Nucleus Urate of Ammonia, succeeded by alternating rings of Phosphates and Urate of Ammonia.
112. Sections of a Calculus. Size  $1\frac{1}{4}$  by 1 by 1 inch. Nucleus Urate of Ammonia in which there is a trace of Oxalate of Lime, then Phosphates, then a ring of Urate of Ammonia, then a thick layer of mixed Phosphates.
113. Section of a flattened oval Calculus. Size  $1\frac{1}{4}$  by 1 inch. Nucleus Urate of Ammonia with a trace of Oxalate and Phosphate, then rings of Phosphate and Oxalate, succeeded by a thick vacuolated layer of Urate of Ammonia.
114. Fragment of a Calculus, consisting of Urate of Ammonia, with a trace of Oxalates in the centre, then Phosphate of Lime with a few rings of Urate of Ammonia and some Carbonate of Lime. Size 1 by  $\frac{3}{4}$  inch.
- Removed by lateral lithotomy in May 1885 from the bladder of a boy, Geo. West, aged 2 years, who had had frequent and painful micturition for 2 years. Uncomplicated recovery.  
Mr. Treves.
115. Sections of a spherical Calculus. Size  $1\frac{5}{8}$  by 1 by 1 inch. Nucleus Urate of Ammonia with Phosphates, then Phosphate of Lime, in which is a narrow ring of Oxalate.
116. Fragments of a Calculus, composed of alternating layers of Urate of Ammonia and Urate of Ammonia mixed with Phosphates, succeeded by a ring of Oxalate, and coated with Phosphates.
117. Sections of a small tuberculated Calculus. Size  $\frac{3}{4}$  by  $\frac{1}{2}$  inch. Nucleus Urate of Ammonia, succeeded by 14 very thin layers of Urate and Oxalate of Lime alternately.
118. Sections of a Calculus. A flattened sphere  $\frac{1}{2}$  inch in diameter. Urate of Ammonia, Oxalate of Lime, then Urate of Ammonia with Phosphates externally.
119. Sections of a flat oval Calculus. Size  $\frac{3}{4}$  by  $\frac{1}{2}$  inch. Nucleus Urate of Ammonia with much Phosphate, succeeded by five rings of Oxalate of Lime and Urate of Ammonia, and coated externally by Calcic Phosphate.
120. Section of a Calculus. Size  $1\frac{3}{8}$  by  $1\frac{1}{8}$  by  $\frac{7}{8}$  inch. Nucleus Urate of Ammonia alternating with Oxalate of Lime, then a mixture of



Urate of Ammonia and Phosphates, then Calcic Phosphate succeeded by a layer of mixed Phosphates.

121. Fragments of a Calculus. Nucleus a mixture of Phosphates and Urate of Ammonia, then a ring of Oxalates, then a layer, loose in texture, of Oxalates, Phosphates, and Carbonate of Lime, then Phosphate of Lime with some Urate of Ammonia.

122. Sections of a Calculus as large as a duck's egg. Nucleus Urate of Ammonia, succeeded by a mixture of Phosphate of Lime and Urate of Ammonia, in which are rings of Urate of Ammonia. Weight 21 drams 23 grains.

It was removed by vaginal lithotomy from a female, E. B., aged 17, admitted on July 3rd, 1883, with a history of hæmaturia and dribbling of urine for nine months, with frequency of and painful micturition only for a fortnight before admission. The wound in the vagina was quite healed 19 days after the operation.

Mr. Rivington.

123. Sections of a Calculus. Size  $2\frac{1}{4}$  by  $1\frac{3}{8}$  by  $\frac{7}{8}$  inch. Nucleus Urate of Ammonia, then ring of Oxalate of Lime, then a narrow ring of Uric Acid, then loose Urate of Ammonia, then Uric Acid, then Urate of Ammonia with some Phosphate intermixed, the whole coated with dense Ammonio-magnesian Phosphate.

124. Sections of a large Calculus. Size  $2\frac{3}{4}$  by  $1\frac{3}{4}$  by  $1\frac{1}{4}$  inch. Nucleus minute, Urate of Ammonia, then ring of Oxalate of Lime, then ring of Phosphates, then layer of Uric Acid, then Urate of Ammonia, then Uric Acid, and lastly at one end a mass of mixed Phosphates.

125. Sections of a large bilobed Calculus, showing two nuclei of irregularly oval shape, composed of Urate of Ammonia; this is succeeded by layers of Oxalate of Lime, then Phosphate of Lime, then Uric Acid, then a mixture of Urate of Ammonia and Phosphates, with a thick deposit of mixed Phosphates externally.

From a man who had suffered from a difficulty of micturition for some years. By the sound a large stone was found in the bladder, for which lateral lithotomy was performed in 1874. This large hourglass stone was extracted, the large end being foremost. The cavity of the supposed bladder was explored by the finger, and found to be roughened over the whole surface. At the autopsy, the wall of this cavity was found to be a mere shell of prostate. The bladder itself was very small and contracted, not larger than a walnut, and in this the upper end of the calculus had been lodged. The kidneys were totally disorganized.

Mr. McCarthy.



## CALCULI OF WHICH THE NUCLEUS CONSISTS OF OXALATE OF LIME.

### CALCULI CONSISTING MAINLY OF OXALATE OF LIME.

126. Sections of a Calculus. Size  $2\frac{3}{4}$  by  $2\frac{3}{8}$  by 2 inches. Weight  $6\frac{3}{4}$  oz. 46 grains. Globular in shape. Consisting of almost pure Oxalate of Lime.

127. A large heavy spherical mulberry Calculus, of a dark-brown colour, tuberculated and spiculated upon the surface. It measures  $1\frac{1}{2}$  inch in diameter, and consists of pure Oxalate of Lime, with possibly a small nucleus of other material. Weight 10 drams 15 grains.

It was removed by the suprapubic operation on January 17, 1890, from the bladder of a boy, E. Lewis, aged 11, R.N. 92, whose only symptoms had been frequency of micturition with incontinence for six years. No stone had been suspected before admission.

Mr. Treves.

128. Section of large Oxalate-of-Lime Calculus. Although yellowish brown in colour, it contains neither Uric Acid nor Urate of Ammonia. Size  $2\frac{3}{4}$  by 2 by  $2\frac{1}{2}$  inches in thickness.

### CALCULI HAVING TWO LAYERS.

#### **Oxalate of Lime. Uric Acid.**

129. Sections of a flat oval Calculus. Size  $2\frac{1}{8}$  by  $1\frac{1}{2}$  by  $\frac{3}{4}$  inch. Nucleus black, hard, almost pure Oxalate of Lime, surrounded by irregular strata of Uric Acid with some organic matter.

130. Sections of a Calculus measuring  $2\frac{1}{4}$  by  $1\frac{5}{8}$  inch. Nucleus Oxalate of Lime surrounded by Uric Acid, containing both Oxalate and Phosphates. Weight 12 drams 28 grains.

Removed by lateral lithotomy from a labourer aged 68, admitted December 7, 1880, with a history of frequency of micturition and severe hypogastric pain for 4 years, which was worse on moving about. He had never passed blood with his water. The urine after exertion had been very dark, but as a rule it was perfectly clear; on admission it was loaded with mucus. The patient made a rapid recovery.

Mr. Rivington.

#### **Oxalate of Lime. Earthy Phosphates.**

131. A small spherical Oxalate-of-Lime Calculus, measuring  $\frac{3}{4}$  of an inch in diameter, with the thinnest possible deposit of Phosphates on its exterior.



132. Sections of a mulberry Calculus. Size  $1\frac{1}{4}$  inch. Weight 9 drams 3 grains. Oxalate of Lime with a thin coating of Phosphates
133. Section of a Calculus of similar size and composition.
134. Fragment of an Oxalate-of-Lime Calculus, with a thin cake of Calcic Phosphate on its exterior.
135. Section of a Calculus. Size  $\frac{7}{8}$  by  $\frac{1}{2}$  inch. Nucleus oval, chiefly Oxalate of Lime with some Phosphate, surrounded by a mixture of Urate of Ammonia and Phosphate of Lime.

Removed by lateral lithotomy from the bladder of Walter Laing, aged 9, admitted Oct. 7, 1889, R.N. 2280. He had suffered from pain in the groin and thighs for some months.

Mr. Treves.

136. Sections of a Calculus consisting of loose Oxalate of Lime with blood, surrounded by a dense ring of Oxalate, then loose Phosphates, then a dense layer of Phosphate and Carbonate of Lime mixed. Size  $1\frac{1}{2}$  by  $1\frac{1}{4}$  inch.

Removed on January 3, 1890, by lateral lithotomy from the bladder of Samuel Lewis, aged 10 years, a Jew, whose mother said he had had much pain on micturition for some months. On admission the urine was normal, and had never contained blood; it was passed frequently. He was discharged cured in five weeks.

Mr. Hutchinson.

#### CALCULI HAVING THREE LAYERS.

##### **Oxalate of Lime. Urate of Ammonia. Phosphates.**

137. Section of an oval Calculus. Size  $2\frac{1}{8}$  by  $1\frac{3}{8}$  by 1 inch. Nucleus Oxalate of Lime, then a layer of Urate of Ammonia with some Phosphate, surrounded by a loose fenestrated layer composed of a mixture of Urate of Ammonia, Oxalates, and Phosphates.

##### **Oxalate of Lime succeeded by four or more layers.**

138. Section of a Calculus, tuberculated on the surface, and measuring  $1\frac{1}{4}$  by 1 inch in section. Nucleus Oxalate of Lime, succeeded by alternating rings of Oxalate of Lime and of Urate of Ammonia.
139. A Calculus in size and shape like a goose's egg. It consists of an Oxalate-of-Lime Calculus as large as a walnut in the centre, surrounded by a mass half an inch thick, composed of Phosphate and



Carbonate of Lime, in which are rings of Urate of Ammonia and a trace of Oxalate of Lime. It weighs 9 oz. 280 grs.

Removed from the bladder of Arthur Harvey, aged 27, who many years ago came to the Hospital with symptoms of stone, but no stone could be found. On March 3, 1888, he again came, and was admitted with retention, his history in the meantime being unknown. An enormous stone was felt per rectum and by the sound. Suprapubic lithotomy was done, and the stone extracted with great difficulty. He died the next day, and at the autopsy the whole genito-urinary tract was found disorganized by suppuration.

Mr. McCarthy.

140. An oval Calculus; the outer casing of Phosphates has been broken into fragments, most probably in removal. Nucleus Oxalate of Lime, then Uric Acid, then Oxalate, then mixture of Urate of Ammonia and Phosphates, with Phosphate of Lime externally.

#### CALCULI CONSISTING OF CYSTIC OXIDE (CYSTINE).

141. Section of a Calculus composed of Cystic Oxide. It measures  $2\frac{1}{8}$  by  $1\frac{5}{8}$  inch, is light green in colour, of a radiating and crystalline structure and soapy feel, and weighs 6 drams 14 grains.

#### CALCULI CONSISTING OF PHOSPHATE OF LIME.

142. Sections of an egg-shaped Calculus, measuring  $2\frac{3}{8}$  by  $1\frac{1}{2}$  inch, and composed of fairly homogeneous chalky Dicalcic Phosphate, with a trace of Oxalate. Analysis shows no Ammonia or Carbonate to be present; the Phosphate is fusible. Weight 13 drams 54 grains.
143. Section of an oval Calculus, 2 inches in length, consisting of concentric rings of Calcic Phosphate, in which is some Oxalate of Lime. Analysis proves ammonia absent.
144. Sections of a Calculus measuring  $1\frac{3}{8}$  by 1 inch. Nucleus Phosphate of Lime surrounded by mixed fusible Phosphates.
145. The outer casing of a Calculus measuring 3 by  $1\frac{1}{2}$  inch, whose nucleus, probably Urate, has been lost. It consists of infusible Tricalcic Phosphate, with a large amount of Urate of Ammonia.
146. Sections of a small flat circular Calculus, measuring  $\frac{1}{2}$  inch in diameter. Phosphates, then Oxalate, then Calcic Phosphate.



## CALCULI COMPOSED OF AMMONIO-MAGNESIC PHOSPHATE.

147. Sections of a flattened globular Calculus measuring  $1\frac{3}{8}$  inch in diameter. Nucleus Ammonio-Magnesian Phosphate, with Urate of Ammonia, surrounded by a loose layer of Phosphates, in which is a trace of Oxalates, and enclosed by a layer of Phosphate, which is fusible and contains some Urate.

Case of Edward Dighton, aged 66, admitted June 12, 1886, R.N. 1306, with a history of frequent attacks of sudden retention, severe pain at the end of, and difficulty of, micturition for  $4\frac{1}{2}$  years. Six months after the onset of symptoms, lithotrity was done at St. Peter's, and was subsequently repeated three times. He has used a catheter regularly, and of late as often as once an hour. For some time before admission he suffered from very severe pain at the neck of the bladder. His urine on admission was sp. gr. 1010, and contained vibriones, pus, and  $\frac{1}{10}$  albumen. His temperature was normal. Enlargement of the prostate was felt per rectum, and difficulty was experienced in feeling the stone with the sound. Suprapubic operation was done, and it was then found that the prostate projected into the bladder as a ledge, beneath which the stone was. It was extracted, but no relief to his symptoms followed. He died on the third day. At the autopsy, June 22, 1886, acute suppurative prostatitis with small subpericardial hæmorrhages were found. The heart and liver were fatty, the kidneys fairly healthy.

Mr. McCarthy.

## CALCULI COMPOSED OF PHOSPHATE OF LIME AND AMMONIO-MAGNESIC PHOSPHATE (FUSIBLE CALCULUS).

148. Sections of a globular Calculus, measuring  $1\frac{1}{8}$  inch in diameter, uniformly loose in texture, composed of a mixture of Calcic and Ammonio-Magnesian Phosphate, and is fusible. Weight 9 drams 22 grains.
149. Section of a Calculus. Size  $1\frac{5}{8}$  by  $1\frac{1}{4}$  inch. Mixed Phosphates.
150. Section of a smaller but similar Calculus, and probably of similar composition.
151. Fragments of a Calculus, probably composed of mixed Phosphates.
152. Fragment of an elongated stone of similar appearance and composition.

## CALCULI DEPOSITED ON FOREIGN BODIES.

**Earthy Phosphates.**

153. A hair-pin, partially embedded in a mass of mixed Phosphatic Calculus, as large as a hen's egg and weighing 6 drams 41 grains.



It was removed from the bladder of a woman aged 22, who was admitted on Nov. 27, 1885, R.N. 1312. She stated she had passed it into her bladder some months previously, elbow first, and had thought no more about it. When admitted one of the ends of the hair-pin was found projecting through the anterior vaginal wall. Vaginal cystotomy was performed by Mr. Rivington, and the stone removed; the wound was sutured, and a perfect recovery resulted.

154. A pen-holder with rough ivory handle, with a thin deposit of Phosphates thereon, removed from the female bladder.

*Presented by Mr. Rivington.*

155. A Calculus as large as a goose's egg, consisting of concentric rings of Phosphate of Lime, with some Urate of Ammonia deposited upon a mass, the consistence of soap, resembling in size and shape half a broad-bean. On the outer surface of the calculus are the marks of forceps, so that probably the calculus, which has been broken into fragments and subsequently repaired, was broken during removal, and not spontaneously fractured in the bladder.

#### CALCULI FROM THE KIDNEY.

156. Twenty-three small smooth facettèd Calculi, weighing 30 grains, and measuring rather less than a quarter of an inch in each diameter, of a light brown colour except on the centre of the facets where there is a blackish spot.

They were found in the pelvis of a kidney which was removed by Mr. Treves in December 1886. The patient, Alfred W., aged 25, had suffered from hæmaturia and pain in both loins at the age of 6 and again at 10 years. Left renal calculus was diagnosed in 1878. No hæmaturia since. On admission on December 2, 1886, R.N. 2656, a large tumour was felt in the left renal region. Abdominal nephrectomy was performed through an incision in the linea alba. The tumour consisted of six cysts, and contained these twenty-three calculi, one of which blocked the ureter.

Mr. Treves.

157. A smooth brown Calculus of flat oblong shape with rounded corners, probably removed from the kidney.

158. Three small Calculi, brown in colour, hard, smooth, and resembling pegs in shape.

Mr. McCarthy.

159. A number of Urate-of-Ammonia Calculi of mostly spherical shape, and as large as dried peas, weighing 1 dram 56 grains; probably renal in origin.

160. A number of small smooth flattened Calculi. Composition, Urate of Ammonia.



## CALCULI FROM THE URETER.

161. A Calculus measuring  $1\frac{1}{4}$  inch in length and  $\frac{5}{8}$  in width near the centre; one half is conical, the other half is cylindrical and faceted at the end, as if it had rested against another calculus. The stone was probably removed from the ureter. It weighs 1 dram 54 grains.
162. Two phosphatic stones cemented together by surfaces which were originally faceted. The larger is cylindrical, measures  $1\frac{1}{4}$  inch in length and  $\frac{1}{4}$  of an inch in width, and is bent at an obtuse angle in the centre. It was probably removed from the ureter.
163. Two small cylindrical Calculi joined end to end; probably from the ureter.

## CALCULI FROM THE PROSTATE GLAND.

164. A large number of minute spherical (prostatic?) Calculi, varying in size from a pin's point to a large pin's head, which were passed *per urethram* by a gentleman, T. B., aged 71, in January 1840.

## FRAGMENTS OF CALCULI AFTER LITHOTRITY.

165. Fragments of a Calculus weighing 136 grains, composed of almost pure Uric Acid.

They were removed by lithotripsy from the bladder of Peter R., aged 62, R.N. 2275, who had had typical symptoms of vesical calculus for four years, and had occasionally passed gravel. The prostate was enlarged.

Mr. Reeves.

166. Fragments of a Uric-Acid Calculus weighing 176 grains.

Removed by litholapaxy from the bladder of Hy. J. E., aged 58, admitted March 5, 1889, R.N. 519, with symptoms of vesical calculus of a year's duration.

Mr. McCarthy.

167. Fragments of a Calculus from the same patient as the preceding. They consist of Phosphate of Calcium deposited upon Uric Acid, and weigh 18 grains.

On May 6, 1889, some 6 weeks after the previous operation, he was again admitted with recurrence of symptoms. This stone was crushed, and he has since been quite well.

Mr. McCarthy.

168. Fragments of a small Calculus, weighing 114 grains, removed from a child aged 2, and consisting of Urate of Ammonia coated with Phosphate of Lime.

They were passed *per urethram* after repeated crushings on October 14th, 28th, November 11th, 18th, December 9th, 16th, 23rd, 1841.



169. Fragments of a Urate-of-Ammonia Calculus coated with Phosphate, removed after lithotrity. Weight 104 grains.

170. Fragments of a Calculus, chiefly composed of Urate of Ammonia and Phosphates, removed by litholapaxy.

The patient, a Lascar, Hodgi Isaak, aged 15, R.N. 2880, from whom no history could be obtained, was admitted on December 24, 1889, suffering from painful micturition. A stone was found by the sound. On March 12, 1890, after recovering from an attack of bronchopneumonia, lithotrity was performed, and these fragments removed. It was noticed, however, that all the water which was injected into the bladder did not return.

Mr. Rivington.

171. Fragments of a Calculus removed after suprapubic lithotomy.

From the same patient as the preceding. The day following the previous operation it was found that the lower part of the abdomen was much distended and dull on percussion below a line drawn between the two iliac spines. The patient had been twice sick during the night, was in great pain, and was getting collapsed. A vertical incision was made in the linea alba just above the pubes, and a quantity of blood-stained water was let out from the cellular tissue in front of the bladder. A minute perforation was found in the anterior bladder-wall; this was enlarged, and on exploration the bladder was found very dilated and sacculated, and these fragments were removed from a deep pouch on the floor. The bladder was stitched to the abdominal walls, and drainage-tubes inserted. Two days after the operation the boy was doing well.

Mr. Rivington.

172. Fragments of an Oxalate-of-Lime Calculus weighing 80 grains, removed from the bladder of Edward C., aged 69, on May 6, 1889.

The patient had suffered from frequent and painful micturition for 18 months. The stone lodged in a pouch behind the prostate, which was enlarged. He made an uncomplicated recovery.

Lithotrity by Mr. E. H. Fenwick.

173. Fragments of an Oxalate-of-Lime Calculus weighing 146 grains.

Removed by lithotrity from the bladder of a youth, Walter Moore, aged 18, admitted June 18, 1889, with typical symptoms of stone for 5 months.

Mr. Rivington.

174. Fragments of a Calculus, chiefly composed of Calcic Phosphate, removed after lithotrity; they weigh 4 drams 22 grains.

#### CALCULI REMOVED FROM OR PASSED BY THE URETHRA.

175. Calculus, about the size and shape of a large barley-corn, which was removed from the scrotum of a boy 8 years of age.

It had been impacted in the urethra near the bulbous portion, had ulcerated through the urethra, and had caused extravasation of urine. The bladder was distended with urine and reached above the umbilicus.

Mr. Rivington.



176. A small oval Urate-of-Ammonia Calculus, most probably passed by or removed from the urethra of an adult.

176 a. Another small oval Calculus with roughened exterior.

177. A small elongated oval phosphatic Calculus, which was removed in two pieces from the urethra of a man admitted with sudden retention.

Mr. Tay.

178. Fragments of Calculi of irregular shape, removed from the perineum.

The patient was admitted on Feb. 9, 1885, R.N. 342, for impermeable stricture, neither the house-surgeon nor Mr. McCarthy being able to pass an instrument. He was anæsthetized and a Wheelhouse's operation was performed. When the stricture had been divided a number of small faceted calculi matted together were found lodged in the substance of the perineum, the urethra having been completely ulcerated through. A catheter was tied in the bladder and the wound took an ordinary course. He subsequently was in St. Peter's Hospital with a hernia of urethral wall bulging into the perineum at each act of micturition.

Mr. McCarthy.

CALCULI REMOVED FROM THE FEMALE BLADDER AFTER DILATATION  
OF THE URETHRA.

179. Two Calculi, one triangular in shape with rounded angles, the other a flattened cylinder. The latter has been divided and is composed of a mixture of Urate of Ammonia and mixed Phosphates, and contains a trace also of Oxalates. They weigh 6 drams 32 grains.

These stones were removed on July 9, 1889, from the bladder of Mary J. H., R.N. 704. Soon after the birth of the last child, 20 years ago, the uterus and anterior vaginal wall prolapsed, and so continued till 3 months before admission, when the uterus was replaced and an instrument adjusted to prevent recurrence of the prolapse. Soon after this she began to be troubled with incontinence of urine and vesical pain, which increased till the present time. The urethra was incised and the stones removed, with perfect relief.

Mr. Mansell-Moullin.



SERIES LVI.—CALCULI AND OTHER CONCRETIONS  
FORMED IN THE DIGESTIVE ORGANS.

---

SALIVARY CALCULI.

180. A small oval calculus, measuring  $\frac{5}{8}$  by  $\frac{3}{8}$  inch, probably removed from a salivary duct.
181. A similar but smaller calculus.
182. Sections of a similar calculus, composed on analysis of Phosphate and Carbonate of Calcium.
183. Three adult molars, with irregular masses of tartar attached.
184. Several irregular and similar masses of tartar, removed from the teeth.

**Rhinolith.**

185. An irregularly cubical mass with numerous nodular projections, very light and of a greenish colour. It was removed from the inferior meatus of a young woman who had been unaware of its presence.

*Presented by Mr. Treves.*

BILIARY CALCULI.

186. Many black spiculated biliary calculi, resembling small grains of black pepper.
187. A large number of small facettèd gall-stones; on section they present the usual characteristics of the concretions—a nucleus of dark inspissated mucus surrounded by a thin shell of white material, probably consisting largely of cholesterine.
188. A collection of many similar calculi, somewhat smaller in size, more rounded, and more deeply stained with bile.
189. A collection of small gall-stones presenting a peculiar worm-eaten appearance upon the surface.



190. A collection of calculi of irregular shape, of the same composition on section as the preceding, but of larger size.
191. A number of biliary calculi, as large as green peas, of irregular shape, white and nodulated on the surface, with a reddish-brown nucleus of inspissated bile.
192. A collection of 11 large biliary calculi.
193. Two calculi, chiefly characterized by their regular hexagonal appearance. On section they are seen to be made up of cholesterine and laminae of concentrated bile.
194. Fragments of fairly large biliary calculi.
195. A collection of three biliary calculi; there is a regular deposit of semitranslucent material on the periphery.
196. Some crystalline powder; cholesterine.
197. Three irregular fragments of bile-stained cholesterine.
198. The half of a biliary calculus, the size and shape of a blackbird's egg, showing a beautiful radiating crystalline structure, and consisting of almost pure cholesterine.
199. Fragments of somewhat similar stones, but with the crystalline structure and purity of the cholesterine not so well-marked.
200. An exact cast of a gall-bladder of normal size, of pyriform shape; it measures  $2\frac{1}{2}$  inches by 1 inch; it is light, soapy to the touch, smooth on the surface, of a yellowish-brown colour. On section it is seen to be made up of a succession of layers varying in tint from yellow to dark red, composed of bile-stained cholesterine.
201. A calculus of similar composition, but showing traces externally of long residence either in a blood-clot or in the alimentary canal.
202. Three gall-stones from the same bladder, of a woman aged 48, each in the fresh state weighing 66 grains. They show a crystalline structure very similar to the preceding.

*Presented by G. Kernott.*

203. Fragments of a biliary calculus, showing very evident signs of having been deposited at different dates; it possesses a central mass



of very perfect crystalline appearance, surrounding which is a deposit of structureless organic material, the whole being encased in a shell of crystalline material similar to that in the central mass.

204. Two honeycombed calculi of oval shape, consisting of almost pure cholesterine in the centre, with a mixture of bile-pigment and phosphate of lime externally.

205. A biliary calculus, tuberculated on the surface, showing brown amorphous material in the centre.

Removed post-mortem from the gall-bladder of Elizabeth C., aged 51, who died of exhaustion following burns; there is no history of the calculus ever having caused symptoms.

Autopsy, March 24, 1888. Mr. McCarthy.

206. A fragment of a large biliary calculus passed per anum. Size  $1\frac{3}{4}$  by 1 inch, and roughly cylindrical in shape.

*Presented by Dr. Shepherd.*

207. A similar calculus, probably also passed per anum.



## SERIES LVII.—PLATES OF DISEASES OF THE SKIN.

## I. Cutaneous affections in specific diseases.

- Cholera : 1.
- Syphilis : 2-11.
  - Early : 2-4.
  - Late : 5-8.
  - Congenital : 9-11.
- Frambesia : 12.

## II. Inflammatory diseases of the skin.

## Acute.

- Urticaria : 13, 14.
- Erythema : 15-21.
- Erythema vel Herpes : 22.
- Herpes Zoster : 23-34.
- Impetigo herpetiformis : 35.

## Chronic.

- Pemphigus : 37-42.
- Psoariasis : 43-48.
- Pityriasis rubra : 49.
- Lichen : 50-54.
- Prurigo : 55-57.
- Strophulus : 58, 59.
- Eczema : 60-70, 74.
- Impetigo : 71-73.

Due to medicines taken internally : 75, 76.

## III. Non-inflammatory diseases of the skin, without destructive tendencies.

- Hypertrophic : 77-87.
  - Tylosis : 77.
  - Ichthyosis : 78, 79.
  - Verruca : 80, 81.
  - Papilloma : 82, 83.
  - Molluscum fibrosum : 84-87.
- Hæmorrhagic : 88.
  - Purpura thrombotica : 88.
- Pigmentary : 89-100.
  - Melasma : 89.
  - Chloasma : 90, 91.
  - Argyria : 92.
  - Melasma supra-renal : 93.
  - Lentigo : 94-96.
  - Leucoderma : 97-100.
- Fatty degeneration :
  - Xanthoma : 101-103.



IV. **Non-inflammatory diseases with profoundly destructive tendencies.**

- Lupus : 104-119.
- Morphæa : 120.
- Lepra : 121-124.
- Elephantiasis : 125, 126.
- Rhinoscleroma : 127.
- Keloid : 128, 129.
- Angeioma : 130, 131.
- Sarcoma : 132.
- Carcinoma : 133-138.

V. **Diseases of the appendages of the skin.**

Of the Hair and of the Hair-follicles.

- Hypertrichosis : 139, 140.
- Alopecia : 141, 142.
- Sycosis : 143-145.

Of the Sebaceous Glands.

- Seborrhœa : 146-149.
- Acne vulgaris : 150-153.
- Rosacea : 154.
- Rhinophyma : 156.
- Miliaria : 157.
- Medicinal Acne : 157.
- Molluscum Contagiosum : 158, 159.

Of the Nails.

- Onychitis : 160.
- Psoariasis : 160.

VI. **Parasitic diseases of the skin.**

Animal Parasites : 161-173.

- Scabies : 161-166.
- Pediculosis : 167-173.

Vegetable Parasites.

- Tinea favosa : 174-177.
- Tinea tonsurans : 178-181.
- Tinea circinata : 182, 183.
- Tinea marginata : 184-186.
- Tinea versicolor : 187-189.

**A tattooed man : 190.**

---

I. **CUTANEOUS AFFECTIONS IN SPECIFIC DISEASES.**

**Cholera.**

**Roseola Choleraica.**

1. The portrait displays the face and chest of a woman with brown hair and eyes ; it shows circumscribed hyperæmia of the face and numerous patches of erythema of the neck, breasts, and axilla ; these patches vary in size from a large pin's head to a sixpence, and are of various



tints, from brightish red to purplish and bruise-colour, some are well-defined, others shade off into the healthy skin; in some places they appear to be attended with exudation into the skin (*erythema exudativum vel urticaria*). H. ix. 1.

### Syphilis.

#### Papulo-scaly syphilide. Indurated Chancres.

2. The portrait shows one of the commonest early secondary syphilitic eruptions. The spots vary in size from a pin's head to a fourpenny-piece. They are red with a coppery tint somewhat raised, and many of them scaly. They occur equally on the two halves of the body, and are arranged with fairly exact symmetry. On the pubes are seen three separate chancres, two small ones side by side, and a very large one below them; the edges of all three are most typically indurated.

The chancres had been present for two months; there were enlarged glands in the groin, and symmetrical ulceration on each tonsil. Under small doses of mercury the chancres healed, and the eruption rapidly disappeared.

N. S. 31.

#### Papular syphilide.

3. The face of a young man presenting numerous papules, generally distributed. Sq.

#### Papular and acneiform syphilide.

4. The neck and back of a male showing papules and pustules, due to syphilitic inflammation of sudoriferous and sebaceous glands of the skin (*lichen et acne syphiliticus*). Sq.

#### Rupia with keloid of scars.

5. This portrait shows the arm of a man with an ulcerative secondary syphilitic exanthem; some of the ulcers are covered with limpet-shell crusts characteristic of rupia, some have healed at the edge and are crusted over in the centre, two are quite healed; of these, one situated at the upper part of the arm shows a thick, elevated, and glossy condition of the scar (keloid induration).

The patient was admitted into the London Hospital with a phagedenic chancre and a commencing papular rash. The chancre was cured by continuous immersion, but in spite of treatment the rash ulcerated and assumed the rupial condition here seen.

N. S. 40.

#### Rupia.

6. The face of a male with prominent elevations covered by a large amount of crust. Sq.



**Serpiginous ulceration.**

7. The portrait shows the thigh, the skin of which presents numerous serpiginous punched-out ulcers, crusts, and cicatrices with pigmentation.
8. The anterior and external aspects of the right leg and foot. The skin of the leg is greatly thickened, and excavated by numerous irregular superficial and deep ulcers with intervening cicatrization.

**Congenital Syphilis.****Erythema infantum.**

9. The back and lower extremities of an infant displaying wide areas of erythema with irregular but circumscribed margin. W.
- 9 a. A portrait showing the head of a man. Upon the scalp is an extensive fungating ulcer with incrustation, and on the nose and eyebrow serpiginous ulceration and purulent crust.

**Gyrate syphilitic psoriasis.**

10. The plate shows the head of an infant six months old with a congenital syphilitic exanthem, chiefly limited to the face. The rash consists of well-defined patches, some of them irregularly ringed, others gyrate. There is more infiltration of the skin and more epidermic and purulent scab than occurs in ringworm, which it somewhat resembles.

From an infant, with a distinct history of inherited syphilis, who made a rapid recovery under mercury, and who was brought to Mr. Hutchinson six years subsequently with interstitial keratitis and no other manifestation of congenital taint.

N. S. 28.

**Rupia psoriasis.**

11. This plate shows the left side of trunk and thigh of a female covered with syphilitic ulcers, some of them circular with heaped-up rupial scabs, some serpiginous, spreading at the edges, and a tendency to heal in the centre.

The patient, a girl aged 11, presented no signs or history of inherited syphilis; her mother and she presented exactly similar eruptions at the same time. The child's symptoms, languor, weakness, spots on the back, sore throat, did not begin until two months after the commencement of the secondary symptoms (severe ulcerating rash and double iritis) in the mother. No clue to a primary chancre could, however, be obtained.

N. S. 37.



**Frambesia.**

12. The portrait shows the upper extremity, the under surface of the foot, and another portion of skin covered by papules and tubercles of various sizes, of a reddish colour, and irregular surface, with stains and pigmentary scars, presenting an appearance which has been compared to a raspberry.

From an Englishman, aged 26, admitted into the hospital for dysentery and malarial liver and spleen. The dysentery commenced ten days after leaving Peru, lasted for a month after admission, and was followed by the present eruption. For the past 10 years he had lived in Peru, and whilst working in silver mines near Lima two years ago he suffered from a slight attack of warts, which enlarged, became pedunculated, and spontaneously dropped off. Many hundreds of the workers in these mines suffered from similar warts, which they attributed to drinking snow-water. He was rapidly cured.

N. S. 41.

## II. INFLAMMATORY DISEASES OF THE SKIN.

## ACUTE.

**Urticaria.**

13. The back, buttocks, and thighs of a male covered by numerous irregular-outlined raised patches of hyperæmia and exudation; the margins of the patches are well-defined, and of a deeper tint than the centres.

H. ix. 2.

**Urticaria alba vel œdematosa.**

14. 1. The portrait shows the back of the forearm and hand, upon which are raised patches varying in size from a pea to a sixpenny-piece, and nearly of the same colour as the skin; some are surmounted by slight blood-crust, as though produced by scratching.

2. The portrait shows the right leg and foot. Upon the former are situated many slightly hyperæmic circumscribed elevations varying in size from a pea to a sixpence, with numerous blood-crusts from scratching. Around the ankle are grouped a number of tense and flaccid bullæ of rounded and oval shape, some irregular from coalescence; they vary in size from a large pea to a chesnut.

H. ix. 4.



**Erythema exudativum.****Erythema nodosum.**

15. The portrait shows in the centre oval patches, raised and of a dusky colour with gradual shading-off at the edges, and situated over the extensor surfaces of the legs and forearms.

From a lad, aged 14, who had had no attack before. The eruption was copious and accurately symmetrical; it occurred on the front of the legs first and then on the backs of the arms; the patches were indurated, tender, and oedematous. It remained at its height a week, then slowly faded, did not relapse, and the patient went out well in one month.

N. S. 21.

16. 1. The portrait displays the left leg and right hand, upon the extensor surfaces of which are congested nodose swellings.

**Herpes Iris.**

2. At the upper part a left foot is shown, upon which are several vesicles and bullæ surrounded by rings of vesicles and hyperæmia (herpes iris).

H. vi. 4.

**Erythema tuberculatum.**

17. The portrait shows the backs of the legs with numerous elevated and hyperæmic patches which fade off into the surrounding skin.

Sq.

**Erythema circinatum.**

18. The portrait of the shoulders and arms of a boy with conspicuous red patches, with abrupt raised margins of a lighter tint. The margins are solid, and therefore not herpetic; they become pale when the skin is stretched. None of the patches are scaly, and only when scratched showed crust.

The patient, aged 5, a healthy robust child, had suffered three times previously from attacks of this eruption. There was no family history; season had no influence. For some weeks before the rash appeared, he felt feeble and ill. Between the attacks he regained his health perfectly. The rash was symmetrical, and rapidly and spontaneously disappeared; its reappearance being prevented by arsenic.

N. S. 24.

**Erythema annulatum.**

19. The portrait shows the right leg with numerous, mostly circular, patches of erythema, which vary in size from sixpence to a crown piece. At the margins the colour is deeper, and fades away into the surrounding healthy skin.

W.



**Erythema multiforme.**

20. The portrait shows the face, left and right upper extremities of a woman with raised patches for the most part circumscribed, and of a colour varying from bright red to purple. The eyelids are swollen and ecchymosed. H. vi. 1.

**Erythema annulatum seu marginatum.**

21. 1. The back of the right forearm, with patches of exudative erythema of irregular outline and purplish colour.

**Erythema iris.**

2. The back of the left wrist and hand, with vesicles surmounted by slight crust and surrounded by a halo of congestion.

**Erythema papulatum.**

3. The back of the lower half of the left forearm and hand, with varying-sized hyperæmic papules and tubercles, and surrounding congestion. H. vi. 2.

**Erythema vel Herpes Iris vel Hydroa.**

22. The face and back of the right forearm of a female, showing groups of vesicles surrounded by hyperæmia, and patches of exudative erythema. H. vi. 3.

**Herpes Zoster.**

23. The back of the forearms and hands, upon which are seen numerous vesicles isolated or in groups, many of which are surrounded by other ringed vesicles. H. vi. 6.

**Herpes labialis.**

24. 1. The face of a woman with clusters of numerous small vesicles on the nose, upper and lower lips.  
2. The back of the right hand, upon which are numerous vesicles and bullæ arranged in a ringed manner.

**Herpes præputialis.**

3. A penis showing clustered vesicles on the mucous surface of the retracted prepuce; in one place rupture of vesicles has led to an excoriation. H. vi. 5.



**Herpes vulvæ.**

24. 4. Clustered vesicles upon the swollen labia minora. H. vi. 5.

25. This portrait shows patches of small and clustered vesicles on the right anterior half of the scalp, the right forehead, upper eyelid, and side of the nose of a child. The skin over these parts is congested, and corresponds with the distribution of the ophthalmic division of the fifth cranial nerve.

Case of W. W., aged  $3\frac{1}{2}$ , previously in good health. On Wednesday he began to feel ill and suffer from headache, on Thursday the skin was reddened, on Friday he was sick and vomited, and later in the day the vesicles began to appear. The rash remained out for about a week and gradually receded, all ulceration being healed in three weeks.

N. S. 8.

26. The portrait shows the head and face of an elderly man with numerous groups of small coalescing vesicles, excoriations and crusts, with hyperæmia of the intervening skin on the left side of scalp, forehead, nose, and cheek. The disease in this case implicates the areas of distribution of the first and second divisions of the fifth cranial nerve. H. vi. 7.

27. The portrait shows the head, neck, and chest of a young man, with clustered small vesicles upon the left side of the nose, cheek, neck, and chest. The vesicles have ruptured in places and formed slight crusts. The disease implicates the areas of skin supplied by the second division of the fifth cranial nerve and ascending and descending superficial branches of the cervical plexus. H. vi. 8.

28. The portraits show clusters of small vesicles distributed with almost perfect symmetry over the forehead, cheek, and upper part of the neck. H. vi. 9.

29. 1. The portrait shows the right side of the face and neck of a man; upon the outer surface of the helix are numerous small mostly isolated vesicles, some are confluent; situated over the thyroid cartilage and over the centre of the sterno-mastoid muscle are a few similar vesicles; upon the right cheek is a large patch of irregular shape composed of confluent pustules and covered with a thick yellow layer of dried exudation. Above the right eyebrow, on the chin and near the angle of the mouth, there are similar patches as large as a sixpence.



29. 2. The portrait shows the ear of the same patient, with numerous small clear vesicles upon the helix.
30. The portrait displays the inner side of an arm and flexor surface of the forearm and hand, upon which are vesicles isolated and in clusters of all shapes and sizes. Some of the vesicles appear to have dried up, leaving crusts. The distribution of the vesicles seems to correspond roughly with the internal cutaneous and lesser internal cutaneous nerves.  
H. vi. 10.
31. The portrait shows the right scapular, axillary and pectoral regions covered with an eruption composed of vesicles and pustules arranged in corymbose groups. The area affected measures five inches over the scapula, two and half inches in the axilla, and three at the nipple-line. Some hyperæmia of the skin immediately surrounding these vesicles is depicted.—A well-marked case of common shingles, and corresponds with the area of distribution of the intercostal nerves.  
H. vi. 11.
32. The portrait of the head and trunk of a woman upon the right side of whose back, axilla, and loin, over an area corresponding to that supplied by the lower intercostal and lumbar nerves, are groups of small and large vesicles with hyperæmia of the intervening and surrounding skin. A few of the vesicles have either desiccated or formed pustules.  
W.

**Herpes Zoster, with scars of former attack.**

33. This portrait is a good example of common shingles. The eruption extends in an oblique half belt from the spinous processes of the mid-dorsal vertebræ forwards under the right nipple to the middle line at the lower part of the sternum. The vesicles are arranged in oval or irregular groups with ill-defined borders; some of the vesicles are still pellucid, some have become purulent, in others the contents have become tinged with blood. The vesicles are in many parts confluent; they have a bright red congested base. Amongst these vesicles are seen the white depressed cicatrices left by a former attack.  
N. S. 23.
34. The portrait shows the lower part of the right side of the abdomen, right gluteal and hamstring regions of a man. Upon the loin are many groups, often elongated in shape, of large opaque vesicles; the long diameter of the groups lies parallel to the course of the inter-



costal nerve. Upon the buttock and thigh are similar arborescent groups of opaque vesicles, covering the area supplied by the small sciatic nerve. H. vi. 12.

### **Impetigo herpetiformis.**

35. The portrait shows the lower part of the abdomen and thighs of a female. The pubes, inner surfaces of each thigh, and anterior surface of the right thigh over an area internal to the sartorius muscle are completely covered with greenish-brown, heaped-up, cracked scabs; these areas are fringed with a zone of hyperæmic skin half an inch in width, upon which are rows of small vesicles with clear contents. Scattered over the thighs, in other parts, and over the right knee are similar patches of circular outline and varying size. H. ix. 9.

36. The chest, abdomen, pubes, and thighs of a woman, upon which are seen vesicles, single, double, and in clusters of all sizes; scattered pustules and areas of all sizes covered with dark brown scab ringed by vesicles upon hyperæmic skin. Around both nipples, over an area measuring three inches in diameter, the skin is covered with a dark scab upon which are radiating furrows. H. ix. 10.

### **CHRONIC.**

#### **Pemphigus.**

37. The shoulders and arm of a girl covered with very large and numerous bullæ. The skin surrounding them is but little inflamed. Some excoriated patches and thin scabs are seen where the bullæ have burst and dried up.

The patient, M. M., aged 10, of brown complexion, good health, and Scotch descent, had had three previous attacks, and was cured by two minims of Fowler's solution given thrice daily. In each attack the rash has been symmetrical, and has affected the trunk and inner surfaces of the arms and thighs.

N. S. 13.

38. The lower half of the neck, the chest, arms, and extensor surfaces of the left forearm and hand of a man showing an eruption of bullæ of all sizes from a pin's head to a green pea arranged in groups, in some cases as large as a half-crown; in the centre of these groups is a dark crust; there is little or no hyperæmia of the adjacent skin.

H. ix. 7.



**Milium progresso Pemphigo.**

39. 1. The dorsum of a right hand upon which are seen groups of innumerable minute discrete vesicles, which are most numerous on the backs of the fingers. On the back of the hand, and adjacent to the vesicles, are several small irregular excoriations.

**Pemphigus vulgaris.**

2. The back of a right arm and upper part of the forearm almost completely covered with large, circular or crescentic, somewhat opaque bullæ, with considerable hyperæmia of the adjacent skin.

H. ix. 6.

**Pemphigus pruriginosus.**

40. The portrait shows upon the left upper extremity of an old woman vesicles and bullæ, several small ulcers of irregular shape, numerous small longitudinal ecchymoses evidently produced by scratching, and much irregularly disposed hyperæmia and thickening of the skin.

H. ix. 5.

**Relapsing Pemphigus.**

41. The portrait shows the right hand and left foot; upon the middle finger is a fairly recent bulla, circular in shape and well-defined in outline, with yellowish contents; upon the ring-finger is an area of hyperæmia; upon the index and dorsum of the foot are thick circular scabs, the dried suppurated contents of previous bullæ; upon the lower part of the leg is a similar dried-up bulla with less crust.

Sq.

**Pemphigus foliaceus.**

42. The portrait shows the left side of the face and neck with the chest and shoulders of a woman, whose skin is everywhere covered with large, irregular, yellowish-green semi-detached flakes composed of thickened epidermis and dried exudation. Areas of red hyperæmic corium are in several places exposed by the detachment of these scales.

H. ix. 8.

**Psoariasis.**

43. The chest and left upper extremity of a girl, exhibiting ringed patches varying in size from a pea to a half-crown, for the most part somewhat circular in shape, of hyperæmic and infiltrated skin, with slight scaling.

H. iii. 5.



**Psooriasis inveterata.**

44. This portrait shows the left arm and chest of a man covered with thick dry scaly crusts of heaped-up epidermis. The eruption was symmetrical and affected the backs of the limbs, especially the olecranon and patella.

A young man of tolerably good general health, who was almost covered with thick patches of silvery scales. He had been under treatment for years, and had been repeatedly cured or nearly so by arsenic.

N. S. 14.

**Psooriasis gyrata.**

45. The chest, abdomen, and right arm of a man, exhibiting the thick epidermic scales with some hyperæmia of the skin as is usual in psooriasis, but distributed in festoons an inch in width. H. iii. 6.

**Psooriasis diffusa.**

46. The head of a middle-aged man, apparently in good health, whose face and scalp are covered by the white, dry, scaly crusts of common psooriasis; at most parts the patches show margins more or less well-defined. N. S. 4.

47. A portrait of the legs of a woman, below whose knees are seen somewhat circular patches of thick white scales upon hyperæmic skin, a large patch on the right and two small ones on the left leg.

Sq.

**Psooriasis inveterata.**

48. The portrait shows the extensor surface of the right upper extremity, almost completely covered with patches of thick epidermic scales of a white colour. W.

**Pityriasis rubra.**

49. The portrait shows the leg, foot, arm and hands of a lady, aged 77, presenting a severe form of this disease. The skin is everywhere intensely congested; on the leg and hands there are large flakes of peeling epidermis; the arm is almost destitute of scales. The nails are greatly thickened, incurved, discoloured, and raised from the nail-bed.

The disease began during the hottest part of the summer without apparent cause, and was not amenable to treatment; it finally got perfectly well spontaneously. Her skin had always been very white and delicate, and was never moistened from perspiration, even in the hottest weather.

N. S. 30.



**Lichen.****Lichen ruber.**

50. The portrait shows on the face, neck, chest, and right arm of a man large patches of infiltrated corium covered with white epidermic scales. The patches are of irregular shape, have fairly abrupt margins, and are surrounded by a narrow ring of hyperæmia. Over the shoulder and lower part of the neck are isolated papules, quadrilateral in outline and darkish red in colour. H. iii. 2.

**Lichen scrofulosorum.**

51. The portrait shows upon the right side of the trunk and over the extensor surface of the right arm groups of papules, the size of pin's heads, in colour either pale yellow, brownish red, or not differing from the normal skin. H. iii. 3.

- 51 a. The portrait shows upon the anterior surface of the legs scattered irregular patches of thick scales upon a slightly raised base.

The patient was a baker, aged 18, and was not benefitted by treatment.

**Lichen inveteratus.**

52. The portrait shows the back of the neck and shoulders covered with a large area of shiny papules; in several places are blood-crusts, the result of scratching. Sq.

**Lichen pilaris.**

53. The plate shows the outer surfaces of the left lower and upper extremities covered from the ankle and wrist upwards with innumerable dark papules, all the size of small pin's heads; there is no hyperæmia, nor evidence of scratching (keratosis pilaris). H. vii. 9.

**Prurigo.****Prurigo simplex.**

54. 1. The portrait of the parts near the knee; the skin is thick, wrinkled, and rough, and presents scattered ill-defined papules. The presence of numerous blood-crusts, the result of scratching, shows that the condition was attended with great irritation.

**Prurigo agria.**

2. A leg showing similar characteristics: papules, vesicles, many excoriated surfaces of irregular shape and size, general thickening and hyperæmia of the skin. H. v. 6.



**Prurigo ferox.**

55. The portrait shows the skin of the thighs and knees, everywhere thickened, wrinkled, roughened, and deeply pigmented, and covered with excoriations and blood-crusts. H. v. 7.

**Prurigo adolescentium vel æstivale.**

56. This portrait presents the head, neck, chest, and upper extremities of a boy, with an eruption of small scattered red papules, in centre of some of which are minute accumulations of pus. The skin is marked all over with very shallow white cicatrices of old eruption.

Case of C. P., aged 13, who was an in-patient at the London Hospital in August 1867. He had had the eruption from infancy; it got well in winter and relapsed in summer. He was covered with eruption from head to foot, the palms and soles alone being exempt. It itched only at night.

N. S. 38.

**Pruriginous Impetigo after Varicella.**

57. The portrait of the face, arm, and leg of a child whose skin in these parts is covered with small pustules and superficial ulcerations which resulted from scratching. In some places there are blood-crusts, in others circumscribed pus-scabs on the spots. On the scalp the pus-scabs are large and thick, and present the condition known as Porrigo (compare No. 73).

The rash is attended with intolerable itching, appears in successive crops, and affects every part, even the palms and soles.

N. S. 32.

**Strophulus.****Lichen infantum vel Strophulus.**

58. The portrait of an infant four months old, presenting a severe case of strophulus or red gum. The eruption consists of small red elevated papules, for the most part discrete, in some parts confluent forming irregular patches.

The eruption prefers the face and chest, but appears anywhere; it occurs in perfectly healthy children, soon after birth, may last for months, and disappears spontaneously.

N. S. 34.

**Urticaria papulosa vel Lichen urticatus.**

59. The plate shows upon the back of the right forearm and hand and front of the right leg many papules and tubercles of a bright red colour; at the apex of many are minute blood-crusts the result of scratching; there are also numerous circular areas of pigmentary staining and a few blood-crusts, probably the relics of excoriated papules which have subsided. H. ix. 3.



**Eczema.****Eczema impetiginosum.**

60. 1. The face of a child with large symmetrical patches of hyperæmic skin covered with partially dried puriform secretion on each cheek, and very small patches over each eyebrow.
2. The lower half of the abdomen of a boy, showing small irregular patches of hyperæmic skin upon which are vesicles, pustules, and dried purulent secretion.
3. The outer surface of the right upper extremity, showing general hyperæmia of the skin. At the upper part are a few small papules, succeeded by vesicles, increasing in size and number, until at the elbow the congested area of skin is almost completely covered by clear vesicles as large as millet-seeds (*eczema vesiculosum*). At the lower part of the forearm are ruptured vesicles, pustules, and purulent scabs.

H. iv. 12.

**Eczema faciei et capilitii.**

61. 1. The head of an infant of good health, fair complexion, and brown eyes, with irregular patches of eczematous eruption on the face and scalp. The crusts are sticky, and the discharge will stiffen linen. The crusts do not accumulate in thick heaped-up scabs like those of *porrigo*. In such cases as that illustrated by the drawing there is always evidence of inflammation of the skin around the crust-covered patches.

N. S. 16.

**Eczema rubrum.**

2. This portrait shows the leg of a healthy labouring man with severe eczema in connection with varicose veins. The internal saphena vein is seen to be enlarged and tortuous in the thigh and behind the ankle. The inflamed surface is more than usually red, and is covered with numerous patches of thickened and partially detached scales and dried secretion.

N. S. 16.

62. The right leg covered with thick, dryish flakes of cuticle of irregular size, dirty yellow in colour, curled up at the edges, and partially detached from the intensely congested deep-red corium beneath.

H. iv. 11.

**Eczema impetiginosum in Prurigo.**

63. 1. The portrait shows the pubes and upper and inner side of the thigh; in the latter situation is a patch where the skin is thickened, hyperæmic, somewhat scaly, with some crust at the margins, which are irregular and ill-defined.

H. v. 5.



**Eczema rubrum.**

63. 2. A right leg presenting from the ankle upwards large dry flakes of thickened epidermis in process of exfoliation ; the skin beneath and between is highly congested and of a bright red colour. H. v. 5.
64. 1. The palmar and dorsal surface of a left hand, exhibiting the epidermis soddened, thickened, and in many places cracked, the subjacent inflamed corium being exposed. H. iv. 5.

**Eczema impetiginosum.**

2. Surrounding the nipple for a radius of two inches the skin is hyperæmic, and is covered at the periphery with thin yellowish exudation, and nearer the nipple with dirty yellow scabs composed of epidermic scales and dried purulent secretion. The edge of the hyperæmic area is ill-defined, it gradually shades off into the surrounding healthy skin. H. iv. 5.
65. The portrait of the head and neck of a woman, showing impetiginous eczema or contagious porrigo of the forehead and face. The eruption is characterized by thick purulent crusts which completely cover the inflamed portion of the skin. It is contagious, easily curable by local remedies, of local origin, and most often seen in children and in the scalp.  
There is so little inflammation in connexion with the purulent crusts that the case may be regarded as a good example of impetigo. N. S. 15.
66. The face of a youth showing pustular eczema of the forehead, eyebrows, eyelids, cheeks, lips, chin, and ear-lobules. H. iv. 2.
67. The right side of the face of a woman with pustular eczema of the pinna and of the adjoining skin and scalp. The disease affects the skin from below the ear to the top of the forehead, and extends forwards to the outer canthus of the eye ; the greenish, heaped-up scabs are typical. There are similar scabs in the scalp. H. iv. 3.
68. The wrinkled face of an old man, showing numerous eczematous vesicles and pustules on the root, side, and tip of the nose, on the cheek, upper and lower lips, and chin. H. iv. 4.
69. The portrait shows the back of the hand, forearm, and lower part of the arm. The skin is everywhere hyperæmic and covered by numerous vesicles. Over the upper part of the forearm is an irregular area covered with dried-up purulent secretion. H. iv. 9.



**Sugar-baker's Eczema.**

70. The portrait of the arm of a sugar-baker, whose skin is covered with large irregular patches of eczematous inflammation. Many of the smaller ones show blood-crusts, and have evidently been scratched. The whole arm is oedematous.

The eruption commenced on the hand and extended to the shoulder; he had had several attacks before; it is caused by some irritant, and relapses owing to constitutional predisposition.

N. S. 25.

**Impetigo.**

71. A photographic portrait of a boy over whose eyebrows and nose is a patch of thick dry brown scab, sharply defined and not surrounded by hyperæmia. Sq.

72. The face of a boy almost covered with thick yellowish crusts of dried secretion and epidermis; there is a little hyperæmia of the adjacent skin and some evidence of excoriation at the edges of some of the crusts. W.

**Impetigo contagiosa after Vaccination.**

73. This portrait shows the thick, heaped-up, dirty scabs of the eruption known as Impetigo or Porrigio contagiosa. The crust completely covers the whole of the inflamed patch.

In the present instance it resulted, as it not unfrequently does, from suppuration under the scab left by vaccination.

N. S. 28.

**Eczema squamosum seu Pityriasis rubra.**

74. The portrait of the head and neck of a girl, showing in the scalp, over the parotid region, and over the back of neck a well-defined area of deeply congested skin upon which are seen thin scattered flakes of epidermis. H. iv. 1.

**Eruption due to medicines taken internally.****Bromide of Potassium.**

75. The portrait of the lower extremities and right arm of a child, showing numerous circumscribed roundish and irregular elevations of the skin; they are of a pink or crimson colour, the summits of the elevations showing vesicles and scabs; in some places clusters of vesicles and



pustules are seen upon a hyperæmic base, these latter are the earliest stage of the lesion, the crust-formation being a late stage.

The eruption had been out between two and three weeks, and followed the administration of 5 grains of bromide of potassium three times a day for about fifteen days.

N. S. 44.

### **Hydroa from Iodide of Potassium.**

76. This portrait of the arm, face, and neck of a woman shows an early stage of the eruption; it consists of bullæ and vesicles of various sizes, with comparatively little congestion of the intervening skin except upon the face. It differs from pemphigus in that few of the vesicles are accurately round or oval, and those which are large are never tense or globose.

Case of J. C., aged 50, married. When first seen she was suffering from a papular rash of the face and forearms resembling variola. Some medicine which she had taken was analyzed, and found to contain iodide of potassium. In the hospital the rash subsided on expectant treatment. Three times subsequently after taking iodide of potassium she developed severe frontal headache, coryza with profuse running of the eyes and nose, high temperature and prostration, and an eruption at first papular, then vesicular, then bullous and pustular, and always situated upon the face and forearms and hands. There were never any papules on the soft palate or pharynx. The eruption always subsided when the medicine was discontinued.

N. S. 33.

## III. NON-INFLAMMATORY DISEASES OF THE SKIN, WITHOUT DESTRUCTIVE TENDENCIES.

### **Hypertrophy.**

#### **Tylosis et gryphosis.**

77. The two hands and a foot, showing great thickening of the epidermis of the palms and sole.

#### **Onychogryphosis.**

Two great thickened elongated and incurved nails of toes, producing talon or claw-like appearance.

H. x. 1.

#### **Ichthyosis Simplex.**

78. The front of the trunk and left upper extremity of a male. The skin is dry, and irregularly covered by thickened epidermic scales unattended by any evidence of inflammation.

H. iii. 10.



**Ichthyosis hystrix.**

79. The disease covers the back, shoulders, and arms of a girl, and presents the characters of a sort of dark brown mail. The mail consists in part of papillary elevations and in part of thick crusts of dried sebaceous and epidermic accumulations adherent to the papillæ. These crusts have at places been detached, leaving the skin red and abraded, and the papillæ exposed. It is the papillæ, or spinous elevations, which give rise to the term *Ichthyosis hystrix*, or porcupine skin. N. S. 7.

**Verruca.**

80. 1. The portrait of the back of the right lower extremity, showing warty growth and pigmentation extending in a linear manner along the course of the great sciatic nerve.

When seen three years later, the pigmentation had much diminished.

2. Papillary growths and thickening of the skin of the left axilla. Above is a separate drawing showing the papillary character of the growth.

**Epidermic or Horny Growths.**

3. A full and also a profile view of the parts about the knee, showing an irregular patch of greatly thickened epidermis from which spring two massive brownish horny excrescences, the larger of which projects nearly an inch from the surface.

- 80 a. The portrait shows a left leg and foot, the subject of chronic inflammation of the skin, with thickening and cracking of the epidermis on the foot and extensive papillary growth on the lower and outer part of the leg.

**Nævus verrucosus.**

81. A large well-defined area of the trunk where the skin is thickened, pigmented, warty, and covered with hair. H. viii. 9.

**Frambæsia Papillomata.**

82. 1. A penis and scrotum, showing numerous raspberry-like warty growths on the dorsum and prepuce of the penis.  
2. A portrait, showing the penis and scrotum; there is a collection of raspberry-like warty growths between the glans and prepuce;



the latter is in a condition of phimosis and has apparently been divided.

3. The external genitals of a female, upon which are situated massive raspberry-like warty growths. H. x. 2.

83. The portrait of an elderly man, showing a massive lobulated and rounded hyperæmic growth, springing from the right upper eyelid.

### **Molluscum fibrosum.**

84. The portrait of a man whose face, trunk, and extremities are covered with small solid fibro-cellular tumours, some subcutaneous, others sessile, and a few pedunculated. The skin over some is healthy, but over others is thickened and its papillæ hypertrophied.

James Gray, aged 27, was first seen by Mr. Hutchinson in 1866, the tumours at that time being quite small, but universally distributed. He had had them ever since he could remember, but his mother said he was not born with them. No other member of his family was affected. They have continued to grow; several of the tumours have been excised for examination from time to time.

N. S. 18.

85. A portrait of the back of a man, showing numerous sessile tumours of varying size and covered with normal skin; one of these tumours is semi-pendulous and lobulated.

86. The portrait of the head, trunk, and upper extremity of an elderly man whose skin is nearly everywhere covered by numerous solid elevations, some sessile and some pedunculated; the skin covering the elevations is for the most part natural in colour. H. vi. 11.

87. The portrait shows scattered over the loins and buttocks numerous sessile round tumours varying in size from a pea to a hazel nut, and in addition a pedunculated globular tumour as large as a tamarind hanging from the right loin by a pedicle an inch in thickness; the skin over this tumour is of a deep red colour, and is superficially ulcerated over an area as large as a shilling.

This portrait is described in Hebra's Atlas as *Molluscum contagiosum*.

H. vii. 12.

### **Hæmorrhagic.**

#### **Purpura thrombotica.**

88. The right leg of a girl, aged 18, presenting an eruption of hæmorrhagic spots with some injection of the surrounding skin. A line of extravasation indicates the position of the garter.

Mr. Nettleship has demonstrated microscopically plugging of the capillaries in this case.



Eliza R., a servant who whilst in the hospital had at least half a dozen relapses; each crop of purpuric spots was preceded for two days by pain in the lower part of the body, and was accompanied by albuminuria and high temperature. Each crop lasted from a few days to a fortnight. She had been previously in good health. There was no history of rheumatism or scurvy. There were no hæmorrhages elsewhere. She menstruated regularly and normally.

N. S. 39.

### **Pigmentary.**

#### **Melasma.**

89. The portrait shows the face, bend of the elbow, and back of the hand of a young woman with dark brown hair and eyes, and dark complexion. The face is everywhere dotted over with small brownish-black pigment-spots the size of a pin's head; there are similar spots of a purplish colour upon the lips. Upon the bend of the elbow the spots are larger and confluent. Upon the extensor surface of the joints (knuckles) of the fingers are similar pigmented spots.

The appearances here depicted, which were symmetrical on the two sides, were stated to have been noticed in infancy or early childhood, and to have followed a convulsive seizure.

Dr. Ramskill, Aug. 30, 1870.

#### **Chloasma uterinum.**

90. The portraits of two women; on the foreheads, cheeks, noses, lips, chin, and neck of each are sharply defined areas of dark-brown pigmented skin; in the left portrait the areas are small, and the face consequently has a mottled appearance; in the right the pigment is distributed with fair uniformity.

H. viii. 6.

#### **Chloasma cachecticum.**

91. The faces of two different men, upon which are seen dark-brown pigmented areas of irregular shape and size. Upon the forehead of the left face are many small pigmented spots the size of a pin's head; upon the right portrait there is a cicatrix on the cheek, at the outer angle of the left orbit. The neck is misshapen, as though from glandular enlargement, and on the lower part of the neck and upper part of chest are a number of white specks which appear to be vesicles and punctate cicatrices.

This condition was ascribed by Hebra to exposure to the sun, dirt, bad living, and malaria.

H. viii. 8.



**Argyria.**

92. The portrait of a woman with brown eyes and hair, whose skin is generally tinted of a purplish or slaty hue. The conjunctiva and lips are similarly stained. Such a condition follows the prolonged internal administration of nitrate of silver. H. viii. 7.

**Morbus Addisonii.**

93. This plate shows the face, the back of one hand, and a section of one suprarenal capsule of an English woman who had shown no unusual darkness of skin before the disease commenced. The skin is nearly as dark as that of a negress, and the pigment is everywhere diffused, but in the hand is more intense over the knuckles. The lips also are pigmented. The conjunctivæ remain of a natural colour.

The disease had existed some years. It is generally associated with a peculiar anæmia and asthenia, all cases tending sooner or later to end fatally.

N. S. 11.

**Lentigines (Ephelides).**

94. The portrait and hand of a red-haired, very light complexioned woman, presenting innumerable reddish-brown well-defined freckles upon the face and back of the hand, unaccompanied by inflammation or desquamation. H. viii. 4.

**Lentigines perstantes.**

95. The portrait shows the male genitals, the loins and buttocks, upon which are numerous similar pigmented spots (freckles). H. viii. 5.
96. The portrait of a woman upon whose forehead, nose, cheek, and upper lip are patches of brownish pigment, of almost perfect symmetry (*Chloasma uterinum?*). Sq.

**Leucoderma congenitale. Albinism.**

97. The portraits of a girl and boy. Both have white hair, and an almost total absence of pigment in the skin, iris, and sclerotics. The pupil is pink, owing to the illumination of the fundus through the transparent sclerotic. H. viii. 1.

**Leucoderma acquisitum. Vitiligo.**

98. The lower half of the abdomen and thighs of a man, showing numerous patches of skin quite devoid of pigment, and presenting a



sharply defined convex border. The skin around these patches is deeply pigmented in many parts. The hairs upon the patch situated at the root of the penis are devoid of pigment. H. viii. 2.

99. The head, chest, and left arm of a man, showing patches of leucoderma, smaller and less well defined than in the preceding plate. There is similar pigmentation of the skin around. The hair of the head and beard is white where it grows upon the patches. H. viii. 3.

100. The portrait shows the trunk, head, and upper extremities of a boy with numerous more or less circular, abruptly defined patches of decolorized skin. There is a rude symmetry about the distribution of the patches. They are smoother and softer to the touch than the rest of the skin. A patch situated in the occipital region grew white hairs. Behind each knee and in front of each thigh were nearly symmetrical patches.

Case of W. M., aged 12, well grown and very dark; the first patch noticed was one on the front of the chest 8 years ago. A blister had been applied, and it was thought to be a scar. From that time the patches have been gradually increasing in size. His bodily health is excellent. Microscopical examination of the scales revealed no cryptogam.

N. S. 10.

### **Fatty Degeneration.**

#### **Xanthoma.**

101. The portrait shows the face, neck, and chest of a woman, and presents small round yellowish patches of fatty degeneration of the skin.

102. The portrait shows the face of an elderly woman showing plaques of pale yellow colour seated on the upper lids and inner margins of the lower lids.

103. 1. The chest and lower part of the face of a stout woman presenting symmetrical areas composed of flat, smooth, yellowish patches, of irregular shape and about the size of a pin's head; some of the spots on the face are raised so as to constitute minute tubercles.

2. A portrait of the palmar aspect of a right hand extensively affected with pale yellow or buff-coloured plaques with well-defined margins.

3. The dorsal surface of a right hand presenting a similar but more well-defined appearance.

4. The portrait of a right elbow (?), showing well-defined tubercles of pinkish-yellow colour, isolated and grouped in masses.



#### IV. NON-INFLAMMATORY DISEASES WITH PROFOUNDLY DESTRUCTIVE TENDENCIES.

##### **Lupus.**

##### **Lupus erythematosus.**

104. 1. The face of a boy, showing well-marked bat's-wing lupus. The body occupies the nose and the wings cover the cheeks. The patches on the cheeks are well-defined at their upper borders, and consist of a dusky erythema with very slight thickening of the skin, with here and there a little desquamation. There are also patches on the chin, upper lip, and in front of each ear. The patch on the upper lip was some raised, what showing a certain amount of deposit. Scattered amongst the hyperæmia are superficial cicatrices.

The patient, John B., aged 16, was thin and delicate and with feeble circulation, of fair complexion and brown eyes, and had had the disease for nearly a year. His family history was good.

N. S. 42.

2. The portrait of a boy's hands, shows deeply congested patches of lupus erythematosus; the patches are well-defined with raised edges, the surface rough from epidermic peeling, but nowhere ulcerated. There are several scars of old patches; the fingers are atrophied and thin.

Arthur D., aged 15, a thin and always a very delicate boy, with very feeble circulation, had had the disease on his nose, cheeks, ears, neck, and forearms since the age of seven. On the face the erythema was especially well marked, but there is now no trace of any former disease in the face and neighbouring parts.

N. S. 42.

105. The face of a woman upon which, in addition to the erythematous congestion, the skin is seen to be stippled over with the plugged or open orifices of diseased sebaceous glands. Upon the left cheek are several thin flat cicatrices.

H. i. 6.

106. The face of a boy with patches of lupus erythematosus on the nose, cheek, and in front of the ear. The patches on the cheeks have a ringed margin of minute papules formed by enlargement of the sebaceous glands; in the centre of the patches are small areas of infiltrated hyperæmic skin and several white glistening cicatrices.

H. i. 8.

##### **Lupus-psoariasis.**

107. The portrait of the head, neck, and left shoulder of a girl, showing tolerably symmetrical patches varying in size from a sixpence to a



half-crown; all the patches are raised, glossy, of a semitransparent appearance, and of a reddish-brown tint, and have a thin epidermic desquamation over them. Some have healed and have left superficial scars, others are healing at the centre and spreading at the edges.

Mary X., aged 9½, a brunette, had had the skin disease for three years when the portrait was taken, and is suffering from caries of the spine. A portion of the lobule of the ear was cut out for examination, and showed a deposit of jelly-like material an eighth of an inch thick, abruptly defined, and involving all the tissues of the skin. It was covered on the surface by a thin epidermic layer. The patches were scraped and arsenic given internally, and in six months the patient was well.

N. S. 19.

### **Lupus vulgaris.**

108. A well-defined patch of lupoid tubercles upon the right cheek of a boy, with much crust and some cicatrization. Sq.
109. The portrait of a dark, middle-aged woman, upon whose nose and cheeks are shown patches composed of numerous small round tubercles as large as a pea. Some are of a reddish colour, others are pale and shiny upon the surface. There are numerous small whitish cicatricial areas, the remains of previous tubercles. H. i. 1.
110. A coloured photograph of the head of a woman upon whose right cheek is an irregular patch composed of small tubercles. Sq.
111. The portrait of a woman over whose right cheek and inferior maxillary region is a patch with very irregular outline composed of tubercles, with different degrees of inflammatory œdema of the subjacent tissues. H. i. 2.
112. The face of a young woman, about 30, with brown hair and eyes. The nose and cheeks are covered with pus-scabs, beneath which the skin is thickened and ulcerated; the alæ and tip of the nose have in part been destroyed; on the cheeks the ulceration is superficial and serpiginous, and is preceded by the deposit in the skin of dusky red semitransparent tubercles. N. S. 3.
113. The portrait of a youth, aged 15, upon the upper lip and upon the tip and alæ of whose nose is a thick heaped-up mass of greenish scab; this is surrounded by a narrow zone of hyperæmic skin; the ala of the nose has in part been destroyed. Sq.
114. The face of a young brunette with blue sclerotics, the tip of whose nose has been destroyed. The disease has spread over the cheeks, and now involves the neck, illustrating at one part the ulcerating, at



another the serpiginous, and at a third the cicatrizing characters of lupus. The scar, which is very extensive, is white. N. S. 7.

115. The portrait of a youth whose face and neck presents lupoid ulceration in all its stages. The side of the neck is covered with whitish linear cicatrices, and has a wrinkled appearance; the lower border of the diseased patch is serpiginous and presents a curved line, upon which are many small red discrete tubercles contiguously placed or isolated. At the upper part are seen cicatrices, tubercles which have softened and are now converted into cheesy purulent matter, and small ulcers of irregular shape, abruptly defined, and with a red surface. H. i. 5.

116. The portrait of a girl, the tip and alæ of whose nose have been destroyed so as to present a sharply defined circular anterior meatus. The lips, chin, and neck present radiating cicatrices, the remains of former ulceration. The serpiginous border is marked by tubercles, some recent, some undergoing disintegration. H. i. 7.

117. The dorsal surface of two hands, the palmar surface of another, and part of a forearm, showing, in the centre of the larger patches, decolorized cicatricial areas, at the margins of these patches and in other parts thick yellow scabs composed of dried disintegrated tubercles, and at several points, especially upon the forearm, irregular well-defined areas of ulceration left by the removal of scabs. H. i. 9.

118. The portrait shows a thigh nearly covered with a patch of lupus, the central parts of which vary in colour from a white cicatrix to deep brown pigmentation. The border of this patch is serpiginous and presents tubercles, crusts, and irregular ulcers. H. i. 10.

119. A coloured photograph of the face of a dark young woman, the tip and alæ of whose nose have been destroyed by ulceration, and the anterior nares are now represented by an oval aperture with an irregular margin. Sq.

### **Morphæa.**

#### **Scleroderma. Morphæa or Addison's Keloid.**

120. The portrait of the bust of a young woman shows the remains of Addison's keloid upon the left half of the face and neck. The brown areas of diseased skin are marked off by a vertical line which passes down the middle of the forehead, nose, lip, and chin, and deviates a little to the left side, more especially at the chin, owing to the contraction of the diseased tissues pulling upon the healthy parts. The skin of the left side of the forehead is brown in colour; the left



cheek is less plump than the right, but otherwise shows no evidence of disease.

Case of Elizabeth Nicholls, aged 32. The disease commenced in 1851 quite suddenly at the age of 14. She went to bed quite well, and in the morning found her left lower extremity stiff and painful; this was followed by swelling, which rapidly spread over the left side of the trunk. She was confined to bed for months, and it was not till the following year that the keloid condition became apparent. In 1855, aged 18, she had never menstruated, her left leg was wasted, the joints stiff, the skin hard, smooth, shiny, and adherent to tibia, and there was an ulcer over the instep. At this date the patch upon the left forehead was white in the centre and had a brown border, and there were also numerous other patches upon the shoulders, breast, abdomen, and back. The disease remained stationary for many years, and the portrait represents the condition of the face in 1867. The tracts of skin which were formerly indurated and discoloured are now supple.

N. S. 43.

### **Lepra.**

#### **Lepra tuberculosa.**

121. 1. The portrait of a woman, showing the tubercular form of leprosy. The skin is everywhere brown and earthy, and on the forehead, cheeks, and chin are seen nodulated folds and tubercles of a yet more dusky tint. The eyebrows have been destroyed and large tuberous masses occupy their position. In both eyes the corneæ have become opaque, with a central leucoma. The eyelashes are wanting. Tubercles are seen on the conjunctiva.

The patient, an Irishwoman, a soldier's wife, had lived in India for twenty years before the onset of the disease by the appearance of small tubercles over her eyebrows. There was no history of inheritance, no contagion, no syphilis, and no prolonged fish diet. When the portrait was taken she had similar nodular patches on most parts of her body; some parts of the skin were numb, but not distinctly anæsthetic. Both ulnar nerves were considerably enlarged.

N. S. 29.

#### **Lepra anæsthetica.**

121. 2. The plate shows the thigh and knee of an adult, with large patches of skin of a bluish-white colour. These patches, which cover more than half the surface, were completely anæsthetic. Between them the skin is thickened, and of a purplish-brown colour, and was exceedingly tender. The margin of each pale area is convex, and is encroaching upon the healthy adjacent skin, whose colour and sensation are being gradually and simultaneously impaired.

The patient, a sailor, a Scotchman, had sailed to and from Barbadoes for thirty years. He denied syphilis and any hereditary tendency. The disease commenced eighteen months before the portrait was taken. Over his eyebrows and cheeks were dusky tuberculated masses, similar but not so large as in the previous portrait; over his arms also were patches similar to but not so well marked as those on the legs.

N. S. 29.



122. The portrait shows the back of the trunk, shoulders, and buttocks, on which are numerous true leprosy patches either circular, oval, or irregular in outline; the margin is well-defined and, as a rule, of a brownish colour, the centres being decolorized. The patches are anæsthetic; hence the terms *lepra macula* and *lepra anæsthetica* applied to this variety.
123. The portrait of the back of the trunk and arms of a man almost universally covered by ill-defined yellowish-brown discoloration, over which the skin is anæsthetic.
124. The portrait shows a right lower extremity, upon which are large patches of brown discoloration, with well-defined margins, enclosing areas of skin which are probably decolorized and anæsthetic.

### **Elephantiasis.**

#### **Elephantiasis with Eczema.**

125. The portrait shows the left foot and lower part of leg greatly swollen and covered by papular and bossy elevations and dried exudation. H. iv. 10.
126. Five portraits showing elephantiasis of the scrotum, hand, and clitoris.

### **Rhino-scleroma.**

127. The portrait of a woman whose nose and upper lip are greatly disfigured by a flattish mass of coalescent tubercles composed of granulation tissue, which in places has undergone suppuration and ulceration. The mass is smooth, glossy, and the colour almost of normal skin. The growth is of stony hardness, and well-defined from the surrounding skin. This disease is confined to the nostrils, upper lip, pharynx, and fauces, and is associated with the presence of a special bacillus. H. x. 1.

### **Keloid (Albert's Keloid).**

128. Two drawings showing scar-like growths sharply defined and abruptly raised; the edges send out claw-like processes, hence the term keloid ( $\chi\eta\lambda\eta$ , a claw); the skin covering the patches is smooth; the most common situation for spontaneous keloid is upon the trunk, especially of the skin covering the sternum. H. x. 5.
129. The portrait of a left arm, showing an irregular cicatricial out-growth occurring in the scars of syphilitic rupia. Sq.



**Angeioma.****Nævus vasculosus.**

130. A coloured photograph, showing upon the right side of a woman's face irregular patches, well-defined in outline, of reddish brown-discoloration of the skin. Sq.

**Lymphangeioma tuberosum multiplex.**

131. The portrait shows upon the neck, chest, and abdomen of a middle-aged woman many prominent, well-defined, spherical nodules, varying in size from a pin's head to a pea, and of a pink colour, the adjacent skin being normal in colour. H. x. 6.

**Sarcoma.****Sarcoma melanodes.**

132. The portrait shows the dorsal surfaces of the two hands and the right foot of an adult, which present bluish-black nodular thickenings of the skin; this infiltration affects the whole of the dorsal surface of the fingers and back of the right hand, the three inner fingers and corresponding part of the metacarpal region of the left hand, and the four inner toes and contiguous part of the dorsum of the right foot; the fingers and toes are thickened to nearly twice the normal diameter, the tips of the fingers are stunted, the nail-beds are atrophied, the nails are ill-nourished and though short project beyond the end of the fingers. Scattered over the wrists, ankle, and dorsum of the foot are similar well-defined raised patches of irregular shape and size, of similar nodular bluish-black infiltration of the skin.

H. x. 9.

**Carcinoma.****Rodent ulcer.**

133. The portrait shows upon the left upper eyelid a bossy mass of induration as large as a hazel-nut, with sinuous edge, and smooth glassy and vascular surface; the induration is half an inch in depth, and at the centre is a small irregular patch of ulceration.

The patient was a healthy man aged 60, and the disease had existed three years; the conjunctiva was healthy.

Mr. Hutchinson.

134. The portrait shows upon the right lower eyelid three small bossy elevations of the skin, each about the size of a pea, upon the surface of one of which is a minute ulcer.

This tumour had been growing for eighteen months, and it is a recurrence in the scar left by the removal of a primary rodent ulcer some three years before.

Mr. Hutchinson.



**Carcinoma.**

135. The portrait of a man whose left eye is concealed by an ulcerated mass of carcinomatous new growth as large as an orange; the surface is excavated, fungating, and irregular, the edge thick, inverted, and sinuous; the growth extends from the side of the nose to the temporal region, and from the eyebrow to the cheek.

136. The portrait shows the foot and right leg, upon which is a large irregular epitheliomatous ulcer, covering an area as large as the two palms upon the extensor surface of the lower part of the leg; the edge of the ulcer is irregular, crescentic, thick, and nodular; the surface is uneven, and presents irregular masses of fungating granulations.

137. The portrait shows scattered over the left mammary region extensive carcinomatous nodular deposits in the skin, probably infiltrated lymphatics.

The patient having pain in the breast poulticed the part and brought out the cancerous eruption depicted; probably there was a primary cancerous growth in the gland itself, but of this there was no proof at the time the sketch was taken.

Mr. Hutchinson.

**Carcinoma melanodes.**

138. The portrait shows the lower part of the abdomen, genitals, and thighs of a woman. On the right thigh, except at the upper part, the skin is normal, but in other parts it is greatly thickened, nodular, of a greenish-black colour, and is covered with sessile masses of new growth, some as large as a walnut; the edge of the growth is very irregular, and here the infiltration is slight. H. x. 10.

**V. DISEASES AFFECTING THE APPENDAGES OF THE SKIN.****Of the Hair and Hair-follicles.****Hypertrichosis.**

139. The portrait of a man whose face is everywhere covered with thick long brown hair. H. x. 7.

140. The portrait of a boy (the son of the above) whose forehead, nose, cheeks, and chin are similarly covered with hair. There is also considerable growth of hair on the chest. H. x. 8.

**Alopecia.**

141. This portrait shows on the head of a boy a single patch totally destitute of hair, smooth and glossy, without the slightest approach



to crust or desquamation. The patch is as large as the palm of a child's hand, and is tolerably well-defined at the margin. The above signs are pathognomonic, and can be confused with no other disease.

N. S. 6.

142. A coloured photograph of the head of an adult presenting similar well-defined patches in the occipital, temporal, and frontal regions.

The patient, aged 40, had had the disease for five months.

Sq.

### **Sycosis.**

143. The portrait of an adult man upon whose eyebrow, upper lip, and chin are many small discrete rounded papules, like those of ordinary acne; in the centre of many a hair is seen. W.

144. The portrait of a man, upon the lower and hairy parts of whose face are small discrete papules, discrete pustules, and irregular areas of raised skin covered with crust. H. vii. 4.

145. Portraits of similar parts presenting discrete papules, pustules, and areas of thickened infiltrated skin covered with crust and devoid of hair. H. vii. 3.

### **Of the Sebaceous Glands.**

#### **Seborrhœa.**

146. The portrait shows upon the cheeks of a middle-aged woman irregularly quadrilateral flat plates of dried imperfectly formed sebum and epidermis (*eczema seborroichum*). W.

147. 1. The portrait shows the head of an infant whose scalp is covered with dried crusts of altered sebum mixed with epidermic scales and dirt; the hair is scanty (*seborrhœa capilitii*). H. iii. 6.

2. A penis with prepuce retracted, presenting a thick crusted mass of dried secretion covering the corona and the inner surface of the prepuce (*seborrhœa preputialis*). H. iii. 6.

3. An infant covered from head to foot with thick, hard, adherent plates of secretion. It is probable that the rigid horny coat which is all cracked into fragments had formed in early intrauterine life, and had become too small to cover the fully grown fœtus. The eyes are fixed by the rigid state of the lids (*ichthyosis congenita neonatorum*). This disease differs from true ichthyosis in being well marked at the time of birth. H. iii. 6.



148. The portrait of a man upon whose chin, upper lip, nose, eyebrow, and along the margin of the hairy scalp are thin, dry, dirty-white or yellowish scales. The hairs where the disease exists are scanty and ill-developed (*seborrhœa sicca*). H. iii. 7.

149. The portrait of a woman upon the vertex of whose head, and upon whose eyebrows, nose, and cheeks are thick yellowish scales of dried and imperfectly formed sebum and altered epidermis. The hair of the scalp is somewhat scanty, and upon the cheek there is some hyperæmia of the subjacent skin. H. iii. 8.

### **Acne vulgaris.**

150. The portrait shows the face of a young man who suffered severely from common pustular acne. The cheeks, chin, and forehead are the parts most severely affected, and present comedones, lichenoid papules, pustules, and scars.

The patient had the same eruption also on his shoulders. His skin was coarse. N. S. 26.

151. The portrait of a man whose forehead, cheeks, and chin present numerous discrete papules, pustules, and comedones. H. vii. 1.

152. The portrait shows the head, chest, and shoulders of a man suffering from *acne disseminata indurata*. The face presents large indurated tubercles of a livid colour, many comedones, and purplish stains and scars, the remains of previous tubercles. Upon the chest and arms are similar but slighter pathological changes. H. vii. 2.

153. The portrait shows the back of the right upper extremity of the trunk, buttocks, and right thigh of a man, almost entirely covered with small patches of irregular shape and as large as a small bean of stained skin whose tint varies from brown to purple. Scattered here and there are numerous pustules (*acne cachecticorum*).

H. vii. 7.

### **Rosacea.**

154. The portrait of a man the skin of whose nose and cheeks is congested and presents red pimples (*acne rosacea*). H. vii. 5.

155. The portrait of a woman the skin of whose forehead, nose, cheeks, and chin is of a dusky-red colour, from chronic congestion, and presents numerous yellowish tubercles and pustules varying in size from a pin's head to a pea. W.



**Rhinophyma.**

156. The portrait shows the face of a man, the tip and alæ of whose nose are represented by a lobulated tuberos mass as large as a small fist, the surface of which is irregular, and presents numerous comedones; the mass entirely conceals the mouth. It is composed of hypertrophied skin and subcutaneous tissue. Upon the forehead and cheeks are numerous acne pustules. H. vii. 6.

**Miliaria.**

157. 1. The portrait of a child, upon whose left cheek are numerous minute round white isolated bodies as large as a pin's head, formed by the distension of the sebaceous glands of hair-follicles; the adjacent skin is normal. H. vii. 8.

**Acne ex Iodo.**

2. A woman's forehead, showing discrete papules becoming vesicular, due to the administration of iodine or its salts. H. vii. 8.

**Acne ex Pice.**

3. The portrait shows the extensor surface of a right leg and foot almost covered with comedones and pustules; the darkened free ends of the plugs in the sebaceous glands, due to the local application of tar, are distinctly seen. H. vii. 8.

**Molluscum contagiosum.**

158. The plate shows characteristic papules upon the breast of a mother and the face and neck of a child eighteen months old. The child was not yet weaned, and there is little doubt that the spots on the mother's breast were produced by direct contagion. The spots begin as very minute pale pimples consisting of enlarged sebaceous glands, they pass through gradations in size until they reach the size of cherries. They are usually somewhat flat upon the surface, with a depression in the centre, producing a resemblance to a mother-of-pearl button; as they increase in size they project, become polypoid, and drop off. When squeezed they yield white sebaceous matter. There is usually little inflammation around the base, but they may inflame, suppurate, and form an ecthymatous pustule.

In figure 2 of the plate some large molluscous tumours after removal are shown, and in figure 3 some free cells from their interior. One of the tumours is cut across and shows a considerable cavity which had been distended by secretion. N. S. 2.



159. The portrait shows upon the penis and scrotum of a man, and the back of the neck of a child, numerous small, round, prominent sessile tumours of translucent appearance, and varying in size from a pin's head to a pea, and presenting in the centre of the larger ones a dark umbilication. H. vii. 10.

### Of the Nails.

#### **Onychia maligna.**

160. 1. The nail in the left upper corner is a typical example of this disease. The swollen clubbed end of the finger, the dusky congestion of the whole, the discoloured, loose, and recurved nail, and the angry-looking sore beneath it, are most characteristic features of the disease. It rarely affects more than one finger, is produced by slight injury, usually in a delicate, maybe syphilitic child. N. S. 17.

#### **Onychitis chronica.**

2. The figure to the left shows the four nails of one hand. The nails become opaque and much thickened. Their edges and surface break up and become rugged and discoloured by the dirt which gets into the cracks. If pared the nail-substance is soft and spongy, the matrix is swollen and readily bleeds. This disease affects both hands and feet with accurate symmetry, and is therefore clearly constitutional in origin. It usually attacks young adults. N. S. 17.

#### **Onychitis syphilitica.**

3. The nails of the fingers are seen to be rough and broken, but not much thickened. The nail of one of the toes is drawn, and it shows a similar condition.

From an old woman who became the subject of primary and secondary syphilis, and in whom, in connection with a general eruption of psoriasis, the nails inflamed.

N. S. 17.

#### **Onychitis syphilitica hereditaria.**

4. The finger-nails of a child which are discoloured and deformed, being much arched, as if they had been pinched in forceps; and also those of an infant, showing discoloration, irregularity, and transverse furrowing.

The nails of both hands and feet were symmetrically affected, and the infant was the subject of a scaly and papular rash, the consequence of inherited syphilis.

N. S. 17.

5. The finger-nails of a young woman, the subject of an inherited syphilitic taint. The inflammation commences at the root, and



transverse furrows are formed by the breaking up of the outer layers of the nail. There is no pain nor much general thickening of the nail, but the whole structure is brittle, and the free edge is usually broken and fissured. N. S. 17.

**Psooriasis diffusa unguium.**

160. 6. The fingers of the right hand of an adult, exhibiting thickened nails ridged both transversely and longitudinally. Around the nail is a zone of hyperæmic skin covering the swollen matrix. N. S. 17.

7. A portrait of the same hand, showing the palm covered with thick white dry epidermic scales upon a red hyperæmic base.

N. S. 17.

VI. PARASITIC DISEASES OF THE SKIN.

ANIMAL PARASITES.

**Scabies.**

161. The portrait shows the abdomen, thighs, and genitals of a man whose skin in these parts is covered with an eruption consisting of minute discrete papules, vesicles, a few pustules, and blood-crusts the result of scratching; many of the papules have a punctate crust at the apex. H. v. 2.

162. The portrait of an infant whose body is universally covered with minute vesicles and papules, which are especially thick over the abdomen. Numerous linear excoriations are seen. The scalp, eyebrows, cheeks, palms, and sole are affected. H. v. 4.

163. A coloured photograph showing a vesicular and pustular eruption, with hæmorrhagic and purulent crusts, on the back of a right hand and between the fingers. Sq.

164. Portraits of the breast, left hand, and buttocks. Upon the breast minute scattered papules, vesicles, and a few excoriations are seen; upon the back of the hand, fingers, and wrist are large and small pustules, small irregular ulcers, and near the roots of the fingers much dried pus-crust; upon the buttocks above are pustules and excoriations of various sizes; upon the left buttock of the lower portrait is a large excoriated area with crusts; in a corresponding situation on the right buttock a dry scaly condition is seen; scattered over the buttocks and thighs are irregular excoriations varying in size from a pin's point to a fourpenny-piece. H. v. 1.



165. The portrait shows the male genitals and inner surfaces of the thighs and right leg, upon which are a few vesicles and pustular areas of very irregular shape and size, many of them covered with thick dried scab and blood-crusts. H. v. 3.

166. 1. The hand of an adult woman, in whom the eruption on the fingers had produced large vesications, looking almost as if she had been scalded, the whole hand being swollen, red, and œdematous.

2. The hand of a child, showing papules, large vesicles, pustules, and crusts, and a considerable amount of inflammation of the adjacent skin, but less than in the adult hand. N. S. 27.

### Scabies Norvegica.

3. The upper hand in the plate represents the rare form of scabies met with in Norway, and shows the palm of the hand and palmar aspect of the fingers much inflamed and covered with large, firm, adherent, thick masses of epidermis. The edges of the nails are thickened and rugged. On the little and ring-finger the whole nail is involved.

The patient, a pale feeble girl of 15, was covered more or less all over with similar crusts. She had had the disease for two years. Whilst in hospital under Professor Boeck she infected the whole ward, though the other patients did not touch her. The rash in the other patients was typical of ordinary scabies. The crusts were shown under the microscope to be made up almost entirely of *Sarcoptes scabiei* in various conditions—Acari, eggs, egg-shells, and excrement. No burrows could be found and no living Acari. A large proportion of the Acari were males. The patient was cured by Vienna ointment, and had no return four years after. Professor Boeck considers this disease ordinary scabies aggravated by filth and neglect; all authorities agree as to the parasite being one and the same.

### Pediculosis.

167. The abdomen, genitals, and thighs of a male covered with minute papules the size of a pin's head, due to the irritation of pediculi.

H. v. 10.

168. The head and neck of a youth, showing small pustules upon the neck and irregular masses of purulent scab in the scalp (*Impetigo e pediculis*).

H. v. 20.

169. The portrait shows the back of the head and neck of a child with thick dirty pus-scabs, which consist of crusts of greenish sticky pus, matted hair, and particles of dirt. The first stage of the eruption is vesicular, and the exudation when recent resembles honey. The



cervical lymphatic glands are as usual enlarged. In this patient the head was swarming with lice, and the consequent scratching probably originated the sores, other sores being produced by local inoculation with the exudation produced at the first spot. It differs from eczema in being rapidly cured by local means, in being contagious, and in having a thick crust and one which covers completely the inflamed patch of skin (*Impetigo e pediculis*). N. S. 20.

170. The portrait represents the eruption produced by the irritation of lice; it consists of small red papules, the consequence of the insect's bites; many of these have been abraded by scratching, and hence the characteristic little blood-scab. In addition there are wheals like those of *Urticaria*, and in many places long lines of abrasion produced by scratching.

The patient, an elderly man, had been liable to lice for months. He was cured by sulphur baths and ointments and the daily application of a hot iron to his underlinen.

N. S. 22.

171. A coloured photograph of a woman's back, showing similar papules, punctate and linear excoriations. Sq.

172. The trunk, buttocks, and left arm of a man with lateral curvature, exhibiting innumerable excoriations which vary in size from a pin's point to a sixpence, and many white crusts of very irregular shape and size. H. v. 8.

173. The back of the trunk and outer surface of the right and inner aspect of left thigh presenting bullæ and excoriations of all sizes, numerous single pustules covered with scab, mostly circular in outline and about the size of a sixpence, and several large irregular patches of confluent bullæ; on the thigh are many white scales. H. v. 9.

#### VEGETABLE PARASITES.

##### ***Tinea favosa.***

##### ***Melasma seu Pityriasis nigra.***

174. The portrait shows the trunk and left arm of a woman whose skin is of a brownish-black colour, and covered with numerous dry scales. H. v. 11.

##### ***Favus.***

175. This portrait represents the head, shoulders, and back of a boy with large patches of true favus. The scalp is almost covered, and



on the shoulders and trunk are several patches as large as the hand. The crusts are thick, raised, and here and there arranged in the form of cups; if crushed they are not sticky, but may be coarsely powdered; they exhibit under the microscope the sporules and mycelium of the fungus (*Achorion Schönleini*) in great abundance; they look dry, and are of a sulphur-yellow colour, rendered grey and dirty by accumulations of dirt &c. The patches are abruptly circumscribed, and rise from the healthy skin with very definite borders.

N. S. 1.

176. A coloured photograph of the head of a boy whose scalp is covered with yellowish cupped scabs of favus. Sq.

177. The portrait shows upon the head of a boy numerous crust-covered patches of favus, of an irregular outline and greenish-yellow colour; the hair is very thin, especially over the vertex; in several parts are seen dark circular spots left after detachment of small favus-scabs.

H. ii. 2.

#### **Tinea tonsurans.**

178. The portrait shows the head and neck of a boy; the scalp is covered with a fine greyish or silvery granular scurf, and the hairs are broken; on the face and neck are circular patches with well-defined vesicular margin (*Tinea circinata*).

H. ii. 3.

#### **Tinea tonsurans et favosa.**

179. This portrait shows the head and shoulders of a boy with large patches of true ringworm (*Tinea tonsurans*), in the centre of some of which are the crusts of true favus. The occurrence together of these two varieties of cryptogamic disease has often been observed before, and the appearances of ringworm always precede the favus. The features of the two crusts are very different indeed; the yellow masses of favus are distinguishable at a glance from the desquamating patches of ringworm.

N. S. 2.

180. The head of an adult male, showing the fine branny desquamation and crusts of *Tinea tonsurans* on the scalp, lip, and face. Two arms showing the yellow-cupped circular crusts of favus.

H. ii. 4.

#### **Kerion from Ringworm.**

181. The portrait shows the scalp of a child, of about 8 years of age, who had suffered for some months from ringworm, and in whom some of the patches had inflamed and passed into the swollen, boggy condition of the scalp known as kerion. The inflammation is seated



in and around the hair-follicles, and the swollen patch is occupied by many small cavities which contain a thin glairy pus.

Kerion may affect the scalp in children or the beard in adults; it may quite destroy the hair, leaving a patch of baldness; it is not specially a disease of the poor; it is a rare disease; it affects children from 5 to 13.

N. S. 35.

### ***Tinea circinata.***

182. The portrait shows the trunk of a male, in whose axilla and above the pubes are rings of eruption with red elevated edges and pale centres. The rings in many places have become confluent, producing patches the margins of which form irregular curves. The surfaces which have been abandoned by the disease still remain a little red, with some branny desquamation. In the axilla is a large patch with several smaller more recently affected areas.

The patient first noticed the patch in the axilla six months before the portrait was taken. The microscope showed the cryptogamic sporules of ringworm. He was cured in ten days by Harrogate-water baths and white precipitate and sulphur ointment.

N. S. 36.

183. A coloured photograph of the head, neck, and shoulders of a girl, showing several circular patches of well-marked *Tinea circinata*. Sq.

### ***Tinea marginata.***

184. The portrait shows the pubes, genitals, and thighs of an adult male; upon the inner side of the thighs is an extensive area of inflamed and excoriated skin, the margin of which is well-defined, raised, and somewhat scaly; it is due to the same fungus (*Trichophyton*) as *Tinea circinata* and *Tinea tonsurans*, and is commonly known as *Eczema marginatum*. H. iv. 6.

185. The portrait shows the abdomen, pubes, genitalia, and thighs, upon which are large patches of inflamed skin, with well-defined, raised, thickened, and scaly edges. H. iv. 7.

186. The portrait of loins, buttocks, and thighs of a male, showing a similar condition. H. iv. 8.

### ***Tinea versicolor.***

187. A photographic portrait of the head and chest of a woman, showing irregular well-defined areas of yellowish-brown pigmentation due to the presence of the *Microsporon furfur*. Sq.



188. The chest, abdomen, and shoulders of an adult man, who was covered with the brown discolorations of *Tinea versicolor*. The patches are of different sizes, some very large, all are of a yellow-brown colour, abruptly margined and slightly branny on the surface.

They occupy the usual situations, and were also present on the thighs and forearms. The man's wife was also affected. A slight itching was the only subjective symptom produced. The microscope demonstrated the presence of the cryptogam in great abundance.

N. S. 12.

189. The portrait of the neck, chest, and shoulders, displaying patches, varying in size, of a yellowish-brown colour and well-defined edge.

H. ii. 6.

#### A TATTOOED MAN.

190. The portrait shows a man, the trunk and great part of whose face are covered with designs of birds, beasts, reptiles, and geometrical and other figures in blue and red, produced by puncture of the skin with pigments.

H. viii. 10.



