

Pathological catalogue of the museum of Guy's Hospital : vocal and respiratory organs / enlarged and revised from the original catalogue of Dr. Hodgkin by S. O. Habershon.

Contributors

Habershon, S. O. 1825-1889.
Habershon, S. O. 1825-1889
Hodgkin, Thomas, 1798-1866.
Royal College of Physicians of London

Publication/Creation

London : William Mackenzie, 1857.

Persistent URL

<https://wellcomecollection.org/works/dzr7c3dm>

Provider

Royal College of Physicians


License and attribution

This material has been provided by This material has been provided by Royal College of Physicians, London. The original may be consulted at Royal College of Physicians, London. where the originals may be consulted. This work has been identified as being free of known restrictions under copyright law, including all related and neighbouring rights and is being made available under the Creative Commons, Public Domain Mark.

You can copy, modify, distribute and perform the work, even for commercial purposes, without asking permission.



Wellcome Collection
183 Euston Road
London NW1 2BE UK
T +44 (0)20 7611 8722
E library@wellcomecollection.org
<https://wellcomecollection.org>




SLF

61 (069.538)



3426-2-h-4






Digitized by the Internet Archive
in 2015

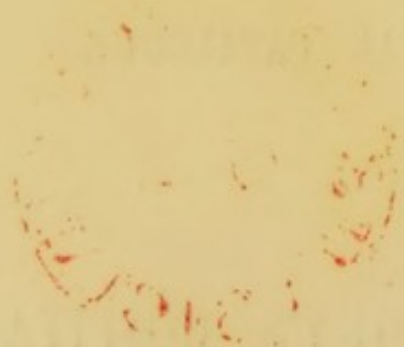<https://archive.org/details/b24756957>

12. 12. 10
The library of the
Royal College of Surgeons
from the author.



*Library of the
Royal College of Physicians
from the ...*

PATHOLOGICAL CATALOGUE
OF THE
MUSEUM OF GUY'S HOSPITAL.



Contained in the 2nd ed. by S. Wilks

PATHOLOGICAL CATALOGUE
OF THE
MUSEUM OF GUY'S HOSPITAL.

VOCAL AND RESPIRATORY ORGANS.

ENLARGED AND REVISED

FROM THE

ORIGINAL CATALOGUE OF DR. HODGKIN, F.R.S., &c.,

BY

S. O. HABERSHON, M.D., LONDIN.,

FELLOW OF THE ROYAL COLLEGE OF PHYSICIANS; ASSISTANT PHYSICIAN AT GUY'S
HOSPITAL; LECTURER ON MATERIA MEDICA AND THERAPEUTICS;
LATE DEMONSTRATOR OF MORBID ANATOMY; AND
CURATOR OF THE MUSEUM.

LONDON:
WILLIAM MACKENZIE, 22 PATERNOSTER ROW.
MDCCCLVII.

56

ROYAL COLLEGE OF PHYSICIANS LIBRARY	
CLASS	61(069.538)
ACCN	29180
SOURCE	
DATE	

ANALYTICAL INDEX.

LIPS.

CONTRACTION AFTER MERCURY, 1677⁷⁵.

CYST, 1678.

CANCER, 1679, 1680, 1680⁵⁰, 1681, 1682, 1682²⁰, 1682⁴⁰, 1682⁶⁰, 1682⁸⁰.

LARYNX.

CARTILAGES, Ossified, 1684.

Necrosed, 1684, 1684²⁵, 1685.

Ulcerated, 1686, 1688, 1689, 1690, 1701, 1701⁵⁰, 1687.

Abscess secondary to ulcerated cartilage, 1685, 1686, 1687, 1701, 1701⁵⁰.

Cancer, 1691, 1691⁵⁰, 1690³², 1690⁶⁴.

MUCOUS MEMBRANE.

Edema, 1696⁴⁰, 1705, 1706⁵⁰, 1706⁷⁵, 1707, 1708, 1709.

Suppuration beneath mucous membrane, 1696⁸⁰.

Effusion of croupous layer, 1692, 1692²⁵, 1692⁵⁰, 1692⁷⁵, 1693, 1693⁵⁰,
1694, 1694⁵⁰, 1694⁵¹, 1695, 1696, 1702, 1694⁵⁵.

Spurious laryngitis, 1713²⁵.

Thickening, 1688, 1699, 1690⁸⁰, 1690⁹⁰, 1696²⁰, 1697, 1697⁵⁰.

Vegetations, 1690⁹⁰, 1702, 1703, 1704.

Ulceration, 1686, 1690⁸⁰, 1696⁴⁰, 1697¹⁰, 1697⁵⁰, 1697¹⁸, 1697²⁵, 1698, 1685,
1701, 1700, 1702, 1713⁷⁵, 1699.

Cicatrix, 1696⁶⁰, 1697⁵⁰, 1697⁷⁵.

SYPHILIS, 1697¹⁰, 1697⁵⁰, 1697⁷⁵, 1684²⁵.

PHTHISIS, 1685, 1689, 1690⁸⁰, 1697¹⁸, 1697²⁵, 1698.

CANCER, 1690³², 1690⁶⁴, 1691, 1704⁵⁰.

OBSTRUCTED BY FOOD, 1710.

CUT-THROAT, 1711, 1710⁵⁰, 1711⁷, 1711⁹, 1711¹¹.

THYROID BODY OR GLAND.

ENLARGED, 1711¹⁴, 1711³⁵.

CYSTIC, 1711²¹, 1711²⁸, 1711³⁹, 1711⁴⁹, 1711⁵³, 1711⁴², 1711⁶³.

CANCER, 1711⁷⁰, 1711⁷³, 1711⁷⁷.

CYST BENEATH STERNO-MASTOID, 1711⁶⁷.

TRACHEA.

CARTILAGES Ossified, 1711⁸⁴, 1711⁸⁶, 1683⁸⁸, (Expectorated, 1711⁸⁷.)

Ossific deposit in mucous membrane, 1711⁸⁵.

PERFORATING ULCER, 1711⁸⁶, 1714, 1715, 1714¹⁰.

ENLARGED FOLLICLES, 1711⁹¹.

EFFUSION OF CROUPOUS MEMBRANE, 1712, 1713.

ULCERATION, 1713⁵⁰, 1713⁷⁵, 1713⁷⁰.

CANCER, 1715⁵⁰, 1716²⁰, 1716²⁵.

TRACHEOTOMY, 1716, 1716²⁰.

FOREIGN BODY, 1716⁵⁰.

PERFORATED BY ANEURISM, 1480⁶⁰.

BRONCHI.

COMPRESSED, 1717³², 1717³⁵, 1717³⁸, 1717³⁹, 1757³⁵, 1480⁴⁰, 1489²⁵.

DILATED, 1717, 1718⁴⁵, 1717⁶⁴, 1727³⁵, 1751³⁵.

Thickened and dilated after pleuro-pneumonia, &c., 1718, 1718³⁰, 1718⁵²,
1718⁵³, 1718⁶⁸, 1718⁷⁰, 1743⁶⁰.

Thickened and dilated with emphysema, &c., 1718³⁸, 1719³⁹, 1718⁶⁰, 1719⁵².

CONTRACTED, 1718⁷².

ULCERATED, 1718⁷¹, 1713⁷⁰.

FIBRO-PLASTIC MOULDS, 1718⁸, 1718¹⁰, 1718¹⁵, 1718¹⁶, 1718¹⁷.

LUNGS.

MALFORMATION, 1718⁹⁰.

EMPHYSEMA, 1718⁹⁰, 1719, 1719²⁵, 1719⁵⁰, 1719⁵¹, 1719⁵², 1719⁵³, 1719⁵⁴, 1719⁵⁵,
1719⁷⁰, 1720, 1720²⁵, 1720³⁰, 1720⁵⁰, 1720⁷⁵, 1721, 1722, 1723, 1724.

COMPRESSED, 1724⁵⁰, 1756⁵⁰, 1758, 1761⁵⁰, 1765, 1767, 1772.

APOPLEXY, 1718⁷⁵, 1725, 1725²⁴, 1725³⁶, 1725⁴⁸, 1725⁶⁰, 1725⁷², 1725⁸⁴.

INFLAMMATION, LOBULAR, 1725⁷², 1725⁷³.

Lobal, 1726, 1727, 1727¹⁶, 1727³², 1727⁶⁴, 1728, 1729, 1729¹⁵, 1729⁴⁵,
1729³⁰, 1729⁶⁰, 1729⁷⁵, 1727³⁵, 1757, 1718¹⁶, 1718¹⁷, 1738⁶⁵.

Chronic, 1726⁶⁴, 1742⁴⁴, 1769⁴⁸.

Contraction, 1729³⁰, 1729⁹³, 1742⁶⁰, 1743.

Black from pigmental deposit, 1726⁷⁰, 1726⁷⁸, 1726⁸⁶, 1726⁸⁷.

GANGRENE, 1730, 1731, 1731⁵⁰, 1718¹⁰, 1731⁵⁵, 1732, 1732³², 1732⁶⁴, 1732⁷⁰.

PHTHISIS:—

TUBERCULAR DEPOSIT, 1721, 1733, 1734, 1735, 1735²⁵, 1735⁵⁰, 1735⁷⁵, 1736,
1737, 1737²⁵, 1737⁵⁰, 1739³², 1742, 1738, 1738³², 1738⁶⁴, 1738⁶⁵, 1739³²,
1739⁶⁴, 1742⁸, 1743³⁰, 1743⁵⁰, (with Emphysema, 1743¹⁰.)

DISORGANIZATION, 1738³², 1738⁶⁴, 1739, 1739³², 1739⁶⁴, 1740, 1741, 1742, 1742⁸,
1742¹⁶, 1742²⁴, 1742³², 1742⁴⁰, 1742⁴⁴, 1742⁴⁸, 1742⁵⁶, 1742⁶⁰, 1742⁷², 1742⁷⁵,
1742⁸⁰, 1742⁸⁸, 1743²⁰, 1743³⁰, 1743⁴⁰, 1743⁵⁵, 1743⁶⁰, 1713⁷⁰, 1743⁷², 1766²¹.

CALCAREOUS DEGENERATION OF DEPOSIT, 1743⁵⁰, 1743⁷⁰, 1743⁸⁰, 1744, 1744⁵⁰,
1745, 1745³⁰, 1746, 1747.

CARTILAGE IN LUNG, 1747⁶⁸.

CANCER OF LUNG, 1747⁵⁰, 1748, 1749, 1749³², 1749⁴⁰, 1749⁶⁴, 1749⁸², 1750, 1750¹⁶, 1750²⁰, 1750³², 1750⁶⁴, 1750⁸⁰, 1751, 1751³², 1751³⁶, 1751⁶⁴, 1752⁵⁰, 1752⁵⁵.

CALCAREOUS DEGENERATION WITH CANCER, 1750⁴⁰, 1750⁴⁵, 1750⁴⁶.

ANEURISM OPENING INTO, 1487⁵⁰, 1489⁵⁰.

HYDATIDS, 1753, 1754, 1755, 1755²⁵, 1755⁵⁰, (with Aneurism, 1753⁵⁰.)

INJURY, 1755⁶⁴, 1755⁷⁵, 1725⁷², 1755⁸⁷.

PLEURA.

INFLAMMATION:—

Fibrinous effusion, 1756²⁵, 1769⁸⁰, 1770, 1770⁵⁰, 1756⁵⁰, 1757, 1758, 1759, 1760, 1761, 1761⁵⁰, 1763, 1764, 1765, 1765⁵⁰, 1766, 1766⁴², 1766⁵⁶, 1766⁸⁴, 1767, 1772.

Thickened, 1727⁷⁰, 1763, 1765, 1766⁴², 1766⁵⁶, 1767⁵⁰, 1769³².

Puckered, 1762⁶⁴.

Adhesions, 1762, 1762¹⁶, 1762³², 1762⁴⁴, 1766¹⁴, 1766⁷⁷, 1766⁸⁴.

Cartilaginous, 1768, 1769, 1769¹⁶, (loose, 1769⁶⁴.)

Ossific deposit, 1766³⁵, 1769⁴⁸, 1773, 1774, 1774⁵⁰, 1775, 1776, 1777, 1777¹⁰, 1777¹⁵, 1777¹⁶, 1777¹⁷, 1777¹⁸, 1777¹⁹, 1777²⁰, 1777³¹, 1777³⁴, 1777⁴⁰, 1777⁶⁰.

Empyema, 1766, 1766⁷⁰, 1766⁸⁴, 1769¹⁶, 1773, 1777⁴⁰, 1743⁷².

Perforation, 1766²⁵, 1766²¹, 1766²³, 1766²⁸, 1766³³, 1773, 1774, (by Aneurism, 1490²¹.)

Gangrene, 1772⁶⁴, 1772⁸⁰.

STRUMOUS TUBERCLE, 1769, 1772³², 1772⁵⁰, 1778.

CANCER, 1777⁸⁰, 1778³², 1779, 1780, 1780³², 1780⁶⁴, 1781, 1782, 1782²⁰, 1782⁴⁰.

HYDATIDS, 1783³², 1783⁶⁴.

INJURY, 1784.

GASTRIC SOLUTION, 1784²⁰.

THE UNIVERSITY OF CHICAGO
LIBRARY

THE UNIVERSITY OF CHICAGO
LIBRARY

THE UNIVERSITY OF CHICAGO
LIBRARY

THE UNIVERSITY OF CHICAGO
LIBRARY

THE UNIVERSITY OF CHICAGO
LIBRARY

THE UNIVERSITY OF CHICAGO
LIBRARY

THE UNIVERSITY OF CHICAGO
LIBRARY

THE UNIVERSITY OF CHICAGO
LIBRARY

THE UNIVERSITY OF CHICAGO
LIBRARY

VOCAL AND RESPIRATORY ORGANS.

LIPS AND PARTS ABOUT THE MOUTH.

- 1677⁷⁵. Mouth extremely contracted and rigid, the consequence of ulceration following the use of mercury.

The patient was a young man, aged 22, whose health was broken down by syphilis and mercury. He was admitted into Guy's under Mr. Morgan's care, who three times operated on the mouth for the purpose of enlarging it, but with only transient benefit. The contraction increased, and the opening became a small round immoveable aperture. The patient became generally anasarcaous; the chest and abdomen were filled with clear serum; the kidneys were mottled and much degenerated; the liver small, firm, and irregular. See Drawing, No. 230.

1. Misc. Insp. Book, page 86.

- 1678⁵. Horny growth from the lower lip.

Removed by Mr. Cock, August 13, 1856, from William A., aged 53. He was a carpenter living at Clapham; the tumor had been growing for six years. The wound soon healed. See Drawing 230⁸⁰.

1678. Cyst in the lip. Stated to be formed by the dilatation of a labial gland.

1679. Cancer of the lip. Removed during life. The growth occupies the whole breadth of the lip, but is more prominent on the right side; irregular processes are seen projecting from its surface.

1680. Cancerous warty tumor of the lip, removed by Mr. C. A. Key.

The patient, a middle-aged man, attributed the origin of the tumor to holding rough packing string between his lips when tying sacks; it was of four months' duration, and had begun to ulcerate.

- 1680⁵⁰. Scirrhus tumor from the lip, removed after death by Mr. C. A. Key.

1681. Cancer of the lip, removed by Mr. C. A. Key.
1682. Portion of lip affected with cancer; the structure remarkably fibrous.
- 1682²⁰. Portion of lip, presenting superficial cancerous ulceration, removed by Mr. J. Morgan.
- 1682⁴⁰. Nearly the whole of the lower lip presenting cancerous ulceration.
- Removed by Mr. J. Morgan, 1829. See Drawings 233, 234, 235. The first shows the condition of the lip before the operation, and the two latter its condition afterwards.
- 1682⁶⁰. Scirrhus affection of the lip. The disease is situated at the angle of the mouth, and the submucous glands appear to be diseased.
- 1682⁸⁰. Nearly the whole of lower lip, and the angle of the mouth, removed for carcinomatous ulceration, by Mr. J. Morgan, 1830.

See Cast No. 245.

LARYNX AND THYROID CARTILAGE.

- 1683⁸⁸. Tracheal cartilages deformed and ossified.
- Presented by Mr. Hilton.
1684. Thyroid cartilage ossified. The posterior portion of the ala is necrosed, and a portion, $1\frac{1}{2}$ inch in length, is detached. The pharynx is ulcerated.
- 1684²⁵. Larynx and part of the trachea, showing necrosis of the right ala of the thyroid cartilage. The dead cartilage was surrounded by pus, and a small opening had formed into the larynx between the vocal cords, and also into the pharynx; paroxysms of very urgent dyspnoea came on every night, and tracheotomy was performed by Mr. Callaway. The vocal cords were swollen, and the sacculi laryngis are involved in the suppuration.

Case of John M., aged 42, admitted into Naaman, April, 1856. Four years previously he had had syphilis. Record of Inspection, 92, 1856.

1685. Diseased thyroid cartilage, with abscess and a sinus in the neighbouring soft parts; the abscess is situated at the side of the larynx. The inferior vocal cord on the same side appears ulcerated. The patient had tubercular phthisis.

C. A. Key's Inspection Book. Case of Thomas B.

1686. Ulceration of larynx and cricoid cartilage. There is an ulcer about one inch in diameter, extending from the situation of the right inferior vocal cord, which is destroyed, to the lower margin of the cricoid. The cricoid is ulcerated, and there is extension of the disease between the cricoid and thyroid cartilages, and by a sinus to the skin; there is also a circular ulcer on the inner aspect of the epiglottis on the left side.

Presented by Sir A. Cooper.

1687. Larynx with abscess and ulceration near the inferior and posterior part of the thyroid cartilage. The abscess apparently arose from the diseased cartilage.

Presented by Mr. J. G. Appleton.

1688. Diseased cricoid cartilage, causing death by closure of the rima glottidis, and thickening of the lining membrane of the larynx. On the pharyngeal aspect there is an opening passing to the cricoid cartilage, described as an ulcer. From a woman aged 35.

Presented by Mr. J. Hardy.

1689. Cricoid cartilage, with considerable cretaceous deposit, accompanied by exfoliation and ulceration. From a young man aged 29, who died from phthisis; he had almost total loss of voice.

Case of C. Bolton, patient of Dr. Babington.

1690. Epiglottis destroyed by ulceration.

- 1690³². Tongue and larynx. The epiglottis has been destroyed, and the pharynx, base of the tongue as far as the rima glottidis, is in a state of ulceration and sloughing, probably cancerous.

1690⁶⁴. Ulceration of the larynx and base of the tongue. The disease, which was probably cancerous, has destroyed the epiglottis.

1690⁸⁰. Larynx and pharynx. There is extensive ulceration on the inner aspect of the epiglottis, and considerable thickening of the mucous membrane generally.

Case of James B., aged about 55. There was extensive disorganization of the lungs.

17. Misc. Insp. Book, page 156.

1690⁹⁰. Chronic thickening of the epiglottis and rima, with wart-like growths upon the mucous membrane, covering the cricoid cartilage in the pharynx.

Case of Maria O., aged 27. Mr. Bryant's Mus. Cat., No. 77, p. 34.

1691. Cancerous tumor from the epiglottis. This tumor was removed from the epiglottis by Sir A. Cooper with his finger during life.

From a woman, aged 50, admitted into Guy's, September, 1804. It produced very urgent dyspnoea, and could be elevated so as to be rendered distinctly visible. She was unable to swallow solid food, and complained much of hunger. The tumor is stated to have had a cancerous aspect, and to have been highly vascular.

The removal of the tumor afforded much relief; but it soon increased beyond its former magnitude. Relief was again obtained by a second removal of the tumor; but again enlarging, and bleeding severely, she died, three months after admission.

Old Mus. Book, No. 46.

1691⁵⁰. Carcinoma of thyroid cartilage and epiglottis. A tumor about $1\frac{1}{2}$ inch in diameter, and apparently carcinomatous, was situated between the hyoid bone and base of the thyroid; some tubercular masses are seen extending through the thyroid cartilage. The epiglottis is pushed backwards, and an irregular growth is seen on the inner surface. The rima was nearly obliterated.

Abraham R., aged 65, admitted Nov., 1845. He had been ill for six months, and a few hours before death had several epileptic fits. No cancerous disease of other structures was found.

1. New Insp. Book, page 66.

1692. Larynx and upper part of the trachea of an infant. The mucous membrane of the larynx and epiglottis are covered

by a firm layer of false membrane; the trachea presents similar effusion in a less degree. (Croup.)

- 1692²⁵. Larynx and trachea of a child, presenting delicate false membrane (croup), covering and adhering to the whole of the mucous membrane. On removing this croupous layer the exposed surface was red, and highly inflamed. The bronchi presented a similar appearance, and one lobe of the right lung was consolidated. The child was rather more than two years of age, and only lived three days after the commencement of the disease.

Mr. Bryant's Mus. Cat., No. 75, p. 34.

- 1692⁵⁰. Larynx lined with adherent false membrane.

Case of Maria L., aged 5, admitted under Dr. Addison's care into Petersham Ward, May, 1835. She had had cough for some time, but was admitted suffering from urgent dyspnoea; the countenance anxious, and a small quantity of viscid mucus was expectorated. She died on the following day. The larger air tubes were filled with thick mucus. The trachea presented the layer shown in the specimen. The lungs were distended. The peritoneum was studded with miliary tubercles, but there were none in the lungs.

- 1692⁷⁵. Croupy membrane in the larynx of a child.

Presented by Mr. Hilton.

1693. Larynx and upper part of the trachea of an infant. The whole of the membrane is covered with a thick false membrane. This case proved fatal in 36 hours from the commencement of the attack.

Presented by Mr. T. Hardy.

- 1693⁵⁰. Larynx presenting partial thin croupous membrane, attached to its mucous surface. A strumous gland has been left attached to the trachea.

Rosella D., aged 4. 19. Misc. Insp. Book, p. 18.

1694. Larynx and upper part of the trachea of a child, with the tongue and fauces. The larynx is lined by a nearly detached recent false membrane

- 1694⁵⁰. Larynx and trachea of a boy, aged 15, presenting croupous membrane. The bronchi to the base of the lung were

filled with fibrinous casts, and this condition was associated with acute pneumonia of nearly the whole lung.

W. J., aged 15, admitted under Dr. Hughes' care, January 19, 1844, and died the following day.

See prep. 1718⁸. 19. Misc. Insp. Book, page 290.

- 1694⁵¹. Larynx of a girl affected with acute laryngitis. The whole of the mucous membrane of the larynx and trachea are covered with a delicate false membrane. The membrane beneath was intensely congested.

Matilda S., aged 17, admitted Feb. 15, 1854, under Dr. Barlow's care. She was a sempstress, and had been ill for six weeks from epileptic fits. Six days before admission urgent dyspnoea came on, with difficulty in deglutition, and the patient died on the 16th. The dura mater was found to be congested, and there was subarachnoid effusion. The kidneys were contracted and much degenerated. Prep. 2038.⁸⁶ There was no anasarca.

Record of Inspection 35. 1854.

- 1694⁵⁵. Larynx of a boy affected with acute laryngitis. The mucous membrane of the larynx was covered with a delicate false membrane, velvety and intensely congested.

Francis R., aged 16, died from confluent small-pox on the ninth day of the eruption, with inflammation of the pharynx, larynx, bronchi, and with pleuro-pneumonia.

Record of Inspection 204, 1854. See Drawing 246²⁶.

1695. Larynx of an adult with adherent fibrinous effusion.
1696. Larynx of an adult with croupous membrane on the mucous surface.
- 1696²⁰. Larynx of an adult, showing great thickening of the whole mucous membrane of the larynx, epiglottis, and aryteno-epiglottidean folds. There is slight ulceration on the inner surface of the epiglottis.
- 1696⁴⁰. Larynx presenting œdema of the epiglottis and adjoining membrane, with several ulcers on the inner surface of the epiglottis.
- 1696⁶⁰. Larynx of an adult, showing a cicatrix on the mucous membrane.

From a patient of Dr. Bright's. See Drawing No. 244.

- 1696⁸⁰. Tongue and larynx, in which the epiglottis and rima are thickened by submucous purulent infiltration.

See Drawing No. 237⁵⁰.

1697. Cordæ vocales and mucous membrane on the upper part of the larynx much thickened, and its surface rough and uneven. There appears to be a small ulcer on the inferior vocal cord.

- 1697¹⁰. Ulceration of the larynx, supposed to be syphilitic. The epiglottis is nearly destroyed, and there is a deep ulcer between the tongue and its glossal surface. The right inferior vocal cord is destroyed by a deep ulcer, the left inferior cord partially so. The arytenoid joints are also destroyed, and there is considerable thickening of the aryteno-epiglottidean folds of membrane.

From Agnes G., aged 43.

Mr. Bryant's Col.: No. 76 Cat. p. 34.

- 1697¹⁸. Ulceration of the larynx. The whole of the laryngeal surface of the epiglottis is ulcerated, the vocal cords destroyed, and the inner wall of the succuli destroyed; the cartilages are exposed, and there was submucous suppuration. There are several small ulcers on the anterior surface of the trachea, and at the lower part of the trachea is an ulcer nearly one inch in length.

Elizabeth A., aged 36, admitted into Guy's, November, 1842. She had been suffering for one year with partial aphonia and constant pain referred to the larynx. There were occasional severe exacerbations and hæmoptysis. Several vomicae were found in the lungs, with low organized and calcareous deposit. The bronchial glands were enlarged. There was ulceration in the cæcum and colon, and a few ulcers in the ileum.

19. Misc. Inspec. Book, p. 115.

- 1697²⁵. Ulceration of the larynx, presenting irregular ulceration of the whole of the mucous membrane of the epiglottis on its inner aspect. The inferior vocal cords, and the mucous membrane beneath them, are also destroyed. The ulceration is deepest at the crico-arytenoid articulation.

W. D., aged 31. For twelve months before death had the symptoms of phthisis; and for two weeks there had been aphonia, pain in the

region of the larynx, and some difficulty in deglutition. There was a large vomica at the apex of the right lung.

Mr. Bryant's Col., No. 69, p. 32.

- 1697⁵⁰. Contracted trachea following a cicatrix. The epiglottis and mucous membrane of the larynx are thickened irregularly granular and "cicatrised." The trachea at the second ring much contracted, and the mucous membrane indurated.

Philip D., aged 37, admitted July, 1835, under Dr. Bright's care. His voice had been affected for nine years. Nine days before death, whilst at work, he had an epileptic fit. These fits increased in frequency and severity, and hemiplegia on the right side came on. On inspection there was a cicatrix on the forehead, and the calvarium at that part was indurated and unequally dense, and the dura mater adherent. There was purulent aractinitis on the left hemisphere of the brain. There was some emphysema of the lungs, the right inferior lobe in a state of pneumonic consolidation. The liver was coarse; the kidneys healthy. The ulceration of the larynx was probably syphilitic.

7. Misc. Inspec. Book, p. 52.

- 1697⁷⁵. Larynx and trachea, showing a cicatrix on the epiglottis and about the centre of the trachea leading to contraction. "The mucous membrane of the lower surface of the epiglottis, as well as that of the trachea, was somewhat granular; and about an inch from the bronchi, the trachea externally was of a very dark color, whilst internally the sides were adherent, and two or three of the rings destroyed, so that the size of the trachea was much diminished."

W. C., aged 34, admitted August, 1839, under Dr. Back's care. It is stated, that six months before death he caught cold and had inflammation of the windpipe. Two months afterwards he had swellings upon the head, and abscess over the clavicle and scapula. Symptoms of fever came on about nine days before death.

16. Misc. Inspec. Book, p. 116.

1698. Larynx, of which the mucous membrane is ulcerated at the posterior angle of the vocal cords.

Hannah S., aged 25, admitted under Dr. Cholmeley's care with variola. She died from phthisis and pneumothorax.

4. Green Inspec. Book, p. 76.

1699. Larynx and trachea with thickening about the rima glottidis. There is ulceration on the internal surface of the epiglottis.

1700. Larynx with extensive ulceration near and below the base of the arytenoid cartilages.

1701. Pharynx and larynx, showing ulceration external to the thyroid and cricoid cartilages.

1701⁵⁰. Abscess in the pharynx connected with diseased thyroid cartilage.

Removed from a woman who had for several years suffered from difficulty, and at last inability to swallow food. There was an opening externally, through which fluids passed when she attempted to swallow them.

2. Note Book, p. 44. Presented by Mr. Gibson.

1702. Larynx of a child, with minute cauliflower vegetation on the cordæ vocales, and a thin layer of coagulable lymph covering the mucous membrane generally, described as chronic croup. The child was about four years of age, and had lost its voice for five months.

1703. Larynx with a cauliflower-shaped vegetation on the edge of the left sacculus laryngis.

A dispensary patient in 1825 or 1826, who suffered from symptoms of laryngitis, and died exhausted. No other disease was found beside this growth and inflammation of the larynx.

Presented by Dr. Addison.

1704. Larynx with cauliflower-shaped vegetations, some of which are very minute, above the sacculus laryngis.

From a middle-aged woman who died suddenly.

Presented by Mr. Hawkins.

1704⁵⁰. Cancerous disease of the larynx and pharynx. The cartilages at the upper part of the trachea are quite destroyed, and the mucous membrane of the whole of the lower part of the pharynx and upper part of the œsophagus is destroyed.

From a patient of Mr. Cocks'.

1705. Larynx with effusion beneath the mucous membrane at its upper part, producing œdema glottidis and epiglottidis.

1706⁵⁰. Larynx with epiglottis and glottis greatly œdematous.

Fr. J., aged 29, admitted under Dr. Back's care with anasarca of

five months' standing. Six weeks before death, his anasarca having left him, pain in the throat, with difficulty of breathing, came on.

1. Misc. Inspec. Book, p. 77.

- 1706⁷⁵. Œdema laryngis. From a man aged 70, affecting more especially the right side, and obliterating the ventricle on that side.

Fotheringillean Essay for 1836. Mr. Bryant's Cat., No. 78, p. 35.

1707. Larynx, but principally the glottis, affected with œdema.

1708. Larynx showing œdema glottidis from syphilis. Epiglottis partially destroyed by previous disease.

1709. Larynx showing œdema glottidis from syphilis.

The patient died in Lazarus ward. He was admitted with slight ulceration of the throat and fauces; was otherwise well; exposed himself to cold, was seized with dyspnœa, and died in three days.

1710. Larynx plugged by a piece of meat.

- 1710⁵⁰. Pharynx, tongue, and larynx, with a large opening below and parallel to the os hyoides, the upper edge of the thyroid cartilage being divided. The epiglottis is situated above the incision. Articulation was not attended with pain, but was performed imperfectly and indistinctly. The man died on the fifty-third day after attempting suicide by cutting his throat, having murdered his wife a few minutes previously.

Case of Richard L., aged 60. See cast No. 18.

1. Misc. Inspec. Book, p. 68.

1711. Larynx showing a transverse incision through the thyroid cartilage, between the superior and inferior vocal cords. There is a second incision through the cricoid cartilage.

W. H., aged 33, admitted May, 1827.

1. Misc. Inspec. Book, p. 4.

- 1711⁷. Larynx of a man, showing an irregular incision through the thyroid body, and immediately below the cricoid cartilage. The left internal jugular was divided. The man died from hæmorrhage six days after the injury.

Case of W. T., aged 30.

2. Misc. Inspec. Book, p. 9. See Preparation of the jugular vein, 1521⁴⁵.

- 1711⁹. The anterior part of the neck with the trachea, from a man who had cut his throat. The anterior portion of the trachea was divided, and the inferior thyroid artery, which was secured by a ligature. He gradually sank from the loss of blood, and died on the sixteenth day from the time of inflicting the wound.

Langstaff's Mns., No. 2352.

- 1711¹¹. Larynx and œsophagus from a man who had attempted suicide by cutting his throat. He had for several years taken food by means of a pipe. The anterior opening passing into the trachea had a cuticular covering. At the position of the incision the trachea was much contracted above, but free below. The incision extended through into the œsophagus. The œsophagus was very much contracted above the opening, and in a rather less degree below.

John S., aged 28, admitted October, 1837. The parietal bone was partially removed from an old wound (preparation 1076⁸⁵), and the opposed dura mater deficient (preparation 1592⁶⁰). There were vomicae in apices of both lungs. See Drawing 244⁶⁰.

13. Misc. Inspec. Book, p. 114.

THYROID GLAND.

- 1711¹⁴. Enlarged thyroid gland pressing on the trachea.
- 1711²¹. Thyroid gland, containing cysts, stated to be incipient bronchocele.
- 1711²⁸. Larynx and trachea with the thyroid gland, of which the left lobe is considerably enlarged, and contains several cysts. Incipient bronchocele.
- 1711³⁵. Larynx with the thyroid gland, the left lobe of which is greatly enlarged. The carotid artery is involved in the thickened structure beneath the tumor.
- 1711³⁹. Lateral lobe of the thyroid gland considerably enlarged. It was removed from the dissecting-room, and appeared

to be of long standing. There are cells with apparently fibro-cartilaginous tissue around them. Bronchocele.

1711⁴². Portion of an enlarged thyroid gland removed after death, containing cysts filled with coagula. The patient, it is stated, died from irritation of the stomach.

1711⁴⁹. Cyst in the thyroid gland, *dried*.

1711⁵⁶. Ossified cyst from the thyroid gland.

Presented by Mr. D. Compton.

1711⁶³. Larynx with a large tumor attached to it. The tumor appears to have originated in the thyroid gland, and is principally formed by one large cyst, the internal surface of which appears to have been long in a state of inflammation. The carotid artery and jugular vein passing over it are much displaced.

Presented by Mr. Joseph Towne.

1711⁶⁷. Larynx and thyroid gland. Above the right corner of the thyroid gland is a cyst placed beneath the sterno-mastoid muscle. It is capable of containing about three ounces of fluid. Its walls are thick and irregular. The carotid artery and pneumogastric were much pressed upon. The cyst is connected with the thyroid by firm tissue. Behind the pillars of the fauces there is an irregular excavation, apparently from ulceration or abscess near the tonsil.

1711⁷⁰. Larynx with the thyroid gland enlarged from carcinomatous disease. Ulceration had taken place.

1711⁷³. Larynx and thyroid, with the right lobe of the gland enlarged from cancerous disease.

The patient, Catherine F., was 42 years of age, and had been an out-patient for some time under Mr. Callaway's care with enlarged thyroid gland; she was subsequently admitted into the hospital, and died. Cancerous tubercles were found in the lungs, and the left supra venal capsule formed a large cancerous mass. See prep. 2021⁸³.

19. Misc. Insp. Book, p. 84.

- 1711⁷⁷. Thyroid gland containing several cysts, and likewise affected with cancerous disease; both lobes of the gland are diseased.

The patient, Sarah G., was about 40 years of age, and was admitted under Mr. Key's care with carcinoma medullare of the breast; she died from an attack of erysipelatous inflammation. See Drawing 413. She was a native of Berkshire, and from childhood had been the subject of enlargement of the thyroid. Sixteen months before death she had a child; the uterus was large, and presented a small firm tubercle in its walls. See prep. of uterus, 2231⁶⁴.

11. Green Insp. Book, p. 21.

TRACHEA.

- 1711⁸⁴. Larynx and part of the trachea. The former and several of the rings of the latter ossified.

Presented by Mr. Jarret Dashwood.

- 1711⁸⁵. Trachea, presenting numerous irregular bony growths of *true bone* on the mucous membrane; the cartilages themselves are not ossified, but these bony plates extend in many places between them. The internal surface of the larynx and upper part of the trachea are ulcerated.

Case of William W., aged 38, admitted June 4, 1856, under Dr. Hughes' care. He was a bricklayer from Lambeth, a man of intemperate habits; ten years previously had inflammation of the lungs, but had enjoyed good health till seven months before admission, when, after exposure to cold, he had cough, &c. On admission there were general bronchial rales, and the symptoms of phthisis gradually became developed.

Record of Inspection, No. 166. 1856.

- 1711⁸⁶. Perforating ulcer of the trachea. The œsophagus presents an irregular opening, about an inch in diameter, with smooth rounded edges. There are four openings into the trachea, one half an inch in diameter, the others merely fissures; they are separated, the one from the other, by portions of the wall of the trachea; the edges are not raised, as if by heterologous deposit. There appears to have been some ulceration at the point of union of the vocal cords. The cartilages of the trachea are ossified.

— W., aged 42, a carrier from Hampton. There was crowing respiration during life, but the report states "that he was never threatened with suffocation;" the expectoration was abundant. The patient gradually sank. Several portions of ossified trachea were expectorated the first six months before his death. See prep. 1711⁸⁷. A second portion six weeks later. There was consolidation of the posterior and inferior lobe of the right lung.

See 2nd Note Book, p. 70. Drawing 246²³. Prep. 1711⁸⁷.

Guy's Reports, 1856, p. 216.

1711⁸⁷. Portion of ossified tracheal ring, expectorated by the patient from whom the preceding specimen was taken.

1711⁹¹. Trachea with enlarged follicles, from a patient of Dr. Cholmeley's, who had been affected with bronchitis and jaundice.

1712. Larynx and trachea of an adult. The mucous membrane of the trachea is covered over with a thick false membrane.

1713. Adventitious membrane in the form of a cylinder, and bearing the impression of the mucous follicles. Expectorated during life.

Thomas S., aged 30, had frequently been the subject of catarrhal symptoms. In January, 1807, having stood for several hours in the water, was in the evening attacked with symptoms of catarrh; he continued at his work for three days, the dyspnoea then became urgent, his face livid, and on the eighth day he expectorated the cast shown in the specimen. His respiration was much relieved, and he was able to walk to the hospital; the following day's respiration again became very difficult, and the patient died. On inspection, a portion of lymph was found on the surface of the epiglottis, and in the bronchi to their smaller divisions, but the trachea was free. The liver was much diseased, and there was old disease of the lungs.

Old Mus. Book, No. 61.

1713²⁵. Larynx with enlarged cervical glands, which had pressed upon the pneumogastric nerve and its branches, and had led to the symptoms of laryngitis; the bronchi also were compressed: laryngismus stridulus. The cervical glands were infiltrated with strumous deposit, and there were miliary tubercles in the lungs and peritoneum, &c.

From an infant aged fourteen months, patient of Dr. Gull's.

1713⁵⁰. Larynx and trachea, the mucous membrane extensively ulcerated, not merely in spots, but in a circumscribed

patch at the posterior part, and in lines along the cartilaginous rings.

See Drawing 246.

- 1713⁷⁰. Trachea and upper part of the lung of a man affected with phthisis. The trachea is extensively and deeply ulcerated, so also the bronchi; the lung presents several vomicae, and at the base a small one connected with one of the bronchi. The larynx and intestines were also ulcerated.

John J., aged 21, patient of Dr. Hughes'.

Record of Insp., No. 9, 1855.

- 1713⁷⁵. Larynx and trachea, the lining of which is marked by numerous deep small ulcers; this ulceration extends as high as the inferior cords.

1714. Perforating ulcer between the trachea and œsophagus. The opening in the œsophagus appears to be larger than that in the trachea. The patient was admitted into Martha for supposed stricture of the œsophagus.

Presented by Mr. Rix.

- 1714¹⁰. Ulcerative communications between the trachea and œsophagus, probably following abscess. There are three irregular openings extending from the upper part of the œsophagus into the trachea. The mucous membrane is destroyed or undermined.

Case of Sarah B., aged 24, admitted into Lydia ward, December, 1854. She was a married woman, and had never had syphilis; six months before admission she felt some enlargement of the throat, with difficulty of swallowing, pain, and shortness of breath; shortly before admission she had swelling of the throat, which suddenly disappeared. On December 25th, dysphagia extreme, so that she refused to swallow, and was fed by injections alone till her death, forty-one days afterwards. There was no evidence of cancerous disease. On January 6th, Mr. Hilton performed tracheotomy. See Drawing No. 246²⁴.

Record of Insp., 1855, No. 21.

1715. Larynx, trachea, and œsophagus, with a communication between the trachea and œsophagus. The opening is oval in form, and about two inches in length, and has smooth rounded edges. It appears to have been the result of ulceration.

1715⁵⁰. Cancerous ulceration of trachea. There is a large cancerous mass on the right side of the trachea compressing the subclavian artery; portions of whalebone are placed beneath the nerves of the right brachial plexus, which were much pressed upon. The front of the bodies of the vertebræ at this part were carious, and a cavity communicated with the ulcerated opening into the trachea. The œsophagus was slightly encroached upon.

Patient aged about 50, under Dr. Addison's care. No tumor was perceptible in the neck, and there was intense pain down the arm, with symptoms of pressure upon the trachea; there was a peculiar sound on respiration, and difficulty in deglutition and dyspnœa.

1716. Trachea opened by operation; the incision vertical through the first four rings.

1716²⁰. Growth situated between the trachea and the œsophagus. The growth is about one and a half inch long, and half an inch in breadth, and contained softened material, the result of inflammatory action. An opening was directed towards the trachea, immediately opposite to the opening made in the operation of tracheotomy, and the trachea was much narrowed at this part. The obstruction of the œsophagus is almost complete. The disease was said to be carcinomatous.

Jane B., aged 57, admitted into Guy's under Dr. Bird's care, July, 1851. Twelve months previously she had had an attack of sore throat and bronchitis; this was followed by dysphagia, pain and occasional dyspnœa. The symptoms increased in severity till three months before admission, when the dysphagia and emaciation became extreme. On the morning she was brought to Guy's, she appeared to be dying from suffocation; tracheotomy was performed by Mr. Poland, which was rendered exceedingly difficult, by the pressure of the growth interfering with the admission of air after the trachea had been opened. The patient was relieved by the operation, but died on the twelfth day from exhaustion and bronchitis.

Guy's Reports, 1851. Vol. vii., part II., p. 322.

1716²⁵. Cancerous disease at the upper part of the right lung, extending into the trachea, and obstructing the superior cava by a growth nearly filling the vessel. There was cancerous infiltration of the bronchial and cervical glands.

The right pulmonary artery was compressed. The superior lobe of the lung was destroyed. The liver contained one or two cancerous masses.

Case of William L., aged 26, admitted in October, 1856, under Dr. Barlow. Two months before admission he had pleurisy, dyspnoea, cough, and occasional hæmoptysis.

Record of Insp., 206. 1856.

- 1716⁵⁰. Sixpence which was coughed up after having passed into the trachea.

BRONCHI.

1717. Bronchial tubes with a portion of the trachea, showing considerable dilatation.

From a boy aged 11, a dispensary patient of Dr. Hodgkin's, who had suffered from dyspnoea and palpitation at the heart for four years.

On inspection, there was recent effusion of lymph in the right pleura; and old adhesions, there were vomices in the lungs, and general dilatation of the bronchi. The substance of the lung was dense. There was general peritonitis and pericarditis. See preparation 1437.

2. Green Insp. Book, p. 140.

- 1717³². Bifurcation of the trachea of a boy, showing the left bronchus, which had been compressed by dilatation of the left auricle.

Fredk. W., aged 15, admitted under Dr. Bright's care into Cornelius, June, 1834. Five years previously he had had rheumatism, which was followed by palpitation and dyspnoea. There was general anasarca. On inspection, the pericardium was universally adherent; the heart, especially the left side, was dilated and hypertrophied; the mitral opaque and granular. The great distension of the left auricle had compressed the left bronchus. The pleura generally was obliterated, except at the left base, where was considerable serous effusion. Kidneys rather small, firm; "cortex too minute."

5. Misc. Insp. Book, p. 135.

- 1717³⁵. Bronchus compressed by the left auricle.

From a child, aged two years and four months, who had suffered from dyspnoea from the first month. Only two pulmonary sigmoid valves were found, and the heart was considerably hypertrophied; the mitral valve was fleshy and red; the lining of the left auricle thickened.

12. Misc. Insp. Book, p. 88. Guy's Hospital Reports, vol. iii., p. 178.

1717³⁸. Bronchus compressed by dilated left auricle.

Case of Lydia P., aged 21, admitted into Lydia ward, April, 1836, under Dr. Cholmeley. There was hypertrophy and dilatation of the heart; the mitral was very much thickened and contracted; the left ventricle compressed the left bronchus; the right lung contained several apoplectic masses.

9. Misc. Insp. Book, p. 73. Guy's Hospital Reports, vol. iii., p. 176.

1717³⁹. Portion of lung with flattened bronchus.

Case of Robert M., aged 28, who died from contracted mitral, with adherent pericardium. The heart was much hypertrophied, and the dilated left auricle was said to have compressed the left bronchus.

6. Misc. Insp. Book, p. 137. Guy's Hospital Reports, vol. iii., p. 176.

1717⁶⁴. Portion of lung with bronchial tubes dilated near their peripheral termination. The bronchi were red and inflamed, but this appearance has disappeared.

Thomas S., aged 50, admitted under Dr. Bright's care, with urgent dyspnoea, and bronchial affection with anasarca. The patient became semi-comatose. On inspection, there was found to have been effusion of blood between the dura mater and arachnoid. See prep. 1593⁶⁰. Drawing 79. The spleen was exceedingly small. 1993⁶⁰. The kidneys were small and much degenerated.

7. Green Insp. Book, p. 1.

1718. Bronchial tubes dilated, and much thickened. The surrounding lung had been compressed, and the pleura had been adherent, probably the result of pleuro-pneumonia.

1718⁸. Bronchi filled with fibro-plastic moulds.

From Fredk. J., aged 15½ years, admitted under Dr. Hughes' care, January, 1844, with acute broncho-pneumonia and laryngitis. He had been ill for 24 days before admission, and was brought to the hospital suffering from urgent dyspnoea; there was dulness on percussion, and tubular breathing. He died the following day. The left lung was consolidated; the right similarly affected, but in rather less degree. There was diphtheritic membrane external to the epiglottis. See prep. 1694⁶⁰.

19. Misc. Insp. Book, p. 290.

1718¹⁰. Portion of lung in a state of grey hepatization, with commencing gangrene. The bronchial tubes were filled with fibro-plastic casts.

From a young man, aged 27, admitted April, 1851, under the care of Dr. Addison, with influenza. The right lung was consolidated, and a circumscribed portion was in the first stage of gangrene. This gangrenous portion was bounded by a red line, which may still be observed in the specimen. The bronchial tube leading to the gangrenous lung is filled with a fibrinous coagulum. This fibrin, examined microscopically, had coagulated by fibrillation, as in blood drawn in inflammation. Intervening between it and the lining of the tube was a puriform matter, consisting of pus cells and columnar ciliated epithelium; the bronchial tubes through the hepatized portion were equally filled by fibrinous coagula. See Drawing 251³⁰. Micros. Exam. by Dr. Gall.

- 1718¹⁵. Two specimens of arborescent lymph coughed up from the bronchial tubes. The patient continued to cough up similar specimens for a considerable time.

Presented by J. Fincham, Esq.

- 1718¹⁶. Lung in a state of hepatization, showing the bronchi filled with fibro-plastic moulds. The pleura covered by recent lymph.

Case of John J., aged 47, admitted, under Dr. Addison, March, 1855, and died in a few hours. He had been ill for seven days, but walked to the hospital, and sat at tea with other patients. The right side was universally dull, and there was an absence of sound; the left lung was healthy, but œdematous; the right universally consolidated. Drawing 248⁴⁹.

Record of Inspections, 1855. No. 42.

- 1718¹⁷. Sections of both lungs of a child. They were in a state of pneumonic consolidation, and the preparation shows the bronchi containing fibro-plastic moulds, extending from the smaller branches to an opening in the trachea. The child, aged 3½ years, had drank some boiling water, and tracheotomy was performed by Mr. Birkett, to prevent suffocation.

Record of Inspections, 1855. No. 74.

- 1718³⁰. The inferior acute margin of a lung, in which are numerous greatly dilated bronchial tubes, which are also thickened.

- 1718³⁸. Portion of lung occupied almost entirely by greatly dilated bronchial tubes. The lung is extremely emphysematous.

William T., aged 34, admitted under the care of Dr. Bright, August, 1841. He expired immediately after admission. The body was wasted, there were very extensive and firm pleural adhesions. The left apex was emphysematous, and a series of cavities were found in connection with the bronchi, arising from their extreme dilatation. At the base of the left lung were several defined portions of lung, which were softened and were fetid (gangrenous). In the right lung were similar portions with hepatization.

18. Misc. Inspec. Book, p. 137.

1718³⁹. Dilated bronchial tubes, resembling vomicae, from the same specimen as the preceding.

1718⁴⁵. Portion of the inferior portion of the lung, showing bronchi much dilated. Some of the tubes expand into sacculated cavities; the pleura is covered by false membrane.

1718⁵². Portion of lung consolidated, but containing very numerous dilated tubes; the mucous membrane weakened.

Catherine M., aged 18, admitted under Dr. Babington's care, Jan., 1842. The left lung was distended and emphysematous, with some general bronchitis and dilatation; the right lung was very small and fleshy; the tubes excessively, but unequally dilated, and filled with mucus. The substance of the lung wasted and indurated.

18. Misc. Inspec. Book, p. 232.

1718⁵³. A similar specimen from the same case as 1718⁵².

1718⁶⁰. Dilated bronchial tubes in the form of large saccular dilations, which were filled with inspissated puriform fluid.

Mary R., aged 27, admitted under Dr. Bright's care, January, 1836, and died during the same month. Bronchial affection commenced when she was three years of age, after an attack of measles; she had anasarca at the time of her death. The pleura presented old adhesions, and on the left side some recent lymph. Both lungs were emphysematous, and the bronchial tubes dilated. At the inferior and posterior angle on the left side there were a series of cavities filled with inspissated pus and cretaceous matter. These communicated with the bronchial tubes, which contained similar secretion; the bronchi were thickened and opaque; the lining of the cells, thin, opaque, and vascular. The right ventricular hypertrophied.

8. Misc. Inspec. Book, p. 87.

1718⁶⁸. Portion of lung, showing dilated bronchial tubes, forming

large cavities. One of these is two to three inches in diameter.

Elizabeth G., aged 33, a Dispensary patient of Dr. Hughes', suffering apparently from emphysema and pneumothorax. She was much relieved; but the expectoration afterwards became very profuse, and was accompanied with hectic symptoms. She was admitted, under Dr. Bright's care, into Guy's. There was flattening of the right side, dulness, and gurgling, with metallic resonance; on the left side the respiration was puerile. There were on the right side old pleuritic adhesions; the upper lobe dense and membranous, and non-crepitant. At this part were some dilated bronchi. The posterior and inferior part of the right lung presented the appearance shown in the specimen. The left lung was fleshy, red, and watery.

19. Misc. Inspec. Book, p. 55.

1718⁷⁰. Portion of lung presenting dilated bronchial tubes and rounded cavities, apparently formed by dilated bronchi. There is grey induration of the lung, with effusion on the surface of the pleura.

1718⁷¹. Bronchial tubes, with the termination of the trachea, showing small ulcers in the bronchi. The case was one of phthisis.

1718⁷². Termination of the trachea and the right bronchus, showing a remarkable constriction in the latter, apparently from a cicatrix.

Case of Charles H., aged 32, admitted under Mr. Birkett's care, September, 1856. He was an intemperate, dissipated man. Several times had had syphilis. Paroxysms of very urgent dyspnoea came on, and tracheotomy was performed in one of these attacks, a short time before his death. The vocal cords were unaffected.

Record of Inspec., p. 191. 1856.

LUNGS

1718⁷⁵. The base of an infant's lung, in which is a fissure described as the result of apoplexy.

From a private patient of Dr. Hodgkin's.

1718⁹⁰. Small supernumerary lobe of the lung slightly affected with emphysema.

1719. Portion of lung affected with emphysema, dried.

1719²⁵. Portion of emphysematous lung, showing a large bleb beneath the pleura.

1719^{50, 51, 52, 53, 54, 55}. Six sections of emphysematous lung from the same patient, showing dilatation of the cells. In some larger cavities are shown; and in 1719⁵², dilatation with some thickening of one of the bronchi.

1719⁷⁰. Portion of emphysematous lung, with dilatation and some thickening of one of the bronchi.

1720. Section of a portion of dried emphysematous lung.

1720²⁵. Section of a portion of lung affected with emphysema, dried, and immersed in turpentine.

Presented by Dr. Clarke, Professor of Anatomy, Cambridge.

1720³⁰. Portion of lung, showing general and intralobular emphysema, with general emphysema of the lung.

Case of Thomas P., admitted under Dr. Barlow's care, December 26, 1849, and died from renal disease.

New Vol. iii., p. 59.

1720⁵⁰. Section of lung affected with emphysema, dried, and immersed in spirits of turpentine.

Case of Francis N., aged 48, who was admitted into Lazarus ward, under Dr. Cholmeley, February, 1831. He was affected with hydrothorax, and had had asthma almost from infancy. The lungs were fully distended. Much fluid mucus was found in the bronchi. The left lung was very emphysematous, especially towards the base. Between the lobules were dark lines of pigmentary matter, and the apex of the lung was very deeply dyed. The right lung was dark and emphysematous. The heart was hypertrophied, especially the right side; the valves sound. The pulmonary artery was very large; so also the bronchial arteries; the aorta small.

2. Misc. Inspec. Book, p. 44.

1720⁷⁵. Two sections of lung considerably affected with emphysema.

The lung appears in some parts to be condensed, and of a dark color. The specimen has apparently been dried before being placed in turpentine, and this may have given rise to the condensation and discoloration mentioned above.

1721. Lung of an infant injected, presenting small cavities (said to be emphysematous) and minute tubercular deposit. The infant died from hydrocephalus.

Presented by Mr. P. A. S. Dodd.

1722. Portion of emphysematous lung, with several large vesicles on the surface.

1723. Partial emphysema of the lung. A large vesicle is shown on the surface distended with air.

1724. Portion of lung, with a large thin cyst immediately under the pleura, stated to be the cyst of an abscess or hydatid, but believed by Dr. Hodgkin to be the result of partial emphysema.

- 1724⁵⁰. Compressed lung, covered with false membrane, dried. After death the lung could not be inflated beyond its present size. The specimen is preserved to show this non-expansion of the lung after removal of the compressing cause.

1725. Portion of lung affected with pulmonary apoplexy. The air cells are seen to be filled with blood, and in the centre of the clot is dark pigmental matter.

- 1725²⁴. A portion of lung affected with pulmonic apoplexy. The effused blood is limited to particular lobules. One of the pulmonary vessels is full of fibrin.

The patient was 17 years of age, who had been accustomed to great muscular exertion. For eight months he had palpitation of the heart, with dyspnœa and cough. There was loud cardiac bruit. Œdema of the lower extremities, and hæmoptysis, came on before death. There was great hypertrophy of the heart, the mitral and aortic valves were thickened and contracted, the pericardium covered partially with

lymph. There was pulmonary apoplexy in both lungs. See prep. 1414³² and 1725³⁶.

9. Green Inspec. Book, p. 77.

1725³⁶. Portion of lung affected with pulmonary apoplexy. From the same case as 1725²⁴.

1725⁴⁸. Portion of lung affected with pulmonary apoplexy, limited to particular lobules. Some of the adjoining pulmonary vessels are filled with coagula.

Elizabeth M., aged 22, was admitted into Guy's, December, 1829, under Dr. Addison's care. Eighteen months before death, she began to complain of symptoms indicative of disease of the heart. A few days before death she had hæmoptysis. On inspection, the mitral was found to be exceedingly contracted, and there were vegetations on the mitral, aortic, and tricuspid valves. See prep. 1725⁶⁰ of old apoplectic lung; 1401²⁴ of heart; 1521³⁰ of obstructed subclavian.

9. Green Insp. Book, p. 8.

1725⁶⁰. Portion of lung of a light color, partially indurated, apparently the result of apoplexy, which had taken place some months before death. From the same case as the preceding specimen, 1725⁴⁸.

1725⁷². Portion of lung, presenting one or two lobules which were of a light color, and indurated, apparently consequent on fractured rib opposed to this portion of lung.

The case of George B., aged 42, who was brought to the hospital, May, 1829, after having, while intoxicated, been kicked on the forehead and chest by a horse; he appeared to do well for three weeks, but left the hospital, and returned intoxicated; he became rapidly worse, and died with symptoms of inflammation of the membranes of the brain. There was caries of the frontal bone, suppuration external to the dura mater, and the cavernous sinus was plugged with softening coagulum. The consolidated lobule was the only portion of the lung diseased. There was a small congested portion of the liver, also opposed to a fractured rib. See preparations:—1050⁸⁵, Fractured Ribs; 1076³⁵, Skull; 1592¹⁴, Dura mater; 1947⁵⁶, Liver. Drawing 348 of Liver.

8. Green Insp. Book, p. 36.

1725⁷³. Portion of lung affected with lobular pneumonia, in a case of pyæmia. The position of the inflamed and suppurating lung tissue is best seen on the pleural surface.

Case of Henry J., aged 50, admitted, under Mr. Birkett's care, with calculus in the bladder. Rigors came twelve days before death. There were abscesses in both kidneys, inflammation of the bladder; the liver was healthy, but there was very extensive lobular pneumonia in the lungs.

Record of Insp., 26. 1856.

- 1725⁸⁴. Portion of lung with a circumscribed condensed mass, about one inch in length, and half an inch in breadth and depth beneath the pleura pulmonalis, which has received a semi-cartilaginous thickening corresponding to it. It was believed to be the result of old pulmonary apoplexy.

Presented by Dr. Stroud.

1726. Portion of lung affected with acute pneumonia. The lung is pale grey, and consolidated, with imperfectly organizable lymph.

- 1726⁶⁴. Portion of lung, the surface of which is remarkably puckered. The parts corresponding to the depressions were of a semi-cartilaginous density, and of a very dark color; the rest of the lung was generally emphysematous. There are old partial adhesions of the pleura. This condition was believed to be the sequel to pneumonia and subsequent atrophy, while the surrounding lung had become more and more emphysematous. The dark fluid which exuded from the excised surface produced an indelible stain.

John M., aged 50, admitted into Clinical ward, April, 1830. He had dyspnœa, and had had winter cough for several years. There were anasarca and coagulable urine. On inspection, there were serous effusion in both pleuræ, and the irregular puckering seen in the preparation; the heart, especially the right ventricle, was much hypertrophied; the kidneys were mottled and degenerated.

9. Green Insp. Book, p. 100.

- 1726⁷⁰. A portion of lung, dense, indurated, and of an almost black color; the pleura is also considerably thickened.

From W. K., aged 39, a patient under Mr. Bryant's care in the Lambeth Infirmary. He had symptoms resembling phthisis. On inspection, the pleura was found to be universally adherent; the lungs were generally firm and unyielding, and of a very deep color.

2. Note Book, p. 19. Presented by Mr. Bryant, Kennington.

1726⁷⁸. Two portions of lung, blackened and indurated in consequence of chronic and acute changes. A lymphatic gland is black and cretaceous. Some of the vessels are obstructed by blood.

1726⁸⁶. Portion of lung affected with chronic induration, and remarkable for the black carbonaceous condition; much of the black deposit has been washed out.

1726⁸⁷. Portion of lung, indurated and carbonaceous as the preceding specimen.

1727. Portion of lung affected with acute pneumonia. It consists of part of two lobes, in one of which the cells are completely filled with white aplastic deposit.

From a patient of Dr. Bright's.

1727¹⁶. Portion of lung in a state of hepatization. Some pigmental deposit is observed between the lobules.

1727³². Vertical section of the upper lobe of the lung affected with recent inflammation. The whole lung was of a yellowish-white color, with a few irregular red spots; a whitish muco-purulent secretion exuded from every part. The whole lung was infiltrated with aplastic deposit. Flakes of lymph are seen deposited on the pleural surface.

George S., aged 19, admitted into Job ward, January, 1832. He was a baker, and was brought to the hospital affected with symptoms of fever, with bed sores, &c., and continued in a weak prostrate condition till death. There were some healing ulcers at the lower part of the ileum.

11. Green Insp. Book, p. 126.

1727³⁵. Lung presenting dilated bronchus, with recent pneumonic consolidation.

1727⁶⁴. A section of a lung completely hepatized by an uniform, pale, recent, and non-plastic inflammation. It is spotted with pigmental deposit. There is also fibrinous pleuritis.

1728. Portions of lung. The larger portion is grey and consolidated; it was removed from the upper lobe of the lung,

which was much distended, mottled, and of a light-color. The smaller portion is a section which has been washed, by which the spongy texture is restored.

Catherine C., aged about 23, a nurse, who was admitted, December, 1826, under Dr. Cholmeley's care, with symptoms considered to be those of fever. She had been ill for ten or twelve days, and had dyspnœa, with lividity of the countenance.

1. Green Insp. Book, p. 174.

1729. Large portion of lung affected with pneumonia. It is uniformly consolidated by aplastic deposit. The pleura is also covered with fibrinous deposit.

- 1729¹⁵. Portion of the upper lobe of a lung affected with inflammation of a non-plastic character. It was of a light reddish color; the pleura was covered with a thin layer of opaque lymph.

Case of Mr. B., aged 48, a butler. Ten days before his death, after exposure to cold, he had rigors, and the symptoms of pneumonia, febrile disturbance, dyspnœa, rust-colored expectoration, &c. On inspection, the right pleura was covered with lymph, and the right upper lobe so much distended as to occupy the greater part of that side of the chest. The stricture of the lung was very lacerable, its incised surface compact, and had a mottled whitish-red color; on slight pressure, a puriform fluid escaped from every part of the incised surface; the lower lobe was less affected. The left lung was healthy. See prep. 1729⁴⁵; and of Old Disease of Gall Bladder, 1952²⁶.

8. Green Insp. Book, p. 28.

- 1729⁴⁵. Another specimen of consolidated lung, with pleurisy, from the same case as the preceding, No. 1729¹⁵.

- 1729³⁰. Portion of lung, presenting some old adhesions and contractions, and a recent pale pneumonic infiltration.

From W. G., aged 44, admitted, July, 1836, under Dr. Bright's care. He had renal anasarca, and small granular kidneys were found after death; the left ventricle hypertrophied.

9. Misc. Insp. Book, p. 107.

- 1729⁶⁰. Portion of lung, of a dark-grey color, partially hepatized. The lymph apparently of a more organizable character than the preceding specimens. There are old adhesions about the serous surface, some cellular and others dense.

- 1729⁷⁵. Portion of the upper lobe of a lung, greatly distended by acute inflammation, the product of which is chiefly of the least plastic form.

Case of Robert W., aged 50, admitted under Dr. Bright's care, June, 1831. He was supposed to be laboring under fever. At the base of the right lung was recent effusion of lymph; the lung was affected with acute grey hepatization, exceedingly lacerable, and infiltrated with puriform secretion; the lower part of the lung of a lightish-red color, and consolidated. The left lung healthy.

10. Green Insp. Book, p. 135.

- 1729⁹⁰. The right lung considerably reduced in size, and closely invested with a dense adventitious layer, by which it was firmly united to the parietes. The substance of the lung greatly condensed, and of a deep grey color. An extensive cavity extended almost from the summit to the base of the lung, and was almost divided into two at the interlobular fissure. There was a small passage of communication through the adhesive matter which united the lobes. The cavity was lined by a smooth false membrane, and the bronchi communicated with it by several of its larger branches, which were truncated. There were no tubercles in this or in the right lung. The chest was greatly distorted. This state of lung was probably the sequel to pneumonia, and had probably been of nearly twenty years' duration.

Case of E. H. Presented by Dr. Hodgkin.

1730. Lung affected with gangrene. A large portion of the lower lobe appears to have been in a state of gangrene, and to have been surrounded by consolidated lung.

From a patient of Dr. Bright's.

1731. Section of gangrenous lung from the same case as the preceding specimen, 1730.

- 1731⁵⁰. Portion of lung, presenting an irregular cavity, the result of inflammation and gangrene. The pleura is entire, but is covered by a layer of fibrin.

- 1731⁵⁵. Portion of the lower lobe of the right lung, presenting a

cavity about the size of a hen's egg, its walls irregular, but having a distinct lining of lymph-like secretion. External to the cavity was a dense layer of dark consolidated lung; in the cavity was a loose shreddy slough, and offensive serum; the slough consisted of lung tissue, fat, and molecules; the pleura over this part was slightly inflamed. The remaining portion of the lower tube on the right side was congested, fleshy, and granular, and had some dilated tubes passing into it. The upper lobes on both sides were emphysematous, and the bronchi contained tenacious mucus.

Charles B., aged 48, admitted into Job, under Dr. Addison's care, Nov. 30, and died Dec. 9th. He had been a town-traveller, and for five years had had attacks of bronchitis. Three weeks before admission his dyspnœa became more urgent, with cough.

4. New Vol. Insp. Book, p. 244.

1732. Portion of the lower lobe of the lung, having on its diaphragmatic surface a sphacelated spot.

Joseph R., admitted under Dr. Cholmeley's care, November, 1826. He had been a man of irregular and intemperate habits. At the time of his admission, four of his children were in the hospital, affected with fever. He was seized with rigors, febrile heat, and pain; his countenance was dusky, and he had dyspnœa. For three days there was delirium; the tongue was dry and brown; he had cough, sickness, and diarrhœa, and the urine was nearly suppressed. On inspection, there were old adhesions at the apices of the lungs, with calcareous deposit, and some recent pleurisy. The substance of both lungs was of a dark-red color; portions of both were indurated, and towards the base the induration was general. In the condensed portion, at the base of the right lung, was a dull black patch, visible through the pleura; the lung tissue at this part very lacerable and highly offensive, but not presenting any detached slough.

1. Green Insp. Book, p. 140.

- 1732³². Portion of lung in which are several irregular cavities and semi-detached sloughs connected with them; the remaining part of the lobe appears distended and consolidated. The pleura is covered by false membrane.

- 1732⁶⁴. Portion of the left lung affected with recent and acute pneumonia, and partial circumscribed gangrene.

John B., aged 37, admitted into Job, under Dr. Back's care, November, 1828. He had been affected with syphilis, and had taken much mercury; there was offensive discharge from the ear and nose; after death, suppuration of the cerebral sinuses and pus beneath the dura mater were found. There were in the lungs numerous gangrenous spots and recent pneumonia; both the pleura and pericardium were inflamed. See prep. 1592⁸⁴, 1674⁸⁴, 1772⁶⁴, 1772⁸⁰.

7. Green Insp. Book, p. 58.

- 1732⁷⁰. Detached slough found in the pleural cavity; there was a sloughing cavity in the opposite lung.

Case of Emma B., September, 1852.

1733. Miliary tubercles in the lung, from a child of three months old; they were supposed to be congenital, both parents being phthisical. She was a spare child, and suffered from shortness of breath from its birth. She died from bronchitis.

Case of Mary A. D. Presented by Dr. Burne.

1734. Portion of lung, exhibiting numerous minute tubercles, with tuberculous infiltration. The affected sides of the chest afforded a dull sound on percussion. The patient had a livid countenance and a very remarkable disposition to sleep.

1735. Portion of lung, presenting numerous miliary tubercles.

- 1735²⁵. Injected specimen of a portion of lung containing miliary tubercles.

See prep. 2006⁶⁴ of spleen. Presented by Sir A. Cooper.

- 1735⁵⁰. Section of the lung of a lad 14 years of age, sprinkled with small miliary tubercles. The lung structure injected.

Henry S., aged 14, admitted under the care of Dr. Bright, June, 1831, with symptoms of fever and much brain disturbance. There were no tubercles found in the brain, but they were very numerous in the lungs, peritoneum, and spleen.

10. Green Insp. Book, p. 140.

- 1735⁷⁵. Another specimen of lung from the same case as 1735⁵⁰, presenting miliary tubercles.

1736. Portion of injected tuberculous lung.

1737. Portion of injected tuberculous lung, from the same specimen as the preceding.

1737²⁵. The lobe of a lung, containing numerous isolated tubercles.

From George B., aged six years, admitted in July, 1856, under Dr. Rees' care. After an attack of measles had bronchitis; he gradually emaciated and died. On inspection, tubercles were found in the spleen, prep. 2008⁸⁰; in the liver, 1915; and in the kidney; none in the brain.

Record of Inspection, 1856. No. 132.

1737⁵⁰. Portion of lung containing numerous tubercles, many of which are small and miliary, with strumous deposit around the bronchial tubes. There is also commencing disorganization, the intervening lung substance is partially inflamed, and there are old pleuritic adhesions.

Joseph H., a Ladrone islander of middle age, who was admitted into Guy's, under Dr. Cholmeley's care, February, 1829, and died from phthisis. See prep. 421⁵⁰, 709⁷⁵, 1641¹⁶, 1739³², 1743⁵⁰.

9. Green Inspec. Book, p. 85.

1738. Portion of lung, presenting vomicae with tubercular infiltration; there are old adhesions on the pleura.

1738³². Portion of lung containing tubercles, and numerous irregular vomicae. One of the cavities is situated near the surface of the lung, and has perforated the pleura; the pleura is covered with old cellular adhesions. The patient was emphysematous beneath the integuments of the chest and abdomen.

See prep. of skin, 1652²⁰; of ileum, 1844⁷⁵.

1738⁶⁴. Section of a lung, presenting numerous irregular vomicae, the surrounding lung consolidated with strumous pneumonic deposit. Adhesions on the pleura.

Case of Elizabeth B., aged 40. 9. Misc. Insp. Book, p. 141.

1738⁶⁵. Portion of lung of a child, showing a mass of low organized products (strumous) extending into the bronchus. The lower lobes of both lungs were in a state of inflammation; that of the right in a state of red hepatization; the left less advanced; a section through the latter, showed that some lobules were more advanced in disease than others.

The portion forming the preparation was from the upper and outer part of the lower lobe of the right lung; the mass of effused substance could easily be enucleated, leaving a cavity lined by smooth membrane; it extended by ulceration into a bronchus which passed on its inner side. There were some old pleuritic adhesions.

Case of William H., aged 5, admitted for a burn; he died on the 10th day.

Record of Inspection, 105. 1855.

1739. Portion of lung, with a phthisical vomica very near the surface. Taken by Mr. Travers from St. Thomas' dissecting room.

1739³². Portion of lung containing numerous irregular vomicae, and low organized deposit chiefly at the upper part; there are numerous miliary tubercles in the lung. The substance of the lung is indurated above by grey, and below by red hepatization.

Case of Joseph H., aged 45. See preps. 421⁵⁰, 709⁷⁵, 1641¹⁶, 1737⁵⁰, 1743⁵⁰. 9. Green Insp. Book, p. 85.

1739⁶⁴. Portion of lung invested in old thickened pleura; it appears to have been in a state of chronic grey pneumonic consolidation, and numerous irregular vomicae have been formed. In some parts there appears to be infiltration of low organized deposit.

1740. Upper lobe of a lung, almost entirely excavated by a large phthisical cavity, and traversed by long ragged bridges, through some of which bristles have been passed from the bronchial tubes and pulmonary artery.

1741. Large vomica occupying nearly the whole upper lobe of the lung; it has a smooth lining, and is bounded externally by dense thickened pleura.

1742. Heart and upper lobe of the right lung, in which there is a vomica about the size of a walnut, having a smooth lining.

The patient, Sarah V., aged 35, was admitted under Dr. Bright's care, October, 1827, affected with anasarca and phthisis. The kidneys were white and mottled; the lungs contained miliary tubercles.

5. Green Inspec. Book, p. 46. See prep. of peritoneum, 2439²⁰.

1742⁸. Two sections of the upper part of the lung, containing a large old tuberculous cavity, the internal surface of which has been tolerably smooth and membranous. Strumous deposit is observed in the lung. The pleura is covered with old adhesions.

1742¹⁶. Section of a lung with a large vomica at the upper part, bounded by condensed lung and some thickened pleural membrane. There is some strumous deposit in the lung; the lower part of the lung was compressed by considerable pleuritic effusion.

Ann N., aged 27. 11. Green Insp. Book, p. 147.

1742²⁴. Portion of lung with several vomicae in it, and some granular strumous deposit; the vomicae are bounded by condensed grey lung and thickened pleura, and on their internal aspect present smooth lining.

Charles B., aged 45, admitted July, 1830, under Dr. Back's care. He had been the subject of cough and ascites for several months. The lung was found to be emphysematous and the bronchial tubes inflamed; the kidneys white and mottled; cysts were found in the spleen.

10. Green Insp. Book, p. 11. See Prep. 2010⁶⁰.

1742³². Portion of lung containing a large irregular cavity at the upper part, which has a smooth internal surface, showing that it has been of some standing. Some small opaque white bodies of a lengthened figure, and terminating at one extremity in the cavity, were proved to be obliterated and truncated pulmonary veins. The remaining portion of the lung is of a deep grey color, indurated by old pulmonary infiltration, and sprinkled with white points stated to be tubercles.

William R., aged 40, a patient of Dr. Bright's, in Lazarus ward, in November, 1831. He was a shoemaker of very intemperate habits, who had had symptoms of disease of the chest for several years. On admission he had symptoms of phthisis. There was no disease of the ileum; but the mucous membrane of the colon was ulcerated.

11. Green Inspec. Book, p. 75. See Drawing 261.

1742⁴⁰. Portion of lung containing a large irregular vomica, excavating nearly the whole of the upper part of the lower

lobe. It is traversed by numerous cord-like processes, consisting of vessels and bronchi more or less obliterated. Several large truncated bronchi open into the cavity, which has a smooth yellowish lining. There are several tubercles in the lower part of the lung, and the pleura is thickened and adherent.

1742⁴⁴. Portion of lung, presenting a vomica surrounded with dense lung, which has been affected with chronic pneumonia. The bronchial tubes and pleura appear much thickened.

1742⁴⁸. A portion of condensed lung, containing an old vomica, and showing the opening of a bronchial tube into it.

1742⁵⁶. Portion of lung, in which a considerable cavity has been formed by rapid disorganization. The internal surface is ragged and uneven, and several branches of vessels are dissected out. They appear to be filled with coagula.

Case of Mary K., aged 28, admitted under Dr. Ashwell's care with *amcuorrhœa*. She had been out of health for some years; but after admission well-marked symptoms of phthisis came on. There were several ulcers in the ileum and colon.

12. Green Inspec. Book, p. 49.

1742⁶⁴. A portion of the upper lobe of a lung, containing a vomica about three-fourths of an inch in diameter. It appears to have been of considerable standing, and has a tolerably smooth internal lining. The surrounding structures, but especially the interlobular cellular membrane, are thickened and indurated. There is some appearance of recent tuberculous deposit in the neighborhood, and depression and puckering on the surface of the pleura corresponding to it.

Presented by Dr. Hodgkin.

1742⁷². The lobe of a lung containing a circumscribed vomica; the surrounding lung crepitant, and described as healthy. The vessels are seen to have been divided, and this had led to hæmoptysis.

- 1742⁷⁵. Portion of lung containing a vomica about two inches in diameter, and having a smooth lining. The lung tissue surrounding it is crepitant. The cavity was filled with blood, and in it is a truncated and perforated vessel, through which a bristle has been passed. The vessel is filled with coagulum.

Case of Dr. Addison's, February, 1850.

- 1742⁸⁰. Central portion of the right lung, containing what appeared to be a large chronic vomica, into which opened large branches of the pulmonary artery and bronchial tubes. The cavity was filled with a mass of recent laminated coagulum. The patient died of hæmoptysis.

Michael N., aged 37, admitted under Dr. Bright's care. There were old adhesions on both sides; but some recent pleurisy on the right side. Both lungs were emphysematous. The inferior lobe of the right lung was consolidated and pale in color. The centre of this lobe contained the vomica shown in the specimen. Both lungs contained tubercles, and there was slight ulceration of the ileum.

6. Misc. Inspec. Book, p. 146.

- 1742⁸⁸. The inferior portion of a lung covered with recent false membrane, and infiltrated with some tuberculous inflammatory matter. It presents two vomicæ, one of which contains a firm sanguineous clot, which is excavated and laminated, and was found to communicate by its cavity with an arterial tube.

John S., aged 47. He had been of intemperate habits, and his health failed for three years before death. The abdomen contained $1\frac{1}{2}$ gallons of serum. The surface of the liver was opaque; the acini indistinct.

4. Misc. Inspec. Book, p. 59.

1743. Depression and puckering of the upper lobe of the lung, described as following the obliteration of a tuberculous cavity. Some "cretaceous" matter is observed in the lung at this part.

- 1743¹⁰. Portion of lung of a child, containing small deposits of tubercular matter, and vesicular cavities containing air (emphysema and dilated bronchi).

W. B., aged about one year. For some months he had labored under catarrh, with dyspnœa; his symptoms were those of chronic rather than acute disease. The infant gradually sank. "The right lung exhibited a rare form of emphysema, being neither the interlobular, nor the ordinary dilated air cells. It consisted of a sprinkling of bullæ or bladders of about the size of peas, mostly situated at or near the surface of the lung, where they were nearly transparent. Besides air, they contained a small quantity of tuberculous matter. These bullæ communicated with the air tube by rather dilated ramifications."

8. Green Inspec. Book, p. 9. Dr. Hodgkin.

The appearance of this specimen is partially changed by the action of the spirit.

- 1743²⁰. Portion of lung of a young girl, containing vomicæ and tubercles; some of the vomicæ bounded by strumous infiltration.

She was a delicate child, aged 11, whose father died of phthisis; she had hooping-cough some months before death, and afterwards symptoms of strumous disease of the abdomen came on.

9. Green Inspec. Book, p. 81. Presented by Drs. Hodgkin and Stroud.

- 1743³⁰. Portion of lung, presenting strumous infiltration, with numerous irregular vomicæ. Some of these resemble large bullæ immediately beneath the pleura.

Sarah G., aged 20, admitted August, 1828.

6. Green Inspec. Book, p. 121.

- 1743⁴⁰. A portion of lung, apparently from a young subject, containing miliary tubercles and strumous deposit, with small cavities, consisting of dilated bronchi.

- 1743⁵⁰. A portion of lung, containing tubercles, some minute. There is a strumous mass, about half an inch in diameter, and some deposit around the tubes; the surrounding lung is grey and indurated, and the pleura puckered.

See Preps. 421⁵⁰, 709⁷⁵, 1641¹⁶, 1737⁵⁰, 1739³².

9. Green Inspec. Book, p. 85.

He was a Ladrone islander, aged 45, who died, under Dr. Cholmeley's care, with phthisis.

- 1743⁵⁵. Portion of a lung, showing a very large phthisical cavity, having a smooth lining, bounded by dense iron-grey lung

tissue; and having a great number of irregular bands irregularly perforated, the remains of bronchial tubes.

Case of Mary D., admitted June, 1853. She had had symptoms of phthisis for two years. General slight anasarca came on soon after admission; the kidneys were found to be granular.

See Drawing of lung, 251²⁰. New Vol. of Inspec., iv. p. 291.

- 1743⁶⁰. Portion of lung, presenting several vomicae, having a smooth lining, and bounded by iron-grey condensed lung; the bronchial tubes are much dilated and thickened, and the intervening lung tissue appears to have been inflamed and compressed. At the lower part of the section are several round masses of low organized deposit, surrounded by white fibrous tissue. The pleura is covered with a thick layer of false membrane, and there was considerable pleuritic effusion.

Charlotte M., aged 30, under Dr. Bright's care, with symptoms of phthisis.

9. Green Inspec. Book, p. 67. See Drawing 260.

- 1743⁷⁰. Portion of condensed grey lung, with several small vomicae and dilated bronchi. There are several indurated strumous masses becoming calcareous in the lung.

The patient died from cancer of the uterus. Ann B., aged 44. See Preps. of lumbar glands, 1558⁴⁰; of liver, 1920⁶⁰; of uterus, 2266¹⁸.

10. Green Inspec. Book, p. 93.

- 1743⁷². Portion of lung, presenting several vomicae in the upper lobe, having smooth lining. The rest of the lung presents iron-grey consolidation, with low organized deposit.

The patient, William S., aged 44, had had diabetes for more than two years; the sugar in the urine was scarcely discoverable a short time before death. The preparation shows firm pleuritic adhesion.

Record of Inspections, 1855. No. 38.

- 1743⁷⁵. Portion of lung in a state of firm iron-grey consolidation, and containing several calcareous masses.

- 1743⁸⁰. Portion of lung, containing a small calculous concretion enveloped in a cyst, and accompanied by partial pleuritic adhesion.

1744. Portion of lung, containing an earthy concretion.

1744⁵⁰. Portion of lung, containing a small firm irregular calcareous concretion, scarcely enclosed in a cyst. The surrounding lung tissue healthy.

Frances F., aged 22, admitted with bronchitis and anasarca. On inspection, the lungs did not collapse; the bronchi were thickened, congested, and full of mucus. A cyst was found in the ovary.

Prep. 2228²⁰. 7. Green Inspec. Book, p. 114.

1745. Earthy concretion from the lung.

1745²⁰. Earthy concretion found in the cavity of a lung.

1746. Particles of earthy matter expectorated.

1747. Calculus expectorated.

1747⁵⁰. Portion of lung, in which the structure uniting the lobules is increased in thickness, and is of a white color. Several cancerous tubercles are observed beneath the pleura.

From a patient, aged 18, who died with cancerous disease of the kidney, &c.

See Preps. 2057⁸⁰, 2469⁵⁶, and 2470⁸⁴. 10. Green Insp. Book, p. 47.

1747⁶⁰. Cartilage developed in the lung.

Presented by Mr. John Birkett.

1748. Large defined tubercles in the lung, which are probably of a carcinomatous character.

1749. Carcinomatous mass in the lung.

Presented by Mr. W. Holt, Tottenham.

1749³². Portion of lung, containing carcinomatous tubercles. At the circumference of some of the masses there is osseous deposit.

From Anne G., aged 17, admitted October, 1828, suffering from dyspnœa, palpitation, and hæmoptysis. In December, 1827, Mr. Key amputated the thigh for osteo-sarcoma. See Preps. 1163 and 1400.

1. Misc. Inspec. Book, p. 133. Presented by Mr. J. Hilton.

1749⁴⁰. Carcinomatous mass in the lung, implicating the right auricle. The superior cava, right pulmonary artery, &c., are encroached upon.

1749⁶⁴. Portion of lung, containing a large cancerous tubercle, in which softening has commenced.

1749⁸². Section of medullary cancer affecting the upper lobe of the lung. The specimen has been macerated in water, and the intervening tissue is distinctly shown.

Mary B., aged 50, admitted under Dr. Bright's care, October, 1840. For six months she had expectorated blood. The upper lobe of the right lung was one mass of medullary matter; the transverse section was of a white cheesy appearance, with bands of cellular tissue slightly mingled with grey matter; upon pressure, a creamy juice exuded; the middle and lower lobe contained smaller masses. A small growth was found in the pulmonary artery. Prep. 1450⁶⁷. The right renal capsule contained a medullary mass about the size of a large marble. Prep. 395⁷⁵. There was a small mass in the liver, and the auxiliary glands were infiltrated.

17. Misc. Inspec. Book, p. 263.

1750. Heart and lung of a child who died of empyema; one lung contained large encephaloid tumors, which showed themselves externally. The remains of the ductus arteriosus are very considerable.

1750¹⁶. Portion of lung containing cancerous tubercles, described as resembling colloid or gum cancer.

1750²⁰. Portion of lung, presenting several isolated cancerous tubercles. At the lower part are three small cancerous tumors, the central one from the neighborhood of the hip joint, the two lateral ones were subcutaneous.

Emily G., aged 49, admitted under Mr. Cock's care, February, 1852. She was the subject of very numerous firm moveable tubercles, developed immediately beneath the skin; the first tubercle had been observed ten years previously. These tumors had not given her any trouble; but one of them, situated in the right gluteal region, had been growing rapidly for six months before admission, and the skin over it was red and elevated two inches above the surrounding parts, and was very painful. This tumor was removed by Mr. Cock in February, 1852, and left a healthy surface; a section of it exhibited a succulent, firm,

and faintly yellow mass streaked with blood, and without any milky juice; it contained a considerable quantity of bright yellow tenacious fluid. The elements of the growth were spindle-shaped nucleated cells. June 15, Mr. Cock removed a cancerous growth from the cicatrix; the growth was opaque, white, lobulated; it contained a milky juice, and was composed of elongated nucleated fibres. She died December, 1852. The body was greatly emaciated. There were several cancerous tubercles in the lungs, but none in the liver or lymphatic system; several tumors were removed from the gluteal region, composed of long fusiform cells; in the lung were globular nucleated elements, as observed in cancer.

- 1750³². Portion of lung containing large cancerous tubercles, some portions present the appearance of colloid or gum cancer.

Presented by Mr. G. Bottomley.

- 1750⁴⁰. Bony masses found in the lungs, from a child who died from cancerous disease of the femur. The lungs contained numerous tubercles about the size of peas and chestnuts, firm, roundish, nodular, semicartilaginous, somewhat translucent, and some very earthy.

Sarah S., aged 14½. 18. Misc. Inspec. Book, p. 85. See Preps. femur 1162⁷⁷ and ⁷⁸; patella 1210⁹⁰; and Drawing 9²⁵.

- 1750⁴⁵. Irregular ossific deposit, removed from the lung of a patient who died after amputation of the thigh for osteo-sarcoma of the knee-joint.

Henry H., admitted under Mr. Key's care, November, 1841.

18. Misc. Insp. Book, p. 190. See Preparations, knee-joint 1165^{50, 51}; Drawing 33³⁸; artery and vein 1559¹²; lung 1750⁴⁶.

- 1750⁴⁶. Portion of lung from the same case as 1750⁴⁵, containing irregular osseous deposit.

- 1750⁶⁴. Large cancerous tumor removed from the lung. Some of the glands near the œsophagus and bronchus are infiltrated.

- 1750⁸⁰. Another cancerous mass from the same as the preceding.

1751. Heart and upper part of the right lung of a man of about 60 years of age; the lung at this part was firmly adherent and indurated by a firm white deposit, chiefly between the lobules, though the substance of the lung was more

or less pervaded by it; a thick layer of the same character forms the bond of union between the two surfaces of the pleura. The bronchial glands are implicated, considerably enlarged, and infiltrated. The cervical glands both above and below the clavicle were enlarged; they were of a pearly whiteness, and almost as hard as cartilage; there was considerable pressure on the trachea, arteria innominata and vein, and bronchus.

The case was admitted under Mr. Key's care, and at first considerably resembled aneurism. F. Williams, aged 60.

3. Green Inspec. Book, p. 41.

- 1751³². Portion of lung, with cancerous tubercles at the root of the lung, extending into the bronchus. The glands at the root of the lung are much enlarged. The patient is said to have died of phthisis.

Presented by Mr. W. Sandy.

- 1751³⁵. Portion of lung, showing cancerous disease affecting the bronchial glands, and extending into the lung.

The left lung was about its normal size, and presented at its root a mass of medullary cancer. This surrounded and infiltrated the bronchial glands situated at that part; it extended forwards, so as to exert considerable pressure upon the left bronchus, and the left branch of the pulmonary artery. The descending aorta was not much encroached upon; but, on opening the left bronchus, it was observed to be expanded laterally, and the growth had so extended into it as merely to leave a fissure. At this part the cancer growth surrounded the bronchus on every side, forming a layer more than an inch in thickness. It extended into the lung with the bronchi and pulmonary artery, as far as their third or fourth divisions, almost obliterating the canals of each. On tracing the bronchi to the lower lobe of the lung, they were found to be filled with a thick yellow purulent mucus, were considerably dilated, and formed at the base irregular sacculi, with thin smooth walls; surrounding many of these dilated tubes at the base of the lung, the tissue had a yellow light fawn-colored appearance; in some parts the whole lobules were of this color, with whitish intervening vessels passing between them. Carefully examining this substance, it was found to be degenerating lung structure, containing pulmonary cells and a considerable quantity of fat. It would appear that the pressure upon the larger bronchus had led to the dilatation and atrophy of the tubes below, increased, probably, by the obliteration of some of the pulmonary vessels. The cells at the circumference of the lobule were

especially infiltrated with this deposit, the centre of the lobule being encroached upon by the dilated tube. The dilated tubes were filled with thick yellow mucus. The patient had hæmoptysis several times; and the passage of blood into the air cells, its subsequent absorption and degeneration, probably led to the appearance presented. The remaining part of the lung was compressed. The medullary growth was composed of nucleated cells and a considerable quantity of fibre tissue, and highly refracting particles. There were firm pleural adhesions on the left side.

From a patient of Dr. Addison's. 1853.

- 1751⁶⁴. The greater part of the left lung, with numerous large excavations, which were believed to be the result of softening of cancerous deposit, rather than ordinary phthisical disease. The substance of the lung is indurated by a deposit of cancerous character; it was of a darkish color, and imparted a stain to the fingers. The pleura was generally adherent and thickened; and some small fungoid tubercles were found in the thick mass of adventitious substance occupying the angle formed by the diaphragm and ribs. There was a chain of enlarged glands in the course of the humero-thoracic artery.

James B., aged 42, a patient of Dr. Bright's in 1829. He was considerably emaciated, and had been affected with a chronic cough, apparently phthisical; cerebral symptoms came on after admission. There were glands enlarged in the neck and axilla, tubercles in the brain (cancerous), and a carious condition of the temporal bone. There were also firm pleuritic adhesions, vomices at both apices, and numerous masses of cancer in the false membrane, bronchial and cervical glands, and in the lungs themselves. Similar tubercles were also found in the liver, and on the peritoneal surface of the stomach. See Prep. 1585⁶⁰.

8. Green Inspec. Book, p. 174.

- 1752⁵⁰. Portion of lung, containing cancerous tubercles, some of them having a dark color resembling melanosis.

From a private patient of Mr. Morgan's, who had cancerous disease of the eye of the same character.

See Preps. 1669³² and 1916⁴⁰.

- 1752⁵⁵. Left lung, in which the whole of the upper lobe is atrophied, irregularly puckered, firm, and of a dark color. Its section had the appearance of old pneumonic atrophied lung; but it contained the elements of cancer. In the brain

were several tubercles connected with the dura mater, and in the cerebellum a larger mass, about the size of a pigeon's egg, composed of cancerous tissue.

Eliza B., aged 37, admitted, under Dr. Addison's care, with epilepsy. The left side was smaller than the right, and at the apex dull on percussion. No other part of the body presented evidence of cancerous disease.

See Drawing 248⁸⁶ and Model 38⁷⁵.

1753. Portion of lung, containing numerous hydatids. *Cysticercus*.

From a patient of Dr. Cholmeley's.

- 1753⁵⁰. Summit of the left lung included in thickened pleura, containing an irregular cavity communicating with the left subclavian artery. The cavity contained clot arranged in fibrous layers, and one or two hydatids which are in the same glass.

John B., aged 45, admitted under Dr. Cholmeley's care, and died from profuse hæmoptysis.

12. Green Inspec. Book, p. 100.

1754. Portion of lung containing hydatids, described as acephalocysts.

1755. Portion of hepatized lung, containing acephalocyst hydatids.

- 1755²⁵. Portion of hydatid cyst removed from a cyst in the lung. Several of the portions of membrane are covered with minute white grains. The cyst in which they were lodged contained about half a pint of fluid, and occupied the inferior part of the lung; it communicated with the liver by a large aperture in the diaphragm, eight inches in circumference.

- 1755⁵⁰. Portion of the lung, containing at its base the dense irregular cyst from which the remains of the hydatid shown in the preceding specimen were taken. The cavity is larger at its base, and the large opening through the diaphragm is shown. The upper part of the cavity is less dense, and is traversed by intersecting bands.

E. P. L., aged 43, admitted under Dr. Cholmeley's care, and died from ascites and hæmoptysis.

3., Misc. Inspec. Book, p. 84.

1755⁶⁴. A portion of the upper lobe of the left lung, the pleura of which is coated with fibrin, and shows a small depression where the rib had pierced, and lobular pneumonia been produced.

Edward L., aged 40. A violent accident produced emphysema and perforation of the diaphragm. The patient survived nine months.

See Preps. 1762⁴⁴, 1072⁵⁰, and 2506⁹⁰.

1755⁷⁵. Portion of lung, extensively lacerated by a wooden peg, $7\frac{1}{2}$ inches in length.

He was a sailor, aged 20, who fell from a mast sixty feet in height upon the deck of the vessel. A belaying pin was forced into his chest. It entered behind the clavicle, passed between the third and fourth ribs without breaking them, and then perforated the lower lobe of the left lung without injuring the diaphragm. It carried with it a portion of the man's jacket, which remained in the lung. The peg was extracted, and the man survived twenty-four hours.

2. Misc. Inspec. Book, p. 23.

1755⁸⁷. Pistol ball. This ball was removed from the back of a man who had shot himself. The ball entered between the sixth and seventh ribs, and wounded the lung.

Case of John G., aged 51.

20. Misc. Inspec. Book, p. 166.

PLEURA.

1756²⁵. A layer of fibrin, formed by expressing the fluid of a coagulum, which formed in a round flat tin bleeding cup, into which had been received the clear fluid from the pleura. Some ounces were removed by paracentesis. They formed an uniform solid mass, almost imperceptibly tinged with blood.

1756⁵⁰. The inferior lobe of a lung recently inflamed, coated with reticular fibrin, and compressed by pleuritic effusion.

Case of Samuel W., aged 16, who was admitted with strumous disease of the cervical glands. There were tubercles in both lungs, in the spleen and kidneys, and on the peritoneum. The liver was solid,

large, and pale. There was enlargement of the lymphatic glands in the neck, chest, and abdomen. See Prep. 1541²⁴ of glands.

7. Misc. Inspec. Book, p. 74.

1757. Portion of lung affected with pneumonia, and having a layer of lymph on the pleura pulmonalis. Part of this layer is turned over, showing the smooth surface of the pleura beneath.
1758. Portion of lung compressed by pleuritic effusion, and covered by a recent fibrinous layer. A portion of the false membrane is turned over.
1759. Portion of the diaphragm, with a recent false membrane on the pleura covering it.
1760. Portion of pleura covered by a thin layer of lymph.
1761. The greater part of one lung consolidated by inflammatory deposit, and covered by layers of fibrin.
- 1761⁵⁰. The greater part of the right lung, the surface of which exhibits the effect of pleurisy in various stages. The pleura pulmonalis and costalis are greatly thickened, firm, and cartilaginous. These are not applied to each other; but in the space are numerous bands of cellular membrane, the meshes being filled with serum. At the base the quantity of effused lymph is greater and less organizable. It was peculiarly thick, and the central part of it was of a soft consistency, and of a lightish yellow color. The lung was compressed. On the left side also there was acute pleurisy. The patient was admitted in a state of extreme cachexia from syphilis and mercury.

Case of Cornelius Lynch, aged 27.

8. Green Inspec. Book, p. 110.

1762. Adhesions between the pleural surfaces; injected, showing their vascular condition.
- 1762¹⁶. Vascular pleuritic adhesions, attached to the inferior acute edge of the lung; dried.

- 1762³². Portion of the lung, with part of the parietes of the thorax, showing long filamentous adhesions between the pleura pulmonalis and costalis.

From John W., aged 30, who died, under Dr. Back's care, from delirium tremens. The pericardium was adherent—prep. 1429¹⁶—and the heart hypertrophied. The kidneys were mottled. The cœcum was inflamed.

6. Green Inspec. Book, p. 4.

- 1762⁴⁴. A fractured fifth rib united, with a portion of omentum adherent, but very little change had been effected towards the reproduction of pericondrium and pleura.

A violent accident produced emphysema, and perforated the diaphragm. The patient survived the accident nine months.

See Preps. 1755⁶⁴, 1072⁶⁰, and 2506⁹⁰. 13. Misc. Inspec. Book, p. 157.

- 1762⁶⁴. Portion of lung, in which there is puckering, extending into the lung tissue as far as a calcareous deposit, probably the result of lobular pneumonia.

1763. Portion of lungs, pleura, and ribs; the surfaces of the pleura are very much thickened, and were generally adherent, except at the cavity shown in the specimen, which contained puriform fluid (spurious empyema). The effusion into the cavity appears to have been of the least organizable kind.

1764. Right lung covered with lymph, and compressed by pleuritic effusion; the lung appears to have been partially adherent. The recent coagulable lymph very feebly organizable.

1765. Lungs, of which the left has been compressed by a puriform pleuritic effusion, constituting empyema; the coagulable part of the effusion of the least organizable kind.

- 1765⁵⁰. Lung universally invested with a false membrane, the product of recent inflammation; in some parts the membrane is close and dense, in others it forms shreds of a reticular character.

Antonis M., a Portuguese. The remains of a cyst were found at the posterior aspect of the liver. 1947⁷⁰, 1947⁸⁴. Tatooed skin from same man. 420⁵⁰.

10. Green Inspec. Book, p. 160.

1766. Pleura covered by an irregular villous layer of lymph, the result of acute inflammation.

1766¹⁴. Portion of a lung, firmly but partially adherent to much thickened costal pleura; the adhesion is prevented from being general by the intervention of non-plastic matter.

1766²¹. Pleura covered by a layer of false membrane, and having a communication with a vomica and with the bronchial tube, occurring after empyema.

1766²⁵. Tubercular lung in a case of pneumothorax; the pleura perforated.

See Bryant's Cat., No. 25, p. 12.

1766²⁸. Plicated portion of diaphragm, the result of pleuritic adhesions. On the right side the diaphragm was drawn several inches into the chest, away from the liver; it then descended again to the liver so as to form a covering to that organ, only interrupted by a small fissure. There was empyema on the right side. The double fold of the diaphragm was perforated in an unsuccessful paracentesis, although its pleural covering formed part of the parietes of an empyema.

Case of John B., aged 25. See Prep. 1766⁷⁰.

10. Misc. Inspec. Book, p. 131.

1766³³. Pleura costalis perforated by a trochar; the intercostal nerve dissected out.

1766³⁵. A portion of diaphragm partly converted into bone.

Langstaff's Museum, No. 1821.

1766⁴². Portion of lung from the base, with a remarkably thick semi-cartilaginous layer upon the pleura, both on the inferior and lateral surfaces. Some unorganizable matter was shut up at the part which corresponds with the angle formed by the diaphragm and ribs. The interlobular fissure seems to have escaped.

1766⁵⁶. Considerable part of the right lung, with an extremely

thick adventitious layer between the surfaces of the pleura; it is partly semi-cartilaginous and partly fibrous. The deposit is of considerable thickness, but of different dates, in the interlobular fissures, and between the base of the lung and diaphragm. In the former there is a nearer approach to cellular membrane than elsewhere; the superior fissure was partially distended by recent lymph and serum; the lower lobes of the lung are much compressed.

Case of Thomas H., aged 45. 9. Green Insp. Book, p. 35.

- 1766⁷⁰. A central portion of lung, presenting an interlobular pleuritic cyst which contained pus; a larger cavity of similar origin is bounded in part by the pericardium; a third empyemal cavity involved the surface of the lung. Some of the bronchial tubes are dilated.

Case of John B., aged 25. See Prep. 1766⁷⁸.

10. Misc. Insp. Book, p. 131.

- 1766⁷⁷. Part of an empyema with reticular false membrane.

Case of Frances M., aged 17. 19. Misc. Inspec. Book.

- 1766⁸⁴. The greater part of the left lung and three ribs, apparently the seventh, eighth, and ninth. The pleura is universally covered by a dense false membrane, and there has been considerable effusion into its cavity, by which the lung has been much compressed. The cavity has been divided by an adventitious septum of considerable breadth, stretched between the ribs throughout its whole length and the lung. There are several vomicae in the lungs, and dilated bronchial tubes.

1767. Left lung covered by false membrane, and compressed by effusion; it is thickly studded with strumous miliary deposit. The false membrane is firm and dense.

Hannah S., aged 25, admitted under Dr. Cholmeley's care with variola. She died from phthisis and pneumo-thorax. See Prep. 1698.

4. Green Inspec. Book, p. 76.

- 1767⁵⁰. Portion of the pleura costalis, on the right side much and uniformly thickened by a deposit on its attached surface; some shreds of lymph are observed on its smooth surface.

1768. Large and thick layer of cartilaginous false membrane between the pleural surfaces.

From a female, aged 61, who died of acute bronchitis.

Presented by Mr. T. Hardy.

1769. Portion of lung thickly studded with strumous miliary deposit and covered by pleura, very much thickened by semi-cartilaginous false membrane, between the layers of which is some friable matter.

Case of J. H., aged 40, under Dr. Bright's care with chronic phthisis; there was ulceration of the larynx and of the intestine.

3. Green Insp. Book, p. 85.

- 1769¹⁶. Portion of lung, with an irregular thick layer of false membrane of cartilaginous firmness; the parts in which the covering is deficient had been occupied by less organizable material. This portion formed part of the walls of an empyema on the left side.

T. T., aged 41, patient of Dr. Cholmeley's in Job ward, 1831; he had inflammation of the pleura a month before his death, and a short time previous to death expectorated eight to ten ounces of pus.

3. Misc. Insp. Book, p. 23.

- 1769³². A portion of lung covered by a dense thickened pleura, about four lines in thickness; an indurated portion penetrates the parenchyma of the lung, probably the sequel of pneumonia.

Presented by Mr. Dolman.

- 1769⁴⁸. Portion of the lower lobe of the right lung, with the opposite portion of the diaphragm attached; the lung is dense and grey from old pneumonia; several calcareous concretions are imbedded in the substance of the lung. The pleura pulmonalis is firmly adherent to the pleura of the diaphragm, on a portion of which there is a large plate of ossific matter.

- 1769⁶⁴. An irregular mammellated semi-cartilaginous body, found nearly or quite loose in the cavity of the left pleura, at the inferior part near the spine; there are a few thin fibres of cellular membrane about its surface.

From a subject in the dissecting-room.

Presented by Mr. T. W. King. 1. Note Book, p. 163.

1769⁸⁰. A pulpy substance, the product of fibrinous inflammation found in the pleural cavity; it is peculiarly micaceous, possibly from decomposition.

From a private patient of Drs. Hodgkin and Lenniker.

1770. Fragment of thick, flocculent, unorganized false membrane from the pleura, with a small portion of lung attached.

The patient, aged about 35, was the subject of aneurism of the aorta, and had also empyema.

2. Green Insp. Book, p. 152. Presented by Dr. Whiting.

1770⁵⁰. A portion of vascular false membrane, covered with blood from an inflamed pleural cavity; this kind of product was very abundant, and was mixed with blood and serum.

Presented by Mr. T. W. King.

1771. Portion of lung and pleura—the latter covered by a dense false membrane, rough and scabrous; the pericardium appears quite free; the lungs contain strumous deposit; the bronchial glands greatly enlarged.

There was a deficiency in the development of the third rib. See cast 54; prep. 1044. The peritoneum was affected with strumous disease, 2456. John Welsh, aged 15, patient of Dr. Cholmeley's, 1827.

4. Green Inspec. Book, p. 120.

1772. Lungs and pleura. Both lungs contained tubercles, and are covered by false membrane and compressed by pleuritic effusion, of which there were 14 pints, apparently of a serous character. The false membrane is scabrous, and appears to have been firm; there are some adhesions in the form of bridges, and on the right side a partial but closer adhesion of the two surfaces of the pleura.

Presented by Mr. G. Babington.

1772³². Two tubercles beneath the pleura pulmonalis, about half an inch in length, and of a yellow color; of strumous or cancerous character.

1772⁵⁰. Portion of lung, with strumous tubera affecting the pleura.

The specimen was taken from a young man who died of tubercular arachnitis, with miliary tubercles of the lungs. The pleura has a puckered appearance, from the contraction of fibrous tissue.

Presented by Dr. Gull.

1772⁶⁴. Gangrene of pleuritic adhesions. Portion of the anterior and lower part of the right lung partially affected with gangrene, which extended to the pleuritic adhesions, old as well as recent, on the surface of the lung. A portion of pericardium attached, shows the effect of recent inflammation of that membrane.

1772⁸⁰. Gangrenous condition of pleuritic adhesions, from the same case as the preceding. Three ribs from the right side are seen to be covered with false membrane, old and recent; the false membrane and cellular tissue beneath are both gangrenous.

John B., aged 37, admitted into Job ward, 1828. He had been affected with syphilis and mercury; there was offensive discharge from the nose and ear, suppuration of cerebral sinuses, gangrene of the lung, &c.

See Preps. 1592⁸⁴, 1674⁸¹, 1732⁶⁴, 1772⁶⁴.

7. Green Insp. Book, p. 58.

1773. Empyema from injury: there was a large collection of pus between the layers of the pleura, the false membrane of which is thick and partially ossific.

James R., admitted May, 1805. He had nine years previously been jammed between two vessels, and afterwards always suffered pain in the side.

Old Mus. Book, No. 41.

1774. Portion of the ossified sac, from the same case as the preceding specimen, dried and immersed in turpentine.

1774⁵⁰. Portion of lung and of three ribs, with the pleura; there is a thick false membrane upon each specimen, with a dense deposit of bony matter; evident marks of contraction are seen upon the false membrane of the pleura costalis.

The patient had cancerous disease of the pharynx. See Prep. 1785⁷⁵, and Drawing 283. Case of Ann M.

1775. Patch of ossific matter behind the pleura.

1776. Two ribs, probably the fifth and sixth of the left side, with a large and thick osseous plate and tumor connected with the pleura costalis.

James T., aged 56, admitted under Mr. Morgan's care in 1827, in consequence of difficulty in passing his urine. He had had pain in his side for some time, with palpitation of the heart and dyspnœa; two months before admission he caught cold, which was followed by dropsy; there was a systolic bruit with the heart. On inspection the abdomen was found much distended, the left pleura was universally adherent and ossified, and there were a few patches of bone matter in the pericardium, in the walls of right auricle—see Prep. 1393—and of aortic semilunar valves. There were thickening and osseous plates in the aorta and other arteries. Kidneys and liver healthy.

4. Green Insp. Book, p. 7.

1777. Large patch of ossific matter from pleura costalis.

Presented by Mr. De Jersey, Clifton.

1777¹⁰. Great contraction of some of the left ribs in consequence of an old pleurisy, which had led to very extensive ossification in the pleural membranes.

Joseph G., aged 40, died from softening of the brain. The vertebræ were convex towards the right side, the right lung hypertrophied, the left side of the chest contracted, the lung atrophied but crepitant.

13. Misc. Inspec. Book, p. 33.

1777¹⁵. Pleuritic bridle ossified.

Joseph G., aged 18, affected with large white kidneys.

20. Misc. Inspec. Book, p. 62.

1777¹⁶. Specimen of ossified pleura.

William C., aged 60, affected with empyema.

20. Misc. Inspec. Book, p. 56.

1777¹⁷. Specimen of ossified pleura.

W. C., aged 61, affected with renal dropsy, from small contracted kidneys.

1. New Vol. Insp. Book, p. 70.

1777¹⁸. Specimen of ossified pleura.

1777¹⁹. Specimen of ossified pleura.

1777²⁰. Portions of four ribs and of pleura, dried to show a large ossific patch involving the serous membrane.

1777³¹. Portions of four ribs, with a layer of inflammatory deposit ossified.

Mary C., aged 54, a patient in Lambeth Workhouse; there was malignant disease of the œsophagus. See Prep. 1789⁴⁰.

See Bryant's Cat., No. 124, p. 98.

1777³⁴. Ribs with an empyemal cavity; the costal pleura ossified.

William W., aged 50. See Bryant's Cat., No. 146, p. 105.

1777⁴⁰. Portion of lung and ribs with greatly thickened pleura, forming part of an empyemal cavity; there are several irregular spots of bony matter, which appear to have formed in the substance of the false membrane.

From a man aged 60, a hall porter, who was supposed to have phthisis. He went into the country and lived for some time; the right lung was healthy; the left pleura was adherent partially, and at its base contained a quart of pus and some loose calcareous masses; the specimen is part of this empyema.

1777⁶⁰. Two considerable portions of adventitious bony matter of irregular figure, from the same cavity as the preceding specimen.

1. Note Book, p. 207. Presented by Mr. J. Rix, St. Neots.

1777⁸⁰. Apex of a lung, the pleura of which is studded with cancerous tubercles, small and firm; there is also pigmental deposit in the lung and dilatation of the tubes.

From James S., aged 61, who died from cancer of the penis. See Prep. 2427⁶⁰. The pericardium also was affected, 1449³².

6. Misc. Inspec. Book, p. 81.

1778. Portion of lung, with adventitious cellular membrane upon the pleura covering it; beneath this membrane and in the lung are numerous strumous tubercles; strumous tubercles were found in the arachnoid and in the peritoneum.

From a young lady aged 12 years. Presented by Dr. Addison.

1. Misc. Insp. Book, p. 150. See Prep. 2457⁶⁰.

1778³². The base of one lung, showing the pleura covered by a false

membrane, and which has in it numerous small cancerous tubercles; there was also cancerous disease of the peritoneum.

See Prep. 2469⁴²; see also 2239¹⁴, 2439¹⁰.

1779. Cancerous tubercles on the pleura, arranged along the intercostal vessels; there was also cancerous disease of the peritoneum, which had led to ascites.

Martha D., aged 40, a patient under Dr. Bright's care, 1826.

See Prep. 2470. Red Insp. Book, p. 153.

1780. Cancerous tubercles on the pleura costalis.

From Sarah G., aged 45, who died from cancer affecting the breast, liver, and uterus; under Mr. Cooper's care, 1827. See Prep. of breast, 2317; of liver, 1922; of uterus, 2278⁴⁰; and casts of breast, 282, and of liver, 260.

3. Green Inspec. Book, p. 15.

- 1780³². Portion of pleura and pericardium, with numerous small well-defined scirrhus tubercles connected with the former.

From a lady beyond the middle period of life, who had long laboured from stricture of the oesophagus of a cancerous character. See Prep. 1793³².

Presented by Mr. Samuel Hallam.

- 1780⁶⁴. Portion of pleura and pericardium, considerably thickened and indurated, probably from scirrhus infiltration; there was cancerous ulceration of the left breast, extensively affecting the neighbouring structures; there were cancerous tubercles in the liver, and scirrhus disease of the uterus.

Case of Tabitha W., aged 40. 3. Misc. Insp. Book, p. 139.

1781. Cancerous tubercles on the pleura, some of them contain pigmental deposit, giving the growth partially the appearance of melanosis.

1782. Portion of lung, presenting numerous cancerous tubercles beneath the pleura; the deposit is observed to extend into the lung tissue around the bronchi.

From John F., aged 30, admitted in December, 1821, suffering from paraplegia. He gradually sank. See Prep. of spine, 1028; cancer of sternum, 1042; of pericardium, 1449; of auxiliary glands, 1544; of bronchial glands, 1548; of liver, 1927; and of spleen, 2012.

1782²⁰. Portion of lung, with several cancerous tubercles beneath the pleura; the pleura is much thickened, and its surface roughened by shreds of recent lymph. The tubercles vary in size and thickness, some of them are four lines in thickness; similar tubercles were imbedded in the substance of the lung, and also beneath the pleura covering the diaphragm.

From a patient of Mr. Morgan's, whose thigh was amputated for osteo-sarcoma. See Preps. 1162⁷², 84, ⁹³, and 2470⁶³.

1782⁴⁰. Portion of pleura affected with cancerous disease; there were also large tumors of a similar kind in the lungs.

From a patient of Mr. W. Holt's.

1783³². Considerable portion of lung with a large well-defined cyst, which appears to be situated immediately beneath the pleura pulmonalis. It appears to have been of long standing; its internal surface is in parts irregular, with numerous minute earthy particles; it may have originated as a simple serous cyst, or contained hydatids; it was found filled with a thick cretaceous paste.

1783⁶⁴. Portion of lung affected by thickening and adhesion of its tissue, and upon it is formed a cyst the size of an egg, of dense cellular substance, and which is probably the cell of a contracted hydatid or of a decreasing empyema.

1784. Partial but firm adhesion of the pleura pulmonalis and costalis, with much adventitious condensed cellular membrane; the result of a fracture of a rib.

1784²⁰. Portion of lung, from which the pleura is dissolved by the gastric juice which had perforated the œsophagus, and allowed the contents of the stomach to enter the chest.

Case of Elizabeth B., aged 19, who died from fever. See Prep. of œsophagus, 1793⁸⁰.

5. Misc. Insp. Book, p. 1.

