Anatomy, descriptive and applied.

Contributors

Gray, Henry, 1825-1861.
Howden, Robert, 1856-
Royal College of Physicians of London

Publication/Creation

London, 1909.

Persistent URL

https://wellcomecollection.org/works/yn7vhade

Provider

Royal College of Physicians

License and attribution

This material has been provided by This material has been provided by Royal College of Physicians, London. The original may be consulted at Royal College of Physicians, London. where the originals may be consulted. Conditions of use: it is possible this item is protected by copyright and/or related rights. You are free to use this item in any way that is permitted by the copyright and related rights legislation that applies to your use. For other uses you need to obtain permission from the rights-holder(s).

wellcome collection

Wellcome Collection
183 Euston Road
London NW1 2BE UK
T +44 (0)20 7611 8722
E library@wellcomecollection.org
https://wellcomecollection.org

GRAY'S
ANATOMY
DESCRIPTIVE
AND
APPLIED

SL
611(02)"18"



J. Purcell Woods

GRAY'S ANATOMY

SL

ROYAL COLLEGE OF PHYSICIANS
LIBRARY

CLASS	611 (02) "18"
ACCN.	35443
SOURCE	Belf. & Ulster Lib. gift
DATE	20 May 1969

THE FIRST EDITION OF THIS WORK
WAS DEDICATED TO

SIR BENJAMIN COLLINS BRODIE, BART.

F.R.S., D.C.L.

IN ADMIRATION OF

HIS GREAT TALENTS

AND IN REMEMBRANCE OF

MANY ACTS OF KINDNESS SHOWN TO THE ORIGINAL
AUTHOR OF THE BOOK

FROM AN

EARLY PERIOD OF HIS PROFESSIONAL CAREER

PREFACE

TO

THE SEVENTEENTH EDITION

IN this Edition the text has been carefully revised and, in several sections, rearranged. The B.N.A. terminology has been added in brackets after the names commonly used by English anatomists.

Increased attention has been given to the clinical applications of anatomical data; the title *Surgical Anatomy* has been replaced by that of *Applied Anatomy*, and under this heading many important medical considerations are discussed. Mr. Fedde Fedden has revised the surgical, and Dr. A. J. Jex-Blake has added the medical, notes in these paragraphs.

Some two hundred additional engravings have been introduced, mostly in the sections of Embryology, Angiology, Neurology and Splanchnology. A few of these have been borrowed from standard works, and some are copied from models by His, Keibel and others, but the majority have been drawn from original preparations.

The Editor acknowledges, with gratitude, the valuable help he has received from Mr. Frank Howson, M.A., Lecturer on Physiology, and Dr. J. Dunlop Lickley, Demonstrator of Anatomy, in this College. Mr. Howson undertook the revision of the Histological part of the book and furnished microscopic slides for drawings. Dr. Lickley has rendered invaluable and ungrudging service in the revision of the text, in the preparation of the Index, and in the making of dissections for the purposes of illustration.

University of Durham College of Medicine,
Newcastle-upon-Tyne: *August* 1909.

CONTENTS

	PAGE
INTRODUCTION	1
HISTOLOGY	
The animal cell	3
The nutritive fluids	7
Blood	7
Lymph	11
Epithelium	12
Connective tissues	15
The connective tissues proper	15
Cartilage	21
Bone	24
Pigment	35
Muscular tissue	36
Nervous tissue	42
The vascular system	55
The skin and its appendages	64
Serous membranes	72
Synovial membranes	73
Mucous membranes	73
Secreting glands	74
EMBRYOLOGY	
Introductory remarks	77
The ovum	78
Coverings of the ovum	79
Maturation of the ovum	79
The spermatozoön	81
Fertilisation of the ovum	83
Segmentation of the fertilised ovum	84
The embryonic area	86
The neural groove and tube	88
The notochord	89
Formation of the body cavity or cœlom	90
The primitive segments or proto-vertebral somites	91
Delimitation of the embryo	91
Membranes and appendages of the embryo	92
Development of the parietes	102
Development of the nervous system and sense organs	115
Development of the vascular system	135
Development of the alimentary and respiratory systems	150
Development of the urinary and generative organs	167
The form of the embryo at different stages of its growth	177
OSTEOLOGY	
General description of bones	181
The vertebral column	182
General characters of a vertebra	183
Cervical vertebræ	184
Thoracic or dorsal vertebræ	187
Lumbar vertebræ	190
Sacral and coccygeal vertebræ	191
The sacrum	191
The coccyx	194
Vertebral column as a whole	198
The thorax	202
The sternum	203
The ribs	206
The costal cartilages	211
The skull	213
Ossa cranii	214
The occipital bone	214
The parietal bones	218
The frontal bone	220
The temporal bones	223
The sphenoid bone	232
The ethmoid bone	238
Supernumerary or Wormian bones	240
Congenital fissures and gaps	240
Ossa faciei	241
Nasal bones	241
The maxillæ or superior maxillary bones	242
The lachrymal bones	247
The malar or zygomatic bones	248
The palate bones	250
The inferior turbinated bones	253
The vomer	254
The mandible or inferior maxilla	255
The hyoid bone	260
Exterior of the skull	261
The skull from above	261
The skull from below	262
The skull in profile	265
The skull from behind	268
The skull from the front	268
Interior of the skull	271
Inner surface of the skull cap	271
Upper surface of base of the skull	271
The nasal fossæ	275
Differences in the skull due to age	277
Sexual differences in the skull	278
Craniology	278
The extremities	286
Bones of the upper extremity	286
The clavicle	286
The scapula	289
The humerus	295
The ulna	301
The radius	306
The hand	311
The carpus	311
The metacarpus	315
The phalanges	318

PAGE

The hand (*continued*)
Ossification of the bones of the hand 319
Bones of the lower extremity . . 320
The os innominatum 320
The pelvis 327
The femur 332
The patella 341
The tibia 343
The fibula 347
The foot 349
The tarsus 349
The metatarsus 358
The phalanges 361
Ossification of the bones of the foot 362
Comparison of the bones of the hand and foot 362
Sesamoid bones 364

SYNDESMOLOGY

General description of articulations . 366
Classification of joints 368
The kinds of movement admitted in joints 370
Articulations of the trunk . . . 372
I. Articulations of the vertebral column 372
II. Articulation of the atlas with the axis 377
III. Articulations of the vertebral column with the cranium 380
IV. Articulation of the mandible 382
V. Articulations of the ribs with the vertebræ . . . 385
VI. Articulations of the cartilages of the ribs with the sternum 388
Articulations of the cartilages of the ribs with each other. . . . 390
VII. Articulations of the sternum 390
Mechanism of the thorax . 391
VIII. Articulation of the vertebral column with the pelvis . 392
IX. Articulations of the pelvis . 393
Mechanism of the pelvis . 397
Articulations of the upper extremity 399
I. Sterno-clavicular articulation 399
II. Acromio-clavicular articulation 401
Ligaments of the scapula . 403
III. Shoulder-joint 404
IV. Elbow-joint 409
V. Radio-ulnar articulations . 412
VI. Radio-carpal or wrist-joint 415
VII. Carpal articulations . . 417
VIII. Carpo-metacarpal articulations 420
IX. Intermetacarpal articulations 422
X. Metacarpo-phalangeal articulations 422
XI. Interphalangeal articulations 423
Articulations of the lower extremity . 423
I. Hip-joint 423
II. Knee-joint 430
III. Articulations between tibia and fibula 439
IV. Ankle-joint 440
V. Intertarsal articulations . . 444
VI. Tarso-metatarsal articulations 449

PAGE

VII. Intermetatarsal articulations 450
VIII. Metatarso-phalangeal articulations 451
IX. Interphalangeal articulations 451
Arches of the foot 452

MYOLOGY

General description of muscles and fasciæ 453
Muscles and Fasciæ of the Cranium and Face . . . 456
I. Cranial region 456
II. Auricular region . . . 458
III. Palpebral region . . . 459
IV. Orbital region 461
V. Nasal region 463
VI. Maxillary region . . . 464
VII. Mandibular region . . 466
VIII. Intermaxillary region . . 466
IX. Temporo-mandibular region. 467
X. Pterygo-mandibular region . 469
Muscles and Fasciæ of the Neck 471
I. Superficial cervical region . 471
II. Infrahyoid region . . . 476
III. Suprahyoid region . . 477
IV. Lingual region 479
V. Pharyngeal region . . . 482
VI. Palatal region 484
VII. Anterior vertebral region . 486
VIII. Lateral vertebral region . . 488
Muscles and Fasciæ of the Trunk 489
I. Muscles of the back . . 489
First layer 489
Second layer 492
Third layer 493
Fourth layer 494
Fifth layer 497
II. Muscles and fasciæ of the thorax 500
Mechanism of respiration. 505
III. Muscles and fasciæ of the abdomen 506
IV. Muscles and fasciæ of the pelvis 517
V. Muscles and fasciæ of the perinæum . . . 521
1. Muscles and fasciæ of the ischio-rectal region 521
2. Muscles and fasciæ of the urogenital region:
(*a*) In the male . 523
(*b*) In the female . . 526
Muscles and Fasciæ of the Upper Extremity 528
I. Muscles and fasciæ of the thoracic region . . 528
Anterior thoracic region . 528
Lateral thoracic region . 532
II. Muscles and fasciæ of the shoulder and arm . . 533
Acromial region . . 533
Anterior scapular region . 534
Anterior humeral region . 536
Posterior humeral region . 538
III. Muscles and fasciæ of the forearm 539
Anterior radio-ulnar region 540
Radial region . . . 545
Posterior radio-ulnar region 545

PAGE
IV. Muscles and fasciæ of the hand 550
Radial region 554
Ulnar region 556
Middle palmar region . . 556
Muscles and Fasciæ of the Lower Extremity 563
I. Muscles and fasciæ of the iliac region 564
II. Muscles and fasciæ of the thigh 566
1. Anterior femoral region . 566
2. Internal femoral region . 571
3. Gluteal region 573
4. Posterior femoral region . 577
III. Muscles and fasciæ of the leg . 579
Anterior tibio-fibular region. 579
Posterior tibio-fibular region 581
Fibular region. 585
IV. Muscles and fasciæ of the foot. 586
Dorsal region 587
Plantar region 587

ANGIOLOGY

Outline of circulation of the blood . 597
Pericardium 598
Structure 599
Heart 601
Right auricle 604
Right ventricle 606
Left auricle 608
Left ventricle 608
Interventricular septum . . . 609
Structure 609
Cardiac cycle and actions of valves 612
Peculiarities in the vascular system of the fœtus 614
Fœtal circulation 614
Changes in the vascular system at birth 616
The Arteries (general description of) 617
Pulmonary artery 618
Aorta 619
Ascending aorta 619
Branches 620
Arch of aorta 620
Branches 623
Innominate artery 623
Common carotid arteries . . . 625
External carotid artery 628
Branches 629
Triangles of the neck 640
Anterior triangle 640
Posterior triangle 643
Internal carotid artery . . . 643
Branches 646
Arteries of the brain 652
Arteries of the Upper Extremity 654
Subclavian artery 654
Branches 659
The axilla 666
Axillary artery 667
Branches 669
Brachial artery 671
Bend of the elbow 672
Branches of brachial artery. . 673
Anastomosis around the elbow-joint 674
Radial artery 675
Branches 677
Ulnar artery 678
Branches 679

PAGE
Arteries of the Trunk 682
Thoracic aorta 682
Branches 684
Abdominal aorta 685
Branches 687
Common iliac arteries 696
Internal iliac artery 698
Branches 699
External iliac artery 705
Branches 706
Arteries of the Lower Extremity 707
Femoral artery 707
Femoral sheath 707
Scarpa's triangle 710
Hunter's canal 710
Branches of the femoral artery . 713
Popliteal space 715
Popliteal artery 716
Branches 717
Circumpatellar anastomosis . . 719
Anterior tibial artery 719
Branches 721
Dorsalis pedis artery 721
Branches 722
Posterior tibial artery 722
Branches 723
Internal plantar artery 724
External plantar artery . . . 725
The Veins (general description of) . 726
Pulmonary veins 727
Cardiac veins 728
Veins of head and neck . . . 729
Veins of the exterior of the head and face 729
Veins of the neck 732
Veins of the diploë 735
Veins of the brain 736
Sinuses of the dura mater . . 737
Emissary veins 743
Veins of the upper extremity and thorax 744
Digital veins 745
Cephalic vein 745
Basilic vein 746
Median vein 746
Axillary vein 747
Subclavian vein 747
Innominate or brachio-cephalic veins 747
Vena cava superior 748
Azygos veins 750
Bronchial veins 750
Spinal veins 751
Veins of the lower extremity, abdomen and pelvis . . . 752
Internal or long saphenous vein . 752
External or short saphenous vein 753
Popliteal vein 755
Femoral vein 755
External iliac vein 755
Internal iliac vein 755
Hæmorrhoidal plexus . . . 757
Vesico-prostatic plexus. . . . 757
Vesical plexus 757
Uterine plexuses 758
Vaginal plexuses 758
Common iliac veins 758
Vena cava inferior 758
Portal system of veins 760

PAGE
THE LYMPHATIC SYSTEM 763
Lymphatic vessels 763
Lymphatic glands 764
Thoracic duct 765
Right lymphatic duct 767
Lymphatics of head, face and neck 767
Lymphatics of the upper extremity 772
Lymphatics of the lower extremity 775
Lymphatics of abdomen and pelvis 778
Parietal glands 778
Visceral glands 781
Lymphatic vessels of the subdiaphragmatic portion of the alimentary canal 784
Lymphatic vessels of the liver . 786
Lymphatic vessels of the spleen and suprarenal glands . . . 787
Lymphatic vessels of the urinary organs 787
Lymphatic vessels of the reproductive organs 789
Lymphatics of the thorax . . 789
Parietal glands 789
Visceral glands 791
Lymphatic vessels of the thoracic viscera 792

NEUROLOGY

General description of nervous system 794
THE SPINAL CORD 795
Structure 799
THE BRAIN 810
The hind-brain 811
Medulla oblongata 811
Structure. 815
Pons 822
Structure 823
Cerebellum 825
Structure. 830
Fourth ventricle 834
The mid-brain 838
Crura cerebri 838
Structure 839
Corpora quadrigemina . . . 843
Structure 843
Aqueduct of Sylvius 844
The fore-brain 844
Diencephalon or inter-brain . . 844
Thalamencephalon 845
Thalamus 845
Metathalamus 848
Epithalamus 849
Hypothalamus 849
Third ventricle 852
Telencephalon 854
Cerebral hemispheres . . 854
Surfaces of cerebral hemispheres 855
Interlobular fissures . . 856
Lobes of hemispheres . . 857
Frontal lobe 857
Parietal lobe 859
Temporal lobe 861
Insula or island of Reil. . 862
Rhinencephalon 863
Interior of the cerebral hemispheres 865
Corpus callosum 865
Lateral ventricles 867
PAGE
Corpus striatum 871
Nucleus caudatus 871
Nucleus lenticularis . . . 872
Claustrum 873
Nucleus amygdalæ 873
Internal capsule. 873
External capsule 874
Substantia innominata of Meynert 874
Fornix 875
Foramen of Monro 876
Anterior commissure 876
Septum pellucidum 876
Cavum septi pellucidi 877
Choroid plexus of lateral ventricle 877
Velum interpositum 878
Structure of the cerebral hemispheres 878
White matter 878
Grey matter 879
Structure of the cerebral cortex . 880
Special types of cerebral cortex . . 882
Weight of encephalon 884
Cerebral localisation 885
Cerebral topography 885
Motor tract 888
Sensory tract 890
Meninges of the brain and spinal cord 892
Dura mater 893
Subdural space 895
Arachnoid membrane 895
Subarachnoid space . . . 896
Glandulæ Pacchionii . . 898
Pia mater 898
Ligamentum denticulatum . 899
THE CRANIAL NERVES 899
First nerve 900
Second nerve 901
Third nerve 903
Fourth nerve 905
Fifth nerve 906
Ophthalmic nerve 908
Ophthalmic ganglion 910
Superior maxillary nerve . . . 911
Spheno-palatine ganglion . . 912
Inferior maxillary nerve . . . 914
Otic ganglion 917
Submaxillary ganglion . . . 918
Sixth nerve 920
Seventh nerve 922
Eighth nerve 927
Ninth nerve 930
Tenth nerve 933
Eleventh nerve 937
Twelfth nerve 939
THE SPINAL NERVES 941
Nerve roots 941
Spinal ganglia 941
Size and direction 943
Points of emergence 943
Connections with sympathetic . . 943
Structure 944
Divisions 945
Posterior primary divisions of the spinal nerves 945
Cervical nerves 945
Thoracic nerves 948
Lumbar nerves 948
Sacral nerves 949
Coccygeal nerve 949

PAGE

THE SPINAL NERVES (*continued*)
Anterior primary divisions of the spinal nerves 949
Cervical nerves 949
Cervical plexus 949
Superficial branches 950
Deep branches (internal series) 952
Deep branches (external series) 953
Brachial plexus 953
Supraclavicular branches . 955
Infraclavicular branches . . 956
Thoracic nerves 966
Lumbo-sacral plexus. 969
Lumbar nerves 969
Lumbar plexus 970
Sacral and coccygeal nerves . 978
Sacral plexus 978
Pudendal plexus 985
SYMPATHETIC NERVES 988
Cervico-cephalic portion of the gangliated cord 990
Thoracic portion of the gangliated cord 993
Lumbar portion of the gangliated cord 994
Pelvic portion of the gangliated cord 996
Great plexuses of the sympathetic. 996
Cardiac plexus 996
Epigastric or solar plexus . . 997
Hypogastric plexus 999
Pelvic plexuses 1000

ORGANS OF SPECIAL SENSE

Organs of taste 1001
The nose 1002
Accessory sinuses of the nose . 1008
The eye 1010
Capsule of Tenon 1010
Tunics of the eye 1011
Sclera and cornea 1011
Vascular and pigmented tunic. 1014
Retina 1020
Refracting media 1024
Aqueous humour 1024
Vitreous body 1025
Crystalline lens 1025
Appendages of the eye . . 1028
Lachrymal apparatus . . . 1032
The ear 1034
The external ear 1034
The middle ear or tympanum . 1039
Ossicles of the tympanum . . 1043
The internal ear or labyrinth . 1047
The osseous labyrinth . . . 1047
The membranous labyrinth . 1051

SPLANCHNOLOGY

PAGE

RESPIRATORY ORGANS 1059
The larynx 1059
The trachea and bronchi . . . 1070
The pleuræ. 1074
The mediastinum 1078
The lungs 1081
ORGANS OF DIGESTION 1088
The mouth 1089
The teeth 1092
Permanent teeth 1094
Temporary teeth 1096
The tongue 1103
The salivary glands 1108
The pharynx 1113
The œsophagus 1116
The abdomen 1118
The peritoneum 1121
The stomach 1132
The small intestine 1139
The large intestine 1148
The liver 1163
Excretory apparatus of the liver 1171
The pancreas 1175
UROGENITAL ORGANS 1180
The urinary organs 1180
The kidneys 1180
The ureters 1191
The bladder 1193
The male urethra 1200
The female urethra 1203
THE MALE REPRODUCTIVE ORGANS . 1203
The testes and their coverings . 1203
The vas deferens 1210
The vesiculæ seminales . . . 1211
The ejaculatory ducts 1212
The penis 1212
The prostate gland 1215
Cowper's glands 1218
THE FEMALE REPRODUCTIVE ORGANS 1218
The ovaries 1218
The Fallopian tubes 1221
The uterus 1222
The vagina 1229
The external organs 1230
The mammary glands 1232
THE DUCTLESS GLANDS 1234
The thyroid body 1235
The parathyroid glands 1237
The thymus gland. 1238
The spleen 1240
The suprarenal glands 1245
The carotid bodies 1247
The coccygeal body 1247

HUMAN ANATOMY

INTRODUCTION

THE term *human anatomy* comprises a consideration of the various structures which make up the human organism. In a restricted sense it deals merely with the parts which form the fully developed individual and which can be rendered evident to the naked eye by various methods of dissection. Regarded from such a standpoint it may be studied by two methods: (1) the various structures may be separately considered—*systematic anatomy;* or (2) the organs and tissues may be studied in relation to one another—*topographical* or *regional anatomy.*

It is, however, of much advantage to add to the facts ascertained by naked-eye dissection those obtained by the use of the microscope. This introduces two fields of investigation, viz. the study of the minute structure of the various component parts of the body—*histology* ; and the study of the human organism in its immature condition, i.e. the various stages of its intra-uterine development from the fertilised ovum up to the period when it assumes an independent existence—*embryology.* Owing to the difficulty of obtaining material illustrating all the stages of this early development, gaps must be filled up by observations on the development of lower forms—*comparative embryology,* or by a consideration of adult forms in the line of human ancestry—*comparative anatomy.* Finally, the direct application of the facts of human anatomy to the various pathological conditions which may occur constitutes the subject of *applied anatomy.*

SYSTEMATIC ANATOMY.—The various systems of which the human body is composed are grouped under the following headings :

1. *Osteology*—the bony system or skeleton.
2. *Syndesmology*—the articulations or joints.
3. *Myology*—the muscles. With the description of the muscles it is convenient to include that of the fasciæ which are so intimately connected with them.
4. *Angiology*—the vascular system, comprising the heart, blood-vessels, lymphatic vessels and lymphatic glands.
5. *Neurology*—the nervous system. The organs of sense may be included in this system.
6. *Splanchnology*—the visceral system. Topographically the viscera form two groups, viz. the thoracic viscera and the abdomino-pelvic viscera. The heart, a thoracic viscus, is best considered with the vascular system. The rest of the viscera may be grouped according to their functions : (*a*) the *respiratory system* ; (*b*) the *alimentary system* ; and (*c*) the *genito-urinary system.* Strictly speaking, the third sub-group should include only such components of the genito-urinary system as are included within the abdomino-pelvic

cavity, but it is convenient to study under this heading certain parts which lie in relation to the surface of the body, e.g. the testes and the external organs of generation.

For descriptive purposes the body is supposed to be in the erect posture, with the arms hanging by the sides and the palms of the hands directed forwards. The *mesial plane* is a vertical antero-posterior plane, passing through the centre of the trunk. This plane will pass approximately through the sagittal suture of the skull, and hence any plane parallel to it is termed a *sagittal plane*. A vertical plane at right angles to the mesial plane passes, roughly speaking, through the central part of the coronal suture or through a line parallel to it ; such a plane is therefore known as a *coronal plane* or sometimes as a *frontal plane*. A plane at right angles to both the mesial and coronal planes is termed a *transverse plane*.

The terms *anterior* or *ventral*, and *posterior* or *dorsal*, are employed to indicate the relation of parts to the front or back of the body, and the terms *superior* or *cephalic*, and *inferior* or *caudal*, to indicate the relative levels of different structures.

HISTOLOGY

THE ANIMAL CELL (fig. 1)

ALL the tissues and organs of the body originate from a microscopic structure (the *fertilised ovum*), which consists of a soft jelly-like granular material enclosed in a membrane, and containing a vesicle or small spherical body inside which are one or more denser spots. This may be regarded as a complete cell. All the solid tissues consist largely of cells essentially similar to it in nature but differing in external form.

In the higher organisms a cell may be defined as 'a nucleated mass of protoplasm of microscopic size.' Its two essentials, therefore, are: a soft jelly-like granular material, similar to that found in the ovum, and usually styled *protoplasm*; and a small spherical body imbedded in it, and termed a *nucleus*.*

FIG. 1.—Diagram of a cell. (Modified from Wilson.)

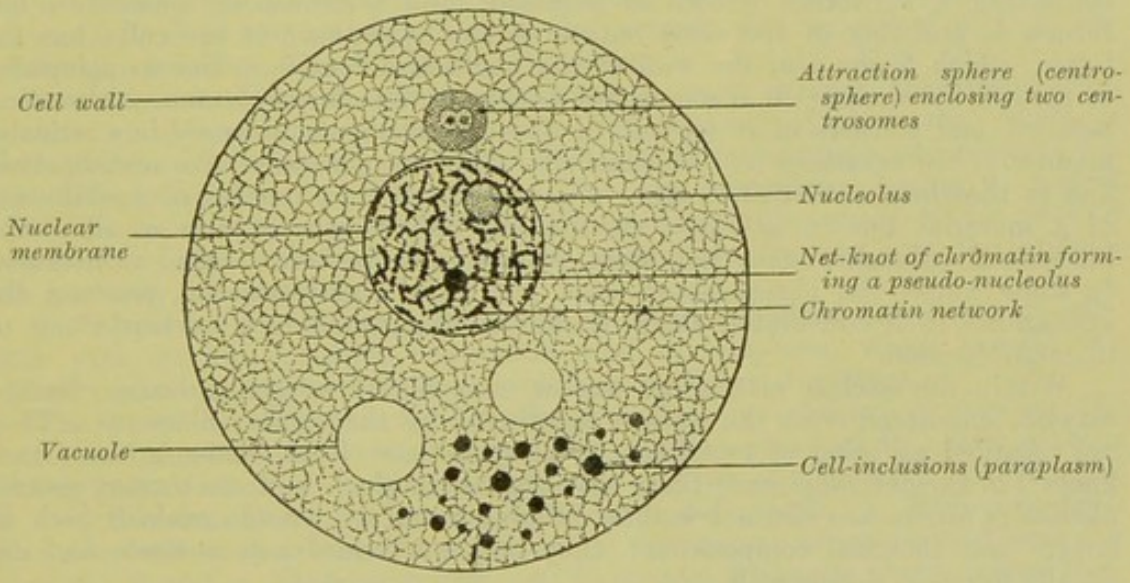

The other constituents of the ovum, viz. its limiting membrane and the denser spot contained in the nucleus, called the *nucleolus*, are not essential to the type-cell, and in fact many cells exist without them.

Protoplasm (*cytoplasm*) is a material probably of variable constitution during life, but yielding on its disintegration bodies chiefly of protein nature. Lecithin and cholesterin are constantly found in it, as well as inorganic salts, chief among which are the phosphates and chlorides of the alkali metals and of calcium. It is of a semi-fluid, viscid consistence, and appears either as a hyaline substance, homogeneous and clear, or else it exhibits a granular appearance. Under a high power of the microscope protoplasm is seen to consist of an elastic and refractile network or reticulum, containing in its meshes a clear, semi-fluid, homogeneous substance. The reticulum is composed of a material known as *spongioplasm*, while the enclosed substance is termed *hyaloplasm*. The granular appearance is often caused by the knots of the network; but, in addition to

* In certain lower forms of life, masses of protoplasm without any nuclei have been described by Huxley and others, as cells.

these, protoplasm frequently contains true granules, some of which are protein in nature and probably essential constituents; others are fat, glycogen or pigment granules, and are regarded as adventitious material taken in from without, and hence are styled cell-inclusions or *paraplasm*. The size and shape of the meshes of the spongioplasm vary in different cells and in different parts of the same cell. The relative amounts of spongioplasm and hyaloplasm also vary in different cells; the latter preponderating in the young cell and the former increasing at the expense of the hyaloplasm as the cell grows. In many fixed cells, e.g. epithelial cells, the periphery becomes denser than the rest, and often altered by the deposition in it of a substance, the so-called *cement*, the nature of which is unknown. This cement substance separates the cells from each other, and has been termed by some histologists the cell-wall; when treated with dilute solutions of silver nitrate and then exposed to light it turns a deep brown or black colour.

The most striking characteristics of protoplasm are its vital properties of *motion* and *nutrition*. Its movements, on account of their resemblance to those observed in the Amœba or Proteus animalcule, have been termed 'amœboid movements.' Nutrition is the power which protoplasm has of attracting to itself from surrounding matter the materials necessary for its growth and maintenance. Any foreign particle which comes in contact with the protoplasmic substance becomes incorporated in it, being enwrapped by one or more processes projected from the parent mass. When thus taken up, it may become an integral part of the cell or may remain in the substance of the protoplasm for some time without change, or may be rapidly extruded.

The **Nucleus** is a minute body, imbedded in the protoplasm, and usually of a spherical or oval form, its size having little relation to the size of the cell. It is surrounded by a well-defined wall, the *nuclear membrane*; this encloses the *nuclear substance* (nuclear matrix), which is composed of a homogeneous material containing a substance known as *paralinin*, and a stroma or network. The former is probably of the same nature as the hyaloplasm of the cell; but the latter, which forms also the wall of the nucleus, differs from the spongioplasm of the cell substance. It is sometimes known as the *chromoplasm* or *intranuclear network*, and consists of a network of fibres or filaments arranged in a reticular manner. The substance of the filaments stains very readily with certain dyes, and is therefore named *chromatin*; it is supported by a number of fine threads of a material known as *linin* which stains only faintly or not at all. The interstitial substance does not stain readily, and is hence called *achromatin*. In some nuclei the chromoplasm does not form a network, but presents the appearance of a convoluted skein, similar to that found in a nucleus about to undergo division.

Within the nuclear matrix are one or more highly refracting bodies, termed *nucleoli*, connected with the nuclear membrane by the nuclear filaments. They are regarded as being of two kinds. Some are mere local condensations ('net-knots') of the chromoplasm; these are irregular in shape and are termed *pseudo-nucleoli*; others are distinct bodies differing from the pseudo-nucleoli both in nature and chemical composition; they may be termed *true nucleoli*, and are usually found in resting cells.

The nuclear substance differs chemically from ordinary protoplasm in containing *nuclein*, in its power of resisting the action of acids and alkalis, in its imbibing more intensely the stain of carmine, hæmatoxylin, &c., and in its remaining unstained by some reagents which colour ordinary protoplasm.

Most living cells contain, in addition to their protoplasm and nucleus, a minute particle which, on account of the power it appears to possess of attracting the surrounding protoplasmic granules, is termed the *attraction particle* or *centrosome*; it usually lies near the nucleus. The spherical arrangement of fibrillar rows of granules surrounding the particle is termed the *attraction sphere* or *centrosphere*. As a rule there are in each cell two spheres connected by a spindle-shaped system of delicate fibrils (*achromatic spindle*). They are best seen in young cells which are about to undergo the process of division, a process believed to commence in these bodies.

Reproduction of cells is effected either by *indirect* or by *direct division*. *Indirect division* or *karyokinesis* (*karyomitosis*) has been observed in all the tissues—generative cells, epithelial tissue, connective tissue, muscular tissue, and nerve tissue, and probably it will ultimately be shown that the division of cells

always takes place in this way, and that the process of reproduction of cells by direct division is, as some observers believe, merely a sort of imperfect or abnormal karyokinesis.

The process of indirect cell division is characterised by a series of complex changes in the nucleus, leading to its subdivision; this is followed by cleavage of the cell protoplasm. Starting with the nucleus in the quiescent or *resting* stage, these changes may be briefly grouped under the four following phases:

1. *Prophase.*—The nuclear network of chromatin filaments assumes the form of a twisted *skein* or *spirem*, while the nuclear membrane and nucleolus disappear. The convoluted skein of chromatin divides into a definite number of V-shaped segments or *chromosomes*. The number of chromosomes varies in different animals —in man it is believed to be always sixteen. Coincident with or preceding these changes the centrosome, or attraction particle, which usually lies by the side of the nucleus, undergoes subdivision, and the two resulting centrosomes, each surrounded by a centrosphere, are seen to be connected by a spindle of delicate achromatic fibres, the *achromatic spindle*. The centrosomes move away from each other—one towards either extremity of the nucleus—and the fibrils of the achromatic spindle are correspondingly lengthened. The centrosomes are now situated one at either extremity or pole of the elongated spindle, and each is surrounded by a centrosphere, from which fibrils radiate into the investing protoplasm. A line encircling the spindle midway between its poles is named the *equator*, and around this the V-shaped chromosomes arrange themselves in the form of a star, thus constituting the *mother star* or *monaster*.

2. *Metaphase.*—Each V-shaped chromosome now undergoes longitudinal cleavage into two equal parts or *daughter chromosomes*, the cleavage commencing at the apex of the V and extending along its divergent limbs. The daughter chromosomes, thus separated, travel in opposite directions along the fibrils of the achromatic spindle towards the centrosomes, around which they group themselves, and thus two star-like figures are formed, one at either pole of the achromatic spindle. This constitutes the *diaster*.

3. *Anaphase.*—The daughter chromosomes now arrange themselves into a *skein* or *spirem*, and eventually form the network of chromatin which is characteristic of the resting nucleus. The nuclear membrane and nucleolus are also differentiated during this phase. The cell protoplasm begins to appear constricted around the equator of the achromatic spindle, where double rows of granules are also sometimes seen. The constriction deepens and the original cell gradually becomes divided.

4. *Telophase.*—In this stage the cell is completely divided into two new cells, each with its own nucleus, centrosome and centrosphere, which assume the ordinary positions occupied by such structures in the resting stage.

The series of diagrams (fig. 2), by Delépine, is intended to explain the formation of some of the most important changes observed in nuclei of cells during karyokinesis; it is based chiefly on the work of Flemming, Strasburger, E. van Beneden, Rabl, O. Hertwig, Henneguy, and others. A. *Resting nucleus.* Nucleolus and nuclear membrane visible. A centrosome is represented near the nucleus. B and C. *Skein* or *spirem.* B. Chromatic filaments much convoluted. Longitudinal splitting is evident in several parts. The centrosome has divided and the nuclear membrane is becoming indistinct. C. The two centrosomes are widely separated, and the space between them is occupied by the achromatic spindle. (Two arrows point to the positions which the centrosomes will ultimately occupy; during their passage to these points the achromatic spindle seems to be within the nucleus.) The nuclear membrane has disappeared. D. *Mother star* or *monaster.* The nuclear segments (chromosomes) resulting from the breaking-up of the chromatic filament into fragments of nearly equal length have moved towards the equator of the spindle, where they now form an equatorial plate. These segments are all split longitudinally. E. *Metaphase.* One half of each chromosome moves in the direction of one pole and the other half in that of the other pole, being guided towards the centrosomes by the achromatic filaments. F. *Daughter stars* or *diaster.* G. *Daughter skeins* or *dispirem*, beginning to form. Segments in the form of thick loops not closely packed. H. *Daughter skeins* or *dispirem*, formed. Segments more closely packed and less distinct, owing to the formation of anastomoses. I. *Resting daughter nuclei.* Cell completely divided into two, but bridges remain between them in the region previously occupied by

FIG. 2.—Karyokinesis : or indirect cell-division.

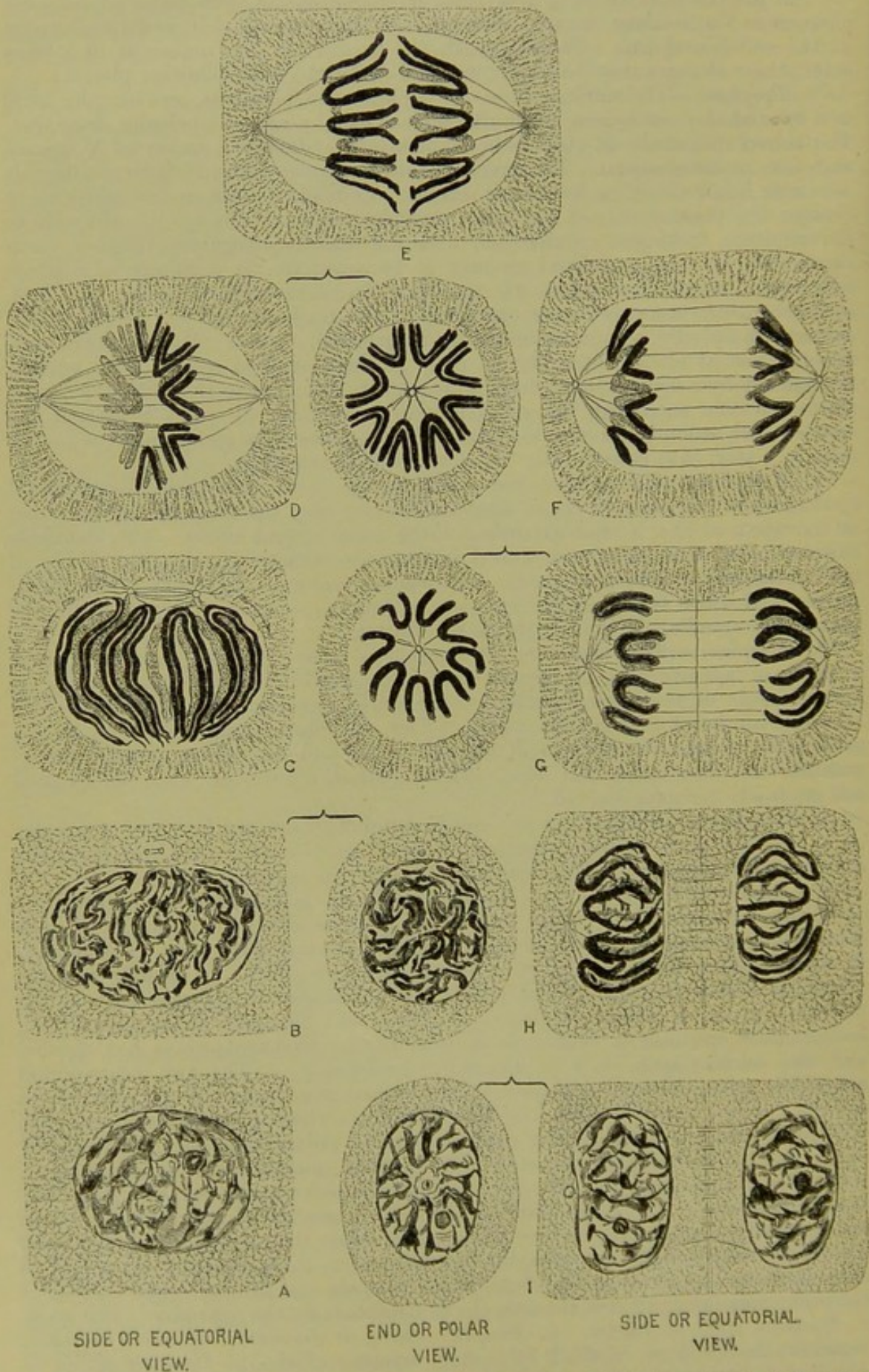

A. Resting nucleus. B. Skein or spirem, close. C. Skein or spirem, open. D. Mother star, monaster. E. Metaphase. F. Daughter stars or diaster. G. Daughter skeins or dispirem, beginning to form. H. Daughter skeins or dispirem formed. I. Resting daughter nuclei.

the achromatic filaments, these being specially distinct in certain cells (e.g. prickle-cells). The nucleus has a distinct nuclear membrane and a nucleolus.

In the reproduction of cells by *direct* division the process is one either of segmentation or of gemmation. In reproduction by *segmentation* or *fission*, the nucleus becomes constricted in its centre, assuming an hour-glass shape, and then divides into two. This is followed by a cleavage or division of the whole protoplasmic mass of the cell; and thus two daughter cells are formed, each containing a nucleus. These daughter cells are at first smaller than the original mother cell; but they grow, and the process may be repeated in them, so that multiplication may take place rapidly. In reproduction by *gemmation*, a budding-off or separation of a portion of the nucleus and parent cell takes place, and, this becoming separated, forms a new organism.

The **cell-wall** is merely the external layer of the protoplasm, firmer than the rest of the cell, and often thickened by the deposit in it of certain chemical substances. It forms a transparent, finely striated membrane, in which are a number of apertures. Through these openings protoplasmic processes can extend from cell to cell. They are often termed intercellular bridges.

THE NUTRITIVE FLUIDS

The **circulating fluids** of the body, which subserve its nutrition, are the blood and the lymph.

Blood

The blood is an opaque, rather viscid fluid, of a bright red or scarlet colour when it flows from the arteries, of a dark red or purple colour when it flows from the veins. It is salt to the taste, and has a peculiar faint odour and an alkaline reaction. Its specific gravity is about 1·06, and its temperature is generally about 99° F., though varying slightly in different parts of the body.

General composition of the blood.—Blood consists of a faintly yellow fluid, the *plasma* or *liquor sanguinis*, in which are suspended numerous minute particles, the *blood corpuscles*, the majority of which are coloured and give to the blood its red tint. If a drop of blood be placed in a thin layer on a glass slide and examined under the microscope, a number of these corpuscles will be seen floating in the clear fluid plasma.

The **blood corpuscles** are chiefly of two kinds: (1) coloured corpuscles or erythrocytes, (2) colourless corpuscles or leucocytes. A third variety, the blood platelets, is of subsidiary importance.

1. **Coloured or red corpuscles** (*erythrocytes*), when examined under the microscope, are seen to be circular discs, biconcave in profile. The disc has no nucleus, but, in consequence of its biconcave shape, presents, according to the alterations of focus under an ordinary high power, a central part, sometimes bright, sometimes dark, which has the appearance of a nucleus (fig. 3, *a*). It is to the aggregation of the red corpuscles that the blood owes its red hue, although when examined by transmitted light their colour appears to be only a faint reddish-yellow. The corpuscles vary slightly in size even in the same drop of blood, but the average diameter of each is about $\frac{1}{3200}$ of an inch, and the thickness about $\frac{1}{12000}$ of an inch, nearly one quarter of the diameter. Besides these there are found certain smaller corpuscles of about one-half or one-third of the size just indicated; these are termed *microcytes*, and are very scarce in normal blood; in diseased conditions (e.g. anæmia), however, they are more numerous. The number of red corpuscles in the blood is enormous; between 4,000,000 and 5,000,000 are contained in a cubic millimetre. Power states that the red corpuscles of an adult would present an aggregate surface of about 3,000 square yards. Each corpuscle consists of a colourless elastic spongework or stroma, condensed at the periphery to form an investing membrane; uniformly diffused throughout the stroma are the coloured fluid contents. The stroma is composed mainly of *nucleo-protein* and of the fatty substances, *lecithin* and *cholesterin*, while the coloured material consists chiefly of the respiratory protein, *hæmoglobin*, which is a compound protein composed of an iron-containing body, hæmatin, and of globin, a protein belonging to the globulin group. Hæmoglobin has a great affinity for oxygen, and, when removed from the body, crystallises readily under certain circumstances;

it is very soluble in water, so that the addition of water to a drop of blood speedily dissolves out the hæmoglobin from the corpuscles.

If the web of a living frog's foot be spread out and examined under the microscope, the blood is seen to flow in a continuous stream through the vessels, and the corpuscles show no tendency to adhere to each other or to the wall of the vessel. Doubtless the same is the case in the human body; but when the blood is drawn and examined on a slide without reagents, the corpuscles often collect into heaps like rouleaux of coins (fig. 3, *b*). It has been suggested that this phenomenon may be explained by alteration in surface tension. During life the red corpuscles may be seen to change their shape under pressure so as to adapt themselves, to some extent, to the size of the vessel. They are, however, highly elastic, and speedily recover their shape when the pressure is removed. They are readily influenced by the medium in which they are placed. In water they swell up, lose their shape, and become globular (*endosmosis*) (fig. 3, *c*). Subsequently the hæmoglobin is dissolved out, and the envelope can barely be distinguished as a faint circular outline. Solutions of salt or sugar, denser than the plasma, give them a stellate or crenated appearance (*exosmosis*) (fig. 3, *d*), but the usual shape may be restored by diluting the solution to the same specific gravity as the plasma. The crenated outline may be produced as the first effect of the passage of an electric shock: subsequently, if sufficiently strong, the shock ruptures the envelope. A solution of salt or sugar, of the same specific gravity as the plasma (i.e. an isotonic solution), merely separates the blood corpuscles mechanically, without changing their shape.

FIG. 3.—Human red blood-corpuscles. Highly magnified.

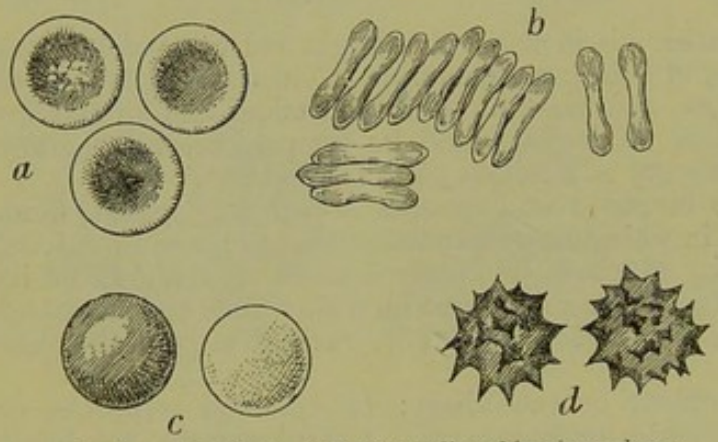

a. Seen from the surface. *b*. Seen in profile and forming rouleaux. *c*. Rendered spherical by water. *d*. Rendered crenate by salt solution.

The **colourless corpuscles** or *leucocytes* are of various sizes, some no larger, others smaller, than the red corpuscles. In human blood, however, the majority are rather larger than the red corpuscles, and measure about $\frac{1}{2000}$ to $\frac{1}{2500}$ of an inch in diameter. On the average from 10,000 to 12,000 leucocytes are found in each cubic millimetre of blood.

They consist of minute masses of nucleated protoplasm, and exhibit several varieties, which are differentiated from each other chiefly by the occurrence or non-occurrence of granules in their protoplasm, and by the staining reactions of these granules when present (fig. 4). (1) The most numerous (70–80 per cent.) and important are spherical in shape, and are characterised by nuclei, which often consist of two or three parts (multipartite) connected together by fine threads of chromatin. The protoplasm is clear, and contains a number of very fine granules, which stain with acid dyes such as eosin (fig. 4, P). These cells are termed the *polymorphonuclear* leucocytes. (2) A second variety comprises from 2 to 4 per cent. of the leucocytes; they are larger than the previous kind, and are made up of coarsely granular protoplasm, the granules being highly refractile and grouped round single nuclei of horse-shoe shape (fig. 4, E). The granules stain deeply with eosin, and the cells are therefore often termed *eosinophil* corpuscles. (3) The third variety is called the *hyaline* cell (fig. 4, H). This is usually about the same size as the eosinophil cell, and, when at rest, is spherical in shape and contains a single round or oval nucleus. The protoplasm is free from granules, but is not quite transparent, having the appearance of ground glass. (4) The fourth kind of colourless corpuscle is designated the *lymphocyte* (fig. 4, L), because it is identical with the lymphoid cell derived from the lymphatic glands, the spleen, tonsil, and thymus. It is the smallest of the leucocytes, and consists chiefly of a spheroidal nucleus with a very little surrounding protoplasm of a homogeneous nature; it is regarded as the immature form of the hyaline cell.

The third and fourth varieties together constitute from 20 to 30 per cent. of the colourless corpuscles, but of these two varieties the lymphocytes are by far the more numerous. Leucocytes having in their protoplasm granules which stain with basic dyes (basophil) have been described as occurring in human blood, but they are rarely found except in disease.

The colourless corpuscles are very various in shape in living blood (fig. 5), because many of them have the power of constantly changing their form by protruding finger-shaped or filamentous processes of their substance, by which they move, and take up granules from the surrounding medium. In locomotion the corpuscle pushes out a process of its substance—a *pseudopodium*, as it is called—and then

Fig. 4.—Varieties of leucocytes found in human blood. Highly magnified.

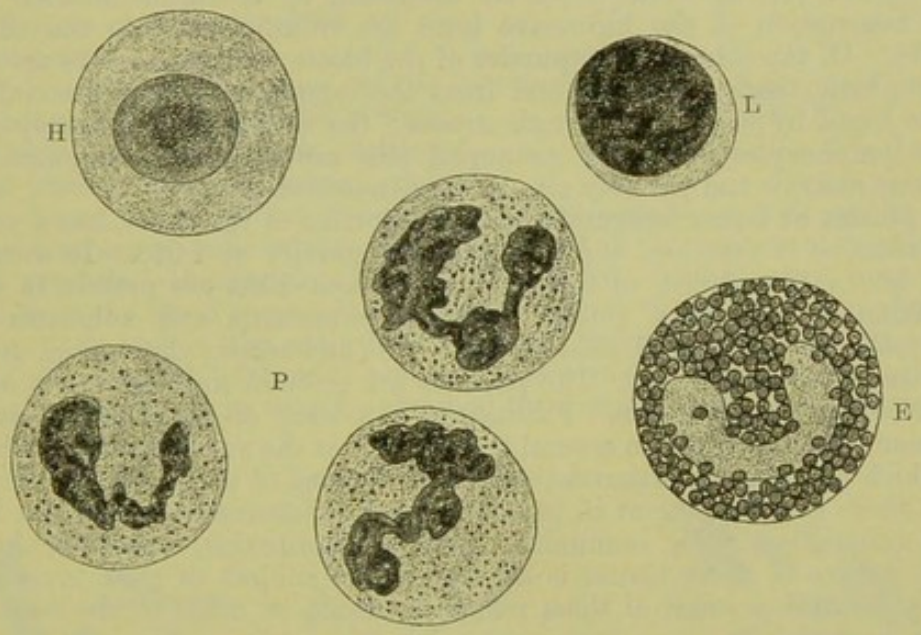

shifts the rest of the body into it. In the same way when any granule or particle comes in its way the corpuscle wraps a pseudopodium round it, and then withdraws the pseudopodium with the contained particle into its own substance. By means of these amœboid properties the cells have the power of wandering or emigrating from the blood-vessels by penetrating their walls and thus finding their way into the extra-vascular spaces. A chemical investigation of the protoplasm of the leucocytes shows the presence of nucleo-protein and of a globulin. The occurrence of small amounts of fat and glycogen may also be demonstrated.

The **blood platelets** are discoid or irregularly shaped, colourless, refractile bodies, much smaller than the red cells. Considerable discussion has arisen as to their significance. Recent observers have shown that under the action of certain

Fig. 5.—Human colourless blood-corpuscle, showing its successive changes of outline within ten minutes when kept moist on a warm stage. (Schofield.)

stains the centrally situated portion of the blood platelet takes on an appearance suggestive of a nucleus. In spite of this, and of the fact that they have been observed in the blood-vessels during life, there is still a tendency to regard them as products of disintegration of the white cells, or as precipitates, possibly of nucleo-protein, and not as living elements of the blood.

Origin of the blood corpuscles.—In the embryo the red corpuscles are developed from cells in the vascular area of the blastoderm. These cells unite with one another to form a network, their nuclei multiply in number, and around some of the nuclei aggregations of coloured protoplasm take place. After a time the fibres of the network become hollowed out by an accumulation of fluid, and form capillary blood-vessels, and in the fluid those nuclei which are surrounded by

coloured protoplasm float as the first red blood cells.* The embryonic corpuscles are thus nucleated, and, further, they have the power of amœboid movement. These cells disappear in later embryonic life, to be replaced by smaller non-nucleated corpuscles, having all the characters of the adult erythrocytes, and formed, according to Schäfer, within certain cells of the connective tissue. Small globules of reddish colouring matter appear in their protoplasm, and the cells eventually becoming larger, more uniform in size and disc-shaped, float in a cavity which results from the coalescence of numerous vacuoles. After birth the important source of the red corpuscles is the red marrow in the ends of the long bones and especially in the ribs and sternum. Here are found special, nucleated, coloured cells, termed *erythroblasts*, which are probably direct descendants of the nucleated, embryonic red cells. These erythroblasts by atrophy and disappearance of their nuclei (or, as some observers maintain, by extrusion of their nuclei) and by assumption of the biconcave form are transformed into the adult red corpuscles. Of the colourless corpuscles of the blood, the lymphocytes are derived from lymphatic tissue generally, and from the lymphatic glands especially, and enter the blood by way of the lymph stream; the hyaline cells probably develop from the lymphocytes, while the eosinophil cells are believed to originate mainly in the bone marrow and possibly also in the connective tissues.

The **plasma** or **liquor sanguinis**, the fluid portion of the blood, has a yellowish tint, is alkaline in reaction, and has a specific gravity of 1·028. It contains in solution about 10 per cent. of solids, of which four-fifths are protein in nature; the remainder being salts, chiefly chlorides, phosphates and sulphates of the alkali metals; carbohydrates, chiefly sugar; fats and soaps; cholesterin, urea, and other nitrogenous extractives. The proteins are three in number, *serum albumin*, *serum globulin*, and *fibrinogen*. Fibrinogen is a body of the globulin class, but differs from serum globulin in several respects. It is the substance from which the *fibrin*, which plays so important a part in the clotting of the blood, is derived. In addition there may be present in plasma several substances of very great importance in connection with immunity, such as antitoxins, opsonins, &c. The chemical nature of these bodies is at present the subject of close investigation, and for a detailed account of them reference should be made to the most recent works on bacteriology.

Coagulation of the blood.—When blood is drawn from the body and allowed to stand, it solidifies in the course of a very few minutes into a jelly-like mass or *clot*, which has the same appearance and volume as the fluid blood, and, like it, looks quite uniform. Soon, however, drops of a transparent yellowish fluid, the *serum*, begin to ooze from the surface of the mass and to collect around it. Coincidently the clot begins to contract, so that in the course of about twenty-four hours it has become considerably smaller and firmer than the first formed jelly-like mass, and is surrounded by a quantity of yellowish serum. The clotting of the blood is due to the formation of a fine meshwork of the insoluble material, *fibrin*, which entangles and encloses the blood corpuscles. Many theories have from time to time been brought forward as to the nature of the processes concerned in the clotting of blood. It is undoubtedly due to a ferment, *fibrin-ferment*, acting on *fibrinogen*, one of the proteins present in plasma. Under the agency of the fibrin-ferment the fibrinogen is split up into an insoluble portion, fibrin, and a soluble portion, fibrino-globulin, which remains in solution in the serum. The mode of formation of the ferment is still the subject of much discussion. It is supposed that when blood is shed, small quantities of a substance, *thrombokinase*, are liberated from the leucocytes and blood platelets; thrombokinase is also present in the tissues. It acts on another substance, *thrombogen*, present in the blood platelets, and converts it into the actual fibrin-ferment. Thrombogen, besides existing in the blood platelets, is also present in minute quantities in the circulating plasma. Calcium salts play an important rôle in the process of the formation of the ferment, for unless they are present in a soluble form the thrombokinase is unable to act on the thrombogen.

Fibrin may be obtained, practically free from corpuscles, by whipping the blood, after it has been withdrawn from the body, with a bundle of twigs; the fibrin adheres to these as it is formed. By various means the clotting of the

* Recent observations tend to show that the endothelial lining of the vessels and the blood corpuscles are of entodermal origin.

blood may be retarded so that the plasma may be obtained free from corpuscles; from this plasma there may be derived fibrin and serum, without the cellular elements. Fibrin thus obtained is a white or buff-coloured stringy substance, and when observed, in the course of formation, under the microscope, shows a meshwork of fine fibrils (fig. 6). After exposure to the air for some time it becomes hard, dry, brown, and brittle. It is one of the class of coagulated proteins, insoluble in hot or cold water, saline solution, alcohol, or ether. Under the action of dilute hydrochloric acid it swells up but does not dissolve, but, when thus swollen, is readily dissolved by a solution of pepsin.

Fig. 6.—Fibrin from human blood.

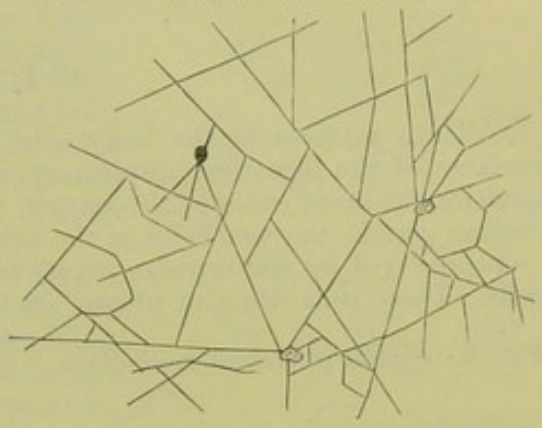

Serum, with the exception of its proteins, has a composition identical with that of plasma. The fibrinogen, characteristic of plasma, has disappeared, and the fibrin ferment and fibrino-globulin are found instead, as well as the serum albumin and serum globulin which are not involved in the process of coagulation.

Blood crystals.—Hæmoglobin, as already stated, readily crystallises when separated from the blood corpuscles. In human blood the crystals are elongated prisms (fig. 7, A), and in the majority of animals belong to the rhombic system, though in the squirrel hexagonal plates are met with. Small brown prismatic crystals of *hæmin* (fig. 7, B) may be obtained by mixing dried blood with common

Fig. 7.—Blood-crystals.

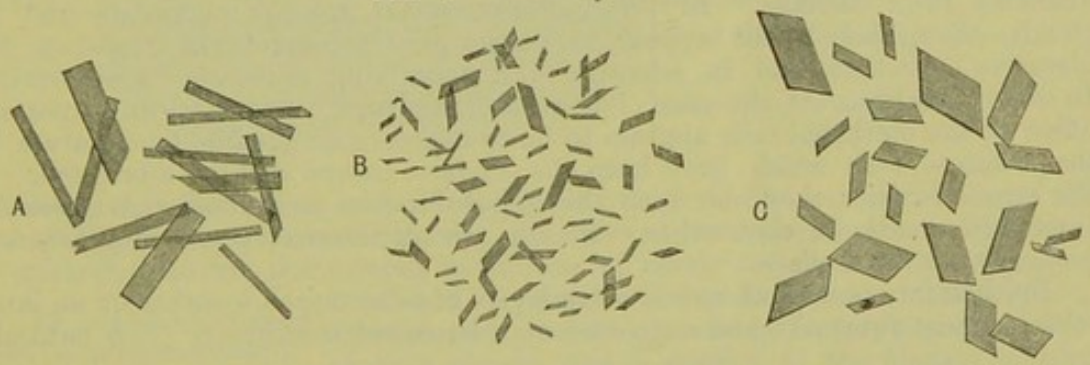

A. Hæmoglobin crystals from human blood. B. Hæmin crystals from blood treated with acetic acid. C. Hæmatoidin crystals from an old apoplectic clot.

salt and boiling with a few drops of glacial acetic acid; a drop of the mixture on a slide will show the characteristic crystals on cooling. *Hæmatoidin* crystals (fig. 7, C) occur sometimes in old blood clots.

Lymph

Lymph is a transparent, colourless or slightly yellow fluid, which is conveyed by a set of vessels, named *lymphatics*, into the blood. These vessels arise in nearly all parts of the body as *lymph capillaries*. They take up the blood plasma which has exuded from the blood capillaries for the nourishment of the tissue elements, and return it into the veins. The greater number of these lymphatics empty themselves into one main duct, the *thoracic duct*, which passes upwards along the front of the vertebral column and opens into the large veins on the left side of the root of the neck. The remainder empty themselves into a smaller duct which ends in the corresponding veins on the right side of the neck.

Lymph is a watery fluid of sp. gr. about 1·015; it closely resembles the blood plasma, but is more dilute, containing only about 5 per cent. of proteins and 1 per cent. of salts and extractives. When examined under the microscope, leucocytes of the lymphocyte class are found floating in the transparent fluid; they are always increased in number after the passage of the lymph through lymphoid tissue, as in lymphatic glands.

Lymph varies greatly in composition in different parts of the body. The lymph leaving the liver contains the greatest percentage of proteins and has the highest specific gravity. In the limbs the lymph is scanty and has a low specific gravity. The intestinal lymph (chyle) is intermediate in composition and contains in addition the fat absorbed by the lacteals, which gives it a milky appearance.

EPITHELIUM

All the surfaces of the body—the external surface of the skin, the internal surfaces of the digestive, respiratory, and genito-urinary tracts, the closed serous cavities, the inner coats of the vessels, the acini and ducts of all secreting and excreting glands, the ventricles of the brain and the central canal of the spinal cord —are covered by one or more layers of simple cells, called *epithelium* or *epithelial cells*. These cells are also present in the terminal parts of the organs of special sense, and in some other structures, such as the pituitary and thyroid bodies. They serve various purposes, forming in some cases a protective layer, in others acting as agents in secretion and excretion, and again in others being concerned in the elaboration of the organs of special sense. Thus, in the skin, the main purpose served by the epithelium (here called the *epidermis*) is that of protection. As the surface is worn away by the agency of friction new cells are supplied, and thus the true skin and the vessels and nerves which it contains are defended from damage. In the gastro-intestinal mucous membrane and its glands, the epithelial cells appear to be the principal agents in preparing the digestive secretions and in selecting and modifying materials for absorption. In other situations (as the nose, fauces, and respiratory passages) an important office of the epithelial cells appears to be to maintain an equable temperature by the moisture with which they keep the surface always slightly lubricated. In the serous cavities they also keep the opposed layers moist, and thus facilitate their movements on each other. Finally, in all internal parts they insure a perfectly smooth surface.

Fig. 8.—Simple pavement epithelium.

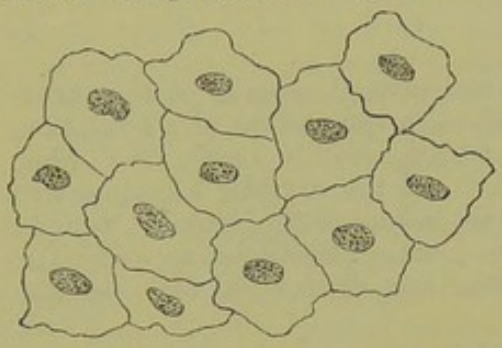

Epithelium consists of one or more layers of cells, united together by an interstitial cement substance and supported on a basement membrane. It is naturally grouped into two classes according as to whether there is a single layer of cells (*simple epithelium*), or more than one (*stratified epithelium* and *transitional epithelium*).

Fig. 9.—Columnar epithelium from an intestinal villus.

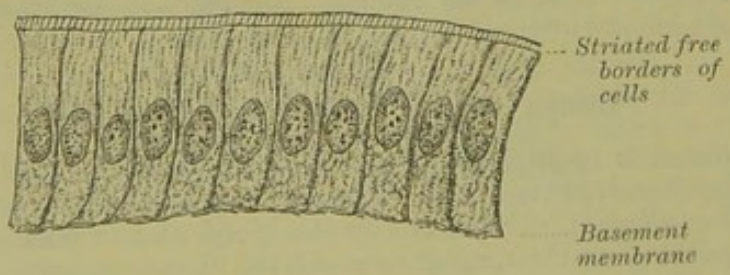

Fig. 10.—Goblet cells. (From Kirke's 'Physiology.')

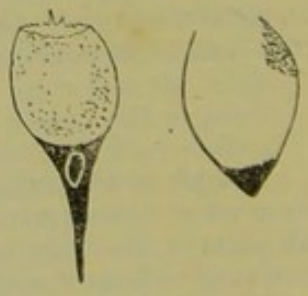

Simple epithelium.—The different varieties of simple epithelium are squamous or pavement, columnar, glandular or spheroidal, and ciliated.

The *pavement* epithelium (fig. 8) is composed of flat, nucleated scales of different shapes, usually polygonal, and varying in size. These cells fit together by their edges, like the tiles of a mosaic pavement. The nucleus is generally flattened, but may be spheroidal; the flattening depends upon the thinness of the cell. The protoplasm of the cell presents a fine reticulum or honeycombed

network, which gives to the cell the appearance of granulation. This kind of epithelium forms the lining of the air-sacs of the lungs. The *endothelium*, which covers the serous membranes, and which lines the heart, blood-vessels, lymphatics, and the anterior chamber of the eye, is also of the pavement type, being composed of a single layer of flattened transparent squamous cells, joined edge to edge in such a manner as to form a membrane of cells. The basement membrane, which supports the epithelial cells, is composed of a homogeneous material. In some instances it has a number of apertures, and is then spoken of as a fenestrated membrane, whilst in other cases it is formed of flattened cells.

Fig. 11.—Spheroidal epithelium. Magnified 250 times.

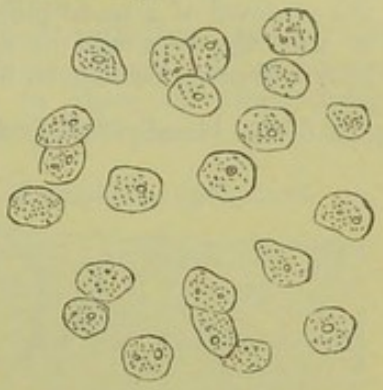

The *columnar* or *cylindrical* epithelium (fig. 9) is formed of cylindrical or rod-shaped cells set together so as to form a complete layer, resembling, when viewed in profile, a palisade. The cells have a prismatic figure, flattened from mutual pressure, and are set upright on the surface on which they are supported. Their protoplasm is always more or less reticulated, and fine longitudinal striæ may be seen in it; the nucleus of each is oval in shape and contains an intranuclear network.

Fig. 12.—Ciliated epithelium from the human trachea.

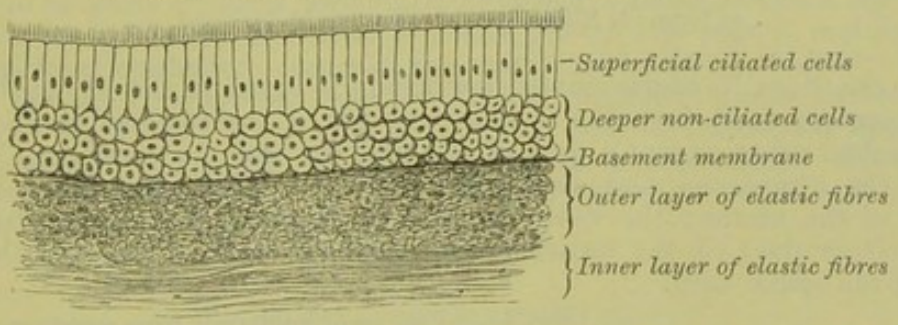

The outer free border of each of these cells is distinctly marked off from the rest of the protoplasm, and contains well marked vertical striations. This form of epithelium covers the mucous membrane of nearly the whole gastro-intestinal tract and its glands, the greater part of the urethra, the vas deferens, the prostate, Cowper's glands, Bartholin's glands, and a portion of the uterine mucous membrane. In a modified form it also covers the ovary.

Fig. 13. — Isolated ciliated cell (semidiagrammatic)

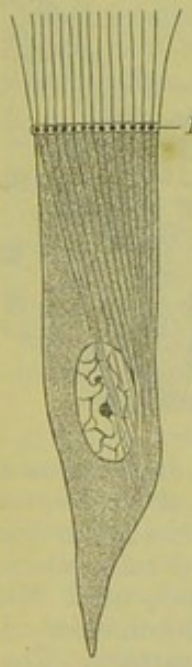

Goblet or *chalice* cells are modified columnar cells. The goblet cell appears to be formed by an alteration in shape of a columnar cell (ciliated or otherwise) consequent on the formation of granules, which consist of a substance called *mucigen*, in the interior of the cell. This distends the upper part of the cell, while the nucleus is pressed down towards its deep part, until the cell bursts and the mucus is discharged on to the surface of the mucous membrane (fig. 10), the cell then assuming the shape of an open cup or chalice.

The *glandular* or *spheroidal* epithelium (fig. 11) is composed of spheroidal or polyhedral cells, but the cells may be columnar or cubical in shape in some situations. As in other forms of epithelial cells, the protoplasm is a fine reticulum, which gives to the cells the appearance of granulation. Glandular cells are found in the terminal recesses of secreting glands, and the protoplasm of the cells usually contains the materials which the cells secrete.

Ciliated epithelium (fig. 12) generally inclines to the columnar shape. It is distinguished by the presence of minute processes, like hairs or eyelashes (cilia)

standing up from the free surface. The cilia (fig. 13) at their points of attachment to the free border of the cell, possess small nodular enlargements (*basal knobs* of Engelmann). Within the cell they converge, and according to some authorities meet at or near the attraction sphere. If the cells be examined during life or immediately on removal from the living body (for which in the human subject the removal of a nasal polypus offers a convenient opportunity) in a weak solution of salt, the cilia will be seen in lashing motion; and if the cells be separated, they will often be seen to be moved about in the field by this ciliary action.

FIG. 14.—Epithelial cells from the oral cavity of man. Magnified 350 times.

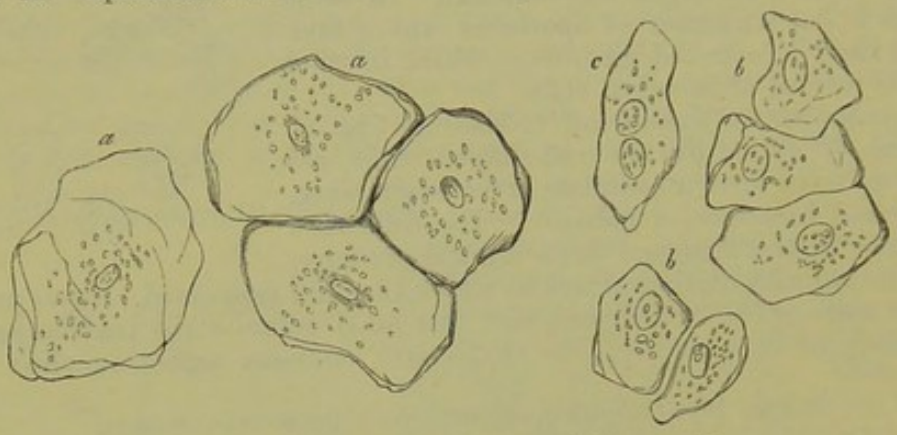

a. Large. *b*. Middle sized. *c*. The same with two nuclei.

The situations in which ciliated epithelium is found in the human body are: the respiratory tract from the nose downwards to the smallest ramifications of the bronchial tubes, except a part of the pharynx and the surfaces of the vocal cords; the tympanum and Eustachian tube; the Fallopian tube and upper portion of the uterus; the vasa efferentia, coni vasculosi and the first part of the excretory duct of the testicle; the ventricles of the brain and the central canal of the spinal cord.

FIG. 15. — Stratified epithelium from the œsophagus.

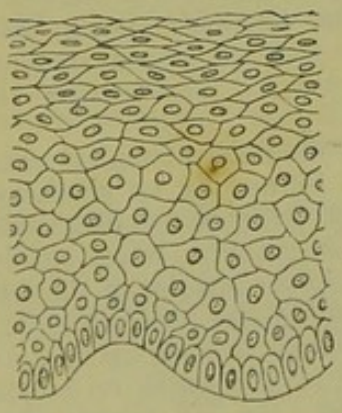

FIG. 16.—Portion of epidermis from a section of the skin of the finger. (Ranvier.) (From Schäfer's 'Essentials of Histology.')

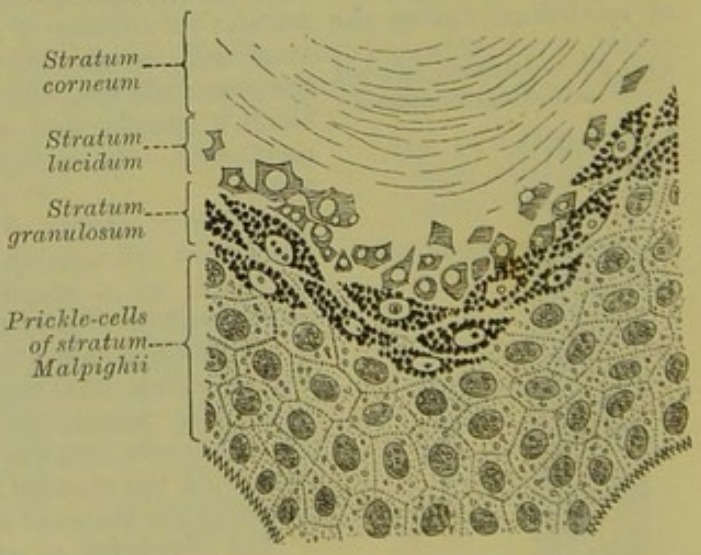

Stratified epithelium (fig. 15) consists of several layers of cells superimposed one on the top of the other and varying greatly in shape. The cells of the deepest layer are for the most part columnar in shape, and are placed vertically on the basement membrane; above these are several layers of spheroidal cells, which as they approach the surface become more and more compressed, until the superficial ones are found to consist of flattened scales (fig. 14), the margins of which overlap one another so as to present an imbricated appearance. The protoplasm of the superficial cells is completely converted into a horny substance termed *keratin*. An intermediate body, *eleidin*, is often present in the deeper layers

of this superficial portion. It exists in the form of coarse granules, and is especially well seen in the stratum granulosum of the epidermis. The most superficial layers lose their nuclei, die, and are thrown or worn off.

Stratified epithelium is found in the skin, in the mucous membrane of the nose, excepting the olfactory portion, in the mucous membrane of the mouth, part of the pharynx, the œsophagus and in the conjunctiva.

Certain cells found in the deeper layers of stratified epithelium, and termed *prickle-cells* (fig. 16), constitute a variety of squamous epithelium. They possess short, fine fibrils, which pass from their margins to those of neighbouring cells, serving to connect them together. They are not closely joined together by cement-substance, but are separated from each other by intercellular channels, across which the fibrils may be seen bridging. When a cell is isolated, it appears to be covered over with a number of short spines, in consequence of the fibrils being broken through. These cells were first described by Max Schultze and Virchow, and it was believed by them that the cells were dovetailed together. Martyn subsequently showed that this was not the case and that the prickles were attached to each other by their apices: and Delépine believes the prickles to be parts of fibrils forming internuclear bundles between the nuclei of the cells of an epithelium in a state of active growth (see page 7, and fig. 2).

Fig. 17.—Transitional epithelium.

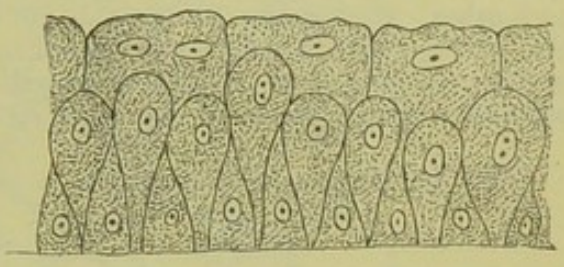

Transitional epithelium occurs in the ureters and urinary bladder. Here the cells of the most superficial layer are cubical, with depressions on their under surfaces, to fit on to the rounded ends of the cells of the second layer, which are pear-shaped, the apices touching the basement membrane. Between the tapering points of the cells of the second layer is a third variety of cells of smaller size than those of the other two layers (fig. 17).

CONNECTIVE TISSUES

The term **connective tissue** includes a number of tissues which possess this feature in common, viz. they support and connect the other tissues of the body. The connective tissues may differ considerably from each other in appearance, but they present many points of relationship, and are, moreover, developed from the same layer of the embryo, the mesoderm. They are divided into three great groups: (1) the connective tissues proper, (2) cartilage, and (3) bone. Blood, which has already been described, is, strictly speaking, a form of connective tissue, and is so dealt with by many histologists.

The Connective Tissues Proper

Several forms or varieties of connective tissue are recognised: (1) Areolar tissue. (2) White fibrous tissue. (3) Yellow elastic tissue. (4) Mucous tissue. (5) Retiform tissue. They are all composed of a homogeneous matrix, in which are imbedded cells and fibres—the latter of two kinds, white, and yellow or elastic. The distinction between the different forms of tissue depends upon the relative preponderance of one or other kind of fibre, of cells, or of matrix.

Connective tissue corpuscles.—The cells of the connective tissues are of three principal kinds: (1) Flattened lamellar cells, which may be either branched or unbranched. The branched lamellar cells are composed of clear cell-substance, and contain oval nuclei. The processes of these cells unite so as to form an open network, as in the cornea. The unbranched cells are joined edge to edge like the cells of an epithelium. The 'tendon cells,' presently to be described, are examples of this variety. (2) Granule cells, which are ovoid or spheroidal in shape. They are formed of a soft protoplasm, containing granules which are albuminous in character and stain deeply with eosin. (3) Plasma cells of Waldeyer, varying greatly in size and form, but distinguished from the other two varieties by containing a vacuolated protoplasm. The vacuoles are filled with fluid, and the

protoplasm between the spaces is clear, with occasionally a few scattered granules.

In addition to these three typical forms of connective tissue corpuscles, areolar tissue may be seen to possess *wandering cells*, i.e. leucocytes which have emigrated from the neighbouring vessels; in some instances, as in the choroid coat of the eye, cells filled with granules of pigment (*pigment cells*) are found.

The connective tissue corpuscles lie in spaces in the ground substance between the bundles of fibres, and these spaces may be brought into view by treating the tissue with nitrate of silver and exposing it to the light. This will colour the ground substance and leave the cell-spaces unstained.

Areolar tissue (fig. 18) is so called because its meshes can be easily distended with air or fluid and thus separated into areolæ or spaces, which open freely into each other. Such spaces, however, do not exist in the natural condition of the body, the whole tissue forming one unbroken membrane composed of a number of interlacing fibres, variously superimposed. The chief use of areolar tissue is to bind parts together; while by the laxity of its fibres, and the permeability of its areolæ,

FIG. 18.—Subcutaneous tissue from a young rabbit. Highly magnified. (Schäfer.)

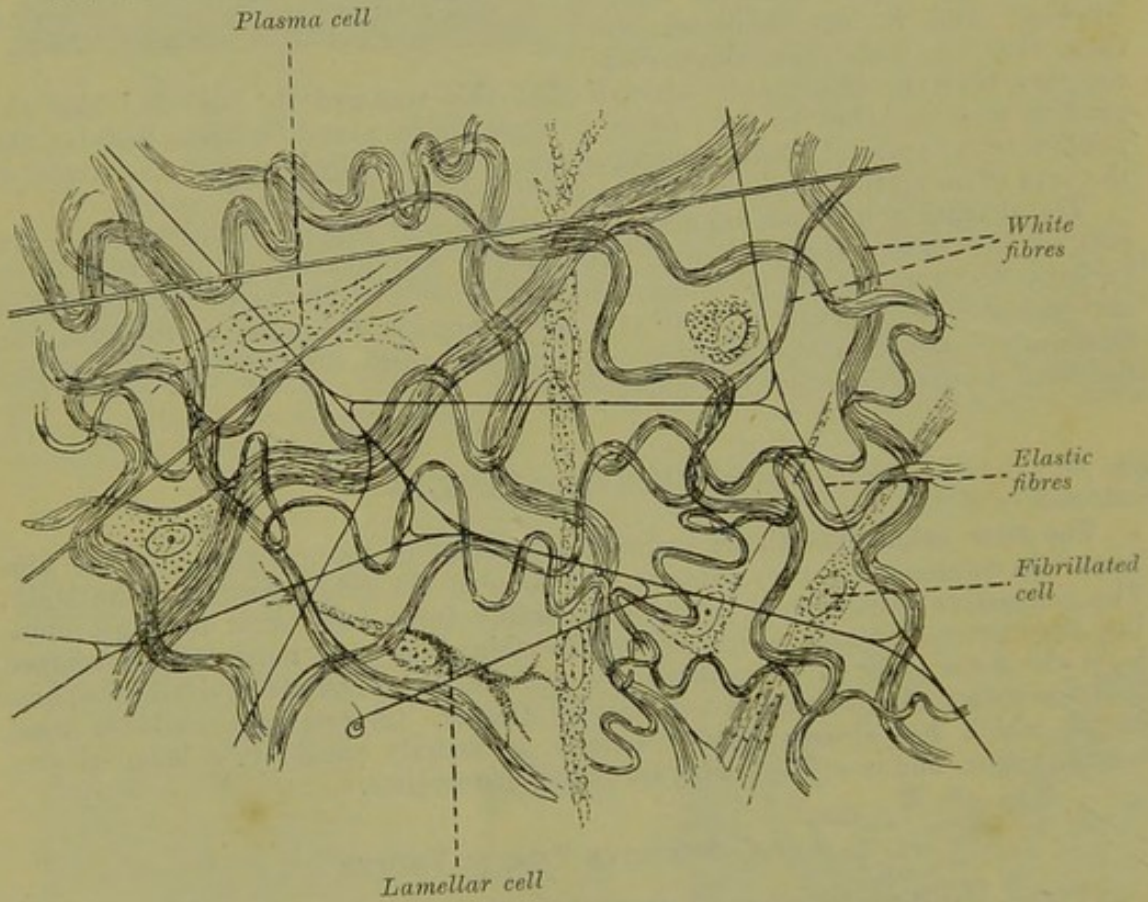

it allows them to move on each other, and affords a ready exit for inflammatory and other effused fluids. It is one of the most extensively distributed of all the tissues. It is found beneath the skin in a continuous layer all over the body, connecting it to the subjacent parts. In the same way it is situated beneath the mucous and serous membranes. It is also found between muscles, vessels, and nerves, forming investing sheaths for them, and connecting them with surrounding structures. In addition to this, it is present in the interior of organs, binding together the various lobes and lobules of the compound glands, the various coats of the hollow viscera, and the fibres of muscles, &c., and thus forms one of the most important connecting media of the various structures or organs of which the body is made up. In many parts the areolæ or interspaces of areolar tissue are occupied by fat-cells, constituting *adipose tissue*, which will presently be described.

Areolar tissue presents to the naked eye an appearance somewhat like spun-silk. When stretched out, it is seen to consist of delicate soft elastic threads interlacing with each other in every direction, and forming a network of extreme delicacy. When examined under the microscope (fig. 18) it is found to be com-

posed of white fibres and yellow elastic fibres intercrossing in all directions, and united together by a homogeneous cement or ground substance, the *matrix*, showing cell-spaces wherein lie the *connective tissue corpuscles*; these contain the protoplasm out of which the whole is developed and regenerated.

The *white fibres* are arranged in waving bands or bundles of minute transparent homogeneous filaments or fibrillæ. The bundles have a tendency to split up

Fig. 19.—Adipose tissue. High power.

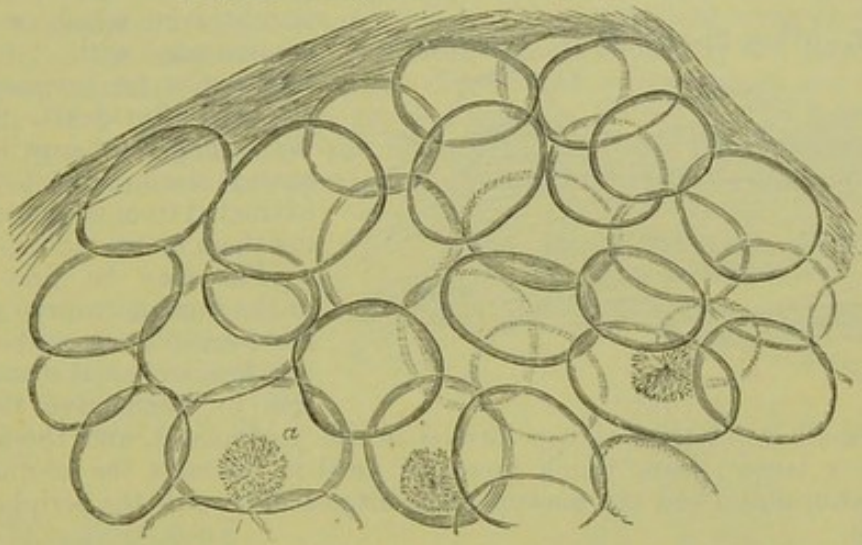

a. Starlike appearance, from crystallisation of fatty acids.

longitudinally or send off slips to join neighbouring bundles, and receive others in return, but the individual fibres are unbranched, and never join other fibres. The *yellow elastic fibres* have well-defined outlines and are considerably larger in size than the white fibrillæ, but vary much, being from the $\frac{1}{24000}$ to the $\frac{1}{4000}$ of an inch in diameter. They form bold and wide curves, branch, and freely anastomose with each other; they are homogeneous in appearance, and tend to curl up, especially at their broken ends.

Fig. 20.—Development of fat.
(Klein and Noble Smith.)

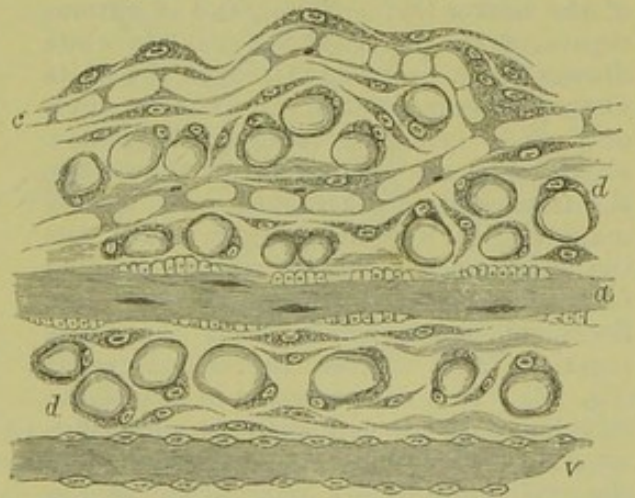

a. Minute artery. *v*. Minute vein. *c*. Capillary blood-vessels in the course of formation; they are not yet completely hollowed out, there being still left in them protoplasmic septa. *d*. The ground substance, containing numerous nucleated cells, some of which are more distinctly branched and flattened than others, and appear therefore more spindle-shaped.

Adipose tissue.—In almost all parts of the body the ordinary areolar tissue contains a variable quantity of fat. The principal situations where it is not found are the subcutaneous tissue of the eyelids, of the penis and scrotum, of the nymphæ; within the cavity of the cranium; and in the lungs, except near their roots. Its distribution is not uniform; in some parts it is collected in great abundance, as in the subcutaneous tissue, especially of the abdomen; around the kidneys, and in some other situations. Lastly, fat enters largely into the formation of the marrow of bones. A distinction must be made between fat and adipose tissue; the latter being a distinct tissue, the former an oily matter, which in addition to forming adipose tissue is also widely present in the body, as in the brain and liver, and in the blood, chyle, &c.

Adipose tissue consists of small vesicles, *fat-cells*, lodged in the meshes of areolar tissue. Fat-cells (fig. 19) vary in size, but are of about the average diameter of $\frac{1}{300}$ of an inch; each consists of an exceedingly delicate protoplasmic membrane, filled with fatty matter, which is liquid during life, but becomes solidified

after death. They are round or spherical where they have not been subjected to pressure; otherwise they assume a more or less polygonal outline. A nucleus is always present and can be easily demonstrated by staining with hæmatoxylin; in the natural condition it is so compressed by the contained oily matter as to be scarcely recognisable. The fat-cells are contained in clusters in the areolæ of fine connective tissue, and are held together mainly by the network of capillary blood-vessels which is distributed to them.

Chemically the oily material in the cells is composed of the fats, olein, palmitin and stearin, which are glycerin compounds with fatty acids. Sometimes fat crystals form in the cells after death (fig. 19, *a*). By boiling the tissue in ether or strong alcohol, the fat may be extracted from the vesicles, leaving them empty and shrunken.

Fig. 21.—White fibrous tissue. High power.

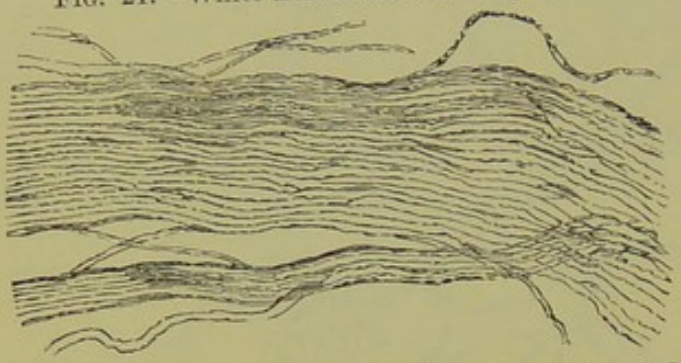

Fat may be first detected in the human embryo about the fourteenth week. The fat-cells are formed by the transformation of connective tissue corpuscles. Small droplets of oil are formed in the protoplasm, and these coalesce to produce a larger drop, which increases until it distends the corpuscle, the remaining protoplasm and the nucleus being displaced towards the periphery of the cell (fig. 20).

White fibrous tissue (fig. 21) is a true connecting structure, and serves three purposes in the animal economy. In the form of ligaments it binds bones together; in the form of tendons it connects muscles to bones or other structures; and it constitutes investing or protecting structures to various organs in the form of membranes. Examples of such membranes are to be found in the muscular fasciæ or sheaths, the periosteum, and perichondrium; the investments of the various glands (such as the tunica albuginea testis, the capsule of the kidney, &c.); the investing sheaths of the nerves (epineurium), and of various organs, as the penis and the eye. In white fibrous tissue, as its name implies, the white fibres predominate; the matrix is apparent only as a cement-substance, the yellow elastic fibres are comparatively few, while the tissue-cells are arranged in a special manner. It presents to the naked eye the appearance of silvery white glistening fibres, covered over with a quantity of loose flocculent tissue which binds the fibres together and carries the blood-vessels (fig. 22). It is not possessed of any elasticity, and only the very slightest extensibility; it is exceedingly strong, so that upon the application of any external violence, a bone with which it is connected may fracture before the fibrous tissue gives way. In ligaments and tendons the bundles of fibres run parallel with each other; in membranes they intersect one another. The cells found in white fibrous tissue are often called 'tendon-cells.' They are situated on the surfaces of groups of bundles and are quadrangular in shape, arranged in rows, in single file, each cell being separated from its neighbours by a narrow line of cement-substance. The nucleus is generally situated at one end of the cell, the nucleus of one of the adjoining cells being in close proximity to it (fig. 23). Upon the addition of acetic acid white fibrous tissue swells up into a glassy-looking indistinguishable mass. When boiled in water it is converted almost completely into gelatin,

Fig. 22.—Connective tissue. (Klein and Noble Smith.)

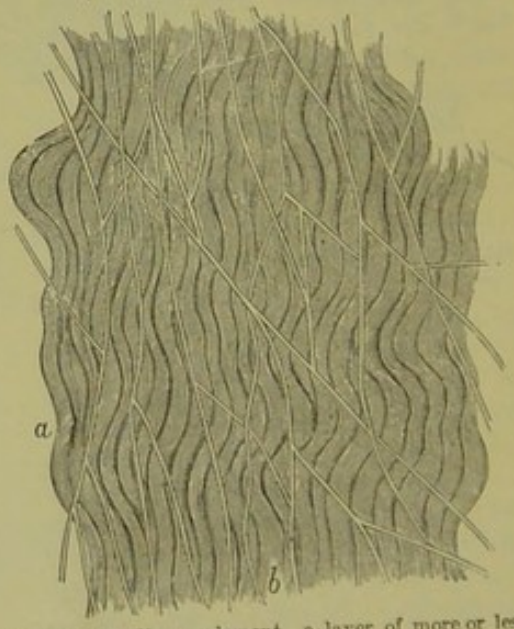

a. The white fibrous element—a layer of more or less sharply outlined, parallel, wavy bundles of connective tissue fibrils. On the surface of this layer is *b*, a network of fine elastic fibres.

the white fibres being composed of the albuminoid *collagen*, which is often regarded as the anhydride of gelatin.

Yellow elastic tissue.—In certain parts of the body a tissue is found which when viewed in mass is of a yellowish colour, and is possessed of great elasticity, so that it is capable of considerable extension, and when the extending force is withdrawn returns at once to its original condition. This is *yellow elastic tissue*, which may be regarded as a connective tissue in which the yellow elastic fibres have developed to the practical exclusion of the other elements. It is found in the ligamenta subflava, in the vocal cords, in the longitudinal coats of the trachea and bronchi, in the inner coats of the blood-vessels, especially the larger arteries, and to a very considerable extent in the thyro-hyoid, crico-thyroid, and stylo-hyoid ligaments. It is also found in the ligamentum nuchæ of the lower animals (fig. 24). In some parts where the fibres are broad and large and the network close, the tissue presents the appearance of a membrane, with gaps or perforations

Fig. 23. — Tendon of mouse's tail, stained with logwood, showing chains of cells between the tendon-bundles. (From Quain's 'Anatomy.' E. A. Schäfer.)

Fig. 24.—Yellow elastic tissue. High power.

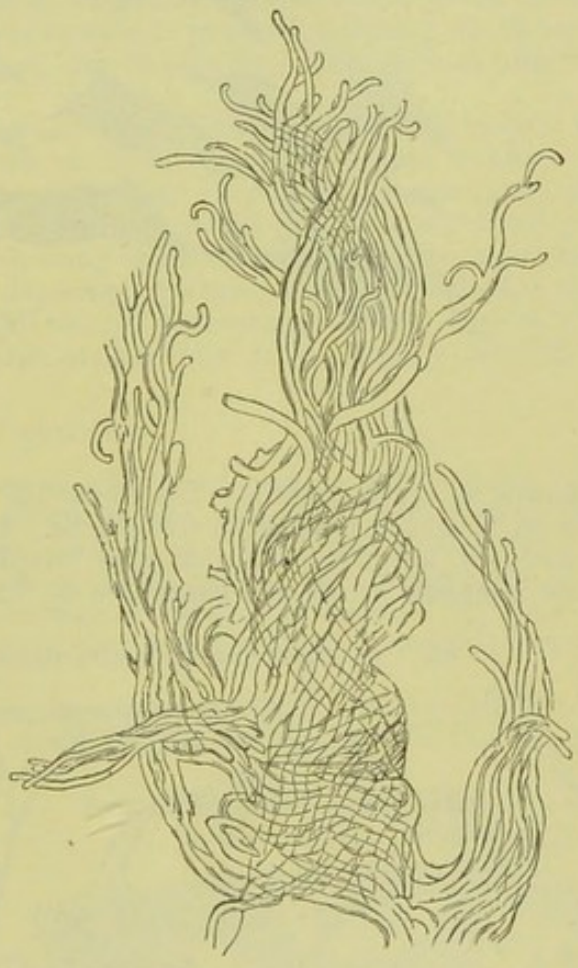

corresponding to the intervening spaces. This is to be found in the inner coats of the arteries, and to it the name of *fenestrated membrane* has been given by Henle. The yellow elastic fibres remain unaltered by acetic acid. Chemically they are composed of the albuminoid body *elastin*.

Mucous tissue exists chiefly in the 'jelly of Wharton,' which forms the bulk of the umbilical cord, but is also found in other situations in the fœtus, chiefly as a stage in the development of connective tissue. It consists of a matrix, largely made up of mucin, in which are nucleated cells with branching and anastomosing processes (fig. 25). Few fibres are seen in typical mucous tissue, though at birth the umbilical cord shows a considerable development of fibres. In the adult the vitreous humour of the eye is a persistent form of mucous tissue, in which there are no fibres, and from which the cells have disappeared, leaving only the mucinous ground substance.

Retiform or reticular tissue (fig. 26) is found extensively in many parts of the body, constituting the framework of some organs and entering into the

construction of many mucous membranes. It is a variety of connective tissue, in which the intercellular or ground substance has, in a great measure, disappeared, and is replaced by fluid. It is apparently composed almost entirely of extremely fine bundles of white fibrous tissue, forming an intricate network, and

Fig. 25.—Mucous tissue from the umbilical cord of the human fœtus (four months).

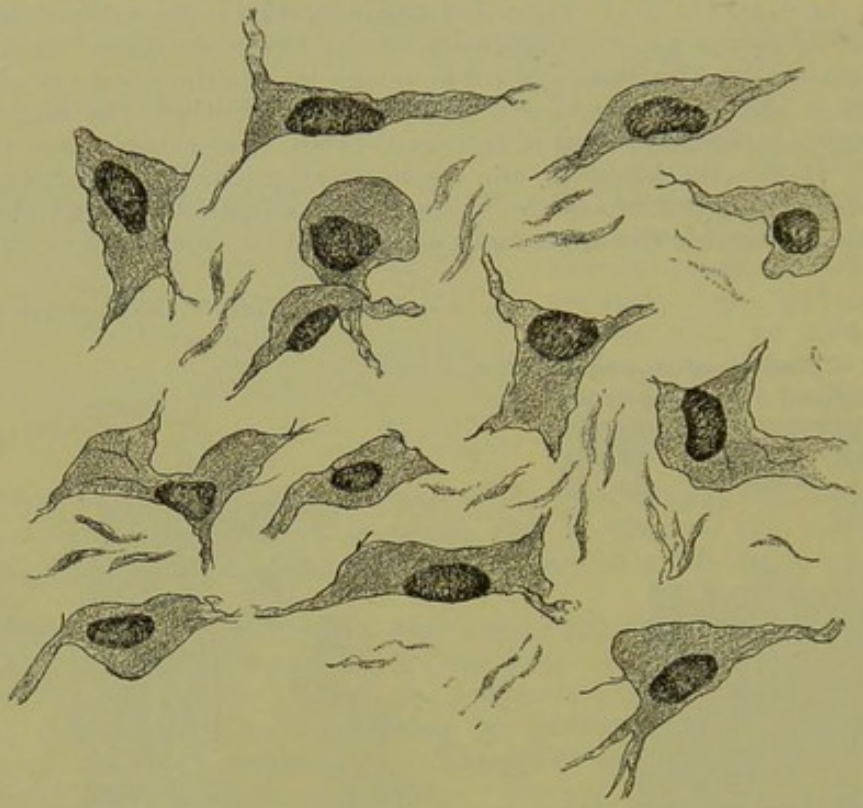

chemically it yields gelatin. The fibres are covered and concealed in places by flattened branched connective tissue cells. In many situations the interstices of the network are filled with rounded lymph-corpuscles, and the tissue is then termed **lymphoid** or **adenoid tissue** (see fig. 83, p. 63).

Fig. 26.—Retiform connective tissue, from a lymphatic gland.

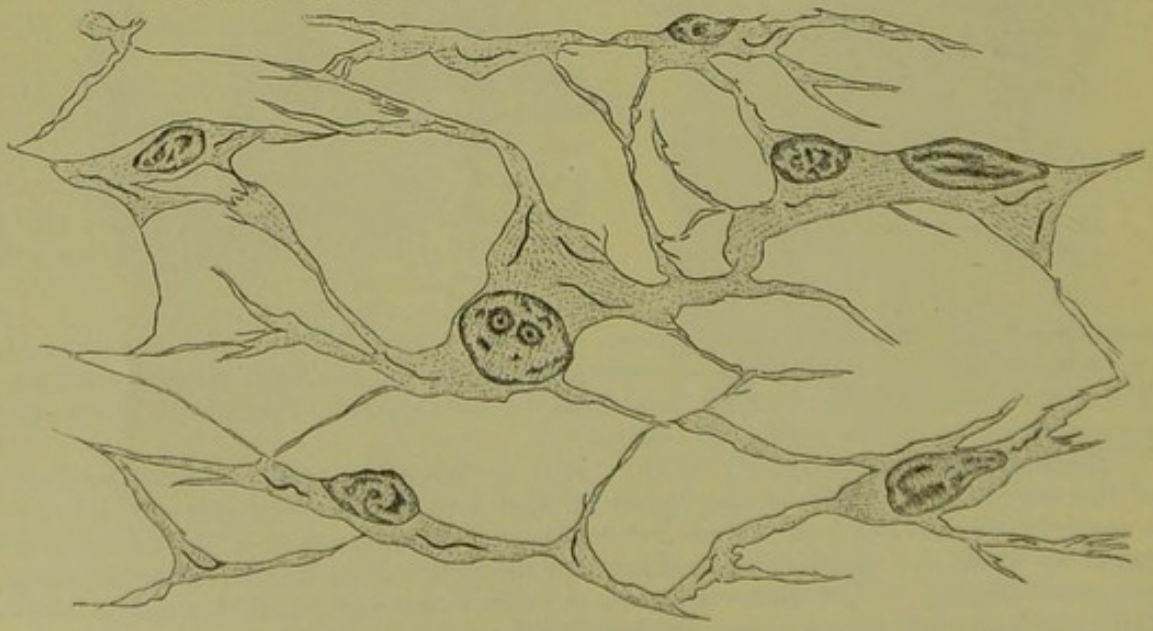

Basement membranes, formerly described as homogeneous membranes, are in most cases really a form of connective tissue. They constitute the supporting membrane, or *membrana propria*, on which is placed the epithelium of mucous membranes or secreting glands, and they are also found in other situations. By means of staining with nitrate of silver they may be shown to consist usually

of flattened cells in close apposition, and joined together by their edges, thus forming an example of an epithelioid arrangement of connective tissue cells. In some situations the cells, instead of adhering by their edges, give off branching processes which join with similar processes of other cells, and so form a network rather than a continuous membrane. Some basement membranes are composed of elastic tissue, as in the cornea, others are merely condensed matrix.

Vessels and nerves of connective tissue. — The *blood-vessels* of connective tissue are very few—that is to say, there are few actually destined for the tissue itself, although many vessels carrying blood to other structures may permeate one of its forms, the areolar tissue. In white fibrous tissue the blood-vessels usually run parallel to the longitudinal bundles and between them, sending transverse communicating branches across; in some forms, as in the periosteum and dura mater, they are fairly numerous. In yellow elastic tissue, the blood-vessels also run between the fibres, and do not penetrate them. *Lymphatic vessels* are very numerous in most forms of connective tissue, especially in the areolar tissue beneath the skin and the mucous and serous surfaces. They are also found in abundance in the sheaths of tendons, as well as in the tendons themselves. *Nerves* are to be found in the white fibrous tissue, where they terminate in a special manner; but it is doubtful whether any nerves terminate in areolar tissue; at all events, they have not yet been demonstrated, and the tissue is possessed of very little sensibility.

Development of connective tissue. — Connective tissue is developed from cells of the mesoderm. These cells, at first rounded, become fusiform and branched, and ultimately form connective tissue corpuscles. A mucinous intercellular substance or matrix, partly derived from the cells themselves and partly from the lymph exuded by the neighbouring blood-vessels, gradually separates the cells. In the matrix the fibres are deposited, probably under the influence of the cells, but not by any transformation of the cell protoplasm. In the case of yellow elastic fibres, rows of granules of elastin are first laid down; these eventually fuse into the fully developed fibre.

Cartilage

Cartilage is a non-vascular structure which is found in various parts of the body—in adult life chiefly in the joints, in the parietes of the thorax, and in various tubes, such as the air-passages, nostrils, and ears, which require to be kept permanently open. In the fœtus, at an early period, the greater part of the skeleton is cartilaginous. As this cartilage is afterwards replaced by bone, it is called *temporary*, in contradistinction to that which remains unossified during the whole of life and is called *permanent*.

Cartilage is divided, according to its minute structure, into hyaline cartilage, white fibro-cartilage, and yellow or elastic fibro-cartilage. Besides these varieties met with in the adult human subject, there is a variety called *cellular cartilage*, which consists entirely, or almost entirely, of cells, united in some cases by a network of very fine fibres, in other cases apparently destitute of any intercellular substance, the cells being separated from each other by their capsules only, which in this variety of cartilage are extremely well marked. Cellular cartilage is found in the external ears of rats, mice, and some other animals, and is present in the notochord of the human embryo, but is not found in any other human structure. The various cartilages in the body are also classified, according to their functions and positions, into articular, interarticular, costal, and membraniform.

Fig. 27.—Human cartilage-cells from the cricoid cartilage. × 350.

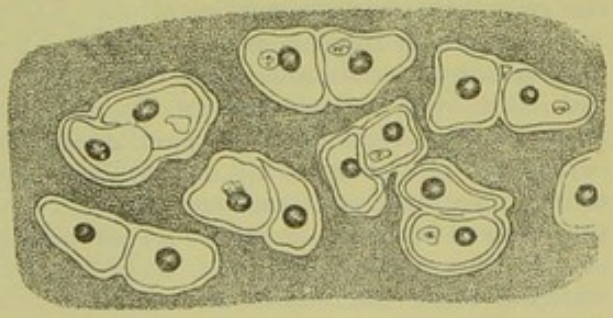

Hyaline cartilage, which may be taken as the type of this tissue, consists of a gristly mass of a firm consistence, but of considerable elasticity and pearly-bluish colour. Except where it coats the articular ends of bones, it is covered externally by a fibrous membrane, the *perichondrium*, from the vessels of which

it imbibes its nutritive fluids, being itself destitute of blood-vessels. It contains no nerves. Its intimate structure is very simple. If a thin slice be examined under the microscope, it will be found to consist of cells of a rounded or bluntly angular form, lying in groups of two or more in a granular or almost homogeneous matrix (fig. 27). The cells, when arranged in groups of two or more, have generally straight outlines where they are in contact with each other, and in the rest of their circumference are rounded. They consist of clear translucent protoplasm, in which fine interlacing filaments and minute granules are sometimes present; imbedded in this are one or two round nuclei, having the usual intranuclear networks. The cells are contained in cavities in the matrix, called *cartilage lacunæ*; around these the matrix is arranged in concentric lines, as if it had been formed in successive portions around the cartilage-cells. This constitutes the so-called *capsule* of the space. Each lacuna is generally occupied by a single cell, but during the division of the cells it may contain two, four, or eight cells.

The matrix is transparent and apparently without structure, or else presents a dimly granular appearance, like ground glass. Some observers have shown that the matrix of hyaline cartilage, and especially of the articular variety, after prolonged maceration, can be broken up into fine fibrils. These fibrils are probably of the same nature, chemically, as the white fibres of connective tissue. It is believed by some histologists that the matrix is permeated by a number of fine channels, which connect the lacunæ with each other, and that these canals communicate with the lymphatics of the perichondrium, and thus the structure is permeated by a current of nutrient fluid.

Fig. 28.—Vertical section of articular cartilage.

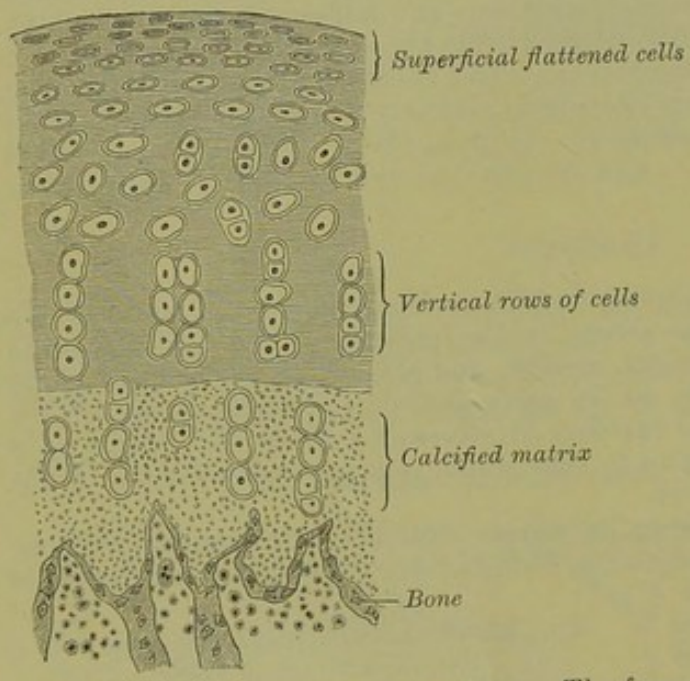

Articular cartilage, costal cartilage, and temporary cartilage are all of the hyaline variety. They present minute differences in the size and shape of their cells and in the arrangement of their matrices.

In **articular cartilage** (fig. 28), which shows no tendency to ossification, the matrix is finely granular; the cells and nuclei are small, and are disposed parallel to the surface in the superficial part, while nearer to the bone they become vertical. Articular cartilages have a tendency to split in a vertical direction; in disease this tendency becomes very manifest. The free surface of articular cartilage, where it is exposed to friction, is not covered by perichondrium, though a layer of connective tissue continuous with that of the synovial membrane can be traced in the adult over a small part of its circumference, and here the cartilage-cells are more or less branched and pass insensibly into the branched connective tissue corpuscles of the synovial membrane. Articular cartilage forms a thin incrustation upon the joint-surfaces of the bones, and its elasticity enables it to break the force of concussions, while its smoothness affords ease and freedom of movement. It varies in thickness according to the shape of the articular surface on which it lies; where this is convex the cartilage is thickest at the centre, the reverse being the case on concave articular surfaces. It appears to derive its nutriment partly from the vessels of the neighbouring synovial membrane and partly from those of the bone upon which it is implanted. Toynbee has shown that the minute vessels of the cancellous tissue as they approach the articular lamella dilate and form arches, and then return into the substance of the bone.

In **costal cartilage** the cells and nuclei are large, and the matrix has a tendency to fibrous striation, especially in old age (fig. 29). In the thickest parts of the costal cartilages a few large vascular channels may be detected. This appears, at first sight, to be an exception to the statement that cartilage is a non-vascular

tissue, but is not so really, for the vessels give no branches to the cartilage substance itself, and the channels may rather be looked upon as involutions of the perichondrium. The ensiform cartilage and the cartilages of the nose, larynx and trachea (except the epiglottis and cornicula laryngis, which are composed of elastic fibro-cartilage) resemble the costal cartilages in microscopical characters.

The hyaline cartilages, especially in adult and advanced life, are prone to calcify—that is to say, to have their matrix permeated by calcium salts without any appearance of true bone. The process of calcification occurs frequently, according to Rollett, in such cartilages as those of the trachea and in the costal cartilages, where it may be succeeded by conversion into true bone.

Fig. 29.—Costal cartilage from a man seventy-six years of age, showing the development of fibrous structure in the matrix. In several portions of the specimen two or three generations of cells are seen enclosed in a parent cell-wall. High power.

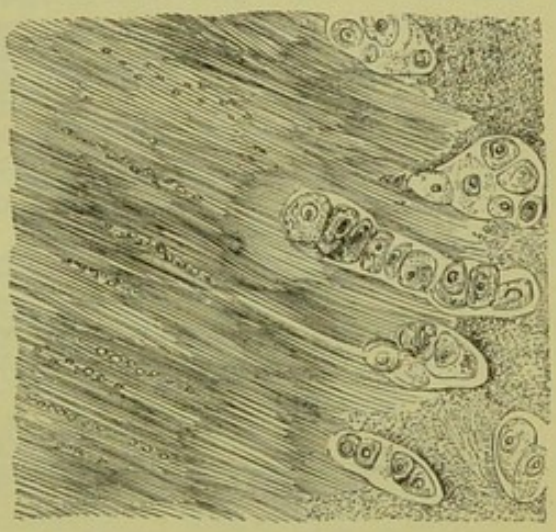

White fibro-cartilage consists of a mixture of white fibrous tissue and cartilaginous tissue in various proportions; to the former of these constituents it owes its flexibility and toughness, and to the latter its elasticity. When examined under the microscope it is found to be made up of fibrous connective tissue arranged in bundles, with cartilage-cells between the bundles; the cells to a certain extent resemble tendon-cells, but may be distinguished from them by being surrounded by a concentrically striated area of cartilage matrix and by being less flattened (fig. 30). The fibro-cartilages admit of arrangement into four groups—interarticular, connecting, circumferential, and stratiform.

1. The *interarticular fibro-cartilages* (*menisci*) are flattened fibro-cartilaginous plates, of a round, oval, triangular, or sickle-like form, interposed between the articular cartilages of certain joints. They are free on both surfaces, usually thinner towards the centre than at the circumference, and held in position by the attachment of their margins and extremities to the surrounding ligaments. The synovial membranes of the joints are prolonged over them. They are found in the temporo-mandibular, sterno-clavicular, acromio-clavicular, wrist- and knee-joints—i.e. in those joints which are most exposed to violent concussion and subject to frequent movement. Their uses are to obliterate the intervals between opposed surfaces in their various motions; to increase the depths of the articular surfaces and give ease to the gliding movements; to moderate the effects of great pressure and deaden the intensity of the shocks to which the parts may be subjected. Humphry has pointed out that these interarticular fibro-cartilages serve an important purpose in increasing the varieties of movement in a joint. Thus, in the knee-joint, there are two kinds of motion, viz. angular movement and rotation, although it is a hinge joint, in which, as a rule, only one variety of motion is permitted; the former movement takes place between the condyles of the femur and the interarticular cartilages, the latter between the cartilages and the head of the tibia. So, also, in the temporo-mandibular joint, the movements

Fig. 30.—White fibro-cartilage from an intervertebral disc.

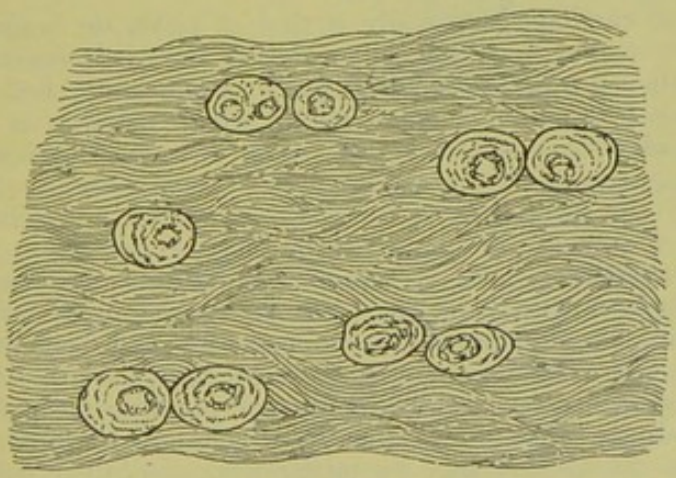

of opening and shutting the mouth take place between the fibro-cartilage and the mandible, the grinding movement between the glenoid cavity and the fibro-cartilage, the latter moving with the mandible.

2. The *connecting fibro-cartilages* are interposed between the bony surfaces of those joints which admit of only slight mobility, as between the bodies of the vertebræ. They form discs which are closely adherent to the opposed surfaces. Each disc is composed of concentric rings of fibrous tissue, with cartilaginous laminæ interposed, the former tissue predominating towards the circumference, the latter towards the centre.

3. The *circumferential fibro-cartilages* consist of rims of fibro-cartilage, which surround the margins of some of the articular cavities, e.g. the cotyloid ligament of the hip, and the glenoid ligament of the shoulder; they serve to deepen the articular cavities and to protect their edges.

Fig. 31.—Yellow cartilage, ear of horse. High power.

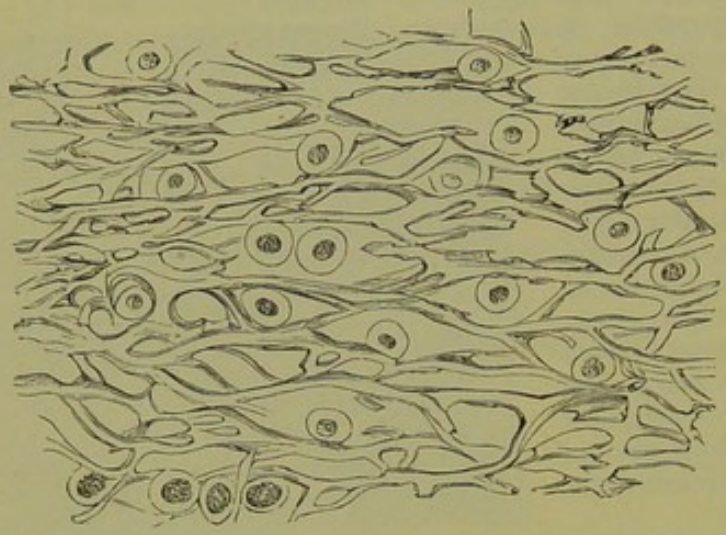

4. The *stratiform fibro-cartilages* are those which form a thin coating to osseous grooves through which the tendons of certain muscles glide. Small masses of fibro-cartilage are also developed in the tendons of some muscles, where they glide over bones, as in the tendons of the Peroneus longus and Tibialis posticus.

Yellow or elastic fibro-cartilage is found in the human body in the auricles of the external ears, the Eustachian tubes, the cornicula laryngis, and the epiglottis. It consists of cartilage-cells and a matrix, the latter being pervaded by a network of yellow elastic fibres, branching and anastomosing in all directions, except immediately around each cell, where there is a variable amount of non-fibrillated hyaline, intercellular substance (fig. 31). The fibres resemble those of yellow elastic tissue, both in appearance and in being unaffected by acetic acid; and according to Rollett their continuity with the elastic fibres of the neighbouring tissue is demonstrable. Not infrequently the base of the epiglottis is composed of a mixture of hyaline and elastic fibro-cartilage.

The distinguishing feature of cartilage chemically is that it yields on boiling a substance called *chondrin*, very similar to gelatin, but differing from it in several of its reactions. It is now believed that chondrin is not a simple body, but a mixture of gelatin with mucinoid substances, chief among which, perhaps, is a compound termed *chondro-mucoid*.

BONE

Structure and physical properties.—Bone is one of the hardest structures of the animal body; it possesses also a certain degree of toughness and elasticity. Its colour, in a fresh state, is pinkish white externally, and deep red within. On examining a section of any bone, it is seen to be composed of two kinds of tissue, one of which is dense in texture, like ivory, and is termed *compact tissue*; the other consists of slender fibres and lamellæ, which join to form a reticular structure; this, from its resemblance to lattice-work, is called *cancellous tissue*. The compact tissue is always placed on the exterior of the bone, the cancellous in the interior. The relative quantity of these two kinds of tissue varies in different bones, and in different parts of the same bone, according as strength or lightness is requisite. Close examination of the compact tissue shows it to be extremely porous, so that the difference in structure between it and the cancellous tissue depends merely upon the different amount of solid matter, and the size and number of spaces in each; the cavities are small in the compact

tissue and the solid matter between them abundant, while in the cancellous tissue the spaces are large and the solid matter is in smaller quantity.

Bone during life is permeated by vessels, and is enclosed, except where it is coated with articular cartilage, in a fibrous membrane, the *periosteum*, by means of which many of these vessels reach the hard tissue. If the periosteum be stripped from the surface of the living bone, small bleeding points are seen which mark the entrance of the periosteal vessels; and on section during life every part of the bone exudes blood from the minute vessels which ramify in it. The interior of each of the long bones of the limbs presents a cylindrical cavity filled with marrow and lined by a highly vascular areolar structure, called the *medullary membrane* or *internal periosteum*, which, however, is rather the areolar envelope of the cells of the marrow than a definite membrane.

The **periosteum** adheres to the surface of each of the bones in nearly every part, but not to cartilaginous extremities. When strong tendons or ligaments are attached to a bone, the periosteum is incorporated with them. It consists of two layers closely united together, the outer one formed chiefly of connective tissue, containing occasionally a few fat-cells; the inner one, of elastic fibres of the

FIG. 32.—Human bone-marrow. (Highly magnified.)

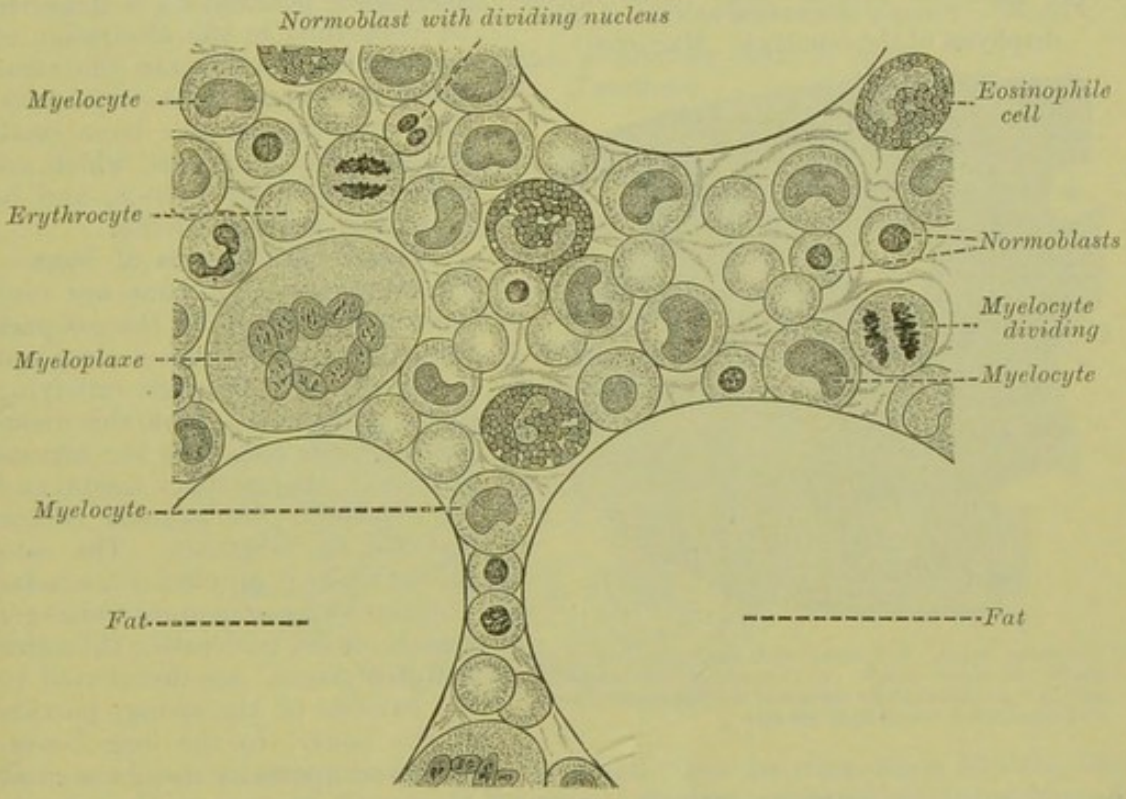

finer kind, forming dense membranous networks, which can be again separated into several layers. In young bones the periosteum is thick and very vascular, and is intimately connected at either end of the bone with the epiphysial cartilage, but less closely with the shaft, from which it is separated by a layer of soft tissue, containing a number of granular corpuscles or 'osteoblasts,' in which ossification proceeds on the exterior of the young bone. Later in life the periosteum is thinner, less vascular, and the osteoblasts are converted into an epithelioid layer on the deep surface of the periosteum. The periosteum serves as a nidus for the ramification of the vessels previous to their distribution in the bone; hence the liability of bone to exfoliation or necrosis, when denuded of this membrane by injury or disease. Fine nerves and lymphatics, which generally accompany the arteries, may also be demonstrated in the periostium.

The **marrow** not only fills up the cylindrical cavities in the shafts of the long bones, but also occupies the spaces of the cancellous tissue and extends into the larger bony canals (Haversian canals) which contain the blood-vessels. It differs in composition in different bones. In the shafts of the long bones the marrow is of a *yellow* colour, and contains, in 100 parts, 96 of fat, 1 of areolar tissue and vessels, and 3 of fluid with extractive matter; it consists of a basis of connective

tissue supporting numerous blood-vessels and cells, most of which are fat-cells, but some are 'marrow-cells,' such as occur in the red marrow to be immediately described. In the flat and short bones, in the articular ends of the long bones, in the bodies of the vertebræ, in the cranial diploë, and in the sternum and ribs, the marrow is of a *red* colour, and contains, in 100 parts, 75 of water, and 25 of solid matter consisting of cell-globulin, nucleo-protein, extractives, salts, and only a small proportion of fat. The red marrow consists of a small quantity of connective tissue, blood-vessels, and numerous cells (fig. 32), some few of which are fat-cells, but the great majority are roundish nucleated cells, the true 'marrow-cells' of Kölliker. These marrow-cells proper, or *myelocytes*, resemble in appearance lymphoid corpuscles, and like them are amœboid; they generally have a hyaline protoplasm, though some show granules either oxyphil or basophil in reaction. A number of eosinophil cells are also present. Among the marrow-cells may be seen smaller cells, which possess a slightly pinkish hue; these are the *erythroblasts* or *normoblasts*, from which, as we have seen, the red corpuscles of the adult are derived, and which may be regarded as descendants of the nucleated coloured corpuscles of the embryo. *Giant-cells* (*myeloplaxes*, *osteoclasts*), large, multinucleated, protoplasmic masses, are also to be found in both sorts of adult marrow, but more particularly in red marrow. They were believed by Kölliker to be concerned in the absorption of bone-matrix, and hence the name which he gave to them—*osteoclasts*. They excavate in the bone small shallow pits or cavities, which are named *Howship's lacunæ*, and in these they are found lying.

FIG. 33.—From a transverse section of the diaphysis of the humerus. Magnified.

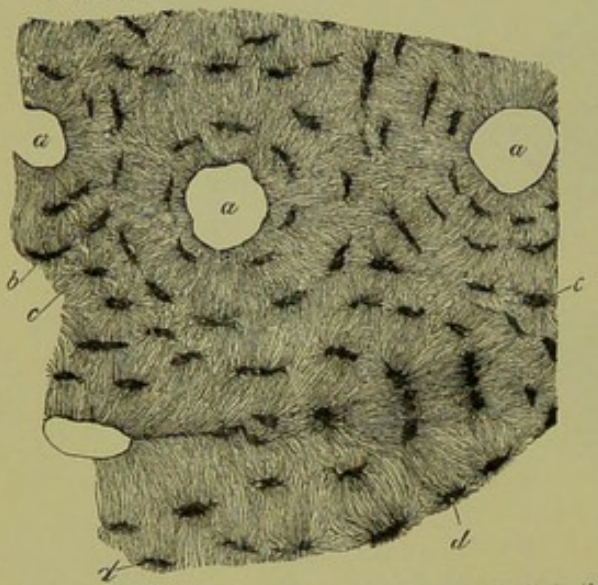

a. Haversian canals. *b*. Lacunæ, with their canaliculi, in the lamellæ of these canals. *c*. Lacunæ of the interstitial lamellæ. *d*. Others at the surface of the Haversian systems, with canaliculi given off from one side.

Vessels and nerves of bone.—The *blood-vessels* of bone are very numerous. Those of the compact tissue are derived from a close and dense network of vessels ramifying in the periosteum. From this membrane vessels pass into the minute orifices in the compact tissue, and run through the canals which traverse its substance. The cancellous tissue is supplied in a similar way, but by less numerous and larger vessels, which, perforating the outer compact tissue, are distributed to the cavities of the spongy portion of the bone. In the long bones, numerous apertures may be seen at the ends near the articular surfaces; some of these give passage to the arteries of the larger set of vessels referred to; but the most numerous and largest apertures are for the veins of the cancellous tissue, which emerge apart from the arteries. The medullary canal in the shaft of a long bone is supplied by one large artery (or sometimes more), which enters the bone at the nutrient foramen (situated in most cases near the centre of the shaft), and perforates obliquely the compact structure. The *medullary* or *nutrient* artery, usually accompanied by one or two veins, sends branches upwards and downwards, which ramify in the medullary membrane, and give twigs to the adjoining canals. The ramifications of this vessel anastomose with the arteries of the cancellous and compact tissues. In most of the flat, and in many of the short spongy bones, one or more large apertures are observed, which transmit, to the central parts of the bone, vessels corresponding to the medullary arteries and veins. The veins emerge from the long bones in three places (Kölliker)—(1) one or two large veins accompany the artery; (2) numerous large and small veins emerge at the articular extremities; (3) many small veins pass out of the compact substance. In the flat cranial bones the veins are large, very numerous, and run in tortuous canals in the diploic tissue, the sides of the canals being formed by thin lamellæ of bone, perforated here and there for the passage of branches from the adjacent cancelli. The same condition is also found in all cancellous

tissue, the veins being enclosed and supported by osseous structure, and having exceedingly thin coats. When the bony structure is divided, the vessels remain patulous, and do not contract in the canals in which they are contained. Hence the occurrence of purulent absorption after amputation, in those cases where the stump becomes inflamed and the cancellous tissue is infiltrated and bathed by pus. *Lymphatic vessels*, in addition to those found in the periosteum, have been traced by Cruikshank into the substance of bone, and Klein describes them as running in the Haversian canals. *Nerves* are distributed freely to the periosteum, and accompany the nutrient arteries into the interior of the bone. They are said by Kölliker to be most numerous in the articular extremities of the long bones, in the vertebræ, and in the larger flat bones.

Minute anatomy.—The intimate structure of bone, in all essential particulars identical in the compact and in the cancellous tissue, is most easily studied in a transverse section from the compact wall of one of the long bones after maceration (fig. 33).

If this be examined with a rather low power the bone will be seen to be mapped out into a number of circular districts each consisting of a central hole surrounded by a number of concentric rings. These districts are termed *Haversian systems*; the central hole is an *Haversian canal*, and the rings are layers of bone-tissue arranged concentrically around the central canal, and termed *lamellæ*. More-

FIG. 34.—Transverse section of compact tissue of bone. Magnified. (Sharpey.)

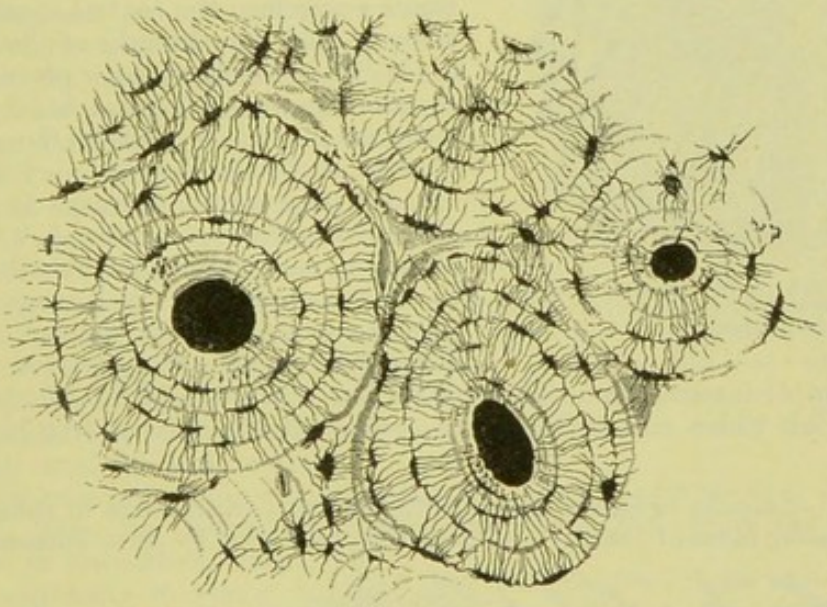

over, on closer examination, it will be found that between these lamellæ, and therefore also arranged concentrically around the central canal, are a number of little dark spots, the *lacunæ*, and that these lacunæ are connected with each other and with the central Haversian canal by a number of fine dark lines, which radiate like the spokes of a wheel and are called *canaliculi*. All these structures—the concentric lamellæ, the lacunæ, and the canaliculi—may be seen in any single Haversian system forming a circular district round a central Haversian canal. Filling in the irregular intervals which are left between these circular systems are other lamellæ, with their lacunæ and canaliculi running in various directions, but more or less curved (fig. 34). These are termed *interstitial* lamellæ. Again, other lamellæ, for the most part found on the surface of the bone, are arranged parallel to the circumference of the bone, constituting, as it were, a single Haversian system of the whole bone, of which the medullary cavity would represent the Haversian canal. These latter lamellæ are termed *circumferential*, or by some authors *primary* or *fundamental* lamellæ, to distinguish them from those laid down around the axes of the Haversian canals, which are then termed *secondary* or *special* lamellæ.

The *Haversian canals*, seen in a transverse section of bone as round holes at or about the centre of each Haversian system, may be demonstrated to be true canals, if a longitudinal section be made (fig. 35). It will then be seen that the

canals run parallel with the longitudinal axis of the bone for a short distance and then branch and communicate. They vary considerably in size, some being as much as $\frac{1}{200}$ of an inch in diameter; the average size is, however, about $\frac{1}{500}$ of an inch. Near the medullary cavity the canals are larger than those near the surface of the bone. Each canal contains one or two blood-vessels, with a small quantity of delicate connective tissue and some nerve filaments. In the larger ones there are also lymphatic vessels, and cells with branching processes which communicate, through the canaliculi, with the branched processes of certain bone cells in the substance of the bone. Those canals near the surface of the bone open upon it by minute orifices, and those near the medullary cavity open in the same way into this space, so that the whole of the bone is permeated by a system of blood-vessels running through the bony canals in the centres of the Haversian systems.

FIG. 35.—Section parallel to the surface from the shaft of the femur. Magnified 100 times.

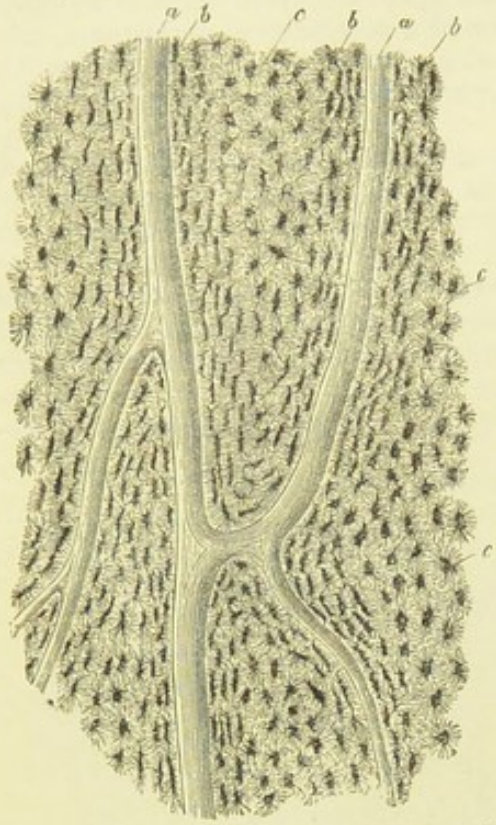

a. Haversian canals. *b*. Lacunæ seen from the side. *c*. Others seen from the surface in lamellæ which are cut horizontally.

The *lamellæ* are thin plates of bone-tissue encircling the central canal, and may be compared, for the sake of illustration, to a number of sheets of paper pasted one over another around a central hollow cylinder. After macerating a piece of bone in dilute mineral acid, these lamellæ may be stripped off in a longitudinal direction as thin films. If one of these be examined with a high power of the microscope, it will be found to be composed of a finely reticular structure, made up of very slender transparent fibres, decussating obliquely, and coalescing at the points of intersection. These fibres are composed of fine fibrils identical with those of white connective tissue. The intercellular matrix between the

FIG. 36.—Lamellæ torn from a decalcified human parietal bone to show the perforating fibres of Sharpey. (Copied from a drawing by Allen Thomson.)

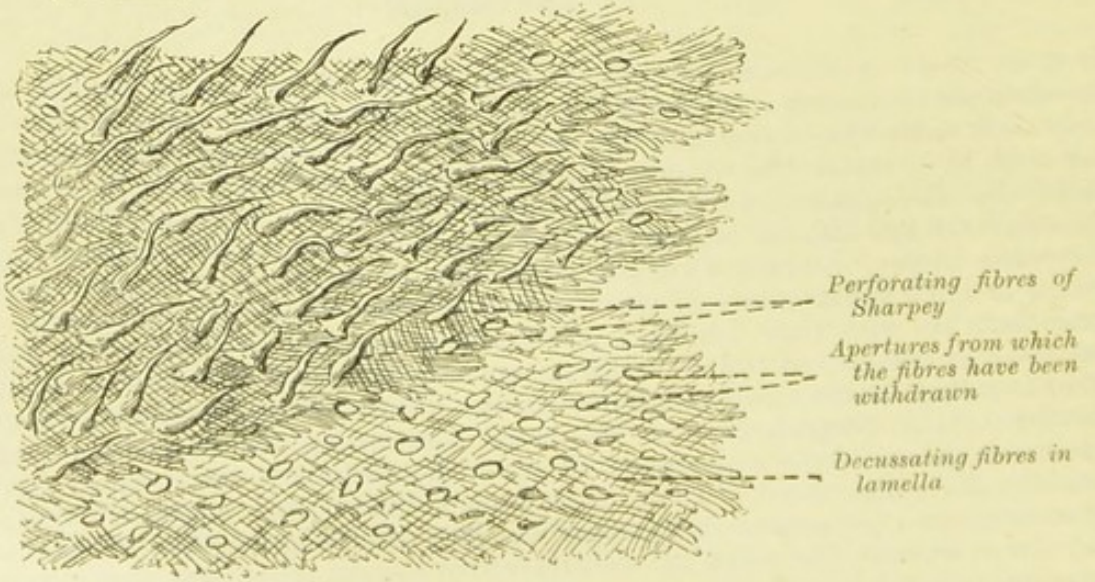

fibres is impregnated by calcareous deposit which the acid dissolves. In many places the various lamellæ may be seen to be held together by tapering fibres, which run obliquely through them, pinning or bolting them together.

These fibres were first described by Sharpey, and were named by him *perforating fibres* (fig. 36).

The *lacunæ* are situated between the lamellæ, and consist of a number of oblong spaces. In an ordinary microscopic section, viewed by transmitted light, they appear as dark, oblong, opaque spots, and were formerly believed to be solid cells. Subsequently, when it was seen that the Haversian canals were channels which lodged the vessels of the part, and the canaliculi minute tubes by which the plasma of the blood circulated through the tissue, the theory was formulated that the lacunæ were hollow spaces filled during life with the same fluid, and only lined (if lined at all) by a delicate membrane. But this view was eventually proved to be erroneous, for examination of the structure of recent bone led Virchow to believe that each lacuna is occupied during life by a branched cell, termed a bone-cell or bone-corpuscle, the processes from which pass down the canaliculi — a view which is now universally accepted (fig. 37). It is by means of these cells that the fluids necessary for nutrition are brought into contact with the ultimate tissue of bone.

Fig. 37.—Nucleated bone-cells and their processes, contained in the bone-lacunæ and their canaliculi respectively. From a section through the vertebra of an adult mouse. (Klein and Noble Smith.)

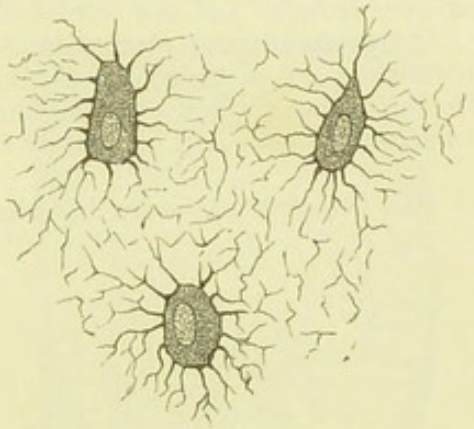

The *canaliculi* are exceedingly minute channels, which pass across the lamellæ and connect the lacunæ with neighbouring lacunæ and also with the Haversian canal. From the Haversian canal a number of canaliculi are given off, which radiate from it, and open into the first set of lacunæ between the first and second lamellæ. From these lacunæ a second set of canaliculi is given off, which passes outwards to the next series of lacunæ, and so on until the periphery of the Haversian system is reached; here the canaliculi given off from the last series of lacunæ do not communicate with the lacunæ of neighbouring Haversian systems, but after passing outwards for a short distance form loops and return to their own lacunæ. Thus every part of an Haversian system is supplied with nutrient fluids derived from the vessels in the Haversian canal and distributed through the canaliculi and lacunæ.

The *bone-cells* are contained in the lacunæ, which, however, they do not completely fill. They are flattened nucleated branched cells, which are homologous with those of connective tissue; the branches, especially in young bones, pass into the canaliculi from the lacunæ.

Fig. 38.—Section of bone after the removal of the earthy matter by the action of acids.

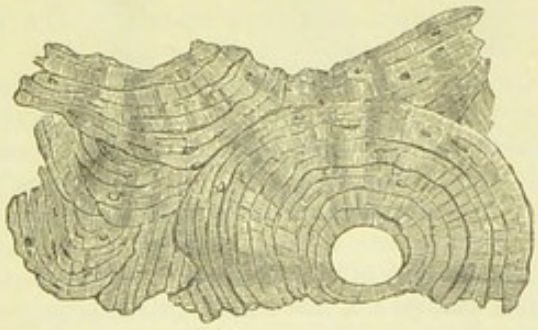

In a longitudinal section (fig. 35) the appearance of concentric rings is replaced by that of lamellæ or rows of lacunæ, parallel to the course of the Haversian canals, and these canals appear as half-tubes instead of circular spaces. The tubes are seen to branch and communicate, so that each separate Haversian canal runs only a short distance.

In thin plates of bone (as in the walls of the spaces which form the cancellous tissue) the Haversian canals are absent, and the canaliculi open into the spaces of the cancellous tissue (medullary spaces), which thus have the same function as the Haversian canals in the more compact bone.

Chemical composition.—Bone consists of an animal and an earthy part intimately combined together.

The animal part may be obtained by immersing a bone for a considerable time in dilute mineral acid, after which process the bone comes out exactly the

same shape as before, but perfectly flexible, so that a long bone (one of the ribs, for example) can easily be tied in a knot. If now a transverse section is made (fig. 38), the same general arrangement of the Haversian canals, lamellæ, lacunæ, and canaliculi, is seen, though not so plainly as in the ordinary section.

The earthy part may be separately obtained by calcination, by which the animal matter is completely burnt out. The bone will still retain its original form, but it will be white and brittle, will have lost about one-third of its original weight, and will crumble down with the slightest force. The earthy matter is composed chiefly of calcium phosphate, forming about 66·7 per cent. of the weight of the bone ; it confers on bone its hardness and rigidity, while the animal matter (*ossein*) determines its tenacity.

Development.—Some bones are preceded by membrane, such as those forming the roof and sides of the skull ; others, such as the bones of the limbs, are preceded by rods of cartilage. Hence two kinds of ossification are described : the *intramembranous* and the *intracartilaginous*.

Intramembranous ossification.—In the case of bones which are developed in membrane, no cartilaginous mould precedes the appearance of the bone tissue. The membrane which occupies the place of the future bone, is of the nature of connective tissue, and ultimately forms the periosteum ; it is composed of fibres

Fig. 39.—Part of the growing edge of the developing parietal bone of a fœtal cat. (After J. Lawrence.)

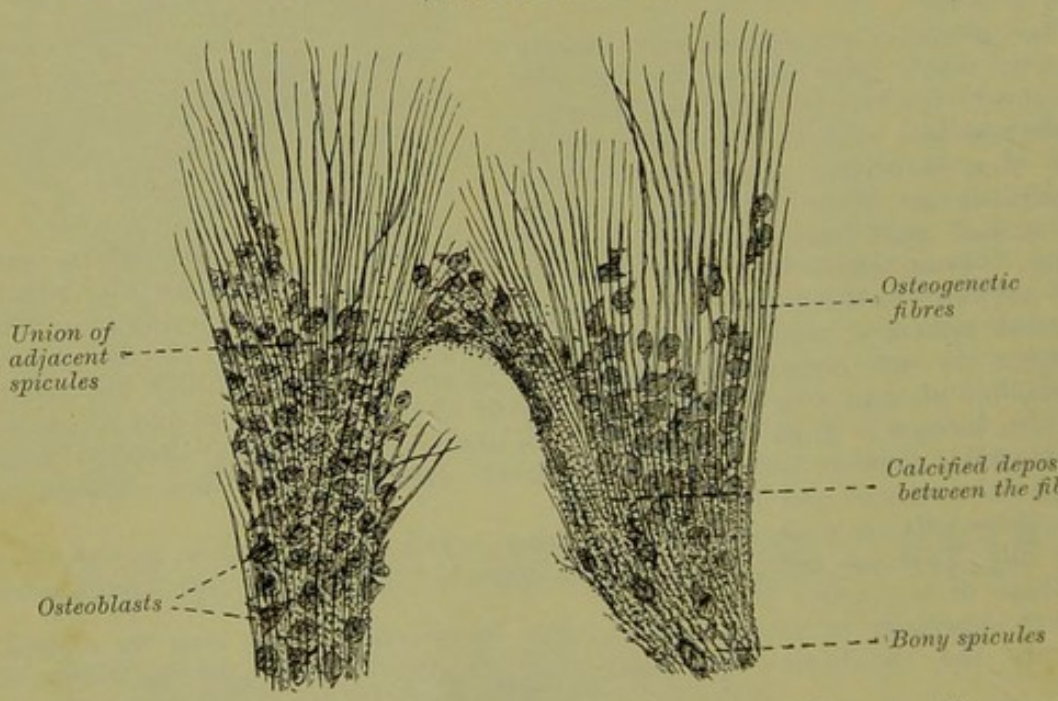

and granular cells in a matrix. The peripheral portion is more fibrous, while, in the interior the cells or *osteoblasts* predominate ; the whole tissue is richly supplied with blood-vessels. At the outset of the process of bone formation a little network of bony spicules is noticed radiating from the point or centre of ossification. These rays consist at their growing points of a network of fine clear fibres and granular corpuscles with an intervening ground substance (fig. 39). The fibres are termed *osteogenetic* fibres, and are made up of fine fibrils differing little from those of white fibrous tissue. Like them they are probably deposited in the matrix through the influence of the cells—in this case the osteoblasts. The membrane soon assumes a dark and granular appearance from the deposition of calcareous granules in the fibres and in the intervening matrix, and in the calcified material some of the granular corpuscles or osteoblasts are enclosed. By the fusion of the calcareous granules the tissue again assumes a more transparent appearance, but the fibres are no longer so distinctly seen. The involved osteoblasts form the corpuscles of the future bone, the spaces in which they are enclosed constituting the lacunæ. As the osteogenetic fibres grow out to the periphery they continue to calcify, and give rise to fresh bone spicules. Thus a network of bone is formed, the meshes of which contain the blood-vessels and a delicate connective tissue crowded with osteoblasts. The bony trabeculæ thicken by the addition of fresh

layers of bone formed by the osteoblasts on their surface, and the meshes are correspondingly encroached upon. Subsequently successive layers of bony tissue are deposited under the periosteum and round the larger vascular channels which become the Haversian canals, so that the bone increases much in thickness.

Intracartilaginous ossification.—Just before ossification begins the mass is entirely cartilaginous, and in a long bone, which may be taken as an example, the process commences in the centre and proceeds towards the extremities, which for some time remain cartilaginous. Subsequently a similar process commences in one or more places in those extremities and gradually extends through them. The extremities do not, however, become joined to the shaft by bony tissue until growth has ceased; between the shaft and either extremity a layer of cartilaginous tissue termed the *epiphysial cartilage* persists for a definite period.

FIG. 40.—Section of fœtal bone of cat.

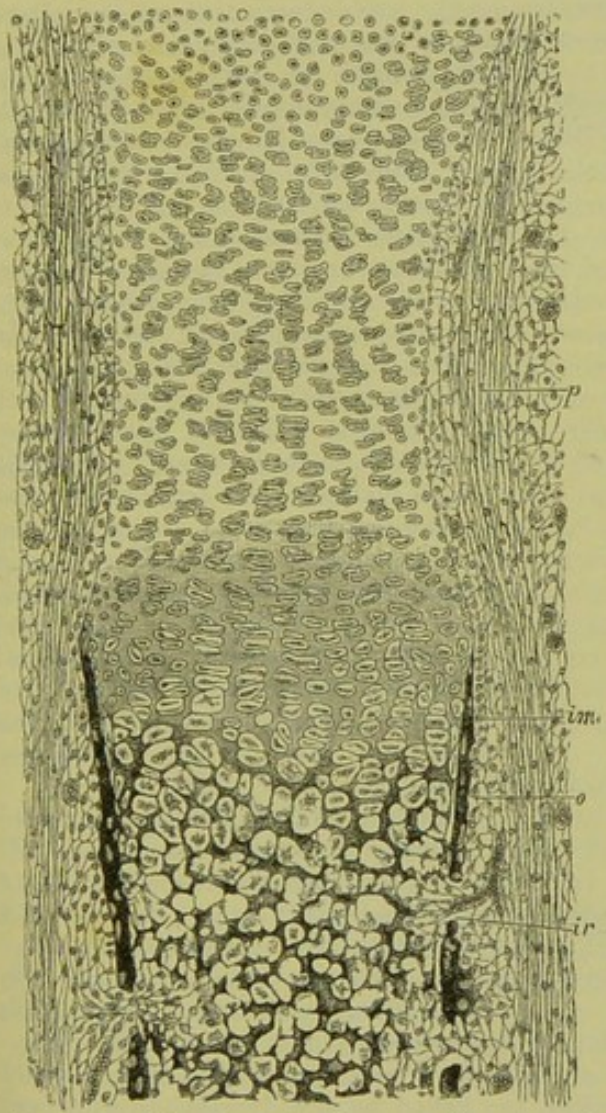

ir. Irruption of the subperiosteal tissue. *p*. Fibrous layer of the periosteum. *o*. Layer of osteoblasts. *im*. Subperiosteal bony deposit. (From Quain's 'Anatomy,' E. A. Schäfer.)

FIG. 41.—Part of a longitudinal section of the developing femur of a rabbit.

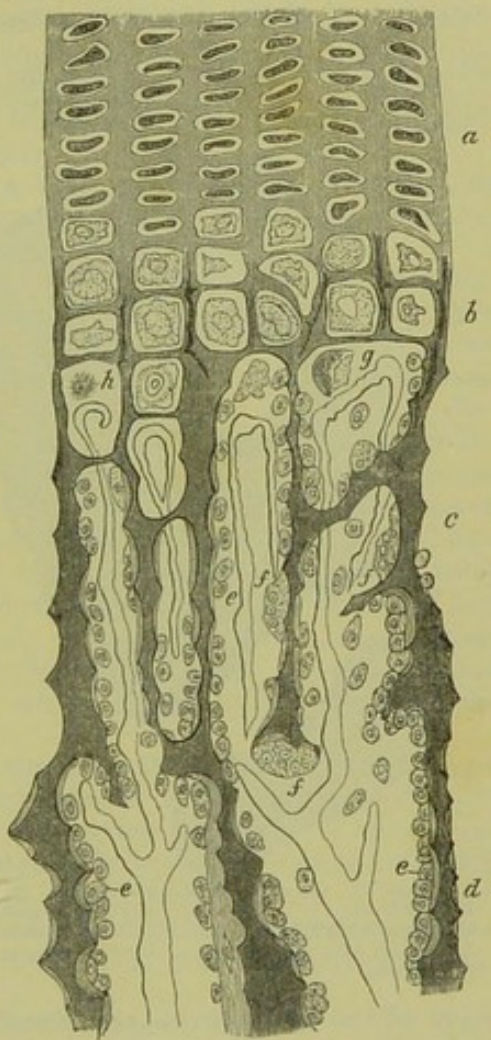

a. Flattened cartilage-cells. *b*. Enlarged cartilage-cells. *c*, *d*. Newly formed bone. *e*. Osteoblasts. *f*. Giant-cells or osteoclasts. *g*, *h*. Shrunken cartilage-cells. (From 'Atlas of Histology,' Klein and Noble Smith.)

The first step in the ossification of the cartilage is that the cartilage-cells, at the point where ossification is commencing and which is termed a *centre of ossification*,[b] enlarge and arrange themselves in rows (fig. 40). The matrix in which they are imbedded increases in quantity, so that the cells become further separated from each other. A deposit of calcareous material now takes place in this matrix, between the rows of cells, so that they become separated from each other by longitudinal columns of calcified matrix, presenting a granular and opaque appearance. Here and there the matrix between two cells of the same row also becomes calcified, and transverse bars of calcified substance stretch across from one calcareous column to another. Thus there are longitudinal groups of the cartilage-cells enclosed in oblong cavities, the walls of which are formed

of calcified matrix which cuts off all nutrition from the cells; the cells, in consequence, waste, leaving spaces called the *primary areolæ* (Sharpey).

At the same time that this process is going on in the centre of the solid bar of cartilage, certain changes are taking place on its surface. This is covered by a very vascular membrane, the *perichondrium*, entirely similar to the embryonic connective tissue already described as constituting the basis of membrane bone; on the inner surface of this—that is to say, on the surface in contact with the cartilage—are gathered the formative cells, the *osteoblasts*. By the agency of these cells a thin layer of bony tissue is formed between the perichondrium and the cartilage, by the *intramembranous* mode of ossification just described. There are then, in this first stage of ossification, two processes going on simultaneously: in the centre of the cartilage the formation of a number of oblong spaces, formed of calcified matrix and containing the withered cartilage-cells, and on the surface of the cartilage the formation of a layer of true membrane-bone. The second stage consists in the prolongation into the cartilage of processes of the deeper or osteogenetic layer of the perichondrium, which has now become periosteum (fig. 40, *ir*). The processes consist of blood-vessels and cells—*osteoblasts*, or bone-formers, and *osteoclasts*, or bone-destroyers. The latter are similar to the giant-cells (myeloplaxes) found in marrow, and they excavate passages through the new-formed bony layer by absorption, and pass through it into the calcified matrix (fig. 40). Wherever these processes come in contact with the calcified walls of the primary areolæ they absorb them, and thus cause a fusion of the original cavities and the formation of larger spaces, which are termed the *secondary areolæ* (Sharpey) or *medullary spaces* (Müller). These secondary spaces become filled with embryonic marrow, consisting of osteoblasts and vessels, derived, in the manner described above, from the osteogenetic layer of the periosteum (fig. 41).

FIG. 42.—Transverse section from the femur of a human embryo about eleven weeks old.

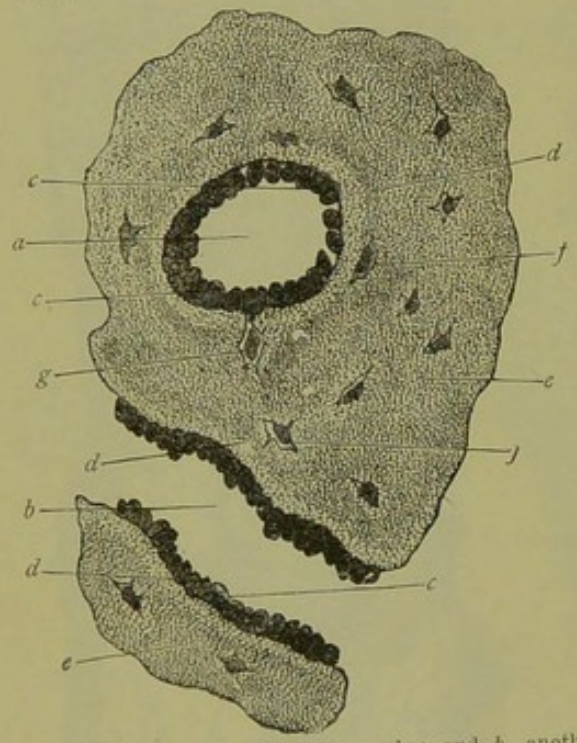

a, A medullary space cut transversely; and *b*, another longitudinally. *c*, Osteoblasts. *d*, Newly formed osseous substance of a lighter colour. *e*, That of greater age. *f*, Lacunæ with their cells. *g*, A cell still united to an osteoblast.

Thus far there has been traced the formation of enlarged spaces (secondary areolæ), the perforated walls of which are still formed by calcified cartilage-matrix, containing an embryonic marrow derived from the processes sent in from the osteogenetic layer of the periosteum, and consisting of blood-vessels and round cells, osteoblasts (fig. 41). The walls of these secondary areolæ are at this time of only inconsiderable thickness, but they become thickened by the deposition of layers of new bone on their interior. This process takes place in the following manner. Some of the osteoblasts of the embryonic marrow, after undergoing rapid division, arrange themselves as an epithelioid layer on the surface of the wall of the space (fig. 42). This layer of osteoblasts forms a bony stratum, and thus the wall of the space becomes gradually covered with a layer of true osseous substance. On this a second layer of osteoblasts is arranged, and in its turn forms an osseous layer. By the repetition of this process the original cavity becomes very much reduced in size, and at last only remains as a small tube in the centre, containing the remains of the embryonic marrow—that is, a blood-vessel and a few osteoblasts. This small cavity constitutes the Haversian canal of the completely ossified bone. The successive layers of osseous matter encircling this central canal constitute the lamellæ of which each Haversian system is made up. As the successive layers of osteoblasts form osseous tissue, certain of the osteoblastic cells remain included between the various bony layers. These persist as

the cells of the future bone, the spaces enclosing them forming the lacunæ (fig. 41). The canaliculi, at first extremely short, are supposed to be extended by absorption, so as to meet those of neighbouring lacunæ.

Such are the changes which may be observed at one particular point, the centre of ossification. While they have been going on a similar process has been set up in the surrounding parts and has been gradually proceeding towards the ends of the shaft, so that in the ossifying bone all the changes described above may be seen in different parts, from the true bone in the centre of the shaft to the hyaline cartilage at the extremities. The bone thus formed differs from the bone of the adult in being more spongy and less regularly lamellated.

The shaft of the bone is at first solid, but a tube is hollowed out in it by absorption around the vessels passing into it, and this becomes the medullary canal. This absorption is supposed to be brought about by large giant-cells, the so-called osteoclasts of Kölliker (fig. 41, *f*). They vary in shape and size, and contain a large number of clear nuclei, sometimes as many as twenty. The occurrence of similar cells in some tumours of bones has led to such tumours being denominated 'myeloid.' The absorption of bone from the interior to form the medullary canal is progressive, and is accompanied by a progressive deposition of bone on the exterior from the periosteum, until the bone has attained the shape and size which it is destined to retain during adult life.

While the ossification of the cartilaginous shaft is extending towards the articular ends, the cartilage immediately in advance of the osseous tissue continues to grow until the length of the adult bone is reached.

During the period of growth the articular end, or epiphysis, remains for some time entirely cartilaginous, then a bony centre appears, and initiates in it the same process of intracartilaginous ossification; but this process never extends to any great distance. The epiphysis remains separated from the shaft by a narrow cartilaginous layer for a definite time. This layer ultimately ossifies, the distinction between shaft and epiphysis is obliterated, and the bone assumes its completed form and shape. The same remarks also apply to such processes of bone as are separately ossified, e.g. the trochanters of the femur. The bones therefore continue to grow until the body has acquired its full stature. They increase in length by ossification continuing to extend behind the epiphysial cartilage, which goes on growing in advance of the ossifying process. They increase in circumference by deposition of new bone, from the deeper layer of the periosteum, on their external surface, and at the same time an absorption takes place from within, by which the medullary cavities are increased.

The medullary spaces which characterise the cancellous tissue are produced by the absorption of the original fœtal bone in a manner similar to that by which the original medullary canal is formed. The distinction between the cancellous and the compact tissue appears to depend essentially upon the extent to which this process of absorption has been carried. In some morbid states of the bone inflammatory absorption produces exactly the same change, and converts portions of bone, naturally compact, into cancellous tissue; in other pathological conditions denser bone may be formed.

The number of ossific centres varies in different bones. In most of the short bones ossification commences by a single point near the centre, and proceeds towards the surface. In the long bones there is a central point of ossification for the shaft or diaphysis: and one or more for each extremity, the epiphysis. That for the shaft is the first to appear. The times of union of the epiphyses with the shaft vary inversely with the times at which their ossifications began (with the exception of the fibula) and regulate the direction of the nutrient arteries of the bones. Thus, the nutrient arteries of the bones of the arm and forearm are directed towards the elbow, since the epiphyses at this joint become united to the shafts before those at the opposite extremities. In the lower limb, on the other hand, the nutrient arteries are directed away from the knee: that is, upwards in the femur, downwards in the tibia and fibula; and in them it is observed that the upper epiphysis of the femur, and the lower epiphyses of the tibia and fibula, become first united to the shafts.

Where there is only one epiphysis, the medullary artery is directed towards the other end of the bone; as towards the acromial end of the clavicle, towards the distal ends of the metacarpal bone of the thumb and the metatarsal bone

of the great toe, and towards the proximal ends of the other metacarpal and metatarsal bones.

Besides these epiphyses for the articular ends, there are others for projecting parts or processes, which are formed separately from the bulk of the bone. For an account of these the reader is referred to the description of the individual bones.

Parsons (*Journal of Anatomy and Physiology*, vol. xxxviii.) groups epiphyses under three headings, viz. (1) *pressure epiphyses*, appearing at the articular ends of the bones and transmitting 'the weight of the body from bone to bone'; (2) *traction epiphyses*, associated with the insertion of muscles; and (3) *atavistic epiphyses*, representing parts of the skeleton which at one time formed separate bones, but which have lost their function 'and only appear as separate ossifications in early life.'

Applied Anatomy.—It has been stated above that the bones increase firstly *in length* by ossification continuing to extend in the epiphysial cartilage, which goes on growing in advance of the ossifying process; and secondly *in circumference* by deposition of new bone from the deeper layer of the periosteum, on the external surface. A thorough realisation of these facts is essential to the student, when he comes to consider the various pathological changes which affect bone. Anything which interferes with the growth at the epiphysial line will lead to a diminution in the length which the bone should attain in adult life, and similarly anything which interferes with the growth from the deeper layer of the periosteum will result in a disproportion in the thickness of the bone. Thus separation of the epiphysis, septic or tuberculous disease about the epiphysial line, and excisions involving the epiphysial line, will result in varying amounts of shortening of the bone, as compared with that of the opposite side; whereas separation or imperfect nutrition of the periosteum results in defective growth in circumference.

It is thus obvious that a careful study of osseous development is of the very greatest utility in the proper understanding of bone disease; and, moreover, an accurate knowledge of the blood supply of a long bone has also many important bearings. The outer portion of the compact tissue being supplied by periosteal vessels, which reach the bone through muscular attachments, it follows that where the muscular structures are well developed, and therefore amply supplied with blood, the periosteum will also be well nourished and the bones proportionately well developed in girth; this is well seen in strong muscular men with well-marked ridges on the bones. Conversely, if the muscular development be poor, the bones are correspondingly thin and light, and if from any cause a limb has been paralysed from early childhood, the whole of the bones of that extremity are remarkable for their extreme thinness—that is to say, the periosteal blood supply has been insufficient to nourish that membrane, and consequently very little fresh osseous tissue has been added to the bones from the outside.

The best example of this condition is seen in connection with the disease known as *infantile paralysis*, where a limb becomes paralysed at a very early period of childhood, where the muscles become flaccid and atonic, and where the blood supply is in consequence very greatly diminished. In such cases, although the limb does continue to grow in length from the epiphysial lines, its length is considerably less than on the normal side, owing to the imperfect nutrition; but the most striking feature about all the long bones of the limb is their remarkable tenuity, little or no addition having been made to their circumferences.

In cases where the periosteum has been separated from the compact tissue by extensive injury or inflammatory exudation, necrosis or death of the underlying portion of bone takes place owing to its blood supply having been cut off, and the dead portion or *sequestrum* has to be subsequently separated and cast off.

Cases, however, occur where the inflammatory process affects the whole or a great portion of the diaphysis of a long bone, and here extensive death of the affected portion takes place, and the condition goes by the name of *acute infective periostitis*. Where this occurs the shaft of the bone dies very rapidly, especially if the single nutrient artery be thrombosed at the same time. The pus which has formed beneath the periosteum is set free by timely incision, or bursts on the surface; the periosteum then falls back on the necrosed diaphysis and rapidly forms a layer of new periosteal bone, surrounding the sequestrum. This layer is called the *involucrum*, and the openings in it through which the pus escapes the *cloacæ*. When the inflammatory process affects mainly the medullary canal, the condition is spoken of as *osteo-myelitis*, and the two conditions very frequently co-exist, and then go by the name of *acute infective necrosis of bone* or *acute diaphysitis*. When the medullary cavity is filled with pus, septic thrombosis of the veins in the Haversian canals takes place, and there is a very great danger of septic emboli being displaced and carried into the general circulation, thus setting up a fatal *pyæmia*. In fact, pyæmia is more frequently due to septic bone conditions than to any other cause.

In the pre-antiseptic days, pyæmia frequently resulted from amputations, where the medullary canal of a long bone was opened by the saw cut. Osteo-myelitis ensued

and if the patient survived, a tubular sequestrum of the divided shaft subsequently separated.

A proper understanding of the epiphyses is of the utmost possible importance to the student, and greatly simplifies many of the problems in the pathology of bone disease.

Speaking generally, the long bones have at either end an epiphysis from the cartilage of which growth occurs, and hence the shaft of the bone increases in length from both ends. In every case, however, one epiphysis is the more active, and also continues in its activity for a longer time. This *actively growing epiphysis* is always the one from which the nutrient foramen in the diaphysis points, and it unites to the shaft at a later date. It follows, therefore, that the increase in length of a long bone is largely dependent on this epiphysis, and hence anything which interferes with the growth from this epiphysial line at any time prior to the union of the epiphysis with the shaft must result in a cessation of growth in length of that bone. Thus when dealing with disease in the neighbourhood of this actively growing epiphysis very great care should be taken not to excise or destroy its line of union with the shaft. These epiphyses are particularly prone to become the seat of tuberculous disease, which especially tends to attack the soft, highly vascular cancellous tissue.

Again, the actively growing epiphysial line is the portion of a long bone which is in the vast majority of cases affected by tumour growth in bone, whether it be innocent or malignant, the former (viz. osteoma) usually appearing about puberty, and the latter (viz. sarcoma) usually towards the end of the active period of epiphysial growth.

Epiphysial growth, moreover, has to be considered by the surgeon when he is about to amputate in a child. If the amputation is being performed through a bone, the actively growing epiphysis of which is at the upper end, and which will continue to grow for many years (i.e. humerus and tibia), it will be necessary to make allowance for this and to cut the flaps long ; as otherwise, owing to continued growth, the sawn end of the bone will ultimately project through the stump, and a condition known as '*conical stump*' will result. This requires removal of a further portion of the bone.

An inflammatory condition termed *acute epiphysitis* also occurs, although it is not so frequent as the acute infective conditions of the diaphysis, owing to the freer blood supply of the epiphysis ; in late years it has been shown that acute epiphysitis in children is very frequently the result of a pneumococcal infection, and it may pass on to complete separation of the epiphysis. In this connection it is worthy of note that some of the epiphysial lines lie entirely within the capsules of their corresponding joints, in other cases entirely without the capsules ; and it must follow that in the former case epiphysial disease, acute or chronic, becomes, *ipso facto*, practically synonymous with disease of that joint. The best examples of intra-articular epiphyses are those for the head of the femur and head of the humerus, and the vast majority of all cases of tuberculous disease of the hip start as a tuberculous epiphysitis about the intra-articular epiphysial line of the femur ; again cases of acute septic arthritis of the shoulder or hip joints generally have their origins in these intra-articular epiphysial lines, and often result in separation of the affected epiphysis. The other class, or extra-articular epiphyses, when diseased, do not tend to involve the neighbouring joint so readily ; and it should be the surgeon's duty to keep the disease from involving the joint. For example, the trochanteric epiphysis of the femur is extra-articular as regards the hip joint, and the epiphysial line of the head of the tibia is well below the level of the knee joint, and should a chronic tuberculous abscess form in the latter situation, it should be attacked from the outside before it has time to spread up and involve the cartilage of the head of the tibia. It is therefore of great surgical interest to note in every case the relations which the various epiphysial lines bear to their respective joint capsules.

A knowledge of the exact periods when the epiphyses become joined to the shaft is often of great importance in medico-legal inquiries. It also aids the surgeon in the diagnosis of many of the injuries to which the joints are liable ; for it not infrequently happens that, on the application of severe force to a joint, the epiphysis becomes separated from the shaft, and such injuries may be mistaken for fracture or dislocation.

PIGMENT

In various parts of the body **pigment** is found ; most frequently in epithelial cells and in the cells of connective tissue. Pigmented *epithelial cells* are found in the external layer of the retina, on the posterior surface of the iris, in the olfactory region of the nose, and in the membranous labyrinth of the ear. Pigment is likewise found in the cells of the deeper layers of the cuticle and in the hairs ; in the skin of the coloured races it is abundantly present, but in the white races it is well marked only in the areolæ round the nipples and in irregular coloured patches.

In the *connective-tissue cells* pigment is frequently met with in the lower vertebrates. In man it is found in the choroid coat of the eye (fig. 43), and

in the iris of all but the light blue eyes and the albino. It is also occasionally met with in the cells of retiform tissue and in the pia mater of the upper part of the spinal cord. The cells are characterised by their large size and by branched processes, which are also filled with granules. The processes of the cells can be withdrawn or protruded under the influence of light. In the retina the cells themselves are also capable of movement in order to protect the delicate rods and cones. The pigment (*melanin*) consists of dark brown or black granules of very small size closely packed together within the cells, but not invading the nucleus. Occasionally the pigment is yellow, and when occurring in the cells of the cuticle constitutes 'freckles.' In the retina another variety of pigment occurs, known as *rhodopsin* or *visual purple*, which on exposure to light is bleached.

FIG. 43.—Pigment-cells from the choroid coat of the eyeball.

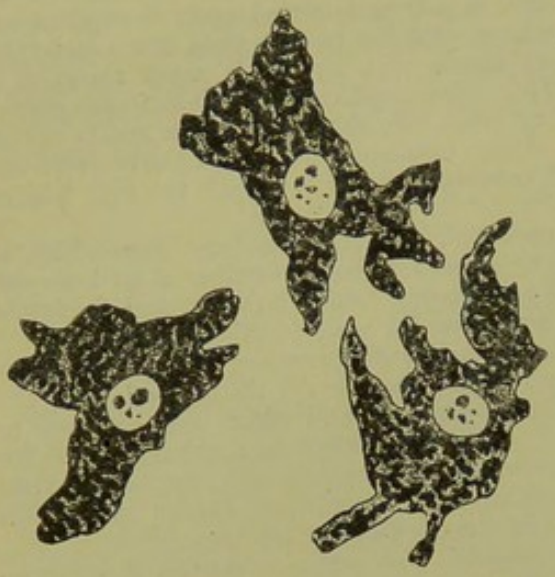

Applied Anatomy.—Abnormal pigmentation of the skin may be congenital, when it often takes the form of dark brown or black nævi (moles), scattered over a greater or smaller area of the body. It may also result from the prolonged consumption of various drugs, particularly of salts of silver or arsenic, being most marked wherever the skin is exposed to the action of light. Progressive darkening or bronzing of the skin is also highly suggestive of Addison's disease, which commonly follows destruction or tuberculosis of the suprarenal glands: it is then most obvious in regions where the skin is normally pigmented, or is subjected to pressure or irritation from the clothes. Pigmentation is also associated with certain disorders of the skin, the female genitalia, and the thyroid gland, and with the later stages of wasting diseases such as cancer and phthisis. It does not yield to any medical treatment as a rule.

MUSCULAR TISSUE

The **muscles** are formed of bundles of reddish fibres, endowed with the property of contractility. There are two principal kinds of muscular tissue. One of these, from the characteristic appearances which its fibres exhibit under the microscope, is known as 'striped' muscle, and, from the fact that it is capable of being put into action and controlled by the will, as 'voluntary' muscle. The fibres of the other kind do not present any cross-striped appearance, and for the most part are not under the control of the will; hence they are known as the 'unstriped' or 'involuntary' muscles. The muscular fibres of the heart differ in certain particulars from both these groups, and they are therefore separately described as 'cardiac' muscular fibres.

It is customary therefore to define three varieties of muscular fibres: (1) transversely striated muscular fibres, which are for the most part under the control of the will, although some are not so, such as the muscles of the pharynx and upper part of the œsophagus. This variety of muscle is sometimes called *skeletal*; (2) transversely striated cardiac muscular fibres, which are not under the control of the will; (3) plain or unstriped muscular fibres, which are involuntary and controlled by a different part of the nervous system from that which controls the activity of the voluntary muscles. Such are the muscular walls of the stomach and intestine, of the uterus and bladder, of the blood-vessels, &c.

Striped or voluntary muscle is composed of bundles of fibres each enclosed in a delicate web called the *perimysium* in contradistinction to the sheath of areolar tissue which invests the entire muscle, the *epimysium* (fig. 44). The bundles are termed *fasciculi*; they are prismatic in shape, of different sizes in different muscles, and are for the most part placed parallel to one another, though they have a tendency to converge towards their tendinous attachments. Each fasciculus is made up of a strand of *fibres*, which also run parallel with each other, and which are separated from one another by a delicate connective tissue derived

from the perimysium and termed *endomysium*. This does not form the sheath of the fibres, but serves to support the blood-vessels and nerves ramifying between them. The fibres are enclosed in separate and distinct sheaths of their own, but these are not areolar tissue, and therefore not derived from the perimysium.

A *muscular fibre* may be said to consist of a soft contractile substance, enclosed in a tubular sheath named by Bowman the *sarcolemma*. The fibres are cylindrical or prismatic in shape, and are of no great length, not exceeding, it is said, an inch and a half. They end either by blending with the tendon or aponeurosis, or else by rounded or tapering extremities which are connected to the neighbouring fibres by means of the sarcolemma. Their breadth varies in man from $\frac{1}{200}$ to $\frac{1}{600}$ of an inch. As a rule, the fibres do not divide or anastomose; but occasionally, especially in the tongue and facial muscles, they may be seen to divide into several branches. The precise mode in which the muscular fibre joins the tendon has been variously described by different observers. It may, perhaps, be sufficient to say that the sarcolemma appears to blend with a small bundle of fibres, into which the tendon becomes subdivided, while the muscular substance terminates abruptly and can be readily made to retract from the point of junction. The areolar tissue between the fibres appears to be prolonged more or less into the tendon, so as to form a kind of sheath around the tendon bundles for a longer or shorter distance. When muscular fibres are attached to skin or

FIG. 44. — Transverse section from the sterno-mastoid in man. Magnified 50 times.

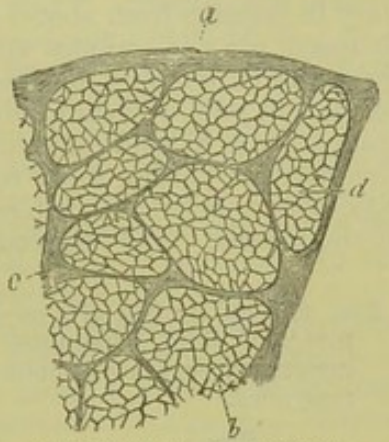

a. Epimysium. *b*. Fasciculus. *c*. Perimysium. *d*. Fibre.

FIG. 45.—Two human muscular fibres. Magnified 350 times.

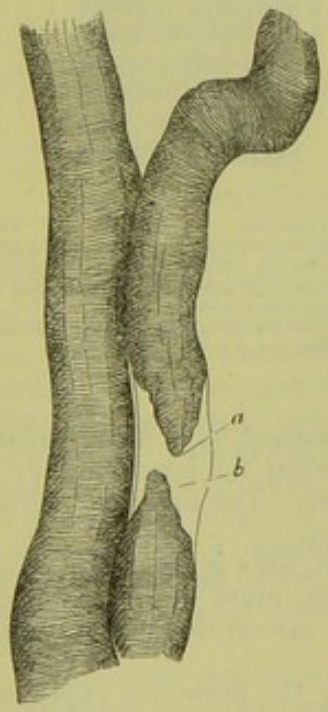

In the one, the bundle of fibrillæ (*a*) is torn, and the sarcolemma (*b*) is seen as an empty tube.

FIG. 46.—Fragments of striped muscular fibres, showing a double cleavage. Magnified 300 diameters.

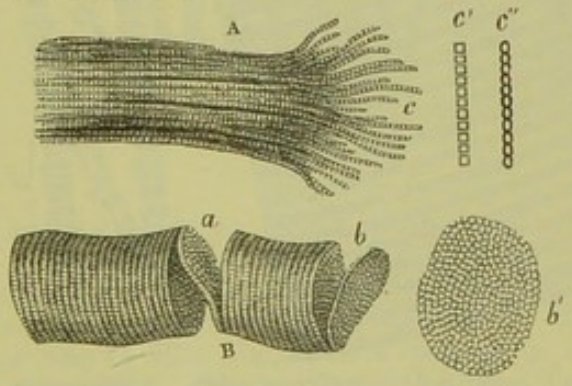

A. Longitudinal cleavage. The longitudinal and transverse lines are both seen. Some longitudinal lines are darker and wider than the rest, and are not continuous from end to end. This results from partial separation of the fibrillæ. *c*. Fibrillæ separated from one another by violence at the broken end of the fibre, and marked by transverse lines equal in width to those on the fibre. *c' c''* represent two appearances commonly presented by the separated single fibrillæ (more highly magnified). At *c'* the borders and transverse lines are all perfectly rectilinear, and the included spaces perfectly rectangular. At *c''* the borders are scalloped and the spaces bead-like. When most distinct and definite the fibrilla presents the former of these appearances.

B. Transverse cleavage. The longitudinal lines are scarcely visible. *a*. Incomplete fracture following the opposite surfaces of a disc, which stretches across the interval, and retains the two fragments in connection. The edge and surfaces of this disc are seen to be minutely granular, the granules corresponding in size to the thickness of the disc, and to the distance between the faint longitudinal lines. *b*. Another disc nearly detached. *b'*. Detached disc, more highly magnified, showing the sarcous elements.

mucous membranes, their fibres are described by Hyde Salter as becoming continuous with those of the areolar tissue.

The *sarcolemma*, or tubular sheath of the fibre, is a transparent, elastic, and apparently homogeneous membrane of considerable toughness, so that it sometimes

remains entire when the included substance is ruptured (fig. 45). On the internal surface of the sarcolemma in mammalia, and also in the substance of the fibre in the lower animals, elongated nuclei are seen, and in connection with these a row of granules, apparently fatty, is sometimes observed.

Upon examination of a voluntary muscular fibre by transmitted light, it is found to be marked by alternate light and dark bands or striæ, which pass transversely, or somewhat obliquely, round the fibre (fig. 47). The dark and light bands are of nearly equal breadth, and alternate with great regularity. They vary in breadth from about $\frac{1}{1200}$ to $\frac{1}{1700}$ of an inch. If the surface be carefully focussed, rows of granules will be detected at the points of junction of the dark and light bands, and very fine longitudinal lines may be seen running through the dark bands and joining these granules together. By treating the specimen with certain reagents (e.g. chloride of gold) fine lines may be seen running transversely between the granules uniting them together. This appearance is believed to be due to a reticulum or network of interstitial substance lying between the contractile portions of the muscle. The longitudinal striation gives the fibre the appearance of being

Fig. 47.—A. Portion of a medium-sized human muscular fibre. Magnified nearly 800 diameters. B. Separated bundles of fibrils, equally magnified.

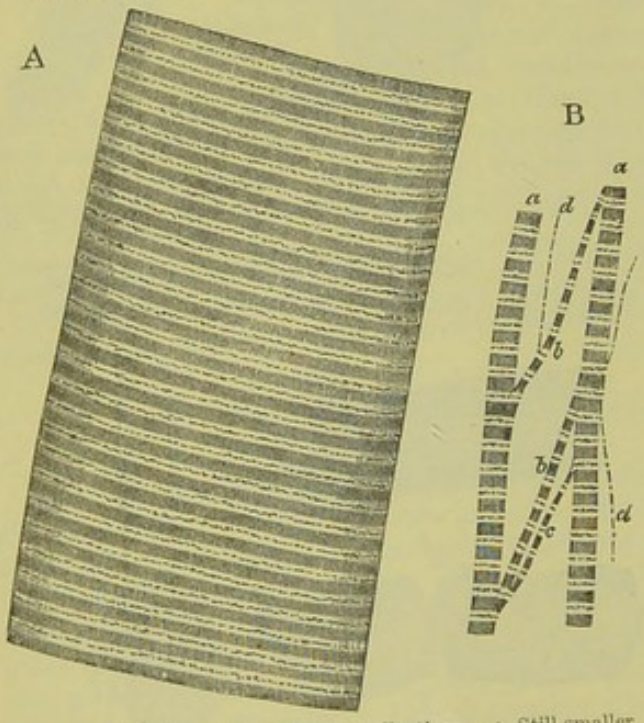

a, *a*. Larger, and *b*, *b*, smaller collections. *c*. Still smaller. *d*, *d*. The smallest which could be detected.

Fig. 48.—Part of a striped muscular fibre of the water-beetle, prepared with absolute alcohol. Magnified 300 diameters. (Klein and Noble Smith.)



a. Sarcolemma. *b*. Membrane of Krause: owing to contraction during hardening, the sarcolemma shows regular bulgings. At the side of Krause's membrane is the transparent lateral disc.
Several nuclei of muscle-corpuscles are shown, and in them a minute network.

made up of a bundle of fibrils, which have been termed *sarcostyles* or *muscle columns*, and if the fibre be hardened in alcohol, it can be broken up longitudinally and the sarcostyles separated from each other (fig. 46, A). The reticulum, with its longitudinal and transverse meshes, is called *sarcoplasm*.

If now a transverse section be made, the muscular fibre is seen to be divided into a number of areas, called the *areas of Cohnheim*, more or less polyhedral in shape and consisting of the transversely divided sarcostyles, surrounded by transparent series of sarcoplasm (fig. 46, B, *b'*).

Upon closer examination, and by somewhat altering the focus, the appearances become more complicated, and are susceptible of various interpretations. The transverse striation, which in figs. 45 and 46 appears as a mere alternation of dark and light bands, is resolved into the appearance seen in fig. 47, which shows a series of broad dark bands, separated by light bands, each of which is divided into two by a dark dotted line. This line is termed *Dobie's line* or *Krause's membrane* (fig. 49, *k*), because it was believed by Krause to be an actual membrane, continuous with the sarcolemma, and dividing the light band into two compartments. It is now more usually regarded as being due to the light being

refracted between discs of different refrangibility. In addition to the membrane of Krause, fine clear lines may be made out, with a sufficiently high power, crossing the centre of the dark band ; these are known as the *lines of Hensen* (fig. 49, H).

Formerly it was supposed by Bowman that a muscular fibre was made up of a number of quadrangular particles, which he named sarcous elements, joined together like so many bricks forming a column, and he came to this conclusion because he found that under the influence of certain reagents the fibre could be broken up transversely into discs, as well as longitudinally into fibrillæ (fig. 46, B). But it is now believed that this cross-cleavage is purely artificial, and that a muscular fibre is built up of fibrillæ and not of small quadrangular particles.

Assuming that this is so, the minute structure of these longitudinal fibrillæ, or sarcostyles, may now be considered. Perhaps there are few subjects in histology which have received more attention, and in which the appearances seen under the microscope have been more differently interpreted, than the minute anatomy of muscular fibre. Schäfer has worked out this subject, particularly in the wing muscles of insects, which are peculiarly adapted for this purpose on account of the large amount of interstitial sarcoplasm which separates the sarcostyles. In the following description that given by Schäfer will be closely followed (fig. 49).

A sarcostyle may be said to be made up of successive portions, each of which is termed a *sarcomere*. The sarcomere is situated between two membranes of Krause, and consists of (1) a central dark part, which forms a portion of the dark band of the whole fibre, and is named a *sarcous element*.* This sarcous element

FIG. 49.—Diagram of a sarcomere. (After Schäfer.)
A. In moderately extended condition. B. In a contracted condition.

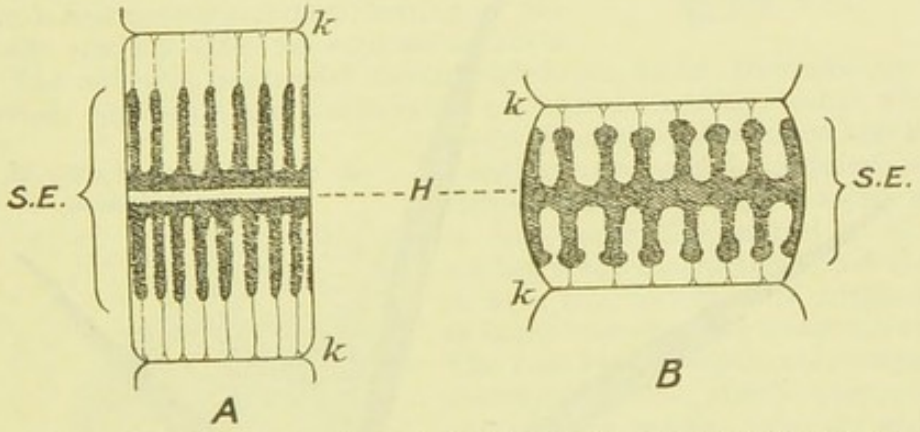

k, *k*. Membranes of Krause. H. Line or plane of Hensen. S.E. Poriferous sarcous element.

really consists of two parts, superimposed one on the top of the other, and when the fibre is stretched these two parts become separated from each other at the line of Hensen (fig. 49, A). (2) On either side of this central dark portion is a clear layer, most visible when the fibre is extended ; this is situated between the dark centre and the membrane of Krause, and when the sarcomeres are joined together to form the sarcostyle, constitutes the light band of the striated muscular fibre.

When the sarcostyle is extended, the clear intervals are well marked and plainly to be seen ; when, on the other hand, the sarcostyle is contracted, that is to say, the muscle is in a state of contraction, these clear portions are very small or they may have disappeared altogether (fig. 49, B). When the sarcostyle is stretched to its full extent, not only is the clear portion well marked, but the dark portion—the sarcous element—is separated into its two constituents along the line of Hensen.

The sarcous element does not lie free in the sarcomere, for when the sarcostyle is stretched, so as to render the clear portion visible, very fine lines, which are probably septa, may be seen running through it from the sarcous element to the membrane of Krause.

Schäfer explains these phenomena in the following way. He considers that each sarcous element is made up of a number of longitudinal channels, which open into the clear part towards the membrane of Krause but are closed at the line of Hensen. When the muscular fibre is contracted the *clear* part of the muscular

* This must not be confused with the 'sarcous element of Bowman' (see above).

substance is driven into these channels or tubes, and is therefore hidden from sight, but at the same time it swells up the sarcous element and widens and shortens the sarcomere. When, on the other hand, the fibre is extended, this clear substance is driven out of the tubes and collects between the sarcous element and the membrane of Krause, and gives the appearance of the light part between these two structures; by this means it elongates and narrows the sarcomere.

If this view be true, it is a matter of great interest, and, as Schäfer has shown, harmonises the contraction of muscle with the amœboid action of protoplasm. In an amœboid cell there is a framework of spongioplasm, which stains with hæmatoxylin and similar reagents, enclosing in its meshes a clear substance, hyaloplasm, which will not stain with these reagents. Under stimulation the hyaloplasm passes into the pores of the spongioplasm; without stimulation it tends to pass out as in the formation of pseudopodia. In muscle there is the same thing, viz. a framework of spongioplasm staining with hæmatoxylin—the substance of the sarcous element—and this encloses a clear hyaloplasm, the clear substance of the sarcomere, which resists staining with this reagent. During contraction of the muscle—i.e. stimulation—this clear substance passes into the pores of the spongioplasm; while during extension of the muscle—i.e. when there is no stimulation—it tends to pass out of the spongioplasm.

In this way the contraction is brought about: under stimulation the protoplasmic material (the clear substance of the sarcomere) recedes into the sarcous

Fig. 50.—Non-striated muscular fibre. (From Kirke's 'Physiology.')

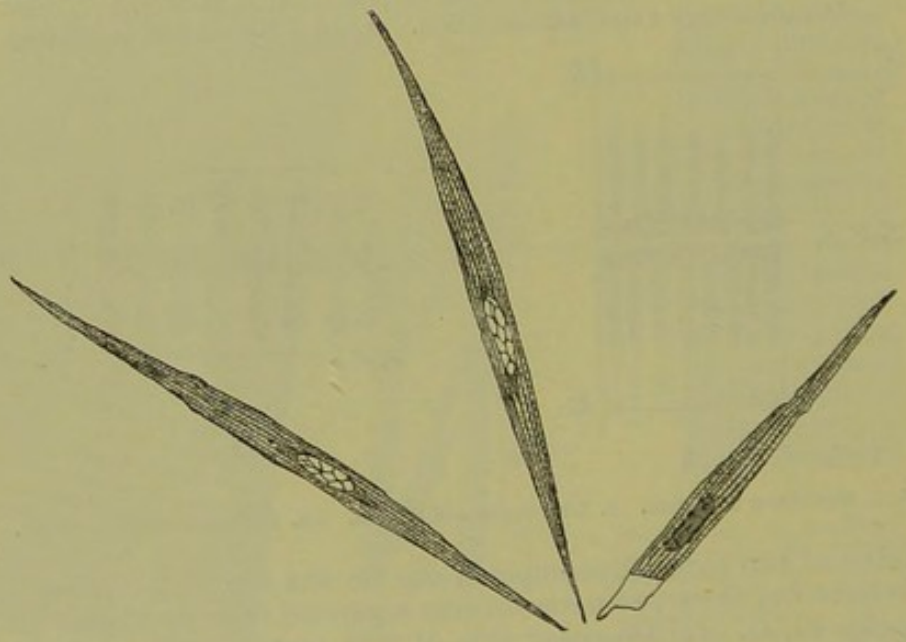

element, causing the sarcomere to widen out and shorten. The contraction of the muscle is merely the sum total of this widening out and shortening of these bodies.

The *capillaries* of striped muscle are very abundant, and form a sort of rectangular network, the branches of which run longitudinally in the endomysium between the muscular fibres, and are joined at short intervals by transverse anastomosing branches. The larger vascular channels, arteries and veins, are found only in the perimysium, between the muscular fasciculi.

Nerves are profusely distributed to striped muscle. Their mode of termination is described on page 53.

The existence of *lymphatic vessels* in striped muscle has not been ascertained, though they have been found in tendons and in the sheaths of the muscles.

Unstriped, plain, or involuntary muscle is found in the following situations—viz. the lower half of the œsophagus and the whole of the remainder of the gastro-intestinal tube; in the trachea and bronchi, and the alveoli and infundibula of the lungs; in the gall-bladder and common bile duct; in the large ducts of the salivary and pancreatic glands; in the pelvis and calyces of the kidney, the ureter, bladder, and urethra; in the female sexual organs—viz. the ovary, the Fallopian tubes, the uterus (enormously developed in pregnancy), the vagina, the broad ligaments, and the erectile tissue of the clitoris;

in the male sexual organs—viz. the dartos of the scrotum, the vas deferens and epididymis, the vesiculæ seminales, the prostate gland, and the corpora cavernosa and corpus spongiosum; in the capsule and trabeculæ of the spleen; in the mucous membranes, forming the muscularis mucosæ; in the skin, forming the arrectores pilorum, and also in the sweat-glands; in the arteries, veins, and lymphatics; in the iris and the ciliary muscle.

Fig. 51. — Anastomosing muscular fibres of the heart seen in a longitudinal section. On the right the limits of the separate cells with their nuclei are exhibited somewhat diagrammatically.

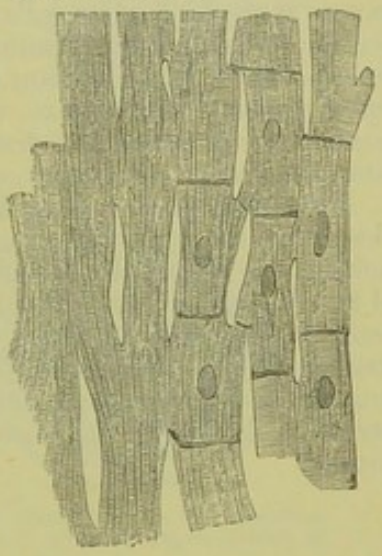

Plain or unstriped muscle is made up of spindle-shaped cells, called *contractile fibre-cells*, collected into bundles and held together by a cement substance (fig. 50). These bundles are further aggregated into larger fasciculi, or flattened bands, and bound together by ordinary connective tissue.

The *contractile fibre-cells* are elongated, spindle-shaped, nucleated cells of various sizes, averaging from $\frac{1}{600}$ to $\frac{1}{300}$ of an inch in length, and $\frac{1}{4500}$ to $\frac{1}{3500}$ of an inch in breadth. On transverse section they are more or less polyhedral in shape, from mutual pressure. Each presents a faint longitudinal striation and consists of an elastic cell-wall containing a central bundle of fibrillæ, representing the contractile substance, and an oval or rod-like nucleus, which includes, within a membrane, a fine network communicating at the poles of the nucleus with the contractile fibres (Klein). The adhesive interstitial cement substance, which connects the fibre-cells together, represents the endomysium of striped muscular tissue, while the tissue connecting the individual bundles together represents the perimysium. Unstriped muscle, except the ciliary muscle, is not under the control of the will, neither is the contraction rapid nor does it, as a rule, involve the whole muscle, as is the case with the voluntary muscles. The membranes which are composed of unstriped muscle slowly contract in a part of their extent, generally under the influence of a mechanical stimulus, as that of distension or of cold; and then the contracted part slowly relaxes while another portion of the membrane takes up the contraction. This peculiarity of action is most strongly marked in the intestines, constituting their *vermicular motion*.

Fig. 52.—Purkinje fibres from the sheep's heart.

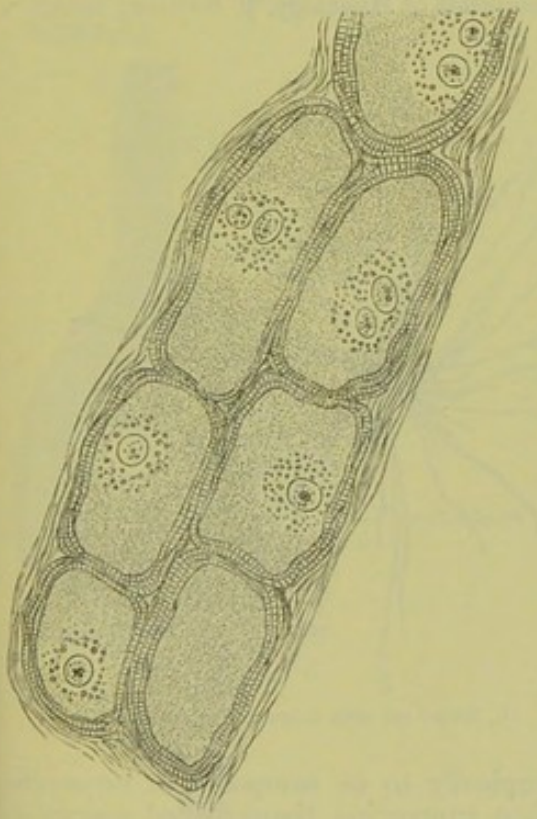

Cardiac muscular tissue.—The fibres of the heart differ very remarkably from those of other striped muscles. They are smaller by one-third, and their transverse striæ are by no means so well marked. The fibres are made up of distinct quadrangular cells joined end to end* (fig. 51). Each cell contains a clear oval nucleus, situated near the centre of the cell. The extremities of the cells have a tendency to branch or divide, the subdivisions uniting with offsets from other cells, and thus producing an anastomosis of the fibres. The connective tissue between

* The junctions between the cells are only occasionally seen, and some histologists maintain that they are only artefacts.

the bundles of fibres is much less than in ordinary striped muscle, and no sarcolemma has been proved to exist.

Purkinje fibres (fig. 52).—Between the endocardium and the ordinary cardiac muscle are found, embedded in a small amount of connective tissue, peculiar fibres known as *Purkinje fibres*. They are found in certain mammals and in birds, and can be best seen in the sheep's heart, where they form a considerable portion of the moderator band and also appear as gelatinous-looking strands on the inner walls of the auricles and ventricles. Recently it has been shown that they also occur in the human heart (bundle of His). The fibres are very much larger in size than the cardiac cells and differ from them in several ways. In longitudinal section they are quadrilateral in shape, being about twice as long as they are broad. The central portion of each fibre contains one or more nuclei and is made up of granular protoplasm, with no indication of striations, while the peripheral portion is clear and has distinct transverse striations. The fibres are intimately connected with each other, possess no definite sarcolemma, and do not branch.*

Development of muscle fibres.—Voluntary muscular fibres are developed from the mesoderm, the embryonic cells of which elongate, show multiplication of nuclei, and eventually become striated; the striation is first obvious at the side of the fibres, spreads around the circumference, and ultimately extends to the centre. The nuclei, at first situated centrally, gradually pass out to assume their final position immediately beneath the sarcolemma. In the case of involuntary muscle the mesodermal cell assumes a pointed shape at the extremities and becomes flattened, the nucleus also lengthening out to its permanent rod-like form.

NERVOUS TISSUE

The **nervous tissues** of the body comprise the brain (including the medulla oblongata), the spinal cord, the cranial, spinal, and sympathetic nerves, and the ganglia connected with them.

FIG. 53.—Neuroglia cells of brain shown by Golgi's method. (After Andriezen.) (Copied from Schäfer's 'Essentials of Histology.')

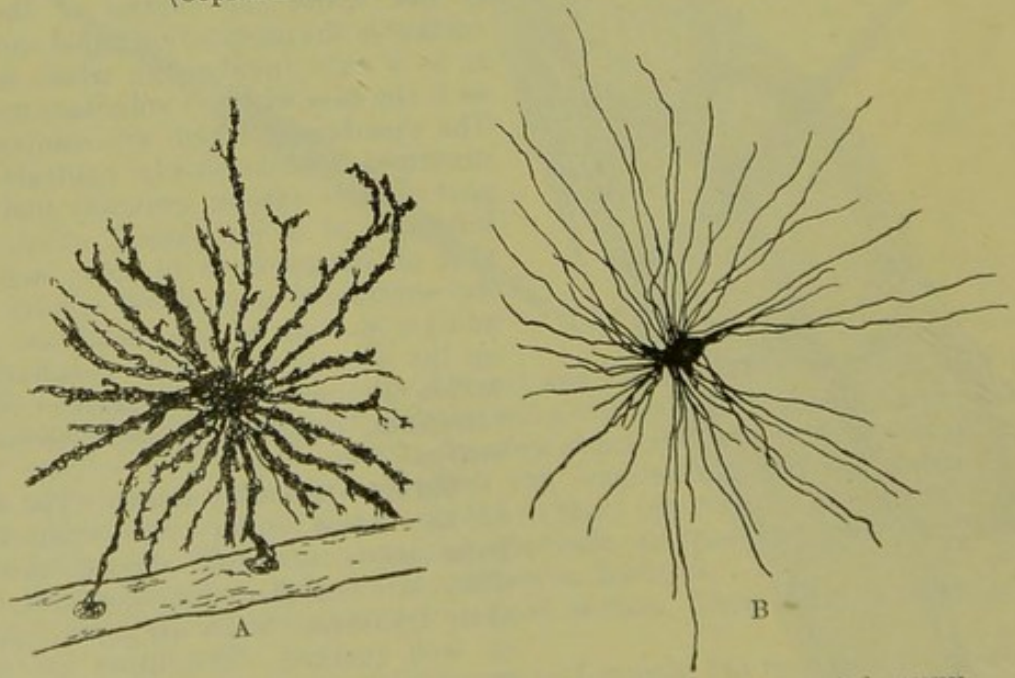

A. Cell with branched processes.

B. Spider cell with unbranched processes.

The nervous tissues are found microscopically to be composed of *nerve-cells* and their various processes, together with a supporting tissue called *neuroglia*, which, however, is found only in the brain and spinal cord. Certain long processes of the nerve-cells are of special importance, and it is convenient to consider them apart from the cells; they are known as *nerve-fibres*.

* In the human heart the primitive muscle tissue is composed of many types of fibres (Gibson: *British Medical Journal*, January 1909).

To the naked eye a difference is obvious between certain portions of the brain and spinal cord, viz. the *grey matter* and the *white matter*. The grey matter is

Fig. 54.—Various forms of nerve-cells.

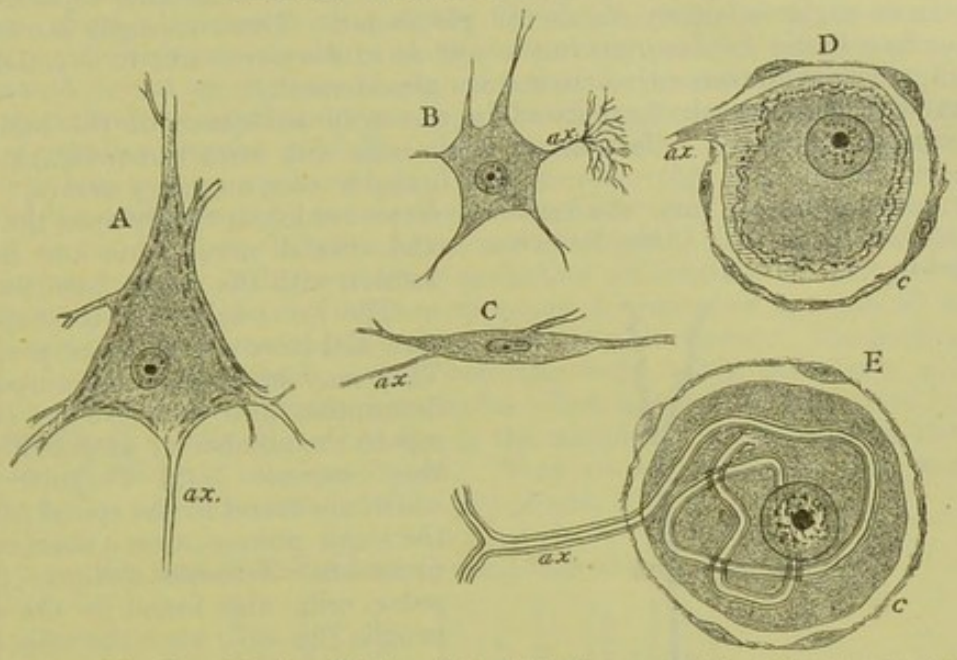

A. Pyramidal cell. B. Small multipolar cell, in which the axon quickly divides into numerous branches. C. Small fusiform cell. D and E. Ganglion cells (E shows T-shaped division of axon). *ax.* Axon. *c.* Capsule.

largely composed of nerve-cells, while the white matter contains only their long processes, the nerve-fibres. It is in the former that nervous impressions and impulses originate, and by the latter that they are conducted. Hence the grey matter forms the essential constituent of all the ganglionic centres, both those in the isolated ganglia and those aggregated in the brain and spinal cord; while the white matter is found in the commissural portions of the nerve-centres and in the peripheral nerves.

Fig. 55.—Bipolar nerve-cell from the spinal ganglion of the pike. (After Kölliker.)

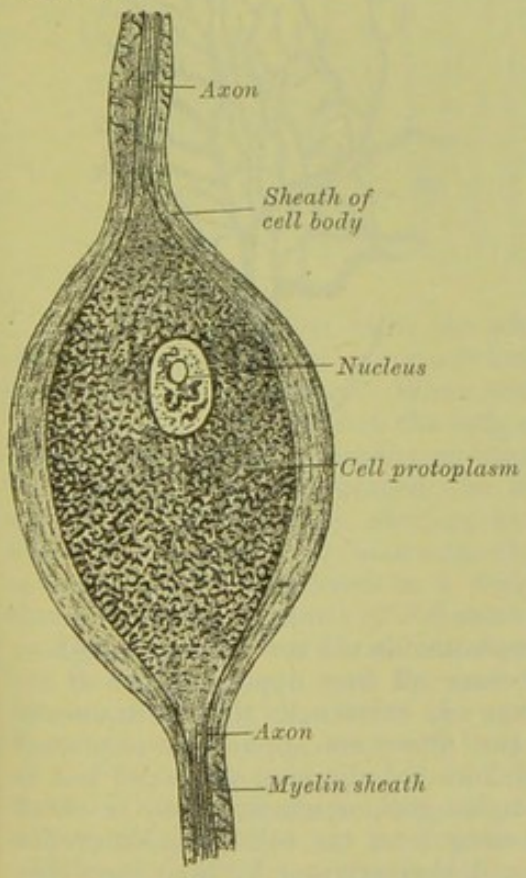

Neuroglia, the peculiar ground substance in which are embedded the true nervous constituents of the brain

Fig. 56.—Motor nerve-cell from ventral horn of spinal cord of rabbit. (After Nissl.) The angular and spindle-shaped Nissl bodies are well shown.

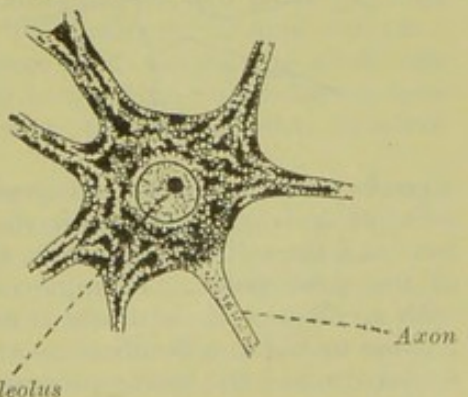

and spinal cord, consists of fibres and cells. Some of the cells are stellate in shape, and their fine processes become neuroglia-fibres, which extend radially and

unbranched (fig. 53, B) among the nerve cells and fibres which they aid in supporting. Other cells give off fibres which branch repeatedly (fig. 53, A). Some of the fibres start from the epithelial cells lining the ventricles of the brain and central canal of the spinal cord, and pass through the nervous tissue, branching repeatedly to terminate in slight enlargements on the pia mater. Thus, neuroglia is evidently a connective tissue in function but is not so in development; it is ectodermal in origin, whereas all connective tissues are mesodermal.

Nerve-cells are largely aggregated in the grey substance of the brain and spinal cord, but smaller collections of these cells also form the swellings, called ganglia, seen on many nerves. These latter are found chiefly upon the spinal and cranial nerve-roots and in connection with the sympathetic nerves.

FIG. 57.—Pyramidal cell from the cerebral cortex of a mouse. (After Ramón y Cajal.)

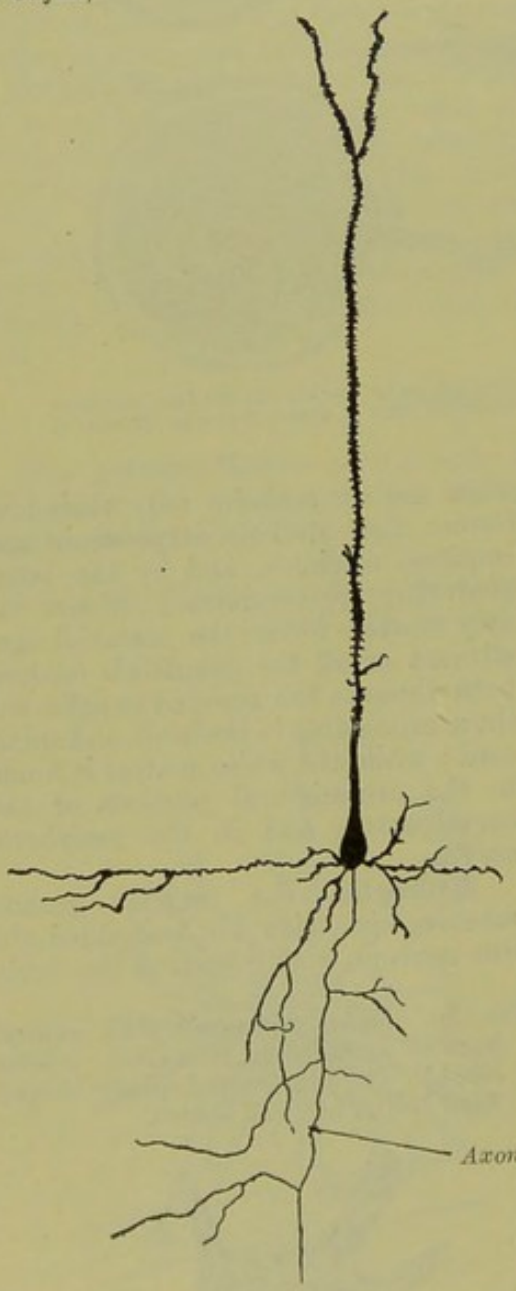

The nerve-cells vary in shape and size, and have one or more processes. They may be divided for purposes of description into three groups, according to the number of processes which they possess: (1) Unipolar cells, which are found in the spinal ganglia; the single process, after a short course, divides in a T-shaped manner. (2) Bipolar cells, also found in the spinal ganglia (fig. 55), when the cells are in an embryonic condition. They are best demonstrated in the sympathetic ganglion-cells of a frog. Sometimes the processes come off from opposite poles of the cell, and the cell then assumes a spindle shape; in other cells they both emerge at the same point. In some cases where two fibres are apparently connected with a cell, one of the fibres is really derived from an adjoining nerve-cell and is passing to end in a ramification around the ganglion-cell, or, again, it may be coiled spirally round the nerve process which is issuing from the cell. (3) Multipolar cells, which are caudate or stellate in shape, and characterised by their large size and by the tail-like processes which issue from them. The processes are of two kinds: one of them is termed the *axis-cylinder process* or *axon* because it becomes

FIG. 58.—Cell of Purkinje from the cerebellum of a cat. (After Ramón y Cajal.)

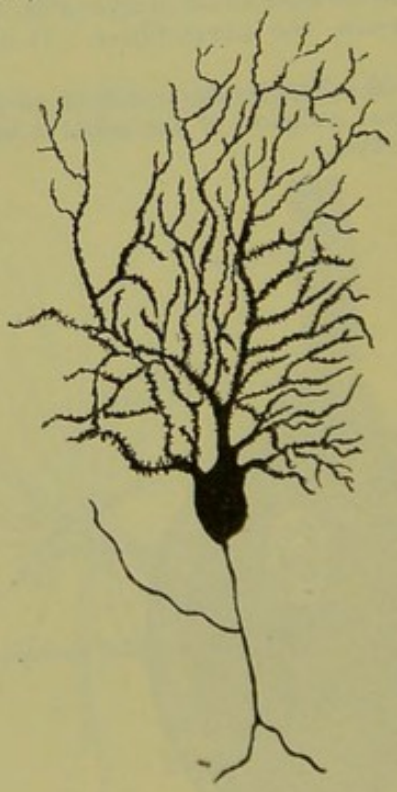

the axis-cylinder of a nerve-fibre (figs. 56, 57, 58). The others are termed the *protoplasmic processes* or *dendrons*; they begin to divide and subdivide as soon as they emerge from the cell, and finally end in minute twigs and become lost among the other elements of the nervous tissue.

Each nerve-cell consists of a finely fibrillated protoplasmic material, of a reddish or yellowish-brown colour, which occasionally presents patches of a deeper tint, caused by the aggregation of pigment-granules at one side of the nucleus, as in the substantia nigra and locus cœruleus of the brain. The protoplasm also contains peculiar angular granules, which stain deeply with basic dyes, such as methylene blue; these are known as *Nissl's granules* (fig. 56). They extend into the dendritic processes but not into the axis cylinder; the small clear area at the point of exit of the axon is termed the *cone of origin*. These granules disappear (*chromatolysis*) during fatigue or after prolonged stimulation of the nerve-fibres connected with the cells. They are supposed to represent a store of nervous energy, and in various mental diseases are deficient or absent. The nucleus is, as a rule, a large, well-defined, round, vesicular body, often presenting an intra-nuclear network, and containing a nucleolus which is peculiarly clear and brilliant.

Nerve-fibres are found universally in the peripheral nerves, and in the white substance of the brain and spinal cord. They are of two kinds—viz. *medullated* or *white* fibres, and *non-medullated* or *grey* fibres.

FIG. 59.—Medullated nerve-fibres stained with silver nitrate.

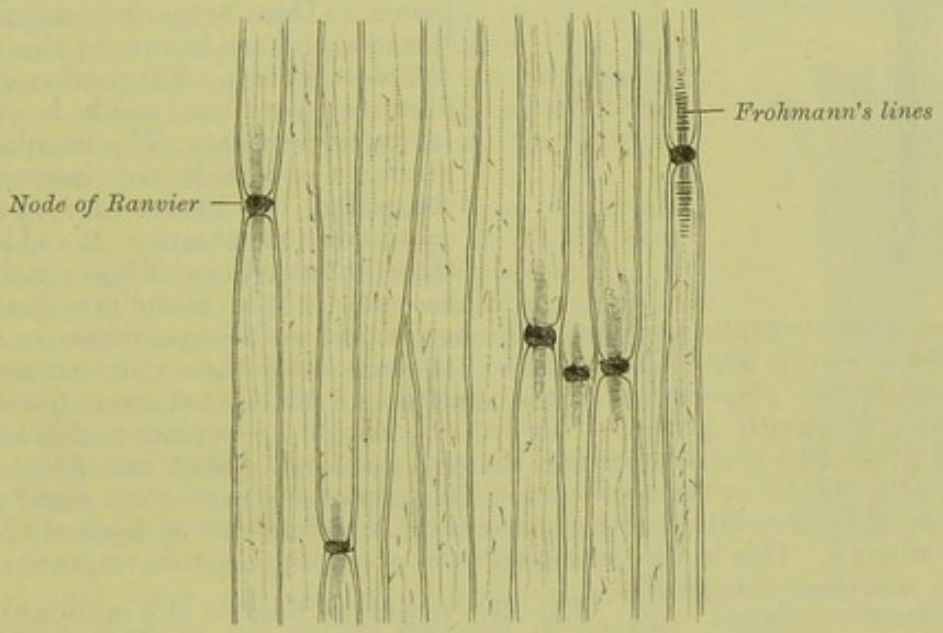

The *medullated fibres* form the white part of the brain and spinal cord, and also the greater part of every cerebro-spinal nerve, and give to these structures their opaque, white aspect. When perfectly fresh they appear to be homogeneous; but soon after removal from the body each fibre presents, when examined by transmitted light, a double outline or contour, as if consisting of two parts (fig. 59). The central portion is named the *axis cylinder of Purkinje*; around this is a sheath of fatty material, staining black with osmic acid, named the *white substance of Schwann* or *medullary sheath*, which gives to the fibre its double contour, and the whole is enclosed in a delicate membrane, the *neurilemma*, *primitive sheath*, or *nucleated sheath of Schwann* (fig. 59).

The *axis cylinder* is the essential part of the nerve-fibre, and is always present; the medullary sheath and the neurilemma are occasionally absent, especially at the origin and termination of the nerve-fibre. It undergoes no interruption from its origin in the nerve-centre to its peripheral termination, and must be regarded as a direct prolongation of a nerve-cell. It constitutes about one-half or one-third of the nerve-fibre, being greater in proportion in the fibres of the central organs than in those of the nerves. It is quite transparent, and is therefore indistinguishable in a perfectly fresh and natural state of the nerve. It is made up of exceedingly fine fibrils, which stain darkly with gold chloride (fig. 60), and at its termination may be seen to break up into these fibrillæ. The fibrillæ have

been termed the *primitive fibrillæ* of Schultze. The axis cylinder is said by some to be enveloped in a special, reticular sheath, which separates it from the medullary sheath, and is composed of a substance called *neurokeratin*. The more common opinion is that this network or reticulum is contained in the white matter of Schwann, and by some it is believed to be produced by the action of the reagents employed to show it.

The *medullary sheath* or *white matter of Schwann* (fig. 60) is regarded as being a fatty matter in a fluid state, which insulates and protects the essential part of the nerve—the axis cylinder. It varies in thickness, in some forming a layer of extreme thinness, so as to be scarcely distinguishable, in others forming about one-half the nerve-fibre. The variation in diameter of the nerve-fibres (from $\frac{1}{1\frac{1}{2}00}$ to $\frac{1}{2000}$ of an inch) depends mainly upon the amount of the white substance, though the axis cylinder also varies within certain limits. The medullary sheath does not always form a continuous sheath to the axis cylinder, but undergoes interruptions in its continuity at regular intervals, giving to the fibre the appearance of constriction at these points. These were first described by Ranvier, and are known as the *nodes of Ranvier* (fig. 61). The portion of nerve-fibre between two nodes is called an *internodal segment*. The neurilemma or primitive sheath is not interrupted at the nodes, but passes over them as a continuous membrane. In addition to these interruptions oblique clefts may be seen in the medullary sheath, subdividing it into irregular portions, which are termed *medullary segments*, or *segments of Lantermann* (fig. 60). There is reason to believe that these clefts are artificially produced in the preparation of the specimens. Medullated nerve-fibres, when examined, frequently present a beaded or varicose appearance: this is due to manipulation and pressure causing the oily matter to collect into drops, and in consequence of the extreme delicacy of the primitive sheath, even slight pressure will cause the transudation of the fatty matter, which collects as drops of oil outside the membrane. This is also promoted by the action of certain reagents.

Fig. 60.—Longitudinal section through a nerve-fibre from the sciatic nerve of a frog. × 830. (After Böhm and Davidoff.)

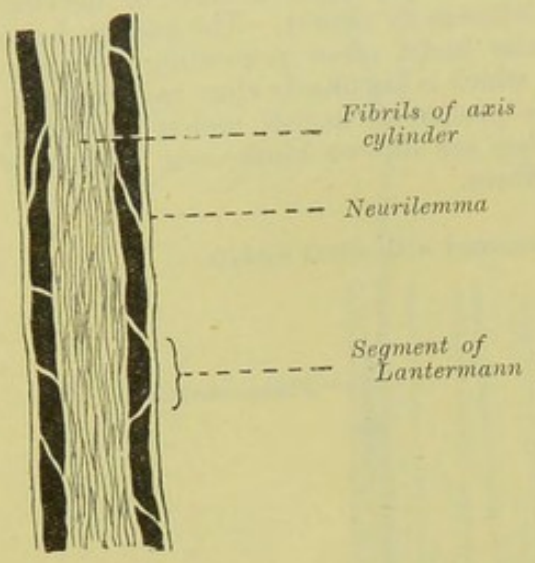

The *neurilemma* or *primitive sheath* presents the appearance of a delicate, structureless membrane. Here and there beneath it, and situated in depressions in the white matter of Schwann, are nuclei surrounded by a small amount of protoplasm. The nuclei are oval and somewhat flattened, and bear a definite relation to the nodes of Ranvier; one nucleus generally lying in the centre of each internode. The primitive sheath is not present in all medullated nerve-fibres, being absent in those fibres which are found in the brain and spinal cord.

Fig. 61.—A node of Ranvier of a medullated nerve-fibre, viewed from above, magnified about 750 diameters. The medullary sheath is discontinuous at the node, whereas the axis cylinder passes from one segment into the other. At the node the neurilemma appears thickened. (Klein and Noble Smith.)

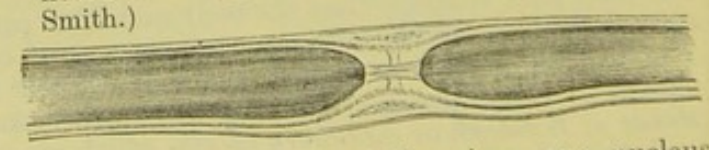

Wallerian Degeneration.—When nerve-fibres are cut across, the central ends of the fibres degenerate as far as the first node of Ranvier; but the peripheral ends degenerate simultaneously throughout their whole lengths. The axons break up into fragments and become surrounded by drops of myelin which are formed from the breaking down of the medullary sheath. The nuclei of the primitive sheath proliferate, and finally absorption of the axons and myelin takes place. If the cut ends of the nerve be sutured together regeneration of the nerve-fibres takes place by the downgrowths of axons from the central end of the nerve. At one time it was believed that the regeneration was peripheral in

origin, but this has been experimentally proved by Halliburton and Mott not to be the case, the proliferated nuclei in the peripheral portions taking part merely in the formation of the so-called scaffolding along which the new axons pass.

Non-medullated fibres.—Most of the fibres of the sympathetic system, and some of the cerebro-spinal, consist of the *grey* or *gelatinous* nerve-fibres—*fibres of Remak* (fig. 62). Each of these consists of a central core or axis cylinder enclosed in a nucleated sheath which tends to split into fibrillæ, and is probably of the nature of neurokeratin. In external appearance the non-medullated nerve-fibres are semi-transparent and grey or yellowish-grey. The individual fibres vary in size, generally averaging about half the size of the medullated fibres.

Development of nerve cells and fibres.—The nerve-cells are developed from certain of the cells which line the neural canal or form the neural crest of the embryo (see section on Embryology). Some of these cells assume a rounded form and are termed *neuroblasts*, and from each neuroblast there grows out a process, the axis-cylinder process or axon, and subsequently the branching processes or dendrons. The axis cylinders, at first naked, acquire their medullary sheaths, possibly by some metamorphosis of their outer layers. The neurilemma is thought to be derived from mesodermal cells which become flattened and wrapped round the fibre, the cement substance at their apposed ends forming the material which stains with silver nitrate at the nodes of Ranvier. Nerve-cells in the sympathetic and peripheral ganglia take their origin from small collections of neuroblasts, which are split off from the rudimentary spinal ganglia. Cells which are, originally, similar to neuroblasts seem to give rise to neuroglia cells, numerous processes sprouting from the cell to form the neuroglial fibres.

FIG. 62.—A small nervous branch from the sympathetic of a mammal.

a. Two medullated nerve-fibres among a number of grey nerve-fibres, *b*.

The nervous structures are divided into two great systems — viz. the *central*, comprising the brain and spinal cord; and the *peripheral*, consisting of the nerves connected with them. All these structures require separate consideration; they are composed of the two kinds of nervous tissue above described, intermingled in various proportions, and having, in some parts, a very intricate arrangement.

The **brain** and **spinal cord** form the central system. In the **brain** the grey nervous matter is found on the surface, forming the convolutions of the cerebrum, and the laminæ of the cerebellum; in the interior it is collected into large and distinct masses or ganglionic bodies, such as the corpus striatum, thalamus, and corpora quadrigemina; or is intermingled intimately with the white as in the pons Varolii and the floor of the fourth ventricle.

In the **spinal cord** the grey matter is accumulated in the centre and the white matter on the periphery. The special arrangement and distribution of the grey and white matter in the central nervous system are described with the anatomy of the nervous system.

The **nerves** are round or flattened cords, formed of the nerve-fibres already described. They are connected at one end with the central nervous system or with the ganglia, and are distributed at the other end to the various textures of the body; they are subdivided into two great classes—the *cerebro-spinal* nerves, which proceed directly from the brain and spinal cord, and the *sympathetic* nerves, which proceed from the ganglia of the sympathetic.

The **cerebro-spinal nerves** consist of numerous nerve-fibres collected together and enclosed in membranous sheaths (fig. 63). A small bundle of fibres, enclosed in a tubular sheath, is called a *funiculus*; if the nerve is of small size, it may consist only of a single funiculus; but if large, the funiculi are collected together into larger bundles or *fasciculi*, which are bound together in a common membranous investment.

In structure, the common membranous investment, or sheath of the whole nerve (*epineurium*), as well as the septa given off from it, to separate the fasciculi,

consist of connective tissue, composed of white and yellow elastic fibres, the latter existing in great abundance. The tubular sheath of the funiculi (*perineurium*) is a fine, smooth, transparent membrane, which may be easily separated, in the form of a tube, from the fibres it encloses; in structure it is made up of connective tissue, which has a distinctly lamellar arrangement. The nerve-fibres are held together and supported within the funiculus by delicate connective tissue, called the *endoneurium*. It is continuous with septa which pass inwards from the innermost layer of the perineurium, and shows a ground substance in which are imbedded fine bundles of fibrous connective tissue which run for the most part longitudinally. It serves to support capillary vessels, which are arranged so as to form a network with elongated meshes. The cerebro-spinal nerves consist almost exclusively of the medullated nerve-fibres, only a very small proportion of the non-medullated being present.

The blood-vessels supplying a nerve terminate in a minute capillary plexus, the vessels composing which pierce the perineurium, and run, for the most part, parallel with the fibres; they are connected together by short, transverse vessels, forming narrow, oblong meshes, similar to the capillary system of muscle. Fine non-medullated nerve-fibres, *vaso-motor fibres*, accompany these capillary vessels, and break up into elementary fibrils, which form a network around the vessels. Horsley has demonstrated certain medullated fibres running in the epineurium and terminating in small spheroidal tactile corpuscles or end-bulbs of Krause. These nerve-fibres, which Marshall believes to be sensory, and which he has termed *nervi nervorum*, are considered by him to have an important bearing upon certain neuralgic pains.

FIG. 63.—Transverse section through a microscopic nerve, representing a compound nerve-bundle, surrounded by perineurium. Magnified 120 diameters.

The medullated fibres are seen as circles with a central dot, viz. medullary sheath and axis cylinder, in transverse section. They are imbedded in endoneurium, containing numerous nuclei, which belong to the connective-tissue cells of the latter. (Klein and Noble Smith.)

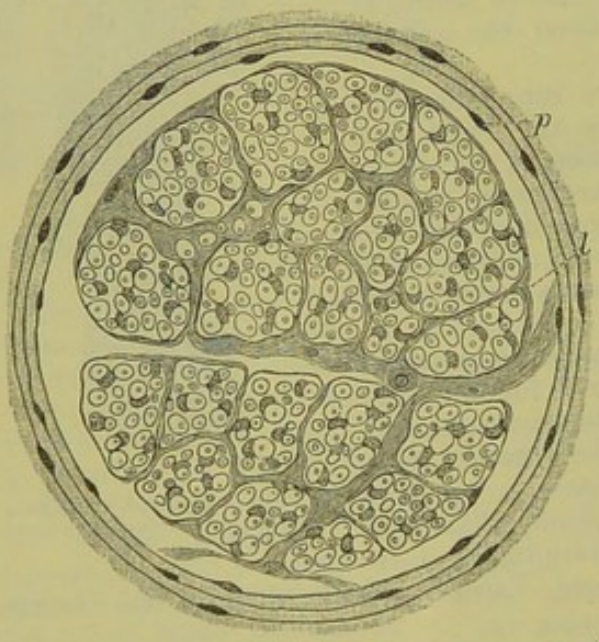

p. Perineurium, consisting of laminæ of fibrous connective tissue, alternating with flattened nucleated connective-tissue cells. *l*. Lymph-space between perineurium and surface of nerve-bundle.

The nerve-fibres, as far as is at present known, do not coalesce, but pursue an uninterrupted course from the centre to the periphery. In separating a nerve, however, into its component funiculi, it may be seen that these do not pursue a perfectly insulated course, but occasionally join at a very acute angle with other funiculi proceeding in the same direction; from this, branches are given off, to join again in like manner with other funiculi. It must be distinctly understood, however, that in these communications the individual nerve-fibres do not coalesce, but merely pass into the sheath of the adjacent nerve, become intermixed with its nerve-fibres, and again pass on, to intermingle with the nerve-fibres in some adjoining funiculus.

Nerves, in their course, subdivide into branches, and these frequently communicate with branches of a neighbouring nerve. The communications which thus take place form what is called a *plexus*. Sometimes a plexus is formed by the primary branches of the trunks of the nerves—as the cervical, brachial, lumbar, and sacral plexuses—and occasionally by the terminal funiculi, as in the plexuses formed at the periphery of the body. In the formation of a plexus, the component nerves divide, then join, and again subdivide in such a complex manner that the individual funiculi become interlaced most intricately; so that each branch leaving a plexus may contain filaments from all the primary nervous trunks which form the plexus. In the formation also of smaller plexuses at the periphery of the

body there is a free interchange of the funiculi and primitive fibres. In each case, however, the individual fibres remain separate and distinct.

It is probable that through this interchange of fibres, every branch passing off from a plexus has a more extensive connection with the spinal cord than if it had proceeded to its distribution without forming connections with other nerves. Consequently the parts supplied by these nerves have more extended relations with the nervous centres; by this means, also, groups of muscles may be associated for combined action.

The **sympathetic nerves** are constructed in the same manner as the cerebro-spinal nerves, but consist mainly of non-medullated fibres, collected in funiculi and enclosed in sheaths of connective tissue. There is, however, in these nerves a certain admixture of medullated fibres, and the amount varies in different nerves, and may be known by their colour. Those branches of the sympathetic which present a well-marked grey colour are composed chiefly of non-medullated nerve-fibres, intermixed with a few medullated fibres; while those of a white colour contain many of the latter fibres, and few of the former.

The cerebro-spinal and sympathetic nerve-fibres convey various impressions. The *sensory* nerves, called also *centripetal* or *afferent* nerves, transmit to the nervous centres impressions made upon the peripheral extremities of the nerves, and in this way the mind, through the medium of the brain, becomes conscious of external objects. The *centrifugal* or *efferent* nerves transmit impressions from the nervous centres to the parts to which the nerves are distributed, these impressions either exciting muscular contraction, or influencing the processes of nutrition, growth, and secretion.

Origins and terminations of nerves.—By the expression 'the terminations of nerve-fibres' is signified their connections with the nerve-centres, and with the parts they supply. The former are sometimes called their *origins*, or *central* terminations; the latter their *peripheral* terminations.

Origins of nerves.—The origin in some cases is single—that is to say, the whole nerve emerges from the nervous centre by a single root; in other instances the nerve arises by two or more roots which come off from different parts of the nerve-centre, sometimes widely apart from each other, and it often happens, when a nerve arises in this way by two roots, that the functions of these two roots are different; as, for example, in the spinal nerves, each of which arises by two roots, the anterior of which is motor, and the posterior sensory. The point where the nerve root or roots emerge from the surface of the nervous centre is named the *superficial* or *apparent* origin, but the fibres of the nerve can be traced for a certain distance into the substance of the nervous centre to some portion of the grey matter, which constitutes the *deep* or *real* origin of the nerve. The centrifugal or efferent nerve-fibres originate in the nerve-cells of the grey substance, the axis-cylinder processes of these cells being prolonged to form the fibres. In the case of the centripetal or afferent nerves the fibres grow inwards either from nerve-cells in the organs of special sense (e.g. the retina) or from nerve-cells in the ganglia. Having entered the nerve-centre they branch and send their ultimate twigs among the cells, without, however, uniting with them.

Peripheral terminations of nerves.—Nerve-fibres terminate peripherally in various ways, and these may be conveniently studied in the sensory and motor nerves respectively.

Sensory nerves would appear to terminate either in *minute primitive fibrillæ* or networks of these; or else in special terminal organs, which have been named *peripheral end-organs*, and of which there are several principal varieties, viz. the end-bulbs of Krause, the tactile corpuscles of Wagner, the Pacinian corpuscles, and the neuro-tendinous and neuro-muscular spindles.

Termination in fibrillæ.—When a medullated nerve-fibre approaches its termination, the white matter of Schwann suddenly disappears, leaving only the axis cylinder surrounded by the neurilemma. After a time the fibre loses its neurilemma, and consists only of an axis cylinder, which can be seen, in preparations stained with chloride of gold, to be made up of fine varicose fibrils. Finally, the axis cylinder breaks up into its constituent primitive nerve-fibrillæ, which often present regular varicosities and anastomose with one another, thus forming a network. This network is always distributed to epithelial tissue, the nerve-fibrils lying in the interstitial substance between the epithelial cells, and there terminating, though some observers maintain that the actual terminations are

within the cells. In this way nerve-fibres have been found to terminate in the epithelium of the skin and mucous membranes, and in the anterior epithelium of the cornea.

The end-bulbs of Krause (fig. 64) are minute cylindrical or oval bodies, consisting of a capsule formed by the expansion of the connective tissue sheath of a medullated fibre, and containing a soft semi-fluid core in which the axis cylinder terminates either as a bulbous extremity, or in a coiled-up plexiform mass. End-bulbs are found in the conjunctiva of the eye, where they are spheroidal in shape in man, but cylindrical in most other animals, in the mucous membrane of the lips and tongue, and in the epineurium of nerve-trunks. They are also found in the genital organs of both sexes, the penis in the male and the clitoris in the female; in these situations they have a mulberry-like appearance, from being constricted by connective tissue septa into from two to six knob-like masses, and have received the name of *genital corpuscles*. Very similar corpuscles are found in the epineurium of nerve-trunks. In the synovial membranes of certain joints (e.g. those of the fingers), rounded or oval end-bulbs have been found; these are designated *articular end-bulbs*.

Fig. 64.—End-bulb of Krause.

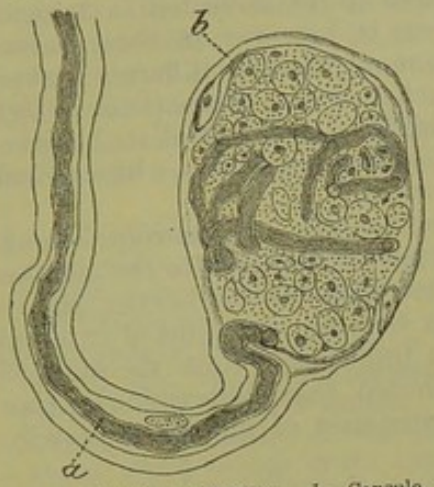

a. Medullated nerve-fibre. *b*. Capsule of corpuscle. (From Klein's 'Elements of Histology.')

Tactile corpuscles have been described by Grandry as occurring in the papillæ of the beak and tongue of birds, and by Merkel as occurring in the papillæ and epithelium of the skin of man and animals, especially in those parts of the skin devoid of hair. Each consists of a capsule composed of a very delicate, nucleated membrane, and contains two or more granular, somewhat flattened cells; between these cells the medullated nerve-fibre, which enters the capsule by piercing its investing membrane, is supposed to end.

The *tactile corpuscles* (fig. 65), described by Wagner and Meissner, are oval-shaped bodies, made up of connective tissue. Each is enveloped by a capsule, and imperfect membranous septa derived from this penetrate the interior. The axis cylinder of the medullated fibre passes through the capsule, and having entered the corpuscle terminates in a small globular or pyriform enlargement, near the inner surface of the capsule. These tactile corpuscles have been described as occurring in the papillæ of the corium of the hand and foot, the front of the forearm, the skin of the lips, the mucous membrane of the tip of the tongue, the palpebral conjunctiva, and the skin of the nipple. They are not found in all the papillæ; but from their existence in those parts in which the skin is highly sensitive, it is probable that they are specially concerned in the sense of touch, though their absence from the papillæ of other tactile parts shows that they are not essential to this sense.

Fig. 65.—Papilla of the hand, treated with acetic acid. Magnified 350 times.

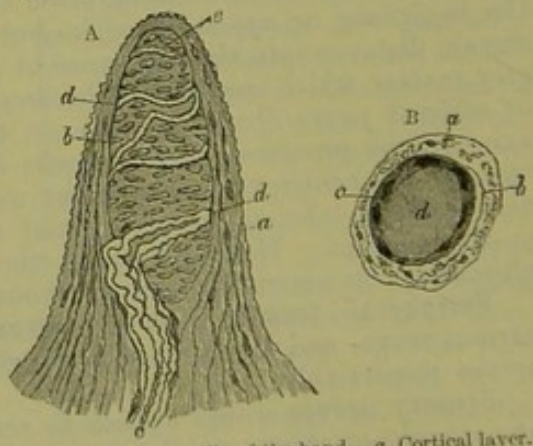

A. Side view of a papilla of the hand. *a*. Cortical layer. *b*. Tactile corpuscle, with transverse nuclei. *c*. Small nerve of the papilla, with neurilemma. *d*. Its two nervous fibres running with spiral coils round the tactile corpuscle. *e*. Apparent termination of one of these fibres. B. A tactile papilla seen from above so as to show its transverse section. *a*. Cortical layer. *b*. Nerve-fibre. *c*. Outer layer of the tactile body, with nuclei. *d*. Clear interior substance.

Ruffini has described a special variety of nerve-ending in the subcutaneous tissue of the human finger (fig. 66). These are usually known as *Ruffini's endings*. They are principally situated at the junction of the corium with the subcutaneous tissue; they are oval in shape, and consist of strong connective tissue sheaths, inside which the nerve-fibres divide into numerous branches, which show varicosities and end in small free knobs. They resemble the organs of Golgi.

The *Pacinian corpuscles*.* (fig. 67) are found in the human subject lying chiefly in the subcutaneous tissue on the nerves of the palm of the hand and

Fig. 66.—Nerve-ending of Ruffini.
(After A. Ruffini, 'Arch. ital. de Biol.,' Turin, t. xxi. 1894.)

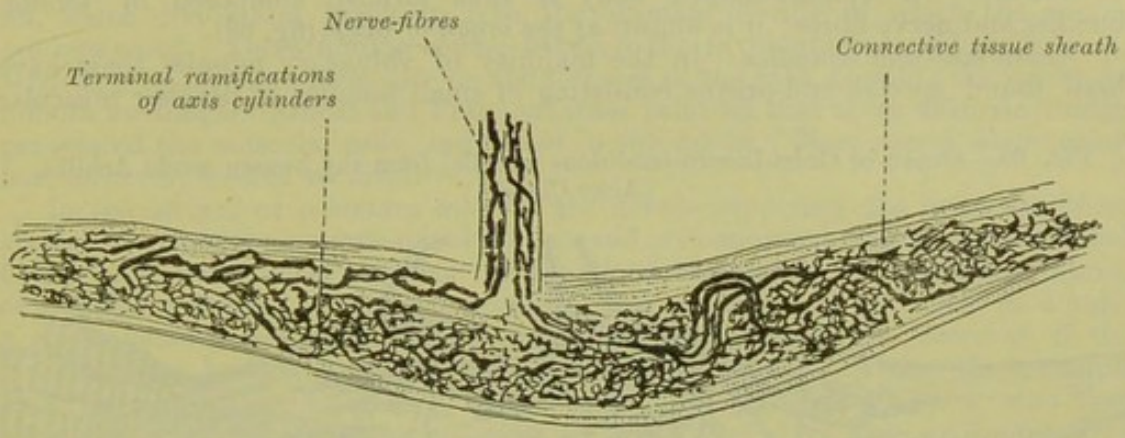

sole of the foot and in the genital organs of both sexes; but they have also been described as connected with the nerves of the joints, and in some other situations, as in the mesentery of the cat and along the tibia of the rabbit. Each of these corpuscles is attached to and encloses the termination of a single nerve-fibre. The corpuscle, which is perfectly visible to the naked eye (and which can be most easily demonstrated in the mesentery of a cat), consists of a number of lamellæ or capsules arranged more or less concentrically around a central clear space, in which the nerve-fibre is contained. Each lamella is composed of bundles of fine connective tissue fibres, and is lined on its inner surface by a single layer of flattened epithelioid cells. The central clear space, which is elongated or cylindrical in shape, is filled with a transparent material, in the middle of which is the single medullated fibre, which traverses the space to near its distal extremity. Here it terminates in a rounded knob or end, sometimes bifurcating previously, in which case each branch has a similar arrangement. Todd and Bowman have described minute arteries as entering by the sides of the nerves and forming capillary loops in the intercapsular spaces, and even penetrating into the central space. Other authors describe the artery as entering the corpuscle at the pole opposite to the nerve-fibre.

Fig. 67.—Pacinian corpuscle, with its system of capsules and central cavity.

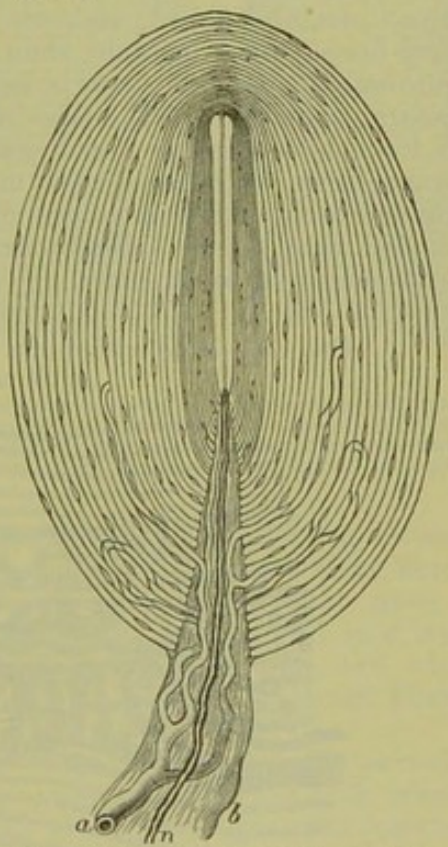

a. Arterial twig, ending in capillaries, which form loops in some of the intercapsular spaces, and one penetrates to the central capsule. *b*. The fibrous tissue of the stalk prolonged from the neurilemma. *n*. Nerve-tube advancing to the central capsule, there losing its white matter, and stretching along the axis to the opposite end, where it is fixed by a tuberculated enlargement.

Herbst has described a nerve-ending somewhat similar to the Pacinian corpuscle, as being found in the mucous membrane of the tongue of the duck, and in some other situations. It differs, however, from the Pacinian corpuscle, in being smaller, its capsule thinner and more closely approximated, and especially in the fact that the axis cylinder in the central clear space is coated with a continuous row of nuclei. These bodies are known as the *corpuscles of Herbst*.

* Often called in German anatomical works 'corpuscles of Vater.'

Neuro-tendinous spindles.—The nerves supplying tendons have special modifications of the terminal fibres, especially numerous at the point where the tendon is becoming muscular. The tendon bundles become enlarged, and the nerve-fibres—one, two, or more in number—penetrate between the fasciculi of the tendon and spread out between the fibres to end in irregular discs or varicosities. A spindle-shaped body is thus formed, composed of tendon bundles and nerve-fibres; it is known as the *organ of Golgi* (fig. 68).

Neuro-muscular spindles.—In the majority of voluntary muscles there have been found special end-organs consisting of small bundles of peculiar muscular

FIG. 68.—Organ of Golgi (neuro-tendinous spindle) from the human tendo Achillis. (After Ciaccio.)

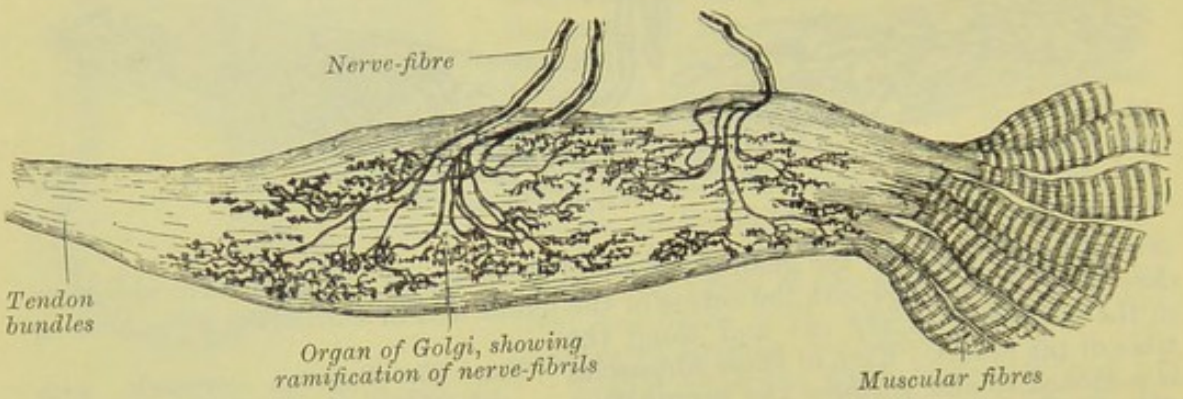

fibres (intrafusal fibres), embryonic in type, invested by capsules, within which nerve-fibres, experimentally shown to be sensory in origin, terminate. These neuro-muscular spindles vary in length from $\frac{1}{30}$ to $\frac{1}{5}$ of an inch and have a distinctly fusiform appearance. The large medullated nerve-fibres passing to the end-organ are from one to three or four in number; entering the fibrous capsule, they divide several times, and, losing their medullary sheaths, ultimately end in naked axis cylinders encircling the intrafusal fibres by flattened expansions, or irregular ovoid or rounded discs (fig. 69). Neuro-muscular spindles have not yet been demonstrated in the tongue or eye muscles.

FIG. 69.—Middle third of a terminal plaque in the muscle spindle of an adult cat. (After Ruffini.)

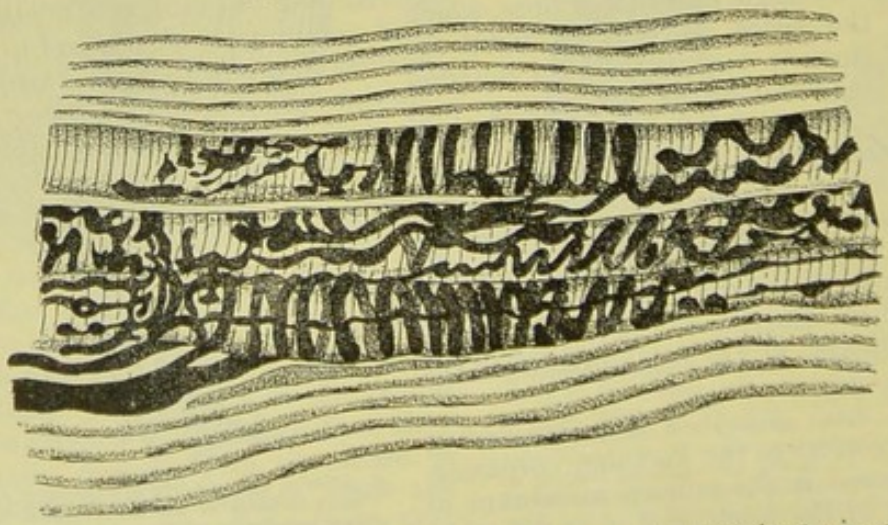

In the organs of **special sense** the nerves appear to terminate in cells which belong to the epithelial class, and have received the name of *sensory* or *nerve-epithelium* cells. This is not, however, the real state of the case; the nerve-fibre is in reality a process from the epithelial cell, and terminates by branching around a ganglion-cell. The stimulus carried by it is continued onwards by an axis cylinder, derived from the ganglion, to the brain. These nerve-epithelium cells must therefore be regarded as modified forms of nerve-cells. They will be more particularly described in the chapter on the organs of special sense.

Motor nerves can be traced into either unstriped or striped muscular fibres. In the *unstriped* or *involuntary muscles* the nerves are derived from the sympathetic, and are composed mainly of the non-medullated fibres. Near their terminations they divide into numerous branches, which communicate and form intimate plexuses. At the junctions of the branches small triangular nuclear bodies (ganglion-cells) are situated. From these plexuses minute branches are given off, which divide and break up into the ultimate fibrillæ of which the nerves are composed. These fibrillæ course between the involuntary muscle-cells, and, according to Elischer, terminate on the surfaces of the cells, opposite the nuclei, in minute swellings. Arnold and Frankenhäuser believed that these ultimate fibrillæ penetrated the muscular cells, and ended in the nuclei. More recent observation has, however, tended to disprove this.

In the *striped* or *voluntary muscle*, the nerves supplying the muscular fibres are derived from the cerebro-spinal nerves, and are composed mainly of medullated fibres. The nerve, after entering the sheath of the muscle, breaks up into fibres, or bundles of fibres, which form plexuses, and gradually divide until, as a rule, a single nerve-fibre enters a single muscular fibre. Sometimes, however, if the muscular fibre be long, more than one nerve-fibre enters it. Within the muscular fibre the nerve terminates in a special expansion, called by Kühne, who first accurately described it, *a motor end-plate* (fig. 70).* The nerve-fibre, on approaching

FIG. 70.—Muscular fibres of *Lacerta viridis* with the terminations of nerves.

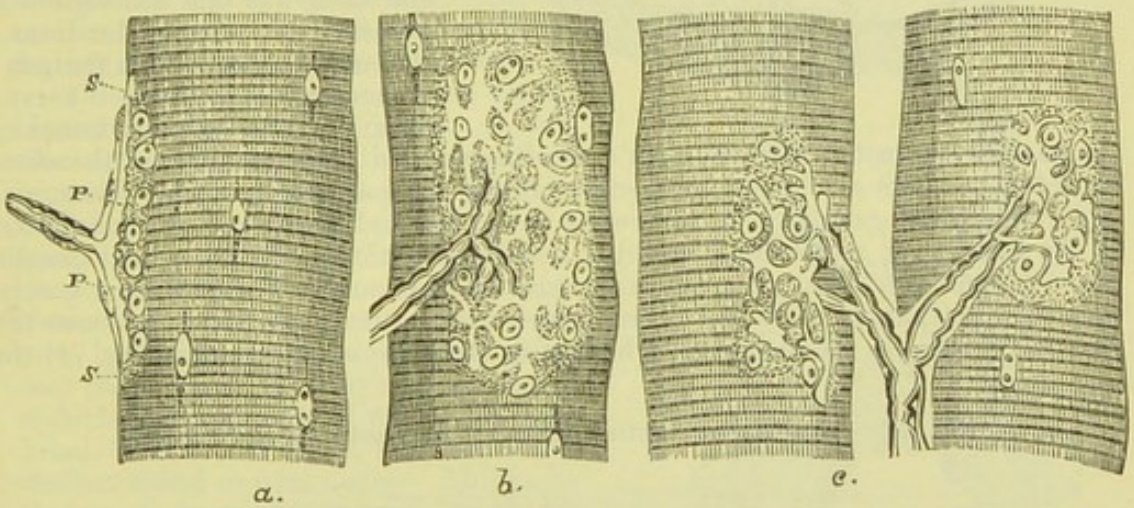

a. Seen in profile. P P. The nerve end-plates. S S. The base of the plate, consisting of a granular mass with nuclei. *b*. The same as seen in looking at a perfectly fresh fibre, the nervous ends being probably still excitable. (The forms of the variously divided plate can hardly be represented in a woodcut by sufficiently delicate and pale contours to reproduce correctly what is seen in nature.) *c*. The same as seen two hours after death from poisoning by curare.

the muscular fibre, suddenly loses its medullary sheath, the neurilemma becomes continuous with the sarcolemma of the muscle, and only the axis cylinder enters the muscular fibre. There it at once spreads out, ramifying like the roots of a tree, immediately beneath the sarcolemma, and becomes imbedded in a layer of granular matter, containing a number of clear, oblong nuclei, the whole constituting an end-plate from which the contractile wave of the muscular fibre is said to start.

Ganglia are small aggregations of nerve-cells. They are found on the posterior roots of the spinal nerves; on the posterior or sensory root of the fifth cranial nerve; on the facial and auditory nerves; on the glosso-pharyngeal and pneumogastric nerves. They are also found in a connected series along either side of the vertebral column, forming the trunk of the sympathetic; and on the branches of sympathetic nerves, generally in the plexuses or at the points of junction of two or more nerves with each other or with branches of the cerebro-spinal system. On section they are seen to consist of a reddish-grey substance, traversed by numerous white nerve-fibres; they vary considerably in form and size; the largest are found in the cavity of the abdomen; the smallest, not visible to the naked eye, exist in considerable numbers upon the nerves distributed to the different viscera.

* They had, however, previously been noticed, though not accurately described, by Doyère, who named them 'nerve-hillocks.'

Each ganglion is invested by a smooth and firm, closely adhering, membranous envelope, consisting of dense areolar tissue; this sheath is continuous with the perineurium of the nerves, and sends numerous processes into the interior to support the blood-vessels supplying the substance of the ganglion.

In structure all ganglia are essentially similar (fig. 71), consisting of the same structural elements—viz. nerve-cells and nerve-fibres. Each nerve-cell has a nucleated sheath which is continuous with the sheath of the nerve-fibre with which the cell is connected. The nerve-cells in the ganglia of the spinal nerves are pyriform in shape, and have only single processes. A short distance from the cell and while still within the ganglion this process divides in a T-shaped manner, one limb of the cross-bar turning into the spinal cord, the other limb passing outwards to the periphery. In the sympathetic ganglia (fig. 71) the nerve-cells are multipolar and each has one axis-cylinder process and several dendrons; the axon emerges from the ganglion as a non-medullated nerve-fibre. Similar cells are found in the ganglia connected with the fifth cranial nerve, and these ganglia are therefore regarded by some as the cranial portions of the sympathetic system. The spinal and sympathetic ganglia differ somewhat in the size and disposition of the cells and in the number of nerve-fibres entering and leaving them. In the spinal ganglia (fig. 72) the nerve-cells are much larger and for the most part collected in groups near the periphery, while the fibres, which are mostly medullated, traverse the central portion of the ganglion; whereas, in the sympathetic ganglia (fig. 71) the

Fig. 71.—Section of a sympathetic ganglion.

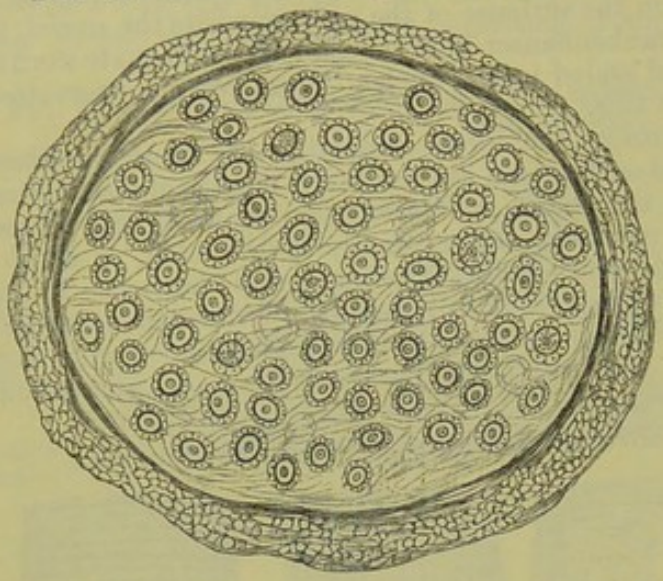

Fig. 72.—Longitudinal section of a part of a posterior root ganglion.

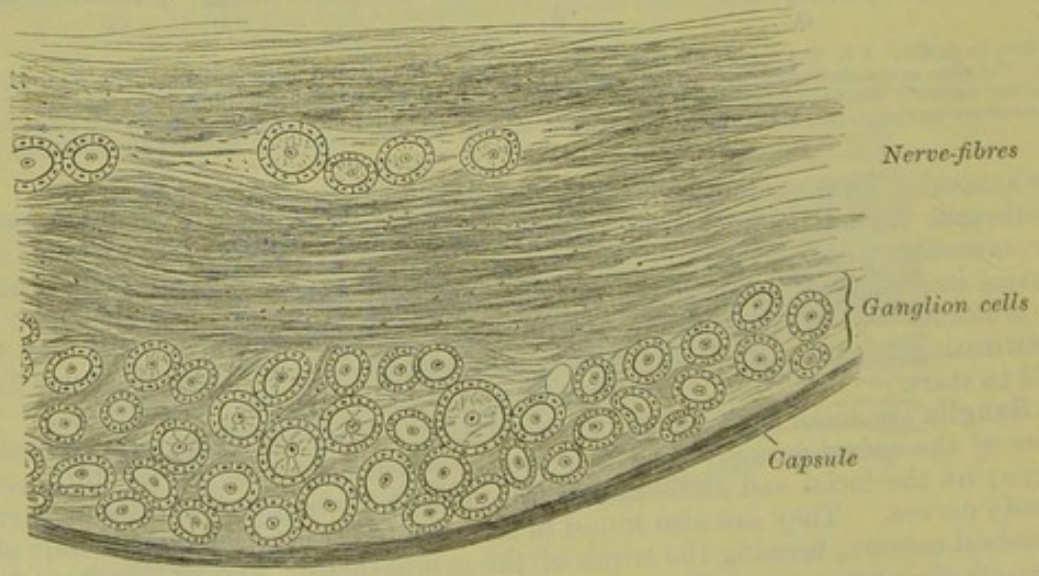

cells are smaller and distributed in irregular groups throughout the whole ganglion; the fibres also are irregularly scattered; some of the entering ones are medullated, while many of those leaving the ganglion are non-medullated.

Neuron theory.—It was formerly believed that the various cells of the nervous system were anatomically in continuity by means of their processes. In 1891 Waldeyer opposed this view, and formulated the doctrine that each nerve-cell and its processes (neuron) was an independent morphological unit, and that no continuity of the processes of one neuron

with those of another neuron existed, although the close relationship of these processes permitted physiological functional continuity. With improved methods of staining and impregnation of nerve-cells and their processes, the neuron theory has gained ground and is now accepted by the majority of anatomists. On the other hand, it is maintained by Bethe, Apathy and others that the nervous system is made up of a network of neuro-fibrillæ which is continuous throughout the whole nervous system, is not confined to the neurons, and can give rise to new axons independent of nerve-cells.

THE VASCULAR SYSTEM

The **Vascular system**, exclusive of its central organ the heart, is divided into four classes of vessels: the arteries, capillaries, veins, and lymphatics. The minute structure of these vessels will be briefly described here, the reader being referred to the body of the work for the details of their ordinary anatomy.

Structure of arteries (fig. 73).—The arteries are composed of three coats: internal or endothelial coat (*tunica intima* of Kölliker); middle muscular coat (*tunica media*); and external connective tissue coat (*tunica adventitia*). The two inner coats together are very easily separated from the external, as by the ordinary operation of tying a ligature round an artery. If a fine string be tied forcibly upon an artery and then taken off, the external coat will be found undivided, but the two inner coats are divided in the track of the ligature and can easily be further dissected from the outer coat.

FIG. 73.—Transverse section through a small artery and vein of the mucous membrane of the epiglottis of a child. Magnified about 350 diameters. (Klein and Noble Smith.)

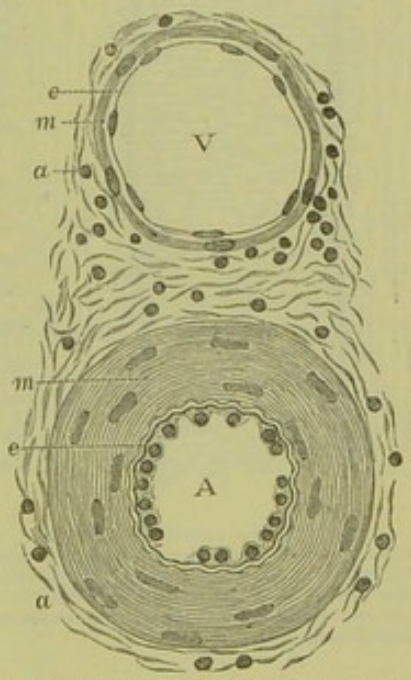

A. Artery, showing the nucleated endothelium, *e*, which lines it: the vessel being contracted, the endothelial cells appear very thick. Underneath the endothelium is the wavy elastic intima. The chief part of the wall of the vessel is occupied by the circular muscle-coat *m*: the staff-shaped nuclei of the muscle-cells are well seen. Outside this is *a*, part of the adventitia. This is composed of bundles of connective tissue fibres, shown in section, with the nuclei of the connective tissue corpuscles. The adventitia gradually merges into the surrounding connective tissue. V. Vein showing a thin endothelial membrane, *e*, raised accidentally from the intima, which on account of its delicacy is seen as a mere line on the media *m*. This latter is composed of a few circular unstriped muscle-cells. *a*. The adventitia, similar in structure to that of an artery.

The *inner coat* (*tunica intima*) can be separated from the middle by a little maceration, or it may be stripped off in small pieces; but, on account of its friability, it cannot be separated as a complete membrane. It is a fine, transparent, colourless structure which is highly elastic, and is commonly corrugated into longitudinal wrinkles. The inner coat consists of: (1) A layer of pavement endothelium, the cells of which are polygonal, oval, or fusiform, and have very distinct round or oval nuclei. This endothelium is brought into view most distinctly by staining with nitrate of silver. (2) A sub-endothelial layer, consisting of delicate connective tissue with branched cells lying in the interspaces of the tissue; in arteries of less than a twelfth of an inch in diameter the sub-endothelial layer consists of a single stratum of stellate cells, and the connective tissue is only largely developed in vessels of a considerable size. (3) An elastic or fenestrated layer, which consists of a membrane containing a network of elastic fibres, having principally a longitudinal direction, and in which, under the microscope, small elongated apertures or perforations may be seen, giving it a fenestrated appearance. It was therefore called by Henle the *fenestrated membrane*. This membrane forms the chief thickness of the inner coat, and can be separated into several layers, some of which present the appearance of a network of longitudinal elastic fibres, and others present a more membranous character, marked by pale lines having a longitudinal direction. The fenestrated membrane in microscopic arteries is a very thin layer; but in the larger arteries, and especially in the aorta, it has a very considerable thickness.

The *middle coat* (*tunica media*) is distinguished from the inner by its colour and by the transverse arrangement of its fibres. In the smaller arteries it consists principally of plain muscle-fibres in fine bundles, arranged in lamellæ and disposed circularly around the vessel. These lamellæ vary in number according to the size of the vessel; the smallest arteries having only a single layer, and those slightly larger three or four layers. It is to this coat that the great thickness of the walls of the artery is mainly due (fig. 73, A, *m*). In the larger vessels, as the iliac, femoral, and carotid, elastic fibres unite to form lamellæ which alternate with the layers of muscular fibres; these lamellæ are united to one another by elastic fibres which pass between the muscular bundles, and are connected with the fenestrated membrane of the inner coat (fig. 75). In the largest arteries, as the aorta and innominate, the amount of elastic tissue is very considerable; in these vessels a few bundles of white connective tissue also have been found in the middle coat. The muscle-fibre cells are about $\frac{1}{500}$ of an inch in length and contain well-marked, rod-shaped nuclei, which are often slightly curved.

The *external coat* (*tunica adventitia*) consists mainly of fine and closely felted bundles of white connective tissue, but also contains elastic fibres in all but the smallest arteries. The elastic tissue is much more abundant next the tunica media, and it is sometimes described as forming here, between the adventitia and media, a special layer, the *tunica elastica externa* of Henle. This layer is most marked in arteries of medium size. In the largest vessels the external coat is relatively thin; but in small arteries it is of greater proportionate thickness. In the smaller arteries it consists of a single layer of white connective tissue and elastic fibres; while in the smallest arteries, just above the capillaries, the elastic fibres are wanting, and the connective tissue of which the coat is composed becomes more nearly homogeneous the nearer it approaches the capillaries, and is gradually reduced to a thin membranous envelope, which finally disappears.

FIG. 74.—Longitudinal section of artery and vein.

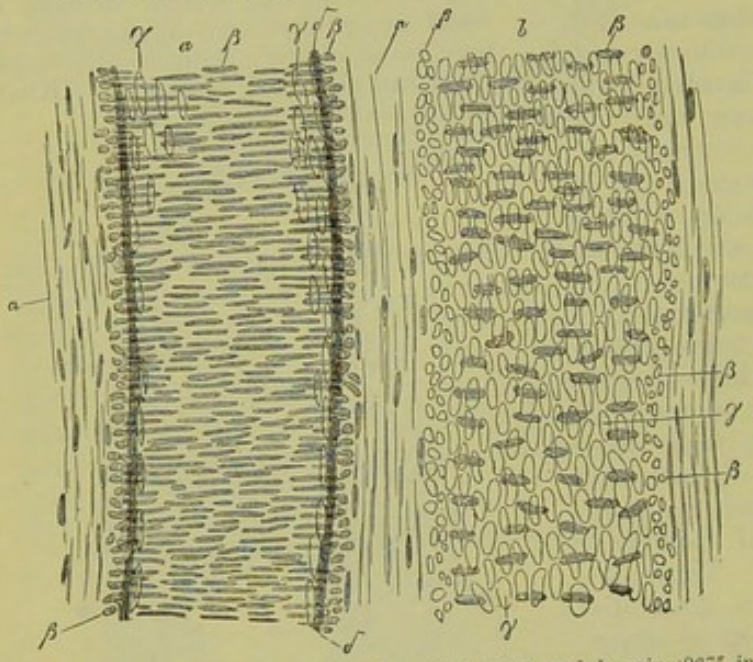

a. An artery from the mesentery of a child, ·062″, and *b*, vein ·067″ in diameter, treated with acetic acid and magnified 350 times. α. Tunica adventitia, with elongated nuclei. β. Nuclei of the contractile fibre-cells of the tunica media, seen partly from the surface, partly apparent in transverse section. γ. Nuclei of the endothelial cells. δ. Elastic longitudinal fibrous coat.

Some arteries have extremely thin coats in proportion to their size; this is especially the case in those situated in the cavity of the cranium and vertebral canal, the difference depending on the thinness of the external and middle coats.

The arteries, in their distribution throughout the body, are included in thin fibro-areolar investments, which form their *sheaths*. In the limbs the sheath is usually formed by a prolongation of the deep fascia; in the upper part of the thigh it consists of a continuation downwards of the transversalis and iliac fasciæ of the abdomen; in the neck, of a prolongation of the deep cervical fascia. The included vessel is loosely connected with its sheath by delicate areolar tissue; and the sheath usually encloses the accompanying veins, and sometimes a nerve. Some arteries, as those in the cranium, are not included in sheaths.

All the larger arteries, like the other organs of the body, are supplied with blood-vessels. These nutrient vessels, called the *vasa vasorum*, arise from a branch of the artery or from a neighbouring vessel, at some considerable distance from the point at which they are distributed; they ramify in the loose areolar tissue connecting the artery with its sheath, and are distributed to the external coat, but do not, in man, penetrate the other coats; in some of the larger

mammals a few vessels have been traced into the middle coat. Minute veins serve to return the blood from these vessels; they empty themselves into the vein or veins accompanying the artery. Lymphatic vessels are also present in the outer coat.

Arteries are also supplied with nerves, which are derived from the sympathetic, but may pass through the cerebro-spinal nerves. They form intricate plexuses upon the surfaces of the larger trunks, and run along the smaller arteries as single filaments, or bundles of filaments which twist around the vessel and unite with each other in a plexiform manner. The branches derived from these plexuses penetrate the external coat and are distributed principally to the muscular tissue of the middle coat, and thus regulate, by causing the contraction and relaxation of this tissue, the amount of blood sent to any part.

The capillaries.—The smaller arterial branches (excepting those of the cavernous structure of the sexual organs, of the spleen, and of the placenta)

FIG. 75.—Section of a medium-sized artery. (After Grünstein.)

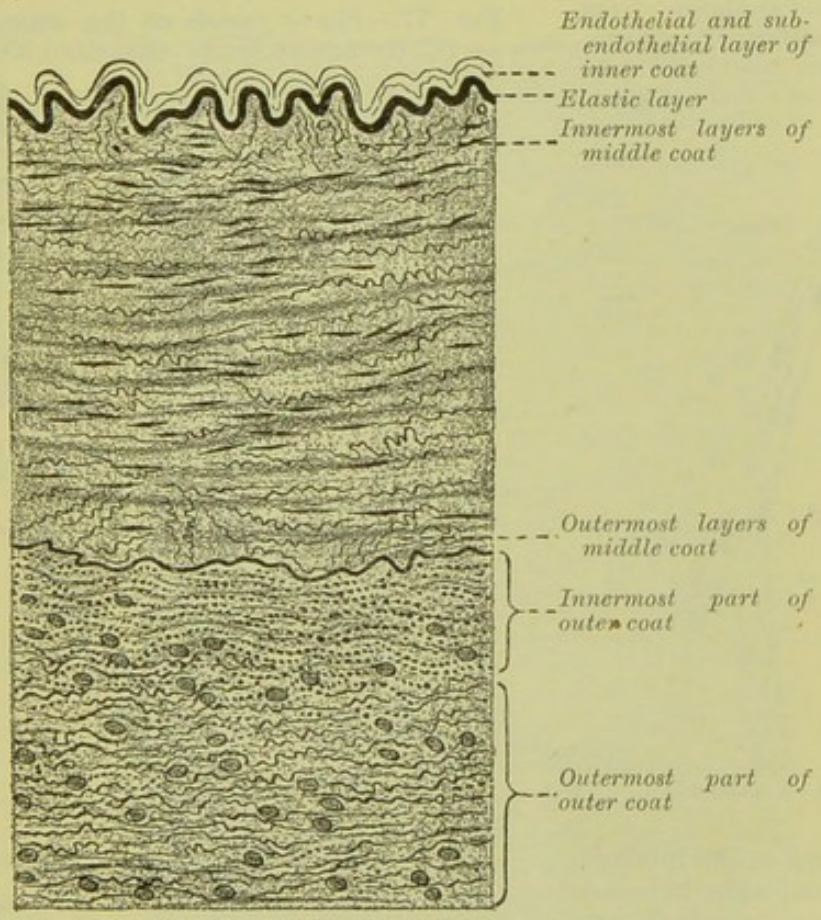

terminate in networks of vessels which pervade nearly every tissue of the body. These vessels, from their minute size, are termed capillaries. They are interposed between the smallest branches of the arteries and the commencing veins, constituting a network, the branches of which maintain the same diameter throughout; the meshes of the network are more uniform in shape and size than those formed by the anastomoses of the small arteries and veins.

The *diameters* of the capillaries vary in the different tissues of the body, the usual size being about $\frac{1}{3000}$ of an inch. The smallest are those of the brain and the mucous membrane of the intestines; and the largest those of the skin and the marrow of bone, where they are stated to be as large as $\frac{1}{1200}$ of an inch in diameter. The *form* of the capillary net varies in the different tissues, the meshes being generally rounded or elongated.

The *rounded form of mesh* is most common, and prevails where there is a dense network, as in the lungs, in most glands and mucous membranes, and in the cutis; the meshes are not of an absolutely circular outline, but more or less angular, sometimes nearly quadrangular, or polygonal, or more often irregular.

Elongated meshes are observed in the muscles and nerves, the meshes resembling parallelograms in form, the long axis of the mesh running parallel with the long axis of the nerve or muscle. Sometimes the capillaries have a *looped* arrangement; a single vessel projecting from the common network and returning after forming one or more loops, as in the papillæ of the tongue and skin.

The number of the capillaries and the size of the meshes determine the degree of vascularity of a part. The closest network and the smallest interspaces are found in the lungs and in the choroid coat of the eye. In these situations the interspaces are smaller than the capillary vessels themselves. In the kidney, in the conjunctiva, and in the cutis, the interspaces are from three to four times as large as the capillaries which form them; and in the brain from eight to ten times as large as the capillaries in their long diameters, and from four to six times as large in their transverse diameters. In the adventitia of arteries the width of the meshes is ten times that of the capillary vessels. As a general rule, the more active the function of the organ, the closer is its capillary net and the larger its supply of blood; the meshes of the network are very narrow in all growing parts, in the glands, and in the mucous membranes; wider in bones and ligaments, which are comparatively inactive; and nearly altogether absent in tendons, in which very little organic change occurs after thei formation. In the liver the capillaries take a more or less radial course towards the intralobular vein, and are believed by some authorities to open freely into the substance of the liver, although not to such a degree as in the spleen.

Fig. 76.—Capillaries from the mesentery of a guinea-pig after treatment with solution of nitrate of silver.

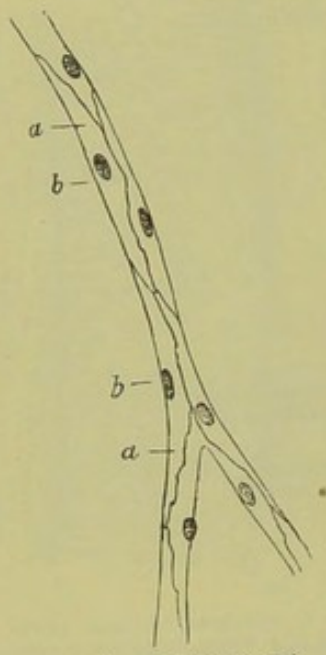

a. Cells. *b*. Their nuclei.

Fig. 77.—Finest vessels on the arterial side. From the human brain. Magnified 300 times.

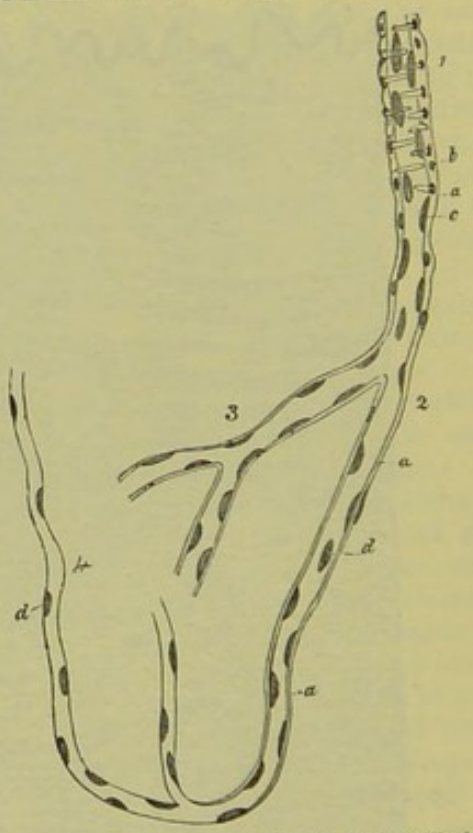

1. Smallest artery. 2. Transition vessel. 3. Coarser capillaries. 4. Finer capillaries. *a*. Structureless membrane still with some nuclei, representative of the tunica adventitia. *b*. Nuclei of the muscular fibre-cells. *c*. Nuclei within the small artery, perhaps appertaining to an endothelium. *d*. Nuclei in the transition vessels.

Structure.—The wall of a capillary consists of a fine transparent endothelial layer, composed of cells joined edge to edge by an interstitial cement-substance, and continuous with the endothelial cells which line the arteries and veins. When stained with nitrate of silver the edges which bound the epithelial cells are brought into view (fig. 76). These cells are of large size and of an irregular polygonal or lanceolate shape, each containing an oval nucleus which may be brought into view by carmine or hæmatoxylin. Between their edges, at various points of their meeting, roundish dark spots are sometimes seen, which have been described as stomata, though they are closed by intercellular substance. They have been believed to be the situations through which the colourless corpuscles of the blood, when

migrating from the blood-vessels, emerge; but this view, though probable, is not universally accepted.

Kolossow describes these cells as having a rather more complex structure. He states that each consists of two parts: of hyaline ground-plates, and of a protoplasmic granular part, in which is imbedded the nucleus, on the outside of the ground-plates. The hyaline internal coat of the capillaries does not form a complete membrane, but consists of 'plates' which are inelastic, and though in contact with each other are not continuous; when therefore the capillaries are subjected to intravascular pressure, the plates become separated from each other; the protoplasmic portions of the cells, on the other hand, are united together.

In many situations a delicate sheath or envelope of branched nucleated connective tissue cells is found around the simple capillary tube, particularly in the larger ones; and in other places, especially in the glands, the capillaries are invested with retiform connective tissue.

FIG. 78.—Section of a medium-sized vein.

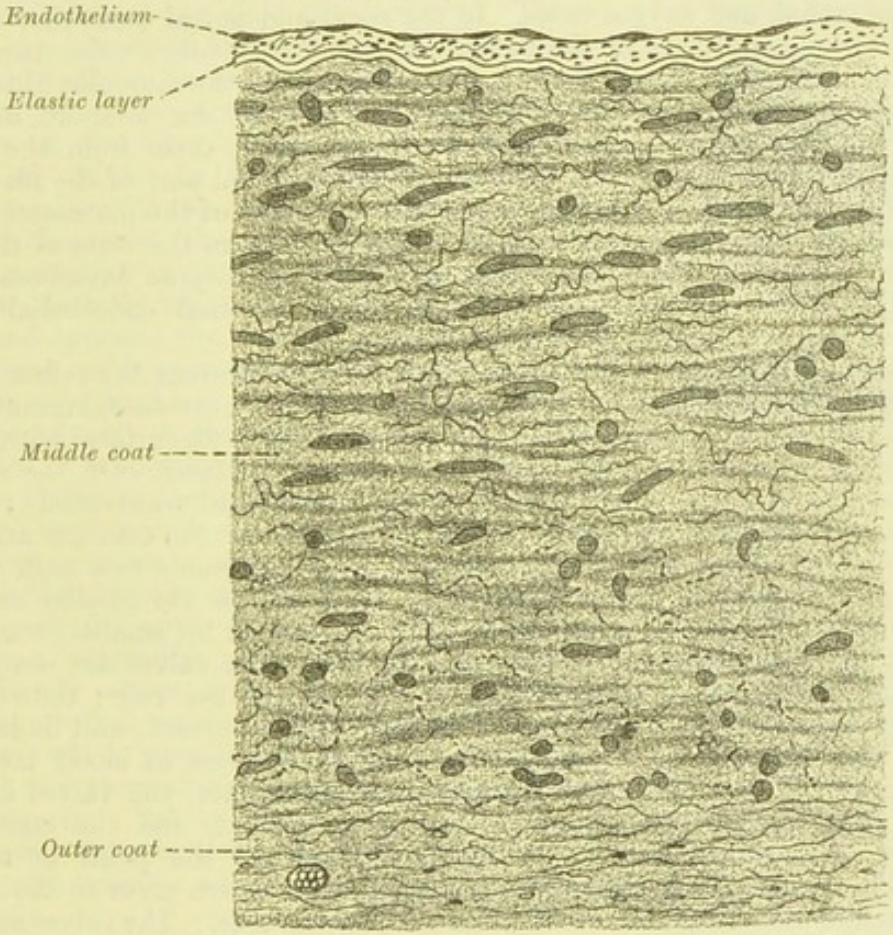

In the largest capillaries (which ought, perhaps, to be described rather as the smallest arteries or pre-capillaries) there is, outside the epithelial layer, a muscular layer consisting of contractile fibre-cells arranged transversely, as in the tunica media of the arteries (fig. 77).

Structure of veins.—The veins, like the arteries, are composed of three coats—internal, middle, and external; and these coats are, with the necessary modifications, analogous to the coats of the arteries; the internal being the endothelial, the middle the muscular, and the external the connective or areolar (fig. 78). The main difference between the veins and the arteries is in the comparative weakness of the middle coat in the former.

In the smallest veins the three coats are hardly to be distinguished. The endothelium is supported on a membrane separable into two layers, the outer of which is the thicker, and consists of a delicate, nucleated membrane (adventitia), while the inner is composed of a network of longitudinal elastic fibres (media). In the veins next above these in size (one-sixtieth of an inch in diameter), according to Kölliker a connective tissue layer containing numerous

muscle-fibres circularly disposed can be traced, forming the middle coat, while the elastic and connective tissue elements of the outer coat become more distinctly perceptible. In the middle-sized veins the typical structure of these vessels becomes clear. The endothelium is of the same character as in the arteries, but its cells are more oval and less fusiform. It is supported by a connective tissue layer, consisting of a delicate network of branched cells, and external to this is a layer of elastic fibres disposed in the form of a network in place of the definite fenestrated membrane seen in arteries. This constitutes the *internal* coat. The *middle* coat is composed of a thick layer of connective tissue with elastic fibres, intermixed, in some veins, with a transverse layer of muscular tissue. The white fibrous element is in considerable excess, and the elastic fibres are in much smaller proportion in the veins than in the arteries. The *outer* coat consists, as in the arteries, of areolar tissue, with longitudinal elastic fibres. In the largest veins the outer coat is from two to five times thicker than the middle coat, and contains a large number of longitudinal muscular fibres. These are most distinct in the inferior vena cava, especially at the termination of this vein in the heart, in the trunks of the hepatic veins, in all the large trunks of the portal vein, and in the external iliac, renal, and azygos veins. In the renal and portal veins they extend through the whole thickness of the outer coat, but in the other veins mentioned a layer of connective and elastic tissue is found external to the muscular fibres. All the large veins which open into the heart are covered for a short distance with a layer of striped muscular tissue continued on to them from the heart. Muscular tissue is wanting—(1) in the veins of the maternal part of the placenta; (2) in the venous sinuses of the dura mater and the veins of the pia mater of the brain and spinal cord; (3) in the veins of the retina; (4) in the veins of the cancellous tissue of bones; (5) in the venous spaces of the corpora cavernosa. The veins of the above-mentioned parts consist of an internal endothelial lining supported on one or more layers of areolar tissue.

Most veins are provided with valves which serve to prevent the reflux of the blood. Each valve is formed by a reduplication of the inner coat, strengthened by connective tissue and elastic fibres, and is covered on both surfaces with endothelium, the arrangement of which differs on the two surfaces. On the surface of the valve next the wall of the vein, the cells are arranged transversely; while on the other surface, over which the current of blood flows, the cells are arranged longitudinally in the direction of the current. Most commonly two such valves are found placed opposite one another, more especially in the smaller veins or in the larger trunks at the point where they are joined by smaller branches; occasionally there are three and sometimes only one. The valves are semilunar. They are attached by their convex edges to the wall of the vein; the concave margins are free, directed in the course of the venous current, and lie in close apposition with the wall of the vein as long as the current of blood takes its natural course; if, however, any regurgitation takes place, the valves become distended, their opposed edges are brought into contact, and the current is interrupted. The wall of the vein on the cardiac side of the point of attachment of each valve is expanded into a pouch or sinus, which gives to the vessel, when injected or distended with blood, a knotted appearance. The valves are very numerous in the veins of the extremities, especially of the lower extremities; these vessels having to conduct the blood against the force of gravity. They are absent in the very small veins, i.e. those less than $\frac{1}{12}$ of an inch in diameter, also in the venæ cavæ, the hepatic veins, portal vein and most of its branches, the renal, uterine, and ovarian veins. A few valves are found in each spermatic vein, and one also at its point of junction with the renal vein or inferior vena cava respectively. The cerebral and spinal veins, the veins of the cancellated tissue of bone, the pulmonary veins, and the umbilical vein and its branches, are also destitute of valves. Valves are occasionally found, few in number, in the azygos and intercostal veins.

The veins, like the arteries, are supplied with nutrient vessels, *vasa vasorum*. Nerves also are distributed to them in the same manner as to the arteries, but in much less abundance.

Structure of lymphatics.—The lymphatic vessels, including in this term the lacteal vessels which are identical in structure with them, are composed of three coats. The *internal* is an endothelial and elastic coat. It is thin, transparent, slightly elastic, and ruptures sooner than the other coats. It is composed of a layer of

elongated endothelial cells with serrated margins, by which the adjacent cells are dovetailed into one another. These are supported on an elastic membrane. The *middle* coat is composed of smooth muscular and fine elastic fibres, disposed in a transverse direction. The *external* coat consists of connective tissue, intermixed with smooth muscular fibres longitudinally or obliquely disposed. It forms a protective covering to the other coats, and serves to connect the vessel with the neighbouring structures. The above description applies only to the larger lymphatics; in the smaller vessels there is no muscular or elastic coat, and the wall consists only of a connective tissue coat, lined by endothelium. The thoracic duct has a more complex structure than the other lymphatics; it presents a distinct sub-endothelial layer of branched corpuscles, similar to that found in the arteries, and in the middle coat is a layer of connective tissue with its fibres arranged longitudinally. The lymphatics are supplied by nutrient vessels, which are distributed to their outer and middle coats; and here also have been traced many non-medullated nerve-fibres in the form of a fine plexus of fibrils.

The lymphatics are very generally provided with valves, which assist materially in effecting the circulation of the fluid they contain. These valves are formed of thin layers of fibrous tissue, lined on both surfaces by endothelium, which presents the same arrangement upon the two surfaces as was described in connection with the valves of veins. In form they are semilunar; they are attached by their convex edges to the sides of the vessel, the concave edges being free and directed along the course of the contained current. Usually two such valves, of equal size, are found opposite one another; but occasionally exceptions occur, especially at or near the anastomoses of lymphatic vessels. Thus, one valve may be of very rudimentary size and the other increased in proportion.

The valves in the lymphatic vessels are placed at much shorter intervals than in the veins. They are most numerous near the lymphatic glands, and are found more frequently in the lymphatics of the neck and upper extremity than in those of the lower extremity. The wall of a lymphatic immediately above the point of attachment of each segment of a valve is expanded into a pouch or sinus, which gives to these vessels, when distended, the knotted or beaded appearance which they present. Valves are wanting in the vessels composing the plexiform network in which the lymphatics usually originate on the surface of the body.

FIG. 79.—Pseudostomata of serous membranes.

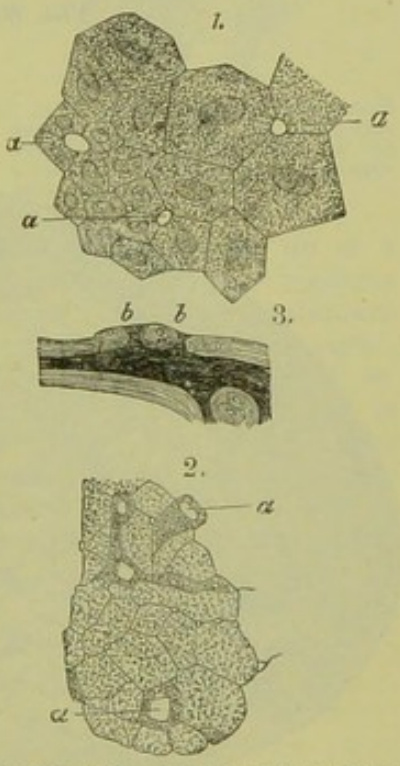

1. Endothelium from the under surface of the *centrum tendinium* of the rabbit. 2. Endothelium of the mediastinum of the dog. 3. Section through the pleura of the same animal. *a*. Pseudostomata. *b*. Free orifices of short lateral passages of the lymph-canals. (Copied from Ludwig, Schweigger-Seidel and Dybkowsky.)

Origin of lymphatics.—The finest lymphatic vessels (lymphatic capillaries) form a plexiform network in the tissues and organs, and their walls consist of a single layer of endothelial plates, with more or less sinuous margins; the vessels of the lymphatic system therefore form a series of closed tubes similar to those of the blood vascular system. The lymphatic vessels for the most part accompany the arteries or veins throughout the body; sometimes a minute artery may be seen to be ensheathed for a certain distance by a lymphatic capillary vessel, which is often many times wider than a blood capillary. These are known as perivascular lymphatics.

Terminations of lymphatics.—The lymphatics, including the lacteals, discharge their contents into the veins at two points: namely, at the angles of junction of the subclavian and internal jugular veins—on the left side by means of the thoracic duct, and on the right side by the right lymphatic duct. (See description of lymphatics.)

Lymphatic glands (*lymph glands*) are small oval or bean-shaped bodies, situated in the course of lymphatic and lacteal vessels so that the lymph and chyle pass

through them on their way to the blood. Each generally presents on one side a slight depression—the *hilus*—through which the blood-vessels enter and leave the interior. The efferent lymphatic vessel also emerges from the gland at this spot, while the afferent vessels enter the organ at different parts of the periphery. On section (fig. 80), a lymphatic gland displays two different structures: an external, of lighter colour—the *cortical*; and an internal, darker—the *medullary*. The cortical structure does not form a complete investment, but is deficient at the hilum, where the medullary portion reaches the surface of the gland; so that the efferent vessel is derived directly from the medullary structure, while the afferent vessels empty themselves into the cortical substance.

A lymphatic gland consists of (1) a fibrous envelope, or *capsule*, from which a framework of processes (*trabeculæ*) proceeds inwards, imperfectly dividing the gland into open spaces freely communicating with each other; (2) a quantity of lymphoid tissue occupying these spaces without completely filling them; (3) a free supply of blood-vessels, which are supported on the trabeculæ; and (4) the *afferent* and *efferent* vessels. The nerves passing into the hilus are few in number and are chiefly distributed to the blood-vessels supplying the gland.

Fig. 80.—Section of a lymphatic gland.

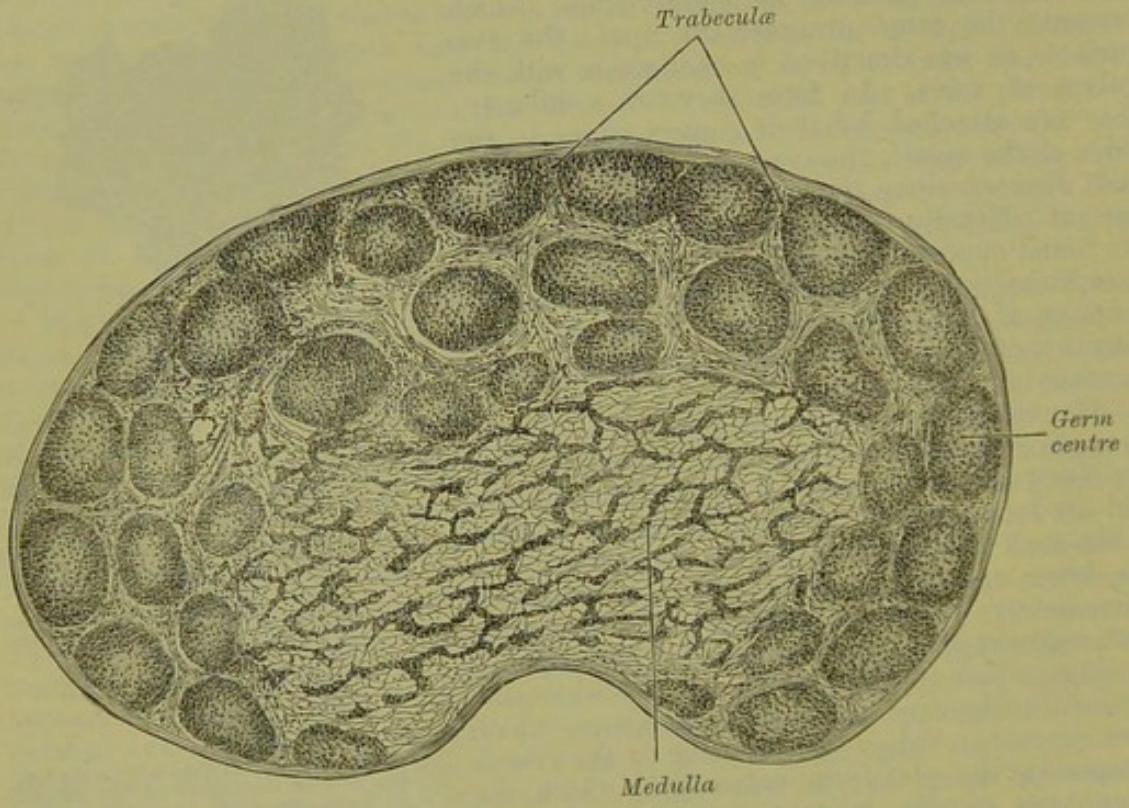

The *capsule* is composed of connective tissue with some plain muscle-fibres, and from its internal surface are given off a number of membranous processes or trabeculæ, consisting, in man, of connective tissue, with a small admixture of plain muscle-fibres; but in many of the lower animals composed almost entirely of involuntary muscle. They pass inwards, radiating towards the centre of the gland, for a certain distance—that is to say, for about one-third or one-fourth of the space between the circumference and the centre of the gland. In some animals they are sufficiently well marked to apparently divide the peripheral or cortical portion of the gland into a number of compartments (so-called follicles), but in man this arrangement is not obvious. The larger trabeculæ springing from the capsule break up into finer bands, and these interlace to form a meshwork in the central or medullary portion of the gland. In these spaces formed by the interlacing trabeculæ (fig. 81) is contained the proper gland-substance or lymphoid tissue. The gland-pulp does not, however, completely fill the spaces, but leaves, between its outer margin and the enclosing trabeculæ, a channel or space of uniform width throughout. This is termed the *lymph-path* or *lymph-sinus* (fig. 83). Running across it are a number of finer trabeculæ of retiform connective tissue, the fibres of which are, for the most part, covered by ramifying cells.

On account of the peculiar arrangement of the framework of the organ, the gland-pulp in the cortical portion is disposed in the form of nodules, and in the medullary part in the form of rounded cords. It consists of ordinary lymphoid

Fig. 81.—Follicle from a lymphatic gland of the dog, in vertical section.

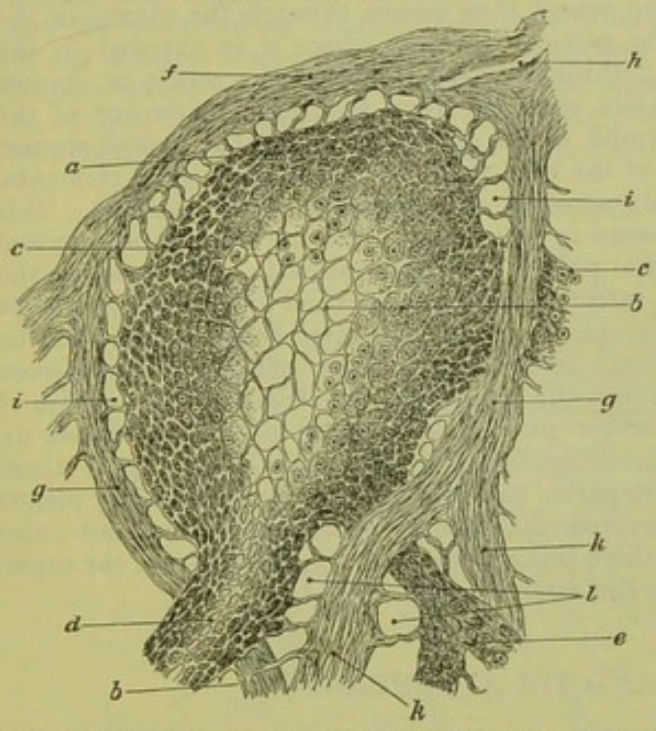

a. Reticular sustentacular substance of the more external portion, *b*, of the more internal, and *c*, of the most external and most finely webbed part on the surface of the follicle. *d*. Origin of a large lymph-tube. *e*. Of a smaller one. *f*. Capsule. *g*. Septa. *h*. Vas afferens. *i*. Investing space of the follicle, with its retinacula. *k*. One of the divisions of the septa. *l*. Attachment of the lymph-tubes to the septa.

Fig. 82.—From the medullary substance of an inguinal gland of the ox. (After His.)

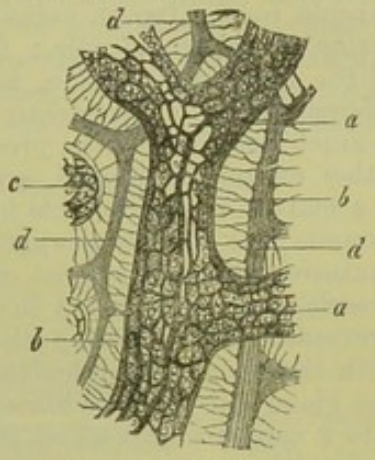

a. Lymph-tube with its complicated system of vessels. *b*. Retinacula stretched between the tube and the septa. *c*. Portion of another lymph-tube. *d*. Septa.

tissue, being made up of a delicate network of retiform tissue, which is continuous with that in the lymph-paths, but marked off from it by a closer reticulation; it is probable, moreover, that the reticular tissue of the gland-pulp and the lymph-paths is continuous with that of the trabeculæ, and ultimately with that of the capsule of the gland. In its meshes are closely packed lymph-corpuscles, traversed by a dense plexus of capillary blood-vessels. The nodules or follicles in

Fig. 83.—Section of lymphatic-gland tissue.

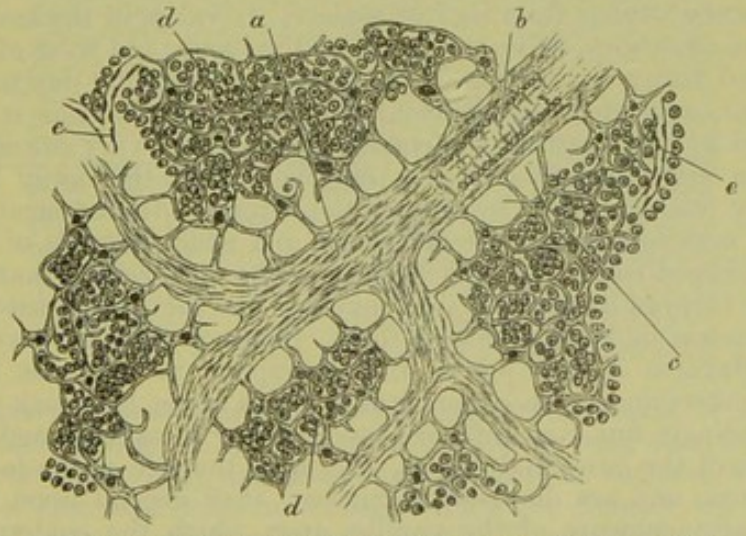

a. Trabeculæ. *b*. Small artery in substance of same. *c*. Lymph-paths. *d*. Lymph-corpuscles. *e*. Capillary plexus.

the cortical portion of the gland frequently show, in their centres, areas where karyokinetic figures indicate a division of the lymph-corpuscles. These areas are termed *germ-centres* (fig. 80). The cells composing them are smaller than the peripheral cells, and often stain less intensely.

The *afferent vessels*, as above stated, enter at all parts of the periphery of the gland, and after branching and forming a dense plexus in the substance of the capsule open into the lymph-sinuses of the cortical part. In doing this they lose all their coats except their endothelial lining, which is continuous with a layer of similar cells lining the lymph-paths. In like manner the *efferent* vessel commences from the lymph-sinuses of the medullary portion. The stream of lymph carried to the gland by the afferent vessel thus passes through the plexus in the capsule to the lymph-paths of the cortical portion, where it is exposed to the action of the gland-pulp; flowing through these it enters the paths or sinuses of the medullary portion, and finally emerges from the hilus by means of the efferent vessel. The stream of lymph in its passage through the lymph-sinuses is much retarded by the presence of the reticulum, hence morphological elements, either normal or morbid, are easily arrested and deposited in the sinuses. This is a matter of considerable importance in connection with the subject of poisoned wounds and the absorption of the poison by the lymphatic system, since the causative micro-organisms of the infective processes carried along the lymphatic vessels may be arrested in the lymph-sinuses of the gland-tissue, and thus be prevented from entering the general circulation. Many lymph-corpuscles pass with the efferent lymph-stream to join the general blood-stream. The arteries of the gland enter at the hilus, and either go at once to the gland-pulp, to break up into a capillary plexus, or else run along the trabeculæ, partly to supply them and partly running across the lymph-paths, to assist in forming the capillary plexus of the gland-pulp. This plexus traverses the lymphoid tissue, but does not enter into the lymph-sinuses. From it the veins commence and emerge from the organ at the same place as that at which the arteries enter.

THE SKIN AND ITS APPENDAGES

The **skin** (fig. 84) is the principal seat of the sense of touch, and may be regarded as a covering for the protection of the deeper tissues; it plays an important part in the regulation of the body temperature, and has also limited excretory and absorbing powers. It consists principally of a layer of vascular connective tissue, named the *dermis*, *corium*, or *cutis vera*, and an external covering of epithelium, termed the *epidermis* or *cuticle*. On the surface of the former layer are the sensitive *papillæ*; and within, or imbedded beneath it, are certain organs with special functions: namely, the *sweat-glands*, *hair-follicles*, and *sebaceous glands*.

The **epidermis** or **cuticle** (*scarf-skin*) is non-vascular, and consists of stratified epithelium (fig. 85). It is accurately moulded on the papillary layer of the dermis. It forms a defensive covering to the surface of the true skin, and limits the evaporation of watery vapour from its free surface. It varies in thickness in different parts. In some situations, as in the palms of the hands and soles of the feet, it is thick, hard, and horny in texture. This may be in a measure due to the fact that these parts are exposed to intermittent pressure, but that this is not the only cause is proved by the fact that the condition exists to a very considerable extent at birth. The more superficial layers of cells, called the *horny* layer (*stratum corneum*), may be separated by maceration from a deeper stratum, which is called the *rete mucosum* or *stratum Malpighii*, and which consists of several layers of differently shaped cells. The free surface of the epidermis is marked by a network of linear furrows of variable size, marking out the surface into a number of spaces of polygonal or lozenge-shaped form. Some of these furrows are large, as opposite the flexures of the joints, and correspond to the folds in the dermis produced by movements. In other situations, as upon the back of the hand, they are exceedingly fine, and intersect one another at various angles. Upon the palmar surface of the hand and fingers, and upon the sole of the foot, these lines are very distinct, and are disposed in curves; they depend upon the large size and peculiar arrangements of the papillæ upon which the epidermis is placed. In each individual the lines on the tips of the fingers form distinct patterns unlike those of any other person. A method of determining the identity of a criminal is based on this fact, impressions ('finger-prints') of these lines being made on paper covered with soot, or on white paper after first covering the fingers with ink. The deep surface of the epidermis is accurately moulded upon the papillary layer of the dermis, each papilla being capped by its epidermic sheath; so that when

the epidermis is removed by maceration, it presents on its under surface a number of pits or depressions corresponding to the papillæ, and ridges corresponding to the intervals between them. Fine tubular prolongations are continued from this layer into the ducts of the sudoriferous and sebaceous glands.

In structure, the epidermis consists of several layers of epithelial cells, agglutinated together and having a laminated arrangement. These several layers may be described as composed of four different strata from within outwards: (1) the *stratum Malpighii*, composed of several layers of epithelial cells; those of the deepest layer are columnar in shape and placed perpendicularly on the surface of the corium, the lower ends of the cells being denticulated, to fit into corresponding denticulations of the true skin; this deepest layer is sometimes termed the basilar

FIG. 84.—A diagrammatic sectional view of the skin (magnified).

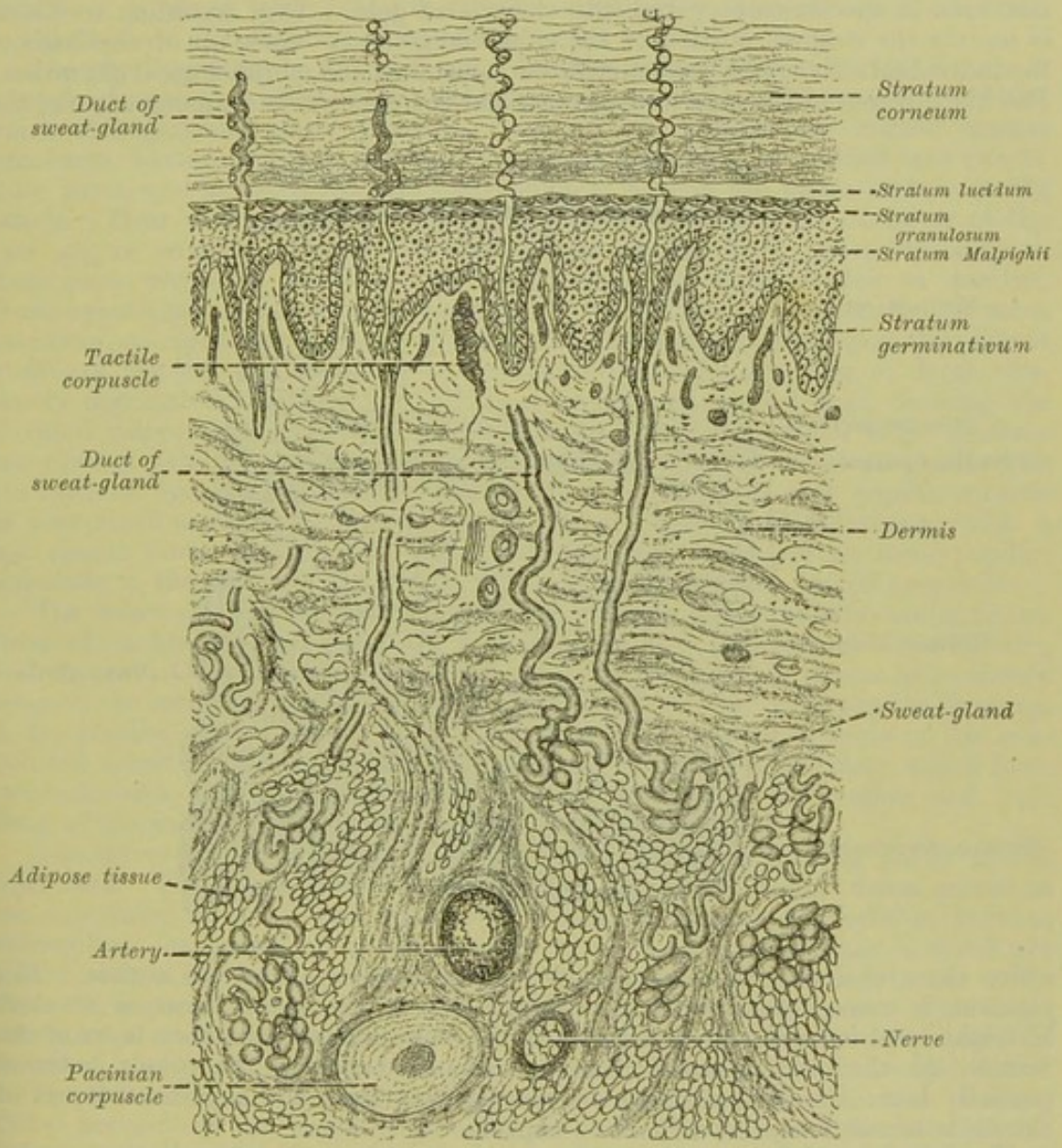

layer or *stratum germinativum*; the succeeding strata consist of cells of a more rounded or polyhedral form, the contents of which are soft, opaque, granular, and soluble in acetic acid. They are often marked on their surfaces with ridges and furrows, and are covered with numerous fibrils which connect the surfaces of the cells: these are known as *prickle-cells* (see page 15). They contain numerous epidermic fibrils, which are stained violet with hæmatoxylin and red with carmine, and form threads of union connecting adjacent cells. Between the cells are fine intercellular clefts which serve for the passage of lymph and in which lymph-corpuscles or pigment-granules may be found. (2) Immediately superficial to these are two or three layers of flattened, spindle-shaped cells, the *stratum granulosum*, which contain granules that are deeply stained by hæmatoxylin; the granules consist

of a material named *eleidin*, an intermediate substance in the formation of keratin. They are supposed to be cells in a transitional stage between the protoplasmic cells of the stratum Malpighii and the horny cells of the superficial layers. (3) Above this layer, the cells become indistinct, and appear in sections to form a homogeneous or dimly striated membrane, composed of closely packed scales in which traces of flattened nuclei may be found. It is called the *stratum lucidum*. (4) The surface layer consists of many lamellæ of horny epithelial scales in which no nuclei are discernible, forming the *stratum corneum*. These cells are unaffected by acetic acid, the protoplasm having become changed into horny material or *keratin*. According to Ranvier they contain granules of a material which has the characters of beeswax.

The deepest layer of the stratum Malpighii is separated from the papillæ by an apparently homogeneous basement membrane, which is most distinctly brought into view in specimens prepared with chloride of gold. This, according to Klein, is merely the deepest portion of the epithelium, and is ' made up of the basis of the individual cells, which have undergone a chemical and morphological alteration.' The black colour of the skin in the negro, and the tawny colour among some of the

FIG. 85.—Section of epidermis. (Ranvier.)

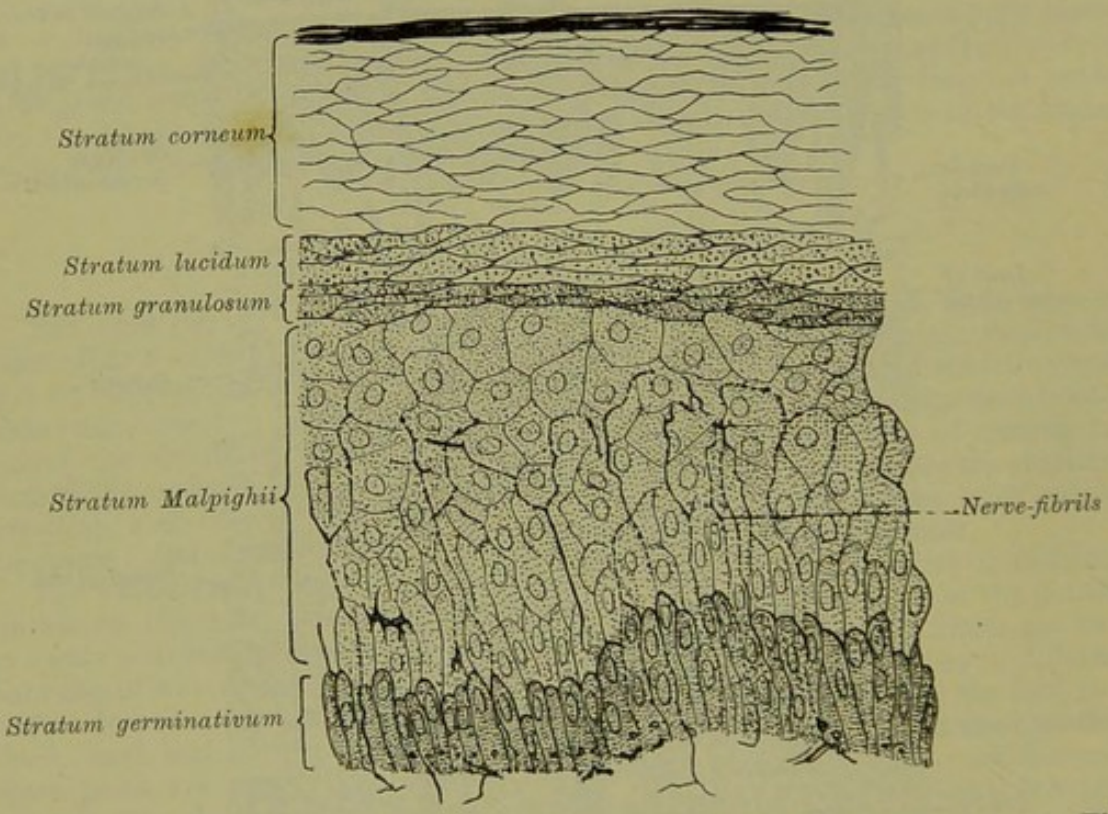

white races, is due to the presence of pigment in the cells of the cuticle. This pigment is more especially distinct in the cells of the deeper layer, or stratum Malpighii, and is similar to that found in the cells of the pigmentary layer of the retina. As the cells approach the surface and desiccate, the colour becomes partially lost; the disappearance of the pigment from the superficial layers of the epidermis is, however, difficult to explain.

The **dermis, corium,** or **cutis vera** is tough, flexible, and highly elastic, in order to defend the parts beneath from violence.

It varies in thickness, from a forty-eighth to an eighth of an inch, in different parts of the body. Thus it is very thick in the palms of the hands and soles of the feet; thicker on the posterior aspect of the body than on the front, and on the outer than on the inner sides of the limbs. In the eyelids, scrotum, and penis it is exceedingly thin and delicate. The skin generally is thicker in the male than in the female, and in the adult than in the child.

The corium consists of felted connective tissue, with a varying amount of elastic fibres and numerous blood-vessels, lymphatics, and nerves. The fibro-areolar tissue forms the framework of the cutis, and is differently arranged in different parts, so that it is usual to describe it as consisting of two layers: the

deeper or *reticular* layer, and the superficial or *papillary* layer. Unstriped muscular fibres are found in the superficial layers of the corium, wherever hairs are present; and in the subcutaneous areolar tissue of the scrotum, penis, labia majora, and nipples. In the nipples the fibres are disposed in bands, closely reticulated and arranged in superimposed laminæ.

The *reticular* layer consists of strong interlacing fibrous bands, composed chiefly of the white variety of fibrous tissue, but also containing some fibres of yellow elastic tissue, which vary in number in different parts; and connective tissue corpuscles, which are often to be found flattened against the white fibrous tissue bundles. Towards the attached surface the fasciculi are large and coarse, and the areolæ which are left by their interlacement are large, and occupied by adipose tissue and sweat-glands. Below this the elements of the skin become gradually blended with the subcutaneous areolar tissue, which, except in a few situations, contains fat. Towards the free surface the fasciculi are much finer, and their mode of interlacing close and intricate.

The *papillary layer* is situated upon the free surface of the *reticular layer*; it consists of numerous small, highly sensitive, and vascular eminences, the *papillæ*, which rise perpendicularly from its surface. The papillæ are minute conical eminences, having round or blunted extremities, occasionally divided into two or more parts, and are received into corresponding pits on the under surface of the cuticle. Their average length is about $\frac{1}{100}$ of an inch, and the diameter of the base $\frac{1}{250}$ of an inch. On the general surface of the body, more especially in those parts which are endowed with slight sensibility, they are few in number, short, exceedingly minute, and irregularly scattered over the surface; but in some situations, as upon the palmar surface of the hands and fingers, upon the plantar surface of the feet and toes, and around the nipple, they are long, of large size, closely aggregated together, and arranged in parallel curved lines, forming the elevated ridges seen on the free surface of the epidermis. Each ridge contains two rows of papillæ, and between the two rows the ducts of the sweat-glands pass outwards to open on the summit of the ridge. In structure each papilla consists of very small and closely interlacing bundles of finely fibrillated tissue, with a few elastic fibres; within this tissue is a capillary loop, and in some papillæ, especially in the palms of the hands and the fingers, there are tactile corpuscles.

The *arteries* supplying the skin form a network in the subcutaneous tissue, from which branches are given off to supply the sweat-glands, the hair-follicles, and the fat. Other branches are given off which constitute a plexus immediately beneath the corium; from this, fine capillary vessels pass into the papillæ, forming, in the smaller ones, a single capillary loop, but in the larger, a more or less convoluted vessel. There are numerous *lymphatics* supplied to the skin, which form two networks, superficial and deep, communicating with each other and with those of the subcutaneous tissue by oblique branches.

The *nerves* of the skin terminate partly in the epidermis and partly in the cutis vera. The former are prolonged into the epidermis from a dense plexus in the superficial layer of the corium and terminate between the cells in bulbous extremities; or, according to some observers, in cup-shaped endings in which are lodged certain of the deeper cells of the Malpighian layer, termed tactile cells; these are especially well seen in the skin covering the pig's snout. The latter terminate in end-bulbs, touch-corpuscles, or Pacinian bodies, in the manner already described; and, in addition to these, a considerable number of fibrils are distributed to the hair-follicles, which are said to entwine the follicle in a circular manner. Other nerve-fibres are supplied to the plain muscular fibres of the hair-follicles (arrectores pilorum) and to the muscular coats of the blood-vessels. These are probably non-medullated fibres.

The **appendages of the skin** are the nails, the hairs, and the sudoriferous and sebaceous glands with their ducts.

The nails and hairs are peculiar modifications of the epidermis, consisting essentially of the same cellular structure as that tissue.

The **nails** (fig. 86) are flattened, elastic structures of a horny texture, placed upon the dorsal surfaces of the terminal phalanges of the fingers and toes. Each nail is convex on its outer surface, concave within, and is implanted by a portion, called the *root*, into a groove in the skin; the exposed portion is called the *body*, and the distal extremity the *free edge*. The nail is firmly adherent to the dermis, being accurately moulded upon its surface, like the epidermis in other

parts. The part beneath the body and root of the nail is called the *matrix*, because from it the nail is produced. Corresponding to the body of the nail, the matrix is thick, and raised into a series of longitudinal ridges which are very vascular, and the colour is seen through the transparent tissue. Behind this, near the root of the nail, there are papillæ which are small, less vascular, and have no regular arrangement, and here the tissue of the nail is somewhat more opaque; hence this portion is of a whiter colour, and is called the *lunula* on account of its shape.

The cuticle as it passes forwards on the dorsal surface of the finger or toe is attached to the surface of the nail a little in advance of its root; at the extremity of the finger it is connected with the under surface of the nail a little behind its free edge. The cuticle and horny substance of the nail (both epidermic structures) are thus directly continuous with each other. The nails consist of a greatly thickened stratum lucidum, the stratum corneum forming merely the thin cuticular fold (*eponychium*) which overlaps the lunula. The cells have a laminated arrangement, and are essentially similar to those composing the epidermis. The cells of the deepest layer, which lie in contact with the papillæ of the matrix, are columnar in form and arranged perpendicularly to the surface; those which succeed them are of a rounded or polygonal form, the more superficial ones becoming broad, thin, and flattened, and so closely packed as to make the limits of each cell very indistinct. It is by the successive growth of new cells at the root and under surface of the body of the nail that it advances forwards and maintains a due thickness, while, at the same time, the growth of the nail in the proper direction is secured. As these cells in their turn become displaced by the growth of new

Fig. 86.—Longitudinal section through human nail and its nail groove (sulcus).

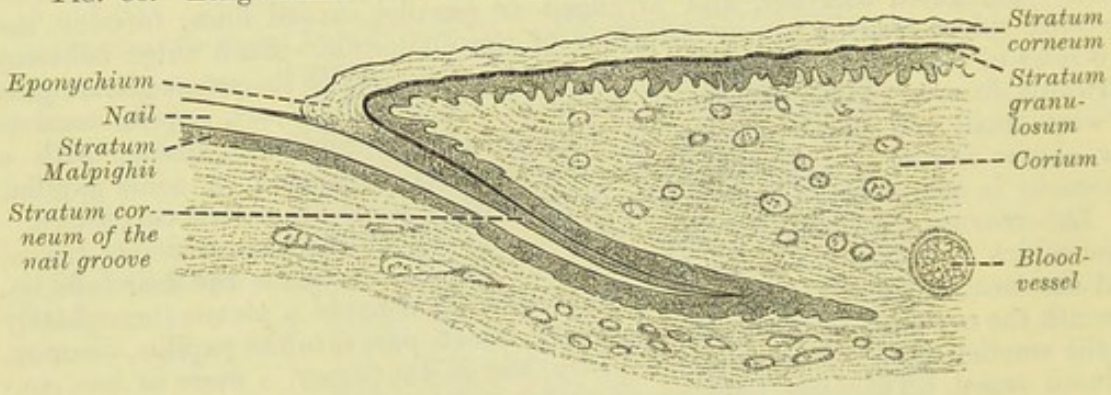

ones, they assume a flattened form, and finally become compacted together into a firm, dense, horny texture. In *chemical composition* the nails resemble the upper layers of the epidermis. According to Mulder, they contain a somewhat larger proportion of carbon and sulphur.

The **hairs** are peculiar modifications of the epidermis, and consist essentially of the same structure as that membrane. They are found on nearly every part of the surface of the body, excepting the palms of the hands, soles of the feet, and the glans penis. They vary much in length, thickness, and colour in different parts of the body and in different races of mankind. In some parts, as in the skin of the eyelids, they are so short as not to project beyond the follicles containing them; in others, as upon the scalp, they are of considerable length; again, in other parts, as the eyelashes, the hairs of the pubic region, and the whiskers and beard, they are remarkable for their thickness. Straight hairs are stronger than curly hairs, and present on transverse section a cylindrical or oval outline; curly hairs, on the other hand, are flattened.

A hair consists of a *root*, the part implanted in the skin; a *shaft* or *stem*, the portion projecting from the surface; and a *point*.

The *root of the hair* presents at its extremity a bulbous enlargement, which is whiter in colour and softer in texture than the shaft, and is lodged in a follicular involution of the epidermis called the *hair-follicle* (fig. 87). When the hair is of considerable length the follicle extends into the subcutaneous cellular tissue. The hair-follicle commences on the surface of the skin with a funnel-shaped opening, and passes inwards in an oblique or curved direction—the latter in curly hairs—to become dilated at its deep extremity, where it corresponds with the bulbous

enlargement of the hair which it contains. Opening into it, near its free extremity, are the ducts of one or more sebaceous glands. At the bottom of each hair-follicle is a small conical, vascular eminence or papilla, similar in every respect to those found upon the surface of the skin ; it is continuous with the dermic layer of the follicle, is highly vascular, and probably supplied with nerve-fibrils. In structure the hair-follicle consists of two coats—an outer or *dermic*, and an inner or *epidermic*.

The *outer* or *dermic* coat is formed mainly of fibrous tissue ; it is continuous with the corium, is highly vascular, and supplied by numerous minute nervous filaments. It consists of three layers (fig. 88). The most internal, next the cuticular lining of the follicle, consists of a hyaline basement membrane having a glassy, transparent appearance, which is well marked in the larger hair-follicles,

FIG. 87.—Section of skin, showing the epidermis and dermis : a hair in its follicle : the arrector pili muscle : sebaceous glands.

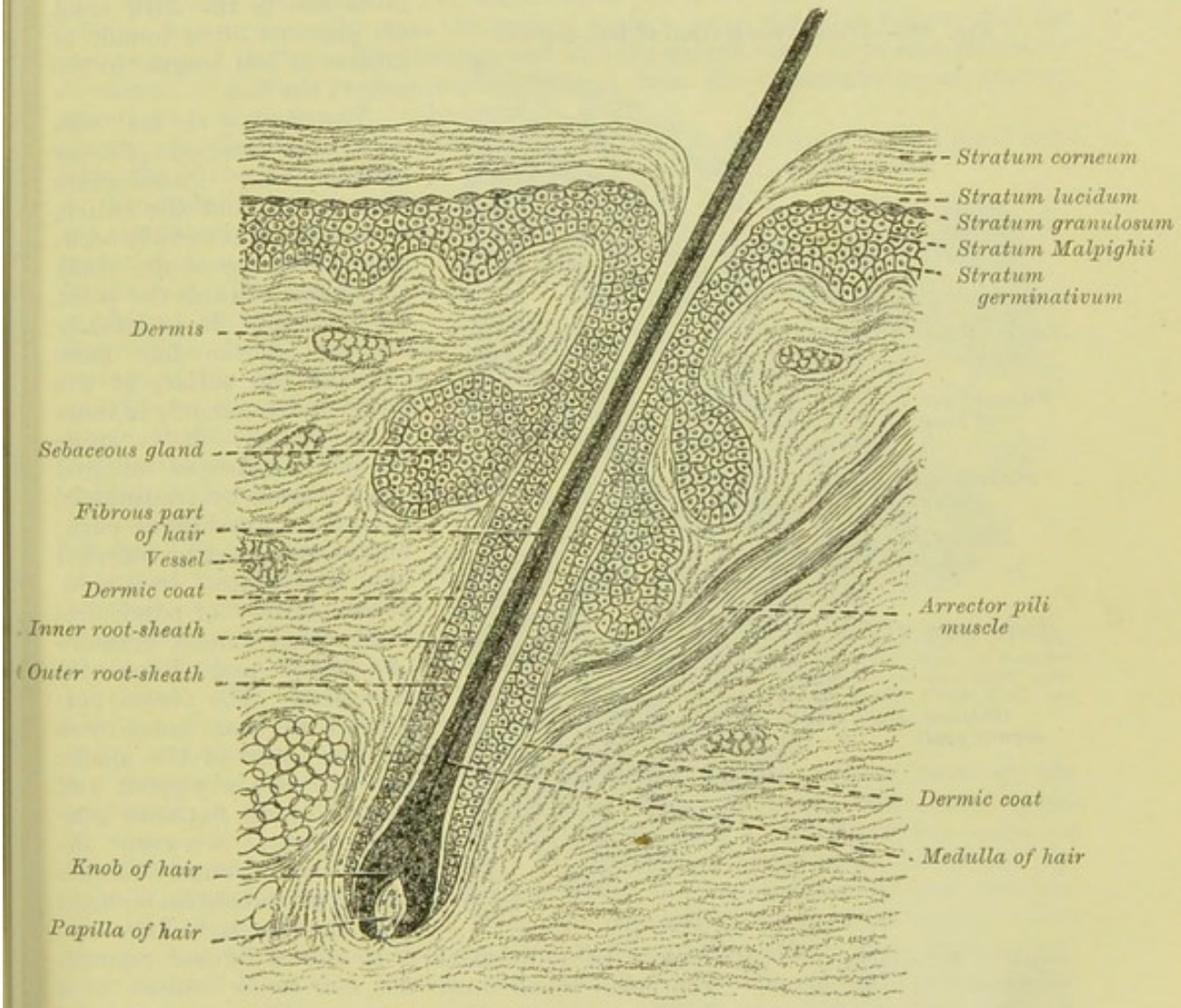

but is not very distinct in the follicles of minute hairs. It is continuous with the basement membrane of the surface of the corium. External to this is a compact layer of fibres and spindle-shaped cells arranged circularly around the follicle. This layer extends from the bottom of the follicle as high as the entrance of the ducts of the sebaceous glands. Externally is a thick layer of connective tissue, arranged in longitudinal bundles, forming a more open texture and corresponding to the reticular part of the corium. In this are contained the blood-vessels and nerves.

The *inner* or *epidermic* layer is closely adherent to the root of the hair, so that when the hair is plucked from its follicle this layer most commonly adheres to it and forms what is called the *root-sheath*. It consists of two strata named respectively the *outer* and *inner root-sheaths* ; the former of these corresponds with the

Malpighian layer of the epidermis, and resembles it in the rounded form and soft character of its cells; at the bottom of the hair-follicle these cells become continuous with those of the root of the hair. The *inner* root-sheath consists of: (1) a delicate cuticle next the hair, composed of a thin layer of imbricated scales having a downward direction, so that they fit accurately over the upwardly directed imbricated scales of the hair itself; (2) one or two layers of horny, flattened, nucleated cells, known as *Huxley's layer*; and (3) a single layer of horny oblong cells without visible nuclei, called *Henle's layer*.

The hair-follicle contains the root of the hair, which terminates in a bulbous extremity, and is excavated so as to fit exactly the papilla from which it grows. The bulb is composed of polyhedral epithelial cells, which as they pass upwards into the root of the hair become elongated and spindle-shaped, except some in the centre which remain polyhedral. Some of these latter cells contain pigment granules which give rise to the colour of the hair. It occasionally happens that these pigment granules completely fill the cells in the centre of the bulb; this gives rise to the dark tract of pigment often found, of greater or less length, in the axis of the hair.

Fig. 88.—Transverse section of hair-follicle.

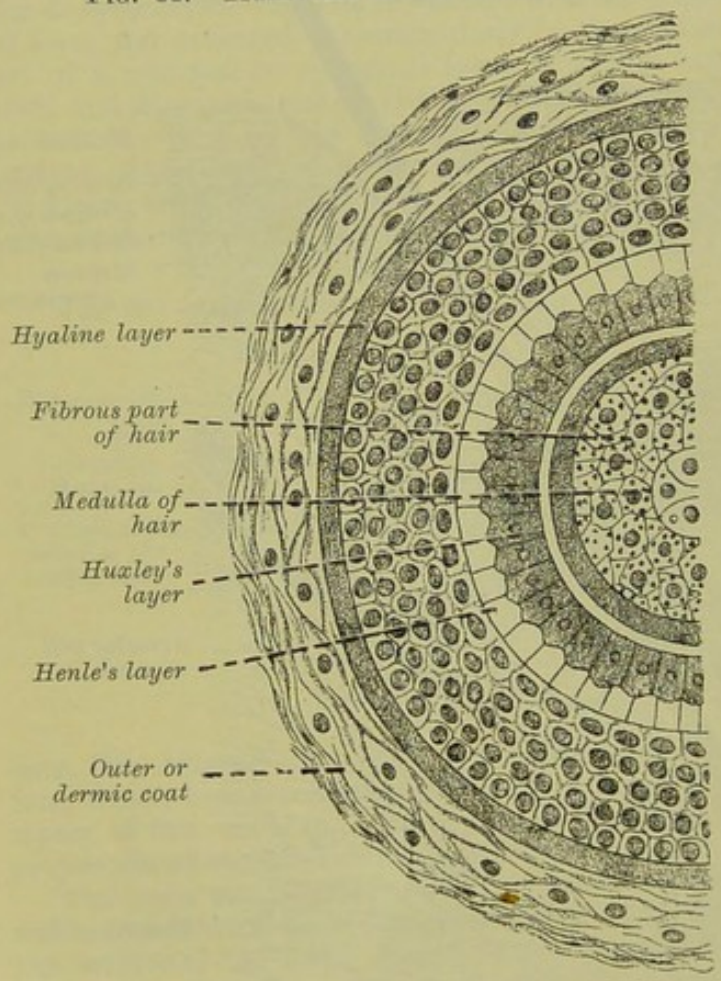

The *shaft of the hair* consists of a central pith or medulla, an intermediate fibrous part, and the cuticle externally. The *medulla* occupies the centre of the shaft and ceases towards the point of the hair. It is usually wanting in the fine hairs covering the surface of the body, and commonly in those of the head. It is more opaque and deeper coloured when viewed by transmitted light than the fibrous part; but when viewed by reflected light it is white. It is composed of rows of polyhedral cells, which contain granules of eleidin and frequently air-spaces. The *fibrous* portion of the hair constitutes the chief part of the shaft; its cells are elongated and unite to form flattened fusiform fibres. Between the fibres are found minute spaces which contain pigment granules in dark hair, and minute air-spaces in white hair. In addition there is also a diffused pigment contained in the fibres. The cells which form the *hair-cuticle* consist of a single layer which surrounds those of the fibrous part; they are converted into thin, flat scales having an imbricated arrangement.

Connected with the hair-follicles are minute bundles of involuntary muscular fibres, termed the *arrectores pilorum*. They arise from the superficial layer of the corium, and are inserted into a thickened portion of the outer surface of the hair-follicle, below the entrance of the duct of the sebaceous gland. They are placed on the side towards which the hair slopes, and by their action elevate the hair (fig. 87).* The sebaceous gland is situated in the angle which the arrector muscle forms with the superficial portion of the hair-follicle, and contraction of

* Arthur Thomson suggests that the contraction of these muscles on follicles which contain weak, flat hairs will tend to produce a permanent curve in the follicle, and this curve will be impressed on the hair which is moulded within it, so that the hair, on emerging through the skin, will be curled. Curved hair-follicles are characteristic of the scalp of the Bushman.

the muscle thus tends to squeeze the sebaceous secretion out from the duct of the gland.

The **sebaceous glands** are small, sacculated, glandular organs, lodged in the substance of the corium. They are found in most parts of the skin, but are especially abundant in the scalp and face; they are also very numerous around the apertures of the anus, nose, mouth, and external ear, but are wanting in the palms of the hands and soles of the feet. Each gland consists of a single duct, more or less capacious, which emerges from a cluster of small secreting pouches or saccules. The sacculi connected with each duct vary, as a rule, in number from two to five, but in some instances may be as many as twenty. Each saccule is composed of a transparent, colourless membrane, enclosing a number of epithelial cells. Those of the outer or marginal layer are small and polyhedral, and are continuous with the lining cells of the duct. The remainder of the sac is filled with larger cells, containing fat, except in the centre, where the cells have become broken up, leaving a cavity filled with their debris and a mass of fatty matter, which constitutes the sebaceous secretion. The ducts open most frequently into the hair-follicles, but occasionally upon the general surface, as in the labia minora and the free margin of the lips. On the nose and face the glands are of large size, distinctly lobulated, and often become much enlarged from the accumulation of pent-up secretion. The largest sebaceous glands are those found in the eyelids—the Meibomian glands.

FIG. 89.—Coiled tube of a sweat-gland cut in various directions.

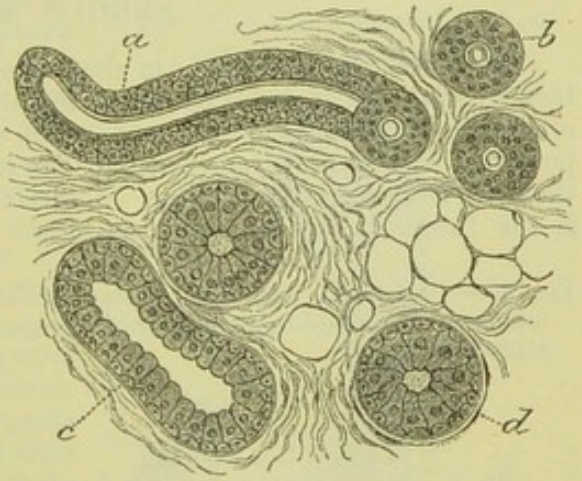

a. Longitudinal section of the proximal part of the coiled tube. *b*. Transverse section of the same. *c*. Longitudinal section of the distal part of the coiled tube. *d*. Transverse section of the same. (From Klein and Noble Smith's 'Atlas of Histology.')

The **sudoriferous** or **sweat glands** are the organs by which water and traces of organic material are excreted by the skin. They are found in almost every part of this structure, and are situated in small pits on the under surface of the corium, or, more frequently, in the subcutaneous areolar tissue, surrounded by a quantity of adipose tissue. They are small, lobular, reddish bodies, consisting of a single convoluted tube, from which the efferent duct proceeds upwards through the corium and cuticle, becomes somewhat dilated at its extremity, and opens on the surface of the cuticle by an oblique valve-like aperture. The duct, as it passes through the epidermis, presents a spiral arrangement, being twisted like a corkscrew in those parts where the epidermis is thick; where, however, the epidermis is thin, the spiral arrangement does not exist; the spiral course of these ducts is particularly distinct in the thick cuticle of the palms of the hands and soles of the feet. In the superficial layers of the corium the duct is straight, but in the deeper layers it is convoluted or even twisted. The size of the glands varies. They are especially large in those regions where the amount of perspiration is great, as in the axillæ, where they form a thin, mammillated layer of a reddish colour, which corresponds exactly to the situation of the hair in this region; they are large also in the groin. Their number varies. They are most numerous on the palms of the hands, presenting, according to Krause, 2,800 orifices on a square inch of the integument, and are rather less numerous on the soles of the feet; in both of these situations the orifices of the ducts are exceedingly regular, and open on the curved ridges. In other situations the glands are more irregularly scattered, but the number in a given extent of surface presents a fairly uniform average. In the neck and back they are least numerous, their number amounting to 417 on the square inch (Krause). Their total number is estimated by the same writer at 2,381,248, and he calculates that the whole of these glands would present an evaporating surface of about eight square inches. Each gland consists of a single tube intricately convoluted, terminating at one end by a blind extremity, and opening at the other end upon the surface of the skin. The wall of the duct is thick, the lumen seldom

exceeding one-third of the diameter of the tubes. The tube, both in the gland and where it forms the excretory duct, consists of two layers—an outer, formed by fine areolar tissue, and an inner layer of epithelium (fig. 89). The external coat is thin, continuous with the superficial layer of the corium, and extends only as high as the surface of the true skin. The epithelial lining in the distal part of the coiled tube of the gland proper consists of a single layer of cubical epithelium, supported on a basement membrane, and beneath it, between the epithelium and the fibro-cellular coat, a layer of longitudinally or obliquely arranged fibres, composed of involuntary muscle, the contraction of which aids the expulsion of the sweat. In the duct and the proximal part of the coiled tube of the gland proper there are two or more layers of polyhedral cells, lined on the internal surface, i.e. next the lumen of the tube, by a delicate membrane or cuticle, and on the outer surface by a limiting membrana propria, but there are no muscular fibres. The epithelium is continuous with the epidermis and with the delicate internal cuticle of the epidermic portion of the tube. When the cuticle is carefully removed from the surface of the cutis, these convoluted tubes of epithelium may be drawn out in the form of short, thread-like processes on its under surface.

The contents of the smaller sweat-glands are quite fluid; but in the larger glands the contents are semi-fluid and opaque, and contain a number of coloured granules and cells which appear analogous to epithelial cells.

SEROUS MEMBRANES

The **serous membranes** form shut sacs, the walls of which are normally in contact so that the enclosed cavity is merely a potential one. The sac consists of one portion which is applied to the walls of the cavity which it lines—the *parietal* portion; and another reflected over the surface of the organ or organs contained in the cavity—the *visceral* portion. Sometimes the sac is arranged quite simply, as is the tunica vaginalis testis; at others with numerous involutions or recesses, as in the peritoneum, in which, nevertheless, the membrane can always be traced continuously around the whole circumference. The sac is completely closed, so that no communication exists between the serous cavity and the parts in its neighbourhood. An exception exists in the peritoneum of the female; for the Fallopian tubes open freely into the peritoneal cavity in the dead subject. This communication, however, is closed during life, except at the moment of the passage of the ovum out of the ovary into the tube, as is proved by the fact that no interchange of fluids ever takes place between the two cavities in dropsy of the peritoneum, or in accumulation of fluid in the Fallopian tubes. The serous membrane is sometimes supported by a firm, fibrous layer, as is the case with the pericardium, and such membranes may be spoken of as *fibro-serous*.

FIG. 90.—Part of the peritoneal surface of the central tendon of the diaphragm of a rabbit, prepared with nitrate of silver.

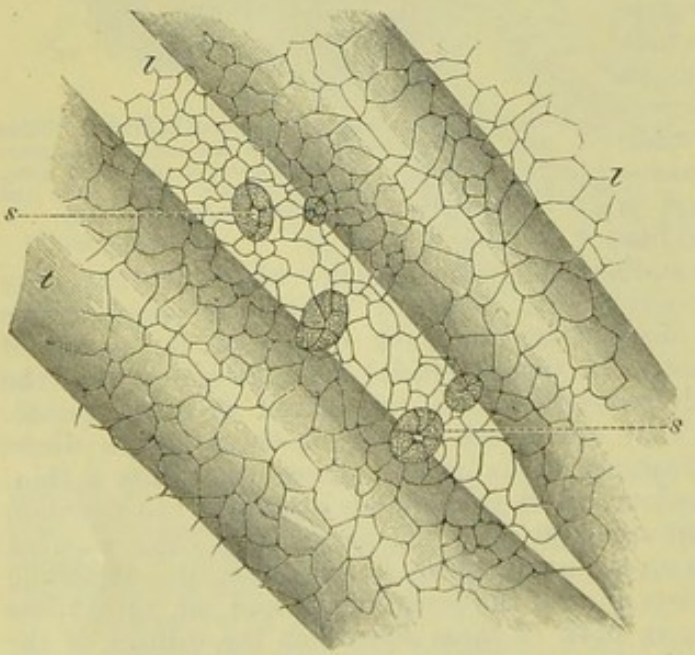

l. Lymph-channels. *t*. Tendon-bundles. *s*. The supposed stomata, clumps of germinating epithelial cells. (From 'Handbook for the Physiological Laboratory.' Klein.)

The various serous membranes are the peritoneum, lining the cavity of the abdomen; the two pleuræ and the pericardium, covering the lungs and heart respectively; and the tunicæ vaginales, surrounding the testicles in the scrotum. Serous membranes are thin, transparent, glistening structures, each consisting of a

homogeneous basement membrane lined on its inner surface by a single layer of polygonal or pavement endothelial cells, supported on a matrix of fibrous connective tissue, with networks of fine elastic fibres, in which are contained numerous capillaries and lymphatics. On the surface of the endothelium between the cells numerous apertures or interruptions are to be seen. Some of these are the structures formerly described as *stomata*, each of which is composed of cubical endothelium (see fig. 90); others (*pseudostomata*) are mere interruptions in the endothelial layer, and are occupied by processes of the branched connective tissue corpuscles of the subjacent tissue or by accumulations of the intercellular cement substance.

The amount of fluid contained in these closed sacs is, in most cases, only sufficient to moisten the surface; when a small quantity can be collected, it is found to resemble lymph, and like that fluid coagulates spontaneously; but when secreted in large quantities, as in dropsy, it is a more watery fluid, yet still contains a considerable amount of protein which is coagulated on boiling.

SYNOVIAL MEMBRANES

Synovial membranes, like serous membranes, are connective tissue membranes. In some cases they form closed sacs (synovial sheaths and bursæ) directly interposed between two movable tissues so as to diminish friction; thus they may be placed between a tendon and a bone where the former glides over the latter, or between the skin and various subcutaneous bony prominences. In other cases they form incomplete linings for the capsules of movable joints; in such cases a diminution of friction between the joint-surfaces is effected by the secretion poured out from the synovial cells.

FIG. 91.—Villus of synovial membrane. (After Hammar.)

The synovial membranes are composed essentially of the typical connective tissue, cells and fibres, containing numerous vessels and nerves. It was formerly supposed that these membranes were analogous in structure to the serous membranes, and consisted of a layer of flattened cells on a basement membrane. No such continuous layer, however, exists, although here and there are patches of epithelioid cells, surrounded and held together by an albuminous ground substance. Long villus-like processes (fig. 91) are often found projecting from the surfaces of synovial membranes; they are covered by small rounded cells, and are supposed to extend the surface for the secretion of the fluid (*synovia*) which moistens the membranes. It is a rich lymph, plus a mucin-like substance, and to the latter constituent it owes its viscidity. A further description of the synovial membranes will be given with the anatomy of the joints.

MUCOUS MEMBRANES

Mucous membranes line all the passages of the internal organs, and are continuous with the skin at the various orifices by which these passages open on the surface of the body. They are soft and very vascular, and the surface is coated over by their secretion, *mucus*, which is of a tenacious consistence and serves to protect them from the foreign substances with which they are brought in contact.

They are described as lining the two tracts—the gastro-pulmonary and the genito-urinary; and all, or almost all, mucous membranes may be classed as belonging to and continuous with the one or the other of these tracts.

The deep surfaces of these membranes are attached to the parts which they line by means of connective tissue, which is sometimes very abundant, forming a loose and lax bed, so as to allow considerable movement of the opposed surfaces on each other. This is termed the *submucous tissue*. In other cases such an intervening tissue is exceedingly scanty, and the membrane is closely connected to the tissue beneath; sometimes, for example, to muscle, as in the tongue; sometimes to cartilage, as in the larynx; and sometimes to bone, as in the nasal fossæ and air sinuses of the skull.

In structure a mucous membrane is composed of *corium* and *epithelium*. The epithelium is of various forms, including the squamous, columnar, and ciliated, and is often arranged in several layers. This epithelial layer is supported by the corium, which is analogous to the dermis of the skin, and consists of connective tissue, either simply areolar, or containing a greater or lesser quantity of lymphoid tissue. The corium is usually covered on its external surface by a transparent basement membrane, generally composed of clear flattened cells placed edge to edge; on this the epithelium rests. It is only in some situations that the basement membrane can be demonstrated. The corium is an exceedingly vascular membrane, containing a dense network of capillaries, which lie immediately beneath the epithelium and are derived from small arteries in the submucous tissue.

The fibro-vascular layer of the corium contains, besides the areolar tissue and vessels, unstriped muscle-cells, which form in many situations a definite layer called the *muscularis mucosæ*. These are situated in the deepest part of the membrane, and are plentifully supplied with nerves. Other nerves pass to the epithelium and terminate between the cells. Lymphatic vessels are found in great abundance, commencing by blind extremities and communicating with plexuses in the submucous tissue.

Imbedded in the mucous membrane are found numerous glands, and projecting from it are processes (villi and papillæ) analogous to the papillæ of the skin. These glands and processes, however, exist only at certain parts, and it will be more convenient to describe them as they occur.

SECRETING GLANDS

The **secreting glands** are organs whose cells produce, by the metabolism of their protoplasm, certain substances, called 'secretions,' of a more or less definite composition; the material for the secretion being primarily selected from the blood. Each cell in the organism forms new products from the material supplied to it. Where these new substances are utilised in some of the other functions of the organism they may be referred to as *secretions* in contradistinction to substances which are merely effete products of protoplasmic activity and are discarded as *excretions*. The term secretion, however, is generally applied to all the products of glandular activity. The essential parts therefore of a secreting gland are (1) *cells*, which have the power of extracting from the blood certain matters, and in most cases of converting these into new chemical compounds; and (2) *blood-vessels*, by which the blood is brought into close relationship with these cells. The general arrangement in all secreting structures—that is to say, not only in secreting glands, but also in secreting membranes—is that the cells are arranged on one surface of an extra-vascular basement membrane, which supports them, while a minute plexus of capillary vessels ramifies on the other surface of the membrane. The cells then select from the blood certain constituents which pass through the membrane into them, and these they prepare and elaborate.

By the various modifications of this secreting surface the different glands are formed. This is generally effected by an invagination of the membrane in different ways, the object being to increase the extent of secreting surface within a given bulk.

In the simplest form a single invagination takes place, constituting a *simple* gland; this may be either in the form of an open tube (fig. 92, A), or the walls of the tube may be dilated so as to form a saccule (fig. 92, B). These are named *simple tubular* or *saccular* glands. Or, instead of a short tube, the invagination

may be lengthened to a considerable extent, and then coiled up to occupy less space. This constitutes the simple *convoluted tubular* gland, an example of which may be seen in the sweat-glands of the skin (fig. 92, C).

If, instead of a single invagination, secondary invaginations take place from the primary one (fig. 92, D and E), the gland is termed a compound one. These secondary invaginations may assume either a saccular or tubular form, and so constitute the two subdivisions—the *compound saccular* or *racemose* gland, and the *compound tubular*. The racemose gland in its simplest form consists of a primary invagination which forms a sort of duct, at the extremity of which are found a number of secondary invaginations, called saccules or alveoli, as in Brunner's glands (fig. 92, D). But, again, in other instances, the duct, instead of being simple, may divide into branches, and these again into other branches, and so on; each ultimate ramification terminating in a dilated cluster of saccules, and thus the secreting surface may be almost indefinitely extended, as in the salivary glands

FIG. 92.—Diagrammatic plan of the varieties of secreting glands.

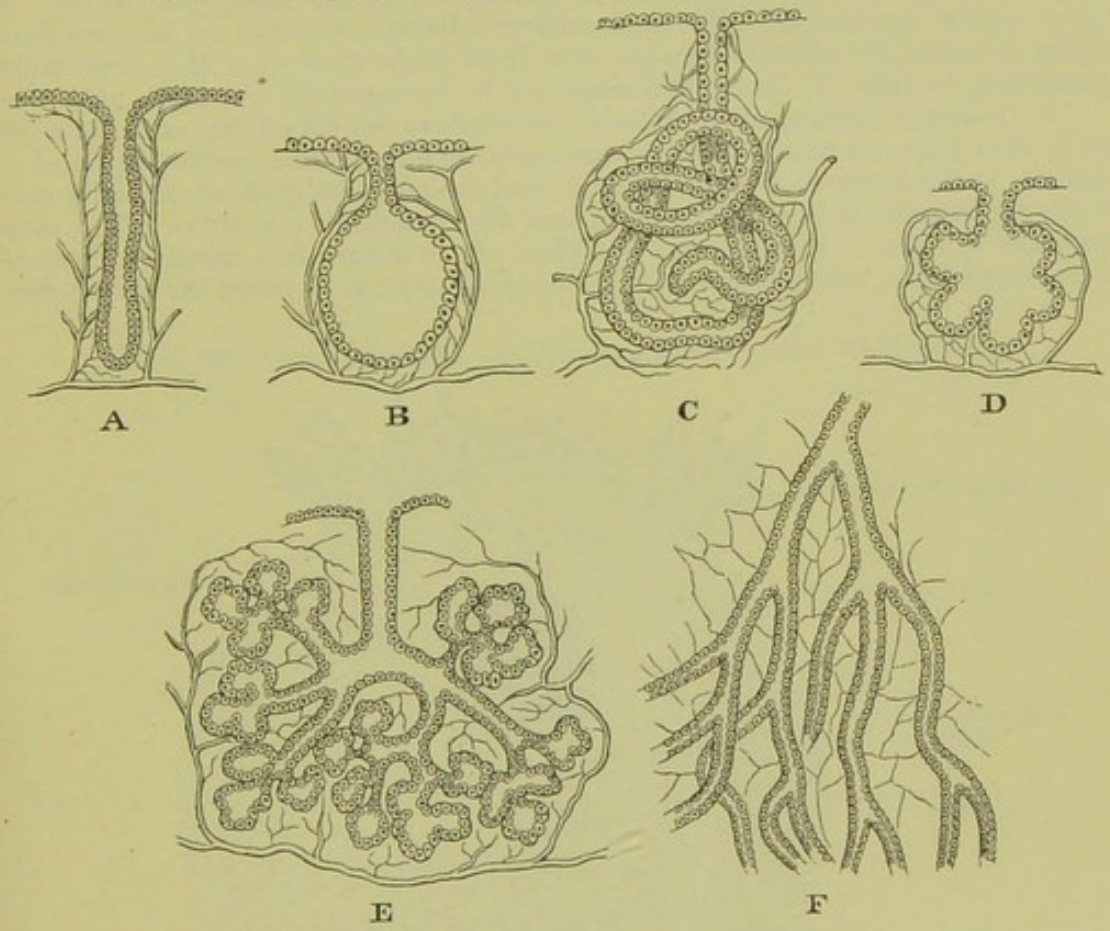

A. Simple gland. B. Sacculated simple gland. C. Simple convoluted tubular gland. D, E. Racemose gland. F. Compound tubular gland.

(fig. 92, E). The ducts of the glands are composed of columnar epithelial cells resting on a basement membrane, outside which is a greater or lesser amount of connective tissue, depending on the size of the duct. In some cases small bundles of involuntary muscle fibres are found external to the basement membrane, and these by their contractions help to expel the contained secretion. In the *compound tubular* glands the division of the primary duct takes place in the same way as in the racemose glands, but the branches retain their tubular form, and do not terminate in saccular recesses, but become greatly lengthened out (fig. 92, F). The best example of this form of gland is to be found in the kidney. All these varieties of glands are produced by a more or less complicated invagination of a secreting membrane, and they are all identical in structure: that is to say, the saccules or tubes, as the case may be, are lined with cells, generally spheroidal or columnar in shape, and on their outer surfaces are intimate plexuses of capillary vessels. The secretion, whatever it may be, is eliminated by the cells from the blood, and is poured into the saccule or tube, and so finds its way out through the primary

invagination on to the free surface of the secreting membrane. In addition, however, to these glands, which are formed by an *invagination* of the secreting membrane, there are some few others which are formed by a *protrusion* of the same structure, as in the vascular fringes of synovial membranes. This form of secreting structure is not nearly so frequently met with.

There are also certain glands which are capable of *internal secretion*, wherein are no ducts leading to any free surface, the secretion being carried either directly into the blood stream, or indirectly through the medium of lymphatics. Such are the thyroid and suprarenal glands, but modern researches have shown that many glands which possess obvious external secretions elaborate at the same time internal secretions.

EMBRYOLOGY

THE term **Embryology**, in its widest sense, is applied to the various changes which take place during the growth of an animal from the egg to the adult condition: it is, however, usually restricted to the phenomena which occur before birth. It may be studied from two aspects: (1) that of *ontogeny*, which deals only with the development of the individual; and (2) that of *phylogeny*, which concerns itself with the evolutionary history of the animal kingdom.

In all vertebrate animals the development of a new being can only take place when a female germ-cell or *ovum* has been fertilised by a male germ-cell or *spermatozoön*. The ovum is a nucleated cell, and all the complicated changes by which the various tissues and organs of the body are formed from it, after it has been fertilised, are the result of two general processes, viz. *segmentation* and *differentiation*

FIG. 93.—Ovum of rabbit. Highly magnified. (After Waldeyer.)

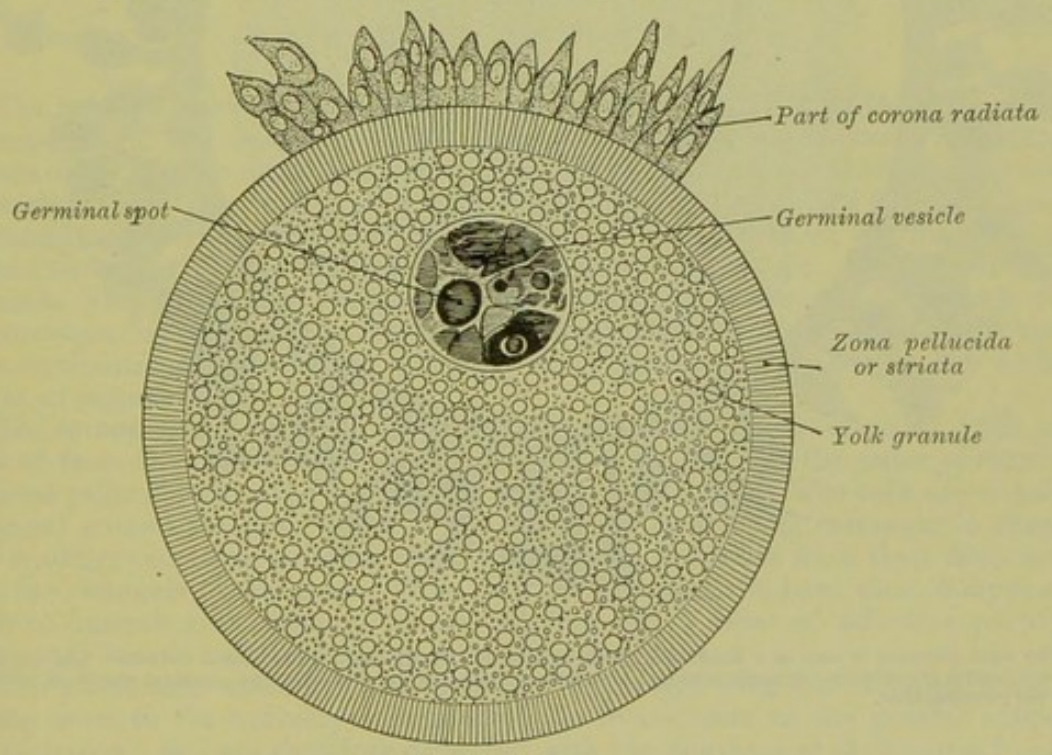

of cells. Thus, the fertilised ovum undergoes repeated segmentation into a number of cells which at first closely resemble one another, but are, sooner or later, differentiated into two groups: (1) *somatic cells*, the function of which is to build up the various tissues of the body; and (2) *germinal cells*, which become imbedded in the sexual glands—the ovaries in the female and the testes in the male—and are destined for the perpetuation of the species.

Having regard to the main purpose of this work, it is impossible, in the space available in this chapter, to describe fully, or illustrate adequately, all the phenomena which occur in the different stages of the development of the human body. The principal facts only will be given—the student being referred for further details to one or other of the text-books on human embryology.

THE OVUM

The ova are developed from the primitive germ-cells which are imbedded in the substance of the ovaries. Each of these cells gives rise, by repeated divisions, to a number of smaller cells termed *oögonia* from which the *ova* or *primary oöcytes* are developed.

Human ova are extremely minute, measuring about ·2 mm. or $\frac{1}{125}$ of an inch in diameter, and are enclosed within the egg-sacs or Graafian follicles of the ovaries.* By the enlargement and subsequent rupture of a Graafian follicle at the surface of the ovary an ovum is liberated and conveyed by the Fallopian tube or oviduct

FIG. 94.—Human ovum examined fresh in the liquor folliculi. (Waldeyer.)

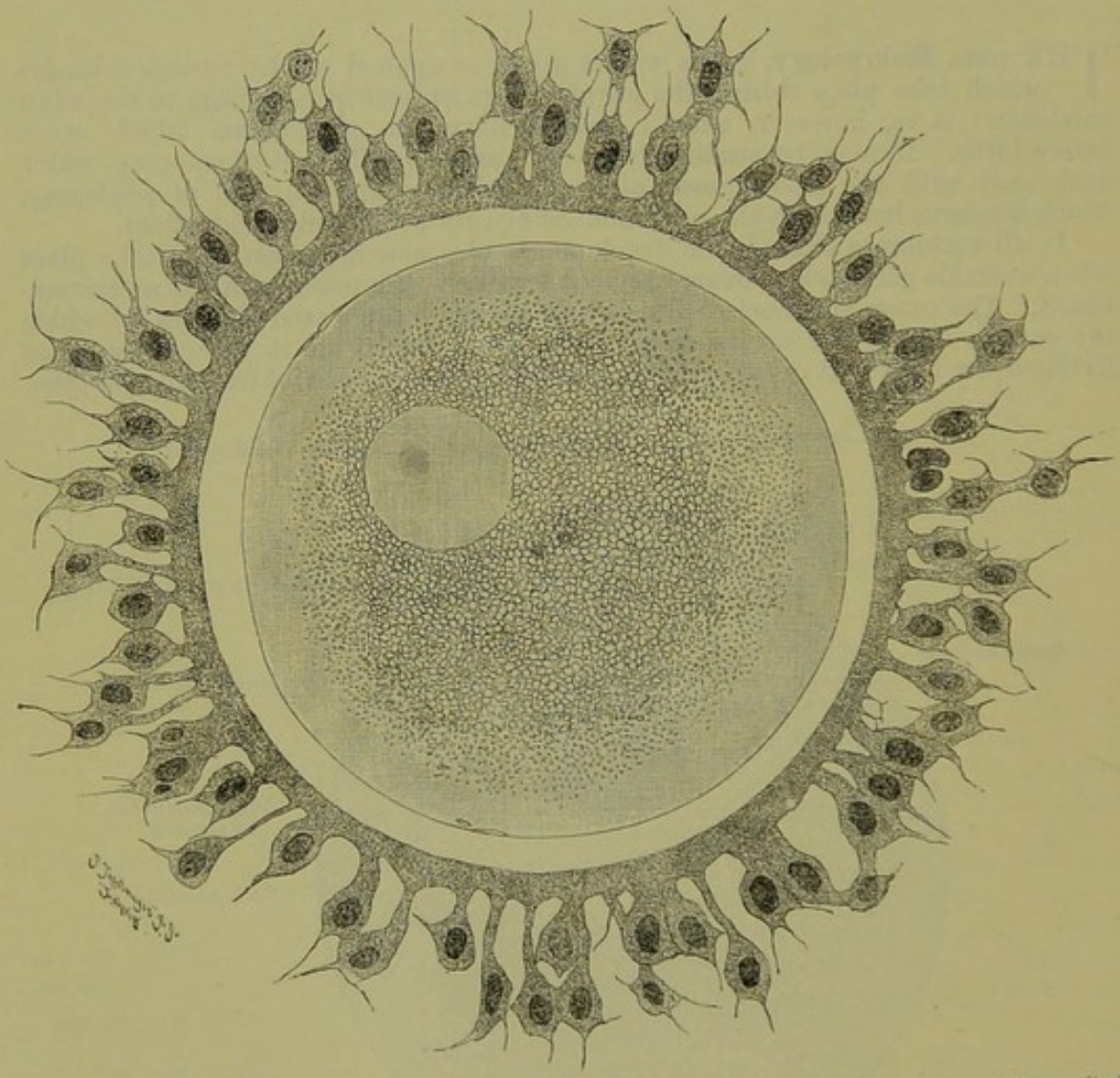

The zona pellucida is seen as a thick clear girdle surrounded by the cells of the corona radiata. The egg itself shows a central granular deutoplasmic area and a peripheral clear layer, and encloses the germinal vesicle, in which is seen the germinal spot.

to the cavity of the uterus. Unless it be fertilised by a spermatozoön it undergoes no further development and is discharged from the uterus, but if fertilisation take place it is retained within the uterus and is developed into a new being.

In appearance and structure the ovum (figs. 93, 94) differs little from an ordinary cell, but distinctive names have been applied to its several parts; thus, the body of the cell is known as the *vitellus* or *yolk*, the nucleus as the *germinal vesicle*, and the nucleolus as the *germinal spot*. The ovum is enclosed within a thick, transparent envelope, the *zona pellucida* or *zona striata*, adhering to the outer surface of which are several layers of cells, derived from those of the Graafian follicle and collectively constituting the *corona radiata*.

* See description of the ovary on a future page.

The **vitellus** or **yolk** comprises (1) the *cytoplasm* of the ordinary animal cell with its reticulum and cytolymph, the cytoplasm of the ovum being frequently termed the *formative yolk*, in order to distinguish it from (2) the *nutritive yolk* or *deutoplasm*, which consists of numerous rounded granules of fatty and albuminoid substances imbedded in the cytoplasm. In the mammalian ovum the nutritive yolk is extremely small in amount, and is of service in nourishing the embryo in the early stages of its development only, whereas in the egg of the bird there is sufficient to supply the chick with nutriment throughout the whole period of incubation. The nutritive yolk not only varies in amount, but in its mode of distribution within the egg: thus, in some animals it is nearly uniformly distributed throughout the cytoplasm; in others it is centrally placed and is surrounded by the cytoplasm; in still others it is accumulated at the lower pole of the ovum, while the cytoplasm occupies the upper pole. An *attraction sphere* with its *centrosome* is present in the ova of the lower animals, and is probably represented in the ova of mammals by the *body of Balbiani*. This body is not visible during all the stages of the development of the ovum, and is 'most readily seen before the space appears in the Graafian follicle. Then the body in question lies in the immediate neighbourhood of the nucleus. It consists of a lighter central sphere enclosing one or two smaller spheres, and surrounded by a more darkly staining protoplasm.'*

The **germinal vesicle** or nucleus is a large spherical body which at first occupies a nearly central position, but becomes eccentric as the growth of the ovum proceeds. Its structure is that of an ordinary cell-nucleus, viz. it consists of a reticulum of achromatin the meshes of which are filled with nuclear sap or karyoplasm; while connected with, or imbedded in, the achromatic reticulum are a number of chromatin masses or chromosomes, which may present the appearance of a skein or may assume the form of rods or loops. The nucleus is enclosed by a delicate nuclear membrane, and contains in its interior a well-defined nucleolus or germinal spot.

COVERINGS OF THE OVUM

The **zona pellucida** or **zona striata** (figs. 93, 94) is secreted by the cells of the corona radiata, and consists of a thick, clear membrane, which, under the higher powers of the microscope, is seen to be perforated by numerous fine radially arranged channels. These give to it a striated appearance, and may suffice for the passage of nutritive materials to the ovum; they may also provide an entrance for the spermatozoa at the time of fertilisation. In some animals (e.g. insects) the zona pellucida presents one or more small perforations or *micropyles*, by which the spermatozoa are believed to enter. The zona pellucida persists for some time after fertilisation has occurred, and may serve for protection during the earlier stages of segmentation.

The **corona radiata** (fig. 94) consists of two or three strata of cells; they are derived from the cells of the Graafian follicle, and adhere to the outer surface of the zona pellucida when the ovum is set free from the follicle. The cells are radially arranged around the zona, those of the innermost layer being columnar in shape, and sending, according to some observers, delicate processes from their deep ends into the channels of the zona. The cells of the corona radiata soon disappear; in some animals they secrete, or are replaced by, a layer of adhesive protein, which may assist in protecting and nourishing the ovum.

The phenomena attending the discharge of the ova from the Graafian follicles belong more to the ordinary functions of the ovary than to the general subject of embryology, and are therefore described with the anatomy of the ovaries.†

MATURATION OF THE OVUM

Before an ovum can be fertilised it must undergo a process of *maturation* or *ripening*. This takes place previous to, or immediately after, its escape from the Graafian follicle, and consists essentially of an unequal subdivision of the ovum (fig. 95) first into two and then into four cells. Three of the four are small, incapable

* Robinson, 'Hunterian Lectures on the Mammalian Ovum and Placenta,' *Journal of Anatomy and Physiology*, vol. xxxviii.

† See description of the ovary on a future page.

of further development, and are termed *polar bodies*, while the fourth is much larger, and constitutes the *mature ovum*. The process of maturation has not been observed

Fig. 95.—Formation of polar bodies in Asterias glacialis. (Slightly modified from Hertwig.)

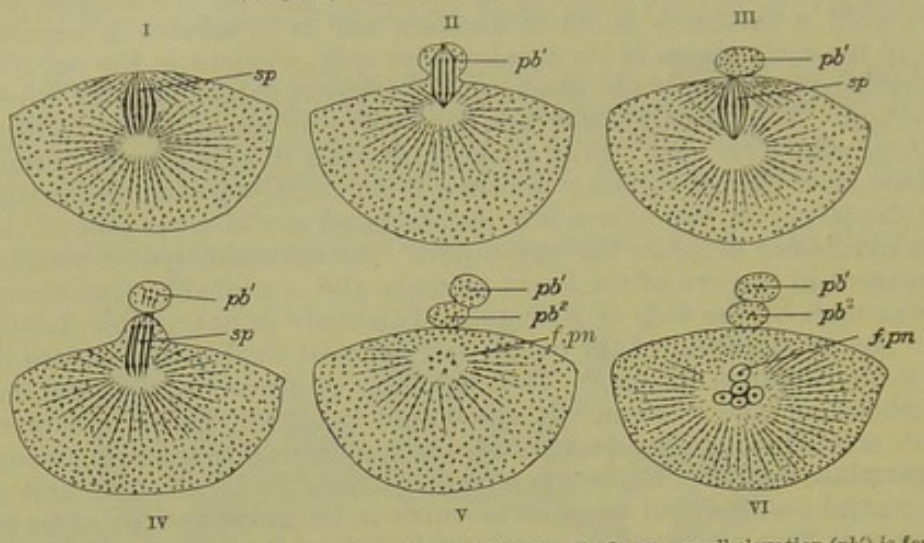

In fig. I the polar spindle (*sp*) has advanced to the surface of the egg. In fig. II a small elevation (*pb'*) is formed which receives half of the spindle. In fig. III the elevation is constricted off, forming the first polar body (*pb'*), and a second spindle is formed. In fig. IV is seen a second elevation which in fig. V has been constricted off as the second polar body (*pb²*). Out of the remainder of the spindle (*f.pn* in fig. VI) the female pronucleus is developed.

in the human ovum, but has been carefully studied in the ova of some of the lower animals, to which the following description applies.

It was pointed out on page 5 that the number of chromosomes found in the nucleus is constant for all the cells in an animal of any given species. This applies not only to the somatic cells but to the primitive ova and their descendants. For the sake of illustration a species may be taken in which the number of nuclear chromosomes is four (fig. 96). If an ovum from such be observed at the beginning of the maturation process it will be seen that the number of its chromosomes is apparently reduced to two. In reality, however, the number is doubled, since each chromosome consists of four granules grouped to form a *tetrad*. During the metaphase (see page 5) each tetrad divides into two *dyads*, which are equally distributed between the nuclei of the two cells formed by the first division of the ovum. One of the two cells is almost as large as the original ovum, and is named the *secondary oöcyte*; the other is small, and is termed the *first polar body*. The secondary oöcyte now undergoes subdivision, during which each dyad divides and contributes a single chromosome to the nucleus of each

Fig. 96.—Diagram showing the reduction in number of the chromosomes in the process of maturation of the ovum.

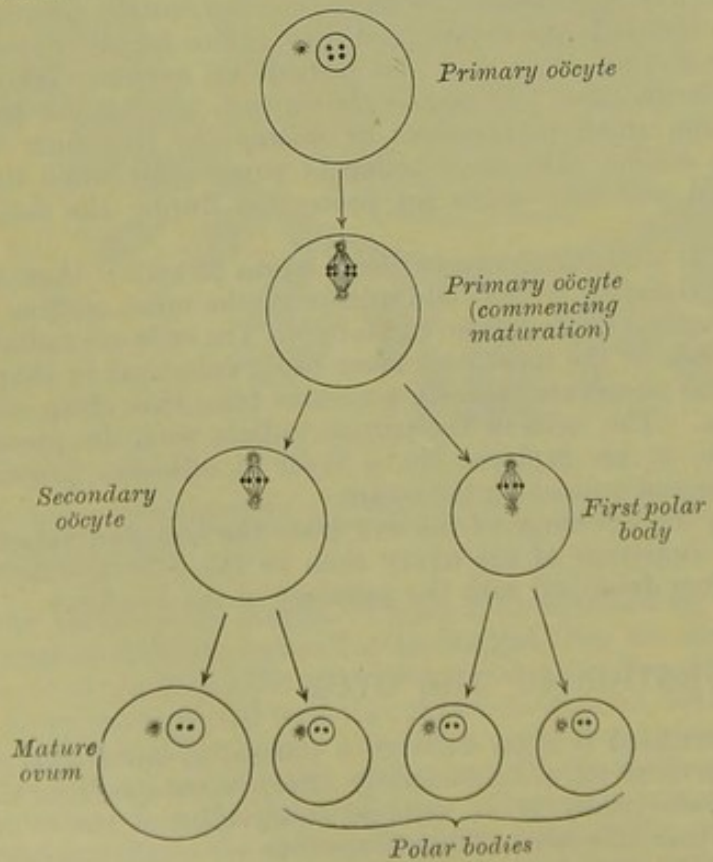

of the two resulting cells. This second division is also unequal, producing a large cell which constitutes the *mature ovum*, and a small cell, the *second polar body*. The first polar body frequently divides while the second is being formed, and as a final result four cells are produced, viz. the mature ovum and three polar bodies, each of which contains two chromosomes, i.e. one half the number present in the nuclei of the somatic cells of members of the same species. The nucleus of the mature ovum is termed the *female pronucleus*. The number of polar bodies varies in the ova of different animals; typically three are formed, but in some animals there is only one, in others there are two—the last condition being probably explained by the fact that the first polar body has not undergone subdivision by the time the second is separated from the ovum.

THE SPERMATOZOÖN

The spermatozoa or male germ-cells are developed within the tubuli seminiferi of the testes. They are present in enormous numbers in the seminal fluid, and consist of small but greatly modified cells. The human spermatozoön possesses a head, a neck, a connecting piece or body, and a tail (fig. 97).

FIG. 97.—Human spermatozoön. (Diagrammatic.)

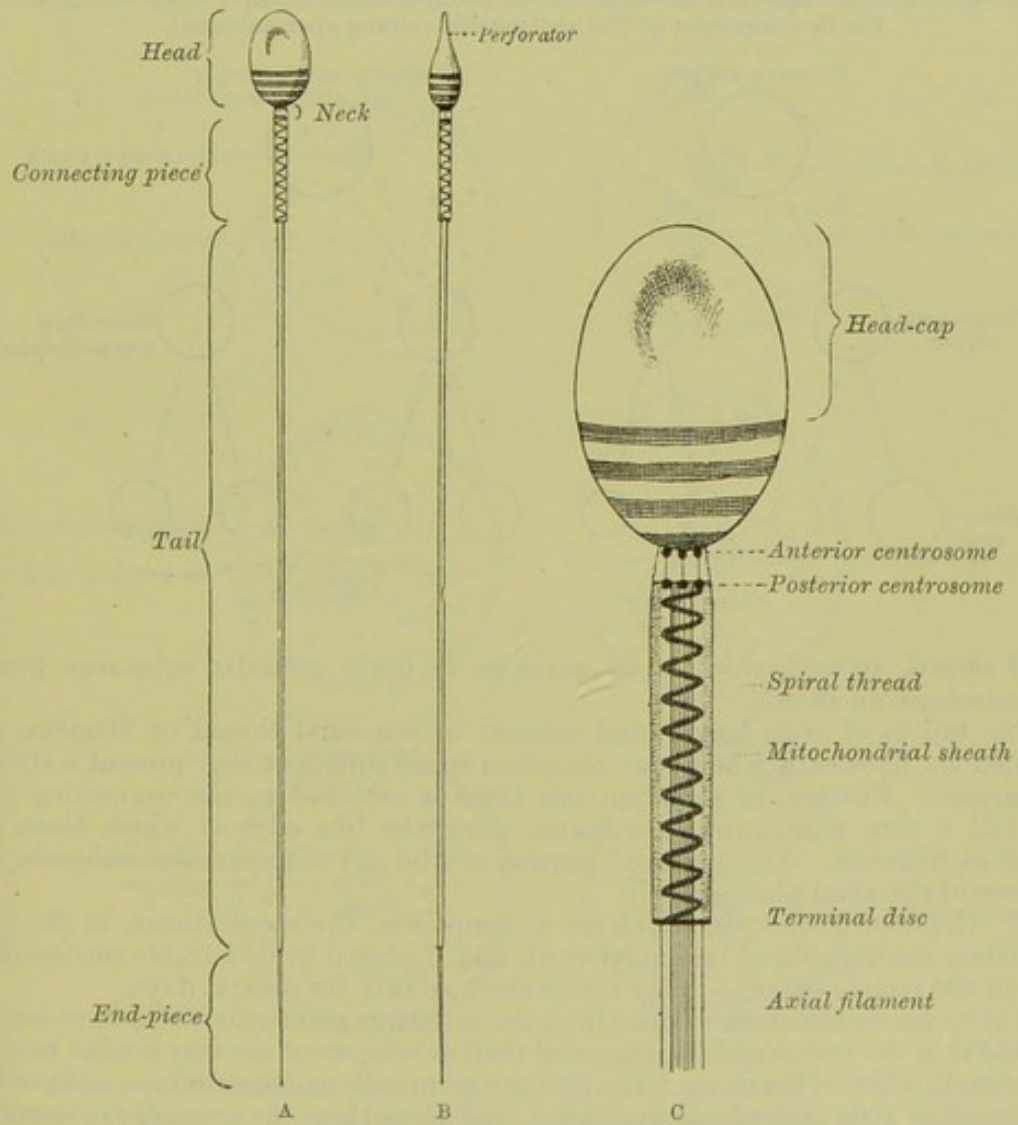

A. Surface view. B. Profile view. In C the head, neck, and connecting piece are highly magnified.

The **head** is oval or elliptical, but flattened, so that when viewed in profile it is pear-shaped. Its anterior two-thirds are covered by a layer of modified protoplasm, which is named the *head-cap*. This, in some animals (e.g. the salamander), is prolonged into a barbed spearlike process or *perforator*, which probably facilitates

the entrance of the spermatozoön into the ovum. von Bardeleben and E. Nelson have described spearlike perforators as being present in the human spermatozoa, but other observers deny their presence. Waldeyer inclines to the view that in man the perforator consists of the anterior sharp margin of the head-cap, and acts as a cutting rather than a boring apparatus. The posterior part of the head exhibits an affinity for certain reagents, and presents a transversely striated appearance, being crossed by three or four dark bands. In some animals a central rodlike filament extends forwards for about two-thirds of the length of the head, while in others a rounded body is seen near its centre. The head contains a mass of chromatin, and is generally regarded as the nucleus of the cell surrounded by a thin envelope.

The **neck** is less constricted in the human spermatozoön than in those of some of the lower animals. The *anterior centrosome*, represented by two or three rounded particles, is situated at the junction of the head and neck, and behind it is a band of homogeneous substance.

The **connecting piece** or **body** is rodlike, and is limited behind by a ring or *terminal disc*. The *posterior centrosome* is placed at the junction of the body and neck and, like the anterior, consists of two or three rounded particles. From this centrosome an *axial filament*, surrounded by a sheath, runs backwards through the body and tail. In the body the sheath of the axial filament is encircled by a

FIG. 98.—Scheme showing analogies in the process of maturation of the ovum and the development of the spermatids (young spermatozoa).

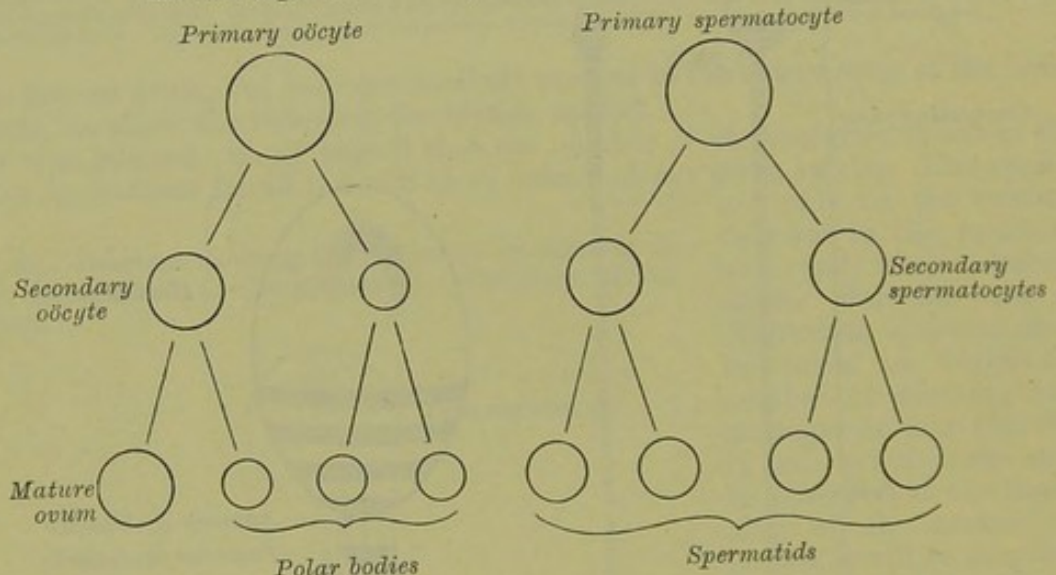

spiral thread, around which is an envelope of finely granular substance termed the *mitochondrial sheath*.

The **tail** is of great length, and consists of the axial thread or filament, surrounded by its sheath which may contain a spiral thread or may present a striated appearance. Further, in some animals there is attached to the connecting piece and tail a thin undulatory membrane, along the free edge of which there is a marginal filament. The terminal portion of the tail is named the *end-piece*, and consists of the axial filament only.

By virtue of their tails, which act as propellers, the spermatozoa, in the fresh condition, are capable of free movement, and if placed in favourable surroundings (e.g. in the female passages) may retain their vitality for several days.

The spermatozoa are developed from the primitive germ-cells which have become imbedded in the testes, and the stages of their development are very similar to those of the maturation of the ovum. The primary germ-cells undergo division and produce a number of cells termed *spermatogonia*, and from these the *primary spermatocytes* are derived. Each primary spermatocyte divides into two *secondary spermatocytes*, and each secondary spermatocyte into two *spermatids* or young spermatozoa; from this it will be seen that a primary spermatocyte gives rise to *four* spermatozoa. On comparing this process with that of the maturation of the ovum (fig. 98) it will be observed that the primary spermatocyte gives rise to two cells, the secondary spermatocytes, and the primary oöcyte to two cells, the secondary oöcyte and the

first polar body. Again, the two secondary spermatocytes by their subdivision give origin to four spermatozoa, and the secondary oöcyte and first polar body to four cells, the mature ovum and three polar bodies. In the development of the spermatozoa, as in the maturation of the ovum, there is a reduction of the nuclear chromosomes to one half of those present in the primary germ cells. But here the similarity ends, for it must be noted that the four spermatozoa are of equal size, and each is capable of fertilising a mature ovum, whereas the three polar bodies are not only very much smaller than the mature ovum but are incapable of further development, and may be regarded as abortive ova.

FERTILISATION OF THE OVUM

Fertilisation consists in the union of the spermatozoön with the mature ovum (fig. 99). This usually takes place in the upper part of the Fallopian tube, and the ovum is then conveyed to the cavity of the uterus—a journey which probably occupies two or three days. Sometimes the fertilised ovum is arrested in the Fallopian tube and there undergoes development, giving rise to a *tubal pregnancy*; or it may fall into the abdominal cavity and produce an *abdominal pregnancy*. Occasionally the ovum is not expelled from the Graafian follicle when the latter

FIG. 99.—The process of fertilisation in the ovum of a mouse. (After Sobotta.)

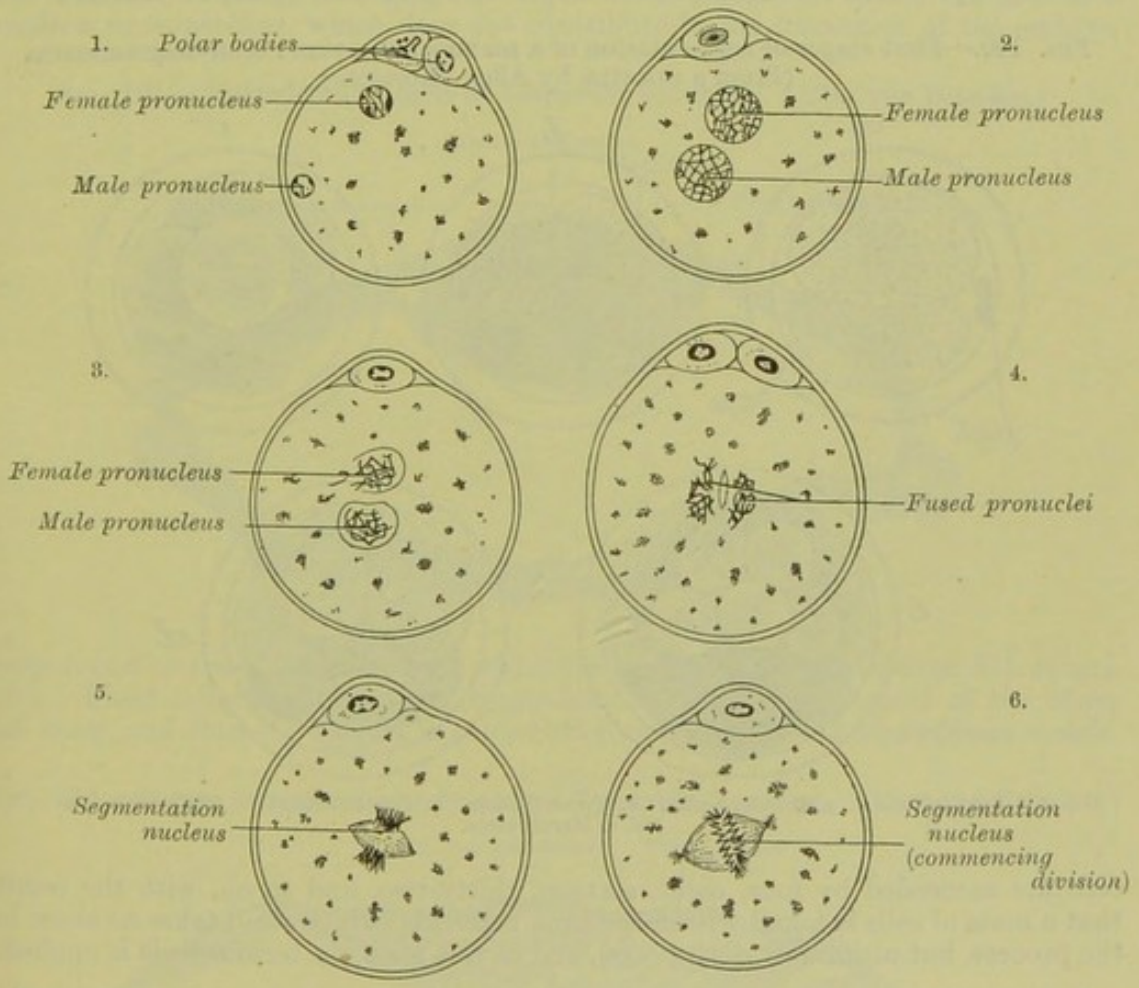

ruptures, but is fertilised within the follicle and produces what is known as an *ovarian pregnancy*. Numerous spermatozoa may pierce the zona pellucida (e.g. in the rabbit as many as sixty have been seen in its interior), but only one, under normal conditions, enters the vitellus and takes part in the process of fertilisation. At the point where the spermatozoön is about to pierce the vitellus the latter is drawn out into a conical elevation, termed the *cone of attraction*. As soon as the spermatozoön has entered at this point the peripheral portion of the vitellus is transformed into a membrane, the *vitelline membrane*, which prevents the passage of

additional spermatozoa. Occasionally a second spermatozoön may enter the vitellus, thus giving rise to a condition of *polyspermy*: when this occurs the ovum usually develops in an abnormal manner and gives rise to a monstrosity. Having pierced the vitellus, the spermatozoön loses its tail, while its head and connecting piece assume the form of a nucleus containing a cluster of chromosomes. This constitutes the *male pronucleus*, and associated with it there are a centrosome and attraction sphere. The male pronucleus passes more deeply into the vitellus, and coincident with this the granules of the cytoplasm surrounding it become radially arranged. The male and female pronuclei migrate towards each other, and, meeting near the centre of the vitellus, fuse to form a new nucleus, the *segmentation nucleus*, which therefore contains both male and female nuclear substance; the former transmits the individualities of the male ancestors, the latter those of the female ancestors, to the future embryo. By the union of the male and female pronuclei the number of chromosomes is restored to that which is present in the nuclei of the somatic cells.

SEGMENTATION OF THE FERTILISED OVUM

After it has been fertilised the ovum undergoes repeated subdivision into a number of small cells (figs. 100, 101). The segmentation nucleus exhibits the usual mitotic changes, and these are succeeded by a division of the ovum into two cells of nearly equal size.* The process is repeated again and again, so that the two

FIG. 100.—First stages of segmentation of a mammalian ovum: semi-diagrammatic. (From a drawing by Allen Thomson.)

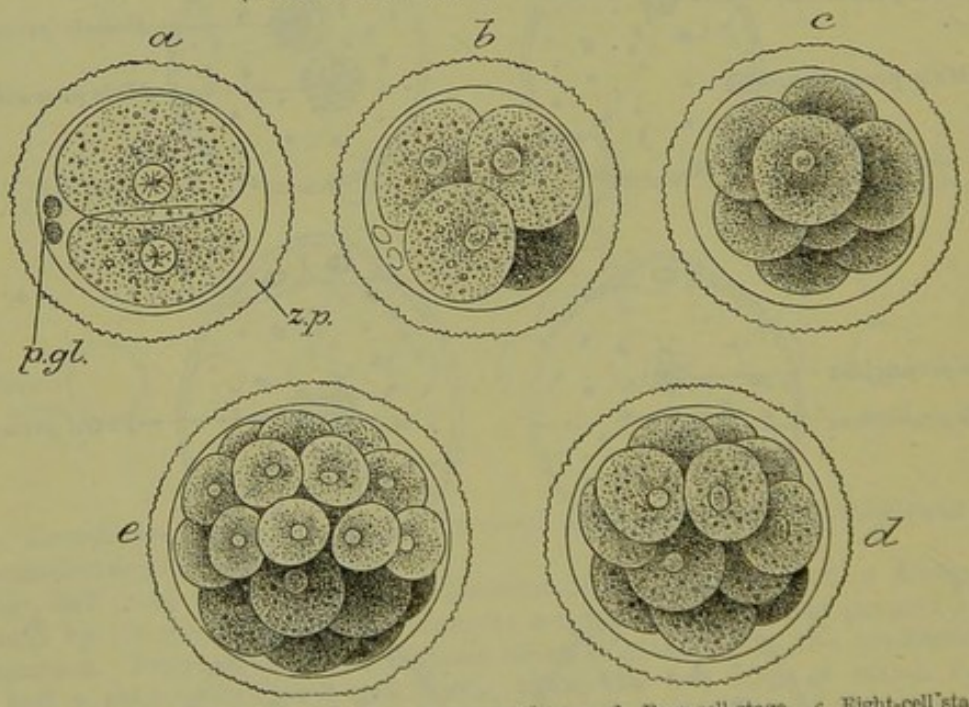

z.p. Zona pellucida. *p.gl.* Polar bodies. *a*. Two-cell stage. *b*. Four-cell stage. *c*. Eight-cell stage. *d*, *e*. Morula stage.

cells are succeeded by four, eight, sixteen, thirty-two, and so on, with the result that a mass of cells is found within the zona pellucida (which itself takes no share in the process, but ultimately disappears), and to this mass the term *morula* is applied.

* In the mammalian ova the nutritive yolk or deutoplasm is small in amount and uniformly distributed throughout the cytoplasm; such ova undergo *complete* division during the process of segmentation, and are therefore termed *holoblastic*. In the ova of birds, reptiles, and fishes where the nutritive yolk forms by far the larger portion of the egg the cleavage is limited to the formative yolk, and is therefore only *partial*; such ova are termed *meroblastic*. Again, it has been observed, in some of the lower animals, that the pronuclei do not fuse but merely lie in apposition. At the commencement of the segmentation process the chromosomes of the two pronuclei group themselves around the equator of the nuclear spindle and then divide; an equal number of male and female chromosomes travel to the opposite poles of the spindle, and thus the male and female pronuclei subscribe equal shares of chromatin to the nuclei of the two cells which result from the subdivision of the fertilised ovum.

The segmentation of the mammalian ovum may not take place in the regular sequence of two, four, eight, &c., since one of the two first-formed cells may subdivide more rapidly than the other, giving rise to a three- or a five-cell stage.

Fig. 101.—Ovum of the rabbit at the end of the process of segmentation.

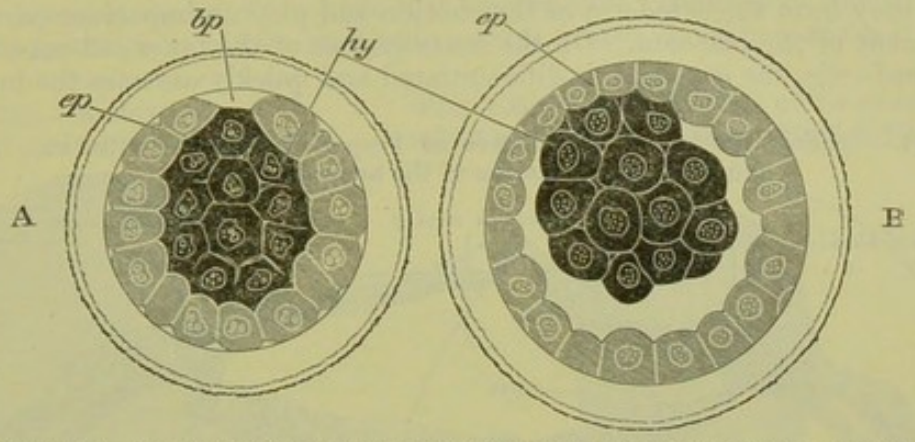

ep. Primitive ectoderm. *hy*. Primitive entoderm. *bp*. Place where the ectoderm has not yet grown over the entoderm. (From Balfour, after Ed. van Beneden.)

The cells of the morula are at first closely aggregated inside the zona pellucida; but soon they become arranged into an outer or peripheral layer, the *primitive ectoderm* or *trophoblast*, which does not contribute to the formation of the embryo

Fig. 102.—Blastodermic vesicle of Vespertilio murinus. (After van Beneden.)

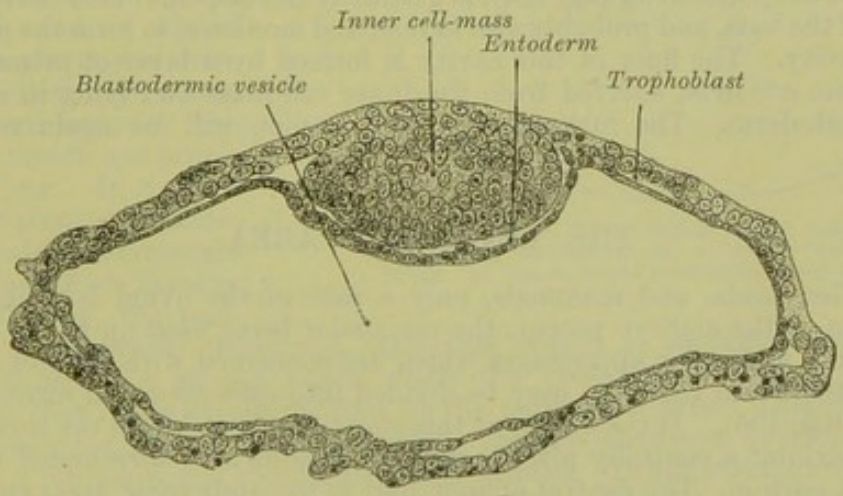

proper, and an *inner cell-mass*, from which the embryo is developed (figs. 101, B, and 102). Fluid collects between the trophoblast and the greater part of the inner cell-mass, and thus the morula is converted into a vesicle, the *blastodermic vesicle*.

Fig. 103.—Section through embryonic area of Vespertilio murinus. (After van Beneden.)

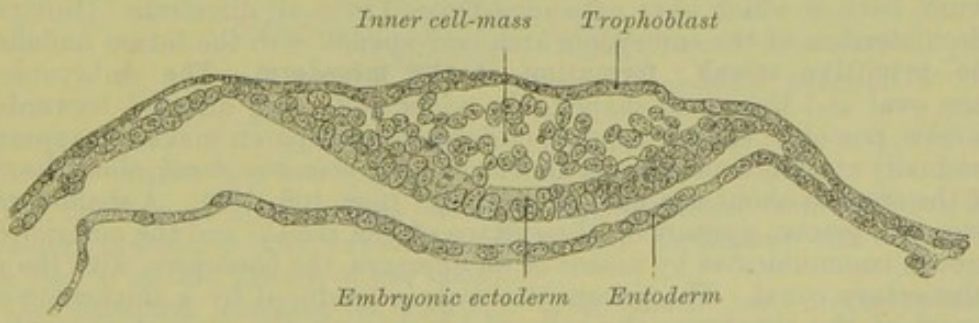

The inner cell-mass remains in contact, however, with the trophoblast at one pole of the ovum; this is named the *embryonic pole*, since it indicates the situation where the future embryo will be developed. The cells of the trophoblast become

differentiated into two strata : an outer, termed the *syncytium* or *plasmodioblast*, so named because it consists of a layer of protoplasm studded with nuclei, but showing no evidence of subdivision into cells ; and an inner layer of prismatic epithelium, which is named the *cytoblast* or *layer of Langhans*. As already stated, the cells of the trophoblast do not contribute to the formation of the embryo proper ; they form the ectoderm of the chorion and play an important part in the development of the placenta. On the inner surface of the inner cell-mass a layer of flattened cells, the *entoderm*, is differentiated and quickly assumes the form of a

FIG. 104.—Section through embryonic area of Vespertilio murinus (after van Beneden) to show the formation of the amniotic cavity.

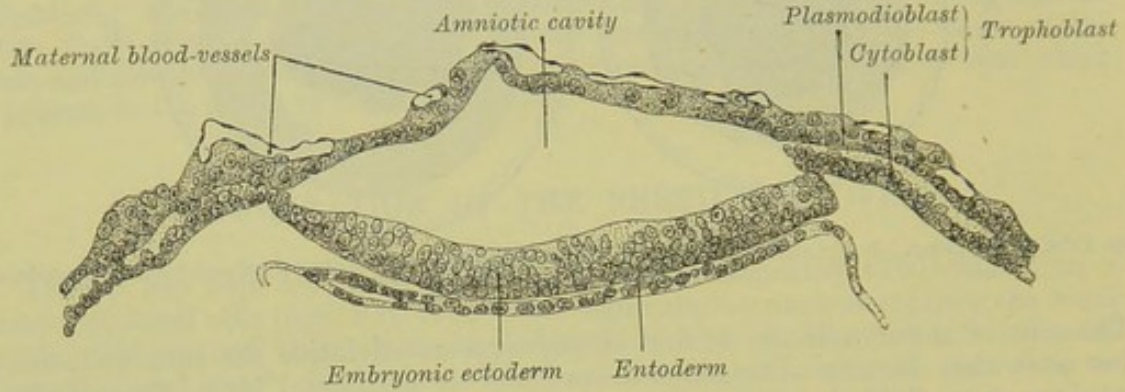

small sac, the *yolk-sac*. Spaces appear between the remaining cells of the mass (fig. 103), and by the enlargement and coalescence of these spaces a cavity, termed the *primitive amniotic cavity* (fig. 104), is gradually developed. This cavity persists in certain of the bats, and probably also in man and monkeys, to form the permanent amniotic cavity. The floor of this cavity is formed by a layer of prismatic cells, the *embryonic ectoderm*, derived from the inner cell-mass and lying in apposition with the entoderm. The formation of the amnion will be again referred to (page 93).

THE EMBRYONIC AREA

In reptiles, birds, and mammals, only a part of the ovum is utilised in the development of the embryo proper, the remainder being used up in the formation of membranes and other appendages which are concerned with its protection and nutrition ; the ovum therefore may be divided into *embryonic* and *extra-embryonic areas* (figs. 105, 106). If the ovum, at this stage, be viewed from the surface it will be seen to exhibit a centrally placed, circular, opaque area surrounded by a more transparent portion. The central opaque part is the embryonic area, and is equal in extent to the embryonic ectoderm already mentioned ; the peripheral clearer portion is the extra-embryonic area. The circumference of the embryonic region remains as a relatively slow-growing area, while the embryonic and extra-embryonic portions of the wall of the ovum rapidly increase in extent. Under these circumstances it follows that the margin of the embryonic area will soon appear as a ring between the upper embryonic and the lower or extra-embryonic parts of the ovum, both of which have expanded beyond it in all directions' (Robinson).* The circumference of the embryonic area corresponds with the future umbilicus.

The primitive streak ; formation of the mesoderm.—The embryonic area becomes oval and then pear-shaped, the wider end being directed forwards. At the narrow, posterior end an opaque, crescent-shaped patch makes its appearance, and gradually extends forwards as a dark streak, the *primitive streak*, along the middle line of the area for about one-half of its length (figs. 105, 106). A shallow groove, the *primitive groove*, appears on the surface of the streak, and the anterior end of this groove communicates by means of an aperture, the *blastopore*, with the primitive alimentary canal. The primitive streak is produced by a thickening of the axial part of the ectoderm, the cells of which multiply, grow downwards, and blend with those of the subjacent entoderm (fig. 107). From the sides of the primitive

* 'The Early Stages of the Development of the Pericardium,' by Professor Arthur Robinson. *Journal of Anatomy and Physiology*, vol. xxxvii.

streak a third layer of cells, the *mesoderm* or *mesoblast*, extends outwards between the ectoderm and entoderm. Although the mesoderm is mainly derived from the primitive streak, possibly the entoderm also contributes to it.

The extension of the mesoderm takes place throughout the whole of the embryonic and extra-embryonic areas of the ovum, except in certain regions. One of these is seen immediately in front of the neural tube. Here the mesoderm extends forwards in the form of two crescentic masses, which curve inwards and meet in

Fig. 105.—Embryo of a rabbit. (After Kölliker.)

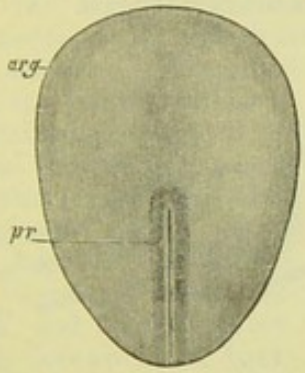

arg. Embryonic area. *pr.* Primitive streak.

Fig. 106.—Embryonic area of the ovum of rabbit at the seventh day. (From Kölliker.)

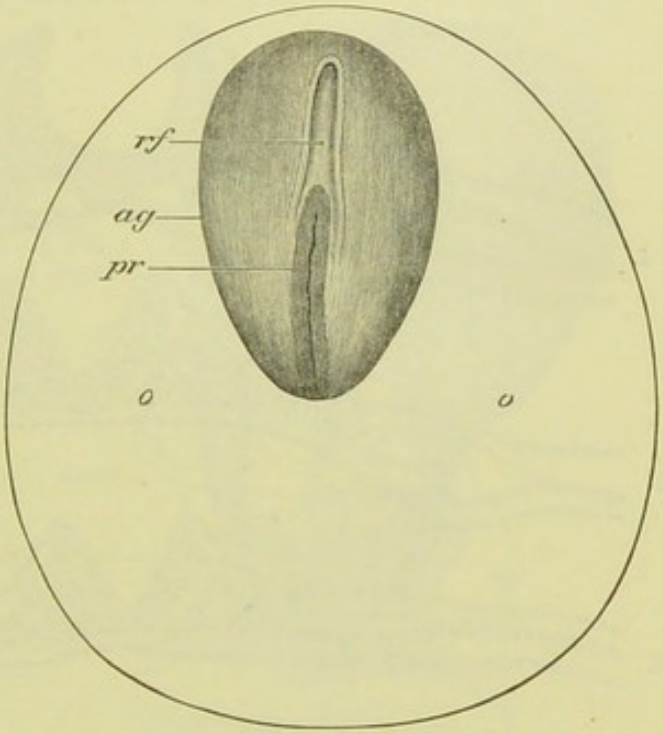

ag. Embryonic area. *o, o.* Region of the blastodermic vesicle immediately surrounding the embryonic area. *pr.* Primitive streak. *rf.* Neural groove between the neural folds.

the middle line so as to enclose behind them an area which is devoid of mesoderm and is named the *bucco-pharyngeal area*, since it afterwards forms the septum between the primitive mouth and primitive pharynx. In front of the bucco-pharyngeal area, where the lateral crescents of mesoderm have fused in the middle line, the pericardium is afterwards developed, and this region is therefore designated the *pericardial area*. A second region where the mesoderm is absent, at least for a time, is that immediately in front of the pericardial area. This is termed the *pro-amniotic area*, and is the region where the *pro-amnion* is developed; in man however, a pro-amnion is apparently never formed. Other regions are: a band on the ventral aspect of the neural tube in the site of the future vertebral column, and an area at the hinder end of the embryo in the position of the cloaca.

Fig. 107.—Section across primitive streak (semi-diagrammatic).

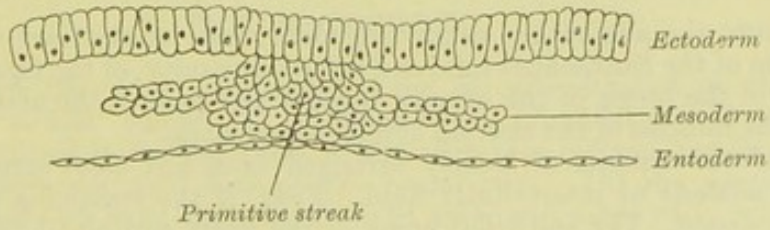

The blastoderm now consists of three layers, named from without inwards, ectoderm, mesoderm and entoderm. Each has distinctive characteristics and gives rise to certain tissues of the body.

The **ectoderm** consists of columnar cells, which are, however, somewhat flattened or cubical towards the margin of the embryonic area. It forms the whole of the nervous system, the epidermis of the skin, the lining cells of the sebaceous, sweat and mammary glands, the hairs and nails, the epithelium of the nose and adjacent air-sinuses, and that of the cheeks and roof of the mouth. From it also

are derived the enamel of the teeth, and the anterior lobe of the pituitary body, the epithelium of the cornea, conjunctiva, and lachrymal glands, and the neuro-epithelium of the sense organs.

The **entoderm** consists at first of flattened cells, which subsequently become columnar. It forms the epithelial lining of the whole of the alimentary canal excepting part of the mouth and pharynx and the terminal part of the rectum (which are lined by involutions of the ectoderm), the lining cells of all the glands

FIG. 108.—A series of transverse sections through an embryo of the dog. (After Bonnet.)

Section I. is the most anterior. In V. the neural plate is spread out nearly flat. The series shows the uprising of the neural folds to form the neural canal.

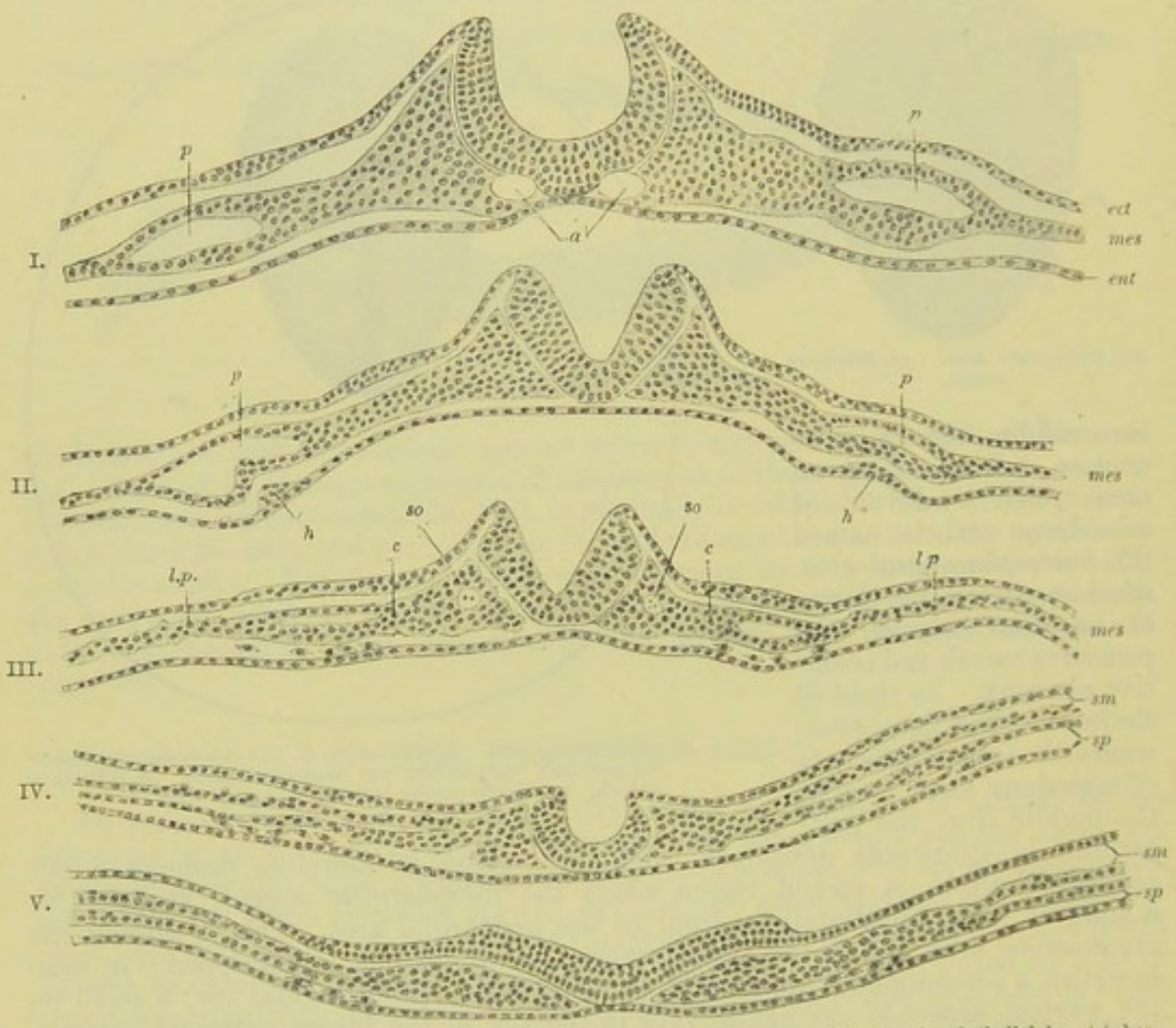

a, aortæ; *c*, intermediate cell-mass; *ect*, ectoderm; *ent*, entoderm; *h*, *h*, rudiments of endothelial heart-tubes. In III., IV., and V. the scattered cells represented between the entoderm and splanchnic layer of mesoderm are the vaso-formative cells which give origin in front, according to Bonnet, to the heart-tubes *h*; *l.p.*, lateral plate still undivided in I., II., and III.: in IV. and V. split into somatic (*sm*) and splanchnic (*sp*) layers of mesoderm; *mes*, mesoderm; *p*, pericardium; *so*, primitive segment.

which open into the alimentary canal, including those of the liver and pancreas, the epithelium of the Eustachian tube and tympanic cavity, of the trachea, bronchi, and air-cells of the lungs, of the urinary bladder and part of the urethra, and that which lines the follicles of the thyroid and thymus glands.

The **mesoderm** consists of loosely arranged branched cells surrounded by a considerable amount of intercellular fluid. From it the remaining tissues of the body are developed. The epithelial lining of the heart and blood-vessels is, however, regarded by some as being of entodermal origin.

THE NEURAL GROOVE AND TUBE

In front of the primitive streak two longitudinal ridges, caused by a looping or folding up of the ectoderm, make their appearance, one on either side of the middle line (fig. 106). These are named the *neural* or *medullary folds*; they commence some distance behind the anterior end of the embryonic area, where they are

continuous with each other, and from there gradually extend backwards, one on either side of the primitive streak. Between these folds is seen a mesial, longitudinal groove, the *neural groove* (figs. 108, 109), which gradually deepens as the medullary folds become elevated. Ultimately the folds meet and coalesce in the middle line, converting the neural groove into a closed tube, the *neural tube* or *canal* (fig. 111), the surrounding ectodermal wall of which forms the rudiment of the nervous system. By the coalescence of the medullary folds over the anterior end of the primitive streak, the blastopore no longer opens on the surface but into the closed canal of the neural tube, and thus a transitory communication, the *neurenteric canal*, is established between the neural tube and the primitive alimentary canal. The coalescence of the medullary folds occurs first in the region of the hind-brain, and from there extends forwards and backwards; the hinder part of the neural groove presents for a time a rhomboidal shape, and to this expanded portion the term *sinus rhomboidalis* has been applied (fig. 110). Before the neural groove is closed to form the neural tube a ridge of ectodermal cells appears along the prominent margin of each medullary fold; this is termed the *neural crest* or *ganglion ridge* (fig. 150), and from it the spinal and cranial nerve ganglia and the ganglia of the sympathetic nervous system are developed.

FIG. 109.—Human embryo—length 2 mm. Dorsal view, with the amnion laid open. × 30. (After Graf Spee; reconstruction.)

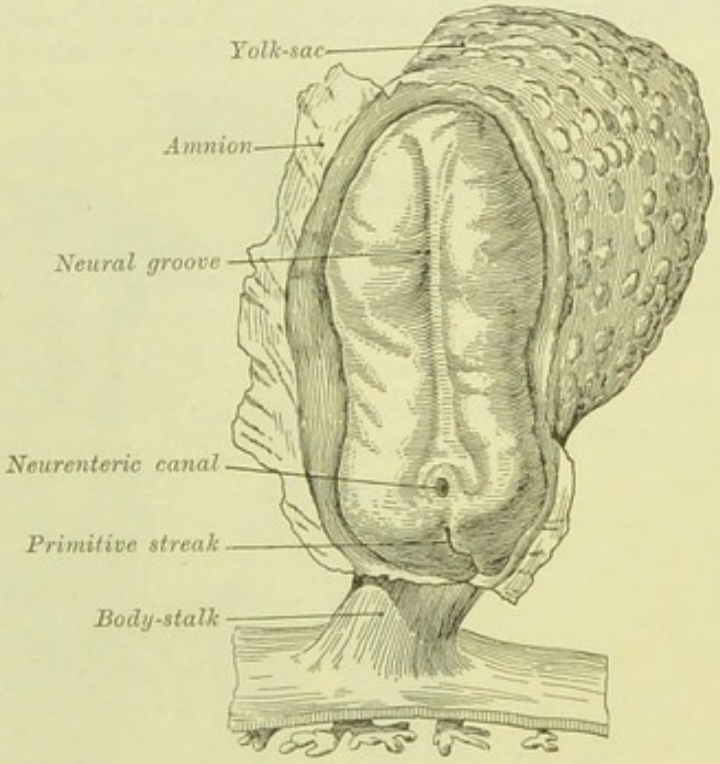

The cephalic end of the neural groove exhibits several dilatations, which, when the tube is closed, assume the form of three vesicles; these constitute the three primary cerebral vesicles, and correspond respectively to the future *fore-brain*, *mid-brain*, and *hind-brain* (fig. 110). Their walls are developed into the nervous tissue and neuroglia of the brain, while their cavities become modified to form its ventricles. The remainder of the tube forms the central canal of the spinal cord, whilst from its ectodermal wall the nervous and neuroglial elements of the spinal cord are developed.

THE NOTOCHORD

The **notochord** (fig. 111) consists of a rod of cells situated on the ventral aspect of the neural tube; it constitutes the foundation of the axial skeleton, since around it the segments of the vertebral column are formed. Its appearance synchronises with that of the neural tube. On the ventral aspect of the neural groove an axial thickening of the entoderm takes place; this thickening assumes the appearance of a furrow—the *chordal furrow*—the margins of which come into contact, and so convert it into a solid rod of cells—the *notochord*—which is then separated from the entoderm. It extends throughout the entire length of the future vertebral column, and reaches as far as the anterior end of the mid-brain. Its cephalic extremity lies immediately behind the pituitary invagination of the stomatodæum, where it ends in a hook-like extremity in the region of the future dorsum sellæ of the sphenoid bone. It lies at first between the neural tube and the entoderm of the primitive alimentary canal, but soon becomes separated from them by the mesoderm, which grows inwards and

surrounds it. From this surrounding mesoderm the vertebral column, the basi-occipital and basi-sphenoidal portions of the skull and the membranes of the brain and spinal cord are developed.

FORMATION OF THE BODY CAVITY OR CŒLOM

As the mesoderm develops between the ectoderm and entoderm it is separated into lateral halves by the neural tube and notochord. A longitudinal groove appears on the dorsal surface of either half and divides it into an inner column, the

FIG. 110.—Chick embryo of thirty-three hours' incubation, viewed from the dorsal aspect. × 30. (From Duval's 'Atlas d'Embryologie.')

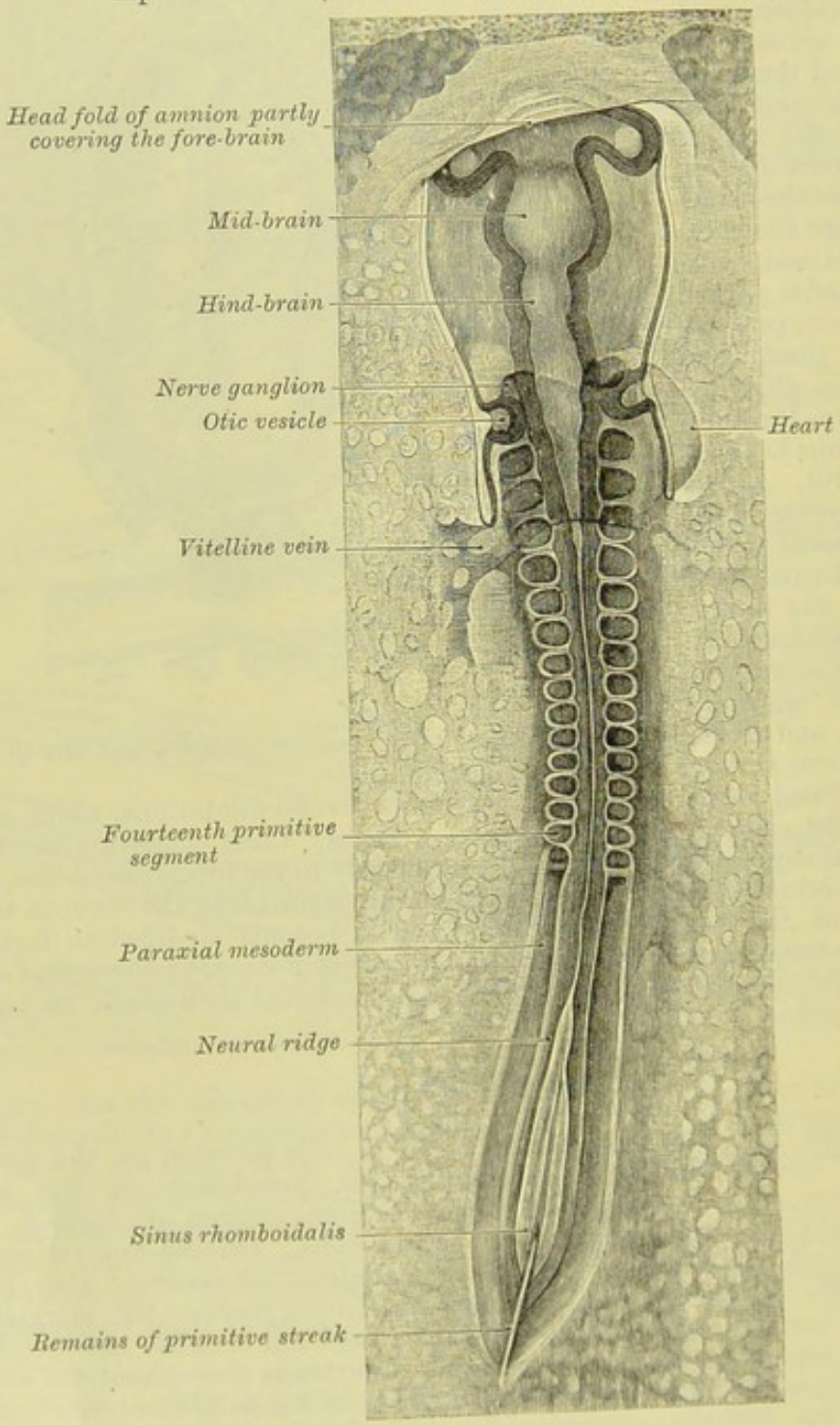

paraxial mesoderm, lying on the side of the neural tube, and an outer portion, the *lateral mesoderm*, which is not confined to the embryonic area but extends beyond it into the extra-embryonic region. The mesoderm lying in the floor of the groove connects the paraxial with the lateral mesoderm and is known as the *intermediate*

cell-mass; in it the genito-urinary organs are developed. The lateral mesoderm splits into two layers, an outer or *somatic*, which becomes applied to the inner surface of the ectoderm, and with it forms the *somatopleure*; and an inner or

FIG. 111.—Section across the dorsal part of a chick embryo of forty-five hours' incubation. (Balfour.)

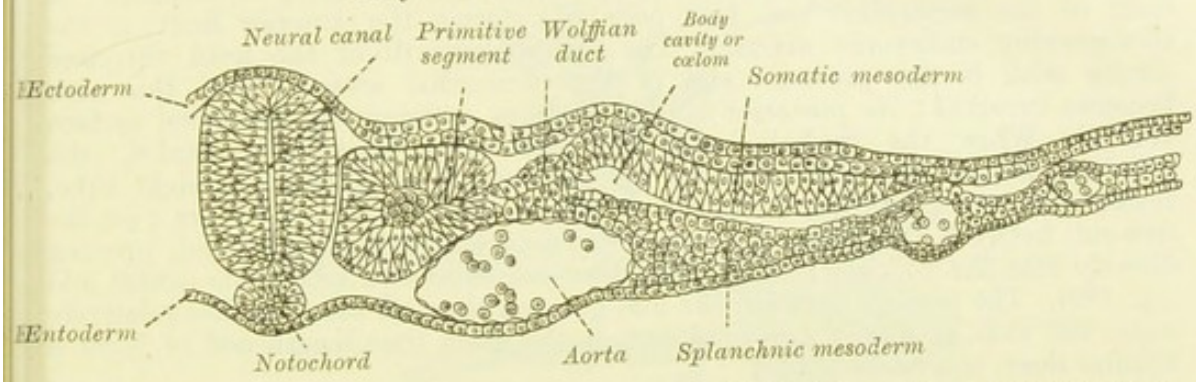

splanchnic, which adheres to the entoderm, and with it forms the *splanchnopleure* (fig. 111). The space between the two layers of the lateral mesoderm is termed the *body cavity* or *cœlom*. A portion of this space is enclosed within the embryo and is named the *embryonic cœlom*; it forms the rudiment of the pleural, pericardial, and peritoneal cavities, while the portion left outside the embryo, the *extra-embryonic cœlom*, envelops the yolk-sac.

FIG. 112.—Dorsum of human embryo, 2·11 mm. in length. (After Eternod.)

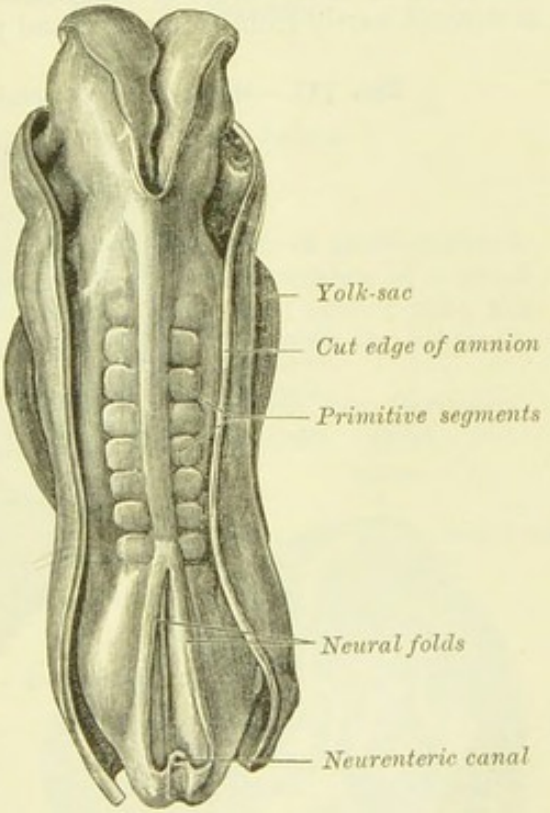

THE PRIMITIVE SEGMENTS OR PROTOVERTEBRAL SOMITES

Towards the end of the second week the paraxial mesoderm becomes segmented and converted into a series of well-defined, more or less cubical areas, the *primitive segments* or *protovertebral somites* (figs. 110, 111, and 112), which extend from the occipital region of the head along the entire length of the trunk on either side of the middle line.

They lie immediately under the ectoderm on the lateral aspect of the neural tube and notochord, and are connected to the lateral mesoderm by the *intermediate cell-mass*. The cells of each somite encircle a central cavity—the *myocœl*—which, however, soon becomes filled with angular and spindle-shaped cells. The somites of the trunk may be arranged in the following groups, viz.: cervical 8, thoracic 12, lumbar 5, sacral 5, and coccygeal from 5 to 8. Those of the occipital region of the head are usually described as being four in number. In mammals primitive segments can only be recognised in the occipital region of the head, but a study of the lower vertebrates leads to the belief that they are present also in the anterior part of the head, and that altogether nine segments are represented in the cephalic region.

DELIMITATION OF THE EMBRYO

As has been pointed out, the margin of the embryonic area is of relatively slow growth, and thus it comes to form a ring of constriction between the embryo and the yolk-sac, and a part of the latter is enclosed within the embryo to form

the primitive alimentary canal (fig. 114). At the same time a part of the cœlom is enclosed within the embryo and forms the rudiment of the pleural, pericardial, and peritoneal cavities. Although the embryo grows in all directions, it increases much more rapidly in length than in width, and its cephalic and caudal extremities are bent downwards to form the *cephalic* and *caudal folds* respectively (figs. 198 and 199). The pro-amniotic area, lying immediately in front of the pericardial area (see page 87), forms the anterior limit of the slow-growing embryonic margin. The forward growth of the head therefore carries with it the posterior end of the pericardial area so that this area becomes inverted; its posterior border becomes anterior and its dorsal surface ventral. When the cephalic and caudal flexures have been formed, the primitive alimentary canal presents the appearance of a nearly straight tube, closed at its two extremities. This tube is divided into three portions, viz.: (*a*) the *fore-gut*, between the pericardium and the notochord; (*b*) the *mid-gut*, opening directly into the yolk-sac; and (*c*) the *hind-gut*, contained within the caudal fold (fig. 199). The passage between the mid-gut and the yolk-sac is at first relatively wide, but it is gradually narrowed and at the same time lengthened to form a tubular duct, the *vitelline duct*.

MEMBRANES AND APPENDAGES OF THE EMBRYO.*

These are concerned with the protection and nourishment of the embryo, and comprise (1) the yolk-sac, the amnion, the allantois, the chorion, and the umbilical cord, which are of embryonic origin; (2) the decidua, which is produced by a modification of the mucous membrane of the uterus; and (3) the placenta, which is derived partly from embryonic and partly from maternal tissues.

FIG. 113.—Model of human embryo 1·3 mm. long. (After Eternod.)

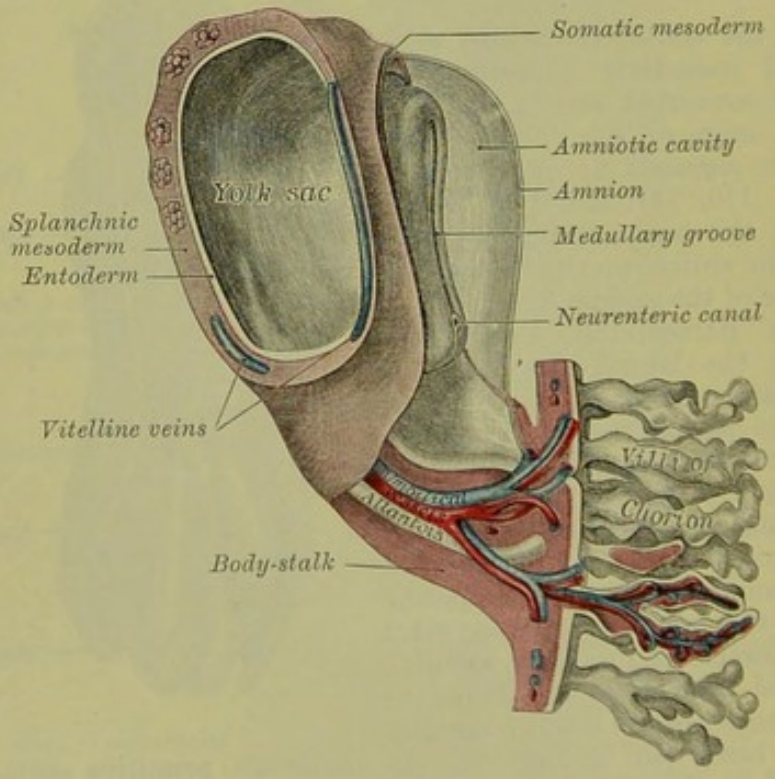

The **yolk-sac** (figs. 113, 114, 115) is an appendage of the alimentary canal and, like that tube, it is lined by entoderm, outside of which is a layer of mesoderm. Situated on the ventral aspect of the embryo, it is at first comparatively large, and communicates with the mid-gut by means of a relatively wide opening. It is filled with fluid, the *vitelline fluid*, which possibly may be utilised for the nourishment of the embryo during the earlier stages of its existence. Blood is conveyed to the

* The term embryo is often confined to a developing ovum up to the age of four months; generally, however, the terms embryo and fœtus are interchangeable.

wall of the sac by the primitive aortæ, and after circulating through a wide-meshed capillary plexus, termed the *vascular area*, is returned by the vitelline veins to the tubular heart of the embryo. This constitutes the *vitelline* circulation, and by means

Fig. 114.—Section through the embryo which is represented in fig. 109. (After Graf Spee.)

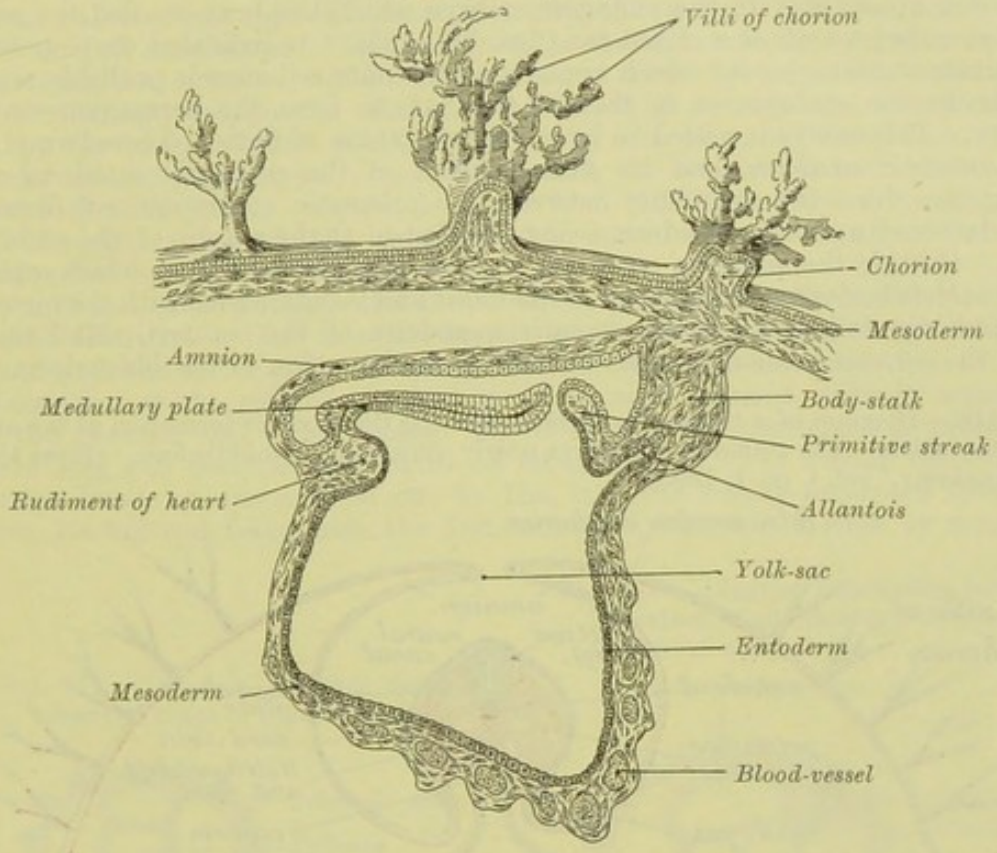

of it nutritive material is absorbed from the yolk-sac and conveyed to the embryo. At the end of the fourth week the yolk-sac presents the appearance of a small pear-shaped vesicle opening into the alimentary canal by a long narrow tube, the *vitelline duct*. The vesicle may be seen at birth as a small sac near the placenta, but the duct is soon obliterated; its proximal part, however, sometimes persists in the adult as a diverticulum from the small intestine. It is known as *Meckel's diverticulum*, is situated from two to four feet above the ileo-colic junction, and may be attached by a fibrous cord to the abdominal wall at the umbilicus.

Fig. 115.—Human embryo from thirty-one to thirty-four days. (His.)

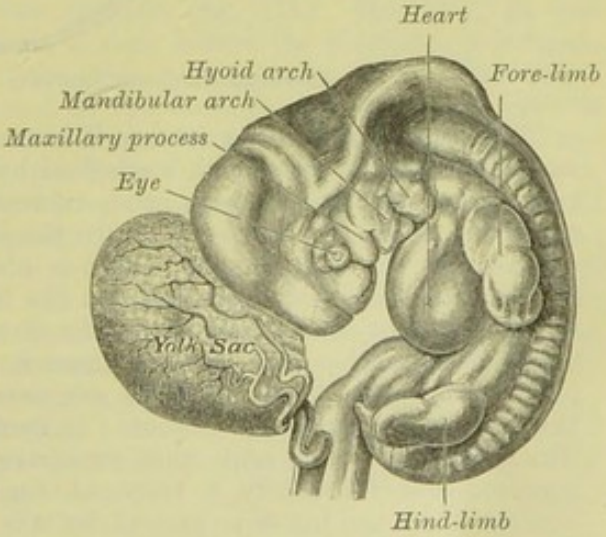

The **amnion** is a membranous sac which surrounds and protects the embryo. It is developed in reptiles, birds, and mammals, which are hence called 'Amniota'; but not in amphibia and fishes, which are consequently termed 'Anamnia.'

In reptiles, birds, and many mammals it is developed in the following manner. At the point of constriction where the primitive alimentary canal of the embryo joins the yolk-sac—i.e. in the region of the future umbilicus—a reflection or folding upwards of the somatopleure takes place. This, the *amniotic fold* (fig. 116), first makes its appearance at the cephalic extremity, and subsequently at the caudal end and sides of the embryo, and gradually rising more and more, its different parts meet and fuse over the dorsal aspect of the embryo, and enclose a cavity, the *amniotic*

cavity. After the fusion of the edges of the amniotic fold, the two layers of the fold become completely separated, the inner forming the *amnion*, the outer the *false amnion* or *serosa* (fig. 116). The space between the amnion and the serosa constitutes the extra-embryonic cœlom, already referred to, and for a time communicates with the embryonic cœlom or primitive pleuro-peritoneal cavity.

In the human embryo the earliest stages of the formation of the amnion have not been observed ; in the youngest embryo which has been studied the amnion was already present as a closed sac (figs. 117, 123). As indicated on page 86, the primitive amniotic cavity which appears in the inner cell mass is probably retained in the human embryo, as in that of the bat, to form the permanent amniotic cavity. This cavity is roofed in by a single stratum of flattened ectodermal cells, the *amniotic ectoderm*, and its floor consists of the prismatic ectoderm of the embryonic disc—the continuity between the prismatic embryonic ectoderm and the flattened amniotic ectoderm being established at the margin of the embryonic area. Outside the amniotic ectoderm is a thin layer of mesoderm, which separates it from the chorionic ectoderm or trophoblast and is continuous with the mesoderm of the body-stalk and with the somatic mesoderm of the embryo. Mall suggests that the human amnion may be formed by an inversion of the blastoderm.

FIG. 116.—Diagram of a transverse section, showing the mode of formation of the amnion in the chick. The amniotic folds have nearly united in the middle line. (From Quain's 'Anatomy,' vol. i. pt. 1, 1890.)

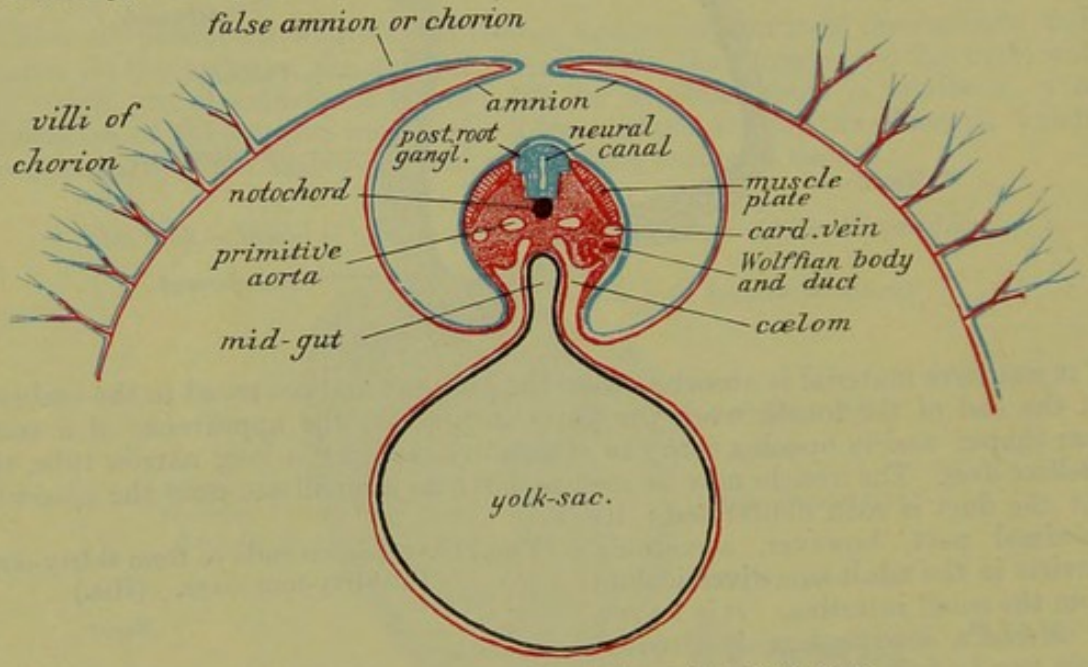

Ectoderm, blue ; mesoderm, red ; entoderm and notochord, black.

When first formed the amnion is in close contact with the body of the embryo, but about the fourth or fifth week fluid begins to accumulate within it. This fluid constitutes the *liquor amnii*, and, increasing in quantity, causes the amnion to expand and ultimately to adhere to the inner surface of the chorion, so that the extra-embryonic part of the cœlom is obliterated. The amnion therefore covers the inner surface of the chorion and the fœtal aspect of the placenta. The liquor amnii increases in quantity up to the sixth or seventh month of pregnancy, after which it diminishes somewhat in amount. It allows of the free movements of the fœtus during the later stages of pregnancy, and also protects it by diminishing the risk of injury from without. It contains less than two per cent. of solids, which consist of urea and other extractives, inorganic salts, a small amount of protein, and frequently a trace of sugar. That part of the liquor amnii is swallowed by the fœtus is proved by the fact that epidermal debris and hairs have been found among the contents of the fœtal alimentary canal.

The **allantois** (figs. 114, 119, 120).—The allantois arises as a diverticulum from that part of the hind-gut which later forms the cloaca : it grows out into the body-stalk, a mass of mesoderm which lies below and around the tail end of the embryo. The diverticulum is lined by entoderm and covered by mesoderm, and in the latter are carried the allantoic or umbilical vessels.

In reptiles, birds, and many mammals the allantois becomes expanded into a vesicle (fig. 199) which projects into the extra-embryonic cœlom, i.e. into the space between the amnion and the serosa. If its further development be traced in the bird, it is seen to project to the right side of the embryo, and, gradually expanding, it spreads over its dorsal surface as a flattened sac between the amnion and the serosa, and, extending in all directions, ultimately surrounds the yolk. Its outer wall becomes applied to, and fuses with, the serosa, which lies immediately inside the shell membrane. Blood is carried to the allantoic sac by the two allantoic or umbilical arteries, which are continuous with the primitive aortæ, and, after circulating through the allantoic capillaries, is returned to the primitive heart by the two umbilical veins. In this way the allantoic circulation, which is of the utmost importance in connection with the respiration and nutrition of the chick, is established. Oxygen is taken from, and carbonic acid is given up to the atmosphere through the egg-shell, while nutritive materials are at the same time absorbed by the blood from the yolk.

In man and other primates the nature of the allantois is entirely different from that just described. Here it exists merely as a narrow, tubular diverticulum of the hind-gut, and never assumes the form of a vesicle outside the embryo. With the formation of the amnion the embryo is, in most animals, entirely separated from the chorion, and is only again united to it when the allantoic mesoderm spreads over and becomes applied to its inner surface. The human embryo, on the other hand, as was pointed out by His, is never wholly separated from the chorion, its tail end being from the first connected with the chorion by means of

Fig. 117.—Diagram showing earliest observed stage of human ovum.

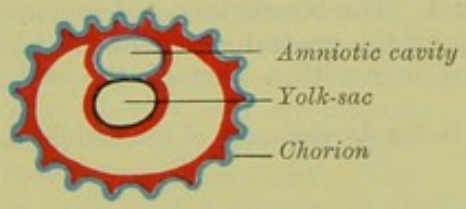

Fig. 118.—Diagram illustrating early formation of allantois and differentiation of body-stalk.

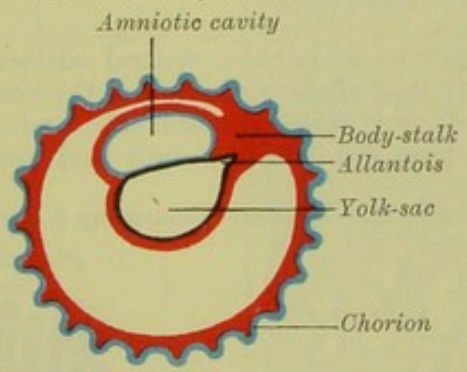

a thick band of mesoderm, named the *body-stalk* (*Bauchstiel*) (figs. 118 and 119); into this stalk the tube of the allantois extends (fig. 113). Moreover, in the human embryo the allantoic diverticulum is seen before the hind-gut is formed, and appears as a tubular protrusion from the yolk-sac (fig. 114). The body-stalk is at first attached to the hind-end of the embryo, but with the growth of the tail and the formation of the caudal flexure it assumes a ventral position, and the tubular allantois is then seen to open from the cloacal part of the hind-gut.

The umbilical orifice divides the allantois into two portions—an intra-abdominal and an extra-abdominal. The latter persists till birth in a rudimentary condition; the proximal part of the intra-abdominal portion takes part in the formation of the cloaca. After the subdivision of the cloacal part of the hind-gut into bladder and rectum has taken place the distal part of the intra-abdominal portion of the allantois becomes obliterated and forms a fibrous cord, the *urachus*, which reaches from the summit of the bladder to the umbilicus.

The **umbilical cord** and **body-stalk** (figs. 119, 120, 121).—The rudiment of the umbilical cord is represented by the tissue which separates the rapidly growing embryo from the extra-embryonic area of the ovum. Included in this tissue are the body-stalk and the vitelline duct—the former containing the allantoic diverticulum and the umbilical vessels, the latter forming the communication between the alimentary canal and the yolk-sac. The *body-stalk* is the posterior segment of the embryonic area, and is attached to the chorion. It consists of a plate of mesoderm covered by thickened ectoderm on which a trace of the neural groove can be seen, indicating its continuity with the embryo. Running through its mesoderm are the two umbilical arteries and the two umbilical veins, together with the canal

of the allantois—the last being lined by entodermal epithelium. Its dorsal surface is covered by the amnion, while its ventral surface is bounded by the extra-embryonic cœlom, and is in contact with the vitelline duct and yolk-sac. With the rapid elongation of the embryo and the formation of the tail fold, the body-stalk

Fig. 119.—Diagram showing later stage of allantoic development with commencing constriction of the yolk sac.

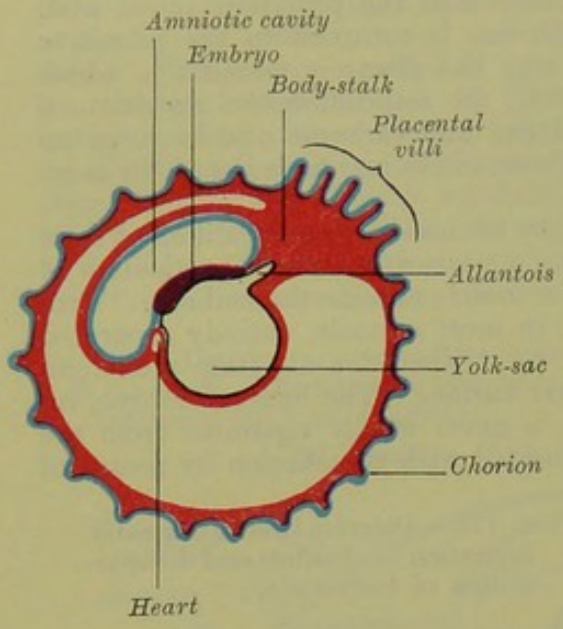

Fig. 120.—Diagram showing the expansion of amnion and delimitation of the umbilicus.

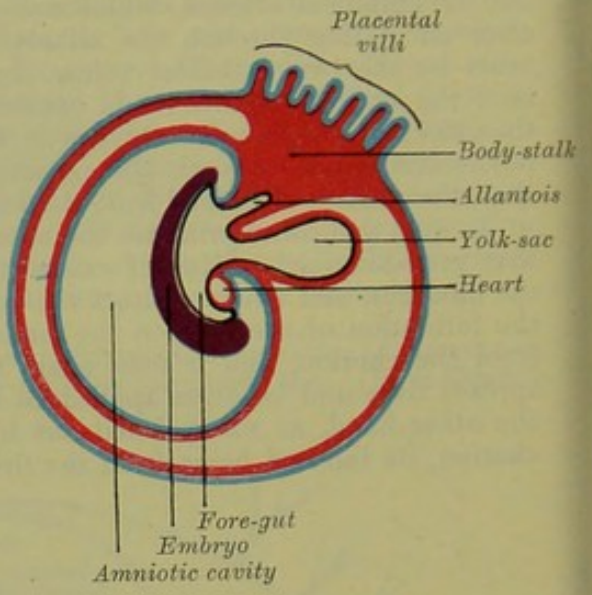

comes to lie on the ventral surface of the embryo, where its mesoderm blends with that of the yolk-sac and the vitelline duct. The lateral leaves of somatopleure then grow round on each side, and, meeting on the ventral aspect of the allantois, enclose the vitelline duct and vessels, together with a part of the embryonic

Fig. 121.—Diagram illustrating a later stage in the development of the umbilical cord.

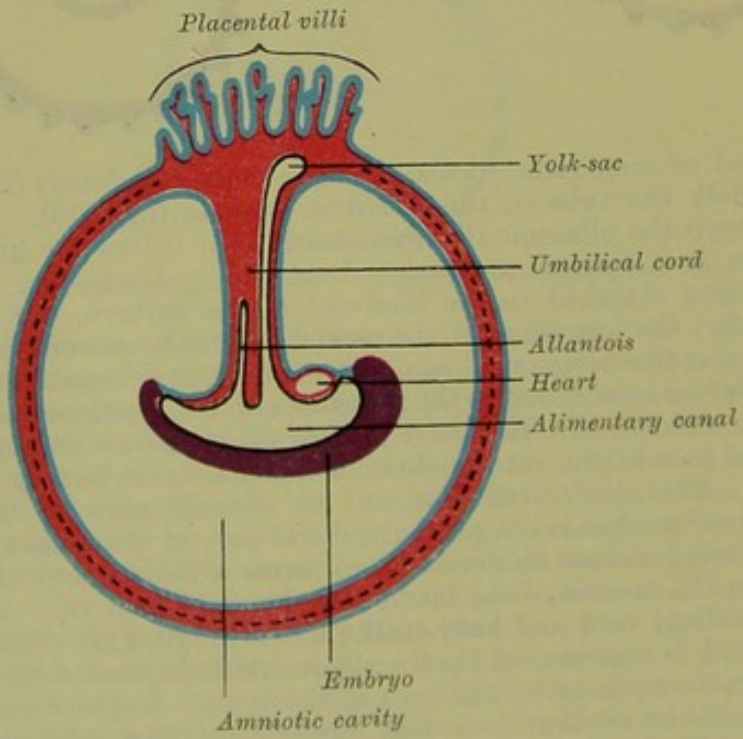

cœlom ; the latter is ultimately obliterated. The cord, therefore, is not covered by the amnion, but by a layer of ectoderm which is continuous with that of the amnion at the placental end of the cord, around which the amnion is attached. The various constituents of the cord are enveloped by embryonic gelatinous tissue (jelly of Wharton). The vitelline vessels and duct, together with the right

umbilical vein, undergo atrophy, and disappear; and thus the cord, at birth, contains a pair of umbilical arteries and one (the left) umbilical vein.

The **chorion** (figs. 117 to 121).—The chorion is developed from the wall of the blastodermic vesicle, and consists of two layers: an outer formed by the primitive ectoderm or trophoblast, and an inner by the somatic mesoderm (figs. 119 and 120). The trophoblast is made up of an internal layer of cubical or prismatic cells, the *cytoblast* or *layer of Langhans*, and an external layer of richly nucleated protoplasm devoid of cell boundaries, the *syncytium*. It undergoes rapid proliferation and forms numerous processes, the *chorionic villi*, which invade and destroy the uterine decidua and at the same time absorb from it nutritive materials for the growth of the embryo. The chorionic villi are at first small and non-vascular, and consist of trophoblast only, but they increase in size and ramify, while the mesoderm, carrying branches of the umbilical vessels, grows into them, and in this way they are vascularised. Blood is carried to the villi by the branches of the umbilical arteries, and after circulating through the capillaries of the villi, is returned to the embryo by the umbilical veins. Until about the end of the second month of pregnancy the villi cover the entire chorion and are almost uniform in size (fig. 119), but after this they develop unequally. The greater part of the chorion is in contact with the decidua capsularis (fig. 124), and over this portion the villi, with their contained vessels, undergo atrophy, so that by the fourth month scarcely a trace of them is left, and hence this part of the chorion becomes smooth, and is named the *chorion lævе*; as it takes no share in the formation of the placenta, it is also named the non-placental part of the chorion. On the other hand, the villi on that part of the chorion which is in contact with the decidua placentalis increase greatly in size and complexity, and hence this part is named the *chorion frondosum*. Since it forms the fœtal portion of the placenta, it is appropriately named the placental part of the chorion, and its villi, the placental villi (fig. 124).

Fig. 122.—Diagrammatic sections of the uterine mucous membrane: (A) of the non-pregnant uterus; (B) of the pregnant uterus, showing the thickened mucous membrane and the altered condition of the uterine glands. (Kundrat and Engelmann.)

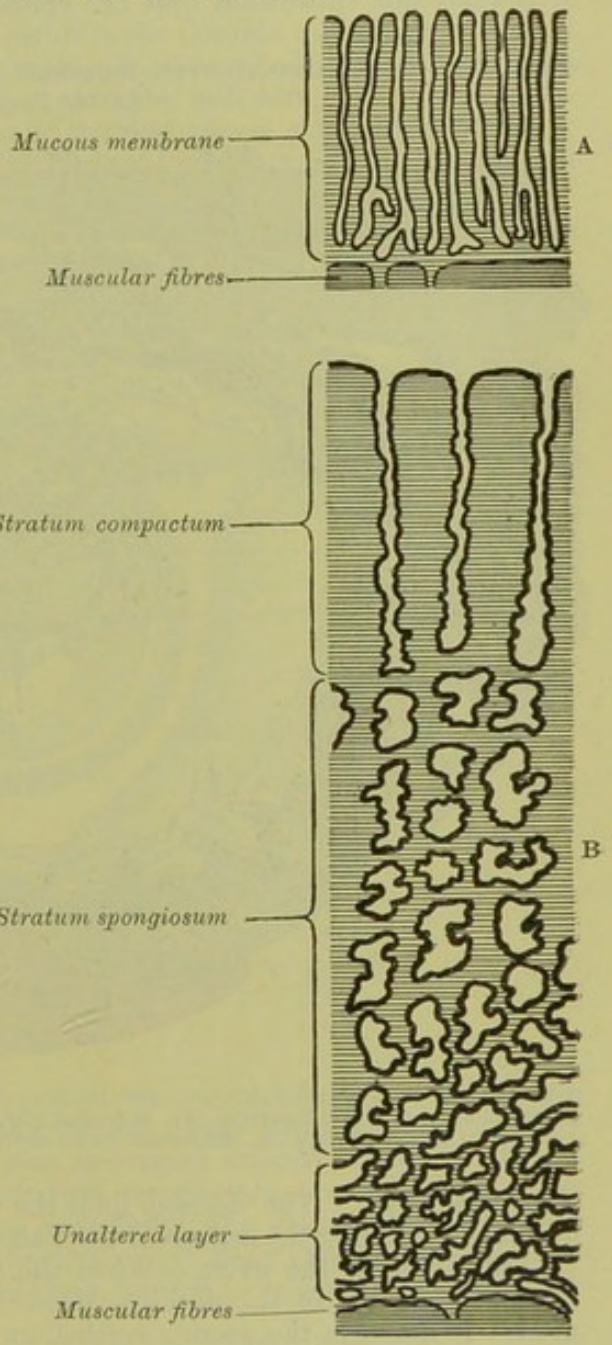

The **decidua.**—Changes take place in the mucous membrane of the uterus in order to render it fit for the reception of the fertilised ovum. It becomes congested and thickened, its connective tissue cells are increased in number, and its glands are expanded; this altered mucous membrane is termed the *decidua*. When the fertilised ovum enters the uterus it becomes imbedded in the decidua, which then undergoes the following changes: its thickness and its vascularity are greatly increased; its glands are elongated and open on its free surface by funnel-shaped

orifices, while their deeper portions are tortuous and dilated into irregular spaces. The interglandular tissue is also increased in quantity, and is crowded with large round, oval, or polygonal cells, termed *decidual cells*. These changes are well advanced by the second month of pregnancy, when the mucous membrane consists of the following strata (fig. 122): (1) *stratum compactum*, next the free surface; in this the uterine glands are only slightly expanded, and are lined by columnar cells; (2) *stratum spongiosum*, in which the gland tubes are greatly dilated and very tortuous, and ultimately come to be separated by only a small amount of interglandular tissue, while their lining cells are flattened or cubical; (3) a thin *unaltered layer*, next the uterine muscular fibres, containing the deepest parts of the uterine glands, which are not dilated, and are lined with columnar epithelium; it is from this epithelium that the epithelial lining of the uterus is regenerated

FIG. 123.—Section through ovum imbedded in the uterine decidua. Semi-diagrammatic. (After Peters.)

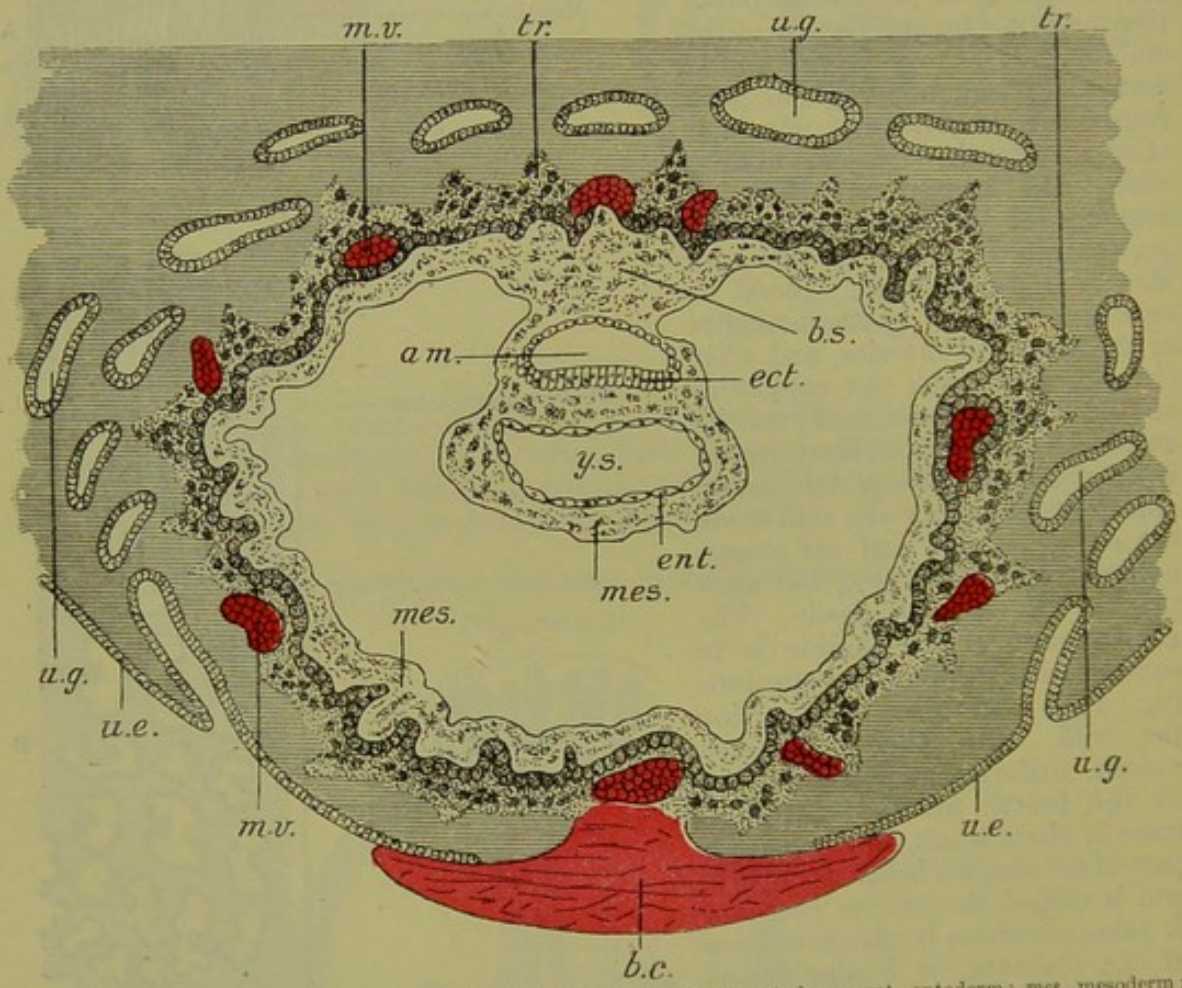

am., amniotic cavity; *b.c.*, blood clot; *b.s.*, body-stalk; *ect.*, embryonic ectoderm; *ent.*, entoderm; *mes.*, mesoderm; *m.v.*, maternal vessels; *tr.*, trophoblast; *u.e.*, uterine epithelium; *u.g.*, uterine glands; *y.s.*, yolk-sac.

after pregnancy. The decidua lines the whole of the *body* of the uterus, without, however, occluding the orifices of the Fallopian tubes.

Imbedding of the ovum.—When the fertilised ovum enters the cavity of the uterus it adheres to the decidua, generally in the neighbourhood of the fundus uteri. It destroys the uterine epithelium over the area of contact and excavates and sinks into the decidua. It expands rapidly and imbeds itself in the decidua, the portion of the latter which overlaps it being named the *decidua capsularis*.* The point at which the ovum entered is at first closed by a mushroom-shaped blood clot, but soon all trace of the aperture is lost and the ovum is then completely enveloped by the decidua (fig. 123). The portion of the decidua which

* The decidua capsularis was formerly named the *decidua reflexa*; this name was applied to it because it was supposed to be produced by the upgrowth of folds of the surrounding decidua over the ovum—these folds gradually overlapping and ultimately fusing so as to completely cover the ovum.

intervenes between the ovum and the uterine wall is named the *decidua basalis* or *decidua placentalis*: it is here that the placenta is subsequently developed. The part of the decidua which lines the remainder of the uterus is known as the *decidua vera*.

The trophoblast of the ovum proliferates rapidly and forms numerous branching villous processes which cover the entire surface of the ovum and invade and destroy the surrounding decidua. They embrace and erode the uterine capillaries so that blood spaces containing maternal blood are formed around the villi and in the trophoblast. These spaces become greatly distended and constitute the *maternal blood sinuses* or *intervillous spaces*. The villi are at first non-vascular and consist of trophoblast only; processes of mesoderm, however, soon invade them and carry into them branches of the umbilical vessels.

Coincidently with the growth of the embryo, the decidua capsularis is thinned and extended (fig. 124). Its vascular supply is diminished, and it undergoes degeneration, and at the same time the non-placental villi atrophy and disappear. The space between the decidua capsularis and decidua vera is gradually obliterated, so that by the third month of pregnancy the two are in contact. By the fifth month

FIG. 124.—Sectional plan of the gravid uterus in the third and fourth month. (Modified from Wagner.)

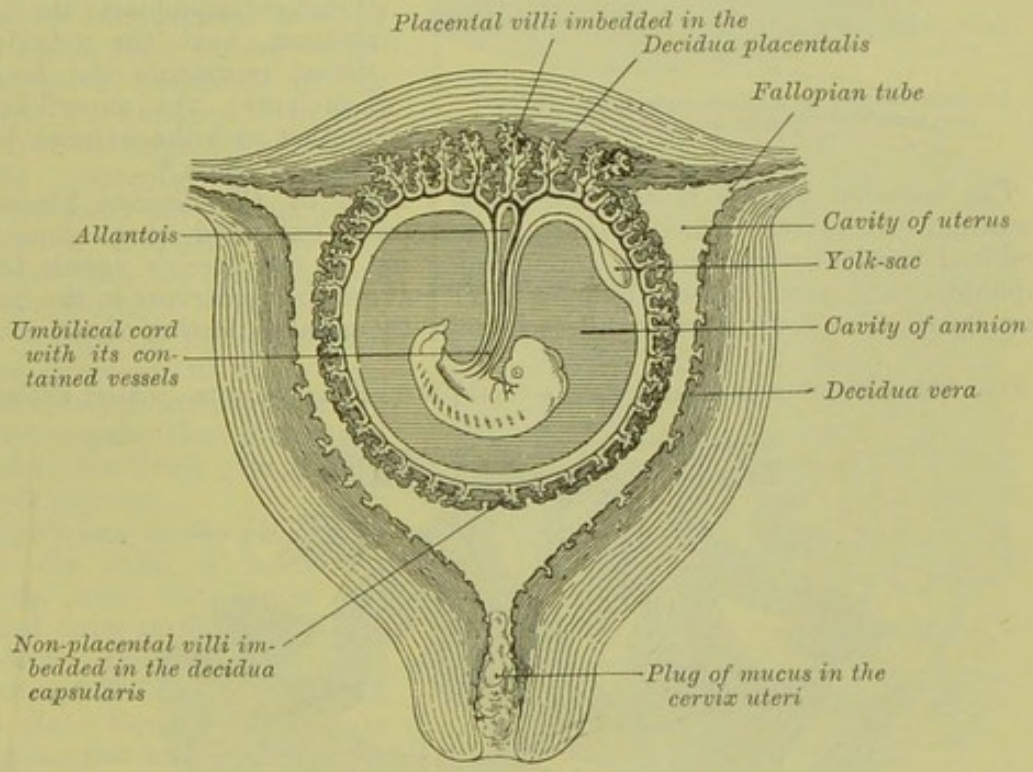

the decidua capsularis has practically disappeared, and, as a consequence, the chorion læva comes directly into contact with the decidua vera. During the succeeding months of pregnancy the decidua vera also undergoes atrophy, owing to the increased pressure. The glands of the stratum compactum are obliterated, and their epithelium is lost. In the stratum spongiosum the glands are compressed and present the appearance of slit-like fissures, while their epithelium undergoes degeneration. In the deepest or unaltered layer, however, the glandular epithelium retains a columnar or cubical form.

The **placenta.**—The placenta connects the fœtus to the uterine wall, and is the organ by means of which the nutritive, respiratory, and excretory functions of the fœtus are carried on. It is composed of fœtal and maternal portions.

The *fœtal portion of the placenta* consists of the villi of the placental part of the chorion. It has already been pointed out that the chorionic villi consist at first of trophoblast (ectoderm) only (fig. 125), and that they become vascularised by the growth into them of the mesoderm which conveys branches of the umbilical vessels (fig. 126). Further, it has been shown that, for a time, they cover the entire surface of the ovum and invade the whole of the surrounding decidua, but owing to the growth of the ovum and consequent extension of the decidua capsularis the

vessels of the latter become atrophied and the villi over the corresponding part of the chorion disappear. On the other hand the placental villi, which invade the decidua placentalis, branch repeatedly, increase enormously in size, and constitute the fœtal part of the placenta (fig. 124). These greatly ramified villi are suspended in the maternal blood sinuses, and are therefore bathed in maternal blood, which is conveyed to the sinuses by the uterine arteries and carried away by the uterine veins. A branch of an umbilical artery enters each villus and ends in a capillary plexus from which the blood is drained by a tributary of the umbilical vein. The vessels of the villus are surrounded by a thin layer of mesoderm consisting of gelatinous connective tissue, which is covered by two strata of ectodermal cells derived from the trophoblast: the deeper stratum, next the mesodermic tissue, represents the layer of Langhans; the superficial, in contact with the maternal blood, the syncytium.*

Fig. 125.—Diagram to illustrate the first phase of the placenta. (After Peters.)

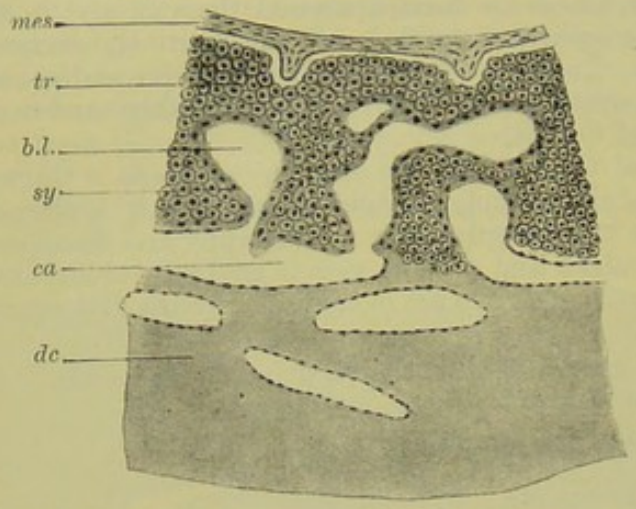

b.l., blood-lacuna; *ca*, maternal capillary; *dc*, decidua; *mes*, mesoderm; *sy*, syncytium; *tr*, trophoblast.

The *maternal portion of the placenta* is formed by the decidua placentalis containing the maternal blood sinuses. As already explained, these sinuses are produced partly by the erosion and opening out of the uterine vessels by the trophoblast and partly by the channels which make their appearance in the trophoblast itself. The destructive changes involve the greater portion of the stratum

Fig. 126.—Diagram to illustrate the second phase of the placenta. (After Peters.)

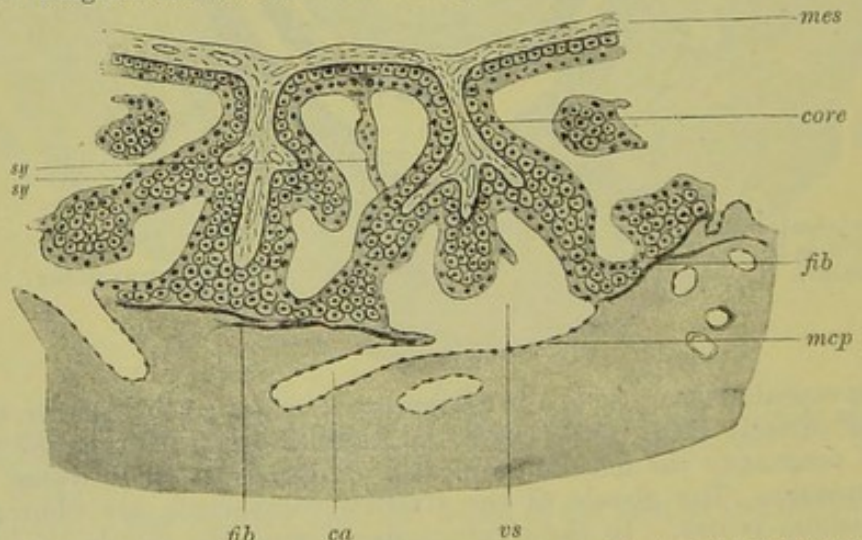

The mesodermic core has now invaded the strands of the trophoblast, and is beginning to branch. *ca*, maternal capillary; *core*, core of villus; *fib*, fibrinous material deposited at junction of trophoblast with decidua; *mcp*, endothelium of maternal capillary; *mes*, mesoderm; *sy*, syncytium; *vs*, intervillous space.

compactum, but the deeper part of this layer persists and is condensed to form what is known as the *basal plate*. Between this plate and the uterine muscular fibres are the stratum spongiosum and the unaltered layer; through these and the basal plate the uterine arteries and veins pass to and from the maternal blood sinuses. The endothelial lining of the uterine vessels ceases at the point where they terminate in the sinuses; the sinuses themselves are lined by the syncytium of the trophoblast. Portions

* This outer layer was regarded by some authorities as being of maternal origin, but recent observations have proved that it is derived from the syncytium. The whole of the structures of the villi, therefore, consist of embryonic tissues.

of the stratum compactum persist and are condensed to form a series of septa, which extend from the basal plate through the thickness of the placenta and subdivide it into the lobes or *cotyledons* seen on the uterine surface of the detached placenta.

The fœtal and maternal blood currents traverse the placenta, the former passing through the blood-vessels of the placental villi and the latter through the maternal blood sinuses or intervillous spaces (fig. 127). The two currents do not intermingle, being separated from each other by the delicate walls of the villi. Nevertheless, the fœtal blood is able to absorb, through the thin walls of the villi, oxygen and nutritive materials from the maternal blood, and give up to the latter its waste products. The blood, so purified, is carried back to the fœtus by the umbilical vein. It will thus be seen that the placenta not only establishes a mechanical connection between the mother and the fœtus, but subserves for the latter the purposes of nutrition, respiration, and excretion. In favour of the view that the placenta possesses certain selective powers may be mentioned the fact that glucose is more plentiful in the maternal than in the fœtal blood. It is interesting to note also that the proportion of iron, and of lime and potash, in the fœtus is increased during the last months of pregnancy. Further, there is evidence that the maternal leucocytes may migrate into the fœtal blood, since leucocytes are much more numerous in the blood of the umbilical vein than in that of the umbilical arteries.

FIG. 127.—Scheme of placental circulation.

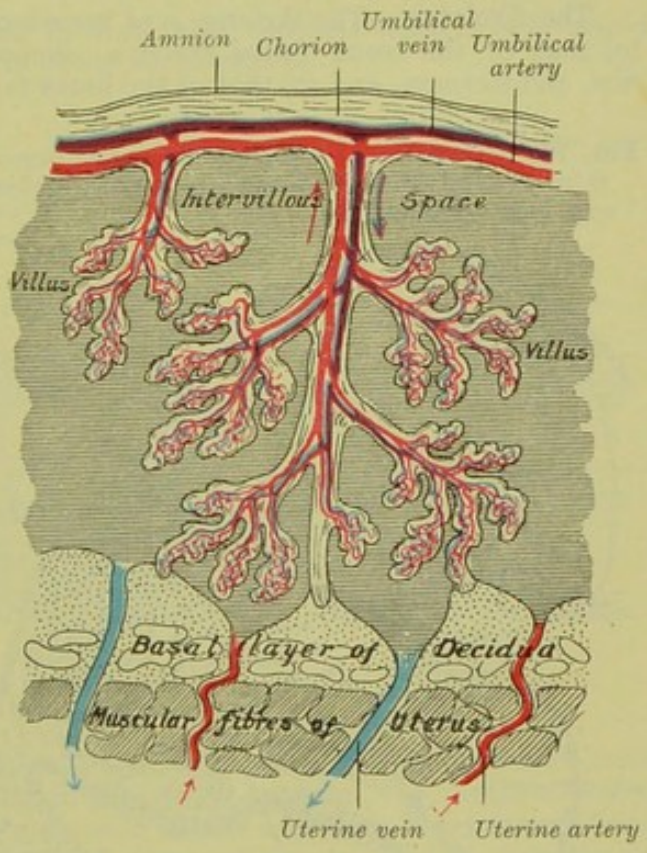

The placenta is usually attached near the fundus uteri, and more frequently on the posterior than on the anterior wall of the uterus. It may, however, occupy a lower position and, in rare cases, its site is close to the os uteri internum, which it may occlude, thus giving rise to the condition known as *placenta prævia*.

Separation of the placenta.—After the child is born, the placenta and membranes are expelled from the uterus as the *after-birth*. The separation of the placenta from the uterine wall takes place through the stratum spongiosum, and necessarily causes rupture of the uterine vessels. The orifices of the torn vessels are, however, closed by the firm contraction of the uterine muscular fibres, and thus *post-partum hæmorrhage* is prevented. The epithelial lining of the uterus is regenerated by the proliferation and extension of the epithelium which lines the persistent portions of the uterine glands in the unaltered layer of the decidua.

The expelled placenta appears as a discoid mass which weighs about a pound, and has a diameter of from six to eight inches. Its average thickness is about an inch and a quarter, but this diminishes rapidly towards the circumference of the disc, which is continuous with the membranes. Its uterine surface is divided by a series of fissures into lobules or *cotyledons*, the fissures containing the remains of the septa which extended between the maternal and fœtal portions. Most of these septa end in irregular or pointed processes; others, especially those near the edge of the placenta, pass through its thickness and are attached to the chorion. In the early months these septa convey branches of the uterine arteries which open into the maternal sinuses on the surfaces of the septa. The fœtal surface of the placenta is smooth, being closely invested by the amnion. Seen through the latter, the chorion presents a mottled appearance, consisting of grey, purple,

or yellowish areas. The umbilical cord is usually attached near the centre of the placenta, but may be inserted anywhere between the centre and the margin. In some cases it is inserted into the membranes, i.e. the *velamentous* insertion. From the attachment of the cord the larger branches of the umbilical vessels radiate under the amnion, the veins being deeper and larger than the arteries. The remains of the vitelline duct and yolk-sac may be sometimes observed beneath the amnion, close to the cord, the former as an attenuated thread, the latter as a minute sac.

On section, the placenta presents a soft, spongy appearance, caused by the greatly branched villi; surrounding them is a varying amount of maternal blood giving the dark red colour to the placenta. Many of the larger villi extend from the chorionic to the decidual surface, while others are attached to the septa which separate the cotyledons; but the great majority hang free in the maternal sinuses, like the branches of a tree.

The further growth of the embryo will be best understood from a description of the principal facts relating to the development of the chief parts of which the body consists.

DEVELOPMENT OF THE PARIETES

The Skeleton.—The skeleton is of mesodermal origin, and may be divided into (*a*) that of the trunk (axial skeleton), comprising the vertebral column, skull, ribs, and sternum, and (*b*) that of the limbs (appendicular skeleton).

The **vertebral column.**—The notochord (fig. 111) is a temporary structure and forms a central axis, around which the segments of the vertebral column are developed.* It is derived from the entoderm, and consists of a rod of cells, which lies on the ventral aspect of the neural tube and reaches from the anterior end of the mid-brain to the extremity of the tail. On either side of it is a column of paraxial mesoderm which divides into a number of more or less cubical segments, the *primitive segments* or *protovertebral somites* (figs. 110, 111, 112). These are separated from one another by *intersegmental septa* and are arranged symmetrically on either side of the neural tube and notochord: to every segment a spinal nerve is distributed. At first each segment contains a central cavity, the *myocœl*, but this is soon filled with a core of angular and spindle-shaped cells. The cells of the segment become differentiated into three groups, which form respectively the cutis-plate or dermatome, the muscle-plate or myotome, and the sclerotome (fig. 128). The *cutis-plate* is placed on the outer and dorsal aspect of the myocœl, and from it the true skin of the corresponding segment is derived; the *muscle-plate* is situated on the inner aspect of the myocœl and furnishes the muscles of the segment. The

FIG. 128.—Transverse section of a human embryo of the third week to show the differentiation of the primitive segment. (Kollmann.)

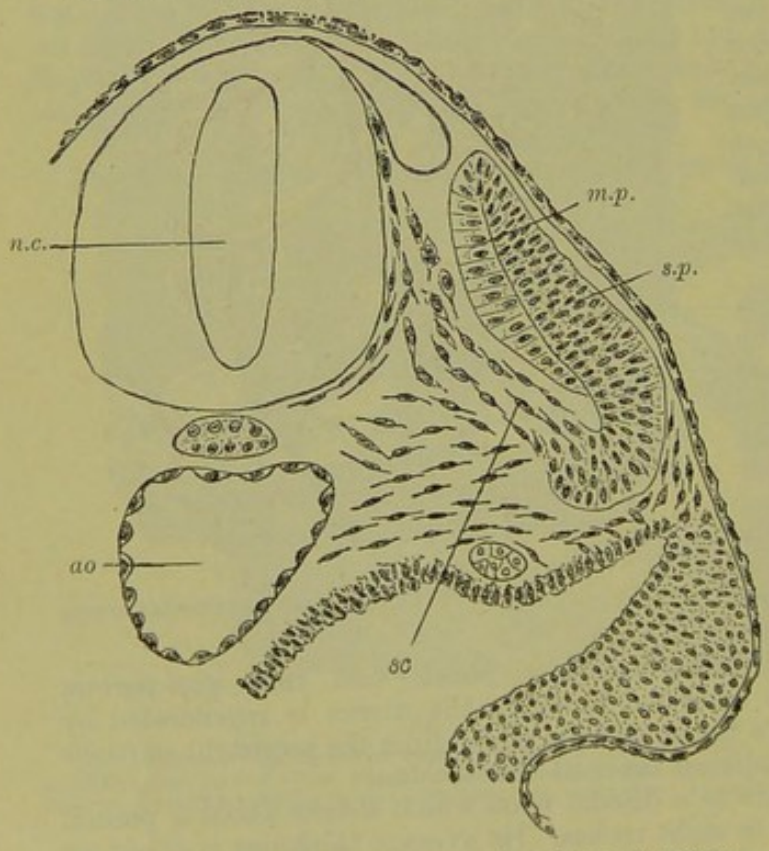

ao, aorta; *m.p.*, muscle-plate; *n.c.*, neural canal; *sc*, sclerotome; *s.p.*, cutis-plate.

* In the amphioxus the notochord persists and forms the only representative of a skeleton in that animal.

cells of the *sclerotome* are largely derived from those which form the core of the myocœl, and lie next the notochord. Fusion of the individual sclerotomes in an antero-posterior direction soon takes place, and thus a continuous strand of cells, the *scleratogenous layer*, is formed along the ventro-lateral aspects of the neural tube. The cells of this layer proliferate rapidly, and extending inwards surround the notochord ; at the same time they grow backwards on the lateral aspects of the neural tube and eventually surround it, and thus the notochord and neural tube are enveloped by a continuous sheath of mesoderm, which is termed the *membranous vertebral column*. In this mesoderm the original segments are still distinguishable, but each is now differentiated into two portions, an anterior, consisting of loosely arranged cells, and a posterior, of more condensed tissue (fig. 129, A and B). Between the two portions the rudiment of the intervertebral disc is laid down (fig. 129, C). Cells from the posterior mass grow out into the intervals between the myotomes (fig. 129, B and C) of the corresponding and succeeding segments to form an arch or bow, the *primitive vertebral bow*. The mesial portion of this bow lies on the ventral aspect of the notochord, and is termed the *hypochordal bar* or *brace*. Its lateral portions extend both dorsally and ventrally ; the dorsal extensions surround the neural tube and represent the future neural arch of the vertebra, while the ventral extend into

FIG. 129.—Scheme showing the manner in which each vertebral centrum is developed from portions of two adjacent segments.

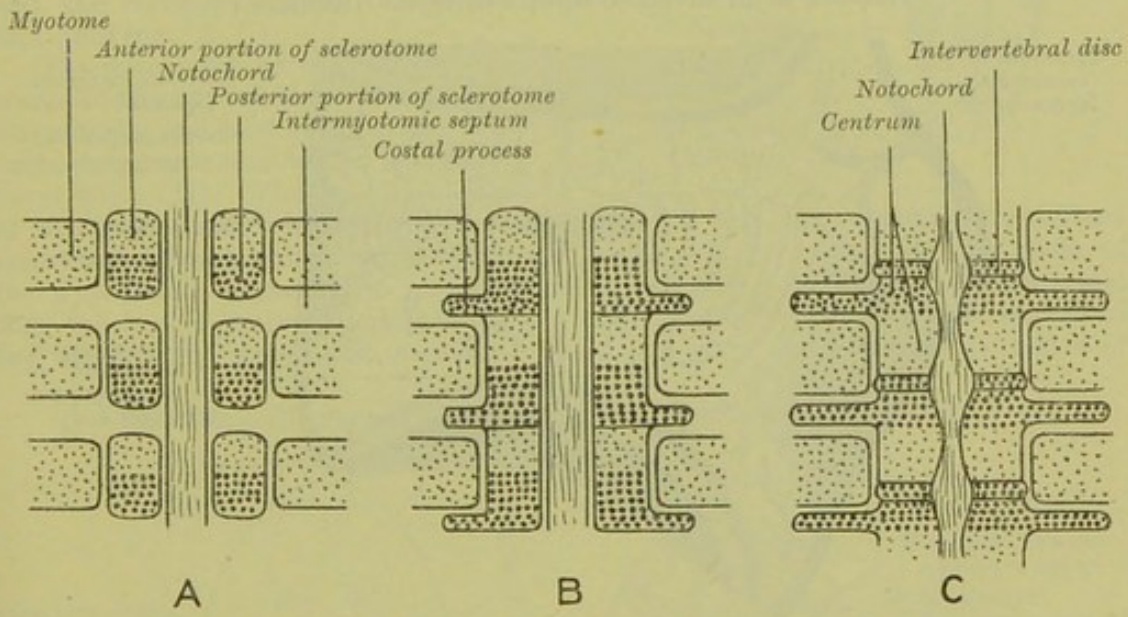

the body-wall as the costal processes. The hinder part of the posterior mass joins the anterior mass of the succeeding segment to form the vertebral body. Each vertebral body is therefore a composite of two segments, being formed from the posterior portion of one segment and the anterior part of that immediately behind it. The neural and costal arches are derivatives of the posterior part of the segment in front of the intersegmental septum with which they are associated.

This stage is succeeded by that of the *cartilaginous vertebral column*. In the fourth week two cartilaginous centres make their appearance on the dorsal aspect of the hypochordal bar, one on either side of the notochord ; these extend round the notochord and form the body of the cartilaginous vertebra. A second pair of cartilaginous foci appear in the lateral parts of the vertebral bow, and grow backwards on either side of the neural tube to form the cartilaginous neural arch. By the eighth week the cartilaginous arch has fused with the body, and in the fourth month the two halves of the arch are joined on the dorsal aspect of the neural tube. The spinous process is developed from the junction of the two halves of the neural arch. The transverse process grows out from the neural arch immediately behind the costal process.

Except in the case of the first cervical vertebra, the hypochordal bar of the primitive vertebral bow disappears by fusing with the intervertebral disc. In this vertebra, however, the entire bow persists and remains separate from the

cartilaginous body. The hypochordal bar becomes developed into the anterior arch of the bone, while the cartilaginous body forms the odontoid process which fuses with the body of the second cervical vertebra.

The portions of the notochord which are surrounded by the bodies of the vertebræ atrophy, and ultimately disappear, while the parts which lie in the centres of the intervertebral discs undergo enlargement, and persist throughout life as the central *nucleus pulposus* of the discs (fig. 130).

The ribs.—The ribs are formed from the ventral or costal processes of the primitive vertebral bows, the processes extending outwards between the muscle-plates. In the *thoracic region* of the vertebral column the costal processes of the vertebral bows grow outwards to form a series of arches, the *primitive costal arches*. As already described, the transverse process grows out behind the vertebral end of each arch. It is at first connected to the costal process by continuous mesoderm, but this becomes differentiated later to form the costo-transverse ligaments; between the costal process and the tip of the transverse process the costo-transverse joint is formed by absorption. The costal process becomes separated from the vertebral bow by the development of the costo-central joint. In the *cervical vertebræ* the transverse process forms the posterior boundary of the foramen transversarium, while the costal process corresponding to the head and neck of the rib fuses with the body of the vertebra, and forms the antero-

FIG. 130.—Sagittal section through the intervertebral disc and adjacent parts of two vertebræ of an advanced sheep's embryo. (Kölliker.)

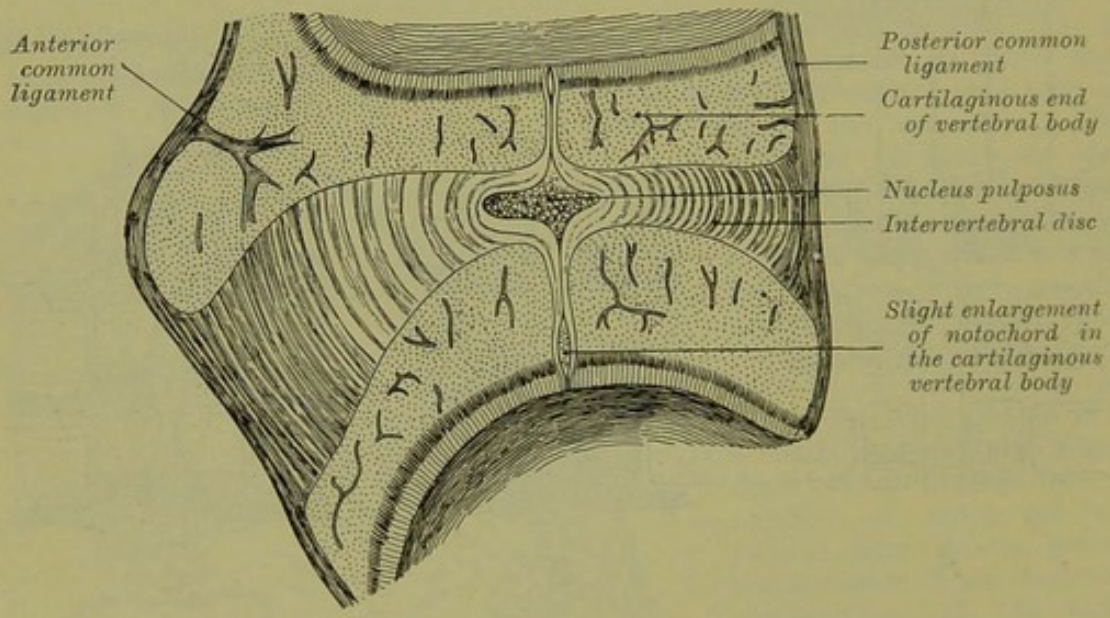

lateral boundary of the foramen. The distal portions of the primitive costal arches remain undeveloped; occasionally the arch of the seventh cervical vertebra undergoes greater development, and by the formation of costo-vertebral joints is separated off as a rib. In the *lumbar region* the distal portions of the primitive costal arches fail; the proximal portions remain undifferentiated and fuse with the transverse processes to form the transverse processes of descriptive anatomy. Occasionally a movable rib is developed in connection with the first lumbar vertebra. In the *sacral region* costal processes are developed only in connection with the upper three, or it may be four, vertebræ; the processes of adjacent segments fuse with one another to form the lateral masses of the sacrum. The *coccygeal vertebræ* are devoid of costal processes.

The sternum.—The view generally held regarding the development of the sternum is that it arises as a paired structure from the ventral ends of the upper nine ribs which join on either side of the middle line to form a cartilaginous strip. The two strips are at first connected by membrane, but they become united in the middle line from before backwards, and so give rise to a longitudinal piece of cartilage, which represents the manubrium and gladiolus. The ventral ends of the eighth and ninth cartilages fuse to form the xiphoid appendix, and subsequently lose their connection with the sternum. Sometimes the eighth retains its original connection, and constitutes an eighth true rib,

which occurs more frequently on the right than on the left side. This bilateral condition of the primitive sternum would serve to explain the occurrence of fissures or holes in the bone, as well as that rare anomaly, a completely divided sternum. Paterson,* on the other hand, after reviewing the literature on this subject, and giving the results of his own observations on the embryonic and adult conditions of the sternum in man and some of the lower animals, says: 'The weight of evidence is all on the side of the primary association of the sternum with the shoulder girdle and its secondary connection with the ribs.' There is reason to believe that the upper part of the manubrium sterni represents the precoracoid element of the shoulder girdle.

Fig. 131.—Sagittal section of cephalic end of notochord. (Keibel.)

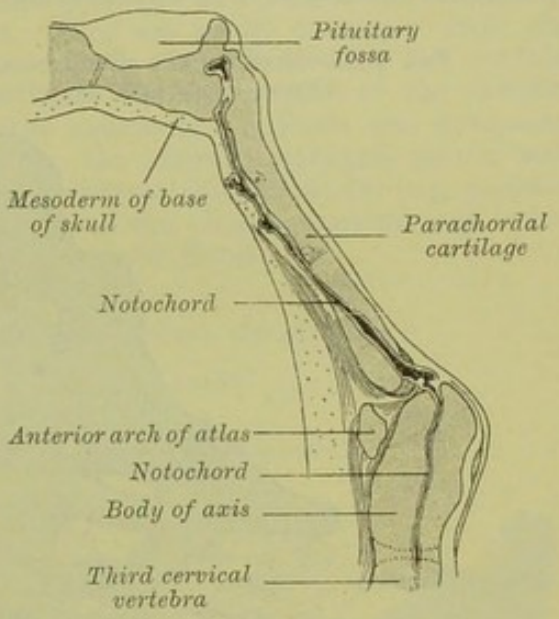

The **skull**.—Up to a certain stage the development of the skull corresponds with that of the vertebral column; but it is modified later in association with the expansion of the brain-vesicles, the formation of the organs of smell, sight, and hearing, and the development of the mouth and pharynx.

The notochord extends as far forwards in the base of the future skull as the anterior end of the mid-brain, and becomes partly surrounded by mesoderm (fig. 131). The posterior part of this mesodermal investment corresponds with the future basi-occiput, and shows a subdivision into four segments, which are separated by the roots of the hypoglossal nerve. The mesoderm then extends over the brain-vesicles, and thus the entire brain is enclosed by a mesodermal investment, which is termed the *membranous primordial cranium*. From the inner layer of this the bones of

Fig. 132.—Diagrams of the cartilaginous cranium. (Wiedersheim.)

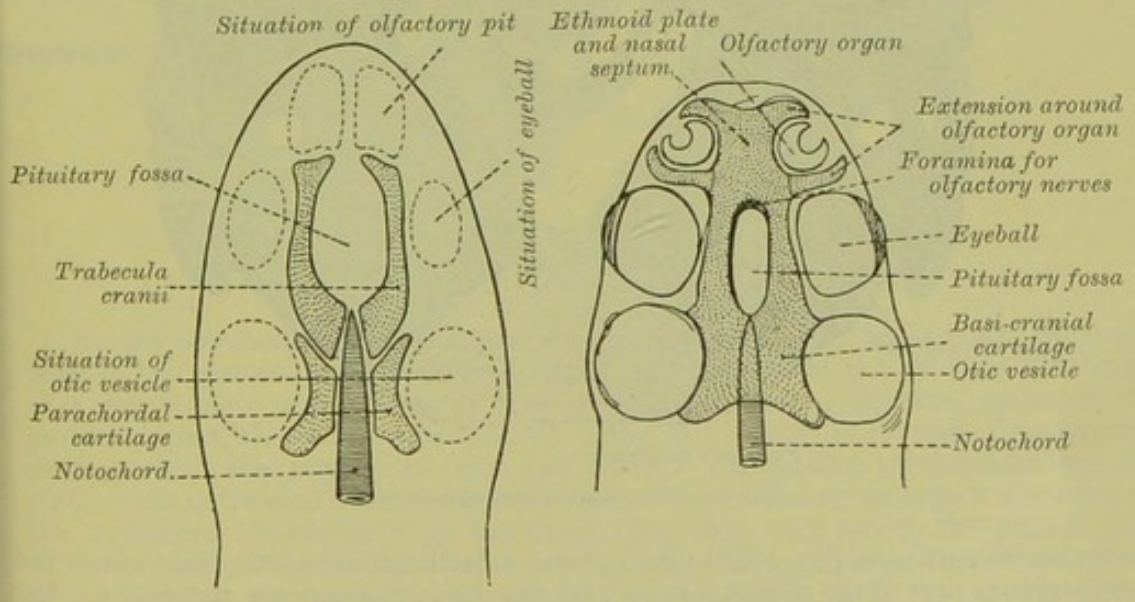

the skull and the membranes of the brain are developed; from the outer layer the muscles, blood-vessels, true skin, and subcutaneous tissues of the scalp. In the shark and dog-fish this membranous cranium undergoes complete chondrification, and forms the cartilaginous skull or *chondrocranium* of these animals. In mammals, on the other hand, the process of chondrification is limited to the base of the skull—the roof and sides being covered in by membrane. Thus

* *The Human Sternum*, by A. Melville Paterson, 1904.

the bones of the base of the skull are preceded by cartilage, those of the roof and sides by membrane. The posterior part of the base of the skull is developed around the notochord, and exhibits a segmented condition analogous to that of the vertebral column, while the anterior part arises in front of the notochord and shows no regular segmentation. The base of the skull may therefore be divided into (*a*) a *chordal* or *vertebral*, and (*b*) a *prechordal* or *prevertebral* portion.

In the lower vertebrates two pairs of cartilages are developed: viz. a pair of parachordal cartilages, one on either side of the notochord; and a pair of prechordal cartilages, the *trabeculæ cranii*, in front of the notochord (fig. 132). The

FIG. 133.—Model of the chondrocranium of a human embryo, 8 cm. long. (From Hertwig's 'Handbuch der Entwickelungslehre.')

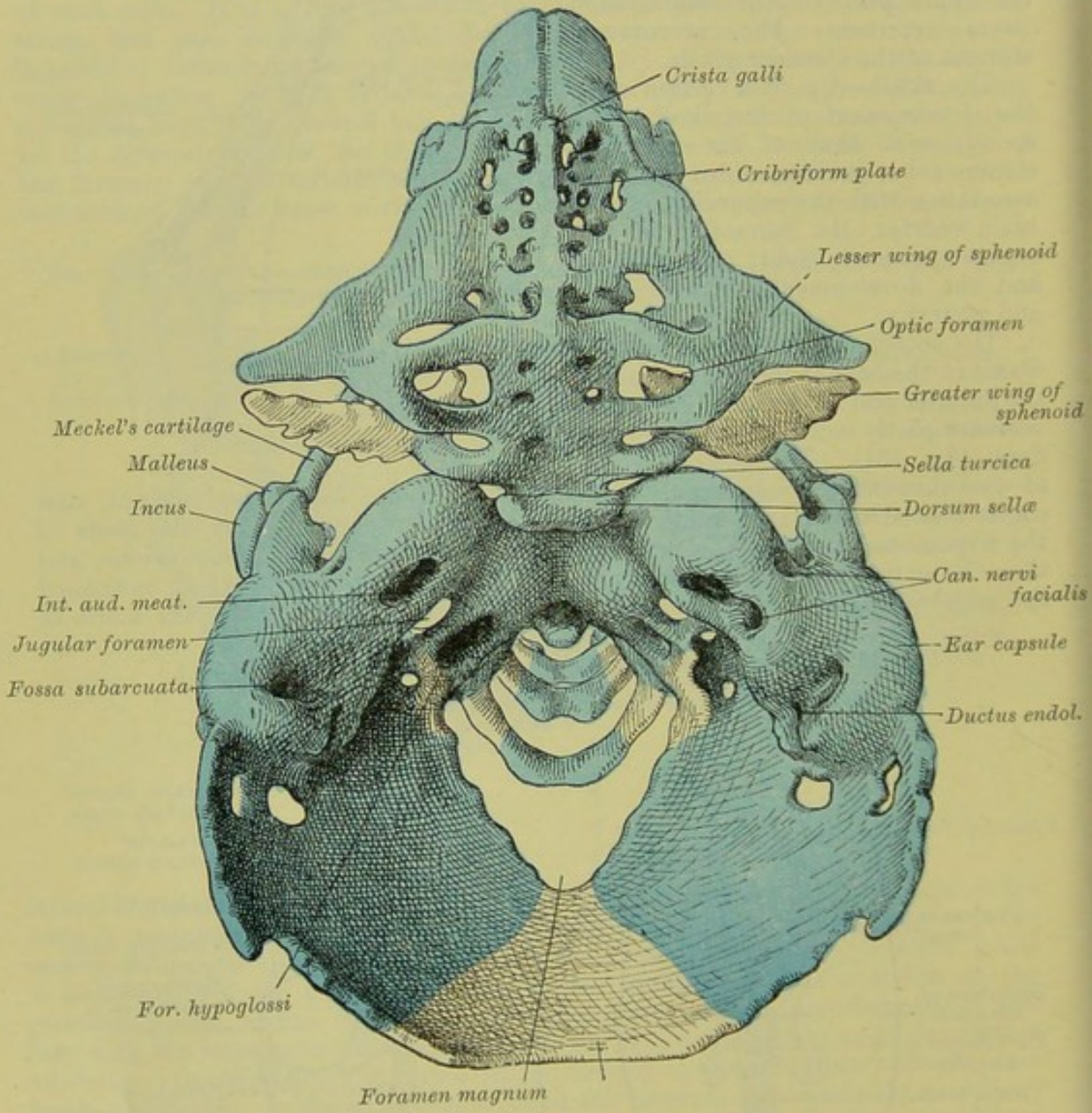

The membrane-bones are not represented.

parachordal cartilages (fig. 132) unite to form a cartilaginous plate, from which the cartilaginous part of the occipital bone and the basi-sphenoid are developed. On the lateral aspect of the parachordal cartilages the *otic* or *auditory vesicles* are situated, and the mesoderm enclosing them is soon converted into cartilage, forming the *cartilaginous ear-capsules*. These cartilaginous ear-capsules, which are of an oval shape, fuse with the lateral aspects of the basilar plate, and from them arise the petro-mastoid portions of the temporal bones. The *trabeculæ cranii* (fig. 132) are two curved bars of cartilage which embrace the pituitary body; their posterior ends soon unite with the basilar plate, while their anterior ends join to form the *ethmoidal plate*, which extends forwards between the fore-brain and the

olfactory pits. Later, the trabeculæ meet and fuse below the pituitary body, forming the floor of the pituitary fossa, and so cutting off the anterior lobe of the pituitary body from the stomatodæum. The mesial part of the ethmoidal plate forms the bony and cartilaginous parts of the nasal septum. From the lateral margins of the trabeculæ cranii three processes grow out on either side. The anterior forms the lateral mass of the ethmoid and the alar cartilages of the nose; the middle gives rise to the lesser wing of the sphenoid, while from the posterior the greater wing and external pterygoid plate of the sphenoid are developed (figs. 133, 134). The bones of the vault are of membranous formation, and are termed *dermal* or *covering bones*. They are partly developed from the mesoderm of the primordial cranium, and partly from that which lies outside the entoderm of the fore-gut. They comprise the upper part of the tabular portion of the occipital (interparietal), the squamous-temporals and tympanic plates, the parietals, the frontal, the vomer, the internal pterygoid plates, and the bones of the face. Some of them remain distinct throughout life (e.g. parietal and frontal), while others join with the bones of the chondrocranium (e.g. interparietal, squamous-temporals, and internal pterygoid plates).

Fig. 134.—The same model as shown in fig. 133 from the left side.

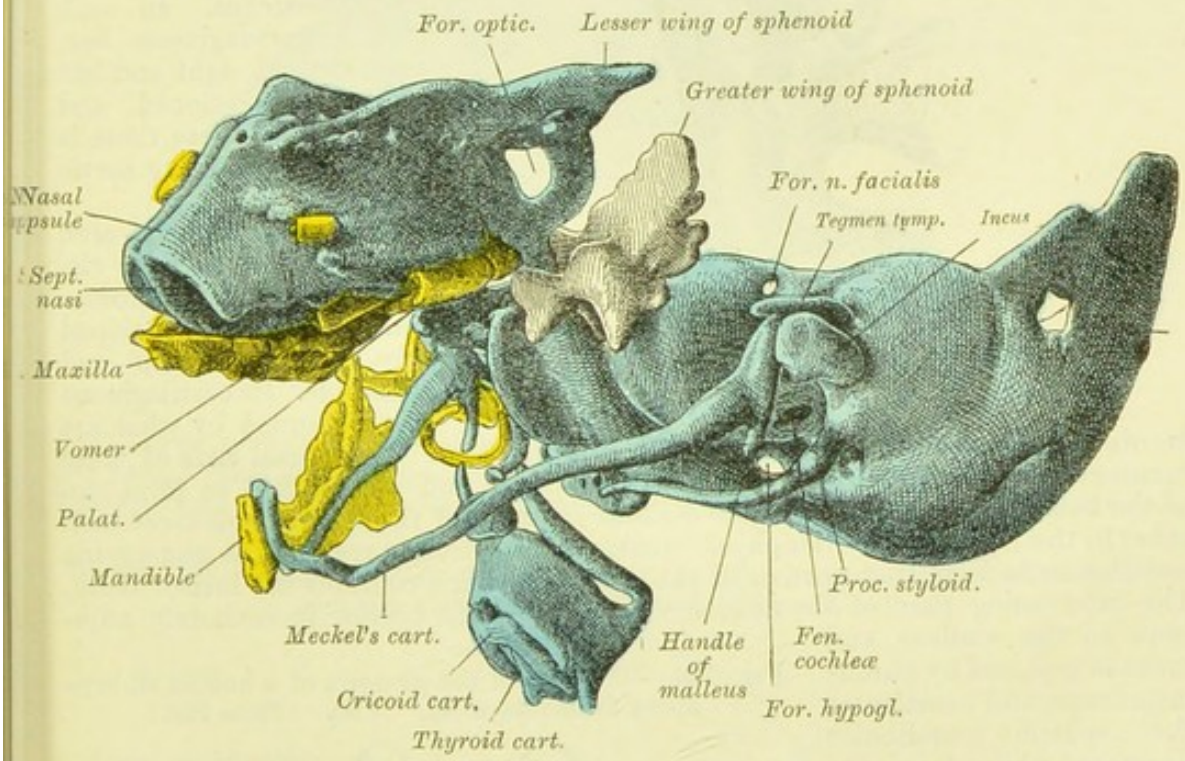

Certain of the membrane-bones of the right side are represented in yellow.

Recent observations have shown that, in mammals, the basi-cranial cartilage, both in the chordal and prechordal regions of the base of the skull, is developed as a single plate which extends from behind forwards. In man, however, its posterior part shows an indication of being developed from two chondrifying centres which fuse rapidly in front and below. The relation of this cartilaginous plate to the notochord differs in different animals. In the rat embryo it lies beneath the notochord (Robinson); in the sheep, pig, calf, and ferret, the cranial part of the notochord is enclosed within it; in man, the anterior and posterior thirds of the cartilage surround the notochord, but its middle third lies on the dorsal aspect of the notochord, which in this region is placed between the cartilage and the wall of the pharynx.

The **visceral arches.**—In the lateral walls of the anterior part of the fore-gut a series of furrows or incomplete clefts appears (fig. 135). These are named the *visceral clefts*, and take origin as paired grooves or pouches in the sides of the fore-gut; over each groove a corresponding indentation of the ectoderm occurs, so that the latter comes into contact with the entodermal lining of the fore-gut, and the two layers unite along the floors of the grooves to form thin septa between the

fore-gut and the exterior. In gill-bearing animals these septa disappear, and the grooves become complete clefts—the gill-clefts—opening from the pharynx on to the exterior; perforation, however, does not occur in birds or mammals. The clefts separate a series of rounded bars or arches, the *visceral arches*, in which thickening of the mesoderm takes place (figs. 135, 136, 137). The dorsal ends of these arches are attached to the sides of the head, while the ventral extremities ultimately meet in the middle line of the neck. In all, five arches make their appearance, but of these only the first four are visible externally, the fifth never being elevated above the surface. The first arch is named the *mandibular*; the second, the *hyoid*; the third, the *thyro-hyoid* (fig. 137); while the others have no distinctive names, but are referred to as the fourth and fifth visceral arches. In each arch a cartilaginous bar, consisting of right and left halves, is developed, and with each of these there is one of the primitive aortic arches.

FIG. 135.—Embryo between eighteen and twenty-one days. (His.)

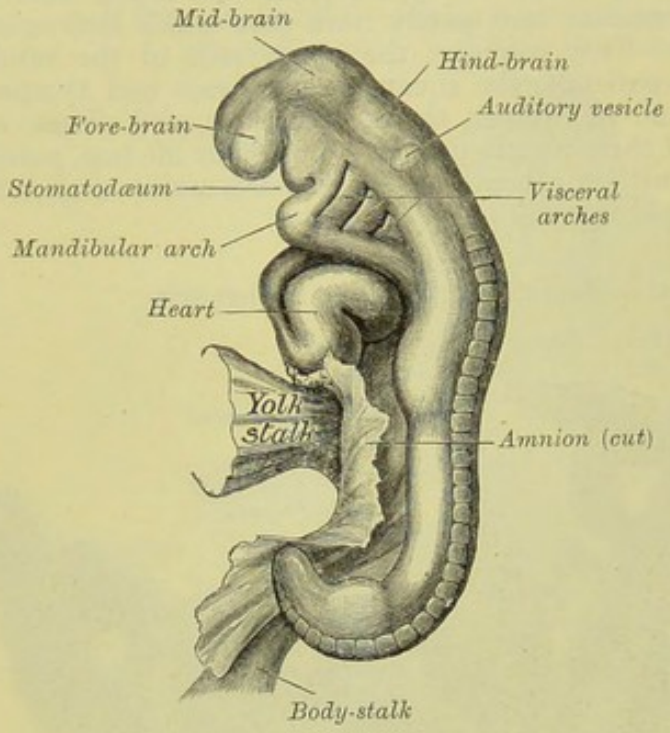

The mandibular arch lies between the first visceral cleft and the stomatodæum, and is developed into the lower lip and mandible. Its cartilaginous bar is formed by what are known as *Meckel's cartilages* (right and left, fig. 138). The dorsal ends of these cartilages are connected with the periotic capsules and are ossified to form two of the bones of the middle ear, the malleus and incus;* the ventral ends meet each other in the region of the symphysis menti, and are usually regarded as undergoing ossification to form that portion of the mandible which contains the incisor teeth. The intervening part of the cartilage disappears; the portion immediately adjacent to the malleus and incus is replaced by fibrous membrane, and constitutes the spheno-mandibular ligament, while from the connective tissue covering the remainder of the cartilage the greater part of the mandible is ossified. The second or hyoid arch assists in forming the side and front of the neck. From its cartilage are developed the styloid process, stylo-hyoid ligament, and lesser cornu of the hyoid bone. The cartilage of the third or thyro-hyoid arch gives origin to the great cornu of the hyoid bone. The ventral ends of the second and third arches unite with those of the opposite side, and form a transverse band, from the cartilages of which the body of the hyoid bone is developed. The ventral

FIG. 136.—The floor of the pharynx of a human embryo about fifteen days old. × 50. (From His.)

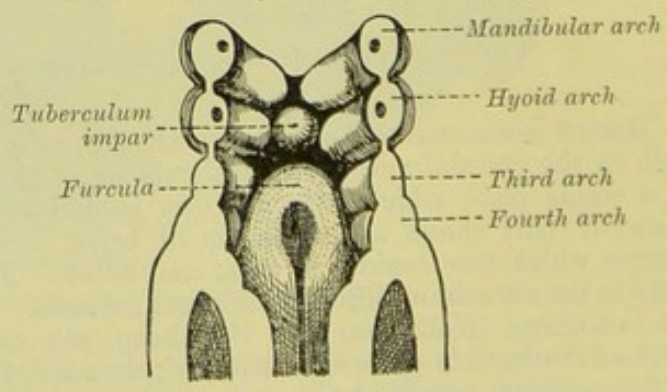

* Some regard the incus as arising from the dorsal end of the hyoid bar, while Gadow (*Phil. Trans.* vol. clxxix.) inclines to the view that the malleus, incus, and stapes arise from a cartilaginous plate, the hyomandibula, which binds the proximal ends of the mandibular and hyoid bars together.

portions of the cartilages of the fourth and fifth arches unite to form the thyroid cartilage.

The first and second arches grow more rapidly than those behind them, with the result that the latter become, to a certain extent, telescoped within the former,

Fig. 137.—Profile view of the head of a human embryo, estimated as twenty-seven days old. (After His.)

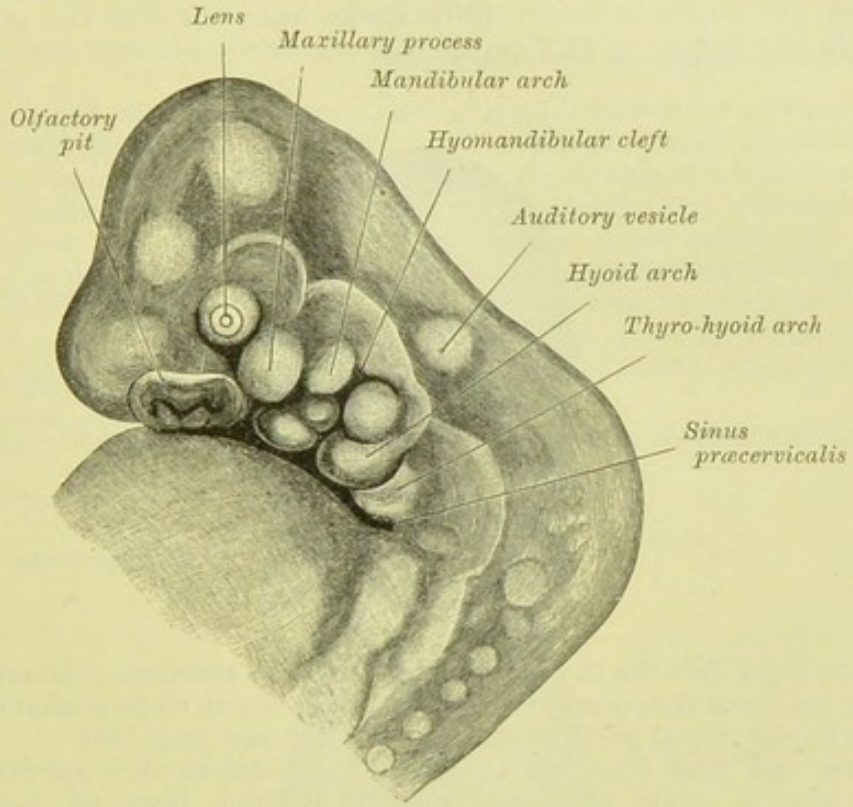

and a deep depression, the *sinus præcervicalis* (fig. 140) is formed on the side of the neck. This sinus is bounded in front by the hyoid arch, and behind by the thoracic wall; it is ultimately obliterated by the fusion of its walls. The outer part

Fig. 138.—Head and neck of a human embryo eighteen weeks old, with Meckel's cartilage and hyoid bar exposed. (After Kölliker.)

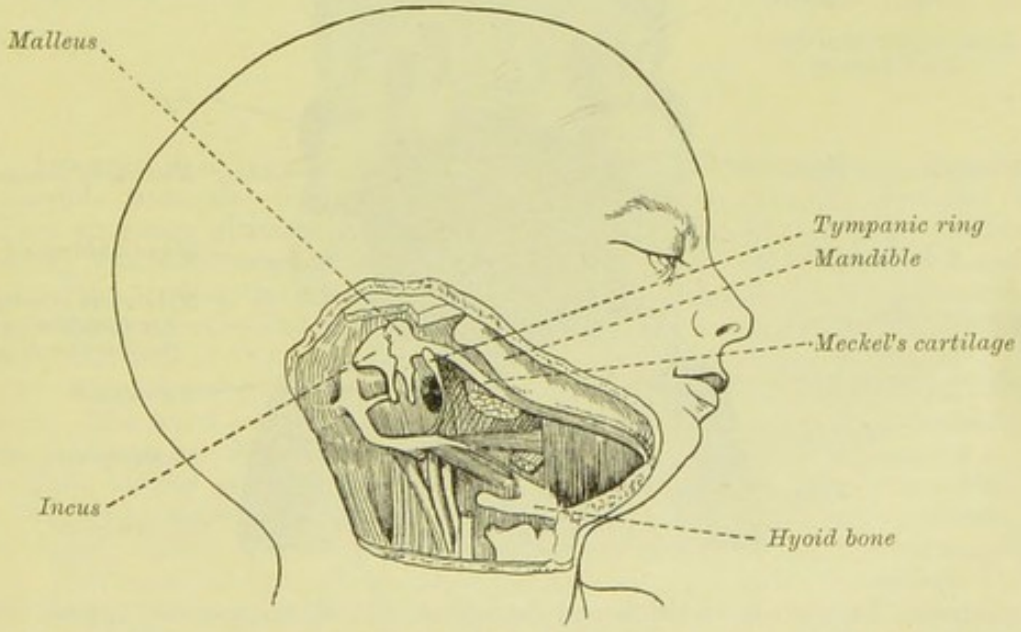

of the first cleft becomes the external auditory meatus, while the inner part of the same cleft forms the Eustachian tube, tympanic cavity and mastoid antrum. The septum between the outer and inner parts of this cleft is invaded by mesoderm, and

forms the membrana tympani. No traces of the outer parts of the second, third, and fourth clefts persist. The inner part of the second cleft is subdivided into an upper and lower portion by the palate. The former persists as the fossa of Rosenmüller. or lateral recess of the naso-pharynx ; in the latter is developed the tonsil, above which a trace of the cleft persists as the supra-tonsillar fossa. From the pharyngeal

Fig. 139.—Under surface of the head of a human embryo about twenty-nine days old. (After His.)

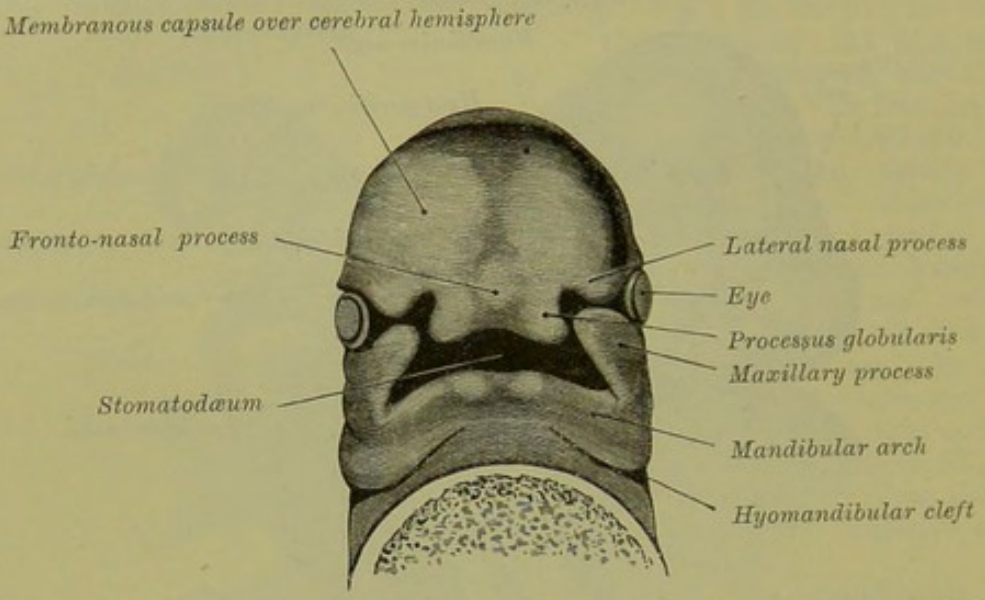

aspect of the third cleft the thymus gland arises as an entodermal diverticulum on either side, and from the corresponding part of the fourth clefts similar diverticula give origin to the lateral parts of the thyroid body (see page 154).

The **face and nose** (figs. 139 to 144).—The nasal cavities are formed from the stomatodæum, while the outer nose is derived from its antero-lateral

Fig. 140.—The head and neck of a human embryo thirty-two days old, seen from the ventral surface. The floor of the mouth and pharynx have been removed. (His.)

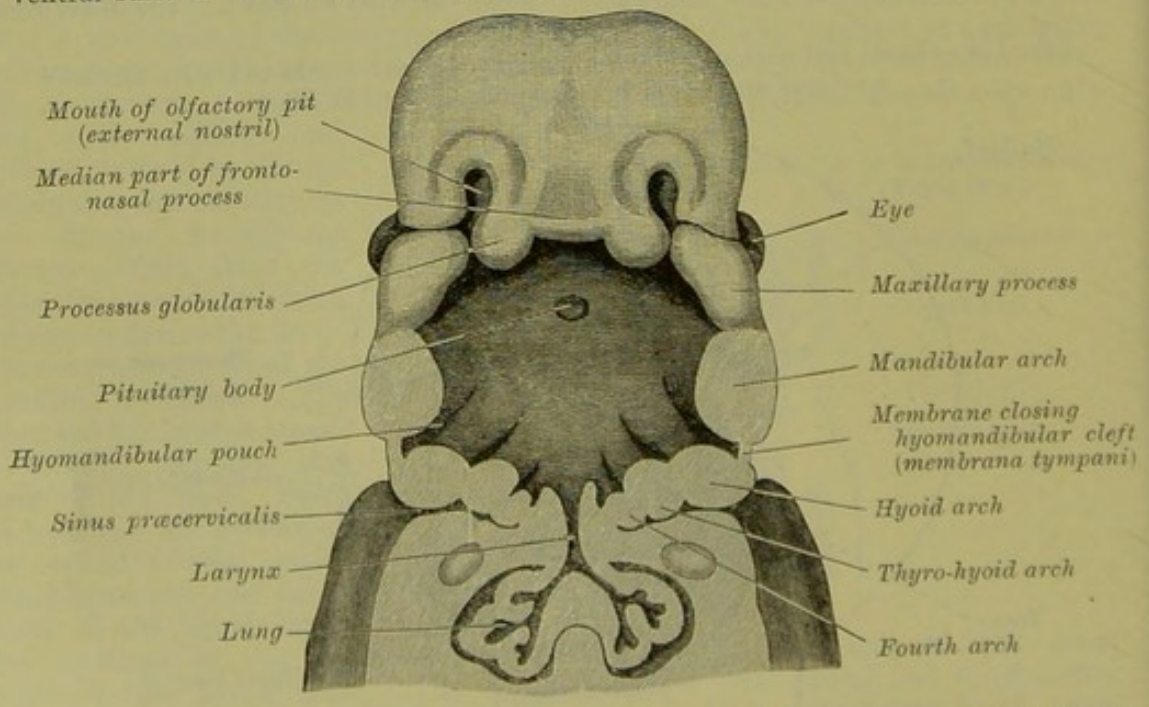

boundaries. Two areas of thickened ectoderm, the *olfactory areas*, appear immediately under the fore-brain in the anterior wall of the stomatodæum, one on either side of the *fronto-nasal process*. By the upgrowth of the surrounding parts these areas are converted into pits, the *olfactory pits* (fig. 140), which divide the fronto-nasal process into a *mesial* and two *lateral nasal processes* (fig. 141).

The rounded lateral angles of the mesial nasal process constitute the *globular processes* of His (figs. 140, 141). The olfactory pits form the rudiments of the nasal cavities, and extend backwards between the mesial and lateral nasal processes into the roof of the stomatodæum. From their ectodermal lining the olfactory epithelium and part of the olfactory bulb are derived. The globular processes are prolonged backwards as plates, termed the *nasal laminæ*: these laminæ are at first some distance apart, but, gradually approaching, they ultimately fuse, and form the nasal septum; the processes themselves meet in the middle line, and form the premaxillæ and the philtrum or central part of the upper lip (fig. 142).

The depressed part of the fronto-nasal process between the globular processes forms the lower part of the nasal septum or *columella*; while above this is seen a prominent angle, which becomes the future point, and still higher a flat area, the future bridge, of the nose (fig. 144). The lateral nasal processes form the alæ of the nose. Continuous with the dorsal end of the mandibular arch, and growing forwards from its cephalic border, is a triangular process—the *maxillary process*—the ventral extremity of which is separated from the mandibular arch by a >-shaped notch (fig. 139). The maxillary process grows forwards to form the outer wall and floor of the orbit, and meets with the lateral nasal process, from

Fig. 141.—Under surface of the head of a human embryo about thirty days old. (After His.)

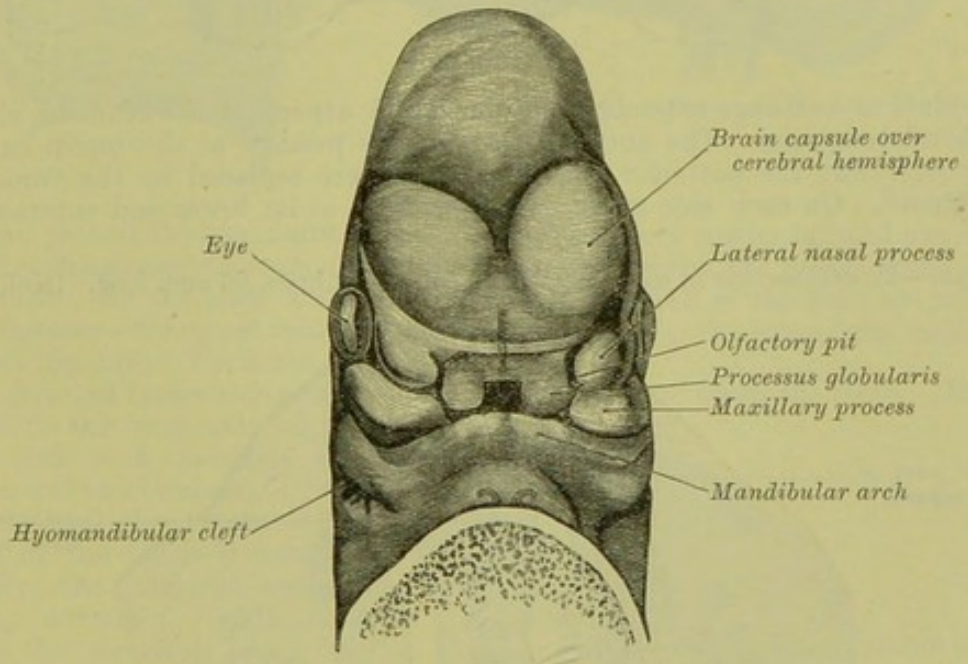

which, however, it is separated for a time by a groove—the *oculo-nasal sulcus*—that extends from the furrow encircling the eyeball to the olfactory pit. The maxillary processes ultimately fuse with the lateral nasal and globular processes, converting the oculo-nasal sulci into the lachrymal sacs and nasal ducts, and at the same time forming the lateral parts of the upper lip and the posterior boundaries of the anterior nares. The maxillary process also gives rise to the lower portion of the lateral wall of the nasal cavity—the upper part of this wall, together with the roof, being developed from the ethmoid plate of the cartilaginous chondrocranium. The nasal cavity is shut off from the buccal part of the stomatodæum by the development of the palate, the greater part of which is formed by a pair of shelf-like *palatal processes* which extend inwards from the maxillary processes (figs. 142, 143); these coalesce with each other in the middle line, and constitute the entire palate, except a small part in front which is formed by the premaxillary bones. The union of the palatal processes with the premaxillæ is deficient in the middle line, where an aperture remains—the naso-palatine canal. The union of the parts which form the palate commences in front, the premaxillary and palatal processes joining in the eighth week, while the region of the future hard palate is completed by the ninth, and that of the soft palate by the eleventh week. The deformity known as cleft palate results from a non-union of the palatal processes,

and that of hare-lip through a non-union of the maxillary and globular processes (see page 285). The nasal cavity becomes divided into the two nasal fossæ by a vertical septum, which extends downwards and backwards from the fronto-nasal process and nasal laminæ, and unites below with the palatal processes. Into

Fig. 142.—The roof of the mouth of a human embryo about two and a half months old, showing the mode of formation of the palate. (His.)

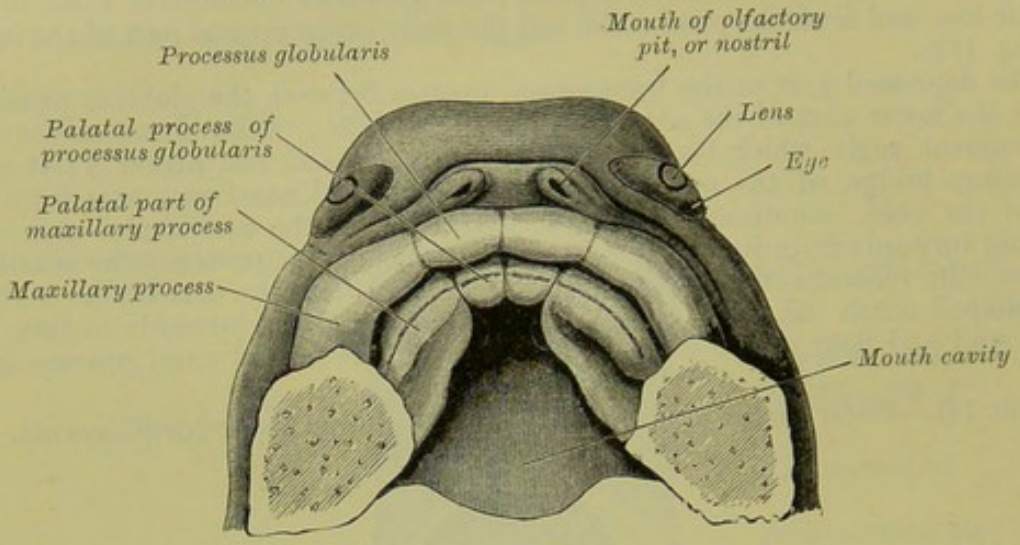

this a plate of cartilage extends from the under aspect of the ethmoid plate of the chondrocranium. The anterior part of this persists as the septal cartilage of the nose, but the posterior and upper parts are replaced by the vomer and mesethmoid. On each side of the nasal septum, at its lower and anterior part,

Fig. 143.—Frontal section of nasal cavity of a human embryo, 28 mm. long. (Kollmann.)

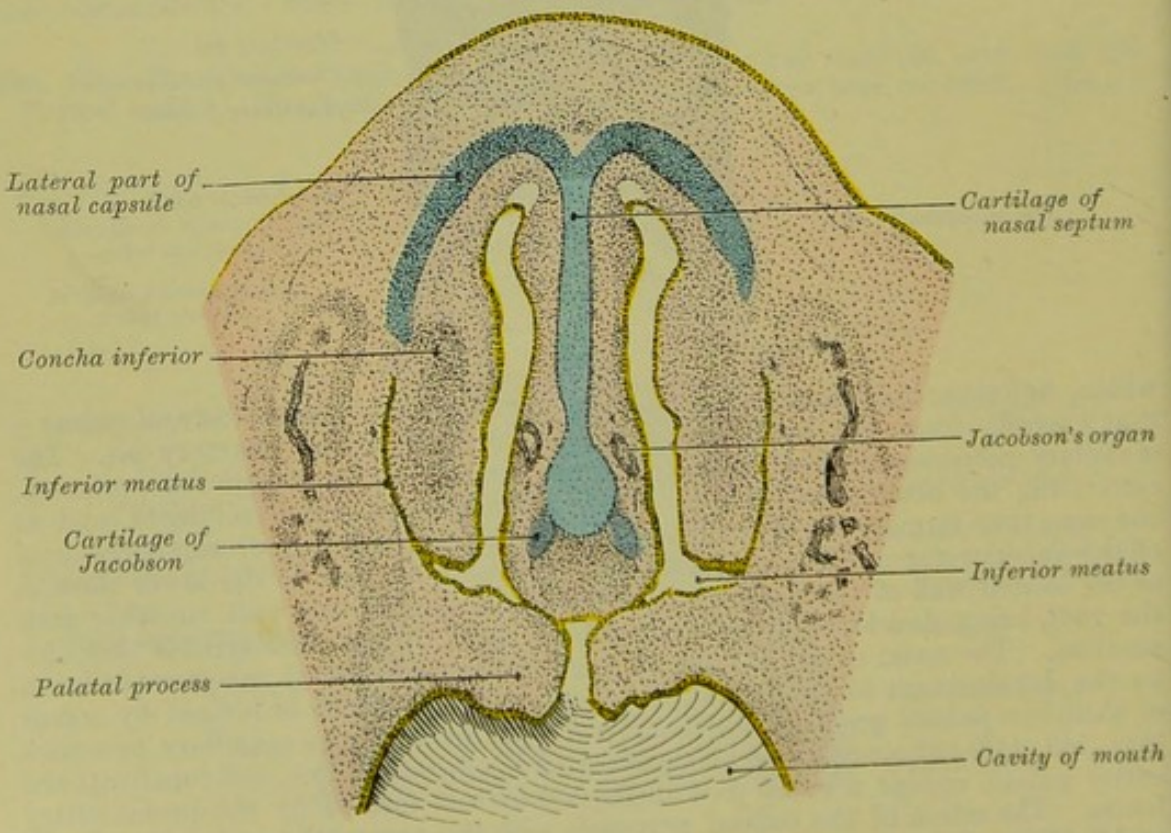

the ectoderm is invaginated to form a blind pouch or diverticulum, which extends backwards and upwards into the nasal septum. These pouches form the rudiments of *Jacobson's organs*, which open below, close to the junction of the premaxillary and maxillary bones.

The Limbs.—The limbs begin to make their appearance in the third week as small elevations or buds at the side of the trunk (fig. 145). Prolongations from the muscle- and cutis-plates of several primitive segments extend into each bud, and carry with them the anterior divisions of the corresponding spinal nerves.

Fig. 144.—Head of a human embryo of about eight weeks, in which the nose and mouth are formed. (His.)

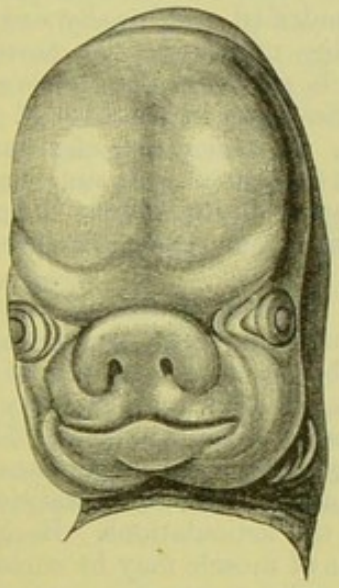

Fig. 145.—Human embryo from thirty-one to thirty-four days. (His.)

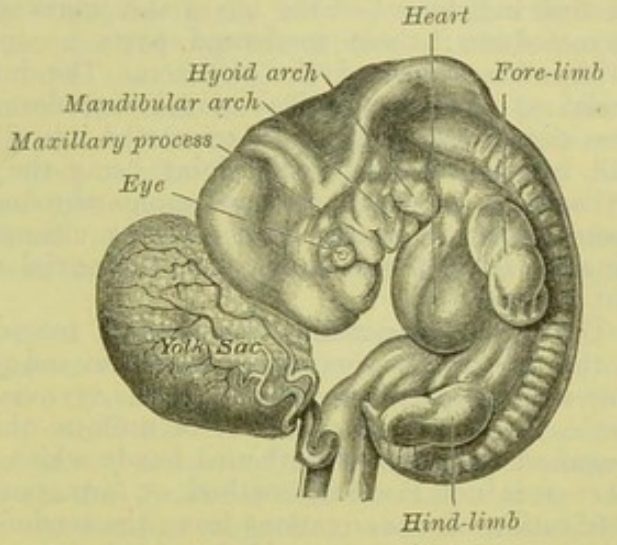

The axial part of the mesoderm of the limb bud becomes condensed and converted into its cartilaginous skeleton, and by the ossification of this the bones of the limbs are formed. By the sixth week the three chief divisions of the limb are marked off by furrows—the upper into arm, forearm, and hand ; the lower into thigh, leg, and foot (fig. 146). The limbs are at first directed backwards nearly parallel to the long axis of the trunk, and each presents two surfaces and two borders. Of the surfaces, one—the future *flexor* surface of the limb—is directed ventrally ; the other, the *extensor* surface, dorsally ; while one border, the *pre-axial*, looks forward towards the cephalic end of the embryo, and the other, the *post-axial*, backwards towards the caudal end. The external condyle of the humerus, the radius and the thumb lie along the pre-axial border in the case of the upper limb ; and the internal condyle of the femur, the tibia and the great toe along the corresponding border of the lower limb. The pre-axial part is derived from the anterior segments, the post-axial from the posterior segments of the limb bud ; and this explains, to a large extent, the innervation of the adult limb, the nerves of the more anterior segments being distributed along the pre-axial (radial or tibial), and those of the more posterior along the post-axial (ulnar or fibular) border of the limb. The limbs next undergo a rotation or torsion through an angle of 90° around their long axes, the rotation

Fig. 146.—Embryo of about six weeks. (His.)

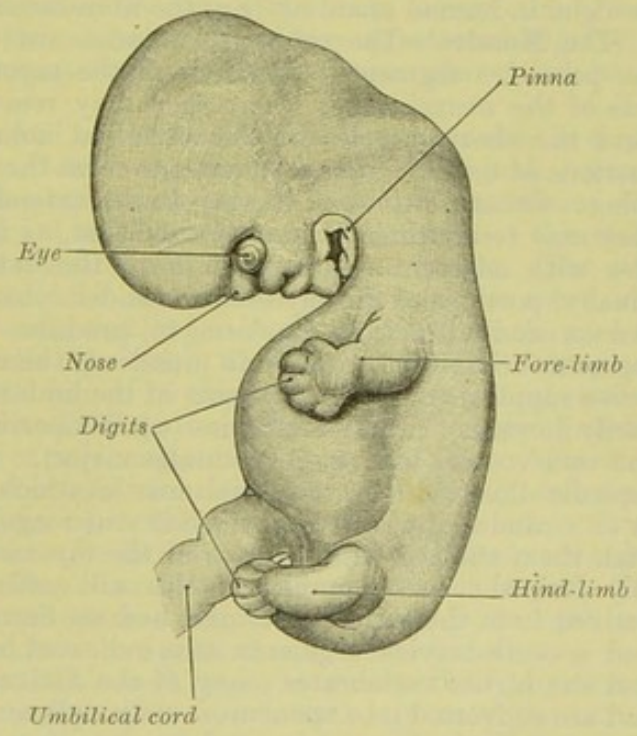

being effected almost entirely at the limb girdles. In the upper limb the rotation is outwards and forwards; in the lower limb, inwards and backwards. In this manner the pre-axial (radial) border of the fore-limb is directed outwards, while the pre-axial (tibial) border of the hind-limb is directed inwards; thus the flexor surface of the fore-limb is turned forwards, and that of the hind-limb backwards.

The Joints.—The mesoderm from which the different parts of the skeleton are formed at first shows no differentiation into masses corresponding with the individual bones. Thus continuous cores of mesoderm form the axes of the limb-buds and a continuous column of mesoderm the future vertebral column. The first indications of the bones and joints are circumscribed condensations of the mesoderm; these condensed parts become chondrified and finally ossified to form the bones of the skeleton. The intervening non-condensed portions consist at first of undifferentiated mesoderm, which may develop in one of three directions. It may be converted into fibrous tissue as in the case of the skull bones, a synarthrodial joint being the result, or it may become partly cartilaginous, in which case an amphiarthrodial joint is formed. Again, it may become looser in texture and a cavity ultimately appear in its midst; the cells lining the sides of this cavity form a synovial membrane and thus a diarthrodial joint is developed.

The tissue surrounding the original mesodermal core forms fibrous sheaths for the developing bones, i.e. periosteum and perichondrium, which are continued between the ends of the bones over the synovial membrane as the capsules of the joints. These capsules are not of uniform thickness, so that in them may be recognised specially strengthened bands which are described as ligaments. This, however, is not the only method of formation of ligaments. In some cases by modification of, or derivations from, the tendons surrounding the joint, additional ligamentous bands are provided to further strengthen the articulations. In other cases (e.g. ligamentum teres of the hip joint) a portion of muscle may be enclosed within the articulation and become modified to form a ligament.

In several of the movable joints the mesoderm which originally existed between the ends of the bones does not become completely absorbed—a portion of it persists and forms an interarticular fibro-cartilage. These interarticular fibro-cartilages may be intimately associated in their development with the muscles surrounding the joint (e.g. the semilunar cartilages of the knee-joint) or with cartilaginous elements, representatives of skeletal structures, which are vestigial in human anatomy (e.g. the fibro-cartilage of the sterno-clavicular joint).

The Muscles.—The voluntary muscles are developed from the myotomes of the primitive segments. Portions of the myotomes retain their position on the side of the neural tube, where they may remain distinct from each other and form the short muscles of the vertebral column, or fuse with corresponding portions of neighbouring myotomes to form the superficial portions of the Erector spinæ. Other portions of the myotomes extend into the trunk wall, where again they may retain their segmental condition, as in the Intercostal muscles, or may fuse with adjacent segments to form the flat muscles of the abdominal wall. Finally, portions of the myotomes wander into the limb buds and there undergo fusions and alterations in form to produce the limb muscles. The original segmental character of the limb muscles is therefore soon lost, but their segmental nerve supplies are retained. Some of the limb muscles expand and migrate secondarily towards the mid-dorsal line (e.g. Trapezius and Latissimus dorsi) or towards the mid-ventral line (e.g. Pectoralis major). Again, muscles may migrate in a cephalic direction (e.g. the facial muscles which are derived from the hyoid arch), or in a caudal direction (e.g. the Serratus magnus). In all cases the muscles carry with them the segmental nerves of the myotomes, from which they were originally derived; two examples of this will suffice, viz.: the Diaphragm, which is derived from the third and fourth, and the Serratus magnus, from the fifth, sixth, and seventh cervical segments as is indicated by their nerves of supply. In man and the higher vertebrates many of the derivatives of the myotomes degenerate and are converted into aponeuroses (e.g. epicranial aponeurosis, or the aponeuroses of the abdominal muscles), or ligaments (e.g. great sacro-sciatic ligament and external lateral ligament of the knee).

The involuntary muscles are derived from the splanchnopleure mesoderm.

The Skin, Glands, and Soft Parts.—The epidermis and its appendages, consisting of the hairs, nails, sebaceous and sweat glands, are developed from the

ectoderm, while the corium or true skin is of mesodermal origin, being derived from the cutis-plates of the primitive segments. About the fifth week the epidermis consists of two layers of cells, the deeper one corresponding to the rete mucosum. The subcutaneous fat appears about the fourth month, and the papillæ of the true skin about the sixth. A considerable desquamation of epidermis takes place during fœtal life, and this desquamated epidermis, mixed with a sebaceous secretion, constitutes the *vernix caseosa*, with which the skin is smeared during the last three months of fœtal life. The nails are formed at the third month, and begin to project from the epidermis about the sixth. The hairs appear between the third and fourth months in the form of solid downgrowths of the deeper layer of the epidermis, the growing extremities of which become inverted by papillary projections from the corium. The central cells of the solid downgrowth undergo alteration to form the hair, while the peripheral cells are retained to form the lining cells of the follicle. About the fifth month, the fœtal hairs (*lanugo*) appear, first on the head and then on the other parts; they drop off after birth, and give place to the permanent hairs. The cellular structures of the sudoriferous and sebaceous glands are formed from the ectoderm, while the connective tissue and blood-vessels are derived from the mesoderm.

The *mammary gland* is also formed partly from mesoderm and partly from ectoderm—its blood-vessels and connective tissue being derived from the former, its cellular elements from the latter. Its first rudiment is seen about the third month, in the form of a number of small inward projections of the ectoderm, which invade the mesoderm; from these, secondary tracts of cellular elements radiate and subsequently give rise to the glandular follicles and ducts. The development of the follicles, however, remains imperfect, except in the adult female.

DEVELOPMENT OF THE NERVOUS SYSTEM AND SENSE ORGANS

The entire nervous system is of ectodermal origin, and its first rudiment is seen in the neural groove which extends along the dorsal aspect of the embryo (fig. 109). By the elevation and ultimate fusion of the medullary folds, the groove is converted into the neural tube (fig. 111). The anterior end of the neural tube becomes expanded to form the three primary brain-vesicles which are subsequently modified to form the ventricular cavities of the brain (except the fifth); the remainder of the tube forms the central canal of the spinal cord (fig. 147). From its surrounding wall the nervous elements and the neuroglia of the brain and spinal cord are developed.

The Spinal Cord.—At first the wall of the neural tube is composed of a single layer of columnar ectodermal cells. Soon the lateral parts of the wall become thickened, while the dorsal and ventral parts remain thin, and are named the *roof* and *floor plates* (figs. 147, 149). A transverse section of the tube at this stage presents an oval outline, while its lumen has the appearance of a slit. The cells which constitute the wall of the tube are differentiated into two sets: viz. (a) *spongioblasts* or young neuroglia-cells, and (b) *germinal cells*, which are the parents of the *neuroblasts* or young nerve-cells (fig. 148). The spongioblasts are elongated and columnar, and extend from the lumen of the tube to its peripheral wall—their inner and outer ends being modified to form the inner and outer limiting membranes of the cord. The parts of the spongioblasts abutting against the central canal retain their columnar character, and ultimately form the layer of columnar ciliated epithelium which lines this canal. Their outer parts, on the other hand, undergo ramification and form a sponge-like network, termed the *myelospongium*, from which the neuroglia or sustentacular tissue of the cord is developed. The branching of the spongioblasts is most marked near the periphery of the cord, and this outer part, in consequence, assumes the appearance of a fine reticulum.

The germinal cells are large, round or oval, and first make their appearance between the inner ends of the neuroglia-cells on the lateral aspects of the central canal. They increase rapidly in number, so that by the fourth week they form an almost continuous layer on each side of the tube. No germinal cells are found in the roof or floor plates; the roof-plate retains, in certain regions of the brain, its epithelial character; elsewhere, its cells become spongioblasts. The nuclei of many of the germinal cells exhibit mitotic changes, indicating that the cells

are undergoing rapid subdivision. By such subdivision they give rise to the neuroblasts or young nerve-cells. The neuroblasts migrate outwards from the sides of the central canal, and at the same time they become pear-shaped; the tapering part of the cell undergoes still further elongation, and forms the axis-cylinder or axon of the cell.

Fig. 147.—Section of spinal cord of a four weeks' embryo. (His.)

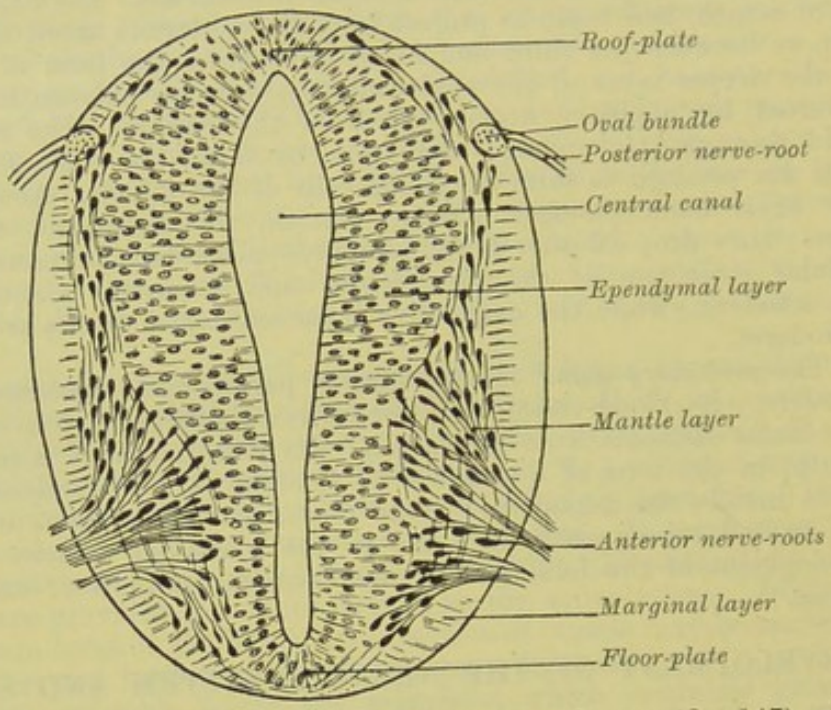

A transverse section of the cord now exhibits three layers (fig. 147), viz.: (1) a *marginal layer* or *marginal veil*, consisting of a fine neuroglial network, in which the future white matter of the cord is developed. (2) An intermediate layer, the representative of the future grey matter of the cord. This is crowded with neuroblasts, and is sometimes termed the *mantle layer*. (3) An internal or *ependymal*

Fig. 148.—Transverse section of the spinal cord of a human embryo at the beginning of the fourth week. (After His.) The left edge of the figure corresponds to the lining of the central canal.

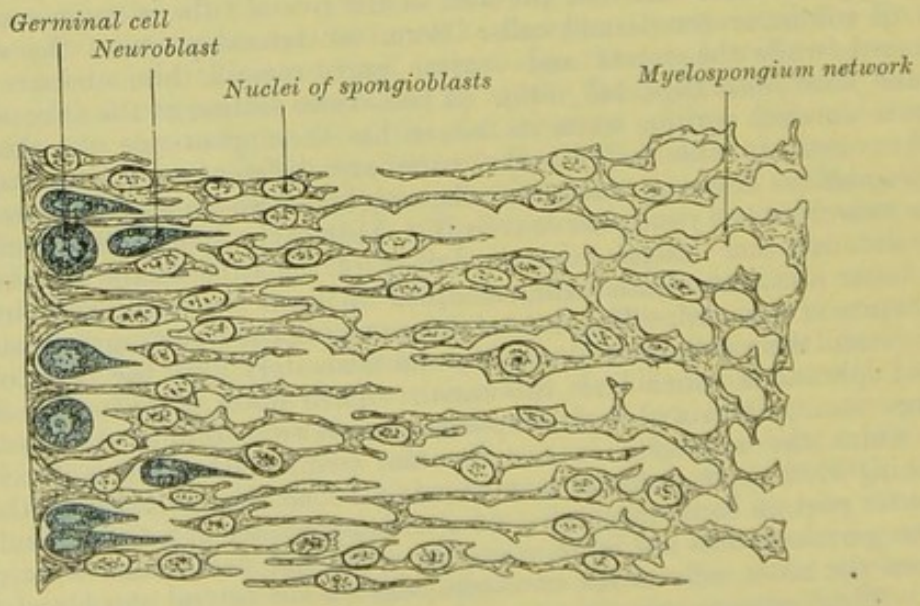

layer, next the central canal, in which the germinal cells were first seen, but which, after their subdivision and migration, becomes the epithelium of the central canal. The lateral walls of the slit-like canal increase in thickness, and the canal itself widens out near its dorsal extremity, and assumes a somewhat lozenge-shaped

appearance. The widest part of the canal serves to subdivide the lateral wall of the neural tube into a *dorsal* or *alar*, and a *ventral* or *basal lamina* (fig. 149), a subdivision which extends forwards into the brain.

The ventral part of the mantle layer becomes thickened, and on cross-section appears as a triangular patch between the marginal and ependymal layers. This thickening is the rudiment of the anterior horn of grey matter, and contains many neuroblasts, the axis-cylinders of which pass out through the marginal layer and form the anterior roots of the spinal nerves (figs. 147, 149). The thickening of the mantle layer gradually extends in a dorsal direction, and forms the posterior horn of grey matter. The axons of many of the neuroblasts in the alar lamina pass forward, and cross in the floor-plate to the opposite side of the cord; these form the rudiment of the anterior white commissure of the cord.

The anterior and lateral white columns of the spinal cord consist at first of the axons of the neuroblasts; they are, however, at a later stage, largely augmented by the pyramidal tracts which descend from the cerebral cortex. The fibres of the posterior nerve-roots grow inwards into the spinal cord from the cells of the spinal ganglia; in the spinal cord of a six months fœtus they form a well-

FIG. 149.—Transverse sections through the spinal cords of human embryos; A, about four and a half weeks old. B, about three months old. (His.)

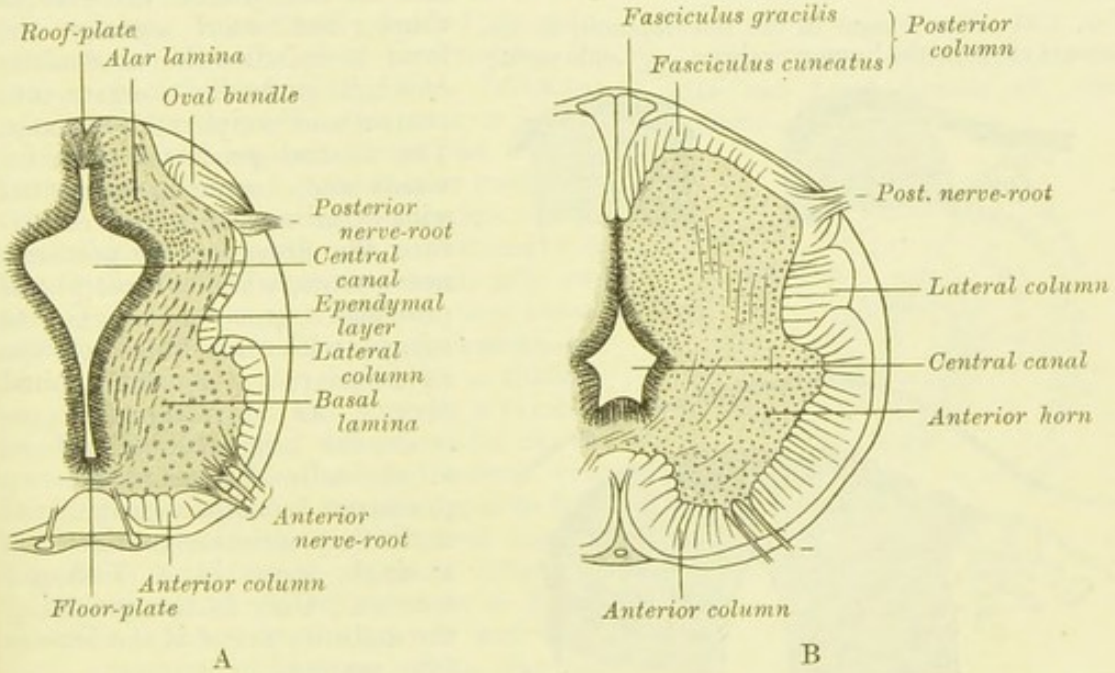

defined *oval bundle* in the peripheral part of the alar lamina. With the subsequent development of the posterior horn of grey matter this bundle is displaced inwards and forms the rudiment of the posterior column.

By the growth of the anterior horns of grey matter, and by the increase in size of the anterior columns, a furrow is formed between the lateral halves of the cord anteriorly; this gradually deepens to form the anterior median fissure. The mode of formation of the posterior fissure is somewhat uncertain. Many believe that it is produced by a growing together of the walls of the posterior part of the central canal. Robinson * traverses this view, and points out that the so-called posterior fissure is occupied by a fibrillated tissue, which is probably of a spongioblastic origin, since its fibrils can be traced directly into the posterior grey commissure.

Up to the fourth month of fœtal life the spinal cord occupies the entire length of the spinal canal, and the spinal nerves pass outwards at right angles from the cord. From this time onwards, the vertebral column grows more rapidly than the cord, and the latter, being fixed above through its continuity with the brain, gradually assumes a higher position within the canal. By the sixth month its lower end reaches only as far as the upper end of the sacral canal; at birth it is

* *Studies in Anatomy*, Owens College, 1891.

on a level with the third lumbar vertebra, and in the adult it terminates at the lower border of the first or upper border of the second lumbar vertebra. A delicate filament, the *filum terminale*, extends from its lower end as far as the coccyx.

The Spinal Nerves.—Each spinal nerve is attached to the cord by an anterior or ventral and a posterior or dorsal root.

The fibres of the anterior roots are formed by the axons of the neuroblasts which lie in the ventral part of the mantle layer; these axons grow out through the overlying marginal layer and become grouped to form the anterior nerve-roots (fig. 147).

The fibres of the posterior roots are developed from the cells of the spinal ganglia. Before the neural groove is closed to form the neural tube a ridge of ectodermal cells, the *ganglion ridge* or *neural crest* (fig. 150), appears along the prominent margin of each medullary lamina. When the laminæ meet in the middle line the two ganglion ridges fuse and form a wedge-shaped area along the line of closure of the tube. The cells of this area proliferate rapidly opposite the primitive segments and then migrate in an outward and ventral direction to the sides of the neural tube, where they form a series of oval-shaped masses, the future spinal ganglia. These ganglia are arranged symmetrically on the two sides of the neural tube and, except in the region of the tail, are equal in number to the primitive segments. The cells of the ganglia are at first round or oval in shape, but soon assume the form of spindles the extremities of which gradually elongate into central and peripheral processes. The central processes grow inwards and, becoming connected with the neural tube, constitute the fibres of the posterior nerve-roots, while the peripheral processes grow outwards to mingle with the fibres of the anterior root in the spinal nerve. As development proceeds the original bipolar form of the cells changes; the two processes become approximated until they ultimately arise from a single stem in a T-shaped manner. Only in the ganglia of the auditory nerve is the bipolar form retained.

FIG. 150.—Two stages in the development of the neural crest in the human embryo. (Lenhossék.)

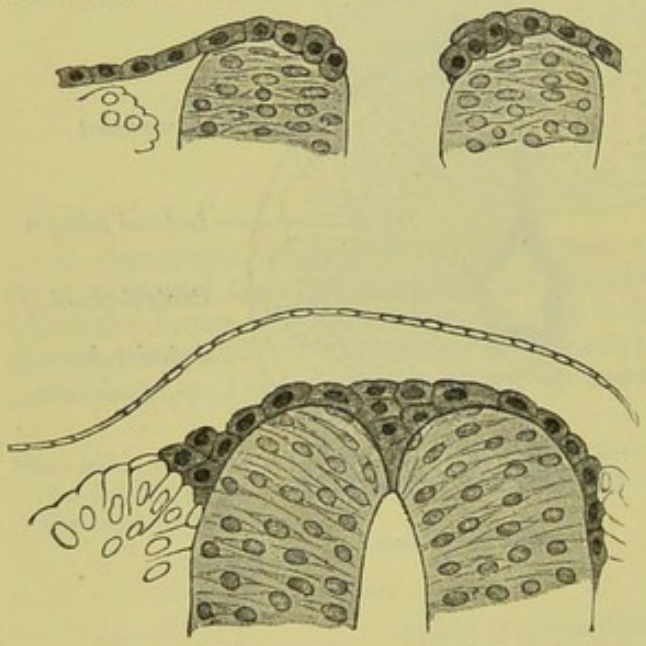

The anterior or ventral and the posterior or dorsal nerve-roots join immediately beyond the spinal ganglion to form the *spinal nerve*, which then divides into anterior, posterior, and visceral divisions. The anterior and posterior divisions proceed directly to their areas of distribution without further association with ganglion cells. The visceral divisions are distributed to the thoracic, abdominal, and pelvic viscera, to reach which they pass through the sympathetic cord, and many of the fibres form arborisations around the ganglion cells of this cord. Visceral branches are not given off from all the spinal nerves; they form two groups, viz.: (*a*) *thoracico-lumbar*, from the first or second thoracic to the second or third lumbar nerves; and (*b*) *pelvic*, from the second and third, or third and fourth sacral nerves.

The ganglia of the sympathetic system are generally regarded as being developed as offshoots from the ganglia on the roots of the cranial and spinal nerves.

The Brain.—The brain is developed from the anterior end of the neural tube, which at an early period becomes expanded into three vesicles, the primary cerebral vesicles (figs. 110 and 135). These are marked off from each other by intervening constrictions, and are named the *fore-brain*, the *mid-brain*, and the *hind-brain* (fig. 154)—the last being continuous with the spinal cord. As the result of unequal growth of these different parts three flexures are formed and the

embryonic brain becomes bent on itself in a somewhat zigzag fashion; the two earliest flexures are concave ventrally and are associated with corresponding flexures of the whole head. The first flexure appears in the region of the mid-brain, and is named the *primary cephalic flexure* (fig. 155). By means of it the fore-brain is bent in a ventral direction around the anterior end of the notochord and fore-gut, with the result that the floor of the fore-brain comes to lie almost parallel with that of the hind-brain (fig. 155). This flexure causes the mid-brain to become, for a time, the most prominent part of the brain, since its dorsal surface corresponds with the convexity of the curve. The second bend appears at the junction of the hind-brain and spinal cord. This is termed the *cervical flexure* (fig. 157), and increases from the third to the end of the fifth week, when the hind-brain forms nearly a right angle with the spinal cord; after the fifth week erection of the head takes place and the cervical flexure diminishes and disappears. The third bend is named the *pontine flexure* (fig. 157), because it is found in the region of the future pons Varolii. It differs from the other two in that (*a*) its convexity is forwards, and (*b*) it does not affect the head. The lateral walls of the brain-tube, like those of the spinal cord, are divided by internal furrows into alar or dorsal and basal or ventral laminæ.

The **hind-brain** or **rhombencephalon.**—The cavity of the hind-brain becomes the fourth ventricle. At the time when the primary cephalic flexure makes its appearance, the length of the hind-brain exceeds the combined lengths of the other two vesicles. Immediately behind the mid-brain it exhibits a marked constriction, the *isthmus rhombencephali* (fig. 154, Isthmus), which is best seen when the brain is viewed from the dorsal aspect. From the isthmus the valve of Vieussens or superior medullary velum and the superior peduncles of the cerebellum are formed. It is customary to divide the rest of the hind-brain into two parts: viz. an upper, called the *metencephalon*, and a lower, the *myelencephalon*. The cerebellum is developed by a thickening of the roof, and the pons by a thickening in the floor and lateral walls of the metencephalon. The floor and lateral walls of the myelencephalon are thickened to form the medulla oblongata; its roof remains thin, and, retaining to a great extent its epithelial nature, is expanded in a lateral direction. Later, by the growth and backward extension of the cerebellum, the roof is folded inwards towards the cavity of the fourth ventricle; it assists in completing the dorsal wall of this cavity, and is also invaginated to form the epithelial covering of its choroid plexuses. Above it is continuous with the inferior medullary velum; below, with the obex and ligulæ.

Fig. 151.—Diagram to illustrate the alar and basal laminæ of brain vesicles. (His.)

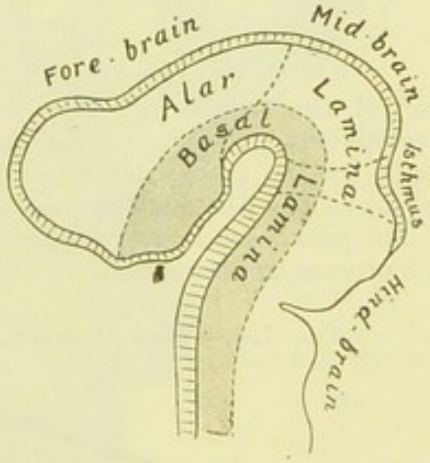

The development of the *medulla oblongata* resembles that of the spinal cord, but at the same time exhibits one or two interesting modifications. On transverse section the myelencephalon at an early stage is seen to consist of two lateral walls, connected across the middle line by floor and roof plates, as in the cord (figs. 152 and 153). Each lateral wall consists of an alar and a basal lamina, separated by an internal furrow, the remains of which are represented in the adult brain by the foveæ on the floor of the fourth ventricle. The contained cavity is more or less triangular in outline, the base being formed by the roof-plate, which is thin and greatly expanded transversely. Pear-shaped neuroblasts are developed in the alar and basal laminæ, and their narrow stalks are elongated to form the axis-cylinders of the nerve-fibres. Opposite the furrow or boundary between the alar and basal laminæ a bundle of nerve-fibres attaches itself to the outer surface of the alar lamina. This is named the *tractus solitarius* (fig. 153), and is formed by the sensory fibres of the glosso-pharyngeal and vagus nerves. It is the homologue of the *oval bundle* seen in the cord, and, like it, is developed by an ingrowth of fibres from the ganglia of the neural crest. At first it is applied to the outer surface of the alar lamina, but it soon becomes buried, owing to the growth over

it of the neighbouring parts. By the fifth week the dorsal part of the alar lamina bends in an outward direction along its entire length, to form what is termed the *rhombic lip* (figs. 153, 156). Within a few days this lip becomes applied to, and unites with, the outer surface of the main part of the alar lamina, and so covers in the tractus solitarius and also the spinal root of the fifth nerve.

Fig. 152.—Transverse section of medulla oblongata of human embryo. × 32. (From Kollmann's 'Entwickelungsgeschichte.')

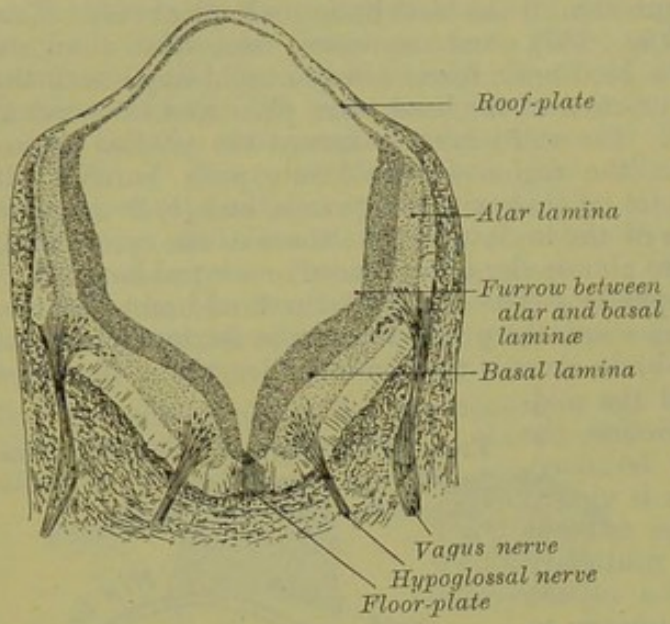

Neuroblasts accumulate in the mantle layer: those in the basal lamina correspond with the cells in the anterior horn of the spinal cord, and, like them, give origin to motor nerve-fibres; in the medulla they are, however, arranged in groups or nuclei, instead of forming a continuous column. From the alar lamina and its rhombic lip, neuroblasts migrate into the basal lamina, and become aggregated to form the olivary nuclei, while many send their axis-cylinders through the floor-plate to the opposite side of the medulla, and thus constitute the rudiment of the raphe of the medulla. By means of this thickening of the ventral portion of the medulla the motor nuclei are buried deeply in the interior, and, in the adult, are found close to the floor of the fourth ventricle. This is still further accentuated: (*a*) by the development of the anterior pyramids, which are formed about the fourth month by the downward growth of the motor fibres from the cerebral cortex; and (*b*) by the fibres which pass to and from the cerebellum.

The *pons Varolii* is developed from the ventro-lateral wall of the metencephalon by a process similar to that which has been described for the medulla.

Fig. 153.—Transverse section of medulla oblongata of human embryo. (After His.)

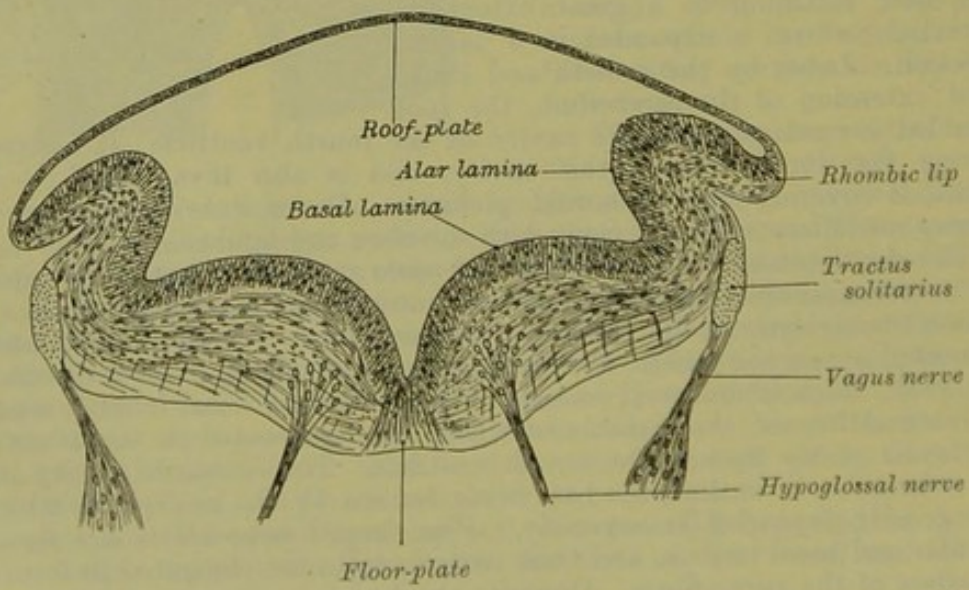

The *cerebellum* is developed in the roof of the anterior part of the hind-brain (figs. 154, 157). The alar laminæ of this region become thickened to form two lateral plates which soon fuse in the middle line and produce a thick lamina which roofs in the upper part of the cavity of the hind-brain vesicle; this constitutes the rudiment of the cerebellum, the outer surface of which is at first smooth and convex. During the second month a pair of fissures, the *floccular fissures*, appear, one on

either side, in the postero-lateral part of the lamina and become continuous with a third fissure, the *post-nodular*, which is developed across the central part of the lamina. By this means a narrow area is mapped off; the central part of this area becomes the nodule, its lateral extremities the flocculi, and the intermediate portions the inferior medullary velum. Three additional furrows are soon developed. One, the *fissura prima* of Elliot-Smith, appears as a transverse groove on the anterior part of the upper surface and extends into the hemispheres; it indicates the preclival fissure of the adult cerebellum. The portion of the cerebellum in front of it is differentiated into the lingula, the lobus centralis, and the lobus culminis. The other two furrows mark off the future pyramid and are named the *supra-pyramidal* and *pre-pyramidal fissures*. The supra-pyramidal is the *fissura secunda* of Elliot-Smith, and forms the post-pyramidal fissure of the adult cerebellum.

During the fourth and fifth months the following fissures appear in the lateral hemispheres: (1) the *post-lunate*, between the posterior crescentic and postero-superior lobes; the union of the two post-lunate fissures across the middle line forms the post-clival fissure which constitutes the posterior boundary of the lobus clivi; (2) the *para-pyramidal*, which blends with the post-pyramidal and separates the lobus tuberis from the lobus pyramidis; (3) the *post-tonsillar*, between the biventral lobe and the amygdala or tonsil; this becomes continuous with the pre-pyramidal, and with it forms the posterior limit of the lobus uvulæ; (4) the *great horizontal fissure*; although an important landmark in the adult cerebellum, this fissure does not appear until about the end of the fifth month, and from a developmental point of view is therefore of secondary interest. Some observers maintain that the folium cacuminis, which connects the postero-superior lobes across the middle line, is not developed until after birth, while others assert that it is present at the sixth month of fœtal life. On the ventricular surface of the cerebellar lamina a transverse furrow, the *incisura fastigii*, appears, and deepens to form the tent-like recess of the roof of the fourth ventricle. The rudiment of the cerebellum at first projects in a dorsal direction; but, by the backward growth of the cerebrum, it is folded downwards and somewhat flattened, and the thin roof-plate of the fourth ventricle, originally continuous with the posterior border of the cerebellum, is projected inwards towards the cavity of the ventricle.

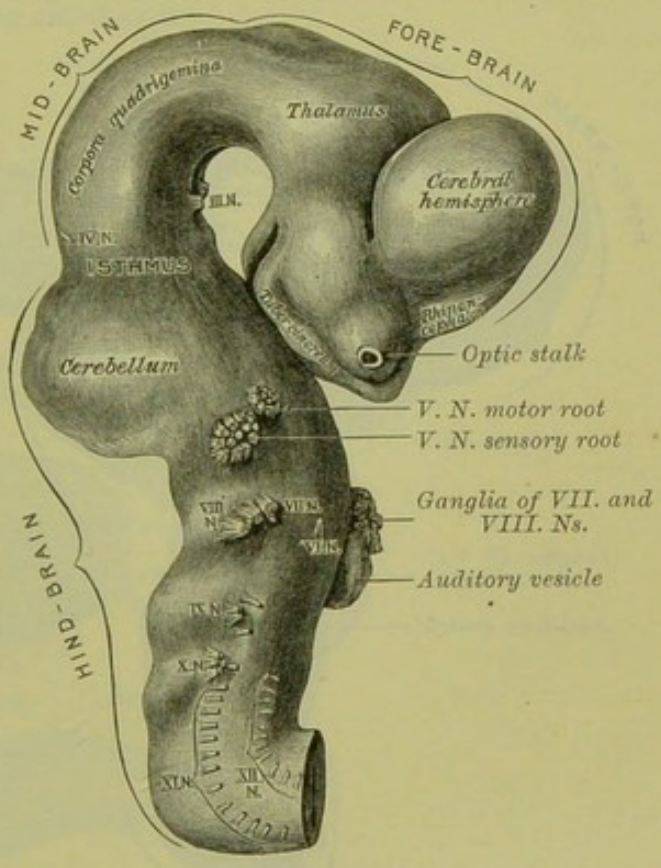

Fig. 154.—Exterior of brain of human embryo of four and a half weeks. (From model by His.)

The **mid-brain** or **mesencephalon**.—The mid-brain (figs. 154 to 157) exists for a time as a thin-walled cavity of some size, and is separated from the isthmus rhombencephali behind, and from the fore-brain in front, by slight constrictions. Its cavity becomes relatively reduced in diameter, and forms the Sylvian aqueduct of the adult brain. Its basal laminæ increase in thickness to form the crura cerebri, which are at first of small size, but rapidly enlarge after the fourth month. The neuroblasts of these laminæ are grouped in relation to the sides and floor of the Sylvian aqueduct, and constitute the nuclei of the third and fourth nerves, and of the descending root of the fifth nerve. By a similar thickening process its alar laminæ are developed into the

corpora quadrigemina. The dorsal part of the wall for a time undergoes expansion, and presents an interior median furrow and a corresponding surface ridge; these, however, disappear, and the latter is replaced by a groove. Subsequently two oblique furrows extend inwards and backwards, and the thickened lamina is thus subdivided into the quadrigeminal bodies.

The **fore-brain.**—A transverse section of the early fore-brain shows the same parts as are displayed in similar sections of the spinal cord and medulla oblongata, viz.: a pair of thick lateral walls connected by thin floor and roof plates. Moreover, each lateral wall exhibits a division into a dorsal or alar and a ventral or basal lamina separated internally by a furrow termed the *sulcus of Monro*. This sulcus ends anteriorly at the inner extremity of the optic stalk, and in the adult brain is retained as a slight groove extending backwards from the foramen of Monro to the Sylvian aqueduct.

At a very early period—in some animals before the closure of the cranial part of the neural tube—two lateral diverticula, the *optic vesicles*, appear, one on either side of the fore-brain; for a time they communicate with the cavity of the fore-brain by relatively wide openings. The peripheral parts of the vesicles expand while the proximal parts are reduced to tubular stalks, the *optic stalks*. The optic vesicle gives rise to the retina and the epithelium on the back of the ciliary body and iris; the optic stalk is invaded by nerve-fibres to form the optic nerve. The fore-brain then grows forwards, and from the alar laminæ of this front portion the cerebral hemispheres originate as diverticula which rapidly expand to form two large pouches, one on either side. The cavities of these diverticula are the rudiments of the lateral ventricles; they communicate with the mesial part of the fore-brain cavity by relatively wide openings, which ultimately form the foramen of Monro in the adult brain. The mesial portion of the wall of the fore-brain vesicle consists of a thin lamina, the *lamina terminalis* (figs. 155, 157), which stretches from the foramen of Monro to the recess at the base of the optic stalk. The anterior part of the fore-brain, including the rudiments of the cerebral hemispheres, is named the *telencephalon*, and its posterior portion is termed the *diencephalon*; both of these contribute to the formation of the third ventricle.

Fig. 155.—Brain of human embryo of four and a half weeks, showing interior of fore-brain. (From model by His.)

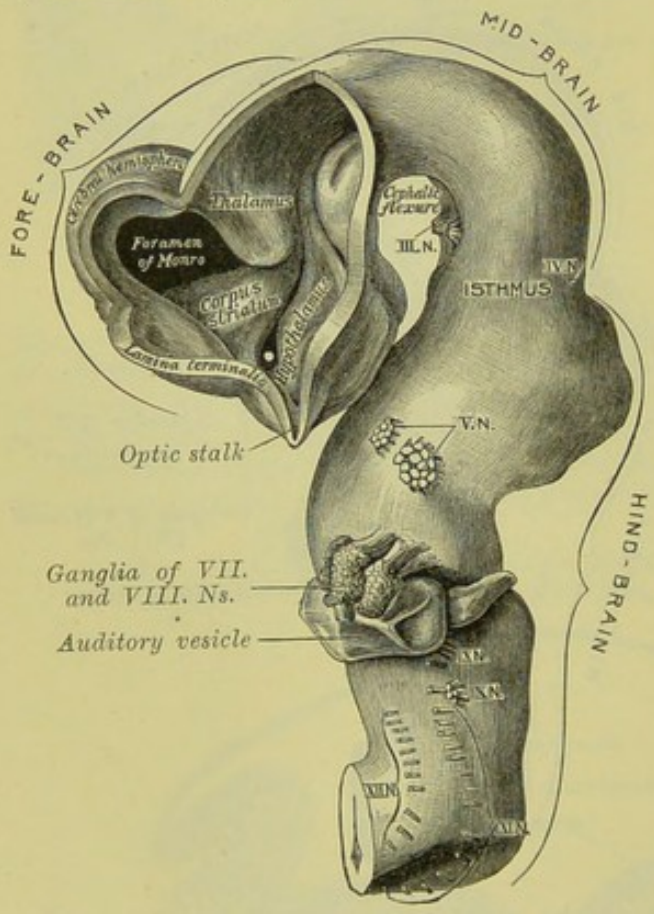

The *diencephalon*.—From the alar lamina of the diencephalon the thalamus, metathalamus, and epithalamus are developed. The *thalamus* (figs. 157, 158) arises as a thickening which involves the anterior two-thirds of the alar lamina. The two thalami are visible, for a time, on the surface of the brain, but are subsequently hidden by the cerebral hemispheres which grow backwards over them. The thalami extend inwards and gradually narrow the cavity between them into a slit-like aperture which forms the greater part of the third ventricle; their mesial surfaces ultimately adhere, in part, to each other, and the *middle* or *grey commissure* of the ventricle is developed across the point of contact. The *metathalamus* comprises the geniculate bodies which originate as slight outward bulgings of the alar lamina. In the adult the external geniculate body appears as an eminence on the

outer part of the posterior end of the thalamus, while the internal is situated on the lateral aspect of the mesencephalon.

The *epithalamus* includes the pineal body, the posterior commissure, and the trigonum habenulæ. The *pineal body* arises as an upward evagination of the roof-plate immediately in front of the mid-brain; this evagination becomes solid with the exception of its proximal part, which persists as the *recessus pinealis*. In lizards the pineal evagination is elongated into a stalk, and its peripheral extremity is expanded into a vesicle, in which a rudimentary lens and retina are formed; the stalk becomes solid and nerve-fibres make their appearance in it, so that in these animals the pineal body forms a rudimentary eye. The *posterior commissure* is formed by the ingrowth of fibres into the depression behind and below the pineal evagination, and the trigonum habenulæ is developed in front of the pineal recess.

From the basal laminæ of the diencephalon the *pars mamillaria hypothalami* is developed; this comprises the corpora mamillaria and the posterior part of the tuber cinereum. The corpora mamillaria arise as a median thickening, which becomes divided into two by a mesial furrow during the third month.

FIG. 156.—Exterior of brain of human embryo of five weeks. (From model by His.)

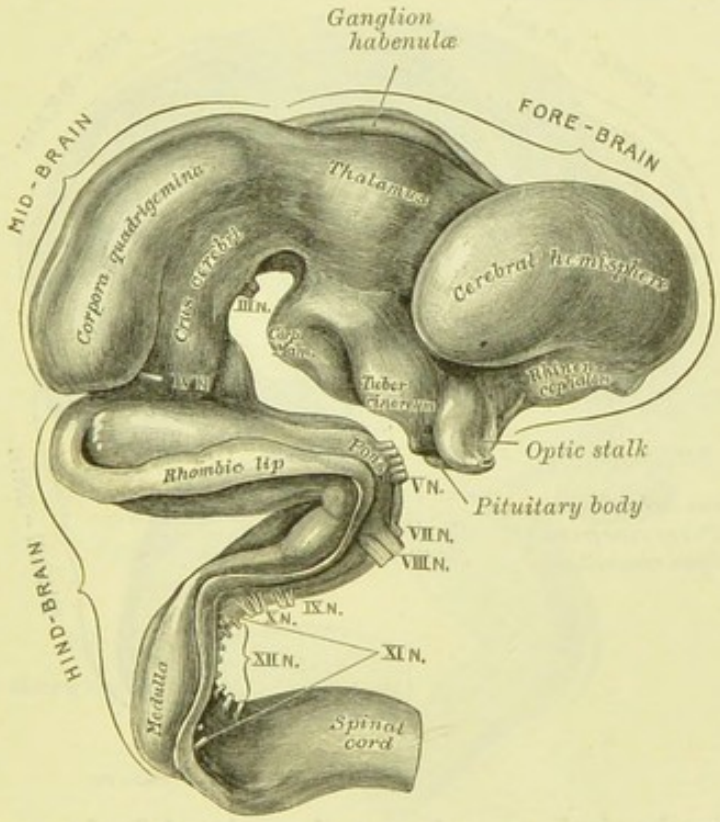

The roof-plate of the diencephalon, in front of the pineal body, remains thin and epithelial in character, and is subsequently invaginated by the choroid plexuses of the third ventricle.

The *telencephalon*.—This consists of a median portion and two lateral diverticula, one on either side. The median portion forms the anterior part of the cavity of the third ventricle, and is closed below and in front by the lamina terminalis. The lateral diverticula consist of outward pouchings of the alar laminæ; the cavities represent the lateral ventricles, and their walls become thickened to form the nervous matter of the cerebral hemispheres. The roof-plate of the telencephalon remains thin, and is continuous in front with the lamina terminalis and behind with the roof-plate of the diencephalon. In the basal laminæ and floor-plate the *pars optica hypothalami* is developed; this comprises the anterior part of the tuber cinereum, the infundibulum and posterior lobe of the pituitary body, and the optic commissure. The anterior part of the tuber cinereum is derived from the posterior part of the floor of the telencephalon. The infundibulum and posterior lobe of the pituitary body arise as a downward diverticulum from the floor. The most

dependent part of the diverticulum becomes solid and forms the posterior lobe of the pituitary body; the anterior lobe of this body is developed from a diverticulum of the ectodermal lining of the stomatodæum (page 155). The optic commissure is developed by the meeting and partial decussation of the optic nerves, which subsequently grow backwards as the optic tracts and terminate in the diencephalon.

The *cerebral hemispheres*.—As already stated, these arise as diverticula of the alar laminæ of the telencephalon (figs. 154 to 157); they increase rapidly in size and ultimately overlap the parts which are developed from the mid- and hind-brains. This great expansion of the hemispheres is a characteristic feature of the brains of mammals, and attains its maximum development in the brain of man. Elliot-Smith divides each cerebral hemisphere into three fundamental parts, viz.: the rhinencephalon, the corpus striatum, and the neopallium.

The *rhinencephalon* (figs. 154, 156) represents the oldest part of the telencephalon, and forms almost the whole of the hemisphere in fishes, amphibians, and reptiles. In man it is feebly developed in comparison with

Fig. 157.—Interior of brain of human embryo of five weeks.
(From model by His.)

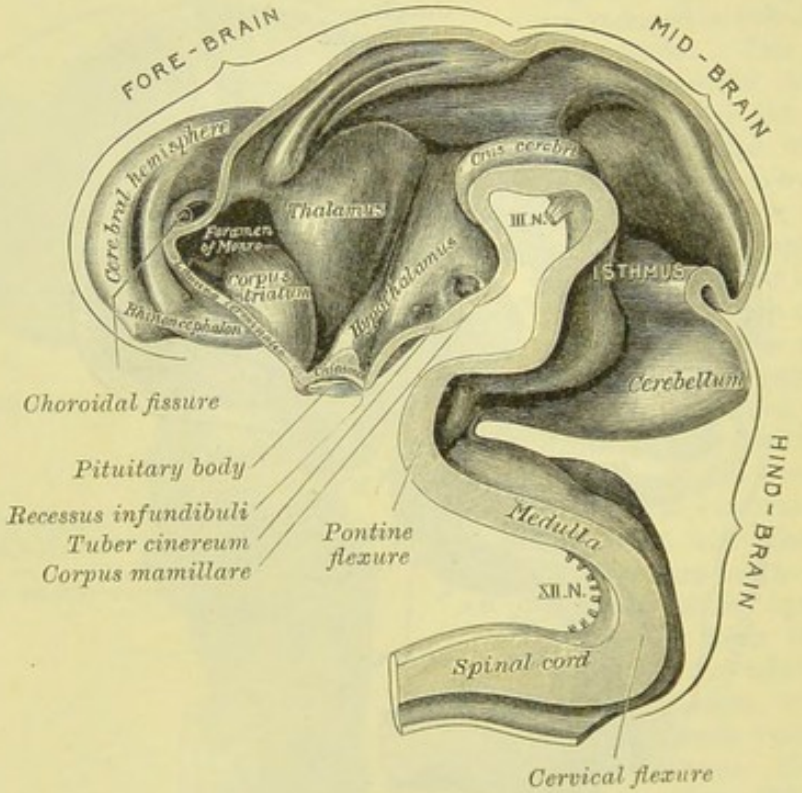

the rest of the hemisphere, and comprises the following parts, viz.: the olfactory lobe (consisting of the olfactory tract and bulb and the trigonum olfactorium), the locus perforatus anticus, the septum pellucidum, the subcallosal, supracallosal, and dentate gyri, the fornix, the hippocampus, and the uncus; the last is the representative of the large pyriform lobe of the lower animals. The olfactory lobe appears as a longitudinal ridge, with a corresponding internal furrow, on the under surface of the hemisphere close to the lamina terminalis. This ridge becomes divided by a groove into an anterior and a posterior part. The anterior grows forwards as a hollow stalk the lumen of which is continuous with the anterior part of the ventricular cavity. The stalk becomes solid and forms the rudiment of the olfactory bulb and tract; a strand of gelatinous tissue in the interior of the bulb indicates the position of the original cavity. From the posterior part the locus perforatus anticus and gyrus subcallosus are developed. The position and connections of the remaining portions of the rhinencephalon are described with the anatomy of the brain.

The *corpus striatum* (figs. 155, 157) appears in the fourth week as a triangular thickening of the wall of the telencephalon between the optic recess and the foramen

of Monro. It increases in size, and by the second month is seen as a swelling in the floor of the future lateral ventricle; this swelling reaches as far as the posterior end of the primitive hemisphere, and as a consequence when this part of the hemisphere grows backwards and downwards to form the temporal lobe, the posterior part of the corpus striatum is carried into the roof of the descending horn, where it is seen as the tail of the caudate nucleus in the adult brain. During the fourth and fifth months the corpus striatum becomes incompletely subdivided by the fibres of the internal capsule into two masses, an inner, the caudate nucleus, and an outer, the lenticular nucleus. In front, the corpus striatum is continuous with the grey matter of the locus perforatus anticus; externally it is confluent for a time with that portion of the wall of the vesicle which is developed into the island of Reil, but the continuity is subsequently interrupted by the fibres of the external capsule.

The *neopallium* forms the remaining, and by far the greater, part of the cerebral hemisphere. It consists, at an early stage, of a relatively large, more or less hemispherical cavity—the primitive lateral ventricle—enclosed by a thin wall

FIG. 158.—Median section of brain of human embryo of three months. (From model by His.)

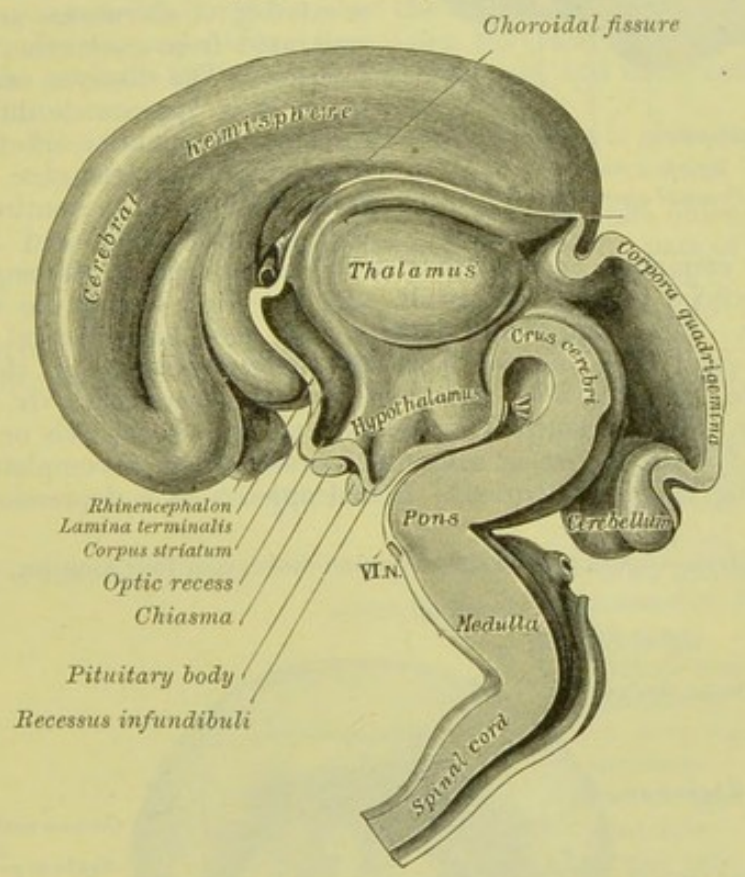

from which the grey cortex of the hemisphere is developed. The vesicle expands in all directions, but more especially upwards and backwards, so that by the third month the hemispheres cover the diencephalon, by the sixth they overlap the mid-brain, and by the eighth the hind-brain.

The hemispheres are separated by a deep cleft, the forerunner of the great longitudinal fissure, and this cleft is occupied by a septum of mesodermal tissue which constitutes the primitive falx cerebri. Coincidently with the expansion of the vesicle, its cavity is drawn out into three prolongations which represent the horns of the future lateral ventricle; the posterior extremity of the vesicle is carried downwards and forwards and forms the descending horn, the posterior horn being produced somewhat later, in association with the backward growth of the occipital lobe of the hemisphere. The roof-plate of the fore-brain remains thin and of an epithelial character; it is invaginated into the lateral ventricle along the mesial wall of the hemisphere. This invagination constitutes the choroidal fissure, and extends from the foramen of Monro to the posterior end of the vesicle. Mesodermal tissue, continuous with

that of the septum in the fissure between the hemispheres, and carrying blood-vessels with it, spreads between the two layers of the invaginated fold and forms the rudiment of the velum interpositum; the margins of the velum become highly vascular and form the choroidal plexuses which for some months completely fill the ventricular cavities. By the downward and forward growth of the posterior end of the vesicle to form the temporal lobe the choroidal fissure finally reaches from the foramen of Monro to the extremity of the descending horn of the ventricle. The portion of the cerebral wall immediately above the choroidal fissure forms what is termed the *hippocampal formation*, and in the adult is represented by the supra-callosal gyrus, the hippocampus, and the gyrus dentatus.

Fig. 159. — Outer surface of cerebral hemisphere of human embryo of about five months.

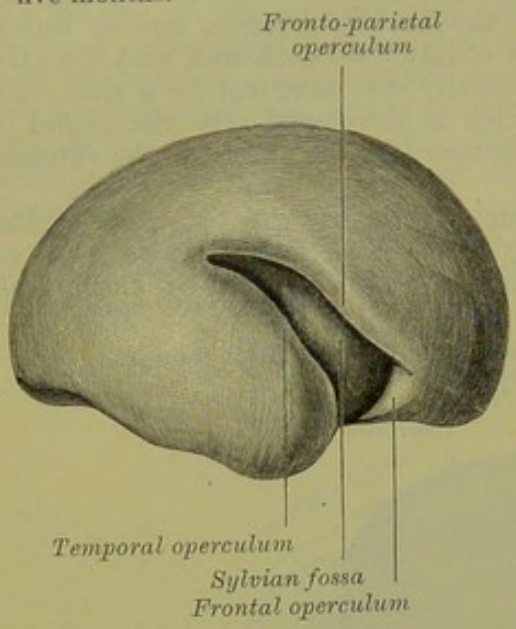

The outer surface of the hemisphere is at first smooth, but later it exhibits a number of elevations or convolutions, separated from each other by furrows or fissures. The fissures, most of which make their appearance during the sixth or seventh months of fœtal life, are divided into (*a*) *complete*, which result from foldings of the entire thickness of the cerebral wall, and thus produce corresponding eminences in the ventricular cavity, and (*b*) *incomplete*, affecting only the superficial part of the wall, and therefore leaving no impressions in the ventricle. The complete fissures are the hippocampal or dentate, the collateral and the anterior part of the calcarine, and these give rise respectively to the following eminences in the ventricle, viz.: the hippocampus major, the eminentia collateralis, and the calcar avis or hippocampus minor. The Sylvian fissure is sometimes described as a complete fissure, but, strictly speaking, this is not correct. It first appears as a depression, the *Sylvian*

Fig. 160.—Median section of brain of human embryo of four months. (Marchand.)

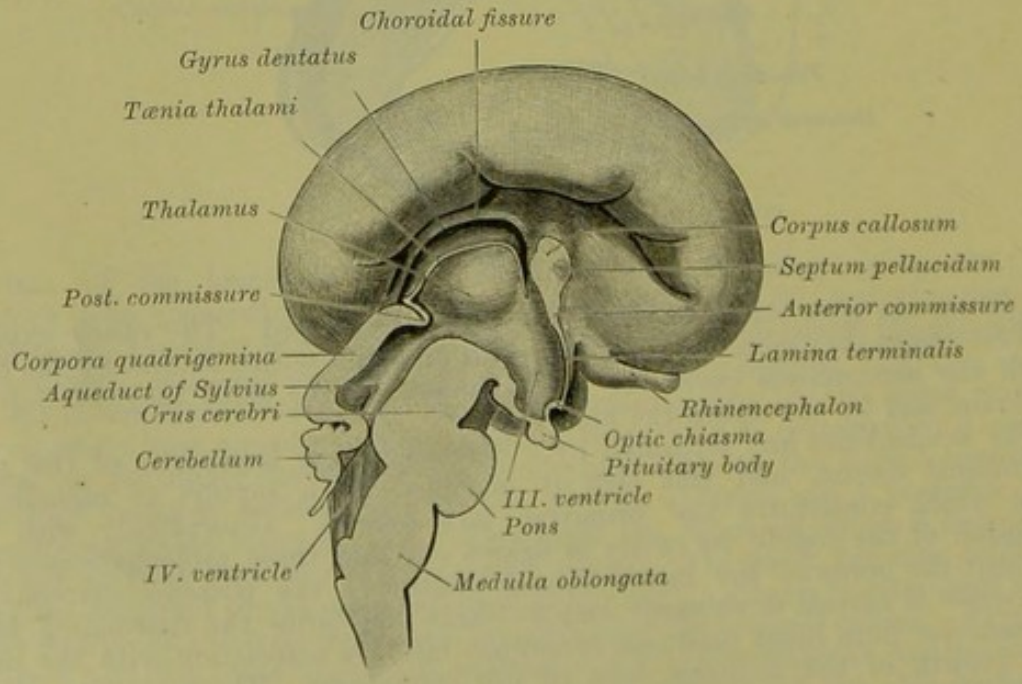

fossa, on the outer surface of the hemisphere (fig. 159); this fossa corresponds with the position of the corpus striatum, and its floor is moulded to form the island of Reil. The intimate connection which exists between the cortex of the island

and the subjacent corpus striatum prevents this part of the hemisphere wall from expanding at the same rate as the portions which surround it. The neighbouring parts of the hemisphere therefore gradually grow over and cover in the island, and constitute the temporal, fronto-parietal, frontal, and orbital opercula of the adult brain. By the end of the first year after birth the island is completely submerged by the approximation of the opercula. The fissures separating the opposed margins of the opercula constitute the composite fissure of Sylvius.

The **commissures** (fig. 160).—The development of the middle (page 122) and posterior (page 123) commissures has already been referred to. The great commissures of the hemispheres, viz.: the corpus callosum, the fornix, and anterior commissure, arise from the lamina terminalis. About the fourth month a small thickening appears in this lamina, immediately in front of the foramen of Monro. The lower part of this thickening is soon constricted off, and fibres appear in it to form the anterior commissure. The upper part continues to grow with the hemispheres, and is invaded by two sets of fibres. Transverse fibres, extending between the hemispheres, pass into its dorsal part, which is now differentiated as the corpus callosum. Into the ventral part longitudinal fibres from the hippocampus pass to the lamina terminalis, and through that structure to the corpora mamillaria; these fibres constitute the fornix. A small portion of the original thickening, lying antero-inferiorly between the corpus callosum and fornix, is not invaded by the commissural fibres; it remains thin, and later a cavity forms in its interior. The cavity is the so-called fifth ventricle, and its bounding walls the septum pellucidum.

A summary of the parts derived from the brain vesicles is given in the following table:—

Hind-brain or rhombencephalon	1. Myelencephalon	Medulla oblongata Lower part of fourth ventricle.
	2. Metencephalon	Pons Varolii Cerebellum Upper part of fourth ventricle.
	3. Isthmus rhombencephali	Valve of Vieussens Superior peduncles of cerebellum.
Mid-brain or mesencephalon		Crura cerebri Corpora quadrigemina Aqueduct of Sylvius.
Fore-brain	1. Diencephalon	Thalamus Metathalamus Epithalamus Pars mamillaria hypothalami Posterior part of third ventricle.
	2. Telencephalon	Anterior part of third ventricle Pars optica hypothalami Cerebral hemispheres Lateral ventricles Foramen of Monro.

The Cranial Nerves.—With the exception of the olfactory and optic nerves, which will be specially considered, the cranial nerves are developed in a similar manner to the spinal nerves (see page 118). The sensory or afferent nerves are derived from the cells of the ganglion rudiments of the neural crest. The central processes of these cells grow into the brain and form the roots of the nerves, while the peripheral processes extend outwards and constitute their fibres of distribution. It has been seen, in considering the development of the medulla oblongata (page 119), that the *tractus solitarius* (fig. 162), derived from the fibres which grow inwards from the ganglion rudiments of the glosso-pharyngeal and vagus

nerves, is the homologue of the *oval bundle* in the cord which had its origin in the posterior nerve-roots. The motor or efferent nerves arise as outgrowths of the neuroblasts situated in the basal laminæ of the mid- and hind-brain. While, however, the anterior spinal nerve-roots arise in one series from the basal lamina, the cranial motor nerves are grouped into two sets, according as they spring from the mesial or lateral parts of the basal lamina. To the former set belong the third, fourth, sixth, and twelfth nerves; to the latter, the eleventh and the motor fibres of the fifth, seventh, ninth, and tenth nerves (figs. 161, 162).

Fig. 161.—Transverse section of medulla oblongata of human embryo. × 32. (From Kollmann's 'Entwickelungsgeschichte.')

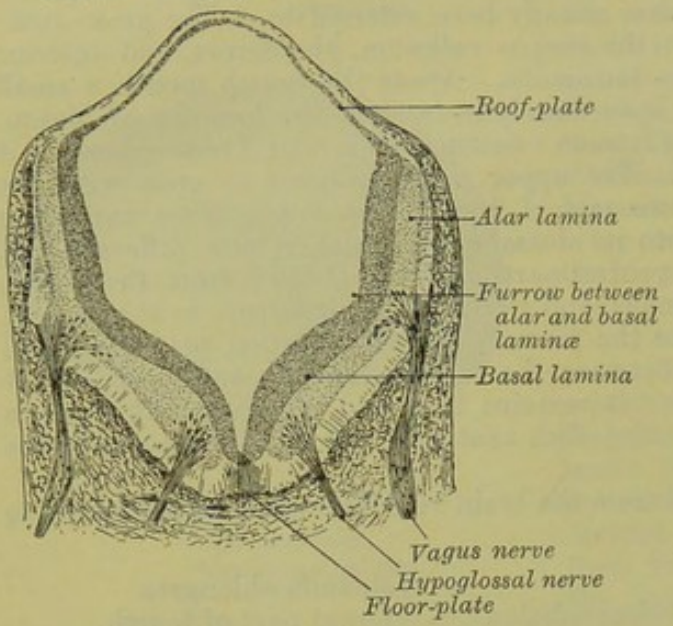

The Nose.—The development of the nose has already been considered (pages 110, 111).

The *olfactory nerves* are developed from the cells of the ectoderm which lines the olfactory pits; these cells undergo proliferation and give rise to what are termed the *olfactory cells* of the nose. The axons of the olfactory cells grow into the overlying olfactory bulb and form the olfactory nerves.

The Eye.—The development of the eyes commences by the protrusion of a pair of diverticula from the lateral aspects of the fore-brain. These diverticula are known as the *optic vesicles*; they project towards the sides of the head, and the peripheral part of each expands to form a hollow bulb, while the proximal part remains narrow and constitutes the *optic stalk* (figs. 163, 164). The ectoderm of the surface of the embryo in the area overlying the bulb becomes thickened, invaginated, and finally severed from the ectodermal covering of the

Fig. 162.—Transverse section of medulla oblongata of human embryo. (After His.)

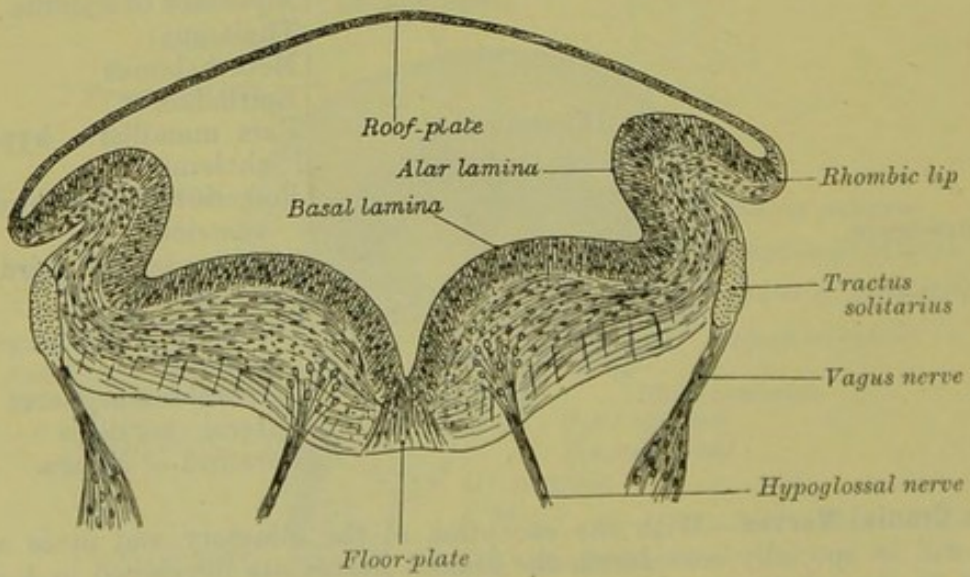

head as a vesicle of cells, the *lens vesicle*, which constitutes the rudiment of the crystalline lens. The outer wall of the bulb is indented by the lens rudiment and invaginated until it comes into contact with the inner wall; the bulb is thus converted into a cup, the *optic cup*, consisting of two strata of cells (fig. 164). These two strata are continuous with each other at the cup margin, which ultimately overlaps the front of the lens and reaches as far forward as

the future aperture of the pupil. The invagination is not limited to the outer wall of the bulb, but involves also its postero-inferior surface and extends in the form of a groove for some distance along the optic stalk, so that, for a time, a gap or fissure, the *choroidal fissure*, exists in the lower part of the cup (fig. 165). Through the groove and fissure the mesoderm extends into the optic stalk and cup, and in this mesoderm a blood-vessel is developed; when the groove and fissure are closed this vessel forms the central artery of the retina. Some-

Fig. 163.—Transverse section of head of chick embryo of forty-eight hours' incubation. (From Duval's 'Atlas d'Embryologie.')

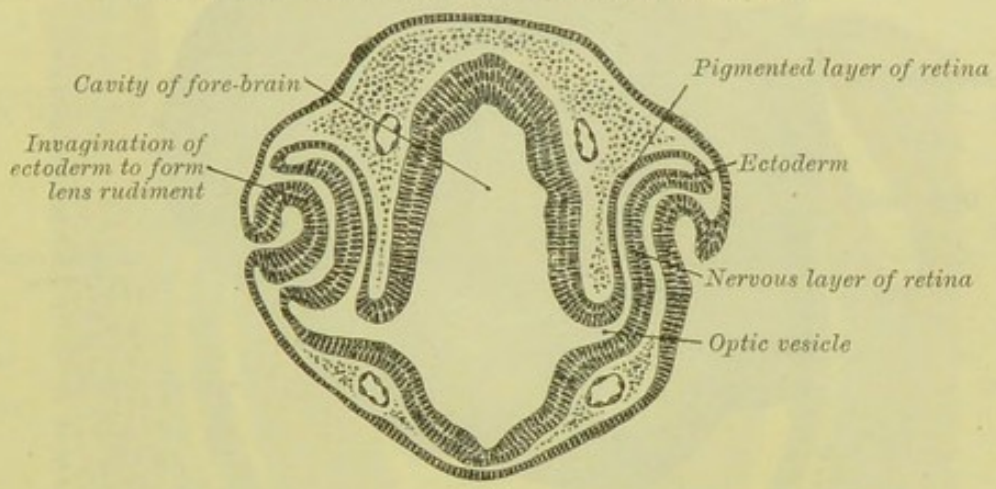

times the choroidal fissure remains patent, giving rise to the condition known as *coloboma*.

The retina is developed from the optic cup. The outer stratum of the cup persists as a single layer of cells which assume a columnar shape, acquire pigment, and form the pigmented layer of the retina. The cells of the inner stratum proliferate and form a layer of considerable thickness from which the nervous elements and the sustentacular fibres of the retina, together with a portion of the vitreous body, are developed. In that portion of the cup which overlaps the lens the inner stratum is not differentiated into nervous elements, but forms a layer of columnar cells which is applied to the pigmented layer, and these two strata form the *pars ciliaris* and *pars iridica retinæ*.

Fig. 164.—Transverse section of head of chick embryo of fifty-two hours' incubation. (From Duval's 'Atlas d'Embryologie.')

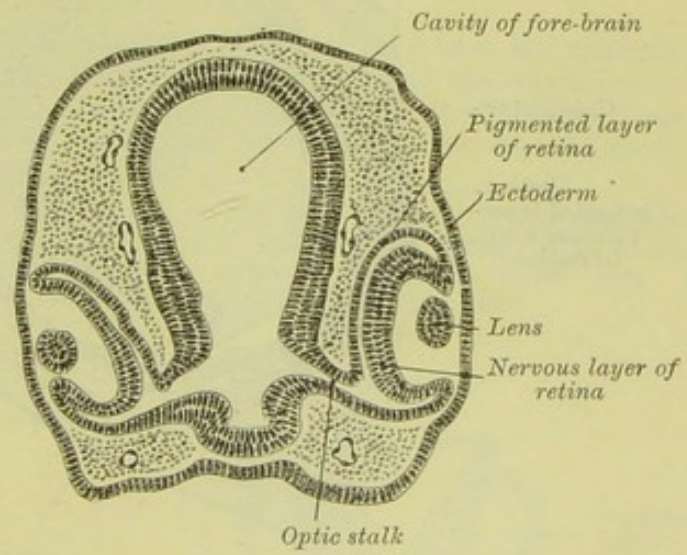

The cells of the inner or retinal layer of the optic cup become differentiated into spongioblasts and germinal cells, and the latter by their subdivisions give rise to neuroblasts. As in the spinal cord, the spongioblasts ramify to form a myelospongium, from which the sustentacular fibres of Müller, the outer and inner limiting membranes, together with the ground-work of the molecular layers of the retina are formed. The neuroblasts become arranged to form the ganglionic and nuclear layers. Cameron,* after careful study of the neuroblasts in the retina, spinal cord, and brain, maintains that they consist of nuclei only, and that they possess no cytoplasmic investment; the 'clear protoplasm, which has been described as surrounding them during mitotic division, being merely the

* Development of the Retina in Amphibia, *Journal of Anatomy and Physiology*, vol. xxxix., 1905.

achromatic nuclear substance set free owing to the disappearance of the nuclear membrane.' He further maintains that the nuclei of the nuclear layers undergo subsequent multiplication by *direct* division. The layer of rods and cones is first developed in the central part of the optic cup, and from there gradually extends towards the cup-margin.

FIG. 165.—Optic cup and choroidal fissure seen from below, from a human embryo of about four weeks. (Kollmann.)

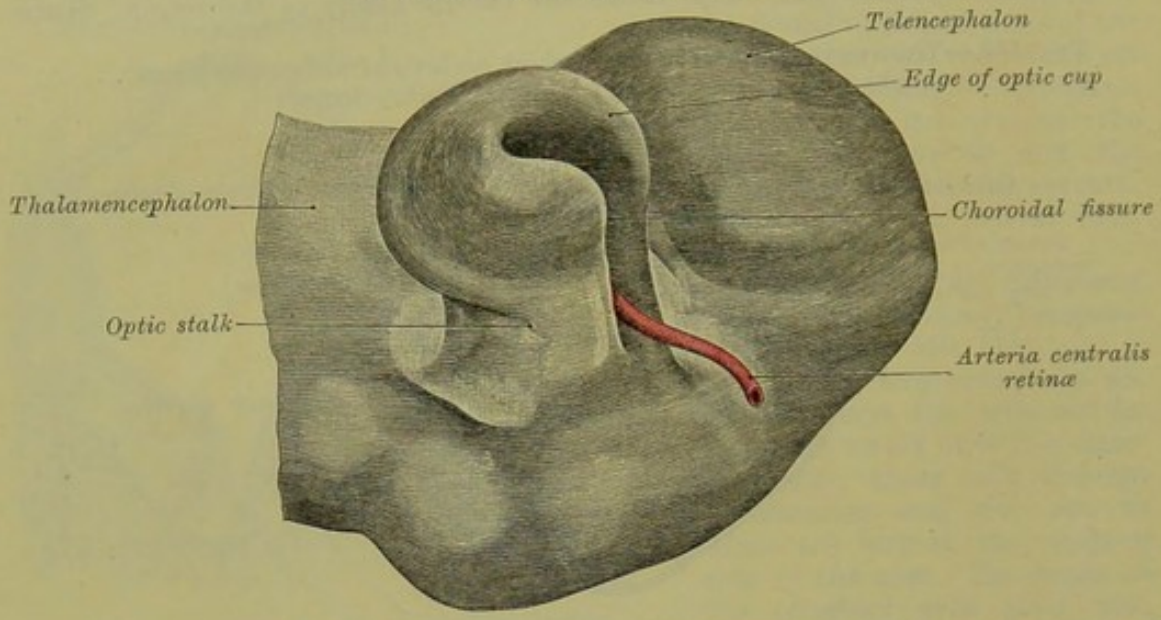

FIG. 166.—Horizontal section through the eye of an eighteen days' embryo rabbit. ×30. (Kölliker.)

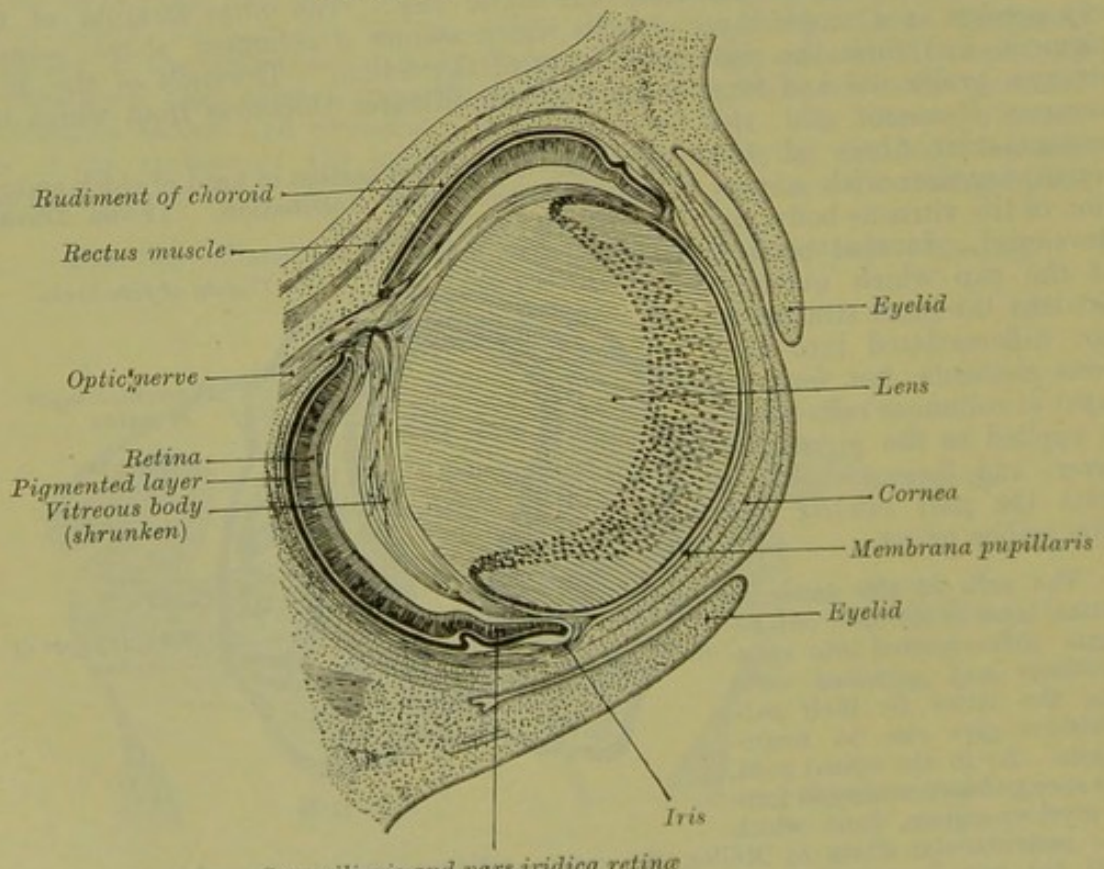

The rods and cones first appear as clear globules, which, after being protruded through the inner limiting membrane, rapidly increase in size—a process which would seem to depend on their power of digesting and absorbing the pigment from the cells of the pigmented layer.

The optic stalk is converted into the optic nerve by the obliteration of its cavity and the growth of nerve-fibres into it. Most of these fibres are centripetal,

and grow into the optic stalk from the nerve-cells of the retina, but a few extend in the opposite direction and are derived from nerve-cells in the brain.

The crystalline lens is developed from the lens vesicle, which recedes within the margin of the cup, and becomes separated from the overlying ectoderm by mesoderm. The cells forming the posterior wall of the vesicle lengthen and are converted into the lens-fibres, which grow forward and fill up the cavity of the vesicle. The cells

Fig. 167.—Sagittal section of eye of human embryo of six weeks. (Kollmann.)

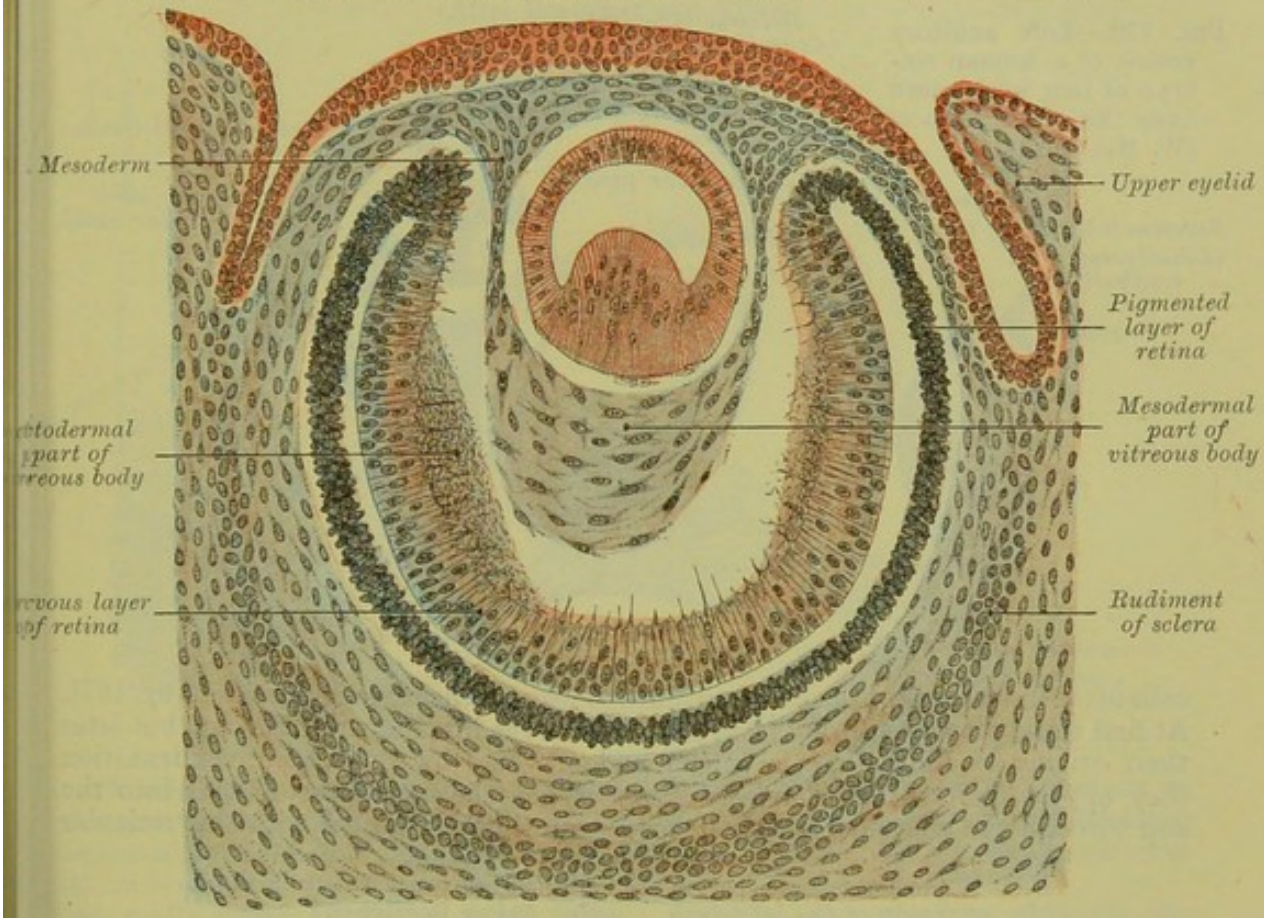

forming the anterior wall retain their cellular character, and form the epithelium on the anterior surface of the adult lens. By the second month the lens is invested by a vascular mesodermal capsule, the *tunica vasculosa lentis*, the blood-vessels of which are chiefly derived from the central artery of the retina; the part of

Fig. 168.—Section through the head of a human embryo, about twelve days old, in the region of the hind-brain. (Kollmann.)

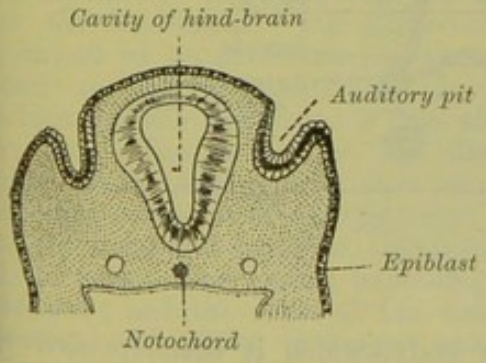

Fig. 169.—Section through hind-brain and auditory vesicles of an embryo more advanced than that of fig. 168. (After His.)

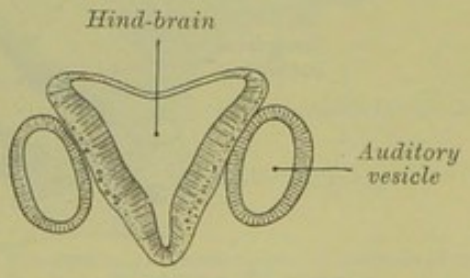

this capsule which covers the front of the lens is named the *membrana pupillaris*. By the sixth month all the vessels of the capsule are atrophied except one, the *arteria hyaloidea*, which disappears during the ninth month; the position of this artery is indicated in the adult by the canalis hyaloideus, which reaches from the

optic disc to the posterior surface of the lens. With the loss of its blood-vessels the tunica vasculosa lentis disappears, but sometimes the membrana pupillaris persists at birth, giving rise to the condition termed *congenital atresia of the pupil.*

The vitreous body is developed between the lens and the optic cup. Primarily it consists of a series of slender protoplasmic processes which project from the

Fig. 170.—Left auditory vesicle of a human embryo of four weeks, seen from the outer surface. (W. His, jun.)

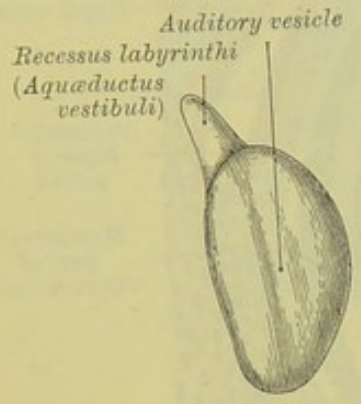

Fig. 171.—Left auditory vesicle of a human embryo of five weeks, seen from the outer surface. (W. His, jun.)

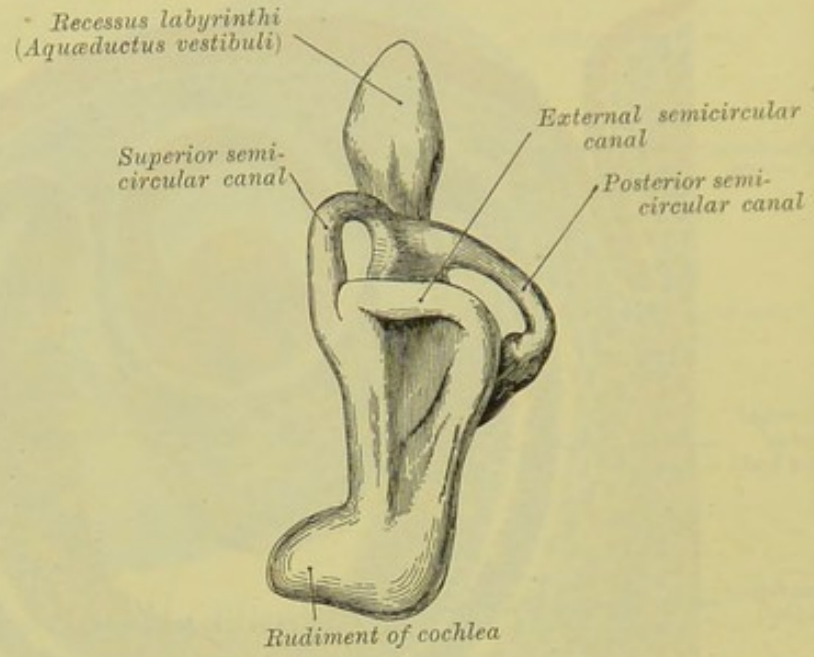

cells of the inner layer of the cup, and unite to form a delicate reticular tissue (fig. 167). At first these processes spring from the whole of the inner layer of the cup, but later their origins are limited to the ciliary region, where by a process of condensation they appear to form the zonule of Zinn. When the mesoderm extends into the cup through the choroidal fissure it becomes intimately united with this reticular

Fig. 172.—Transverse section through head of fœtal sheep, in the region of the labyrinth. × 30. (After Boettcher.)

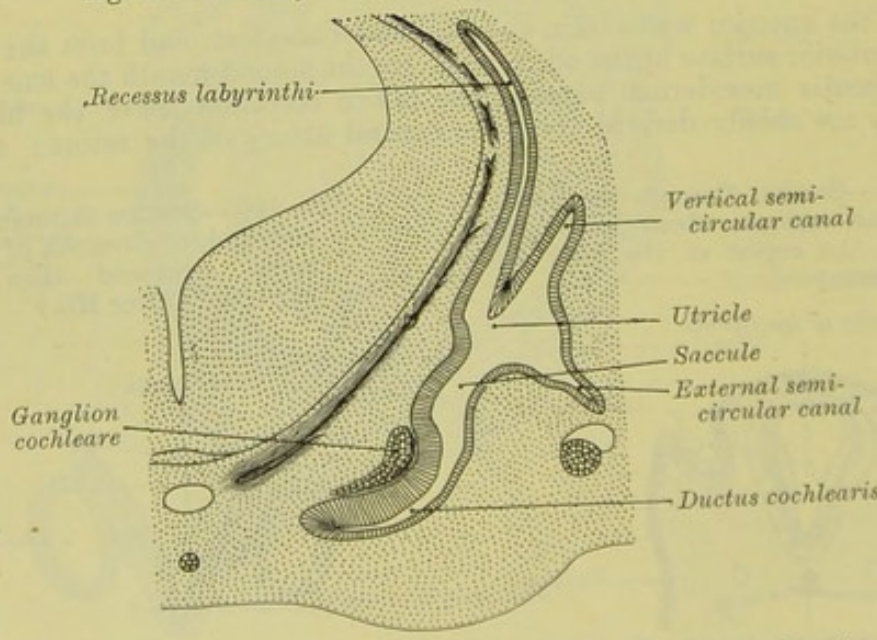

tissue, and contributes to form the vitreous body, which is therefore derived partly from the ectoderm and partly from the mesoderm.

The anterior chamber of the eye appears as a cleft in the mesoderm separating the lens from the overlying ectoderm. The layer of mesoderm in front of the cleft forms the substantia propria of the cornea, that behind the cleft the stroma of the iris and the membrana pupillaris.

The sclerotic and choroid coats of the eyeball are derived from the mesoderm surrounding the optic cup.

The eyelids are formed as small cutaneous folds (fig. 166), which at the end of the third month come together and unite in front of the globe and cornea. This union is broken up and the eyelids separate before the end of fœtal life.

Fig. 173.—Transverse section of the canal of the cochlea of a fœtal cat. (After Boettcher and Ayres.)

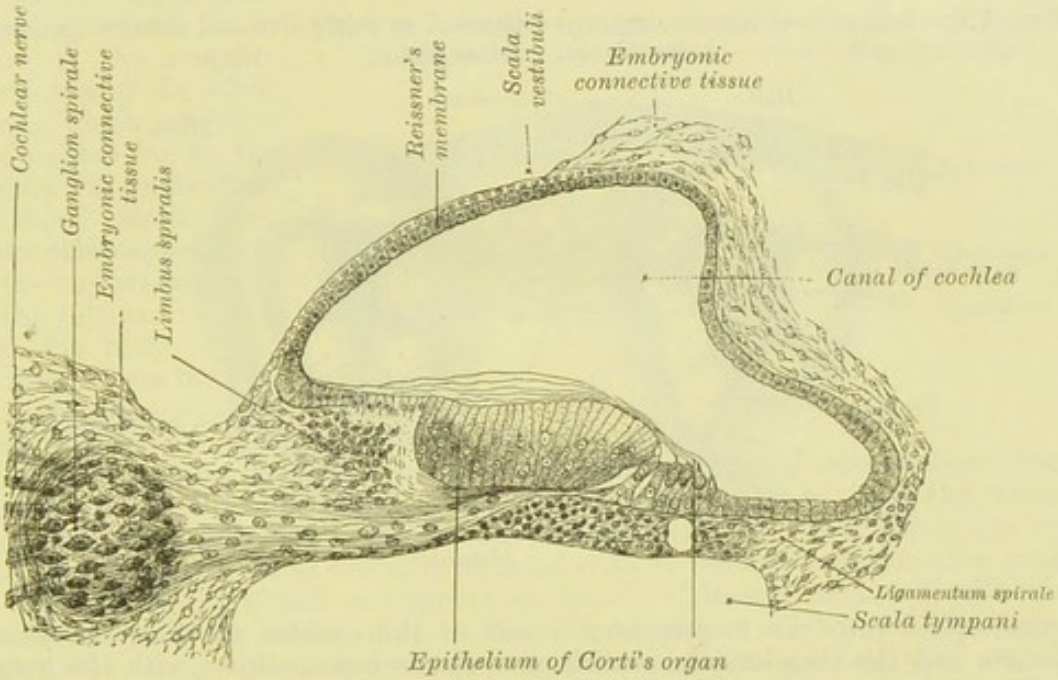

The lachrymal sac and nasal duct result from a thickening of the ectoderm in the groove between the lateral nasal and maxillary processes. This thickening becomes hollowed out into a channel, and the lips of the groove meet over it, and convert it into a duct, which eventually opens into the nasal fossa. The epithelium of the cornea and conjunctiva, and that which lines the ducts and alveoli of the lachrymal gland, are of ectodermal origin, as are also the eyelashes and the lining cells of the glands which open on the lid-margins.

Fig. 174.—Tubercles from which the different parts of the pinna are developed. (His.)

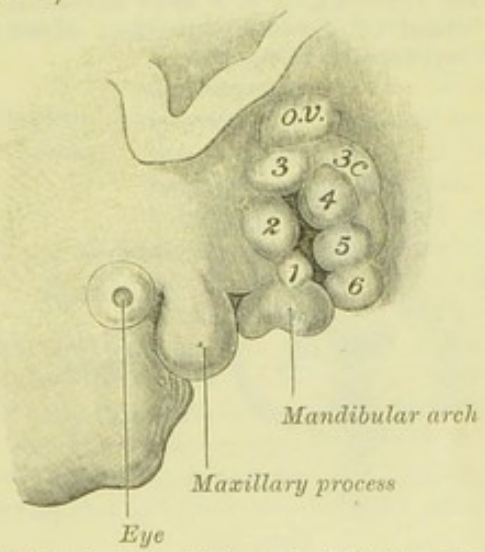

1, 2. Tubercles on mandibular arch. 3. Tubercle above cleft. 3, *c*. Prolongation of 3 downwards. 4, 5, 6. Tubercles on hyoid arch. *o.v.* Auditory vesicle.

The Ear.—The first rudiment of the internal ear appears shortly after that of the eye, in the form of a thickening of the surface ectoderm over the region of the hind-brain. The thickening is followed by an involution of the ectoderm to form the *auditory pit* (fig. 168), which deepens and forms a flask-shaped cavity. The mouth of the flask is then closed, and thus a shut sac, the *auditory vesicle*, is formed (fig. 169); from it the epithelial lining of the labyrinth is formed. The vesicle becomes pear-shaped; and the neck of the flask, or *recessus labyrinthi*, prolonged upwards, forms the ductus endolymphaticus. From the vesicle certain diverticula are given off which form the various parts of the labyrinth. One from the anterior end gradually elongates, and, forming a tube coiled on itself, becomes the membranous canal of the cochlea, the vestibular extremity of which is subsequently constricted to form the canalis reuniens. Three others appear as disc-like evaginations on the surface

of the vesicle; the central parts of the walls of the discs coalesce and disappear, while the peripheral portions persist to form the membranous semicircular canals, of which the external canal is the last to be developed (figs. 171, 172). The central part of the vesicle represents the membranous vestibule, and is subdivided by a constriction into a smaller anterior part, the saccule, and a larger posterior part, the utricle. This subdivision involves the proximal part of the ductus endolymphaticus, with the result that the utricle and saccule ultimately communicate with each other by means of a Y-shaped canal. The

Fig. 175.—Left ears of human embryos estimated at thirty-five and thirty-eight days respectively. (After His.)

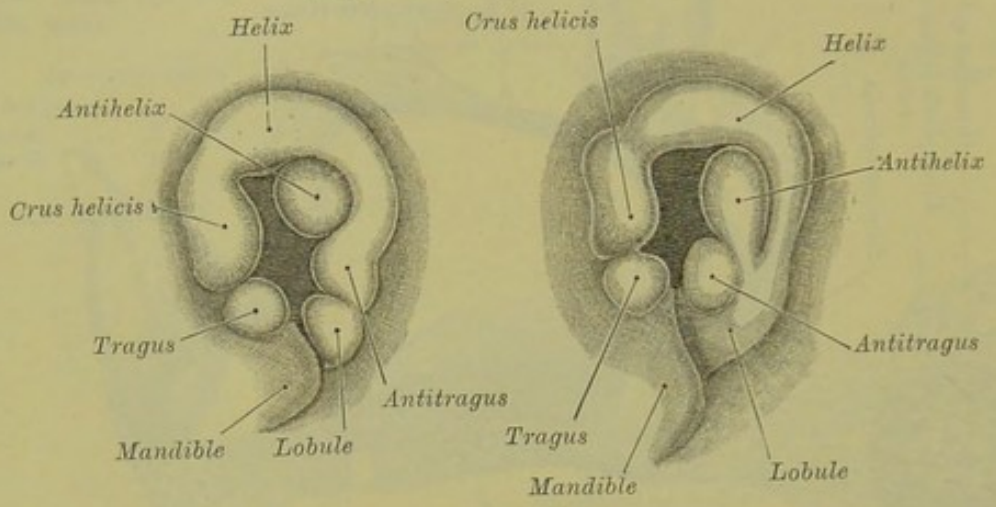

saccule opens into the membranous canal of the cochlea through the canalis reuniens and the membranous semicircular canals communicate with the utricle.

The auditory vesicle is imbedded in a mass of mesodermal tissue, which rapidly undergoes chondrification and ossification to form the bony labyrinth.

The middle ear, Eustachian tube, and mastoid antrum are developed from the inner part of the first branchial (hyomandibular) cleft, and are closed externally by the membrana tympani, which originally consists of a layer of ectoderm externally, and a layer of entoderm internally; between these two layers the mesoderm extends to form the substantia propria of the membrane. With regard to the exact mode of development of the ossicles of the middle ear there is some difference of opinion. The view generally maintained is that the *incus* and *malleus* are developed from the proximal end of the mandibular (Meckel's) cartilage (fig. 138); that the base of the *stapes* is formed by the ossification of the mesoderm which fills in the foramen ovale, while its arch is developed around a small vessel, the stapedial artery, which subsequently undergoes atrophy. As already stated (footnote, page 108), Gadow regards all three ossicles as being derived from the hyomandibula.

Fig. 176.—Pinna in a more advanced stage of development than those represented in fig. 175.

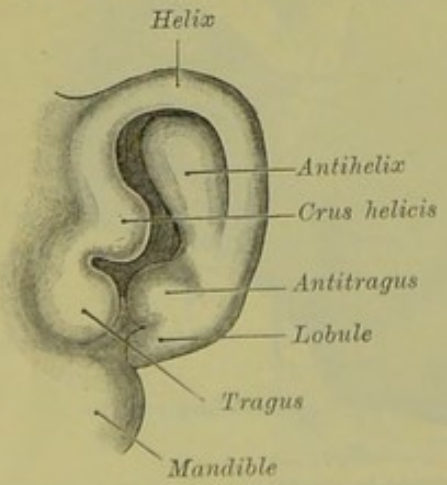

The external auditory meatus is formed from the outer part of the hyomandibular cleft, while the pinna is developed by the gradual differentiation of six tubercles which appear around the outer margin of the cleft. Two tubercles appear on the posterior edge of the mandibular arch; these represent the rudiments of the tragus and crus helicis. Three are found on the hyoid arch, and indicate, from below upwards, the lobule, antitragus, and antihelix. One arises above the cleft, and grows downwards behind the antitragus and antihelix; from it and its downward prolongation the upper and posterior parts of the helix are developed (figs. 174, 175, 176).

DEVELOPMENT OF THE VASCULAR SYSTEM

There are three distinct stages in the development of the circulatory system, each in accordance with the manner in which nourishment is provided for at different periods of the existence of the individual. In the first stage there is the *vitelline circulation*, during which nutriment is extracted from the *vitellus* or contents of the yolk-sac. In the second stage there is the *placental circulation*, during which nutriment is obtained by means of the placenta from the blood of the mother. In the third stage, commencing after birth, there is the *complete circulation of the adult*, during which nutrition is provided for by the organs of the individual.

Fig. 177.—Section through vascular area to show commencing development of blood-vessel. (Semi-diagrammatic.)

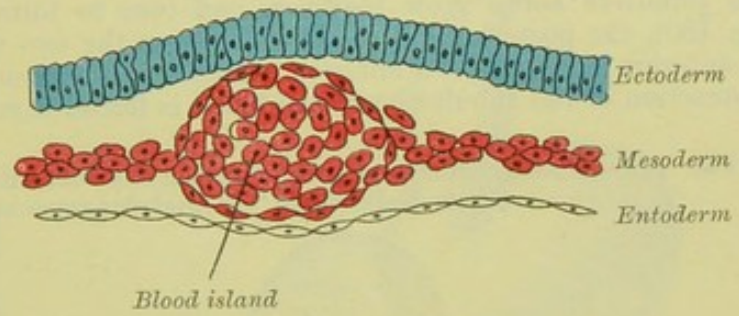

Blood-vessels first make their appearance in the mesodermal wall of the yolk-sac, i.e. outside the body of the embryo. Here the cells become arranged into solid strands or cords which join to form a close-meshed network. The peripheral cells of these strands become flattened and joined to each other by their edges to form the walls of the primitive blood-vessels. Fluid collects within the strands and converts them into tubes, and the more centrally situated cells of the cell-cords are thus pushed to the sides of the vessels and appear as masses of loosely arranged cells which project towards the lumen of the tube. These masses are termed *blood islands* (fig. 177); their cells acquire colouring matter (hæmoglobin), and are then detached to form the blood-corpuscles (fig. 178).* The earliest blood-corpuscles are all nucleated: they are also capable of subdivision and of executing amœboid movements, and in these respects resemble colourless blood-corpuscles. Soon, however, true colourless blood-corpuscles make their appearance, and, according to Beard,† are first derived from the rudiments of the thyroid gland.

Fig. 178.—Later stage.

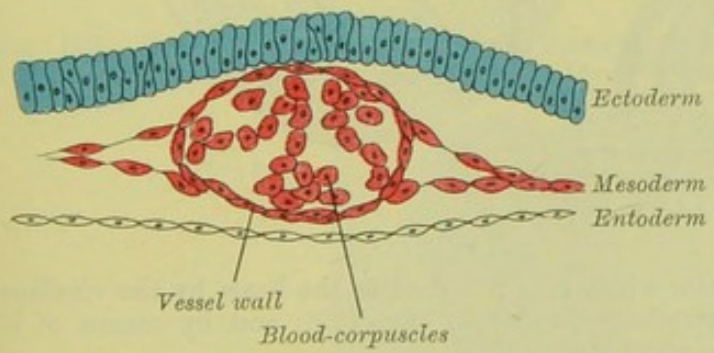

Coincidently with the development of the blood-vessels in the vascular area, the first rudiment of the heart appears as a pair of tubular vessels which are developed in the splanchnopleure of the pericardial area. These are named the *primitive aortæ*, and a direct continuity is soon established between them and the vessels of the vascular area. Each receives anteriorly a vein—the vitelline vein—from the yolk-sac, and is prolonged backwards on the lateral aspect of the notochord under the name of the dorsal aorta. The dorsal aortæ end at first on the yolk-sac; but with the development of the allantois they are continued backwards through the body-stalk as the umbilical arteries to the villi of the chorion.

By the forward growth and flexure of the head the pericardial area and the anterior portions of the primitive aortæ are folded backwards on the ventral

* Some observers incline to the view that the endothelium of the vessels is of entodermal origin. The blood-corpuscles are developed from these endothelial cells, and are therefore also entodermal, the sequence of the development of the different structures being: first the heart, then the blood-vessels, and lastly the blood-corpuscles. (Consult Dr. E. Mehnert's *Biomechanik*, Jena, 1898.)

† *Anatomischer Anzeiger*, December 1900.

aspect of the fore-gut, and the original relation of the somatopleure and splanchnopleure layers of the pericardial area is reversed, the latter being placed on the dorsal aspect of the former. Each primitive aorta now consists of a ventral and a dorsal part connected anteriorly by an arch. These three parts are named respectively the anterior ventral aorta, the dorsal aorta, and the first cephalic arch. The first cephalic arches pass through the mandibular arches, and behind them five additional pairs subsequently develop, so that in all six pairs of aortic arches are formed. The vitelline veins which enter the embryo through the anterior wall of the umbilical orifice are now continuous with the posterior ends of the anterior ventral aortæ. With the formation of the tail-fold the posterior parts of the primitive aortæ are carried forward in a ventral direction to form the posterior ventral aortæ and primary caudal arches.* In the pericardial region the two primitive aortæ grow together, and fuse to form a single tubular heart (fig. 180), the posterior end of which receives the two vitelline veins, while from its anterior end the two anterior ventral aortæ emerge.† By the rhythmical contraction of the tubular heart the blood is forced through the aortæ and blood-

Fig. 179.—Human embryo of about fourteen days old with yolk-sac. (After His.) (From Kollmann's 'Entwickelungsgeschichte.')

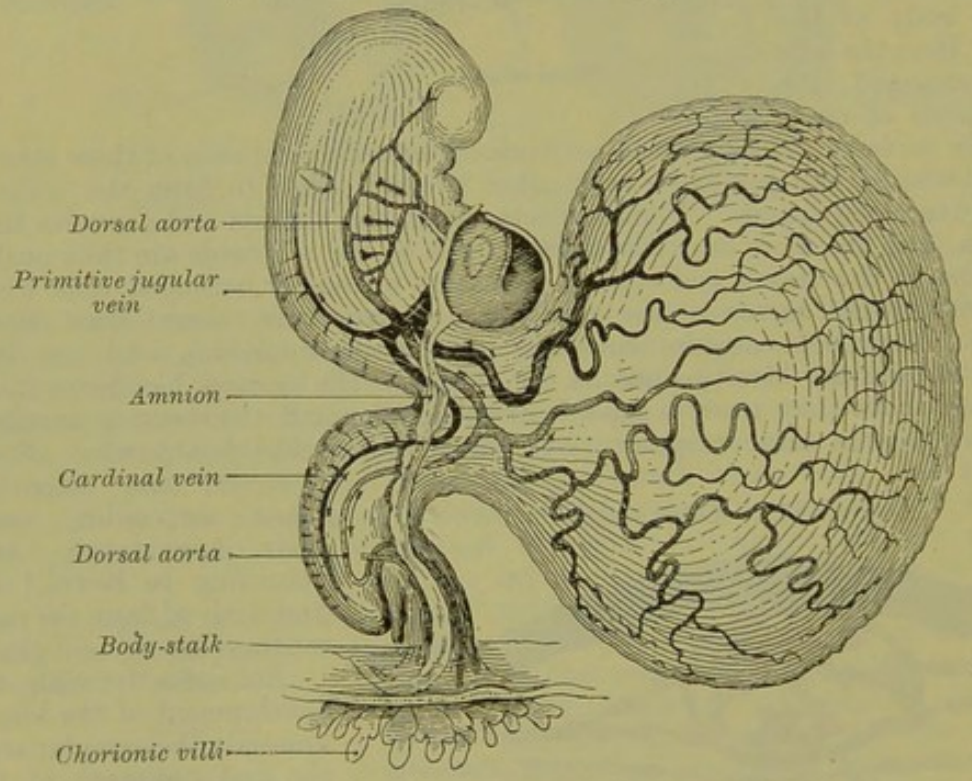

vessels of the vascular area, from which it is returned to the heart by the vitelline veins. This constitutes the vitelline circulation (fig. 179), and by means of it nutriment is absorbed from the vitellus.

The vitelline veins at first open separately into the posterior end of the tubular heart, but after a time their terminal portions fuse, and the two vessels communicate with the heart through a common orifice. The vitelline veins ultimately drain the blood from the alimentary canal, and are modified to form the portal vein. This is caused by the growth of the liver, which interrupts their direct continuity with the heart; and the blood returned by them circulates through the liver before reaching the heart.

With the atrophy of the yolk-sac the vitelline circulation diminishes and ultimately ceases, while an increasing amount of blood is carried through the umbilical arteries to the villi of the chorion. Subsequently, as the non-placental chorionic villi atrophy, their vessels disappear; and then the umbilical arteries convey the whole of their contents to the placenta, whence it is returned to the heart by the umbilical veins. In this manner the placental circulation is

* Young and Robinson, *Journal of Anatomy and Physiology*, vol. xxxii.

† In most fishes and in the amphibia the heart originates as a single median tube.

established, and by means of it nutritive materials are absorbed from, and waste products given up to, the maternal blood.

The umbilical veins, like the vitelline, become interrupted by the liver, and the blood returned by them passes through this organ before reaching the heart. Ultimately the right umbilical vein shrivels up and disappears, as will be explained later (pages 145, 146).

Fig. 180.—Diagram to illustrate the simple tubular condition of the heart. (Drawn from Ecker-Ziegler model.)

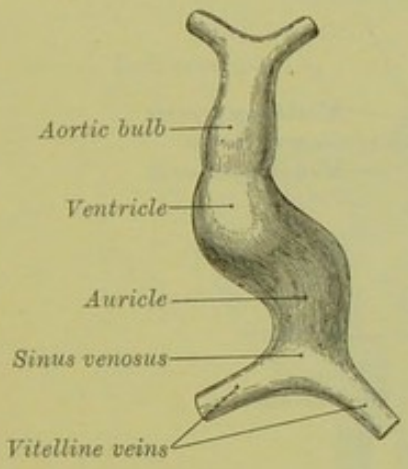

Fig. 181.—Heart further advanced than in fig. 180. (Drawn from Ecker-Ziegler model.)

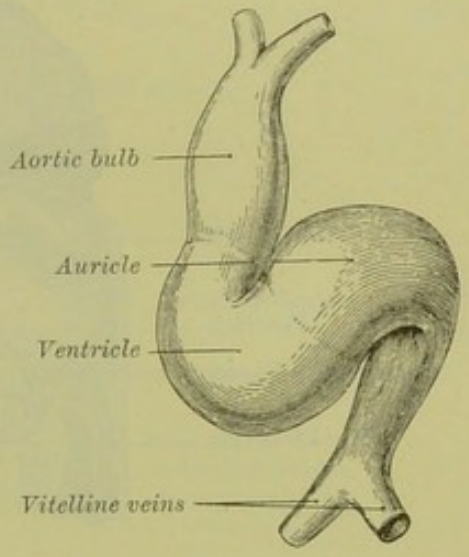

During the occurrence of these changes great alterations take place in the primitive heart and blood-vessels, and now require description.

Further development of the heart.—The simple tubular heart, already described, becomes elongated and bent on itself so as to form an S-shaped loop, the anterior part bending to the right and the posterior part to the left. The intermediate portion arches transversely from right to left, and then turns sharply forward into the anterior part of the loop. Slight constrictions make

Fig. 182.—Head of chick embryo of about thirty-eight hours' incubation, viewed from the ventral surface. × 26. (From Duval's 'Atlas d'Embryologie.')

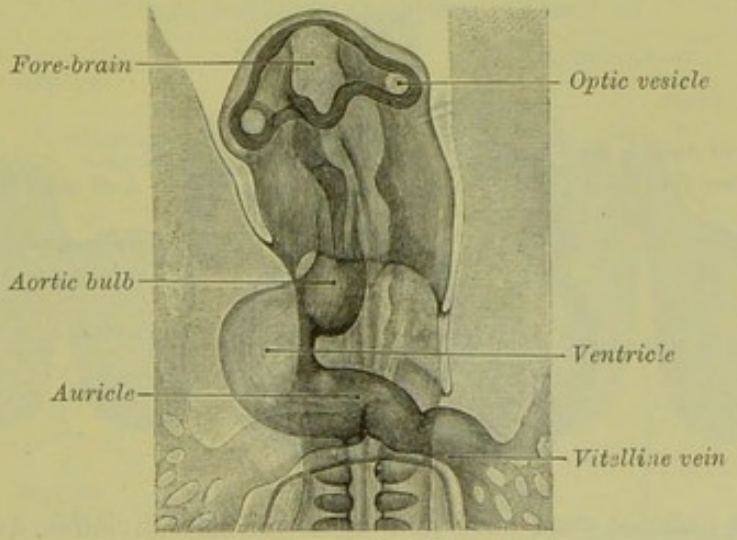

their appearance in the tube and divide it from behind forwards into four parts, viz.: (1) the *sinus venosus*; (2) the *primitive auricle*; (3) the *primitive ventricle*; (4) the *aortic bulb*, which consists of two portions, a proximal muscular portion known as the *bulbus cordis*, and a distal portion, the *primitive aortic stem* (figs. 180 to 182). The constriction between the auricle and ventricle constitutes the *auricular canal*, and indicates the site of the future auriculo-ventricular valves.

The sinus venosus is at first situated in the septum transversum (a layer of mesoderm in which the liver and the central tendon of the Diaphragm are developed) behind the common auricle, and is formed by the union of the vitelline veins. The veins or ducts of Cuvier from the body of the embryo and the umbilical veins from the placenta subsequently open into it (fig. 185). The sinus is at first placed transversely, and opens by a median aperture into the common auricle. Soon, however, it assumes an oblique position, and becomes crescentic in

Fig. 183.—Heart of human embryo of about fifteen days. (Reconstruction by His.)

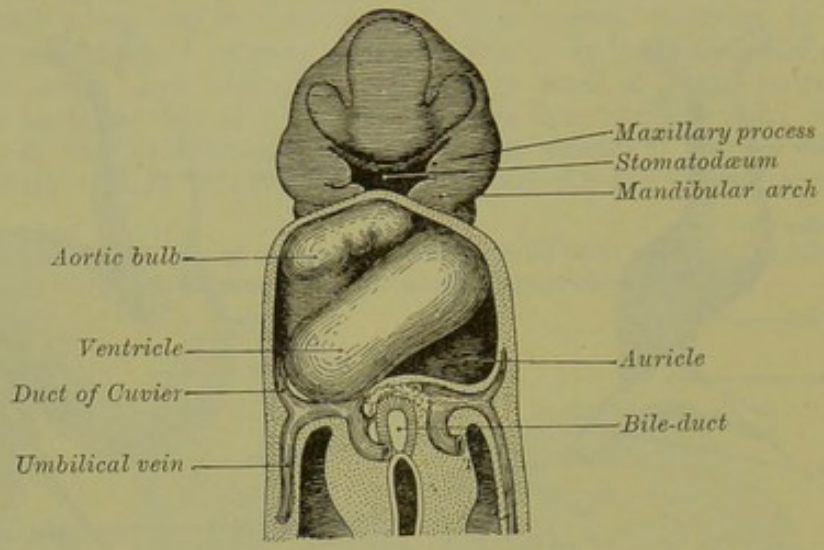

form; its right half or horn increases more rapidly than the left, while the opening into the auricle now communicates with the right portion of the auricular cavity. The right horn ultimately becomes incorporated with and forms a part of the right auricle, the line of union between it and the auricle proper being indicated in the interior of the adult auricle by a vertical crest, the *crista terminalis* of His. The left horn, which ultimately receives only the left duct of Cuvier, persists as the coronary sinus (fig. 192). The vitelline and umbilical veins are soon replaced by a single vessel, the inferior vena cava, and

Fig. 184.—Heart showing expansion of auricles.
(Drawn from Ecker-Zeigler model.)

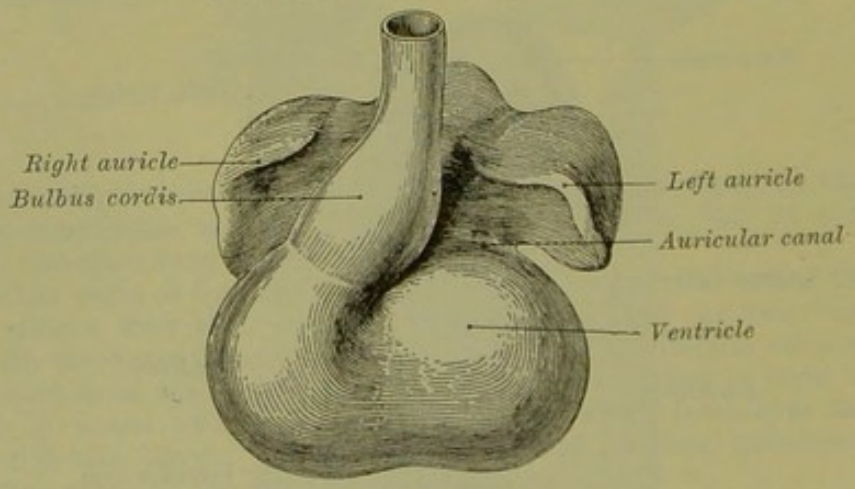

the three veins (inferior vena cava and right and left Cuvierian ducts) open into the dorsal aspect of the auricle by a common slit-like aperture (fig. 189). The upper part of this aperture represents the opening of the permanent superior vena cava, the lower that of the inferior vena cava, and the intermediate part the orifice of the coronary sinus. The slit-like aperture lies obliquely, and is guarded by two valves, the *right* and *left venous valves*, which unite with each other above the opening and are continuous with a fold named the *septum spurium*. The left venous valve practically disappears, while the right is

subsequently divided to form the Eustachian and Thebesian valves. At the lower extremity of the slit is a triangular thickening, the *spina vestibuli* of His, which partly closes the aperture between the two auricles, and, according to His, takes a part in the formation of both the interauricular and interventricular septa.

The auricular canal is at first a short straight tube connecting the auricular with the ventricular portion of the heart, but its growth is relatively slow, and it

Fig. 185.—Heart of human embryo, 4·2 mm. long, seen from behind. (His.)

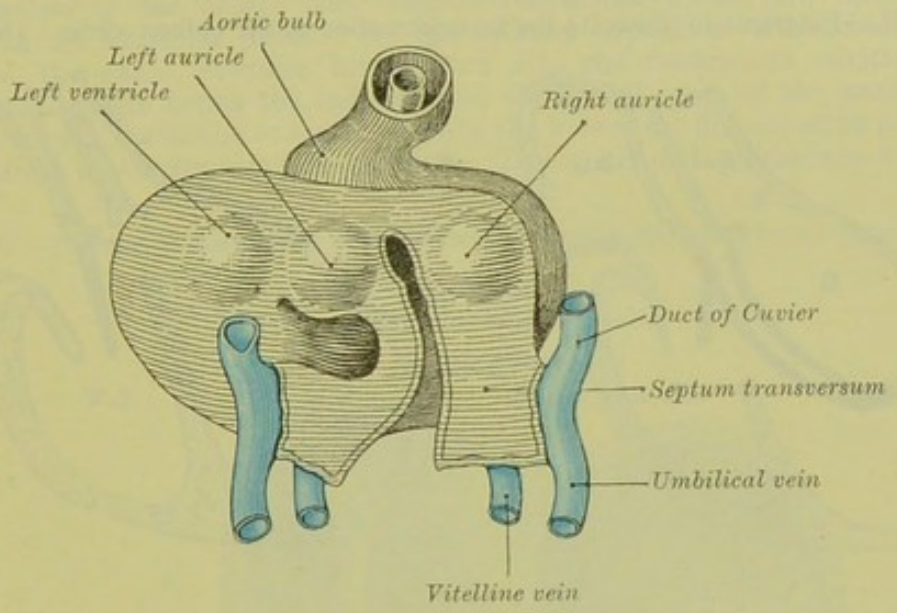

becomes overlapped by the auricles and ventricles so that its position on the surface of the heart is indicated only by an annular constriction (fig. 184). Its lumen is reduced to a transverse slit, and two thickenings appear, one on its dorsal and another on its ventral wall. These thickenings, or *endocardial cushions* (fig. 189) as they are termed, project into the canal, and, meeting in the middle line, unite to form the *septum intermedium* which divides the canal into two channels, the future right and left auriculo-ventricular orifices.

Fig. 186.—Diagrams to show the development of the septum of the aortic bulb and of the ventricles. (Born.)

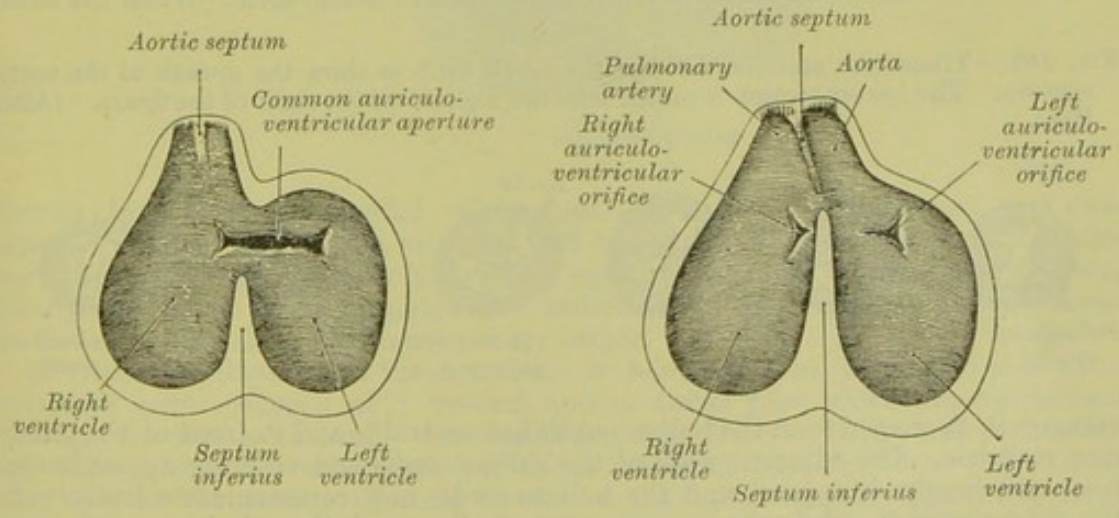

The primitive auricular cavity becomes subdivided into right and left auricles by an incomplete septum, the *septum primum* (fig. 189), which grows downwards into the auricular cavity. For a time the two auricles communicate with each other by an opening, the ostium primum of Born, below the free margin of the septum. This opening is, however, closed by the union of the septum primum with the septum intermedium, and the communication between the auricles

is re-established through an opening which is developed in the upper part of the septum primum; this opening is known as the foramen ovale (ostium secundum of Born) and persists until birth. A second septum, the *septum secundum*, semilunar in shape, grows downwards from the upper wall of the auricle to the right of the primary septum and foramen ovale. Shortly after birth it fuses with the primary septum, and by this means the foramen ovale is closed, but sometimes the fusion is incomplete and the upper part of the foramen remains patent. The annulus ovalis denotes the free margin of the septum secundum.

FIG. 187.—Diagrams to illustrate the transformation of the bulbus cordis. (Keith.)

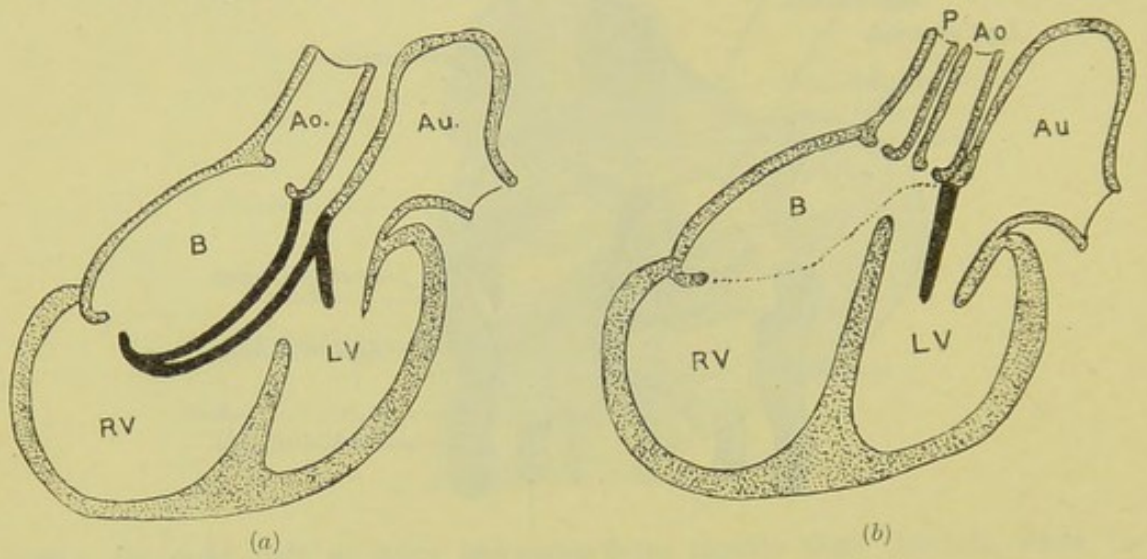

Ao, Primitive aortic stem. *Au*, auricle. *B*, Bulbus cordis. *RV*, Right ventricle. *LV*, Left ventricle. *P*, Pulmonary artery.

The primitive ventricle becomes divided by a septum, the *septum inferius* or *ventricular septum* (figs. 186, 189), which grows upwards from the lower part of the ventricle, its position being indicated on the surface of the heart by a furrow. Its dorsal part grows more rapidly than its ventral portion, and fuses with the dorsal part of the septum intermedium. For a time an interventricular foramen exists above its ventral portion, but this foramen is ultimately closed by the fusion of the aortic septum with the ventricular septum.

As already stated, the aortic bulb consists of a proximal muscular portion, the bulbus cordis, and a distal portion, the primitive aortic stem. When the heart

FIG. 188.—Transverse sections through the aortic bulb to show the growth of the aortic septum. The lowest section is on the left, the highest on the right of the figure. (After His.)

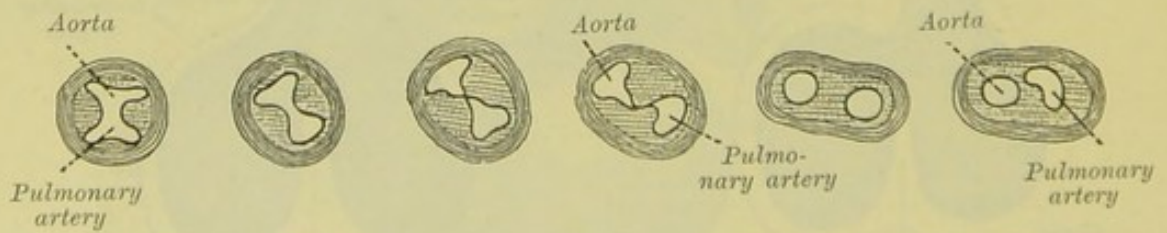

assumes its S-shaped form the bulbus cordis lies ventral to and in front of the primitive ventricle. The adjacent walls of the bulbus cordis and ventricle approximate, fuse, and finally disappear, and the bulbus cordis now communicates freely with the right ventricle, while the junction of the bulbus with the primitive aortic stem is brought directly ventral to and applied to the auricular canal. By the upgrowth of the ventricular septum the bulbus cordis is in great measure separated from the left ventricle, but remains an integral part of the right ventricle, of which it forms the infundibulum (fig. 187).

The primitive aortic stem is divided by the *aortic septum* (fig. 186). This makes its appearance as two ridge-like thickenings which project into the lumen

of the tube; these increase in size, and ultimately meet and fuse to form the septum, and thus the primitive aortic stem is divided into the pulmonary artery and the aorta. The aortic septum takes a spiral course towards the proximal end of the stem, so that the two vessels lie side by side above, but near the heart the pulmonary artery is in front of the aorta (fig. 188). The septum grows down into the ventricle as an oblique partition, which ultimately blends with the ventricular septum in such a way as to bring the bulbus cordis into communication with the pulmonary artery, and through the latter with the sixth pair of aortic arches; while the left ventricle is brought into continuity with the aorta, which communicates with the remaining aortic arches.

The valves of the heart.—The auriculo-ventricular valves are developed in relation to the auricular canal. By the upward expansion of the bases of the ventricles the canal becomes invaginated into the ventricular cavities. The invaginated margin forms the rudiments of the lateral cusps of the auriculo-ventricular valves; the mesial or septal cusps of the valves are developed as downward prolongations of the septum intermedium. The aortic and pulmonary valves are

FIG. 189.—Interior of dorsal half of heart from a human embryo 10 mm. long. (His.)

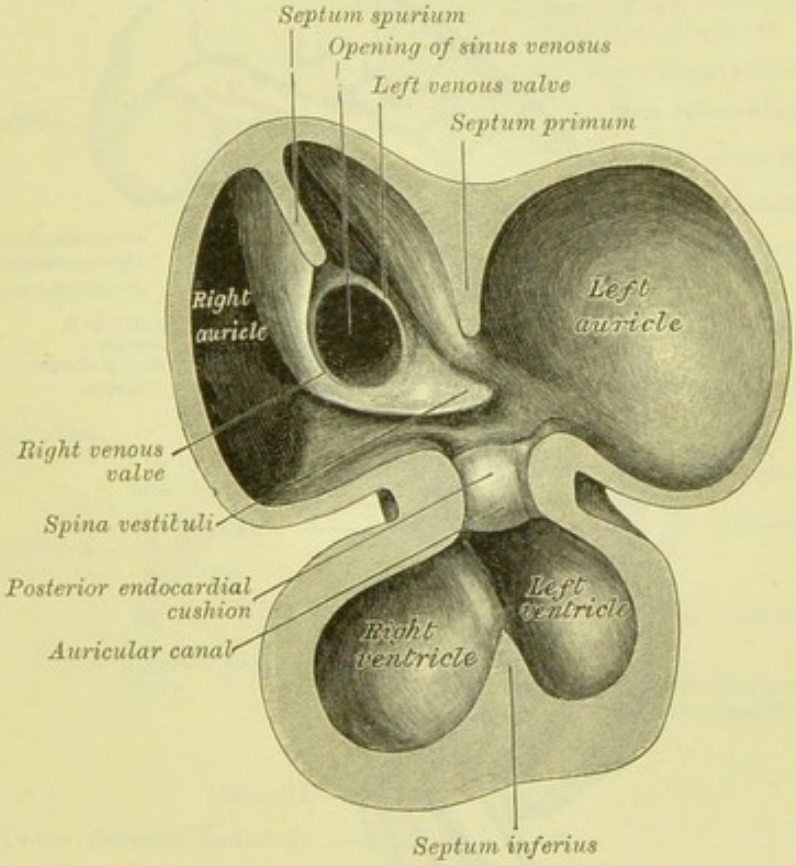

formed from four endocardial thickenings—an anterior, a posterior, and two lateral—which appear at the proximal end of the primitive aortic stem. As the aortic septum grows downwards it divides each of the lateral thickenings into two, thus giving rise to six thickenings—the rudiments of the semilunar valves—three at the aortic and three at the pulmonary orifice.

Further Development of the Arteries.—It has been seen (page 136) that each primitive aorta consists of a ventral and a dorsal part which are continuous through the first aortic arch. The dorsal aortæ at first run backwards separately on either side of the notochord, but about the third week they fuse from about the level of the fourth thoracic to that of the fourth lumbar segment to form a single trunk, the descending aorta. The first aortic arches pass through the mandibular arches, and behind them five additional pairs are developed within the visceral arches; so that, in all, six pairs of aortic arches are formed (fig. 191). The first and second arches pass between the ventral and dorsal aortæ, while the others arise at first by a common trunk from the aortic bulb, but terminate separately in the dorsal aortæ. As the neck elongates, the ventral

aortæ are drawn out, and the third and fourth arches arise directly from these vessels.

In fishes these arches persist and give off branches to the gills, in which the blood is oxygenated. In mammals some of them remain as permanent structures, while others disappear or become obliterated (fig. 191).

The anterior ventral aortæ.—These persist on both sides. The right forms (*a*) the innominate artery, (*b*) the right common and external carotid arteries. The left gives rise to (*a*) the short portion of the aortic arch, which reaches from the origin of the innominate artery to that of the left common carotid artery; (*b*) the left common and external carotid trunks.

The aortic arches.—The first and second disappear; the third constitutes the commencement of the internal carotid artery, and is therefore named the *carotid*

FIG. 190.—Profile view of a human embryo estimated at twenty or twenty-one days old. (After His.)

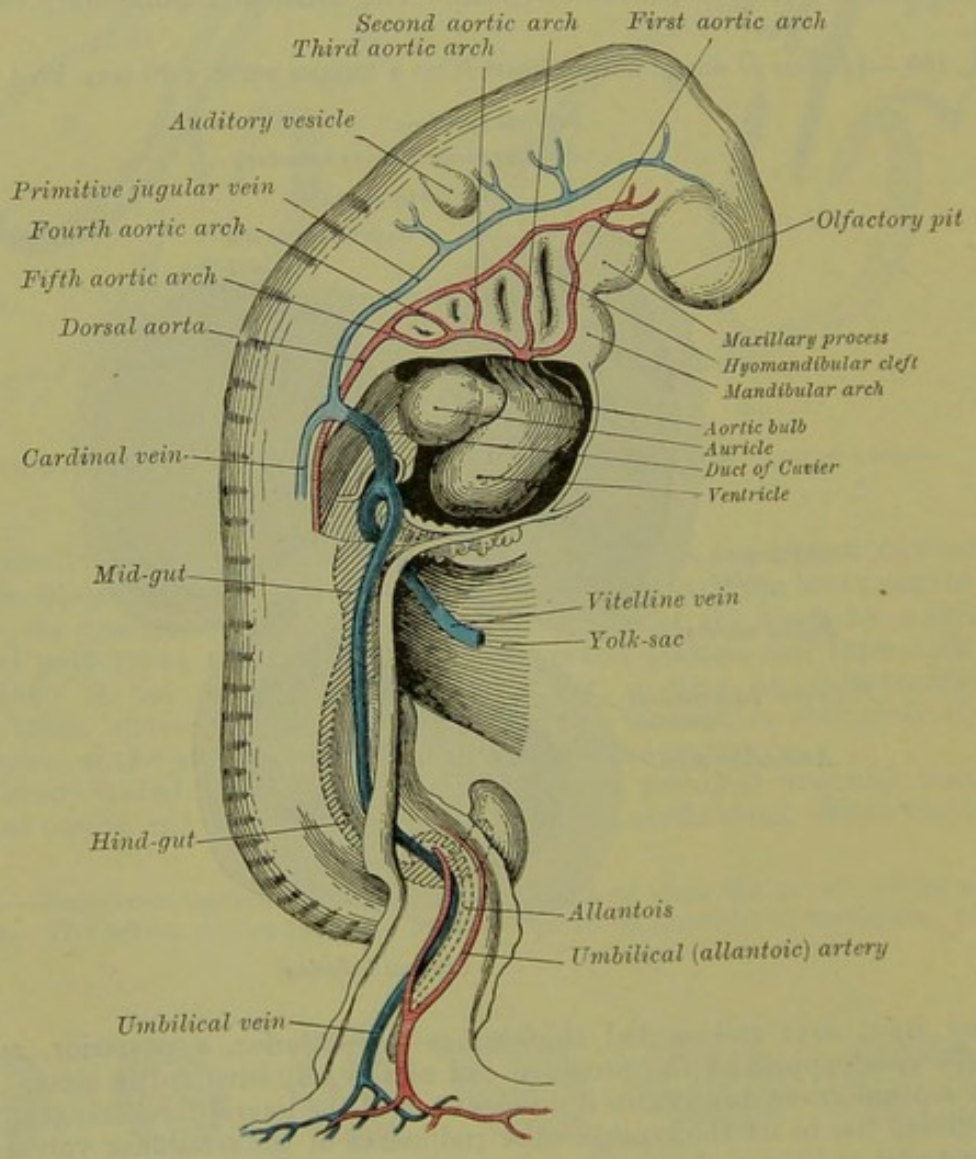

arch. The fourth right arch forms the right subclavian as far as the origin of its internal mammary branch; while the fourth left arch constitutes the arch of the aorta between the origin of the left carotid artery and the termination of the ductus arteriosus. The fifth arch disappears on both sides. The sixth right arch disappears; the sixth left arch gives off the pulmonary arteries and forms the ductus arteriosus; this duct remains pervious during the whole of fœtal life, but a few days after birth becomes obliterated. His found that in the early embryo the right and left arches each gives a branch to the lungs, but that later both pulmonary arteries take origin from the left arch.

The dorsal aortæ.—In front of the third aortic arches the dorsal aortæ persist and form the forward continuation of the internal carotid arteries. Behind the

third arch the right dorsal aorta disappears as far as the point where the two dorsal aortæ fuse to form the descending aorta. The part of the left dorsal aorta which intervenes between the third and fourth arches disappears, while the remainder persists to form the descending part of the arch of the aorta. A constriction, the *aortic isthmus*, is sometimes seen in the aorta between the origin of the left subclavian and the attachment of the ductus arteriosus.

Sometimes the right subclavian artery arises from the aortic arch beyond the origin of the left subclavian and passes upwards and to the right behind the trachea and œsophagus. This condition may be explained by the persistence of the right dorsal aorta and the obliteration of the fourth right arch.

In birds the fourth right arch forms the arch of the aorta; in reptiles the fourth arch on both sides persists and gives rise to the double aortic arch in these animals.

The heart originally lies on the ventral aspect of the pharynx, immediately behind the stomatodæum. With the elongation of the neck and development of the lungs it recedes within the thorax, and, as a consequence, the anterior

Fig. 191.—Scheme of the aortic arches and their destination. (Modified from Kollmann.)

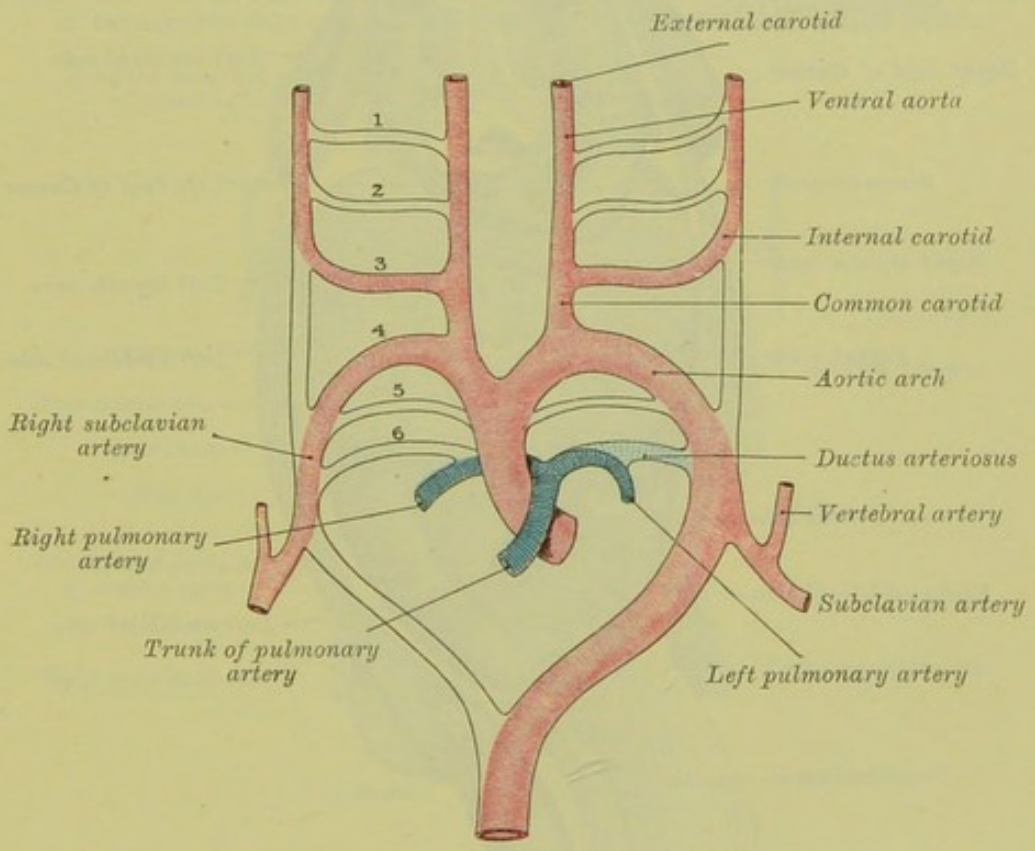

ventral aortæ are drawn out and the original position of the fourth and fifth arches is greatly modified. Thus, on the right side the fourth recedes to the root of the neck, while on the left side it is withdrawn within the thorax. The recurrent laryngeal nerves originally pass to their distribution under the sixth pair of arches, and are therefore pulled backwards with the descent of these structures, so that in the adult the left hooks round the ductus arteriosus; owing to the disappearance of the fifth and the sixth right arches the right nerve hooks round that immediately above them, i.e. the commencement of the subclavian artery. A series of segmental arteries arises from the primitive dorsal aortæ, those in the neck alternating with the cervical segments of the spine. The seventh segmental artery which lies between the sixth and seventh cervical segments is of special interest, since it forms the lower part of the vertebral artery and, when the forelimb bud appears, sends a branch to it (i.e. the subclavian artery); the upper part of the vertebral artery is formed by an inter-segmental anastomosis between the higher segmental arteries. From the seventh segmental arteries the entire left subclavian and the greater part of the right subclavian are formed.

The subclavian artery is prolonged into the limb under the names of the axillary and brachial arteries, and these together constitute the arterial stem for the upper arm. The direct continuation of this stem in the forearm forms the anterior interosseous artery ; while the radial and ulnar vessels, which ultimately exceed this artery in size, are in reality lateral branches of the main stem.

The formation of the primary caudal arches has already been referred to (page 136), and the fusion of the dorsal aortæ to form the greater part of the systemic aorta has been pointed out (page 135). The middle sacral artery of the adult was formerly regarded as the direct continuation of the adult aorta, but Young and Robinson (*op. cit.*) maintain that it 'is a secondary branch, probably representing fused segmental arteries.' They have also pointed out that while the dorsal and ventral extremities of the primary caudal arches remain, their middle portions 'disappear and are replaced by "secondary" caudal arches

FIG. 192.—Human embryo with heart and anterior body wall removed to show the sinus venosus and its tributaries. (After His.) (From Kollmann's 'Entwickelungsgeschichte.')

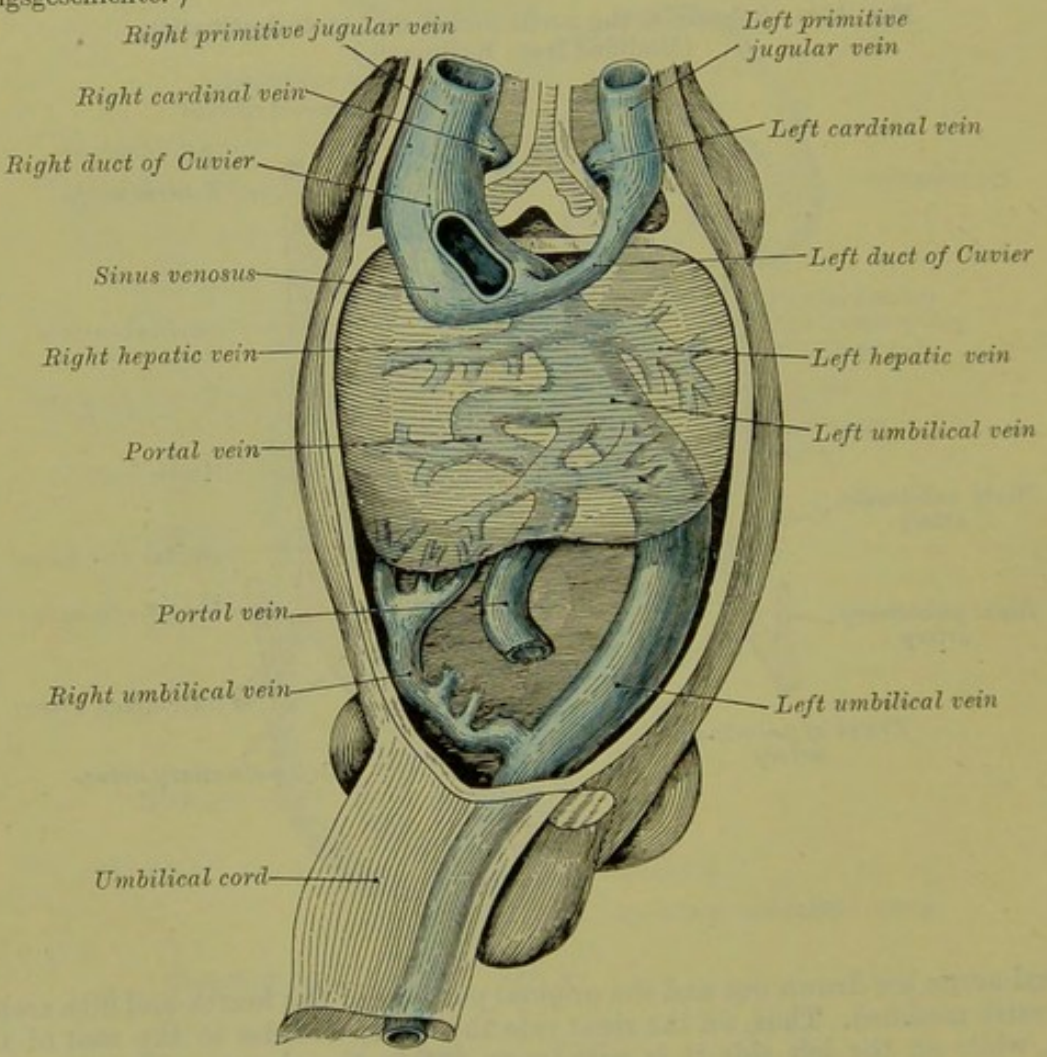

which lie to the outer sides of the Wolffian ducts.' 'The vessels which are to be looked upon as the posterior continuations of the primitive aorta in the adult in man, rodents, &c., are the common iliac, internal iliac, and hypogastric arteries.'

The hypogastric arteries are continued into the umbilical cord as the umbilical arteries. After birth they become obliterated from the umbilicus as far as the origin of the superior vesical arteries.

The primary arterial stem for the lower limb is formed by the sciatic artery, which accompanies the great sciatic nerve along the posterior aspect of the thigh to the back of the knee, whence it is continued as the peroneal artery. This arrangement exists in reptiles and amphibians. The femoral artery arises later as a branch of the common iliac, and, passing down the front and inner side of the thigh to the bend of the knee, joins the sciatic artery. The femoral quickly enlarges, and, coincidently with this, the part of the sciatic immediately above the

knee undergoes atrophy. The anterior and posterior tibial arteries are branches of the main arterial stem.

Further development of the Veins.—The formation of the great veins of the embryo may be best considered by dividing them into two groups, visceral and parietal.

The *visceral veins* are the two vitelline or omphalo-mesenteric veins bringing the blood from the yolk-sac, and the two umbilical or allantoic veins returning the blood from the placenta ; these four veins open close together into the sinus venosus (fig. 194).

The vitelline veins run upwards at first in front, and subsequently on either side of the intestinal canal. They unite on the ventral aspect of the canal, and beyond this are connected to one another by two cross branches, the first on the dorsal, the second on the ventral aspect of the duodenal portion of the intestine which is thus encircled by two venous rings (fig. 193). The portions of the veins above the upper ring become invaded by the developing liver and broken up by it into a plexus of small capillary-like vessels termed *sinusoids* (Minot). The branches conveying the blood to this plexus are named

Fig. 193.—The liver and the veins in connection with it, of a human embryo, twenty-four or twenty-five days old, as seen from the ventral surface. (After His.)

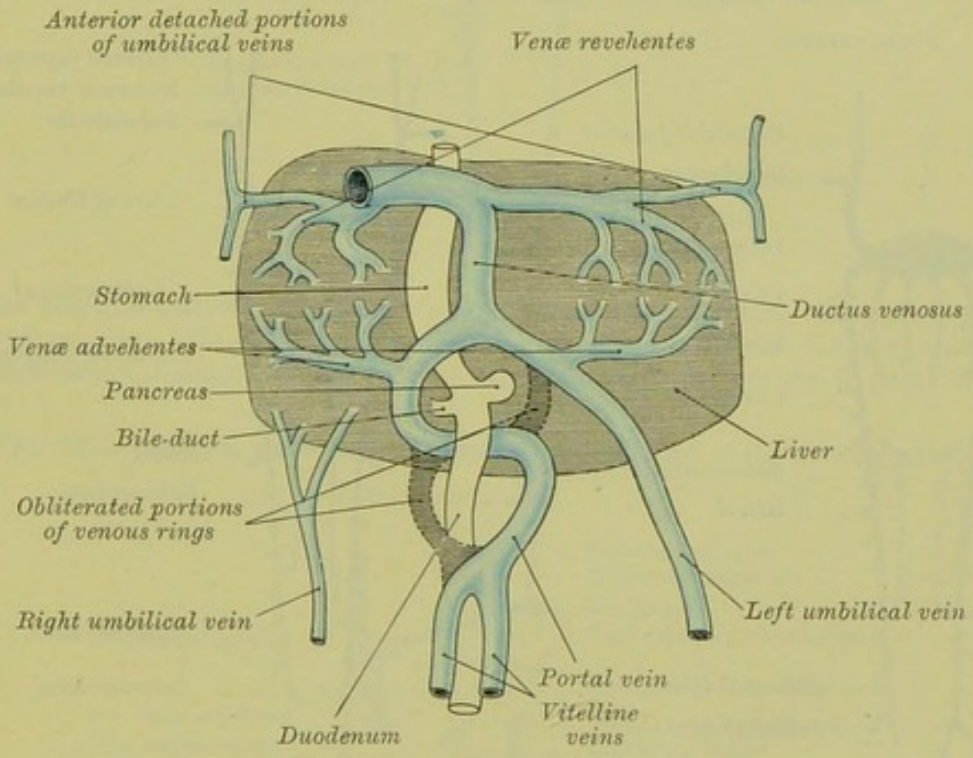

the *venæ advehentes*, and become the branches of the portal vein ; while the vessels draining the plexus into the sinus venosus are termed the *venæ revehentes*, and form the future hepatic veins (figs. 192 and 193). Ultimately the left vena revehens no longer communicates directly with the sinus venosus, but opens into the right vena revehens. The lower part of the *portal vein* is formed from the fused vitelline veins which receive the veins from the alimentary canal ; its upper part is derived from the venous rings by the persistence of the left half of the lower and the right half of the upper ring, so that the vessel forms a spiral turn round the duodenum (fig. 193).

The two umbilical veins fuse early to form a single trunk in the body-stalk, but remain separate within the embryo and pass forwards to the sinus venosus in the side walls of the body. Like the vitelline veins, their direct connection with the sinus venosus becomes interrupted by the invasion of the liver, and thus at this stage the whole of the blood from the yolk-sac and placenta passes through the substance of the liver before it reaches the heart. The right umbilical vein shrivels and disappears ; the left, on the other hand, becomes enlarged and opens into the upper venous ring of the vitelline veins.

Finally a direct branch is established between this ring and the right hepatic vein; this branch is named the *ductus venosus*, and, enlarging rapidly, it forms a wide channel through which most of the blood, returned from the placenta, is carried direct to the heart without passing through the liver. A small proportion of the blood from the placenta is, however, conveyed from the left umbilical vein to the liver through the left vena advehens. The left umbilical vein and the ductus venosus undergo atrophy and obliteration after birth, and form respectively the ligamentum teres and ligamentum venosum of the liver.

The parietal veins.—The first indication of a parietal system consists in the appearance of two short transverse veins (the *ducts of Cuvier*), which open, one on either side, into the sinus venosus. Each of these ducts receives an ascending and descending vein. The ascending veins return the blood from the parietes of the trunk and from the Wolffian bodies, and are called *cardinal* veins. The descending veins return the blood from the head, and are called *primitive jugular* veins (fig. 190). The blood from the lower limbs is collected by the right and left iliac veins, which, in the earlier stages of development, open into the corresponding right and left cardinal veins (fig. 190); later on, a transverse branch (the left common iliac vein) is developed between the lower parts of the

FIG. 194.—Scheme of arrangement of parietal veins.

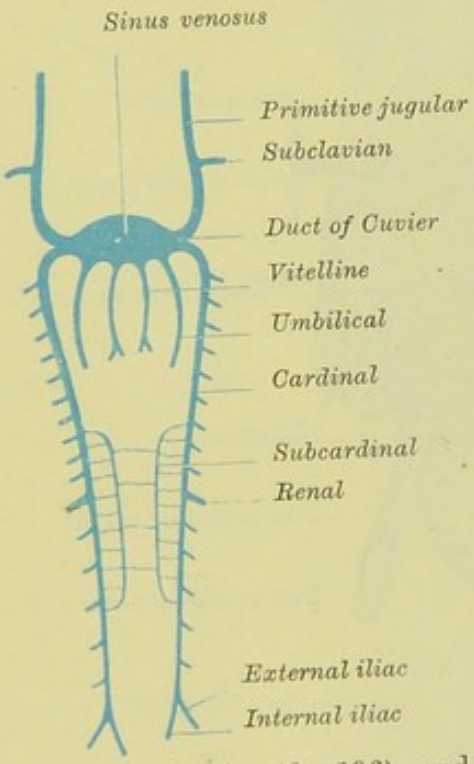

FIG. 195.—Scheme showing early stages of development of the inferior vena cava.

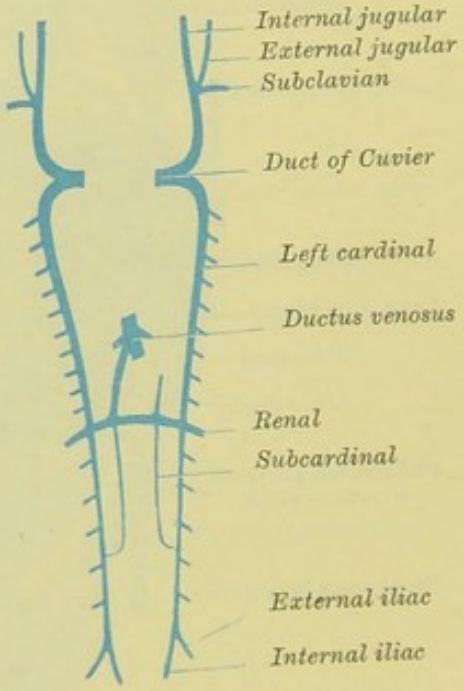

two cardinal veins (fig. 196), and through this the blood is carried into the right cardinal vein. The portion of the left cardinal vein below the left renal vein atrophies and disappears up to the point of entrance of the left spermatic vein; the portion above the left renal vein persists as the superior and inferior azygos minor veins and the lower portion of the left superior intercostal vein. The right cardinal vein, which now receives the blood from both lower extremities, forms a large venous trunk along the posterior abdominal wall; up to the level of the renal veins it forms the lower part of the inferior vena cava. Above the level of the renal veins the right cardinal vein persists as the vena azygos major, and receives the right intercostal veins, while the azygos minor veins are brought into communication with it by the development of transverse branches in front of the vertebral column (figs. 196, 197).

Inferior vena cava.—The development of the inferior vena cava is associated with the formation of two veins, the *subcardinal veins* (figs. 194 and 195). These lie parallel to, and on the ventral aspect of, the cardinal veins, and originate as longitudinal anastomosing channels which link up the tributaries from the mesentery to the cardinal veins; they communicate with the cardinal veins above and below, and also by a series of transverse branches. The two

subcardinals are for a time connected with each other in front of the aorta by cross branches, but these disappear and are replaced by a single transverse channel at the level where the renal veins join the cardinals, and at the same level

Fig. 196.—Diagram showing development of main cross branches between jugulars and between cardinals.

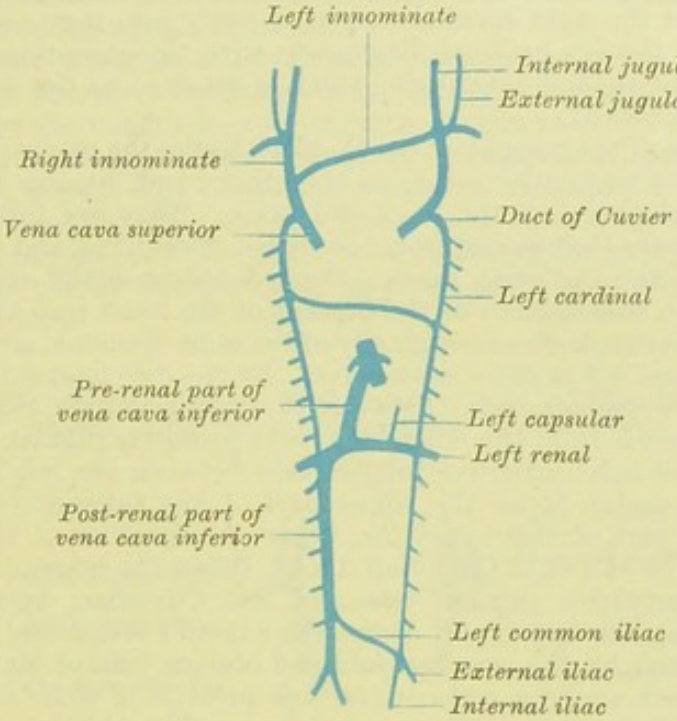

a cross communication is established on either side between the cardinal and subcardinal (fig. 195). The portion of the right subcardinal behind this cross communication disappears, while that in front (i.e. the pre-renal part) forms a

Fig. 197.—Diagram showing completion of development of the parietal veins.

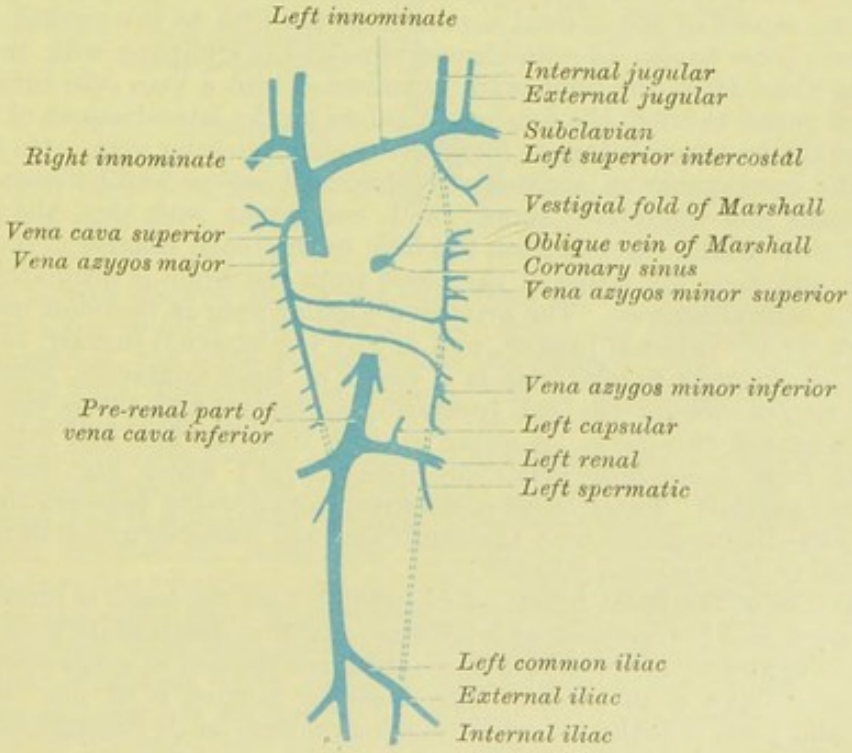

connection with the ductus venosus at the point of opening of the hepatic veins, and, rapidly enlarging, receives the blood from the post-renal part of the right cardinal through the cross communication referred to. In this manner a single

trunk, the *inferior vena cava* (fig. 197), is formed, and consists of the proximal part of the ductus venosus, the pre-renal part of the right subcardinal vein, the post-renal part of the right cardinal vein, and the cross branch which joins these two veins. The left subcardinal disappears, except the part immediately in front of the renal vein, which is retained as the left suprarenal vein. The spermatic (or ovarian) vein opens into the post-renal part of the corresponding cardinal vein. This portion of the right cardinal, as already explained, forms part of the inferior vena cava, so that the right spermatic opens directly into that vessel. The post-renal segment of the left cardinal disappears, with the exception of the portion between the spermatic and renal vein, which is retained as the proximal part of the left spermatic vein.

In consequence of the atrophy of the Wolffian bodies the cardinal veins diminish in size; the primitive jugular veins, on the other hand, become enlarged, owing to the rapid development of the head and brain. They are further augmented by receiving the veins (*subclavian*) from the upper extremities, and so come to form the chief veins of the Cuvierian ducts; these ducts gradually assume an almost vertical position in consequence of the descent of the heart into the thorax. The right and left Cuvierian ducts are originally of the same diameter, and are frequently termed the *right* and *left superior venæ cavæ*. By the development of a transverse branch (the *left innominate vein*) between the two primitive jugular veins, the blood is carried across from the left to the right primitive jugular (figs. 196, 197). The portion of the right primitive jugular vein between the left innominate and the vena azygos major forms the upper part of the superior vena cava of the adult; the lower part of this vessel (i.e. below the entrance of the vena azygos major) is formed by the right Cuvierian duct. Below the origin of the transverse branch the left primitive jugular vein and left Cuvierian duct atrophy, the former constituting the upper part of the left superior intercostal vein, while the latter is represented by the vestigial fold and oblique vein of Marshall (fig. 197). Both right and left superior venæ cavæ are present in some animals, and are occasionally found in the adult human being. The oblique vein of Marshall passes downwards across the back of the left auricle to open into the coronary sinus, which, as already indicated, represents the persistent left horn of the sinus venosus.

The primitive jugular or anterior cardinal veins are situated on the ventral surface of the brain, on the mesial side of the cranial nerve-roots. A considerable portion of each of these veins disappears and is replaced by a vein which is developed on the lateral aspect of the cranial nerves from the fifth to the twelfth inclusive. This new vein (*vena capitis lateralis*) leaves the skull in company with the seventh nerve. The blood from the hind-brain is collected into a vein (the future lateral sinus) which passes through the foramen jugulare on the lateral aspect of the vagus nerve; here the two vessels join to form the internal jugular vein. On the dorsal aspect of the ear-capsule an anastomotic channel is opened up between the vena capitis lateralis and the lateral sinus; and, coincident with this, the portion of the former vein which extends from the fifth to the tenth cranial nerve becomes obliterated, and thus the whole of the blood from the brain is ultimately drained away by the lateral sinuses. The primitive jugular vein is therefore represented in the adult by the internal jugular, and not by the external jugular, as is usually stated.* The external jugular vein is a vessel of later formation, which at first drains the region behind the ear (posterior auricular) and enters the primitive jugular as a lateral tributary. A group of veins from the face and lingual region converge to form a common vein, the linguo-facial,† which also terminates in the primitive jugular. Later, cross communications develop between the external jugular and the linguo-facial, with the result that the posterior group of facial veins is transferred to the external jugular.

Peculiarities of the fœtal heart.—In early fœtal life the heart is placed directly under the head and is relatively of large size. Later it assumes its position in the thorax, but lies at first in the middle line; towards the end of pregnancy it gradually becomes oblique in direction. The auricular portion is at first larger than the ventricular part, and the two auricles communicate freely through the foramen

* Consult *Die Entwickelung des Blutgefäss-systems*, by Hochstetter, in Hertwig's *Entwickelungslehre*; and also an article by Mall in the *American Journal of Anatomy*, vol. iv., December 1904.

† Lewis, *American Journal of Anatomy*, vol. ix., No. 1, Feb. 1909.

ovale. In consequence of the communication between the pulmonary artery and the aorta, through the ductus arteriosus, the contents of the right ventricle are mainly carried into the latter vessel instead of to the lungs, and hence the wall of the right ventricle is as thick as that of the left. At the end of fœtal life, however, the left ventricle is thicker than the right, a difference which becomes more and more emphasised after birth.

The fœtal circulation and the changes which take place in the circulation after birth are described on pages 614 to 616.

The lymphatic vessels.—The lymphatic system begins as a series of sacs * at the points of junction of certain of the embryonic veins. These lymph-sacs are developed by the confluence of numerous venous radicles, which at first lose their connections with the venous system, but subsequently, on the formation of the sacs, regain them. The lymphatic system is therefore developmentally an offshoot of the venous system, and the lining walls of its vessels are always endothelial. As already stated in the chapter on Histology (page 61), it forms a closed system, and has not as was formerly supposed any direct communication with tissue clefts or spaces.

Fig. 198.—Scheme showing relative positions of primary lymph-sacs based on the description given by Florence Sabin.

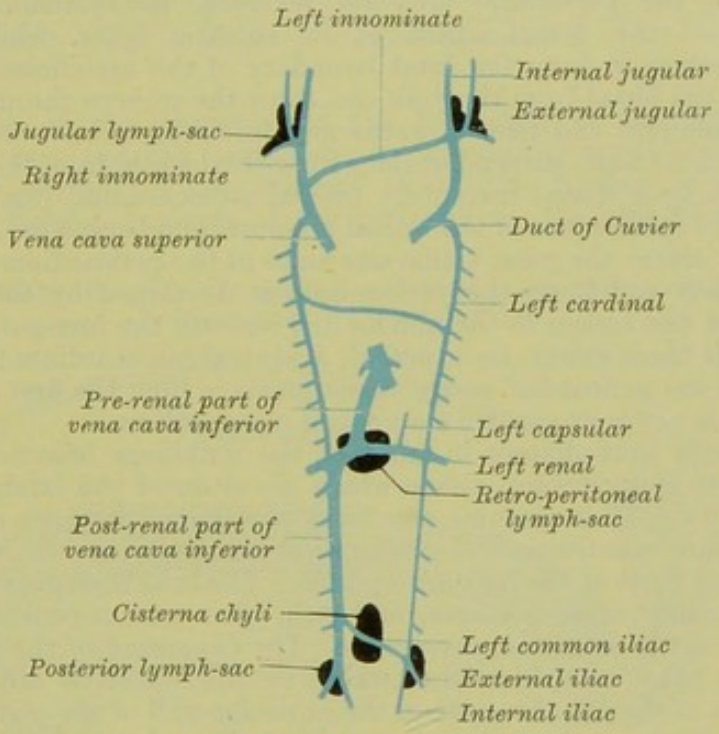

In the human embryo the lymph-sacs from which the lymphatic vessels are derived are six in number : two paired, the jugular and the posterior lymph-sacs ; and two unpaired, the retro-peritoneal and the cisterna chyli. In lower mammals an additional pair, subclavian, is present, but in the human embryo these are merely extensions of the jugular sacs.

The position of the sacs is as follows : (1) jugular sac, at the junction of the subclavian vein with the primitive jugular ; (2) posterior sac, at the junction of the iliac vein with the posterior cardinal ; (3) retro-peritoneal, in the position of the cross branch between the renal veins ; (4) cisterna chyli at the site of the cross branch between the two iliac veins (fig. 198). From the lymph-sacs the lymphatic vessels bud out along fixed lines corresponding more or less closely to the course of the embryonic blood-vessels. They all arise as endothelial outgrowths, which later become canalised. Both in the body wall and in the wall of the intestine,† the deeper plexuses are the first to be developed ; by continued growth of these the vessels in the superficial layers are gradually formed. It is as yet undetermined whether the thoracic duct is formed from anastomosing outgrowths from the jugular sac and cisterna chyli or whether it is developed by the transformation

* Sabin. *American Journal of Anatomy*, vol. ix., No. 1, Feb. 1909. † Heuer. *Ibid.*

of some of the radicles of the azygos veins. At its connection with the cisterna chyli it is at first double, but the right vessel soon joins with the left.

All the lymph-sacs except the cisterna chyli are, at a later stage, divided up by slender connective tissue bridges and transformed into groups of lymphatic glands. The lower portion of the cisterna chyli is similarly converted, but its upper portion remains as the receptaculum chyli.

The Pericardium.—As already pointed out (page 87), the anterior portion of the embryonic area in front of the oral plate or bucco-pharyngeal membrane is named the pericardial area. Previous to the formation of the head-fold the mesoderm has divided into its somatic and splanchnic layers, and these two layers, together with the intervening cœlomic space, extend forwards on either side of the bucco-pharyngeal membrane into the pericardial area ; the part of the cœlom contained within this area becomes the cavity of the pericardium. This is, at first, in the shape of a crescent, the lateral horns of which extend backwards on either side of the bucco-pharyngeal membrane and are continuous with the pleuro-peritoneal part of the cœlomic space. The primitive blood-vessels, which, in the pericardial region, fuse to form the primitive heart, are developed in the splanchnic mesoderm of the pericardial area. By the rapid elongation of the embryo, and the formation of the head-fold, the pericardial area and its contained blood-vessels are folded backwards to form the ventral wall of the fore-gut. By means of this process the surfaces of the pericardial area are reversed, its splanchnic layer being now situated on the dorsal aspect of its somatic layer, while its original anterior limit comes to form the front boundary of the umbilicus. The vitelline veins, bringing the blood from the yolk-sac, enter the embryo through the anterior wall of the umbilicus and pass upwards and forwards to open into the tubular heart, which is, for a time, suspended along its entire length, from the ventral aspect of the fore-gut, by a dorsal mesentery (dorsal mesocardium) (fig. 225). By the absorption of the middle part of this dorsal mesocardium behind the ascending aorta and pulmonary artery the great transverse sinus of the pericardium is formed.

In amphibians and birds the pericardium is developed by the fusion of the lateral halves of the cœlom in the middle line beneath the fore-gut, and therefore in these animals there exists, for a period, a ventral mesocardium ; but Robinson has shown that the pericardial cavity in mammals is from the first a single cavity, and that there is never at any time a ventral mesocardium.

The mesoderm immediately in front of the umbilicus becomes thickened to form the septum transversum, above which are situated the lateral horns of the pericardial cavity. These assume the form of tubular passages on the sides of the fore-gut, and constitute the communications between the pericardial and pleuro-peritoneal parts of the cœlom (fig. 225). The lung buds grow out behind the ducts of Cuvier into these passages, and push their way outwards and forwards into the tissue of the septum transversum. The expansion of the pleural cavities therefore takes place in the septum, which by this means is differentiated into the central part of the Diaphragm and the posterior wall of the pericardium. The anterior limit of the septum transversum is indicated by the Cuvierian ducts (superior venæ cavæ), by the growth of which the passages between the pericardium and pleuræ are closed.

DEVELOPMENT OF THE ALIMENTARY AND RESPIRATORY SYSTEMS

The Alimentary Canal.—As already indicated (page 92), the primitive alimentary canal consists of three parts, viz. : (1) the *fore-gut*, within the cephalic flexure, and dorsal to the heart ; (2) the *mid-gut*, opening freely into the yolk-sac ; and (3) the *hind-gut*, within the caudal flexure (figs. 199, 200). At first the fore-gut and hind-gut end blindly. The anterior end of the fore-gut is separated from the stomatodæum by the pharyngeal septum (fig. 201) ; the hind-gut terminates posteriorly in the cloaca, which is closed externally by the cloacal membrane.

The pharynx, œsophagus, stomach, and greater part of the duodenum are developed from the fore-gut,* while the liver and pancreas are formed as diverticula

* The level of the opening of the common bile-duct is usually regarded as the junction of the fore-gut with the mid-gut.

from the duodenum; the descending, iliac, and pelvic parts of the colon, the rectum, and the tubular stalk of the allantois are developed from the hind-gut; the mid-gut gives origin to the remainder of the alimentary tube.

The **mouth.** — The mouth is developed partly from the stomatodæum, and partly from the floor of the anterior portion of the fore-gut. By the growth

Fig. 199.—Diagrammatic outline of a sagittal section of the chick on the fourth day. (From Quain's 'Anatomy,' Allen Thomson.)

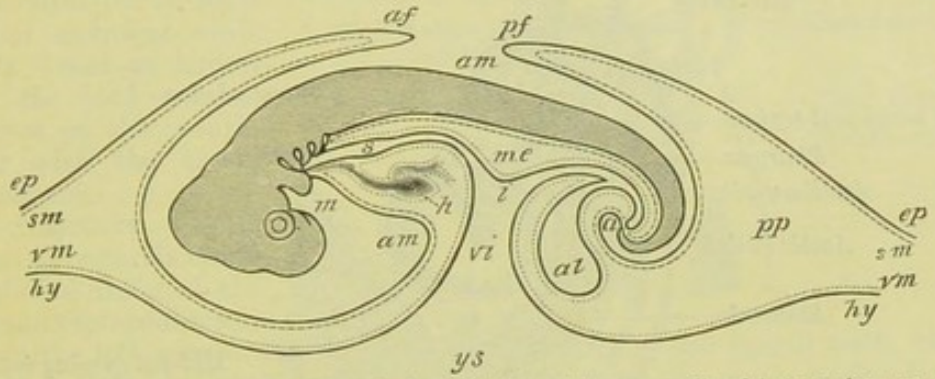

a. future anus, still closed; *af.* cephalic fold; *al.* the allantoic vesicle; *am.* cavity of true amnion; *ep.* ectoderm; *h.* heart; *hy.* entoderm; *l.* intestine; *m.* the mouth; *me.* the mesentery; *pf.* caudal fold; *pp.* space between inner and outer folds of amnion; *s.* fore-gut; *sm.* somatic mesoderm; *vi.* vitelline duct; *vm.* splanchnic mesoderm; *ys.* yolk-sac.

of the head end of the embryo, and the formation of the cephalic flexure, the pericardial area and the oral plate or bucco-pharyngeal area come to lie on the ventral surface of the embryo. With the further expansion of the brain, and the bulging forwards of the pericardium, the oral plate is depressed

Fig. 200.—Diagram of a sagittal section of a mammalian embryo. Very early. (After Quain.)

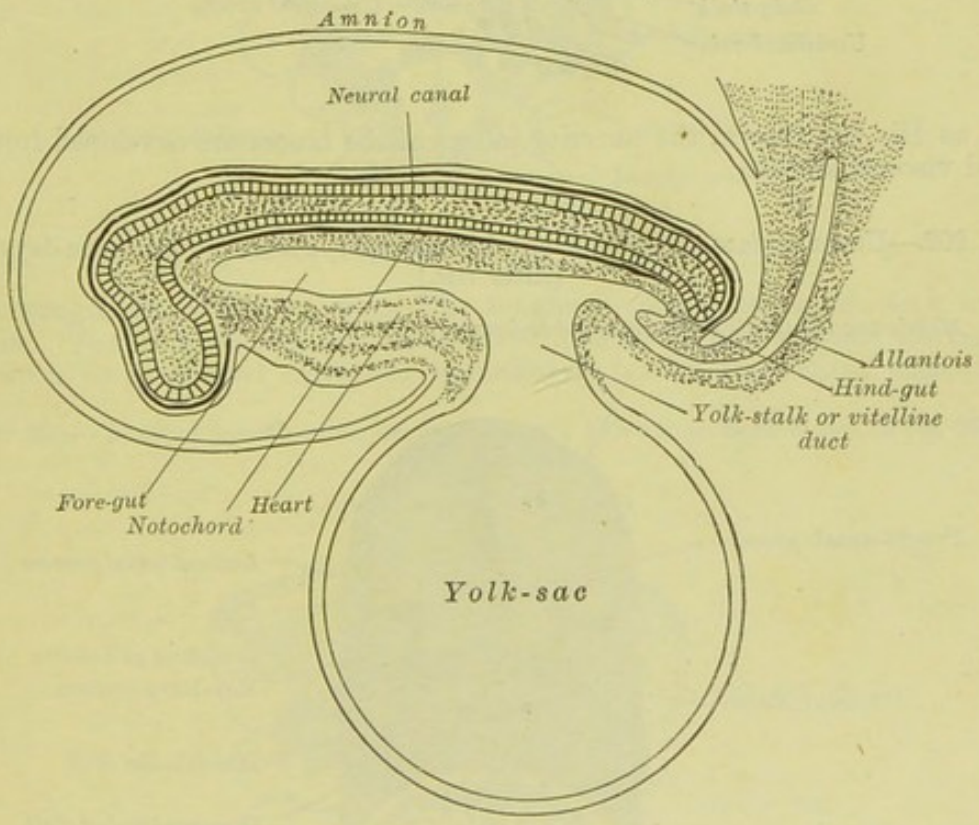

between these two prominences. This depression constitutes the *stomatodæum* (fig. 201). It is lined by ectoderm, and is separated from the anterior end of the fore-gut by the oral plate, which is now named the *pharyngeal septum* (fig. 201). This septum is devoid of mesoderm, being formed by the apposition of the stomatodæal ectoderm with the fore-gut entoderm; at the end of a fortnight it

disappears, and thus a communication is established between the mouth and the future pharynx. No trace of the pharyngeal septum is found in the adult; and the communication just mentioned must not be confused with the isthmus faucium,

Fig. 201.—Human embryo about fifteen days old. Brain and heart represented from right side. Alimentary canal and yolk-sac in mesial section. (After His.)

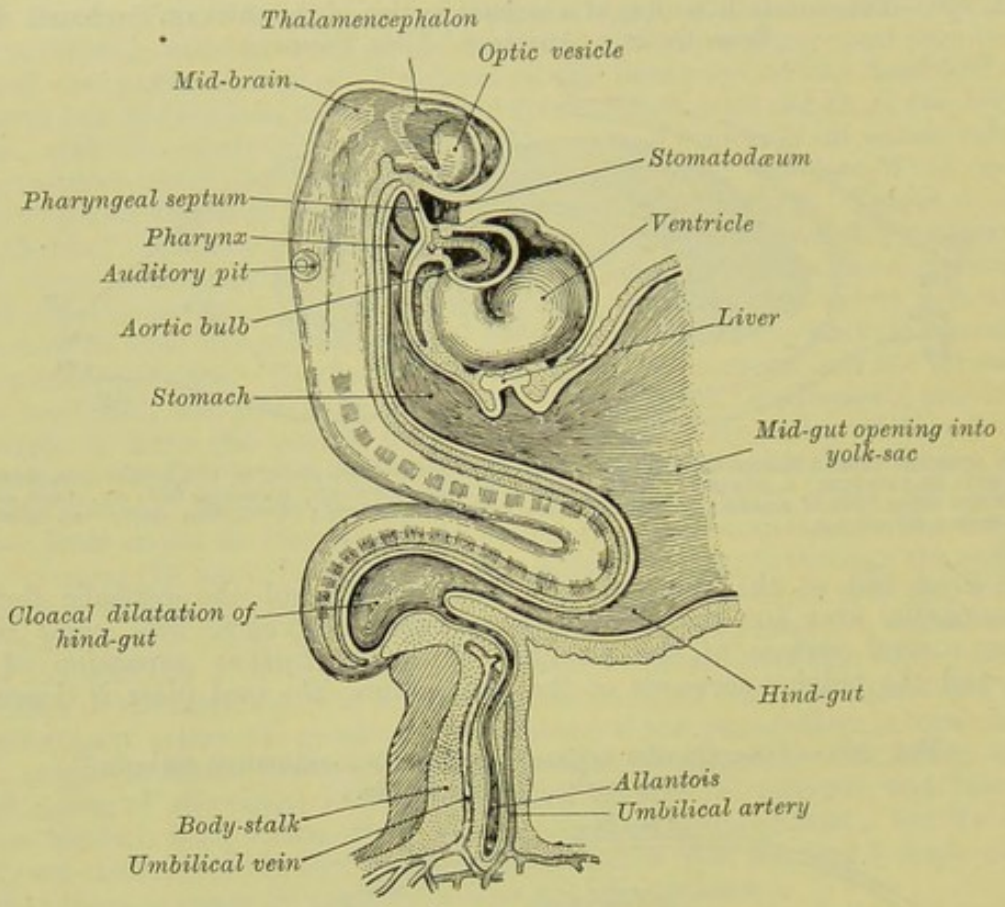

since, as His has shown, the anterior pillars of the fauces are developed from the second visceral arches.

Fig. 202.—Under surface of the head of a human embryo about twenty-nine days old. (After His.)

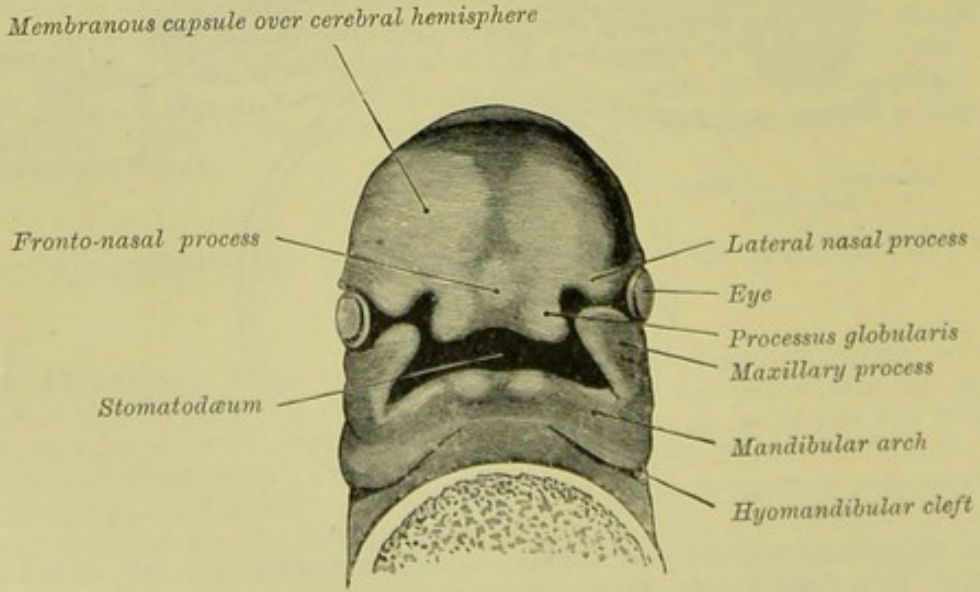

The visceral arches extend in a ventral direction between the stomatodæum and the pericardium; and with the completion of the mandibular arch and the formation of the maxillary processes, the mouth assumes the appearance of a

pentagonal orifice. The orifice is bounded in front by the fronto-nasal process which covers the fore-brain and contains the anterior part of the coalesced trabeculæ cranii, behind by the mandibular arch, and laterally by the maxillary processes (fig. 202). With the inward growth and fusion of the palatal processes (figs. 142, 143), the upper portion of the stomatodæum is shut off to form the nasal cavities, while from its lower or buccal portion the roof and anterior part of the mouth, together with the teeth, are developed.

Fig. 203.—The floor of the pharynx of a human embryo about fifteen days old. × 50. (From His.)

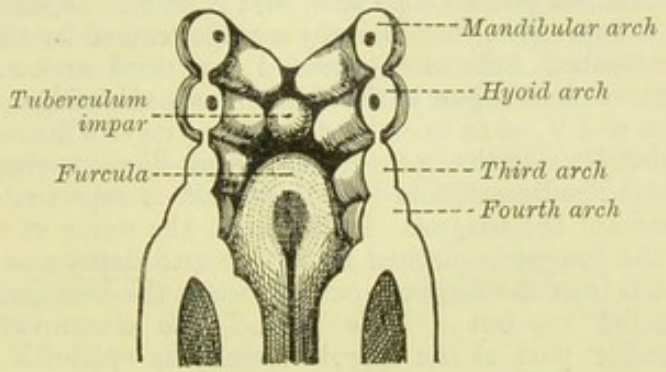

The **salivary glands** arise as diverticula from the epithelial lining of the mouth, and their rudiments appear in the following order, viz. : the parotid during the fourth week, the submaxillary in the sixth week, and the sublingual during the ninth week (Hammar).

Fig. 204.—The floor of the pharynx of a human embryo about twenty-three days old. × 30. (From His.)

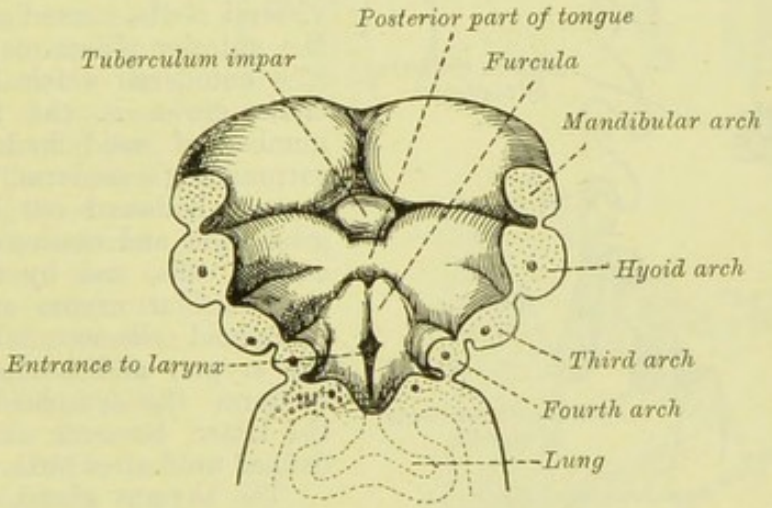

The tongue (figs. 203 to 205).—The tongue is developed in the floor of the pharynx. The rudiment of the anterior or buccal portion appears during the third week as a rounded elevation, immediately behind the ventral ends of the

Fig. 205.—Floor of mouth of an embryo slightly older than that shown in fig. 204. × 16. (From His.)

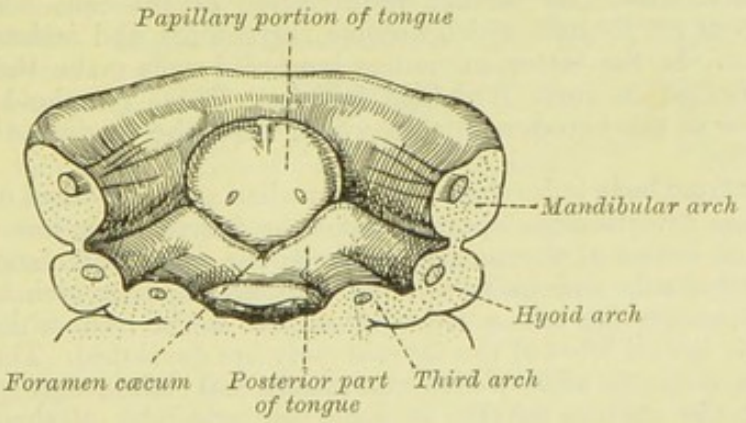

mandibular arches. This elevation is named the *tuberculum impar* (figs. 203 and 204); it extends forwards on the oral surface of the mandibular arch, and increases markedly in size by the development of a pair of lateral tongue-elevations,

which raise themselves from the inner surfaces of the mandibular arches, and, blending with the tuberculum impar, form the tip and greater portion of the buccal part of the tongue. These lateral growths correspond with similar structures which were described by E. Kallius in the development of the tongue of the lizard. From the ventral ends of the fourth arch there arises a second and larger elevation, in the centre of which is a median groove or furrow. This elevation is named the *furcula* (fig. 203), and is at first separated from the tuberculum impar by a depression, but later by a ridge formed by the forward growth and fusion of the ventral ends of the second and third arches. The posterior or pharyngeal part of the tongue is developed from this ridge, which extends forwards in the form of a V, so as to embrace between its two limbs the tuberculum impar (figs. 204 and 205). At the apex of the V a pit-like invagination occurs, to form the middle thyroid rudiment, and this depression is represented in the adult by the *foramen cæcum* of the tongue. In the adult the union of the anterior and posterior parts of the tongue is marked by a V-shaped depression (sulcus terminalis), the apex of which is at the foramen cæcum, while the two limbs run outwards and forwards, parallel to, but a little behind, the circumvallate papillæ. The prominent anterior part of the furcula forms the epiglottis; the furrow behind it is the entrance to the larynx; and the anterior parts of its lateral margins constitute the aryteno-epiglottidean folds.

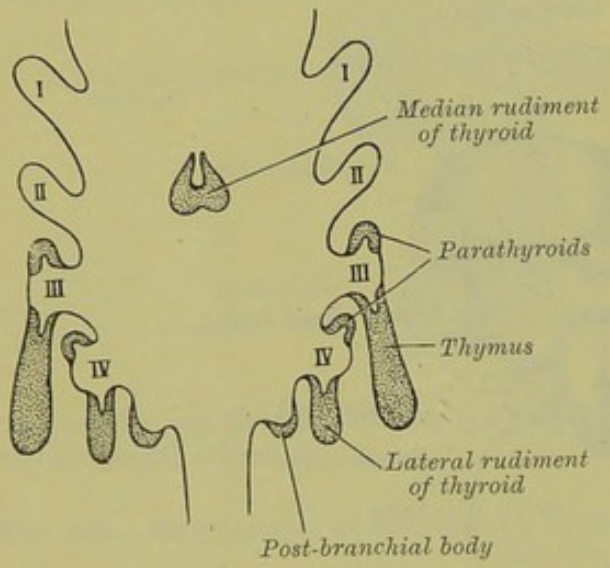

FIG. 206. — Scheme showing development of branchial epithelial bodies. (Modified from Kohn.)

I, II, III, IV, visceral clefts.

The **tonsils** are developed from the lower parts of the second visceral clefts, immediately behind the anterior pillars of the fauces. The entoderm which lines these clefts grows in the form of a number of solid buds into the surrounding mesoderm. These buds become hollowed out by the degeneration and casting off of their central cells, and by this means the tonsillar crypts are formed. Lymphoid cells accumulate around the crypts, and become grouped to form the lymphoid follicles; the latter, however, are not well defined until after birth.

The **thymus gland** appears in the form of two flask-shaped entodermal diverticula, which arise, one on either side, from the third visceral cleft (fig. 206), and extend outwards and backwards into the surrounding mesoderm to meet in front of the ventral aortæ. The pharyngeal opening of each diverticulum is soon obliterated, but the neck of the flask persists for some time as a cellular cord. By further proliferation of the cells which line the flask, buds of cells are formed, which become surrounded and isolated by the invading mesoderm. In the latter, numerous lymphoid cells make their appearance, and are aggregated to form lymphoid follicles. These lymphoid cells are probably derivatives of the entodermal cells which lined the original diverticulum and its subdivisions.

The **thyroid body** is developed from a median and two lateral diverticula (fig. 206). The median diverticulum appears about the fourth week, immediately behind the tuberculum impar of the tongue, between the mandibular and hyoid arches. It grows downwards and backwards as a tubular duct, which bifurcates and subsequently subdivides into a series of cellular cords, from which the isthmus and part of the lateral lobes of the thyroid body are developed. The lateral diverticula arise from the inner aspects of the fourth visceral clefts; they grow backwards and fuse with the median portion to form the remainder of the lateral lobes. The connections of the lateral diverticula with the pharynx disappear early. That of the median rudiment is termed the *thyro-glossal duct*; its continuity is subsequently interrupted by the development of the body of the hyoid bone, and it

undergoes degeneration, its upper end being represented by the foramen cæcum of the tongue, and its lower by the pyramidal lobe of the thyroid body.

The *parathyroid bodies* are developed as outgrowths from the inner aspects of the third and fourth visceral clefts (fig. 206).

A pair of diverticula arise behind the fifth arch and form what are termed the *postbranchial bodies* (fig. 206); these degenerate and disappear at an early stage.

The **pituitary body**, or **hypophysis cerebri**.—This consists of a large anterior, and a small posterior, lobe: the former is derived from the ectoderm of the stomatodæum, the latter from the floor of the fore-brain. About the fourth week there appears a pouch-like diverticulum of the ectodermal lining of the roof of the stomatodæum. This, the pituitary involution or *pouch of Rathke* (fig. 207), is the rudiment of the anterior lobe of the pituitary body; it extends upwards in front of the cephalic end of the notochord and the remnant of the pharyngeal septum, and comes into contact with the under surface of the fore-brain. It is then constricted off to form a closed vesicle, but remains for a time connected to the ectoderm of the stomatodæum by a solid cord of cells. The vesicle sends out hollow processes into the surrounding mesoderm, and is gradually converted into a mass of small, tortuous tubules lined with columnar or cubical cells. The upwardly directed pituitary involution becomes applied to the antero-lateral aspect of a downwardly directed diverticulum from the base of the fore-brain (page 123). This diverticulum constitutes the future infundibulum in the floor of the third ventricle, while its lower extremity becomes modified to form the posterior lobe of the pituitary body. In some of the lower animals the posterior lobe contains nerve-cells and nerve-fibres, but in man and the higher vertebrates these are replaced by connective tissue. A canal (*cranio-pharyngeal canal*) is sometimes found extending from the pituitary fossa to the under surface of the skull, and marks the original position of Rathke's pouch.

FIG. 207.—Vertical section of the head in early embryos of the rabbit. Magnified. (From Mihalkovics.)

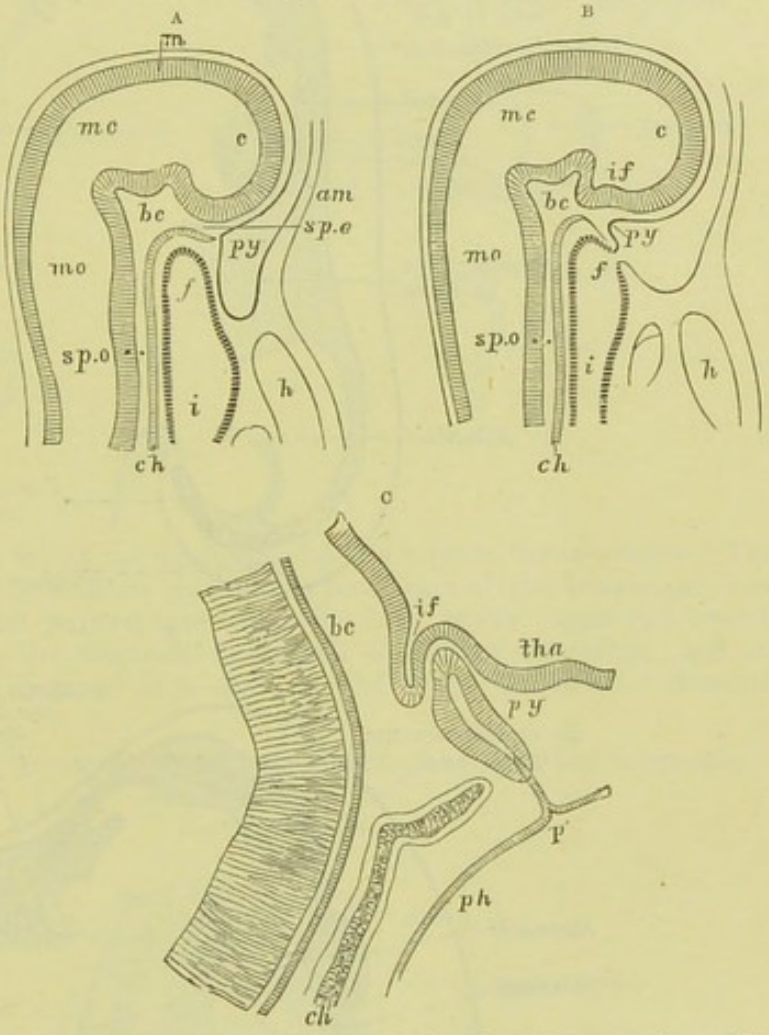

A. From an embryo of five millimetres in length. B. From an embryo of six millimetres in length. C. Vertical section of the anterior end of the notochord and pituitary body, &c., from an embryo sixteen millimetres long. In A the bucco-pharyngeal membrane is still present. In B it is in the process of disappearing, and the stomatodæum now communicates with the primitive pharynx. *am.* Amnion. *c.* Fore-brain. *ch.* Notochord. *f.* Anterior extremity of fore-gut, *i.* *h.* Heart. *if.* Infundibulum. *m.* Wall of brain cavity. *mc.* Mid-brain. *mo.* Hind-brain. *p.* Original position of pituitary diverticulum, *py.* *ph.* Pharynx. *sp.e.* Spheno-ethmoidal; *bc.* Central; and *sp.o.* Spheno-occipital parts of basis cranii. *tha.* Thalamus.

The further development of the alimentary canal.—The upper part of the fore-gut becomes dilated to form the pharynx (fig. 208), in relation to which the branchial arches are developed (fig. 136) (see page 107); the succeeding part remains tubular, and with the descent of the stomach is elongated to form the œsophagus. About the fourth week a fusiform dilatation, the future stomach,

makes its appearance, and beyond this the mid-gut opens freely into the yolk-sac (figs. 208 and 209). The opening is at first wide, but is gradually narrowed into a tubular stalk, the *yolk-stalk* or *vitelline duct*.* At this stage, therefore, the

FIG. 208.—Sketches in profile of two stages in the development of the human alimentary canal. (His.) Fig. A × 30. Fig. B × 20.

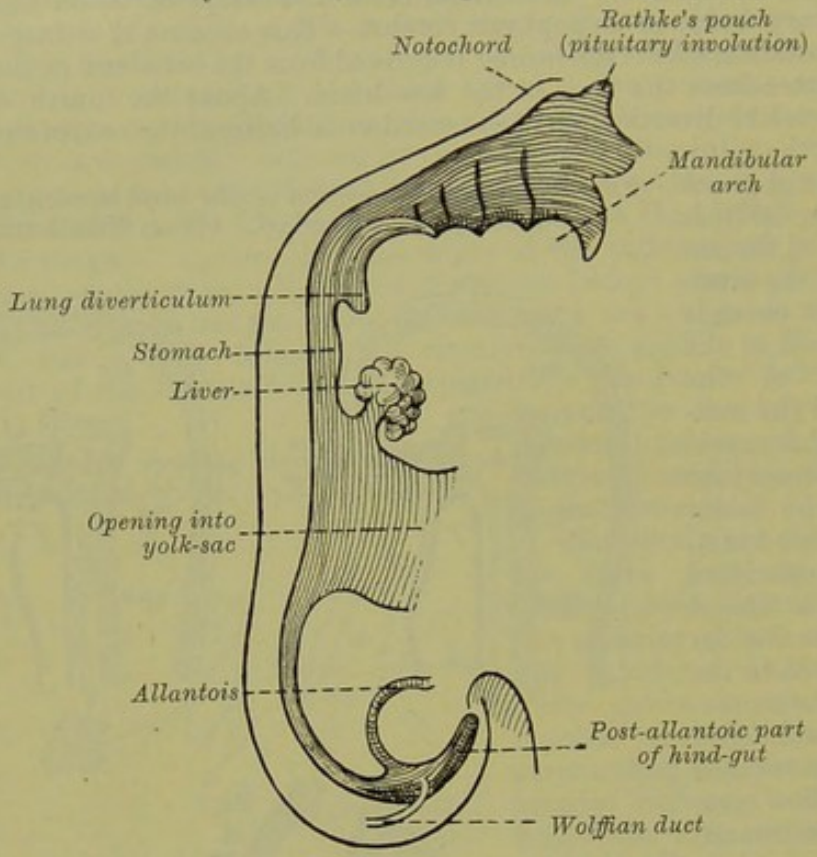

* The proximal part of the vitelline duct persists in about two per cent. of subjects and constitutes *Meckel's diverticulum* of the small intestine, which is found about three or four feet above the ileo-cæcal valve, and may be attached to the umbilicus by a fibrous cord.

alimentary canal forms a nearly straight tube in front of the notochord and primitive aortæ (fig. 200). From the stomach to the rectum it is attached to the notochord by a band of mesoderm, from which the common mesentery of the gut is subsequently developed. The stomach has an additional attachment, viz. : to the

Fig. 209.—Front view of two successive stages in the development of the alimentary canal. (His.)

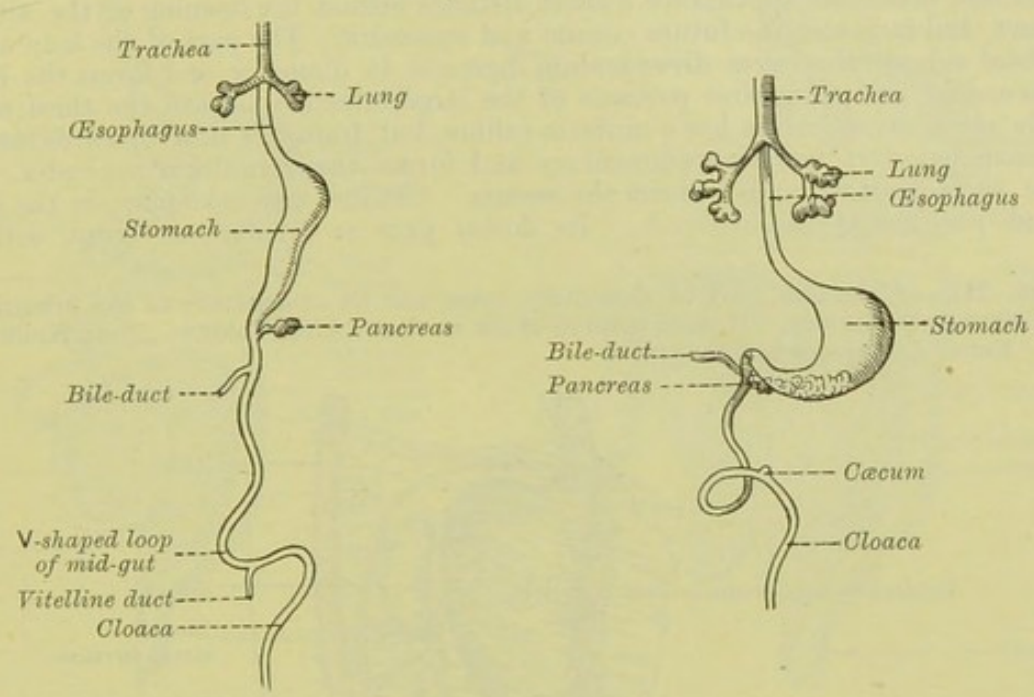

ventral abdominal wall as far as the umbilicus by the septum transversum. The cephalic portion of the septum takes part in the formation of the Diaphragm (see page 167), while the caudal portion into which the liver grows forms the *ventral mesogastrium* (fig. 210). The stomach undergoes a further dilatation, and its two curvatures can be recognised (figs. 208, B, and 210), the greater directed

Fig. 210.—The primitive mesentery of a six weeks' human embryo, half schematic. (Kollmann.)

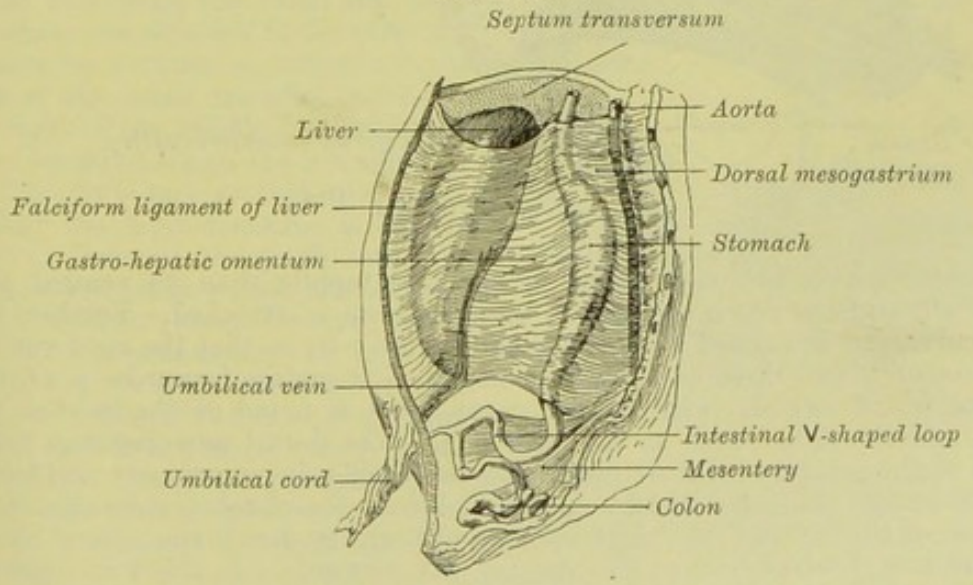

towards the vertebral column and the lesser towards the anterior wall of the abdomen, while its two surfaces look to the right and left respectively. The mid-gut undergoes great elongation, and forms a V-shaped loop which projects downwards and forwards ; from the bend or angle of the loop the vitelline duct passes to the umbilicus (fig. 211). For a time a part of the loop extends beyond

the abdominal cavity into the umbilical cord, but by the end of the third month it is withdrawn within the cavity. With the lengthening of the tube, the mesoderm, which attaches it to the future vertebral column and carries the blood-vessels for the supply of the gut, is thinned and drawn out to form the *posterior common mesentery*. The portion of this mesentery attached to the greater curvature of the stomach is named the *dorsal mesogastrium*, and the part which suspends the colon is termed the *mesocolon* (fig. 211). About the sixth week a lateral diverticulum makes its appearance a short distance behind the opening of the vitelline duct, and indicates the future cæcum and appendix. The part of the loop on the distal side of the cæcal diverticulum increases in diameter and forms the future ascending and transverse portions of the large intestine. Until the third month the cæcal diverticulum has a uniform calibre, but from this time onwards its most dependent part remains rudimentary and forms the vermiform appendix, while its upper part expands to form the cæcum. Changes also take place in the shape and position of the stomach. Its dorsal part or greater curvature, with the

FIG. 211.—Abdominal part of alimentary canal and its attachment to the primitive or common mesentery. Human embryo of six weeks. (After Toldt.) (From Kollmann's 'Entwickelungsgeschichte.')

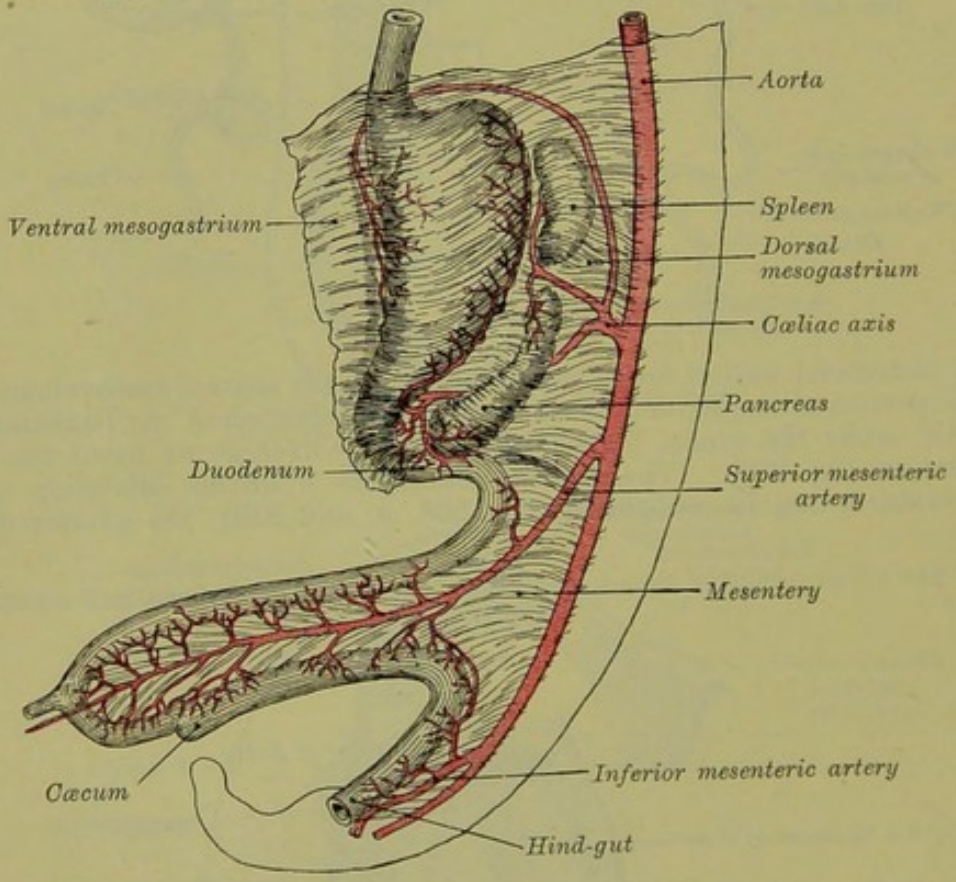

dorsal mesogastrium attached, grows much more rapidly than its ventral part or lesser curvature to which the ventral mesogastrium is attached. Further, the greater curvature is carried downwards and to the left, so that the right surface of the stomach is now directed backwards and the left surface forwards—a change in position which explains why the left vagus nerve is found on the front of the stomach and the right vagus on the back of it. The dorsal mesogastrium being attached to the greater curvature must necessarily follow its movements, and hence it becomes greatly elongated and drawn outwards from the vertebral column, and, as in the case of the stomach, the right surfaces of both the dorsal and ventral mesogastria are now directed backwards, and the left forwards. In this way a pouch, the *bursa omentalis*, is formed behind the stomach; this pouch is the future lesser sac of the peritoneum, and it increases in size as the alimentary tube undergoes further development; the entrance to the pouch constitutes the future *foramen of Winslow* (figs. 212, 215). The duodenum is developed from that part of the tube which immediately succeeds the stomach; it undergoes little elongation, being more or less fixed in position by the liver and pancreas, which arise as diverticula

from it. The duodenum is at first suspended by a mesentery, and projects forwards in the form of a loop. The loop and its mesentery are subsequently displaced by the transverse colon, so that the right surface of the duodenal

Fig. 212.—Diagrams to illustrate two stages in the development of the human alimentary canal and its mesentery. The arrow indicates the entrance to the bursa omentalis.

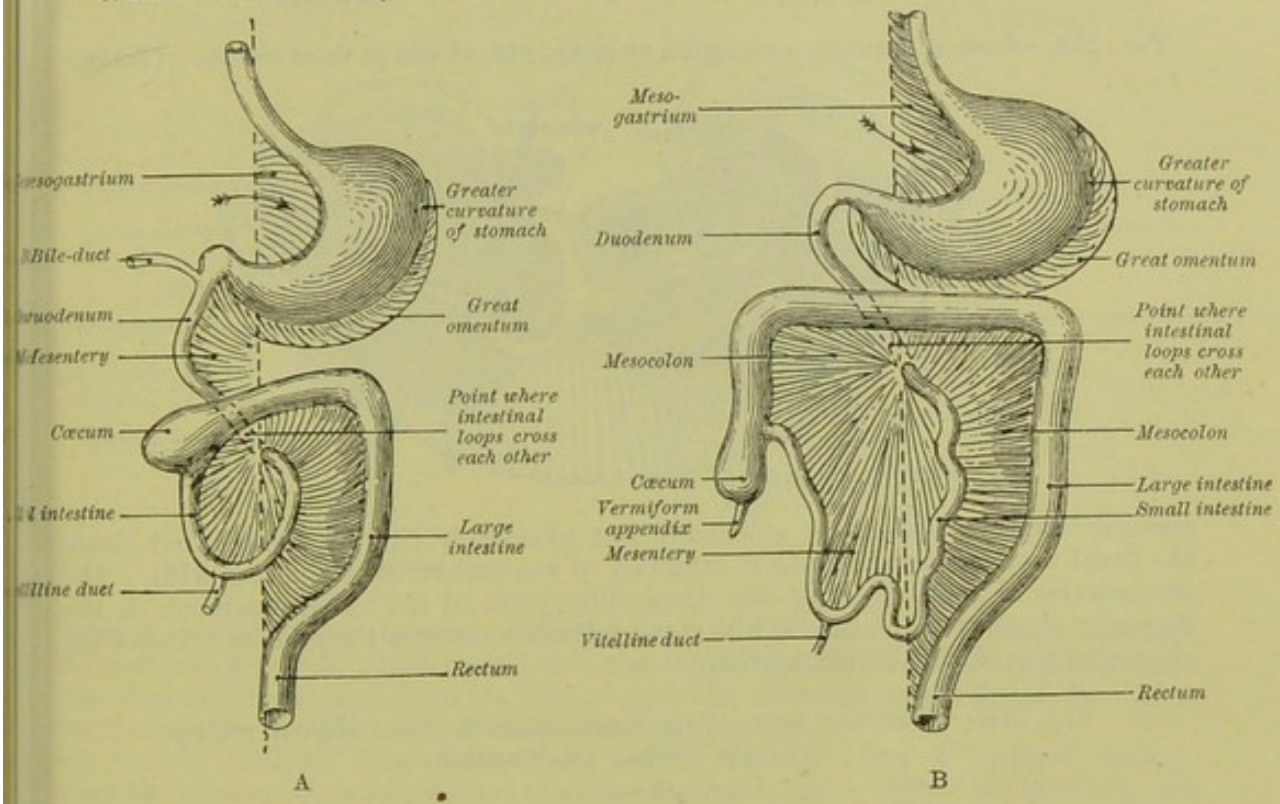

mesentery is directed backwards, and, adhering to the parietal peritoneum, is lost. The remainder of the alimentary canal becomes greatly elongated, and as a consequence the tube is coiled on itself, and this elongation demands a corresponding increase in the width of the intestinal attachment of the mesentery, which becomes folded.

At this stage the small and large intestines are attached to the vertebral column by a common mesentery, the coils of the small intestine falling to the right of the middle line, while the large intestine lies on the left side.*

Fig. 213.—Schematic and enlarged cross section through the body of a human embryo in the region of the meso-gastrium. Beginning of third month. (Toldt.)

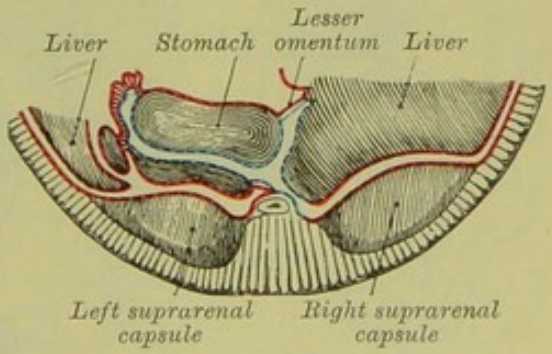

The gut is now rotated upon itself, so that the large intestine is carried over in front of the small intestine, and the cæcum is placed immediately below the liver; about the sixth month the cæcum descends into the right iliac fossa, and the large intestine forms an arch consisting of the ascending, transverse, and descending portions of the colon—the transverse portion crossing in front of the duodenum and lying just below the greater curvature of the stomach; within this arch the coils of the small intestine are disposed (figs. 212, 217). Sometimes the downward progress of the cæcum is arrested, so that in the adult it may be found lying immediately below the liver instead of in the right iliac region.

* Sometimes this condition persists throughout life, and it is then found that the duodenum does not cross from the right to the left side of the vertebral column, but lies entirely on the right side of the mesial plane, where it is continued into the jejunum; the arteries to the small intestine (rami intestini tenuis) also arise from the right instead of the left side of the superior mesenteric artery.

Further changes take place in the bursa omentalis and in the common mesentery, and give rise to the peritoneal relations seen in the adult. The bursa omentalis, which at first reaches only as far as the greater curvature of the stomach, grows downwards to form the great omentum, and this downward extension lies in front of the transverse colon and the coils of the small intestine. The anterior layer of the transverse mesocolon is at first quite distinct from the

Fig. 214.—Section through same region as in fig. 213, at end of third month. (Toldt.)

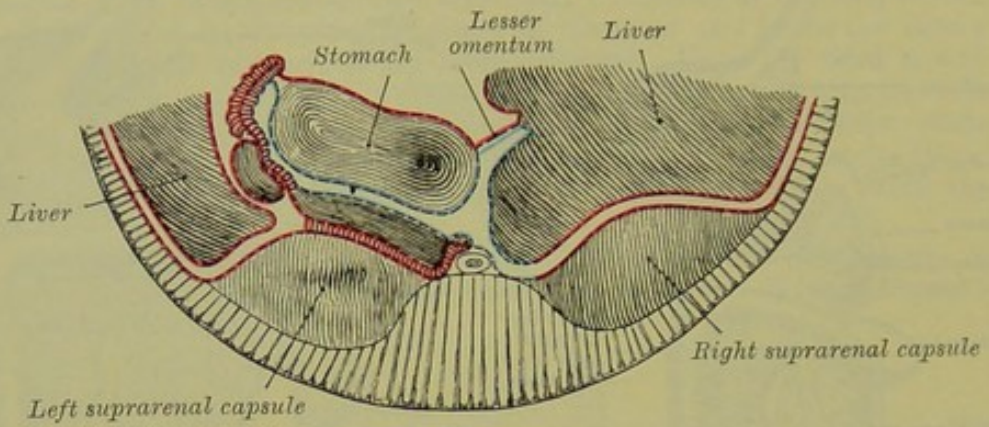

posterior layer of the great omentum, but ultimately the two blend, and hence the great omentum appears as if attached to the transverse colon (fig. 216). The mesenteries of the ascending and descending parts of the colon disappear in the majority of cases, while that of the small intestine assumes the oblique attachment characteristic of its adult condition.

Fig. 215.—Schematic figure of the bursa omentalis, &c. Human embryo of eight weeks. (Kollmann.)

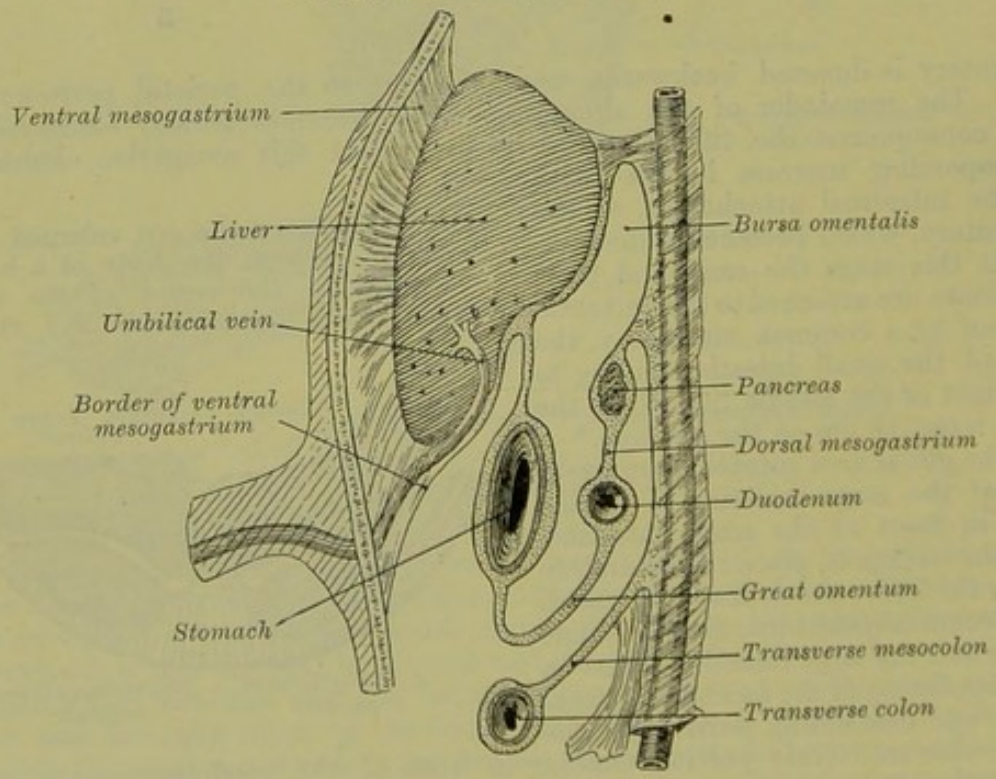

The small omentum is formed, as indicated above, by a thinning of the mesoderm or *ventral mesogastrium*, which attaches the stomach and duodenum to the anterior abdominal wall. By the subsequent growth of the liver this leaf of mesoderm is divided into two parts, viz. : the small omentum between the stomach and liver, and the falciform and coronary ligaments between the liver and the abdominal wall and Diaphragm (fig. 210).

The **rectum** and **anal canal.**—The hind-gut is at first prolonged backwards into the body-stalk as the tube of the allantois ; but, with the growth and

flexure of the tail-end of the embryo, the body-stalk, with its contained allantoic tube, is carried forwards to the ventral aspect of the body, and consequently a

Fig. 216.—Diagrams to illustrate the development of the great omentum and transverse mesocolon.

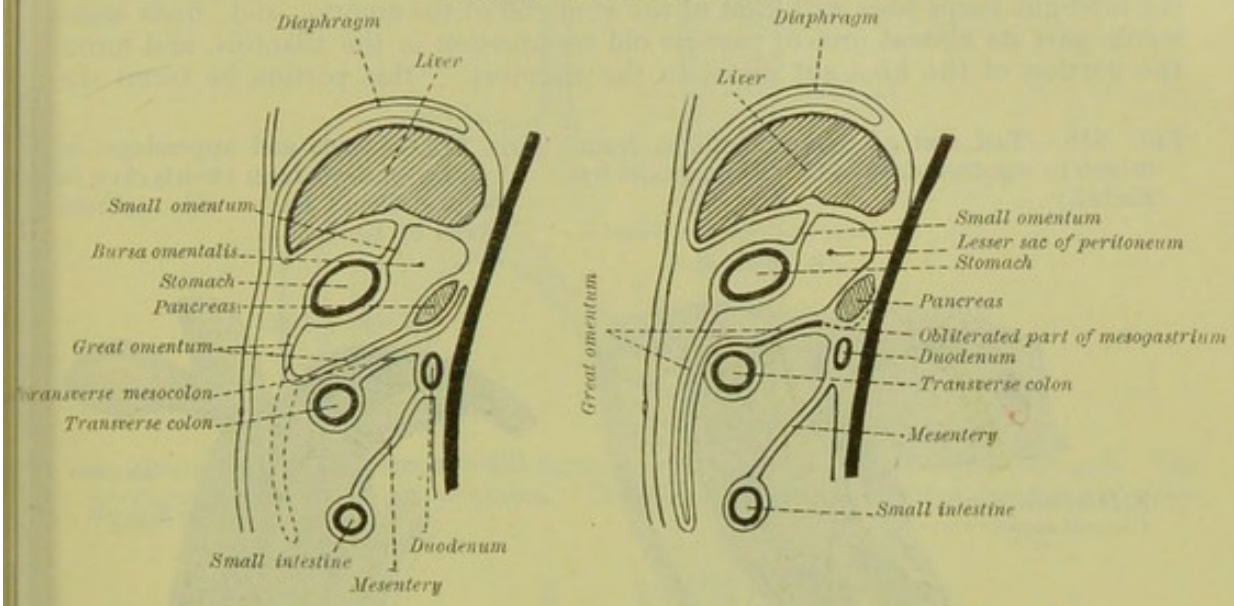

bend is formed at the junction of the hind-gut and allantois. This bend becomes dilated into a pouch, which constitutes the *entodermal cloaca*; into its dorsal part the hind-gut opens, and from its ventral part the allantois passes forwards. At a later stage the Wolffian and Müllerian ducts open into its ventral portion. The cloaca is, for a time, shut off from the exterior by a membrane, the *cloacal membrane*, formed by the apposition of the ectoderm and entoderm, and reaching, at first, as far forwards as the future umbilicus. Behind the umbilicus, however, the mesoderm subsequently extends inwards to form the lower part of the abdominal wall and symphysis pubis. By the growth of the surrounding tissues the cloacal membrane comes to lie at the bottom of a depression, which is lined by ectoderm and named the *ectodermal cloaca* (fig. 218).

Fig. 217.—Final disposition of the intestines and their vascular relations. (Jonnesco.)

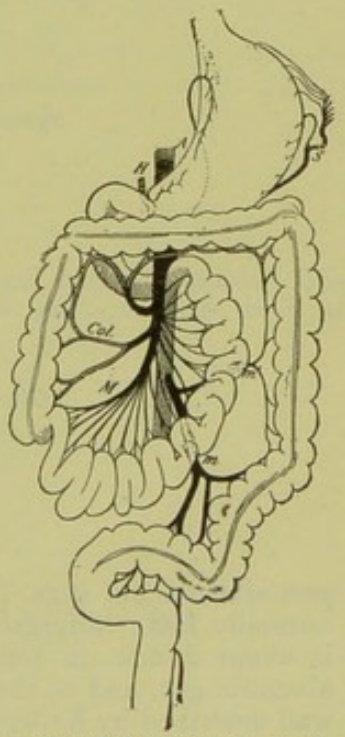

A. Aorta. *H*. Hepatic artery. *M*, *Col*. Branches of superior mesenteric artery. *m*, *m'*, Branches of inferior mesenteric artery. *S*. Splenic artery.

The entodermal cloaca is divided into a dorsal and a ventral part by means of a partition consisting of two lateral mesodermal folds which grow inwards and unite with each other in the middle line. The dorsal part forms the rectum, and the anterior part the urogenital sinus and bladder. By the rupture of the cloacal membrane the entodermal cloaca opens on the exterior, thus giving rise to a condition which exists permanently in the reptile, bird, and monotreme. Into this cloacal channel in these animals the urine, the fæces, and the products of the genital organs are discharged. The communication of the rectum with the cloaca is obliterated by the inward growth of two eminences, which make their appearance one on either side of the cloaca. These join in the middle line to form the perineal septum, and also fuse with the hinder edge of the septum which separates the urogenital sinus and bladder from the rectum. The anal canal is not developed from the cloacal opening of the hind-gut, but is formed by an invagination of the ectoderm behind the perineal septum. This invagination is termed the *proctodæum* (fig. 223), and it meets with the ventral aspect of the hind-gut and forms with it the *anal membrane*. By the absorption of this membrane the anal canal becomes continuous with

the rectum (fig. 224). A small part of the hind-gut projects backwards beyond the anal membrane ; it is named the *post-anal gut*, and usually becomes obliterated and disappears.*

F. Wood-Jones† gives a different account from the above as to the manner in which the rectum is separated from the cloaca. He maintains that the growth of the hind-gut keeps pace with that of the hind-end of the embryo, and ' buds backwards past its cloacal orifice, past its old termination in the allantois, and forms the portion of the hind-gut distal to the allantois ' ; this portion he terms the

Fig. 218.—Tail end of human embryo from fifteen to eighteen days old. (From model by Keibel.)

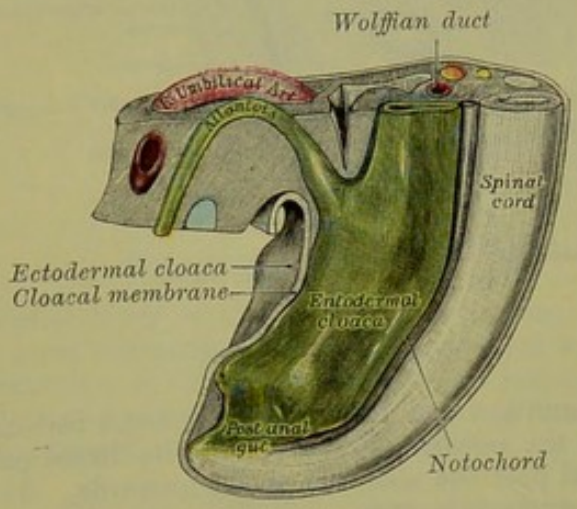

Fig. 219.—Cloaca and appendages of human embryo from twenty-five to twenty-seven days old. (From model by Keibel.)

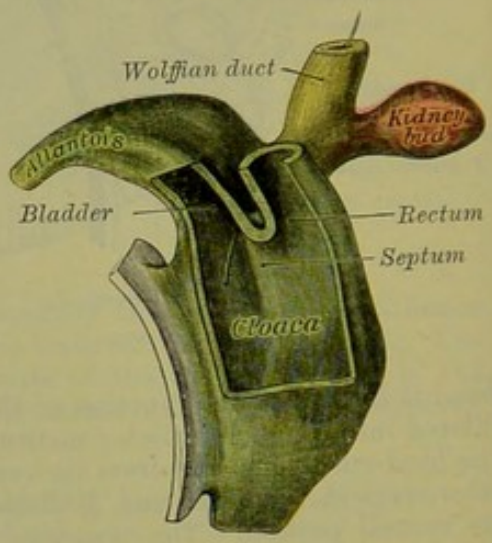

Fig. 220.—Tail end of human embryo, from eight and a half to nine weeks old. (From model by Keibel.)

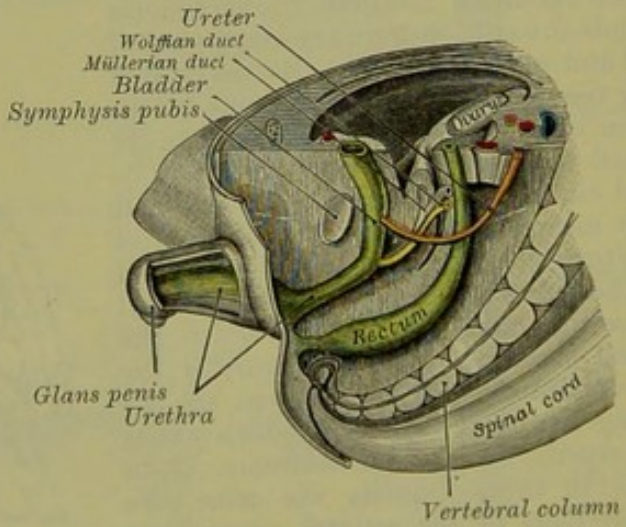

post-allantoic gut (figs. 221, 222). ' The cloacal opening of the hind-gut is now normally lost ; originally a small opening in the embryo of 12 somites (which is about 2 mm. in total length), the rapid growth of the hind-gut, the post-allantoic gut, and of the allantois itself, together with the lateral infolding of the wall described by Keibel, serve to close the opening of the hind-gut into the cloaca ' (fig. 223). This view, which affords a satisfactory explanation of the varieties of imperforate rectum and anus which are sometimes found, leads to the conclusion

* Consult, in this connection, the following article: ' A Contribution to the Morphology of the Human Urino-genital Tract,' by D. Berry Hart, M.D., F.R.C.P.E. *Journal of Anatomy and Physiology*, April 1901, vol. xxxv.

† ' The Nature of the Malformations of the Rectum and Urogenital Passages,' by F. Wood-Jones, M.B., B.Sc., M.R.C.S. *British Medical Journal*, December 17, 1904.

FIG. 221.—Diagram to illustrate the development of the post-allantoic gut. The hind-gut opens freely into the cloaca. (After Wood-Jones.)

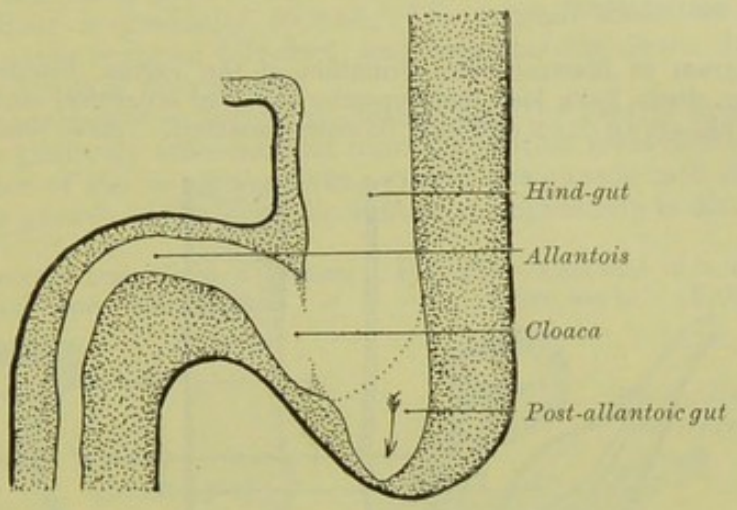

FIG. 222.—Diagram to illustrate the further development of the post-allantoic gut. The hind-gut still opens into the cloaca. The opening of the Müllerian ducts is also seen. (After Wood-Jones.)

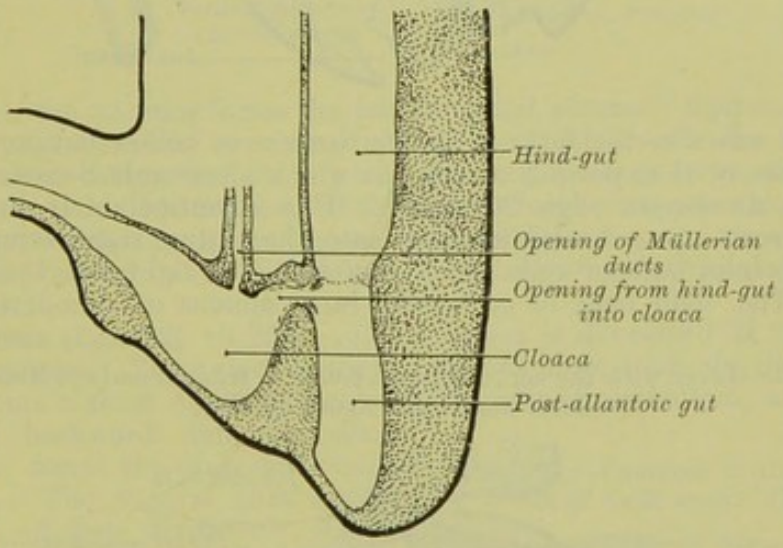

FIG. 223.—Diagram to illustrate the separation of the hind-gut from the cloaca. The hind-gut has now lost its cloacal opening. The post-allantoic gut is about to meet the proctodæal depression. (After Wood-Jones.)

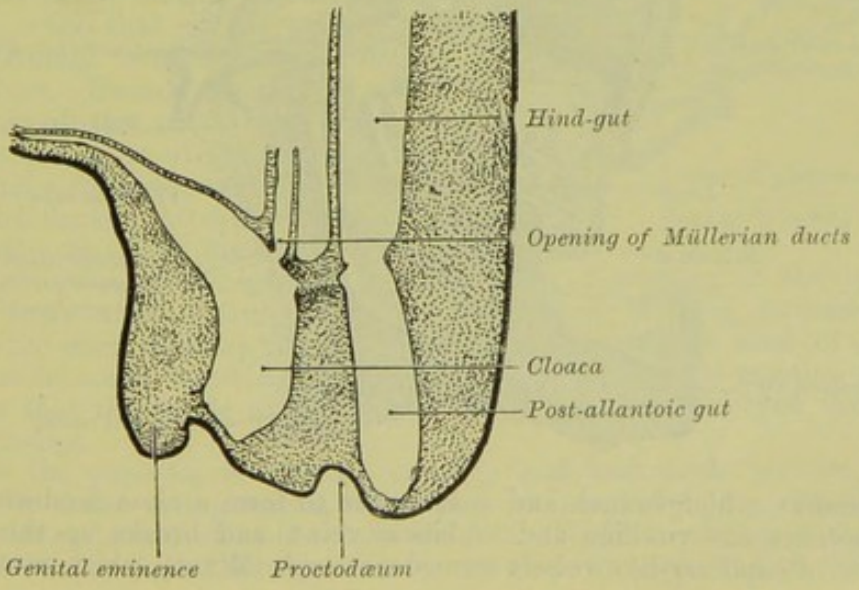

that the cloaca does not contribute to the formation of the rectum, and that the septa which have been described as fusing in the middle line to form the perinæum are non-existent.

Fig. 224.—Diagram to illustrate the formation of the vagina, bladder, and urethra. The Müllerian ducts have lost their opening into the urogenital sinus, and the new solid vagina has grown down and later becomes canalised. (After Wood-Jones.)

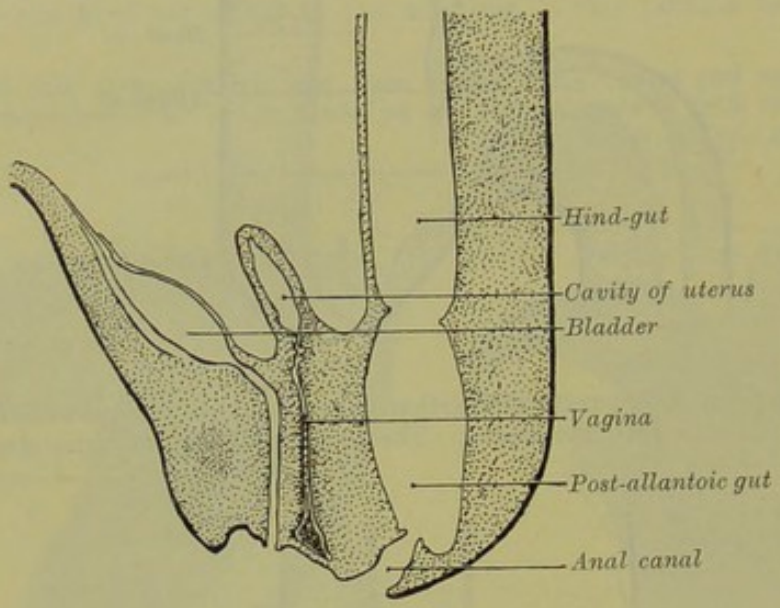

The **liver** arises in the form of a diverticulum or hollow outgrowth from the ventral surface of that portion of the gut which afterwards becomes the second part of the duodenum (figs. 208, 225). This diverticulum is lined by entoderm, and grows upwards and forwards into the septum transversum, and there gives off two solid buds of cells which represent the right and the left lobes of the liver. The solid buds of cells grow into columns or cylinders, termed the

Fig. 225.—Liver with the septum transversum. Human embryo 3 mm. long. (After model and figure by His.)

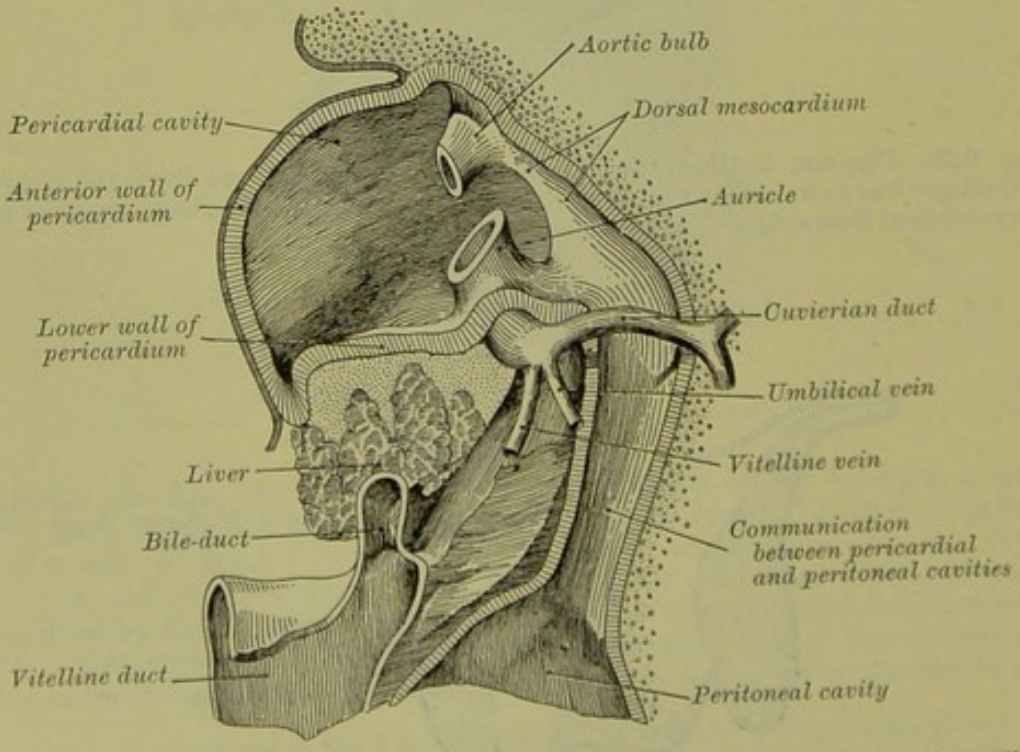

hepatic cylinders, which branch and anastomose to form a close meshwork. This network invades the vitelline and umbilical veins, and breaks up these vessels into a series of capillary-like vessels termed *sinusoids* (Minot), which ramify in the

meshes of the cellular network and ultimately form the venous capillaries of the liver. By the continued growth and ramification of the hepatic cylinders the mass of the liver is gradually formed. The original diverticulum from the duodenum forms the common bile-duct, and from this the cystic duct and gall-bladder arise as a hollow evagination.

As the liver undergoes enlargement, both it and the ventral mesogastrium of the fore-gut are gradually differentiated from the septum transversum ; and from the under surface of the latter the liver projects downwards into the abdominal cavity. By the growth of the liver the ventral mesogastrium is divided into two

Fig. 226.—Pancreatic buds from a human embryo 7·5 mm. long. (Kollmann.)

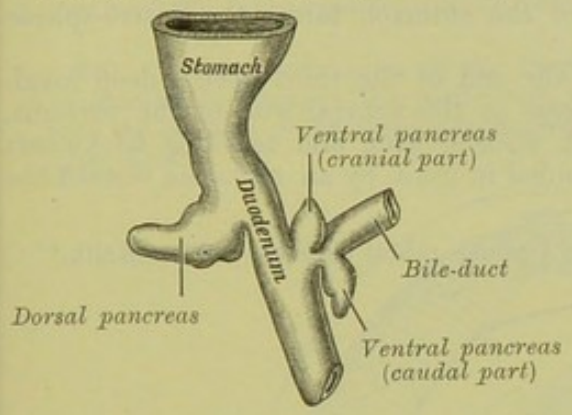

Fig. 227.—Pancreas of a human embryo of five weeks. (Kollmann.)

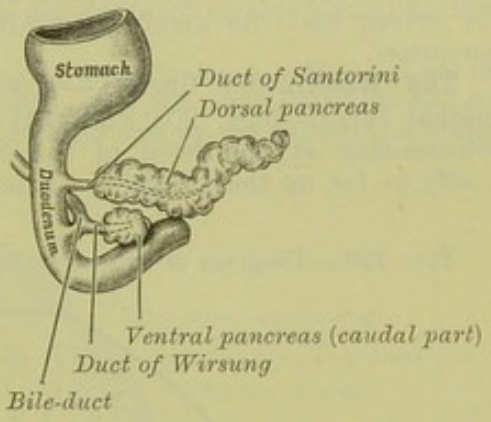

parts, of which the anterior forms the falciform and coronary ligaments, and the posterior the gastro-hepatic omentum. About the third month the liver almost fills the abdominal cavity, and its left lobe is nearly as large as its right. From this period the relative development of the liver is less active, more especially that of the left lobe, which actually undergoes some degeneration and becomes smaller than the right ; but up to the end of fœtal life the liver remains relatively larger than in the adult.

The **pancreas** (figs. 226 to 228).—The pancreas is developed in two parts, a dorsal and a ventral. The former arises as a diverticulum from the dorsal aspect of the duodenum a short distance above the hepatic diverticulum, and, growing upwards and backwards into the dorsal mesogastrium, forms the body and tail of the pancreas. The ventral part appears in the form of two diverticula, cranial and caudal, from the primitive bile-duct ; the caudal enlarges to form the head of the pancreas, while the cranial atrophies and disappears. The duct of the dorsal part (duct of Santorini) therefore opens into the duodenum, while that of the ventral part (duct of Wirsung) terminates with the common bile-duct. During the sixth week, in consequence of the rotation of the duodenum, the two parts of the pancreas meet and fuse, and a communication is established between their ducts. After this has occurred the terminal part of the duct of Santorini, i.e. the part between the duodenum and the point of meeting of the two ducts, undergoes little or no enlargement, while the duct of Wirsung increases in size and forms the main duct of the gland. The opening of the duct of Santorini into the duodenum is sometimes obliterated, and even when it remains patent it is probable that the whole of the pancreatic secretion is conveyed through the duct of Wirsung.

Fig. 228.—Pancreas of human embryo at end of sixth week. (Kollmann.)

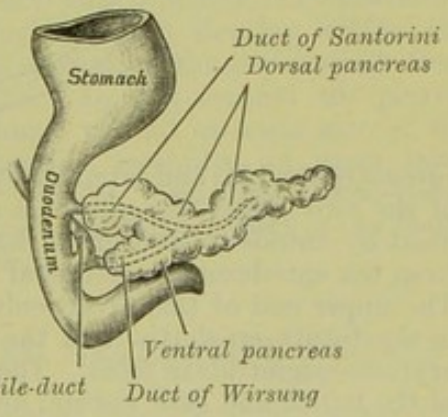

At first the pancreas is directed upwards and backwards between the two layers of the dorsal mesogastrium which give to it a complete peritoneal investment, and its surfaces look to the right and left. With the change in the position of the stomach the dorsal mesogastrium is drawn downwards and to the left, and

the right side of the pancreas is directed backwards and the left forwards. The right surface becomes applied to the posterior abdominal wall, and the peritoneum which covered it undergoes absorption; and thus, in the adult, the gland appears to lie behind the peritoneal cavity.

The **spleen** (fig. 211).—Although the spleen belongs to the group of ductless glands, its development may be conveniently referred to here. It appears in the second month as a localised thickening of the mesoderm in the dorsal mesogastrium above the tail of the pancreas. It grows towards the left side of the dorsal mesogastrium, and thus comes into contact with the right surface of the stomach. With the change in position of this viscus the spleen is carried to the left, and comes to lie behind the cardiac part of the stomach and in contact with the left kidney. The part of the dorsal mesogastrium which intervened between the spleen and the greater curvature of the stomach forms the gastro-splenic omentum.

The Respiratory Organs.—Towards the end of the third week a deep longitudinal furrow (figs. 203 and 204) appears in the ventral wall of the fore-gut, commencing at the level of the fourth visceral arch and reaching backwards nearly as far as the stomach. It is bounded in front by an elevation termed the

FIG. 229.—Diagram of transverse section through rabbit embryo. (After Keith.)

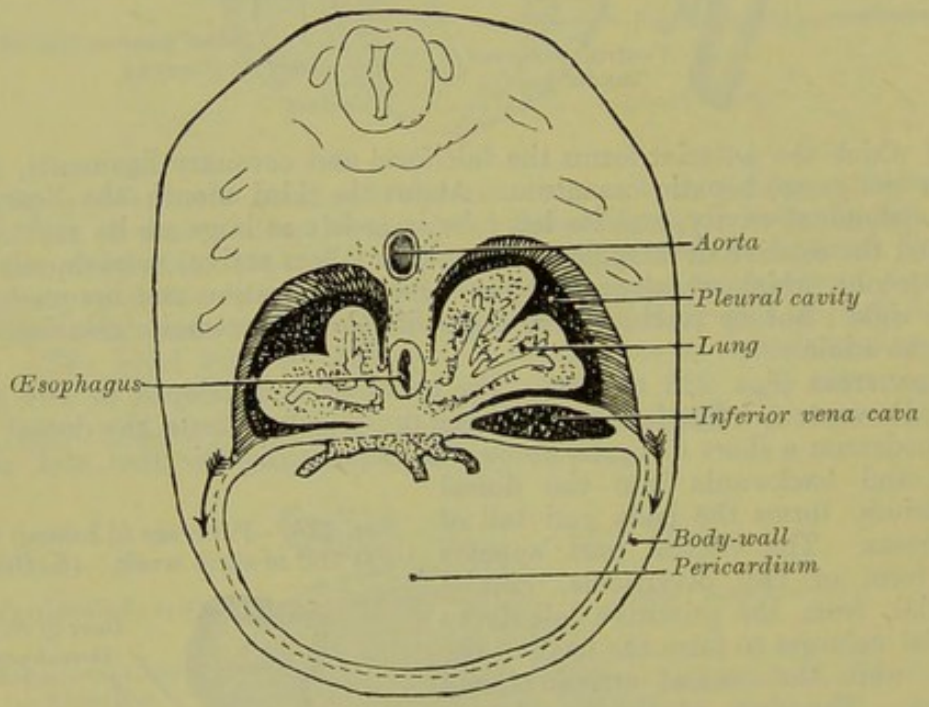

furcula (page 154) and laterally by two ridges. By the union of the posterior parts of the two ridges the groove is converted into a tube-like diverticulum, which is lined by entoderm and grows backwards on the ventral aspect of the œsophagus; from the entoderm the epithelial lining of the entire respiratory tract is developed. The upper end of this diverticulum is expanded to form the larynx; the furcula is the future epiglottis, and the upper parts of the lateral ridges constitute the aryteno-epiglottidean folds. The thyroid cartilage is developed from the cartilages of the fourth and fifth visceral arches, while that of the sixth visceral arch appears to be modified to form the cricoid and arytenoid cartilages and the cartilages of the trachea.

The lower end of the tube-like diverticulum bifurcates into a larger right and a smaller left bud, the *right* and *left lung buds*, the stalks of which form the right and left bronchi. The right divides into three and the left into two parts; these subdivisions are the early indications of the corresponding lobes of the lungs (fig. 208). The buds undergo further subdivision and ramification, and ultimately end in minute expanded extremities—the infundibula of the lung. After the sixth month the air-sacs begin to make their appearance on the infundibula in the form of minute pouches. The pulmonary arteries are derived from the sixth aortic arches.

The **Diaphragm** and **pleuræ** (figs. 229 and 230).—The following description is based on that given by Keith.* The *central tendon* of the Diaphragm is derived from the septum transversum; each half of its muscular portion is developed in two parts, viz.: (*a*) a *sterno-costal* portion, derived from the ventral longitudinal musculature of the embryonic neck; and (*b*) a *spinal* or *vertebral* portion, arising from the bodies of the vertebræ and arcuate ligaments, and derived from the cervical part of the Transversalis. The pleuro-peritoneal opening is closed by the approximation of the sterno-costal and vertebral parts; and the spino-costal fibrous hiatus, best seen on the left half of the adult Diaphragm, marks its position after closure. Sometimes the opening remains patent, and may allow of the formation of a congenital diaphragmatic hernia.

The formation or separation of the Diaphragm—for at first it forms part of the wall of the body-cavity—results from the development of the pleural cavities

Fig. 230.—The thoracic aspect of the Diaphragm of a newly born child in which the communication between the peritoneum and pleura has not been closed on the left side; the position of the opening is marked on the right side by the spino-costal hiatus. (After Keith.)

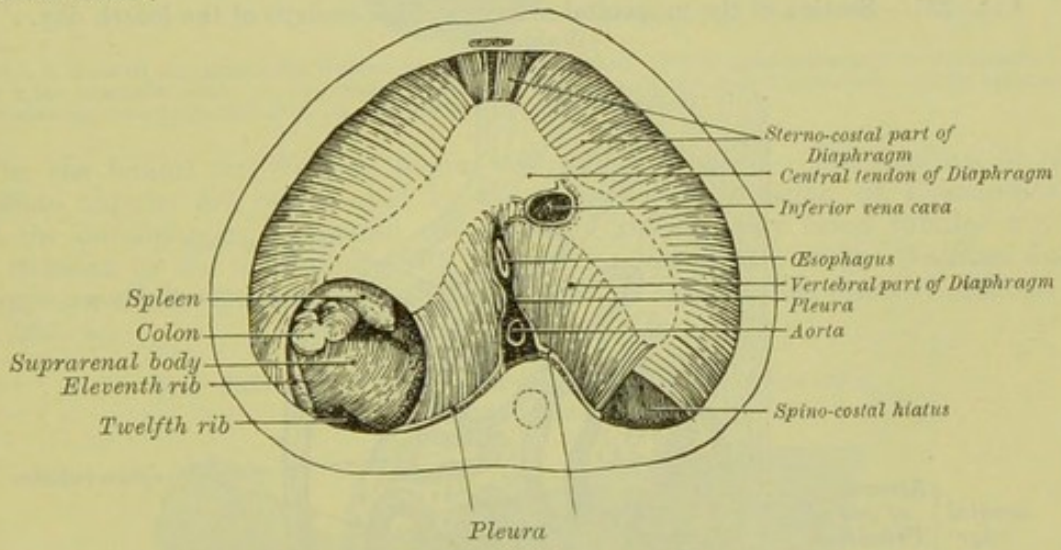

and lungs. The lung buds appear in the cervical region of the embryo, and they, together with the parts of the cœlom in which they are contained, undergo a rapid development, growing forwards and outwards into the tissue of the dorsal part of the septum transversum and of the body-wall; within that tissue the pleural cavities are excavated. The pleural cavities also develop within the body-wall towards the ventral median line, thus separating the pericardium from the lateral thoracic wall (see arrows in fig. 229). In this manner the pleural cavities are excavated within the body-wall, dorsal to and on each side of the pericardium. The formation of the pleural cavities separates an inner layer from the ventro-lateral aspect of the body-wall to form the sterno-costal part of the Diaphragm, and also an inner layer from the dorsal aspect of the body-wall to form the vertebral part of the Diaphragm.

DEVELOPMENT OF THE URINARY AND GENERATIVE ORGANS

The urinary and generative organs are developed from the intermediate cell-mass which is situated between the primitive segments and the lateral plates of mesoderm. The permanent organs of the adult are preceded by a set of structures which are purely embryonic, and which with the exception of the ducts disappear almost entirely before the end of fœtal life. These embryonic structures are on either side: the pronephros, the mesonephros, the Wolffian and Müllerian ducts. The pronephros disappears very early; the structural elements of the mesonephros mostly degenerate, but in their place is developed the genital gland

* *Human Embryology and Morphology*, by Arthur Keith, M.D., F.R.C.S., 2nd edition, 1904. Consult also an article on the development of the Diaphragm, by the same author, in vol. xxxix. of the *Journal of Anatomy and Physiology*.

in association with which the Wolffian duct remains as the duct of the male genital gland, the Müllerian as that of the female.

The Pronephros and Wolffian duct.—In the outer part of the intermediate cell-mass, immediately under the ectoderm, a longitudinal cord of cells makes its appearance. This cellular cord sinks into the subjacent mesoderm, and, acquiring a lumen, constitutes the *Wolffian duct*,* which passes backwards and opens into the ventral part of the cloaca.

In front of the duct there are developed a number of tubules which form the *pronephros* or *head-kidney*—an early embryonic structure in all vertebrates. This consists of a series of transverse tubules which open into a duct termed the *pronephric duct*; this duct is continuous posteriorly with the Wolffian duct. Each pronephric tubule communicates by means of a funnel-shaped ciliated opening with the cœlomic cavity, and in the course of each duct a glomerulus also is developed. The pronephros undergoes rapid atrophy and practically disappears. In the female the remains of it are probably represented by the hydatids of Morgagni at the fimbriated end of the Fallopian tube; in the male, by the stalked hydatid at the upper end of the testicle.

FIG. 231.—Section of the urogenital area of a chick embryo of the fourth day. (Waldeyer.)

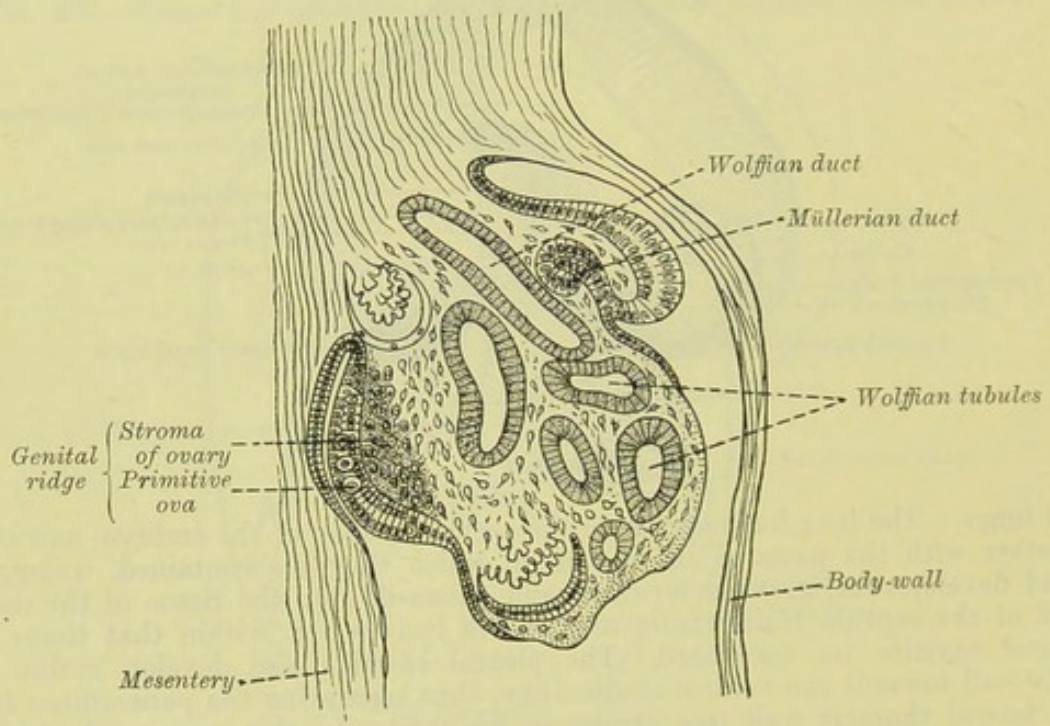

The Mesonephros, Müllerian duct, and Genital gland.—On the inner side of the Wolffian duct a series of tubules, the *Wolffian tubules*, are developed. Each tubule opens externally into the duct, while its opposite end is invaginated by a tuft of capillary blood-vessels to form a glomerulus. These tubules increase in number, and collectively constitute the *mesonephros* or *Wolffian body* (figs. 231, 232). At the beginning of the second month this body forms an elongated spindle-shaped structure, which projects into the cœlomic cavity at the side of the dorsal mesentery, and reaches from the septum transversum in front to the fifth lumbar somite behind. The Wolffian body persists and forms the permanent kidney in fishes and amphibians, but in reptiles, birds, and mammals it is superseded by the *metanephros*, which forms the permanent kidney in these animals. The anterior tubules of the Wolffian body become attached to the sexual eminence or *genital ridge* from which the ovary in the female and the testicle in the male are developed. During the development of the permanent kidneys, the Wolffian bodies atrophy, and this process proceeds to a much greater extent in the female than in the male.

* The Wolffian duct is regarded by some embryologists as being of ectodermal origin, formed by a longitudinal invagination of the ectoderm which overlies the intermediate cell-mass.

In the male the Wolffian duct persists, and forms the tube of the epididymis, the vas deferens, and common ejaculatory duct, while the seminal vesicle arises as a lateral diverticulum from its hinder end. The anterior Wolffian tubules form the rete testis, vasa efferentia, and coni vasculosi of the testicle; while the posterior tubules are represented by the vasa aberrantia of the globus minor, and by the organ of Giraldès, which is sometimes found in front of the spermatic cord above the globus major (fig. 235, C).

FIG. 232.—Enlarged view from the front of the left Wolffian body before the establishment of the distinction of sex. (From Farre, after Kobelt.)

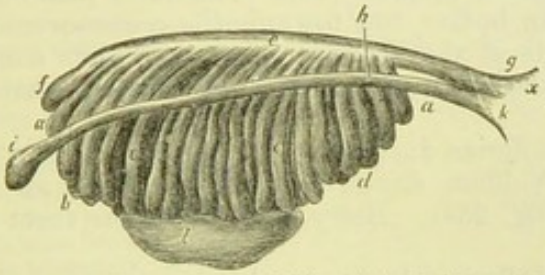

a, a, b, c, d. Tubular structure of the Wolffian body. *e.* Wolffian duct. *f.* Its upper extremity. *g.* Its termination in *x*, the urogenital sinus. *h.* The duct of Müller. *i.* Its upper, funnel-shaped extremity. *k.* Its lower end, terminating in the urogenital sinus. *l.* The genital ridge, ovary or testicle.

In the female the Wolffian bodies and ducts atrophy. The remains of the Wolffian tubules are represented by the epoöphoron or organ of Rosenmüller, and the paroöphoron, two small collections of rudimentary blind tubules which are situated in the mesosalpinx (fig. 233). The lower part of the Wolffian duct disappears, while the upper part persists as the functionless duct of Gärtner * (fig. 235, B.)

FIG. 233.—Adult ovary, parovarium, and Fallopian tube. (From Farre, after Kobelt.)

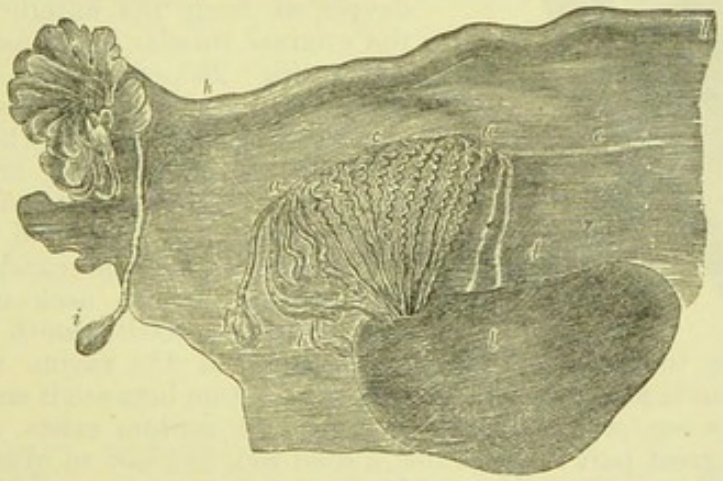

a, a. Epoöphoron formed from the upper part of the Wolffian body. *b.* Remains of the uppermost tubes sometimes forming hydatids. *c.* Middle set of tubes. *d.* Some lower atrophied tubes. *e.* Atrophied remains of the Wolffian duct. *f.* The terminal bulb or hydatid. *h.* The Fallopian tube, originally the duct of Müller. *i.* Hydatid attached to the extremity. *l.* The ovary.

The **suprarenal bodies** are generally regarded as being developed from two sources. The medullary part of the organ is of ectodermal origin, and is derived from the tissues forming the sympathetic ganglia of the abdomen, while the cortical portion is of mesodermal origin, and appears to be derived from invaginations of that portion of the cœlomic epithelium which overlies the Wolffian body. The

* Berry Hart (*op. cit.*) has described the Wolffian ducts as ending at the site of the future hymen in bulbous enlargements, which he has named the *Wolffian bulbs*; and states that the hymen is formed by these bulbs, 'aided by a special involution from below of the cells lining the urogenital sinus.' He further believes that 'the lower third of the vagina is due to the coalescence of the upper portion of the urogenital sinus and the lower ends of the Wolffian ducts,' and that 'the epithelial lining of the vagina is derived from the Wolffian bulbs.' He also regards the colliculus seminalis of the male urethra as being formed from the lower part of the Wolffian ducts.

two parts are at first quite distinct, but become combined in the process of development. The suprarenal bodies are at first larger than the kidneys; about the tenth week they equal them in size, and from that time decrease relatively to the kidneys, though they remain, throughout fœtal life, proportionately much larger than in the adult.

The Müllerian ducts.—Shortly after the formation of the Wolffian ducts a second pair of ducts is developed; these are named the *Müllerian ducts*. Each arises on the outer aspect of the corresponding Wolffian body as a tubular invagination of the cells lining the cœlom (fig. 231). The orifice of the invagination remains patent, and undergoes enlargement and modification to form the abdominal ostium of the Fallopian tube. The ducts pass backwards on the outer aspects of the Wolffian bodies, but towards the posterior end of the embryo they cross to the inner side of the Wolffian ducts, and thus come to lie side by side between and behind the latter—the four ducts forming what is termed the *genital cord* (fig. 234).

Ultimately, the Müllerian ducts open into the ventral part of the cloaca between the orifices of the Wolffian ducts, and terminate on an elevation named the *Müllerian eminence* (fig. 234). Berry Hart describes them as ending blindly on this eminence.

In the male the Müllerian ducts atrophy, but traces of their anterior ends are represented by the sessile hydatids of the epididymis, while their terminal fused portions form the uterus masculinus or sinus pocularis in the floor of the prostatic portion of the urethra (fig. 235, C).

Fig. 234.—Urogenital sinus of female human embryo of eight and a half to nine weeks old.

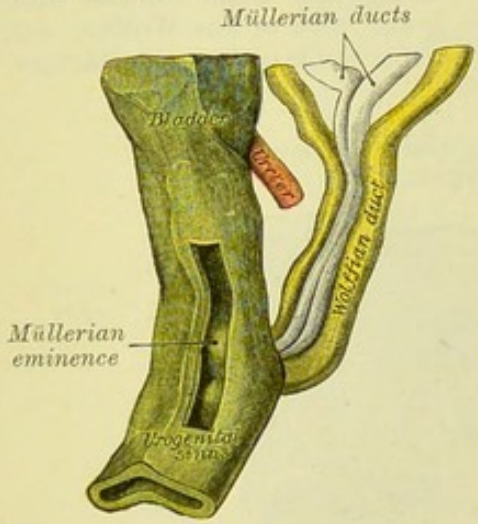

In the female the Müllerian ducts persist and undergo further development. The portions which lie in the genital cord fuse to form the uterus and vagina; the parts in front of this cord remain separate, and each forms the corresponding Fallopian tube—the abdominal ostium of which is developed from the anterior extremity of the original tubular invagination from the cœlom (fig. 235, B). The fusion of the Müllerian ducts begins in the third month, and the septum formed by their fused mesial walls disappears from below upwards, and thus the cavities of the vagina and uterus are produced. About the fifth month an annular constriction marks the position of the neck of the uterus, and after the sixth month the walls of the uterus begin to thicken. The development of the vagina in the manner just described would necessitate the growth of a septum between it and the urethra; but Wood-Jones (*op. cit.*) maintains that no such septum exists, and that 'the vagina is, for a great part of fœtal life, a solid rod, and not an open canal at all' (fig. 224). He says: 'Early in the history of the embryo the Müllerian ducts open into the urogenital sinus at its upper part (fig. 223); late in its history they open at the hind-end of the vagina, and for a considerable interval they have no opening at all—the old one being lost and the new one not yet formed. No septal division is employed in this change; but as the hind-gut, when its cloacal opening is lost, re-establishes communication with the exterior by a new down-growth, so the Müllerian ducts, when their cloacal opening becomes obliterated, tunnel a new passage to the hind-end. The active agents in this strange growth are two epithelial masses that have been described by Berry Hart as the Wolffian bulbs, but to give this name to them is to give a definite idea as to their origin, and this seems to be by no means clear.'

Genital gland.—The first appearance of the genital gland is essentially the same in the two sexes, and consists in a thickening of the epithelial layer which lines the peritoneal or body cavity on the inner side of the Wolffian ridge. Beneath this thickened epithelium an increase in the mesoderm takes place, forming a distinct projection. This is termed the *genital ridge* (fig. 231), and from it the testis in the male and the ovary in the female are developed.

FIG. 235.—Diagrams to show the development of male and female generative organs from a common type. (Allen Thomson.)

A

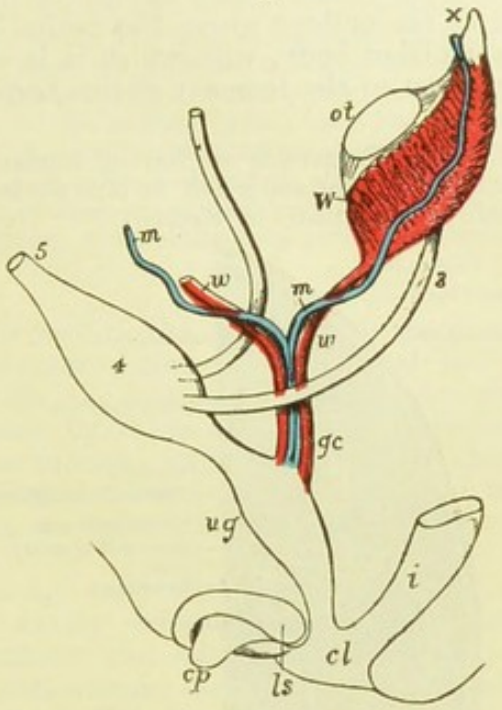

A.—Diagram of the primitive urogenital organs in the embryo previous to sexual distinction.

3. Ureter. 4. Urinary bladder. 5. Urachus. *cl.* Cloaca. *cp.* Elevation which becomes clitoris or penis. *i.* Lower part of the intestine. *ls.* Fold of integument from which the labia majora or scrotum are formed. *m, m.* Right and left Müllerian ducts uniting together and running with the Wolffian ducts in *gc*, the genital cord. *ot.* The genital ridge from which either the ovary or testicle is formed. *ug.* Sinus urogenitalis. *W.* Left Wolffian body. *w, w.* Right and left Wolffian ducts.

B

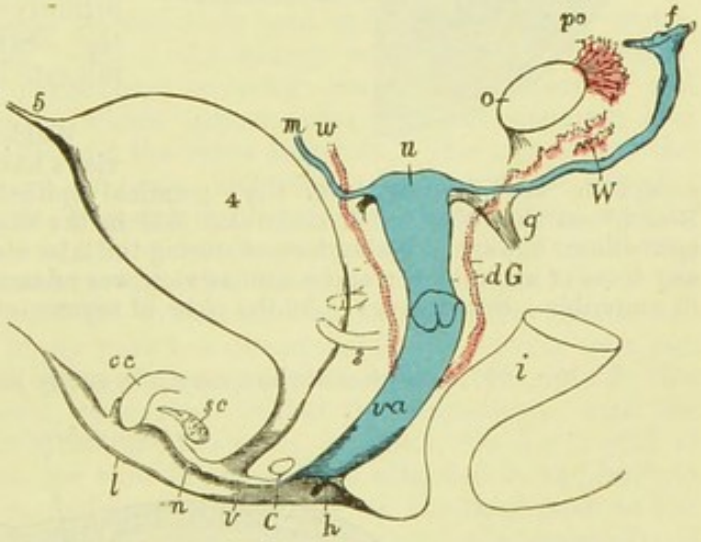

B.—Diagram of the female type of sexual organs.

C. Gland of Bartholin, and immediately above it the urethra. *cc.* Corpus cavernosum clitoridis. *dG.* Remains of the left Wolffian duct, such as give rise to the duct of Gärtner, represented by dotted lines; that of the right side is marked *w*. *f.* The abdominal opening of the left Fallopian tube. *g.* Round ligament, corresponding to gubernaculum. *h.* Situation of the hymen. *i.* Lower part of the intestine. *l.* Labium. *n.* Nympha. *o.* The left ovary. *po.* Parovarium (epoöphoron of Waldeyer). *sc.* Vascular bulb or corpus spongiosum. *u.* Uterus. The Fallopian tube of the right side is marked *m*. *v.* Vulva. *va.* Vagina. *W.* Scattered remains of Wolffian tubes near it (paroöphoron of Waldeyer).

C

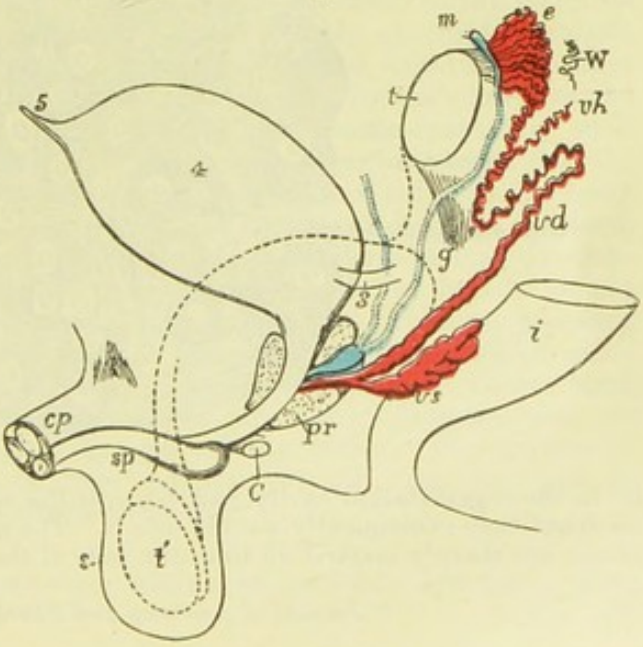

C.—Diagram of the male type of sexual organs.

C. Cowper's gland of one side. *cp.* Corpora cavernosa penis cut short. *e.* Caput epididymis. *g.* The gubernaculum. *i.* Lower part of the intestine. *m.* Müllerian duct, the upper part of which remains as the hydatid of Morgagni; the lower part, represented by a dotted line descending to the prostatic vesicle, constitutes the occasionally existing cornu and tube of the uterus masculinus. *pr.* The prostate gland. *s.* Scrotum. *sp.* Corpus spongiosum urethræ. *t.* Testicle in the place of its original formation. *t'*, together with the dotted lines above, indicates the direction in which the testicle and epididymis descend from the abdomen into the scrotum. *vd.* Vas deferens. *vh.* Vas aberrans. *vs.* The vesicula seminalis. *W.* Scattered remains of the Wolffian body, constituting the organ of Giraldès, or the paradidymis of Waldeyer.

At first the Wolffian body and genital ridge are suspended by a common mesentery, but as the embryo grows the genital ridge gradually becomes pinched off from the Wolffian body, with which it is at first continuous, though it still remains connected to the remnant of this body by a fold of peritoneum, the *mesorchium* or *mesovarium* (fig. 236). About the seventh week the distinction of sex in the genital ridge begins to be perceptible.

Fig. 236.—Transverse section of human embryo of eight and a half to nine weeks old. (From model by Keibel.)

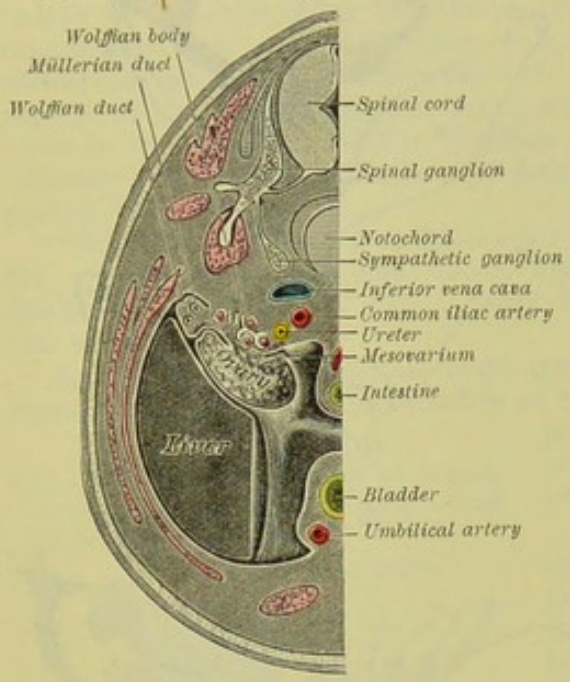

The **ovary**, thus formed from the genital ridge, consists of a central part of connective tissue covered by a layer of epithelium, the *germinal epithelium*. Between the cells of the germinal epithelium a number of larger cells, the *primitive ova*, are found, and these are carried into the subjacent stroma by bud-like ingrowths of the germinal epithelium, the cells of which surround the primitive ova; in this manner the primitive Graafian follicles are formed. The rest of the germinal epithelium on the surface of the ovary forms the permanent epithelial covering of this organ (fig. 237). According to Beard the primitive ova are early set apart during the segmentation of the ovum and migrate into the germinal ridge.

Waldeyer taught, and for many years his views have been accepted, that the primitive germ-cells are derived from the 'germinal epithelium' covering the genital ridge. Beard,* on the other hand, maintains that in the skate they are not derived from this epithelium, but are probably formed during the later stages of cell-cleavage, before there is any trace of an embryo; and a similar view was advanced by Nussbaum as to their origin in amphibia. Beard says: 'At the close of segmentation many of the future germ-cells

Fig. 237.—Section of the ovary of a newly born child. (Waldeyer.)

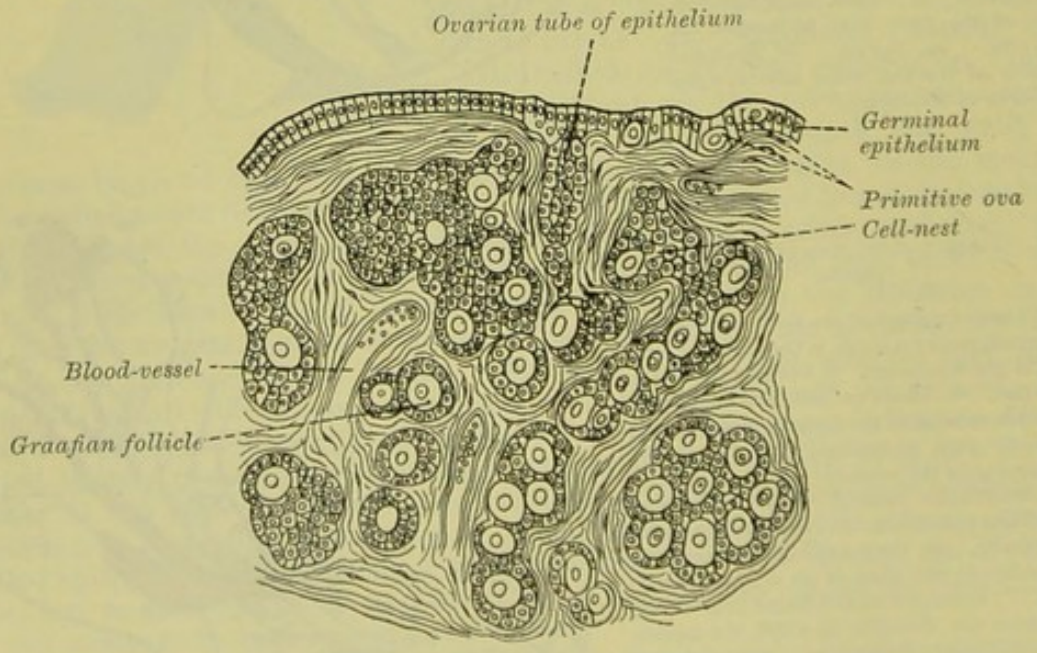

lie in the segmentation cavity just beneath the site of the future embryo, and there is no doubt they subsequently wander into it.' The germ-cells, 'after they enter the resting phase, are sharply marked off from the cells of the embryo by entire absence of mitoses

* *Journal of Anatomy and Physiology*, vol. xxxviii.

among them.' They can be further recognised by their irregular form and amœboid processes, and by the fact that their cytoplasm has no affinity for ordinary stains, but assumes a brownish tinge when treated by osmic acid. The path along which they travel into the embryo is a very definite one—viz. 'from the yolk-sac upwards between the splanchnopleure and gut in the hinder portion of the embryo.' This pathway, named by Beard the *germinal path*, 'leads them directly to the position which they ought finally to take up in the "germinal ridge" or nidus.' A considerable number apparently never reach their proper destination, since 'vagrant germ-cells are found in all sorts of places, but more particularly on the mesentery.' Some of these may possibly find their way into the germinal ridge; some probably undergo atrophy, while others may persist and become the seat of dermoid tumours.

The **testis** is developed in a very similar way to the ovary. Like the ovary, in its earliest stages it consists of a central mass of connective tissue covered by germinal epithelium, among which larger cells, the *primitive sperm-cells*, are seen. These are carried into the subjacent stroma by tubes of germinal epithelium, which form the lining of the seminiferous tubules, while the primitive sperm-cells form the spermatogonia. The seminiferous tubules become connected with outgrowths from the Wolffian body, which, as before mentioned, form the rete testis and vasa efferentia.

Descent of the testes.—The testes, at an early period of fœtal life, are placed at the back part of the abdominal cavity, behind the peritoneum and a little below the kidneys; their anterior surfaces and sides are invested by peritoneum. About the third month of intra-uterine life a peculiar structure, the *gubernaculum testis*, makes its appearance. This is at first a slender band, extending from that part of the skin of the groin which afterwards forms the scrotum through the inguinal canal to the body and epididymis of the testis, and thence continued upwards in front of the kidney towards the Diaphragm. As development advances, the peritoneum covering the testis encloses it and forms a mesentery, the *mesorchium*, which encloses also the gubernaculum and forms two folds, one above the testis and the other below it. The one above the testis is the *plica vascularis*, and contains ultimately the spermatic vessels; the one below, the *plica gubernatrix*, contains the lower part of the gubernaculum, which has now grown into a thick cord; it terminates below at the internal ring in a tube of peritoneum, the processus vaginalis, which protrudes itself down the inguinal canal. The lower part of the gubernaculum by the fifth month has become a thick cord, while the upper part has disappeared. The lower part can now be seen to consist of a central core of unstriped muscle-fibre, and outside this of a firm layer of striped elements, connected, behind the peritoneum, with the abdominal wall. As the scrotum develops, the main portion of the lower end of the gubernaculum is carried with the skin to which it is attached to the bottom of this pouch; other bands are carried to the inner side of the thigh and to the perineum. The fold of peritoneum constituting the processus vaginalis projects itself downwards into the inguinal canal, and emerges at the external abdominal ring, pushing before it a part of the Internal oblique and the aponeurosis of the External oblique, which form respectively the Cremaster muscle and the external spermatic fascia. It forms a gradually elongating pouch or *cul-de-sac*, which eventually reaches the bottom of the scrotum, and behind this the testis is drawn by the growth of the body of the fœtus, for the gubernaculum does not grow commensurately with the growth of other parts, and therefore the testis, being attached by the gubernaculum to the bottom of the scrotum, is prevented from rising as the body grows, and is drawn first into the inguinal canal and eventually into the scrotum. It seems certain also that the gubernacular cord becomes shortened as development proceeds, and this assists in causing the testis to reach the bottom of the scrotum. By the eighth month the testis has reached the scrotum, preceded by the lengthened pouch of peritoneum, the processus vaginalis, which communicates by its upper extremity with the peritoneal cavity. Just before birth the upper part of the pouch usually becomes closed, and this obliteration extends gradually downwards to within a short distance of the testis. The process of peritoneum surrounding the testis is now entirely cut off from the general peritoneal cavity and constitutes the *tunica vaginalis*.*

* The obliteration of the process of peritoneum which accompanies the cord, and is hence called the *funicular process*, is often incomplete.

In the female there is also a gubernaculum, which effects a considerable change in the position of the ovary, though not so extensive a change as in that of the testis in the male. The gubernaculum in the female, as it lies on either side in contact with the fundus of the uterus, contracts adhesions to this organ, and thus the ovary is prevented from descending below this level. The upper part of the gubernaculum, i.e. the part between the ovary and the uterus, becomes ultimately the round ligament of the ovary, while the lower part, i.e. the part between the attachment of the cord to the uterus and its termination in the labium majus, ultimately forms the round ligament of the uterus. A pouch of peritoneum analogous to the processus vaginalis in the male accompanies it along the inguinal canal: it is called the *canal of Nuck*. In rare cases the gubernaculum may fail to contract adhesions to the uterus, and then the ovary descends through the inguinal canal into the labium majus, extending down the canal of Nuck, and under these circumstances its position resembles that of the testis in the male.

Fig. 238.—Tail end of human embryo of twenty-five to twenty-nine days old. (From model by Keibel.)

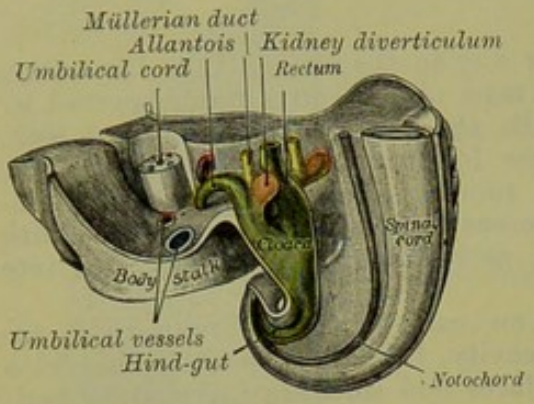

The Metanephros or Permanent Kidney.—The rudiments of the permanent kidneys make their appearance about the end of the first or beginning of the second month. Each arises as a diverticulum from the hind-end of the Wolffian duct, close to where the latter opens into the cloaca (figs. 238, 239). This diverticulum grows upwards and forwards into the posterior part of the intermediate cell-mass, where its blind or anterior extremity becomes dilated and subsequently divides into several buds, which form the rudiments of the pelvis and calyces of the kidney. By further subdivision it gives rise to the collecting tubules of the kidney; whether the secretory tubules are developed from the renal diverticulum or from the surrounding mesoderm is not as yet determined. The mesoderm around the subdivisions of the diverticulum becomes condensed to form the connective tissue and vessels of the kidney. The diverticulum is elongated to form the ureter, the posterior extremity of which opens at first into the hind-end of the Wolffian duct; after the sixth week it separates from the Wolffian duct, and opens independently into the part of the cloaca which ultimately becomes the bladder (fig. 240). The manner in which this separation is brought about is not fully known.*

Fig. 239.—Tail end of human embryo of thirty-two to thirty-three days old. (From model by Keibel.)

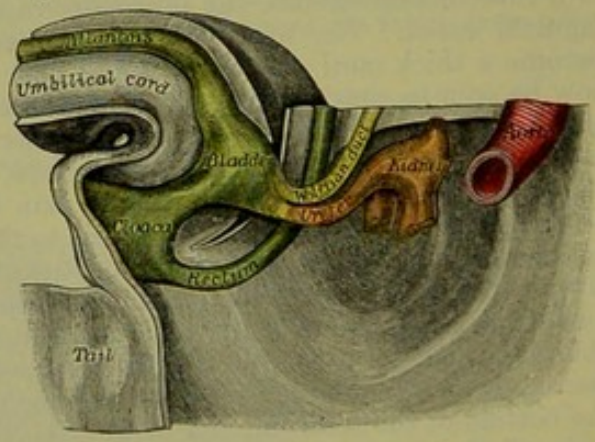

The secretory tubules of the kidney become arranged into pyramidal masses

* The separation of the ureter from the Wolffian duct may be brought about by the absorption of the hinder end of the latter into the genito-urinary chamber, and by the growth of the wall of this chamber between the openings. Robinson (*Proceedings of the Anatomical Society of Great Britain and Ireland*, May 1903, page lxiii) states, regarding an embryo of about seven weeks, that 'from the posterior or lower opening of the Wolffian duct a grooved ridge, the *Wolffian ledge*, runs caudally on the wall of the genito-urinary chamber and gradually disappears at the junction of the Wolffian angle with the body of the chamber. The lateral margins of the groove are continuous anteriorly with the lateral margins of the Wolffian duct, and apparently fuse together to form the ventral wall of the lower part of the duct. . . . Obviously, if the lateral margins of the groove were to fuse from before backwards, the aperture of the Wolffian duct would be carried further backward in the chamber, and its distance from the opening of the ureter increased.'

or lobules, and the lobulated condition of the kidneys exists for some time after birth, while traces of it may be found even in the adult. The kidney of the ox and many other animals remains lobulated throughout life.

The Urethra.—In the female the urethra is formed from the upper part of the urogenital sinus, viz. that part which lies above the openings of the Wolffian and Müllerian ducts. The portion of the sinus below these openings becomes gradually shortened, and is ultimately opened out to form the vestibule, and in this manner the urethra and vagina come to open separately on the surface. Wood-Jones regards the female urethra as 'the cloacal remnant in its simplest form,' and points out that it does not remain tubular throughout fœtal life, but is for a time 'obliterated more or less completely by the proliferation of the vaginal bulbs.' Developmentally considered, the male urethra consists of two parts: (1) the prostatic and membranous portions, which are derived from the urogenital sinus, and correspond to the whole of the female urethra; (2) the penile portion, which is formed by the fusion of the inner genital folds (see below).

The Prostate Gland originally consists of two separate portions, each of which arises as a series of diverticular buds from the epithelial lining of the urogenital sinus, between the third and fourth months. These buds become tubular, and form the glandular substance of the two lobes, which ultimately meet and fuse behind the urethra and also extend on to its ventral aspect. The third or middle lobe is formed as an extension of the lateral lobes between the common ejaculatory ducts and the bladder. *Skene's ducts* in the female urethra are regarded as the homologues of the prostatic glands.

The *glands of Cowper* in the male, and *of Bartholin* in the female, also arise as diverticula from the epithelial lining of the urogenital sinus.

Fig. 240.—Tail end of human embryo, from eight and a half to nine weeks old. (From model by Keibel.)

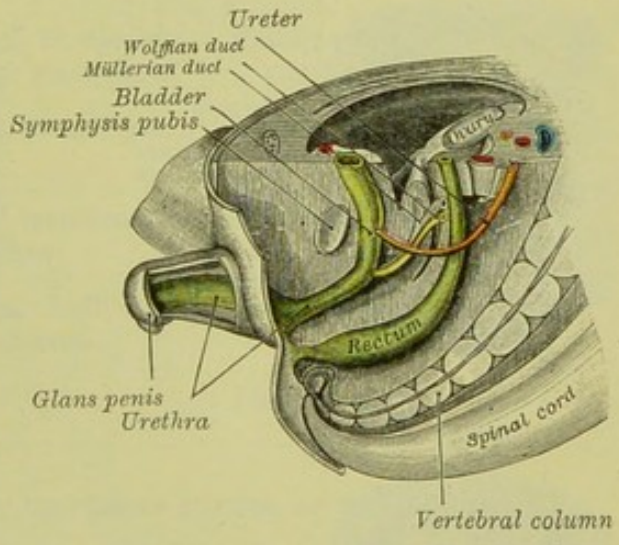

The Urinary Bladder.—The trigone of the bladder is formed from the upper part of the urogenital sinus (page 161); the remainder of the viscus is developed from the part of the cloaca which lies above the sinus (fig. 239). The bladder is at first tubular in shape, its canal being continuous with that of the allantois, but after the second month its cavity expands to form a sac, from the summit of which the tube of the allantois extends to the umbilicus; this tube undergoes obliteration to form the fibrous cord of the urachus. In some cases the allantoic canal remains patent, and urine may escape by it at the umbilicus. If the urethra be looked upon as the remnant of the cloaca, then the bladder, with the exception of the trigone, must be regarded as being developed by a dilatation of the proximal part of the allantois.

The External Organs of Generation (fig. 241), like the internal, pass during development through an indifferent stage in which there is no distinction of sex. It is therefore necessary to describe this stage, and then follow the development of the female and male organs respectively.

As already stated (page 161), the cloacal membrane, which is composed of ectoderm and entoderm, originally reaches from the umbilicus to the tail. The mesoderm around the cloacal chamber gradually extends between the layers of the membrane, stopping short, however, round the margins of the entodermal cloaca, so that the bilaminar cloacal membrane is limited to this part. About the fifth week a prominence, the *genital tubercle*, arises in front of the cloacal membrane, while at the sides the edges of the mesoderm are elevated to form the *labio-scrotal* or *outer genital folds*.

Along the under surface of the genital tubercle the ectoderm is thickened, and at the apex of the tubercle projects forwards as an epithelial horn. In this ectodermal

thickening a longitudinal groove, the genital groove, appears, and into its lips the mesoderm extends to form the *inner genital folds*. After the rupture of the cloacal membrane this groove becomes continuous with the urogenital sinus. With the formation of these parts the *indifferent stage* of the external genital organs is reached.

In the *female* this stage is largely retained; the lower part of the urogenital sinus persists as the vestibule, the genital tubercle forms the clitoris, the labio-scrotal folds the labia majora, and the inner genital folds the labia minora.

FIG. 241.—Stages in the development of the external sexual organs in the male and female. (Drawn from the Ecker-Ziegler models.)

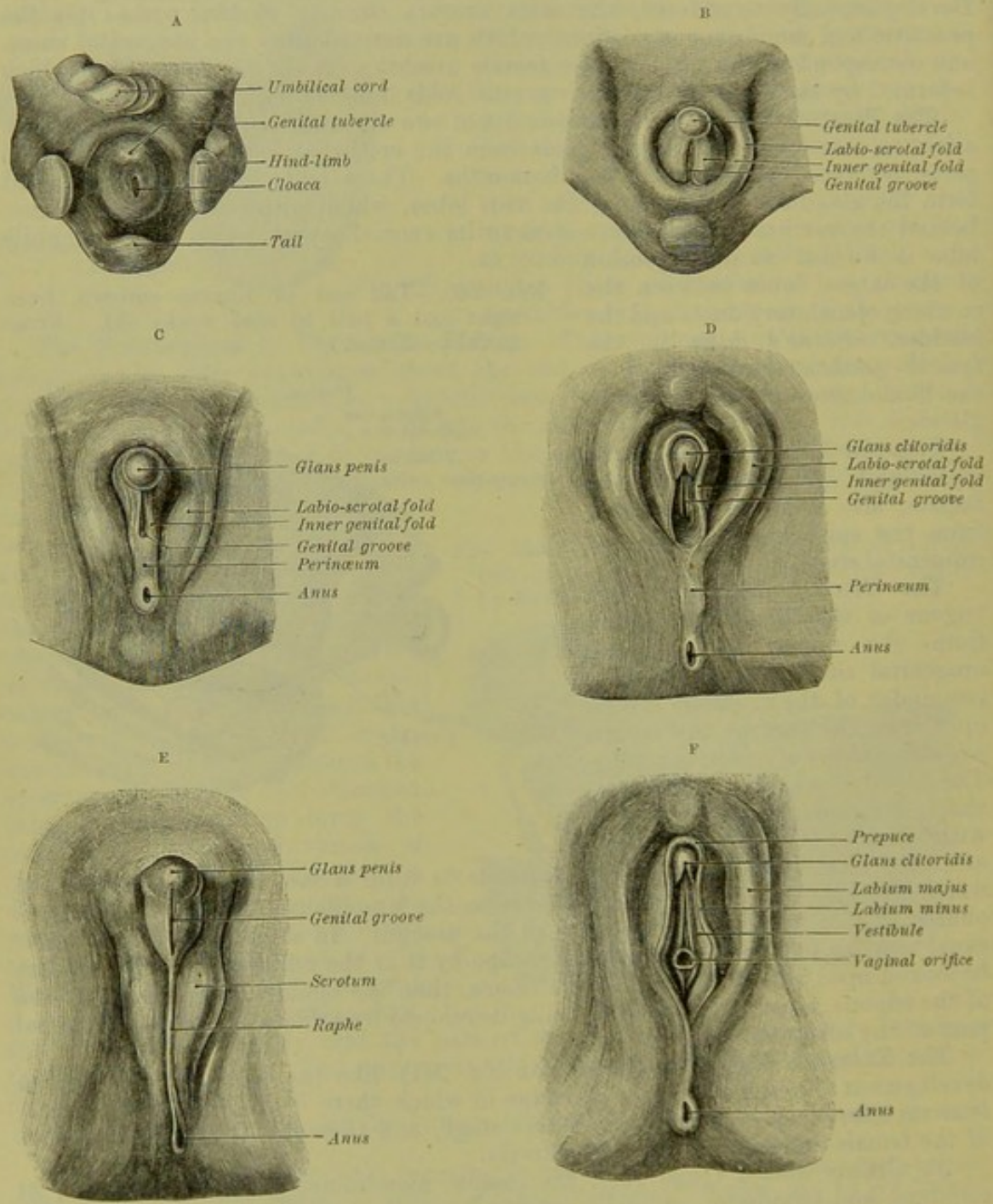

In the *male* the changes are greater on account of the development of the penile portion of the urethra. The genital tubercle enlarges to form the corpora cavernosa and glans penis. The lips of the inner genital folds meet and fuse from behind forwards to form the penile urethra, the bulb, and the corpus spongiosum. The part of the urethral groove on the glans penis is closed independently, and the last part of the urethral tube to be completed is that at the junction of the glans and body of the penis. If the lips of the groove fail to close, the condition known as *hypospadias* results.

The labio-scrotal folds meet and unite in the middle line to form the scrotum, their line of union being indicated by the median raphe.

The *prepuce* is formed by the growth of a solid plate of ectoderm into the superficial part of the genital tubercle; on coronal section this plate presents the shape of a horseshoe. By the breaking down of its more centrally situated cells this plate is split into two lamellæ, and a cutaneous fold, the prepuce, is liberated and forms a hood over the glans. 'Adherent prepuce is not an adhesion really, but a hindered central desquamation' (Berry Hart, *op. cit.*).*

The homologies of the different parts of the sexual organs may be stated in tabular form as follows :—

Indifferent Stage	Male	Female
Genital ridge .	Testis.	Ovary.
Wolffian body. .	Rete testis, vasa efferentia, coni vasculosi, organ of Giraldès.	Epoöphoron or organ of Rosenmüller. Paroöphoron.
Wolffian duct . .	Canal of epididymis, vas deferens, common ejaculatory duct. Seminal vesicle.	Hydatid of Morgagni. (Duct of Gärtner.)
Müllerian ducts .	Sessile hydatids of epididymes. Uterus masculinus.	Fallopian tubes, uterus, vagina.
Genital tubercle .	Corpora cavernosa and glans penis.	Clitoris.
Urogenital sinus .	Prostatic and membranous parts of urethra.	Urethra. Vestibule.
Inner genital folds.	Penile urethra, bulb and corpus spongiosum.	Labia minora.
Labio-scrotal folds	Scrotum.	Labia majora.

THE FORM OF THE EMBRYO AT DIFFERENT STAGES OF ITS GROWTH

First Week.—During the early part of this period the ovum is in the Fallopian tube. Having been fertilised in the upper part of the tube, it slowly passes down, undergoing segmentation, and reaches the uterus before the end of the first week. Peters† described a specimen, the age of which he reckoned as from three to four days. It was imbedded in the decidua on the posterior wall of the uterus and enveloped by a decidua capsularis, the central part of which, however, consisted merely of a layer of fibrin. The ovum was in the form of a sac, the outer wall of which consisted of a layer of trophoblast; inside this was a thin layer of mesoderm composed of round, oval, and spindle-shaped cells. Numerous villous processes—some consisting of trophoblast only, others possessing a core of mesoderm—projected from the surface

* Spicer (*Journal of Anatomy and Physiology*, vol. xliii. 1909) describes the prepuce as arising in the form of an annular hood of mesodermal tissue which proceeds forwards *within the substance of the surrounding epithelium*. 'The main portion of this hood springs from mesoblastic tissue considerably posterior to the cervix glandis, in the form of a crescentic swelling or collar, and this creeps forward, burrowing always in the epithelial layers, bridging over the groove of the cervix which is filled with epidermal cells, and finally overlaps the body of the glans. This hood is the prepuce.'

'The epidermis covering the glans thus becomes divided into two layers: an outer, which forms the superficial covering of the prepuce, and an inner, which remains as a more or less solid layer between the prepuce and the glans until after birth. From it is differentiated a basal layer of cubical or cylindrical epithelium to line the inner aspect of the prepuce, and another to cover the surface of the glans, while central desquamation ensues later and prepares the way for a movable prepuce.'

† *Die Einbettung des Menschlichen Eies*, 1899.

of the ovum into the surrounding decidua. Inside this sac the rudiment of the embryo was found in the form of a patch of ectoderm, covered by a small but completely closed amnion. It possessed a minute yolk-sac and was surrounded by mesoderm, which was connected by a band to that lining the trophoblast (fig. 123).*

Fig. 242.—Human embryo of about fifteen days old. (His.)

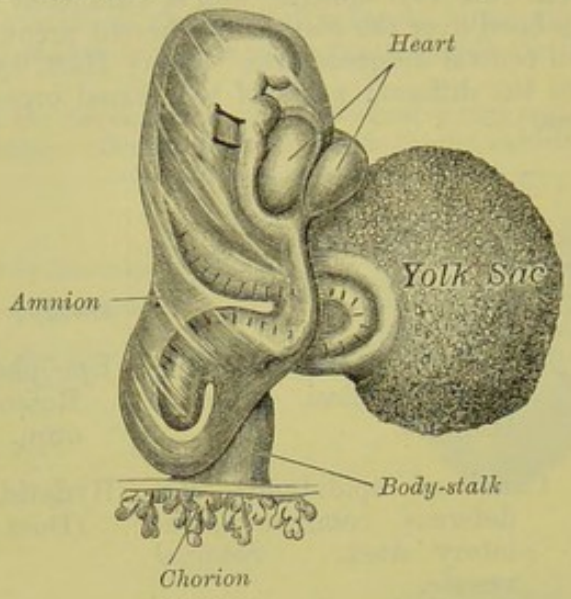

Second Week.—By the end of this week the ovum has increased considerably in size, and the majority of its villi are vascularised. The embryo has assumed a definite form, and its cephalic and caudal extremities are easily distinguished. The neural or medullary folds are partly united. The embryo is more completely separated from

Fig. 243.—Human embryo between eighteen and twenty-one days old. (His.)

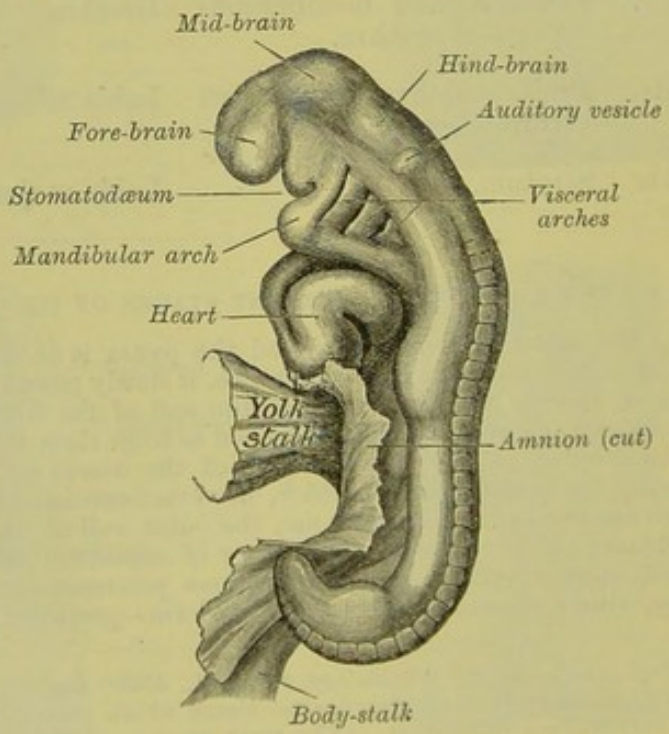

the yolk-sac, and the paraxial mesoderm is being divided into the primitive segments (fig. 242).

Third Week.—By the end of the third week the embryo is strongly curved, and the primitive segments number about thirty. The primary divisions of the brain are visible,

* Bryce and Teacher (*Early Development and Imbedding of the Human Ovum*, 1908) have described an ovum which they regard as thirteen to fourteen days old. In it the two vesicles, the amnion and yolk-sac, were present, but there was no trace of a layer of embryonic ectoderm. They are of opinion that the age of Peters' ovum has been understated, and estimate it as between 13½ and 14½ days.

and the ocular and auditory vesicles are formed. Four visceral clefts are present; the stomatodæum is well marked, and the bucco-pharyngeal membrane has disappeared. The rudiments of the limbs are seen as short buds, and the Wolffian bodies are visible (fig. 243).

Fourth Week.—The embryo is markedly curved on itself, and when viewed in profile is almost circular in outline. The cerebral hemispheres appear as hollow buds, and the elevations which form the rudiments of the pinna are visible. The limbs now appear as oval flattened projections (fig. 244).

Fig. 244.—Human embryo, twenty-seven to thirty days old. (His.)

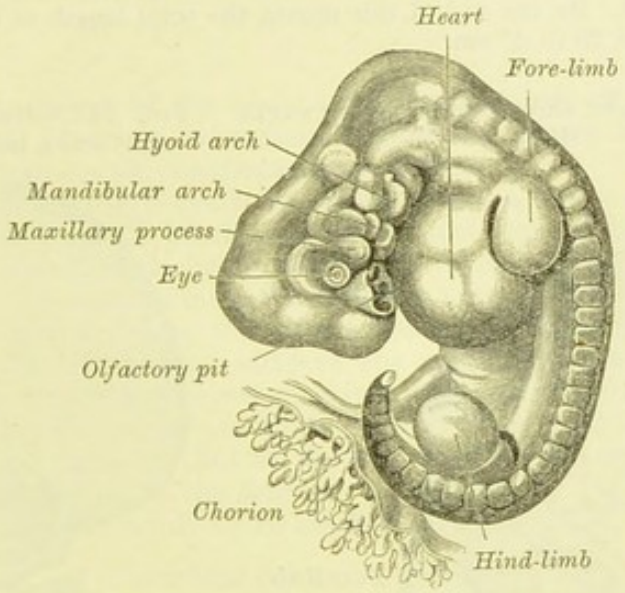

Fifth Week.—The embryo is less curved and the head is relatively of large size. Differentiation of the limbs into their segments occurs. The nose forms a short, flattened projection. The genital tubercle is evident (fig. 245).

Sixth Week.—The curvature of the embryo is further diminished. The visceral clefts—except the first—have disappeared, and the rudiments of the fingers and toes can be recognised (fig. 246).

Fig. 245.—Human embryo, thirty-one to thirty-four days old. (His.)

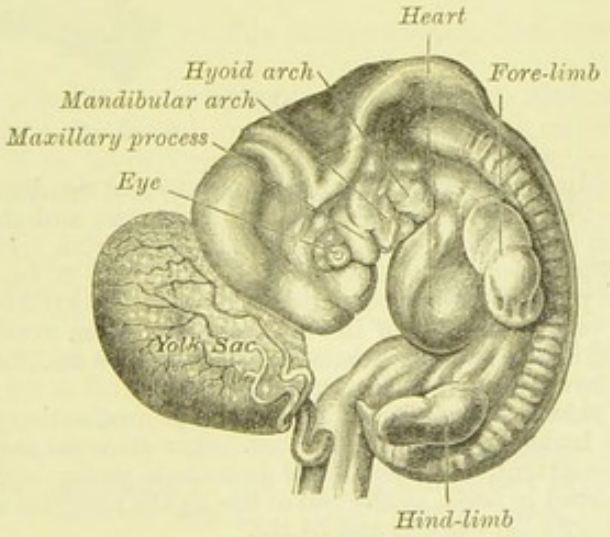

Seventh and Eighth Weeks.—The flexure of the head is gradually reduced and the neck is somewhat lengthened. The upper lip is completed and the nose is more prominent. The nostrils are directed forwards and the palate is not completely developed. The eyelids are present in the shape of folds above and below the eye, and the different parts of the pinna are distinguishable. By the end of the second month the fœtus measures from 28 to 30 mm. in length (fig. 247).

Third Month.—The head is extended and the neck is lengthened. The eyelids meet and fuse, remaining closed until the end of the seventh month. The limbs are well developed and nails appear on the digits. The external organs are so far differentiated that it is possible to distinguish the sex. By the end of this month the length of the fœtus is about 7 cm., but if the legs be included it is from 9 to 10 cm.

Fourth Month.—The loop of gut which projected into the umbilical cord is withdrawn within the fœtus. The hairs begin to make their appearance. There is a general increase in size so that by the end of the fourth month the fœtus is from 12 to 13 cm. in length, but if the legs be included it is from 16 to 20 cm.

Fifth Month.—It is during this month that the first movements of the fœtus are usually observed. The eruption of hair on the head commences, and the *vernix caseosa* begins to be deposited. By the end of this month the total length of the fœtus, including the legs, is from 25 to 27 cm.

FIG. 246.—Human embryo of about six weeks. (His.)

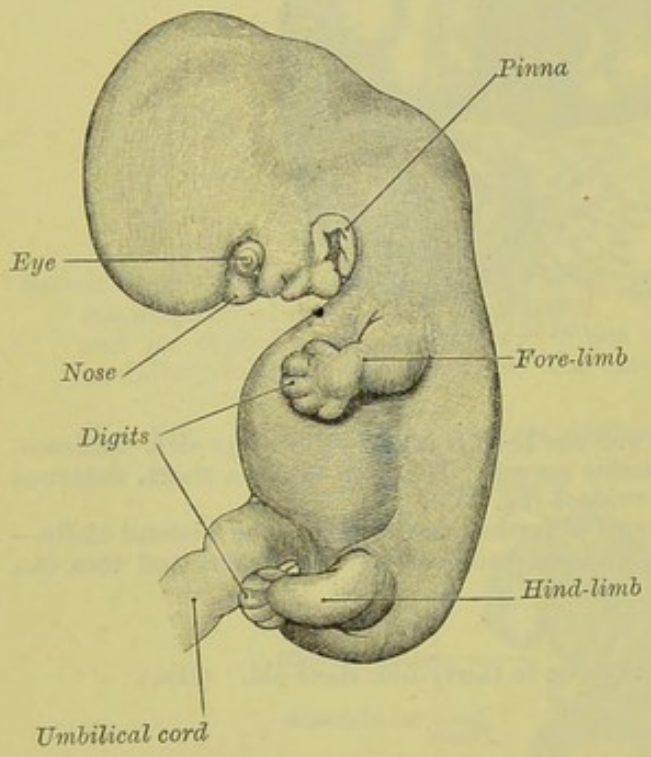

FIG. 247.—Human embryo about eight and a half weeks old. (His.)

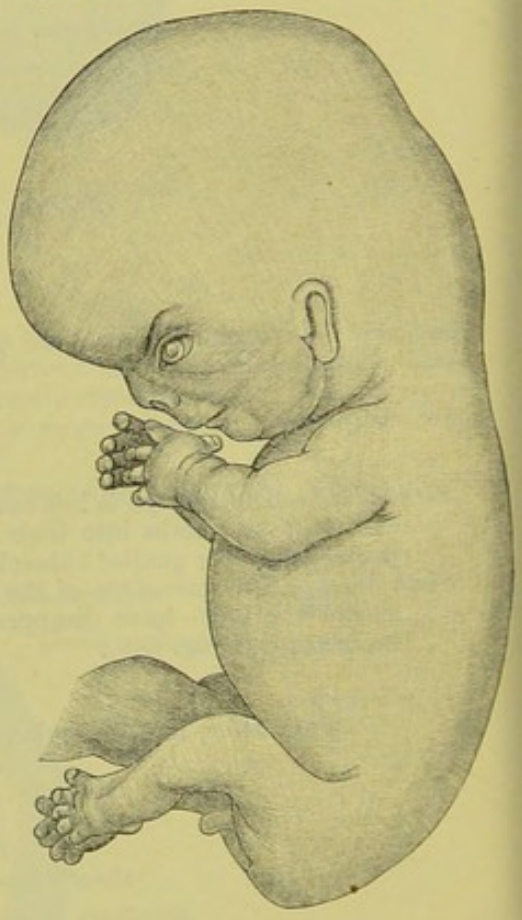

Sixth Month.—The body is covered by fine hairs (*lanugo*) and the deposit of vernix caseosa is considerable. The papillæ of the skin are developed and the free border of the nail projects from the corium of the dermis. Measured from vertex to heels, the total length of the fœtus at the end of this month is from 30 to 32 cm.

Seventh Month.—The pupillary membrane atrophies and the eyelids reopen. The testis passes into the vaginal process of the peritoneum. From vertex to heels the total length at the end of the seventh month is from 35 to 36 cm., i.e. about 14 in. The weight is a little over three pounds.

Eighth Month.—The skin assumes a pink colour and is now entirely coated with vernix caseosa, and the lanugo begins to disappear. Subcutaneous fat has been developed to a considerable extent, and the fœtus presents a plump appearance. The total length, i.e. from head to heels, at the end of the eighth month is about 40 cm. (16 in.), and the weight varies between 4½ and 5½ lbs.

Ninth Month.—The lanugo has largely disappeared from the trunk. The umbilicus is almost in the middle of the body and the testes are in the scrotum. At full time the fœtus weighs from 6½ to 8 lbs., and measures from head to heels about 50 cm. (20 in.).

OSTEOLOGY

THE general framework of the body is built up mainly of a series of bones, supplemented, however, in certain regions by pieces of cartilage; the bony part of the framework constitutes the *skeleton*.

In comparative anatomy the term skeleton has a wider application, as in some of the lower animals hard, protective and supporting structures are more extensively distributed, being developed in association with the integumentary system. In such animals the skeleton may be described as consisting of an internal or deep skeleton, the *endoskeleton*, and an external or superficial, the *exoskeleton*. In the human subject the exoskeleton is extremely rudimentary, its only important representatives being the teeth and nails. The term skeleton is, therefore, confined to the endoskeleton, and this is divisible into an *axial* part, which includes that of the head and trunk, and an *appendicular* part, which comprises that of the limbs.

In the skeleton of the adult there are 206 distinct bones, as follows :—

Axial Skeleton	Vertebral column	26	
	Skull	22	
	Hyoid bone	1	
	Ribs and sternum	25	
		—	74
Appendicular Skeleton	Upper limbs	64	
	Lower limbs	62	
		—	126
Auditory ossicles			6
	Total		206

The patellæ are included in this enumeration, but the smaller sesamoid bones are not reckoned.

Bones are divisible into four classes : *Long*, *Short*, *Flat*, and *Irregular*.

The **Long bones** are found in the limbs, and each consists of a shaft and two extremities. The *shaft*, or diaphysis, is a hollow cylinder, the central cavity being termed the *medullary canal* ; the wall consists of dense, compact tissue of considerable thickness in the middle part of the shaft, but becoming thinner towards the extremities ; the cancellous tissue is scanty. The *extremities* are generally expanded, for the purposes of articulation, and to afford broad surfaces for muscular attachment. They are usually developed from separate centres of ossification termed *epiphyses*, and consist of cancellous tissue surrounded by a thin layer of compact bone. The medullary canal and the spaces in the cancellous tissue are filled with marrow. The long bones are not straight, but curved; the curve generally taking place in two planes, thus affording greater strength to the bone. The bones belonging to this class are : the *clavicle*, *humerus*, *radius*, *ulna*, *femur*, *tibia*, *fibula*, *metacarpals*, *metatarsals*, and *phalanges*.

Short bones.—Where a part of the skeleton is intended for strength and compactness combined with limited movement, it is divided into a number of small bones, as in the *carpus* and *tarsus*. These consist of cancellous tissue covered by a thin crust of compact substance. The *patellæ*, together with the other sesamoid bones, are by some regarded as short bones.

Flat bones.—Where the principal requirement is either extensive protection or the provision of broad surfaces for muscular attachment, the bones

are expanded into broad, flat plates, as in the skull and the shoulder-blade. These bones are composed of two thin layers of compact tissue enclosing between them a variable quantity of cancellous tissue. In the cranial bones, the layers of compact tissue are familiarly known as the *tables* of the skull; the outer one is thick and tough; the inner is thin, dense, and brittle, and hence is termed the *vitreous table*. The intervening cancellous tissue is called the *diploë*, and this, in certain regions of the skull, becomes absorbed so as to leave spaces filled with air (*air-sinuses*) between the two tables. The flat bones are: the *occipital*, *parietal*, *frontal*, *nasal*, *lachrymal*, *vomer*, *scapula*, *os innominatum*, *sternum*, *ribs*, and, according to some, the *patella*.

The **irregular bones** are such as, from their peculiar form, cannot be grouped under the preceding heads. They consist of cancellous tissue enclosed within a thin layer of compact bone. The irregular bones are: the *vertebræ*, *sacrum*, *coccyx*, *temporal*, *sphenoid*, *ethmoid*, *malar*, *maxilla*, *mandible*, *palate*, *inferior turbinated*, and *hyoid*.

Surfaces of bones.—If the surface of a bone be examined, certain eminences and depressions are seen, to which descriptive anatomists have given the following names.

These eminences and depressions are of two kinds: articular and non-articular. Well-marked examples of *articular eminences* are found in the heads of the humerus and femur; and of *articular depressions* in the glenoid cavity of the scapula, and the acetabulum of the os innominatum. *Non-articular eminences* are designated according to their form. Thus, a broad, rough, uneven elevation is called a *tuberosity*, *protuberance*, or *process*; a small, rough prominence, a *tubercle*; a sharp, slender, pointed eminence, a *spine*; a narrow, rough elevation, running some way along the surface, a *ridge*, *crest*, or *line*. *Non-articular depressions* are also of variable form, and are described as *fossæ*, *pits*, *depressions*, *grooves*, *furrows*, *fissures*, *notches*, &c. These non-articular eminences and depressions serve to increase the extent of surface for the attachment of ligaments and muscles, and are usually well marked in proportion to the muscularity of the subject; the grooves, fissures and notches transmit vessels and nerves.

In describing the various surfaces or aspects of a bone, or indeed of any other structure, the body is supposed to be in the erect position. Any surface, extremity, or other part directed upwards towards the head is termed *superior*, while those directed downwards towards the feet are termed *inferior*. Surfaces directed forwards towards the front of the body are termed *anterior* or *ventral*, while those directed backwards are *posterior* or *dorsal*. Those surfaces which are directed towards a median antero-posterior vertical plane are termed *internal* or *mesial*, while those directed away from this plane are *external* or *lateral*.

The minute structure, growth, and composition of bone are described on pages 24 to 34.

THE VERTEBRAL COLUMN

The **vertebral** or **spinal column** (columna vertebralis) is a flexuous and flexible column, formed of a series of bones called *vertebræ*.

The **vertebræ** are thirty-three in number, and are grouped under the names *cervical*, *thoracic* or *dorsal*, *lumbar*, *sacral*, and *coccygeal*, according to the regions they occupy; seven being found in the cervical region, twelve in the thoracic, five in the lumbar, five in the sacral, and four in the coccygeal.

This number is sometimes increased by an additional vertebra in one region, or it may be diminished in one region, the deficiency being supplied by an additional vertebra in another. The number of cervical vertebræ is, however, very rarely increased or diminished.

The vertebræ in the upper three regions of the column remain distinct throughout life, and are known as *true* or *movable* vertebræ; those of the sacral and coccygeal regions, on the other hand, are termed *false* or *fixed* vertebræ, because they are united in the adult to form two bones—five forming the upper bone or *sacrum*, and four the terminal bone or *coccyx*.

With the exception of the first and second cervical, the true or movable vertebræ present certain common characters which are best studied by examining one from the middle of the thoracic region.

General Characters of a Vertebra

A typical **vertebra** consists of two essential parts—viz. an anterior segment, the *body* or *centrum* (corpus vertebræ), and a posterior part, the *neural arch* (arcus vertebræ); these enclose a foramen, the *spinal* or *vertebral foramen* (foramen vertebrale). The neural arch consists of a pair of *pedicles* and a pair of *laminæ*, and supports seven *processes*—viz. four *articular* (zygapophyses), two *transverse* (processus transversi), and one *spinous* (processus spinosus).

When the vertebræ are articulated with each other the bodies form a strong pillar for the support of the head and trunk, and the spinal foramina constitute a canal for the protection of the spinal cord, whilst between every pair of vertebræ are two apertures, the intervertebral foramina (foramina intervertebralia), one on either side, for the transmission of the spinal nerves and vessels. Each of these constituent parts must now be considered.

The **body** or **centrum** is the largest part of a vertebra, and is more or less cylindrical in shape. Its upper and lower surfaces are flattened and rough, and give attachment to the intervertebral fibro-cartilages, and each presents a rim around its circumference. In front, it is convex from side to side and concave from above downwards. Behind, it is flat from above downwards and slightly concave from side to side. Its anterior surface presents a few small apertures, for the passage of nutrient vessels; on the posterior surface is a single large, irregular aperture, or occasionally more than one, for the exit of veins from the body of the vertebra—the *venæ basis vertebræ*.

Fig. 248.—Sagittal section of a lumbar vertebra.

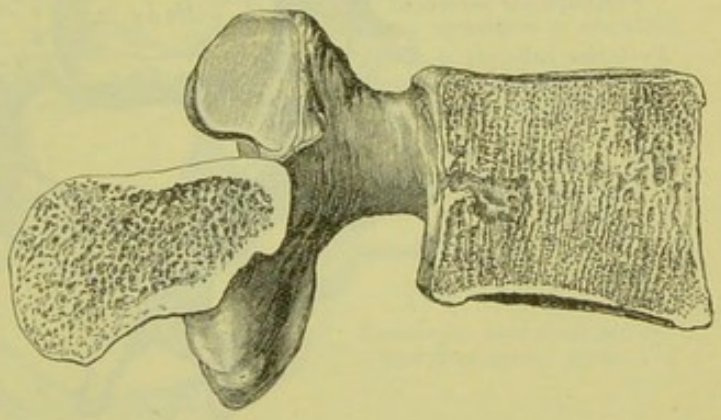

The **pedicles** are two short, thick processes of bone, which project backwards, one on either side, from the upper part of the body, at the junction of its posterior and lateral surfaces. The concavities above and below the pedicles are named the *intervertebral notches*; and when the vertebræ are articulated, the notches of each contiguous pair of bones form the *intervertebral foramina*, already referred to.

The **laminæ** are two broad plates directed backwards and inwards from the pedicles. They fuse in the middle line posteriorly, and so complete the posterior boundary of the vertebral foramen. Their upper borders and the lower parts of their anterior surfaces are rough for the attachment of the ligamenta subflava.

The **spinous process** is directed backwards and downwards from the junction of the laminæ, and serves for the attachment of muscles and ligaments.

The **articular processes**, two superior and two inferior, spring from the junction of the pedicles and laminæ. The superior project upwards, and their articular surfaces are directed more or less backwards; the inferior project downwards, and their surfaces look more or less forwards.

The **transverse processes**, two in number, project one at either side from the point where the lamina joins the pedicle, between the superior and inferior articular processes. They serve for the attachment of muscles and ligaments.

Structure of a vertebra (fig. 248).—The body is composed of cancellous tissue, covered by a thin coating of compact bone; the latter is perforated by numerous orifices, some of large size, for the passage of vessels; the interior of the bone is traversed by one or two large canals, for the reception of veins, which converge towards a single large, irregular aperture, or several small apertures, at the posterior part of the body. The arch and processes projecting from it have a thick covering of compact tissue.

Cervical Vertebræ (fig. 249)

The **cervical vertebræ** (vertebræ cervicales) are the smallest of the true vertebræ, and can be readily distinguished from those of the thoracic or lumbar regions by the presence of a foramen (foramen transversarium) in each transverse process. The first, second, and seventh present exceptional features and must be separately described; the following characters are common to the remaining four.

The *body* is small, and broader from side to side than from before backwards. The anterior and posterior surfaces are flattened and of equal depth; the former is placed on a lower level than the latter, and its inferior border is prolonged downwards, so as to overlap the upper and fore part of the vertebra below. Its upper surface is concave transversely, and presents a projecting lip on either side; its lower surface is concave from before backwards, convex from side to side, and presents laterally a shallow concavity, which receives the corresponding projecting lip of the subjacent vertebra. The *pedicles* are directed outwards and backwards, and are attached to the body midway between its upper and lower borders, so that the superior intervertebral notch is as deep as the inferior, but it is, at the same time, narrower. The *laminæ* are narrow, and thinner above than below; the *spinal foramen* is large, and of a triangular form. The *spinous process* is

Fig. 249.—A cervical vertebra.

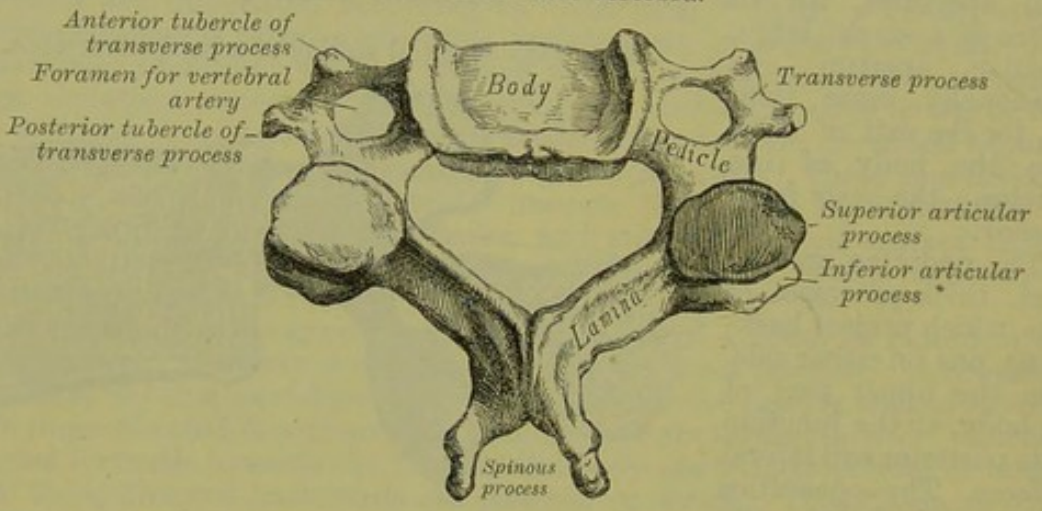

short and bifid, the two divisions being often of unequal size. The *superior* and *inferior articular processes* of each side are fused to form an articular pillar, which projects outwards from the junction of the pedicle and lamina. The articular facets are flat and of an oval form: the superior look backwards, upwards, and slightly inwards; the inferior forwards, downwards, and slightly outwards. The *transverse processes* are each pierced by a *foramen transversarium*, which, in the upper six vertebræ, gives passage to the vertebral artery and vein and a plexus of sympathetic nerves. Each process consists of an anterior and a posterior part. The anterior portion is the homologue of the rib in the thoracic region, and is therefore named the *costal process* or *costal element*: it arises from the side of the body, is directed outwards in front of the foramen, and ends in a tubercle, the *tuberculum anterius*. The posterior part, the true transverse process, springs from the neural arch behind the foramen, and is directed forwards and outwards; it terminates in a tubercle, the *tuberculum posterius*. These two parts are joined, outside the foramen, by a bar of bone which exhibits a deep groove (sulcus n. spinalis) on its upper surface for the passage of the corresponding spinal nerve.*

Chassaignac first pointed out that the common carotid artery can be easily compressed against the anterior tubercle of the transverse process of the sixth cervical vertebra, and

* The *costal element* of a cervical vertebra not only includes the portion which springs from the side of the body, but the anterior and posterior tubercles and the bar of bone which connects them.

therefore this tubercle is named the *tuberculum caroticum* or *Chassaignac's tubercle.* It also constitutes an important guide to the vertebral artery which enters the foramen transversarium of this vertebra.

The **first cervical vertebra** (fig. 250) is named the **atlas** because it supports the globe of the head. Its chief peculiarities are that it has neither body nor spinous process, but is ring-like, and consists of an anterior and a posterior arch, and two lateral masses. The *anterior* arch (arcus anterior) forms about one-fifth of the ring: its anterior surface is convex, and presents at its centre a *tubercle* (tuberculum anterius) for the attachment of the Longus colli; posteriorly it is concave, and marked by a smooth, oval or circular facet (fovea dentis), for articulation with the odontoid process of the axis. The upper and lower borders respectively give attachment to the anterior occipito-atlantal and the anterior atlanto-axial ligaments; the former connects it with the occipital bone above and the latter with the axis below. The *posterior* arch forms about two-fifths of the circumference of the ring: it terminates behind in a *tubercle* (tuberculum posterius) which is the rudiment of a spinous process and gives origin to the Rectus capitis posticus minor. The diminutive size of this process prevents any interference with the movements between the atlas and the cranium. The posterior part of the arch presents above and behind a rounded edge for the attachment of the posterior occipito-atlantal ligament, while immediately behind each superior articular process is a groove (sulcus arteriæ vertebralis), sometimes converted into a foramen by a

FIG. 250.—First cervical vertebra, or Atlas.

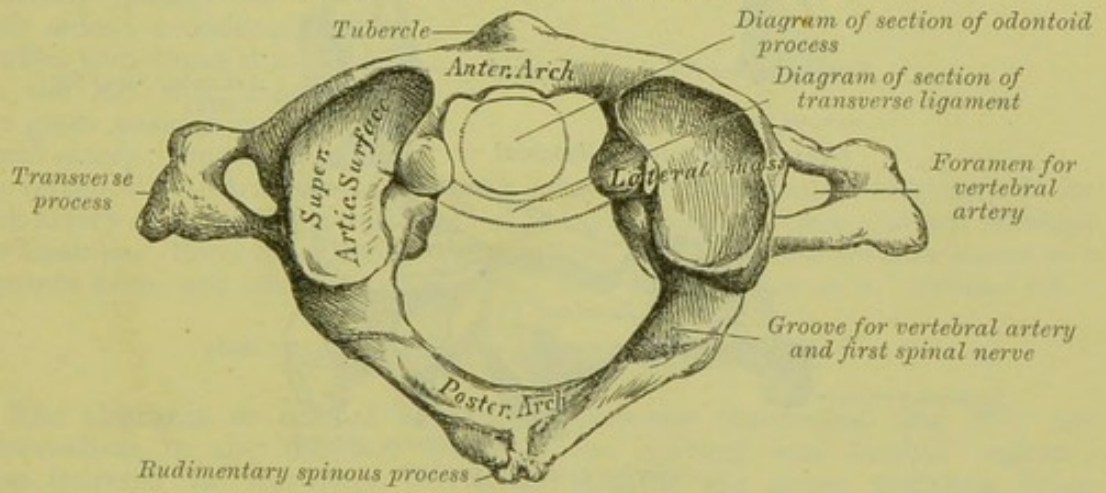

delicate bony spiculum which arches backwards from the posterior extremity of the superior articular process. This groove represents the superior intervertebral notch, and serves for the transmission of the vertebral artery, which, after ascending through the foramen in the transverse process, winds round the lateral mass in a direction backwards and inwards. It also transmits the suboccipital (first spinal) nerve. On the under surface of the posterior arch, behind the articular facets, are two shallow grooves, which represent the inferior intervertebral notches of other vertebræ. The lower border gives attachment to the posterior atlanto-axial ligament, which connects it with the axis. The *lateral masses* are the most bulky and solid parts of the atlas, in order to support the weight of the head. Each presents an articular facet above, and one below. The superior facets are of large size, oval, concave, and approach each other in front, but diverge behind: they are directed upwards, inwards, and a little backwards, each forming a cup for the corresponding condyle of the occipital bone, and are admirably adapted to the nodding movements of the head. Not infrequently they are partially subdivided by more or less deep indentations which encroach upon their lateral margins. The inferior articular facets are circular in form, flattened or slightly convex and directed downwards and inwards, articulating with the axis, and permitting the rotatory movements of the head. Just below the inner margin of each superior facet is a small tubercle, for the attachment of the transverse ligament which stretches across the ring of the atlas and divides the

vertebral foramen into two unequal parts—the anterior or smaller receiving the odontoid process of the axis, the posterior transmitting the spinal cord and its membranes. This part of the spinal canal is of considerable size, much greater than is required for the accommodation of the spinal cord, and hence lateral displacement of the atlas may occur without compression of this structure. The *transverse processes* are large; they project outwards and downwards from the lateral masses, and serve for the attachment of muscles which assist in rotating the head. They are long, and do not present anterior and posterior tubercles, since these have become fused into one mass; the foramen for the vertebral artery is directed from below, upwards and backwards.

The **second cervical vertebra** (fig. 251) is named the **axis** or **epistropheus** because it forms the pivot upon which the first vertebra, carrying the head, rotates. The most distinctive character of this bone is the strong tooth-like odontoid process which rises perpendicularly from the upper surface of the body. The *body* is deeper in front than behind, and prolonged downwards anteriorly so as to overlap the upper and fore part of the third vertebra. It presents in front a median longitudinal ridge, separating two lateral depressions for the attachment of the Longus colli muscles. Its under surface is concave from before backwards and convex from side to side. The *odontoid process* (dens) exhibits a slight constriction, or neck, where it joins the body. On its anterior surface is an oval or nearly circular facet for articulation with

Fig. 251.—Second cervical vertebra, or Axis.

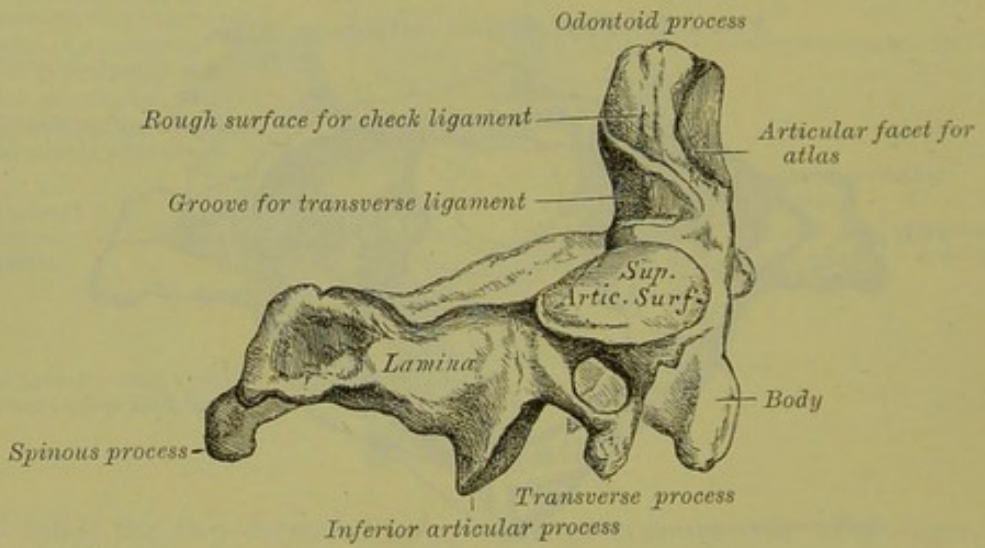

that on the anterior arch of the atlas. On the back of the neck, and frequently extending on to its lateral aspects, is a shallow groove for the transverse ligament which retains the process in position. The apex is pointed, and gives attachment to the middle odontoid or check ligament; below the apex the process is somewhat enlarged, and presents on either side a rough impression for the attachment of the lateral odontoid or check ligament; these ligaments connect the odontoid process to the occipital bone. The internal structure of the odontoid process is more compact than that of the body. The *pedicles* are broad and strong, especially in front, where they coalesce with the sides of the body and the root of the odontoid process. They are covered above by the superior articulating surfaces. The *laminæ* are thick and strong, and the spinal foramen large, but smaller than that of the atlas. The *transverse processes* are very small, not bifid, but terminating in a single tubercle; each is perforated by the foramen for the vertebral artery, which is directed obliquely upwards and outwards. The *superior articular surfaces* are round, slightly convex, directed upwards and outwards, and are supported on the body, pedicles, and transverse processes. The *inferior articular surfaces* have the same direction as those of the other cervical vertebræ. The *superior intervertebral notches* are very shallow, and lie behind the articular processes; the *inferior* lie in front of the articular processes, as in the other cervical vertebræ. The *spinous process* is large, very strong, deeply channelled on its under surface, and presents a bifid, tubercular extremity

for the attachment of muscles which serve to rotate the head upon the spine.

The **seventh cervical vertebra** (fig. 252).—The most distinctive characteristic of this vertebra is the existence of a long and prominent spinous process; hence the name *vertebra prominens*. This process is thick, nearly horizontal in direction, not bifurcated, but terminating in a tubercle, to which the lower end of the ligamentum nuchæ is attached. The *transverse processes* are of considerable size, their posterior tubercles are large and prominent, while the anterior are small and faintly marked; the upper surface of each has usually a shallow groove, and its extremity seldom presents more than a trace of bifurcation. The foramen in the transverse process may be as large as that in the other cervical vertebræ, but is generally smaller on one or both sides; occasionally it is double, sometimes it is absent. On the left side it occasionally gives passage to the vertebral artery; more frequently the vertebral vein traverses it on both sides; but the usual arrangement is for both artery and vein to pass in front of the transverse process, and not through the foramen. Sometimes the anterior root of the transverse process exists as a separate bone, and attains a large size. It is then known as a 'cervical rib.'

Fig. 252.—Seventh cervical vertebra, or vertebra prominens.

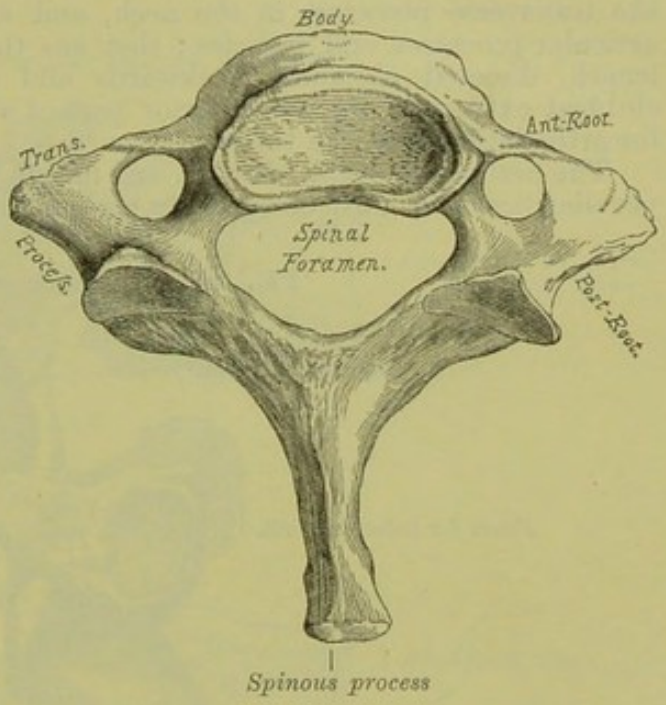

Thoracic or Dorsal Vertebræ

The **thoracic** or **dorsal vertebræ** (vertebræ thoracales) (fig. 253) are intermediate in size between those of the cervical and lumbar regions; they increase in size from above downwards, the upper vertebræ being much smaller than those in the lower part of the region. They are distinguished by the presence of facets on the sides of the bodies for articulation with the heads of the ribs, and facets on the transverse processes of all, except the eleventh and twelfth, for articulation with the tubercles of the ribs.

The *bodies* in the middle of the thoracic region possess a very characteristic form, being heart-shaped and as broad in the antero-posterior as in the transverse direction. At the ends of the thoracic region they resemble respectively those of the cervical and lumbar vertebræ. They are slightly thicker behind than in front, flat above and below, convex from side to side, deeply concave behind, and slightly constricted laterally and in front. They present, on either side, two costal demi-facets, one above, near the root of the pedicle, the other below, in front of the inferior intervertebral notch; these are covered with cartilage in the recent state, and, when the vertebræ are articulated with one another, form, with the intervening intervertebral discs, oval surfaces for the reception of the heads of the ribs. The *pedicles* are directed backwards and slightly upwards, and the inferior intervertebral notches are of large size, and deeper than in any other region of the vertebral column. The *laminæ* are broad, thick, and imbricated—that is to say, they overlap one another like tiles on a roof. The *spinal foramen* is small, and of a circular form. The *spinous process* is long, triangular on coronal section, directed obliquely downwards, and terminates in a tubercular extremity. These processes overlap one another from the fifth to the eighth, but are less oblique in direction above

and below.* The *superior articular processes* are thin plates of bone projecting upwards from the junctions of the pedicles and laminæ; their articular facets are practically flat, and are directed backwards and a little outwards and upwards. The *inferior articular processes* are fused to a considerable extent with the laminæ, and project but slightly beyond their lower borders; their facets are directed forwards and a little inwards and downwards. The *transverse processes* arise from the same parts of the arch as the posterior roots of the transverse processes in the neck, and are situated behind the superior articular processes and pedicles; they are thick, strong, and of considerable length, directed obliquely backwards and outwards, and each presents a clubbed extremity, on the anterior part of which is a small, concave surface, for articulation with the tubercle of a rib.

The *first*, *ninth*, *tenth*, *eleventh*, and *twelfth* thoracic vertebræ present certain peculiarities, and must be specially considered (fig. 254).

Fig. 253.—A thoracic vertebra.

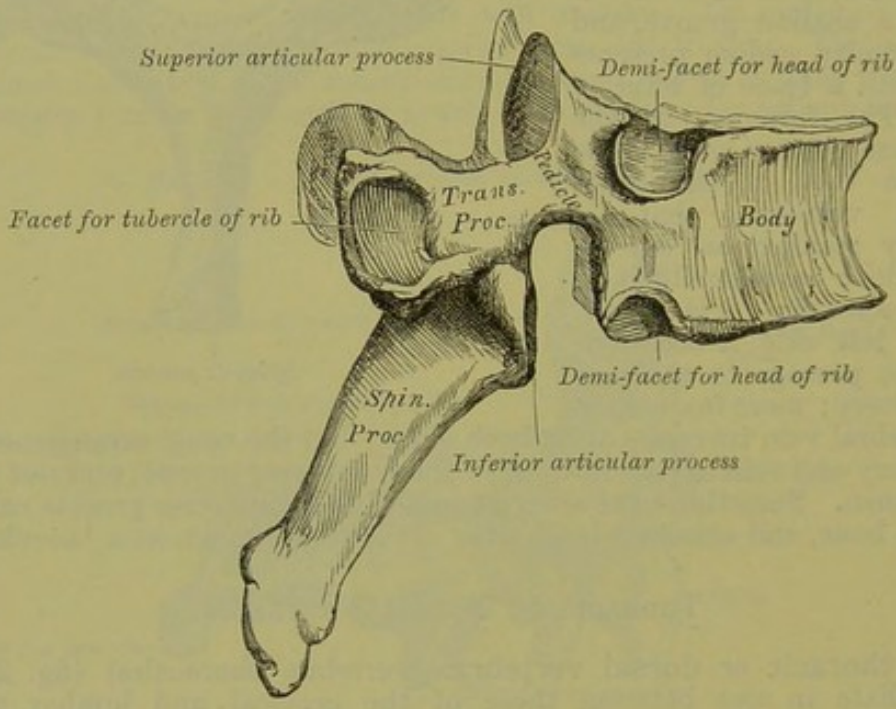

The **first thoracic vertebra** presents, on either side of the *body*, an entire articular facet for the head of the first rib, and a demi-facet for the upper half of the head of the second rib. The body is like that of a cevical vertebra, being broad transversely; its upper surface is concave, and lipped on either side. The *superior articular surfaces* are oblique, directed upwards and backwards, but not outwards; the *spinous process* is thick, long, and almost horizontal. The *transverse processes* are long, and the upper intervertebral notches are deeper than in the other vertebræ of this series.

The **ninth thoracic vertebra** may have no demi-facets below. In some subjects, however, it has two demi-facets on either side; when this occurs the tenth has demi-facets at the upper part only.

The **tenth thoracic vertebra** has (except in the cases just mentioned) an entire articular facet on either side, which is placed partly on the outer surface of the pedicle.

In the **eleventh thoracic vertebra** the *body* approaches in its form and size to that of the lumbar vertebræ. The articular facets for the heads of the ribs, one on either side, are of large size, and placed chiefly on the pedicles, which

* In quadrupeds the majority of the spinous processes of the thoracic vertebræ project upwards and backwards, while those of the lumbar region are directed upwards and forwards. The change in inclination is effected in one of the lower thoracic vertebræ, the spine of which points almost directly upwards. This vertebra is known as the *anticlinal*, and in man its representative is the eleventh thoracic.

are thicker and stronger in this and the next vertebra than in any other part of the thoracic region. The *spinous process* is short, and nearly horizontal in direction. The *transverse processes* are very short, tubercular at their extremities, and have no articular facets.

The **twelfth thoracic vertebra** has the same general characteristics as the eleventh, but may be distinguished from it by its inferior articular processes being convex and turned outwards, like those of the lumbar vertebræ; by

FIG. 254.—Peculiar thoracic vertebræ.

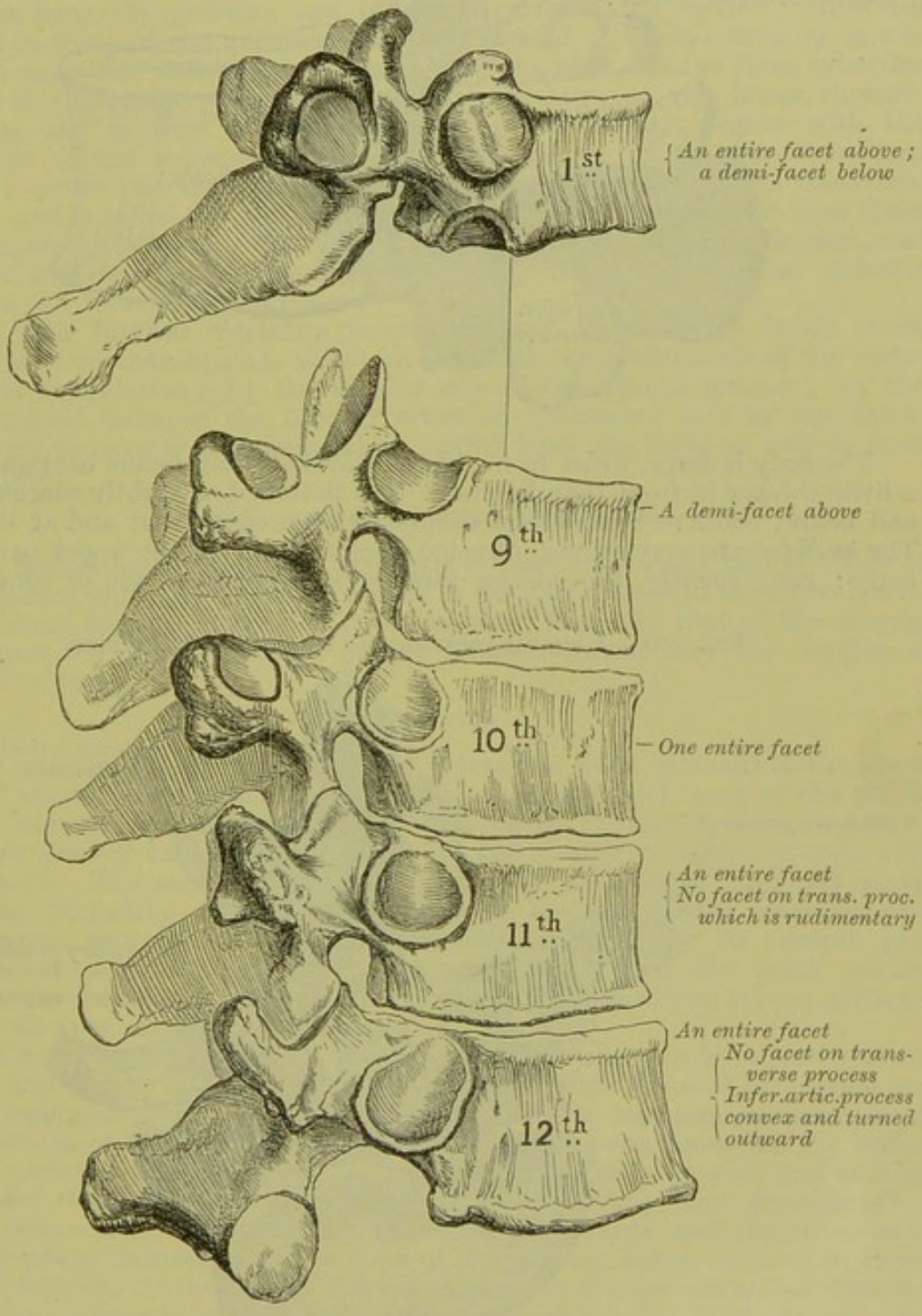

the general form of the body, laminæ, and spinous process, in which it resembles the lumbar vertebræ; and by the transverse processes being subdivided into three elevations, the superior, inferior, and external tubercles; the superior and inferior correspond to the mamillary and accessory processes of the lumbar vertebræ. Traces of similar elevations are found on the transverse processes of the tenth and eleventh thoracic vertebræ.

Lumbar Vertebræ

The **lumbar vertebræ** (vertebræ lumbales) (figs. 255 and 256) are the largest segments of the movable part of the vertebral column, and can be distinguished by the absence of a foramen in the transverse process, and by the absence of facets on the sides of the body.

Fig. 255.—A lumbar vertebra seen from the side.

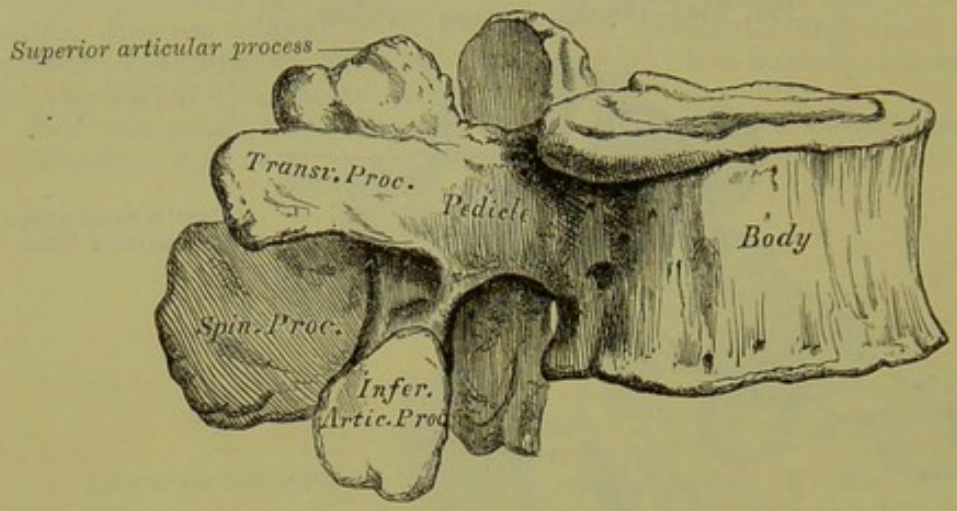

The *body* is large, wider from side to side than from before backwards, and a little thicker in front than behind. It is flattened or slightly concave above and below, concave behind, and deeply constricted in front and at the sides. The *pedicles* are very strong, directed backwards from the upper part of the body; consequently, the inferior intervertebral notches are of considerable

Fig. 256.—A lumbar vertebra seen from above and behind.

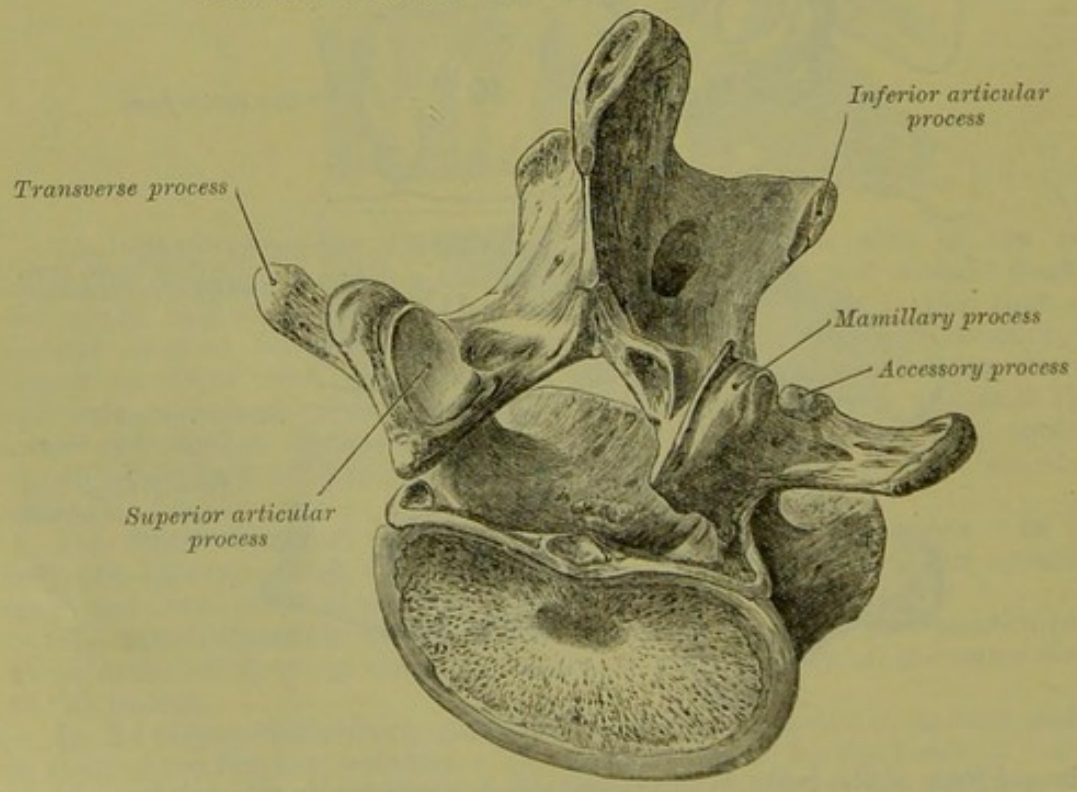

depth. The *laminæ* are broad, short, and strong; the *spinal foramen* is triangular, larger than in the thoracic, but smaller than in the cervical region. The *spinous process* is thick, broad, and somewhat quadrilateral; it projects backwards and terminates in a rough, uneven border. The *superior* and

inferior articular processes are well defined, projecting respectively upwards and downwards from the junctions of pedicles and laminæ. The facets on the superior processes are concave, and look backwards and inwards; those on the inferior are convex, and are directed forwards and outwards. The former are wider apart than the latter, since in the articulated column the inferior articular processes are embraced by the superior processes of the subjacent vertebra. The *transverse processes* are long, slender, and directed transversely outwards in the upper three lumbar vertebræ; they incline a little upwards in the lower two. In the upper three vertebræ they arise from the junctions of the pedicles and the laminæ, but in the lower two they are set further forward and arise from the pedicles and posterior parts of the bodies. They are situated in front of the articular processes instead of behind them as in the thoracic vertebræ, and are homologous with the ribs. Of the three tubercles noticed in connection with the transverse processes of the lower thoracic vertebræ, the *superior* one is connected in the lumbar region with the back part of the superior articular process, and is named the *mamillary* process; the *inferior* is situated at the back part of the base of the transverse process, and is called the *accessory* process (fig. 256). Although in man these are comparatively small, in some animals they attain considerable size, and serve to lock the vertebræ more closely together. The *external* tubercle becomes the transverse process.

The **fifth lumbar vertebra** is characterised by its body being much thicker in front than behind, which accords with the prominence of the sacro-vertebral articulation; by the smaller size of its spinous process; by the wide interval between the inferior articular processes; and by the thickness of its transverse processes, which spring from the body as well as from the pedicles.

Sacral and Coccygeal Vertebræ

The **sacral** and **coccygeal vertebræ** consist at an early period of life of nine separate segments which are united in the adult, so as to form two bones, five entering into the formation of the sacrum, four into that of the coccyx. Sometimes the coccyx consists of five bones; occasionally the number is reduced to three.

The Sacrum

The **sacrum** (os sacrum) is a large, triangular bone, situated in the lower part of the vertebral column and at the upper and back part of the pelvic cavity, where it is inserted like a wedge between the two innominate bones; its upper part or base articulates with the last lumbar vertebra, its apex with the coccyx. The sacrum is curved upon itself, and placed very obliquely, its base projecting forwards, and forming the prominent *sacro-vertebral angle* when articulated with the last lumbar vertebra; its central part is projected backwards, so as to give increased capacity to the pelvic cavity. It presents for examination an anterior, a posterior, and two lateral surfaces, a base, an apex, and a central canal.

The *anterior surface* (facies pelvina) (fig. 257) is concave from above downwards, and slightly so from side to side. In the middle are seen four transverse ridges, indicating the original division of the bone into five separate pieces. The portions of bone intervening between the ridges correspond to the bodies of the vertebræ. The body of the first segment is of large size, and in form resembles that of a lumbar vertebra; the succeeding ones diminish from above downwards, are flattened from before backwards, and curved so as to accommodate themselves to the form of the sacrum, being concave in front, convex behind. At the ends of the ridges are seen the *anterior sacral foramina* (foramina sacralia anteriora), four in number on either side, somewhat rounded in form, diminishing in size from above downwards, and directed outwards and forwards: they give exit to the anterior primary divisions of the sacral nerves and entrance to the lateral sacral arteries. External to these foramina is the *lateral mass* (pars lateralis), consisting of separate segments at an early period of life; in the adult, these become blended with the bodies and with each other. Each lateral mass is traversed by four broad, shallow grooves, which lodge the anterior divisions of the sacral nerves as

they pass outwards, the grooves being separated by prominent ridges of bone which give origin to the Pyriformis.

If a sagittal section be made through the centre of the sacrum (fig. 259), the bodies are seen to be united at their circumferences by bone, wide intervals being left centrally, which, in the recent state, are filled by the intervertebral discs. In some bones this union is more complete between the lower than between the upper segments.

The *posterior surface* (facies dorsalis) (fig. 258) is convex and narrower than the anterior. In the middle line it displays a crest (crista sacralis media) surmounted by three or four tubercles, the rudimentary spinous processes of the upper three or four sacral vertebræ. On either side of the spinous processes is a shallow groove, the *sacral groove,* which gives origin to the Multifidus spinæ, the floor of the groove being formed by the united laminæ of the corresponding vertebræ. The laminæ of the fifth sacral vertebra, and

FIG. 257.—Sacrum, anterior surface.

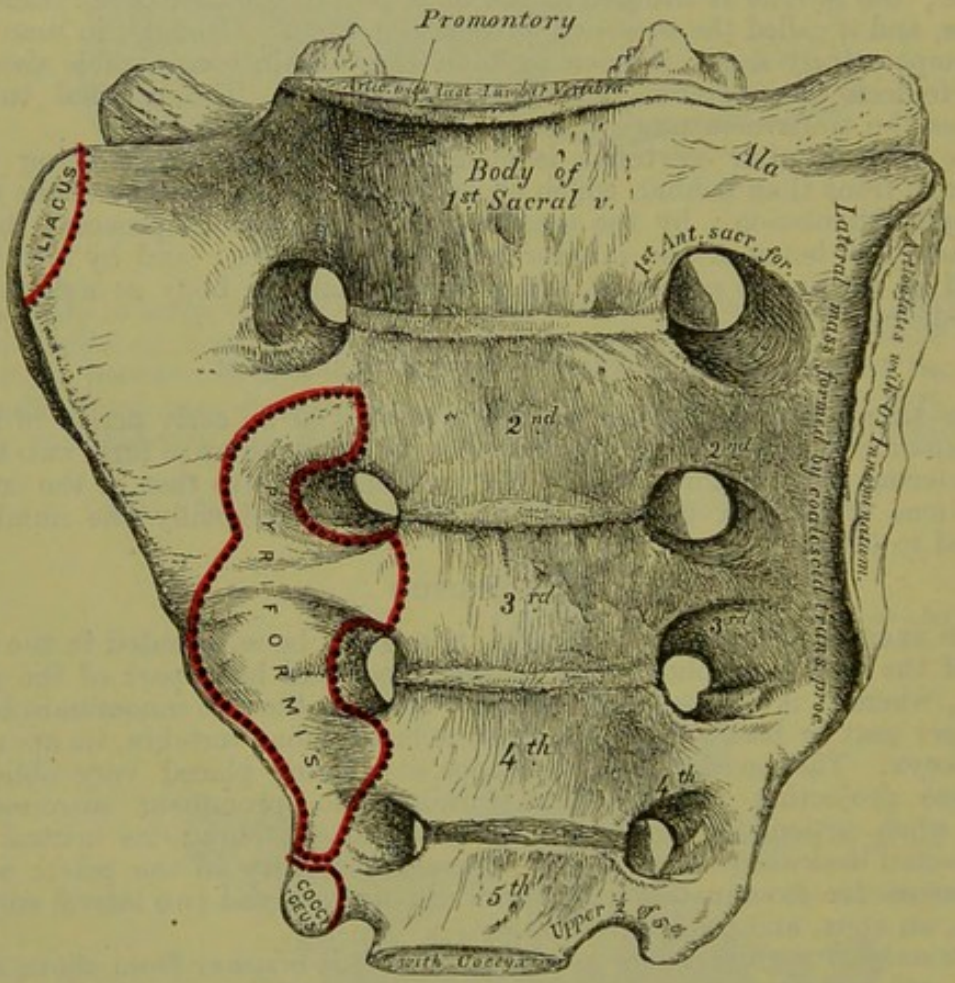

sometimes those of the fourth, fail to meet behind, and thus a deficiency (hiatus sacralis) occurs in the posterior wall of the sacral canal. On the lateral aspect of the sacral groove is a linear series of tubercles produced by the fusion of the articular processes which together form indistinct crests (cristæ sacrales articulares). The articular processes of the first sacral vertebra are large and oval in shape; their facets are concave from side to side, look backwards and inwards, and articulate with the facets on the inferior processes of the fifth lumbar vertebra. The tubercles which represent the inferior articular processes of the fifth sacral vertebra are prolonged downwards as rounded processes, which are named the *sacral cornua* (cornua sacralis) and are connected to the cornua of the coccyx. External to the articular processes are the four *posterior sacral foramina* (foramina sacralia posteriora); they are smaller in size and less regular in form than the anterior, and transmit the posterior divisions of the sacral nerves. On the outer side of the posterior sacral foramina is a series of tubercles, which represent the *transverse processes* of the

sacral vertebræ, and form the lateral crests of the sacrum (cristæ sacrales laterales). The transverse tubercles of the first sacral vertebra are of large size, very distinct, and correspond with the superior angles of the bone; they, together with the transverse tubercles of the second vertebra, give attachment to the horizontal parts of the posterior sacro-iliac ligaments; those of the third vertebra give attachment to the oblique fasciculi of the posterior sacro-iliac ligaments; and those of the fourth and fifth to the great sacro-sciatic ligaments.

The *lateral surface*, broad above, becomes narrowed into a thin edge below. The upper half presents in front a broad, ear-shaped surface for articulation with the ilium. This is called the *auricular* surface (facies auricularis), and in the fresh state is coated with fibro-cartilage. Behind it are three deep and uneven impressions, for the attachment of the posterior sacro-iliac ligament. The lower half is thin, and terminates in a projection called the *inferior*

Fig. 258.—Sacrum, posterior surface.

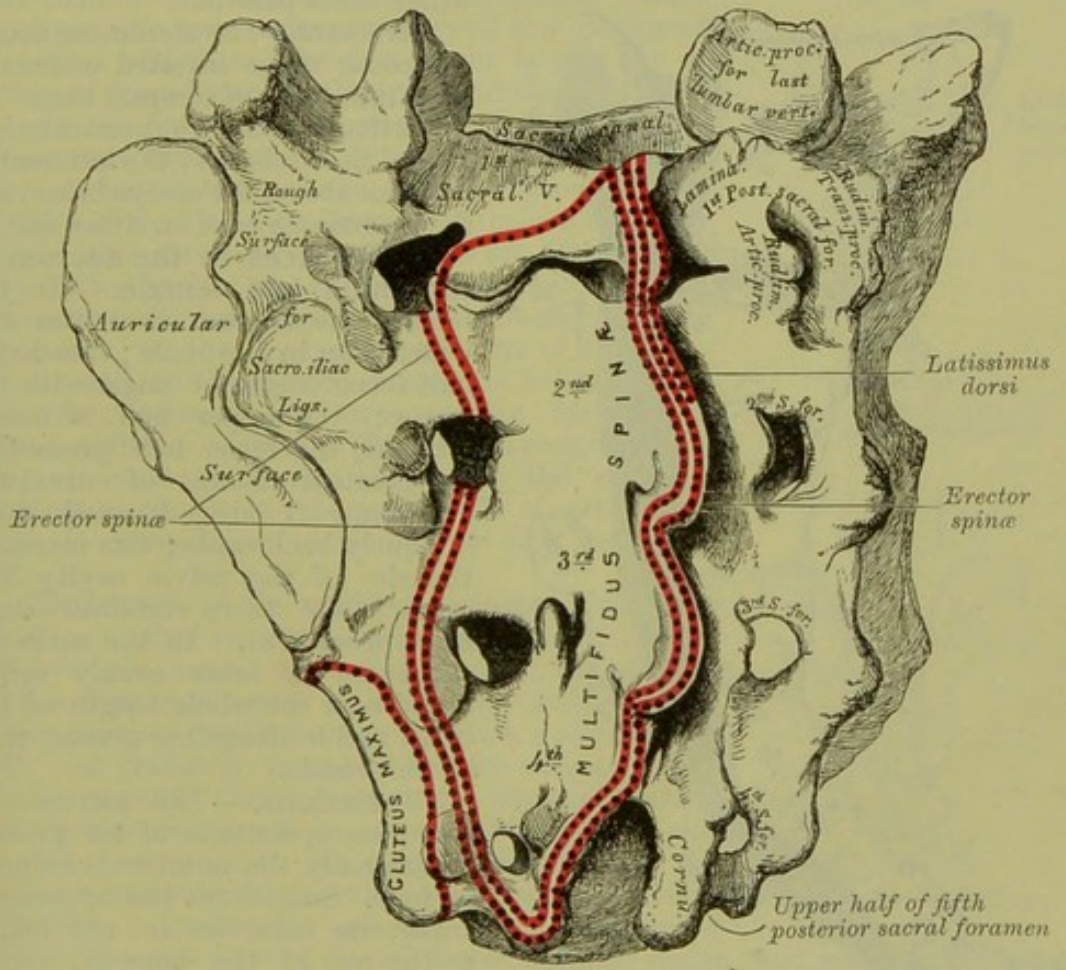

lateral angle; internal to this angle is a notch, which is converted into a foramen by the transverse process of the upper piece of the coccyx, and transmits the anterior division of the fifth sacral nerve. The thin lower half of the lateral surface gives attachment to the great and small sacro-sciatic ligaments, and to some fibres of the Gluteus maximus behind, and to the Coccygeus in front.

The *base* of the sacrum, which is broad and expanded, is directed upwards and forwards. In the middle is seen a large oval articular surface, the upper surface of the body of the first sacral vertebra, which is connected with the under surface of the body of the last lumbar vertebra by an intervertebral disc. Behind it, is the large triangular orifice of the sacral canal, which is completed by the laminæ and spinous process of the first sacral vertebra. The superior articular processes project from it on each side; they are oval, concave, directed backwards and inwards, like the superior articular processes of a lumbar vertebra; in front of each is an intervertebral notch, which forms

the lower part of the foramen between the last lumbar and first sacral vertebræ. On either side of the body is a broad triangular surface, which extends outwards, supports the Psoas magnus and lumbo-sacral cord, and in the articulated pelvis is continuous with the iliac fossa. This is called the *ala* (ala sacralis); it is slightly concave from side to side, convex from before backwards, and gives attachment to a few of the fibres of the Iliacus. The posterior part of the ala represents the transverse process, and its anterior part the costal process of the first sacral segment.

The *apex* is directed downwards and presents an oval facet for articulation with the coccyx.

The *spinal canal* (fig. 259) runs throughout the greater part of the bone; it is large and triangular in form above; small and flattened from before backwards; below, its posterior wall is incomplete, from the non-development of the laminæ and spinous processes. It lodges the sacral nerves, and its walls are perforated by the anterior and posterior sacral foramina, through which these pass out.

Fig. 259.—Sagittal section of the sacrum.

Structure.—The sacrum consists of cancellous tissue invested externally by a thin layer of compact bone.

Articulations.—The sacrum articulates with four bones; the last lumbar vertebra above, the coccyx below, and the innominate bone on either side.

Differences in the sacrum of the male and female. — In the female the sacrum is shorter and wider than in the male; the lower half forms a greater angle with the upper; the upper half is nearly straight, the lower half presenting the greatest amount of curvature. The bone is also directed more obliquely backwards; this increases the size of the pelvic cavity and renders the sacro-vertebral angle more prominent. In the male the curvature is more evenly distributed over the whole length of the bone, and is altogether greater than in the female.

Variations. — The sacrum, in some cases, consists of six pieces; occasionally the number is reduced to four. Sometimes the uppermost transverse tubercles are not joined to the rest of the bone on one or both sides, or the sacral canal may be open throughout a considerable part of its length, in consequence of the imperfect development of the laminæ and spinous processes. The sacrum, also, varies considerably with respect to its degree of curvature.

The Coccyx

The **coccyx** (os coccygis) (fig. 260), so called from having been compared to a cuckoo's beak, is usually formed of four rudimentary vertebræ; the number may however be increased to five or diminished to three. In each of the first three segments may be traced a rudimentary body, articular and transverse processes; the last piece (sometimes the third) is a mere nodule of bone. All the segments are destitute of pedicles, laminæ, and spinous processes, and, consequently, of intervertebral and spinal foramina. The first is the largest; it resembles the lowest sacral vertebra, and often exists as

a separate piece; the last three, diminishing in size from above downwards, are usually fused to form a single bone. The gradual diminution in the size of the segments gives this bone a triangular form, the base of the triangle joining the end of the sacrum. It presents for examination an anterior and a posterior surface, two borders, a base, and an apex. The *anterior surface* is slightly concave, and marked with three transverse grooves, indicating the lines of junction of the different segments. It gives attachment to the anterior sacro-coccygeal ligament and Levator ani, and supports the middle part of the rectum. The *posterior surface* is convex, marked by transverse grooves similar to those on the anterior surface; and presents on either side a linear row of tubercles, the rudimentary articular processes of the coccygeal vertebræ. Of these, the superior pair are large, and are called the *cornua coccygea*; they project upwards, and articulate with the cornua of the sacrum, and on either side complete the fifth posterior sacral foramen for the transmission of the posterior primary division of the fifth sacral nerve. The *lateral borders* are thin, and exhibit a series of small eminences, which represent the transverse processes of the coccygeal vertebræ. Of these, the first is the largest; it is flattened from before backwards, and often ascends to join the lower part of the thin lateral edge of the sacrum, thus completing the fifth anterior sacral foramen for the transmission of the anterior primary division of the fifth sacral nerve; the others diminish in size from above downwards, and are often wanting. The *borders* of the coccyx are narrow, and give attachment on either side to the sacro-sciatic ligaments, to the Coccygeus in front of the ligaments, and to the Gluteus maximus behind them. The *base* presents an oval surface for articulation with the sacrum. The *apex* is rounded, and has attached to it the tendon of the external Sphincter muscle of the anus. It may be bifid, and is sometimes deflected to one or other side.

FIG. 260.—Coccyx.

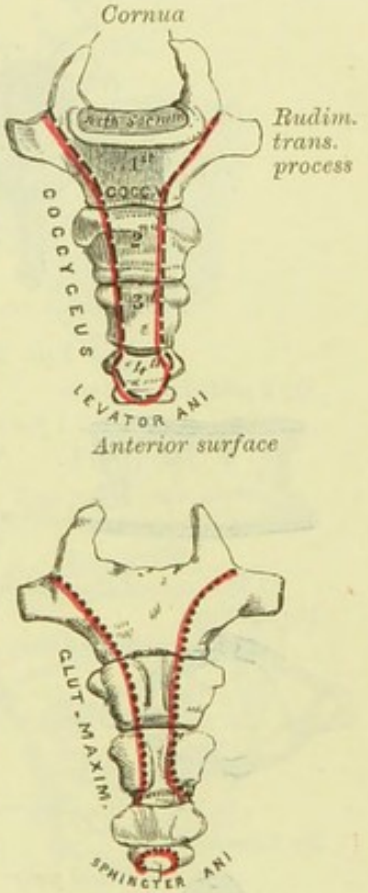

Ossification of the vertebral column.—Each vertebra is ossified from three primary centres (fig. 261), two for the neural arch, and one for the body.* Ossification commences in the neural arches of the upper cervical vertebræ about the sixth week of fœtal life, and gradually extends down the column. The ossific granules first appear in the situations where the transverse processes afterwards project, and spread backwards to the spine, forwards into the pedicles, and outwards into the transverse and articular processes. Ossification of the body commences about the eighth week in the lower thoracic region, and subsequently extends upwards and downwards along the column. At birth these three pieces are perfectly separate. The ossific centre for the body does not give rise to the whole of the body of the adult vertebra; the postero-lateral portions of the body are ossified by extensions from the neural arch centres. The body of the vertebra during the first few years of life shows, therefore, two synchondroses (*neurocentral synchondroses*) traversing it along the lines of junction of the three centres. In the thoracic region, the facets for the heads of the ribs lie behind the neuro-central synchondroses and are ossified from the centres for the neural arch. During the first year the laminæ become united behind, union taking place first in the lumbar region and then extending upwards through the thoracic and lower cervical regions. About the third year the bodies of the upper cervical vertebræ are joined to the arches on either side; in the lower lumbar vertebræ the union is not completed until the sixth year. Before puberty, no other changes

* A vertebra is occasionally found in which the body consists of two lateral portions—a condition which proves that the body is sometimes ossified from two primary centres, one on either side of the middle line.

occur, excepting a gradual increase in the growth of these primary centres, the upper and under surfaces of the bodies, and the ends of the transverse and spinous processes, being cartilaginous. About the sixteenth year (fig. 262), five secondary centres appear, one for the tip of each transverse process, one for the extremity of the spinous process, and two epiphysial plates, one for the upper and the other for the lower surface of the body (fig. 263). These fuse with the rest of the bone about the age of twenty-five.

Exceptions to this mode of development occur in the first, second, and seventh cervical vertebræ, and in those of the lumbar region.

The **atlas** is usually ossified from three centres (fig. 264). Two of these are destined for the lateral masses, the ossification of which commences about the seventh week of fœtal life near the articular processes, and extends backwards; at birth, these portions of bone are separated from one another behind by a narrow interval filled with cartilage. Between the third and fourth years they unite either directly or through the medium of a separate centre developed in the cartilage. The anterior arch, at birth, is altogether cartilaginous and consists of the hypochordal brace or bar (see page 103), which persists in the case of this vertebra; in this a separate nucleus appears about the end of the first year after birth, and joins the lateral masses from the sixth to the eighth year —their lines of union extending across the anterior portions of the superior articular facets. Sometimes two nuclei, one on either side of the median line, are developed in the cartilage, and join to form a single mass. Occasionally there is no separate centre, the anterior arch being formed by the forward extension and ultimate junction of the two lateral masses.

The **axis** is ossified from five primary and two secondary centres (fig. 265). The body and neural arch are ossified in the same manner as the corresponding parts in the other vertebræ, viz., one centre for the lower part of the body, and two for the neural arch. The centres for the neural arch appear about the

Fig. 261.—Ossification of a vertebra.

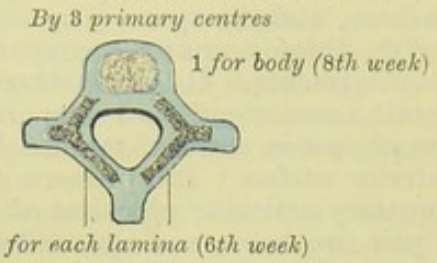

Fig. 262.

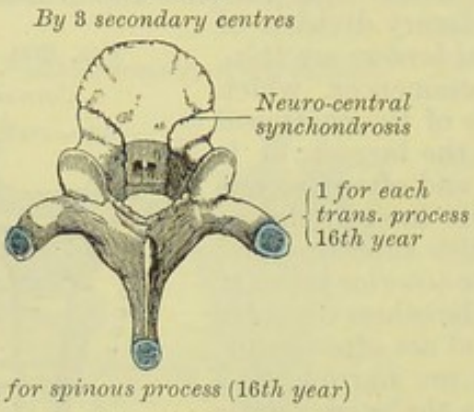

Fig. 263.



Fig. 264.—Atlas.

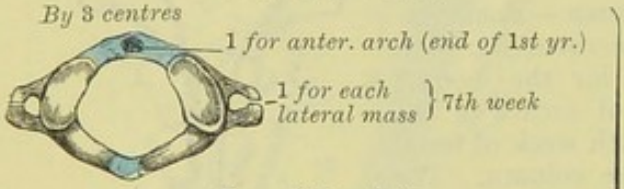

Fig. 265.—Axis.

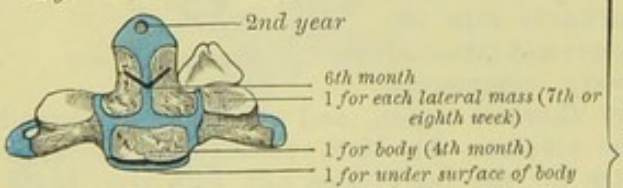

Fig. 266.—Lumbar vertebra.

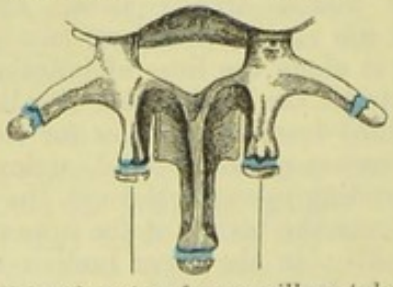

seventh or eighth week of fœtal life, that for the body about the fourth or fifth month. The odontoid process consists originally of an extension upwards of the cartilaginous mass, in which the lower part of the body is formed. About the sixth month of fœtal life, two centres make their appearance in the base of this process: they are placed laterally, and join before birth to form a conical bilobed mass deeply cleft above; the interval between the cleft and the summit of the process is formed by a wedge-shaped piece of cartilage. The base of the process is separated from the body by a cartilaginous disc, which gradually becomes ossified at its circumference, but remains cartilaginous in its centre until advanced age.* In this cartilage, rudiments of the lower epiphysial lamella of the atlas and the upper epiphysial lamella of the axis may sometimes be found. Finally, as Humphry has demonstrated, the apex of the odontoid process has a separate centre, which appears in the second year and joins about the twelfth year. This is the upper epiphysial lamella of the atlas. In addition to these there is a secondary centre for a thin epiphysial plate on the under surface of the body of the bone.

Fig. 267.—Ossification of the sacrum.

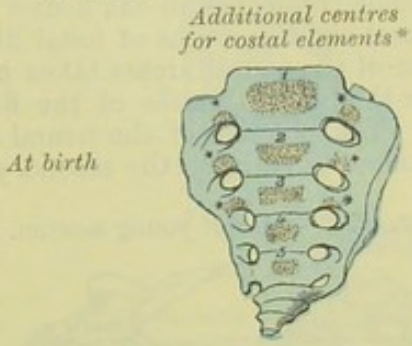

Fig. 268.

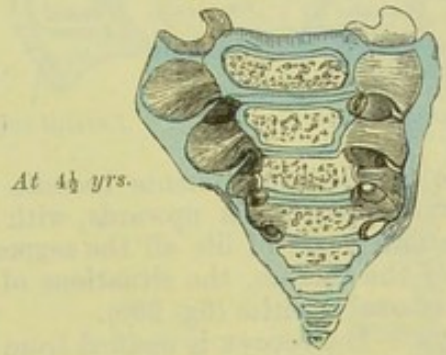

Fig. 269.

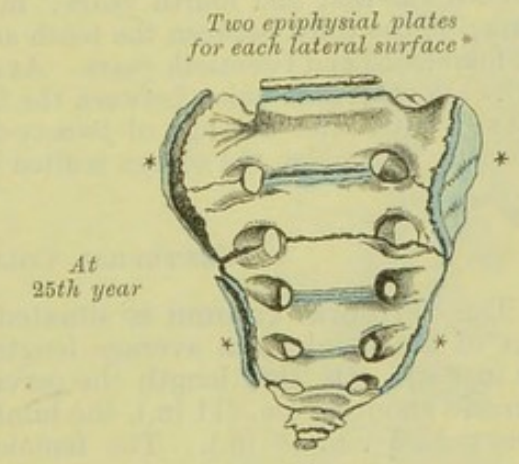

The **seventh cervical vertebra**.—The anterior or costal part of the transverse process of this vertebra is sometimes ossified from a separate centre which appears about the sixth month of fœtal life, and joins the body and posterior part of the transverse process between the fifth and sixth years. Occasionally the costal part persists as a separate piece, and, becoming lengthened outwards and forwards, constitutes what is known as a cervical rib. Separate ossific centres have also been found in the costal processes of the fourth, fifth, and sixth cervical vertebræ.

The **lumbar vertebræ** (fig. 266) have *two additional centres* for the mamillary tubercles. The transverse process of the first lumbar is sometimes developed as a separate piece, which may remain permanently ununited with the rest of the bone, thus forming a lumbar rib—a peculiarity, however, rarely met with.

Sacrum (figs. 267 to 270).—The *body* of each sacral vertebra is ossified from a primary centre and two epiphysial plates, one for its upper and another for its under surface, whilst each neural arch is ossified from two centres.

The anterior portions of the *lateral masses* have six additional centres, two for each of the first three vertebræ; these represent the costal elements, and make their appearance above and to the outer side of the anterior sacral foramina (figs. 268 and 269).†

* See Cunningham, *Journ. Anat.*, vol. xx., p. 238.

† The extremities of the spinous processes of the upper three sacral vertebræ are sometimes developed from separate epiphyses, and Fawcett (*Anatomischer Anzeiger*, Band XXX., 1907) states that a number of epiphysial nodules may be seen in the sacrum at the age of eighteen years. These are distributed as follows: One for each of the mamillary processes of the first sacral vertebra; twelve—six on either side—in connection with the costal elements (two each for the first and second and one each for the third and fourth) and eight for the

On each *lateral surface* two epiphysial plates are developed (fig. 269) : one for the auricular surface, and another for the remaining part of the thin lateral edge of the bone.

Periods of Ossification.—About the eighth or ninth week of fœtal life, ossification of the central part of the body of the first sacral vertebra commences, and is rapidly followed by deposit of ossific matter in the second and third ; but ossification does not commence in the bodies of the lower two segments until between the fifth and eighth months of fœtal life. Between the sixth and eighth months ossification of the neural arches takes place ; and about the same time the costal centres for the lateral masses of the first three sacral vertebræ make their appearance. The junction of the neural arches with the bodies takes place in the lower vertebræ as early as the second year, but is not effected in the uppermost until the fifth or sixth year. About the sixteenth year the epiphysial plates for the upper and under surfaces of the bodies are formed ; and between the eighteenth and twentieth years, those for the lateral surfaces make their appearance. The bodies of the sacral vertebræ are, during early life, separated from each other by intervertebral discs, but about the eighteenth year the two lowest segments become united by bone, and the process of bony union gradually extends upwards, with the result that between the twenty-fifth and thirtieth years of life all the segments are united. On examining a sagittal section of the sacrum, the situations of the intervertebral discs are indicated by a series of oval cavities (fig. 259).

Fig. 270.—Base of young sacrum.

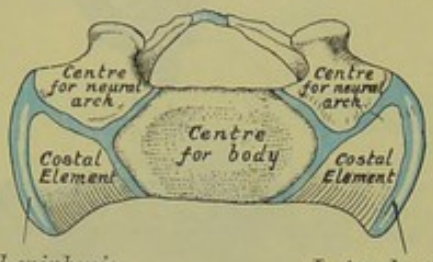

Coccyx.—The coccyx is ossified from four centres, one for each segment. The ossific nuclei make their appearance in the following order : in the first segment between the first and fourth years ; in the second between the fifth and tenth years ; in the third between the tenth and fifteenth years ; in the fourth between the fourteenth and twentieth years. As age advances, the segments become united with each other, the union between the first and second segments being frequently delayed until after the age of twenty-five or thirty. At a late period of life, especially in females, the coccyx is often joined to the sacrum.

Vertebral Column as a Whole

The **vertebral column** is situated in the median line, at the posterior part of the trunk ; its average length in the male is about 71 centimetres (28 inches). Of this length the cervical part measures 12·5 cm. (5 in.), the thoracic about 28 cm. (11 in.), the lumbar 18 cm. (7 in.), and the sacrum and coccyx 12·5 cm. (5 in.). The female column is about 61 cm. (24 in.) in length.

Curves.—Viewed laterally (fig. 271), the vertebral column presents several curves, which correspond to the different regions of the column, and are called cervical, thoracic, lumbar, and pelvic. The *cervical* curve, convex forwards, begins at the apex of the odontoid process, and ends at the middle of the second thoracic vertebra ; it is the least marked of all the curves. The *thoracic* curve, concave forwards, begins at the middle of the second and ends at the middle of the twelfth thoracic vertebra. Its most prominent point behind corresponds to the spine of the seventh thoracic. The *lumbar* curve is more marked in the female than in the male ; it begins at the middle of the last thoracic vertebra, and ends at the sacro-vertebral angle. It is convex anteriorly ; the convexity of the lower three vertebræ being much greater than that of the upper two. The *pelvic* curve begins at the sacro-vertebral articulation, and ends at the

transverse processes—four on either side—one each for the first, third, fourth, and fifth. He is further of opinion that the lower part of each lateral surface of the sacrum is formed by the extension and union of the third and fourth 'costal' and fourth and fifth 'transverse' epiphyses.

point of the coccyx; its concavity is directed downwards and forwards. The thoracic and pelvic curves are termed primary curves, because they alone are present during fœtal life. The cervical and lumbar curves are compensatory or secondary, and are developed after birth, the former when the child is able to sit upright and hold up its head, the latter when the child begins to walk.

If a body be enveloped in plaster of Paris and divided in the median plane it will be found, as pointed out by Humphry, that a plumb-line dropped from the middle of the odontoid process of the axis will pass through the middle of the bodies of the second and twelfth thoracic vertebræ, through the middle and antero-inferior edge of the last lumbar, and will bisect a line drawn transversely through the heads of the thigh bones. It is known from experiment that the line of gravity of the head passes through the middle of the odontoid process; it therefore follows that this line passes through the points of confluence of the three superior curves of the vertebral column and through a line joining the heads of the thigh bones, so that the weight of the skull and its contents is directly transmitted to the pelvis and lower extremities when the body is in the erect position.

The vertebral column has also a slight *lateral* curvature, the convexity of which is directed towards the right side. This, as Bichat first explained, may be produced by muscular action, most persons using the right arm in preference to the left, especially in making long-continued efforts, when the body is curved to the right side. In support of this explanation it has been found, by Béclard, that in one or two individuals who were left-handed, the lateral curvature was directed to the left side. Others regard this curvature as being produced by the aortic arch and upper part of the descending thoracic aorta—a view which is supported by the fact that in cases where the viscera are transposed and the aorta is on the right side, the convexity of the lateral curvature is directed to the left side.

Anterior surface.—Viewed from in front, the width of the bodies of the vertebræ will be seen to increase from the second cervical to the first thoracic; there is then a slight diminution in the next three vertebræ; below this there

FIG. 271.—Lateral view of the vertebral column.

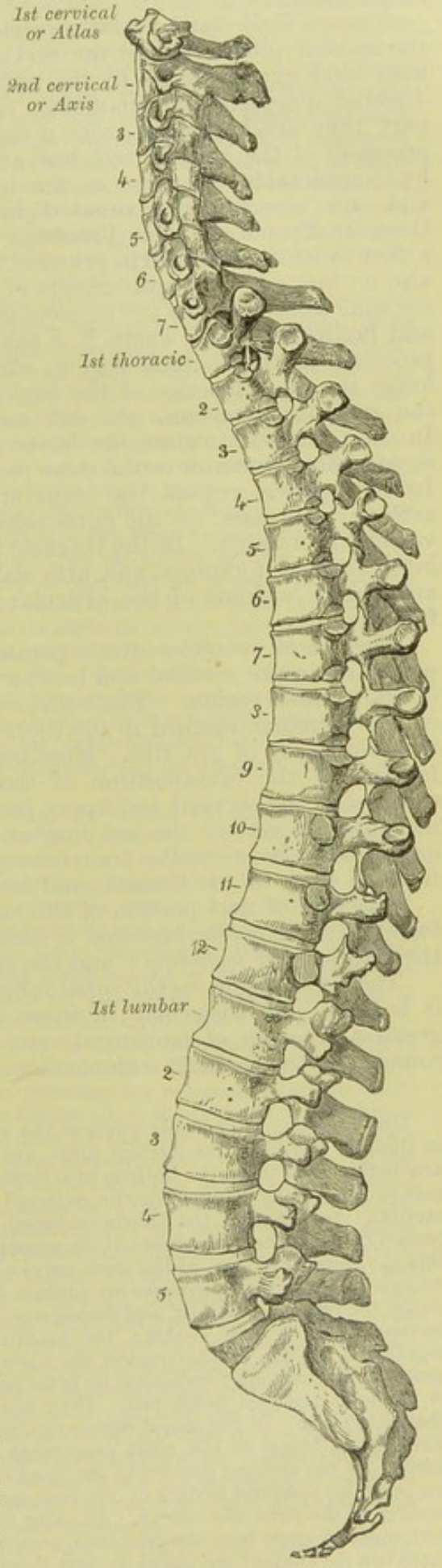

is again a gradual and progressive increase in width as low as the sacro-vertebral angle. From this point there is a rapid diminution, to the apex of the coccyx.

The *posterior surface* of the vertebral column presents in the median line the spinous processes. In the cervical region these are short and horizontal, with bifid extremities. In the upper part of the thoracic region they are directed obliquely; in the middle they are almost vertical, and in the lower part they are horizontal, with a slight inclination downwards. The spinous processes of the lumbar vertebræ are nearly horizontal. They are separated by considerable intervals in the loins, by narrower intervals in the neck, and are closely approximated in the middle of the thoracic region. Occasionally one of these processes deviates a little from the median line—a fact to be remembered in practice, as irregularities of this sort are attendant also on fractures or displacements of the vertebral column. On either side of the spinous processes is the *vertebral groove* formed by the laminæ in the cervical and lumbar regions, where it is shallow, and by the laminæ and transverse processes in the thoracic region, where it is deep and broad; these grooves lodge the deep muscles of the back. External to the vertebral grooves are the articular processes, and still more externally the transverse processes. In the thoracic region, the latter processes stand backwards, on a plane, considerably posterior to the same processes in the cervical and lumbar regions. In the cervical region, the transverse processes are placed in front of the articular processes, on the outer sides of the pedicles and between the inter-vertebral foramina. In the thoracic region they are posterior to the pedicles, intervertebral foramina, and articular processes. In the lumbar region they are placed in front of the articular processes, but behind the intervertebral foramina.

The *lateral surfaces* are separated from the posterior by the articular processes in the cervical and lumbar regions, and by the transverse processes in the thoracic region. These surfaces present, in front, the sides of the bodies of the vertebræ, marked in the thoracic region by the facets for articulation with the heads of the ribs. More posteriorly are the intervertebral foramina, formed by the juxtaposition of the intervertebral notches, oval in shape, smallest in the cervical and upper part of the thoracic regions, and gradually increasing in size to the last lumbar. They transmit the spinal nerves and are situated between the transverse processes in the cervical region, and in front of them in the thoracic and lumbar regions.

The *base* of that portion of the vertebral column which is made up of the twenty-four movable vertebræ is formed by the under surface of the body of the fifth lumbar vertebræ; and the *summit*, by the upper surface of the atlas.

The *vertebral* or *spinal canal* follows the different curves of the column; it is large and triangular in those regions of the column which enjoy the greatest freedom of movement, viz. the neck and loins; and is small and rounded in the thoracic region, where motion is more limited.

Surface Form.—The only parts of the vertebral column which are subcutaneous, and so directly influence the surface form, are the apices of the spinous processes. These are distinguishable at the bottom of a furrow, which, more or less evident, runs down the mesial line of the back from the external occipital protuberance to the middle of the sacrum. In the neck the furrow is broad, and ends below in a conspicuous projection caused by the spinous processes of the seventh cervical and first thoracic vertebræ. Above this the spinous process of the sixth cervical vertebra sometimes forms a projection; the other cervical spinous processes are sunken, but that of the axis can be felt. In the thoracic region the furrow is shallow, and during stooping disappears, and then the spinous processes become more or less visible; the markings produced by them are small and close together. In the lumbar region the furrow is deep, and the situation of the spinous processes is frequently indicated by little pits or depressions, especially when the muscles in the loins are well developed. They are much larger and farther apart than in the thoracic region. In the sacral region the furrow is shallower, presenting a flattened area which ends below at the most prominent part of the posterior surface of the sacrum, formed by the spinous process of the third sacral vertebra. At the bottom of the furrow the irregular posterior surface of the bone may be felt, and below this, in the deep groove leading to the anus, the coccyx. In order to identify any particular spinous process, it is customary to count from the prominence caused by the seventh cervical and first thoracic; of these two the spinous process of the first thoracic is the more prominent. It is useful, how-

ever, to bear in mind that the root of the spine of the scapula is on a level with the interval between the spinous processes of the third and fourth thoracic vertebræ and the inferior angle with the interval between the seventh and eighth thoracic ; the highest point of the crest of the ilium is on a level with the spinous process of the fourth lumbar and the posterior superior spine of the ilium with that of the second sacral. The only other portions of the vertebral column which can be felt from the surface are the transverse processes of three of the cervical vertebræ—viz. the first, the sixth, and the seventh. That of the atlas can be felt as a rounded nodule of bone just below and in front of the apex of the mastoid process, at the anterior border of the Sterno-mastoid. The transverse process of the sixth cervical vertebra is of surgical importance. If deep pressure be made in the neck, in the course of the carotid artery, opposite the cricoid cartilage, the prominent anterior tubercle of this process can be felt. This has been named *Chassaignac's tubercle*, and against it the carotid artery may be most conveniently compressed by the finger. The transverse process of the seventh cervical vertebra can be often felt. Sometimes its costal process is large and segmented off, forming a cervical rib.

Applied Anatomy.—Occasionally the coalescence of the laminæ is not completed, and consequently a cleft is left in the arches of the vertebræ, through which a protrusion of the spinal membranes (dura mater and arachnoid), and generally of the spinal cord itself, takes place, constituting the malformation known as *spina bifida*. This condition is most common in the lumbo-sacral region, but it may occur in the thoracic or cervical region, or the arches throughout the whole length of the canal may remain incomplete.

The construction of the movable part of the vertebral column of a number of pieces, securely connected together and enjoying only a slight degree of movement between any two individual pieces, but permitting of a very considerable range as a whole, allows a sufficient degree of mobility without any material diminution of strength. The many joints of which the column is composed, together with the very varied movements to which it is subjected, render it liable to sprains ; but, so closely are the individual vertebræ articulated that these sprains are rarely severe, and an amount of violence sufficiently great to produce tearing of the ligaments would tend rather to cause a dislocation or fracture. The further safety of the column and its slight liability to injury is provided for by its disposition in curves, instead of in a straight line. For it is an elastic column, and must bend before it breaks ; under these circumstances, being made up of three curves, it represents three columns, and greater force is required to produce bending of a short column than of a longer one that is equal to it in breadth and material. Again, the safety of the column is largely provided for by the presence between the bodies of the intervertebral discs, which act as buffers in counteracting the effects of violent jars or shocks.

Fracture-dislocation of the vertebral column may be caused by direct or indirect violence. Fractures from indirect violence are the more common, and here the bodies of the vertebræ are compressed, while the arches are torn asunder ; in fracture from direct violence, on the other hand, the arches are compressed and the bodies of the vertebræ separated from each other. It will therefore be seen that in both classes of injury the spinal cord is the part least likely to be injured, and may escape damage even where there has been considerable lesion of the bony framework. When a fracture-dislocation is produced by indirect violence, the displacement is almost always the same ; the upper segment being driven forwards on the lower, so that the cord is compressed between the body of the vertebra below and the arch of the vertebra above.

Diseases of the Spine.—Spinal caries, or tuberculous disease affecting the cancellous tissue of the bodies of the vertebræ, is a very common condition. When the bodies, having been destroyed, begin to fall together, the spinous processes are necessarily thrown backwards and stand out prominently, especially if the disease affect the thoracic region, which is most commonly the case. The condition then goes by the name of *angular curvature* and great rigidity of the muscles in the affected region accompanies it. Pressure, by the inflammatory thickenings of the disease, is apt to involve the spinal nerves in the affected region, giving rise to peripheral pains, and if the disease be in the lower thoracic vertebræ the pains are referred to the epigastric or umbilical regions, and often the chief thing complained of is ' belly-ache.' Chronic abscess formation in spinal caries is very frequent, and it nearly always forms in front of the vertebral bodies. When the disease is in the lower thoracic region, the abscess usually tracks down behind the Diaphragm and enters the psoas sheath, forming the well-known *psoas abscess*, which may present above Poupart's ligament, or may pass beneath it into the thigh. In other cases the abscess takes a backward course between the transverse processes and presents as a *dorsal* or *lumbar abscess* ; if the disease affect the cervical region of the spine, a *post-pharyngeal abscess* results.

Lateral curvature of the spine is a common affection in girls who are outgrowing their strength and who sit or stand long at lessons, and is due to the uneven transmission of weight down the column. In addition to the lateral displacement of the spinous processes there is a marked rotation of the bodies of the vertebræ, the displacement of which is far in excess of that of the spinous processes. When the curve is severe and the bones have actually become distorted, the condition is past treatment.

Kyphosis is an affection in which there is an increase in the normal thoracic curve, and is due to bending forwards of the upper part of the body carrying the weight of

the head. It is seen in rickety children, in rapidly growing adolescents, in senile conditions, and in certain diseases, such as osteo-arthritis and osteitis deformans. In the senile kyphosis often met with in aged labourers, the head is firmly fixed and bent forwards and downwards on to the chest, and the spinal column is curved and rigid. The ribs are immobilised, the chest is flattened antero-posteriorly, and breathing becomes almost entirely abdominal. *Post-mortem*, bony ankylosis of the ligaments and capsules of the intervertebral joints is found, with ossification of the ligamenta subflava, interspinous and other ligaments.

It may be noted that in marked cases of spinal deformity the trachea and aorta follow closely along the line of a spinal curvature occurring in their vicinity, whereas the œsophagus between the tracheal bifurcation and the stomach often passes like a bowstring across the concavity of the curve.

Lordosis, on the other hand, is an exaggeration of the normal lumbar curve, the trunk being thrown backwards. This is always a compensatory curve, and is seen in any enlargement of the abdomen, such as pregnancy or tumours ; but it is more strongly marked in cases of disease of the hip-joint where the latter is permanently retained in a flexed position, so that in order to bring the foot down to the ground the pelvis has to be tilted forwards, and this is accomplished by an increase of the normal lumbar curve forwards.

Laminectomy.—The operation of laminectomy is performed in cases of pressure on the spinal cord, where the continuity of the nerve-tracts has not been completely destroyed. It consists of cutting down on and removing the laminæ and spinous processes in the affected region, so as to relieve the cord from pressure ; but it is useless in cases of complete destruction of the cord. Laminectomy is chiefly performed (i) for fracture-dislocation, (ii) for localised cord-pressure in cases of spinal caries, the object here being to remove the laminæ against which the cord is pressed by the inflammatory mass ; and (iii) for the removal of tumours growing inside the spinal canal and compressing the cord. If such cases be taken early, very satisfactory results are obtained.

THE THORAX

The skeleton of the **thorax,** or **chest,** is an osseo-cartilaginous cage, containing and protecting the principal organs of respiration and circulation. It is conical in shape, being narrow above and broad below, flattened from before backwards, and longer behind than in front. It is somewhat reniform on transverse section on account of the projection of the vertebral bodies into the cavity.

Boundaries.—The *posterior surface* is formed by the twelve thoracic vertebræ and the posterior parts of the ribs. It is convex from above downwards, and presents on either side of the middle line a deep groove, in consequence of the direction backwards and outwards which the ribs take from their vertebral extremities to their angles. The *anterior surface* formed by the sternum and costal cartilages is flattened or slightly convex, and inclined from above downwards and forwards. The *lateral surfaces* are convex; they are formed by the ribs, separated from each other by the *intercostal spaces*. These spaces are eleven in number, and are occupied by the Intercostal muscles and membranes.

The *upper opening* of the thorax is reniform in shape, being broader from side to side than from before backwards. It is formed by the first thoracic vertebra behind, the upper margin of the sternum in front, and the first rib on either side. It slopes downwards and forwards, so that the anterior part of the ring is on a lower level than the posterior. Its antero-posterior diameter is about two, and its transverse diameter about four inches. The *lower opening* is formed by the twelfth thoracic vertebra behind, by the eleventh and twelfth ribs at the sides, and in front by the cartilages of the tenth, ninth, eighth, and seventh ribs, which ascend on either side and form an angle, the *subcostal angle*, into the apex of which the ensiform cartilage projects. It is wider transversely than from before backwards, and slopes obliquely downwards and backwards. The Diaphragm closes the lower opening and forms the floor of the thorax.

The thorax of the female differs from that of the male as follows: 1. Its capacity is less. 2. The sternum is shorter. 3. The upper margin of the sternum is on a level with the lower part of the body of the third thoracic vertebra, whereas in the male it is on a level with the lower part of the body of the second. 4. The upper ribs are more movable, and so allow a greater enlargement of the upper part of the thorax.

The Sternum

The **sternum** (figs. 272 and 273) is an elongated, flattened bone, forming the middle portion of the anterior wall of the thorax. Its upper end supports the clavicles and its margins articulate with the cartilages of the first seven pairs of ribs. It consists of three parts, named from above downwards, the

Fig. 272.—Anterior surface of sternum and costal cartilages.

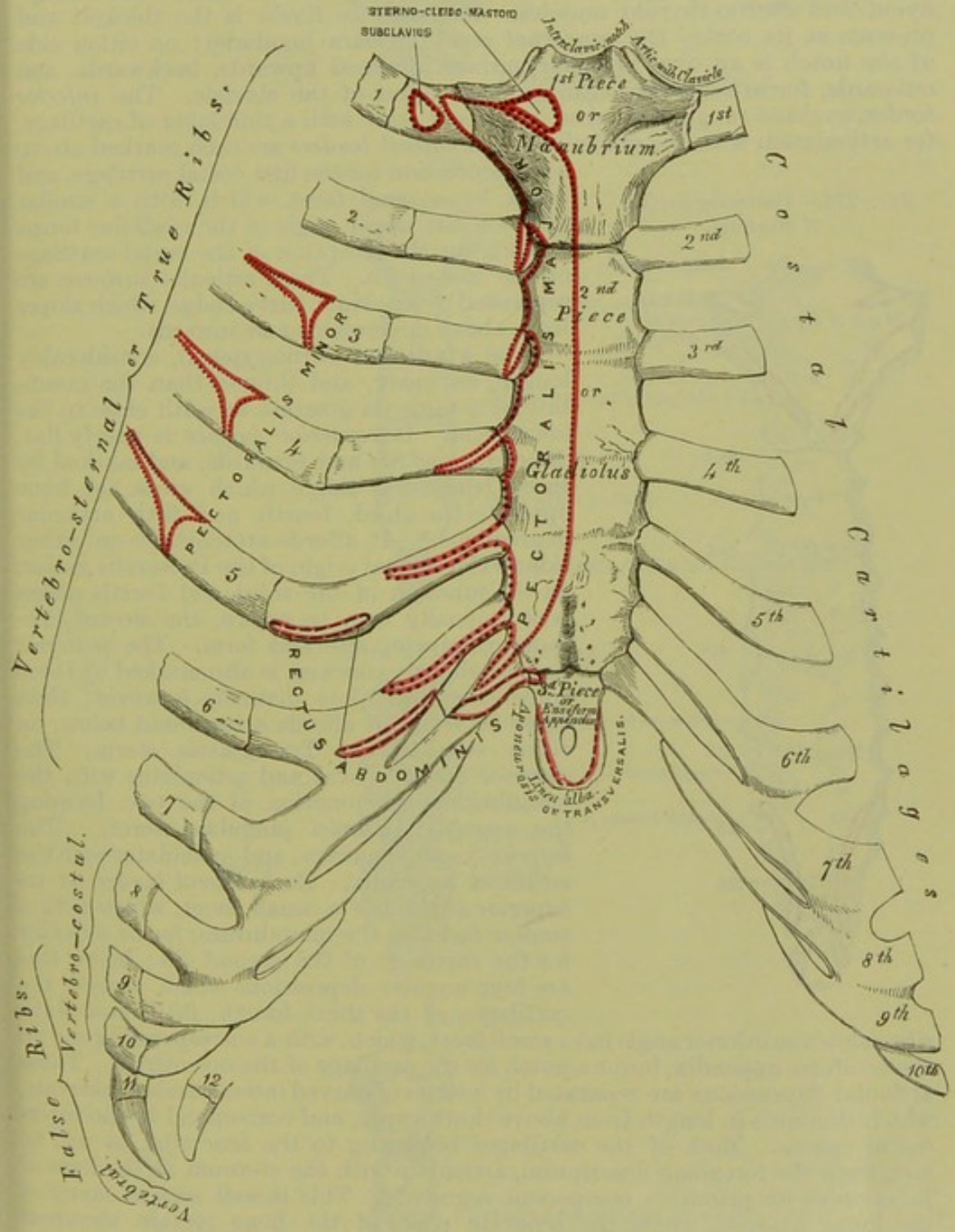

manubrium (presternum), the *body* or *gladiolus* (mesosternum), and the *xiphoid* or *ensiform process* (metasternum); in early life the gladiolus consists of four segments or *sternebræ*. In its natural position its inclination is oblique from above, downwards and forwards. It is slightly convex in front and concave behind; broad above, becoming narrowed at the point where the manubrium joins the gladiolus, after which it again widens a little, and

then rapidly narrows to its lower extremity. Its average length in the adult is about seven inches, and is rather greater in the male than in the female.

The **manubrium** (manubrium sterni) is of a somewhat quadrangular form, broad and thick above, narrow below at its junction with the gladiolus. Its *anterior surface*, convex from side to side, concave from above downwards, is smooth, and affords attachment on either side to the sternal origins of the Pectoralis major and Sterno-mastoid muscles. In well-marked bones the ridges limiting the attachments of these muscles are very distinct. Its *posterior surface*, concave and smooth, affords attachment on either side to the Sterno-hyoid and Sterno-thyroid muscles. The *superior border* is the thickest and presents at its centre the *presternal notch* (incisura jugularis); on either side of the notch is an oval articular surface, directed upwards, backwards, and outwards, for articulation with the sternal end of the clavicle. The *inferior border*, oval and rough, is covered in a recent state with a thin layer of cartilage, for articulation with the gladiolus. The *lateral borders* are each marked above by a depression for the first costal cartilage, and below by a small facet, which, with a similar facet on the upper angle of the gladiolus forms a notch for the reception of the costal cartilage of the second rib. These articular surfaces are separated by a narrow, curved edge, which slopes from above downwards and inwards.

Fig. 273.—Posterior surface of sternum.

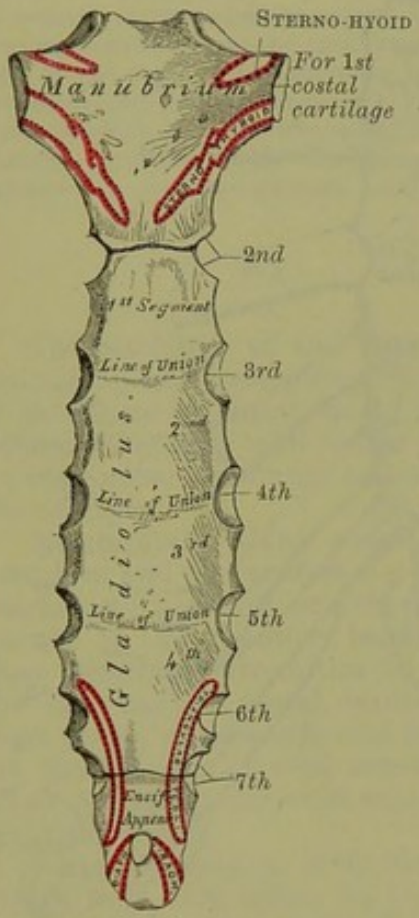

The **gladiolus** (corpus sterni), considerably longer, narrower, and thinner than the manubrium, attains its greatest breadth close to the lower end. Its *anterior surface* is nearly flat, directed upwards and forwards, and marked by three transverse ridges which cross the bone opposite the third, fourth, and fifth articular depressions.* It affords attachment on either side to the sternal origin of the Pectoralis major. At the junction of the third and fourth pieces is occasionally seen an orifice, the *sternal foramen*, of varying size and form. The *posterior surface*, slightly concave, is also marked by three transverse lines, less distinct, however, than those in front; it affords attachment below, on either side, to the Triangularis sterni. The *superior border* is oval and articulates with the manubrium, the junction of the two forming the *angulus Ludovici* (angulus sterni). The *inferior border* is narrow, and articulates with the ensiform appendix. Each *lateral border*, at its superior angle, has a small facet, which with a similar facet on the manubrium, forms a cavity for the cartilage of the second rib; below this are four angular depressions which receive the cartilages of the third, fourth, fifth, and sixth ribs, while the inferior angle has a small facet, which, with a corresponding one on the ensiform appendix, forms a notch for the cartilage of the seventh rib. These articular depressions are separated by a series of curved interarticular intervals, which diminish in length from above downwards, and correspond to the intercostal spaces. Most of the cartilages belonging to the true ribs, as will be seen from the foregoing description, articulate with the sternum at the lines of junction of its primitive component segments. This is well seen in many of the lower animals, where the separate parts of the bone remain ununited longer than in man.

The **ensiform process** or **xiphoid appendix** (processus xiphoideus) is the smallest of the three pieces: it is thin and elongated in form, cartilaginous

* Paterson (*The Human Sternum*, 1904), who examined 524 specimens, points out that these ridges are altogether absent in 26·7 per cent.; that in 69 per cent. a ridge exists opposite the third costal attachment; in 39 per cent. opposite the fourth; and in 4 per cent. only, opposite the fifth.

Fig. 274.—Ossification of the sternum, by six centres.

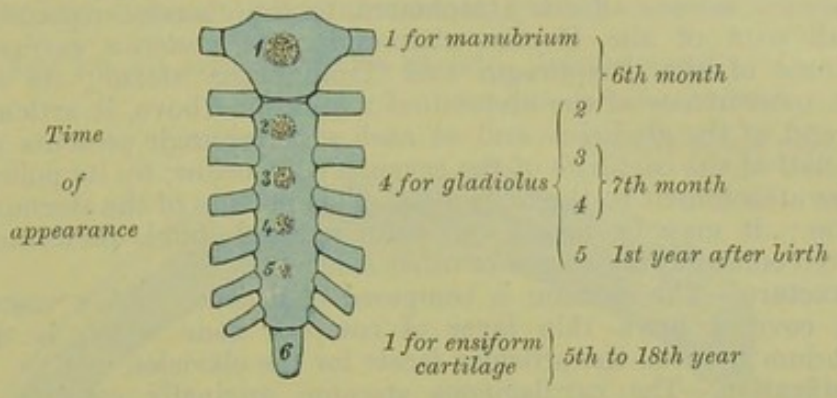

Fig. 275.

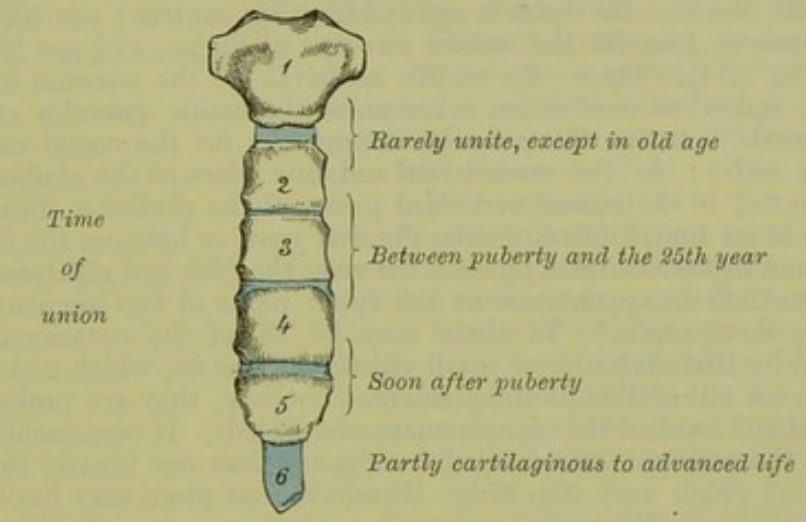

Fig. 276.—Peculiarities.

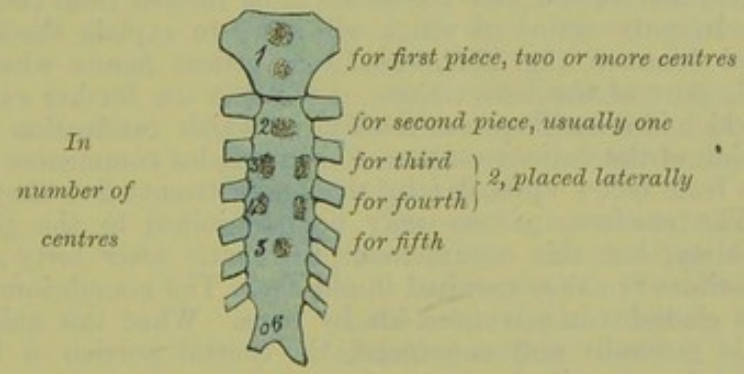

Fig. 277.

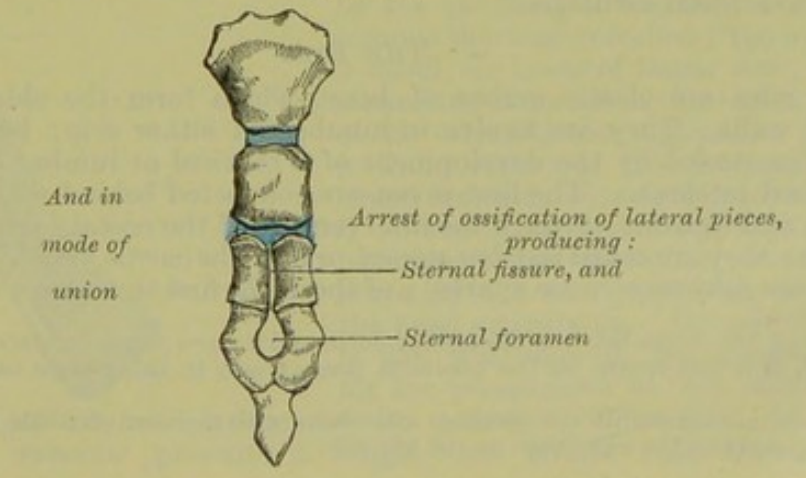

in structure in youth, but more or less ossified at its upper part in the adult. Its *anterior surface* affords attachment to the chondro-xiphoid ligament and a small part of the Rectus abdominis; its *posterior surface*, to some of the fibres of the Diaphragm and Triangularis sterni; its *lateral borders*, to the aponeuroses of the abdominal muscles. Above, it articulates with the lower end of the gladiolus, and at each superior angle presents a facet for the lower half of the cartilage of the seventh rib; below, by its pointed extremity, it gives attachment to the linea alba. This portion of the sternum varies much in form; it may be broad and thin, pointed, bifid, perforated, curved, or deflected considerably to one or other side.

Structure.—The sternum is composed of delicate, highly vascular cancellous tissue, covered by a thin layer of compact bone which is thickest in the manubrium between the articular facets for the clavicles.

Ossification.—The cartilaginous sternum originally consists of two bars, situated one on either side of the mesial plane and connected with the cartilages of the upper nine ribs of its own side. These two bars fuse with each other along the middle line and the bone is ossified from *six* centres: one for the first piece or manubrium, four for the second piece or gladiolus, and one for the ensiform process (fig. 274). Up to the middle of fœtal life the sternum is entirely cartilaginous, and when ossification takes place the ossific granules are deposited in the intervals between the articular depressions for the costal cartilages, in the following order: in the manubrium and first piece of the gladiolus, during the sixth month; in the second and third pieces of the gladiolus, during the seventh month; in its fourth piece, during the first year, or between the first and second years; and in the ensiform process, between the fifth and eighteenth years. The centres make their appearance at the upper parts of the segments, and proceed gradually downwards.* To these may be added the occasional existence, as described by Breschet, of two small episternal centres, which make their appearance one on either side of the presternal notches; they are probably vestiges of the episternal bone of the monotremata and lizards. It occasionally happens that some of the segments are formed from more than one centre, the number and position of which vary (fig. 276). Thus, the first piece may have two, three, or even six centres. When two are present, they are generally situated one above the other, the upper being the larger; the second piece has seldom more than one; the third, fourth, and fifth pieces are often formed from two centres placed laterally, the irregular union of which will serve to explain the rare occurrence of the sternal foramen (fig. 277), or of the vertical fissure which occasionally intersects this part of the bone; these conditions are further explained by the manner in which the cartilaginous matrix, in which ossification takes place, is formed. Union of the various centres of the gladiolus commences about puberty, and proceeds from below upwards; by the age of twenty-five they are all united (fig. 275). The ensiform process may become joined to the gladiolus before the age of thirty, but this occurs more frequently after forty; on the other hand, it sometimes remains ununited in old age. The manubrium is occasionally joined to the gladiolus in advanced life by bone. When this union takes place, however, it is generally only superficial, the central portion of the intervening cartilage remaining unossified.

Articulations.—The sternum articulates on either side with the clavicle and upper seven costal cartilages.

The Ribs

The ribs are elastic arches of bone, which form the chief part of the thoracic walls. They are twelve in number on either side; but this number may be increased by the development of a cervical or lumbar rib, or may be diminished to eleven. The first seven are connected behind with the vertebral column, and in front, through the intervention of the costal cartilages, with the sternum; they are called *vertebro-sternal*, or *true* ribs (costæ veræ).† The remaining five are *false* ribs (costæ spuriæ); of these, the first three have their cartilages

* Out of 141 sterna between the ages of birth and sixteen years, Paterson (*op. cit.*) found the fourth or lowest centre for the gladiolus present only in thirty-eight cases—*i.e.* 26·9 per cent.

† Sometimes the eighth rib cartilage articulates with the sternum; this condition occurs more frequently on the right than on the left side.

attached to the cartilage of the rib above (*vertebro-chondral*): the last two are free at their anterior extremities and are termed *floating* or *vertebral* ribs. The

Fig. 278.—A central rib of the left side. Inferior aspect.

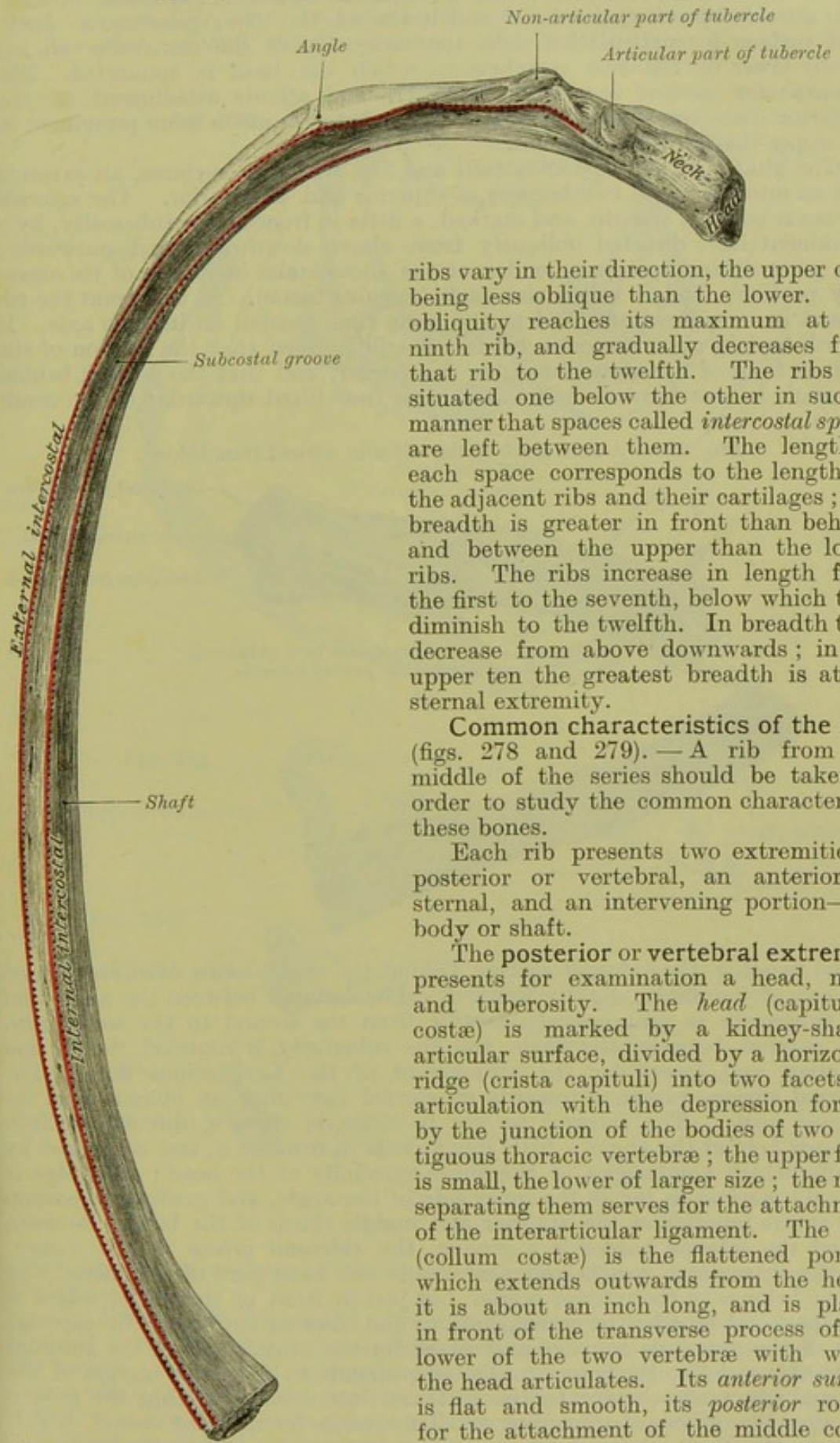

ribs vary in their direction, the upper ones being less oblique than the lower. The obliquity reaches its maximum at the ninth rib, and gradually decreases from that rib to the twelfth. The ribs are situated one below the other in such a manner that spaces called *intercostal spaces* are left between them. The length of each space corresponds to the lengths of the adjacent ribs and their cartilages; the breadth is greater in front than behind, and between the upper than the lower ribs. The ribs increase in length from the first to the seventh, below which they diminish to the twelfth. In breadth they decrease from above downwards; in the upper ten the greatest breadth is at the sternal extremity.

Common characteristics of the ribs (figs. 278 and 279). — A rib from the middle of the series should be taken in order to study the common characters of these bones.

Each rib presents two extremities, a posterior or vertebral, an anterior or sternal, and an intervening portion—the body or shaft.

The **posterior** or **vertebral extremity** presents for examination a head, neck, and tuberosity. The *head* (capitulum costæ) is marked by a kidney-shaped articular surface, divided by a horizontal ridge (crista capituli) into two facets for articulation with the depression formed by the junction of the bodies of two contiguous thoracic vertebræ; the upper facet is small, the lower of larger size; the ridge separating them serves for the attachment of the interarticular ligament. The *neck* (collum costæ) is the flattened portion which extends outwards from the head; it is about an inch long, and is placed in front of the transverse process of the lower of the two vertebræ with which the head articulates. Its *anterior surface* is flat and smooth, its *posterior* rough, for the attachment of the middle costo-transverse ligament, and perforated by numerous foramina. Of its two borders the *superior* presents a rough crest (crista colli costæ) for the

attachment of the anterior costo-transverse ligament; its *inferior border* is rounded. On the posterior surface at the junction of the neck and shaft, and nearer the lower than the upper border, is an eminence—the *tubercle* (tuberculum costæ); it consists of an articular and a non-articular portion. The *articular portion*, the inner and lower of the two, presents a small, oval surface for articulation with the extremity of the transverse process of the lower of the two vertebræ to which the head is connected. The *non-articular portion* is a rough elevation, and affords attachment to the posterior costo-transverse ligament. The tubercle is much more prominent in the upper than in the lower ribs.

The **shaft** (corpus costæ) is thin and flat, with two surfaces, an external and an internal; and two borders, a superior and an inferior. The *external surface* is convex, smooth, and marked, a little in front of the tuberosity, by a prominent line, directed obliquely from above downwards and outwards; this gives attachment to a tendon of the Ilio-costalis or of one of its accessory portions, and is called the *angle* (angulus costæ). At this point the rib is bent in two directions, and at the same time twisted on its long axis. If the rib be laid upon its lower border, it will be seen that the portion of the shaft in front of the angle rests upon this border, and that the portion behind the angle is bent inwards and at the same time tilted upwards; as the result

Fig. 279.—A central rib of the left side, viewed from behind.

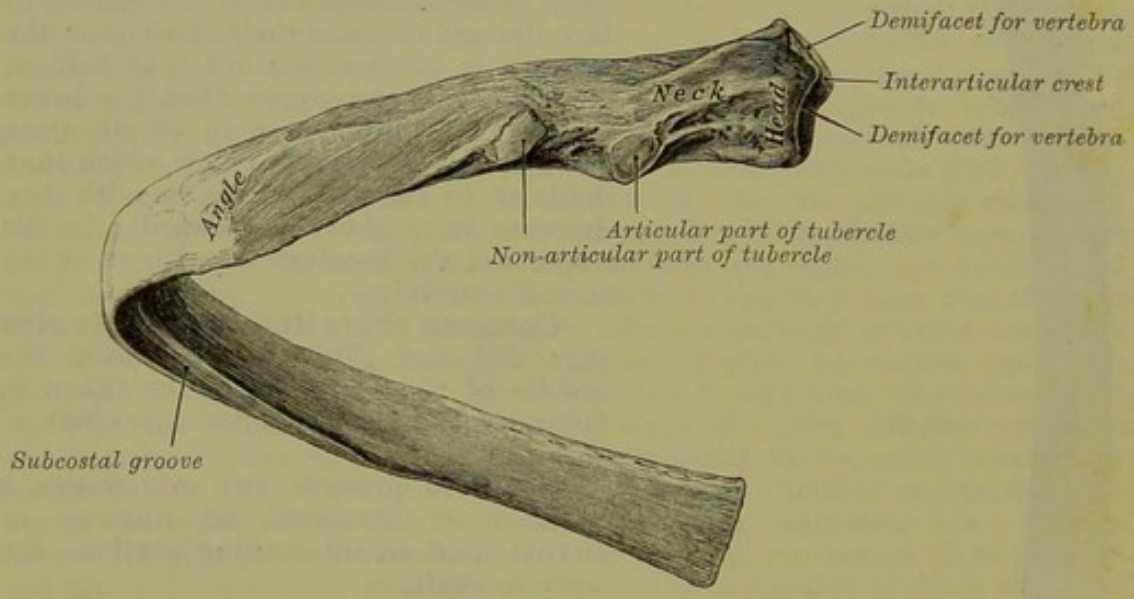

of the twisting, the external surface, behind the angle, looks downwards, and in front of the angle, slightly upwards. The distance between the angle and the tuberosity is progressively greater from the second to the tenth ribs. The portion between the angle and the tuberosity is rounded, rough, and irregular, and serves for the attachment of the Longissimus dorsi. The external surface presents, towards its sternal extremity, an oblique line, the *anterior angle*. The *internal surface* is concave, smooth, directed a little upwards behind the angle, a little downwards in front of it, and is marked by a ridge which commences at the lower extremity of the head; this ridge is strongly marked as far as the inner side of the angle, and gradually becomes lost at the junction of the anterior and middle thirds of the bone. Between it and the inferior border is a groove, the *subcostal groove* (sulcus costæ), for the intercostal vessels and nerve. At the back part of the bone, this groove belongs to the inferior border, but just in front of the angle, where it is deepest and broadest, it corresponds to the internal surface. The superior edge of the groove is rounded and serves for the attachment of the Internal intercostal muscle; the inferior edge corresponds to the lower margin of the rib, and gives attachment to the External intercostal. Within the groove are seen the orifices of numerous small foramina for nutrient vessels, which traverse the shaft obliquely from before backwards. The *superior border*, thick and rounded, is marked by an external and an internal lip, more

distinct behind than in front, which serve for the attachment of the External and Internal intercostal muscles. The *inferior border*, thin and sharp, has attached to it the External intercostal muscle.

The **anterior** or **sternal extremity** is flattened, and presents a porous, oval, concave depression, into which the costal cartilage is received.

The first, second, tenth, eleventh, and twelfth ribs present certain

Peculiar ribs.

Fig. 280.

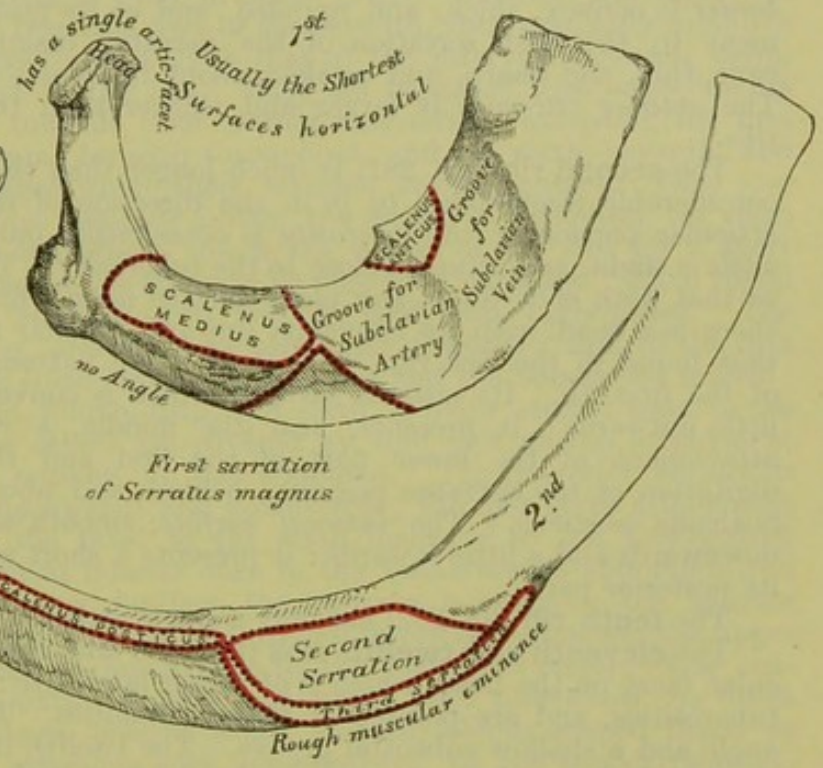

Fig. 281.

Fig. 282.

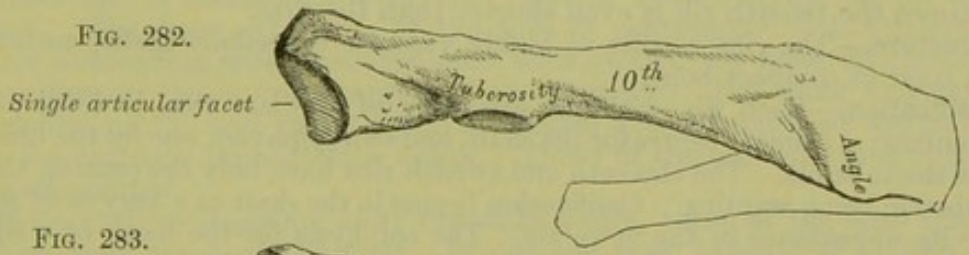

Fig. 283.

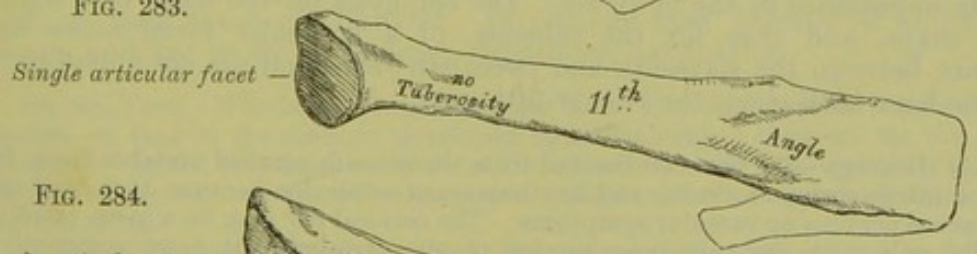

Fig. 284.

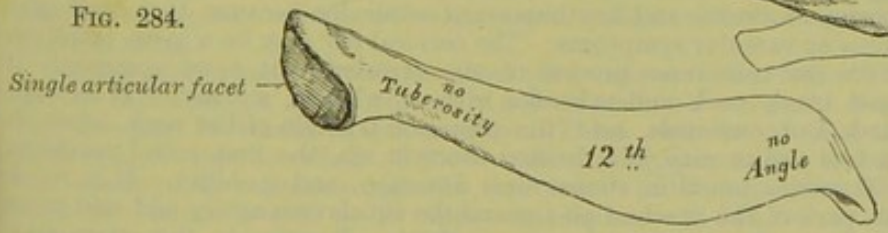

variations from the common characters described above, and require special consideration.

The **first rib** (fig. 280) is the most curved and usually the shortest of all the ribs; it is broad and flat, its surfaces looking upwards and downwards, and its borders inwards and outwards. The *head* is small, rounded, and presents only a single articular facet, for articulation with the body of the first thoracic vertebra. The *neck* is narrow and rounded. The *tuberosity*, thick and prominent, is placed on the outer border. There is no angle, but at the tuberosity the rib is slightly bent, with the convexity of the bend upwards,

so that the head of the bone is directed downwards. The *upper surface* of the shaft is marked by two shallow grooves, separated from each other by a slight ridge prolonged internally into a tubercle, the *scalene tubercle* (tuberculum scaleni [Lisfranci]), for the attachment of the Scalenus anticus; the anterior groove transmits the subclavian vein, the posterior the subclavian artery. Between the groove for the subclavian artery and the tuberosity is a rough surface for the attachment of the Scalenus medius. The *under surface* is smooth, and destitute of a subcostal groove. The *outer border* is convex, thick, and rounded, and at its posterior part gives attachment to the first serration of the Serratus magnus; the *inner* is concave, thin, and sharp, and marked about its centre by the scalene tubercle. The *anterior extremity* is larger and thicker than that of any of the other ribs.

The **second rib** (fig. 281) is much longer than the first, but bears a very considerable resemblance to it in the direction of its curvature. The non-articular portion of the *tuberosity* is occasionally only feebly marked. The *angle* is slight, and situated close to the tuberosity. The *shaft* is not twisted, so that both ends touch any plane surface upon which it may be laid; but there is a bend, with its convexity upwards, similar to, though smaller than that found in the first rib. The shaft is not flattened horizontally like that of the first rib. Its *external surface*, which is convex, looks upwards and a little outwards; it presents, near the middle, a rough eminence for the attachment of the lower part of the first and the whole of the second digitation of the Serratus magnus; behind and above this is attached the Scalenus posticus. The *internal surface*, smooth and concave, is directed downwards and a little inwards: it presents a short subcostal groove towards its posterior part.

The **tenth rib** (fig. 282) has only a single articular facet on its head.

The **eleventh** and **twelfth ribs** (figs. 283 and 284) have each a single articular facet on the head, which is of rather large size; they have no necks or tuberosities, and are pointed at their extremities. The eleventh has a slight angle and a shallow subcostal groove. The twelfth has neither, and is much shorter than the eleventh, and the head has a little inclination downwards. Sometimes the twelfth rib is even shorter than the first.

Structure.—The ribs consist of highly vascular cancellous tissue, enclosed in a thin layer of compact bone.

Ossification.—Each rib, with the exception of the last two, is developed by *three* centres; a primary centre for the shaft, and two epiphyses, one for the head and one for the tubercle. The eleventh and twelfth ribs have only *two* centres, that for the tubercle being wanting. Ossification begins in the shaft at a very early period, before its appearance in the vertebræ. The epiphysis for the head, of a slightly angular shape, and that for the tubercle, of a lenticular form, make their appearance between the sixteenth and twentieth years, and are not united to the rest of the bone until about the twenty-fifth year.

Applied Anatomy.—Cervical ribs derived from the seventh cervical vertebra (page 187) are of not infrequent occurrence, and are important clinically because they may give rise to obscure nervous or vascular symptoms. The cervical rib may be a mere epiphysis articulating only with the transverse process of the vertebra, but more commonly it consists of a defined head, neck and tubercle, with or without a body. It extends outwards, or forwards and outwards, into the posterior triangle of the neck, where it may terminate in a free end or may join the first thoracic rib, the first costal cartilage, or the sternum.* It varies much in shape, size, direction, and mobility. If it reach far enough forwards, part of the brachial plexus and the subclavian artery and vein cross over it, and are apt to suffer compression in so doing. Pressure on the artery may obstruct the circulation so much that arterial thrombosis results, causing gangrene of the finger-tips. Pressure on the nerves is commoner, and affects the eighth cervical and first thoracic nerves, causing paralysis of the muscles they supply, and neuralgic pains and paræsthesia in the area of skin to which they are distributed; no oculo-pupillary changes are to be found. If these symptoms be severe, removal of the rib or as much of it as causes pressure on the vessels and nerves is called for. The operation is not free from difficulty, and has been followed by paralysis of the muscles and by subclavian aneurysm, due to injuries inflicted in the course of the operation.

* W. Thorburn, *The Med. Chronicle*, Manchester, 1907, 4th series, xiv., No. 3.

The Costal Cartilages

The **costal cartilages** (cartilagines costales) (fig. 272) are bars of white, hyaline cartilage, which serve to prolong the ribs forward to the front of the chest, and contribute very materially to the elasticity of its walls. The first seven pairs are connected with the sternum; the next three are each articulated with the lower border of the cartilage of the preceding rib; the last two have pointed extremities, which end in the walls of the abdomen. Like the ribs, the costal cartilages vary in their length, breadth, and direction. They increase in length from the first to the seventh, then gradually diminish to the last. Their breadth, as well as that of the intervals between them, diminishes from the first to the last. They are broad at their attachments to the ribs, and taper towards their sternal extremities, excepting the first two, which are of the same breadth throughout, and the sixth, seventh, and eighth, which are enlarged where their margins are in contact. They also vary in direction: the first descends a little, the second is horizontal, the third ascends slightly, while the others follow the course of the ribs for a short distance, and then ascend to the sternum or preceding cartilage. Each costal cartilage presents two surfaces, two borders, and two extremities. The *anterior surface* is convex, and looks forwards and upwards: that of the first gives attachment to the costo-clavicular ligament and the Subclavius muscle; that of the second, third, fourth, fifth, and sixth, at their sternal ends, to the Pectoralis major.* The others are covered by, and give partial attachment to, some of the flat muscles of the abdomen. The *posterior surface* is concave, and directed backwards and downwards; the first gives attachment to the Sterno-thyroid, the third to the sixth inclusive to the Triangularis sterni, and the six or seven inferior ones to the Transversalis abdominis and the Diaphragm. Of the two borders, the *superior* is concave, the *inferior* convex; they afford attachment to the Internal intercostal muscles: the upper border of the sixth gives attachment also to the Pectoralis major. The contiguous borders of the sixth, seventh, and eighth, and sometimes the ninth and tenth, costal cartilages present small, smooth, oblong-shaped facets at the points where they articulate with one another. Of the two extremities, the *outer* one is continuous with the osseous tissue of the rib to which it belongs. The *inner* extremity of the first is continuous with the sternum; the six succeeding ones have rounded ends, which are received into shallow concavities on the lateral margins of the sternum. The inner extremities of the eighth, ninth, and tenth costal cartilages are pointed, and are connected with the cartilage immediately above. Those of the eleventh and twelfth are free and pointed.

The costal cartilages are most elastic in youth, those of the false ribs being more so than those of the true. In old age they become of a deep yellow colour, and are prone to undergo superficial ossification.

Surface Form.—The bones of the chest are to a very considerable extent covered by muscles, so that in the strongly developed muscular subject they are for the most part concealed. In the emaciated subject, on the other hand, the ribs, especially in the lower and lateral regions, stand out as prominent ridges with the sunken, intercostal spaces between them.

In the middle line, in front, the superficial surface of the sternum can be felt throughout its entire length, at the bottom of a deep median furrow, the *sternal furrow*, situated between the Pectoralis major muscles. These muscles overlap the anterior surface somewhat, so that the whole of the sternum in its entire width is not subcutaneous, and this overlapping is greater opposite the centre of the bone than above and below, so that the furrow is wide at its upper and lower part, but narrow in the middle. The centre of the upper border of the sternum constitutes the *presternal notch*, and is in the same horizontal plane as the lower border of the body of the second thoracic vertebra; the lateral parts of this border are obscured by the tendinous origins of the Sterno-mastoid muscles, which appear as oblique tendinous cords, narrowing and deepening the notch. Lower down on the subcutaneous surface a well-defined transverse ridge, the *angulus Ludovici*, is always to be felt. This denotes the line of junction of the manubrium and gladiolus; it lies at the level of the fifth thoracic vertebra, and is a useful guide to the second costal cartilage, and thus to the identity of any given rib. The second rib being found, through its costal cartilage, it is easy to count downwards and find any

* The first and seventh in addition occasionally give origin to the same muscle.

other. From the middle of the sternum the furrow spreads out, and, exposing more of the surface of the bone, terminates at the junction of the gladiolus with the ensiform cartilage, on the same level as the disc between the ninth and tenth thoracic vertebræ. Immediately below this is the *infrasternal notch*; between the points of junction of the seventh costal cartilages to the sternum, and below the notch is a triangular depression, the *epigastric fossa*, or pit of the stomach (scrobiculus cordis), bounded laterally by the cartilages of the seventh ribs; in it the ensiform cartilage can be felt. The sternum in its vertical diameter presents a general convexity forwards, the most prominent point of which is at the joint between the manubrium and gladiolus.

On either side of the sternum the costal cartilages and ribs on the front of the chest are partially obscured by the Pectoralis major, through which, however, they can be felt as ridges, with yielding intervals between them, corresponding to the intercostal spaces. Of these spaces, that between the second and third ribs is the widest, the next two somewhat narrower, and the remainder, with the exception of the last two, comparatively narrow.

The lower border of the Pectoralis major corresponds to the fifth rib, and below this, on the front of the chest, the broad, flat outline of the ribs, as they begin to ascend, and the more rounded outline of the costal cartilages, are often visible. The lower boundary of the front of the thorax, the *abdomino-thoracic arch*, which is most plainly seen by bending the body backwards, is formed by the ensiform cartilage and the cartilages of the seventh, eighth, ninth, and tenth ribs, and the extremities of the cartilages of the eleventh and twelfth ribs.

On either side of the chest, from the axilla downwards, the flattened external surfaces of the ribs may be defined in the form of oblique ridges, separated by depressions corresponding to the intercostal spaces. They are, however, covered by muscles, which, when strongly developed, obscure their outline to a certain extent. Nevertheless, the ribs, with the exception of the first, can generally be followed over the front and sides of the chest without difficulty. The first rib, being almost completely covered by the clavicle and scapula, can only be distinguished in a small portion of its extent. At the back, the angles of the ribs lie on a slightly marked oblique line, on either side of and some distance from the spinous processes of the vertebræ. This line diverges somewhat as it descends, and external to it is a broad, convex surface, caused by the projection of the ribs beyond their angles. Over this surface, except where covered by the scapula, the individual ribs can be distinguished.

For clinical purposes and convenience of description, the surface of the chest has been mapped out by arbitrary lines into certain definite areas. On the front of the chest the most important vertical lines are the *mid-sternal*, which runs down the median line of the sternum, and the *mammary*, which runs vertically downwards from a point midway between the centre of the presternal notch and the tip of the acromion process. This line, if prolonged, will cross Poupart's ligament at a point midway between the anterior superior spine of the ilium and the symphysis pubis. The lateral area is bounded by two vertical lines—that in front, the *anterior axillary line*, being drawn from the anterior fold of the axilla; and that behind, the *posterior axillary line*, from the posterior fold. By some this lateral area of the thorax is further divided by a *mid-axillary* line, drawn downwards from the apex of the axilla. On the posterior aspect of the thorax the *scapular line* is drawn vertically through the inferior angle of the scapula.

Applied Anatomy.—Fracture of the sternum is by no means common, owing, no doubt, to the elasticity of the ribs and their cartilages which support it like so many springs. The fracture usually occurs in the upper half of the gladiolus. Dislocation of the gladiolus from the manubrium may take place, and is sometimes described as a fracture.

The bone is frequently the seat of gummatous tumours and not uncommonly is affected with caries.

The ribs are frequently broken, though from their connections and shape they are able to withstand great force, yielding under the injury and recovering themselves like a spring. The middle ones of the series are the most liable to fracture. The first and to a less extent the second, being protected by the clavicle, are rarely fractured; and the eleventh and twelfth on account of their loose and floating condition enjoy a like immunity. The fracture generally occurs from indirect violence, from forcible compression of the chest wall, and the bone then gives way at its weakest part, i.e., just in front of the angle. But the ribs may also be broken by direct violence, in which case the bone is driven inwards at the point struck. Fracture of the ribs is frequently complicated with some injury to the viscera contained within the thorax or upper part of the abdominal cavity; this is most likely to occur in fractures from direct violence.

Fracture of the costal cartilages or separation of the cartilages from the ribs, may also take place, though they are comparatively rare injuries. In workmen the pressure of tools may displace the ensiform cartilage inwards.

The ribs are frequently the seat of tuberculous disease, with the formation of a chronic abscess in the chest wall. This may not immediately overlie the carious portion of rib, as the pus is often directed a considerable distance along the subcostal groove before appearing beneath the integument.

Resection of a portion of a rib is often required in order to give efficient drainage to an empyema ; this is referred to in the description of the respiratory organs.

The *thorax* is frequently found to be altered in shape in certain diseases.

In *rickets*, the ends of the ribs, where they join the costal cartilages, become enlarged, giving rise to the so-called ' rickety rosary,' which in mild cases is only found on the internal aspect of the chest-wall. Outside these enlargements the softened ribs sink in, so as to present a groove passing downwards and outwards on either side of the sternum. This bone is forced forwards by the bending of the ribs, and the antero-posterior diameter of the chest is increased. The ribs from the second to the eighth are the ones affected, the lower ones being prevented from falling in by the presence of the liver, stomach, and spleen ; and when the abdomen is distended, as it often is in rickets, the lower ribs may be pushed outwards, causing a transverse groove (Harrison's sulcus) just above the costal arch. This deformity is known under the name of ' pigeon-breast,' and is primarily due to some chronic obstruction to the entry of air into the thorax, though it is more prone to occur in the softened bones of rickety children than in the healthy, where the resistance of the thoracic walls is greater. The *phthisical chest* is often long and narrow, flattened from before backwards, and with great obliquity of the ribs and projection of the scapulæ. In *pulmonary emphysema* the chest is enlarged in all its diameters, and presents on section an almost circular outline. It has received the name of the ' barrel-shaped chest.' In severe cases of *lateral curvature of the spine* the thorax becomes much distorted. In consequence of the rotation of the bodies of the vertebræ, which takes place in this disease, the ribs opposite the convexity of the dorsal curve become extremely convex behind, being thrown out and bulging, and at the same time flattened in front, so that the two ends of the same rib are almost parallel. Coincident with this the ribs on the opposite side, on the concavity of the curve, are sunk and depressed behind, and bulging and convex in front.

It is commonly said that in tuberculosis of the lungs the chest is characteristically ' flat,' that is to say, that the ratio of its antero-posterior to its transverse diameter is less than the normal. But by careful measurement in a large number of cases, Woods Hutchinson has shown that this is not so. Taking the transverse diameter of the chest at the nipple level as = 100, he finds that in the normal adult man between the ages of 20 and 44 the antero-posterior diameter = 71. In 82 phthisical subjects it was = 79·5, and in 30 ' flat-chested ' persons was = 80. He explains the error as an optical illusion, due to rolling forwards of the shoulders in the ' flat-chested ' ; the back is seen to be correspondingly rounded and protuberant, while the forward position of the shoulders and clavicles lends an appearance of flattening to the chest.

More or less shrinkage of one side of the thorax is often seen as a consequence of adhesive pleurisy, in which the visceral and parietal pleuræ adhere closely to one another and the lung becomes collapsed and fibrosed. If this process be at all complete, great deformity of the chest results, the ribs on the affected side falling in, together with obliteration of the intercostal spaces ; the contents of the mediastina are pulled over towards the affected side, the other lung becomes emphysematous compensatorily. The vertebral column becomes scoliotic, with the concavity of the curve towards the affected side.

THE SKULL

The **skull** is supported on the summit of the vertebral column, and is of an oval shape, wider behind than in front. It is composed of a series of flattened or irregular bones which, with one exception (the mandible, or lower jaw), are immovably jointed together. It consists of two parts : (1) the *cranium*, which lodges and protects the brain and comprises eight bones (ossa cranii), and (2) the *skeleton of the face*, which consists of fourteen bones (ossa faciei), as follows :

- *Skull*, 22 bones
  - *Ossa cranii*, 8 bones
    - Occipital.
    - Two Parietals.
    - Two Temporals.
    - Sphenoid.
    - Frontal.
    - Ethmoid.
  - *Ossa faciei*, 14 bones
    - Two Nasals.
    - Two Lachrymals.
    - Two Maxillæ.
    - Two Palates.
    - Two Inferior Turbinateds.
    - Two Malars.
    - Vomer.
    - Mandible.

According to the Basle nomenclature, certain bones developed in association with the nasal capsule, viz. the inferior turbinateds, the lachrymals, the nasals, and the vomer, are grouped as cranial and not as facial bones.

The Hyoid bone, situated at the root of the tongue and attached to the base of the skull by ligaments, has also to be considered in this section.

OSSA CRANII

The Occipital Bone

The **occipital bone** (os occipitale) (figs. 285 and 286), situated at the back and lower part of the cranium, is trapezoid in shape and much curved on itself. It is pierced by a large oval aperture, the *foramen magnum*, through which the cranial cavity communicates with the vertebral canal.

The curved, expanded plate behind the foramen magnum is named the *tabular* or *squamous portion*; the thick, somewhat quadrilateral piece in front of the foramen is called the *basilar process*, whilst that on either side of the foramen constitutes the *lateral* or *condylic portion*.

Fig. 285.—Occipital bone. Outer surface.

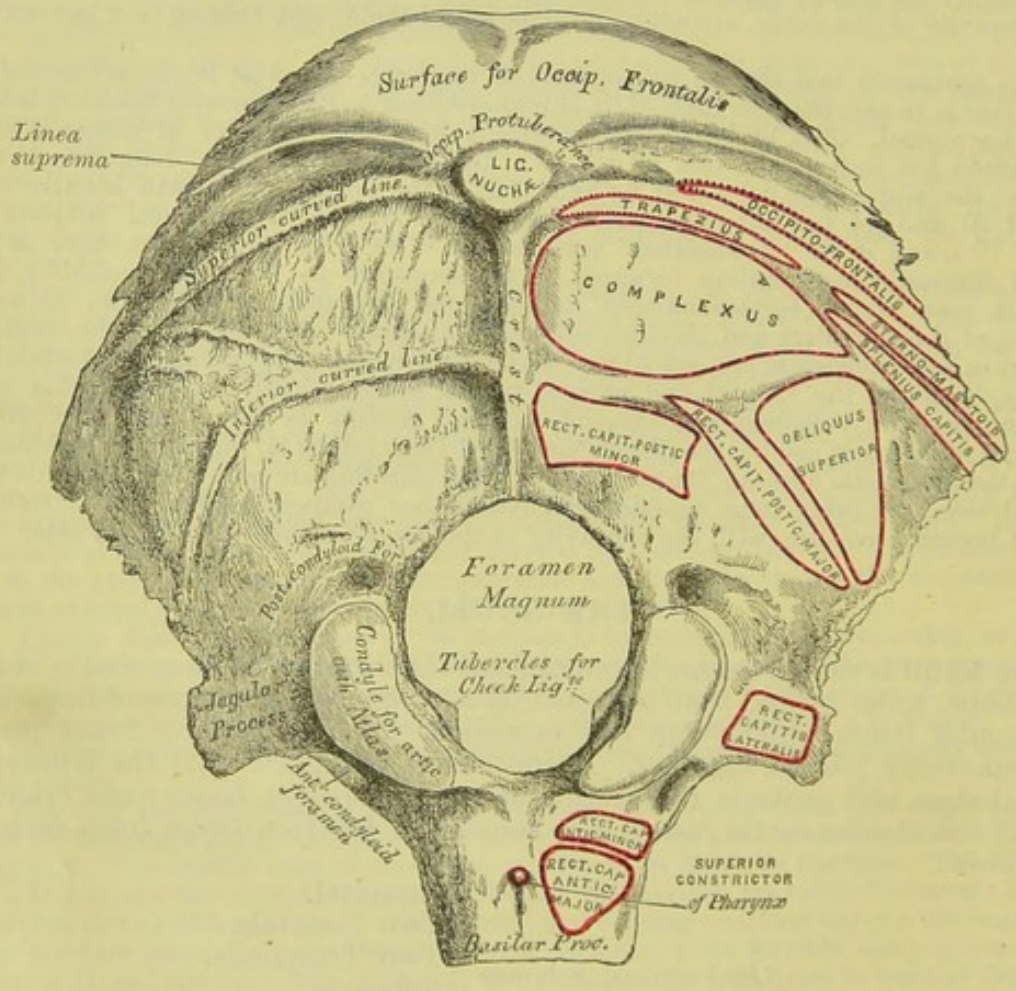

The **tabular portion** (squama occipitalis), situated above and behind the foramen magnum, is curved from above downwards and from side to side.

The *external surface* is convex and presents midway between the summit of the bone and the foramen magnum a prominence, the *inion* or *external occipital protuberance* (protuberantia occipitalis externa). Extending outwards from this on either side are two curved lines, one a little above the other. The upper, often faintly marked, is named the *highest curved line* (linea nuchæ suprema) and to it the epicranial aponeurosis is attached. The lower is termed the *superior curved line* (linea nuchæ superior). That part of the squama which lies above the lineæ supremæ is named the *planum occipitale*, and is

covered by the Occipito-frontalis muscle; that below, termed the *planum nuchale*, is rough and irregular for the attachment of several muscles. From the external occipital protuberance a ridge or crest (linea nuchæ mediana), often faintly marked, descends to the foramen magnum, and affords attachment to the ligamentum nuchæ; running outwards from the middle of this crest across each half of the nuchal plane is the *inferior curved line* (linea nuchæ inferior) Several muscles are attached to the outer surface of the squama occipitalis, thus: the superior curved line gives origin to the Occipito-frontalis and Trapezius, and insertion to the Sterno-mastoid and Splenius; into the surface between the superior and inferior curved lines the Complexus and the Superior oblique are inserted, whilst the inferior curved line and the area below it receive the insertions of the Recti capitis postici major and minor. The

FIG. 286.—Occipital bone. Inner surface.

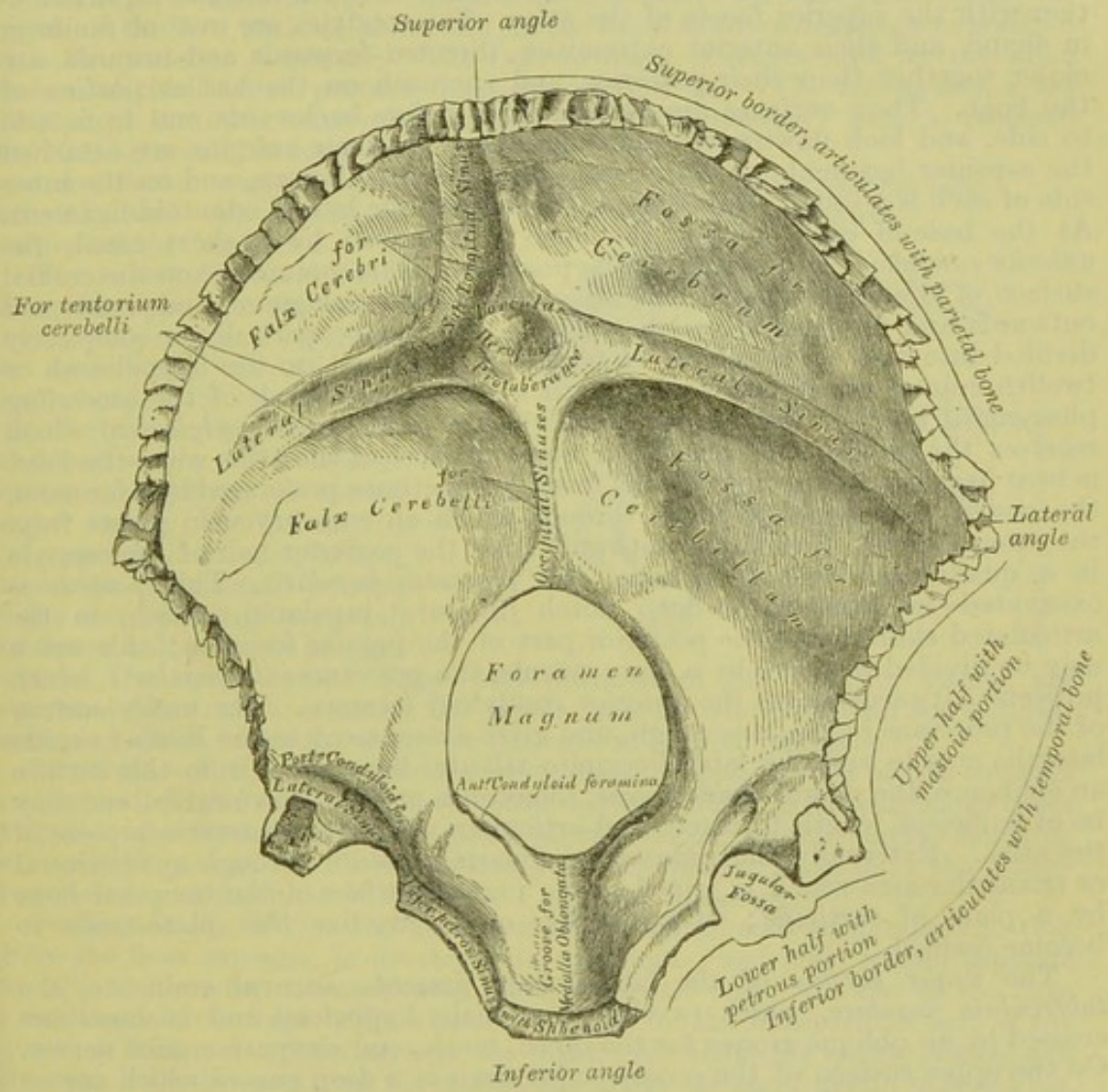

posterior occipito-atlantal ligament is attached around the postero-lateral part of the foramen magnum, just outside the margin of the foramen.

The *internal surface* is deeply concave and divided into four fossæ by a crucial ridge, the *eminentia cruciata*. The upper two fossæ are triangular and lodge the occipital lobes of the cerebrum; the lower two are quadrilateral and accommodate the hemispheres of the cerebellum. At the point of intersection of the four divisions of the crucial ridge is the *internal occipital protuberance* (protuberantia occipitalis interna). From this eminence the upper division of the ridge runs to the superior angle of the bone, and on one side of it (generally the right) is a deep groove, the *sulcus sagittalis*, which lodges the hinder part of the superior longitudinal sinus; to the margins of this sulcus the falx cerebri is attached. The lower division of the crucial ridge is prominent, and is named

the *crista occipitalis interna*; it bifurcates near the foramen magnum and gives attachment to the falx cerebelli; in the attached margin of this falx is the occipital sinus, which is sometimes duplicated. Transverse grooves, one on either side, extend outwards from the internal occipital protuberance to the lateral angles of the bone; these grooves accommodate the lateral sinuses, and their prominent margins give attachment to the tentorium cerebelli. The groove on the right side is usually larger than that on the left, and is continuous with that for the superior longitudinal sinus. Exceptions to this condition are, however, not infrequent; the left may be larger than the right or the two may be almost equal in size. The angle of union of the superior longitudinal and lateral sinuses is named the *torcular Herophili*,* and its position is indicated by a depression situated on one or other side of the protuberance.

The **lateral** or **condylic portions** (partes laterales) are situated at the sides of the foramen magnum; on their under surfaces are the *condyles* for articulation with the superior facets of the atlas. The condyles are oval or reniform in shape, and their anterior extremities, directed forwards and inwards, are closer together than their posterior, and encroach on the basilar portion of the bone. Their surfaces are convex from before backwards and from side to side, and look downwards and outwards. To their margins are attached the capsular ligaments of the occipito-atlantal articulations, and on the inner side of each is a rough impression or tubercle for the lateral odontoid ligament. At the base of each condyle the bone is tunnelled by a short canal, the *anterior condyloid foramen* (canalis hypoglossi). This commences on the cranial surface of the bone immediately above the foramen magnum, and is directed outwards and forwards above the condyle. It may be partially or completely divided into two by a spicule of bone; it gives exit to the hypoglossal or twelfth cranial nerve, and entrance to a meningeal branch of the ascending pharyngeal artery. Behind each condyle is a fossa (*fossa condyloidea*) which receives the posterior margin of the superior facet of the atlas when the head is bent backwards; the floor of this fossa is sometimes perforated by a foramen, the *posterior condyloid foramen*, through which an emissary vein passes from the lateral sinus. Extending outwards from the posterior half of the condyle is a quadrilateral plate of bone, the *processus jugularis*. This process is excavated in front by a deep notch (incisura jugularis), which, in the articulated skull, forms the posterior part of the jugular foramen; this notch may be divided into two by a bony spicule, the *processus intrajugularis*, which projects outwards above the anterior condyloid foramen. The under surface of the processus jugularis is rough, and gives attachment to the Rectus capitis lateralis muscle and the lateral occipito-atlantal ligament; from this surface an eminence, the *paramastoid process*, sometimes projects downwards, and may be of sufficient length to reach, and articulate with, the transverse process of the atlas. Externally the processus jugularis presents a rough quadrilateral or triangular area which is joined to the jugular surface of the temporal bone by a plate of cartilage; after the age of twenty-five this plate tends to become ossified.

The *upper surface* of the lateral part presents an oval eminence, the *tuberculum jugulare*, which overlies the canalis hypoglossi and is sometimes crossed by an oblique groove for the ninth, tenth, and eleventh cranial nerves. On the upper surface of the processus jugularis is a deep groove which curves inwards and forwards and is continuous with the notch on the anterior surface. This groove lodges the terminal part of the lateral sinus, and opening into it, close to its inner margin, is the orifice of the posterior condyloid foramen.

The **basilar process** (pars basilaris) extends forwards and upwards from the foramen magnum, and presents *in front* an area more or less quadrilateral in outline. In the young skull this area is rough and uneven, and is joined to the body of the sphenoid by a plate of cartilage. By the twenty-fifth year this cartilaginous plate is ossified, and the occipital and sphenoid must be severed by a saw.

On its *lower surface*, about half an inch in front of the foramen magnum,

* The columns of blood coming in different directions were supposed to be pressed together at this point (*torcular*, a wine-press).

is the *pharyngeal tubercle* (tuberculum pharyngeum) which gives attachment to the fibrous raphe of the pharynx. On either side of the middle line the Recti capitis antici major and minor are inserted, and immediately in front of the foramen magnum the anterior occipito-atlantal ligament is attached.

The *upper surface* presents a broad, shallow groove which inclines upwards and forwards from the foramen magnum; it supports the *medulla oblongata*, and near the margin of the foramen magnum gives attachment to the *membrana tectoria* or occipito-axial ligament. On the lateral margins of this surface are faint grooves for the inferior petrosal sinuses.

The *foramen magnum* is a large oval aperture with its long diameter antero-posterior; it is wider behind than in front where it is encroached upon by the condyles. It transmits the medulla oblongata and its membranes, the spinal accessory nerves, the vertebral arteries, the anterior and posterior spinal arteries, and the occipito-axial ligaments.

The *superior angle* of the occipital bone articulates with the postero-superior angles of the two parietal bones and, in the fœtal skull, corresponds in position with the *posterior fontanelle*. The *inferior angle* is represented by the sawn surface of the basilar process, already referred to. The *lateral angles* are situated at the outer extremities of the transverse grooves: each is received into the interval between the postero-inferior angle of the parietal and the mastoid portion of the temporal.

FIG. 287.—Ossification of occipital bone. Usually by seven centres.

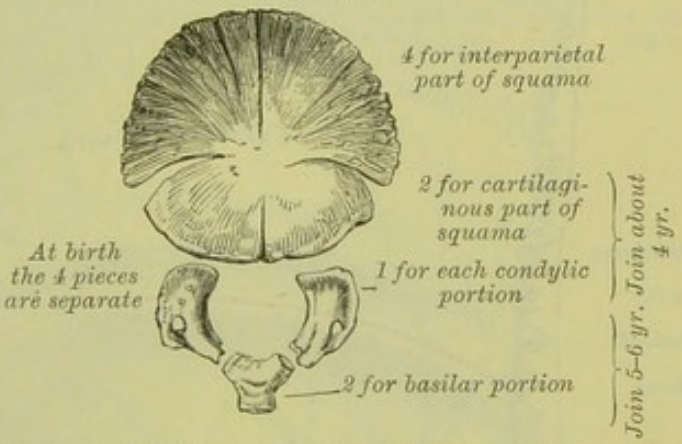

The *superior borders* extend from the superior to the lateral angles: they are deeply serrated for articulation with the posterior borders of the parietal, and form by this union the *lambdoid suture*. The *inferior borders* extend from the lateral angles to the inferior angle; the upper half of each articulates with the mastoid portion of the corresponding temporal, the lower half with the petrous part of the same bone. These two portions of the inferior border are separated from one another by the jugular process, the notch on the anterior surface of which forms the posterior part of the jugular foramen.

Structure.—The occipital, like the other cranial bones, consists of two compact lamellæ, called the *outer* and *inner tables*, between which is the cancellous tissue or diploë; the bone is especially thick at the ridges, protuberances, condyles, and anterior part of the basilar process; in the inferior fossæ it is thin, semi-transparent, and destitute of diploë.

Ossification (fig. 287).—The upper portion of the squama occipitalis, viz. that above the linea suprema, is developed in membrane, and may remain separate throughout life when it constitutes the *interparietal* bone; the rest of the bone is developed in cartilage. The number of nuclei for the interparietal part of the squama is four, two appearing near the middle line about the second month, and two some little distance from the middle line about the third month of fœtal life. The cartilaginous portion of the squama is ossified from two centres, which appear about the seventh week of fœtal life and soon unite to form a single piece. Union of the upper and lower portions of the squama takes place about the third or fourth month after birth. Each of the condylic parts begins to ossify from a single centre about the end of the eighth week of fœtal life. The basilar portion is ossified from two centres, one in front of the other; these appear about the sixth week of fœtal life and rapidly coalesce, so that this part is frequently described as ossifying from one centre. About the fourth year the tabular and the two condylic portions unite, and about the sixth year the bone consists of a single piece. Between the eighteenth and twenty-fifth years the occipital and sphenoid become united, forming a single bone.

Articulations.—The occipital articulates with six bones: the two parietals, the two temporals, the sphenoid, and the atlas.

The Parietal Bones

The **parietal bones** (ossa parietales) form, by their union, the sides and roof of the skull. Each is irregularly quadrilateral in form, and presents for examination two surfaces, four borders, and four angles.

The *external surface* (fig. 288) is convex, smooth, and marked about its centre by an eminence, the *parietal eminence* (tuber parietale), which indicates the point where ossification commenced. Crossing the middle of the bone in an arched direction are two curved lines, the *superior* and *inferior temporal lines* (lineæ temporales); the former gives attachment to the temporal fascia, while the latter indicates the upper limit of the muscular origin of the Temporal muscle. Above these lines the bone is covered by the aponeurosis of the Occipito-frontalis; below them it forms part of the temporal fossa, and

Fig. 288.—Left parietal bone. External surface.

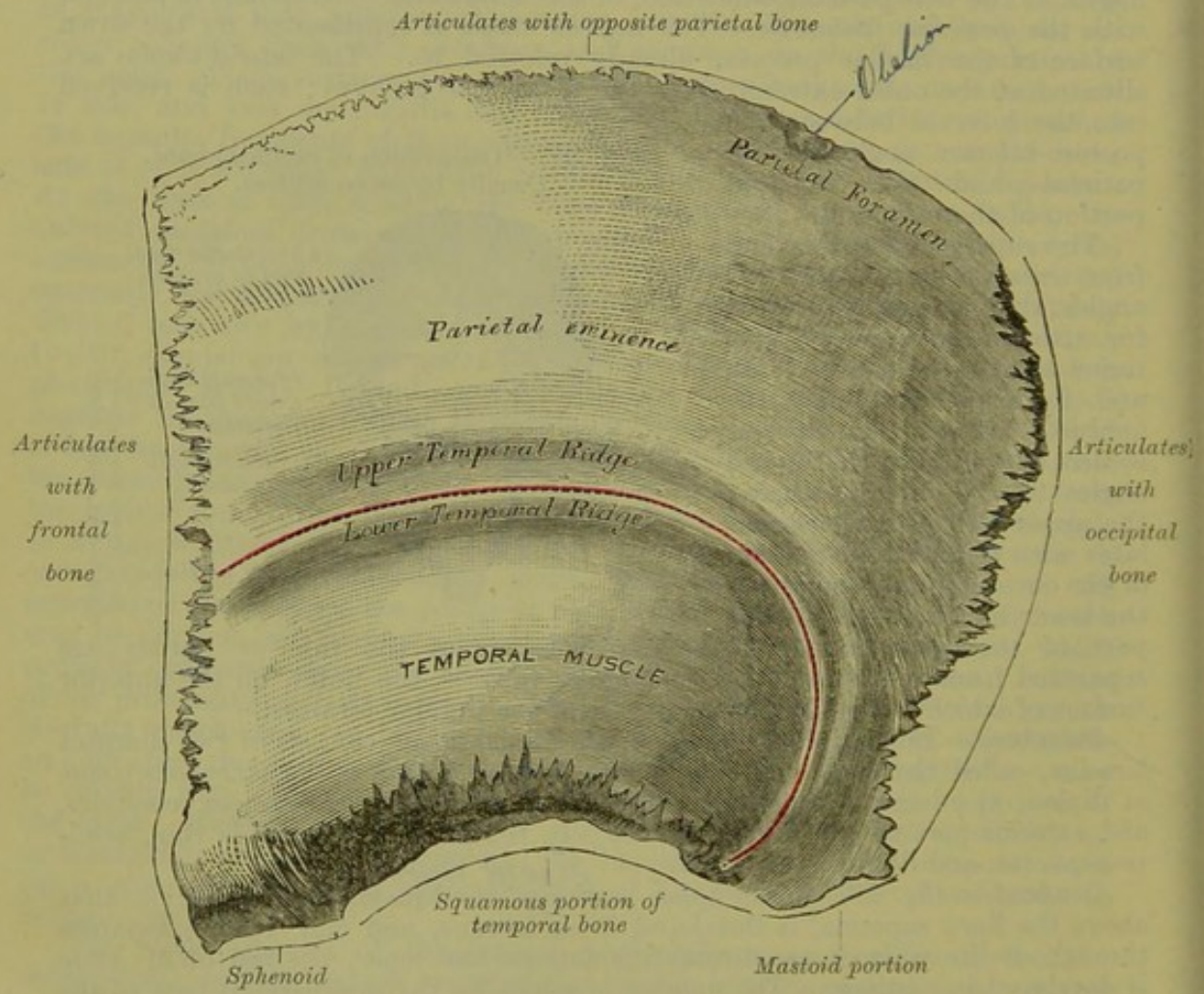

affords attachment to the Temporal muscle. At the back part of the superior border, close to the sagittal suture, is the *parietal foramen* (foramen parietale), which transmits a vein to the superior longitudinal sinus, and sometimes a small branch of the occipital artery. It is not constantly present, and its size varies considerably.

The *internal surface* (fig. 289) is concave; it presents depressions corresponding to the cerebral convolutions, and numerous furrows for the ramifications of the middle meningeal artery; the latter run upwards and backwards from the antero-inferior angle, and from the central and posterior part of the lower border. Along the upper margin is a shallow groove, which, together with that on the opposite parietal, forms a channel (sulcus sagittalis) for the superior longitudinal sinus; the edges of the sulcus afford attachment to the falx cerebri. Near the groove are seen several depressions, best marked in the skulls of old persons, for the Pacchionian bodies. The internal opening of the parietal foramen is also seen when that aperture exists.

The *superior border* (margo sagittalis), the longest and thickest, is dentated and articulates with its fellow of the opposite side, forming the sagittal suture. The *inferior border* (margo squamosus) is divided into three parts: of these, the anterior is thin and pointed, bevelled at the expense of the outer surface, and overlapped by the tip of the great wing of the sphenoid; the middle portion is arched, bevelled at the expense of the outer surface, and overlapped by the squamous portion of the temporal; the posterior part is thick and serrated for articulation with the mastoid portion of the temporal. The *anterior border* (margo frontalis) is deeply serrated, and bevelled at the expense of the outer surface above and of the inner below; it articulates with the frontal bone, forming one half of the *coronal suture*. The *posterior border* (margo occipitalis), deeply denticulated, articulates with the occipital, forming one half of the *lambdoid suture*.

The *antero-superior angle* (angulus frontalis), thin and pointed, corresponds with the union of the sagittal and coronal sutures; this point is named the

FIG. 289.—Left parietal bone. Internal surface.

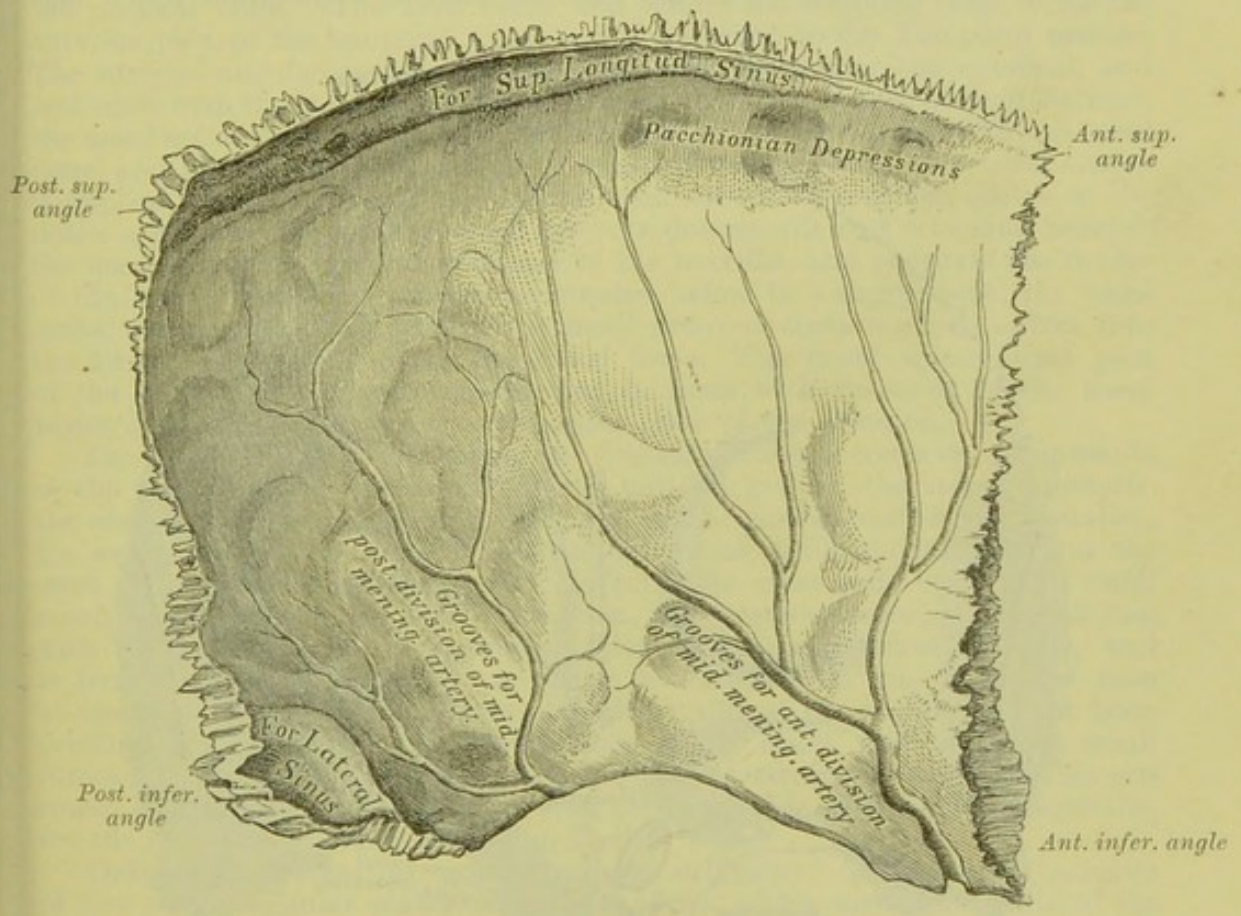

bregma; in the fœtal skull this region is membranous, and is called the *anterior fontanelle*. The *antero-inferior angle* (angulus sphenoidalis), thin and pointed, is received into the interval between the frontal and the great wing of the sphenoid. Its inner surface is marked by a deep groove, sometimes a canal, for the anterior branch of the middle meningeal artery. The *postero-superior angle* (angulus occipitalis) corresponds with the point of junction of the sagittal and lambdoid sutures—a point which is termed the *lambda*; in the fœtus this part of the skull is membranous, and is called the *posterior fontanelle*. The *postero-inferior angle* (angulus mastoideus) articulates with the occipital and with the mastoid portion of the temporal, and presents on its inner surface a broad, shallow groove which lodges part of the lateral sinus. The point of union of this angle with the occipital and the mastoid part of the temporal is named the *asterion*.

Ossification.—The parietal bone is ossified in membrane from a single centre, which appears at the parietal eminence about the seventh or eighth

week of fœtal life. Ossification gradually extends in a radial manner from the centre towards the margins of the bone; the angles are consequently the parts last formed, and it is here that the fontanelles exist. Occasionally the parietal bone is divided into two parts, upper and lower, by an antero-posterior suture

Articulations.—The parietal articulates with five bones: the opposite parietal, the occipital, frontal, temporal, and sphenoid.

The Frontal Bone

The **frontal bone** (os frontale) resembles a cockle-shell in form, and consists of two portions—a *frontal* or *vertical* portion corresponding with the region of the forehead; and an *orbital* or *horizontal* portion, which enters into the formation of the roofs of the orbits and nasal fossæ.

Frontal or **vertical portion** (squama frontalis).—The *external surface* (fig. 290) of this portion is convex and usually exhibits, in the lower part of the middle line, the remains of the *frontal* or *metopic suture*; in infancy this *suture* divides the bone into right and left halves, a condition which may

Fig. 290.—Frontal bone. Outer surface.

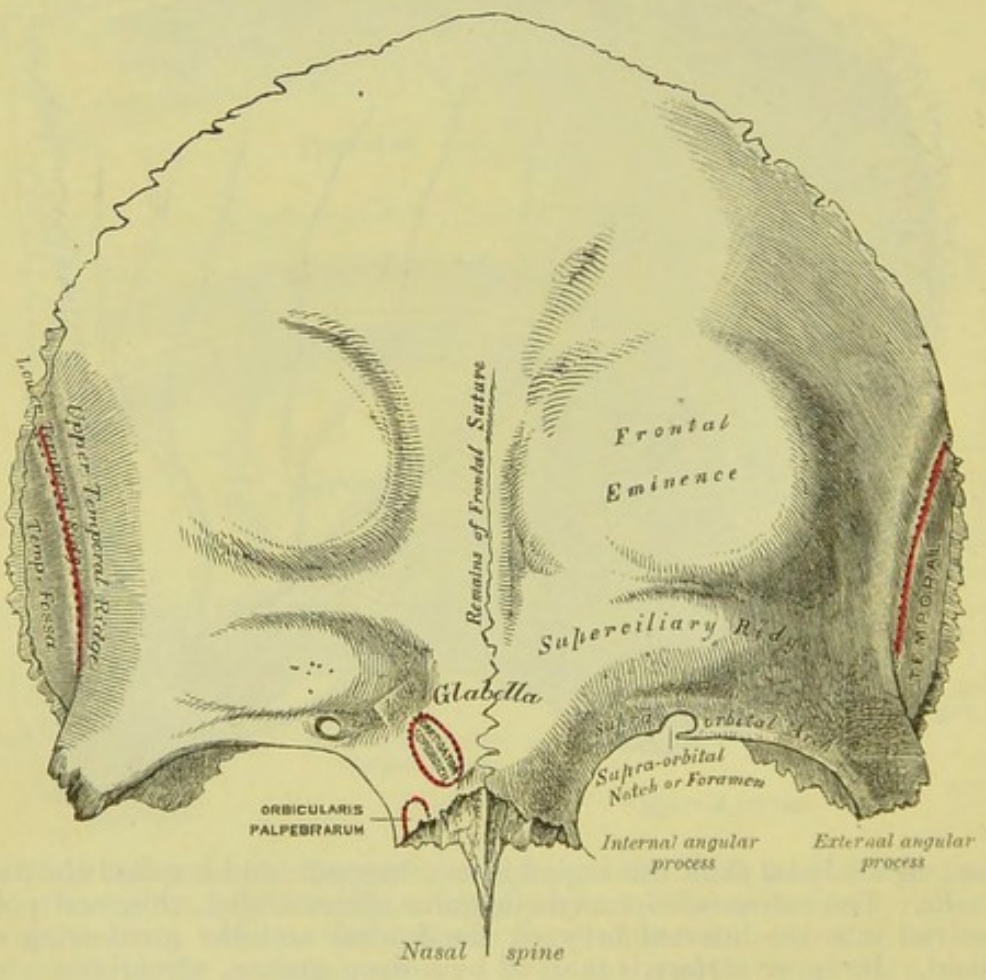

persist throughout life. On either side of this suture, a little more than an inch above the supra-orbital margin, is a rounded elevation, the *frontal eminence* (tuber frontale). These eminences vary in size in different individuals, are occasionally unsymmetrical, and are especially prominent in young skulls; the surface of the bone above them is smooth, and covered by the aponeurosis of the Occipito-frontalis. Below the frontal eminences, and separated from them by a shallow groove, are two arched elevations, the *superciliary ridges* (arcus superciliares); these are prominent internally, and are joined across the middle line by a smooth elevation named the *glabella*. These ridges are larger in the male than in the female, and their degree of prominence depends to

some extent on the size of the frontal air sinuses,* but it must be noted that prominent ridges are occasionally associated with small air sinuses and *vice versa*. Beneath each superciliary ridge is a curved and prominent margin, the *supra-orbital margin* (margo supraorbitalis), which forms the upper boundary of the base of the orbit, and separates the frontal from the orbital portion of the bone. The outer part of this margin is sharp and prominent, affording to the eye, in that situation, considerable protection from injury; the inner part is rounded. At the junction of its inner and middle thirds is a notch, sometimes converted into a foramen, the *supra-orbital notch* or *foramen* (incisura sive foramen supraorbitalis), which transmits the supra-orbital vessels and nerve. A small aperture in the upper part of the notch transmits a vein from the diploë to join the supra-orbital vein. The supra-orbital margin terminates externally in the *external angular process*, and internally in the *internal angular process*. The external angular process (processus zygomaticus) is strong, prominent, and articulates with the malar bone. Running upwards and backwards from this process is a well-marked ridge, the *temporal ridge* (linea temporalis); this ridge divides into the *upper* and *lower temporal lines*, which are continuous, in the articulated skull, with the corresponding lines on the parietal bone. The area below and behind the temporal ridge forms the anterior part of the temporal fossa, and gives origin to the Temporal muscle. The internal angular processes descend to a lower level than the external, and articulate with the lachrymal bones; between them is a rough, uneven interval, the *nasal notch*, which articulates on either side of the middle line with the nasal bone, and laterally with the frontal process of the maxilla. The term *nasion* is applied to the middle of the fronto-nasal suture. From the centre of the notch a process, the *nasal process*, projects downwards and forwards beneath the nasal bones and frontal processes of the maxillæ, and supports the bridge of the nose. The nasal process terminates below in a sharp spine, the *nasal spine*, and on either side of this is a small grooved surface which enters into the formation of the roof of the nasal fossa. The nasal spine forms part of the septum of the nose, articulating in front with the crest of the nasal bones and behind with the perpendicular plate of the ethmoid.

The *internal surface* (fig. 291) of the frontal portion is concave and presents in the upper part of the middle line a vertical groove, the *sulcus sagittalis*, the edges of which unite below to form a ridge, the *frontal crest* (crista frontalis); the sulcus lodges the superior longitudinal sinus, while its margins and the crest afford attachment to the falx cerebri. The crest ends below in a small notch which is converted into a foramen, the *foramen cæcum*, by articulation with the ethmoid. This foramen varies in size in different subjects, and is frequently impervious; when open, it transmits a vein from the nose to the superior longitudinal sinus. On either side of the middle line the bone presents depressions for the convolutions of the brain, and numerous small furrows for the anterior branches of the middle meningeal arteries. Several small, irregular fossæ may also be seen on either side of the sulcus sagittalis, for the reception of the Pacchionian bodies.

Orbital or horizontal portion (pars orbitalis).—This portion consists of two thin triangular plates, the *orbital plates*, which form the vaults of the orbits, and are separated from one another by a median gap, the *ethmoidal notch*.

The *inferior surface* (fig. 291) of each orbital plate is smooth and concave, and presents, under cover of the external angular process, a shallow depression, the *lachrymal fossa* (fossa glandulæ lacrimalis), for the lachrymal gland; near the internal angular process is a depression, the *fovea trochlearis*, for the attachment of the cartilaginous pulley of the Superior oblique muscle of the eyeball. The *superior surface* is convex, and marked by depressions for the convolutions of the frontal lobes of the brain, and faint grooves for the meningeal branches of the ethmoidal arteries.

* Some confusion is occasioned to students commencing the study of anatomy by the name 'sinus' having been given to two different kinds of space connected with the skull. It may be as well, therefore, to state here that the 'sinuses' in the interior of the cranium which produce the grooves on the inner surfaces of the bones are venous channels which convey the blood from the brain, while the 'sinuses' external to the cranial cavity (the frontal, sphenoidal, ethmoidal, and maxillary) are hollow spaces in the bones themselves which communicate with the nasal cavities, and contain air.

The *ethmoidal notch* (incisura ethmoidalis) separates the two orbital plates; it is quadrilateral, and filled up, in the articulated skull, by the cribriform plate of the ethmoid. The margins of the notch present several half-cells which, when united with corresponding half-cells on the upper surface of the ethmoid, complete the ethmoidal air-cells. Two grooves cross these edges transversely; they are converted into the *anterior* and *posterior ethmoidal canals* by the ethmoid bone, and open on the inner wall of the orbit. The anterior canal transmits the nasal nerve and anterior ethmoidal vessels; the posterior, the posterior ethmoidal vessels. In front of the ethmoidal notch, on either side of the nasal spine, are the openings of the *frontal air sinuses*. These are two irregular cavities, which extend backwards, upwards and outwards, for a variable distance between the two tables of the skull, and are separated from one another by a thin bony septum, which often deviates to one or other side, with the result that the sinuses are rarely symmetrical. Absent at birth, they

FIG. 291.—Frontal bone. Inner surface.

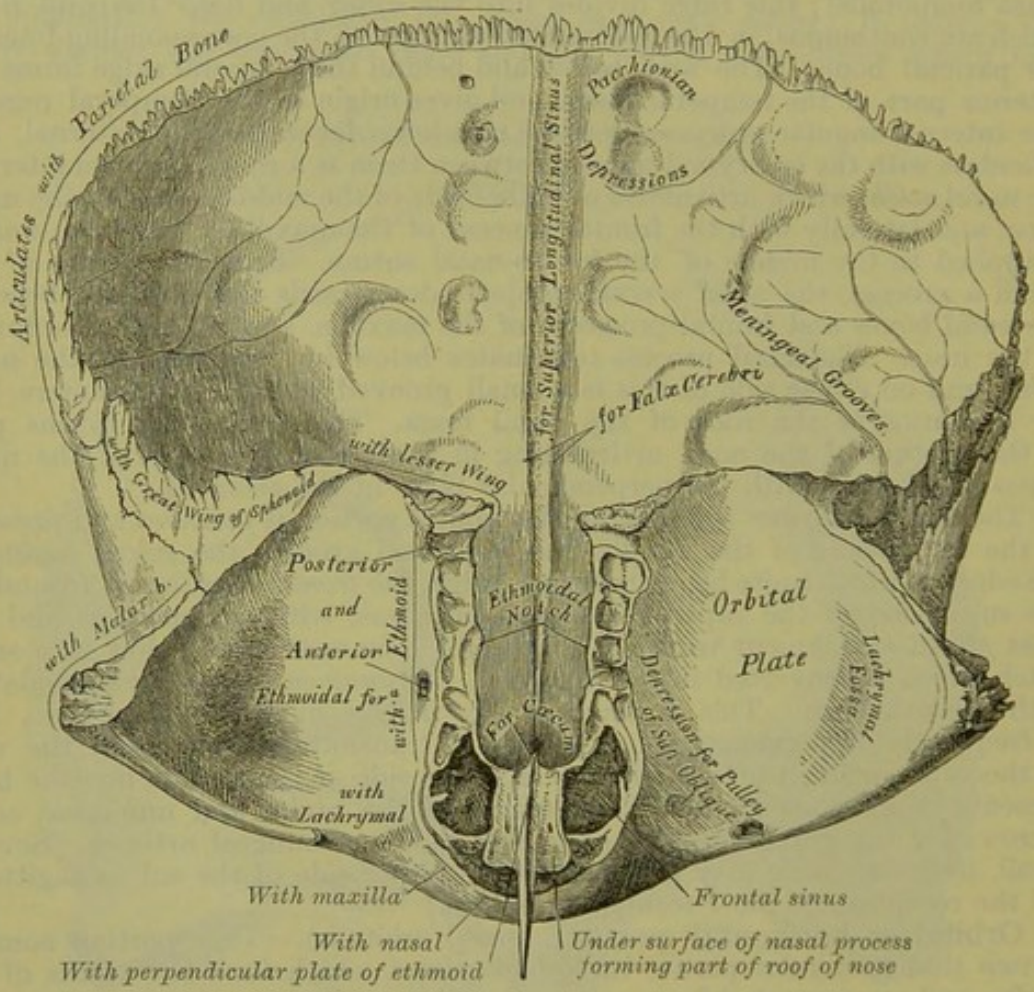

are usually fairly well developed between the ninth and twelfth years, but only reach their full size after puberty. They vary in size in different persons, and are larger in men than in women. Aldren Turner (*The Accessory Sinuses of the Nose*, 1901) gives the following measurements for a sinus of average size: height, 1¼ in.; breadth, 1 in.; depth from before backwards, 1 in. They are lined by mucous membrane, and each communicates with the corresponding nasal fossa by means of a passage called the *infundibulum*.

The *border of the vertical portion* is thick, strongly serrated, bevelled at the expense of the inner table above, where it rests upon the parietal bones, and at the expense of the outer table on either side, where it receives the lateral pressure of those bones; this border is continued below into a triangular, rough surface, which articulates with the great wing of the sphenoid. The *posterior borders of the orbital plates* are thin, serrated, and articulate with the lesser wings of the sphenoid.

Structure.—The frontal portion and external angular processes are very thick, consisting of diploic tissue contained between two compact laminæ; in the regions described above the diploic tissue is replaced by the frontal air sinuses. The orbital portion is thin, translucent, and composed entirely of compact tissue; hence the facility with which instruments can penetrate the cranium through this part of the orbit; when the frontal sinuses are exceptionally large they may extend backwards for a considerable distance between the two tables of the orbital portion.

Fig. 292.—Frontal bone at birth. Ossified from two primary centres.

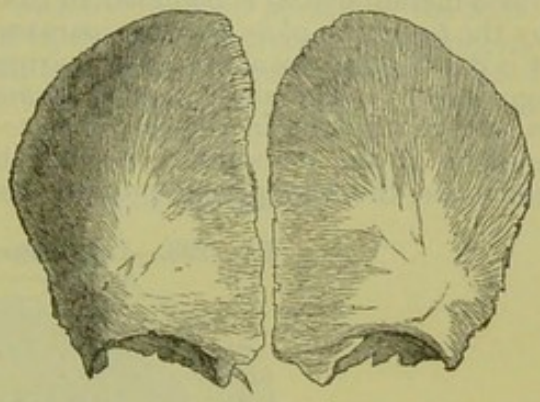

Ossification (fig. 292). —The frontal bone is ossified in membrane from *two primary* centres, one for each lateral half, which appear about the seventh week of fœtal life, above the orbital arches. From each of these centres ossification extends upwards to form the corresponding half of the frontal portion, and backwards to form the orbital plate. The nasal spine is ossified from a pair of *secondary* centres, one on either side of the middle line; and similar centres appear in the regions of the internal and external angular processes. At birth the bone consists of two pieces, which afterwards become united, along the middle line, by the *metopic* suture which runs from the vertex of the bone to the root of the nose. This suture usually becomes obliterated within a few years after birth; but it occasionally persists throughout life.

Articulations.—The frontal articulates with twelve bones: the sphenoid, the ethmoid, the two parietals, the two nasals, the two maxillæ, the two lachrymals, and the two malars.

The Temporal Bones

The **temporal bones** (ossa temporalia) are situated at the sides and base of the skull. Each consists of four parts, viz. the *squamous* or *squamo-zygomatic*, the *petro-mastoid*, the *tympanic plate*, and the *styloid process*.

The **squamous portion** (squama temporalis), the anterior and upper part of the bone, is scale-like, thin and translucent. Its *outer surface* (fig. 293) is smooth and convex; it affords attachment to the Temporal muscle, and forms part of the temporal fossa; on its hinder part is a vertical groove for the middle temporal artery. A curved ridge, the *temporal ridge*, or *supra-mastoid crest*, runs backwards and upwards across its posterior part; it serves for the attachment of the temporal fascia, and limits the origin of the Temporal muscle. The boundary between the squamous and mastoid portions of the bone, as indicated by traces of the original suture, lies about half an inch below this ridge. Projecting from the lower part of the squamous portion is a long, arched process, the *zygomatic process* (processus zygomaticus). This process is at first directed outwards, its two surfaces looking upwards and downwards; it then appears as if twisted inwards upon itself, and runs forwards, its surfaces now looking inwards and outwards. The superior border of the process is long, thin, and sharp, and serves for the attachment of the temporal fascia; the inferior, short, thick, and arched, has attached to it some fibres of the Masseter. The outer surface is convex and subcutaneous; the inner is concave, and affords attachment to the Masseter. The extremity is deeply serrated and articulates with the malar bone. The zygomatic process is connected to the squamous portion by two *roots*—anterior and posterior. The anterior root, continuous with the lower border, is short but broad and strong; it is directed inwards and terminates in a rounded eminence, the *eminentia articularis* (tuberculum articulare). This eminence forms the front boundary of the glenoid fossa, and in the recent state is covered with cartilage. In front of the articular eminence is a small triangular area which assists in forming the zygomatic fossa; this area is separated from the outer surface of the squamous portion by a ridge which is continuous posteriorly with the anterior root of the zygoma, and anteriorly, in the articulated

skull, with the infra-temporal crest on the greater wing of the sphenoid. The posterior root, a prolongation of the upper border, is strongly marked; it runs backwards above the external auditory meatus, and is continuous with the *supra-mastoid crest* already referred to. At the junction of the anterior root with the zygomatic process is a projection, called the *tubercle*, for the attachment of the external lateral ligament of the temporo-mandibular joint; and behind the anterior root is an oval depression, forming part of the glenoid fossa, for the reception of the condyle of the mandible. The *glenoid fossa* (fossa mandibularis) is bounded, in front, by the eminentia articularis; behind, by the *tympanic plate* which separates it from the external auditory meatus; it is divided into two parts by a narrow slit, the *Glaserian fissure* (fissura petro-tympanica). The anterior part, formed by the squamous portion of the bone, is smooth, covered in the recent state with cartilage, and articulates with the condyle of the mandible. Behind this part of the fossa is a small conical eminence, the *post-glenoid process*; this is the representative of a prominent

FIG. 293.—Left temporal bone. Outer surface.

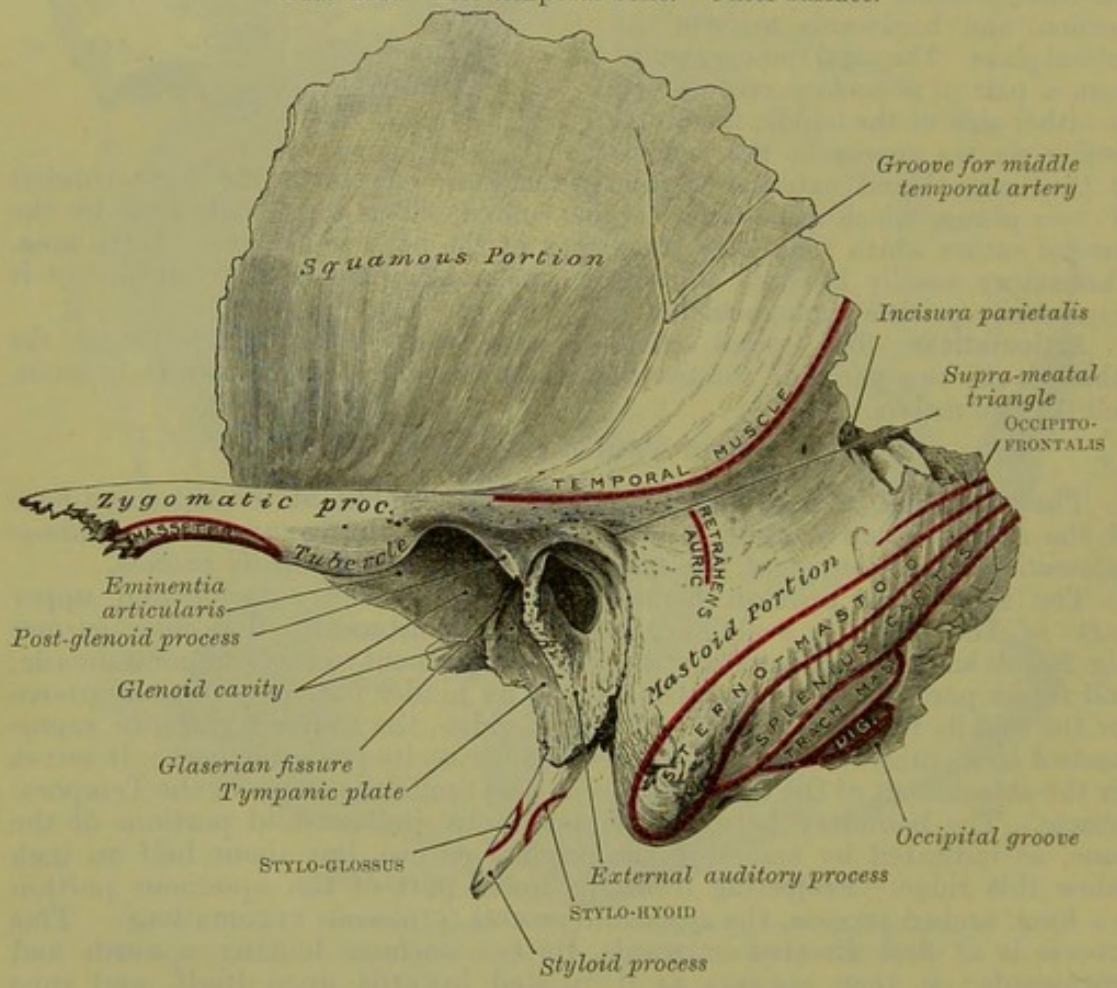

tubercle which, in some mammals, descends behind the condyle of the mandible, and prevents its backward displacement. The posterior part of the glenoid fossa, formed by the tympanic plate, is non-articular, and lodges a portion of the parotid gland. The Glaserian fissure leads into the middle ear or tympanic cavity; it lodges the processus gracilis of the malleus, and transmits the tympanic branch of the internal maxillary artery. The chorda tympani nerve passes through a canal (*canal of Huguier*), separated from the anterior edge of the Glaserian fissure by a thin scale of bone and situated on the outer side of the Eustachian tube, in the retiring angle between the squamous and petrous portions of the temporal. This thin scale of bone is derived from the tegmen tympani, and forms the greater part of the outer wall of the bony portion of the Eustachian tube. Between the posterior wall of the external auditory meatus and the posterior root of the zygoma is the area called the *suprameatal triangle* of Macewen, through which an instrument may be pushed into the mastoid antrum.

The *internal surface* of the squamous portion (fig. 294) is concave; it presents depressions corresponding to the convolutions of the temporal lobe of the brain, and grooves for the branches of the middle meningeal artery.

The *superior border* is thin, and bevelled at the expense of the internal table, so as to overlap the lower border of the parietal bone, forming with it the squamous suture. The *antero-inferior border* is thick, serrated, and bevelled at the expense of the inner table above and of the outer below, for articulation with the greater wing of the sphenoid. Posteriorly, the superior border forms an angle (*incisura parietalis*) with the mastoid portion of the bone.

The **petro-mastoid portion** consists of (*a*) the *mastoid process*, a prominent, nipple-like mass behind the external auditory meatus; and (*b*) the *petrous portion*, which is pyramidal in shape, and projects inwards and forwards to form part of the floor of the skull.

FIG. 294.—Left temporal bone. Inner surface.

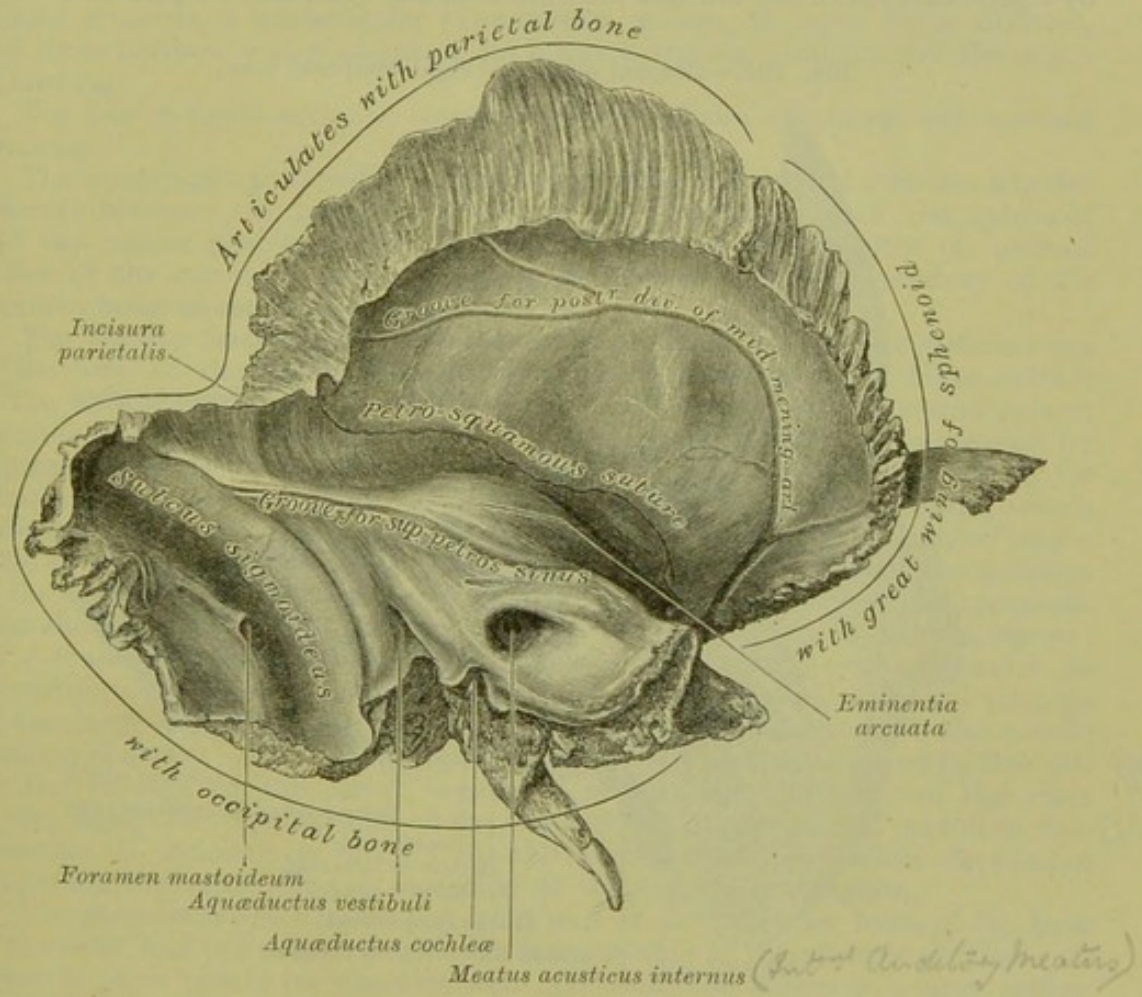

The **mastoid portion** (pars mastoidea) forms the posterior part of the bone. Its *outer surface* (fig. 293) is rough, and gives attachment to the Occipito-frontalis and Retrahens auriculam. It is perforated by numerous foramina; one of these, of large size, situated near the posterior border, is termed the *foramen mastoideum*; it transmits a vein to the lateral sinus and a small branch of the occipital artery to the dura mater. The position and size of this foramen are very variable; it is not always present; sometimes it is situated in the occipital bone, or in the suture between the temporal and the occipital. The mastoid portion is continued below into a conical projection, the *mastoid process* (processus mastoideus), the size and form of which vary somewhat; it is larger in the male than in the female. This process serves for the attachment of the Sterno-mastoid, Splenius capitis, and Trachelo-mastoid. On the inner side of the process is a deep groove, the *digastric fossa* (incisura mastoidea), for the attachment of the Digastric; internal to this is a shallow furrow, the *occipital groove*, which lodges the occipital artery.

The *inner surface* of the mastoid portion presents a deep, curved groove, the *sulcus sigmoideus*, which lodges part of the lateral sinus ; in it may be seen the opening of the mastoid foramen. The groove for the lateral sinus is separated from the innermost of the mastoid air-cells by only a thin lamina of bone, and even this may be partly deficient. A section of the mastoid process (fig. 295) shows it to be hollowed out into a number of spaces, the *mastoid cells* (cellulæ mastoideæ), which exhibit the greatest possible variety as to their size and number. At the upper and front part of the bone they are large and irregular and contain air, but towards the lower part of the bone they diminish in size, while those at the apex of the process are frequently quite small and contain marrow. Occasionally they are entirely absent, and the mastoid is then solid throughout. In addition to these a large irregular cavity is situated at the upper and front part of the bone. It is called the *mastoid antrum* (antrum tympanicum), and must be distinguished from the mastoid cells, though it communicates with them. Like the mastoid cells it is filled with air and lined by a prolongation of the mucous membrane of the tympanic cavity, with which

Fig. 295.—Coronal section of right temporal bone.

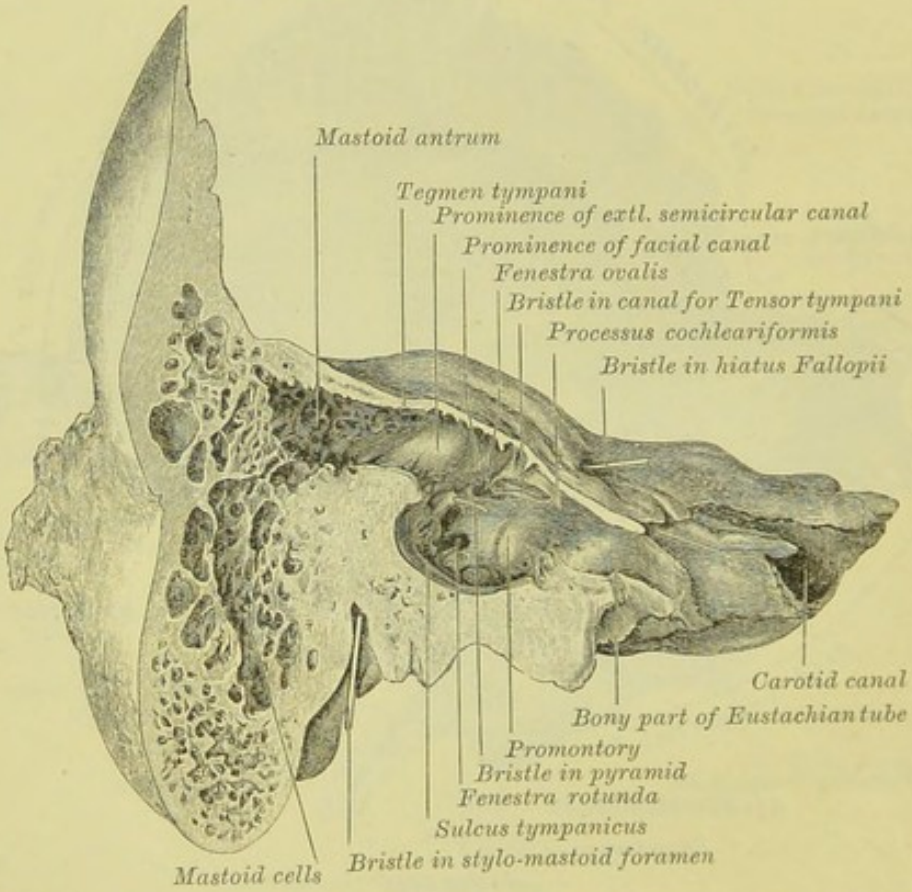

it communicates. The mastoid antrum is bounded above by a thin plate of bone, the *tegmen tympani*, which separates it from the middle fossa of the base of the skull ; below by the mastoid process ; externally by the squamous portion of the bone just below the supra-mastoid crest, and internally by the external semicircular canal of the internal ear which projects into its cavity. It opens in front into that portion of the tympanic cavity which is known as the *attic* or *epitympanic recess*.

The mastoid antrum is a cavity of some considerable size at the time of birth, and is derived, together with the tympanic cavity and the Eustachian tube, from the inner part of the first visceral cleft. The mastoid air-cells may be regarded as diverticula from the antrum, and begin to appear at or before birth ; by the fifth year they are well marked, but their development is not completed until towards puberty.

Applied Anatomy.—In consequence of the direct continuity which exists between the tympanic cavity and mastoid antrum, inflammation of the lining membrane of the

former cavity is always associated with a similar condition in the latter, and may easily spread thence into the mastoid air-cells, leading to caries and necrosis of their walls and the risk of transference of the inflammation to the lateral sinus or brain. The mastoid antrum in fact forms a reservoir for pus which, if unable to drain away, may set up serious and often fatal intracranial complications.

The *superior border* of the mastoid portion is broad and serrated, for articulation with the postero-inferior angle of the parietal. The *posterior border*, also serrated, articulates with the inferior border of the occipital between the lateral angle and jugular process. Anteriorly the mastoid portion is fused with the descending process of the squamous portion above, and below it enters into the formation of the external auditory meatus and the cavity of the tympanum.

The **petrous portion** (pars petrosa or pyramis), so named from its extreme density and hardness, is pyramidal and wedged in at the base of the skull between the sphenoid and occipital bones. Directed inwards, forwards, and a little upwards, it presents for examination a base, an apex, three surfaces, and three borders, and contains, in its interior, the essential parts of the organ of hearing.

The *base* is fused with the internal surfaces of the squamous and mastoid portions.

The *apex* (apex pyramidis), rough and uneven, is received into the angular interval between the posterior border of the greater wing of the sphenoid and the basilar process of the occipital; it presents the anterior or internal orifice of the carotid canal, and forms the postero-external boundary of the foramen lacerum medium.

The *anterior surface* (fig. 294) forms the posterior part of the middle fossa of the base of the skull. This surface is continuous with the inner surface of the squamous portion, to which it is united by the *petro-squamous suture*, remains of which are distinct even at a late period of life. It is marked by depressions for the convolutions of the brain, and presents six points for examination: (1) an eminence (*eminentia arcuata*) near the centre, which indicates the situation of the superior semicircular canal; (2) in front of and a little to the outer side of this eminence a depression, indicating the position of the tympanic cavity: here the layer of bone which separates the tympanic from the cranial cavity is extremely thin, and is known as the *tegmen tympani*; (3) a shallow groove, sometimes double, leading outwards and backwards to an oblique opening, the *hiatus Fallopii* (hiatus canalis facialis), for the passage of the large superficial petrosal nerve and the petrosal branch of the middle meningeal artery; (4) a smaller opening, occasionally seen, external to the last, for the passage of the small superficial petrosal nerve; (5) near the apex of the bone, the termination of the carotid canal, the wall of which in this situation is deficient in front; (6) above this canal a shallow depression (impressio trigemini) for the reception of the Gasserian ganglion.

The *posterior surface* forms the front part of the posterior fossa of the base of the skull, and is continuous with the inner surface of the mastoid portion. It presents three points for examination. (1) Near the centre is a large orifice, the *meatus acusticus internus*, the size of which varies considerably; its margins are smooth and rounded, and it leads into a short canal, about one-third of an inch in length, which runs directly outwards. It transmits the seventh and eighth cranial nerves and the auditory branch of the basilar artery. This canal is closed externally by a vertical plate, the *lamina cribrosa*, which is divided by a horizontal crest, the *crista falciformis*, into two unequal portions (fig. 296). Each portion is further subdivided by a vertical ridge into an anterior and a posterior part. The portion beneath the crista falciformis presents three sets of foramina; one group, just below the posterior part of the crest, situated in the *area cribrosa media*, consists of a number of small openings for the nerves to the saccule; below and posterior to this is the *foramen singulare*, or opening for the nerve to the posterior semicircular canal; in front of and below the first is the *tractus spiralis foraminosus*, consisting of a number of small spirally arranged openings, which encircle the *canalis centralis cochleæ* and transmit the nerves to the cochlea. The portion above the crista presents behind the *area cribrosa superior*, pierced by a series of small openings, for the

passage of filaments to the utricle and the superior and external semicircular canals, and, in front, the *area facialis*, with one large opening, the commencement of the *aquæductus Fallopii* (canalis facialis), for the passage of the facial nerve. (2) Behind the meatus acusticus is a small slit almost hidden by a thin plate of bone, leading to a canal, the *aquæductus vestibuli*, which transmits the *ductus endolymphaticus* together with a small artery and vein. (3) In the interval between these two openings, but above them, is an irregular depression which lodges a process of the dura mater and transmits a small vein. In the infant this depression is represented by a large fossa, the *fossa subarcuata*, which extends backwards as a blind tunnel under the superior semicircular canal.

The *inferior surface* (fig. 297) is rough and irregular, and forms part of the exterior of the base of the skull. It presents eleven points for examination: (1) near the apex a rough surface, quadrilateral in form, which serves partly for the attachment of the Levator palati and the cartilaginous portion of the Eustachian tube, and partly for connection with the basilar process of the occipital bone through the intervention of the dense fibrous tissue; (2) behind this the large circular aperture of the *carotid canal* (canalis caroticus), which ascends at first vertically, and then, making a bend, runs horizontally forwards and inwards; it transmits into the cranium the internal carotid artery, and the carotid plexus of nerves; (3) to the inner side of the opening for the carotid canal and close to the posterior border, in front of the jugular fossa, is a triangular depression, on the floor of which is a small opening, the *aquæductus cochleæ*, which lodges a tubular prolongation of the dura mater and transmits a vein from the cochlea to join the internal jugular; (4) behind these openings a deep depression, the *jugular fossa*, of variable depth and size in different skulls; it lodges the bulb of the internal jugular vein, and, with a similar depression on the front of the jugular process of the occipital bone, forms the jugular foramen; (5) a small foramen for the passage of Jacobson's nerve (the tympanic branch of the glosso-pharyngeal); this foramen is seen in the bony ridge dividing the carotid canal from the jugular fossa; (6) a small foramen in the outer part of the jugular fossa, for the entrance of the auricular branch of the pneumogastric nerve (Arnold's nerve); (7) behind the jugular fossa, a quadrilateral area, the *jugular surface*, which is covered with cartilage in the recent state, and articulates with the jugular process of the occipital bone; (8) the *vaginal process*, a sheath-like plate of bone, which extends backwards from the carotid canal and divides behind into two laminæ; the outer lamina is continuous with the tympanic plate, the inner with the outer margin of the jugular surface; between these laminæ is (9) the *styloid process*, a sharp spine, about an inch in length; (10) the *stylo-mastoid foramen*, a rather large orifice, placed between the styloid and mastoid processes; it is the termination of the aquæductus Fallopii, and transmits the facial nerve and stylo-mastoid artery; (11) the *auricular fissure* (fissura tympanomastoidea), situated between the tympanic plate and mastoid process, for the exit of the auricular branch of the pneumogastric nerve.

FIG. 296. — Diagrammatic view of the fundus of the right internal auditory meatus. (Testut.)

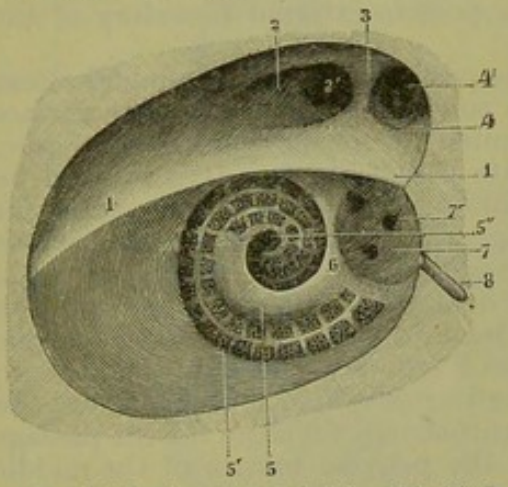

1. Crista falciformis. 2. Area facialis, with (2') Internal opening of the aquæductus Fallopii. 3. Ridge separating the area facialis from the area cribrosa superior. 4. Area cribrosa superior, with (4') Openings for nerve filaments. 5. Anterior inferior cribriform area, with (5') the tractus spiralis foraminosus, and (5'') the canalis centralis of the cochlea. 6. Ridge separating the tractus spiralis foraminosus from the area cribrosa media. 7. Area cribrosa media, with (7') Orifices for nerves to saccule. 8. Foramen singulare.

The *superior border*, the longest, is grooved for the superior petrosal sinus, and gives attachment to the tentorium cerebelli; at its inner extremity is a notch, in which the fifth cranial nerve lies. The *posterior border* is intermediate in length between the superior and the anterior. Its inner half is marked by

a sulcus, which forms, with a corresponding sulcus on the occipital bone, the channel for the inferior petrosal sinus. Its outer half presents an excavation —the *jugular fossa*—which, with a similar notch on the occipital, forms the jugular foramen. A projecting eminence occasionally stands out from the centre of the notch, and divides the foramen into two. The *anterior border* is divided into two parts—an outer joined to the squamous portion by a suture (*petro-squamous*), the remains of which are more or less distinct; an inner, free, which articulates with the spinous process of the sphenoid. At the angle of junction of the petrous and squamous portions are seen two canals, one above the other, and separated by a thin plate of bone, the *processus cochleariformis* (septum canalis musculotubarii); they both lead into the tympanum. The upper one (semicanalis m. tensoris tympani) transmits the Tensor tympani, the lower one (semicanalis tubæ auditivæ) forms the bony part of the Eustachian tube.

FIG. 297.—Left temporal bone. Inferior surface.

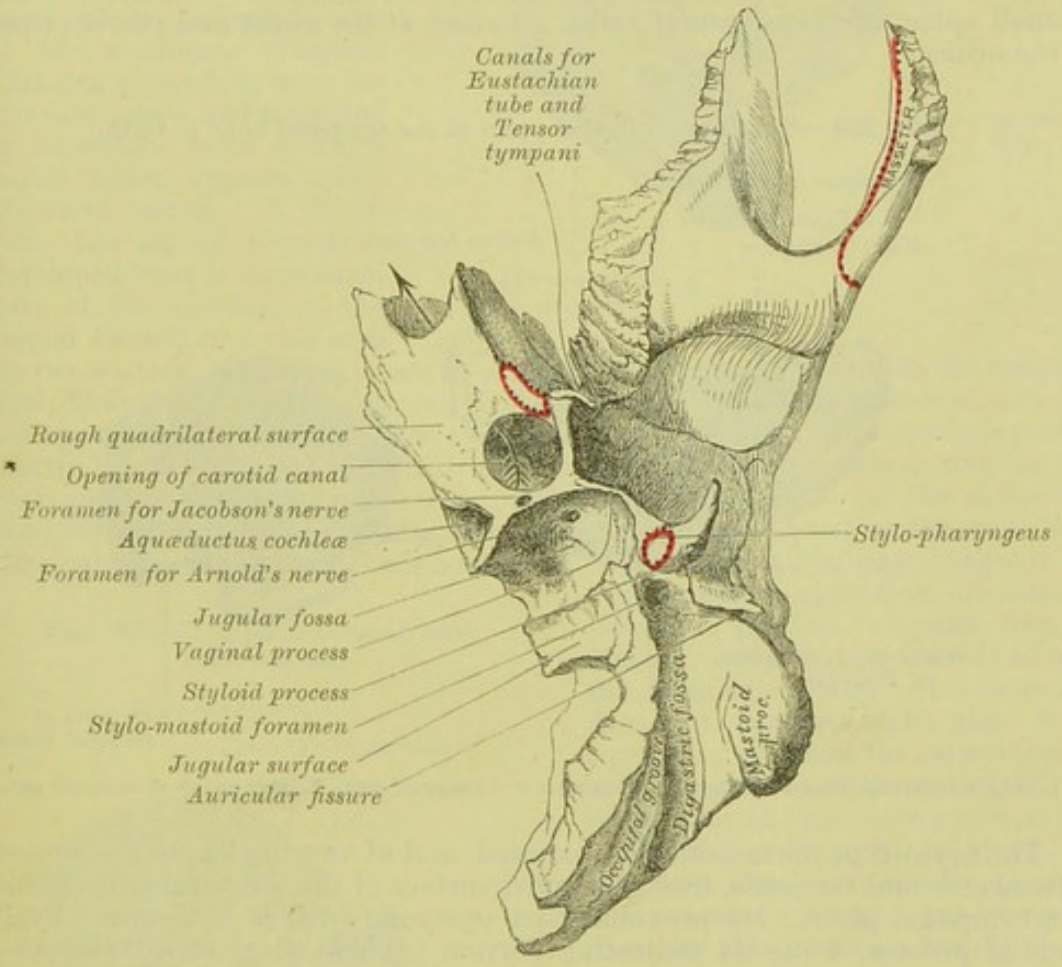

The tympanic cavity and auditory ossicles, and the internal ear, are described with the organ of hearing.

The **tympanic plate** (pars tympanica) consists of a curved plate of bone lying below the squamous portion and in front of the mastoid process. Its *postero-superior surface* is concave, and forms the anterior wall, the floor, and part of the posterior wall of the bony external auditory meatus. Internally, it presents a narrow furrow, the *sulcus tympanicus*, for the attachment of the membrana tympani. Its *antero-inferior surface* is quadrilateral and slightly concave; it constitutes the posterior boundary of the glenoid cavity, and is in contact with the retro-mandibular part of the parotid gland. Its *outer border* is free and rough; it is named the *external auditory process*, and gives attachment to the cartilaginous part of the external auditory meatus. Internally, the tympanic plate is fused with the petrous portion, and appears in the retreating angle between it and the squamous portion, where it lies below and to the outer side of the orifice of the Eustachian tube. Posteriorly, it blends with the squamous and mastoid parts, and forms the anterior boundary

of the auricular fissure. Its *antero-superior border* fuses externally with the back of the post-glenoid process, while internally it bounds the Glaserian fissure. The *lower border* is thin and sharp at its inner part; its outer part splits to enclose the root of the styloid process, and is therefore named the *vaginal process*. The central portion of the tympanic plate is thin, and in a considerable percentage of skulls is perforated by a hole, the *foramen of Huschke*.

The *external auditory meatus* (meatus acusticus externus) is directed inwards and slightly forwards: at the same time it forms a slight curve, so that the floor of the canal is convex upwards. It measures about three-quarters of an inch in length, and presents an oval or elliptical shape—its long axis being directed downwards and slightly backwards. As has been pointed out, its anterior wall, its floor, and the lower part of its posterior wall are formed by the tympanic plate; the roof and upper part of the posterior wall are constituted by the squamous portion. Its inner end is closed, in the recent state, by the membrani tympani; the upper limit of its outer orifice is formed by the posterior root of the zygoma, immediately below which there is sometimes seen a small spine, the *suprameatal spine*, situated at the upper and posterior part of the orifice.

FIG. 298.—The three principal parts of the temporal bone at birth.

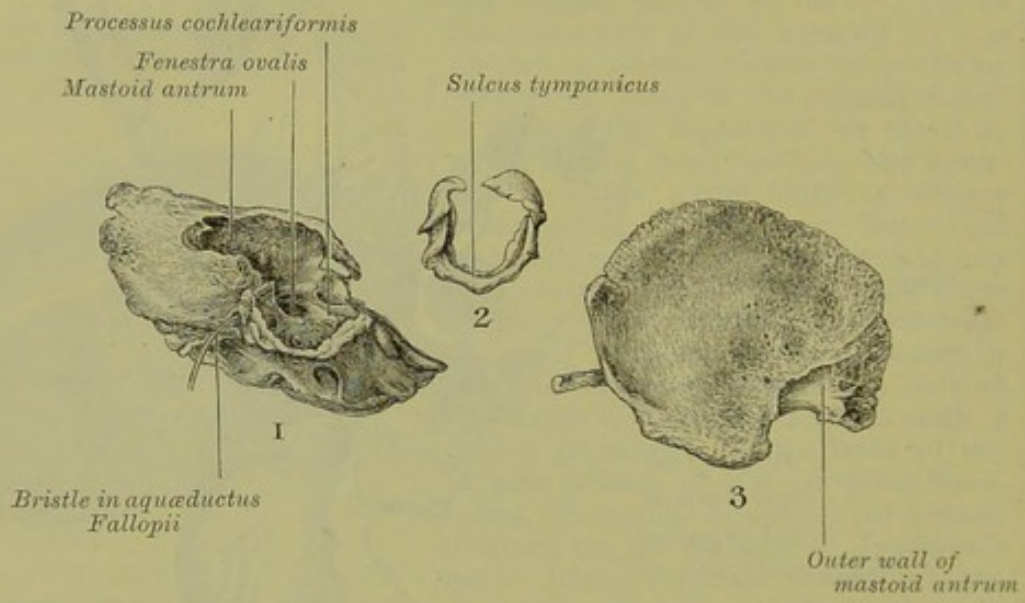

1. Outer surface of petro-mastoid part. 2. Outer surface of tympanic ring. 3. Inner surface of squamous part.

The **styloid process** is slender, pointed, and of varying length; it projects downwards and forwards, from the under surface of the temporal bone, beyond the tympanic plate. Its proximal part (*tympano-hyal*) is ensheathed by the vaginal process, while its projecting portion (*stylo-hyal*) gives attachment to the stylo-hyoid and stylo-mandibular ligaments, and to the Stylo-glossus, Stylo-hyoid and Stylo-pharyngeus muscles. The stylo-hyoid ligament extends from the apex of the process to the lesser cornu of the hyoid bone, and may undergo partial or complete ossification.

Structure.—The structure of the squamous portion is like that of the other cranial bones: the mastoid portion is cellular, and the petrous portion dense and hard.

Ossification.—The temporal bone is ossified from *eight* centres, exclusive of those for the internal ear and the tympanic ossicles—viz. one for the squamous portion including the zygoma, one for the tympanic plate, four for the petro-mastoid part, and two for the styloid process. Just before the close of fœtal life (fig. 298) the temporal bone consists of three principal parts. 1. The *squamo-zygomatic* is ossified in membrane from a single nucleus, which appears near the root of the zygoma about the second month. 2. The *petro-mastoid* is developed from four centres, which make their appearance in the cartilaginous ear-capsule about the fifth or sixth month. One (*prootic*) appears in the neighbourhood of the eminentia arcuata, spreads in front and above the internal auditory meatus

and extends to the apex of the bone; it forms part of the cochlea, vestibule, superior semicircular canal, and inner wall of the tympanic cavity. A second (*opisthotic*) appears at the promontory on the inner wall of the tympanum and surrounds the fenestra rotunda; it forms the floor of the tympanum and vestibule, surrounds the carotid canal, invests the outer and lower part of the cochlea, and spreads inwards below the internal auditory meatus. A third (*pterotic*) roofs in the antrum and tympanic cavity; while the fourth (*epiotic*) appears near the posterior semicircular canal and extends to form the mastoid process (Vrolik). 3. The *tympanic ring* is an incomplete circle in the concavity of which is a groove, the *sulcus tympanicus*, for the attachment of the circumference of the membrana tympani. This ring expands to form the tympanic plate, and is ossified in membrane from a single centre which appears about the third month. A fourth part, the *styloid process*, is developed from the proximal part of the cartilage of the second visceral or hyoid arch by two centres: one for the base appears before birth and is termed the *tympano-hyal*; the other, comprising the rest of the process, is named the *stylo-hyal*, and does not appear until after birth. The tympanic ring unites with the squamous portion shortly before birth; the petromastoid and squamous portions join during the first year, and the tympano-hyal portion of the styloid process about the same time (figs. 299 and 300). The stylo-hyal does not unite with the rest of the bone until after puberty, and in some skulls never at all. The chief subsequent changes in the temporal bone apart from increase in size are: (1) The tympanic ring extends outwards and backwards to form the tympanic plate. This extension does not, however, take place at an equal rate all round the circumference of the ring, but occurs most rapidly on its anterior and posterior portions, and these outgrowths meet and blend, and thus, for a time, there exists in the floor of the meatus a foramen, the *foramen of Huschke*: this foramen is usually closed about the fifth year, but may persist throughout life. (2) The glenoid cavity is at first extremely shallow, and looks outwards as well as downwards; it becomes deeper and is ultimately directed downwards. Its change in direction is accounted for as follows: The part of the squamous temporal which supports it lies at first *below* the level of the zygoma. As, however, the base of the skull increases in width, this lower part of the squama is directed horizontally inwards to contribute to the middle fossa of the skull, and its surfaces therefore come to look upwards and downwards; the attached portion of the zygomatic arch also becomes everted, and projects like a shelf at right angles to the squama. (3) The mastoid portion is at first quite flat, and the stylo-mastoid foramen and rudimentary styloid process lie immediately behind the tympanic ring. With the development of the air-cells the outer part

FIG. 299.—Temporal bone at birth. Outer aspect.

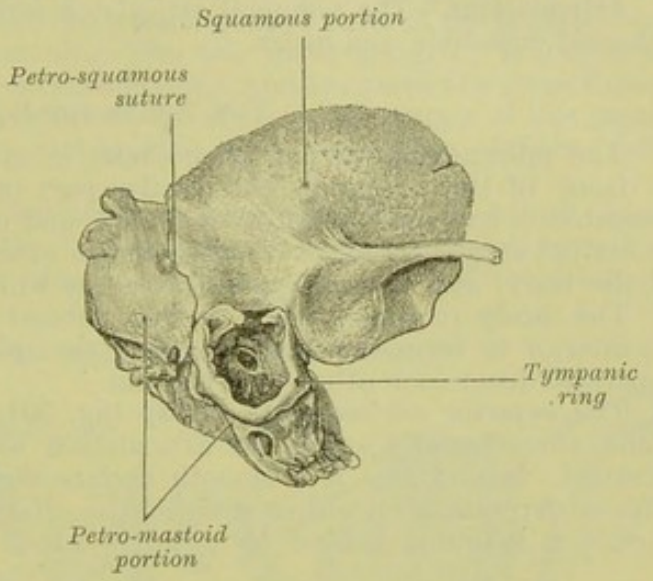

FIG. 300.—Temporal bone at birth. Inner aspect.

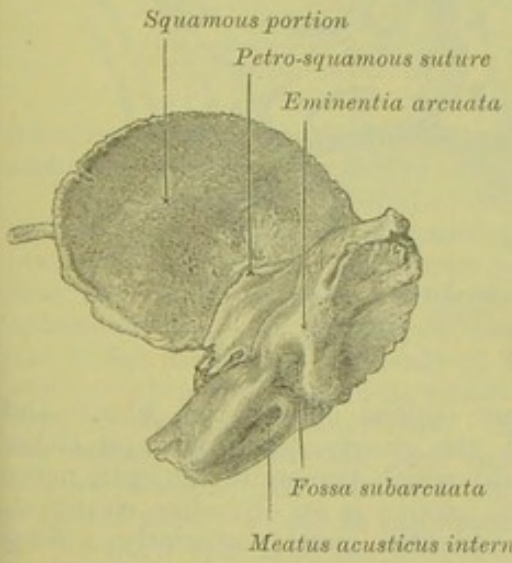

of the mastoid portion grows downwards and forwards to form the mastoid process, and the styloid process and stylo-mastoid foramen now come to lie on the under surface. The descent of the foramen is necessarily accompanied by a corresponding lengthening of the aqueduct of Fallopius. (4) The downward and forward growth of the mastoid process also pushes forward the tympanic plate, so that the portion of it which formed the original floor of the meatus and contained the foramen of Huschke is ultimately found in the anterior wall. (5) The *fossa subarcuata* becomes filled up and almost obliterated.

Articulations.—The temporal articulates with five bones: occipital, parietal, sphenoid, mandible, and malar.

The Sphenoid Bone

The **sphenoid bone** (os sphenoidale) is situated at the base of the skull in front of the temporals and basilar part of the occipital. It somewhat resembles a bat with its wings extended, and is divided into a central portion or body, two greater and two lesser wings extending outwards from the sides of the body, and two pterygoid processes which project from it below.

The **body** (corpus), more or less cubical in shape, is hollowed out in its interior to form two large cavities, the *sphenoidal air sinuses*, which are separated from each other by a septum.

The *superior surface* of the body (fig. 301) presents in front a prominent spine, the *ethmoidal spine*, for articulation with the cribriform plate of the ethmoid; behind this is a smooth surface slightly raised in the middle line, with a depression on either side for the olfactory lobes of the brain. This surface is bounded behind by a ridge, which forms the anterior border of a

Fig. 301.—Sphenoid bone. Upper surface.

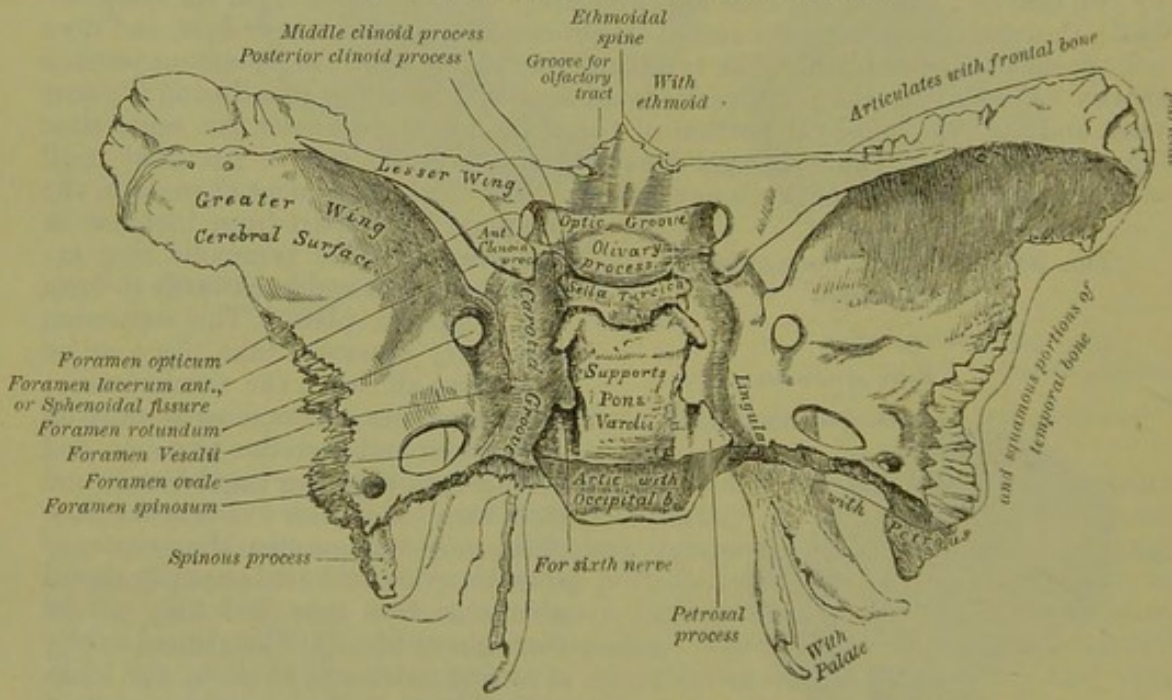

narrow, transverse groove, the *optic groove* (sulcus chiasmatis), above and behind which lies the optic commissure; the groove terminates on either side in the *optic foramen* (foramen opticum) which transmits the optic nerve and ophthalmic artery. Behind the optic groove is an olive-like elevation, the *olivary eminence* (tuberculum sellæ); and still more posteriorly, a deep depression, the *pituitary fossa*, or *sella turcica* (fossa hypophyseos), which lodges the pituitary body. This fossa is bounded in front by two small eminences, one on either side, called the *middle clinoid processes* (processus clinoidei medii), and behind by a square-shaped plate of bone, the *dorsum sellæ*, terminating at its superior angles in two tubercles, the *posterior clinoid processes* (processus clinoidei posteriores), the size and form of which vary considerably in different individuals. The posterior clinoid processes deepen the pituitary fossa, and give attachment to the tentorium cerebelli. On

either side of the dorsum sellæ is a notch for the passage of the sixth nerve, and below it presents a sharp process, the *petrosal process*, which articulates with the apex of the petrous portion of the temporal bone, forming the inner boundary of the foramen lacerum medium. Behind the dorsum sellæ, the bone presents a shallow depression, the *clivus*, which slopes obliquely backwards, and is continuous with the basilar groove of the occipital bone; it supports the upper part of the pons Varolii.

The *lateral surfaces* of the body are united with the greater wings and internal pterygoid plates. Above the attachment of each of the greater wings is a broad groove, curved something like the italic letter *f*; it lodges the internal carotid artery and the cavernous sinus, and is named the *carotid groove* (sulcus caroticus). Along the posterior part of the outer margin of this groove, in the angle between the body and greater wing, is a ridge of bone, called the *lingula*.

The *posterior surface*, quadrilateral in form (fig. 303), is joined, during infancy and adolescence, to the basilar process of the occipital bone by a plate of cartilage. Between the eighteenth and twenty-fifth years this

Fig. 302.—Sphenoid bone. Anterior surface.*

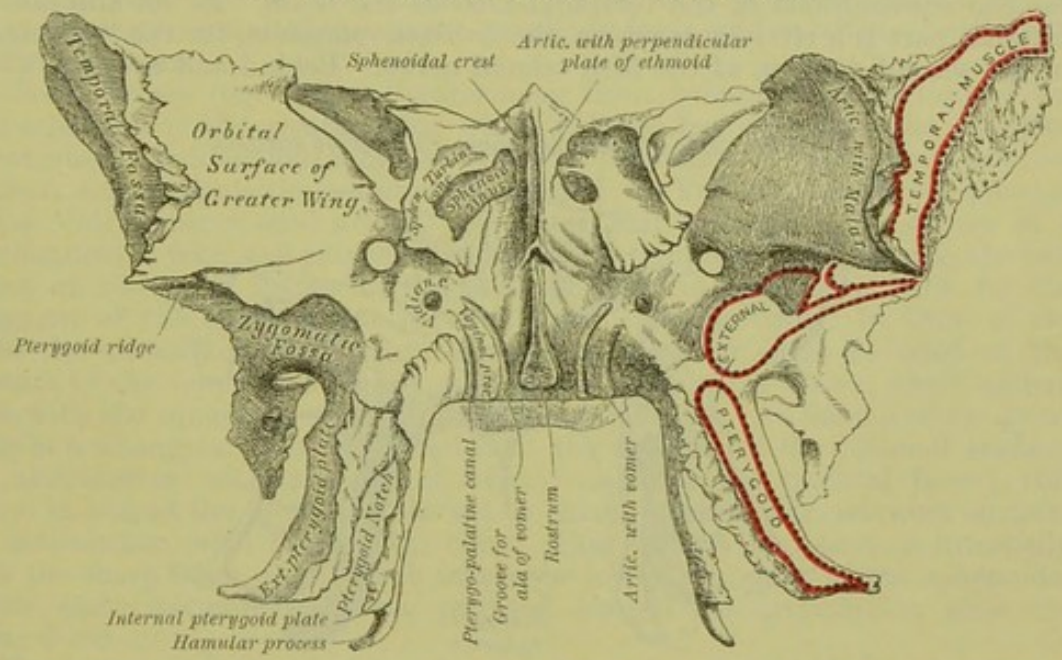

becomes ossified, ossification commencing above and extending downwards, and the two bones then form one piece.

The *anterior surface* of the body (fig. 302) presents, in the middle line, a vertical crest, the *crista sphenoidalis*, which articulates with the perpendicular plate of the ethmoid, and forms part of the septum of the nose. On either side of the crest is an irregular opening leading into the corresponding *sphenoidal air sinus*. These sinuses are two large, irregular cavities hollowed out of the interior of the body of the sphenoid bone, and separated from one another by a bony septum, which is seldom quite vertical, being commonly bent to one or the other side. They vary considerably in form and size,† are seldom symmetrical, and are often partially subdivided by irregular osseous laminæ. Occasionally, they extend into the basilar process of the occipital nearly as far as the foramen magnum. They begin to be developed in the third year, and are of a considerable size by the age of six. They are partially closed, in front and below, by two thin, curved plates of bone, the *sphenoidal turbinated bones* (see p. 236), leaving in the articulated skull a round opening at the upper part of each sinus by which it communicates with the upper and back part of the nose and occasionally with the posterior

* In this figure both the anterior and inferior surfaces of the body of the sphenoid bone are shown, the bone being held with the pterygoid processes almost horizontal.

† Aldren Turner (*op. cit.*) gives the following as their average measurements: vertical height, $\frac{7}{8}$ in.; antero-posterior depth, $\frac{7}{8}$ in.; transverse breadth, $\frac{3}{4}$ in.

ethmoidal air-cells. The lateral margin of the anterior surface is serrated, and articulates with the os planum of the ethmoid, completing the posterior ethmoidal cells; the lower margin articulates with the orbital process of the palate bone, and the upper with the orbital plate of the frontal bone.

The *inferior surface* presents, in the middle line, a triangular spine, the *rostrum sphenoidale*, which is continuous with the crista sphenoidalis on the anterior surface, and is received in a deep fissure between the alæ of the vomer. On either side of the rostrum is a projecting lamina, the *processus vaginalis*, directed inwards from the base of the internal pterygoid plate, with which it will be described.

The **greater wings,** or ali-sphenoids (alæ magnæ), are two strong processes of bone, which arise from the sides of the body, and are curved in a direction outwards, upwards, and backwards; the posterior part of each projects outwards and backwards as a triangular process which fits into the angle between the squamous and petrous portions of the temporal and presents at its apex a downwardly directed process, the *sphenoidal spine* (spina angularis).

The *superior* or *cerebral surface* of each greater wing (fig. 301) forms part of the middle fossa of the skull; it is deeply concave, and presents depressions for the convolutions of the temporal lobe of the brain. At its anterior and internal part is a circular aperture, the *foramen rotundum*, for the transmission of the second division of the fifth cranial nerve. Behind and external to this

Fig. 303.—Sphenoid bone. Posterior surface.

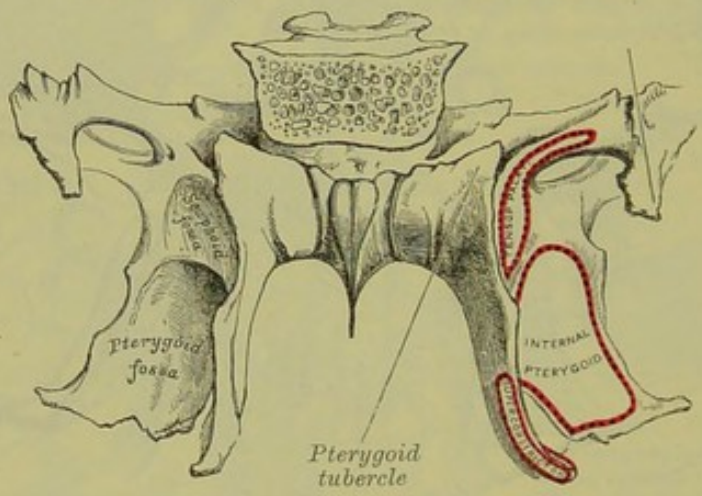

is a large, oval opening, the *foramen ovale*, for the transmission of the third division of the fifth nerve, the small meningeal artery, and sometimes the small superficial petrosal nerve.* At the inner side of the foramen ovale, a small aperture, the *foramen Vesalii*, may occasionally be seen opposite the root of the pterygoid process; it opens below near the scaphoid fossa, and transmits a small vein from the cavernous sinus. Lastly, in the posterior angle, near to and in front of the spine, is a short canal, sometimes double, the *foramen spinosum*, which transmits the middle meningeal artery and vein and a recurrent branch from the third division of the fifth cranial nerve.

The *external surface* (fig. 302) is convex, and divided by a transverse ridge, the *infratemporal crest* (crista infratemporalis), into two portions. The superior or larger (facies temporalis), convex from above downwards, concave from before backwards, forms a part of the temporal fossa, and gives attachment to the Temporal muscle. The inferior portion (facies infratemporalis), smaller in size and concave, enters into the formation of the zygomatic fossa, and, together with the infratemporal crest, affords attachment to the External pterygoid muscle. It presents the openings of the foramen ovale and foramen spinosum, and, at its posterior part, the sphenoidal spine, which is frequently grooved on its inner aspect for the chorda tympani nerve. To the sphenoidal

* The small superficial petrosal nerve sometimes passes through a special canal (*canaliculus innominatus* of Arnold) situated on the inner side of the foramen spinosum.

spine are connected the internal lateral ligament of the temporo-mandibular joint and the Tensor palati. Internal to the anterior extremity of the infra-temporal crest is a triangular process which serves to increase the attachment of the External pterygoid; extending downwards and inwards from this process on to the front part of the external pterygoid plate is a ridge which forms the anterior limit of the zygomatic surface, and, in the articulated skull, the posterior boundary of the *pterygo-maxillary fissure*.

The *anterior* or *orbital surface* of the greater wing (facies orbitalis) (fig. 302), smooth, and quadrilateral in shape, is directed forwards and inwards and forms the posterior part of the outer wall of the orbit. It is bounded above by a serrated edge, for articulation with the orbital plate of the frontal; below, by a rounded border, which forms the postero-external boundary of the spheno-maxillary fissure. Internally, it is limited by a sharp margin, which forms the lower boundary of the sphenoidal fissure and has projecting from about its centre a little tubercle of bone, which gives attachment to the inferior head of the External rectus muscle of the eyeball; at the upper part of this margin is a notch for the transmission of a recurrent branch of the lachrymal artery. Externally, it presents a serrated margin for articulation with the malar bone. At the inner and lower part of the anterior surface, immediately below the inner end of the sphenoidal fissure, is a grooved surface, which forms the posterior wall of the spheno-maxillary fossa, and on which the foramen rotundum opens.

Circumference (fig. 301).—Commencing from behind, that portion of the circumference of the greater wing which extends from the body to the spine is irregular. Its inner half forms the anterior boundary of the foramen lacerum medium, and presents the posterior aperture of the Vidian canal for the passage of the Vidian nerve and artery. Its outer half articulates, by means of a synchondrosis, with the petrous portion of the temporal, and between the two bones, on the under surface of the skull, is a furrow, the *sulcus tubæ*, for the lodgment of the cartilaginous part of the Eustachian tube. In front of the spine the circumference presents a concave, serrated edge, bevelled at the expense of the inner table below, and of the outer table above, which articulates with the squamous portion of the temporal bone. At the tip of the great wing is a triangular portion, bevelled at the expense of the internal surface, for articulation with the antero-inferior angle of the parietal bone; this region is named the *pterion*. Internal to this is a triangular, serrated surface, for articulation with the frontal bone; this surface is continuous internally with the sharp inner edge, which forms the lower boundary of the sphenoidal fissure, and externally with the serrated margin for articulation with the malar bone.

The **lesser wings** or orbitosphenoids (alæ parvæ) are two thin, triangular plates, which arise from the upper and anterior parts of the body, and, projecting transversely outwards, terminate in sharp points (fig. 301). The *superior surface* of each is smooth, flat, broader internally than externally, and supports part of the frontal lobe of the brain. The *inferior surface* forms the back part of the roof of the orbit, and the upper boundary of the *sphenoidal fissure* (fissura orbitalis superior). This fissure is of a triangular form, and leads from the cavity of the cranium into that of the orbit: it is bounded internally by the body; above, by the lesser wing; below, by the inner margin of the orbital surface of the greater wing; and is completed externally by the frontal bone. It transmits the third, the fourth and the sixth nerves, the three branches of the ophthalmic division of the fifth nerve, some filaments from the cavernous plexus of the sympathetic, the orbital branch of the middle meningeal artery, a recurrent branch from the lachrymal artery to the dura mater, and the ophthalmic vein. The *anterior border* is serrated for articulation with the frontal bone. The *posterior border*, smooth and rounded, is received into the Sylvian fissure of the brain; the inner extremity of this border forms the *anterior clinoid process* (processus clinoideus anterius), which gives attachment to the tentorium cerebelli; it is sometimes joined to the middle clinoid process by a spicule of bone, and when this occurs the termination of the groove for the internal carotid artery is converted into a foramen (*carotico-clinoid*). The lesser wing is connected to the body by two roots, the upper thin and flat, the lower thick and triangular; between the two roots

is the *optic foramen* (foramen opticum), for the transmission of the optic nerve and ophthalmic artery.

The **pterygoid processes** (processus pterygoidei), one on either side, descend perpendicularly from the points where the body and greater wings unite. Each process consists of an internal and an external plate, fused above and in front, but separated below by an angular cleft, the *pterygoid notch* (fissura pterygoidea), the margins of which are rough for articulation with the tuberosity of the palate bone. The two plates diverge behind and enclose between them a V-shaped fossa, the *pterygoid fossa* (fossa pterygoidea), which contains the Internal pterygoid and Tensor palati. Above this fossa is a small, oval, shallow depression, the *fossa scaphoidea*, which gives origin to the Tensor palati. The anterior surface of the pterygoid process is broad and triangular near its root, where it forms the posterior wall of the spheno-maxillary fossa and presents the anterior orifice of the Vidian canal.

The *external pterygoid plate* (lamina lateralis processus pterygoidei) is broad, thin, and everted; its *outer surface* forms part of the inner wall of the zygomatic fossa, and gives attachment to the External pterygoid; its *inner surface* forms part of the pterygoid fossa, and gives attachment to the Internal pterygoid.

The *internal pterygoid plate* (lamina medialis processus pterygoidei) is much narrower and longer than the external; it curves outwards, at its lower extremity, into a hook-like process, the *hamular process* (hamulus pterygoidei), around which the tendon of the Tensor palati muscle glides. The *outer surface* of this plate forms part of the pterygoid fossa, the *inner surface* constitutes the outer boundary of the posterior aperture of the nares. Superiorly the internal pterygoid plate is carried inwards on the under surface of the body as a thin lamina, named the *vaginal process*; which articulates in front with the sphenoidal process of the palate and internally with the ala of the vomer. The angular prominence between the posterior margin of the vaginal process and the inner margin of the scaphoid fossa is named the *pterygoid tubercle*, immediately above which is the posterior opening of the Vidian canal (canalis pterygoideus). On the under aspect of the vaginal process is a furrow, the *sulcus pterygopalatinus*, which is converted into the *pterygo-palatine canal* by the sphenoidal process of the palate bone, and transmits the pterygo-palatine vessels and the pharyngeal nerve. Projecting backwards from near the middle of the posterior edge of the internal pterygoid plate is an angular process, the *processus tubarius*, which supports the pharyngeal end of the Eustachian tube. The pharyngeal aponeurosis is attached to the entire length of the posterior edge of the internal plate, and the Superior constrictor of the pharynx takes origin from its lower third. The anterior margin of the internal pterygoid plate articulates with the posterior border of the vertical plate of the palate.

The **sphenoidal turbinated bones** (conchæ sphenoidales) are two thin, curved plates, situated at the anterior and inferior part of the body of the sphenoid; they exist as separate pieces until puberty, and occasionally are not joined to the sphenoid in the adult. An aperture of variable size exists in the anterior wall of each, and through this the sphenoidal sinus opens into the nasal fossa. Each is irregular in form, and tapers to a point behind, being broader and thinner in front. Its upper surface, which looks towards the cavity of the sinus, is concave; its under surface is convex, and forms part of the roof of the corresponding nasal fossa. Each bone articulates in front with the ethmoid, externally with the palate; its pointed posterior extremity is placed above the vomer, and is received between the root of the pterygoid process on the outer side and the rostrum of the sphenoid on the inner.*

Ossification.—Until the seventh or eighth month of fœtal life the body of the sphenoid consists of two parts—viz. one in front of the olivary eminence, the *pre-sphenoid*, with which the lesser wings are continuous; the other, comprising the sella turcica, the *post-sphenoid*, with which are associated the greater wings

* A small portion of sphenoidal turbinated bone sometimes enters into the formation of the inner wall of the orbit, between the os planum of the ethmoid in front, the orbital plate of the palate below, and the frontal above. Cleland, *Roy. Soc. Trans.* 1862.

and pterygoid processes. With the exception of the internal pterygoid plates, the bone is ossified in cartilage. There are fourteen centres in all (fig. 304), six for the pre-sphenoid and eight for the post-sphenoid division.

Pre-sphenoid division.—About the ninth week of fœtal life an ossific centre appears for each of the lesser wings (orbito-sphenoids) just outside the optic foramen. Shortly afterwards two nuclei for the pre-sphenoid part of the body appear on the inner sides of the optic foramina. The sphenoidal turbinated bones are each developed from a centre which makes its appearance about the fifth month; * at birth they consist of small triangular laminæ, and it is not till the third year that they become hollowed out and cone-shaped; about the fourth year they fuse with the lateral masses of the ethmoid, and between the ninth and twelfth years they unite with the sphenoid.

Fig. 304.—Plan of ossification of the sphenoid.

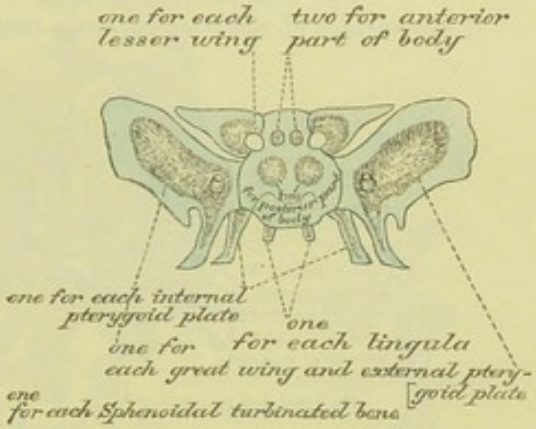

Post-sphenoid division. — The first ossific nuclei are those for the greater wings (ali-sphenoids). They make their appearance between the foramen rotundum and foramen ovale about the eighth week, and from them the external pterygoid plates also are formed.† Soon after, the centres for the post-sphenoid part of the body appear, one on either side of the sella turcica, and become blended together about the middle of fœtal life. Each internal pterygoid plate (with the exception of its hamular process) is ossified in membrane, and its centre probably appears about the ninth or tenth week; the hamular process becomes chondrified during the third month, and almost at once undergoes ossification (Fawcett, *op. cit.*). The internal joins the external pterygoid plate about the sixth month. About the fourth month a centre appears for each lingula and speedily joins the rest of the bone.

The pre-sphenoid is united to the post-sphenoid about the eighth month, and at birth (fig. 305) the bone consists of three pieces: a central, consisting of the body and lesser wings, and two lateral, each comprising a greater wing and pterygoid process. In the first year after birth the greater wings and body become united, and the orbito-sphenoids extend inwards above the anterior part of the body, and, meeting with each other in the middle line, form an elevated smooth surface, termed the *jugum sphenoidale*. By the twenty-fifth year the sphenoid and occipital are completely fused. Between the pre- and post-sphenoid divisions there are occasionally seen the remains of a canal, the *canalis craniopharyngeus*, through which, in early fœtal life, the pituitary diverticulum (or pouch of Rathke) of the buccal ectoderm is transmitted (see page 155).

Fig. 305.—Sphenoid bone at birth. Posterior aspect.

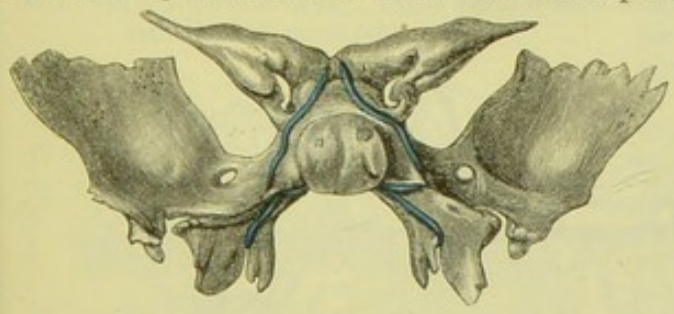

The sphenoid has attached to it certain intrinsic ligaments, which have received special names. The most important of these are: the *pterygo-spinous*, which stretches between the sphenoidal spine and the external pterygoid plate (see *cervical fascia*); the *interclinoid*, a fibrous process which passes from the anterior to the posterior clinoid process; and the *carotico-clinoid*, which passes from the anterior to the middle clinoid process. These ligaments occasionally ossify, and form adventitious foramina.

* According to Cleland, the sphenoidal turbinated bones are ossified from four distinct centres.

† Fawcett (*Anatomischer Anzeiger*, March 1905) states that the external pterygoid plate is ossified in membrane, and is not a downward continuation of the cartilaginous great wing.

Articulations.—The sphenoid articulates with twelve bones: four single, the vomer, ethmoid, frontal and occipital; and four paired, the parietal, temporal, malar, and palate. The exact extent of articulation with each bone is shown in the accompanying figures.*

The Ethmoid Bone

The **ethmoid bone** (os ethmoidale) is an exceedingly light, spongy bone, of a cubical shape; it is situated at the anterior part of the base of the cranium, between the two orbits, at the roof of the nose, and contributes to each of these cavities. It consists of four parts: a horizontal or cribriform plate, which forms part of the base of the cranium; a perpendicular plate, which constitutes part of the nasal septum; and two lateral masses.

Fig. 306.—Ethmoid bone.
Outer surface of right lateral mass (enlarged).

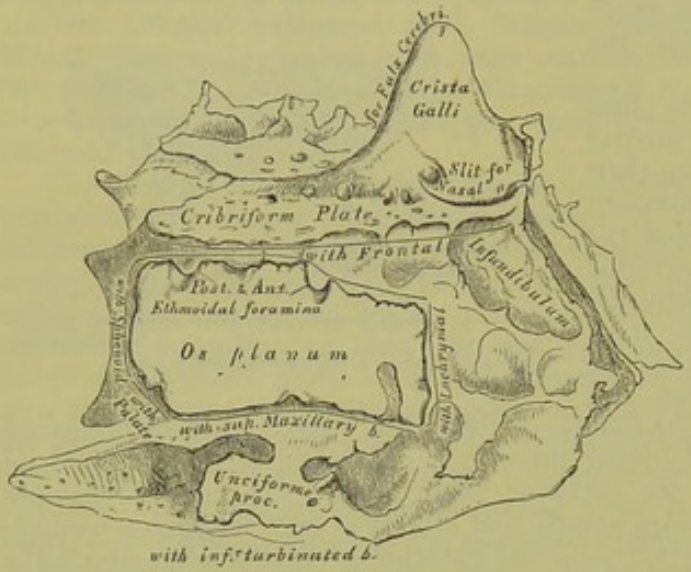

The **cribriform plate** (lamina cribrosa) (fig. 306) is received into the ethmoid notch of the frontal bone and roofs in the nasal fossæ. Projecting upwards from the middle line of this plate is a thick, smooth, triangular process, the *crista galli*, so called from its resemblance to a cock's comb. Its base joins the cribriform plate. Its posterior border, long, thin, and slightly curved, serves for the attachment of the falx cerebri. Its anterior border, short and thick, articulates with the frontal bone, and presents two small projecting *alar processes*, which are received into corresponding depressions in the frontal bone and complete the foramen cæcum. Its sides are smooth, and sometimes bulging from the presence of a small air-

Fig. 307.—Perpendicular plate of ethmoid (enlarged). Shown by removing the right lateral mass.

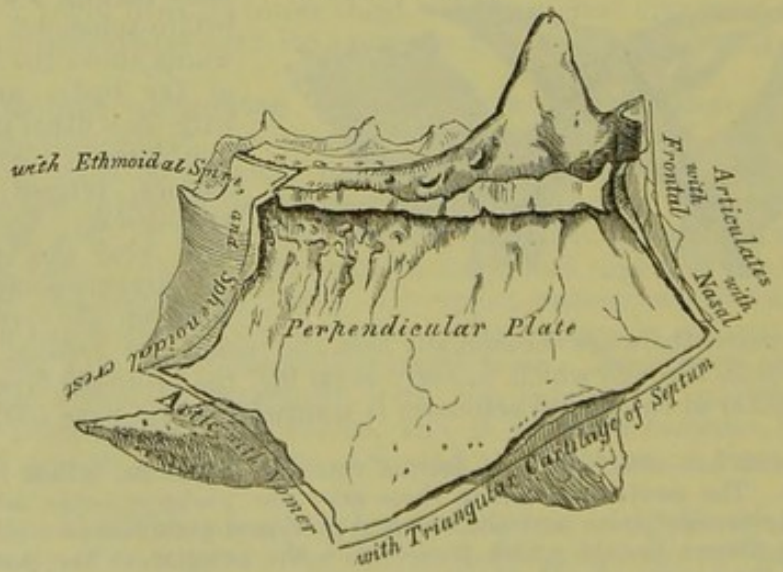

sinus in the interior. On each side of the crista galli, the cribriform plate is narrow and deeply grooved; it supports the bulb of the olfactory lobe of the brain, and is perforated by foramina for the passage of the olfactory nerves. The foramina in the middle of the groove are small and transmit the nerves

* It also sometimes articulates with the tuberosity of the maxilla (see page 242).

to the roof of the nose; those at the inner and outer parts of the groove are larger—the former transmit the nerves to the upper part of the nasal septum, the latter those to the superior turbinated process. At the front part of the cribriform plate, on either side of the crista galli, is a small fissure which is occupied by a process of dura mater. External to this fissure is a notch or foramen which transmits the nasal branch of the ophthalmic nerve; from it a groove extends backwards to the anterior ethmoidal foramen.

The **perpendicular plate** (lamina perpendicularis) (figs. 307 and 308) is a thin, flattened lamella, polygonal in form, which descends from the under surface of the cribriform plate, and assists in forming the septum of the nose; it is generally deflected a little to one or other side. Its *anterior border* articulates with the nasal spine of the frontal bone and the crest of the nasal bones. Its *posterior border* articulates by its upper half with the crista sphenoidalis, by its lower half with the vomer. The *inferior border* is thicker than the posterior, and serves for the attachment of the septal cartilage of the nose. The surfaces of the plate are smooth, except above, where numerous grooves and canals are seen; these lead from the inner foramina on the cribriform plate and lodge filaments of the olfactory nerves.

Fig. 308.—Ethmoid bone from behind.

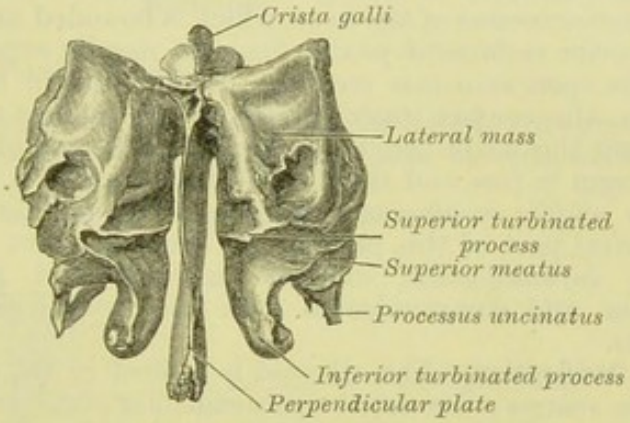

The **lateral mass** (labyrinthus ethmoidalis) (fig. 308) consists of a number of thin-walled cellular cavities, the *ethmoidal cells*, arranged in three groups, *anterior*, *middle*, and *posterior*, and interposed between two vertical plates of bone; the outer plate forms part of the orbit, the inner, part of the corresponding nasal fossa. In the disarticulated bone many of these cells are opened into; but when the bones are articulated, they are closed in at every part, except where they open into the nasal fossa. The *upper surface* of the lateral mass presents a number of half-broken cells, the walls of which are completed, in the articulated skull, by the edges of the ethmoidal notch of the frontal bone. Crossing this surface are two grooves, converted into canals by articulation with the frontal; they are the *anterior* and *posterior ethmoidal canals*, and open on the inner wall of the orbit. The *posterior surface* presents large irregular cellular cavities, which are closed in by articulation with the sphenoidal turbinated bone and orbital process of the palate.

Fig. 309.—Ethmoid bone. Inner surface of right lateral mass (enlarged).

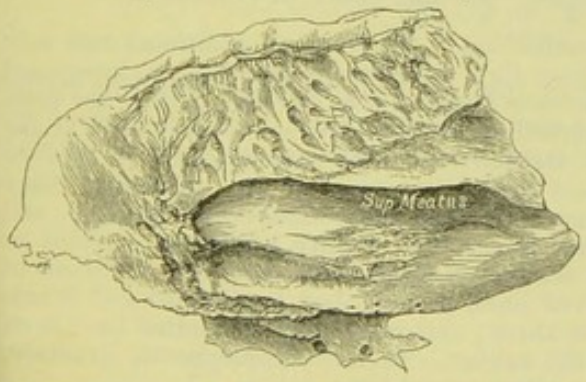

The *outer surface* is formed of a thin, smooth, oblong plate, the *os planum* (lamina papyracea), which covers in the middle and posterior ethmoidal cells and forms a large part of the inner wall of the orbit; it articulates above with the orbital plate of the frontal, below with the maxilla and orbital process of the palate, in front with the lachrymal, and behind with the sphenoid.

In front of the lamina papyracea are some broken air-cells which are overlapped and completed by the lachrymal bone and the frontal process of the maxilla. An irregular lamina, the *processus uncinatus*, projects downwards and backwards from this part of the lateral mass. This process, which is often

broken in disarticulating the bones, forms a small part of the inner wall of the maxillary sinus or antrum of Highmore, and articulates with the ethmoidal process of the inferior turbinated bone.

The *inner surface* of the lateral mass (fig. 309) forms part of the outer wall of the corresponding nasal fossa. It consists of a thin lamella, which descends from the under surface of the cribriform plate, and terminates below in a free, convoluted margin, the *middle turbinated process* (concha nasalis media). The whole of this surface is rough, and marked above by numerous grooves, which run nearly vertically downwards from the cribriform plate; they lodge branches of the olfactory nerves, which are distributed to the mucous membrane covering the superior turbinated process. The back part of this surface is subdivided by a narrow oblique fissure, the *superior meatus* of the nose, which is bounded above by a thin, curved plate, the *superior turbinated process* (concha nasalis superior); the posterior ethmoidal cells open into this meatus. Below, and in front of the superior meatus, is seen the convex inner surface of the middle turbinated process. It extends along the whole length of the inner surface of the lateral mass, and its lower margin is free and thick; its outer surface is concave, and assists in forming the *middle meatus* of the nose. The middle ethmoidal cells open into the central part of this meatus and from its front part a sinuous passage, termed the *infundibulum*, extends upwards and forwards through the lateral mass and communicates with the frontal sinus and the anterior ethmoidal cells.

Ossification.—The ethmoid is ossified in the cartilage of the nasal capsule by *three* centres: one for the perpendicular plate, and one for each lateral mass.

The lateral masses are first developed, ossific granules making their appearance in the region of the os planum between the fourth and fifth months of fœtal life, and extending into the turbinated processes. At birth, the bone consists of the two lateral masses, which are small and ill developed. During the first year after birth, the perpendicular plate and crista galli begin to ossify from a single nucleus, and are joined to the lateral masses about the beginning of the second year. The cribriform plate is ossified partly from the perpendicular plate and partly from the lateral masses. The formation of the ethmoidal cells does not commence until about the fourth or fifth year.

Articulations.—The ethmoid articulates with fifteen bones: four of the cranium—the sphenoid, two sphenoidal turbinateds, and the frontal; and eleven of the face—the two nasals, two maxillæ, two lachrymals, two palates, two inferior turbinateds, and the vomer.

Supernumerary or Wormian* Bones (ossa suturarum)

In addition to the constant centres of ossification of the cranium, additional ones may be found in the course of the sutures. These form irregular, isolated bones, interposed between the cranial bones, and termed *Wormian bones* or *ossa triquetra*. They are most frequently found in the course of the lambdoid suture, but are occasionally seen at the fontanelles, especially the posterior. One, the *pterion ossicle*, sometimes exists between the antero-inferior angle of the parietal and the greater wing of the sphenoid. They have a tendency to be more or less symmetrical on the two sides of the skull, and vary much in size, being in some cases not larger than a pin's head, and confined to the outer table, in other cases so large that one pair of these bones may form the whole of the occipital bone above the superior curved lines, as described by Béclard and Ward. Their number is generally limited to two or three; but more than a hundred have been found in the skull of an adult hydrocephalic subject. In their development, structure, and mode of articulation, they resemble the other cranial bones.

Congenital Fissures and Gaps

An arrest in the ossifying process may give rise to deficiencies, gaps, or fissures which are of importance from a medico-legal point of view, as they are liable to be mistaken for fractures. The fissures generally extend from the margins towards the centre of a bone, but the gaps may be found in the middle as well as at the edges. In course of time they may become filled with thin laminæ of bone. In many of these cases, however, the gaps must be regarded as due to absorption of bone already formed rather

* Ole Worm, Professor of Anatomy at Copenhagen, 1624–1639, was erroneously supposed to have given the first detailed description of these bones.

than as congenital deficiencies; this is especially the case when they appear in the centre of a bone such as the parietal, the ossification of which has already been described as occurring in a regular manner radiating from one centre. The condition is most commonly seen in very badly nourished children affected with congenital syphilis, and is called *craniotabes*.

OSSA FACIEI

The bones of the face (ossa faciei), fourteen in number, comprise the

Two Nasals	Two Palates
Two Maxillæ	Two Inferior Turbinateds
Two Lachrymals	Vomer
Two Malars	Mandible

Nasal Bones

The **Nasal Bones** (ossa nasalia) are two small oblong bones, varying in size and form in different individuals; they are placed side by side at the

Fig. 310.—Nasal bone and lachrymal bone *in situ*.

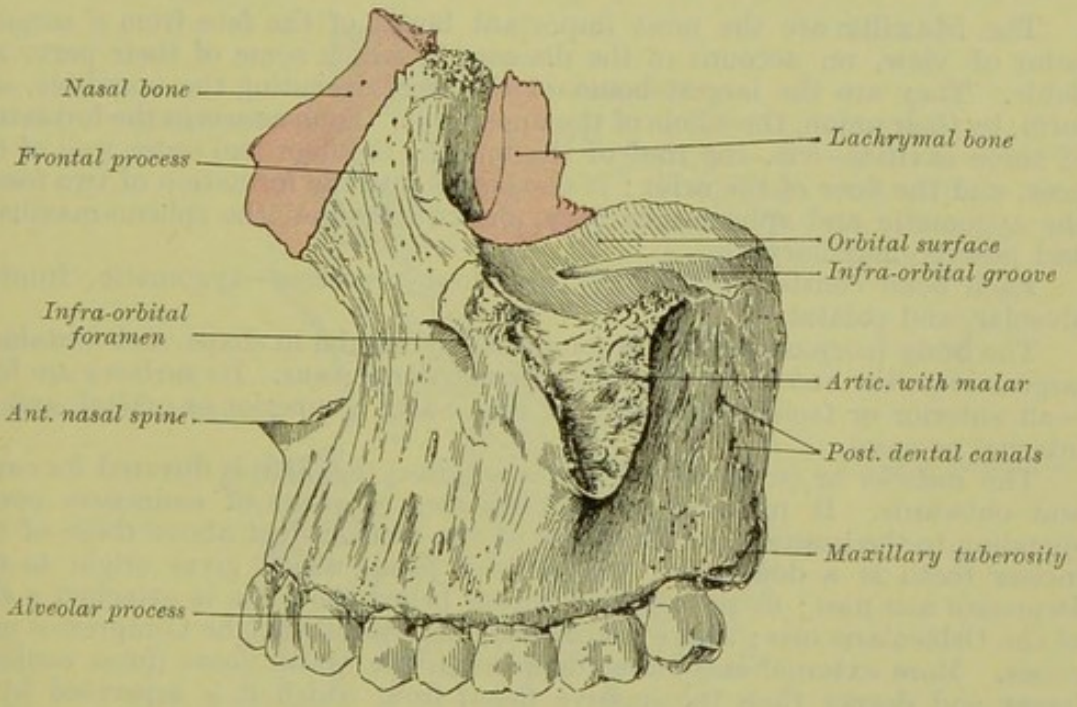

middle and upper part of the face, and form, by their junction, 'the bridge' of the nose (fig. 310). Each presents two surfaces and four borders. The *outer surface* (fig. 311) is concavo-convex from above downwards, convex from side

Fig. 311.—Right nasal bone. Outer surface.

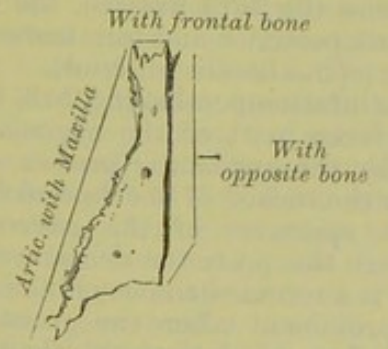

Fig. 312.—Left nasal bone. Inner surface.

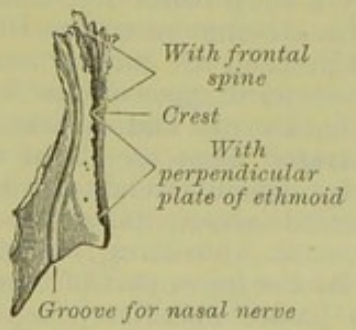

to side; it is covered by the Pyramidalis and Compressor nasi muscles, and perforated about its centre by a foramen, for the transmission of a small vein. The *inner surface* (fig. 312) is concave from side to side, and is traversed from

above downwards by a groove for the passage of a branch of the nasal nerve. The *superior border* is narrow, thick, and serrated for articulation with the nasal notch of the frontal bone. The *inferior border* is thin, and serves for the attachment of the upper lateral cartilage of the nose. It presents, about its middle, a notch which marks the termination of the groove for the nasal nerve. The *external border* is serrated, bevelled at the expense of the inner surface above, and of the outer below, to articulate with the frontal process of the maxilla. The *internal border*, thicker above than below, articulates with its fellow of the opposite side, and is prolonged behind into a vertical crest, which forms part of the septum of the nose : this crest articulates, from above downwards, with the nasal spine of the frontal, the perpendicular plate of the ethmoid, and the septal cartilage of the nose.

Ossification.—Each bone is ossified from *one* centre, which appears about the eighth week of fœtal life in the membrane overlying the front part of the cartilaginous nasal capsule.

Articulations.—The nasal articulates with four bones : two of the cranium, the frontal and ethmoid, and two of the face, the opposite nasal and the maxilla.

The Maxillæ or Superior Maxillary Bones

The **Maxillæ** are the most important bones of the face from a surgical point of view, on account of the diseases to which some of their parts are liable. They are the largest bones of the face, excepting the mandible, and form, by their union, the whole of the upper jaw. Each assists in the formation of three cavities—viz. the roof of the mouth, the floor and outer wall of the nose, and the floor of the orbit ; it also enters into the formation of two fossæ, the zygomatic and spheno-maxillary, and two fissures, the spheno-maxillary and pterygo-maxillary.

Each bone consists of a body and four processes—zygomatic, frontal, alveolar, and palatal.

The **body** (corpus maxillæ) is somewhat pyramidal in shape, and contains a large cavity, the *antrum of Highmore*, or *maxillary sinus*. Its surfaces are four —an anterior or facial, a posterior or zygomatic, a superior or orbital, and an internal or nasal.

The *anterior* or *facial surface* (facies anterior) (fig. 313) is directed forwards and outwards. It presents at its lower part a series of eminences corresponding to the positions of the fangs of the teeth. Just above those of the incisor teeth is a depression, the *incisive fossa*, which gives origin to the Depressor alæ nasi ; to the alveolar border below the fossa is attached a slip of the Orbicularis oris ; above and a little external to it, the Compressor nasi arises. More external is another depression, the *canine fossa* (fossa canina), larger and deeper than the incisive fossa, from which it is separated by a vertical ridge, the *canine eminence*, corresponding to the socket of the canine tooth. The canine fossa gives origin to the Levator anguli oris. Above the fossa is the *infra-orbital foramen* (foramen infraorbitale), the termination of the infra-orbital canal ; it transmits the infra-orbital vessels and nerve. Above the foramen is the margin of the orbit, which affords partial attachment to the Levator labii superioris. Internally, the facial surface is limited by a deep concavity, the *nasal notch* (incisura nasalis), the margin of which gives attachment to the Dilator naris posterior and terminates below in a pointed process, the *anterior nasal spine* (spina nasalis anterior).

The *posterior* or *zygomatic surface* (facies infratemporalis) (fig. 313) is convex, directed backwards and outwards, and forms part of the zygomatic fossa. It is separated from the facial surface by the zygomatic process and by a strong ridge, which extends upwards from the socket of the first molar tooth. It is pierced about its centre by the apertures of the *posterior dental canals* (canales alveolares). which transmit the posterior dental vessels and nerves. At the lower part of this surface is a rounded eminence, the *maxillary tuberosity* (tuber maxillare), especially prominent after the growth of the wisdom-tooth ; it is rough on its inner side for articulation with the tuberosity of the palate-bone and in some cases articulates with the external pterygoid plate of the sphenoid. It gives origin to a few fibres of the Internal pterygoid. Immediately above this is a smooth surface, which forms the anterior boundary

of the spheno-maxillary fossa, and presents a groove, for the second division of the fifth cranial nerve ; this groove is directed outwards and slightly upwards, and becomes continuous with the infra-orbital groove on the orbital surface.

The *superior* or *orbital surface* (facies orbitalis) (fig. 313) is smooth and triangular, and forms the greater part of the floor of the orbit. It is bounded *internally* by an irregular margin which in front presents a notch, the *lachrymal notch* (incisura lacrimalis) ; behind this notch the margin articulates with the lachrymal, the os planum of the ethmoid and the orbital process of the palate. It is bounded *behind* by a smooth rounded edge which forms the anterior margin of the spheno-maxillary fissure, and sometimes articulates at its outer extremity with the orbital plate of the sphenoid. It is limited *in front* by part of the circumference of the orbit, which is continuous on the inner side with the frontal process, and on the outer side with the zygomatic process. Near the middle line of the posterior part of the orbital surface is a deep groove, the *infra-orbital* (sulcus infraorbitalis), for the passage of the infra-orbital vessels and nerve. The groove begins at the middle of the posterior border, where it is continuous with that near the upper edge of the posterior

FIG. 313.—Left maxilla. Outer surface.

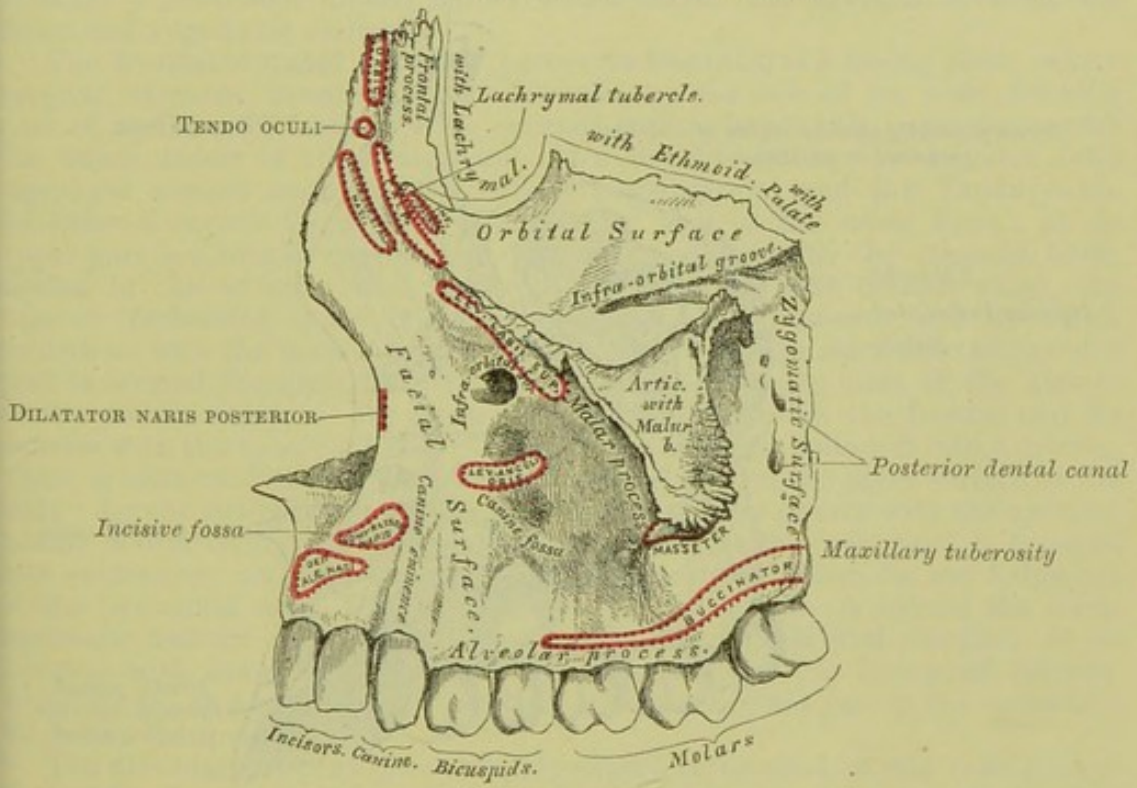

surface, and, passing forwards, ends in a canal, which subdivides into two branches. One of the canals, the *infra-orbital* (canalis infraorbitalis), opens just below the margin of the orbit ; the other, which is smaller, runs downwards in the substance of the anterior wall of the antrum ; it is called the *anterior dental canal*, and transmits the anterior dental vessels and nerve to the front teeth of the maxilla. From the back part of the infra-orbital canal, a second small canal is sometimes given off, which runs downwards in the outer wall of the antrum, and conveys the middle dental nerve to the bicuspid teeth ; occasionally, this canal is derived from the anterior dental. At the inner and fore part of the orbital surface, just external to the lachrymal groove, is a depression, which gives origin to the Inferior oblique muscle of the eyeball.

The *internal surface* (facies nasalis) (fig. 314) presents a large, irregular opening leading into the *antrum of Highmore*. At the upper border of this aperture are some broken air-cells, which, in the articulated skull, are closed in by the ethmoid and lachrymal bones. Below the aperture is a smooth concavity which forms part of the inferior meatus of the nasal fossa, and behind it is a rough surface for articulation with the perpendicular plate of the palate bone ; this surface is traversed by a groove, commencing near the

middle of the posterior border and running obliquely downwards and forwards; this groove is converted into a canal, the *posterior palatine canal* by the palate bone. In front of the opening of the antrum is a deep groove, the *lachrymal groove* (sulcus lacrimalis), which is converted into a canal (canalis nasolacrimalis) by the lachrymal and inferior turbinated bones; this canal opens into the inferior meatus of the nose and transmits the nasal duct. More anteriorly is a well-marked oblique ridge, the *inferior turbinated crest* (crista conchalis), for articulation with the inferior turbinated bone. The shallow concavity above this ridge forms part of the atrium of the middle meatus of the nose; while that below it forms part of the inferior meatus.

The **antrum of Highmore** (sinus maxillaris) is a large pyramidal cavity, hollowed out of the body of the maxilla: its *apex*, directed outwards, is formed by the zygomatic process; its *base*, directed inwards, by the outer wall of the nose. Its walls are everywhere exceedingly thin, and correspond to the orbital, facial, and zygomatic surfaces of the body of the bone. Its *inner wall*, or *base*, presents, in the disarticulated bone, a large, irregular aperture, which

FIG. 314.—Left maxilla. Inner surface.

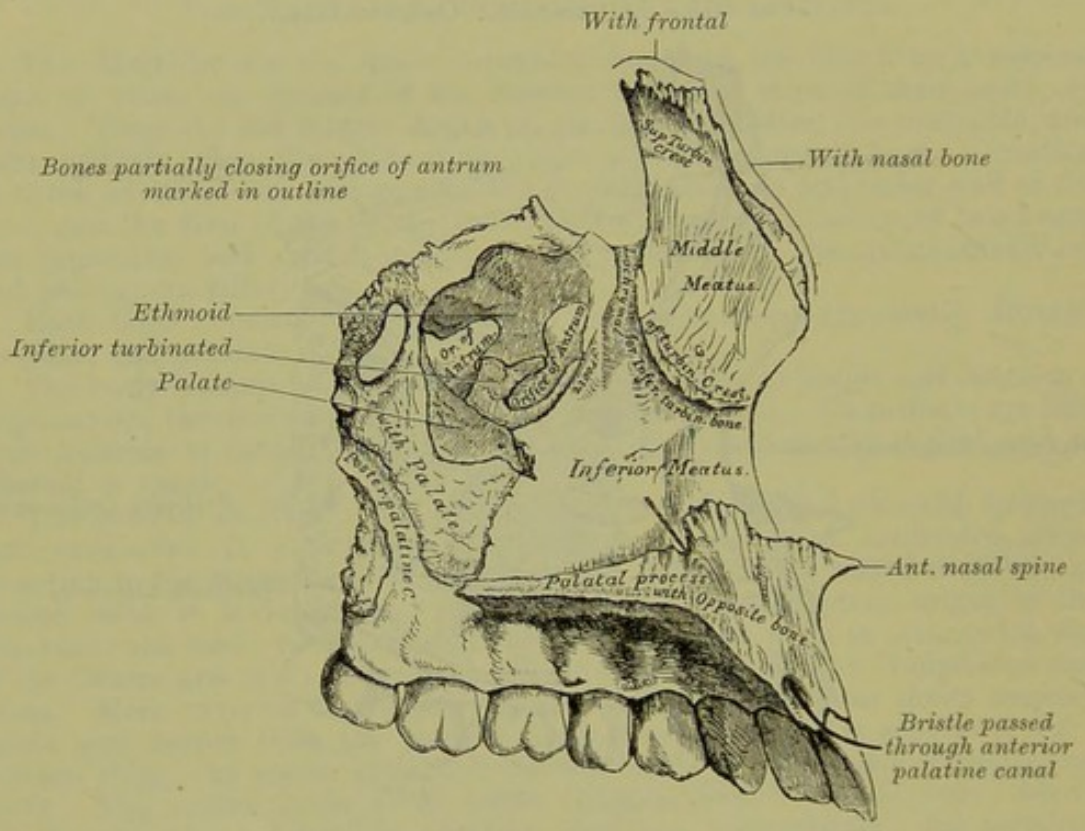

communicates with the nasal fossa. In the articulated skull this aperture is much reduced in size by the following bones: the uncinate process of the ethmoid above, the ethmoidal process of the inferior turbinated below, the vertical plate of the palate behind, and a small part of the lachrymal above and in front. It communicates with the middle meatus of the nose, generally by two small apertures left between the above-mentioned bones. In the recent state, usually only one small opening exists, near the upper part of the cavity, sufficiently large to admit the end of a probe; the other is closed by mucous membrane. On the *posterior wall* are the *posterior dental canals*, transmitting the posterior dental vessels and nerves to the molar teeth. The *floor* is formed by the alveolar process of the jaw, and, in a cavity of average size, is on a level with the floor of the nose; where the cavity is large it reaches below this level.

Projecting into the floor of the antrum are several conical processes, corresponding to the roots of the first and second molar teeth:* in some cases the floor is perforated by the fangs of the teeth. The infra-orbital canal usually

* The number of teeth whose fangs are in relation with the floor of the antrum is variable. The antrum 'may extend so as to be in relation to all the teeth of the true maxilla, from the canine to the *dens sapientiæ*.'—(Salter.)

projects into the cavity as a well-marked ridge which passes downwards and inwards from the roof to the anterior wall; additional ridges are sometimes seen in the posterior wall of the cavity, and are caused by the posterior dental canals. The size of the cavity varies in different skulls, and even on the two sides of the same skull. Aldren Turner (*op. cit.*) gives the following measurements as those of an average-sized antrum: vertical height opposite first molar tooth, 1½ in.; transverse breadth, 1 in.; and antero-posterior depth, 1¼ in.

Applied Anatomy.—The extreme thinness of the walls of this cavity affords an explanation of the fact that a tumour growing from the antrum and encroaching upon the adjacent parts may push up the floor of the orbit, and displace the eyeball; may project inwards into the nose; may protrude forwards on to the cheek; or may make its way backwards into the zygomatic fossa, or downwards into the mouth.

The **zygomatic** or **malar process** (processus zygomaticus) is a rough triangular eminence, situated at the angle of separation of the facial, zygomatic, and orbital surfaces. *In front* it forms part of the facial surface; *behind*, it is concave, and forms part of the zygomatic fossa; *above*, it is rough and serrated for articulation with the malar bone; while *below*, it presents a prominent arched border which marks the division between the facial and zygomatic surfaces.

The **frontal** or **nasal process** (processus frontalis) is a strong plate, which projects upwards, inwards, and backwards, by the side of the nose, forming part of its lateral boundary. Its *external surface* is smooth, continuous with the facial aspect of the body, and gives attachment to the Levator labii superioris alæque nasi, the Orbicularis palpebrarum, and the Tendo oculi. Its *internal surface* forms part of the outer wall of the nasal fossa; at its upper part is a rough, uneven area, which articulates with the ethmoid bone, closing in the anterior ethmoidal cells; below this is an oblique ridge, the *superior turbinated crest* (crista ethmoidalis), the posterior end of which articulates with the middle turbinated process of the ethmoid, while the anterior part is termed the *agger nasi*; the crest forms the upper limit of the atrium of the middle meatus. Its *upper border* articulates with the frontal and its *anterior* with the nasal; its *posterior border* is thick, and hollowed into a groove, which is continuous below with the *lachrymal groove* on the inner surface of the body: by the articulation of the inner margin of the groove with the anterior border of the lachrymal a corresponding groove on the lachrymal is brought into continuity, and together they form the *lachrymal fossa* for the lodgment of the lachrymal sac. The outer margin of the groove is named the *crista lacrimalis anterior*, and is continuous below with the orbital margin; at its junction with the orbital surface is a small tubercle, the *lachrymal tubercle*, which serves as a guide to the position of the lachrymal sac in the operation for fistula lacrimalis.

The **alveolar process** (processus alveolaris) is the thickest and most spongy part of the bone. It is broader behind than in front, and excavated into deep cavities for the reception of the teeth. These cavities are eight in number, and vary in size and depth according to the teeth they contain. That for the canine tooth is the deepest; those for the molars are the widest, and are subdivided into minor cavities by septa; those for the incisors are single, but deep and narrow. The Buccinator arises from the outer surface of this process, as far forward as the first molar tooth. When the maxillæ are articulated with each other, their alveolar processes together form the *alveolar arch*; the centre of the anterior margin of this arch is named the *alveolar point*.

The **palatal process** (processus palatinus), thick and strong, projects horizontally inwards from the inner surface of the bone. It forms a considerable part of the floor of the nose and the roof of the mouth and is much thicker in front than behind. Its *inferior surface* (fig. 315) is concave, rough and uneven, and forms, with the palatal process of the opposite bone, the anterior three-fourths of the hard palate. It is perforated by numerous foramina for the passage of the nutrient vessels; is channelled at the back part of its alveolar border by a groove, sometimes a canal, for the transmission of the posterior palatine vessels, and the anterior or large palatine nerve from Meckel's ganglion; and presents little depressions for the lodgment

of the palatine glands. When the two maxillæ are articulated, a depression, the *anterior palatine fossa*, is seen in the middle line, immediately behind the incisor teeth. On examining the bottom of this fossa four canals are visible: two are situated laterally, and two in the middle line. The lateral canals are named the *incisor foramina* or *foramina of Stenson*; they contain the remains of the organ of Jacobson, and through each of them passes the terminal branch of the posterior palatine artery, which ascends from the mouth to the nasal fossa. The canals in the middle line are termed the *foramina of Scarpa*, and transmit the naso-palatine nerves, the left passing through the anterior, and the right through the posterior canal. On the under surface of the palatal process, a delicate linear suture, well seen in young skulls, may sometimes be noticed extending outwards and forwards from the anterior palatine fossa to the interval between the lateral incisor and the canine tooth. The small part in front of this suture constitutes the *premaxilla* or *os incisivum*, which in most vertebrates forms an independent

Fig. 315.—The palate and alveolar arch.

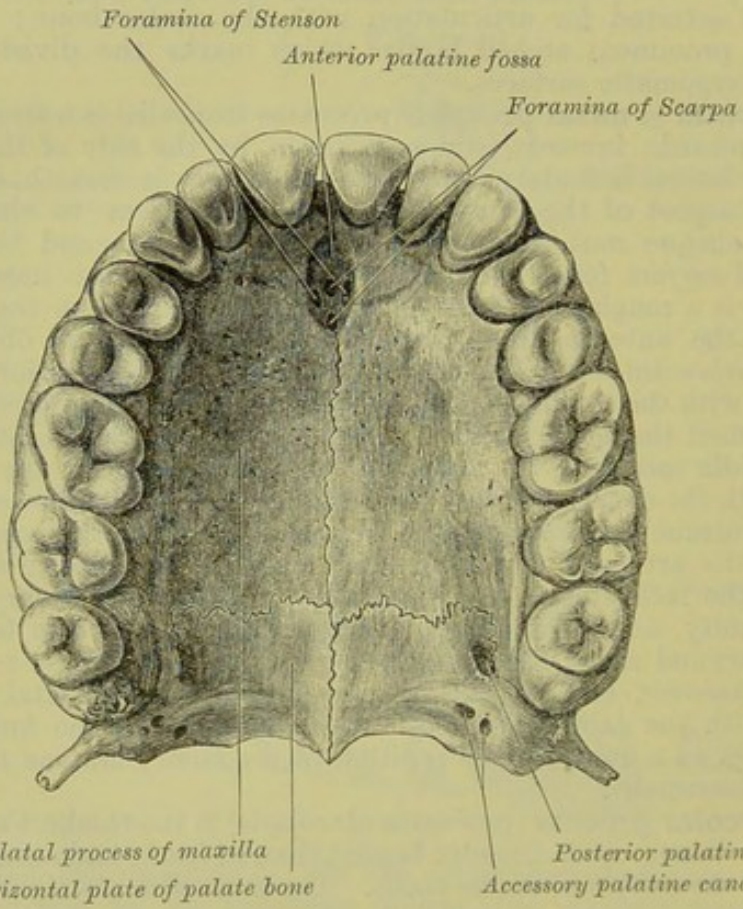

bone. It includes the whole thickness of the alveolus, the corresponding part of the floor of the nose and the anterior nasal spine, and contains the sockets of the incisor teeth. The *upper surface* of the palatal process is concave from side to side, smooth, and forms the greater part of the floor of the nasal fossa. It presents, close to its inner margin, the upper orifice of the foramen of Stenson. The *outer border* of the process is incorporated with the rest of the bone. The *inner border* is thicker in front than behind, and is raised above into a ridge, the *nasal crest* (crista nasalis), which, with the corresponding ridge of the opposite bone, forms a groove for the reception of the vomer. The front part of this ridge rises to a considerable height, and is named the *incisor crest*; it is prolonged forwards into a sharp process, which forms, together with a similar process of the opposite bone, the *anterior nasal spine* (spina nasalis anterior). The middle of the inferior border of the anterior nasal aperture at the base of the nasal spine is named the *subnasal point*. The *posterior border* is serrated for articulation with the horizontal plate of the palate-bone.

Ossification.—The maxilla begins to ossify at a very early period, and ossification proceeds in it with such rapidity that it is difficult to ascertain with certainty its precise number of centres. It appears probable, however, that it is ossified from six centres, which are deposited in membrane. One, the *orbito-nasal*, forms that portion of the body of the bone which lies internal to the infra-orbital canal, including the inner part of the floor of the orbit and the outer wall of the nasal fossa; a second, the *malar* or *zygomatic*, gives origin to the portion which lies external to the infra-orbital canal, including the zygomatic process; from a third, the *palatine*, is developed the palatal process posterior to Stenson's canal together with the adjoining part of the nasal wall; a fourth, the *premaxillary*, forms the front part of the alveolus which carries the incisor teeth and corresponds to the premaxilla of the lower vertebrates;* a fifth, the *nasal*, gives rise to the frontal process and the portion above the canine tooth; and a sixth, the *infravomerine*, lies between the palatine and premaxillary centres and beneath the vomer; this centre, together with the corresponding centre of the opposite bone, separates the foramina of Stenson from each other. These various

Fig. 316.—The maxilla at birth.

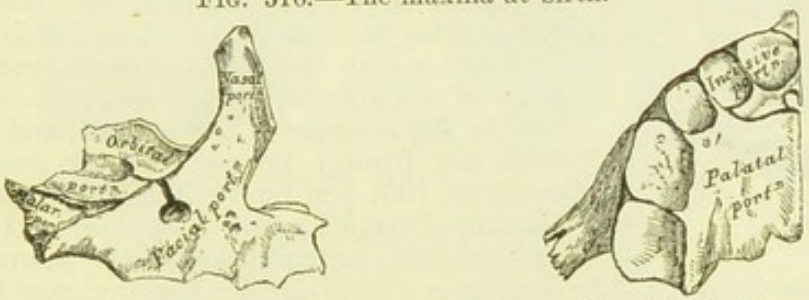

ANTERIOR SURFACE INFERIOR SURFACE

centres appear about the eighth week, and by the tenth week the bone consists of two portions, one the maxilla proper, and the other the premaxilla. The suture between these two portions persists on the palate till middle life, but is not to be seen on the facial surface. This is believed by Callender to be due to the fact that the front wall of the sockets of the incisor teeth is not formed by the premaxillary bone, but by an outgrowth from the facial part of the maxilla proper. The antrum is developed at an earlier period than any of the other accessory nasal sinuses; it appears as a shallow groove on the inner surface of the bone about the fourth month of fœtal life, but does not reach its full size until after the second dentition. The sockets for the teeth are formed by the downward growth of two plates from the dental groove, and by the subsequent development of partitions jutting across from the one to the other.

Articulations.—The maxilla articulates with nine bones: two of the cranium, the frontal and ethmoid, and seven of the face—viz. the nasal, malar, lachrymal, inferior turbinated, palate, vomer, and its fellow of the opposite side. Sometimes it articulates with the orbital plate, and sometimes with the external pterygoid plate of the sphenoid.

Changes produced in the Maxilla by Age

At birth the transverse and antero-posterior diameters of the bone are each greater than the vertical. The frontal process is well marked and the body of the bone consists of little more than the alveolar process, while the teeth-sockets reach almost to the floor of the orbit. The antrum of Highmore presents the appearance of a slit-like furrow on the outer wall of the nose. In the adult the vertical diameter is the greater, owing to the development of the alveolar process and the increase in size of the antrum. In old age the bone reverts in some measure to the infantile condition: its height is diminished, and after the loss of the teeth the alveolar process is absorbed, and the lower part of the bone contracted and diminished in thickness.

The Lachrymal Bones

The **Lachrymal Bone** (os lacrimale), the smallest and most fragile bone of the face, is situated at the front part of the inner wall of the orbit (fig. 310).

* Some anatomists believe that the premaxillary bone is ossified by two centres (see page 285).

It presents for examination two surfaces and four borders. The *external* or *orbital surface* (fig. 317) is divided by a vertical ridge, the *lachrymal crest* (crista lacrimalis posterior), into two parts. The portion in front of this crest presents a longitudinal groove (sulcus lacrimalis), the inner margin of which unites with the frontal process of the maxilla, and the lachrymal fossa is thus completed. The upper part of this fossa lodges the lachrymal sac, the lower part, the nasal duct. The portion behind the crest is smooth, and forms part of the inner wall of the orbit. The crest, with a part of the orbital surface immediately behind it, gives origin to the Tensor tarsi muscle, and terminates below in a small, hook-like projection, the *hamular process* (hamulus lacrimalis), which articulates with the lachrymal tubercle of the maxilla, and completes the upper orifice of the lachrymal canal. It sometimes exists as a separate piece, and is then called the *lesser lachrymal bone*. The *internal* or *nasal surface* presents a longitudinal furrow, corresponding to the crest on the outer surface. The area in front of this furrow forms part of the middle meatus of the nose; that behind it articulates with the ethmoid bone, and completes some of the anterior ethmoidal cells. Of the *four borders* the *anterior* is the longest, and articulates with the frontal process of the maxilla. The *posterior*, thin and uneven, articulates with the os planum of the ethmoid. The *superior*, the shortest and thickest, articulates with the internal angular process of the frontal. The *inferior* is divided by the lower edge of the vertical crest into two parts: the posterior part articulates with the orbital plate of the maxilla; the anterior is prolonged downwards as the *descending* or *turbinal process*, which articulates with the lachrymal process of the inferior turbinated bone, and assists in forming the canal for the nasal duct.

Fig. 317.—Left lachrymal bone. External surface. (Slightly enlarged.)

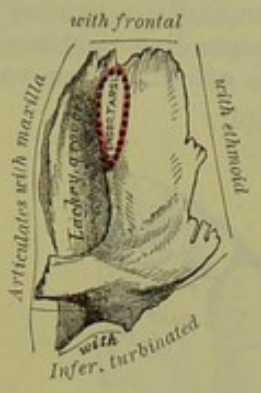

Ossification.—The lachrymal is ossified from a single centre, which appears about the eighth or ninth week in the membrane covering the cartilaginous nasal capsule.

Articulations.—The lachrymal articulates with four bones: two of the cranium, the frontal and ethmoid, and two of the face, the maxilla and the inferior turbinated.

The Malar or Zygomatic Bones

The **Malar** or **Zygomatic Bone** (os zygomaticum) is a small, quadrangular bone, situated at the upper and outer part of the face: it forms the prominence of the cheek, part of the outer wall and floor of the orbit, and parts of the temporal and zygomatic fossæ (fig. 318). It presents an external and an internal surface; four processes, the fronto-sphenoidal, orbital, maxillary, and temporal or zygomatic; and four borders.

The *external surface* (facies malaris) (fig. 319) is convex and perforated near its centre by a small aperture, the *malar foramen* (foramen zygomatico-faciale), for the passage of the malar nerve and vessels. It is covered by the Orbicularis palpebrarum, and presents, below the malar foramen, a slight elevation, the *malar tubercle*, which gives origin to the Zygomatici.

The *internal surface* (facies temporalis) (fig. 320), directed backwards and inwards, is concave, presenting internally a rough, triangular area, for articulation with the maxilla, and externally a smooth, concave surface, the upper part of which forms the anterior boundary of the temporal fossa, the lower a part of the zygomatic fossa. On this surface, a little above its centre, is the aperture of a malar canal (foramen zygomaticotemporale), for the transmission of the temporal branch of the temporo-malar nerve.

The **fronto-sphenoidal process** is thick and serrated, and articulates with the external angular process of the frontal bone. To its orbital margin is attached the external tarsal ligament. The **orbital process** is a thick, strong plate, projecting backwards and inwards from the orbital margin. Its *antero-internal surface*, smooth and concave, forms, by its junction with the orbital surface of the maxilla and with the greater wing of the sphenoid, part of the floor and outer wall of the orbit. On it are seen the orifices of two

canals (foramina zygomaticoorbitalia); one of these canals opens into the temporal fossa, the other on the anterior surface of the bone; the former transmits the temporal branch, the latter the malar branch of the temporo-malar nerve. Its *postero-external surface*, smooth and convex, forms parts of

Fig. 318.—Right malar bone *in situ*.

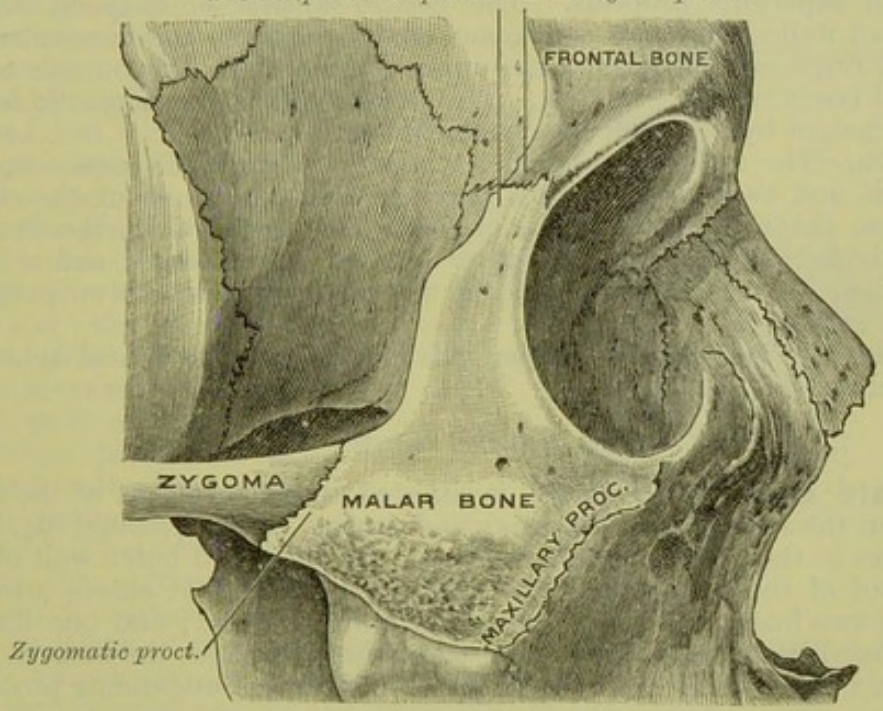

the zygomatic and temporal fossæ. Its *anterior margin*, smooth and rounded, forms part of the circumference of the orbit. Its *superior margin*, rough, and directed horizontally, articulates with the frontal bone behind the external angular process. Its *posterior margin* is serrated for articulation with the greater wing of the sphenoid and the orbital surface of the maxilla. At

Fig. 319.—Left malar bone. Outer surface.

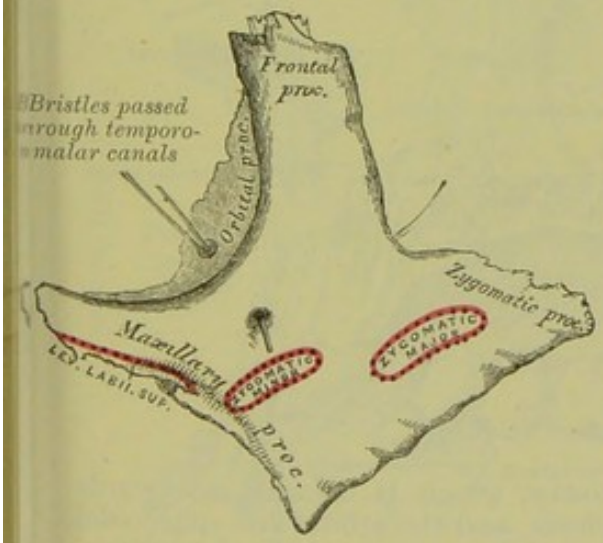

Fig. 320.—Left malar bone. Inner surface.

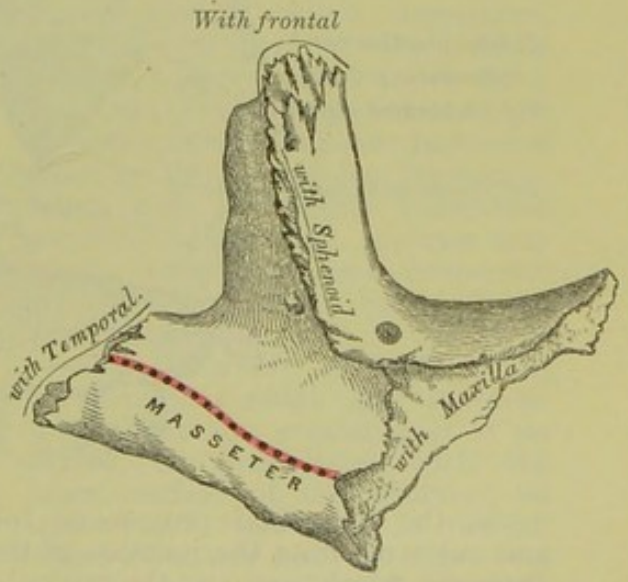

the angle of junction of the sphenoidal and maxillary portions, a short, rounded, non-articular margin is generally seen; this forms the anterior boundary of the spheno-maxillary fissure: occasionally, this non-articular margin does not exist, the fissure being completed by the junction of the maxilla and sphenoid, or by the interposition of a small Wormian bone in the angular

interval between them. The **maxillary process** is a rough, triangular surface which articulates with the maxilla. The **temporal process**, long, narrow, and serrated, articulates with the zygomatic process of the temporal.

Of the *four borders*, the *antero-superior* or *orbital* is smooth, concave, and forms a considerable part of the circumference of the orbit. The *antero-inferior* or *maxillary border* is rough, and bevelled at the expense of its inner table, to articulate with the maxilla; near the orbital margin it gives origin to the Levator labii superioris proprius. The *postero-superior* or *temporal border*, curved like an italic letter *f*, is continuous above with the commencement of the temporal ridge, and below with the upper border of the zygomatic arch; the temporal fascia is attached to it. The *postero-inferior* or *zygomatic border* affords attachment by its rough edge to the Masseter.

Ossification.—The malar bone ossifies generally from three centres—one for the zygomatic and two for the orbital portion; these appear about the eighth week and fuse about the fifth month of fœtal life. After birth, the bone is sometimes divided by a horizontal suture into an upper larger, and a lower smaller division. In some quadrumana the malar bone consists of two parts, an orbital and a malar.

Articulations.—The malar articulates with four bones: the frontal, sphenoid, temporal, and maxilla.

The Palate Bones

The **Palate Bone** (os palatinum) is situated at the back part of the nasal fossa between the maxilla and the pterygoid process of the sphenoid (fig. 321). It contributes to the walls of three cavities: the floor and outer wall of the nose, the roof of the mouth, and the floor of the orbit; it enters into the formation of two fossæ, the spheno-maxillary and pterygoid; and one fissure, the spheno-maxillary. The palate bone somewhat resembles the letter L, and consists of a horizontal and a vertical plate and three outstanding processes

Fig. 321.—Palate bone *in situ*.

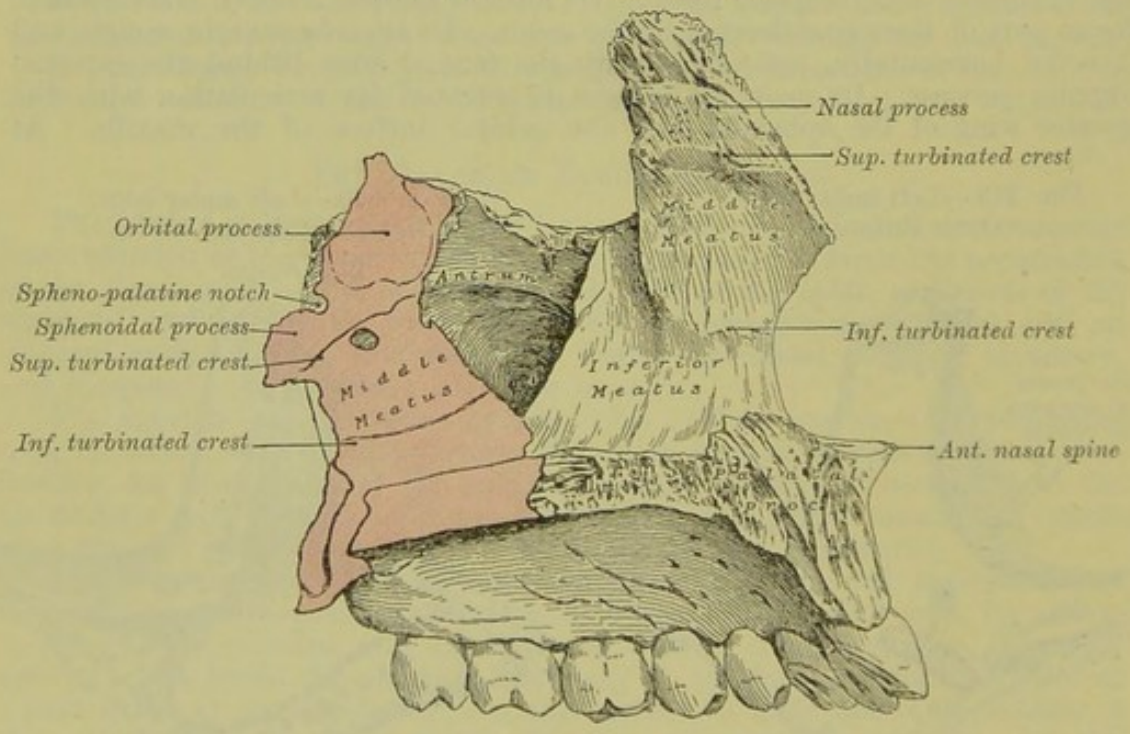

—viz. the pyramidal process or tuberosity, which is directed backwards and outwards from the junction of the plates, and the orbital and sphenoidal processes, which surmount the vertical plate, and are separated by a deep notch, the spheno-palatine notch.

The **horizontal plate** (pars horizontalis) (figs. 322 and 323) is quadrilateral, and has two surfaces and four borders. The *superior surface*, concave from side to side, forms the back part of the floor of the nose. The *inferior surface*, slightly concave and rough, forms, with the corresponding surface

of the opposite bone, the posterior fourth of the hard palate. At its posterior part may be seen a transverse ridge, more or less marked, for the attachment of part of the aponeurosis of the Tensor palati. The *anterior border* is serrated, and articulates with the palatal process of the maxilla. The *posterior border* is concave, free, and serves for the attachment of the soft palate. Its inner extremity is sharp and pointed, and, when united with the opposite bone, forms a projecting process, the *posterior nasal spine* (spina nasalis posterior) for the attachment of the Azygos uvulæ. The *external border* is united with the lower part of the perpendicular plate, and is grooved by the lower end of the posterior palatine canal. The *internal border*, the thickest, is serrated for articulation with its fellow of the opposite side; its superior edge is raised into a ridge, which, united with the ridge of the opposite bone, forms a crest for articulation with the posterior part of the lower edge of the vomer.

FIG. 322.—Left palate bone. Internal view. (Enlarged.)

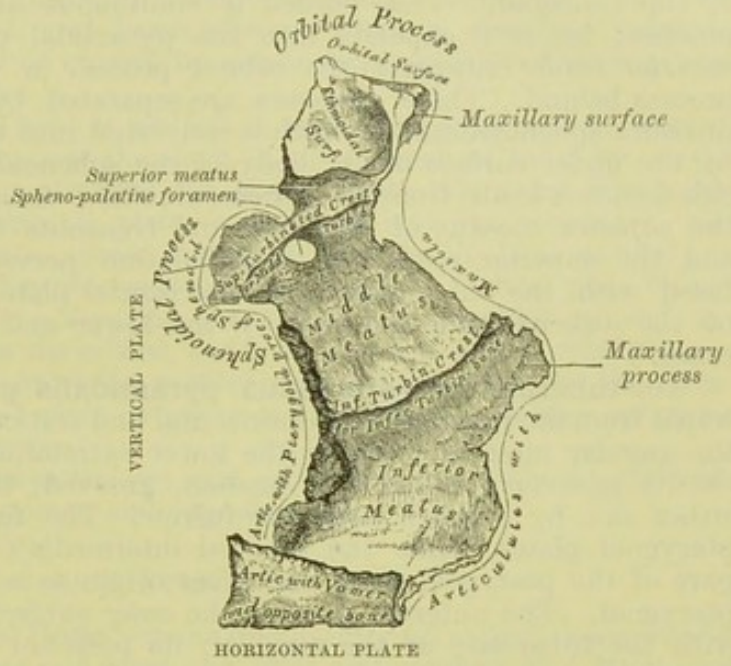

The **vertical plate** (pars perpendicularis) (figs. 322 and 323) is thin, of an oblong form, and presents two surfaces and four borders.

The *internal surface* (facies nasalis) exhibits at its lower part a broad, shallow depression, which forms part of the inferior meatus of the nose. Immediately above this is a well-marked horizontal ridge, the *inferior turbinated crest* (crista conchalis), for articulation with the inferior turbinated bone; still higher is a second broad, shallow depression, which forms part of the middle meatus, and is limited above by a horizontal ridge less prominent than the inferior, the *superior turbinated crest* (crista ethmoidalis), for articulation with the middle turbinated process. Above the superior turbinated crest is a narrow, horizontal groove, which forms part of the superior meatus.

FIG. 323.—Left palate bone. Posterior view. (Enlarged.)

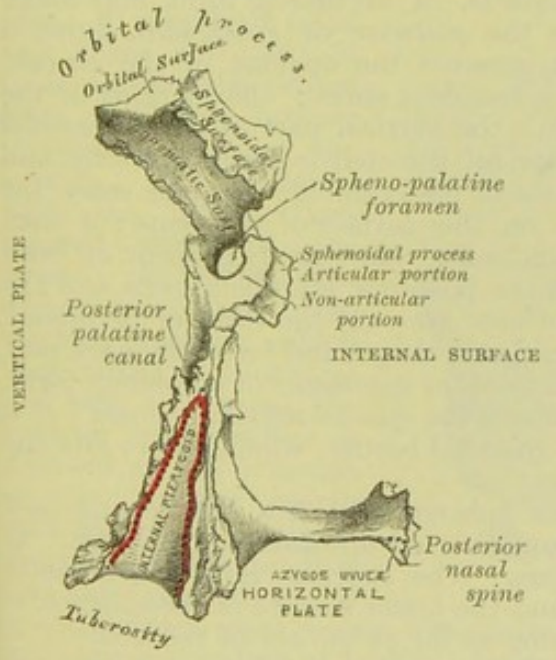

The *external surface* (facies maxillaris) is rough and irregular throughout the greater part of its extent, for articulation with the inner surface of the maxilla; its upper and back part is smooth where it enters into the formation of the spheno-maxillary fossa; it is also smooth in front, where it covers the posterior part of the orifice of the antrum. Towards the posterior part of this surface is a deep vertical groove, converted into the *posterior palatine canal*, by articulation with the maxilla; this canal transmits the posterior or descending palatine vessels, and the large palatine nerve.

The *anterior border* is thin, irregular, and presents, opposite the inferior turbinated crest, a pointed, projecting lamina, the *maxillary process*, which is directed forwards, and closes in the lower and back part of the opening of the antrum of Highmore. The *posterior border* (fig. 323) presents a deep groove, the edges of which are serrated for articulation with the internal pterygoid plate of the sphenoid. This border is continuous above with the sphenoidal process; below it expands into the pyramidal process or tuberosity. The *superior border* supports the orbital process in front and the sphenoidal process behind. These processes are separated by the *spheno-palatine notch* (incisura sphenopalatina), which is converted into the *spheno-palatine foramen* by the under surface of the body of the sphenoid. In the articulated skull this foramen leads from the spheno-maxillary fossa into the posterior part of the superior meatus of the nose, and transmits the spheno-palatine vessels and the superior nasal and naso-palatine nerves. The *inferior border* is fused with the outer edge of the horizontal plate, and immediately in front of the tuberosity is grooved by the lower end of the posterior palatine canal.

The **tuberosity** or **processus pyramidalis** projects backwards and outwards from the junction of the horizontal and vertical plates, and is received into the angular interval between the lower extremities of the pterygoid plates. On its *posterior surface* is a median, grooved, triangular area, limited on either side by a rough articular furrow. The furrows articulate with the pterygoid plates, while the grooved intermediate area completes the lower part of the pterygoid fossa and gives origin to a few fibres of the Internal pterygoid. The anterior part of the *outer surface* is rough, for articulation with the tuberosity of the maxilla; its posterior part consists of a smooth triangular area which appears, in the articulated skull, between the tuberosity of the maxilla and the lower part of the external pterygoid plate, and completes the lower part of the zygomatic fossa. The *base* of the tuberosity presents, close to its union with the horizontal plate, the apertures of the *posterior* and *accessory palatine canals* (foramina palatina minora) for the transmission of the posterior and external palatine nerves.

The **orbital process** (processus orbitalis) is placed on a higher level than the sphenoidal, and is directed upwards and outwards from the front part of the vertical plate, to which it is connected by a constricted neck. It presents five surfaces, which enclose an air-cell. Of these surfaces, three are articular and two non-articular. The articular surfaces are: (1) the *anterior* or *maxillary*, directed forwards, outwards, and downwards, of an oblong form, and rough for articulation with the maxilla; (2) the *posterior* or *sphenoidal*, directed backwards, upwards, and inwards; it presents the opening of the air-cell, which usually communicates with the sphenoidal sinus; the margins of the opening are serrated for articulation with the vertical part of the sphenoidal turbinated bone; (3) the *internal* or *ethmoidal*, directed inwards, upwards, and forwards, articulates with the lateral mass of the ethmoid. In some cases, the cellular cavity above mentioned opens on this surface of the bone; it then communicates with the posterior ethmoidal cells. More rarely it opens on both surfaces, and then communicates with the posterior ethmoidal cells and the sphenoidal sinus. The non-articular surfaces are: (1) the *superior* or *orbital*, directed upwards and outwards, is triangular in shape, and forms the back part of the floor of the orbit; and (2) the *external* or *zygomatic*, of an oblong form, is directed outwards and downwards towards the spheno-maxillary fossa; it is separated from the orbital surface by a rounded border, which enters into the formation of the spheno-maxillary fissure.

The **sphenoidal process** (processus sphenoidalis) is a thin, compressed plate, much smaller than the orbital, and directed upwards and inwards. It presents three surfaces and two borders. The *superior surface* articulates with the root of the pterygoid process and the under surface of the sphenoidal turbinated bone, its inner border reaching as far as the ala of the vomer; it presents a groove which contributes to the formation of the pterygo-palatine canal. The *internal surface* is concave, and forms part of the outer wall of the nasal fossa. The *external surface* is divided into an articular and a non-articular portion: the former is rough, for articulation with the inner surface of the internal pterygoid plate of the sphenoid; the latter is smooth,

and forms part of the spheno-maxillary fossa. The *anterior border* forms the posterior boundary of the spheno-palatine notch. The *posterior border*, serrated at the expense of the outer table, articulates with the inner surface of the internal pterygoid plate.

The orbital and sphenoidal processes are separated from one another by the *spheno-palatine notch* (incisura sphenopalatina). Sometimes the two processes are united above, and form between them a complete foramen (fig. 322), or the notch may be crossed by one or more spicules of bone, giving rise to two or more foramina.

Ossification.—The palate bone is ossified in membrane from a single centre, which makes its appearance about the sixth or eighth week of fœtal life at the angle of junction of the two plates of the bone. From this point ossification spreads inwards to the horizontal plate, downwards into the tuberosity, and upwards into the vertical plate. Some authorities describe the bone as ossifying from four centres : one for the tuberosity and portion of the vertical plate behind the posterior palatine groove ; a second for the rest of the vertical and the horizontal plates ; a third for the orbital, and a fourth for the sphenoidal process. At the time of birth the height of the vertical plate is about equal to the transverse width of the horizontal plate, whereas in the adult the former measures about twice as much as the latter.

Articulations.—The palate articulates with six bones : the sphenoid, ethmoid, maxilla, inferior turbinated, vomer, and opposite palate.

The Inferior Turbinated Bones

The **Inferior Turbinated Bone** (concha nasalis inferior) extends horizontally along the outer wall of the nasal fossa (fig. 324) and consists of a lamina of spongy bone, curled upon itself like a scroll. It presents two surfaces, two borders, and two extremities.

The *internal surface* (fig. 325) is convex, perforated by numerous apertures, and traversed by longitudinal grooves for the lodgment of vessels. The *external surface* is concave (fig. 326), and forms part of the inferior meatus. Its *upper border* is thin, irregular, and connected to various bones along the outer wall of the nose. It may be divided into three portions : of these, the anterior articulates with the inferior turbinated crest of the maxilla ; the posterior with the inferior turbinated crest of the palate ; the middle portion presents three well-marked processes, which vary much in their size and form. Of these, the anterior and smallest is situated at the junction of the anterior fourth with the posterior three-fourths of the bone : it is small and pointed, and is called the *lachrymal process* (processus lacrimalis) ; it articulates, by its apex, with the descending or turbinal process of the lachrymal bone, and, by its margins, with the groove on the back of the frontal process of the maxilla, and thus assists in forming the canal for the nasal duct. Behind this process a broad, thin plate, the *ethmoidal process* (processus ethmoidalis) ascends to join the uncinate process of the ethmoid ; from its lower border a thin lamina

Fig. 324.—Inferior turbinated bone and lachrymal bone *in situ*.

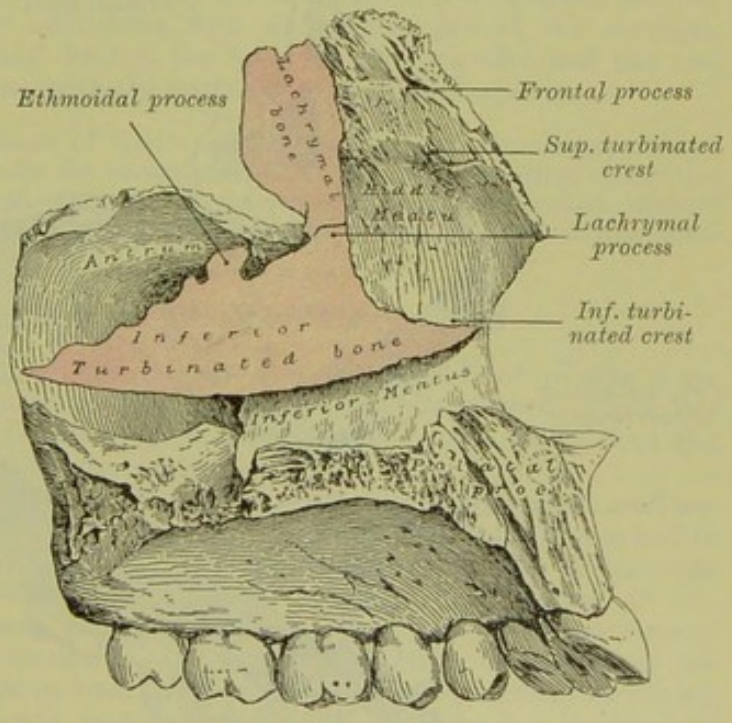

curves downwards and outwards, hooking over the lower edge of the orifice of the antrum, which it narrows below; this lamina fixes the bone firmly to the outer wall of the nasal fossa and is called the *maxillary process* (processus maxillaris). The *inferior border* is free, thick, and cellular in structure, more especially in the middle of the bone. Both *extremities* are more or less narrow and pointed, the posterior being the more tapering.

Fig. 325.—Right inferior turbinated bone. Internal surface.

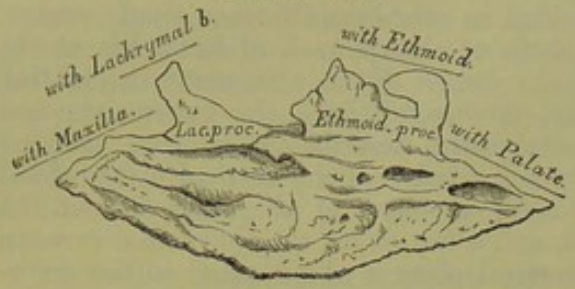

Fig. 326.—Right inferior turbinated bone. External surface.

Ossification.—The inferior turbinated bone is ossified from a single centre, which appears about the fifth month of fœtal life in the outer wall of the cartilaginous nasal capsule.

Articulations.—The inferior turbinated articulates with four bones: the ethmoid, maxilla, lachrymal, and palate.

The Vomer

The **Vomer** (vomer) is situated in the mesial plane, and forms the hinder and lower part of the septum of the nose (fig. 327). It is thin, somewhat quadrilateral in shape, and its anterior portion is frequently bent to one or

Fig. 327.—Vomer *in situ*.

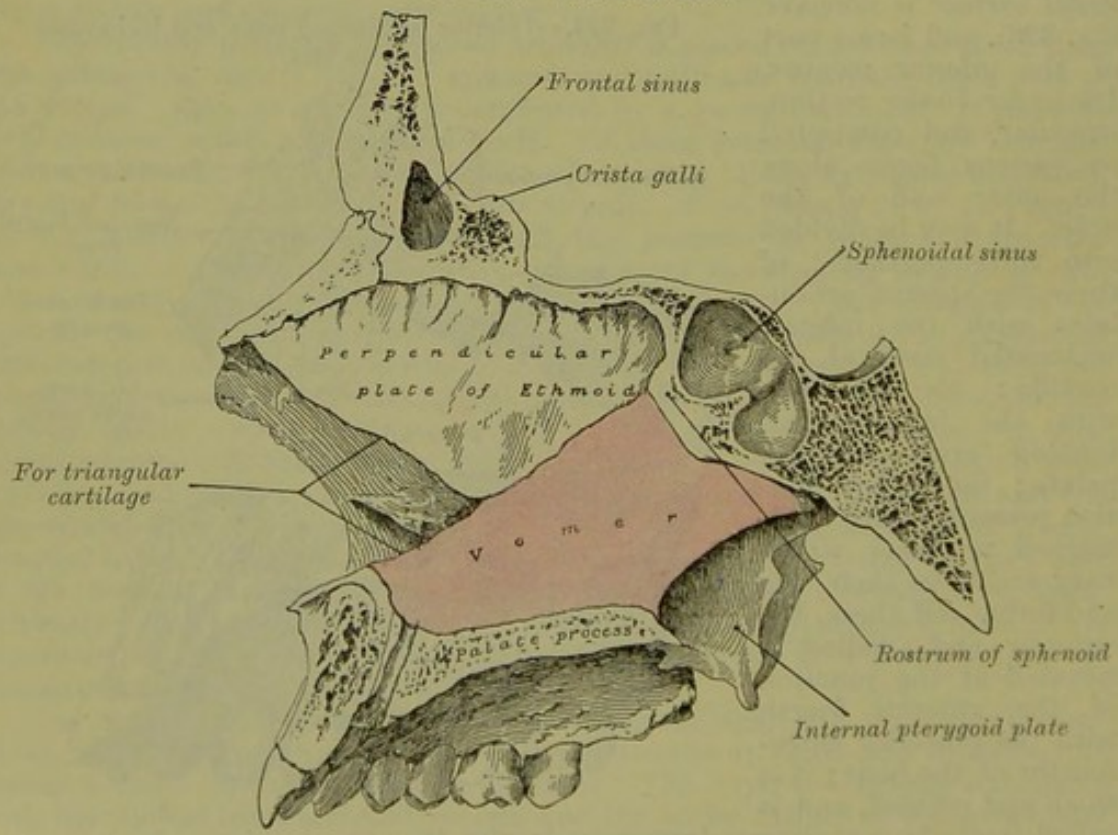

other side; it has two surfaces and four borders. The *surfaces* (fig. 328) are marked by small furrows for blood-vessels, and each presents a groove, the *naso-palatine*, which runs obliquely downwards and forwards, and transmits the naso-palatine nerve and vessels. The *superior border*, the thickest, presents a deep furrow, bounded on either side by a horizontal projecting ala of bone;

the furrow receives the rostrum of the sphenoid, while the margins of the alæ articulate with the vaginal processes of the internal pterygoid plates of the sphenoid behind, and with the sphenoidal processes of the palate bones in front. The *inferior border* articulates with the crest formed by the maxillæ and palate bones. The *anterior border* is the longest and slopes downwards and forwards. Its upper half is fused with the perpendicular plate of the ethmoid ; its lower half is grooved for the inferior margin of the septal cartilage of the nose. The *posterior border* is free, concave, and separates the nasal fossæ behind. It is thick and bifid above, thin below.

Ossification.—At an early period the septum of the nose consists of a plate of cartilage, the *ethmo-vomerine cartilage*. The postero-superior part of this cartilage is ossified to form the perpendicular plate of the ethmoid ; its antero-inferior portion persists as the septal cartilage, whilst the vomer is ossified in the membrane covering its postero-inferior part. Two ossific centres, one on either side of the middle line, appear about the eighth week of fœtal life in this part of the membrane, and hence the vomer consists primarily of two lamellæ. About the third month these unite below, and thus a deep groove is formed in which the cartilage is lodged. As growth proceeds, the union of the lamellæ extends upwards and forwards, and at the same time the intervening plate of cartilage undergoes absorption. By the age of puberty the lamellæ are united to form a mesial plate, but evidence of the bilaminar origin of the bone is seen in the everted alæ of its upper border and the groove on its anterior margin.

Fig. 328.—The vomer.

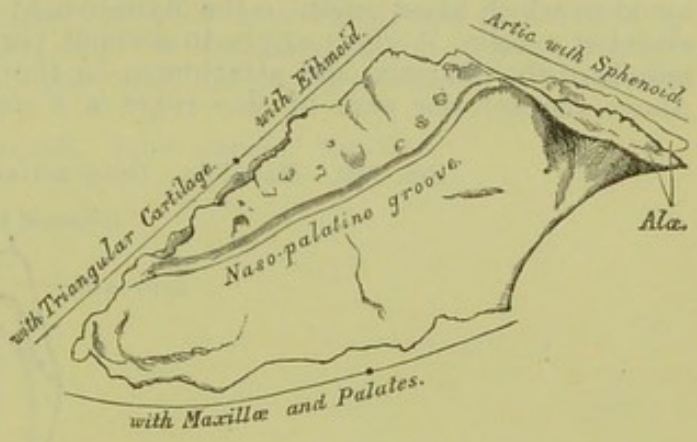

Articulations.—The vomer articulates with six bones : two of the cranium, the sphenoid and ethmoid ; and four of the face, the two maxillæ and the two palate bones ; it also articulates with the cartilage of the nasal septum.

Applied Anatomy.—The surfaces of the vomer are covered by mucous membrane, which is intimately connected with the periosteum, little, if any, submucous connective tissue intervening. Hence polypi are rarely found growing from this surface, though they frequently grow from the outer walls of the nasal fossæ, where the submucous tissue is abundant.

The Mandible or Inferior Maxilla

The **Mandible** (mandibula), the largest and strongest bone of the face, serves for the reception of the lower teeth. It consists of a curved, horizontal portion, the *body*, and two perpendicular portions, the *rami*, which join the back part of the body nearly at right angles.

The **body** (corpus mandibulæ) is curved somewhat like a horseshoe, and has two surfaces and two borders. The **external surface** (fig. 329) is marked in the median line by a faint ridge, indicating the *symphysis* or line of junction of the two pieces of which the bone is composed at an early period of life. This ridge divides below and encloses a triangular eminence, the *mental protuberance* (protuberantia mentalis), the base of which is depressed in the centre but raised on either side to form the *mental tubercle* (tuberculum mentale). On either side of the symphysis, just below the incisor teeth, is a depression, the *incisive fossa*, which gives origin to the Levator menti and a small portion of the Orbicularis oris. Below the second bicuspid tooth, on either side, midway between the upper and lower borders of the body, is the *mental foramen*, for the passage of the mental vessels and nerve. Running backwards and upwards from each mental tubercle is a faint ridge, the *external oblique line* (linea obliqua), which is continuous with the anterior border of the

ramus : it affords attachment to the Depressor labii inferioris and Depressor anguli oris ; the Platysma is attached below it.

The *internal surface* (fig. 330) is concave from side to side, and presents, near the lower part of the symphysis, a pair of laterally placed tubercles, termed the *genial* or *mental spines* (spinæ mentales), which give origin to the Genio-hyo-glossi. Immediately below these is a second pair of spines, or more frequently a median ridge or impression, for the origin of the Genio-hyoid muscles. In some cases the mental spines are fused to form a single eminence, in others they are absent and their position is indicated merely by an irregularity of the surface. Above the mental spines a median foramen and furrow are sometimes seen ; they mark the line of union of the halves of the bone. Below the mental spines, on either side of the middle line, is an oval depression for the attachment of the anterior belly of the Digastric. Extending upwards and backwards on either side from the lower part of the symphysis is the *internal oblique line* or *mylo-hyoid ridge* (linea mylo-hyoidea) which gives origin to the Mylo-hyoid ; at its posterior end, near the alveolar margin, it gives origin to a small part of the Superior constrictor muscle of the pharynx, and attachment to the pterygo-mandibular ligament. Above the anterior part of this ridge is a smooth triangular area against

Fig. 329.—Mandible. Outer surface. Side view.

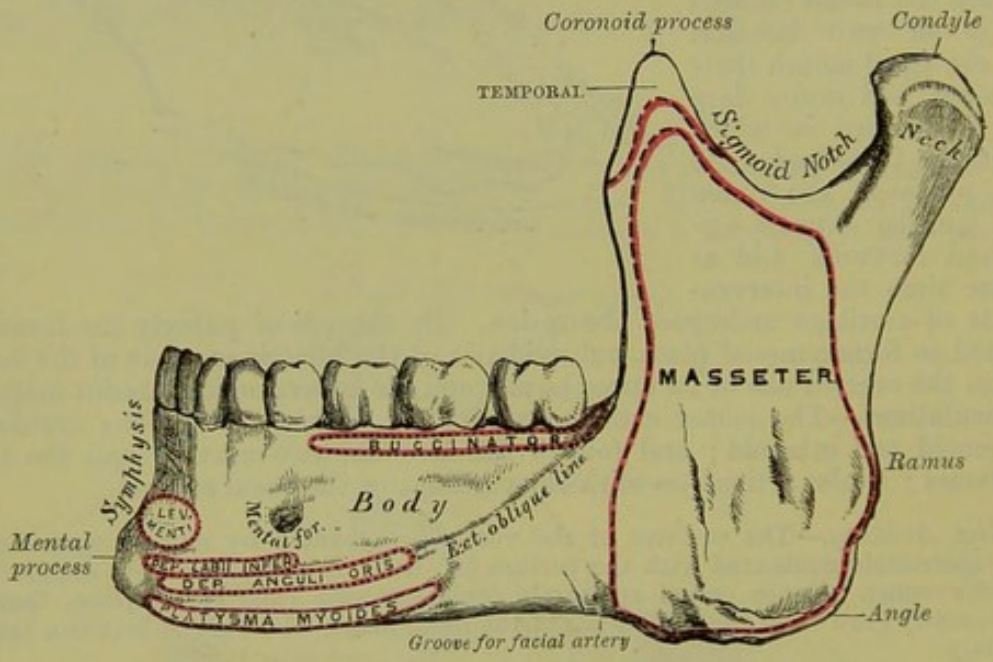

which the sublingual gland rests, and below the hinder part of the ridge is an oval fossa for the submaxillary gland.

The *superior* or *alveolar border*, wider behind than in front, is hollowed into cavities, for the reception of the teeth ; these cavities are sixteen in number, and vary in depth and size according to the teeth which they contain. To its outer lip, on either side, the Buccinator is attached as far forward as the first molar tooth. The *inferior border* is rounded, longer than the superior, and thicker in front than behind ; at the point where it joins the lower border of the ramus a shallow groove, for the facial artery, may be present.

The **perpendicular portion,** or **ramus** (ramus mandibulæ) is quadrilateral in shape, and presents for examination two surfaces, four borders, and two processes. The *external surface* (fig. 329) is flat and marked by oblique ridges at its lower part ; it gives attachment throughout nearly the whole of its extent to the Masseter. The *internal surface* (fig. 330) presents about its centre the oblique *aperture of the inferior dental canal* (foramen mandibulare), for the passage of the inferior dental vessels and nerve. The margin of this opening is irregular ; it presents in front a prominent ridge, surmounted by a sharp spine, the *lingula mandibulæ*, which gives attachment to the spheno-mandibular ligament ; at its lower and back part is a notch from which the *mylo-hyoid groove* runs obliquely downwards and forwards, and lodges the

mylo-hyoid vessels and nerve. Behind this groove is a rough surface, for the insertion of the Internal pterygoid. The *inferior dental canal* (canalis mandibulæ) runs obliquely downwards and forwards in the substance of the ramus, and then horizontally forwards in the body, where it is placed under the alveoli, and communicates with them by small openings. On arriving at the incisor teeth, it turns back to communicate with the mental foramen, giving off two small canals, which run forward to be lost in the cancellous tissue beneath the incisor teeth. The canal in the posterior two-thirds of the bone is situated nearer the internal surface of the mandible ; and in the anterior third, nearer its external surface. Its walls are composed of compact tissue at either extremity, and of cancellous in the centre. It contains the inferior dental vessels and nerve, from which branches are distributed to the teeth through small apertures at the bases of the alveoli. The *lower border* of the ramus is thick, straight, and continuous with the inferior border of the body of the bone. At its junction with the posterior border is the *angle* (angulus mandibulæ), which may be either inverted or everted, and is marked by rough, oblique ridges on each side, for the attachment of the Masseter externally, and the Internal pterygoid internally ; the stylo-mandibular

FIG. 330.—Mandible. Inner surface. Side view.

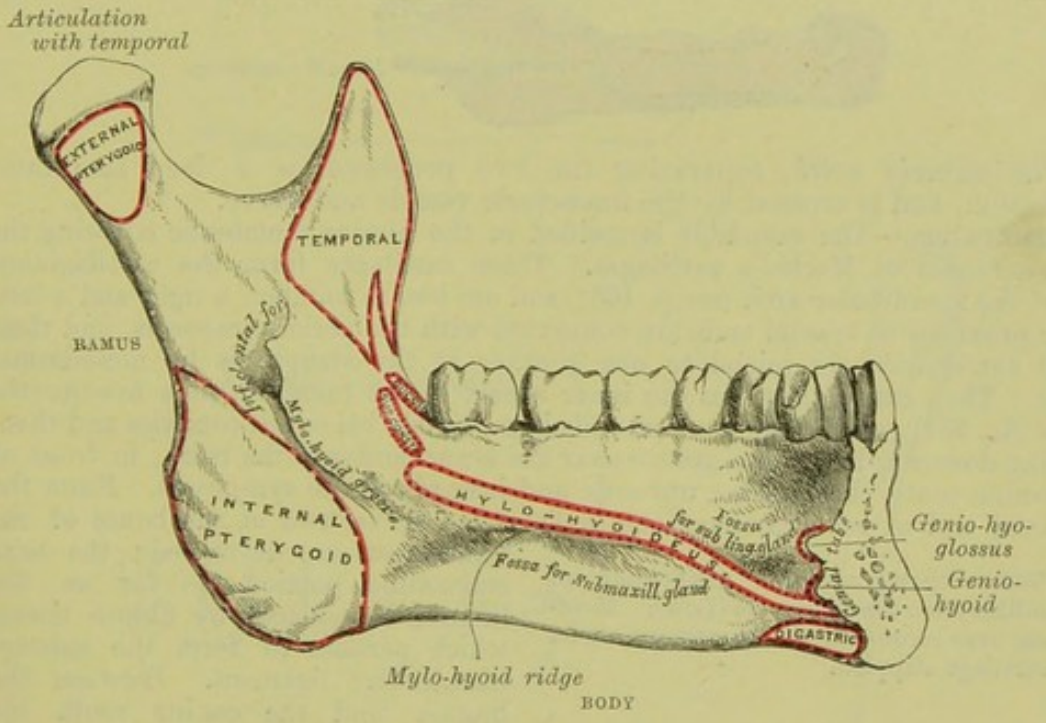

ligament is attached to the angle between these muscles. The *anterior border* is thin above, thicker below, and continuous with the external oblique line. The *posterior border* is thick, smooth, rounded, and covered by the parotid gland. The *upper border* is thin, and presents two processes, separated by a deep concavity, the *sigmoid notch*. Of these processes, the anterior is the *coronoid*, the posterior the *condylar*.

The **coronoid process** (processus coronoideus) is a thin, triangular eminence, which varies in shape and size. Its *anterior border* is convex and is continuous below with the anterior border of the ramus ; its *posterior border* is concave and forms the anterior boundary of the sigmoid notch. Its *external surface* is smooth, and affords insertion to the Temporal and Masseter muscles. Its *internal surface* gives insertion to the Temporal muscle, and presents a ridge which begins near the apex of the process and runs downwards and forwards to the inner side of the last molar tooth. Between this ridge and the anterior border is a grooved triangular area, the upper part of which gives attachment to the Temporal, the lower part to some fibres of the Buccinator.

The **condylar process** (processus condyloideus) is thicker than the coronoid, and consists of two portions : the *condyle*, and the constricted portion

which supports it, the *neck*. The *condyle* presents an articular surface which articulates with the glenoid cavity of the temporal bone ; it is convex from before backwards, and from side to side, and extends farther on the posterior than on the anterior aspect. Its long axis is directed inwards and slightly backwards, and if prolonged to the middle line will meet that of the opposite condyle near the anterior margin of the foramen magnum. At the outer extremity of the condyle is a small tubercle for the attachment of the external lateral ligament of the temporo-mandibular joint. The *neck* (collum mandibulæ) is flattened from before backwards, and strengthened by ridges which descend from the fore part and sides of the condyle. Its posterior surface is convex ; its anterior presents a depression for the attachment of the External pterygoid muscle.

Fig. 331.—Scheme showing ossification of the mandible, inner side (Low). The membrane bone is coloured red. The greater part of Meckel's cartilage is coloured blue. The upturned, stippled portion near the symphysis represents the part of Meckel's cartilage which is surrounded and invaded by the membrane bone. The accessory nuclei of cartilage in the condyle, coronoid process, alveolar border and body are indicated by stippled areas.

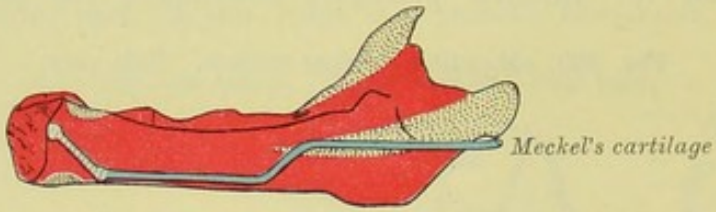

The *sigmoid notch*, separating the two processes, is a deep semilunar depression, and is crossed by the masseteric vessels and nerve.

Ossification.—The mandible is ossified in the fibrous membrane covering the outer surfaces of Meckel's cartilages. These cartilages form the cartilaginous bar of the mandibular arch (see p. 108), and are two in number, a right and a left. Their proximal or cranial ends are connected with the periotic capsules, and their distal extremities are joined to one another at the symphysis by mesodermal tissue. They can be seen on the inner aspect of the mandible of a five-months fœtus (fig. 331), where they run forwards immediately below the condyles and then, bending downwards, lie in a groove near the lower border of the bone ; in front of the canine tooth they incline upwards and inwards to the symphysis. From the proximal end of each cartilage the malleus and incus, two of the bones of the middle ear, are developed ; the next succeeding portion, as far as the lingula, is replaced by fibrous tissue, which persists to form the sphenomandibular ligament. Between the lingula and the canine tooth the cartilage disappears, whilst the portion of it which lies below and behind the incisor teeth becomes ossified and incorporated with this part of the mandible.

Fig. 332.—Scheme showing ossification of mandible from the outer side (Low). Membrane bone coloured red. Accessory nuclei of cartilage stippled.

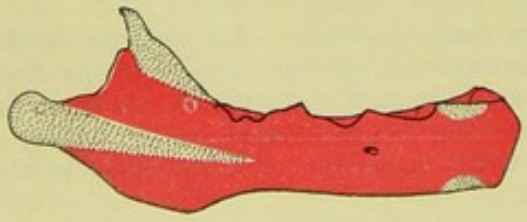

Ossification takes place in the membrane covering the outer surface of Meckel's cartilage (fig. 332), and each half of the bone is formed from a single centre which appears, near the mental foramen, about the sixth week of fœtal life—i.e. earlier than in any other bone except the clavicle. By the tenth week the portion of Meckel's cartilage which lies below and behind the incisor teeth is surrounded and invaded by the membrane-bone. Somewhat later, accessory nuclei of cartilage make their appearance—viz. a wedge-shaped nucleus in the condyle, a small one in the coronoid process, and smaller ones in the front part of both alveolar walls and along the front of the lower border of the bone. These accessory nuclei possess no separate ossific centres, but ossification extends into them from the adjacent membrane-bone and they undergo absorption. The inner alveolar border, usually described as arising from a separate ossific centre (*splenial centre*), is formed in the human mandible by an ingrowth from the main mass of the bone. At birth the

Side View of the Mandible at Different Periods of Life

Fig. 333.—At birth.

Fig. 334.—In childhood.

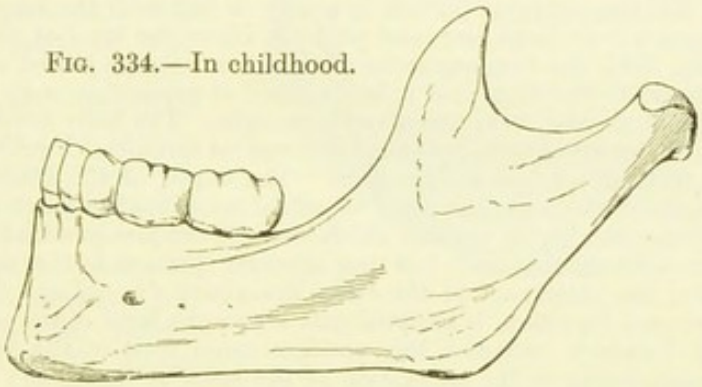

Fig. 335.—In the adult.

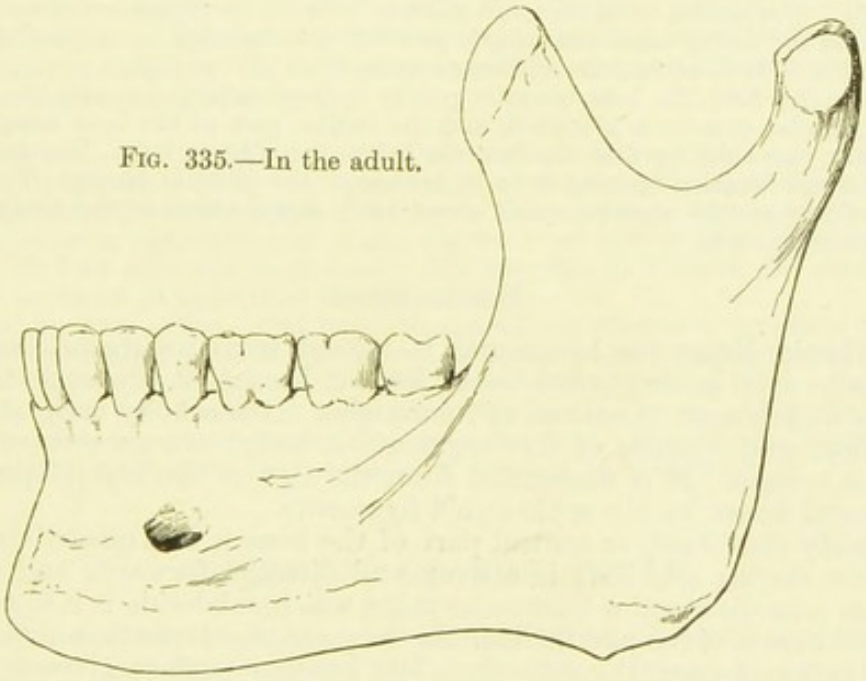

Fig. 336.—In old age.

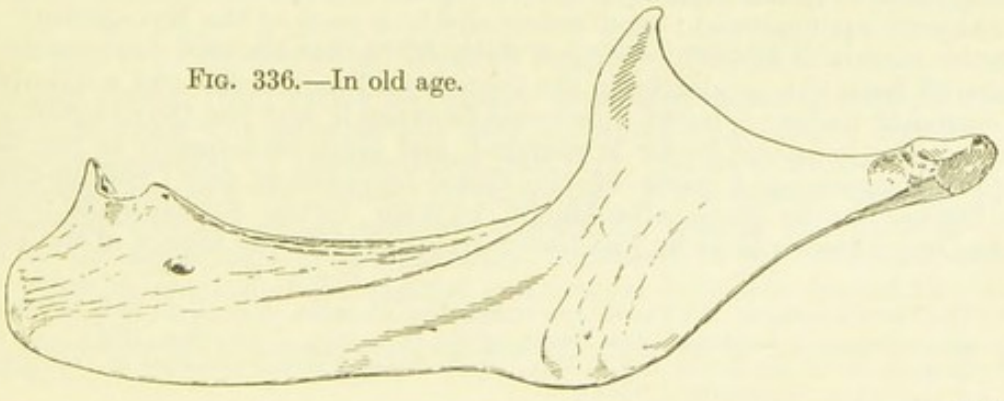

bone consists of two halves, united by a fibrous symphysis, in which ossification takes place during the first year.

The above description of the ossification of the mandible is based on the researches of Low* and Fawcett,† and differs somewhat from that usually given.

Articulations.—The mandible articulates with the two temporal bones.

Changes produced in the Mandible by Age

At birth (fig. 333), the body of the bone is a mere shell, containing the sockets of the two incisor, the canine, and the two temporary molar teeth, imperfectly partitioned off from one another. The dental canal is of large size, and runs near the lower border of the bone; the mental foramen opens beneath the socket of the first molar tooth. The angle is obtuse (175°), and the condylar portion is nearly in line with the body. The coronoid process is of comparatively large size, and projects above the level of the condyle.

After birth (fig. 334), the two segments of the bone become joined at the symphysis, from below upwards, in the first year; but a trace of separation may be visible in the beginning of the second year, near the alveolar margin. The body becomes elongated in its whole length, but more especially behind the mental foramen, to provide space for the three additional teeth developed in this part. The depth of the body increases owing to increased growth of the alveolar part, to afford room for the fangs of the teeth, and by thickening of the subdental portion which enables the jaw to withstand the powerful action of the masticatory muscles; but the alveolar portion is the deeper of the two, and, consequently, the chief part of the body lies above the oblique line. The dental canal, after the second dentition, is situated just above the level of the mylo-hyoid ridge; and the mental foramen occupies the position usual to it in the adult. The angle becomes less obtuse, owing to the separation of the jaws by the teeth; about the fourth year it is 140°.

In the adult (fig. 335), the alveolar and basilar portions of the body are usually of equal depth. The mental foramen opens midway between the upper and lower borders of the bone, and the dental canal runs nearly parallel with the mylo-hyoid line. The ramus is almost vertical in direction, the angle measuring from 110° to 120°.

In old age (fig. 336), the bone becomes greatly reduced in size, for with the loss of the teeth the alveolar process is absorbed, and the basilar part of the bone alone remains; consequently, the chief part of the bone is below the oblique line. The dental canal, with the mental foramen opening from it, is close to the alveolar border. The ramus is oblique in direction, the angle measures about 140°, and the neck of the condyle is more or less bent backwards.

Hyoid Bone

The **Hyoid Bone** (os hyoideum) is named from its resemblance to the Greek upsilon; it is also called the *os linguæ*, because it supports the tongue, and gives attachment to several of its muscles. It is a bony arch, shaped like a horseshoe, and consists of five segments, a body, two greater cornua, and two lesser cornua. It is suspended from the tips of the styloid processes of the temporal bones by the stylo-hyoid ligaments.

The **body** (*basi-hyal*) or central part of the bone is of a quadrilateral form. Its *anterior surface* (fig. 337) is convex and directed forwards and upwards; it presents a median and a transverse ridge which subdivide it into four areas, two on either side of the middle line. At the point of intersection of these ridges is an elevation named the *tubercle*. The anterior surface gives attachment to the Genio-hyoid in the greater part of its extent; above, to the Genio-hyo-glossus; below, to the Mylo-hyoid, Stylo-hyoid, and aponeurosis of the Digastric (suprahyoid aponeurosis); and externally to a part of the Hyo-glossus. The *posterior surface* is smooth, concave, directed backwards and downwards, and separated from the epiglottis by the thyro-hyoid membrane and a quantity of loose areolar tissue; a bursa intervenes between it and the thyro-hyoid membrane. The *superior border* is rounded, and gives attachment to the thyro-hyoid membrane and parts of the Genio-hyo-glossus and Chondro-glossus. The *inferior border* gives attachment, in front, to the Sterno-hyoid; behind to the Omo-hyoid, and at its junction with the great cornu to part of the Thyro-

* 'The Development of the Lower Jaw in Man,' by Alexander Low, M.A., M.B. (*Proceedings of the Anatomical and Anthropological Society of the University of Aberdeen*, 1905).

† 'Ossification of the Lower Jaw in Man,' by Professor Fawcett (*Journal of the American Medical Association*, September 2, 1905).

hyoid. It also gives attachment to the Levator glandulæ thyroideæ, when this muscle is present. In early life the *lateral surfaces* are connected to the greater cornua by synchondroses; after middle life usually by bony union.

The **greater cornua** (*thyro-hyals*) project backwards from the lateral surfaces of the body; they are flattened from above downwards and diminish in size from before backwards; each terminates in a tubercle for the attachment of the lateral thyro-hyoid ligament. The outer surface gives attachment to the Hyo-glossus; the upper border to the Middle constrictor of the pharynx, and the lower to part of the Thyro-hyoid.

Fig. 337.—Hyoid bone. Anterior surface (enlarged).

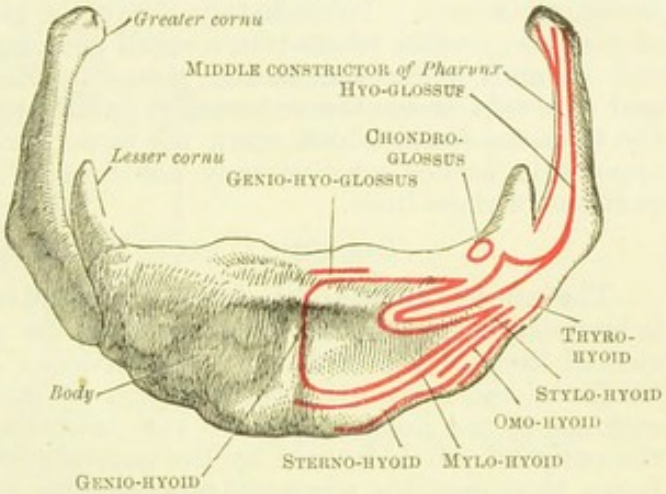

The **lesser cornua** (*cerato-hyals*) are two small, conical eminences, attached by their bases to the angles of junction between the body and greater cornua, and giving attachment by their apices to the stylo-hyoid ligaments.* The smaller cornua are connected to the body of the bone by distinct diarthrodial joints, which usually persist throughout life, but occasionally become ankylosed.

Ossification.—The hyoid is ossified from *six* centres: two for the body, and one for each cornu. Ossification commences in the body about the eighth month, in the greater cornua towards the end of fœtal life, and in the lesser cornua during the first or second year after birth.

Surface Form.—The hyoid bone can be felt in the receding angle below the chin, and the finger can be carried along the whole length of the bone to the greater cornu, which is situated on a level with the angle of the jaw. This process of bone is best perceived by making pressure on one cornu and so pushing the bone over to the opposite side, when the cornu of that side will be distinctly felt immediately beneath the skin. It is an important landmark in ligature of the lingual artery.

Applied Anatomy.—The hyoid bone is occasionally fractured, generally from direct violence, as in hanging, forcible grasping of the throat in garotting or throttling, or by a blow. The fracture generally occurs about the junction of the greater cornu with the body of the bone, but sometimes takes place through the latter. Since the muscles of the tongue have important connections with this bone, there is great pain upon any attempt being made to move the tongue, as in speaking or swallowing.

EXTERIOR OF THE SKULL

The skull as a whole may be viewed from different points, and the views so obtained are termed the *normæ* of the skull; thus, it may be examined from above (norma verticalis), from below (norma basalis), from the side (norma lateralis), from behind (norma occipitalis), or from the front (norma frontalis).

The Skull from Above (norma verticalis)

When viewed from above the outline presented varies greatly in different skulls; in some it is more or less oval, in others more nearly circular. The surface is traversed by three sutures, viz.: (1) the *coronal*, nearly transverse in direction, between the frontal and parietals; (2) the *sagittal*, mesially placed, and deeply serrated in its anterior two-thirds, uniting the parietal bones; and (3) the upper part of the *lambdoid*, between the parietals and occipital. The point of junction of the sagittal and coronal sutures is named the *bregma*,

* These ligaments in many animals are distinct bones, and in man may undergo partial ossification.

that of the sagittal and lambdoid sutures, the *lambda*; these points indicate respectively the positions of the anterior and posterior fontanelles in the fœtal skull. On either side of the sagittal suture are the *parietal eminence* and *parietal foramen*—the latter, however, is frequently absent on one or both sides. The skull is often somewhat flattened in the neighbourhood of the parietal foramina, and the term *obelion* is applied to that point of the sagittal suture which is on a level with the foramina. In front is the *glabella*, and on its lateral aspects are the *superciliary ridges*, and above these the *frontal eminences*. Immediately above the glabella may be seen the remains of the *inter-frontal suture*; in a small percentage of skulls this suture persists and extends along the mesial plane to the bregma. Passing backwards and upwards from the external angular processes of the frontal bone are the *temporal lines*, which mark the upper limits of the temporal fossæ. The zygomatic arches may or may not be seen projecting beyond the anterior portions of these lines.

The Skull from Below (norma basalis)

The inferior surface of the base of the skull exclusive of the mandible (fig. 338) is bounded in front by the incisor teeth in the maxillæ; behind, by the superior curved lines of the occipital; and laterally by the alveolar arch, the lower border of the malar, the zygoma, and an imaginary line, extending from the zygoma to the mastoid process and extremity of the superior curved line of the *occipital*. It is formed by the palatal processes of the maxillæ and palate bones, the vomer, the pterygoid processes, the under surfaces of the greater wings, spinous processes, and part of the body of the sphenoid, the under surfaces of the squamous, mastoid, and petrous portions of the temporals, and the under surface of the occipital bone. The anterior part or hard palate is raised above the level of the rest of the surface (when the skull is turned over for the purpose of examination), and is bounded in front and laterally by the alveolar arch containing the sixteen teeth of the maxillæ. Immediately behind the incisor teeth is the *anterior palatine fossa*. At the bottom of this fossa four apertures may usually be seen: two placed laterally, the *foramina of Stenson*, open above, into the floor of the nose, and transmit the anterior branches of the posterior palatine vessels, and two in the median line, the *foramina of Scarpa*, the anterior transmitting the left, and the posterior the right naso-palatine nerve. The vault of the hard palate is concave, uneven, perforated by numerous foramina, marked by depressions for the palatine glands, and traversed by a crucial suture formed by the junction of the four bones of which it is composed. In the young skull a suture may be seen passing outwards and forwards on either side from the anterior palatine fossa to the interval between the lateral incisor and canine teeth, and marking off the premaxillary portion of the bone. At each posterior angle of the hard palate is the *posterior palatine foramen*, for the transmission of the posterior palatine vessels and large descending palatine nerve; and running forwards and inwards from it a groove, for the same vessels and nerve. Behind the posterior palatine foramen is the *tuberosity of the palate-bone*, perforated by one or more *accessory posterior palatine canals*, and marked by the commencement of a ridge, which runs transversely inwards, and serves for the attachment of the tendinous expansion of the Tensor palati. Projecting backwards from the centre of the posterior border of the hard palate is the *posterior nasal spine*, for the attachment of the Azygos uvulæ. Behind and above the hard palate are the posterior apertures of the nares (*choanæ*), measuring about an inch in their vertical and half an inch in their transverse diameters. They are separated from one another by the vomer, and each is bounded above by the body of the sphenoid, below by the horizontal plate of the palate-bone, and laterally by the internal pterygoid plate of the sphenoid. At the base of the vomer may be seen the expanded alæ of this bone, receiving between them the rostrum of the sphenoid. Near the lateral margins of the alæ of the vomer, at the root of the pterygoid processes, are the *pterygo-palatine canals*. The pterygoid process, which bounds the posterior nares on either side, presents near its base the *pterygoid* or *Vidian canal*, for the Vidian nerve and artery. Each process consists of two plates, separated behind by the pterygoid fossa, which lodges the Internal pterygoid and Tensor palati. The internal plate is

long and narrow, presenting on the outer side of its base the *scaphoid fossa*, for the origin of the Tensor palati, and at its lower extremity the *hamular process*, around which the tendon of this muscle turns. The external pterygoid plate is

FIG. 338.—Base of skull. Inferior surface.

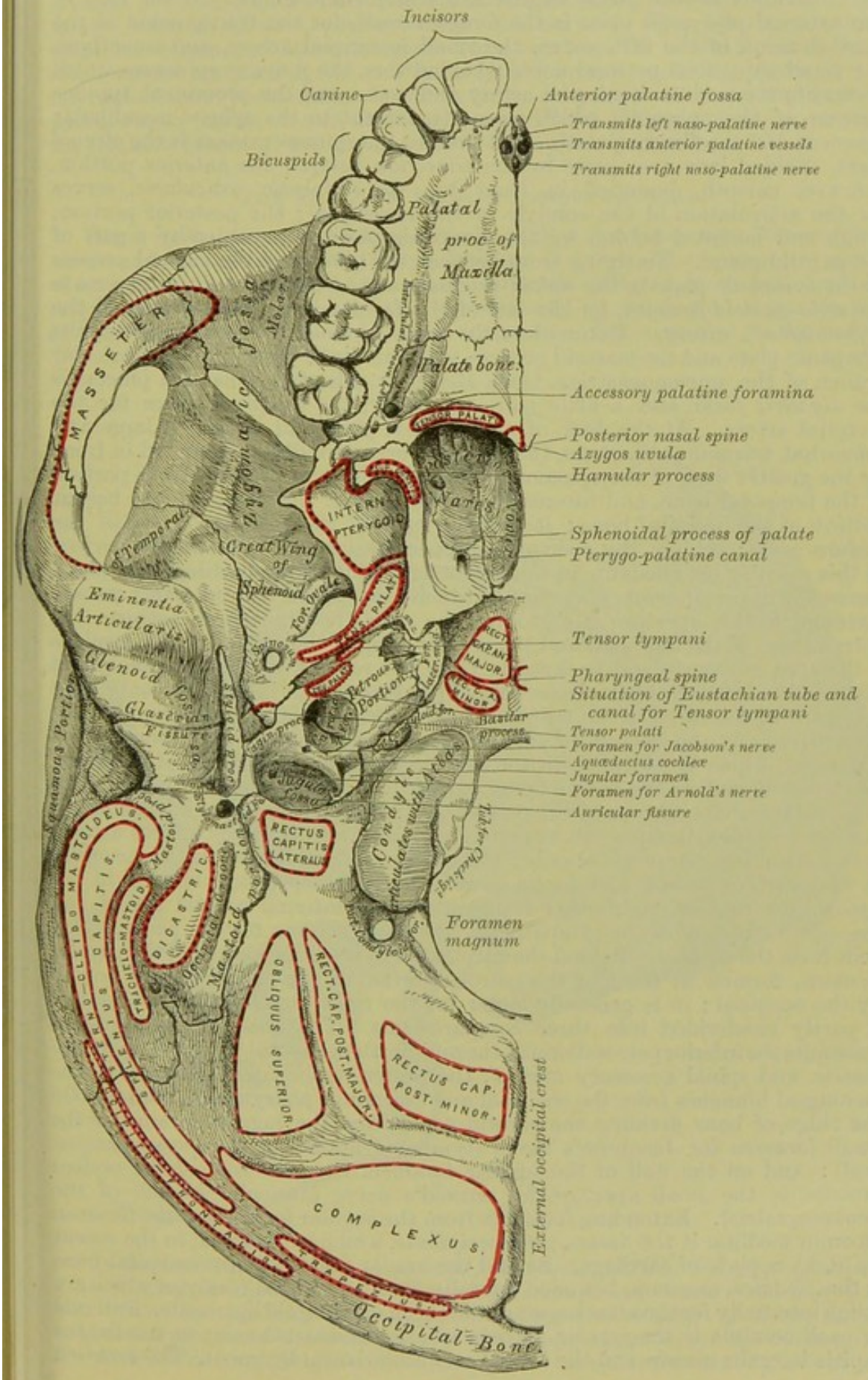

broad; its outer surface forms the inner boundary of the zygomatic fossa, and affords attachment to the External pterygoid.

Behind the nasal fossæ in the middle line is the basilar portion of the occipital bone, presenting near its centre the *pharyngeal tubercle* for the attachment of the fibrous raphe of the pharynx, with depressions on either side for the insertions of the Recti capitis antici major and minor. At the base of the external pterygoid plate is the *foramen ovale*, for the transmission of the third division of the fifth nerve, the small meningeal artery, and sometimes the small superficial petrosal nerve; behind this, the *foramen spinosum* which transmits the middle meningeal artery and veins, and the prominent spinous process of the sphenoid, which gives attachment to the spheno-mandibular ligament and the Tensor palati. External to the spinous process is the *glenoid fossa*, divided into two parts by the *Glaserian fissure*; the anterior portion, concave, smooth, bounded in front by the *eminentia articularis*, serves for the articulation of the condyle of the lower jaw; the posterior portion, rough and bound d behind by the tympanic plate, is occupied by a part of the parotid gland. Emerging from between the laminæ of the vaginal process of the tympanic plate is the *styloid process*; and at the base of this process is the *stylo-mastoid foramen*, for the exit of the facial nerve, and entrance of the stylo-mastoid artery. External to the stylo-mastoid foramen, between the tympanic plate and the mastoid process, is the *auricular fissure*, for the auricular branch of the pneumogastric. Upon the inner side of the mastoid process is the *digastric fossa*, and a little more internally, the *occipital groove* for the occipital artery. At the base of the internal pterygoid plate is a large and somewhat triangular aperture, the *foramen lacerum medium*, bounded in front by the greater wing of the sphenoid, behind by the apex of the petrous portion of the temporal bone, and internally by the body of the sphenoid and basilar portion of the occipital bone; it presents in front the posterior orifice of the *Vidian canal*; behind, the aperture of the *carotid canal*. The basilar surface of this opening is filled up in the recent state by a fibro-cartilaginous plate, across the upper or cerebral surface of which the internal carotid artery passes. External to this aperture is a groove, the *sulcus tubæ auditivæ*, between the petrous part of the temporal and the greater wing of the sphenoid. This sulcus is directed outwards and backwards from the root of the internal pterygoid plate and lodges the cartilaginous part of the Eustachian tube; it is continuous behind with the canal in the temporal bone which forms the bony part of the same tube. At the bottom of this sulcus is a narrow cleft, the *fissura petro-squamosa*, which is occupied, in the recent condition, by a plate of cartilage, the bones bounding the fissure being united by a synchondrosis. Behind this suture is the under surface of the petrous portion of the temporal bone, presenting, near its apex, the quadrilateral rough surface, part of which affords attachment to the Levator palati muscle; to the outer side of this surface is the orifice of the carotid canal, and to its inner side, the depression leading to the *aquæductus cochleæ*, the former transmitting the internal carotid artery and the carotid plexus of the sympathetic, the latter serving for the passage of a vein from the cochlea. Behind the carotid canal is a large aperture, the *jugular foramen*, formed in front by the petrous portion of the temporal, and behind by the occipital; it is generally larger on the right than on the left side, and is partly subdivided into three compartments. The anterior compartment transmits the inferior petrosal sinus; the middle, the glosso-pharyngeal, pneumogastric, and spinal accessory nerves; the posterior, the lateral sinus and some meningeal branches from the occipital and ascending pharyngeal arteries. On the ridge of bone dividing the carotid canal from the jugular foramen is the small foramen for Jacobson's nerve (tympanic branch of the glosso-pharyngeal); and on the wall of the jugular foramen, near the root of the styloid process, is the small aperture for Arnold's nerve (auricular branch of the pneumogastric). Extending forwards from the jugular foramen to the foramen lacerum medium is the *fissura petro-occipitalis*, which is occupied, in the recent state, by a plate of cartilage. Behind the basilar portion of the occipital bone is the *foramen magnum*, bounded laterally by the occipital condyles which are rough internally for the attachment of the check or odontoid ligaments. External to each condyle is the *jugular process*, which gives attachment to the Rectus capitis lateralis muscle and the lateral occipito-atlantal ligament. The foramen

magnum transmits the medulla oblongata and its membranes, the spinal accessory nerves, the vertebral arteries, the anterior and posterior spinal arteries, and the occipito-axial ligaments. The mid-points on the anterior and posterior margins of the foramen magnum are respectively termed the *basion* and the *opisthion*. In front of each condyle is the *anterior condyloid foramen*, for the passage of the hypoglossal nerve and a meningeal artery. Behind each condyle is the *fossa condyloidea*, perforated on one or both sides by the posterior condyloid foramen, for the transmission of a vein from the lateral sinus. Behind the foramen magnum is the *external occipital crest*, terminating above at the *external occipital protuberance*, while on either side are the *superior* and *inferior curved lines*; these, as well as the surfaces of bone between them, are rough for the attachment of the muscles which are enumerated on page 215.

The Skull in Profile (norma lateralis)

When viewed from the side (fig. 339) the skull is seen to consist of the cranium above and behind, and of the face below and in front. The cranium is somewhat ovoid in shape, but its contour varies in different cases and depends largely on the length and height of the skull and on the degree of prominence of the superciliary ridges and frontal eminences. Entering into its formation

Fig. 339.—Side view of the skull.

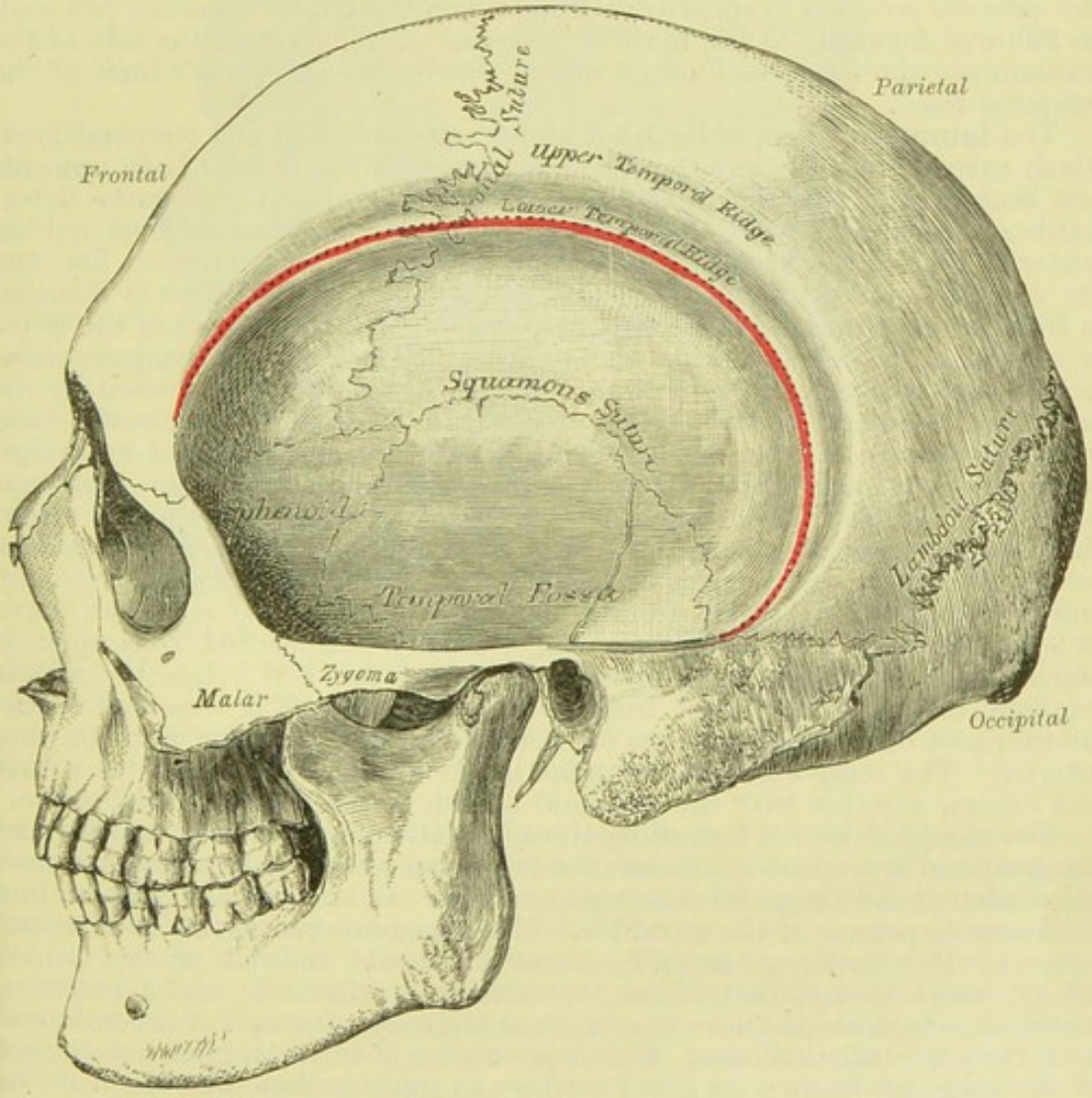

are to be seen the frontal, the parietal, the occipital, the temporal, and the greater wing of the sphenoid. These bones are joined to one another and to the malar by the following sutures: the *zygomatico-temporal* between the zygomatic process of the temporal and the temporal process of the malar; the *fronto-malar* uniting the malar with the external angular process of the frontal;

the sutures surrounding the great wing of the sphenoid, viz. : the *spheno-malar* in front, the *spheno-frontal* and *spheno-parietal* above, and the *spheno-squamosal* behind. The spheno-parietal suture varies in length in different skulls, and is absent in those cases where the frontal articulates with the squamous part of the temporal. The point corresponding with the posterior end of the spheno-parietal suture is named the *pterion* ; it is situated about an inch and a quarter behind, and a little above the level of the external angular process of the frontal bone.

The *squamous suture* arches backwards from the pterion and connects the squamous part of the temporal with the lower border of the parietal : this suture is continuous behind with the short, nearly horizontal *parieto-mastoid suture*, which unites the mastoid process of the temporal with the region of the postero-inferior angle of the parietal. Extending from above downwards and forwards across the cranium are the *coronal* and *lambdoid sutures* ; the former connects the parietal with the frontal, the latter, the parietal with the occipital. The lambdoid suture is continuous below with the *occipito-mastoid suture* between the occipital and the mastoid portion of the temporal. In or near this suture is the *mastoid foramen*, for the transmission of an emissary vein. The point of meeting of the parieto-mastoid, occipito-mastoid, and lambdoid sutures is known as the *asterion*. Immediately above the orbital margin is the *superciliary ridge*, and, at a higher level, the *frontal eminence*. Near the centre of the parietal bone is the *parietal eminence*. Posteriorly is the *external occipital protuberance*, from which the superior curved line may be followed forwards to the mastoid process. Arching across the side of the cranium are the *temporal lines* or ridges, which mark the upper limit of the temporal fossa.

The **temporal fossa** is bounded above and behind by the temporal lines, which extend from the external angular process of the frontal bone upwards and backwards across the frontal and parietal bones, and then curve downwards and forwards to become continuous with the supra-mastoid crest and the posterior root of the zygoma. The point where the upper temporal line cuts the coronal suture is named the *stephanion*. The temporal fossa is bounded in front by the frontal and malar bones, and opening on the back of the latter is a foramen which transmits the temporal branch of the temporo-malar nerve. Externally the fossa is limited by the zygomatic arch, formed by the malar and temporal bones ; below, it is separated from the zygomatic fossa by the *infra-temporal crest* on the greater wing of the sphenoid, and by a ridge, continuous with this crest, which is carried backwards across the squamous part of the temporal to the anterior root of the zygoma. In front and below, the fossa communicates with the orbital cavity through the *spheno-maxillary fissure*. The floor of the fossa is deeply concave in front and convex behind, and is formed by the malar, frontal, parietal, sphenoid, and temporal bones. It is traversed by vascular furrows : one, usually well marked, runs upwards above and in front of the external auditory meatus, and lodges the middle temporal artery. Two others, frequently indistinct, may be observed on the anterior part of the floor, and are for the anterior and posterior deep temporal arteries. The temporal fossa contains the Temporal muscle and its vessels and nerves, together with the temporal branch of the temporo-malar nerve.

The *zygomatic arch* is formed by the zygomatic process of the temporal and the temporal process of the malar, the two being united by an oblique suture ; the tendon of the Temporal muscle passes under the arch to gain insertion into the coronoid process of the mandible. The zygomatic process of the temporal arises by two roots, an anterior, directed inwards in front of the glenoid cavity, where it expands to form the eminentia articularis, and a posterior, which runs backwards above the external auditory meatus and is continuous with the supra-mastoid crest. The upper border of the arch gives attachment to the temporal fascia ; its lower border and inner surface give origin to the Masseter.

Below the posterior root of the zygoma is the elliptical orifice of the *external auditory meatus*, bounded in front, below, and behind by the tympanic plate ; to the outer margin of this plate the cartilaginous part of the external auditory meatus is attached. The small triangular area between the posterior root of the zygoma and the postero-superior part of the

orifice is termed the *supra-meatal triangle*, on the anterior border of which a small spinous process, the *supra-meatal spine*, is sometimes seen. Between the tympanic plate and the eminentia articularis is the *glenoid cavity*, divided into two parts by the Glaserian fissure. The anterior and larger part of the cavity articulates with the condyle of the mandible and is limited behind by the post-glenoid process : the posterior part lodges a portion of the parotid gland. The styloid process extends downwards and forwards for a variable distance from the lower part of the tympanic plate, and gives attachment to the Stylo-glossus, Stylo-hyoid, and Stylo-pharyngeus, and to the stylo-hyoid and stylo-mandibular ligaments. Projecting downwards behind the external auditory meatus is the mastoid process, to the outer surface of which the Sterno-mastoid, Splenius capitis, and Trachelo-mastoid are attached.

The **zygomatic** or **infra-temporal fossa** (fig. 340) is an irregularly shaped cavity, situated below and on the inner side of the zygoma. It is bounded,

Fig. 340.—Left zygomatic fossa.

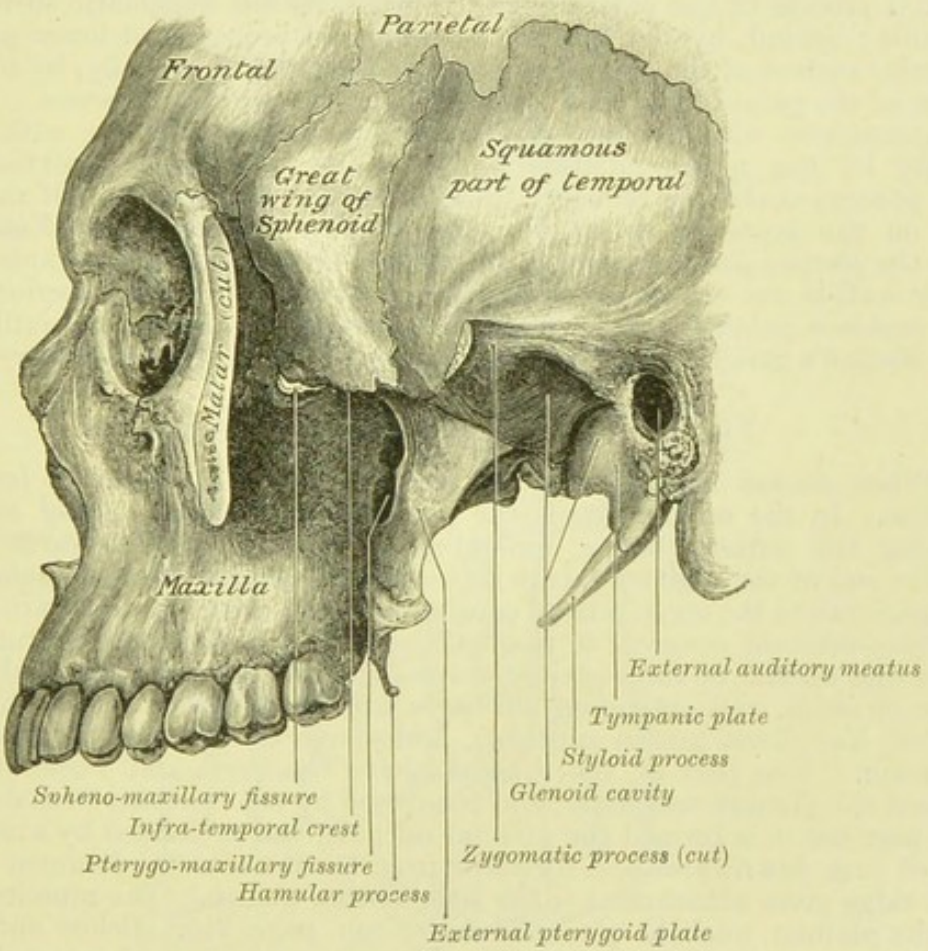

in front, by the zygomatic surface of the maxilla and the ridge which descends from its malar process ; behind, by the eminentia articularis of the temporal and the spine of the sphenoid ; above, by the greater wing of the sphenoid below the infra-temporal crest, and by the under surface of the squamous temporal ; below, by the alveolar border of the maxilla ; internally, by the external pterygoid plate. It contains the lower part of the Temporal muscle, the External and Internal pterygoids, together with the internal maxillary vessels and inferior maxillary nerve and their branches. The *foramen ovale* and *foramen spinosum* open on its roof, and the *posterior dental canals* on its anterior wall. At its upper and inner part may be observed two fissures, which together form a T-shaped fissure, the horizontal limb being named the spheno-maxillary, and the vertical one the pterygo-maxillary fissure.

The *spheno-maxillary fissure* (fissura orbitalis inferior), horizontal in direction, opens into the outer and back part of the orbit. It is bounded above by the lower border of the orbital surface of the greater wing of the sphenoid ;

below, by the external border of the orbital surface of the maxilla and the orbital process of the palate bone; externally, by a small part of the malar bone *: internally, it joins at right angles with the pterygo-maxillary fissure. Through the spheno-maxillary fissure the orbit communicates with the temporal, zygomatic, and spheno-maxillary fossæ; the fissure transmits the superior maxillary nerve and its temporo-malar branch, the infra-orbital vessels, the ascending branches from Meckel's ganglion, and a vein which connects the ophthalmic vein with the pterygoid venous plexus.

The *pterygo-maxillary fissure* is vertical, and descends at right angles from the inner extremity of the preceding; it is a triangular interval, formed by the divergence of the maxilla from the pterygoid process of the sphenoid. It connects the spheno-maxillary fossa with the zygomatic fossa, and transmits the terminal part of the internal maxillary artery.

The **spheno-maxillary fossa** (fossa pterygo-palatina) is a small, triangular space situated at the angle of junction of the spheno-maxillary and pterygo-maxillary fissures, and placed beneath the apex of the orbit. It is bounded above by the under surface of the body of the sphenoid and by the orbital process of the palate bone; in front, by the zygomatic surface of the maxilla; behind, by the base of the pterygoid process and lower part of the anterior surface of the greater wing of the sphenoid; internally, by the vertical plate of the palate bone with its orbital and sphenoidal processes. This fossa communicates with the orbit by the spheno-maxillary fissure, with the nasal cavity by the spheno-palatine foramen, and with the zygomatic fossa by the pterygo-maxillary fissure. Five foramina open into it. Of these, three are on the posterior wall, viz.: the *foramen rotundum*, the *Vidian canal*, and the *pterygo-palatine canal*, from without downwards and inwards. On the inner wall is the *spheno-palatine foramen*, and below is the superior orifice of the *posterior palatine canal*. The fossa contains the superior maxillary nerve and Meckel's ganglion, and the termination of the internal maxillary artery.

The Skull from Behind (norma occipitalis)

When viewed from behind the cranium presents a more or less circular outline. In the middle line is the posterior part of the *sagittal suture* connecting the parietal bones; extending downwards and outwards from the hinder end of the sagittal suture is the deeply serrated *lambdoid suture* joining the parietals to the occipital and continuous below with the parieto-mastoid and occipito-mastoid sutures; it frequently contains one or more Wormian bones. Near the middle of the squama occipitalis is the external occipital protuberance or *inion*, and extending outwards from it on either side is the *superior curved line* (linea nuchæ superior), and above this the faintly marked *linea suprema*. The part of the squama above the inion and lineæ supremæ is named the planum occipitale, and is covered by the Occipito-frontalis muscle; the part below is termed the planum nuchale, and is divided by a mesial ridge which runs downwards and forwards from the inion to the foramen magnum; this ridge gives attachment to the ligamentum nuchæ. The muscles attached to the planum nuchale are enumerated on page 215. Below and in front are the mastoid processes, convex externally and grooved internally by the digastric fossæ. In or near the occipito-mastoid suture is the *mastoid foramen* for the passage of the mastoid emissary vein.

The Skull from the Front (norma frontalis)

When viewed from the front (fig. 341) the skull exhibits a somewhat oval outline, limited above by the frontal bone, below by the body of the mandible, and laterally by the malar bones and the mandibular rami. The upper part, formed by the vertical plate of the frontal, is smooth and convex; the lower part, made up of the bones of the face, is irregular, and is excavated laterally by the orbital cavities, and presents in the middle line the anterior nasal aperture leading to the cavity of the nose, and below this the transverse slit between the upper and lower dental arcades. Above, the *frontal eminences*

* Occasionally the superior maxillary bone and the sphenoid articulate with each other at the anterior extremity of this fissure; the malar is then excluded from it.

stand out more or less prominently, and beneath these are the *superciliary ridges*, joined to one another in the middle by the *glabella*. On and above the glabella a trace of the *interfrontal suture* sometimes persists; beneath it is the fronto-nasal suture, the mid-point of which is termed the *nasion*. Behind and below the fronto-nasal suture the internal angular process of the frontal articulates with the lachrymal and with the frontal process of the maxilla. Arching between the internal and external angular processes of the frontal is the upper part of the margin of the orbit, thin and prominent in its outer two-thirds, rounded in its inner third, and presenting, at the junction of these two portions, the *supra-orbital notch* or *foramen* for the supra-orbital nerve and vessels. The external angular process articulates with the malar, and from it the temporal line extends upwards and backwards. Below the

FIG. 341.—Anterior region of the skull.

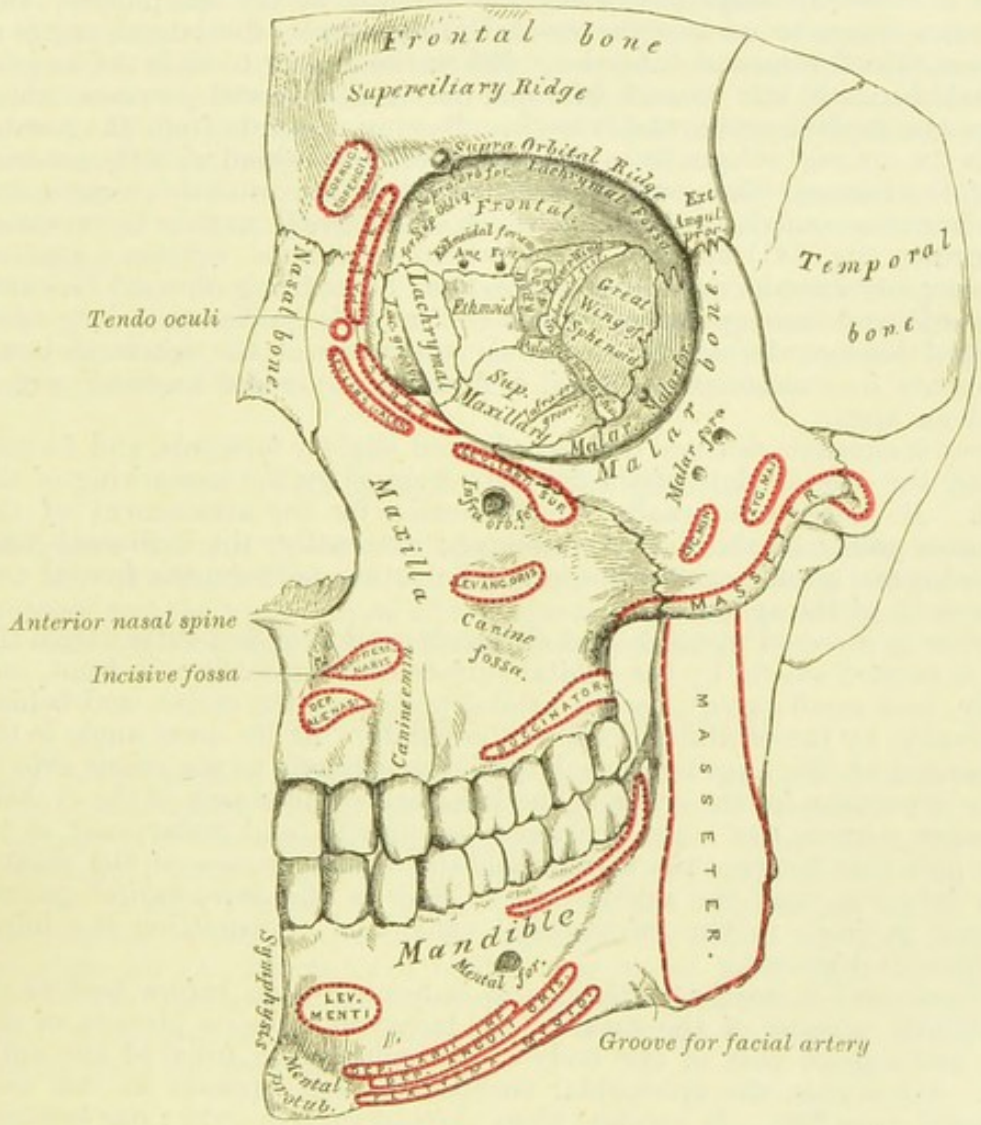

fronto-nasal suture is the bridge of the nose, convex from side to side, concavo-convex from above downwards, and formed by the two nasal bones supported in the middle line by the perpendicular plate of the ethmoid, and laterally by the frontal processes of the maxillæ which are prolonged upwards between the nasal and lachrymal bones and form the lower and inner part of the circumference of each orbit. Below the nasal bones and between the maxillæ is the anterior aperture of the nose, pyriform in shape, with the narrow end directed upwards. Laterally this opening is bounded by sharp margins, to which the lateral cartilages of the nose are attached; below, the margins are thicker and curve inwards and forwards to end in the *anterior nasal spine*. On looking into the nasal cavity, the bony septum which separates the nasal fossæ presents, in front, a large triangular deficiency; this, in the recent

state, is filled up by the septal cartilage. On the lateral wall of each nasal fossa the anterior part of the inferior turbinated bone is visible. Below and external to the anterior nasal aperture are the facial surfaces of the maxillæ, each perforated, near the lower margin of the orbit, by the *infra-orbital foramen* for the passage of the infra-orbital nerve and vessels. Below and internal to this foramen is the canine eminence separating the incisive from the canine fossa. Beneath these fossæ are the alveolar processes of the maxillæ containing the upper teeth, which overlap the teeth of the mandible in front. The malar bone on either side forms the prominence of the cheek, the lower and outer portion of the orbital cavity, and the anterior part of the zygomatic arch. It articulates internally with the maxilla, behind with the zygomatic process of the temporal, and above with the greater wing of the sphenoid and the external angular process of the frontal; it is perforated by the *malar foramen* for the passage of the malar branch of the temporo-malar nerve. On the body of the mandible is a median ridge, indicating the position of the symphysis; this ridge divides below to enclose the mental protuberance, the lateral angles of which constitute the mental tubercles. Below the incisor teeth is the incisive fossa, and beneath the second bicuspid tooth the *mental foramen* which transmits the mental nerve and vessels. Passing upwards from the mental tubercle is the *external oblique line*, which is continuous behind with the anterior border of the ramus. The posterior border of the ramus runs downwards and forwards from the condyle to the angle, which is frequently more or less everted.

The **orbits** (fig. 341) are two quadrilateral pyramidal cavities, situated at the upper and anterior part of the face, their bases being directed forwards and outwards, and their apices backwards and inwards, so that their long axes, if continued backwards, would meet over the body of the sphenoid bone. Each presents for examination a roof, a floor, an inner and an outer wall, a base, and an apex.

The *roof* is concave, directed downwards, and slightly forwards, and formed in front by the orbital plate of the frontal; behind by the lesser wing of the sphenoid. It presents internally the depression for the attachment of the cartilaginous pulley of the Superior oblique; externally, the *lachrymal fossa* for the lachrymal gland; and posteriorly, the suture between the frontal and the lesser wing of the sphenoid.

The *floor* is directed upwards and outwards, and is of less extent than the roof; it is formed chiefly by the orbital surface of the maxilla; in front, and externally, to a small extent, by the orbital process of the malar, and behind and internally, by the orbital process of the palate. At its inner angle is the upper opening of the naso-lachrymal canal, immediately to the outer side of which is a depression for the origin of the Inferior oblique muscle of the eyeball. On its outer part is the suture between the maxilla and malar, and at its posterior part that between the maxilla and the orbital process of the palate. Running forwards near the middle of the floor is the *infra-orbital groove*, terminating in front in the infra-orbital canal and transmitting the infra-orbital nerve and vessels.

The *inner wall* is nearly vertical, and is formed from before backwards by the frontal process of the maxilla, the lachrymal, the os planum of the ethmoid, and a small part of the body of the sphenoid in front of the optic foramen. Sometimes the sphenoidal turbinated bone appears in this wall (see footnote, page 236). It exhibits three vertical sutures—viz.: one between the frontal process of the maxilla and the lachrymal, another between the lachrymal and ethmoid, and a third between the ethmoid and sphenoid. In front is seen the *lachrymal groove*, which lodges the lachrymal sac, and behind the groove is the *lachrymal crest*, from which the Tensor tarsi arises. At the junction of the inner wall and the roof is the suture which joins the frontal bone to the frontal process of the maxilla, the lachrymal, and the ethmoid. The point of junction between the anterior border of the lachrymal and the frontal is named the *dacryon*. In the suture between the frontal and the os planum of the ethmoid are the *anterior* and *posterior ethmoidal foramina*, the former transmitting the nasal nerve and anterior ethmoidal vessels, the latter the posterior ethmoidal vessels.

The *outer wall*, directed inwards and forwards, is formed by the orbital process of the malar and the orbital surface of the greater wing of the sphenoid;

these are united by a vertical suture which terminates below at the front end of the spheno-maxillary fissure. On the orbital process of the malar are the orifices of one or two canals which transmit the temporal and malar branches of the temporo-malar nerve. Between the roof and the outer wall, near the apex of the orbit, is the *sphenoidal fissure*. Through this fissure the third, the fourth, the ophthalmic division of the fifth, and the sixth nerves enter the orbital cavity, also some filaments from the cavernous plexus of the sympathetic and the orbital branches of the middle meningeal artery. Passing backwards through the fissure are the ophthalmic vein and the recurrent branch from the lachrymal artery to the dura mater. The outer wall and the floor are separated posteriorly by the *spheno-maxillary fissure* which transmits the superior maxillary nerve and its temporo-malar branch, the infra-orbital vessels, and the ascending branches from Meckel's ganglion.

The *base* of the orbit, quadrilateral in shape, is formed above by the supra-orbital arch of the frontal bone, in which is the *supra-orbital notch* or *foramen* for the passage of the supra-orbital vessels and nerve; below by the malar and maxilla, united by the *malo-maxillary suture*; externally by the malar and the external angular process of the frontal joined by the *fronto-malar suture*; internally by the internal angular process of the frontal and the frontal process of the maxilla, the *fronto-maxillary suture* intervening.

The *apex*, situated at the back of the orbit, corresponds to the optic foramen,* a short, circular canal, which transmits the optic nerve and ophthalmic artery.

It will thus be seen that there are *nine* openings communicating with each orbit—viz.: the optic foramen, sphenoidal fissure, spheno-maxillary fissure, supra-orbital foramen, infra-orbital canal, anterior and posterior ethmoidal foramina, malar foramen, and the canal for the nasal duct.

INTERIOR OF THE SKULL

In order to study the interior of the skull the skull-cap should be removed by a saw-cut carried round the cranium about the level of the frontal eminences and the upper limits of the squamous sutures, cutting the occipital bone about an inch above the external protuberance.

Inner Surface of the Skull-cap

The inner surface of the skull-cap is concave and presents depressions for the convolutions of the cerebrum, together with numerous furrows for the lodgment of branches of the meningeal arteries. Along the middle line is a longitudinal groove, narrow in front, where it commences at the frontal crest, but broader behind; it lodges the superior longitudinal sinus, and its margins afford attachment to the falx cerebri. On either side of it are several depressions for the Pacchionian bodies, and at its back part, the openings of the *parietal foramina* when these are present. It is crossed, in front, by the *coronal suture*, and behind by the *lambdoid*, whilst the *sagittal* lies in the mesial plane between the parietal bones.

Upper Surface of the Base of the Skull

The upper surface of the base of the skull or floor of the cranial cavity (fig. 342) presents three fossæ, called the *anterior*, *middle*, and *posterior cranial fossæ*.

Anterior fossa.—The floor of the anterior fossa is formed by the orbital plates of the frontal, the cribriform plate of the ethmoid, and the lesser wings and front part of the body of the sphenoid; it is limited behind by the posterior borders of the lesser wings of the sphenoid and by the anterior margin

* Some anatomists describe the apex of the orbit as corresponding with the inner end of the sphenoidal fissure. It seems better, however, to adopt the statement in the text, since the muscles of the eyeball take origin around the optic foramen, and diverge from it to the globe of the eye.

of the optic groove. It is traversed by three sutures, the *fronto-ethmoidal*, *spheno-ethmoidal* and *spheno-frontal*. Its lateral portions roof in the orbital cavities and support the frontal lobes of the cerebrum; they are convex

Fig. 342.—Base of the skull. Upper surface.

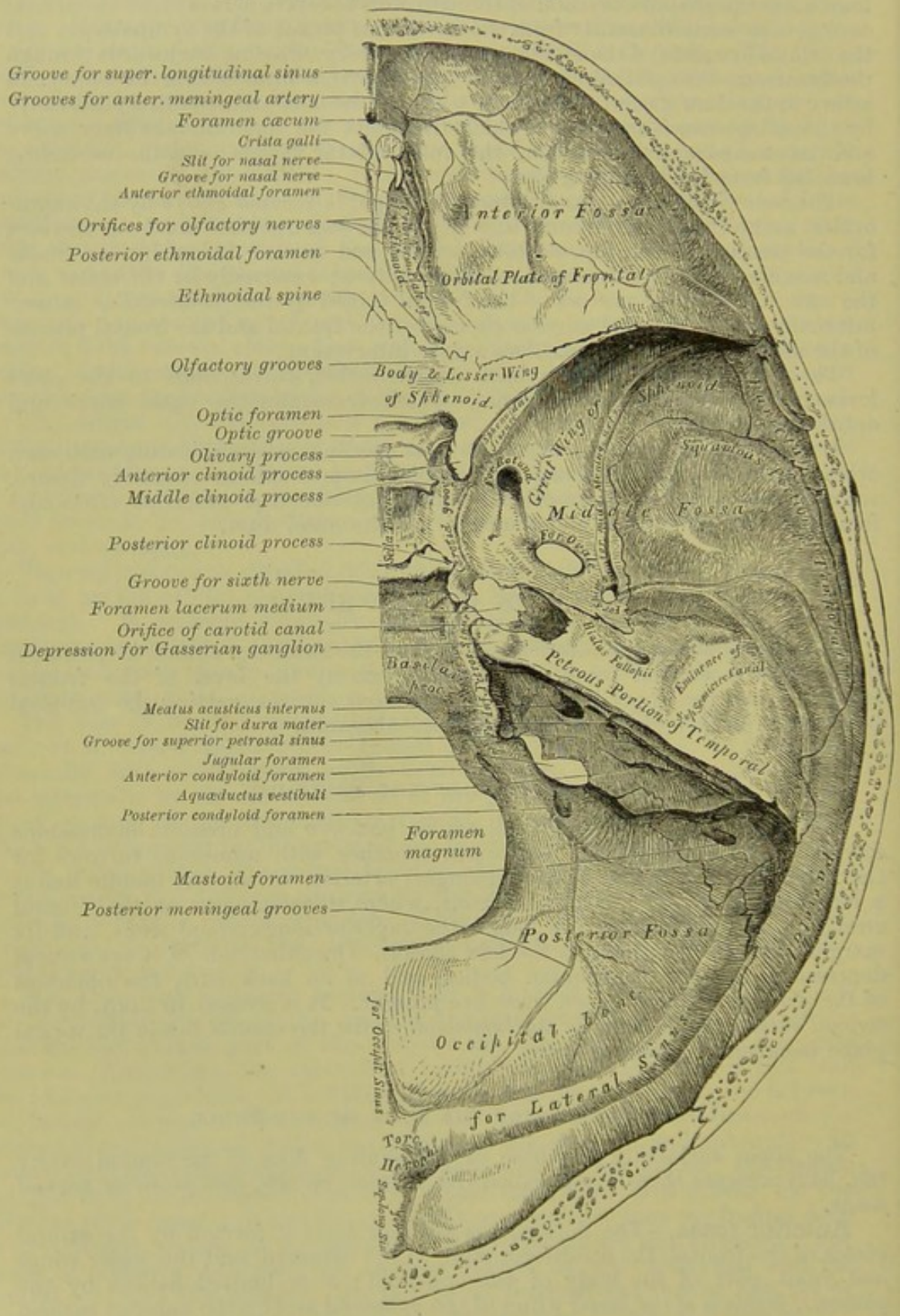

and marked by depressions for the brain convolutions, and grooves for branches of the meningeal arteries. The central portion corresponds with the roof of the nose, and is markedly depressed on either side of the crista galli. It presents, in and near the median line, from before backwards, the commence-

ment of the *frontal crest* for the attachment of the falx cerebri ; the *foramen cæcum*, between the frontal bone and the crista galli of the ethmoid, which usually transmits a small vein from the nose to the superior longitudinal sinus ; behind the foramen cæcum, the *crista galli*, the free margin of which affords attachment to the falx cerebri ; on either side of the crista galli, the *olfactory groove* formed by the cribriform plate, which supports the olfactory bulb, and presents foramina for the transmission of the olfactory nerves to the nose, and in front a slit-like opening for the nasal branch of the ophthalmic division of the fifth nerve. On the outer side of each olfactory groove are the internal openings of the *anterior* and *posterior ethmoidal foramina* ; the anterior, situated about the middle of the outer margin of the olfactory groove, transmits the anterior ethmoidal vessels and the nasal nerve ; the nerve runs in a groove along the outer edge of the cribriform plate to the slit-like opening above mentioned ; the posterior ethmoidal foramen opens at the back part of this margin under cover of the projecting lamina of the sphenoid, and transmits a meningeal branch from the posterior ethmoidal artery. Farther back in the middle line is the *ethmoidal spine*, bounded behind by a slight elevation separating two shallow longitudinal grooves which support the olfactory lobes. Behind this is the anterior margin of the optic groove, running outwards on either side to the upper margin of the optic foramen.

The **middle fossa,** deeper than the preceding, is narrow in the middle line, but becomes wider at the side of the skull. It is bounded in front by the posterior margins of the lesser wings of the sphenoid, the anterior clinoid processes, and the ridge forming the anterior margin of the optic groove ; behind, by the superior borders of the petrous portions of the temporals, and the dorsum sellæ, externally by the squamous portions of the temporals, antero-inferior angles of the parietals, and greater wings of the sphenoid. It is traversed by four sutures, the *squamous*, *spheno-parietal*, *spheno-squamosal*, and *spheno-petrosal*.

The middle part of the fossa presents, in front, the *optic groove* and *olivary eminence* ; the optic groove terminates on either side at the *optic foramen*, which transmits the optic nerve and ophthalmic artery to the orbital cavity. Behind the optic foramen the *anterior clinoid process* is directed backwards and inwards and gives attachment to the tentorium cerebelli. Behind the olivary eminence is a deep depression, the *sella turcica*, which lodges the pituitary body and presents on its anterior wall, the *middle clinoid processes*. The sella turcica is bounded posteriorly by a quadrilateral plate of bone, the *dorsum sellæ*, the upper angles of which are surmounted by the *posterior clinoid processes* : these afford attachment to the tentorium cerebelli, and below each is a notch for the sixth nerve. On either side of the sella turcica is the *carotid groove*, which is broad, shallow, and curved somewhat like the italic letter *f*. It begins behind at the foramen lacerum medium, and ends on the inner side of the anterior clinoid process, where it is sometimes converted into a foramen (carotico-clinoid) by the union of the anterior with the middle clinoid process ; posteriorly, it is bounded on the outer side by the *lingula*. This groove lodges the cavernous sinus and the internal carotid artery, the latter being surrounded by a plexus of sympathetic nerves.

The lateral parts of the middle fossa are of considerable depth, and support the temporal lobes of the brain. They are marked by depressions for the brain convolutions and traversed by furrows for the anterior and posterior branches of the middle meningeal artery. These furrows begin near the foramen spinosum, and the anterior runs forwards and upwards to the antero-inferior angle of the parietal, where it is sometimes converted into a bony canal ; the posterior runs backwards and outwards across the squamous portion of the temporal and passes on to the parietal near the middle of its lower border. The following apertures are also to be seen. In front is the *sphenoidal fissure*, bounded above by the lesser wing, below, by the greater wing, and internally, by the body of the sphenoid ; it is usually completed externally by the orbital plate of the frontal bone. It transmits to the orbital cavity the third, the fourth, the ophthalmic division of the fifth, and the sixth nerves, some filaments from the cavernous plexus of the sympathetic, and the orbital branch of the middle meningeal artery; and from the orbital cavity a recurrent branch from the lachrymal artery to the dura mater, and the

* Or : Pituitary Fossa.

ophthalmic vein. Behind the inner extremity of the sphenoidal fissure is the *foramen rotundum*, for the passage of the second division of the fifth nerve; still more posteriorly is the *foramen Vesalii*, which varies in size in different individuals, and is often absent; when present, it opens below at the outer side of the scaphoid fossa, and transmits a small vein. Behind and external to the latter opening is the *foramen ovale*, which transmits the third division of the fifth nerve, the small meningeal artery, and the small superficial petrosal nerve.* On the outer side of the foramen ovale is the *foramen spinosum*, for the passage of the middle meningeal artery and veins, and a recurrent branch from the inferior maxillary nerve. On the inner side of the foramen ovale is the *foramen lacerum medium*; in the recent state the lower part of this aperture is filled up by a layer of fibro-cartilage, while its upper and inner parts transmit the internal carotid artery surrounded by a plexus of sympathetic nerves. The Vidian nerve and a meningeal branch from the ascending pharyngeal artery pierce the layer of fibro-cartilage. On the anterior surface of the petrous portion of the temporal bone are seen, from without inwards, the eminence caused by the projection of the superior semicircular canal; in front and a little to the outer side of this a depression corresponding to the roof of the tympanic cavity; the groove leading to the *hiatus Fallopii*, for the transmission of the great superficial petrosal nerve and the petrosal branch of the middle meningeal artery; beneath it, the smaller groove, for the passage of the small superficial petrosal nerve; and, near the apex of the bone, the depression for the Gasserian ganglion and the orifice of the carotid canal.

The **posterior fossa** is the largest and deepest of the three. It is formed by the dorsum sellæ and clivus of the sphenoid, the occipital, the petrous and mastoid portions of the temporals, and the postero-inferior angles of the parietal bones; it is crossed by two sutures, the *occipito-mastoid* and the *parieto-mastoid*, and lodges the cerebellum, pons Varolii, and medulla oblongata. It is separated from the middle fossa in and near the median line by the dorsum sellæ, and on either side by the superior border of the petrous portion of the temporal bone. This border gives attachment to the tentorium cerebelli, is grooved for the superior petrosal sinus, and presents at its inner extremity a notch upon which the fifth nerve rests. The fossa is limited behind by the grooves for the lateral sinuses. In its centre is the *foramen magnum*, on either side of which is a rough tubercle for the attachment of the lateral odontoid or check ligaments; a little above this tubercle is the *anterior condyloid foramen*, which transmits the hypoglossal nerve and a meningeal branch from the ascending pharyngeal artery. In front of the foramen magnum the basilar process of the occipital and the posterior part of the body of the sphenoid form a grooved surface which supports the medulla oblongata and pons Varolii; in the young skull these bones are joined by a synchondrosis. This grooved surface is separated on either side from the petrous portion of the temporal by the *petro-occipital fissure*, which is occupied in the recent state by a plate of cartilage. This fissure is continuous behind with the jugular foramen, and its margins are grooved for the inferior petrosal sinus. The *jugular foramen* is situated between the lateral portion of the occipital and the petrous part of the temporal. The anterior portion of this foramen transmits the inferior petrosal sinus; the posterior, the lateral sinus and some meningeal branches from the occipital and ascending pharyngeal arteries; and the middle, the glosso-pharyngeal, pneumogastric, and spinal accessory nerves. Above the jugular foramen is the *internal auditory meatus*, for the facial and auditory nerves and auditory artery; behind and external to this is the slit-like opening leading into the aquæductus vestibuli, which lodges the ductus endolymphaticus; while between these, and near the superior border of the petrous portion, is a small triangular depression, the remains of the fossa subarcuata, which lodges a process of the dura mater and occasionally transmits a small vein. Behind the foramen magnum are the *inferior occipital fossæ*, which support the hemispheres of the cerebellum, separated from one another by the *internal occipital crest*, which serves for the attachment of the falx cerebelli, and lodges the occipital sinus. The posterior fossæ are surmounted by the deep transverse grooves for the *lateral sinuses*. Each of

* See footnote, page 234.

these channels, in its passage to the jugular foramen, grooves the occipital, the postero-inferior angle of the parietal, the mastoid portion of the temporal, and the jugular process of the occipital, and terminates at the back part of the jugular foramen. Where this sinus grooves the mastoid portion of the temporal, the orifice of the *mastoid foramen* may be seen; and, just previous to its termination, the *posterior condyloid foramen* opens into it; neither foramen is constant.

The Nasal Fossæ

The **nasal fossæ** are two irregular cavities, situated one on either side of the middle line of the face, extending from the base of the cranium to the roof of the mouth, and separated from each other by a thin vertical septum. They open on the face through the pear-shaped *anterior nasal aperture*, and communicate behind with the nasal part of the pharynx by the *posterior nares* or *choanæ*. They are much narrower above than below, and in the middle than at their anterior or posterior openings: their depth, which is considerable, is greatest in the middle. They communicate with the frontal, ethmoidal, sphenoidal, and maxillary sinuses. Each fossa is bounded by a roof, a floor, an inner and an outer wall.

Fig. 343.—Inner wall of left nasal fossa.

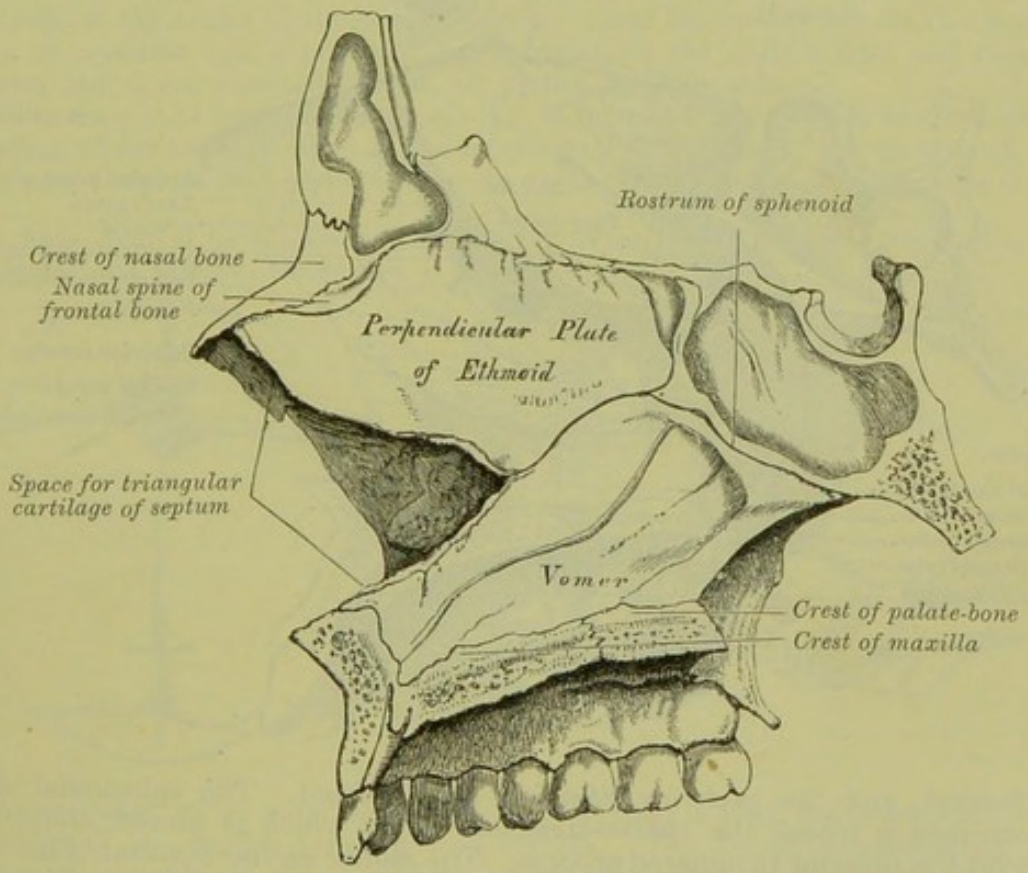

The *roof* (figs. 343 and 344) is horizontal in its central part, but slopes downwards in front and behind; it is formed in front by the nasal bones and nasal spine of the frontal; in the middle, by the cribriform plate of the ethmoid; and behind, by the body of the sphenoid, the sphenoidal turbinated bones, the ala of the vomer and the sphenoidal process of the palate-bone. The cribriform plate of the ethmoid presents the foramina for the olfactory nerves; on the posterior part of the roof is the opening into the sphenoidal sinus.

The *floor* is flattened from before backwards and concave from side to side. It is formed by the palatal processes of the maxilla and palate; near its anterior extremity is the opening of the incisor foramen.

The *inner wall*, or septum nasi (fig. 343), is frequently deflected to one or other side. It is formed, in front, by the crest of the nasal bones and nasal

spine of the frontal ; in the middle, by the perpendicular plate of the ethmoid ; behind, by the vomer and rostrum of the sphenoid ; below, by the crest of the maxillæ and palate bones. It presents, in front, a large, triangular notch, which receives the septal cartilage of the nose ; and behind, the free edge of the vomer. Its surface is marked by numerous furrows for vessels and nerves and by the groove for the naso-palatine nerve, and is traversed by sutures connecting the bones of which it is formed.

The *outer wall* (fig. 344) is formed, in front, by the frontal process of the maxilla and by the lachrymal bone ; in the middle, by the ethmoid, maxilla and inferior turbinated bones ; behind, by the vertical plate of the palate-bone, and the internal pterygoid plate of the sphenoid. This surface presents three irregular longitudinal passages, termed the superior, middle, and inferior meatuses of the nose. The *superior meatus*, the smallest of the three, occupies the middle third of the outer wall. It lies between the superior and middle turbinated processes of the ethmoid ; the *spheno-palatine* foramen opens into

Fig. 344.—Roof, floor, and outer wall of left nasal fossa.

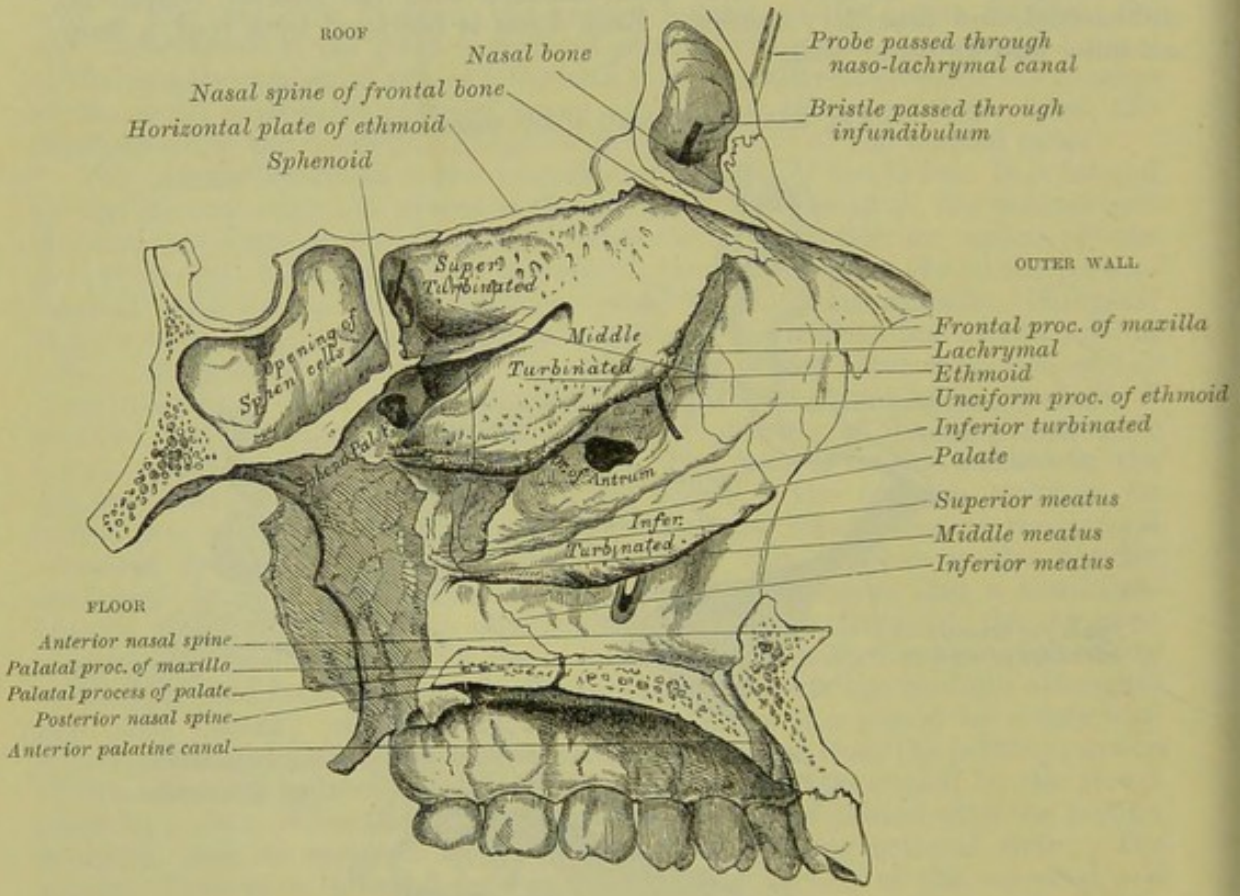

it behind, and the *posterior ethmoidal cells* in front. The sphenoidal sinus opens into a recess, the *spheno-ethmoidal recess*, which is placed above and behind the superior turbinated process. The *middle meatus* is situated between the middle turbinated process and the inferior turbinated bone, and extends from the anterior to the posterior end of the latter. It presents in front the orifice of the *infundibulum*, by which the middle meatus communicates with the frontal sinus and anterior ethmoidal cells. The infundibulum leads downwards into a curved groove, the *hiatus semilunaris*, in the posterior part of which is seen the orifice of the antrum of Highmore. In a considerable percentage of skulls the antral orifice is duplicated, the second opening being usually situated behind the hiatus. Above the hiatus semilunaris is a smooth convex surface—the *bulla ethmoidalis*—on which the middle ethmoidal cells open. The *inferior meatus*, the largest of the three, is the space between the inferior turbinated bone and the floor of the nasal fossa. It extends almost the entire length of the outer wall of the nose, is broader in front than behind, and presents anteriorly the lower *orifice of the canal for the nasal duct*.

The *anterior nasal aperture* is a heart-shaped or pyriform opening, whose long axis is vertical, and narrow extremity upwards. This opening in the recent state is much contracted by the cartilages of the nose. It is bounded above by the inferior borders of the nasal bones ; laterally by the thin, sharp margins which separate the facial from the nasal surfaces of the maxillæ ; and below by the same borders, where they slope inwards to join each other at the anterior nasal spine.

The *posterior nares* or *choanæ* are each bounded above by the under surface of the body of the sphenoid and ala of the vomer ; below, by the posterior border of the horizontal plate of the palate-bone ; externally, by the inner surface of the internal pterygoid plate ; they are separated from each other by the posterior border of the vomer.

Differences in the Skull due to Age

At birth the skull as a whole is large in proportion to the other parts of the skeleton, but its facial portion is small, and equals only about one-eighth of the bulk of the cranium as compared with one-half in the adult. The frontal and parietal eminences are prominent, and the greatest width of the skull is at the level of the latter ; on the other hand, the glabella, superciliary ridges, and mastoid processes are not developed. Ossification of the skull-bones is not completed, and many of them—e.g. the occipital, temporals, sphenoid, frontal, and mandible—consist of more than one piece. Unossified membranous intervals, termed *fontanelles*, are seen at the angles of the parietal bones ; these fontanelles are six in number : two, an anterior and a posterior, are situated in the middle line, and two, an antero-lateral and a postero-lateral, are placed on either side.

The *anterior* or *bregmatic fontanelle* (fig. 345) is the largest, and is situated at the junction of the sagittal, coronal, and interfrontal sutures ; it is lozenge-shaped, and measures about an inch and a half in its antero-posterior and an inch in its trans-

Fig. 345.—Skull at birth, showing the anterior and posterior fontanelles.

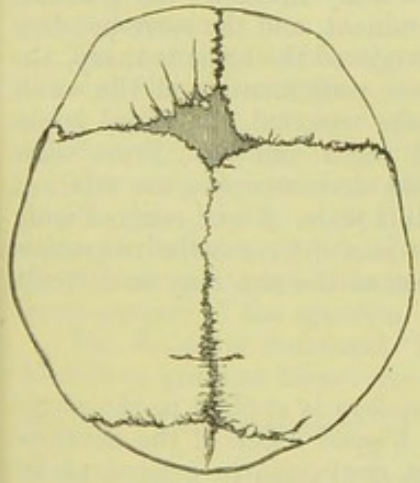

Fig. 346.—The lateral fontanelles.

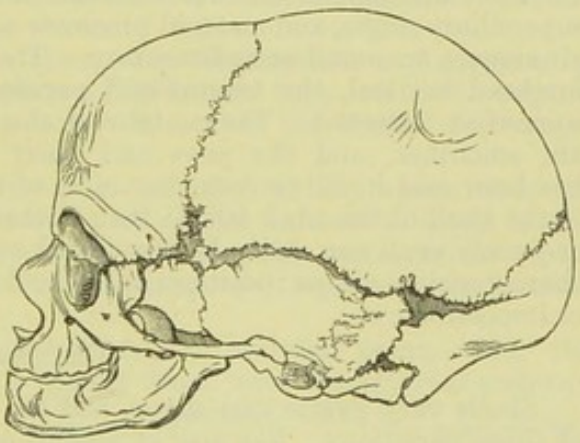

verse diameter. The *posterior fontanelle* is triangular in form and is situated at the junction of the sagittal and lambdoid sutures. The *lateral fontanelles* (fig. 346) are small, irregular in shape, and correspond respectively with the antero-inferior and postero-inferior angles of the parietal bones. An additional fontanelle is sometimes seen in the sagittal suture at the region of the obelion. The fontanelles are usually closed by the growth and extension of the bones which surround them, but sometimes they are the sites of separate ossific centres which develop into Wormian bones. The posterior and lateral fontanelles are obliterated within a month or two after birth, but the anterior is not completely closed until the first half of the second year ; sometimes it remains open beyond the second year, a condition which is usually due to malnutrition in rickets. A knowledge of the shape and position of the fontanelles is of service to the accoucheur in enabling him to determine which part of the fœtal head is presenting during parturition.

The small size of the face at birth is mainly accounted for by the rudimentary condition of the jaws, the non-eruption of the teeth, and the small size of the

maxillary air-sinuses and nasal cavities. At birth the nasal cavities lie almost entirely between the orbits, and the lower border of the anterior nasal aperture is only a little below the level of the orbital floor. With the eruption of the milk-teeth there is an enlargement of the face and jaws, and these changes are still more marked after the second dentition.

The skull grows rapidly from birth to the seventh year, by which time the foramen magnum and petrous parts of the temporals have reached their full size and the orbital cavities are only a little smaller than those of the adult. Growth is slow from the seventh year until the approach of puberty, when a second period of activity takes place: this consists of an increase in all directions, but it is especially marked in the frontal and facial regions, where it is associated with the development of the air-sinuses.

Obliteration of the sutures of the vault of the skull takes place as age advances. This process may commence between the ages of thirty and forty, and is first seen on the inner surface, and some ten years later on the outer surface of the skull. The dates given are, however, only approximate, as it is impossible to state with anything like accuracy the time at which the sutures are closed. Obliteration usually occurs first in the posterior part of the sagittal suture, next in the coronal, and then in the lambdoid.

In old age the skull generally becomes thinner and lighter, but in a small proportion of cases it increases in thickness and weight, owing to a hypertrophy of the inner table. The most striking feature of the old skull is the diminution in the size of the jaws consequent on the loss of the teeth and the absorption of the alveolar processes. This is associated with a marked reduction in the vertical measurement of the face and with an alteration in the angles of the mandible.

Sexual Differences in the Skull

Until the age of puberty there is little difference between the skull of the female and that of the male. The skull of an adult female is as a rule lighter and smaller, and its cranial capacity about 10 per cent. less, than that of the male. Its walls are thinner and its muscular ridges less strongly marked; the glabella, superciliary ridges, and mastoid processes are less prominent, and the corresponding air-sinuses are small or rudimentary. The upper margin of the orbit is sharp, the forehead vertical, the frontal and parietal eminences prominent, and the vault somewhat flattened. The contour of the face is more rounded, the facial bones are smoother, and the jaws and their contained teeth smaller. From what has been said it will be seen that more of the infantile characteristics are retained in the skull of the adult female than in that of the adult male. A well-marked male or female skull can easily be recognised as such, but in some cases the respective characteristics are so indistinct that the determination of the sex may be difficult or impossible.

Craniology

Skulls vary in size and shape, and the term *craniology* is applied to the study of these variations. The size of a skull constitutes a good index of the development of the brain which it contained, and is most conveniently arrived at by ascertaining the *capacity* of the cranial cavity. This is accomplished by filling the cavity with shot and measuring the contents in a graduated vessel. Skulls may be classified according to their capacities as follows:

1. *Microcephalic*, with a capacity of less than 1350 cubic centimetres—e.g. those of native Australians and Andaman Islanders.
2. *Mesocephalic*, with a capacity of from 1350 c.cm. to 1450 c.cm.—e.g. those of African negroes and Chinese.
3. *Megacephalic*, with a capacity of over 1450 c.cm.—e.g. those of Europeans, Japanese, and Eskimos.

In comparing the shape of one skull with that of another it is necessary to adopt some definite position in which the skull should be placed during the process of examination. It should be so placed that a line carried through the lower margin of the orbit and upper margin of the external auditory meatus is in the horizontal plane. The normæ of one skull can then be compared with those of another, and the differences in contour and surface-form noted. Further, it is necessary that the various linear measurements used to determine the shape of the

skull should be made between definite and easily localised points on its surface. The principal points have already been mentioned in the descriptions of the individual skull-bones, but are here tabulated for convenience of reference. They may be divided into two groups : (1) those in the mesial plane, and (2) those on either side of it.

The points in the mesial plane are the :

Mental point. The most prominent point of the chin.

Alveolar point or *prosthion.* The central point of the anterior margin of the upper alveolar arch.

Sub-nasal point. The middle of the lower border of the anterior nasal aperture, at the base of the nasal spine.

Nasion. The central point of the fronto-nasal suture.

Glabella. The point in the middle line at the level of the superciliary ridges.

Ophryon. The point in the middle line at the level where the temporal lines most nearly approach each other.

Bregma. The meeting point of the coronal and sagittal sutures.

Obelion. A point in the sagittal suture on a level with the parietal foramina.

Lambda. The point of junction of the sagittal and lambdoid sutures.

Occipital point. The point in the middle line of the occipital bone farthest from the glabella.

Inion. The external occipital protuberance.

Opisthion. The mid-point of the posterior margin of the foramen magnum.

Basion. The mid-point of the anterior margin of the foramen magnum.

The points on either side of the mesial plane are the :

Gonion. The outer margin of the angle of the mandible.

Dacryon. The point of union of the antero-superior angle of the lachrymal with the frontal bone and the frontal process of the maxilla.

Stephanion. The point where the temporal line intersects the coronal suture.

Pterion. The point where the greater wing of the sphenoid joins the antero-inferior angle of the parietal.

Auricular point. The centre of the orifice of the external auditory meatus.

Asterion. The point of meeting of the lambdoid, masto-occipital, and masto-parietal sutures.

The *horizontal circumference* of the cranium is measured in a plane passing through the glabella (Turner) or the ophryon (Flower) in front, and the occipital point behind ; it averages about twenty inches (50 cm.) in the female and twenty-one inches (52·5 cm.) in the male.

The *occipito-frontal* or *longitudinal arc* is measured from the nasion over the middle line of the vertex to the opisthion ; while the *basi-nasal length* is the distance between the basion and the nasion. These two measurements, plus the antero-posterior diameter of the foramen magnum, represent the *vertical circumference* of the cranium.

The *length* is measured from the glabella to the occipital point, while the *breadth* or greatest transverse diameter is usually found near the external auditory meatus. The proportion of breadth to length $\frac{(\text{breadth} \times 100)}{\text{length}}$ is termed the *cephalic index* or *index of breadth.*

The *height* is usually measured from the basion to the bregma, and the proportion of height to length $\frac{(\text{height} \times 100)}{\text{length}}$ constitutes the *vertical* or *height index.*

In studying the face the principal points to be noticed are the proportion of its length and breadth, the shape of the orbits and of the anterior nasal aperture, and the degree of projection of the jaws.

The *length of the face* may be measured from the ophryon or nasion to the chin, or, if the mandible be wanting, to the alveolar point ; while its *width* is represented by the distance between the zygomatic arches. By comparing the length with the width of the face, skulls may be divided into two groups : *dolichofacial* or *leptoprosope* (long-faced) and *brachyfacial* or *chæmoprosope* (short-faced).

The *orbital index* signifies the proportion which the orbital height bears to the orbital width, thus :

$$\frac{\text{orbital height} \times 100}{\text{orbital width}}.$$

The *nasal index* expresses the proportion which the width of the anterior nasal aperture bears to the height of the nose, the latter being measured from the nasion to the lower margin of the nasal aperture, thus :

$$\frac{\text{nasal width} \times 100}{\text{nasal height}}.$$

The degree of projection of the jaws is determined by the *gnathic* or *alveolar index*, which represents the proportion between the basi-alveolar and basi-nasal lengths, thus :

$$\frac{\text{basi-alveolar length} \times 100}{\text{basi-nasal length}}.$$

The following table, modified from that given by Duckworth,* illustrates how these different indices may be utilised in the classification of skulls :

Index	Classification	Nomenclature	Examples
1. Cephalic . .	Below 75 . . .	Dolichocephalic .	Kaffirs and Native Australians
	Between 75 and 80	Mesaticephalic .	Europeans and Chinese
	Above 80 . . .	Brachycephalic .	Mongolians and Andamans
2. Orbital . .	Below 84 . . .	Microseme . .	Tasmanians and Native Australians
	Between 84 and 89	Mesoseme . . .	Europeans
	Above 89 . . .	Megaseme. . .	Chinese and Polynesians
3. Nasal . . .	Below 48 . . .	Leptorhine . .	Europeans
	Between 48 and 53	Mesorhine. . .	Japanese and Chinese
	Above 53 . . .	Platyrhine . .	Negroes and Native Australians
4. Gnathic . .	Below 98 . . .	Orthognathous .	Europeans
	Between 98 and 103	Mesognathous .	Chinese and Japanese
	Above 103 . . .	Prognathous . .	Native Australians

Surface Form.—The various bony prominences or landmarks which are easily felt and recognised in the head and face, and which afford the means of mapping out the important structures comprised in this region, are as follows :

1. Supra-orbital arch
2. Internal angular process.
3. External angular process.
4. Zygomatic arch.
5. Mastoid process.
6. External occipital protuberance.
7. Superior curved line of occipital bone.
8. Parietal eminence.
9. Temporal ridge.
10. Frontal eminence.
11. Superciliary ridge.
12. Nasal bone.
13. Lower margin of orbit.
14. Mandible.

1. The *supra-orbital arch* can be felt throughout its entire extent, covered by the eyebrow. It forms the upper boundary of the circumference of the orbit and separates the face from the forehead. It terminates internally at the root of the nose, in the *internal angular process* which articulates with the lachrymal bone and frontal process of the maxilla, and externally in the *external angular process* which articulates with the malar bone. At the junction of the inner and middle thirds of the arch, a slight interruption in the outline may sometimes be felt ; this is the *supra-orbital notch*. When the notch

* *Morphology and Anthropology*, by W. L. H. Duckworth, M.A., Cambridge University Press.

is converted into a foramen, the interruption does not exist. A line carried from this notch or foramen downwards over the face, to the second bicuspid tooth of the mandible, passes over the infra-orbital and the mental foramina, and thus constitutes a guide to the points of exit of the three largest cutaneous branches of the fifth cranial nerve. In the less civilised races, as the forehead recedes backwards, the supra-orbital arch becomes more prominent and approaches more to the condition seen in the monkey tribe, in which the supra-orbital arches are very largely developed and acquire additional prominence from the oblique direction of the frontal bone. 2. The *internal angular process* can scarcely be felt. Its position is indicated by the angle formed by the supra-orbital arch with the frontal process of the maxilla and the lachrymal bone at the inner side of the orbit. Between the internal angular processes is a broad surface, which assists in forming the root of the nose, and immediately above this an expanded, smooth, somewhat triangular area, the *glabella*, situated between and connecting the superciliary ridges. 3. The *external angular process* is much more strongly marked than the internal, and can be plainly felt. It is formed by the junction of the supra-orbital and temporal ridges, and, articulating with the malar bone, it serves to a very considerable extent to support the bones of the face. In carnivorous animals the external angular process dŏes not articulate with the malar, and therefore this lateral support to the bones of the face is not present. 4. The *zygomatic arch* can be felt throughout its entire length, and is formed by the malar bone and the zygomatic process of the temporal bone. Its anterior part is broad, and constitutes the prominence of the cheek ; its posterior part is narrow, and terminates just in front and a little above the tragus of the external ear. Its upper border may be traced backwards, as the posterior root, above the tragus and the external auditory meatus to join the posterior part of the lower temporal ridge, forming the *supramastoid crest*. A spot in this line, immediately in front of the upper border of the tragus and between it and the condyle of the mandible, is known as the *pre-auricular point*. This is an important landmark, since the temporal vessels and the auriculo-temporal nerve cross it, and two inches vertically above it is the lower end of the fissure of Rolando. The lower border of the zygomatic arch is more plainly to be felt than the upper, in consequence of the dense temporal fascia being attached to the latter, which somewhat obscures its outline. 5. Behind the ear the *mastoid portion of the temporal bone* can be plainly felt, terminating below in a nipple-shaped process. Its anterior border lies immediately behind the concha, and its apex is about on a level with the lobule of the ear. It is rudimentary in infancy, but gradually develops in childhood. 6. The *external occipital protuberance* (*inion*) can be felt at the level where the skin of the neck joins that of the head. At this point the skull is thick for the purposes of safety, while radiating from it are numerous curved arches or buttresses of bone which give to this portion of the skull further security. 7. Running outwards on either side from the external occipital protuberance is an arched ridge of bone, the *superior curved line*, which gives attachment to some of the muscles which keep the head erect on the vertebral column. Below this line the surface of bone is obscured by the overlying muscles, except in the middle, where the external occipital crest can generally be felt at the bottom of the nuchal furrow. Above it, the vault of the cranium is thinly covered with soft structures, so that the form of this part of the head is almost exactly that of the upper portion of the occipital, the parietal, and the frontal bones themselves ; in bald persons, even the lines of junction of the bones (especially that of the occipital and parietals at the lambdoid suture) may be defined as slight depressions, caused by the thickening of the borders of the bones. 8. Near the line of the greatest transverse diameter of the head are the *parietal eminences*, one on either side of the middle line ; they denote the points where ossification of the parietal bones began. The parietal eminence is particularly exposed to injury from blows or falls on the head, but fracture is to a certain extent prevented by the shape of the bone, which forms a dome, so that the force of the blow is diffused over the bone in every direction. 9. At the side of the head is the *temporal ridge*. Commencing at the external angular process, it may be felt as a curved ridge, passing upwards on the frontal bone, and then curving backwards, separating the forehead from the temporal fossa. It may then be traced, in a curved direction, over the parietal bone, where, though less marked, it can generally be recognised. Finally, the ridge curves downwards and forwards, and terminates in the posterior root of the zygoma. 10. The *frontal eminences* vary in prominence in different individuals, and are frequently unsymmetrical. Their prominence depends more upon the general shape of the bone than upon the size of the eminences themselves. As the skull is more highly developed in consequence of increased intellectual capacity, so the frontal bone becomes more upright, and the frontal eminences stand out in bolder relief. Thus they may be considered as affording, to a certain extent, an indication of the development of the frontal lobes of the brain, and of the mental powers of the individual. 11. Below the frontal eminences are the *superciliary ridges*, which denote the position of the frontal sinuses, and vary in different individuals, being, as a rule, small in the female, absent in children, and sometimes unusually prominent in the male, when the frontal sinuses are largely developed. The degree of prominence of the superciliary ridges is not, however, necessarily dependent on the size of the frontal sinuses, for large sinuses may be present in cases where there is but little elevation of the ridges,

and, on the other hand, strongly marked ridges may be associated with small air-sinuses. They commence on either side of the glabella, and here present a rounded form, which gradually fades away at their outer ends. 12. The *nasal bones* form the prominence of the nose. They vary much in size and shape, and to them is due the varieties in the contour of this organ and much of the character of the face. 13. The *lower margin of the orbit*, formed by the maxilla and malar bone, can be felt throughout its entire length. It is continuous internally with the frontal process of the maxilla, and at their point of junction is a little tubercle, which serves as a guide to the position of the lachrymal sac, which is situated above and behind it. 14. The outline of the *mandible* can be felt throughout its entire length. Just in front of the tragus of the external ear, and below the zygomatic arch, the condyle can be made out. When the mouth is opened, this prominence of bone advances out of the glenoid fossa on to the eminentia articularis, and recedes when the mouth is closed. From the condyle the posterior border of the ramus can be followed down to the angle, and from the angle to the symphysis menti the lower rounded border of the body of the bone is plainly to be felt. At the point of junction of the two halves of the bone is a well-marked triangular eminence, the *mental process*, which forms the prominence of the chin.

Applied Anatomy.—Occasionally a protrusion of the brain or its membranes may take place through one of the sutures, owing to non-closure. When the protrusion consists of membranes only, and is filled with cerebro-spinal fluid, it is called a *meningocele* ; when it consists of brain as well as membranes, it is termed an *encephalocele.* These malformations are usually found in the middle line, and most frequently at the back of the head, the protrusion taking place between the centres of ossification of the tabular portion of the occipital bone (see page 217). They generally occur through the upper part of the vertical fissure, which is the last to ossify, but not uncommonly through the lower part, when the foramen magnum may be incomplete. More rarely these protrusions are met with in other situations, as in the sagittal, lambdoid, and other sutures, or through abnormal gaps and deficiencies at the sides or base of the skull.

The chief function of the skull is to protect the brain from any form of violence to which it may be subjected. We find, therefore, that those portions of the skull which are most exposed to external violence are thicker than those which are shielded from injury by overlying muscles. Thus, the skull-cap is thick and dense, whereas the squamous portion of the temporal bone, being protected by the Temporal muscle, and the inferior occipital fossæ, being shielded by the muscles at the back of the neck, are thin and fragile. Fracture of the skull is further prevented by its elasticity, its rounded shape, and its construction of a number of secondary elastic arches, each made up of a single bone. The manner in which vibrations are transmitted through the bones of the skull is also of importance as regards its protective mechanism, at all events as far as the base is concerned. In the vault, the bones being of a fairly equal thickness and density, vibrations are transmitted in a uniform manner in all directions, but in the base, owing to the varying thickness and density of the bones, this is not so ; and therefore in this situation there are special buttresses which serve to carry the vibrations in certain definite directions. At the front of the skull, on either side, is the ridge which separates the anterior from the middle fossa of the base ; and behind, the ridge or buttress which separates the middle from the posterior fossa ; and if any violence is applied to the vault, the vibrations would be carried along these buttresses to the sella turcica, where they meet. This part has been termed the 'centre of resistance,' and here there is a special protective mechanism to guard the brain. The subarachnoid space is dilated, and the increased quantity of cerebro-spinal fluid acts as a water-cushion to shield the brain from injury. In like manner, when violence is applied to the base of the skull, as in falls upon the feet, the vibrations are carried backwards through the occipital crest, and forwards through the basilar process and body of the sphenoid to the vault of the skull.

Fractures of the skull are best considered as affecting either the vault or the base. Fractures of the vault may, and generally do, involve the whole thickness of the bone ; but sometimes the inner table only may be fractured, and portions of it driven inwards. As a rule, in fractures of the skull, the inner table is more splintered and comminuted than the outer, and this is due to several causes. It is thinner and more brittle ; the force of the violence as it passes inwards becomes broken up, and is more diffused by the time it reaches the inner table ; the bone being in the form of an arch bends as a whole and spreads out, and thus presses the particles together on the convex surface of the arch, i.e. the outer table, and forces them asunder on the concave surface or inner table ; and, lastly, there is nothing firm under the inner table to support it and oppose the force. Fractures of the vault may be simple fissures, or may be starred and comminuted, and the fragments may be depressed or elevated. Cases of fracture with elevation of the fractured portion are uncommon, and can only be produced by direct wound. In comminuted fracture, a portion of the skull is broken into several pieces, the lines of fracture radiating from a centre where the chief impact of the blow was felt ; if the fracture is also depressed, a fissure circumscribes the radiating lines, enclosing a portion of the skull. If this area is circular it is termed a 'pond' fracture, and would in all probability have been caused by a round instrument, as a life preserver or hammer ; if

elliptical in shape it is termed a 'gutter' fracture, and would owe its shape to the instrument which had produced it, as a poker. Fracture of the outer table alone only occurs in the region of the frontal sinuses where the two tables are completely separated.

Fractures of the base of the skull may be produced by *indirect* or *direct* violence. I. In cases of the former class the violence is applied to the vertex or some part of the cranial convexity, as when a person falls from a height on to his head and a fracture of the base results. The mechanism of this form of fracture was formerly explained by the doctrine of *contre-coup*, i.e. that the force was transmitted from one side of the skull to the other; but this idea is now completely exploded, and there are at the present day two theories as to mode of causation of these fractures. (*a*) According to Aran's theory of *irradiation* all fractures of the base are produced by a fissure, which starts from the point of injury and radiates to the base. There can be little doubt that many cases of fracture of the base, especially of the middle fossæ, are caused in this way, but it is insufficient to explain all, since instances have been met with of fracture of the base of the skull in which there has been no fracture of the vault. (*b*) To explain these cases, another theory, known as the *compression* or *bursting* theory, has been suggested. If a hollow, elastic sphere is compressed from above downwards, it will bulge laterally, and, if the compression is sufficient, it will eventually burst in the situation where it bulges. Now, the skull is an elastic sphere, and when compression is applied to it, its diameter will be reduced along the line of greatest pressure and will therefore be increased in other directions, and may increase to such an extent that bursting occurs. In a hollow elastic sphere of uniform thickness, the bulging and subsequent bursting take place at the equatorial line midway between the two points of compression; but the skull is not of uniform thickness, and therefore the bulging and subsequent bursting take place at the weakest part.

II. Direct violence applied to the base of the skull may cause fracture in several different ways: by the impact of the vertebral column against the condyles of the occipital bone, in falls on the buttocks or feet; by the condyle of the lower jaw being driven against the glenoid fossa, in blows or falls on the chin; by the thrusting of a pointed instrument through the orbit or nose; by gunshot wounds through the mouth; and by a fall or a stab on the back of the head.

In the majority of cases of fracture of the base, the fracture is compound. In the anterior fossa, if the fissure extend across the cribriform plate, the nasal mucous membrane is usually torn and the fracture rendered compound into the nose. In the middle fossa, the fracture usually opens up the tympanic cavity, and if the membrana tympani be torn, the fracture is compound, *via* the external auditory meatus. Continued bleeding from the nose or ear is one of the most constant symptoms in these cases.

The most common place for fracture of the base to occur is through the middle fossa, and here the fissure usually takes a fairly definite course. Starting from the point struck, which is generally somewhere in the neighbourhood of the parietal eminence, it runs downwards through the parietal and the squamous portion of the temporal and across the petrous portion of this bone, frequently traversing and implicating the internal auditory meatus, to the middle lacerated foramen. From this it may pass across the body of the sphenoid, through the pituitary fossa, to the foramen lacerum medium of the other side, and may indeed travel round the whole cranium, so as to completely separate the anterior from the posterior part. The course of the fracture should be borne in mind, as it explains the symptoms to which fracture in this region may give rise: thus, if the fissure pass across the internal auditory meatus, injury to the facial and auditory nerves may result, with consequent facial paralysis and deafness; or the tubular prolongation of the arachnoid around these nerves in the meatus may be torn and thus permit of the escape of the cerebro-spinal fluid should there be a communication between the internal ear and the tympanum together with rupture of the membrana tympani, as is frequently the case: again, if the fissure pass across the pituitary fossa and the muco-periosteum covering the under surface of the body of the sphenoid is torn, blood will find its way into the pharynx and be swallowed, and after a time vomiting of blood will result. Fractures of the anterior fossa, involving the bones forming the roof of the orbit and nasal fossa, are generally the result of blows on the forehead; but fracture of the cribriform plate of the ethmoid may be a complication of fracture of the nasal bone. When the fracture implicates the roof of the orbit, the blood finds its way into this cavity, and, travelling forwards, appears as a subconjunctival ecchymosis. If the roof of the nasal fossa be fractured, the blood escapes from the nose. In rare cases there may be also escape of cerebro-spinal fluid from the nose, should the dura mater and arachnoid have been torn. In fractures of the posterior fossa, extravasation of blood may appear at the nape of the neck, beneath the muscles attached to the superior curved line of the occipital bone.

Diseases of the Skull.—An inflammatory condition affecting the bones and the pericranium together is generally caused by septic infection either of a scalp wound, exposing and bruising the bone, or of a compound fracture, and is termed *septic osteomyelitis*. Occasionally it may occur independently of injury, and then follows the same course, and is due to the same causes, as acute infective osteomyelitis in the long bones.

The most common chronic disease of the skull is due to syphilis. In *acquired syphilis* the disease usually occurs as *nodes*, which arise most commonly in the pericranium, but may also arise in the diploë, or more rarely on the inner surface of the skull. The formation of *gummata* under the periosteum generally leads to *caries*, which may be either limited if the gumma is localised, or widespread if the gumma is diffuse. The caries is often complicated by *necrosis*, for a condition of sclerosis is frequently set up in the surrounding bone, and the vessels in the Haversian canals become compressed and the vitality of the bone is interfered with ; hence we often find a central necrosing area surrounded by a zone of caries. Large carious sequestra may be thrown off after prolonged suppuration, leaving considerable areas of the dura mater exposed. A common result of syphilitic disease of the skull is the production of large hard masses of bones on its surface, which give it a tuberculated appearance ; in other cases, the skull presents a curious worm-eaten appearance ; this is due to the fact that the osteogenetic powers of the pericranium are small and the formation of bone on the surface slight. In *hereditary syphilis*, in addition to the formation of gummata, which are usually of the subperiosteal variety, atrophic or hypertrophic changes may take place. In the atrophic cases the bone becomes abnormally thin, or even perforated, generally where there is pressure, as from the pillow or nurse's arm. Hence they are usually met with in the parietal bones or vertical plate of the occiput. This condition is known as craniotabes, and may also occur as a consequence of rickets ; it gives rise to a peculiar sensation known as that of 'egg-shell crackling' when the affected bones, reduced to a membranous or parchment-like consistency, are palpated. In the hypertrophic cases, a deposit of porous bone takes place around the anterior fontanelle in the parietal and frontal bones ; these deposits are separated by the coronal and sagittal sutures, and give to the skull an appearance like a 'hot cross bun.' They are known as *Parrot's nodes*, and such a skull has received the name of the 'hot cross bun' skull.

The most common tumours of the skull are the osteomata and the sarcomata. The osteoma is generally the ivory exostosis, though cases of spongy exostosis do occur. Sarcomata of the skull may arise either from the pericranium or the diploë, but it is usually impossible to distinguish clinically between the two. Carcinoma, if it occurs in the skull, is always secondary to cancer in some other part of the body.

Hypertrophic changes occur in the skull in ostitis deformans, acromegaly, leontiasis ossea, and in rickets. In these latter cases the skull becomes enlarged from the formation of periosteal outgrowths of soft pumice-like osteoid tissue on the outer side of the skull. These deposits are very rich in blood-vessels, and occur between the ridges of the cranial bones and their centres of ossification, and are symmetrically arranged—often about the anterior fontanelle. The anterior fontanelle itself, instead of closing between the 18th and 24th months, as it normally does, remains patent in rickets until the third or even the sixth year. The general shape of the skull alters. The forehead is high and square, with prominent frontal eminences, and the head tends to be cubical or box-shaped, whereas in hydrocephalus it is rather globular ; the enlargement of the head in rickets appears to be greater than it really is because the development of the facial bones is retarded. The base of the nose may appear sunken, from retarded development of the basis cranii. In marked cases of rickets these changes in the shape of the skull are permanent. In congenital hydrocephalus, or enlargement of the head due to the presence of excess of fluid in the ventricles of the brain, the cranium becomes globular, and its bones are thin and atrophic. Often they are widely separated, the intervening fontanelles being much enlarged and partially filled in by numerous Wormian bones ; the atrophy of the cranium and brain may be so extreme that the light of a candle may be plainly visible through the whole thickness of the enlarged head.

The head may be abnormally small (microcephalus) with premature ossification of its sutures, a condition usually associated with idiocy. Linear craniotomy, or the excision of a strip of bone on either side of the median line, has been proposed as an operation likely to improve the patient's mental development by allowing room for the growth and expansion of the brain. Unfortunately in these cases the brain always shows imperfect or prematurely arrested development, so that the operation is foredoomed to failure ; in addition, premature ossification of the sutures is not invariably present in microcephalus.

The mastoid antrum, situated in the mastoid portion of the temporal bone, is sometimes the seat of suppuration as a result of infection extending backwards from the tympanic cavity. In such cases, the surgeon has to open the antrum in order to give exit to the pus. This he does by introducing his gouge in the suprameatal triangle (see page 224). A line is drawn horizontally through the upper border of the bony external auditory meatus, and a second vertically through the posterior wall of the meatus, and the gouge is applied in the angle where these two lines intersect each other ; if the instrument be introduced at a higher level it will open the cavity of the skull. It is to be carried in the direction of the external auditory canal—inwards, forwards, and a little upwards—for the distance of from 1 to 1½ cm., when the antrum will be reached. In some cases of middle-ear trouble, septic thrombosis of the lateral sinus takes place, and it becomes necessary to trephine and explore the sinus.

In connection with the bones of the face a common malformation is *cleft palate*. The cleft usually starts posteriorly, and in its most elementary form may consist simply of a bifid uvula; or the cleft may extend through the soft palate; or the posterior part or the whole of the hard palate may be involved, the cleft extending as far forwards as the anterior palatine canal. In the severest forms, the cleft extends through the alveolus and passes between the premaxillary bone and the rest of the upper jaw; that is to say, between the lateral incisor and canine teeth. In some instances, the cleft has been noticed to pass outwards between the central and lateral incisor teeth; and this has induced some anatomists to believe that the premaxillary bone is developed from two centres (fig. 347) and not from one, as was stated in the description of the bone. The mesial segment, bearing a central incisor, is called an *endognathion*; the lateral segment, bearing the lateral incisor, is called a *mesognathion*; and the rest of the maxilla is termed the *exognathion*. The cleft may affect one or both sides; if the latter, the central part is frequently displaced forwards and remains united to the septum of the nose, the deficiency in the alveolus being complicated with a cleft in the lip (hare-lip). On examining a cleft palate in which the alveolus is not implicated, the cleft will generally appear to be in the mesial line, but occasionally is unilateral and in some cases bilateral. To understand this it must be borne in mind that three processes are concerned in the formation of the palate—the two palatal processes of the maxillæ, which grow in horizontally and unite in the middle line; and the ethmo-vomerine process, which grows downwards from the base of the skull and fronto-nasal process to unite with the palatal process in the mesial line. In those cases where the palatal processes fail to unite with each other and with the mesial process, the cleft of the palate is median; where one palatal process unites with the mesial septum, the other failing to do so, the cleft in the palate is unilateral. The right process is the one which usually joins, and the cleft is therefore on the left side. In some cases where the palatal processes fail to meet in the middle, the ethmo-vomerine process grows downwards into the cleft and thus produces a bilateral cleft. Occasionally there may be a hole in the middle line of the hard palate, the anterior part of the hard and the soft palate being perfect, but this is rare, because, as a rule, the union of the various processes progresses from before backwards, and therefore the posterior part of the palate is more frequently defective than the anterior.

Fig. 347.—The premaxilla and its sutures (after Albrecht)

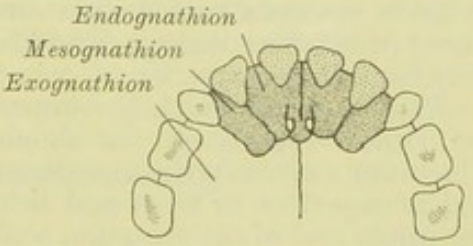

The bones of the face are sometimes fractured as the result of direct violence. The two most commonly broken are the nasal bone and the mandible, and of these, the latter is by far the most frequently fractured of all the bones of the face. Fracture of the *nasal* bone is for the most part transverse, and takes place about half an inch from the free margin. The broken portion may be displaced backwards or more generally to one side by the force which produced the lesion, as there are no muscles here which can cause displacement. The *malar* bone is probably never broken alone—that is to say, without fracture of some of the other bones of the face. The *zygomatic arch* is occasionally fractured, and when this occurs from direct violence, as is usually the case, the fragments may be displaced inwards. Fractures of the *maxilla* may vary much in degree, from the chipping off of a portion of the alveolar arch, to an extensive comminution of the whole bone from severe violence, as the kick of a horse. The most common situation for a fracture of the *mandible* is in the neighbourhood of the canine tooth, as at this spot the bone is weakened by the deep socket for the fang of this tooth; it is next most frequently fractured at the angle; then at the symphysis; and finally the neck of the condyle or the coronoid process may be broken. Occasionally a double fracture may occur, one in either half of the bone. The fractures are usually compound, from laceration of the mucous membrane covering the gums. The displacement is mainly the result of the same violence as produced the injury, but may be further increased by the action of the muscles passing from the neighbourhood of the symphysis to the hyoid bone.

The maxilla and the mandible are frequently the seat of necrosis; but the disease more often affects the lower than the upper jaw. It may be the result of periostitis from tooth irritation, injury, or the action of some specific poison, as syphilis, or from salivation by mercury; it sometimes occurs in children after attacks of the exanthematous fevers, and a special form occurs from the action of the fumes of phosphorus in persons engaged in the manufacture of matches. In the vast majority of cases, however, it is of dental origin.

Tumours originate in the jaw-bones not infrequently, and may be either innocent or malignant. In the maxilla cysts may occur in the antrum; or in either jaw in connection with the teeth; those connected with the roots of fully developed teeth are known as dental cysts; those connected with unerupted teeth, dentigerous cysts. Malignant tumours show a marked degree of malignancy when occurring in the maxilla.

The maxilla sometimes requires removal for tumours or other conditions. In order to remove it, the patient should be placed in the recumbent position, in a good light, with

the head and shoulders just raised. The central incisor tooth on the affected side is then extracted. One incision is begun just below the inner canthus of the eye and passes along the side of the nose, round the ala, and down the middle line of the upper lip into the mouth. A second incision is made from the commencement of the first, along the lower border of the orbit as far as the prominence of the malar bone. The flap thus formed is reflected outwards, so as to expose the bone. The periosteum attached along the lower margin of the orbit is now to be incised, and with the handle of the scalpel the periosteum covering the floor of the orbit is to be raised from the bone ; for in all cases it is essential that this fibrous layer should not be removed. The mouth is now widely opened with a gag, and the mucous membrane covering the hard palate incised down to the bone in the middle line, and the soft palate separated from the hard. The surgeon now proceeds to divide the connections of the bone with the other bones of the face, having first separated the ala of the nose from its bony attachment. They are (1) the junction with the malar bone, the line of section being carried into the spheno-maxillary fissure ; (2) the frontal process of the maxilla ; a small portion of its upper extremity, connected with the nasal bone in front, the lachrymal bone behind, and the frontal bone above, being left ; (3) the connection with opposite maxilla and with the palate bone in the roof of the mouth. The bone is now firmly grasped with lion-forceps ; and by means of a rocking movement upwards and downwards, the remaining attachments of the orbital plate with the ethmoid, and of the back of the bone with the palate, are broken through. Occasionally, in removing the upper jaw, it will be found that the orbital plate can be saved, and this should always be done if possible. A horizontal saw-cut is to be made just below the infra-orbital foramen, and the bone cut through in this situation.

THE EXTREMITIES

The extremities, or limbs, are long, jointed appendages of the body, each of which is connected to the trunk by one end, and is free in the rest of its extent. They are *four* in number : an *upper* or *thoracic pair*, connected with the thorax and subservient mainly to prehension ; and a *lower pair*, connected with the vertebral column, intended for support and locomotion. Both pairs of limbs are constructed after one common type, but certain differences are observed between the upper and lower pairs, dependent on the peculiar offices they have to perform.

The bones by which the upper and lower limbs are attached to the trunk are named respectively the shoulder and pelvic girdles. The *shoulder girdle* (cingulum extremitatis superioris) is formed by the scapulæ and clavicles, and is imperfect in front and behind. In front, however, it is completed by the upper end of the sternum, with which the inner extremities of the clavicles articulate. Behind, it is widely imperfect, the scapulæ being connected to the trunk by muscles only. The *pelvic girdle* (cingulum extremitatis inferioris) is formed by the innominate bones, which articulate with each other in front, at the symphysis pubis. It is imperfect behind, but the gap is filled in by the upper part of the sacrum. The pelvic girdle therefore presents, with the sacrum, a complete ring, massive and comparatively rigid, in marked contrast to the lightness and mobility of the shoulder girdle.

BONES OF THE UPPER EXTREMITY

The Clavicle

The **Clavicle** (clavicula), or collar-bone (figs. 348 and 349), forms the anterior portion of the shoulder girdle. It is a long bone, curved somewhat like the italic letter *f*, and placed nearly horizontally at the upper and anterior part of the thorax, immediately above the first rib. It articulates by its inner extremity with the upper end of the sternum, and by its outer with the acromion process of the scapula.* It presents a double curvature, the convexity being directed forwards at the sternal end, and the concavity at the scapular end. Its outer third is flattened from above downwards, whilst its

* The clavicle acts especially as a fulcrum to enable the muscles to give lateral motion to the arm. It is accordingly absent in those animals whose fore-limbs are used only for progression, but is present for the most part in animals whose anterior extremities are clawed and used for prehension, though in some of them—as, for instance, in a large number of the carnivora—it is merely a rudimentary bone suspended among the muscles, and not articulating with either the scapula or sternum.

inner portion, consisting of the inner two-thirds, is of a rounded or prismatic form.

The **outer third** presents two surfaces, an upper and a lower; and two borders, an anterior and a posterior. The *upper surface* is flat, rough, and marked by impressions for the attachments of the Deltoid in front, and the Trapezius behind; between these two impressions a small portion of the bone is subcutaneous. The *under surface* is flat. At its posterior border, a little external to the point where the prismatic joins with the flattened portion, is a rough eminence, the *conoid tubercle*; this, in the natural position of the bone,

FIG. 348.—Left clavicle. Superior surface.

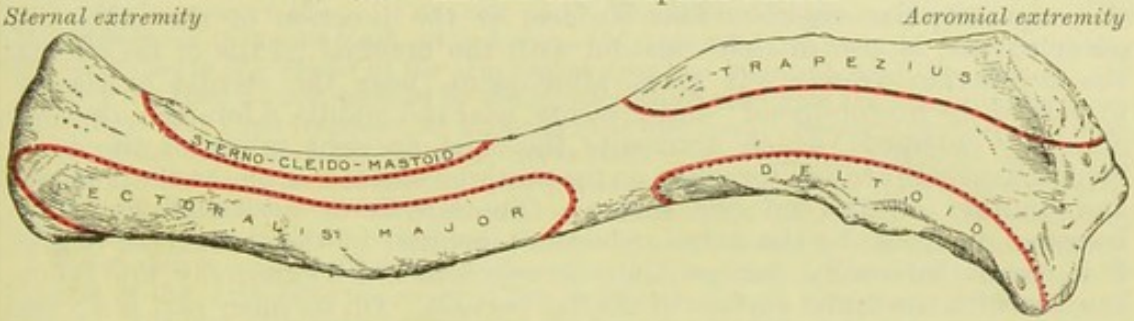

surmounts the coracoid process of the scapula, and gives attachment to the conoid ligament. From this tubercle an oblique ridge, the *oblique* or *trapezoid ridge*, passes forwards and outwards, and affords attachment to the trapezoid ligament. The *anterior border* is concave, thin, and rough, and gives attachment to the Deltoid; it frequently presents, at its inner part, a tubercle, the *deltoid tubercle*. The *posterior border* is convex, rough, thicker than the anterior, and gives attachment to the Trapezius.

The **inner two-thirds** constitute the prismatic portion of the bone, which is curved so as to be convex in front, concave behind, and is marked by three borders, separating three surfaces. The *anterior border* is continuous with the anterior margin of the flat portion. Its outer portion is smooth, and

FIG. 349.—Left clavicle. Inferior surface.

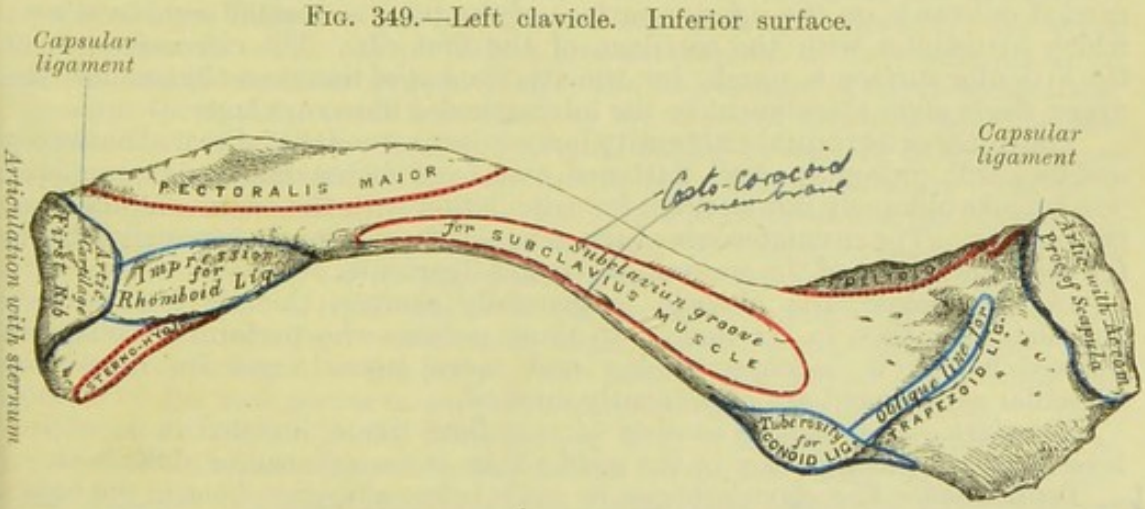

corresponds to the interval between the attachment of the Pectoralis major and Deltoid; its inner part forms the lower boundary of an elliptical space for the attachment of the clavicular portion of the Pectoralis major, and approaches the posterior border of the bone. The *superior border* is continuous with the posterior margin of the flat portion, and separates the anterior from the posterior surface. Smooth and rounded externally, it becomes rough towards the inner third for the attachment of the Sterno-mastoid, and terminates at the upper angle of the sternal extremity. The *posterior* or *subclavian border* separates the posterior from the inferior surface, and extends from the conoid tubercle to the rhomboid impression; it forms the posterior boundary of the groove for the Subclavius muscle, and gives attachment to a layer of cervical fascia which envelops the Omo-hyoid.

The *anterior surface* is included between the superior and anterior borders. Its outer part looks upwards, and is continuous with the superior surface of the flattened portion; it is smooth, convex, and nearly subcutaneous, being covered only by the Platysma. Its inner portion is divided by a narrow subcutaneous area into two parts: a lower, elliptical in form, and directed forwards, for the attachment of the Pectoralis major; and an upper, for the attachment of the Sterno-cleido-mastoid. The *posterior* or *cervical surface* is smooth, and looks backwards towards the root of the neck. It is limited, above, by the superior border; below, by the subclavian border; internally, by the margin of the sternal extremity; and externally, by the conoid tubercle. It is concave from within outwards, and is in relation, by its lower part, with the suprascapular vessels. This surface, at the junction of the inner and outer curves, is also in close relation with the brachial plexus of nerves and the subclavian vessels. It gives attachment, near the sternal extremity, to part of the Sterno-hyoid; and presents, near the middle, a foramen, directed obliquely outwards, which transmits the chief nutrient artery of the bone. Sometimes there are two foramina on the posterior surface, or one on the posterior and another on the inferior surface. The *inferior* or *subclavian surface* is bounded, in front, by the anterior border; behind, by the subclavian border. It is narrow internally, but gradually increases in width externally, and is continuous with the under surface of the flat portion. On its inner part is a broad rough surface, the *rhomboid impression* (tuberositas costalis), rather more than an inch in length, for the attachment of the costo-clavicular or rhomboid ligament. The rest of this surface is occupied by a groove, broad and smooth externally, narrow and more uneven internally, which gives attachment to the Subclavius; the costo-coracoid membrane, which splits to enclose the muscle, is attached to the margins of the groove. Not infrequently this groove is subdivided longitudinally by a line which gives attachment to the intermuscular septum of the Subclavius.

The **inner** or **sternal extremity** (extremitas sternalis) of the clavicle is triangular in form, directed inwards, and a little downwards and forwards; it presents an articular facet, concave from before backwards, convex from above downwards, which articulates with the manubrium sterni through the intervention of an interarticular fibro-cartilage. The lower part of the facet is carried outwards on the inferior surface of the bone as a small semi-oval area which articulates with the cartilage of the first rib. The circumference of the articular surface is rough, for the attachment of numerous ligaments; the upper angle gives attachment to the interarticular fibro-cartilage.

The **outer** or **acromial extremity** (extremitas acromialis), directed outwards and forwards, presents a small, flattened, oval facet (facies articularis acromialis) which looks obliquely downwards, for articulation with the acromion process of the scapula. The circumference of the articular facet is rough, especially above, for the attachment of the acromio-clavicular ligaments.

In the female, the clavicle is generally shorter, thinner, less curved, and smoother than in the male. In those persons who perform considerable manual labour it becomes thicker and more curved, and its ridges for muscular attachment are prominently marked.

Structure.—The clavicle consists of cancellous tissue, invested in a compact layer, which is much thicker in the middle than at the extremities of the bone.

Ossification.—The clavicle begins to ossify before any other bone in the body; it is ossified from two centres—viz. a primary centre for the shaft and outer end, which appears during the fifth or sixth week of fœtal life, and a secondary centre for the sternal end, which makes its appearance about the eighteenth or twentieth year, and unites with the rest of the bone about the twenty-fifth year.

Surface Form.—The clavicle can be felt throughout its entire length. At the inner end, the enlarged sternal extremity, where the bone projects above the upper margin of the sternum, can be felt, forming with the sternum and the rounded tendon of the Sterno-mastoid a V-shaped notch, the *presternal notch*. Passing outwards, the shaft of the bone can be defined immediately under the skin, with its convexity forwards in the inner two-thirds; the surface is partially obscured above and below by the attachments of the Sterno-mastoid and Pectoralis major. In the outer third it is concave forwards, and terminates externally in a somewhat enlarged extremity which articulates with the acromion process of the scapula. The direction of the clavicle is almost, if not quite, horizontal when the

arm is lying quietly by the side, though in well-developed subjects it may incline a little upwards at its outer end. Its direction, however, varies with the varying movements of the shoulder-joint. The clavicle inclines backwards, so that its outer or acromial extremity is on a plane posterior to its sternal end. This causes the shoulder to be thrown backwards away from the thorax.

Applied Anatomy.—The clavicle is very frequently fractured. This is due to the fact that it is much exposed to violence, and is the only bony connection between the upper limb and the trunk, acting as a buttress to keep the point of the shoulder away from the thorax. It is, moreover, slender, and is very superficial. It may be broken by direct or indirect violence. The most common cause is, however, indirect violence, as the result of force applied to the hand or shoulder, and the bone then gives way at the junction of its outer with its inner two-thirds, that is to say, at the junction of the two curves, for this is its weakest part. The fracture is generally oblique, and the displacement of the outer fragment is downwards, forwards, and inwards. The deformity is mainly due to the weight of the arm acting upon the fragment when the buttress-like action of the bone is gone, assisted by the muscles which pass from the thorax to the upper extremity. The inner fragment, as a rule, is little displaced. Beneath the bone the main vessels of the upper limb and the great nerve-cords of the brachial plexus lie on the first rib and are liable to be wounded in fracture, especially in fracture from direct violence, when the force of the blow drives the broken ends inwards. Fortunately the Subclavius intervenes between these structures and the clavicle, and often protects them from injury.

The clavicle is occasionally the seat of sarcomatous tumours, rendering the operation of excision of the entire bone necessary. This is an operation of considerable difficulty and danger. It is best performed by exposing the bone freely, disarticulating at the acromial end, and turning it inwards. The removal of the outer part is comparatively easy, but resection of the inner part is fraught with difficulty, the main danger being the risk of wounding the great veins which are in relation with its under surface.

Great deformity of the clavicle may be met with in rickets, the natural curvatures of the bone being exaggerated until it takes on an S-shape.

The Scapula

The **Scapula** or shoulder-blade forms the posterior part of the shoulder girdle. It is a flat, triangular bone, and presents for examination two surfaces, three borders, and three angles.

The *ventral surface* (facies costalis) (fig. 350) presents a broad concavity, the *fossa subscapularis*. The inner two-thirds of the fossa are marked by several oblique ridges, which are directed outwards and upwards; the outer third is smooth. The oblique ridges give attachment to the tendinous intersections, and the surfaces between them to the fleshy fibres, of the Subscapularis. The outer third of the fossa is covered by the fibres of this muscle. The subscapular fossa is separated from the internal border by smooth triangular areas at the superior and inferior angles, and in the interval between these by a narrow ridge which is often deficient. These triangular areas and the intervening ridge afford attachment to the Serratus magnus. The subscapular fossa presents a transverse depression at its upper part, where the bone appears to be bent on itself along a line at right angles to and passing through the centre of the glenoid cavity, forming a considerable angle, called the *subscapular angle*; this gives greater strength to the body of the bone by its arched form, while the summit of the arch serves to support the spine and acromion process.

The *dorsal surface* (facies dorsalis) (fig. 351) is arched from above downwards, and is alternately concave and convex from side to side. It is subdivided unequally into two parts by the *spine*; the portion above the spine is called the *supraspinous fossa*, and that below it the *infraspinous fossa*.

The *supraspinous fossa* (fossa supraspinata), the smaller of the two, is concave, smooth, and broader at the vertebral than at the humeral extremity. It affords attachment by its inner two-thirds to the Supraspinatus.

The *infraspinous fossa* (fossa infraspinata) is much larger than the preceding; towards its vertebral margin a shallow concavity is seen at its upper part; its centre presents a prominent convexity, while near the axillary border is a deep groove which runs from the upper towards the lower part. The inner two-thirds of the fossa affords attachment to the Infraspinatus; the outer third is covered by this muscle.

The dorsal surface is marked near the axillary border by an elevated ridge, which runs from the lower part of the glenoid cavity, downwards and backwards to the vertebral border, about an inch above the inferior angle.

The ridge serves for the attachment of a strong aponeurosis, which separates the Infraspinatus from the two Teres muscles. The surface of bone between the ridge and the axillary border is narrow in the upper two-thirds of its extent, and is crossed near its centre by a groove for the passage of the dorsalis scapulæ vessels ; it affords attachment to the Teres minor. Its lower third presents a broader, somewhat triangular surface, which gives origin to the Teres major, and over which the Latissimus dorsi glides ; frequently the

Fig. 350.—Left scapula. Anterior surface.

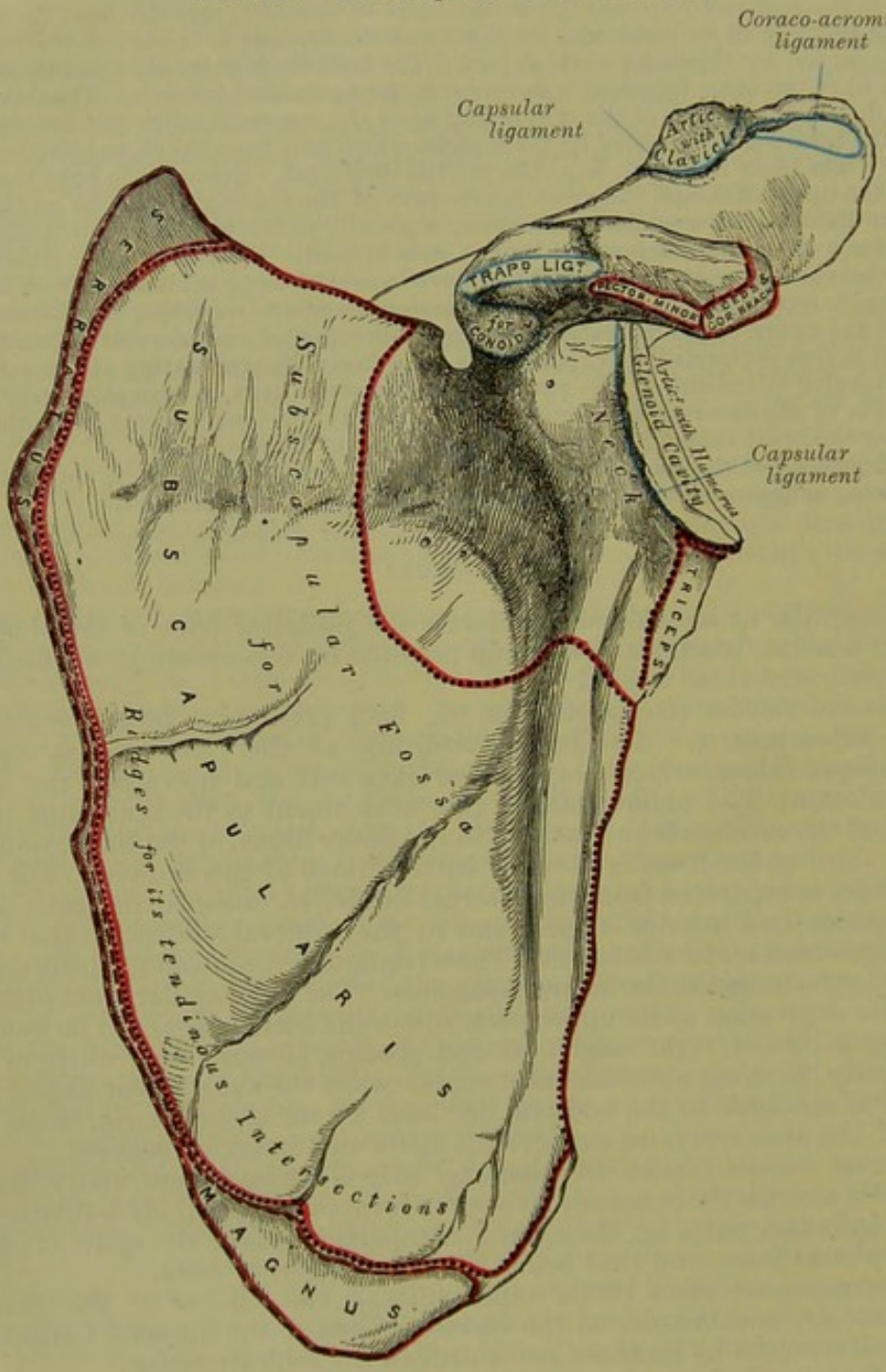

latter muscle takes origin by a few fibres from this part. The broad and narrow portions of bone above alluded to are separated by an oblique line, which runs from the axillary border, downwards and backwards, to meet the elevated ridge : to it is attached the aponeurosis which separates the Teres muscles from each other.

The **spine** (spina scapulæ) is a prominent plate of bone, which crosses obliquely the inner four-fifths of the dorsal surface of the scapula at its upper part, and separates the supra- from the infra-spinous fossa. It begins at the

vertebral border by a smooth, triangular area over which the tendon of insertion of the lower part of the Trapezius glides, and, gradually becoming more elevated as it passes outwards, ends in the acromion process, which overhangs the shoulder-joint. The spine is triangular, and flattened from above downwards, its apex being directed inwards, its base outwards. It presents two surfaces and three borders. Its *superior surface* is concave; it assists in

Fig. 351.—Left scapula. Posterior surface.

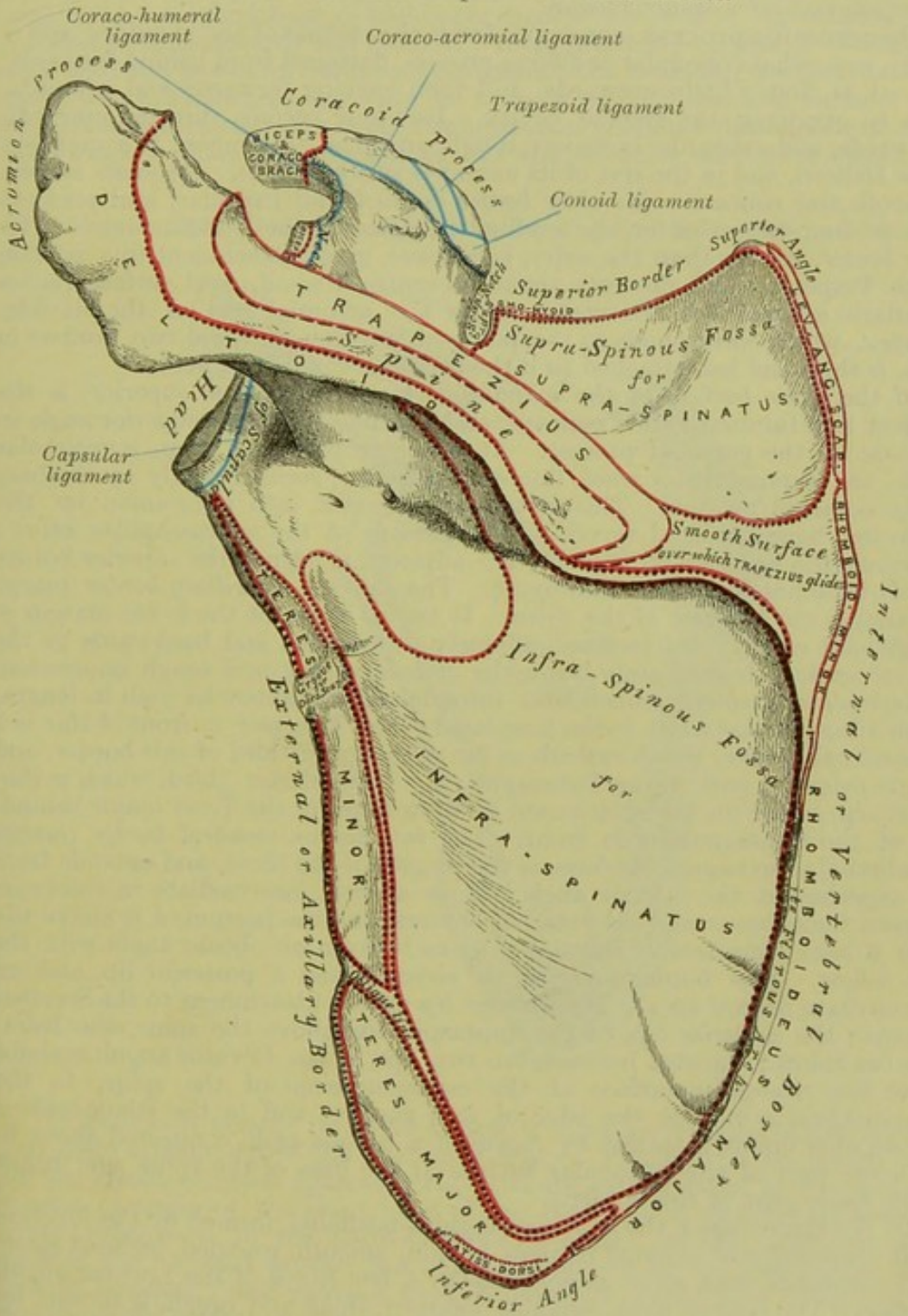

forming the supraspinous fossa, and affords attachment to part of the Supraspinatus. Its *inferior surface* forms part of the infraspinous fossa, gives origin to a portion of the Infraspinatus, and presents near its centre the orifice of a nutrient canal. Of the three borders, the *anterior* is attached to the dorsum of the bone; the *posterior*, or *crest of the spine*, is broad, and presents two lips and an intervening rough interval. The Trapezius is attached to the

superior lip, and a rough tubercle is generally seen on that portion of the spine which receives the tendon of insertion of the lower part of this muscle. The Deltoid is attached to the whole length of the inferior lip. The interval between the lips is subcutaneous and partly covered by the tendinous fibres of these muscles. The *external border*, or *base*, the shortest of the three, is slightly concave ; its edge, thick and round, is continuous above with the under surface of the acromion process, below with the neck of the scapula. It forms the inner boundary of a notch, the *great scapular notch*, which serves to connect the supra- and infra-spinous fossæ.

The **acromion process** (acromion) forms the summit of the shoulder, and is a large, somewhat triangular or oblong process, flattened from behind forwards, directed at first a little outwards, and then curving forwards and upwards, so as to overhang the glenoid cavity. Its *upper surface*, directed upwards, backwards, and outwards, is convex, rough, and gives attachment to some fibres of the Deltoid, and in the rest of its extent is subcutaneous. Its *under surface* is smooth and concave. Its *outer border* is thick and irregular, and presents three or four tubercles for the tendinous origins of the Deltoid muscle. Its *inner border*, shorter than the outer, is concave, gives attachment to a portion of the Trapezius, and presents about its centre a small, oval surface (facies articularis acromii) for articulation with the acromial end of the clavicle. Its *apex*, which corresponds to the point of meeting of these two borders in front, is thin, and has attached to it the coraco-acromial ligament.

Of the three *borders* of the scapula, the *superior* (margo superior) is the shortest and thinnest ; it is concave, and extends from the superior angle to the base of the coracoid process. At its outer part is a deep, semicircular notch, the *suprascapular notch* (incisura scapulæ), formed partly by the base of the coracoid process. This notch is converted into a foramen by the transverse ligament, and serves for the passage of the suprascapular nerve ; sometimes the ligament is ossified. The adjacent margin of the superior border affords attachment to the Omo-hyoid. The *external* or *axillary border* (margo axillaris) is the thickest of the three. It begins above at the lower margin of the glenoid cavity, and inclines obliquely downwards and backwards to the inferior angle. Immediately below the glenoid cavity is a rough impression, the *infraglenoid tubercle* (tuberositas infraglenoidalis) about an inch in length, which affords attachment to the long head of the Triceps ; in front of this is a longitudinal groove, which extends as far as the lower third of this border, and affords origin to part of the Subscapularis. The inferior third, which is thin and sharp, serves for the attachment of a few fibres of the Teres major behind, and of the Subscapularis in front. The *internal* or *vertebral border* (margo vertebralis), also named the *base*, is the longest of the three, and extends from the superior to the inferior angle. It is arched, intermediate in thickness between the superior and the external borders, and the portion of it above the spine is bent considerably outwards, so as to form an obtuse angle with the part below. This border presents an anterior and a posterior lip, and an intermediate narrow area. The *anterior lip* affords attachment to the Serratus magnus ; the *posterior lip*, to the Supraspinatus above the spine, the Infra-spinatus below ; the area between the two lips, to the Levator anguli scapulæ above the triangular surface at the commencement of the spine, to the Rhomboideus minor on the edge of that surface, and to the Rhomboideus major ; this last is attached by means of a fibrous arch, connected above to the lower part of the triangular surface at the base of the spine, and below to the lower part of the border.

Of the three *angles*, the *superior* (angulus medialis), formed by the junction of the superior and internal borders, is thin, smooth, rounded, inclined some-what outwards, and gives attachment to a few fibres of the Levator anguli scapulæ. The *inferior angle* (angulus inferior), thick and rough, is formed by the union of the vertebral and axillary borders, its outer surface affording attachment to the Teres major and frequently to a few fibres of the Latissimus dorsi. The *external angle* (angulus lateralis) is the thickest part of the bone, and forms what is called the head of the scapula. The *head* presents a shallow, pyriform, articular surface, the *glenoid cavity* (cavitas glenoidalis), directed outwards and forwards. It is broader below than above and its vertical diameter is the longest. At its apex is a slight elevation, the *supraglenoid tubercle*

(tuberositas supraglenoidalis), to which the long tendon of the Biceps is attached. The surface is covered with cartilage in the recent state; and its margins, slightly raised, give attachment to a fibro-cartilaginous structure, the *glenoid ligament*, which deepens the cavity. The *neck* of the scapula (collum scapulæ) is the slightly depressed surface which surrounds the head; it is more distinct behind where it forms part of the great scapular notch, than in front, and below than above.

The **coracoid process** (processus coracoideus) is a thick curved process attached by a broad base to the upper part of the neck of the scapula; it is directed at first upwards and inwards; then, becoming smaller, it changes its direction, and passes forwards and outwards. The ascending portion, flattened from before backwards, presents in front a smooth concave surface, over which the Subscapularis passes. The horizontal portion is flattened from above downwards; its upper surface is convex and irregular, and gives attachment

Fig. 352.—Plan of ossification of the scapula. From seven centres.

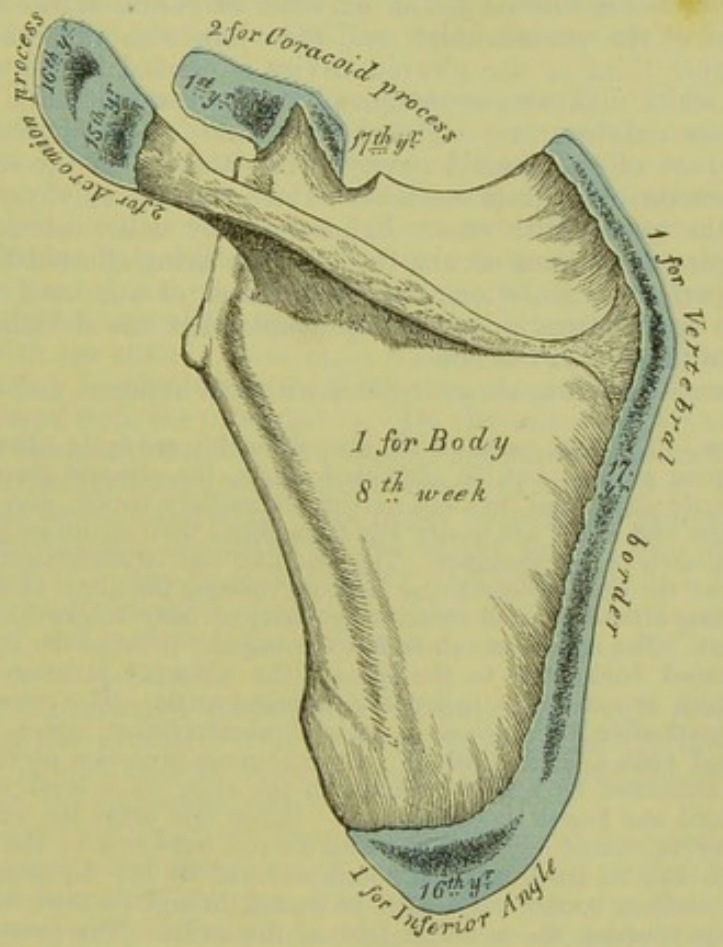

to the Pectoralis minor; its under surface is smooth; its inner border is rough, and gives attachment to the Pectoralis minor; its outer border is also rough for the coraco-acromial ligament, while the apex is embraced by the conjoined tendon of origin of the short head of the Biceps and Coraco-brachialis and gives attachment to the costo-coracoid ligament. At the inner side of the root of the coracoid process is a rough impression for the attachment of the conoid ligament; and running from it obliquely forwards and outwards, on to the upper surface of the horizontal portion, is an elevated ridge for the attachment of the trapezoid ligament.

Structure.—The head, processes, and the thickened parts of the bone, contain cancellous tissue; the rest of the bone consists of a thin layer of compact tissue. The central part of the supraspinous fossa and the upper part of the infraspinous fossa, but especially the former, are usually so thin as to be semi-transparent; occasionally the bone is found wanting in this situation, and the adjacent muscles are separated only by fibrous tissue.

Ossification (fig. 352).—The scapula is ossified from *seven* or more centres: one for the body, two for the coracoid process, two for the acromion, one for the vertebral border, and one for the inferior angle.

Ossification of the body begins about the second month of fœtal life, by the formation of an irregular quadrilateral plate of bone, immediately behind the glenoid cavity. This plate extends so as to form the chief part of the bone, the spine growing up from its posterior surface about the third month. At birth, a large part of the scapula is osseous, but the glenoid cavity, the coracoid and acromion processes, the posterior border, and inferior angle are cartilaginous. From the fifteenth to the eighteenth month after birth, ossification takes place in the middle of the coracoid process, which as a rule becomes joined with the rest of the bone about the fifteenth year. Between the fourteenth and twentieth years, ossification of the remaining parts takes place in quick succession, and usually in the following order; first, in the root of the coracoid process, in the form of a broad scale; secondly, near the base of the acromion process; thirdly, in the inferior angle and contiguous part of the posterior border; fourthly, near the extremity of the acromion; fifthly, in the posterior border. The base of the acromion process is formed by an outward extension of the spine; the two separate nuclei of the process unite, and then join with the extension from the spine. The upper third of the glenoid cavity is ossified from a separate centre (subcoracoid), which makes its appearance between the tenth and eleventh years and joins between sixteen and eighteen. Further, an epiphysial plate appears for the lower part of the glenoid cavity, while the tip of the coracoid process frequently presents a separate nucleus. These various epiphyses are joined to the bone by the twenty-fifth year. Failure of bony union between the acromion process and spine sometimes occurs, the junction being effected by fibrous tissue, or by an imperfect articulation; in some cases of supposed fracture of the acromion with ligamentous union, it is probable that the detached segment was never united to the rest of the bone.

Articulations.—The scapula articulates with the humerus and clavicle.

Surface Form.—The only parts of the scapula which are truly subcutaneous are the spine and acromion process, but, in addition to these, the coracoid process, the vertebral border and inferior angle, and, to a less extent, the axillary border, may be defined. The acromion process and spine are easily felt throughout their entire length, forming, with the clavicle, the arch of the shoulder. The acromion can be ascertained to be connected to the clavicle at the acromio-clavicular joint by running the finger along it, the position of the joint being often indicated by an irregularity or bony outgrowth from the clavicle close to the joint. The acromion can be felt forming the point of the shoulder, and from this can be traced backwards to the spine. The place of junction is denoted by a prominence, which is sometimes called the acromial angle. The spine can be felt as a distinct ridge, marked on the surface as an oblique depression, which becomes less and less distinct and ends a little external to the spinous processes of the vertebræ. Its termination is indicated by a slight dimple in the skin, on a level with the interval between the third and fourth thoracic spines. Below this point the vertebral border of the scapula may be traced, running downwards and outwards to the inferior angle of the bone, which can be recognised, although covered by the Latissimus dorsi. From this angle the axillary border can usually be traced through its thick muscular covering, forming, with the muscles, the posterior fold of the axilla. The coracoid process may be felt about an inch below the junction of the middle and outer third of the clavicle. It is covered by the anterior border of the Deltoid, and lies a little to the outer side of a slight depression, corresponding to the interval between the Pectoralis major and Deltoid. When the arm is hanging by the side, the upper angle of the scapula corresponds to the upper border of the second rib or the interval between the first and second thoracic spines, the inferior angle to the upper border of the eighth rib or the interval between the seventh and eighth thoracic spines.

Applied Anatomy.—Fractures of the body of the scapula are rare, owing to the mobility of the bone, the thick layer of muscles by which it is encased, and the elasticity of the ribs on which it rests. Fracture of the neck is also uncommon. The most frequent course of the fracture is from the suprascapular notch to the infraglenoid tubercle, and it derives its principal interest from its simulation of a subglenoid dislocation of the humerus. The diagnosis can be made by noting the alteration in the position of the coracoid process. The acromion process is more frequently broken than any other part of the bone, and fibrous union is very liable to occur in this situation.

The presence of 'winged scapulæ' (scapulæ alatæ) described in thin persons of feeble muscular development in whom the lower angles of the blade-bones project unduly, is due partly to abnormal roundness of the thoracic wall ('barrel-shaped chest,' page 213),

and partly to weakness and flaccidity of the Latissimus dorsi and Serratus magnus. The shoulders are held low in these subjects, and the clavicles slope downwards and forwards, carrying with them the scapulæ, which fit ill to the posterior wall of the chest and so tend to project from it.

Tumours of various kinds grow from the scapula. Of the innocent form probably the osteomata are the most common. When an osteoma grows from the venter of the scapula, as it sometimes does, it is of the compact variety, such as usually grows from membrane-formed bones, as the bones of the skull. Sarcomatous tumours sometimes grow from the scapula, and may necessitate removal of the bone, with or without amputation of the upper limb. The bone may be excised by a T-shaped incision, and the flaps being reflected, the removal is commenced from the posterior or vertebral border, so that the subscapular vessels which lie along the axillary border are amongst the last structures divided, and can be at once secured.

The Humerus

The **Humerus** (figs. 353 and 354) is the longest and largest bone of the upper extremity ; it presents for examination a shaft and two extremities.

The **upper extremity** consists of a large rounded *head* joined to the shaft by a constricted portion called the *neck*, and two eminences, the *greater* and *lesser tuberosities*.

The **head** (caput humeri), nearly hemispherical in form,* is directed upwards, inwards, and a little backwards, and articulates with the glenoid cavity of the scapula. The circumference of its articular surface is slightly constricted, and is termed the *anatomical neck*, in contradistinction to the constriction which exists below the tuberosities. The latter is called the *surgical neck* (collum chirurgicum), since it is frequently the seat of fracture. Fracture of the anatomical neck does sometimes, though rarely, occur.

The *anatomical neck* (collum anatomicum) is obliquely directed, forming an obtuse angle with the shaft. It is most distinctly marked in the lower half of its circumference ; in the upper half it is represented by a narrow groove separating the head from the tuberosities. Its circumference affords attachment to the capsular ligament, and is perforated by numerous vascular foramina.

The **greater tuberosity** (tuberculum majus) is situated on the outer side of the head and lesser tuberosity. Its upper surface is rounded and marked by three flat impressions, separated by two slight ridges : the highest impression gives insertion to the Supraspinatus ; the middle to the Infraspinatus ; the lowest one, and the shaft of the bone below it, to the Teres minor. The outer surface of the greater tuberosity is convex, rough, and continuous with the outer surface of the shaft.

The **lesser tuberosity** (tuberculum minus), although smaller, is more prominent than the greater : it is situated in front, and is directed inwards and forwards. Above and in front it presents an impression for the insertion of the tendon of the Subscapularis.

The tuberosities are separated from each other by a deep groove, the *bicipital groove* (sulcus intertubercularis) which lodges the long tendon of the Biceps, and transmits a branch of the anterior circumflex artery to the shoulder-joint. It begins above between the two tuberosities, runs obliquely downwards and a little inwards, and ends near the junction of the upper with the middle third of the bone. In the recent state its upper part is covered with a thin layer of cartilage, lined by a prolongation of the synovial membrane of the shoulder-joint ; its lower portion gives insertion to the tendon of the Latissimus dorsi. It is deep and narrow above, and becomes shallow and a little broader as it descends. Its lips are called, respectively, the anterior and posterior *bicipital ridges* (cristæ tuberculi majoris et minoris), and form the upper parts of the anterior and internal borders of the shaft of the bone.

The **shaft** (corpus humeri) is almost cylindrical in the upper half of its extent, prismatic and flattened below, and presents three borders and three surfaces for examination.

* Though the head is nearly hemispherical in form, its margin, as Humphry has shown, is by no means a true circle. Its greatest diameter is, from the top of the bicipital groove in a direction downwards, inwards, and backwards. Hence it follows that the greatest elevation of the arm can be obtained by rolling the articular surface in this direction—that is to say, obliquely upwards, outwards, and forwards.

FIG. 353.—Left humerus. Anterior view.

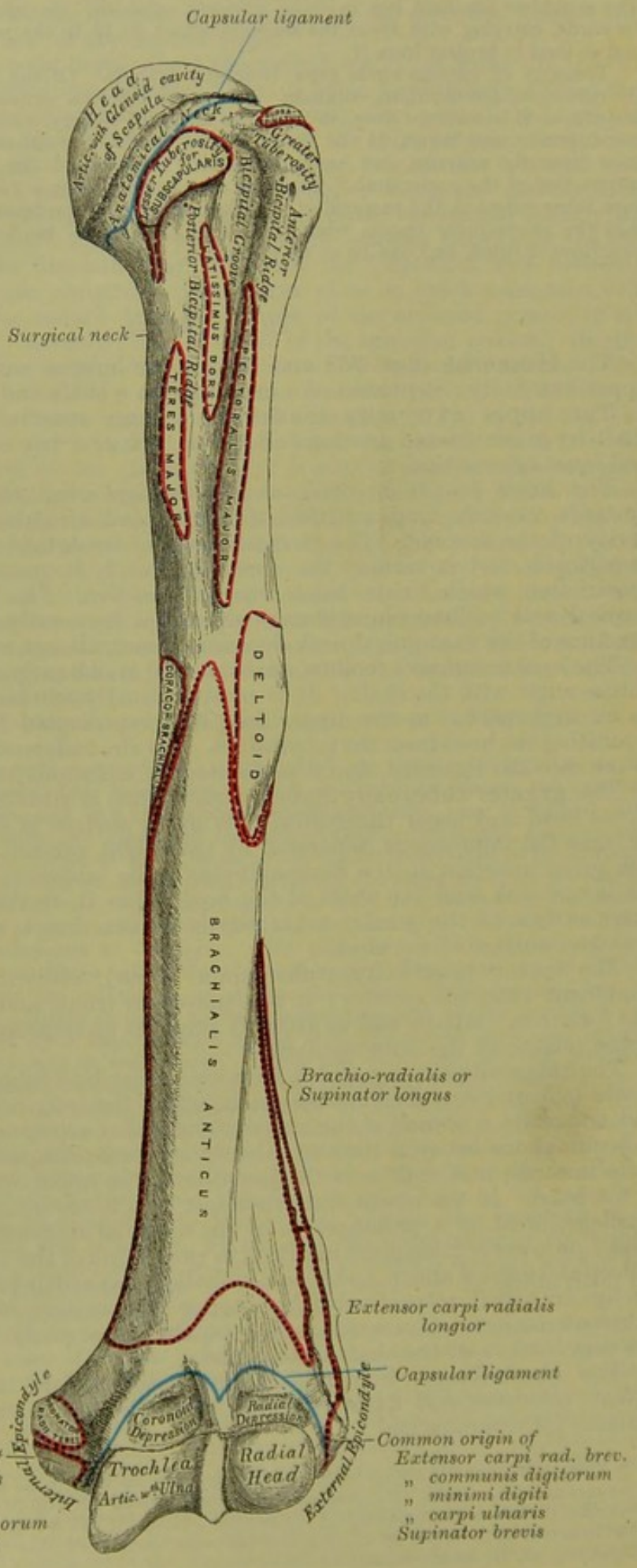

The *anterior border* (margo anterior) runs from the front of the greater tuberosity above to the coronoid fossa below, separating the internal from the external surface. Its upper part is very prominent and rough, and forms the outer lip of the bicipital groove ; it is sometimes called the *anterior bicipital* or *pectoral ridge*, and serves for the insertion of the tendon of the Pectoralis major. About its centre it forms the anterior boundary of the rough deltoid impression ; below, it is smooth and rounded, affording attachment to the Brachialis anticus.

The *external border* (margo lateralis) runs from the back part of the greater tuberosity to the external epicondyle, and separates the external from the posterior surface. Its upper half is rounded and indistinctly marked, serving for the attachment of the lower part of the insertion of the Teres minor, and below this giving origin to the external head of the Triceps muscle ; its centre is traversed by a broad, but shallow oblique depression, the *musculo-spiral groove* (sulcus radialis). Its lower part forms a prominent, rough margin, a little curved from behind forwards, the *external supracondylar ridge*, which presents an anterior lip for the origin of the Brachio-radialis above, and Extensor carpi radialis longior below, a posterior lip for the Triceps, and an intermediate space for the attachment of the external intermuscular septum.

The *internal border* (margo medialis) extends from the lesser tuberosity to the internal epicondyle. Its upper third consists of a prominent ridge, the *posterior bicipital ridge*, which gives insertion to the tendon of the Teres major. About its centre is a slight impression for the insertion of the Coraco-brachialis, and just below this is the entrance of the nutrient canal, directed downwards ; sometimes there is a second nutrient canal situated at the commencement of the musculo-spiral groove. The inferior third of this border is raised into a slight ridge, the *internal supracondylar ridge*, which becomes very prominent below ; it presents an anterior lip for the

FIG. 354.—Left humerus. Posterior view.

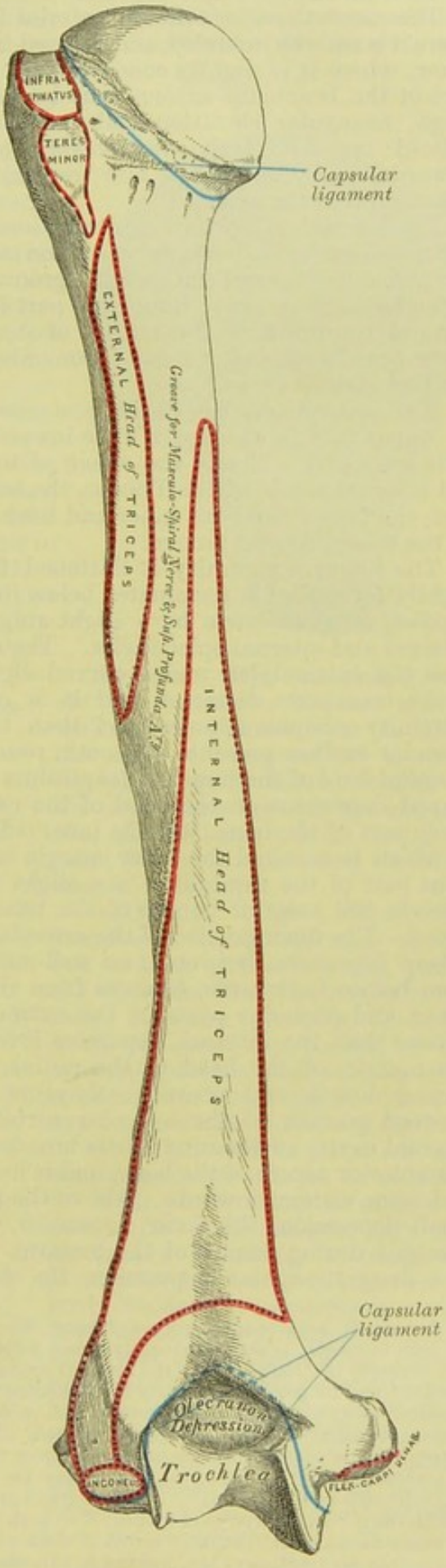

origins of the Brachialis anticus and Pronator teres, a posterior lip for the internal head of the Triceps, and an intermediate space for the attachment of the internal intermuscular septum.

The *external surface* (facies anterior lateralis) is directed outwards above, where it is smooth, rounded, and covered by the Deltoid; forwards and outwards below, where it is slightly concave from above downwards, and gives origin to part of the Brachialis anticus muscle. About the middle of this surface is a rough, triangular elevation (tuberositas deltoidea) for the insertion of the Deltoid; below this is the *musculo-spiral groove*, directed obliquely from behind, forwards, and downwards, and transmitting the musculo-spiral nerve and superior profunda artery.

The *internal surface* (facies anterior medialis), less extensive than the external, is directed inwards above, forwards and inwards below; its upper part is narrow, and forms the floor of the bicipital groove which gives insertion to the tendon of the Latissimus dorsi; its middle part is slightly rough for the attachment of some of the fibres of the tendon of insertion of the Coraco-brachialis; its lower part is smooth, concave from above downwards, and gives origin to the Brachialis anticus.*

The *posterior surface* (facies posterior) appears somewhat twisted, so that its upper part is directed a little inwards, its lower part backwards and a little outwards. Nearly the whole of this surface is covered by the external and internal heads of the Triceps, the former arising from its upper and outer part, the latter from its inner and back part, the two heads being separated by the musculospiral groove.

The **lower extremity** is flattened from before backwards, and curved slightly forwards; it terminates below in a broad, articular surface, which is divided into two parts by a slight ridge. Projecting on either side are the external and internal epicondyles. The *articular surface* extends a little lower than the epicondyles, and is curved slightly forwards; its greatest breadth is in the transverse diameter, and it is obliquely directed, so that its inner extremity occupies a lower level than the outer. The outer portion of the articular surface presents a smooth, rounded eminence, named the *capitellum*, or *radial head* of the humerus (capitulum humeri); it articulates with the cup-shaped depression on the head of the radius, and is limited to the front and lower part of the bone. On the inner side of this eminence is a shallow groove, in which is received the inner margin of the head of the radius. Above the front part of the capitellum is a slight depression, the *fossa radialis*, which receives the anterior border of the head of the radius, when the forearm is flexed. The inner portion of the articular surface, the *trochlea humeri*, presents a deep depression between two well-marked borders. The trochlea is convex from before backwards, concave from side to side, and occupies the anterior, lower, and posterior parts of the extremity. The external border, less prominent than the internal, separates it from the groove which articulates with the margin of the head of the radius. The internal border is thicker, of greater length, and consequently more prominent, than the external. The grooved portion of the articular surface fits accurately within the greater sigmoid cavity of the ulna; it is broader and deeper on the posterior than on the anterior aspect of the bone, and is inclined obliquely from behind forwards, and from without inwards. Above the front part of the trochlear surface is a small depression, the *fossa coronoidea*, which receives the coronoid process of the ulna during flexion of the forearm. Above the back part of the trochlea is a deep triangular depression, the *olecranon fossa* (fossa olecrani), in which

* A small, hook-shaped process of bone, the *supracondylar process*, varying from $\frac{1}{10}$ to $\frac{3}{4}$ of an inch in length, is not infrequently found projecting from the inner surface of the shaft of the humerus two inches above the internal epicondyle. It is curved downwards, forwards, and inwards, and its pointed extremity is connected to the internal border, just above the inner epicondyle, by a ligament or fibrous band, which gives origin to a portion of the Pronator teres; through the arch completed by this fibrous band the median nerve and brachial artery pass, when these structures deviate from their usual course. Sometimes the nerve alone is transmitted through it, or the nerve may be accompanied by the ulnar artery, in cases of high division of the brachial. A well-marked groove is usually found behind the process, in which the nerve and artery are lodged. This arch is the homologue of the supracondyloid foramen in many animals, and probably serves in them to protect the nerve and artery from compression during the contraction of the muscles in this region.

the summit of the olecranon process is received in extension of the forearm. These fossæ are separated from one another by a thin, transparent lamina of bone, which is sometimes perforated, forming the *supratrochlear foramen*; their margins afford attachment to the anterior and posterior ligaments of the elbow-joint; the fossæ are lined, in the recent state, by the synovial membrane of this articulation. The *external epicondyle* (epicondylus lateralis) is a small, tubercular eminence, less prominent than the internal, curved a little forwards, and giving attachment to the external lateral ligament of the elbow-joint, and to a tendon common to the origin of some of the Extensor and Supinator muscles. The *internal epicondyle* (epicondylus medialis), larger, more prominent, and therefore more liable to fracture than the external, is directed a little backwards; it gives attachment to the internal lateral ligament of the elbow-joint, to the Pronator teres, and to a tendon common to the origin of some of the Flexor muscles of the forearm. The ulnar nerve runs in a groove (sulcus n. ulnaris) on the back of the internal epicondyle. These epicondyles are directly continuous above with the external and internal supracondylar ridges.

Fig. 355.—Longitudinal section of head of left humerus.

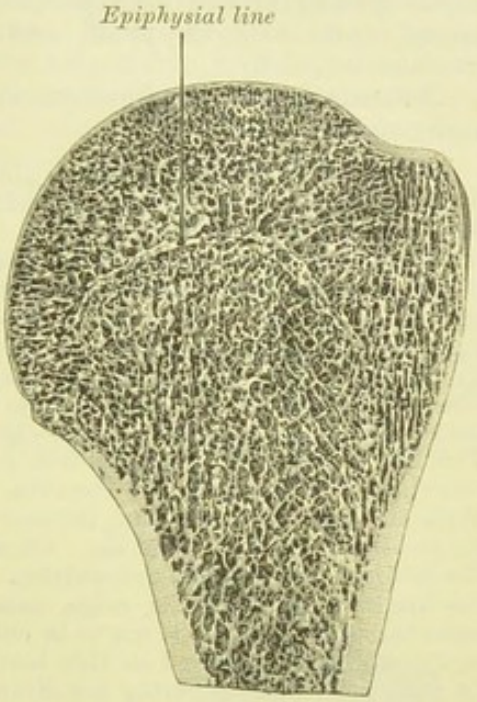

Fig. 356.—Plan of ossification of the humerus.

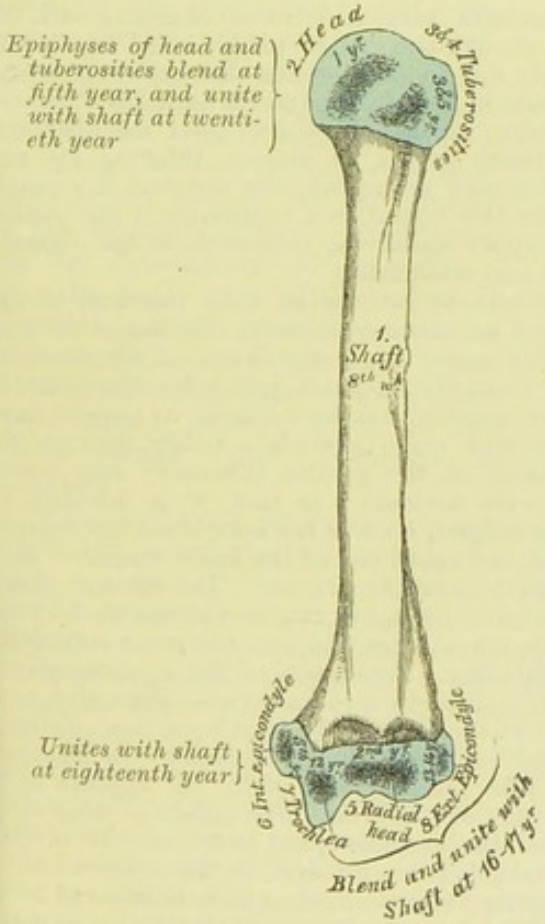

Structure.—The extremities consist of cancellous tissue, covered with a thin, compact layer (fig. 355); the shaft is composed of a cylinder of compact tissue, thicker at the centre than towards the extremities, and contains a large medullary canal which extends along its whole length.

Ossification (fig. 356). — The humerus is ossified from *eight* centres, one for each of the following parts: the shaft, the head, the greater tuberosity, the lesser tuberosity, the radial head, the trochlear portion of the articular surface, and one for each epicondyle. The centre for the shaft appears near the middle of the bone in the eighth week of fœtal life, and soon extends towards the extremities. At birth the humerus is ossified in nearly its whole length, only the extremities remaining cartilaginous. During the first year, sometimes before birth, ossification commences in the head of the bone, and during the third year the centre for the greater tuberosity, and during the fifth that for the lesser tuberosity, make their appearance. By the sixth year the centres for the head and tuberosities have increased in size and become joined, so as to form a single large epiphysis, which fuses with the shaft about the twentieth year. The lower end of the humerus is ossified as follows. At the end of the second year

ossification begins in the capitellum, and extends inwards, to form the chief part of the articular end of the bone, the centre for the inner part of the trochlea not appearing until about the age of twelve. Ossification commences in the internal epicondyle about the fifth year, and in the external about the thirteenth or fourteenth year. About the sixteenth or seventeenth year, the outer epicondyle and both portions of the articulating surface, having already joined, unite with the shaft, and at the eighteenth year the inner epicondyle becomes joined to it.

Articulations.—The humerus articulates with the scapula, and with the ulna and radius.

Surface Form.—The humerus is almost entirely clothed by the muscles which surround it, and the only parts of the bone which are strictly subcutaneous are small portions of the internal and external epicondyles. In addition to these, the tuberosities and a part of the head of the bone can be felt under the skin and muscles by which they are covered. Of these the greater tuberosity forms the most prominent bony point of the shoulder, extending beyond the acromion process and covered by the Deltoid. It influences materially the surface form of the shoulder. It is best felt while the arm is lying loosely by the side ; if the arm be raised, it recedes from under the finger. The lesser tuberosity, directed forwards and inwards, can be felt on the inner side of the greater tuberosity, just below the acromio-clavicular joint. Between the two tuberosities lies the bicipital groove. This can be defined by making firm pressure with the finger, just internal to the greater tuberosity ; on rotating the humerus, the groove will be felt to pass under the finger. With the arm abducted from the side the lower part of the head of the bone can be felt by pressing deeply in the axilla. On either side of the elbow-joint, and just above it, are the internal and external epicondyles. Of these the internal is the more prominent, but the internal supracondylar ridge, passing upwards from it, is much less marked than the external, and, as a rule, is not to be felt. Occasionally, however, the hook-shaped process mentioned above is found on this border. The position of the external epicondyle is to be seen most plainly during semiflexion of the forearm, and is indicated by a depression between the attachments of the adjacent muscles. From it a strong bony ridge can be felt running up the outer border of the shaft of the bone. This is the external supracondylar ridge ; it is concave forwards, and corresponds with the curved direction of the lower extremity of the humerus.

Applied Anatomy.—There are several points of surgical interest connected with the ossification of the humerus. The upper end, though the first to ossify, is the last to join the shaft, and the length of the bone is mainly due to growth from the upper epiphysial line. Hence, in cases of amputation of the arm in young subjects, the humerus continues to grow considerably, and the end of the bone which immediately after the operation was covered with a thick cushion of soft tissue begins to project, thinning the soft parts and rendering the stump conical. This may necessitate the removal of a couple of inches or so of the bone, and even after this operation a recurrence of the conical stump may take place. The region of the upper epiphysis, moreover, is the common site for the growth of tumours, both innocent and malignant.

There are several points of surgical interest in connection with fractures of the humerus. The bone may be broken by direct or indirect violence, like the other long bones, but, in addition to this, it is probably more frequently fractured by muscular action than any other bone of this class. It is usually the shaft, just below the insertion of the Deltoid, which is thus broken, and the accident has been known to happen from throwing a stone. Fractures of the upper end may take place either through the anatomical or surgical neck, or a separation of the greater tuberosity may occur. Fracture of the anatomical neck is a very rare accident ; in fact, it is doubted by some whether it ever occurs. Fracture of the surgical neck of the bone is not uncommon, and impaction may occur ; on the other hand, the upper end of the lower fragment may be displaced into the axilla and may damage the vessels or nerves. The fracture somewhat closely simulates dislocation of the shoulder-joint, but can be distinguished by the fact that the head of the bone remains in its normal position and the great tuberosity still forms the most prominent point of the shoulder. Separation of the upper epiphysis sometimes occurs in the young subject, and is marked by a characteristic deformity, consisting in the presence of an abrupt projection at the front of the joint some short distance below the coracoid process, caused by the upper end of the lower fragment. In fractures of the shaft of the humerus the lesion may take place at any point, but appears to be more common in the lower than the upper part of the bone. The points of interest in connection with these fractures are : (1) that the musculo-spiral nerve may be injured as it lies in the groove on the bone, or may become involved in the callus which is subsequently thrown out ; and (2) the frequency of non-union, which is believed to be more common in the humerus than in any other bone. An important distinction to make in fractures of the lower end is between those that involve the elbow-joint and those which do not ; the former are always serious, as they may lead to impairment of the utility of the limb. They include the T-shaped fracture and oblique fractures which

involve the articular surface. Those which do not involve the joint are the transverse fracture above the epicondyles, and the so-called epitrochlear fracture, where the tip of the internal epicondyle is broken off, generally from direct violence.

The Ulna

The **Ulna** (figs. 358 and 359) is a long bone, prismatic in form, placed at the inner side of the forearm, parallel with the radius. Its upper extremity, of great thickness and strength, forms a large part of the articulation of the elbow-joint; the bone diminishes in size from above downwards, its lower extremity being very small, and excluded from the wrist-joint by the interposition of an interarticular fibro-cartilage. It is divisible into a shaft and two extremities.

The **upper extremity** (fig. 357), the strongest part of the bone, presents two curved processes, the olecranon process and the coronoid process; and two concave, articular cavities, the greater and lesser sigmoid cavities.

The **olecranon process** (olecranon) is a large, thick, curved eminence, situated at the upper and back part of the ulna. It is bent forwards at the summit so as to present a prominent lip which is received into the olecranon fossa in extension of the forearm. Its *base* is contracted where it joins the shaft; this is the narrowest part of the upper end of the ulna, and, consequently, the most usual seat of fracture. Its *posterior surface*, directed backwards, is triangular, smooth, subcutaneous, and covered by a bursa. Its *superior surface* is of quadrilateral form, marked behind by a rough impression for the insertion of the Triceps muscle; and in front, near the margin, by a slight transverse groove for the attachment of part of the posterior ligament of the elbow-joint. Its *anterior surface* is smooth, concave, covered with cartilage in the recent state, and forms the upper and back part of the greater sigmoid cavity. Its *lateral borders* present continuations of the groove on the margin of the superior surface; they serve for the attachment of ligaments—viz. the back part of the internal lateral ligament internally, and the posterior ligament externally. From the inner border a part of the Flexor carpi ulnaris arises; while to the outer border the Anconeus is attached.

Fig. 357.—Upper extremity of left ulna. Outer aspect.

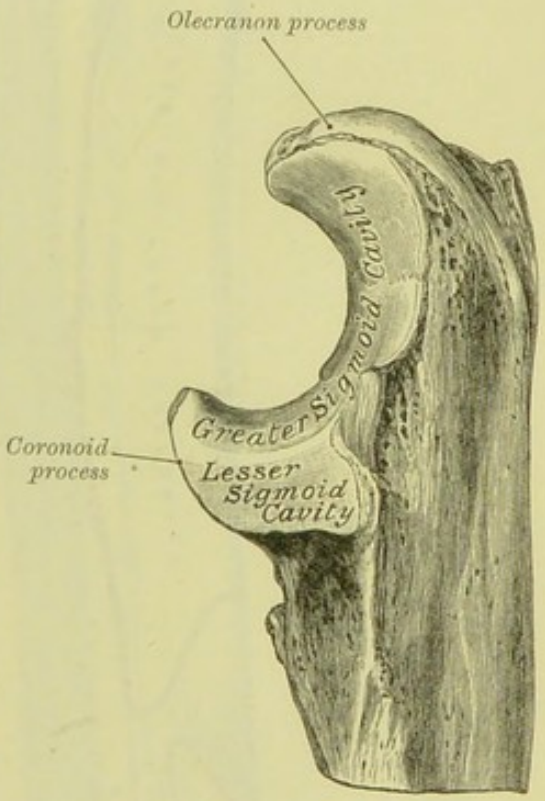

The **coronoid process** (processus coronoideus) is a triangular eminence projecting horizontally forwards from the upper and front part of the ulna. Its *base* is continuous with the shaft, and of considerable strength; so much so that fracture of it is an accident of rare occurrence. Its *apex* is pointed, slightly curved upwards, and in flexion of the forearm is received into the coronoid depression of the humerus. Its *upper surface* is smooth, concave, and forms the lower part of the greater sigmoid cavity. Its *antero-inferior surface* is concave, and marked internally by a rough impression for the insertion of the Brachialis anticus. At the junction of this surface with the front of the shaft is a rough eminence, the *tubercle of the ulna* (tuberositas ulnæ), which gives insertion to a part of the Brachialis anticus; to the outer border of this tubercle the oblique ligament is attached. Its *outer surface* presents a narrow, oblong, articular depression, the *lesser sigmoid cavity*. Its *inner surface*, by its prominent, free margin, serves for the attachment of part of the internal lateral ligament. At the front part of this surface is a small rounded eminence for the origin of one head of the Flexor sublimis digitorum; behind the eminence

FIG. 358.—Bones of left forearm. Anterior aspect.

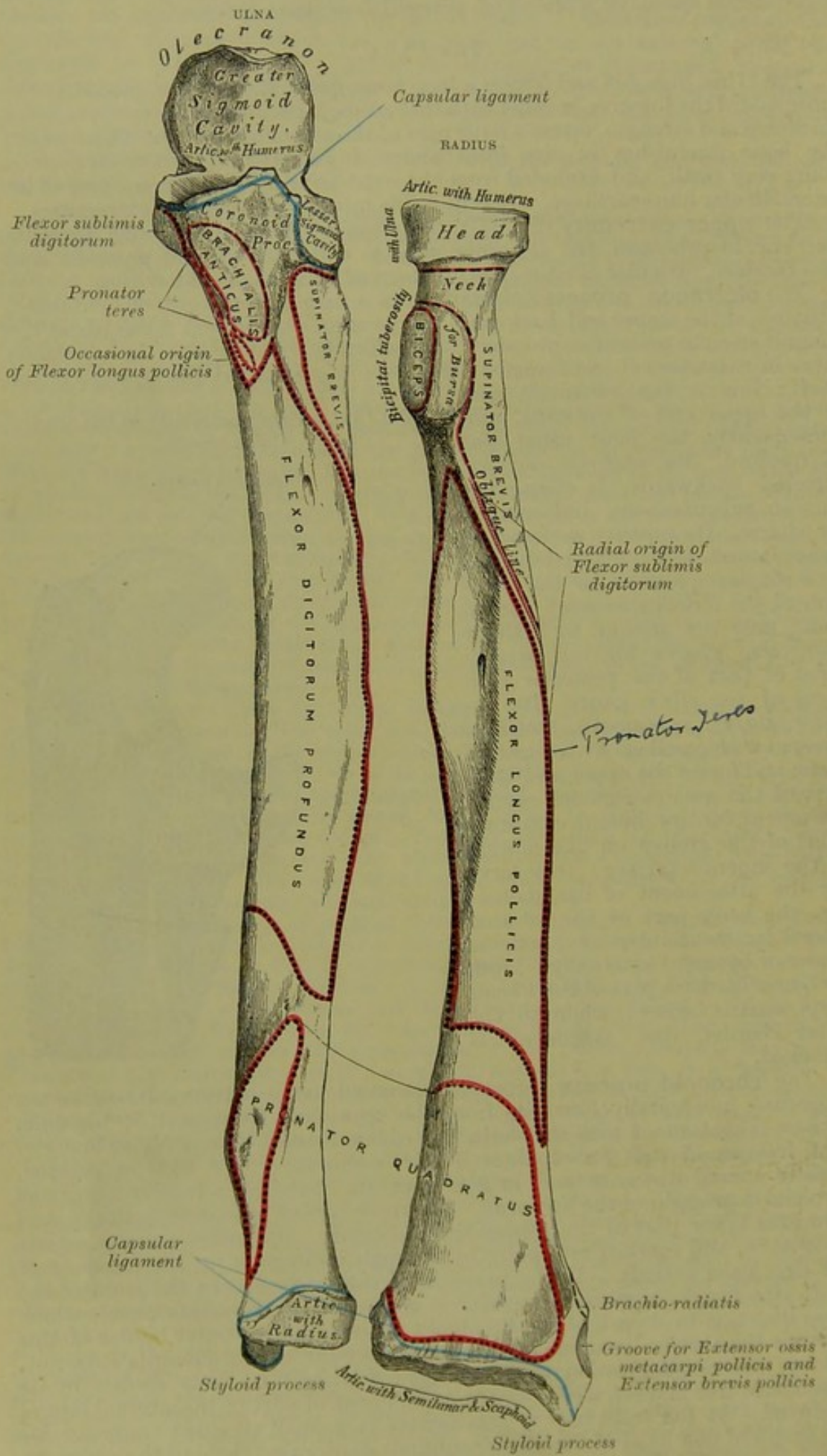

FIG. 359.—Bones of left forearm. Posterior aspect.

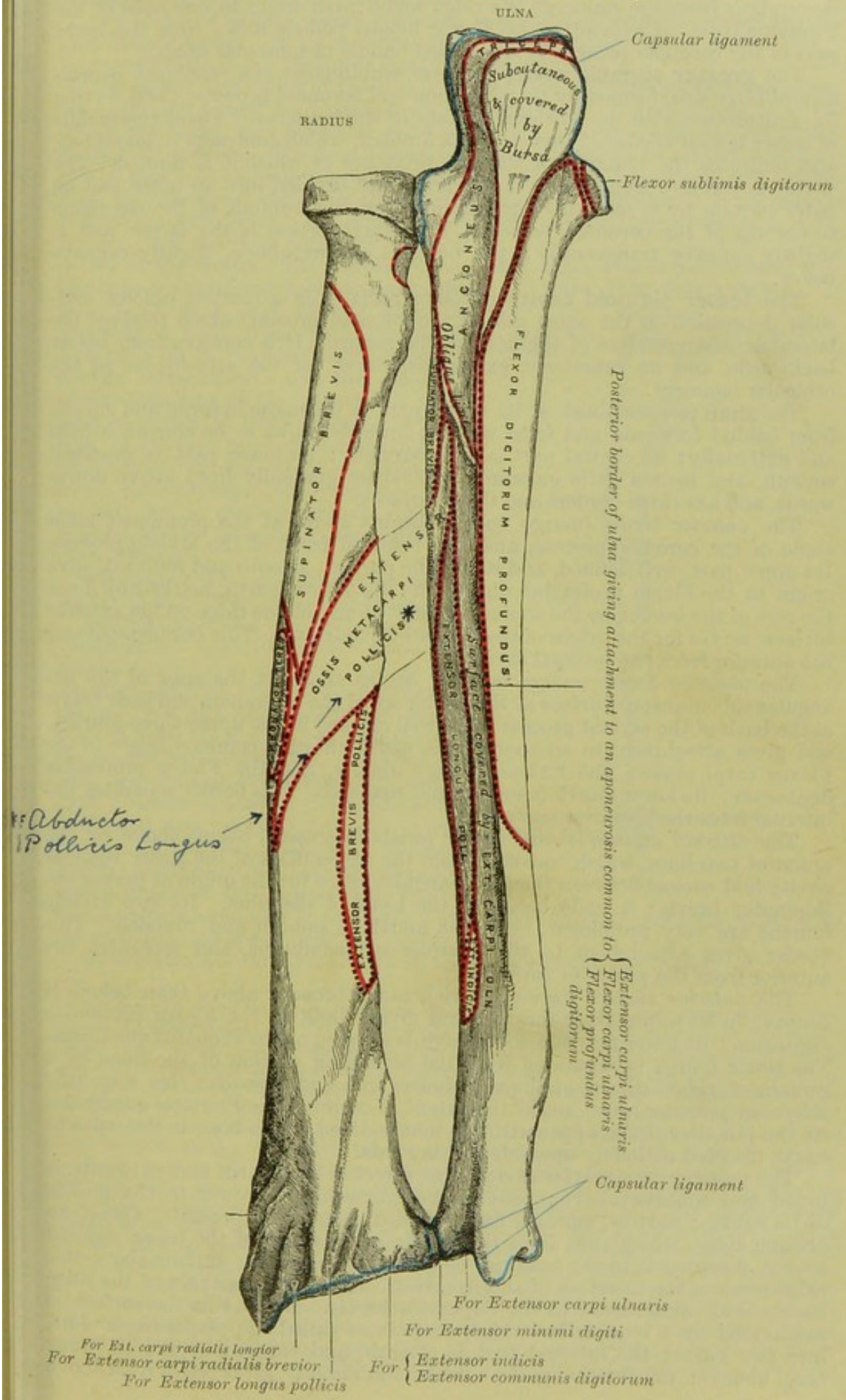

is a depression for part of the origin of the Flexor profundus digitorum; descending from the eminence is a ridge which gives origin to one head of the Pronator teres. Frequently, the Flexor longus pollicis arises from the lower part of the coronoid process by a rounded bundle of muscular fibres.

The **greater sigmoid cavity** (incisura semilunaris) is a semilunar depression of large size, formed by the olecranon and coronoid processes, and serving for articulation with the trochlear surface of the humerus. About the middle of either lateral border of this cavity is a notch, which contracts it somewhat, and indicates the junction of the two processes of which it is formed. The cavity is concave from above downwards, and divided into an inner and an outer portion by a smooth ridge running from the summit of the olecranon to the tip of the coronoid process. The inner portion is the larger, and is slightly concave transversely; the outer is convex above, slightly concave below.

The **lesser sigmoid cavity** (incisura radialis) is a narrow, oblong, articular depression on the outer side of the coronoid process, which receives the lateral articular surface of the head of the radius. It is concave from before backwards, and its prominent extremities serve for the attachment of the orbicular ligament.

The **shaft** (corpus ulnæ), at its upper part, is prismatic in form, and curved from behind forwards and from without inwards, so as to be convex behind and externally; its central part is quite straight; its lower part is rounded, smooth, and bent a little outwards. It tapers gradually from above downwards, and has three borders and three surfaces.

The *anterior border* (margo volaris) begins above at the prominent inner angle of the coronoid process, and ends below in front of the styloid process. Its upper part, well defined, and its middle portion, smooth and rounded, give origin to the Flexor profundus digitorum; its lower fourth, marked off from the rest of the border by the commencement of an oblique ridge on the anterior surface, serves for the origin of the Pronator quadratus. This border separates the anterior from the internal surface.

The *posterior border* (margo dorsalis) begins above at the apex of the triangular subcutaneous surface at the back part of the olecranon, and ends below at the back of the styloid process; it is well marked in the upper three-fourths, and gives attachment to an aponeurosis which affords a common origin to the Flexor carpi ulnaris, the Extensor carpi ulnaris, and the Flexor profundus digitorum; its lower fourth is smooth and rounded. This border separates the internal from the posterior surface.

The *external* or *interosseous border* (crista interossea) begins above by the union of two lines, which converge from the extremities of the lesser sigmoid cavity and enclose between them a triangular space for the origin of part of the Supinator brevis; it ends below at the head of the ulna. Its two middle fourths are very prominent, its lower fourth is smooth and rounded. This border gives attachment to the interosseous membrane, and separates the anterior from the posterior surface.

The *anterior surface* (facies volaris), much broader above than below, is concave in its upper three-fourths, and gives origin to the Flexor profundus digitorum; its lower fourth, also concave, is covered by the Pronator quadratus. The lower fourth is separated from the remaining portion of the bone by a prominent ridge, directed obliquely downwards and inwards; this ridge (the *oblique* or *pronator ridge*) marks the extent of origin of the Pronator quadratus. At the junction of the upper with the middle third of the bone is the nutrient canal, directed obliquely upwards and inwards.

The *posterior surface* (facies dorsalis), directed backwards and outwards, is broad and concave above; convex and somewhat narrower in the middle of its course; narrow, smooth, and rounded below. It presents, above, an oblique ridge, which runs from the posterior extremity of the lesser sigmoid cavity, downwards to the posterior border; the triangular surface above this ridge receives the insertion of the Anconeus, while the upper part of the ridge itself affords attachment to the Supinator brevis. Below this the surface is subdivided by a longitudinal ridge, sometimes called the *perpendicular line*, into two parts: the internal part is smooth, and covered by the Extensor carpi ulnaris; the external portion, wider and rougher, gives origin from above

downwards to the Supinator brevis, the Extensor ossis metacarpi pollicis, the Extensor longus pollicis, and the Extensor indicis.

The *internal surface* (facies medialis) is broad and concave above, narrow and convex below. It gives origin by its upper three-fourths to the Flexor profundus digitorum : its lower fourth is subcutaneous.

The **lower extremity** of the ulna is of small size, and presents two eminences; the outer and larger is a rounded, articular eminence, termed the head of the ulna ; the inner, narrower and more projecting, is a non-articular eminence, the styloid process. The *head* (capitulum ulnæ) presents an articular surface, part of which, of an oval or semilunar form, is directed downwards, and articulates with the upper surface of the interarticular fibro-cartilage which separates it from the wrist-joint ; the remaining portion, directed outwards, is narrow, convex, and received into the sigmoid cavity of the radius. The *styloid process* (processus styloideus) projects from the inner and back part of the bone; it descends a little lower than the head, and ends in a rounded summit, which affords attachment to the internal lateral ligament of the wrist-joint. The head is separated from the styloid process, internally, by a depression for the attachment of the apex of the triangular interarticular fibro-cartilage, and behind, by a shallow groove for the passage of the tendon of the Extensor carpi ulnaris.

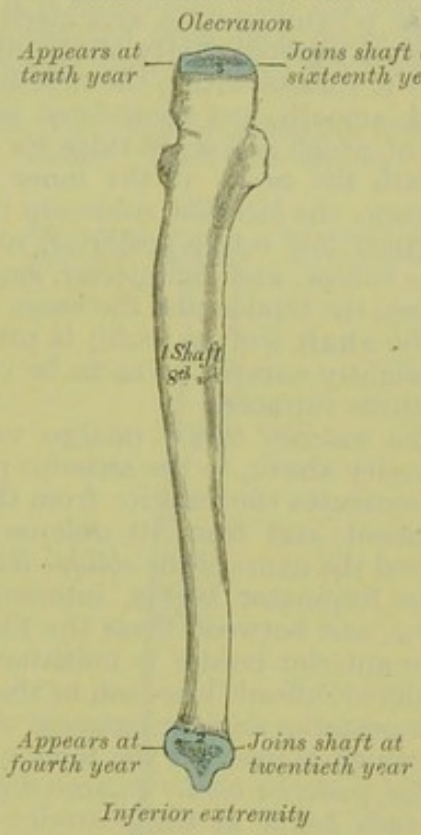

Fig. 360.—Plan of ossification of the ulna. From three centres.

Structure.—The structure of the ulna is similar to that of the other long bones.

Ossification.—The ulna is ossified from *three* centres : one each for the shaft, the inferior extremity, and the top of the olecranon (fig. 360). Ossification begins near the middle of the shaft about the eighth week of fœtal life, and soon extends through the greater part of the bone. At birth the ends are cartilaginous. About the fourth year, a centre appears in the middle of the head, and soon extends into the styloid process. About the tenth year, a centre appears in the olecranon near its extremity, the chief part of this process being formed by an upward extension of the shaft. The upper epiphysis joins the shaft about the sixteenth, the lower about the twentieth year.

Articulations.—The ulna articulates with the humerus and radius.

Surface Form.—The most prominent part of the ulna, the olecranon process, can always be identified at the back of the elbow-joint. When the forearm is flexed, the upper quadrilateral surface can be felt, directed backwards ; during extension it recedes into the olecranon fossa, and the contracting fibres of the Triceps prevent its being perceived. On the back of the olecranon is the smooth, triangular, subcutaneous surface, continuous with the posterior border of the shaft. During extension, the upper border of the olecranon is slightly above the level of the internal epicondyle, and the process itself is nearer to this epicondyle than to the external one. Running down the back of the forearm, from the apex of the triangular surface, is the prominent posterior border of the ulna, which can be felt throughout its entire length. As it passes down the forearm it pursues a sinuous course and inclines to its inner side, so that it is situated in the middle of the back of the limb above, and on the inner side of the wrist below. It is rounded off in its lower third, and may be traced below to the small subcutaneous surface of the styloid process. Internal to this border the lower fourth of the inner surface can be felt. The styloid process forms a prominent tubercle, continuous above with the posterior subcutaneous border, and terminating below in a blunt apex, which lies on a level with the wrist-joint. The styloid process is best perceived when the hand is in a position midway between supination and pronation. If the forearm be pronated while the finger is placed on the process, the latter will be felt to recede, and another prominence will

appear just behind and above it. This is the head of the ulna, which articulates with the lower end of the radius and the triangular interarticular fibro-cartilage, and now projects between the tendon of the Extensor carpi ulnaris and that of the Extensor minimi digiti.

The Radius

The **Radius** (figs. 358 and 359) is situated on the outer side of the ulna, which exceeds it in length and size. Its upper end is small, and forms only a small part of the elbow-joint; but its lower end is large, and forms the chief part of the wrist-joint. It is a long bone, prismatic in form, slightly curved longitudinally, and, like other long bones, has a shaft and two extremities.

The **upper extremity** presents a head, neck, and tuberosity. The *head* (capitulum radii) is of a cylindrical form, depressed on its upper surface into a shallow cup (fovea capituli radii) which articulates with the capitellum of the humerus. Around the circumference of the head is a smooth, articular surface (circumferentia articularis), broad internally where it articulates with the lesser sigmoid cavity of the ulna, narrow in the rest of its circumference, where it rotates within the orbicular ligament. The head is supported on a round, smooth, and constricted portion called the *neck* (collum radii), on the back of which is a slight ridge for the insertion of part of the Supinator brevis. Beneath the neck, at the inner and front aspect of the bone, is a rough eminence, the *bicipital tuberosity* (tuberositas radii); its surface is divided by a vertical line into a posterior, rough portion, for the insertion of the tendon of the Biceps, and an anterior, smooth portion, on which a bursa is interposed between the tendon and the bone.

The **shaft** (corpus radii) is prismoid in form, narrower above than below, and slightly curved, so as to be convex outwards. It presents three borders and three surfaces.

The *anterior border* (margo volaris) extends from the lower part of the tuberosity above, to the anterior part of the base of the styloid process below, and separates the anterior from the external surface. Its upper third is very prominent, and from its oblique direction, downwards and outwards, has received the name of the *oblique line* of the radius; it gives insertion, externally, to the Supinator brevis, internally, there arises from it the Flexor longus pollicis, and between these the Flexor sublimis digitorum. The middle third of the anterior border is indistinct and rounded. Its lower fourth is sharp, prominent, affords insertion to the Pronator quadratus, and gives attachment to the posterior annular ligament of the wrist; it terminates in a small tubercle, into which is inserted the tendon of the Brachio-radialis.

The *posterior border* (margo dorsalis) begins above at the back of the neck, and ends below at the posterior part of the base of the styloid process; it separates the posterior from the external surface. It is indistinct above and below, but well marked in the middle third of the bone.

The *internal* or *interosseous border* (crista interossea) begins above, at the back part of the tuberosity, where it is rounded and indistinct; it becomes sharp and prominent as it descends, and at its lower part divides into two ridges, which are continued to the anterior and posterior margins of the sigmoid cavity. To the posterior of the two ridges the lower part of the interosseous membrane is attached, while the triangular surface between the ridges gives insertion to part of the Pronator quadratus. This border separates the anterior from the posterior surface, and throughout the greater part of its extent gives attachment to the interosseous membrane.

The *anterior surface* (facies volaris) is concave in its upper three-fourths, and gives origin to the Flexor longus pollicis; it is broad and flat in its lower fourth, and affords insertion to the Pronator quadratus. A prominent ridge limits the insertion of the Pronator quadratus below, and between this and the inferior border is a triangular rough surface for the attachment of the anterior ligament of the wrist-joint. At the junction of the upper and middle thirds of this surface is the nutrient foramen, which is directed obliquely upwards.

The *posterior surface* (facies dorsalis) is round, convex, and smooth in the upper third of its extent, and covered by the Supinator brevis. Its middle third is broad, slightly concave, and gives origin to the Extensor ossis metacarpi pollicis above, and the Extensor brevis pollicis below. Its lower third is broad,

convex and covered by the tendons of the muscles which subsequently run in the grooves on the lower end of the bone.

The *external surface* (facies lateralis) is round and convex throughout its entire extent. Its upper third gives insertion to the Supinator brevis. About its centre is seen a rough ridge, for the insertion of the Pronator teres. Its lower part is narrow, and covered by the tendons of the Extensor ossis metacarpi pollicis and Extensor brevis pollicis.

The **lower extremity** is large, of quadrilateral form, and provided with two articular surfaces—one on the inferior surface, for articulation with the carpus, and another at the inner side, for articulation with the ulna. The *carpal articular surface* is triangular, concave, smooth, and divided by a slight antero-posterior ridge into two parts. Of these, the external, triangular, articulates with the scaphoid bone; the inner, quadrilateral, with the semilunar. The *articular surface for the ulna* is called the *sigmoid cavity* (incisura ulnaris) of the radius; it is narrow, concave, smooth, and articulates with the head of the ulna. These two articular surfaces are separated from each other by a prominent ridge, to which the base of the triangular fibro-cartilage is attached; this structure separates the wrist-joint from the inferior radio-ulnar articulation. This end of the bone presents three non-articular surfaces—anterior, posterior, and external. The *anterior surface*, rough and irregular, affords attachment to the anterior ligament of the wrist-joint. The *posterior surface* is convex, affords attachment to the posterior ligament of the wrist-joint, and is marked by three grooves. Enumerated from without inwards, the first groove is broad, but shallow, and subdivided into two by a slight ridge: the outer of these two transmits the tendon of the Extensor carpi radialis longior, the inner the tendon of the Extensor carpi radialis brevior. The second, near the centre of the bone, is a deep but narrow groove, bounded on its outer side by a sharply defined ridge; it is directed obliquely from above, downwards and outwards, and transmits the tendon of the Extensor longus pollicis. The third and most internal is broad, for the passage of the tendons of the Extensor indicis and Extensor communis digitorum. The *external surface* is prolonged obliquely downwards into a strong, conical projection, the *styloid process* (processus styloideus), which gives attachment by its base to the tendon of the Brachio-radialis, and by its apex to the external lateral ligament of the wrist-joint. The outer surface of this process is marked by a flat groove, for the tendons of the Extensor ossis metacarpi pollicis and Extensor brevis pollicis.

FIG. 361.—Plan of ossification of the radius. From three centres.

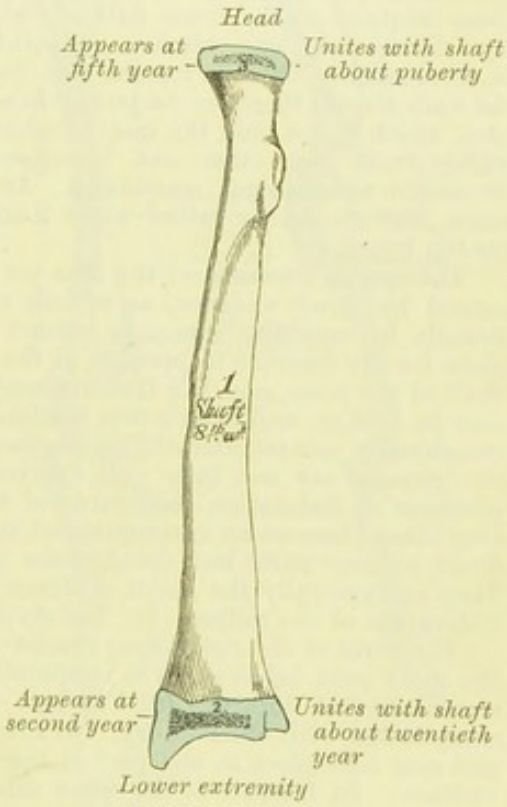

Structure.—The structure of the radius is similar to that of the other long bones.

Ossification (fig. 361).—The radius is ossified from *three* centres: one for the shaft, and one for either extremity. That for the shaft makes its appearance near the centre of the bone, during the eighth week of fœtal life. About the end of the second year, ossification commences in the lower end; and at the fifth year, in the upper end. The upper epiphysis fuses with the shaft, at the age of seventeen or eighteen, the lower about the age of twenty. An additional centre, sometimes found in the bicipital tuberosity, appears about the fourteenth or fifteenth year.

Articulations.—The radius articulates with four bones: the humerus, ulna, scaphoid, and semilunar.

Surface Form.—Below, and a little in front of, the posterior surface of the external condyle a part of the head of the radius may be felt; its position is indicated by a little dimple in the skin, which is most visible when the arm is extended. If the finger be placed on this dimple and the semiflexed forearm pronated and supinated, the head of the bone will be distinctly perceived rotating in the lesser sigmoid cavity. The upper half of the shaft cannot be felt, as it is surrounded by the fleshy bellies of the muscles arising from the external condyle. The lower half can be readily examined, though covered by tendons and muscles and not strictly subcutaneous, and if traced downwards is felt to terminate in a lozenge-shaped, convex surface on the outer side of the base of the styloid process. This is the only subcutaneous part of the bone, and from its lower extremity the apex of the styloid process will be felt bending inwards towards the wrist. About the middle of the posterior aspect of the lower extremity is a well-marked ridge, the *dorsal radial tubercle*, best perceived when the hand is slightly flexed on the wrist. It forms the outer boundary of the oblique groove, through which the tendon of the Extensor longus pollicis runs, and helps to keep that tendon in its place.

Applied Anatomy.—The two bones of the forearm are more often broken together, than is either the radius or ulna separately. It is therefore convenient to consider the fractures of both bones in the first instance and subsequently to mention the principal fractures which take place in each bone. Fractures of both bones may be produced by either direct or indirect violence, though more commonly by direct violence. When indirect force is applied to the forearm the radius as a rule gives way, though both bones may suffer. Fracture from indirect force generally takes place somewhere about the middle of the bones, while that from direct violence may occur at any part, but is most frequent in the lower half of the bones. The fracture is usually transverse, but may be more or less oblique. A point of interest in connection with these fractures is the tendency there is for the two bones to unite across the interosseous membrane; the limb should therefore be put up in a position midway between supination and pronation, which is not only the most comfortable position, but also separates the bones most widely from each other and therefore diminishes the risk of their becoming united across the interosseous membrane. Anterior and posterior splints are applied in these cases, and should be rather wider than the limb, so as to prevent any lateral pressure on the bones.

The special fractures of the ulna are:—(1) Fracture of the olecranon, which is usually caused by direct violence, as in falls on the elbow with the forearm flexed, but occasionally by muscular action in sudden contraction of the Triceps. The most common place for the fracture to occur is at the constricted portion where the olecranon joins the shaft of the bone, and the fracture may be either transverse or oblique; but any part may be broken, and even a thin shell may be torn off. Fractures from direct violence are occasionally comminuted. The displacement is slight, if the fibrous structures around the process are not torn. (2) Fracture of the coronoid process may occur as a complication of dislocation backwards of the bones of the forearm, but it is doubtful if it ever takes place as an uncomplicated injury. (3) Fractures of the shaft of the ulna may occur at any part, but usually take place at or a little below the middle of the bone. They are generally the result of direct violence, but may occur as a complication of dislocation of the radius. (4) The styloid process may be knocked off by direct violence.

Fractures of the radius may consist of—(1) Fracture of the head of the bone; this for the most part takes place in conjunction with some other lesion, but may occur as an uncomplicated injury. (2) Fracture of the neck may also occur, but is usually complicated with other injury. (3) Fractures of the shaft of the radius are very common, and may take place at any part of the bone. They may be caused by direct or indirect violence. In fracture of the upper third of the shaft—that is to say, above the insertion of the Pronator teres—the displacement is very great. The upper fragment is strongly supinated by the Biceps and Supinator brevis, and flexed by the Biceps; while the lower fragment is pronated and drawn towards the ulna by the two Pronators. If such a fracture be put up in the ordinary position, midway between supination and pronation, the bone will unite with the upper fragment in a position of supination, and the lower one in the mid-position, and thus considerable impairment of the movement of supination will result; the limb should therefore be put up with the forearm supinated. (4) The most important fracture of the radius is that of the lower end (Colles's fracture). The fracture is transverse, and generally takes place about an inch from the lower extremity. It is caused by falls on the palm of the hand, and is an injury of advanced life, occurring more frequently in the female than in the male. In consequence of the manner in which the fracture is caused, the upper fragment is driven into the lower, and impaction is the result; excess of violence may, however, disimpact, the lower fragment being split into two or more pieces, so that no fixation occurs. Separation of the lower epiphysis of the radius may take place in the young. This injury and Colles's fracture may be distinguished from other injuries in this neighbourhood—especially dislocation, with which they are liable to be confounded—by observing the relative positions of the styloid processes of the ulna and radius. In the natural condition of parts, with the arm hanging by the side, the styloid process of the radius is on a lower level than that of the ulna: that is to

FIG. 362.—Bones of the left hand. Palmar surface.

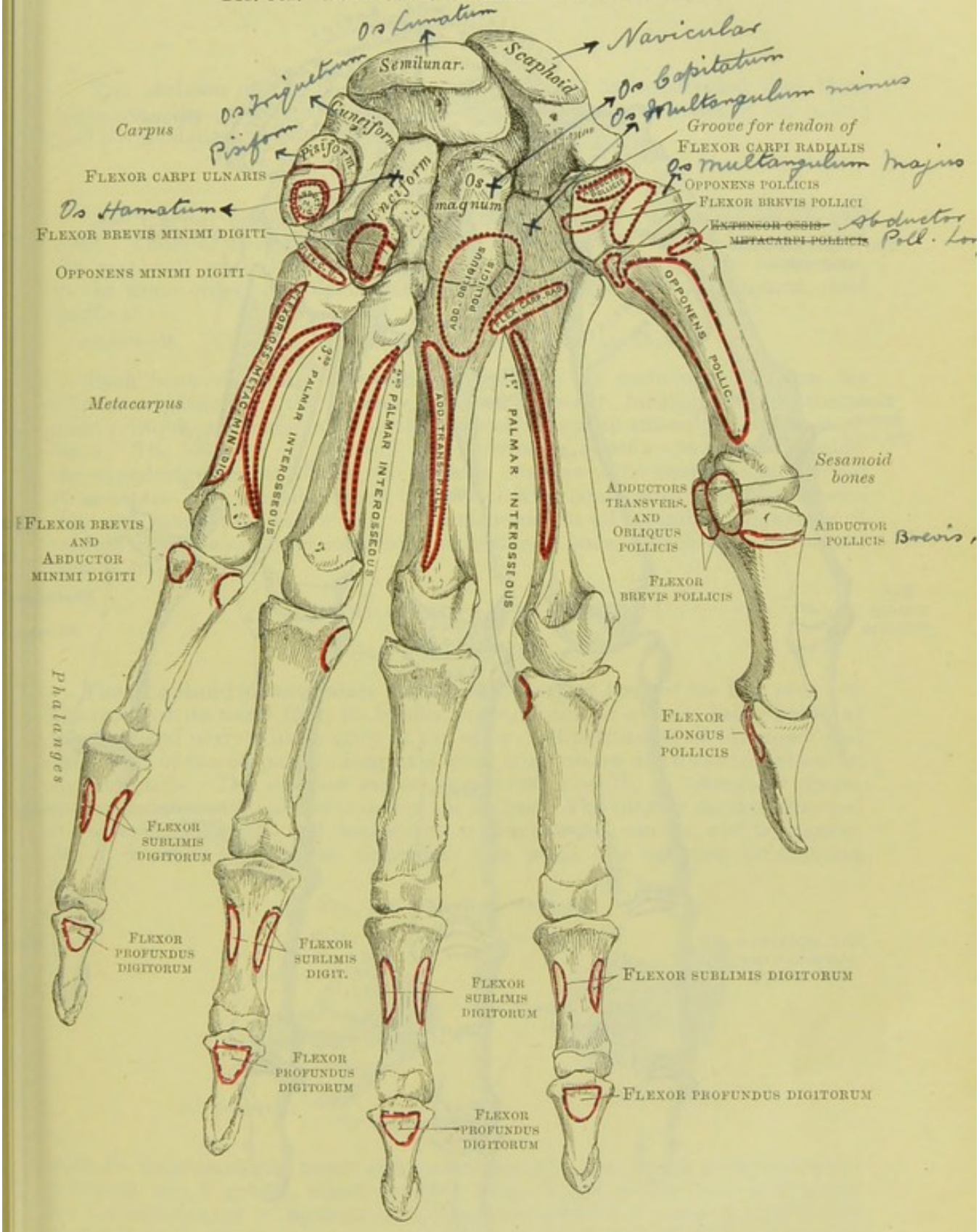

FIG. 363.—Bones of the left hand. Dorsal surface.

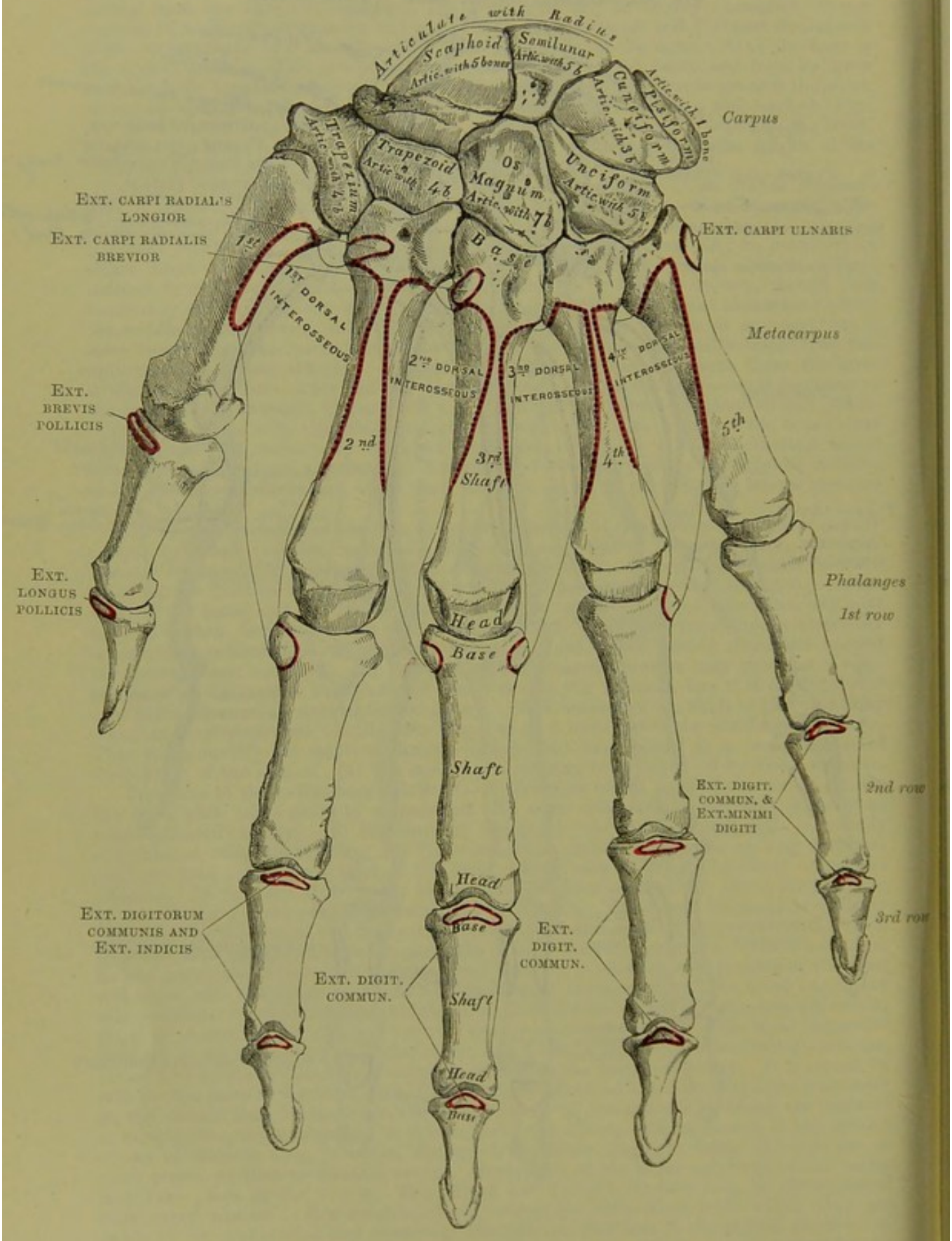

say, nearer the ground. After fracture or separation of the epiphysis the styloid process of the radius is on the same level as, or on a higher level than, that of the ulna, whereas it would be unaltered in position in dislocation. Reduction in the case of Colles's fracture is usually easily effected by traction on the hand, the limb being subsequently splinted with the hand in the position of ulnar flexion.

THE HAND

The skeleton of the hand (figs. 362 and 363) is subdivided into three segments—the carpus or wrist bones; the metacarpus or bones of the palm; and the phalanges or bones of the digits.

THE CARPUS

The **Carpal bones** (ossa carpi), eight in number, are arranged in two rows. Those of the upper row, from the radial to the ulnar side, are named the scaphoid, semilunar, cuneiform, and pisiform; those of the lower row, in the same order, are named the trapezium, trapezoid, os magnum, and unciform.

Common Characters of the Carpal Bones

Each bone (excepting the pisiform) presents six surfaces. Of these the *anterior* or *palmar* and the *posterior* or *dorsal* are rough, for ligamentous attachment; the dorsal surfaces being the broader, except in the scaphoid and semilunar. The *superior* or *proximal*, and *inferior* or *distal surfaces* are articular, the superior generally convex, the inferior concave; the *internal* and *external surfaces* are also articular when in contact with contiguous bones, otherwise they are rough and tubercular. The structure in all is similar, consisting of cancellous tissue enclosed in a layer of compact bone. Each bone is ossified from a single centre.

Bones of the Upper Row

Scaphoid (fig. 364)

The **Scaphoid** (os naviculare manus) is the largest bone of the first row. It has received its name from its fancied resemblance to a boat, being broad at one end, and narrow like a prow at the other. It is situated at the upper and outer part of the carpus, its long axis being from above downwards, outwards, and forwards. The *superior surface* is convex, smooth, of triangular shape, and articulates with the lower end of the radius. The *inferior surface*, directed downwards, outwards, and backwards, is also smooth, convex, and triangular, and is divided by a slight ridge into two parts, the external articulating

Fig. 364.—The left scaphoid.

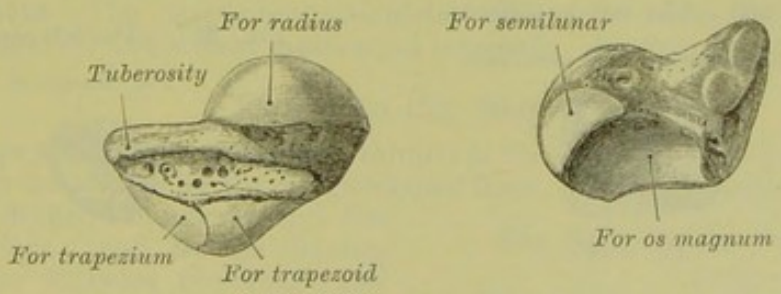

with the trapezium, the inner with the trapezoid. The *dorsal surface* presents a narrow, rough groove, which runs the entire length of the bone, and serves for the attachment of ligaments. The *palmar surface* is concave above, and elevated at its lower and outer part into a rounded projection, the *tuberosity* (tuberculum oss. navicularis), which is directed forwards and gives attachment to the anterior annular ligament of the wrist and sometimes origin to a few fibres of the Abductor pollicis. The *external surface* is rough and narrow, and gives attachment to the external lateral ligament of the wrist. The *internal*

surface presents two articular facets; of these, the superior or smaller is flattened, of semilunar form, and articulates with the semilunar; the inferior or larger is concave, forming with the semilunar bone a concavity for the head of the os magnum.

Articulations.—The scaphoid articulates with five bones: the radius above, trapezium and trapezoid below, os magnum and semilunar internally.

Semilunar (fig. 365)

The **Semilunar** (os lunatum) may be distinguished by its deep concavity and crescentic outline. It is situated in the centre of the upper row of the carpus, between the scaphoid and cuneiform. The *superior surface*, convex and smooth, articulates with the radius. The *inferior surface* is deeply concave, and of greater extent from before backwards than transversely: it articulates with the head of the os magnum, and, by a long, narrow facet (separated by a ridge from the general surface), with the unciform. The *palmar* and *dorsal surfaces* are rough, for the attachment of ligaments, the former being the broader, and of a somewhat rounded form. The *external surface* presents a narrow, flattened, semilunar facet for articulation with the scaphoid. The *internal surface* is marked by a smooth, quadrilateral facet, for articulation with the cuneiform.

Fig. 365.—The left semilunar.

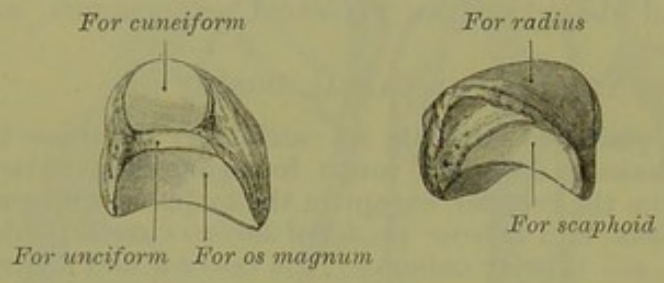

Articulations.—The semilunar articulates with five bones: the radius above, os magnum and unciform below, scaphoid externally and cuneiform internally.

Cuneiform (fig. 366)

The **Cuneiform** (os triquetrum) may be distinguished by its pyramidal shape, and by an oval isolated facet for articulation with the pisiform bone. It is situated at the upper and inner side of the carpus. The *superior surface* presents an internal, rough, non-articular portion, and an external convex articular portion, which articulates with the triangular fibro-cartilage of the wrist. The *inferior surface*, directed outwards, is concave, sinuously curved, and smooth for articulation with the unciform. The *dorsal surface* is rough for the attachment of ligaments. The *palmar surface* presents, on its inner part, an oval facet, for articulation with the pisiform; its outer part is rough for ligamentous attachment. The *external surface*, the base of the pyramid, is marked by a flat, quadrilateral, smooth facet, for articulation with the semilunar. The *internal surface*, the summit of the pyramid, is pointed and roughened, for the attachment of the internal lateral ligament of the wrist.

Fig. 366.—The left cuneiform.

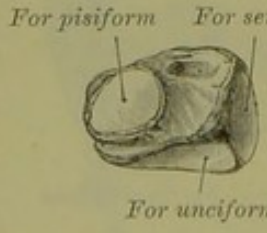

Fig. 367.—The left pisiform.

Articulations.—The cuneiform articulates with three bones: the semilunar externally, the pisiform in front, the unciform below; and with the triangular, interarticular fibro-cartilage which separates it from the lower end of the ulna.

Pisiform (fig. 367)

The **Pisiform** (os pisiforme) may be known by its small size, and by its presenting a single articular facet. It is situated on a plane anterior to the other carpal bones and is spheroidal in form, with its long diameter directed vertically. Its *dorsal* surface presents a smooth, oval facet, for articulation with the cuneiform : this facet approaches the superior, but not the inferior border of the bone. The *palmar surface* is rounded and rough, and gives attachment to the anterior annular ligament of the wrist, and to the Flexor carpi ulnaris and Abductor minimi digiti. The *outer* and *inner surfaces* are also rough, the former being concave, the latter usually convex.

Articulation.—The pisiform articulates with one bone, the cuneiform.

Bones of the Lower Row

Trapezium (fig. 368)

The **Trapezium** (os multangulum majus) may be distinguished by a deep groove, for the tendon of the Flexor carpi radialis. It is situated at the external and inferior part of the carpus, between the scaphoid and first metacarpal bone. The *superior surface* is directed upwards and inwards ; internally, it is smooth, and articulates with the scaphoid ; externally, it is rough, and continuous with the external surface. The *inferior surface*, directed downwards and outwards, is oval, concave from side to side, convex from before backwards, so as to form a saddle-shaped surface, for articulation with the base of the first metacarpal bone. The *palmar surface* is narrow

Fig. 368.—The left trapezium.



and rough. At its upper part is a deep groove, running from above obliquely downwards and inwards : it transmits the tendon of the Flexor carpi radialis, and is bounded externally by an oblique ridge. This surface gives origin to the Abductor, Opponens, and Flexor brevis pollicis muscles, and also affords attachment to the anterior annular ligament of the wrist. The *dorsal surface* is rough. The *external surface* is broad and rough, for the attachment of ligaments. The *internal surface* presents two facets : the upper, large and concave, articulates with the trapezoid ; the lower, small and oval, with the base of the second metacarpal.

Articulations.—The trapezium articulates with four bones : the scaphoid above, the trapezoid and second metacarpal internally, the first metacarpal below.

Trapezoid (fig. 369)

The **Trapezoid** (os multangulum minus) is the smallest bone in the second row. It may be known by its wedge-shaped form, the broad end of the wedge forming the dorsal, the narrow end the palmar, surface ; and by its having four articular surfaces touching each other, and separated by sharp edges. The *superior surface*, quadrilateral, smooth, and slightly concave, articulates with the scaphoid. The *inferior surface* articulates with the upper end of the second metacarpal bone ; it is convex from side to side, concave from before backwards, and subdivided, by an elevated ridge, into two unequal lateral facets. The *dorsal* and *palmar*

Fig. 369.—The left trapezoid.

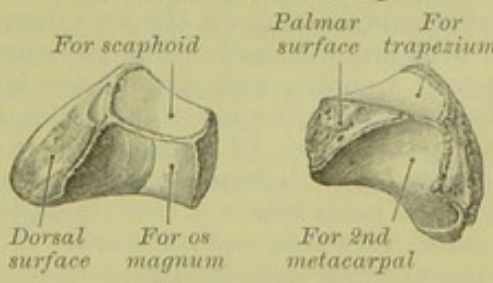

surfaces are rough for the attachment of ligaments, the former being the larger of the two. The *external surface*, convex and smooth, articulates with the trapezium. The *internal surface* is concave and smooth in front, for articulation with the os magnum; rough behind, for the attachment of an interosseous ligament.

Articulations.—The trapezoid articulates with four bones: the scaphoid above, second metacarpal below, trapezium externally, and os magnum internally.

Os Magnum (fig. 370)

The **Os magnum** (os capitatum) is the largest of the carpal bones, and occupies the centre of the wrist. It presents, above, a rounded portion or head, which is received into the concavity formed by the scaphoid and semilunar bones; a constricted portion or neck; and below this, the body. The *superior surface* is round, smooth, and articulates with the semilunar. The *inferior surface* is divided by two ridges into three facets, for articulation with the second, third, and fourth metacarpal bones, that for the third (the middle facet) being the largest. The *dorsal surface* is broad and rough. The *palmar surface* is narrow, rounded, and rough, for the attachment of ligaments and a part of the Adductor obliquus pollicis. The *external surface* articulates

Fig. 370.—The left os magnum.

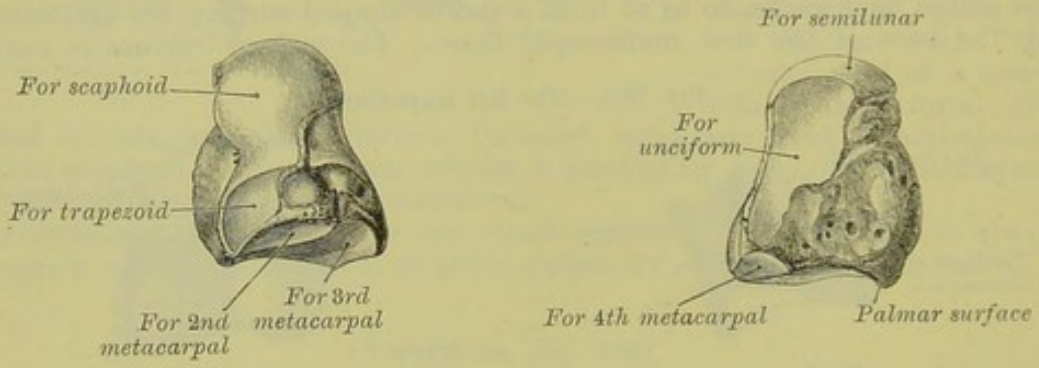

with the trapezoid by a small facet at its anterior inferior angle, behind which is a rough depression for the attachment of an interosseous ligament. Above this is a deep, rough groove, which forms part of the neck, and serves for the attachment of ligaments; it is bounded superiorly by a smooth, convex surface, for articulation with the scaphoid. The *internal surface* articulates with the unciform by a smooth, concave, oblong facet, which occupies its posterior and superior parts; it is rough in front, for the attachment of an interosseous ligament.

Articulations.—The os magnum articulates with seven bones: the scaphoid and semilunar above; the second, third, and fourth metacarpals below; the trapezoid on the radial side; and the unciform on the ulnar side.

Unciform (fig. 371)

The **Unciform** (os hamatum) may be readily distinguished by its wedge-shaped form, and the hook-like process which projects from its palmar surface. It is situated at the inner and lower angle of the carpus, with its base downwards, resting on the two inner metacarpal bones, and its apex directed upwards and outwards. The *superior surface*, the apex of the wedge, is narrow, convex, smooth, and articulates with the semilunar. The *inferior surface* articulates with the fourth and fifth metacarpal bones, by concave facets which are separated by an antero-posterior ridge. The *dorsal surface* is triangular and rough, for ligamentous attachment. The *palmar surface* presents, at its lower and inner side, a curved, hook-like process, the *unciform process* (hamulus), directed forwards and outwards. This process gives attachment, by its apex, to the anterior annular ligament of the wrist and the Flexor carpi ulnaris; by its inner surface to the Flexor brevis and Opponens minimi digiti; its outer

side is grooved for the passage of the Flexor tendons into the palm of the hand. It is one of the four eminences on the front of the carpus to which the anterior annular ligament of the wrist is attached ; the others being the pisiform internally, the oblique ridge of the trapezium and the tuberosity of the scaphoid externally. The *internal surface* articulates with the cuneiform by an oblong

Fig. 371.—The left unciform.

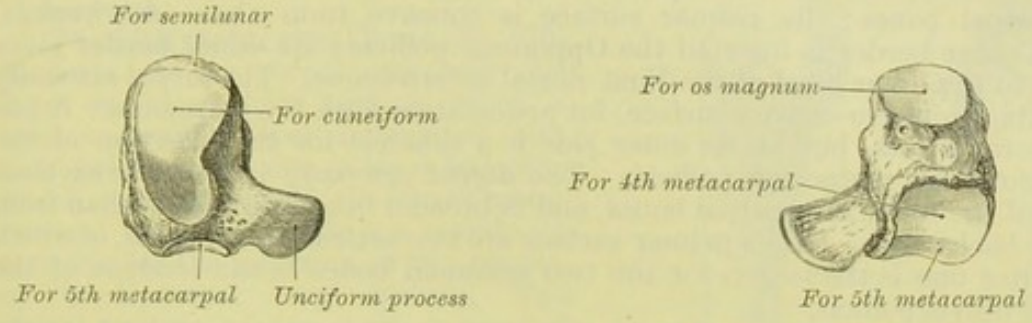

facet, cut obliquely from above, downwards and inwards. The *external surface* articulates with the os magnum by its upper and posterior part, the remaining portion being rough, for the attachment of ligaments.

Articulations.—The unciform articulates with five bones : the semilunar above, the fourth and fifth metacarpals below, the cuneiform internally, the os magnum externally.

THE METACARPUS

The **Metacarpus** consists of five cylindrical bones which are numbered from without inwards (ossa metacarpalia I–V) ; each consists of a shaft and two extremities.

Common Characters of the Metacarpal Bones

The **shaft** (corpus) is prismoid in form, and curved, so as to be convex in the longitudinal direction behind, concave in front. It presents three surfaces : two lateral and one dorsal. The *lateral surfaces* are concave, for the attachment of the Interosseous muscles, and separated from one another by a prominent anterior ridge. The *dorsal surface* presents in its distal two-thirds a smooth, triangular, flattened area which is covered, in the recent state, by the tendons of the Extensor muscles. This surface is bounded by two lines, which commence in small tubercles situated on either side of the digital extremity, and, running upwards, converge to meet some distance behind the centre of the bone and form a ridge which runs along the rest of the dorsal surface to the carpal extremity. This ridge separates two lateral sloping surfaces for the attachment of the Dorsal interossei.* To the tubercles on the digital extremities are attached the lateral ligaments of the metacarpo-phalangeal joints.

The **carpal extremity** or **base** (basis) is of a cuboidal form, and broader behind than in front : it articulates above with the carpus, and on either side with the adjoining metacarpal bones ; its *dorsal* and *palmar surfaces* are rough, for the attachment of ligaments.

The **digital extremity** or **head** (capitulum) presents an oblong surface markedly convex from before backwards, less so from side to side, and flattened laterally ; it articulates with the proximal phalanx. It is broader, and extends farther forwards, on the palmar than on the dorsal aspect, and is longer in the antero-posterior than in the transverse diameter. On either side of the head is a tubercle for the attachment of the lateral ligament of the metacarpo-phalangeal joint. The *dorsal surface*, broad and flat, supports the Extensor tendons ; the *palmar surface* is grooved in the middle line for the passage of the Flexor tendons, and marked on either side by an articular eminence continuous with the terminal articular surface.

* By these sloping surfaces the metacarpal bones may be at once distinguished from the metatarsal bones.

Peculiar Characters of the Metacarpal Bones

The **first metacarpal bone** (fig. 372) is shorter and stouter than the others, diverges to a greater degree from the carpus, and its palmar surface is directed inwards towards the palm. The *shaft* is flattened and broad on its dorsal surface, and does not present the ridge which is found on the other metacarpal bones; its palmar surface is concave from above downwards. On its outer border is inserted the Opponens pollicis; its inner border gives origin to the outer head of the First dorsal interosseous. The *carpal extremity* presents a concavo-convex surface, for articulation with the trapezium; it has no lateral facets, but on its outer side is a tubercle for the insertion of the Extensor ossis metacarpi pollicis. The *digital extremity* is less convex than those of the other metacarpal bones, and is broader from side to side than from before backwards. On its palmar surface are two articular eminences, of which the outer one is the larger, for the two sesamoid bones in the tendons of the Flexor brevis pollicis.

The **second metacarpal bone** (fig. 373) is the longest, and its base the largest, of the four remaining bones. Its *carpal extremity* is prolonged upwards and inwards, forming a prominent ridge. It presents four articular facets: three on the upper surface and one on the inner or ulnar side. Of the facets on the upper surface the middle is the largest and is concave from side to side, convex from before backwards for articulation with the trapezoid; the external is small, flat and oval for articulation with the trapezium; the internal, on the summit of the ridge, is long and narrow for articulation with the os magnum. The facet on the ulnar side articulates with the third metacarpal. The Extensor carpi radialis longior is inserted on the dorsal surface and the Flexor carpi radialis on the palmar surface of this extremity.

Fig. 372.—The first metacarpal. (Left.)

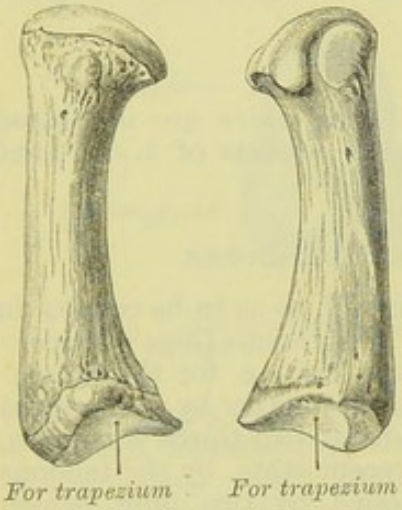

Fig. 373.—The second metacarpal. (Left.)

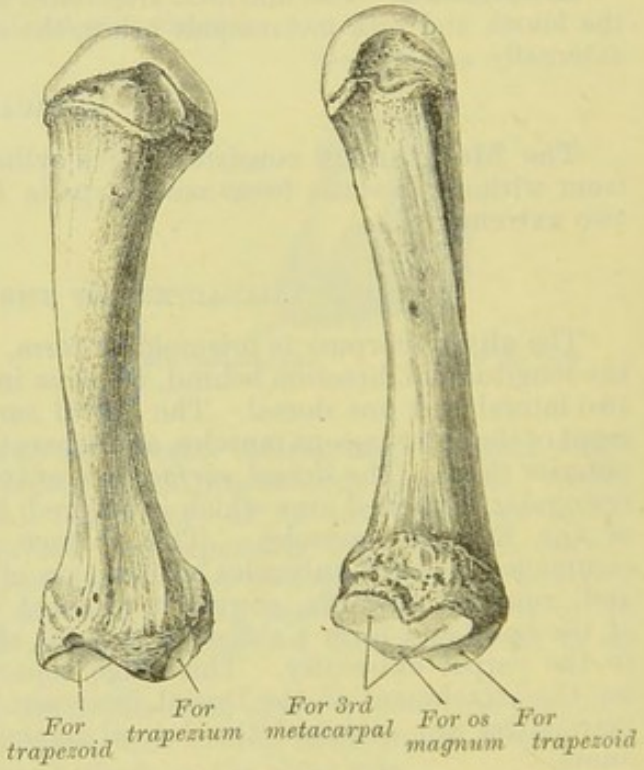

The **third metacarpal bone** (fig. 374) is a little smaller than the preceding. The dorsal aspect of its *carpal extremity* presents on its radial side a pyramidal eminence, the *styloid process*, which extends upwards behind the os magnum; immediately below this is a rough surface for the attachment of the Extensor carpi radialis brevior. The carpal articular facet is concave behind, flat in front, and articulates with the os magnum. On the radial side is a smooth, concave facet for articulation with the second metacarpal, and on the ulnar side two small oval facets for articulation with the fourth metacarpal.

The **fourth metacarpal bone** (fig. 375) is shorter and smaller than the preceding. The *carpal extremity* is small and quadrilateral; its superior surface presents two facets, a large one externally for articulation with the unciform and a small one internally for the os magnum. On the radial side are two oval facets, for articulation with the third metacarpal; and on the ulnar side, a single concave facet, for the fifth metacarpal.

Fig. 374.—The third metacarpal. (Left.)

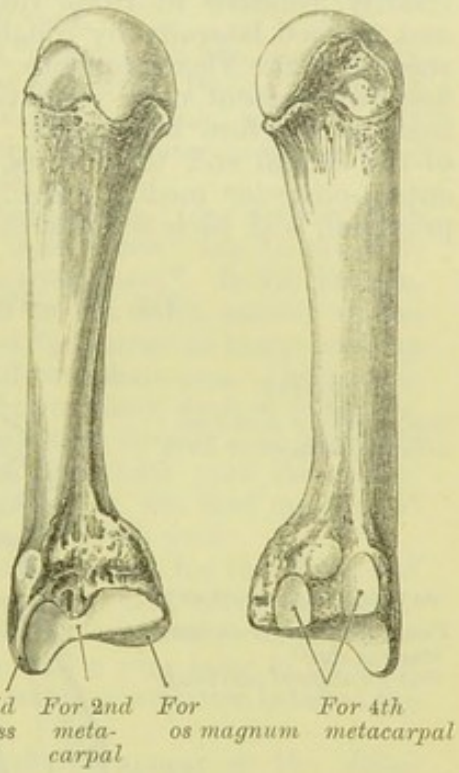

The **fifth metacarpal bone** (fig. 376) presents on its *carpal extremity* one facet on its superior surface, which is concavo-convex, and articulates with the unciform, and one on its radial side, which articulates with the fourth metacarpal. On its ulnar side is a prominent tubercle for the insertion of the tendon of the Extensor carpi ulnaris. The dorsal surface of the shaft is marked by an oblique ridge, which extends from near the ulnar side of the upper extremity to the radial side of the lower. The outer division of this surface serves for the attachment of the Fourth dorsal interosseous muscle; the inner division is smooth, triangular, and covered by the Extensor tendons of the little finger.

Articulations.—Besides their phalangeal articulations, the metacarpal bones articulate as follows: the first with the trapezium; the second with the trapezium, trapezoid, os magnum and third metacarpal; the third with the os magnum and second and fourth metacarpals; the fourth with the os magnum, unciform, and third and fifth metacarpals; and the fifth with the unciform and fourth metacarpal.

Fig. 375.—The fourth metacarpal. (Left.)

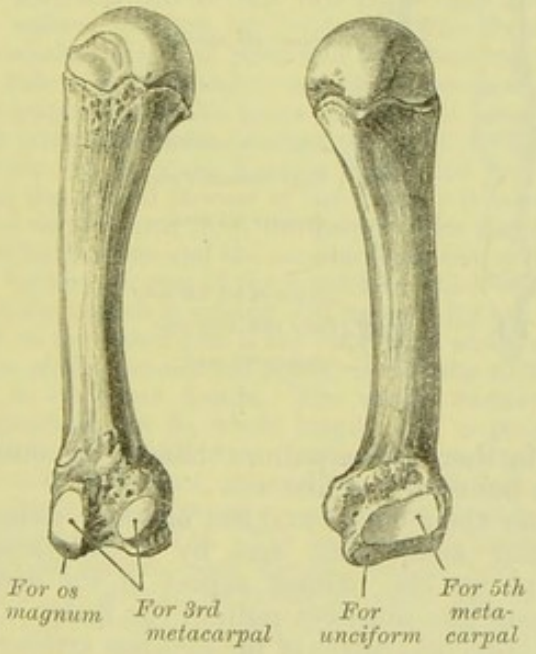

Fig. 376.—The fifth metacarpal. (Left.)

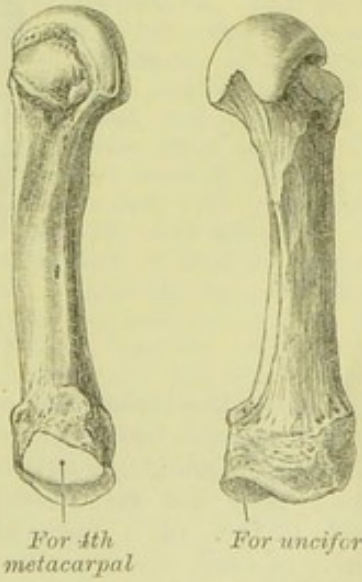

The first has no lateral facets on its carpal extremity; the second has no lateral facet on its radial, but one on its ulnar side; the third has one on its radial and two on its ulnar side; the fourth has two on its radial and one on its ulnar side; and the fifth has one on its radial side only.

THE PHALANGES

The **Phalanges** (phalanges digitorum manus) are fourteen in number, three for each finger, and two for the thumb. Each consists of a shaft and two extremities. The *shaft* tapers from above downwards, is convex posteriorly, concave in front from above downwards, flat from side to side, and marked laterally by rough ridges, which give attachment to the fibrous sheaths of the Flexor tendons. The *metacarpal extremities* of the bones of the first row present oval, concave articular surfaces, broader from side to side than from before backwards. The *proximal extremity* of each of the bones of the second and third rows presents a double concavity separated by an antero-posterior median ridge. The *distal extremities* are smaller than the proximal, and each terminates in two lateral condyles separated by a shallow

Fig. 377.—Plan of ossification of the hand.

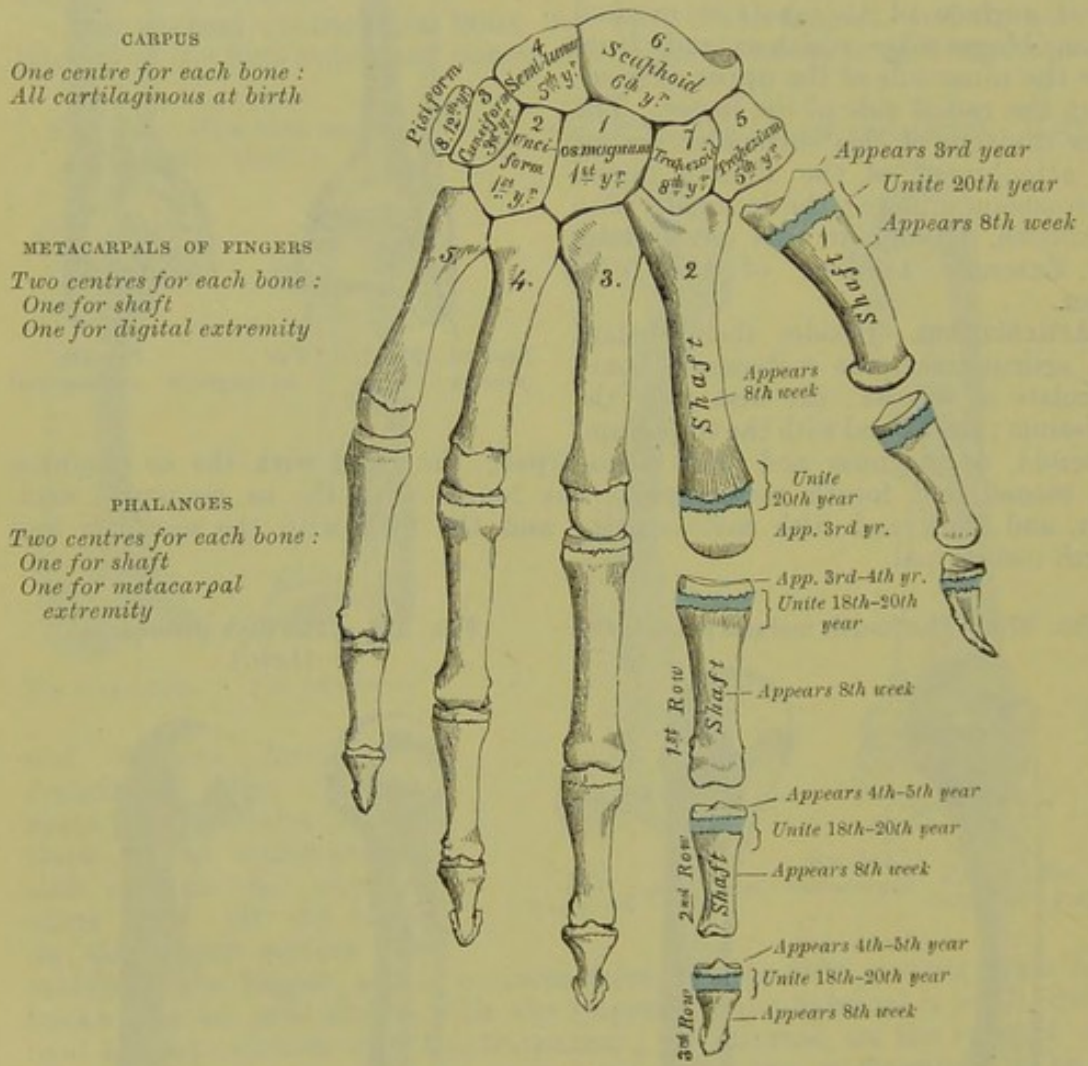

groove ; the articular surface extends farther on the palmar than on the dorsal aspect, a condition best marked in the bones of the first row.

The *ungual phalanges* are convex on their dorsal and flat on their palmar surfaces ; they are recognised by their small size, and by a roughened, elevated surface of a horse-shoe form on the palmar aspect of the distal extremity of each which serves to support the sensitive pulp of the finger.

Articulations.—In the four inner digits the phalanges of the first row articulate with those of the second row and with the metacarpals ; the phalanges of the second row with those of the first and third rows, and the ungual phalanges with those of the second row. In the thumb, which has only two phalanges, the first phalanx articulates by its proximal extremity with the metacarpal bone and by its distal with the ungual phalanx.

Ossification of the Bones of the Hand

The **Carpal Bones** are each ossified from a single centre, and ossification proceeds in the following order (fig. 377): in the os magnum and unciform during the first year, the former preceding the latter; in the cuneiform, during the third year; in the semilunar and trapezium, during the fifth year, the former preceding the latter; in the scaphoid, during the sixth year; in the trapezoid, during the eighth year; and in the pisiform, about the twelfth year.

Occasionally an additional bone, the *os centrale*, is found on the back of the carpus, lying between the scaphoid, trapezoid, and os magnum. During the second month of fœtal life it is represented by a small cartilaginous nodule, which usually fuses with the cartilaginous scaphoid. Sometimes the styloid process of the third metacarpal is detached and forms an additional ossicle.

The **Metacarpal Bones** are each ossified from *two* centres; one for the shaft and one for the digital extremity of each of the four inner bones; one for the shaft and one for the carpal extremity of the first metacarpal bone.* It will be seen, therefore, that the first metacarpal bone is ossified in the same manner as the phalanges, and this has led some anatomists to regard the thumb as being made up of three phalanges, and not of a metacarpal bone and two phalanges. Ossification commences in the middle of the shaft about the eighth or ninth week of fœtal life, the centre for the first metacarpal bone being the last to appear, and gradually proceeds towards either end of the bone; about the third year the digital extremities of the four inner metacarpals, and the base of the first metacarpal begin to ossify; they unite with the shafts about the twentieth year.

The **Phalanges** are each ossified from *two* centres; one for the shaft, and one for the proximal extremity. Ossification begins in the shaft, about the eighth week of fœtal life. Ossification of the proximal extremity commences in the bones of the first row between the third and fourth years, and a year later in those of the second and third rows. The two centres become united in each row between the eighteenth and twentieth years.

In the ungual phalanges the centres for the shafts appear at the distal extremities of the phalanges, instead of at the middle of the shafts, as in the other phalanges. Moreover, of all the bones of the hand, the ungual phalanges are the first to begin to ossify.

Surface Form.—On the front of the wrist are two subcutaneous eminences, one on the radial side, the larger and flatter, produced by the tuberosity of the scaphoid and the ridge on the trapezium; the other on the ulnar side, caused by the pisiform bone. The tuberosity of the scaphoid can be felt just below and internal to the apex of the styloid process of the radius, between the tendons of the Extensor ossis metacarpi pollicis and Flexor carpi radialis; it is best perceived by extending the hand on the forearm. Half an inch below this tubercle another and better marked prominence can be felt; this is the ridge on the trapezium, which gives attachment to some of the short muscles of the thumb. On the inner side of the front of the wrist the pisiform bone forms a small but prominent projection. It is some distance below the lower end of the ulna, and just below the level of the styloid process of the radius; it is crossed by the crease which separates the front of the forearm from the palm of the hand. The rest of the front of the carpus is covered by tendons and the annular ligament, and is entirely concealed, with the exception of the hooked process of the unciform, which can be made out only with difficulty. The back of the carpus is convex and covered by the Extensor tendons, so that the posterior surface of the cuneiform is the only bone which can be felt. Below the carpus the dorsal surfaces of the metacarpal bones, except the fifth, are covered by tendons, and are only visible in very thin hands. The dorsal surface of the fifth is, however, subcutaneous throughout almost its whole length, and is plainly to be perceived and felt. Slightly external to the middle line of the hand is a prominence, frequently well marked, but occasionally indistinct, formed by the styloid process of the metacarpal bone of the middle finger. This prominence is in the same line as the dorsal radial tubercle, and is an inch and a half below it. The heads of the metacarpals are plainly to be felt and seen, rounded in contour and standing out in bold relief under the skin, when the fist is clenched. It should be borne in mind that when the fingers are flexed on the hand, the articular surfaces of the first phalanges glide off the heads of the metacarpals on to their anterior surfaces; so that the heads of these bones form the prominences of the

* Allen Thomson demonstrated the fact that the first metacarpal bone is often developed from three centres: that is to say, there is a separate nucleus for the distal end, forming a distinct epiphysis visible at the age of seven or eight years. He also states that there are traces of a proximal epiphysis in the second metacarpal bone. *Journal of Anat. and Physiol.*, 1869.

knuckles and receive the force of any blow which may be given. The head of the third metacarpal bone is the most prominent, and receives the greater part of the shock of the blow. This bone articulates with the os magnum, so that the concussion is carried through this bone to the scaphoid and semilunar, with which the head of the os magnum articulates, and by these bones is transferred to the radius, along which it may be carried to the capitellum of the humerus. The enlarged extremities of the phalanges can be plainly felt. When the digits are bent, the proximal phalanges of the joints form prominences, which in the joints between the first and second phalanges are slightly hollowed, in accordance with the grooved shape of their articular surfaces, while in those between the second and third rows the prominences are flattened and square-shaped. In the palm of the hand the four inner metacarpal bones are covered by muscles, tendons, and the palmar fascia, and no part of them but their heads is to be distinguished. With regard to the thumb, the base of the metacarpal bone forms a prominence on the dorsal aspect, below the styloid process of the radius; the shaft can be felt, covered by tendons; it terminates at its head in a flattened prominence, in front of which can be felt the sesamoid bones.

Applied Anatomy.—The carpal bones are little liable to fracture, except from extreme violence, when the parts are so comminuted as to necessitate amputation. Occasionally they are the seat of tuberculous disease. The metacarpal bones and the phalanges are sometimes broken from direct violence. There are two diseases of the metacarpal bones and phalanges which require special mention on account of their frequent occurrence. One is tuberculous dactylitis, consisting in a deposit of tuberculous material in the medullary canal, expansion of the bone, with subsequent caseation and necrosis. The other is chondroma, which is perhaps more commonly found in connection with the metacarpal bones and phalanges than with any other bones. The tumours are usually multiple, and spring from beneath the periosteum about the epiphysial line.

BONES OF THE LOWER EXTREMITY

The Os Innominatum

The **Os Innominatum** (os coxæ) is a large, irregularly shaped, flattened bone, constricted in the centre and expanded above and below. It meets its fellow of the opposite side in the middle line in front, and together they form the sides and anterior wall of the pelvic cavity. It consists of three parts, the ilium, ischium, and pubis, which are distinct from each other in the young subject, but are fused in the adult to form a single bone; the union of the three parts takes place in and around a large cup-shaped articular cavity, the acetabulum, which is situated near the middle of the outer surface of the bone. The *ilium*, so called because it supports the flank, is the superior broad and expanded portion which extends upwards from the acetabulum. The *ischium* is the lowest and strongest portion of the bone; it proceeds downwards from the acetabulum, expands into a large tuberosity, and then, curving forwards, forms, with the pubis, a large aperture, the obturator foramen. The *pubis* extends inwards and downwards from the acetabulum and articulates in the middle line with the bone of the opposite side: it forms the front of the pelvis and supports the external organs of generation.

The **Ilium** (os ilium) presents for examination two surfaces—an external and an internal—a crest, and two borders—an anterior and a posterior.

The *external surface* of the ilium (fig. 378) is divided into two parts—an upper or gluteal, and a lower or acetabular. The *upper* or *gluteal portion*, known as the *dorsum ilii*, is directed backwards and outwards behind, and downwards and outwards in front. It is smooth, convex in front, deeply concave behind; bounded above by the crest, below by the upper border of the acetabulum, in front and behind by the anterior and posterior borders. This surface is crossed in an arched direction by three lines—the superior, middle, and inferior curved lines. The *superior* or *posterior curved line* (linea glutaea posterior), the shortest of the three, begins at the crest, about two inches in front of its posterior extremity; it is at first distinctly marked, but as it passes downwards to the upper part of the great sacro-sciatic notch, where it ends, it becomes less distinct, and is often altogether lost. Behind this line is a narrow semilunar surface, the upper part of which is rough and gives origin to a portion of the Gluteus maximus; the lower part is smooth and has no muscular fibres attached to it. The *middle curved line* (linea glutaea anterior), the longest of the three, begins at the crest, about an inch and a

half behind its anterior extremity, and, taking a curved direction downwards and backwards, ends at the upper part of the great sacro-sciatic notch. The space between the superior and middle curved lines and the crest is concave, and gives origin to the Gluteus medius. Near the middle of this line a nutrient foramen is often seen. The *inferior curved line* (linea glutaea inferior), the least distinct of the three, begins in front at the notch on the anterior border, and, curving backwards and downwards, ends near

FIG. 378.—Right os innominatum. External surface.

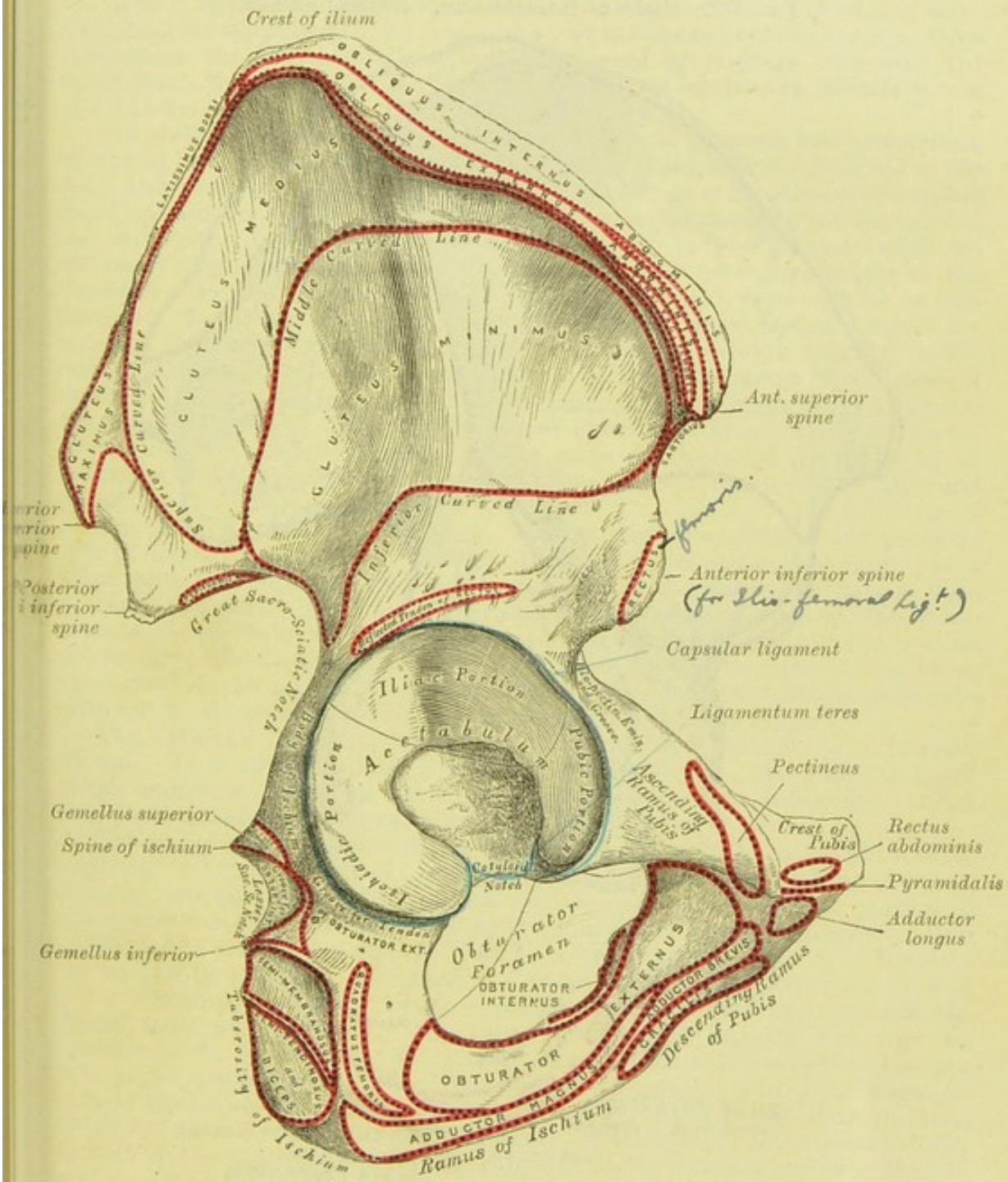

the middle of the great sacro-sciatic notch. The surface of bone included between the middle and inferior curved lines is concave from above downwards, convex from before backwards, and gives origin to the Gluteus minimus. Between the inferior curved line and the upper part of the acetabulum is a rough, shallow groove, from which the reflected tendon of the Rectus femoris arises. The *lower* or *acetabular part* of the external surface enters into the formation of the acetabulum, of which it forms rather less than two-

fifths. It is separated from the gluteal portion by a prominent rim, which forms part of the margin of the acetabular cavity.

The *internal surface* (fig. 379) of the ilium is bounded above by the crest; below, it is continuous with the pelvic surfaces of the pubis and ischium, only a faint line indicating the place of union; in front and behind, it is bounded by the anterior and posterior borders. It presents a large, smooth, concave surface, called the *iliac fossa* (fossa iliaca), which gives origin to the Iliacus and is perforated at its inner part by a nutrient canal; and below this

FIG. 379.—Right os innominatum. Internal surface.

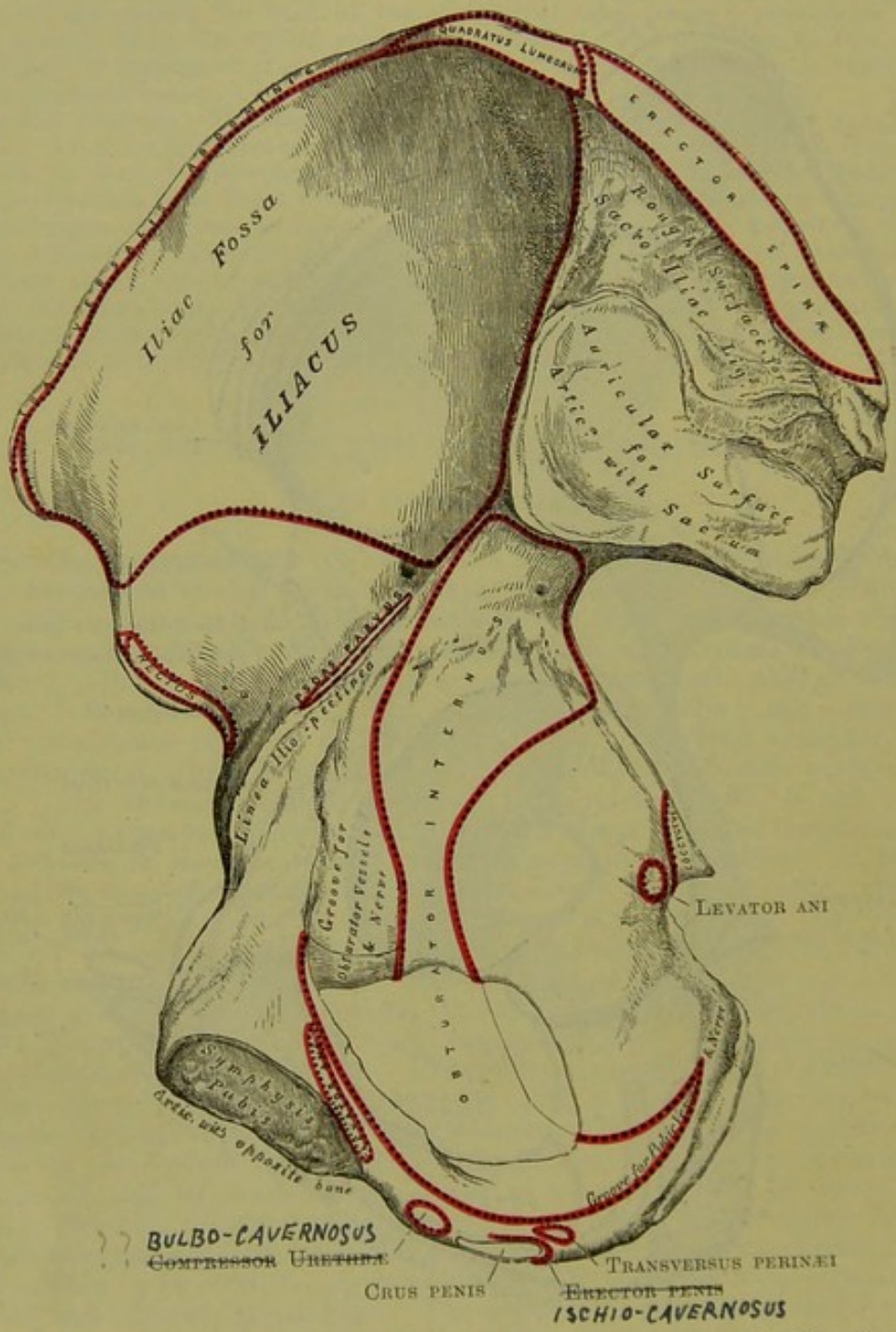

a smooth, rounded border, the *linea ilio-pectinea*, separating the iliac fossa from the portion of the internal surface which enters into the formation of the true pelvis and gives origin to part of the Obturator internus. Behind the iliac fossa is a rough surface, divided into two portions, an anterior and a posterior. The anterior or *auricular surface* (facies auricularis), so called from its resemblance in shape to the ear, is coated with cartilage in the recent state, and articulates with a similar surface on the side of the sacrum. The posterior portion (tuberositas iliaca) is elevated and rough, for the attachment of the

posterior sacro-iliac ligaments and for the origins of the Erector and Multifidus spinæ.

The *crest* of the ilium (crista iliaca) is convex in its general outline but is sinuously curved, being concave inwards in front, concave outwards behind. It is thinner at the centre than at the extremities, and terminates in the *anterior* and *posterior superior iliac spines*. The surface of the crest is broad, and divided into an external lip, an internal lip, and an intermediate space. About two inches behind the anterior superior iliac spine there is a prominent tubercle on the outer lip. To the external lip (labium externum) are attached the Tensor fasciæ femoris, Obliquus externus abdominis, and Latissimus dorsi, and along its whole length the fascia lata; to the space between the lips (linea intermedia) the Internal oblique; to the internal lip (labium internum), the fascia iliaca, the Transversalis abdominis, Quadratus lumborum, Erector spinæ, and Iliacus.

The *anterior border* of the ilium is concave. It presents two projections, separated by a notch. Of these, the uppermost, situated at the junction of the crest and anterior border, is called the *anterior superior iliac spine* (spina iliaca anterior superior); its outer border gives attachment to the fascia lata, and the Tensor fasciæ femoris; its inner border, to the Iliacus; while its extremity affords attachment to Poupart's ligament and gives origin to the Sartorius. Beneath this eminence is a notch which gives origin to the Sartorius, and across which the external cutaneous nerve passes. Below the notch is the *anterior inferior iliac spine* (spina iliaca anterior inferior), which ends in the upper lip of the acetabulum; it gives attachment to the straight tendon of the Rectus femoris and to the ilio-femoral ligament of the hip-joint. On the inner side of the anterior inferior spine is a broad, shallow groove, over which the Ilio-psoas passes. This groove is bounded internally by an eminence, the *ilio-pectineal*, which marks the point of union of the ilium and pubis.

The *posterior border* of the ilium, shorter than the anterior, also presents two projections separated by a notch, the *posterior superior iliac spine* (spina iliaca posterior superior) and the *posterior inferior iliac spine* (spina iliaca posterior inferior). The former corresponds with that portion of the inner surface of the ilium which serves for the attachment of the oblique portion of the sacro-iliac ligaments and the Multifidus spinæ; the latter to the lower extremity of the auricular surface. Below the posterior inferior spine is a deep notch, the *great sacro-sciatic notch* (incisura ischiadica major).

The **Ischium** (os ischii) forms the lower and back part of the os innominatum. It is divisible into a thick and solid portion, the *body*; a large, rough eminence, on which the trunk rests in sitting, the *tuberosity*; and a thin part, which passes forwards and slightly upwards, the *ramus*.

The **body** (corpus oss. ischii), somewhat triangular in form, presents three surfaces, external, internal, and posterior; and three borders, external, internal, and posterior. The *external surface* corresponds to that portion of the acetabulum which is formed by the ischium; it is smooth and concave, and constitutes a little more than two-fifths of the acetabular cavity. Between the acetabulum and the tuberosity is a deep groove, along which the tendon of the Obturator externus runs as it passes outwards to be inserted into the digital fossa of the femur. The *internal surface* is smooth, concave, and enters into the formation of the lateral boundary of the true pelvic cavity; it is perforated by two or three large, vascular foramina, and gives origin to part of the Obturator internus. The *posterior surface* is quadrilateral in form, broad and smooth. It is limited, externally, by the margin of the acetabulum; behind by the posterior border; it supports the Pyriformis, the two Gemelli, and the Obturator internus, in their passage outwards to the great trochanter. Below, where it joins the tuberosity, it presents a groove continuous with that on the external surface for the tendon of the Obturator externus; the lower edge of this groove is formed by the tuberosity of the ischium, and gives origin to the Gemellus inferior. The *external border* forms the prominent rim of the acetabulum, and separates the posterior from the external surface. To it is attached the cotyloid ligament. The *internal border* is thin, and forms the outer circumference of the obturator foramen. The *posterior border* presents a thin and pointed triangular eminence, the *spine of the ischium* (spina

ischiadica), more or less elongated in different subjects; its external surface gives attachment to the Gemellus superior, its internal surface to the Coccygeus, Levator ani, and the pelvic fascia; while to the pointed extremity is attached the small sacro-sciatic ligament. Above the spine is a large notch, the *great sacro-sciatic notch* (incisura ischiadica major), converted into a foramen by the small sacro-sciatic ligament; it transmits the Pyriformis, the gluteal vessels, the superior and inferior gluteal nerves, the sciatic vessels, the greater and lesser sciatic nerves, the internal pudic vessels and nerve, and the nerves to the Obturator internus and Quadratus femoris. Of these, the gluteal vessels and superior gluteal nerve pass out above the Pyriformis, the other structures below it. Below the spine is a smaller notch, the *small sacro-sciatic* (incisura ischiadica minor); it is smooth, coated in the recent state with cartilage, the surface of which presents two or three ridges corresponding to the subdivisions of the tendon of the Obturator internus, which winds over it. It is converted into a foramen by the sacro-sciatic ligaments, and transmits the tendon of the Obturator internus, the nerve which supplies that muscle, and the internal pudic vessels and nerve.

The **tuberosity** (tuber ischiadicum) presents for examination three surfaces: external, internal, and posterior. The *external surface* is quadrilateral in shape, and rough for the attachment of muscles. It is bounded above by the groove for the tendon of the Obturator externus; in front it is limited by the posterior margin of the obturator foramen, and below it is continuous with the ramus; behind, it is bounded by a prominent margin which separates it from the posterior surface. In front of this margin the surface gives origin to the Quadratus femoris, and anterior to this to some of the fibres of origin of the Obturator externus; the lower part of the surface gives origin to part of the Adductor magnus. The *internal surface* forms part of the bony wall of the true pelvis. In front, it is limited by the posterior margin of the obturator foramen. Behind, it is bounded by a sharp ridge, which gives attachment to a falciform prolongation of the great sacro-sciatic ligament, and, more anteriorly, gives origin to the Transversus perinæi and Erector penis vel clitoridis. The *posterior surface* is divided into two portions: a lower, rough, somewhat triangular part, and an upper, smooth, quadrilateral portion. The anterior portion is subdivided by a prominent longitudinal ridge, passing from base to apex, into two parts; the outer gives attachment to the Adductor magnus, the inner to the great sacro-sciatic ligament. The upper portion is subdivided into two areas by an oblique ridge, which runs downwards and outwards; from the upper and outer area the Semi-membranosus arises; from the lower and inner, the long head of the Biceps and the Semitendinosus.

The **ramus** (ramus inferior oss. ischii) is the thin, flattened part of the ischium, which ascends from the tuberosity upwards and inwards, and joins the descending ramus of the pubis—the junction being indicated in the adult by a raised line. The *outer surface* is uneven, for the origin of the Obturator externus, and some of the fibres of the Adductor magnus; its *inner surface* forms part of the anterior wall of the pelvis. Its *inner border* is thick, rough, slightly everted, forms part of the outlet of the pelvis, and presents two ridges and an intervening space. The ridges are continuous with similar ones on the descending ramus of the pubis: to the outer is attached the deep layer of the superficial perineal fascia (fascia of Colles), and to the inner the superficial layer of the triangular ligament of the perinæum. If these two ridges be traced downwards, they will be found to join with each other just behind the point of origin of the Transversus perinæi; here the two layers of fascia are continuous behind the posterior border of the muscle. To the intervening space, just in front of the point of junction of the ridges, the Transversus perinæi is attached, and in front of this a portion of the crus penis vel clitoridis and the Erector penis vel clitoridis muscle. Its *outer border* is thin and sharp, and forms part of the inner margin of the obturator foramen.

The **Pubis** (os pubis), the anterior part of the os innominatum, is divisible into a body, an ascending, and a descending ramus.

The **body** (corpus oss. pubis) is somewhat quadrilateral in shape, and presents for examination two surfaces and three borders. The *anterior surface* is rough, directed downwards and outwards, and serves for the origin of various muscles. The Adductor longus arises from the upper and inner angle,

immediately below the crest; lower down, from without inwards, the Obturator externus, the Adductor brevis, and the upper part of the Gracilis take origin. The *posterior surface*, convex from above downwards, concave from side to side, is smooth, and forms part of the anterior wall of the pelvis. It gives origin to the Levator ani and Obturator internus, and attachment to the pubo-prostatic ligaments and to a few muscular fibres prolonged from the bladder. The *upper border* presents a prominent tubercle, which projects forwards, the *pubic spine* (tuberculum pubicum); the outer pillar of the external abdominal ring and Poupart's ligament are attached to it. Passing upwards and outwards from the pubic spine is a well-defined ridge, forming a part of the linea ilio-pectinea which marks the brim of the true pelvis: to it are attached a portion of the conjoined tendon of the Internal oblique and Transversalis, Gimbernat's ligament and the triangular fascia of the abdomen. Internal to the spine of the os pubis is the *crest*, which extends from this process to the inner extremity of the bone. It affords attachment to the conjoined tendon of the Internal oblique and Transversalis, and to the Rectus and Pyramidalis. The point of junction of the crest with the inner border of the bone is called the *angle*; to it, as well as to the symphysis, the internal pillar of the external abdominal ring is attached. The *internal border* is articular; it is oval, covered by eight or nine transverse ridges, or a series of nipple-like processes arranged in rows, separated by grooves; they serve for the attachment of a thin layer of cartilage, placed between it and the central fibro-cartilage. The *outer border* presents a sharp margin, which forms part of the circumference of the obturator foramen and affords attachment to the obturator membrane.

The **ascending** or **superior ramus** (ramus superior oss. pubis) extends from the body to the point of junction of the pubis with the ilium, and forms the upper part of the circumference of the obturator foramen. It presents for examination superior, inferior, and posterior surfaces, and an outer extremity. The *superior surface* presents a continuation of the ilio-pectineal line, already mentioned as commencing at the pubic spine. In front of this line, the surface of bone is triangular in form, wider externally than internally, smooth, and is covered by the Pectineus. The surface is bounded externally by a rough eminence, *eminentia ilio-pectinea*, which serves to indicate the point of junction of the ilium and pubis, and below by a prominent ridge, the *obturator crest* (crista obturatoria), which extends from the cotyloid notch to the spine of the pubis. The *inferior surface* forms the upper boundary of the obturator foramen, and presents, externally, a broad and deep, oblique groove, for the passage of the obturator vessels and nerve; and internally, a sharp margin which forms part of the circumference of the obturator foramen, and gives attachment to the obturator membrane. The *posterior surface* constitutes part of the anterior boundary of the true pelvis. It is smooth, convex from above downwards, and affords origin to some fibres of the Obturator internus. The *outer extremity*, the thickest part of the ramus, forms one-fifth of the acetabulum.

The **descending** or **inferior ramus** (ramus inferior oss. pubis) is thin and flattened. It passes outwards and downwards, becoming narrower as it descends and joins with the ramus of the ischium. Its *anterior surface* is rough, for the origin of muscles—the Gracilis along its inner border; a portion of the Obturator externus where it enters into the formation of the Obturator foramen; and between these two, the Adductores brevis et magnus from within outwards. The *posterior surface* is smooth, and gives origin to the Obturator internus, and, close to the inner margin, to the Compressor urethræ. The *inner border* is thick, rough, and everted, especially in females. It presents two ridges, separated by an intervening space. The ridges extend downwards, and are continuous with similar ridges on the ramus of the ischium; to the external is attached the fascia of Colles, and to the internal the superficial layer of the triangular ligament of the urethra. The *outer border* is thin and sharp, forms part of the circumference of the obturator foramen, and gives attachment to the obturator membrane.

The *acetabulum*, or *cotyloid cavity*, is a deep, cup-shaped, hemispherical depression, directed downwards, outwards, and forwards. It is formed internally by the pubis, above by the ilium, behind and below by the ischium; a little less than two-fifths being contributed by the ilium, a little more than two

fifths by the ischium, and the remaining fifth by the pubic bone. It is bounded by a prominent, uneven rim, which is thick and strong above, and serves for the attachment of the *cotyloid ligament*, which contracts its orifice, and deepens the surface for articulation. It presents below a deep notch, the *cotyloid notch* (incisura acetabuli), which is continuous with a circular depression, the *fossa acetabuli*, at the bottom of the cavity: this depression is perforated by numerous apertures, and lodges a mass of fat. The notch is converted into a foramen by the transverse ligament; through the foramen nutrient vessels and nerves enter the joint; the margins of the notch serve for the attachment of the ligamentum teres.

The *obturator* or *thyroid foramen* (foramen obturatum) is a large aperture, situated between the ischium and pubis. In the male it is large and of an oval form, its longest diameter being obliquely from before backwards; in the female it is smaller, and more triangular. It is bounded by a thin, uneven margin, to which a strong membrane is attached; and presents, superiorly, a deep

FIG. 380.—Plan of ossification of the os innominatum.

By eight centres { *Three primary (Ilium, Ischium, and Os Pubis)* / *Five secondary*

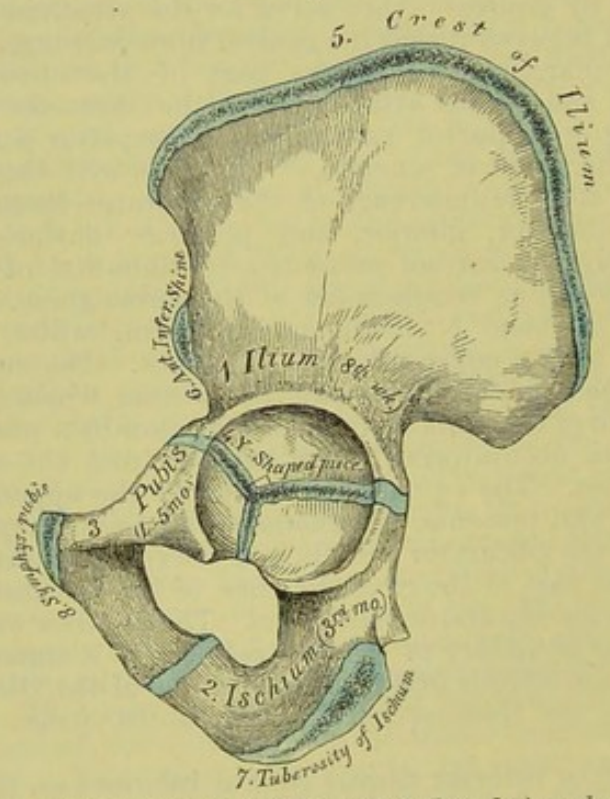

The three primary centres unite through Y-shaped piece about puberty. Epiphyses appear about puberty, and unite about 25th year.

groove (sulcus obturatorius), which runs from the pelvis obliquely inwards and downwards. This groove is converted into a foramen by a ligamentous band, a specialised part of the obturator membrane, attached to two tubercles, one (tuberculum obturatorium posterius) on the internal border of the ischium, just in front of the cotyloid notch, the other (tuberculum obturatorius anterius) on the inferior margin of the posterior surface of the ascending ramus of the pubis. Through the foramen the obturator vessels and nerve pass out of the pelvis.

Structure.—The thickest parts of the bone consist of cancellous tissue, enclosed between two layers of compact tissue. The thinner parts of the bone, as at the bottom of the acetabulum and centre of the iliac fossa, are usually semi-transparent, and composed entirely of compact tissue.

Ossification (fig. 380).—The os innominatum is ossified from *eight* centres: *three* primary—one each for the ilium, ischium, and pubis; and *five* secondary—one for the crest of the ilium, one for the anterior inferior spine (said to occur more

frequently in the male than in the female), one for the tuberosity of the ischium, one for the symphysis pubis (more frequent in the female than in the male), and one or more for the Y-shaped piece at the bottom of the acetabulum. The centres appear in the following order: in the lower part of the ilium, immediately above the sciatic notch, about the eighth or ninth week of fœtal life; in the body of the ischium, about the third month; in the body of the pubis, between the fourth and fifth months. At birth, the three primary centres are quite separate, the crest, the bottom of the acetabulum, the ischial tuberosity, and the rami of the ischium and pubis being still cartilaginous. By the seventh or eighth year, the rami of the pubis and ischium are almost completely united by bone. About the thirteenth or fourteenth year, the three primary centres have extended their growth into the bottom of the acetabulum, and are there separated from each other by a Y-shaped portion of cartilage, which now presents traces of ossification, often by two or more centres. One of these, the *os acetabuli*, appears about the age of twelve, between the ilium and pubis, and fuses with them about the age of eighteen; it forms the pubic part of the acetabulum. The ilium and ischium then become joined, and lastly the pubis and ischium, through the intervention of this Y-shaped portion. At about the age of puberty, ossification takes place in each of the remaining portions, and they join with the rest of the bone between the twentieth and twenty-fifth years. Separate centres are frequently found for the pubic and ischial spines, and for the crest and angle of the pubis.

Articulations.—The os innominatum articulates with its fellow of the opposite side, and with the sacrum and femur.

The Pelvis

The **Pelvis**, so called from its resemblance to a basin, is stronger and more massively constructed than the walls of the cranial or thoracic cavities; it is a bony ring, interposed between the movable vertebræ of the spinal column which it supports, and the lower limbs upon which it rests. It is composed of four bones: the two ossa innominata laterally and in front; and the sacrum and coccyx behind.

The pelvis is divided by an oblique plane passing through the prominence of the sacrum, the linea ilio-pectinea, and the upper margin of the symphysis pubis, into the false and true pelvis. The circumference of this plane is termed the *pelvic brim*.

The **false pelvis** (pelvis major) is the expanded portion of the cavity situated above and in front of the pelvic brim. It is bounded on each side by the ilium; in front it is incomplete, presenting a wide interval between the spinous processes of the ilia on either side, which is filled up in the recent state by the parietes of the abdomen; behind, in the middle line, is a deep notch. Its walls support the intestines, and transmit part of their weight to the anterior wall of the abdomen; the term false pelvis is therefore incorrect, and the space ought more properly to be regarded as part of the hypogastric and iliac regions of the abdomen.

The **true pelvis** (pelvis minor) is that part of the pelvic cavity which is situated below and behind the pelvic brim. It is smaller than the false pelvis, but its bony walls are more perfect. For convenience of description, it is divided into an inlet bounded by the superior circumference, an outlet bounded by the inferior circumference and a cavity.

The *superior circumference* forms the brim of the pelvis, the included space being called the *inlet* (apertura pelvis superior) (fig. 381). It is formed laterally by the ilio-pectineal lines, in front by the crests of the pubic bones, and behind by the anterior margin of the base of the sacrum and sacro-vertebral angle. The inlet of the pelvis is somewhat heart-shaped, obtusely pointed in front, diverging on either side, and encroached upon behind by the projection forwards of the promontory of the sacrum. It has three principal diameters: antero-posterior, transverse, and oblique. The *antero-posterior* or *conjugate diameter* extends from the sacro-vertebral angle to the symphysis pubis; its average measurement is four inches in the male, four and three-quarters in the female. The *transverse diameter* extends across the greatest width of the inlet, from the middle of the brim on one side to the same point on the opposite; its average measurement is four and a half inches in the male, five and a

quarter in the female. The *oblique diameter* extends from the ilio-pectineal eminence of one side to the sacro-iliac articulation of the opposite side; its average measurement is four and a quarter inches in the male, and five in the female.

The *cavity* of the true pelvis is bounded in front and below by the symphysis pubis and the bodies of the pubic bones; above and behind, by the

Fig. 381.—Diameters of the pelvic inlet (female).

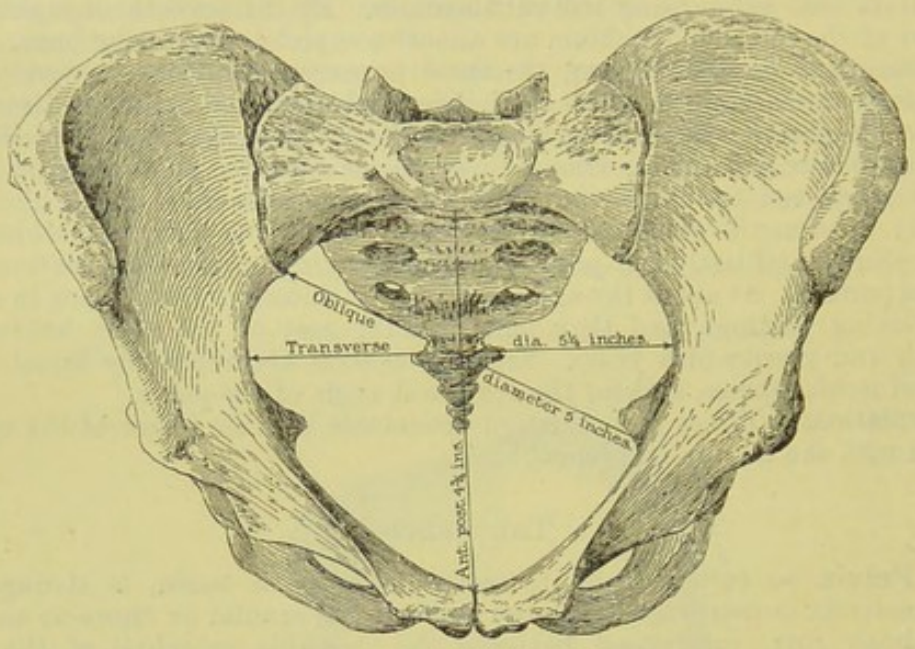

anterior concave surfaces of the sacrum and coccyx, which, curving forwards above and below, contract the inlet and outlet of the canal; laterally, by a broad, smooth, quadrangular area of bone, corresponding to the inner surface of the body of the ischium and that part of the ilium which is below the ilio-pectineal line. The cavity measures an inch and a half in depth in front,

Fig. 382.—Diameters of the pelvic outlet (female).

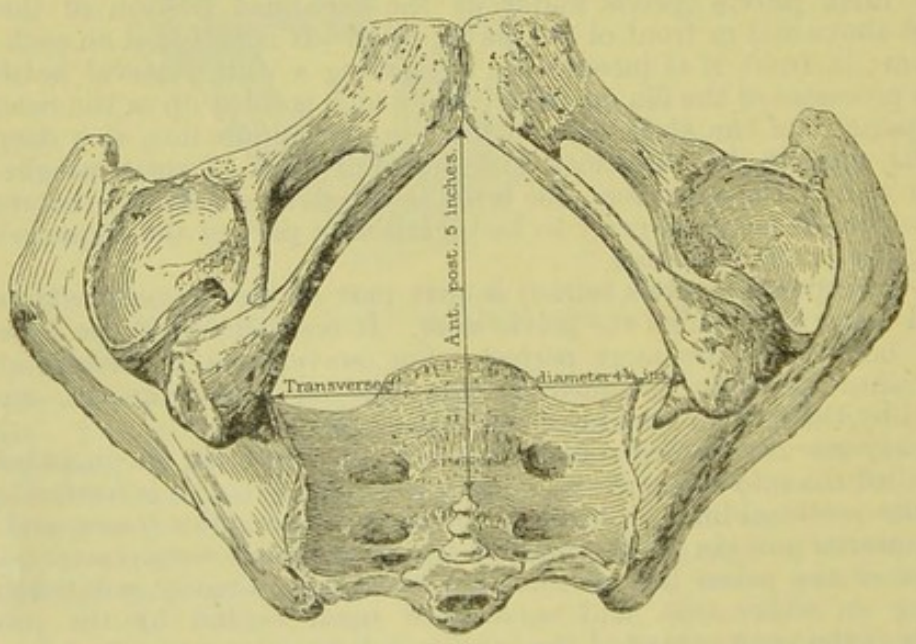

three inches and a half in the middle, and four inches and a half posteriorly. From this description, it will be seen that the cavity of the pelvis is a short, curved canal, considerably deeper on its posterior than on its anterior wall. It contains, in the recent subject, the pelvic colon, rectum, bladder, and part of the organs of generation. The rectum is placed at the back of the pelvis, and corresponds to the curve of the sacrum and coccyx; the bladder is in front,

behind the symphysis pubis. In the female, the uterus and vagina occupy the interval between these viscera.

The *lower circumference* of the pelvis is very irregular; the space enclosed by it is named the *outlet* (apertura pelvis inferior) (fig. 382) and is bounded behind by the point of the coccyx; and laterally by the tuberosities of the ischia. These eminences are separated by three notches: one in front, the *pubic arch* (arcus pubis), formed by the convergence of the rami of the ischium and pubis on either side. The other notches, one on either side, are formed by the sacrum and coccyx behind, the ischium in front, and the ilium above: they are called the *sacro-sciatic notches*; in the natural state they are converted into foramina by the great and small sacro-sciatic ligaments. When the ligaments are *in situ*, the outlet of the pelvis is lozenge-shaped, bounded, in front, by the subpubic ligament and the rami of the pubes and ischia; laterally by the tuberosities of the ischia; and behind, by the great sacro-sciatic ligaments and the tip of the coccyx.

The diameters of the outlet of the pelvis are two, antero-posterior and transverse. The *antero-posterior diameter* extends from the tip of the coccyx to the lower part of the symphysis pubis; its average measurement is three and three-quarter inches in the male, and five inches in the female. It varies with the length of the coccyx, and is capable of increase or diminution, on account of the mobility of that bone. The *transverse diameter*, measured between the posterior parts of the ischial tuberosities, is three and a half inches in the male, and four and three-quarters in the female.*

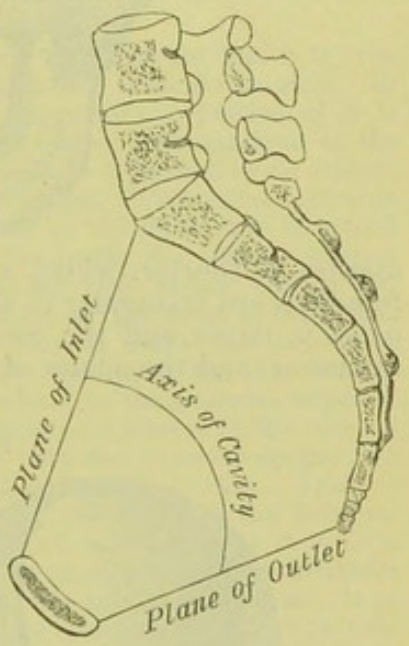

Fig. 383.—Mesial sagittal section of pelvis.

Axes (fig. 383).—A line at right angles to the plane of the inlet at its centre would, if prolonged, pass through the umbilicus above and the middle of the coccyx below: the axis of the inlet is therefore directed downwards and backwards. The axis of the outlet, produced upwards, would touch the base of the sacrum, and is also directed downwards, and slightly backwards. The axis of the cavity—i.e. an axis at right angles to a series of planes between those of the inlet and outlet—is curved like the cavity itself: this curve corresponds to the concavity of the sacrum and coccyx, the extremities being indicated by the central points of the inlet and outlet. A knowledge of the direction of these axes serves to explain the course of the fœtus in its passage through the pelvis during parturition.

Position of the pelvis (fig. 383).—In the erect posture, the pelvis is placed obliquely with regard to the trunk: the plane of the pelvic inlet forms an angle of from 50° to 60°, and that of the outlet one of about 15° with the horizontal plane. The pelvic surface of the symphysis pubis looks upwards and backwards, the concavity of the sacrum and coccyx downwards and forwards; the base of the sacrum in well-formed female bodies being nearly four inches above the upper border of the symphysis pubis, and the apex of the coccyx a little more than half an inch above its lower border. In consequence of this obliquity of the pelvis, the line of gravity of the head, which passes through the middle of the odontoid process of the axis and the points of junction of the curves of the vertebral column to the sacro-vertebral angle, descends towards the front of the cavity, so that it bisects a line drawn transversely through the centres of the heads of the thigh-bones (see page 199).

Differences between the male and female pelves.—The *female* pelvis (fig. 385) is distinguished from that of the *male* (fig. 384) by its bones being more delicate and its depth less. The whole pelvis is less massive, and its

* The measurements of the pelvis given above are fairly accurate, but different measurements are given by various authors, no doubt due in a great measure to differences in the physique and stature of the population from whom the measurements have been taken.

muscular impressions are slightly marked. The ilia are less sloped, and the anterior iliac spines more widely separated ; hence the greater prominence of the hips. The *inlet* in the female is larger than in the male ; it is more nearly circular, and its obliquity is greater. The *cavity* is shallower and wider ; the

Fig. 384.—Male pelvis.

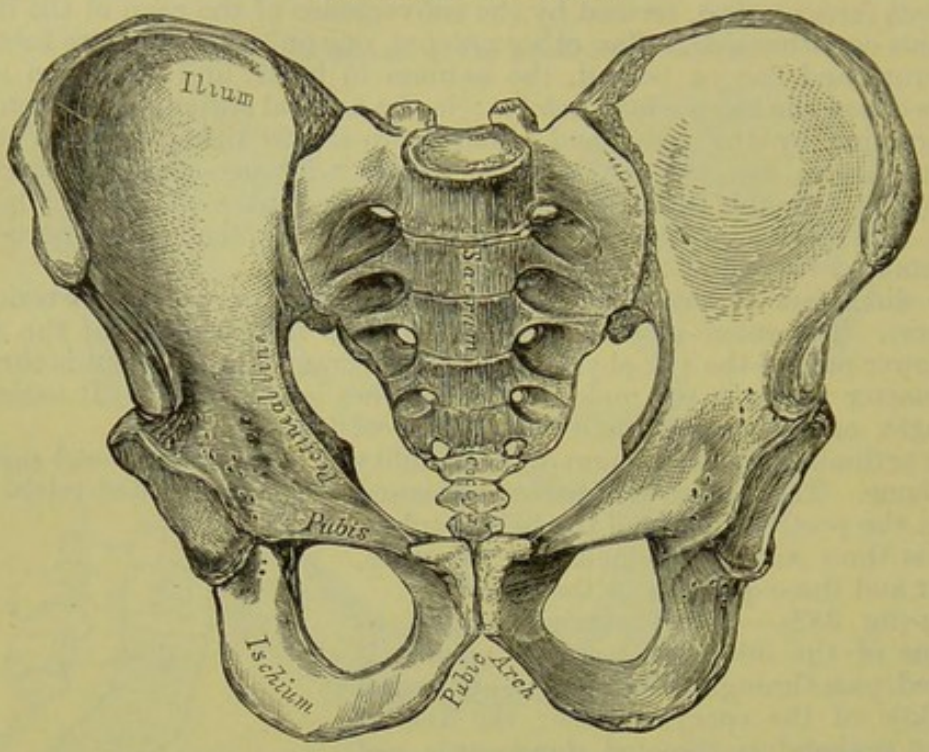

sacrum is shorter, wider, and its upper part is less curved ; the obturator foramina are triangular in shape and smaller in size than in the male. The *outlet* is larger and the coccyx more movable. The sacro-sciatic notches are shallower, and the spines of the ischia project less inwards. The tuberosities

Fig. 385.—Female pelvis.

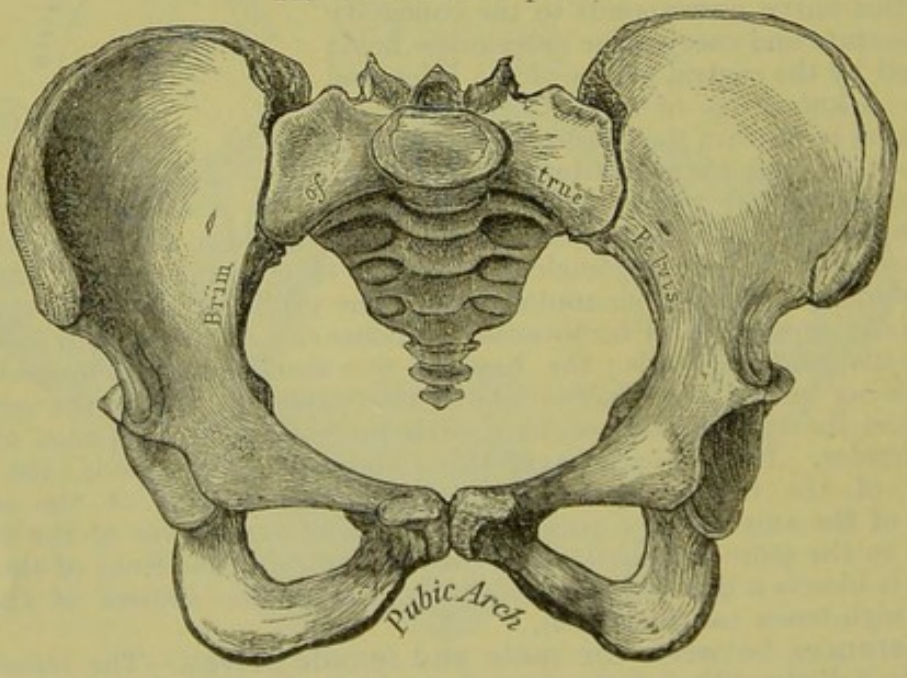

of the ischia, and the acetabula are wider apart, and the former are more everted. The pubic symphysis is less deep, and the pubic arch is wider and more rounded than in the male, where it is an angle rather than an arch. In consequence of this the width of the fore part of the pelvic outlet is greater, a condition which facilitates the passage of the fœtal head during parturition.

The size of the pelvis varies not only in the two sexes, but also in different members of the same sex, and does not appear to be influenced in any way by the height of the individual. Women of short stature, as a rule, have broad pelves. Occasionally the pelvis is equally contracted in all its dimensions, so much so that all its diameters measure an inch less than the average, and this even in well-formed women of average height. The principal divergences, however, are found at the inlet, and affect the relation of the antero-posterior to the transverse diameter. Thus the inlet of the pelvis may be elliptical either in a transverse or an antero-posterior direction ; the transverse diameter in the former, and the antero-posterior in the latter, greatly exceeding the other diameters. Again, the inlet of the pelvis in some instances is seen to be almost circular.

The same differences are found in various races. European women are said to have the most roomy pelves. That of the negress is smaller, circular in shape, and with a narrow pubic arch. The Hottentots and Bushwomen possess the smallest pelves.

In the *fœtus*, and for several years after birth, the pelvis is small in proportion to that of the adult, and the projection of the sacro-vertebral angle less marked. The generally accepted opinion that the pelvis does not acquire its sexual characteristics until after puberty has been shown to be erroneous,* the characteristic differences between the male and female pelvis being distinctly indicated as early as the fourth month of fœtal life.

Surface Form.—The pelvic bones are so thickly covered with muscles that it is only at certain points that they approach the surface and can be felt through the skin. In front, the anterior superior spine of the ilium is easily recognised ; a portion of it is subcutaneous, and in thin subjects may be seen to stand out as a prominence at the outer extremity of the fold of the groin. In fat subjects its position is marked by an oblique depression, at the bottom of which the bony process may be felt. Proceeding upwards and outwards from this process, the sinuously curved crest of the ilium may be traced throughout its whole length. Its highest point is on a level with the spinous process of the fourth lumbar vertebra : upon its outer lip, about two inches behind the anterior superior spine, is a prominent tubercle. The position of the crest is indicated, in muscular subjects, by a groove or furrow, the *iliac furrow*, below the projection of the fleshy fibres of the External oblique muscle of the abdomen ; the iliac furrow lies slightly below the level of the crest. It terminates behind in the posterior superior spine, the position of which is indicated by a slight depression on a level with the spinous process of the second sacral vertebra. Between the two posterior superior spines, but at a lower level, is to be felt the spinous process of the third sacral vertebra. Another part of the bony pelvis which is accessible to touch is the tuberosity of the ischium, situated beneath the gluteal fold, and, when the hip is flexed, easily felt, as it is then uncovered by muscle. Finally, the spine of the pubis can be readily felt, and constitutes an important surgical guide, especially in connection with the subject of hernia. It is in nearly the same horizontal plane as the upper edge of the great trochanter. In thin subjects it is very apparent, but in the obese it is obscured by the pubic fat. It can, however, be detected by following up the tendon of origin of the Adductor longus muscle. A line drawn from the anterior superior spine of the ilium to the most prominent part of the tuberosity of the ischium passes across the hip at a level with the upper border of the great trochanter. It is known as *Nélaton's line*, and is of service in detecting any displacement of the trochanter in fractures or dislocations in this situation. If a line be drawn from the posterior superior spine of the ilium to the outer part of the tuberosity of the ischium, it will cross the spine of the ischium about four inches below the posterior superior iliac spine. The great sciatic foramen will lie above, and the lesser foramen below this point.

Applied Anatomy.—There is arrest of development in the bones of the pelvis in cases of extroversion of the bladder ; the anterior part of the pelvic girdle being deficient, the bodies of the pubic bones imperfectly developed, and the symphysis absent. 'The pubic bones are separated to the extent of from two to four inches, the superior rami shortened and directed forwards, and the obturator foramen diminished in size, narrowed, and turned outwards. The iliac bones are straightened out more than normal. The sacrum is very peculiar. The lateral curve, instead of being concave, is flattened out or even convex, with the ilio-sacral facets turned more outward than normal, while the vertical curve is straightened.' †

* Fehling, *Zeitschr. für Geburt. u. Gynäk.* Bd. ix. und x. ; and Arthur Thomson, *Journal of Anatomy and Physiology*, vol. xxxiii.

† Wood. Heath's *Dictionary of Practical Surgery*, i. 426.

Fractures of the pelvis are divided into those of the false and those of the true pelvis. Fractures of the false pelvis vary in extent; a small portion of the crest may be broken, or one of the spinous processes may be torn off, or the bone may be extensively comminuted. This latter accident is the result of some crushing violence, and may be complicated with fracture of the true pelvis. These cases may be accompanied by injury to the intestine as it lies in the hollow of the bone, or to the iliac vessels as they course along the margin of the true pelvis. A fracture of the true pelvis generally occurs through the ascending ramus of the pubis and the ramus of the ischium, as these are the weakest parts of the bony ring, and may be caused either by crushing violence applied in an antero-posterior direction, when the fracture occurs from direct force, or by compression laterally, when the acetabula are pressed together and the bone gives way in the same place from indirect violence. Sometimes the fracture may be double, occurring on both sides of the body. It is in these cases that the contained viscera are likely to be injured: the urethra, the bladder, the rectum, the vagina in the female, the small intestines, and even the uterus, have all been lacerated by displaced fragments. Fractures of the acetabulum are occasionally met with: either a portion of the rim may be broken off, or a fracture may take place through the bottom of the cavity, and the head of the femur be driven inwards and project into the pelvic cavity. Separation of the Y-shaped cartilage at the bottom of the acetabulum may also occur in the young subject, splitting the bone into its three portions.

The coccyx is not infrequently fractured or displaced forwards to nearly a right angle with the sacrum by kicks or by falls backwards. The fracture is attended with great pain in walking and on making any expiratory effort, such as coughing, defæcation, &c., because the Coccygeus, which is attached to this bone, forms part of the pelvic diaphragm. Falls or blows on the coccyx, unaccompanied by fracture, sometimes give rise to severe pain, which is exceedingly intractable and difficult of cure. The condition is known as *coccygodynia*, and for its relief removal of the coccyx has been practised.

The pelvic bones often undergo important deformity in *rickets*, the effects of which in the adult woman may interfere seriously with child-bearing. The deformity is due mainly to the weight of the spine and trunk, which presses on the sacro-vertebral angle and greatly increases it, so that the antero-posterior diameter of the pelvis is diminished, and may measure as little as 1½ inches, the entrance into the pelvis becoming reniform. In other cases all the pelvic bones give way, so that a general diminution in all the diameters of the pelvis results, the pelvic entrance becoming triangular or asymmetrical. If the pubic symphysis be forced forwards, the rickety pelvis may even come to resemble closely the deformed pelvis of *osteomalacia*; in this disease the weight of the trunk causes an increase in the sacro-vertebral angle, and a lessening of the antero-posterior diameter of the inlet, and at the same time the pressure of the heads of the thigh-bones on the acetabula causes these cavities, with the adjacent bone, to be pushed upwards and backwards, so that the oblique diameters of the pelvis are also diminished, and the cavity of the pelvis assumes a tri-radiate shape, with the symphysis pubis pushed forwards.

The Femur

The **Femur** (figs. 387 and 388), the longest, largest, and strongest bone in the skeleton, is almost perfectly cylindrical in the greater part of its extent. In the erect posture it is not vertical, being separated above from its fellow by a considerable interval, which corresponds to the breadth of the pelvis, but inclining gradually downwards and inwards, so as to approach its fellow towards its lower part, for the purpose of bringing the knee-joint near the line of gravity of the body. The degree of this inclination varies in different persons, and is greater in the female than in the male, on account of the greater breadth of the pelvis. The femur, like other long bones, is divisible into a shaft and two extremities.

The **upper extremity** (fig. 386) presents for examination a head, a neck, a great and a small trochanter.

The **head** (caput femoris), which is globular, and forms rather more than a hemisphere, is directed upwards, inwards, and a little forwards, the greater part of its convexity being above and in front. Its surface is smooth, coated with cartilage in the recent state, except over a depressed ovoid area (fovea capitis femoris), which is situated a little below and behind its centre, and gives attachment to the ligamentum teres.

The **neck** (collum femoris) is a flattened pyramidal process of bone, which connects the head with the shaft, and forms with the latter a wide angle. The angle is widest in infancy, and becomes lessened during growth, so that at puberty it forms a gentle curve from the axis of the shaft. In the adult, the neck forms an angle of about 125° with the shaft, but this varies in inverse

proportion to the development of the pelvis and the stature. In consequence of the prominence of the hips and widening of the pelvis in the female, the neck of the thigh-bone forms more nearly a right angle with the shaft than it does in the male. It has been stated that the angle diminishes in old age and that the direction of the neck becomes horizontal, but this statement is founded on insufficient evidence. Humphry found that the angle decreases during the period of growth, but after full growth has been attained it does not usually undergo any change, even in old age; it varies considerably in different persons of the same age. It is smaller in short than in long bones, and when the pelvis is wide.* The neck is flattened from before backwards, contracted in the middle, and broader externally than internally. The vertical diameter of the outer half is increased by the obliquity of the lower edge, which slopes downwards to join the shaft at the level of the small trochanter, so that it measures one-third more than the antero-posterior diameter. The inner half is smaller, and of a more circular shape. The *anterior surface* of the neck is perforated by numerous vascular foramina. The *posterior surface* is smooth, and is broader and more concave than the anterior; it gives attachment to the posterior part of the capsular ligament of the hip-joint, about half an inch above the posterior intertrochanteric line.

FIG. 386.—Upper extremity of right femur viewed from behind and above.

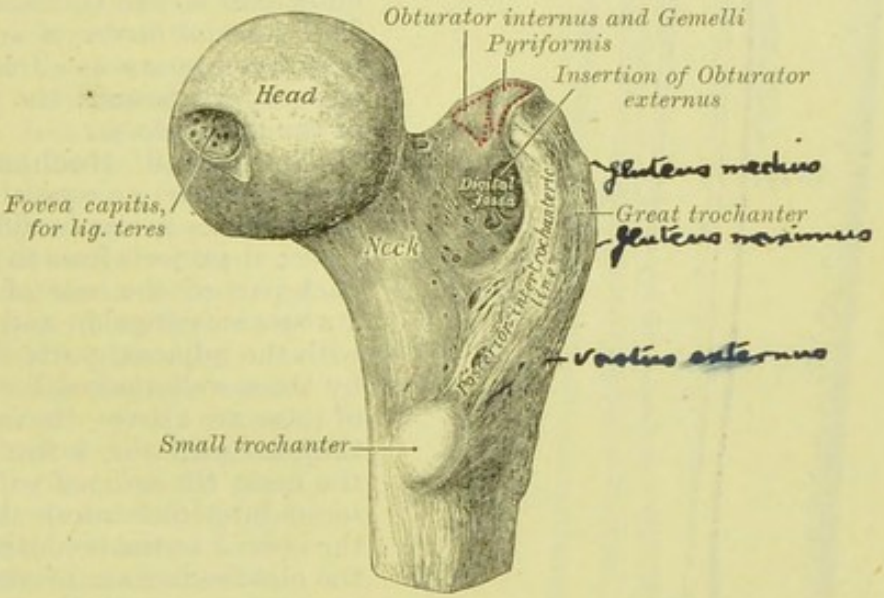

The *superior border* is short and thick, and terminates externally at the great trochanter; its surface is perforated by large foramina. The *inferior border*, long and narrow, curves a little backwards, to terminate at the small trochanter.

The **trochanters** are prominent processes of bone which afford leverage to the muscles which rotate the thigh on its axis. They are two in number, the great and the small.

The **great trochanter** (trochanter major) is a large, irregular, quadrilateral eminence, situated at the outer side of the neck, at its junction with the upper part of the shaft. It is directed a little outwards and backwards, and, in the adult, is about three-quarters of an inch lower than the head. It presents for examination two surfaces and four borders. The *external surface*, quadrilateral in form, is broad, rough, convex, and marked by a diagonal impression, which extends from the postero-superior to the antero-inferior angle, and serves for the insertion of the tendon of the Gluteus medius. Above the impression is a triangular surface, sometimes rough for part of the tendon of the same muscle, sometimes smooth for the interposition of a bursa between the tendon and the bone. Below and behind the diagonal impression is a smooth, triangular surface, over which the tendon of the Gluteus maximus plays, a bursa being interposed. The *internal surface*, of much less extent

* *Journal of Anatomy and Physiology*, vol. xxiii.

Fig. 387.—Right femur. Anterior surface.

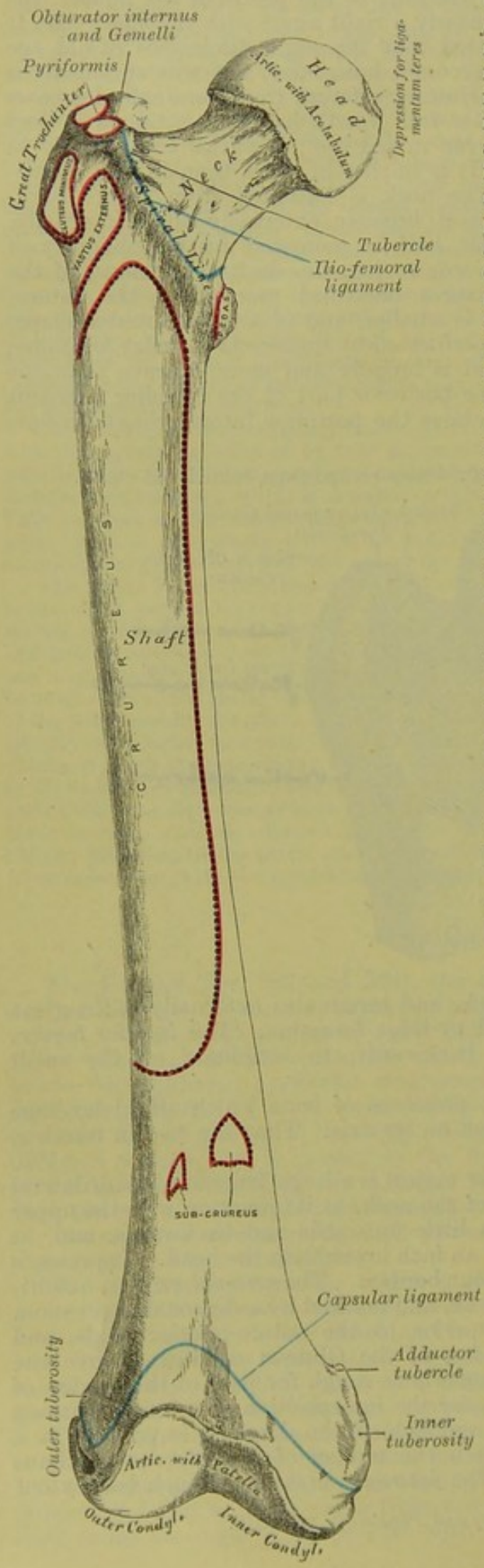

than the external, presents at its base a deep depression, the *digital fossa* (fossa trochanterica), for the insertion of the tendon of the Obturator externus, and above and in front of this an impression for the insertion of the Obturator internus and Gemelli. The *superior border* is free; it is thick and irregular, and marked near the centre by an impression for the insertion of the Pyriformis. The *inferior border* corresponds to the line of junction of the base of the trochanter with the outer surface of the shaft; it is marked by a rough, prominent, slightly curved ridge, which gives origin to the upper part of the Vastus externus. The *anterior border* is prominent and somewhat irregular; it affords insertion at its outer part to the Gluteus minimus. The *posterior border* is very prominent, and appears as a free, rounded edge, which bounds the back part of the digital fossa.

The **small trochanter** (trochanter minor) is a conical eminence, which varies in size in different subjects; it projects from the lower and back part of the base of the neck. Its *base* is triangular, and connected with the adjacent parts of the bone by three well-marked borders: two of these are above—the *internal* continuous with the lower border of the neck, the *external* with the posterior intertrochanteric line—while the *inferior border* is continuous with the middle division of the linea aspera. Its *summit*, directed inwards and backwards, is rough, and gives insertion to the tendon of the Psoas.

A well-marked prominence, of variable size, which projects at the junction of the upper part of the neck with the great trochanter, is called the *tubercle* of the femur; it is the point of meeting of five muscles: the Gluteus minimus externally, the Vastus externus below, and the tendon of the Obturator internus and two Gemelli above. Running obliquely downwards and inwards from the tubercle is the *spiral line* of the femur, or *anterior intertrochanteric line* (linea intertrochanterica); it winds round the inner side of the shaft, below the lesser trochanter, and terminates about two inches below this eminence in the linea aspera. Its upper half is rough, and affords attachment

to the ilio-femoral ligament of the hip-joint; its lower half is less prominent, and gives origin to the upper part of the Vastus internus. Running obliquely downwards and inwards from the summit of the great trochanter on the posterior surface of the neck is a very prominent ridge, the *posterior intertrochanteric line* (crista intertrochanterica). Its upper half forms the posterior border of the great trochanter, and its lower half runs downwards and inwards to the upper and back part of the lesser trochanter. A slight ridge is sometimes seen commencing about the middle of the posterior intertrochanteric line, and passing vertically downwards for about two inches along the back part of the shaft: it is called the *linea quadrata*, and gives attachment to the Quadratus femoris and a few fibres of the Adductor magnus. Generally there is merely a slight thickening about the middle of the intertrochanteric line, marking the attachment of the upper part of the Quadratus femoris. This is termed by some anatomists the *tubercle of the Quadratus*.

The **shaft** (corpus femoris) is almost cylindrical in form, but is a little broader above than in the centre, broadest and somewhat flattened from before backwards below. It is slightly arched, so as to be convex in front, and concave behind, where it is strengthened by a prominent longitudinal ridge, the *linea aspera*. It presents for examination three borders, separating three surfaces. Of the three borders, one, the linea aspera, is posterior; the other two are placed laterally.

The *linea aspera* (fig. 388) is a prominent longitudinal ridge or crest, on the middle third of the bone, presenting an inner and an outer lip, and a narrow, rough, intermediate space. Above, the linea aspera is prolonged by three ridges. The external ridge is very rough, and runs almost vertically upwards to the base of the great trochanter. It is termed

FIG. 388.—Right femur. Posterior surface.

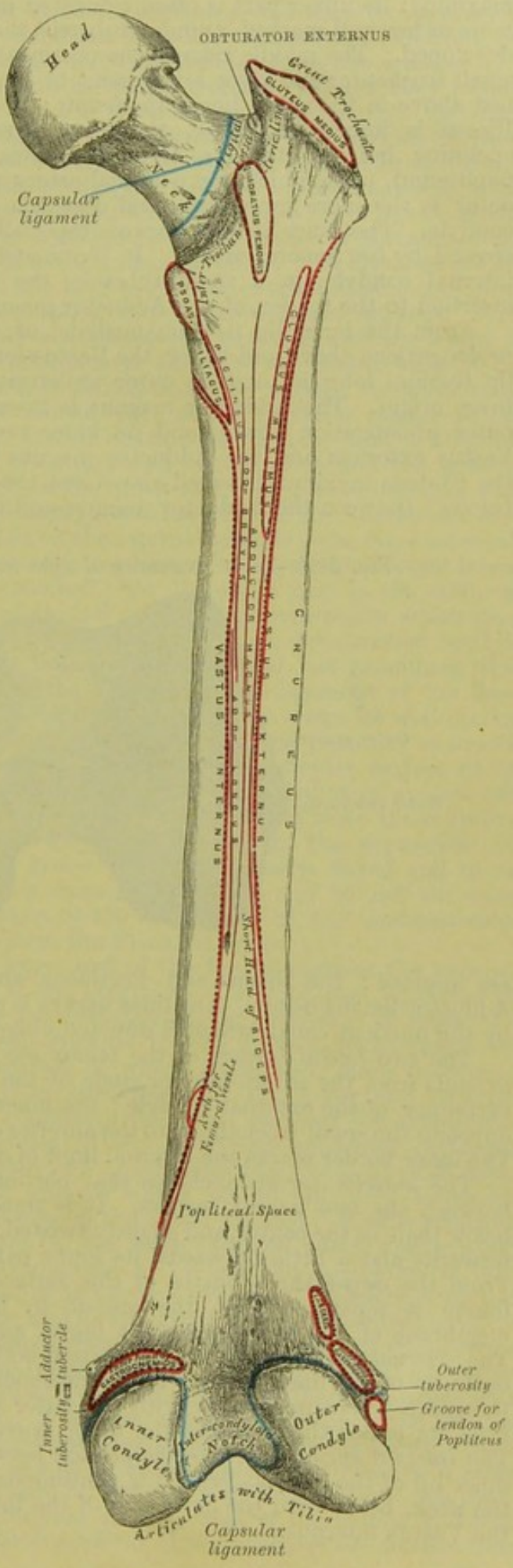

the *gluteal ridge* (tuberositas glutaea), and gives attachment to part of the Gluteus maximus: its upper part is often elongated into a roughened crest, on which a more or less well-marked, rounded tubercle, the *trochanter tertius*, is occasionally developed. The middle ridge (linea pectinea) is continued to the base of the small trochanter and gives attachment to the Pectineus; the internal ridge is lost above in the spiral line of the femur; between these two a portion of the Iliacus is inserted. Below, the linea aspera is prolonged by two ridges, enclosing between them a triangular area, the *popliteal surface* (planum popliteum), upon which the popliteal artery rests. Of these two ridges, the outer is the more prominent, and descends to the summit of the external condyle. The inner is less marked, especially at its upper part, where it is crossed by the femoral artery. It terminates, below, at the summit of the internal condyle, in a small tubercle, the *adductor tubercle*, which affords insertion to the tendon of the Adductor magnus.

From the inner lip (labium mediale) of the linea aspera and its inner prolongations above and below, the Vastus internus arises; and from the outer lip (labium laterale) and its outer prolongation above, the Vastus externus takes origin. The Adductor magnus is inserted into the linea aspera, to its outer prolongation above, and its inner prolongation below. Between the Vastus externus and the Adductor magnus two muscles are attached—viz. the Gluteus maximus inserted above and the short head of the Biceps arising below. Between the Adductor magnus and the Vastus internus four muscles

Fig. 389.—Lower extremity of right femur viewed from below.

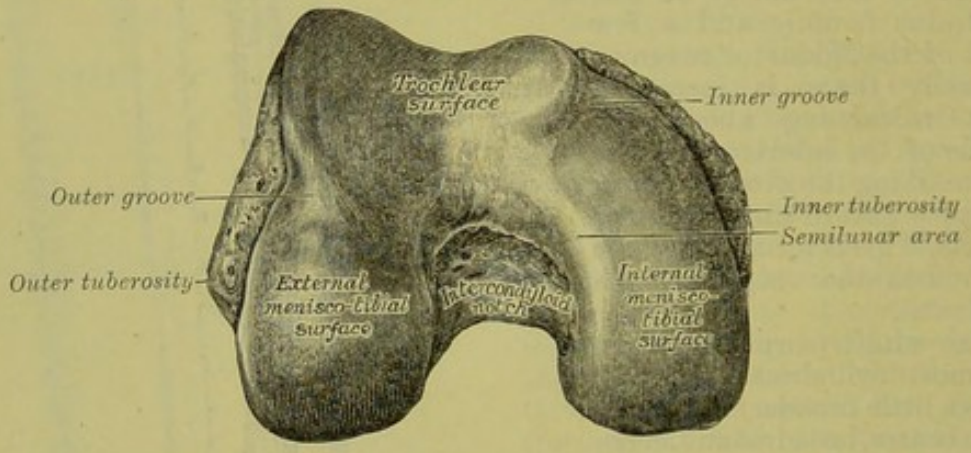

are inserted: the Iliacus and Pectineus above; the Adductor brevis and Adductor longus below. The linea aspera is perforated a little below its centre by the nutrient canal, which is directed obliquely upwards.

The two *lateral borders* of the femur are only slightly marked: the outer extends from the antero-inferior angle of the great trochanter to the anterior extremity of the external condyle; the inner from the spiral line, at a point opposite the small trochanter, to the anterior extremity of the internal condyle. The inner border marks the internal limit of attachment of the Crureus.

The *anterior surface* includes that portion of the shaft which is situated between the two lateral borders. It is smooth, convex, broader above and below than in the centre, and slightly twisted, so that its upper part is directed forwards and a little outwards, its lower part forwards and a little inwards. From the upper three-fourths of this surface the Crureus arises; the lower fourth is separated from the muscle by the intervention of the synovial membrane of the knee-joint and a bursa, and gives origin to the Subcrureus. The *external surface* includes the portion between the external border and the outer lip of the linea aspera; it is continuous above with the outer surface of the great trochanter, below with the outer surface of the external condyle: from its upper three-fourths the outer portion of the Crureus takes origin. The *internal surface* includes the portion between the internal border and the inner lip of the linea aspera; it is continuous above with the lower border of the neck, below with the inner side of the internal condyle: it is covered by the Vastus internus.

The **lower extremity** (fig. 389), larger than the upper, is somewhat cuboid in form, but its transverse diameter is greater than its antero-posterior; it consists of two lateral oblong eminences known as the *condyles*. In front, the condyles are but slightly prominent, and are separated from one another by a smooth shallow articular depression called the *trochlea*; behind, they project considerably, and the interval between them forms a deep notch, the *intercondyloid notch* (fossa intercondyloidea). The *external condyle* (condylus lateralis) is the more prominent and the broader both in its antero-posterior and transverse diameters; the *internal condyle* (condylus medialis) is the longer and, when the femur is held with its shaft perpendicular, projects to a lower level. When, however, the femur is in its natural oblique position the lower surfaces of the two condyles lie practically in the same horizontal plane. The condyles are not quite parallel with one another; the long axis of the external is almost directly antero-posterior, but that of the internal runs backwards and inwards. Their opposed surfaces, viz. the inner surface of the external and the outer of the internal, are small, rough, and concave, and form the lateral walls of the intercondyloid notch. This notch is limited above by a ridge, the *linea intercondyloidea*, and below by the central part of the posterior margin of the trochlear surface. The posterior crucial ligament of the knee-joint is attached to the lower and front part of the inner wall of the notch and the anterior crucial ligament to an impression on the upper and back part of its outer wall. The outer surface of the external condyle and the inner of the internal are each surmounted by a tuberosity. That on the internal condyle—the *inner tuberosity* (epicondylus medialis)—is a large convex eminence to which the internal lateral ligament of the knee-joint is attached. At its upper part is the adductor tubercle, already referred to, and behind it is a rough impression which gives origin to the inner head of the Gastrocnemius. That on the external condyle, the *outer tuberosity* (epicondylus lateralis), smaller and less prominent than the internal, gives attachment to the external lateral ligament of the knee-joint. Directly below it is a small depression from which a smooth well-marked groove curves obliquely upwards and backwards to the posterior extremity of the condyle. This groove is separated from the articular surface of the condyle by a prominent lip across which a second, shallower groove runs vertically downwards from the depression. In the recent state these grooves are covered with cartilage. The Popliteus arises from the depression; its tendon is lodged in the oblique groove when the knee is flexed and in the vertical groove when the knee is extended. Above and behind the outer tuberosity is an area for the origin of the outer head of the Gastrocnemius, above and to the inner side of which the Plantaris arises.

The *articular surface* of the lower end of the femur occupies the anterior, inferior, and posterior surfaces of the condyles. Its front part is named the *trochlea* (facies patellaris) and articulates with the patella; it presents a median groove which extends downwards to the intercondyloid notch and two lateral convexities, the external of which is broader, more prominent, and extends farther upwards than the internal. The lower and posterior parts of the articular surface constitute the *tibial surfaces* for articulation with the corresponding tuberosities of the tibia and semilunar cartilages. These surfaces are separated from one another by the intercondyloid notch and from the trochlea by faint grooves which extend obliquely across the condyles. The outer of these grooves is the better marked; it runs outwards and forwards from the front part of the intercondyloid notch, and expands externally to form a triangular depression. When the knee-joint is fully extended, the outer triangular part of this groove rests upon the anterior portion of the external semilunar cartilage, and its inner part comes into contact with the inner margin of the outer articular surface of the tibia in front of the external tubercle of the tibial spine. The inner groove is less distinct than the outer. It does not reach as far as the intercondyloid notch and therefore exists only on the inner part of the condyle; it receives the anterior edge of the internal semilunar cartilage when the knee-joint is extended. Where the groove ceases externally the trochlear surface is seen to be continued backwards as a semilunar area close to the anterior part of the intercondyloid notch; this semilunar area articulates with the internal vertical facet of the patella in forced flexion of the knee-joint. The tibial surfaces of the condyles are convex from

side to side and from before backwards. Each presents a double curve, its posterior segment being an arc of a circle, its anterior, part of a cycloid.*

Fig. 390.—Longitudinal section of head and neck of femur.

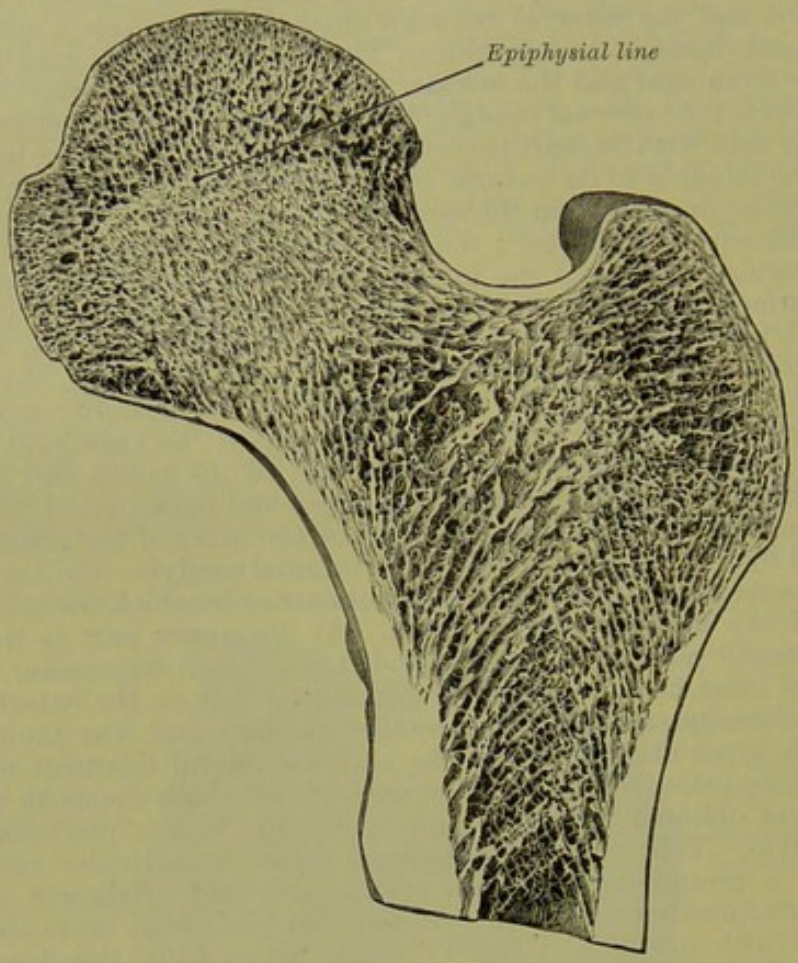

Structure.—The shaft of the femur is a cylinder of compact tissue, hollowed by a large medullary canal. The wall of the cylinder is of great thickness and density in the middle third of the shaft, where the bone is narrowest and the medullary canal best formed; but above and below this the wall becomes thinner, while the medullary canal is gradually filled up by cancellous tissue, so that the upper and lower ends of the shaft (fig. 390), and the articular extremities more especially, consist of cancellous tissue, invested by a thin compact layer.

Fig. 391.—Scheme showing disposition of principal cancellous lamellæ in upper extremity of femur.

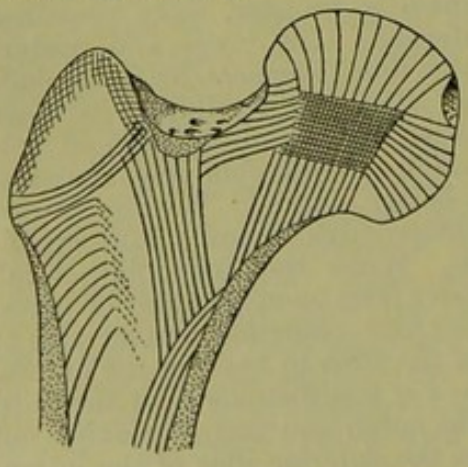

The cancelli in the ends of the femur are disposed along the lines of greatest pressure and tension. In the upper end (fig. 391) the chief lamellæ are arranged in the following manner. A series of bony planes at right angles to the articular surface of the head converge to a central dense wedge, which presents few and dense cancelli. The wedge is supported by strong lamellæ, which extend to the sides of the neck and are specially marked along its upper and lower borders. Any force therefore applied to the head of the femur is transmitted directly to the central wedge and thence to the junction of the neck

* A *cycloid* is a curve traced by a point in the circumference of a wheel when the wheel is rolled along in a straight line.

with the shaft. This junction is specially strengthened by a series of dense lamellæ which extend from the lesser trochanter to the outer end of the superior border of the neck; this arrangement will obviously oppose considerable resistance to either tensile or shearing force. A smaller bar stretching across the junction of the great trochanter with the neck and shaft resists the shearing force of the muscles attached to this prominence. These two bars, one at the junction of shaft and neck, the other at the junction of shaft and great trochanter, form the upper layers of a series of arches which extend across between the sides of the shaft and transmit to the shaft forces applied to the upper end of the bone. In the midst of the cancellous tissue of the neck is a vertical plane of compact bone, the *femoral spur* (*calcar femorale*) which commences at the point where the neck joins the shaft midway between the small trochanter and the internal border of the shaft of the bone, and extends in the direction of the digital fossa (fig. 392). This materially strengthens this portion of the bone. Another point in connection with the structure of the neck of the femur requires mention, especially on account of its influence on the production of fracture in this situation. It will be noticed that a considerable portion of the great trochanter lies behind the level of the posterior surface of the neck, and if a section be made through the trochanter at this level, it will be seen that the posterior wall of the neck is prolonged into the trochanter. This prolongation is termed by Bigelow the 'true neck,'* and forms a thin, dense plate of bone, which passes beneath the posterior intertrochanteric ridge towards the outer surface of the bone.

Fig. 392.—Calcar femorale.

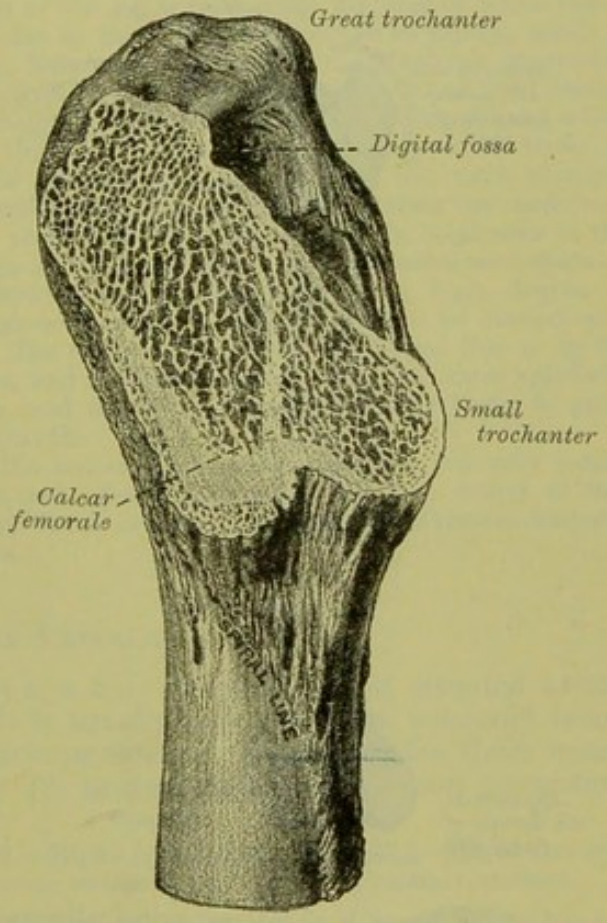

In the lower end, the cancelli spring on all sides from the inner surface of the cylinder, and descend in a perpendicular direction to the articular surface, the cancelli being strongest and having a more accurately perpendicular course above the condyles. In addition to this, however, horizontal planes of cancellous tissue are to be seen, so that the spongy tissue in this situation presents an appearance of being mapped out into a series of cubical compartments.

Articulations. — The femur articulates with three bones: the os innominatum, tibia, and patella.

Ossification (fig. 393). — The femur is ossified from *five* centres: one for the shaft, one for the head, one for each trochanter, and one for the lower extremity. Of all the long bones, except the clavicle, it is the first to show traces of ossification; this commences in the middle of the shaft, at about the seventh week of fœtal life, and rapidly extends upwards and downwards. The centres in the epiphyses appear in the following order: in the lower end of the bone, at the ninth month of fœtal life (from this centre the condyles and tuberosities are formed); in the head, at the end of the first year after birth; in the great trochanter, during the fourth year; and in the small trochanter, between the thirteenth and fourteenth years. The order in which the epiphyses are joined to the shaft is the reverse of that of their appearance: they are not united until after puberty, the small trochanter being first joined, then the great, then the head, and, lastly, the inferior extremity, which is not united until the twentieth year.

* *Bigelow on the Hip*, Philadelphia, 1869.

Surface Form.—The femur is covered with muscles, so that in fairly muscular subjects the shaft cannot be detected, and the only parts accessible to the touch are the outer surface of the great trochanter and the lower expanded end of the bone. The situation of the great trochanter is generally indicated by a depression, owing to the thickness of the Gluteus medius and minimus, which project above it. When, however, the thigh is flexed, and especially if it be crossed over the opposite one, the trochanter produces a blunt eminence on the surface. The upper border is about on a level with the centre of the hip-joint, and is indicated by a line drawn from the anterior superior spine of the ilium, over the outer side of the hip, to the most prominent point of the tuberosity of the ischium. This is known as Nélaton's line. The outer and inner condyles of the lower extremity are accessible to the touch. The outer one is more subcutaneous than the inner one, and readily felt. The tuberosity on it is comparatively little developed, but can be more or less easily recognised. The inner condyle is more thickly covered, and this gives a general convex outline to this part, especially when the knee is flexed. The tuberosity on it is easily felt, and at the upper part of the condyle the sharp *adductor tubercle* for the insertion of the tendon of the Adductor magnus can be recognised without difficulty. When the knee is flexed, and the patella situated in the interval between the condyles and the upper end of the tibia, a part of the trochlear surface of the femur can be made out above the patella.

Fig. 393.—Plan of ossification of the femur. From five centres.

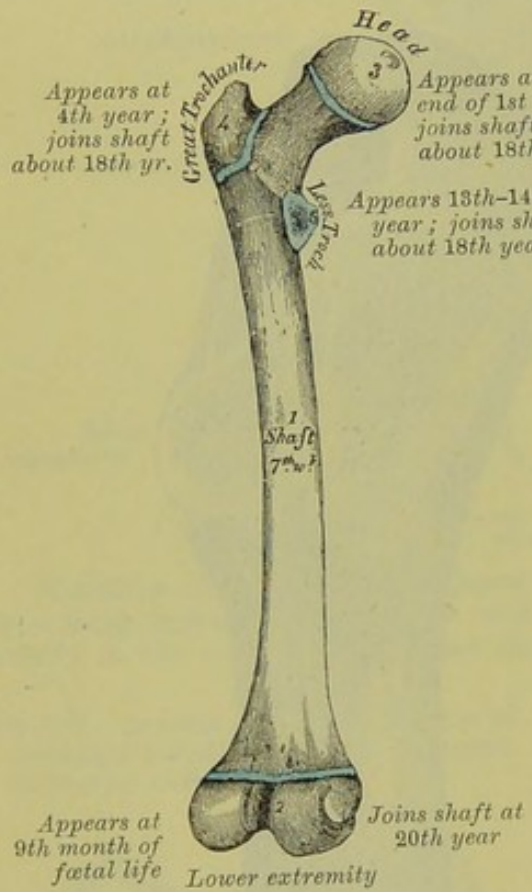

Applied Anatomy.—There are one or two points about the ossification of the femur bearing on practice to which allusion must be made. The lower end of the femur is the only epiphysis in which ossification has commenced at the time of birth. The presence of this ossific centre is, therefore, a proof, in a newly born child found dead, that the child has arrived at the full period of utero-gestation, and is always relied upon in medico-legal investigations. The position of the epiphysial line should be carefully noted. It is on a level with the adductor tubercle, and the epiphysis does not, therefore, form the whole of the cartilage-clad portion of the lower end of the bone. It is essential to bear this point in mind in performing excision of the knee, since growth in length of the femur takes place chiefly from the lower epiphysis, and any interference with the epiphysial cartilage in a young child would involve such ultimate shortening of the limb, from want of growth, as to render the limb almost useless. Separation of the lower epiphysis may take place up to the age of twenty, at which time it becomes completely joined to the shaft of the bone; but, as a matter of fact, few cases occur after the age of sixteen or seventeen. The epiphysis of the head of the femur is of interest principally on account of its being the seat of origin, in a large number of cases, of tuberculous disease of the hip-joint. In the majority of cases the disease begins in the highly vascular and growing tissue at the end of the shaft in the neighbourhood of the epiphysial cartilage, and extends into the joint. It should be noted that the epiphysis for the head is entirely intracapsular.

Fractures of the femur are divided, like those of the other long bones, into fractures of the upper end; of the shaft; and of the lower end. The fractures of the upper end may be classified into (1) fracture of the neck; (2) fracture at the junction of the neck with the great trochanter; (3) fracture of the great trochanter; and (4) separation of the epiphysis, either of the head or of the great trochanter. The first of these, fracture of the neck, is usually termed *intracapsular* fracture, but this is scarcely a correct designation, as, owing to the attachment of the capsular ligament, the fracture is partly within and partly without the capsule when the fracture occurs at the lower part of the neck. It generally takes place in old people, principally women, and usually from a very slight degree of indirect violence. Probably the main cause of its occurrence in old people is the senile degenerative change which takes place in the bone. Merkel believes that it is mainly due to the absorption of the calcar femorale. As a rule the

fragments become united by fibrous tissue, but frequently no union takes place, and the opposed surfaces become smooth and eburnated.

Fractures at the junction of the neck with the great trochanter are usually termed *extra-capsular*, but this designation is also incorrect, as the fracture is partly within the capsule, owing to its attachment in front to the anterior intertrochanteric line, which is situated below the line of fracture. These fractures are produced by direct violence to the great trochanter, as from a fall laterally on the hip. From the manner in which the accident is caused the neck of the bone is driven into the trochanter, where it may remain impacted, or the trochanter may be split into two or more fragments, disimpaction resulting.

Fractures of the shaft may occur at any part, but the most usual situation is at or near the centre of the bone. They may be caused by direct or indirect violence. Fractures of the upper third of the shaft are almost always the result of indirect violence, while those of the lower third are the result, for the most part, of direct violence. Fractures of the shaft are generally oblique, but they may be transverse, longitudinal, or spiral. The transverse fracture occurs most frequently in children. The fractures of the lower end of the femur include transverse fracture above the condyles, the most common; and this may be complicated by a vertical fracture between the condyles, constituting the T-shaped fracture. In these cases the popliteal artery is in danger of being wounded. Oblique fracture separating either the internal or external condyle, and a longitudinal incomplete fracture between the condyles, may also take place.

The femur as well as the other bones of the leg is frequently the seat of acute osteomyelitis in children. This is no doubt due to their greater exposure to injury, which is often the exciting cause of this disease. Necrosis of portions of the diaphysis frequently ensues, especially in the region of the popliteal surface of the femur, and the disease may continue for years, great trouble being experienced with discharging sinuses which periodically close and reopen to allow of the exit of a piece of dead bone.

Tumours are not infrequently found growing from the femur: the most common forms being sarcoma which may grow either from the periosteum or from the medullary tissue within the interior of the bone, and exostosis which commonly originates in the neighbourhood of the epiphysial cartilage of the lower end. The periosteal sarcomata of the femur and most of the central growths are usually of a very high degree of malignancy; although the 'myeloid' growth, which nowadays cannot be classed as a malignant tumour, may also be found. The region of the lower epiphysial line is by far the commoner seat for all these tumours, and it should be noted that the lower epiphysis has the longest period of active growth, and that these tumours usually begin to grow towards the end of the period of active growth.

Sarcomata about the upper end of the femur are seen occasionally, but very rarely in comparison with those at the lower end. Secondary carcinoma also occurs in this bone, most commonly due to a primary focus in the breast, and spontaneous fracture of the bone may take place in these cases.

The Patella

The **Patella** (figs. 394 and 395) is a flat, triangular bone, situated at the anterior part of the knee-joint. It is usually regarded as a sesamoid bone, developed in the tendon of the Quadriceps extensor, and resembles these bones (1) in being developed in a tendon; (2) in its centre of ossification presenting a knotty or tubercular outline; (3) in being composed mainly of dense cancellous tissue. It serves to protect the front of the joint, and increases the leverage of the Quadriceps extensor by making it act at a greater angle. It presents an anterior and a posterior surface, three borders, and an apex.

Fig. 394.—Right patella. Anterior surface.

Fig. 395.—Right patella. Posterior surface.

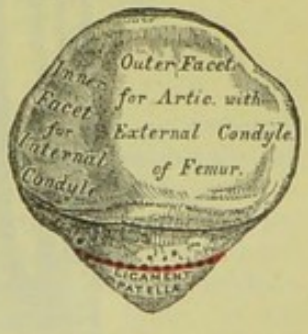

The *anterior surface* is convex, perforated by small apertures, for the passage of nutrient vessels, and marked by numerous rough, longitudinal striæ. This surface is covered, in the recent state, by an expansion from the tendon of the Quadriceps extensor, which is continuous below with the superficial fibres of the ligamentum patellæ. It is separated from the integument by a bursa. The *posterior surface* (facies articularis)

Fig. 396. — Bones of the right leg. Anterior surface.

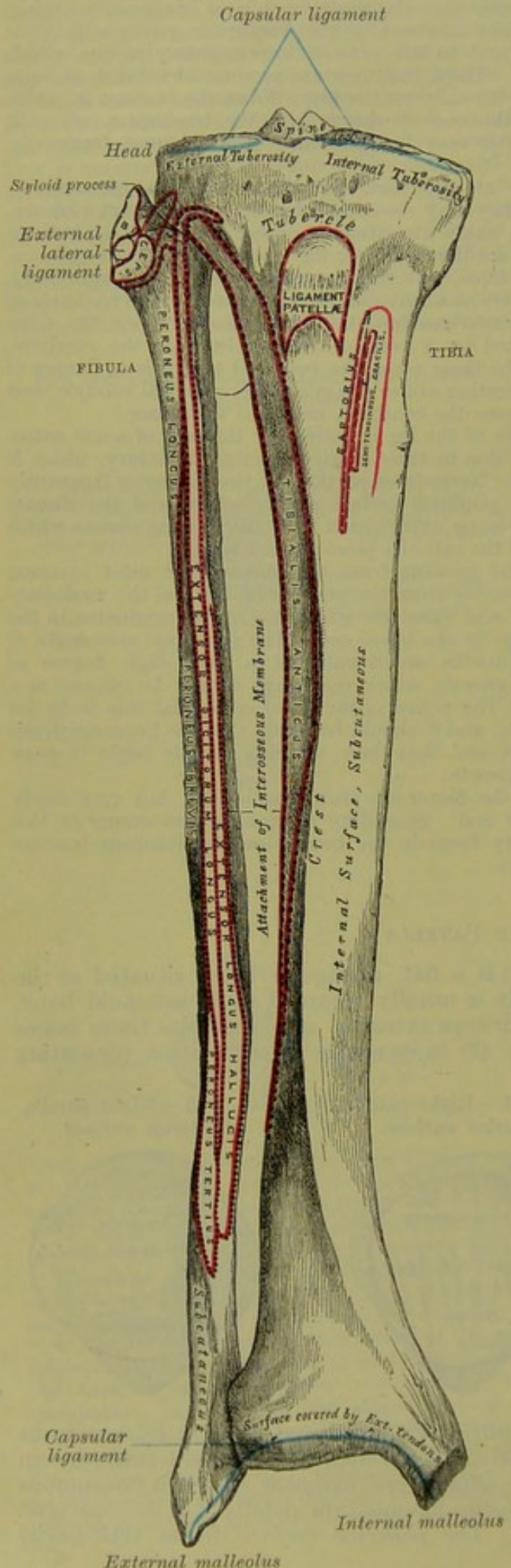

presents above a smooth, oval, articular area, covered with cartilage in the recent state, and divided into two facets by a vertical ridge, which descends from the superior border towards the inferior angle of the bone. The ridge corresponds to the groove on the trochlea of the femur, and the two facets to the inner and outer parts of the same surface; the outer facet is the broader and deeper. Below the articular surface is a rough, convex, non-articular depression, the lower half of which gives attachment to the ligamentum patellæ; the upper half is separated from the head of the tibia by adipose tissue.

The *superior border* (basis patellæ) is thick, and sloped from behind, downwards, and forwards: it gives attachment to that portion of the Quadriceps extensor which is derived from the Rectus and Crureus. The *lateral borders* are thinner, converging below: they give attachment to those portions of the Quadriceps extensor which are derived from the external and internal Vasti.

The *apex* (apex patellæ) is pointed, and gives attachment to the ligamentum patellæ.

Structure.—The patella consists of a nearly uniform dense cancellous tissue, covered by a thin compact lamina. The cancelli immediately beneath the anterior surface are arranged parallel with it. In the rest of the bone they radiate from the posterior articular surface towards the other parts of the bone.

Ossification. — The patella is ossified from a single centre, which usually makes its appearance in the second or third year, but may be delayed until the sixth year. More rarely, the bone is developed by two centres, placed side by side. Ossification is completed about the age of puberty.

Articulations. — The patella articulates with the femur.

Surface Form. — The external surface of the patella can be felt in front of the knee. In the extended position of the limb the inner border of the bone is a little more prominent than the outer, and if the Quadriceps extensor be relaxed, the

bone can be moved from side to side and appears to be loosely fixed. When the joint is flexed, the patella recedes into the hollow between the condyles of the femur and the upper end of the tibia, and becomes firmly applied to the femur.

Applied Anatomy.—The main surgical interest about the patella is in connection with fractures, which are of frequent occurrence. They are most frequently produced by muscular action—that is to say, by violent contraction of the Quadriceps extensor, while the limb is in a position of semiflexion, so that the bone is snapped across the condyles, and the fracture is transverse. Fracture of the patella is also produced by direct violence, such as falls on the knee, and here the fracture is usually stellate and the bone comminuted. The principal interest in these cases attaches to their treatment. Owing to the displacement of the fragments, and the difficulty there is in maintaining them in apposition, union takes place by fibrous tissue, and this may subsequently stretch, producing wide separation of the fragments and permanent lameness. Truly satisfactory results after this fracture are generally only to be obtained by opening the joint and wiring the fragments together, and this is especially so when there is marked separation of the fragments owing to laceration of the lateral aponeurosis.

It is an anatomical possibility, if the fracture involve only the lower and non-articular part of the bone, for this to take place without injury to the synovial membrane and without involving the cavity of the knee-joint.

The Tibia

The **Tibia** (figs. 396 and 398) is situated at the front and inner side of the leg, and, excepting the femur, is the longest and largest bone of the skeleton. It is prismoid in form, expanded above, where it enters into the knee-joint, more slightly enlarged below. In the male, its direction is vertical, and parallel with the bone of the opposite side ; but in the female it has a slightly oblique direction downwards and outwards, to compensate for the greater obliquity of the femur inwards. It presents for examination a shaft and two extremities.

The **upper extremity, or head,** is large, and expanded into two lateral eminences, the *tuberosities.* The *superior surface* (facies articularis superior) presents two smooth articular facets, one on either side of the middle line (fig. 397). The inner of these is oval in shape, and slightly concave from side

Fig. 397.—Upper surface of right tibia, showing attachment of crucial ligaments and semilunar cartilages.

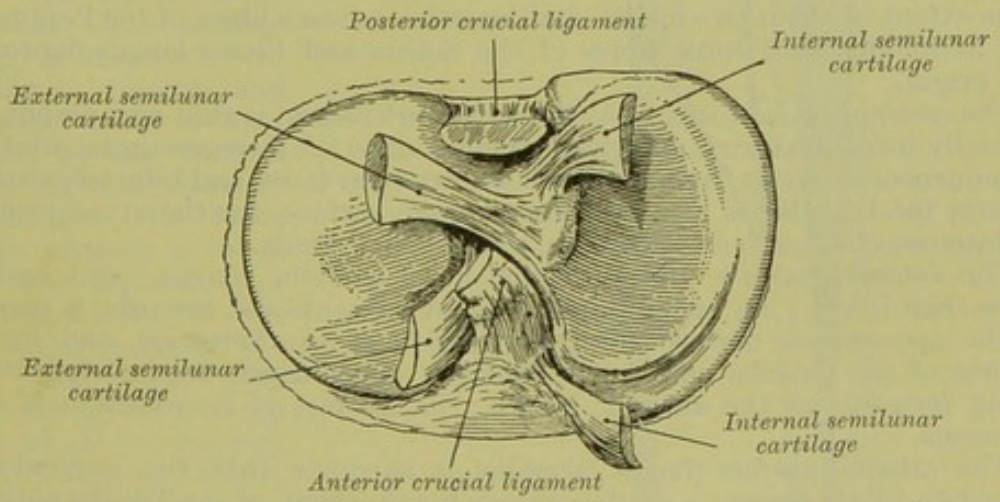

to side, and from before backwards. The outer, nearly circular, is concave from side to side, but slightly convex from before backwards, especially at its posterior part, where it is prolonged on to the posterior surface for a short distance. The central portions of these facets articulate with the condyles of the femur, while their peripheral portions support the semilunar cartilages of the knee, which here intervene between the two bones. In the middle line, but nearer the posterior than the anterior aspect of the bone, is an eminence, the *spine* of the tibia (eminentia intercondyloidea), surmounted on either side by a prominent tubercle, on to the lateral aspects of which the facets just described are prolonged ; in front of and behind the spinous process are rough depressions for the attachment of the anterior and posterior crucial ligaments and the semilunar fibro-cartilages (fig. 397). The *anterior*

surfaces of the tuberosities are continuous with one another, forming a single large somewhat flattened area: this area is triangular, broad above, and perforated by large vascular foramina: narrow below where it terminates in a prominent oblong elevation of large size, the *tubercle* of the tibia (tuberositas tibiæ), which gives attachment to the ligamentum patellæ; a bursa intervenes between the deep surface of the ligament and the part of the bone immediately above the tubercle. *Posteriorly*, the tuberosities are separated from each other by a shallow depression, the *popliteal notch*, which gives attachment to part of the posterior crucial ligament, and part of the posterior ligament of the knee-joint. The *inner tuberosity* (condylus medialis) presents posteriorly a deep transverse groove, for the insertion of the tendon of the Semimembranosus. Its *lateral surface* is convex, rough and prominent; it gives attachment to the internal lateral ligament. The *outer tuberosity* (condylus lateralis) presents posteriorly a flat articular facet, nearly circular in form, directed downwards, backwards, and outwards, for articulation with the head of the fibula. Its *lateral surface* is convex and rough, more prominent in front than the internal: it presents an eminence, situated on a level with the upper border of the tubercle of the tibia at the junction of its anterior and outer surfaces, for the attachment of the ilio-tibial band. Just below this a part of the Extensor longus digitorum takes origin and a slip from the Biceps tendon is inserted.

The **shaft** (corpus tibiæ) is of a triangular prismoid form, broad above, gradually decreasing in size to the commencement of its lower fourth, which is its most slender part. It then enlarges again towards its lower extremity. It presents for examination three borders and three surfaces.

The *anterior border*, the most prominent of the three, is called the *crest* or *shin* (crista anterior); it commences above at the tubercle, and terminates below at the anterior margin of the inner malleolus. It is sinuous and prominent in the upper two-thirds of its extent, but smooth and rounded below; it gives attachment to the deep fascia of the leg.

The *internal border* (margo medialis) is smooth and rounded above and below, but more prominent in the centre; it begins at the back part of the inner tuberosity, and ends at the posterior border of the internal malleolus; its upper part gives attachment to the internal lateral ligament of the knee to the extent of about two inches, and insertion to some fibres of the Popliteus; from its middle third some fibres of the Soleus and Flexor longus digitorum take origin.

The *external* or *interosseous border* (crista interossea) is thin and prominent, especially its central part, and gives attachment to the interosseous membrane; it commences above in front of the fibular articular facet, and bifurcates below, to form the boundaries of a triangular rough surface, for the attachment of the interosseous ligament connecting the tibia and fibula.

The *internal surface* (facies medialis) is smooth, convex, and broader above than below; its upper third, directed forwards and inwards, is covered by the aponeurosis derived from the tendon of the Sartorius, and by the tendons of the Gracilis and Semitendinosus, all of which are inserted nearly as far forward as the anterior border; in the rest of its extent it is subcutaneous.

The *external surface* (facies lateralis) is narrower than the internal; its upper two-thirds present a shallow groove for the origin of the Tibialis anticus; its lower third is smooth, convex, curves gradually forwards to the anterior aspect of the bone, and is covered from within outwards by the tendons of the Tibialis anticus, Extensor longus hallucis, and Extensor longus digitorum.

The *posterior surface* (facies posterior) (fig. 398) presents, at its upper part, a prominent ridge, the *oblique line* of the tibia (linea poplitea), which extends from the back part of the articular facet for the fibula obliquely downwards, to the internal border, at the junction of its upper and middle thirds; it marks the lower limit of the insertion of the Popliteus, serves for the attachment of the popliteal fascia and gives origin to part of the Soleus, Flexor longus digitorum and Tibialis posticus. The triangular area, above and to the inner side of this line, gives insertion to the Popliteus. The middle third of the posterior surface is divided by a vertical ridge into two parts: the ridge is well marked at its commencement at the oblique line, but gradually becomes

indistinct below; the inner and broader portion gives origin to the Flexor longus digitorum, the outer and narrower to part of the Tibialis posticus. The remaining part of the posterior surface is smooth and covered by the Tibialis posticus, Flexor longus digitorum, and Flexor longus hallucis. Immediately below the oblique line is the medullary foramen, which is large and directed obliquely downwards.

The **lower extremity**, much smaller than the upper, presents five surfaces; it is prolonged downwards on its inner side as a strong process, the *internal malleolus*. The *inferior surface* (facies articularis inferior) is quadrilateral, and smooth for articulation with the astragalus. It is concave from before backwards, broader in front than behind, and traversed from before backwards by a slight elevation, separating two lateral depressions. It is continuous internally with that on the inner malleolus. The *anterior surface* of the lower extremity is smooth and rounded above, and covered by the tendons of the Extensor muscles of the toes; its lower margin presents a rough transverse depression for the attachment of the anterior ligament of the ankle-joint. The *posterior surface* is traversed by a shallow groove directed obliquely downwards and inwards, continuous with a similar groove on the posterior surface of the astragalus, and serving for the passage of the tendon of the Flexor longus hallucis. The *external surface* presents a triangular rough depression for the attachment of the inferior interosseous ligament connecting it with the fibula; the lower part of this

FIG. 398.—Bones of the right leg. Posterior surface.

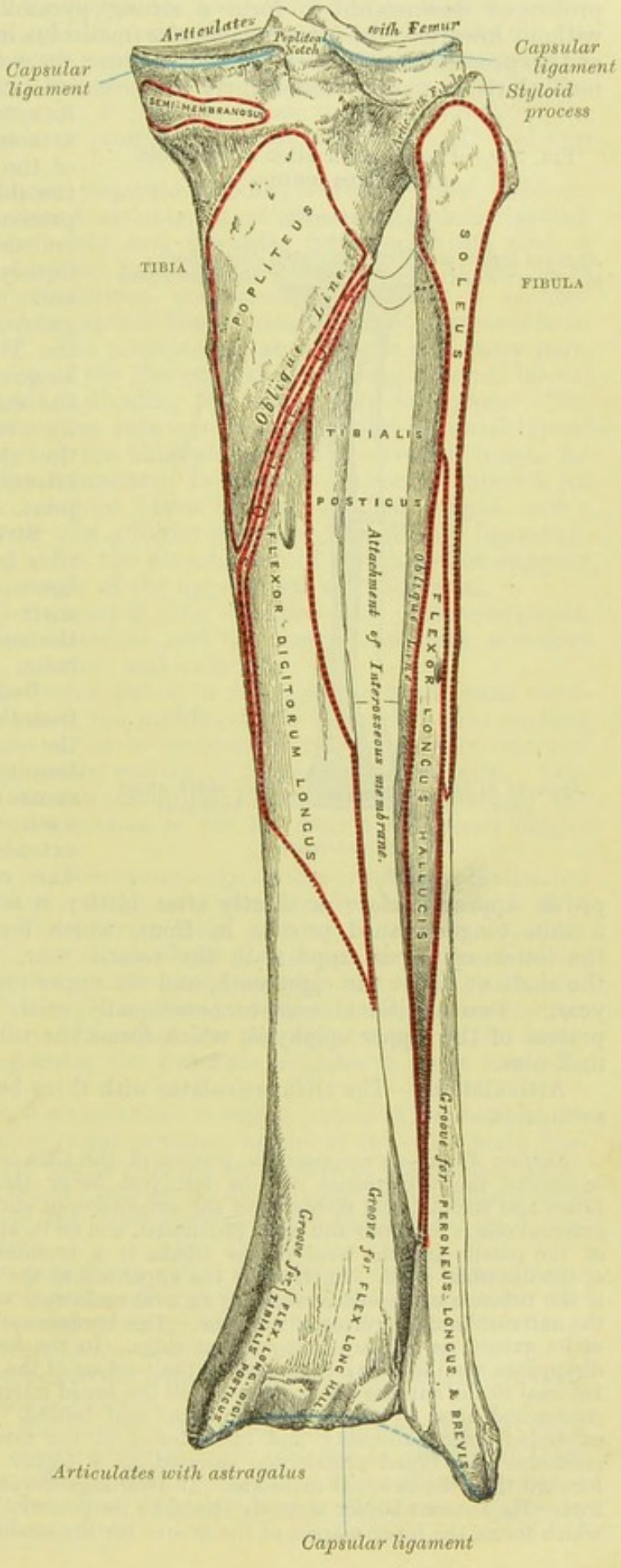

depression is smooth, covered with cartilage in the recent state, and articulates with the fibula. The surface is bounded by two prominent borders, continuous above with the interosseous ridge; they afford attachment to the anterior and posterior inferior tibio-fibular ligaments. The *internal surface* is prolonged downwards to form a strong pyramidal process, flattened from without inwards—the *internal malleolus* (malleolus medialis). The *inner surface* of this process is convex and subcutaneous; its *outer surface* (facies articularis malleolaris) is smooth and slightly concave, and articulates with the astragalus; its *anterior border* is rough, for the attachment of the anterior fibres of the internal lateral ligament of the ankle-joint; its *posterior border* presents a broad and deep groove (sulcus malleolaris), directed obliquely downwards and inwards, and occasionally double; this groove transmits the tendons of the Tibialis posticus and Flexor longus digitorum. The *summit* of the internal malleolus is marked by a rough depression behind, for the attachment of the internal lateral ligament of the ankle-joint.

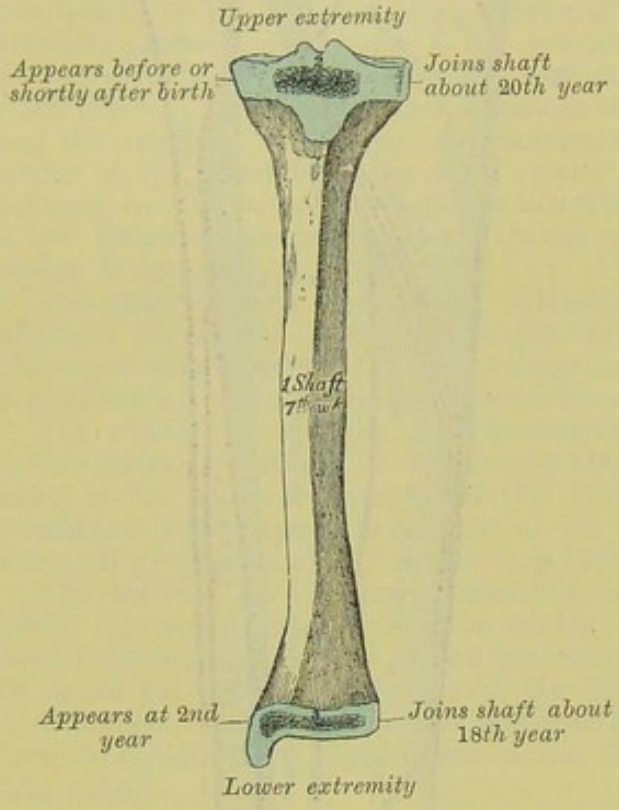

Fig. 399.—Plan of ossification of the tibia. From three centres.

Structure.—The structure of the tibia is like that of the other long bones. The compact wall of the shaft is thickest at the junction of the middle and lower thirds of the bone.

Ossification.—The tibia is ossified from *three* centres (fig. 399): one for the shaft, and one for each extremity. Ossification begins in the centre of the shaft about the seventh week of fœtal life, and gradually extends towards the extremities. The centre for the upper epiphysis appears before or shortly after birth; it is flattened in form, and has a thin tongue-shaped process in front, which forms the tubercle; that for the lower epiphysis appears in the second year. The lower epiphysis joins the shaft at about the eighteenth, and the upper one joins about the twentieth year. Two additional centres occasionally exist, one for the tongue-shaped process of the upper epiphysis, which forms the tubercle, and one for the inner malleolus.

Articulations.—The tibia articulates with three bones: the femur, fibula, and astragalus.

Surface Form.—A considerable portion of the tibia is subcutaneous. At the upper extremity the tuberosities can be felt just below the knee. The internal one is broad and smooth, and merges into the subcutaneous surface of the shaft below. The external one is narrower and more prominent, and on it, about midway between the apex of the patella and the head of the fibula, is a prominent tubercle for the insertion of the ilio-tibial band. In front of the upper end of the bone, between the tuberosities, is the tubercle of the tibia, forming an oval eminence, which is continuous below with the anterior border or crest of the bone. This border can be felt, in the upper two-thirds of its extent, as a sharp and flexuous ridge. In the lower third of the leg the border disappears, and the bone is concealed by the tendons of the muscles on the front of the leg. Internal to the anterior border is to be felt the broad internal surface of the tibia, slightly encroached upon by the muscles in front and behind. It begins above at the wide expanded inner tuberosity and ends below at the internal malleolus. The internal malleolus is a broad prominence situated on a higher level and somewhat farther forward than the external malleolus. It overhangs the inner border of the arch of the foot. Its anterior border is nearly straight; its posterior border presents a sharp edge, which forms the inner margin of the groove for the tendon of the Tibialis posticus.

The Fibula

The **Fibula** (figs. 396 and 398) is placed on the outer side of the tibia, with which it is connected above and below. It is the smaller of the two bones, and, in proportion to its length, the most slender of all the long bones. Its upper extremity is small, placed towards the back of the head of the tibia, below the level of the knee-joint, and excluded from the formation of this joint; the lower extremity inclines a little forwards, so as to be on a plane anterior to that of the upper end; it projects below the tibia, and forms the outer part of the ankle. The bone presents for examination a shaft and two extremities.

The **upper extremity** or **head** (capitulum fibulæ) is of an irregular quadrate form, presenting above a flattened articular facet (facies articularis capituli fibulæ), directed upwards, forwards and inwards, for articulation with a corresponding facet on the external tuberosity of the tibia. On the outer side is a thick and rough prominence, continued behind into a pointed eminence, the *styloid process* (apex capituli fibulæ), which projects upwards from the posterior part of the head. The prominence, at its upper and outer part, gives attachment to the tendon of the Biceps, and to the long external lateral ligament of the knee, the ligament dividing the tendon into two parts. The summit of the styloid process gives attachment to the short external lateral ligament. The remaining part of the circumference of the head is rough, for the attachment of muscles and ligaments. It presents in front a tubercle for the origin of the upper and anterior fibres of the Peroneus longus, and a surface for the attachment of the anterior superior tibio-fibular ligament; and behind, another tubercle, for the attachment of the posterior superior tibio-fibular ligament and the origin of the upper fibres of the Soleus.

The **shaft** (corpus fibulæ) presents four borders—the antero-external, the antero-internal, the postero-external, and the postero-internal; and four surfaces—anterior, posterior, internal, and external.

The *antero-external border* begins above in front of the head, runs vertically downwards to a little below the middle of the bone, and then curving somewhat outwards, bifurcates so as to embrace a triangular subcutaneous surface immediately above the outer surface of the external malleolus. This border gives attachment to an intermuscular septum, which separates the Extensor muscles on the anterior surface of the leg from the Peronei longus et brevis on the outer surface.

The *antero-internal border*, or *interosseous ridge* (crista interossea) is situated close to the inner side of the preceding, and runs nearly parallel with it in the upper third of its extent, but diverges from it so as to include a broader space in the lower two-thirds. It begins above just beneath the head of the bone (sometimes it is quite indistinct for about an inch below the head), and ends at the apex of a rough triangular surface immediately above the articular facet of the external malleolus. It serves for the attachment of the interosseous membrane, which separates the Extensor muscles in front from the Flexor muscles behind.

The *postero-external border* is prominent; it begins above at the base of the styloid process, and ends below in the posterior border of the outer malleolus. It is directed outwards above, backwards in the middle of its course, backwards and a little inwards below, and gives attachment to an aponeurosis which separates the Peronei on the outer surface of the shaft from the Flexor muscles on the posterior surface.

The *postero-internal border*, sometimes called the *oblique line*, begins above at the inner side of the head, and ends by becoming continuous with the antero-internal border or interosseous ridge at the lower fourth of the bone. It is well marked and prominent at the upper and middle parts of the bone. It gives attachment to an aponeurosis which separates the Tibialis posticus from the Soleus and Flexor longus hallucis.

The *anterior surface* is the interval between the antero-external and antero-internal borders. It is extremely narrow and flat in the upper third of its extent; broader and grooved longitudinally in its lower third; it serves for the origin of three muscles, the Extensor longus digitorum, Extensor proprius hallucis, and Peroneus tertius.

The *posterior surface* is the space included between the postero-external and the postero-internal borders; it is continuous below with the triangular surface above the articular facet of the outer malleolus; it is directed backwards above, backwards and inwards at its middle, directly inwards below. Its upper third is rough, for the origin of the Soleus; its lower part presents a triangular surface, connected to the tibia by a strong interosseous ligament; the intervening part of the surface is covered by the fibres of origin of the Flexor longus hallucis. Near the middle of this surface is the medullary foramen, which is directed downwards.

The *internal surface* is the interval included between the antero-internal and the postero-internal borders. It is grooved for the origin of the Tibialis posticus.

The *external surface* is the space between the antero-external and postero-external borders. It is much broader than the preceding, and often deeply grooved; it is directed outwards in the upper two-thirds of its course, backwards in the lower third, where it is continuous with the posterior border of the external malleolus. This surface is completely occupied by the Peronei longus et brevis.

Fig. 400.—Lower extremity of right fibula. Internal aspect.

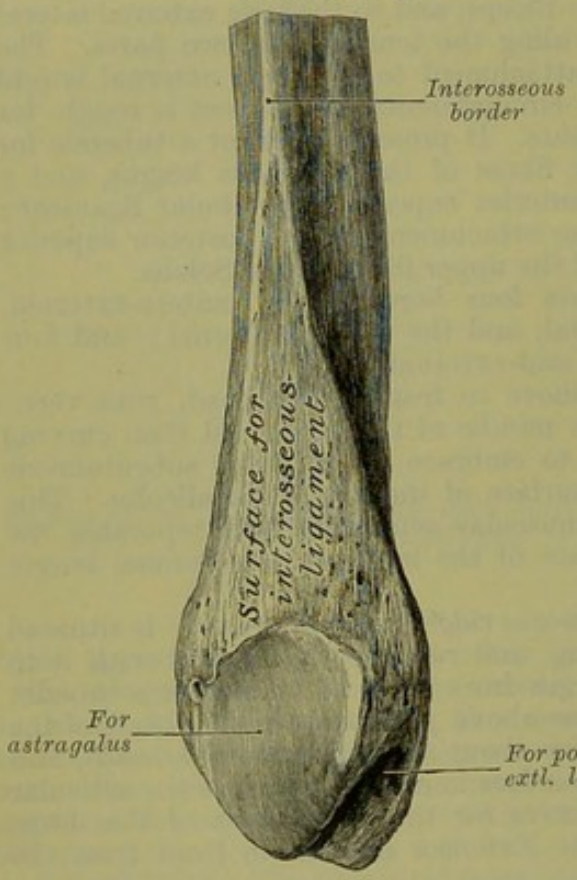

The **lower extremity**, or **external malleolus** (malleolus lateralis), is of a pyramidal form, somewhat flattened from without inwards, and is longer, and descends lower, than the internal malleolus. The *external surface* is convex, subcutaneous, and continuous with the triangular, subcutaneous surface on the outer side of the shaft. The *internal surface* (fig. 400) presents in front a smooth triangular facet (facies articularis malleoli), broader above than below, and convex from above downwards, which articulates with a corresponding surface on the outer side of the astragalus. Behind and beneath the articular surface is a rough depression, which gives attachment to the posterior fasciculus of the external lateral ligament of the ankle. The *anterior border* is thick and rough, and marked below by a depression for the attachment of the anterior fasciculus of the external lateral ligament. The *posterior border* is broad and presents a shallow groove (sulcus malleolaris), for the passage of the tendons of the Peronei longus et brevis. The *summit* is rounded, and gives attachment to the middle fasciculus of the external lateral ligament.

Articulations.—The fibula articulates with two bones: the tibia and astragalus.

Ossification.—The fibula is ossified from *three* centres (fig. 401): one for the shaft, and one for each extremity. Ossification begins in the shaft about the eighth week of fœtal life, a little later than in the tibia, and extends towards the extremities. At birth both ends are cartilaginous. Ossification commences in the lower end in the second year, and in the upper one about the fourth year. The lower epiphysis, the first to ossify, unites with the shaft about the twentieth year; the upper epiphysis joins about the twenty-fifth year.

Surface Form.—The only parts of the fibula which are subcutaneous are the head, the lower part of the outer surface of the shaft, and the external malleolus. The head can be felt behind and to the outer side of the outer tuberosity of the tibia, and presents

a small, prominent, triangular eminence slightly above the level of the tubercle of the tibia. The external malleolus is a narrow, elongated prominence, situated on a plane posterior to the internal malleolus and reaching to a lower level. From it may be traced the lower third or half of the external surface of the shaft of the bone in the interval between the Peroneus tertius in front and the tendons of the other two Peronei behind.

Applied Anatomy.—In fractures of the bones of the leg, both bones are generally fractured, but either bone may be broken separately, the fibula more frequently than the tibia. Fracture of both bones may be caused by either direct or indirect violence. When it occurs from indirect force, the fracture in the tibia is at the junction of the middle and lower third of the bone. Many causes conduce to render this the weakest part of the bone. The fracture of the fibula is usually at a rather higher level. These fractures present great variety, both as regards their direction and condition. They may be oblique, transverse, longitudinal, or spiral. When oblique, they are for the most part the result of indirect violence, and the direction of the fracture is downwards, forwards, and inwards in many cases, but may be downwards and outwards, or downwards and backwards. When transverse, the fracture is often at the upper part of the bone, and is the result of direct violence. The spiral fracture of the tibia generally starts as a vertical fissure, involving the ankle-joint, and is associated with fracture of the fibula higher up. It is the result of torsion, from twisting of the body while the foot is fixed.

Fig. 401.—Plan of ossification of the fibula. From three centres.

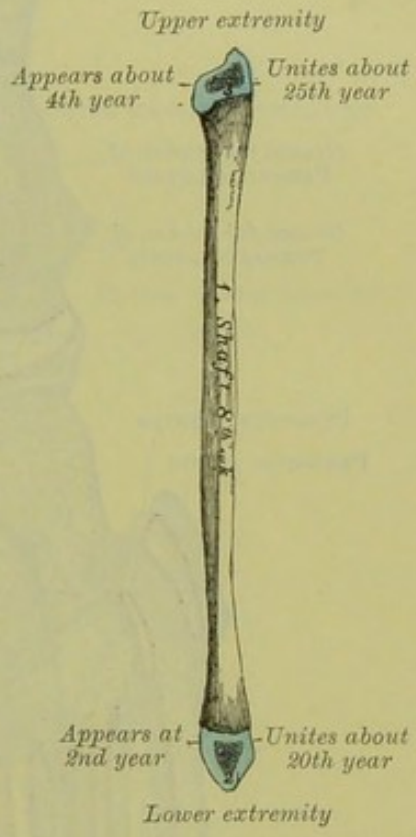

Fractures of the tibia alone are almost always the result of direct violence, except where the malleolus is broken off by twists of the foot. Fractures of the fibula alone may arise from indirect or direct force, those of the lower end being usually the result of the former, and those higher up being caused by a direct blow on the part.

The tibia is the bone which is most commonly and most extensively distorted in rickets. It bends at the junction of the middle and lower third, its weakest part, and presents a curve forwards with generally some lateral displacement.

The tibia is more often the seat of acute infective necrosis than any other bone in the body, and with the formation of the sequestrum, a large amount of new bony material is thrown out by the periosteum. The sequence of events in this disease can be very closely followed in the case of the tibia, and it is not uncommon to find a patient from whom the whole diaphysis of the tibia has been removed, going about with a new bone entirely of periosteal formation. Chronic bone abscess is more frequently met with in the cancellous tissue of the head or lower end of the tibia than in any other bone in the body. These abscesses are very chronic, and in most cases the result of tuberculous osteitis, although they are sometimes due to the organisms of suppuration or even the Bacillus typhosus.

THE FOOT

The skeleton of the foot (figs. 402 and 403) consists of three parts: the tarsus, metatarsus, and phalanges.

THE TARSUS

The **Tarsal bones** (ossa tarsi) are seven in number: viz. the os calcis, astragalus, cuboid, navicular, and the internal, middle, and external cuneiforms.

The Os Calcis (fig. 404)

The **Os Calcis** (calcaneus) is the largest and strongest of the tarsal bones. It is situated at the lower and back part of the foot, serving to transmit the weight of the body to the ground, and forming a strong lever for the muscles of the calf. It is irregularly cuboidal in form, having its long axis directed forwards and outwards; it presents for examination six surfaces.

Fig. 402.—Bones of the right foot. Dorsal surface.

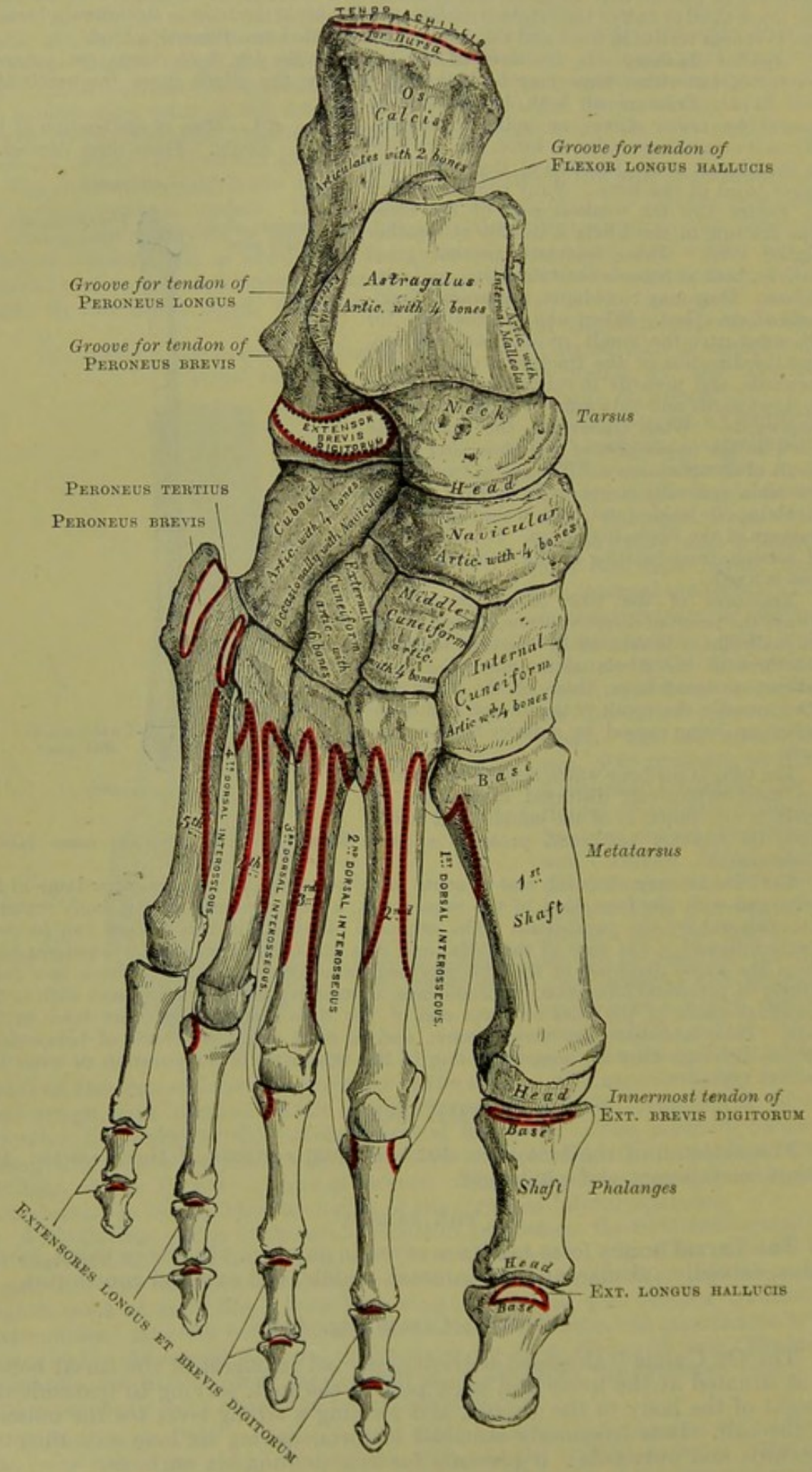

FIG. 403.—Bones of the right foot. Plantar surface.

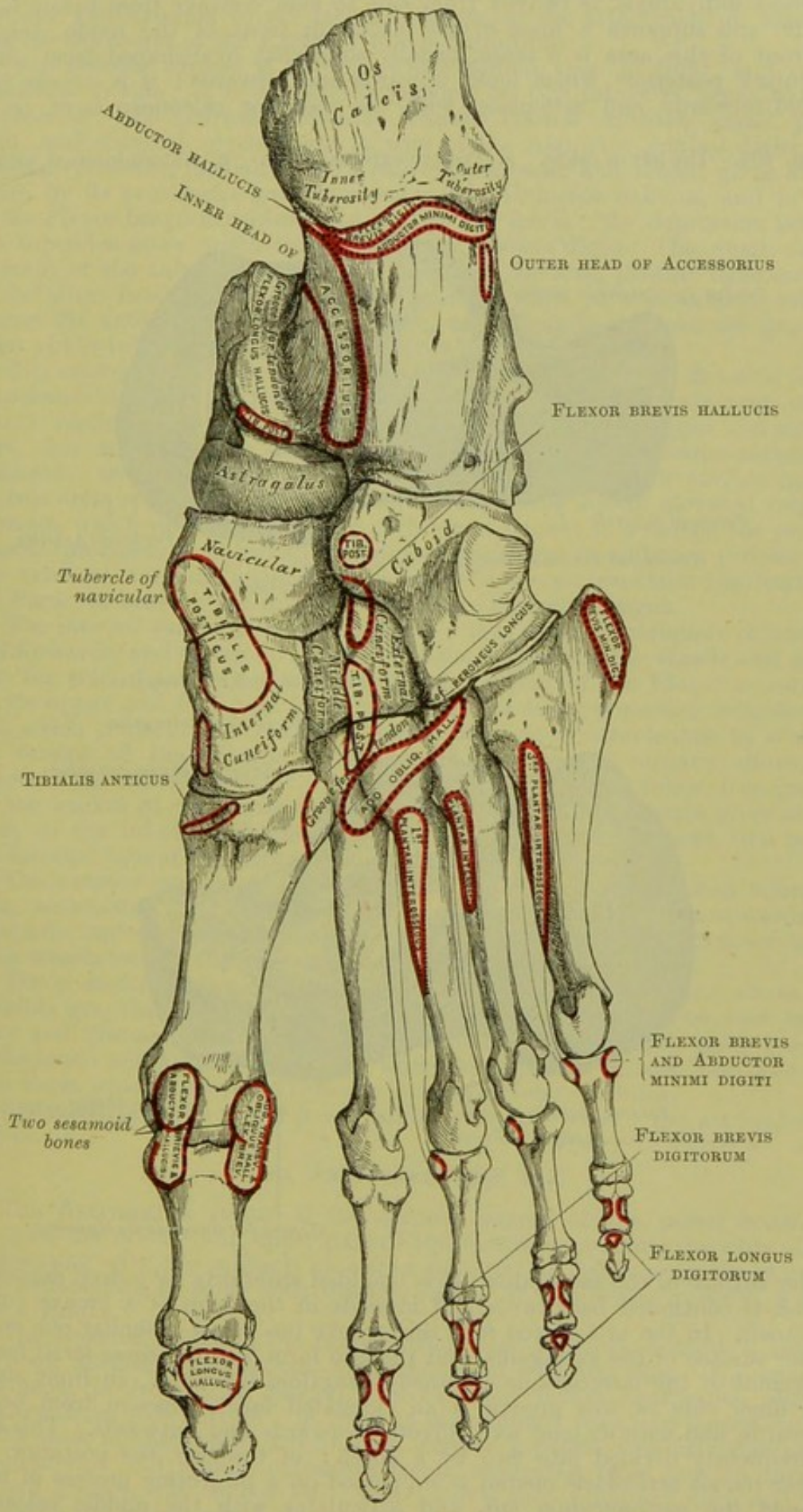

The *superior surface* is formed behind by the upper aspect of that part of the bone which projects backwards to form the heel. This varies in length in different individuals, is convex from side to side, concave from before backwards, and supports a mass of fat placed in front of the tendo Achillis. In front of this area is a large, usually somewhat oval-shaped facet (facies articularis posterior), which looks upwards and forwards; it is convex from behind forwards, and articulates with the posterior calcanean facet on the

FIG. 404.—The left os calcis. A. Postero-external view. B. Antero-internal view.

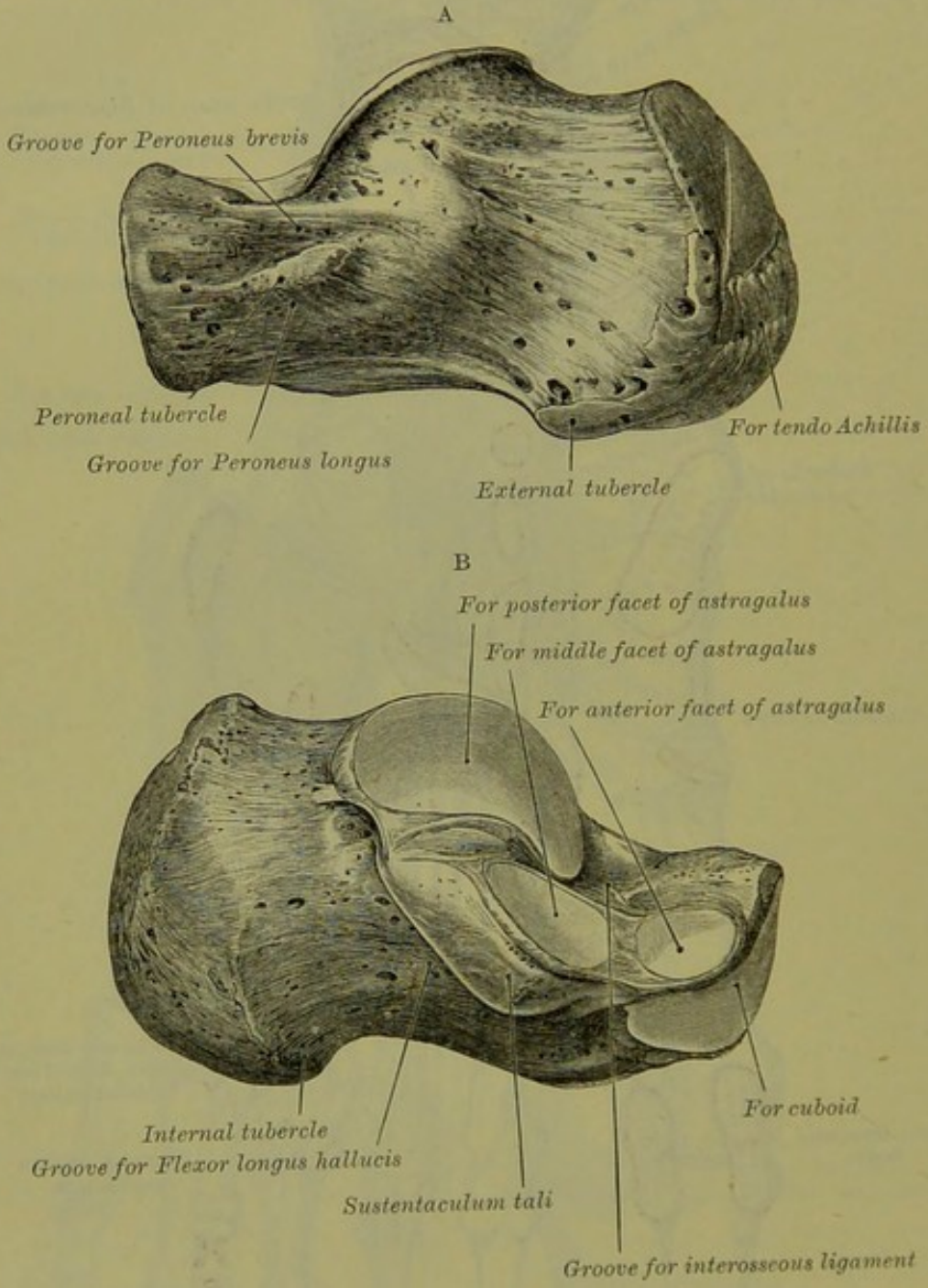

under surface of the astragalus. It is bounded anteriorly by a deep depression which is continued backwards and inwards in the form of a groove (sulcus calcanei). In the articulated foot this groove lies below a similar one on the under surface of the astragalus, and the two form a canal (*sinus tarsi*) for the lodgment of the interosseous calcaneo-astragaloid ligament. In front and to the inner side of this groove is an elongated facet, concave from behind forwards, and with its long axis directed forwards and outwards. This facet is frequently divided into two by a notch: of the two, the posterior, and larger (facies articularis media) is supported on a projecting process of bone, termed the *sustentaculum tali*, and articulates with the middle calcanean facet on the under surface of the astragalus; the anterior, and smaller (facies

articularis anterior) is placed on the anterior part of the body, and articulates with the anterior calcanean facet on the astragalus. The upper surface, anterior and external to the facets, is rough for the attachment of ligaments and for the origin of the Extensor brevis digitorum.

The *inferior surface* is uneven, wider behind than in front, and convex from side to side; it is bounded posteriorly by two tubercles, separated by a depression; the *external* (processus lateralis tuberis calcanei), small, prominent, and rounded, gives origin to part of the Abductor minimi digiti; the *internal* (processus medialis tuberis calcanei), broader and larger, gives attachment, by its prominent inner margin, to the Abductor hallucis, and in front to the Flexor brevis digitorum and the plantar fascia; the depression between the tubercles gives origin to the Abductor minimi digiti. The rough surface in front of the tubercles gives attachment to the long plantar ligament, and to the outer head of the Flexor accessorius; while to a prominent tubercle nearer the anterior part of this surface, as well as to a transverse groove in front of the tubercle, is attached the short plantar ligament.

The *external surface* is broad behind, and narrow in front, flat and almost subcutaneous; near its centre is a tubercle, for the attachment of the middle fasciculus of the external lateral ligament. At its upper and anterior part, this surface gives attachment to the external calcaneo-astragaloid ligament; and in front of the tubercle it presents a narrow surface marked by two oblique grooves. The grooves are separated by an elevated ridge, or tubercle, which varies much in size in different bones; it is named the *peroneal tubercle* (processus trochlearis), and gives attachment to a fibrous process from the external annular ligament. The *superior groove* transmits the tendon of the Peroneus brevis; the *inferior*, that of the Peroneus longus.

The *internal surface* is deeply concave; it is directed obliquely downwards and forwards, and serves for the transmission of the plantar vessels and nerves into the sole of the foot; it affords origin to part of the Flexor accessorius. At its upper and fore part is an eminence, the *lesser process* or *sustentaculum tali*, which projects horizontally inwards, and gives attachment to a slip of the tendon of the Tibialis posticus. This process is concave above, and supports the middle articular surface of the astragalus; below, it is grooved for the tendon of the Flexor longus hallucis; its anterior margin gives attachment to the inferior calcaneo-navicular ligament, and its inner, to a part of the internal lateral ligament of the ankle-joint.

The *anterior surface* (facies articularis cuboidea), of a somewhat triangular form, articulates with the cuboid. It is concave from above, downwards and outwards, and convex in a direction at right angles to this. Its inner border gives attachment to the inferior calcaneo-navicular ligament.

The *posterior surface* is prominent, convex, wider below than above, and divisible into three areas. The lowest of these is rough, and covered by the fatty and fibrous tissue of the heel; the middle, also rough, gives insertion to the tendo Achillis and Plantaris; while the highest is smooth, and is covered by a bursa which intervenes between it and the tendo Achillis.

Articulations.—The os calcis articulates with two bones: the astragalus and cuboid.

The Astragalus (fig. 405)

The **Astragalus** (talus) is the second largest of the tarsal bones. It occupies the middle and upper part of the tarsus, supporting the tibia above, articulating with the malleoli on either side, resting below upon the os calcis, and articulating in front with the navicular. It consists of a body, a neck and a head.

The *superior surface* of the **body** (corpus tali) presents, behind, a smooth trochlear surface (trochlea tali) for articulation with the tibia. The trochlea is broader in front than behind, convex from before backwards, slightly concave from side to side: in front it is confluent with the upper surface of the neck of the bone. The *inferior surface* presents two articular areas, the posterior and middle calcanean facets, separated from one another by a deep groove, the *sulcus tali*. The groove runs obliquely forwards and outwards, becoming gradually broader and deeper in front: it corresponds with a similar groove upon the upper surface of the os calcis, and forms,

when articulated with that bone, a canal (*sinus tarsi*) filled up in the recent state by the interosseous calcaneo-astragaloid ligament. The *posterior calcanean*

Fig. 405.—The left astragalus. A. Supero-external view. B. Infero-internal view. C. Inferior view.

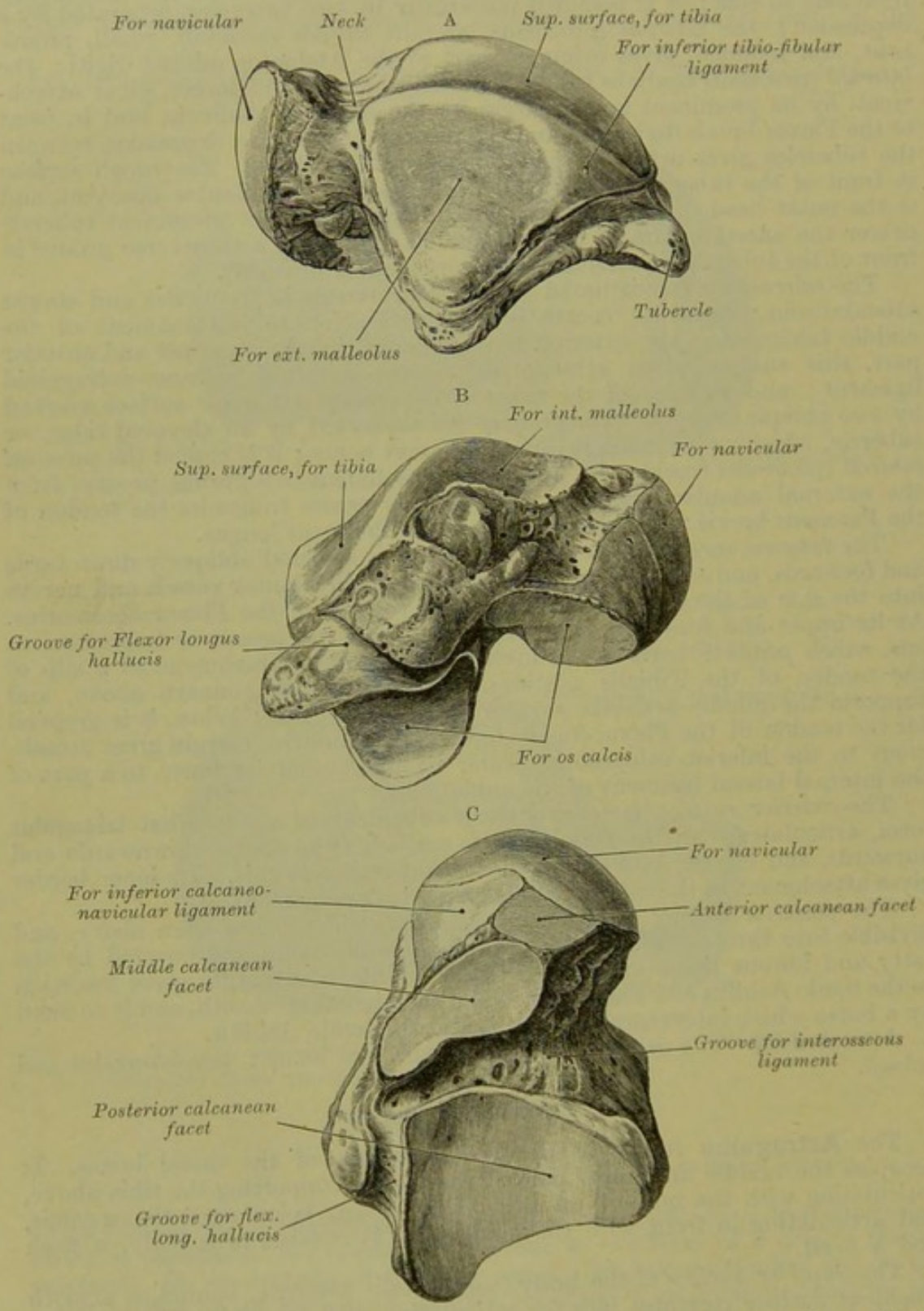

facet (facies articularis calcanea posterior) is larger and of an oval or oblong form. It articulates with the corresponding facet on the upper surface of the os calcis,* and is deeply concave in the direction of its long axis which runs

* Sewell (*Journal of Anatomy and Physiology*, vol. xxxviii.) pointed out that in about 10 per cent. of these bones a small triangular facet, continuous with the posterior calcanean facet, is present at the junction of the external surface of the body with the posterior wall of the sulcus tali.

forwards and outwards at an angle of about 45° with the antero-posterior axis of the body. The *middle calcanean facet* (facies calcanea articularis media) is small, oval in form and slightly convex; it articulates with the upper surface of the sustentaculum tali of the os calcis. The *internal surface* presents at its upper part a pear-shaped articular facet for the inner malleolus, continuous above with the trochlear surface; below the articular surface is a rough depression for the attachment of the deep portion of the internal lateral ligament of the ankle-joint. The *external surface* presents a large triangular facet, concave from above downwards, for articulation with the external malleolus; its anterior half is continuous above with the trochlear surface; and in front of it is a rough depression for the attachment of the anterior fasciculus of the external lateral ligament of the ankle-joint. Fawcett * has directed attention to a facet which comes into contact with the inferior tibio-fibular ligament during flexion of the ankle-joint. It is situated between the posterior half of the outer border of the trochlea and the corresponding part of the base of the triangular facet for the external malleolus. It is triangular in shape, the base being directed backwards; below the base is a groove which affords attachment to the posterior fasciculus of the external lateral ligament of the ankle-joint. The *posterior surface* is narrow, and traversed by a groove, which runs obliquely downwards and inwards, and transmits the tendon of the Flexor longus hallucis. External to the groove is a prominent tubercle, to which the posterior fasciculus of the external lateral ligament is attached; this tubercle (processus posterior tali) is sometimes separated from the rest of the astragalus, and is then known as the *os trigonum*. To the inner side of the groove is a second smaller tubercle.

The **neck** (collum tali) is directed forwards and inwards, and comprises the constricted portion of the bone between the body and the oval head. Its *upper* and *inner surfaces* are rough, for the attachment of ligaments; its *external surface* is concave, directed downwards and outwards, and is continuous below with the deep groove for the interosseous calcaneo-astragaloid ligament.

The **head** (caput tali) looks forwards and inwards; its *anterior surface* presents a large, oval, convex facet (facies articularis navicularis), for articulation with the navicular. Its *inferior surface* has two facets, which are best seen in the recent condition. The inner of these, situated immediately in front of the middle calcaneal facet, is convex, triangular or semi-oval in shape, and rests on the inferior calcaneo-navicular ligament; the outer is named the *anterior calcanean facet*; it is somewhat flattened, and articulates with the facet on the upper surface of the anterior part of the os calcis.

Articulations.—The astragalus articulates with four bones: tibia, fibula, os calcis, and navicular.

The Cuboid (fig. 406)

The **Cuboid** (os cuboideum) is placed on the outer side of the foot, in front

Fig. 406.—The left cuboid. A. Antero-internal view. B. Postero-external view.

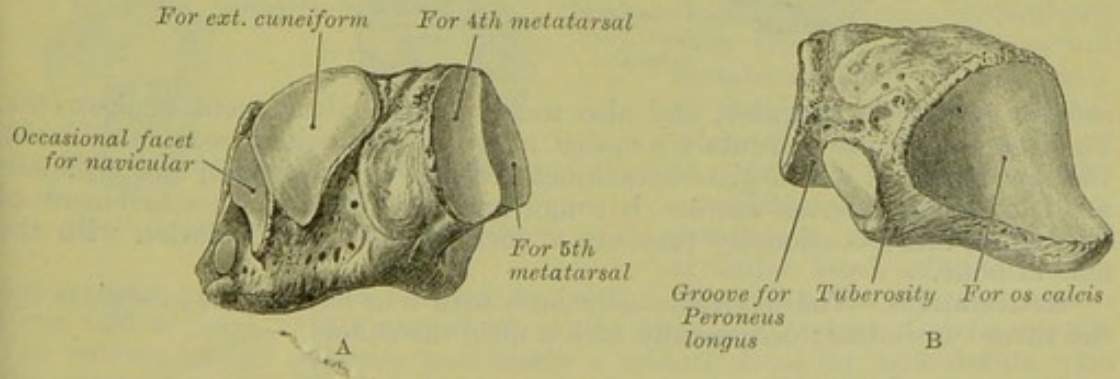

of the os calcis, and behind the fourth and fifth metatarsal bones. It is of a pyramidal shape, its base being directed inwards.

* *Edinburgh Medical Journal*, 1895.

The *superior* or *dorsal surface*, directed upwards and outwards, is rough, for the attachment of numerous ligaments. The *inferior* or *plantar surface* presents in front a deep groove (sulcus m. peronæi), which runs obliquely from without, forwards and inwards; it lodges the tendon of the Peroneus longus, and is bounded behind by a prominent ridge, to which the long calcaneo-cuboid ligament is attached. The ridge terminates externally in an eminence, the *tuberosity* (tuberositas oss. cuboidei), the surface of which presents a convex facet; on this facet glides the sesamoid bone or cartilage frequently found in the tendon of the Peroneus longus. The surface of bone behind the groove is rough, for the attachment of the short plantar ligament, a few fibres of the Flexor brevis hallucis, and a fasciculus from the tendon of the Tibialis posticus. The *external surface* presents a deep notch formed by the commencement of the peroneal groove. The *posterior surface* is smooth, triangular, and concavo-convex, for articulation with the anterior surface of the os calcis. The *anterior surface*, of smaller size, but also irregularly triangular, is divided by a vertical ridge into two facets: the inner, quadrilateral in form, articulates with the fourth metatarsal; the outer, larger and more triangular, articulates with the fifth. The *internal surface* is broad, rough, irregularly quadrilateral, presenting at its middle and upper part a smooth oval facet, for articulation with the external cuneiform; and behind this (occasionally) a smaller facet, for articulation with the navicular; it is rough in the rest of its extent, for the attachment of strong interosseous ligaments.

Articulations.—The cuboid articulates with four bones: the os calcis, external cuneiform, and fourth and fifth metatarsals; occasionally with a fifth, the navicular.

The Navicular (fig. 407)

The **Navicular** or **Scaphoid** (os naviculare pedis) is situated at the inner side of the tarsus, between the astragalus behind and the three cuneiform bones in front.

The *anterior surface* is convex from side to side, and subdivided by two ridges into three facets, for articulation with the three cuneiform bones. The *posterior surface* is oval, concave, broader externally than internally, and articulates with the rounded head of the astragalus. The *superior surface* is convex from side to side, and rough for the attachment of ligaments. The

Fig. 407.—The left navicular. A. Antero-external view. B. Postero-internal view.

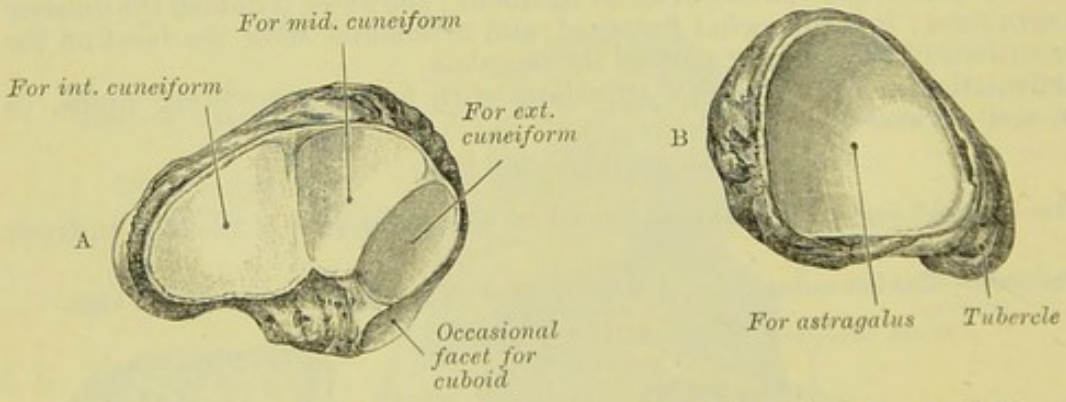

inferior surface is irregular, and also rough for the attachment of ligaments. The *internal surface* presents a rounded *tubercle* (tuberositas ossis navicularis), the lower part of which gives attachment to part of the tendon of the Tibialis posticus. The *external surface* is rough and irregular for the attachment of ligaments, and occasionally presents a small facet for articulation with the cuboid bone.

Articulations.—The navicular articulates with four bones: the astragalus and the three cuneiforms; occasionally with a fifth, the cuboid.

The Internal Cuneiform (fig. 408)

The **Internal Cuneiform** (os cuneiforme primum) is the largest of the three cuneiforms. It is situated at the inner side of the foot, between the navicular behind and the base of the first metatarsal in front.

The *internal surface* is subcutaneous, and forms part of the inner border of the foot; it is broad, quadrilateral, and presents at its anterior inferior angle a smooth oval impression, into which part of the tendon of the Tibialis anticus is inserted; in the rest of its extent it is rough for the attachment of ligaments. The *external surface* is concave, presenting, along its superior and posterior borders, a narrow reversed L-shaped surface, the vertical limb and posterior part of the horizontal limb of which articulate with the middle cuneiform, and the anterior part of the horizontal limb with the second metatarsal bone: the rest of this surface is rough for the attachment of ligaments and part of the tendon of the Peroneus longus. The *anterior surface*, kidney-shaped and much larger than the posterior, articulates with the metatarsal bone of the great toe. The *posterior surface* is triangular, concave, and articulates with the innermost and largest of the three facets on the anterior surface of the navicular. The *inferior* or *plantar surface* is rough, and forms the base of the wedge; at its back part is a prominent tuberosity for the insertion of part of the tendon of the Tibialis posticus. It also gives insertion in front to part of the tendon of the Tibialis anticus. The *superior surface* is the narrow pointed end of the wedge, and is directed upwards and outwards; it is rough for the attachment of ligaments.

FIG. 408.—The left internal cuneiform. A. Antero-internal view. B. Postero-external view.

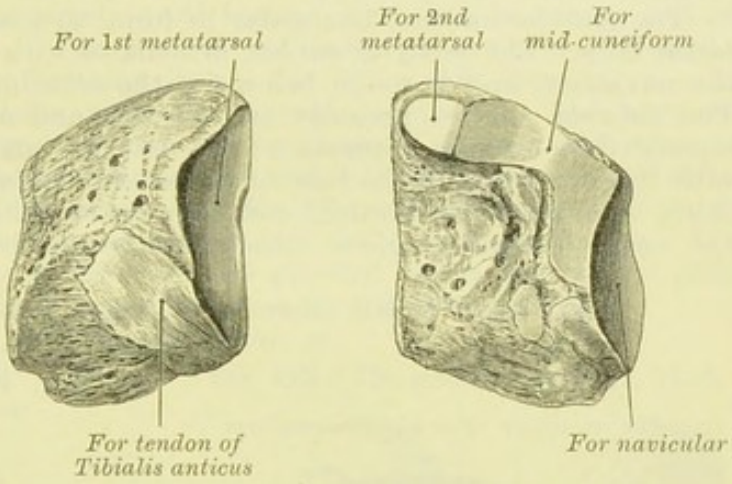

Articulations.—The internal cuneiform articulates with four bones: the navicular, middle cuneiform and first and second metatarsals.

THE MIDDLE CUNEIFORM (fig. 409)

The **Middle Cuneiform** (os cuneiforme secundum), the smallest of the three, is of very regular wedge-like form, the broad extremity being placed upwards, the narrow end downwards. It is situated between the other two cuneiforms, and articulates with the navicular behind, and the second metatarsal in front.

FIG. 409.—The left middle cuneiform. A. Antero-internal view. B. Postero-external view.

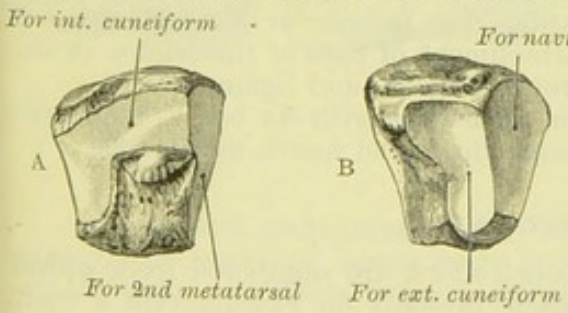

The *anterior surface*, triangular in form, and narrower than the posterior, articulates with the base of the second metatarsal bone. The *posterior surface*, also triangular, articulates with the middle facet on the anterior surface of the navicular. The *internal surface* presents a reversed L-shaped articular facet, running along the superior and posterior borders, for articulation with the internal cuneiform, and is rough in the rest of its extent for the attachment of ligaments. The *external surface* presents posteriorly a smooth facet for articulation with the external cuneiform bone. The *superior surface* forms the base of the wedge; it is quadrilateral, broader behind than in front, and rough for the attachment of ligaments. The *inferior surface*, sharp and tubercular, is also rough for ligamentous attachment, and for the insertion of a slip from the tendon of the Tibialis posticus.

Articulations.—The middle cuneiform articulates with four bones: the navicular, internal and external cuneiforms, and second metatarsal.

The External Cuneiform (fig. 410)

The **External Cuneiform** (os cuneiforme tertium), intermediate in size between the two preceding, is of a very regular wedge-like form, the broad extremity being placed upwards, the narrow end downwards. It occupies the centre of the front row of the tarsal bones, between the middle cuneiform internally, the cuboid externally, the navicular behind, and the third metatarsal in front.

The *anterior surface*, triangular in form, articulates with the third metatarsal bone. The *posterior surface* articulates with the most external facet of the navicular, and is rough below for the attachment of ligamentous fibres. The *internal surface* presents an anterior and a posterior articular facet, separated by a rough depression: the anterior, sometimes divided, articulates with the outer side of the base of the second metatarsal bone; the posterior skirts the posterior border, and articulates with the middle cuneiform; the rough depression gives attachment to an interosseous ligament. The

Fig. 410.—The left external cuneiform. A. Postero-internal view. B. Antero-external view.

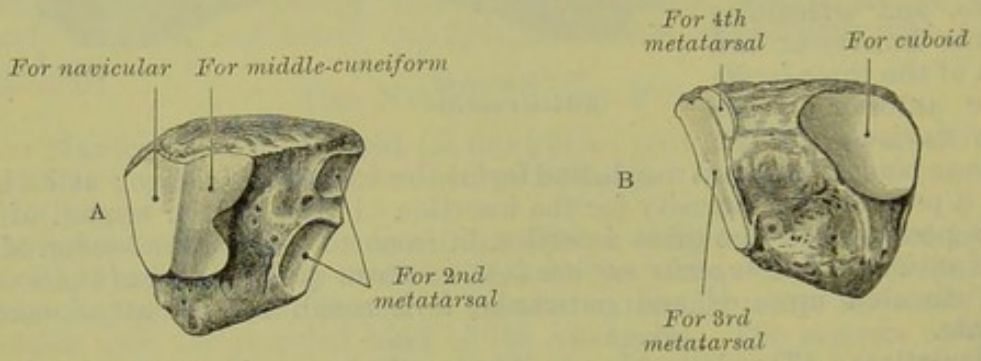

external surface also presents two articular facets, separated by a rough non-articular surface; the anterior facet, situated at the superior angle of the bone, is small and semi-oval in shape, and articulates with the inner side of the base of the fourth metatarsal bone; the posterior and larger one is triangular or oval, and articulates with the cuboid; the rough, non-articular surface serves for the attachment of an interosseous ligament. The three facets for articulation with the three metatarsal bones are continuous with one another; those for articulation with the middle cuneiform and navicular are also continuous, but that for articulation with the cuboid is usually separate. The *superior* or *dorsal surface* is of an oblong form, its postero-external angle being prolonged backwards. The *inferior* or *plantar surface* is a rounded margin, and serves for the attachment of part of the tendon of the Tibialis posticus, part of the Flexor brevis hallucis, and ligaments.

Articulations.—The external cuneiform articulates with six bones: the navicular, middle cuneiform, cuboid, and second, third, and fourth metatarsals.

The Metatarsus

The **Metatarsus** consists of five bones which are numbered from within outwards (ossa metatarsalia I.–V.); each presents for examination a shaft and two extremities.

Common Characters of the Metatarsal Bones

The *shaft* (corpus) is prismoid in form, tapers gradually from the tarsal to the phalangeal extremity, and is curved longitudinally, so as to be concave below, slightly convex above. The *posterior extremity*, or *base* (basis), is wedge-shaped, articulating by its terminal surface with the tarsal bones, and by its lateral surfaces with the contiguous metatarsal bones: its dorsal and

plantar surfaces are rough for the attachment of ligaments. The *anterior extremity*, or *head* (capitulum), presents a terminal convex articular surface, oblong from above downwards, and extending farther backwards below than above. Its sides are flattened, and on each is a depression, surmounted by a tubercle, for ligamentous attachment. Its under surface is grooved in the middle line for the passage of the Flexor tendons, and marked on either side by an articular eminence continuous with the terminal articular surface.

Peculiar Characters of the Metatarsal Bones

The **first metatarsal bone** (fig. 411) is remarkable for its great thickness, and is the shortest of all the metatarsal bones. The *shaft* is strong, and of well-marked prismoid form. The *posterior extremity* presents, as a rule, no lateral articular facets, but occasionally on the outer side there is an oval facet, by which it articulates with the second metatarsal. Its terminal articular surface is of large size and kidney-shaped; its circumference is grooved, for the tarso-metatarsal ligaments, and internally gives insertion to part of the tendon of the Tibialis anticus; its inferior angle presents a rough oval prominence for the insertion of the tendon of the Peroneus longus. The *head* is large; on its plantar surface are two grooved facets, over which glide sesamoid bones; the facets are separated by a smooth elevated ridge.

Fig. 411.—The first metatarsal. (Left.)

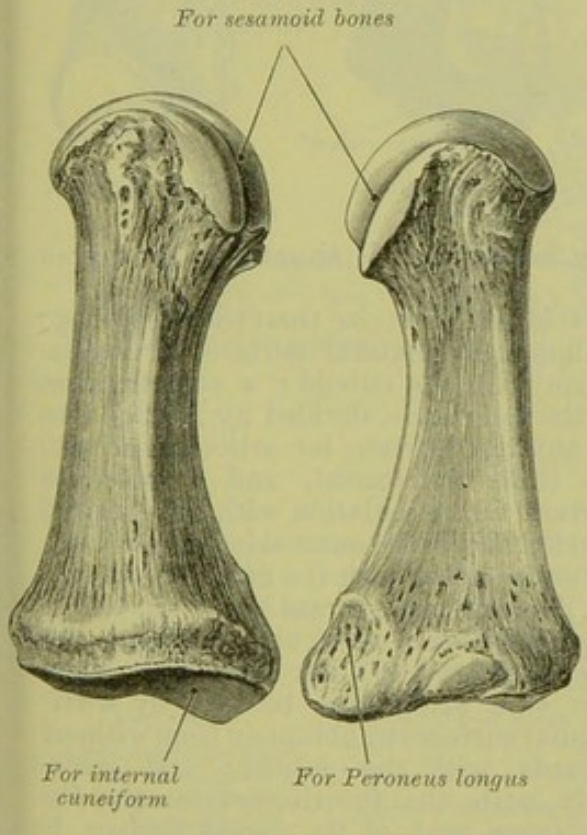

Fig. 412.—The second metatarsal. (Left.)

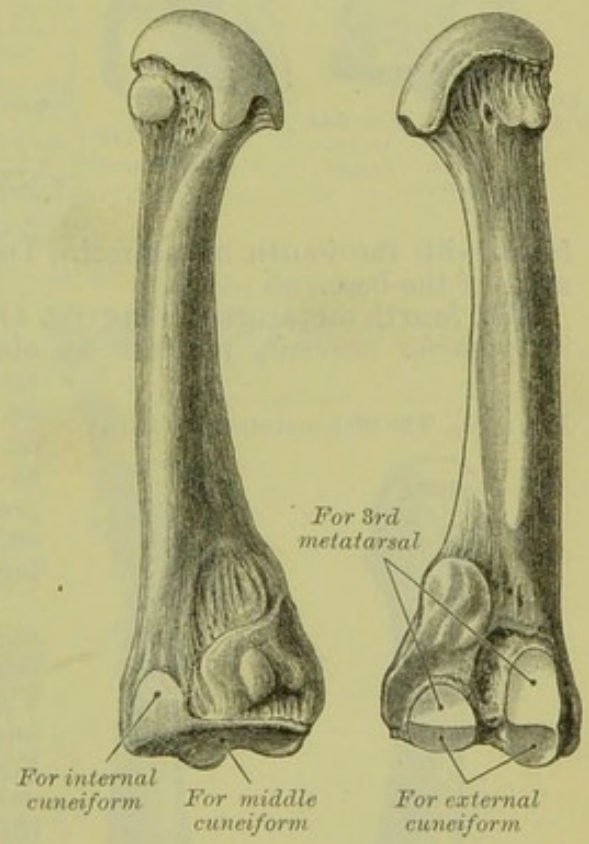

The **second metatarsal bone** (fig. 412) is the longest and largest of the remaining metatarsal bones, being prolonged backwards into the recess formed by the three cuneiform bones. Its *posterior extremity* is broad above, narrow and rough below. It presents four articular surfaces: one behind, of a triangular form, for articulation with the middle cuneiform; one at the upper part of its internal surface, for articulation with the internal cuneiform; and two on its external surface, an upper and lower, separated by a rough non-articular interval. Each of these external articular surfaces is divided into two by a vertical ridge; the two anterior facets articulate with the third metatarsal; the two posterior (sometimes continuous) with the external cuneiform. A fifth facet is occasionally present for articulation with the first metatarsal; it is oval in shape, and is situated on the inner side of the shaft near the base.

The **third metatarsal bone** (fig. 413) articulates behind, by means of a triangular smooth surface, with the external cuneiform ; on its inner side, by two facets, with the second metatarsal ; and on its outer side, by a single facet, with the fourth metatarsal. The latter facet is situated at the upper angle of the base.

Fig. 413.—The third metatarsal. (Left.)

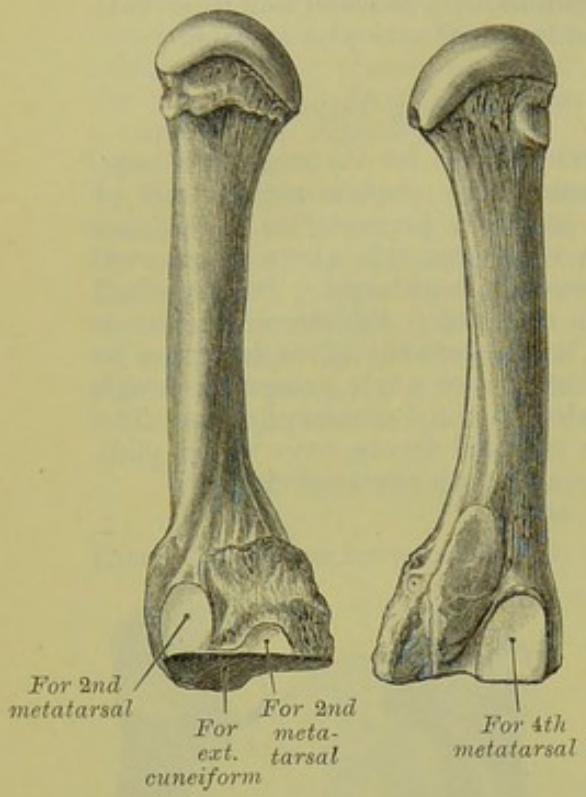

Fig. 414.—The fourth metatarsal. (Left.)

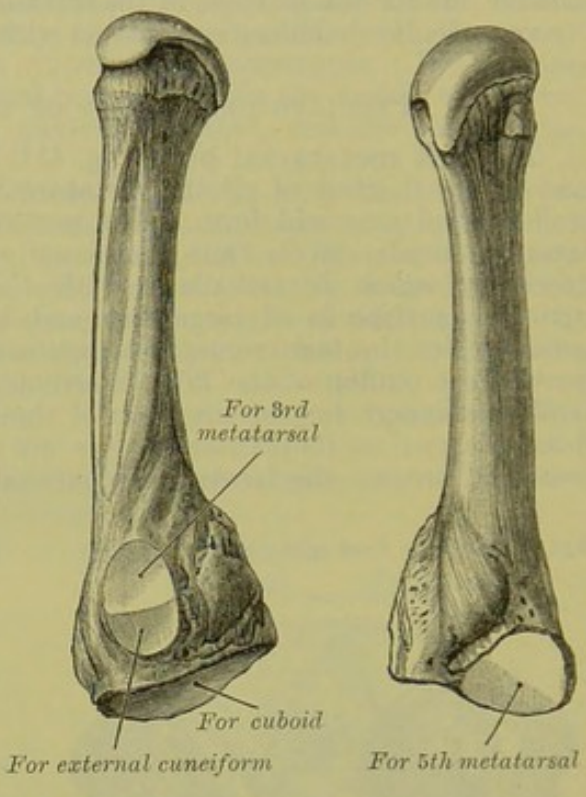

The **fourth metatarsal bone** (fig. 414) is smaller in size than the preceding ; its *posterior extremity* presents an oblique quadrilateral surface for articulation with the cuboid ; a smooth facet on the inner side, divided by a ridge into an anterior portion for articulation with the third metatarsal, and a posterior portion for articulation with the external cuneiform ; on the outer side a single facet, for articulation with the fifth metatarsal.

Fig. 415.—The fifth metatarsal. (Left.)

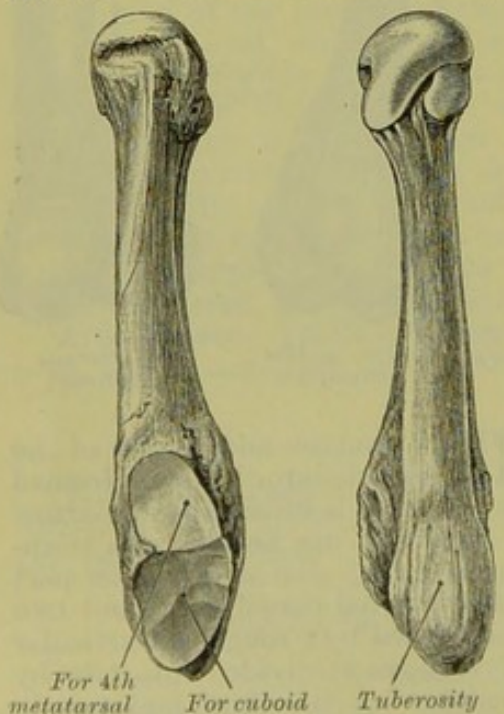

The **fifth metatarsal bone** (fig. 415) is recognised by a tubercular eminence, the *tuberosity*, on the outer side of its base. The *base* articulates behind, by a triangular surface cut obliquely from without inwards, with the cuboid ; and internally, with the fourth metatarsal. On the inner part of its dorsal surface is inserted the tendon of the Peroneus tertius, and on the dorsal surface of the tuberosity that of the Peroneus brevis. A strong band of the plantar fascia connects the projecting part of the tuberosity with the outer tuberosity on the under surface of the os calcis. The plantar surface of the base is grooved for the tendon of the Abductor minimi digiti, and gives origin to the Flexor brevis minimi digiti.

Articulations.—Each metatarsal bone articulates with one or more of the tarsal bones by its proximal extremity, and by the other with one of the first row of

phalanges. The first metatarsal articulates with the internal cuneiform, the second with all three cuneiforms, the third with the external cuneiform, the fourth with the external cuneiform and the cuboid, and the fifth with the cuboid.

Phalanges

The **Phalanges** (phalanges digitorum pedis), both in number and general arrangement, resemble those of the hand; there being two in the great toe, and three in each of the other toes. They differ from them, however, in their size, the shafts being much reduced in length, and, especially in the first row, laterally compressed.

The phalanges of the **first row** closely resemble those of the hand. The *shaft* of each is compressed from side to side, convex above, concave below. The *posterior extremity* is concave; and the *anterior extremity* presents a trochlear surface for articulation with the second phalanx.

Fig. 416.—Plan of ossification of the foot.

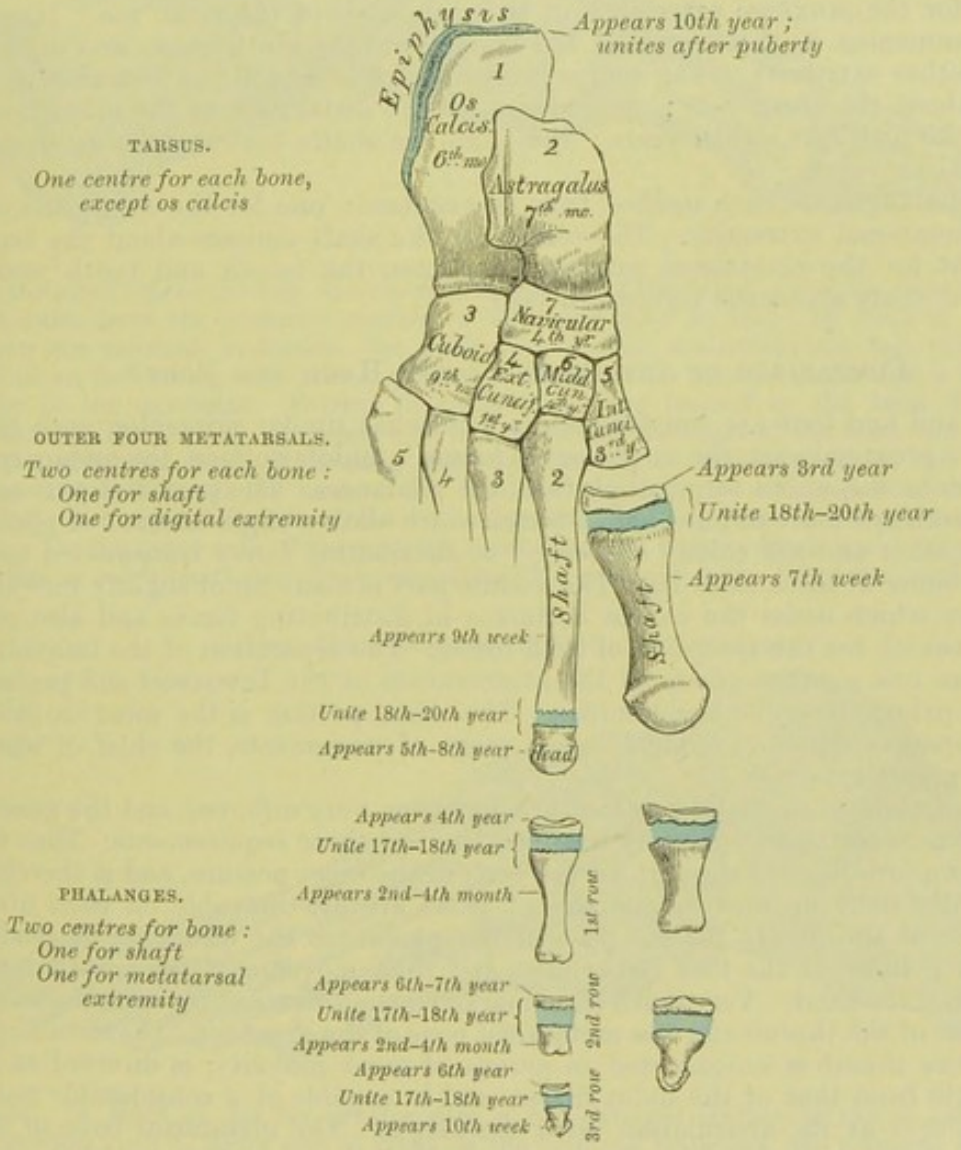

The phalanges of the **second row** are remarkably small and short, but rather broader than those of the first row.

The **ungual phalanges**, in form, resemble those of the fingers; but they are smaller, flattened from above downwards; each presents a broad base for articulation with the corresponding bone of the second row, and an expanded extremity for the support of the nail and end of the toe.

Articulations.—In the four outer toes, the phalanges of the first row articulate behind with the metatarsal bones, and in front with the second phalanges, which

in their turn articulate with the first and third : the ungual phalanges articulate with the second. In the great toe the first phalanx articulates behind with the metatarsal bone and in front with the ungual phalanx.

Ossification of the Bones of the Foot (fig. 416)

The **Tarsal bones** are each ossified from a single centre, excepting the os calcis, which has an epiphysis for its posterior extremity. The centres make their appearance in the following order : os calcis, at the sixth month of fœtal life ; astragalus, about the seventh month ; cuboid, at the ninth month ; external cuneiform, during the first year ; internal cuneiform, in the third year ; middle cuneiform and navicular, in the fourth year. The epiphysis for the posterior extremity of the os calcis appears at the tenth year, and unites with the rest of the bone soon after puberty. The tubercle on the posterior surface of the astragalus is sometimes ossified from a separate centre, and may remain distinct from the main mass of the bone, when it is named the *os trigonum*.

The **Metatarsal bones** are each ossified from *two* centres : one for the shaft, and one for the digital extremity, in the four outer metatarsals ; one for the shaft, and one for the proximal extremity, in the metatarsal of the great toe.* Ossification commences in the centre of the shaft about the ninth week, and extends towards either extremity. The centre for the proximal end of the first metatarsal appears about the third year ; the centres for the distal ends of the other bones between the fifth and eighth years ; they join the shafts between the eighteenth and twentieth years.

The **Phalanges** are each ossified from *two* centres : one for the shaft, and one for the metatarsal extremity. The centre for the shaft appears about the tenth week, that for the metatarsal extremity between the fourth and tenth years ; it joins the shaft about the eighteenth year.

Comparison of the Bones of the Hand and Foot

The hand and foot are constructed on somewhat similar principles, each consisting of a proximal part, the carpus or the tarsus, a middle portion, the metacarpus or the metatarsus, and a terminal portion, the phalanges. The proximal part consists of a series of more or less cubical bones which allow a slight amount of gliding on one another and are chiefly concerned in distributing forces transmitted to or from the bones of the arm or leg. The middle part is made up of slightly movable long bones which assist the carpus or tarsus in distributing forces and also give greater breadth for the reception of such forces. The separation of the individual bones from one another allows of the attachments of the Interossei and protects the dorsi-palmar vascular anastomoses. The distal portion is the most movable, and its separate elements enjoy a varied range of movements, the chief of which are flexion and extension.

The functions of the hand and foot are, however, very different, and the general similarity between them is greatly modified to meet these requirements. Thus the foot forms a firm basis of support for the body in the erect posture, and is therefore more solidly built up and its component parts are less movable on each other than those of the hand. In the case of the phalanges the difference is readily noticeable ; those of the foot are smaller and their movements are more limited than those of the hand. Very much more marked is the difference between the metacarpal bone of the thumb and the metatarsal bone of the great toe. The metacarpal bone of the thumb is constructed to permit of great mobility, is directed at an acute angle from that of the index finger, and is capable of a considerable range of movements at its articulation with the carpus. The metatarsal bone of the great toe assists in supporting the weight of the body, is constructed with great solidity, lies parallel with the other metatarsals, and has a very limited degree of mobility. The carpus is small in proportion to the rest of the hand, is placed in line with the forearm, and forms a transverse arch, the concavity of which constitutes a bed for the flexor tendons and the palmar vessels and nerves. The tarsus forms a considerable part of the foot, and is placed at right angles to the leg, a position which is almost peculiar to man, and has relation to his erect

* As was noted in the first metacarpal, so in the first metatarsal, there is often a second epiphysis for its distal extremity (see footnote, page 319).

posture. In order to allow of their supporting the weight of the body with the least expenditure of material the tarsus and a part of the metatarsus are constructed in a series of arches (figs. 417 and 418), the disposition of which will be considered after the articulations of the foot have been described.

Surface Form.—On the dorsum of the foot the individual bones cannot be distinguished, with the exception of the head of the astragalus, which forms a rounded projection in front of the ankle-joint when the foot is forcibly extended. The whole surface of the dorsum of the foot forms a smooth convex outline, the summit of which is the ridge formed by the head of the astragalus, the navicular, the middle cuneiform, and the second metatarsal bones ; from this it inclines gradually outwards and rapidly inwards.

Fig. 417.—Skeleton of foot. Inner aspect.

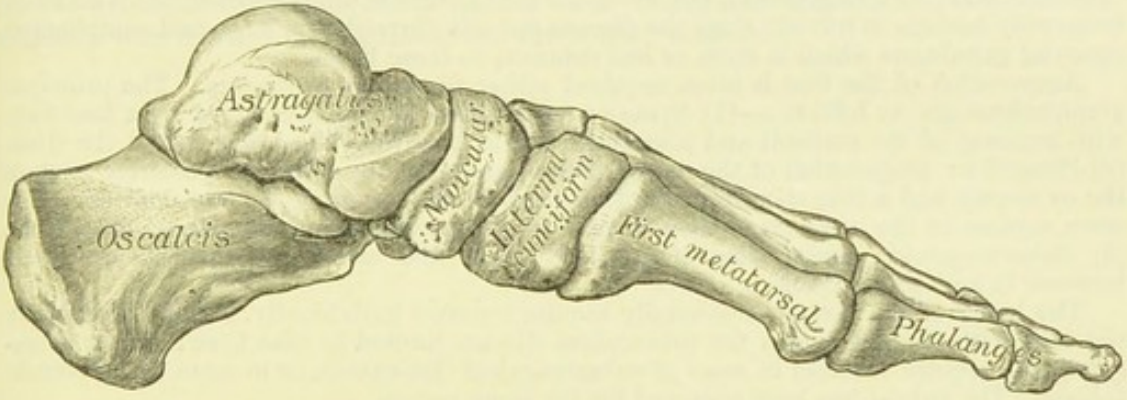

On the inner side of the foot, the internal tuberosity of the os calcis and the ridge separating the inner from the posterior surface of the bone may be felt. In front of this, and below the internal malleolus, the projection of the sustentaculum tali can be felt. About an inch or an inch and a quarter in front of the internal malleolus is the tuberosity of the navicular. Farther forwards, the ridge formed by the base of the first metatarsal bone can be obscurely felt, and from this the shaft of the bone can be traced to the expanded head articulating with the base of the first phalanx of the great toe. Immediately beneath the base of this phalanx, the internal sesamoid bone can be felt. Lastly, the expanded ends of the bones forming the last joint of the great toe can be felt. On the outer side of the foot the most posterior bony point is the outer tuberosity of the os calcis, with the ridge separating the posterior from the outer surface of the

Fig. 418.—Skeleton of foot. Outer aspect.

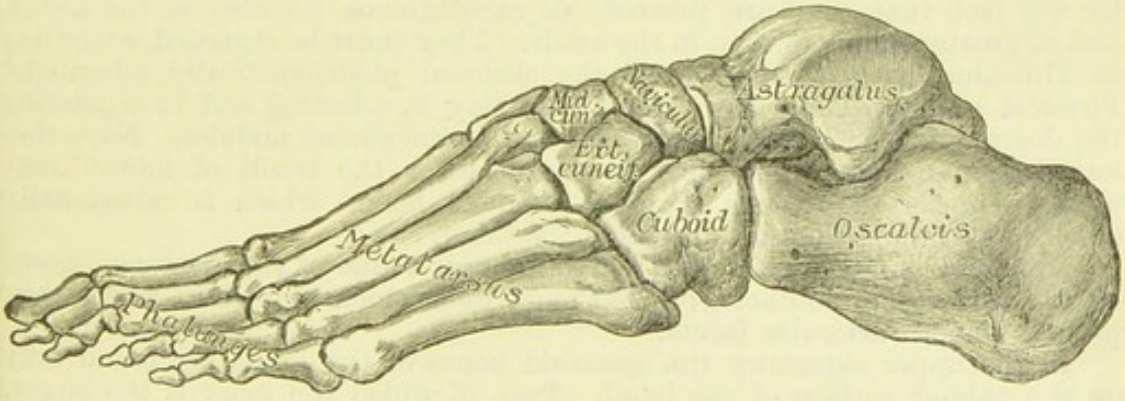

bone. In front of this the greater part of the external surface of the os calcis is subcutaneous ; on it, below and in front of the external malleolus, the peroneal ridge when present can be felt. Farther forwards, the base of the fifth metatarsal bone forms a prominent and well-defined landmark, and in front of this the shaft of the bone, with its expanded head, and the base of the first phalanx, may be made out.

Applied Anatomy.—Considering the injuries to which the foot is subjected, it is surprising how seldom the tarsal bones are fractured. This is no doubt due to the fact that the tarsus is composed of a number of bones, articulated by a considerable extent of surface, and joined together by very strong ligaments which serve to break the force of violence applied to this part of the body. When fracture does occur, these bones being composed for the most part of a soft cancellous structure, covered only by a thin shell of compact tissue, are often extensively comminuted, especially as most of the fractures

are produced by direct violence; and, as there is only a very scanty amount of soft parts over the bones, the fractures are very often compound, and amputation is often necessary.

When fracture occurs in the anterior group of tarsal bones, it is almost invariably the result of direct violence; but fractures of the posterior group—that is, of the os calcis and astragalus—are usually produced by falls from a height on to the feet.

In club-foot (talipes), especially in congenital cases, the bones of the tarsus become altered in shape and size, and displaced from their proper positions. This is principally the case in congenital talipes equino-varus, in which the astragalus, particularly about the head, becomes twisted and atrophied, and a similar condition may be present in the other bones, more especially the navicular. The tarsal bones are peculiarly liable to become the seat of tuberculous caries following comparatively trivial injuries, especially as they are not maintained in a condition of rest to the same extent as some other parts of the body after similar injuries. Caries of the os calcis or astragalus may remain limited to the one bone for a long period, but when one of the other bones is affected, the remainder frequently become involved, since the disease spreads through the large and complicated synovial membrane which is more or less common to these bones.

Amputation of the foot is often required either for injury or disease. The principal amputations are as follows:—(1) Syme's: amputation at the ankle-joint by a heel-flap, with removal of the malleoli and sometimes a thin slice from the lower end of the tibia. (2) Pirogoff's: amputation of the whole of the tarsal bones (except the posterior part of the os calcis), and a thin slice from the tibia and fibula including the two malleoli. The sawn surface of the os calcis is then turned up and united to the cut surface of the tibia. (3) Subastragaloid: amputation of the foot below the astragalus through the joint between it and the os calcis.

The bones of the tarsus occasionally require removal individually. This is especially the case with the astragalus for tuberculous disease limited to that bone; or the astragalus may require excision in cases of subastragaloid dislocation, or in cases of inveterate talipes. The cuboid has been removed for the same reason.

Fractures of the metatarsal bones and phalanges are nearly always the result of direct violence, and in the majority of cases the injury is caused by severe crushing accidents, necessitating amputation. The metatarsal bones, and especially that of the great toe, are frequently diseased, either in tuberculous subjects or in patients with perforating ulcer of the foot.

SESAMOID BONES

Sesamoid bones (ossa sesamoidea) are small more or less rounded masses imbedded in certain tendons and usually related to joint surfaces. Their functions probably are to modify pressure, to diminish friction, and occasionally to alter the direction of a muscle pull. That they are not developed to meet certain physical requirements in the adult is evidenced by the fact that they are present as cartilaginous nodules in the fœtus, and in greater numbers than in the adult. They must be regarded, according to Thilenius, as integral parts of the skeleton phylogenetically inherited.* Physical necessities probably come into play in selecting and in regulating the degree of development of the original cartilaginous nodules. Nevertheless, irregular nodules of bone may appear as the result of intermittent pressure in certain regions, e.g. the 'rider's bone,' which is occasionally developed in the Adductor muscles of the thigh.

Sesamoid bones are invested by the fibrous tissue of the tendons, except on the surfaces in contact with the parts over which they glide, where they present smooth articular facets.

In the upper extremity the sesamoid bones of the joints are found only on the palmar surface of the hand. Two, of which the inner is the larger, are constant at the metacarpo-phalangeal joint of the thumb; one is frequently present in the corresponding joint of the little finger, and one (or two) in the same joint of the index finger. Sesamoid bones are also found occasionally at the metacarpo-phalangeal joints of the middle and ring fingers, at the interphalangeal joint of the thumb, and at the distal interphalangeal joint of the index finger.

In the lower extremity the largest sesamoid bone of the joints is the patella, developed in the tendon of the Quadriceps extensor muscle. On the plantar aspect of the foot, two, of which the inner is the larger, are always present at the metatarso-phalangeal joint of the great toe; one sometimes at the

* *Morpholog. Arbeiten*, 1906, v. p. 309.

metatarso-phalangeal joints of the second and fifth toes, one occasionally at the corresponding joint of the third and fourth toes, and one at the inter-phalangeal joint of the great toe.

Sesamoid bones apart from joints are seldom found in the tendons of the upper limb ; one is sometimes seen in the tendon of the Biceps opposite the tubercle of the radius. They are, however, present in several of the tendons of the lower limb, viz. one in the tendon of the Peroneus longus, where it glides on the cuboid ; one, appearing late in life, in the tendon of the Tibialis anticus, opposite the smooth facet of the internal cuneiform bone ; one in the tendon of the Tibialis posticus, opposite the inner side of the head of the astragalus ; one in the outer head of the Gastrocnemius, behind the outer condyle of the femur ; and one in the conjoined tendon of the Psoas and Iliacus, where it glides over the pubis. Sesamoid bones are found occasionally in the tendon of the Gluteus maximus, as it passes over the great trochanter, and in the tendons which wind round the inner and outer malleoli.

SYNDESMOLOGY

THE various bones of the Skeleton are connected to adjacent bones at different parts of their surfaces, and such connections are termed *Joints* or *Articulations*. Where the joints are *immovable*, as in the articulations between the bones of the skull (with the exception of those of the mandible), the adjacent margins of the bones are almost in contact, being separated merely by a thin layer of fibrous membrane, named the *sutural ligament*. In certain regions at the base of the skull this fibrous membrane is replaced by a layer of cartilage. Where *slight movement* combined with great strength is required, the osseous surfaces are united by tough and elastic *fibro-cartilages*, as in the joints between the vertebral bodies, and in the interpubic articulation. In the *freely movable* joints the surfaces are completely separated ; the bones forming the articulation are generally expanded for greater convenience of mutual connection, covered by *cartilage* and held together by strong bands or capsules of fibrous tissue, called *ligaments* ; such joints are partially lined by a membrane, the *synovial membrane*, which secretes a fluid to lubricate the various parts of which the joint is formed. The structures, therefore, which enter into the formation of a movable joint are bone, cartilage, fibro-cartilage, ligament, and synovial membrane.

Bone constitutes the fundamental element of all the joints. In the long bones, the extremities are the parts which form the articulations ; they are generally somewhat enlarged, and consist of spongy cancellous tissue with a thin coating of compact substance. In the flat bones, the articulations usually take place at the edges ; and in the short bones at various parts of their surfaces. The layer of compact bone which forms the joint surface, and to which the articular cartilage is attached, is called the *articular lamella*. It is white, extremely dense, and varies in thickness. It differs from ordinary bone-tissue in that it contains no Haversian canals, and its lacunæ are larger, and have no canaliculi. The vessels of the cancellous tissue, as they approach the articular lamella, turn back in loops, and do not perforate it ; this layer is consequently denser and firmer than ordinary bone, and is evidently designed to form an unyielding support for the articular cartilage.

The **articular cartilage**, which covers the articular surfaces of bones, is of the hyaline variety, and has been described in the section on Histology (page 21).

Ligaments, properly so called, are peculiar to the movable joints, and serve to connect together the articular surfaces of bones. They are composed mainly of bundles of *white fibrous tissue* placed parallel with, or closely interlaced with one another, and presenting a white, shining, silvery aspect. In the freely movable joints, or diarthrodia, they form envelopes or capsules connecting together the articular extremities of bones. Portions of these capsules undergo thickening and form strong ligamentous bands. These constituent parts of the capsule are usually described as distinct ligaments, but in addition to them there are other ligaments derived from the muscles surrounding the joints. Ligaments are pliant and flexible, so as to allow of the most perfect freedom of movement, but strong, tough, and inextensible, so as not to yield readily under the most severely applied force. Some

ligaments consist entirely of *yellow elastic tissue*, as the ligamenta subflava, which connect together the laminæ of adjacent vertebræ, and the ligamentum nuchæ in the lower animals. In these cases it will be observed that the elasticity of the ligament is intended to act as a substitute for muscular power.

Synovial membrane is composed of a thin, delicate, connective tissue, with branched connective-tissue corpuscles. Its secretion is thick, viscid, and glairy, like the white of egg, and is hence termed *synovia*. The synovial membranes in the body admit of subdivision into three kinds—articular, bursal, and vaginal.

The *articular synovial membranes* are found in all the freely movable joints. The membrane invests the inner surface of the capsule enclosing the joint, and is reflected over any tendons passing through its cavity, as the tendon of the Popliteus in the knee, and the tendon of the Biceps in the shoulder. Hence the articular synovial membrane may be regarded as a short wide tube, attached by its open ends to the margins of the articular cartilages and covering the inner surface of the capsule which connects the articular surfaces. In the fœtus this membrane is said, by Toynbee, to be continued over the surfaces of the cartilages; but in the adult it is wanting, excepting at the circumference of the cartilage, upon which it encroaches for a short distance and to which it is firmly attached. In some of the joints the synovial membrane is thrown into folds, which pass across the cavity. They are called *synovial ligaments*, and are especially distinct in the knee. In other joints there are flattened folds, subdivided at their margins into fringe-like processes, which contain convoluted vessels. These folds generally project from the synovial membrane near the margin of the cartilage, and lie flat upon its surface. They consist of connective tissue, covered with endothelium, and contain fat-cells in variable quantities, and, more rarely, isolated cartilage-cells. The larger folds often contain considerable quantities of fat. Under certain diseased conditions, similar processes are found covering the entire surface of the synovial membrane, forming a mass of pedunculated fibro-fatty growths which project into the joint. Similar structures are also found in some of the bursal and vaginal synovial membranes.

The *bursal synovial membranes* are found interposed between surfaces which move upon each other, as between tendon and bone, or between the integument and projecting bony surfaces. They admit of subdivision into two kinds, the *bursæ mucosæ* and the *bursæ synoviæ*. The *bursæ mucosæ* are large, simple, or irregular sacs in the subcutaneous areolar tissue, enclosing a clear viscid fluid. They are found below the integument in various situations, e.g. over the front of the patella, the olecranon, the malleoli, and other prominent parts. The *bursæ synoviæ* are interposed between muscles or tendons, and the projecting bony surfaces over which they play, as between the Gluteus maximus and the great trochanter. Each consists of a thin wall of connective tissue, partially covered by patches of cells, and contains a viscid fluid. Where one of these exists in the neighbourhood of a joint, it may communicate with the joint cavity, as in the case of the bursa between the tendon of the Psoas and Iliacus and the capsular ligament of the hip, or that interposed between the deep surface of the Subscapularis and the capsular ligament of the shoulder-joint.

The *vaginal synovial membranes* (*synovial sheaths*) serve to facilitate the gliding of tendons in the osseo-fibrous canals through which they pass. The membrane is here arranged in the form of a sheath, one layer of which adheres to the wall of the canal, and the other is reflected upon the surface of the enclosed tendon, the space between the free surfaces of the membrane containing synovia. These sheaths are chiefly found surrounding the tendons of the Flexor and Extensor muscles of the fingers and toes, as they pass through the osseo-fibrous canals in the hand or foot.

Synovia is a transparent, yellowish-white, or slightly reddish fluid, viscid like the white of egg, and has an alkaline reaction and slightly saline taste.

Applied Anatomy.—All synovial membranes, whether articular, bursal, or vaginal, are liable to be affected by acute or chronic forms of inflammation, and the processes are essentially similar, no matter which kind of synovial membrane is affected.

CLASSIFICATION OF JOINTS

The articulations are divided into three classes : *synarthroses* or immovable, *amphiarthroses* or mixed, and *diarthroses* or movable, joints.

1. Synarthroses. Immovable Articulations

Synarthroses include all those articulations in which the surfaces of the bones are in almost direct contact, fastened together by an intervening mass of connective tissue or hyaline cartilage, and in which there is no appreciable motion, as in the joints between the bones of the skull, excepting those of the mandible. There are four varieties of synarthrosis : Sutura, Schindylesis, Gomphosis, and Synchondrosis.

Sutura is that form of articulation where the contiguous margins of the bones are united by a thin layer of fibrous tissue, the *sutural ligament* (fig. 419). It is met with only in the skull. When the articulating surfaces are connected by a series of processes and indentations interlocked together, the articulation

Fig. 419.—Section across the sagittal suture.

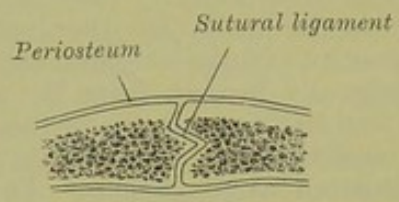

Fig. 420.—Section through occipito-sphenoid synchondrosis of an infant.

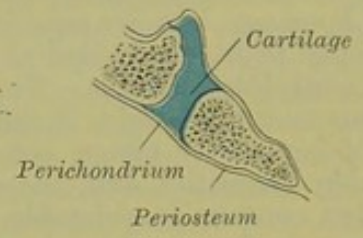

is termed a *true suture* (*sutura vera*) ; and of this there are three varieties: sutura dentata, serrata, and limbosa. The surfaces of the bones are not in direct contact, being separated by a layer of membrane, continuous externally with the pericranium, internally with the dura mater. The *sutura dentata* is so called from the tooth-like form of the projecting articular processes, as in the suture between the parietal bones. In the *sutura serrata* the edges of the bones are serrated like the teeth of a fine saw, as between the two portions of the frontal bone. In the *sutura limbosa*, there is besides the dentated processes, a certain degree of bevelling of the articular surfaces, so that the bones overlap one another, as in the suture between the parietal and frontal bones. When the articulation is formed by roughened surfaces placed in apposition with one another, it is termed a *false suture* (*sutura notha*), of which there are two kinds, the *sutura squamosa*, formed by the overlapping of contiguous bones by broad bevelled margins, as in the squamo-parietal (squamous) suture ; and the *sutura harmonia*, where there is simple apposition of contiguous rough surfaces, as in the articulation between the maxillæ, or between the horizontal plates of the palate bones.

Fig. 421.—Diagrammatic section of a symphysis.

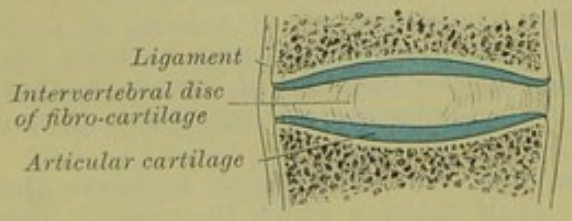

Schindylesis is that form of articulation in which a thin plate of bone is received into a cleft or fissure formed by the separation of two laminæ in another bone, as in the articulation of the rostrum of the sphenoid and perpendicular plate of the ethmoid with the vomer, or in the reception of the latter in the fissure between the maxillæ and between the palate bones.

Gomphosis is articulation by the insertion of a conical process into a socket, as a nail is driven into a board ; this is not illustrated by any articulation between bones, properly so called, but is seen in the articulations of the teeth with the alveoli of the mandible and maxillæ.

Synchondrosis.—Where the connecting medium is cartilage the joint is termed a synchondrosis (fig. 420). This is a temporary form of joint, for the cartilage becomes converted into bone before adult life. Such joints are found between the epiphyses and shafts of long bones, between the occipital and the sphenoid at, and for some years after, birth, and between the petrous portion of the temporal and the jugular process of the occipital.

2. Amphiarthroses. Mixed Articulations

In this form of articulation only a slight amount of movement is possible. The contiguous bony surfaces are either connected together by broad flattened discs of fibro-cartilage, of a more or less complex structure, as in the articulations between the bodies of the vertebræ (fig. 421); or are united by an interosseous ligament, as in the inferior tibio-fibular articulation. The first form is termed a **Symphysis**, the second a **Syndesmosis.**

3. Diarthroses. Movable Articulations

This form of articulation includes the greater number of the joints in the body, mobility being their distinguishing characteristic. A diarthrodial joint is formed by the approximation of two contiguous bony surfaces covered with cartilage, and connected by ligaments lined by synovial membrane (fig. 422). It may be divided, completely or incompletely, by an interarticular fibro-cartilage or *meniscus*, the periphery of which is continuous with the capsular ligament while its free surfaces are covered by synovial membrane (fig. 423).

Fig. 422.—Diagrammatic section of a diarthrodial joint.

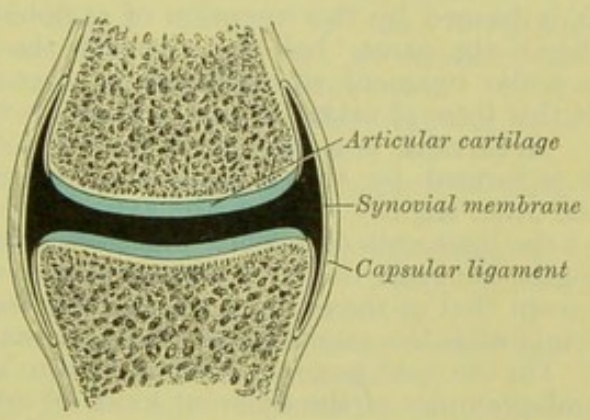

The varieties of joints in this class have been determined by the kind of motion permitted in each. There are two varieties in which the movement is uniaxial; that is to say, all movements take place around one axis. In one form, the Ginglymus, this axis is, practically speaking, transverse; in the other, the Trochoid or pivot-joint, it is longitudinal. There are two varieties where the movement is bi-axial, or around two horizontal axes at right angles to each other, or at any intervening axis between the two. These are the Condyloid and the Saddle-joint. There is one form where the movement is polyaxial, the Enarthrosis or ball-and-socket joint; and finally there are the Arthrodia or gliding joints.

Fig. 423. — Diagrammatic section of a diarthrodial joint, with an interarticular fibro-cartilage.

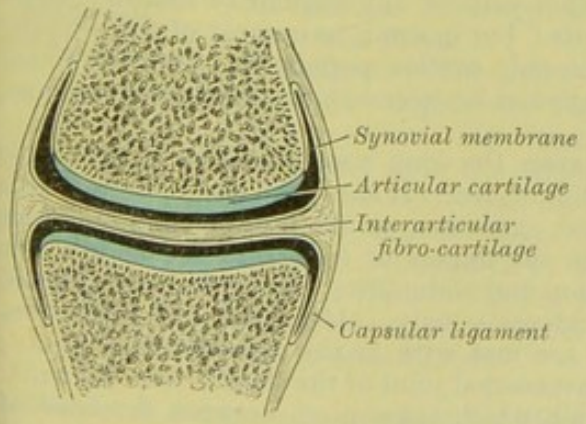

Ginglymus or **Hinge-joint.**—In this form of joint the articular surfaces are moulded to each other in such a manner as to permit motion only in one plane, forwards and backwards, the extent of motion at the same time being considerable. The direction which the distal bone takes in this motion is never in the same plane as that of the axis of the proximal bone; there is always a certain amount of deviation from the straight line during flexion. The articular surfaces are connected together by strong lateral ligaments, which form their chief bond of union. The best examples of ginglymus

are the interphalangeal joints and the joint between the humerus and ulna; the knee and ankle-joints are less typical, as they allow a slight degree of rotation or lateral movement in certain positions of the limb.

Trochoid or Pivot-joint.—Where the movement is limited to rotation, the joint is formed by a pivot-like process turning within a ring, or a ring on a pivot, the ring being formed partly of bone, partly of ligament. In the superior radio-ulnar articulation, the ring is formed by the lesser sigmoid cavity of the ulna and the orbicular ligament; here, the head of the radius rotates within the ring. In the articulation of the odontoid process of the axis with the atlas, the ring is formed in front by the anterior arch of the atlas, behind, by the transverse ligament; here, the ring rotates round the odontoid process.

Condyloid Articulation.—In this form of joint, an ovoid articular head, or condyle, is received into an elliptical cavity in such a manner as to permit of flexion, extension, adduction, abduction and circumduction, but no axial rotation. The articular surfaces are connected together by anterior, posterior, and lateral ligaments. The wrist-joint is an example of this form of articulation.

Articulation by Reciprocal Reception (*saddle-joint*).—In this variety the opposing surfaces are reciprocally concavo-convex. The movements are the same as in the preceding form; that is to say, flexion, extension, adduction, abduction, and circumduction are allowed, but no axial rotation. The articular surfaces are connected by a capsular ligament. The best example of this form is the carpo-metacarpal joint of the thumb.

Enarthrosis is that variety of joint in which the distal bone is capable of motion around an indefinite number of axes, which have one common centre. It is formed by the reception of a globular head into a deep cup-like cavity (hence the name 'ball-and-socket'), the parts being kept in apposition by a capsular ligament strengthened by accessory ligamentous bands. Examples of this form of articulation are found in the hip and shoulder.

Arthrodia is a variety of joint which admits of only gliding movement; it is formed by the apposition of plane surfaces, or one slightly concave, the other slightly convex, the amount of motion between them being limited by the ligaments or osseous processes surrounding the articulation; as in the joints between the articular processes of the vertebræ, the carpal joints, except that of the os magnum with the scaphoid and semilunar, and the tarsal joints with the exception of that between the astragalus and the navicular.

On the next page, in a tabular form, are the names, distinctive characters, and examples of the different kinds of articulations.

The Kinds of Movement admitted in Joints

The movements admissible in joints may be divided into four kinds: gliding and angular movements, circumduction, and rotation. These movements are often, however, more or less combined in the various joints, so as to produce an infinite variety, and it is seldom that we find only one kind of motion in any particular joint.

Gliding movement is the simplest kind of motion that can take place in a joint, one surface gliding or moving over another without any angular or rotatory movement. It is common to all movable joints; but in some, as in most of the articulations of the carpus and tarsus, it is the only motion permitted. This movement is not confined to plane surfaces, but may exist between any two contiguous surfaces, of whatever form.

Angular movement occurs only between the long bones, and by it the angle between the two bones is increased or diminished. It may take place: (1) forwards and backwards constituting flexion and extension, or (2) inwards and outwards from the mesial line of the body (or in the fingers or toes from the middle line of the hand or foot) constituting adduction and abduction. The strictly ginglymoid or hinge-joints admit of flexion and extension only. Abduction and adduction, combined with flexion and extension, are met with in the more movable joints; as in the hip, the shoulder, the carpo-metacarpal joint of the thumb, and the wrist.

Circumduction is that form of motion which takes place between the head of a bone and its articular cavity, when the bone is made to circumscribe a conical space; the base of the cone is described by the inferior extremity of the bone, the apex is in the articular cavity; this kind of motion is best seen in the shoulder- and hip-joints.

Synarthrosis, or Immovable Joint. Surfaces separated by fibrous membrane or cartilage, without any intervening synovial cavity, and immovably connected with each other. As in joints of cranium and face (except the mandible).

Sutura. Articulation by processes and indentations interlocked together.

Sutura vera (true) articulates by indented borders.

dentata, having tooth-like processes; as in interparietal suture.

serrata, having serrated edges like the teeth of a saw; as in interfrontal suture.

limbosa, having bevelled margins, and dentated processes; as in fronto-parietal suture.

Sutura notha (false) articulates by rough surfaces.

squamosa, formed by thin bevelled margins, overlapping each other; as in squamo-parietal suture.

harmonia, formed by the apposition of contiguous rough surfaces; as in inter-maxillary suture.

Schindylesis.—Articulation formed by the reception of a thin plate of one bone into a fissure in another; as in articulation of rostrum of sphenoid with vomer.

Gomphosis.—Articulation formed by the insertion of a conical process into a socket; as in the teeth.

Synchondrosis.—When the connecting medium is cartilage, as in the occipito-sphenoid joint.

Amphiarthrosis, Mixed Articulation.

Symphysis.—Surfaces connected by fibro-cartilage, not separated by synovial membrane, and having limited motion; as in joints between bodies of vertebræ.

Syndesmosis.—Surfaces united by an interosseous ligament. As in the inferior tibio-fibular articulation.

Diarthrosis, Movable Joint.

Ginglymus.—Hinge-joint; motion limited to two directions, forwards and backwards. Articular surfaces fitted together so as to permit of movement in one plane; as in the interphalangeal joints and the joint between the humerus and the ulna.

Trochoid or pivot-joint.—Articulation by a pivot-process turning within a ring, or a ring round a pivot; as in superior radio-ulnar articulation, and atlanto-axial joint.

Condyloid.—Ovoid head received into elliptical cavity. Movements in every direction except axial rotation; as the wrist-joint.

Reciprocal Reception (*saddle-joint*).—Opposed articular surfaces reciprocally convex in one direction and concave in the other. Movement in every direction but no axial rotation; as in the carpo-metacarpal joint of the thumb.

Enarthrosis.—Ball-and-socket joint; capable of motion in all directions. Articulation by a globular head received into a cup-like cavity; as in hip- and shoulder-joints.

Arthrodia. — Gliding-joint; articulation by plane surfaces, which glide upon each other; as in the carpal and tarsal articulations.

Rotation is a form of movement in which a bone moves round a central axis without undergoing any lateral displacement; the axis of rotation may lie in a separate bone, as in the case of the pivot formed by the odontoid process of the axis vertebra around which the atlas turns; or a bone may rotate around its own longitudinal axis, as in the rotation of the humerus at the shoulder-joint; or the axis of rotation may not be quite parallel to the long axis of the bone, as in the

movement of the radius on the ulna during pronation and supination of the hand, where it is represented by a line connecting the centre of the head of the radius above with the centre of the head of the ulna below.

Ligamentous Action of Muscles.—The movements of the different joints of a limb are combined by means of the long muscles passing over more than one joint. These, when relaxed and stretched to their greatest extent, act as elastic ligaments in restraining certain movements of one joint, except when combined with corresponding movements of the other—the latter movements being usually in the opposite direction. Thus the shortness of the hamstring muscles prevents complete flexion of the hip, unless the knee-joint is also flexed so as to bring their attachments nearer together. The uses of this arrangement are threefold. 1. It co-ordinates the kinds of movements which are the most habitual and necessary, and enables them to be performed with the least expenditure of power. 'Thus in the usual gesture of the arms, whether in grasping or rejecting, the shoulder and the elbow are flexed simultaneously, and simultaneously extended,' in consequence of the passage of the Biceps and Triceps over both joints. 2. It enables the short muscles which pass over only one joint to act upon more than one. 'Thus, if the Rectus femoris remain tonically of such length that when, stretched over the extended hip, it compels extension of the knee, then the Gluteus maximus becomes, not only an extensor of the hip, but an extensor of the knee as well.' 3. It provides the joints with ligaments which, while they are of very great power in resisting movements to an extent incompatible with the mechanism of the joint, at the same time spontaneously yield when necessary. 'Taxed beyond its strength a ligament will be ruptured, whereas a contracted muscle is easily relaxed; also, if neighbouring joints be united by ligaments, the amount of flexion or extension of each must remain in constant proportion to that of the other; while, if the union be by muscles, the separation of the points of attachment of those muscles may vary considerably in different varieties of movement, the muscles adapting themselves tonically to the length required.' The quotations are from a very interesting paper by Cleland in the 'Journal of Anatomy and Physiology,' No. 1, 1866, p. 85; by whom this important fact in the mechanism of joints was first clearly pointed out, though it was independently observed afterwards by other anatomists. W. W. Keen points out how important it is 'that the surgeon should remember this ligamentous action of muscles in making passive motion—for instance, at the wrist after Colles's fracture. If the fingers be extended, the wrist can be flexed to a right angle. If, however, they be first flexed as in "making a fist," flexion at the wrist is quickly limited to from forty to fifty degrees in different persons, and is very painful beyond that point. Hence passive motion here should be made with the fingers extended. In the leg, when flexing the hip, the knee should be flexed.' Keen further points out that 'a beautiful illustration of this is seen in the perching of birds, whose toes are forced to clasp the perch by just such a passive ligamentous action so soon as they stoop. Hence they can go to sleep and not fall off the perch.'

The articulations may be grouped into those of the trunk, those of the upper extremity, and those of the lower extremity.

ARTICULATIONS OF THE TRUNK

These may be divided into the following groups, viz.:

I. Of the vertebral column.
II. Of the atlas with the axis.
III. Of the vertebral column with the cranium.
IV. Of the mandible.
V. Of the ribs with the vertebræ.
VI. Of the cartilages of the ribs with the sternum, and with each other.
VII. Of the sternum.
VIII. Of the vertebral column with the pelvis.
IX. Of the pelvis.

I. ARTICULATIONS OF THE VERTEBRAL COLUMN

There are two varieties of articulation in the vertebral column: 1. Those between the bodies of the vertebræ, which form a series of amphiarthrodial joints, and are termed the *intercentral*. 2. Those between the articular processes, which form a series of arthrodial joints, and are termed *interneural*.

1. Intercentral Articulations

The intercentral articulations, or articulations between the bodies of the vertebræ, belong to the class of amphiarthrodial joints, and the individual vertebræ move only slightly on each other. When, however, this slight degree of movement between the pairs of bones takes place in all the joints of the vertebral column, the total range of movement is very considerable. The ligaments of these articulations are the following :

Anterior Common Ligament. Posterior Common Ligament.
Intervertebral Discs.

The **Anterior Common Ligament** (lig. longitudinale anterius) (figs. 424, 435, and 442) is a broad and strong band of fibres, which extends along the anterior surfaces of the bodies of the vertebræ, from the axis to the sacrum. It is broader below than above, thicker in the thoracic than in the cervical or lumbar region, and somewhat thicker opposite the bodies of the vertebræ than opposite the intervertebral discs. It is attached, above, to the body of the axis, where it is continuous with the anterior atlanto-axial ligament, and

Fig. 424.—Vertical section of two lumbar vertebræ and their ligaments.

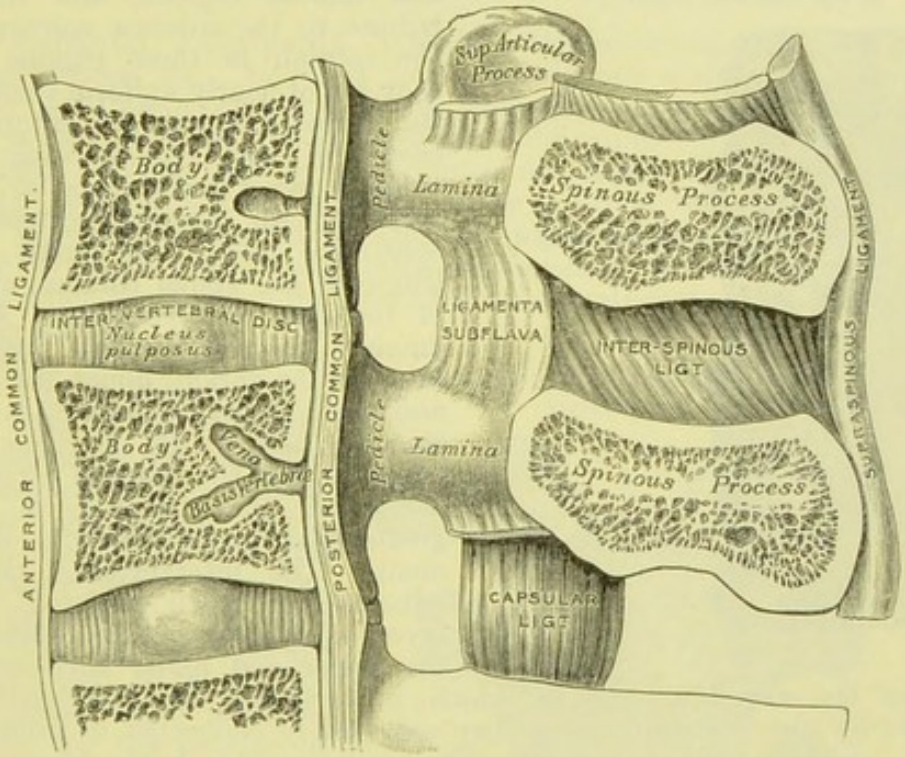

extends down as far as the upper part of the front of the sacrum. It consists of dense longitudinal fibres, which are intimately adherent to the intervertebral discs, and the prominent margins of the vertebræ, but not to the middle parts of the bodies. In the latter situation the fibres are exceedingly thick, and serve to fill up the concavities on the anterior surfaces, and to make the front of the vertebral column more even. The ligament is composed of several layers of fibres, which vary in length, but are closely interlaced with each other. The most superficial fibres are the longest and extend between four or five vertebræ. A second, subjacent set extends between two or three vertebræ; while a third set, the shortest and deepest, extends from one vertebra to the next. At the sides of the bodies the ligament consists of a few short fibres, which pass from one vertebra to the next, separated from the median portion by oval apertures for the passage of vessels.

The **Posterior Common Ligament** (lig. longitudinale posterius) (figs. 424, 425) is situated within the spinal canal, and extends along the posterior surfaces of the bodies of the vertebræ, from the body of the axis, where it is continuous with the occipito-axial ligament, to the sacrum. It is broader above than

below, and thicker in the thoracic than in the cervical or lumbar regions. In the situation of the intervertebral discs and contiguous margins of the vertebræ, where the ligament is more intimately adherent, it is broad, and in the thoracic and lumbar regions presents a series of dentations with intervening concave margins; but it is narrow and thick over the centres of the bodies, from which it is separated by the *venæ basis vertebræ*. This ligament is composed of smooth, shining, longitudinal fibres, denser and more compact than those of the anterior ligament, and consists of superficial layers occupying the interval between three or four vertebræ, and deeper layers which extend between one vertebra and the next adjacent to it. It is separated from the dura mater of the spinal cord by some loose connective tissue.

The **Intervertebral Discs** (fibrocartilagines intervertebrales) (figs. 424, 436) are interposed between the adjacent surfaces of the bodies of the vertebræ, from the axis to the sacrum, and form the chief bonds of connection between the vertebræ. They vary in shape, size, and thickness, in different parts of the vertebral column. In *shape* and *size* they correspond with the surfaces of the bodies between which they are placed, except in the cervical region, where they are slightly smaller from side to side than the corresponding bodies. In *thickness* they vary not only in the different regions of the column, but in different parts of the same disc; they are thicker in front than behind in the cervical and lumbar regions, and thus contribute to the anterior convexities of the column in these regions; while they are of nearly uniform thickness in the thoracic region, the anterior concavity of this region being almost entirely owing to the shape of the vertebral bodies. The intervertebral discs constitute about one-fourth of the length of the spinal column, exclusive of the first two vertebræ; but this amount is not equally distributed between the various bones, the cervical and lumbar portions having, in proportion to their length, a much greater amount than the thoracic region, with the result that these parts possess greater pliancy and freedom of movement. The intervertebral discs are adherent, by their surfaces, to thin layers of hyaline cartilage which cover the upper and under surfaces of the bodies of the vertebræ, and in which, in early life, the epiphysial plates develop; by their circumferences they are closely connected in front to the anterior, and behind to the posterior, common ligaments. In the thoracic region they are joined laterally, by means of the interarticular ligaments, to the heads of those ribs which articulate with two vertebræ: they consequently form parts of the articular cavities in which the heads of these ribs are received.

Fig. 425.—Posterior common ligament, in the thoracic region.

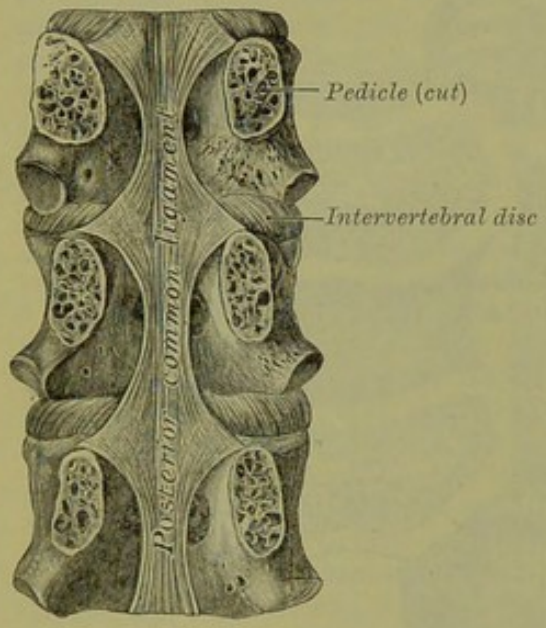

Structure of the Intervertebral Discs.—Each is composed, at its circumference, of laminæ of fibrous tissue and fibro-cartilage, forming the *annulus fibrosus*; and, at its centre, of a soft, pulpy, highly elastic substance, of a yellowish colour, which rises up considerably above the surrounding level when the disc is divided horizontally. This pulpy substance (*nucleus pulposus*), especially well developed in the lumbar region, is the remains of the notochord. The laminæ are arranged concentrically; the outermost consist of ordinary fibrous tissue, the others of white fibro-cartilage. The laminæ are not quite vertical in their direction, those near the circumference being curved outwards and closely approximated; while those nearest the centre curve in the opposite direction, and are somewhat more widely separated. The fibres of which each lamina is composed are directed, for the most part, obliquely from above downwards, the fibres of adjacent laminæ passing in opposite directions and varying in every layer: so that the fibres of one layer are directed across those of another, like the limbs of the letter X. This

laminar arrangement belongs to about the outer half of each disc. The pulpy substance presents no concentric arrangement, and consists of a fine fibrous matrix, containing angular cells united to form a reticular structure.

Applied Anatomy.—When an aneurysm presses on the vertebral column, the vertebral bodies are often deeply eroded by the tumour, while the intervertebral discs remain intact. The discs are the first to be destroyed, however, in tuberculosis of the spine, where, as not infrequently happens, the disease begins in the discs, and spreads thence to the bodies of the two adjoining vertebræ simultaneously.

2. Interneural Articulations

The interneural articulations, or articulations between the articular processes of the vertebræ, belong to the arthrodial variety of movable joints. The processes are connected together by capsular ligaments, which are lined by synovial membranes; but in addition to these are a number of accessory ligaments, which connect together the laminæ, spinous and transverse processes. The ligaments of the interneural articulations are:

Capsular.
Ligamenta subflava.
Supraspinous.
Interspinous.
Intertransverse.

The **Capsular Ligaments** (capsulæ articulares) (fig. 424) are thin and loose ligamentous sacs, attached to the contiguous margins of the articular processes of adjacent vertebræ. Each ligament is defective internally, where the sac is completed by the ligamentum subflavum. They are longer and looser in the cervical than in the thoracic or lumbar regions. The capsular ligaments are lined on their inner surfaces by synovial membrane.

The **Ligamenta Subflava** (ligg. flava) (fig. 426) connect the laminæ of adjacent vertebræ, from the axis to the first segment of the sacrum. They are best seen when viewed from the interior of the spinal canal: when looked at from the outer surface they appear short, being overlapped by the laminæ. Each ligament consists of two lateral portions, which commence one on either side at the roots of the articular processes, and extend backwards to the point where the laminæ converge to form the spinous process; the posterior margins of the two portions are in contact and to a certain extent united, slight intervals being left for the passage of small vessels. Each ligament consists of yellow elastic tissue, the fibres of which, almost perpendicular in direction, are attached to the anterior surface of the lamina above, some distance from its inferior margin, and to the posterior surface and upper margin of the lamina below. In the cervical region the ligaments are thin, but very broad and long; they become thicker in the thoracic region, and in the lumbar region acquire very considerable thickness. Their highly elastic property serves to preserve the upright posture, and to assist the vertebral column in resuming it, after flexion. These ligaments do not exist between the occiput and atlas, or between the atlas and axis.

Fig. 426.—Neural arches of three thoracic vertebræ viewed from the front.

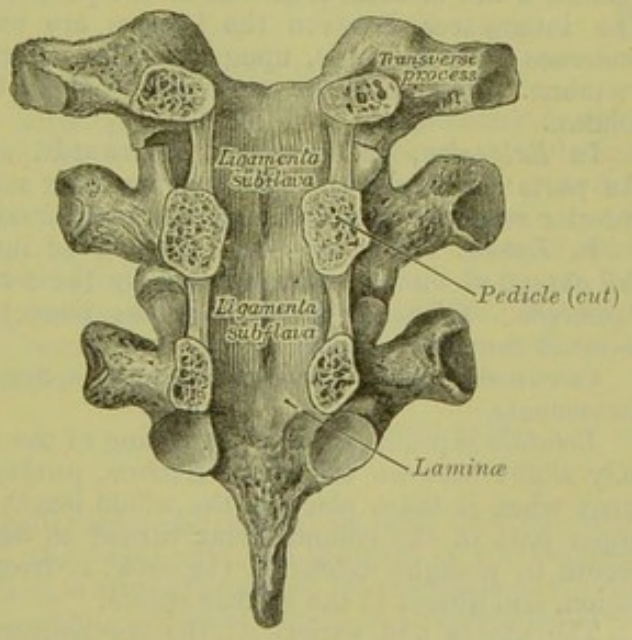

The **Supraspinous Ligament** (lig. supraspinale) (fig. 424) is a strong fibrous cord, which connects together the apices of the spinous processes

from the seventh cervical vertebra to the sacrum. It is thicker and broader in the lumbar than in the thoracic region, and intimately blended, in both situations, with the neighbouring aponeurosis. The most superficial fibres of this ligament connect three or four vertebræ; those more deeply seated pass between two or three vertebræ; while the deepest connect the spinous processes of neighbouring vertebræ. It is continued upwards to the external occipital protuberance and crest, as the ligamentum nuchæ.

The **Ligamentum nuchæ** is a fibrous membrane, which, in the neck, represents the supraspinous ligaments of the lower vertebræ. It extends from the external occipital protuberance and crest to the spinous process of the seventh cervical vertebra. From its anterior border a fibrous lamina is given off, which is attached to the posterior tubercle of the atlas, and the spinous processes of all the cervical vertebræ, so as to form a septum between the muscles on either side of the neck. In man it is merely the rudiment of an important elastic ligament, which, in some of the lower animals, serves to sustain the weight of the head.

The **Interspinous Ligaments** (ligg. interspinalia) (fig. 424), thin and membranous, are interposed between the spinous processes. These ligaments extend from the root to the apex of each spinous process, connecting together their adjacent margins. They meet the ligamenta subflava in front and the supraspinous ligament behind. They are narrow and elongated in the thoracic region; broader, quadrilateral in form, and thicker in the lumbar region; and only slightly developed in the neck.

The **Intertransverse Ligaments** (ligg. intertransversaria) are interposed between the transverse processes. In the cervical region they consist of a few irregular, scattered fibres; in the thoracic region they are rounded cords intimately connected with the deep muscles of the back; in the lumbar region they are thin and membranous.

Movements.—The movements permitted in the vertebral column are, Flexion, Extension, Lateral movement, Circumduction, and Rotation.

In *Flexion*, or movement forwards, the anterior common ligament is relaxed, and the intervertebral discs are compressed in front; while the posterior common ligament, the ligamenta subflava, and the inter- and supra-spinous ligaments are stretched, as well as the posterior fibres of the intervertebral discs. The interspaces between the laminæ are widened, and the inferior articular processes glide upwards, upon the superior articular processes of the subjacent vertebræ. Flexion is the most extensive of all the movements of the vertebral column.

In *Extension*, or movement backwards, an exactly opposite disposition of the parts takes place. This movement is not extensive, being limited by the anterior common ligament, and by the approximation of the spinous processes.

In *Lateral Movement*, the sides of the intervertebral discs are compressed, the extent of motion being limited by the resistance offered by the surrounding ligaments. This movement may take place in any part of the column, but is freest in the neck and loins.

Circumduction is very limited, and is merely a succession of the preceding movements.

Rotation is produced by the twisting of the intervertebral discs; this, although only slight between any two vertebræ, produces a considerable extent of movement when it takes place in the whole length of the column, the front of the upper part of the column being turned to one or other side. This movement occurs to a slight extent in the neck, is freer in the upper part of the thoracic region, and absent in the lumbar region.

The extent and variety of the movements are influenced by the shape and direction of the articular surfaces.

In the *cervical* region the upward inclination of the superior articular surfaces allows of free flexion and extension. Extension can be carried farther than flexion; at the upper end of the region it is checked by the locking of the posterior edges of the superior atlantal facets in the posterior condyloid fossæ of the occipital bone; at the lower end it is limited by a mechanism whereby the inferior articular processes of the seventh cervical vertebra slip into grooves behind and below the superior articular processes of the first thoracic. Flexion is arrested when the cervical convexity is straightened; the movement is checked by the apposition of the

projecting lower lips of the bodies of the vertebræ with the shelving surfaces on the bodies of the subjacent vertebræ. Lateral flexion and rotation are free in the cervical region; they are, however, always combined. The upward and inward inclinations of the superior articular surfaces impart a rotatory movement during lateral flexion, while pure rotation is prevented by the slight inward slope of these surfaces.

In the *thoracic* region, notably in its upper part, all the movements are limited in order to reduce interference with respiration to a minimum. The almost complete absence of an upward inclination of the superior articular surfaces prohibits any marked flexion, while extension is checked by the contact of the inferior articular margins with the laminæ, and the contact of the spinous processes with one another. The mechanism between the seventh cervical and the first thoracic vertebræ, which limits extension of the cervical region, will also serve to limit flexion of the thoracic region when the neck is extended. Rotation is free in the thoracic region: the superior articular processes are segments of a cylinder whose axis is in the mid-ventral line of the vertebral bodies. The direction of the articular facets would allow of free lateral flexion, but this movement is considerably limited in the upper part of the region by the resistance of the ribs and sternum.

In the *lumbar* region flexion and extension are free. Flexion can be carried farther than extension, and is possible up to the straightening of the lumbar curve; it is, therefore, greatest at the lowest part where the curve is sharpest. The inferior articular facets are not in close apposition with the superior facets of the subjacent vertebræ, and on this account a considerable amount of lateral flexion is permitted. For the same reason a slight amount of rotation can be carried out, but this is so soon checked by the interlocking of the articular surfaces that it is negligible.

The principal muscles which produce *flexion* are the Sterno-mastoid, Rectus capitis anticus major, and Longus colli; the Scaleni; the abdominal muscles and the Psoas magnus. *Extension* is produced by the fourth layer of the muscles of the back, assisted in the neck by the Splenius, Semispinales dorsi et colli, and the Multifidus spinæ. *Lateral* motion is produced by the fourth and fifth layers of the muscles of the back, by the Splenius, the Scaleni, the Quadratus lumborum and the Psoas magnus, the muscles of one side only acting; and *rotation* by the action of the following muscles of one side only, viz. the Sterno-mastoid, the Rectus capitis anticus major, the Scaleni, the Multifidus spinæ, the Complexus, and the abdominal muscles.

II. ARTICULATION OF THE ATLAS WITH THE AXIS

The articulation of the Atlas with the Axis is of a complicated nature, comprising no fewer than four distinct joints. There is a pivot articulation between the odontoid process of the axis and the ring formed by the anterior arch of the atlas and the transverse ligament (see fig. 429); here there are two joints: one in front between the posterior surface of the anterior arch of the atlas and the front of the odontoid process; the other between the anterior surface of the transverse ligament and the back of the process. Between the articular processes of the two bones there is on either side an arthrodial or gliding joint. The ligaments which connect these bones are:

Two Capsular.	Posterior Atlanto-axial.
Anterior Atlanto-axial.	Transverse.*

The **Capsular Ligaments** (capsulæ articulares) are two thin, loose capsules, connecting the lateral masses of the atlas with the margins of the superior articular surfaces of the axis. Each is strengthened at its posterior and inner part by a ligamentous band, the *accessory ligament*, which is attached below to the body of the axis near the base of the odontoid process, and above to the lateral mass of the atlas near the transverse ligament.

The **Anterior Atlanto-axial Ligament** (fig. 427) is a strong membrane, fixed, above, to the lower border of the anterior arch of the atlas; below,

* It has been found necessary to describe the transverse ligament with those of the atlas and axis; but the student must remember that it is really a portion of the mechanism by which the movements of the head on the vertebral column are regulated; so that the connections between the atlas and axis ought always to be studied in association with those between the axis and the skull.

to the front of the body of the axis. It is strengthened in the middle line by a rounded cord, which is connected, above, to the tubercle on the anterior arch of the atlas, and below to the body of the axis, and is a continuation upwards of the anterior common ligament. The ligament is in relation, in front, with the Recti antici majores.

The **Posterior Atlanto-axial Ligament** (fig. 428) is a broad, thin membrane, attached, above, to the lower border of the posterior arch of the atlas; below, to the upper edges of the laminæ of the axis. This ligament supplies the place of the ligamenta subflava, and is in relation, behind, with the Inferior oblique muscles.

The **Transverse Ligament** (lig. transversum atlantis) (figs. 429, 430), is a thick, strong band, which arches across the ring of the atlas, and serves to retain the odontoid process in contact with its anterior arch. It is concave in front, convex behind, broader and thicker in the middle than at either extremity, and firmly attached on either side to a small tubercle on the inner surface of the lateral mass of the atlas. As it crosses the odontoid process, a

FIG. 427.—Occipito-atlantal and atlanto-axial ligaments. Front view.

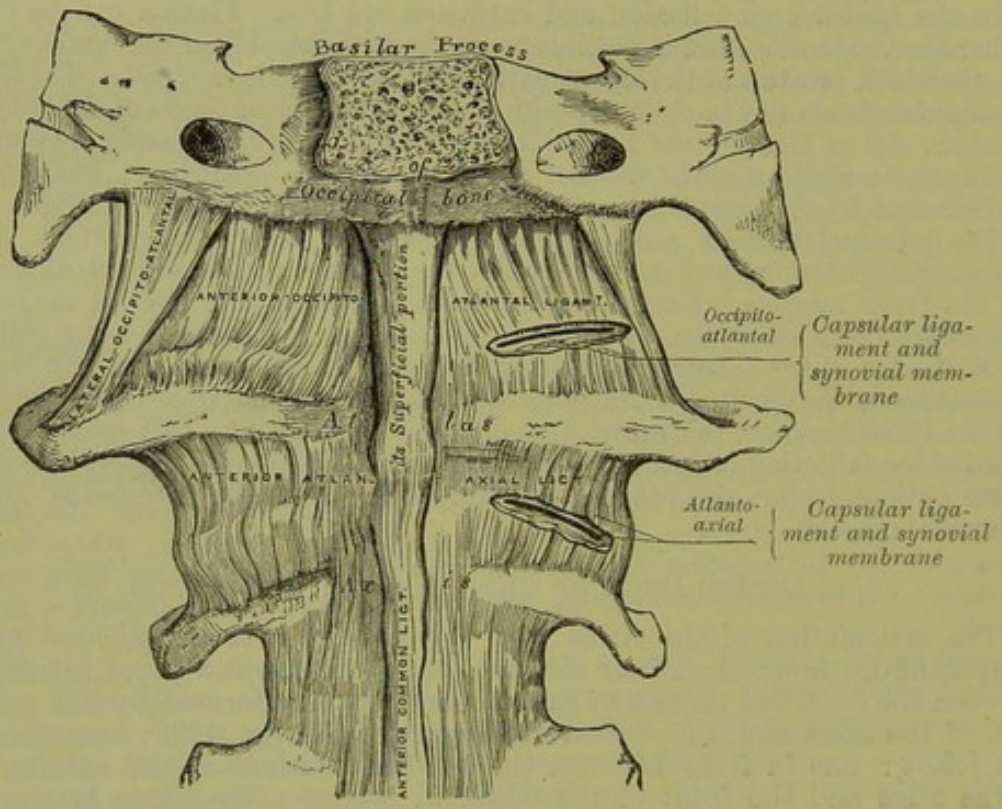

small fasciculus (*crus superius*) is prolonged upwards, and another (*crus inferius*) downwards, from the superficial or posterior fibres of the ligament. The former is inserted into the basilar process of the occipital bone, in close relation with the occipito-axial ligament; the latter descends, to be attached to the posterior surface of the body of the axis; hence, the whole ligament has received the name of *cruciform* (lig. cruciatum atlantis). The transverse ligament divides the ring of the atlas into two unequal parts: of these, the posterior and larger serves for the transmission of the spinal cord and its membranes and the spinal accessory nerves; the anterior and smaller contains the odontoid process. The neck of the odontoid process is constricted where it is embraced posteriorly by the transverse ligament, so that this ligament suffices to retain the odontoid process in position after all the other ligaments have been divided.

There are *four* **Synovial Membranes** in this articulation: one lining the inner surface of each of the capsular ligaments; one between the anterior surface of the odontoid process and the anterior arch of the atlas, and one between the posterior surface of the odontoid process and the transverse ligament. The latter often communicates with those between the condyles of the occipital bone and the articular surfaces of the atlas.

Movements.—This joint allows the rotation of the atlas (and, with it, of the cranium) upon the axis, the extent of rotation being limited by the odontoid ligaments.

Fig. 428.—Occipito-atlantal and atlanto-axial ligaments. Posterior view.

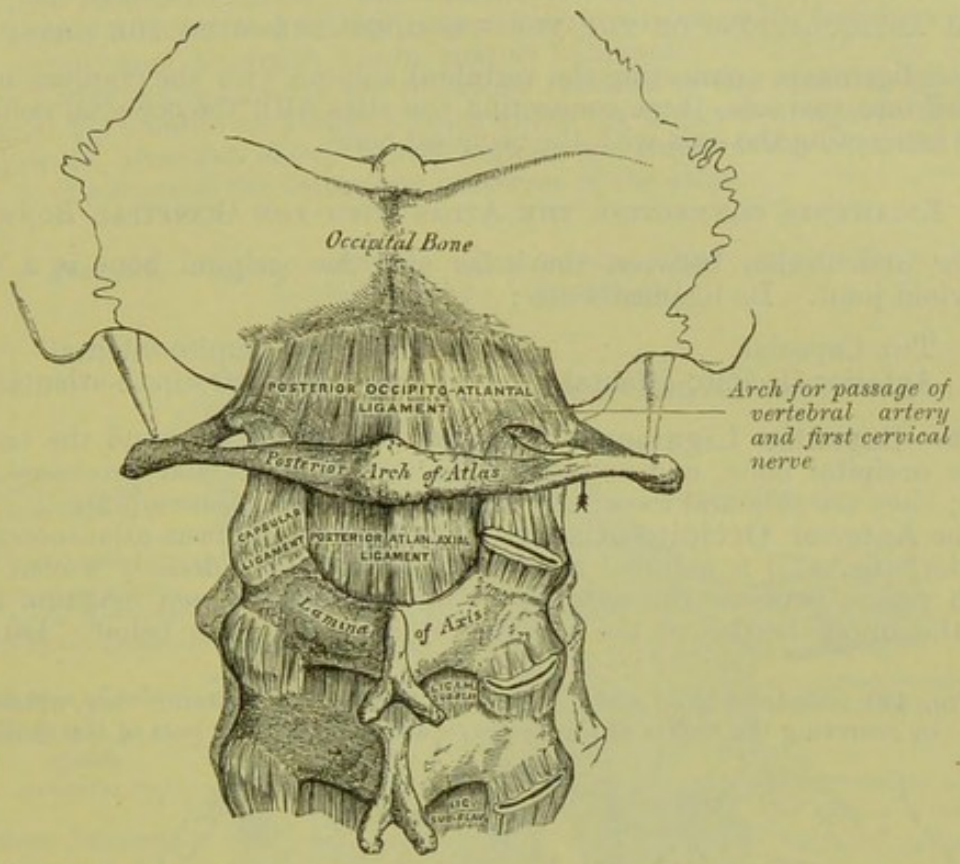

The opposed articular surfaces of the atlas and axis are not reciprocally curved; both surfaces are convex in their long axes. When, therefore, the upper facet glides forwards on the lower it also descends; the fibres of the capsular ligament

Fig. 429.—Articulation between odontoid process and atlas.

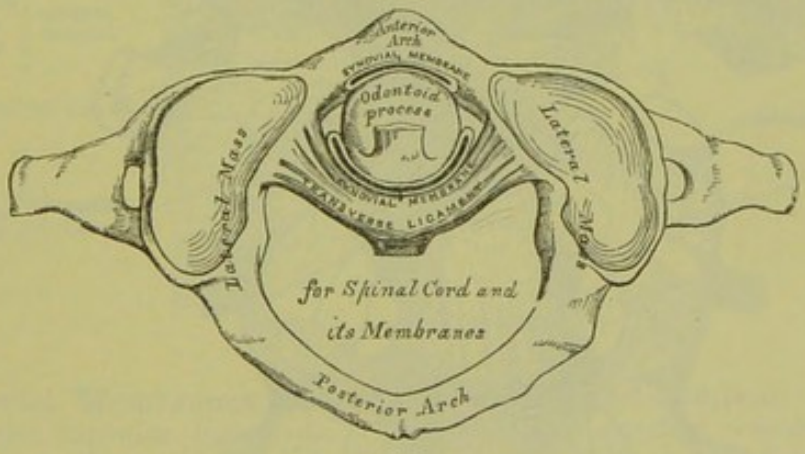

are relaxed in a vertical direction, and will then permit of movement in an antero-posterior direction. By this means a shorter capsule suffices and the strength of the joint is materially increased.*

* Corner ('The Physiology of the Atlanto-axial Joints,' *Journal of Anatomy and Physiology*, vol. xli.) states that the movements which take place at these articulations are of a complex nature. The first part of the movement is an eccentric or asymmetrical one; the atlanto-axial joint of the side to which the head is moved is fixed, or practically fixed, by the muscles of the neck, and forms the centre of the movement, while the opposite atlantal facet is carried downwards and forwards on the corresponding axial facet. The second part of the movement is centric and symmetrical, the odontoid process forming the axis of the movement.

The principal muscles by which these movements are produced are the Sterno-mastoid and Complexus of one side, acting with the Rectus capitis anticus major, Splenius, Trachelo-mastoid, Rectus capitis posticus major, and Inferior and Superior oblique of the other side.

III. ARTICULATIONS OF THE VERTEBRAL COLUMN WITH THE CRANIUM

The ligaments connecting the vertebral column with the cranium may be divided into two sets, those connecting the atlas with the occipital bone, and those connecting the axis with the occipital bone.

Ligaments connecting the Atlas with the Occipital Bone

The articulation between the atlas and the occipital bone is a double condyloid joint. Its ligaments are :

Two Capsular.	Posterior Occipito-atlantal.
Anterior Occipito-atlantal.	Two Lateral Occipito-atlantal.

The **Capsular Ligaments** (capsulæ articulares) surround the condyles of the occipital bone, and connect them with the articular processes of the atlas ; they are thin and loose, and are lined by synovial membrane.

The **Anterior Occipito-atlantal Ligament** (membrana atlantooccipitalis anterior) (fig. 427) is a broad membrane, composed of densely woven fibres, which passes between the anterior margin of the foramen magnum above, and the upper border of the anterior arch of the atlas below. Laterally,

Fig. 430.—Occipito-axial and atlanto-axial ligaments. Posterior view, obtained by removing the arches of the vertebræ and the posterior part of the skull.

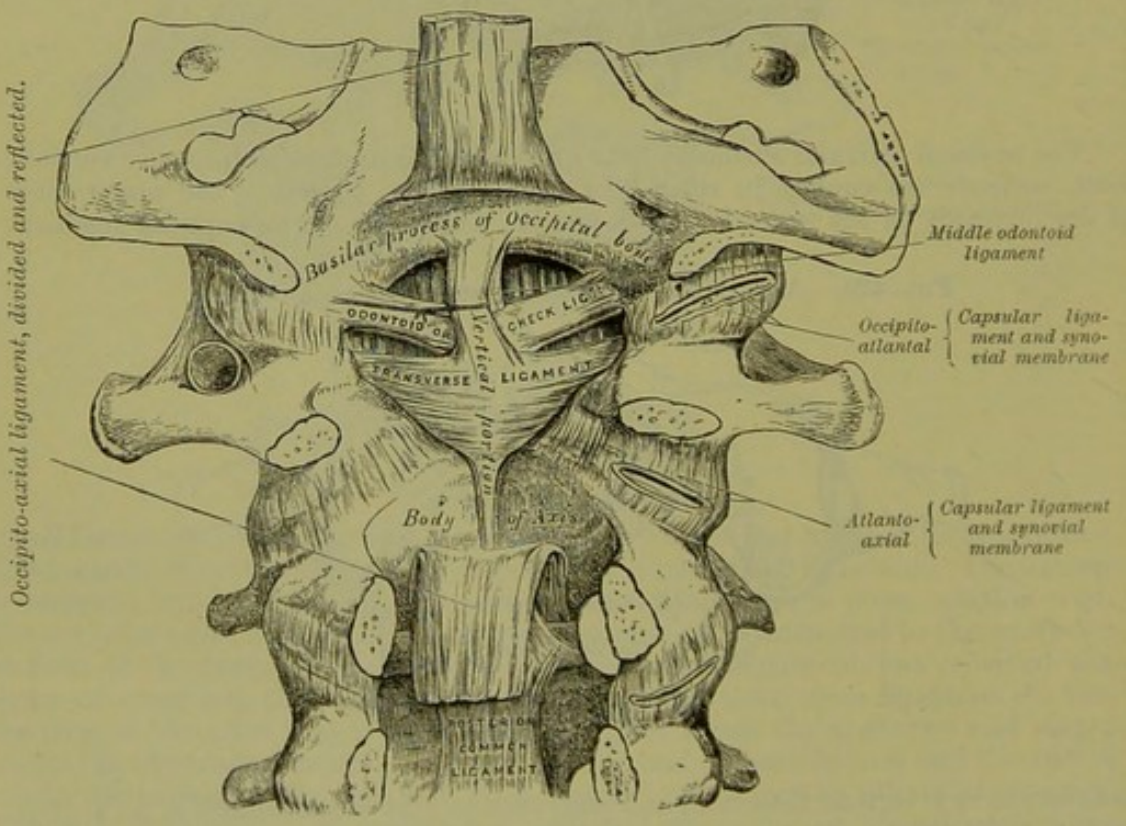

it is continuous with the capsular ligaments. In front, it is strengthened in the middle line by a strong, rounded cord, which is attached, above, to the basilar process of the occiput, and, below, to the tubercle on the anterior arch of the atlas. This ligament is in relation in front with the Recti antici minores, behind with the odontoid ligaments.

The **Posterior Occipito-atlantal Ligament** (membrana atlantooccipitalis posterior) (fig. 428) is a broad but thin membrane connected, above, to the posterior margin of the foramen magnum ; below, to the upper border of the

posterior arch of the atlas. On either side this ligament is defective below, over the superior intervertebral notch, and forms with this notch the boundary of an opening for the passage of the vertebral artery and suboccipital nerve. The free border of the ligament, which arches over the artery and nerve, sometimes becomes ossified. The ligament is in relation, behind, with the Recti postici minores and Obliqui superiores; in front, with the dura mater of the spinal canal, to which it is intimately adherent.

The **Lateral Ligaments** are thickened portions of the capsular ligament, reinforced by bundles of fibrous tissue, which are directed obliquely upwards and inwards, attached above to the jugular processes of the occipital bone, below, to the bases of the transverse processes of the atlas.

FIG. 431.—Sagittal section through the occipital bone and first three cervical vertebræ. (Spalteholz.)

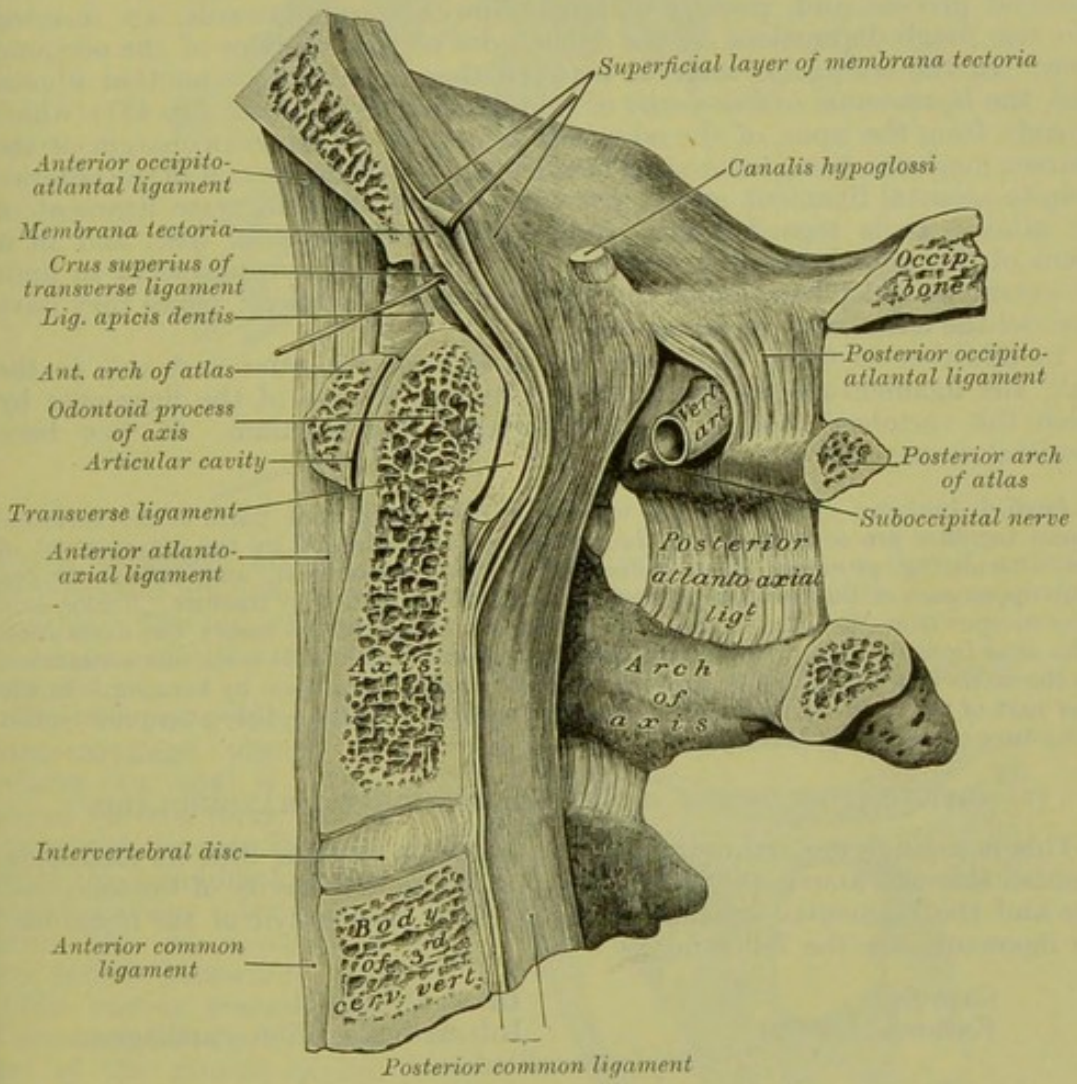

Synovial Membranes.—There are two synovial membranes: one lining each of the capsular ligaments. The joints occasionally communicate with that between the posterior surface of the odontoid process and the transverse ligament.

Movements.—The movements permitted in this joint are (*a*) flexion and extension, which give rise to the ordinary forward and backward nodding of the head, and (*b*) slight lateral motion to one or other side. *Flexion* is produced mainly by the action of the Recti capitis antici major and minor; *extension* by the Recti capitis postici major and minor, the Superior oblique, the Complexus, Splenius, Sterno-mastoid, and upper fibres of the Trapezius. The Recti laterales are concerned in the *lateral movement*, assisted by the Trapezius, Splenius, Complexus, and the Sterno-mastoid of the same side, all acting together. According to Cruveilhier, there is a slight movement of rotation in this joint.

Ligaments connecting the Axis with the Occipital Bone

Occipito-axial. Three Odontoid.

The **Occipito-axial Ligament** (membrana tectoria) is situated within the spinal canal. It is a broad, strong band, which covers the odontoid process and its ligaments, and appears to be a prolongation upwards of the posterior common ligament of the vertebral column. It is attached, below, to the posterior surface of the body of the axis, and, becoming expanded as it ascends, is inserted into the basilar groove of the occipital bone, in front of the foramen magnum, where it blends with the dura mater of the skull. It is in relation by its anterior surface with the transverse ligament, by its posterior surface with the dura mater.

The **Odontoid or Check Ligaments** (ligamenta alaria) (fig. 430) are strong, rounded fibrous cords, which arise one on either side of the upper part of the odontoid process, and, passing obliquely upwards and outwards, are inserted into the rough depressions on the inner sides of the condyles of the occipital bone. In the triangular interval between these ligaments is another fibrous cord, the *ligamentum apicis dentis* or *middle odontoid ligament* (fig. 431), which extends from the apex of the odontoid process to the anterior margin of the foramen magnum, being intimately blended with the deep portion of the anterior occipito-atlantal ligament and upper fasciculus of the transverse ligament of the atlas. It is regarded as a rudimentary intervertebral disc, and in it traces of the notochord may persist. The odontoid ligaments serve to limit the extent to which rotation of the cranium may be carried; hence they have received the name of *check ligaments*.

In addition to these ligaments which connect the atlas and axis to the skull, the ligamentum nuchæ must be regarded as one of the ligaments by which the vertebral column is connected with the cranium. It has been described on page 376.

Applied Anatomy.—The ligaments which unite the component parts of the vertebral column together are so strong, and the bones are so interlocked by the arrangement of their articulating processes, that dislocation is very uncommon, and, indeed, except in the upper part of the neck, rarely occurs unless accompanied by fracture. Dislocation of the occiput from the atlas has been recorded only in one or two cases; but dislocation of the atlas from the axis, with rupture of the transverse ligament, is much more common: it is the mode in which death is produced in many cases of execution by hanging. In the lower part of the neck—that is, below the third cervical vertebra—dislocation unattended by fracture occasionally takes place.

IV. Articulation of the Mandible (Articulatio Mandibularis)

This is a ginglymo-arthrodial joint; the parts entering into its formation on either side are, above, the anterior part of the glenoid cavity of the temporal bone and the eminentia articularis; and, below, the condyle of the mandible. The ligaments are the following:

Capsular. Internal Lateral.
External Lateral. Interarticular Fibro-cartilage.
Stylo-mandibular.

The **Capsular Ligament** (capsula articularis) forms a thin and loose, but distinct capsule, attached above to the circumference of the glenoid cavity and the articular surface immediately in front; below, to the neck of the condyle of the mandible. It is thinnest on the inner side.

The **External Lateral Ligament** (lig. temporomandibulare) (fig. 432) is an accessory band of the capsular ligament, and is not separable from it. It consists of two short, narrow fasciculi, one in front of the other, attached, above, to the outer surface of the zygoma and to the tubercle on its lower border; below, to the outer surface and posterior border of the neck of the mandible. It is broader above than below; its fibres are parallel with one another, and directed obliquely downwards and backwards. Externally, it is covered by the parotid gland, and by the integument.

The **Internal Lateral Ligament** (lig. sphenomandibulare) (fig. 433) is a flat thin band which is attached above to the spinous process of the sphenoid

bone, and, becoming broader as it descends, is inserted into the lingula of the dental foramen. Its outer surface is in relation, above, with the External pterygoid; lower down, it is separated from the neck of the condyle by the

Fig. 432.—Temporo-mandibular articulation. External view.

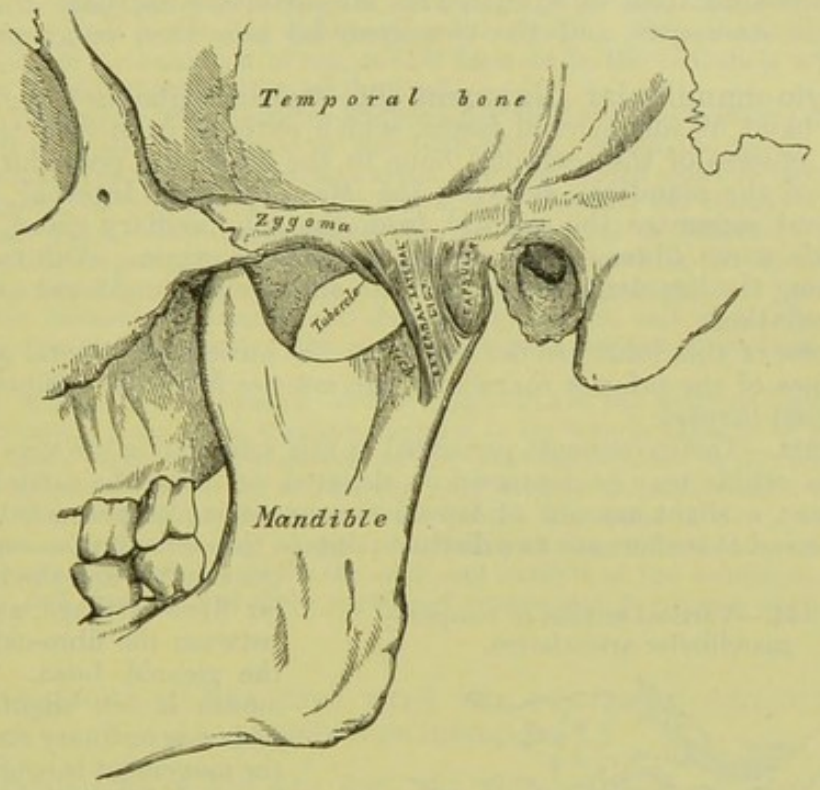

internal maxillary artery; still more inferiorly, the inferior dental vessels and nerve and a lobule of the parotid gland separate it from the ramus of the mandible. The inner surface is in relation with the Internal pterygoid.

Fig. 433.—Temporo-mandibular articulation. Internal view.

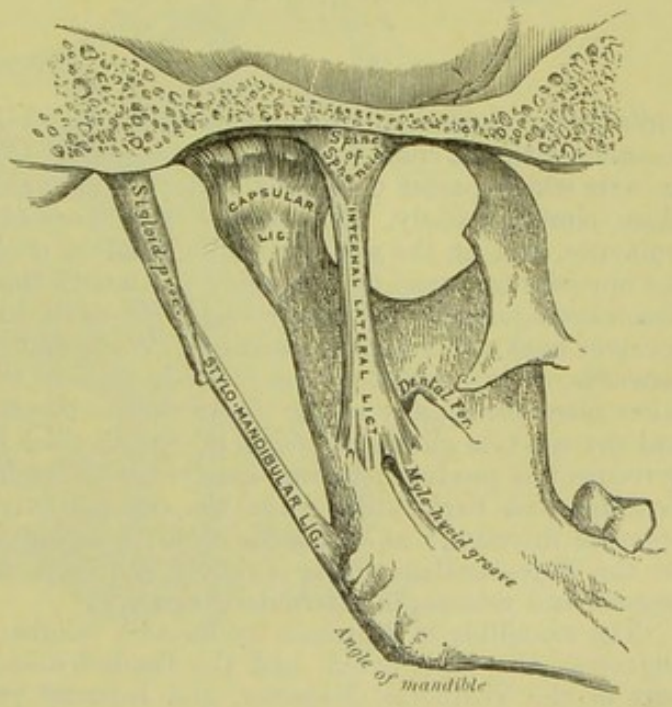

The **Interarticular Fibro-cartilage** (discus articularis) (fig. 434) is a thin plate of an oval form, placed horizontally between the condyle of the mandible and the glenoid cavity. Its upper surface is concavo-convex from before backwards, and a little convex transversely, to accommodate itself to the form of the glenoid cavity. Its under surface, which is in contact with the condyle, is concave. Its circumference is connected to the capsular ligament; and in front to the tendon of the External pterygoid. It is thicker at its periphery, especially behind, than at its centre. The fibres of which it is composed have a concentric arrangement, more apparent at the circumference than at the centre. Its surfaces are smooth. It divides the joint into two cavities, each of which is furnished with a synovial membrane.

The **Synovial Membranes,** two in number, are placed one above, and the other below, the fibro-cartilage. The upper one, the larger and looser of the two, is continued from the margin of the cartilage covering the glenoid cavity and eminentia articularis on to the upper surface of the fibro-cartilage. The lower one passes from the under surface of the fibro-cartilage to the neck of the condyle, being prolonged a little farther downwards behind than in front. The interarticular cartilage is sometimes perforated in its centre, and the two synovial sacs then communicate with each other.

The **Stylo-mandibular Ligament** (lig. stylomandibulare) (fig. 433) is a specialised band of the cervical fascia, which extends from near the apex of the styloid process of the temporal bone to the angle and posterior border of the ramus of the mandible, between the Masseter and Internal pterygoid. This ligament separates the parotid from the submaxillary gland, and from its inner side some fibres of the Stylo-glossus take origin. Although usually classed among the ligaments of the jaw, it can only be considered as accessory to the articulation.

The *nerves* of this joint are derived from the auriculo-temporal and masseteric branches of the inferior maxillary, the *arteries* from the temporal branch of the external carotid.

Movements.—The movements permitted in this articulation are very extensive. Thus, the mandible may be depressed or elevated, or it may be carried forwards or backwards; a slight amount of lateral movement is also permitted. It must be borne in mind that there are two distinct joints in this articulation—one between the condyle and the interarticular fibro-cartilage, and another between the fibro-cartilage and the glenoid fossa. When the mouth is but slightly opened, as during ordinary conversation, the movement is confined to the lower of the two joints. On the other hand, when the mouth is opened more widely, both joints are concerned in the movement; in the lower joint, viz. that between the condyle and the fibro-cartilage, the movement is of a hinge-like character, the condyle moving round a transverse axis on the fibro-cartilage, while in the upper joint the movement is of a gliding character, the fibro-cartilage, together with the condyle, gliding forwards on to the eminentia articularis, round an axis which passes through the dental foramina. These two movements take place simultaneously, the condyle and fibro-cartilage move forwards on the eminence, and at the same time the condyle revolves on the fibro-cartilage. In the opposite movement of shutting the mouth the reverse action takes place; the fibro-cartilage glides back, carrying the condyle with it, and this at the same time revolves back to its former position. When the mandible is carried horizontally forwards, as in protruding the lower incisors in front of the upper, the movement takes place principally in the upper compartment of the joint, the fibro-cartilage and the condyle gliding forwards on the glenoid fossa. The grinding or chewing movement is produced by one condyle, with its fibro-cartilage, gliding alternately forwards and backwards, while the other condyle moves simultaneously in the opposite direction; at the same time the condyle undergoes a vertical rotation on the fibro-cartilage. One condyle advances and rotates, the other condyle recedes and rotates, in alternate succession.

FIG. 434.—Vertical section of temporo-mandibular articulation.

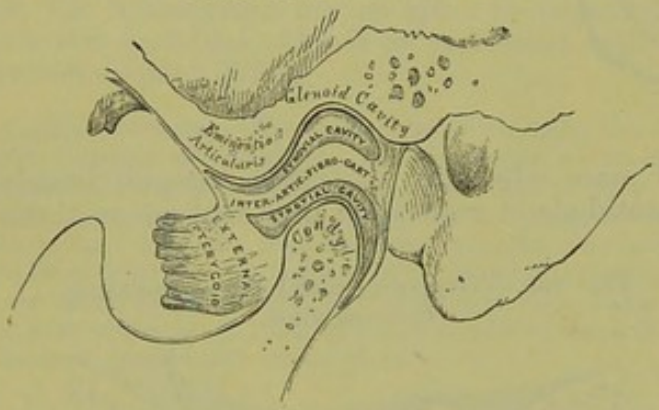

The mandible is *depressed* by its own weight, assisted by the Platysma, the Digastric, the Mylo-hyoid, and the Genio-hyoid. It is *elevated* by the anterior part of the Temporal, Masseter, and Internal pterygoid. It is drawn *forwards* by the simultaneous action of the External and Internal pterygoids, the superficial fibres of the Masseter and the anterior fibres of the Temporal; and it is drawn *backwards* by the deep fibres of the Masseter and the posterior fibres of the Temporal.

The grinding movement is caused by the alternate action of the two Pterygoids of either side.

Surface Form.—The temporo-mandibular articulation is quite superficial, and is situated below the base of the zygoma, in front of the tragus and external auditory meatus, and behind the posterior border of the upper part of the Masseter. Its position can be ascertained by feeling for the condyle of the jaw, the movements of which can be distinctly felt in opening and shutting the mouth. When the mouth is opened wide, the condyle advances out of the glenoid fossa on to the eminentia articularis, and a depression is felt in the situation of the joint.

Applied Anatomy.—The mandible is dislocated only in one direction—viz. forwards. The accident is caused by violence or muscular action. When the mouth is open, the condyle is situated on the eminentia articularis, and any sudden violence, or even a sudden muscular spasm, as during a convulsive yawn, may displace the condyle forwards into the zygomatic fossa. The displacement may be unilateral or bilateral. Reduction is accomplished by depressing the jaw with the thumbs placed on the last molar teeth, and at the same time elevating the chin. The downward pressure overcomes the spasm of the Masseter, Temporal and Internal pterygoid, and elevation of the chin throws the condyle backwards; the above-mentioned muscles then draw the condyle back into its normal position.

In close relation to the condyle of the mandible are the external auditory meatus and the tympanum; any force, therefore, applied to the bone is liable to be attended with damage to these parts, or inflammation in the joint may extend to the ear; or on the other hand inflammation of the middle ear may involve the articulation and cause its destruction, thus leading to ankylosis of the joint. The joint is also occasionally the seat of osteo-arthritis, leading to great suffering during efforts of mastication. A peculiar affection sometimes attacks the neck and condyle of the mandible, consisting in hypertrophy and elongation of these parts and consequent protrusion of the chin to the opposite side.

V. ARTICULATIONS OF THE RIBS WITH THE VERTEBRÆ (ARTICULATIONES COSTOVERTEBRALES)

The articulations of the ribs with the vertebral column may be divided into two sets: 1, those which connect the heads of the ribs with the bodies

FIG. 435.—Costo-central and costo-transverse articulations. Anterior view.

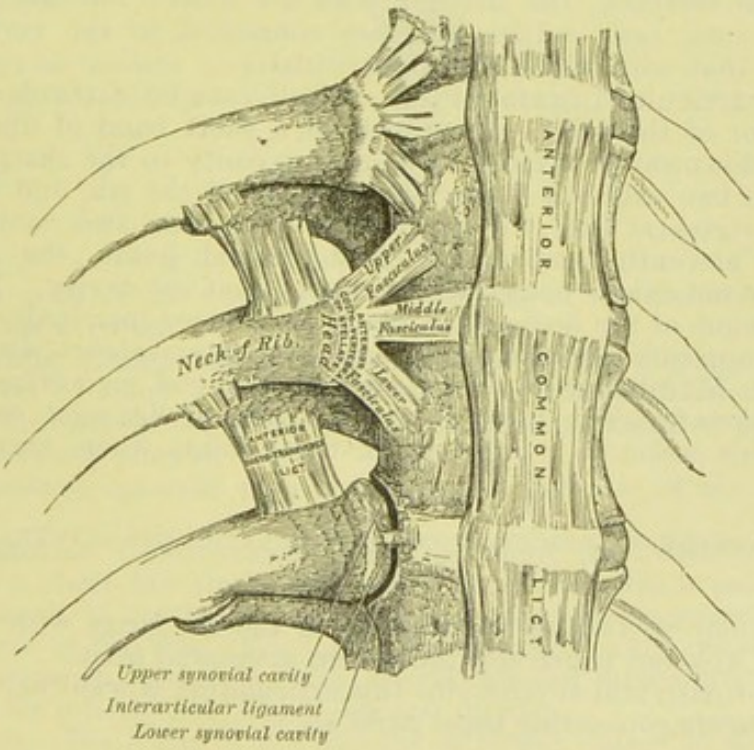

of the vertebræ (*costo-central*); 2, those which connect the necks and tubercles of the ribs with the transverse processes (*costo-transverse*).

1. Costo-central Articulations (Articulationes Capitulorum) (fig. 435)

These constitute a series of gliding or arthrodial joints, and are formed by the articulation of the heads of the ribs with the facets on the contiguous margins of the bodies of the thoracic vertebræ and with the intervertebral discs between them; in the case of the first, tenth, eleventh, and twelfth ribs the cavity is formed by a single vertebra. The ligaments of the joints are:

Capsular. Anterior Costo-vertebral or Stellate.
Interarticular.

The **Capsular Ligament** (capsula articularis) surrounds and encloses the joint, being composed of short, strong fibres, which pass between the head of the rib and the circumference of the articular cavity formed by the intervertebral disc and the adjacent vertebræ. It is most distinct at the upper and lower parts of the articulation; some of its upper fibres pass through the intervertebral foramen to the back of the intervertebral disc, while its posterior fibres are continuous with the middle costo-transverse ligament.

The **Anterior Costo-vertebral** or **Stellate Ligament** (lig. capituli costæ radiatum) is a specialised part of the capsule, and connects the anterior part of the head of each rib with the sides of the bodies of two vertebræ, and the intervertebral disc between them. It consists of three flat bundles of ligamentous fibres, which are attached to the anterior part of the head of the rib, just beyond the articular surface. The superior bundle passes upwards to be connected with the body of the vertebra above; the inferior one descends to the body of the vertebra below; and the middle one, the smallest and least distinct, passes horizontally inwards, to be attached to the intervertebral disc. The ligament is in relation, in front, with the thoracic ganglia of the sympathetic, the pleura, and, on the right side, with the vena azygos major; behind, with the interarticular ligament and synovial membranes.

In the first costo-central joint, where the rib articulates with a single vertebra, this ligament does not present a distinct division into three fasciculi; its fibres, however, radiate, and are attached to the body of the last cervical vertebra, as well as to the body of the first thoracic. In the costo-central articulations of the tenth, eleventh, and twelfth ribs, each of which articulates with a single vertebra, the division does not exist; but the fibres of the ligament in each case radiate and are connected to the vertebra above, as well as to that with which the rib articulates.

The **Interarticular Ligament** (lig. capituli costæ interarticulare) is situated in the interior of the joint. It consists of a short band of fibres, flattened from above downwards, attached by one extremity to the sharp crest which separates the two articular facets on the head of the rib, and by the other to the intervertebral disc; it divides the joint into two cavities. In the first, tenth, eleventh, and twelfth costo-central joints, the interarticular ligament does not exist; consequently, there is but one cavity. This ligament is the homologue of the *ligamentum conjugale* of some mammals, which unites the heads of opposite ribs across the back of the intervertebral disc.

Synovial Membranes.—There are two synovial membranes in each of the articulations in which there is an interarticular ligament, one above and one below this structure: only one in those joints where there is a single cavity.

2. Costo-transverse Articulations (Articulationes Costotransversariæ) (fig. 436)

The articular portion of the tubercle of the rib forms with the articular facet on the adjacent transverse process an arthrodial joint.

In the eleventh and twelfth ribs this articulation is wanting.

The ligaments connecting these parts are:

Capsular. Middle Costo-transverse (Interosseous).
Anterior Costo-transverse. Posterior Costo-transverse.

The **Capsular Ligament** (capsula articularis) is a thin, membranous

sac attached to the circumferences of the articular surfaces, and lined by a synovial membrane.

The **Anterior** or **Superior Costo-transverse Ligament** (lig. costotransversarium anterius) consists of two sets of fibres: one (anterior) is attached below to the sharp crest on the upper border of the neck of the rib, and passes obliquely upwards and outwards to the lower border of the transverse process immediately above; the other (posterior) is attached below to the neck of the rib, and passes upwards and inwards to the base of the transverse process and outer border of the inferior articular process of the vertebra above. This ligament is in relation, in front, with the intercostal vessels and nerves; behind, with the Longissimus dorsi. Its *internal border* is thickened and free, and bounds an aperture which transmits the posterior branches of the intercostal vessels and nerves. Its *external border* is continuous with a thin aponeurosis, which covers the External intercostal muscle.

The first rib has no anterior costo-transverse ligament; a band of fibres (*lig. lumbocostale*) in series with the anterior costo-transverse ligaments

Fig. 436.—Costo-transverse articulation. Seen from above.

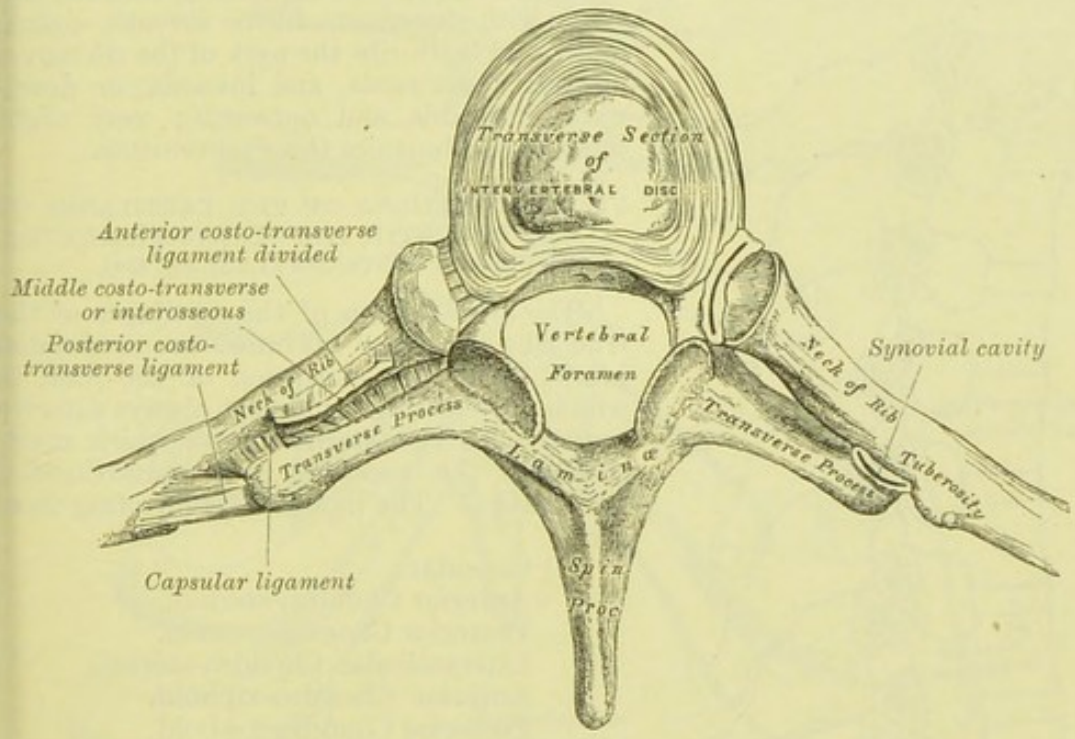

connects the neck of the twelfth rib to the base of the transverse process of the first lumbar vertebra.

The **Middle Costo-transverse** or **Interosseous Ligament** (lig. colli costæ) consists of short but strong fibres, which pass between the rough surface on the back of the neck of the rib and the anterior surface of the adjacent transverse process.

A rudimentary ligament may be present in the case of the eleventh and twelfth ribs.

The **Posterior Costo-transverse Ligament** (lig. costotransversarium posterius) is a short but thick and strong fasciculus, which passes obliquely from the summit of the transverse process to the rough non-articular portion of the tubercle of the rib. The ligaments attached to the upper ribs ascend from the transverse processes; they are shorter and more oblique than those attached to the inferior ribs, which descend slightly.

Movements.—The heads of the ribs are so closely connected to the bodies of the vertebræ by the stellate and interarticular ligaments that only slight gliding movements of the articular surfaces on one another can take place. Similarly, the strong costo-transverse ligaments binding the necks and tuberosities of the

ribs to the transverse processes limit the movements of the costo-transverse joints to slight gliding, the nature of which is determined by the shape and direction of the articular surfaces (fig. 437). In the upper six ribs the articular surfaces on the tuberosities are oval in shape and convex from above downwards; they fit into corresponding concavities on the *anterior surfaces* of the transverse processes, so that upward and downward movements of the tuberosity are associated with rotation of the rib neck on its long axis. In the seventh, eighth, ninth, and tenth ribs the articular surfaces on the tuberosities are flat, and are directed obliquely downwards, inwards, and backwards. The surfaces with which they articulate are placed on the *upper margins* of the transverse processes; when, therefore, the tuberosities are drawn up they are at the same time carried backwards and inwards. The two joints, costo-central and costo-transverse, move simultaneously and in the same directions, the total effect being that the neck of the rib moves as if on a single joint, of which the costo-central and costo-transverse articulations form the extremities. In the upper six ribs the neck of the rib moves but slightly upwards and downwards; its chief movement is one of rotation round its own long axis, rotation backwards being associated with depression, rotation forwards with elevation. In the seventh, eighth, ninth, and tenth ribs the neck of the rib moves upwards, backwards, and inwards, or downwards forwards and outwards; very slight rotation accompanies these movements.

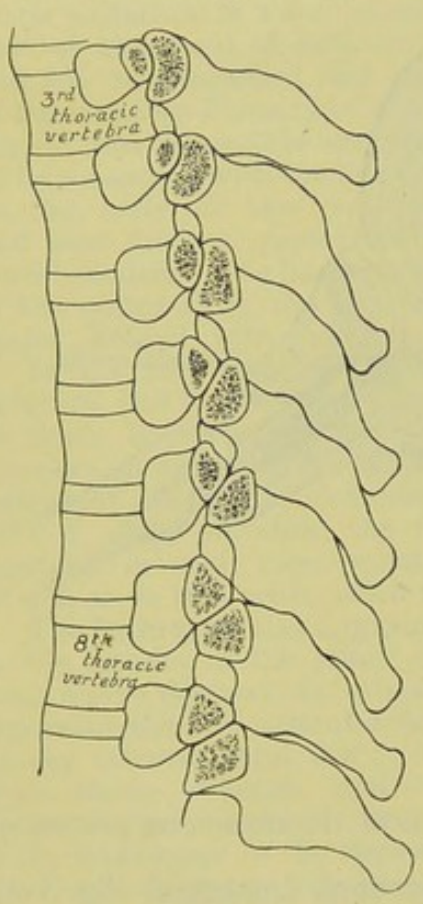

FIG. 437.—Section of the costo-transverse joints from the third to the ninth inclusive. Contrast the concave facets on the upper with the flattened facets on the lower transverse processes.

VI. ARTICULATIONS OF THE CARTILAGES OF THE RIBS WITH THE STERNUM (ARTICULATIONES STERNOCOSTALES) (fig. 438).

The articulations of the cartilages of the true ribs with the sternum are arthrodial joints, with the exception of the first, in which the cartilage is almost always directly united with the sternum, and which must, therefore, be regarded as a synarthrodial articulation. The ligaments connecting them are:

Capsular.
Anterior Chondro-sternal.
Posterior Chondro-sternal.
Interarticular Chondro-sternal.
Anterior Chondro-xiphoid.
Posterior Chondro-xiphoid.

The **Capsular Ligaments** (capsulæ articulares) surround the joints formed between the cartilages of the true ribs and the sternum. They are very thin, intimately blended with the anterior and posterior ligaments, and strengthened at the upper and lower parts of the articulations by a few fibres, which pass from the cartilages to the side of the sternum.

The **Anterior Chondro-sternal Ligaments** (ligg. sternocostalia radiata) are accessory parts of the capsular ligaments, and consist of broad and thin membranous bands that radiate from the front of the inner extremities of the cartilages of the true ribs to the anterior surface of the sternum. They are composed of fasciculi which pass in different directions. The *superior fasciculi* ascend obliquely, the *inferior* pass obliquely downwards, and the *middle fasciculi* horizontally. The superficial fibres are the longest; they intermingle with the fibres of the ligaments above and below them, with those of the opposite side, and with the tendinous fibres of origin of the Pectoralis major, forming a thick fibrous membrane (membrana sterni) which covers the front of the sternum. This is more distinct at the lower than at the upper part.

The **Posterior Chondro-sternal Ligaments** are also parts of the capsular ligaments, but are less thick and distinct than the anterior; they are composed of fibres which radiate from the posterior surfaces of the sternal ends of the cartilages of the true ribs to the posterior surface of the sternum, becoming blended with the periosteum.

The **Interarticular Chondro-sternal Ligaments** (ligg. sternocostalia interarticularia).—These are found constantly only between the second costal

Fig. 438.—Sterno-costal and interchondral articulations. Anterior view.

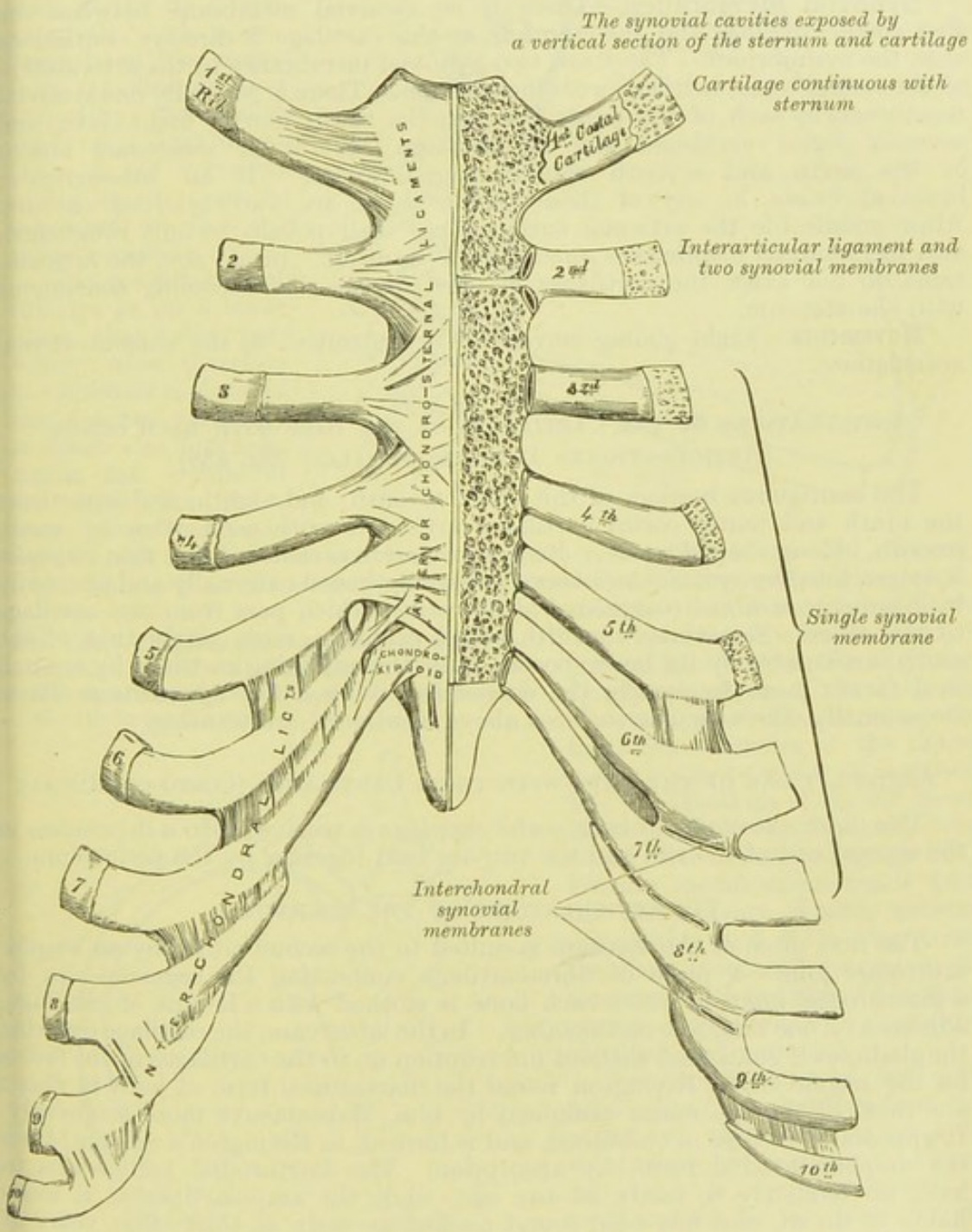

cartilages and the sternum. The cartilage of the *second rib* is connected with the sternum by means of an interarticular ligament, attached by one extremity to the cartilage of the rib, and by the other to the fibro-cartilage which unites the first and second pieces of the sternum. This articulation is provided with two synovial membranes. Occasionally the cartilage of the *third rib* is connected with the sternum by means of an interarticular ligament which is attached by one extremity to the cartilage of the rib, and by

the other to the point of junction of the second and third pieces of the sternum. Still more rarely similar ligaments are found in the other four joints of the series. In the lower two the ligament sometimes completely obliterates the cavity, so as to convert the articulation into an amphiarthrosis.

The **Anterior Chondro-xiphoid** (lig. costoxiphoideum anterius).—This is a band of fibres which connects the anterior surface of the seventh costal cartilage, and occasionally also that of the sixth, to the anterior surface of the ensiform process. It varies in length and breadth in different subjects.

The **Posterior Chondro-xiphoid** (lig. costoxiphoideum posterius) is a similar though less distinct band on the posterior surface.

Synovial Membranes.—There is no synovial membrane between the first costal cartilage and the sternum, as this cartilage is directly continuous with the manubrium. There are two synovial membranes in the articulation of the second costal cartilage with the sternum. There is generally one synovial membrane in each of the joints between the third, fourth, fifth, sixth, and seventh costal cartilages and the sternum; but it is sometimes absent in the sixth and seventh chondro-sternal joints. If an interarticular ligament exists in any of these joints, there are two synovial cavities. After middle life the articular surfaces lose their polish, become roughened, and the synovial membranes appear to be wanting. In old age, the articulations do not exist, the cartilages of most of the ribs becoming continuous with the sternum.

Movements.—Slight gliding movements are permitted in the chondro-sternal articulations.

Articulations of the Cartilages of the Ribs with each other (Articulationes Interchondrales) (fig. 438)

The contiguous borders of the sixth, seventh, and eighth, and sometimes the ninth and tenth, costal cartilages articulate with each other by small, smooth, oblong-shaped facets. Each articulation is enclosed in a thin *capsular ligament*, lined by *synovial membrane* and strengthened externally and internally by ligamentous fibres (*interchondral ligaments*) which pass from one cartilage to the other. Sometimes the fifth costal cartilage, more rarely that of the ninth, articulates by its lower border with the adjoining cartilage by a small oval facet; more frequently the connection is by a few ligamentous fibres. Occasionally, the articular surfaces above mentioned are wanting.

Articulations of the Ribs with their Cartilages (Costo-chondral)

The outer extremity of each costal cartilage is received into a depression in the sternal end of the rib, and the two are held together by the periosteum.

VII. Articulations of the Sternum

The first piece of the sternum is united to the second either by an amphiarthrodial joint—a piece of fibro-cartilage connecting the segments—or by a diarthrodial joint, in which each bone is clothed with a lamina of cartilage, adherent on one side, free on the other. In the latter case, the cartilage covering the gladiolus is continued without interruption on to the cartilages of the facets for the second ribs. Rivington found the diarthrodial form of joint in about one-third of the specimens examined by him, Maisonneuve more frequently. It appears to be rare in childhood, and is formed, in Rivington's opinion, from the amphiarthrodial form, by absorption. The diarthrodial joint seems to have no tendency to ossify at any age, while the amphiarthrodial is more liable to do so, and has been found ossified as early as thirty-four years of age. The two segments are further connected by anterior and posterior intersternal ligaments.

The **Anterior Intersternal Ligament** consists of longitudinal fibres, which blend with those of the anterior chondro-sternal ligaments and with the tendinous fibres of origin of the Pectoralis major. This ligament is rough, irregular, and much thicker below than above.

The **Posterior Intersternal Ligament** is disposed in a somewhat similar manner on the posterior surface of the articulation.

Mechanism of the Thorax

Each rib possesses its own range and variety of movements, but the movements of all are combined in the respiratory excursions of the thorax. Each rib may be regarded as a lever the fulcrum of which is situated immediately outside the costo-transverse articulation, so that when the shaft of the rib is elevated the neck is depressed and *vice versa*; from the disproportion in length of the arms of the lever a slight movement at the vertebral end of the rib is greatly magnified at the anterior extremity.

Fig. 439.—Lateral view of first and seventh ribs in position, showing the movements of the sternum and ribs in, A, ordinary expiration; B, quiet inspiration; C, forced inspiration.

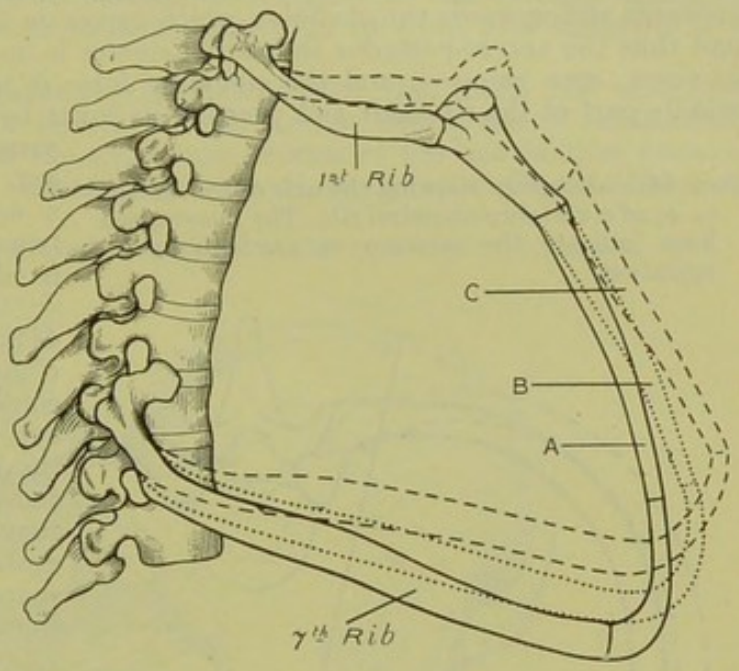

The anterior ends of the ribs lie on a lower plane than the posterior; when therefore the rib-shaft is elevated the anterior extremity is thrust also forwards. Again, the middle of the shaft lies in a plane below that passing through the two extremities, so that when the shaft is elevated relatively to its ends it is at the same time carried outwards from the median plane of the thorax. Further, each rib forms the segment of a curve which is greater than that of the rib immediately above, and therefore the elevation of a rib increases the transverse diameter of the thorax in the plane to which it is raised. The modifications of the rib movements at their vertebral ends have already been described (page 387). Further modifications result from the attachments of their anterior extremities, and it is convenient therefore to consider separately the movements of the ribs of the three groups—vertebro-sternal, vertebro-chondral, and vertebral.

Fig. 440.—Diagram showing the axes of movement (A B and C D) of a vertebro-sternal rib. The interrupted lines indicate the position of the rib in inspiration.

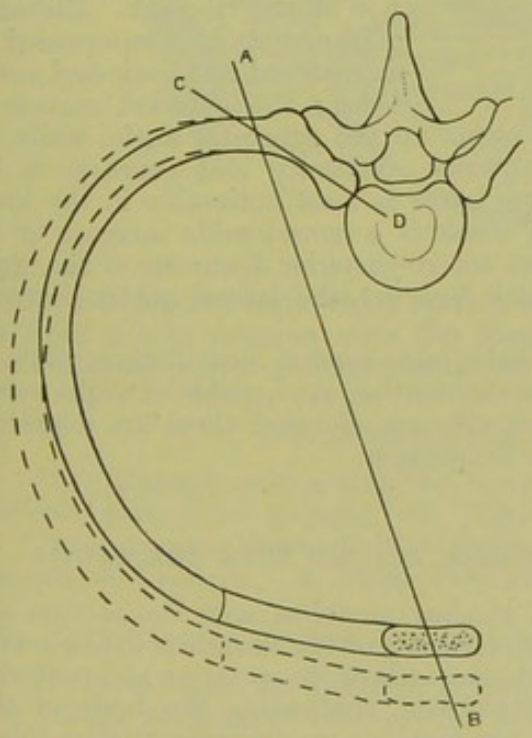

Vertebro-sternal ribs (figs. 439, 440).—The first rib differs from the others of this group in that its attachment to the sternum is a rigid one; this is counterbalanced to some extent by the fact that its head possesses no interarticular ligament, and is therefore more movable. The first pair of ribs with the manubrium sterni move as a single piece, the anterior portion being elevated by rotatory movements at the vertebral extremities. In normal quiet respiration the movement of this arc is practically *nil*; when it does occur the anterior part is raised and carried

forwards, increasing the antero-posterior and transverse diameters of this region of the chest. The movement of the second rib is also slight in normal respiration, as its anterior extremity is fixed to the manubrium, and prevented therefore from moving upwards. The chondro-sternal articulation, however, allows the middle of the shaft to be drawn up, and in this way the transverse thoracic diameter is increased. Elevation of the third, fourth, fifth and sixth ribs raises and thrusts forwards their anterior extremities, the greater part of the movement being effected by the rotation of the rib-neck backwards. The thrust of the anterior extremities carries forwards and upwards the gladiolus, which moves on the manubrio-gladiolar joint, and thus the antero-posterior thoracic diameter is increased. This movement is, however, soon arrested, and the elevating force is then expended in raising the middle part of the rib-shaft and everting its lower border; at the same time the costo-chondral angle is opened out. By these latter movements a considerable increase in the transverse diameter of the thorax is effected.

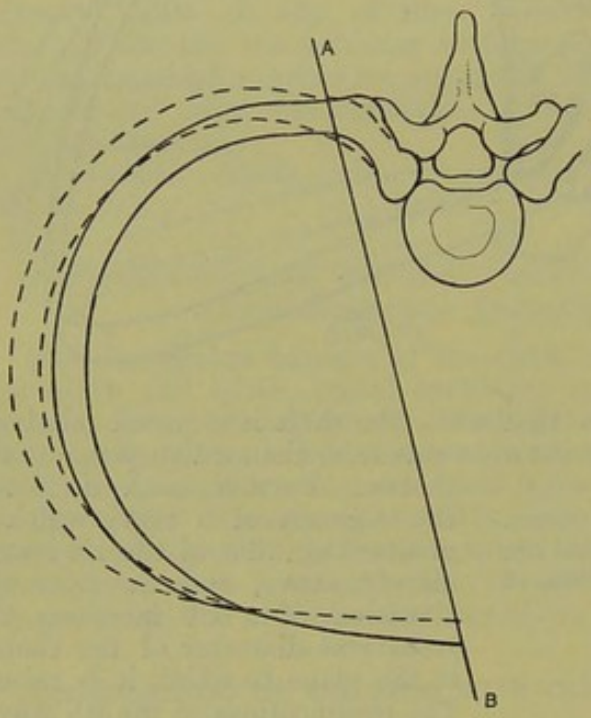

FIG. 441.—Diagram showing the axis of movement (A B) of a vertebro-chondral rib. The interrupted lines indicate the position of the rib in inspiration.

Vertebro-chondral ribs (fig. 441).—The seventh rib is included with this group, as it conforms more closely to their type. While the movements of these ribs assist in enlarging the thorax for respiratory purposes they are also concerned in increasing the upper abdominal space for viscera displaced by the action of the Diaphragm. The costal cartilages articulate with one another, so that each pushes up that above it, the final thrust being directed to pushing forwards and upwards the lower end of the gladiolus. The amount of elevation of the anterior extremities is limited on account of the very slight rotation of the rib-neck. Elevation of the shaft is accompanied by an outward and backward movement; the outward movement everts the anterior end of the rib and opens up the subcostal angle, while the backward movement pulls back the anterior extremity and counteracts the forward thrust due to its elevation; this latter is most noticeable in the lower ribs, which are the shortest. The total result is a considerable increase in the transverse and a diminution in the median antero-posterior diameters of the upper part of the abdomen; at the same time, however, the lateral antero-posterior diameters of the abdomen are increased.

Vertebral ribs.—These ribs, having only costo-central articulations with no interarticular ligaments and free anterior extremities, are capable of slight movements in all directions. When the other ribs are elevated these are depressed and fixed to form points of action for the Diaphragm.

VIII. ARTICULATION OF THE VERTEBRAL COLUMN WITH THE PELVIS

The ligaments connecting the last lumbar vertebra with the sacrum are similar to those which join the movable segments of the vertebral column with each other—viz.: 1. The continuation downwards of the anterior and posterior common ligaments. 2. The intervertebral disc, connecting the body of the last lumbar to that of the first sacral and forming an amphiarthrodial joint. 3. Ligamenta subflava, connecting the arch of the last lumbar vertebra with the posterior border of the sacral canal. 4. Capsular ligaments connecting

the articular processes and forming a double arthrodia. 5. Inter- and supra-spinous ligaments.

Two additional ligaments connect the pelvis with the vertebral column; these are the lumbo-sacral and the ilio-lumbar.

The **Lumbo-sacral Ligament** (fig. 442) is a short, thick, triangular fasciculus, which is connected above to the lower and front part of the transverse process of the last lumbar vertebra, passes obliquely outwards, and is attached below to the lateral surface of the base of the sacrum, becoming blended with the anterior sacro-iliac ligament. In front this ligament is in relation with the Psoas.

The **Ilio-lumbar Ligament** (lig. iliolumbale) (fig. 442), the thickened lower edge of the anterior lamella of the lumbar fascia, passes horizontally outwards from the apex of the transverse process of the last lumbar vertebra to the crest of the ilium immediately in front of the sacro-iliac articulation.

FIG. 442.—Articulations of pelvis and hip. Anterior view.

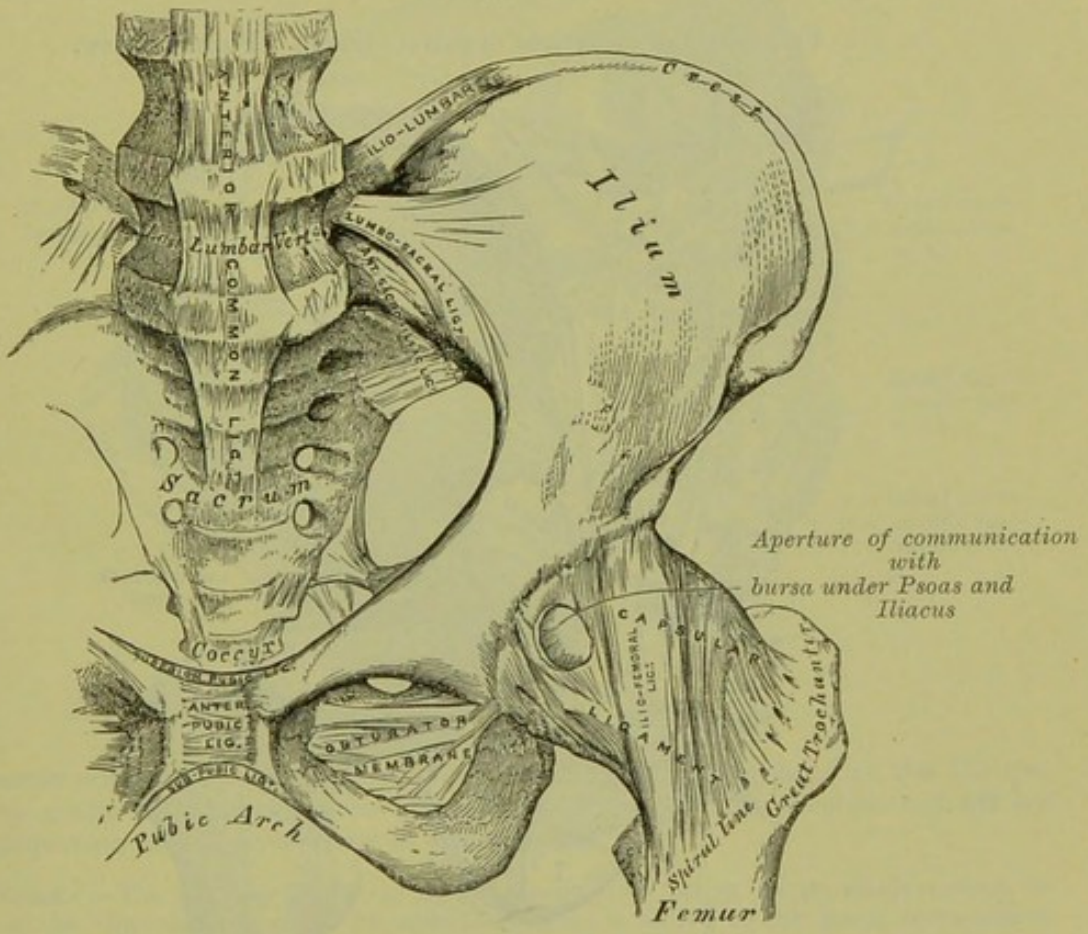

It is of a triangular form, thick and narrow internally, broad and thin externally. In front it is in relation with the Psoas; behind, with the muscles occupying the vertebral groove; above, with the Quadratus lumborum.

IX. ARTICULATIONS OF THE PELVIS

The ligaments connecting the bones of the pelvis with each other may be divided into four groups: 1. Those connecting the sacrum and ilium. 2. Those passing between the sacrum and ischium.. 3. Those uniting the sacrum and coccyx. 4. Those between the two pubic bones.

1. Articulation of the Sacrum and Ilium (Articulatio Sacroiliaca)

The sacro-iliac articulation is an amphiarthrodial joint, formed between the lateral surfaces of the sacrum and the ilium. The articular, ear-shaped surface of each bone is covered with a thin plate of cartilage, thicker on the sacrum than on the ilium. These cartilaginous plates are in close contact with each other, and to a certain extent are united together by irregular

patches of softer fibro-cartilage, and at their upper and posterior part by fine interosseous fibres. In a considerable part of their extent, especially in advanced life, they are not connected together, but are separated by a space containing a synovia-like fluid, and hence the joint presents the characters of a diarthrosis.

The ligaments connecting these surfaces are the anterior and posterior sacro-iliac.

The **Anterior Sacro-iliac Ligament** (lig. sacroiliacum anterius) (fig. 442) consists of numerous thin bands, which connect the anterior surfaces of the sacrum and ilium.

The **Posterior Sacro-iliac Ligament** (lig. sacroiliacum posterius) (fig. 443) is a strong ligament, situated in a deep depression between the sacrum and ilium behind, and forming the chief bond of connection between those bones. It consists of numerous strong fasciculi, which pass between the bones in various directions. The upper part of the ligament (lig. sacroiliacum posterius breve) is nearly horizontal in direction, and passes

Fig. 443.—Articulations of pelvis and hip. Posterior view.

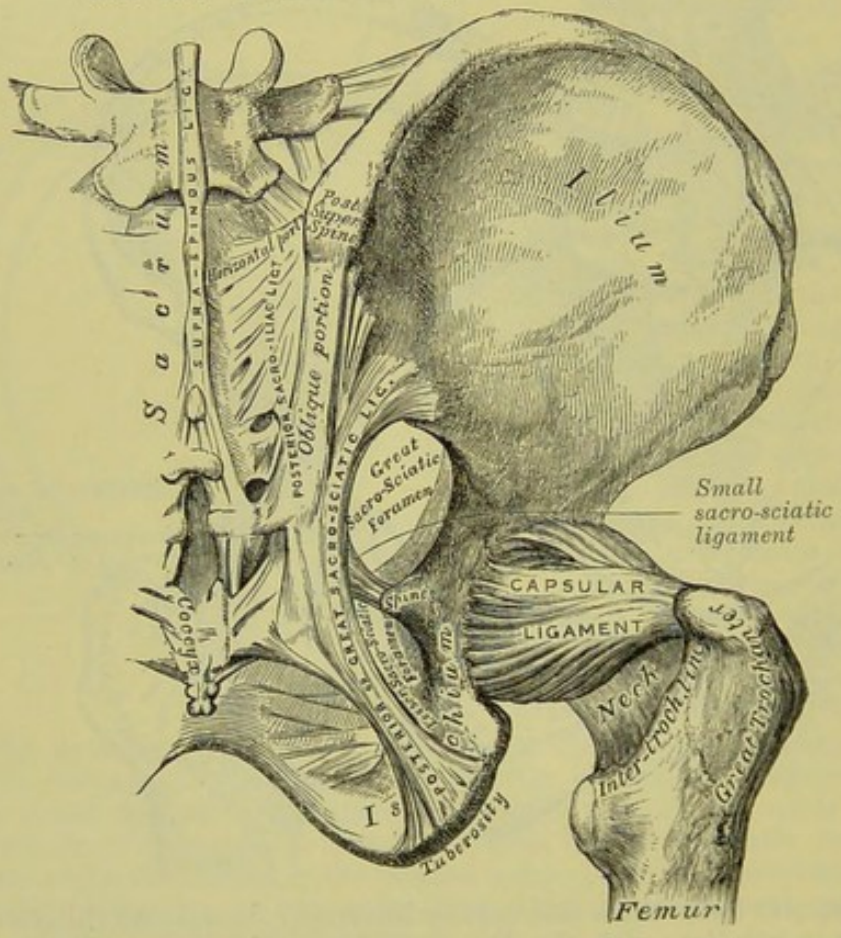

from the first and second transverse tubercles on the posterior surface of the sacrum to the rough, uneven surface at the posterior part of the inner surface of the ilium. The lower part (lig. sacroiliacum posterius longum), oblique in direction, is attached by one extremity to the third transverse tubercle on the posterior surface of the sacrum, and by the other to the posterior superior spine of the ilium; the lower part is sometimes called the *oblique sacro-iliac ligament.*

Surface Form.—The position of the sacro-iliac joint is indicated by the posterior superior spine of the ilium. This process is immediately behind the centre of the articulation.

2. Ligaments passing between the Sacrum and Ischium (fig. 444)

The Great Sacro-sciatic. The Small Sacro-sciatic.

The **Great or Posterior Sacro-sciatic Ligament** (lig. sacrotuberosum) is situated at the lower and back part of the pelvis. It is flat, and triangular in

form ; narrower in the middle than at the extremities ; attached by its broad base to the posterior inferior spine of the ilium, to the fourth and fifth transverse tubercles of the sacrum, and to the lower part of the lateral margin of that bone and the coccyx. Passing obliquely downwards, outwards, and forwards, it becomes narrow and thick, but at its insertion into the inner margin of the tuberosity of the ischium, it increases in breadth, and is prolonged forwards along the inner margin of the ramus, forming what is known as the *falciform ligament*, the free concave edge of which gives attachment to the obturator fascia. One of its surfaces is turned towards the perinæum, the other towards the Obturator internus. The lower border of the ligament

FIG. 444.—Side view of pelvis, showing the great and lesser sacro-sciatic ligaments.

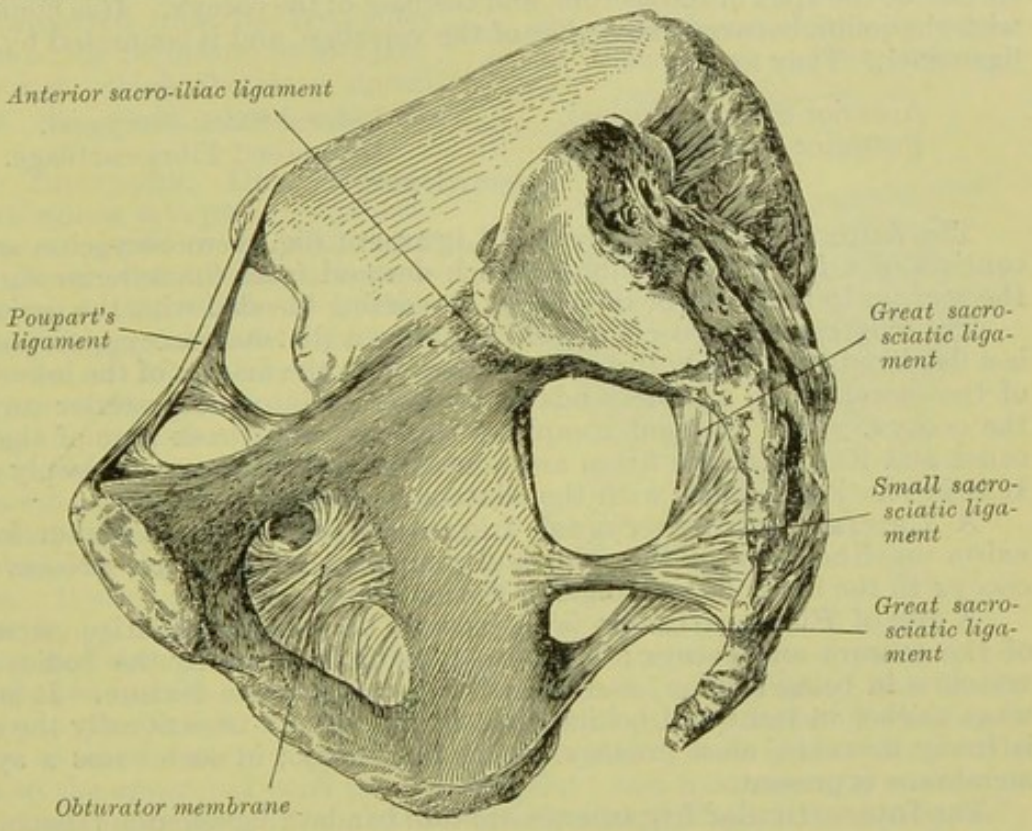

is directly continuous with the tendon of origin of the long head of the Biceps, and by many is believed to be the proximal end of this muscle, cut off by the projection of the tuberosity of the ischium.

Relations.—The *posterior surface* of this ligament gives origin, by its whole extent, to fibres of the Gluteus maximus. Its *anterior surface* is united to the lesser sacro-sciatic ligament. Its *external border* forms, above, the posterior boundary of the great sacro-sciatic foramen, and, below, the posterior boundary of the small sacro-sciatic foramen. Its *lower border* forms part of the boundary of the perinæum. It is pierced by the coccygeal branch of the sciatic artery, and coccygeal nerve.

The **Small** or **Anterior Sacro-sciatic Ligament** (lig. sacrospinosum), much shorter and smaller than the preceding, is thin, triangular in form, attached by its apex to the spine of the ischium, and internally, by its broad base, to the lateral margin of the sacrum and coccyx, in front of the attachment of the great sacro-sciatic ligament with which its fibres are intermingled.

Relations.—It is in relation *anteriorly*, with the Coccygeus to which it is closely connected ; *posteriorly*, it is covered by the great sacro-sciatic ligament, and crossed by the internal pudic vessels and nerve. Its *superior border* forms the lower boundary of the great sacro-sciatic foramen ; its *inferior border*, part of the margin of the small sacro-sciatic foramen.

These two ligaments convert the sacro-sciatic notches into foramina. The *superior* or *great* sacro-sciatic foramen (foramen ischiadicum majus) is bounded, in front and above, by the posterior border of the os innominatum ; behind, by the great sacro-

sciatic ligament; and below, by the small sacro-sciatic ligament. It is partially filled up, in the recent state, by the Pyriformis which passes through it. Above this muscle, the gluteal vessels and superior gluteal nerve emerge from the pelvis; and below it, the sciatic vessels and nerves, the internal pudic vessels and nerve, the inferior gluteal nerve, and the nerves to the Obturator internus and Quadratus femoris make their exit from the pelvis. The *inferior* or *small* sacro-sciatic foramen (foramen ischiadicum minus) is bounded, in front, by the tuber ischii; above, by the spine of the ischium and small sacro-sciatic ligament; behind, by the great sacro-sciatic ligament. It transmits the tendon of the Obturator internus, its nerve, and the internal pudic vessels and nerve.

3. Articulation of the Sacrum and Coccyx

This articulation is an amphiarthrodial joint, formed between the oval surface at the apex of the sacrum, and the base of the coccyx. It is homologous with the joints between the bodies of the vertebræ, and is connected by similar ligaments. They are:

Anterior Sacro-coccygeal.	Lateral Sacro-coccygeal.
Posterior Sacro-coccygeal.	Interposed Fibro-cartilage.

Interarticular.

The **Anterior Sacro-coccygeal Ligament** (lig. sacrococcygeum anterius) consists of a few irregular fibres, which descend from the anterior surface of the sacrum to the front of the coccyx, becoming blended with the periosteum.

The **Posterior Sacro-coccygeal Ligament** (lig. sacrococcygeum posterius) is a flat band, of a pearly tint, which arises from the margin of the lower orifice of the sacral canal, and descends to be inserted into the posterior surface of the coccyx. This ligament completes the lower and back part of the sacral canal and its superficial fibres are much longer than the more deeply seated. It is in relation, behind, with the Gluteus maximus.

A **Lateral Sacro-coccygeal Ligament** (lig. sacrococcygeum laterale) exists on either side of the joint and connects the transverse process of the coccyx to the lower lateral angle of the sacrum.

A disc of **Fibro-cartilage** is interposed between the contiguous surfaces of the sacrum and coccyx; it differs from those between the bodies of the vertebræ in being thinner, and its central part firmer in texture. It is somewhat thicker in front and behind than at the sides. Occasionally the coccyx is freely movable, most notably during pregnancy; in such cases a synovial membrane is present.

The **Interarticular Ligaments** are thin bands of ligamentous tissue, which unite the cornua of the two bones.

The different segments of the coccyx are connected together by the extension downwards of the anterior and posterior sacro-coccygeal ligaments, thin annular discs of fibro-cartilage being interposed between the segments. In the adult male, all the pieces become ossified together at a comparatively early period; but in the female, this does not commonly occur until a later period of life. At a more advanced age the joint between the sacrum and coccyx is obliterated.

Movements.—The movements which take place between the sacrum and coccyx, and between the different pieces of the latter bone, are forwards and backwards; they are very limited. Their extent increases during pregnancy.

4. Articulation of the Pubic Bones (Symphysis Pubis)

The articulation between the pubic bones is an amphiarthrodial joint, formed between the two oval articular surfaces of the pubic bones. The ligaments of this articulation are:

Anterior Pubic.	Superior Pubic.
Posterior Pubic.	Subpubic.

Interpubic Disc.

The **Anterior Pubic Ligament** (lig. pubicum anterius) (fig. 442) consists of several superimposed layers, which pass across the front of the articulation. The superficial fibres pass obliquely from one bone to the other, decussating

and forming an interlacement with the fibres of the aponeurosis of the External oblique and the inner tendons of origin of the Recti. The deep fibres pass transversely across the symphysis, and are blended with the fibro-cartilage.

The **Posterior Pubic Ligament** (lig. pubicum posterius) consists of a few thin, scattered fibres, which unite the two pubic bones posteriorly.

The **Superior Pubic Ligament** (lig. pubicum superius) is a band of fibres, which connects together the two pubic bones superiorly.

The **Subpubic Ligament** (lig. pubicum inferius) is a thick, triangular arch of ligamentous fibres, connecting together the two pubic bones below, and forming the upper boundary of the pubic arch. Above, it is blended with the interarticular fibro-cartilage; laterally, it is attached to the descending rami of the pubic bones; below, it is free, and is separated from the triangular ligament of the perinæum by an opening through which the deep dorsal vein of the penis passes into the pelvis.

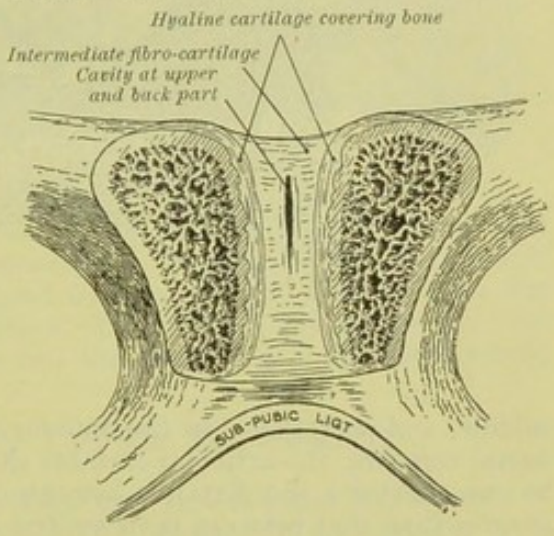

Fig. 445.—Coronal section of the symphysis pubis. Made near its posterior surface.

The **Interpubic Disc** (lamina fibrocartilaginea interpubica) connects the opposed surfaces of the pubic bones. Each of the bony surfaces is covered by a thin layer of hyaline cartilage firmly connected to the bone by a series of nipple-like processes which accurately fit within corresponding depressions on the osseous surfaces. These opposed cartilaginous surfaces are connected together by an intermediate lamina of fibro-cartilage which varies in thickness in different subjects. It often contains a cavity in its interior, probably formed by the softening and absorption of the fibro-cartilage, since it rarely appears before the tenth year of life and is not lined by synovial membrane. This cavity is larger in the female than in the male, but it is very doubtful whether it enlarges, as was formerly supposed, during pregnancy. It is most frequently limited to the upper and back part of the joint; but it occasionally reaches to the front, and may extend the entire length of the cartilage. It may be easily demonstrated by making a coronal section of the symphysis pubis near its posterior surface (fig. 445).

The **Obturator Membrane** (membrana obturatoria) is more properly regarded as analogous to the muscular fasciæ, with which it will be described (page 575).

Mechanism of the Pelvis

The pelvic girdle supports and protects the contained viscera and affords surfaces for the attachments of the trunk and lower limb muscles. Its most important mechanical function, however, is to transmit the weight of the trunk and upper limbs to the lower extremities.

It may be divided into two arches by a vertical plane passing through the acetabular cavities; the posterior of these arches is the one chiefly concerned in the function of transmitting the weight. Its essential parts are the upper three sacral vertebræ and two strong pillars of bone running from the sacro-iliac articulations to the acetabular cavities. For the reception and diffusion of the weight the acetabular cavity is strengthened by two additional bars running towards the pubis and ischium. In order to lessen concussion in rapid changes of distribution of the weight, joints (sacro-iliac articulations) are interposed between the sacrum and the iliac bones; an accessory joint (symphysis pubis) exists in the middle of the anterior arch. The sacrum forms the summit of the posterior arch; the weight transmitted falls on it at the lumbo-sacral articulation and, theoretically, has a component in each of two directions. One component of the force is expended in driving the sacrum downwards and backwards between the iliac bones,

while the other thrusts the upper end of the sacrum downwards and forwards towards the pelvic cavity.

The movements of the sacrum are regulated by its form. Viewed as a whole, it presents the shape of a wedge with its base upwards and forwards. The first component of the force is therefore acting against the resistance of the wedge, and its tendency to separate the iliac bones is resisted by the sacro-iliac and ilio-lumbar ligaments and by the ligaments of the symphysis pubis.

If a series of coronal sections of the sacro-iliac joints be made, it will be found possible to divide the articular portion of the sacrum into three segments : anterior,

Fig. 446.—Coronal section of anterior sacral segment.

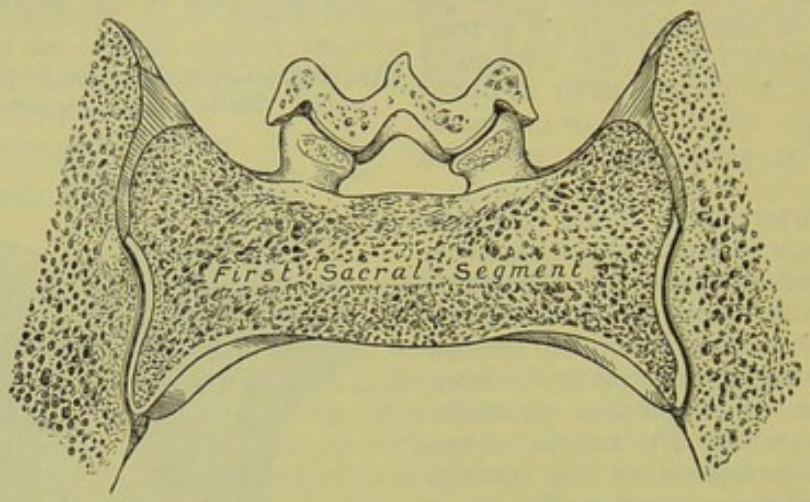

middle, and posterior. In the *anterior segment* (fig. 446), which involves the first sacral vertebra, the articular surfaces show slight sinuosities and are almost parallel to one another ; the distance between their dorsal margins is, however, slightly greater than that between their ventral margins. This segment therefore presents a slight wedge shape with the truncated apex downwards. The *middle segment* (fig. 447) is a narrow band across the centres of the articulations. Its dorsal width is distinctly greater than its ventral, so that the segment is more definitely wedge-shaped, the truncated apex being again directed downwards. Each

Fig. 447.—Coronal section of middle sacral segment.

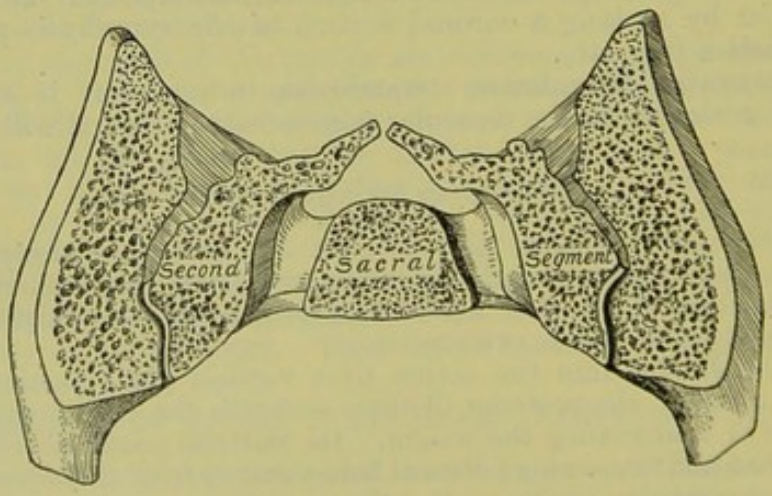

articular surface presents in the centre a marked concavity from above downwards, and into this a corresponding convexity of the iliac articular surface fits, forming an interlocking mechanism. In the *posterior segment* (fig. 448) the ventral width is greater than the dorsal, so that the wedge form is the reverse of those of the other segments—i.e. the truncated apex is directed upwards. The articular surfaces are only slightly concave.

Dislocation downwards and forwards of the sacrum by the second component of the force applied to it is prevented therefore by the middle segment, which

interposes the resistance of its wedge shape and that of the interlocking mechanism on its surfaces; a rotatory movement, however, is produced by which the anterior segment is tilted downwards and the posterior upwards; the axis of this rotation passes through the dorsal part of the middle segment. The movement of the anterior segment is slightly limited by its wedge form, but chiefly by the posterior sacro-iliac ligaments; that of the posterior segment is checked to a slight extent by its wedge form, but the chief limiting factors are the great and small sacro-sciatic ligaments. In all these movements the effect of the sacro-iliac and ilio-lumbar ligaments and the ligaments of the symphysis pubis in resisting the separation of the iliac bones must be recognised.

FIG. 448.—Coronal section of posterior sacral segment.

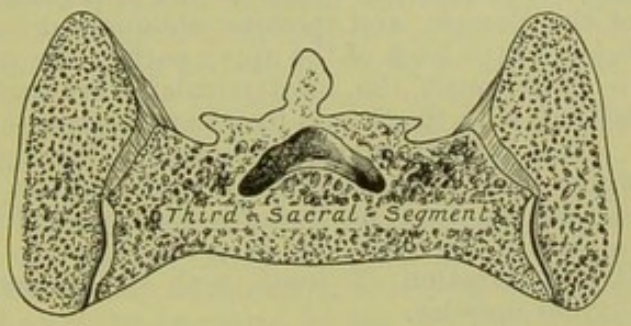

During pregnancy the pelvic joints and ligaments are relaxed, and capable therefore of more extensive movements. When the fœtus is being expelled the force is applied to the front of the sacrum. Upward dislocation is again prevented by the interlocking mechanism of the middle segment. As the fœtal head passes the anterior segment the latter is carried upwards, enlarging the antero-posterior diameter of the pelvic inlet; when the head reaches the posterior segment this also is pressed upwards against the resistance of its wedge, the movement only being possible by the laxity of the joints and the stretching of the sacro-sciatic ligaments.

ARTICULATIONS OF THE UPPER EXTREMITY

The articulations of the Upper Extremity may be arranged as follows:

I. Sterno-clavicular.
II. Acromio-clavicular.
III. Shoulder.
IV. Elbow.
V. Radio-ulnar.
VI. Wrist.
VII. Carpal.
VIII. Carpo-metacarpal.
IX. Intermetacarpal.
X. Metacarpo-phalangeal.
XI. Interphalangeal.

I. STERNO-CLAVICULAR ARTICULATION (ARTICULATIO STERNOCLAVICULARIS)

The sterno-clavicular articulation (fig. 449) is regarded by most anatomists as an arthrodial joint; but Cruveilhier considers it to be an articulation by reciprocal reception. Probably the former opinion is correct, the variety of movements which the joint enjoys being due to the interposition of an inter-articular fibro-cartilage between the joint surfaces. The parts entering into its formation are the sternal end of the clavicle, the upper and lateral part of the manubrium sterni, and the cartilage of the first rib. The articular surface of the clavicle is much larger than that of the sternum, and is invested with a layer of cartilage,* which is considerably thicker than that on the latter bone. The ligaments of this joint are:

Capsular.
Anterior Sterno-clavicular.
Posterior Sterno-clavicular.
Interclavicular.
Costo-clavicular (rhomboid).
Interarticular fibro-cartilage.

The **Capsular Ligament** (capsula articularis) completely surrounds the articulation and consists of fibres of varying degrees of thickness and strength. Those in front and behind are of considerable thickness, and form the anterior and posterior sterno-clavicular ligaments; but those above, and especially those below, are thin and scanty, and partake more of the character of areolar than of true fibrous tissue.

* According to Bruch, the sternal end of the clavicle is covered by a tissue which is fibrous rather than cartilaginous in structure.

The **Anterior Sterno-clavicular Ligament** (lig. sternoclaviculare ant.) is a broad band of fibres, which covers the anterior surface of the articulation; it is attached above to the upper and front part of the inner extremity of the clavicle, and, passing obliquely downwards and inwards, is attached below to the front of the upper part of the manubrium sterni. This ligament is covered by the sternal portion of the Sterno-cleido-mastoid and the integument; behind, it is in relation with the capsule, the interarticular fibro-cartilage and the two synovial membranes.

The **Posterior Sterno-clavicular Ligament** (lig. sternoclaviculare post.) is a similar band of fibres, which covers the posterior surface of the articulation; it is attached above to the upper and back part of the inner extremity of the clavicle, and, passing obliquely downwards and inwards, is attached below to the back of the upper part of the manubrium sterni. It is in relation, in front, with the interarticular fibro-cartilage and synovial membranes; behind, with the Sterno-hyoid and Sterno-thyroid.

The **Interclavicular Ligament** (lig. interclaviculare) is a flattened band, which varies considerably in form and size in different individuals; it passes in a curved direction from the upper part of the inner extremity of one clavicle to that of the other, and is also attached to the upper margin of the sternum. It is in relation, in front, with the integument; behind, with the Sterno-thyroid muscles.

Fig. 449.—Sterno-clavicular articulation. Anterior view.

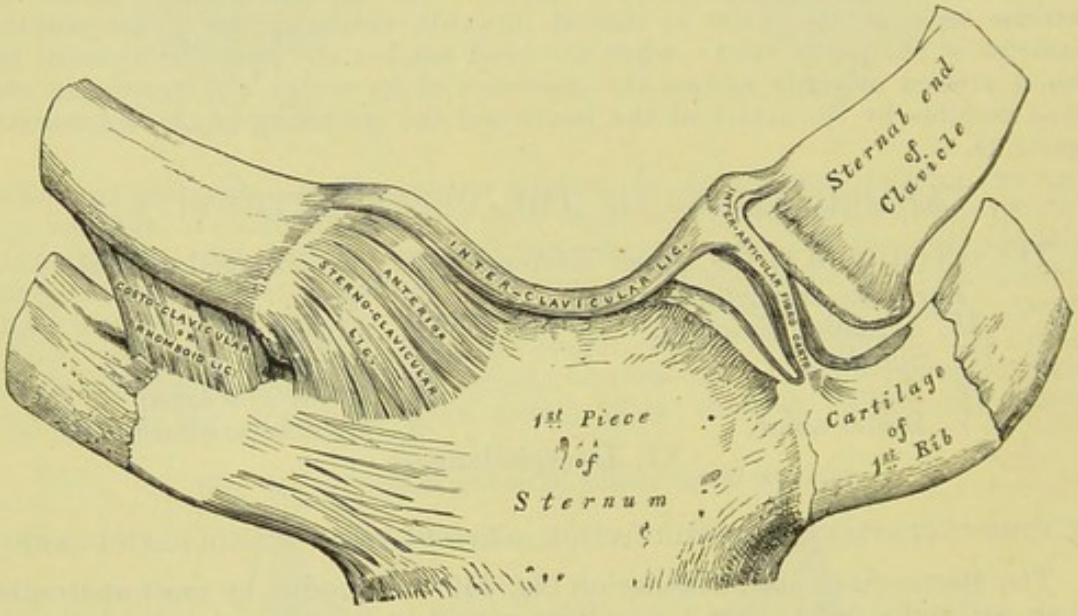

The **Costo-clavicular** or **Rhomboid Ligament** (lig. costoclaviculare) is short, flat, strong, and rhomboid in form. Attached below to the upper and inner part of the cartilage of the first rib, it ascends obliquely backwards and outwards, and is attached above to the rhomboid depression on the under surface of the clavicle. It is in relation, in front, with the tendon of origin of the Subclavius; behind, with the subclavian vein.

The **Interarticular Fibro-cartilage** (discus articularis) is a flat and nearly circular disc, interposed between the articulating surfaces of the sternum and clavicle. It is attached, above, to the upper and posterior border of the articular surface of the clavicle; below, to the cartilage of the first rib, near its junction with the sternum; and by its circumference to the inter-clavicular and anterior and posterior sterno-clavicular ligaments. It is thicker at the circumference, especially its upper and back part, than at its centre. It divides the joint into two cavities, each of which is furnished with a synovial membrane.

Of the two **Synovial Membranes** found in this articulation, the outer is reflected from the sternal end of the clavicle, over the adjacent surface of the fibro-cartilage, and over the cartilage of the first rib; the inner is attached to the margin of the articular surface of the sternum and clothes the adjacent surface of the fibro-cartilage; the latter is the larger of the two.

Movements.—This articulation is the centre of the movements of the shoulder, and admits of a limited amount of motion in nearly every direction—upwards, downwards, backwards, forwards, as well as circumduction. When these movements take place in the joint, the clavicle in its motion carries the scapula with it, this bone gliding on the outer surface of the chest. This joint therefore forms the centre from which all movements of the supporting arch of the shoulder originate, and is the only point of articulation of this part of the skeleton with the trunk. 'The movements attendant on elevation and depression of the shoulder take place between the clavicle and the interarticular fibro-cartilage, the bone rotating upon the ligament on an axis drawn from before backwards through its own articular facet. When the shoulder is moved forwards and backwards, the clavicle, with the interarticular fibro-cartilage, rolls to and fro on the articular surface of the sternum, revolving, with a sliding movement, round an axis drawn nearly vertically through the sternum. In the circumduction of the shoulder, which is compounded of these two movements, the clavicle revolves upon the interarticular fibro-cartilage, and the latter, with the clavicle, rolls upon the sternum.' * Elevation of the shoulder is limited principally by the costo-clavicular ligament; depression, by the interclavicular ligament and interarticular fibro-cartilage. The muscles which *raise* the clavicle, as in shrugging the shoulders, are the upper fibres of the Trapezius, the Levator anguli scapulæ, and the clavicular head of the Sterno-mastoid, assisted to a certain extent by the two Rhomboids, which pull the vertebral border of the scapula backwards and upwards and so raise the clavicle. The *depression* of the clavicle is principally effected by gravity assisted by the Subclavius, Pectoralis minor, and lower fibres of the Trapezius. It is drawn *backwards* by the Rhomboids and the middle and lower fibres of the Trapezius, and *forwards* by the Serratus magnus and Pectoralis minor.

Surface Form.—The sterno-clavicular joint is subcutaneous and its position may be easily ascertained by feeling the enlarged sternal end of the clavicle just external to the long, cord-like, sternal origin of the Sterno-mastoid. If this muscle be relaxed by bending the head forwards, a depression just internal to the end of the clavicle, and between it and the sternum, can be felt, indicating the exact position of the joint.

Applied Anatomy.—The strength of this joint mainly depends upon its ligaments, and it is owing to this, and to the fact that the force of the blow is usually transmitted along the long axis of the clavicle, that dislocation rarely occurs, and that the bone is broken rather than displaced. When dislocation does occur, the course which the displaced bone takes depends more upon the direction in which the violence is applied than upon the anatomical construction of the joint; it may be either forwards, backwards, or upwards. Should it be displaced backwards it may cause pressure on the trachea. The chief point worthy of note, as regards the construction of the joint, in connection with dislocation, is the fact that, owing to the shape of the articular surfaces, and the strength of the joint mainly depending upon the ligaments, the displacement when reduced is very liable to recur, and hence it is extremely difficult to keep the end of the bone in its proper place.

II. ACROMIO-CLAVICULAR ARTICULATION (ARTICULATIO ACROMIO-CLAVICULARIS)

The acromio-clavicular articulation (fig. 450) is an arthrodial joint between the outer extremity of the clavicle and the inner margin of the acromion process of the scapula. Its ligaments are:

Capsular.	Interarticular Fibro-cartilage.
Superior Acromio-clavicular.	Coraco-clavicular { Trapezoid and Conoid.
Inferior Acromio-clavicular.	

The **Capsular Ligament** (capsula articularis) completely surrounds the articular margins, and is specially strong above and below, where it forms the superior and inferior acromio-clavicular ligaments. It consists of fibres arranged parallel to each other and passing between the adjacent borders of the two bones.

The **Superior Acromio-clavicular Ligament** (lig. acromioclaviculare sup.) is a quadrilateral band, which covers the superior part of the articulation, extending between the upper part of the outer end of the clavicle and the adjoining part of the upper surface of the acromion. It is composed of parallel fibres,

* Humphry, *On the Human Skeleton*, page 402.

which interlace with the aponeuroses of the Trapezius and Deltoid; below, it is in contact with the interarticular fibro-cartilage when this is present.

The **Inferior Acromio-clavicular Ligament** (lig. acromioclaviculare inf.) is somewhat thinner than the preceding; it covers the under part of the articulation, and is attached to the adjoining surfaces of the two bones. It is in relation, above, in rare cases with the interarticular fibro-cartilage; below, with the tendon of the Supraspinatus.

The **Interarticular Fibro-cartilage** (discus articularis) is frequently absent in this articulation. When it exists, it generally only partially separates the articular surfaces, and occupies the upper part of the articulation. More rarely, it completely separates the joint into two cavities.

The **Synovial Membrane.**—There is usually only one synovial membrane in this articulation, but when a complete interarticular fibro-cartilage exists, there are two.

Fig. 450.—The left shoulder-joint, acromio-clavicular articulation, and proper ligaments of scapula.

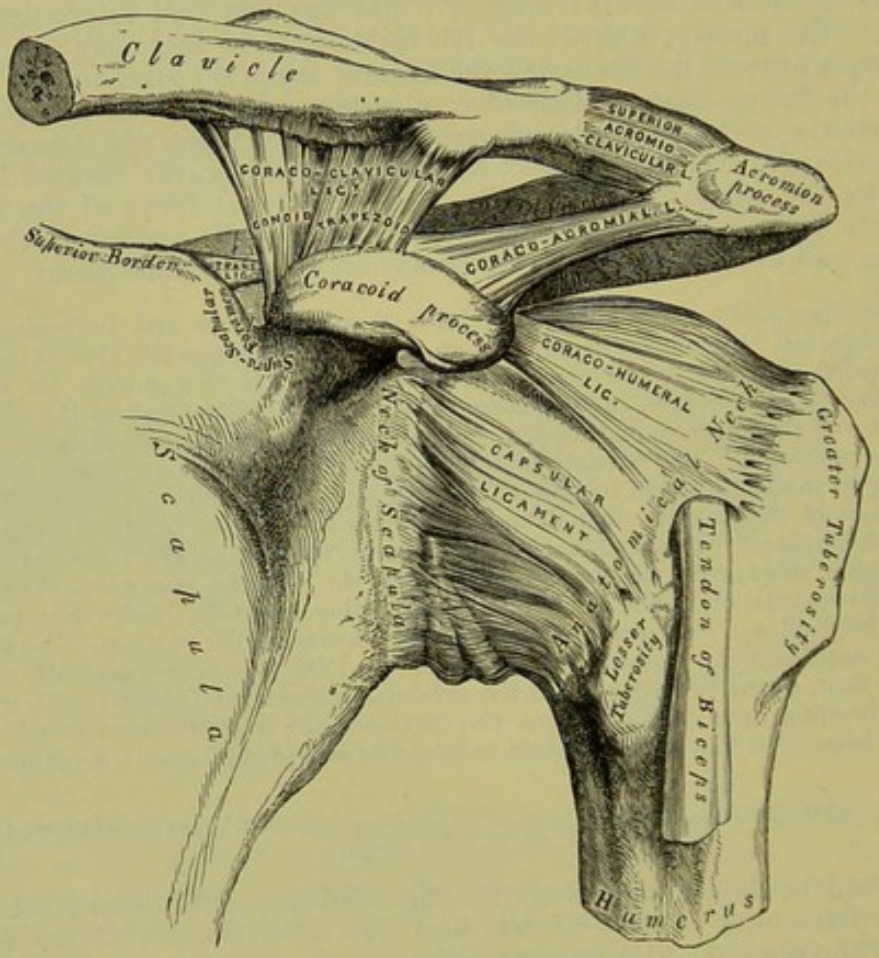

The **Coraco-clavicular Ligament** (lig. coracoclaviculare) (fig. 450) serves to connect the clavicle with the coracoid process of the scapula. It does not properly belong to this articulation, but as it forms a most efficient means of retaining the clavicle in contact with the acromial process, it is usually described with it. It consists of two fasciculi, called the *trapezoid* and *conoid ligaments.*

The *Trapezoid Ligament* (lig. trapezoideum), the anterior and external fasciculus, is broad, thin, and quadrilateral: it is placed obliquely between the coracoid process and the clavicle. It is attached, below, to the upper surface of the coracoid process; above, to the oblique line on the under surface of the clavicle. Its anterior border is free; its posterior border is joined with the conoid ligament, the two forming, by their junction, an angle projecting backwards.

The *Conoid Ligament* (lig. conoideum), the posterior and internal fasciculus, is a dense band of fibres, conical in form, with its base directed upwards. It is

attached by its apex to a rough impression at the base of the coracoid process, internal to the preceding; above, by its expanded base, to the conoid tubercle on the under surface of the clavicle, and to a line proceeding internally from it for half an inch. These ligaments are in relation, in front, with the Subclavius and Deltoid; behind, with the Trapezius.

Movements.—The movements of this articulation are of two kinds: 1. A gliding motion of the articular end of the clavicle on the acromion. 2. Rotation of the scapula forwards and backwards upon the clavicle; the extent of this rotation is limited by the two portions of the coraco-clavicular ligament, the trapezoid limiting rotation forwards and the conoid backwards.

The acromio-clavicular joint has important functions in the movements of the upper extremity. It has been well pointed out by Humphry, that if there had been no joint between the clavicle and scapula, the circular movement of the scapula on the ribs (as in throwing the shoulders backwards or forwards) would have been attended with a greater alteration in the direction of the shoulder than is consistent with the free use of the arm in such positions, and it would have been impossible to give a blow straight forwards with the full force of the arm; that is to say, with the combined force of the scapula, arm, and forearm. 'This joint,' as he happily says, 'is so adjusted as to enable either bone to turn in a hinge-like manner upon a vertical axis drawn through the other, and it permits the surfaces of the scapula, like the baskets in a roundabout swing, to look the same way in every position, or nearly so.' Again, when the whole arch formed by the clavicle and scapula rises and falls (in elevation or depression of the shoulders), the joint between these two bones enables the scapula still to maintain its lower part in contact with the ribs.

Surface Form.—The position of the acromio-clavicular joint can generally be ascertained by defining the slightly enlarged extremity of the outer end of the clavicle, which projects above the level of the acromion process of the scapula. Sometimes this enlargement is so considerable as to form a rounded eminence, which is easily felt. The joint lies in the plane of a vertical line passing up the middle of the front of the arm.

Applied Anatomy.—The acromio-clavicular joint owes its security mainly to the coraco-clavicular ligament, which limits the amount of movement of the outer end of the clavicle either upwards, backwards, or forwards. Owing to the slanting shape of the articular surfaces of this joint, dislocation generally occurs upwards: that is to say, the outer end of the clavicle is displaced above the acromion process of the scapula. The displacement is often incomplete, on account of the strong coraco-clavicular ligaments, which remain untorn. The same difficulty exists, as in the sterno-clavicular dislocation, in maintaining the ends of the bone in position after reduction.

LIGAMENTS OF THE SCAPULA

The ligaments of the scapula (fig. 450) are:

Coraco-acromial, Transverse, and Spino-glenoid.

The **Coraco-acromial Ligament** (lig. coracoacromiale) is a strong triangular band, extending between the coracoid and acromion processes. It is attached, by its apex, to the summit of the acromion just in front of the articular surface for the clavicle; and by its broad base to the whole length of the outer border of the coracoid process. Its posterior fibres are directed inwards, its anterior fibres forwards and inwards. This ligament, together with the coracoid and acromion processes, forms a vault for the protection of the head of the humerus. It is in relation, above, with the clavicle and under surface of the Deltoid; below, with the tendon of the Supraspinatus muscle, a bursa being interposed. Its outer border is continuous with a dense lamina that passes beneath the Deltoid upon the tendons of the Supra- and Infra-spinatus muscles. The ligament is sometimes described as consisting of two marginal bands and a thinner intervening portion, the two bands being attached respectively to the apex and base of the coracoid process, and joining together at their attachment into the acromion process. When the Pectoralis minor is inserted, as occasionally is the case, into the capsule of the shoulder-joint instead of into the coracoid process, it passes between these two bands, and the intervening portion is then deficient.

The **Transverse** or **Suprascapular Ligament** (lig. transversum scapulæ superius) converts the suprascapular notch into a foramen. It is a thin and

flat fasciculus, narrower at the middle than at the extremities, attached by one end to the base of the coracoid process, and by the other to the inner extremity of the scapular notch. The suprascapular nerve passes through the foramen; the suprascapular vessels pass over the ligament. The ligament is sometimes ossified.

The **Spino-glenoid Ligament** (lig. transversum scapulæ inferius) consists of a band of fibres, situated on the posterior surface of the neck of the scapula and stretching from the outer border of the spine to the margin of the glenoid cavity. It forms an arch under which the suprascapular vessels and nerve pass as they enter the infraspinous fossa.

III. SHOULDER-JOINT (ARTICULATIO HUMERI)

The shoulder-joint (fig. 450) is an enarthrodial or ball-and-socket joint. The bones entering into its formation are the large hemispherical head of the humerus and the shallow glenoid cavity of the scapula, an arrangement which permits of very considerable movement, while the joint itself is protected against displacement by the tendons which surround it. The ligaments do not maintain the joint surfaces in apposition, because when they alone remain the humerus can be separated to a considerable extent from the glenoid cavity; their use, therefore, is to limit the amount of movement. The joint is protected above by an arch, formed by the coracoid and acromion processes, and the coraco-acromial ligament. The articular surfaces are covered by cartilage: that on the head of the humerus is thicker at the centre than at the circumference, the reverse being the case in the glenoid cavity. The ligaments of the shoulder are:

Capsular.	Gleno-humeral.
Coraco-humeral.	Transverse Humeral.
Glenoid.*	

The **Capsular Ligament** (capsula articularis) completely encircles the articulation, being attached, above, to the circumference of the glenoid cavity beyond the glenoid ligament; below, to the anatomical neck of the humerus, approaching nearer to the articular cartilage above than in the rest of its extent. It is thicker above and below than elsewhere, and is remarkably loose and lax, and much larger and longer than is necessary to keep the bones in contact, allowing them to be separated from each other more than an inch, an evident provision for that extreme freedom of movement which is peculiar to this articulation. It is strengthened, above, by the Supraspinatus; below, by the long head of the Triceps; behind, by the tendons of the Infraspinatus and Teres minor; and in front, by the tendon of the Subscapularis. The capsular ligament usually presents three openings. One anteriorly, below the coracoid process, establishes a communication between the joint and a bursa beneath the tendon of the Subscapularis muscle. The second, which is not constant, is at the posterior part, where a communication sometimes exists between the joint and a bursal sac under the tendon of the Infraspinatus muscle. The third is seen between the tuberosities of the humerus, for the passage of the long tendon of the Biceps.

The **Coraco-humeral Ligament** (lig. coracohumerale) is a broad band which strengthens the upper part of the capsular ligament. It arises from the outer border of the coracoid process, and passes obliquely downwards and outwards to the front of the great tuberosity of the humerus, being blended with the tendon of the Supraspinatus. This ligament is intimately united to the capsular ligament by its hinder and lower border; but its superior and anterior border presents a free edge, which overlaps the capsular ligament.

Gleno-humeral Ligaments.—In addition to the coraco-humeral ligament, three supplemental bands, which are named the *gleno-humeral ligaments*, strengthen the capsular ligament. These may be best seen by opening the capsule at the back of the joint and removing the head of the humerus. One

* The long tendon of origin of the Biceps also acts as one of the ligaments of this joint. See the observations on page 372, on the function of the muscles passing over more than one joint.

of them is situated on the inner side of the joint, and passes from the inner edge of the glenoid cavity to the lower part of the lesser tuberosity of the humerus. A second is situated at the lower part of the joint, and passes from the under edge of the glenoid cavity to the under part of the anatomical neck of the humerus. A third is situated at the upper part of the joint, and is fixed above to the apex of the glenoid cavity close to the root of the coracoid process, and passing downwards along the inner edge of the tendon of the Biceps, is attached below to a small depression above the lesser tuberosity of the humerus. In addition to these, the capsule is strengthened externally on its anterior aspect by two bands derived from the tendons of the Pectoralis major and Teres major respectively.

The **Transverse Humeral Ligament** is a broad band of fibrous tissue passing from the lesser to the greater tuberosity of the humerus, and always limited to that portion of the bone which lies above the epiphysial line. It converts the bicipital groove into an osseo-aponeurotic canal, and is the homologue of the strong process of bone which connects the summits of the two tuberosities in the musk ox.

The **Glenoid Ligament** (labrum glenoidale) is a fibro-cartilaginous rim attached round the margin of the glenoid cavity. It is triangular on section,

FIG. 451.—Coronal sections through the shoulder-joint (A) with the arm hanging by the side; (B) with the arm abducted at right angles. (After Henle.)

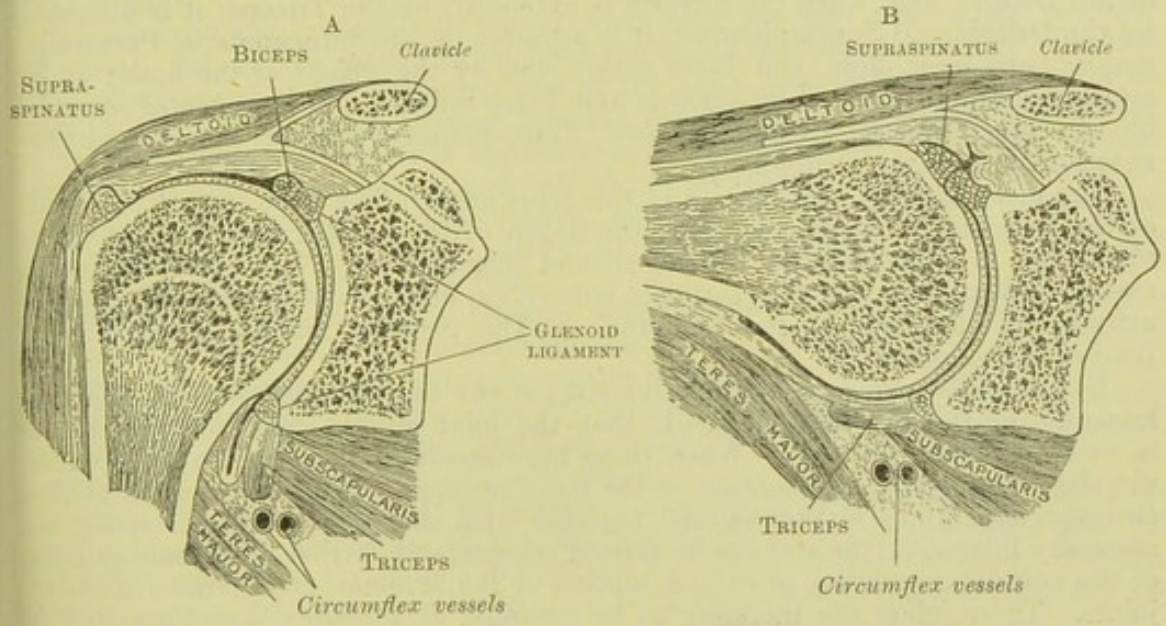

the thickest portion being fixed to the circumference of the cavity, the free edge being thin and sharp. It is continuous above with the long tendon of the Biceps, which gives off two fasciculi, to blend with the fibrous tissue of the ligament. This ligament deepens the cavity for articulation, and protects the edges of the bone.

The **Synovial Membrane** is reflected from the margin of the glenoid cavity over the glenoid ligament; it is then reflected over the internal surface of the capsular ligament, and covers the lower part and sides of the anatomical neck of the humerus as far as the cartilage covering the head of the bone. The long tendon of the Biceps which passes through the capsular ligament is enclosed in a tubular sheath of synovial membrane, which is reflected upon it at the point where it perforates the capsule, and is continued around it as far as the summit of the glenoid cavity. The tendon of the Biceps thus traverses the articulation, but it is not contained in the interior of the synovial cavity.

Bursæ.—The bursæ in the neighbourhood of the shoulder-joint are the following: (1) A constant bursa is situated between the tendon of the Subscapularis muscle and the capsule of the joint; it communicates with the synovial cavity through an opening in the front of the capsular ligament: (2) a bursa which occasionally communicates with the joint is sometimes found between the tendon

of the Infraspinatus and the capsule: (3) a large bursa exists between the under surface of the Deltoid and the capsule, but does not communicate with the joint; this bursa is prolonged under the acromion process and coraco-acromial ligament, and intervenes between these structures and the capsule of the joint: (4) a large bursa mucosa is situated on the summit of the acromion: (5) a bursa is frequently found between the coracoid process and the capsule of the joint: (6) there is a bursa beneath the Coraco-brachialis: (7) one lies between the Teres major and the long head of the Triceps: (8) one is placed in front of, and another behind, the tendon of the Latissimus dorsi.

The *Muscles* in relation with the joint are, above, the Supraspinatus; below, the long head of the Triceps; in front, the Subscapularis; behind, the Infraspinatus and Teres minor; within, the long tendon of the Biceps. The Deltoid is placed most externally, and covers the articulation on its outer side, as well as in front and behind.

The *Arteries* supplying the joint are articular branches of the anterior and posterior circumflex, and suprascapular.

The *Nerves* are derived from the circumflex and suprascapular.

Movements.—The shoulder-joint is capable of every variety of movement, flexion, extension, abduction, adduction, circumduction, and rotation. The humerus is *flexed* (drawn forwards) by the Pectoralis major, anterior fibres of the Deltoid, Coraco-brachialis, and when the forearm is flexed, by the Biceps; *extended* (drawn backwards) by the Latissimus dorsi, Teres major, posterior fibres of the Deltoid, and, when the forearm is extended, by the Triceps; it is *abducted* by the Deltoid and Supraspinatus; it is *adducted* by the Subscapularis, Pectoralis major, Latissimus dorsi, and Teres major, and by the weight of the limb; it is *rotated outwards* by the Infraspinatus and Teres minor; and it is *rotated inwards* by the Subscapularis, Latissimus dorsi, Teres major, Pectoralis major, and the anterior fibres of the Deltoid.

The most striking peculiarities in this joint are: 1. The large size of the head of the humerus in comparison with the depth of the glenoid cavity, even when this latter is supplemented by the glenoid ligament. 2. The looseness of the capsule of the joint. 3. The intimate connection of the capsule with the muscles attached to the head of the humerus. 4. The peculiar relation of the Biceps tendon to the joint.

It is in consequence of the relative sizes of the two articular surfaces, and the looseness of the capsular ligament, that the joint enjoys such free movement in every possible direction. When these movements of the arm are arrested in the shoulder-joint by the contact of the bony surfaces, and by the tension of the corresponding fibres of the capsule, together with that of the muscles acting as accessory ligaments, the arm can be carried considerably farther by the movements of the scapula, involving, of course, motion at the acromio- and sterno-clavicular joints. These joints are therefore to be regarded as accessory structures to the shoulder-joint (see pp. 401 to 403). The extent of these movements of the scapula is very considerable, especially in extreme elevation of the arm, which movement is best accomplished when the arm is thrown somewhat forwards and outwards, because the margin of the head of the humerus is by no means a true circle; its greatest diameter is from the bicipital groove, downwards, inwards, and backwards, and the greatest elevation of the arm can be obtained by rolling its articular surface in the direction of this measurement. The great width of the central portion of the humeral head also allows of very free horizontal movement when the arm is raised to a right angle, in which movement the arch formed by the acromion, the coracoid process, and the coraco-acromial ligament, constitutes a sort of supplemental articular cavity for the head of the bone.

The looseness of the capsule is so great that the arm will fall about an inch from the scapula when the muscles are dissected from the capsular ligament, and an opening made in it to counteract the atmospheric pressure. The movements of the joint, therefore, are not regulated by the capsule so much as by the surrounding muscles and by the pressure of the atmosphere, an arrangement which 'renders the movements of the joint much more easy than they would otherwise have been, and permits a swinging, pendulum-like vibration of the limb when the muscles are at rest' (Humphry). The fact, also, that in all ordinary positions of the joint the capsule is not put on the stretch, enables the arm to move freely in all directions. Extreme movements are checked by the tension of appropriate

portions of the capsule, as well as by the interlocking of the bones. Thus it is said that 'abduction is checked by the contact of the great tuberosity with the upper edge of the glenoid cavity; adduction by the tension of the coraco-humeral ligament' (Beaunis et Bouchard). Cleland * maintains that the limitations of movement at the shoulder-joint are due to the structure of the joint itself, the glenoid ligament fitting, in different positions of the elevated arm, into the anatomical neck of the humerus.

The scapula is capable of being moved upwards and downwards, forwards and backwards, or, by a combination of these movements, circumducted on the wall of the chest. The muscles which *raise* the scapula are the upper fibres of the Trapezius, the Levator anguli scapulæ, and the two Rhomboids; those which *depress* it are the lower fibres of the Trapezius, the Pectoralis minor, and, through the clavicle, the Subclavius. The scapula is drawn *backwards* by the Rhomboids and the middle and lower fibres of the Trapezius, and *forwards* by the Serratus magnus and Pectoralis minor, assisted, when the arm is fixed, by the Pectoralis major. The mobility of the scapula is very considerable, and greatly assists the movements of the arm at the shoulder-joint. Thus, in raising the arm from the side, the Deltoid and Supraspinatus can only lift it to a right angle with the trunk, the further elevation of the limb being effected by the Trapezius and Serratus magnus moving the scapula on the wall of the chest. This mobility is of special importance in ankylosis of the shoulder-joint, the movements of this bone compensating to a very great extent for the immobility of the joint.

Cathcart † has pointed out that in abducting the arm and raising it above the head, the scapula rotates throughout the whole movement with the exception of a short space at the beginning and at the end; that the humerus moves on the scapula not only while passing from the hanging to the horizontal position but also in travelling upwards as it approaches the vertical above; that the clavicle moves not only during the second half of the movement but in the first as well, though to a less extent—i.e. the scapula and clavicle are concerned in the first stage as well as in the second; and that the humerus is partly involved in the second as well as chiefly in the first.

The intimate union of the tendons of the Supraspinatus, Infraspinatus, Teres minor and Subscapularis muscles with the capsule, converts these muscles into elastic and spontaneously acting ligaments of the joint. It is regarded as being also intended to prevent the folds into which all portions of the capsule would alternately fall in the varying positions of the joint from being driven between the bones by the pressure of the atmosphere.

The peculiar relations of the Biceps tendon to the shoulder-joint appear to subserve various purposes. In the first place, by its connection with both the shoulder and elbow the muscle harmonises the action of the two joints, and acts as an elastic ligament in all positions, in the manner previously discussed (see page 372). Next, it strengthens the upper part of the articular cavity, and prevents the head of the humerus from being pressed up against the acromion process, when the Deltoid contracts; it thus fixes the head of the humerus as the centre of motion in the glenoid cavity. By its passage along the bicipital groove it assists in rendering the head of the humerus steady in the various movements of the arm. When the arm is raised from the side it assists the Supra- and Infra-spinatus in rotating the head of the humerus in the glenoid cavity. It also holds the head of the bone firmly in contact with the glenoid cavity, and prevents its slipping over its lower edge, or being displaced by the action of the Latissimus dorsi and Pectoralis major, as in climbing and many other movements.

Surface Form.—The direction and position of the shoulder-joint may be indicated by a line drawn from the middle of the coraco-acromial ligament, in a curved direction, with its convexity inwards, to the innermost part of that portion of the head of the humerus which can be felt in the axilla when the arm is forcibly abducted from the side. When the arm hangs by the side, not more than one-third of the head of the bone is in contact with the glenoid cavity, and three-quarters of its circumference is in front of a vertical line drawn from the anterior border of the acromion process.

Applied Anatomy.—Owing to the construction of the shoulder-joint and the freedom of movement which it enjoys, as well as in consequence of its exposed situation, it is more

* *Journ. of Anat. and Phys.* No. 1, 1867, p. 85.

† *Ibid.* vol. xviii. 1884

frequently dislocated than any other joint in the body. Dislocation occurs when the arm is abducted, and when, therefore, the head of the humerus presses against the lower and front part of the capsule, which is the thinnest and least supported part of the ligament. The rent in the capsule almost invariably takes place in this situation, and through it the head of the bone escapes, so that the dislocation in most instances is primarily *subglenoid*. The head of the bone does not usually remain in this situation, between the tendons of the Subscapularis and the Triceps, but generally assumes some other position, which varies according to the direction and amount of force producing the dislocation and the relative strength of the muscles in front of and behind the joint. As the muscles at the back are stronger than those in front, and especially since the long head of the Triceps prevents the bone from passing backwards, dislocation forwards is much more common than backwards. The most frequent position which the head of the humerus ultimately assumes is on the front of the neck of the scapula, beneath the coracoid process, and hence named subcoracoid.

FIG. 452.—Left elbow-joint, showing anterior and internal ligaments.

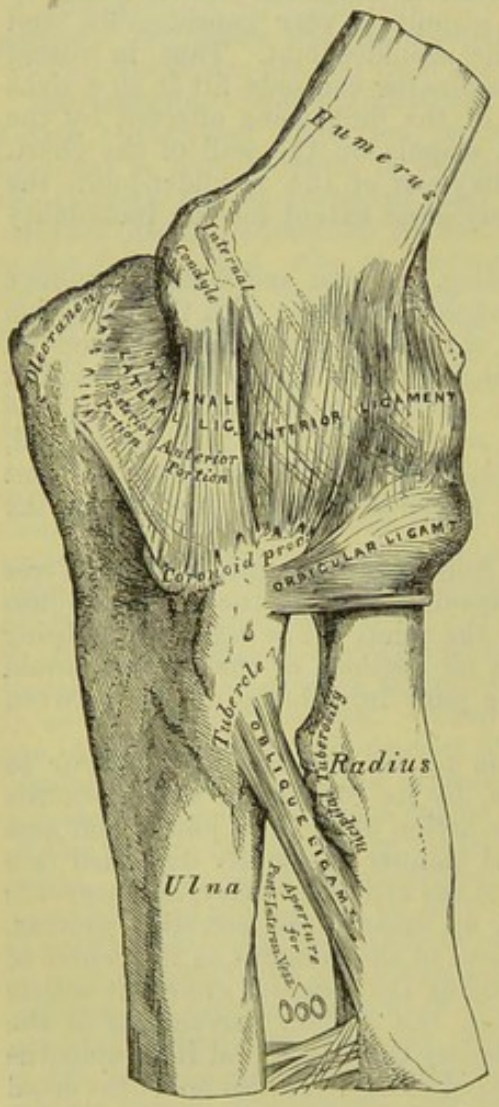

FIG. 453.—Left elbow-joint, showing posterior and external ligaments.

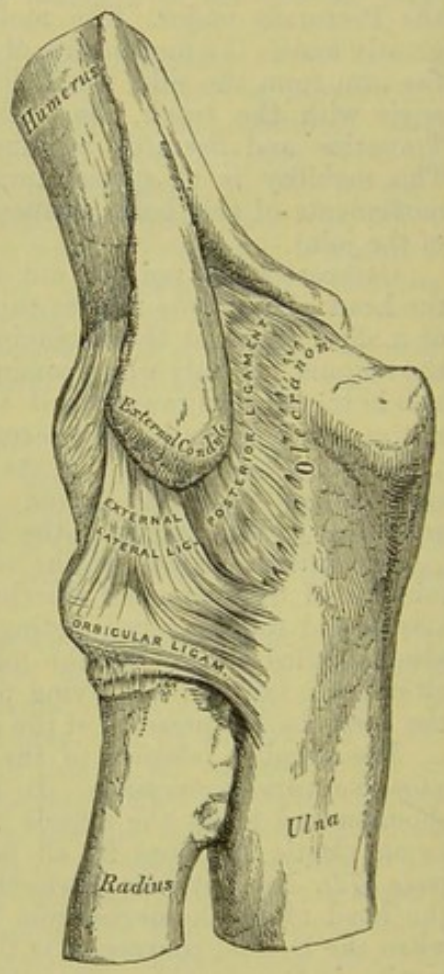

Occasionally, in consequence probably of a greater amount of force being brought to bear on the limb, the head is driven farther inwards, and rests on the upper part of the front of the chest, beneath the clavicle (subclavicular). Sometimes it remains in the position in which it was primarily displaced, resting on the axillary border of the scapula (subglenoid), and rarely it passes backwards and remains in the infraspinous fossa, beneath the spine (subspinous).

The shoulder-joint may be the seat of any of those inflammatory affections, either acute or chronic, which attack joints, though perhaps less frequently than some other articulations of equal size and importance. Acute synovitis may result from injury, rheumatism, or pyæmia, or may follow secondarily on acute epiphysitis in infants. It is attended with effusion into the joint, and when this occurs the capsule is evenly distended, and the contour of the joint rounded. Special projections may occur at the sites of the openings in the capsular ligament. Thus a swelling may appear just in front of the joint, internal to the lesser tuberosity, from effusion into the bursa beneath the Subscapularis ; or, again, a swelling which is sometimes bilobed may be seen in the interval between the Deltoid and Pectoralis major, from effusion into the diverticulum which runs down the bicipital groove with the tendon of the Biceps. The effusion into the synovial cavity can be best

ascertained by examination from the axilla, where a soft, elastic, fluctuating swelling can usually be felt. In cases of septic synovitis, where incision is required, the opening should be made in front, over the most prominent point of the swelling. After the pus has been evacuated a counter-opening should be made behind, so as to ensure efficient drainage.

Tuberculous arthritis not infrequently attacks the shoulder-joint, and may lead to total destruction of the articulation, when ankylosis may result, or long-protracted suppuration may necessitate excision. This joint is also one of those which is most liable to be the seat of osteo-arthritis, and may also be affected in gout and rheumatism ; or in locomotor ataxy, when it becomes the seat of Charcot's disease.

Ankylosis is occasionally met with in the shoulder-joint as the result of destructive changes. The ankylosis usually takes place with the arm in a dependent position, and any attempt to raise the arm is attended by a rotation of the scapula on the wall of the chest.

Excision of the shoulder-joint may be required in cases of arthritis (especially the tuberculous form) which have gone on to destruction of the articulation ; in compound dislocations and fractures, particularly those arising from gunshot injuries, in which there has been extensive injury to the head of the bone ; in some cases of old unreduced dislocation, where there is much pain ; and possibly in some few cases of growth connected with the upper end of the bone. The operation is best performed by making an incision from the middle of the coraco-acromial ligament down the arm for about three inches : this will expose the bicipital groove containing the tendon of the Biceps, which should be hooked out of the way. The capsule is freely opened, and the muscles attached to the greater and lesser tuberosities of the humerus are stripped off with the capsule, without dividing their attachments to the latter. The head of the bone can then be thrust out of the wound and sawn off ; or divided with a narrow saw *in situ* and subsequently removed. The section should be made, if possible, just below the articular surface, so as to leave the bone as long as possible. The glenoid cavity must then be examined, and gouged if carious.

IV. ELBOW-JOINT (ARTICULATIO CUBITI)

The elbow-joint (figs. 452, 453) is a ginglymus or hinge-joint. The trochlea of the humerus is received into the greater sigmoid cavity of the ulna, so as to admit of the movements peculiar to this joint, viz. flexion and extension ; while the capitellum of the humerus articulates with the cup-shaped depression on the head of the radius. The articular surfaces are each covered with a thin layer of cartilage, and connected together by a **Capsular Ligament** (capsula articularis), which is especially thickened on its two sides, and, to a less extent, in front and behind. These thickened portions are usually described as distinct ligaments under the following names :

Anterior.	Internal Lateral.
Posterior.	External Lateral.

The **Anterior Ligament** (fig. 452) is a broad and thin fibrous layer, which covers the anterior surface of the joint. It is attached to the front of the internal epicondyle and to the front of the humerus immediately above the coronoid and radial fossæ ; below, to the anterior surface of the coronoid process of the ulna and to the orbicular ligament (page 413), being continuous on either side with the lateral ligaments. Its superficial fibres pass obliquely from the inner condyle of the humerus outwards to the orbicular ligament. The middle fibres, vertical in direction, pass from the upper part of the coronoid depression and become partly blended with the preceding, but mainly inserted into the anterior surface of the coronoid process. The deep or transverse set intersects these at right angles. This ligament is in relation, in front, with the Brachialis anticus, except at its outermost part.

The **Posterior Ligament** (fig. 453) is thin and membranous, and consists of transverse and oblique fibres. Above, it is attached to the humerus immediately behind the capitellum and close to the inner margin of the trochlear surface, to the lateral margins of the olecranon fossa, and to the back of the external condyle some little distance from the trochlear surface. Below, it is fixed to the upper and outer margins of the olecranon process, to the posterior part of the orbicular ligament, and to the ulna behind the lesser sigmoid cavity. The transverse fibres form a strong band which bridges across the olecranon fossa ; under cover of this band a pouch of synovial membrane and a pad of fat project into the upper part of the fossa when the joint is extended. In the fat are a few scattered fibrous bundles, which pass from

the deep aspect of the transverse band to the upper part of the fossa. This ligament is in relation, behind, with the tendon of the Triceps and the Anconeus.

The **Internal Lateral Ligament** (lig. collaterale ulnare) (fig. 452) is a thick triangular band consisting of two portions, an anterior and posterior, united by a thinner intermediate portion. The *anterior portion*, directed obliquely forwards, is attached, above, by its apex, to the front part of the internal epicondyle of the humerus; and, below, by its broad base, to the inner margin of the coronoid process. The *posterior portion*, also of triangular form, is attached, above, by its apex, to the lower and back part of the internal epicondyle; below, to the inner margin of the olecranon. Between these two bands a few intermediate fibres descend from the internal epicondyle to blend with a *transverse band* of ligamentous tissue which bridges across the notch between the olecranon and coronoid processes. This ligament is in relation, internally, with the Triceps and Flexor carpi ulnaris and the ulnar nerve, and gives origin to part of the Flexor sublimis digitorum.

Fig. 454.—Sagittal section of right elbow-joint taken somewhat obliquely and seen from the radial aspect. (After Braune.)

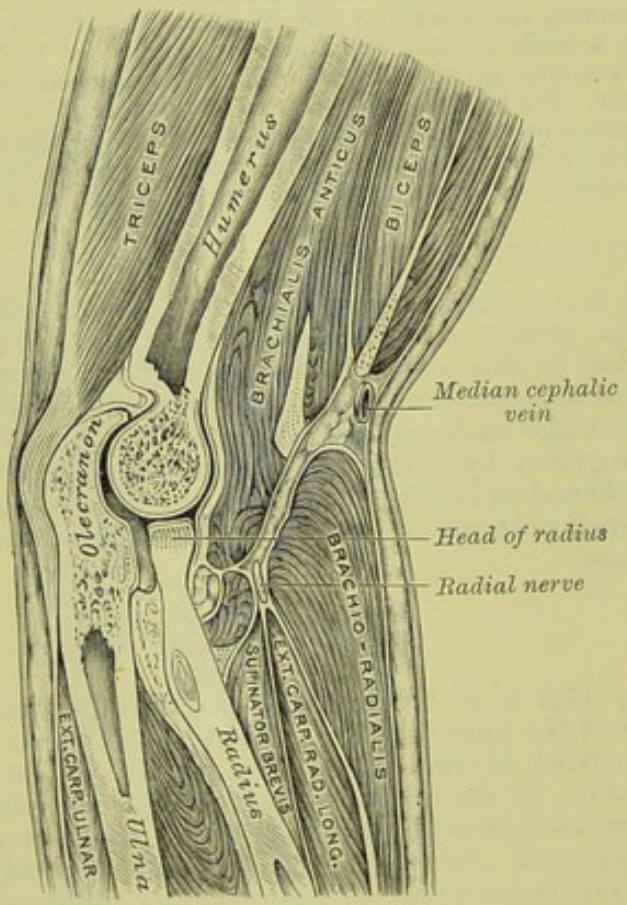

The **External Lateral Ligament** (lig. collaterale radiale) (fig. 453) is a short and narrow fibrous band, less distinct than the internal, attached, above, to a depression below the external epicondyle of the humerus; below, to the orbicular ligament, some of its most posterior fibres passing over that ligament, to be inserted into the outer margin of the ulna. It is intimately blended with the tendon of origin of the Supinator brevis.

The **Synovial Membrane** is very extensive. It extends from the margin of the articular surface of the humerus, and lines the coronoid and olecranon fossæ on that bone; it is reflected over the anterior, posterior, and lateral ligaments, and forms a pouch between the lesser sigmoid cavity, the internal surface of the orbicular ligament, and the circumference of the head of the radius. Projecting between the radius and ulna into the cavity is a crescentic fold of synovial membrane, suggesting the division of the joint into two: one the humero-radial, the other the humero-ulnar.

Between the capsular ligament and the synovial membrane are three masses of fat. The largest, over the olecranon fossa, is pressed into the fossa by the Triceps during flexion; the second, over the coronoid fossa, and the third, over the radial fossa, are pressed into their respective fossæ during extension.

The *Muscles* in relation with the joint are, in front, the Brachialis anticus; behind, the Triceps and Anconeus; externally, the Supinator brevis, and the common tendon of origin of the Extensor muscles; internally, the common tendon of origin of the Flexor muscles, and the Flexor carpi ulnaris (fig. 454).

The *Arteries* supplying the joint are derived from the anastomosis between the superior profunda, inferior profunda, and anastomotic branches of the brachial, with the anterior, posterior, and interosseous recurrent branches of the ulnar,

and the recurrent branch of the radial. These vessels form a complete anastomotic chain around the joint.

The *Nerves* of the joint are a twig from the ulnar, as it passes between the internal condyle and the olecranon; a filament from the musculo-cutaneous, and two from the median.

Movements. — The elbow-joint comprises three different portions, viz. the joint between the ulna and humerus, that between the head of the radius and the humerus, and the superior radio-ulnar articulation, described below. All these articular surfaces are enveloped by a common synovial membrane, and the movements of the whole joint should be studied together. The combination of the movements of flexion and extension of the forearm with those of pronation and supination of the hand, which is ensured by the two being performed at the same joint, is essential to the accuracy of the various minute movements of the hand.

The portion of the joint between the ulna and humerus is a simple hinge-joint, and allows of movements of flexion and extension only. Owing to the obliquity of the trochlear surface of the humerus, this movement does not take place in the plane of the shaft of the humerus. When the forearm is extended and supinated, the axes of the arm and forearm are not in the same line, the upper portion of the limb forming an obtuse angle with the lower, the hand and forearm being directed outwards. During flexion, on the other hand, the forearm and the hand tend to approach the middle line of the body, and thus enable the hand to be easily carried to the face. The shape of the trochlear surface of the humerus, with its prominences and depressions accurately adapted to the great sigmoid cavity, prevents any lateral movement. *Flexion* is produced by the action of the Biceps and Brachialis anticus, assisted by the Brachio-radialis and the muscles arising from the internal condyle of the humerus; *extension*, by the Triceps and Anconeus, assisted by the Extensors of the wrist, the Extensor communis digitorum and the Extensor minimi digiti.

The joint between the head of the radius and the capitellum or radial head of the humerus is an arthrodial joint. The bony surfaces would of themselves constitute an enarthrosis and allow of movement in all directions, were it not for the orbicular ligament, by which the head of the radius is bound down firmly to the sigmoid cavity of the ulna, and which prevents any separation of the two bones laterally. It is to the same ligament that the head of the radius owes its security from dislocation, which would otherwise tend to occur, from the shallowness of the cup-like surface on the head of the radius. In fact, but for this ligament, the tendon of the Biceps would be liable to pull the head of the radius out of the joint.* The head of the radius is not in complete contact with the capitellum of the humerus in all positions of the joint. The capitellum occupies only the anterior and inferior surfaces of the lower end of the humerus, so that in complete extension a part of the radial head can be plainly felt projecting at the back of the articulation. In full flexion the movement of the radial head is hampered by the compression of the surrounding soft parts, so that the freest rotatory movement of the radius on the humerus (pronation and supination) takes place in semiflexion, in which position the two articular surfaces are in freest and most intimate contact. Flexion and extension of the elbow-joint are limited by the tension of the structures on the front and back of the joint; the limitation of flexion is also aided by the soft structures of the arm and forearm coming into contact.

In any position of flexion or extension, the radius, carrying the hand with it, can be rotated in the upper radio-ulnar joint. The hand is directly articulated to the lower surface of the radius only, and the concave or sigmoid surface on the lower end of the radius travels round the lower end of the ulna. The latter bone is excluded from the wrist-joint by the interarticular fibro-cartilage. Thus, rotation of the head of the radius round an axis which passes through the centre of the radial head of the humerus imparts circular movement to the hand through a very considerable arc.

Surface Form.—If the forearm be slightly flexed, a curved crease or fold with its convexity downwards is seen in the front of the elbow, extending from one condyle to the other. The centre of this fold is some slight distance above the line of the joint. The position

* Humphry, *op. cit.* p. 419.

of the radio-humeral joint can be ascertained by feeling for a slight groove or depression between the head of the radius and the capitellum of the humerus at the back of the articulation.

Applied Anatomy.—From the great breadth of the joint, and the manner in which the articular surfaces are interlocked, and also on account of the strong lateral ligaments and the support which the joint derives from the mass of muscles attached to each condyle of the humerus, lateral displacement of the bones is very uncommon; whereas antero-posterior dislocation, on account of the shortness of the antero-posterior diameter, the weakness of the anterior and posterior ligaments, and the want of support of muscles, occurs much more frequently. Dislocation backwards takes place when the forearm is in a position of extension, and forwards when in a position of flexion. For, in the extended position, the coronoid process is not locked into the coronoid fossa, and loses its grip to a certain extent, whereas the olecranon process is in the olecranon fossa, and entirely prevents displacement forwards. On the other hand, during flexion, the coronoid process is in the coronoid fossa, and prevents dislocation backwards, while the olecranon, having left the olecranon fossa, is not so efficient in preventing a forward displacement. When lateral dislocation does take place it is generally incomplete. Dislocation of the elbow-joint is of common occurrence in children, far more common than dislocation of any other articulation. As a rule, in young persons, the application of any severe violence to a joint is more likely to produce a fracture of bone than dislocation. In lesions of this joint there is often very great difficulty in ascertaining the exact nature of the injury.

The elbow-joint is occasionally the seat of acute synovitis. The joint-cavity then becomes distended with fluid, the bulging showing itself principally around the olecranon process, that is to say, on its inner and outer sides and above, in consequence of the laxness of the posterior ligament. Again, there is often some swelling just above the head of the radius, in the line of the radio-humeral joint, or the whole elbow may assume a fusiform appearance. There is not generally much swelling at the front of the joint, though sometimes deep-seated fulness beneath the Brachialis anticus may be noted. When suppuration occurs the abscess usually points at one or other border of the Triceps; occasionally the pus discharges itself in front, near the insertion of the Brachialis anticus. In cases of suppurative synovitis, incisions should be made into the joint on either side of the olecranon, care being taken to avoid wounding the ulnar nerve on the inner side. Chronic synovitis, usually of tuberculous origin, is of common occurrence in the elbow-joint: in such cases the forearm tends to assume the position of semiflexion, which is that of greatest ease and relaxation of ligaments. It should be borne in mind that if ankylosis occur in this or the extended position, the limb will not be nearly so useful as if ankylosed in a position of rather less than a right angle. The elbow-joint is also sometimes affected with osteo-arthritis, but less commonly than some of the larger joints.

Excision of the elbow is principally required for one of three conditions—viz. tuberculous arthritis, injury and its results, or faulty ankylosis—but may be necessary for some other rarer conditions, such as disorganising arthritis after pyæmia and unreduced dislocations. The results of the operation are, as a rule, more favourable than those of excision of any other joint, and it is one, therefore, that the surgeon should never hesitate to perform, especially in any of the first three conditions mentioned above. The operation is best performed by a vertical incision down the back of the joint; a straight incision is made about four inches long, the mid-point of which is on a level with and a little to the inner side of the tip of the olecranon. This incision is made down to the bone, through the substance of the Triceps. The operator, guarding the soft parts with his thumb-nail, separates them from the bone with the point of his knife. In doing this there are two structures which he should carefully avoid: the ulnar nerve, which lies parallel to his incision, but a little internal, as it courses down between the internal condyle and the olecranon process; and the prolongation of the Triceps into the deep fascia of the forearm over the Anconeus. Having cleared the bones and divided the lateral and posterior ligaments, the forearm is strongly flexed and the ends of the bones turned out and sawn off. The turning out of the ends of the bones is rendered easier by first cutting off the olecranon process with a pair of cutting bone forceps. The section of the humerus should be through the base of the condyles, that of the ulna and radius should be just below the level of the lesser sigmoid cavity of the ulna and the neck of the radius. In this operation the object is to obtain such union as shall allow free motion of the bones of the forearm; and, therefore, passive movements must be commenced early—that is to say, about the tenth day. It is most important to maintain the continuity of the Triceps with the deep fascia of the forearm, so as to obtain good power of extension in the new joint.

V. RADIO-ULNAR ARTICULATIONS

The articulation of the radius with the ulna is effected by ligaments, which connect together both extremities as well as the shafts of these bones. The ligaments may, consequently, be subdivided into three sets: 1, those of the superior radio-ulnar articulation; 2, the middle radio-ulnar ligaments; 3, those of the inferior radio-ulnar articulation.

1. Superior Radio-ulnar Articulation (Articulatio Radioulnaris Proximalis)

This articulation is a trochoid or pivot-joint between the circumference of the head of the radius and the ring formed by the lesser sigmoid cavity of the ulna and the *annular* or *orbicular* ligament.

The **Annular** or **Orbicular Ligament** (lig. annulare radii) (fig. 455) is a strong band of fibres, which encircles the head of the radius, and retains it in contact with the lesser sigmoid cavity of the ulna. It forms about four-fifths of the osseo-fibrous ring, and is attached to the anterior and posterior margins of the lesser sigmoid cavity; a few of its lower fibres are, however, continued round below the cavity and form at this level a complete fibrous ring. Its upper border blends with the anterior and posterior ligaments of the elbow, while from its lower border a thin loose membrane passes to be attached to the neck of the radius; a thickened band which extends from

Fig. 455.—Orbicular ligament of radius, from above. The head of the radius has been sawn off and the bone dislodged from the ligament.

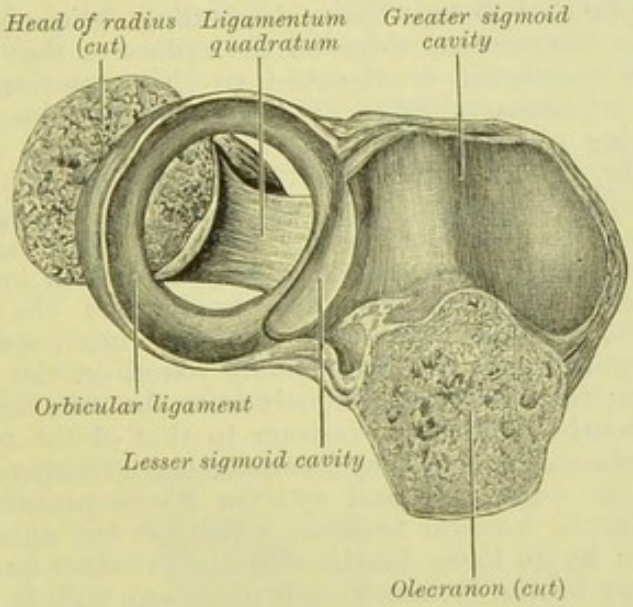

the lower border of the orbicular ligament below the lesser sigmoid cavity to the neck of the radius is known as the *ligamentum quadratum*. The *outer surface* of the orbicular ligament is strengthened by the external lateral ligament of the elbow, and affords origin to part of the Supinator brevis. Its *inner surface* is smooth, and lined by synovial membrane, which is continuous with that of the elbow-joint.

Movements.—The movements which take place in this articulation are limited to rotatory movements of the head of the radius within the ring formed by the orbicular ligament and the lesser sigmoid cavity of the ulna; rotation forwards being called *pronation*; rotation backwards, *supination*. Supination is performed by the Biceps and Supinator brevis, assisted to a slight extent by the Extensor muscles of the thumb, and, in certain positions, by the Brachio-radialis. Pronation is performed by the Pronator teres and Pronator quadratus, assisted, in some positions, by the Brachio-radialis.

Surface Form.—The position of the superior radio-ulnar joint is marked on the surface by a dimple on the back of the elbow which indicates the position of the head of the radius.

Applied Anatomy.—Dislocation of the head of the radius alone is a not uncommon accident, and occurs most frequently in young persons from falls on the hand when the forearm is extended and supinated, the head of the bone being displaced forward. It is attended by rupture of the orbicular ligament. Occasionally a peculiar injury, which is supposed to be a subluxation, occurs in young children in lifting them from the ground by the hand or forearm. It is believed that the head of the radius is displaced downwards in the orbicular ligament, the upper border of which becomes folded over the head of the

radius, between it and the capitellum of the humerus. The forearm becomes fixed in a position of semiflexion, midway between supination and pronation, and great pain is complained of upon any attempt to move the joint. It should be noted that the synovial membrane of the superior radio-ulnar joint is directly continuous with that of the elbow-joint, and, therefore, any septic or tuberculous disease which affects the latter also involves the former joint. The superior radio-ulnar joint is always removed in an excision of the elbow (see p. 412).

2. Middle Radio-ulnar Union

The shafts of the radius and ulna are connected by the

Oblique ligament and the Interosseous membrane.

The **Oblique Ligament** (chorda obliqua) (fig. 452) is a small, flattened, fibrous band, which extends obliquely downwards and outwards, from the outer side of the tubercle of the ulna at the base of the coronoid process to the radius a little below the bicipital tuberosity. Its fibres run in the opposite direction to those of the interosseous membrane ; and it appears to be placed as a substitute for it in the upper part of the interosseous interval. It is sometimes wanting.

The **Interosseous Membrane** (membrana interossea antibrachii) is a broad and thin plane of fibrous tissue descending obliquely downwards and inwards, from the interosseous ridge on the radius to that on the ulna ; the lower part of the membrane is attached to the posterior of the two lines into which the interosseous ridge of the radius divides. It is deficient above, commencing about an inch beneath the bicipital tuberosity of the radius ; is broader in the middle than at either extremity ; and presents an oval aperture just above its lower margin for the passage of the anterior interosseous vessels to the back of the forearm. This ligament serves to connect the bones, and to increase the extent of surface for the attachment of the deep muscles. Between its upper border and the oblique ligament an interval exists, through which the posterior interosseous vessels pass. Two or three fibrous bands are occasionally found on the posterior surface of this membrane ; they descend obliquely from the ulna towards the radius, and have consequently a direction contrary to that of the other fibres. The membrane is in relation, *in front*, by its upper three-fourths, with the Flexor longus pollicis on the outer side, and with the Flexor profundus digitorum on the inner, lying in the interval between which are the anterior interosseous vessels and nerve ; by its lower fourth with the Pronator quadratus ; *behind*, with the Supinator brevis, Extensor ossis metacarpi pollicis, Extensor brevis pollicis, Extensor longus pollicis, Extensor indicis ; and, near the wrist, with the anterior interosseous artery and posterior interosseous nerve.

3. Inferior Radio-ulnar Articulation (Articulatio Radioulnaris Distalis)

This is a pivot-joint formed between the head of the ulna and the sigmoid cavity on the inner side of the lower end of the radius. The articular surfaces are connected together by the following ligaments :

Anterior Radio-ulnar. Posterior Radio-ulnar.
Interarticular Fibro-cartilage.

The **Anterior Radio-ulnar Ligament** (fig. 456) is a narrow band of fibres extending from the anterior margin of the sigmoid cavity of the radius to the anterior surface of the head of the ulna.

The **Posterior Radio-ulnar Ligament** (fig. 457) extends between corresponding surfaces on the posterior aspect of the articulation.

The **Interarticular Fibro-cartilage** (discus articularis) (fig. 459) is triangular in shape, and is placed transversely beneath the head of the ulna, binding the lower ends of the ulna and radius firmly together. Its periphery is thicker than its centre, which is thin and occasionally perforated. It is attached by its apex to a depression which separates the styloid process of the ulna from the head of that bone ; and by its base, which is thin, to the prominent edge of the radius, which separates the sigmoid cavity from the carpal articular surface. Its margins are united to the ligaments of the

wrist-joint. Its *upper surface*, smooth and concave, articulates with the head of the ulna, forming an arthrodial joint; its *under surface*, also concave and smooth, forms part of the wrist-joint and articulates with the cuneiform and inner part of the semilunar. Both surfaces are clothed by synovial membrane: the upper surface, by one peculiar to the radio-ulnar articulation; the under surface, by the synovial membrane of the wrist.

The **Synovial Membrane** (fig. 459) of this articulation has been called, from its extreme looseness, the *membrana sacciformis*; it extends upwards between the radius and the ulna, forming here a very loose *cul-de-sac* (recessus sacciformis). The quantity of synovia which it contains is usually considerable.

Movements.—The movements in the inferior radio-ulnar articulation are just the reverse of those in the superior radio-ulnar joint. They consist of movements of rotation of the lower end of the radius round an axis which passes through the centre of the head of the ulna. When the radius rotates forwards, *pronation* of the forearm and hand is the result; and when backwards, *supination*. It will thus be seen that in pronation and supination of the forearm and hand the radius describes the segment of a cone, the axis of which extends from the centre of the head of the radius to the middle of the head of the ulna. In this movement the head of the ulna is not stationary, but describes a curve in a direction opposite to that taken by the head of the radius. This, however, is not to be regarded as a rotation of the ulna—the curve which the head of this bone describes is due to a combined antero-posterior and lateral movement, the former taking place almost entirely at the elbow-joint, the latter at the shoulder-joint.

Surface Form.—The position of the inferior radio-ulnar joint may be ascertained by feeling for a slight groove at the back of the wrist, between the prominent head of the ulna and the lower end of the radius, when the forearm is in a state of almost complete pronation.

VI. RADIO-CARPAL OR WRIST-JOINT (ARTICULATIO RADIOCARPEA)

The wrist-joint (figs. 456, 457) is a condyloid articulation. The parts entering into its formation are the lower end of the radius and under surface of the interarticular fibro-cartilage above; and the scaphoid, semilunar, and

Fig. 456.—Ligaments of wrist and hand. Anterior view.

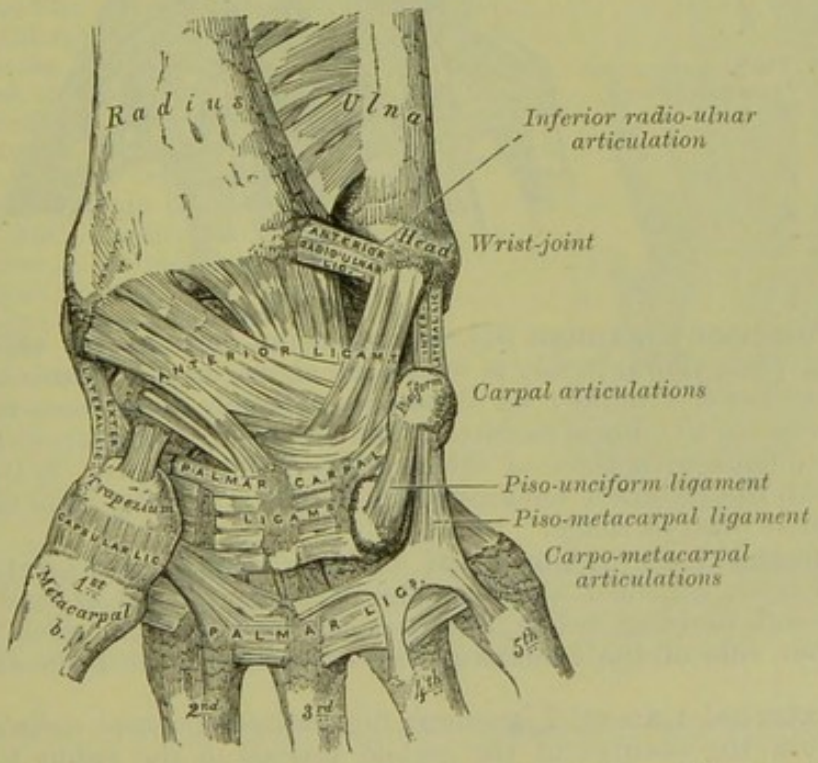

cuneiform bones below. The articular surface of the radius and the under surface of the interarticular fibro-cartilage form together a transversely elliptical concave surface, the *receiving cavity*. The articular surfaces of the scaphoid, semilunar, and cuneiform present a smooth, convex surface, the

condyle, which is received into the concavity above mentioned. All the bony surfaces of the articulation are covered with cartilage, and connected together by a **Capsule**, strengthened by the following ligaments :

Anterior.	Internal lateral.
Posterior.	External lateral.

The **Anterior Ligament** (lig. radiocarpeum volare) (fig. 456) is a broad membranous band, attached above to the anterior margin of the lower end of the radius, to its styloid process and to the front of the lower end of the ulna; its fibres pass downwards and inwards to be inserted into the palmar surfaces of the scaphoid, semilunar, and cuneiform, some of the fibres being continued to the os magnum. In addition to this broad membrane, there is a distinct rounded fasciculus, superficial to the rest, which passes from the base of the styloid process of the ulna to the semilunar and cuneiform. The ligament is perforated by numerous apertures for the passage of vessels, and is in relation, in front, with the tendons of the Flexor profundus digitorum and Flexor longus pollicis ; behind, it is closely adherent to the anterior border of the triangular fibro-cartilage of the inferior radio-ulnar articulation.

FIG. 457.—Ligaments of wrist and hand. Posterior view.

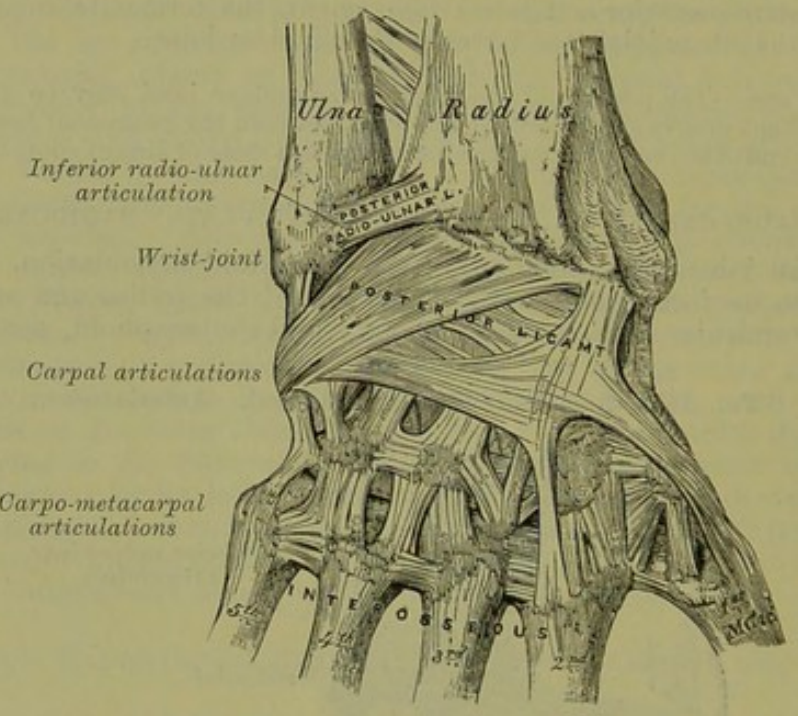

The **Posterior Ligament** (lig. radiocarpeum dorsale) (fig. 457), less thick and strong than the anterior, is attached, above, to the posterior border of the lower end of the radius ; its fibres pass obliquely downwards and inwards, to be attached to the dorsal surfaces of the scaphoid, semilunar, and cuneiform, being continuous with those of the dorsal carpal ligaments. It is in relation, behind, with the Extensor tendons of the fingers ; in front, it is blended with the triangular fibro-cartilage.

The **Internal Lateral Ligament** (lig. collaterale carpi ulnare) (fig. 456) is a rounded cord, attached above to the extremity of the styloid process of the ulna, and dividing below into two fasciculi, one of which is attached to the inner side of the cuneiform, the other to the pisiform and annular ligament.

The **External Lateral Ligament** (lig. collaterale carpi radiale) (fig. 456) extends from the summit of the styloid process of the radius to the outer side of the scaphoid, some of its fibres being prolonged to the trapezium and annular ligament. It has in relation with it the radial artery, which separates the ligament from the tendons of the Extensor ossis metacarpi and Extensor brevis pollicis.

The **Synovial Membrane** (fig. 459) lines the inner surfaces of the ligaments above described, extending from the lower end of the radius and interarticular fibro-cartilage above to the articular surfaces of the carpal bones below. It is loose and lax, and presents numerous folds, especially behind.

The wrist-joint is covered in front by the Flexor, and behind by the Extensor tendons; it is also in relation with the radial and ulnar arteries.

The *Arteries* supplying the joint are the anterior and posterior carpal branches of the radial and ulnar, the anterior and posterior interosseous, and some ascending branches from the deep palmar arch.

The *Nerves* are derived from the ulnar and posterior interosseous.

Movements.—The movements permitted in this joint are flexion, extension, abduction, adduction, and circumduction. They will be studied with those of the carpus, with which they are combined.

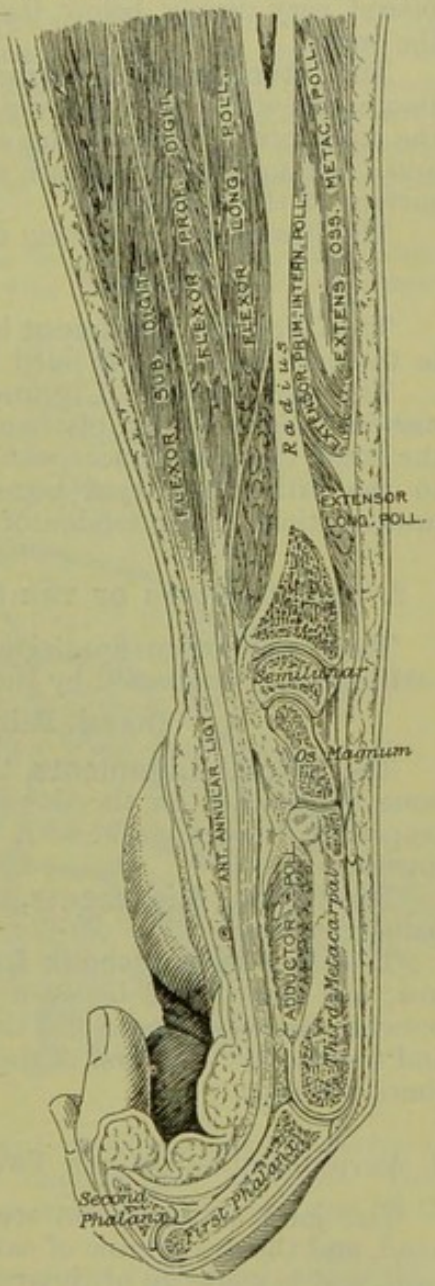

FIG. 458.—Longitudinal section of the right forearm, hand, and third finger, viewed from the ulnar aspect. (After Braune.)

Surface Form.—On the front of the wrist three transverse furrows may be generally seen: the uppermost is on a level with the styloid process of the ulna; the middle corresponds fairly accurately with the wrist-joint; and the lowest indicates the position of the mid-carpal articulation.

Applied Anatomy.—The wrist-joint is rarely dislocated, its strength depending mainly upon the numerous strong tendons which surround the articulation. Its security is further provided for by the number of small bones of which the carpus is made up, and which are united by very strong ligaments. The slight movements which take place between the several bones serve to break the jars that result from falls or blows on the hand. Dislocation backwards, which is the more common, simulates to a considerable extent Colles's fracture of the radius, and is liable to be mistaken for it. The differential diagnosis can be easily made by observing the relative positions of the styloid processes of the radius and the ulna. In the natural condition the styloid process of the radius is on a lower level, i.e. nearer the ground, when the arm hangs by the side, than that of the ulna, and this relationship is not disturbed in dislocation. In Colles's fracture, on the other hand, the styloid process of the radius is on the same, or even a higher level than that of the ulna.

The wrist-joint is occasionally the seat of acute synovitis. When the synovial sac is distended with fluid, the swelling is greatest on the dorsal aspect of the wrist, showing a general fulness, with some bulging between the tendons. The inflammation is prone to extend to the intercarpal joints and to attack also the sheaths of the tendons in the neighbourhood. Chronic inflammation of the wrist is generally tuberculous, and often leads to similar disease in the synovial sheaths of adjacent tendons and of the intercarpal joints. The disease, therefore, when progressive, frequently leads to caries of the carpal bones, and the result is often an ankylosis. A free incision of the joint by a straight posterior cut leads, in some cases, to most satisfactory results.

VII. CARPAL ARTICULATIONS (ARTICULATIONES INTERCARPEÆ)

These articulations may be subdivided into three sets:

1. The Articulations of the First Row of Carpal Bones.
2. The Articulations of the Second Row of Carpal Bones.
3. The Articulations of the Two Rows with each other.

1. Articulations of the First or Proximal Row of Carpal Bones

These are arthrodial joints. The ligaments connecting the scaphoid, semilunar, and cuneiform are :

Dorsal, Palmar, and two Interosseous.

The **Dorsal Ligaments,** two in number, are placed transversely behind the bones of the first row ; they connect the scaphoid and semilunar, and the semilunar and cuneiform.

The **Palmar Ligaments,** also two, connect the scaphoid and semilunar, and the semilunar and cuneiform ; they are less strong than the dorsal, and placed very deeply below the Flexor tendons and the anterior ligament of the wrist.

The **Interosseous Ligaments** (fig. 456) are two narrow bundles of fibrous tissue, one connecting the semilunar with the scaphoid, the other joining it to the cuneiform. They are on a level with the superior surfaces of these bones, and their upper surfaces are smooth, and form part of the convex articular surface of the wrist-joint.

The ligaments connecting the pisiform bone are—

Capsular. Two Palmar.

The **Capsular Ligament** is a thin membrane which connects the pisiform to the cuneiform. It is lined with a separate synovial membrane.

The two **Palmar Ligaments** are strong fibrous bands; one, *the piso-unciform ligament* (lig. pisohamatum), connects the pisiform to the unciform, the other, the *piso-metacarpal ligament* (lig. pisometacarpeum), joins the pisiform to the fifth metacarpal bone (fig. 456). These ligaments are, in reality, prolongations of the tendon of the Flexor carpi ulnaris.

2. Articulations of the Second or Distal Row of Carpal Bones

These also are arthrodial joints. The articular surfaces are covered with cartilage, and connected by the following ligaments :

Dorsal, Palmar, and three Interosseous.

The **Dorsal Ligaments,** three in number, extend transversely from one bone to another on the dorsal surface, connecting the trapezium with the trapezoid, the trapezoid with the os magnum, and the os magnum with the unciform.

The **Palmar Ligaments,** also three, have a similar arrangement on the palmar surface.

The three **Interosseous Ligaments,** much thicker than those of the first row, are placed one between the os magnum and the unciform, a second between the os magnum and the trapezoid, and a third between the trapezium and trapezoid. The first of these is much the strongest, and the third is sometimes wanting.

3. Articulations of the Two Rows of Carpal Bones with each other

The joint between the scaphoid, semilunar, and cuneiform on the one hand, and the second row of carpal bones on the other, is named the *mid-carpal joint*, and is made up of three distinct portions : in the centre the head of the os magnum and the superior surface of the unciform articulate with the deep cup-shaped cavity formed by the scaphoid and semilunar, and constitute a sort of ball-and-socket joint. On the outer side the trapezium and trapezoid articulate with the scaphoid, and on the inner side the unciform articulates with the cuneiform, forming gliding joints.

The ligaments are :

Anterior or Palmar. Internal Lateral.
Posterior or Dorsal. External Lateral.

The **Anterior** or **Palmar Ligament** consists of short fibres, which pass, for the most part, from the palmar surfaces of the bones of the first row to the front of the os magnnm.

The **Posterior** or **Dorsal Ligament** consists of short, irregular bundles of fibres passing between the bones of the first and second rows on the dorsal surface of the carpus.

The **Lateral Ligaments** are very short: one is placed on the radial, the other on the ulnar side of the carpus; the former, the stronger and more distinct, connects the scaphoid and trapezium, the latter the cuneiform and unciform; they are continuous with the lateral ligaments of the wrist-joint. In addition to these ligaments, a slender interosseous band sometimes connects the os magnum and the scaphoid.

The **Synovial Membrane of the Carpus** is very extensive (fig. 459); it passes from the margins of the under surfaces of the scaphoid, semilunar, and cuneiform bones to the margins of the upper surfaces of the bones of the second row. It sends two prolongations upwards—between the scaphoid and semilunar, and the semilunar and cuneiform—and three prolongations downwards between the four bones of the second row. The prolongation between the trapezium and trapezoid, or that between the trapezoid and os magnum, is often continued onwards, owing to the absence of the interosseous ligament, into the carpo-metacarpal joints, sometimes of the four inner metacarpal bones, sometimes of the second and third only. In the latter condition the joint between the unciform and the fourth and fifth metacarpal bones has a separate synovial membrane. The synovial membranes of these joints are prolonged for a short distance between the metacarpal bones. There is a separate synovial membrane between the pisiform and cuneiform.

FIG. 459.—Vertical section through the articulations at the wrist, showing the five synovial membranes.

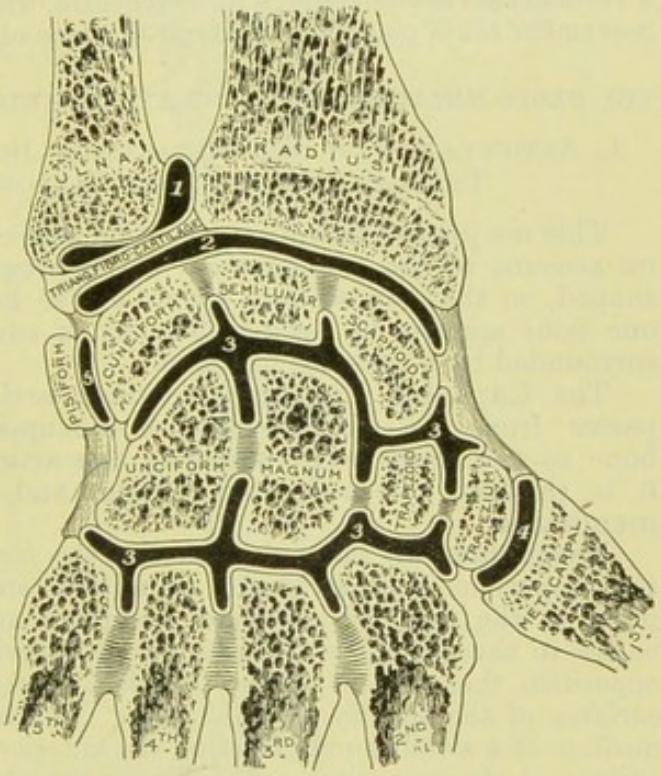

Movements.—The articulation of the hand and wrist considered as a whole involves four articular surfaces: (*a*) the inferior surfaces of the radius and triangular fibro-cartilage; (*b*) the superior surfaces of the scaphoid, semilunar, and cuneiform, the pisiform having no essential part in the movement of the hand; (*c*) the S-shaped surface formed by the inferior surfaces of the scaphoid, semilunar, and cuneiform; (*d*) the reciprocal surface formed by the trapezium, trapezoid, os magnum, and unciform. These four surfaces form two joints: (1) the superior or wrist-joint proper; and (2) the inferior or mid-carpal joint.

(1) The articulation between the forearm and carpus is a true condyloid articulation, and therefore all movements but rotation are permitted. Flexion and extension are the most free, and of these a greater amount of extension than of flexion is permitted since the articulating surfaces extend farther on the dorsal than on the palmar surfaces of the carpal bones. In this movement the carpal bones rotate on a transverse axis drawn between the tips of the styloid processes of the radius and ulna. A certain amount of adduction (or ulnar flexion) and abduction (or radial flexion) is also permitted. The former is considerably greater in extent than the latter on account of the shortness of the styloid process of the ulna, abduction being soon limited by the contact of the styloid process of the radius with the trapezium. In this movement the carpus revolves upon an antero-posterior axis drawn through the centre of the wrist. Finally, circumduction is permitted by the combined and consecutive movements of

adduction, extension, abduction, and flexion. No rotation is possible, but the effect of rotation is obtained by the supination and pronation of the radius on the ulna. The movement of *flexion* is performed by the Flexor carpi radialis, the Flexor carpi ulnaris, and the Palmaris longus; *extension* by the Extensores carpi radialis longior et brevior and the Extensor carpi ulnaris; *adduction* (ulnar flexion), by the Flexor carpi ulnaris and the Extensor carpi ulnaris; and *abduction* (radial flexion) by the Extensors of the thumb, and the Extensores carpi radialis longior et brevior and the Flexor carpi radialis. When the fingers are extended, flexion of the wrist is performed by the Flexores carpi radialis et ulnaris and extension by the Extensor communis digitorum. When the fingers are flexed, flexion of the wrist is performed by the Flexores sublimis et profundus digitorum, and extension by the Extensores carpi radiales et ulnaris.

(2) The chief movements permitted in the transverse or mid-carpal joint are flexion and extension and a slight amount of rotation. In flexion and extension, which are the movements most freely enjoyed, the trapezium and trapezoid on the radial side and the unciform on the ulnar side glide forwards and backwards on the scaphoid and cuneiform respectively, while the head of the os magnum and the superior surface of the unciform rotate in the cup-shaped cavity of the scaphoid and semilunar. Flexion at this joint is freer than extension. A very trifling amount of rotation is also permitted, the head of the os magnum rotating round a vertical axis drawn through its own centre, while at the same time a slight gliding movement takes place in the lateral portions of the joint.

VIII. CARPO-METACARPAL ARTICULATIONS (ARTICULATIONES CARPOMETACARPEÆ)

1. Articulation of the Metacarpal Bone of the Thumb with the Trapezium (Articulatio Carpometacarpea Pollicis)

This is a joint of reciprocal reception, and enjoys great freedom of movement on account of the configuration of its articular surfaces, which are saddle-shaped, so that, on section, either in the long axis or at right angles to it, one bone appears to be received into a cavity in the other. The joint is surrounded by a capsular ligament.

The **Capsular Ligament** (capsula articularis) is thick but loose, and passes from the circumference of the upper extremity of the metacarpal bone to the rough edge bounding the articular surface of the trapezium; it is thickest externally and behind, and lined by a separate **synovial membrane.**

Movements.—In the articulation of the metacarpal bone of the thumb with the trapezium the movements permitted are flexion and extension in the plane of the palm of the hand, abduction and adduction in a plane at right angles to the palm, circumduction, and opposition. It is by the movement of opposition that the tip of the thumb is brought into contact with the palmar surfaces of the slightly flexed fingers. This movement is effected through the medium of a small sloping facet on the anterior lip of the saddle-shaped articular surface of the trapezium. The Flexor muscles pull the corresponding part of the articular surface of the metacarpal bone on to this facet, and the movement of opposition is then carried out by the Adductors.

Flexion of this carpo-metacarpal joint is produced by the Flexores longus et brevis pollicis assisted by the Opponens pollicis and the Adductores transversus et obliquus pollicis. Extension is effected mainly by the Extensor ossis metacarpi pollicis, assisted by the Extensores longus et brevis pollicis. Adduction is carried out by the two Adductors; abduction mainly by the Abductor pollicis, assisted by the Extensors.

2. Articulations of the Four Inner Metacarpal Bones with the Carpus

The joints formed between the carpus and the four inner metacarpal bones are arthrodial joints. The ligaments are:

Dorsal, Palmar, and Interosseous.

The **Dorsal Ligaments,** the strongest and most distinct, connect the carpal and metacarpal bones on their dorsal surfaces. The second metacarpal bone receives two fasciculi, one from the trapezium, the other from

the trapezoid; the third metacarpal receives two, one from the trapezoid, and one from the os magnum; the fourth two, one from the os magnum, and one from the unciform; the fifth receives a single fasciculus from the unciform, and this is continuous with a similar ligament on the palmar surface, forming an incomplete capsule.

The **Palmar Ligaments** have a somewhat similar arrangement on the palmar surface, with the exception of those of the third metacarpal, which are three in number, an external one from the trapezium, situated above the sheath of the tendon of the Flexor carpi radialis; a middle one from the os magnum; and an internal one from the unciform.

The **Interosseous Ligaments** consist of short, thick fibres, which are limited to one part of the carpo-metacarpal articulation; they connect the contiguous inferior angles of the os magnum and unciform with the adjacent surfaces of the third and fourth metacarpal bones.

The **Synovial Membrane** is frequently a continuation of that between the two rows of carpal bones. Occasionally, the articulation of the unciform with the fourth and fifth metacarpal bones has a separate synovial membrane.

The synovial membranes of the wrist and carpus (fig. 459) are thus seen to be five in number. The *first*, the *membrana sacciformis*, passes from the lower end of the ulna to the sigmoid cavity of the radius, and lines the upper surface of the interarticular fibro-cartilage. The *second* passes from the lower end of the radius and interarticular fibro-cartilage above, to the bones of the first row below. The *third*, the most extensive, passes between the contiguous margins of the two rows of carpal bones, and sometimes, in the event of one of the interosseous ligaments being absent, between the bones of the second row to the carpal extremities of the four inner metacarpal bones. The *fourth*, from the margin of the trapezium to the metacarpal bone of the thumb. The *fifth*, between the adjacent margins of the cuneiform and pisiform bones. Occasionally the carpo-metacarpal joints have a separate synovial membrane (see page 419).

FIG. 460.—Articulations of the phalanges.

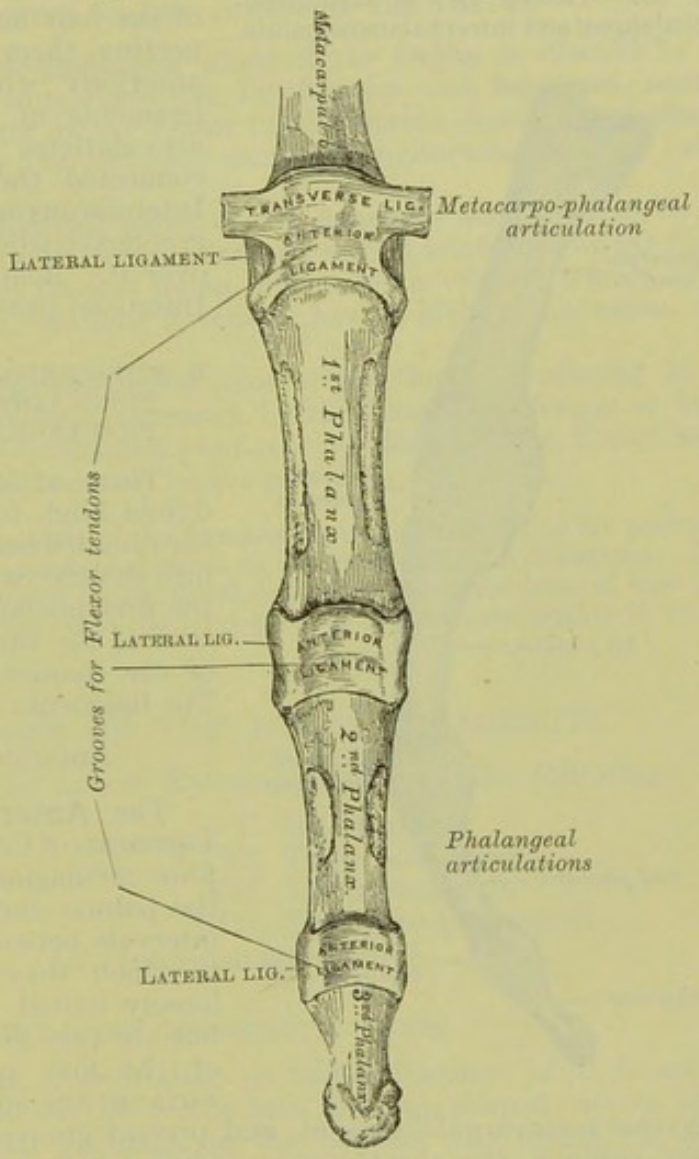

Movements.—The movements permitted in the carpo-metacarpal articulations of the fingers are limited to slight gliding of the articular surfaces upon each other, the extent of which varies in the different joints. Thus the articulation of the metacarpal bone of the little finger is most movable, then that of the ring-finger; the metacarpal bones of the index and middle fingers are almost immovable.

IX. INTERMETACARPAL ARTICULATIONS (ARTICULATIONES INTERMETACARPEÆ)

The carpal extremities of the four inner metacarpal bones articulate with one another by small surfaces covered with cartilage, and connected together by dorsal, palmar, and interosseous ligaments.

The **Dorsal** and **Palmar Ligaments** pass transversely from one bone to another on the dorsal and palmar surfaces. The **Interosseous Ligaments** pass between their contiguous surfaces, just beneath their lateral articular facets.

The **Synovial Membrane** between the lateral facets is a reflection from that between the two rows of carpal bones.

The **Transverse Metacarpal Ligament** (fig. 460) is a narrow fibrous band, which passes transversely across the anterior surfaces of the digital extremities of the four inner metacarpal bones, connecting them together. It is blended anteriorly with the anterior (glenoid) ligaments of the metacarpo-phalangeal articulations. To its posterior border is connected the fascia which covers the Interosseous muscles. Its anterior surface is concave where the Flexor tendons pass over it. Behind it the tendons of the Interossei pass to their insertions.

FIG. 461.—Lateral view of metacarpo-phalangeal and interphalangeal joints.

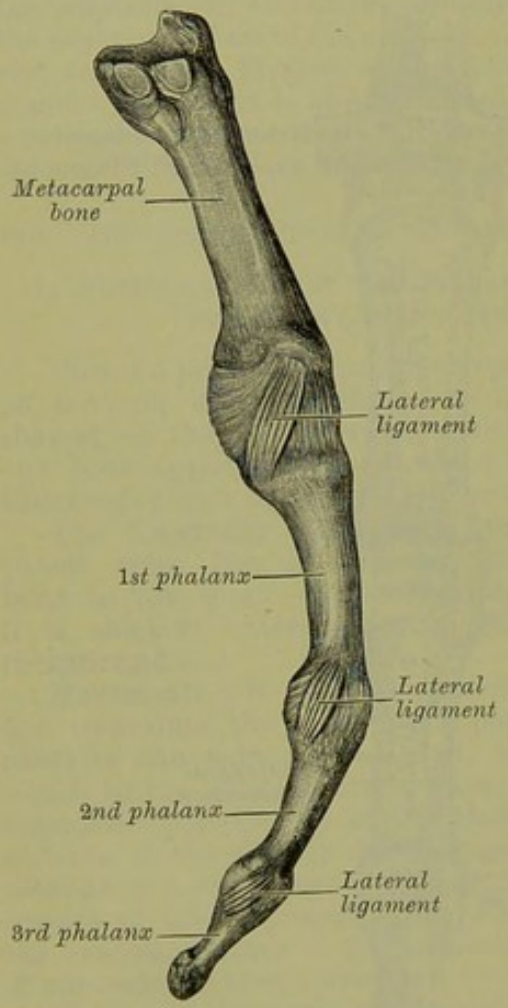

X. METACARPO-PHALANGEAL ARTICULATIONS (ARTICULATIONES METACARPO-PHALANGEÆ) (figs. 460, 461)

These articulations are of the condyloid kind, formed by the reception of the rounded heads of the metacarpal bones into shallow cavities in the extremities of the first phalanges, with the exception of that of the thumb, which presents more of the characters of a ginglymoid joint. The ligaments are—

Anterior and Two Lateral.

The **Anterior Ligaments** (*Glenoid Ligaments* of Cruveilhier) are thick, dense, fibro-cartilaginous structures, placed upon the palmar surfaces of the joints in the intervals between the lateral ligaments, to which they are connected; they are loosely united to the metacarpal bones, but are very firmly attached to the bases of the first phalanges. Their palmar surfaces are intimately blended with the transverse metacarpal ligament, and present grooves for the passage of the Flexor tendons, the sheaths surrounding which are connected to the sides of the grooves. By their deep surfaces, they form part of the articular facets for the heads of the metacarpal bones, and are lined by synovial membranes.

The **Lateral Ligaments** (ligg. collateralia) are strong, rounded cords, placed on the sides of the joints; each is attached by one extremity to the posterior tubercle and adjacent depression on the side of the head of the metacarpal bone, and by the other to the contiguous extremity of the phalanx.

Movements.—The movements which occur in these joints are flexion, extension, adduction, abduction, and circumduction; the movements of abduction and adduction are very limited, and cannot be performed when the fingers are flexed.

XI. INTERPHALANGEAL ARTICULATIONS (ARTICULATIONES DIGITORUM MANUS)

These are hinge joints. The ligaments are :

Anterior. Two Lateral.

The arrangement of these ligaments is similar to those in the metacarpo-phalangeal articulations. The Extensor tendon supplies the place of a posterior ligament.

Movements.—The only movements permitted in the phalangeal joints are flexion and extension ; these movements are more extensive between the first and second phalanges than between the second and third. The amount of flexion is very considerable, but extension is limited by the anterior and lateral ligaments.

Muscles Acting on the Joints of the Digits

Flexion of the metacarpo-phalangeal joints of the fingers is effected by the Flexores sublimis et profundus digitorum, Lumbricales, and Interossei, assisted in the case of the little finger by the Flexor brevis minimi digiti. Extension of these joints is produced by the Extensor communis digitorum, Extensor indicis and Extensor minimi digiti.

Flexion of the interphalangeal joints of the fingers is accomplished by the Flexor profundus digitorum acting on the first and second joints and by the Flexor sublimis digitorum acting on the first joints. Extension is effected mainly by the Lumbricales and Interossei, the long Extensors having little or no action upon these joints.

Flexion of the metacarpo-phalangeal joint of the thumb is effected by the Flexores longus et brevis pollicis : extension by the Extensores longus et brevis pollicis. Flexion of the interphalangeal joint is accomplished by the Flexor longus pollicis and extension by the Extensor longus pollicis.

Surface Form.—The prominences of the knuckles do not correspond to the position of the joints either of the metacarpo-phalangeal or interphalangeal articulations. These prominences are invariably formed by the distal ends of the proximal bone of each joint, and the line indicating the position of the joint must be sought considerably in front of the middle of the knuckle.

ARTICULATIONS OF THE LOWER EXTREMITY

The articulations of the Lower Extremity comprise the following :

I. Hip.
II. Knee.
III. Tibio-fibular.
IV. Ankle.
V. Intertarsal.
VI. Tarso-metatarsal.
VII. Intermetatarsal.
VIII. Metatarso-phalangeal.
IX. Interphalangeal.

I. HIP-JOINT (ARTICULATIO COXÆ)

This articulation is an enarthrodial, or ball-and-socket joint, formed by the reception of the head of the femur into the cup-shaped cavity of the acetabulum. The articular cartilage on the head of the femur, thicker at the centre than at the circumference, covers the entire surface with the exception of the depression just below its centre for the ligamentum teres; that covering the acetabulum is much thinner at the centre than at the circumference, and forms an incomplete cartilaginous ring, of a horse-shoe shape, being deficient below, where there is a circular depression, occupied in the recent state by a mass of fat, covered by synovial membrane. The ligaments of the joint are :

Capsular. Teres.
Ilio-femoral. Cotyloid.
Transverse.

The **Capsular Ligament** (capsula articularis), strong and dense, embraces the margin of the acetabulum above, and surrounds the neck of the femur

below. Its *upper circumference* is attached to the rim of the acetabulum, two or three lines external to the cotyloid ligament, above and behind ; but in front, it is attached to the outer margin of the ligament, and, opposite to the notch where the margin of the cavity is deficient, it is connected to the transverse ligament, and by a few fibres to the edge of the obturator foramen. Its *lower circumference* surrounds the neck of the femur, being attached, in front, to the spiral or anterior intertrochanteric line ; above, to the base of the neck ; behind, to the neck, about half an inch above the posterior intertrochanteric line ; below, to the lower part of the neck, close to the lesser trochanter. From this insertion some of the fibres are reflected upwards along the neck as longitudinal bands, termed *retinacula*. The capsule is much thicker at the upper and fore part of the joint, where the greatest amount of resistance is required, than below and internally, where it is thin, loose, and longer than in any other part. It consists of two sets of fibres, circular and longitudinal. The circular

FIG. 462.—Right hip-joint from the front. (Spalteholz.)

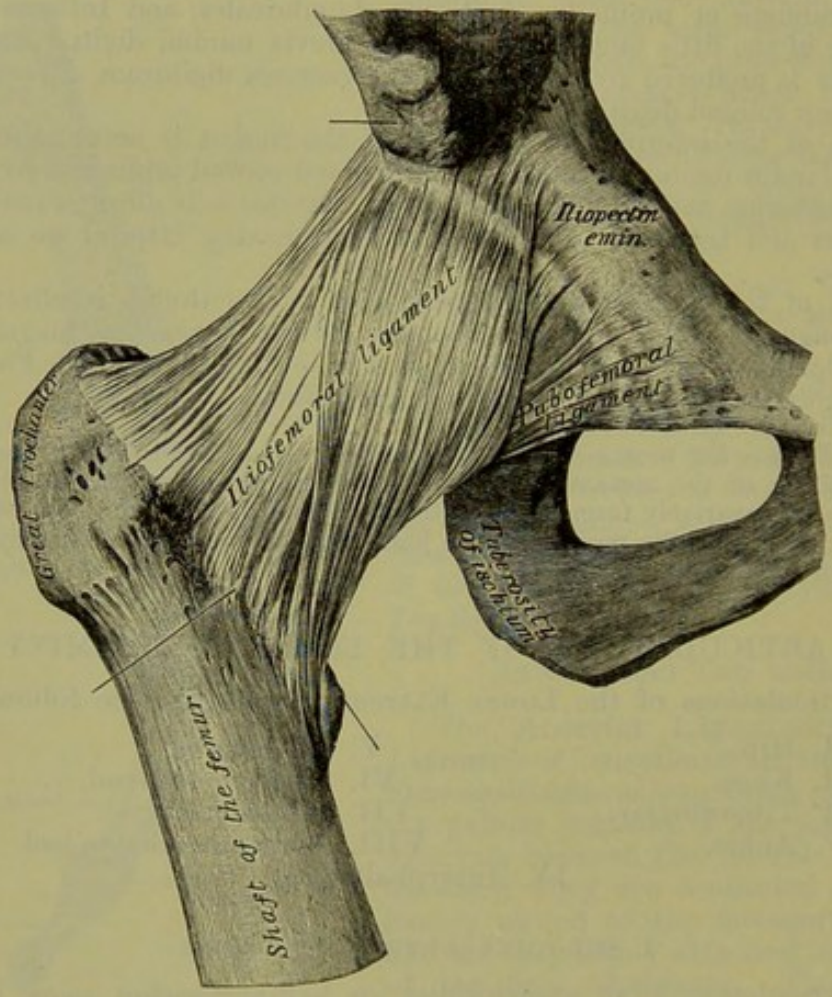

fibres (*zona orbicularis*) are most abundant at the lower and back part of the capsule, and form a sling or collar around the neck of the femur. Anteriorly they blend with the deep surface of the ilio-femoral ligament, and through its medium reach the anterior inferior spine of the ilium. The longitudinal fibres are greatest in amount at the upper and front part of the capsule, where they are reinforced by distinct bands, or accessory ligaments, of which the most important is the *ilio-femoral* (lig. iliofemorale). The other accessory bands are known as the *pubo-femoral* (lig. pubocapsulare), passing from the ilio-pectineal eminence and obturator crest to the front of the capsule, where some of its fibres blend with the lower segment of the ilio-femoral ligament ; and the *ischio-capsular* (lig. ischiocapsulare), passing from the ischium, just below the acetabulum, to blend with the circular fibres at the lower part of the joint. The external surface (fig. 442, page 393) is rough, covered by numerous muscles, and separated in front from the Psoas and Iliacus by a synovial bursa, which

not infrequently communicates by a circular aperture with the cavity of the joint. It differs from the capsular ligament of the shoulder in being much less loose and lax, and in not being perforated for the passage of a tendon.

The **Ilio-femoral Ligament** (figs. 462 and 467) is a band of great strength which lies in front of the joint; it is intimately connected with the capsular ligament, and serves to strengthen it in this situation. It is attached, above, to the lower part of the anterior inferior spine of the ilium; and, dividing below, forms two bands, of which one passes downwards to be inserted into the lower part of the anterior intertrochanteric line; the other passes downwards and outwards to be inserted into the upper part of the same line. Between the two bands is a thinner part of the capsule. In some joints there is no division, and the ligament spreads out into a flat triangular band which is attached below into the whole length of the anterior intertrochanteric line. This ligament is frequently called the Y-shaped ligament of Bigelow; and the outer or upper of the two bands is sometimes described as a separate ligament, under the name of the *ilio-trochanteric ligament.*

FIG. 463.—Left hip-joint laid open.

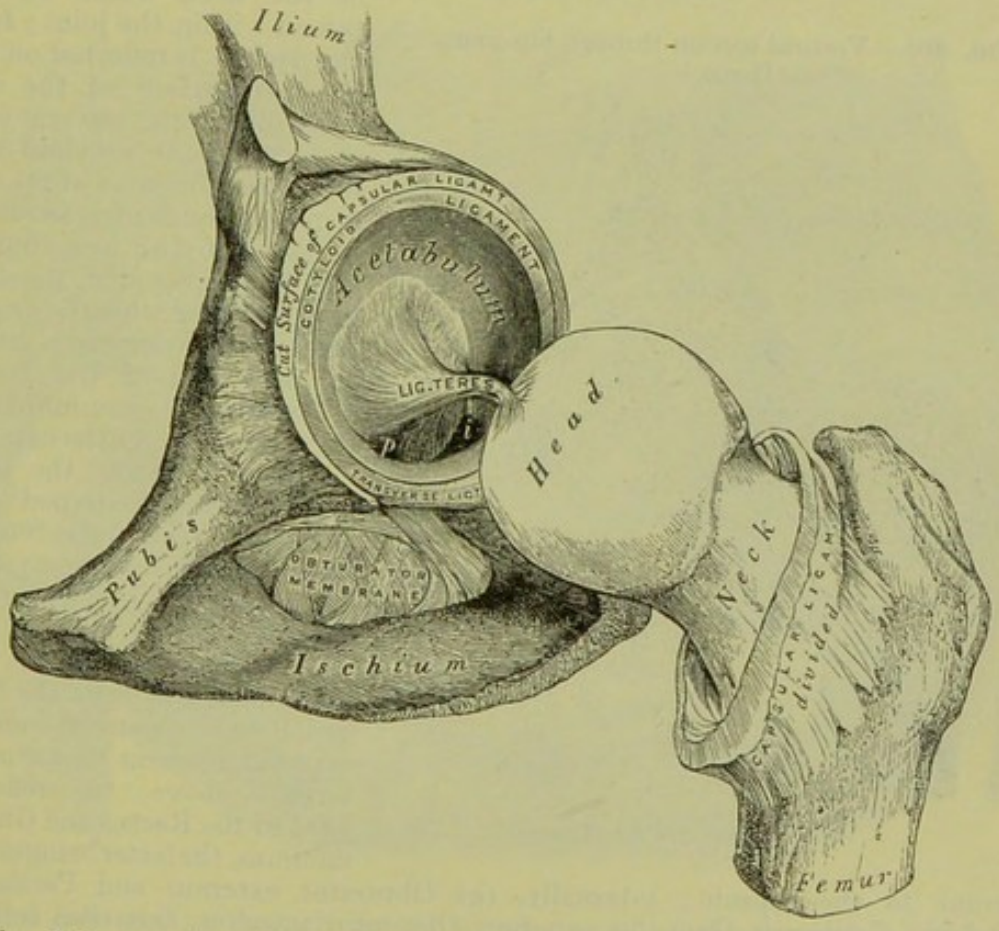

The **Ligamentum Teres** (lig. teres femoris) is a triangular, somewhat flattened band implanted by its apex into the depression a little behind and below the centre of the head of the femur; its base is attached by three bands, one into either side of the cotyloid notch, where they blend with the transverse ligament, and the third into the surface of the bone outside the notch. It is formed of connective tissue, surrounded by a tubular sheath of synovial membrane. Occasionally only the synovial fold exists, or the ligament may be altogether absent. The ligament is made tense when the hip is semiflexed, and the limb then adducted or rotated outwards; it is, on the other hand, relaxed when the limb is abducted. It has, however, but little influence as a ligament, though it may to a certain extent limit movement.

The **Cotyloid Ligament** (labrum glenoidale) is a fibro-cartilaginous rim attached to the margin of the acetabulum, the cavity of which it deepens; at the same time it protects the edge of the bone, and fills up the inequalities on its surface. It bridges over the notch as the *transverse ligament*, and thus

forms a complete circle, which closely surrounds the head of the femur and assists in holding it in its place. It is triangular on section, its base being attached to the margin of the acetabulum, and its opposite edge being free and sharp. Its two surfaces are invested by synovial membrane, the external one being in contact with the capsular ligament, the internal one being inclined inwards so as to narrow the acetabulum, and embrace the cartilaginous surface of the head of the femur. It is much thicker above and behind than below and in front, and consists of close compact fibres, which arise from different points of the circumference of the acetabulum, and interlace with each other at very acute angles.

The **Transverse Ligament** (lig. transversum acetabuli) is in reality a portion of the cotyloid ligament, though differing from it in having no cartilage cells among its fibres. It consists of strong, flattened fibres, which cross the notch at the lower part of the acetabulum, and convert it into a foramen. Thus an interval is left beneath the ligament for the passage of nutrient vessels to the joint.

The **Synovial Membrane** is very extensive. Commencing at the margin of the cartilaginous surface of the head of the femur, it covers all that portion of the neck which is contained within the joint; from the neck it is reflected on the internal surface of the capsular ligament, covers both surfaces of the cotyloid ligament and the mass of fat contained in the depression at the bottom of the acetabulum, and is prolonged in the form of a tubular sheath around the ligamentum teres as far as the head of the femur. It sometimes communicates through a hole in the capsular ligament between the inner band of the Y-shaped ligament and the pubo-femoral ligament with a bursa situated on the under surface of the Ilio-psoas.

Fig. 464.—Vertical section through hip-joint. (Henle.)

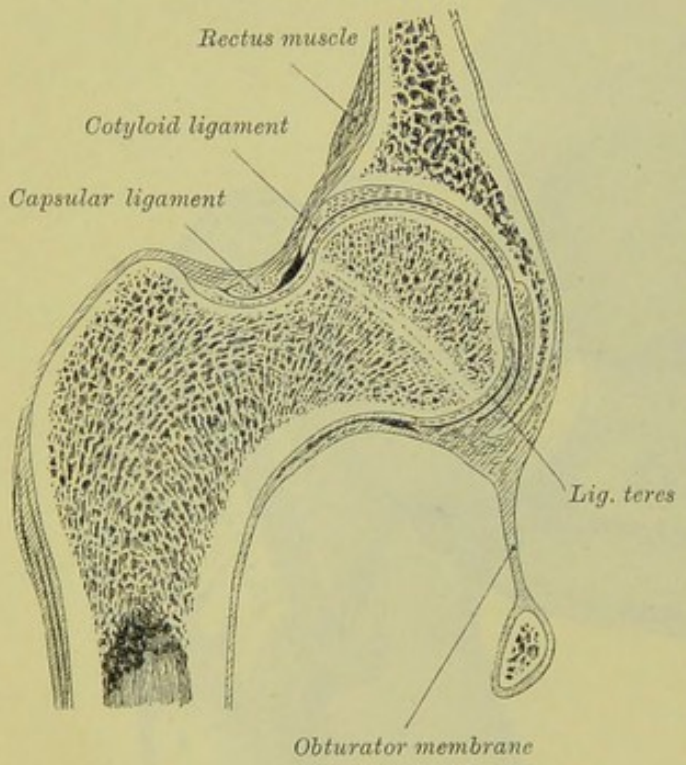

The *Muscles* in relation with the joint are, in front, the Psoas and Iliacus, separated from the capsular ligament by a synovial bursa; above, the reflected head of the Rectus and Gluteus minimus, the latter being closely adherent to the capsule; internally, the Obturator externus and Pectineus; behind, the Pyriformis, Gemellus superior, Obturator internus, Gemellus inferior, Obturator externus, and Quadratus femoris (fig. 465).

The *Arteries* supplying the joint are derived from the obturator, sciatic, internal circumflex, and gluteal.

The *Nerves* are articular branches from the sacral plexus, great sciatic, obturator, accessory obturator, and a filament from the branch of the anterior crural supplying the Rectus.

Movements.—The movements of the hip are very extensive, and consist of flexion, extension, adduction, abduction, circumduction, and rotation.

The length of the neck of the femur and its inclinations to the shaft have the effect of converting the angular movements of flexion, extension, adduction, and abduction partially into rotatory movements in the joint. Thus when the thigh is flexed or extended, the head of the femur, on account of the *inward* inclination of the neck, rotates within the acetabulum with only a slight amount of gliding to and fro. The *forward* slope of the neck similarly affects the movements of adduction and abduction. Conversely rotation of the thigh which is permitted by the

upward inclination of the neck, is not a simple rotation of the head of the femur in the acetabulum, but is accompanied by a certain amount of gliding.

The hip-joint presents a very striking contrast to the shoulder-joint in the much more complete mechanical arrangements for its security and for the limitation of its movements. In the shoulder, as has been seen, the head of the humerus is not adapted at all in size to the glenoid cavity, and is hardly restrained in any of its ordinary movements by the capsular ligament. In the hip-joint, on the contrary, the head of the femur is closely fitted to the acetabulum for a distance extending over nearly half a sphere, and at the margin of the bony cup it is still more closely embraced by the cotyloid ligament, so that the head of the femur is held in its place by that ligament even when the fibres of the capsule have been quite divided (Humphry). The ilio-femoral ligament is the strongest of all the ligaments in the body, and is put on the stretch by any attempt to extend the femur beyond a straight line with the trunk. That is to say, this ligament is the chief agent in maintaining the erect position without muscular fatigue; for a

FIG. 465.—Relation of muscles to the capsule of the hip-joint.
(From a drawing by F. A. Barton.)

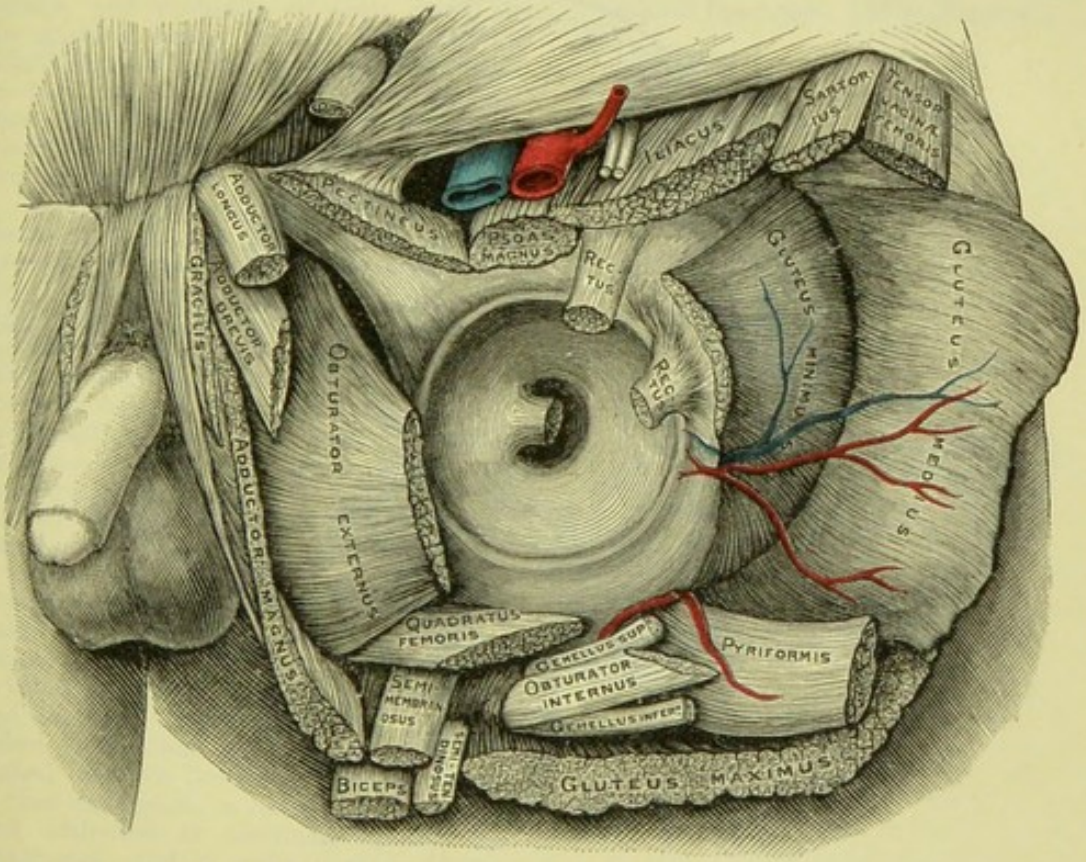

vertical line passing through the centre of gravity of the trunk falls behind the centres of rotation in the hip-joints, and therefore the pelvis tends to fall backwards, but is prevented by the tension of the ilio-femoral and capsular ligaments. The security of the joint may be also provided for by the two bones being directly united through the ligamentum teres; but it is doubtful whether this so-called ligament can have much influence upon the mechanism of the joint. Flexion of the hip-joint is arrested by the soft parts of the thigh and abdomen being brought into contact, when the leg is flexed on the thigh, and by the action of the hamstring muscles when the leg is extended; extension by the tension of the ilio-femoral ligament; adduction by the thighs coming into contact; adduction with flexion by the outer band of the ilio-femoral ligament and the outer part of the capsular ligament; abduction by the inner band of the ilio-femoral ligament and the pubo-femoral band; rotation outwards by the outer band of the ilio-femoral ligament; and rotation inwards by the ischio-capsular ligament and the hinder part of the capsule. The muscles which *flex* the femur on the pelvis are the Psoas, Iliacus, Rectus, Sartorius, Pectineus, Adductores longus et brevis,

and the anterior fibres of the Glutei medius and minimus. *Extension* is mainly performed by the Gluteus maximus, assisted by the hamstring muscles and the ischial head of the Adductor magnus. The thigh is *adducted* by the Adductors magnus, longus and brevis, the Pectineus, the Gracilis, and lower part of the Gluteus maximus, and *abducted* by the Gluteus medius and Gluteus minimus, and the upper part of the Gluteus maximus. The muscles which *rotate* the thigh *inwards* are the Gluteus minimus and the anterior fibres of the Gluteus medius, the Tensor fasciæ femoris and the Ilio-psoas; while those which rotate it *outwards* are the posterior fibres of the Gluteus medius, the Pyriformis, Obturators externus and internus, Gemelli superior and inferior, Quadratus femoris, Gluteus maximus, the three Adductors, the Pectineus, and the Sartorius.

Surface Form.—A line drawn from the anterior superior spine of the ilium to the most prominent part of the tuberosity of the ischium (Nélaton's line) (fig. 466) runs through the centre of the acetabulum, and would, therefore, indicate the level of the hip-joint; in other words, the upper border of the great trochanter, which touches Nélaton's line, is on a level with the centre of the hip-joint.

FIG. 466.—Nélaton's line and Bryant's triangle.

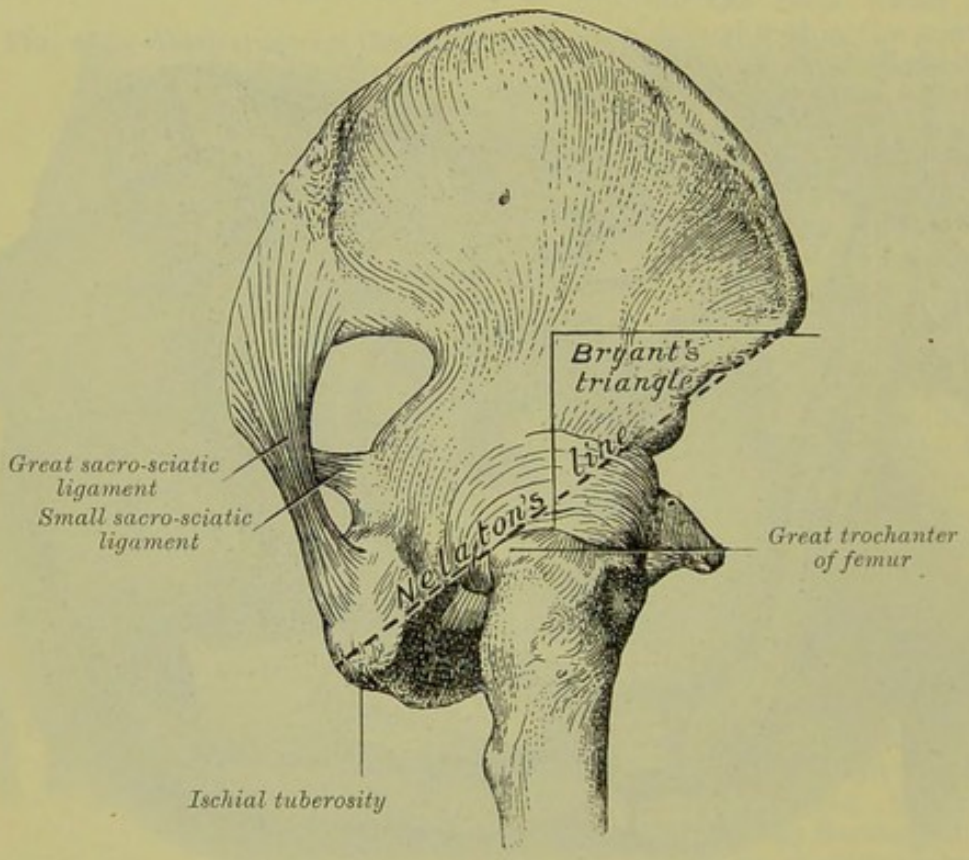

Applied Anatomy.—In dislocation of the hip, 'the head of the thigh-bone may rest at any point around its socket' (Bryant); but whatever position the head ultimately assumes, the primary displacement is generally downwards and inwards, the capsule giving way at its weakest—that is, its lower and inner—part. The situation that the head of the bone subsequently assumes is determined by the degree of flexion or extension, and of outward or inward rotation of the thigh at the moment of luxation, influenced, no doubt, by the ilio-femoral ligament, which is not easily ruptured. When, for instance, the head is forced backwards, this ligament forms a fixed axis, round which the head of the bone rotates, and is thus driven on to the dorsum of the ilium. The ilio-femoral ligament also influences the position of the thigh in the various dislocations: in the dislocations backwards it is tense, and produces inversion of the limb; in the dislocation on to the pubes, it is relaxed, and therefore allows the external rotators to evert the thigh; while in the thyroid dislocation it is tense, and produces flexion. The muscles inserted into the upper part of the femur, with the exception of the Obturator internus, have very little direct influence in determining the position of the bone. Bigelow, however, has endeavoured to show that the Obturator internus is the principal agent in deciding whether, in the backward dislocations, the head of the bone shall be ultimately lodged on the dorsum of the ilium, or in or near the sciatic notch; in both dislocations the head passes, in the first instance, in the same direction; but, as Bigelow asserts, in the displacement on to the dorsum the

head of the bone travels up behind the acetabulum, in front of the muscle; while in the dislocation into the sciatic notch the head passes behind the muscle, and is prevented from reaching the dorsum, in consequence of the tendon of the muscle arching over the neck of the bone, and it therefore remains in the neighbourhood of the sciatic notch. Bigelow distinguishes these two forms of dislocation by describing them as dislocations backwards, 'above and below' the Obturator internus.

The ilio-femoral ligament is rarely torn in dislocations of the hip, and this fact is taken advantage of by the surgeon in reducing these dislocations by manipulation. It is made to act as the fulcrum to a lever, of which the long arm is the shaft of the femur, and the short arm the neck of the bone.

The hip-joint is rarely the seat of acute synovitis from injury, on account of its deep position and its thick covering of soft parts. Acute inflammation may, and does, frequently occur as the result of constitutional conditions, as rheumatism, pyæmia, &c. When, in these cases, effusion takes place, and the joint becomes distended with fluid, the swelling is not very easy to detect on account of the thickness of the capsule and the depth of the articulation. It is principally to be found on the front of the joint, just internal to the ilio-femoral ligament; or behind, at the lower and back part. In these two places the capsule is thinner than elsewhere. Disease of the hip-joint is much oftener of a chronic character, and is usually of tuberculous origin. It begins either in the bones or in the synovial membrane; usually in the former, and probably, in most cases, in the growing, highly vascular tissue in the neighbourhood of the epiphysial cartilage. In this respect it differs very materially from tuberculous arthritis of the knee, where the disease usually commences in the synovial membrane.

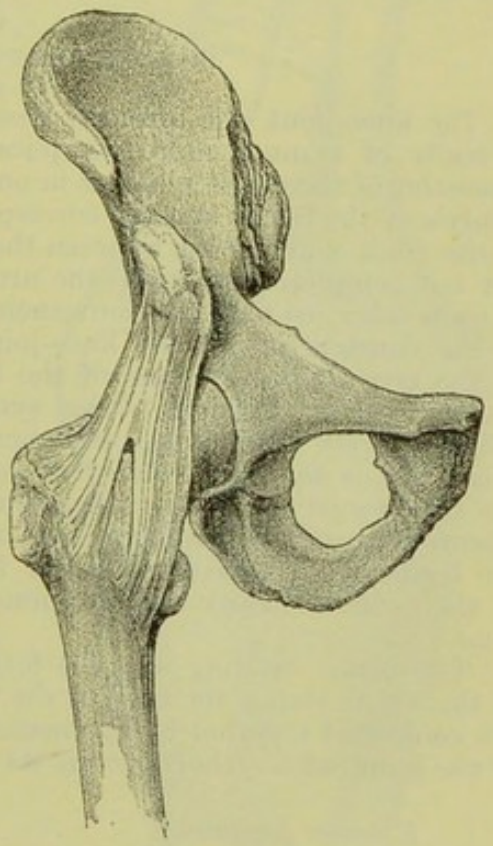

FIG. 467.—Hip-joint, showing the ilio-femoral ligament. (After Bigelow.)

In chronic hip-disease the affected limb assumes an altered position, the cause of which it is important to understand. In the early stage of a typical case, the limb is flexed, abducted, and rotated outwards. In this position all the ligaments of the joint are relaxed: the front of the capsule by flexion; the outer band of the ilio-femoral ligament by abduction; and the inner band of this ligament and the back of the capsule by rotation outwards. It is, therefore, the position of greatest ease. The condition is not quite obvious at first, upon examining a patient. If the patient is laid in the supine position, the affected limb will be found to be extended and parallel with the other. But it will be seen that the pelvis is tilted downwards on the diseased side and the limb apparently longer than its fellow, and that the lumbar spine is arched forwards (lordosis). The condition is thus explained: a limb which is flexed and abducted is obviously useless for progression, and in order to overcome the difficulty the patient depresses the affected side of his pelvis, thus producing parallelism of his limbs, and at the same time rotates his pelvis on its transverse horizontal axis, so as to direct the limb downwards, instead of forwards. In the later stages of the disease the limb becomes flexed and adducted and inverted. This position probably depends upon muscular action, at all events as regards the adduction. The Adductor muscles are supplied by the obturator nerve, which also largely supplies the joint. These muscles are therefore thrown into reflex action by the irritation of the peripheral terminations of this nerve in the inflamed articulation.

Osteo-arthritis is not uncommon in the hip-joint, and is said to be more common in the male than in the female, in whom the knee-joint is more frequently affected. It is a disease of middle age or advanced life. When much deformity is associated with chronic osteo-arthritis the condition is spoken of as *Arthritis deformans of the hip*, or *Morbus coxæ senilis*. The head of the femur is worn away, and after it often the neck too, until the irregular articular surface comes to lie on the femur between the two trochanters. New formation of bone occurs at its edges, and also at the edges of the acetabulum, which is widened and eroded by a similar chronic process. Pain in the joint, shortening of the limb, and great limitation of movement result, with much creaking and grating when the joint is moved.

Congenital dislocation is more commonly met with in the hip-joint than in any other articulation. The displacement usually takes place on to the dorsum ilii. It gives rise to extreme lordosis, and a waddling gait is noticed as soon as the child commences to walk.

Excision of the hip may be required for disease or for injury, especially gunshot. It may be performed either by an anterior incision or by a posterior one. The former entails less interference with important structures, especially muscles, than the latter, but permits of less efficient drainage. In these days, however, when the surgeon aims at securing healing of the wound without suppuration, this second desideratum is not of so much importance. In the operation from the front, an incision is made three to four inches in length, starting immediately below and external to the anterior superior spinous process of the ilium, downwards and inwards between the Sartorius and Tensor fasciæ femoris, to the neck of the bone, dividing the capsule at its upper part. A narrow-bladed saw now divides the neck of the femur, and the head of the bone is extracted with sequestrum forceps. All diseased tissue is carefully removed with a sharp spoon or scissors, and the cavity thoroughly flushed out with a hot antiseptic or sterile fluid.

The posterior method consists in making an incision three or four inches long, commencing midway between the top of the great trochanter and the crest of the ilium, and extending down the posterior border of the trochanter. The muscles are detached from the great trochanter, and the capsule opened freely. The head and neck are freed from the soft parts and the bone sawn through just below the top of the trochanter with a narrow saw. The head of the bone is then levered out of the acetabulum. In both operations, if the acetabulum is eroded, it must be freely gouged.

II. KNEE-JOINT (ARTICULATIO GENU)

The knee-joint was formerly described as a ginglymus or hinge-joint, but is really of a much more complicated character. It must be regarded as consisting of three articulations in one : two condyloid joints, one between each condyle of the femur and the corresponding semilunar cartilage and tuberosity of the tibia, and a third between the patella and the femur, partly arthrodial, but not completely so, since the articular surfaces are not mutually adapted to each other, so that the movement is not a simple gliding one. This view of the construction of the knee-joint receives confirmation from the study of the articulation in some of the lower mammals, where, corresponding to these three subdivisions, three synovial membranes are sometimes found, either entirely distinct or only connected together by small communications. This view is further rendered probable by the existence within the joint of the two crucial ligaments, which must be regarded as the external and internal lateral ligaments of the inner and outer joints respectively. The existence of the ligamentum mucosum would further indicate a tendency to separation of the synovial cavity into two minor sacs, one corresponding to each lateral joint.

The bones entering into the formation of the knee-joint are the condyles of the femur above, the head of the tibia below, and the patella in front. They are connected together by ligaments, some of which are placed on the exterior of the joint, while others occupy its interior.

Exterior Ligaments	*Interior Ligaments*	
Capsular.	Anterior or External Crucial.	
Anterior, or Ligamentum Patellæ.	Posterior or Internal Crucial.	
Posterior, or Ligamentum Posticum Winslowii.	Two Semilunar Fibro-cartilages.	
Internal Lateral.	Transverse.	
External Lateral.	Coronary.	
	Ligamentum mucosum	Processes of Synovial membrane.
	Ligamenta alaria	

The **Capsular Ligament** (capsula articularis) consists of a thin, but strong, fibrous membrane which is strengthened in almost its entire extent by bands inseparably connected with it. Above and in front, beneath the tendon of the Quadriceps extensor muscle, it is so thin that it is usually described as defective. Its chief strengthening bands are derived from the fascia lata and from the tendons surrounding the joint. In front, expansions from the Vasti and from the fascia lata and its ilio-tibial band fill in the intervals between the anterior and lateral ligaments, constituting the *lateral patellar*

ligaments. Behind, the capsular ligament consists of vertical fibres which arise from the condyles and intercondyloid notch of the femur, and are augmented by fibres derived from the tendon of the Semimembranosus, to form the posterior ligament. On the outer side of the joint, a prolongation from the ilio-tibial band fills in the interval between the posterior and the external lateral ligaments, and partly covers the latter. On the inner side, expansions from the Sartorius and Semimembranosus pass upwards to the internal lateral ligament and strengthen the capsule.

The **Anterior Ligament,** or **Ligamentum Patellæ** (fig. 468), is the central portion of the common tendon of the Extensor muscles of the thigh, which is continued from the patella to the tubercle of the tibia, supplying the place of an anterior ligament. It is a strong, flat, ligamentous band, about three inches in length, attached, above, to the apex and adjoining margins of the patella and the rough depression on its posterior surface; below, to the tubercle of the tibia; its superficial fibres are continuous over the front of the patella with those of the tendon of the Quadriceps extensor. The lateral portions of the tendon of the Extensor muscles pass down on either side of the patella, to be inserted into the upper extremity of the tibia on either side of the tubercle; these portions merge into the capsular ligament, as stated above, forming the lateral patellar ligaments. The posterior surface of the ligamentum patellæ is separated from the synovial membrane of the joint by a large pad (*infrapatellar*) of fat, and from the tibia by a synovial bursa.

Fig. 468.—Right knee-joint. Anterior view.

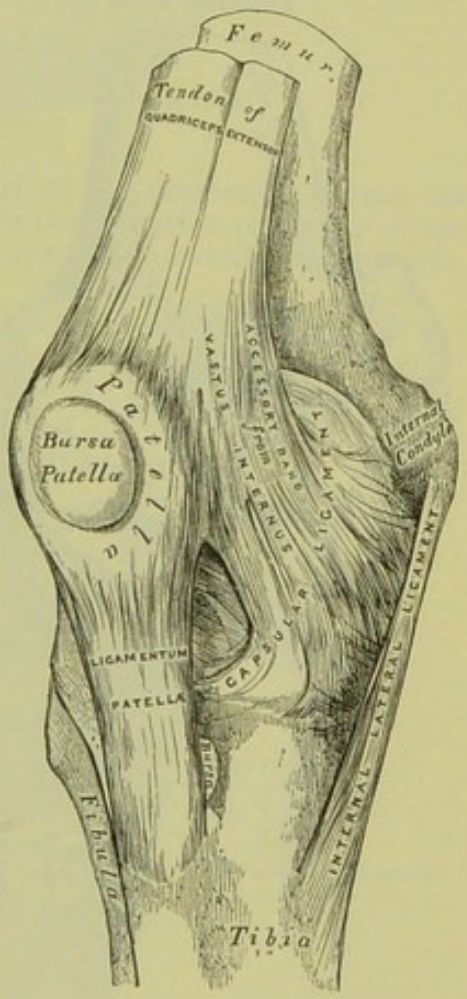

The **Posterior Ligament** (lig. posticum Winslowii) (fig. 469) is a broad, flat, fibrous band, formed of fasciculi separated from one another by apertures for the passage of vessels and nerves. It is attached above to the upper margin of the intercondyloid notch and posterior surface of the femur close to the articular margins of the condyles, and below to the posterior margin of the head of the tibia. Superficial to the main part of the ligament is a strong fasciculus, derived from the tendon of the Semimembranosus and passing from the back part of the inner tuberosity of the tibia obliquely upwards and outwards to the back part of the outer condyle of the femur, where it becomes lost in the general ligament.* The posterior ligament forms part of the floor of the popliteal space, and the popliteal artery rests upon it.

The **Internal Lateral Ligament** (lig. collaterale tibiale) is a broad, flat, membranous band, situated nearer to the back than to the front of the joint. It is attached, above, to the inner tuberosity of the femur immediately below the Adductor tubercle; below, to the inner tuberosity and inner surface of the shaft of the tibia. The fibres of the posterior part of the ligament are short, and are inserted into the inner part of the tuberosity of the tibia above the groove for the Semimembranosus muscle. They incline backwards as they descend. The anterior part of the ligament is a flattened band, about four inches in length, which inclines forwards as it descends. It is inserted into the inner surface of the shaft of the tibia about an inch

* This oblique band is sometimes termed the ligamentum posticum Winslowii, in contradistinction to the posterior ligament, which is then regarded as part of the capsular ligament.

and a half below the level of the tuberosity. It is crossed, at its lower part, by the tendons of the Sartorius, Gracilis, and Semitendinosus muscles, a synovial bursa being interposed. Its *deep surface* covers the anterior portion of the tendon of the Semimembranosus, with which it is connected by a few fibres, and the inferior internal articular vessels and nerve; it is intimately adherent to the internal semilunar fibro-cartilage.

The **External Lateral Ligament** (lig. collaterale fibulare) is a strong, rounded, fibrous cord, attached, above, to the back part of the outer tuberosity of the femur, immediately above the groove for the Popliteus muscle; below, to the outer side of the head of the fibula, in front of the styloid process. Its *outer surface* is covered by the tendon of the Biceps, which divides at its insertion into two parts, separated by the ligament. Passing beneath the ligament are the tendon of the Popliteus muscle, and the inferior external articular vessels and nerve. It has no attachment to the external semilunar fibro-cartilage.

Fig. 469.—Right knee-joint. Posterior view.

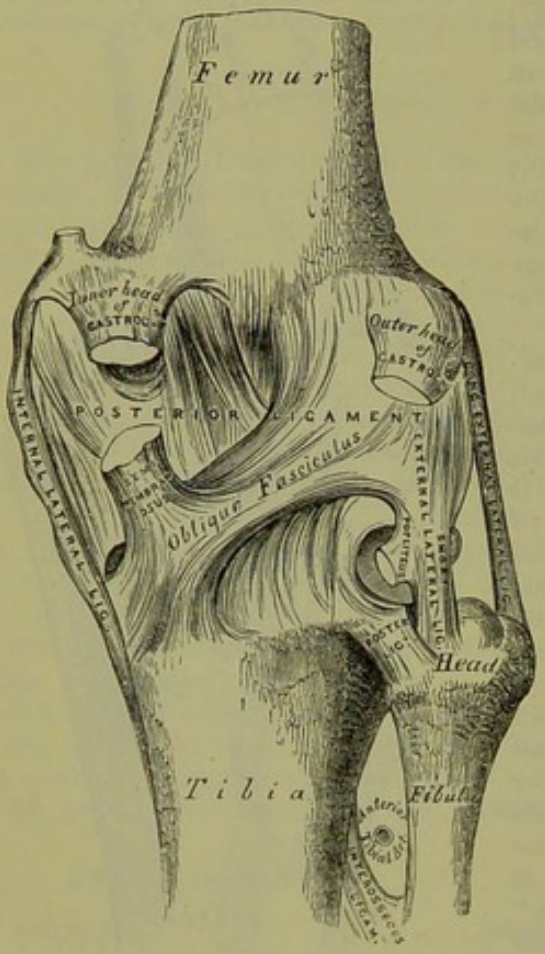

Fig. 470.—Right knee-joint. Showing interior ligaments.

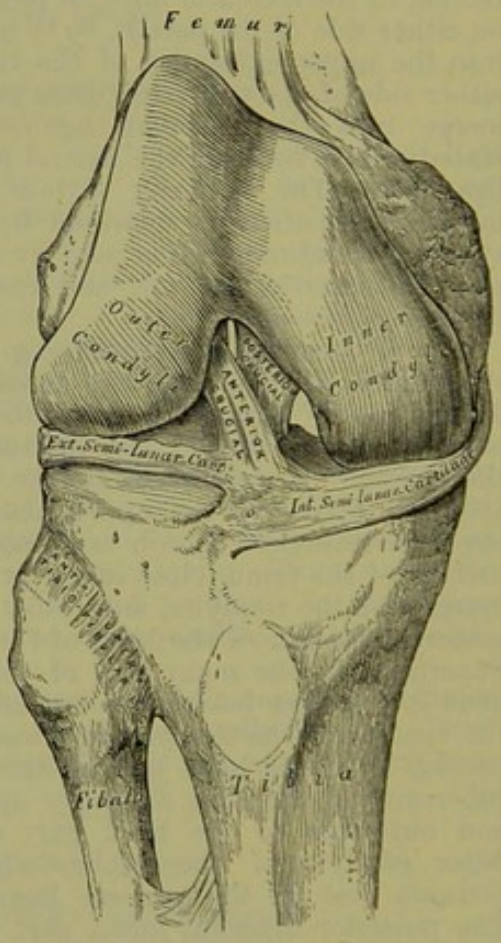

The **Short External Lateral Ligament** is an inconstant bundle of fibres placed behind and parallel with the preceding, attached, above, to the lower and back part of the outer tuberosity of the femur; below, to the summit of the styloid process of the fibula. This ligament is intimately connected with the capsular ligament, while passing beneath it are the tendon of the Popliteus muscle, and the inferior external articular vessels and nerve.

The **Crucial Ligaments** (ligg. cruciata genu) are of considerable strength, situated in the interior of the joint, nearer its posterior than its anterior part. They are called *crucial* because they cross each other somewhat like the lines of the letter X; and have received the names *anterior* and *posterior*, from the position of their attachments to the tibia.

The **Anterior** or **External Crucial Ligament** (lig. cruciatum anterius) (figs. 470, 471) is attached to the depression in front of the spine of the tibia, being blended with the anterior extremity of the external semilunar fibro-

cartilage; it passes obliquely upwards, backwards, and outwards, and is fixed into the inner and back part of the outer condyle of the femur.

The **Posterior** or **Internal Crucial Ligament** (lig. cruciatum posterius) (figs. 471, 472) is stronger, but shorter and less oblique in its direction, than

Fig. 471.—Head of tibia, with semilunar fibro-cartilages. Seen from above. Right side.

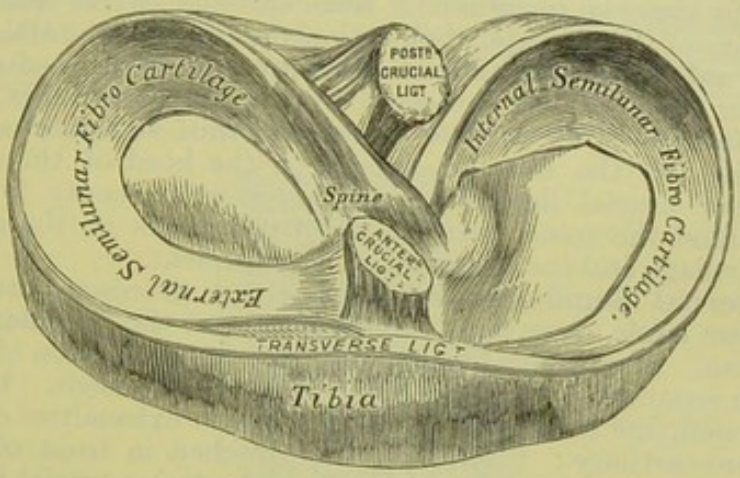

the anterior. It is attached to the back part of the depression behind the spine of the tibia, to the popliteal notch, and to the posterior extremity of the external semilunar fibro-cartilage; and passes upwards, forwards, and inwards,

Fig. 472.—Left knee-joint from behind, showing interior ligaments.

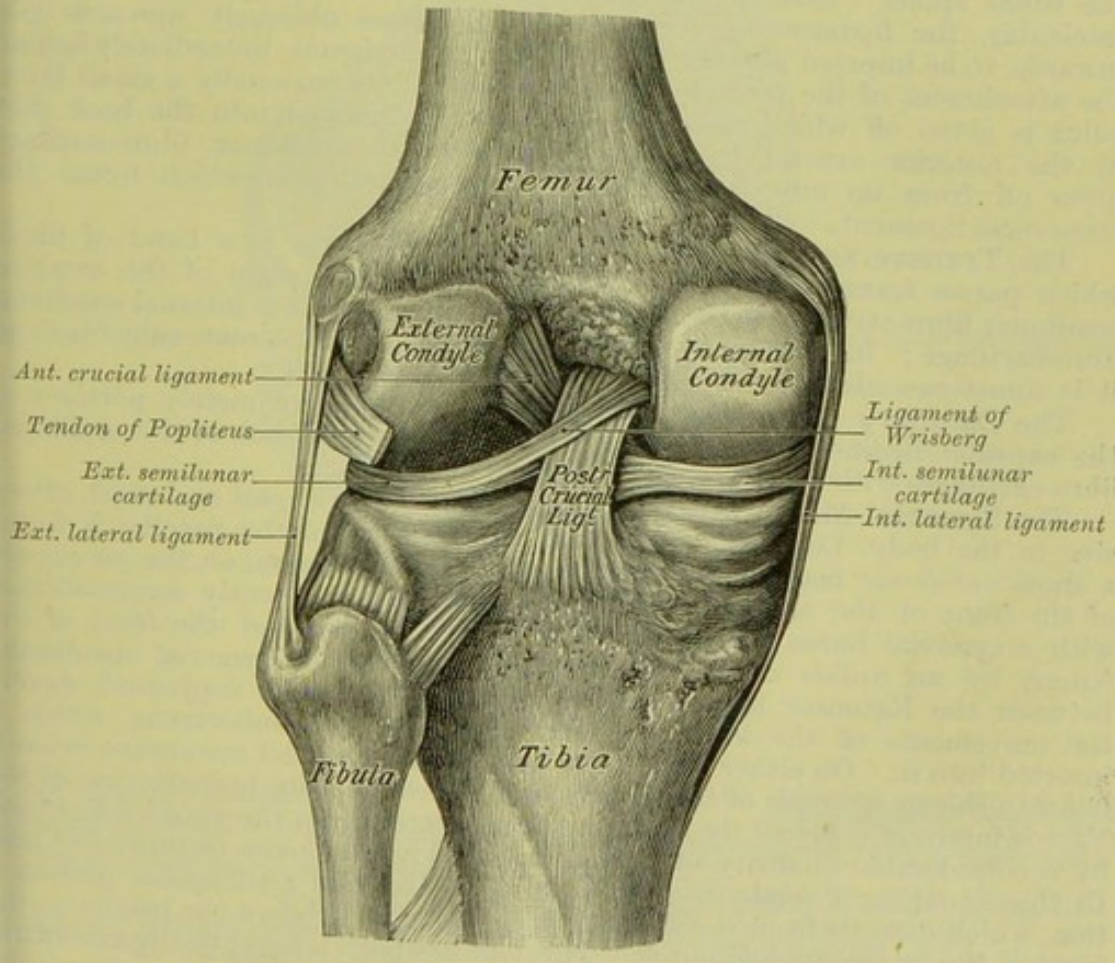

to be fixed into the outer and fore part of the inner condyle of the femur. It is in relation, in front, with the anterior crucial ligament; behind, with the capsular ligament.

The **Semilunar Fibro-cartilages** (fig. 471) are two crescentic lamellæ, which serve to deepen the surfaces of the head of the tibia for articulation with the condyles of the femur. The peripheral border of each cartilage is thick, convex, and attached to the inside of the capsule of the knee; the opposite border is thin, concave, and free. Their upper surfaces are concave, and in relation with the condyles of the femur; their lower surfaces are flat, and rest upon the head of the tibia; both surfaces of the cartilages are smooth, and invested by synovial membrane. Each cartilage covers nearly two-thirds of the periphery of the corresponding articular surface of the tibia.

The **Internal Semilunar Fibro-cartilage** (meniscus medialis) is nearly semicircular in form, a little elongated from before backwards, and broader behind than in front; its anterior extremity, thin and pointed, is attached to a depression on the anterior margin of the head of the tibia, in front of the anterior crucial ligament; its posterior extremity is fixed to the depression behind the spine, between the attachments of the external semilunar fibro-cartilage and the posterior crucial ligament.

The **External Semilunar Fibro-cartilage** (meniscus lateralis) forms nearly an entire circle, covering a larger portion of the articular surface than the internal one. It is grooved on its outer side for the tendon of the Popliteus muscle, which separates it from the external lateral ligament. Its extremities, at their insertion, are interposed between the two extremities of the internal semilunar fibro-cartilage; the anterior is attached in front of the spine of the tibia to the outer side of, and behind, the anterior crucial ligament, with which it blends; the posterior is attached behind the spine of the tibia and in front of the posterior extremity of the internal semilunar fibro-cartilage. The anterior attachment of the external semilunar cartilage is twisted on itself so that its free margin looks backwards and upwards, its anterior end resting on a sloping shelf of bone on the front of the external tubercle of the tibial spine. Close to its posterior attachment it gives off a strong fasciculus, the *ligament of Wrisberg*, which passes obliquely upwards and inwards, to be inserted into the inner condyle of the femur, immediately behind the attachment of the posterior crucial ligament. Occasionally a small fasciculus is given off which passes forwards to be inserted into the back part of the anterior crucial ligament. The external semilunar fibro-cartilage gives off from its anterior convex margin a fasciculus which forms the transverse ligament.

The **Transverse Ligament** (lig. transversum genu) is a band of fibres which passes transversely from the anterior convex margin of the external semilunar fibro-cartilage to the anterior convex margin of the internal semilunar fibro-cartilage; its thickness varies considerably in different subjects, and it is sometimes absent.

The **Coronary Ligaments** (ligamenta coronaria) are merely portions of the capsular ligament, which connect the periphery of each of the semilunar fibro-cartilages with the margin of the head of the tibia.

The **Synovial Membrane** of the knee-joint is the largest and most extensive in the body. Commencing at the upper border of the patella, it forms a short *cul-de-sac* beneath the Quadriceps extensor tendon, on the lower part of the front of the shaft of the femur: this very frequently communicates with a synovial bursa interposed between the tendon and the front of the femur, by an orifice of variable size. The pouch of synovial membrane between the Extensor tendon and front of the femur is supported, during the movements of the knee, by a small muscle, the Subcrureus, which is inserted into it. On either side of the patella, the synovial membrane extends beneath the aponeurosis of the Vastus, and more especially beneath that of the Vastus internus. Below the patella it is separated from the anterior ligament by a considerable quantity of adipose tissue, known as the *infrapatellar pad*. In this situation it sends into the interior of the joint a triangular prolongation, which extends from the anterior part of the joint below the patella to the front of the intercondyloid notch. This fold has been termed the **ligamentum mucosum** (plica synovialis patellaris). It also sends off two fringe-like folds, called the **ligamenta alaria** (plicæ alares) which extend from the sides of the ligamentum mucosum, upwards and laterally between the patella and femur. On either side of the joint, it passes downwards from the femur, lining the

capsule to its point of attachment to the semilunar cartilages ; it may then be traced over the upper surfaces of these cartilages to their free borders, and thence along their under surfaces to the tibia. At the back part of the external one it forms a *cul-de-sac* between the groove on its surface and the tendon of the Popliteus ; it surrounds the crucial ligaments, and lines the inner surfaces of the ligaments which enclose the joint.

Bursæ.—The bursæ about the knee-joint are the following :

In front there are four bursæ : one is interposed between the patella and the skin ; another of small size between the upper part of the tibia and the ligamentum patellæ ; a third between the lower part of the tuberosity of

FIG. 473.—Sagittal section of right knee-joint.

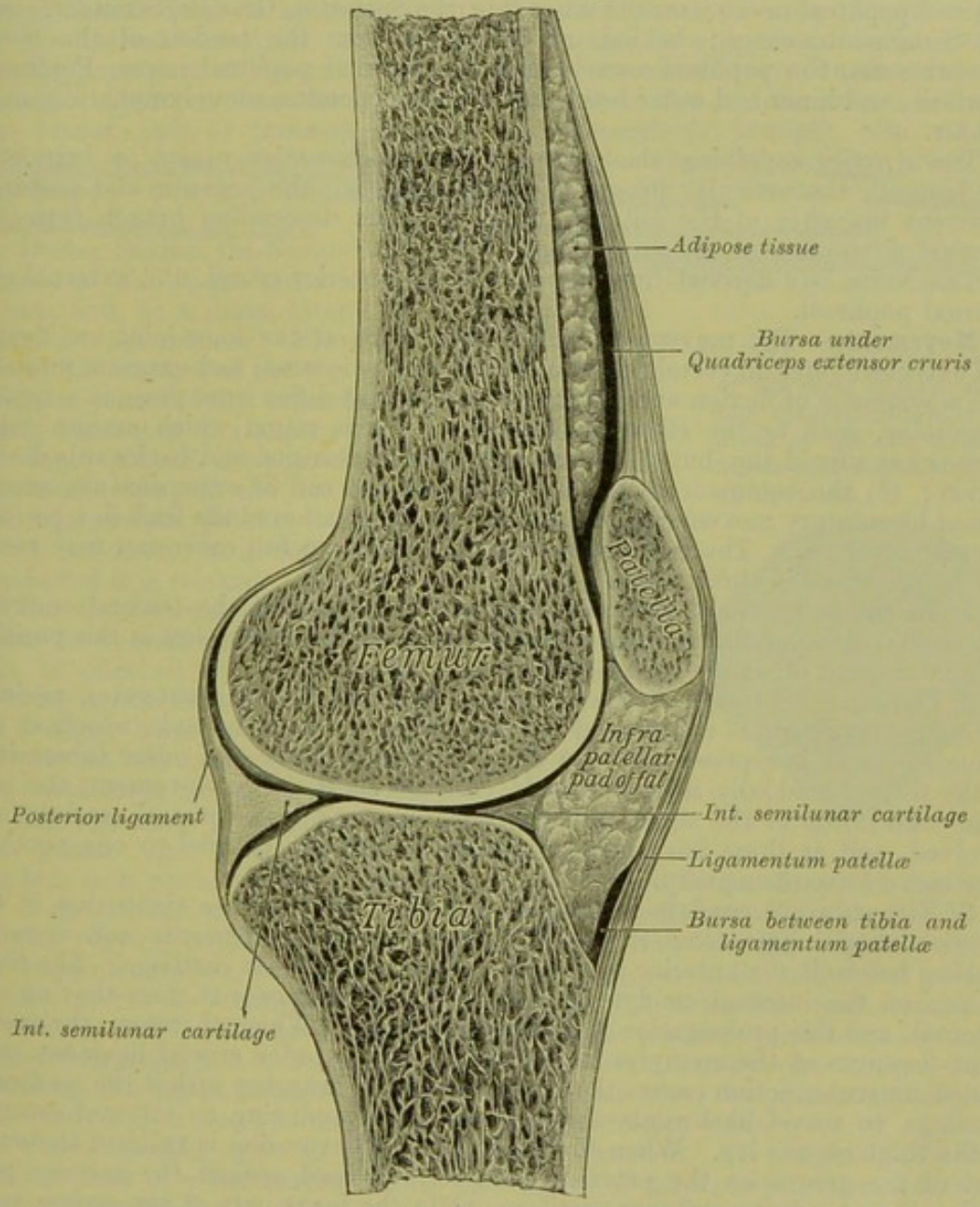

the tibia and the skin ; and a fourth between the anterior surface of the lower end of the femur and the under surface of the Quadriceps extensor cruris, usually communicating with the knee-joint. On the outer side there are four bursæ : (1) one (which sometimes communicates with the joint) between the outer head of the Gastrocnemius and the capsule ; (2) one above the external lateral ligament, between it and the tendon of the Biceps ; (3) one beneath the external lateral ligament, between it and the tendon of the Popliteus (this is sometimes only an expansion from the next bursa) ; (4) one beneath the tendon of the Popliteus, between it and the condyle of the femur, which is almost always an extension from the synovial membrane.

On the inner side there are five bursæ : (1) one between the inner head of the Gastrocnemius and the capsule; this sends a prolongation between the tendons of the Gastrocnemius and Semimembranosus and often communicates with the joint ; (2) one above the internal lateral ligament between it and the tendons of the Sartorius, Gracilis, and Semitendinosus ; (3) one beneath the internal lateral ligament, between it and the tendon of the Semimembranosus (this is sometimes only an expansion from the next bursa) ; (4) one beneath the tendon of the Semimembranosus, between it and the head of the tibia ; (5) occasionally there is a bursa between the tendons of the Semimembranosus and Semitendinosus.

Structures around the Joint.—In front, and at the sides, is the Quadriceps extensor ; on the outer side, the tendons of the Biceps and Popliteus and the external popliteal nerve ; on the inner side, the Sartorius, Gracilis, Semitendinosus and Semimembranosus ; behind, an expansion from the tendon of the Semimembranosus, the popliteal vessels, and the internal popliteal nerve, Popliteus, Plantaris, and inner and outer heads of the Gastrocnemius, some lymphatic glands, and fat.

The *Arteries* supplying the joint are the anastomotica magna, a branch of the femoral, the articular branches of the popliteal, the anterior and posterior recurrent branches of the anterior tibial, and the descending branch from the external circumflex of the profunda.

The *Nerves* are derived from the obturator, anterior crural, and external and internal popliteal.

Movements.—The movements which take place at the knee-joint are flexion and extension, and, in certain positions of the joint, internal and external rotation. The movements of flexion and extension at this joint differ from those in a typical hinge-joint, such as the elbow, in that (*a*) the axis round which motion takes place is not a fixed one, but shifts forwards during extension and backwards during flexion ; (*b*) the commencement of flexion and the end of extension are accompanied by rotatory movements associated with the fixation of the limb in a position of great stability. The movement from full flexion to full extension may therefore be described in three phases.

1. In the fully flexed condition the posterior parts of the femoral condyles rest on the corresponding portions of the menisco-tibial surfaces, and in this position a slight amount of simple rolling movement is allowed.

2. During the passage of the limb from the flexed to the extended position a gliding movement is superposed on the rolling, so that the axis, which at the commencement is represented by a line through the inner and outer tuberosities of the femur, gradually shifts forwards. In this part of the movement, the posterior two-thirds of the tibial articular surfaces of the two femoral condyles are involved, and as these have similar curvatures and are parallel to one another, they move forwards equally.

3. The external condyle is brought almost to rest by the tightening of the anterior crucial ligament ; it moves, however, slightly forwards and inwards, pushing before it the anterior part of the external semilunar cartilage. The tibial surface on the internal condyle is prolonged farther forwards than that on the external, and this prolongation is directed outwards. When, therefore, the movement forwards of the condyles is checked by the anterior crucial ligament, continued muscular action causes the internal condyle, dragging with it the semilunar cartilage, to travel backwards and inwards, thus producing an internal rotation of the thigh on the leg. When the position of full extension is reached the outer part of the groove on the external condyle is pressed against the anterior part of the corresponding semilunar cartilage, while the inner part of the groove rests on the articular margin in front of the external tubercle of the tibial spine. Into the groove on the internal condyle is fitted the anterior part of the internal semilunar cartilage, while the anterior crucial ligament and the articular margin in front of the inner tubercle of the tibial spine are received into the fore part of the intercondyloid notch. This third phase by which all these parts are brought into accurate apposition is known as the ' screwing home,' or locking movement of the joint.

The complete movement of flexion is the converse of that described above, and is therefore preceded by an external rotation of the femur which unlocks the extended joint.

The axes round which the movements of flexion and extension take place are not precisely at right angles to either bone; in flexion, the femur and tibia are in the same plane, but in extension the one bone forms an angle with the other.

In addition to the rotatory movements associated with the completion of extension and the initiation of flexion, rotation inwards or outwards can be effected when the joint is partially flexed. These latter rotatory movements take place mainly between the tibia and the semilunar cartilages, and are freest when the leg is bent at right angles with the thigh.

Movements of Patella.—The articular surface of the patella is indistinctly divided into seven facets—upper, middle, and lower horizontal pairs, and an internal perpendicular facet (fig. 474). When the knee is forcibly flexed, the internal perpendicular facet is in contact with the semilunar surface on the outer part of the internal condyle; this semilunar surface is a prolongation backwards of the inner part of the trochlea. As the leg is carried from the flexed to the extended position, first the uppermost pair, then the middle pair, and lastly the lowest pair of horizontal facets are successively brought into contact with the trochlear surface of the femur. In the extended position, when the Quadriceps extensor is relaxed, the patella lies loosely on the front of the lower end of the femur.

During flexion, the ligamentum patellæ is put upon the stretch, and in extreme flexion so also is the posterior crucial ligament; the lateral and posterior ligaments, and, to a slight extent, the anterior crucial ligament, are relaxed. Flexion is checked during life by the contact of the leg with the thigh. When the knee-joint is fully extended the lateral and posterior ligaments, the anterior crucial ligament, and the inner part of the posterior crucial ligament, are rendered tense; in the act of extending the knee, the ligamentum patellæ is tightened by the Quadriceps extensor, but in full extension with the heel supported it is relaxed. Rotation inwards is checked by the anterior crucial ligament; rotation outwards tends to uncross and relax the crucial ligaments, but is checked by the internal lateral ligament. The main function of the crucial ligaments is to act as a direct bond between the tibia and femur and to prevent the former bone from being carried too far backwards or forwards. They also assist the lateral ligaments in resisting any lateral bending of the joint. The interarticular cartilages are intended, as it seems, to adapt the surface of the tibia to the shape of the femur to a certain extent, so as to fill up the intervals which would otherwise be left in the varying positions of the joint, and to obviate the jars which would be so frequently transmitted up the limb in jumping or by falls on the feet; also to permit of the two varieties of motion, flexion and extension, and rotation, as explained above. The patella is a great defence to the knee-joint from any injury inflicted in front, and it distributes upon a large and tolerably even surface, during kneeling, the pressure which would otherwise fall upon the prominent ridges of the condyles; it also affords leverage to the Quadriceps extensor.

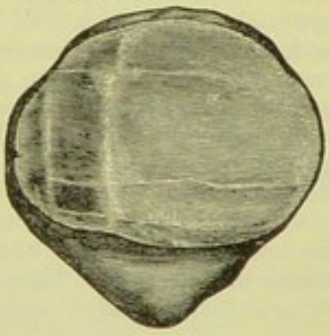

Fig. 474.—Posterior surface of the right patella, showing diagrammatically the areas of contact with the femur in different positions of the knee.

When standing erect in the attitude of 'attention,' the weight of the body falls in front of a line carried across the centres of the knee-joints, and therefore tends to produce over-extension of the articulations; this, however, is prevented by the tension of the anterior crucial, posterior, and lateral ligaments.

Extension of the leg on the thigh is performed by the Quadriceps extensor; *flexion* by the hamstring muscles, assisted by the Gracilis and Sartorius, and by the Gastrocnemius, Popliteus, and Plantaris. *Rotation outwards* is effected by the Biceps, and *rotation inwards* by the Popliteus, Semitendinosus, and, to a slight extent, the Semimembranosus, the Sartorius, and the Gracilis. The Popliteus comes into action especially at the commencement of the movement of flexion of the knee; by its contraction the leg is rotated inwards, or, if the tibia be fixed, the thigh is rotated outwards, and the knee-joint is unlocked.

Surface Form.—The interval between the femur and tibia can always be easily felt. If the limb be extended, it is situated on a slightly higher level than the apex of the patella; but if the limb be slightly flexed, a knife carried horizontally backwards immediately below the apex of the patella would pass directly into the joint. When the knee is semi-flexed, the internal border of the inner condyle of the femur, the upper border of the inner tuberosity of the tibia, and the inner margin of the patella form a triangular depressed area, which coincides with the level of the joint and with the internal semilunar fibro-cartilage. If this cartilage be displaced inwards, a gap will be felt in this situation. When the knee-joint is distended with fluid, the outline of the synovial membrane at the front of the knee may be fairly well mapped out.

Applied Anatomy.—From a consideration of the construction of the knee-joint, it would at first sight appear to be one of the least secure of any of the joints in the body. It is formed between the two longest bones, and therefore the amount of leverage which can be brought to bear upon it is considerable; the articular surfaces are but ill-adapted to each other, and the range of motion which it enjoys is great. All these circumstances tend to render the articulation insecure; nevertheless, on account of the powerful ligaments which bind the bones together, the joint is one of the strongest in the body, and dislocation from traumatism is a rare occurrence. When, on the other hand, the ligaments have been softened or destroyed by disease, partial displacement is liable to occur, and is frequently brought about by the mere action of the muscles displacing the articular surfaces from each other. The tibia may be dislocated forwards, backwards, inwards, or outwards; or a combination of two of these dislocations may occur, and any of these dislocations may be complete or incomplete.

One or other of the semilunar cartilages may become displaced and nipped between the femur and tibia. The accident is produced by a twist of the leg when the knee is flexed, and is accompanied by a sudden pain and fixation of the knee in a flexed position. The cartilage may be displaced either inwards or outwards: that is to say, either inwards towards the tibial spine, so that the cartilage becomes lodged in the intercondyloid notch; or outwards, so that the cartilage projects beyond the margin of the two articular surfaces. The internal cartilage is much more commonly the one affected.

Acute synovitis, the result of traumatism, is very common in the knee, on account of the superficial position of the joint. When the cavity is distended with fluid, the swelling shows itself above and at the sides of the patella, reaching about an inch, occasionally two inches or more, above the trochlear surface of the femur, and extending a little higher under the Vastus internus than under the Vastus externus. The lower level of the synovial membrane is just above the level of the head of the tibia. Chronic synovitis shows itself principally in the form of pulpy degeneration of the synovial membrane, leading to tuberculous arthritis. The reasons why tuberculous disease of the knee usually commences in the synovial membrane appear to be (*a*) the complex and extensive nature of this sac, and (*b*) the fact that injuries are generally diffused and applied to the front of the joint rather than to the ends of the bones. Syphilitic disease not infrequently attacks the knee-joint. In the tertiary form of the disease, gummatous infiltration of the synovial membrane may take place. The knee is one of the joints most commonly affected with osteo-arthritis, and is said to be more frequently the seat of this disease in women than in men. The occurrence of the so-called loose cartilages is almost confined to the knee, though they are occasionally met with in other joints. Many of them occur in cases of osteo-arthritis, in which calcareous or cartilaginous material is formed in one of the synovial fringes and constitutes the foreign body, and may or may not become detached, in the former case only meriting the usual term, 'loose' cartilage. In other cases they have their origin in the exudation of inflammatory lymph, and possibly, in some rare instances, a portion of the articular cartilage or one of the semilunar cartilages becomes detached and constitutes the foreign body.

In inflammatory affections of the knee-joint, the position of greatest ease, and therefore the one which is always assumed, is that of slight flexion. In this position there is the most complete relaxation of ligamentous structures, and, therefore, the greatest diminution in the tension caused by the effusion. If this flexed position be maintained for any length of time, it becomes permanent from fibrous adhesions taking place, and the utility of the limb is materially impaired. Attention should therefore be paid by the surgeon to the position of the limb; and by carefully applied splints, with the leg in an extended position, this untoward result should be prevented. In cases of septic synovitis, incisions to evacuate the pus should be made vertically on either side of the patella, between it and the condyles of the femur.

Genu valgum, or knock knee, is a common deformity of childhood. In this condition, owing to changes in and about the joint, the angle between the outer borders of the tibia and femur is diminished, so that as the patient stands the two internal condyles of the femora are in contact, but the two internal malleoli of the tibiæ are more or less widely separated from each other. When, however, the knees are flexed to a right angle, the two legs are practically parallel with each other. At the commencement of the disease there is a yielding of the internal lateral ligament and other fibrous structures on the inner side of the joint; as a result of this there is a constant undue pressure of the outer

tuberosity of the tibia against the outer condyle of the femur. This extra pressure causes arrest of growth, and, possibly, wasting of the outer condyle, and a consequent tendency for the tibia to become separated from the internal condyle. Irregular overgrowth from the inner portion of the epiphysial line takes place, giving rise to apparent enlargement of the inner condyle of the femur, the line of the epiphysis becoming oblique, with a direction downwards and inwards, instead of at right angles to the axis of the bone. If the deformity be marked, an osteotomy of the femur is required to correct it.

Excision of the knee-joint is most frequently required for tuberculous disease of this articulation, but is also practised in cases of disorganisation of the knee from other causes. It is also occasionally called for in cases of injury, gunshot or otherwise. The operation is best performed by a horse-shoe incision, starting from one condyle, descending as low as the tubercle of the tibia, and then carried upwards to the other condyle. The bone having been cleared, and in those cases where the operation is performed for tuberculous disease all pulpy tissue having been carefully removed, the section of the femur is first made. This should never include, in children, more than, at the most, two-thirds of the articular surface, otherwise the epiphysial cartilage will be involved, with disastrous results as regards the growth of the limb. Afterwards a thin slice should be removed from the upper end of the tibia, not more than half an inch. If any diseased tissue still appears to be left in the bones, it should be removed with the gouge, rather than that a further section of the bones should be made.

The bursæ about the knee-joint are sometimes the seat of enlargement. The prepatellar bursa—i.e. the bursa between the front of the patella and the skin—is frequently affected in individuals who are in the habit of constantly kneeling, and the condition is then known as 'housemaid's knee.' The bursa beneath the Semimembranosus tendon also occasionally becomes enlarged, and forms a fluctuating swelling at the back of the knee. During extension, the swelling is firm and tense ; but during flexion it becomes soft, and, as the bursa often communicates with the synovial cavity, the fluid it contains can be made to disappear by pressure when the knee is flexed. Extension of septic processes within the joint is apt to occur along the tendon sheath of the Popliteus muscle, and this may lead to deep-seated suppuration in the popliteal space, often associated with septic thrombosis of the popliteal vein ; when this occurs amputation of the limb becomes necessary.

III. ARTICULATIONS BETWEEN THE TIBIA AND FIBULA

The articulations between the tibia and fibula are effected by ligaments which connect both extremities ; in addition the shafts of the bones are bound together. The ligaments may consequently be subdivided into three sets : 1. Those of the Superior Tibio-fibular articulation. 2. The Middle Tibio-fibular ligament or interosseous membrane. 3. Those of the Inferior Tibio-fibular articulation.

1. Superior Tibio-fibular Articulation (Articulatio Tibiofibularis)

This articulation is an arthrodial joint. The contiguous surfaces of the bones present flat, oval facets covered with cartilage and connected together by the following ligaments :

Capsular.
Anterior Superior Tibio-fibular. Posterior Superior Tibio-fibular.

The **Capsular Ligament** (capsula articularis) surrounds the articulation, being attached round the margins of the articular facets on the tibia and fibula ; it is much thicker in front than behind.

The **Anterior Superior Tibio-fibular Ligament** (lig. capituli fibulæ anterius) (fig. 470) consists of two or three broad and flat bands, which pass obliquely upwards and inwards from the front of the head of the fibula to the front of the outer tuberosity of the tibia.

The **Posterior Superior Tibio-fibular Ligament** (lig. capituli fibulæ posterius) (fig. 469) is a single thick and broad band, which passes upwards and inwards from the back part of the head of the fibula to the back part of the outer tuberosity of the tibia. It is covered by the tendon of the Popliteus muscle.

A **Synovial Membrane** lines the capsule, and at its upper and back part is occasionally continuous with that of the knee-joint.

2. Middle Tibio-fibular Ligament or Interosseous Membrane

An **Interosseous Membrane** (membrana interossea cruris) extends between the interosseous margins of the tibia and fibula, and separates the muscles on

the front from those on the back of the leg. It consists of a thin, aponeurotic lamina composed of oblique fibres, which for the most part pass downwards and outwards ; some few fibres, however, pass in the opposite direction. It is broader above than below. Its upper margin does not quite reach the superior tibio-fibular joint, but presents a free concave border, above which is a large, oval aperture for the passage of the anterior tibial vessels to the front of the leg. At its lower part is an opening for the passage of the anterior peroneal vessels. It is continuous below with the inferior interosseous ligament, and presents numerous perforations for the passage of small vessels. It is in relation, in front, with the Tibialis anticus, Extensor longus digitorum, Extensor proprius hallucis, Peroneus tertius, and the anterior tibial vessels and nerve ; behind, with the Tibialis posticus and Flexor longus hallucis.

3. Inferior Tibio-fibular Articulation (Syndesmosis Tibio-fibulare)

This articulation is formed by the rough, convex surface of the inner side of the lower end of the fibula, and a concave rough surface on the outer side of the tibia. Below, to the extent of about a sixth of an inch, these surfaces are smooth, and covered with cartilage, which is continuous with that of the ankle-joint. The ligaments of this joint are :

Anterior Inferior Tibio-fibular.	Transverse Inferior.
Posterior Inferior Tibio-fibular.	Interosseous.

The **Anterior Inferior Tibio-fibular Ligament** (lig. malleoli lateralis anterius) (fig. 476) is a flat, triangular band of fibres, broader below than above, which extends obliquely downwards and outwards between the adjacent margins of the tibia and fibula, on the front aspect of the articulation. It is in relation, in front, with the Peroneus tertius, the aponeurosis of the leg, and the integument ; behind, with the inferior interosseous ligament ; and lies in contact with the cartilage covering the astragalus.

The **Posterior Inferior Tibio-fibular Ligament** (lig. malleoli lateralis posterius), smaller than the preceding, is disposed in a similar manner on the posterior surface of the articulation.

The **Transverse Inferior Ligament** lies under cover of the posterior ligament, and is a strong, thick band of yellowish fibres which passes transversely across the back of the joint, from the external malleolus to the posterior border of the articular surface of the tibia, almost as far as its malleolar process. This ligament projects below the margin of the bones, and forms part of the articulating surface for the astragalus.

The **Interosseous Ligament** consists of numerous short, strong, fibrous bands, which pass between the contiguous rough surfaces of the tibia and fibula, and constitute the chief bond of union between the bones. It is continuous, above, with the interosseous membrane.

The **Synovial Membrane** which is associated with the small arthrodial part of this joint is continuous with that of the ankle-joint.

IV. Ankle-joint (Articulatio Talocruralis)

The ankle-joint is a ginglymus, or hinge-joint. The structures entering into its formation are the lower extremity of the tibia and its malleolus, the external malleolus of the fibula, and the transverse ligament, which together form a mortise to receive the upper convex surface of the astragalus and its two lateral facets. The surfaces are connected by a capsule, which in places forms thickened bands constituting the following ligaments :

Capsular.

Anterior.	Internal Lateral.
Posterior.	External Lateral.

The **Capsular Ligament** (capsula articularis) is an imperfect ligamentous structure which surrounds the joint, and is attached, above, to the borders of the articular surface of the tibia ; and below, to the astragalus around its

upper articular surface. The parts of which it is composed vary considerably in strength.

The **Anterior Ligament** (fig. 475) is a broad, thin, membranous layer, attached, above, to the anterior margin of the lower extremity of the tibia, below, to the astragalus, in front of its superior articular surface. It is in relation, in front, with the Extensor tendons of the toes, the tendons of the Tibialis anticus and Peroneus tertius, and the anterior tibial vessels and nerve.

The **Posterior Ligament** is very thin, and consists principally of transverse fibres. It is attached, above, to the margin of the articular surface of the tibia, blending with the transverse tibio-fibular ligament; below, to the astragalus behind its superior articular facet. Externally, where a somewhat thickened band of transverse fibres is attached to the hollow on the inner surface of the external malleolus, it is stouter than internally.

The **Internal Lateral** or **Deltoid Ligament** (lig. deltoideum) (fig. 475) is a strong, flat, triangular band, attached, above, to the apex and anterior and posterior borders of the inner malleolus. It consists of two sets of fibres,

FIG. 475.—Ankle-joint, tarsal and tarso-metatarsal articulations. Internal view. Right side.

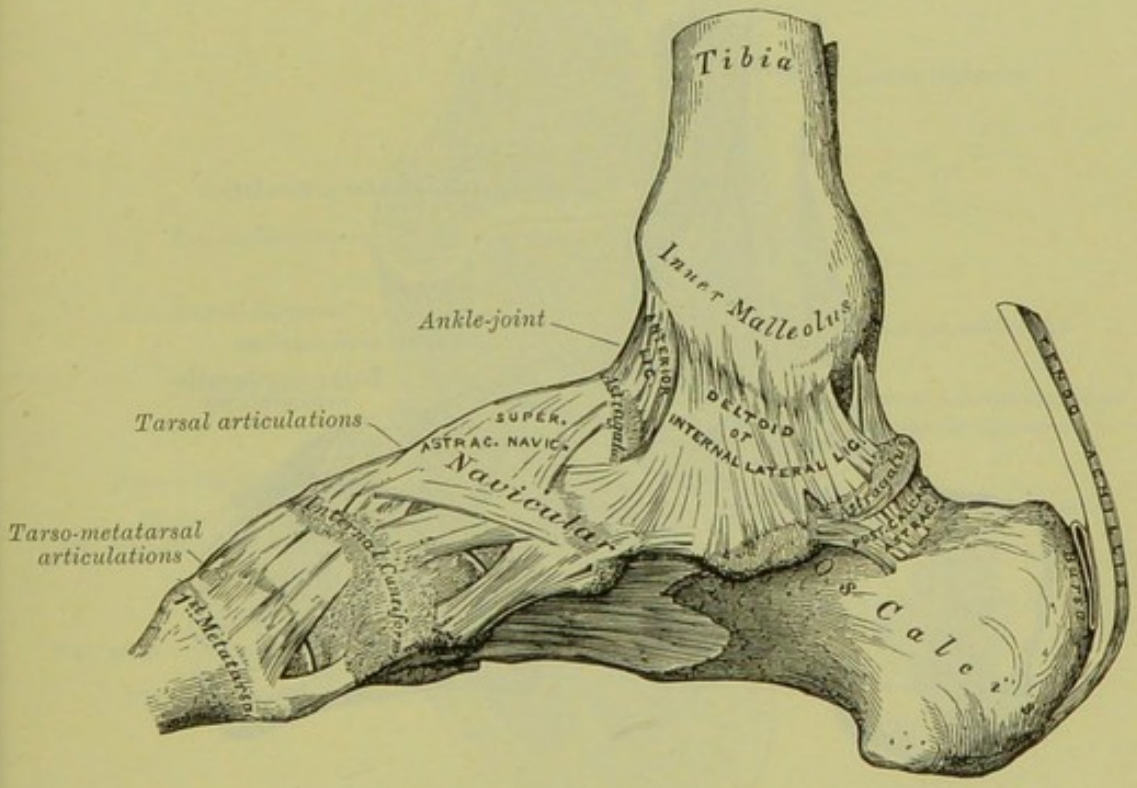

superficial and deep. Of the superficial fibres the most anterior pass forwards to be inserted into the tuberosity of the navicular bone, and immediately behind this they blend with the inner margin of the inferior calcaneo-navicular ligament; the middle descend almost perpendicularly to be inserted into the whole length of the sustentaculum tali of the os calcis; the posterior fibres pass backwards and outwards to be attached to the inner side of the astragalus, and to the prominent tubercle on its posterior surface, internal to the groove for the tendon of the Flexor longus hallucis. The deep fibres are attached, above, to the tip of the inner malleolus, and, below, to the inner surface of the astragalus. This ligament is covered by the tendons of the Tibialis posticus and Flexor longus digitorum.

The **External Lateral Ligament** (fig. 476) consists of three fasciculi, taking different directions, and separated by distinct intervals, for which reason it is described by some anatomists as three distinct ligaments.

The *anterior fasciculus* (lig. talofibulare anterius), the shortest of the three, passes from the anterior margin of the external malleolus, forwards and inwards to the astragalus, in front of its external articular facet.

The *posterior fasciculus* (lig. talofibulare posterius), the strongest and most deeply seated, passes inwards from the depression at the inner and back part of the external malleolus to a prominent tubercle on the posterior surface of the astragalus immediately external to the groove for the tendon of the Flexor longus hallucis. Its fibres are almost horizontal in direction.

The *middle fasciculus* (lig. calcaneofibulare), the longest of the three, is a narrow, rounded cord, running from the apex of the external malleolus downwards and slightly backwards to a tubercle on the outer surface of the os calcis. It is covered by the tendons of the Peronei longus et brevis.

The **Synovial Membrane** invests the inner surfaces of the ligaments, and sends a duplicature upwards between the lower extremities of the tibia and fibula for a short distance.

Relations.—The tendons, vessels, and nerves in connection with the joint are, in front, from within outwards, the Tibialis anticus, Extensor proprius hallucis, anterior tibial vessels, anterior tibial nerve, Extensor longus digitorum, and Peroneus tertius; behind, from within outwards, the Tibialis posticus, Flexor longus digitorum, posterior tibial vessels, posterior tibial nerve, Flexor longus

FIG. 476.—Ankle-joint, tarsal and tarso-metatarsal articulations. External view. Right side.

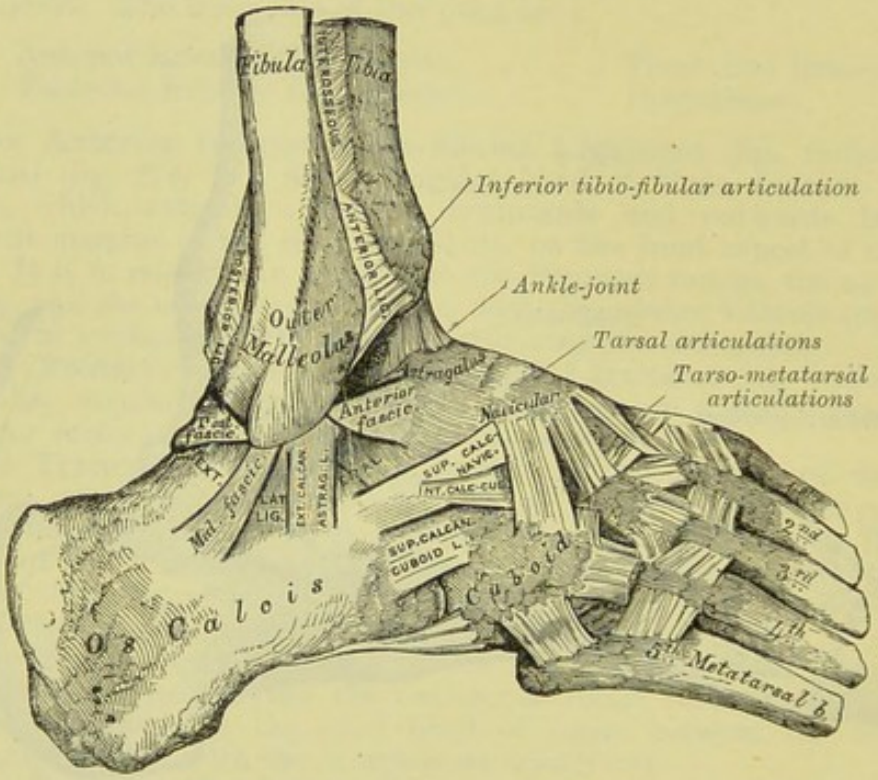

hallucis; and, in the groove behind the external malleolus, the tendons of the Peronei longus et brevis.

The *Arteries* supplying the joint are derived from the malleolar branches of the anterior tibial and the peroneal.

The *Nerves* are derived from the anterior and posterior tibial.

Movements.—When the body is in the erect position, the foot is at right angles to the leg. The movements of the joint are those of dorsiflexion and extension; dorsiflexion consists in the approximation of the dorsum of the foot to the front of the leg, while in extension the heel is drawn up and the toes pointed downwards. The malleoli tightly embrace the astragalus in all positions of the joint, so that any slight degree of lateral movement which may exist is simply due to stretching of the inferior tibio-fibular ligaments, and slight bending of the shaft of the fibula. The superior articular surface of the astragalus is broader in front than behind. In dorsiflexion, therefore, greater space is required between the two malleoli. This is obtained by a slight outward rotatory movement of the lower end of the fibula and a stretching of the inferior tibio-fibular ligaments; this outward movement is facilitated by a slight gliding at the superior tibio-fibular

articulation, and possibly also by the bending of the shaft of the fibula. Of the ligaments, the internal lateral is of very great power—so much so, that it usually resists a force which fractures the process of bone to which it is attached. Its middle portion, together with the middle fasciculus of the external lateral ligament, binds the bones of the leg firmly to the foot, and resists displacement in every direction. Its anterior and posterior fibres limit extension and flexion of the foot respectively, and the anterior fibres also limit abduction. The posterior portion of the external lateral ligament assists the middle portion in resisting the displacement of the foot backwards, and deepens the cavity for the reception of the astragalus. The anterior fasciculus is a security against the displacement of the foot forwards, and limits extension of the joint.

The movements of inversion and eversion of the foot, together with the minute changes in form by which it is applied to the ground or takes hold of an object in climbing, &c., are mainly effected in the tarsal joints; the joint which enjoys the greatest amount of motion being that between the astragalus and os calcis behind,

Fig. 477.—Coronal section of right ankle-joint and foot.

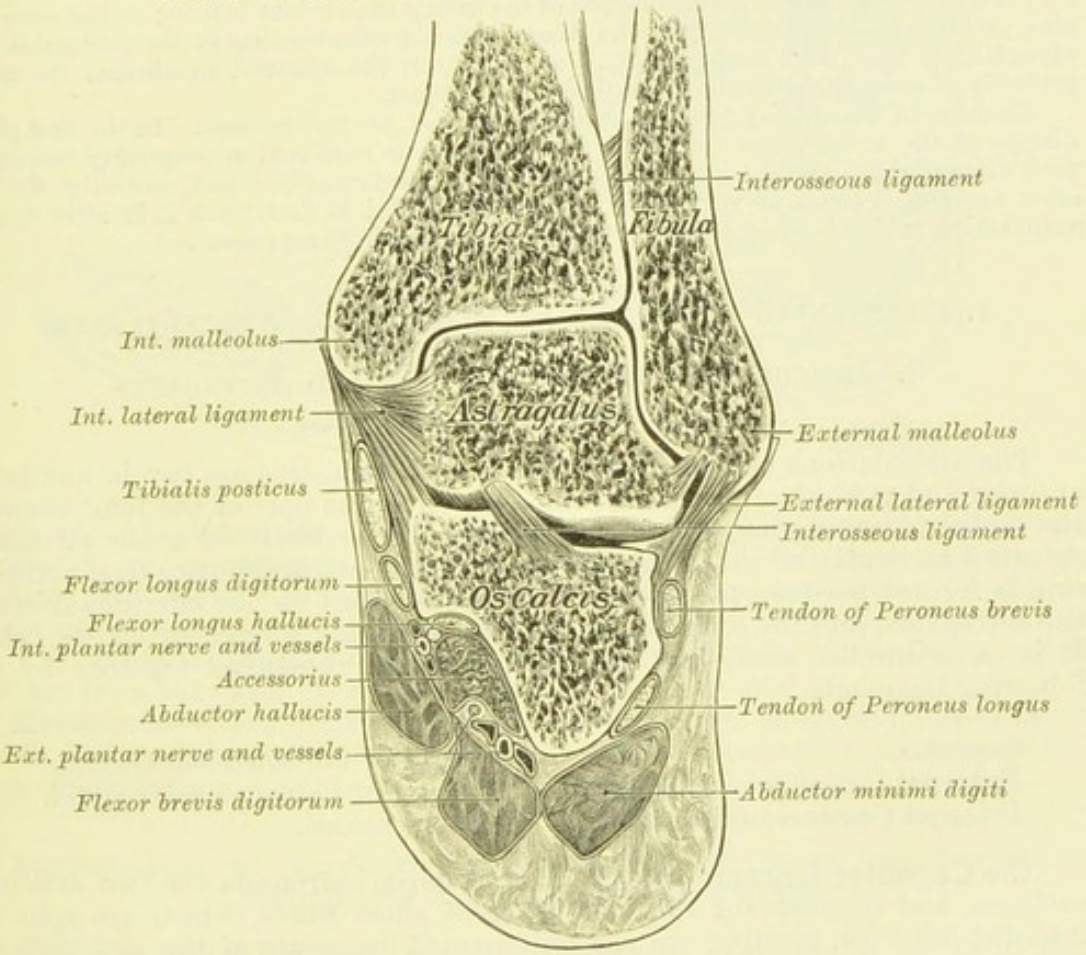

and the navicular and cuboid in front. This is often called the *transverse* or *mediotarsal joint*, and it can, with the subordinate joints of the tarsus, replace the ankle-joint in a great measure when the latter has become ankylosed.

Extension of the foot upon the tibia and fibula is produced by the Gastrocnemius, Soleus, Plantaris, Tibialis posticus, Peronei longus et brevis, Flexor longus digitorum, and Flexor longus hallucis; *dorsiflexion*, by the Tibialis anticus, Peroneus tertius, Extensor longus digitorum, and Extensor proprius hallucis.*

Surface Form.—The level of the ankle-joint may be indicated by a transverse line drawn across the front of the lower part of the leg, about half an inch above the level of the tip of the internal malleolus. The joint can be felt on either side of the Extensor tendons; and during extension of the foot, the superior facet of the astragalus can be perceived below the anterior border of the lower end of the tibia.

* The student must bear in mind that the Extensor longus digitorum and Extensor proprius hallucis are *extensors* of the toes, but *flexors* of the ankle; and that the Flexor longus digitorum and Flexor longus hallucis are *flexors* of the toes, but *extensors* of the ankle.

Applied Anatomy.—As the ankle-joint is a very strong and powerful articulation, displacement of the trochlear surface of the astragalus from the tibio-fibular mortise is not of common occurrence, and great force is required to produce it. Nevertheless, dislocation does occasionally occur, both in an antero-posterior and a lateral direction. In the latter, which is the more common, fracture is a necessary accompaniment of the injury. The dislocation in these cases is somewhat peculiar, and is not a displacement in a horizontally lateral direction, such as usually occurs in lateral dislocations of ginglymoid joints, but the astragalus undergoes a partial rotation round an antero-posterior axis drawn through its own centre, so that the superior surface, instead of being directed upwards, is inclined more or less inwards or outwards according to the variety of the displacement.

The ankle-joint is more frequently sprained than any joint in the body, and this may lead to acute synovitis. In these cases, when the synovial sac is distended with fluid, the bulging appears principally in the front of the joint, beneath the anterior tendons, and on either side, between the Tibialis anticus and the internal lateral ligament on the inner side, and between the Peroneus tertius and the external lateral ligament on the outer side. In addition to this, bulging often occurs posteriorly, and a fluctuating swelling may be detected on either side of the tendo Achillis.

Chronic synovitis may result from frequent sprains, and when once this joint has been sprained it is more liable to a recurrence of the injury than it was before ; or the synovitis may be tuberculous in its origin, the disease usually commencing in the astragalus and extending to the joint, though it may commence in the synovial membrane, the result probably of some slight strain in a tuberculous subject.

Excision of the ankle-joint is not often performed, for two reasons. In the first place, disease of the articulation for which this operation is indicated is frequently associated with disease of the tarsal bones, which prevents its performance ; and, secondly, the foot after excision is often of very little use ; far less useful, in fact, than it is after Syme's amputation, which is, therefore, a preferable operation in these cases.

V. INTERTARSAL ARTICULATIONS (ARTICULATIONES INTERTARSEÆ)

1. Articulation of the Os Calcis and Astragalus (Articulatio Talocalcanea)

The articulations between the os calcis and astragalus are two in number—anterior and posterior. Of these, the anterior forms part of the joint between the os calcis, astragalus, and navicular, and will be described as the astragalo-calcaneo-navicular articulation. The posterior or astragalo-calcanean articulation is formed between the posterior and larger facet on the inferior surface of the astragalus, and the external facet on the superior surface of the os calcis. It is an arthrodial joint, and the two bones are connected together by the following ligaments :

Capsular.	Anterior Calcaneo-astragaloid.
External Calcaneo-astragaloid.	Posterior Calcaneo-astragaloid.
Internal Calcaneo-astragaloid.	Interosseous.

The **Capsular Ligament** (capsula articularis) surrounds the two articular surfaces, and consists for the most part of short fibres, which are split up into distinct slips, forming the specially named ligaments of the articulation ; between them there is only a weak fibrous investment.

The **External Calcaneo-astragaloid Ligament** (lig. talocalcaneum laterale) (fig. 476) is a short, strong fasciculus, passing from the outer surface of the astragalus, immediately beneath its external facet, to the outer surface of the os calcis. It is placed in front of, but on a deeper plane than, the middle fasciculus of the external lateral ligament of the ankle-joint, with the fibres of which it is parallel.

The **Internal Calcaneo-astragaloid Ligament** (lig. talocalcaneum mediale) is a band of fibres connecting the internal tubercle of the back of the astragalus with the back of the sustentaculum tali. Its fibres blend with those of the inferior calcaneo-navicular ligament.

The **Anterior Calcaneo-astragaloid Ligament** (lig. talocalcaneum anterius) extends from the front and outer surface of the neck of the astragalus to the superior surface of the os calcis. It forms the posterior boundary of the anterior calcaneo-astragaloid joint, and is sometimes described as the *anterior interosseous ligament.*

The **Posterior Calcaneo-astragaloid Ligament** (lig. talocalcaneum posterius) (fig. 475) connects the external tubercle of the astragalus with the upper and inner part of the os calcis ; it is a short band, the fibres of which radiate from their narrow attachment to the astragalus.

The **Interosseous Ligament** (lig. talocalcaneum interosseum) (fig. 477) forms the chief bond of union between the bones. It is, in fact, the united capsular ligaments of the two joints mentioned above, the astragalo-calcaneo-navicular and the astragalo-calcanean, and consists of two partially united layers of fibres, one belonging to the anterior and the other to the posterior joint. It is attached by one extremity to the groove between the articular

FIG. 478.—Sagittal section of the right foot near its inner border, dividing the tibia, astragalus, navicular, internal cuneiform, and first metatarsal bone, and the first phalanx of the great toe. (After Braune.)

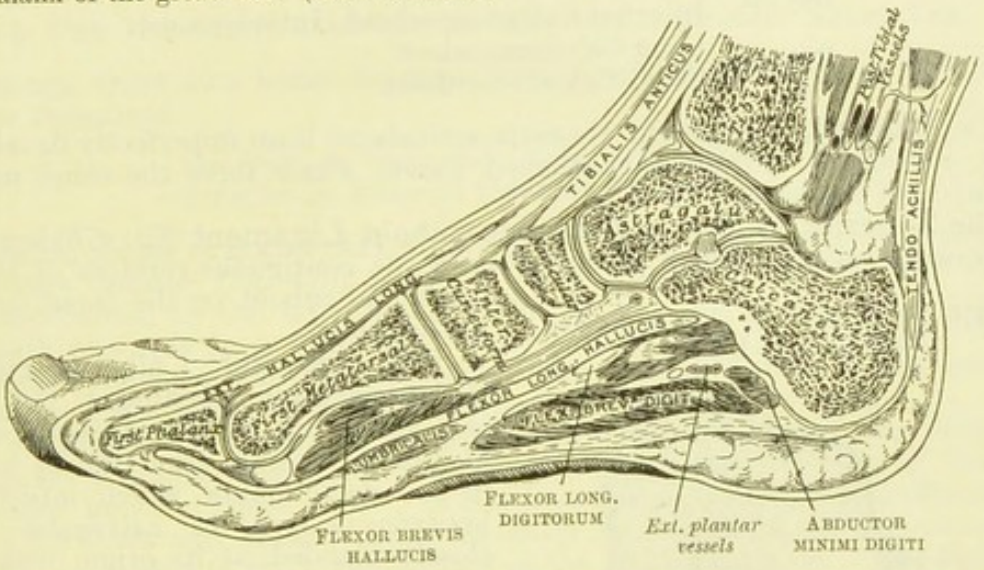

facets of the under surface of the astragalus ; by the other, to a corresponding depression on the upper surface of the os calcis. It is very thick and strong, being at least an inch in breadth from side to side, and serves to unite the os calcis and astragalus solidly together.

The **Synovial Membrane** (fig. 480) lines the capsule of the joint, and is distinct from the other synovial membranes of the tarsus.

Movements.—The movements permitted between the astragalus and os calcis are limited to gliding of the one bone on the other backwards and forwards and from side to side.

2. Articulation of the Astragalus with the Os Calcis and Navicular (Articulatio Talocalcaneonavicularis)

The articulation between the astragalus and navicular is an arthrodial joint : the rounded head of the astragalus being received into the concavity formed by the posterior surface of the navicular, the anterior articular surface of the calcaneum, and the upper surface of the inferior calcaneo-navicular ligament, which are all directly continuous with each other. There are two ligaments in this joint :

Capsular. Superior Astragalo-navicular.

The **Capsular Ligament** (capsula articularis) consists of a layer of fibres, imperfectly developed except posteriorly, where it becomes greatly increased, and forms, with a part of the capsule of the astragalo-calcanean joint, the strong interosseous ligament which fills in the canal formed by the opposing grooves on the os calcis and astragalus, as above mentioned.

The **Superior Astragalo-navicular Ligament** (lig. talonaviculare dorsale) (fig. 475) is a broad band, which passes obliquely forwards from the neck of the astragalus to the superior surface of the navicular bone. It is weak, and thin

in texture, and covered by the Extensor tendons. The inferior calcaneo-navicular supplies the place of an inferior ligament.

The **Synovial Membrane** lines all parts of the capsule of the joint.

Movements.—This articulation permits of a considerable range of gliding movements; its feeble construction allows occasionally of dislocation of the other bones of the tarsus from the astragalus.

3. Articulations of the Os Calcis with the Cuboid (Articulatio Calcaneocuboidea)

The ligaments connecting the os calcis with the cuboid are five in number:

Capsular

Dorsal { Superior Calcaneo-cuboid.
Internal Calcaneo-cuboid (Interosseous).

Plantar { Long Calcaneo-cuboid.
Short Calcaneo-cuboid.

The **Capsular Ligament** (capsula articularis) is an imperfectly developed layer, containing certain strengthened bands, which form the other named ligaments of the joint.

The **Superior** or **Dorsal Calcaneo-cuboid Ligament** (fig. 476) is a thin but broad fasciculus, which passes between the contiguous surfaces of the os calcis and cuboid, on the dorsal surface of the joint.

Fig. 479.—Ligaments of plantar surface of the right foot.

The **Internal Calcaneo-cuboid (Interosseous) Ligament** (fig. 476) is a short, but thick and strong band of fibres, arising from the os calcis, in the deep hollow which intervenes between it and the astragalus, and closely blended at its origin with the superior calcaneo-navicular ligament, so as to form with it a V-shaped structure. It is inserted into the inner side of the cuboid bone. This ligament forms one of the chief bonds of union between the first and second rows of the tarsus.

The **Long Calcaneo-cuboid** or **Long Plantar Ligament** (lig. plantare longum) (fig. 479), the more superficial of the two plantar ligaments, is the longest of all the ligaments of the tarsus: it is attached to the under surface of the os calcis, from near the tuberosities to the anterior tubercle; its fibres pass forwards to be attached to the ridge on the under surface of the cuboid bone, the more superficial fibres being continued onwards to the bases of the second, third, and fourth metatarsal bones. This ligament crosses the groove on the under surface of the cuboid bone, converting it into a canal for the passage of the tendon of the Peroneus longus.

The **Short Calcaneo-cuboid** or **Short Plantar Ligament** (lig. calcaneocuboideum plantare) (fig. 479) lies nearer to the bones than the preceding, from which it is separated by a little areolar tissue. It is exceedingly broad, about an inch in length, and extends from the tubercle and the depression in front of it, on the fore part

of the under surface of the os calcis, to the inferior surface of the cuboid bone behind the peroneal groove.

Synovial Membrane.—The synovial membrane in this joint is distinct from that of the other tarsal articulations (fig. 480). It lines the inner surface of the capsule.

Movements.—The movements permitted between the os calcis and cuboid are limited to slight gliding movements of the bones upon each other.

The *transverse tarsal* or *medio-tarsal joint* is formed by the articulation of the os calcis with the cuboid, and the articulation of the astragalus with the navicular. The movement which takes place in this joint is more extensive than that in the other tarsal joints, and consists of a sort of rotation by means of which the foot may be slightly flexed or extended, the sole being at the same time carried inwards (inverted) or outwards (everted).

4. The Ligaments connecting the Os Calcis and Navicular

Though these two bones do not directly articulate, they are connected by two ligaments :

Superior or External Calcaneo-navicular.
Inferior or Internal Calcaneo-navicular.

The **Superior** or **External Calcaneo-navicular Ligament** (lig. calcaneo-naviculare dorsale) (fig. 476) arises, as already mentioned, with the internal calcaneo-cuboid in the deep hollow between the astragalus and os calcis ; it passes forwards from the upper surface of the anterior extremity of the os calcis to the outer side of the navicular bone. These two ligaments resemble the letter Y, being blended together behind but separated in front.

The **Inferior** or **Internal Calcaneo-navicular Ligament** (lig. calcaneo-naviculare plantare) (fig. 479) is by far the larger and stronger of the two ligaments between these bones ; it is a broad and thick band of fibres, and passes forwards and inwards from the anterior margin of the sustentaculum tali of the os calcis to the under surface of the navicular bone. This ligament not only serves to connect the os calcis and navicular, but supports the head of the astragalus, forming part of the articular cavity in which it is received. The *upper surface* presents a fibro-cartilaginous facet, lined by the synovial membrane continued from the anterior calcaneo-astragaloid articulation, and upon this a portion of the head of the astragalus rests. The *under surface* is in contact with the tendon of the Tibialis posticus muscle ; its *inner border* is blended with the fore part of the internal lateral ligament of the ankle-joint, thus completing the socket for the head of the astragalus.

Applied Anatomy.—The inferior calcaneo-navicular ligament, by supporting the head of the astragalus, is principally concerned in maintaining the arch of the foot. When it yields, the head of the astragalus is pressed downwards, inwards, and forwards by the weight of the body, and the foot becomes flattened, expanded, and turned outwards, and exhibits the condition known as *flat-foot*. This ligament contains a considerable amount of elastic fibres, so as to give elasticity to the arch and spring to the foot ; hence it is sometimes called the 'spring' ligament. It is supported, on its under surface, by the tendon of the Tibialis posticus, which spreads out at its insertion into a number of fasciculi, which are attached to most of the tarsal and metatarsal bones. This prevents undue stretching of the ligament, and is a protection against the occurrence of flat-foot, hence muscular weakness is, in most cases, the primary cause of the deformity.

5. The Articulation of the Navicular with the Cuneiform Bones (Articulatio Cuneonavicularis)

The navicular is connected to the three cuneiform bones by :

Dorsal and Plantar ligaments.

The **Dorsal Ligaments** are small, longitudinal bands, arranged as three bundles, one to each of the cuneiform bones. The bundle connecting the navicular with the internal cuneiform is continuous round the inner side of the articulation with the plantar ligament which connects these two bones.

The **Plantar Ligaments** have a similar arrangement to those on the dorsum. They are strengthened by processes given off by the tendon of the Tibialis posticus.

The **Synovial Membrane** of these joints is part of the great tarsal synovial membrane.

Movements.—Mere gliding movements are permitted between the navicular and cuneiform bones.

6. The Articulation of the Navicular with the Cuboid (Articulatio Cuboideonavicularis)

The navicular bone is connected with the cuboid by:

Dorsal, Plantar, and Interosseous ligaments.

The **Dorsal Ligament** extends obliquely forwards and outwards from the navicular to the cuboid bone.

The **Plantar Ligament** passes nearly transversely between these two bones.

The **Interosseous Ligament** consists of strong transverse fibres, and connects the rough non-articular portions of the lateral surfaces of the two bones.

The **Synovial Membrane** of this joint is part of the great tarsal synovial membrane.

Movements.—The movements permitted between the navicular and cuboid bones are limited to a slight gliding upon each other.

7. The Articulation of the Cuneiform Bones with each other (Articulationes Intercuneiformes)

These bones are connected together by:

Dorsal, Plantar, and Interosseous ligaments.

The **Dorsal Ligaments** consist of two transverse bands: one connecting the internal with the middle cuneiform, and the other connecting the middle with the external cuneiform.

The **Plantar Ligaments** have a similar arrangement to those on the dorsum. They are strengthened by processes given off from the tendon of the Tibialis posticus.

The **Interosseous Ligaments** consist of strong transverse fibres which pass between the rough non-articular portions of the lateral surfaces of the adjacent cuneiform bones.

The **Synovial Membrane** of these joints is part of the great tarsal synovial membrane.

Movements.—The movements permitted between the cuneiform bones are limited to a slight gliding upon each other.

8. The Articulation of the External Cuneiform Bone with the Cuboid (Articulatio Cuneocuboidea)

These bones are connected together by:

Dorsal, Plantar, and Interosseous ligaments.

The **Dorsal Ligament** passes transversely between the two bones.

The **Plantar Ligament** has a similar arrangement. It is strengthened by a process given off from the tendon of the Tibialis posticus.

The **Interosseous Ligament** consists of strong transverse fibres which connect the adjacent rough non-articular surfaces of the two bones.

The **Synovial Membrane** of this joint is part of the great tarsal synovial membrane.

Movements.—The movements permitted between the external cuneiform and cuboid are limited to a slight gliding upon each other.

Nerve-supply.—All the joints of the tarsus are supplied by the anterior tibial nerve.

Applied Anatomy.—In spite of the great strength of the ligaments which connect the tarsal bones together, dislocation at some of the tarsal joints does occasionally occur; though, on account of the spongy character of the bones, they are more frequently broken as the result of violence, than dislocated. When dislocation takes place, it is most commonly in connection with the astragalus; for not only may this bone be dislocated from the tibia and fibula at the ankle-joint, but the other bones may be dislocated from it, the trochlear surface of the bone remaining *in situ* in the tibio-fibular mortise. This constitutes what is known as the *sub-astragaloid* dislocation. Or, again, the astragalus may be dislocated from all its connections—from the tibia and fibula above, the os calcis below, and the navicular in front—and may even undergo a rotation, on either a vertical or a horizontal axis. In the former case the long axis of the bone becoming directed across the joint, so that the head faces the articular surface on one or other malleolus; or, in the latter, the lateral surfaces becoming directed upwards and downwards, so that the trochlear surface faces to one or the other side. Reduction in these cases is often very difficult or impossible, and the displaced astragalus may then require removal by open operation. Dislocation may also occur at the medio-tarsal joint, the anterior tarsal bones being luxated from the astragalus and calcaneum. The other tarsal bones are also, occasionally, though rarely, dislocated from their connections.

VI. TARSO-METATARSAL ARTICULATIONS (ARTICULATIONES TARSOMETATARSEÆ)

These are arthrodial joints. The bones entering into their formation are four tarsal bones, viz. the internal, middle and external cuneiform, and the cuboid, which articulate with the bases of the metatarsal bones of the five toes. The metatarsal bone of the great toe articulates with the internal cuneiform; that of the second is deeply wedged in between the internal and external cuneiforms resting against the middle cuneiform, and is the most strongly articulated of all the metatarsal bones; the third metatarsal articulates with the external cuneiform; the fourth, with the cuboid and external cuneiform; and the fifth, with the cuboid. The bones are connected by the following ligaments:

Dorsal. Plantar. Interosseous.

The **Dorsal Ligaments** consist of strong, flat bands, which connect the tarsal with the metatarsal bones. The first metatarsal is connected to the internal cuneiform by a single broad, thin band; the second has three dorsal ligaments, one from each cuneiform bone; the third has one from the external cuneiform; the fourth has two, one from the external cuneiform and one from the cuboid; and the fifth, one from the cuboid.

The **Plantar Ligaments** consist of longitudinal and oblique bands connecting the tarsal and metatarsal bones, but disposed with less regularity than the dorsal ligaments. Those for the first and second metatarsals are the most strongly marked; the second and third metatarsals receive strong bands, which pass obliquely across from the internal cuneiform; the plantar ligaments of the fourth and fifth metatarsals consist of a few fibres derived from the cuboid.

The **Interosseous Ligaments** are three in number: internal, middle, and external. The *internal* is the strongest of the three, and passes from the outer surface of the internal cuneiform to the adjacent angle of the second metatarsal. The *middle*, less strong than the preceding, connects the external cuneiform with the adjacent angle of the second metatarsal. The *external* connects the outer angle of the external cuneiform with the adjacent side of the third metatarsal.

The **Synovial Membrane** between the internal cuneiform bone and the first metatarsal is a distinct sac. The synovial membrane between the middle and external cuneiforms behind, and the second and third metatarsal bones in front, is part of the great tarsal synovial membrane. Two prolongations are sent forwards from it, one between the adjacent sides of the second and third and another between those of the third and fourth metatarsal bones. The synovial membrane between the cuboid and the fourth and fifth metatarsal bones is a distinct sac. From it a prolongation is sent forwards between the fourth and fifth metatarsal bones.

Movements.—The movements permitted between the tarsal and metatarsal bones are limited to slight gliding movements of the bones upon each other.

VII. INTERMETATARSAL ARTICULATIONS (ARTICULATIONES INTERMETATARSEÆ)

The base of the first metatarsal is not connected with the second metatarsal by any ligaments ; in this respect the great toe resembles the thumb.

The bases of the four outer metatarsals are connected by dorsal, plantar, and interosseous ligaments.

The **Dorsal Ligaments** pass transversely between the dorsal surfaces of the adjacent metatarsal bones.

The **Plantar Ligaments** have a similar arrangement to those on the dorsum.

The **Interosseous Ligaments** consist of strong transverse fibres which pass between the rough non-articular portions of the lateral surfaces.

The **Synovial Membranes** between the second and third, and that between the third and fourth metatarsal bones are part of the great tarsal synovial membrane ; that between the fourth and fifth is a prolongation of the synovial membrane of the cubo-metatarsal joint.

Movements.—The movement permitted in the tarsal ends of the metatarsal bones is limited to a slight gliding of the articular surfaces upon one another.

The digital extremities of all the metatarsal bones are connected together by the *transverse metatarsal ligament.*

The **Transverse Metatarsal Ligament** is a narrow band which passes transversely across the anterior extremities of all the metatarsal bones, connecting them together. It is blended anteriorly with the plantar (glenoid) ligaments of the metatarso-phalangeal articulations ; to its posterior border is connected the fascia covering the Interosseous muscles. Its inferior surface is concave where the Flexor tendons run below it ; above it the tendons of the Interosseous muscles pass to their insertion. It differs from the transverse metacarpal ligament in that it is attached to the first digit and connects it with the others.

The Synovial Membranes in the Tarsal and Metatarsal Joints

The **Synovial Membranes** (fig. 480) found in the articulations of the tarsus and metatarsus are six in number : one for the posterior calcaneo-astragaloid articulation ; a second for the anterior calcaneo-astragaloid and the astragalo-navicular articulations ; a third for the calcaneo-cuboid articulation ; and a fourth for the articulations of the navicular with the

Fig. 480.—Oblique section of the articulations of the tarsus and metatarsus. Showing the six synovial membranes.

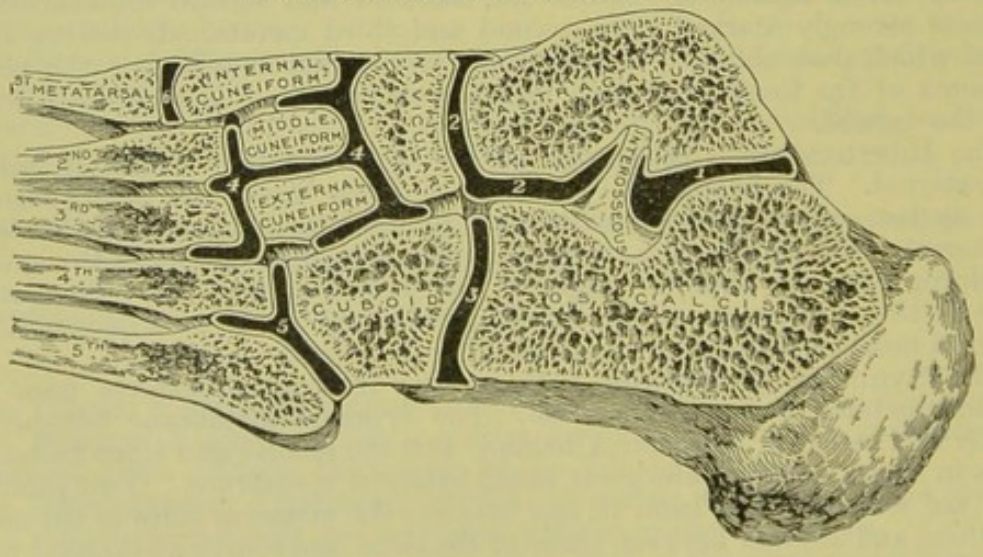

three cuneiforms, the three cuneiforms with each other, the external cuneiform with the cuboid, and the middle and external cuneiforms with the bases of the second and third metatarsal bones, and the lateral surfaces of the second, third, and fourth metatarsal bones with each other ; a fifth for the internal cuneiform with the metatarsal bone of the great toe ; and a sixth for the

articulation of the cuboid with the fourth and fifth metatarsal bones. A small synovial membrane is sometimes found between the contiguous surfaces of the navicular and cuboid bones.

Nerve-supply.—The nerves supplying the tarso-metatarsal joints are derived from the anterior tibial.

VIII. METATARSO-PHALANGEAL ARTICULATIONS (ARTICULATIONES METATARSOPHALANGEÆ)

The metatarso-phalangeal articulations are of the condyloid kind, formed by the reception of the rounded heads of the matatarsal bones into shallow cavities in the extremities of the first phalanges.

The ligaments are :

Plantar. Two Lateral.

The **Plantar Ligaments** (Glenoid ligaments of Cruveilhier) are thick, dense, fibrous structures. They are placed on the plantar surfaces of the joints in the intervals between the lateral ligaments, to which they are connected ; they are loosely united to the metatarsal bones, but very firmly to the bases of the first phalanges. Their plantar surfaces are intimately blended with the transverse metatarsal ligament, and present grooves for the passage of the Flexor tendons, the sheaths surrounding which are connected to the sides of the grooves. Their deep surfaces form parts of the articular facets for the heads of the metatarsal bones, and are lined by synovial membrane.

The **Lateral Ligaments** are strong, rounded cords, placed one on either side of each joint, and attached, by one extremity, to the posterior tubercle on the side of the head of the metatarsal bone, and, by the other, to the contiguous extremity of the phalanx.

The place of a *Dorsal Ligament* is supplied by the Extensor tendon on the back of each joint.

Movements.—The movements permitted in the metatarso-phalangeal articulations are flexion, extension, abduction, and adduction.

IX. INTERPHALANGEAL ARTICULATIONS (ARTICULATIONES DIGITORUM PEDIS)

The articulations of the phalanges are ginglymoid joints.

The ligaments are :

Plantar. Two Lateral.

The arrangement of these ligaments is similar to that in the metatarso-phalangeal articulations : the Extensor tendon supplies the place of a dorsal ligament.

Movements.—The only movements permitted in the phalangeal joints are flexion and extension ; these movements are more extensive between the first and second phalanges than between the second and third. The amount of flexion is very considerable, but extension is limited by the plantar and lateral ligaments.

Surface Form.—The principal joints which it is necessary to distinguish, with regard to the surgery of the foot, are the mid-tarsal and the tarso-metatarsal ; the mid-tarsal joint consists of the astragalo-navicular and calcaneo-cuboid articulations. The joint between the astragalus and the navicular lies immediately behind the tubercle of the latter bone. If the foot be grasped and forcibly extended, a rounded prominence, the head of the astragalus, appears on the inner side of the dorsum in front of the ankle-joint, and if a knife were carried downwards, just in front of this prominence and behind the line of the navicular tubercle, it would enter the astragalo-navicular joint. The calcaneo-cuboid joint is situated midway between the external malleolus and the prominent base of the fifth metatarsal bone. The plane of the joint is in the same line as that of the astragalo-navicular. The position of the joint between the fifth metatarsal bone and the cuboid is easily found by the projection of the base of the fifth metatarsal bone, which is the guide to it. The direction of the line of the joint is very oblique, so that, if continued inwards, it would pass through the inner side of the head of the first metatarsal bone. The joints between the third and fourth metatarsal bones and the cuboid and external cuneiform are the direct continuation inwards of the previous joint, but their planes are less oblique. The tarso-metatarsal articulation of the great toe corresponds to a groove which can be felt by making firm pressure on the inner side of the foot one inch in front of the tubercle on the navicular bone ; and the joint between the second

metatarsal bone and the middle cuneiform is to be found on the dorsum of the foot, half an inch behind the level of the tarso-metatarsal joint of the great toe. The line of the joints between the metatarsal bones and the first phalanges is about an inch behind the webs of the corresponding toes.

Applied Anatomy.—Gout peculiarly affects the metatarso-phalangeal joint of the big toe, beginning with the deposit of sodium and calcium urates in the cartilage on the bones forming the joint, and slow necrosis of the surrounding tissue. Later the circum-articular fibrous tissue becomes the seat of these gouty deposits, and considerable thickening and deformity may result. The other chief joint-affections, such as rheumatism, gonorrhœal arthritis, tuberculosis, or syphilis, comparatively seldom attack the big toe joint.

Arches of the Foot

In order to allow of its supporting the weight of the body in the erect posture with the least expenditure of material, the foot is constructed of a series of arches which are formed by the tarsal and metatarsal bones, but are strengthened by the ligaments and tendons of the foot.

The main arches are the antero-posterior arches, which may, for descriptive purposes, be regarded as divisible into two types—an inner and an outer. The *inner arch* (see fig. 417, page 363) is made up by the os calcis, the astragalus, the navicular, the three cuneiforms, and the inner three metatarsals. Its summit is at the superior articular surface of the astragalus, and its two extremities or piers, on which it rests in standing, are the tubercles on the inferior surface of the os calcis posteriorly and the heads of the inner three metatarsal bones anteriorly. The chief characteristic of this arch is its elasticity, due to its height and to the number of small joints between its component parts. Its weakest part, i.e. the part where it is most liable to yield from over-pressure, is the joint between the astragalus and navicular, but this portion is braced by the inferior calcaneo-navicular ligament which is elastic and is thus able to quickly restore the arch to its pristine condition when the disturbing force is removed. This ligament is supported internally by blending with the internal lateral ligament of the ankle-joint and inferiorly by the tendon of the Tibialis posticus which is spread out in a fan-shaped insertion, and prevents undue tension of the ligament or such an amount of stretching as would permanently elongate it. The arch is further supported by the plantar fascia, by the small muscles in the sole of the foot, by the tendons of the Tibiales anticus et posticus and Peroneus longus, and by the ligaments of all the articulations involved. The *outer arch* (see fig. 418, page 363) is composed of the os calcis, the cuboid, and the fourth and fifth metatarsals. Its summit is at the calcaneo-astragaloid articulation, and its chief joint is the calcaneo-cuboid, which possesses a special mechanism for locking and allows only a limited movement. The most marked features of this arch are its solidity and its slight elevation; two strong ligaments, the long and short inferior calcaneo-cuboid, together with the outer Extensor tendons and the short muscles of the little toe, preserve its integrity.

While these inner and outer arches may be readily demonstrated as the component antero-posterior arches of the foot, yet the *fundamental longitudinal arch* is contributed to by both, and consists of the os calcis, cuboid, external cuneiform, and third metatarsal: all the other bones of the foot may be removed without destroying this arch.

In addition to the longitudinal arches the foot presents a series of transverse arches. At the hinder part of the metatarsus and the anterior part of the tarsus the arches are complete, but in the middle of the tarsus they present more the characters of half-domes the concavities of which are directed downwards and inwards, so that when the inner borders of the feet are placed in apposition a complete tarsal dome is formed. The transverse arches are strengthened by the interosseous, plantar and dorsal ligaments, by the short muscles of the first and fifth toes (especially the Adductor transversus hallucis), and by the Peroneus longus, whose tendon stretches across between the piers of the arches.

MYOLOGY*

THE Muscles are connected with the bones, cartilages, ligaments, and skin, either directly or through the intervention of fibrous structures, called tendons or aponeuroses. Where a muscle is attached to bone or cartilage, the fibres terminate in blunt extremities upon the periosteum or perichondrium, and do not come into direct relation with the osseous or cartilaginous tissue. Where muscles are connected with the skin, they lie as a flattened layer beneath it, and are connected with its areolar tissue by larger or smaller bundles of fibres, as in the muscles of the face.

The muscles vary extremely in their form. In the limbs, they are of considerable length, especially the more superficial ones; they surround the bones, and constitute an important protection to the various joints. In the trunk, they are broad, flattened, and expanded, forming the parietes of the cavities which they enclose. Hence the reason of the terms, *long*, *broad*, *short*, &c., used in the description of a muscle.

There is considerable variation in the arrangement of the fibres of certain muscles with reference to the tendons to which they are attached. In some muscles the fibres are parallel and run directly from their origin to their insertion; these are quadrilateral muscles, such as the Thyro-hyoid. A modification of these is found in the fusiform muscles, in which the fibres are not quite parallel, but slightly curved, so that the muscle tapers at either end; in their actions, however, they resemble the quadrilateral muscles. Secondly, in other muscles the fibres are convergent; arising by a broad origin, they converge to a narrow or pointed insertion. This arrangement of fibres is found in the triangular muscles—e.g. the Temporal. In some muscles, which otherwise would belong to the quadrilateral or triangular type, the origin and insertion are not in the same plane, but the plane of the line of origin intersects that of the line of insertion: such is the case in the Pectineus muscle. Thirdly, in some muscles the fibres are oblique and converge, like the plumes of a quill pen, to one side of a tendon which runs the entire length of the muscle. Such muscles are rhomboidal or penniform, as the Peronei. A modification of these rhomboidal muscles is found in those cases where oblique fibres converge to both sides of a central tendon which runs down the middle of the muscle; these are called bipenniform, and an example is afforded in the Rectus femoris. Finally, we have muscles in which the fibres are arranged in curved bundles in one or more planes, as in the Sphincter muscles. The arrangement of the fibres is of considerable importance in respect to the relative strength and range of movement of the muscle. Those muscles where the fibres are long and few in number have great range, but diminished strength; where, on the other hand, the fibres are short and more numerous, there is great power, but lessened range.

The names applied to the various muscles have been derived: 1, from their situation, as the Tibialis, Radialis, Ulnaris, Peroneus; 2, from their direction, as the Rectus abdominis, Obliqui capitis, Transversalis; 3, from their uses, as Flexors,

* The Muscles and Fasciæ are described conjointly, in order that the student may consider the arrangement of the latter in his dissection of the former. It is rare for the student of anatomy in this country to have the opportunity of dissecting the fasciæ separately; and it is for this reason, as well as from the close connection that exists between the muscles and their investing sheaths, that they are considered together. Some general observations are first made on the anatomy of the muscles and fasciæ, the special descriptions being given in connection with the different regions.

Extensors, Abductors, &c.; 4, from their shape, as the Deltoid, Trapezius, Rhomboideus; 5, from the number of their divisions, as the Biceps, and Triceps; 6, from their points of attachment, as the Sterno-cleido-mastoid, Sterno-hyoid, Sterno-thyroid.

In the description of a muscle, the term *origin* is meant to imply its more fixed or central attachment; and the term *insertion* the movable point on which the force of the muscle is applied; but the origin is absolutely fixed in only a very small number of muscles, such as those of the face which are attached by one extremity to the bone, and by the other to the movable integument; in the greater number, the muscle can be made to act from either extremity.

In the dissection of the muscles, the student should pay especial attention to the exact *origin*, *insertion*, and *actions* of each, and its more important *relations* with surrounding parts. While accurate knowledge of the points of attachment of the muscles is of great importance in the determination of their actions, it is not to be regarded as conclusive. The action of a muscle deduced from its attachments, or even by pulling on it in the dead subject, is not necessarily its action in the living. By pulling, for example, on the Brachio-radialis in the cadaver the hand may be slightly supinated when in the prone position and slightly pronated when in the supine position, but there is no evidence that these actions are performed by the muscle during life. It is impossible for an individual to throw into action any one muscle; in other words, movements, not muscles, are represented in the central nervous system. To carry out a movement a definite combination of muscles is called into play, and the individual has no power either to leave out a muscle from this combination, or to add one to it. One (or more) muscle of the combination is the chief moving force; when this muscle passes over more than one joint other muscles (synergic muscles) come into play to inhibit the movements not required; a third set of muscles (fixation muscles) fix the limb—i.e. in the case of the limb-movements—and also prevent disturbances of the equilibrium of the body generally. As an example, the movement of the closing of the fist may be considered: (1) the prime movers are the Flexores digitorum, Flexor longus pollicis, and the small muscles of the thumb; (2) the synergic muscles are the Extensores carpi, which prevent flexion of the wrist; while (3) the fixation muscles are the Biceps and Triceps, which steady the elbow and shoulder. A further point which must be borne in mind in considering the actions of muscles is that in certain positions a movement can be effected by gravity, and in such a case the muscles acting are the antagonists of those which might be supposed to be in action. Thus in flexing the trunk when no resistance is interposed the Erectores spinæ contract to regulate the action of gravity, and the Recti abdominis are relaxed.*

By a consideration of the action of the muscles, the surgeon is able to explain the causes of displacement in various forms of fracture, and the causes which produce distortion in various deformities, and, consequently, to adopt appropriate treatment in each case. The relations, also, of some of the muscles, especially those in immediate apposition with the larger blood-vessels, and the surface-markings they produce, should be carefully remembered, as they form useful guides in the application of ligatures to those vessels.

Applied Anatomy.—Degeneration of muscular tissue is important clinically, and is met with in two main conditions. In one, the degeneration is myopathic, or primary in the muscles themselves; in the other it is neuropathic, or secondary to some lesion of the nervous system—a hæmorrhage into the brain, for example, or injury or inflammation of some part of the spinal cord or peripheral nerves. In either case more or less paralysis and atrophy of the affected muscles result. When the degeneration begins primarily in the muscles, however, it often happens that though the muscle-fibres waste away, their place is taken by fibrous and fatty tissue to such an extent that the affected muscles increase in volume, and actually appear to hypertrophy.

Ossification of muscular tissue as a result of repeated strain or injury is not infrequent. It is oftenest found about the tendon of the Adductor longus and Vastus internus in horsemen, or in the Pectoralis major and Deltoid of soldiers. It may take the form of exostoses firmly fixed to the bone—e.g. 'rider's bone' on the femur (page 573)—or of layers or spicules of bone lying in the muscles or their fasciæ and tendons. Busse states that these bony deposits are preceded by a hæmorrhagic myositis due to injury, the effused blood organising and being finally converted into bone. In the rarer disease, progressive myositis ossificans,

* Consult in this connection the Croonian Lectures (1903) on 'Muscular Movements and their representation in the Central Nervous System,' by Charles E. Beevor, M.D.

there is an unexplained tendency for practically any of the voluntary muscles to become converted into solid and brittle bony masses which are completely rigid.

Tendons are white, glistening, fibrous cords, varying in length and thickness, sometimes round, sometimes flattened, of considerable length, and devoid of elasticity. They consist almost entirely of white fibrous tissue, the fibrils of which have an undulating course parallel with each other and are firmly united together. They are very sparingly supplied with blood-vessels, the smaller tendons presenting in their interior no trace of them. Nerves supplying tendons have special modifications of their terminal fibres, named organs of Golgi (see page 52). The tendons consist principally of a substance which yields gelatin.

Aponeuroses are flattened or ribbon-shaped tendons, of a pearly-white colour, iridescent, glistening, and similar in structure to the tendons. They are only sparingly supplied with blood-vessels.

The tendons and aponeuroses are connected, on the one hand, with the muscles, and, on the other hand, with the movable structures, as the bones, cartilages, ligaments, and fibrous membranes (for instance, the sclera). Where the muscular fibres are in a direct line with those of the tendon or aponeurosis, the two are directly continuous, the muscular fibre being distinguishable from that of the tendon only by its striation. But where the muscular fibres join the tendon or aponeurosis at an oblique angle, the former terminate, according to Kölliker, in rounded extremities which are received into corresponding depressions on the surface of the latter, the connective tissue between the fibres being continuous with that of the tendon. The latter mode of attachment occurs in all the penniform and bipenniform muscles, and in those muscles the tendons of which commence in a membranous form, as the Gastrocnemius and Soleus.

The *fasciæ* are fibro-areolar or aponeurotic laminæ, of variable thickness and strength, found in all regions of the body, investing the softer and more delicate organs. The fasciæ have been subdivided, from the situations in which they are found, into two groups, superficial and deep.

The *superficial fascia* is found immediately beneath the integument over almost the entire surface of the body. It connects the skin with the deep fascia, and consists of fibro-areolar tissue, containing in its meshes pellicles of fat in varying quantity. In the eyelids and scrotum, where fat is rarely deposited, this tissue is very liable to serous infiltration. The superficial fascia varies in thickness in different parts of the body; in the groin it is so thick as to be capable of being subdivided into several laminæ. Beneath the fatty layer of the superficial fascia, which is immediately subcutaneous, there is generally another layer of the same structure, comparatively devoid of adipose tissue, in which the trunks of the subcutaneous vessels and nerves are found, as the superficial epigastric vessels in the abdominal region, the superficial veins in the forearm, the saphenous veins in the leg and thigh, and the superficial lymphatic glands. Certain cutaneous muscles also are situated in the superficial fascia, as the Platysma in the neck, and the Orbicularis palpebrarum around the eyelids. This fascia is most distinct at the lower part of the abdomen, the scrotum, perinæum, and extremities; it is very thin in those regions where muscular fibres are inserted into the integument, as on the side of the neck, the face, and around the margin of the anus. It is very dense in the scalp, in the palms of the hands, and soles of the feet, forming a fibro-fatty layer, which binds the integument firmly to the underlying structures.

The superficial fascia connects the skin to the subjacent parts, facilitates the movement of the skin, serves as a soft nidus for the passage of vessels and nerves to the integument, and retains the warmth of the body, since the fat contained in its areolæ is a bad conductor of heat.

The *deep fascia* is a dense, inelastic, unyielding fibrous membrane, forming sheaths for the muscles, and in some cases affording them broad surfaces for attachment. It consists of shining tendinous fibres, placed parallel with one another, and connected together by other fibres disposed in a rectilinear manner. It forms a strong investment which not only binds down collectively the muscles in each region, but gives a separate sheath to each, as well as to the vessels and nerves. The fasciæ are thick in unprotected

situations, as on the outer side of a limb, and thinner on the inner side. The deep fasciæ assist the muscles in their actions, by the degree of tension and pressure they make upon their surfaces; and, in certain situations, where they are strengthened by the presence in them of degenerated muscular fibres which have become converted into fibrous sheets, the degree of tension and pressure is regulated by the associated muscles, as, for instance, by the Tensor fasciæ femoris and Gluteus maximus in the thigh, by the Biceps in the upper and lower extremities, and Palmaris longus in the hand. In the limbs, the fasciæ not only invest the entire limb, but give off septa which separate the various muscles, and are attached beneath to the periosteum: these prolongations of fasciæ are usually spoken of as intermuscular septa.

The Muscles and Fasciæ may be arranged, according to the general division of the body, into those of the cranium, face, and neck; those of the trunk; those of the upper extremity; and those of the lower extremity.

MUSCLES AND FASCIÆ OF THE CRANIUM AND FACE

The Muscles of the Cranium and Face consist of ten groups, arranged according to the region in which they are situated.

I. Cranial Region.
II. Auricular Region.
III. Palpebral Region.
IV. Orbital Region.
V. Nasal Region.
VI. Maxillary Region.
VII. Mandibular Region.
VIII. Intermaxillary Region.
IX. Temporo-mandibular Region.
X. Pterygo-mandibular Region.

The muscles contained in each of these groups are the following:

I. Cranial Region.
Occipito-frontalis.

II. Auricular Region.
Attrahens auriculam.
Attollens auriculam.
Retrahens auriculam.

III. Palpebral Region.
Orbicularis palpebrarum.
Tensor tarsi.
Corrugator supercilii.

IV. Orbital Region.
Levator palpebræ superioris
Rectus superior.
Rectus inferior.
Rectus internus.
Rectus externus.
Obliquus oculi superior.
Obliquus oculi inferior.

V. Nasal Region.
Pyramidalis nasi.
Levator labii superioris alæque nasi.
Dilatator naris posterior.
Dilatator naris anterior.
Compressor naris.
Compressor narium minor.
Depressor alæ nasi.

VI. Maxillary Region.
Levator labii superioris proprius.
Levator anguli oris.
Zygomaticus major.
Zygomaticus minor.

VII. Mandibular Region.
Levator menti.
Depressor labii inferioris.
Depressor anguli oris.

VIII. Intermaxillary Region.
Orbicularis oris.
Buccinator.
Risorius.

IX. Temporo-mandibular Region.
Masseter.
Temporal.

X. Pterygo-mandibular Region.
Pterygoideus externus.
Pterygoideus internus.

I. Cranial Region

Occipito-frontalis

The **superficial fascia** in the cranial region is a firm, dense, fibro-fatty layer, intimately adherent to the integument, and to the Occipito-frontalis and its tendinous aponeurosis; it is continuous, behind, with the superficial fascia at the back part of the neck; and, laterally, is continued over the temporal fascia. It contains between its layers the superficial vessels and nerves and much granular fat.

The **Occipito-frontalis** (m. epicranius) (fig. 481) is a broad, musculo-fibrous layer, which covers the whole of one side of the vertex of the skull, from the occiput to the eyebrow. It consists of two muscular bellies, connected by an intervening tendinous aponeurosis, the epicranial aponeurosis. The *occipital portion* (m. occipitalis) is thin, quadrilateral in form, and about an inch and a half in length; it arises from the outer two-thirds of the superior curved line of the occipital bone, and from the mastoid portion of the temporal. Its

Fig. 481.—Muscles of the head, face, and neck.

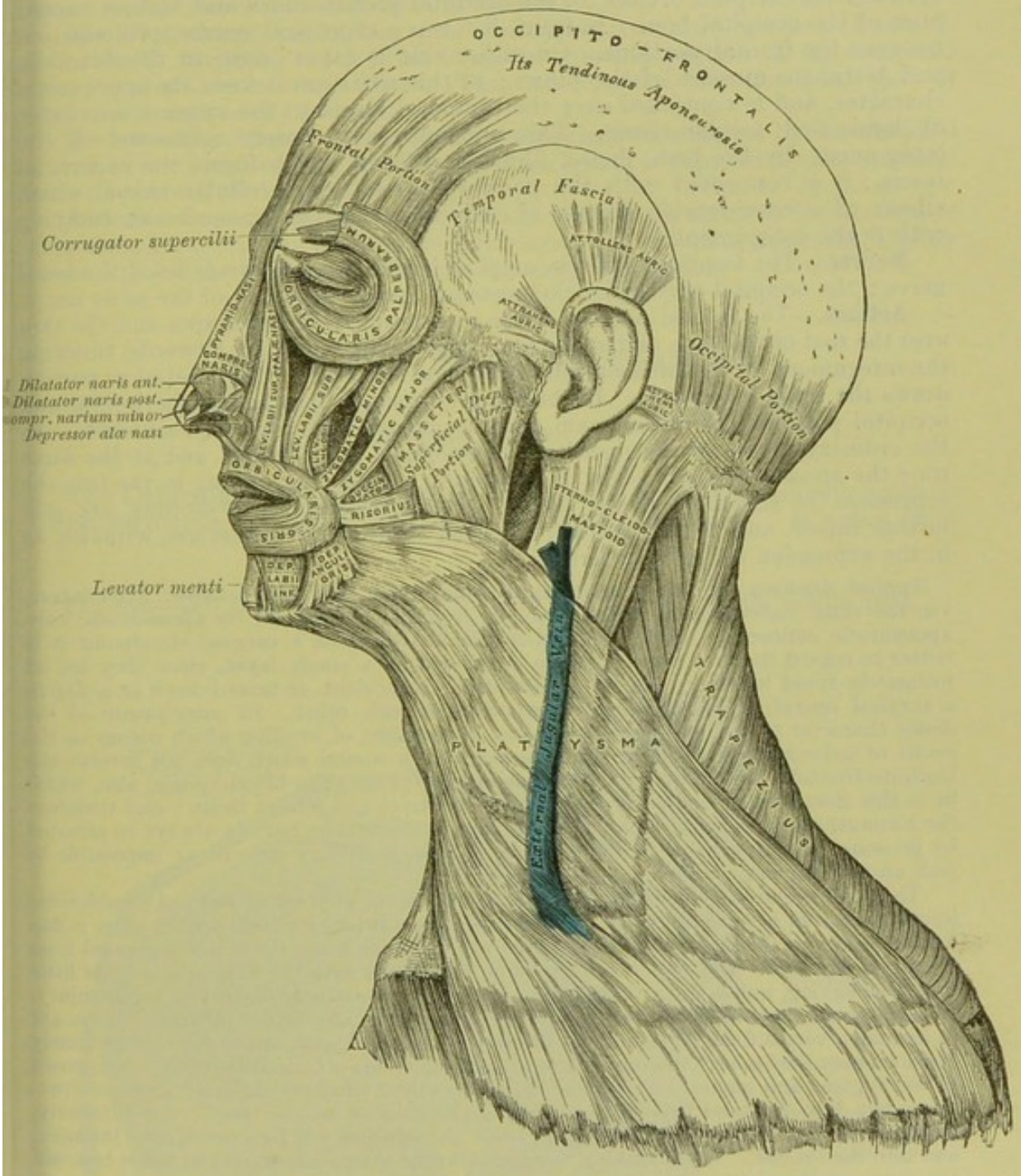

fibres of origin are tendinous, but they soon become muscular, and ascend in a parallel direction to terminate in the tendinous aponeurosis. The *frontal portion* (m. frontalis) is thin, of a quadrilateral form, and intimately adherent to the superficial fascia. It is broader, and its fibres are longer and paler in colour than those of the occipital portion. It has no bony attachments. Its internal fibres are continuous with those of the Pyramidalis nasi. Its middle fibres become blended with the Corrugator supercilii and Orbicularis palpebrarum; and the outer fibres are also blended with the latter muscle

over the external angular process. From these attachments the fibres are directed upwards, and join the aponeurosis below the coronal suture. The inner margins of the frontal portions of the two muscles are joined together for some distance above the root of the nose; but between the occipital portions there is a considerable, though variable, interval, which is occupied by the aponeurosis.

The **epicranial aponeurosis** (galea aponeurotica) covers the upper part of the vertex of the skull, being continuous across the middle line with the aponeurosis of the opposite muscle. Behind, it is attached, in the interval between the occipital origins, to the occipital protuberance and highest curved lines of the occipital bone; in front, it forms a short and narrow prolongation between the frontal portions. On either side it gives origin to the Attollens and Attrahens muscles of the pinna; in this situation it loses its aponeurotic character, and is continued over the temporal fascia to the zygoma as a layer of laminated areolar tissue. This aponeurosis is closely connected to the integument by the firm, dense, fibro-fatty layer which forms the superficial fascia: it is connected with the pericranium by loose cellular tissue, which allows of a considerable degree of movement of the aponeurosis, carrying with it the integument.

Nerves.—The frontal portion is supplied by the temporal branches of the facial nerve; the occipital portion by the posterior auricular branch of the same nerve.

Actions.—The frontal portion of the muscle raises the eyebrows and the skin over the root of the nose, and at the same time draws the scalp forwards, throwing the integument of the forehead into transverse wrinkles. The posterior portion draws the scalp backwards. By bringing alternately into action the frontal and occipital portions the entire scalp may be moved forwards and backwards. In the ordinary action of the muscles, the eyebrows are elevated, and at the same time the aponeurosis is fixed by the posterior portion, thus giving to the face the expression of surprise: if the action be exaggerated, the eyebrows are still further raised, and the skin of the forehead thrown into transverse wrinkles, as in the expression of fright or horror.

Applied Anatomy.—From an anatomical point of view, the scalp consists of five layers, viz. the skin, subcutaneous tissue, Occipito-frontalis muscle and its aponeurosis, subaponeurotic connective tissue, and pericranium. But from a surgical standpoint it is better to regard the first three of these structures as a single layer, since they are all intimately fused together, and when torn off in an accident, or turned down as a flap in a surgical operation, remain firmly connected to each other. In consequence of the dense character of the subcutaneous tissue, the amount of swelling which occurs as the result of inflammation is slight; and the edges of a wound which does not involve the Occipito-frontalis muscle or its aponeurosis do not gape. The blood-vessels, also, which lie in this tissue, when wounded, are unable to contract and retract freely; and therefore the hæmorrhage from scalp wounds is often very considerable, but can always be arrested by pressure—a matter of great importance, as it is often very difficult or impossible to pick up with forceps a wounded vessel in the scalp.

The subaponeurotic connective tissue is, from a surgical point of view, of considerable importance. It is loose and lax, and is easily torn through; and hence, when a flap wound occurs in the scalp, this is the tissue which is torn when the flap is separated from the parts beneath. The vessels are therefore torn down with the flap, and there is little risk of sloughing, unless the vitality of the part has been actually destroyed by the injury. In consequence of its loose nature and feeble vitality, any septic inflammation is apt to assume a very diffuse form and spread all over the skull, and, unless relieved by timely incisions may lead to serious complications. Owing to the attachments of the aponeurosis to the zygoma and highest curved line, subaponeurotic effusions sag down in these situations, but do not extend beyond to the zygomatic fossa or into the neck; but anteriorly, where there is no definite attachment to bone, the effusion will pass down over the nose, and into the eyelids. When making incisions into the scalp, care should be taken to avoid the course of the main arteries.

The skin of the scalp is abundantly supplied with sebaceous and sudoriparous glands. The former are sometimes the seat of cystic enlargement, constituting the so-called *sebaceous cysts* or *wens*.

II. Auricular Region (fig. 481)

Attrahens auriculam. Attollens auriculam.
Retrahens auriculam.

These three small muscles are placed immediately beneath the skin around the pinna. In man, in whom the pinna is almost immovable, they are

rudimentary. They are the homologues of large and important muscles in some of the mammalia.

The **Attrahens auriculam** (m. auricularis anterior), the smallest of the three, is thin, fan-shaped, and its fibres are pale and indistinct. It arises from the lateral edge of the aponeurosis of the Occipito-frontalis, and its fibres converge to be inserted into a projection on the front of the helix.

The **Attollens auriculam** (m. auricularis superior), the largest of the three, is thin and fan-shaped. Its fibres arise from the aponeurosis of the Occipito-frontalis, and converge to be inserted by a thin, flattened tendon into the upper part of the cranial surface of the pinna.

The **Retrahens auriculam** (m. auricularis posterior) consists of two or three fleshy fasciculi, which arise from the mastoid portion of the temporal bone by short aponeurotic fibres. They are inserted into the lower part of the cranial surface of the concha.

Nerves.—The Attrahens and Attollens auriculam are supplied by the temporal branch of the facial nerve; the Retrahens auriculam is supplied by the posterior auricular branch of the same nerve.

Actions.—In man, these muscles possess very little action: the Attrahens auriculam draws the ear forwards and upwards; the Attollens auriculam slightly raises it; and the Retrahens auriculam draws it backwards.

III. Palpebral Region (figs. 481 and 482)

Orbicularis palpebrarum. Tensor tarsi.
Corrugator supercilii.

The **Orbicularis palpebrarum** (m. orbicularis oculi) is a sphincter muscle which surrounds the circumference of the orbit and eyelids. It arises from

Fig. 482.—Left Orbicularis palpebrarum, seen from behind. (From Toldt's Atlas, published by Rebman, Ltd., London.)

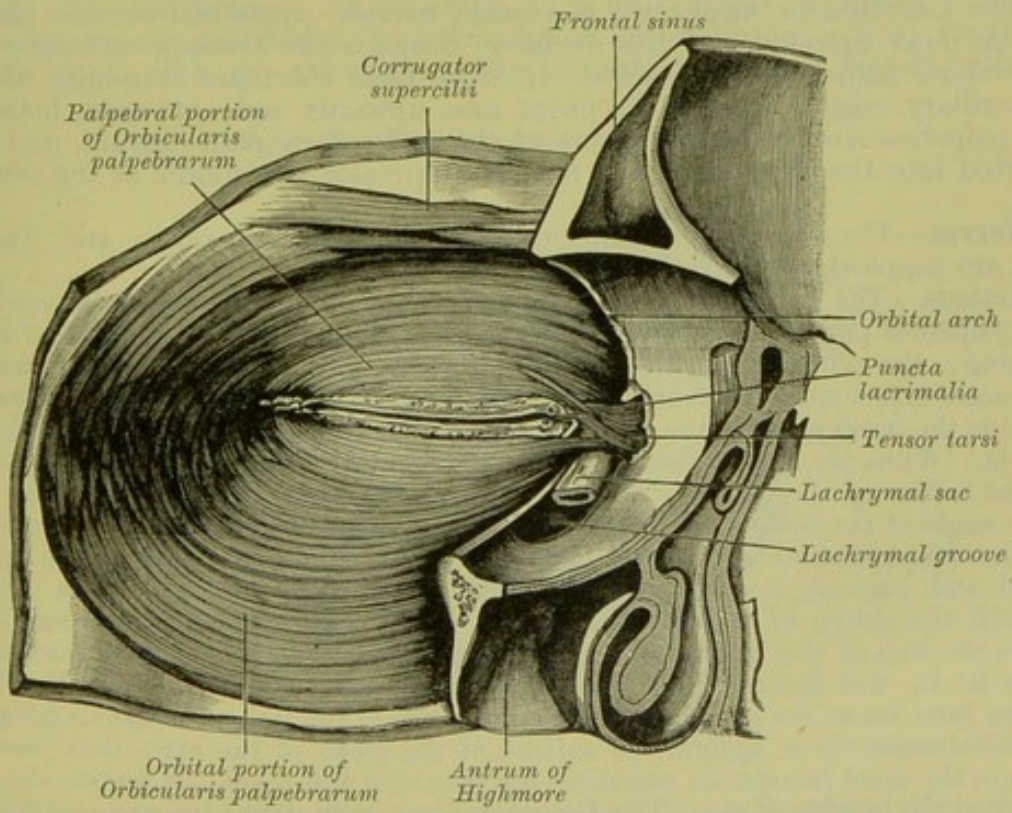

the internal angular process of the frontal bone, from the frontal process of the maxilla in front of the lachrymal groove for the nasal duct, and

from the anterior surface and borders of a short tendon, the *tendo oculi*, or *internal tarsal ligament*, placed at the inner angle of the orbit. From this origin, the fibres are directed outwards, forming a broad, thin, and flat layer, which covers the eyelids, surrounds the circumference of the orbit, and spreads out over the temple, and downwards on the cheek. The palpebral portion (pars palpebralis) of the Orbicularis is thin and pale; it arises from the bifurcation of the tendo oculi, forms a series of concentric curves, and is inserted into the external tarsal ligament. The orbital portion (pars orbitalis) is thicker and of a reddish colour: its fibres are well developed, and form complete ellipses. The upper fibres of this portion blend with the Occipito-frontalis and Corrugator supercilii.

The *tendo oculi*, or *internal tarsal ligament*, is a short tendon, about two lines in length and one in breadth, attached to the frontal process of the maxilla in front of the lachrymal groove. Crossing the lachrymal sac, it divides into two parts, each division being attached to the inner extremity of the corresponding tarsal plate. As the tendon crosses the lachrymal sac, a strong aponeurotic lamina is given off from the posterior surface, which expands over the sac, and is attached to the ridge on the lachrymal bone. This is the reflected aponeurosis of the tendo oculi.

The *external tarsal ligament* is a much weaker structure than the tendo oculi. It is attached to the margin of the frontal process of the malar bone, and passes inwards to the outer commissure of the eyelid, where it divides into two slips, which are attached to the margins of the respective tarsal plates.

The **Tensor tarsi** or muscle of Horner (pars lacrimalis m. orbicularis oculi) is a small thin muscle, about three lines in breadth and six in length, situated at the inner side of the orbit, behind the tendo oculi and lachrymal sac (fig. 482). It arises from the crest and adjacent part of the orbital surface of the lachrymal bone, and passing across the lachrymal sac, divides into two slips, which cover the lachrymal canals, and are inserted into the tarsal plates internal to the puncta lacrimalia. Its fibres appear to be continuous with those of the palpebral portion of the Orbicularis palpebrarum, from which they are usually considered to be derived; it is occasionally very indistinct.

The **Corrugator supercilii** is a small, narrow, pyramidal muscle, placed at the inner extremity of the eyebrow, beneath the Occipito-frontalis and Orbicularis palpebrarum muscles. It arises from the inner extremity of the superciliary ridge; whence its fibres pass upwards and outwards, between the palpebral and orbital portions of the Orbicularis palpebrarum, and are inserted into the deep surface of the skin, opposite the middle of the orbital arch.

Nerves.—The Orbicularis palpebrarum, Corrugator supercilii, and Tensor tarsi are supplied by the facial nerve.

Actions.—The Orbicularis palpebrarum is the sphincter muscle of the eyelids. The palpebral portion acts involuntarily, closing the lids gently, as in sleep or in blinking; the orbicular portion is subject to the will. When the entire muscle is brought into action, the skin of the forehead, temple, and cheek is drawn inwards towards the inner angle of the orbit, and the eyelids are firmly closed, as in photophobia. When the skin of the forehead, temple, and cheek is thus drawn inwards by the action of the muscle it is thrown into folds, especially radiating from the outer angle of the eyelids, which give rise in old age to the so-called 'crow's feet.' The Levator palpebræ is the direct antagonist of this muscle; it raises the upper eyelid and exposes the globe of the eye. Each time the eyelids are closed through the action of the Orbicularis, the tendo oculi becomes tightened, and draws the wall of the lachrymal sac outwards and forwards, so that a vacuum is made in it, and the tears are sucked along the lachrymal canals into it. The Tensor tarsi draws the eyelids and the extremities of the lachrymal canals inwards and compresses them against the surface of the globe of the eye; thus placing them in the most favourable situation for receiving the tears. It serves, also, to compress the lachrymal sac. The Corrugator supercilii draws the eyebrow downwards and inwards, producing the vertical wrinkles of the forehead. It is the 'frowning' muscle, and may be regarded as the principal agent in the expression of suffering.

IV. Orbital Region

Levator palpebræ superioris.
Rectus superior.
Rectus inferior.
Rectus internus.
Rectus externus.
Obliquus oculi superior.
Obliquus oculi inferior.

The **Levator palpebræ superioris** (fig. 483) is thin, flat, and triangular in shape. It arises from the under surface of the lesser wing of the sphenoid, above and in front of the optic foramen, from which it is separated by the origin

Fig. 483.—Sagittal section of right orbital cavity.

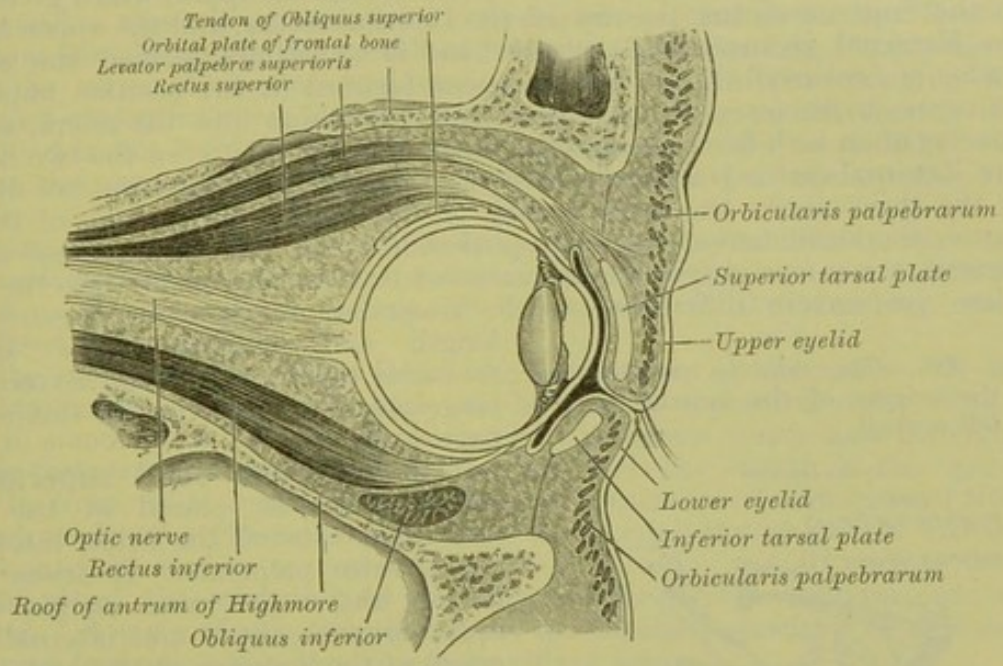

of the Superior rectus. At its origin, it is narrow and tendinous, but soon becomes broad and fleshy, and terminates anteriorly in a wide expansion which splits into three lamellæ. The superficial lamella blends with the

Fig. 484.—Muscles of the right orbit.

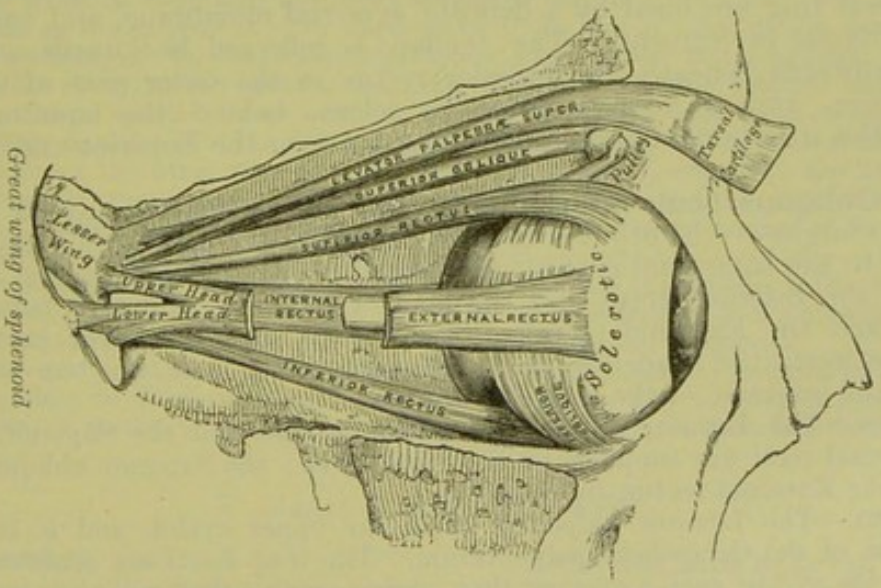

superior palpebral ligament, and is prolonged forwards above the superior tarsal plate to the palpebral part of the Orbicularis palpebrarum, and to the deep surface of the skin of the upper eyelid. The middle lamella, largely made up of non-striped muscular fibres, is inserted into the upper margin

of the superior tarsal plate, whilst the deepest lamella blends with an expansion from the sheath of the Superior rectus, and with it is attached to the superior fornix of the conjunctiva.

The **Four Recti** (fig. 484) arise from a fibrous ring (annulus tendineus communis) which surrounds the upper, inner, and lower margins of the optic foramen and encircles the optic nerve. The ring is completed by a little tendinous bridge prolonged over the lower and inner part of the sphenoidal fissure and attached to a tubercle on the margin of the greater wing of the sphenoid, bounding the sphenoidal fissure (fig. 485). Two specialised parts of this fibrous ring may be made out: a lower, the *ligament* or *tendon of Zinn*, which gives origin to the Inferior rectus, part of the Internal rectus, and the lower head of origin of the External rectus; and an upper, which gives origin to the Superior rectus, the rest of the Internal rectus, and the upper head of the External rectus. This upper band is sometimes termed the *superior tendon of Lockwood*. Each muscle passes forward in the position implied by its name, to be inserted by a tendinous expansion into the sclera, about a quarter of an inch from the margin of the cornea. Between the two heads of the External rectus is a narrow interval, through which pass the two divisions of the third nerve, the nasal branch of the ophthalmic division of the fifth nerve, the sixth nerve, and the ophthalmic vein. Although these muscles present a common origin and are inserted in a similar manner into the sclera, there are certain differences to be observed in them as regards their length and breadth. The Internal rectus is the broadest, the External the longest, and the Superior the thinnest and narrowest.

FIG. 485.—The relative positions of the origins of the muscles of the left eyeball.

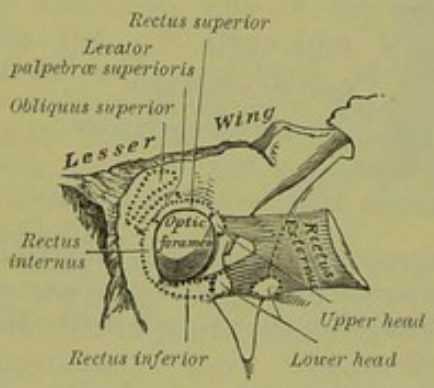

The **Obliquus oculi superior** is a fusiform muscle, placed at the upper and inner side of the orbit, internal to the Levator palpebræ. It arises immediately above the inner margin of the optic foramen, above and internal to the origin of the Superior rectus, and, passing forwards to the inner angle of the orbit, terminates in a rounded tendon, which plays in a fibro-cartilaginous ring or pulley attached to the trochlear fossa near the internal angular process of the frontal bone. The contiguous surfaces of the tendon and ring are lined by a delicate synovial membrane, and enclosed in a thin fibrous investment. The tendon is reflected backwards, outwards, and downwards beneath the Superior rectus to the outer part of the globe of the eye, and is inserted into the sclera, behind the equator of the eyeball, the insertion of the muscle lying between the Superior and External recti.

The **Obliquus oculi inferior** is a thin, narrow muscle, placed near the anterior margin of the orbit. It arises from the orbital plate of the maxilla, external to the lachrymal groove. Passing outwards, backwards, and upwards, between the Inferior rectus and the floor of the orbit, and then between the eyeball and the External rectus, it is inserted into the outer part of the sclera between the Superior and External recti, near to, but somewhat behind, the insertion of the Superior oblique.

Nerves.—The Levator palpebræ, Inferior oblique, and the Superior, Inferior and Internal recti are supplied by the third nerve; the Superior oblique, by the fourth; the External rectus, by the sixth.

Actions.—The Levator palpebræ raises the upper eyelid, and is the direct antagonist of the Orbicularis palpebrarum. The four Recti are attached to the globe of the eye in such a manner that, acting singly, they will turn its corneal surface either upwards, downwards, inwards, or outwards, as expressed by their names. The movement produced by the Superior or Inferior rectus is not quite a simple one, for inasmuch as each passes obliquely outwards and forwards to the eyeball, the elevation or depression of the cornea is accompanied by a certain deviation inwards, with a slight amount of rotation. These latter movements

are corrected by the Oblique muscles, the Inferior oblique correcting the deviation inwards of the Superior rectus, and the Superior oblique that of the Inferior rectus. The contraction of the External or Internal rectus, on the other hand, produces a purely horizontal movement. If any two contiguous Recti of one eye act together they carry the globe of the eye in the diagonal of these directions, viz. upwards and inwards, upwards and outwards, downwards and inwards, or downwards and outwards. A little consideration will show that sometimes the corresponding Recti of the two eyes act in unison, and at others the opposite Recti act together. Thus, in turning the eyes to the right, the External rectus of the right eye will act in unison with the Internal rectus of the left eye; but if both eyes are directed to an object in the middle line at a short distance, the two Internal recti will act in unison. The movement of circumduction, as in looking round a room, is performed by the successive action of the four Recti. The Oblique muscles rotate the eyeball on its antero-posterior axis, the Superior directing the cornea downwards and outwards, and the Inferior directing it upwards and outwards; these movements are required for the correct viewing of an object when the head is moved laterally, as from shoulder to shoulder, in order that the picture may fall in all respects on the same part of the retina of either eye.

Fasciæ of the orbit.—The connective tissue of the orbit is in various places condensed into thin membranous layers, which may be conveniently described as (1) the orbital fascia; (2) the sheaths of the muscles; and (3) the fascia of the eyeball.

(1) The *orbital fascia*. This forms the periosteum of the orbit. It is loosely connected to the bones, and can be readily separated from them. Behind, it is connected with the dura mater by processes which pass through the optic foramen and sphenoidal fissure, and with the sheath of the optic nerve. In front, it is connected with the periosteum at the margin of the orbit, and sends off a process which assists in forming the palpebral fascia. From its internal surface two processes are given off: one to enclose the lachrymal gland, the other to hold the pulley of the Superior oblique muscle in position. A layer of non-striped muscle, the *Orbitalis muscle* of H. Müller, may be seen bridging across the spheno-maxillary fissure.

(2) The *sheaths of the muscles* give off expansions to the margins of the orbit, which limit the action of the muscles.

(3) The *fascia of the eyeball*—Tenon's capsule—will be described with the anatomy of the eyeball.

Applied Anatomy.—The positions and exact points of insertion of the tendons of the Internal and External recti into the globe should be carefully examined from the front of the eyeball, as the surgeon is often required to divide one or other of the muscles for the cure of strabismus. In convergent strabismus, which is the more common form of the disease, the eye is turned inwards, requiring the division of the Internal rectus. In the divergent form, which is more rare, the eye is turned outwards, the External rectus being especially implicated. The deformity produced in either case is to be remedied by division of one or the other muscle. The operation is thus performed: the lids are to be well separated; the eyeball is rotated outwards or inwards, and the conjunctiva raised by a pair of forceps, and incised immediately beneath the lower border of the tendon of the muscle to be divided, a little behind its insertion into the sclera; the submucous areolar tissue is then divided, and into the small aperture thus made, a blunt hook is passed upwards between the muscle and the globe, and the tendon of the muscle divided by a pair of blunt-pointed scissors passed between the hook and the globe.

A more recent operation is that of *advancement* in which either the Internal or External rectus (depending on the form of strabismus) is shortened. The muscle is exposed in the same manner; a portion is then cut out of it and the cut ends are sewn together.

V. Nasal Region (fig. 486)

Pyramidalis nasi.
Levator labii superioris alæque nasi.
Dilatator naris posterior.
Dilatator naris anterior.
Compressor naris.
Compressor narium minor.
Depressor alæ nasi.

The **Pyramidalis nasi** (m. procerus) is a small pyramidal slip placed over the nasal bone. Its origin is by tendinous fibres from the fascia covering the

lower part of the nasal bone and upper part of the cartilage, where it blends with the Compressor naris, and it is inserted into the skin over the lower part of the forehead between the two eyebrows, its fibres decussating with those of the Occipito-frontalis.

The **Levator labii superioris alæque nasi** is a thin triangular muscle, placed by the side of the nose, and extending between the inner margin of the orbit and the upper lip. It arises by a pointed extremity from the upper part of the frontal process of the maxilla, and, passing obliquely downwards and outwards, divides into two slips, one of which is inserted into the cartilage of the ala of the nose; the other is prolonged into the upper lip, blending with the Orbicularis oris and Levator labii superioris proprius.

The **Dilatator naris posterior** is a small muscle, which is placed partly beneath the elevator of the nose and lip. It arises from the margin of the nasal notch of the maxilla, and from the sesamoid cartilages, and is inserted into the skin near the margin of the nostril.

The **Dilatator naris anterior** is a thin delicate fasciculus, passing from the cartilage of the ala of the nose to the integument near its margin. This muscle is situated in front of the preceding.

The **Compressor naris** is a small, thin, triangular muscle, arising by its apex from the maxilla, above and a little external to the incisive fossa; its fibres proceed upwards and inwards, expanding into a thin aponeurosis which is continuous on the bridge of the nose with that of the muscle of the opposite side, and with the aponeurosis of the Pyramidalis nasi.

The **Compressor narium minor** is a small muscle, attached by one end to the alar cartilage, and by the other to the integument at the end of the nose.

The **Depressor alæ nasi** is a short radiated muscle, arising from the incisive fossa of the maxilla; its fibres ascend to be inserted into the septum, and back part of the ala of the nose. This muscle lies between the mucous membrane and muscular structure of the lip.

Nerves.—All the muscles of this group are supplied by the facial nerve.

Actions.—The Pyramidalis nasi draws down the inner angle of the eyebrows and produces transverse wrinkles over the bridge of the nose. The Levator labii superioris alæque nasi draws upwards the upper lip and ala of the nose; its most important action is upon the nose, which it dilates to a considerable extent. The action of this muscle produces a marked influence over the countenance, and it is the principal agent in the expression of contempt and disdain. The two Dilatatores enlarge the aperture of the nose. Their action in ordinary breathing is to resist the tendency of the nostrils to close from atmospheric pressure, but in difficult breathing, as well as in some emotions, such as anger, they may be noticed to be in violent action. The Depressor alæ nasi is a direct antagonist of the other muscles of the nose, drawing the ala of the nose downwards, and thereby constricting the aperture of the nares. The Compressor naris depresses the cartilaginous part of the nose and draws the alæ together.

VI. Maxillary Region (fig. 486)

Levator labii superioris proprius.
Levator anguli oris.
Zygomaticus major.
Zygomaticus minor.

The **Levator labii superioris proprius** is a thin muscle, of a quadrilateral form. It arises from the lower margin of the orbit immediately above the infra-orbital foramen, some of its fibres being attached to the maxilla, others to the malar bone; its fibres converge to be inserted into the muscular substance of the upper lip, between the attachment of the Levator labii superioris alæque nasi and the Levator anguli oris.

The **Levator anguli oris** (m. caninus) arises from the canine fossa, immediately below the infra-orbital foramen; its fibres incline downwards and a little outwards, to be inserted into the angle of the mouth, intermingling with those of the Zygomaticus major, the Depressor anguli oris, and the Orbicularis oris.

The **Zygomaticus major** is a slender fasciculus, which arises from the malar bone, in front of the zygomatic suture, and descending obliquely down-

wards and inwards, is inserted into the angle of the mouth, where it blends with the fibres of the Levator anguli oris, the Orbicularis oris, and the Depressor anguli oris.

The **Zygomaticus minor** arises from the malar bone, immediately behind the maxillary suture, and passing downwards and inwards, is continuous with the Orbicularis oris at the outer margin of the Levator labii superioris. It lies anterior to the preceding.

Fig. 486.—Muscles of the head, face, and neck.

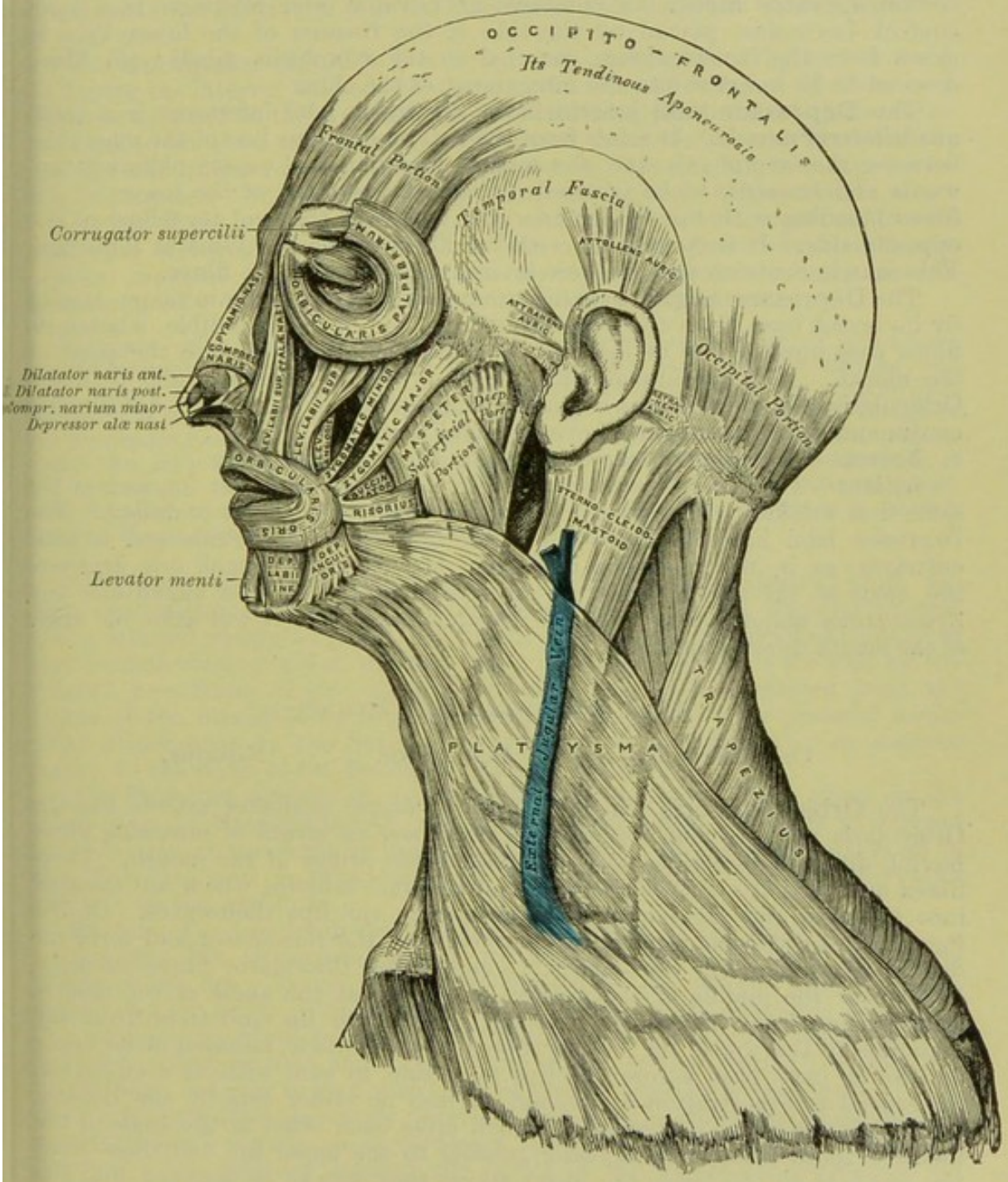

Nerves.—This group of muscles is supplied by the facial nerve.

Actions.—The Levator labii superioris is the proper elevator of the upper lip, carrying it at the same time a little forwards. It assists in forming the naso-labial ridge, which passes from the side of the nose to the upper lip and gives to the face an expression of sadness. The Levator anguli oris raises the angle of the mouth and assists the Levator labii superioris in producing the naso-labial ridge. The Zygomaticus major draws the angle of the mouth backwards and upwards, as in laughing; while the Zygomaticus minor, being inserted into the outer part of

the upper lip and not into the angle of the mouth, draws it backwards, upwards, and outwards, and thus gives to the face an expression of sadness.

VII. Mandibular Region (fig. 486)

Levator menti.
Depressor labii inferioris.
Depressor anguli oris.

The **Levator menti** (m. mentalis) or Levator labii inferioris is a small conical fasciculus, placed on the side of the frænum of the lower lip. It arises from the incisive fossa, external to the symphysis menti; its fibres descend to be inserted into the integument of the chin.

The **Depressor labii inferioris** (m. quadratus labii inferioris) is a small quadrilateral muscle. It arises from the external oblique line of the mandible, between the symphysis and the mental foramen, and passes obliquely upwards and inwards, to be inserted into the integument of the lower lip, its fibres blending with the Orbicularis oris, and with those of its fellow of the opposite side. It is continuous with the fibres of the Platysma at its origin. This muscle contains much yellow fat intermingled with its fibres.

The **Depressor anguli oris** (m. triangularis) is triangular in shape, arising by its broad base, from the external oblique line of the mandible, whence its fibres pass upwards, to be inserted, by a narrow fasciculus, into the angle of the mouth. It is continuous with the Platysma at its origin, and with the Orbicularis oris and Risorius at its insertion, and some of its fibres are directly continuous with those of the Levator anguli oris.

Nerves.—This group of muscles is supplied by the facial nerve.

Actions.—The Levator menti raises and protrudes the lower lip, and at the same time wrinkles the integument of the chin, expressing doubt or disdain. The Depressor labii inferioris draws the lower lip directly downwards and a little outwards, as in the expression of irony. The Depressor anguli oris depresses the angle of the mouth, being the antagonist of the Levator anguli oris and Zygomaticus major; acting with the Levator anguli oris, it will draw the angle of the mouth directly inwards.

VIII. Intermaxillary Region

Orbicularis oris. Buccinator. Risorius.

The **Orbicularis oris** (fig. 486) is not a simple sphincter muscle like the Orbicularis palpebrarum, but consists of numerous strata of muscular fibres having different directions and surrounding the orifice of the mouth. These fibres are partially derived from the other facial muscles which are inserted into the lips, and are partly fibres proper to the lips themselves. Of the former, a considerable number are derived from the Buccinator and form the deeper stratum of the Orbicularis. Some of the Buccinator fibres—namely, those near the middle of the muscle—decussate at the angle of the mouth, those arising from the maxilla passing to the lower lip, and those from the mandible to the upper lip. Other fibres of the muscle, situated at its upper and lower part, pass across the lips from side to side without decussation. Superficial to this stratum is a second, formed on either side by the Levator and Depressor anguli oris muscles, which cross each other at the angle of the mouth; those from the Depressor passing to the upper lip, and those from the Levator to the lower lip, along which they run to be inserted into the skin near the median line. In addition to these there are fibres from other muscles inserted into the lips, the Levator labii superioris, the Levator labii superioris alæque nasi, the Zygomatici, and the Depressor labii inferioris; these intermingle with the transverse fibres above described, and have principally an oblique direction. The proper fibres of the lips are oblique, and pass from the under surface of the skin to the mucous membrane, through the thickness of the lip. Finally there are fibres by which the muscle is connected with the maxillæ and the septum of the nose and with the mandible. In the upper lip these consist of two bands, inner and outer, on each side of

the middle line ; the outer band (*m. incisivus superior*) arises from the alveolar border of the maxilla, opposite the lateral incisor tooth, and arching outwards is continuous at the angle of the mouth with the other muscles inserted into this part ; the inner band (*m. nasolabialis*) connects the upper lip to the back of the septum of the nose. The interval between the two inner bands corresponds with the depression, called the *philtrum*, seen on the lip beneath the septum of the nose. The additional fibres for the lower lip constitute a slip (*m. incisivus inferior*) on either side of the middle line which arises from the mandible, external to the Levator labii inferioris, and arches outwards to the angle of the mouth, to join the Buccinator and the other muscles attached to this part.

The **Buccinator** (fig. 494) is a broad, thin muscle, quadrilateral in form, occupying the interval between the jaws at the side of the face. It arises from the outer surfaces of the alveolar processes of the upper and lower jaws, corresponding to the three molar teeth ; and behind, from the anterior border of the pterygo-mandibular ligament which separates it from the Superior constrictor of the pharynx. The fibres converge towards the angle of the mouth, where the central fibres intersect each other, those from below being continuous with the upper segment of the Orbicularis oris, and those from above with the inferior segment; the uppermost and lowermost fibres continue forward uninterruptedly into the corresponding lip without decussation.

Relations.—The Buccinator is in relation by its *superficial surface*, behind, with a large mass of fat, which separates it from the ramus of the lower jaw, from the Masseter, and from a small portion of the Temporal, and which has been named the *suctorial pad*, because it is supposed to assist in the act of sucking. In front the superficial surface of the Buccinator is in relation with the Zygomatici, Risorius, Levator anguli oris, Depressor anguli oris, and Stenson's duct which pierces it opposite the second molar tooth of the upper jaw ; the facial artery and vein cross it from below upwards ; it is also crossed by the branches of the facial and buccal nerves. The *deep surface* is in relation with the buccal glands and mucous membrane of the mouth.

The *pterygo-mandibular ligament* is a tendinous band, derived from the deep cervical fascia and attached by one extremity to the hamular process of the internal pterygoid plate, and by the other to the posterior extremity of the internal oblique line of the mandible. Its *inner surface* is covered by the mucous membrane of the mouth. Its *outer surface* is separated from the ramus of the mandible by a quantity of adipose tissue. Its *posterior border* gives attachment to the Superior constrictor of the pharynx ; its *anterior border*, to the fibres of the Buccinator (see fig. 494).

The **Risorius** consists of a narrow bundle of fibres, which arises in the fascia over the Masseter muscle and, passing horizontally forwards, is inserted into the skin at the angle of the mouth (fig. 486). It is placed superficial to the Platysma, and is broadest at its outer extremity. This muscle varies much in its size and form.

Nerves.—The muscles in this group are all supplied by the facial nerve.

Actions.—The Orbicularis oris in its ordinary action produces the direct closure of the lips ; by its deep fibres, assisted by the oblique ones, it closely applies the lips to the alveolar arch. The superficial part, consisting principally of the decussating fibres, brings the lips together and also protrudes them forwards. The Buccinators contract and compress the cheeks, so that, during the process of mastication, the food is kept under the immediate pressure of the teeth. When the cheeks have been previously distended with air, the Buccinator muscles expel it from between the lips, as in blowing a trumpet. Hence the name (*buccina*, a trumpet). The Risorius retracts the angles of the mouth, and produces the unpleasant expression which is sometimes seen in tetanus, and is known as 'risus sardonicus.'

IX. Temporo-mandibular Region

Masseter. Temporal.

Masseteric fascia.—Covering the Masseter muscle, and firmly connected with it, is a strong layer of fascia, derived from the deep cervical fascia. Above, this fascia is attached to the lower border of the zygoma, and behind it invests the parotid gland, constituting the *parotid fascia*.

The **Masseter** (fig. 486) is a short, thick muscle, somewhat quadrilateral in form, consisting of two portions, superficial and deep. The *superficial portion*, the larger, arises by a thick, tendinous aponeurosis from the malar process of the maxilla, and from the anterior two-thirds of the lower border of the zygomatic arch : its fibres pass downwards and backwards, to be inserted into the angle and lower half of the outer surface of the ramus of the mandible. The *deep portion* is much smaller, and more muscular in texture ; it arises from the posterior third of the lower border and the whole of the inner surface of the zygomatic arch ; its fibres pass downwards and forwards, to be inserted into the upper half of the ramus and the outer surface of the coronoid process of the mandible. The deep portion of the muscle is partly concealed, in front, by the superficial portion ; behind, it is covered by the parotid gland. The fibres of the two portions are continuous at their insertion.

Relations.—The Masseter is in relation by its *superficial surface* with the integument, Platysma, Risorius, Zygomatici, the parotid gland and socia parotidis, and with Stenson's duct, and the branches of the facial nerve and the transverse facial vessels which cross it. By its *deep surface*, it is in relation with the insertion of the Temporal muscle, the

FIG. 487.—The Temporal muscle ; the zygoma and Masseter have been removed.

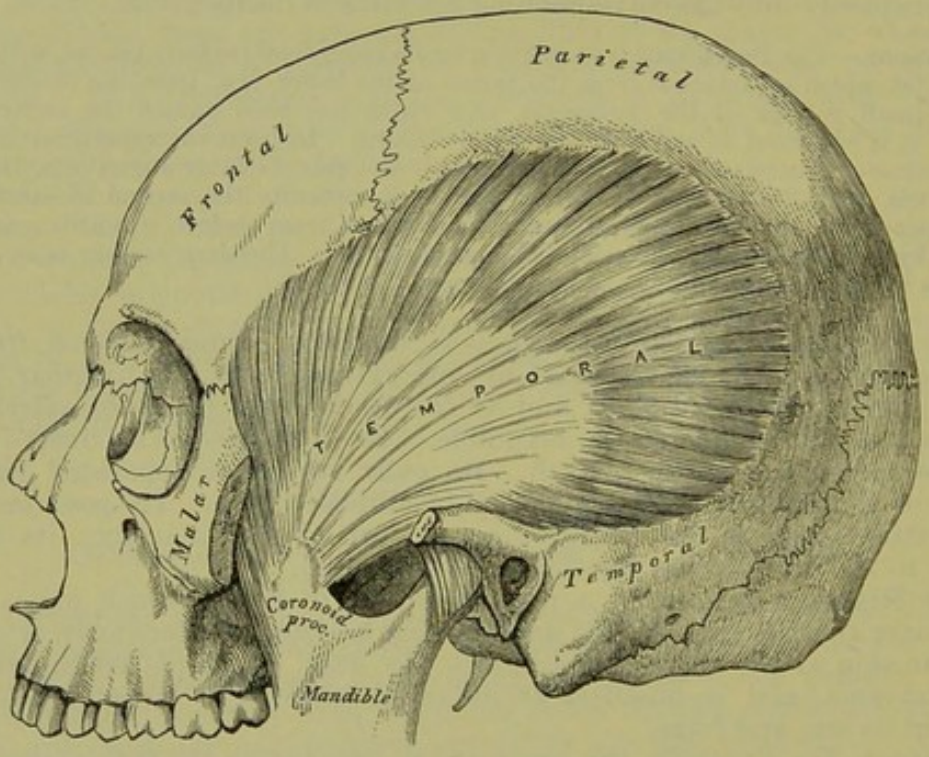

ramus of the mandible, the Buccinator and the long buccal nerve from which it is separated by a mass of fat. The masseteric nerve and artery enter it on its deep surface. Its *posterior margin* is overlapped by the parotid gland. Its *anterior margin*, which projects over the Buccinator muscle, is crossed below by the facial vein.

The **temporal fascia** covers the Temporal muscle. It is a strong, fibrous investment, covered, on its outer surface, by the Attrahens and Attollens auriculam muscles, the aponeurosis of the Occipito-frontalis, and by part of the Orbicularis palpebrarum. The temporal vessels and the auriculo-temporal nerve cross it from below upwards. Above, it is a single layer, attached to the entire extent of the upper temporal ridge ; but below, where it is attached to the zygoma, it consists of two layers, one of which is inserted into the outer, and the other into the inner border of the zygomatic arch. A small quantity of fat, the orbital branch of the temporal artery, and a filament from the orbital or temporo-malar branch of the superior maxillary nerve, are contained between these two layers. It affords attachment by its inner surface to the superficial fibres of the Temporal muscle.

The **Temporal** (m. temporalis) (fig. 487) is a broad, radiating muscle, situated at the side of the head, and occupying the entire extent of the temporal fossa. It arises from the whole of the temporal fossa (except that portion of it which is formed by the malar bone) and from the inner surface of the temporal fascia. Its fibres converge as they descend, and terminate in a tendon, which is inserted into the inner surface, apex, and anterior border of the coronoid process, and the anterior border of the ramus of the mandible, nearly as far forwards as the last molar tooth.

Relations.—The Temporal is in relation by its *superficial surface* with the integument, the Attrahens and Attollens auriculam muscles, the temporal fascia, the superficial temporal vessels, the auriculo-temporal nerve, the temporal branches of the facial and temporo-malar nerves, the aponeurosis of the Occipito-frontalis, the zygoma, and the Masseter. By its *deep surface*, it is in relation with the temporal fossa, the External pterygoid and part of the Buccinator muscles, the internal maxillary artery, and its deep temporal branches, the deep temporal nerves, and the buccal vessels and nerve. Behind the tendon are the masseteric vessels and nerve. Its anterior border is separated from the malar bone by a mass of fat.

Nerves.—Both muscles are supplied by the inferior maxillary nerve.

X. Pterygo-Mandibular Region (fig. 488)

Pterygoideus externus. Pterygoideus internus.

The **Pterygoideus externus** is a short, thick muscle, somewhat conical in form, which extends almost horizontally between the zygomatic fossa and the condyle of the mandible. It arises by two heads, separated by a slight interval: the *upper* from the inferior portion of the external surface of the greater wing

Fig. 488.—The Pterygoid muscles; the zygomatic arch and a portion of the ramus of the jaw have been removed.

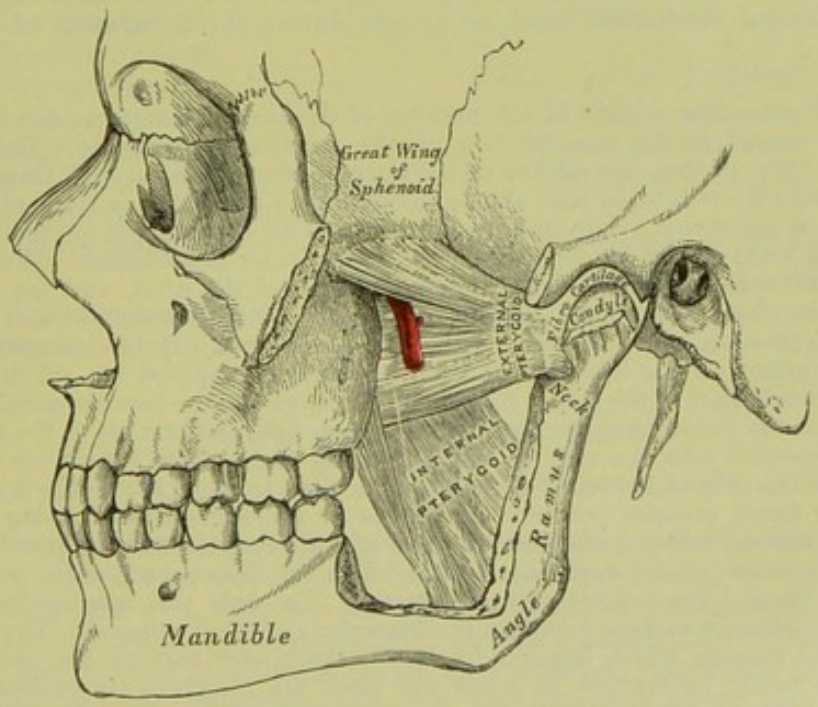

of the sphenoid and from the pterygoid ridge which separates the zygomatic from the temporal fossa; the *lower* from the outer surface of the external pterygoid plate. Its fibres pass horizontally backwards and outwards, to be inserted into a depression in front of the neck of the condyle of the mandible, and into the front of the interarticular fibro-cartilage of the temporo-mandibular articulation.

Relations.—By its *external surface* it is in relation with the ramus of the lower jaw, the internal maxillary artery, which crosses it,* the tendon of the Temporal muscle, and the Masseter. Its *internal surface* rests against the upper part of the Internal pterygoid, the internal lateral ligament, the middle meningeal artery, and the inferior maxillary nerve; by its *upper border* it is in relation with the temporal and masseteric branches of the inferior maxillary nerve; by its *lower border* it is in relation with the inferior dental and lingual nerves. Through the interval between the two portions of the muscle, the buccal nerve emerges and the internal maxillary artery passes, when the trunk of this vessel lies on the lower part of the muscle (see fig. 488).

The **Pterygoideus internus** is a thick, quadrilateral muscle, and resembles the Masseter in form. It arises from the pterygoid fossa, being attached to the inner surface of the external pterygoid plate, and to the grooved surface of the tuberosity of the palate bone, and by a second slip from the outer surface of the tuberosities of the palate and maxilla; its fibres pass downwards, outwards, and backwards, to be inserted, by a strong tendinous lamina, into the lower and back part of the inner side of the ramus and angle of the mandible, as high as the dental foramen.

Relations.—By its *external surface* it is in relation with the ramus of the mandible, from which it is separated, at its upper part, by the External pterygoid, the internal lateral ligament, the internal maxillary artery, the inferior dental vessels and nerves, the lingual nerve, and a process of the parotid gland. By its *internal surface* it is in relation with the Tensor palati, being separated from the Superior constrictor of the pharynx by a cellular interval.

Nerves.—These muscles are supplied by the inferior maxillary nerve.

Actions.—The Temporal, Masseter and Internal pterygoid raise the mandible against the maxillæ with great force. The External pterygoids assist in opening the mouth, but their main action is to draw forward the condyles and interarticular cartilages so that the mandible is protruded and the inferior incisors projected in front of the upper; in this action they are assisted by the Internal pterygoids. The mandible is retracted by the posterior fibres of the Temporal. If the Internal and External pterygoids of one side act, the corresponding side of the mandible is drawn forward while the opposite condyle remains comparatively fixed, and lateral movement, such as occurs during the trituration of food, takes place.

Surface Form.—The outline of the muscles of the head and face cannot be traced on the surface, except in the case of two of the masticatory muscles. The muscles of the head are thin, so that the outline of the bone is perceptible beneath them. Those of the face are small, covered by soft skin, and often by a considerable layer of fat, so that their outline is concealed; but they serve to round off and smooth prominent borders, and to fill up what would be otherwise unsightly angular depressions. Thus, the Orbicularis palpebrarum rounds off the prominent margin of the orbit, and the Pyramidalis nasi fills in the sharp depression beneath the glabella, and thus softens and tones down the abrupt depression which is seen on the unclothed skull. In like manner, the labial muscles, converging to the lips, and assisted by the superimposed fat, fill in the sunken hollow of the lower part of the face. Although the muscles of the face are usually described as arising from the bones, and inserted into the nose, lips, and corners of the mouth, they have fibres inserted into the skin of the face along their whole extent, so that almost every point of the skin of the face has its muscular fibre to move it. Hence it is that when in action the facial muscles produce alterations in the skin-surface, giving rise to the formation of various folds or wrinkles, or otherwise altering the relative position of parts, so as to produce the varied expressions with which the face is endowed; these muscles are therefore termed the 'muscles of expression.' The only two muscles in this region which greatly influence surface-form are the Masseter and the Temporal. The Masseter is a quadrilateral muscle, which imparts fulness to the hinder part of the cheek. When the muscle is firmly contracted, as when the teeth are clenched, its outline is plainly visible; the anterior border forms a prominent vertical ridge, behind which is a considerable fulness, especially marked at the lower part of the muscle. The Temporal muscle is fan-shaped, and fills the temporal fossa, substituting for it a somewhat convex form, the anterior part of which, on account of the absence of hair over the temple, is more marked than the posterior, and stands out in strong relief when the muscle is in a state of contraction.

* In many cases the artery will be found under cover of the muscle.

MUSCLES AND FASCIÆ OF THE NECK

The muscles of the neck may be arranged into groups, corresponding with the regions in which they are situated.

These groups are nine in number :

I. Superficial Region.
II. Infrahyoid Region.
III. Suprahyoid Region.
IV. Lingual Region.
V. Pharyngeal Region.
VI. Palatal Region.
VII. Anterior Vertebral Region.
VIII. Lateral Vertebral Region.
IX. Muscles of the Larynx.

The muscles contained in each of these groups are the following :

I. Superficial Region.
Platysma.
Sterno-cleido-mastoid.

II. Infrahyoid Region.
Sterno-hyoid.
Sterno-thyroid.
Thyro-hyoid.
Omo-hyoid.

III. Suprahyoid Region.
Digastric.
Stylo-hyoid.
Mylo-hyoid.
Genio-hyoid.

IV. Lingual Region.
Extrinsic.
Genio-hyo-glossus.
Hyo-glossus.
Chondro-glossus.
Stylo-glossus.
Palato-glossus.
Intrinsic.
Superior lingualis.
Inferior lingualis.
Transverse lingualis.
Vertical lingualis

V. Pharyngeal Region.
Inferior constrictor.
Middle constrictor.
Superior constrictor.
Stylo-pharyngeus.
Palato-pharyngeus.
Salpingo-pharyngeus.

VI. Palatal Region.
Levator palati.
Tensor palati.
Azygos uvulæ.
Palato-glossus.
Palato-pharyngeus.
Salpingo-pharyngeus.

VII. Anterior Vertebral Region.
Rectus capitis anticus major.
Rectus capitis anticus minor.
Rectus capitis lateralis.
Longus colli.

VIII. Lateral Vertebral Region.
Scalenus anticus.
Scalenus medius.
Scalenus posticus.

IX. Muscles of the Larynx
Included in the description of the Larynx.

I. Superficial Cervical Region

Platysma. Sterno-cleido-mastoid.

The **superficial cervical fascia** is a thin lamina, which is hardly demonstrable as a separate membrane. It invests the Platysma.

The **Platysma** (fig. 486) is a broad, thin plane of muscular fibres situated on the side of the neck. It arises by thin, fibrous bands from the fascia covering the upper part of the Pectoralis major and Deltoid; its fibres pass over the clavicle, and proceed obliquely upwards and inwards along the side of the neck. The anterior fibres interlace, below and behind the symphysis menti, with the fibres of the muscle of the opposite side; the posterior fibres pass over the mandible, some of them being attached to the bone below the external oblique line, others passing on to be inserted into the skin and subcutaneous tissue of the lower part of the face, many of these fibres blending with the muscles about the angle and lower part of the mouth. Sometimes fibres can be traced to the Zygomatic muscles, or to the margin of

the Orbicularis oris. Beneath the Platysma, the external jugular vein may be seen descending from the angle of the mandible to the clavicle.

Actions.—The Platysma produces a slight wrinkling of the surface of the skin of the neck, in an oblique direction, when the entire muscle is brought into action. Its anterior portion, the thickest part of the muscle, depresses the lower jaw; it also serves to draw down the lower lip and angle of the mouth on each side, being one of the chief agents in the expression of melancholy.

The **deep cervical fascia** (fig. 489) lies under cover of the Platysma, and constitutes a complete investment for the neck. It also forms sheaths for

FIG. 489.—Section of the neck at about the level of the sixth cervical vertebra. Showing the arrangement of the deep cervical fascia.

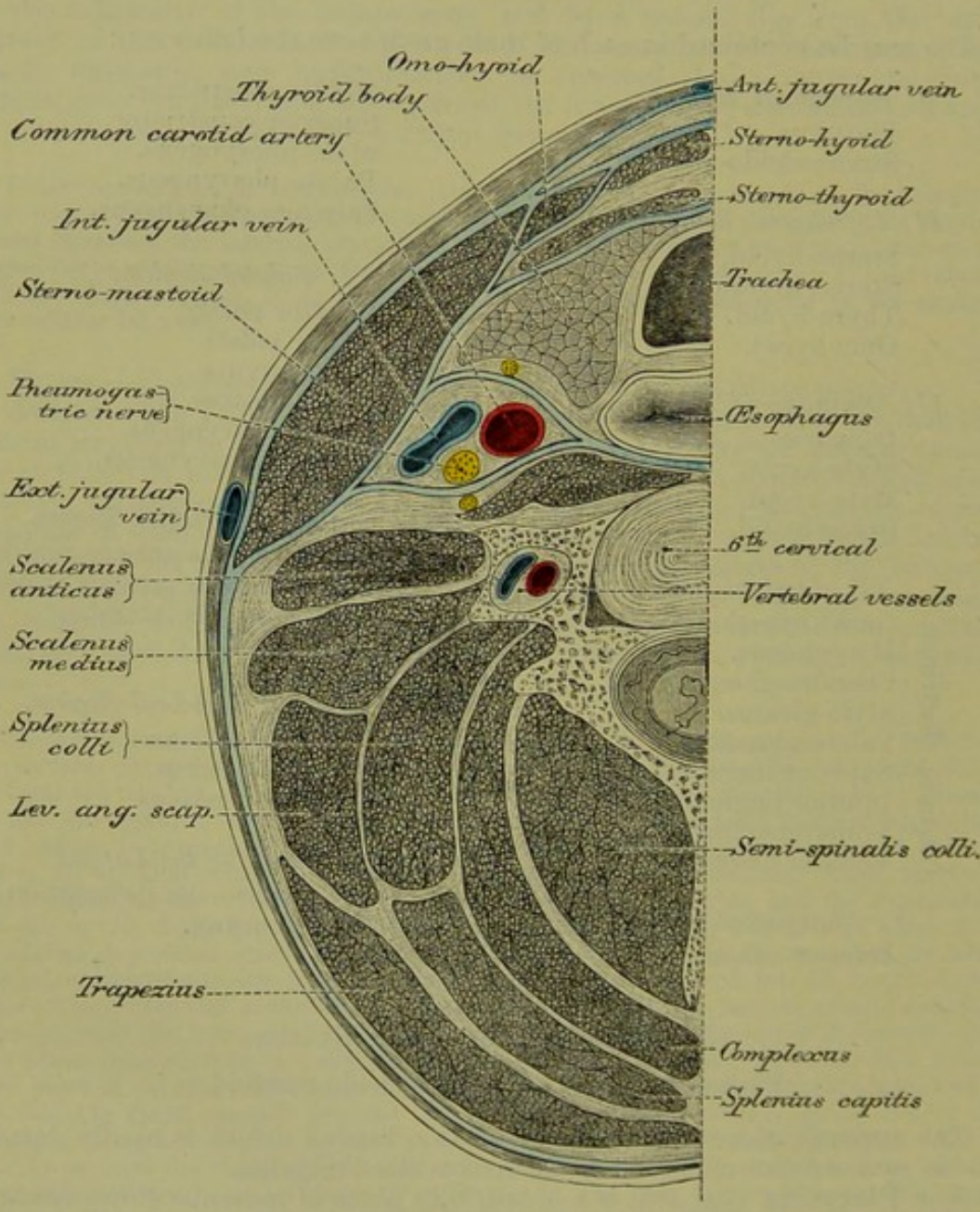

the carotid vessels, and, in addition, is prolonged deeply in the shape of certain processes or lamellæ, which come into close relation with the structures situated in front of the vertebral column.

The investing portion of the fascia is attached behind to the ligamentum nuchæ and to the spine of the seventh cervical vertebra. It forms a thin investment to the Trapezius muscle, and at its anterior border is continued forwards as a rather loose areolar layer, covering the posterior triangle of the neck, to the posterior border of the Sterno-mastoid muscle, where it begins to assume the appearance of a fascial membrane. Along the hinder edge of the

Sterno-mastoid it divides to enclose the muscle, and at the anterior margin again forms a single lamella, which roofs in the anterior triangle of the neck, and reaches forwards to the middle line, to become continuous with the corresponding part from the opposite side of the neck. In the middle line of the neck it is attached to the symphysis menti and body of the hyoid bone.

Above, the fascia is attached to the superior curved line of the occipital, to the mastoid process of the temporal, and to the whole length of the body of the mandible. Opposite the angle of the mandible the fascia is very strong, and binds the anterior edge of the Sterno-mastoid firmly to that bone. Between the mandible and the mastoid process it ensheathes the parotid gland—the layer which covers the gland extending upwards under the name of the *parotid fascia* to be fixed to the zygomatic arch. From the layer which passes under the parotid a strong band extends upwards to the styloid process, forming the *stylo-mandibular ligament*. Three other bands may be defined: the *spheno-mandibular*, the *pterygo-mandibular* and the *pterygo-spinous ligaments*. The *pterygo-spinous ligament* is a membranous band which stretches across from the upper half of the posterior free border of the external pterygoid plate to the spinous process of the sphenoid. It occasionally ossifies, and produces between its upper border and the base of the skull, an adventitious foramen which transmits the branches of the third division of the fifth nerve to the muscles of mastication.

Below, the fascia is attached to the acromion process, the clavicle, and the manubrium sterni. Some little distance above the last, however, it splits into two layers, superficial and deep. The former is attached to the anterior border of the manubrium, the latter to its posterior border and to the interclavicular ligament. Between these two layers is a slit-like interval, the *suprasternal space*, or *space of Burns*. It contains a small quantity of areolar tissue, and sometimes a lymphatic gland, the lower portions of the anterior jugular veins and their transverse connecting branch, and also the sternal heads of the Sterno-mastoid muscles.

The fascia which lines the deep surface of the Sterno-mastoid gives off the following important processes. (1) A process envelops the tendon of the Omo-hyoid, and binds it down to the sternum and first costal cartilage. (2) A strong sheath, the *carotid sheath*, encloses the carotid artery, internal jugular vein, and pneumogastric nerve. (3) The *prevertebral fascia* extends inwards behind the carotid vessels, where it assists in forming their sheath, and passes in front of the prevertebral muscles. It forms the posterior limit of a fibrous compartment, which contains the larynx and trachea, the thyroid gland, and the pharynx and œsophagus. The prevertebral fascia is fixed above to the base of the skull, while below it is continued into the thorax in front of the Longus colli muscles. Parallel to the carotid sheath and along its inner aspect the prevertebral fascia gives off a thin lamina, the *bucco-pharyngeal fascia*, which closely invests the Constrictor muscles of the pharynx, and is continued forward from the Superior constrictor on to the Buccinator. It is attached to the prevertebral layer by loose connective tissue only, and thus an easily distended space, the *retro-pharyngeal space*, is found between them. This space is limited above by the base of the skull, while below it extends behind the œsophagus into the thorax, where it is continued into the posterior mediastinum. The prevertebral fascia is prolonged downwards and outwards behind the carotid vessels and in front of the Scaleni, and forms a sheath for the brachial nerves and subclavian vessels in the posterior triangle of the neck; it is continued under the clavicle as the axillary sheath and is attached to the deep surface of the costo-coracoid membrane. Immediately above and behind the clavicle an areolar space exists between the investing layer and the sheath of the subclavian vessels, and in its upper portion are found the lower part of the external jugular vein, the descending clavicular nerves, the suprascapular and transversalis colli vessels, and the posterior belly of the Omo-hyoid muscle. This space is limited below by the fusion of the costo-coracoid membrane with the anterior wall of the axillary sheath. (4) The *pretracheal fascia* extends inwards in front of the carotid vessels, and assists in forming the carotid sheath. It is further continued behind the depressor muscles of the hyoid bone, and, after enveloping the thyroid body, is prolonged in front of the trachea to meet the corresponding

layer of the opposite side. Above, it is fixed to the hyoid bone, while below it is carried downwards in front of the trachea and large vessels at the root of the neck, and ultimately blends with the fibrous pericardium. This layer is fused on either side with the prevertebral layer, with which it completes the compartment containing the larynx and trachea, the thyroid gland, the pharynx and œsophagus.

Applied Anatomy.—The deep cervical fascia is of considerable importance from a surgical point of view. As will be seen from the foregoing description, it may be divided into three layers: (1) an investing layer; (2) a layer passing in front of the trachea, and forming with the superficial layer a sheath for the depressors of the hyoid bone; (3) a prevertebral layer passing in front of the bodies of the cervical vertebræ, and forming with the second layer a space in which is contained the trachea, œsophagus &c. The investing layer would oppose the extension of abscesses towards the surface, and pus forming beneath it would have a tendency to extend laterally. If the pus be contained in the anterior triangle, it may find its way into the anterior mediastinum, being situated in front of the layer of fascia which passes down into the thorax to become continuous

Fig. 490.—Muscles of the neck. Lateral view.

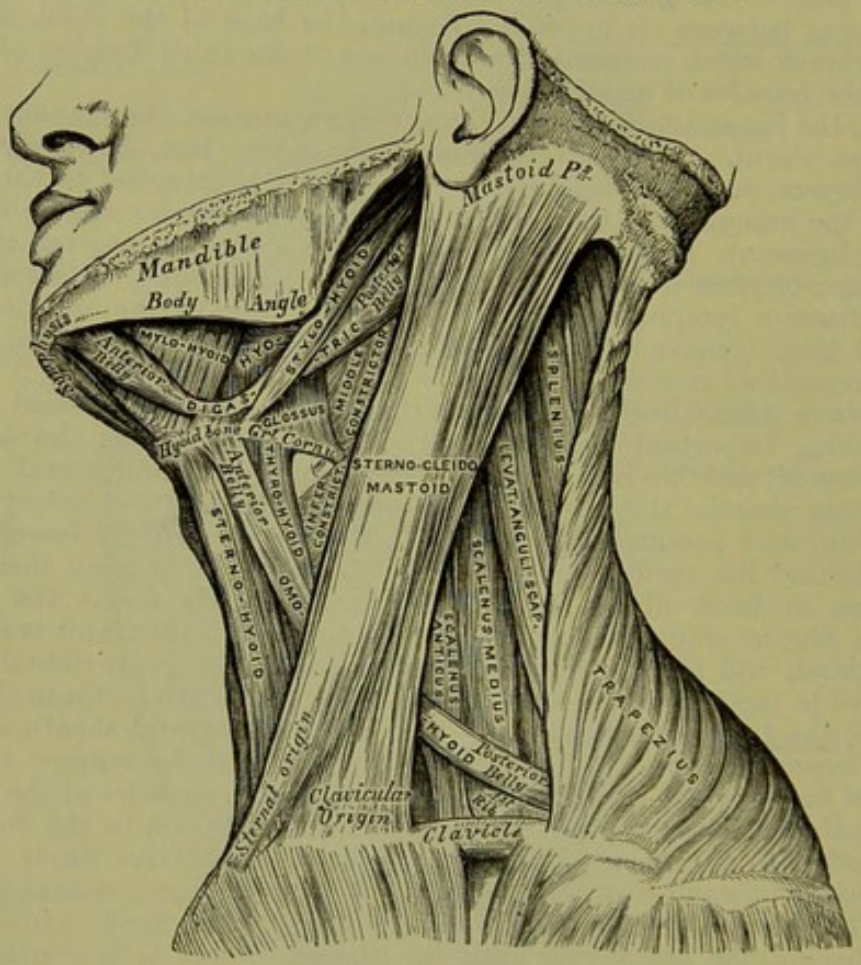

with the pericardium; but owing to the less density and thickness of the fascia in this situation it more frequently finds its way through it and points above the sternum. Pus forming beneath the second layer would in all probability find its way into the posterior mediastinum. Pus forming behind the prevertebral layer, in cases, for instance, of caries of the bodies of the cervical vertebræ, might extend towards the posterior and lateral part of the neck and point in this situation, or might perforate this layer of fascia and the pharyngeal fascia and point into the pharynx (retro-pharyngeal abscess).

In cases of cut throat the cervical fascia is of considerable importance. When the wound involves only the investing layer the injury is usually trivial, the special danger being injury to the external jugular vein, and the special complication, diffuse cellulitis. But where the second of the two layers is opened up, important structures may be injured, and serious results follow.

The sternal head of origin of the Sterno-mastoid is contained in Burns's space, so that this space is opened in division of this tendon. The lower part of the anterior jugular vein is also contained in the same space.

The **Sterno-mastoid** (m. sternocleidomastoideus) (fig. 490) is a large, thick muscle, which passes obliquely across the side of the neck, being enclosed between the two laminæ of the investing layer of the deep cervical fascia. It is thick and narrow at its central part, but broader and thinner at either extremity. It arises by two heads from the sternum and clavicle. The *sternal portion* is a rounded fasciculus, tendinous in front, fleshy behind, which arises from the upper and anterior part of the manubrium sterni, and is directed upwards, outwards, and backwards. The *clavicular portion* arises from the superior border and anterior surface of the inner third of the clavicle, being composed of fleshy and aponeurotic fibres; it is directed almost vertically upwards. These two portions are separated from one another at their origin by a triangular interval, but become gradually blended, below the middle of the neck, into a thick, rounded muscle which is inserted, by a strong tendon, into the outer surface of the mastoid process, from its apex to its superior border, and by a thin aponeurosis into the outer half of the superior curved line of the occipital bone. The Sterno-mastoid varies much in its extent of attachment to the clavicle: in one case the clavicular may be as narrow as the sternal portion; in another, as much as three inches in breadth. When the clavicular origin is broad, it is occasionally subdivided into numerous slips, separated by narrow intervals. More rarely, the adjoining margins of the Sterno-mastoid and Trapezius have been found in contact.

This muscle divides the quadrilateral area of the side of the neck into two triangles, an anterior and a posterior. The boundaries of the *anterior triangle* are, in front, the median line of the neck; above, the lower border of the body of the mandible, and an imaginary line drawn from the angle of the mandible to the Sterno-mastoid; behind, the anterior border of the Sterno-mastoid muscle. The apex of the triangle is at the upper border of the sternum. The boundaries of the *posterior triangle* are, in front, the posterior border of the Sterno-mastoid; below, the middle third of the clavicle; behind, the anterior margin of the Trapezius. The apex corresponds with the meeting of the Sterno-mastoid and Trapezius on the occipital bone.*

Relations.—By its *superficial surface* it is in relation with the integument and Platysma, from which it is separated by the external jugular vein, several of the superficial branches of the cervical plexus, and the anterior layer of the deep cervical fascia.[1] By its *deep surface* it is in relation with the sterno-clavicular articulation, the process of the deep cervical fascia which binds the posterior belly of the Omo-hyoid to the sternum and clavicle, the Sterno-hyoid, Sterno-thyroid, Omo-hyoid, posterior belly of the Digastric, Levator anguli scapulæ, Splenius and Scaleni muscles, the common carotid artery, the internal and anterior jugular veins, the origins of the internal and external carotid arteries, the occipital, subclavian, transversalis colli, and suprascapular arteries and veins, the phrenic, pneumogastric, hypoglossal, descendens and communicantes hypoglossi nerves, the spinal accessory nerve which pierces its upper third, the cervical plexus, the upper part of the brachial plexus, parts of the thyroid and parotid glands and their vessels, and the deep lymphatic glands.

Actions.—When only one Sterno-mastoid muscle acts, it draws the head towards the shoulder of the same side, assisted by the Splenius and the Obliquus capitis inferior of the opposite side. At the same time it rotates the head so as to carry the face towards the opposite side. If the head be fixed, the two muscles assist in elevating the thorax in forced inspiration. Acting together from their sterno-clavicular attachments the muscles will flex the cervical part of the vertebral column.

Nerves.—The Platysma is supplied by the facial nerve; the Sterno-mastoid by the spinal accessory and branches from the anterior primary divisions of the second and third cervical nerves.

Surface Form.—The anterior edge of the muscle forms a very prominent ridge beneath the skin and constitutes a guide to the surgeon in making the necessary incisions for ligature of the common or external carotid artery, or of the internal jugular vein.

Applied Anatomy.—The surgical anatomy of the Sterno-mastoid muscle is of importance in connection with the deformity known as *wry-neck*, which is due to a contracted condition of this muscle. The wry-neck may be temporary, as the result of direct

* The anatomy of these triangles will be more fully described with that of the vessels of the neck (p. 640).

irritation of the muscle or of the nerves which supply it, and may occur in acute glandular enlargement, cellulitis of the neck, myositis of the muscle, or cervical caries. It may, however, be permanent, and is then most often due to injury to the muscle during birth, especially in breech presentations; rupture of the muscle and subsequent cicatricial contraction taking place. In these cases, division of the muscle is often necessary to effect a cure, and this may be done either subcutaneously or through an open wound. The subcutaneous method is thus performed: the external jugular and anterior jugular veins having been, if possible, defined, a tenotomy knife is introduced close to the margin of one tendon of origin of the muscle, about half an inch above the clavicle, and the tenotome passed flat behind the tendon and then turned forwards, and the tendon divided from behind forwards while the muscle is put well upon the stretch by an assistant. The other tendon is then divided in a similar manner. In dividing the clavicular origin, it is always desirable to introduce the tenotome along the posterior border, in order to avoid the external jugular vein. The open method is, however, much to be preferred, as being the more effectual and the less dangerous, if precautions are taken to keep the wound aseptic. The tendons of origin are freely exposed by a horizontal incision across the root of the neck and carefully divided; any tense bands of fascia which can be felt should also be divided. The wound is now sutured and dressed, and the head fixed in as straight a position as possible.

There is also a condition coming on in adult life (spasmodic torticollis), which is a very distressing form of functional nervous disease. It begins with tonic or clonic spasm of one of the Sterno-mastoids, which is soon followed by spasm of the Trapezius, particularly its clavicular portion. The Splenius of the opposite side, the Scaleni, Complexi, and Trachelo-mastoids, may all become involved in turn, with secondary contracture of the deep cervical fascia. Operation in these cases often fails to give satisfactory results. Tenotomy of the affected muscles or section of the nerves supplying them may afford temporary relief, but the spasm often returns when the cut nerves or muscles rejoin.

II. Infrahyoid Region (figs. 490, 491)

Sterno-hyoid.	Thyro-hyoid.
Sterno-thyroid.	Omo-hyoid.

The **Sterno-hyoid** (m. sternohyoideus) is a thin, narrow, riband-like muscle, which arises from the posterior surface of the inner extremity of the clavicle, the posterior sterno-clavicular ligament, and the upper and posterior part of the manubrium sterni; passing upwards and inwards, it is inserted, by short, tendinous fibres, into the lower border of the body of the hyoid bone. Below, this muscle is separated from its fellow by a considerable interval; but the two muscles come into contact with one another in the middle of their course, and from this upwards, lie side by side. It sometimes presents, immediately above its origin, a transverse tendinous intersection, like those in the Rectus abdominis.

The **Sterno-thyroid** (m. sternothyreoideus) is shorter and wider than the preceding muscle, beneath which it is situated. It arises from the posterior surface of the manubrium sterni, below the origin of the Sterno-hyoid, and from the edge of the cartilage of the first rib, and sometimes of the second rib also; and is inserted into the oblique line on the side of the ala of the thyroid cartilage. This muscle is in close contact with its fellow at the lower part of the neck; and is occasionally traversed by a transverse or oblique tendinous intersection like those in the Rectus abdominis.

The **Thyro-hyoid** (m. thyreohyoideus) is a small, quadrilateral muscle appearing like a continuation of the Sterno-thyroid. It arises from the oblique line on the side of the thyroid cartilage, and passes vertically upwards to be inserted into the lower border of the body and greater cornu of the hyoid bone.

The **Omo-hyoid** (m. omohyoideus) passes across the side of the neck, from the scapula to the hyoid bone. It consists of two fleshy bellies united by a central tendon. It arises from the upper border of the scapula, and occasionally from the transverse ligament which crosses the suprascapular notch, its extent of attachment to the scapula varying from a few lines to an inch. From this origin, the posterior belly forms a flat, narrow fasciculus, which inclines forwards and slightly upwards across the lower part of the neck, being bound down to the clavicle by a fibrous expansion; it then passes behind the Sterno-mastoid muscle, becomes tendinous and changes its direction, forming an obtuse angle. It terminates in the anterior belly, which

passes almost vertically upwards, close to the outer border of the Sterno-hyoid, to be inserted into the lower border of the body of the hyoid bone, just external to the insertion of the Sterno-hyoid. The central tendon of this muscle, which varies much in length and form, is held in position by a process of the deep cervical fascia, which sheathes it. This process is prolonged down to be attached to the clavicle and first rib. It is by this means that the angular form of the muscle is maintained.

The posterior belly of the Omo-hyoid divides the posterior triangle of the neck into an upper or *occipital* and a lower or *subclavian* triangle, while its anterior belly divides the anterior triangle into an upper or *carotid* and a lower or *muscular* triangle.

Nerves.—The Thyro-hyoid is supplied by a branch from the hypoglossal nerve; the anterior belly of the Omo-hyoid by the descendens hypoglossi; the Sterno-hyoid, Sterno-thyroid, and posterior belly of the Omo-hyoid, are supplied

FIG. 491.—Muscles of the neck. Anterior view.

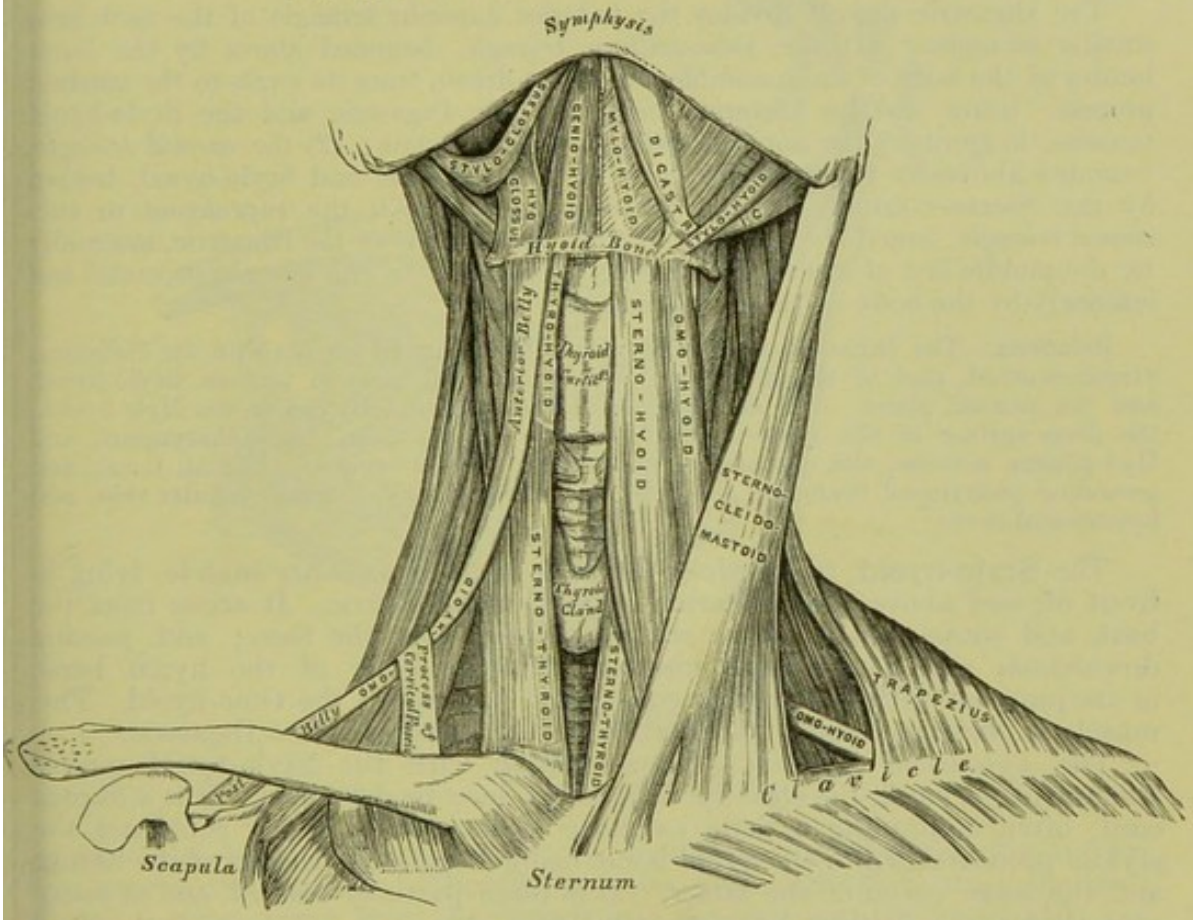

by branches from the loop of communication between the descendens and communicantes hypoglossi.

Actions.—These muscles depress the larynx and hyoid bone, after they have been drawn up with the pharynx in the act of deglutition. The Omo-hyoid muscles not only depress the hyoid bone, but carry it backwards and to one or the other side. They are concerned especially in prolonged inspiratory efforts; for by rendering the lower part of the cervical fascia tense they lessen the inward suction of the soft parts, which would otherwise compress the great vessels and the apices of the lungs. The Thyro-hyoid may act as an elevator of the thyroid cartilage, when the hyoid bone ascends, drawing the thyroid cartilage up behind the hyoid bone. The Sterno-thyroid acts as a depressor of the thyroid cartilage.

III. SUPRAHYOID REGION (figs. 490, 491)

Digastric.	Mylo-hyoid.
Stylo-hyoid.	Genio-hyoid.

The **Digastric** (m. digastricus) consists of two fleshy bellies united by an intermediate, rounded tendon. It is a small muscle, situated below the

body of the mandible, and extending, in a curved form, from the mastoid process of the temporal to the symphysis menti. The *posterior belly* (venter posterior), longer than the anterior, arises from the digastric groove on the inner side of the mastoid process, and passes downwards, forwards, and inwards. The *anterior belly* (venter anterior) arises from a depression on the inner side of the lower border of the mandible, close to the symphysis, and passes downwards and backwards. The two bellies terminate in the central tendon which perforates the Stylo-hyoid muscle, and is held in connection with the side of the body and the greater cornu of the hyoid bone by a fibrous loop, lined by a synovial membrane. A broad aponeurotic layer is given off from the tendon of the Digastric on either side, to be attached to the body and greater cornu of the hyoid bone ; this is termed the *suprahyoid aponeurosis*. It forms a strong layer of fascia between the anterior portions of the two muscles, and a firm investment for the deeper muscles of the supra-hyoid region.

The Digastric muscle divides the anterior superior triangle of the neck into smaller triangles : (1) the *submaxillary triangle*, bounded above by the lower border of the body of the mandible and a line drawn from its angle to the mastoid process, below by the posterior belly of the Digastric and the Stylo-hyoid muscles, in front by the anterior belly of the Digastric ; (2) the *carotid triangle*, bounded above by the posterior belly of the Digastric and Stylo-hyoid, behind by the Sterno-mastoid, below by the Omo-hyoid ; (3) the *suprahyoid* or *submental triangle*, bounded externally by the anterior belly of the Digastric, internally by the middle line of the neck from the hyoid bone to the symphysis menti and inferiorly by the body of the hyoid bone.

Relations.—The Digastric is in relation by its *superficial surface* with the Platysma, Sterno-mastoid, part of the Splenius, Trachelo-mastoid, mastoid process, Stylo-hyoid, and the parotid gland. The *deep surface* of the anterior belly lies on the Mylo-hyoid ; the deep surface of the posterior belly on the Stylo-glossus, Stylo-pharyngeus, and Hyo-glossus muscles, the external carotid artery and its occipital, lingual, facial, and ascending pharyngeal branches, the internal carotid artery, internal jugular vein, and hypoglossal nerve.

The **Stylo-hyoid** (m. stylohyoideus) is a small, slender muscle, lying in front of, and above, the posterior belly of the Digastric. It arises from the back and outer surface of the styloid process, near the base ; and, passing downwards and forwards, is inserted into the body of the hyoid bone, at its junction with the greater cornu, and just above the Omo-hyoid. This muscle is perforated, near its insertion, by the tendon of the Digastric.

The *stylo-hyoid ligament.*—In connection with the Stylo-hyoid muscle a ligamentous band, the *stylo-hyoid ligament*, may be described. It is a fibrous cord, often containing a little cartilage in its centre, which continues the styloid process down to the hyoid bone, being attached to the tip of the former and the lesser cornu of the latter. It is often partially ossified, and in many animals forms a distinct bone, the *epihyal*.

The **Mylo-hyoid** (m. mylohyoideus) is a flat, triangular muscle, situated immediately above the anterior belly of the Digastric, and forming, with its fellow of the opposite side, a muscular floor for the cavity of the mouth. It arises from the whole length of the mylo-hyoid ridge of the mandible, extending from the symphysis in front to the last molar tooth behind. The posterior fibres pass inwards and slightly downwards, to be inserted into the body of the hyoid bone. The middle and anterior fibres are inserted into a median fibrous raphe extending from the symphysis menti to the hyoid bone, where they join at an angle with the fibres of the opposite muscle. This median raphe is sometimes wanting ; the muscular fibres of the two sides are then directly continuous with one another.

Relations.—The mylo-hyoid is in relation by its *superficial* or *under surface* with the Platysma, the anterior belly of the Digastric, the suprahyoid aponeurosis, the superficial part of the submaxillary gland, the facial and submental vessels, and the mylo-hyoid vessels and nerve. By its *deep* or *superior surface* it is in relation with the Genio-hyoid, part of the Hyo-glossus, and Stylo-glossus muscles, the hypoglossal and lingual nerves, the submaxillary ganglion, the sublingual gland, the deep portion of the submaxillary gland and Wharton's duct, the sublingual and ranine vessels, and the buccal mucous membrane.

The **Genio-hyoid** (m. geniohyoideus) is a narrow, slender muscle, situated above the inner border of the preceding. It arises from the inferior genial tubercle on the inner side of the symphysis menti, and passes downwards and backwards, to be inserted into the anterior surface of the body of the hyoid bone. This muscle lies in close contact with its fellow of the opposite side, and increases slightly in breadth as it descends.

Nerves.—The Mylo-hyoid and anterior belly of the Digastric are supplied by the mylo-hyoid branch of the inferior dental; the Stylo-hyoid and posterior belly of the Digastric, by the facial; the Genio-hyoid, by the hypoglossal.

Actions.—These muscles perform two very important actions. They raise the hyoid bone, and with it the base of the tongue, during the act of deglutition;

Fig. 492.—Muscles of the tongue. Left side.

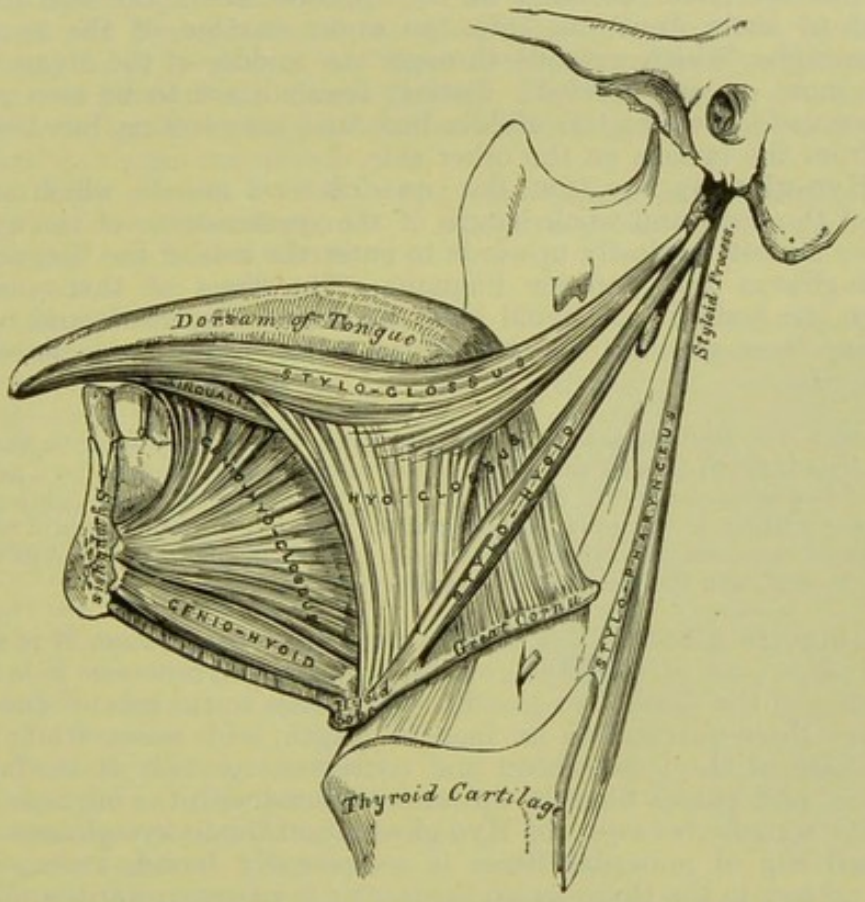

or, when the hyoid bone is fixed by its depressors and those of the larynx, they depress the mandible. During the first act of deglutition, when the mass of food is being driven from the mouth into the pharynx, the hyoid bone and with it the tongue, is carried upwards and forwards by the anterior belly of the Digastric, the Mylo-hyoid, and Genio-hyoid muscles. In the second act, when the mass is passing through the pharynx, the direct elevation of the hyoid bone takes place by the combined action of all the muscles; and after the food has passed, the hyoid bone is carried upwards and backwards by the posterior belly of the Digastric and the Stylo-hyoid, which assist in preventing the return of the food into the mouth.

IV. Lingual Region (fig. 492)

Genio-hyo-glossus.	Chondro-glossus.
Hyo-glossus.	Stylo-glossus.

Palato-glossus.*

The **Genio-hyo-glossus** (m. genioglossus) has received its name from its triple attachment to the mandible, hyoid bone, and tongue, but its

* The *Palato-glossus*, or *Constrictor isthmi faucium*, although one of the muscles of the tongue, serving to draw its base upwards during the act of deglutition, is more closely associated with the soft palate, both in situation and function; it will, consequently, be described with the muscles of that structure (p. 485).

connection with the hyoid bone is very slight and may be altogether absent. It is a flat, triangular muscle, placed vertically close to the middle line, its apex corresponding with its point of origin from the mandible, its base with its insertion into the tongue and hyoid bone. It arises by a short tendon from the superior genial tubercle on the inner surface of the symphysis menti, immediately above the Genio-hyoid, and from this point spreads out in a fan-like form. The inferior fibres extend downwards, to be attached by a thin aponeurosis to the upper part of the body of the hyoid bone, a few passing between the Hyo-glossus and Chondro-glossus to blend with the Constrictor muscles of the pharynx; the middle fibres pass backwards, and the superior ones upwards and forwards, to enter the whole length of the under surface of the tongue, from the base to the apex. Behind, the muscle is quite distinct from its fellow of the opposite side; the two muscles are separated at their insertions into the under surface of the tongue by a tendinous raphe, which extends through the middle of the organ; in front, they are more or less blended: distinct fasciculi are to be seen passing off from one muscle, crossing the middle line, and intersecting bundles of fibres derived from the muscle on the other side.

The **Hyo-glossus** is a thin, flat, quadrilateral muscle, which arises from the side of the body and whole length of the greater cornu of the hyoid bone, and passes almost vertically upwards to enter the side of the tongue, between the Stylo-glossus and Inferior lingualis. The fibres of this muscle which arise from the body of the hyoid bone are directed upwards and backwards, overlapping those arising from the greater cornu, which are inclined upwards and forwards.

Relations.—The Hyo-glossus is in relation by its *external surface* with the Digastric, the Stylo-hyoid, Stylo-glossus and Mylo-hyoid muscles, the submaxillary ganglion, the lingual and hypoglossal nerves, Wharton's duct, the ranine vein, the sublingual gland, and the deep portion of the submaxillary gland. By its *deep surface* it is in relation with the stylo-hyoid ligament, the Genio-hyo-glossus, Inferior lingualis, and Middle constrictor, the lingual vessels, and the glosso-pharyngeal nerve.

The **Chondro-glossus** is a distinct muscular slip, though it is sometimes described as a part of the Hyo-glossus, from which, however, it is separated by the fibres of the Genio-hyo-glossus, which pass to the side of the pharynx. It is about three-quarters to an inch in length, and arises from the inner side and base of the lesser cornu and contiguous portion of the body of the hyoid bone, and passes directly upwards to blend with the intrinsic muscular fibres of the tongue, between the Hyo-glossus and Genio-hyo-glossus.

A small slip of muscular fibres is occasionally found, arising from the cartilago triticea in the thyro-hyoid ligament; it passes upwards and forwards and enters the tongue with the hindermost fibres of the Hyo-glossus.

The **Stylo-glossus,** the shortest and smallest of the three styloid muscles, arises from the anterior and outer side of the styloid process, near its apex, and from the stylo-mandibular ligament. Passing downwards and forwards between the internal and external carotid arteries, and becoming nearly horizontal in its direction, it divides upon the side of the tongue into two portions: one, longitudinal, enters the side of the tongue near its dorsal surface, blending with the fibres of the Inferior lingualis in front of the Hyo-glossus; the other, oblique, overlaps the Hyo-glossus muscle and decussates with its fibres.

Nerves.—The muscles of this group are supplied by the hypoglossal.

Muscular substance of tongue (fig. 493).—The tongue consists of two symmetrical portions separated from each other in the middle line by a fibrous septum. Its muscular fibres run in various directions, but may be grouped into two sets—extrinsic and intrinsic. The extrinsic muscles are those which have their origin external to, and their terminal fibres contained in, the substance of the organ. They are: the Stylo-glossus, the Hyo-glossus, the Palato-glossus, the Genio-hyo-glossus, and part of the superior constrictor of the pharynx (Pharyngo-glossus). The intrinsic are those which are contained entirely within the tongue; they form the greater part of its muscular structure.

Immediately beneath the mucous membrane is a submucous, fibrous layer, into which the muscular fibres which terminate on the surface of the tongue are

inserted. Upon removing this with the mucous membrane, the first stratum of muscular fibres is exposed. This belongs to the group of intrinsic muscles, and has been named the *Superior lingualis*. It consists of a thin layer of oblique and longitudinal fibres, which arise from the submucous fibrous layer, close to the epiglottis, and from the fibrous septum, and pass forwards and outwards to the edges of the tongue. Between its fibres pass some vertical fibres derived from the Genio-hyo-glossus and from the Vertical intrinsic muscle, which will be described later on. Beneath this layer is the second stratum of muscular fibres, derived principally from the extrinsic muscles. In front, it is formed by the fibres derived from the Stylo-glossus, running along the side of the tongue, and sending one set of fibres over the dorsum which runs obliquely forwards and inwards to the middle line, and another set of fibres, on to the under surface of the sides of the anterior part of the tongue, which runs forwards and inwards, between the fibres of the Hyo-glossus, to the middle line. Behind this layer of fibres, derived from the Stylo-glossus, are fibres derived from the Hyo-glossus, together with some few fibres of the Palato-glossus. The Hyo-glossus, entering the side of the under surface of the tongue, between the Stylo-glossus and Inferior lingualis, passes round its margin and spreads out into a layer on the dorsum, which occupies the middle third of the organ, and runs almost transversely inwards to the septum. It is reinforced by some fibres from the Palato-glossus; other fibres of this muscle pass more deeply and intermingle with the next layer. The posterior part of the second layer of the muscular fibres of the tongue is derived from those fibres of the Hyo-glossus which arise from the lesser cornu of the hyoid bone, and are here described as a separate muscle—the Chondro-glossus. The fibres of this muscle are arranged in a fan-shaped manner, and spread out over the posterior third of the tongue. Beneath this layer is the great mass of the intrinsic muscles of the tongue, intersected at right angles by the terminal fibres of one of the extrinsic muscles—the Genio-hyo-glossus. This portion of the tongue is paler in colour and softer in texture than that already described, and is sometimes designated the medullary portion in contradistinction to the firmer superficial part, which is termed the cortical portion. It consists largely of transverse fibres, the *Transverse lingualis*, and of vertical fibres, the *Vertical lingualis*. The Transverse lingualis forms the largest portion of the third layer of muscular fibres of the tongue. The fibres arise from the median septum, and pass outwards to be inserted into the submucous fibrous layer at the sides of the tongue. Intermingled with these transverse intrinsic fibres are transverse extrinsic fibres derived from the Palato-glossus and the Superior constrictor of the pharynx. These Transverse extrinsic fibres, however, run in the opposite direction, passing inwards towards the septum. Intersecting the transverse fibres are a large number of vertical fibres derived partly from the Genio-hyo-glossus and partly from intrinsic fibres, the Vertical lingualis. The fibres derived from the Genio-hyo-glossus enter the under surface of the tongue on either side of the median septum from base to apex. They ascend in a radiating manner to the dorsum, being inserted into the submucous fibrous layer covering the tongue on either side of the middle line. The Vertical lingualis is found only at the borders of the fore part of the tongue, external to the fibres of the Genio-hyo-glossus. Its fibres extend from the upper to the under surface of the organ, decussating with the fibres of the other muscles,

FIG. 493.—Coronal section of tongue, showing intrinsic muscles. (Altered from Krause.)

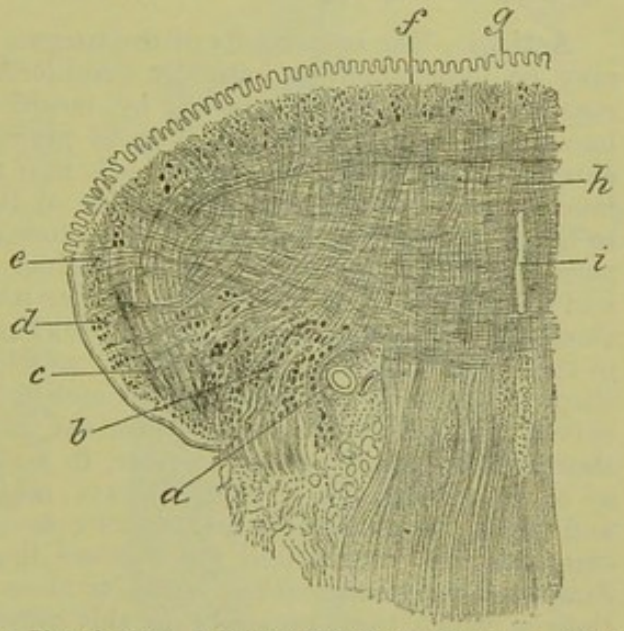

a. Lingual artery. *b*. Inferior lingualis, cut through. *c*. Fibres of Hyo-glossus. *d*. Oblique fibres of Stylo-glossus. *e*. Insertion of Transverse lingualis. *f*. Superior lingualis. *g*. Papillæ of tongue. *h*. Vertical fibres of Genio-hyo-glossus intersecting Transverse lingualis. *i*. Septum.

and especially with the Transverse lingualis. The fourth layer of muscular fibres of the tongue consists partly of extrinsic fibres derived from the Stylo-glossus, and partly of intrinsic fibres, the *Inferior lingualis*. At the sides of the under surface of the organ are some fibres derived from the Stylo-glossus; as this muscle runs forwards at the side of the tongue, it gives off fibres which pass forwards and inwards between the fibres of the Hyo-glossus and form an inferior oblique stratum which joins in front with the anterior fibres of the Inferior lingualis. The Inferior lingualis is a longitudinal band, situated on the under surface of the tongue, and extending from the base to the apex of the organ. Behind, some of its fibres are connected with the body of the hyoid bone. It lies between the Hyo-glossus and the Genio-hyo-glossus; in front of the Hyo-glossus it comes into relation with the Stylo-glossus, with the fibres of which it blends. It is in relation by its under surface with the ranine artery.

Applied Anatomy.—The fibrous septum which exists between the two halves of the tongue is very complete, so that the anastomosis between the two lingual arteries is not very free.

This is a point of considerable importance in connection with removal of one-half of the tongue for cancer, an operation which is now frequently resorted to when the disease is strictly confined to one side of the organ. If the mucous membrane be divided longitudinally exactly in the middle line, the tongue can be split into halves along the median raphe, without any appreciable hæmorrhage, and the diseased half can then be removed.

Actions.—The movements of the tongue, although numerous and complicated, may be understood by carefully considering the direction of the fibres of its muscles. The Genio-hyo-glossi, by means of their posterior fibres, draw the base of the tongue forwards, so as to protrude the apex from the mouth. The anterior fibres draw the tongue back into the mouth. The whole of these two muscles acting along the middle line of the tongue draw it downwards, so as to make it concave from side to side, forming a channel along which fluids may pass towards the pharynx, as in sucking. The Hyo-glossi depress the tongue, and draw down its sides, so as to render it convex from side to side. The Stylo-glossi draw the tongue upwards and backwards. The Palato-glossi draw the base of the tongue upwards. The intrinsic muscles are mainly concerned in altering the shape of the tongue, whereby it becomes shortened, narrowed from side to side, or curved in different directions; thus, the Superior and Inferior linguales tend to shorten the tongue, but the former, in addition, turn the tip and sides upwards so as to render the dorsum concave, while the latter pull the tip downwards and cause the dorsum to become convex. The Transverse lingualis narrows and elongates the tongue, and the Vertical lingualis flattens and broadens it. The complex arrangement of the muscular fibres of the tongue, and the various directions in which they run, give to this organ the power of assuming the various forms necessary for the enunciation of the different consonantal sounds; and Macalister states 'there is reason to believe that the musculature of the tongue varies in different races owing to the hereditary practice and habitual use of certain motions required for enunciating the several vernacular languages.'

V. Pharyngeal Region (fig. 494)

Inferior constrictor.
Middle constrictor.
Palato-pharyngeus. } (See next section.)
Salpingo-pharyngeus. }
Superior constrictor.
Stylo-pharyngeus.

The **Inferior constrictor** (m. constrictor pharyngis inferior), the thickest of the three constrictors, arises from the sides of the cricoid and thyroid cartilages. To the cricoid cartilage it is attached in the interval between the Crico-thyroid muscle in front, and the articular facet for the inferior cornu of the thyroid cartilage behind. To the thyroid cartilage it is attached to the oblique line on the side of the ala, to the cartilaginous surface behind it, nearly as far as its posterior border, and to the inferior cornu. From these attachments the fibres spread backwards and inwards, to be inserted into the fibrous raphe in the posterior median line of the pharynx. The inferior fibres are horizontal, and continuous with the circular fibres of the œsophagus; the rest ascend, increasing in obliquity, and overlap the Middle constrictor.

Relations.—The Inferior constrictor is covered by a thin membrane which surrounds the entire pharynx (bucco-pharyngeal fascia). *Behind*, it is in relation with the vertebral column and the prevertebral fascia and muscles; *laterally*, with the thyroid gland, the common carotid artery, and the Sterno-thyroid muscle; by its *internal surface*, with the Middle constrictor, the Stylo-pharyngeus, Palato-pharyngeus, the pharyngeal aponeurosis and mucous membrane of the pharynx. The internal laryngeal nerve and the laryngeal branch of the superior thyroid artery run near the upper border, and the inferior or recurrent laryngeal nerve and the laryngeal branch of the inferior thyroid artery pass beneath the lower border of this muscle, before they enter the larynx.

The **Middle constrictor** (m. constrictor pharyngis medius) is a flattened, fan-shaped muscle, smaller than the preceding. It arises from the whole length of the upper border of the greater cornu of the hyoid bone, from the lesser cornu, and from the stylo-hyoid ligament. The fibres diverge from their origin: the lower ones descending beneath the Inferior constrictor, the middle fibres passing transversely, and the upper fibres ascending and overlapping the Superior constrictor. The muscle is inserted into the posterior median fibrous raphe, blending in the middle line with the one of the opposite side.

FIG. 494.—Muscles of the pharynx. External view.

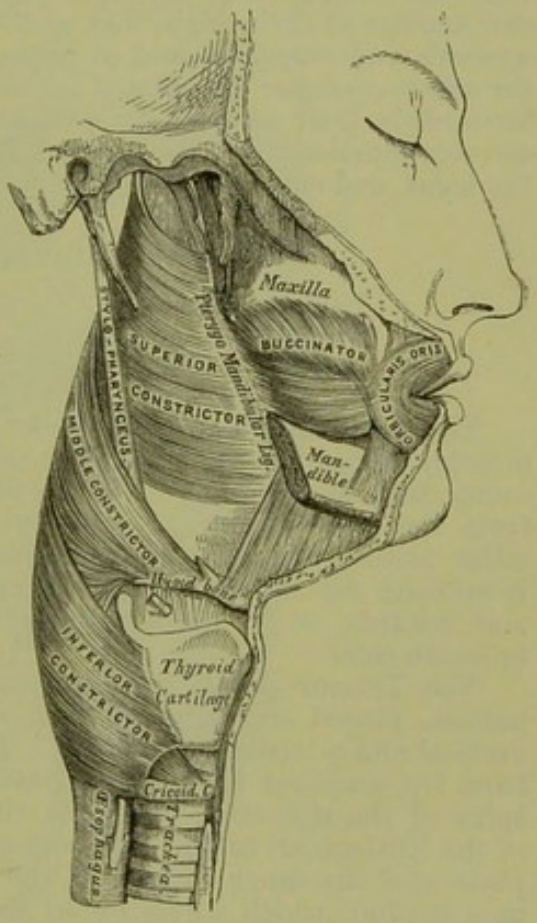

Relations.—This muscle is separated from the Superior constrictor by the glosso-pharyngeal nerve and the Stylo-pharyngeus and stylo-hyoid ligament; and from the Inferior constrictor by the internal laryngeal nerve and laryngeal branch of the superior thyroid artery. *Behind*, it lies on the prevertebral fascia, the Longus colli, and the Rectus capitis anticus major. *On its outer side* it is in relation with the carotid vessels, the pharyngeal plexus, and some lymphatic glands. Near its origin it is covered by the Hyo-glossus, from which it is separated by the lingual vessels. It lies upon the Superior constrictor, the Stylo-pharyngeus, the Palato-pharyngeus, the pharyngeal aponeurosis, and the mucous membrane of the pharynx.

The **Superior constrictor** (m. constrictor pharyngis superior) is a quadrilateral muscle, thinner and paler than the other Constrictors, and situated at the upper part of the pharynx. It arises from the lower third of the posterior margin of the internal pterygoid plate and its hamular process, from the pterygo-mandibular ligament, from the alveolar process of the mandible above the posterior extremity of the mylo-hyoid ridge, and by a few fibres from the side of the tongue. From these points the fibres curve backwards, to be inserted into the median raphe, being also prolonged by means of an aponeurosis to the pharyngeal spine on the basilar process of the occipital bone. The superior fibres arch beneath the Levator palati and the Eustachian tube. The interval between the upper border of the muscle and the base of the skull is deficient in muscular fibres, and closed by the pharyngeal aponeurosis; it is known as the *sinus of Morgagni*.

Relations.—The Superior constrictor is in relation by its *outer surface* with the prevertebral fascia and muscles, the vertebral column, the internal carotid and ascending pharyngeal arteries, the internal jugular vein and pharyngeal venous plexus, and the glosso-pharyngeal, pneumogastric, spinal accessory, hypoglossal, lingual, and sympathetic nerves, the Middle constrictor and Internal pterygoid muscles, the styloid process, the stylo-hyoid ligament, and the Stylo-pharyngeus. By its *internal surface* it is in relation

with the Palato-pharyngeus, the tonsil, the pharyngeal aponeurosis and mucous membrane of the pharynx. Its *lower border* is separated from the Middle constrictor of the pharynx by the Stylo-pharyngeus muscle and the glosso-pharyngeal nerve.

The **Stylo-pharyngeus** is a long, slender muscle, cylindrical above, broad and thin below. It arises from the inner side of the base of the styloid process, passes downwards along the side of the pharynx between the Superior and Middle constrictors, and spreads out beneath the mucous membrane. Some of its fibres are lost in the Constrictor muscles, while others, joining with the Palato-pharyngeus, are inserted into the posterior border of the thyroid cartilage. The glosso-pharyngeal nerve runs on the outer side of this muscle, and crosses over it in passing forward to the tongue.

Nerves.—The Constrictors are supplied by branches from the pharyngeal plexus, the Inferior constrictor by additional branches from the external and recurrent laryngeal nerves, and the Stylo-pharyngeus by the glosso-pharyngeal nerve.

Actions.—When deglutition is about to be performed, the pharynx is drawn upwards and dilated in different directions, to receive the food propelled into it from the mouth. The Stylo-pharyngei, which are much farther removed from one another at their origin than at their insertion, draw the sides of the pharynx upwards and outwards, and so increase its transverse diameter; its breadth in the antero-posterior direction is increased by the larynx and tongue being carried forwards in their ascent. As soon as the bolus is received in the pharynx, the elevator muscles relax, the pharynx descends, and the Constrictors contract upon the bolus, and convey it gradually downwards into the œsophagus.

VI. Palatal Region (fig. 495)

Levator palati.	Palato-glossus.
Tensor palati.	Palato-pharyngeus.
Azygos uvulæ.	Salpingo-pharyngeus.

The **Levator palati** (m. levator veli palatini) is a long, thick, rounded muscle, placed on the outer side of the posterior nares. It arises from the under surface of the apex of the petrous portion of the temporal bone, and from the inner surface of the cartilaginous portion of the Eustachian tube. After passing above the upper concave margin of the Superior constrictor, it spreads out in the soft palate, its fibres extending obliquely downwards and inwards, as far as the middle line, where they blend with those of the opposite side.

The **Tensor palati** (m. tensor veli palatini) is a broad, thin, riband-like muscle, placed on the outer side of the Levator palati, and consisting of a vertical and a horizontal portion. The vertical portion arises by a flat lamella from the scaphoid fossa at the base of the internal pterygoid plate, from the spine of the sphenoid, and from the outer side of the cartilaginous portion of the Eustachian tube. Descending vertically between the internal pterygoid plate and the inner surface of the Internal pterygoid muscle, it terminates in a tendon, which winds round the hamular process, being retained in this situation by some of the fibres of origin of the Internal pterygoid muscle. Between the hamular process and the tendon is a small bursa. The tendon or horizontal portion then passes inwards, and is inserted into a broad aponeurosis, the *palatine aponeurosis*, and into the transverse ridge on the horizontal portion of the palate bone.

Palatine aponeurosis.—Attached to the posterior border of the hard palate is a thin, firm, fibrous lamella which supports the muscles and gives strength to the soft palate. It is thicker above than below, where it becomes very thin and difficult to define. Laterally, it is continuous with the pharyngeal aponeurosis.

The **Azygos uvulæ** (m. uvulæ) is not a single muscle, as would be inferred from its name, but a pair of narrow cylindrical fleshy fasciculi, placed one on either side of the median line of the soft palate. Each muscle arises from the posterior nasal spine of the palate bone, and from the contiguous tendinous aponeurosis of the soft palate, and descends to be inserted into the uvula.

The **Palato-glossus** (m. glossopalatinus) is a small fleshy fasciculus, narrower in the middle than at either extremity, forming, with the mucous membrane covering its surface, the anterior pillar of the fauces. It arises from the anterior surface of the soft palate, where it is continuous with the muscle of the opposite side, and passing downwards, forwards, and outwards in front of the tonsil, is inserted into the side of the tongue, some of its fibres spreading over the dorsum, and others passing deeply into the substance of the organ to intermingle with the Transverse lingualis.

The **Palato-pharyngeus** (m. pharyngopalatinus) is a long, fleshy fasciculus narrower in the middle than at either extremity, forming, with the mucous membrane covering its surface, the posterior pillar of the fauces. It is separated from the Palato-glossus by an angular interval, in which the tonsil is lodged. It arises from the soft palate by an expanded fasciculus, which is divided into

Fig. 495.—Muscles of the soft palate. The pharynx is laid open from behind.

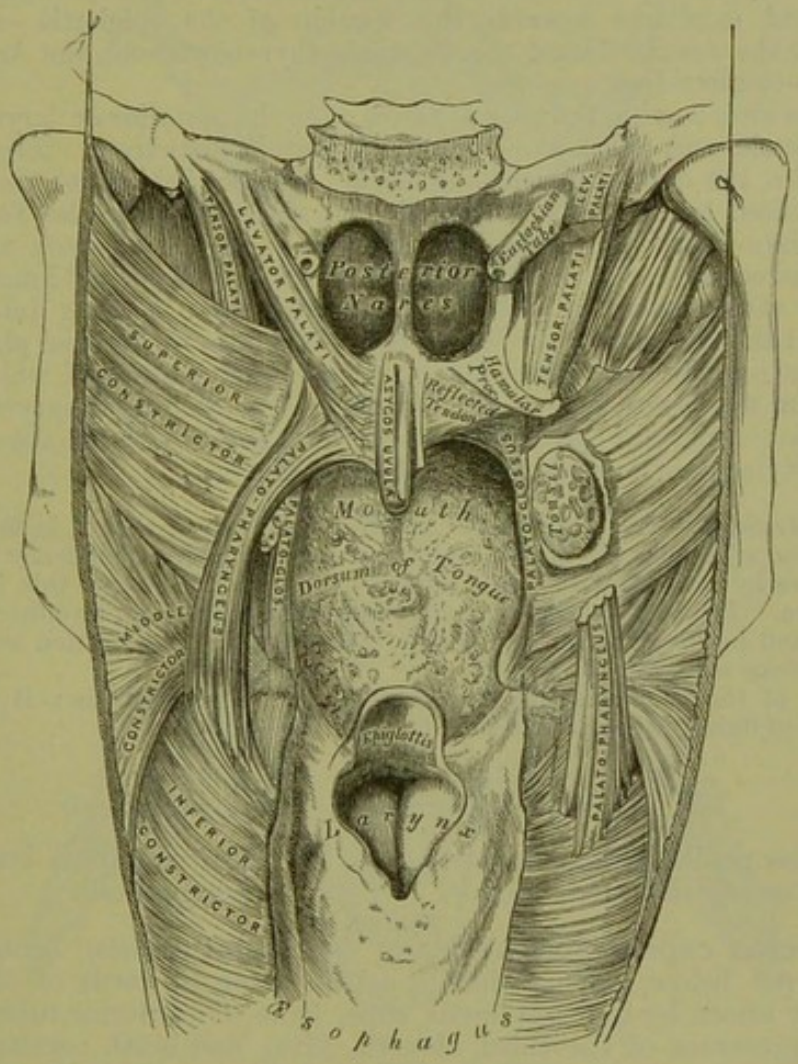

two parts by the Levator palati and Azygos uvulæ. The *posterior fasciculus* lies in contact with the mucous membrane, and joins with the corresponding muscle in the middle line; the *anterior fasciculus*, the thicker, lies in the soft palate between the Levator and Tensor, and joins in the middle line the corresponding part of the opposite muscle. Passing outwards and downwards behind the tonsil, the Palato-pharyngeus joins the Stylo-pharyngeus, and is inserted with that muscle into the posterior border of the thyroid cartilage, some of its fibres being lost on the side of the pharynx, and others passing across the middle line posteriorly, to decussate with the muscle of the opposite side.

The **Salpingo-pharyngeus.**—This muscle arises from the inferior part of the Eustachian tube near its orifice; it passes downwards and blends with the posterior fasciculus of the Palato-pharyngeus.

In a dissection of the soft palate from its posterior or nasal surface to its anterior or oral surface, the muscles would be exposed in the following order: viz. the posterior fasciculus of the Palato-pharyngeus, covered by a continuation of the mucous membrane of the floor of the nasal fossæ; the Azygos uvulæ; the Levator palati; the anterior fasciculus of the Palato-pharyngeus; the aponeurosis of the Tensor palati, and the Palato-glossus covered by a continuation of the oral mucous membrane.

Nerves.—The Tensor palati is supplied by a branch from the otic ganglion; the remaining muscles of this group are in all probability supplied by the bulbar portion of the spinal accessory through the pharyngeal plexus.*

Actions.—During the *first stage* of deglutition, the bolus is driven back into the fauces by the pressure of the tongue against the hard palate, the base of the tongue being, at the same time, retracted, and the larynx raised with the pharynx, and carried forwards under it. During the second stage the entrance to the larynx is closed, not, as was formerly supposed, by the folding backwards of the epiglottis over it, but, as Anderson Stuart has shown, by the drawing forward of the arytenoid cartilages towards the cushion of the epiglottis—a movement produced by the contraction of the External thyro-arytenoid, the Arytenoid and the Aryteno-epiglottidean muscles.

The bolus after leaving the tongue passes on to the posterior or laryngeal surface of the epiglottis, and glides along this for a certain distance;† then the Palato-glossi muscles, the constrictors of the fauces, contract behind it; the soft palate is slightly raised by the Levator palati, and made tense by the Tensor palati; and the Palato-pharyngei, by their contraction, pull the pharynx upwards over the bolus, and come nearly together, the uvula filling up the slight interval between them. By these means the food is prevented from passing into the naso-pharynx; at the same time, the Palato-pharyngei form an inclined plane, directed obliquely downwards and backwards, along the under surface of which the bolus descends into the lower part of the pharynx. The Salpingo-pharyngei raise the upper and lateral parts of the pharynx—i.e. those parts which are above the points where the Stylo-pharyngei are attached to the pharynx.

Applied Anatomy.—After the operation for the closure of a cleft in the palate, the palate muscles, especially the Tensor and Levator palati, have a tendency to retard the healing process by active traction upon the line of suture. To obviate this, it is necessary to divide them. This is best done by making longitudinal incisions, on either side, parallel to the cleft and just internal to the hamular process, in such a position as to avoid the posterior palatine artery.

Paralysis of the soft palate is a common sequel of diphtheria; it gives rise to regurgitation of fluids through the nose.

VII. Anterior Vertebral Region (fig. 496)

Rectus capitis anticus major.
Rectus capitis anticus minor.
Rectus capitis lateralis.
Longus colli.

The **Rectus capitis anticus major** (m. longus capitis), broad and thick above, narrow below, appears like a continuation upwards of the Scalenus anticus. It arises by four tendinous slips, from the anterior tubercles of the transverse processes of the third, fourth, fifth, and sixth cervical vertebræ, and ascends, converging towards its fellow of the opposite side, to be inserted into the basilar process of the occipital bone.

The **Rectus capitis anticus minor** (m. rectus capitis anterior) is a short, flat muscle, situated immediately behind the upper part of the preceding. It arises from the anterior surface of the lateral mass of the atlas, and from the root of its transverse process, and passing obliquely upwards and inwards, is inserted into the basilar process immediately behind the preceding muscle.

The **Rectus capitis lateralis** is a short, flat muscle, which arises from the upper surface of the transverse process of the atlas, and is inserted into the under surface of the jugular process of the occipital bone.

* 'The Innervation of the Soft Palate,' by Aldren Turner, *Journal of Anatomy and Physiology*, vol. xxiii. p. 523.

† Walton (quoted by Anderson Stuart) maintains that the epiglottis is not essential to the deglutition even of liquids.

The **Longus colli** is a long, flat muscle, situated on the anterior surface of the vertebral column, between the atlas and the third thoracic vertebra. It is broad in the middle, narrow and pointed at each extremity, and consists of three portions, a superior oblique, an inferior oblique, and a vertical portion. The *superior oblique portion* arises from the anterior tubercles of the transverse processes of the third, fourth, and fifth cervical vertebræ ; and, ascending obliquely inwards, is inserted by a narrow tendon into the tubercle on the anterior arch of the atlas. The *inferior oblique portion*, the smallest part of the muscle, arises from the front of the bodies of the first two or three thoracic vertebræ ; and, ascending obliquely outwards, is inserted into the anterior tubercles of the transverse processes of the fifth and sixth cervical vertebræ. The *vertical portion* lies directly on the front of the spine ; it arises,

Fig. 496.—The prevertebral muscles.

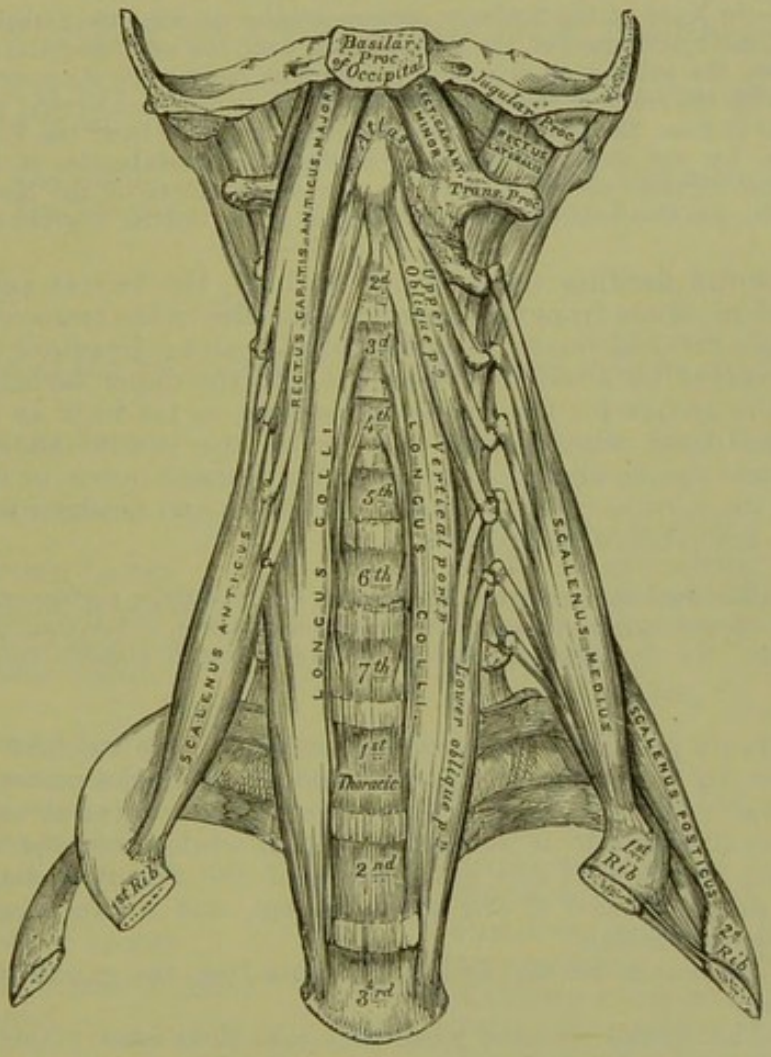

below, from the front of the bodies of the upper three thoracic and lower three cervical vertebræ, and is inserted into the front of the bodies of the second, third, and fourth cervical vertebræ above.

Nerves.—The Rectus capitis anticus minor and the Rectus lateralis are supplied from the loop between the first and second cervical nerves ; the Rectus capitis anticus major by branches from the second, third, and fourth cervical ; the Longus colli by branches from the second to the seventh cervical nerves.

Actions.—The Rectus capitis anticus major and minor are the direct antagonists of the muscles at the back of the neck, serving to restore the head to its natural position after it has been drawn backwards. These muscles also serve to flex the head, and from their obliquity, rotate it, so as to turn the face to one or the other side. The Rectus lateralis, acting on one side, bends the head laterally. The Longus colli flexes and slightly rotates the cervical portion of the spine.

VIII. Lateral Vertebral Region (fig. 496)

Scalenus anticus. Scalenus medius.
Scalenus posticus.

The **Scalenus anticus** (m. scalenus anterior) is a cone-shaped muscle, situated deeply at the side of the neck, behind the Sterno-mastoid. It arises from the anterior tubercles of the transverse processes of the third, fourth, fifth, and sixth cervical vertebræ, and descending, almost vertically, is inserted by a narrow, flat tendon into the scalene tubercle on the inner border of the first rib, and also into the upper surface of the rib between the grooves for the subclavian artery and vein. The lower part of this muscle separates the subclavian artery and vein: the latter being in front, and the former, with the brachial plexus, behind.

Relations.—*In front* of the Scalenus anticus are the clavicle, the Subclavius, Sterno-mastoid, and Omo-hyoid muscles, the transversalis colli, the suprascapular and ascending cervical arteries, the subclavian vein, and the phrenic nerve. By its *posterior surface*, it is in relation with the cords of the brachial plexus, the subclavian artery, and the pleura, which separate it from the Scalenus medius. It is separated from the Longus colli, on the inner side, by the vertebral artery. On the anterior tubercles of the transverse processes of the cervical vertebræ, between the attachments of the Scalenus anticus and Longus colli, lies the ascending cervical branch of the inferior thyroid artery.

The **Scalenus medius** (m. scalenus medius), the largest and longest of the three Scaleni, arises from the posterior tubercles of the transverse processes of the lower six cervical vertebræ, and descending along the side of the vertebral column, is inserted by a broad attachment into the upper surface of the first rib, behind the groove for the subclavian artery, as far back as the tubercle. It is separated from the Scalenus anticus by the subclavian artery below, and the cervical nerves above. The posterior thoracic nerve, or nerve of Bell, is formed in the substance of the Scalenus medius and emerges from it. The nerve to the Rhomboids also pierces it.

Relations.—The Scalenus medius is in relation by its *anterior surface* with the Sterno-mastoid; it is crossed by the clavicle, the Omo-hyoid muscle, subclavian artery, and the cervical nerves. To its *outer side* are the Levator anguli scapulæ and the Scalenus posticus.

The **Scalenus posticus** (m. scalenus posterior), the smallest of the three Scaleni, arises, by two or three separate tendons, from the posterior tubercles of the transverse processes of the lower two or three cervical vertebræ, and diminishing as it descends, is inserted by a thin tendon into the outer surface of the second rib, behind the attachment of the Serratus magnus. This is the most deeply placed of the three Scaleni, and is occasionally blended with the Scalenus medius.

Nerves.—The Scaleni are supplied by branches from the second to the seventh cervical nerves.

Actions.—The Scaleni muscles, when they take their fixed points from above, elevate the first and second ribs, and are, therefore, inspiratory muscles. When they take their fixed points from below, they bend the spinal column to one or other side. If the muscles of both sides act, lateral movement is prevented, but the spine is slightly flexed.

Surface Form.—The muscles in the neck, with the exception of the Platysma, are invested by the deep cervical fascia. The *Platysma* does not influence surface form unless it is in action, when it produces wrinkling of the skin of the neck, which is thrown into oblique ridges parallel with the fasciculi of the muscle. The *Sterno-mastoid* is the most important muscle of the neck as regards its surface form. If the muscle be put into action by drawing the chin downwards and to the opposite shoulder, its surface form will be plainly outlined. The sternal origin will stand out as a sharply defined ridge, while the clavicular origin will present a flatter and less prominent outline. The fleshy middle portion will appear as an oblique roll or elevation, with a thick rounded anterior border gradually becoming less marked above. When the muscle is at rest its anterior border is still visible, forming an oblique rounded ridge, terminating below in the sharp outline of the sternal head. The posterior border of the muscle does not show above

the clavicular head. The anterior border is defined by drawing a line from the tip of the mastoid process to the sterno-clavicular joint. It is an important surface-marking in the operation of ligature of the common carotid artery. Between the sternal and clavicular heads is a slight depression, most marked when the muscle is in action, which overlies the lower part of the internal jugular vein. This is bounded below by the prominent sternal extremity of the clavicle. Between the sternal origins of the two muscles is a V-shaped depression, the *suprasternal notch*, more pronounced below, and less so above, where the Sterno-hyoid and Sterno-thyroid muscles, lying upon the trachea, become more prominent. Above the hyoid bone, in the middle line, the anterior belly of the *Digastric* to a certain extent influences surface form. It corresponds to a line drawn from the symphysis menti to the side of the body of the hyoid bone, and renders this part of the hyo-mental region convex. In the posterior triangle of the neck, the posterior belly of the *Omo-hyoid*, when in action, forms a conspicuous object, especially in thin necks, presenting a cord-like form running across this region, almost parallel with, and a little above, the clavicle.

MUSCLES AND FASCIÆ OF THE TRUNK

The Muscles of the Trunk may be arranged in four groups, corresponding with the regions in which they are situated.

I. The Back.
II. The Thorax.
III. The Abdomen.
IV. The Pelvis.
V. The Perinæum.

I. Muscles of the Back

The muscles of the back are very numerous, and may be subdivided into five layers.

First Layer

Trapezius.
Latissimus dorsi.

Second Layer

Levator anguli scapulæ.
Rhomboideus minor.
Rhomboideus major.

Third Layer

Serratus posticus superior.
Serratus posticus inferior.
Splenius capitis.
Splenius colli.

Fourth Layer

Sacral and Lumbar Regions

Erector spinæ.

Thoracic Region.

Ilio-costalis.
Musculus accessorius ad ilio-costalem.
Longissimus dorsi.
Spinalis dorsi.

Cervical Region

Cervicalis ascendens.
Transversalis cervicis.
Trachelo-mastoid.
Complexus.
Biventer cervicis.
Spinalis colli.

Fifth Layer

Semispinalis dorsi.
Semispinalis colli.
Multifidus spinæ.
Rotatores spinæ.
Interspinales.
Extensor coccygis.
Intertransversales.
Rectus capitis posticus major.
Rectus capitis posticus minor.
Obliquus capitis inferior.
Obliquus capitis superior.

First Layer

Trapezius. Latissimus dorsi.

The **superficial fascia** forms a layer of considerable thickness and strength, in which a quantity of granular pinkish fat is contained. It is continuous with the general superficial fascia. The **deep fascia** is a dense fibrous layer, attached above to the superior curved line of the occipital bone; in the middle line it is attached to the ligamentum nuchæ, and to the spinous processes and supraspinous ligaments of all the vertebræ below the seventh cervical; laterally, in the neck it is continuous with the deep cervical fascia; over the shoulder it is attached to the spine of the scapula and the

acromion process, and is continued downwards over the Deltoid muscle to the arm ; on the thorax it is continuous with the deep fascia of the axilla and chest, and on the abdomen with that covering the abdominal muscles ; below, it is attached to the crest of the ilium.

The **Trapezius** (fig. 497) is a broad, flat, triangular muscle, placed immediately beneath the skin and fascia, and covering the upper and back part of the neck and shoulders. It arises from the external occipital protuberance and the inner third of the superior curved line of the occipital bone, from the ligamentum nuchæ, the spinous process of the seventh cervical, and the spinous processes of all the thoracic vertebræ, and from the corresponding portion of the supraspinous ligament. From this origin, the superior fibres proceed downwards and outwards, the inferior upwards and outwards, and the middle horizontally ; the superior fibres are inserted into the posterior border of the outer third of the clavicle ; the middle fibres into the inner margin of the acromion process, and into the superior lip of the posterior border or crest of the spine of the scapula ; the inferior fibres converge near the scapula, and terminate in an aponeurosis, which glides over the smooth triangular surface on the inner extremity of the crest of the spine, to be inserted into a tubercle at the apex of this smooth triangular surface. The Trapezius is fleshy in the greater part of its extent, but tendinous at its origin and insertion. At its occipital origin, it is connected to the bone by a thin fibrous lamina, firmly adherent to the skin, and wanting the lustrous, shining appearance of aponeurosis. At the middle of its origin from the spines of the vertebræ, it is connected to the bones by means of a broad semi-elliptical aponeurosis ; this occupies the space between the sixth cervical and the third thoracic vertebræ, and forms, with the aponeurosis of the opposite muscle, a tendinous ellipse. The rest of the muscle arises by numerous short tendinous fibres. The two Trapezius muscles together resemble a trapezium, or diamond-shaped quadrangle : two angles corresponding to the shoulders ; a third to the occipital protuberance ; and the fourth to the spinous process of the last thoracic vertebra.

The clavicular insertion of this muscle varies in extent : it sometimes advances as far as the middle of the clavicle, and may occasionally become blended with the posterior edge of the Sterno-mastoid, or overlap it.

The **Latissimus dorsi** (fig. 497) is a broad, flat muscle, which covers the lumbar and the lower half of the thoracic regions, and is gradually contracted into a narrow fasciculus at its insertion into the humerus. It arises by tendinous fibres from the spinous processes of the six inferior thoracic vertebræ and from the posterior layer of the lumbar fascia (see page 493), by which it is attached to the spines of the lumbar and sacral vertebræ, to the supraspinous ligament, and to the posterior part of the crest of the ilium. It also arises by muscular fibres from the external lip of the crest of the ilium external to the margin of the Erector spinæ, and from the three or four lower ribs by fleshy digitations, which are interposed between similar processes of the External oblique muscle (fig. 502, page 507). From this extensive origin the fibres pass in different directions, the upper ones horizontally, the middle obliquely upwards, and the lower vertically upwards, so as to converge and form a thick fasciculus, which crosses the inferior angle of the scapula, and usually receives a few fibres from it. The muscle curves around the lower border of the Teres major, and is twisted upon itself, so that the superior fibres become at first posterior and then inferior, and the vertical fibres at first anterior and then superior. It terminates in a short quadrilateral tendon, about three inches in length, which passes in front of the tendon of the Teres major, and is inserted into the bottom of the bicipital groove of the humerus ; its insertion extending higher on the humerus than that of the tendon of the Pectoralis major. The lower border of the tendon of this muscle is united with that of the Teres major, the surfaces of the two being separated near their insertions by a bursa ; another bursa is sometimes interposed between the muscle and the inferior angle of the scapula. The muscle at its insertion gives off an expansion to the deep fascia of the arm.

A muscular slip, the *axillary arch*, varying from 3 to 4 inches in length, and from ¼ to ¾ of an inch in breadth, occasionally arises from the upper edge of the Latissimus

FIG. 497.—Muscles of the back. On the left side, the first layer is exposed; on the right side, the second layer and part of the third.

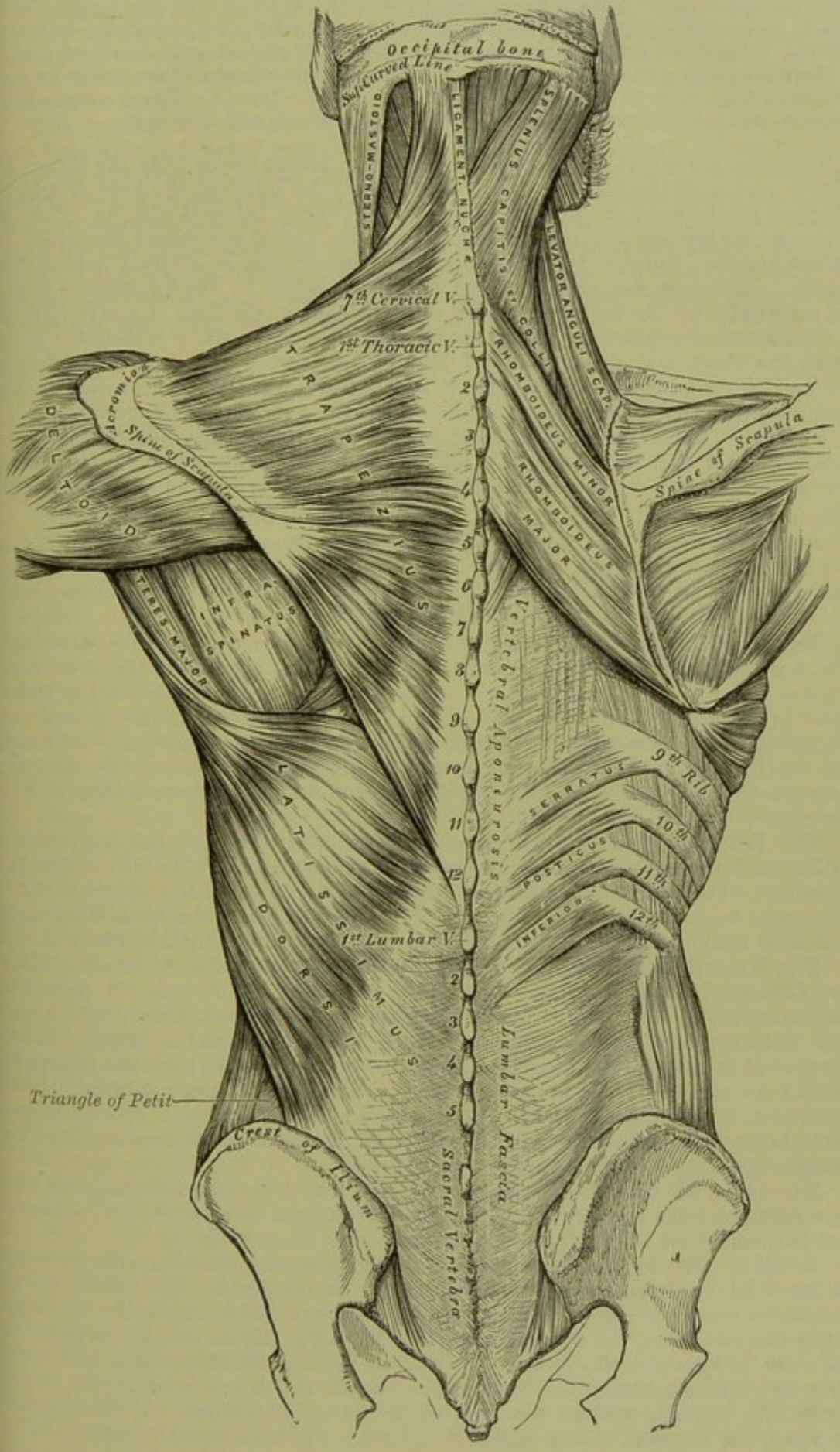

dorsi about the middle of the posterior fold of the axilla, and crosses the axilla in front of the axillary vessels and nerves, to join the under surface of the tendon of the Pectoralis major, the Coraco-brachialis, or the fascia over the Biceps. The position of this abnormal slip is a point of interest in its relation to the axillary artery, as it crosses the vessel just above the spot usually selected for the application of a ligature, and may mislead the surgeon during the operation. It may be easily recognised by the transverse direction of its fibres. Struthers found it, in 8 out of 105 subjects, occurring seven times on both sides.

There is usually a fibrous slip which passes from the lower border of the tendon of the Latissimus dorsi, near its insertion, to the long head of the Triceps. This is occasionally muscular, and is the representative of the *Dorso-epitrochlearis* muscle of apes.

The outer margin of the Latissimus dorsi is separated below from the External oblique muscle of the abdomen by a small triangular interval, the base of which is formed by the crest of the ilium, and its floor by the Internal oblique. This is known as the *triangle of Petit* (trigonum lumbale), and is sometimes the site of a lumbar hernia. Another triangle of practical importance is situated behind the scapula. It is bounded above by the Trapezius, below by the Latissimus dorsi, and externally by the vertebral border of the scapula; the floor is partly formed by the Rhomboideus major. If the scapula be drawn forwards by folding the arms across the chest, and the trunk bent forwards, a part of the sixth and seventh ribs and the interspace between them become subcutaneous and available for auscultation. The space is therefore known as the *triangle of auscultation.*

Nerves.—The Trapezius is supplied by the spinal accessory, and by branches from the third and fourth cervical nerves; the Latissimus dorsi by the sixth, seventh, and eighth cervical nerves through the middle or long subscapular nerve.

Second Layer (fig. 497)

Levator anguli scapulæ. Rhomboideus minor.
Rhomboideus major.

The **Levator anguli scapulæ** (m. levator scapulæ) is situated at the back part and side of the neck. It arises by tendinous slips from the transverse processes of the atlas and axis and from the posterior tubercles of the transverse processes of the third and fourth cervical vertebræ; these tendons, becoming fleshy, are united to form a flat muscle, which passes downwards and backwards, and is inserted into the posterior border of the scapula, between the superior angle and the triangular smooth surface at the root of the spine.

The **Rhomboideus minor** arises from the lower part of the ligamentum nuchæ and the spinous processes of the seventh cervical and first thoracic vertebræ. Passing downwards and outwards, it is inserted into the base of the triangular smooth surface at the root of the spine of the scapula. This small muscle is usually separated from the Rhomboideus major by a slight interval.

The **Rhomboideus major** is situated immediately below the preceding, the adjacent margins of the two being occasionally united. It arises by tendinous fibres from the spinous processes of the second, third, fourth, and fifth thoracic vertebræ and the supraspinous ligament, and is inserted into a narrow tendinous arch, attached above to the lower part of the triangular surface at the root of the spine, below, to the inferior angle, the arch being connected to the border of the scapula by a thin membrane. When the arch extends, as it occasionally does, only a short distance, the muscular fibres are inserted into the scapula itself.

Nerves.—The Rhomboid muscles are supplied by a branch from the fifth cervical nerve; the Levator anguli scapulæ by the third and fourth cervical nerves, and frequently by a branch from the nerve to the Rhomboids.

Actions.—The movements effected by the preceding muscles are numerous, as may be conceived from their extensive attachments. The whole of the Trapezius when in action retracts the scapula and braces back the shoulder; if the head be fixed, the upper part of the Trapezius will elevate the point of the shoulder, as in supporting weights; when the lower fibres are brought into action they assist in depressing the bone. The middle and lower fibres of the muscle rotate the scapula, causing elevation of the acromion process. If the shoulders be fixed, the Trapezii, acting together, will draw the head directly backwards; or if only one act, the head is drawn to the corresponding side.

The Latissimus dorsi, when it acts upon the humerus, depresses it, draws it backwards, and at the same time rotates it inwards. It is the muscle which is principally employed in giving a downward blow, as in felling a tree or in sabre practice. If the arm be fixed, the muscle may act in various ways upon the trunk: thus, it may raise the lower ribs and assist in forcible inspiration; or, if both arms be fixed, the two muscles may assist the Abdominal and great Pectoral muscles in suspending and drawing the whole trunk forwards, as in climbing or walking on crutches.

The Levator anguli scapulæ raises the superior angle of the scapula, assisting the Trapezius in bearing weights or in shrugging the shoulders. If the shoulder be fixed, the Levator anguli scapulæ inclines the neck to the corresponding side and rotates it in the same direction. The Rhomboid muscles carry the inferior angle backwards and upwards, thus producing a slight rotation of the scapula upon the side of the chest, the Rhomboideus major acting especially on the lower angle of the scapula, through the tendinous arch by which it is inserted. The Rhomboid muscles, acting together with the middle and inferior fibres of the Trapezius, will retract the scapula.

Third Layer (fig. 497)

Serratus posticus superior. Serratus posticus inferior.

Splenius { Splenius capitis. / Splenius colli.

The **Serratus posticus superior** is a thin, flat, quadrilateral muscle, situated at the upper and back part of the thorax. It arises by a thin and broad aponeurosis from the lower part of the ligamentum nuchæ, from the spinous processes of the last cervical and upper two or three thoracic vertebræ and from the supraspinous ligament. Inclining downwards and outwards, it becomes muscular, and is inserted, by four fleshy digitations, into the upper borders of the second, third, fourth, and fifth ribs, a little beyond their angles.

The **Serratus posticus inferior** is situated at the junction of the thoracic and lumbar regions: it is of an irregularly quadrilateral form, broader than the preceding, and separated from it by a wide interval. It arises by a thin aponeurosis from the spinous processes of the last two thoracic and upper two or three lumbar vertebræ, and from the supraspinous ligament. Passing obliquely upwards and outwards, it becomes fleshy, and divides into four flat digitations, which are inserted into the lower borders of the lower four ribs, a little beyond their angles. The thin aponeurosis of origin is intimately blended with the lumbar fascia.

The **vertebral fascia** is a thin, fibrous lamina, extending along the whole length of the back part of the thoracic region, serving to bind down the long extensor muscles of the back which support the vertebral column and head, and to separate them from those muscles which connect the vertebral column to the upper extremity. It consists of longitudinal and transverse fibres blended together, forming a thin lamella, which is attached in the median line to the spinous processes of the thoracic vertebræ; externally, to the angles of the ribs; and below, to the upper border of the Serratus posticus inferior and to the portion of the lumbar fascia which gives origin to the Latissimus dorsi; above, it passes beneath the Serratus posticus superior and the Splenius, and blends with the deep fascia of the neck.

The **lumbar fascia** or **aponeurosis** (fig. 498), which may be regarded as the posterior aponeurosis of the Transversalis abdominis muscle, consists of three laminæ, which are attached as follows: the posterior layer, to the spines of the lumbar and sacral vertebræ and the supraspinous ligament; the middle, to the tips of the transverse processes of the lumbar vertebræ and the intertransverse ligaments; the anterior, to the roots of the lumbar transverse processes. The posterior layer is continued above as the vertebral fascia, while inferiorly it is fixed to the outer lip of the iliac crest. With this layer are blended the aponeurotic origin of the Serratus posticus inferior and part of that of the Latissimus dorsi. The middle layer is attached above to the last rib, and below to the iliac crest; the anterior layer is fixed below to the

ilio-lumbar ligament and iliac crest; while above it is thickened to form the external arcuate ligament of the Diaphragm, and stretches from the tip of the last rib to the transverse process of the first or second lumbar vertebra. These three layers, together with the vertebral column, enclose two spaces, the posterior of which is occupied by the Erector spinæ muscle, and the anterior by the Quadratus lumborum.

The **Splenius** is a broad sheet situated at the back of the neck and upper part of the thoracic region. At its origin, it is a single muscle, which arises, by tendinous fibres, from the lower half of the ligamentum nuchæ, from the spinous processes of the last cervical and upper six thoracic vertebræ, and from the supraspinous ligament. From this origin the fleshy fibres proceed obliquely upwards and outwards, forming a broad flat muscle, which divides as it ascends, into two portions, the Splenius capitis and Splenius colli.

The **Splenius capitis** (m. splenius capitis) is inserted, under cover of the Sterno-mastoid, into the mastoid process of the Temporal bone, and into the rough surface on the occipital bone just below the outer third of the superior curved line.

The **Splenius colli** (m. splenius cervicis) is inserted, by tendinous fasciculi, into the posterior tubercles of the transverse processes of the upper two or three cervical vertebræ.

Nerves.—The Splenius is supplied by the external branches of the posterior primary divisions of the middle and lower cervical nerves; the Serratus posticus superior is supplied by branches from the upper three or four intercostal nerves;

Fig. 498.—Diagram of a transverse section of the posterior abdominal wall, to show the three layers of the lumbar aponeurosis.

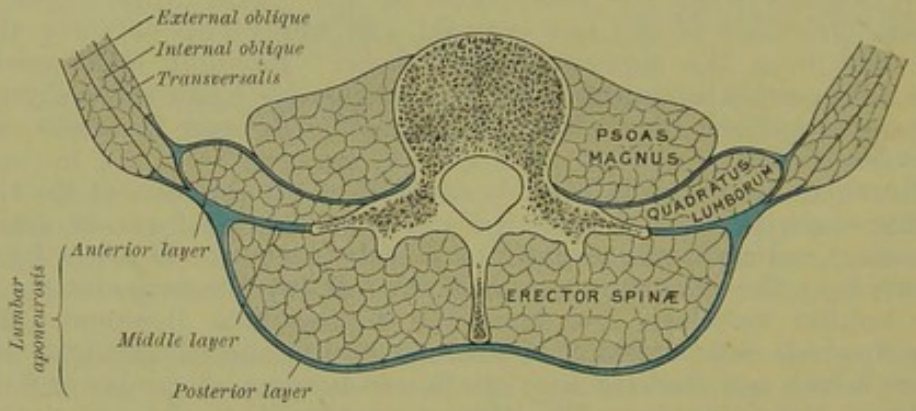

the Serratus posticus inferior by branches from the ninth, tenth, and eleventh intercostal nerves.

Actions.—The Serrati are respiratory muscles. The Serratus posticus superior elevates the ribs and is therefore an inspiratory muscle. The Serratus posticus inferior draws the lower ribs downwards and backwards, and thus elongates the thorax; it also fixes the lower ribs, thus assisting the inspiratory action of the Diaphragm and resisting the tendency which it has to draw the lower ribs upwards and forwards. It must therefore be regarded as a muscle of inspiration. This muscle is also probably a tensor of the vertebral fascia. The Splenii of the two sides, acting together, draw the head directly backwards, assisting the Trapezius and Complexus; acting separately, they draw the head to one side, and slightly rotate it, turning the face to the same side. They also assist in supporting the head in the erect position.

Fourth Layer

1. Erector spinæ.

a. Outer Column.	*b. Middle Column.*	*c. Inner Column.*
Ilio-costalis.	Longissimus dorsi.	Spinalis dorsi.
Musculus accessorius.	Transversalis cervicis.	
Cervicalis ascendens.	Trachelo-mastoid.	

2. Complexus.

The **Erector spinæ** (m. sacrospinalis) (fig. 499), and its prolongations in the thoracic and cervical regions, fill up the groove on either side of the

Fig. 499.—Muscles of the back. Deep layers.

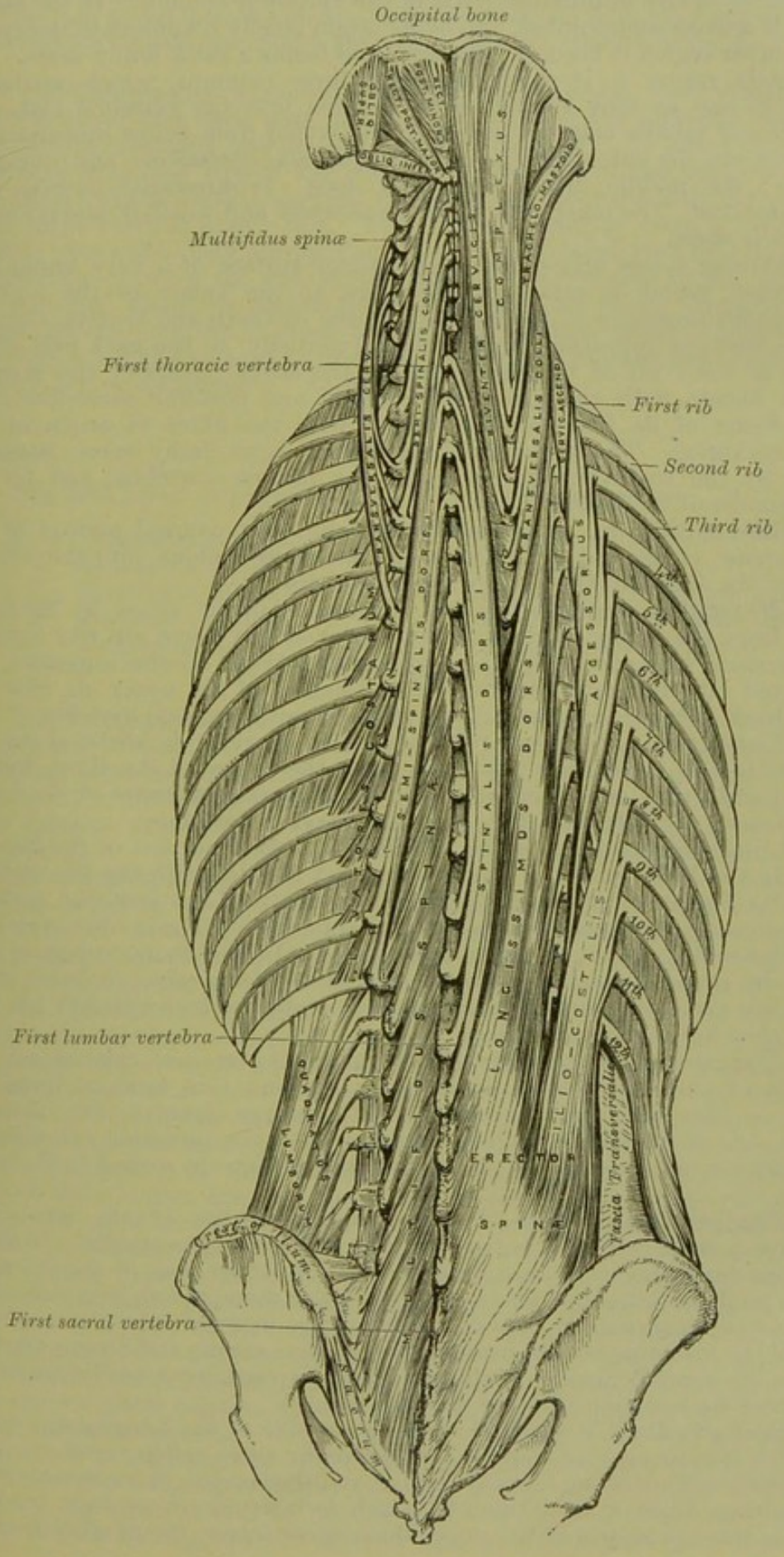

vertebral column. They are covered in the lumbar region by the lumbar fascia, in the thoracic region by the Serrati and the vertebral fascia, and in the cervical region by a layer of cervical fascia continued beneath the Trapezius and the Splenius. This large muscular and tendinous mass varies in size and structure at different parts of the vertebral column. In the sacral region it is narrow and pointed, and at its origin chiefly tendinous in structure. In the lumbar region it becomes enlarged, and forms a thick fleshy mass. In the thoracic region it is subdivided into three columns, which gradually diminish in size as they ascend to be inserted into the vertebræ and ribs. The outer and middle columns are each subdivided from below upwards into three parts, viz. the outer into *Ilio-costalis*, *Musculus accessorius*, and *Cervicalis ascendens*; the middle into *Longissimus dorsi*, *Transversalis cervicis*, and *Trachelo-mastoid*. The inner column is the shortest and weakest, and is named the *Spinalis dorsi*.

The Erector spinæ arises from the anterior surface of a very broad and thick tendon, which is attached, internally, to the spines of the sacrum, to the spinous processes of the lumbar and the eleventh and twelfth thoracic vertebræ, and the supraspinous ligament; externally, to the back part of the inner lip of the crest of the ilium, and to the lateral crests of the sacrum, where it blends with the great sacro-sciatic and posterior sacro-iliac ligaments. Some of its fibres are continuous with the fibres of origin of the Gluteus maximus. The muscular fibres form a large fleshy mass, bounded in front by the transverse processes of the lumbar vertebræ, and by the middle lamella of the lumbar fascia.

The **Ilio-costalis** (m. iliocostalis lumborum), the external portion of the Erector spinæ, is inserted, by six or seven flattened tendons, into the inferior borders of the angles of the lower six or seven ribs.

The **Musculus accessorius** (m. iliocostalis dorsi) arises by flattened tendons from the upper borders of the angles of the lower six ribs internal to the tendons of insertion of the Ilio-costalis; these become muscular, and are inserted into the upper borders of the angles of the upper six ribs and into the back of the transverse process of the seventh cervical vertebra.

The **Cervicalis ascendens** (m. iliocostalis cervicis) is situated on the inner side of the Accessorius; it arises from the angles of the third, fourth, fifth, and sixth ribs, and is inserted into the posterior tubercles of the transverse processes of the fourth, fifth, and sixth cervical vertebræ.

The **Longissimus dorsi** is the middle and largest portion of the Erector spinæ. In the lumbar region, where it is as yet blended with the Ilio-costalis, some of its fibres are attached to the whole length of the posterior surfaces of the transverse processes and the accessory processes of the lumbar vertebræ, and to the middle layer of the lumbar fascia. In the thoracic region it is inserted, by rounded tendons, into the tips of the transverse processes of all the thoracic vertebræ, and by fleshy processes into the lower nine or ten ribs between their tubercles and angles.

The **Transversalis cervicis** (m. longissimus cervicis), placed on the inner side of the Longissimus dorsi, arises by long thin tendons from the summits of the transverse processes of the upper four or five thoracic vertebræ, and is inserted by similar tendons into the posterior tubercles of the transverse processes of the cervical vertebræ from the second to the sixth inclusive.

The **Trachelo-mastoid** (m. longissimus capitis) lies on the inner side of the Transversalis cervicis, between it and the Complexus muscle. It arises by tendons from the transverse processes of the upper four or five thoracic vertebræ, and the articular processes of the lower three or four cervical. The fibres form a small muscle, which ascends to be inserted into the posterior margin of the mastoid process, beneath the Splenius capitis and Sterno-mastoid muscles. This small muscle is almost always crossed by a tendinous intersection near its insertion into the mastoid process.

The **Spinalis dorsi** is situated at the inner side of the Longissimus dorsi, with which it is intimately blended, and arises by three or four tendons from the spinous processes of the first two lumbar and the last two thoracic vertebræ: these, uniting, form a small muscle which is inserted by separate tendons into the spinous processes of the upper thoracic vertebræ, the number varying

from four to eight. It is intimately united with the Semispinalis dorsi, which lies beneath it.

The *Spinalis colli* is an inconstant muscle, which arises from the lower part of the ligamentum nuchæ, the spine of the seventh cervical, and sometimes from the spines of the first and second thoracic vertebræ, and is inserted into the spinous process of the axis, and occasionally into the spinous processes of the two vertebræ below it.

The **Complexus** (m. semispinalis capitis) is a broad, thick muscle, situated at the upper and back part of the neck, beneath the Splenius, and internal to the Transversalis cervicis and Trachelo-mastoid. It arises by a series of tendons from the tips of the transverse processes of the upper six or seven thoracic and the seventh cervical vertebræ, and from the articular processes of the three cervical above this. The tendons, uniting, form a broad muscle, which passes obliquely upwards and inwards, and is inserted into the innermost depression between the two curved lines of the occipital bone. This muscle is traversed about its middle by an imperfect tendinous intersection. The term *Biventer cervicis* is given to the inner portion of the Complexus; this portion is usually separated from the rest of the muscle, and consists of two fleshy bellies connected by an intervening tendon.

Fifth Layer

The fifth layer, or rather group, of muscles comprises the

Semispinalis dorsi.	Extensor coccygis.
Semispinalis colli.	Intertransversales.
Multifidus spinæ.	Rectus capitis posticus major.
Rotatores spinæ.	Rectus capitis posticus minor.
Interspinales.	Obliquus capitis inferior.
	Obliquus capitis superior.

The **Semispinalis dorsi** (fig. 499) consists of thin, narrow, fleshy fasciculi, interposed between tendons of considerable length. It arises by a series of small tendons from the transverse processes of the lower thoracic vertebræ, from the sixth to the tenth inclusive, and is inserted, by five or six tendons, into the spinous processes of the upper four thoracic and lower two cervical vertebræ.

The **Semispinalis colli** (m. semispinalis cervicis), thicker than the preceding, arises by a series of tendinous and fleshy fibres from the transverse processes of the upper five or six thoracic vertebræ, and is inserted into the cervical spinous processes, from the axis to the fifth inclusive. The fasciculus connected with the axis is the largest, and is chiefly muscular in structure.

The **Multifidus spinæ** (m. multifidus) consists of a number of fleshy and tendinous fasciculi, which fill up the groove on either side of the spinous processes of the vertebræ, from the sacrum to the axis. In the sacral region, these fasciculi arise from the back of the sacrum, as low as the fourth sacral foramen, from the aponeurosis of origin of the Erector spinæ, from the inner surface of the posterior superior spine of the ilium, and from the posterior sacro-iliac ligaments; in the lumbar region, from the mamillary processes; in the thoracic region, from the transverse processes; and in the cervical region, from the articular processes of the four lower vertebræ. Each fasciculus, passing obliquely upwards and inwards, is inserted into the whole length of the spinous process of one of the vertebræ above. These fasciculi vary in length: the most superficial, the longest, pass from one vertebra to the third or fourth above; those next in order pass from one vertebra to the second or third above; while the deepest connect two contiguous vertebræ.

The **Rotatores spinæ** (mm. rotatores) are found only in the thoracic region of the vertebral column, beneath the Multifidus spinæ; they are eleven in number on either side. Each muscle is small and somewhat quadrilateral in form; it arises from the upper and back part of the transverse process, and is inserted into the lower border and outer surface of the lamina of the vertebra above, the fibres extending inwards as far as the root of the spinous process. The first is found between the first and second thoracic vertebræ; the last,

between the eleventh and twelfth. Sometimes the number of these muscles is diminished by the absence of one or more from the upper or lower end.

The **Interspinales** are short muscular fasciculi, placed in pairs between the spinous processes of the contiguous vertebræ, one on either side of the interspinous ligament. In the *cervical region* they are most distinct, and consist of six pairs, the first being situated between the axis and third vertebra, and the last between the last cervical and the first thoracic. They are small narrow bundles, attached, above and below, to the apices of the spinous processes. In the *thoracic region*, they are found between the first and second vertebræ, and sometimes between the second and third ; and below, between the eleventh and twelfth. In the *lumbar region*, there are four pairs of these muscles in the intervals between the five lumbar vertebræ. There is also occasionally one in the interspinous space, between the last thoracic and first lumbar, and one between the fifth lumbar and the sacrum.

The **Extensor coccygis** is a slender muscular fasciculus, which is not always present ; it extends over the lower part of the posterior surface of the sacrum and coccyx. It arises by tendinous fibres from the last segment of the sacrum, or first piece of the coccyx, and passes downwards to be inserted into the lower part of the coccyx. It is a rudiment of the Extensor muscle of the caudal vertebræ of the lower animals.

The **Intertransversales** are small muscles placed between the transverse processes of the vertebræ. In the *cervical region* they are most developed, consisting of rounded muscular and tendinous fasciculi, and are placed in pairs, passing between the anterior and the posterior tubercles respectively of the transverse processes of two contiguous vertebræ, and separated from one another by the anterior primary division of the cervical nerve, which lies in the groove between them. In this region there are seven pairs of these muscles, the first pair being between the atlas and axis, and the last pair between the seventh cervical and first thoracic vertebræ. In the *thoracic region* they are least developed, consisting chiefly of rounded tendinous cords in the intertransverse spaces of the upper thoracic vertebræ, but between the transverse processes of the lower three thoracic vertebræ, and between the transverse processes of the last thoracic and the first lumbar, they are muscular in structure. In the *lumbar region* they are arranged in pairs, on either side of the vertebral column ; one set occupying the entire interspace between the transverse processes of the lumbar vertebræ, the *Intertransversales laterales* ; the other set, *Intertransversales mediales*, passing from the accessory process of one vertebra to the mamillary process of the vertebra below.*

The **Rectus capitis posticus major** (m. rectus capitis posterior major) arises by a pointed tendinous origin from the spinous process of the axis, and, becoming broader as it ascends, is inserted into the outer part of the inferior curved line of the occipital bone and the surface of bone immediately below it. As the muscles of the two sides pass upwards and outwards, they leave between them a triangular space, in which are seen the Recti capitis postici minores.

The **Rectus capitis posticus minor** (m. rectus capitis posterior minor), the smallest of the four muscles in this region, is of a triangular shape ; it arises by a narrow pointed tendon from the tubercle on the posterior arch of the atlas, and, becoming broader as it ascends, is inserted into the inner part of the inferior curved line of the occipital bone and the surface between it and the foramen magnum.

The **Obliquus capitis inferior,** the larger of the two Oblique muscles, arises from the apex of the spinous process of the axis, and passes outwards and slightly upwards, to be inserted into the lower and back part of the transverse process of the atlas.

The **Obliquus capitis superior,** narrow below, wide and expanded above, arises by tendinous fibres from the upper surface of the transverse process of the atlas, joining with the insertion of the preceding. It passes obliquely upwards and inwards, and is inserted into the occipital bone, between the two curved lines, external to the Complexus.

* The student is referred to an article on the morphology of the human intertransverse muscles, by J. Dunlop Lickley ; *Journal of Anatomy and Physiology*, vol. xxxix. 1904.

The Suboccipital triangle.—Between the two Oblique muscles and the Rectus capitis posticus major a triangular interval exists, the *suboccipital triangle*. This triangle is bounded, above and internally, by the Rectus capitis posticus major; above and externally, by the Obliquus capitis superior; below and externally, by the Obliquus capitis inferior. It is covered in by a layer of dense fibro-fatty tissue, situated beneath the Complexus muscle. The floor is formed by the posterior occipito-atlantal ligament, and the posterior arch of the atlas. It contains the vertebral artery running in a deep groove on the upper surface of the posterior arch of the atlas, and the posterior primary division of the suboccipital nerve.

Nerves.—The fourth and fifth layers of the muscles of the back are supplied by the posterior primary divisions of the spinal nerves.

Actions.—When both the Spinales dorsi contract, they extend the thoracic portion of the vertebral column; when only one contracts, it helps to bend it to one side. The Erector spinæ, comprising the Ilio-costalis and the Longissimus dorsi with their accessory muscles, serves, as its name implies, to maintain the column in the erect posture; it also serves to bend the trunk backwards when it is required to counterbalance the influence of any weight at the front of the body—as, for instance, when a heavy weight is suspended from the neck, or when there is any great abdominal distension, as in pregnancy or dropsy; the peculiar gait under such circumstances depends upon the vertebral column being drawn backwards, by the counterbalancing action of the Erector spinæ muscles. The muscles which form the continuation of the Erector spinæ upwards steady the head and neck, and fix them in the upright position. If the Ilio-costalis and Longissimus dorsi of one side act, they serve to draw down the chest and vertebral column to the corresponding side. The Cervicales ascendentes, taking their fixed points from the cervical vertebræ, elevate those ribs to which they are attached; taking their fixed points from the ribs, both muscles help to extend the neck; while one muscle bends the neck to its own side. The Transversales cervicis, when both muscles act, taking their fixed points from below, bend the neck backwards. The Trachelo-mastoids, when both muscles act, taking their fixed points from below, bend the head backwards; while, if only one muscle acts, the face is turned to the side on which the muscle is acting, and then the head is bent to the shoulder. The two Recti draw the head backwards. The Rectus capitis posticus major, owing to its obliquity, rotates the cranium, with the atlas, round the odontoid process, turning the face to the same side. The Multifidus spinæ acts successively upon the different parts of the column: thus, the sacrum furnishes a fixed point from which the fasciculi of this muscle act upon the lumbar region; these then become the fixed points for the fasciculi moving the thoracic region, and so on throughout the entire length of the column; it is by the successive contraction and relaxation of the separate fasciculi of this and other muscles that the erect posture is preserved without the fatigue that would necessarily have been produced had this position been maintained by the action of a single muscle. The Multifidus spinæ, besides preserving the erect position of the column, serves to rotate it, so that the front of the trunk is turned to the side opposite to that from which the muscle acts, this muscle being assisted in its action by the Obliquus externus abdominis. The Complexi draw the head directly backwards; if one muscle acts, it draws the head to one side, and rotates it so that the face is turned to the opposite side. The Superior oblique draws the head backwards and to its own side. The Inferior oblique rotates the atlas, and with it the cranium, round the odontoid process, turning the face to the same side. The Semispinales, when the muscles of the two sides act together, help to extend the vertebral column; when the muscles of only one side act, they rotate the thoracic and cervical parts of the column, turning the body to the opposite side. The Interspinales by approximating the spinous process help to extend the column. The Intertransversales approximate the transverse processes, and help to bend the column to one side. The Rotatores spinæ assist the Multifidus spinæ to rotate the vertebral column, so that the front of the trunk is turned to the side opposite to that from which the muscles act.

Surface Form.—The surface forms produced by the muscles of the back are numerous and difficult to analyse unless they are considered in systematic order. The most superficial layer influences to a certain extent the surface form, and at the same time reveals the forms of the layers beneath. The *Trapezius* at the upper part of the back, and in the neck, covers over and softens down the outline of the underlying muscles. Its anterior

border forms the posterior boundary of the posterior triangle of the neck, and presents a slight ridge which passes downwards and forwards from the occiput to the junction of the middle and outer thirds of the clavicle. The inferior border of the muscle may be traced as an undulating ridge to the spinous process of the twelfth thoracic vertebra. In like manner, the *Latissimus dorsi* softens down and obscures the underlying structures at the lower part of the back and side of the chest. The anterior border of the muscle is the only part which gives a distinct surface form. This border may be traced, when the muscle is in action, as a rounded edge, starting from the crest of the ilium, and passing obliquely forwards and upwards to the posterior border of the axilla, where together with the Teres major it forms a thick rounded fold, the posterior boundary of the axillary space. The muscles in the second layer influence to a very considerable extent the surface form of the back of the neck and upper part of the trunk. The *Levator anguli scapulæ* reveals itself as an elevation, running downwards and outwards, from the transverse processes of the upper cervical vertebræ to the angle of the scapula, covered over and toned down by the overlying Trapezius. The *Rhomboidei* produce, when in action, a vertical eminence between the vertebral border of the scapula and the spinal furrow, varying in intensity according to the condition of contraction or relaxation of the Trapezius muscle, by which they are for the most part covered. The lowermost part of the Rhomboideus major is uncovered by the Trapezius and forms on the surface an oblique ridge running upwards and inwards from the inferior angle of the scapula. The *Splenii* by their divergence serve to broaden out the upper part of the back of the neck and produce a fulness in this situation. In the loin, the *Erector spinæ*, bound down by the lumbar fascia, forms a rounded vertical eminence, which determines the depth of the spinal furrow, and tapers below to a point on the posterior surface of the sacrum. In the back it forms a flattened plane which gradually becomes lost on passing upwards.

Applied Anatomy.—In cases of tuberculous caries of the vertebral bodies, and in other diseases affecting the vertebral column, rigidity of the spinal muscles is one of the earliest and most constant symptoms. A child with commencing spinal disease always maintains the affected portion of the column in a state of absolute rigidity, to prevent the inflamed structures from being moved against each other; this is one of the best examples of nature's method of producing rest of the affected part.

II. Muscles and Fasciæ of the Thorax

The muscles belonging exclusively to this region are the

Intercostales externi.	Triangularis sterni.
Intercostales interni.	Levatores costarum.
Infracostales.	Diaphragm.

Intercostal fasciæ.—In each intercostal space thin but firm layers of fascia cover the outer surface of the External intercostal and the inner surface of the Internal intercostal muscle; and a third layer, the *middle intercostal fascia*, more delicate, is interposed between the two planes of muscular fibres. They are best marked in those situations where the muscular fibres are deficient, as between the External intercostal muscles and sternum in front, and between the Internal intercostals and vertebral column, behind.

The **Intercostal muscles** (fig. 518) are two thin planes of muscular and tendinous fibres occupying each of the intercostal spaces. They are named *external* and *internal* from their surface relations—the external being superficial to the internal.

The **External intercostals** (mm. intercostales externi) are eleven in number on either side. They extend from the tubercles of the ribs, behind, to the outer ends of the cartilages of the ribs, in front, where they terminate in a thin membrane, the *anterior intercostal membrane*, which is continued forwards to the sternum. Each arises from the lower border of a rib, and is inserted into the upper border of the rib below. In the two lower spaces they extend to the ends of the cartilages, and in the upper two or three spaces they do not quite reach the ends of the ribs. They are thicker than the Internal intercostals, and their fibres are directed obliquely downwards and outwards on the back of the chest, and downwards, forwards, and inwards on the front.

The **Internal intercostals** (mm. intercostales interni) are also eleven in number on either side. They commence anteriorly at the sternum, in the interspaces between the cartilages of the true ribs, and at the anterior extremities of the cartilages of the false ribs, and extend backwards as far as the angles of the ribs, whence they are continued to the vertebral column by a thin aponeurosis, the *posterior intercostal membrane*. Each arises from

the ridge on the inner surface of a rib, as well as from the corresponding costal cartilage, and is inserted into the upper border of the rib below. Their fibres are also directed obliquely, but pass in a direction opposite to those of the External intercostals.

The **Infracostales** (mm. subcostales) consist of muscular and aponeurotic fasciculi, which vary in number and length: they are placed on the inner surfaces of the ribs, where the Internal intercostal muscles cease; each arises from the inner surface of one rib, and is inserted into the inner surface of the first, second, or third rib below. Their fibres run in the same direction as those of the Internal intercostals. They are most frequent between the lower ribs.

FIG. 500.—Posterior surface of sternum and costal cartilages, showing Triangularis sterni muscle. (From a preparation in the Museum of the Royal College of Surgeons of England.)

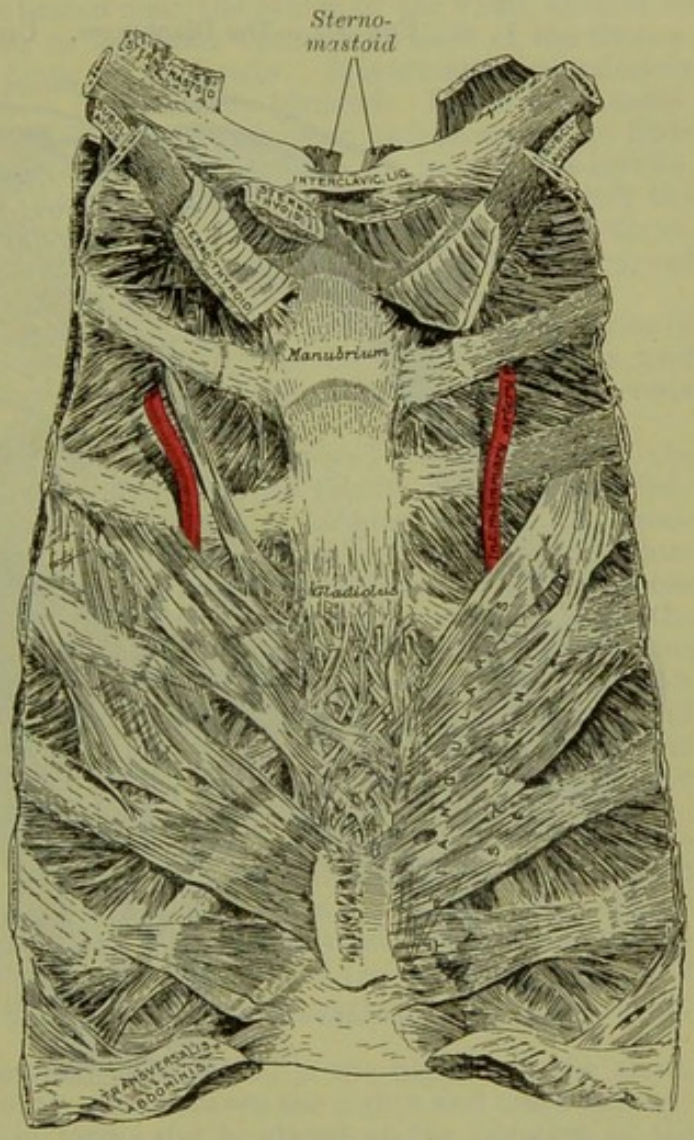

The **Triangularis sterni** (m. transversus thoracis) is a thin plane of muscular and tendinous fibres, situated upon the inner wall of the front of the chest (fig. 500). It arises on either side from the lower third of the posterior surface of the sternum, from the posterior surface of the ensiform cartilage, and from the sternal ends of the costal cartilages of the lower three or four true ribs. Its fibres diverge upwards and outwards, to be inserted by digitations into the lower borders and inner surfaces of the costal cartilages of the second, third, fourth, fifth, and sixth ribs. The lowest fibres of this muscle are horizontal in their direction, and are continuous with those of the Transversalis; those which succeed are oblique, while the superior fibres are almost vertical. This muscle varies much in its attachment, not only in different bodies, but on opposite sides of the same body.

The **Levatores costarum** (fig. 499), twelve in number on either side, are small tendinous and fleshy bundles, which arise from the extremities of the transverse processes of the seventh cervical and upper eleven thoracic vertebræ; they pass obliquely downwards and outwards, like the fibres of the External intercostals, and each is inserted into the upper border of the rib immediately below the vertebra from which it takes origin, between the tubercle and the angle. Each of the inferior Levatores divides into two fasciculi, one of which is inserted as above described; the other fasciculus passes down to the second rib below its origin; thus, each of the lower ribs receives fibres from the transverse processes of two vertebræ.

Nerves.—The muscles of this group are supplied by the intercostal nerves.

The **Diaphragm** (diaphragma) (fig. 501) is a dome-shaped musculo-fibrous septum which separates the thoracic from the abdominal cavity, its convex

upper surface forming the floor of the former, and its concave under surface the roof of the latter. Its peripheral part consists of muscular fibres which take origin from the circumference of the thoracic outlet and converge to be inserted into a central tendon.

It arises anteriorly by two fleshy slips from the back of the ensiform cartilage; on either side from the inner surfaces of the cartilages and adjacent portions of the lower six ribs interdigitating with the Transversalis abdominis; behind from aponeurotic arches, named the *ligamenta arcuata*, and from the lumbar vertebræ by two pillars or *crura*. The ligamenta arcuata are five in number—one mesial, and two, an internal and an external, on either side.

The *ligamentum arcuatum internum* is a tendinous arch in the fascia covering the upper part of the Psoas magnus; its inner end is continuous with the outer tendinous margin of the corresponding crus, and is attached to the outer

Fig. 501.—The Diaphragm. Under surface.

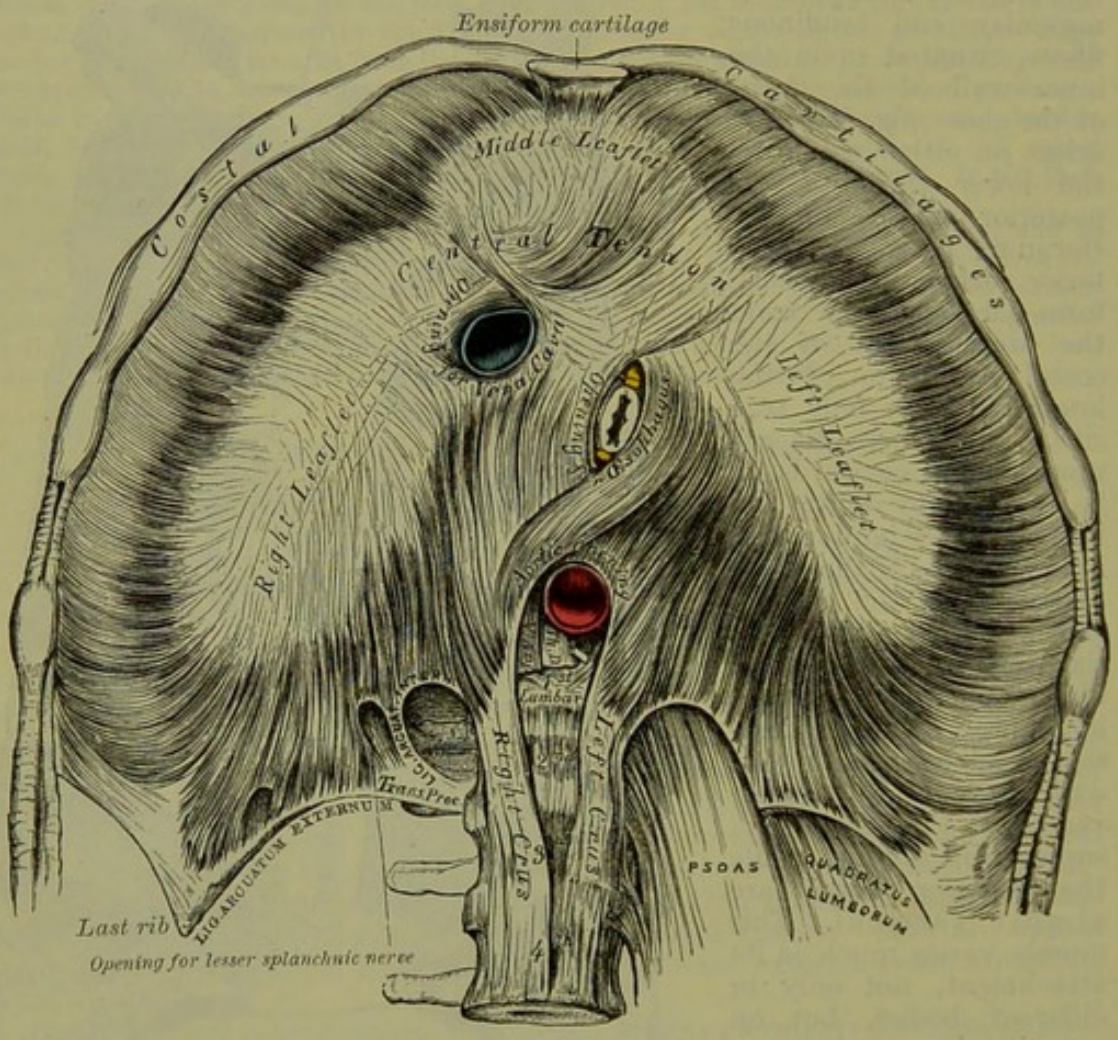

side of the body of the first or second lumbar vertebra; its outer end is fixed to the front of the transverse process of the first and, sometimes also, to that of the second lumbar vertebra.

The *ligamentum arcuatum externum* is the thickened upper margin of the anterior lamella of the lumbar aponeurosis. It arches across the upper part of the Quadratus lumborum, and is attached by its inner extremity to the front of the transverse process of the first lumbar vertebra, by its outer to the tip and lower margin of the twelfth rib.

The *crura*.—At their origins the crura are tendinous in structure, and blend with the anterior common ligament of the vertebral column. The *right crus*, larger and longer than the left, arises from the anterior surfaces of the bodies and intervertebral discs of the upper three lumbar vertebræ, while the *left crus* arises from the corresponding parts of the upper two only. The internal tendinous margins of the crura pass forwards and inwards, and meet

in the middle line to form an arch across the front of the aorta; this arch, which is often poorly defined, is known as the *ligamentum arcuatum medium.*

From this series of origins the fibres of the Diaphragm converge to be inserted into the central tendon. The fibres arising from the ensiform cartilage are very short, and occasionally aponeurotic; those from the internal and external arcuate ligaments, and more especially those from the ribs and their cartilages, are longer, and describe marked curves as they ascend and converge to their insertion. The fibres of the crura and those from the ligamentum arcuatum medium diverge as they ascend, the outermost being directed upwards and outwards to the central tendon, the innermost decussating in front of the aorta, and then diverging to surround the œsophagus before reaching their insertion. The fibres from the right crus are more numerous than those from the left, and pass in front of them.

The *central tendon* (centrum tendineum) of the Diaphragm is a thin but strong tendinous aponeurosis situated near the centre of the vault formed by the muscle, but somewhat closer to the front than to the back of the thorax, so that the posterior muscular fibres are the longer. It is situated immediately below the pericardium, with which it is partially blended. It is shaped somewhat like a trefoil leaf, consisting of three divisions or leaflets separated from one another by slight indentations. The right leaflet is the largest, the middle, directed towards the ensiform cartilage the next in size, and the left the smallest. In structure the tendon is composed of several planes of fibres, which intersect one another at various angles and unite into straight or curved bundles—an arrangement which affords it additional strength.

Openings in the Diaphragm.—The Diaphragm is pierced by a series of apertures to permit of the passage of structures between the thorax and abdomen. Three large openings—the aortic, the œsophageal, and the vena caval—and a series of smaller ones are described.

The *aortic opening* (hiatus aorticus) is the lowest and most posterior of the three large apertures; it lies at the level of the twelfth thoracic vertebra. Strictly speaking, it is not an aperture in the Diaphragm but an osseo-aponeurotic opening between it and the vertebral column, and therefore behind the Diaphragm; occasionally some tendinous fibres prolonged across the bodies of the vertebræ from the inner parts of the lower ends of the crura pass behind the aorta, and thus convert the opening into a fibrous ring. The aperture is situated slightly to the left of the middle line, and is bounded in front by the ligamentum arcuatum medium and crura, and behind by the body of the first lumbar vertebra. Through it pass the aorta, the vena azygos major and the thoracic duct; occasionally the vena azygos major is transmitted through the right crus.

The *œsophageal opening* (hiatus œsophageus) is situated at the level of the tenth thoracic vertebra; it is elliptical in form, muscular in structure, and bounded by the decussating fibres of the two crura.* The anterior edge is occasionally formed by the margin of the central tendon. The aperture is placed above, in front, and a little to the left of the aortic opening, and transmits the œsophagus, the pneumogastric nerves, and some small œsophageal arteries.

The *vena caval opening* (foramen venæ cavæ) is the highest of the three, and is situated about the level of the disc between the eighth and ninth thoracic vertebræ. It is quadrilateral in form, and is placed at the junction of the right and middle leaflets of the central tendon, so that its margins are tendinous. It transmits the inferior vena cava, the wall of which is adherent to the margins of the opening, and some branches of the right phrenic nerve.

Of the *lesser apertures*, two in the right crus transmit the greater and lesser right splanchnic nerves; three in the left crus give passage to the greater and lesser left splanchnic nerves and the vena azygos minor. The gangliated cords of the sympathetic usually enter the abdominal cavity behind the Diaphragm, under the internal arcuate ligaments. On either side two small intervals exist at which the muscular fibres of the Diaphragm are deficient

* Low (*Journal of Anatomy and Physiology*, vol. xlii.), in twenty-five cases which he examined, failed to find a fasciculus from the left crus to the right margin of the œsophageal opening. He regards the œsophageal passage in the Diaphragm as formed by the splitting of the mesial fibres of the right crus.

and are replaced by areolar tissue. One between the fibres of origin from the ensiform cartilage and those from the cartilages of the adjoining ribs transmits the superior epigastric branch of the internal mammary artery and some lymphatics from the abdominal wall and convex surface of the liver. The other, between the fibres springing from the internal and external arcuate ligaments, is less constant; when this interval exists, the upper and back part of the kidney is separated from the pleura by areolar tissue only.

Relations.—The upper surface of the Diaphragm is in relation with three serous membranes, viz. on either side the pleura, which separates it from the base of the corresponding lung, and on the middle leaflet of the central tendon the pericardium, which intervenes between it and the heart. The central portion lies on a slightly lower level than the summits of the lateral portions. The greater part of the under surface is covered by the peritoneum. The right side is accurately moulded over the convex surface of the right lobe of the liver, the right kidney, and right suprarenal capsule, the left over the left lobe of the liver, the fundus of the stomach, the spleen, the left kidney, and left suprarenal capsule.

Nerves.—The Diaphragm is supplied by the phrenic and lower intercostal nerves.

Actions.—The Diaphragm is the principal muscle of inspiration, and presents the form of a dome concave towards the abdomen. The central part of the dome is tendinous, and the pericardium is attached to its upper surface; the circumference is muscular. During inspiration the lowest ribs are fixed, and from these and the crura the muscular fibres contract and draw downwards and forwards the central tendon with the attached pericardium. In this movement the curvature of the Diaphragm is scarcely altered, the dome moving downwards nearly parallel to its original position and pushing before it the abdominal viscera. The descent of the abdominal viscera is permitted by the elasticity of the abdominal wall, but the limit of this is soon reached. The central tendon applied to the abdominal viscera then becomes a fixed point for the action of the Diaphragm, the effect of which is to elevate the lower ribs and through them to push forwards the gladiolus sterni and the upper ribs. The right cupola of the Diaphragm, lying on the liver, has a greater resistance to overcome than the left, which lies over the stomach, but to compensate for this the right crus and the fibres of the right side generally are stronger than those of the left.

In all expulsive acts the Diaphragm is called into action to give additional power to each expulsive effort. Thus, before sneezing, coughing, laughing, crying, or vomiting, and previous to the expulsion of urine or fæces, or of the fœtus from the uterus, a deep inspiration takes place. The height of the Diaphragm is constantly varying during respiration; it also varies with the degree of distension of the stomach and intestines and with the size of the liver. After a forced expiration the right cupola is on a level in front with the fourth costal cartilage, at the side with the fifth, sixth, and seventh ribs, and behind with the eighth rib; the left cupola is a little lower than the right. Halls Dally* states that the absolute range of movement between deep inspiration and deep expiration averages in the male and female 30 mm. on the right side and 28 mm. on the left; in quiet respiration the average movement is 12·5 mm. on the right side and 12 mm. on the left.

Skiagraphy shows that the height of the Diaphragm in the thorax varies considerably with the position of the body. It stands highest when the body is horizontal and the patient on his back, and in this position it performs the largest respiratory excursions with normal breathing. When the body is erect the dome of the Diaphragm falls, and its respiratory movements become smaller. The dome falls still lower when the sitting posture is assumed, and in this position its respiratory excursions are smallest. These facts may, perhaps, explain why it is that patients suffering from severe dyspnœa are most comfortable and least short of breath when they sit up. When the body is horizontal and the patient on his side, the two halves of the Diaphragm do not behave alike. The uppermost half sinks to a level lower even than when the patient sits, and moves little with respiration; the lower half rises higher in the thorax than it does when the patient is supine, and its respiratory excursions are much increased. In unilateral disease of the pleura or lungs analogous interference with the position or movement of the Diaphragm can generally be observed skiagraphically.

* 'Inquiry into the Physiological Mechanism of Respiration.' *Journal of Anatomy and Physiology*, vol. xliii. 1908.

It appears that the position of the Diaphragm in the thorax depends upon three main factors, viz.: (1) the elastic retraction of the lung-tissue, tending to pull it upwards; (2) the pressure exerted on its under surface by the viscera: this naturally tends to be a negative pressure, or downward suction, when the patient sits or stands, and positive, or an upward pressure, when he lies; (3) the intra-abdominal tension due to the abdominal muscles. These are in a state of contraction in the standing position and not in the sitting; hence the Diaphragm, when the patient stands, is pushed up higher than when he sits.

The Intercostal muscles, internal and external, have probably no action in moving the ribs. They contract simultaneously and form strong elastic supports which prevent the intercostal spaces being pushed out or drawn in during respiration. The anterior portions of the Internal intercostals probably have an additional function in keeping the chondro-sternal and interchondral joint surfaces in apposition, the posterior parts of the External intercostals performing a similar function for the costo-vertebral articulations.

The Levatores costarum being inserted near the fulcra of the ribs can have little action on the ribs; they act as rotators and lateral flexors of the vertebral column.

The Triangularis sterni draws down the costal cartilages, and is therefore a muscle of expiration.

Mechanism of Respiration

The respiratory movements must be examined during (*a*) quiet respiration, and (*b*) forced respiration.

Quiet respiration.—The first and second pairs of ribs are fixed by the Scaleni and by the resistance of the cervical structures; the last pair, and through it the eleventh, by the Quadratus lumborum. The other ribs are elevated, so that the first two intercostal spaces are diminished while the others are increased in width. It has already been shown (p. 392) that elevation of the third, fourth, fifth, and sixth ribs leads to an increase in the antero-posterior and transverse diameters of the thorax: the vertical diameter is increased by the descent of the diaphragmatic dome so that the lungs are expanded in all directions except backwards and upwards. Elevation of the eighth, ninth, and tenth ribs is accompanied by an outward and backward movement, leading to an increase in the transverse diameter of the upper part of the abdomen; the elasticity of the anterior abdominal wall allows a slight increase in the antero-posterior diameter of this part, and in this way the decrease in the vertical diameter of the abdomen is compensated and space provided for its displaced viscera. Expiration is effected by the elastic recoil of its walls and by the action of the abdominal muscles, which push back the viscera displaced downwards by the Diaphragm.

Forced respiration.—All the movements of quiet respiration are here carried out, but to a greater extent. In inspiration the shoulders and the vertebral borders of the scapulæ are fixed and the limb muscles, Trapezius, Serratus magnus, Pectorals, and Latissimus dorsi, are called into play. The Scaleni are in stronger action, and the Sterno-mastoids also assist when the head is fixed by drawing up the sternum and by fixing the clavicles. The first rib is therefore no longer stationary, but, with the sternum, is raised; with it all the other ribs except the last are raised to a higher level. In conjunction with the increased descent of the Diaphragm this provides for a considerable augmentation of all the thoracic diameters. The anterior abdominal muscles come into action so that the umbilicus is drawn upwards and backwards, but this allows the Diaphragm to exert a more powerful influence on the lower ribs; the transverse diameter of the upper part of the abdomen is greatly increased and the subcostal angle opened out. The deeper muscles of the back, e.g. the Serrati postici superiores and Erectores spinæ, are also brought into action; the thoracic curve of the vertebral column is partially straightened, and the whole column, above the lower lumbar vertebræ, drawn backwards. This increases the antero-posterior diameters of the thorax and upper part of the abdomen and widens the intercostal spaces. Forced expiration is effected by the recoil of the walls and by the contraction of the antero-lateral muscles of the abdominal wall, and the Serrati postici inferiores and Triangularis sterni.

Halls Dally (*op. cit.*) gives the following figures as representing the average changes which occur during deepest possible respiration. The presternum moves 30 mm. in an

upward and 14 mm. in a forward direction; the width of the subcostal angle, at a level of 30 mm. below the meso-metasternal articulation, is increased by 26 mm.; the umbilicus is retracted and drawn upwards for a distance of 13 mm.

III. Muscles of the Abdomen

The muscles of the abdomen may be divided into two groups: 1, The antero-lateral muscles; 2, The posterior muscles.

1. Antero-lateral Muscles

The muscles of this group are:

Obliquus Externus.
Obliquus Internus.
Transversalis.
Rectus.
Pyramidalis.

The **superficial fascia** of the abdomen consists, over the greater part of the abdominal wall, of a single layer of fascia which contains a variable amount of fat; but as this layer approaches the groin it is easily divisible into two, between which are found the superficial vessels and nerves and the superficial inguinal lymphatic glands. The superficial layer (*fascia of Camper*) is thick, areolar in texture, and contains in its meshes adipose tissue, the quantity of which varies in different subjects. Below, it passes over Poupart's ligament, and is continuous with the superficial fascia of the thigh. In the male, this fascia is continued over the penis and outer surface of the cord to the scrotum, where it helps to form the dartos. As it passes to the scrotum it changes its character, becoming thin, destitute of adipose tissue, and of a pale reddish colour, and in the scrotum it acquires some involuntary muscular fibres. From the scrotum it may be traced backwards to be continuous with the superficial fascia of the perinæum. In the female, this fascia is continued into the labia majora. The deeper layer (*fascia of Scarpa*) is thinner and more membranous in character than the superficial layer, and contains a considerable quantity of yellow elastic fibres. It is loosely connected by areolar tissue to the aponeurosis of the External oblique, but in the middle line it is more intimately adherent to the linea alba and to the symphysis pubis, and is prolonged on to the dorsum of the penis, forming the suspensory ligament; above, it is continuous with the superficial fascia over the rest of the trunk; below and externally, it blends with the fascia lata of the thigh a little below Poupart's ligament; internally and below, it is continued over the penis and spermatic cord to the scrotum, where it helps to form the dartos. From the scrotum it may be traced backwards into continuity with the deep layer of the superficial fascia of the perinæum (*fascia of Colles*). In the female, it is continued into the labia majora and thence to the fascia of Colles.

The **Obliquus externus abdominis** (fig. 502) is situated on the side and fore part of the abdomen, being the largest and the most superficial of the three flat muscles in this region. It is broad, thin, and irregularly quadrilateral, its muscular portion occupying the side, its aponeurosis the anterior wall of the abdomen. It arises, by eight fleshy digitations, from the external surfaces and lower borders of the lower eight ribs; these digitations are arranged in an oblique line which runs downwards and backwards, the upper ones being attached close to the cartilages of the corresponding ribs, the lowest to the apex of the cartilage of the last rib, the intermediate ones to the ribs at some distance from their cartilages. The five superior serrations increase in size from above downwards, and are received between corresponding processes of the Serratus magnus; the three lower ones diminish in size from above downwards, receiving between them corresponding processes from the Latissimus dorsi. From these attachments the fleshy fibres proceed in various directions. Those from the lowest ribs pass nearly vertically downwards, to be inserted into the anterior half of the outer lip of the crest of the ilium; the middle and upper fibres, directed downwards and forwards, terminate in an aponeurosis, opposite a line drawn from the prominence of the ninth costal cartilage to the anterior superior spine of the ilium.

The *aponeurosis of the External oblique* is a thin but strong membranous structure, the fibres of which are directed obliquely downwards and inwards.

It is joined with that of the opposite muscle along the median line, and covers the whole of the front of the abdomen; above, it is covered by and gives origin to the lower border of the Pectoralis major; below, its fibres are closely aggregated together, and extend obliquely across from the anterior superior spine of the ilium to the spine of the pubis and the linea iliopectinea. In the median line, it interlaces with the aponeurosis of the opposite muscle, forming the linea alba, which extends from the ensiform cartilage to the symphysis pubis.

Fig. 502.—The External oblique muscle.

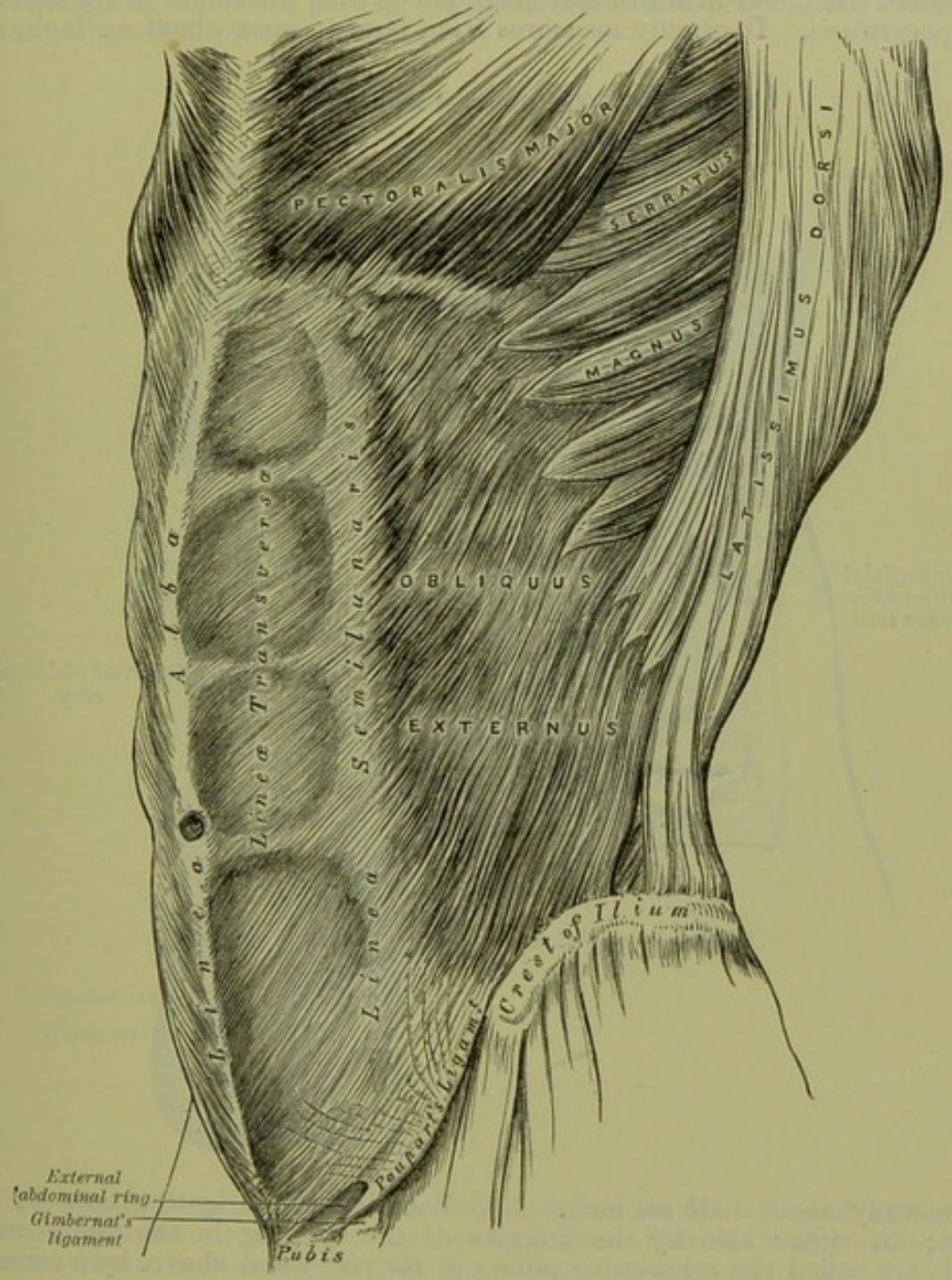

That portion of the aponeurosis which extends between the anterior superior spine of the ilium and the spine of the pubis is a thick band, folded inwards, and continuous below with the fascia lata; it is called *Poupart's ligament.* The portion which is reflected from Poupart's ligament at the spine of the pubis along the pectineal line is called *Gimbernat's ligament.* From the point of attachment of the latter to the pectineal line, a few fibres pass upwards and inwards, behind the inner pillar of the external abdominal ring, to the linea alba. They diverge as they ascend, and form a thin triangular fibrous layer, which is called the *triangular fascia.*

In the aponeurosis of the External oblique, immediately above the crest of the pubis, is a triangular opening, the *external abdominal ring*, formed by a separation of the fibres of the aponeurosis in this situation.

The following parts of the aponeurosis of the External oblique muscle require further description, viz. the external abdominal ring, the intercolumnar fibres and fascia, Poupart's ligament, Gimbernat's ligament, and the triangular fascia.

The **external** or **superficial abdominal ring** (annulus inguinalis subcutaneus) is an interval in the aponeurosis of the External oblique, just above and to the outer side of the crest of the pubis. The aperture is oblique in direction, somewhat triangular in form, and corresponds with the course of the fibres of the aponeurosis. It usually measures from base to apex about an inch, and

FIG. 503.—The external abdominal ring.

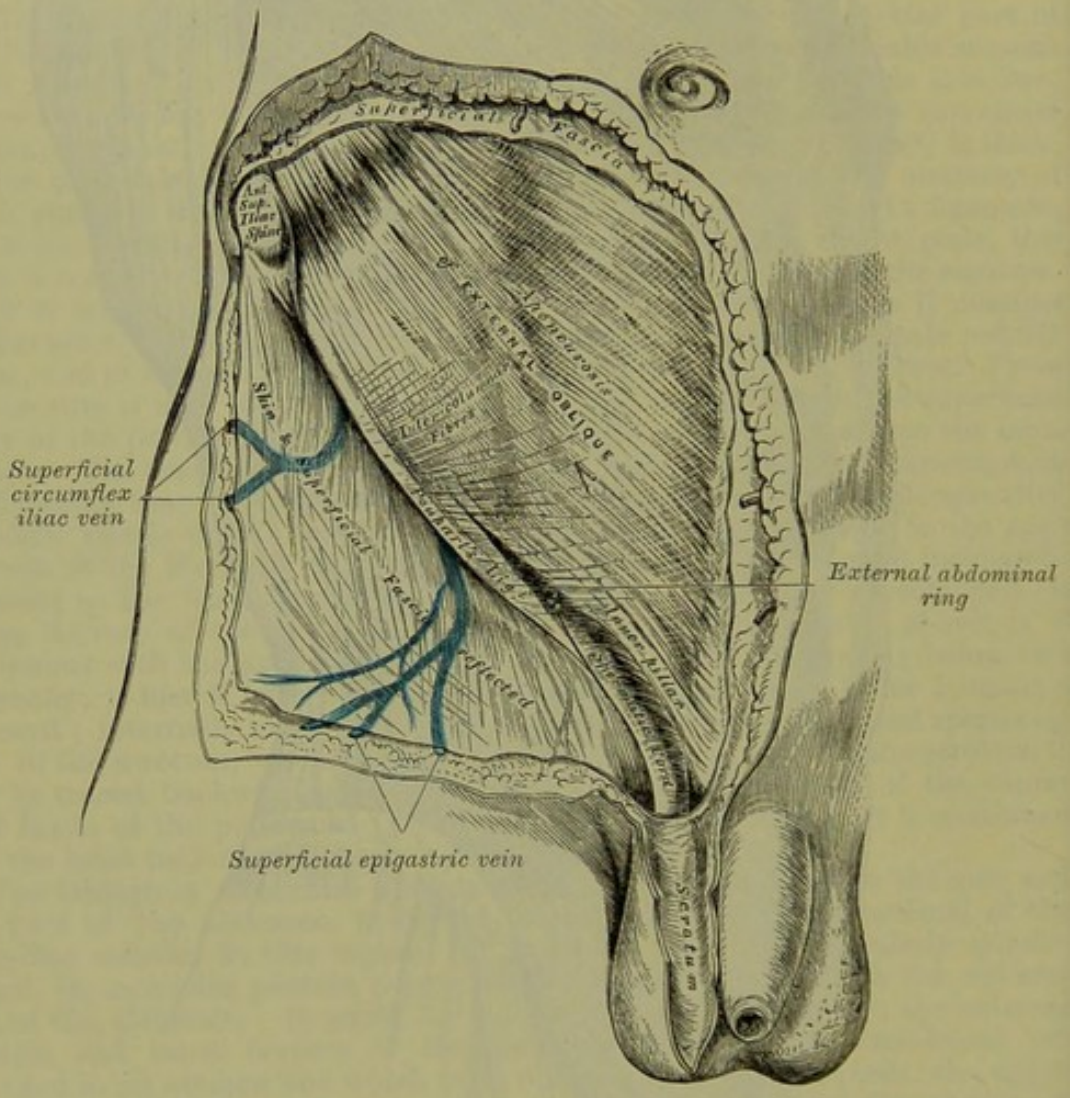

transversely about half an inch. It is bounded below by the crest of the pubis; on either side by the margins of the opening in the aponeurosis, which are called the *columns* or *pillars of the ring*; and above, by a series of curved fibres, the *intercolumnar* (fig. 503), which pass across the upper angle of the ring, so as to increase its strength.

The external or inferior pillar (crus inferius) is the stronger; it is formed by that portion of Poupart's ligament which is inserted into the spine of the pubis; it is curved so as to form a kind of groove, upon which the spermatic cord rests. The internal or superior pillar (crus superius) is a broad, thin, flat band, which is attached to the front of the symphysis pubis, interlacing with its fellow of the opposite side, that of the right side being superficial.

The external abdominal ring gives passage to the spermatic cord and ilio-inguinal nerve in the male, and to the round ligament of the uterus and

the ilio-inguinal nerve in the female : it is much larger in men than in women, on account of the large size of the spermatic cord.

The **intercolumnar fibres** (fibræ intercrurales) are a series of curved tendinous fibres, which arch across the lower part of the aponeurosis of the External oblique, describing a curve with the convexity downwards. They have received their name from stretching across between the two pillars of the external ring. They are much thicker and stronger at the outer margin of the external ring, where they are connected to Poupart's ligament, than internally, where they are inserted into the linea alba. They are more strongly developed in the male than in the female. The intercolumnar fibres increase the strength of the lower part of the aponeurosis, and prevent the divergence of the pillars from one another.

FIG. 504.—The Internal oblique muscle.

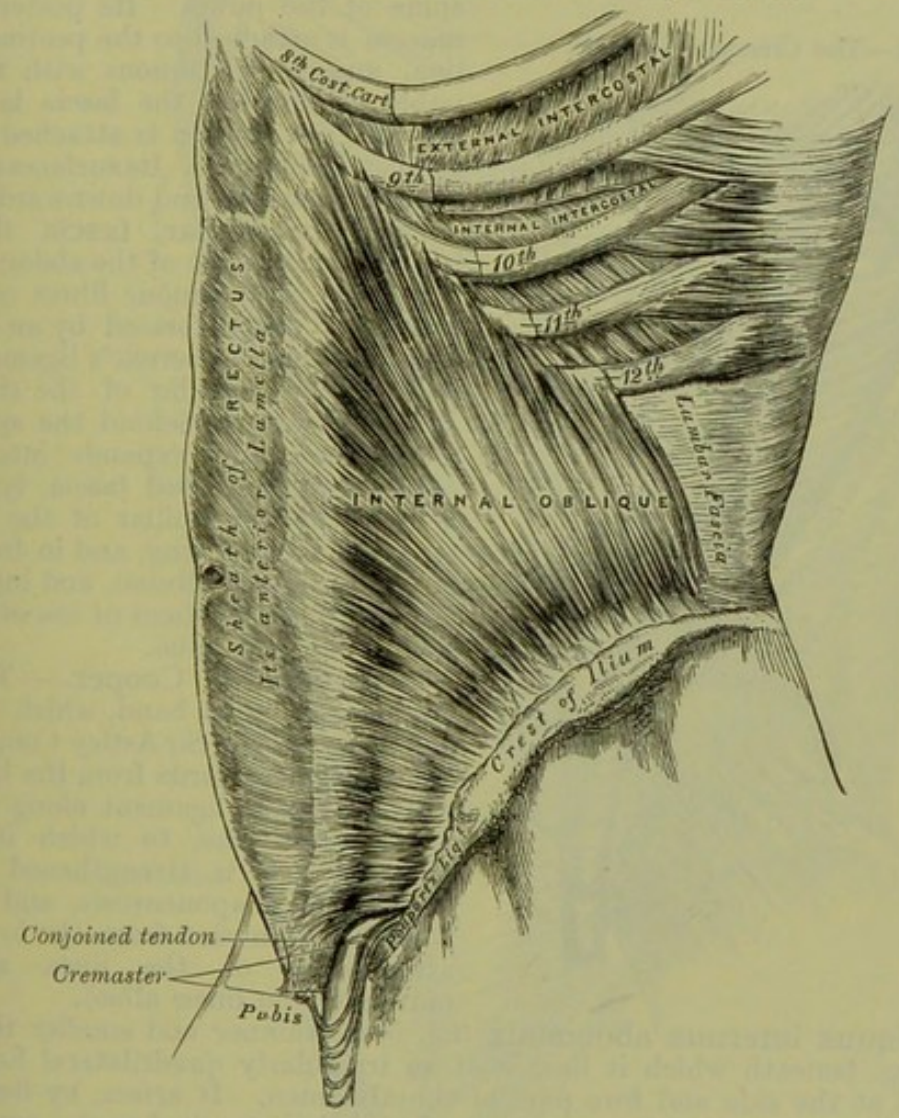

These intercolumnar fibres, as they pass across the external abdominal ring, are themselves connected together by delicate fibrous tissue, thus forming a fascia, which, as it is attached to the pillars of the ring, covers it in, and is called the *intercolumnar fascia*. This **intercolumnar fascia** is continued down as a tubular prolongation around the spermatic cord and testis, and encloses them in a distinct sheath ; hence it is also called the *external spermatic fascia*. The external abdominal ring is only seen as a distinct aperture after the external spermatic fascia has been removed from its pillars.

Poupart's ligament (lig. inguinale) is the lower border of the aponeurosis of the External oblique muscle, and extends from the anterior superior spine of the ilium to the spine of the pubis. From this latter point it is reflected backwards and outwards to be attached to the pectineal line for about half an inch, forming Gimbernat's ligament. Its general direction is convex

downwards towards the thigh, where it is continuous with the fascia lata. Its outer half is rounded, and oblique in direction. Its inner half gradually widens at its attachment to the pubis, is more horizontal in direction, and lies beneath the spermatic cord.

Nearly the whole of the space included between the crural arch and the innominate bone is filled in by the parts which descend from the abdomen into the thigh.

Gimbernat's ligament (lig. lacunare) is that part of the aponeurosis of the External oblique muscle which is reflected backwards and outwards from the spine of the pubis to be inserted into the pectineal line. It is about half an inch in length, larger in the male than in the female, almost horizontal in direction in the erect posture, and of a triangular form with the base directed outwards. Its base, or outer margin, is concave, thin, and sharp, and forms the inner boundary of the crural ring. Its apex corresponds to the spine of the pubis. Its posterior margin is attached to the pectineal line, and is continuous with the pubic portion of the fascia lata. Its anterior margin is attached to Poupart's ligament. Its surfaces are directed upwards and downwards.

Fig. 505.—The Cremaster muscle.

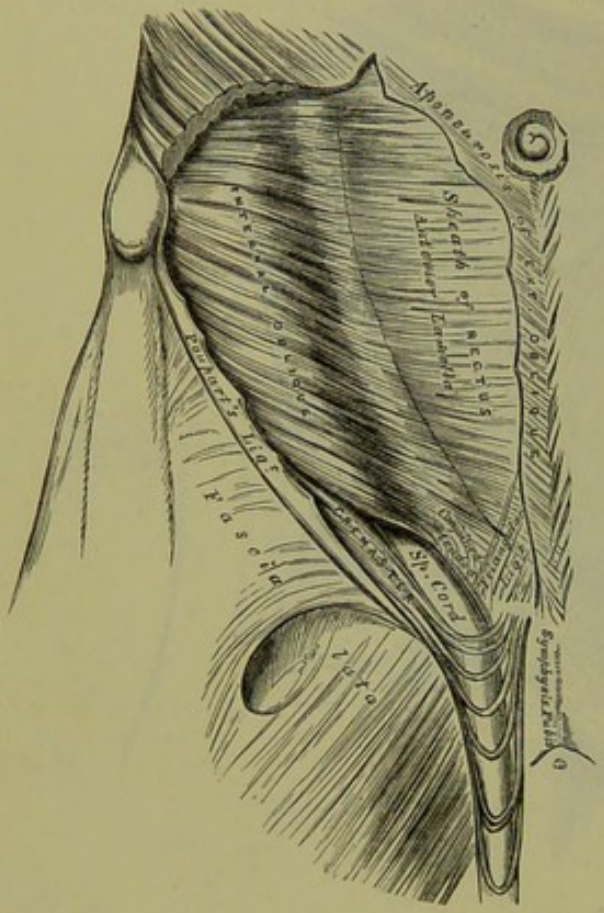

The **triangular fascia** (lig. inguinale reflexum) of the abdomen is a layer of tendinous fibres of a triangular shape, formed by an expansion from Gimbernat's ligament and the outer pillar of the ring. It passes inwards behind the spermatic cord, and expands into a somewhat fan-shaped fascia, lying behind the inner pillar of the external abdominal ring, and in front of the conjoined tendon, and interlaces with the ligament of the other side at the linea alba.

Ligament of Cooper. — This is a strong fibrous band, which was first described by Sir Astley Cooper. It extends outwards from the base of Gimbernat's ligament along the ilio-pectineal line, to which it is attached. It is strengthened by the pectineal aponeurosis, and by a lateral expansion from the lower attachment of the linea alba (adminiculum lineæ albæ).

The **Obliquus internus abdominis** (fig. 504), thinner and smaller than the preceding, beneath which it lies, is of an irregularly quadrilateral form, and situated at the side and fore part of the abdomen. It arises, by fleshy fibres, from the outer half of Poupart's ligament, being attached to the groove on its upper surface, from the anterior two-thirds of the middle lip of the crest of the ilium, and from the posterior lamella of the lumbar fascia. From this origin the fibres diverge, those from Poupart's ligament, few in number, and paler in colour than the rest, arch downwards and inwards across the spermatic cord in the male and the round ligament in the female, and, becoming tendinous, are inserted, conjointly with those of the Transversalis, into the crest of the pubis and inner part of the ilio-pectineal line behind Gimbernat's ligament, forming what is known as the conjoined tendon of the Internal oblique and Transversalis. Those from the anterior third of the iliac origin are horizontal in their direction, and, becoming tendinous along the lower fourth of the linea semilunaris, pass in front of the Rectus muscle to be inserted into the linea alba. Those arising from the middle third of the origin from the crest of the ilium pass obliquely upwards and inwards, and terminate

in an aponeurosis; this divides at the outer border of the Rectus muscle into two lamellæ, which are continued forwards, one in front of and the other behind this muscle, to the linea alba: the posterior lamella being also connected to the cartilages of the seventh, eighth, and ninth ribs. The most posterior fibres pass almost vertically upwards, to be inserted into the lower borders of the cartilages of the three lower ribs, being continuous with the Internal intercostal muscles.

Fig. 506.—The Transversalis, Rectus, and Pyramidalis muscles.

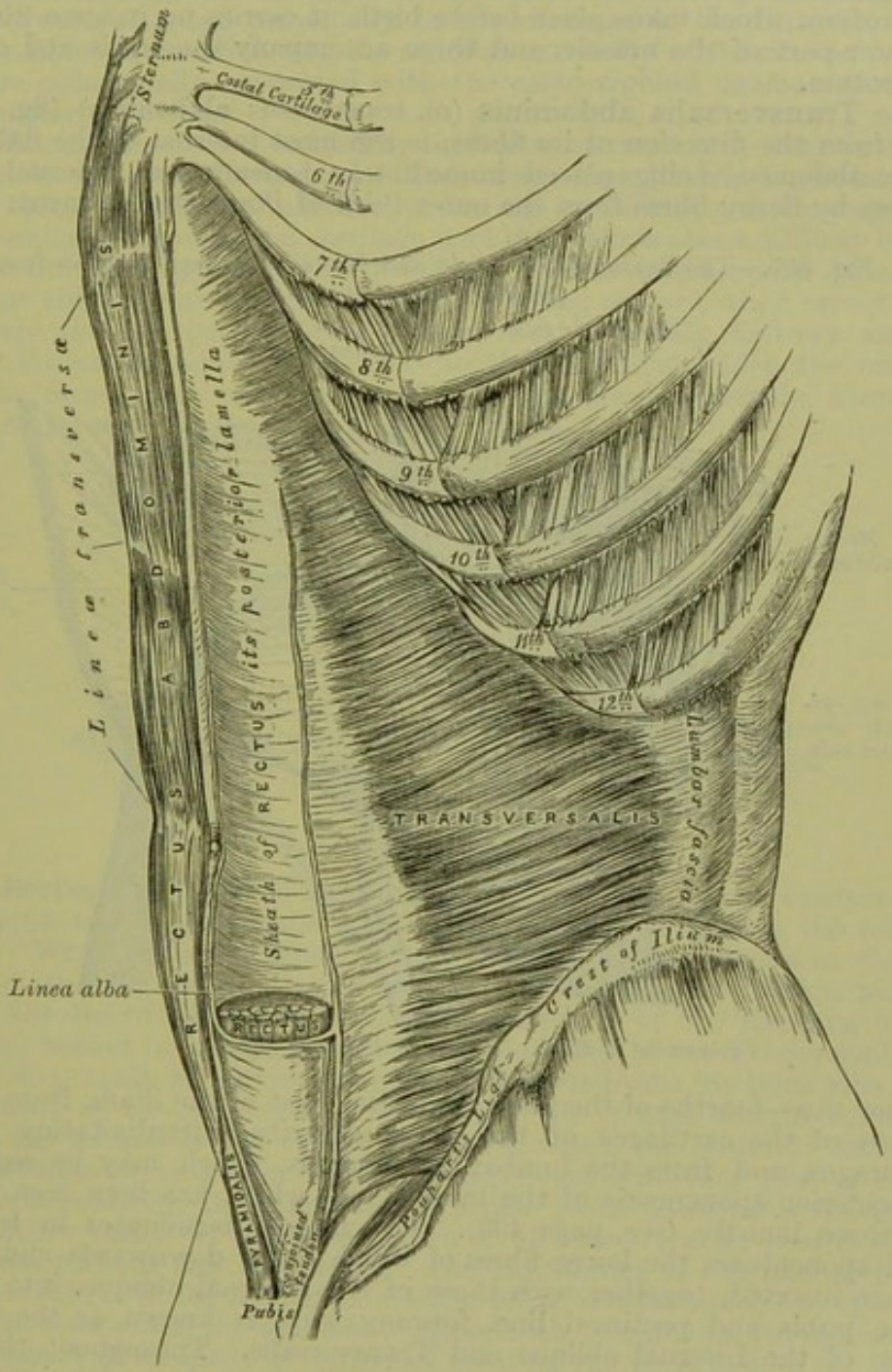

The **Cremaster** (fig. 505) is a thin muscular layer, composed of a number of fasciculi which arise from the middle of Poupart's ligament where its fibres are continuous with those of the Internal oblique and also occasionally with the Transversalis. It passes along the outer side of the spermatic cord, descends with it through the external abdominal ring upon the front and sides of the cord, and forms a series of loops which differ in thickness and length in different subjects. Those at the upper part of the cord are exceedingly short, but they become in succession longer and longer, the longest reaching down as

low as the testicle, where a few are inserted into the tunica vaginalis. These loops are united together by areolar tissue, and form a thin covering over the cord and testis, the *cremasteric fascia*. The fibres ascend along the inner side of the cord, and are inserted by a small pointed tendon into the spine and crest of the pubis and into the front of the sheath of the Rectus.

It will be observed that the origin and insertion of the Cremaster are precisely similar to those of the lower fibres of the Internal oblique. This fact is explained by the manner in which the testis and cord are invested by this muscle. At an early period of fœtal life the testis is placed at the lower and back part of the abdominal cavity, but during its descent towards the scrotum, which takes place before birth, it carries on it some fibres from the lower part of the muscle, and these accompany the testis and cord into the scrotum.

The **Transversalis abdominis** (m. transversus abdominis) (fig. 506), so called from the direction of its fibres, is the most internal of the flat muscles of the abdomen, being placed immediately beneath the Internal oblique. It arises by fleshy fibres from the outer third of Poupart's ligament, from the

FIG. 507.—The ligaments of Henle and Hesselbach, seen from in front. (Modified from Braune.)

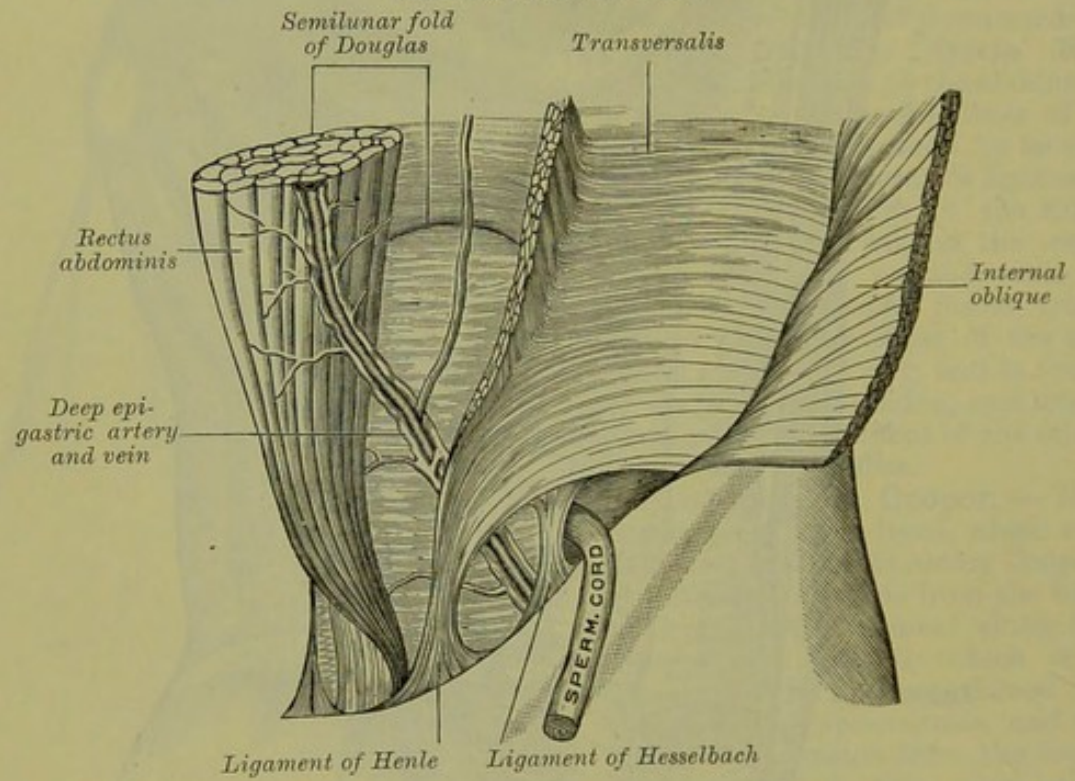

anterior three-fourths of the inner lip of the crest of the ilium, from the inner surfaces of the cartilages of the lower six ribs, interdigitating with the Diaphragm, and from the lumbar aponeurosis, which may be regarded as the posterior aponeurosis of the muscle, and which has been seen to divide into three lamellæ (see page 493). The muscle terminates in front in a broad aponeurosis, the lower fibres of which curve downwards and inwards, and are inserted, together with those of the Internal oblique, into the crest of the pubis and pectineal line, forming what is known as the conjoined tendon of the Internal oblique and Transversalis. Throughout the rest of its extent the aponeurosis passes horizontally inwards, and is inserted into the linea alba; its upper three-fourths passing behind the Rectus muscle, blending with the posterior lamella of the Internal oblique; its lower fourth passing in front of the Rectus.

The *conjoined tendon* of the Internal oblique and Transversalis is mainly formed by the lower part of the tendon of the Transversalis, and is inserted into the crest of the pubis and ilio-pectineal line immediately behind the external abdominal ring, serving to protect what would otherwise be a weak point in the abdominal wall. The conjoined tendon is sometimes divided

into an outer and an inner portion—the former being termed the *ligament of Hesselbach*; the latter, the *ligament of Henle* (fig. 507).

The **Rectus abdominis** is a long flat muscle, which extends along the whole length of the front of the abdomen, being separated from its fellow of the opposite side by the linea alba. It is much broader, but thinner, above than below, and arises by two tendons, the external or larger being attached to the crest of the pubis, the internal, smaller portion, interlacing with its fellow of the opposite side, and being connected with the ligaments covering the front of the symphysis pubis. The muscle is inserted by three portions of unequal size into the cartilages of the fifth, sixth, and seventh ribs. The upper portion, attached principally to the cartilage of the fifth rib, usually has some fibres of insertion into the anterior extremity of the rib itself. Some fibres are occasionally connected with the costo-xiphoid ligaments, and side of the ensiform cartilage.

The Rectus muscle is traversed by tendinous intersections, three in number, which have received the name of *lineæ transversæ* (inscriptiones tendineæ). One of these is usually situated opposite the umbilicus, one corresponds to the extremity of the ensiform cartilage, and the other is about midway between the ensiform cartilage and the umbilicus. These intersections pass transversely or obliquely across the muscle in a zigzag course; they rarely extend completely through its substance; they may pass only halfway across it, and are intimately adherent in front to the sheath in which the muscle is enclosed. Sometimes one or two additional lines, generally incomplete, may be seen below the umbilicus.

FIG. 508.—Diagram of sheath of Rectus.

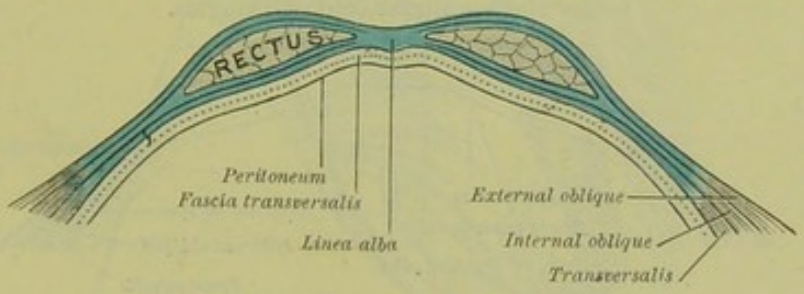

The Rectus is enclosed in a sheath (fig. 508) formed by the aponeuroses of the Oblique and Transversalis muscles, which are arranged in the following manner. When the aponeurosis of the Internal oblique arrives at the outer margin of the Rectus, it divides into two lamellæ, one of which passes in front of the Rectus, blending with the aponeurosis of the External oblique, the other, behind it, blending with the aponeurosis of the Transversalis, and these, joining again at its inner border, are inserted into the linea alba. This arrangement of the aponeurosis exists from the costal margin to midway between the umbilicus and symphysis pubis, where the posterior wall of the sheath terminates in a thin curved margin, the *semilunar fold of Douglas* (linea semicircularis), the concavity of which looks downwards towards the pubis: below this level the aponeuroses of all three muscles pass in front of the Rectus without any separation. The extremities of the fold of Douglas descend as pillars to the pubis. The inner pillar is attached to the symphysis pubis; the outer pillar, the ligament of Hesselbach, or outer part of the conjoined tendon, passes downwards as a distinct band on the inner side of the internal abdominal ring, and there its fibres divide into two sets, internal and external: the internal fibres are attached to the ascending ramus of the pubis and the pectineal fascia; the external ones pass to the Psoas fascia, to the deep surface of Poupart's ligament, and to the tendon of the Transversalis on the outer side of the ring. The Rectus muscle, in the situation where its sheath is deficient below, is separated from the peritoneum by the fascia transversalis (fig. 509). Since the tendons of the Internal oblique and Transversalis only reach as high as the costal margin, it follows that above this level the sheath of the Rectus is also deficient behind, the muscle resting directly on

the cartilages of the ribs, and being covered merely by the tendon of the External oblique.

The **Pyramidalis** is a small muscle, triangular in shape, placed at the lower part of the abdomen in front of the Rectus, and contained in the sheath of that muscle. It arises by tendinous fibres from the front of the pubis and the anterior pubic ligament; the fleshy portion of the muscle passes upwards, diminishing in size as it ascends, and terminates by a pointed extremity which is inserted into the linea alba, midway between the umbilicus and the pubis. This muscle may be wanting on one or both sides; the lower end of the Rectus then becomes proportionately increased in size. Occasionally it is double on one side, and the muscles of the two sides are sometimes of unequal size. It may extend higher than the level stated above.

Besides the Rectus and Pyramidalis muscles, the sheath of the Rectus contains the superior and deep epigastric arteries, and the terminations of the lumbar arteries and lower intercostal arteries and nerves.

Nerves.—The abdominal muscles are supplied by the lower intercostal nerves. The Transversalis and Internal oblique also receive filaments from the hypogastric branch of the ilio-hypogastric and sometimes from the ilio-inguinal. The Cremaster is supplied by the genital branch of the genito-crural and the Pyramidalis usually by the twelfth thoracic.

The **linea alba** is a tendinous raphe seen along the middle line of the abdomen, extending from the ensiform cartilage to the symphysis pubis, and attached to both. It is placed between the inner borders of the Recti, and is formed by the blending of the aponeuroses of the Obliqui and Trans-

Fig. 509.—Diagram of a transverse section through the anterior abdominal wall, below the semilunar fold of Douglas.

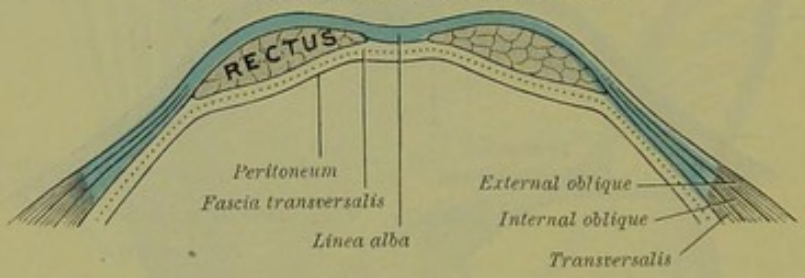

versales muscles. It is narrow below, corresponding to the linear interval existing between the Recti; but broader above, as these muscles diverge from one another in their ascent; it becomes of considerable breadth after great distension of the abdomen from pregnancy or ascites. At its lower end the linea alba has a double attachment—its superficial fibres passing in front of the inner heads of the Recti to the symphysis pubis, while its deeper fibres form a triangular lamella, attached behind the Recti to the posterior lip of the crest of the pubis, and named the *adminiculum lineæ albæ*. It presents numerous apertures for the passage of vessels and nerves; the umbilicus, which in the fœtus exists as an aperture and transmits the umbilical vessels, is obliterated in the adult, the cicatrix being stronger than the neighbouring parts; hence umbilical hernia occurs in the adult *near* the umbilicus, while in the fœtus it occurs *at* the umbilicus.

The **lineæ semilunares** are two curved tendinous lines placed one on either side of the linea alba. Each corresponds with the outer border of the Rectus muscle, extends from the cartilage of the ninth rib to the pubic spine, and is formed by the aponeurosis of the Internal oblique at its point of division to enclose the Rectus, reinforced in front by that of the External oblique, and behind by that of the Transversalis.

Actions.—When the pelvis and thorax are fixed, the abdominal muscles compress the abdominal viscera, by constricting the cavity of the abdomen, in which action they are materially assisted by the descent of the Diaphragm. By these means assistance is given in expelling the fœtus from the uterus, the fæces from the rectum, the urine from the bladder, and the contents of the stomach in vomiting.

If the pelvis and vertebral column be fixed, these muscles compress the lower part of the thorax, materially assisting expiration. If the pelvis alone be fixed, the thorax is bent directly forward, when the muscles of both sides act; when the muscles of only one side contract the trunk is bent towards that side and rotated towards the opposite side.

If the thorax be fixed, the muscles, acting together, draw the pelvis upwards, as in climbing; or, acting singly, they draw the pelvis upwards, and bend the vertebral column to one side or the other. The Recti, acting from below, depress the thorax, and consequently flex the vertebral column; when acting from above, they flex the pelvis upon the vertebral column. The Pyramidales are tensors of the linea alba.

The **fascia transversalis** is a thin aponeurotic membrane which lies between the inner surface of the Transversalis muscle and the extra-peritoneal fat. It forms part of the general layer of fascia lining the abdominal parietes, and is directly continuous with the iliac and pelvic fasciæ. In the inguinal region, the transversalis fascia is thick and dense in structure and joined by

Fig. 510.—The left internal abdominal ring.

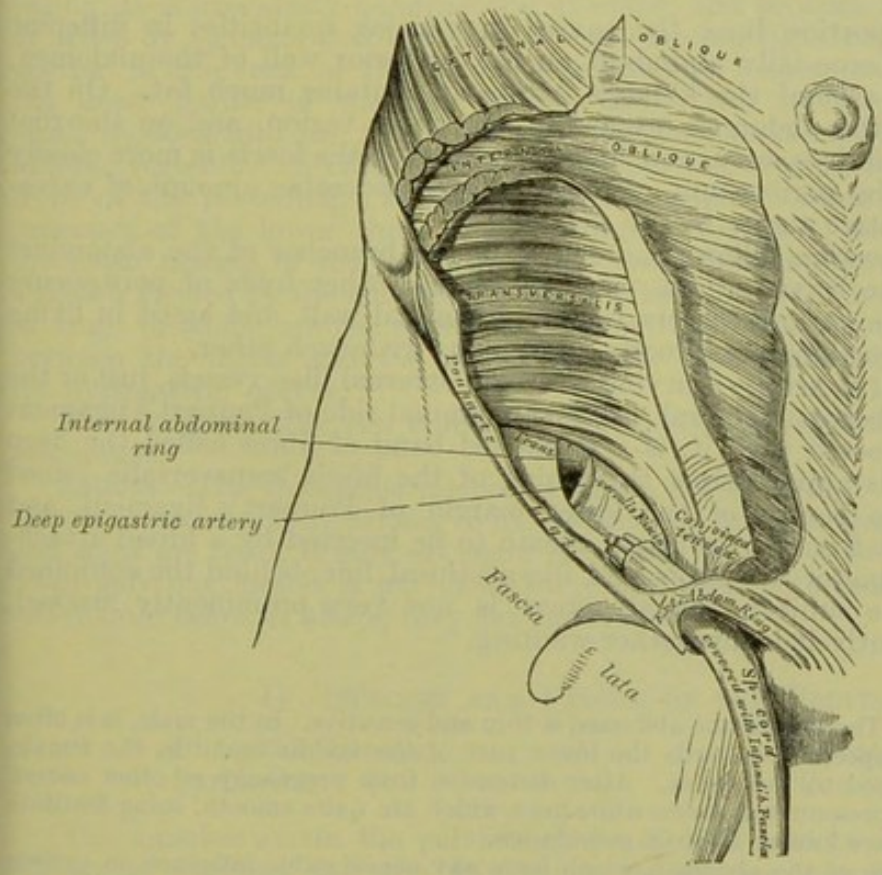

fibres from the aponeurosis of the Transversalis muscle, but it becomes thin as it ascends to the Diaphragm, and blends with the fascia covering the under aspect of this muscle. In front, it unites across the middle line with the fascia on the opposite side of the body; and behind, it becomes lost in the fat which covers the posterior surfaces of the kidneys. Below, it has the following attachments: posteriorly, to the whole length of the crest of the ilium, between the attachments of the Transversalis and Iliacus muscles; between the anterior superior spine of the ilium and the femoral vessels it is connected to the posterior margin of Poupart's ligament, and is there continuous with the iliac fascia. Internal to the femoral vessels it is thin and attached to the pubis and ilio-pectineal line, behind the conjoined tendon, with which it is united; it descends in front of the femoral vessels to form the anterior wall of the femoral sheath. Beneath Poupart's ligament it is strengthened by a band of fibrous tissue, which is only loosely connected to Poupart's ligament, and is specialised as the *deep crural arch*. The spermatic cord in the male and the round ligament in the female pass through the

transversalis fascia at a point called the *internal abdominal ring*. This opening is not visible externally since the transversalis fascia is prolonged on these structures as the *infundibuliform fascia*.

The **internal** or **deep abdominal ring** (annulus inguinalis abdominalis) is situated in the transversalis fascia, midway between the anterior superior spine of the ilium and the symphysis pubis, and about half an inch above Poupart's ligament (fig. 510). It is of an oval form, the long axis of the oval being vertical; it varies in size in different subjects, and is much larger in the male than in the female. It is bounded, above and externally, by the arched fibres of the Transversalis; below and internally, by the deep epigastric vessels. It transmits the spermatic cord in the male and the round ligament in the female. From its circumference a thin funnel-shaped membrane, the *infundibuliform fascia*, is continued round the cord and testis, enclosing them in a distinct covering.

Extra-peritoneal connective tissue. — Between the inner surface of the general layer of the fascia which lines the interior of the abdominal and pelvic cavities, and the peritoneum, there is a considerable amount of connective tissue, termed the *extra-peritoneal* or *subperitoneal connective tissue*.

The *parietal* portion lines the cavity in varying quantities in different situations. It is especially abundant on the posterior wall of the abdomen, and particularly around the kidneys, where it contains much fat. On the anterior wall of the abdomen, except in the pubic region, and on the roof of the abdomen, it is scanty, and here the transversalis fascia is more closely connected with the peritoneum. There is a considerable amount of extra-peritoneal connective tissue in the pelvis.

The *visceral* portion follows the course of the branches of the abdominal aorta between the layers of the mesenteries and other folds of peritoneum which connect the various viscera to the abdominal wall, and assist in fixing them. The two portions are directly continuous with each other.

The **deep crural arch.**—Curving over the external iliac vessels, just at the point where they become femoral, on the abdominal side of Poupart's ligament and loosely connected with it, is a thickened band of fibres called the deep crural arch. It is apparently a thickening of the fascia transversalis, joined externally to the centre of the lower margin of Poupart's ligament, and arching across the front of the crural sheath to be inserted by a broad attachment into the spine of the pubis and ilio-pectineal line, behind the conjoined tendon. In some subjects this structure is not very prominently marked, and not infrequently it is altogether wanting.

Surface Form.—The skin of the abdomen is thin and sensitive. In the male, it is often thickly hair-clad, especially towards the lower part of the middle line. In the female, the hairs are confined to the pubes. After distension from pregnancy or other causes, the skin commonly presents transverse white lines, which are quite smooth, being destitute of papillæ. These are known as *striæ gravidarum*.

The only muscles of the abdomen which have any considerable influence on surface form are the External oblique and Rectus. With regard to the External oblique, the upper digitations of its origin from the ribs are well marked in a muscular subject, interdigitating with those of the Serratus magnus; the lower digitations are not visible, being covered by the thick border of the Latissimus dorsi. Its attachment to the crest of the ilium, in conjunction with the Internal oblique, forms a thick oblique roll, which determines the iliac furrow. Sometimes on the front of the lateral region of the abdomen an undulating outline marks the spot where the muscular fibres terminate and the aponeurosis commences. The outer border of the Rectus is defined by the *linea semilunaris*, which may be exactly determined by putting the muscle into action. It corresponds with a curved line, with its convexity outwards, drawn from the end of the cartilage of the ninth rib to the spine of the pubis; at the level of the umbilicus, it is about three inches from the median line. The surface of the Rectus presents three transverse furrows, the *lineæ transversæ*. The upper two of these, viz. one opposite or a little below the tip of the ensiform cartilage, and the other midway between this point and the umbilicus, are usually well marked; the third, opposite the umbilicus, is not so distinct. The umbilicus, situated in the linea alba, varies in position as regards its height. It is placed from three-quarters of an inch to an inch above the level of the tubercles of the iliac crests, and usually corresponds to the disc between the third and fourth lumbar vertebræ.

2. Posterior Muscles of the Abdomen

Psoas magnus.	Iliacus.
Psoas parvus.	Quadratus lumborum.

The Psoas magnus, the Psoas parvus, and the Iliacus muscles, with the fasciæ covering them, will be described with the muscles of the lower extremity (see page 564).

The fascia covering the Quadratus lumborum.—This is the most anterior of the three layers of the lumbar aponeurosis. It is a thin layer of fascia covering the anterior surface of the Quadratus lumborum, and attached, internally, to the bases of the transverse processes of the lumbar vertebræ; below, to the ilio-lumbar ligament; above, to the apex and lower border of the last rib.

The upper margin of this fascia, which extends from the transverse process of the first lumbar vertebra to the apex and lower border of the last rib, constitutes the ligamentum arcuatum externum (page 502).

The **Quadratus lumborum** (fig. 499, page 495) is situated in the lumbar region. It is irregularly quadrilateral in shape, and broader below than above. It arises by aponeurotic fibres from the ilio-lumbar ligament and the adjacent portion of the crest of the ilium for about two inches, and is inserted into the lower border of the last rib for about half its length, and by four small tendons into the apices of the transverse processes of the upper four lumbar vertebræ. Occasionally a second portion of this muscle is found in front of the preceding. It arises from the upper borders of the transverse processes of the lower three or four lumbar vertebræ, and is inserted into the lower margin of the last rib. The Quadratus lumborum is contained in a sheath formed by the anterior and middle lamellæ of the lumbar aponeurosis, in front of which are the colon, the kidney, the Psoas, and the Diaphragm; between the fascia and the muscle are the last thoracic, ilio-inguinal, and ilio-hypogastric nerves.

Nerve-supply.—The last thoracic and first and second lumbar nerves supply this muscle.

Actions.—The Quadratus lumborum draws down the last rib, and acts as a muscle of inspiration by helping to fix the origin of the Diaphragm. If the thorax and spine are fixed, it may act upon the pelvis, raising it towards its own side when only one muscle is put in action; and when both muscles act together, either from below or above, they flex the trunk.

IV. Muscles and Fasciæ of the Pelvis

Obturator internus.	Levator ani.
Pyriformis.	Coccygeus.

The muscles within the pelvis may be divided into two groups: (1) the Obturator internus and the Pyriformis, which are muscles of the lower extremity, and will be described with these (page 575); (2) the Levator ani and the Coccygeus, which together form the *pelvic diaphragm* and are associated with the pelvic viscera. The classification of the two groups under a common heading is convenient in connection with the fasciæ investing the muscles. These fasciæ are closely related to one another and to the deep fascia of the perinæum, and in addition have special connections with the fibrous coverings of the pelvic viscera; it is customary therefore to describe them together under the term *pelvic fascia*.

Pelvic fascia.—The fascia of the pelvis may be resolved into: (A) the fascial sheaths of the Obturator internus, Pyriformis, and pelvic diaphragm; (B) the fascia associated with the pelvic viscera.

The *fascia of the Obturator internus* covers the pelvic surface of, and is attached round the margin of the origin of, the muscle. Above, it is loosely connected to the back part of the ilio-pectineal line, and here it is continuous with the iliac fascia. In front of this, as it follows the line of origin of the Obturator internus, it gradually separates from the iliac fascia and the continuity between the two is retained only through the periosteum. It arches

beneath the obturator vessels and nerve, completing the obturator canal, and at the front of the pelvis is attached to the back of the body of the pubis. Below, the obturator fascia is attached to the falciform process of the great sacro-sciatic ligament and to the pubic arch where it becomes continuous with the deep layer of the fascial sheath of the Compressor urethræ (deep layer of the triangular ligament). Behind, it is prolonged out on the Obturator internus into the gluteal region.

The pudic vessels and nerve cross the pelvic surface of the Obturator internus and are enclosed in a special canal—*Alcock's canal*—formed by the obturator fascia.

The *fascia of the Pyriformis* is very thin and is attached to the front of the sacrum and the sides of the great sacro-sciatic foramen; it is prolonged out on the muscle into the gluteal region. At its sacral attachment round the margins of the anterior sacral foramina it comes into intimate association with and ensheathes the nerves emerging from these foramina. Hence the sacral nerves are frequently described as lying behind the fascia. The internal iliac vessels and their branches, on the other hand, lie in the subperitoneal

Fig. 511.—Coronal section of pelvis, showing arrangement of fasciæ from behind.

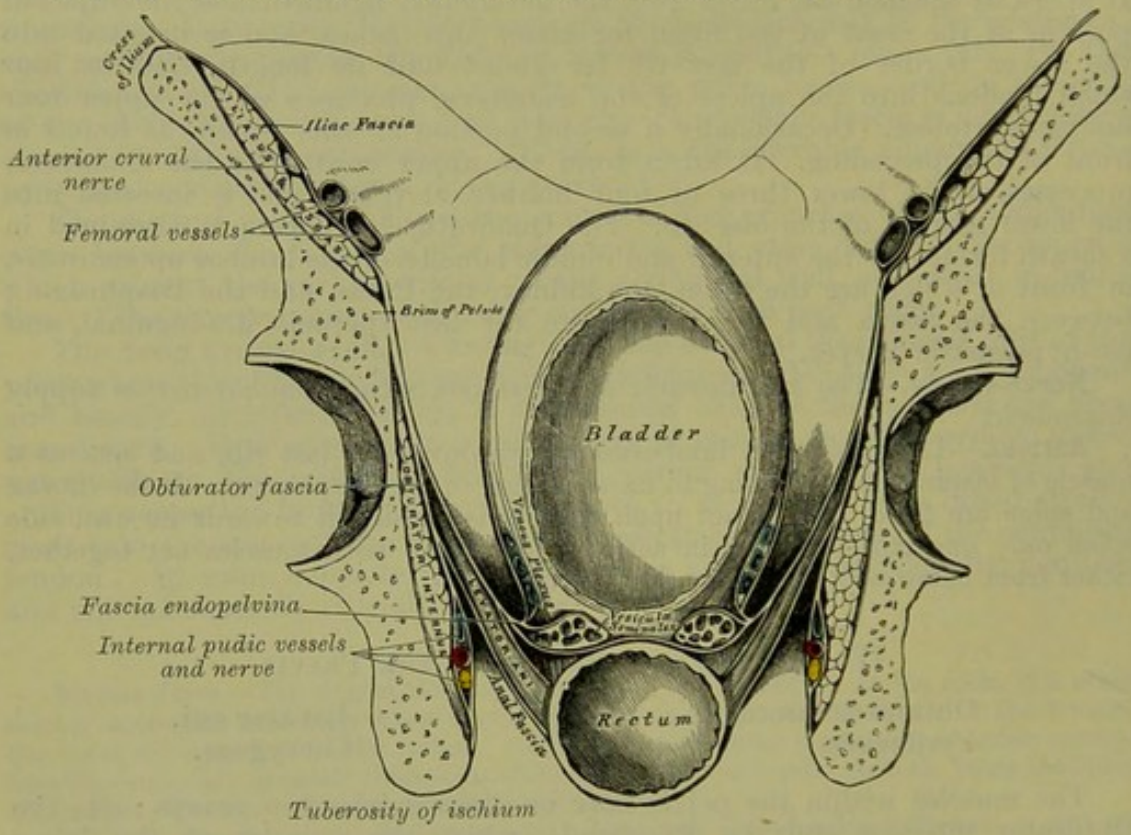

tissue in front of the fascia, and the branches to the gluteal region emerge in special sheaths of this tissue, above and below the Pyriformis muscle.

The *fascia of the pelvic diaphragm* covers both surfaces of the muscles. The layer covering the lower surface (fascia inferior diaphragmatis pelvis) is known as the *anal fascia*. It is attached above to the obturator fascia along the line of origin of the Levator ani, while below it is continuous with the deep layer of the triangular ligament and with the fascia on the Internal sphincter ani. The layer covering the upper surface of the pelvic diaphragm (pars diaphragmatica fasciæ pelvis) follows, above, the line of origin of the Levator ani and is therefore somewhat variable. In front it is attached to the back of the symphysis pubis about three-quarters of an inch above its lower border. It can then be traced outwards across the back of the body of the pubis for a distance of about half an inch, when it reaches the obturator fascia. It is attached to this fascia along a line which pursues a somewhat irregular course to the spine of the ischium. The irregularity of this line is due to the fact that the origin of the Levator ani, which in lower forms is from the pelvic brim, is in man lower down, on the obturator fascia. Tendinous fibres of origin

of the muscle are therefore often found extending up towards, and in some cases reaching, the pelvic brim, and on these the fascia is carried.

It will be evident that the fascia covering that part of the Obturator internus above the origin of the Levator ani is a composite fascia and includes the following: (*a*) the obturator fascia; (*b*) the fascia of the Levator ani; (*c*) degenerated fibres of origin of the Levator ani. This portion was formerly described as *the* pelvic fascia.

The lower margin of the fascia covering the upper surface of the pelvic diaphragm is attached along the line of insertion of the muscle.

At the level of a line extending from the lower part of the symphysis pubis to the spine of the ischium is a thickened whitish band in this upper layer of the pelvic diaphragmatic fascia. It is termed the *white line* (arcus tendineus fasciæ pelvis), and marks the line of attachment of the special fascia (pars endopelvina fasciæ pelvis) which is associated with the pelvic viscera.

The *fascia endopelvina* is to be regarded as a thickening of the subperitoneal tissue round the various pelvic viscera, to form for them fibrous coverings

Fig. 512.—Side view of pelvic viscera of the male subject, showing the fascia endopelvina.

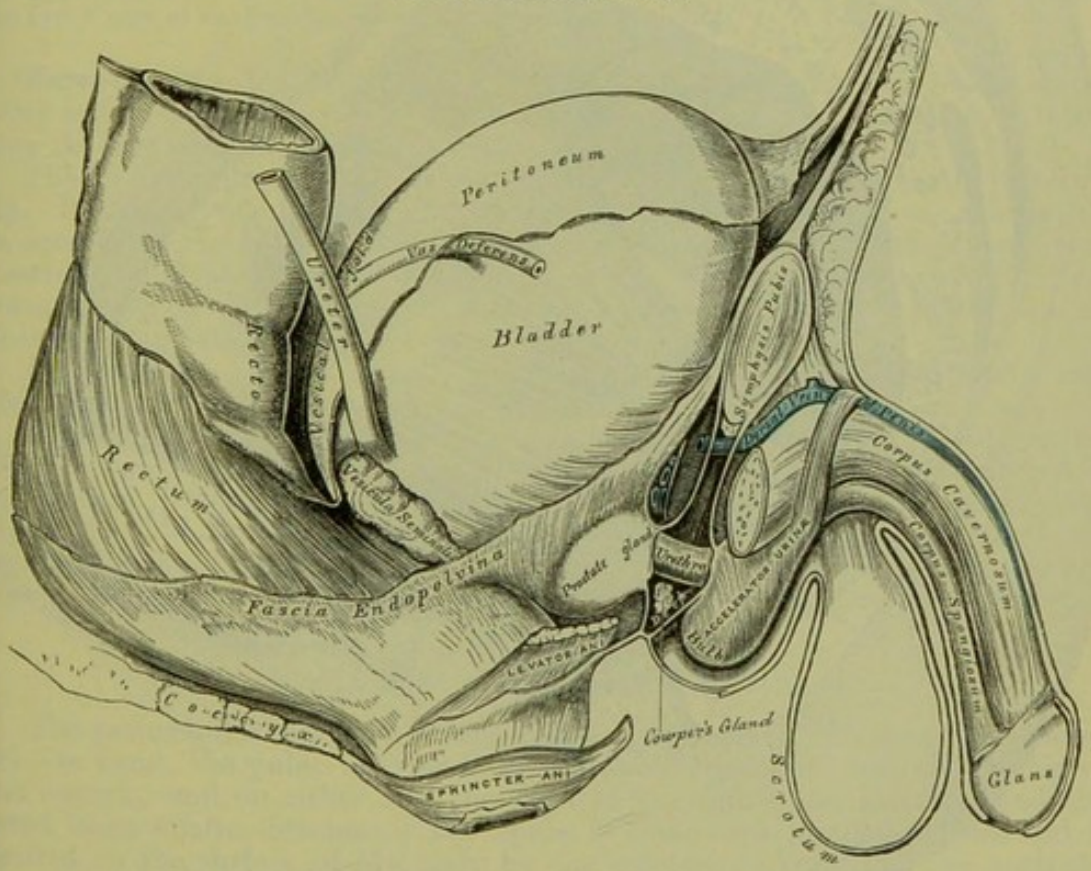

which will be described later (see section on Splanchnology). It is attached to the fascia on the upper surface of the pelvic diaphragm along the white line, and has been subdivided in accordance with the viscera to which it is related. Thus its anterior part, known as the *vesical layer*, forms the anterior and lateral ligaments of the bladder. Its middle part crosses the floor of the pelvis between the rectum and vesiculæ seminales as the *recto-vesical layer*; in the female this is perforated by the vagina. Its posterior portion passes to the side of the rectum; it forms a loose sheath for the rectum, but is firmly attached round the anal canal; this portion is known as the *rectal layer*.

The **Levator ani** (fig. 513) is a broad, thin muscle, situated on the side of the pelvis. It is attached to the inner surface of the side of the true pelvis, and descends to unite with its fellow of the opposite side and form the greater part of the floor of the pelvic cavity. It supports the viscera in this cavity and surrounds the various structures which pass through it. It arises, in front, from the posterior surface of the body of the pubis on the outer side

of the symphysis ; behind, from the inner surface of the spine of the ischium ; and between these two points, from the obturator fascia. Posteriorly, this fascial origin corresponds, more or less closely, with the white line (page 519), but in front, the muscle arises from the fascia at a varying distance above the white line, in some cases reaching nearly as high as the canal for the obturator vessels and nerve. The fibres pass downwards to the middle line of the floor of the pelvis ; the most posterior are inserted into the sides of the last two segments of the coccyx ; those placed more anteriorly unite with the muscle of the opposite side, in a median fibrous raphe (*ano-coccygeal raphe*), which extends between the coccyx and the margin of the anus. The

Fig. 513.—Left levator ani from within.

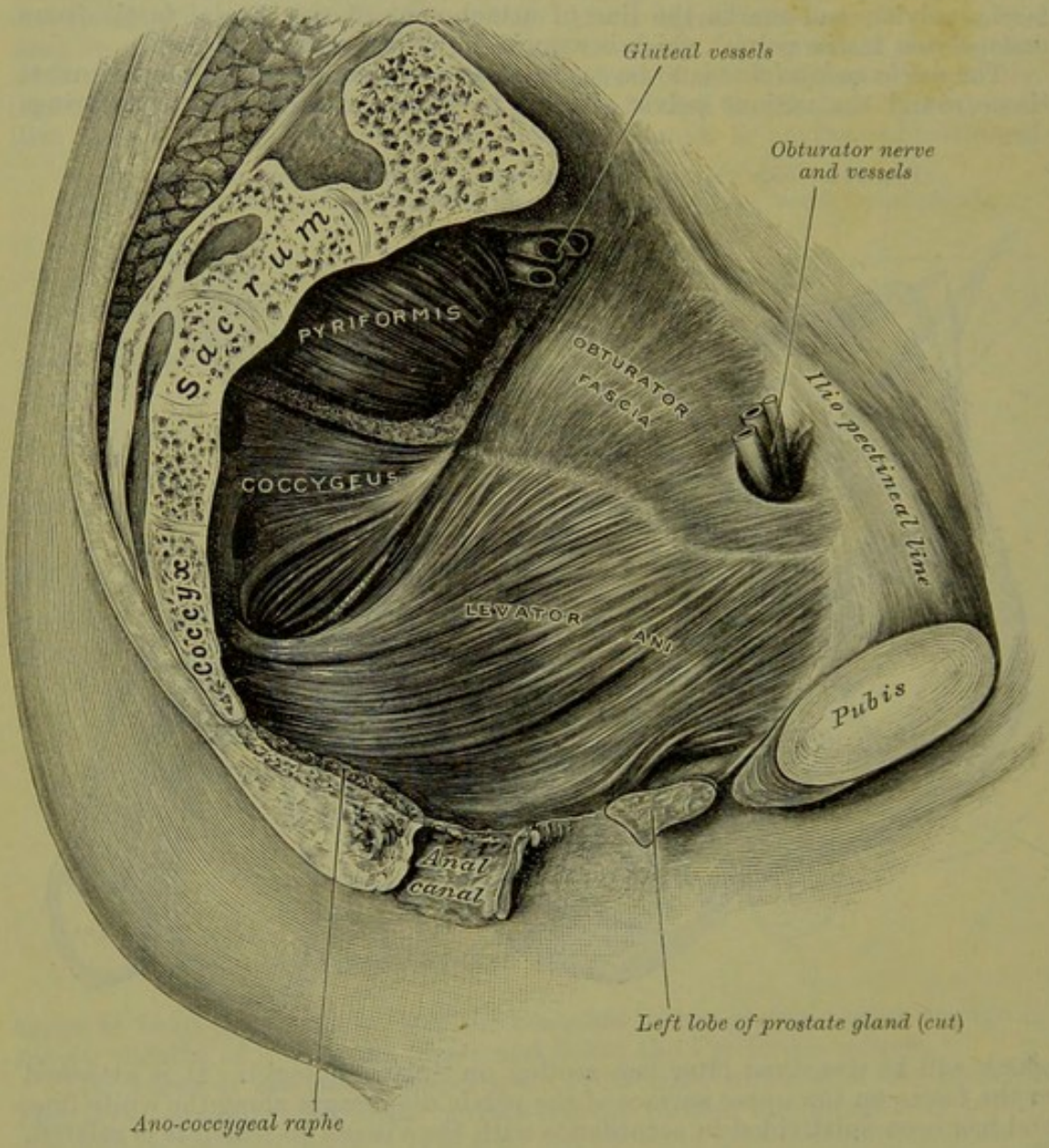

middle fibres are inserted into the side of the rectum, blending with the fibres of the Sphincter muscles ; lastly, the anterior fibres descend upon the side of the prostate gland to unite beneath it with the muscle of the opposite side, joining with the fibres of the External sphincter and Transversus perinæi muscles at the central tendinous point of the perinæum.

The anterior portion is occasionally separated from the rest of the muscle by connective tissue. From this circumstance, as well as from its peculiar relation with the prostate gland, descending by its side, and surrounding it as in a sling, it has been described by Santorini and others as a distinct muscle, under the name of *Levator prostatæ*. In the female the anterior fibres of the Levator ani descend upon the side of the vagina.

Relations.—By its *upper* or *pelvic surface*, with the fascia which separates it from the bladder, prostate, rectum, and peritoneum. By its *lower* or *perineal surface*, it forms the inner boundary of the ischio-rectal fossa, and is covered by a thin layer of fascia, the *ischio-rectal* or *anal fascia*, given off from the obturator fascia. Its *posterior border* is free and separated from the Coccygeus muscle by a cellular interspace. Its *anterior border* is separated from the muscle of the opposite side by a triangular space, through which the urethra, and in the female the vagina, pass from the pelvis.

The Levator ani may be divided into ilio-coccygeal and pubo-coccygeal parts.

The *Ilio-coccygeus* arises from the ischial spine and from the posterior part of the pelvic fascia, and is attached to the coccyx and ano-coccygeal raphe: it is usually thin, and may fail entirely, or be largely replaced by fibrous tissue. An accessory slip at its posterior part is sometimes named the *Ilio-sacralis*. The *Pubo-coccygeus* arises from the back of the pubis and from the anterior part of the obturator fascia, and 'is directed backwards almost horizontally along the side of the anal canal towards the coccyx and sacrum, to which it finds attachment. Between the termination of the vertebral column and the anus, the two pubo-coccygei muscles come together and form a thick, fibro-muscular layer lying on the raphe formed by the Ilio-coccygei' (Thompson). The greater part of this muscle is inserted into the coccyx and into the last one or two pieces of the sacrum. This insertion into the vertebral column is, however, not admitted by all observers. The fibres which form a sling for the rectum are named the *Pubo-rectalis* or *Sphincter recti*. They arise from the lower part of the symphysis pubis, and from the upper layer of the triangular ligament. They meet with the corresponding fibres of the opposite side around the lower part of the rectum, and form for it a strong sling.

Nerve-supply.—The Levator ani is supplied by a branch from the fourth sacral nerve and by a branch which is sometimes derived from the perineal, sometimes from the inferior hæmorrhoidal division of the pudic nerve.

The **Coccygeus** (fig. 513) is situated behind and parallel with the preceding. It is a triangular plane of muscular and tendinous fibres, arising by its apex from the spine of the ischium and lesser sacro-sciatic ligament, and inserted by its base into the margin of the coccyx and into the side of the lowest piece of the sacrum. It assists the Levator ani and Pyriformis in closing in the back part of the outlet of the pelvis.

Nerve-supply.—The Coccygeus is supplied by a branch from the fourth and fifth sacral nerves.

Actions.—The Levatores ani constrict the lower end of the rectum and vagina. They elevate and invert the lower end of the rectum after it has been protruded and everted during the expulsion of the fæces. They are also muscles of forced expiration. The Coccygei muscles pull forward and support the coccyx, after it has been pressed backwards during defæcation or parturition. The Levatores ani and Coccygei together form a muscular diaphragm which supports the pelvic viscera.

V. Muscles and Fasciæ of the Perinæum

The perinæum corresponds to the outlet of the pelvis. Its deep boundaries are—in front, the pubic arch and the subpubic ligament; behind, the tip of the coccyx; and on either side the rami of the pubis and ischium, and the great sacro-sciatic ligament. The space is somewhat lozenge-shaped and is limited on the surface of the body by the scrotum in front, by the buttocks behind, and on either side by the inner side of the thigh. A line drawn transversely across in front of the ischial tuberosities divides the space into two portions. The posterior contains the termination of the anal canal and is known as the *ischio-rectal* or *anal region*; the anterior, which contains the external urogenital organs, is termed the *urogenital region*.

The muscles of the perinæum may therefore be divided into two groups:

1. Those of the ischio-rectal region.
2. Those of the urogenital region: A, In the male; B, In the female.

1. Muscles and Fasciæ of the Ischio-rectal Region

Corrugator cutis ani. External sphincter ani. Internal sphincter ani.

The **superficial fascia** is very thick, areolar in texture, and contains much fat in its meshes. On either side a pad of fatty tissue extends deeply between

the Levator ani and Obturator internus into a space known as the *ischio-rectal fossa*.

The **deep fascia** forms the lining of the ischio-rectal fossa ; it comprises the anal fascia, and the portion of obturator fascia below the origin of Levator ani.

Ischio-rectal fossa.—The fossa is somewhat prismatic in shape, with its base directed to the surface of the perinæum, and its apex at the line of meeting of the obturator and anal fasciæ. It is bounded internally by the External sphincter ani, and the anal fascia ; externally by the tuberosity of the ischium and the obturator fascia ; anteriorly by the fascia of Colles covering the transversus perinæi, and by the deep layer of the triangular ligament ; posteriorly by the Gluteus maximus and the great sacro-sciatic ligament. Crossing the space transversely are the inferior hæmorrhoidal vessels and nerves ; at the back part are the perineal and perforating cutaneous branches of the pudendal plexus ; while from the fore part the superficial perineal vessels and nerves emerge. The internal pudic vessels and nerve lie in Alcock's canal on the external wall. The fossa is filled with fatty tissue across which numerous fibrous bands extend from side to side.

Applied Anatomy.—Abscess in the ischio-rectal fossa commonly occurs ; it is most often the result of infection from the bowel, and is especially prone to occur in tuberculous subjects ; occasionally it follows perforation by a foreign body which has been swallowed, such as a fish bone. The abscess may bulge at the side of the anus, at the border of Gluteus maximus, or against the rectal wall. There is great pain on defæcation, and, on examining the bowel, fulness on the side of the abscess may be detected. If left to itself the pus will find exit through the skin, or into the rectum, between the two Sphincters ; and the condition will degenerate into one of the varieties of fistula, owing to the constant pull of the Sphincter preventing closure of the walls of the cavity. These abscesses should be opened at the earliest possible moment, as they tend to track and burrow widely into the soft fat in the fossa, and also in the subcutaneous tissues. An incision should be made tangential to the anus over the region of the ischio-rectal fossa, and should then be converted into a T, by making another incision outwards at right angles to it, so that the wound may be kept open and may heal up from the bottom. Frequently, however, in spite of care, a fistula ensues which requires division of the External sphincter for its cure.

The **Corrugator cutis ani.**—Around the anus is a thin stratum of involuntary muscular fibre, which radiates from the orifice. Internally, the fibres fade off into the submucous tissue, while externally they blend with the true skin. By its contraction it raises the skin into ridges around the margin of the anus.

The **Sphincter ani externus** (fig. 514) is a thin, flat plane of muscular fibres, elliptical in shape and intimately adherent to the integument surrounding the margin of the anus. It measures about three or four inches in length, from its anterior to its posterior extremity, being about an inch in breadth, opposite the anus. It consists of two strata, superficial and deep. The *superficial*, constituting the main portion of the muscle, arises from a narrow tendinous band, the *ano-coccygeal raphe*, which stretches from the tip of the coccyx to the posterior margin of the anus ; it forms two flattened planes of muscular tissue, which encircle the anus and meet in front to be inserted into the central tendinous point of the perinæum, joining with the Transversus perinæi, the Levator ani, and the Accelerator urinæ. The *deeper portion* forms a complete sphincter to the anal canal. Its fibres surround the canal, closely applied to the Internal sphincter, and in front blend with the other muscles at the central point of the perinæum. In a considerable proportion of cases the fibres decussate in front of the anus, and are continuous with the Transversus perinæi. Posteriorly, they are not attached to the coccyx, the fibres of opposite sides being continuous behind the anal canal. The upper edge of the muscle is ill-defined, since fibres are given off from it to join the Levator ani.

Nerve-supply.—A branch from the fourth sacral and twigs from the inferior hæmorrhoidal branch of the internal pudic supply the muscle.

Actions.—The action of this muscle is peculiar. 1. It is, like other muscles, always in a state of tonic contraction, and having no antagonistic muscle it keeps the anal canal and orifice closed. 2. It can be put into a condition of greater contraction under the influence of the will, so as more firmly to occlude the anal aperture in expiratory efforts, unconnected with defæcation. 3. Taking its fixed

point at the coccyx, it helps to fix the central point of the perinæum, so that the Accelerator urinæ may act from this fixed point.

The **Sphincter ani internus** is a muscular ring which surrounds the anal canal for about an inch ; its inferior border being contiguous with, but quite separate from, the External sphincter. This muscle is about a sixth of an inch in thickness, and is formed by an aggregation of the involuntary circular fibres of the intestine. Its lower border is about a quarter of an inch from the external orifice. It is paler in colour and less coarse in texture than the External sphincter.

Actions.—Its action is entirely involuntary. It helps the External sphincter to occlude the anal aperture.

2. A. Muscles and Fasciæ of the Urogenital Region in the Male (figs. 514, 515)

Transversus perinæi.	Erector penis.
Accelerator urinæ.	Compressor urethræ.

Superficial fascia.—The superficial fascia of this region consists of two layers, superficial and deep.

The *superficial layer* is thick, loose, areolar in texture, and contains in its meshes much adipose tissue, the amount of which varies in different subjects. In front, it is continuous with the dartos of the scrotum ; behind, it is continuous with the subcutaneous areolar tissue surrounding the anus ; and,

Fig. 514.—The perinæum.
The integument and superficial layer of superficial fascia reflected.

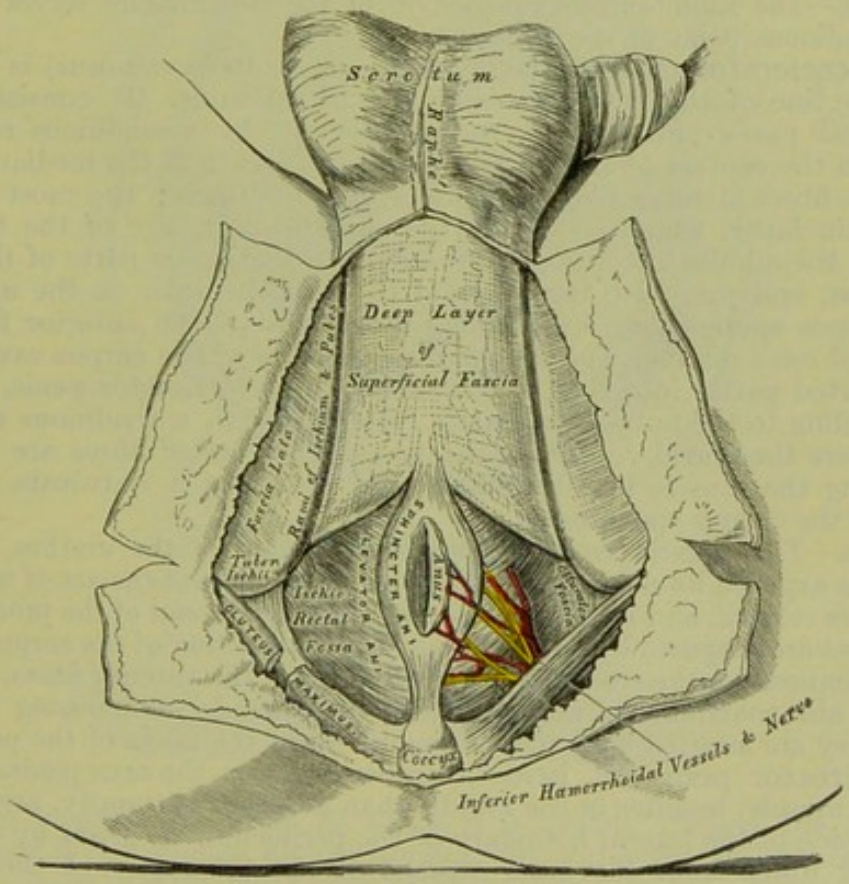

on either side, with the same fascia on the inner sides of the thighs. In the middle line, it is adherent to the skin of the raphe and to the deep layer of the superficial fascia.

The *deep layer of superficial fascia* (fascia of Colles) (fig. 514) is thin, aponeurotic in structure, and of considerable strength, serving to bind down the muscles of the root of the penis. It is continuous, in front, with the dartos of the scrotum, the deep fascia of the penis, the fascia of the spermatic

cord, and Scarpa's fascia upon the anterior wall of the abdomen; on either side it is firmly attached to the margins of the rami of the pubis and ischium, external to the crus penis and as far back as the tuberosity of the ischium; posteriorly, it curves round the Transversus perinæi muscles to join the lower margin of the triangular ligament. In the middle line, it is connected with the superficial fascia and with the median septum of the Accelerator urinæ muscle. This fascia not only covers the muscles in this region, but sends upwards a vertical septum from its deep surface, which separates the back part of the subjacent space into two, the septum being incomplete in front.

The central tendinous point of the perinæum.—This is a fibrous point in the middle line of the perinæum, between the urethra and the rectum, and about half an inch in front of the anus. At this point six muscles converge and are attached: viz. the External sphincter ani, the Accelerator urinæ, the two Transversi perinæi, and the anterior fibres of the Levatores ani; so that by the contraction of these muscles, which extend in different directions, it serves as a fixed point of support.

The **Transversus perinæi** is a narrow muscular slip, which passes more or less transversely across the perineal space in front of the anus. It arises by tendinous fibres from the inner and fore part of the tuberosity of the ischium, and, running inwards, is inserted into the central tendinous point of the perinæum, joining in this situation with the muscle of the opposite side, with the External sphincter ani behind, and with the Accelerator urinæ in front. In some cases, the fibres of the deeper layer of the Sphincter ani decussate in front of the anus and are continued into this muscle. Occasionally it gives off fibres, which join with the Accelerator urinæ of the same side.

Nerve-supply.—It is supplied by the perineal branch of the internal pudic.

Actions.—The simultaneous contraction of the two muscles serves to fix the central tendinous point of the perinæum.

The **Accelerator** or **Ejaculator urinæ** (m. bulbocavernosus) is placed in the middle line of the perinæum, in front of the anus. It consists of two symmetrical parts, united along the median line by a tendinous raphe. It arises from the central tendon of the perinæum and from the median raphe in front. Its fibres diverge like the plumes of a quill-pen; the most posterior form a thin layer, which is lost on the superficial surface of the triangular ligament; the middle fibres encircle the bulb and adjacent parts of the corpus ~~spongiosum~~, and join with the fibres of the opposite side, on the upper part of the ~~corpus spongiosum~~, in a strong aponeurosis; the anterior fibres, the longest and most distinct, spread out over the side of the corpus cavernosum to be inserted partly into that body, anterior to the ~~Erector penis~~, occasionally extending to the pubis, and partly terminating in a tendinous expansion which covers the dorsal vessels of the penis. The latter fibres are best seen by dividing the muscle longitudinally, and reflecting it outwards from the surface of the corpus spongiosum.

Actions.—This muscle serves to empty the canal of the urethra, after the bladder has expelled its contents; during the greater part of the act of micturition its fibres are relaxed, and it only comes into action at the end of the process. The middle fibres are supposed by Krause to assist in the erection of the corpus spongiosum, by compressing the erectile tissue of the bulb. The anterior fibres, according to Tyrrel, also contribute to the erection of the penis by compressing the dorsal vein, as they are inserted into, and continuous with, the fascia of the penis.

The **Erector penis** (m. ischiocavernosus) covers the crus penis. It is an elongated muscle, broader in the middle than at either extremity, and situated on either side of the lateral boundary of the perinæum. It arises by tendinous and fleshy fibres from the inner surface of the tuberosity of the ischium, behind the crus penis; and from the rami of the pubis and ischium on either side of the crus. From these points fleshy fibres succeed, and end in an aponeurosis which is inserted into the sides and under surface of the crus penis.

Nerve-supply.—The Erector penis is supplied by the perineal branch of the internal pudic.

Action.—The Erector penis compresses the crus penis, and retards the return of the blood through the veins, and thus serves to maintain the organ erect.

Between the muscles just examined a triangular space exists, bounded internally by the Accelerator urinæ, externally by the Erector penis, and behind by the Transversus perinæi. The floor of this space is formed by the triangular ligament of the urethra (deep perineal fascia), and running from behind forwards in it are the superficial perineal vessels and nerves, and the long pudendal nerve. The transverse perineal artery courses along the posterior boundary of the space on the Transversus perinæi.

The **deep fascia** of the urogenital region forms an investment for the Compressor urethræ, but within it lie also the deep vessels and nerves of this part, the whole forming a transverse septum which is known as the

FIG. 515.—Muscles of male perinæum.

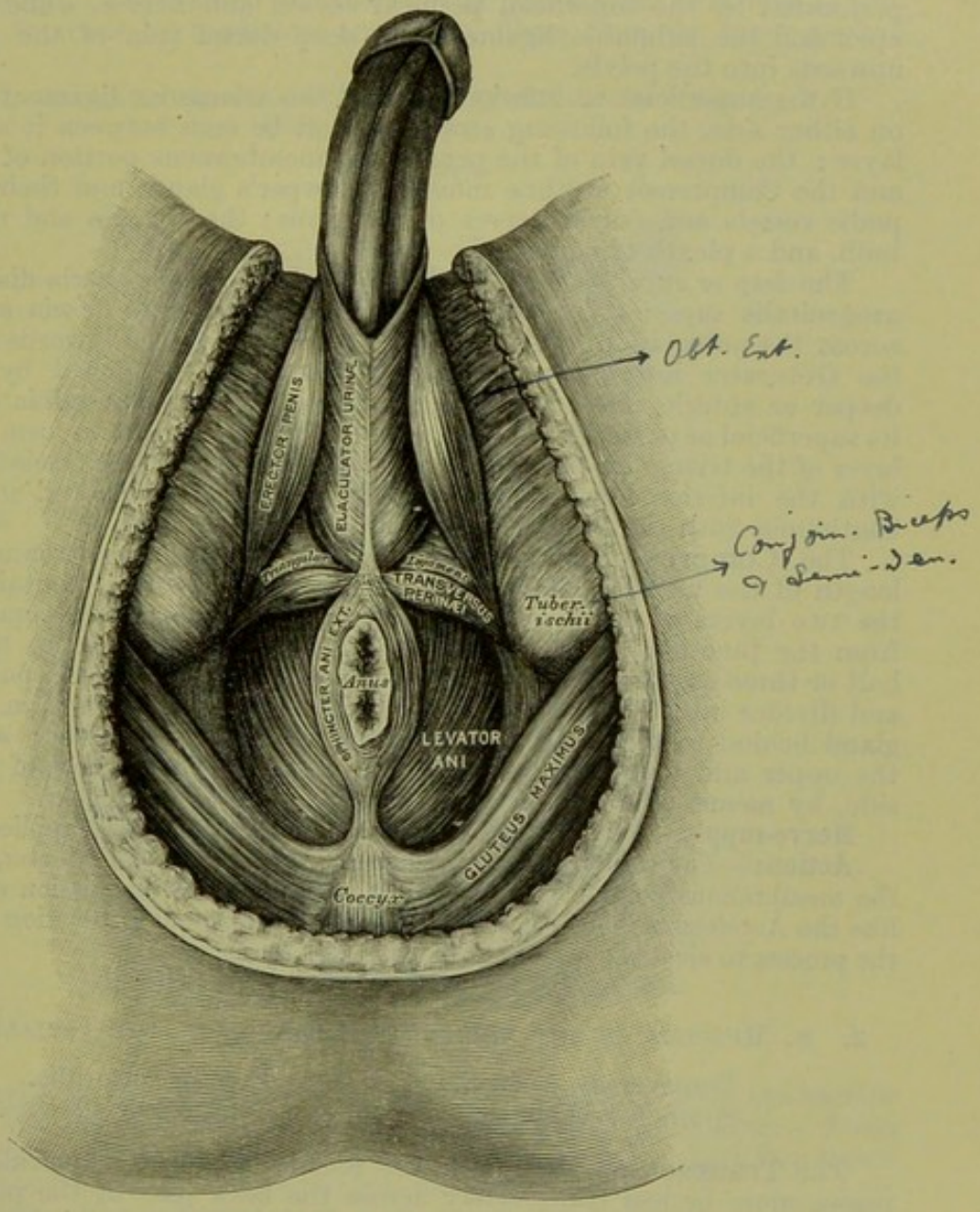

diaphragma urogenitale. From its shape it is usually termed the *triangular ligament*, and it is stretched almost horizontally across the pubic arch, so as to close in the front part of the outlet of the pelvis. It consists of two dense membranous laminæ, which are united along their posterior borders, but are separated in front by intervening structures. The superficial of these two layers, the *inferior layer of the triangular ligament* (fascia diaphragmatica urogenitalis inferior), is triangular in shape, and about an inch and a half in depth. Its apex is directed forwards, and is separated from the subpubic ligament by an oval opening for the transmission of the dorsal vein of the penis. Its lateral margins are attached on either side to the rami of the pubis and

ischium, above the crus penis. Its base is directed towards the rectum, and connected to the central tendinous point of the perinæum. It is continuous with the deep layer of the superficial fascia behind the Transversus perinæi muscle, and with a thin fascia which covers the under surface of the Levator ani muscle (*anal fascia*).

This layer of the triangular ligament is perforated, about an inch below the symphysis pubis, by the urethra, the aperture for which is circular in form and about a quarter of an inch in diameter; by the arteries to the bulb and the ducts of Cowper's glands close to the urethral orifice; by the arteries to the corpora cavernosa—one on either side close to the pubic arch and about halfway along the attached margin of the ligament; by the dorsal arteries and nerves of the penis near the apex of the ligament. Its base is also perforated by the superficial perineal vessels and nerves, while between its apex and the subpubic ligament the deep dorsal vein of the penis passes upwards into the pelvis.

If the superficial or inferior layer of the triangular ligament be detached on either side, the following structures will be seen between it and the deep layer: the dorsal vein of the penis; the membranous portion of the urethra, and the Compressor urethræ muscle; Cowper's glands and their ducts; the pudic vessels and dorsal nerves of the penis; the arteries and nerves of the bulb, and a plexus of veins.

The *deep or superior layer of the triangular ligament* (fascia diaphragmatica urogenitalis superior) is continuous with the obturator fascia and stretches across the pubic arch. If the obturator fascia be traced inwards after leaving the Obturator internus muscle, it will be found attached by some of its deeper or anterior fibres to the inner margin of the ischio-pubic ramus, while its superficial or posterior fibres pass over this attachment to form the superior layer of the triangular ligament. Behind, this layer of the fascia is continuous with the inferior layer and with the fascia of Colles, and in front it is continuous with the fascial sheath of the prostate gland.

The **Compressor urethræ** (m. constrictor urethræ) surrounds the whole length of the membranous portion of the urethra, and is contained between the two layers of the triangular ligament. It arises by aponeurotic fibres from the junction of the rami of the pubis and ischium, to the extent of half or three-quarters of an inch: each segment of the muscle passes inwards, and divides into two fasciculi, which surround the urethra from the prostate gland behind to the bulbous portion of the urethra in front; and unite, at the upper and lower surfaces of this tube, with the muscle of the opposite side, by means of a tendinous raphe.

Nerve-supply.—The perineal branch of the internal pudic supplies this muscle.

Actions.—The muscles of both sides act together as a sphincter, compressing the membranous portion of the urethra. During the transmission of fluids they, like the Acceleratores urinæ, are relaxed, and only come into action at the end of the process to eject the last drops of the fluid.

2. B. Muscles of the Urogenital Region in the Female (fig. 516)

Transversus perinæi.	Erector clitoridis.
Sphincter vaginæ.	Compressor urethræ.

The **Transversus perinæi** in the female is a narrow muscular slip, which passes more or less transversely across the back part of the perineal space. It arises by a small tendon from the inner and fore part of the tuberosity of the ischium, and, passing inwards, is inserted into the central point of the perinæum, joining in this situation with the muscle of the opposite side, the External sphincter ani behind, and the Sphincter vaginæ in front.

Nerve-supply.—This muscle is supplied by the perineal branch of the internal pudic.

Action.—The simultaneous contraction of the two muscles serves to fix the central tendinous point of the perinæum.

The **Sphincter vaginæ** (m. bulbocavernosus) surrounds the orifice of the vagina, and is homologous with the Accelerator urinæ in the male. It covers the outer aspect of the vestibular bulbs, and is attached posteriorly

to the central tendinous point of the perinæum, where it blends with the External sphincter ani. Its fibres pass forwards on either side of the vagina, to be inserted into the corpora cavernosa of the clitoris, a fasciculus crossing over the body of the organ so as to compress the dorsal vein.

Nerve-supply.—It is supplied by the perineal branch of the internal pudic.

Actions.—The Sphincter vaginæ diminishes the orifice of the vagina. The anterior fibres contribute to the erection of the clitoris, as they are inserted into and are continuous with the fascia of the clitoris, compressing the dorsal vein during the contraction of the muscle.

The **Erector clitoridis** (m. ischiocavernosus) corresponds with the Erector penis in the male, but is smaller. It covers the unattached surface of the crus clitoridis. It is an elongated muscle, broader at the middle than at either extremity, and situated on the side of the lateral boundary of the perinæum. It arises by tendinous and fleshy fibres from the inner surface

Fig. 516.—Muscles of the female perinæum. (Modified from a drawing by Peter Thompson.)

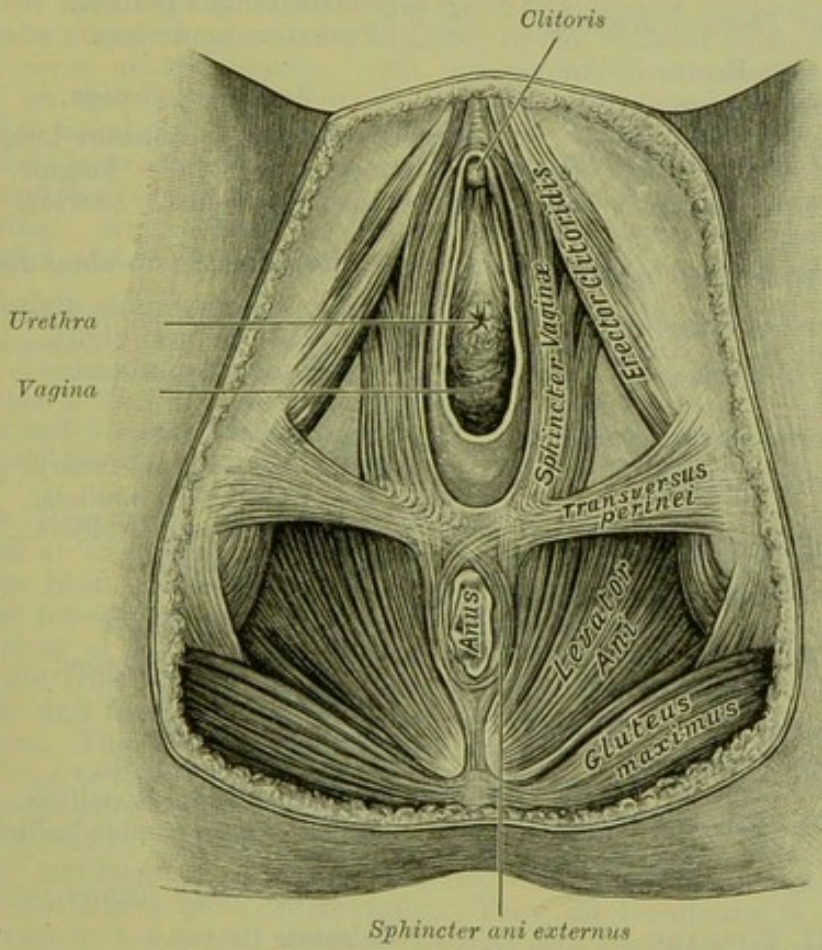

of the tuberosity of the ischium, behind the crus clitoridis ; from the surface of the crus ; and from the adjacent portion of the ramus of the ischium. From these points fleshy fibres succeed, and end in an aponeurosis, which is inserted into the sides and under surface of the crus clitoridis.

Nerve-supply.—The perineal branch of the internal pudic supplies this muscle.

Actions.—The Erector clitoridis compresses the crus clitoridis and retards the return of blood through the veins, and thus serves to maintain the organ erect.

The **triangular ligament** in the female is not so strong as in the male. It is attached to the pubic arch, its apex being connected with the subpubic ligament. It is divided in the middle line by the aperture of the vagina, with the external coat of which it becomes blended, and in front of this is perforated by the urethra. Its posterior border is continuous, as in the male, with the deep layer of the superficial fascia around the Transversus perinæi muscle.

Like the triangular ligament in the male, it consists of two layers, between which are to be found the following structures : the dorsal vein of the clitoris,

a portion of the urethra and the Compressor urethræ muscle, the glands of Bartholin and their ducts; the pudic vessels and the dorsal nerves of the clitoris; the arteries and nerves of the bulbi vestibuli, and a plexus of veins.

The **Compressor urethræ** (m. constrictor urethræ) arises on either side from the margin of the descending ramus of the pubis. The fibres, passing inwards, divide into two sets: those of the fore part of the muscle are directed across the subpubic arch in front of the urethra to blend with the muscular fibres of the opposite side; while those of the hinder and larger part pass inwards to blend with the wall of the vagina behind the urethra.

Nerve-supply.—It is supplied by the perineal branch of the internal pudic.

MUSCLES AND FASCIÆ OF THE UPPER EXTREMITY

The muscles of the upper extremity are divisible into groups, corresponding with the different regions of the limb.

I. Thoracic Region

1. *Anterior Thoracic Region.*

Pectoralis major. Pectoralis minor. Subclavius.

2. *Lateral Thoracic Region.*

Serratus magnus.

II. Shoulder and Arm

3. *Acromial Region.*

Deltoid.

4. *Anterior Scapular Region.*

Subscapularis.

5. *Posterior Scapular Region.*

Supraspinatus. Infraspinatus. Teres minor. Teres major.

6. *Anterior Humeral Region.*

Coraco-brachialis. Biceps. Brachialis anticus.

7. *Posterior Humeral Region.*

Triceps. Subanconeus.

III. Forearm

8. *Anterior Radio-ulnar Region.*

Superficial Layer.
- Pronator teres.
- Flexor carpi radialis.
- Palmaris longus.
- Flexor carpi ulnaris.
- Flexor sublimis digitorum.

Deep Layer.
- Flexor profundus digitorum.
- Flexor longus pollicis.
- Pronator quadratus.

9. *Radial Region.*

Brachio-radialis (Supinator longus).
Extensor carpi radialis longior.
Extensor carpi radialis brevior.

10. *Posterior Radio-ulnar Region.*

Superficial Layer.
- Extensor communis digitorum.
- Extensor minimi digiti.
- Extensor carpi ulnaris.
- Anconeus.

Deep Layer.
- Supinator brevis.
- Extensor ossis metacarpi pollicis.
- Extensor brevis pollicis.
- Extensor longus pollicis.
- Extensor indicis.

IV. Hand

11. *Radial Region.*

Abductor pollicis.
Opponens pollicis.
Flexor brevis pollicis.
Adductor obliquus pollicis.
Adductor transversus pollicis.

12. *Ulnar Region.*

Palmaris brevis.
Abductor minimi digiti.
Flexor brevis minimi digiti.
Opponens minimi digiti.

13. *Middle Palmar Region.*

Lumbricales. Interossei palmares. Interossei dorsales.

I. Muscles and Fasciæ of the Thoracic Region

1. *Anterior Thoracic Region*

Pectoralis major. Pectoralis minor. Subclavius.

The **superficial fascia** of the anterior thoracic region is a loose cellulo-fibrous layer, enclosing masses of fat in its spaces. It is continuous with the

superficial fascia of the neck and upper extremity above, and of the abdomen below. Opposite the mamma it divides into two layers, one of which passes in front of, the other behind that gland; from both layers numerous septa pass into the gland, supporting its various lobes: from the anterior layer, fibrous processes pass forwards to the integument and nipple. These processes were called by Sir A. Cooper the *ligamenta suspensoria*, from the support they afford to the gland in this situation.

The **deep fascia** of the anterior thoracic region (fascia pectoralis) is a thin lamina, covering the surface of the Pectoralis major, and sending numerous prolongations between its fasciculi: it is attached, in the middle line, to the front of the sternum; above, to the clavicle; externally and below it becomes continuous with the fascia over the shoulder, axilla, and thorax. It is very thin over the upper part of the Pectoralis major muscle, thicker in the interval between it and the Latissimus dorsi, where it closes in the axillary space, and forms the *fascia axillaris*; it divides at the outer margin of the latter muscle into two layers, one of which passes in front, and the other behind it; these proceed as far as the spinous processes of the thoracic vertebræ, to which they are attached. As the fascia leaves the lower edge of the Pectoralis major to pass across the floor of the axilla it sends a layer upwards under cover of the muscle: this lamina splits to envelop the Pectoralis minor, at the upper edge of which it becomes continuous with the costo-coracoid membrane. The hollow of the armpit, seen when the arm is abducted, is produced mainly by the traction of this fascia on the axillary floor, and hence the lamina is sometimes named the *suspensory ligament* of the axilla. At the lower part of the thoracic region the deep fascia is well developed, and is continuous with the fibrous sheaths of the Recti abdominis.

Applied Anatomy.—In cases of suppuration in the axilla, the axillary fascia prevents the extension of the pus in a downward direction, and so it has a tendency to spread upwards, beneath the Pectoral muscles, towards the root of the neck. Early evacuation is therefore necessary. The incision should be made midway between the anterior and posterior axillary folds, so as to avoid the long thoracic and subscapular vessels, and the edge of the knife should be directed away from the axillary vessels.

The **Pectoralis major** (fig. 517) is a broad, thick, triangular muscle, situated at the upper and fore part of the chest and in front of the axilla. It arises from the anterior surface of the sternal half of the clavicle; from half the breadth of the anterior surface of the sternum, as low down as the attachment of the cartilage of the sixth or seventh rib; from the cartilages of all the true ribs, with the exception, frequently, of the first, or seventh, or both, and from the aponeurosis of the External oblique muscle of the abdomen. The fibres from this extensive origin converge towards their insertion, giving to the muscle a radiated appearance. Those fibres which arise from the clavicle pass obliquely outwards and downwards, and are usually separated from the rest by a slight interval: those from the lower part of the sternum, and the cartilages of the lower true ribs, run upwards and outwards; while the middle fibres pass horizontally. They all terminate in a flat tendon, about two inches broad, which is inserted into the outer bicipital ridge of the humerus. This tendon consists of two laminæ, placed one in front of the other, and usually blended together below. The anterior lamina, the thicker, receives the clavicular and the upper fibres of the sternal portion of the muscle; its fibres are inserted in the same order as that in which they arisé: that is to say, the outermost fibres of origin from the clavicle are inserted at the uppermost part of the bicipital ridge; the upper fibres of origin from the sternum pass down to the lowermost part of this anterior lamina of the tendon and extend as low as the tendon of the Deltoid and join with it. The posterior lamina of the tendon receives the attachment of the lower fibres of the sternal portion and the deeper part of the muscle from the costal cartilages. These deep fibres, and particularly those from the lower costal cartilages, ascend the higher, turning backwards successively behind the superficial and upper ones, so that the tendon appears to be twisted. The posterior lamina reaches higher on the humerus than the anterior one, and from it an expansion is given off which covers the bicipital groove and blends with the capsule of the shoulder-joint. From the deepest fibres of this lamina at its insertion an expansion

is given off which lines the bicipital groove of the humerus, while from the lower border of the tendon a third expansion passes downwards to the fascia of the arm.

Relations.—The Pectoralis major is in relation by its *anterior surface* with the integument, the superficial fascia, the Platysma, some of the branches of the descending cervical nerves, the mammary gland, and the deep fascia; by its *posterior surface*, with the sternum, the ribs and costal cartilages, the costo-coracoid membrane, the Subclavius, Pectoralis minor, Serratus magnus, and the Intercostals; it forms the anterior wall of the

Fig. 517.—Muscles of the chest and front of the arm. Superficial view.

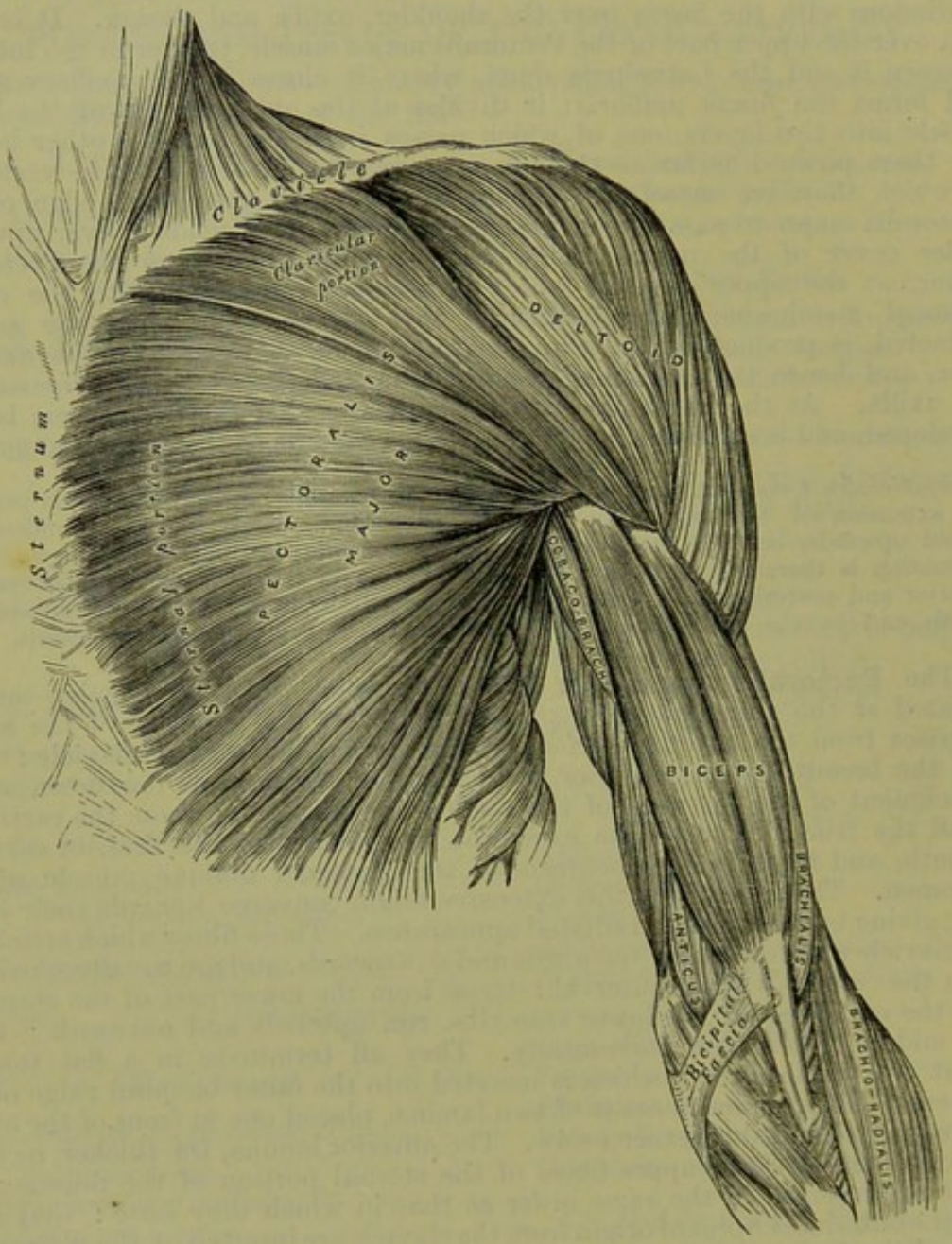

axillary space, and covers the axillary vessels and nerves and the Biceps and Coracobrachialis. Its *upper border* lies parallel with the Deltoid, from which it is separated by a slight interspace in which lie the cephalic vein and humeral branch of the acromio-thoracic artery. Its *lower border* forms the anterior margin of the axilla, being separated internally from the Latissimus dorsi by a considerable interval; but the two muscles gradually converge towards the outer part of the space.

The **costo-coracoid membrane** (fascia coracoclavicularis) is a strong fascia situated under cover of the clavicular portion of the Pectoralis major muscle. It occupies the interval between the Pectoralis minor and Subclavius muscles,

and protects the axillary vessels and nerves. Traced upwards, it splits to enclose the Subclavius muscle, and its two layers are attached to the clavicle, one in front of and the other behind the muscle ; the latter layer fuses with the deep cervical fascia and with the sheath of the axillary vessels. Internally, it blends with the fascia covering the first two intercostal spaces, and is attached also to the first rib internal to the origin of the Subclavius muscle. Externally, it is very thick and dense, and is attached to the coracoid process. The portion extending from the first rib to the coracoid process is often whiter and denser than the rest, and is sometimes called the *costo-coracoid ligament*. Below this, it is thin, and at the upper border of the Pectoralis minor it splits into two layers to invest the muscle ; from the lower border of the Pectoralis minor it is continued downwards to join the axillary fascia, and outwards to join

FIG. 518.—Muscles of the chest and front of the arm, with the boundaries of the axilla.

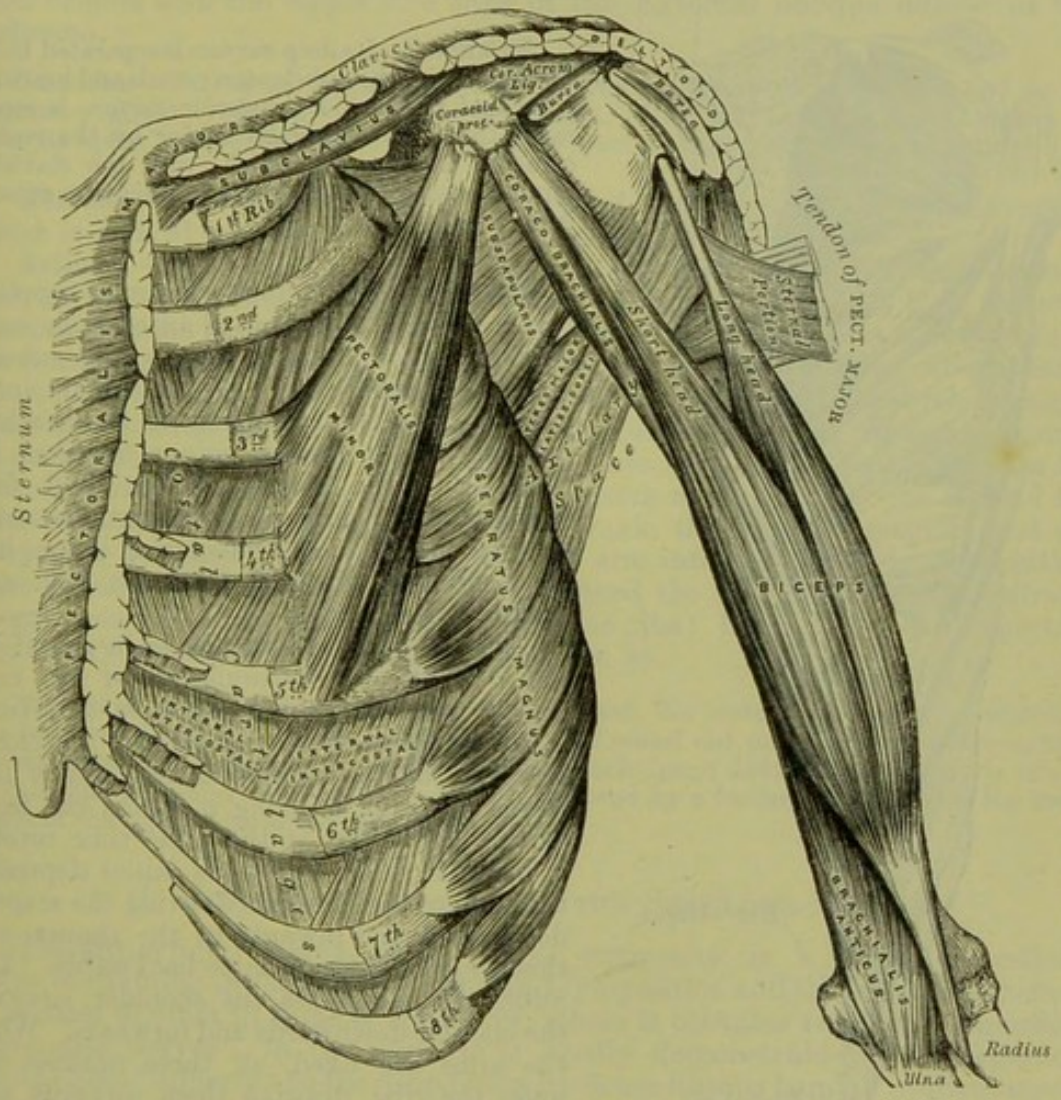

the fascia over the short head of the Biceps. The costo-coracoid membrane is pierced by the cephalic vein, acromio-thoracic artery and vein, superior thoracic artery, and external anterior thoracic nerve.

The **Pectoralis minor** (fig. 518) is a thin, flat, triangular muscle, situated at the upper part of the thorax, beneath the Pectoralis major. It arises by three tendinous digitations, from the upper margins and outer surfaces of the third, fourth, and fifth ribs, near their cartilages, and from the aponeuroses covering the Intercostal muscles ; the fibres pass upwards and outwards, and converge to form a flat tendon, which is inserted into the inner border and upper surface of the coracoid process of the scapula.

Relations.—By its *anterior surface* it is in relation with the Pectoralis major, the external anterior thoracic nerve, and the thoracic branches of the acromio-thoracic artery.

By its *posterior surface*, with the ribs, Intercostal muscles, Serratus magnus, the axillary space, and the axillary vessels and brachial plexus of nerves. Its *upper border* is separated from the clavicle by a narrow triangular interval which is occupied by the costo-coracoid membrane, behind which are the axillary vessels and nerves. Running parallel to the *lower border* of the muscle is the long thoracic artery, and piercing the muscle is the internal anterior thoracic nerve.

The **Subclavius** is a small triangular muscle, placed in the interval between the clavicle and the first rib. It arises by a short, thick tendon from the first rib and its cartilage at their junction, in front of the rhomboid ligament; the fleshy fibres proceed obliquely upwards and outwards, to be inserted into the groove on the under surface of the clavicle between the rhomboid and conoid ligaments.

Fig. 519.—Serratus magnus. (From a preparation in the Museum of the Royal College of Surgeons of England.)

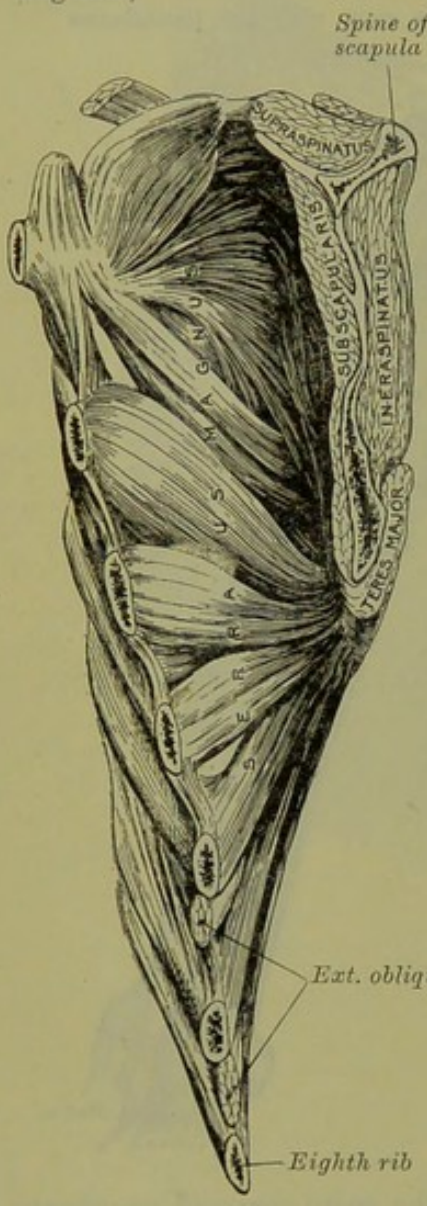

Relations.—Its *deep surface* is separated from the first rib by the subclavian vessels and brachial plexus of nerves. Its *anterior surface* is separated from the Pectoralis major by the costo-coracoid membrane, which, with the clavicle, forms an osseo-fibrous sheath in which the muscle is enclosed.

Nerves.—The Pectoralis major is supplied by the external and internal anterior thoracic nerves; through these nerves the muscle receives filaments from all the spinal nerves entering into the formation of the brachial plexus; the Pectoralis minor receives its fibres from the eighth cervical and first thoracic nerves through the internal anterior thoracic nerve. The Subclavius is supplied by a filament derived from the fifth and sixth cervical nerves.

Actions.—If the arm has been raised by the Deltoid, the Pectoralis major will, conjointly with the Latissimus dorsi and Teres major, depress it to the side of the chest. If acting alone, it adducts and draws forwards the arm, bringing it across the front of the chest, and at the same time rotates it inwards. The Pectoralis minor depresses the point of the shoulder, drawing the scapula downwards and inwards to the thorax, and throwing the inferior angle backwards. The Subclavius depresses the shoulder, drawing the clavicle downwards and forwards. When the arms are fixed, all three muscles act upon the ribs, drawing them upwards and expanding the chest, and thus becoming very important agents in forced inspiration. During an attack of asthma patients always assume an attitude which fixes the shoulders, so that all these muscles may be brought into action to assist in dilating the cavity of the chest.

2. *Lateral Thoracic Region*

Serratus magnus.

The **Serratus magnus** (m. serratus anterior) (fig. 519) is a thin, irregularly quadrilateral muscle, situated between the ribs and the scapula at the upper and lateral part of the chest. It arises by fleshy digitations from the outer

surfaces and upper borders of the upper eight or nine ribs, and from the aponeuroses covering the intervening Intercostal muscles. Each digitation (except the first) arises from the corresponding rib ; the first digitation arises from the first and second ribs, and from the fascia covering the first intercostal space. From this extensive attachment the fibres pass backwards, closely applied to the chest-wall, and reach the vertebral border of the scapula, and are inserted into its ventral aspect in the following manner. The first digitation, arising from the first and second ribs, is inserted into a triangular area on the ventral surface of the superior angle. The next two digitations (i.e. from the second and third ribs) spread out to form a thin, triangular sheet, the base of which is directed backwards and is inserted into nearly the whole length of the ventral surface of the vertebral border. The lower five or six digitations converge to form a fan-shaped mass, the apex of which is inserted, by muscular and by tendinous fibres, into a triangular impression on the ventral surface of the inferior angle. The lower four slips interdigitate at their origins with the upper five slips of the External oblique muscle of the abdomen.

Relations.—This muscle is partly covered, in front, by the Pectoral muscles and by the mammary gland ; behind, by the Subscapularis. The axillary vessels and nerves lie upon its upper part, while its deep surface rests upon the ribs and Intercostal muscles.

Nerves.—The Serratus magnus is supplied by the posterior thoracic nerve, which is derived from the fifth, sixth, and seventh cervical nerves.

Actions.—The Serratus magnus, as a whole, carries the scapula forwards, and at the same time raises the vertebral border of the bone. It is therefore concerned in the action of pushing. Its lower and stronger fibres move forwards the lower angle and assist the Trapezius in rotating the bone at the sterno-clavicular joint, and thus assist this muscle in raising the acromion and supporting weights upon the shoulder. It is also an assistant to the Deltoid in raising the arm, inasmuch as during the action of this latter muscle it fixes the scapula and so steadies the glenoid cavity on which the head of the humerus rotates. After the Deltoid has raised the arm to a right angle with the trunk, the Serratus magnus and the Trapezius, by rotating the scapula, raise the arm into an almost vertical position. It is possible that when the shoulders are fixed the lower fibres of the Serratus magnus may assist in raising and everting the ribs ; but it is not the important inspiratory muscle it was formerly believed to be.

Applied Anatomy.—When the muscle is paralysed, the vertebral border, and especially the lower angle of the scapula, leave the ribs and stand out prominently on the surface, giving a peculiar ' winged ' appearance to the back (page 294). The patient is unable to raise the arm, and an attempt to do so is followed by a further projection of the lower angle of the scapula from the back of the thorax.

II. Muscles and Fasciæ of the Shoulder and Arm

The **superficial fascia** of the upper extremity is a thin fibro-cellular layer, containing the superficial veins and lymphatics and the cutaneous nerves. It is most distinct in front of the elbow, where it contains very large superficial veins and nerves ; in the hand it is hardly demonstrable, the integument being closely adherent to the deep fascia by dense fibrous bands. Subcutaneous bursæ are found in this fascia over the acromion, the olecranon, and the knuckles.

The **deep fascia** of the upper extremity comprises the fascia of the shoulder, arm, and forearm, the anterior and posterior annular ligaments of the carpus, and the palmar fascia. These will be considered in the description of the muscles of the several regions.

3. *Acromial Region*

Deltoid.

The **deep fascia** covering the Deltoid invests the muscle, and sends numerous prolongations between its fasciculi. In front it is continuous with the fascia covering the Pectoralis major ; behind, where it is thick and strong, with that covering the Infraspinatus ; above, it is attached to the clavicle,

the acromion, and the spine of the scapula; below, it is continuous with the deep fascia of the arm.

The **Deltoid** (m. deltoideus) (fig. 517) is a large, thick, triangular muscle, which gives the rounded outline to the shoulder, and has received its name from its resemblance to the Greek letter Δ inverted. It covers the shoulder-joint in front, behind, and on the outer side. It arises from the anterior border and upper surface of the outer third of the clavicle; from the outer margin and upper surface of the acromion process, and from the lower lip of the posterior border of the spine of the scapula, as far back as the triangular surface at its inner end. From this extensive origin the fibres converge towards their insertion, the middle passing vertically, the anterior obliquely backwards and outwards, the posterior obliquely forwards and outwards; they unite to form a thick tendon, which is inserted into a rough triangular prominence on the middle of the outer side of the shaft of the humerus. At its insertion the muscle gives off an expansion to the deep fascia of the arm. This muscle is remarkably coarse in texture, and the arrangement of its fibres is somewhat peculiar; the central portion of the muscle—that is to say, the part arising from the acromion process—consists of oblique fibres; these arise in a bipenniform manner from the sides of tendinous intersections, generally four in number, which are attached above to the acromion process and pass downwards parallel to one another in the substance of the muscle. The oblique fibres thus formed are inserted into similar tendinous intersections, generally three in number, which pass upwards from the insertion of the muscle and alternate with the descending septa. The portions of the muscle which arise from the clavicle and spine of the scapula are not arranged in this manner, but pass from their origin above to be inserted into the margins of the inferior tendon.

Relations.—The Deltoid is in relation by its *superficial surface* with the integument, the superficial and deep fascia, Platysma, and supra-acromial nerves. Its *deep surface* is separated from the capsule of the shoulder-joint by a large synovial bursa, and covers the coracoid process, coraco-acromial ligament, Pectoralis minor, Coraco-brachialis, both heads of the Biceps, the tendon of the Pectoralis major, the insertions of the Supraspinatus, Infraspinatus, and Teres minor, the scapular and external heads of the Triceps, the circumflex vessels and nerve, and the upper part of the shaft of the humerus. Its *anterior border* is separated at its upper part from the Pectoralis major by a cellular interspace, which lodges the cephalic vein and humeral branch of the acromio-thoracic artery: lower down the two muscles are in close contact. Its *posterior border* rests on the Infraspinatus and Triceps muscles.

Nerves.—The Deltoid is supplied by the fifth and sixth cervical through the circumflex nerve.

Actions.—The Deltoid raises the arm directly from the side, so as to bring it at right angles with the trunk. Its anterior fibres, assisted by the Pectoralis major, draw the arm forwards; and its posterior fibres, aided by the Teres major and Latissimus dorsi, draw it backwards.

Applied Anatomy.—The Deltoid is very liable to atrophy, and in this condition dislocation of the shoulder-joint is simulated as there is flattening of the shoulder and apparent prominence of the acromion process; the distance also between the acromion process and the head of the bone is increased, and the tips of the fingers can be inserted between them. Atrophy of the Deltoid may be due to disuse, such as follows chronic arthritis or permanent injury of the shoulder-joint. It also frequently results from degenerations occurring in the spinal cord, or injury to the circumflex nerve ('crutch-palsy'). The Deltoid and Spinati often escape in myopathic atrophies affecting the other muscles of the upper arm or shoulder in young persons.

4. *Anterior Scapular Region*

Subscapularis.

The **fascia subscapularis** is a thin membrane attached to the entire circumference of the subscapular fossa, and affording attachment by its inner surface to some of the fibres of the Subscapularis muscle.

The **Subscapularis** (fig. 518) is a large triangular muscle which fills up the subscapular fossa, and arises from its internal two-thirds and from the lower

two-thirds of the groove on the axillary border of the bone. Some fibres arise from tendinous laminæ which intersect the muscle and are attached to ridges on the bone ; others from an aponeurosis, which separates the muscle from the Teres major and the long head of the Triceps. The fibres pass outwards, and, gradually converging, terminate in a tendon which is inserted into the lesser tuberosity of the humerus and the front of the capsular ligament of the shoulder-joint. The tendon of the muscle is separated from the neck of the scapula and anterior part of the capsular ligament of the shoulder-joint by a large bursa, which communicates with the cavity of the joint by an aperture in the capsular ligament.

FIG. 520.—Muscles on the dorsum of the scapula and the Triceps.

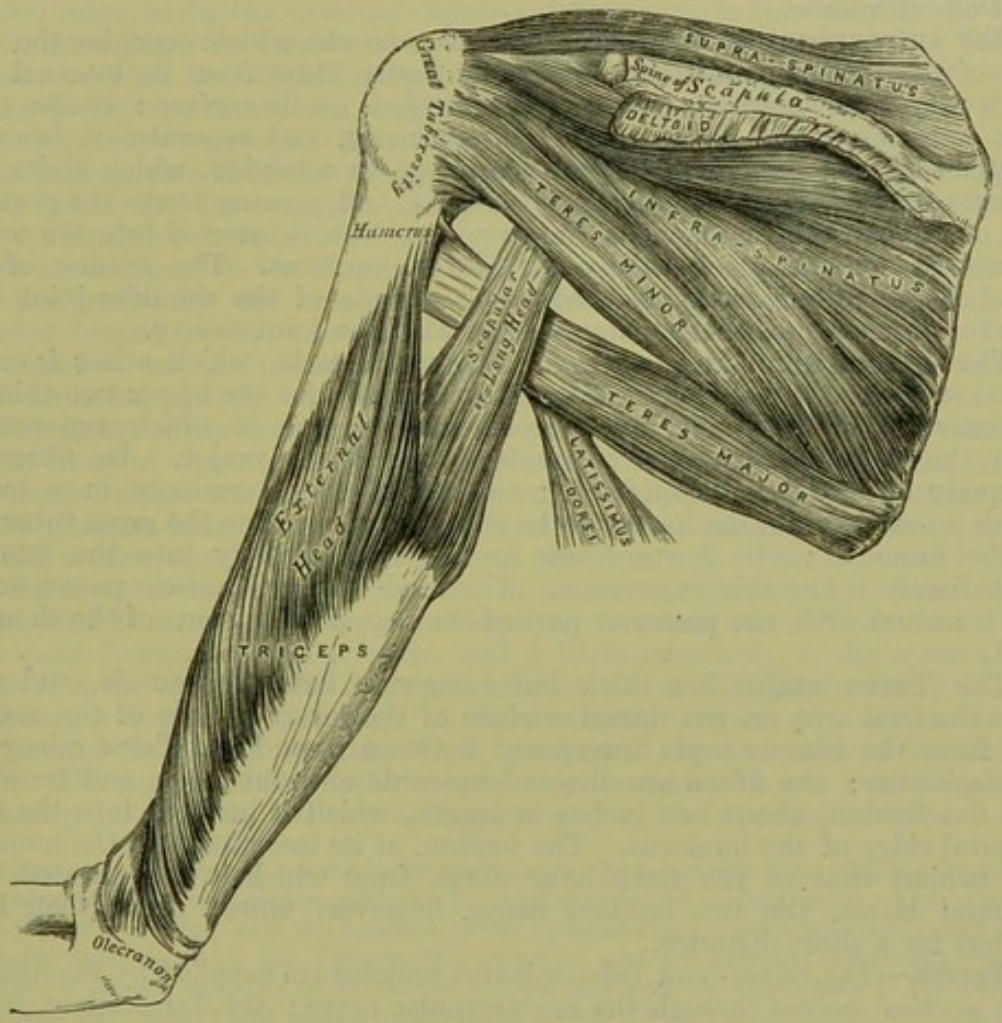

Relations.—The *anterior surface* of this muscle forms a considerable part of the posterior wall of the axilla, and is in relation with the Serratus magnus, Coraco-brachialis, and Biceps, the axillary vessels and brachial plexus of nerves, and the subscapular vessels and nerves. Its *posterior surface* is in relation with the scapula and the capsular ligament of the shoulder-joint. Its *lower border* is in contact with the Teres major and Latissimus dorsi.

Nerves.—The Subscapularis is supplied by the fifth and sixth cervical nerves through the upper and lower subscapular nerves.

Actions.—The Subscapularis rotates the head of the humerus inwards ; when the arm is raised, it draws the humerus forwards and downwards. It is a powerful defence to the front of the shoulder joint, preventing displacement of the head of the bone.

5. *Posterior Scapular Region* (fig. 520)

Supraspinatus.	Teres minor.
Infraspinatus.	Teres major.

The **fascia supraspinata** completes the osseo-fibrous case in which the Supraspinatus muscle is contained ; it affords attachment, by its deep

surface, to some of the fibres of the muscle. It is thick internally, but thinner externally under the coraco-acromial ligament.

The **Supraspinatus** occupies the whole of the supraspinous fossa, arising from its internal two-thirds, and from the strong fascia which covers its surface. The muscular fibres converge to a tendon, which passes across the upper part of the capsular ligament of the shoulder-joint, to which it is intimately adherent, and is inserted into the highest of the three impressions on the great tuberosity of the humerus.

The **fascia infraspinata** is a dense fibrous membrane, covering in the Infraspinatus muscle and fixed to the circumference of the infraspinous fossa; it affords attachment, by its inner surface, to some fibres of that muscle. It is intimately attached to the deltoid fascia along the overlapping border of the Deltoid muscle.

The **Infraspinatus** is a thick triangular muscle, which occupies the chief part of the infraspinous fossa, arising by fleshy fibres from its internal two-thirds; and by tendinous fibres from the ridges on its surface: it also arises from a strong fascia which covers it externally, and separates it from the Teretes major et minor. The fibres converge to a tendon, which glides over the external border of the spine of the scapula, and, passing across the posterior part of the capsular ligament of the shoulder-joint, is inserted into the middle impression on the great tuberosity of the humerus. The tendon of this muscle is sometimes separated from the capsule of the shoulder-joint by a synovial bursa, which may communicate with the joint cavity.

The **Teres minor** is a narrow, elongated muscle, which arises from the dorsal surface of the axillary border of the scapula for the upper two-thirds of its extent, and from two aponeurotic laminæ, one of which separates it from the Infraspinatus, the other from the Teres major. Its fibres run obliquely upwards and outwards; the upper ones terminate in a tendon which is inserted into the lowest of the three impressions on the great tuberosity of the humerus; the lower fibres are inserted directly into the humerus immediately below this impression. The tendon of this muscle passes across, and is united with, the posterior part of the capsular ligament of the shoulder-joint.

The **Teres major** is a thick but somewhat flattened muscle, and arises from the oval area on the dorsal surface of the inferior angle of the scapula, and from the fibrous septa interposed between it and the Teres minor and Infraspinatus; the fibres are directed upwards and outwards, and terminate in a flat tendon, about two inches in length, which is inserted into the inner bicipital ridge of the humerus. The tendon, at its insertion into the humerus, lies behind that of the Latissimus dorsi, from which it is separated by a synovial bursa, the two tendons being, however, united along their lower borders for a short distance.

Nerves.—The Supra- and Infra-spinatus muscles are supplied by the fifth and sixth cervical nerves through the suprascapular nerve; the Teres minor, by the fifth cervical, through the circumflex; and the Teres major, by the fifth and sixth cervical, through the lower subscapular.

Actions.—The Supraspinatus assists the Deltoid in raising the arm from the side, and fixes the head of the humerus in the glenoid cavity. The Infraspinatus and Teres minor rotate the head of the humerus outwards: they also assist in carrying the arm backwards. One of the most important uses of these three muscles is the great protection they afford to the shoulder-joint, the Supraspinatus supporting it above, and preventing displacement of the head of the humerus upwards, while the Infraspinatus and Teres minor protect it behind, and prevent dislocation backwards. The Teres major assists the Latissimus dorsi in drawing the previously raised humerus downwards and backwards, and in rotating it inwards; when the arm is fixed it may assist the Pectorals and Latissimus dorsi in drawing the trunk forwards.

6. *Anterior Humeral Region* (fig. 518)

Coraco-brachialis. Biceps. Brachialis anticus.

The **deep fascia** of the arm (fascia brachii) is continuous with that covering the Deltoid and the Pectoralis major, by means of which it is attached, above,

to the clavicle, acromion, and spine of the scapula; it forms a thin, loose, membranous sheath investing the muscles of the arm, and sends inwards septa between them; it is composed of fibres disposed in a circular or spiral direction, and connected together by vertical and oblique fibres. It differs in thickness at different parts, being thin over the Biceps, but thicker where it covers the Triceps, and over the condyles of the humerus: it is strengthened by fibrous aponeuroses, derived from the Pectoralis major and Latissimus dorsi on the inner side, and from the Deltoid externally. On either side it gives off a strong intermuscular septum, which is attached to the corresponding supracondylar ridge and condyle of the humerus. These septa serve to separate the muscles of the anterior from those of the posterior brachial region. The *external intermuscular septum* extends from the lower part of the anterior bicipital ridge, along the external supracondylar ridge, to the outer epicondyle; it is blended with the tendon of the Deltoid, gives attachment to the Triceps behind, to the Brachialis anticus, Brachio-radialis and Extensor carpi radialis longior in front, and is perforated by the musculo-spiral nerve and superior profunda artery. The *internal intermuscular septum*, thicker than the preceding, extends from the lower part of the posterior lip of the bicipital groove below the Teres major, along the internal supracondylar ridge to the inner epicondyle; it is blended with the tendon of the Coraco-brachialis, and affords attachment to the Triceps behind and the Brachialis anticus in front. It is perforated by the ulnar nerve, the inferior profunda artery, and the posterior branch of the anastomotic artery. At the elbow, the deep fascia is attached to all the prominent points round the joint, viz. the epicondyles of the humerus and the olecranon process of the ulna, and is continuous with the deep fascia of the forearm. Just below the middle of the arm, on its inner side, in front of the internal intermuscular septum, is an oval opening in the deep fascia, which transmits the basilic vein and some lymphatic vessels.

The **Coraco-brachialis,** the smallest of the three muscles in this region, is situated at the upper and inner part of the arm. It arises by fleshy fibres from the apex of the coracoid process, in common with the short head of the Biceps, and from the intermuscular septum, between the two muscles; the fibres pass downwards, backwards, and a little outwards, to be inserted by means of a flat tendon into an impression at the middle of the inner surface and internal border of the shaft of the humerus between the origins of the Triceps and Brachialis anticus. It is perforated by the musculo-cutaneous nerve. The inner border of the muscle forms a guide to the position of the terminal portion of the axillary and upper part of the brachial arteries.

Relations.—The Coraco-brachialis is in relation by its *anterior surface* with the Pectoralis major above, and at its insertion with the brachial vessels and median nerve which cross it; by its *posterior surface*, with the tendons of the Subscapularis, Latissimus dorsi, and Teres major, the inner head of the Triceps, the humerus, and the anterior circumflex vessels; by its *inner border*, with the third part of the axillary and the upper part of the brachial artery and the median and musculo-cutaneous nerves; by its *outer border*, with the short head of the Biceps and Brachialis anticus.

The **Biceps** (m. biceps brachii) is a long fusiform muscle, occupying the anterior surface of the arm, and divided above into two portions or heads, from which circumstance it has received its name. The short head (caput breve) arises by a thick flattened tendon from the apex of the coracoid process, in common with the Coraco-brachialis. The long head (caput longum) arises from the supraglenoid tubercle at the upper margin of the glenoid cavity, and is continuous with the glenoid ligament. This tendon arches over the head of the humerus, being enclosed in a special sheath of the synovial membrane of the shoulder-joint; it then passes through an opening in the capsular ligament at its attachment to the humerus, and descends in the bicipital groove, in which it is retained by the transverse humeral ligament and by a fibrous prolongation from the tendon of the Pectoralis major. Each tendon is succeeded by an elongated muscular belly, and the two bellies, although closely applied to each other, can readily be separated until within about three inches of the elbow-joint. Here they end in a flattened tendon, which is inserted into the rough posterior portion of the tuberosity of the radius, a synovial bursa being interposed between the tendon and the front part of

the tuberosity. As the tendon of the muscle approaches the radius it is twisted upon itself, so that its anterior surface becomes external and is applied to the tuberosity of the radius at its insertion. Opposite the bend of the elbow the tendon gives off, from its inner side, a broad aponeurosis, the *bicipital fascia* (*semilunar fascia*), which passes obliquely downwards and inwards across the brachial artery, and is continuous with the deep fascia covering the origins of the Flexor muscles of the forearm (fig. 517).

A third head to the Biceps is occasionally found, arising at the upper and inner part of the Brachialis anticus with the fibres of which it is continuous, and inserted into the bicipital fascia and inner side of the tendon of the Biceps. In most cases this additional slip passes behind the brachial artery in its course down the arm. In some instances the third head consists of two slips, which pass down, one in front of, the other behind the artery, concealing the vessel in the lower half of the arm.

Relations.—Its *anterior surface* is overlapped above by the Pectoralis major and Deltoid; in the rest of its extent it is covered by the superficial and deep fasciæ and the integument. Its *posterior surface* rests above on the shoulder-joint and upper part of the humerus; below, it lies on the Brachialis anticus, with the musculo-cutaneous nerve intervening between the two, and on the Supinator brevis. Its *inner border* is in relation with the Coraco-brachialis, and overlaps the brachial vessels and median nerve; its *outer border*, with the Deltoid and Brachio-radialis.

The **Brachialis anticus** (m. brachialis) is a broad muscle, which covers the elbow-joint and the lower half of the front of the humerus. It is somewhat compressed from before backwards, and is broader in the middle than at either extremity. It arises from the lower half of the front of the humerus; and commences above at the insertion of the Deltoid, which it embraces by two angular processes. Its origin extends below to within an inch of the margin of the articular surface. It also arises from the intermuscular septa, but more extensively from the inner than the outer; it is separated from the outer below by the Brachio-radialis and Extensor carpi radialis longior. Its fibres converge to a thick tendon, which is inserted into the tubercle of the ulna and the rough depression on the anterior surface of the coronoid process, being received into an interval between two fleshy slips of the Flexor profundus digitorum.

Relations.—The Brachialis anticus is in relation by its *anterior surface* with the Biceps, the brachial vessels, musculo-cutaneous and median nerves; by its *posterior surface*, with the humerus and front of the elbow-joint; by its *inner border*, with the Triceps, ulnar nerve, and Pronator teres, from which it is separated by the intermuscular septum; by its *outer border*, with the musculo-spiral nerve, radial recurrent artery, the Brachio-radialis, and Extensor carpi radialis longior.

Nerves.—The muscles of this group are supplied by the musculo-cutaneous nerve. The Brachialis anticus usually receives an additional filament from the musculo-spiral. The Coraco-brachialis receives its supply primarily from the seventh cervical, the Biceps and Brachialis anticus from the fifth and sixth cervical nerves.

Actions.—The Coraco-brachialis draws the humerus forwards and inwards, and at the same time assists in retaining the head of the bone in contact with the glenoid cavity. The Biceps is a flexor of the elbow and, to a less extent, of the shoulder: it is also a powerful supinator, and serves to render tense the deep fascia of the forearm by means of the bicipital fascia given off from its tendon. The Brachialis anticus is a flexor of the forearm, and forms an important defence to the elbow-joint. When the forearm is fixed, the Biceps and Brachialis anticus flex the arm upon the forearm, as is seen in efforts of climbing.

Applied Anatomy.—The long tendon of the Biceps is sometimes dislocated from the bicipital groove. When this takes place, the arm becomes fixed in a position of abduction, but the head of the humerus can be felt in its proper position. It can generally be replaced by flexing the forearm on the arm and rotating the limb. Rupture of the long tendon of the Biceps may also take place.

7. *Posterior Humeral Region*

Triceps. Subanconeus.

The **Triceps** (m. triceps brachii) (fig. 520) is situated on the back of the arm, extending the entire length of the posterior surface of the humerus. It is of large size, and divided above into three parts, hence its name. These

three portions have been named (1) the middle, scapular, or long head ; (2) the external, or long humeral head ; and (3) the internal, or short humeral head. The external and internal heads are separated by the musculo-spiral groove containing the musculo-spiral nerve and superior profunda vessels.

The *middle* or *scapular head* (caput longum) arises by a flattened tendon from a rough triangular depression on the scapula, immediately below the glenoid cavity, being blended at its upper part with the capsular ligament ; the muscular fibres pass downwards between the two other portions of the muscle, and join with them in the tendon of insertion.

The *external head* (caput laterale) arises from the posterior surface of the shaft of the humerus, between the insertion of the Teres minor and the upper part of the musculo-spiral groove and from the external border of the humerus and the external intermuscular septum ; the fibres from this origin converge towards the tendon of insertion.

The *internal head* (caput mediale) arises from the posterior surface of the shaft of the humerus, below the musculo-spiral groove : it is narrow and pointed above, and extends from the insertion of the Teres major to within an inch of the trochlear surface : it also arises from the internal border of the humerus and from the back of the whole length of the internal and lower part of the external intermuscular septa. Some of the fibres are directed downwards to the olecranon, while others converge to the tendon of insertion.

The *tendon* of the Triceps commences about the middle of the back part of the muscle : it consists of two aponeurotic laminæ, one of which is subcutaneous and covers the posterior surface of the muscle for the lower half of its extent ; the other is more deeply seated in the substance of the muscle. After receiving the attachment of the muscular fibres, they join together above the elbow, and are inserted, for the most part, into the posterior portion of the upper surface of the olecranon process ; a band of fibres is, however, continued downwards, on the outer side, over the Anconeus, to blend with the deep fascia of the forearm.

The long head of the Triceps descends between the Teres minor and Teres major, dividing the triangular space between these two muscles and the humerus into two smaller spaces, one triangular, the other quadrangular (fig. 520). The triangular space contains the dorsalis scapulæ vessels ; it is bounded by the Teres minor above, the Teres major below, and the scapular head of the Triceps externally. The quadrangular space transmits the posterior circumflex vessels and the circumflex nerve ; it is bounded by the Teres minor above, the Teres major below, the scapular head of the Triceps internally, and the humerus externally.

The **Subanconeus** is the name given to a few fibres from the under surface of the lower part of the Triceps muscle, which are inserted into the posterior ligament and synovial membrane of the elbow-joint. By some authors it is regarded as the homotype of the Subcrureus in the lower limb, but it is not a separate muscle.

Nerves.—The Triceps is supplied by the seventh and eighth cervical nerves through the musculo-spiral nerve.

Actions.—The Triceps is the great extensor muscle of the forearm, serving, when the forearm is flexed, to extend the elbow-joint. It is the direct antagonist of the Biceps and Brachialis anticus. When the arm is extended, the long head of the muscle may assist the Teres major and Latissimus dorsi in drawing the humerus backwards and in adducting it to the thorax. The long head protects the under part of the shoulder-joint, and prevents displacement of the head of the humerus downwards and backwards. The Subanconeus draws up the synovial membrane of the elbow-joint during extension of the forearm.

Applied Anatomy.—The existence of the strong insertion from the Triceps into the fascia of the forearm is of importance in excision of the elbow ; it should always be carefully preserved from injury by the operator. By means of these fibres the patient is enabled to extend the forearm, a movement which would otherwise mainly be accomplished by gravity—that is to say, by allowing the forearm to drop from its own weight.

III. Muscles and Fasciæ of the Forearm

The **deep fascia** of the forearm (fascia antibrachii), continuous above with that enclosing the arm, is a dense, highly glistening membranous investment,

which forms a general sheath enclosing the muscles in this region ; it is attached, behind, to the olecranon and posterior border of the ulna, and gives off from its deep surface numerous intermuscular septa, which enclose each muscle separately. In front it is continuous with the anterior annular ligament of the wrist, and forms a sheath for the tendon of the Palmaris longus muscle which passes over the annular ligament to be inserted into the palmar fascia. Behind, near the wrist-joint, it becomes much thickened by the addition of many transverse fibres, and forms the posterior annular ligament. It consists of circular and oblique fibres, connected together by numerous vertical fibres. It is much thicker on the posterior than on the anterior surface, and at the lower than at the upper part of the forearm, and is strengthened above by tendinous fibres derived from the Biceps in front, and from the Triceps behind. Its deep surface gives origin to muscular fibres, especially at the upper part of the inner and outer sides of the forearm, and forms the boundaries of a series of cone-shaped cavities, in which the muscles are contained. Besides the vertical septa separating the individual muscles, transverse septa are given off both on the anterior and posterior surfaces of the forearm, separating the deep from the superficial layers of muscles. Numerous apertures exist in the fascia for the passage of vessels and nerves ; one of these, of large size, situated at the front of the elbow, serves for the passage of a communicating branch between the superficial and deep veins. Near the wrist, it is perforated on its anterior surface by the ulnar artery and nerve.

The muscles of the forearm may be subdivided into groups corresponding to the regions they occupy. One group occupies the inner and anterior aspect of the forearm, and comprises the Flexor and Pronator muscles. Another group occupies its outer side ; and a third its posterior aspect. The two latter groups include all the Extensor and Supinator muscles.

8. *Anterior Radio-ulnar Region*

The muscles in this region are divided for convenience of description into two groups or layers, superficial and deep.

Superficial Layer (fig. 521)

Pronator teres. Palmaris longus.
Flexor carpi radialis. Flexor carpi ulnaris.
Flexor sublimis digitorum.

These muscles take origin from the internal epicondyle of the humerus by a common tendon ; they receive additional fibres from the deep fascia of the forearm near the elbow, and from the septa which pass inwards from this fascia between the individual muscles.

The **Pronator teres** has two heads of origin. One (caput humerale), the larger and more superficial, arises from the humerus, immediately above the internal epicondyle, and from the tendon common to the origin of the other muscles ; also from the fascia of the forearm, and intermuscular septum between it and the Flexor carpi radialis. The deep head (caput ulnare) is a thin fasciculus, which arises from the inner side of the coronoid process of the ulna, and joins the preceding at an acute angle. The median nerve enters the forearm between the two heads of the muscle, and is separated from the ulnar artery by the deep head. The muscle passes obliquely across the forearm, and terminates in a flat tendon, which turns over the outer margin of the radius, and is inserted into a rough impression at the middle of the outer surface of the shaft of that bone. The outer border of the muscle forms the inner boundary of a triangular space (*antecubital fossa*) situated in front of the elbow-joint and containing the brachial artery, median nerve, and tendon of the Biceps.

Applied Anatomy.—This muscle, when suddenly brought into very active use, as in the game of lawn tennis, is apt to be strained, producing slight swelling, tenderness, and pain on putting the muscle into action. This is known as ' lawn-tennis arm.'

The **Flexor carpi radialis** lies on the inner side of the preceding muscle. It arises from the internal epicondyle by the common tendon ; from the fascia

of the forearm; and from the intermuscular septa between it and the Pronator teres externally, the Palmaris longus internally, and the Flexor sublimis digitorum beneath. Slender and aponeurotic in structure at its commencement, it increases in size, and terminates in a tendon, which forms rather more than the lower half of its length. This tendon passes through a canal in the outer part of the annular ligament, runs through a groove in the trapezium (which is converted into a canal by a fibrous sheath, and lined by a synovial membrane), and is inserted into the base of the metacarpal bone of the index finger, and by a slip into the base of the metacarpal bone of the middle finger. The radial artery, in the lower part of the forearm, lies between the tendon of this muscle and the Brachio-radialis, and may easily be tied in this situation.

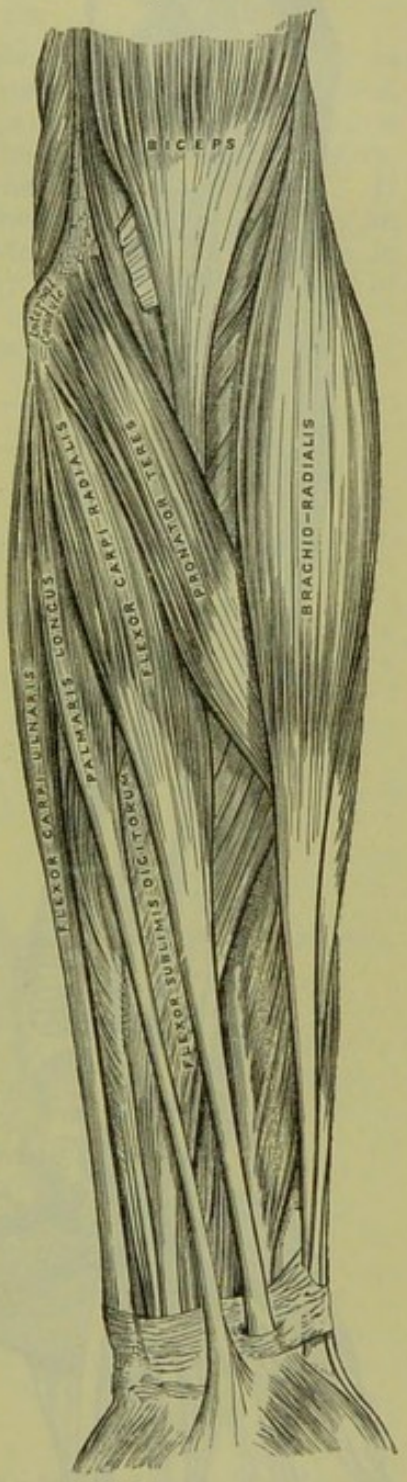

Fig. 521.—Front of the left forearm. Superficial muscles.

The **Palmaris longus** is a slender, fusiform muscle, lying on the inner side of the preceding. It arises from the inner epicondyle of the humerus by the common tendon, from the deep fascia, and the intermuscular septa between it and the adjacent muscles. It terminates in a slender, flattened tendon, which passes over the upper part of the annular ligament, to end in the central part of the palmar fascia and lower part of the annular ligament, frequently sending a tendinous slip to the short muscles of the thumb. This muscle is often absent, and is subject to very considerable variations: it may be tendinous above and muscular below; or it may be muscular in the centre with a tendon above and below; or it may present two muscular bundles with a central tendon; or finally it may consist solely of a tendinous band. Just above the wrist, the median nerve lies close to the tendon, on its outer and posterior aspects.

The **Flexor carpi ulnaris** lies along the ulnar side of the forearm. It arises by two heads, connected by a tendinous arch, beneath which pass the ulnar nerve and posterior ulnar recurrent artery. One head (caput humerale) arises from the inner epicondyle of the humerus by the common tendon; the other (caput ulnare) from the inner margin of the olecranon and from the upper two-thirds of the posterior border of the ulna by an aponeurosis, common to it and the Extensor carpi ulnaris and Flexor profundus digitorum; and from the intermuscular septum between it and the Flexor sublimis digitorum. The fibres terminate in a tendon, which occupies the anterior part of the lower half of the muscle, and is inserted into the pisiform bone, and is prolonged from this to the unciform and fifth metacarpal bones by the piso-unciform and piso-metacarpal ligaments; it is also attached by a few fibres to the annular ligament. The ulnar vessels and nerve lie on the outer side of the tendon of this muscle, in the lower two-thirds of the forearm; the tendon forming a guide in tying the artery in this situation.

The **Flexor sublimis digitorum** (m. flexor digitorum sublimis) is placed beneath the Flexor carpi ulnaris; it is the largest of the muscles of the superficial layer, and arises by three heads. One head (caput humerale) arises from the internal epicondyle of the humerus by the common tendon,

Fig. 522.—Front of the left forearm. Deep muscles.

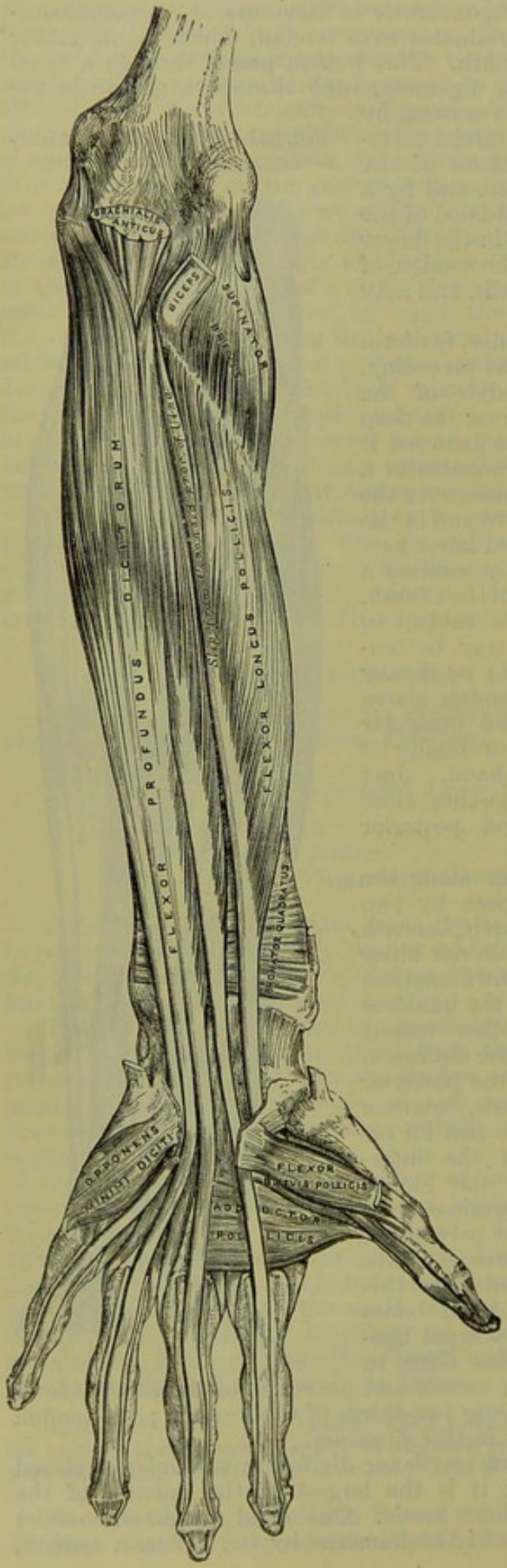

from the internal lateral ligament of the elbow-joint, and from the intermuscular septa between it and the preceding muscles. The second head (caput ulnare) arises from the inner side of the coronoid process of the ulna, above the ulnar origin of the Pronator teres (see fig. 358, page 302). The third head (caput radiale) arises from the oblique line of the radius, extending from the bicipital tuberosity to the insertion of the Pronator teres. The fibres pass vertically downwards, forming a broad and thick muscle, which speedily separates into two planes of muscular fibres, superficial and deep: the superficial plane divides into two parts which end in tendons for the middle and ring fingers; the deep plane gives off a muscular slip to join the part of the superficial plane which is associated with the tendon of the ring finger, and then divides into two parts, which end in tendons for the index and little fingers. As the four tendons thus formed pass beneath the annular ligament into the palm of the hand, they are arranged in pairs, the superficial pair corresponding to the middle and ring fingers, the deep pair to the index and little fingers. The tendons diverge from one another as they run onwards, and form posterior relations to the superficial palmar arch and digital branches of the median and ulnar nerves. Opposite the bases of the first phalanges each tendon divides into two slips, to allow of the passage of the corresponding tendon of the Flexor profundus digitorum; the two portions of the tendon then unite and form a grooved channel for the reception of the accompanying deep Flexor tendon. Finally they subdivide a second time, to be inserted into the sides of the second phalanges about their middle. After leaving the palm, these tendons, accompanied by the deep Flexor tendons, lie in osseo-aponeurotic canals (fig. 522). The canals are completed by strong fibrous sheaths, which arch across the tendons, and are attached on each side to the margins of the phalanges.

Opposite the middle of the proximal and second phalanges the sheaths are very strong, and the fibres pass transversely; but opposite the joints they are much thinner, and the fibres are directed obliquely. Each sheath is lined by a synovial membrane, which is reflected on the contained tendons.

Deep Layer (fig. 522)

Flexor profundus digitorum. Flexor longus pollicis.
Pronator quadratus.

The **Flexor profundus digitorum** (m. flexor digitorum profundus) is situated on the ulnar side of the forearm, immediately beneath the superficial Flexors. It arises from the upper three-fourths of the anterior and inner surfaces of the shaft of the ulna, embracing the insertion of the Brachialis anticus above, and extending below, to within a short distance of the Pronator quadratus. It also arises from a depression on the inner side of the coronoid process; by an aponeurosis from the upper three-fourths of the posterior border of the ulna, in common with the Flexor and Extensor carpi ulnaris; and from the ulnar half of

Fig. 523.—Vincula accessoria and tendons of forefinger.

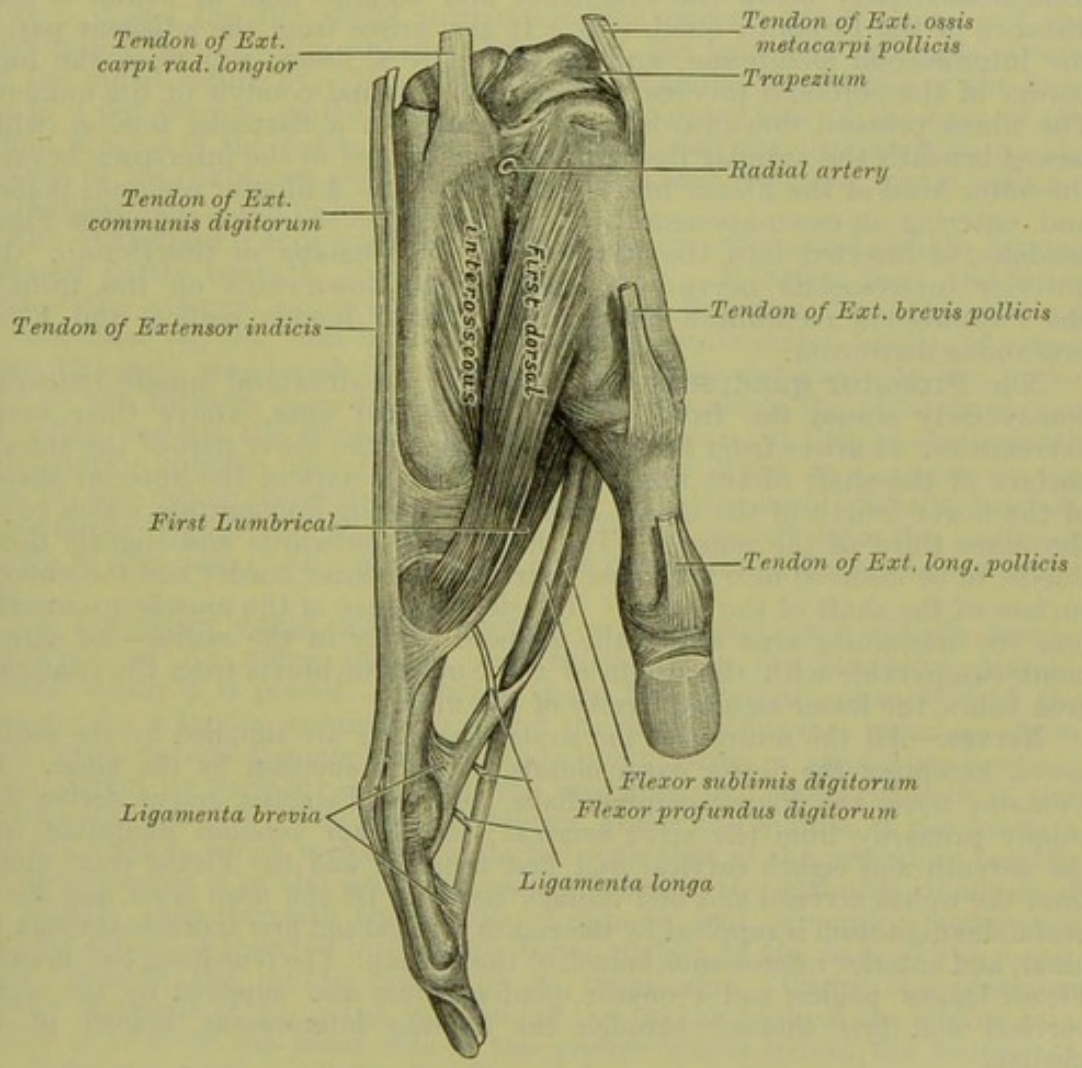

the interosseous membrane. The fibres form a fleshy belly of considerable size, which divides into four tendons: these run under the annular ligament beneath the tendons of the Flexor sublimis digitorum. Opposite the first phalanges, the tendons pass through the openings in the tendons of the Flexor sublimis digitorum, and are finally inserted into the bases of the last phalanges. The portion of the muscle for the index finger is usually distinct throughout, but the tendons for the three inner fingers are connected together by cellular tissue and tendinous slips, as far as the palm of the hand. The tendons of

this muscle and those of the Flexor sublimis digitorum, while contained in the osseo-aponeurotic canals of the fingers, are invested in synovial sheaths, and are connected to each other, and to the phalanges, by slender, tendinous filaments, called *vincula accessoria* (fig. 523). There are two sets of these: (*a*) the *ligamenta brevia*, which are two in number in each finger, and consist of triangular bands of fibres connecting the tendon of the Flexor sublimis digitorum to the front of the first interphalangeal joint and head of the first phalanx, and the tendon of the Flexor profundus digitorum to the front of the second interphalangeal joint and head of the second phalanx; (*b*) the *ligamenta longa*, which connect the under surfaces of the tendons of the Flexor profundus digitorum to those of the subjacent Flexor sublimis after the tendons of the former have passed through the latter. The ligamenta brevia of the deep Flexor tendons consist largely of yellow elastic tissue, and may assist in drawing down the tendons after flexion of the finger.

Four small muscles, the Lumbricales, are connected with the tendons of the Flexor profundus in the palm. They will be described with the muscles of the hand.

The **Flexor longus pollicis** (m. flexor pollicis longus) is situated on the radial side of the forearm, lying in the same plane as the preceding. It arises from the grooved anterior surface of the shaft of the radius, extending from immediately below the tuberosity and oblique line, to within a short distance of the Pronator quadratus. It also arises from the adjacent part of the interosseous membrane, and generally by a fleshy slip from the inner border of the coronoid process, or from the internal condyle of the humerus. The fibres proceed downwards, and terminate in a flattened tendon, which passes beneath the annular ligament, is then lodged in the interspace between the outer head of the Flexor brevis pollicis and the Adductor obliquus pollicis, and, entering an osseo-aponeurotic canal similar to those for the other Flexor tendons, is inserted into the base of the last phalanx of the thumb. The anterior interosseous nerve and vessels pass downwards on the front of the interosseous membrane between the Flexor longus pollicis and Flexor profundus digitorum.

The **Pronator quadratus** is a small, flat, quadrilateral muscle, extending transversely across the front of the radius and ulna, above their carpal extremities. It arises from the pronator ridge on the lower part of the anterior surface of the shaft of the ulna; from the inner part of the anterior surface of the lower fourth of the ulna; and from a strong aponeurosis which covers the inner third of the muscle. The fibres pass outwards and slightly downwards, to be inserted into the lower fourth of the outer border and the anterior surface of the shaft of the radius. The deeper fibres of the muscle are inserted into the triangular area above the sigmoid cavity of the radius—an attachment comparable with the origin of the Supinator brevis from the triangular area below the lesser sigmoid cavity of the ulna.

Nerves.—All the muscles of the superficial layer are supplied by the median nerve, excepting the Flexor carpi ulnaris, which is supplied by the ulnar. The Pronator teres, the Flexor carpi radialis, and the Palmaris longus derive their supply primarily from the sixth cervical; the Flexor sublimis digitorum from the seventh and eighth cervical and first thoracic, and the Flexor carpi ulnaris from the eighth cervical and first thoracic nerves. Of the deep layer, the Flexor profundus digitorum is supplied by the eighth cervical and first thoracic through the ulnar, and anterior interosseous branch of the median. The remaining two muscles, Flexor longus pollicis and Pronator quadratus, are also supplied by the eighth cervical and first thoracic through the anterior interosseous branch of the median.

Actions.—These muscles act upon the forearm, the wrist, and hand. The Pronator teres helps to rotate the radius upon the ulna, rendering the hand prone; when the radius is fixed, it assists the other muscles in flexing the forearm. The Flexor carpi radialis is one of the flexors of the wrist; when acting alone, it flexes the wrist, inclining it to the radial side. It can also assist in pronating the forearm and hand, and, by continuing its action, in bending the elbow. The Flexor carpi ulnaris is one of the flexors of the wrist; when acting alone, it flexes the wrist, inclining it to the ulnar side; and by continuing to contract, it bends the elbow. The Palmaris longus is a tensor of the palmar fascia. It also assists

in flexing the wrist and elbow. The Flexor sublimis digitorum flexes first the middle, and then the proximal phalanges. It assists in flexing the wrist and elbow. The Flexor profundus digitorum is one of the flexors of the phalanges. After the Flexor sublimis has bent the second phalanx, the Flexor profundus flexes the terminal one; but it cannot do so until after the contraction of the superficial muscle. It also assists in flexing the wrist. The Flexor longus pollicis is a flexor of the phalanges of the thumb; when the thumb is fixed, it also assists in flexing the wrist. The Pronator quadratus helps to rotate the radius upon the ulna, rendering the hand prone.

9. *Radial Region* (figs. 520, 522)

Brachio-radialis (*Supinator longus*). Extensor carpi radialis longior. Extensor carpi radialis brevior.

The **Brachio-radialis** (*Supinator longus*) is the most superficial muscle on the radial side of the forearm: it is fleshy for the upper two-thirds of its extent, tendinous below. It arises from the upper two-thirds of the external supracondylar ridge of the humerus, and from the external intermuscular septum, being limited above by the musculo-spiral groove. Interposed between it and the Brachialis anticus are the musculo-spiral nerve and the anastomosis between the anterior branch of the superior profunda artery and the radial recurrent. The fibres terminate above the middle of the forearm in a flat tendon, which is inserted into the outer side of the base of the styloid process of the radius. The tendon is crossed near its insertion by the tendons of the Extensor ossis metacarpi pollicis and Extensor brevis pollicis; on its ulnar side is the radial artery.

The **Extensor carpi radialis longior** (m. extensor carpi radialis longus) is placed partly beneath the preceding muscle. It arises from the lower third of the external supracondylar ridge of the humerus, from the external intermuscular septum, and by a few fibres from the common tendon of origin of the Extensor muscles of the forearm. The fibres terminate at the upper third of the forearm in a flat tendon, which runs along the outer border of the radius, beneath the Extensor tendons of the thumb; it then passes beneath the posterior annular ligament of the wrist, where it lies in a groove on the back of the radius common to it and the Extensor carpi radialis brevior, immediately behind the styloid process. It is inserted into the posterior surface of the base of the metacarpal bone of the index finger, on its radial side.

The **Extensor carpi radialis brevior** (m. extensor carpi radialis brevis) is shorter, as its name implies, and thicker than the preceding muscle, beneath which it is placed. It arises from the external epicondyle of the humerus, by a tendon common to it and the three following muscles; from the external lateral ligament of the elbow-joint; from a strong aponeurosis which covers its surface; and from the intermuscular septa between it and the adjacent muscles. The fibres terminate about the middle of the forearm in a flat tendon, which is closely connected with that of the preceding muscle, and accompanies it to the wrist; it passes beneath the Extensor tendons of the thumb, then beneath the annular ligament, and, diverging somewhat from its fellow, is inserted into the posterior surface of the base of the metacarpal bone of the middle finger, on its radial side. Under the posterior annular ligament of the wrist the tendon lies on the back of the radius in a shallow groove, to the ulnar side of the groove which lodges the tendon of the Extensor carpi radialis longior, and separated from it by a faint ridge.

The tendons of the two preceding muscles pass through the same compartment of the annular ligament, and are lubricated by a single synovial membrane.

10. *Posterior Radio-Ulnar Region* (fig. 524)

The muscles in this region are divided for purposes of description into two groups or layers, superficial and deep.

Fig. 524.—Posterior surface of the forearm. Superficial muscles.

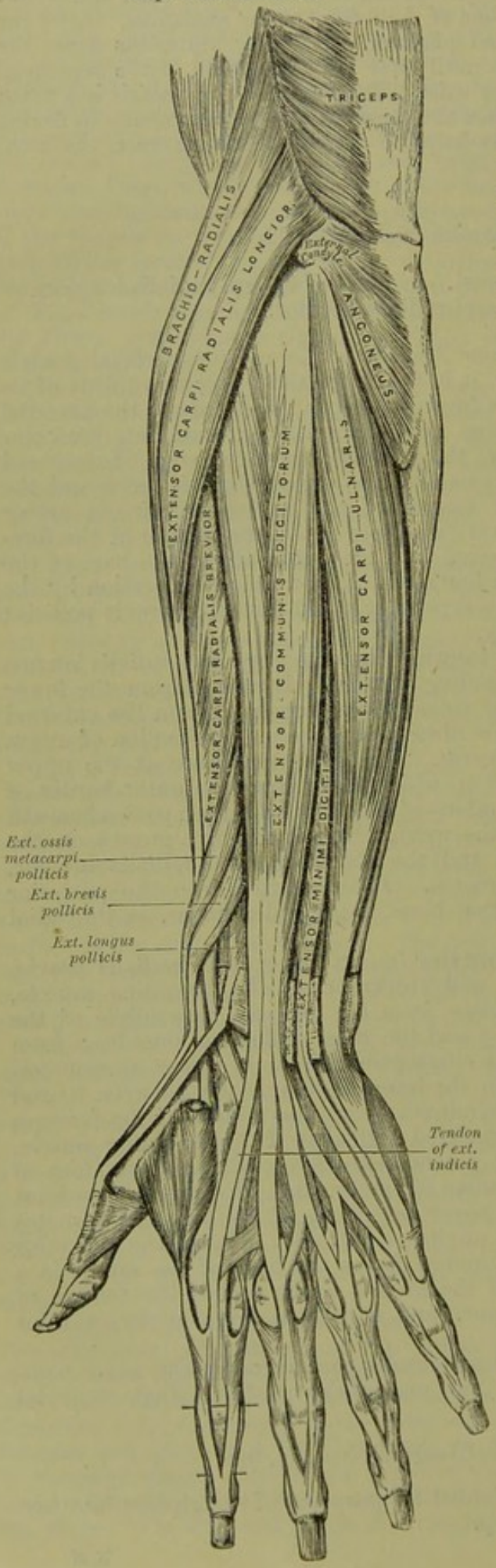

Superficial Layer

Extensor communis digitorum.
Extensor minimi digiti.
Extensor carpi ulnaris.
Anconeus.

The **Extensor communis digitorum** (m. extensor digitorum communis) is situated at the back part of the forearm. It arises from the external epicondyle of the humerus, by the common tendon; from the deep fascia, and the intermuscular septa between it and the adjacent muscles. It divides below into four tendons, which pass, together with that of the Extensor indicis, through a separate compartment of the annular ligament, lubricated by a synovial membrane. The tendons then diverge, and, after passing across the back of the hand, are inserted into the second and third phalanges of the fingers in the following manner. Opposite the metacarpo-phalangeal articulation each tendon is bound by fasciculi to the lateral ligaments and serves as the posterior ligament; after having passed the joint, it spreads out into a broad aponeurosis, which covers the dorsal surface of the first phalanx and is reinforced, in this situation, by the tendons of the Interossei and Lumbricales. Opposite the first interphalangeal joint this aponeurosis divides into three slips, a middle and two lateral: the former is inserted into the base of the second phalanx; and the two lateral, which are continued onwards along the sides of the second phalanx, unite by their contiguous margins, and are inserted into the dorsal surface of the last phalanx. As the tendons cross the interphalangeal joints, they furnish them with posterior ligaments. The tendon to the index finger is accompanied by the Extensor indicis, which lies on its inner side. On the back of the hand, the three inner tendons — those to the middle, ring, and little fingers—are connected by two obliquely placed bands, one from the third tendon passing downwards and outwards to the second tendon, and the other passing from the

same tendon downwards and inwards to the fourth. Occasionally the first tendon is connected to the second by a thin transverse band.

The **Extensor minimi digiti** (m. extensor digiti quinti proprius) is a slender muscle placed on the inner side of the Extensor communis, with which it is generally connected. It arises from the common Extensor tendon by a thin tendinous slip; and from the intermuscular septa between it and the adjacent muscles. Its tendon runs through a separate compartment in the annular ligament behind the inferior radio-ulnar joint, then divides into two as it crosses the hand, and is finally inserted into the expansion of the Extensor tendon on the dorsum of the first phalanx of the little finger.

Fig. 525.—Supinator brevis. (From a preparation in the Museum of the Royal College of Surgeons of England.)

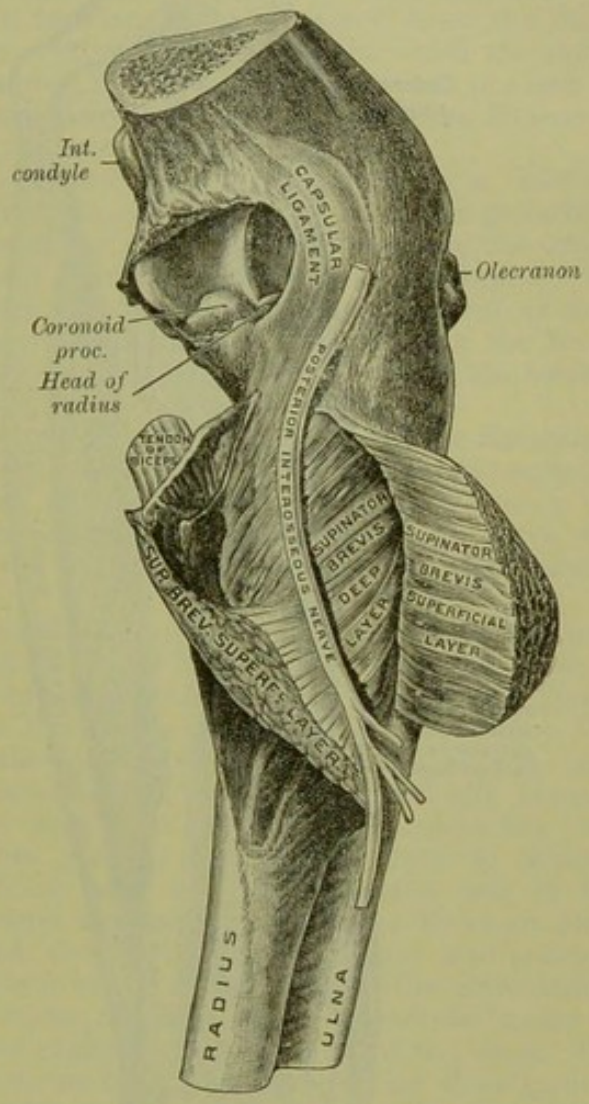

The **Extensor carpi ulnaris** is the most superficial muscle on the ulnar side of the forearm. It arises from the external epicondyle of the humerus, by the common tendon; by an aponeurosis from the posterior border of the ulna in common with the Flexor carpi ulnaris and the Flexor profundus digitorum; and from the deep fascia of the forearm. This muscle terminates in a tendon, which runs through a groove behind the styloid process of the ulna, passing through a separate compartment in the annular ligament, and is inserted into the prominent tubercle on the ulnar side of the base of the metacarpal bone of the little finger.

The **Anconeus** is a small triangular muscle, placed on the back of the elbow-joint, and appears to be a continuation of the external portion of the Triceps. It arises by a separate tendon from the back part of the external epicondyle of the humerus, and is inserted into the side of the olecranon, and upper fourth of the posterior surface of the shaft of the ulna; its fibres diverge from their origin, the upper ones being directed transversely, the lower obliquely inwards.

Deep Layer (figs. 525, 526)

Supinator brevis.
Extensor ossis metacarpi pollicis.
Extensor brevis pollicis.
Extensor longus pollicis.
Extensor indicis.

The **Supinator brevis** (m. supinator) (fig. 525) is a broad muscle, of a hollow cylindrical form, curved round the upper third of the radius. It consists of two distinct planes of muscular fibres, between which the posterior interosseous nerve lies. The two planes arise in common, the superficial one by tendinous, and the deeper by muscular fibres: from the external epicondyle of the humerus; from the external lateral ligament of the elbow-joint, and the orbicular ligament; from the ridge on the ulna, which runs obliquely downwards from the posterior extremity of the lesser sigmoid cavity;

from the triangular depression below that cavity; and from a tendinous expansion which covers the surface of the muscle. The superficial fibres surround the upper part of the radius, and are inserted into the outer edge of the bicipital tuberosity and the oblique line of the radius, as low down as the insertion of the Pronator teres. The upper fibres of the deeper plane form a sling-like fasciculus, which encircles the neck of the radius above the tuberosity and is attached to the back part of its inner surface: the greater part of this portion of the muscle is inserted into the posterior and external surface of the shaft, midway between the oblique line and the head of the bone.

Fig. 526.—Posterior surface of the forearm. Deep muscles.

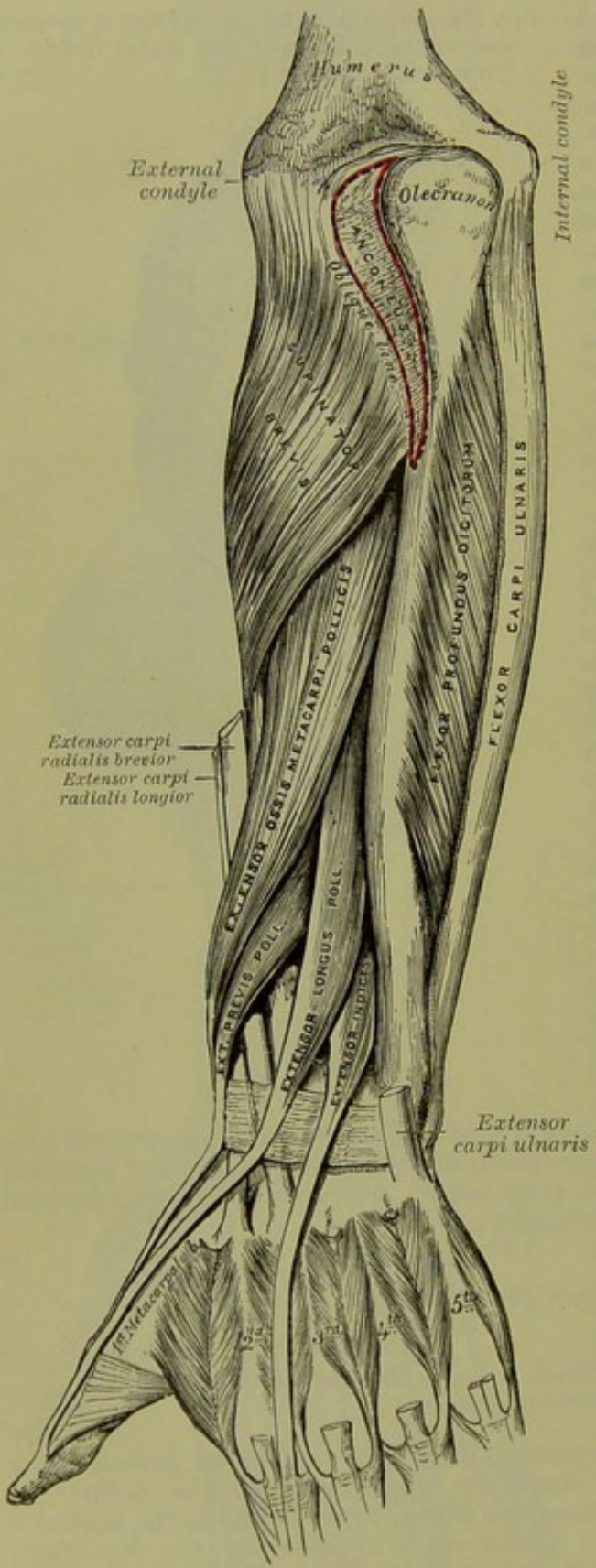

The **Extensor ossis metacarpi pollicis** (m. abductor pollicis longus) is the most external and the largest of the deep Extensor muscles; it lies immediately below the Supinator brevis, with which it is sometimes united. It arises from the outer part of the posterior surface of the shaft of the ulna below the insertion of the Anconeus, from the interosseous membrane, and from the middle third of the posterior surface of the shaft of the radius. Passing obliquely downwards and outwards, it terminates in a tendon, which runs through a groove on the outer side of the lower end of the radius, accompanied by the tendon of the Extensor brevis pollicis, and is inserted into the outer side of the base of the metacarpal bone of the thumb. It occasionally gives off two slips near its insertion: one to the trapezium, and the other to blend with the origin of the Abductor pollicis.

The **Extensor brevis pollicis,** the smallest muscle of this group, lies on the inner side of the preceding. It arises from the posterior surface of the shaft of the radius below the Extensor ossis metacarpi pollicis, and from the interosseous membrane. Its direction is similar to that of the Extensor ossis metacarpi pollicis, its tendon passing through the same groove on the outer side of the lower end of the radius, to be inserted into the base of the first phalanx of the thumb. It is closely connected

with the Extensor ossis metacarpi pollicis, of which it is usually regarded as a segment.

The **Extensor longus pollicis** is much larger than the preceding muscle, the origin of which it partly covers. It arises from the outer part of the middle third of the posterior surface of the shaft of the ulna below the origin of the Extensor ossis metacarpi pollicis, and from the interosseous membrane. It terminates in a tendon, which passes through a separate compartment in the annular ligament, lying in a narrow, oblique groove at the back part of the lower end of the radius. It then crosses obliquely the tendons of the Extensor carpi radialis longior and brevior, being separated from the other Extensor tendons of the thumb by a triangular interval, in which the radial artery is found; and is finally inserted into the base of the last phalanx of the thumb. The radial artery is crossed by the tendons of all three Extensors of the thumb as they pass from the radius to the digit.

The **Extensor indicis** (m. extensor indicis proprius) is a narrow, elongated muscle, placed on the inner side of, and parallel with, the preceding. It arises from the posterior surface of the shaft of the ulna below the origin of the Extensor longus pollicis, and from the interosseous membrane. Its tendon passes under the annular ligament in the same compartment as that which transmits the Extensor communis digitorum, and opposite the lower end of the corresponding metacarpal bone, joins the ulnar side of the tendon of the Extensor communis which belongs to the index finger.

Nerves.—The Brachio-radialis is supplied by the fifth and sixth, the Extensores carpi radialis longior et brevior by the sixth and seventh, and the Anconeus by the seventh and eighth cervical nerves, all through the musculo-spiral nerve; the remaining muscles are innervated through the posterior interosseous nerve, the Supinator brevis being supplied by the sixth cervical, and all the other muscles by the seventh cervical.

Actions.—The muscles of the radial and posterior aspects of the forearm, which comprise all the Extensor and Supinator muscles, act upon the forearm, wrist, and hand; they are the direct antagonists of the Pronator and Flexor muscles. The Anconeus assists the Triceps in extending the forearm. The Brachio-radialis is a flexor of the elbow-joint, but only acts as such when the movement of flexion has been initiated by the Biceps and Brachialis anticus. The Supinator brevis is a supinator: that is to say, when the radius has been carried across the ulna in pronation, and the back of the hand is directed forwards, this muscle carries the radius back again to the outer side of the ulna, and the palm of the hand is again directed forwards. The Extensor carpi radialis longior extends the wrist and abducts the hand. It may also assist in bending the elbow-joint; at all events it serves to fix or steady this articulation. The Extensor carpi radialis brevior assists the Extensor carpi radialis longior in extending the wrist, and may also act slightly as an abductor of the hand. The Extensor carpi ulnaris helps to extend the hand, but when acting alone inclines it towards the ulnar side: by its continued action it extends the elbow-joint. The Extensor communis digitorum extends the phalanges, then the wrist, and finally the elbow. It acts principally on the proximal phalanges, the middle and terminal phalanges being acted upon mainly by the Interossei and Lumbricales. It has also a tendency to separate the fingers as it extends them. The Extensor minimi digiti extends the little finger, and by its continued action assists in extending the wrist. It is owing to this muscle that the little finger can be extended or pointed while the others are flexed. The chief action of the Extensor ossis metacarpi pollicis is to carry the thumb outwards and backwards from the palm of the hand, and hence it has been called the *Abductor pollicis longus*. By its continued action it helps to extend and abduct the wrist. The Extensor brevis pollicis extends the proximal phalanx of the thumb. By its continued action it helps to extend and abduct the wrist. The Extensor longus pollicis extends the terminal phalanx of the thumb. By its continued action it helps to extend and abduct the wrist. The Extensor indicis extends the index finger, and by its continued action assists in extending the wrist.

Applied Anatomy.—The tendons of the Extensor muscles of the thumb are liable to become strained, and their sheaths inflamed, after excessive exercise, producing a sausage-shaped swelling along the course of the tendons and giving a peculiar grating sensation

to the finger when the muscles act. The condition is known as *tenosynovitis*, and the coarse grating is quite distinctive.

Paralysis of the Extensor muscles of the wrists and fingers is common in acute or chronic lead-poisoning, and is known as 'wrist-drop.' The Brachio-radialis usually escapes in these cases, unless the muscles of the upper arm are paralysed also. Usually the different Extensor muscles are affected to different extents; thus the thumb, or index, or little finger, may be but slightly implicated, and may recover rapidly while the Extensors of the other fingers or the wrist remain powerless. Some paresis is often shown by the Flexors of the fingers also, these muscles being thrown into a state of tremor whenever extension of the fingers is attempted. Atrophy often follows paralysis in lead poisoning.

IV. Muscles and Fasciæ of the Hand

The muscles of the hand are subdivided into three groups: 1, Those of the thumb, which occupy the radial side and produce the *thenar* eminence;

Fig. 527.—Transverse section through the wrist, showing the annular ligaments and the canals for the passage of the tendons.

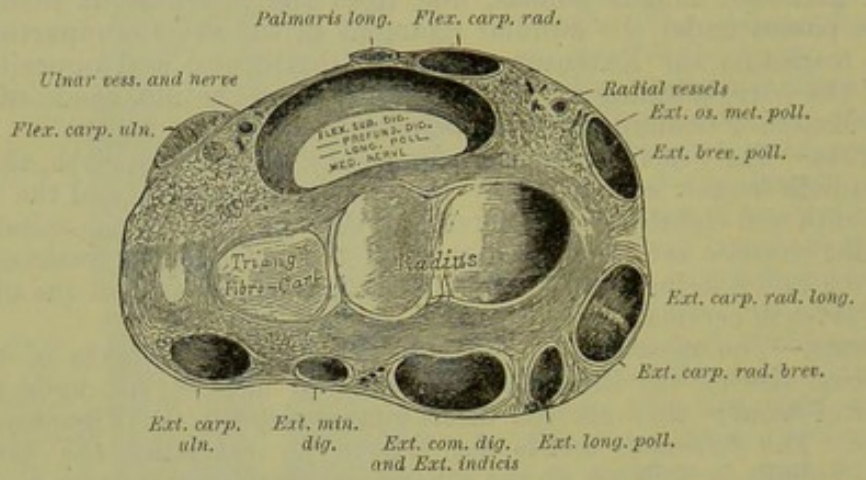

2, those of the little finger, which occupy the ulnar side and give rise to the *hypothenar* eminence; 3, those in the middle of the palm and within the interosseous spaces.

Fig. 528.—Transverse section through the carpus, showing the relative positions of the tendons, vessels, and nerves. (Henle.)

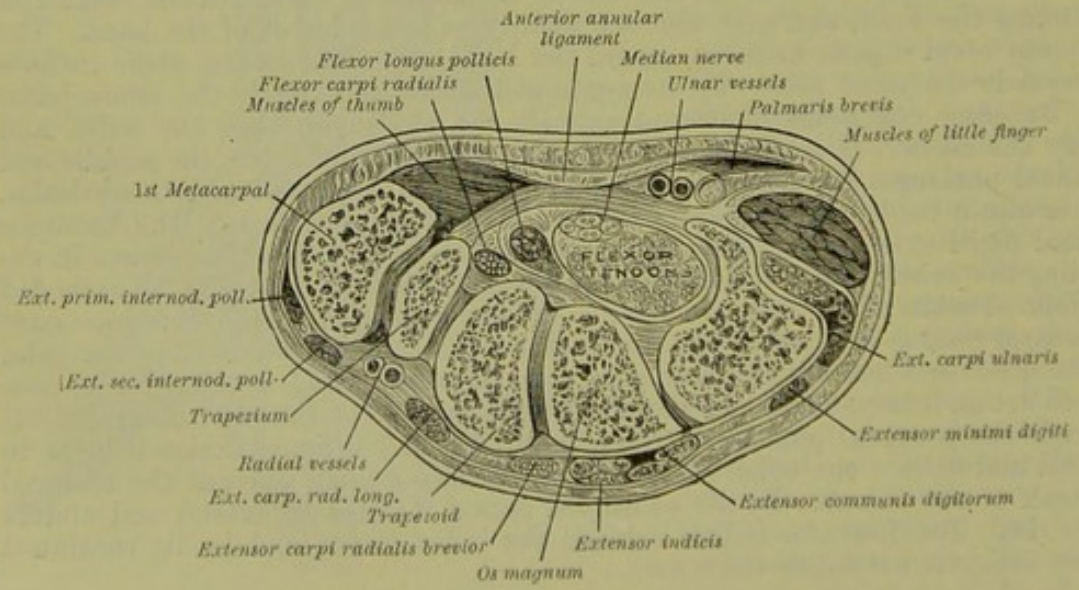

The **anterior annular ligament** (lig. carpi volare) (figs. 527, 528) is a strong, fibrous band, which arches over the carpus, converting the deep groove on the front of the carpal bones into a tunnel, through which the Flexor

tendons of the digits pass. It is attached, internally, to the pisiform and the hook of the unciform; externally, to the tuberosity of the scaphoid, and to the inner part of the anterior surface and the ridge of the trapezium. It is continuous, above, with the deep fascia of the forearm, and may be regarded as a thickened portion of this; and below, with the palmar fascia. It is crossed by the ulnar vessels and nerve, and the cutaneous branches of the median and ulnar nerves. At its outer extremity is the tendon of the Flexor carpi radialis, which lies in the groove on the trapezium between the attachments of the annular ligament to the bone. It has inserted into its anterior surface a part of the tendon of the Palmaris longus and part of the tendon of the Flexor carpi ulnaris, and has arising from it, below, the small muscles of the thumb and little finger. Beneath it pass the tendons of the Flexores sublimis et profundus digitorum, the tendon of the Flexor longus pollicis, and the median nerve.

The **synovial membranes of the flexor tendons at the wrist.**—There are two synovial membranes which enclose all the tendons as they pass beneath this ligament, one for the Flexores sublimis et profundus digitorum, the other for the Flexor longus pollicis (fig. 529). They extend up into the forearm for about an inch above the annular ligament, and occasionally communicate with each other under the ligament. The sheath which surrounds the Flexor tendons of the fingers extends downwards about halfway along the metacarpal bones, where it terminates in blind diverticula around the tendons to the index, middle, and ring fingers. In the case of the little finger, it is prolonged on its tendons, and usually communicates with the synovial sheath of that digit. The sheath which envelops the tendon of the Flexor longus pollicis is continued along the thumb as far as the insertion of the tendon.

Fig. 529.—Diagram showing the arrangement of the synovial sheaths of the palm and fingers.

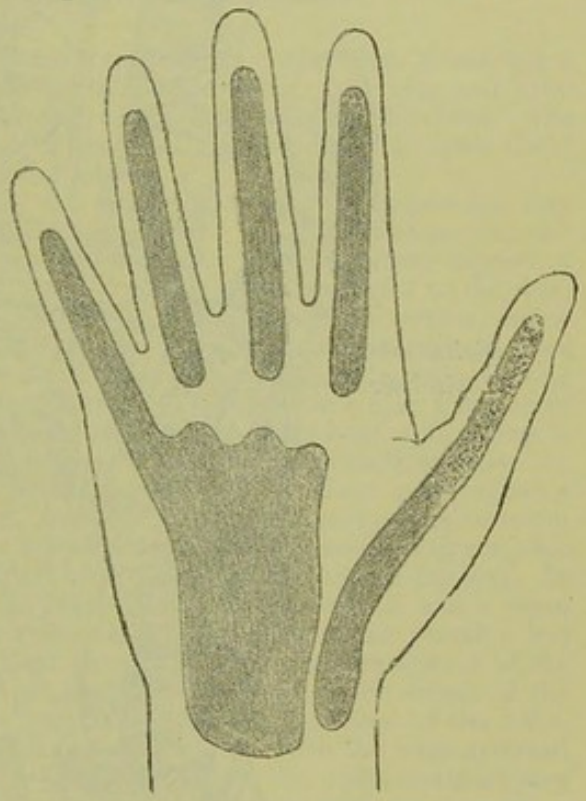

The **posterior annular ligament** (lig. carpi dorsale) (figs. 527, 528) is a strong, fibrous band, extending obliquely downwards and inwards across the back of the wrist, and consisting of part of the deep fascia of the back of the forearm, strengthened by the addition of some transverse fibres. It binds down the Extensor tendons in their passage to the fingers, being attached, internally, to the styloid process of the ulna and to the cuneiform and pisiform; externally, to the outer margin of the radius; and, in its passage across the wrist, to the elevated ridges on the posterior surface of the radius. Between it and the bones are formed six compartments for the passage of tendons, each of which is lined by a separate synovial membrane. One is found in each of the following positions: 1, on the outer side of the styloid process, for the tendons of the Extensor ossis metacarpi and Extensor brevis pollicis; 2, behind the styloid process, for the tendons of the Extensores carpi radialis longior et brevior; 3, about the middle of the posterior surface of the radius, for the tendon of the Extensor longus pollicis; 4, to the inner side of the latter, for the tendons of the Extensor communis digitorum and Extensor indicis; 5, opposite the interval between the radius and ulna, for the Extensor minimi digiti; 6, grooving the back of the ulna, for the tendon of the Extensor carpi ulnaris. The synovial membranes lining these sheaths are usually very extensive, reaching from above the annular ligament, down upon the tendons for a variable distance on the back of the hand.

The **deep palmar fascia** (aponeurosis palmaris) (fig. 530) forms a common sheath which invests the muscles of the hand. It consists of a central and two lateral portions.

The *central portion* occupies the middle of the palm, is triangular in shape, of great strength and thickness, and binds down the tendons and protects the vessels and nerves in this situation. It is narrow above, where it is attached to the lower margin of the annular ligament, and receives the expanded tendon of the Palmaris longus muscle. Below, it is broad and expanded, and divides into four slips, one for each finger. Each slip gives off superficial fibres, which are inserted into the skin of the palm and finger, those to the

FIG. 530.—Palmar fascia.
(From a preparation in the Museum of the Royal College of Surgeons of England.)

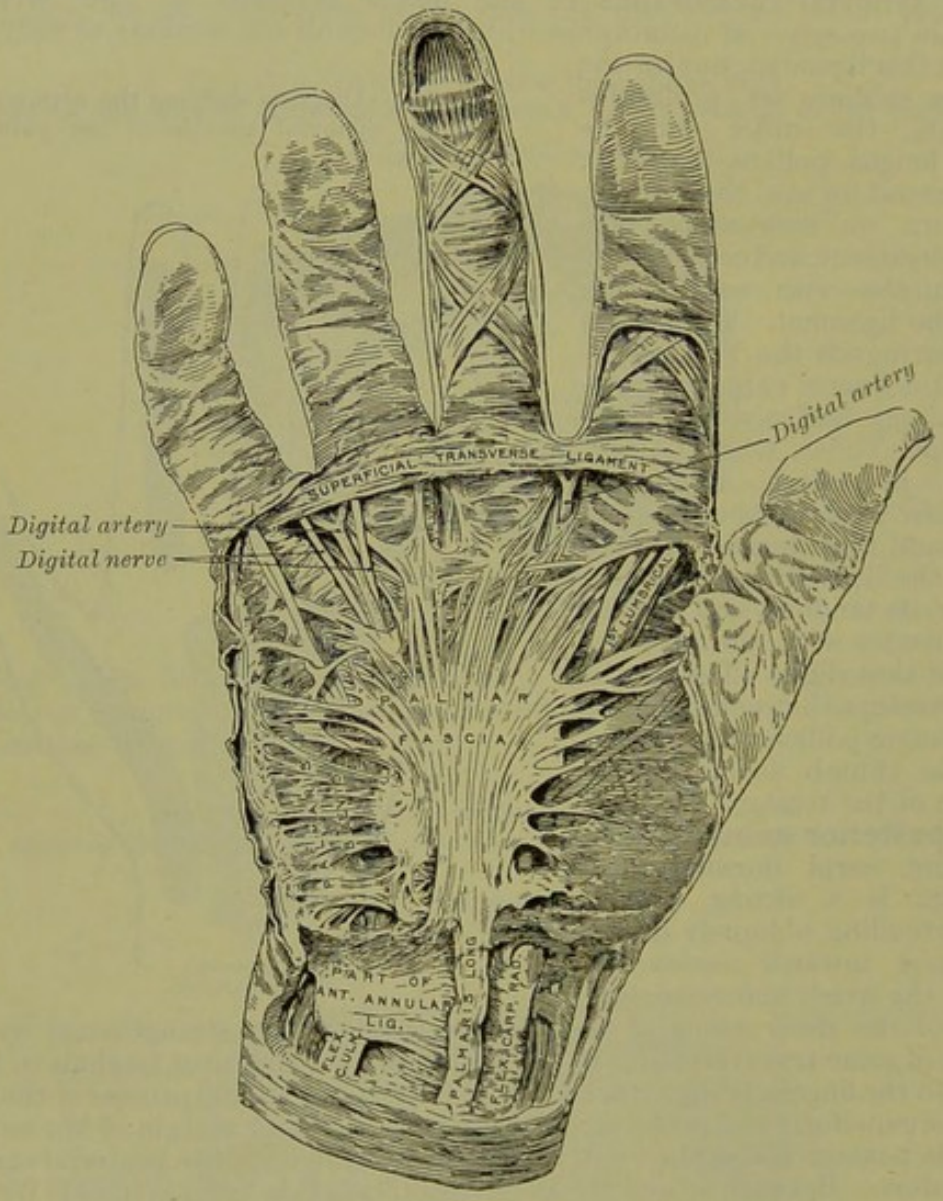

palm joining the skin at the furrow corresponding to the metacarpo-phalangeal articulation, and those to the fingers passing into the skin at the transverse fold at the base of the fingers. The deeper part of each slip subdivides into two processes, which are inserted into the fibrous sheaths which confine the Flexor tendons. From the sides of these processes offsets are sent backwards, to be attached to the transverse metacarpal ligament. By this arrangement short channels are formed on the front of the lower ends of the metacarpal bones, through which the Flexor tendons pass. Between the two processes into which each slip divides is attached the *digital sheath*. The intervals left between the four fibrous slips transmit the digital vessels and nerves, and the tendons of the Lumbricales. At the points of division of the

palmar fascia into the slips above mentioned, numerous strong, transverse fibres (fasciculi transversi) bind the separate processes together. The palmar fascia is intimately adherent to the integument by dense fibro-areolar tissue forming the superficial palmar fascia, and gives origin by its inner margin to the Palmaris brevis. It covers the superficial palmar arch, the tendons of the Flexor muscles, and the branches of the median and ulnar nerves; and on each side it gives off a vertical septum, which is continuous with the interosseous aponeurosis, and separates the lateral from the middle palmar group of muscles.

The *lateral portions* of the palmar fascia are thin, fibrous layers, which cover, on the radial side, the muscles of the ball of the thumb, and, on the ulnar side, the muscles of the little finger; they are continuous with the central portion of the palmar fascia and with the fascia on the dorsum of the hand.

The **superficial transverse ligament** of the fingers is a thin band of transverse fibres (fasciculi transversi); it stretches across the roots of the four fingers, and is closely attached to the skin of the clefts, and internally to the fifth metacarpal bone, forming a sort of rudimentary web. Beneath it the digital vessels and nerves pass onwards to their destination.

Applied Anatomy.—The palmar fascia is liable to undergo contraction, producing a very inconvenient deformity, known as 'Dupuytren's contraction.' The ring and little fingers are most frequently implicated, but the others may also be involved. The proximal phalanx is drawn down and cannot be straightened, and the two distal phalanges become similarly flexed as the disease advances.

Owing to their constant exposure to injury and septic influences, the fingers are very liable to become the seat of serious inflammatory mischief. To this inflammation the term *paronychia* or *whitlow* is given, and this affection may assume various degrees of severity. In the mildest cases the disease is confined to the superficial layer of the skin, and suppuration takes place beneath it. This is known as *subcuticular paronychia*, and is a comparatively simple condition, for an incision through the epidermis will at once relieve it. The only complication is that the pus may burrow under the nail, causing increased pain. A more severe condition is the *paronychia cellulosa*, in which the pulp of the end of the finger is involved. This is attended with intense throbbing pain, owing to the fact that the inflamed area is covered by thick and often horny epithelium, when the disease occurs in the labouring classes, as it so frequently does. In these cases, unless a timely incision is made, the inflammation is liable to involve the periosteum covering the phalanx, as there is least resistance in this direction, and *subperiosteal paronychia* is set up, which is followed by necrosis of a part or the whole of the ungual phalanx. In other cases, the inflammation may involve the theca of the Flexor tendons, and a *thecal paronychia* may be set up. The inflammation then rapidly spreads up the sheath; but the extent will depend upon the particular digit involved. From the description of the Flexor sheaths given above, it will be evident that inflammation of the sheath of the thumb and little finger may prove a far more formidable affection than that of the other three digits, because the sheaths of these two digits communicate with the large synovial sheaths which surround the Flexor tendons (page 551), and the inflammation may extend into the palm of the hand and beneath the annular ligament into the forearm.

In order to relieve these conditions, free and early incisions are necessary, and must be made with discrimination, in order to avoid wounding important structures. In the pulp of the finger—i.e. over the distal phalanx—the incision should be made in the middle line and down to the bone. In the rest of the finger, the incision should be made in the middle line over the phalanges, and not over the interphalangeal joints. In the palm of the hand, incisions may be made either on the distal or proximal side of the superficial palmar arch. On the distal sides the incisions should be made over the metacarpal bones, preferably those of the index and middle finger. On the proximal side, the safest line of incision is along the radial side of the hypothenar eminence, between the ulnar artery and nerve internally, and the median nerve externally. When suppuration has extended under the annular ligament, and incisions are required in the forearm, the positions in which they should be made are over the tendons of the Flexor sublimis digitorum, between the median nerve and the ulnar artery, and over the tendon of the Flexor longus pollicis, between the radial artery and the tendon of the Flexor carpi radialis.

Chronic inflammation of the common flexor sheath is occasionally met with, constituting a disease known as 'compound palmar ganglion': it presents an hourglass outline, with a swelling in front of the wrist and in the palm of the hand, and a constriction, corresponding to the annular ligament, between the two. The fluid can be forced from the one swelling to the other under the ligament, and when this is done, a creaking sensation is sometimes perceived, from the presence of 'melon-seed' bodies in the interior of the ganglion.

11. *Radial Region* (figs. 531, 532)

Abductor pollicis. Flexor brevis pollicis.
Opponens pollicis. Adductor obliquus pollicis.
Adductor transversus pollicis.

The **Abductor pollicis** (m. abductor pollicis brevis) is a thin, flat muscle, placed immediately beneath the integument. It arises from the annular ligament, the tuberosity of the scaphoid, and the ridge of the trapezium, frequently by two distinct slips. Running outwards and downwards, it is inserted by a thin, flat tendon into the radial side of the base of the first phalanx of the thumb and the capsule of the metacarpo-phalangeal articulation.

The **Opponens pollicis** is a small, triangular muscle, placed beneath the preceding. It arises from the palmar surface of the ridge on the trapezium and from the annular ligament, passes downwards and outwards, and is inserted into the whole length of the metacarpal bone of the thumb on its radial side.

Fig. 531.—Muscles of the thumb.
(From a preparation in the Museum of the Royal College of Surgeons of England.)

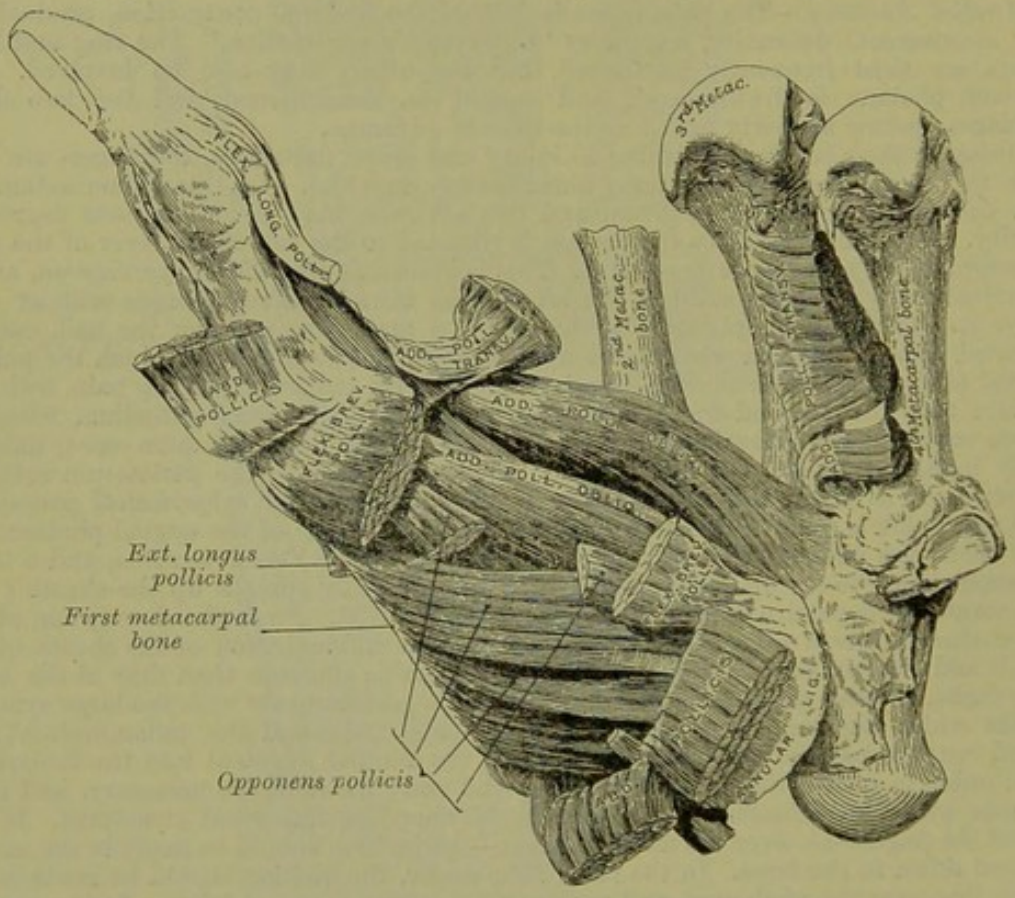

The **Flexor brevis pollicis** consists of two portions, outer and inner. The *outer and more superficial portion* arises from the outer two-thirds of the lower border of the annular ligament and the lower part of the ridge on the trapezium ; it passes along the outer side of the tendon of the Flexor longus pollicis, and, becoming tendinous, has a sesamoid bone developed in its tendon, and is inserted into the outer side of the base of the first phalanx of the thumb. The *inner and deeper portion* of the muscle is very small, and arises from the ulnar side of the first metacarpal bone between the Adductor obliquus pollicis and the outer head of the First dorsal interosseous, and is inserted into the inner side of the base of the first phalanx with the Adductor obliquus pollicis.

The **Adductor obliquus pollicis** arises by several slips from the os magnum, the bases of the second and third metacarpal bones, the anterior carpal ligaments, and the sheath of the tendon of the Flexor carpi radialis.

From this origin the greater number of fibres pass obliquely downwards and converge to a tendon, which, uniting with the tendons of the deeper portion of the Flexor brevis pollicis and the Adductor transversus, is inserted into the inner side of the base of the first phalanx of the thumb, a sesamoid bone being developed in the tendon of insertion. A considerable fasciculus, however,

Fig. 532.—Muscles of the left hand. Palmar surface.

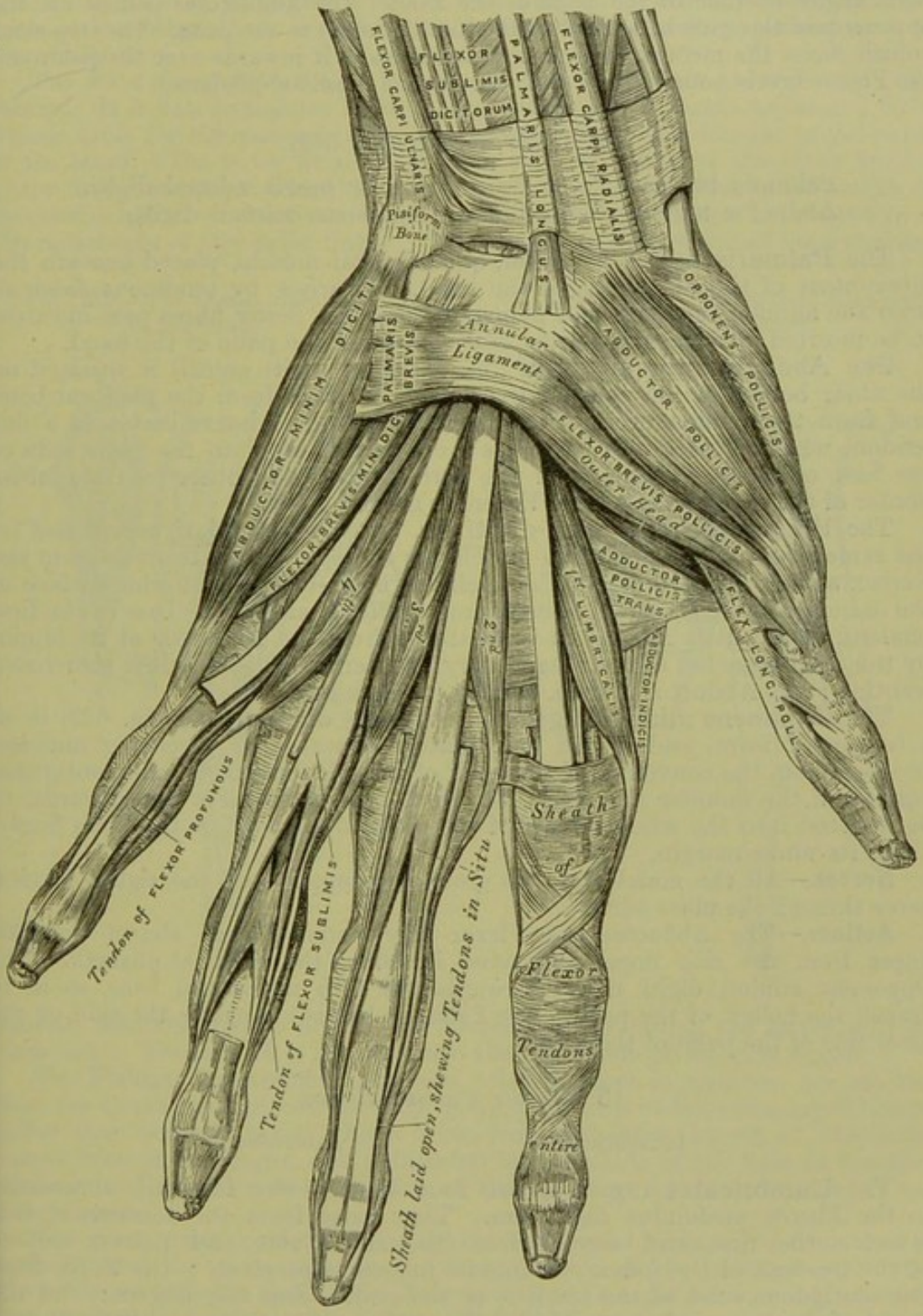

passes more obliquely outwards beneath the tendon of the long Flexor to join the superficial portion of the short Flexor and the Abductor pollicis.

The **Adductor transversus pollicis** (fig. 531) is the most deeply seated of this group of muscles. It is of a triangular form, arising by its broad base from the lower two-thirds of the metacarpal bone of the middle finger on its palmar surface; the fibres, proceeding outwards, converge, to be inserted,

with the inner part of the Flexor brevis pollicis, and the Adductor obliquus pollicis, into the ulnar side of the base of the first phalanx of the thumb.

Nerves.—The Abductor, Opponens, and outer head of the Flexor brevis pollicis are supplied by the sixth cervical nerve through the median nerve; the inner head of the Flexor brevis, and the Adductors, by the eighth cervical through the ulnar nerve.

Actions.—The Abductor pollicis draws the thumb forwards in a plane at right angles to that of the palm of the hand. The Adductores pollicis are the opponents of this muscle, and approximate the thumb to the palm. The Opponens pollicis flexes the metacarpal bone: that is, draws it inwards over the palm and the Flexor brevis pollicis flexes and adducts the proximal phalanx.

12. *Ulnar Region* (fig. 532)

Palmaris brevis.	Flexor brevis minimi digiti.
Abductor minimi digiti.	Opponens minimi digiti.

The **Palmaris brevis** is a thin, quadrilateral muscle, placed beneath the integument of the ulnar side of the hand. It arises by tendinous fasciculi from the annular ligament and palmar fascia; the fleshy fibres pass inwards, to be inserted into the skin on the inner border of the palm of the hand.

The **Abductor minimi digiti** (m. abductor digiti quinti) is situated on the ulnar border of the palm of the hand. It arises from the pisiform bone and from the tendon of the Flexor carpi ulnaris, and terminates in a flat tendon, which divides into two slips; one is inserted into the ulnar side of the base of the first phalanx of the little finger; the other into the ulnar border of the aponeurosis of the Extensor minimi digiti.

The **Flexor brevis minimi digiti** (m. flexor digiti quinti brevis) lies on the same plane as the preceding muscle, on its radial side. It arises from the convex surface of the hook of the unciform bone, and the anterior surface of the annular ligament, and is inserted into the inner side of the base of the first phalanx of the little finger. It is separated from the Abductor at its origin, by the deep branches of the ulnar artery and nerve. This muscle is sometimes wanting; the Abductor is then, usually, of large size.

The **Opponens minimi digiti** (m. opponens digiti quinti) (fig. 522) is of a triangular form, and placed immediately beneath the preceding muscles. It arises from the convexity of the hook of the unciform bone, and contiguous portion of the annular ligament; its fibres pass downwards and inwards, to be inserted into the whole length of the metacarpal bone of the little finger, along its ulnar margin.

Nerves.—All the muscles of this group are supplied by the eighth cervical nerve through the ulnar nerve.

Actions.—The Abductor and Flexor brevis minimi digiti abduct the little finger from the ring finger and assist in flexing the proximal phalanx. The Opponens minimi digiti draws forwards the fifth metacarpal bone, so as to deepen the hollow of the palm. The Palmaris brevis corrugates the skin on the inner side of the palm of the hand.

13. *Middle Palmar Region*

Lumbricales.	Interossei.

The **Lumbricales** (fig. 532) are four small fleshy fasciculi, accessories to the Flexor profundus digitorum. They arise from the tendons of this muscle: the first and second, from the radial side and palmar surface of the tendons of the index and middle fingers respectively; the third, from the contiguous sides of the tendons of the middle and ring fingers; and the fourth, from the contiguous sides of the tendons of the ring and little fingers. Each passes to the radial side of the corresponding finger, and opposite the metacarpo-phalangeal articulation is inserted into the tendinous expansion of the Extensor communis digitorum covering the dorsal aspect of the finger.

The **Interossei** (figs. 533, 534) are so named from occupying the intervals between the metacarpal bones, and are divided into two sets, a dorsal and a palmar.

The **Dorsal interossei** (interossei dorsales) are four in number, larger than the Palmar, and occupy the intervals between the metacarpal bones. They are bipenniform muscles, each arising by two heads from the adjacent sides of the metacarpal bones, but more extensively from the metacarpal bone of the finger into which the muscle is inserted. They are inserted into the bases of the first phalanges and into the aponeuroses of the common Extensor tendons. Between the double origin of each of these muscles is a narrow triangular interval, through the first of which the radial artery passes ; through each of the other three a perforating branch from the deep palmar arch is transmitted.

The *First dorsal interosseous muscle*, or *Abductor indicis*, is larger than the others. It is flat, triangular in form, and arises by two heads, separated by a fibrous arch, for the passage of the radial artery from the dorsum to the palm of the hand. The outer head arises from the upper half of the ulnar border of the first metacarpal bone ; the inner head, from almost the entire length of the radial border of the second metacarpal bone ; the tendon is inserted into the radial side of the index finger. The *Second* and *Third dorsal interossei* are

Fig. 533.—The Dorsal interossei of left hand.

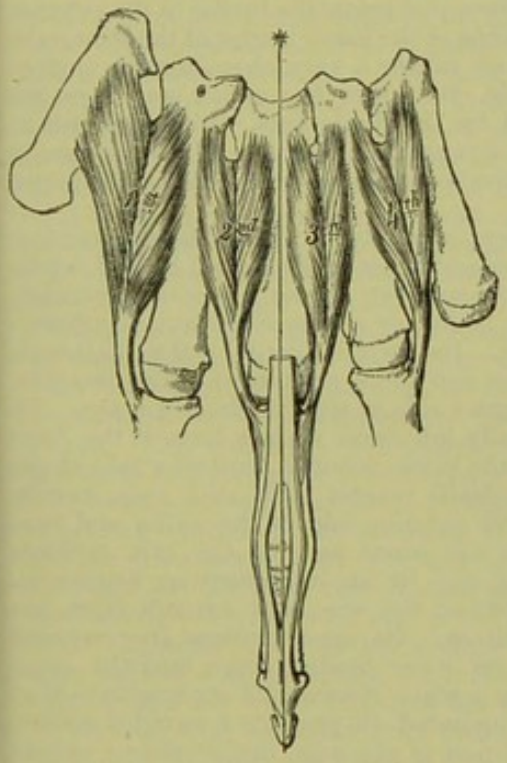

Fig. 534.—The Palmar interossei of left hand.

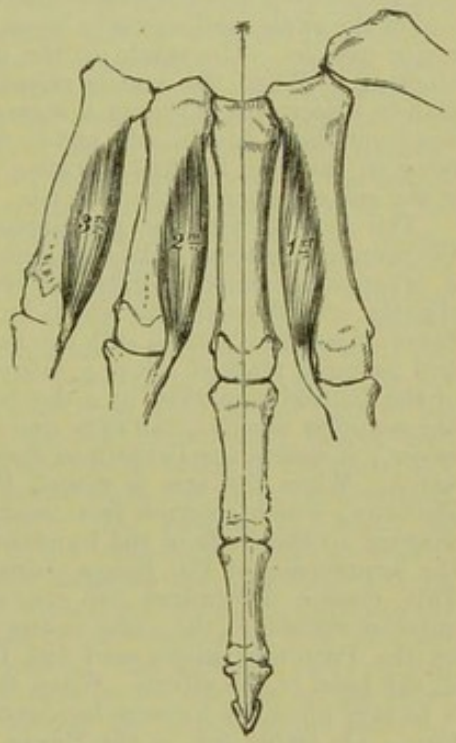

inserted into the middle finger, the former into its radial, the latter into its ulnar side. The *Fourth* is inserted into the ulnar side of the ring finger.

The **Palmar interossei** (interossei volares), three in number, are smaller than the Dorsal, and placed upon the palmar surfaces of the metacarpal bones, rather than between them. Each arises from the entire length of the metacarpal bone of one finger, and is inserted into the side of the base of the first phalanx and aponeurotic expansion of the common Extensor tendon of the same finger.

The *First* arises from the ulnar side of the second metacarpal bone, and is inserted into the same side of the first phalanx of the index finger. The *Second* arises from the radial side of the fourth metacarpal bone, and is inserted into the same side of the ring finger. The *Third* arises from the radial side of the fifth metacarpal bone, and is inserted into the same side of the little finger. From this account it may be seen that each finger is provided with two Interossei, with the exception of the little finger, in which the Abductor muscle takes the place of one of the pair.

Nerves.—The two outer Lumbricales are supplied by the sixth cervical nerve, through the third and fourth digital branches of the median nerve : the two inner

Lumbricales and all the Interossei are supplied by the eighth cervical nerve, through the deep palmar branch of the ulnar nerve. The third Lumbrical frequently receives a twig from the median.

Actions.—The Palmar interosseous muscles adduct the fingers to an imaginary line drawn longitudinally through the centre of the middle finger; and the Dorsal interossei abduct the fingers from that line. In addition to this the Interossei, in conjunction with the Lumbricales, flex the first phalanges at the metacarpo-phalangeal joints, and extend the second and third phalanges in consequence of their insertions into the expansions of the Extensor tendons. The Extensor communis digitorum is believed to act almost entirely on the first phalanges.

Surface Form.—The *Pectoralis major* largely influences surface form and conceals a considerable part of the thoracic wall in front. Its sternal origin presents a border, which bounds and determines the width of the sternal furrow. Its clavicular origin is somewhat depressed and flattened, and between the two portions of the muscle there is often an oblique depression. The outer margin of the muscle is generally well marked above, and forms the inner boundary of a triangular depression, the infraclavicular fossa, which separates the Pectoralis major from the Deltoid. It gradually becomes less marked as it approaches the tendon of insertion, and is more closely blended with the Deltoid muscle. The lower border of the Pectoralis major forms the rounded anterior axillary fold, and corresponds with the direction of the fifth rib. When the arm is raised, the lowest slip of origin of the *Pectoralis minor* produces a local fulness just below the border of the anterior fold of the axilla, and serves to break the sharp outline of the lower border of the Pectoralis major muscle. The origin of the *Serratus magnus* causes a very characteristic surface marking. When the arm is raised from the side, the lower five or six serrations are plainly discernible, forming a zigzag line, caused by the digitations, which diminish in size from above downwards, and have their apices arranged on a curve. When the arm is lying by the side, the first serration to appear at the lower margin of the Pectoralis major is the one attached to the fifth rib.

The *Deltoid*, with the prominence of the upper extremity of the humerus, produces the rounded contour of the shoulder. It is rounder and fuller in front than behind, where it presents a somewhat flattened form. Above, its anterior border presents a rounded, slightly curved eminence, which forms the outer boundary of the infraclavicular fossa; below, it is closely united with the Pectoralis major. Its posterior border is thin, flattened, and scarcely marked above; below, it is thicker and more prominent. The insertion of the Deltoid is marked by a depression on the outer side of the middle of the arm. Of the scapular muscles, the only one which materially influences surface form is the *Teres major*; it assists the Latissimus dorsi in forming the thick, rounded, posterior fold of the axilla. When the arm is raised, the *Coraco-brachialis* reveals itself as a long, narrow elevation, which emerges from under cover of the anterior fold of the axilla and runs internal to the shaft of the humerus. The front and inner part of the arm presents the prominence of the Biceps, bounded on either side by an intermuscular depression. This muscle determines the contour of the front of the arm, and extends from the anterior margin of the axilla to the bend of the elbow. Its upper tendons are concealed by the Pectoralis major and the Deltoid, and its lower tendon sinks into the space at the bend of the elbow. When the muscle is in a state of complete contraction—that is to say, when the forearm has been flexed and supinated—it presents a rounded convex form. On either side of the Biceps, at the lower part of the arm, the *Brachialis anticus* is discernible. On the outer side it forms a narrow eminence, which extends some distance up the arm; on the inner side it shows itself only as a little fulness just above the elbow. On the back of the arm the long head of the *Triceps* may be seen as a longitudinal eminence emerging from under cover of the Deltoid, and gradually merging into the longitudinal flattened plane of the tendon of the muscle on the lower part of the back of the arm. The tendon of insertion of the muscle extends about halfway up the back of the arm, and forms an elongated flattened plane when the muscle is in action. Under similar conditions the surface forms produced by the inner and outer heads of the muscle are well seen.

On the anterior aspect of the elbow are two muscular elevations, one on either side, separated above, and converging below so as to form the inner and outer boundaries of a triangular space, the anticubital fossa. Of these, the inner elevation, consisting of the Pronator teres and the Flexors, forms the prominence along the inner side and front of the forearm. It is a fusiform mass, pointed above at the internal condyle, and gradually tapering off below. The *Pronator teres*, the outermost muscle of the group, forms the inner boundary of the anticubital fossa. It is shorter, less prominent, and more oblique than the outer boundary. The most prominent part of the eminence is produced by the *Flexor carpi radialis*, the muscle next in order on the inner side of the preceding one. It forms a rounded prominence above, and may be traced downwards to its tendon, which can be felt lying on the front of the wrist, nearer its radial than its ulnar border, and to the inner side of the radial artery. The *Palmaris longus* presents no surface marking

above, but below, its tendon is the most prominent of the tendons on the front of the wrist, standing out, when the muscle is in action, as a sharp tense cord beneath the skin. The *Flexor sublimis digitorum* does not directly influence surface form. The position of its four tendons on the front of the lower part of the forearm is indicated by an elongated depression between the tendons of the Palmaris longus and the Flexor carpi ulnaris. The *Flexor carpi ulnaris* occupies a small part of the posterior surface of the forearm, and is separated from the Extensor and Supinator group, which occupies the greater part of this surface, by the ulnar furrow, produced by the subcutaneous posterior border of the ulna. Its tendon can be perceived along the ulnar border of the front of the forearm, and is most marked when the hand is flexed and adducted. The external group of muscles, consisting of the Brachio-radialis, the Extensors and Supinator brevis, occupies the outer, and a considerable portion of the posterior, surface of this region. It forms a fusiform mass, which is altogether on a higher level than that produced by the Pronator teres and Flexors. Its apex is between the Triceps and Brachialis anticus muscles some distance above the elbow-joint ; it acquires its greatest breadth opposite the external condyle, below which it shades off into a flattened surface. About the middle of the forearm it divides into two longitudinal eminences which diverge from each other, leaving a triangular interval between them. The outer of these eminences consists of the Brachio-radialis and the Extensores carpi radialis longior et brevior, and descends from the external condylar ridge in the direction of the styloid process of the radius. The inner consists of the Extensor communis digitorum, the Extensor minimi digiti, and the Extensor carpi ulnaris ; it commences above as a tapering mass at the external condyle of the humerus ; above it is separated from the Anconeus by a well-marked furrow, and below, from the Pronator teres and Flexor mass by the ulnar furrow. The only two muscles of this region which require special mention, as independently influencing surface form, are the Brachio-radialis and the Anconeus. The inner border of the *Brachio-radialis* forms the outer boundary of the anticubital fossa. It commences as a rounded border above the condyle, and is longer, less oblique, and more prominent than the inner boundary. Lower down the muscle forms a full fleshy mass on the outer side of the upper part of the forearm, and below tapers into a tendon, which may be traced to the styloid process of the radius. The *Anconeus* presents a distinct and characteristic surface form in the shape of a triangular, slightly elevated area, immediately external to the subcutaneous posterior surface of the olecranon, and differentiated from the common Extensor group by an oblique depression. The upper angle of the triangle corresponds to the external condyle, and is marked by a depression or dimple in this situation. In the interval, caused by the divergence from each other of the two masses into which the Extensor and Supinator group is divided at the lower part of the forearm, an oblique elongated eminence is seen, caused by the emergence of two of the Extensors of the thumb from their deep origin at the back of the forearm. This eminence, full above, flattened and partially subdivided below, runs downwards and outwards over the back and outer surface of the radius to the outer side of the wrist-joint, where it forms a ridge, especially marked when the thumb is extended, and passing onwards to the posterior aspect of the thumb. The tendons of most of the Extensor muscles are to be seen and felt at the level of the wrist-joint. Most externally are those of the Extensor ossis metacarpi pollicis and the Extensor brevis pollicis, forming a vertical ridge over the outer side of the joint, from the styloid process of the radius to the thumb. Internal to this is the oblique ridge produced by the tendon of the Extensor longus pollicis, very noticeable when the muscle is in action. The Extensor carpi radialis longior is scarcely to be felt, but the Extensor carpi radialis brevior can be perceived as a vertical ridge emerging from under the ulnar border of the tendon of the Extensor longus pollicis, when the hand is forcibly extended at the wrist. Internal to this the tendons of the Extensor indicis, Extensor communis digitorum, and Extensor minimi digiti can be felt ; the last being separated from those of the Extensor communis by a slight furrow.

The muscles of the hand are principally concerned, as far as regards surface form, in producing the thenar and hypothenar eminences, and cannot be individually distinguished on the surface. The thenar eminence is larger and rounder than the hypothenar, which presents a long, narrow eminence along the ulnar side of the hand. When the *Palmaris brevis* is in action it produces a wrinkling of the skin over the hypothenar eminence, and a dimple on the ulnar border of the hand. On the back of the hand the *Dorsal interossei* produce elongated swellings between the metacarpal bones. When the thumb is closely adducted to the hand, the First dorsal interosseous (Abductor indicis) forms a prominent fusiform bulging ; the other Interossei are not so marked.

The skin over the inner side and front of the forearm is thin, smooth, and sensitive ; it contains few hairs and many sweat-glands. Over the outer side and back of the arm and forearm it is thicker, denser, and less sensitive ; it contains more hairs and fewer sweat-glands. Over the olecranon the cuticle is thick and rough ; the skin is loosely connected to the underlying tissues, and transversely wrinkled when the forearm is extended. At the front of the wrist, the skin presents three transverse furrows, which correspond from above downwards to the position of the styloid process of the ulna, the wrist-joint, and the mid-carpal joint respectively. The skin of the palm of the hand differs

considerably from that of the forearm. At the wrist it suddenly becomes hard and dense and covered with a thick layer of cuticle. The skin in the thenar region presents these characteristics less than elsewhere. In spite of this hardness and density, the skin of the palm is exceedingly sensitive and very vascular. It is destitute of hair, and contains no sebaceous follicles. It is tied down by fibrous bands along the lines of flexion of the digits, producing certain furrows of a permanent character. One of these starting from about the tubercle of the scaphoid, curves round the thenar eminence, and ends on the radial border of the hand, a little above the metacarpo-phalangeal joint of the index finger. It corresponds to the outer border of the central portion of the palmar fascia, and is produced by the movement of the thumb at the carpo-metacarpal joint. A second line begins at the end of the first, and extends obliquely across the palm, upwards and inwards, to the ulnar margin about the middle of the fifth metacarpal bone. A third commences at the ulnar border of the hand, about an inch below the termination of the second, and extends outwards across the palm over the heads of the third, fourth, and fifth metacarpal bones. The last two lines are caused by flexion of the fingers at the metacarpo-phalangeal joints. Over the fingers the skin again becomes thinner, especially at the flexures of the joints ; and over the terminal phalanges it is thrown into numerous ridges, in consequence of the arrangement of the papillæ in it. These ridges form, in different individuals, distinctive and permanent patterns, which may be used for purposes of identification. The superficial fascia in the palm is made up of dense fibro-fatty tissue. This tissue binds down the skin so firmly to the deep palmar fascia that very little movement is permitted between the two.

Fig. 535.—Fracture of the middle of the clavicle.

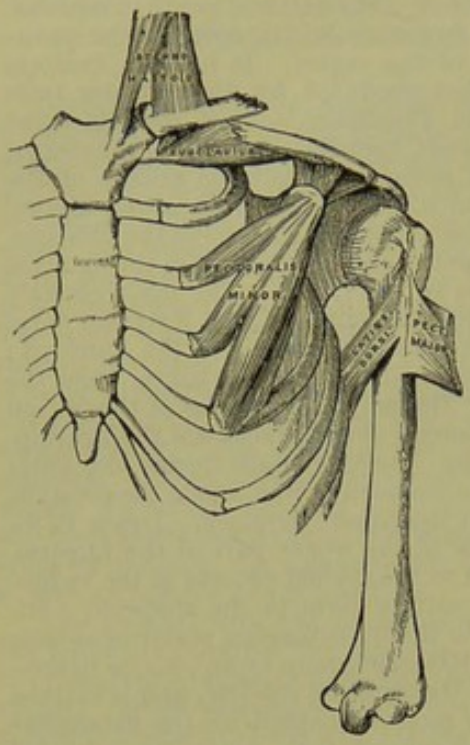

Applied Anatomy.—In considering the actions of the various muscles upon fractures of the upper extremity, the most common forms of injury have been selected both for illustration and description.

Fracture of the *middle of the clavicle* (fig. 535) is usually attended with considerable displacement of the outer fragment, which is drawn downwards and inwards, and at the same time rotated, so that its outer end is carried forwards and its inner end backwards.

The displacement is produced as follows: the outer fragment is drawn *downwards* by the weight of the arm, the Trapezius not being able to support the weight of the limb. It is drawn *inwards* by the Subclavius and Pectoralis minor, possibly assisted by the Pectoralis major and Latissimus dorsi ; and is rotated on an axis drawn through its own centre by the Serratus magnus, which causes the scapula to rotate on the wall of the chest, and carries the acromion and outer end of the outer fragment of the clavicle forwards, and so carries the inner end of the outer portion backwards. The depression of the whole outer fragment is produced by the weight of the arm and by the contraction of the Deltoid. The causes of displacement having been ascertained, it is easy to apply the appropriate treatment. The outer fragment is to be drawn outwards, and, together with the scapula, raised upwards to a level with the inner fragment, and retained in that position.

Fig. 536.—Fracture of the surgical neck of the humerus.

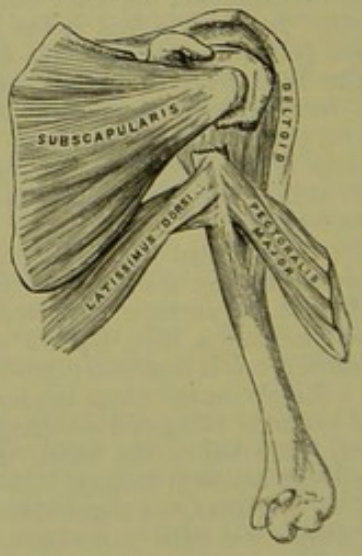

In fracture of the *acromial end of the clavicle*, between the conoid and trapezoid ligaments, only slight displacement occurs, as these ligaments, from their oblique insertion, serve to hold both portions of the bone in apposition. Fracture, also, of the *sternal end*, internal to the costo-clavicular ligament, is attended with only slight displacement, this ligament serving to retain the fragments in close apposition.

Fracture of the *acromion process* outside the ligaments usually arises from violence applied to the upper and outer part of the shoulder. There is great displacement ; the

outer fragment being drawn downwards by the weight of the arm, and rotated forwards and inwards, so that it forms a right angle with the rest of the bone.

Fracture of the *surgical neck of the humerus* (fig. 536) is very common, is attended with considerable displacement, and its appearances correspond somewhat with those of dislocation of the head of the humerus into the axilla. The upper fragment remains in its place under the coraco-acromial ligament; the lower fragment is drawn inwards by the Pectoralis major, Latissimus dorsi, and Teres major; and the humerus is thrown obliquely outwards from the side by the Deltoid, and occasionally elevated so as to cause the upper end of the lower fragment to project beneath and in front of the coracoid process. The deformity is reduced by fixing the shoulder, and drawing the arm outwards and downwards. To counteract the opposing muscles, and to keep the fragments in position, a cone-shaped pad should be placed in the axilla, and the arm bandaged to the side by a broad roller passed round the chest in such a manner that the elbow is carried slightly forwards, so as to throw the upper end of the lower fragment backwards and outwards towards the head of the bone. The whole is then covered with a carefully moulded guttapercha or poroplastic shoulder-cap.

Fig. 537.—Fracture of the humerus above the condyles.

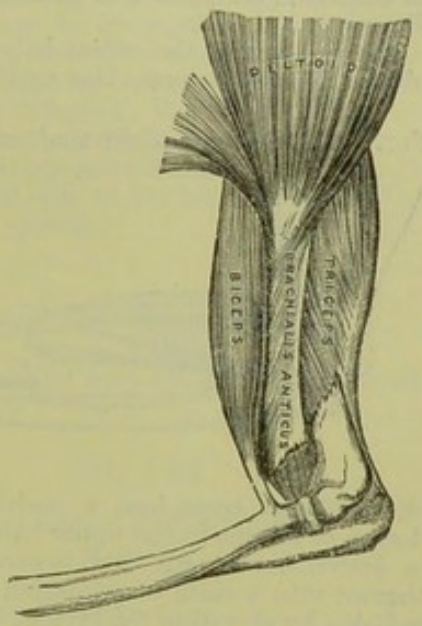

In fracture of the *shaft of the humerus* below the insertion of the Pectoralis major, Latissimus dorsi, and Teres major, and above the insertion of the Deltoid, there is also considerable deformity, the upper fragment being drawn inwards by the first-mentioned muscles, and the lower fragment upwards and outwards by the Deltoid. Shortening of the limb results, with a considerable prominence at the seat of fracture, from the fractured ends of the bone riding over one another, especially if the fracture take place in an oblique direction. The fragments may be brought into apposition by extension from the elbow, and retained in that position by adopting the same means as in the preceding injury.

In fracture of the *shaft of the humerus* immediately below the insertion of the Deltoid, the amount of deformity depends greatly upon the direction of the fracture. If it occur in a transverse direction, only slight displacement takes place, the upper fragment being drawn a little forwards; but in oblique fracture, the combined actions of the Biceps and Brachialis anticus muscles in front and the Triceps behind draw upwards the lower fragment, causing it to glide over the upper fragment, either backwards or forwards, according to the direction of the fracture. Simple extension reduces the deformity, and the application of a shoulder-cap and splints to the arm will retain the fragments in apposition. Care should be taken not to raise the elbow; but the forearm and hand may be supported in a sling.

Fig. 538.—Fracture of the olecranon.

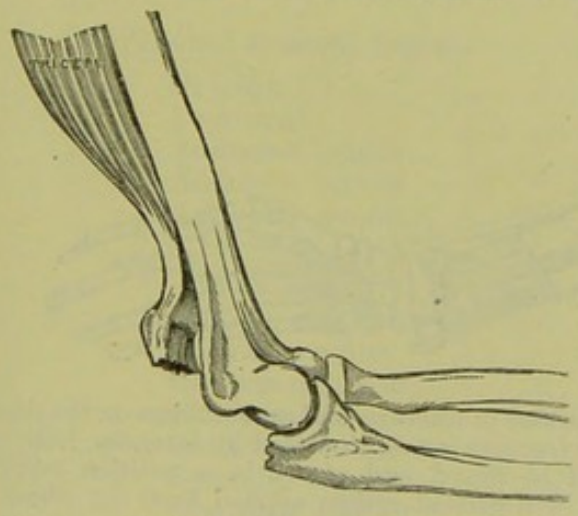

Fracture of the *humerus* (fig. 537) immediately above the condyles deserves very attentive consideration, as the general appearances correspond somewhat with those produced by separation of the epiphysis of the humerus, and with those of dislocation of the radius and ulna backwards. If the direction of the fracture is oblique, from above, downwards and forwards, the lower fragment is drawn upwards by the Brachialis anticus and Biceps in front, and the Triceps behind; and at the same time is drawn backwards behind the upper fragment by the Triceps. This injury may be diagnosed from dislocation by the increased mobility in fracture, the existence of crepitus, and the fact that the deformity is remedied by extension, but is reproduced on the discontinuance of it. The age of the patient is of importance in distinguishing this form of injury from separation of the epiphysis. In some cases where the injury has been produced by falls on the elbow, the lower fragment is drawn upwards and forwards, causing a considerable

prominence in front; and the upper fragment projects backwards beneath the tendon of the Triceps.

In fracture of the *olecranon process* (fig. 538) the detached fragment is displaced upwards, by the action of the Triceps muscle, from half an inch to two inches; the prominence of the elbow is consequently lost, and a deep hollow is felt at the back part of the joint, which is much increased on flexing the limb. The patient at the same time loses, more or less, the power of extending the forearm. The treatment consists in wiring the fragments together; but if for some reason this operation is not desirable, the fragments should be approximated by strapping or a figure-of-8 bandage, and the arm put up in an extended position in order to relax the Triceps. Massage and passive movements must be employed early, for fear of ankylosis. Union, when wiring is not resorted to, is usually fibrous.

In fracture of the *radius* below the insertion of the Biceps, but above the insertion of the Pronator teres, the upper fragment is strongly supinated by the Biceps and Supinator brevis, and at the same time drawn forwards and flexed by the Biceps; the lower fragment is pronated and drawn inwards towards the ulna by the Pronators. Thus there is extreme displacement with very little deformity. In treating such a fracture the arm must be put up in a position of supination, otherwise union will take place with great impairment of the movements of the hand. In fractures of the radius below the insertion of the Pronator teres (fig. 539), the upper fragment is drawn upwards by the Biceps, and inwards by the Pronator teres, into a position midway between pronation and supination, and a degree of fulness in the upper half of the forearm is thus produced. The lower fragment is drawn downwards and inwards towards the ulna by the Pronator quadratus, and thrown into a state of pronation by the same muscle; at the same time, the Brachio-radialis, by elevating the styloid process, into which it is inserted, will serve to depress the upper end of the lower fragment still more towards the ulna. In order to relax the opposing muscles the forearm should be bent, and the limb placed in a position midway between pronation and supination; the fracture is then easily reduced by extension from the wrist and elbow. Well-padded splints should be applied on both sides of the forearm from the elbow to the wrist; the hand being allowed to fall will, by its own weight, counteract the action of the Pronator quadratus and Brachio-radialis, and elevate the lower fragment to the level of the upper one.

Fig. 539.—Fracture of the shaft of the radius.

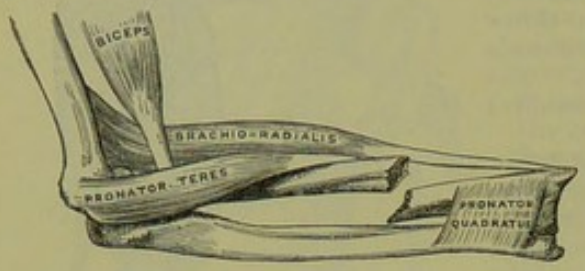

In fracture of the *shaft of the ulna* the upper fragment retains its usual position, but the lower fragment is drawn outwards towards the radius by the Pronator quadratus,

Fig. 540.—Fracture of the lower end of the radius.

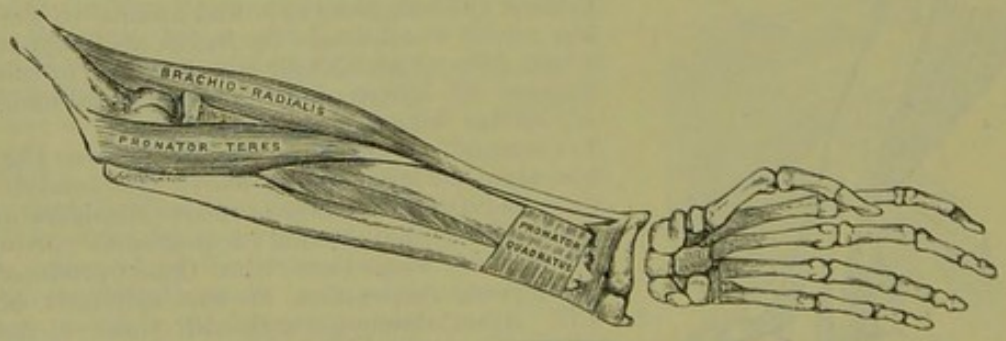

producing a well-marked depression at the seat of fracture, and some fulness on the dorsal and palmar surfaces of the forearm. The fracture is easily reduced by extension from the wrist and forearm. The forearm should be flexed, and placed in a position midway between pronation and supination, and well-padded splints applied from the elbow to the ends of the fingers.

In fracture of the *shafts of the radius and ulna together*, the lower fragments are drawn upwards, sometimes forwards, sometimes backwards, according to the direction of the fracture, by the combined actions of the Flexor and Extensor muscles, producing a degree of fulness on the dorsal or palmar surface of the forearm. At the same time the lower fragments are drawn into contact by the Pronator quadratus, the radius being in a state of pronation. The upper fragment of the radius is drawn upwards and inwards by the Biceps and Pronator teres to a higher level than the ulna; the upper portion of the

ulna is slightly elevated by the Brachialis anticus. The fracture may be reduced by extension from the wrist and elbow, and the forearm should be placed in the same position as in fracture of the ulna.

In fracture of the *lower end of the radius* (fig. 540) the displacement produced is very considerable, and bears some resemblance to dislocation of the carpus backwards, from which it should be carefully distinguished. The lower fragment is displaced backwards and upwards, but this displacement is due to the force of the blow driving the portion of the bone into this position, and not to any muscular influence. The upper fragment projects forwards, often lacerating the substance of the Pronator quadratus, and is drawn by this muscle into close contact with the lower end of the ulna, causing a projection on the anterior surface of the forearm, immediately above the carpus, from the Flexor tendons being thrust forwards. This fracture may be distinguished from dislocation by the relative positions of the styloid processes of the radius and ulna, the former of which is displaced upwards in fracture, and by the deformity being removed on making sufficient extension, when crepitus may be occasionally detected. The age of the patient will assist in determining whether the injury is fracture or separation of the epiphysis. The treatment consists in flexing the forearm, and making powerful extension from the wrist and elbow, depressing at the same time the radial side of the hand, and retaining the parts in that position by well-padded *pistol-shaped* splints.

MUSCLES AND FASCIÆ OF THE LOWER EXTREMITY

The muscles of the lower extremity are subdivided into groups, corresponding with the different regions of the limb.

I. Iliac Region

Psoas magnus.
Psoas parvus.
Iliacus.

II. Thigh

1. *Anterior Femoral Region.*

Tensor fasciæ femoris.
Sartorius.
Quadriceps extensor: Rectus femoris. Vastus externus. Vastus internus. Crureus.
Subcrureus.

2. *Internal Femoral Region.*

Gracilis.
Pectineus.
Adductor longus.
Adductor brevis.
Adductor magnus.

3. *Gluteal Region.*

Gluteus maximus.
Gluteus medius.
Gluteus minimus.
Pyriformis.
Obturator internus.
Gemellus superior.
Gemellus inferior.
Quadratus femoris.
Obturator externus.

4. *Posterior Femoral Region.*

Hamstring muscles: Biceps. Semitendinosus. Semimembranosus.

III. Leg

5. *Anterior Tibio-fibular Region.*

Tibialis anticus.
Extensor proprius hallucis.
Extensor longus digitorum.
Peroneus tertius.

6. *Posterior Tibio-fibular Region*

Superficial Layer.

Gastrocnemius.
Soleus.
Plantaris.

Deep Layer.

Popliteus.
Flexor longus hallucis.
Flexor longus digitorum.
Tibialis posticus.

7. *Fibular Region.*

Peroneus longus.
Peroneus brevis.

IV. Foot

8. *Dorsal Region.*

Extensor brevis digitorum.

9. *Plantar Region.*

First Layer.

Abductor hallucis.
Flexor brevis digitorum.
Abductor minimi digiti.

Second Layer.

Flexor accessorius.
Lumbricales.

Third Layer.

Flexor brevis hallucis.

Adductor obliquus hallucis.
Adductor transversus hallucis.
Flexor brevis minimi digiti.

Fourth Layer.

Interossei.

I. Muscles and Fasciæ of the Iliac Region (fig. 542)

Psoas magnus. Psoas parvus. Iliacus.

The **fascia covering the Psoas and Iliacus** is the layer which lines the back part of the abdominal cavity. It is thin above, and becomes gradually thicker below as it approaches Poupart's ligament.

The *portion covering the Psoas* is thickened above to form the ligamentum arcuatum internum, which stretches from the transverse process of the first lumbar vertebra to the body of the second; internally, it is attached by a series of arched processes to the intervertebral discs, and prominent margins of the bodies of the vertebræ, and to the upper part of the sacrum; the intervals left, opposite the constricted portions of the bodies, transmit the lumbar arteries and veins and filaments of the sympathetic cord. Externally, above the crest of the ilium, this portion of the fascia is continuous with the anterior lamella of the lumbar fascia covering the front of the Quadratus lumborum (see page 493), but below the crest of the ilium it is continuous with the fascia covering the Iliacus.

The *portion investing the Iliacus* (fascia iliaca) is connected, externally, to the whole length of the inner border of the crest of the ilium; and internally, to the brim of the true pelvis, where it is continuous with the periosteum. At the ilio-pectineal eminence it receives the tendon of insertion of the Psoas parvus, when that muscle exists. External to the femoral vessels, this fascia is intimately connected to the posterior margin of Poupart's ligament, and is continuous with the fascia transversalis. Immediately to the outer side of the femoral vessels the fascia iliaca is prolonged backwards and inwards from Poupart's ligament as a band, the *ilio-pectineal ligament*, which is attached to the ilio-pectineal eminence. This ligament divides the space between Poupart's ligament and the innominate bone into two parts, the inner of which transmits the femoral vessels, the outer the Ilio-psoas and the anterior crural nerve (fig. 444). Internal to the vessels the iliac fascia is attached to the ilio-pectineal line behind the conjoined tendon, where it is again continuous with the fascia transversalis; where the external iliac vessels pass into the thigh, the fascia descends behind them forming the posterior wall of the femoral sheath. The portion of the iliac fascia which passes behind the femoral vessels is also attached to the ilio-pectineal line beyond the limits of the attachment of the conjoined tendon; at this part it is continuous with the pubic portion of the fascia lata of the thigh. The external iliac vessels lie in front of the iliac fascia, but all the branches of the lumbar plexus are behind it; it is separated from the peritoneum by a quantity of loose areolar tissue.

The **Psoas magnus** (m. psoas major) (fig. 542) is a long fusiform muscle placed on the side of the lumbar region of the vertebral column and brim of the pelvis. It arises (1) from the anterior surfaces of the bases and lower borders of the transverse processes of all the lumbar vertebræ; (2) from the sides of the bodies and the corresponding intervertebral discs of the last thoracic and all the lumbar vertebræ by five slips, each of which is attached to the adjacent upper and lower margins of two vertebræ, and to the intervertebral disc; (3) from a series of tendinous arches which extend across the constricted parts of the bodies of all the lumbar vertebræ between the previous slips; the lumbar arteries and veins and filaments of the sympathetic cord pass beneath these tendinous arches. The muscle proceeds downwards across the brim of the pelvis, and, diminishing gradually in size, passes beneath Poupart's ligament, and terminates in a tendon, which, after receiving nearly the whole of the fibres of the Iliacus, is inserted into the lesser trochanter of the femur.

Relations.—In the abdomen the Psoas magnus is in relation by its *anterior surface* with the ligamentum arcuatum internum, the fascia covering the muscle, the extra-peritoneal fat and peritoneum, the kidney, Psoas parvus, renal vessels, ureter, spermatic vessels, and genito-crural nerve. In front of the right Psoas is the inferior vena cava and the terminal portion of the ileum, and in front of the left the ilio-pelvic colon. By its *posterior surface* it is in relation with the transverse processes of the lumbar vertebræ, and the Quadratus lumborum from which it is separated by the anterior lamella of the lumbar fascia. The lumbar plexus is situated in the posterior part of the substance of the muscle. By its *inner side*, the muscle is in relation with the bodies of the lumbar vertebræ, the lumbar arteries, the gangliated cord of the sympathetic, and the lumbar glands; with the vena cava inferior on the right, and the aorta on the left side, and along the brim of the pelvis with the external iliac artery.

In the thigh it is in relation, in front, with the fascia lata; behind, with the capsular ligament of the hip, from which it is separated by a synovial bursa which frequently communicates with the cavity of the joint through an opening of variable size; by its *inner border*, with the Pectineus and internal circumflex artery, and also with the femoral artery, which slightly overlaps it; by its *outer border*, with the anterior crural nerve and Iliacus.

The **Psoas parvus** (m. psoas minor) is a long slender muscle, placed in front of the Psoas magnus. It arises from the sides of the bodies of the last thoracic and first lumbar vertebræ and from the intervertebral disc between them. It forms a small muscular bundle, which ends in a long flat tendon, inserted into the ilio-pectineal line and eminence, and, by its outer border, into the fascia iliaca. This muscle is often absent, and sometimes double.

The **Iliacus** is a flat, triangular muscle, which fills up the whole of the iliac fossa. It arises from the upper two-thirds of this fossa, and from the inner margin of the crest of the ilium; behind, from the anterior sacro-iliac and the ilio-lumbar ligaments, and base of the sacrum; in front, it reaches as far as the anterior superior and anterior inferior spinous processes of the ilium, and the notch between them. The fibres converge to be inserted into the outer side of the tendon of the Psoas, some of them being prolonged on to the shaft of the femur for about an inch below and in front of the lesser trochanter.*

Relations.—Within the abdomen the Iliacus is in relation by its *anterior surface* with the iliac fascia, which separates the muscle from the extra-peritoneal fat and peritoneum, and with the external cutaneous nerve; on the right side, with the cæcum; on the left side, with the iliac colon; by its *posterior surface*, with the iliac fossa; by its *inner border*, with the Psoas magnus, and anterior crural nerve.

In the thigh, it is in relation, by its *anterior surface*, with the fascia lata, Rectus, Sartorius, and profunda femoris artery; behind, with the capsule of the hip-joint, a synovial bursa common to it and the Psoas magnus being interposed.

Nerves.—The Psoas magnus is supplied by branches of the second and third lumbar nerves; the Psoas parvus by a branch of the first lumbar nerve; and the Iliacus by branches of the second and third lumbar nerves through the anterior crural.

Actions.—The Psoas, acting from above, flexes the thigh upon the pelvis, being assisted by the Iliacus; acting from below, with the femur fixed, the Psoas bends the lumbar portion of the vertebral column forwards and to its own side, and then, in conjunction with the Iliacus, tilts the pelvis forwards. When the muscles of both sides are acting from below, they serve to maintain the erect posture, by supporting the vertebral column and pelvis upon the femora, or in continued action bend the trunk and pelvis forwards, as in raising the trunk from the recumbent posture.

The Psoas parvus is a tensor of the iliac fascia.

Applied Anatomy.—There is no definite septum between the portions of fascia covering the Psoas and Iliacus respectively, and the fascia is only connected to the subjacent muscles by a quantity of loose connective tissue. When an abscess forms beneath this fascia, as it is very apt to do, the matter is contained in an osseo-fibrous cavity which is closed on all sides within the abdomen, and is open only at its lower part, where the fascia is prolonged over the muscle into the thigh.

* The Psoas and Iliacus are sometimes regarded as a single muscle, the *Ilio-psoas*, having two heads of origin and a single insertion.

Abscess within the sheath of the Psoas muscle (*psoas abscess*) is generally due to tuberculous caries of the bodies of the lower thoracic or the lumbar vertebræ. When the disease is in the thoracic region, the matter tracks down the posterior mediastinum, in front of the bodies of the vertebræ, and, passing beneath the ligamentum arcuatum internum, enters the sheath of the Psoas muscle, down which it travels as far as the pelvic brim; it then gets beneath the iliac portion of the fascia, and fills up the iliac fossa. In consequence of the attachment of the fascia to the pelvic brim, it rarely finds its way into the pelvis, but passes by a narrow opening under Poupart's ligament into the thigh, to the outer side of the femoral vessels. It thus follows that a psoas abscess may be described as consisting of four parts: (1) a somewhat narrow channel at its upper part, in the psoas sheath; (2) a dilated sac in the iliac fossa; (3) a constricted neck under Poupart's ligament; and (4) a dilated sac in the upper part of the thigh. When the lumbar vertebræ are the seat of the disease, the matter finds its way directly into the substance of the Psoas. The muscular fibres are destroyed, and the nerves contained in the abscess are isolated and exposed in its interior; the iliac vessels which lie in front of the fascia remain intact, and the peritoneum seldom becomes implicated. All psoas abscesses do not, however, pursue this course: the matter may leave the sheath of the muscle above the crest of the ilium, and tracking backwards may point in the loin (*lumbar abscess*); or it may point above Poupart's ligament in the inguinal region; or it may follow the course of the iliac vessels into the pelvis, and, passing through the great sacro-sciatic notch, discharge itself on the back of the thigh.

II. Muscles and Fasciæ of the Thigh

1. *Anterior Femoral Region* (figs. 541, 542)

Tensor fasciæ femoris.
Sartorius.
Quadriceps extensor: Rectus femoris. Vastus externus. Vastus internus. Crureus.
Subcrureus.

The **superficial fascia** forms a continuous layer over the whole of the thigh; it consists of areolar tissue, containing in its meshes much fat, and is capable of being separated into two or more layers, between which are found the superficial vessels and nerves. It varies in thickness in different parts of the limb; in the groin it is thick, and the two layers are separated from one another by the superficial inguinal lymphatic glands, the internal saphenous vein, and several smaller vessels. One of these two layers, the superficial, is continuous above with the superficial fascia of the abdomen. The deep layer of the superficial fascia is a very thin, fibrous layer, best marked on the inner side of the long saphenous vein and below Poupart's ligament. It is placed beneath the subcutaneous vessels and nerves and upon the surface of the fascia lata. It is intimately adherent to the fascia lata a little below Poupart's ligament. It covers the saphenous opening in the fascia lata, being closely united to its circumference, and is connected to the sheath of the femoral vessels. The portion of fascia covering this aperture is perforated by the internal saphenous vein and by numerous blood and lymphatic vessels, hence it has been termed the *cribriform fascia*. the openings for these vessels having been likened to the holes in a sieve. A large subcutaneous bursa is found in the superficial fascia over the patella.

The **deep fascia** of the thigh is named, from its great extent, the *fascia lata*; it constitutes a uniform investment for the whole of this region of the limb, but varies in thickness in different parts. Thus, it is thicker in the upper and outer part of the thigh, where it receives a fibrous expansion from the Gluteus maximus muscle, and where the Tensor fasciæ femoris is inserted between its layers: it is very thin behind and at the upper and inner part, where it covers the Adductor muscles, and again becomes stronger around the knee, receiving fibrous expansions from the tendon of the Biceps externally, from the Sartorius internally, and from the Quadriceps extensor cruris in front. The fascia lata is attached, above and behind, to the back of the sacrum and coccyx; externally, to the crest of the ilium; in front, to Poupart's ligament, and to the body of the pubis; and internally, to the descending ramus of the pubis, to the ramus and tuberosity of the ischium, and to the lower border of the great sacro-sciatic ligament. From its attachment to the crest of the ilium it passes down over the Gluteus medius to the

upper border of the Gluteus maximus, where it splits into two layers, one passing superficial to and the other beneath this muscle; at the lower border of the muscle the two layers reunite. Externally, the fascia lata receives the greater part of the tendon of insertion of the Gluteus maximus, and becomes proportionately thickened. The portion of the fascia lata attached to the front part of the crest of the ilium, and corresponding to the origin of the Tensor fasciæ femoris, passes down the outer side of the thigh as two layers, one superficial to and the other beneath this muscle; these at the lower end of the muscle become blended together into a thick and strong band, having first received the insertion of the muscle. This band is continued downwards, under the name of the *ilio-tibial band*, to be inserted into the external tuberosity of the tibia. The part of the ilio-tibial band which lies beneath the Tensor fasciæ femoris is prolonged upwards to the capsule of the hip, with the outer

Fig. 541.—The saphenous opening.

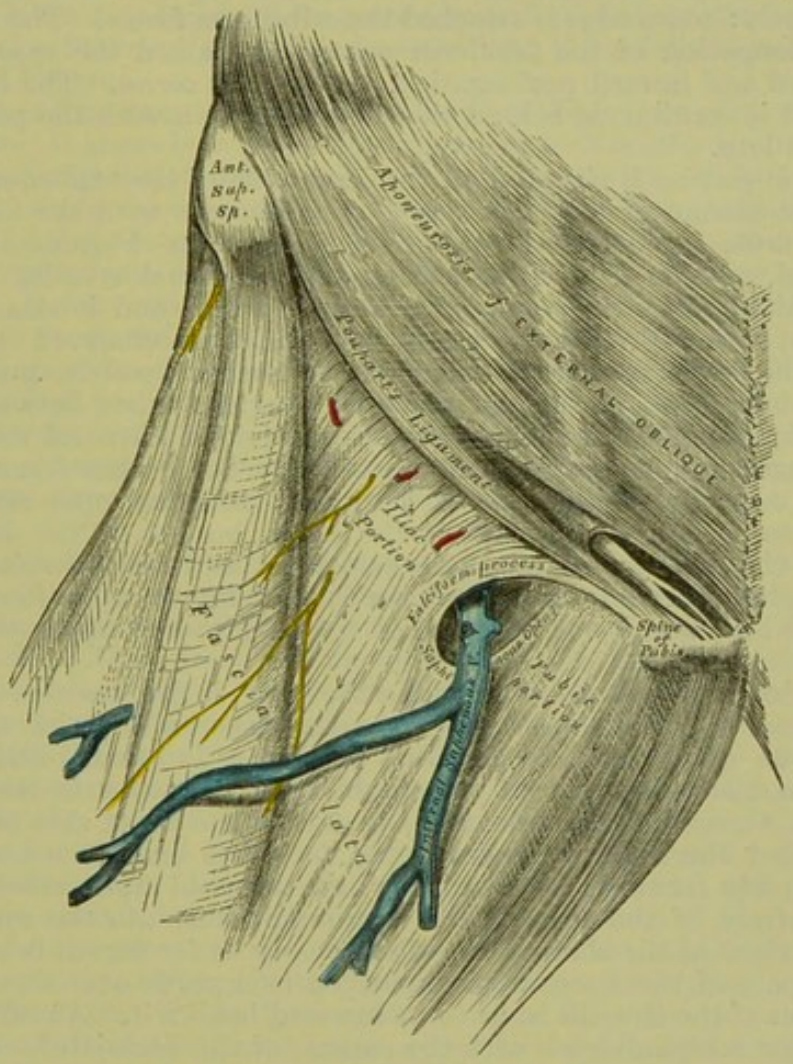

part of which it becomes continuous. Below, the fascia lata is attached to all the prominent points around the knee-joint, viz. the condyles of the femur, tuberosities of the tibia, and head of the fibula. On either side of the patella it is strengthened by transverse fibres given off from the lower part of the Vastus muscles, which are attached to and support this bone. Of these the outer are the stronger, and are continuous with the ilio-tibial band. From the inner surface of the fascia lata are given off two strong intermuscular septa, which are attached to the whole length of the linea aspera and its prolongations above and below: the external and stronger one, which extends from the insertion of the Gluteus maximus to the outer condyle, separates the Vastus externus in front from the short head of the Biceps behind, and gives partial origin to these muscles; the inner one, the thinner of the two, separates the Vastus internus from the Adductor and Pectineus muscles. Besides these

there are numerous smaller septa, separating the individual muscles, and enclosing each in a distinct sheath.

The **saphenous opening** (fig. 541).—At the upper and inner part of the thigh, a little below the inner end of Poupart's ligament, is a large oval-shaped aperture in the fascia lata; it transmits the internal saphenous vein, and other smaller vessels, and is termed the *saphenous opening*. The cribriform fascia, which is pierced by the structures passing through the opening, closes the aperture and must be removed to expose it. The fascia lata in this part of the thigh is described as consisting of an iliac and a pubic portion.

The *iliac portion* of the fascia lata is the part on the outer side of the saphenous opening. It is attached, externally, to the crest and anterior superior spine of the ilium and to the whole length of Poupart's ligament, and to the pectineal line in conjunction with Gimbernat's ligament. From the spine of the pubis it is reflected downwards and outwards, forming an arched margin, the *falciform process*, or boundary of the saphenous opening; this margin overlies and is adherent to the anterior layer of the sheath of the femoral vessels: to its edge is attached the cribriform fascia. The upward and inward prolongation of the falciform process is named the *superior cornu*; its downward and inward prolongation, the *inferior cornu*. The latter is well defined, and is continuous behind the saphenous vein with the pubic portion of the fascia lata.

The *pubic portion* is situated on the inner side of the saphenous opening; at the lower margin of this aperture it is continuous with the iliac portion; traced upwards, it covers the Pectineus, Adductor longus, and Gracilis muscles, and, passing behind the sheath of the femoral vessels, to which it is closely united, is continuous with the fascia iliaca, and is attached to the ilio-pectineal line. From this description it may be observed that the iliac portion of the fascia lata lies in front of the femoral vessels, and the pubic portion behind them, so that an apparent aperture exists between the two, through which the internal saphenous passes to join the femoral vein.

The **Tensor fasciæ femoris** (m. tensor fasciæ latæ) arises from the anterior part of the outer lip of the crest of the ilium; from the outer surface of the anterior superior spine, and part of the outer border of the notch below it, between the Gluteus medius and Sartorius; and from the inner surface of the fascia lata. It is inserted between the two layers of the ilio-tibial band of the fascia lata about the junction of the middle and upper thirds of the thigh.

The **Sartorius,** the longest muscle in the body, is flat, narrow, and ribbon-like; it arises by tendinous fibres from the anterior superior spine of the ilium and the upper half of the notch below it. It passes obliquely across the upper and anterior part of the thigh, from the outer to the inner side of the limb, then descends vertically, as far as the inner side of the knee, passing behind the inner condyle of the femur to end in a tendon. This curves obliquely forwards and expands into a broad aponeurosis, which is inserted, in front of the Gracilis and Semitendinosus, into the upper part of the inner surface of the shaft of the tibia, nearly as far forwards as the crest. The upper part of the aponeurosis is curved backwards over the upper edge of the tendon of the Gracilis so as to be inserted behind it. An offset, derived from its upper margin, blends with the capsule of the knee-joint, and another, given off from its lower border, blends with the fascia on the inner side of the leg.

The relations of this muscle to the femoral artery should be carefully examined, as it constitutes the chief guide in tying the vessel. In the upper third of the thigh it forms the outer side of a triangular space, *Scarpa's triangle*, the inner side of which is formed by the inner border of the Adductor longus, and the base, turned upwards, by Poupart's ligament; the femoral artery passes perpendicularly through the middle of this space from its base to its apex. In the middle third of the thigh, the femoral artery is contained in Hunter's canal, on the roof of which lies the Sartorius.

The **Quadriceps extensor** (m. quadriceps femoris) includes the four remaining muscles on the front of the thigh. It is the great extensor muscle of the leg, forming a large fleshy mass, which covers the front and sides of the femur, being united below into a tendon, attached to the patella,

and above, subdivided into separate portions, which have received distinct names. Of these, one occupying the middle of the thigh, and connected above with the ilium, is called the *Rectus femoris*, from its straight course. The other divisions lie in immediate connection with the shaft of the femur, which they cover from the trochanters to the condyles. The portion on the outer side of the femur is termed the *Vastus externus*; that covering the inner side, the *Vastus internus*; and that in front, the *Crureus*.

The **Rectus femoris** is situated in the middle of the anterior region of the thigh; it is fusiform in shape, and its superficial fibres are arranged in a bipenniform manner, the deep fibres running straight down to the deep aponeurosis. It arises by two tendons: one, the anterior or straight, from the anterior inferior spine of the ilium; the other, the posterior or reflected tendon, from a groove above the brim of the acetabulum. The two unite at an acute angle, and spread into an aponeurosis which is prolonged downwards on the anterior surface of the muscle, and from this the muscular fibres arise. The muscle terminates in a broad and thick aponeurosis, which occupies the lower two-thirds of its posterior surface, and, gradually becoming narrowed into a flattened tendon, is inserted into the patella in common with the Vasti and Crureus.

The **Vastus externus** (m. vastus lateralis) is the largest part of the Quadriceps extensor. It arises by a broad aponeurosis, which is attached to the upper part of the anterior intertrochanteric line, to the anterior and inferior border of the root of the great trochanter, to the outer lip of the gluteal ridge, and to the upper half of the outer lip of the linea aspera: this aponeurosis covers the upper three-fourths of the muscle, and from its inner surface many fibres take origin. A few additional fibres arise from the tendon of the Gluteus maximus, and from the external intermuscular septum between the Vastus externus and short head of the Biceps. The fibres form a large fleshy mass, which is attached to a strong aponeurosis, placed on the under surface of the muscle at its lower part: this becomes contracted and thickened into a flat tendon inserted into the outer border of the patella, blending with the Quadriceps extensor tendon, and giving an expansion to the capsule of the knee-joint.

The **Vastus internus** and **Crureus** appear to be inseparably united, but when the Rectus femoris has been reflected a narrow interval will be observed extending upwards from the inner border of the patella between the two muscles. Here they can be separated, and the separation may be continued upwards as far as the lower part of the anterior intertrochanteric line, where, however, the two muscles are frequently continuous.

The **Vastus internus** (m. vastus medialis) arises from the lower half of the anterior intertrochanteric line, the spiral line, the inner lip of the linea aspera, the upper part of the internal supracondylar line, the tendons of the Adductor longus and Adductor magnus and the internal intermuscular septum. Its fibres are directed downwards and forwards, and are chiefly attached to an aponeurosis which lies on the deep surface of the muscle and is inserted into the inner border of the patella and the Quadriceps extensor tendon, an expansion being sent to the capsule of the knee-joint.

The **Crureus** (m. vastus intermedius) arises from the front and outer aspect of the shaft of the femur in its upper two-thirds and from the lower part of the external intermuscular septum. Its fibres end in a superficial aponeurosis, which forms the deep part of the Quadriceps extensor tendon.

The *tendons* of the different portions of the Quadriceps extensor unite at the lower part of the thigh, so as to form a single strong tendon, which is inserted into the upper part of the patella, some few fibres passing over it to blend with the ligamentum patellæ. More properly, the patella may be regarded as a sesamoid bone, developed in the tendon of the Quadriceps; and the ligamentum patellæ, which is continued from the lower part of the patella to the tuberosity of the tibia, as the proper tendon of insertion of the muscle, the lateral patellar ligaments (see page 430) being fascial expansions from its borders. A synovial bursa, which usually communicates with the cavity of the knee-joint, is situated between the femur and the portion of the Quadriceps extensor tendon above the patella; another is interposed between the tendon and the upper part of the front of the tibia; and a third,

Fig. 542.—Muscles of the iliac and anterior femoral regions.

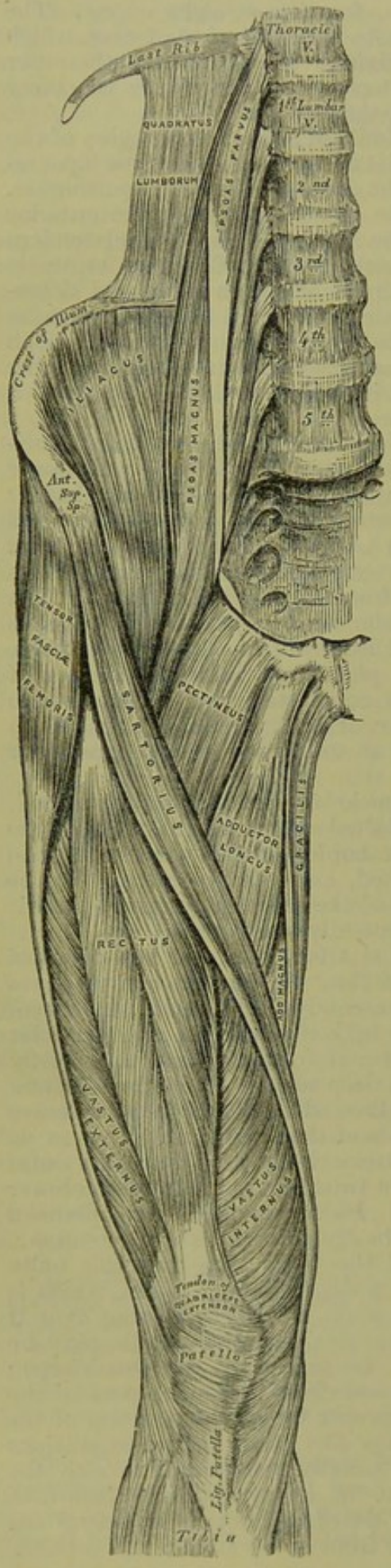

the *pre-patellar bursa*, is placed over the patella itself. The last often becomes enlarged, constituting 'housemaid's knee.'

The **Subcrureus** (m. articularis genu) is a small muscle, usually distinct from the Crureus, but occasionally blended with it, which arises from the anterior surface of the lower part of the shaft of the femur, and is inserted into the upper part of the synovial membrane of the knee-joint. It sometimes consists of several separate muscular bundles.

Nerves.—The Tensor fasciæ femoris is supplied by the fourth and fifth lumbar and first sacral nerves through the superior gluteal nerve; the other muscles of this region, by the second, third, and fourth lumbar nerves, through branches of the anterior crural.

Actions.—The Tensor fasciæ femoris is a tensor of the fascia lata; continuing its action, the oblique direction of its fibres enables it to abduct the thigh and to rotate it inwards. In the erect posture, acting from below, it will serve to steady the pelvis upon the head of the femur; and by means of the ilio-tibial band it steadies the condyles of the femur on the articular surfaces of the tibia, and assists the Gluteus maximus in supporting the knee in the extended position. The Sartorius flexes the leg upon the thigh, and, continuing to act, flexes the thigh upon the pelvis; it next abducts and rotates the thigh outwards. It was formerly supposed to adduct the thigh, so as to cross one leg over the other, as in the squatting position, and hence received its name of Sartorius, or tailor's muscle. When the knee is bent, the Sartorius assists the Semitendinosus, Semimembranosus, and Popliteus in rotating the tibia inwards. Taking its fixed point from the leg, it flexes the pelvis upon the thigh, and, if one muscle acts, assists in rotating the pelvis. The Quadriceps extensor extends the leg upon the thigh. The Rectus muscle assists the Psoas and Iliacus in supporting the pelvis and trunk upon the femur. It also assists in flexing the thigh on the pelvis, or if the thigh be fixed it will flex the pelvis. The Vastus internus draws the patella inwards as well as upwards.

Applied Anatomy. — A few fibres of the Rectus muscle are occasionally ruptured from severe strain. This accident is especially liable to occur during the games of football and cricket, and is sometimes known as 'cricket thigh.' The patient experiences a sudden pain in the part, as if he had been struck, and the Rectus muscle stands out and is felt to be tense and rigid. The accident is often followed by considerable swelling from inflammatory effusion. Occasionally the Quadriceps extensor

may be torn away from its insertion into the patella; or the tendon of the patella may be ruptured about an inch above the bone. This accident is caused in the same manner as fracture of the patella by muscular action, viz. by a violent muscular effort to prevent falling while the knee is in a position of semiflexion. A distinct gap can be felt above the patella, and, owing to the retraction of the muscular fibres, union may fail to take place.

2. *Internal Femoral Region*

Gracilis. Adductor longus.
Pectineus. Adductor brevis.
Adductor magnus.

The **Gracilis** (figs. 542, 544) is the most superficial muscle on the inner side of the thigh. It is thin and flattened, broad above, narrow and tapering below. It arises by a thin aponeurosis from the anterior margins of the lower half of the symphysis pubis and the upper half of the pubic arch. The fibres run vertically downwards, and terminate in a rounded tendon, which passes behind the internal condyle of the femur, and, curving round the inner tuberosity of the tibia, becomes flattened, and is inserted into the upper part of the inner surface of the shaft of the tibia, below the tuberosity. A few of the fibres of the lower part of the tendon are prolonged into the deep fascia of the leg. At its insertion the tendon is situated immediately above that of the Semitendinosus, and its upper edge is overlapped by the tendon of the Sartorius, with which it is in part blended. As it passes across the internal lateral ligament of the knee-joint, it is separated from it by a synovial bursa common to it and the Semitendinosus.

The **Pectineus** (fig. 542) is a flat, quadrangular muscle, situated at the anterior part of the upper and inner aspect of the thigh. It arises from the ilio-pectineal line, and to a slight extent from the surface of bone in front of it, between the pectineal eminence and spine of the pubis, and from the fascia covering the anterior surface of the muscle; the fibres pass downwards, backwards, and outwards, to be inserted into a rough line leading from the small trochanter to the linea aspera.

Relations.—It is in relation by its *anterior surface* with the pubic portion of the fascia lata, which separates it from the femoral vessels and internal saphenous vein; by its *posterior surface*, with the capsular ligament of the hip-joint and the Adductor brevis and Obturator externus muscles, the obturator vessels and nerve being interposed; by its *outer border*, with the Psoas, a cellular interval separating them, through which pass the internal circumflex vessels; by its *inner border*, with the margin of the Adductor longus.

The **Adductor longus** (fig. 543), the most superficial of the three Adductors, is a flat, triangular muscle, lying in the same plane as the Pectineus. It arises by a flat, narrow tendon, from the front of the pubis, at the angle of junction of the crest with the symphysis; and soon expands into a broad fleshy belly. This passes downwards, backwards, and outwards, and is inserted, by an aponeurosis, into the linea aspera, between the Vastus internus and the Adductor magnus, with both of which it is usually blended.

Relations.—It is in relation by its *anterior surface* with the fascia lata, the Sartorius, and, near its insertion, with the femoral artery and vein; by its *posterior surface*, with the Adductores brevis et magnus, the anterior division of the obturator nerve, and near its insertion with the profunda artery and vein; by its *outer border*, with the Pectineus; by its *inner border*, with the Gracilis.

The **Adductor brevis** (fig. 543) is situated immediately behind the two preceding muscles. It is somewhat triangular in form, and arises by a narrow origin from the outer surface of the body and descending ramus of the pubis, between the Gracilis and Obturator externus. Its fibres, passing backwards, outwards, and downwards, are inserted, by an aponeurosis, into the line leading from the small trochanter to the linea aspera and into the upper part of the linea aspera, immediately behind the Pectineus and upper part of the Adductor longus.

Relations.—It is in relation by its *anterior surface* with the Pectineus, Adductor longus, profunda femoris artery, and anterior division of the obturator nerve; by its *posterior surface*, with the Adductor magnus, and posterior division of the obturator nerve; by its *outer border*, with the internal circumflex artery, the Obturator externus, and conjoined tendon of the Psoas and Iliacus; by its *inner border*, with the Gracilis and Adductor magnus. It is pierced near its insertion by the second or first and second perforating branches of the profunda femoris artery.

Fig. 543.—Deep muscles of the internal femoral region.

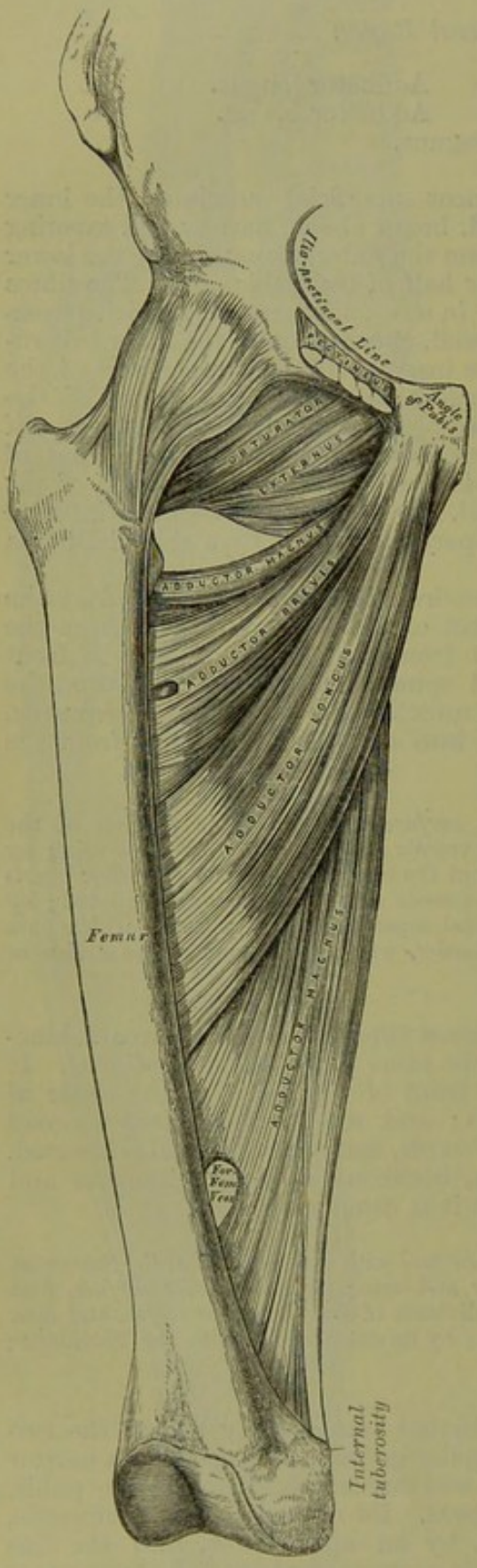

The **Adductor magnus** (fig. 543) is a large triangular muscle, forming a septum between the muscles on the inner and those on the back of the thigh. It arises from a small part of the descending ramus of the pubis, from the ramus of the ischium, and from the outer margin of the inferior part of the tuberosity of the ischium. Those fibres which arise from the ramus of the pubis are very short, horizontal in direction, and are inserted into the rough line leading from the great trochanter to the linea aspera, internal to the Gluteus maximus; those from the ramus of the ischium are directed downwards and outwards with different degrees of obliquity, to be inserted, by means of a broad aponeurosis, into the linea aspera and the upper part of its internal prolongation below. The internal portion of the muscle, composed principally of the fibres arising from the tuberosity of the ischium, forms a thick fleshy mass consisting of coarse bundles which descend almost vertically, and terminate about the lower third of the thigh in a rounded tendon, which is inserted into the adductor tubercle on the inner condyle of the femur, and is connected by a fibrous expansion to the line leading upwards from the tubercle to the linea aspera. At the insertion of the muscle, a series of osseo-aponeurotic openings, formed by tendinous arches attached to the bone, is seen. The upper four openings are small, and give passage to the perforating branches of the profunda femoris artery. The lowest is of large size, and transmits the femoral vessels from Hunter's canal to the popliteal space.

Relations.—It is in relation by its *anterior surface* with the Pectineus, Adductor brevis, Adductor longus, and the femoral and profunda vessels and obturator nerve; by its *posterior surface*, with the great sciatic nerve, the Gluteus maximus, Biceps, Semitendinosus, and Semimembranosus. Its *superior* or *shortest border* lies parallel with the Quadratus femoris, the internal circumflex artery passing between them. Its

internal or *longest border* is in relation with the Gracilis, Sartorius, and fascia lata. By its *external* or *attached border*, it is inserted into the femur, behind the Adductor brevis and Adductor longus which separate it from the Vastus internus, and in front of the Gluteus maximus and short head of the Biceps which separate it from the Vastus externus.

Nerves.—The three Adductor muscles and the Gracilis are supplied by the third and fourth lumbar nerves through the obturator nerve; the Adductor magnus receiving an additional branch from the sacral plexus through the great sciatic. The Pectineus is supplied by the second, third, and fourth lumbar nerves through the anterior crural, and from the third lumbar by the accessory obturator when it exists. Occasionally it receives a branch from the obturator nerve.*

Actions.—The Pectineus and three Adductors adduct the thigh powerfully; they are especially used in horse exercise, the sides of the saddle being grasped between the knees by the contraction of these muscles. In consequence of the obliquity of their insertions into the linea aspera, they rotate the thigh outwards, assisting the external Rotators, and when the limb has been abducted, they draw it inwards, carrying the thigh across that of the opposite side. The Pectineus and Adductores brevis et longus assist the Psoas and Iliacus in flexing the thigh upon the pelvis. In progression, also, all these muscles assist in drawing forwards the lower limb. The Gracilis assists the Sartorius in flexing the leg and rotating it inwards; it is also an adductor of the thigh. If the lower extremities be fixed, these muscles, taking their fixed points below, may act upon the pelvis, serving to maintain the body in an erect posture; or, if their action be continued, flex the pelvis forwards upon the femur.

Applied Anatomy.—The Adductor longus is liable to be severely strained in those who ride much on horseback, or its tendon may be ruptured by suddenly gripping the saddle. Occasionally, especially in cavalry soldiers, the tendon may become ossified, constituting the 'rider's bone.'

3. *Gluteal Region* (fig. 544)

Gluteus maximus.	Obturator internus.
Gluteus medius.	Gemellus superior.
Gluteus minimus.	Gemellus inferior.
Pyriformis.	Quadratus femoris.

Obturator externus.

The **Gluteus maximus**, the most superficial muscle in the gluteal region, is a very broad and thick fleshy mass, of a quadrilateral shape, and forms the prominence of the nates. Its large size is one of the most characteristic points in the muscular system in man, connected as it is with the power he has of maintaining the trunk in the erect posture. In structure the muscle is remarkably coarse, being made up of muscular fasciculi lying parallel with one another, and collected together into large bundles separated by deep cellular intervals. It arises from the superior curved line of the ilium, and the rough portion of bone, including the crest, immediately above and behind it; from the posterior surface of the lower part of the sacrum and the side of the coccyx; from the aponeurosis of the Erector spinæ, the great sacro-sciatic ligament, and the fascia (gluteal aponeurosis) covering the Gluteus medius. The fibres are directed obliquely downwards and outwards; those forming the upper and larger portion of the muscle, together with the superficial fibres of the lower portion, terminate in a thick tendinous lamina, which passes across the great trochanter, and is inserted into the fascia lata covering the outer side of the thigh; the deeper fibres of the lower portion of the muscle are inserted into the rough line leading from the great trochanter to the linea aspera between the Vastus externus and Adductor magnus.

* Paterson describes the Pectineus as consisting of two incompletely separated strata; the outer or dorsal stratum, which is constant, is supplied by a branch from the anterior crural nerve, or in the absence of this branch by the accessory obturator, with which it is intimately related; while the inner or ventral stratum, when present, is supplied by the obturator nerve.—*Journal of Anatomy and Physiology*, vol. xxvi. p. 43.

FIG. 544.—Muscles of the hip and thigh.

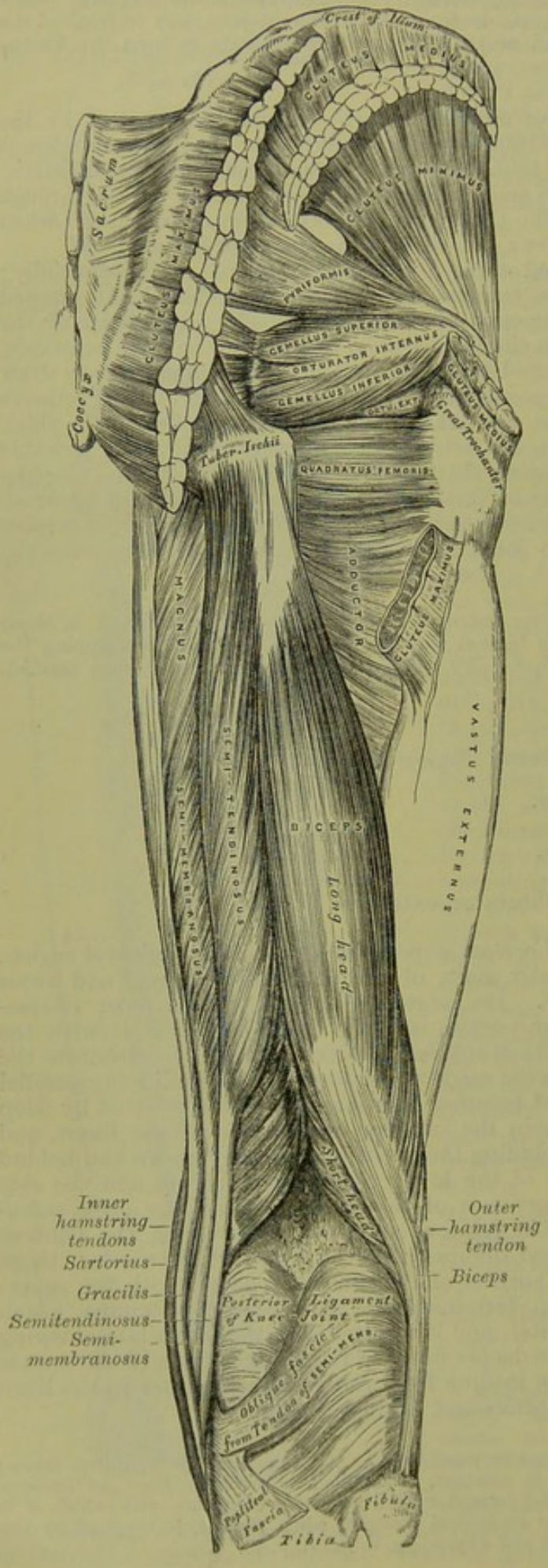

Three *synovial bursæ* are usually found in relation with the deep surface of this muscle. One of these, of large size, and generally multilocular, separates it from the great trochanter. A second, often wanting, is situated on the tuberosity of the ischium. A third is found between the tendon of the muscle and that of the Vastus externus.

Relations. — The Gluteus maximus is in relation by its *superficial surface* with a thin fascia which separates it from the subcutaneous tissue; by its *deep surface*, from above downwards, with the ilium, sacrum, coccyx, and great sacro-sciatic ligament, part of the Gluteus medius, Pyriformis, Gemelli, Obturator internus, Quadratus femoris, the tuberosity of the ischium, great trochanter, the origins of the Biceps, Semitendinosus, Semimembranosus, and the Adductor magnus. The superficial part of the gluteal artery reaches the deep surface of the muscle by passing between the Pyriformis and the Gluteus medius; the sciatic and internal pudic vessels and nerves, and muscular branches from the sacral plexus, issue from the pelvis below the Pyriformis. The first perforating artery and the terminal branches of the internal circumflex artery are also found under cover of the lower part of the muscle. Its *upper border* is thin, and connected with the Gluteus medius by the fascia lata. Its *lower border* is free and prominent, and is crossed by the fold of the nates.

The **Gluteus medius** is a broad, thick, radiating muscle, situated on the outer surface of the pelvis. Its posterior third is covered by the Gluteus maximus, its anterior two-thirds by the fascia lata, which separates it from the superficial fascia and integument. It arises from the outer surface of the ilium, between the superior and middle curved lines, and from the outer lip of that portion of the crest which is between them; it also arises from the dense fascia (gluteal

aponeurosis) covering its outer surface. The fibres converge to a strong flattened tendon, which is inserted into the oblique ridge which runs downwards and forwards on the outer surface of the great trochanter. A synovial bursa separates the tendon of the muscle from the surface of the trochanter in front of its insertion.

The **Gluteus minimus,** the smallest of the three Glutei, is placed immediately beneath the preceding. It is fan-shaped, arising from the outer surface of the ilium, between the middle and inferior curved lines, and behind, from the margin of the great sacro-sciatic notch. The fibres converge to the deep surface of a radiated aponeurosis, which, terminating in a tendon, is inserted into an impression on the anterior border of the great trochanter, and gives an expansion to the capsule of the hip-joint. A synovial bursa is interposed between the tendon and the great trochanter. Between the Gluteus medius and Gluteus minimus are the deep branches of the gluteal vessels and the superior gluteal nerve. The deep surface of the Gluteus minimus is in relation with the reflected tendon of the Rectus femoris and the capsular ligament of the hip-joint.

The **Pyriformis** is a flat muscle, pyramidal in shape, lying almost parallel with the posterior margin of the Gluteus medius. It is situated partly within the pelvis against its posterior wall, and partly at the back of the hip-joint. It arises from the front of the sacrum by three fleshy digitations, attached to the portions of bone between the first, second, third, and fourth anterior sacral foramina, and also to the grooves leading from the foramina: a few fibres also arise from the margin of the great sacro-sciatic foramen, and from the anterior surface of the great sacro-sciatic ligament. The muscle passes out of the pelvis through the great sacro-sciatic foramen, the upper part of which it fills, and is inserted by a rounded tendon into the upper border of the great trochanter, behind, but often partly blended with, the tendon of the Obturator internus and Gemelli.

Relations.—*Within the pelvis* the Pyriformis is in relation by its *anterior surface* with the rectum (especially on the left side), the sacral plexus of nerves, and the branches of the internal iliac vessels, and by its *posterior surface* with the sacrum. *External to the pelvis*, its *anterior surface* is in contact with the posterior surface of the ischium and capsular ligament of the hip-joint; and its *posterior surface*, with the Gluteus maximus; its *upper border* is in relation with the Gluteus medius, and the gluteal vessels and superior gluteal nerve; its *lower border*, with the Gemellus superior and Coccygeus, the sciatic vessels and nerves, the internal pudic vessels and nerve, and muscular branches from the sacral plexus, passing from the pelvis in the interval between the two muscles. The muscle is frequently pierced by the external popliteal nerve.

The **obturator membrane** (fig. 444) is a thin layer of interlacing fibres, which almost completely closes the obturator foramen. It is attached, externally, to the margin of the foramen; internally, to the posterior surface of the ischio-pubic ramus, below and internal to the margin of the foramen. At its upper and outer part it is deficient, leaving a small canal, which is bounded below by a thickened band of fibres, and gives passage to the obturator vessels and nerve (see page 326). Both Obturator muscles are connected with this membrane.

The **Obturator internus,** like the preceding muscle, is situated partly within the cavity of the pelvis, and partly at the back of the hip-joint. It arises from the inner surface of the antero-lateral wall of the pelvis, where it surrounds the greater part of the obturator foramen, being attached to the descending ramus of the pubis and the ramus of the ischium, and at the side to the inner surface of the innominate bone below and behind the pelvic brim, reaching from the upper part of the great sacro-sciatic foramen above and behind to the obturator foramen below and in front. It also arises from the inner surface of the obturator membrane except at its posterior part, from the tendinous arch which completes the canal for the passage of the obturator vessels and nerve, and to a slight extent from the obturator layer of the pelvic fascia, which covers it. The fibres converge rapidly towards the small sacro-sciatic foramen, and terminate in four or five tendinous bands, which are found on the deep surface of the muscle; these bands are reflected at a right angle over the grooved surface of the ischium between its spine

and tuberosity. This bony surface is covered by smooth cartilage, which is separated from the tendon by a synovial bursa, and presents one or more ridges corresponding with the furrows between the tendinous bands. These bands leave the pelvis by the small sacro-sciatic foramen and unite into a single flattened tendon, which passes horizontally outwards, and, after receiving the attachments of the Gemelli, is inserted into the fore part of the inner surface of the great trochanter in front of the Pyriformis. A synovial bursa, narrow and elongated in form, is usually found between the tendon and the capsular ligament of the hip: it occasionally communicates with the bursa between the tendon and the tuberosity of the ischium.

Relations.—*Within the pelvis*, this muscle is in relation, by its *anterior surface*, with the obturator membrane and inner surface of the anterior wall of the pelvis; by its *posterior surface*, with the obturator fascia, and the origin of the Levator ani, and with the internal pudic vessels and nerve which cross it. The posterior surface forms the outer boundary of the ischio-rectal fossa. *External to the pelvis*, the muscle is covered by the Gluteus maximus, crossed by the great sciatic nerve, and rests on the back part of the hip-joint. When the tendon of the Obturator internus emerges from the small sacro-sciatic foramen it is overlapped both in front and behind by the two Gemelli which form a muscular canal for it; near its insertion the Gemelli pass in front of the tendon and form a groove in which it lies.

The **Gemelli** are two small muscular fasciculi, accessories to the tendon of the Obturator internus which is received into a groove between them. They are called *superior* and *inferior*.

The **Gemellus superior**, the smaller of the two, arises from the outer surface of the spine of the ischium, and passing horizontally outwards becomes blended with the upper part of the tendon of the Obturator internus, and is inserted with it into the inner surface of the great trochanter. It is sometimes wanting.

The **Gemellus inferior** arises from the upper part of the tuberosity of the ischium, where it forms the lower edge of the groove for the Obturator internus tendon. Passing horizontally outwards, it blends with the lower part of the tendon of the Obturator internus, and is inserted with it into the inner surface of the great trochanter.

The **Quadratus femoris** is a flat, quadrilateral muscle, between the Gemellus inferior and the upper margin of the Adductor magnus; it is separated from the latter by the terminal branches of the internal circumflex vessels. It arises from the upper part of the external lip of the tuberosity of the ischium, and, proceeding horizontally outwards, is inserted into the upper part of the linea quadrata—that is, the line which extends vertically downwards from the posterior intertrochanteric line. A synovial bursa is often found between the front of this muscle and the small trochanter which it covers.

The **Obturator externus** (fig. 545) is a flat, triangular muscle, which covers the outer surface of the anterior wall of the pelvis. It arises from the margin of bone immediately around the inner side of the obturator foramen, viz. from the body and ramus of the pubis, and the ramus of the ischium; it also arises from the inner two-thirds of the outer surface of the obturator membrane, and from the tendinous arch which completes the canal for the passage of the obturator vessels and nerves. The fibres from the pubic arch extend on to the inner surface of the bone, where they obtain a narrow origin between the margin of the foramen and the attachment of the membrane. The fibres converge and pass backwards, outwards, and upwards, and terminate in a tendon which runs across the back part of the hip-joint and is inserted into the digital fossa of the femur. The obturator vessels lie between the muscle and the obturator membrane; the superficial part of the obturator nerve reaches the thigh by passing in front of the muscle, and the deep branch of the same nerve by piercing it.

Nerves.—The Gluteus maximus is supplied by the fifth lumbar and first and second sacral nerves through the inferior gluteal nerve from the sacral plexus; the Gluteus medius and minimus, by the fourth and fifth lumbar and first sacral nerves through the superior gluteal; the Pyriformis is supplied by the first and second sacral nerves; the Gemellus inferior and Quadratus femoris by the last lumbar and first sacral nerves; the Gemellus superior and Obturator internus by the first, second, and third sacral nerves, and the Obturator externus by the third and fourth lumbar nerves through the obturator.

Actions.—The Gluteus maximus, when it takes its fixed point from the pelvis, extends the femur and brings the bent thigh into a line with the body. Taking its fixed point from below, it acts upon the pelvis, supporting it and the trunk upon the head of the femur; this is especially obvious in standing on one leg. Its most powerful action is to cause the body to regain the erect position after stooping, by drawing the pelvis backwards, being assisted in this action by the Biceps, Semitendinosus, and Semimembranosus. The Gluteus maximus is a tensor of the fascia lata, and by its connection with the ilio-tibial band steadies the femur on the articular surfaces of the tibia during standing, when the Extensor muscles are relaxed. The lower part of the muscle also acts as an adductor and

Fig. 545.—Obturator externus muscle.
(From a preparation in the Museum of the Royal College of Surgeons of England.)

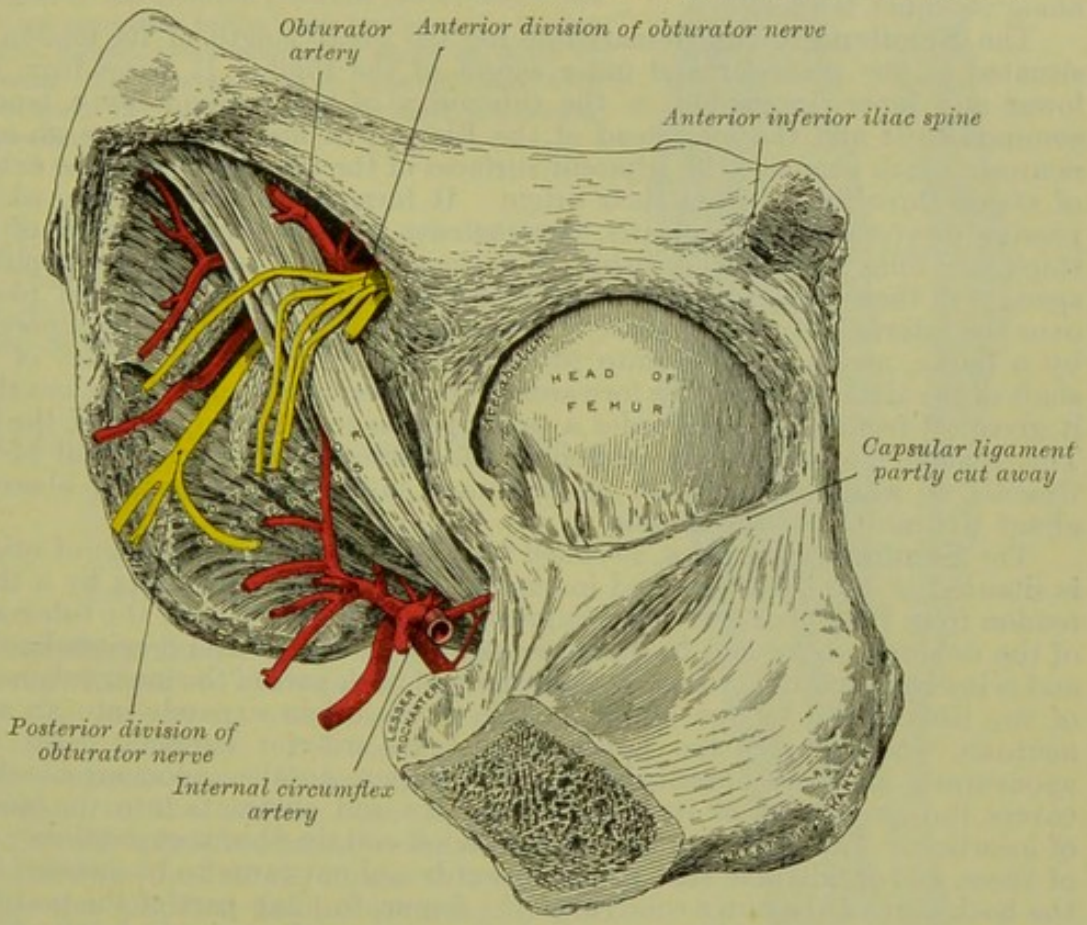

external rotator of the limb. The Gluteus medius and minimus abduct the thigh, when the limb is extended, and are principally called into action in supporting the body on one limb, in conjunction with the Tensor fasciæ femoris. Their anterior fibres, by drawing the great trochanter forwards, rotate the thigh inwards, in which action they are also assisted by the Tensor fasciæ femoris. The remaining muscles are powerful rotators of the thigh outwards. In the sitting posture, when the thigh is flexed upon the pelvis, their action as rotators ceases, and they become abductors, with the exception of the Obturator externus, which still rotates the femur outwards.

4. *Posterior Femoral Region* (fig. 544)

Biceps. Semitendinosus. Semimembranosus.

The **Biceps** (m. biceps femoris) is a large muscle, of considerable length, situated on the posterior and outer aspect of the thigh. It has two heads of origin: one, the long head (caput longum), arises from the lower and inner impression on the back part of the tuberosity of the ischium, by a tendon common to it and the Semitendinosus, and from the lower part of the great sacro-sciatic ligament; the other, or short head (caput breve), from the outer lip of the linea aspera, between the Adductor magnus and

Vastus externus, extending up almost as high as the insertion of the Gluteus maximus ; from the outer prolongation of the linea aspera to within two inches of the outer condyle ; and from the external intermuscular septum. The fibres of the long head form a fusiform belly, which passes obliquely downwards and outwards across the great sciatic nerve to terminate in an aponeurosis which covers the posterior surface of the muscle, and receives the fibres of the short head : this aponeurosis becomes gradually contracted into a tendon, which is inserted into the outer side of the head of the fibula, and by a small slip into the lateral surface of the external tuberosity of the tibia. At its insertion the tendon divides into two portions, which embrace the long external lateral ligament of the knee-joint. From the posterior border of the tendon a thin expansion is given off to the fascia of the leg. The tendon of this muscle forms the outer hamstring ; the external popliteal nerve descends along its inner border.

The **Semitendinosus**, remarkable for the great length of its tendon, is situated at the posterior and inner aspect of the thigh. It arises from the lower and inner impression on the tuberosity of the ischium, by a tendon common to it and the long head of the Biceps ; it also arises from an aponeurosis which connects the adjacent surfaces of the two muscles to the extent of about three inches from their origin. It forms a fusiform muscle, which, passing downwards and inwards, terminates a little below the middle of the thigh in a long round tendon which lies along the inner side of the popliteal space ; it then curves around the inner tuberosity of the tibia and passes over the internal lateral ligament of the knee-joint, from which it is separated by a bursa, and is inserted into the upper part of the inner surface of the shaft of the tibia, nearly as far forwards as its anterior border. At its insertion it gives off from its lower border a prolongation to the deep fascia of the leg. This tendon lies behind the tendon of the Sartorius, and below that of the Gracilis, to which it is united. A tendinous intersection is usually observed about the middle of the muscle.

The **Semimembranosus**, so called from its membranous tendon of origin, is situated at the back part and inner side of the thigh. It arises by a thick tendon from the upper and outer impression on the back part of the tuberosity of the ischium, above and to the outer side of the Biceps and Semitendinosus, and is inserted into the groove on the inner and back part of the inner tuberosity of the tibia. The tendon of the muscle at its origin expands into an aponeurosis, which covers the upper part of its anterior surface : from this aponeurosis muscular fibres arise, and converge to another aponeurosis which covers the lower part of its posterior surface and contracts into the tendon of insertion. The tendon of insertion gives off certain fibrous expansions : one of these, of considerable size, passes upwards and outwards to be inserted into the back part of the outer condyle of the femur, forming part of the posterior ligament of the knee-joint ; a second is continued downwards to the fascia which covers the Popliteus muscle ; while a few fibres join the internal lateral ligament of the joint and the fascia of the leg. The muscle overlaps the upper part of the popliteal vessels.

The tendons of the two preceding muscles form the inner hamstrings.

Nerves.—The muscles of this region are supplied by the fourth and fifth lumbar and the first, second, and third sacral nerves through the great sciatic nerve.

Actions.—The hamstring muscles flex the leg upon the thigh. When the knee is semiflexed, the Biceps, in consequence of its oblique direction downwards and outwards, rotates the leg slightly outwards ; and the Semitendinosus, and to a slight extent the Semimembranosus, rotate the leg inwards, assisting the Popliteus. Taking their fixed point from below, these muscles serve to support the pelvis upon the head of the femur, and to draw the trunk directly backwards, as in raising it from the stooping position or in feats of strength, when the body is thrown backwards in the form of an arch. As already indicated on page 427, complete flexion of the hip cannot be effected unless the knee-joint is also flexed, on account of the shortness of the hamstring muscles.

Applied Anatomy.—In disease of the knee-joint, contraction of the hamstring tendons is a frequent complication ; this causes flexion of the leg, and a partial dislocation of the

tibia backwards, with a slight degree of rotation outwards, probably due to the action of the Biceps muscle. The hamstring tendons occasionally require subcutaneous division in some forms of spurious ankylosis of the knee-joint dependent upon permanent contraction and rigidity of the Flexor muscles, or from contracture of the ligamentous and other tissues surrounding the joint, the result of disease. This is effected by putting the tendon upon the stretch, and inserting a narrow, sharp-pointed knife between it and the skin: the cutting edge being then turned towards the tendon, it should be divided, taking care that the wound in the skin is not at the same time enlarged. The relation of the external popliteal nerve, which lies in close apposition to the inner border of the tendon of the Biceps, must always be borne in mind in dividing this tendon, and a free incision with exposure of the tendon, before division, is the safer proceeding.

III. Muscles and Fasciæ of the Leg

The muscles of the leg may be divided into three groups: those on the anterior, those on the posterior, and those on the outer side.

5. *Anterior Tibio-fibular Region* (fig. 546)

Tibialis anticus.
Extensor proprius hallucis.
Extensor longus digitorum.
Peroneus tertius.

The **deep fascia** of the leg forms a complete investment to the muscles, and is fused with the periosteum over the subcutaneous surfaces of the bones. It is continuous above with the fascia lata, and is attached around the knee to the patella, the ligamentum patellæ, the tubercle and tuberosities of the tibia, and the head of the fibula. Behind, it forms the popliteal fascia, covering in the popliteal space; here it is specially thick, being strengthened by transverse fibres, and is perforated by the external saphenous vein. It receives an expansion from the tendon of the Biceps on the outer side, and from the tendons of the Sartorius, Gracilis, Semitendinosus, and Semimembranosus on the inner side; in front, it blends with the periosteum covering the subcutaneous surface of the tibia, and with that covering the head and external malleolus of the fibula; below, it is continuous with the annular ligaments of the ankle. It is thick and dense in the upper and anterior part of the leg, and gives attachment, by its deep surface, to the Tibialis anticus and Extensor longus digitorum muscles; but thinner behind, where it covers the Gastrocnemius and Soleus muscles. It gives off from its deep surface, on the outer side of the leg, two strong intermuscular septa, the *anterior* and *posterior peroneal*

Fig. 546.—Muscles of the front of the leg.

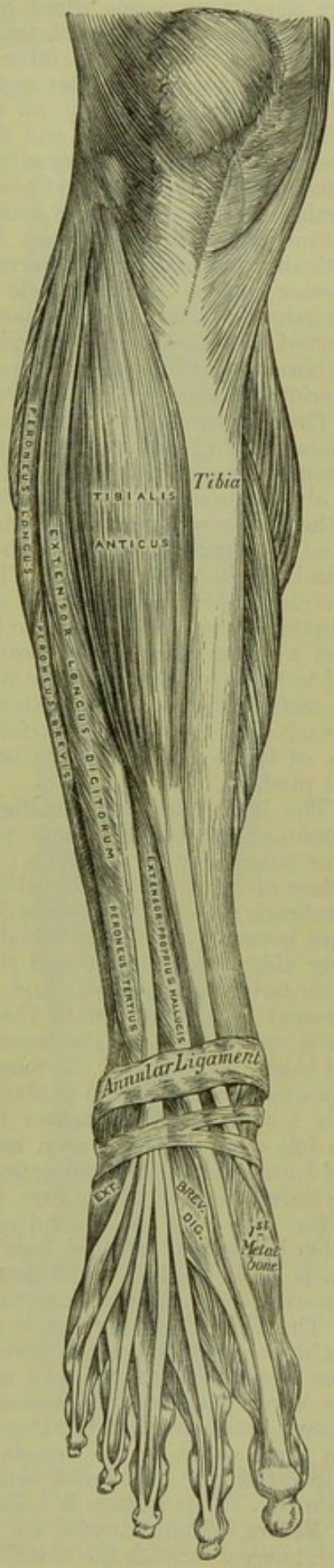

septa, which enclose the Peronei longus et brevis, and separate them from the muscles on the anterior and posterior tibial regions, and several smaller and more slender processes which enclose the individual muscles in each region. At the same time a broad transverse intermuscular septum, called the *deep transverse fascia of the leg*, intervenes between the superficial and deep muscles in the posterior tibio-fibular region.

The **Tibialis anticus** (m. tibialis anterior) is situated on the outer side of the tibia; it is thick and fleshy at its upper part, tendinous below. It arises from the outer tuberosity and upper half or two-thirds of the external surface of the shaft of the tibia; from the adjoining part of the interosseous membrane; from the deep surface of the fascia; and from the intermuscular septum between it and the Extensor longus digitorum. The fibres pass vertically downwards, and terminate in a tendon, which is apparent on the anterior surface of the muscle at the lower third of the leg. After passing through the innermost compartment of the anterior annular ligament, it is inserted into the inner and under surface of the internal cuneiform bone, and the base of the metatarsal bone of the great toe. This muscle overlaps the anterior tibial vessels and nerve in the upper part of the leg.

The **Extensor proprius hallucis** (m. extensor hallucis longus) is a thin, elongated, and flattened muscle, situated between the Tibialis anticus and Extensor longus digitorum. It arises from the anterior surface of the fibula for about the middle two-fourths of its extent, its origin being internal to that of the Extensor longus digitorum; it also arises from the interosseous membrane to a similar extent. The anterior tibial vessels and nerve lie between it and the Tibialis anticus. The fibres pass downwards, and terminate in a tendon, which occupies the anterior border of the muscle, passes through a distinct compartment in the lower portion of the annular ligament, crosses, from without inwards, the anterior tibial vessels near the bend of the ankle, and is inserted into the base of the last phalanx of the great toe. Opposite the metatarso-phalangeal articulation, the tendon gives off a thin prolongation on each side, to cover the surface of the joint. An expansion, from the inner side of the tendon, usually passes across to be inserted into the base of the first phalanx.

The **Extensor longus digitorum** is an elongated, flattened, penniform muscle, situated at the outer part of the front of the leg. It arises from the outer tuberosity of the tibia; from the upper three-fourths of the anterior surface of the shaft of the fibula; from the upper part of the interosseous membrane; from the deep surface of the fascia; and from the intermuscular septa between it and the Tibialis anticus on the inner, and the Peronei on the outer side. Between it and the Tibialis anticus are the upper portions of the anterior tibial vessels and nerve. The tendon passes under the annular ligament in company with the Peroneus tertius, and divides into four slips, which run forward on the dorsum of the foot, and are inserted into the second and third phalanges of the four lesser toes. Each of the three inner tendons, opposite the metatarso-phalangeal articulation, is joined, on its outer side, by a tendon of the Extensor brevis digitorum. The tendons are inserted in the following manner: each receives a fibrous expansion from the Interossei and Lumbricales, and then spreads out into a broad aponeurosis, which covers the dorsal surface of the first phalanx: this aponeurosis, at the articulation of the first with the second phalanx, divides into three slips, a middle one, which is inserted into the base of the second phalanx; and two lateral slips, which, after uniting on the dorsal surface of the second phalanx, are continued onwards, to be inserted into the base of the third.

The **Peroneus tertius** is a part of the Extensor longus digitorum, and might be described as its fifth tendon. The fibres belonging to this tendon arise from the lower third or more of the anterior surface of the fibula; from the lower part of the interosseous membrane; and from an intermuscular septum between it and the Peroneus brevis. The tendon, after passing through the same canal in the annular ligament as the Extensor longus digitorum, is inserted into the dorsal surface of the base of the metatarsal bone of the little toe. This muscle is sometimes wanting.

Nerves.—These muscles are supplied by the fourth and fifth lumbar and first sacral nerves through the anterior tibial nerve.

Actions.—The Tibialis anticus and Peroneus tertius are the direct flexors of the foot at the ankle-joint; the former muscle, when acting in conjunction with the Tibialis posticus, raises the inner border of the foot (i.e. inverts the foot); and the latter, acting with the Peronei brevis et longus, raises the outer border of the foot (i.e. everts the foot). The Extensor longus digitorum and Extensor proprius hallucis extend the phalanges of the toes, and, continuing their action, flex the foot upon the leg. Taking their fixed points from below, in the erect posture, all these muscles serve to fix the bones of the leg in the perpendicular position, and give increased strength to the ankle-joint.

FIG. 547.—Muscles of the back of the leg. Superficial layer.

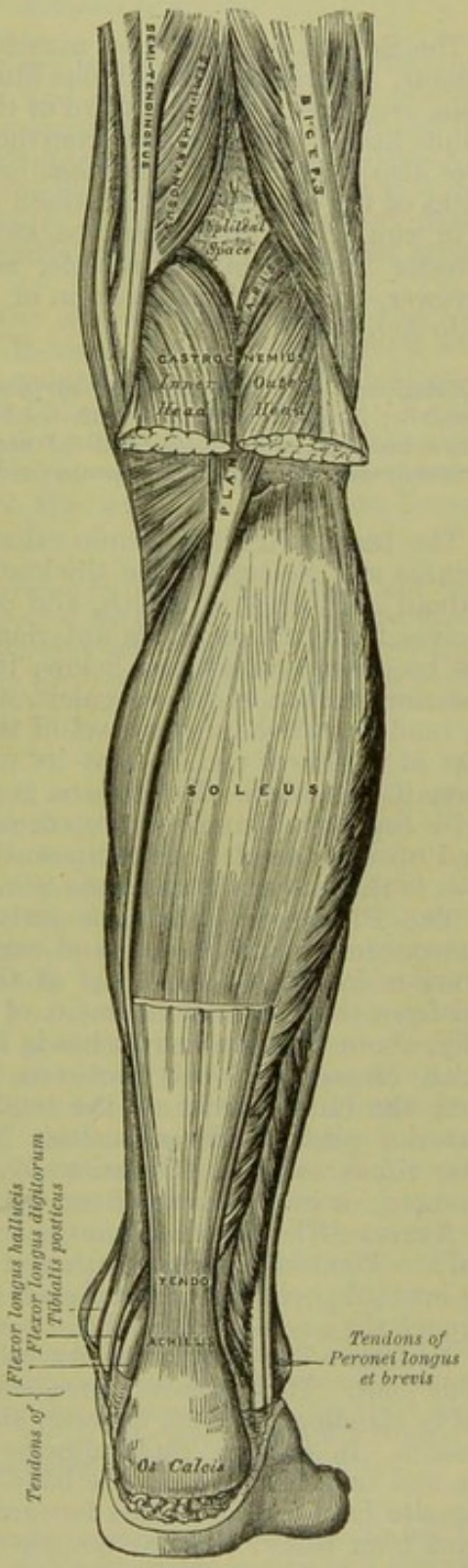

6. *Posterior Tibio-fibular Region*

The muscles in this region of the leg are subdivided into two layers—superficial and deep. Those of the superficial layer constitute a powerful muscular mass, forming the calf of the leg. Their large size is one of the most characteristic features of the muscular apparatus in man, and bears a direct relation to his ordinary attitude and mode of progression.

Superficial Layer (fig. 547)

Gastrocnemius. Soleus.
Plantaris.

The **Gastrocnemius** is the most superficial muscle, and forms the greater part of the calf. It arises by two heads, which are connected to the condyles of the femur by two strong, flat tendons. The inner and larger head (caput mediale) takes its origin from a depression at the upper and back part of the inner condyle and from the adjacent part of the femur. The outer head (caput laterale) arises from an impression on the outer side of the external condyle and from the posterior surface of the femur immediately above the outer part of the condyle. Both heads, also, arise from the subjacent part of the capsular ligament of the knee. Each tendon spreads out into an aponeurosis, which covers the posterior surface of that portion of the muscle to which it belongs. From the anterior surfaces of these tendinous expansions, muscular fibres are given off; those of the inner head being thicker and extending lower than those of the outer. The fibres in the median line unite at an angle in a median tendinous raphe, which expands into a broad aponeurosis on the anterior surface of the muscle, and into this the remaining fibres are inserted. The aponeurosis, gradually contracting, unites with the tendon of the Soleus, and forms with it the tendo Achillis.

Relations.—The Gastrocnemius is in relation by its *superficial surface* with the fascia of the leg, which separates it from the external saphenous vein and nerve; by its *deep surface* with the posterior ligament of the knee-joint, the Popliteus, Soleus, Plantaris, popliteal vessels, and internal popliteal nerve. Beneath the tendon of the inner head is a synovial bursa, which, in some cases, communicates with the cavity of the knee-joint. The tendon of the outer head sometimes contains a sesamoid fibro-cartilage or bone, where it plays over the corresponding outer condyle; and one is occasionally found in the tendon of the inner head.

The **Soleus** is a broad flat muscle situated immediately beneath the Gastrocnemius. It arises by tendinous fibres from the back part of the head of the fibula, and from the upper third of the posterior surface of its shaft; from the oblique line of the tibia, and from the middle third of its internal border; some fibres also arise from a tendinous arch placed between the tibial and fibular origins of the muscle, beneath which the popliteal vessels and internal popliteal nerve run. The fibres pass backwards to an aponeurosis which covers the posterior surface of the muscle, and this, gradually becoming thicker and narrower, joins with the tendon of the Gastrocnemius, and forms with it the tendo Achillis.

Relations.—By its *superficial surface* it is in relation with the Gastrocnemius and Plantaris; by its *deep surface*, with the Flexor longus digitorum, Flexor longus hallucis, Tibialis posticus, and posterior tibial vessels and nerve, from which it is separated by the transverse intermuscular septum or deep transverse fascia of the leg.

The **tendo Achillis** (tendo calcaneus), the common tendon of the Gastrocnemius and Soleus, is the thickest and strongest tendon in the body. It is about six inches in length, and commences near the middle of the leg, but receives fleshy fibres on its anterior surface, almost to its lower end. Gradually becoming contracted below, it is inserted into the middle part of the posterior surface of the os calcis, a synovial bursa being interposed between the tendon and the upper part of this surface. The tendon spreads out somewhat at its lower end, so that its narrowest part is about an inch and a half above its insertion. The tendon is covered by the fascia and the integument, and is separated from the deep muscles and vessels by a considerable interval filled up with areolar and adipose tissue. Along its outer side, but superficial to it, is the external saphenous vein.

The **Plantaris** is an extremely diminutive muscle, placed between the Gastrocnemius and Soleus, and remarkable for its long and delicate tendon. It arises from the lower part of the outer prolongation of the linea aspera, and from the posterior ligament of the knee-joint. It forms a small fusiform belly, about three or four inches in length, terminating in a long slender tendon which crosses obliquely between the two muscles of the calf, and runs along the inner border of the tendo Achillis, to be inserted with it into the posterior part of the os calcis. This muscle is sometimes double, and at other times wanting. Occasionally, its tendon is lost in the internal annular ligament, or in the fascia of the leg.

Nerves.—The Gastrocnemius is supplied by the first and second sacral nerves, and the Plantaris by the fourth and fifth lumbar and first sacral nerves, through the ~~internal popliteal~~. The Soleus is supplied by the first and second sacral nerves through the ~~internal popliteal~~ and posterior tibial.

Actions.—The muscles of the calf are the chief extensors of the foot at the ankle-joint. They possess considerable power, and are constantly called into use in standing, walking, dancing, and leaping; hence the large size they usually present. In walking, these muscles draw powerfully upon the os calcis, raising the heel from the ground; the body being thus supported on the raised foot, the opposite limb can be carried forwards. In standing, the Soleus, taking its fixed point from below, steadies the leg upon the foot and prevents the body from falling forwards, to which there is a constant tendency from the superincumbent weight. The Gastrocnemius, acting from below, serves to flex the femur upon the tibia, assisted by the Popliteus. The Plantaris is the rudiment of a large muscle which in some of the lower animals is continued over the os calcis to be inserted into the plantar fascia. In man it is an accessory to the Gastrocnemius, extending the ankle if the foot be free, or bending the knee if the foot be fixed.

Possibly, acting from below, by its attachment to the posterior ligament of the knee-joint, it may pull that ligament backwards during flexion, and so protect it from being compressed between the two articular surfaces.

Deep Layer (fig. 548)

Popliteus.	Flexor longus digitorum.
Flexor longus hallucis.	Tibialis posticus.

The **deep transverse fascia** of the leg is a transversely placed, intermuscular septum, between the superficial and deep muscles in the posterior tibio-fibular region. On either side it is connected to the margins of the tibia and fibula. Above, where it covers the Popliteus, it is thick and dense, and receives an expansion from the tendon of the Semimembranosus ; it is thinner in the middle of the leg ; but below, where it covers the tendons passing behind the malleoli, it is thickened and continuous with the internal annular ligament.

The **Popliteus** is a thin, flat, triangular muscle, which forms the lower part of the floor of the popliteal space. It arises by a strong tendon about an inch in length, from a depression at the anterior part of the popliteal groove on the outer side of the external condyle of the femur, and to a small extent from the posterior ligament of the knee-joint ; and is inserted into the inner two-thirds of the triangular surface above the oblique line on the posterior surface of the shaft of the tibia, and into the tendinous expansion covering the surface of the muscle.

Relations.—The tendon of the muscle is covered by that of the Biceps and by the external lateral ligament of the knee-joint ; it grooves the posterior border of the external semilunar fibro-cartilage, and is invested by the synovial membrane of the knee-joint. The fascia covering the muscle separates it from the Gastrocnemius, Plantaris, popliteal vessels, and internal popliteal nerve. The deep surface of the muscle is in contact with the posterior ligament of the knee-joint and the back of the tibia.

The **Flexor longus hallucis** is situated on the fibular side of the leg. It arises from the lower two-thirds of the posterior surface of the shaft of the fibula, with the exception of an inch at its lowest part ; from the lower part of the interosseous membrane ; from an intermuscular septum between it and the Peronei, externally ; and from the fascia covering the Tibialis posticus internally. The fibres pass obliquely downwards and backwards, and terminate in a tendon which occupies nearly the whole length of the posterior surface of the muscle. This tendon lies in a groove which crosses the posterior surface of the lower end of the tibia, the posterior surface of the astragalus, and the under surface of the sustentaculum tali of the os calcis ; in the sole of the foot it runs forwards between the two heads of the Flexor brevis hallucis, and is inserted into the base of the last phalanx of the great toe. The grooves on the astragalus and os calcis, which contain the tendon of the muscle, are converted by tendinous fibres into distinct canals, lined by synovial membrane. As the tendon passes forwards in the sole of the foot, it is situated above, and crosses, from without inwards, the tendon of the Flexor longus digitorum, to which it is connected by a tendinous slip.

Relations.—The Flexor longus hallucis is in relation by its *superficial surface* with the Soleus and tendo Achillis, from which it is separated by the deep transverse fascia ; by its *deep surface*, with the fibula, Tibialis posticus, the peroneal vessels, the lower part of the interosseous membrane, and the ankle-joint ; by its *outer border*, with the Peronei ; by its *inner border*, with the Tibialis posticus and posterior tibial vessels and nerve.

The **Flexor longus digitorum** is situated on the tibial side of the leg. At its origin it is thin and pointed, but it gradually increases in size as it descends. It arises from the posterior surface of the shaft of the tibia, from immediately below the oblique line to within three inches of its lower extremity, internal to the tibial origin of the Tibialis posticus ; it also arises from the fascia covering the Tibialis posticus. The fibres terminate in a tendon, which runs nearly the whole length of the posterior surface of the muscle. This

tendon passes behind the internal malleolus, in a groove, common to it and the Tibialis posticus, but separated from the latter by a fibrous septum, each tendon being contained in a special sheath lined by a separate synovial membrane. It passes obliquely forwards and outwards, superficial to the internal lateral ligament, into the sole of the foot (fig. 550), where it crosses the tendon of the Flexor longus hallucis,* lying on its plantar aspect and receiving from it a strong tendinous slip. It then becomes expanded and is joined by the Flexor accessorius, and finally divides into four tendons, which are inserted into the bases of the last phalanges of the four lesser toes, each tendon passing through an opening in the corresponding tendon of the Flexor brevis digitorum opposite the base of the first phalanx.

FIG. 548.—Muscles of the back of the leg. Deep layer.

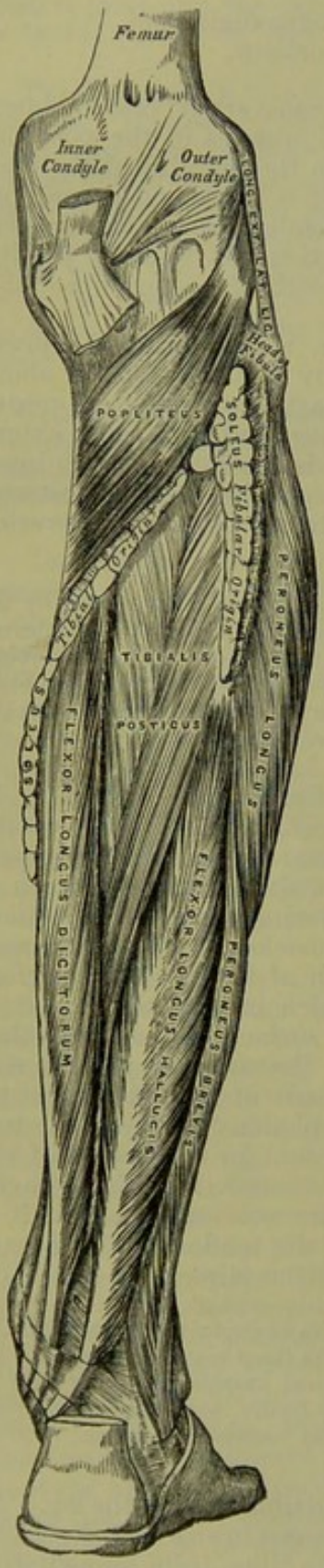

Relations.—In the leg this muscle is in relation by its *superficial surface* with the posterior tibial vessels and nerve, and the deep transverse fascia which separates it from the Soleus ; by its *deep surface*, with the tibia and Tibialis posticus. In the foot, it is covered by the Abductor hallucis and Flexor brevis digitorum, and crosses superficial to the Flexor longus hallucis.

The **Tibialis posticus** (m. tibialis posterior) lies between the two preceding muscles, and is the most deeply seated of all the muscles in the leg. It commences above by two pointed processes, separated by an angular interval, through which the anterior tibial vessels pass forwards to the front of the leg. It arises from the whole of the posterior surface of the interosseous membrane, excepting its lowest part ; from the outer portion of the posterior surface of the shaft of the tibia, between the commencement of the oblique line above and the junction of the middle and lower thirds of the shaft below ; and from the upper two-thirds of the internal surface of the fibula ; some fibres also arise from the deep transverse fascia, and from the intermuscular septa separating it from the adjacent muscles on either side. In the lower fourth of the leg it passes in front of the Flexor longus digitorum and terminates in a tendon, which lies in a groove behind the inner malleolus, with the tendon of that muscle, but enclosed in a separate sheath ; it then passes through another sheath, over the internal lateral ligament into the foot, and then beneath the inferior calcaneo-navicular ligament. The tendon contains a sesamoid fibro-cartilage, as it runs under the inferior calcaneo-navicular ligament. It is inserted into the tuberosity of the navicular bone, and gives off fibrous expansions, one of which passes backwards to the sustentaculum tali of the os calcis, others forwards and outwards to the three cuneiforms, the cuboid, and the bases of the second, third, and fourth metatarsal bones.

* That is, in the order of dissection of the sole of the foot.

Relations.—The Tibialis posticus is in relation by its *superficial surface* with the Soleus, from which it is separated by the deep transverse fascia, the Flexor longus digitorum, the posterior tibial vessels and nerve, and the peroneal vessels; by its *deep surface*, with the interosseous ligament, the tibia, fibula, and ankle-joint.

Nerves.—The Popliteus is supplied by the fourth and fifth lumbar, and first sacral nerves, through the internal popliteal nerve; the Flexor longus digitorum and Tibialis posticus by the fifth lumbar and first sacral, and the Flexor longus hallucis by the fifth lumbar, and the first and second sacral nerves, through the posterior tibial nerve.

Actions.—The Popliteus assists in flexing the leg upon the thigh; when the leg is flexed, it will rotate the tibia inwards. It is especially called into action at the beginning of the act of bending the knee, inasmuch as it produces the slight inward rotation of the tibia which is essential in the early stage of this movement. The Tibialis posticus is a direct extensor of the foot at the ankle joint; acting in conjunction with the Tibialis anticus, it turns the sole of the foot inwards (i.e. inverts the foot), antagonising the Peronei, which turn it outwards (evert it). In the sole of the foot the tendon of the Tibialis posticus lies directly below the inferior calcaneo-navicular ligament, and is therefore an important factor in maintaining the arch of the foot. The Flexor longus digitorum and Flexor longus hallucis are the direct flexors of the phalanges, and, continuing their action, extend the foot upon the leg; they assist the Gastrocnemius and Soleus in extending the foot, as in the act of walking, or in standing on tiptoe. In consequence of the oblique direction of the tendon of the Flexor longus digitorum, the toes would be drawn inwards, were it not for the Flexor accessorius muscle, which is inserted into the outer side of its tendon, and draws it to the middle line of the foot during its action. Taking their fixed point from the foot, these muscles serve to maintain the upright posture by steadying the tibia and fibula perpendicularly upon the ankle-joint. They also serve to raise these bones from the oblique position they assume in the stooping posture.

7. *Fibular region*

Peroneus longus. Peroneus brevis.

The **Peroneus longus** is situated at the upper part of the outer side of the leg, and is the more superficial of the two muscles. It arises from the head and upper two-thirds of the outer surface of the shaft of the fibula, from the deep surface of the fascia, and from the intermuscular septa between it and the muscles on the front and back of the leg: occasionally also by a few fibres from the outer tuberosity of the tibia. Between its attachments to the head and to the shaft of the fibula there is a small area of bone from which no muscular fibres arise; here the external popliteal nerve passes beneath the muscle. It terminates in a long tendon, which runs behind the outer malleolus, in a groove common to it and the tendon of the Peroneus brevis, behind which it lies; the groove is converted into a canal by a fibrous band, and the tendons in it are invested by a common synovial membrane. The tendon then extends obliquely forwards across the outer side of the os calcis, below the peroneal tubercle, in a separate fibrous sheath lined by a prolongation of the synovial membrane which lines the groove behind the malleolus. It crosses the outer side of the cuboid, and then runs on the under surface of that bone in a groove, which is converted into a canal by the long calcaneo-cuboid ligament and lined by a synovial membrane: the tendon then crosses the sole of the foot obliquely, and is inserted into the outer side of the base of the metatarsal bone of the great toe and the outer side of the internal cuneiform. Occasionally it sends a slip to the base of the second metatarsal bone. The tendon changes its direction at two points: first, behind the external malleolus; secondly, on the outer side of the cuboid bone; in both of these situations the tendon is thickened, and, in the latter, a sesamoid fibro-cartilage, or sometimes a bone, is usually developed in its substance.

The **Peroneus brevis** lies under cover of the Peroneus longus, and is a shorter and smaller muscle. It arises from the lower two-thirds of the external surface of the shaft of the fibula, internal to the Peroneus longus;

and from the intermuscular septa separating it from the adjacent muscles on the front and back part of the leg. The fibres pass vertically downwards, and terminate in a tendon which runs in front of that of the preceding muscle, through the same groove behind the external malleolus, in the same fibrous sheath, and lubricated by the same synovial membrane. It then passes through a separate sheath on the outer side of the os calcis, above that for the tendon of the Peroneus longus, the two tendons being here separated by the peroneal tubercle, and is finally inserted into the tuberosity at the base of the metatarsal bone of the little toe, on its outer side.

Nerves.—The Peronei longus et brevis are supplied by the fourth and fifth lumbar and first sacral nerves through the musculo-cutaneous branch of the external popliteal nerve.

Actions.—The Peronei longus et brevis extend the foot upon the leg, in conjunction with the Tibialis posticus, antagonising the Tibialis anticus and Peroneus tertius, which are flexors of the foot. The Peroneus longus also everts the sole of the foot, and from the oblique direction of the tendon across the sole of the foot is an important agent in the maintenance of the transverse arch. Taking their fixed points below, the Peronei serve to steady the leg upon the foot. This is especially the case in standing upon one leg, when the tendency of the superincumbent weight is to throw the leg inwards: the Peroneus longus overcomes this tendency by drawing on the outer side of the leg, and thus maintains the perpendicular direction of the limb.

Applied Anatomy.—The student should now consider the position of the tendons of the various muscles of the leg, their relation with the ankle-joint and surrounding blood-vessels, and especially their actions upon the foot, as their rigidity and contraction give rise to one or other of the kinds of deformity known as *club foot*. The most simple and common deformity, and one that is rarely, if ever, congenital, is *talipes equinus*, the heel being raised by rigidity and contraction of the Gastrocnemius so that the patient walks upon the ball of the foot. In *talipes varus*, the foot is forcibly adducted and the inner side of the sole raised, sometimes to a right angle with the ground, by the action of the Tibiales anticus and posticus. In *talipes valgus*, the outer edge of the foot is raised by the Peronei, and the patient walks on the inner ankle. In *talipes calcaneus* the toes are raised by the Extensor muscles, the heel is depressed and the patient walks upon it. Other varieties of deformity are met with, as *talipes equinovarus*, *equinovalgus*, and *calcaneovalgus*, whose names sufficiently indicate their nature. Of these, talipes equinovarus is the most common congenital form; the heel is raised by the tendo Achillis, the inner border of the foot drawn upwards by the Tibialis anticus, the anterior two-thirds twisted inwards by the Tibialis posticus, and the arch increased by the contraction of the plantar fascia, so that the patient walks on the middle of the outer border of the foot. Each of these deformities may sometimes be successfully relieved by division of the opposing tendons and fascia: by this means the foot regains its proper position, and the tendons heal by the organisation of lymph thrown out between the divided ends. The operation is easily performed by putting the contracted tendon upon the stretch, and dividing it by means of a narrow, sharp-pointed knife inserted beneath it.

Rupture of a few of the fibres of the Gastrocnemius, or rupture of the Plantaris tendon, not uncommonly occurs, especially in men somewhat advanced in life, from some sudden exertion, and frequently occurs during the game of lawn tennis, and is hence known as 'lawn-tennis leg.' The accident is accompanied by a sudden pain, and produces a sensation as if the individual had been struck a violent blow on the part. The tendo Achillis is also sometimes ruptured. It is stated that John Hunter ruptured his tendo Achillis while dancing, at the age of forty. The bursa beneath the tendo Achillis, between it and the posterior surface of the os calcis, sometimes becomes inflamed, especially in pedestrians and 'long-distance' walkers. It causes great and disabling pain, and entirely prevents the sufferer from continuing his walk.

IV. Muscles and Fasciæ of the Foot

The fibrous bands, or thickened portions of the fascia of the leg, which bind down the tendons in front of and behind the ankle in their passage to the foot, are termed the *annular ligaments*, and are three in number—anterior, internal and external.

The **anterior annular ligament** (fig. 546) consists of a superior or transverse portion, which binds down the Extensor tendons as they descend on the front of the tibia and fibula; and an inferior or Y-shaped portion, which retains them in connection with the tarsus, the two portions being joined by a thin intervening layer of fascia. The transverse portion is attached externally to the lower end of the fibula and internally to the tibia; above,

it is continuous with the fascia of the leg; it contains one synovial sheath for the tendon of the Tibialis anticus; the other tendons and the anterior tibial vessels and nerve pass beneath it, but without any synovial sheaths. The Y-shaped portion is placed in front of the ankle-joint, the stem of the Y being attached externally to the upper surface of the os calcis, in front of the depression for the interosseous ligament; it is directed inwards as a double layer, one lamina passing in front of, and the other behind, the tendons of the Peroneus tertius and Extensor longus digitorum. At the inner border of the latter tendon these two layers join together, forming a sheath in which the tendons are enclosed, surrounded by a synovial membrane. From the inner extremity of this sheath the two limbs of the Y diverge: one is directed upwards and inwards, to be attached to the internal malleolus, passing over the Extensor proprius hallucis and the vessels and nerves, but enclosing the Tibialis anticus and its synovial sheath by a splitting of its fibres. The other limb extends downwards and inwards to be attached to the inner border of the plantar fascia, and passes over the tendons of the Extensor proprius hallucis and Tibialis anticus and also the vessels and nerves. These two tendons are contained in separate synovial sheaths situated beneath the ligament.

The **internal annular ligament** is a strong fibrous band, which extends from the internal malleolus above to the margin of the os calcis below, converting a series of grooves in this situation into canals, for the passage of the tendons of the Flexor muscles and the posterior tibial vessels and nerve into the sole of the foot. It is continuous by its upper border with the deep fascia of the leg, and by its lower border with the plantar fascia and the fibres of origin of the Abductor hallucis muscle. The four canals which it forms transmit, from within outwards, the tendon of the Tibialis posticus; the tendon of the Flexor longus digitorum; the posterior tibial vessels and nerve, which run through a broad space beneath the ligament; and lastly, in a canal formed partly by the astragalus, the tendon of the Flexor longus hallucis. The canals for the tendons are lined by separate synovial membranes.

The **external annular ligament** extends from the extremity of the external malleolus to the outer surface of the os calcis: it binds down the tendons of the Peronei longus et brevis in their passage beneath the outer ankle. The two tendons are enclosed in one synovial sheath.

8. *Dorsal Region* (fig. 546)

Extensor brevis digitorum.

The **fascia** on the dorsum of the foot (fascia dorsalis pedis) is a thin membranous layer, continuous above with the anterior margin of the lower part of the annular ligament; on either side it blends with the lateral portions of the plantar fascia; anteriorly it forms a sheath for the tendons on the dorsum of the foot.

The **Extensor brevis digitorum** (fig. 546) is a broad, thin muscle, which arises from the fore part of the upper and outer surfaces of the os calcis, in front of the groove for the Peroneus brevis; from the external calcaneo-astragaloid ligament; and from the common limb of the Y-shaped portion of the anterior annular ligament. It passes obliquely across the dorsum of the foot, and terminates in four tendons. The innermost, which is the largest, is inserted into the dorsal surface of the base of the first phalanx of the great toe, crossing the dorsalis pedis artery; the other three, into the outer sides of the long Extensor tendons of the second, third, and fourth toes.

Nerves.—It is supplied by the anterior tibial nerve.

Actions.—The Extensor brevis digitorum extends the phalanges of the four inner toes, but in the great toe acts only on the first phalanx. The obliquity of its direction counteracts the oblique movement given to the toes by the long Extensor, so that when both muscles act, the toes are evenly extended.

9. *Plantar Region*

The **plantar fascia** (aponeurosis plantaris) is of great strength, and consists of pearly-white glistening fibres, disposed, for the most part, longitudinally: it is divided into a central and two lateral portions.

The *central portion*, the thickest, is narrow behind and attached to the inner tubercle of the os calcis, posterior to the origin of the Flexor brevis digitorum; and becoming broader and thinner in front, divides near the heads of the metatarsal bones into five processes, one for each of the toes. Each of these processes divides opposite the metatarso-phalangeal articulation into two strata, superficial and deep. The superficial stratum is inserted into the skin of the transverse sulcus which separates the toes from the sole. The deeper stratum divides into two slips which embrace the side of the Flexor tendons of the toes, and blend with the sheaths of the tendons, and laterally with the transverse metatarsal ligament, thus forming a series of arches through which the tendons of the short and long Flexors pass to the toes. The intervals left between the five processes allow the digital vessels and nerves, and the tendons of the Lumbricales to become superficial. At the point of division of the fascia, numerous transverse fibres (fasciculi transversi) are superadded, which serve to increase the strength of the fascia at this part by binding the processes together, and connecting them with the integument. The central portion of the plantar fascia is continuous with the lateral portions at either side, and sends upwards into the foot, at the lines of junction, two strong vertical intermuscular septa, broader in front than behind, which separate the middle from the external and internal plantar group of muscles; from these again are derived thinner transverse septa which separate the various layers of muscles in this region. The upper surface of this fascia gives attachment behind to the Flexor brevis digitorum.

The *lateral portions* of the plantar fascia are thinner than the central piece, and cover the sides of the foot.

The *outer portion* covers the under surface of the Abductor minimi digiti; it is thin in front and thick behind, where it forms a strong band between the outer tubercle of the os calcis and the base of the fifth metatarsal bone; it is continuous internally with the middle portion of the plantar fascia, and externally with the dorsal fascia.

The *inner portion* is thin, and covers the under aspect of the Abductor hallucis; it is attached behind to the internal annular ligament, and is continuous around the side of the foot with the dorsal fascia, and externally with the middle portion of the plantar fascia.

The muscles in the plantar region of the foot may be divided into three groups, in a similar manner to those in the hand. Those of the internal plantar region are connected with the great toe, and correspond with those of the thumb; those of the external plantar region are connected with the little toe, and correspond with those of the little finger; and those of the middle plantar region are connected with the tendons intervening between the two former groups. But in order to facilitate the description of these muscles, it will be found more convenient to divide them into four layers, in the order in which they are successively exposed.

First Layer (fig. 549)

Abductor hallucis. Flexor brevis digitorum.
Abductor minimi digiti.

The **Abductor hallucis** lies along the inner border of the foot and covers the origins of the plantar vessels and nerves. It arises from the inner tubercle on the under surface of the os calcis; from the internal annular ligament; from the plantar fascia covering it; and from the intermuscular septum between it and the Flexor brevis digitorum. The fibres terminate in a tendon, which is inserted, together with the innermost tendon of the Flexor brevis hallucis, into the inner side of the base of the first phalanx of the great toe.

The **Flexor brevis digitorum** lies in the middle of the sole of the foot, immediately beneath * the central part of the plantar fascia, with which it is firmly united. Its deep surface is separated from the external plantar vessels and nerves by a thin layer of fascia. It arises by a narrow tendinous process, from the inner tubercle of the os calcis, from the central part of the

* That is, in the order of dissection of the sole of the foot.

plantar fascia, and from the intermuscular septa between it and the adjacent muscles. It passes forwards, and divides into four tendons, one for each of the four outer toes. Opposite the bases of the first phalanges, each tendon divides into two slips, to allow of the passage of the corresponding tendon of the Flexor longus digitorum ; the two portions of the tendon then unite and form a grooved channel for the reception of the accompanying long Flexor tendon. Finally, it divides a second time, to be inserted into the sides of the second phalanx about its middle. The mode of division of the tendons of the Flexor brevis digitorum, and of their insertion into the phalanges, is analogous to that of the tendons of the Flexor sublimis digitorum in the hand.

Fig. 549.—Muscles of the sole of the foot. First layer.

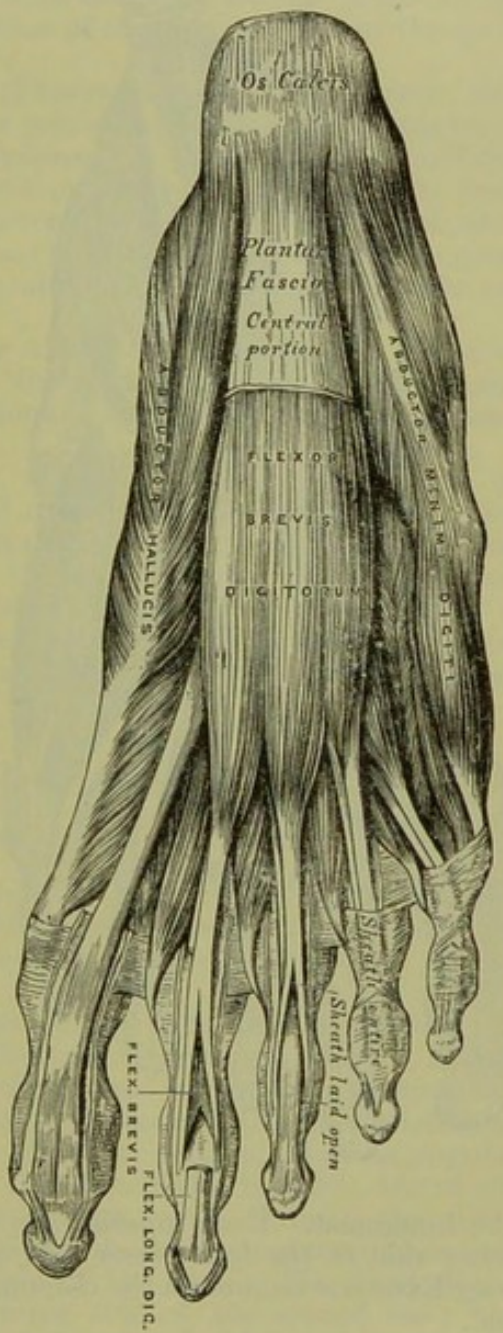

Fibrous sheaths of the Flexor tendons.—These are not so well marked as in the fingers. The Flexor tendons of the toes as they run along the phalanges are retained against the bones by fibrous sheaths. These sheaths are formed by strong fibrous bands, which arch across the tendons, and are attached on each side to the margins of the phalanges. Opposite the middle of the proximal and second phalanges the sheath is very strong, and the fibres pass transversely ; but opposite the joints it is much thinner, and the fibres are directed obliquely. Each sheath is lined by a synovial membrane, which is reflected on the contained tendon.

The **Abductor minimi digiti** (m. abductor quinti digiti) lies along the outer border of the foot, and is in relation by its inner margin with the external plantar vessels and nerves. It arises, by a very broad origin, from the outer tubercle of the os calcis, from the under surface of the os calcis between the two tubercles, from the fore part of the inner tubercle, from the plantar fascia, and from the intermuscular septum between it and the Flexor brevis digitorum. Its tendon, after gliding over a smooth facet on the under surface of the base of the fifth metatarsal bone, is inserted, with the short Flexor of the little toe, into the outer side of the base of the first phalanx of this toe.

Second Layer (fig. 550)

Flexor accessorius.
Lumbricales.

The **Flexor accessorius** (m. quadratæ plantæ) is separated from the muscles of the first layer by the external plantar vessels and nerves. It arises by two heads, which are separated from each other by the long plantar ligament : the inner or larger, which is muscular, is attached to the inner concave surface of the os calcis, below the groove which lodges the tendon of the Flexor longus hallucis ; the outer head, flat and tendinous, to the outer border of the inferior surface of the os calcis, in front of its lesser tubercle, and to the long plantar ligament. The two portions join at an acute angle, and are inserted into the outer margin and upper and under surfaces of the tendon

of the Flexor longus digitorum, forming a kind of groove, in which the tendon is lodged.*

The **Lumbricales** are four small muscles, accessory to the tendons of the Flexor longus digitorum : they arise from the tendons of the long Flexor, as far back as their angles of division, each arising from two tendons, except

Fig. 550.—Muscles of the sole of the foot. Second layer.

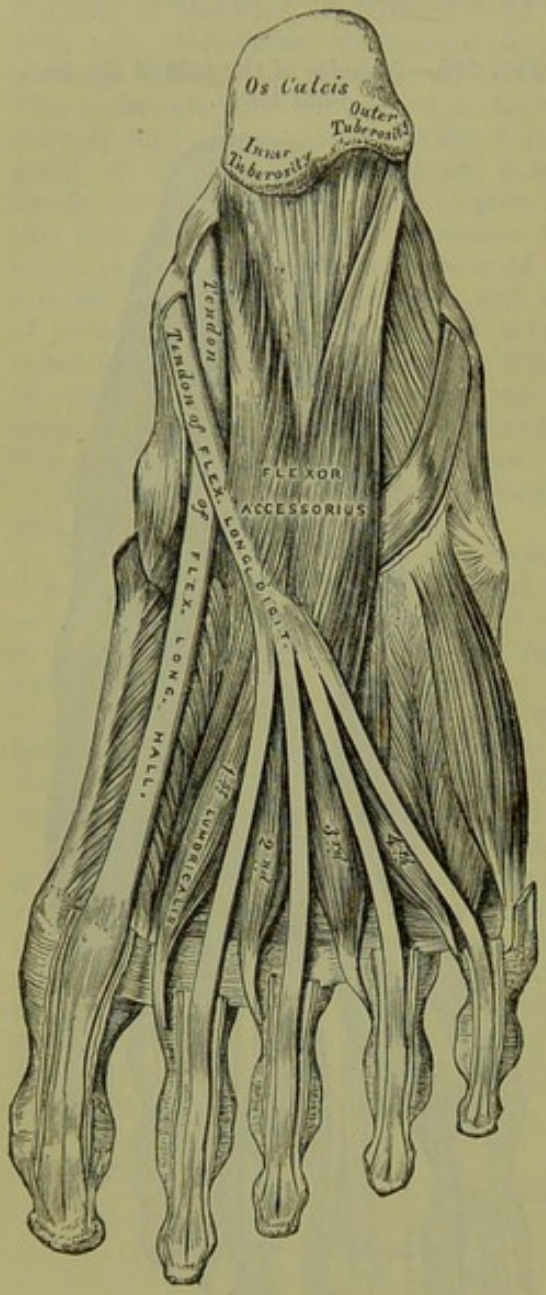

Fig. 551.—Muscles of the sole of the foot. Third layer.

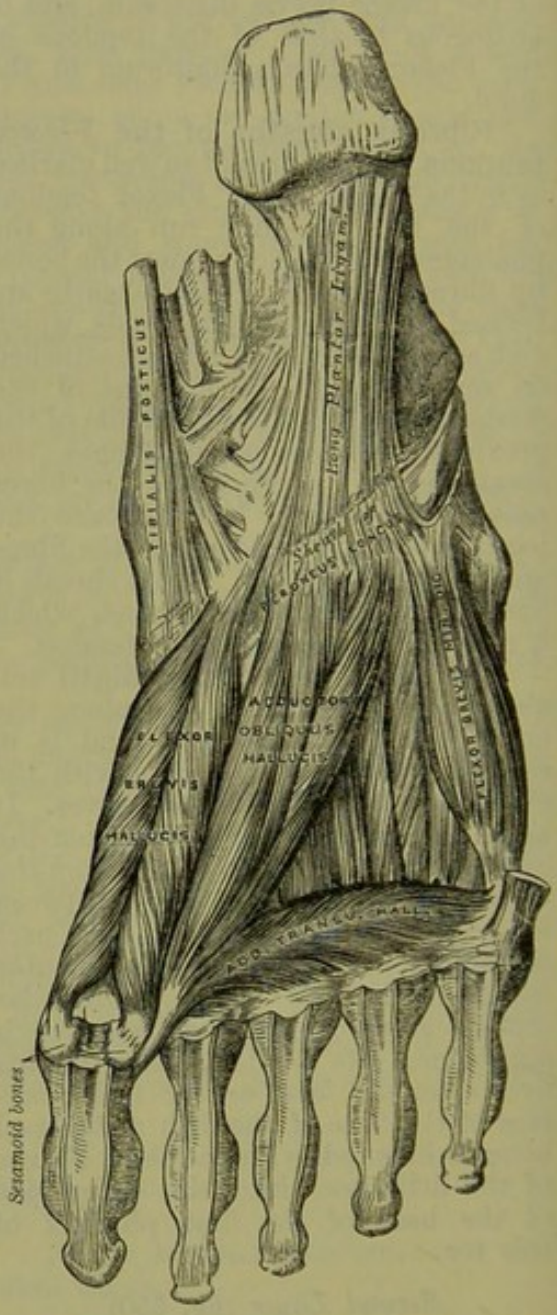

the innermost. Each muscle ends in a tendon, which passes forwards on the inner side of the four lesser toes, and is inserted into the expansion of the long Extensor tendon on the dorsum of the first phalanx of the corresponding toe.

Third Layer (fig. 551)

Flexor brevis hallucis.	Adductor transversus hallucis.
Adductor obliquus hallucis.	Flexor brevis minimi digiti.

The **Flexor brevis hallucis** arises, by a pointed tendinous process, from the inner part of the under surface of the cuboid bone, from the contiguous

* Turner pointed out that the fibres of the Flexor accessorius end in aponeurotic bands, which contribute slips to the second, third, and fourth digits.

portion of the external cuneiform, and from the prolongation of the tendon of the Tibialis posticus which is attached to that bone. The muscle divides in front into two portions, which are inserted into the inner and outer sides of the base of the first phalanx of the great toe, a sesamoid bone being developed in each tendon at its insertion. The inner portion of this muscle is blended with the Abductor hallucis previous to its insertion; the outer with the Adductor obliquus hallucis; the tendon of the Flexor longus hallucis lies in a groove between them.

The **Adductor obliquus hallucis** is a large, thick, fleshy mass, passing obliquely across the foot, and occupying the hollow space between the inner four metatarsal bones. It arises from the tarsal extremities of the second, third, and fourth metatarsal bones, and from the sheath of the tendon of the Peroneus longus, and is inserted, together with the outer portion of the Flexor brevis hallucis, into the outer side of the base of the first phalanx of the great toe.

The **Adductor transversus hallucis** (*Transversus pedis*) is a narrow, flat, muscular fasciculus, stretched transversely across the heads of the metatarsal bones, between them and the Flexor tendons. It arises from the inferior metatarso-phalangeal ligaments of the three outer toes, sometimes only from the third and fourth, and from the transverse ligament of the metatarsus. It is inserted into the outer side of the base of the first phalanx of the great toe, its fibres being blended with the tendon of insertion of the Adductor obliquus hallucis.

The small muscles of the great toe, the Abductor, Flexor brevis, Adductor obliquus, and Adductor transversus, like the similar muscles of the thumb, give off, at their insertions, fibrous expansions to blend with the long Extensor tendons.

The **Flexor brevis minimi digiti** (m. flexor brevis digiti quinti) lies on the metatarsal bone of the little toe, and much resembles one of the Interossei. It arises from the base of the metatarsal bone of the little toe, and from the sheath of the Peroneus longus; its tendon is inserted into the base of the first phalanx of the little toe on its outer side. Occasionally some of the deeper fibres of the muscle are inserted into the outer part of the distal half of the fifth metatarsal bone; these are described by some as a distinct muscle, the Opponens minimi digiti.

Fourth Layer (figs. 552, 553)

Interossei.

The **Interossei** in the foot are similar to those in the hand, with this exception, that they are grouped around the middle line of the *second* digit, instead of that of the *third*. They are seven in number, and consist of two groups, dorsal and plantar.

The **Dorsal interossei** (interossei dorsales) (fig. 552), four in number, are situated between the metatarsal bones. They are bipenniform muscles, arising by two heads from the adjacent sides of the metatarsal bones between which they are placed; their tendons are inserted into the bases of the first phalanges, and into the aponeurosis of the common Extensor tendon. In the angular interval left between the heads of each of the three outer muscles, one of the perforating arteries passes to the dorsum of the foot; through the space between the heads of the First interosseous muscle the communicating branch of the dorsalis pedis artery enters the sole of the foot. The First dorsal interosseous muscle is inserted into the inner side of the second toe; the other three are inserted into the outer sides of the second, third, and fourth toes.

The **Plantar interossei** (interossei plantares) (fig. 553), three in number, lie beneath rather than between the metatarsal bones, and each is connected with but one metatarsal bone. They arise from the bases and inner sides of the shafts of the third, fourth, and fifth metatarsal bones, and are inserted into the inner sides of the bases of the first phalanges of the same toes, and into the aponeuroses of the common Extensor tendons.

Nerves.—The Flexor brevis digitorum, the Flexor brevis and Abductor hallucis, and the innermost Lumbrical are supplied by the internal plantar nerve; all

the other muscles in the sole of the foot by the external plantar. The First dorsal interosseous muscle frequently receives an extra filament from the internal branch of the anterior tibial nerve on the dorsum of the foot, and the Second dorsal interosseous a twig from the external branch of the same nerve.

Actions.—All the muscles of the foot act upon the toes, and in describing their action they may be grouped as Abductors, Adductors, Flexors, or Extensors. The *abductors* are the Dorsal interossei, the Abductor hallucis, and the Abductor minimi digiti. The Dorsal interossei are abductors from an imaginary line passing through the axis of the second toe, so that the first muscle draws the second toe inwards, towards the great toe, the second muscle draws the same toe outwards, the third draws the third toe, and the fourth draws the fourth toe in the same direction. Like the Interossei in the hand, each assists in flexing the proximal phalanx and extending the two terminal phalanges. The Abductor hallucis abducts the great toe from the others, and also flexes the proximal phalanx of this toe. In the same way the action of the Abductor minimi digiti is two-fold, as an abductor of this toe from the others, and also as a flexor of its proximal phalanx. The *adductors* are the Plantar interossei, the Adductor obliquus

Fig. 552.—The Dorsal interossei. Left foot.

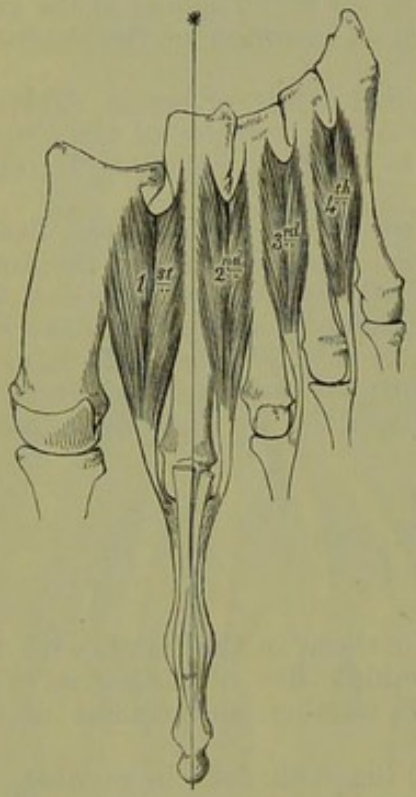

Fig. 553.—The Plantar interossei. Left foot.

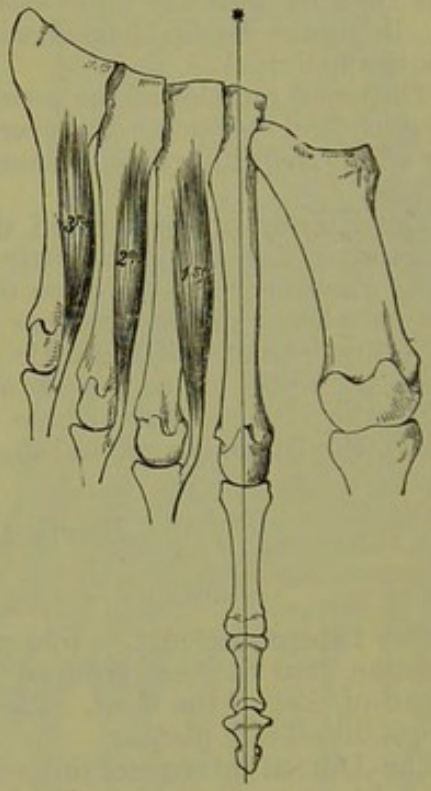

hallucis, and the Adductor transversus hallucis. The Plantar interosseous muscles adduct the third, fourth, and fifth toes towards the imaginary line passing through the second toe, and by means of their insertions into the aponeuroses of the Extensor tendons they assist in flexing the proximal phalanges and extending the middle and terminal phalanges. The Adductor obliquus hallucis is chiefly concerned in adducting the great toe towards the second one, but also assists in flexing this toe. The Adductor transversus hallucis approximates all the toes and thus increases the curve of the transverse arch of the metatarsus. The *flexors* are the Flexor brevis digitorum, the Flexor accessorius, the Flexor brevis hallucis, the Flexor brevis minimi digiti, and the Lumbricales. The Flexor brevis digitorum flexes the second phalanges upon the first, and, continuing its action, flexes the first phalanges also, and brings the toes together. The Flexor accessorius assists the long Flexor of the toes and converts the oblique pull of the tendons of that muscle into a direct backward pull upon the toes. The Flexor brevis minimi digiti flexes the little toe and draws its metatarsal bone downwards and inwards. The Lumbricales, like the corresponding muscles in the hand, assist in flexing the proximal phalanges, and by their insertions into the long

Extensor tendons aid that muscle in straightening the middle and terminal phalanges. The only muscle in the *extensor* group is the Extensor brevis digitorum. It extends the first phalanx of the great toe and assists the long Extensor in extending the next three toes, and at the same time gives to the toes an outward direction when they are extended.

Surface Form.—The skin of the thigh, especially above in the hollow of the groin and on the inner side, is thin, smooth, and elastic, and contains few hairs, except in the neighbourhood of the pubes. Towards the outer side it becomes thicker, and the hairs are more numerous. The skin over the buttock is also fairly thick, with low sensibility and vascularity. As a rule, it is destitute of conspicuous hairs, except towards the post-anal furrow, where, in some males, an abundant development of hair is present. The skin over the front of the knee is covered by thickened epidermis ; it is loose and thrown into transverse wrinkles when the leg is extended : that of the leg is thin, especially on the inner side, and covered with numerous large hairs. On the dorsum of the foot the skin is thin, loosely connected to subjacent parts, and contains few hairs. On the sole, and especially the heel, the epidermis is of great thickness, and here, as in the palm of the hand, there are no hairs or sebaceous follicles.

Of the muscles of the thigh, those of the anterior femoral region largely contribute to the surface form of this part of the limb. The *Tensor fasciæ femoris* produces a broad elevation immediately below the anterior portion of the crest of the ilium and behind the anterior superior spinous process. From its lower border, a longitudinal groove, corresponding to the ilio-tibial band, extends to the outer side of the knee-joint. The *Sartorius*, when it is brought into action by flexing the leg on the thigh, and the thigh on the pelvis, and rotating the thigh outwards, presents a well-marked surface form. At its upper part, where it constitutes the outer boundary of Scarpa's triangle, it forms a prominent oblique ridge, which becomes changed into a flattened plane below, and this gradually merges in a general fulness on the inner side of the knee-joint. When the Sartorius is not in action, a depression exists between the Quadriceps extensor and the Adductor muscles, and extends obliquely downwards and inwards from the apex of Scarpa's triangle to the inner side of the knee. In the angle formed by the divergence of the Sartorius and Tensor fasciæ femoris muscles, just below the anterior superior spine of the ilium, the *Rectus femoris* muscle appears, and, below this, determines to a great extent the convex form of the front of the thigh. In a well-developed subject, the borders of the muscle, when in action, can be clearly defined. The *Vastus externus* forms a long flattened plane on the outer side of the thigh, traversed by the longitudinal groove formed by the ilio-tibial band. The *Vastus internus*, on the inner side of the lower half of the thigh, gives rise to a considerable prominence, which increases towards the knee and terminates somewhat abruptly in this situation with a full, curved outline. The *Crureus* and *Subcrureus* are completely hidden, and do not directly influence surface form. The *Adductor muscles*, constituting the internal femoral group, cannot be distinguished from each other, with the exception of the upper tendon of the Adductor longus and the lower tendon of the Adductor magnus. When the *Adductor longus* is in action its upper tendon stands out as a prominent ridge, which runs obliquely downwards and outwards from the neighbourhood of the pubic spine, and forms the inner boundary of Scarpa's triangle. The lower tendon of the *Adductor magnus* can be distinctly felt as a short ridge extending down to the adductor tubercle on the internal condyle, between the Sartorius and Vastus internus. The Adductor group of muscles fills in the triangular space at the upper part of the thigh, between the oblique femur and the pelvis, and to them is due the contour of the inner border of the thigh, the *Gracilis* largely contributing to the smoothness of the outline. These muscles are not marked off on the surface from the hamstrings by any intermuscular depression ; but on the outer side of the thigh the latter are defined from the Vastus externus by a distinct marking, corresponding to the external intermuscular septum. The *Gluteus maximus*, and the *Gluteus medius* in its upper part, are the only muscles of the buttock which influence surface form. The lower part of the Gluteus medius, the Gluteus minimus, and the External rotators are completely hidden. The *Gluteus maximus* forms the full rounded outline of the buttock ; it is more prominent behind, compressed in front, and terminates at its tendinous insertion in a depression immediately behind the great trochanter. Its lower border does not correspond to the gluteal fold, but is much more oblique, being marked by a line drawn from the side of the coccyx to the junction of the upper with the middle third of the thigh on the outer side. From beneath the lower margin of this muscle the *Hamstring muscles* appear, at first narrow and not well marked, but, as they descend, they become more prominent, and eventually divide into two well-marked ridges formed by their tendons, which constitute the upper boundaries of the popliteal space. In the upper part of the thigh these muscles cannot be individually distinguished from each other ; but lower down, the separation between the Semitendinosus and Semimembranosus is denoted by a slight intermuscular marking. The external hamstring tendon formed by the *Biceps* is seen as a thick cord running down to the head of the fibula. The inner hamstring tendons comprise the Semitendinosus and the Semimembranosus. The *Semitendinosus* is the more internal, and can be felt, in certain

positions of the limb, as a sharp cord, while the *Semimembranosus* is thick. The *Gracilis* is situated a little in front of them.

The *Tibialis anticus* presents a fusiform enlargement at the outer side of the tibia, and projects beyond the crest of the shin bone. From the muscular mass, its tendon may be traced downward, standing out boldly, when the muscle is in action, on the front of the tibia and ankle-joint, and coursing down along the inner border of the foot to its insertion. The fleshy fibres of the *Peroneus longus* are strongly marked at the upper part of the outer side of the leg, especially when the muscle is in action. It forms a bold swelling, separated by furrows from the Extensor longus digitorum in front and the Soleus behind. Below, the fleshy fibres terminate abruptly in a tendon which overlaps the more flattened form of the *Peroneus brevis*. Below the external malleolus the tendon of the Peroneus brevis is more marked than that of the Peroneus longus. On the dorsum of the foot the tendons emerging from beneath the anterior annular ligament spread out, and can be distinguished, as follows: the innermost and largest is the Tibialis anticus; the next is the Extensor proprius hallucis; then the Extensor longus digitorum, dividing into four tendons to the four outer toes; and lastly, the Peroneus tertius. The flattened form of the dorsum of the foot is relieved by the rounded outline of the fleshy belly of the *Extensor brevis digitorum*, which produces a fulness on the outer side of the tarsus in front of the external malleolus, and by the Dorsal interossei, which bulge between the metatarsal bones. At

FIG. 554.—Fracture of the neck of the femur within the capsular ligament.

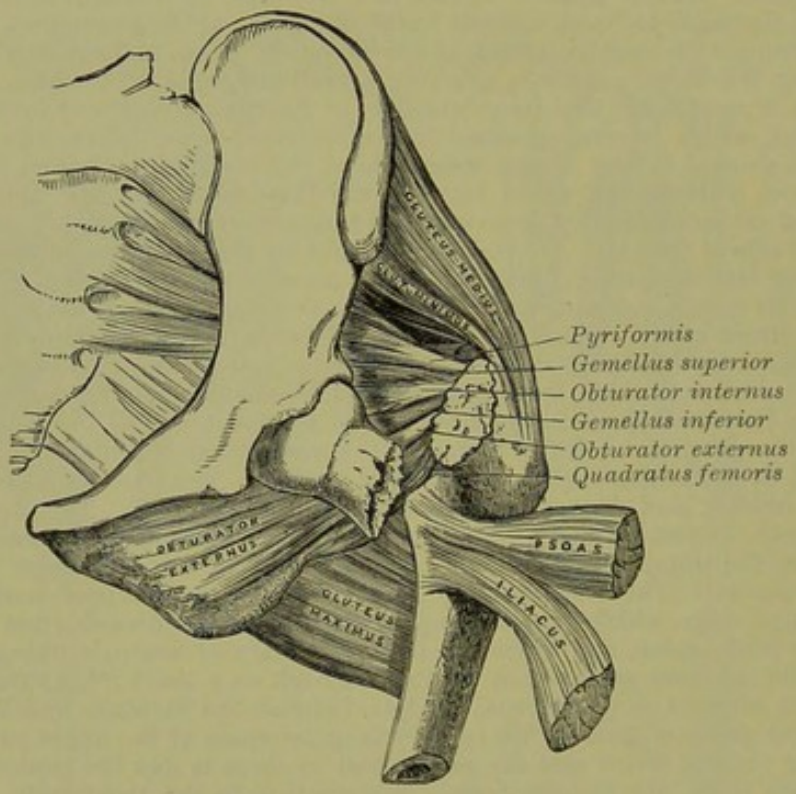

the back of the knee is the popliteal space, bounded above by the tendons of the Hamstring muscles; below, by the two heads of the Gastrocnemius. Below this space is the prominent fleshy mass of the calf of the leg, produced by the *Gastrocnemius* and *Soleus*. When these muscles are in action, as in standing on tiptoe, the borders of the Gastrocnemius are well defined, presenting two curved lines, which converge to the tendon of insertion. Of these borders, the inner is more prominent than the outer. The fleshy mass of the calf terminates somewhat abruptly below in the tendo Achillis, which stands out prominently on the lower part of the back of the leg. It presents a somewhat tapering form in the upper three-fourths of its extent, but widens out slightly below. When the muscles of the calf are in action, the lateral portions of the *Soleus* may be seen, forming curved eminences, of which the outer is the longer, on either side of the Gastrocnemius. Behind the inner border of the lower part of the shaft of the tibia, a well-marked ridge, produced by the tendon of the Tibialis posticus, is visible when this muscle is in a state of contraction.

On the sole of the foot the superficial layer of muscles influences surface form. The *Abductor minimi digiti* forms a narrow rounded elevation along the outer border of the foot, while the *Abductor hallucis* does the same, though to a less extent, on the inner side. The *Flexor brevis digitorum*, bound down by the plantar fascia, is not very apparent; it produces a flattened form, and is covered by the thickened skin of the sole, which is here thrown into numerous wrinkles.

Applied Anatomy.—The student should now consider the effects produced by the action of the various muscles in fractures of the bones of the lower extremity. The more common forms of fracture are selected for illustration and description.

In fracture of the *neck of the femur internal to the capsular ligament* (fig. 554), the characteristic signs are slight shortening of the limb, and eversion of the foot, neither of which occurs, however, in some cases until some time after the injury. The eversion is caused by the weight of the limb rotating it outwards. The shortening is produced by the action of the Glutei, and by the Rectus femoris in front, and the Biceps, Semitendinosus and Semimembranosus behind.

In fracture of the *femur just below the trochanters* (fig. 555), the upper fragment is tilted forwards almost at right angles with the pelvis, by the Ilio-psoas ; and, at the same time, everted and drawn outwards by the external rotator muscles and Glutei, causing a marked prominence at the upper and outer side of the thigh, and much pain from the bruising and laceration of the muscles. The limb is shortened, because the lower

FIG. 555.—Fracture of the femur below the trochanters.

FIG. 556.—Fracture of the femur above the condyles.

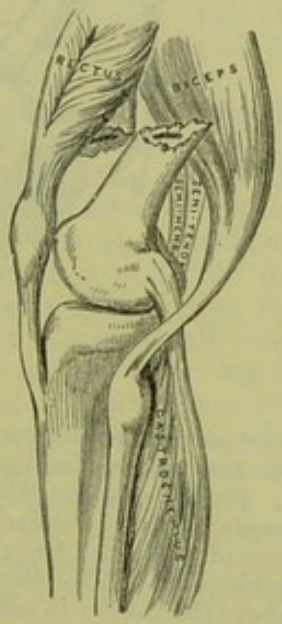

FIG. 557.—Fracture of the patella.

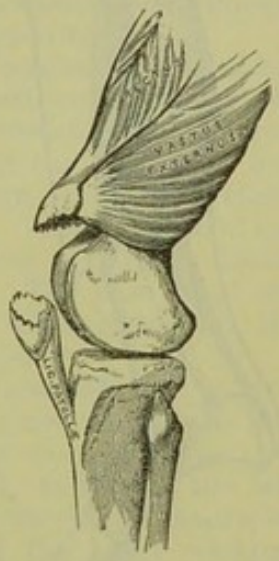

fragment is drawn upwards by the Rectus in front, and the Biceps, Semimembranosus and Semitendinosus behind ; it is, at the same time, everted. This fracture may be reduced by relaxation of all the muscles involved, to effect which the limb should be put up with the thigh flexed on the pelvis and the leg on the thigh.

Oblique fracture of the femur *immediately above the condyles* (fig. 556) is a formidable injury, and attended with considerable displacement. On examination of the limb, the lower fragment may be felt deep in the popliteal space, being drawn backwards by the Gastrocnemius, and upwards by the Hamstring and Rectus muscles. The pointed end of the upper fragment is drawn inwards by the Pectineus and Adductor muscles, and tilted forwards by the Psoas and Iliacus, piercing the Rectus muscle, and occasionally the integument. Relaxation of these muscles, and direct approximation of the broken fragments, are effected by placing the limb on a double inclined plane. The greatest care is requisite in keeping the pointed extremity of the upper fragment in proper position ; otherwise, after union of the fracture, the power of extension of the limb is partially destroyed, the Rectus muscle being held down by the fractured end of the bone, and the patella, when elevated, being drawn upwards against the projecting fragment.

In transverse fracture of the *patella* (fig. 557) the fragments are separated by the action of the Quadriceps extensor and by the effusion which takes place into the joint ; the extent of separation of the two fragments depending upon the degree of laceration of the ligamentous structures around the bone.

In oblique fracture of the *shaft of the tibia* (fig. 558), if the fracture has taken place obliquely from above, downwards and forwards, the fragments ride over one another, the lower fragment being drawn backwards and upwards by the powerful action of the muscles of the calf ; the pointed extremity of the upper fragment projects forwards immediately beneath the integument, often protruding through it, and rendering the

fracture a compound one. If the direction of the fracture is the reverse of that shown in the figure, the pointed extremity of the lower fragment projects forwards, rising up on the lower end of the upper one. By bending the knee, which relaxes the opposing muscles, and making extension from the ankle and counter-extension at the knee, the fragments may be brought into apposition. It is sometimes necessary, however, in compound fracture to remove a portion of the projecting bone with the saw before complete adaptation can be effected.

Fig. 558.—Oblique fracture of the shaft of the tibia.

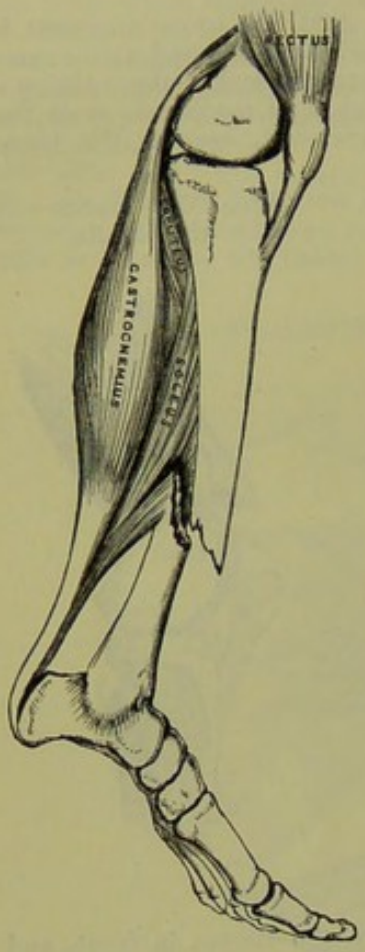

Fig. 559.—Fracture of the fibula, with dislocation of the foot outwards—' Pott's fracture.'

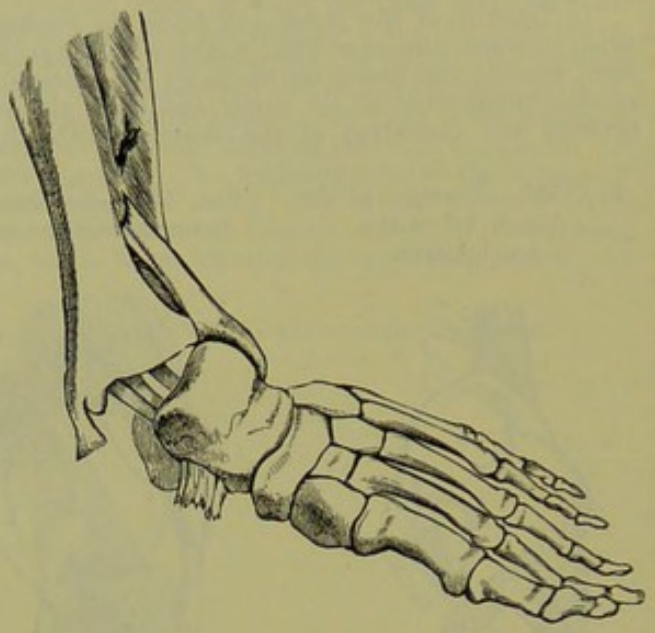

Fracture of the *fibula with dislocation of the foot outwards* (fig. 559), commonly known as 'Pott's fracture,' is one of the most frequent injuries in the region of the ankle-joint. The fibula is fractured about three inches above the ankle ; in addition to this the internal malleolus is broken off, or the deltoid ligament torn through, and the astragalus displaced from the corresponding surface of the tibia. The foot is markedly everted, and the sharp edge of the upper end of the fractured malleolus presses strongly against the skin ; at the same time, the heel is drawn up by the muscles of the calf. This injury can generally be reduced by flexing the leg at right angles with the thigh, which relaxes all the opposing muscles, and by making extension from the ankle and counter-extension at the knee. There is later a great tendency for the foot to fall backwards at the ankle-joint, and constant supervision is required to counteract this.

ANGIOLOGY

THE vascular system is divided for descriptive purposes into (*a*) the *blood vascular system*, which comprises the heart and blood-vessels for the circulation of the blood; and (*b*) the *lymph vascular system*, consisting of lymphatic glands and vessels, through which a colourless fluid, the lymph, circulates. It must be noted, however, that the two systems communicate with each other and are intimately associated developmentally.

The heart is the central organ of the blood vascular system, and consists of a hollow muscle; by its contraction the blood is pumped to all parts of the body through a complicated series of tubes, termed *arteries*. The arteries undergo enormous ramification in their course throughout the body, and end in very minute vessels, called *arterioles*, which in their turn open into a close-meshed network of microscopic vessels, termed *capillaries*. After the blood has passed through the capillaries it is collected into a series of larger vessels, called *veins*, by which it is again returned to the heart. The passage of the blood through the heart and blood-vessels constitutes what is termed the *circulation* of the blood, of which the following is an outline.*

The human heart is divided by a septum into right and left halves, and each half is further divided into two cavities, an upper termed the *auricle* and a lower the *ventricle*. The heart therefore consists of four chambers, two, the right auricle and right ventricle, forming the right half, and two, the left auricle and left ventricle, the left half. The auricles are receiving chambers, and the ventricles distributing ones. The right half of the heart contains venous or impure blood; the left, arterial or pure blood. From the cavity of the left ventricle the pure blood is carried into a large artery, the *aorta*, through the numerous branches of which it is distributed to all parts of the body, with the exception of the lungs. In its passage through the capillaries of the body the blood gives up to the tissues the materials necessary for their growth and nourishment, and at the same time receives from the tissues the waste products resulting from their metabolism. In doing so it becomes changed from arterial into venous blood, which is collected by the veins and through them returned to the right auricle of the heart. From this cavity the impure blood passes into the right ventricle, and is thence conveyed through the *pulmonary arteries* to the lungs. In the capillaries of the lungs it again becomes arterialised, and is then carried to the left auricle by the *pulmonary veins*. From the left auricle it passes into the left ventricle, from which the cycle once more begins.

The course of the blood from the left ventricle through the body generally to the right side of the heart constitutes the greater or *systemic* circulation, while its passage from the right ventricle through the lungs to the left side of the heart is termed the lesser or *pulmonary* circulation.

It is necessary, however, to state that the blood which circulates through the spleen, pancreas, stomach, small intestine, and the greater part of the large intestine is not returned directly from these organs to the heart, but is collected into a large vein, termed the *portal vein*, by which it is carried to the liver. In the liver this vein divides, after the manner of an artery, and ultimately ends in capillary vessels, from which the rootlets of a series of veins, called the *hepatic veins*, arise; these carry the blood into the inferior vena cava, whence it is conveyed to the right auricle. From this it will be seen that

* The composition of the blood and the structure of the blood-vessels are described in the section on Histology.

the blood contained in the portal vein passes through two sets of capillary vessels: (1) those in the spleen, pancreas, stomach, &c., and (2) those in the liver.

Speaking generally, the arteries may be said to contain pure, and the veins impure, blood. This is true of the systemic, but not of the pulmonary vessels, since it has been seen that the impure blood is conveyed from the heart to the lungs by the pulmonary arteries, and the pure blood returned from the lungs to the heart by the pulmonary veins. Arteries, therefore, must be defined as vessels which convey blood *from* the heart, and veins as vessels which return blood *to* the heart.

The heart and lungs are situated in the thorax, the walls of which afford them protection. The heart lies between the two lungs, and is enclosed within a membranous bag, the *pericardium*, while each lung is invested by a serous membrane, the *pleura*. The skeleton of the thorax, and the shape and boundaries of the cavity, have already been described (page 202).

The cavity of the thorax.—The capacity of the cavity of the thorax does not correspond with its apparent size externally, because (1) the space enclosed by the lower ribs is occupied by some of the abdominal viscera; and (2) the cavity extends above the first rib into the neck. The size of the thoracic cavity is constantly varying during life with the movements of the ribs and Diaphragm, and with the degree of distension of the abdominal viscera. From the collapsed state of the lungs as seen when the thorax is opened in the dead body, it would appear as if the viscera only partly filled the cavity, but during life there is no vacant space, that which is seen after death being filled up by the expanded lungs.

The upper opening of the thorax.—The parts which pass through the upper opening of the thorax are, from before backwards in or near the middle line, the Sterno-hyoid and Sterno-thyroid muscles, the remains of the thymus gland, the inferior thyroid veins, the trachea, œsophagus, thoracic duct, and the Longus colli muscles; at the sides, the innominate artery, the left common carotid and left subclavian arteries, the internal mammary and superior intercostal arteries, the innominate veins, the pneumogastric, cardiac, phrenic, and sympathetic nerves, the greater part of the anterior primary divisions of the first thoracic nerves, and the recurrent laryngeal nerve of the left side. The apex of each lung, covered by the pleura, also projects through this aperture, a little above the level of the anterior end of the first rib.

The **lower opening of the thorax** is wider transversely than from before backwards. It slopes obliquely downwards and backwards, so that the thoracic cavity is much deeper behind than in front. The Diaphragm (see page 501) closes the opening and forms the floor of the thorax. The floor is flatter at the centre than at the sides, and higher on the right side than on the left; in the dead body the right side reaches the level of the upper border of the fifth costal cartilage, while the left extends only to the corresponding part of the sixth costal cartilage. From the highest point on each side the floor slopes suddenly downwards to the costal and vertebral attachments of the Diaphragm; this slope is more marked behind than in front, so that only a narrow space is left between the Diaphragm and the posterior wall of the thorax.

The Pericardium

The **Pericardium** (fig. 560) is a conical fibro-serous sac, in which the heart and the roots of the great vessels are contained. It is placed behind the sternum and the cartilages of the third, fourth, fifth, sixth, and seventh ribs of the left side, in the interval between the pleuræ.

In *front*, it is separated from the anterior wall of the thorax, in the greater part of its extent, by the lungs and pleuræ; but a small area, somewhat variable in size, and usually corresponding with the left half of the lower portion of the gladiolus of the sternum and the inner extremities of the cartilages of the fourth and fifth ribs of the left side, comes into direct relationship with the chest-wall. The lower extremity of the thymus gland, in the child, is in contact with the front of the upper part of the pericardium. *Behind*, it rests upon the bronchi, the œsophagus, and the descending thoracic aorta. *Laterally*, it is covered by the pleuræ, and is in relation with the inner

surfaces of the lungs; the phrenic nerve, with its accompanying vessels, descends between the pericardium and pleura on either side.

Structure of the Pericardium.—Although the pericardium is usually described as a single sac, an examination of its structure shows that it consists essentially of two sacs intimately connected with one another, but totally different in structure. The outer sac, known as the *fibrous pericardium*, consists of fibrous tissue. The inner sac, or *serous pericardium*, is composed of a delicate membrane which lies within the fibrous sac and lines its walls; the heart invaginates the wall of the serous sac from above and behind, and practically obliterates its cavity, the space being a potential one, except in front, where a small interspace exists below the apex of the heart.

FIG. 560.—Posterior wall of the pericardial sac, showing the lines of reflection of the serous pericardium on the great vessels.

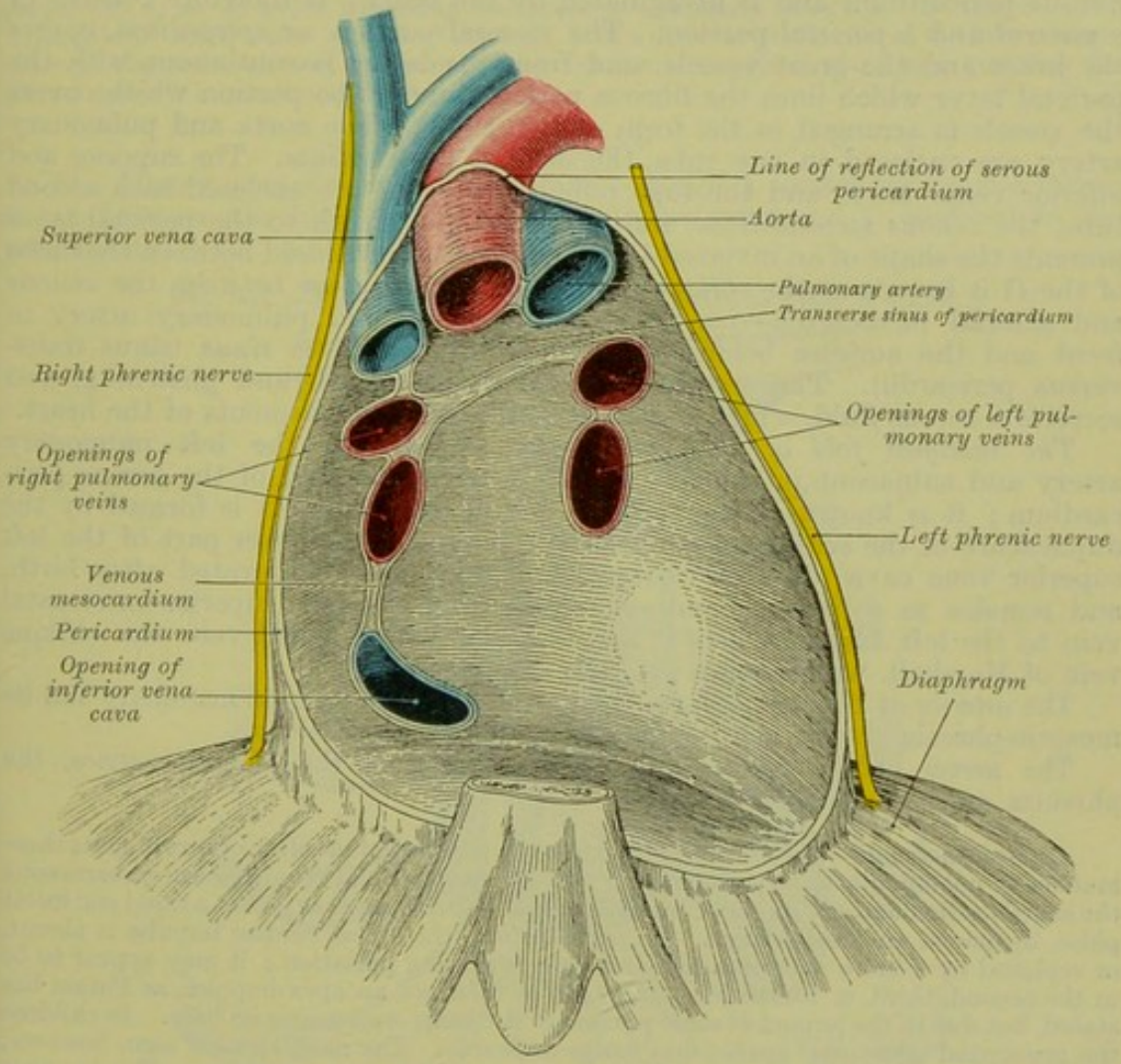

The *fibrous pericardium* forms a flask-shaped bag, the neck of which is closed by its fusion with the external coats of the great vessels, while its base is attached to the central tendon and to the muscular fibres of the left side of the Diaphragm. In some of the lower mammals the base is either completely separated from the Diaphragm or joined to it by some loose areolar tissue; in man much of its diaphragmatic attachment consists of loose fibrous tissue which can be readily broken down, but over a small area the central tendon of the Diaphragm and the pericardium are completely fused. Above, the fibrous pericardium not only blends with the external coats of the great vessels, but is continuous with the pretracheal layer of the deep cervical fascia. By means of these upper and lower connections it is securely anchored within the thoracic cavity. It is also attached to the posterior surface of the sternum by two fibrous bands, the *superior* and *inferior sterno-pericardiac ligaments* (ligg. sternopericardiaca); the upper passing to the manubrium, and the

lower to the ensiform cartilage. On either side of the ascending aorta it sends upwards a diverticulum : the one on the left side, somewhat conical in shape, passes upwards and outwards, between the arch of the aorta and the pulmonary artery, as far as the obliterated ductus arteriosus, where it terminates in a cæcal extremity which is attached by loose connective tissue to the obliterated duct. The one on the right side passes upwards and to the right, between the ascending aorta and vena cava superior, and also terminates in a blind extremity.

The vessels receiving fibrous prolongations from this membrane are, the aorta, the superior vena cava, the right and left pulmonary arteries, the four pulmonary veins, and the obliterated ductus arteriosus. The inferior vena cava enters the pericardium through the central tendon of the Diaphragm, and receives no covering from the fibrous layer.

The *serous pericardium* is, as already stated, a closed sac which lines the fibrous pericardium and is invaginated by the heart ; it therefore consists of a *visceral* and a *parietal* portion. The visceral portion, or *epicardium*, covers the heart and the great vessels, and from the latter is continuous with the parietal layer which lines the fibrous pericardium. The portion which covers the vessels is arranged in the form of two tubes. The aorta and pulmonary artery are enclosed in one tube, the *arterial mesocardium*. The superior and inferior venæ cavæ and the four pulmonary veins are enclosed in a second tube, the *venous mesocardium*, the attachment of which to the parietal layer presents the shape of an inverted U. The *cul-de-sac* enclosed between the limbs of the ∩ is known as the *oblique sinus*, while the passage between the venous and arterial mesocardia—i.e. between the aorta and pulmonary artery in front and the auricles behind—is termed the *transverse sinus* (sinus transversus pericardii). The serous pericardium is smooth and glistening, and secretes a serous fluid, which serves to facilitate the movements of the heart.

The vestigial fold of the pericardium. — Between the left pulmonary artery and subjacent pulmonary vein is a triangular fold of the serous pericardium ; it is known as the *vestigial fold of Marshall*. It is formed by the duplicature of the serous layer over the remnant of the lower part of the left superior vena cava (duct of Cuvier), which becomes obliterated after birth, and remains as a fibrous band stretching from the left superior intercostal vein to the left auricle, where it is continuous with a small vein, the oblique vein of Marshall, which opens into the coronary sinus.

The *arteries* of the pericardium are derived from the internal mammary and its musculo-phrenic branch, and from the descending thoracic aorta.

The *nerves* of the pericardium are derived from the pneumogastrics, the phrenics, and the sympathetic.

Applied Anatomy.—The effusion of fluid into the pericardial sac often occurs in acute rheumatism or pneumonia, or in patients with chronic vascular and renal disease, embarrassing the heart's action and giving rise to signs of cardiac distress, such as pallor, a rapid and feeble pulse, dyspnœa, and restlessness. On examination, the apical cardiac impulse is absent, or replaced by a more extensive indefinite and wavering pulsation ; it may appear to be in the second, third, or fourth left space, and is then not an apex-impulse, as Potain has stated, but due to the impact of some portion of the heart-wall nearer its base. In children the præcordial intercostal spaces may bulge outwards. The most striking sign, however, is the great increase in all directions of the præcordial dulness on percussion. This becomes pear-shaped, the stalk of the pear reaching up to about the left sterno-clavicular articulation : the dulness also extends some distance to the right of the sternum, particularly in the fifth interspace (Rotch). The fluid collects mainly on either side of the heart, and below it, especially on the left side, where the Diaphragm can yield more readily to pressure than it can on the right. Ewart has drawn attention to the presence of a square patch of dulness over the base of the left lung behind, reaching up to the level of the ninth or tenth rib, and extending outwards as far as the lower angle of the scapula ; the underlying lung-tissue gives the physical signs of compression or collapse.

Paracentesis of the pericardium is often required to relieve the urgent cardiac or respiratory distress in these cases, and should be performed without hesitation and before the patient is *in extremis*. It may also be required when the pericardium is filled with blood or pus, and as it is advisable to perform this operation without transfixing the pleura, the puncture should be made either in the fifth or sixth intercostal space on the left side and close to the sternum, so as to avoid wounding the internal mammary artery, which descends about half an inch from the sternal margin ; or the needle may be entered at the left costo-xiphoid angle and made to pass upwards and backwards behind the lower

end of the body of the sternum into the pericardial sac. Curschmann,* however, argues that the heart itself necessarily lies almost in contact with the anterior wall of the thorax even in cases of the largest pericardial effusion, so that there is risk of piercing it if the puncture is made in the fourth or fifth left intercostal space within even so much as two or three inches of the sternal margin. He therefore advises that in moderately large pericardial effusions the trochar should be inserted in the left mamillary line, and outside it if the effusion is very large, in the fifth or sixth interspace. In consequence of the uncertain and varying position of the anterior reflexion of the pleura, transfixion of the pleural sac cannot always be avoided. *Pericardiotomy* is required when the effusion is of a purulent nature. In this operation a portion of the fifth or sixth costal cartilage is excised. An incision is made along the left border of the sternum from the upper border of the fourth cartilage to the seventh. Transverse incisions an inch long are then made outwards from either extremity of this, and the rectangular flap thus formed reflected outwards. The fifth costal cartilage is now separated from the sternum by means of a gouge, great care being taken not to let the instrument slip and penetrate too deeply. The cartilage is then seized with lion forceps and raised, the tissues beneath it being peeled off, so as to avoid wounding the internal mammary artery or the pleura. The Triangularis sterni is now scratched through, with a director or the nail of the index finger, close to the sternum, and the pericardium felt for and opened, the finger guarding the pleura and left internal mammary artery.

The Heart

The **Heart** (cor) is a hollow muscular organ of a somewhat conical form; it lies between the lungs in the middle mediastinum and is enclosed in the pericardium.

Fig. 561.—Showing relations of opened heart to front of chest.

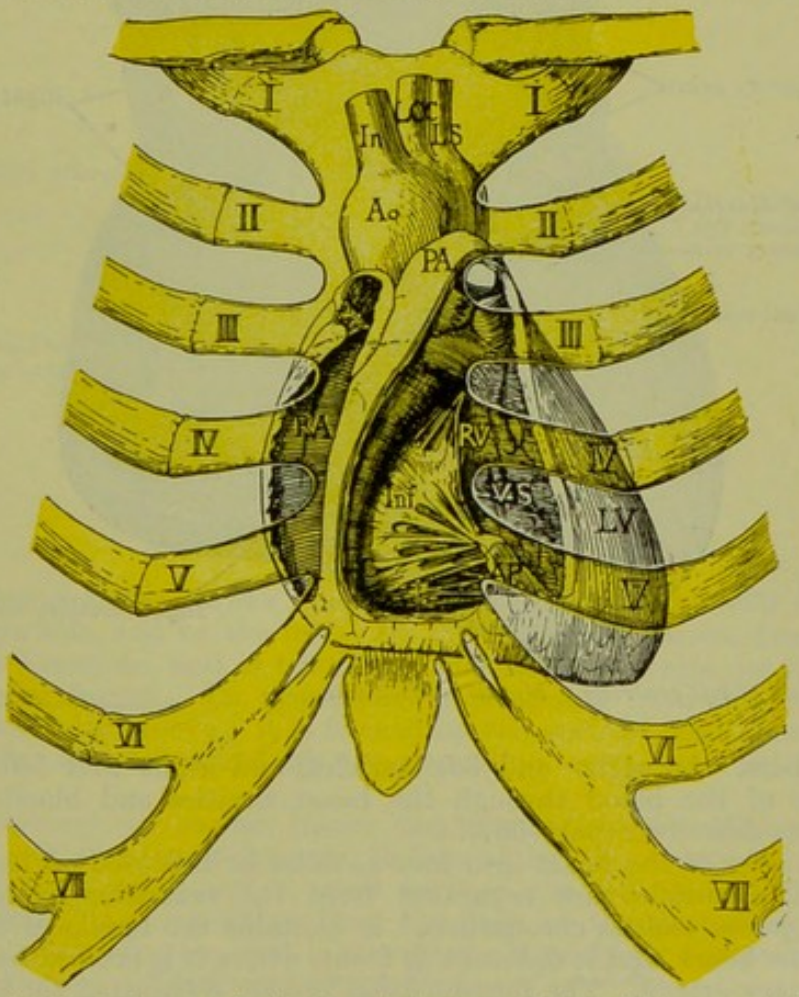

Ao. Aorta. AP. Anterior papillary muscle. In. Innominate artery. Inf. Infundibular segment of tricuspid valve. LCC. Left common carotid artery. LS. Left subclavian artery. LV. Left ventricle. PA. Pulmonary artery. RA. Right auricle. RV. Right ventricle. VS. Ventricular septum.

Position (fig. 561).—It is placed obliquely in the chest behind the gladiolus and adjoining parts of the rib cartilages, and projects farther into the left than into the right half of the thoracic cavity, so that about one-

* *Therapie der Gegenwart*, 1905.

third of it is situated on the right and two-thirds on the left of the mesial plane.

Size.—The heart, in the adult, measures about five inches in length, three inches and a half in breadth at the broadest part, and two inches and a half in thickness. Its weight, in the male, varies from ten to twelve ounces ; in the female, from eight to ten : the proportions to the body-weight being as 1 to 169 in males ; 1 to 149 in females. The heart continues to increase in weight and size up to an advanced period of life : this increase is more marked in men than in women.

Component Parts.—As has already been stated (page 597), the heart is subdivided by a septum into right and left halves, and a transverse constriction subdivides each half of the organ into two cavities, the upper cavity being called the *auricle*, the lower the *ventricle*. The heart therefore consists of

FIG. 562.—Base and postero-inferior surface of heart.

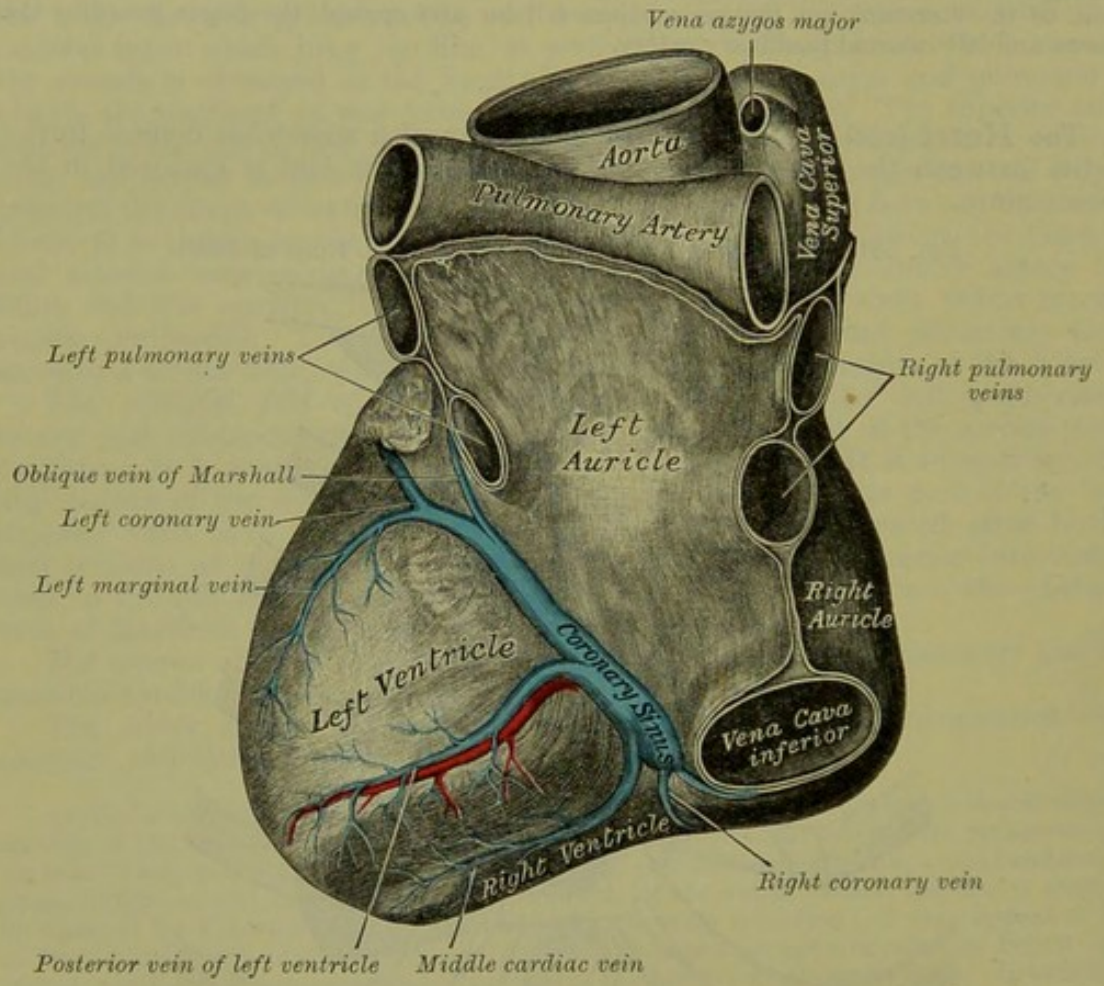

four chambers, viz. right and left auricles, and right and left ventricles. The course of the blood through the heart cavities and blood-vessels has already been described (page 597).

The division of the heart into four cavities is indicated on its surface by grooves. The auricles are separated from the ventricles by the *auriculo-ventricular groove* (sulcus coronarius). It contains the trunks of the nutrient vessels of the heart, and is deficient in front, where it is crossed by the root of the pulmonary artery. The *interauricular groove*, separating the two auricles, is scarcely marked on the posterior surface, while anteriorly it is hidden by the pulmonary artery and aorta. The ventricles are separated by two grooves, the *interventricular grooves*, one of which (sulcus longitudinalis anterior) is situated on the antero-superior surface close to the left margin of the heart, the other (sulcus longitudinalis posterior) on the postero-inferior surface near the right margin ; these grooves extend from the base of the ventricular portion to a point a little to the right of the apex of the heart.

The *base* (basis cordis) (fig. 562), directed upwards, backwards, and to the right, is separated from the fifth, sixth, seventh, and eighth thoracic vertebræ by the œsophagus, aorta, and thoracic duct. It is formed mainly by the left auricle, and, to a small extent, by the back part of the right auricle. Somewhat quadrilateral in form, it is in relation above with the bifurcation of the pulmonary artery, and is bounded below by the posterior part of the auriculo-ventricular sulcus, containing the coronary sinus. On the right it is limited by the sulcus terminalis of the right auricle, and on the left by the vestigial fold and oblique vein of Marshall. The four pulmonary veins, two on either side, open into the left auricle, whilst the superior vena cava opens into the upper, and the inferior vena cava into the lower, part of the right auricle.

The *apex* (apex cordis) is directed downwards, forwards, and to the left, and is overlapped by the left lung and pleura: it lies behind the fifth left intercostal space, three and a half inches from the mid-sternal line, or about an inch and a half below and three-quarters of an inch to the inner side of the left nipple.

FIG. 563.—Antero-superior surface of heart.

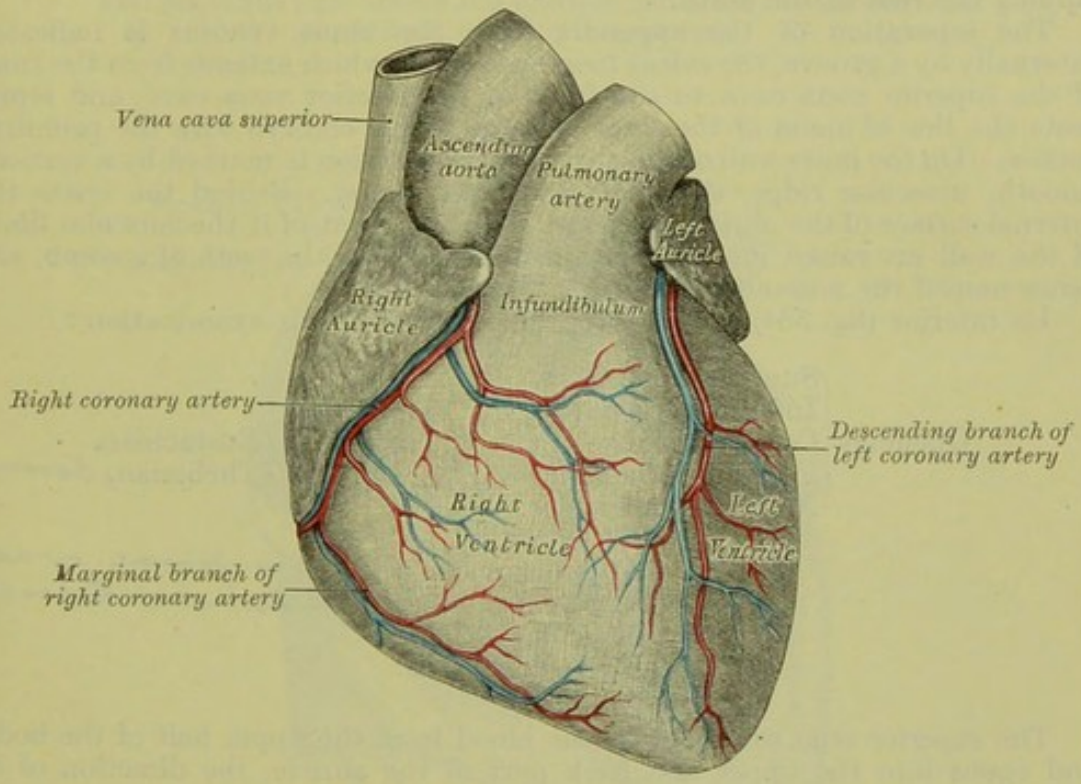

The *antero-superior surface* (facies sternocostalis) (fig. 563) is directed forwards, upwards, and to the left. Its lower part is convex, formed chiefly by the right ventricle, and is traversed near its left margin by the anterior interventricular furrow. Its upper part is separated from the lower by the auriculo-ventricular groove; it is formed by the auricles, and presents a deep concavity (fig. 566), occupied by the ascending aorta and the pulmonary artery.

The *postero-inferior surface* (facies diaphragmatica) (fig. 562), which looks downwards and slightly backwards, is formed by the ventricles, and rests upon the central tendon and a small part of the left muscular portion of the Diaphragm. It is separated from the base by the posterior part of the auriculo-ventricular furrow, and is traversed obliquely by the posterior ~~inter-ventricular groove~~. (Posterior longitudinal sulcus)

The *right margin* of the heart is long, and is formed by the right auricle above and the right ventricle below. The auricular portion is almost vertical, and is situated behind the third, fourth, and fifth right costal cartilages about half an inch from the margin of the sternum. The ventricular portion, thin and sharp, is named the *margo acutus*; it is nearly horizontal, and extends from the sternal end of the sixth right costal cartilage behind the lower end of the gladiolus to the apex of the heart.

The *left margin*, or *margo obtusus*, is short, thick, and rounded: it is formed mainly by the left ventricle, but to a slight extent, above, by the left auricle. It extends from a point in the second left intercostal space, about an inch from the sternal margin, obliquely downwards, with a convexity to the left, to the apex of the heart.

The **Right Auricle** (atrium dextrum) is the larger of the two auricles, although its walls are somewhat thinner than those of the left, measuring about 2 mm.; its cavity is capable of containing about two ounces. It consists of two parts: a principal cavity, or *sinus venosus* (sinus venarum), situated posteriorly, and an anterior, smaller portion, the *appendix auriculæ*.

The *sinus venosus* is the large quadrangular cavity placed between the two venæ cavæ. Its walls, which are extremely thin, are connected below with the right ventricle, and internally with the left auricle, but are free in the rest of their extent.

The *appendix auriculæ*, so called from its fancied resemblance to a dog's ear, is a small conical muscular pouch, the margins of which present a dentated edge. It projects from the sinus forwards and towards the left side, overlapping the root of the aorta.

The separation of the appendix from the sinus venosus is indicated externally by a groove, the *sulcus terminalis* (His), which extends from the front of the superior vena cava to the front of the inferior vena cava, and represents the line of union of the sinus venosus of the embryo with the primitive auricle. On the inner wall of the auricle the separation is marked by a vertical, smooth, muscular ridge, the *crista terminalis* (His). Behind the crista the internal surface of the auricle is smooth, while in front of it the muscular fibres of the wall are raised into parallel ridges resembling the teeth of a comb, and hence named the *musculi pectinati*.

Its interior (fig. 564) presents the following parts for examination:

- Openings
  - Superior vena cava.
  - Inferior vena cava.
  - Coronary sinus.
  - Foramina Thebesii.
  - Auriculo-ventricular.
- Valves
  - Eustachian.
  - (Thebesian.)
- Fossa ovalis.
- Annulus ovalis.
- Tubercle of Lower.
- Musculi pectinati.
- Crista terminalis.

The *superior vena cava* returns the blood from the upper half of the body, and opens into the upper and back part of the auricle, the direction of its orifice being downwards and forwards. Its opening has no valve.

The *inferior vena cava*, larger than the superior, returns the blood from the lower half of the body, and opens into the lowest part of the auricle, near the interauricular septum, its orifice being directed upwards and inwards, and guarded by a rudimentary valve, the *Eustachian valve*. The blood which enters the auricle through the superior vena cava is directed downwards and forwards, i.e. towards the auriculo-ventricular orifice, whilst that entering it through the inferior vena cava is directed upwards and backwards towards the interauricular septum. This is the normal direction of the two currents in fœtal life.

The *coronary sinus* opens into the auricle, between the inferior vena cava and the auriculo-ventricular opening. It returns blood from the substance of the heart, and is protected by a semicircular valve, the *coronary valve*, or *valve of Thebesius*.

The *foramina Thebesii* (foramina venarum minimarum) are depressions in the walls of the auricle: the majority of these are culs-de-sac, but about one-third are the orifices of minute veins (*venæ minimæ cordis*), which return blood directly from the muscular substance of the heart.

The *auriculo-ventricular opening* is the large oval aperture of communication between the auricle and the ventricle; it will be described with the right ventricle.

The *Eustachian valve* (valvula venæ cavæ inferioris) is situated in front of the orifice of the inferior vena cava. It is semilunar in form, its convex margin being attached to the anterior margin of the caval orifice ; its concave margin, which is free, terminates in two cornua, of which the left is continuous with the anterior edge of the annulus ovalis while the right is lost on the wall of the auricle. The valve is formed by a duplicature of the lining membrane of the auricle, containing a few muscular fibres. *In the fœtus* this valve is of large size, and serves to direct the blood from the inferior vena cava, through the foramen ovale, into the left auricle. *In the adult* it occasionally persists, and may assist in preventing the reflux of blood into the inferior vena cava ; more commonly it is small, and may present a cribriform or filamentous appearance ; sometimes it is altogether wanting.

The *Thebesian valve* (valvula sinus coronarii) is a semicircular fold of the lining membrane of the auricle, at the orifice of the coronary sinus. It prevents the regurgitation of blood into the sinus during the contraction of the auricle. This valve may be double.

Fig. 564.—The right auricle and ventricle laid open, the anterior walls of both having been removed.

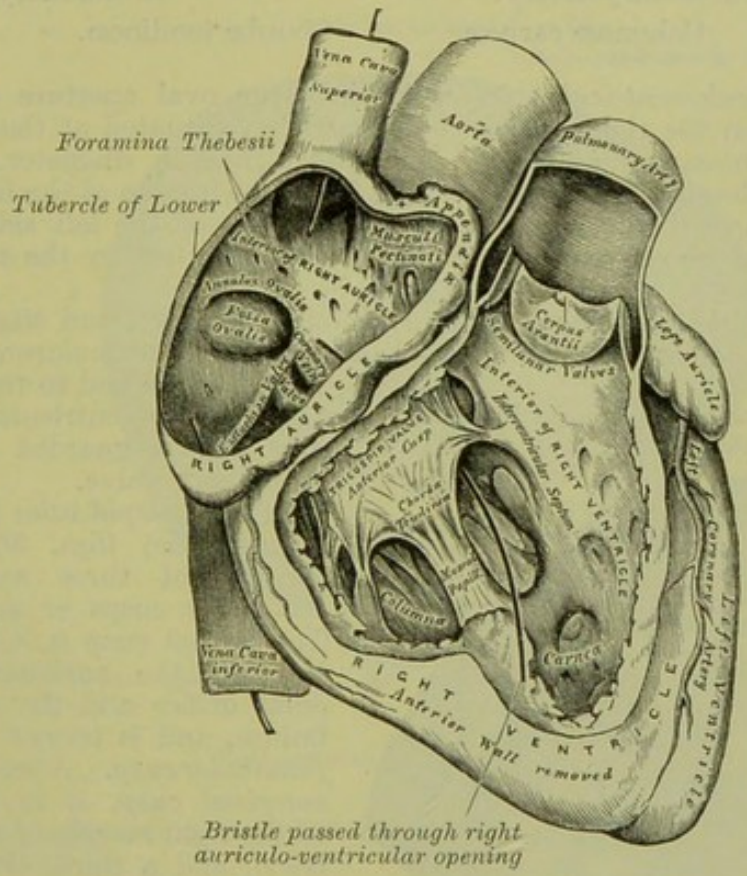

The *fossa ovalis* is an oval depression on the posterior wall of the auricle, and corresponds to the situation of the foramen ovale in the fœtus. It is situated at the lower part of the auricular septum, above and to the left of the orifice of the inferior vena cava.

The *annulus ovalis* (limbus fossæ ovalis) is the prominent oval margin of the fossa ovalis. It is most distinct above and at the sides of the fossa ; below, it is deficient. A small slit-like valvular opening is occasionally found, at the upper margin of the fossa ovalis, leading upwards, beneath the annulus, into the left auricle ; it is the remains of the fœtal aperture between the two auricles.

The *tubercle of Lower* (tuberculum intervenosum) is a small projection on the posterior wall of the auricle, above the fossa ovalis. It is distinct in the hearts of quadrupeds, but in man is scarcely visible. It was supposed by Lower to direct the blood from the superior vena cava towards the auriculo-ventricular opening.

The **Right Ventricle** (ventriculus dexter) is triangular in form, and extends from the right auricle to near the apex of the heart. Its antero-superior surface is rounded and convex, and forms the larger part of the front of the heart. Its under surface is flattened, rests upon the Diaphragm, and forms a small part of the postero-inferior surface of the heart. Its posterior wall is formed by the septum between the two ventricles, the *septum ventriculorum*, which bulges into the right ventricle, so that a transverse section of the cavity presents a semilunar outline. Its upper and inner angle forms a conical pouch, the *infundibulum*, or *conus arteriosus*, from which the pulmonary artery arises. A tendinous band, which may be named the *tendon of the conus arteriosus*, extends upwards from the right auriculo-ventricular fibrous ring and connects the posterior surface of the conus arteriosus to the aorta. The wall of the right ventricle is thinner than that of the left, the proportion between them being as 1 to 3; it is thickest at the base, and gradually becomes thinner towards the apex. The cavity equals in size that of the left ventricle, and is capable of containing about three fluid ounces.

Its interior (fig. 564) presents the following parts for examination :

Openings	Right auriculo-ventricular. Pulmonary artery.	Valves	Tricuspid. Pulmonary.
~~Columnæ~~ carneæ.		Chordæ tendineæ.	

Trabeculae

The *right auriculo-ventricular orifice* is the large oval aperture of communication between the right auricle and ventricle. Situated at the base of the ventricle, it measures about an inch and a half in diameter, and is surrounded by a fibrous ring, covered by the lining membrane of the heart ; it is considerably larger than the corresponding aperture on the left side, being sufficient to admit the ends of four fingers. It is guarded by the tricuspid valve.

The *opening of the pulmonary artery* is circular in form, and situated at the summit of the conus arteriosus, close to the septum ventriculorum. It is placed above and to the left of the auriculo-ventricular opening, and is guarded by the pulmonary valve.

Fig. 565.—Base of ventricles exposed by removal of the auricles.

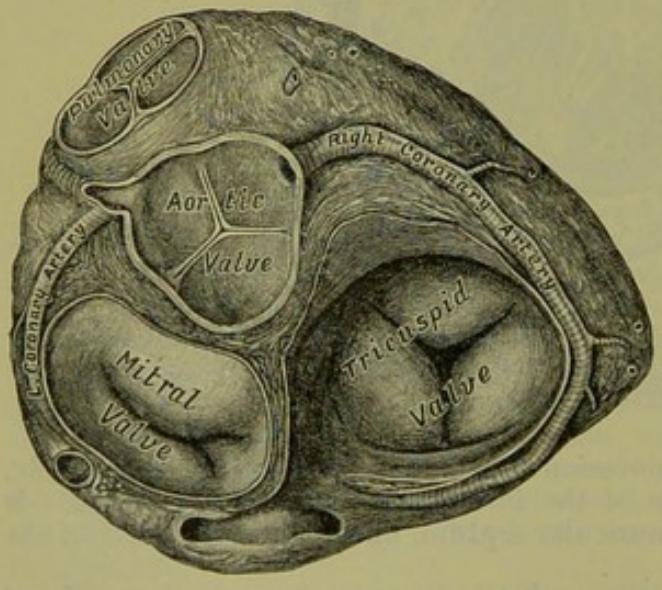

The *tricuspid valve* (valvula tricuspidalis) (figs. 564, 565) consists of three somewhat triangular cusps or segments. The largest cusp is interposed between the auriculo-ventricular orifice and the infundibulum, and is termed the *infundibular cusp*. A second, the *marginal cusp*, is in relation to the right margin of the ventricle, and a third, the *septal cusp*, to the interventricular septum. They are formed by duplicatures of the lining membrane of the heart, strengthened by intervening layers of fibrous tissue : their central parts are thick and strong, their marginal portions thin and translucent, and in the angles between the latter small intermediate segments are sometimes seen. Their bases are attached to a fibrous ring surrounding the auriculo-ventricular orifice and are also joined to each other so as to form a continuous annular membrane, while their apices project into the ventricular cavity. Their auricular surfaces, directed towards the blood current from the auricle, are smooth ; their ventricular surfaces, directed towards the wall of the ventricle, are rough and irregular and, together with the apices and margins of the cusps, give attachment to a number of delicate tendinous cords, the *chordæ tendineæ*.

The *columnæ carneæ* (trabeculæ carneæ) are rounded or irregular muscular columns which project from the whole of the inner surface of the ventricle, with the exception of the conus arteriosus. They are of three kinds : some are attached along their entire length on one side and merely form prominent ridges, others are fixed at their extremities but free in the middle, while a third set (*musculi papillares*) are continuous by their bases with the wall of the ventricle, while their apices give origin to the chordæ tendineæ which pass to be attached to the segments of the tricuspid valve. There are two papillary muscles, anterior and posterior : of these, the anterior is the larger, and its chordæ tendineæ are connected with the marginal and infundibular cusps of the valve ; the posterior sometimes consists of two or three muscular columns ; its chordæ tendineæ are connected with the septal and marginal segments. In addition to these, some chordæ tendineæ spring directly from the ventricular septum, or from small papillary eminences on it, and pass to the septal and infundibular segments. A fleshy band, well marked in sheep and some other animals, frequently extends from the base of the anterior papillary muscle to the interventricular septum. From its attachments it may assist in

FIG. 566.—Heart seen from above.

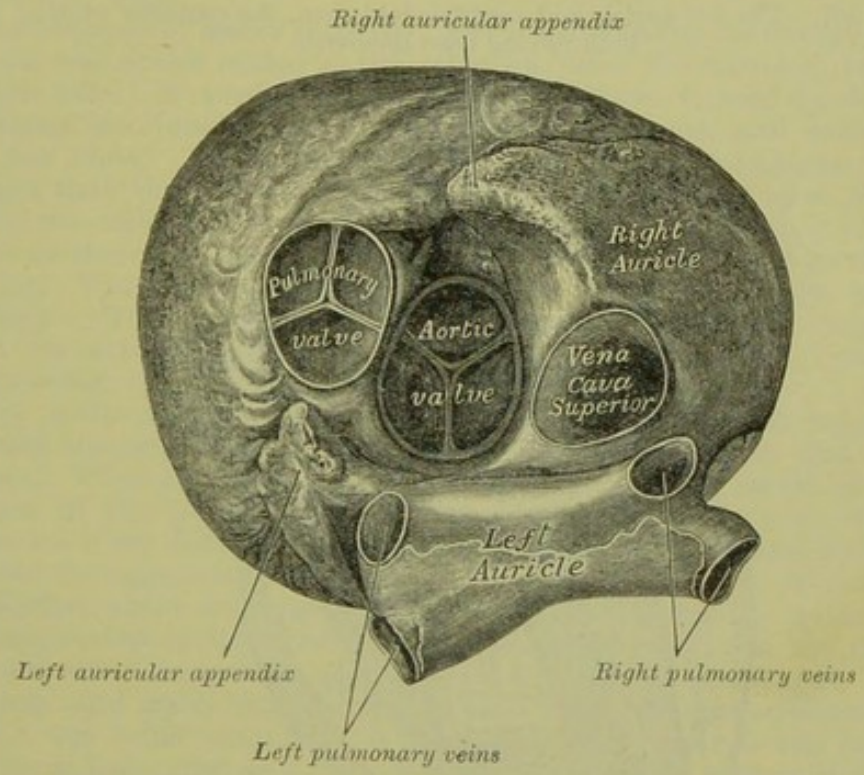

preventing over-distension of the ventricle, and so has been named the *moderator band*.

The *pulmonary valve* (fig. 566) consists of three semilunar segments (valvulæ semilunares a. pulmonalis), two in front and one behind, formed by a duplicature of the lining membrane, strengthened by fibrous tissue. They are attached, by their outer convex margins, to the wall of the artery, at its junction with the ventricle, their inner borders being free and directed upwards into the lumen of the vessel. The free and attached margins of each are strengthened by tendinous fibres, and the former presents, at its middle, a small projecting thickened nodule, called the *corpus Arantii* (nodulus valvulæ semilunaris). From this nodule tendinous fibres radiate through the segment to its attached margin, but are absent from two narrow crescentic portions, the *lunulæ* (lunulæ valvularum semilunarum), placed one on either side of the nodule immediately adjoining the free margin.

Between the semilunar segments and the wall of the pulmonary artery are three pouches or dilatations, the *sinuses of Valsalva*. Similar but larger sinuses exist between the semilunar segments of the aortic valve and the wall of the aorta.

The **Left Auricle** (atrium sinistrum) is rather smaller than the right, but its walls are thicker, measuring about 3 mm.; it consists, like the right, of two parts, a *principal cavity* and an *appendix auriculæ*.

The *principal cavity* is cuboidal in form, and concealed, in front, by the pulmonary artery and aorta; in front and to the right, it is separated from the right auricle by the septum auricularum; behind, it receives on either side the two pulmonary veins.

The *appendix auriculæ* is somewhat constricted at its junction with the principal cavity; it is longer, narrower, and more curved than that of the right side, and its margins are more deeply indented. It is directed forwards and towards the right and overlaps the root of the pulmonary artery.

The interior of the left auricle (fig. 567) presents the following parts for examination:

The openings of the four pulmonary veins.
Left auriculo-ventricular opening.
Musculi pectinati.

The *pulmonary veins*, four in number, open into the upper part of the posterior surface of the left auricle—two on either side of its middle line:

FIG. 567.—The left auricle and ventricle laid open, the posterior walls of both having been removed.

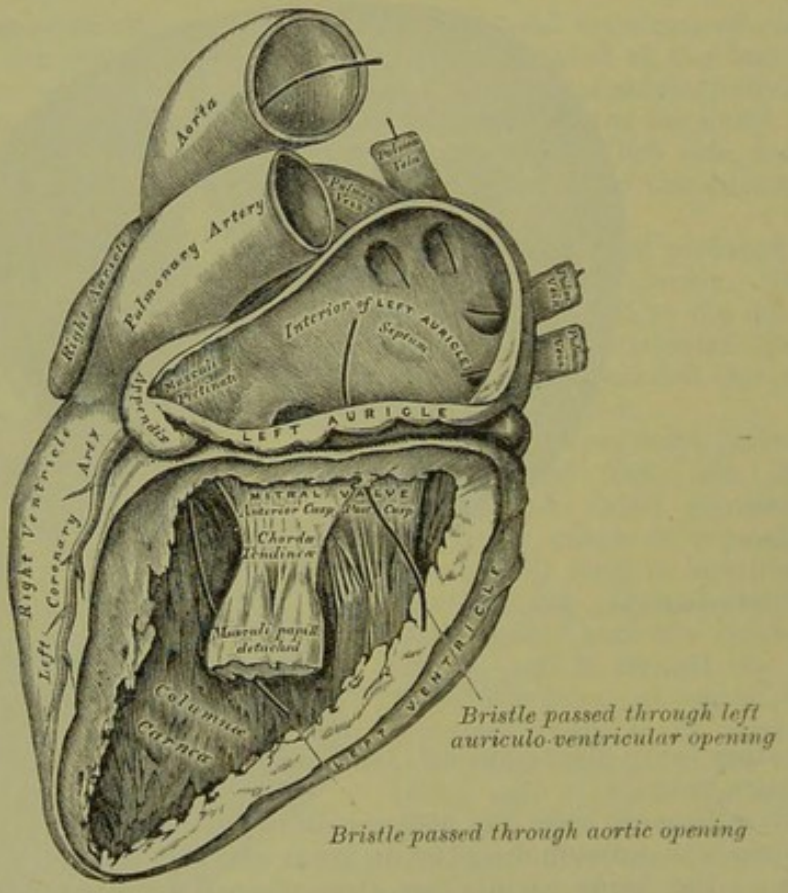

they are not provided with valves. The two left veins frequently terminate by a common opening.

The *left auriculo-ventricular opening* is the aperture between the left auricle and ventricle, and is rather smaller than the corresponding opening on the right side.

The *musculi pectinati*, fewer and smaller than in the right auricle, are confined to the inner surface of the appendix.

On the septum auricularum may be seen a lunated impression, bounded below by a crescentic ridge, the concavity of which is turned upwards. The depression is just above the fossa ovalis of the right auricle.

The **Left Ventricle** (ventriculus sinister) is longer and more conical in shape than the right, and on transverse section its cavity presents an oval or

nearly circular outline. It forms a small part of the antero-superior surface and a considerable part of the postero-inferior surface of the heart. It also forms the apex of the heart. Its walls are about three times as thick as those of the right ventricle.

Its interior (fig. 567) presents the following parts for examination :

Openings	Left auriculo-ventricular. Aortic.	Valves	Bicuspid or Mitral. Aortic.
Chordæ tendineæ.		Columnæ carneæ.	

The *left auriculo-ventricular opening* is placed below and to the left of the aortic orifice. It is a little smaller than the corresponding aperture of the opposite side, admitting only two fingers. It is surrounded by a dense fibrous ring, covered by the lining membrane of the heart, and is guarded by the bicuspid or mitral valve.

The *aortic opening* is a circular aperture, in front and to the right side of the auriculo-ventricular, from which it is separated by the aortic cusp of the mitral valve. Its orifice is guarded by the *aortic valve*, which consists of three semilunar segments. The portion of the ventricle immediately below the aortic orifice is termed the *aortic vestibule*, and possesses fibrous instead of muscular walls.

The *bicuspid* or *mitral valve* (fig. 565) is attached to the circumference of the auriculo-ventricular orifice in the same way that the tricuspid valve is on the opposite side. It consists of two triangular cusps, formed by duplicatures of the lining membrane, strengthened by fibrous tissue, and containing a few muscular fibres. The cusps are of unequal size, and are larger, thicker, and stronger than those of the tricuspid valve. The larger cusp is placed in front and to the right between the auriculo-ventricular and aortic orifices, and is known as the *aortic cusp* ; the smaller is placed behind and to the left of the opening. Two smaller cusps are usually found at the angles of junction of the larger. The cusps of the mitral valve are furnished with chordæ tendineæ, which are attached in a manner similar to those on the right side ; they are, however, thicker, stronger, and less numerous.

The *aortic valve* (fig. 566) consists of three semilunar segments, which surround the orifice of the aorta ; two are posterior (right and left) and one anterior. They are similar in structure, and in their mode of attachment, to those of the pulmonary valve, but larger, thicker, and stronger ; the lunulæ are more distinct, and the corpora Arantii thicker and more prominent. Opposite the segments the wall of the aorta presents slight dilatations (*sinuses of Valsalva*), which are larger than those at the origin of the pulmonary artery.

The *columnæ carneæ* are of three kinds, like those upon the right side, but they are more numerous, and present a dense interlacement, especially at the apex, and upon the posterior wall. The *musculi papillares* are two in number, one being connected to the anterior, the other to the posterior wall ; they are of large size, and terminate by free rounded extremities, from which the chordæ tendineæ arise. The chordæ tendineæ from each papillary muscle are connected to both cusps of the mitral valve.

The **interventricular septum** (septum ventriculorum) (fig. 568) is directed obliquely backwards and to the right, and is curved with the convexity towards the right ventricle : its margins correspond with the interventricular grooves. The greater portion of it is thick and muscular (septum musculare ventriculorum), but its upper and posterior part, which separates the aortic vestibule from the lower part of the right auricle and upper part of the right ventricle, is thin and fibrous, and is termed the *pars membranacea* (septum membranaceum ventriculorum). An abnormal communication may exist between the ventricles at this part owing to defective development of the septum.

Structure.—The heart consists of muscular fibres, and of fibrous rings which serve for their attachment. It is covered by the visceral layer of the serous pericardium (*epicardium*), and lined by the *endocardium*. Between these two membranes is the muscular wall or *myocardium*.

The *endocardium* is a thin, smooth membrane which lines and gives the glistening appearance to the inner surface of the heart ; it assists in forming the valves by its reduplications, and is continuous with the lining membrane of the large blood-vessels. It consists of connective tissue and elastic fibres, and is

attached to the muscular structure by loose elastic tissue which contains blood-vessels and nerves ; its free surface is covered by endothelial cells.

The *fibrous rings* (annuli fibrosi) surround the auriculo-ventricular and arterial orifices, and are stronger upon the left than on the right side of the heart. The auriculo-ventricular rings serve for the attachment of the muscular fibres of the auricles and ventricles, and for the attachment of the mitral and tricuspid valves. The left auriculo-ventricular ring is closely connected, by its right margin, with the aortic arterial ring ; between these and the right auriculo-ventricular ring is a triangular mass of fibrous tissue (trigonum fibrosum) which represents the *os cordis* seen in the heart of some of the larger animals, as the ox and elephant. Lastly, there is the tendinous band, already referred to (p. 606), on the posterior surface of the conus arteriosus.

The fibrous rings surrounding the arterial orifices serve for the attachment of the great vessels and semilunar valves. Each ring receives, by its ventricular margin, the attachment of some of the muscular fibres of the ventricles ; its opposite margin presents three deep semicircular notches, to which the middle coat of the

FIG. 568.—Section of the heart showing the interventricular septum.

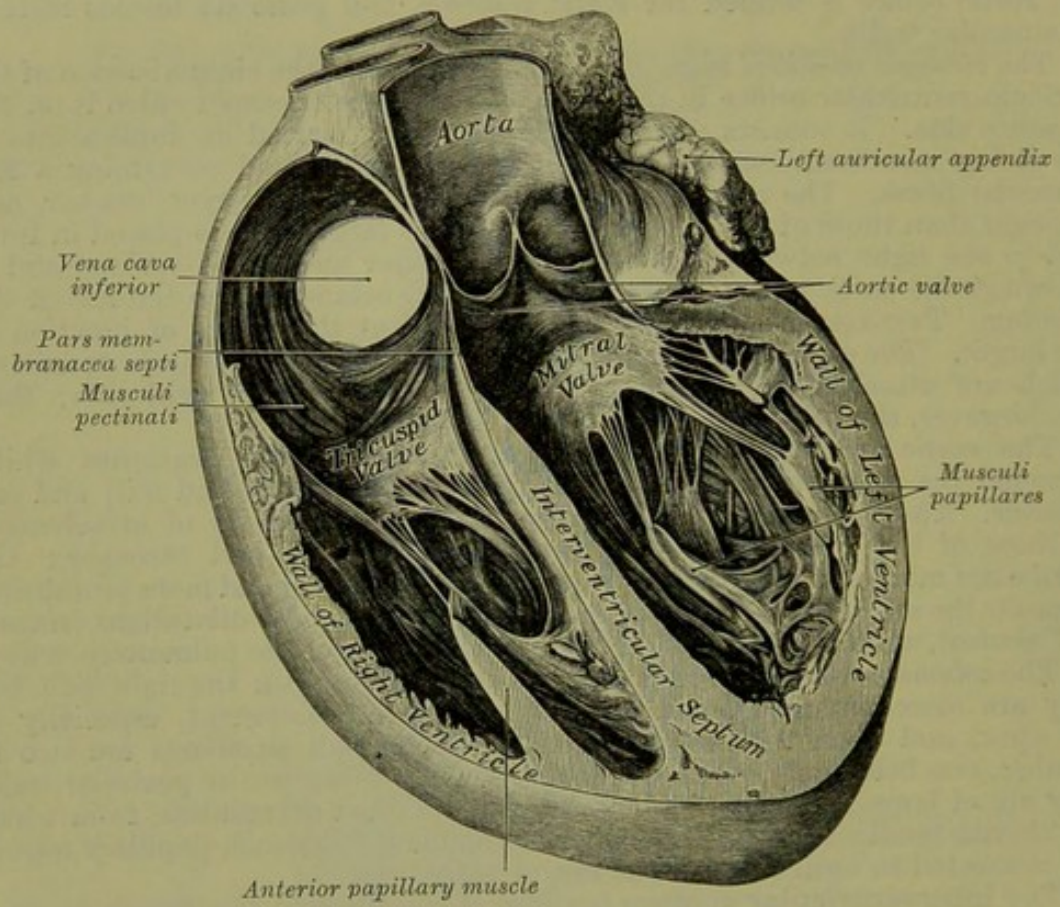

artery is firmly fixed. The attachment of the artery to its fibrous ring is strengthened by the thin cellular coat and serous membrane externally, and by the endocardium internally. From the margins of the semicircular notches, the fibrous structure of the ring is continued into the segments of the valve. The middle coat of the artery in this situation is thin, and the wall of the vessel is dilated to form the sinuses of Valsalva.

The *muscular structure of the heart* consists of bands of fibres, which present an exceedingly intricate interlacement. They consist of (*a*) the fibres of the auricles, (*b*) the fibres of the ventricles, and (*c*) the auriculo-ventricular bundle of His.

The *fibres of the auricles* are arranged in two layers—a superficial common to both cavities, and a deep proper to each. The *superficial fibres* are more distinct on the front of the auricles, across the bases of which they run in a transverse direction, forming a thin and incomplete layer. Some of these fibres run into the septum auricularum. The *deep fibres* consist of looped and annular fibres. The

looped fibres pass upwards over each auricle, being attached by their two extremities to the corresponding auriculo-ventricular ring, in front and behind. The *annular fibres* surround the appendices auricularum, and form annular bands around the terminations of the veins and around the fossa ovalis.

The *fibres of the ventricles* are arranged in a complex manner, and various accounts have been given of their course and connections. The following description is based on the work of McCallum.* They consist of superficial and deep layers, all of which, with the exception of two, are inserted into the papillary muscles of the ventricles. The *superficial layers* consist of the following. (*a*) Fibres which spring from the tendon of the conus arteriosus and sweep downwards and towards the left across the anterior interventricular furrow and around the apex of the heart, where they pass upwards and inwards to terminate in the papillary muscles of the left ventricle. Those which spring from the upper half of the tendon of the conus arteriosus pass to the anterior papillary muscle, those from the lower half to the posterior papillary muscle and the papillary muscles of the septum. (*b*) Fibres which arise from the right auriculo-ventricular ring and run diagonally across the back of the right ventricle and round its right border on to its anterior surface, where they dip beneath the fibres just described, and, crossing the interventricular groove, wind around the apex of the heart and terminate in the posterior papillary muscle of the left ventricle. (*c*) Fibres which spring from the left auriculo-ventricular ring, and, crossing the posterior interventricular furrow, pass successively into the right ventricle and end in its papillary muscles. The *deep layers* are three in number: they arise in the papillary muscles of one ventricle and, curving in an S-shaped manner, turn in at the interventricular furrow and end in the papillary muscles of the other ventricle. The layer which is most superficial in the right ventricle lies next the lumen of the left, and *vice versa*. Those of the first layer almost encircle the right ventricle, and, crossing in the septum to the left, unite with the superficial fibres from the right auriculo-ventricular ring to form the posterior papillary muscle. Those of the second layer have a less extensive course in the wall of the right ventricle, and a correspondingly greater course in the left, where they join with the superficial fibres from the anterior half of the tendon of the conus arteriosus to form the papillary muscles of the septum. Those of the third layer pass almost entirely round the left ventricle and unite with the superficial fibres from the lower half of the tendon of the conus arteriosus to form the anterior papillary muscle. Besides the layers just described there are two bands which do not end in papillary muscles. One springs from the right auriculo-ventricular ring and crosses in the auriculo-ventricular septum: it then encircles the deep layers of the left ventricle and ends in the left auriculo-ventricular ring. The second band is apparently confined to the left ventricle; it is attached to the left auriculo-ventricular ring, and encircles the portion of the ventricle adjacent to the aortic orifice.

The *auriculo-ventricular bundle of His* is the only direct muscular connection known to exist between the auricles and the ventricles. It arises near the orifice of the coronary sinus in the annular and septal fibres of the right auricle, passes forwards in the lower part of the pars membranacea septi, and divides into right and left fasciculi. These run down in the right and left ventricles, one on either side of the interventricular septum, just covered by endocardium. In the lower parts of the ventricles they break up into numerous strands which end in the papillary muscles and in the ventricular muscle generally. The undivided portion of the auriculo-ventricular bundle consists of narrow, somewhat fusiform fibres, but its two divisions and their terminal strands are composed of Purkinje fibres.

Applied Anatomy.—Clinical and experimental evidence go to prove that this bundle conveys the impulse to systolic contraction from the auricular septum to the ventricles, and much attention has recently been paid to it, because it appears to become fibrosed and to lose much of its conducting power (heart-block) in many cases of Stokes-Adams' disease. This condition is characterised by a slow pulse, a tendency to syncopal or epileptiform seizures, and the fact that while the cardiac auricles beat at a normal rate, the ventricles contract much less frequently.

Vessels and Nerves.—The *arteries* supplying the heart are the right and left coronary from the aorta.

* Johns Hopkins' *Hospital Reports*, vol. ix.

The *veins* terminate in the right auricle, and will be described with the general venous system.

The *lymphatics* end in the thoracic and right lymphatic ducts.

The *nerves* are derived from the cardiac plexuses, which are formed partly from the pneumogastrics, and partly from the sympathetic. They are freely distributed both on the surface and in the substance of the heart, the separate filaments being furnished with small ganglia.

The cardiac cycle and the actions of the valves.—By the contractions of the heart the blood is pumped through the arteries to all parts of the body. These contractions occur regularly and at the rate of about seventy per minute. Each wave of contraction or *period of activity* is followed by a *period of rest*, the two periods constituting what is known as a *cardiac cycle*.

Each cardiac cycle consists of three phases, which succeed each other as follows : (1) a short simultaneous contraction of both auricles, termed the *auricular systole*, followed, after a slight pause, by (2) a simultaneous, but more prolonged, contraction of both ventricles, named the *ventricular systole*, and (3) a *period of rest*, during which the whole heart is relaxed, i.e. in a state of *diastole*. The auricular contraction commences around the venous openings and sweeping over the auricles forces their contents through the auriculo-ventricular openings into the ventricles, regurgitation into the veins being prevented by the contraction of their muscular coats. When the ventricles contract the auriculo-ventricular valves are closed, and prevent the passage of the blood back into the auricles ; the musculi papillares at the same time are shortened, and, pulling on the chordæ tendineæ, prevent the inversion of the valves into the auricles. As soon as the pressure in the ventricles exceeds that in the pulmonary artery and aorta, the valves guarding the orifices of these vessels are opened and the blood is driven from the right ventricle into the pulmonary artery and from the left into the aorta. The moment the systole of the ventricles ceases, the pressure of the blood in the pulmonary artery and aorta closes the pulmonary and aortic valves to prevent regurgitation of blood into the ventricles, the valves remaining shut until reopened by the next ventricular systole. During the period of rest the tension of the auriculo-ventricular valves is relaxed, and blood is flowing from the veins into the auricles and slightly also from the auricles into the ventricles, being aspirated by negative *intrathoracic* pressure. The average duration of a cardiac cycle is about $\frac{8}{10}$ of a second, made up as follows :

Auricular systole, $\frac{1}{10}$.	Auricular diastole, $\frac{7}{10}$.
Ventricular systole, $\frac{3}{10}$.	Ventricular diastole, $\frac{5}{10}$.
Total systole, $\frac{4}{10}$.	Complete diastole, $\frac{4}{10}$.

The rhythmical action of the heart is *muscular* in origin, that is to say, the heart muscle itself possesses the inherent property of contraction apart from any nervous stimulation. The more embryonic the muscle the better is it able to initiate and propagate the contraction wave ; this explains why the normal systole of the heart starts at the entrance of the veins, for there the muscle is most embryonic in nature. At the auriculo-ventricular junction there is a slight pause in the wave of muscular contraction due to the tissue there being less irritable (i.e. less embryonic). To obviate this as far as possible a peculiar band of marked embryonic type passes across the junction and so carries on the contraction wave to the ventricles. This band, composed of special fibres, the fibres of Purkinje (p. 42), is the auriculo-ventricular bundle of His (p. 611). The nerves, although not concerned in originating the contractions of the heart muscle, play an important rôle in regulating their force and frequency in order to subserve the physiological needs of the organism.

Surface Marking.—To show the extent of the heart in relation to the front of the chest (fig. 569), draw a line from the lower border of the second left costal cartilage, one inch from the sternum, to the upper border of the third right costal cartilage, half an inch from the sternum. This represents the base line, or upper limit of the organ. Take a point an inch and a half below, and three-quarters of an inch internal to the left nipple—that is, about three and a half inches to the left of the median line of the body. This represents the apex of the heart. Draw a line from this apex point, with a slight convexity downwards, to the junction of the seventh right costal cartilage with the sternum. This represents the lower limit of the heart. Join the right extremity of the first line—that is, the base line—with the right extremity of this line—that is, to the seventh right chondrosternal joint—with a slight curve outwards, so that it projects about an inch and a half from the middle line of the sternum. Lastly, join the left extremity of the base line and the apex point by a line curved slightly to the left.

The position of the various orifices is as follows : the pulmonary orifice is situated in the upper angle formed by the articulation of the third left costal cartilage with the sternum ; the aortic orifice is a little below and internal to this, behind the left border of the sternum, close to the third left chondrosternal articulation. The left auriculo-ventricular opening is behind the sternum, rather to the left of the median line and opposite the fourth costal cartilages. The right auriculo-ventricular opening is a little lower, opposite the fourth interspace and in the middle line of the body (fig. 569).

A portion of the area of the heart thus mapped out is uncovered by lung, and therefore gives a dull note on percussion ; the remainder, being overlapped by the lung, gives a more or less resonant note. The former is known as the area of superficial cardiac dulness ; the latter, as the area of deep cardiac dulness. The area of superficial cardiac dulness is included between a line drawn from the centre of the sternum, on a level with the fourth

FIG. 569.—Front view of thorax, showing relation of the heart, lungs, &c., to the ribs and sternum.

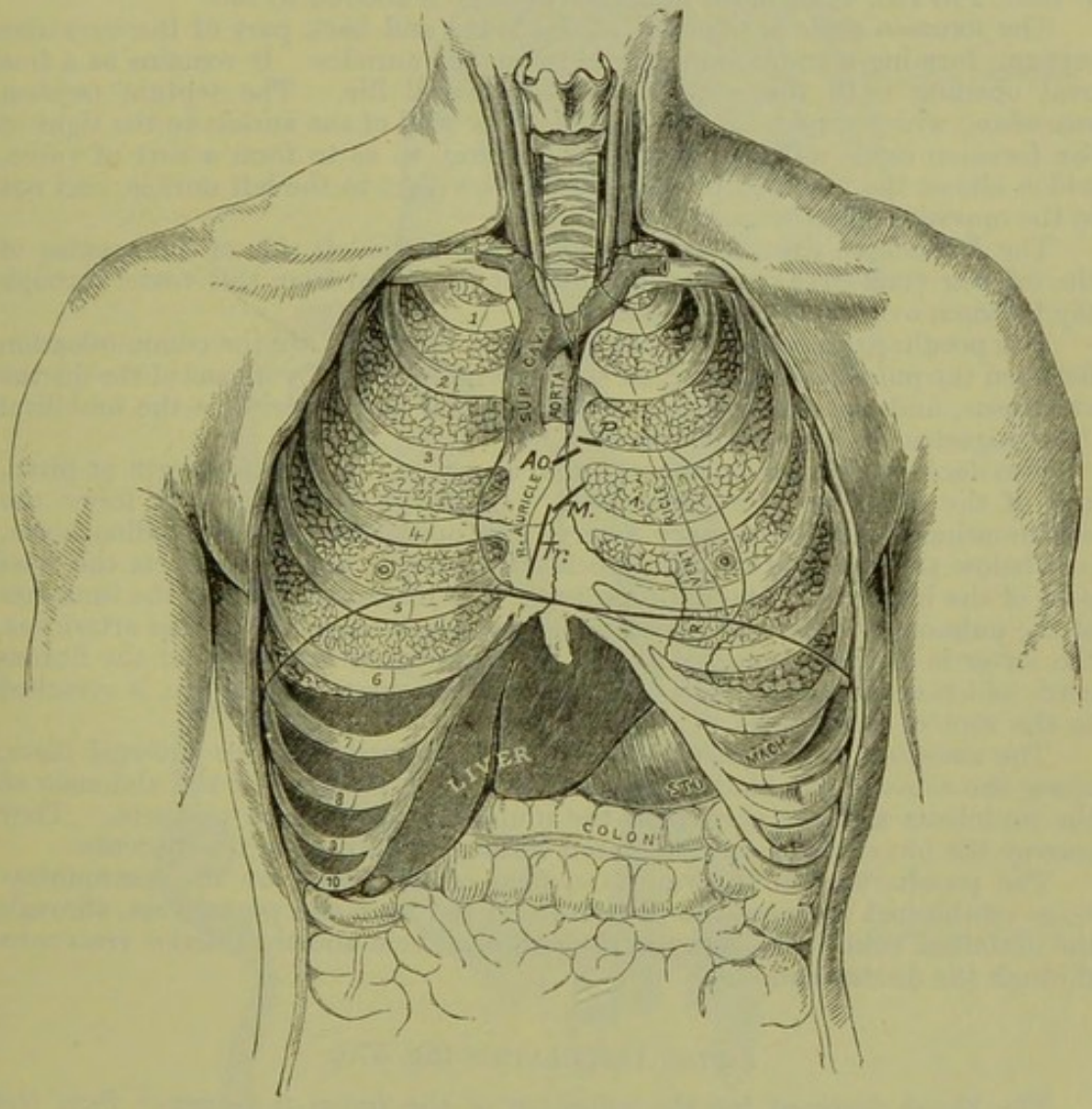

A. Aortic orifice. M. Left auriculo-ventricular orifice. P. Pulmonary orifice. Tr. Right auriculo-ventricular orifice.

costal cartilages, to the junction of the body of the sternum with the ensiform cartilage : from the two extremities of this line, two others are to be drawn to the position of the apex of the heart in the fifth intercostal space. Below, this area merges into the dulness which corresponds to the liver. Latham lays down the following rule as a sufficient practical guide for the definition of the portion of the heart which is uncovered by lung or pleura : ' Make a circle of two inches in diameter round a point midway between the nipple and the end of the sternum.'

Applied Anatomy.—Wounds of the heart are often immediately fatal, but not necessarily so. They may be non-penetrating, when death may occur from hæmorrhage if one of the coronary vessels has been wounded, or subsequently from pericarditis. Even a penetrating wound is not necessarily fatal, as a considerable number of cases have now been recorded in which the wound has been sutured.

Peculiarities in the Vascular System of the Fœtus

The development of the heart and vascular system is described on pp. 135 to 150.

The chief peculiarities of the fœtal heart are the direct communication between the auricles through the foramen ovale, and the large size of the Eustachian valve. Amongst other peculiarities the following may be noted. (1) In early fœtal life it lies immediately below the mandibular arch, and as development proceeds is gradually drawn back within the thorax. (2) For a time the auricular portion exceeds the ventricular in size, and the walls of the ventricles are of equal thickness: towards the end of fœtal life the ventricular portion becomes the larger and the wall of the left ventricle exceeds that of the right in thickness. (3) Its size is large as compared with that of the rest of the body, the proportion at the second month being 1 to 50, and at birth 1 to 120, while in the adult the average is about 1 to 160.

The *foramen ovale* is situated at the lower and back part of the auricular septum, forming a communication between the auricles. It remains as a free oval opening until the middle period of fœtal life. The septum (*septum secundum*) which grows down from the upper wall of the auricle to the right of the foramen ovale advances over the opening, so as to form a sort of valve, which allows the blood to pass only from the right to the left auricle, and not in the opposite direction.

The *Eustachian valve* is directed upwards on the left side of the opening of the inferior vena cava, and serves to direct the blood from this vessel through the foramen ovale into the left auricle.

The peculiarities in the arterial system of the fœtus are the communication between the pulmonary artery and the descending aorta by means of the ductus arteriosus, and the continuation of the internal iliac arteries as the umbilical or hypogastric arteries to the placenta.

The *ductus arteriosus* is a short tube, about half an inch in length at birth, and of the diameter of a goose-quill. In the early condition it forms the continuation of the pulmonary artery, and opens into the descending aorta, just below the origin of the left subclavian artery; and so conducts the chief part of the blood from the right ventricle into the aorta. When the branches of the pulmonary artery have become larger relatively to the ductus arteriosus, the latter is chiefly connected to the left pulmonary artery; and the fibrous cord, which is all that remains of the ductus arteriosus in later life, is attached to the root of that vessel.

The *umbilical* or *hypogastric arteries* are continued from the internal iliacs, along the sides of the bladder to its apex; they pass out of the abdomen at the umbilicus and are carried in the umbilical cord to the placenta. They convey the blood which has circulated through the fœtus to the placenta.

The peculiarities in the venous system of the fœtus are the communications established between the placenta and the liver and portal vein, through the umbilical vein; and between the umbilical vein and the inferior vena cava through the ductus venosus.

Fœtal Circulation (fig. 570)

The blood destined for the nutrition of the fœtus is returned from the placenta to the fœtus by the umbilical vein. This vein enters the abdomen at the umbilicus, and passes upwards along the free margin of the falciform ligament of the liver to the under surface of that organ, where it gives off two or three branches, one of which is of large size, to the left lobe, and others to the lobus quadratus and lobus Spigelii. At the transverse fissure it divides into two branches: of these, the larger is joined by the portal vein, and enters the right lobe; the smaller is continued upwards, under the name of the ductus venosus, and joins the left hepatic vein at the point of junction of that vessel with the inferior vena cava. The blood, therefore, which traverses the umbilical vein, passes to the inferior vena cava in three different ways. The greater quantity circulates through the liver with the portal venous blood, before entering the vena cava by the hepatic veins; some enters the liver directly, and is also returned to the inferior cava by the hepatic veins:

the smaller quantity passes directly into the vena cava, by the junction of the ductus venosus with the left hepatic vein.

In the inferior cava, the blood carried by the ductus venosus and hepatic veins becomes mixed with that returning from the lower extremities and

FIG. 570.—Plan of the fœtal circulation.

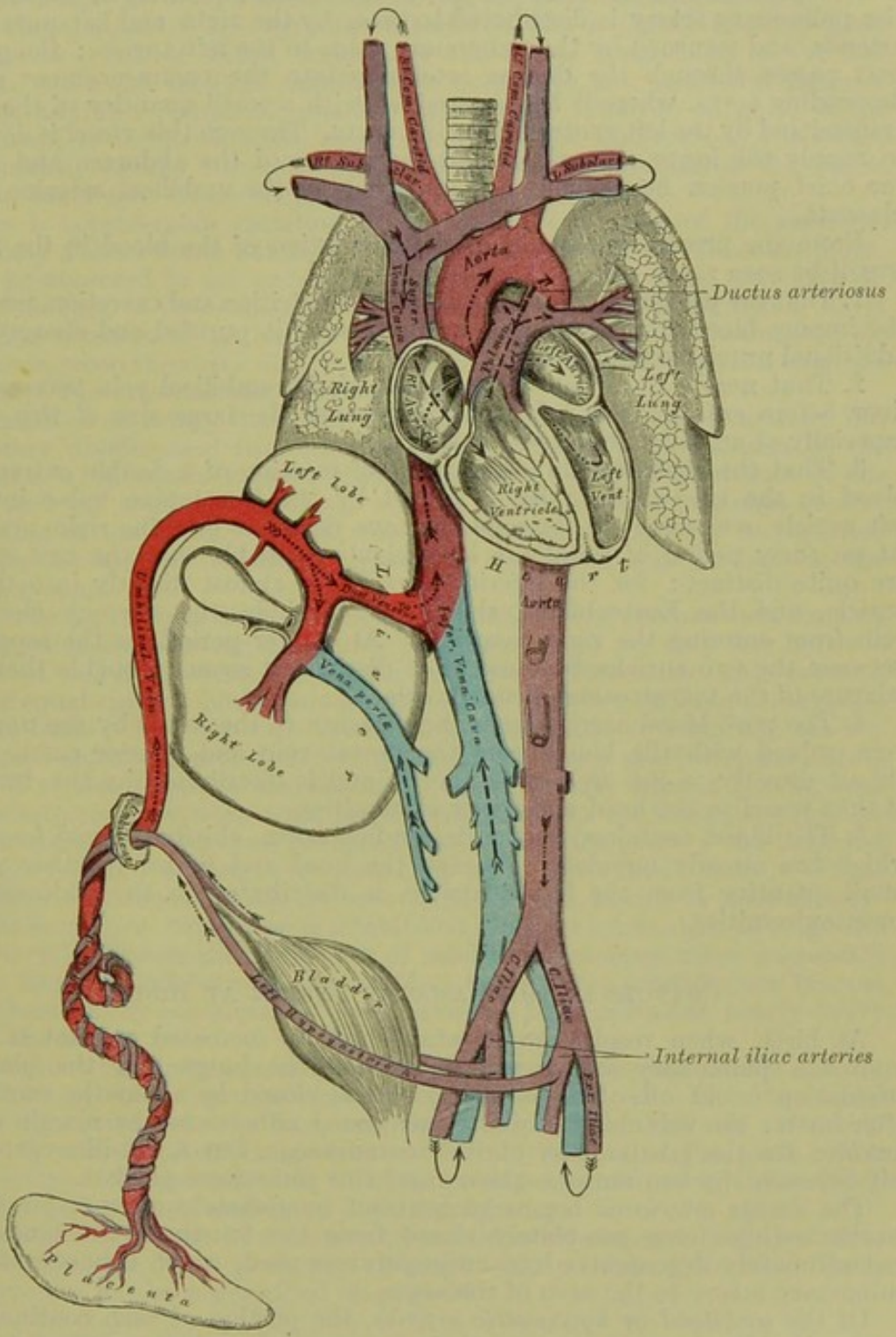

In this plan the figured arrows represent the kind of blood, as well as the direction which it takes in the vessels. Thus—arterial blood is figured ; venous blood, ; mixed (arterial and venous) blood, .

abdominal wall. It enters the right auricle, and, guided by the Eustachian valve, passes through the foramen ovale into the left auricle, where it mixes with a small quantity of blood returned from the lungs by the pulmonary veins. From the left auricle it passes into the left ventricle; and from the left ventricle into the aorta, by means of which it is distributed almost

entirely to the head and upper extremities, a small quantity being probably carried into the descending aorta. From the head and upper extremities the blood is returned by the superior vena cava to the right auricle, where it becomes mixed with a small portion of the blood from the inferior cava. From the right auricle it descends over the Eustachian valve into the right ventricle; and from the right ventricle passes into the pulmonary artery. The lungs of the fœtus being inactive, only a small quantity of the blood of the pulmonary artery is distributed to them by the right and left pulmonary arteries, and returned by the pulmonary veins to the left auricle: the greater part passes through the ductus arteriosus into the commencement of the descending aorta, where it becomes mixed with a small quantity of the blood transmitted by the left ventricle into the aorta. Through this vessel it descends to supply the lower extremities and the viscera of the abdomen and pelvis, the chief portion being, however, conveyed by the umbilical arteries to the placenta.

From the preceding account of the circulation of the blood in the fœtus, it will be seen:

1. That the placenta serves the purposes of nutrition and excretion, receiving the impure blood from the fœtus, and returning it purified and charged with additional nutritive material.

2. That nearly the whole of the blood of the umbilical vein traverses the liver before entering the inferior cava; hence the large size of this organ, especially at an early period of fœtal life.

3. That the right auricle is the point of meeting of a double current, the blood in the inferior cava being guided by the Eustachian valve into the left auricle, while that in the superior cava descends into the right ventricle. At an early period of fœtal life it is highly probable that the two streams are quite distinct; for the inferior cava opens almost directly into the left auricle, and the Eustachian valve would exclude the current along the vein from entering the right ventricle. At a later period, as the separation between the two auricles becomes more distinct, it seems probable that some mixture of the two streams must take place.

4. The pure blood carried from the placenta to the fœtus by the umbilical vein, mixed with the blood from the portal vein and inferior cava, passes almost directly to the arch of the aorta, and is distributed by the branches of that vessel to the head and upper extremities.

5. The blood contained in the descending aorta, chiefly derived from that which has already circulated through the head and limbs, together with a small quantity from the left ventricle, is distributed to the abdomen and lower extremities.

Changes in the Vascular System at Birth

At birth, when respiration is established, an increased amount of blood from the pulmonary artery passes through the lungs, and the placental circulation is cut off. The foramen ovale is closed by about the tenth day after birth: the valvular fold above mentioned adheres to the margin of the foramen for the greater part of its circumference, but a slit-like opening is left between the two auricles above, and this sometimes persists.

The *ductus arteriosus* begins to contract immediately after respiration is established, becomes completely closed from the fourth to the tenth day, and ultimately degenerates into an impervious cord, which connects the left pulmonary artery to the arch of the aorta.

Of the *umbilical* or *hypogastric arteries*, the portion of each continued on to the bladder from the trunk of the corresponding internal iliac remains pervious, as the superior vesical artery; the part extending from the side of the bladder to the umbilicus becomes obliterated between the second and fifth days after birth, and projects as a fibrous cord towards the abdominal cavity, carrying on it a fold of peritoneum.

The *umbilical vein* and *ductus venosus* are completely obliterated between the second and fifth days after birth, and ultimately dwindle to fibrous cords; the former becoming the ligamentum teres, the latter the ligamentum venosum of the liver.

THE ARTERIES

Arteries are cylindrical tubular vessels, which convey blood from the ventricles of the heart to the different parts of the body. These vessels were named arteries from the belief entertained by the ancients that they contained air. Galen was the first to show that during life they contain blood.

The distribution of the systemic arteries is like a highly ramified tree, the common trunk of which, formed by the aorta, commences at the left ventricle, while the smallest ramifications extend to the peripheral parts of the body and the contained organs. Arteries are found in all parts of the body, except in the hairs, nails, epidermis, cartilages, and cornea; the larger trunks usually occupy the most protected situations, running, in the limbs, along the flexor side, where they are less exposed to injury.

There is considerable variation in the mode of division of the arteries: occasionally a short trunk subdivides into several branches at the same point, as may be observed in the cœliac and thyroid axes; the vessel may give off several branches in succession, and still continue as the main trunk, as is seen in the arteries of the limbs; or the division may be dichotomous, as, for instance, when the aorta divides into the two common iliacs, or the common carotid into the external and internal carotids.

A branch of an artery is smaller than the trunk from which it arises; but if an artery divides into two branches, the combined sectional area of the two vessels is, in nearly every instance, somewhat greater than that of the trunk; and the combined sectional area of all the arterial branches greatly exceeds that of the aorta; so that the arteries collectively may be regarded as a cone, the apex of which corresponds to the aorta, and the base to the capillary system.

The arteries, in their distribution, communicate with one another, forming what are called *anastomoses*, and these communications are very free between the large as well as between the smaller branches. The anastomosis between trunks of equal size is found where great activity of the circulation is requisite, as in the brain; here the two vertebral arteries unite to form the basilar, and the two anterior cerebral arteries are connected by a short communicating trunk; it is also found in the abdomen, the intestinal arteries having very ample anastomoses between their larger branches. In the limbs, the anastomoses are most numerous and of largest size around the joints; the branches of an artery above uniting with branches from the vessels below. These anastomoses are of considerable interest to the surgeon, as it is by their enlargement that a *collateral circulation* is established after the application of a ligature to an artery. The smaller branches of arteries anastomose more frequently than the larger; and between the smallest twigs these anastomoses become so numerous as to constitute a close network that pervades nearly every tissue of the body.

Throughout the body generally the larger arterial branches pursue a fairly straight course, but in certain situations they are tortuous. Thus the facial artery in its course over the face, and the arteries of the lips, are extremely tortuous to accommodate themselves to the movements of the parts. The uterine arteries are also tortuous, to accommodate themselves to the increase of size which the uterus undergoes during pregnancy.

The arteries are dense in structure, of considerable strength, highly elastic, and, when divided, they preserve, although empty, their cylindrical form. Their structure has been described on page 55.

Applied Anatomy.—All the arteries, and most of all the aorta, are liable to a degenerative process known as atheroma, arteriosclerosis, or, more recently, atherosclerosis (Marchand), that is of the greatest clinical importance. It is essentially a senile change, although it may begin at any age and is predisposed to by renal disease, gout, diabetes mellitus, lead poisoning, and a number of other morbid states, and results in the replacement of the arterial elastic tissue by fibrous tissue. Its chief ill effects are two. In the first place, it is associated with a permanent and often considerable rise in the arterial blood-pressure, entailing a corresponding hypertrophy of the heart; in the second, it weakens the vessel walls, rendering them more liable to rupture, while at the same time it is apt to lessen the calibre of the affected vessels.

The arteries are also frequently attacked by syphilis, which gives rise to inflammation and degeneration of their middle coats. Recent researches * go to prove that arterial aneurysms, other than those due to direct injury, occur almost solely in syphilitic patients.

Pulmonary Artery (fig. 571)

The **pulmonary artery** (a. pulmonalis) conveys the venous blood from the right side of the heart to the lungs. It is a short, wide vessel, about 5 cm. in length and 30 mm. in diameter, arising from the left side of the base (conus arteriosus) of the right ventricle. It extends obliquely upwards and backwards, passing at first in front and then to the left of the ascending aorta, as far as the under surface of the arch, but on a plane posterior to it, where it divides, about the level of the intervertebral disc between the fifth and sixth thoracic vertebræ, into right and left branches of nearly equal size.

Relations.—The whole of this vessel is contained within the pericardium. It is enclosed with the ascending aorta in a single tube of the visceral layer of the

Fig. 571.—Transverse section of thorax, showing relations of pulmonary artery.

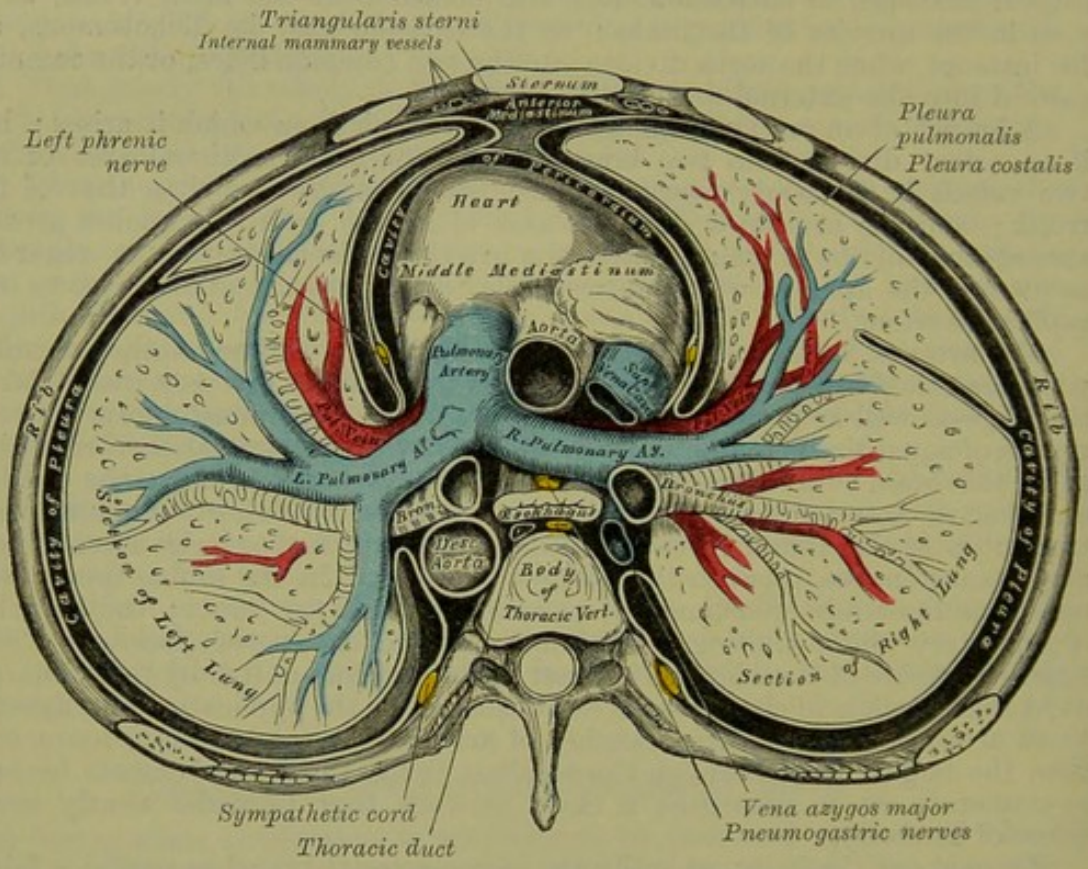

serous pericardium, which is continued upwards upon them from the base of the heart. The fibrous layer of the pericardium becomes gradually lost upon the external coats of its two branches. In front, the pulmonary artery is separated from the anterior extremity of the second left intercostal space by the pleura and left lung, in addition to the pericardium ; it rests at first upon the ascending aorta, and higher up lies in front of the left auricle on a plane posterior to the ascending aorta. On either side of its origin is the appendix of the corresponding auricle and a coronary artery, the left coronary artery passing, in the first part of its course, behind the vessel. The superficial cardiac plexus lies above its bifurcation, between it and the arch of the aorta.

The **right branch of the pulmonary artery** (ramus dexter), longer and larger than the left, runs horizontally outwards, behind the ascending aorta and superior vena cava and in front of the right bronchus, to the root of the right lung, where it divides into two branches. The lower and larger of these goes to the middle and lower lobes of the lung ; the upper and smaller is distributed to the upper lobe.

* C. U. Aitchison, *Arch. of the Pathological Institute of the London Hosp.*, 1908, ii. p. 1.

The **left branch of the pulmonary artery** (ramus sinister), shorter and somewhat smaller than the right, passes horizontally in front of the descending aorta and left bronchus to the root of the left lung, where it divides into two branches for the two lobes of the lung.

The root of the left branch of the pulmonary artery is connected to the under surface of the arch of the aorta by a short fibrous cord, the *ligamentum arteriosum*; this is the remains of a fœtal vessel, the *ductus arteriosus*.

The terminal branches of the pulmonary artery will be described with the anatomy of the lung.

Applied Anatomy.—Stenosis of the pulmonary artery, either with, or, more rarely, without defective formation of the interventricular septum, is one of the commonest congenital defects of the heart. It may be due either to fœtal endocarditis, or to maldevelopment of the bulbus cordis (p. 140).* As in most forms of congenital heart-disease, the child is cyanosed (morbus cœruleus), especially when excited or on exertion, and rarely lives to grow up, commonly dying of heart-failure in infancy, or of pulmonary tuberculosis or intercurrent disease in childhood. The chief signs of the condition are the loud, harsh systolic cardiac murmur best heard over the second left costal cartilage, cyanosis, clubbing of the finger-tips, and the presence of an excess of red corpuscles in the blood.

Embolism of the pulmonary artery by a clot of blood coming from the right side of the heart in patients with heart-disease, or from a thrombosed vein in cases, for example, of influenza, enteric fever, puerperal sepsis, or fractured limbs, is a common cause of sudden or rapid death. The patient may cry out with sudden excruciating pain in the præcordia when the detached embolus lodges, and after a brief period of intense dyspnœa, pallor, and anguish, die.

The Aorta

The **aorta** is the main trunk of a series of vessels which convey the oxygenated blood to the tissues of the body for their nutrition. It commences at the upper part of the left ventricle, where it is about 30 mm. in diameter, and after ascending for a short distance, arches backwards, and to the left side, over the root of the left lung; it then descends within the thorax on the left side of the vertebral column, passes into the abdominal cavity through the aortic opening in the Diaphragm, and terminates, considerably diminished in size (about 17·5 mm. in diameter), opposite the lower border of the fourth lumbar vertebra, by dividing into the right and left common iliac arteries. Hence it is described in several portions, viz. the *ascending aorta*, the *arch* of the aorta, and the *descending aorta*, which last is again divided into the *thoracic* and *abdominal aortæ*.

Ascending Aorta

The **ascending aorta** (aorta ascendens) (fig. 572) is about two inches in length. It commences at the upper part of the base of the left ventricle, on a level with the lower border of the third costal cartilage behind the left half of the sternum; it passes obliquely upwards, forwards, and to the right, in the direction of the heart's axis, as high as the upper border of the second right costal cartilage, describing a slight curve in its course, and being situated, when distended, about a quarter of an inch behind the posterior surface of the sternum. At its origin it presents, opposite the segments of the aortic valve, three small dilatations called the sinuses of Valsalva. At the union of the ascending with the transverse part of the aorta the calibre of the vessel is increased, owing to a bulging outwards of its right wall. This dilatation is termed the *great sinus of the aorta* (bulbus aortæ), and on transverse section presents a somewhat oval figure. The ascending aorta is contained within the pericardium, and is enclosed in a tube of the serous pericardium, common to it and the pulmonary artery.

Relations.—The ascending aorta is covered at its commencement by the trunk of the pulmonary artery and the right auricular appendix, and, higher up, is separated from the sternum by the pericardium, the right pleura, and the anterior margin of the right lung, some loose areolar tissue, and the remains of the thymus gland; *behind*, it rests upon the right pulmonary artery and left auricle. On the

* Keith (*Studies in Pathology*, Aberdeen University, 1906) believes that the great majority of cases which are classified as congenital stenosis of the pulmonary or of the aortic orifices are, in reality, due to an arrest of development or malformation of the bulbus cordis.

right side, it is in relation with the superior vena cava and right auricle, the former lying partly behind it ; on the *left side*, with the pulmonary artery.

Branches.—The only branches of the ascending aorta are the coronary arteries which supply the heart. They are two in number, right and left, and arise near the commencement of the aorta immediately above the attached margins of the semilunar valves.

The **right coronary artery** (a. coronaria [cordis] dextra), about the size of a crow's quill, arises from the anterior sinus of Valsalva. It passes forwards between the pulmonary artery and the right auricular appendix, then runs obliquely to the right side, in the groove between the right auricle and ventricle, and, curving around the right border of the heart, runs along the posterior surface as far as the posterior interventricular groove, where it divides into two branches. One of these (*transverse*) continues onwards in the groove between the left auricle and ventricle, and anastomoses with the left coronary ; the other (*descending*) courses along the posterior interventricular furrow, supplies branches to both ventricles and to the septum, and anastomoses at the apex of the heart with the descending branches of the left coronary.

This vessel sends a large branch (*marginal*) along the thin margin of the right ventricle to the apex, and from this numerous small branches are given to the anterior and posterior surfaces of the ventricle. It also gives a branch close to its origin (*right auricular*), which passes upwards between the right auricle and the aorta, and distributes twigs to the right auricle, the auricular septum, the aorta, and the pulmonary artery.

The **left coronary artery** (a. coronaria [cordis] sinistra), larger than the former, arises from the left posterior sinus of Valsalva ; it passes forwards between the pulmonary artery and the left auricular appendix, and divides into two branches. Of these, one (*transverse*) runs transversely outwards in the left auriculo-ventricular groove, and winds around the left border of the heart to the posterior surface, where it anastomoses with the transverse branch of the right coronary ; the other (*descending*) passes along the anterior interventricular groove to the apex of the heart, where it anastomoses with the descending branch of the right coronary. The left coronary supplies the left auricle and its appendix, gives branches to both ventricles, and numerous twigs to the pulmonary artery and commencement of the aorta.

In addition to the already mentioned anastomosis in the auriculo-ventricular and interventricular grooves there is a free anastomosis between the minute branches of the two coronary arteries in the substance of the heart.

Peculiarities.—These vessels occasionally arise by a common trunk, or their number may be increased to three, the additional branch being of small size. More rarely, there are two additional branches.

Applied Anatomy.—The sudden blocking of a coronary artery by an embolus, or its more gradual obstruction by arterial disease or thrombosis, is a common cause of sudden death in persons past middle age. If the obstruction to the passage of blood is incomplete, true *angina pectoris* may occur. In this condition the patient is suddenly seized with a spasm of agonising pain in the præcordial region and down the left arm, together with an indescribable sense of anguish. He may die in such an attack, or succumb a few hours or days later from heart failure, or survive a number of attacks.

Arch of the Aorta

The **arch of the aorta** (arcus aortæ) (fig. 572) begins at the upper border of the second chondro-sternal articulation of the right side, and runs at first upwards, backwards, and to the left in front of the trachea ; it is then directed backwards on the left side of the trachea, and finally passes downwards on the left side of the body of the fourth thoracic vertebra, at the lower border of which it becomes continuous with the descending aorta. It thus forms two curvatures : one with its convexity upwards, the other with its convexity forwards and to the left. Its upper border is usually about an inch below the upper margin of the sternum.

Relations.—The arch of the aorta is covered *in front* by the pleuræ and anterior margins of the lungs, and by the remains of the thymus gland. As the vessel runs backwards its *left* side is in contact with the left lung and pleura. Passing downwards on the left side of this part of the arch are four nerves—in order from before

backwards these are : the left phrenic, the inferior cervical cardiac branch of the left pneumogastric, the superior cardiac branch of the left sympathetic, and the trunk of the left pneumogastric. As the last nerve crosses the arch it gives off its recurrent laryngeal branch, which hooks round below the vessel and then passes upwards on its right side. The left superior intercostal vein runs obliquely upwards and forwards, on the left side of the arch between the phrenic and pneumogastric nerves. On the *right* are the deep cardiac plexus, the left recurrent laryngeal nerve, the œsophagus, and the thoracic duct ; the trachea lies behind and to the right of the vessel. *Above* are the innominate, left common carotid, and left subclavian arteries,

Fig. 572.—The arch of the aorta, and its branches.

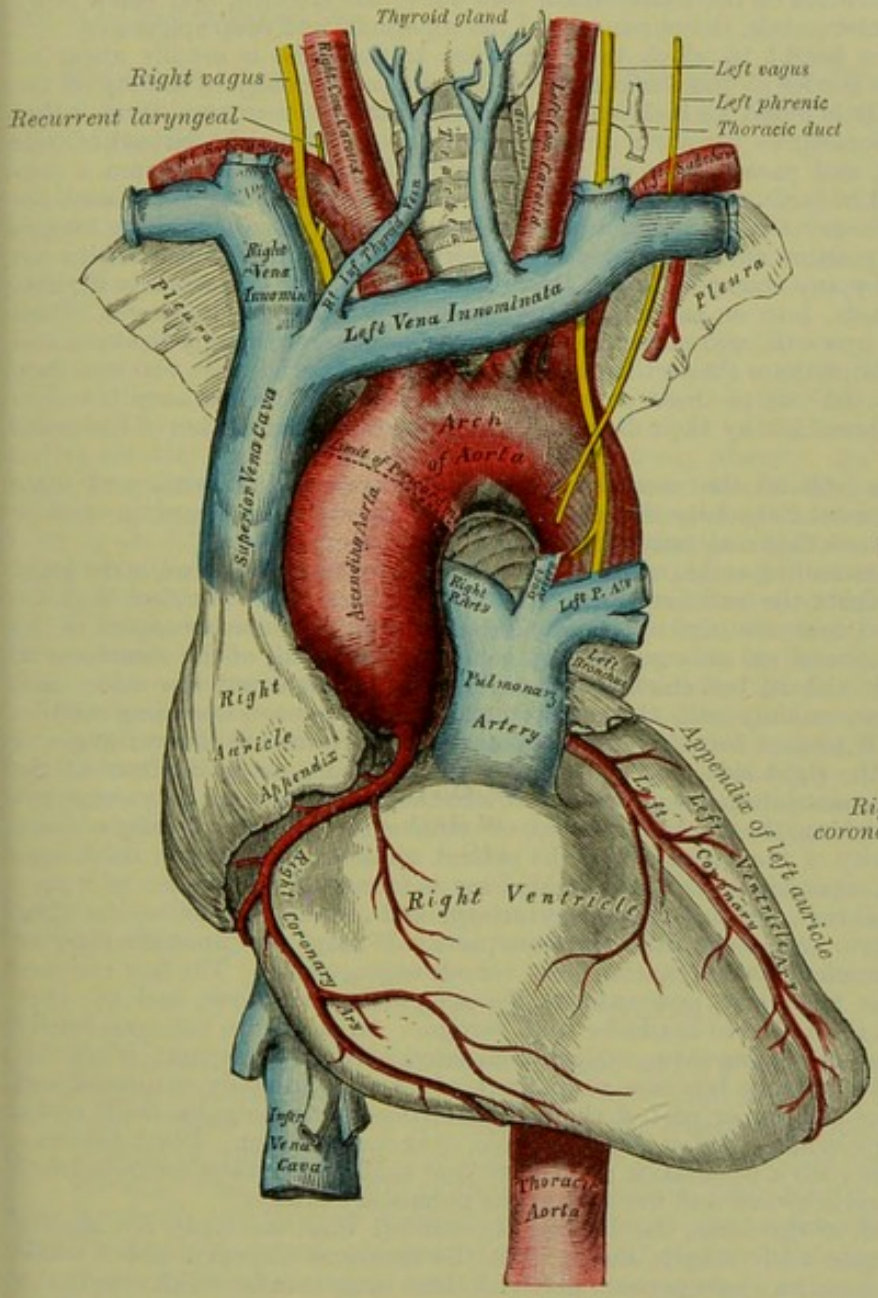

Fig. 573.
Plan of the branches.

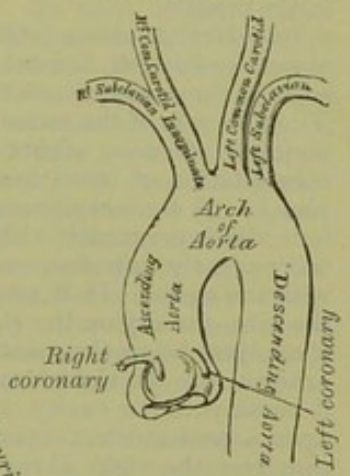

which arise from the convexity of the arch and are crossed close to their origins by the left innominate vein. *Below* are the bifurcation of the pulmonary artery, the left bronchus, the ligamentum arteriosum, the superficial cardiac plexus, and the left recurrent laryngeal nerve. As already stated, the ligamentum arteriosum connects the commencement of the left pulmonary artery to the aortic arch.

Between the origin of the left subclavian artery and the attachment of the ductus arteriosus the lumen of the fœtal aorta is considerably narrowed, forming what is termed the *isthmus aortæ*, while immediately beyond the ductus arteriosus the vessel presents a fusiform dilatation which His has named the *aortic spindle* —the point of junction of the two parts being marked in the concavity of the

arch by an indentation or angle. These conditions persist, to some extent, in the adult, where His found that the average diameter of the spindle exceeded that of the isthmus by 3 mm. (about one-eighth of an inch).

Distinct from this diffuse and moderate stenosis at the isthmus is the condition known as *coarctation of the aorta*, or marked stenosis often amounting to complete obliteration of its lumen, seen in adults and occurring at or near, oftenest a little below, the insertion of the ductus arteriosus into the aorta. According to Bonnet * this coarctation is never found in the fœtus or at birth, and is due to an abnormal extension of the peculiar tissue of the ductus into the aortic wall, which gives rise to a simultaneous stenosis of both vessels as it contracts after birth—the ductus is usually obliterated in these cases. An extensive collateral circulation is set up, by the superior intercostals, internal mammaries, and the posterior scapular branches of the transversalis colli above the stenosis, and below it by the first four aortic intercostals, the phrenics, and the superficial and deep epigastrics.

Peculiarities.—The height to which the aorta rises in the chest is usually about an inch below the upper border of the sternum; but it may ascend nearly to the top of the bone. Occasionally it is found an inch and a half, more rarely two or even three inches below this point. Sometimes the aorta arches over the root of the right instead of over that of the left lung, and passes down on the right side of the vertebral column, a condition which is found in birds. In such cases all the thoracic and abdominal viscera are transposed. Less frequently the aorta, after arching over the root of the right lung, is directed to its usual position on the left side of the vertebral column, this peculiarity not being accompanied by any transposition of the viscera. The aorta occasionally divides, as in some quadrupeds, into an ascending and a descending trunk, the former of which is directed vertically upwards, and subdivides into three branches, to supply the head and upper extremities. Sometimes the aorta subdivides soon after its origin into two branches, which soon reunite. In one of these cases the œsophagus and trachea were found to pass through the interval left by their division; this is the normal condition of the vessel in the reptilia.

Applied Anatomy.—Of all the vessels of the arterial system, the aorta, and more especially its arch, is most frequently the seat of disease; hence it is important to consider some of the consequences that may ensue from aneurysm of this part.

Aneurysm of the ascending aorta, in the situation of the sinuses of Valsalva, in the great majority of cases, affects the anterior sinus; this is mainly owing to the fact that the regurgitation of blood upon the sinuses takes place chiefly on the anterior aspect of the vessel. As the aneurysmal sac enlarges, it may compress any or all of the structures in immediate proximity with it, but chiefly projects towards the right anterior side; and, consequently, interferes mainly with those structures that have a corresponding relation with the vessel. If it project forwards, it may absorb the sternum and the cartilages of the ribs, usually on the right side, and appear as a pulsating tumour on the front of the chest, just below the manubrium; or it may burst into the pericardium, or may compress, or open into the right lung, the trachea, bronchi, or œsophagus. In the majority of cases it bursts into the cavity of the pericardium, the patient suddenly drops down dead, and, upon a post-mortem examination, the pericardial sac is found full of blood; or it may compress the right auricle, or the pulmonary artery, and adjoining part of the right ventricle, and open into one or the other of these parts. It may press upon the superior vena cava or the innominate veins, causing great venous engorgement. The face becomes livid and swollen, the right arm and anterior thoracic wall œdematous, and the congestion of the brain gives rise to headache and vertigo. An aneurysm has occasionally perforated into the superior vena cava, setting up an arterio-venous aneurysm. When this happens the patient suddenly becomes very short of breath, intensely congested and œdematous in the face and upper part of the body, and develops a palpable thrill and a continuous humming murmur, loudest during systole, over the sternum. Death follows a few days or weeks after such a perforation; and somewhat similar symptoms are occasioned when an aortic aneurysm erodes and bursts into the pulmonary artery.

Regarding the arch of the aorta, the student is reminded that the vessel lies against the trachea, œsophagus, and thoracic duct; that the recurrent laryngeal nerve winds around it; and that from its upper part are given off three large trunks, which supply the head, neck, and upper extremities. Now, an aneurysmal tumour taking origin from the posterior part of the vessel, its most usual site, may press upon the trachea and give rise to the sign known as "tracheal tugging," impede the breathing, or produce cough, dyspnœa, bronchiectasis, hæmoptysis, or stridulous breathing, or it may ultimately burst into that tube, producing fatal hæmorrhage. Again, its pressure on the left recurrent laryngeal nerve may give rise to symptoms of laryngeal paralysis; or it may press upon the thoracic duct and destroy life by inanition; or it may involve the œsophagus, producing dysphagia, and has not infrequently been mistaken for œsophageal stricture; or it may burst into the œsophagus, when fatal hæmorrhage will occur. Compression or stretching of the sympathetic filaments may, in the former case, produce dilatation of the pupil; in the latter,

* *Rev. de Méd.*, Paris, 1903.

contraction, if the conducting power is abolished, on the affected side. This has proved to be an important diagnostic sign in this disease. Again, the innominate artery, or the subclavian, or left carotid, may be so obstructed by clots as to produce a weakness, or even a disappearance, of the pulse in one or the other wrist, or in the left temporal artery; or the tumour may present itself at or above the manubrium, generally either in the median line, or to the right of the sternum, and may simulate an aneurysm of one of the arteries of the neck.

It is important to remember that many of the physical signs of an aortic aneurysm may be simulated with extraordinary fidelity by the preternatural pulsation or throbbing of a distended and elastic aorta, when no true aneurysmal dilatation exists. This condition may be met with in young persons with aortic reflux and greatly hypertrophied hearts, in patients who are of a neurotic or hysterical temperament, and in cases of Graves's disease or of marked anæmia. The condition is known as dynamic dilatation of the aorta, and in no way threatens life.

Branches (figs. 572, 573).—The branches given off from the arch of the aorta are three in number: the innominate, the left common carotid, and the left subclavian.

Peculiarities.—Position of the branches.—The branches, instead of arising from the highest part of the arch, may spring from the commencement of the arch or upper part of the ascending aorta; or the distance between them at their origins may be increased or diminished, the most frequent change in this respect being the approximation of the left carotid towards the innominate artery.

The *number* of the primary branches may be reduced to one, or more commonly two: the left carotid arising from the innominate artery; or (more rarely) the carotid and subclavian arteries of the left side arising from a left innominate artery. But the number may be increased to four, from the right carotid and subclavian arteries arising directly from the aorta, the innominate being absent. In most of these latter cases the right subclavian has been found to arise from the left end of the arch; in other cases it is the second or third branch given off, instead of the first. Another common form in which there are four primary branches is that in which the left vertebral artery arises from the arch of the aorta between the left carotid and subclavian arteries. Lastly, the number of trunks from the arch may be increased to five or six; in these instances, the external and internal carotids arise separately from the arch, the common carotid being absent on one or both sides. In some few cases six branches have been found, and this condition is associated with the origin of both vertebral arteries from the arch.

Number usual, arrangement different.—When the aorta arches over to the right side, the three branches have an arrangement the reverse of what is usual, the innominate artery is a left one, and the right carotid and subclavian arise separately. In other cases, where the aorta takes its usual course, the two carotids may be joined in a common trunk, and the subclavians arise separately from the arch, the right subclavian generally arising from the left end of the arch.

In some instances other arteries spring from the arch of the aorta. Of these the most common are the bronchial, one or both, and the thyreoidea ima; but the internal mammary and the inferior thyroid have been seen to arise from this vessel.

Innominate Artery

The **innominate** or **brachio-cephalic artery** (a. anonyma) (fig. 572) is the largest branch given off from the arch of the aorta. It arises, on a level with the upper border of the second right costal cartilage, from the commencement of the arch of the aorta, on a plane anterior to the origin of the left carotid, and, ascending obliquely upwards, backwards, and outwards to the level of the upper border of the right sterno-clavicular articulation, divides into the right common carotid and right subclavian arteries. This vessel varies from an inch and a half to two inches in length.

Relations.—*In front*, it is separated from the first piece of the sternum by the Sterno-hyoid and Sterno-thyroid muscles, the remains of the thymus gland, the left innominate and right inferior thyroid veins which cross its root, and sometimes the inferior cervical cardiac branch of the right pneumogastric. *Behind*, it lies upon the trachea, which it crosses obliquely. On the *right side* are the right innominate vein, the superior vena cava, the right phrenic nerve, and the pleura; and on the *left side*, the remains of the thymus gland, the origin of the left carotid artery, the left inferior thyroid vein, and the trachea.

Branches.—The innominate usually gives off no branches; but occasionally a small branch, the *thyreoidea ima*, arises from this vessel. It also sometimes gives off a *thymic* or *bronchial branch*.

The **thyreoidea ima** ascends in front of the trachea to the lower part of the thyroid body, which it supplies. It varies greatly in size, and appears to compensate for deficiency or absence of one of the other thyroid vessels. It occasionally arises from the aorta, the right common carotid, the subclavian or the internal mammary.

Peculiarities in point of division.—When the bifurcation of the innominate artery varies from the point above mentioned, the vessel sometimes ascends a considerable distance above the sternal end of the clavicle; less frequently it divides below it. In cases of the former class, its length may exceed two inches; and, in the latter, be reduced to an inch or less.

Position.—When the aorta arches over to the right side, the innominate is directed to the left side of the neck instead of the right.

Collateral Circulation.—Allan Burns demonstrated, on the dead subject, the possibility of the establishment of the collateral circulation after ligature of the innominate artery, by tying and dividing that artery. He then found that 'Even coarse injection, impelled into the aorta, passed freely by the anastomosing branches into the arteries of the right arm, filling them and all the vessels of the head completely.'* The branches by which this circulation would be carried on are very numerous; thus, all the communications across the middle line between the branches of the carotid arteries of opposite sides would be available for the supply of blood to the right side of the head and neck; while the anastomosis between the superior intercostal of the subclavian and the first aortic intercostal (see *infra* on the collateral circulation after obliteration of the thoracic aorta) would bring the blood, by a free and direct course, into the right subclavian. The numerous connections, also, between the intercostal arteries and the branches of the axillary and internal mammary arteries would, doubtless, assist in the supply of blood to the right arm, while the deep epigastric from the external iliac would, by means of its anastomosis with the internal mammary, compensate for any deficiency in the vascularity of the wall of the chest.

Applied Anatomy.—Aneurysm of the innominate artery not infrequently occurs as an accompaniment to aneurysm of the arch of the aorta. It causes bulging of the right sterno-clavicular articulation, pushing forwards the Sterno-mastoid muscle and filling up the suprasternal notch. It produces serious pressure symptoms: from pressure on the innominate veins it may cause œdema of the upper extremities, and of the head and neck; from pressure on the trachea it produces dyspnœa; and from pressure on the right recurrent laryngeal nerve, hoarseness and laryngeal cough.

Although the operation of tying the innominate artery has been performed by several surgeons, not many successes have been recorded. The chief danger of the operation appears to be the frequency of secondary hæmorrhage; but in the present day, with the practice of aseptic surgery and our greater knowledge of the use of the ligature, more favourable results may be anticipated. The main obstacles to the operation are, the deep situation of the artery behind and beneath the sternum, and the number of important structures which surround it in every part.

In order to apply a ligature to this vessel, the patient is to be placed upon his back with the thorax slightly raised, the head bent a little backwards, and the right shoulder strongly depressed, so as to draw out the artery from behind the sternum into the neck. An incision three or more inches long is then made along the anterior border of the Sterno-mastoid muscle, terminating at the sternal end of the clavicle. From this point, a second incision is carried about the same length along the upper border of the clavicle. The skin is then dissected back, and the Platysma divided on a director: the sternal end of the Sterno-mastoid is now brought into view, and a director being passed beneath it, and close to its under surface, so as to avoid any small vessels, it is to be divided; in like manner the clavicular origin is to be divided throughout the whole or greater part of its attachment. By pressing aside any loose cellular tissue or vessels that may now appear, the Sterno-hyoid and Sterno-thyroid muscles will be exposed, and must be divided, a director being previously passed beneath them. The inferior thyroid veins may come into view, and must be carefully drawn either upwards or downwards, by means of a blunt hook, or tied with double ligatures and divided. After tearing through a strong fibro-cellular lamina, the right carotid is brought into view, and being traced downwards, the arteria innominata is arrived at. The left innominate vein should now be depressed; the right innominate vein, the internal jugular vein, and the pneumogastric nerve drawn to the right side; and a curved aneurysm needle may then be passed around the vessel, close to its surface, and in a direction from below upwards and inwards; care being taken to avoid the right pleural sac, the trachea, and cardiac nerves. The ligature should be applied to the artery as high as possible, in order to allow room between it and the aorta for the formation of the coagulum. The importance of avoiding the thyroid plexus of veins during the primary steps of the operation, and the pleural sac while including the vessel in the ligature, should be most carefully borne in mind.

* *Surgical Anatomy of the Head and Neck*, p. 62.

ARTERIES OF THE HEAD AND NECK

The principal arteries of supply to the head and neck are the two common carotids; they ascend in the neck and each divides into two branches, viz. (1) the external carotid, supplying the superficial parts of the head and face, and the greater part of the neck; (2) the internal carotid, supplying to a great extent the parts within the cranial cavity.

Common Carotid Arteries

The **common carotid arteries** differ in length and in their mode of origin. The *right* (a. carotis communis dextra) begins at the bifurcation of the innominate artery behind the sterno-clavicular joint and is confined to the neck. The *left* (a. carotis communis sinistra) springs from the highest part of the arch of the aorta to the left of and on a plane posterior to the innominate artery, and therefore consists of a thoracic and a cervical portion.

The **thoracic portion of the left common carotid artery** ascends from the arch of the aorta through the superior mediastinum to the level of the left sterno-clavicular joint, where it is continuous with the cervical portion.

Relations.—*In front*, it is separated from the first piece of the sternum by the Sterno-hyoid and Sterno-thyroid muscles, the anterior portions of the left pleura and lung, the left innominate vein, and the remains of the thymus gland; *behind*, it lies on the trachea, œsophagus, left recurrent laryngeal nerve, and thoracic duct. To its *right side* below is the innominate artery, and above, the trachea, the inferior thyroid veins, and the remains of the thymus gland; to its *left side* are the left pneumogastric and phrenic nerves, left pleura, and lung. The left subclavian artery is posterior and slightly external to it.

The **cervical portions** of the two common carotids resemble each other so closely, that one description will apply to both (fig. 574). Each vessel passes obliquely upwards, from behind the sterno-clavicular articulation, to the level of the upper border of the thyroid cartilage, opposite the lower border of the third cervical vertebra, where it divides into the external and internal carotid arteries.

At the lower part of the neck the two common carotid arteries are separated from each other by a very small interval, which contains the trachea; but at the upper part, the thyroid body, the larynx and pharynx project forwards between the two vessels, and give them the appearance of being placed farther back in this situation. The common carotid artery is contained in a sheath, which is derived from the deep cervical fascia and encloses also the internal jugular vein and pneumogastric nerve, the vein lying on the outer side of the artery, and the nerve between the artery and vein, on a plane posterior to both. On opening the sheath, these three structures are seen to be separated from one another, each being enclosed in a separate fibrous investment.

Relations.—At the lower part of the neck the common carotid artery is very deeply seated, being *covered by* the integument, superficial fascia, Platysma, and deep cervical fascia, the Sterno-mastoid, Sterno-hyoid, Sterno-thyroid and Omo-hyoid muscles; in the upper part of its course it is more superficial, being covered merely by the integument, the superficial fascia, Platysma, deep cervical fascia, and inner margin of the Sterno-mastoid. When the latter muscle is drawn backwards, the artery is seen to be contained in a triangular space, the *carotid triangle*, bounded behind by the Sterno-mastoid, above by the Stylo-hyoid and posterior belly of the Digastric, and below by the anterior belly of the Omo-hyoid. This part of the artery is crossed obliquely, from within outwards, by the sterno-mastoid artery; it is also crossed by the superior and middle thyroid veins which terminate in the internal jugular; descending on its sheath in front is the descendens hypoglossi nerve, this filament being joined by one or two branches from the cervical nerves, which cross the vessel from without inwards. Sometimes the descendens hypoglossi is contained within the sheath. The superior thyroid vein crosses the artery near its termination, and the middle thyroid vein a little below the level of the cricoid cartilage; the anterior jugular vein crosses the artery just above the clavicle, but is separated from it by the Sterno-hyoid and Sterno-thyroid muscles. *Behind*, the artery is separated from

the transverse processes of the cervical vertebræ by the Longus colli and Rectus capitis anticus major, the sympathetic cord being interposed between it and the muscles. The recurrent laryngeal nerve and inferior thyroid artery cross behind the vessel at its lower part. *Internally*, it is in relation with the œsophagus, trachea, and thyroid gland (which overlaps it), the inferior thyroid artery and recurrent laryngeal nerve being interposed; higher up, with the larynx and pharynx. On its *outer side* are placed the internal jugular vein and pneumogastric nerve.

FIG. 574.—Superficial dissection of the right side of the neck, showing the carotid and subclavian arteries.

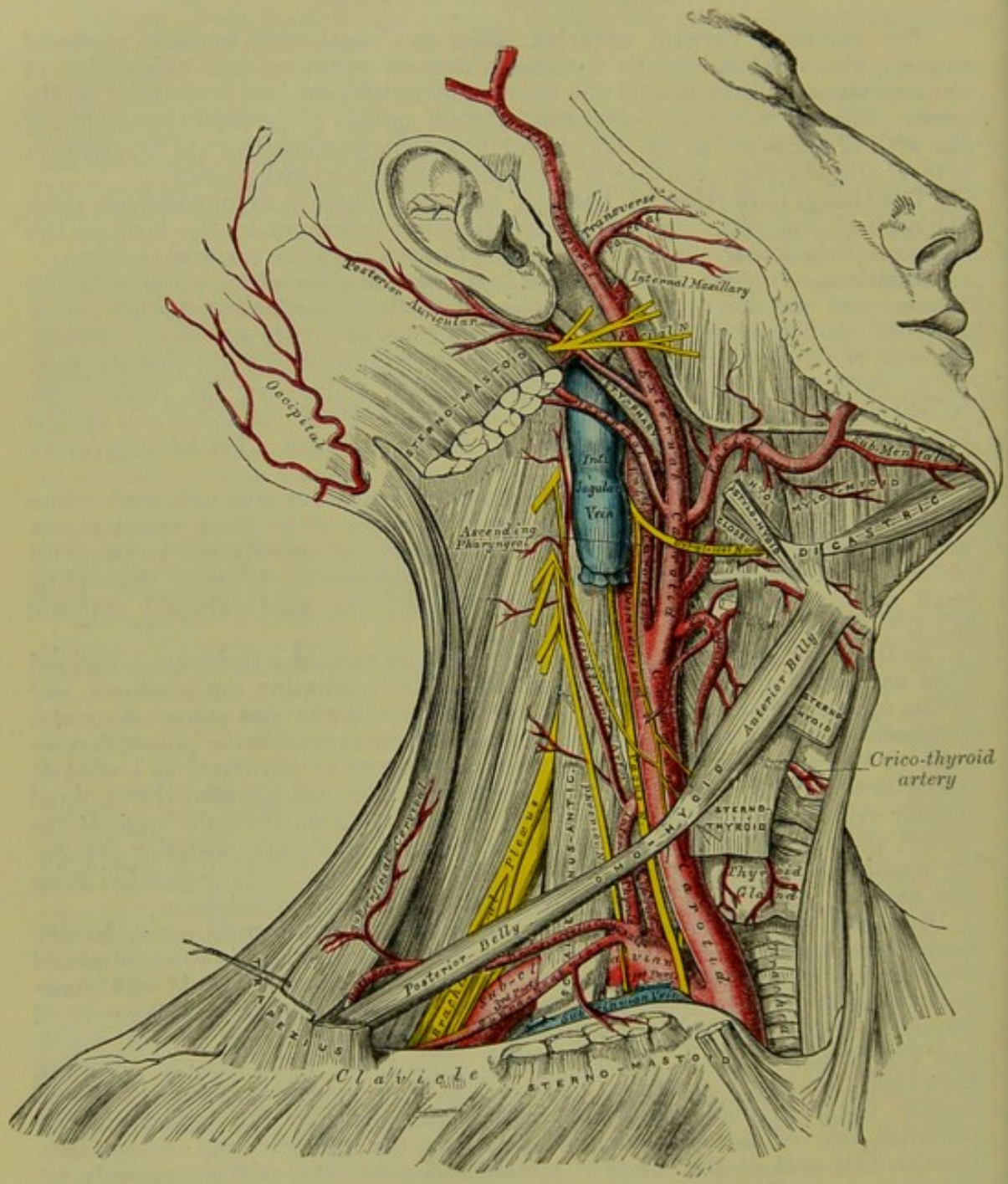

At the lower part of the neck, the internal jugular vein on the right side diverges from the artery, but on the left side it approaches it, and often overlaps its lower part.

On the posterior aspect of the angle of bifurcation of the common carotid artery is a reddish-brown oval body, known as the *carotid body*. It is similar in structure to the coccygeal body, which is situated on the middle sacral artery.

Peculiarities as to origin.—The *right common carotid* may arise above the upper border of the sterno-clavicular articulation; this variation occurs in about 12 per cent. of

cases. In other cases the artery arises as a separate branch from the arch of the aorta, or it may arise in conjunction with the left carotid. The *left common carotid* varies in its origin more than the right. In the majority of abnormal cases it arises with the innominate artery, or, if the innominate artery is absent, the two carotids arise usually by a single trunk. It is rarely joined with the left subclavian, except in cases of transposition of the arch.

Peculiarities as to point of division.—In the majority of abnormal cases, this occurs higher than usual, the artery dividing into two branches opposite the hyoid bone, or even higher; more rarely, it occur sbelow, opposite the middle of the larynx, or the lower border of the cricoid cartilage; and one case is related by Morgagni, where the common carotid, only an inch and a half in length, divided at the root of the neck. Very rarely, the common carotid ascends in the neck without any subdivision, either the external or the internal carotid being wanting; and in a few cases the common carotid has been found to be absent, the external and internal carotids arising directly from the arch of the aorta. This peculiarity existed on both sides in some instances, on one side in others.

Occasional branches.—The common carotid usually gives off no branch previous to its bifurcation; but it occasionally gives origin to the superior thyroid or its laryngeal branch, the ascending pharyngeal, the inferior thyroid, or, more rarely, the vertebral artery.

Surface Marking.—The course of the artery is indicated by a line drawn from the upper part of the sternal end of the clavicle below, to a point midway between the angle of the jaw and the mastoid process above. The portion of this line below the level of the upper border of the thyroid cartilage represents the course of the vessel.

Applied Anatomy.—Aneurysms are not commonly met with on the common carotid; when they do occur they are usually situated low down at the root of the neck, or just below the point of bifurcation of the vessel. They do not frequently assume a large size, and are more commonly found on the right side. As they increase in size they displace the trachea and larynx, and therefore dyspnœa becomes a prominent symptom. Dysphagia also may be present from pressure on the œsophagus, especially if the aneurysm is on the left side; and pressure on the recurrent laryngeal nerve may produce hoarseness and laryngeal cough. Pressure on the sympathetic will cause pupillary changes—dilatation of the pupil when the sympathetic is irritated, contraction when it has become paralysed—and may also give rise to unilateral sweating. Pressure on the superficial branches of the cervical plexus may give rise to pain in the head, face, and neck; pressure on the vagus to irregular action of the heart and to asthmatic attacks. It is important to bear in mind that an enlarged gland in the superior carotid triangle, receiving a transmitted pulsation from the carotid artery, may simulate aneurysm of that vessel, but may be distinguished from it by the character of the pulsation, which is not distensile.

Embolism of the left common carotid has been known to produce aphasia by interference with the blood supply of the brain.

Digital compression of the common carotid is sometimes required, and is best effected by compressing the vessel with the thumb against the anterior tubercle of the transverse process of the sixth cervical vertebra (see page 185). *Ligature* of the common carotid artery may be necessary in a case of wound of that vessel or its branches, in aneurysm, or in a case of pulsating tumour of the orbit or skull. If the wound involves the trunk of the common carotid, it will be necessary to tie the artery above and below the wounded part. In cases of aneurysm, the whole of the artery is accessible, and any part may be tied, except close to either end. When the case is such as to allow of a choice being made, the lower part of the carotid should never be selected as the spot upon which to place a ligature, for not only is the artery in this situation placed very deeply in the neck, but it is covered by three layers of muscles, and, on the left side, the internal jugular vein, in the great majority of cases, passes obliquely in front of it. Neither should the upper end be selected, for here the superior thyroid vein and its tributaries would give rise to very considerable difficulty in the application of a ligature. The part of the vessel which is most favourable for the operation is that opposite the level of the cricoid cartilage. It occasionally happens that the carotid artery bifurcates below its usual position: if the artery be exposed at its point of bifurcation, both divisions of the vessel should be tied near their origin, in preference to tying the trunk of the artery near its termination; and if, in consequence of the entire absence of the common carotid, or from its early division, two arteries, the external and internal carotids, are met with, the ligature should be placed on that vessel which is found on compression to be connected with the diseased area.

In this operation, the direction of the vessel and the inner margin of the Sterno-mastoid are the chief guides to its performance. The patient should be placed on his back with the head extended and turned slightly to the opposite side: an incision is to be made, three inches long, in the direction of the anterior border of the Sterno-mastoid, so that the centre corresponds to the level of the cricoid cartilage. After dividing the integument, superficial fascia, and Platysma, the deep fascia must be cut through on a director, so as to avoid wounding numerous small veins that are usually found beneath. The head may now be brought forwards so as to relax the parts somewhat, and the margins of the wound held asunder by retractors. The descendens hypoglossi nerve may now be exposed, and

must be avoided, and the sheath of the vessel having been raised by forceps, is to be opened to a small extent over the artery at its inner side. The internal jugular vein may present itself alternately distended and relaxed; this should be compressed both above and below, and drawn outwards, in order to facilitate the operation. The aneurysm needle is passed from the outside, care being taken to keep the needle in close contact with the artery, and thus avoid the risk of injuring the internal jugular vein, or including the vagus nerve. Before the ligature is tied, it should be ascertained that nothing but the artery is included in it.

Ligature of the common carotid at the lower part of the neck.—This operation is sometimes required in cases of aneurysm of the upper part of the carotid, especially if the sac is of large size. It is best performed by dividing the sternal origin of the Sterno-mastoid muscle, but may be done in some cases, if the aneurysm is not of very large size, by an incision along the anterior border of the Sterno-mastoid, extending down to the sterno-clavicular articulation, and by then retracting the muscle. The easiest and best plan, however, is to make an incision two or three inches long down the lower part of the anterior border of the Sterno-mastoid muscle to the sterno-clavicular joint, and a second incision, starting from the termination of the first, along the upper border of the clavicle for about two inches. This incision is made through the superficial and deep fasciæ and the sternal origin of the muscle is exposed. This is to be divided on a director and turned up, with the superficial structures, as a triangular flap. Some loose connective tissue is to be divided or torn through, and the outer border of the Sterno-hyoid muscle exposed. In doing this, care must be taken not to wound the anterior jugular vein, which crosses the muscle to reach the external jugular or subclavian vein. The Sterno-hyoid and Sterno-thyroid are to be drawn inwards by means of a retractor, and the sheath of the vessel exposed. This must be opened with great care on its inner or tracheal side, so as to avoid the internal jugular vein. This is especially necessary on the left side, where the artery is commonly overlapped by the vein. On the right side there is usually an interval between the artery and the vein, and the risk of wounding the vein is less.

The common carotid artery, being a long vessel without any branches, is particularly suitable for the performance of Brasdor's operation for the cure of an aneurysm of the lower part of the vessel. Brasdor's procedure consists in ligaturing the artery on the distal side of the aneurysm, and in the case of the common carotid there are no branches given off from the vessel between the aneurysm and the site of the ligature; hence the flow of blood through the sac of the aneurysm is diminished, and cure takes place in the usual way by the deposit of laminated fibrin.

Collateral Circulation.—After ligature of the common carotid, the collateral circulation can be perfectly established, by the free communication which exists between the carotid arteries of opposite sides, both without and within the cranium, and by enlargement of the branches of the subclavian artery on the side corresponding to that on which the vessel has been tied. The chief communications outside the skull take place between the superior and inferior thyroid arteries, and the profunda cervicis and arteria princeps cervicis of the occipital; the vertebral takes the place of the internal carotid within the cranium.

External Carotid Artery

The **external carotid artery** (a. carotis externa) (fig. 574) commences opposite the upper border of the thyroid cartilage, and, taking a slightly curved course, passes upwards and forwards, and then inclines backwards to the space behind the neck of the mandible, where it divides into the superficial temporal and internal maxillary arteries. It rapidly diminishes in size in its course up the neck, owing to the number and large size of the branches given off from it. In the child, it is somewhat smaller than the internal carotid; but in the adult, the two vessels are of nearly equal size. At its origin, this artery is more superficial, and placed nearer the middle line than the internal carotid, and is contained within the carotid triangle.

Relations.—The external carotid artery is *covered by* the skin, superficial fascia, Platysma, deep fascia, and anterior margin of the Sterno-mastoid; it is crossed by the hypoglossal nerve, by the lingual, ranine, facial, and superior thyroid veins; and by the Digastric and Stylo-hyoid muscles; higher up it passes deeply into the substance of the parotid gland, where it lies beneath the facial nerve and the junction of the temporal and internal maxillary veins. *Internally* are the hyoid bone, the wall of the pharynx, the superior laryngeal nerve, and a portion of the parotid gland. *Externally*, in the lower part of its course, is the internal carotid artery. *Behind* it, near its origin, is the superior laryngeal nerve; and higher up, it is separated from the internal carotid by the Stylo-glossus and Stylo-pharyngeus muscles, the glosso-pharyngeal nerve, the pharyngeal branch of the vagus, and part of the parotid gland.

Surface Marking.—The position of the external carotid artery may be marked out with sufficient accuracy by a line drawn from the side of the cricoid cartilage to the front of the meatus of the external ear, arching the line slightly forwards.

Applied Anatomy.—The application of a ligature to the external carotid may be required in cases of wound of this vessel, or of its branches when these cannot be tied, and in some cases of pulsating tumours of the scalp or face. It is also done as a preliminary measure to excision of the maxilla. The operation is to be preferred to ligature of the common carotid, as it does not interfere with the cerebral circulation. The seat of election for ligature is between the origins of the superior thyroid and lingual branches, about a finger's breadth below the tip of the great cornu of the hyoid bone. To tie the vessel, an incision is to be made from the angle of the mandible to the upper border of the thyroid cartilage, and the superficial tissues and the deep fascia divided. The anterior border of the Sterno-mastoid must be retracted and the lower border of the parotid gland raised, so as to expose the tendon of the Digastric and the hypoglossal nerve, which cross the artery. The great difficulty in doing this is due to the plexus of veins derived from the superior thyroid and lingual veins, which overlie the artery. If necessary, these must be ligatured and divided. Care must be taken not to mistake the lingual and facial, when they arise by a common trunk, as they sometimes do, for the external carotid. When the vessel is exposed, the needle is to be passed from without inwards, carefully avoiding the superior laryngeal nerve, which lies in close proximity to the artery. The circulation is at once re-established by the free communication between most of the large branches of the artery (facial, lingual, superior thyroid, occipital) and the corresponding arteries of the opposite side, and by the anastomosis of its branches with those of the internal carotid, and of the occipital with branches of the subclavian, &c.

Branches of the External Carotid Artery

The external carotid artery gives off eight branches, which, for convenience of description, may be divided into four sets. (See fig. 575.)

Anterior.	*Posterior.*	*Ascending.*	*Terminal.*
Superior thyroid.	Occipital.	Ascending	Superficial temporal.
Lingual.	Posterior auricular.	pharyngeal.	Internal maxillary.
Facial.			

1. The **superior thyroid artery** (a. thyreoidea superior) (fig. 574) arises from the external carotid artery just below the level of the great cornu of the hyoid bone and terminates in the thyroid gland.

Relations.—From its origin under the anterior border of the Sterno-mastoid it runs upwards and forwards for a short distance in the carotid triangle, where it is covered by the skin, Platysma, and fascia; it then arches downwards beneath the Omo-hyoid, Sterno-hyoid, and Sterno-thyroid. To its inner side are the Inferior constrictor of the pharynx and the external laryngeal nerve.

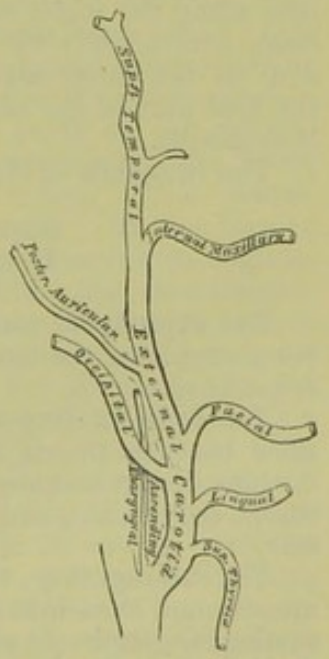

Fig. 575.—Plan of the branches of the external carotid

Branches. — It distributes twigs to the adjacent muscles, and numerous branches to the thyroid gland, anastomosing with its fellow of the opposite side, and with the inferior thyroid arteries. The branches to the gland are generally two in number: one, the larger, supplies principally the anterior surface of the gland; it courses along the inner border of the lateral lobe to the isthmus, in which it anastomoses with the corresponding artery of the opposite side: a second branch descends on the posterior surface of the lateral lobe and anastomoses with the inferior thyroid artery.

Besides the arteries distributed to the muscles and to the thyroid gland, the branches of the superior thyroid are:

Infrahyoid.	Superior laryngeal.
Sterno-mastoid.	Crico-thyroid.

The **infrahyoid branch** (ramus hyoideus) is small and runs along the lower border of the hyoid bone beneath the Thyro-hyoid muscle; after supplying the muscles connected to the hyoid bone, it forms an arch, by anastomosing with the vessel of the opposite side.

The **sterno-mastoid branch** (ramus sternocleidomastoideus) runs downwards and outwards across the sheath of the common carotid artery, and supplies the Sterno-mastoid and neighbouring muscles and integument. There is frequently a separate branch from the external carotid distributed to the Sterno-mastoid.

The **superior laryngeal** (a. laryngea superior), larger than either of the preceding, accompanies the internal laryngeal nerve, beneath the Thyro-hyoid muscle; it pierces the thyro-hyoid membrane, and supplies the muscles, mucous membrane, and glands of the larynx, anastomosing with the branch from the opposite side.

The **crico-thyroid branch** (ramus cricothyreoideus) is small and runs transversely across the crico-thyroid membrane, communicating with the artery of the opposite side.

Applied Anatomy.—The superior thyroid, or one of its branches, is often divided in cases of cut throat, giving rise to considerable hæmorrhage. In such cases, the artery should be secured, the wound being enlarged for that purpose, if necessary. The operation may be easily performed, the artery being very superficial, and the only structures of importance covering it being a few small veins. The operation of tying the superior thyroid artery in bronchocele has been performed, but the collateral circulation between this vessel and the artery of the opposite side, and the inferior thyroid, is so free that the operation has been given up, especially as better results are obtained by other means.

The position of the sterno-mastoid branch is of importance in connection with the operation of ligature of the common carotid artery. It crosses and lies on the sheath of this vessel and may chance to be wounded in opening the sheath. The position of the crico-thyroid branch should be remembered, as it may prove the source of troublesome hæmorrhage during the operation of laryngotomy.

2. The **lingual artery** (a. lingualis) (fig. 580) arises from the external carotid between the superior thyroid and facial; it first runs obliquely upwards and inwards to the great cornu of the hyoid bone; it then curves downwards and forwards, forming a loop which is crossed by the hypoglossal nerve, and passing beneath the Digastric and Stylo-hyoid muscles it runs horizontally forwards, beneath the Hyo-glossus, and finally, ascending almost perpendicularly to the tongue, turns forwards on its lower surface as far as the tip, under the name of the *ranine artery*.

Relations.—Its first, or oblique, portion is superficial, being contained within the carotid triangle; it rests upon the Middle constrictor of the pharynx, and is covered by the Platysma and the fascia of the neck. Its second, or curved, portion also lies upon the Middle constrictor, being covered at first by the tendon of the Digastric and by the Stylo-hyoid muscle, and afterwards by the Hyo-glossus. Its third, or horizontal, portion lies between the Hyo-glossus and Genio-hyo-glossus muscles. The fourth, or terminal, part, under the name of the *ranine*, runs along the under surface of the tongue to its tip: here it is very superficial, being covered only by the mucous membrane; above it is the Lingualis inferior, and on the inner side the Genio-hyo-glossus. The hypoglossal nerve crosses the first part of the lingual artery, but is separated from the second part by the Hyo-glossus.

The branches of the lingual artery are:

Suprahyoid.	Sublingual.
Dorsales linguæ.	Ranine.

The **suprahyoid** (ramus hyoideus) runs along the upper border of the hyoid bone, supplying the muscles attached to it and anastomosing with its fellow of the opposite side.

The **dorsales linguæ** consist usually of two or three small branches which arise beneath the Hyo-glossus muscle; they ascend to the back part of the dorsum of the tongue, and supply the mucous membrane in this situation, the tonsil, soft palate, and epiglottis; anastomosing with the vessels of the opposite side.

The **sublingual** (a. sublingualis) arises at the anterior margin of the Hyo-glossus muscle, and runs forward between the Genio-hyo-glossus and Mylo-hyoid to the sublingual gland. It supplies the substance of the gland, giving branches to the Mylo-hyoid and neighbouring muscles, and to the mucous membrane of the mouth and gums. One branch runs behind the alveolar process of the mandible in the substance of the gum to anastomose with a similar artery from the other side.

The **ranine** (a. profunda linguæ) is the terminal portion of the lingual artery; it pursues a tortuous course and runs along the under surface of the tongue, below the Inferior lingualis, and above the mucous membrane; it lies on the outer side of the Genio-hyo-glossus, accompanied by the lingual nerve. On arriving at the tip of the tongue, it has been said to anastomose with the artery of the opposite side; but this is denied by Hyrtl. In the mouth, these vessels are placed one on either side of the frænulum.

Applied Anatomy.—The lingual artery may be divided near its origin in cases of cut throat, a complication that not infrequently happens in wounds of this class; or severe hæmorrhage, which cannot be restrained by ordinary means, may ensue from a wound, or deep ulcer, of the tongue. In the former case, the primary wound may be enlarged if necessary, and the bleeding vessel secured. In the latter case, it has been suggested that the lingual artery should be tied near its origin. Ligature of the lingual artery has been also occasionally practised, as a palliative measure, in cases of cancer of the tongue, in order to check the progress of the disease by starving the growth, and it is sometimes tied as a preliminary measure to removal of the tongue. The operation is a difficult one on account of the depth of the artery, the number of important parts by which it is surrounded, the loose and yielding nature of the parts upon which it is supported, and its occasional irregularity of origin. An incision is to be made in a curved direction from a finger's breadth external to the symphysis of the jaw downwards to the cornu of the hyoid bone, and then upwards to near the angle of the jaw. Care must be taken not to carry this incision too far backwards, for fear of endangering the facial vein. In the first incision the skin, superficial fascia, and Platysma will be divided, and the deep fascia exposed. This is then to be incised and the submaxillary gland exposed and pulled upwards by retractors. A triangular space is now seen, bounded internally by the posterior border of the Mylo-hyoid muscle; below and externally, by the tendon of the Digastric; and above, by the hypoglossal nerve. The floor of the space is formed by the Hyo-glossus muscle, beneath which the artery lies. The parts are to be drawn forwards by a blunt hook inserted beneath the tendon of the Digastric muscle, and the fibres of the Hyo-glossus cut through horizontally just above the Digastric. The vessel will then be exposed; and in passing the aneurysm needle, care must be taken not to open the pharynx. The hypoglossal nerve must also be avoided.

Troublesome hæmorrhage may occur in the division of the frænulum linguæ in children, if the ranine arteries, which lie one on either side of it, be wounded. The operation should always be performed with a pair of blunt-pointed scissors, and only the mucous membrane divided by a very superficial cut, which cannot endanger any vessel. Any further liberation of the tongue which may be necessary can be effected by tearing.

3. The **facial** or **external maxillary artery** (a. maxillaris externa) (fig. 576) arises a little above the lingual, and passes obliquely upwards, beneath the Digastric and Stylo-hyoid muscles, and frequently beneath the hypoglossal nerve, and runs forwards under cover of the body of the mandible, lodged in a groove on the posterior surface of the submaxillary gland; this may be called the cervical part of the artery. It then curves upwards over the body of the mandible at the antero-inferior angle of the Masseter muscle; passes forwards and upwards across the cheek to the angle of the mouth, then upwards along the side of the nose, and terminates at the inner canthus of the eye, under the name of the *angular artery*. This vessel, both in the neck and on the face, is remarkably tortuous: in the former situation, to accommodate itself to the movements of the pharynx in deglutition; and in the latter, to the movements of the mandible, lips, and cheeks.

Relations.—*In the neck*, its origin is superficial, being covered by the integument, Platysma, and fascia; it then passes beneath the Digastric and Stylo-hyoid muscles, and part of the submaxillary gland. It lies upon the Middle constrictor of the pharynx, and is separated from the Stylo-glossus and Hyo-glossus by a portion of the submaxillary gland. *On the face*, where it passes over the body of the mandible, it is comparatively superficial, lying immediately beneath the Platysma. In this situation its pulsation may be distinctly felt, and compression of the vessel against the bone can be effectually made. In its course over the face, it is covered by the integument, the fat of the cheek, and, near the angle of the mouth, by the Platysma, Risorius, and Zygomatici muscles. It rests on the Buccinator, the Levator anguli oris, and the Levator labii superioris (sometimes piercing or passing under this last muscle). The facial vein lies to the outer side of the artery, and takes a more direct course across the face, where it is separated from the artery by a considerable interval. In the neck it lies superficial to the

artery. The branches of the facial nerve cross the artery, and the infra-orbital nerve lies beneath it.

The branches of the facial artery may be divided into two sets: those given off below the mandible (cervical), and those on the face (facial).

Cervical Branches.	*Facial Branches.*
Ascending palatine.	Inferior labial.
Tonsillar.	Inferior coronary.
Submaxillary.	Superior coronary.
Submental.	Lateral nasal.
Muscular.	Angular.
	Muscular.

The **ascending palatine** (a. palatina ascendens) (fig. 580) passes up between the Stylo-glossus and Stylo-pharyngeus to the outer side of the pharynx, along

Fig. 576.—The arteries of the face and scalp.*

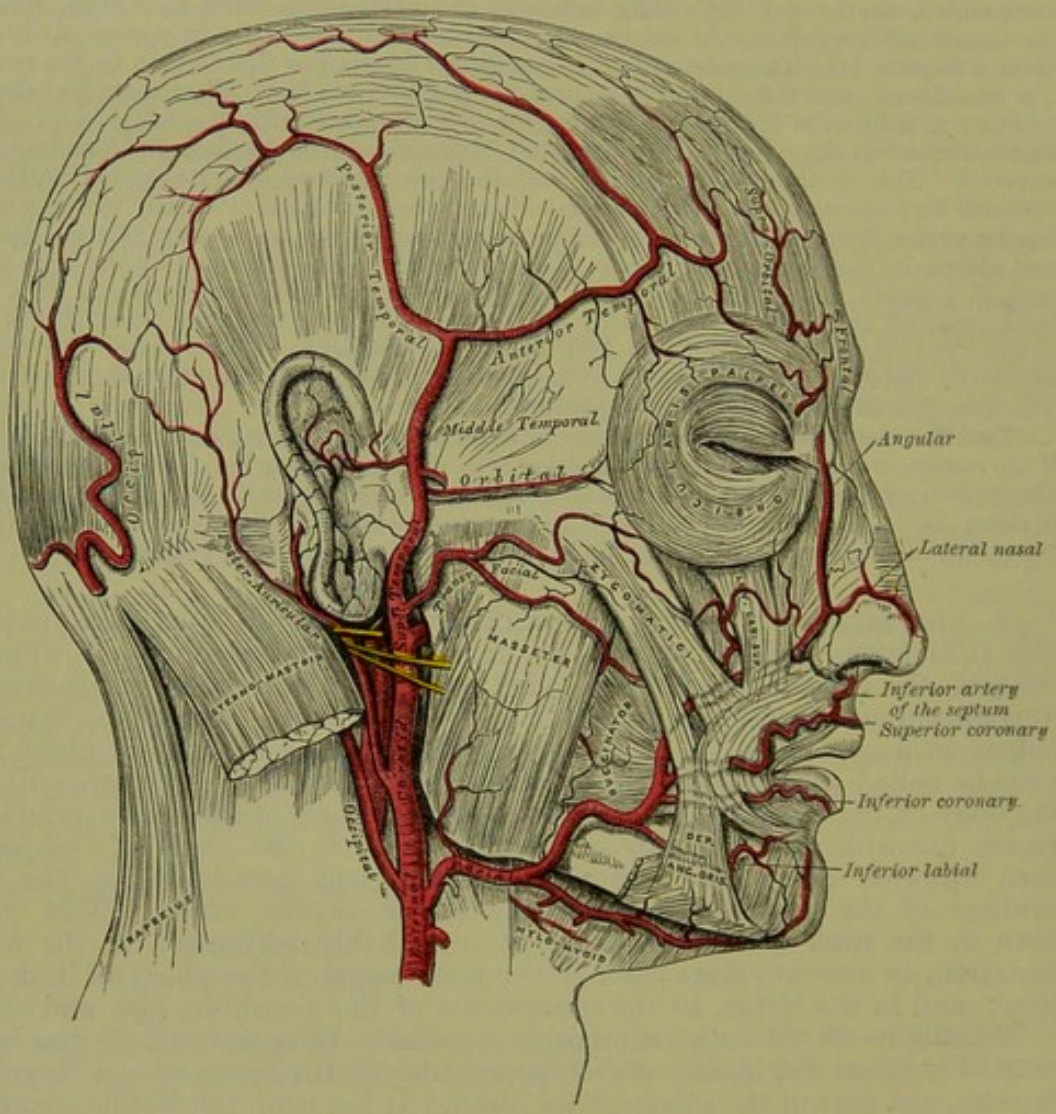

which it is continued between the Superior constrictor and the Internal pterygoid to near the base of the skull. It divides, near the Levator palati, into two branches: one follows the course of the Levator palati, and, winding over the upper border of the Superior constrictor, supplies the soft palate and the palatine glands, anastomosing with its fellow of the opposite side and with the posterior palatine branch of the internal maxillary artery; the other pierces the Superior constrictor and supplies the tonsil and Eustachian tube, anastomosing with the tonsillar and ascending pharyngeal arteries.

* The muscular tissue of the lips must be supposed to have been cut away, in order to show the course of the coronary arteries.

The **tonsillar branch** (ramus tonsillaris) (fig. 580) ascends between the Internal pterygoid and Stylo-glossus, and then along the side of the pharynx, perforating the Superior constrictor, to ramify in the substance of the tonsil and root of the tongue.

The **submaxillary** or **glandular branches** (rami glandulares) consist of three or four large vessels, which supply the submaxillary gland, some being prolonged to the neighbouring muscles, lymphatic glands, and integument.

The **submental** (a. submentalis), the largest of the cervical branches, is given off from the facial artery just as that vessel quits the submaxillary gland: it runs forwards upon the Mylo-hyoid muscle, just below the body of the mandible, and beneath the Digastric. After supplying the surrounding muscles, and anastomosing with the sublingual artery by branches which perforate the Mylo-hyoid muscle, it arrives at the symphysis menti, where it turns over the border of the mandible and divides into a superficial and a deep branch. The superficial branch passes between the integument and Depressor labii inferioris, supplies both, and anastomoses with the inferior labial artery; the deep branch runs between the muscle and the bone, supplies the lip, and anastomoses with the inferior labial and mental arteries.

The **inferior labial** passes beneath the Depressor anguli oris, to supply the muscles and integument of the lower lip, anastomosing with the inferior coronary and submental branches of the facial, and with the mental branch of the inferior dental artery.

The **inferior coronary** (a. labialis inferior) arises near the angle of the mouth; it passes upwards and inwards beneath the Depressor anguli oris, and, penetrating the Orbicularis oris muscle, runs in a tortuous course along the edge of the lower lip between this muscle and the mucous membrane, anastomosing with the artery of the opposite side. It supplies the labial glands, the mucous membrane, and the muscles of the lower lip; and anastomoses with the inferior labial, and the mental branch of the inferior dental artery.

The **superior coronary** (a. labialis superior) is larger and more tortuous than the preceding. It follows a similar course along the edge of the upper lip, lying between the mucous membrane and the Orbicularis oris, and anastomoses with the artery of the opposite side. It supplies the textures of the upper lip, and gives off in its course two or three vessels which ascend to the nose. One, named the *inferior artery of the septum*, ramifies on the nasal septum as far as the point of the nose; another, the *artery of the ala*, supplies the ala of the nose.

The **lateral nasal** is derived from the facial, as that vessel ascends along the side of the nose; it supplies the ala and dorsum of the nose, anastomosing with its fellow, and with the nasal branch of the ophthalmic, the inferior artery of the septum, the artery of the ala, and the infra-orbital.

The **angular** (a. angularis) is the termination of the trunk of the facial; it ascends to the inner angle of the orbit, imbedded in the fibres of the Levator labii superioris alæque nasi, and accompanied by a large vein, the *angular*. It distributes branches on the cheek which anastomose with the infra-orbital, and, after supplying the lachrymal sac and Orbicularis palpebrarum muscle, terminates by anastomosing with the nasal branch of the ophthalmic artery.

The **muscular branches** (rami musculares) in the neck are distributed to the Internal pterygoid and Stylo-hyoid, and on the face to the Masseter and Buccinator.

The anastomoses of the facial artery are very numerous, not only with the vessel of the opposite side, but, *in the neck*, with the sublingual branch of the lingual; with the ascending pharyngeal; with the posterior palatine branch of the internal maxillary, by its inferior or ascending palatine and tonsillar branches; *on the face*, with the mental branch of the inferior dental as it emerges from the mental foramen; with the transverse facial branch of the superficial temporal; with the infra-orbital branch of the internal maxillary; and with the nasal branch of the ophthalmic.

Peculiarities.—The facial artery not infrequently arises by a trunk common to it and the lingual. It varies in its size and in the extent to which it supplies the face. It occasionally terminates as the submental, and not infrequently extends only as high as the angle of the mouth or nose. The deficiency is then compensated for by enlargement of one of the neighbouring arteries.

Applied Anatomy.—The passage of the facial artery over the body of the mandible would appear to afford a favourable position for the application of pressure in cases of

hæmorrhage from the lips, the result either of an accidental wound or during an operation ; but its application is useless, except for a very short time, on account of the free communication of this vessel with its fellow, and with numerous branches from different sources. In a wound involving the lip, it is better to seize the part between the fingers, and evert it, when the bleeding vessel may be at once secured with pressure-forceps. In order to prevent hæmorrhage in cases of removal of growths from the part, the lip should be compressed on either side between the fingers and thumb, or by a pair of specially devised clamp-forceps, while the surgeon excises the diseased part. In order to stop hæmorrhage when the lip has been divided in an operation, it is necessary, in uniting the edges of the wound, to pass the sutures through the cut edges, almost as deep as its mucous surface ; by these means, not only are the cut surfaces more neatly and securely adapted to each other, but the possibility of hæmorrhage is prevented by including in the suture the divided artery. If, on the contrary, the suture be passed through merely the cutaneous portion of the wound, hæmorrhage occurs into the cavity of the mouth. The student should, lastly, observe the relation of the angular artery to the lachrymal sac ; as the vessel passes up along the inner margin of the orbit, it ascends on the nasal side of the sac. In operating for fistula lacrimalis, the sac should always be opened on its outer side, in order that this vessel may be avoided.

4. The **occipital artery** (a. occipitalis) (fig. 576) arises from the posterior part of the external carotid, opposite the facial, near the lower margin of the posterior belly of the Digastric, and terminates in the posterior part of the scalp.

Relations.—At its origin, it is covered by the posterior belly of the Digastric and Stylo-hyoid, and the hypoglossal nerve winds around it from behind forwards ; higher up, it crosses the internal carotid artery, the internal jugular vein, and the pneumogastric and spinal accessory nerves. It next ascends to the interval between the transverse process of the atlas and the mastoid process of the temporal bone, and passes horizontally backwards, grooving the surface of the latter bone, being covered by the Sterno-mastoid, Splenius, Trachelo-mastoid, and Digastric muscles, and resting upon the Rectus lateralis, the Superior oblique, and Complexus muscles. It then changes its course and runs vertically upwards, pierces the fascia connecting the cranial attachment of the Trapezius with the Sterno-mastoid, and ascends in a tortuous course in the superficial fascia of the scalp, where it divides into numerous branches, which reach as high as the vertex of the skull and anastomose with the posterior auricular and superficial temporal arteries. Its terminal portion is accompanied by the great occipital nerve.

The branches of the occipital artery are :

Muscular. Sterno-mastoid. Auricular.
Meningeal. Arteria princeps cervicis.

The **muscular branches** (rami musculares) supply the Digastric, Stylo-hyoid, Splenius, and Trachelo-mastoid.

The **sterno-mastoid branch** (a. sternocleidomastoidea) is large and constant, generally arising from the artery close to its commencement, but sometimes springing directly from the external carotid. It passes downwards and backwards over the hypoglossal nerve, and enters the substance of the muscle, in company with the spinal accessory nerve.

The **auricular branch** (ramus auricularis) supplies the back of the concha and frequently gives off a branch, which enters the skull through the mastoid foramen and supplies the dura mater, the diploë, and the mastoid cells. This branch sometimes arises from the occipital artery, and is then known as the *mastoid* branch.

The **meningeal branches** (rami meningei) ascend with the internal jugular vein, and enter the skull through the jugular and posterior condyloid foramina, to supply the dura mater in the posterior fossa.

The **arteria princeps cervicis** (ramus descendens) (fig. 580), the largest branch of the occipital, descends on the back of the neck, and divides into a superficial and deep portion. The superficial portion runs beneath the Splenius, giving off branches which pierce that muscle to supply the Trapezius and anastomose with the superficial cervical branch of the transversalis colli : the deep portion passes beneath the Complexus, between it and the Semispinalis colli, and anastomoses with branches from the vertebral and with the deep cervical artery, a branch of the superior intercostal. The anastomosis between these vessels assists in establishing the collateral circulation after ligature of the common carotid or subclavian artery.

The cranial branches of the occipital artery are distributed upon the occiput: they are very tortuous, and lie between the integument and Occipito-frontalis, anastomosing with the artery of the opposite side and with the posterior auricular and temporal arteries. They supply the back part of the Occipito-frontalis muscle, the integument, and pericranium.

5. The **posterior auricular artery** (a. auricularis posterior) (fig. 576) is small and arises from the external carotid, above the Digastric and Stylo-hyoid muscles, opposite the apex of the styloid process. It ascends, under cover of the parotid gland, on the styloid process of the temporal bone, to the groove between the cartilage of the ear and the mastoid process, immediately above which it divides into its auricular and mastoid branches.

Besides several small branches to the Digastric, Stylo-hyoid, and Sterno-mastoid muscles, and to the parotid gland, this vessel gives off three branches:

Stylo-mastoid. Auricular. Mastoid.

The **stylo-mastoid branch** (a. stylomastoidea) enters the stylo-mastoid foramen and supplies the tympanum, mastoid cells, and semicircular canals. In the young subject a branch from this vessel forms, with the tympanic branch from the internal maxillary, a vascular circle, which surrounds the membrana tympani, and from which delicate vessels ramify on that membrane. It anastomoses with the petrosal branch of the middle meningeal artery by a twig which enters the hiatus Fallopii.

The **auricular branch** (ramus auricularis) ascends behind the ear, beneath the Retrahens auriculam muscle, and is distributed to the back part of the cartilage of the ear, upon which it ramifies minutely, some branches curving round the margin of the fibro-cartilage, others perforating it, to supply the anterior surface. It anastomoses with the posterior branch and also with the anterior auricular branches of the superficial temporal.

The **mastoid branch** (ramus occipitalis) passes backwards, over the Sterno-mastoid muscle, to the scalp above and behind the ear. It supplies the posterior belly of the Occipito-frontalis muscle and the scalp in this situation. It anastomoses with the occipital artery.

6. The **ascending pharyngeal artery** (a. pharyngea ascendens) (fig. 580), the smallest branch of the external carotid, is a long, slender vessel, deeply seated in the neck, beneath the other branches of the external carotid and under the Stylo-pharyngeus muscle. It arises from the back part of the external carotid, near the commencement of that vessel, and ascends vertically between the internal carotid and the side of the pharynx, to the under surface of the base of the skull, lying on the Rectus capitis anticus major. It ends by dividing into branches which supply the pharynx and soft palate.

Its branches may be divided into five sets:

Pharyngeal. Prevertebral.
Palatine. Tympanic.
Meningeal.

The **pharyngeal branches** (rami pharyngei) are three or four in number. Two of these descend to supply the Middle and Inferior constrictors and the Stylo-pharyngeus, ramifying in their substance and in the mucous membrane lining them.

The **palatine branch** varies in size, and may take the place of the ascending palatine branch of the facial artery, when that vessel is small. It passes inwards upon the Superior constrictor, sends ramifications to the soft palate and tonsil, and supplies a branch to the Eustachian tube.

The **prevertebral branches** are numerous small vessels, which supply the Recti capitis antici and Longi colli, the sympathetic, hypoglossal, and pneumogastric nerves, and the lymphatic glands; they anastomose with the ascending cervical artery.

The **tympanic branch** (a. tympanica inferior) is a small artery which passes through a minute foramen in the petrous portion of the temporal bone, in company with the tympanic branch of the glosso-pharyngeal nerve, to supply the inner wall of the tympanum and anastomose with the other tympanic arteries.

The **meningeal branches** consist of several small vessels, which supply the dura mater. One, the *posterior meningeal* (a. meningea posterior), enters the cranium through the jugular foramen; a second passes through the foramen lacerum medium; and occasionally a third through the anterior condyloid foramen.

Applied Anatomy.—The ascending pharyngeal artery has been wounded from the throat; as in the case in which the stem of a tobacco-pipe was driven into the vessel, causing fatal hæmorrhage.

7. The **superficial temporal artery** (a. temporalis superficialis) (fig. 576), the smaller of the two terminal branches of the external carotid, appears, from its direction, to be the continuation of that vessel. It commences in the substance of the parotid gland, behind the neck of the mandible, and crosses over the posterior root of the zygoma. It then passes beneath the Attrahens auriculam muscle, lying on the temporal fascia, and divides, about two inches above the zygomatic arch, into two branches, an anterior and a posterior temporal.

Relations.—As it crosses the zygoma, it is covered by the Attrahens auriculam muscle, and by a dense fascia: it is crossed by the temporo-facial division of the facial nerve and one or two veins, and is accompanied by the auriculo-temporal nerve, which lies behind it.

Besides some twigs to the parotid gland, to the temporo-mandibular joint, and to the Masseter muscle, its branches are:

Transverse facial.	Anterior auricular.
Middle temporal.	Anterior temporal.
Posterior temporal.	

The **transverse facial** (a. transversa faciei) is given off from the superficial temporal before that vessel quits the parotid gland; running forwards through the substance of the gland, it passes transversely across the side of the face, between Stenson's duct and the lower border of the zygoma, and divides into numerous branches, which supply the parotid gland, the Masseter muscle, and the integument, and anastomose with the facial, masseteric, and infra-orbital arteries. This vessel rests on the Masseter, and is accompanied by one or two branches of the facial nerve. It is sometimes a branch of the external carotid.

The **middle temporal** (a. temporalis media) arises immediately above the zygomatic arch, and, perforating the temporal fascia, gives branches to the Temporal muscle, anastomosing with the deep temporal branches of the internal maxillary. It occasionally gives off an *orbital* branch, which runs along the upper border of the zygoma, between the two layers of the temporal fascia, to the outer angle of the orbit. This branch, which may arise directly from the superficial temporal artery, supplies the Orbicularis palpebrarum, and anastomoses with the lachrymal and palpebral branches of the ophthalmic artery.

The **anterior auricular branches** (rami auriculares anteriores) are distributed to the anterior portion of the pinna, the lobule, and part of the external meatus, anastomosing with branches of the posterior auricular.

The **anterior temporal** (ramus frontalis) runs tortuously upwards and forwards to the forehead, supplying the muscles, integument, and pericranium in this region, and anastomoses with the supra-orbital and frontal arteries.

The **posterior temporal** (ramus parietalis), larger than the anterior, curves upwards and backwards along the side of the head, lying superficial to the temporal fascia, and anastomoses with its fellow of the opposite side, and with the posterior auricular and occipital arteries.

Applied Anatomy.—The temporal artery, as it crosses the zygoma, lies immediately beneath the skin, and its pulsations may be readily felt during the administration of an anæsthetic, or under circumstances where the radial pulse is not available; or it may be easily compressed against the bone in order to check bleeding from the temporal region of the scalp. When a flap is raised from this part of the head, as in the operation of trephining, the incision should be shaped like a horse-shoe, with its convexity upwards, so that the flap shall contain the temporal artery, which ensures a sufficient supply of blood. The same principle is applied, as far as possible, in making incisions to raise flaps in other parts of the scalp. Formerly the operation of arteriotomy was performed upon this vessel in cases of inflammation of the eye or brain, but this operation is now obsolete.

8. The **internal maxillary artery** (a. maxillaris interna) (fig. 577), the larger of the two terminal branches of the external carotid, arises behind the neck of the mandible, and is at first imbedded in the substance of the parotid gland; it passes inwards between the ramus of the mandible and the internal lateral ligament, and then upon the outer surface of the External pterygoid muscle to the spheno-maxillary fossa to supply the deep structures of the face. For convenience of description, it is divided into maxillary, pterygoid, and spheno-maxillary portions.

The *first* or *maxillary portion* passes horizontally forwards and inwards, between the ramus of the mandible and the internal lateral ligament, where

Fig. 577.—The internal maxillary artery, and its branches.

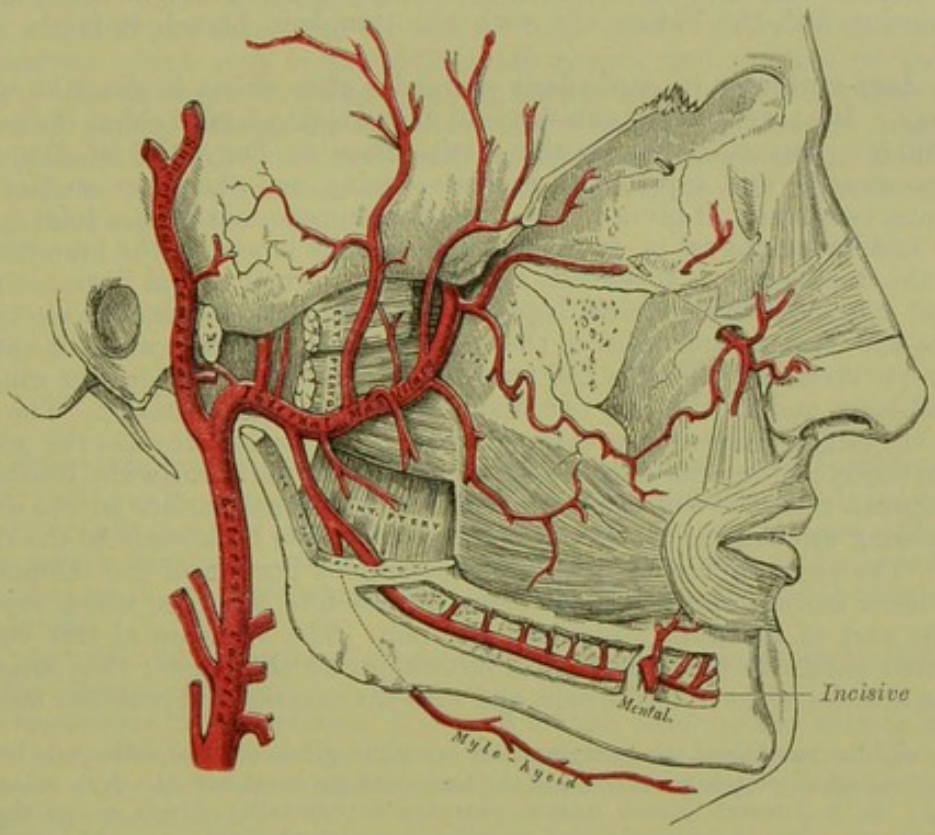

Fig. 578.—Plan of the branches.

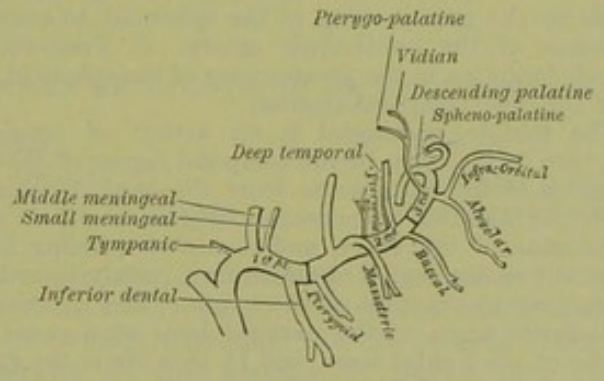

it lies parallel to and a little below the auriculo-temporal nerve; it crosses the inferior dental nerve, and runs along the lower border of the External pterygoid.

The *second* or *pterygoid portion* runs obliquely forwards and upwards under cover of the ramus of the mandible, on the outer (very frequently on the inner) surface of the External pterygoid; it then passes between the two heads of origin of this muscle and enters the spheno-maxillary fossa.

The *third* or *spheno-maxillary portion* lies in the spheno-maxillary fossa in relation with Meckel's ganglion.

The branches of this vessel may be divided into three groups (fig. 578), corresponding with its three divisions.

Branches of the First or Maxillary Portion

Tympanic (anterior).	Middle meningeal.
Deep auricular.	Small meningeal.
Inferior dental.	

The **tympanic** (a. tympanica anterior) passes upwards behind the temporo-mandibular articulation, enters the tympanum through the Glaserian fissure, and ramifies upon the membrana tympani, forming a vascular circle around the membrane with the stylo-mastoid branch of the posterior auricular, and anastomosing with the Vidian and with the tympanic branch from the internal carotid.

The **deep auricular** (a. auricularis profunda) often arises in common with the preceding. It ascends in the substance of the parotid gland, behind the temporo-mandibular articulation, pierces the cartilaginous or bony wall of the external auditory meatus, and supplies its cuticular lining and the outer surface of the membrana tympani. It gives a branch to the temporo-mandibular joint.

The **middle meningeal** (a. meningea media) is the largest of the branches which supply the dura mater. It ascends between the internal lateral ligament and the External pterygoid muscle, and between the two roots of the auriculo-temporal nerve to the foramen spinosum of the sphenoid bone, through which it enters the cranium ; it then runs upwards and forwards in a groove on the greater wing of the sphenoid bone, and divides into two branches, anterior and posterior. The *anterior branch*, the larger, crosses the greater wing of the sphenoid, reaches the groove, or canal, in the antero-inferior angle of the parietal bone, and then divides into branches which spread out between the dura mater and internal surface of the cranium, some passing upwards as far as the vertex, and others backwards to the occipital region. The *posterior branch* crosses the squamous portion of the temporal, and on the inner surface of the parietal bone divides into branches which supply the posterior part of the dura mater and cranium. The branches of this vessel are distributed partly to the dura mater, but chiefly to the bones ; they anastomose with the arteries of the opposite side, and with the anterior and posterior meningeal.

The middle meningeal on entering the cranium gives off the following branches: 1. Numerous small vessels which supply the Gasserian ganglion and the dura mater in this situation. 2. A *petrosal* branch (ramus petrosus superficialis), which enters the hiatus Fallopii, supplies the facial nerve, and anastomoses with the stylo-mastoid branch of the posterior auricular artery. 3. A minute *tympanic* branch (a. tympanica superior), which runs in the canal for the Tensor tympani muscle, and supplies this muscle and the lining membrane of the canal. 4. *Orbital* branches, which pass through the sphenoidal fissure or through separate canals in the greater wing of the sphenoid, to anastomose with the lachrymal or other branches of the ophthalmic artery. 5. *Temporal* or *anastomotic* branches, which pass through foramina in the greater wing of the sphenoid, and anastomose in the temporal fossa with the deep temporal arteries.

Applied Anatomy.—The middle meningeal is an artery of considerable surgical importance, as it may be torn in fractures of the temporal region of the skull, or, indeed, by injuries causing separation of the dura mater from the bone, without fracture. The injury may be followed by considerable hæmorrhage between the bone and dura mater, which may produce compression of the brain, and require trephining for its relief. As the compression implicates the motor region of the cortex, paralysis on the opposite side of the body forms the prominent symptom of the lesion. The anterior branch of this artery crosses the antero-inferior angle of the parietal bone at a point 1½ inch behind the external angular process of the frontal bone, and 1¾ inch above the zygoma (fig. 753). From this point it passes upwards and slightly backwards to the sagittal suture, lying about ½ inch to ¾ inch behind the coronal suture. The posterior branch runs backwards over the squamous portion of the temporal bone. In order to expose the anterior branch of the artery, a point is taken 1½ inch above the zygoma and the same distance behind the external angular process of the frontal bone. Here the pin of the trephine is to be applied. A horseshoe-shaped flap, measuring three inches in length and transversely, and consisting of all the structures of the scalp down to the pericranium, is now to be made, with its base just above the zygoma. This flap is reflected, the pericranium is turned back, and an inch trephine applied. After the crown of bone has been removed, the blood-clot is exposed, and gently got rid of, and if possible the bleeding point must be found and controlled.

The **small meningeal** (ramus meningeus accessorius) is sometimes derived from the preceding. It enters the skull through the foramen ovale, and supplies the Gasserian ganglion and dura mater.

The **inferior dental** (a. alveolaris inferior) descends with the inferior dental nerve to the foramen on the inner side of the ramus of the mandible. It runs along the dental canal in the substance of the bone, accompanied by the nerve, and opposite the first bicuspid tooth divides into two branches, incisor and mental. The incisor branch is continued forwards beneath the incisor teeth as far as the symphysis menti, where it anastomoses with the artery of the opposite side; the *mental* branch (a. mentalis) escapes with the nerve at the mental foramen, supplies the chin, and anastomoses with the submental, inferior labial, and inferior coronary arteries. Near its origin the inferior dental artery gives off a *lingual* branch, which descends with the lingual nerve and supplies the mucous membrane of the mouth. As the inferior dental artery enters the foramen, it gives off a *mylo-hyoid* branch (ramus mylohyoideus) which runs in the mylo-hyoid groove, and ramifies on the under surface of the Mylo-hyoid. The inferior dental artery and its incisor branch during their course through the substance of the bone give off a few twigs which are lost in the cancellous tissue, and a series of branches which correspond in number to the roots of the teeth: these enter the minute apertures at the extremities of the fangs, and supply the pulp of the teeth.

Branches of the Second or Pterygoid Portion

Deep temporal.	Masseteric.
Pterygoid.	Buccal.

The **deep temporal branches**, two in number, anterior (a. temporalis profunda anterior) and posterior (a. temporalis profunda posterior), ascend between the Temporal muscle and the pericranium; they supply the muscle, and anastomose with the middle temporal artery; the anterior communicates with the lachrymal by means of small branches which perforate the malar bone and greater wing of the sphenoid.

The **pterygoid branches** (rami pterygoidei), irregular in their number and origin, supply the Pterygoid muscles.

The **masseteric** (a. masseterica) is a small branch which passes outwards, above the sigmoid notch of the mandible, to the deep surface of the Masseter. It supplies the muscle, and anastomoses with the masseteric branches of the facial and with the transverse facial artery.

The **buccal** (a. buccinatoria) is a small branch which runs obliquely forwards, between the Internal pterygoid and the ramus of the jaw, to the outer surface of the Buccinator, to which it is distributed, anastomosing with branches of the facial artery.

Branches of the Third or Spheno-maxillary Portion

Alveolar.	Vidian.
Infra-orbital.	Pterygo-palatine.
Descending palatine.	Naso- or Spheno-palatine.

The **alveolar** or **posterior dental** (a. alveolaris superior posterior) is given off from the internal maxillary, frequently in conjunction with the infra-orbital just as the trunk of the vessel is passing into the spheno-maxillary fossa. Descending upon the tuberosity of the maxilla, it divides into numerous branches, some of which enter the posterior dental canals, to supply the molar and bicuspid teeth and the lining of the antrum, while others are continued forwards on the alveolar process to supply the gums.

The **infra-orbital** (a. infraorbitalis) appears, from its direction, to be the continuation of the trunk of the internal maxillary, but often arises from that vessel in conjunction with the preceding branch. It runs along the infra-orbital canal with the superior maxillary nerve, and emerges on the face through the infra-orbital foramen, beneath the Levator labii superioris. While in the canal, it gives off (*a*) branches which ascend into the orbit, and assist in supplying the

Inferior rectus and Inferior oblique muscles and the lachrymal gland, and (*b*) *anterior dental* branches (aa. alveol. superiores anteriores) which descend through the anterior dental canals in the bone to supply the mucous membrane of the antrum and the front teeth of the maxilla. On the face, some branches pass upwards to the inner angle of the orbit and the lachrymal sac, anastomosing with the angular branch of the facial artery; others run inwards towards the nose, anastomosing with the nasal branch of the ophthalmic; and others descend beneath the Levator labii superioris and anastomose with the transverse facial and buccal arteries.

The four remaining branches arise from that portion of the internal maxillary which is contained in the spheno-maxillary fossa.

The **descending palatine** (a. palatina descendens) descends through the posterior palatine canal with the anterior palatine branch of Meckel's ganglion, and, emerging from the posterior palatine foramen, runs forwards in a groove on the inner side of the alveolar border of the hard palate to the anterior palatine canal. The terminal branch of the artery passes upwards through the foramen of Stenson to anastomose with the naso-palatine artery. Branches are distributed to the gums, the mucous membrane of the hard palate, and the palatine glands. In the palatine canal it gives off branches which descend in the accessory palatine canals to supply the soft palate and tonsil, anastomosing with the ascending palatine artery.

Applied Anatomy.—The position of the descending palatine artery on the hard palate should be borne in mind in performing an operation for the closure of a cleft in the hard palate, as it is in danger of being wounded, and may give rise to formidable hæmorrhage; it has even been found necessary to plug the posterior palatine canal in order to arrest the bleeding.

The **Vidian** (a. canalis pterygoidei) passes backwards along the Vidian canal with the Vidian nerve. It is distributed to the upper part of the pharynx and to the Eustachian tube, sending into the tympanum a small branch which anastomoses with the other tympanic arteries.

The **pterygo-palatine**, a very small branch, runs backwards through the pterygo-palatine canal with the pharyngeal nerve, and is distributed to the upper part of the pharynx and to the Eustachian tube.

The **spheno-palatine** (a. sphenopalatina) passes through the spheno-palatine foramen into the cavity of the nose, at the back part of the superior meatus, and divides into several branches. One, the *naso-palatine*, courses obliquely downwards and forwards along the septum nasi, supplies the mucous membrane, and anastomoses in front with the terminal branch of the descending palatine; the other branches, two or three in number, are distributed to the lateral wall of the nose, the antrum, and the ethmoidal and sphenoidal cells.

The Triangles of the Neck (fig. 579)

The student having considered the relative anatomy of the large arteries of the neck and their branches, and the relations they bear to the veins and nerves, should now examine these structures collectively, as they present themselves in certain regions of the neck, in each of which important operations are constantly being performed.

The side of the neck presents a somewhat quadrilateral outline, limited, above, by the lower border of the body of the mandible, and an imaginary line extending from the angle of the mandible to the mastoid process; below, by the prominent upper border of the clavicle; in front, by the middle line of the neck; behind, by the anterior margin of the Trapezius muscle. This space is subdivided into two large triangles by the Sterno-mastoid muscle, which passes obliquely across the neck, from the sternum and clavicle below, to the mastoid process and occipital bone above. The triangular space in front of this muscle is called the *anterior triangle*; and that behind it, the *posterior triangle*.

Anterior Triangle of the Neck

The **anterior triangle** is bounded, in front, by a line extending from the symphysis menti to the sternum; behind, by the anterior margin of the

Sterno-mastoid; its base, directed upwards, is formed by the lower border of the body of the mandible, and a line extending from the angle of the mandible to the mastoid process; its apex is below, at the sternum. This space is subdivided into four smaller triangles by the Digastric muscle above, and the anterior belly of the Omo-hyoid below. These smaller triangles are named the inferior carotid, the superior carotid, the submaxillary, and the supra-hyoid triangles.

The **inferior carotid,** or **muscular triangle,** is bounded, in front, by the median line of the neck from the hyoid bone to the sternum; behind, by the anterior margin of the Sterno-mastoid; above, by the anterior belly of the Omo-hyoid. It is covered by the integument, superficial fascia, Platysma, and deep fascia; ramifying in which are some of the descending branches of the superficial cervical plexus. Beneath these superficial structures are the Sterno-hyoid and Sterno-thyroid muscles, which, together with the anterior margin of the Sterno-mastoid, conceal the lower part of the common carotid artery.* This vessel is enclosed within its sheath, together with the internal jugular vein and pneumogastric nerve; the vein lies on the outer side of the artery on the right side of the neck, but overlaps it below

FIG. 579.—The triangles of the neck.

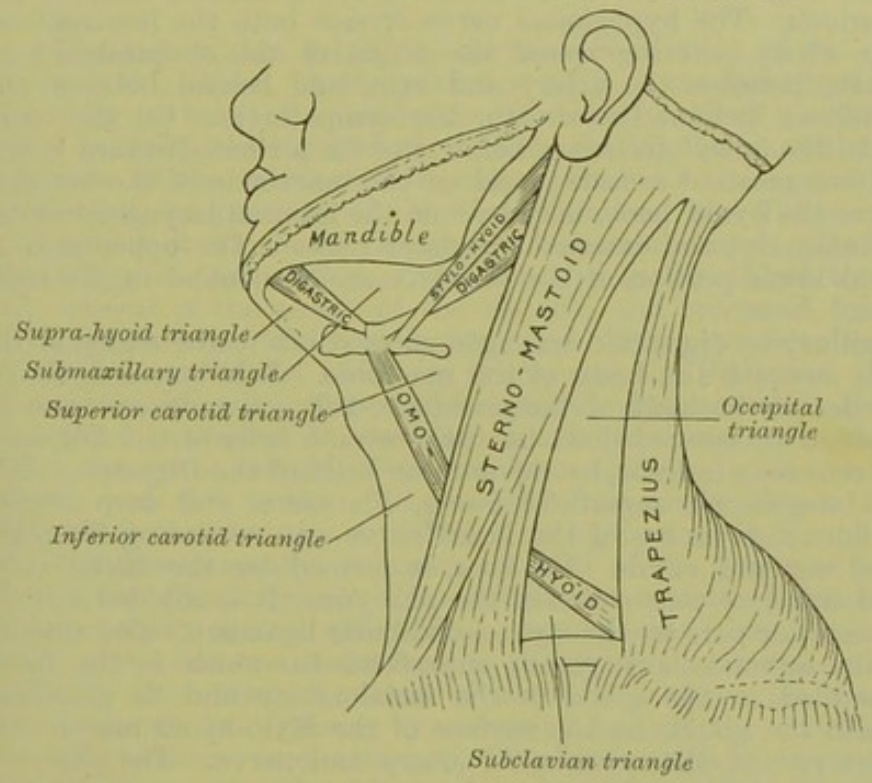

on the left side; the nerve lies between the artery and vein, on a plane posterior to both. In front of the sheath are a few filaments descending from the loop of communication between the descendens and communicantes hypoglossi; behind the sheath are the inferior thyroid artery, the recurrent laryngeal nerve, and the sympathetic cord; and on its inner side, the œsophagus, the trachea, the thyroid gland—much more prominent in the female than in the male—and the lower part of the larynx. By cutting into the upper part of this space, and slightly displacing the Sterno-mastoid muscle, the common carotid artery may be tied below the Omo-hyoid muscle.

The **superior carotid,** or **carotid triangle,** is bounded, behind, by the Sterno-mastoid; below, by the anterior belly of the Omo-hyoid; and above,

* Therefore the common carotid artery and internal jugular vein are not, strictly speaking, contained in this triangle, since they are covered by the Sterno-mastoid muscle; that is to say, they lie under that muscle, which forms the posterior border of the triangle. But as they lie very close to the structures which are really contained in the triangle, and whose position it is essential to remember in operating on this part of the artery, it is expedient to study the relations of all these parts together.

by the Stylo-hyoid muscle and the posterior belly of the Digastric. It is covered by the integument, superficial fascia, Platysma, and deep fascia; ramifying in which are branches of the facial and superficial cervical nerves. Its floor is formed by parts of the Thyro-hyoid, Hyo-glossus, and the Inferior and Middle constrictor muscles of the pharynx. This space when dissected is seen to contain the upper part of the common carotid artery, which bifurcates opposite the upper border of the thyroid cartilage into the external and internal carotid. These vessels are somewhat concealed from view by the anterior margin of the Sterno-mastoid muscle, which overlaps them. The external and internal carotids lie side by side, the external being the more anterior of the two. The following branches of the external carotid are also met with in this space: the superior thyroid, running forwards and downwards; the lingual, directly forwards; the facial, forwards and upwards; the occipital, backwards; and the ascending pharyngeal, directly upwards on the inner side of the internal carotid. The veins met with are: the internal jugular, which lies on the outer side of the common and internal carotid arteries; and veins corresponding to the above-mentioned branches of the external carotid—viz. the superior thyroid, the lingual, facial, ascending pharyngeal, and sometimes the occipital—all of which accompany their corresponding arteries, and terminate in the internal jugular. The nerves in this space are the following. In front of the sheath of the common carotid is the descendens hypoglossi. The hypoglossal nerve crosses both the internal and external carotids above, curving round the origin of the occipital artery. Within the sheath, between the artery and vein, and behind both, is the pneumogastric nerve; behind the sheath, the sympathetic. On the outer side of the vessels, the spinal accessory nerve runs for a short distance before it pierces the Sterno-mastoid muscle; and on the inner side of the external carotid, just below the hyoid bone, may be seen the internal laryngeal nerve; and, still more inferiorly, the external laryngeal nerve. The upper portion of the larynx and lower portion of the pharynx are also found in the front part of this space.

The **submaxillary** or **digastric triangle** corresponds to the region of the neck immediately beneath the body of the mandible. It is bounded, above, by the lower border of the body of the mandible, and a line drawn from its angle to the mastoid process; below, by the posterior belly of the Digastric and Stylo-hyoid muscles; in front, by the anterior belly of the Digastric. It is covered by the integument, superficial fascia, Platysma, and deep fascia; ramifying in which are branches of the facial nerve and ascending filaments of the superficial cervical nerve. Its floor is formed by the Mylo-hyoid, Hyo-glossus, and Superior constrictor of the pharynx. It is divided into an anterior and a posterior part by the stylo-mandibular ligament. The anterior part contains the submaxillary gland, superficial to which is the facial vein, while imbedded in the gland is the facial artery and its glandular branches; beneath the gland, on the surface of the Mylo-hyoid muscle, are the submental artery and the mylo-hyoid artery and nerve. The posterior part of this triangle contains the external carotid artery, ascending deeply in the substance of the parotid gland; this vessel lies here in front of, and superficial to, the internal carotid, being crossed by the facial nerve, and gives off in its course the posterior auricular, temporal, and internal maxillary branches: more deeply are the internal carotid, the internal jugular vein, and the pneumogastric nerve, separated from the external carotid by the Stylo-glossus and Stylo-pharyngeus muscles, and the glosso-pharyngeal nerve.*

The **supra-hyoid triangle** is limited behind by the anterior belly of the Digastric, in front by the middle line of the neck between the symphysis menti and the hyoid bone, below by the body of the hyoid bone; its floor is formed by the Mylo-hyoid. It contains one or two lymphatic glands and some small veins; the latter unite to form the anterior jugular vein.

* The remark made about the carotid triangle applies also to this one. The structures enumerated as contained in its posterior part lie, strictly speaking, beneath the muscles which form the posterior boundary of the triangle; but as it is very important to bear in mind their close relation to the parotid gland, all these parts are spoken of together.

Posterior Triangle of the Neck

The **posterior triangle** is bounded, in front, by the Sterno-mastoid muscle; behind by the anterior margin of the Trapezius; its base corresponds to the middle third of the clavicle; its apex, to the occiput. The space is crossed, about an inch above the clavicle, by the posterior belly of the Omo-hyoid, which divides it into two triangles, an upper or occipital, and a lower or subclavian.

The **occipital triangle**, the larger division of the posterior triangle, is bounded, in front, by the Sterno-mastoid; behind, by the Trapezius; below, by the Omo-hyoid. Its floor is formed from above downwards by the Splenius capitis, Levator anguli scapulæ, and the Middle and Posterior scaleni. It is covered by the integument, the superficial and deep fasciæ, and by the Platysma below. The spinal accessory nerve is directed obliquely across the space from the Sterno-mastoid, which it pierces, to the under surface of the Trapezius; below, the descending branches of the cervical plexus and the transversalis colli vessels and the upper part of the brachial plexus cross the space. A chain of lymphatic glands is also found running along the posterior border of the Sterno-mastoid, from the mastoid process to the root of the neck. These glands are frequently enlarged and often require removal; when this is the case particular care must be taken not to divide the spinal accessory nerve.

The **subclavian triangle**, the smaller division of the posterior triangle, is bounded, above, by the posterior belly of the Omo-hyoid; below, by the clavicle; its base is formed by the posterior border of the Sterno-mastoid. Its floor is formed by the first rib with the first digitation of the Serratus magnus. The size of the subclavian triangle varies with the extent of attachment of the clavicular portions of the Sterno-mastoid and Trapezius, and also with the height at which the Omo-hyoid crosses the neck. Its height also varies according to the position of the arm, being diminished by raising the limb, on account of the ascent of the clavicle, and increased by drawing the arm downwards, when that bone is depressed. This space is covered by the integument, the superficial and deep fasciæ and the Platysma, and crossed by the descending branches of the cervical plexus. Just above the level of the clavicle, the third portion of the subclavian artery curves outwards and downwards from the outer margin of the Scalenus anticus, across the first rib, to the axilla, and this is the situation most commonly chosen for ligaturing the vessel. Sometimes this vessel rises as high as an inch and a half above the clavicle; occasionally, it passes in front of the Scalenus anticus, or pierces the fibres of that muscle. The subclavian vein lies behind the clavicle, and is not usually seen in this space; but in some cases it rises as high as the artery, and has even been seen to pass with that vessel behind the Scalenus anticus. The brachial plexus of nerves lies above the artery, and in close contact with it. Passing transversely behind the clavicle are the suprascapular vessels; and traversing its upper angle in the same direction, the transversalis colli artery and vein. The external jugular vein runs vertically downwards behind the posterior border of the Sterno-mastoid, to terminate in the subclavian vein; it receives the transversalis colli and suprascapular veins, which form a plexus in front of the artery, and occasionally a small vein which crosses the clavicle from the cephalic. The small nerve to the Subclavius muscle also crosses this triangle about its middle, and some lymphatic glands are usually found in the space.

Internal Carotid Artery

The **internal carotid artery** (a. carotis interna) (fig. 580) supplies the anterior part of the brain, the eye and its appendages, and sends branches to the forehead and nose. Its size, in the adult, is equal to that of the external carotid, though, in the child, it is larger than that vessel. It is remarkable for the number of curvatures that it presents in different parts of its course. It occasionally has one or two flexures near the base of the skull, while in its passage through the carotid canal and along the side of the body of the sphenoid bone it describes a double curvature and resembles the italic letter *S*.

Relations.—In considering the course and relations of this vessel it may be divided into four portions : cervical, petrous, cavernous, and cerebral.

Cervical Portion.—This portion of the internal carotid commences at the bifurcation of the common carotid, opposite the upper border of the thyroid cartilage, and runs perpendicularly upwards, in front of the transverse processes of the upper three cervical vertebræ, to the carotid canal in the petrous portion

Fig. 580.—The internal carotid and vertebral arteries. Right side.

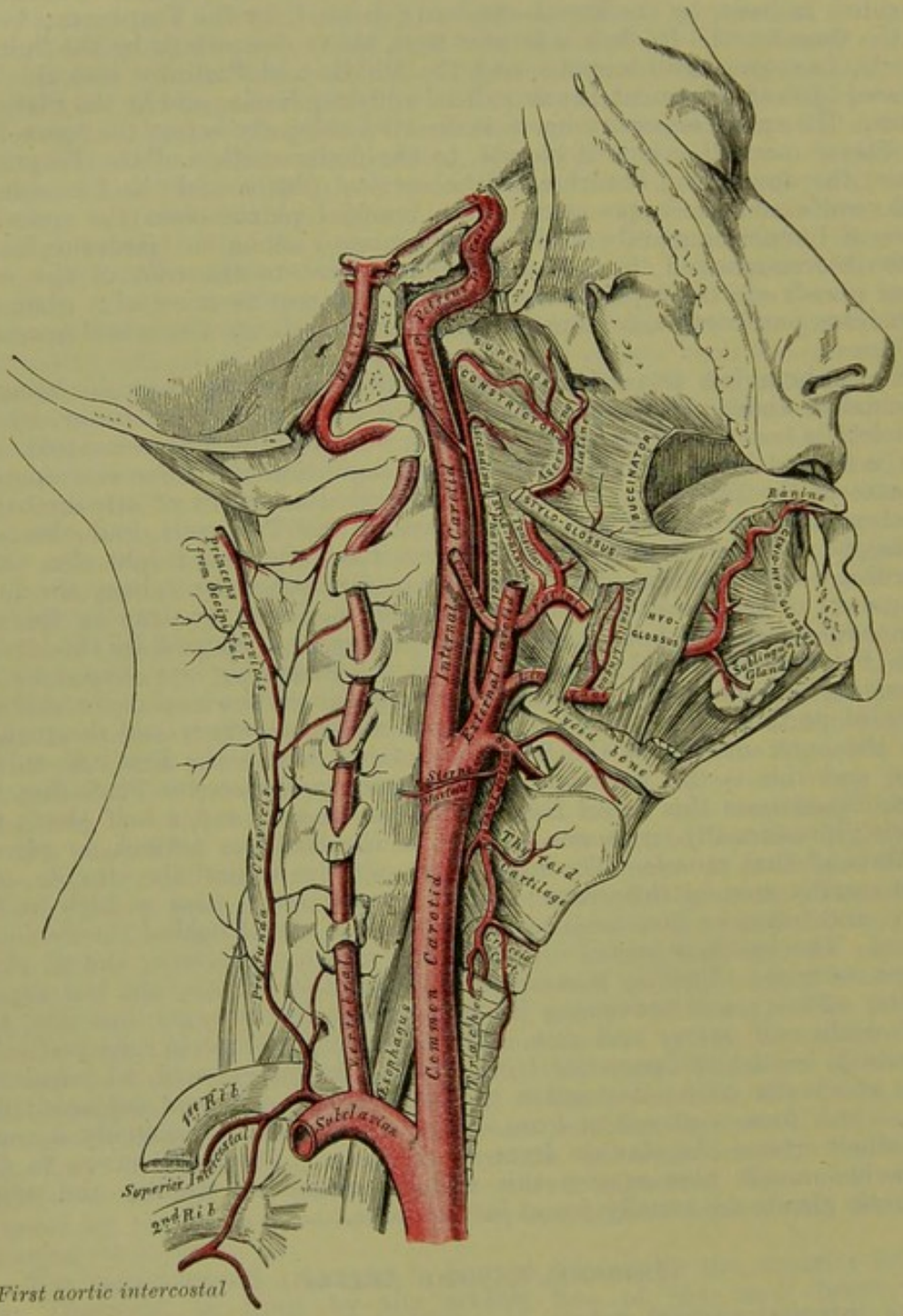

of the temporal bone. It is comparatively superficial at its commencement, where it is contained in the carotid triangle, and lies behind and to the outer side of the external carotid, overlapped by the Sterno-mastoid, and covered by the deep fascia, Platysma, and integument : it then passes beneath the parotid gland, being crossed by the hypoglossal nerve, the Digastric and Stylo-hyoid muscles, and the occipital and posterior auricular arteries. Higher up, it is separated from the external carotid by the Stylo-glossus and Stylo-pharyngeus muscles,

the tip of the styloid process and the stylo-hyoid ligament, the glosso-pharyngeal nerve and the pharyngeal branch of the pneumogastric. It is in relation, *behind*, with the Rectus capitis anticus major, the superior cervical ganglion of the sympathetic, and the superior laryngeal nerve; *externally*, with the internal jugular vein and pneumogastric nerve, the nerve lying on a plane posterior to the artery; *internally*, with the pharynx, tonsil, the superior laryngeal nerve, and ascending pharyngeal artery. At the base of the skull the glosso-pharyngeal, vagus, spinal accessory, and hypoglossal nerves lie between the artery and the internal jugular vein.

Petrous Portion.—When the internal carotid artery enters the canal in the petrous portion of the temporal bone, it first ascends a short distance, then curves forwards and inwards, and again ascends as it leaves the canal to enter the cavity of the skull between the lingula and petrosal process of the sphenoid. The artery lies at first in front of the cochlea and tympanic cavity; from the latter cavity it is separated by a thin, bony lamella, which is cribriform in the young subject, and often partly absorbed in old age. Farther forwards it is separated from the Gasserian ganglion by a thin plate of bone, which forms the floor of the fossa for the ganglion and the roof of the horizontal portion of the canal. Frequently this bony plate is more or less deficient, and then the ganglion is separated from the artery by fibrous membrane. The artery is separated from the bony wall of the carotid canal by a prolongation of dura mater, and is surrounded by a number of small veins and by filaments of the carotid plexus, derived from the ascending branch of the superior cervical ganglion of the sympathetic.

Cavernous Portion.—The internal carotid artery, in this part of its course, is situated between the layers of the dura mater forming the cavernous sinus, but covered by the lining membrane of the sinus. It at first ascends towards the posterior clinoid process, then passes forwards by the side of the body of the sphenoid bone, and again curves upwards on the inner side of the anterior clinoid process, and perforates the dura mater forming the roof of the sinus. In this part of its course it is surrounded by filaments of the sympathetic nerve, and on its outer side is the sixth nerve.

Cerebral Portion.—Having perforated the dura mater on the inner side of the anterior clinoid process, the internal carotid passes between the second and third cranial nerves to the anterior perforated space at the inner extremity of the fissure of Sylvius, where it gives off its terminal or cerebral branches. This portion of the artery has the optic nerve on its inner side, and the third nerve on its outer.

Peculiarities.—The length of the internal carotid varies according to the length of the neck, and also according to the point of bifurcation of the common carotid. It arises sometimes from the arch of the aorta; in such rare instances, this vessel has been found to be placed nearer the middle line of the neck than the external carotid, as far upwards as the larynx, when the latter vessel crossed the internal carotid. The course of the artery, instead of being straight, may be very tortuous. A few instances are recorded in which this vessel was altogether absent; in one of these the common carotid passed up the neck, and gave off the usual branches of the external carotid; the cranial portion of the internal carotid was replaced by two branches of the internal maxillary, which entered the skull through the foramen rotundum and foramen ovale, and joined to form a single vessel.

Applied Anatomy.—The cervical part of the internal carotid is very rarely wounded. It is, however, sometimes injured by a stab or gunshot wound in the neck, or even occasionally by a stab from within the mouth, as when a person receives a thrust from the end of a parasol, or falls down with a tobacco-pipe in his mouth. Although the internal carotid lies about three-quarters of an inch behind and external to the tonsil, instances have occurred in which the artery has been wounded during the operation of scarifying the tonsil, and fatal hæmorrhage has supervened. The incision for ligature of the cervical portion of the internal carotid should be made along the anterior border of the Sterno-mastoid, from the angle of the jaw to the upper border of the thyroid cartilage. The superficial structures being divided, and the Sterno-mastoid defined and drawn outwards, the cellular tissue must be carefully separated and the posterior belly of the Digastric and hypoglossal nerve sought for as guides to the vessel. When the artery is found, the external carotid should be drawn inwards and the Digastric muscle upwards, and the aneurysm needle passed from without inwards.

Obstruction of the internal carotid by embolism or thrombosis may give rise to symptoms of cerebral anæmia and softening if the collateral circulation is ill-developed. The patient suffers from giddiness, with failure of the mental powers, and convulsions, coma, or hemiplegia on the opposite side of the body, may be observed.

Branches.—The cervical portion of the internal carotid gives off no branches. Those from the other portions are :

From the Petrous portion	Tympanic (internal or deep). Vidian.
From the Cavernous portion	Arteriæ receptaculi. Pituitary. Gasserian. Anterior meningeal. Ophthalmic.
From the Cerebral portion	Anterior cerebral. Middle cerebral. Posterior communicating. Anterior choroidal.

1. The **tympanic** (ramus caroticotympanicus) is a small branch which enters the cavity of the tympanum, through a minute foramen in the carotid canal, and

Fig. 581.—The ophthalmic artery and its branches.

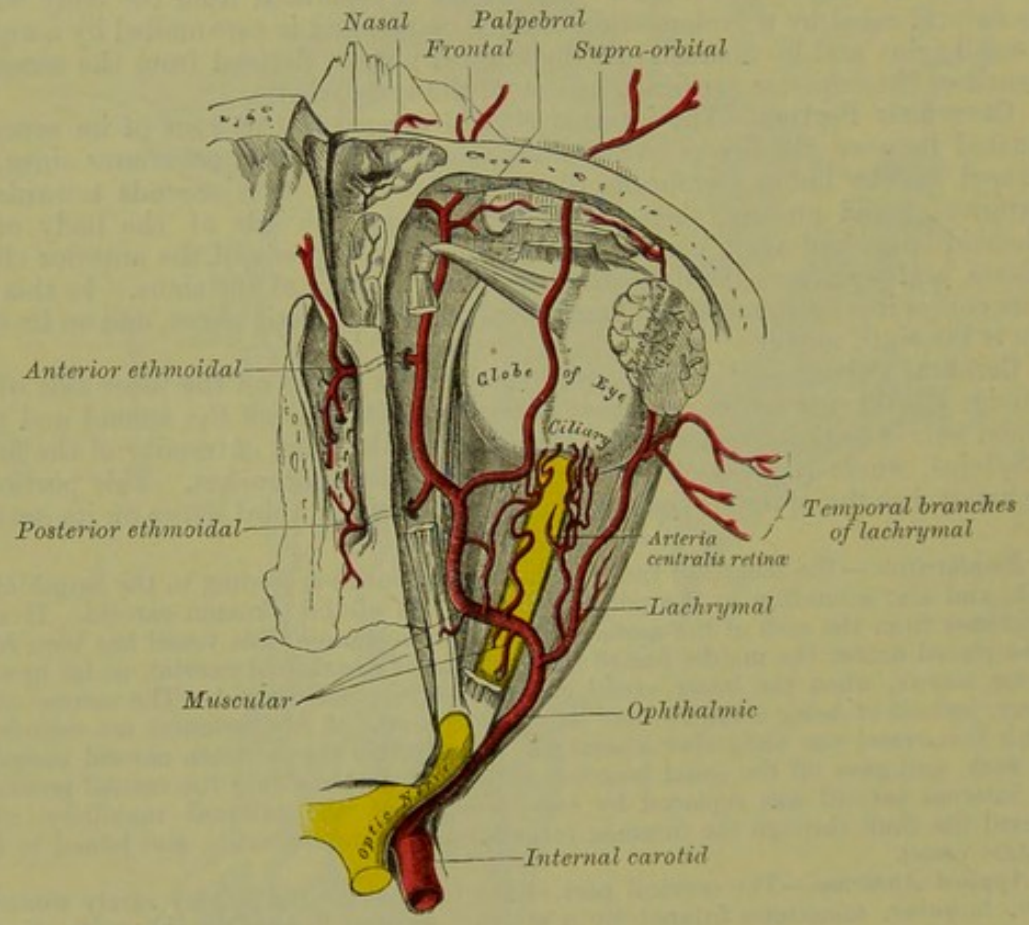

anastomoses with the tympanic branch of the internal maxillary, and with the stylo-mastoid artery.

2. The **Vidian** is a small, inconstant branch which passes through the Vidian canal and anastomoses with the Vidian branch of the internal maxillary artery.

3. The **arteriæ receptaculi** are numerous small vessels which supply the pituitary body, the Gasserian ganglion, and the walls of the cavernous and inferior petrosal sinuses. Some of them anastomose with branches of the middle meningeal.

4. The **pituitary** branches are one or two minute vessels supplying the pituitary body.

5. The **Gasserian** branches are small vessels to the Gasserian ganglion.

6. The **anterior meningeal** is a small branch which passes over the lesser wing of the sphenoid to supply the dura mater of the anterior cranial fossa ; it anastomoses with the meningeal branch from the posterior ethmoidal artery.

7. The **ophthalmic artery** (a. ophthalmica) (fig. 581) arises from the internal carotid, just as that vessel is emerging from the cavernous sinus, on the inner side of the anterior clinoid process, and enters the orbital cavity through the optic foramen, below and on the outer side of the optic nerve. It then passes over the nerve to the inner wall of the orbit, and thence horizontally forwards, beneath the lower border of the Superior oblique muscle, to a point behind the internal angular process of the frontal bone, where it divides into two terminal branches, the *frontal* and *nasal*. As the artery crosses the optic nerve it is accompanied by the nasal nerve, and is separated from the frontal nerve by the Rectus superior and Levator palpebræ superioris muscles.

The branches of the ophthalmic artery may be divided into an *orbital group*, distributed to the orbit and surrounding parts ; and an *ocular group*, to the muscles and globe of the eye.

Orbital Group.	*Ocular Group.*
Lachrymal.	Central artery of the retina.
Supra-orbital.	Short ciliary.
Posterior ethmoidal.	Long ciliary.
Anterior ethmoidal.	Anterior ciliary.
Internal palpebral.	Muscular.
Frontal.	
Nasal.	

The *lachrymal* (a. lacrimalis) arises close to the optic foramen, and is one of the largest branches derived from the ophthalmic : not infrequently it is given off before the artery enters the orbit. It accompanies the lachrymal nerve along the upper border of the External rectus muscle, and is distributed to the lachrymal gland. Its terminal branches, escaping from the gland, are distributed to the eyelids and conjunctiva : of those supplying the eyelids, two are of considerable size and are named the *external palpebral* (aa. palpebrales laterales) ; they run inwards in the upper and lower lids respectively and anastomose with the internal palpebral arteries, forming an arterial circle in this situation. The lachrymal artery gives off one or two *malar branches*, one of which passes through a foramen in the malar bone, to reach the temporal fossa, and anastomoses with the deep temporal arteries ; another appears on the cheek through the malar foramen, and anastomoses with the transverse facial. A recurrent branch passes backwards through the sphenoidal fissure to the dura mater, and anastomoses with a branch of the middle meningeal artery. The lachrymal artery is sometimes derived from one of the anterior branches of the middle meningeal artery.

The *supra-orbital* (a. supraorbitalis) springs from the ophthalmic as that vessel is crossing over the optic nerve. Ascending so as to rise above all the muscles of the orbit, it runs forwards, with the supra-orbital nerve, between the periosteum and Levator palpebræ ; and, passing through the supra-orbital foramen, divides into a superficial and a deep branch, which supply the integument, the muscles, and the pericranium of the forehead, anastomosing with the frontal, the anterior branch of the temporal, and the artery of the opposite side. This artery in the orbit supplies the Superior rectus and the Levator palpebræ, and sends a branch inwards, across the pulley of the Superior oblique muscle, to supply the parts at the inner canthus. At the supra-orbital foramen it frequently transmits a branch to the diploë.

The *ethmoidal branches* are two in number : posterior and anterior. The posterior (a. ethmoidalis posterior), which is the smaller, passes through the posterior ethmoidal canal, supplies the posterior ethmoidal cells, and, entering the cranium, gives off a meningeal branch to the adjacent dura mater, and nasal branches which descend into the nose through apertures in the cribriform plate, anastomosing with branches of the spheno-palatine. The anterior ethmoidal artery (a. ethmoidalis anterior) accompanies the nasal nerve through the anterior ethmoidal canal, supplies the anterior and middle ethmoidal cells and frontal sinuses, and, entering the cranium, gives off a meningeal branch to the adjacent dura mater, and nasal branches. These latter descend into the nose through the slit by the side of the crista galli, and, running along the groove on the under surface of the nasal bone, supply the skin of the nose.

The *palpebral arteries* (aa. palpebrales mediales), two in number, superior and inferior, arise from the ophthalmic, opposite the pulley of the Superior oblique muscle ; they leave the orbit to encircle the eyelids near their free margins, forming a superior and an inferior arch, which lie between the Orbicularis muscle and tarsal plates. The superior palpebral anastomoses, at the outer angle of the orbit, with the orbital branch of the temporal artery, and with the upper of the two external palpebral branches from the lachrymal artery ; the inferior palpebral anastomoses, at the outer angle of the orbit, with the lower of the two external palpebral branches from the lachrymal and with the transverse facial artery, and, at the inner side of the lid, with a branch from the angular artery.

From this last anastomosis a branch passes to the nasal duct, ramifying in its mucous membrane, as far as the inferior meatus.

The *frontal artery* (a. frontalis), one of the terminal branches of the ophthalmic, leaves the orbit at its inner angle with the supra-trochlear nerve, and, ascending on the forehead, supplies the integument, muscles, and pericranium, anastomosing with the supra-orbital artery, and with the artery of the opposite side.

The *nasal artery* (a. dorsalis nasi), the other terminal branch of the ophthalmic, emerges from the orbit above the tendo oculi, and, after giving a branch to the upper part of the lachrymal sac, divides into two branches, one of which crosses the root of the nose, and anastomoses with the angular artery; the other runs along the dorsum of the nose, supplies its outer surface, and anastomoses with the artery of the opposite side, and with the lateral nasal branch of the facial.

The *central artery of the retina* (a. centralis retinæ) is the first and one of the smallest branches of the ophthalmic artery. It runs for a short distance within the dural sheath of the nerve, but about half an inch behind the eyeball it pierces the optic nerve obliquely, and runs forward in the centre of its substance, and enters the globe of the eye through the porus opticus. Its mode of distribution will be described in the account of the anatomy of the eye.

The *ciliary arteries* are divisible into three groups, the long and short posterior, and the anterior. The *short posterior ciliary arteries* (aa. ciliares posteriores breves), from six to twelve in number, arise from the ophthalmic, or some of its branches; they pass forwards around the optic nerve to the posterior part of the eyeball, pierce the sclera around the entrance of the nerve, and supply the choroid coat and ciliary processes. The *long posterior ciliary arteries* (aa. ciliares posteriores longæ), two in number, pierce the posterior part of the sclera at some little distance from the optic nerve, and run forwards, along each side of the eyeball, between the sclera and choroid, to the ciliary muscle, where they divide into two branches; these form an arterial circle, the *circulus iridis major*, around the circumference of the iris, from which numerous converging branches run inwards, in the substance of the iris, to its free margin, where they form a second arterial circle, the *circulus iridis minor*. The *anterior ciliary arteries* (aa. ciliares anteriores) are derived from the muscular branches; they run to the front of the eyeball in company with the tendons of the Recti, form a vascular zone beneath the conjunctiva, and then pierce the sclera a short distance from the cornea and terminate in the circulus major iridis.

The *muscular branches* (rami musculares), two in number, superior and inferior, frequently spring from a common trunk. The superior, the smaller, often wanting, supplies the Levator palpebræ, Superior rectus, and Superior oblique. The inferior, more constantly present, passes forwards between the optic nerve and Inferior rectus, and is distributed to the External, Internal, and Inferior recti, and the Inferior oblique. This vessel gives off most of the anterior ciliary arteries. Additional muscular branches are given off from the lachrymal and supra-orbital branches, or from the trunk of the ophthalmic.

8. The **anterior cerebral artery** (a. cerebri anterior) (fig. 582) arises from the internal carotid, at the inner extremity of the fissure of Sylvius. It passes forwards and inwards across the anterior perforated space, above the optic nerve, to the commencement of the great longitudinal fissure. Here it comes into close relationship with the artery of the opposite side, and the two vessels are connected by a short trunk, the *anterior communicating artery* (a. communicans anterior). From this point, the two vessels run side by side in the longitudinal fissure, curve round the genu, and turning backwards continue along the upper surface of the corpus callosum to its posterior part, where they terminate by anastomosing with the posterior cerebral arteries.

In its course the anterior cerebral artery gives off the following branches:

Antero-median ganglionic. Anterior internal frontal.
Inferior internal frontal. Middle internal frontal.
Posterior internal frontal.

The *antero-median ganglionic* branches are a group of small arteries which arise at the commencement of the anterior cerebral artery; they pierce the anterior perforated space and lamina terminalis, and supply the rostrum of the corpus callosum, the septum pellucidum, and the head of the caudate nucleus. The *inferior internal frontal branches*, two or three in number, are distributed to the orbital surface of the frontal lobe, where they supply the olfactory lobe, gyrus rectus, and internal orbital convolution. The *anterior internal frontal branches* supply a part of the marginal convolution, and send branches over the edge of the hemisphere to the superior and middle frontal convolutions and upper part of the ascending frontal convolution. The *middle internal frontal branches* supply the corpus callosum,

the callosal convolution, the inner surface of the superior frontal convolution, and the upper part of the ascending frontal convolution. The *posterior internal frontal branches* supply the lobus quadratus and adjacent outer surface of the hemisphere.

FIG. 582.—The arteries of the base of the brain. The right half of the cerebellum and pons have been removed.

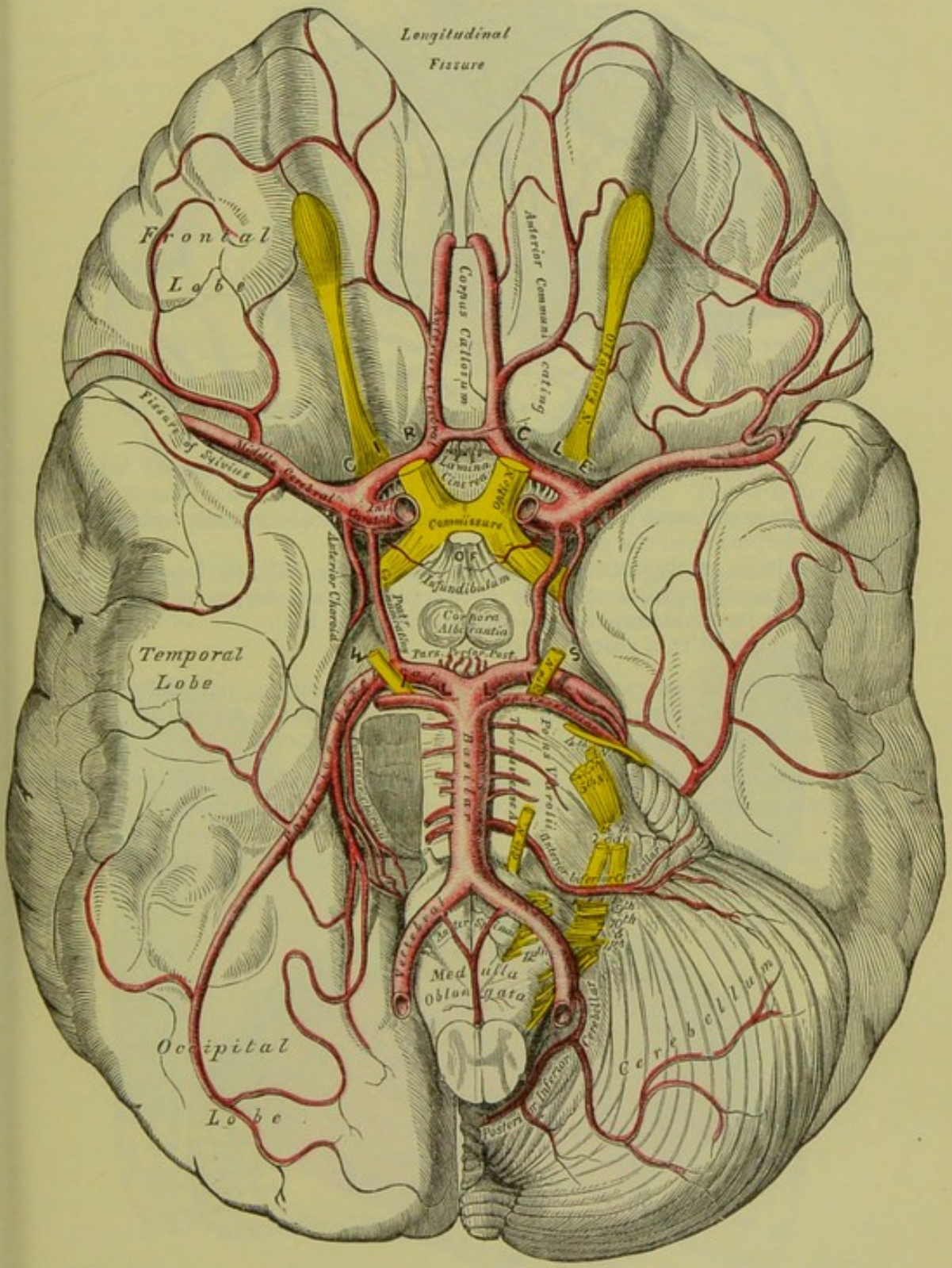

N.B.—It will be noticed that in the illustration the two anterior cerebral arteries have been drawn at a considerable distance from each other; this makes the anterior communicating artery appear longer than it really is.

The *anterior communicating artery* is a short branch, about 4 mm. in length, but of moderate size, connecting together the two anterior cerebral arteries across

the longitudinal fissure. Sometimes this vessel is wanting, the two arteries joining together to form a single trunk, which afterwards divides; or the vessel may be wholly, or partially, divided into two; frequently it is longer and smaller than

Fig. 583.—The distribution of the middle cerebral artery. (After Charcot.)

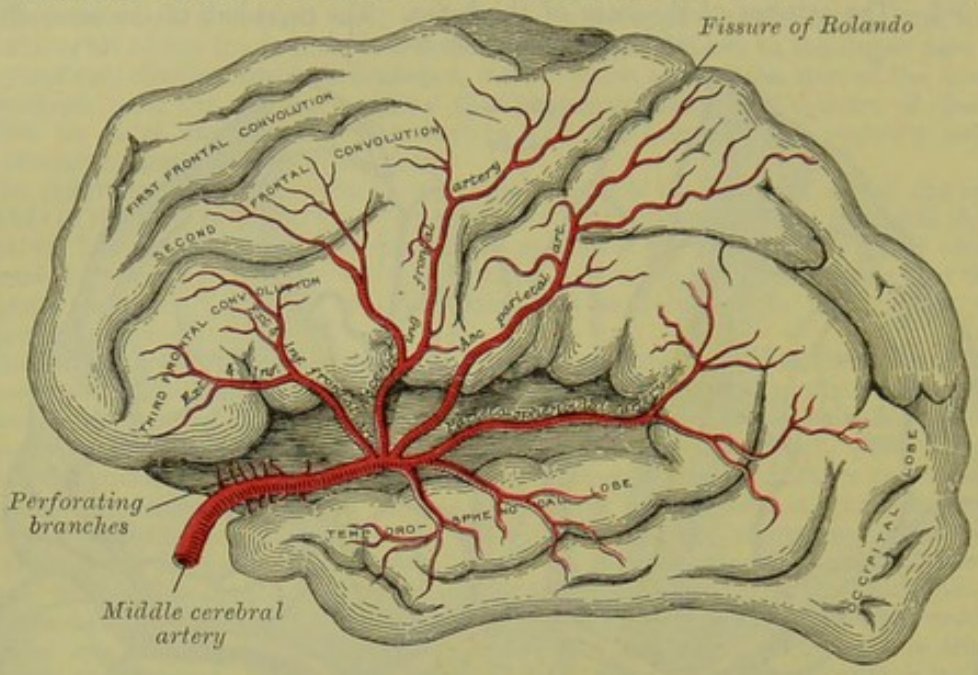

usual. It gives off some of the antero-median ganglionic vessels, but these are principally derived from the anterior cerebral.

9. The **middle cerebral artery** (a. cerebri media) (fig. 583), the largest branch of the internal carotid, passes obliquely outwards along the fissure of Sylvius, and divides into its terminal branches opposite the island of Reil.

The branches of this vessel are the:

Antero-lateral ganglionic.	Ascending parietal.
Inferior external frontal.	Parieto-temporal.
Ascending frontal.	Temporal.

The *antero-lateral ganglionic branches*, a group of small arteries which arise at the commencement of the middle cerebral artery, are arranged in two sets:

Fig. 584.—Outer surface of cerebral hemisphere, showing areas supplied by cerebral arteries.

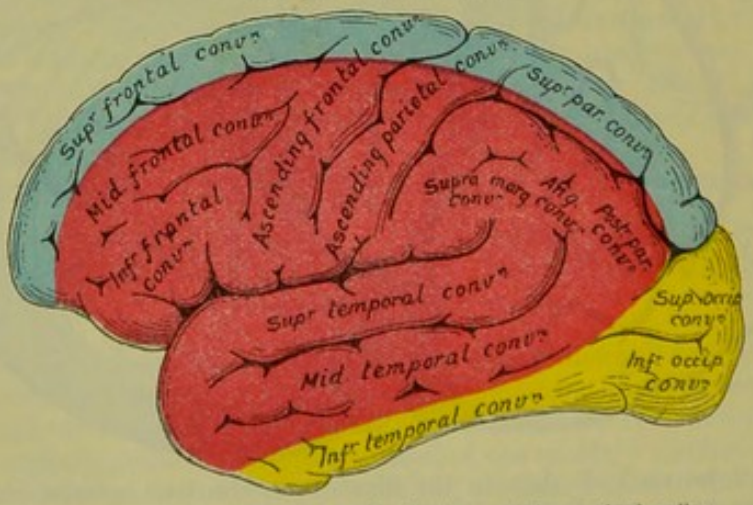

Anterior cerebral, blue; middle cerebral, red; posterior cerebral, yellow.

one, the *internal striate*, passes upwards through the inner segments of the lenticular nucleus, and supplies it, the caudate nucleus and the internal capsule; the other, the *external striate*, ascends through the outer segment of the lenticular nucleus,

and supplies the caudate nucleus and the thalamus. One artery of this group is of larger size than the rest, and is of special importance, as being the artery in the brain most frequently ruptured; it has been termed by Charcot, the '*artery*

Fig. 585.—Mesial surface of cerebral hemisphere, showing areas supplied by cerebral arteries.

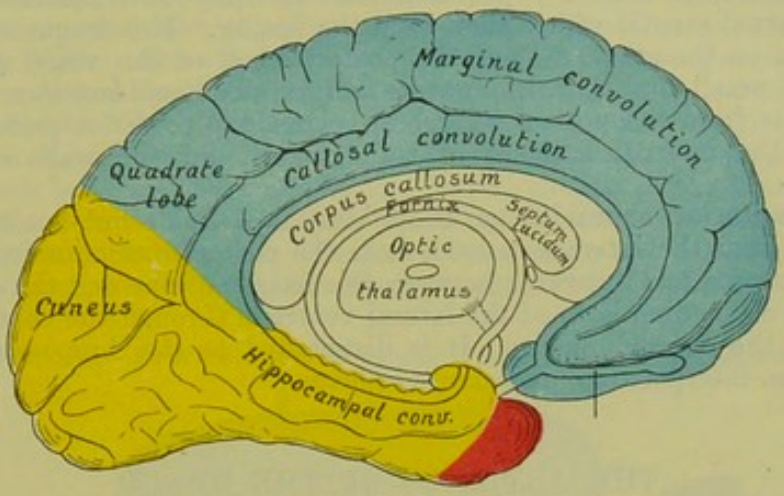

Anterior cerebral, blue; middle cerebral, red; posterior cerebral, yellow.

of cerebral hæmorrhage.' It passes up between the lenticular nucleus and the external capsule, and ultimately ends in the caudate nucleus. The *inferior external frontal* supplies the third or inferior frontal convolution (Broca's convolution) and

Fig. 586.—Upper surface of cerebral hemisphere, showing areas supplied by cerebral arteries.

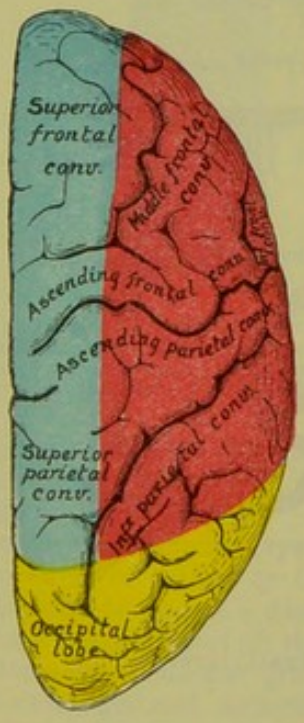

Anterior cerebral, blue; middle cerebral, red; posterior cerebral, yellow.

Fig. 587.—Under surface of cerebral hemisphere, showing areas supplied by cerebral arteries.

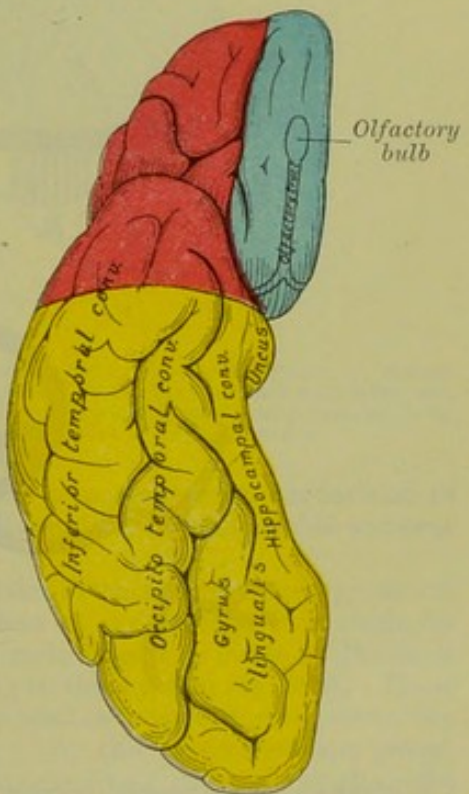

Anterior cerebral, blue; middle cerebral, red; posterior cerebral, yellow.

the outer part of the orbital surface of the frontal lobe. The *ascending frontal* supplies the ascending frontal convolution. The *ascending parietal* is distributed to the ascending parietal and the lower part of the superior parietal convolutions.

The *parieto-temporal* supplies the supra-marginal and angular gyri, and the posterior parts of the superior and middle temporal convolutions. The *temporal branches*, two or three in number, are distributed to the outer surface of the temporal lobe.

10. The **posterior communicating artery** (a. communicans posterior) runs backwards from the internal carotid, and anastomoses with the posterior cerebral, a branch of the basilar. This artery varies in size, being sometimes small, and occasionally so large that the posterior cerebral may be considered as arising from the internal carotid rather than from the basilar. It is frequently larger on one side than on the other. From the posterior half of this vessel are given off a number of small branches, the *postero-median ganglionic branches*, which, with similar vessels from the posterior cerebral, pierce the posterior perforated space and supply the internal surfaces of the thalami and the walls of the third ventricle.

11. The **anterior choroidal** (a. chorioidea) is a small but constant branch, which arises from the internal carotid, near the posterior communicating artery. Passing backwards and outwards between the temporal lobe and the crus cerebri, it enters the descending horn of the lateral ventricle through the choroidal fissure and ends in the choroid plexus. It is distributed to the hippocampus major, fimbria, velum interpositum, and choroid plexus.

THE ARTERIES OF THE BRAIN

Investigations show that the mode of distribution of the vessels of the brain has an important bearing upon a considerable number of the pathological lesions which may occur in this part of the nervous system; it is therefore important

FIG. 588.—Diagram of the arterial circulation at the base of the brain. (After Charcot.)

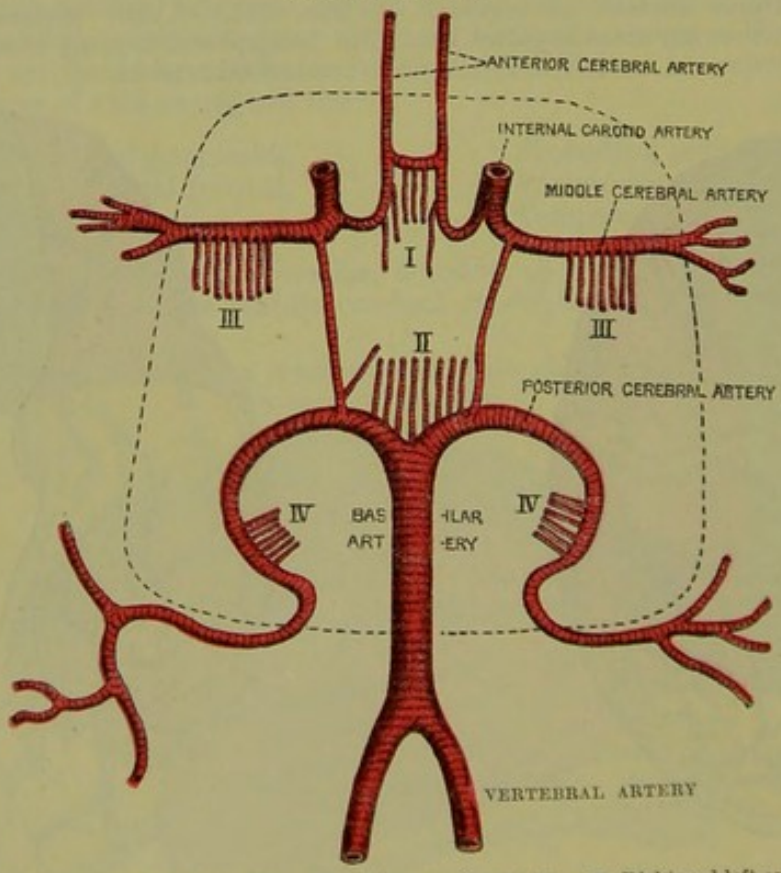

I. Antero-median group of ganglionic branches. II. Postero-median group. III. Right and left antero-lateral group. IV. Right and left postero-lateral group. The dotted line shows the limit of the ganglionic circle.

to consider a little more in detail the manner in which the cerebral vessels are distributed.

The cerebral arteries are derived from the internal carotid and vertebral, which at the base of the brain form a remarkable anastomosis known as the *circle*

of Willis (circulus arteriosus). It is formed in front by the anterior cerebral arteries, branches of the internal carotid, which are connected together by the anterior communicating; behind by the two posterior cerebral arteries, branches of the basilar, which are connected on either side with the internal carotid by the posterior communicating (figs. 582, 588). The parts of the brain included within this arterial circle are the lamina terminalis, the optic commissure, the infundibulum, the tuber cinereum, the corpora albicantia, and the posterior perforated space.

The three trunks which together supply each cerebral hemisphere arise from the circle of Willis. From its anterior part proceed the two anterior cerebrals; from its antero-lateral parts the middle cerebrals, and from its posterior part the posterior cerebrals. Each of these principal arteries gives origin to two different systems of secondary vessels. One of these is named the *central ganglionic system*, and the vessels belonging to it supply the central ganglia of the brain; the other is the *cortical system*, and its vessels ramify in the pia mater and supply the cortex and subjacent brain substance. These two systems do not communicate at any point of their peripheral distribution, but are entirely independent of each other,

Fig. 589.—Distribution of the cortical arteries. (After Charcot.)

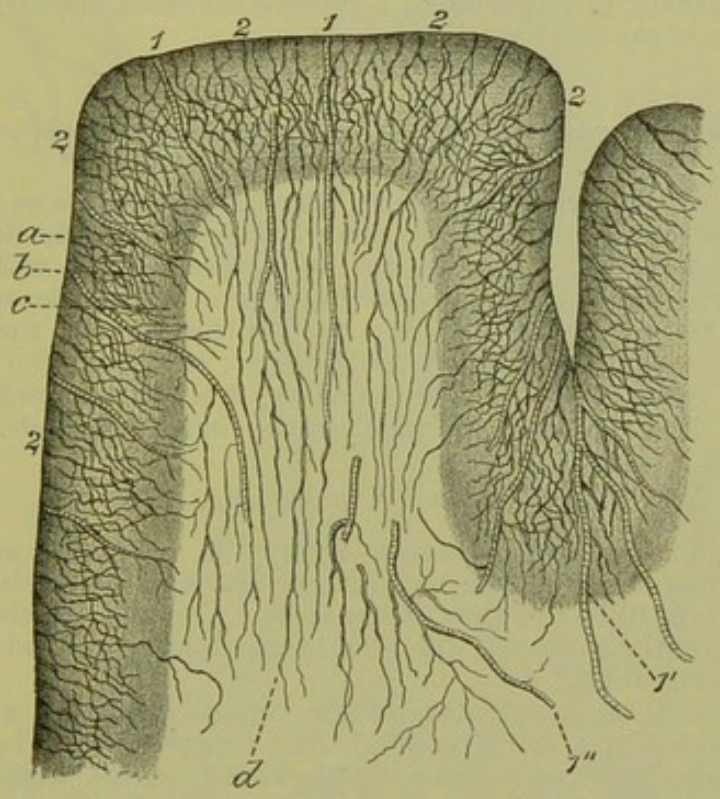

1. Medullary arteries. 1'. Group of medullary arteries in the sulcus between two adjacent convolutions. 1''. Arteries situated among the short association fibres. 2, 2. Cortical arteries. *a*. Capillary network with fairly wide meshes, situated beneath the pia mater. *b*. Network with more compact, polygonal meshes, situated in the cortex. *c*. Transitional network with wider meshes. *d*. Capillary network in the white matter.

and there is between the parts supplied by the two systems a borderland of diminished nutritive activity, where, it is said, softening is especially liable to occur in the brains of old people.

The central ganglionic system.—All the vessels of this system are given off from the circle of Willis, or from the vessels close to it; so that if a circle be drawn parallel to and at a distance of about an inch from the circle of Willis, it will include the origins of all the arteries belonging to this system (fig. 588). These vessels form six principal groups: (I) the *antero-median group*, derived from the anterior cerebrals and anterior communicating; (II) the *postero-median group*, from the posterior cerebrals and posterior communicating; (III and IV) the right and left *antero-lateral groups*, from the middle cerebrals; and (V and VI) the right and left *postero-lateral groups*, from the posterior cerebrals, after they have wound round the crura cerebri. The vessels of this system are larger than those of the cortical system, and are what Cohnheim has designated 'terminal' arteries—that is to say, vessels which from their origin to their termination neither supply nor receive any anastomotic branch, so that, through any one of the vessels only a

limited area of the central ganglia can be injected, and the injection cannot be driven beyond the area of the part supplied by the particular vessel which is the subject of the experiment.

The cortical arterial system.—The vessels forming this system are the terminal branches of the anterior, middle, and posterior cerebral arteries. These vessels divide and ramify in the substance of the pia mater, and give off nutrient arteries which penetrate the brain cortex perpendicularly. The nutrient vessels are divisible into two classes, long and short. The *long*, or *medullary arteries*, pass through the grey matter and penetrate the subjacent white matter to the depth of about an inch and a half, without intercommunicating otherwise than by very fine capillaries, and thus constitute so many independent small systems. The *short vessels* are confined to the cortex, where they form with the long vessels a compact network in the middle zone of the grey matter, the outer and inner zones being sparingly supplied with blood (fig. 589). The vessels of the cortical arterial system are not so strictly 'terminal' as those of the central ganglionic system, but they approach this type very closely, so that injection of one area from the vessel of another area, though possible, is frequently very difficult, and is only effected through vessels of small calibre. As a result of this, obstruction of one of the main branches, or its divisions, may have the effect of producing softening in a limited area of the cortex.

ARTERIES OF THE UPPER EXTREMITY

The artery which supplies the upper extremity continues as a single trunk from its commencement down to the elbow; but different portions of it have received different names, according to the regions through which they pass. That part of the vessel which extends from its origin to the outer border of the first rib is termed the *subclavian*; beyond this point to the lower border of the axilla, the artery is termed the *axillary*; and from the lower margin of the axillary space to the bend of the elbow, it is termed *brachial*; here, the trunk ends by dividing into two branches, the *radial* and *ulnar*.

Subclavian Arteries (fig. 590)

On the right side the **subclavian artery** (a. subclavia) arises from the innominate artery opposite the right sterno-clavicular articulation; on the left side it springs from the arch of the aorta. The two vessels, therefore, in the first part of their course, differ in length, direction, and relation with neighbouring structures.

In order to facilitate the description, more especially from a surgical point of view, each subclavian artery is divided into three parts. The first portion, on the right side, passes upwards and outwards from the origin of the vessel to the inner border of the Scalenus anticus. On the left side it ascends nearly vertically, to gain the inner border of that muscle. The second part passes outwards, behind the Scalenus anticus; and the third part extends from the outer margin of that muscle, beneath the clavicle, to the outer border of the first rib, where it becomes the axillary artery. The first portions of the two vessels differ so much in their course and relations with neighbouring parts, that they will be described separately. The second and third parts are practically alike on the two sides.

First Part of the Right Subclavian Artery (figs. 572, 590)

The **first part of the right subclavian artery** arises from the arteria innominata, opposite the upper part of the right sterno-clavicular articulation, and passes upwards and outwards to the inner margin of the Scalenus anticus muscle. It ascends a little above the clavicle, the extent to which it does so varying in different cases.

Relations.—It is covered, *in front*, by the integument, superficial fascia, Platysma, deep fascia, the clavicular origin of the Sterno-mastoid, the Sterno-hyoid, and Sterno-thyroid muscles, and another layer of the deep fascia. It is crossed by the internal jugular and vertebral veins, and by the pneumogastric

nerve and the cardiac branches of the pneumogastric and sympathetic. A loop of the sympathetic trunk also crosses the artery, forming a ring (*annulus Vieussenii*) around the vessel. The anterior jugular vein passes outwards in front of the artery, but is separated from it by the Sterno-hyoid and Sterno-thyroid muscles.

FIG. 590.—Superficial dissection of the right side of the neck, showing the carotid and subclavian arteries.

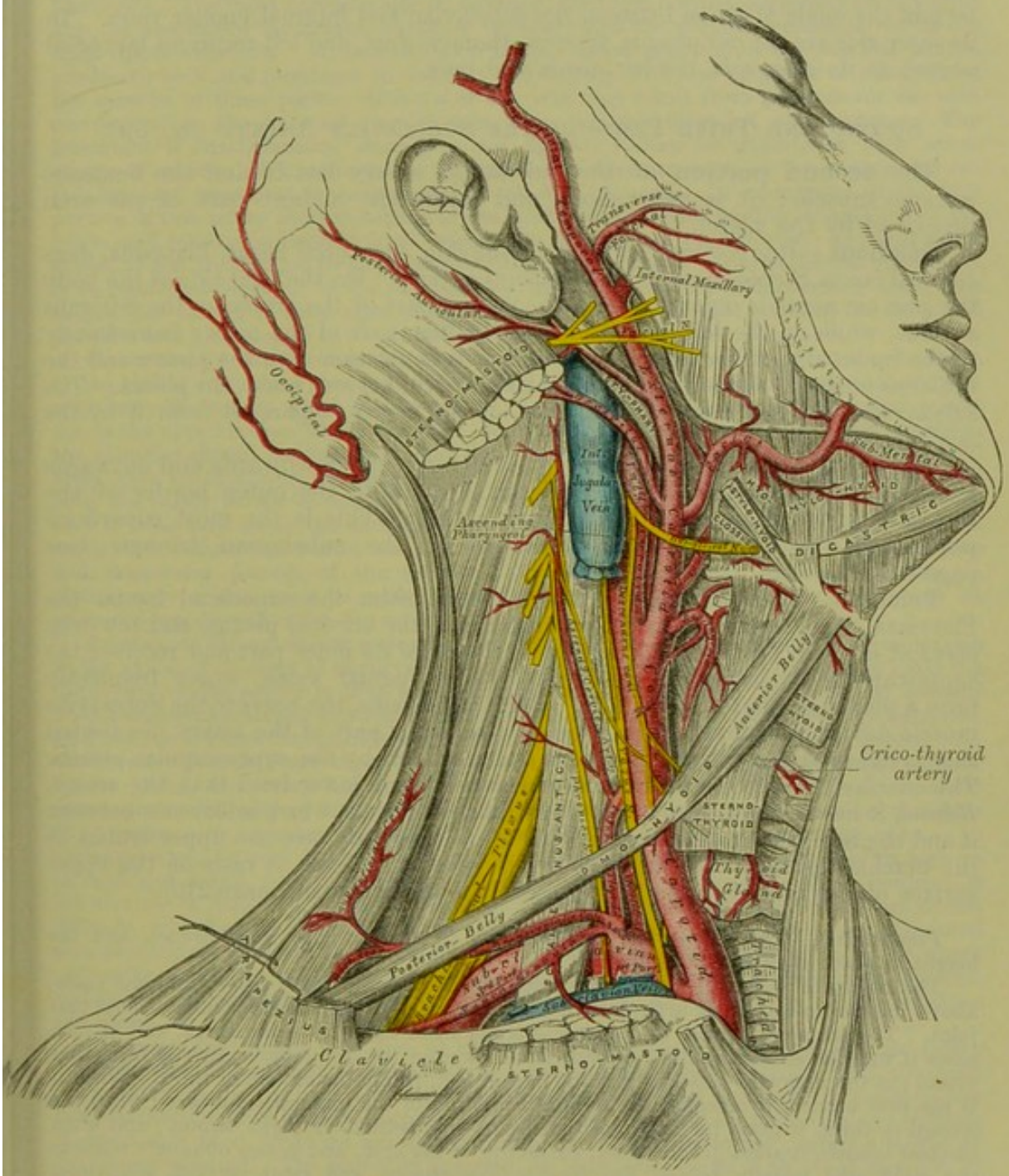

Below and behind the artery is the pleura, which separates it from the apex of the lung; *behind* is the gangliated cord of the sympathetic, the Longus colli muscle and the first thoracic vertebra. The right recurrent laryngeal nerve winds round the lower and back part of the vessel.

FIRST PART OF THE LEFT SUBCLAVIAN ARTERY (fig. 572)

The **first part** of the **left subclavian artery** arises from the arch of the aorta, behind the left common carotid, and at the level of the fourth thoracic vertebra; it ascends nearly vertically to the root of the neck and then arches outwards to the inner margin of the Scalenus anticus.

Relations.—It is in relation, *in front*, with the pneumogastric, cardiac, and phrenic nerves, which lie parallel with it, the left common carotid artery, left internal jugular and vertebral veins, and the commencement of the left innominate vein, and is covered by the Sterno-thyroid, Sterno-hyoid, and Sterno-mastoid muscles; *behind*, it is in relation with the œsophagus, thoracic duct, inferior cervical ganglion of the sympathetic, and Longus colli; higher up, however, the œsophagus and thoracic duct lie to its right side; the latter ultimately arching over the vessel to join the angle of union between the subclavian and internal jugular veins. To its *inner side* are the œsophagus, trachea, thoracic duct, and left recurrent laryngeal nerve; to its *outer side*, the left pleura and lung.

Second and Third Parts of the Subclavian Artery (fig. 590)

The **second portion** of the subclavian artery lies behind the Scalenus anticus muscle; it is very short, and forms the highest part of the arch described by the vessel.

Relations.—It is covered, *in front*, by the skin, superficial fascia, Platysma, deep cervical fascia, Sterno-mastoid, and Scalenus anticus. On the right side of the body the phrenic nerve is separated from the second part of the artery by the Scalenus anticus, while on the left side it crosses the first part of the artery immediately to the inner edge of the muscle. *Behind*, it is in relation with the pleura and the Scalenus medius. *Above* it, is the brachial plexus of nerves; *below*, the pleura. The subclavian vein lies below and in front of the artery, separated from it by the Scalenus anticus.

The **third portion** of the subclavian artery runs downwards and outwards from the outer margin of the Scalenus anticus to the outer border of the first rib, where it becomes the axillary artery. This is the most superficial portion of the vessel, and is contained in the subclavian triangle (see page 643).

Relations.—It is covered *in front*, by the skin, the superficial fascia, the Platysma, the descending clavicular branches of the cervical plexus, and the deep cervical fascia. The external jugular vein crosses its inner part and receives the suprascapular, transversalis colli and anterior jugular veins, which frequently form a plexus in front of the artery. Behind the veins, the nerve to the Subclavius muscle descends in front of the artery. The outer part of the artery lies behind the clavicle and the Subclavius muscle and is crossed by the suprascapular vessels. The subclavian vein lies in front of and at a slightly lower level than the artery. *Behind*, it lies on the lowest trunk of the brachial plexus, which intervenes between it and the Scalenus medius. . *Above* and to its *outer* side, are the upper trunks of the brachial plexus, and the Omo-hyoid muscle. *Below*, it rests on the upper surface of the first rib, or on the cervical rib if one be present (page 210).

Peculiarities.—The subclavian arteries vary in their origin, their course, and the height to which they rise in the neck.

The origin of the right subclavian from the innominate takes place, in some cases, above the sterno-clavicular articulation, and occasionally, but less frequently, below that joint. The artery may arise as a separate trunk from the arch of the aorta, and in such cases it may be either the first, second, third, or even the last branch derived from that vessel; in the majority however it is the first or last, rarely the second or third. When it is the first branch, it occupies the ordinary position of the innominate artery; when the second or third, it gains its usual position by passing behind the right carotid; and when the last branch, it arises from the left extremity of the arch, and passes obliquely towards the right side, usually behind the trachea, œsophagus, and right carotid, sometimes between the œsophagus and trachea, to the upper border of the first rib, whence it follows its ordinary course. In very rare instances, this vessel arises from the thoracic aorta, as low down as the fourth thoracic vertebra. Occasionally, it perforates the Scalenus anticus; more rarely it passes in front of that muscle. Sometimes the subclavian vein passes with the artery behind the Scalenus anticus. The artery may ascend as high as an inch and a half above the clavicle, or any intermediate point between this and the upper border of the bone, the right subclavian usually ascending higher than the left.

The left subclavian is occasionally joined at its origin with the left carotid.

Surface Marking.—The course of the subclavian artery in the neck may be mapped out by describing a curve with its convexity upwards, at the base of the posterior triangle. The inner end of this curve corresponds to the sterno-clavicular joint, the outer end to the centre of the lower border of the clavicle. The curve is to be drawn with such an amount of convexity that its mid-point reaches half an inch above the upper border of the clavicle.

The left subclavian artery is more deeply placed than the right in the first part of its course, and, as a rule, does not reach quite as high a level in the neck. It should be borne in mind that the posterior border of the Sterno-mastoid muscle corresponds pretty closely to the outer border of the Scalenus anticus, so that the third portion of the artery, the part most accessible for operation, lies immediately external to the posterior border of the Sterno-mastoid.

Applied Anatomy.—An *aneurysm* may form on any part of the subclavian artery, except the intrathoracic portion of the left vessel, which is said never to be the seat of aneurysm. The most common site is, however, the third portion, especially on the right side, on account of the greater exposure to injury and the greater amount of use of the right upper extremity. In this situation it may cause pressure on the brachial plexus, producing pain and numbness in the arm and fingers, with loss of power or paralysis of the muscles of these parts. Œdema of the arm may result from pressure on the subclavian vein. The external jugular vein may become distended and varicose. The treatment is unsatisfactory, since proximal ligature cannot be undertaken with much chance of success. If constitutional treatment and direct pressure on the aneurysmal sac fail, the best treatment is excision of the sac, if it be small. In aneurysms of the first portion of this artery there is œdema of the head and face, with lividity, congestion of the brain, and semi-consciousness from pressure on the internal jugular vein; and spasmodic action of the Diaphragm from pressure on the phrenic nerve. The collateral circulation is so good that blocking of the subclavian artery by embolism or thrombosis often fails to give rise to any striking signs or symptoms, beyond occasional pains in the neck and shoulder and some degree of weakness and wasting in the muscles of the arm.

Compression of the subclavian artery is required in cases of operations about the shoulder, in the axilla, or at the upper part of the arm; and the student will observe that there is only one situation in which it can be effectually applied, viz. where the artery passes across the upper surface of the first rib. In order to compress the vessel in this situation, the shoulder should be depressed, and the surgeon grasping the side of the neck should press with his thumb in the angle formed by the posterior border of the Sterno-mastoid with the upper border of the clavicle, downwards, backwards, and inwards against the rib; if from any cause the shoulder cannot be sufficiently depressed, pressure may be made from before backwards, so as to compress the artery against the Scalenus medius and transverse process of the seventh cervical vertebra. In appropriate cases, a preliminary incision may be made through the cervical fascia, and the finger may be pressed down directly upon the artery.

Ligature of the subclavian artery may be required in cases of wounds, or of aneurysm in the axilla, or in cases of aneurysm on the cardiac side of the point of ligature; and the third part of the artery is that which is most favourable for an operation, on account of its being comparatively superficial, and most remote from the origin of the large branches. In those cases where the clavicle is not displaced, this operation may be performed with comparative facility; but where the clavicle is pushed up by a large aneurysmal tumour in the axilla, the artery lies at a great depth from the surface, and this materially increases the difficulty of the operation. Under these circumstances, it becomes a matter of importance to consider the height to which this vessel reaches above the bone. In ordinary cases, its arch is about half an inch above the clavicle, occasionally as high as an inch and a half, and sometimes so low as to be on a level with its upper border. If the clavicle be displaced, these variations will necessarily make the operation more or less difficult, according as the vessel is less or more accessible. The vessel is also ligatured as a preliminary measure to the complete interscapulo-thoracic amputation of the upper extremity, in which case the suprascapular and transverse cervical arteries may, if found, be ligatured at the same time, making the 'fore-quarter' amputation an almost bloodless procedure.

The procedure in the operation of tying the third portion of the subclavian artery is as follows: The patient being placed on a table in the supine position, with the head drawn over to the opposite side, and the shoulder depressed as much as possible, the integument should be pulled downwards over the clavicle, and an incision made through it, upon that bone, from the anterior border of the Trapezius to the posterior border of the Sterno-mastoid. The object in drawing the skin downwards is to avoid any risk of wounding the external jugular vein, for as it perforates the deep fascia above the clavicle, it cannot be drawn downwards with the skin. The soft parts should now be allowed to glide up, and the cervical fascia divided upon a director, and if the interval between the Trapezius and Sterno-mastoid muscles be insufficient for the performance of the operation, a portion of one or both may be divided. The external jugular vein will now be seen towards the inner side of the wound; this and the suprascapular and transverse cervical veins which terminate in it should be held aside. If the external jugular vein be at all in the way and exposed to injury, it should be tied in two places and divided. The suprascapular artery should be avoided, and the Omo-hyoid muscle held aside if necessary. In the space beneath this muscle, careful search must be made for the vessel a deep layer of fascia and some connective tissue having been divided carefully, the outer margin of the Scalenus anticus muscle must be felt for, and the finger being guided by it to the

first rib, the pulsation of the subclavian artery will be felt as it passes over the rib. The sheath of the vessels having been opened, the aneurysm needle may then be passed around the artery from above downwards and inwards so as to avoid including any of the branches of the brachial plexus. If the clavicle be so raised by the tumour that the application of the ligature cannot be effected in this situation, the artery may be tied above the first rib, or even behind the Scalenus anticus muscle; the difficulties of the operation in such a case will be materially increased, on account of the greater depth of the artery, and the alteration in position of the surrounding parts.

The second part of the subclavian artery, from being that portion which rises highest in the neck, has been considered favourable for the application of the ligature when it is difficult to tie the artery in the third part of its course. There are, however, many objections to the operation in this situation. It is necessary to divide the Scalenus anticus muscle, upon which lies the phrenic nerve, and at the inner side of which is situated the internal jugular vein; and a wound of either of these structures might lead to the most dangerous consequences. Again, the artery is in contact, below, with the pleura, which must also be avoided; and, lastly, the proximity of so many of its large branches arising internal to this point must be a still further objection to the operation. In cases, however, where the sac of an axillary aneurysm encroaches on the neck, it may be necessary to divide the outer half or two-thirds of the Scalenus anticus muscle, so as to place the ligature on the vessel at a greater distance from the sac. The operation is performed exactly in the same way as ligature of the third portion, until the Scalenus anticus is exposed, when it is to be divided on a director (never to a greater extent than its outer two-thirds), and it immediately retracts. The operation is therefore merely an extension of the operation for ligature of the third portion of the vessel.

In those cases of aneurysm of the axillary or subclavian artery which encroach upon the outer portion of the Scalenus anticus to such an extent that a ligature cannot be applied in that situation, it may be deemed advisable, as a last resource, to tie the first portion of the subclavian artery. On the left side, this operation is almost impracticable; the great depth of the artery from the surface, its intimate relation with the pleura, and its close proximity to the thoracic duct and to so many important veins and nerves, present a series of difficulties which it is next to impossible to overcome.* On the right side, the operation is practicable, and has been performed on several occasions. The main objection to the operation in this situation is the smallness of the interval which usually exists between the commencement of the vessel and the origin of the nearest branch. The operation may be performed in the following manner: The patient being placed on the table in the supine position, with the neck extended, an incision should be made along the upper border of the inner part of the clavicle, and a second along the inner border of the Sterno-mastoid, meeting the former at an angle. The attachments of both heads of the Sterno-mastoid must be divided on a director, and turned outwards; a few small arteries and veins, and occasionally the anterior jugular, must be avoided, or, if necessary, ligatured in two places and divided, and the Sterno-hyoid and Sterno-thyroid muscles divided in the same manner as the preceding muscle. After tearing through the deep fascia with the finger-nail, the internal jugular vein will be seen crossing the subclavian artery; this should be pressed aside, and the artery secured by passing the needle from below upwards, by which the pleura is more effectually avoided. The exact position of the vagus, the recurrent laryngeal, the phrenic and sympathetic nerves should be borne in mind, and the ligature should be applied near the origin of the vertebral, in order to afford as much room as possible for the formation of a coagulum between the ligature and the origin of the vessel. It should be remembered that the right subclavian artery is occasionally deeply placed in the first part of its course, when it arises from the left side of the aortic arch, and passes in such cases behind the œsophagus, or between it and the trachea.

Collateral Circulation.—After ligature of the third part of the subclavian artery, the collateral circulation is established mainly by three sets of vessels, thus described in a dissection:

'1. A posterior set, consisting of the suprascapular and posterior scapular branches of the subclavian, anastomosing with the subscapular from the axillary.

'2. An internal set, produced by the connection of the internal mammary on the one hand, with the superior and long thoracic arteries, and the branches from the subscapular on the other.

'3. A middle or axillary set, consisting of a number of small vessels derived from branches of the subclavian, above, and, passing through the axilla, terminated either in the main trunk, or some of the branches of the axillary below. This last set presented most conspicuously the peculiar character of newly formed or, rather, dilated arteries, being excessively tortuous, and forming a complete plexus.

'The chief agent in the restoration of the axillary artery below the tumour was the subscapular artery, which communicated most freely with the internal mammary, supra-

* The operation has, however, been performed by J. K. Rodgers, by Halsted, and by Schumpert.

scapular, and posterior scapular branches of the subclavian, from all of which it received so great an influx of blood as to dilate it to three times its natural size.' *

When a ligature is applied to the first part of the subclavian artery, the collateral circulation is carried on by: 1, the anastomosis between the superior and inferior thyroid; 2, the anastomosis of the two vertebrals; 3, the anastomosis of the internal mammary with the deep epigastric and the aortic intercostals; 4, the superior intercostal anastomosing with the aortic intercostals; 5, the profunda cervicis anastomosing with the princeps cervicis; 6, the scapular branches of the thyroid axis anastomosing with the branches of the axillary; and 7, the thoracic branches of the axillary anastomosing with the aortic intercostals.

Branches.—The branches given off from the subclavian artery are:

Vertebral.	Internal mammary.
Thyroid axis.	Superior intercostal.

On the left side all four branches generally arise from the first portion of the vessel; but on the right side (fig. 591) the superior intercostal usually springs from the second portion of the vessel. On both sides of the body, the first three branches arise close together at the inner margin of the Scalenus anticus; in the majority of cases, a free interval of from half an inch to an inch exists between the commencement of the artery and the origin of the nearest branch.

1. The **vertebral artery** (a. vertebralis) is the first branch of the subclavian, and arises from the upper and back part of the first portion of the vessel. It is surrounded by a plexus of nerve fibres derived from the inferior cervical ganglion of the sympathetic trunk, and ascends through the foramina in the transverse processes of the upper six cervical vertebræ; † it then winds behind the superior articular process of the atlas and, entering the skull through the foramen magnum, unites, at the lower border of the pons Varolii, with the vessel of the opposite side to form the basilar artery.

Fig. 591.—Plan of the branches of the right subclavian artery.

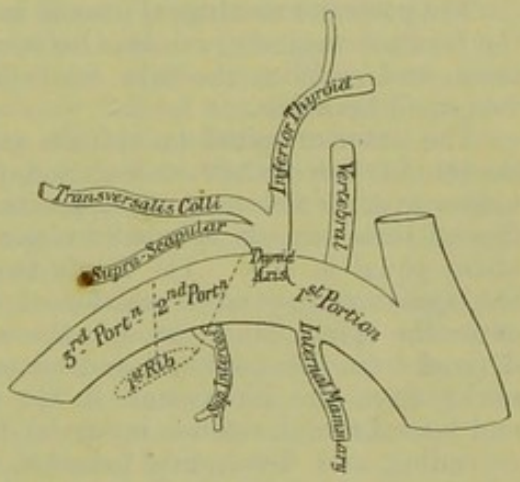

Relations.—The vertebral artery may be divided into four parts. The *first part* runs upwards and backwards between the Longus colli and the Scalenus anticus. In front of it are the internal jugular and vertebral veins, and it is crossed by the inferior thyroid artery; the left vertebral is crossed by the thoracic duct also. Behind it are the transverse process of the seventh cervical vertebra and the sympathetic cord. The *second part* runs upwards through the foramina in the transverse processes of the upper six cervical vertebræ, and is surrounded by a plexus of veins which unite to form the vertebral vein at the lower part of the neck. It is situated in front of the trunks of the cervical nerves, and pursues an almost vertical course as far as the transverse process of the atlas, above which it runs upwards and outwards to the foramen in the transverse process of the atlas. The *third part* issues from the latter foramen on the inner side of the Rectus lateralis muscle, and inclines backwards and inwards behind the superior articular process of the atlas; it lies in the groove on the upper surface of the posterior arch of the atlas, and enters the spinal canal by passing beneath the posterior occipito-atlantal ligament. This part of the artery is covered by the Complexus muscle and contained in the *suboccipital triangle*—a triangular space bounded by the Rectus capitis posticus major and the Superior and Inferior oblique muscles. The suboccipital nerve lies between the artery and the posterior arch

* *Guy's Hospital Reports*, vol. i. 1836. Case of axillary aneurysm, in which Aston Key had tied the subclavian artery on the outer edge of the Scalenus anticus, twelve years previously.

† The vertebral artery sometimes enters the foramen in the transverse process of the fifth vertebra. Smyth, who tied this artery in the living subject, found it, in one of his dissections, passing into the foramen in the seventh vertebra.

of the atlas. The *fourth part* pierces the dura mater and inclines inwards to the front of the medulla oblongata; it is placed between the hypoglossal nerve and the anterior root of the suboccipital nerve and beneath the first digitation of the ligamentum denticulatum. At the lower border of the pons Varolii it unites with the vessel of the opposite side to form the basilar artery.

The branches of the vertebral artery may be divided into two sets—those given off in the neck, and those within the cranium.

Cervical Branches.	*Cranial Branches.*
Spinal.	Posterior meningeal.
Muscular.	Anterior spinal.
	Posterior spinal.
	Posterior inferior cerebellar.
	Bulbar.

Spinal branches (rami spinales) enter the spinal canal through the intervertebral foramina, and each divides into two branches. Of these, one passes along the roots of the nerves to supply the spinal cord and its membranes, anastomosing with the other arteries of the spinal cord; the other divides into an ascending and a descending branch, which unite with similar branches from the arteries above and below, so that two lateral anastomotic chains are formed on the posterior surfaces of the bodies of the vertebræ, near the attachment of the pedicles. From these anastomotic chains branches are supplied to the periosteum and the bodies of the vertebræ, and others form communications with similar branches from the opposite side; from these communications small twigs arise which join similar branches above and below, to form a central anastomotic chain on the posterior surface of the bodies of the vertebræ.

Muscular branches are given off to the deep muscles of the neck, where the vertebral artery curves round the articular process of the atlas. They anastomose with the occipital, and with the ascending and deep cervical arteries.

The **posterior meningeal** (ramus meningeus) springs from the vertebral opposite the foramen magnum, ramifies between the bone and dura mater in the cerebellar fossa, and supplies the falx cerebelli. It is frequently represented by one or two small branches.

The **anterior spinal** (a. spinalis anterior) is a small branch, which arises near the termination of the vertebral, and, descending in front of the medulla oblongata, unites with its fellow of the opposite side at the level of the foramen magnum. One of these vessels is usually larger than the other, but occasionally they are about equal in size. The single trunk, thus formed, descends on the front of the spinal cord, and is reinforced by a succession of small branches which enter the spinal canal through the intervertebral foramina; these branches are derived from the vertebral and ascending cervical of the inferior thyroid in the neck; from the intercostals in the thorax; and from the lumbar, ilio-lumbar, and lateral sacral arteries in the abdomen and pelvis. They unite, by means of ascending and descending branches, to form a single anterior median artery, which extends as far as the lower part of the spinal cord, and is continued as a slender twig on the filum terminale. This vessel is placed in the pia mater along the anterior median fissure; it supplies that membrane, and the substance of the cord, and sends off branches at its lower part to be distributed to the cauda equina.

The **posterior spinal** (a. spinalis posterior) arises from the vertebral, at the side of the medulla oblongata; passing backwards to the posterior aspect of the spinal cord, it descends on the spinal cord, lying in front of the posterior roots of the spinal nerves, and is reinforced by a succession of small branches, which enter the spinal canal through the intervertebral foramina; by means of these it is continued to the lower part of the cord, and to the cauda equina. Branches from the posterior spinal arteries form a free anastomosis round the posterior roots of the spinal nerves, and communicate, by means of very tortuous transverse branches, with the vessels of the opposite side. Close to its origin each gives off an ascending branch, which terminates at the side of the fourth ventricle.

Applied Anatomy.—Bleeding into the spinal membranes or into the substance of the spinal cord itself is not common, but may occur from injuries received at birth when labour is unduly prolonged or instruments are used. It is also met with in chronic insanity, and in tetanus or strychnine poisoning.

The **posterior inferior cerebellar** (a. cerebelli inferior posterior) (fig. 582), the largest branch of the vertebral, winds backwards round the upper part of the medulla oblongata, passing between the origins of the pneumogastric and spinal accessory nerves, over the restiform body to the under surface of the cerebellum, where it divides into two branches. The internal branch is continued backwards to the notch between the two hemispheres of the cerebellum; while the external supplies the under surface of the cerebellum, as far as its outer border, where it anastomoses with the anterior inferior cerebellar and the superior cerebellar branches of the basilar artery. Branches from this artery supply the choroid plexus of the fourth ventricle.

The **bulbar arteries** are several minute vessels which spring from the vertebral and its branches and are distributed to the medulla oblongata.

The **basilar artery** (a. basilaris) (fig. 582), so named from its position at the base of the skull, is a single trunk formed by the junction of the two vertebral arteries; it extends from the posterior to the anterior border of the pons Varolii, lying in its median groove, under cover of the arachnoid. It ends by dividing into the two *posterior cerebral arteries*.

Its branches, on either side, are the following:

Transverse.	Anterior inferior cerebellar.
Auditory.	Superior cerebellar.
Posterior cerebral.	

The **transverse branches** (rami ad pontem) are a number of small vessels which come off at right angles on either side of the basilar artery and supply the pons Varolii and adjacent parts of the brain.

The **auditory** (a. auditiva interna), a long slender branch, arises from near the middle of the artery; it accompanies the corresponding auditory nerve into the internal auditory meatus, and is distributed to the internal ear.

The **anterior inferior cerebellar** (a. cerebelli inferior anterior) passes backwards, to be distributed to the anterior part of the under surface of the cerebellum, anastomosing with the posterior inferior cerebellar branch of the vertebral.

The **superior cerebellar** (a. cerebelli superior) arises near the termination of the basilar. It passes outwards, immediately behind the third nerve, which separates it from the posterior cerebral artery, winds round the crus cerebri, close to the fourth nerve, and, arriving at the upper surface of the cerebellum, divides into branches which ramify in the pia mater and anastomose with the branches of the inferior cerebellar artery. Several branches are given to the pineal gland, the valve of Vieussens, and the velum interpositum.

The **posterior cerebral** (a. cerebri posterior) is larger than the preceding, from which it is separated near its origin by the third nerve. Passing outwards, parallel to the superior cerebellar artery, and receiving the posterior communicating from the internal carotid, it winds round the crus cerebri, and reaches the under surface of the occipital lobe of the cerebrum, where it breaks up into branches for the supply of the temporal and occipital lobes.

The branches of the posterior cerebral artery are divided into two sets, ganglionic and cortical:

Ganglionic	Postero-median.	Cortical	Anterior temporal.
	Posterior choroidal.		Posterior temporal.
	Postero-lateral.		Calcarine.
			Parieto-occipital.

Ganglionic.—The *postero-median ganglionic branches* (fig. 582) are a group of small arteries which arise at the commencement of the posterior cerebral artery: these, with similar branches from the posterior communicating, pierce the posterior perforated space, and supply the internal surfaces of the thalami and the walls of the third ventricle. The *posterior choroidal branches* enter the interior of the brain beneath the splenium of the corpus callosum, and supply the velum interpositum and the choroid plexus. The *postero-lateral ganglionic branches* are small arteries which arise from the posterior cerebral artery after it has turned round the crus cerebri; they supply a considerable portion of the thalamus.

Cortical.—The cortical branches are: the *anterior temporal*, distributed to the anterior parts of the uncinate and occipito-temporal gyri; the *posterior temporal*,

to the occipito-temporal and the third temporal convolutions ; the *calcarine* to the cuneate and lingual lobules and the back part of the outer surface of the occipital lobe ; and the *parieto-occipital* to the cuneus and the quadrate lobe.

2. The **thyroid axis** (truncus thyreocervicalis) (fig. 590) is a short thick trunk, which arises from the front of the first portion of the subclavian artery, close to the inner border of the Scalenus anticus, and divides almost immediately into three branches, the *inferior thyroid*, *suprascapular*, and *transverse cervical*.

The **inferior thyroid artery** (a. thyreoidea inferior) passes upwards, in front of the vertebral artery and Longus colli muscle ; then turns inwards behind the carotid sheath and its contents, and also behind the sympathetic cord, the middle cervical ganglion resting upon the vessel. Reaching the lower border of the lateral lobe of the thyroid gland it divides into two branches, which supply the postero-inferior parts of the gland, and anastomose with the superior thyroid, and with the corresponding artery of the opposite side. The recurrent laryngeal nerve passes upwards generally behind, but occasionally in front of, the artery.

The branches of the inferior thyroid are :

Inferior laryngeal.	Œsophageal.
Tracheal.	Ascending cervical.
Muscular.	

The **inferior laryngeal branch** (a. laryngea inferior) ascends upon the trachea to the back part of the larynx under cover of the Inferior constrictor, in company with the recurrent laryngeal nerve, and supplies the muscles and mucous membrane of this part, anastomosing with the branch from the opposite side, and with the laryngeal branch from the superior thyroid artery.

The **tracheal branches** (rami tracheales) are distributed upon the trachea, anastomosing below with the bronchial arteries.

The **œsophageal branches** (rami œsophagei) supply the œsophagus, and anastomose with the œsophageal branches of the aorta.

The **ascending cervical** (a. cervicalis ascendens) is a small branch which arises from the inferior thyroid, just where that vessel is passing behind the carotid sheath, and runs up on the anterior tubercles of the transverse processes of the cervical vertebræ in the interval between the Scalenus anticus and Rectus capitis anticus major. It gives to the muscles of the neck branches which anastomose with branches of the vertebral, and it sends one or two twigs (rami spinales) into the spinal canal through the intervertebral foramina to be distributed to the spinal cord and its membranes, and to the bodies of the vertebræ, in the same manner as the lateral spinal branches from the vertebral. It anastomoses with the ascending pharyngeal and occipital arteries.

The **muscular branches** supply the depressors of the hyoid bone, the Longus colli, the Scalenus anticus, and the Inferior constrictor of the pharynx.

The **suprascapular artery** (a. transversa scapulæ) (fig. 592) passes at first downwards and outwards across the Scalenus anticus and phrenic nerve, being covered by the Sterno-mastoid ; it then crosses the subclavian artery and the cords of the brachial plexus, and runs outwards, behind and parallel with the clavicle and Subclavius, and beneath the posterior belly of the Omo-hyoid, to the superior border of the scapula ; it passes over the transverse ligament of the scapula, which separates it from the suprascapular nerve, and enters the supraspinous fossa. In this situation it lies close to the bone, and ramifies between it and the Supraspinatus, to which it supplies branches. It then descends behind the neck of the scapula, through the great scapular notch, to reach the infraspinous fossa, where it anastomoses with the dorsalis scapulæ and posterior scapular arteries. Besides distributing branches to the Sterno-mastoid, Subclavius, and neighbouring muscles, it gives off a *suprasternal branch*, which crosses over the sternal end of the clavicle to the skin of the upper part of the chest ; and a *supra-acromial branch*, which pierces the Trapezius and supplies the skin over the acromion, anastomosing with the acromio-thoracic artery. As the artery passes over the transverse ligament of the scapula, a branch of it descends into the subscapular fossa, ramifies beneath the Subscapularis, and anastomoses with the posterior and subscapular arteries. It also sends articular branches to the acromio-clavicular and shoulder joints, and a nutrient artery to the clavicle.

The **transverse cervical artery** (a. transversa colli), larger than the suprascapular, passes transversely outwards, across the upper part of the subclavian

triangle, to the anterior margin of the Trapezius muscle, beneath which it divides into two branches, the *superficial cervical* and the *posterior scapular*. It crosses in front of the phrenic nerve and Scaleni muscles, and in front of or between the divisions of the brachial plexus, and is covered by the Platysma, Sterno-mastoid, Omo-hyoid, and Trapezius muscles.

Fig. 592.—The scapular and circumflex arteries.

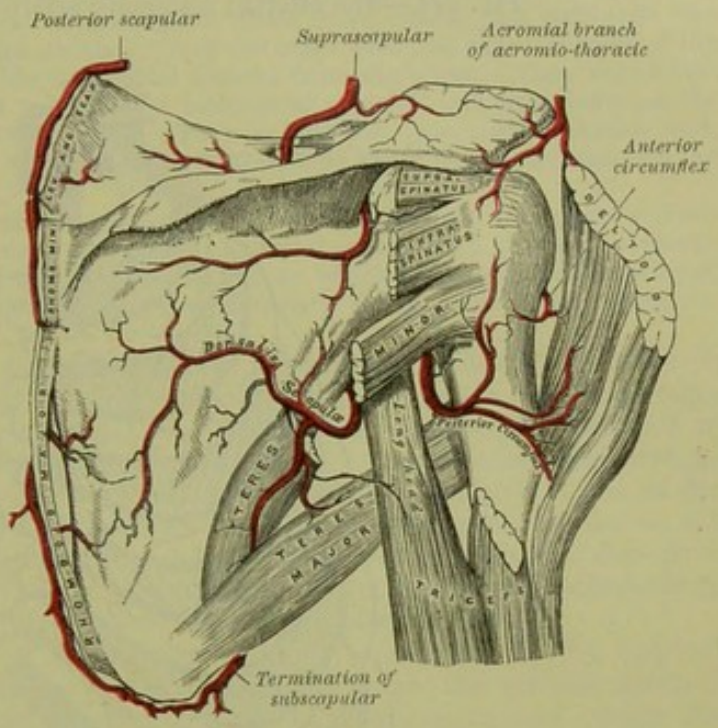

The **superficial cervical** (ramus ascendens) ascends beneath the anterior margin of the Trapezius, distributing branches to it, and to the neighbouring muscles and glands in the neck, and anastomoses with the superficial branch of the arteria princeps cervicis.

The **posterior scapular** (ramus descendens) (fig. 592) passes beneath the Levator anguli scapulæ to the superior angle of the scapula, and then descends along the posterior border of that bone as far as the inferior angle. It is covered by the Rhomboid muscles, supplying them and the Latissimus dorsi and Trapezius, and anastomosing with the suprascapular and subscapular arteries, and with the posterior branches of some of the intercostal arteries.

Peculiarities.—The superficial cervical frequently arises as a separate branch from the thyroid axis ; and the posterior scapular, from the third, more rarely from the second, part of the subclavian.

3. The **internal mammary** (a. mammaria interna) (fig. 593) arises from the under surface of the first portion of the subclavian artery, opposite the thyroid axis. It descends behind the cartilages of the upper six ribs at a distance of about half an inch from the margin of the sternum, and at the level of the sixth intercostal space divides into the *musculo-phrenic* and *superior epigastric* arteries.

Relations.—It is directed at first downwards, forwards, and inwards behind the inner end of the clavicle, the subclavian and internal jugular veins, and the first costal cartilage. As it enters the thorax it is crossed from without inwards by the phrenic nerve, and passes forwards close to the outer side of the innominate vein. Below the first costal cartilage it descends almost vertically to its point of bifurcation. It is covered in front by the Pectoralis major and the cartilages of the upper six ribs with their intervening intercostal muscles, and is crossed by the terminal portions of the upper six intercostal nerves. *Behind*, it rests on the pleura, as far as the third costal cartilage ; below this level, upon the Triangularis sterni muscle. It is accompanied by a pair of veins : these unite above to form a single vessel, which passes to the inner side of the artery and ends in the corresponding innominate vein.

The branches of the internal mammary are :

Comes nervi phrenici.	Anterior intercostal.
Mediastinal.	Perforating.
Pericardial.	Musculo-phrenic.
Sternal.	Superior epigastric.

The **comes nervi phrenici** (a. pericardiacophrenica) is a long slender branch, which accompanies the phrenic nerve, between the pleura and pericardium, to the Diaphragm, to which it is distributed ; it anastomoses with the other phrenic arteries from the internal mammary and abdominal aorta.

The **mediastinal branches** (aa. mediastinales anteriores) are small vessels, distributed to the areolar tissue and lymphatic glands in the anterior mediastinum, and to the remains of the thymus gland.

FIG. 593.—The internal mammary artery and its branches.

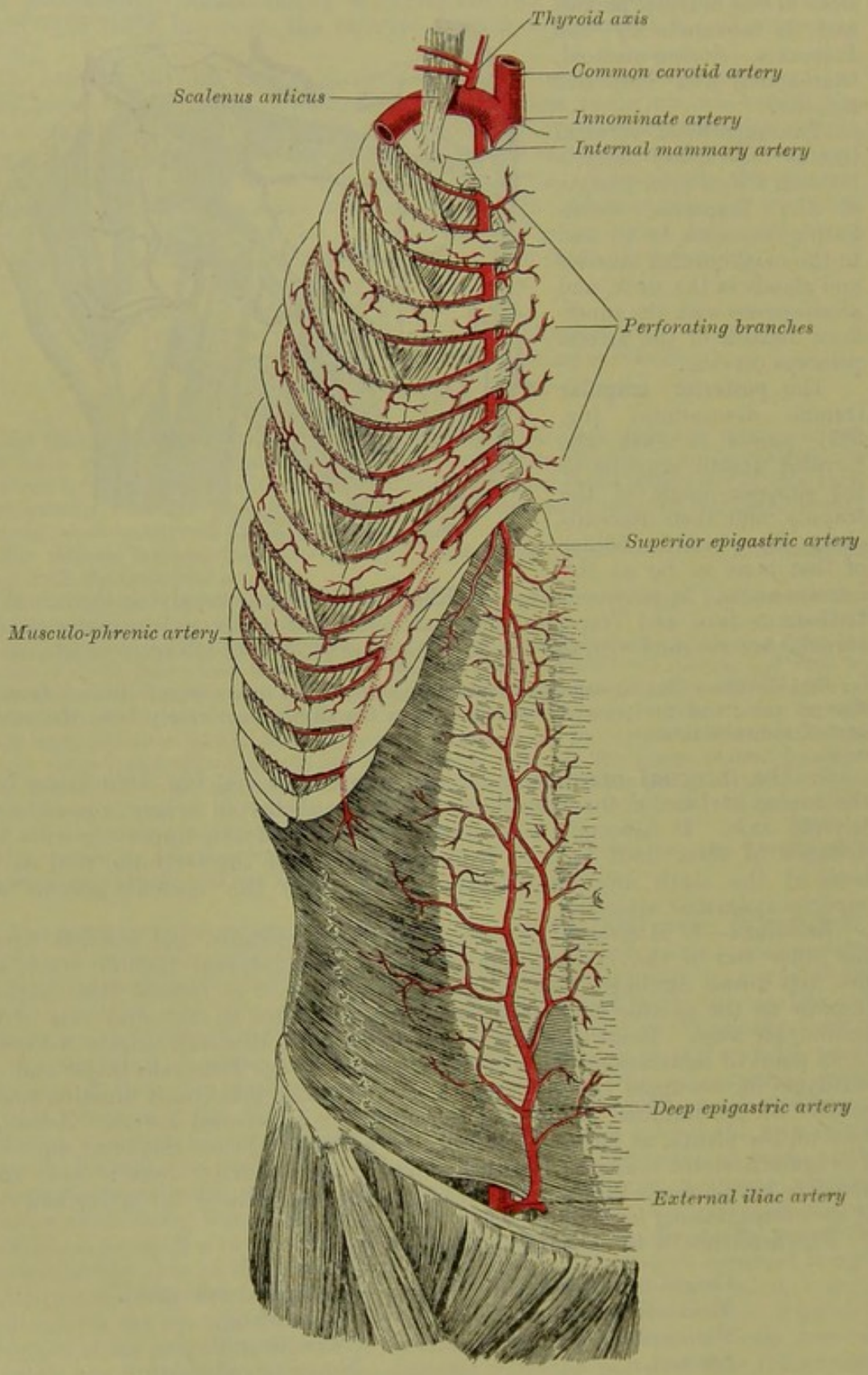

The **pericardial branches** supply the upper part of the anterior surface of the pericardium, the lower part receiving branches from the musculo-phrenic artery.

The **sternal branches** (rami sternales) are distributed to the Triangularis sterni, and to the posterior surface of the sternum.

The mediastinal, pericardial, and sternal branches, together with some twigs from the comes nervi phrenici, anastomose with branches from the intercostal and bronchial arteries, and form a minute plexus beneath the pleura, which has been named by Turner the *subpleural mediastinal plexus*.

The **anterior intercostal branches** (rami intercostales) supply the upper five or six intercostal spaces. Two in number in each space, these small vessels pass outwards, one lying near the lower margin of the rib above, and the other near the upper margin of the rib below, and anastomose with the intercostal arteries from the aorta. They are at first situated between the pleura and the Internal intercostal muscles, and then between the Internal and External intercostal muscles. They supply the Intercostal muscles and, by branches which perforate the External intercostal muscle, the Pectoral muscles and the mammary gland.

The **perforating branches** (rami perforantes) correspond to the five or six upper intercostal spaces. They pass forwards through the intercostal spaces, and, curving outwards, supply the Pectoralis major and the integument. Those which correspond to the second, third, and fourth spaces are distributed to the mammary gland, and during lactation are of large size.

The **musculo-phrenic** (a. musculophrenica) is directed obliquely downwards and outwards, behind the cartilages of the false ribs, perforates the Diaphragm at the eighth or ninth costal cartilage, and terminates, considerably reduced in size, opposite the last intercostal space. It gives off anterior intercostal arteries to the seventh, eighth, and ninth intercostal spaces; these diminish in size as the spaces decrease in length, and are distributed in a manner precisely similar to the anterior intercostals from the internal mammary. The musculo-phrenic also gives branches to the lower part of the pericardium, and others which run backwards to the Diaphragm, and downwards to the abdominal muscles.

The **superior epigastric** (a. epigastrica superior) continues in the original direction of the internal mammary; it descends through the cellular interval between the costal and sternal attachments of the Diaphragm, and enters the sheath of the Rectus abdominis muscle, at first lying behind the muscle, and then perforating and supplying it, and anastomosing with the deep epigastric artery from the external iliac. Some vessels perforate the anterior wall of the sheath of the Rectus, and supply the muscles of the abdomen and the integument, and a small branch, which passes inwards upon the side of the ensiform appendix, anastomoses in front of that cartilage with the artery of the opposite side. It also gives some twigs to the Diaphragm, while from the artery of the right side small branches extend into the falciform ligament of the liver and anastomose with the hepatic artery.

Applied Anatomy.—The course of the internal mammary artery may be defined by a line drawn half an inch outside and parallel with the sternal margin. The vessel is liable to be wounded in stabs of the chest-wall and in the operation of paracentesis pericardii (page 600). It is most easily reached by a transverse incision in the second intercostal space.

4. The **superior intercostal** (truncus costocervicalis) (fig. 580) arises from the upper and back part of the subclavian artery, behind the Scalenus anticus on the right side, and internal to that muscle on the left side. Passing backwards, it gives off the *profunda cervicis*, and then descends behind the pleura in front of the necks of the first and second ribs, and anastomoses with the first aortic intercostal. As it crosses the neck of the first rib it lies to the inner side of the anterior division of the first thoracic nerve, and to the outer side of the first thoracic ganglion of the sympathetic.

In the first intercostal space, it gives off a branch which is distributed in a manner similar to the distribution of the aortic intercostals. The branch for the second intercostal space usually joins with one from the highest aortic intercostal. This branch is not constant, but is more commonly found on the right side; when absent, its place is supplied by an intercostal branch from the aorta. Each intercostal gives off a branch to the posterior spinal muscles, and a small one which passes through the corresponding intervertebral foramen to the spinal cord and its membranes.

The **profunda cervicis** (a. cervicalis profunda) arises, in most cases, from the superior intercostal, and is analogous to the posterior branch of an aortic intercostal artery: occasionally it is a separate branch from the subclavian artery. Passing backwards, above the eighth cervical nerve and between the transverse process of the seventh cervical vertebra and the neck of the first rib, it runs up

the back of the neck, between the Complexus and Semispinalis colli, as high as the axis, supplying these and adjacent muscles, and anastomosing with the deep branch of the arteria princeps cervicis of the occipital, and with branches which pass outwards from the vertebral. It gives off a special branch which enters the spinal canal through the intervertebral foramen between the seventh cervical and first thoracic vertebræ.

The Axilla

The **axilla** is a pyramidal space, situated between the upper lateral part of the chest and the inner side of the arm.

Boundaries.—Its *apex*, which is directed upwards towards the root of the neck, corresponds to the interval between the first rib, the upper border of the scapula, and the clavicle, and through it the axillary vessels and nerves pass. The *base*, directed downwards, is formed by the integument and a thick layer of fascia, the *axillary fascia*, extending between the lower border of the Pectoralis major in front, and the lower border of the Latissimus dorsi behind; it is broad internally, at the chest, but narrow and pointed externally, at the arm. The *anterior wall* is formed by the Pectoralis major and minor muscles, the former covering the whole of the anterior wall, the latter only its central part. The space between the inner border of the Pectoralis minor and the clavicle is occupied by the costo-coracoid membrane. The *posterior wall*, which extends somewhat lower than the anterior, is formed by the Subscapularis above, the Teres major and Latissimus dorsi below. On the *inner side* are the first four ribs with their corresponding Intercostal muscles, and part of the Serratus magnus. On the *outer side*, where the anterior and posterior walls converge, the space is narrow, and bounded by the humerus, the Coraco-brachialis, and the Biceps.

Contents.—It contains the axillary vessels, and the brachial plexus of nerves, with their branches, some branches of the intercostal nerves, and a large number of lymphatic glands, together with a quantity of fat and loose areolar tissue. The axillary artery and vein, with the brachial plexus of nerves, extend obliquely along the outer boundary of the axilla, from its apex to its base, and are placed much nearer to the anterior than to the posterior wall, the vein lying to the inner or thoracic side of the artery and partially concealing it. At the fore part of the axilla, in contact with the Pectoral muscles, are the thoracic branches of the axillary artery, and along the lower margin of the Pectoralis minor the long thoracic artery extends to the side of the chest. At the back part, in contact with the lower margin of the Subscapularis, are the subscapular vessels and nerves; winding around the outer border of this muscle are the dorsalis scapulæ vessels; and, close to the neck of the humerus, the posterior circumflex vessels and the circumflex nerve curve backwards to the shoulder.

Along the inner or thoracic side no vessel of any importance exists, the upper part of the space being crossed merely by a few small branches from the superior thoracic artery. There are some important nerves, however, in this situation, viz. the posterior thoracic or external respiratory nerve, descending on the surface of the Serratus magnus, to which it is distributed; and the intercosto-humeral nerve or nerves, perforating the upper and anterior part of this wall, and passing across the axilla to the inner side of the arm.

The position and arrangement of the lymphatic glands are described on a subsequent page.

Applied Anatomy.—The axilla is a space of considerable surgical importance. It transmits the large vessels and nerves to the upper extremity, and these may be the seat of injury or disease: it contains numerous lymphatic glands which may require removal; in it is a quantity of loose connective and adipose tissue which may be readily infiltrated with blood or inflammatory exudation; and it may be the seat of rapidly growing tumours. Moreover, it is covered at its base by thin skin, which is largely supplied with sebaceous and sweat glands, and is frequently the seat of small cutaneous abscesses and boils.

Penetrating wounds in the axilla are sometimes accompanied by extensive hæmorrhage, either from wound of the main vessels, or of one of the large branches of the axillary artery, *e.g.* the long thoracic or the subscapular. Where the blood cannot find an easy exit externally, it collects in the axillary space and forms a large swelling which projects in the floor of the axilla and also bulges forwards the Pectoralis major. The treatment consists in freely opening up the cavity and searching for and securing the bleeding vessel.

In *suppuration in the axilla*, the arrangement of the fasciæ plays a very important part in the direction which the pus takes. As described on page 529, the costo-coracoid membrane, after covering in the space between the clavicle and the upper border of the Pectoralis minor, splits to enclose this muscle, and, reblending at its lower border, becomes incorporated with the axillary fascia at the anterior fold of the axilla. This is known as the *clavipectoral fascia*. Suppuration may take place either superficial to or beneath this layer of fascia; that is, either between the Pectorals or below the Pectoralis minor: in the former case, the abscess would point either at the anterior border of the axillary fold, or in the groove between the Deltoid and the Pectoralis major; in the latter, the pus would have a tendency to surround the vessels and nerves, and ascend into the neck, that being the direction in which there is least resistance. Its progress towards the surface is prevented by the axillary fascia; its progress backwards, by the insertion of the Serratus magnus; forwards, by the clavipectoral fascia; inwards, by the wall of the thorax; and outwards, by the upper limb. The pus in these cases, after extending into the neck, has been known to spread through the superior opening of the thorax into the mediastinum. Some instances have been recorded where the pus found its way along the course of the vessels into the upper arm.

In opening an axillary abscess, the knife should be entered in the floor of the axilla, midway between the anterior and posterior margins and near the thoracic side of the space. After an incision has been made through the skin and fascia it is well to use a director and dressing forceps in the manner directed by Hilton.

The relations of the vessels and nerves in the several parts of the axilla are important, for it is the almost universal plan, in the present day, to remove the glands from the axilla in operating for cancer of the breast. In performing such an operation, it is necessary to proceed with much caution in the direction of the outer wall and apex of the space, as here the axillary vessels are in danger of being wounded. The subscapular, dorsalis scapulæ, and posterior circumflex vessels on the posterior wall and the thoracic branches along the anterior wall must be avoided. In clearing out the axilla, the axillary vein should be first defined and traced up to the apex of the space by means of an elevator or other blunt instrument. The Pectoralis major is retracted by an assistant; or, as is more commonly the practice in the present day, the sternal origin of this muscle is first removed. This proceeding not only lessens the chance of recurrence of the disease, but also enables the surgeon to clear out the axillary cavity more thoroughly. When the apex of the space is reached all fat and glands must be carefully removed and the whole axilla cleared by separating the tissues along the inner and posterior walls, so that when the proceeding is completed the axilla is emptied of all its contents except the main vessels and nerves.

Axillary Artery

The **axillary artery** (a. axillaris) (fig. 594), the continuation of the subclavian, commences at the outer border of the first rib, and terminates at the lower border of the tendon of the Teres major muscle, where it takes the name of brachial. Its direction varies with the position of the limb: thus the vessel is nearly straight when the arm is directed at right angles with the trunk, concave upwards when the arm is elevated above this, and convex upwards and outwards when the arm lies by the side. At its commencement the artery is very deeply situated, but near its termination is superficial, being covered only by the skin and fascia. To facilitate the description of the vessel it is divided into three portions; the first part lies above, the second behind, and the third below the Pectoralis minor.

The **first portion** of the axillary artery is in relation, *in front*, with the clavicular portion of the Pectoralis major, the costo-coracoid membrane, the external anterior thoracic nerve, and the acromio-thoracic and cephalic veins; *behind*, with the first intercostal space, the corresponding Intercostal muscle, the first and second digitations of the Serratus magnus, and the posterior thoracic and internal anterior thoracic nerves; on its *outer side*, with the brachial plexus, from which it is separated by a little areolar tissue; on its *inner*, or thoracic side, with the axillary vein which overlaps the artery. It is enclosed, together with the axillary vein and the brachial plexus, in a fibrous sheath—the *axillary sheath*—continuous above with the deep cervical fascia.

The **second portion** of the axillary artery is covered, *in front*, by the Pectorales major and minor; *behind* it, is the posterior cord of the brachial plexus, and some areolar tissue which intervenes between it and the Subscapularis muscle; on the *inner side* is the axillary vein, separated from the artery by the inner cord of the brachial plexus and the internal anterior thoracic nerve; on the *outer side* is the outer cord of the brachial plexus. The brachial plexus of nerves thus surrounds

the artery on three sides, and separates it from direct contact with the vein and adjacent muscles.

The **third portion** of the axillary artery extends from the lower border of the Pectoralis minor to the lower border of the tendon of the Teres major. *In front*, it is covered by the lower part of the Pectoralis major above, but only by the integument and fascia below; *behind*, it is in relation with the lower part of the Subscapularis, and the tendons of the Latissimus dorsi and Teres major; on its

Fig. 594.—The axillary artery and its branches.

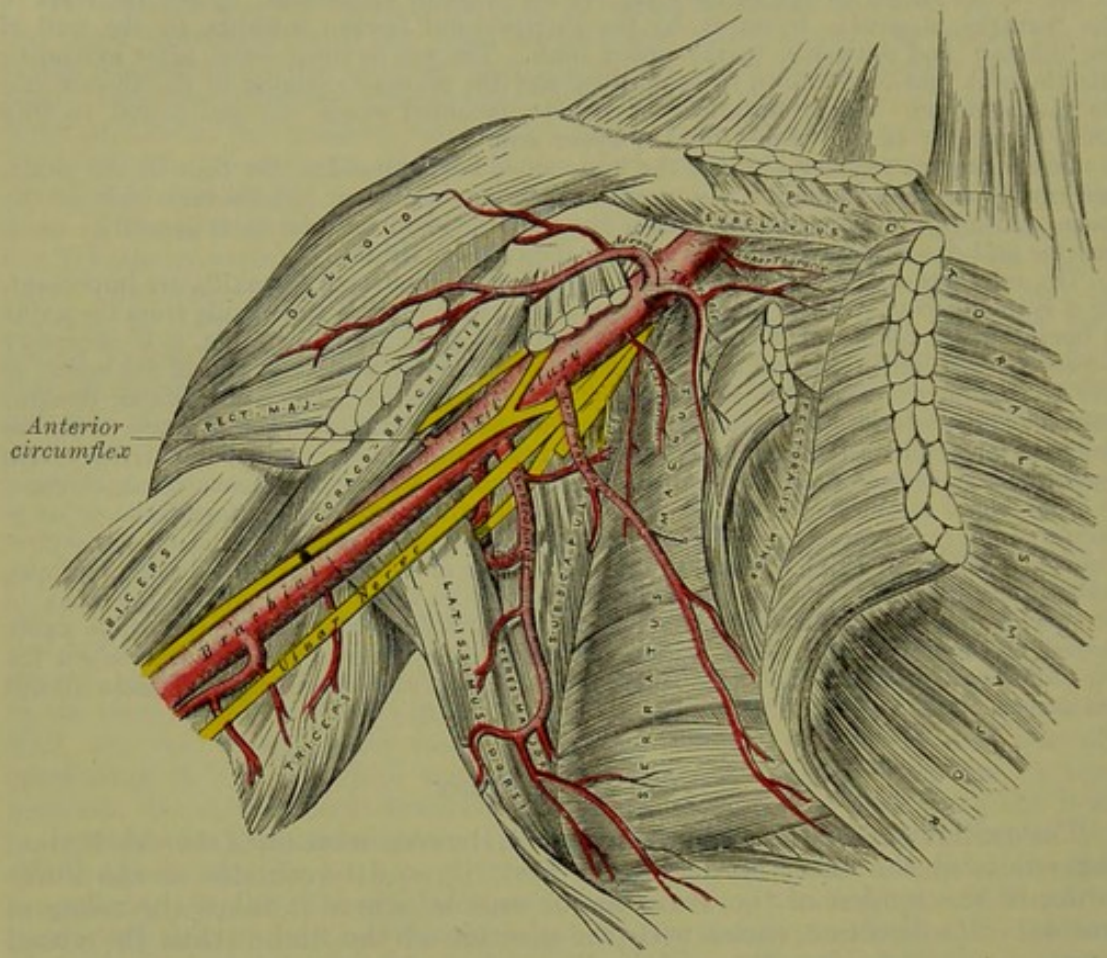

outer side is the Coraco-brachialis, and on its *inner*, or thoracic side, the axillary vein. The nerves of the brachial plexus bear the following relations to this part of the artery: on the *outer side* are the outer head and trunk of the median, and the musculo-cutaneous for a short distance; on the *inner side* the ulnar (between the vein and artery) and lesser internal cutaneous nerves (to the inner side of the vein); *in front* are the inner head of the median and the internal cutaneous, and *behind*, the musculo-spiral and circumflex, the latter only as far as the lower border of the Subscapularis.

Surface Marking.—The course of the axillary artery may be marked out by raising the arm to a right angle and drawing a line from the middle of the clavicle to the point where the tendon of the Pectoralis major crosses the prominence caused by the Coraco-brachialis as it emerges from under cover of the anterior fold of the axilla. The third portion of the artery can be felt pulsating beneath the skin and fascia, at the junction of the anterior with the middle third of the space between the anterior and posterior folds of the axilla, close to the inner border of the Coraco-brachialis.

Applied Anatomy.—Compression of the vessel may be required in the removal of tumours, or in amputation of the upper part of the arm; and the only situation in which this can be effectually made is in the lower part of its course; by pressing on it in this situation from within outwards against the humerus, the circulation may be effectually arrested.

With the exception of the popliteal, the axillary artery is perhaps more frequently lacerated than any other artery in the body by violent movements, especially in those cases where its coats are diseased. It has occasionally been ruptured in attempts to

reduce old dislocations of the shoulder-joint. This lesion is most likely to occur during the preliminary breaking down of adhesions, in cases where the artery has become fixed to the capsule of the joint. Aneurysm of the axillary artery sometimes occurs: a large number of the cases are traumatic in their origin, due to the injuries to which the artery is exposed in the varied, extensive, and often violent movements of the limb.

The *application of a ligature to the axillary artery* may be required in cases of aneurysm of the upper part of the brachial, or as a distal operation for aneurysm of the subclavian; and there are only two situations in which it can be secured, viz. in the first and in the third parts of its course; for the axillary artery at its central part is so deeply seated, and, at the same time, so closely surrounded with large nervous trunks, that the application of a ligature to it there would be almost impracticable.

In the *third part* of its course the operation is most simple, and may be performed in the following manner. The patient being placed on a bed, and the arm separated from the side, with the hand supinated, an incision about two inches in length is made through the integument forming the floor of the axilla, a little nearer to the anterior than to the posterior fold of the axilla. After carefully dissecting through the areolar tissue and fascia, the median nerve and axillary vein are exposed; the former is displaced to the outer, and the latter to the inner side of the arm, the elbow being at the same time bent so as to relax the structures and facilitate their separation; the ligature may be passed round the artery from the ulnar to the radial side. This portion of the artery is occasionally crossed by a muscular slip, the *axillary arch* (page 490), derived from the Latissimus dorsi.

The *first portion* of the axillary artery may be tied in cases of aneurysm encroaching so far upwards that a ligature cannot be applied in the lower part of its course. Notwithstanding that this operation has been performed in some few patients with success, its performance is attended with much difficulty and danger. The student will remark that, in this situation, it would be necessary to divide a thick muscle, and, after incising the costo-coracoid membrane, the artery would be exposed at the bottom of a more or less deep space, with the cephalic and axillary veins in such relation with it as must render the application of a ligature to it particularly hazardous. Under such circumstances, it is an easier and, at the same time, more advisable operation, to tie the third part of the subclavian artery.

The first part of the axillary can be best secured by a curved incision with the convexity downwards from a point half an inch external to the sterno-clavicular joint to a point half an inch internal to the coracoid process. The limb is to be well abducted and the head inclined to the opposite side, and the incision carried through the superficial structures, care being taken of the cephalic vein at the outer angle of the incision. The clavicular origin of the Pectoralis major is then divided in the whole extent of the wound. The arm is now brought to the side, and the upper edge of the Pectoralis minor defined and drawn downwards. The costo-coracoid membrane is carefully divided on a director, close to the coracoid process, and the axillary sheath exposed; this is to be opened with especial care on account of the vein overlapping the artery. The needle should be passed from below, so as to avoid wounding the vein.

Collateral circulation after ligature of the axillary artery.—If the artery be tied above the origin of the acromio-thoracic, the collateral circulation will be carried on by the same branches as after the ligature of the subclavian; if at a lower point, between the acromio-thoracic and subscapular arteries, the latter vessel, by its free anastomoses with the other scapular arteries, branches of the subclavian, will become the chief agent in carrying on the circulation; the long thoracic, if it be below the ligature, will materially contribute by its anastomoses with the intercostal and internal mammary arteries. If the point included in the ligature is below the origin of the subscapular artery, it will most probably also be below the origins of the two circumflex arteries. The chief agents in restoring the circulation will then be the subscapular and the two circumflex arteries anastomosing with the superior profunda from the brachial. The cases in which the operation has been performed are few in number, and no published account of dissections of the collateral circulation appears to exist.

The branches of the axillary artery are:

From first part, Superior thoracic.

From second part
- Acromio-thoracic.
- Long thoracic.
- Alar thoracic.

From third part
- Subscapular.
- Posterior circumflex.
- Anterior circumflex.

1. The **superior thoracic** (a. thoracalis suprema) is a small artery, which may arise by a common trunk with the acromio-thoracic. Running forwards and inwards along the upper border of the Pectoralis minor, it passes between it and the Pectoralis major to the side of the chest. It supplies these muscles, and

the parietes of the thorax, anastomosing with the internal mammary and intercostal arteries.

2. The **acromio-thoracic** (a. thoracoacromialis) is a short trunk, which arises from the fore part of the axillary artery, its origin being generally overlapped by the upper edge of the Pectoralis minor. Projecting forwards to the upper border of this muscle, it pierces the costo-coracoid membrane and divides into four branches—*pectoral*, *acromial*, *clavicular*, and *humeral*. The *pectoral branch* (ramus pectoralis) runs forwards and inwards between the two Pectoral muscles, and is distributed to them and to the mammary gland, anastomosing with the intercostal branches of the internal mammary. The *acromial branch* (ramus acromialis) is directed outwards towards the acromion, supplying the Deltoid muscle, and anastomosing, on the surface of the acromion, with the suprascapular and posterior circumflex arteries. The *clavicular branch* (ramus clavicularis) runs upwards and inwards to the sterno-clavicular joint, supplying this articulation, and the Subclavius muscle. The *humeral branch* (ramus deltoideus) passes, in the same groove as the cephalic vein, between the Pectoralis major and Deltoid, and gives branches to both muscles.

3. The **long thoracic** (a. thoracalis lateralis) passes downwards and inwards along the lower border of the Pectoralis minor to the side of the chest, supplying the Serratus magnus, the Pectoral muscles, and mammary gland, and sending branches across the axilla to the axillary glands and Subscapularis; it anastomoses with the internal mammary and intercostal arteries.

Fig. 595.—The scapular and circumflex arteries.

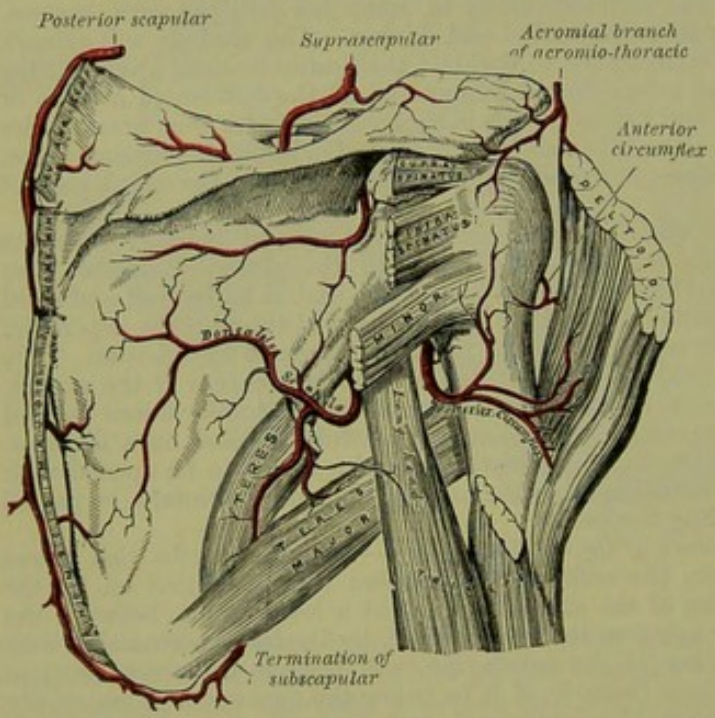

4. The **alar thoracic** is a small branch, which supplies the glands and areolar tissue of the axilla. Its place is frequently taken by branches from some of the other thoracic arteries.

5. The **subscapular** (a. subscapularis), the largest branch of the axillary artery, arises opposite the lower border of the Subscapularis, and passes downwards and backwards along this border to the inferior angle of the scapula, where it anastomoses with the long thoracic and intercostal arteries and with the posterior scapular branch of the transversalis colli, and terminates by supplying branches to the muscles in the neighbourhood. About an inch and a half from its origin it gives off a branch, the *dorsalis scapulæ*.

The **dorsalis scapulæ** (a. circumflexa scapulæ) is generally larger than the continuation of the subscapular. It curves round the axillary border of the scapula, leaving the axilla through the space between the Subscapularis above, the Teres major below, and the long head of the Triceps externally (fig. 595); it enters the infraspinous fossa under cover of the Teres minor, and anastomoses with the posterior scapular and suprascapular arteries. In its course it gives off two branches: one (*infrascapular*) enters the subscapular fossa beneath the Subscapularis which it supplies, anastomosing with the posterior scapular and suprascapular arteries; the other is continued along the axillary border of the scapula, between the Teres major and minor, and at the dorsal surface of the inferior angle anastomoses with the posterior scapular. In addition to these, small branches are distributed to the back part of the Deltoid muscle and the long head of the Triceps, anastomosing with an ascending branch of the superior profunda of the brachial.

6. The **posterior circumflex** (a. circumflexa humeri posterior) (fig. 595) arises from the back part of the axillary artery opposite the lower border of the Subscapularis muscle, and runs backwards with the circumflex veins and nerve

through the quadrangular space bounded by the Teres major and minor, the scapular head of the Triceps and the humerus. It winds round the neck of the humerus and is distributed to the Deltoid muscle and shoulder-joint, anastomosing with the anterior circumflex and acromio-thoracic arteries, and with the superior profunda branch of the brachial artery.

7. The **anterior circumflex** (a. circumflexa humeri anterior) (fig. 595), considerably smaller than the preceding, arises nearly opposite it, from the outer side of the axillary artery. It passes horizontally outwards, beneath the Coraco-brachialis and short head of the Biceps, lying upon the fore part of the neck of the humerus. On reaching the bicipital groove, it gives off an ascending branch which ascends along the groove to supply the head of the humerus and the shoulder-joint. The trunk of the vessel is then continued outwards beneath the Deltoid, which it supplies, and anastomoses with the posterior circumflex artery.

Peculiarities.—The branches of the axillary artery vary considerably in different subjects. Occasionally the subscapular, circumflex, and profunda arteries arise from a common trunk, and when this occurs the branches of the brachial plexus surround this trunk instead of the main vessel. Sometimes the axillary artery divides into the radial and ulnar arteries, and occasionally it gives origin to the anterior interosseous artery of the forearm.

Fig. 596.—The brachial artery.

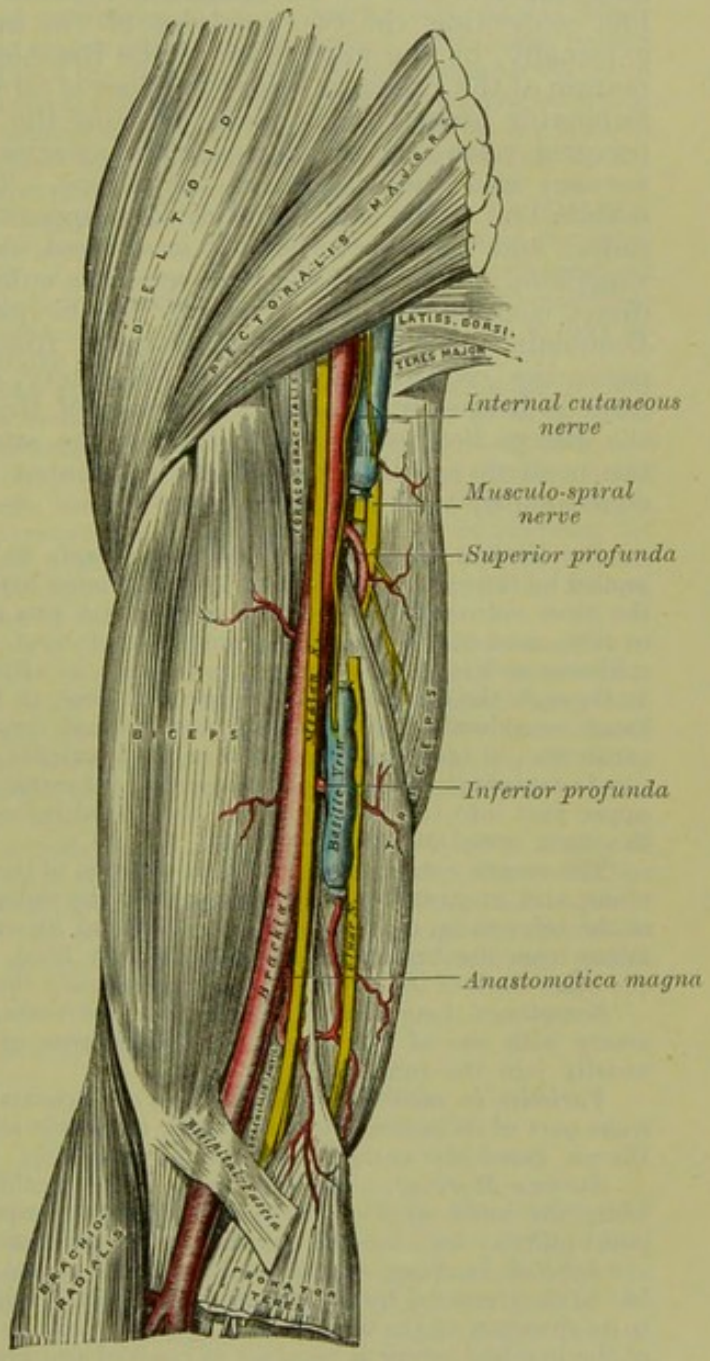

Brachial Artery
(fig. 596)

The **Brachial artery** (a. brachii) commences at the lower margin of the tendon of the Teres major, and, passing down the inner and anterior aspect of the arm, terminates about half an inch below the bend of the elbow, where it divides into the *radial* and *ulnar* arteries. At first the brachial artery lies internal to the humerus; but as it runs down the arm it gradually gets in front of the bone, and at the bend of the elbow it lies midway between the two condyles.

Relations.—The artery is superficial throughout its entire extent, being covered, *in front*, by the integument and the superficial and deep fasciæ; the bicipital fascia lies in front of it opposite the elbow and separates it from the vena mediana cubiti; the median nerve crosses it from without inwards opposite the insertion of the Coraco-brachialis. *Behind*, it is separated from the long head of the Triceps by the musculo-spiral nerve and superior profunda artery. It then lies upon the inner head of the Triceps, next upon the insertion of the Coraco-brachialis, and lastly on the Brachialis anticus. By its *outer side*, it is in relation with the commencement of the median nerve, and the Coraco-brachialis and Biceps,

the two muscles overlapping the artery to a considerable extent. By its *inner side*, its upper half is in relation with the internal cutaneous and ulnar nerves, its lower half with the median nerve. The basilic vein lies on its inner side, but is separated from it in the lower part of the arm by the deep fascia. The artery is accompanied by two venæ comites, which lie in close contact with it, being connected together at intervals by short transverse communicating branches.

Anatomy of the Bend of the Elbow (anticubital fossa)

At the bend of the elbow the brachial artery sinks deeply into a triangular interval. The base of the triangle is directed upwards, and is represented by a line connecting the two condyles of the humerus; the sides are bounded, externally, by the inner edge of the Brachio-radialis, internally, by the outer margin of the Pronator teres; the floor is formed by the Brachialis anticus and Supinator brevis. This space contains the brachial artery, with its accompanying veins; the radial and ulnar arteries: the median and musculo-spiral nerves; and the tendon of the Biceps. The brachial artery occupies the middle line of the space, and divides opposite the neck of the radius into the radial and ulnar arteries; it is covered, *in front*, by the integument, the superficial fascia, and the vena mediana cubiti, the vein being separated from direct contact with the artery by the bicipital fascia. *Behind*, it lies on the Brachialis anticus, which separates it from the elbow-joint. The median nerve lies on the inner side of the artery, close to it above, but separated from it below by the coronoid origin of the Pronator teres. The tendon of the Biceps lies to the outer side of the artery, and still more externally is the musculo-spiral nerve which is situated upon the Supinator brevis, and concealed by the Brachio-radialis.

Peculiarities of the brachial artery as regards its Course.—The brachial artery, accompanied by the median nerve, may leave the inner border of the Biceps, and descend towards the inner epicondyle of the humerus; about two inches above the epicondyle it usually in such cases curves round a prominence of bone, the *supracondylar process*, from which a fibrous arch is in most cases thrown over the artery; it then inclines outwards, beneath or through the substance of the Pronator teres, to the bend of the elbow. This variation bears considerable analogy with the normal condition of the artery in some of the carnivora: it has been referred to in the description of the humerus (page 298).

As regards its division.—Occasionally, the artery is divided for a short distance at its upper part into two trunks, which are united below. A similar peculiarity may occur in the main vessel of the lower limb.

The vessels concerned in the high division of the brachial artery are three: viz. radial, ulnar, and interosseous. Most frequently the radial is given off high up, the other limb of the bifurcation consisting of the ulnar and interosseous. In some instances the ulnar arises from the brachial above the ordinary level, and the radial and interosseous form the other limb of the division; and occasionally the interosseous arises high up.

Sometimes, long slender vessels, *vasa aberrantia*, connect the brachial or the axillary artery with one of the arteries of the forearm, or branches from them. These vessels usually join the radial.

*Varieties in muscular relations.**—The brachial artery is occasionally concealed, in some part of its course, by muscular or tendinous slips derived from the Coraco-brachialis, Biceps, Brachialis anticus, or Pronator teres.

Surface Marking.—The direction of the brachial artery is marked by a line drawn along the inner edge of the Biceps from the insertion of the Teres major muscle to a point midway between the epicondyles of the humerus.

Applied Anatomy.—In spite of the fact that the brachial artery is very superficial and but little protected by surrounding tissues, it is seldom wounded. This, no doubt, is due to its situation on the inner side of the arm, which is little exposed to injury. *Compression* of the brachial artery is required in cases of amputation and some other operations in the arm and forearm, and may be effected in almost any part of the course of the artery. If pressure be made in the upper part of the limb, it should be directed from within outwards; if in the lower part, from before backwards, as the artery lies on the inner side of the humerus above, and in front of it below. The most favourable situation is about the middle of the arm, where the artery lies on the tendon of the Coraco-brachialis on the inner surface of the humerus.

The *application of a ligature* to the brachial artery may be required in cases of wound of the vessel, and in some cases of wound of the palmar arch. It is also sometimes necessary in cases of aneurysm of the brachial, radial, ulnar, or interosseous arteries. The

* See Struthers's *Anatomical and Physiological Observations.*

artery may be secured in any part of its course. The chief guides in determining its position are the surface markings produced by the inner margins of the Coraco-brachialis and Biceps, and the known course of the vessel; its pulsation should be carefully felt for before any operation is performed, as the vessel occasionally deviates from its usual position. It is essential in applying a ligature to this vessel that the arm should be held away from the side, and supported only from the elbow, for if the arm be allowed to rest on any firm structure the Triceps is pressed forwards and overlaps the vessel, thus making the operation much more difficult.

In the upper third of the arm the artery may be exposed in the following manner. The patient being placed supine upon a table, the affected limb should be raised from the side, and the hand supinated. An incision about two inches in length should be made on the inner side of the Coraco-brachialis muscle, and the subjacent fascia cautiously divided, so as to avoid wounding the internal cutaneous nerve or basilic vein, as the latter sometimes runs on the surface of the artery as high as the axilla. The fascia having been divided, it should be remembered that the ulnar and internal cutaneous nerves lie on the inner side of the artery, the median on the outer side, the latter nerve being occasionally superficial to the artery in this situation, and that the venæ comites are also in relation with the vessel, one on either side. These being carefully separated, the aneurysm needle should be passed round the artery from the inner to the outer side.

In the case of a high division, the two arteries are usually placed side by side; and if they are exposed in an operation, the surgeon should endeavour to ascertain, by alternately pressing on each vessel, which of the two communicates with the wound or aneurysm, when a ligature may be applied accordingly; or if pulsation or hæmorrhage ceases only when both vessels are compressed, both vessels must be tied, as it may be concluded that the two communicate above the seat of disease, or are reunited.

In the middle of the arm the brachial artery may be exposed by making an incision along the inner margin of the Biceps muscle. The forearm being bent so as to relax the muscle, it should be drawn slightly aside, and the fascia carefully divided, when the median nerve will be exposed lying upon (sometimes beneath) the artery; this being drawn inwards and the muscle outwards, the artery should be separated from its accompanying veins and secured. In this situation the inferior profunda may be mistaken for the main trunk, especially if enlarged from the collateral circulation having become established; this may be avoided by directing the incision externally towards the Biceps, rather than inwards or backwards towards the Triceps.

The lower part of the brachial artery is of interest from a surgical point of view, on account of the relation which it bears to the veins most commonly opened in venesection. Of these vessels, the vena mediana cubiti is the largest and most prominent, and, consequently, the one usually selected for the operation. It should be remembered that this vein runs parallel with the brachial artery, from which it is separated by the bicipital fascia, and that care should be taken, in opening the vein, not to carry the incision too deep, so as to endanger the artery.

Collateral Circulation.—After the application of a ligature to the brachial artery in the upper third of the arm, the circulation is carried on by branches from the circumflex and subscapular arteries anastomosing with ascending branches from the superior profunda. If the brachial be tied *below* the origin of the profunda arteries, the circulation is maintained by the branches of the profundæ anastomosing with the recurrent radial, ulnar, and interosseous arteries.

The branches of the brachial artery are:

Superior profunda.	Inferior profunda.
Nutrient.	Anastomotica magna.
Muscular.	

1. The **superior profunda** (a. profunda brachii) arises from the inner and back part of the brachial, just below the lower border of the Teres major, and passes backwards to the interval between the outer and inner heads of the Triceps muscle, accompanied by the musculo-spiral nerve. It winds round the back of the shaft of the humerus in the spiral groove, between the outer head of the Triceps and the bone, to the external intermuscular septum where it divides into two terminal branches. One of these pierces the septum, and descends, in company with the musculo-spiral nerve, to the space between the Brachialis anticus and Brachio-radialis, where it anastomoses with the recurrent branch of the radial artery; the other, much larger, descends behind the external intermuscular septum to the back of the elbow-joint, where it anastomoses with the posterior interosseous recurrent, the posterior ulnar recurrent, the anastomotica magna, and inferior profunda (fig. 597). The superior profunda supplies the Triceps muscle and gives off a nutrient artery which enters the humerus at the upper end of the musculo-spiral groove. Near its commencement it sends a branch upwards

between the external and long heads of the Triceps muscle to anastomose with the posterior circumflex artery; and, while in the groove, a small branch which accompanies a branch of the musculo-spiral nerve through the substance of the Triceps muscle and ends in the Anconeus below the outer epicondyle of the humerus.

2. The **nutrient artery** of the shaft of the humerus arises about the middle of the arm and enters the nutrient canal near the insertion of the Coraco-brachialis muscle.

3. The **inferior profunda** (a. collateralis ulnaris superior), of small size, arises a little below the middle of the arm. It pierces the internal intermuscular septum, and descends on the surface of the inner head of the Triceps muscle, to the space between the inner epicondyle and olecranon, accompanied by the ulnar nerve, and terminates by anastomosing with the posterior ulnar recurrent and anastomotica magna. It sometimes sends a branch in front of the internal epicondyle, to anastomose with the anterior ulnar recurrent.

4. The **anastomotica magna** (a. collateralis ulnaris inferior) arises about two inches above the elbow-joint. It passes transversely inwards upon the Brachialis anticus, and piercing the internal intermuscular septum, winds round the back part of the humerus between the Triceps and the bone, forming, by its junction with the posterior branch of the superior profunda, an arch above the olecranon fossa. As the vessel lies on the Brachialis anticus, branches ascend to join the inferior profunda; others descend in front of the inner epicondyle, to anastomose with the anterior ulnar recurrent. Behind the internal epicondyle a branch is given off to anastomose with the inferior profunda and posterior ulnar recurrent arteries and supply the Triceps.

5. The **muscular** are three or four large branches, which are distributed to the muscles in the course of the artery. They supply the Coraco-brachialis, Biceps, and Brachialis anticus.

FIG. 597.—Diagram of the anastomosis around the elbow-joint.

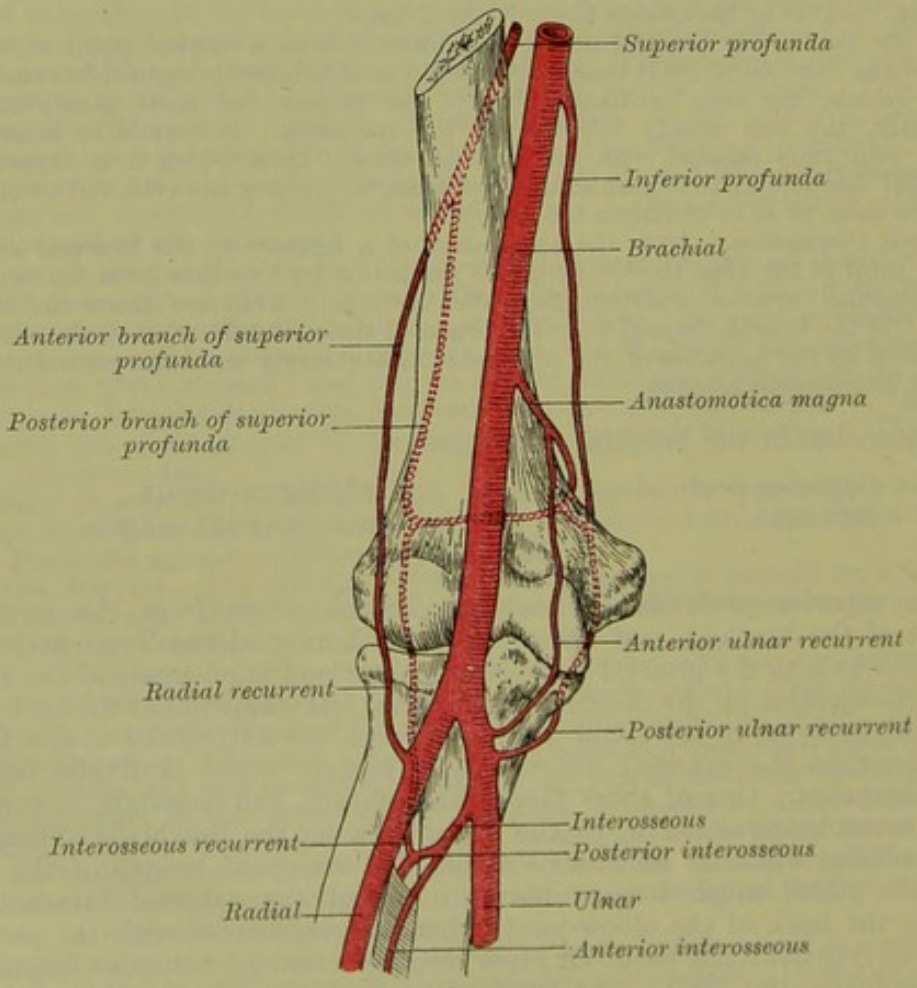

The **Anastomosis around the Elbow-joint** (fig. 597).—The vessels engaged in this anastomosis may be conveniently divided into those situated *in front* of,

and those *behind* the internal and external epicondyles. The branches anastomosing *in front* of the internal epicondyle are: the anterior branch of the anastomotica magna, the anterior ulnar recurrent, and the anterior branch of the inferior profunda. Those *behind* the internal epicondyle are: the anastomotica magna, the posterior ulnar recurrent, and the posterior terminal branch of the inferior profunda. The branches anastomosing *in front* of the external epicondyle are: the radial recurrent and the anterior terminal branch of the superior profunda. Those *behind* the external epicondyle (perhaps more properly described as being situated between the external epicondyle and the olecranon) are: the anastomotica magna, the interosseous recurrent, and the posterior terminal branch of the superior profunda. There is also a large arch of anastomosis above the olecranon, formed by the interosseous recurrent joining with the anastomotica magna and posterior ulnar recurrent (fig. 600).

From this description it will be observed that the anastomotica magna is the vessel most engaged, the only part of the anastomosis in which it is not employed being that in front of the external epicondyle.

Fig. 598.—The radial and ulnar arteries.

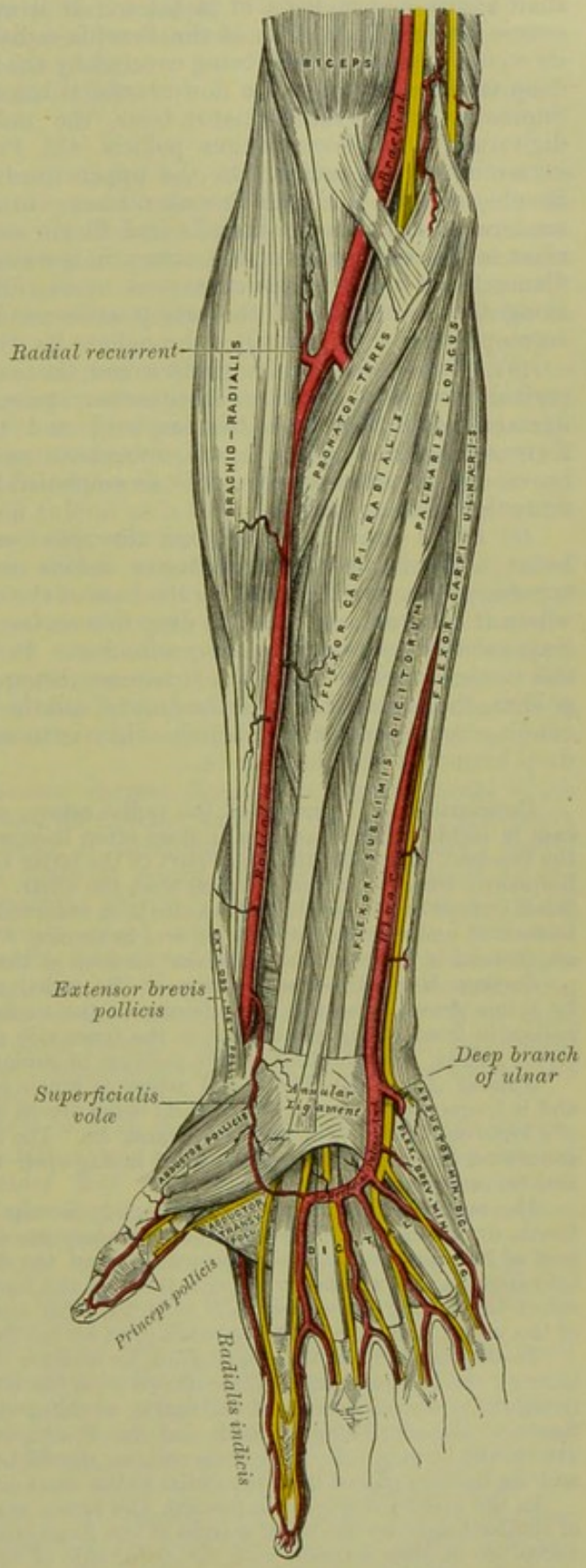

Radial Artery (fig. 598)

The **radial artery** (a. radialis) appears, from its direction, to be the continuation of the brachial, but it is smaller in calibre than the ulnar. It commences at the bifurcation of the brachial, just below the bend of the elbow, and passes along the radial side of the forearm to the wrist. It then winds backwards, round the outer side of the carpus, beneath the Extensor tendons of the thumb to the upper end of the space between the metacarpal bones of the thumb and index finger, and, finally, passes forwards between the two heads of the First dorsal interosseous muscle, into the palm of the hand, where it crosses the metacarpal bones to the ulnar border of the hand, to form the deep palmar arch. At its termination, it anastomoses with the deep branch of the ulnar artery. The relations of this

vessel may thus be conveniently divided into three parts, viz. in the forearm, at the back of the wrist, and in the hand.

Relations.—(*a*) *In the forearm* the artery extends from opposite the neck of the radius to the fore part of the styloid process, being placed to the inner side of the shaft above, and in front of it below. It is overlapped in the upper part of its course by the fleshy belly of the Brachio-radialis muscle; throughout the rest of its course it is superficial, being covered by the integument and the superficial and deep fasciæ. In its course downwards, it lies upon the tendon of the Biceps, the Supinator brevis, the Pronator teres, the radial origin of the Flexor sublimis digitorum, the Flexor longus pollicis, the Pronator quadratus, and the lower extremity of the radius. In the upper third of its course it lies between the Brachio-radialis and the Pronator teres; in its lower two-thirds, between the tendons of the Brachio-radialis and Flexor carpi radialis. The radial nerve lies close to the outer side of the artery in the middle third of its course; and some filaments of the musculo-cutaneous nerve, after piercing the deep fascia, run along the lower part of the artery as it winds round the wrist. The vessel is accompanied by venæ comites throughout its whole course.

(*b*) *At the wrist* as it winds round the outer side of the carpus, from the styloid process to the first interosseous space, it lies upon the external lateral ligament, and then upon the scaphoid and trapezium, being covered by the Extensor tendons of the thumb, subcutaneous veins, some filaments of the radial nerve, and the integument. It is accompanied by two veins, and a filament of the musculo-cutaneous nerve.

(*c*) *In the hand*, it passes from the upper end of the first interosseous space, between the heads of the Abductor indicis or First dorsal interosseous muscle, transversely across the palm, to the base of the metacarpal bone of the little finger, where it anastomoses with the deep branch from the ulnar artery, completing the *deep palmar arch* (arcus volaris profundus). It lies upon the carpal extremities of the metacarpal bones and the Interossei, being covered by the Adductor obliquus pollicis, the flexor tendons of the fingers, and the Lumbricales. Alongside of it, but running in the opposite direction—that is to say, from within outwards—is the deep branch of the ulnar nerve.

Peculiarities.—The origin of the radial artery, according to Quain, is, in nearly one case in eight, higher than usual; more often it arises from the axillary or upper part of the brachial, than from the lower part of the latter vessel. In the forearm it deviates less frequently from its normal position than the ulnar. It has been found lying on the deep fascia instead of beneath it. It has also been observed on the surface of the Brachio-radialis, instead of under its inner border; and in turning round the wrist, it has been seen lying on, instead of beneath, the Extensor tendons of the thumb.

Surface Marking.—The position of the radial artery in the forearm is represented by a line drawn from the outer border of the tendon of the Biceps in the centre of the hollow in front of the elbow-joint to the inner side of the fore part of the styloid process of the radius, with the limb in the position of supination.

Applied Anatomy.—The radial artery is much exposed to injury in its lower third, and is frequently wounded by the hand being driven through a pane of glass, by the slipping of a knife or chisel held in the other hand, &c. The injury may be followed by a traumatic aneurysm, for which the operation of laying open the sac and securing the vessel above and below is required.

The operation of tying the radial artery is required in cases of wounds either of its trunk, or of some of its branches, or for aneurysm: and the vessel may be exposed in any part of its course through the forearm without the division of any muscular fibres. The operation in the middle or inferior third of the forearm is easily performed; but in the upper third, near the elbow, it is attended with some difficulty, from the greater depth of the vessel, and from its being overlapped by the Brachio-radialis.

To tie the artery in the upper third, an incision three inches in length should be made through the integument, in a line drawn from the centre of the bend of the elbow to the front of the styloid process of the radius, avoiding the branches of the median vein; the fascia of the arm being divided, and the Brachio-radialis drawn a little outwards, the artery will be exposed. The venæ comites should be carefully separated from the vessel and the ligature passed from the radial to the ulnar side.

In the middle third of the forearm the artery may be exposed by making an incision of similar length on the inner margin of the Brachio-radialis. In this situation, the radial nerve lies in close relation with the outer side of the artery, and should, as well as the veins, be carefully avoided.

In the lower third, the artery is easily secured by dividing the integument and fascia in the interval between the tendons of the Brachio-radialis and Flexor carpi radialis.

The branches of the radial artery may be divided into three groups, corresponding with the three regions in which the vessel is situated.

In the forearm.	*At the wrist.*	*In the hand.*
Radial recurrent.	Posterior radial carpal.	Princeps pollicis.
Muscular.	First dorsal interosseous.	Radialis indicis.
Anterior radial carpal.	Dorsales pollicis.	Perforating.
Superficialis volæ.	Dorsalis indicis.	Palmar interosseous.
		Recurrent.

The **radial recurrent** (a. recurrens radialis) is given off immediately below the elbow. It ascends between the branches of the musculo-spiral nerve, lying on the Supinator brevis and then between the Brachio-radialis and Brachialis anticus, supplying these muscles and the elbow-joint, and anastomosing with the anterior terminal branch of the superior profunda.

The **muscular branches** (rami musculares) are distributed to the muscles on the radial side of the forearm.

The **anterior radial carpal** (ramus carpeus volaris) is a small vessel which arises near the lower border of the Pronator quadratus, and, running inwards in front of the carpus, anastomoses with the anterior carpal branch of the ulnar artery. In this way an arterial anastomosis, the *anterior carpal arch*, is formed in front of the wrist: it is joined by branches from the anterior interosseous above, and by recurrent branches from the deep palmar arch below, and gives off twigs which descend to supply the articulations of the wrist and carpus.

The **superficialis volæ** (ramus volaris superficialis) arises from the radial artery, just where this vessel is about to wind round the outer side of the wrist. Running forwards, it passes through, occasionally over, the muscles of the thumb, which it supplies, and sometimes anastomoses with the terminal portion of the ulnar artery, completing the superficial palmar arch. This vessel varies considerably in size: usually it is very small, and terminates in the muscles of the thumb; sometimes it is as large as the continuation of the radial.

The **posterior radial carpal** (ramus carpeus dorsalis) is a small vessel which arises beneath the Extensor tendons of the thumb; crossing the carpus transversely towards the inner border of the hand, it anastomoses with the posterior carpal branch of the ulnar, forming the *posterior carpal arch*, which is joined by the termination of the anterior interosseous artery. From this arch are given off two slender *dorsal interosseous arteries*, which run forwards on the Third and Fourth dorsal interossei and bifurcate into dorsal digital branches which supply the adjacent sides of the middle, ring, and little fingers respectively, communicating with the collateral digital branches of the superficial palmar arch. Near their origins they anastomose with the deep palmar arch by the *superior perforating arteries*, and near their points of bifurcation with the digital vessels of the superficial palmar arch by the *inferior perforating arteries*.

The **first dorsal interosseous** arises beneath the Extensor tendons of the thumb, sometimes with the posterior radial carpal; running forwards on the Second dorsal interosseous muscle it divides into two dorsal digital branches, which supply the adjoining sides of the index and middle fingers; it forms anastomoses similar to those of the other two dorsal interosseous arteries.

The **dorsales pollicis** are two small vessels which run along the sides of the dorsal aspect of the thumb. They usually arise separately, but occasionally by a common trunk, near the base of the first metacarpal bone.

The **dorsalis indicis**, also a small branch, runs along the radial side of the back of the index finger, sending a few branches to the Abductor indicis.

The **princeps pollicis** (a. princeps pollicis) arises from the radial just as it turns inwards to the deep part of the hand; it descends between the Abductor indicis and Adductor obliquus pollicis, along the ulnar side of the metacarpal bone of the thumb to the base of the first phalanx, where it lies beneath the tendon of the Flexor longus pollicis and divides into two branches. These make their appearance between the inner and outer insertions of the Adductor obliquus pollicis, and run along the sides of the palmar aspect of the thumb, forming on the palmar surface of the last phalanx an arch, from which branches are distributed to the integument and subcutaneous tissue of the thumb.

The **radialis indicis** (a. volaris indicis radialis) arises close to the preceding, descends between the Abductor indicis and Adductor transversus pollicis, and runs along the radial side of the index finger to its extremity, where it anastomoses with the collateral digital artery from the superficial palmar arch. At the lower border of the Adductor transversus pollicis, this vessel anastomoses with the princeps pollicis, and gives a communicating branch to the superficial palmar arch.

Fig. 599.—Ulnar and radial arteries. Deep view.

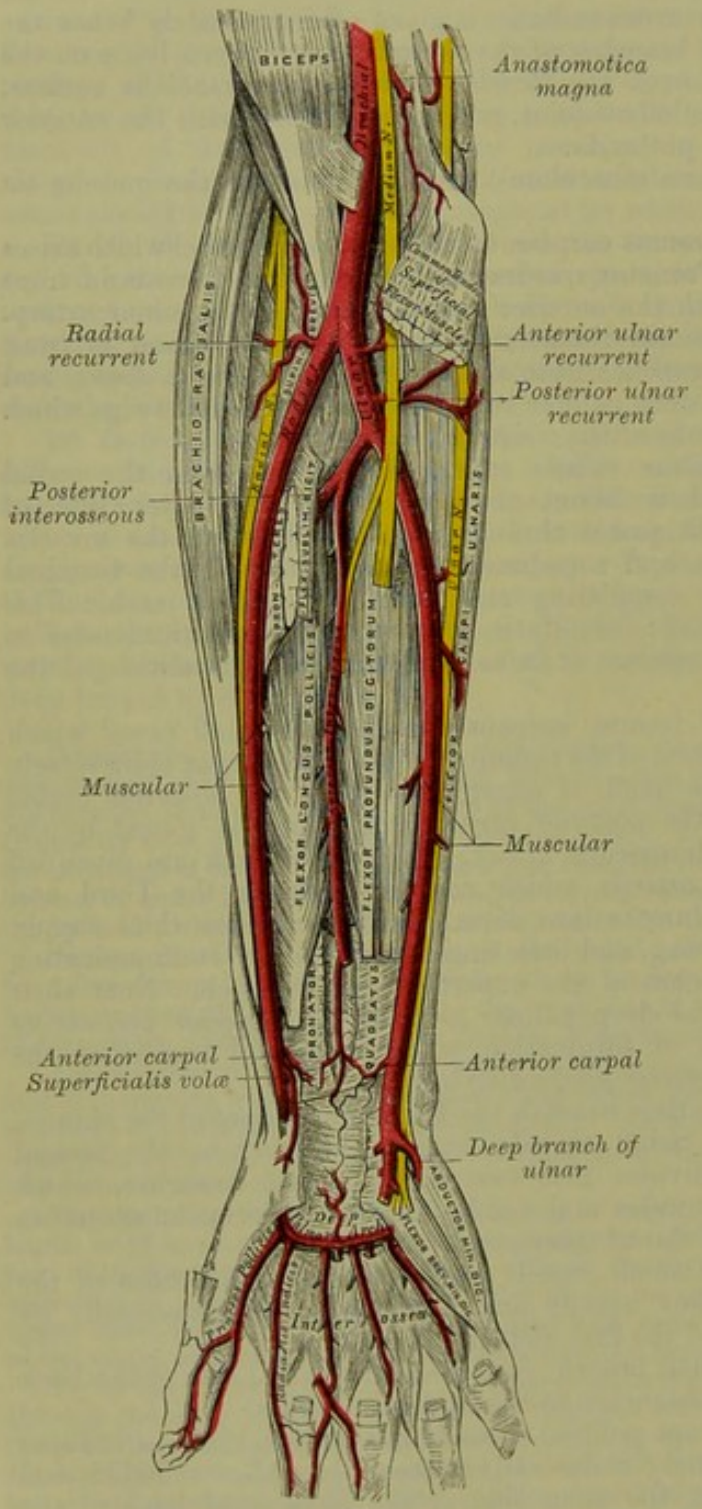

The **perforating arteries** (rami perforantes), three in number, pass backwards from the deep palmar arch, through the second, third, and fourth interosseous spaces and between the heads of the corresponding Interossei, to anastomose with the dorsal interosseous arteries.

The **palmar interosseous** (aa. metacarpeæ volares), three or four in number, arise from the convexity of the deep palmar arch; they run downwards upon the Interossei, and anastomose at the clefts of the fingers with the digital branches of the superficial arch.

The **recurrent branches** arise from the concavity of the deep palmar arch. They ascend in front of the wrist, supplying the carpal articulations and anastomosing with the anterior carpal arch.

Ulnar Artery (fig. 599)

The **ulnar artery** (a. ulnaris), the larger of the two terminal branches of the brachial, commences a little below the bend of the elbow, and, passing obliquely downwards and inwards, reaches the inner side of the forearm at a point about midway between the elbow and the wrist. It then runs along the ulnar border to the wrist, crosses the annular ligament on the radial side of the pisiform bone, and immediately beyond this bone divides into two branches, which enter into the formation of the superficial and deep palmar arches.

Relations. (*a*) *In the forearm.*—In its *upper half*, it is deeply seated, being covered by all the superficial Flexor muscles, except the Flexor carpi ulnaris; it lies upon the Brachialis anticus and Flexor profundus digitorum muscles. The median nerve is in relation with the inner side of the artery for about an inch and then crosses the vessel, being separated from it by the deep head of the Pronator

teres. In the *lower half* of the forearm, it lies upon the Flexor profundus, being covered by the integument, and the superficial and deep fasciæ, and is placed between the Flexor carpi ulnaris and Flexor sublimis digitorum muscles. It is accompanied by two venæ comites, and is overlapped in its middle third by the Flexor carpi ulnaris; the ulnar nerve lies on its inner side for the lower two-thirds of its extent, and a small branch from the nerve descends on the lower part of the vessel to the palm of the hand.

(*b*) *At the wrist* (fig. 598) the ulnar artery is covered by the integument and fascia, and lies upon the anterior annular ligament. On its inner side is the pisiform bone, and, somewhat behind the artery, the ulnar nerve. The nerve and artery are crossed by a band of fibres, which extends from the pisiform bone to the anterior annular ligament.

Peculiarities.—The ulnar artery has been found to vary in its origin nearly in the proportion of one in thirteen cases; it may arise lower than usual, about two or three inches below the elbow, but usually much higher, the brachial being more often the source of origin than the axillary. Variations in the position of this vessel are more common than in the radial. When its origin is normal, the course of the vessel is rarely changed. When it arises high up, it is almost invariably superficial to the Flexor muscles in the forearm, lying commonly beneath the fascia, more rarely between the fascia and integument. In a few cases, its position was subcutaneous in the upper part of the forearm, and subaponeurotic in the lower part.

Surface Marking.—On account of the curved direction of the ulnar artery, the line on the surface of the limb which indicates its course is somewhat complicated. First, draw a line from the front of the internal epicondyle of the humerus to the radial side of the pisiform bone; the lower two-thirds of this line represent the course of the middle and lower thirds of the artery. Secondly, draw a line from the centre of the hollow in front of the elbow-joint to the junction of the upper and middle thirds of the first line; this represents the course of the upper third of the artery.

Applied Anatomy.—The application of a ligature to this vessel is required in cases of wound of the artery, or of its branches, or in consequence of aneurysm. In the upper half of the forearm the artery is deeply seated beneath the superficial Flexor muscles, and the application of a ligature in this situation is attended with some difficulty. An incision is to be made in the course of a line drawn from the front of the internal epicondyle of the humerus to the outer side of the pisiform bone, so that the centre of the incision is three fingers' breadth below the internal epicondyle. The skin and superficial fascia having been divided, and the deep fascia exposed, the white line which separates the Flexor carpi ulnaris from the other Flexor muscles is to be sought for, and the fascia incised in this line. The Flexor carpi ulnaris is now to be carefully separated from the other muscles, when the ulnar nerve will be exposed lying on the Flexor profundus digitorum, and must be drawn aside. Some little distance below the nerve, the artery will be found accompanied by its venæ comites, and may be ligatured, the needle being passed from within outwards. In the middle and lower thirds of the forearm, this vessel may be easily secured by making an incision on the radial side of the tendon of the Flexor carpi ulnaris: when the deep fascia is divided, and the Flexor carpi ulnaris and the Flexor sublimis separated from each other, the vessel will be exposed, accompanied by its venæ comites, the ulnar nerve lying on its inner side. The veins being separated from the artery, the ligature should be passed from the ulnar to the radial side, taking care to avoid the ulnar nerve.

The branches of the ulnar artery may be arranged in the following groups:

- *In the forearm*
  - Recurrent
    - Anterior.
    - Posterior.
  - Interosseous
    - Anterior interosseous.
    - Posterior interosseous.
  - Muscular.
- *At the wrist*
  - Anterior ulnar carpal.
  - Posterior ulnar carpal.
- *In the hand*
  - Profunda.
  - Superficial palmar arch.

The **recurrent branches** (aa. recurrentes ulnares) are two in number, anterior and posterior. The *anterior ulnar recurrent* arises immediately below the elbow-joint, runs upwards and inwards between the Brachialis anticus and Pronator teres, supplies twigs to those muscles, and, in front of the inner epicondyle, anastomoses with the anastomotica magna and inferior profunda. The *posterior ulnar recurrent* is much larger, and arises somewhat lower than the preceding.

It passes backwards and inwards, beneath the Flexor sublimis, and ascends behind the inner epicondyle of the humerus. In the interval between this process and the olecranon, it lies beneath the Flexor carpi ulnaris, and ascending between the heads of that muscle, in relation with the ulnar nerve, it supplies

Fig. 600.—Arteries of the back of the forearm and hand.

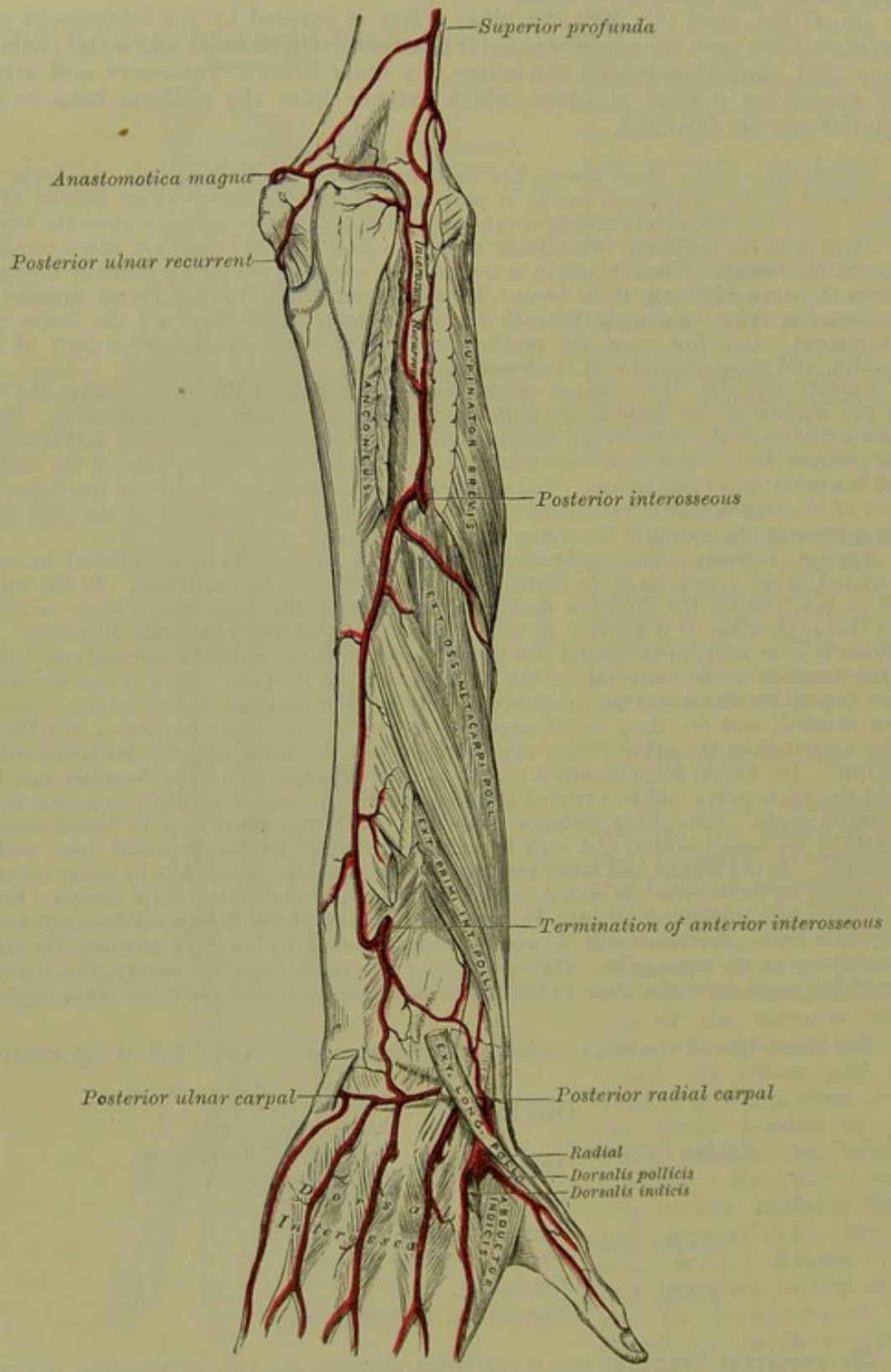

the neighbouring muscles and the elbow-joint, and anastomoses with the inferior profunda, anastomotica magna, and interosseous recurrent arteries (fig. 600).

The **interosseous** (a. interossea communis) (fig. 599) is a short trunk about half an inch in length, and of considerable size, which arises immediately below

the tuberosity of the radius, and, passing backwards to the upper border of the interosseous membrane, divides into two branches, the *anterior* and *posterior interosseous arteries.*

The **anterior interosseous** (a. interossea volaris) (fig. 599) passes down the forearm on the anterior surface of the interosseous membrane. It is accompanied by the interosseous branch of the median nerve, and overlapped by the contiguous margins of the Flexor profundus digitorum and Flexor longus pollicis, giving off in this situation *muscular* branches, and the *nutrient* arteries of the radius and ulna. At the upper border of the Pronator quadratus, a branch descends beneath that muscle, to anastomose in front of the carpus with the anterior carpal arch. The continuation of the artery passes behind the Pronator quadratus, and, piercing the interosseous membrane, reaches the back of the forearm, and anastomoses with the posterior interosseous artery (fig. 600). It then descends, in company with the terminal portion of the posterior interosseous nerve, to the back of the wrist to join the posterior carpal arch. The anterior interosseous gives off a long, slender branch, the *comes nervi mediani* (a. mediana), which accompanies the median nerve, and gives offsets to its substance; this artery is sometimes much enlarged, and runs with the nerve into the palm of the hand.

The **posterior interosseous** (a. interossea dorsalis) passes backwards through the interval between the oblique ligament and the upper border of the interosseous membrane. It appears between the contiguous borders of the Supinator brevis and the Extensor ossis metacarpi pollicis, and runs down the back of the forearm between the superficial and deep layers of muscles, to both of which it distributes branches (fig. 600). Where it lies upon the Extensor ossis metacarpi pollicis and the Extensor brevis pollicis, it is accompanied by the posterior interosseous nerve. At the lower part of the forearm it anastomoses with the termination of the anterior interosseous artery, and with the posterior carpal arch. It gives off, near its origin, the *interosseous recurrent branch* (a. interossea recurrens), which ascends to the interval between the external epicondyle and olecranon, on or through the fibres of the Supinator brevis, but beneath the Anconeus, and anastomoses with the posterior branch of the superior profunda, and with the posterior ulnar recurrent and anastomotica magna.

The **muscular branches** are distributed to the muscles along the ulnar side of the forearm.

The **anterior ulnar carpal** (ramus carpeus volaris) is a small vessel which crosses the front of the carpus beneath the tendons of the Flexor profundus, and anastomoses with a corresponding branch of the radial artery.

The **posterior ulnar carpal** (ramus carpeus dorsalis) arises immediately above the pisiform bone, and winds backwards beneath the tendon of the Flexor carpi ulnaris; it passes across the dorsal surface of the carpus beneath the Extensor tendons, to anastomose with a corresponding branch of the radial artery, and complete the *posterior carpal arch.* Immediately after its origin, it gives off a small branch, which runs along the ulnar side of the fifth metacarpal bone, and supplies the ulnar side of the dorsal surface of the little finger.

The **profunda branch** (ramus volaris profundus) (fig. 599) passes between the Abductor minimi digiti and Flexor brevis minimi digiti, near their origins; it anastomoses with the termination of the radial artery, and completes the deep palmar arch.

The **superficial palmar arch** (arcus volaris superficialis) (fig. 598) is formed by the ulnar artery in the hand, and is usually completed on the outer side by a branch from the radialis indicis, but sometimes by the superficialis volæ or by a branch from the princeps pollicis of the radial artery. The arch passes across the palm, describing a curve, with its convexity downwards.

Relations.—The superficial palmar arch is covered by the skin, the Palmaris brevis and the palmar fascia. It lies upon the annular ligament, the Flexor brevis and Opponens minimi digiti, the tendons of the Flexor sublimis digitorum, the Lumbrical muscles, and the divisions of the median and ulnar nerves.

Four digital arteries (aa. digitales volares communes) (fig. 598) are given off from the convexity of this arch. The innermost accompanies the inner digital branch of the ulnar nerve, and runs along the ulnar side of the little finger; it is joined by a twig from the deep palmar arch or from the innermost palmar interosseous artery. The three outer run downwards in front of the three inner interosseous spaces, superficial to the corresponding nerves and Lumbrical muscles.

A little above the interdigital clefts they are joined by the palmar interosseous arteries, and by the inferior perforating branches of the dorsal interosseous arteries. Each then divides into *collateral digital arteries* (aa. digitales volares propriæ) for the supply of the contiguous sides of the index, middle, ring, and little fingers. These collateral branches lie behind the corresponding digital nerves; they anastomose freely in the subcutaneous tissue of the finger-tip, and by smaller branches near the interphalangeal joints. Each gives off a couple of dorsal branches which anastomose with the dorsal digital arteries, and supply the soft parts on the back of the second and third phalanges, including the matrix of the finger-nail.

Surface Marking.—The superficial palmar arch is represented by a curved line, starting from the outer side of the pisiform bone, and carried downwards and outwards as far as the base of the thumb, with the convexity towards the fingers. The lowest point of the arch is usually on a level with the lower border of the outstretched thumb.

The deep palmar arch is situated about half an inch nearer to the carpus.

Applied Anatomy.—Wounds of the palmar arches are of special interest, and are always difficult to deal with. When the superficial arch is wounded it is generally possible, enlarging the wound when necessary, to secure the vessel and tie it on both sides of the bleeding point; or in cases where it is found impossible to encircle the vessel with a ligature, a pair of Wells's artery clips may be applied and left on for twenty-four or forty-eight hours. Failing this, the wound may be plugged with gauze and an outside dressing carefully bandaged on. The plug should be allowed to remain untouched for three or four days. It is useless in these cases to ligature one of the arteries of the forearm alone, and indeed simultaneous ligature of both radial and ulnar arteries above the wrist is often unsuccessful, on account of the anastomosis carried on by the carpal arches. Therefore, upon the failure of pressure to arrest hæmorrhage, it is expedient to apply a ligature to the brachial artery. When an incision for deep-seated suppuration in the tendon-sheath is required, the situation of the superficial arch must always be borne in mind, and the incisions placed either above or below it. The position of the digital branches of the artery must also be remembered, and incisions must be made opposite the heads of the metacarpal bones and not between them.

ARTERIES OF THE TRUNK

The Descending Aorta

The **descending aorta** is divided into two portions, the *thoracic* and *abdominal*, in correspondence with the two great cavities of the trunk in which it is situated.

The Thoracic Aorta

The **thoracic aorta** (aorta thoracalis) is contained in the back part of the posterior mediastinum. It commences at the lower border of the fourth thoracic vertebra, and terminates in front of the lower border of the twelfth at the aortic opening in the Diaphragm. At its commencement, it is situated on the left side of the vertebral column; it approaches the median line as it descends; and, at its termination, lies directly in front of the column. Its direction being influenced by the vertebral column, upon which it rests, the vessel describes a curve which is concave forwards. As the branches given off from it are small, its diminution in size is inconsiderable.

Relations.—It is in relation, *in front*, from above downwards, with the root of the left lung, the pericardium, the œsophagus, and the Diaphragm; *behind*, with the vertebral column, and the azygos minor veins; on the *right side*, with the vena azygos major, and thoracic duct; on the *left side*, with the left pleura and lung. The œsophagus, with its accompanying nerves, lies on the right side of the aorta above; but at the lower part of the thorax it is placed in front of the aorta, and, close to the Diaphragm, is situated to its left side.

Peculiarities.—The aorta is occasionally found to be obliterated at the junction of the arch with the thoracic aorta, just below the ductus arteriosus. Whether this is the result of disease, or of congenital malformation, is immaterial to our present purpose; it affords an interesting opportunity of observing the resources of the collateral circulation. The course of the anastomosing vessels, by which the blood is brought from the upper to the lower part of the artery, will be found well described in an account of two cases in the 'Pathological Transactions,' vols. viii. and x. In the former, Sydney Jones thus sums up the detailed description of the anastomosing vessels: 'The principal

communications by which the circulation was carried on, were—Firstly, the internal mammary, anastomosing with the intercostal arteries, with the phrenic of the abdominal aorta by means of the musculo-phrenic and comes nervi phrenici, and largely with the deep epigastric. Secondly, the superior intercostal, anastomosing anteriorly by means of a large branch with the first aortic intercostal, and posteriorly with the posterior branch of the same artery. Thirdly, the inferior thyroid, by means of a branch about the size of an ordinary radial, forming a communication with the first aortic intercostal. Fourthly,

Fig. 601.—Thoracic aorta from right side.

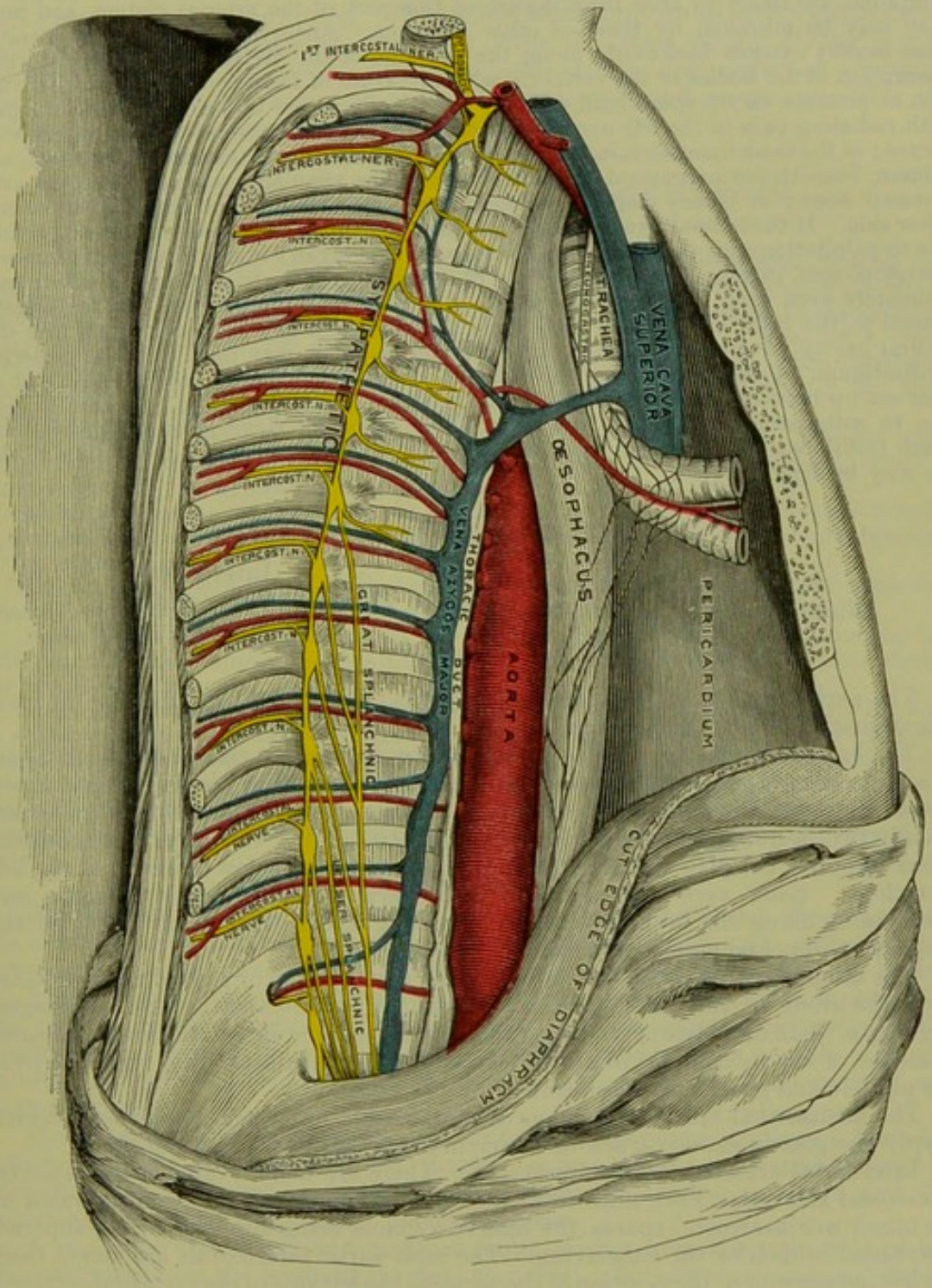

the transversalis colli, by means of very large communications with the posterior branches of the intercostals. Fifthly, the branches (of the subclavian and axillary) going to the side of the chest were large, and anastomosed freely with the lateral branches of the intercostals.' In the second case Wood describes the anastomoses in a somewhat similar manner, adding the remark, that 'the blood which was brought into the aorta through the anastomoses of the intercostal arteries appeared to be expended principally in supplying the abdomen and pelvis; while the supply to the lower extremities had passed through the internal mammary and epigastrics.'

In a few cases an apparently double descending thoracic aorta has been found, the two vessels lying side by side, and eventually fusing to form a single tube in the lower part of the thorax or in the abdomen. One of them is the aorta, the other represents a dissecting aortic aneurysm which has become canalised, opening above and below into the true aorta, and at first sight presenting the appearances of a proper blood-vessel.

Applied Anatomy.—The effects likely to be produced by aneurysm of the thoracic aorta, a disease of common occurrence, must now be considered. When the great depth of the vessel from the surface, and the number of important structures which surround it on every side are remembered, it may easily be conceived what a variety of obscure symptoms are likely to arise from disease of this part of the arterial system, and how they may be mistaken for those of other affections. Aneurysm of the thoracic aorta most usually extends backwards, along the left side of the vertebral column, producing absorption of the bodies of the vertebræ, with curvature of the column; while the irritation or pressure on the spinal cord will give rise to pain, either in the chest, back, or loins, with radiating pain in the left upper intercostal spaces, from pressure on the intercostal nerves; at the same time the tumour may project backwards on either side of the vertebral column, beneath the integument, as a pulsating swelling, simulating abscess connected with diseased bone; or it may displace the œsophagus, and compress the lungs on one or the other side. If the tumour extend forward, it may press upon and displace the heart, giving rise to palpitation and other symptoms of disease of that organ; it may displace or compress the œsophagus, causing pain and difficulty of swallowing, as in stricture of that tube; and ultimately even open into it by ulceration, producing fatal hæmorrhage. If the disease extend to the right side, it may press upon the thoracic duct; or it may burst into the pleural cavity, or into the trachea or lung; and lastly, it may open into the posterior mediastinum. Pressure on one of the bronchi, usually the left, will cause cough, and in time set up bronchiectasis; pressure on the left pulmonary plexus has been said to give rise to asthmatic attacks. Of late years, the diagnosis of thoracic aneurysm has been much facilitated by the employment of the *x*-rays, by means of which the outline of the sac may be demonstrated.

Branches of the Thoracic Aorta

- Visceral
  - Pericardial.
  - Bronchial.
  - Œsophageal.
  - Mediastinal.
- Parietal
  - Intercostal.
  - Subcostal.
  - Superior phrenic.

The **pericardial** (rami pericardiaci) are a few small vessels, irregular in their origin, distributed to the pericardium.

The **bronchial arteries** (aa. bronchiales) vary in number, size, and origin. There is as a rule only one *right bronchial artery*, which arises from the first aortic intercostal, or from the upper left bronchial artery. The *left bronchial arteries* are usually two in number, and arise from the thoracic aorta. The upper left bronchial arises opposite the fifth thoracic vertebra, the lower just below the level of the left bronchus. Each vessel runs on the back part of its bronchus, dividing and subdividing along the bronchial tubes, supplying them, the cellular tissue of the lungs, the bronchial glands, and the œsophagus.

The **œsophageal arteries** (aa. œsophageæ), usually four or five in number, arise from the front of the aorta, and pass obliquely downwards to the œsophagus, forming a chain of anastomoses along that tube, anastomosing with the œsophageal branches of the inferior thyroid arteries above, and with ascending branches from the phrenic and gastric arteries below.

The **mediastinal branches** (rami mediastinales) are numerous small vessels which supply the glands and loose areolar tissue in the posterior mediastinal space.

Intercostal arteries (aa. intercostales). There are usually nine pairs of aortic intercostal arteries. They arise from the back of the aorta, and are distributed to the nine lower intercostal spaces, the first two spaces being supplied by the superior intercostal branch of the subclavian. The *right* aortic intercostals are longer than the left, on account of the position of the aorta on the left side of the vertebral column; they pass across the bodies of the vertebræ behind the œsophagus, thoracic duct, and vena azygos major, and are covered by the right lung and pleura. The *left* aortic intercostals run backwards on the sides of the vertebræ and are covered by the left lung and pleura; the two upper vessels are crossed by the left superior intercostal vein, the lower vessels by the azygos minor veins. The further course of the intercostal arteries is practically the same on both sides. Opposite the heads of the ribs the sympathetic cord passes downwards in front of them, and the splanchnic nerves also descend in front of the lower arteries. Each artery crosses

the corresponding intercostal space obliquely towards the angle of the upper rib, and thence is continued forward in the subcostal groove. It is placed at first between the pleura and the posterior intercostal membrane, then it pierces this membrane, and lies between it and the External intercostal muscle as far as the rib angle ; from this onward it runs between the External and Internal intercostal muscles, and anastomoses in front with the anterior intercostal branch of the internal mammary or musculo-phrenic. Each artery is accompanied by a vein and a nerve, the former being above and the latter below the artery, except in the upper spaces, where the nerve is at first above the artery. The highest aortic intercostal artery anastomoses with the superior intercostal, and may form the chief supply of the second intercostal space. The two lower intercostal arteries are continued anteriorly from the intercostal spaces into the abdominal wall, and anastomose with the subcostal, superior epigastric and lumbar arteries.

Each intercostal artery gives off the following branches :

Posterior or dorsal.	Collateral intercostal.
Muscular.	Lateral cutaneous.

The *posterior* or *dorsal branch* (ramus posterior) runs with the posterior division of a spinal nerve and passes backwards through a small opening which is bounded above and below by the necks of the ribs and adjacent transverse processes, internally by the vertebral body, and externally by the anterior costo-transverse ligament. It gives off a *spinal branch*, which enters the spinal canal through the intervertebral foramen and is distributed to the spinal cord and its membranes, and to the bodies of the vertebræ, in the same manner as the lateral spinal branches from the vertebral.

The *collateral intercostal branch* comes off from the intercostal artery near the angle of the rib, and descends to the upper border of the rib below, along which it courses to anastomose with the anterior intercostal branch of the internal mammary.

Muscular branches (rami musculares) are given to the Intercostal and Pectoral muscles and to the Serratus magnus ; they anastomose with the superior and long thoracic branches of the axillary artery.

The *lateral cutaneous branches* (rami cutanei laterales) accompany the lateral cutaneous branches of the intercostal nerves, and divide into anterior and posterior branches.

Mammary branches are given off by the intercostal arteries in the third, fourth, and fifth spaces. They supply the mammary gland, and increase considerably in size during the period of lactation.

Applied Anatomy.—The position of the intercostal vessels should be borne in mind in performing the operation of paracentesis thoracis. The puncture should never be made nearer the middle line posteriorly than the angle of the rib, as the artery crosses the space internal to this point. In the lateral portion of the chest, where the puncture is usually made, the artery lies at the upper part of the intercostal space, and therefore the puncture should be made just above the upper border of the rib forming the lower boundary of the space.

The **subcostal arteries**, so named because they lie below the last ribs, constitute the lowest pair of branches derived from the thoracic aorta, and are in series with the intercostal arteries. Each passes along the lower border of the twelfth rib behind the kidney and in front of the Quadratus lumborum muscle, and is accompanied by the twelfth thoracic nerve. It then pierces the posterior aponeurosis of the Transversalis abdominis, and, passing forward between this muscle and the Internal oblique, anastomoses with the superior epigastric, lower intercostal, and lumbar arteries.

The **superior phrenic branches** (aa. phrenicæ superiores) are small branches arising from the lower part of the thoracic aorta ; they are distributed to the posterior part of the upper surface of the Diaphragm, and anastomose with the musculo-phrenic and comes nervi phrenici arteries.

A small *aberrant* artery is sometimes found arising from the right side of the thoracic aorta near the origin of the right bronchial. It passes upwards and to the right behind the trachea and the œsophagus, and may anastomose with the right superior intercostal artery. It represents the remains of the right dorsal aortic trunk, and in a small proportion of cases is enlarged to form the first part of the right subclavian artery.

The Abdominal Aorta (fig. 602)

The **abdominal aorta** (aorta abdominalis) commences at the aortic opening of the Diaphragm, in front of the lower border of the body of the

last thoracic vertebra, and, descending a little to the left side of the vertebral column, terminates on the body of the fourth lumbar vertebra, commonly a little to the left of the middle line,* by dividing into the two common

FIG. 602.—The abdominal aorta and its branches.

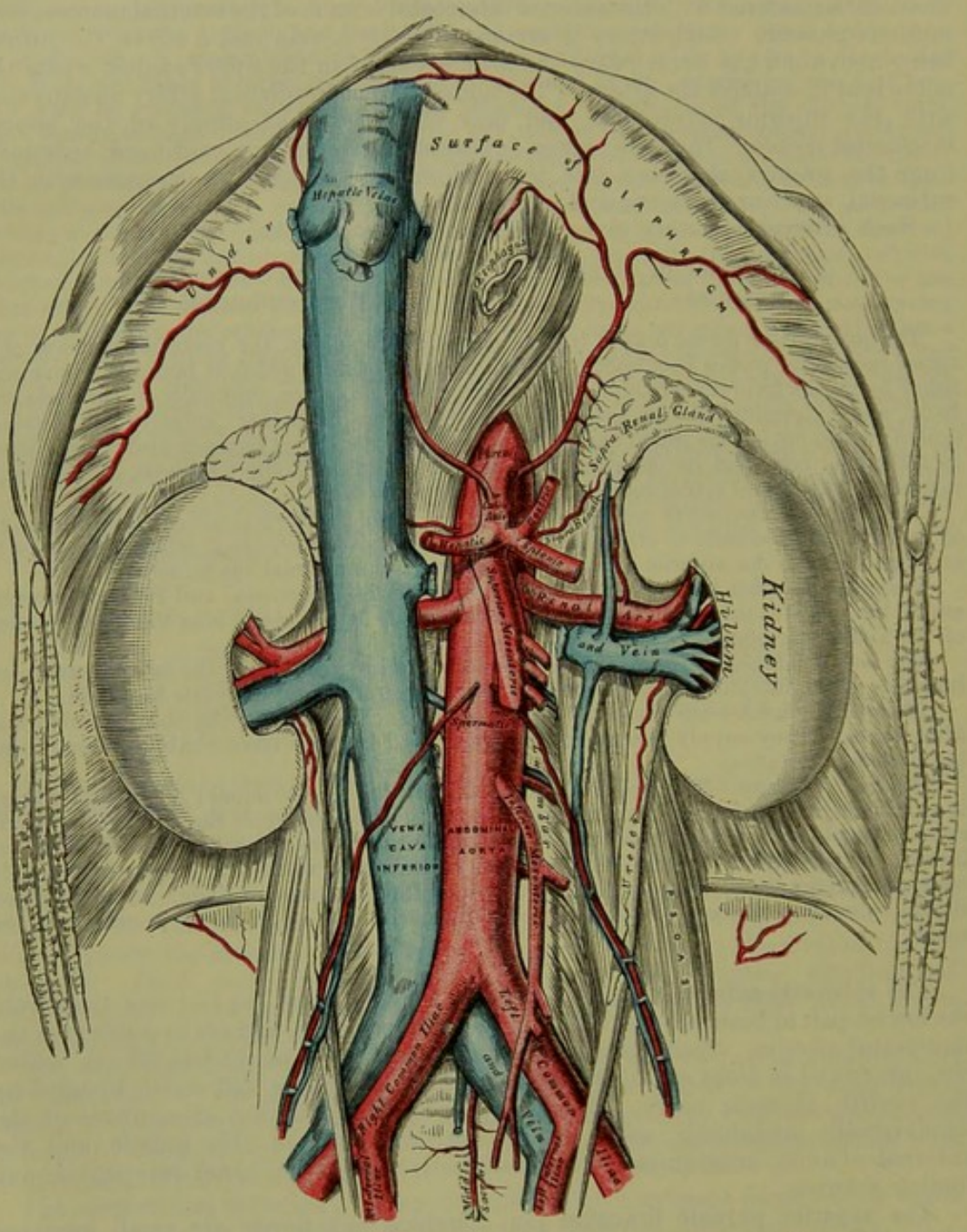

iliac arteries. It diminishes rapidly in size, in consequence of the many large branches which it gives off. As it lies upon the bodies of the vertebræ, the curve which it describes is convex forwards, the summit of the convexity corresponding to the third lumbar vertebra.

Relations.—The abdominal aorta is covered, *in front*, by the lesser omentum and stomach, behind which are the branches of the cœliac axis, and the solar plexus; below these, by the splenic vein, the pancreas, the left renal vein, the third portion of the duodenum, the mesentery, and aortic plexus. *Behind*, it is separated from the lumbar vertebræ and intervening discs by the anterior

* Lord Lister, having accurately examined 30 bodies in order to ascertain the exact point of termination of this vessel, found it 'either absolutely, or almost absolutely, mesial in 15, while in 13 it deviated more or less to the left, and in two was slightly to the right.'—*System of Surgery*, edited by T. Holmes, 2nd ed. vol. v. p. 652.

common ligament and left lumbar veins. On the *right side* it is in relation above with the vena azygos major, receptaculum chyli, thoracic duct, and the right crus of the Diaphragm—the last separating it from the upper part of the inferior vena cava, and from the right semilunar ganglion; the inferior vena cava is in contact with the aorta below. On the *left side* are the left crus of the Diaphragm, the left semilunar ganglion, the fourth part of the duodenum, and some coils of the small intestine.

Surface Marking.—In order to map out the abdominal aorta on the surface of the abdomen, a line must be drawn from the middle line of the body, on a level with the seventh costal cartilages, downwards and slightly to the left, so that it just skirts the umbilicus, to a zone drawn round the body opposite the highest point of the crest of the ilium. This point is generally half an inch below and to the left of the umbilicus, but as the position of this structure varies with the obesity of the individual, it is not a reliable landmark for the situation of the bifurcation of the aorta.

Applied Anatomy.—The abdominal aorta may be the seat of an aneurysm either at its upper part, close to and often involving the cœliac axis, or at its lower part, near the bifurcation. Occasionally aneurysms are met with on some of the branches of the aorta, the mesenteric or splenic, quite independent of the main trunk.

When an aneurysmal sac is connected with the back part of the abdominal aorta, it usually produces absorption of the bodies of the vertebræ, and forms a pulsating tumour that presents itself in the left hypochondriac or epigastric regions, and is accompanied by symptoms of disturbance in the alimentary canal. Pain is invariably present, and is usually of two kinds—a fixed and constant pain in the back, caused by the tumour pressing on or displacing the branches of the solar plexus and splanchnic nerves; and a sharp lancinating pain, radiating along those branches of the lumbar nerves which are pressed on by the tumour; hence the pain in the loins, the testes, the hypogastrium, and in the lower limb (generally of the left side). This form of aneurysm usually bursts into the peritoneal cavity, or behind the peritoneum, in the left hypochondriac region; or it may form a large aneurysmal sac, extending down as low as Poupart's ligament.

When an aneurysmal sac is connected with the front of the aorta near the cœliac axis, it forms a pulsating tumour in the left hypochondriac or epigastric regions, usually attended with symptoms of disturbance of the alimentary canal, as sickness, dyspepsia, or constipation, and accompanied by pain, which is constant, but nearly always fixed, in the loins, epigastrium, or some part of the abdomen; the radiating pain being rare, as the lumbar nerves are seldom implicated. This form of aneurysm may burst into the peritoneal cavity, behind the peritoneum, between the layers of the mesentery, or, more rarely, into the duodenum; it rarely extends backwards so as to affect the spine.

Occlusion of the abdominal aorta by thrombosis or embolism is rare, but produces very severe symptoms when it does occur. The patient complains of intense pain in the legs; pallor of the legs, followed by coldness, lividity, paresis, paralysis, and finally gangrene, are likely to succeed, death usually supervening within a fortnight.

The abdominal aorta has been tied several times, and although none of the patients permanently recovered, still, as one case lived forty-eight days, the possibility of the re-establishment of the circulation may be considered to be proved.

Collateral Circulation.—The collateral circulation would be carried on by the anastomoses between the internal mammary and the deep epigastric; by the free communication between the superior and inferior mesenterics, if the ligature were placed above the latter vessel; or by the anastomosis between the inferior mesenteric and the internal pudic, when (as is more common) the point of ligature is below the origin of the inferior mesenteric; and possibly by the anastomoses of the lumbar arteries with the branches of the internal iliac.

Branches of the Abdominal Aorta

The branches of the abdominal aorta may be divided into three sets: visceral, parietal, and terminal.

Visceral Branches.	*Parietal Branches.*
Cœliac axis (Gastric. Hepatic. Splenic.)	Inferior phrenic.
Superior mesenteric.	Lumbar.
Inferior mesenteric.	Middle sacral.
Suprarenal.	
Renal.	*Terminal Branches.*
Spermatic or Ovarian.	Common iliacs.

Of the visceral branches, the cœliac axis and the superior and inferior mesenteric arteries are single, while the suprarenal, renal, and spermatic or

ovarian are paired. The inferior phrenic and lumbar are paired parietal branches; the middle sacral is unpaired.

Cœliac Axis (fig. 603)

The **cœliac axis artery** (a. cœliaca) is a short thick trunk, about half an inch in length, which arises from the aorta, close to the margin of the opening in the Diaphragm, and, passing nearly horizontally forwards, divides

Fig. 603.—The cœliac axis and its branches; the liver has been raised, and the lesser omentum and anterior layer of the great omentum removed.

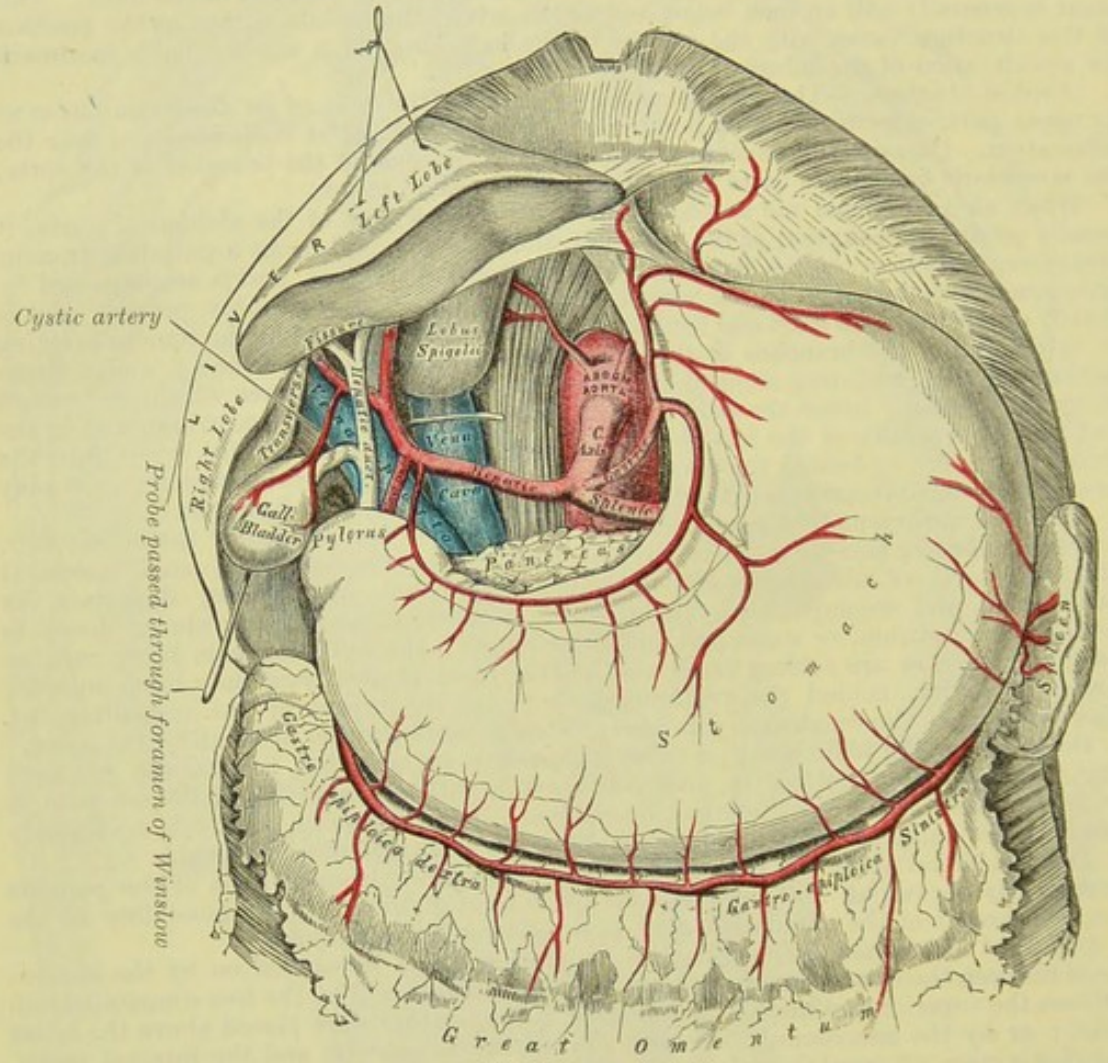

into three large branches, the *gastric* or *coronary*, the *hepatic*, and the *splenic*; it occasionally gives off one of the phrenic arteries.

Relations.—The cœliac axis is covered by the lesser omentum. On the *right side*, it is in relation with the right semilunar ganglion and the lobus Spigelii; on the *left side*, with the left semilunar ganglion and cardiac end of the stomach. *Below*, it is in relation to the upper border of the pancreas, and the splenic vein.

1. The **gastric** or **coronary artery** (a. gastrica sinistra), the smallest of the three branches of the cœliac axis, passes upwards and to the left, behind the lesser sac of the peritoneum, to the cardiac orifice of the stomach, where it distributes branches to the œsophagus (rami oesophagei), which anastomose with the aortic œsophageal arteries; others supply the cardiac end of the stomach, anastomosing with branches of the splenic artery. It then runs from left to right, along the lesser curvature of the stomach to the pylorus, between the layers of the lesser omentum; it gives branches to both surfaces of the organ and at its termination anastomoses with the pyloric branch of the hepatic.

2. The **hepatic artery** (a. hepatica), in the adult, is intermediate in size between the gastric and splenic; in the fœtus, it is the largest of the

three branches of the cœliac axis. It is first directed forwards and to the right, to the upper margin of the first part of the duodenum, forming the lower boundary of the foramen of Winslow. It then passes upwards between the layers of the lesser omentum, and in front of the foramen of Winslow, to the transverse fissure of the liver, where it divides into two branches, right and left, which supply the corresponding lobes of that organ, accompanying the ramifications of the portal vein and hepatic ducts. The hepatic artery, in its course along the right border of the lesser omentum, is in relation with the common bile-duct and portal vein, the duct lying to the right of the artery, and the vein behind.

Its branches are :

Pyloric.
Gastro-duodenal { Right gastro-epiploic. / Superior pancreatico-duodenal.
Cystic.

The **pyloric** (a. gastrica dextra) arises from the hepatic, above the pylorus, descends to the pyloric end of the stomach, and passes from right to left along its lesser curvature, supplying it with branches, and anastomosing with the gastric branches of the coronary artery.

The **gastro-duodenal** (a. gastroduodenalis) (fig. 604) is a short but large branch, which descends, near the pylorus, behind the first portion of the duodenum, and

FIG. 604.—The cœliac axis and its branches; the stomach has been raised and the peritoneum removed.

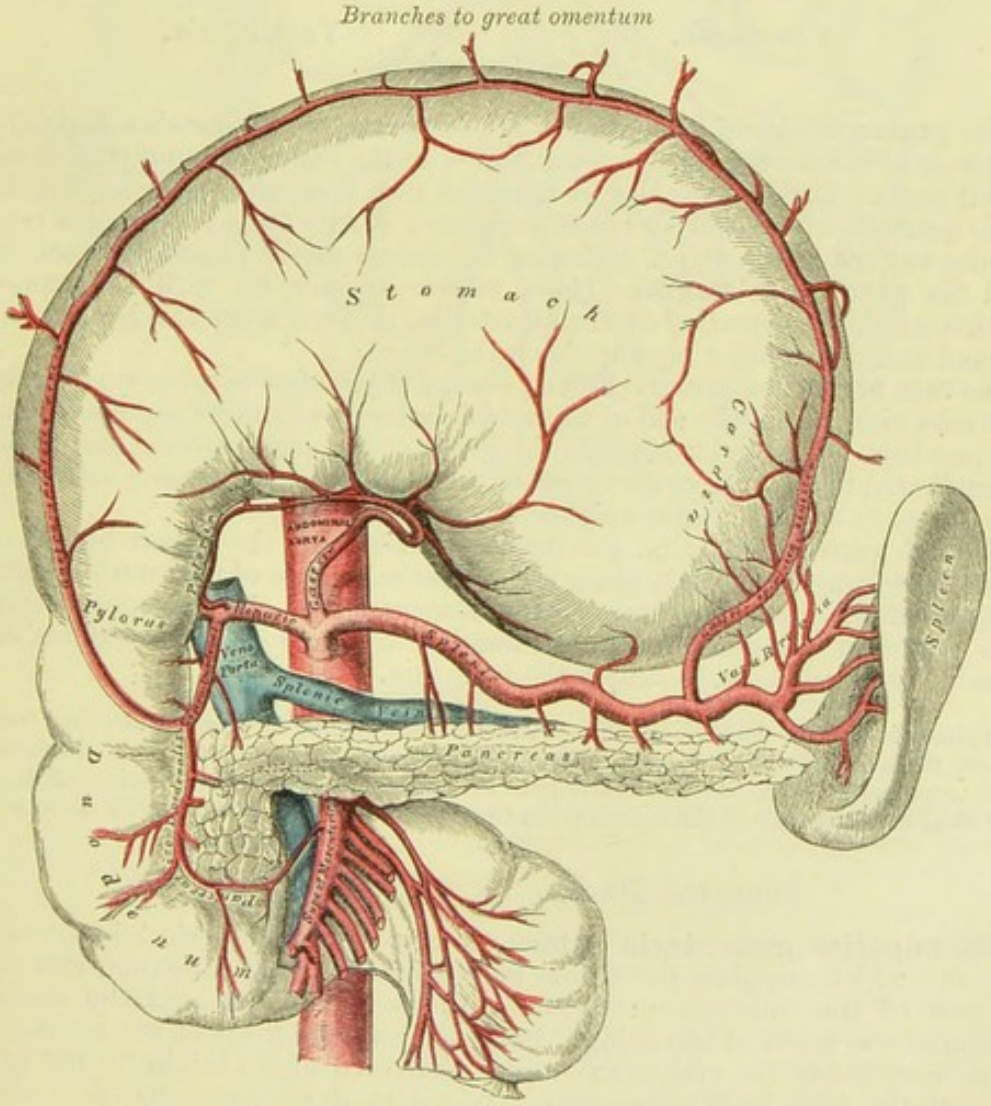

divides at the lower border of this viscus into two branches, the *right gastro-epiploic* and the *superior pancreatico-duodenal*. Previous to its division it gives off two

or three small inferior pyloric branches to the pyloric end of the stomach and pancreas.

The **right gastro-epiploic** (a. gastroepiploica dextra) runs from right to left along the greater curvature of the stomach, between the layers of the great omentum, anastomosing about the middle of the lower border of the stomach with the right gastro-epiploic from the splenic artery. This vessel gives off numerous branches, some of which ascend to supply both surfaces of the stomach, while others descend to supply the great omentum.

The **superior pancreatico-duodenal** (a. pancreaticoduodenalis superior) descends between the contiguous margins of the duodenum and pancreas. It supplies both these organs, and anastomoses with the inferior pancreatico-duodenal branch of the superior mesenteric artery, and with the pancreatic branches of the splenic.

The **cystic** (a. cystica) (fig. 603), usually a branch of the right hepatic, passes downwards and forwards along the neck of the gall-bladder, and divides into two branches, one of which ramifies on its free surface, the other between it and the surfaces of the liver.

3. The **splenic artery** (a. lienalis), in the adult, is the largest of the three branches of the cœliac axis, and is remarkable for the extreme tortuosity of its course. It passes horizontally to the left side, behind the peritoneum and along the upper border of the pancreas, accompanied by the splenic vein, which lies below it; it crosses in front of the upper part of the left kidney, and, on arriving near the spleen, divides into branches, some of which enter the hilus of that organ between the two layers of the lieno-renal ligament to be distributed to its structure; some are distributed to the pancreas, while others pass to the greater curvature of the stomach between the layers of the gastro-splenic omentum. Its branches are:

Pancreatic. Vasa brevia.
Left gastro-epiploic.

The **pancreatic** (rami pancreatici) are numerous small branches derived from the splenic as it runs behind the upper border of the pancreas, supplying its middle and left parts. One of these, larger than the rest, is sometimes given off from the splenic near the left extremity of the pancreas; it runs from left to right near the posterior surface of the gland, following the course of the pancreatic duct, and is called the **pancreatica magna**. These vessels anastomose with the pancreatic branches of the pancreatico-duodenal arteries, derived from the hepatic on the one hand and the superior mesenteric on the other.

The **vasa brevia** (aa. gastricæ breves) consist of from five to seven small branches, which arise either from the end of the splenic artery, or from its terminal branches. They pass from left to right, between the layers of the gastro-splenic omentum, and are distributed to the greater curvature of the stomach, anastomosing with branches of the coronary and left gastro-epiploic arteries.

The **left gastro-epiploic** (a. gastroepiploica sinistra), the largest branch of the splenic, runs from left to right along the greater curvature of the stomach, between the layers of the great omentum, and anastomoses with the right gastro-epiploic. In its course it distributes several ascending branches to both surfaces of the stomach; others descend to supply the omentum.

Applied Anatomy.—Embolism of branches of the splenic artery is tolerably common in heart disease, the embolus coming from the left side of the heart. It is characterised by the occurrence of a sudden sharp pain or 'stitch' in the splenic region, with subsequent local enlargement of the spleen from the formation of an infarct in its substance.

Superior Mesenteric Artery (fig. 605)

The **superior mesenteric artery** (a. mesenterica superior) is a vessel of large size which supplies the whole length of the small intestine, except the first part of the duodenum; it also supplies the cæcum and the ascending and transverse parts of the colon. It arises from the front of the aorta, about half an inch below the cœliac axis, and is covered at its origin by the splenic vein and the neck of the pancreas. It passes downwards and forwards, in front of the lower part of the head of the pancreas and third portion of the duodenum, and descends between the layers of the mesentery to the right

iliac fossa, where, considerably diminished in size, it anastomoses with one of its own branches, viz. the ileo-colic. In its course it forms an arch, the convexity of which is directed forwards and downwards to the left side,

FIG. 605.—The superior mesenteric artery and its branches.

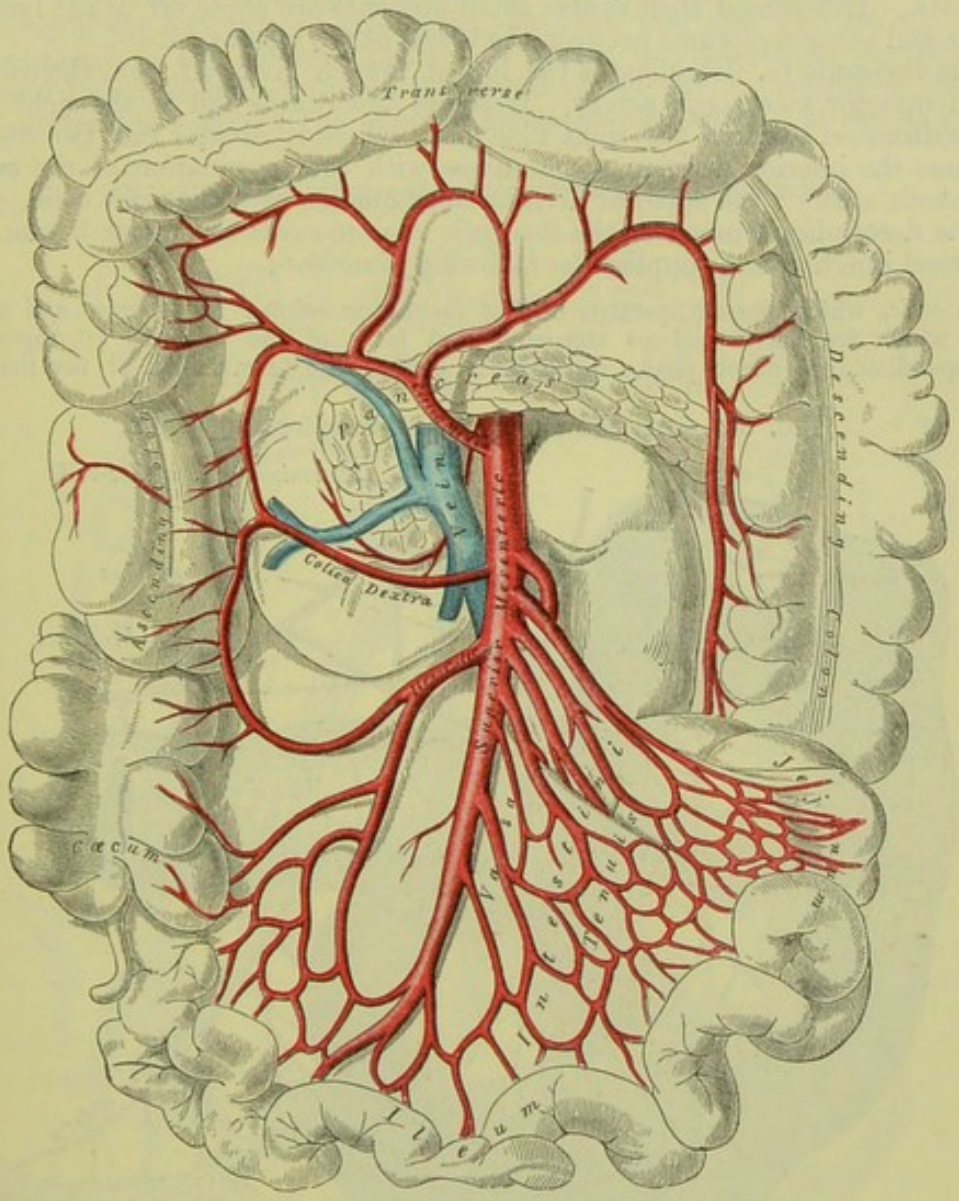

the concavity backwards and upwards to the right. It is accompanied by the superior mesenteric vein, which lies to its right side, and it is surrounded by the superior mesenteric plexus of nerves. Its branches are :

Inferior pancreatico-duodenal.	Ileo-colic.
Vasa intestini tenuis.	Right colic.
Middle colic.	

The **inferior pancreatico-duodenal** (a. pancreaticoduodenalis inferior) is given off from the superior mesenteric or from its first intestinal branch, opposite the upper border of the third part of the duodenum. It courses to the right between the head of the pancreas and duodenum, and then ascends to anastomose with the superior pancreatico-duodenal artery. It distributes branches to the head of the pancreas and to the second and third portions of the duodenum.

The **vasa intestini tenuis** (aa. intestinales) arise from the convex side of the superior mesenteric artery. They are usually from twelve to fifteen in number, and are distributed to the jejunum and ileum. They run parallel with one another between the layers of the mesentery, each vessel dividing into two branches, which unite with adjacent branches, forming a series of arches, the convexities of which are directed towards the intestine. From this first set of arches branches

arise, which unite with similar branches from above and below, and thus a second series of arches is formed; and from these latter, a third, a fourth, or even a fifth series of arches may be constituted, diminishing in size the nearer they approach the intestine. From the terminal arches numerous small straight vessels arise which encircle the intestine, upon which they are distributed, ramifying between its coats. Throughout their course small branches are given off to the lymphatic glands and other structures between the layers of the mesentery.

The **ileo-colic** (a. ileocolica) is the lowest branch given off from the concavity of the superior mesenteric artery. It passes downwards and to the right behind the peritoneum towards the right iliac fossa, where it divides into two branches. Of these the inferior division anastomoses with the termination of the superior mesenteric artery; the superior division anastomoses with the right colic.

The descending branch of the ileo-colic runs towards the upper border of the ileo-cæcal junction and supplies the following branches:

(*a*) *colic*, which passes upwards on the ascending colon; (*b*) *anterior and posterior cæcal*, which are distributed to the front and back of the cæcum; (*c*) *appendicular* (a. appendicularis) which passes downwards behind the termination of the ileum and

Fig. 606.—Arteries of cæcum and vermiform appendix.

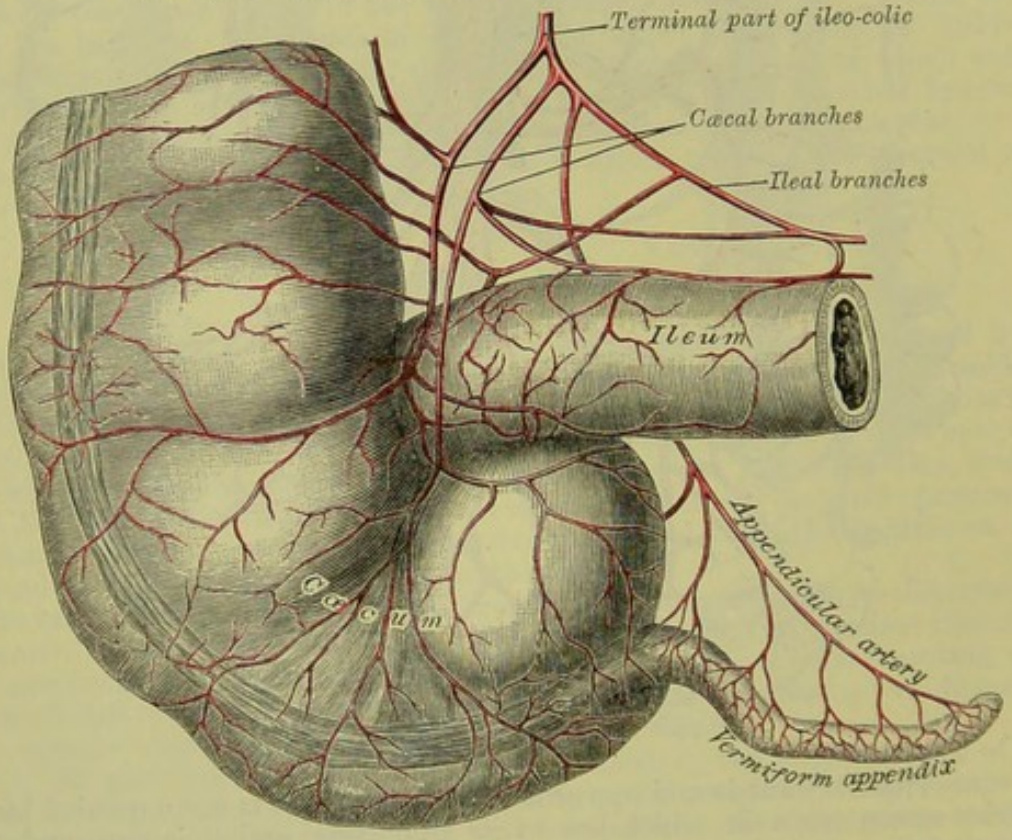

runs in the meso-appendix close to its free margin for the supply of the vermiform appendix; and (*d*) *ileal*, which runs upwards and to the left on the lower part of the ileum, and anastomoses with the termination of the superior mesenteric (fig. 606).

The **right colic** (a. colica dextra) arises from about the middle of the concavity of the superior mesenteric artery; it passes to the right behind the peritoneum, and in front of the right spermatic or ovarian vessels, the right ureter and the Psoas, towards the middle of the ascending colon, where it divides into a descending branch, which anastomoses with the ileo-colic, and an ascending branch, which anastomoses with the middle colic. These branches form arches, from the convexity of which vessels are distributed to the ascending colon.

The **middle colic** (a. colica media) arises from the upper part of the concavity of the superior mesenteric, and, passing downwards and forwards between the layers of the transverse mesocolon, divides into two branches, right and left; the former anastomoses with the right colic; the latter with the left colic, a branch of the inferior mesenteric. From the arches thus formed, branches are distributed to the transverse colon.

Inferior Mesenteric Artery (fig. 607)

The **inferior mesenteric artery** (a. mesenterica inferior) supplies the descending, iliac, and pelvic portions of the colon, and the greater part of the rectum. It is smaller than the superior mesenteric, and arises from the front and towards the left side of the aorta, between one and two inches above the division into the common iliacs. It passes downwards to the left iliac fossa, and then descends, between the layers of the pelvic mesocolon, into the pelvis, under the name of the *superior hæmorrhoidal artery*. It lies at first in

Fig. 607.—The inferior mesenteric artery and its branches.

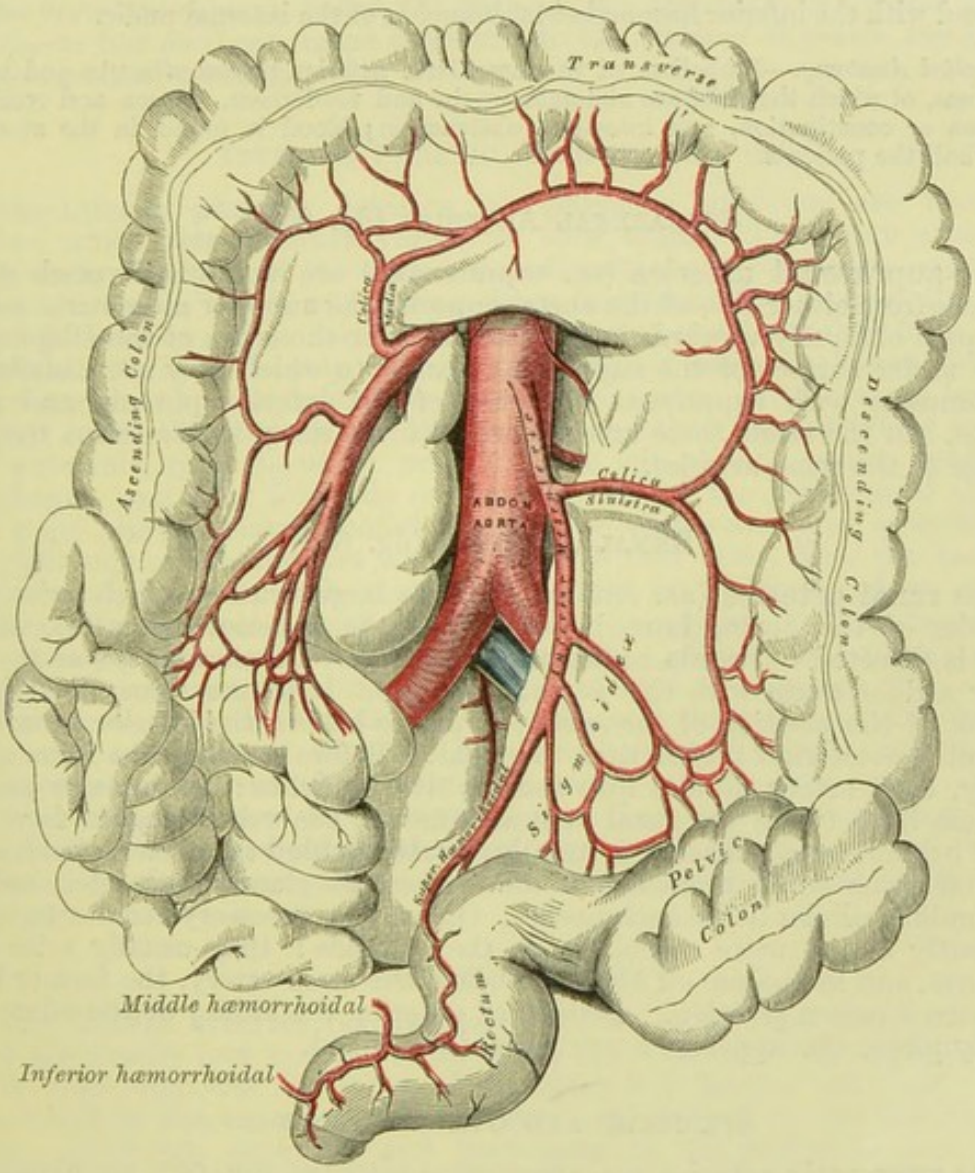

close relation with the left side of the aorta, and then passes as the superior hæmorrhoidal in front of the left common iliac artery. Its branches are:

Left colic. Sigmoid. Superior hæmorrhoidal.

The **left colic** (a. colica sinistra) passes behind the peritoneum, in front of the left kidney, to reach the descending colon; it divides into an ascending branch which runs between the two layers of the transverse mesocolon and anastomoses with the middle colic, and a descending branch which anastomoses with the upper sigmoid artery. From the arches formed by these anastomoses branches are distributed to the descending colon.

The **sigmoid arteries** (aa. sigmoideæ) run obliquely downwards and outwards behind the peritoneum and in front of the Psoas and ureter to the iliac colon. They divide into branches which supply the lower part of the descending colon, the

iliac colon, and the pelvic colon; anastomosing above with the left colic, and below with the superior hæmorrhoidal artery.

The **superior hæmorrhoidal** (a. hæmorrhoidalis superior), the continuation of the inferior mesenteric, descends into the pelvis between the layers of the mesentery of the pelvic colon, crossing, in its course, the ureter and left common iliac vessels. It divides, opposite the third sacral vertebra, into two branches, which descend one on either side of the rectum, and about four or five inches from the anus break up into several small branches. These pierce the muscular coat of the bowel and run downwards, as straight vessels, placed at regular intervals from each other in the wall of the gut between its muscular and mucous coats, to the level of the internal sphincter; here they form a series of loops around the lower end of the rectum, and communicate with the middle hæmorrhoidal branches of the internal iliac, and with the inferior hæmorrhoidal branches of the internal pudic.

Applied Anatomy.—Embolism of the mesenteric arteries produces acute and severe symptoms, of which the chief are abdominal pain and tenderness, nausea and vomiting, diarrhœa or constipation, and intestinal obstruction; blood is found in the stools of nearly half the patients.

Suprarenal Arteries (fig. 602)

The **suprarenal arteries** (aa. suprarenales) are two small vessels which arise, one from either side of the aorta, opposite the superior mesenteric artery. They pass obliquely upwards and outwards, over the crura of the Diaphragm, to the under surface of the suprarenal glands, to which they are distributed, anastomosing with suprarenal branches of the inferior phrenic and renal arteries. In the adult these arteries are of small size; in the fœtus they are as large as the renal arteries.

Renal Arteries (fig. 602)

The **renal arteries** (aa. renales) are two large trunks, which arise from the sides of the aorta, immediately below the superior mesenteric artery. Each is directed outwards across the crus of the Diaphragm, so as to form nearly a right angle with the aorta. The right is longer than the left, on account of the position of the aorta; it passes behind the inferior vena cava. The left is somewhat higher than the right. Before reaching the hilus of the kidney, each artery divides into four or five branches; the greater number of these lie between the renal vein and ureter, the vein being in front, the ureter behind, but one branch is usually situated behind the ureter. Each vessel gives off some small branches to the suprarenal gland, the ureter, and the surrounding cellular tissue and muscles. One or two accessory renal arteries are frequently found, more especially on the left side: they usually arise from the aorta, and may come off above or below the main artery, the former being the more common position. Instead of entering the kidney at the hilus, they usually pierce the upper or lower part of the gland.

Spermatic and Ovarian Arteries

The **spermatic arteries** (aa. spermaticæ internæ) (fig. 602) are distributed to the testes. They are two slender vessels of considerable length, and arise from the front of the aorta a little below the renal arteries. Each artery passes obliquely outwards and downwards behind the peritoneum, resting on the Psoas magnus, the right spermatic lying in front of the inferior vena cava and behind the terminal part of the ileum, the left behind the iliac colon. It crosses obliquely over the ureter and the lower part of the external iliac artery to reach the internal abdominal ring, through which it passes, and accompanies the other constituents of the spermatic cord along the inguinal canal to the scrotum, where it becomes tortuous, and divides into several branches. Two or three of these accompany the vas deferens, and supply the epididymis, anastomosing with the artery of the vas deferens; others pierce the back part of the tunica albuginea, and supply the substance of the testis. The spermatic artery supplies one or two small branches to the ureter, and in the inguinal canal gives one or two twigs to the Cremaster.

The **ovarian arteries** (aa. ovaricæ) are the corresponding arteries in the female to the spermatic in the male. They supply the ovaries, are shorter than the spermatic, and do not pass out of the abdominal cavity. The origin and course of the first part of each artery are the same as those of the spermatic, but on arriving at the margin of the pelvis the ovarian artery passes inwards, between the two layers of the broad ligament of the uterus, to be distributed to the ovary. Small branches are given to the ureter and the Fallopian tube; and one passes on to the side of the uterus, and anastomoses with the uterine artery. Other offsets are continued along the round ligament, through the inguinal canal, to the integument of the labium and groin.

At an early period of fœtal life, when the testes or ovaries lie by the side of the vertebral column, below the kidneys, the spermatic or ovarian arteries are short; but as these organs descend into the scrotum or pelvis, the arteries become gradually lengthened.

Inferior Phrenic Arteries (fig. 602)

The **inferior phrenic arteries** (aa. phrenicæ inferiores) are two small vessels, which present much variety in their origin. They may arise separately from the front of the aorta, immediately above the cœliac axis, or by a common trunk, which may spring either from the aorta or from the cœliac axis. Sometimes one is derived from the aorta, and the other from one of the renal arteries. In only one out of thirty-six cases examined did these arteries arise as two separate vessels from the aorta. They diverge from one another across the crura of the Diaphragm, and then pass obliquely upwards and outwards upon its under surface. The left phrenic passes behind the œsophagus, and runs forwards on the left side of the œsophageal opening. The right phrenic passes behind the inferior vena cava, and ascends along the right side of the aperture which transmits that vein. Near the back part of the central tendon each vessel divides into an internal and an external branch. The internal branch runs forwards, supplying the Diaphragm, and anastomosing with its fellow of the opposite side, and with the musculo-phrenic and comes nervi phrenici branches of the internal mammary. The external branch passes towards the side of the thorax, and anastomoses with the lower intercostal arteries, and with the musculo-phrenic. The internal branch of the right phrenic gives off a few vessels to the inferior vena cava; and the left one, some branches to the œsophagus. Each vessel also sends glandular branches to the suprarenal gland of its own side. The spleen and the liver also receive a few branches from the left and right vessels respectively.

Lumbar Arteries

The **lumbar arteries** (aa. lumbales) are in series with the intercostals. They are usually four in number on either side, and arise from the back part of the aorta, opposite the bodies of the upper four lumbar vertebræ. A fifth pair, small in size, is occasionally present: it arises from the middle sacral artery. They run outwards and backwards on the bodies of the lumbar vertebræ, behind the sympathetic cord, to the intervals between the adjacent transverse processes, and are then continued into the abdominal wall. The arteries of the right side pass behind the inferior vena cava, and the upper two on each side run behind the corresponding crus of the Diaphragm. The arteries of both sides pass beneath the tendinous arches which give origin to the Psoas magnus, and are then continued behind this muscle and the lumbar plexus. They now cross the Quadratus lumborum, the upper three arteries running behind, the last usually in front of the muscle. At the outer border of the Quadratus lumborum they pierce the posterior aponeurosis of the Transversalis abdominis and are carried forwards between this muscle and the Internal oblique. They anastomose with the lower intercostals, the subcostal, the ilio-lumbar, the deep circumflex iliac, and the deep epigastric arteries.

Branches.—In the interval between the adjacent transverse processes each lumbar artery gives off a *dorsal branch* (ramus dorsalis) which is continued backwards between

the transverse processes and is distributed to the muscles and skin of the back. It gives off a *spinal branch* (ramus spinalis) which enters the spinal canal and is distributed in a similar manner to the lateral spinal branches of the vertebral (page 660). *Muscular branches* are supplied from each lumbar artery and from its dorsal branch to the neighbouring muscles.

Middle Sacral Artery

The **middle sacral artery** (a. sacralis media) is a small vessel, which arises from the back of the aorta, at or a little above its bifurcation. It descends upon the last lumbar vertebra, and along the middle line of the front of the sacrum, to the upper part of the coccyx ; it anastomoses with the lateral sacral arteries, and terminates in the coccygeal body. From it, minute branches pass to the posterior surface of the rectum. Other branches are given off on each side, which anastomose with the lateral sacral arteries, and send offsets into the anterior sacral foramina. It is crossed by the left common iliac vein, and is accompanied by a pair of venæ comites ; these unite to form a single vessel, which opens into the left common iliac vein.

Common Iliac Arteries (fig. 602)

The abdominal aorta divides, on the left side of the body of the fourth lumbar vertebra, into the two **common iliac arteries**. Each is about two inches in length. They diverge from the termination of the aorta, pass downwards and outwards to the margin of the pelvis, and divide, opposite the intervertebral disc between the last lumbar vertebra and the sacrum, into two branches, the *external* and *internal iliac arteries* : the former supplies the lower extremity ; the latter, the viscera and parietes of the pelvis.

The **right common iliac** (fig. 608) is somewhat longer than the left, and passes more obliquely across the body of the last lumbar vertebra. *In front* of it are the peritoneum, the small intestines, branches of the sympathetic nerves, and, at its point of division, the ureter. *Behind*, it is separated from the bodies of the fourth and fifth lumbar vertebræ, and the intervening disc, by the two common iliac veins. On its *outer side*, it is in relation, above, with the inferior vena cava and the right common iliac vein ; and, below, with the Psoas magnus muscle. On its *inner side*, above, is the left common iliac vein.

The **left common iliac** is in relation, *in front*, with the peritoneum, the small intestines, branches of the sympathetic nerves, and the superior hæmorrhoidal artery ; and is crossed at its point of bifurcation by the ureter. It rests on the bodies of the fourth and fifth lumbar vertebræ, and the intervening disc. The left common iliac vein lies partly on the *inner side* of, and partly behind the artery ; on its *outer side*, the artery is in relation with the Psoas magnus muscle.

Branches.—The common iliac arteries give off small branches to the peritoneum, Psoas magnus, ureters, and the surrounding cellular tissue, and occasionally give origin to the ilio-lumbar, or accessory renal arteries.

Peculiarities.—The *point of origin* varies according to the bifurcation of the aorta. In three-fourths of a large number of cases, the aorta bifurcated either upon the fourth lumbar vertebra, or upon the disc between it and the fifth ; the bifurcation being, in one case out of nine, below, and in one out of eleven above this point. In about eighty per cent. of the cases the aorta bifurcated within half an inch above or below the level of the crest of the ilium : more frequently below than above.

The *point of division* is subject to great variety. In two-thirds of a large number of cases it was between the last lumbar vertebra and the upper border of the sacrum ; being above that point in one case out of eight, and below it in one case out of six. The left common iliac artery divides lower down more frequently than the right.

The *relative lengths*, also, of the two common iliac arteries vary. The right common iliac was the longer in sixty-three cases ; the left in fifty-two ; while they were equal in fifty-three. The length of the arteries varied, in five-sevenths of the cases examined, from an inch and a half to three inches ; in about half of the remaining cases the artery was longer, and in the other half, shorter : the minimum length being less than half an inch, the maximum four and a half inches. In rare instances, the right common iliac has been found wanting, the external and internal iliacs arising directly from the aorta.

Surface Marking.—Draw a line between the highest points of the iliac crests: this is usually half an inch below the umbilicus; in this line take a point half an inch to the left of the middle line. From this draw two lines to points midway between the anterior superior iliac spines and the symphysis pubis. These two diverging lines will represent the course of the common and external iliac arteries. Draw a second line corresponding to the level of the anterior superior spines of the ilium: the portion of the diverging lines between these two levels on either side will represent the course of the common iliac artery; the portion below the lower zone, that of the external iliac artery.

Applied Anatomy.—The application of a ligature to the common iliac artery may be required on account of aneurysm or hæmorrhage, implicating the external or internal iliacs. The easiest and best method of tying the artery is by a transperitoneal route. The abdomen is opened, the intestines are drawn to one side and the peritoneum

FIG. 608.—Arteries of the pelvis.

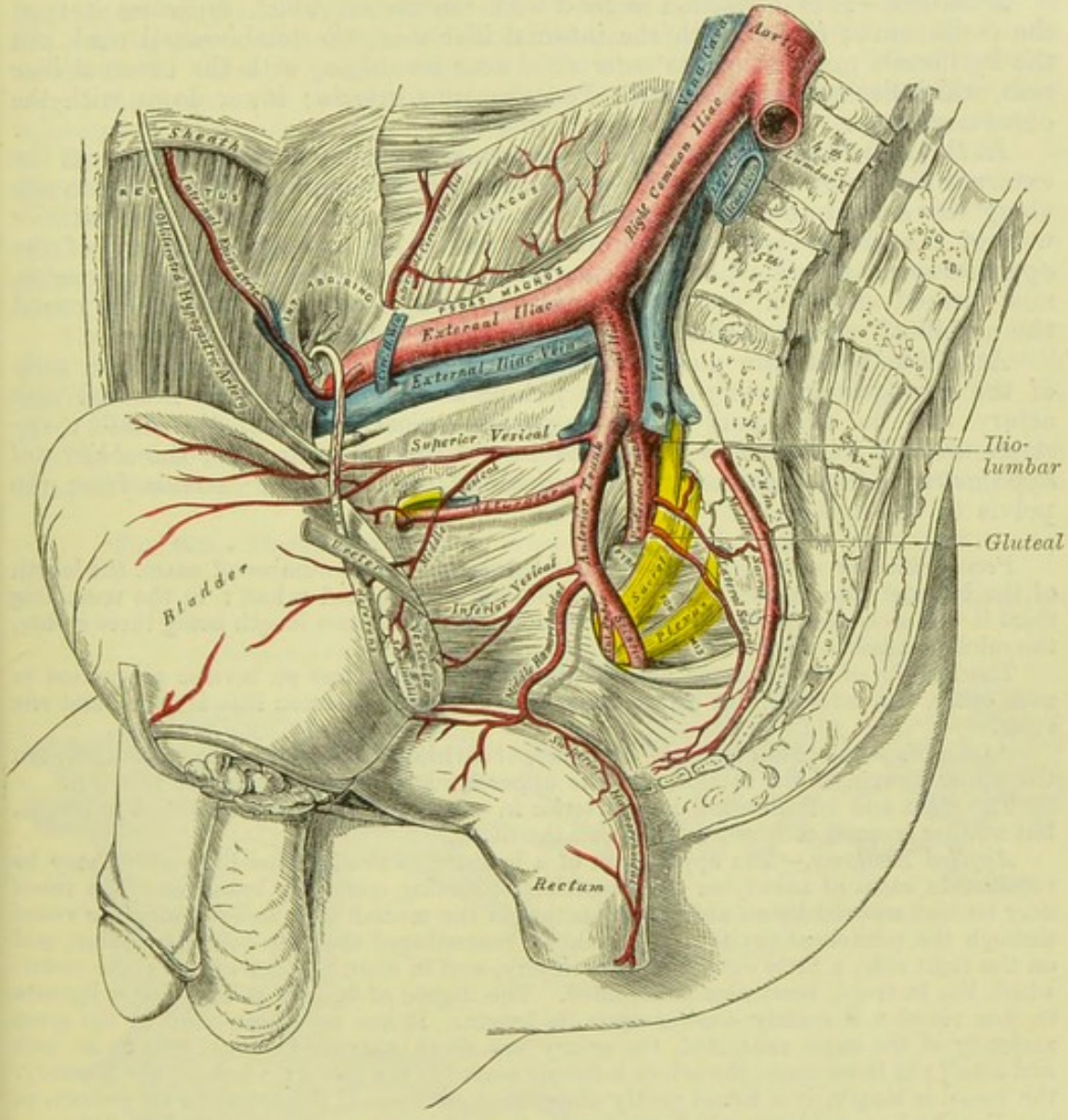

covering the artery divided; the sheath is then opened and the needle passed from within outwards. On the right side great care must be exercised in passing the needle, since both the common iliac veins lie behind the artery. After the vessel has been tied, the incision in the peritoneum over the artery should be sutured. Formerly there were two different methods by which the common iliac artery was tied, without opening the peritoneal cavity: (1) an anterior or iliac incision, by which the vessel was approached more directly from the front; and (2) a posterior abdominal or lumbar incision, by which the vessel was reached from behind.

Collateral Circulation.—The principal agents in carrying on the collateral circulation after the application of a ligature to the common iliac are: the anastomoses of the hæmorrhoidal branches of the internal iliac with the superior hæmorrhoidal from the inferior mesenteric; of the uterine, ovarian, and vesical arteries of the opposite sides; of the

lateral sacral with the middle sacral artery ; of the epigastric with the internal mammary, inferior intercostal, and lumbar arteries ; of the circumflex iliac with the lumbar arteries ; of the ilio-lumbar with the last lumbar artery ; of the obturator artery, by means of its pubic branch, with the vessel of the opposite side and with the deep epigastric.

Internal Iliac Artery (fig. 608)

The **internal iliac** or **hypogastric artery** (a. hypogastrica) supplies the walls and viscera of the pelvis, the buttock, the generative organs, and the inner side of the thigh. It is a short, thick vessel, smaller than the external iliac, and about an inch and a half in length. It arises at the bifurcation of the common iliac, opposite the lumbo-sacral articulation, and, passing downwards to the upper margin of the great sacro-sciatic foramen, divides into two large trunks, an *anterior* and a *posterior*.

Relations.—It is in relation *in front* with the ureter, which separates it from the peritoneum ; *behind*, with the internal iliac vein, the lumbo-sacral cord, and the Pyriformis muscle ; on its *outer side*, near its origin, with the external iliac vein, which lies between it and the Psoas magnus muscle ; lower down, with the obturator nerve.

In the fœtus, the internal iliac or hypogastric artery is twice as large as the external iliac, and is the direct continuation of the common iliac. It ascends along the side of the bladder, and runs upwards on the back of the anterior wall of the abdomen to the umbilicus, converging towards its fellow of the opposite side. Having passed through the umbilical opening, the two arteries, now termed *umbilical*, enter the umbilical cord, where they are coiled round the umbilical vein, and ultimately ramify in the placenta.

At birth, when the placental circulation ceases, the pelvic portion only of the hypogastric artery remains patent and constitutes the internal iliac artery and the first part of the superior vesical artery of the adult ; the remainder of the vessel is converted into a solid fibrous cord, the *obliterated hypogastric artery* (ligamentum umbilicale laterale), which extends from the pelvis to the umbilicus.

Peculiarities as regards length.—In two-thirds of a large number of cases, the length of the internal iliac varied between an inch and an inch and a half ; in the remaining third it was more frequently longer than shorter, the maximum length being three inches, the minimum half an inch.

The lengths of the common and internal iliac arteries bear an inverse proportion to each other, the internal iliac artery being long when the common iliac is short, and *vice versa*.

As regards its place of division.—The place of division of the internal iliac varies between the upper margin of the sacrum and the upper border of the sacro-sciatic foramen.

The right and left internal iliac arteries in a series of cases often differed in length, but neither seemed constantly to exceed the other.

Applied Anatomy.—The application of a ligature to the internal iliac artery may be required in cases of aneurysm or hæmorrhage affecting one of its branches. The vessel may be best secured by an abdominal section in the median line, and reaching the vessel through the peritoneal cavity. It should be remembered that the vein lies behind, and on the right side, a little external to the artery, and in close contact with it ; the ureter, which lies in front, must also be avoided. The degree of facility in applying a ligature to this vessel will mainly depend upon its length. It has been seen that, in the great majority of the cases examined, the artery was short, varying from an inch to an inch and a half ; in these cases, the artery is deeply seated in the pelvis : when, on the contrary, the vessel is longer, it is found partly above that cavity. If the artery be very short, as occasionally happens, it would be preferable to apply a ligature to the common iliac.

Collateral Circulation.—The circulation after ligature of the internal iliac artery is carried on by the anastomoses of the uterine and ovarian arteries ; of the vesical arteries of the two sides ; of the hæmorrhoidal branches of the internal iliac with those from the inferior mesenteric ; of the obturator artery, by means of its pubic branch, with the vessel of the opposite side, and with the epigastric and internal circumflex ; of the circumflex and perforating branches of the profunda femoris with the sciatic ; of the gluteal with the posterior branches of the sacral arteries ; of the ilio-lumbar with the last lumbar ; of the lateral sacral with the middle sacral ; and of the circumflex iliac with the ilio-lumbar and gluteal.*

* For a description of a case in which Owen made a dissection ten years after ligature of the internal iliac artery, see *Med.-Chir. Trans.* vol. xvi.

The branches of the internal iliac are :

From the Anterior Trunk.	*From the Posterior Trunk.*
Superior vesical.	Ilio-lumbar.
Middle vesical.	Lateral sacral.
Inferior vesical.	Gluteal.
Middle hæmorrhoidal.	
Obturator.	
Internal pudic.	
~~Sciatic.~~ Inferior gluteal	
Uterine } *In the female.*	
Vaginal }	

The **superior vesical** (a. vesicalis superior) supplies numerous branches to the upper part of the bladder. From one of these a slender vessel, the artery to the vas deferens, takes origin and accompanies the vas deferens in its course to the testis, where it anastomoses with the spermatic artery. Other branches supply the ureter. As already explained, the first part of the superior vesical artery represents the terminal section of the pervious portion of the hypogastric artery.

The **middle vesical** (a. vesicalis media), usually a branch of the superior, is distributed to the base of the bladder and under surface of the vesiculæ seminales.

The **inferior vesical** (a. vesicalis inferior) frequently arises in common with the middle hæmorrhoidal, and is distributed to the base of the bladder, the prostate gland, and the vesiculæ seminales. The branches to the prostate communicate with the corresponding vessels of the opposite side.

The **middle hæmorrhoidal** (a. hæmorrhoidalis media) usually arises together with the preceding vessel. It is distributed to the rectum, anastomosing with the inferior vesical and with the superior and inferior hæmorrhoidal arteries. It gives offsets to the seminal vesicle and prostate gland.

The **uterine** (a. uterina) (fig. 609) springs from the anterior division of the internal iliac and runs inwards on the Levator ani towards the cervix uteri ; about

Fig. 609.—The arteries of the internal organs of generation of the female, seen from behind. (After Hyrtl.)

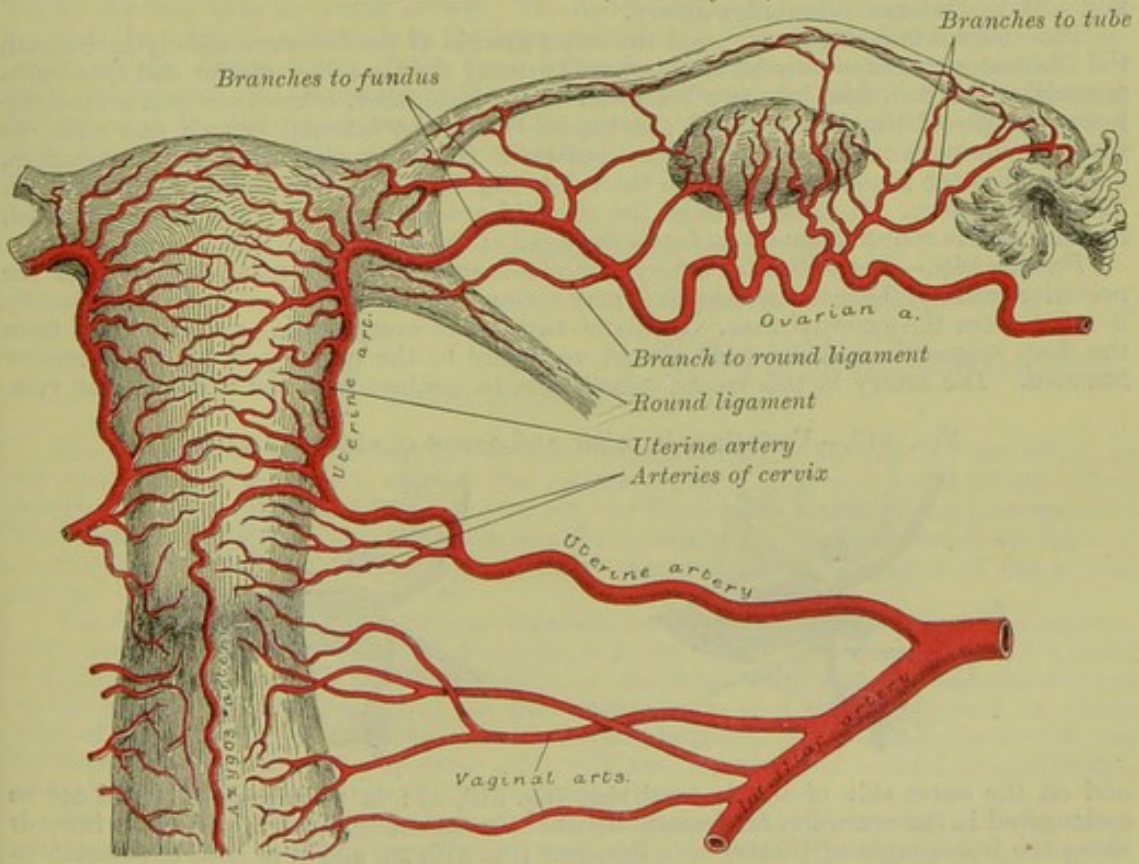

three-quarters of an inch from the cervix it crosses above and in front of the ureter, to which it supplies a small branch. Reaching the side of the uterus it ascends

in a tortuous manner between the two layers of the broad ligament to the junction of the Fallopian tube and uterus. It then runs outwards towards the hilus of the ovary, and terminates by anastomosing with the ovarian artery. It supplies branches to the cervix uteri and others which descend on the vagina; the latter anastomose with branches of the vaginal arteries and form with them two median longitudinal vessels—the *azygos arteries of the vagina*—which run down one in front and the other on the back of the vagina. It supplies numerous branches to the body of the uterus, and from its terminal portion branches are distributed to the Fallopian tube and the round ligament of the uterus.

The **vaginal** (a. vaginalis) usually corresponds to the inferior vesical in the male; it descends upon the vagina, supplying its mucous membrane, and sends branches to the bulb of the vestibule, the neck of the bladder, and the contiguous part of the rectum. It assists in forming the azygos arteries of the vagina, and is frequently represented by two or three branches.

The **obturator** (a. obturatoria) passes forwards and downwards on the lateral wall of the pelvis, to the upper part of the obturator foramen, and, escaping from the pelvic cavity through a short canal, formed by a groove on the under surface of the ascending ramus of the pubis and the arched border of the obturator fascia, it divides into an internal and an external branch. In the pelvic cavity this vessel is in relation, externally, with the obturator fascia; internally, with the ureter, vas deferens, and peritoneum; while a little below it, is the obturator nerve.

Branches.—Inside the pelvis, the obturator artery gives off an *iliac branch* to the iliac fossa, which supplies the bone and the Iliacus muscle, and anastomoses with the ilio-lumbar artery; a *vesical branch*, which runs backwards to supply the bladder; and a *pubic branch*, which is given off from the vessel just before it leaves the pelvic cavity. The pubic branch ascends upon the back of the pubis, communicating with offsets from the deep epigastric artery, and with the corresponding vessel of the opposite side; it is sometimes placed on the inner side of the femoral ring.

Outside the pelvis, the obturator artery divides into an *internal* and an *external branch*, which are deeply situated beneath the Obturator externus.

The *internal branch* curves downwards along the inner margin of the obturator foramen, lying beneath the Obturator externus muscle; it distributes branches to the Obturator externus, Pectineus, Adductors, and Gracilis, and anastomoses with the external branch, and with the internal circumflex artery.

The *external branch* curves round the outer margin of the foramen, also lying beneath the Obturator externus muscle, to the space between the Gemellus inferior and Quadratus femoris, where it divides into two branches. One, the smaller, courses inwards around the lower margin of the foramen and anastomoses with the internal branch and with the internal circumflex; the other inclines outwards in the groove below the acetabulum, and supplies the muscles attached to the tuberosity of the ischium and anastomoses with the sciatic artery. It sends through the cotyloid notch a branch to the hip-joint, which ramifies on the round ligament as far as the head of the femur.

Peculiarities.—The obturator artery sometimes arises from the main stem or from the posterior trunk of the internal iliac, or it may spring from the gluteal artery. Occasionally it arises from the external iliac. In about two out of every seven cases it springs from the deep epigastric and descends almost vertically to the upper part of the obturator foramen. The artery in this course usually lies in contact with the external iliac vein,

Fig. 610.—Variations in origin and course of obturator artery.

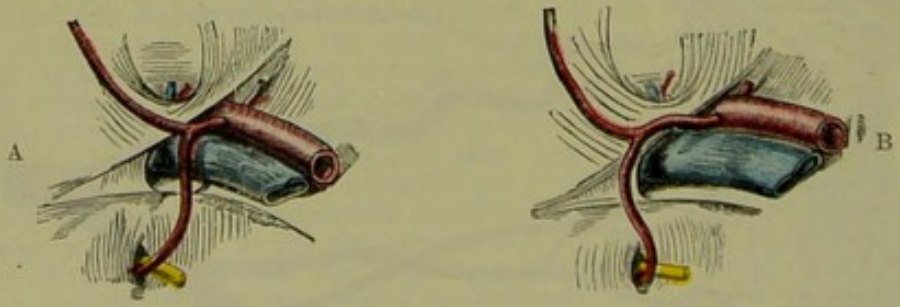

and on the outer side of the femoral ring (fig. 610, A); in such cases it would not be endangered in the operation for femoral hernia. Occasionally, however, it curves inwards along the free margin of Gimbernat's ligament (fig. 610, B), and if in such circumstances a femoral hernia occurred, the vessel would almost completely encircle the neck of the hernial sac, and would be in great danger of being wounded if an operation were performed for strangulation.

The **internal pudic** (a. pudenda interna) is the smaller of the two terminal branches of the anterior trunk of the internal iliac, and supplies the external organs of generation. Though the course of the artery is the same in the two sexes, the vessel is much smaller in the female than in the male, and the distribution of its branches somewhat different. The description of its arrangement in the male will first be given, and subsequently the differences which it presents in the female will be mentioned.

The **internal pudic artery in the male** passes downwards and outwards to the lower border of the great sacro-sciatic foramen, and emerges from the pelvis between the Pyriformis and Coccygeus muscles; it then crosses the spine of the ischium, and enters the perinæum through the lesser sacro-sciatic foramen. The artery now crosses the Obturator internus muscle, along the outer wall of the ischio-rectal fossa, being situated about an inch and a half above the lower margin of the ischial tuberosity. It gradually approaches the margin of the ramus of the ischium and passes forwards between the two layers of the triangular ligament of the perinæum; it then runs forwards along the inner margin of the ramus of the pubis and about half an inch behind the sub-pubic ligament it pierces the superficial layer of the triangular ligament and divides into its two terminal branches, the *dorsal artery of the penis* and the *artery of the corpus cavernosum*.

Relations.—Within the pelvis, it lies in front of the Pyriformis muscle, the sacral plexus of nerves, and the sciatic artery, and on the outer side of the rectum (on the left side). As it crosses the spine of the ischium, it is covered by the Gluteus maximus and overlapped by the great sacro-sciatic ligament. Here the pudic nerve lies to the inner side and the nerve to the Obturator internus to the outer side of the vessel. In the perinæum it lies on the outer side of the ischio-rectal fossa, in a canal (*Alcock's canal*) formed by the splitting of the obturator fascia. It is accompanied by the pudic veins and the pudic nerve.

Peculiarities.—The internal pudic is sometimes smaller than usual, or fails to give off one or two of its usual branches; in such cases the deficiency is supplied by branches derived from an additional vessel, the *accessory pudic*, which generally arises from the internal pudic artery before its exit from the great sacro-sciatic foramen. It passes forwards along the lower part of the bladder and across the side of the prostate gland to the root of the penis, where it perforates the triangular ligament, and gives off the branches usually derived from the pudic artery. The deficiency most frequently met with is that in which the internal pudic ends as the artery of the bulb, the artery of the corpus cavernosum and the dorsal artery of the penis being derived from the accessory pudic. The pudic artery may also terminate as the superficial perineal, the artery of the bulb being derived, with the other two branches, from the accessory vessel. Occasionally the accessory pudic artery is derived from one of the other branches of the internal iliac, most frequently the inferior vesical or the obturator.

Branches.—The branches of the internal pudic artery are:

Muscular.	Transverse perineal.
Inferior hæmorrhoidal.	Artery of the bulb.
Superficial perineal.	Artery of the corpus cavernosum.
	Dorsal artery of the penis.

The *muscular branches* consist of two sets: one given off in the pelvis; the other, as the vessel crosses the ischial spine. The former consists of several small offsets which supply the Levator ani, the Obturator internus, the Pyriformis, and the Coccygeus muscles. The branches given off outside the pelvis are distributed to the adjacent part of the Gluteus maximus and external rotator muscles. They anastomose with branches of the sciatic artery.

The *inferior hæmorrhoidal* (a. hæmorrhoidalis inferior) (fig. 611) arises from the interna pudic as it passes above the tuberosity of the ischium. Piercing the wall of Alcock's canal it divides into two or three branches which cross the ischio-rectal fossa, and are distributed to the muscles and integument of the anal region, and send offshoots round the lower edge of the Gluteus maximus to the skin of the buttock. They anastomose with the corresponding vessels of the opposite side, with the superior and middle hæmorrhoidal, and with the transverse and superficial perineal arteries.

The *superficial perineal* (a. perinei) supplies the scrotum and the muscles and integument of the perinæum. It arises from the internal pudic, in front of the preceding branches, and turns upwards, crossing either over or under the Transversus perinæi muscle, and runs forwards, parallel to the pubic arch, in the interspace between the Ejaculator urinæ and Erector penis muscles, both of which it supplies, and is finally distributed to the skin and

dartos muscle of the scrotum. In its passage through the perinæum it lies under cover of the superficial perineal fascia.

Fig. 611.—The superficial branches of the internal pudic artery.

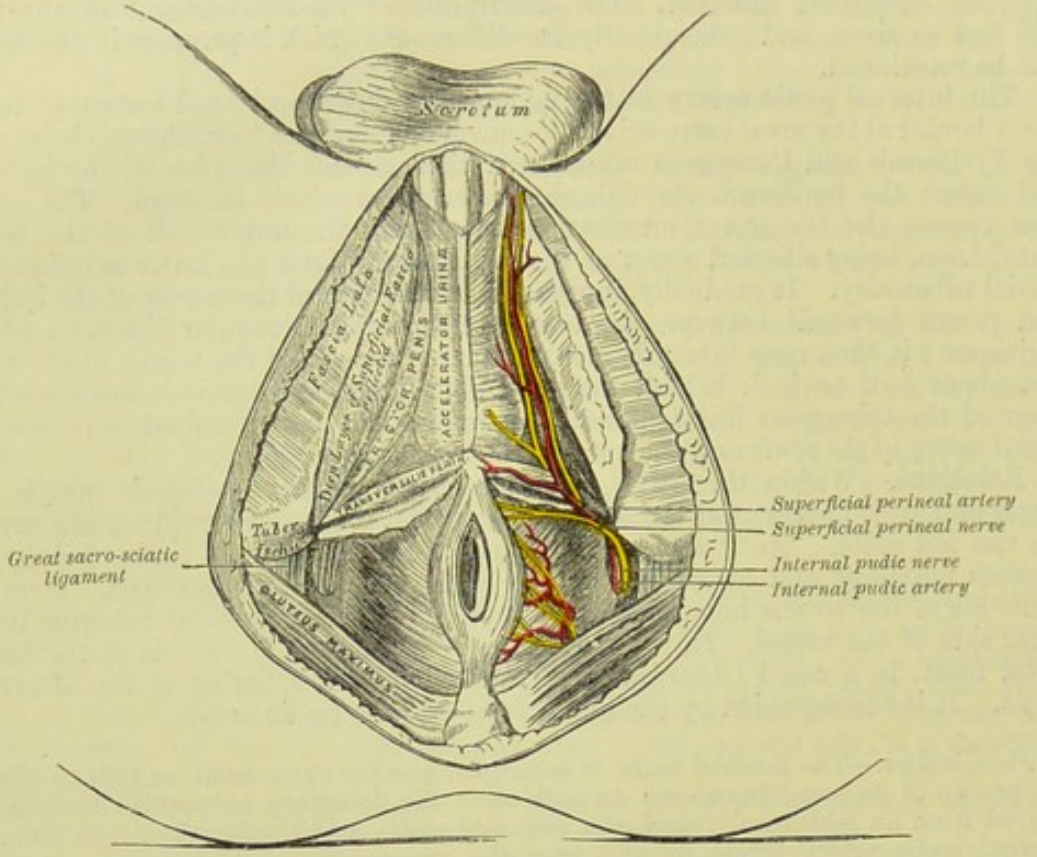

Fig. 612.—The deeper branches of the internal pudic artery.

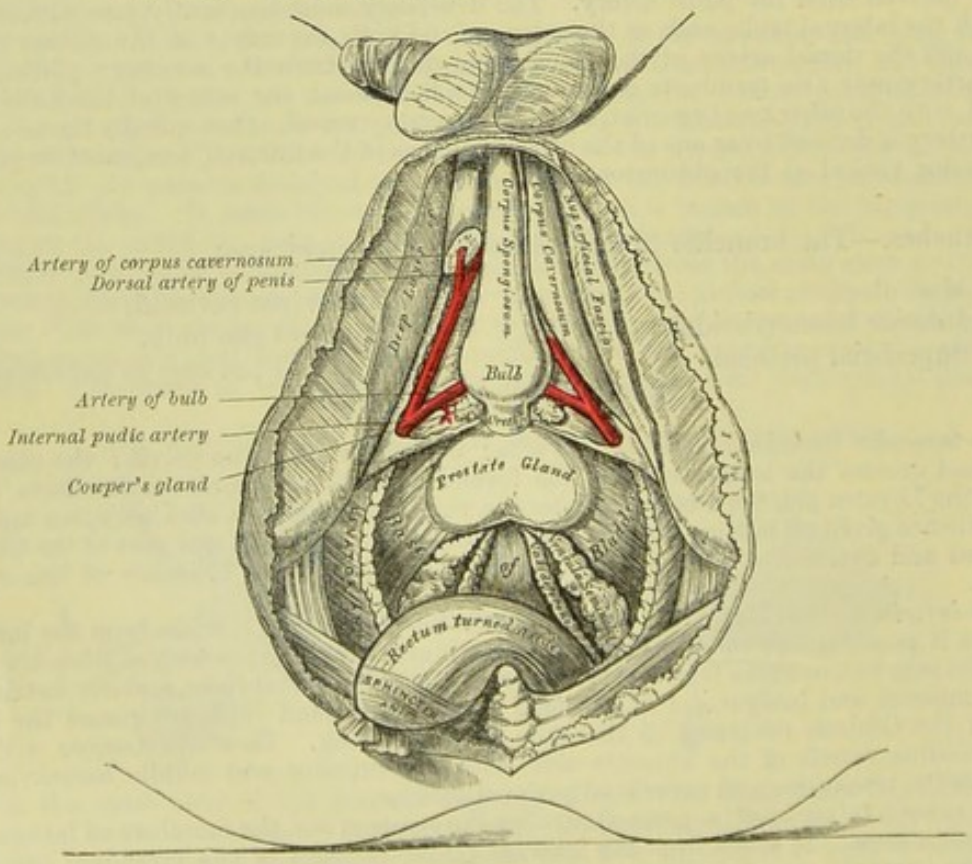

The *transverse perineal* is a small branch which arises either from the internal pudic, or from the superficial perineal artery as it crosses the Transversus perinæi muscle. It

runs transversely inwards along the cutaneous surface of the Transversus perinæi muscle, and anastomoses with the corresponding vessel of the opposite side and with the superficial perineal and inferior hæmorrhoidal arteries. It supplies the Transversus perinæi and the structures between the anus and the bulb of the urethra.

The *artery of the bulb* (a. bulbi urethræ) (fig. 612) is a short vessel of large calibre which arises from the internal pudic between the two layers of the triangular ligament; it passes nearly transversely inwards through the fibres of the Compressor urethræ muscle, pierces the superficial layer of the triangular ligament, and gives off branches which ramify in the bulb of the urethra. It is then continued forwards in the corpus spongiosum to the glans penis. It gives off a small branch to Cowper's gland.

The *artery of the corpus cavernosum* (a. profunda penis), one of the terminal branches of the internal pudic, arises from that vessel while it is situated between the two layers of the triangular ligament; it pierces the superficial layer, and, entering the crus penis obliquely, runs forwards in the centre of the corpus cavernosum, to which its branches are distributed.

The *dorsal artery of the penis* (a. dorsalis penis) ascends between the crus and the pubic symphysis, and, piercing the triangular ligament, passes between the two layers of the suspensory ligament of the penis, and runs forwards on the dorsum of the penis to the glans, where it divides into two branches, which supply the glans and prepuce. On the penis, it lies between the dorsal nerve and deep dorsal vein, the former being on its outer side. It supplies the integument and fibrous sheath of the corpus cavernosum, sending branches through the sheath to anastomose with the preceding vessel.

Fig. 613.—The arteries of the gluteal and posterior femoral regions.

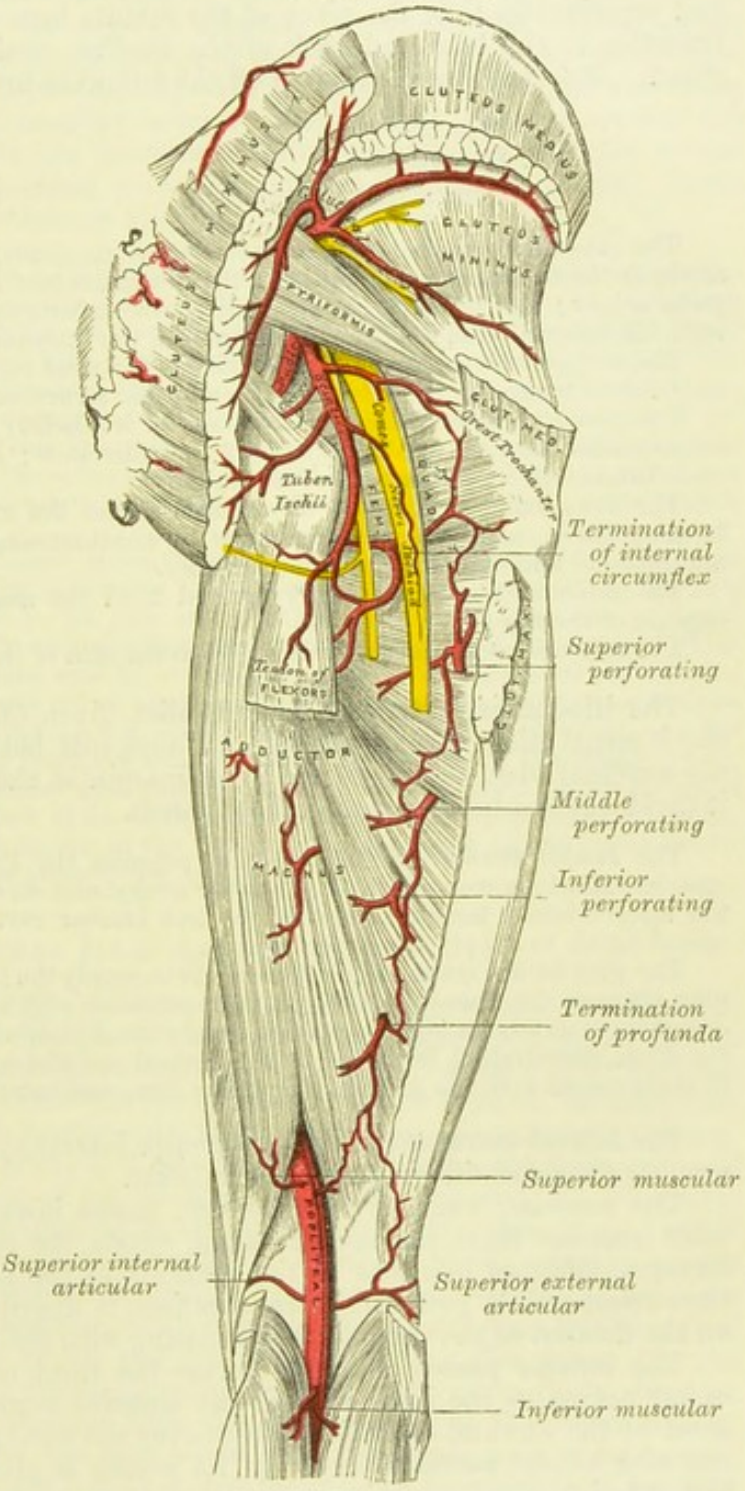

The **internal pudic artery in the female** is smaller than in the male. Its origin and course are similar, and there is considerable analogy in the distribution of its branches. The superficial perineal artery supplies the labia pudendi; the artery of the bulb supplies the bulbus vestibuli and the erectile tissue of the vagina; the artery of the corpus cavernosum supplies the cavernous body of the clitoris; and the arteria dorsalis clitoridis supplies the dorsum of that organ, and terminates in the glans and in the membranous fold corresponding to the prepuce of the male.

The **sciatic artery** (a. glutæa inferior) (fig. 613), the larger of the two terminal branches of the anterior trunk of the internal iliac, is distributed chiefly on the buttock and back of the thigh. It passes down on the sacral plexus of nerves and the

Pyriformis muscle behind the internal pudic artery to the lower part of the great sacro-sciatic foramen, through which it escapes from the pelvis between the Pyriformis and Coccygeus. It then descends in the interval between the great trochanter of the femur and tuberosity of the ischium, accompanied by the sciatic nerves, and covered by the Gluteus maximus, and is continued down the back of the thigh, supplying the skin, and anastomosing with branches of the perforating arteries.

Inside the pelvis it distributes branches to the Pyriformis, Coccygeus, and Levator ani muscles; some hæmorrhoidal branches, which supply the rectum, and occasionally take the place of the middle hæmorrhoidal artery; and vesical branches to the base and neck of the bladder, vesiculæ seminales, and prostate gland. *Outside the pelvis* it gives off the following branches:

Muscular.	Anastomotic.
Coccygeal.	Articular.
Comes nervi ischiadici.	Cutaneous.

The *muscular branches* supply the Gluteus maximus, anastomosing with the gluteal artery in the substance of the muscle; the external rotators, anastomosing with the internal pudic artery; and the muscles attached to the tuberosity of the ischium, anastomosing with the external branch of the obturator and the internal circumflex arteries.

The *coccygeal branch* runs inwards, pierces the great sacro-sciatic ligament, and supplies the Gluteus maximus, the integument, and other structures on the back of the coccyx.

The *comes nervi ischiadici* (a. comitans n. ischiadici) is a long, slender vessel, which accompanies the great sciatic nerve for a short distance; it then penetrates it, and runs in its substance to the lower part of the thigh.

The *anastomotic* is directed downwards across the external rotators, and assists in forming the so-called *crucial anastomosis* by anastomosing with the superior perforating and internal and external circumflex arteries.

The *articular branch*, generally derived from the anastomotic, is distributed to the capsule of the hip-joint.

The *cutaneous branches* are distributed to the skin of the buttock and back of the thigh.

The **ilio-lumbar artery** (a. iliolumbalis), given off from the posterior trunk of the internal iliac, turns upwards and outwards behind the obturator nerve and the external iliac vessels, to the inner margin of the Psoas muscle, behind which it divides into a lumbar and an iliac branch.

The *lumbar branch* (ramus lumbalis) supplies the Psoas and Quadratus lumborum muscles, anastomoses with the last lumbar artery, and sends a small *spinal branch* through the intervertebral foramen between the last lumbar vertebra and the sacrum, into the spinal canal, to supply the cauda equina.

The *iliac branch* (ramus iliacus) descends to supply the Iliacus muscle; some offsets, running between the muscle and the bone, anastomose with the iliac branch of the obturator; one of these enters an oblique canal to supply the diploë, while others run along the crest of the ilium, distributing branches to the gluteal and abdominal muscles, and anastomosing in their course with the gluteal, circumflex iliac, and external circumflex arteries.

The **lateral sacral arteries** (aa. sacrales laterales) (fig. 608) are usually two in number on either side, superior and inferior.

The *superior*, which is of large size, passes inwards, and, after anastomosing with branches from the middle sacral, enters the first or second anterior sacral foramen, supplies branches to the contents of the sacral canal, and, escaping by the corresponding posterior sacral foramen, is distributed to the skin and muscles on the dorsum of the sacrum, anastomosing with the gluteal.

The *inferior* passes obliquely across the front of the Pyriformis muscle and sacral nerves to the inner side of the anterior sacral foramina, descends on the front of the sacrum, and anastomoses over the coccyx with the middle sacral and opposite lateral sacral artery. In its course it gives off branches, which enter the anterior sacral foramina; these, after supplying the contents of the sacral canal, escape by the posterior sacral foramina, and are distributed to the muscles and skin on the dorsal surface of the sacrum, anastomosing with the gluteal.

The **gluteal artery** (a. glutæa superior) is the largest branch of the internal iliac, and appears to be the continuation of the posterior division of that vessel. It is a short, thick trunk, which runs backwards between the lumbo-sacral cord and the first sacral nerve, and, passing out of the pelvis above the upper border of the Pyriformis muscle, immediately divides into a *superficial* and a *deep branch*. Within

the pelvis it gives off a few muscular branches to the Iliacus, Pyriformis, and Obturator internus, and just previous to quitting that cavity, a nutrient artery which enters the ilium.

The *superficial branch* enters the deep surface of the Gluteus maximus, and divides into numerous branches, some of which supply the muscle, while others perforate its tendinous origin, and supply the integument covering the posterior surface of the sacrum, anastomosing with the posterior branches of the sacral arteries.

The *deep branch* lies under the Gluteus medius and almost immediately subdivides into two. Of these, the *superior division*, continuing the original course of the vessel, passes along the upper border of the Gluteus minimus to the anterior superior spine of the ilium, anastomosing with the circumflex iliac and ascending branches of the external circumflex artery. The *inferior division* crosses the Gluteus minimus obliquely to the trochanter major, distributing branches to the Gluteus muscles, and anastomoses with the external circumflex artery. Some branches pierce the Gluteus minimus to supply the hip-joint.

Surface Marking.—The three main branches of the internal iliac, the sciatic, internal pudic, and gluteal, may occasionally be the objects of surgical interference, and their positions are indicated on the surface in the following way. With the limb slightly flexed and rotated inwards draw a line from the posterior superior iliac spine to the posterior superior angle of the great trochanter: the point of emergence of the *gluteal artery* from the upper part of the great sacro-sciatic foramen will correspond with the junction of the upper with the middle third of this line. Draw a second line from the posterior superior iliac spine to the outer part of the tuberosity of the ischium; the junction of the lower with the middle third marks the point of emergence of the *sciatic* and *pudic arteries* from the great sacro-sciatic foramen.

Applied Anatomy.—Any of these three vessels may require ligaturing for a wound or for aneurysm, which is generally traumatic. The *gluteal* artery is ligatured by turning the patient two-thirds over on to his face and making an incision from the posterior superior spine of the ilium to the upper and posterior angle of the great trochanter. This must expose the Gluteus maximus muscle, and its fibres are to be separated through the whole thickness of the muscle and pulled apart with retractors. The contiguous margins of the Gluteus medius and Pyriformis are now to be separated from each other, and the artery will be exposed emerging from the sciatic notch. In ligature of the *sciatic* artery, the incision should be made parallel with that for ligature of the gluteal but an inch and a half lower down. After the fibres of the Gluteus maximus have been separated, the vessel is to be sought for at the lower border of the Pyriformis; the great sciatic nerve, which lies just above it, forms the chief guide to the artery.

External Iliac Artery (fig. 608)

The **external iliac artery** (a. iliaca externa) is larger than the internal iliac, and passes obliquely downwards and outwards along the inner border of the Psoas muscle, from the bifurcation of the common iliac to a point beneath Poupart's ligament, midway between the anterior superior spine of the ilium and the symphysis pubis, where it enters the thigh and becomes the femoral artery.

Relations.—*In front*, the artery is in relation with the peritoneum, subperitoneal areolar tissue, the termination of the ileum on the right side, and the ilio-pelvic colon on the left, and a thin layer of fascia, derived from the iliac fascia, which surrounds the artery and vein. At its origin it is crossed by the ovarian vessels in the female, and occasionally by the ureter. The spermatic vessels lie for some distance upon it near its termination, and it is crossed in this situation by the genital branch of the genito-crural nerve and the deep circumflex iliac vein; the vas deferens in the male, and the round ligament in the female, curve down along its inner side. *Behind*, it is in relation with the inner border of the Psoas muscle, from which it is separated by the iliac fascia. At the upper part of its course, the external iliac vein lies partly behind it, but lower down lies entirely to its inner side. *Externally*, it rests against the Psoas magnus, from which it is separated by the iliac fascia. Numerous lymphatic vessels and glands lie on the front and on the inner side of the vessel.

Surface Marking.—The surface line indicating the course of the external iliac artery has been already given (see page 697).

Applied Anatomy.—The application of a ligature to the external iliac may be required in cases of aneurysm of the femoral artery, ilio-femoral aneurysm, or for a wound of the

artery. The vessel may be secured in any part of its course, excepting near its upper end, which is to be avoided on account of the proximity of the internal iliac, and near its lower end, which should also be avoided on account of the proximity of the deep epigastric and circumflex iliac vessels. The operation may be performed by opening the abdomen and incising the peritoneum over the artery (*transperitoneal*); or by an incision in the iliac region, dividing all the structures down to the peritoneum, which is then reflected inwards unopened from the iliac fossa until the artery is reached (*retroperitoneal*).

Transperitoneal ligature.—An incision four inches in length is made in the semilunar line, commencing about an inch below the umbilicus, and carried through the abdominal wall into the peritoneal cavity. The intestines are then pushed upwards and held out of the way by a broad abdominal retractor, and an incision made through the peritoneum at the margin of the pelvis in the course of the artery: the vessel is secured in any part of its course which may seem desirable to the operator. The advantages of this operation appear to be, that if it is found necessary the common iliac artery can be ligatured instead of the external iliac without extension or modification of the incision; and secondly, that the vessel can be ligatured without in any way interfering with the sac of an aneurysm.

The retroperitoneal ligature may be performed either by the modified Abernethy's method, which consists in making an incision from an inch above and internal to the anterior superior spine of the ilium in a curved direction, with its convexity outwards and downwards to a point an inch and a half above the middle of Poupart's ligament; or by Astley Cooper's method, in which an incision is made in a curved direction from a little above and outside the external abdominal ring to an inch from the inner side of the anterior superior spinous process of the ilium. In both, the abdominal muscles and transversalis fascia having been cautiously divided, the peritoneum should be separated from the iliac fossa and raised towards the pelvis; and on introducing the finger to the bottom of the wound, the artery may be felt pulsating along the inner border of the Psoas muscle. The external iliac vein is generally found on the inner side of the artery, and must be cautiously separated from it by the finger-nail, or handle of the knife, and the aneurysm needle should be introduced on the inner side, between the artery and vein.

Collateral Circulation.—The principal anastomoses in carrying on the collateral circulation, after the application of a ligature to the external iliac, are: the ilio-lumbar with the circumflex iliac; the gluteal with the external circumflex; the obturator with the internal circumflex; the sciatic with the superior perforating and circumflex branches of the profunda artery; and the internal pudic with the external pudic. When the obturator arises from the epigastric, it is supplied with blood by branches, from either the internal iliac, the lateral sacral, or the internal pudic. The epigastric receives its supply from the internal mammary and inferior intercostal arteries, and from the internal iliac by the anastomoses of its branches with the obturator.*

Branches.—Besides several small branches to the Psoas magnus and the neighbouring lymphatic glands, the external iliac gives off two branches of considerable size:

Deep epigastric Deep circumflex iliac.

The **deep epigastric artery** (a. epigastrica inferior) arises from the external iliac, immediately above Poupart's ligament. It curves forwards below the peritoneum, and then ascends obliquely along the inner margin of the internal abdominal ring, between the transversalis fascia and peritoneum; continuing its course upwards, it pierces the transversalis fascia, and, passing in front of the semilunar fold of Douglas, ascends between the Rectus and the posterior lamella of its aponeurotic sheath. It finally divides into numerous branches, which anastomose, above the umbilicus, with the superior epigastric branch of the internal mammary and with the lower intercostal arteries (fig. 593). As the deep epigastric artery passes obliquely upwards and inwards from its origin it lies along the lower and inner margin of the internal abdominal ring, and behind the commencement of the spermatic cord. This part of the vessel is crossed by the vas deferens in the male and the round ligament of the uterus in the female.

The branches of the vessel are: the *cremasteric* (a. spermatica externa), which accompanies the spermatic cord, and supplies the Cremaster muscle and other coverings of the cord, anastomosing with the spermatic artery (in the female it is very small and accompanies the round ligament); a *pubic branch* (ramus pubicus) which runs along Poupart's ligament, and then descends behind the pubis to the inner side of the femoral ring, and anastomoses with offsets from the obturator

* Sir Astley Cooper describes in vol. i. of the *Guy's Hospital Reports* the dissection of a limb eighteen years after successful ligature of the external iliac artery.

artery; *muscular branches*, some of which are distributed to the abdominal muscles and peritoneum, anastomosing with the lumbar and circumflex iliac arteries; branches which perforate the tendon of the External oblique, and supply the integument, anastomosing with branches of the superficial epigastric.

Peculiarities.—The origin of the deep epigastric may take place from any part of the external iliac between Poupart's ligament and a point two inches and a half above it; or it may arise below this ligament, from the femoral. It frequently arises from the external iliac, by a common trunk with the obturator. Sometimes it arises from the obturator, the latter vessel being furnished by the internal iliac, or it may be formed of two branches, one derived from the external iliac, the other from the internal iliac.

Applied Anatomy.—The deep epigastric artery follows a line drawn from the middle of Poupart's ligament towards the umbilicus; but shortly after this line crosses the linea semilunaris, the direction changes, and the course of the vessel is upwards along the line of junction of the inner with the middle third of the Rectus abdominis. It has important surgical relations, and is one of the principal means, through its anastomosis with the internal mammary, of establishing the collateral circulation after ligature of either the common or external iliac arteries. It lies close to the internal abdominal ring, and is therefore *internal* to an oblique inguinal hernia, but *external* to a direct inguinal hernia, as these emerge from the abdomen. It forms the outer boundary of Hesselbach's triangle, and is in close relationship with the spermatic cord, which lies in front of it in the inguinal canal, separated only by the transversalis fascia. The vas deferens hooks round its outer side.

The **deep circumflex iliac artery** (a. circumflexa ilium profunda) arises from the outer side of the external iliac nearly opposite the deep epigastric artery. It ascends obliquely outwards behind Poupart's ligament, contained in a fibrous sheath formed by the junction of the transversalis and iliac fasciæ, to the anterior superior spine of the ilium, where it anastomoses with the ascending branch of the external circumflex artery. It then pierces the transversalis fascia and passes along the inner surface of the crest of the ilium to about its middle, where it perforates the Transversalis, and runs backwards between that muscle and the Internal oblique, to anastomose with the ilio-lumbar and gluteal arteries. Opposite the anterior superior spine of the ilium it gives off a large branch, which ascends between the Internal oblique and Transversalis muscles, supplying them, and anastomosing with the lumbar and epigastric arteries.

ARTERIES OF THE LOWER EXTREMITY

The artery which supplies the greater part of the lower extremity is the direct continuation of the external iliac. It continues as a single trunk from Poupart's ligament to the lower border of the Popliteus muscle, where it divides into two branches, the *anterior* and *posterior tibial*. The upper part of the main trunk is named the *femoral*, the lower part the *popliteal*.

Femoral Artery (figs. 617, 618)

The **femoral artery** (a. femoralis) commences immediately behind Poupart's ligament, midway between the anterior superior spine of the ilium and the symphysis pubis, and passes down the front and inner side of the thigh. It terminates at the junction of the middle with the lower third of the thigh where it passes through an opening in the Adductor magnus to become the popliteal artery. The vessel, at the upper part of the thigh, lies in front of the hip-joint, on a line with the innermost part of the head of the femur; in the lower part of its course it lies to the inner side of the shaft, and between these two parts, where it crosses the angle between the head and shaft, the vessel is some distance from the bone. The first inch and a half of the vessel is enclosed, together with the femoral vein, in a fibrous sheath—the *femoral sheath*. In the upper third of the thigh the femoral artery is contained in a triangular space, called *Scarpa's triangle*, and in the middle third of the thigh, in an aponeurotic canal, named *Hunter's canal*.

The **femoral sheath** (fig. 614) is formed by a prolongation downwards, behind Poupart's ligament, of the fasciæ which line the abdomen, the fascia transversalis being continued down in front of the femoral vessels and the

fascia transversalis behind them. The sheath assumes the form of a short funnel-shaped tube, the wide end of which is directed upwards, while the lower, narrow end fuses with the fascial investment of the vessels, about an inch and a half below the level of Poupart's ligament. It is strengthened in front by a band termed the *deep crural arch* (p. 516). The outer wall of the sheath is vertical and is perforated by the genital branch of the genito-crural nerve; the inner wall is directed obliquely downwards and outwards and is pierced by the internal saphenous vein and by some lymphatic vessels. The sheath is divided by two vertical partitions which stretch between its anterior and posterior walls. The outermost compartment contains the femoral artery and the middle the femoral vein, while the innermost and smallest compartment is named the *crural canal*, and contains some lymphatic vessels and a lymphatic

Fig. 614.—Femoral sheath laid open to show its three compartments.

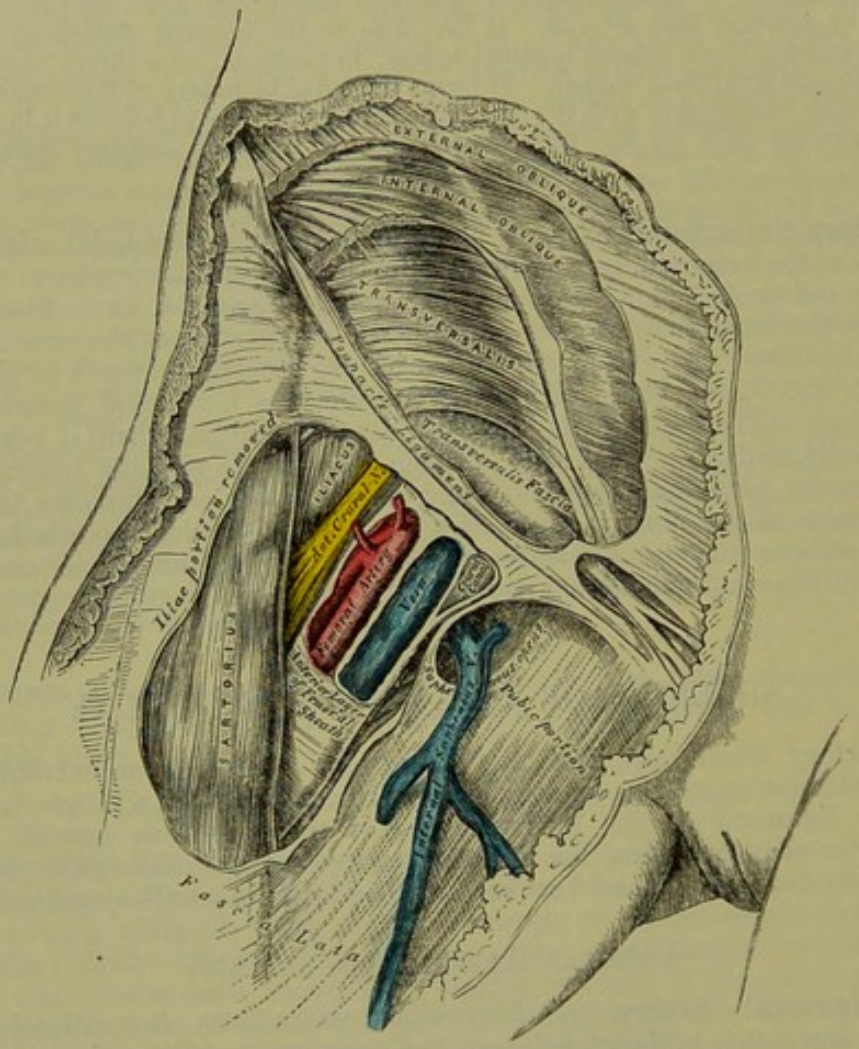

gland imbedded in a small amount of areolar tissue. The crural canal is conical and measures about half an inch in length. Its base, directed upwards and named the *crural ring*, is oval in form, its long diameter being directed transversely and measuring about half an inch. The crural ring (figs. 615, 616) is bounded in front by Poupart's ligament, behind by the Pectineus muscle covered by the pubic portion of the fascia lata, internally by the crescentic base of Gimbernat's ligament, and externally by the fibrous septum on the inner side of the femoral vein. The spermatic cord in the male and the round ligament of the uterus in the female lie immediately above the anterior margin of the ring, while the deep epigastric artery is close to its upper and outer angle. The crural ring is closed by a somewhat condensed portion of the extra-peritoneal fatty tissue, named the *septum crurale*, the abdominal surface of which supports a small lymphatic gland and is covered by the parietal layer of the peritoneum. The septum crurale is pierced by numerous lymphatic vessels passing from the

deep inguinal to the external iliac glands, and the parietal peritoneum immediately above it presents a slight depression named the *femoral fossa*.

FIG. 615.—Structures passing behind Poupart's ligament.

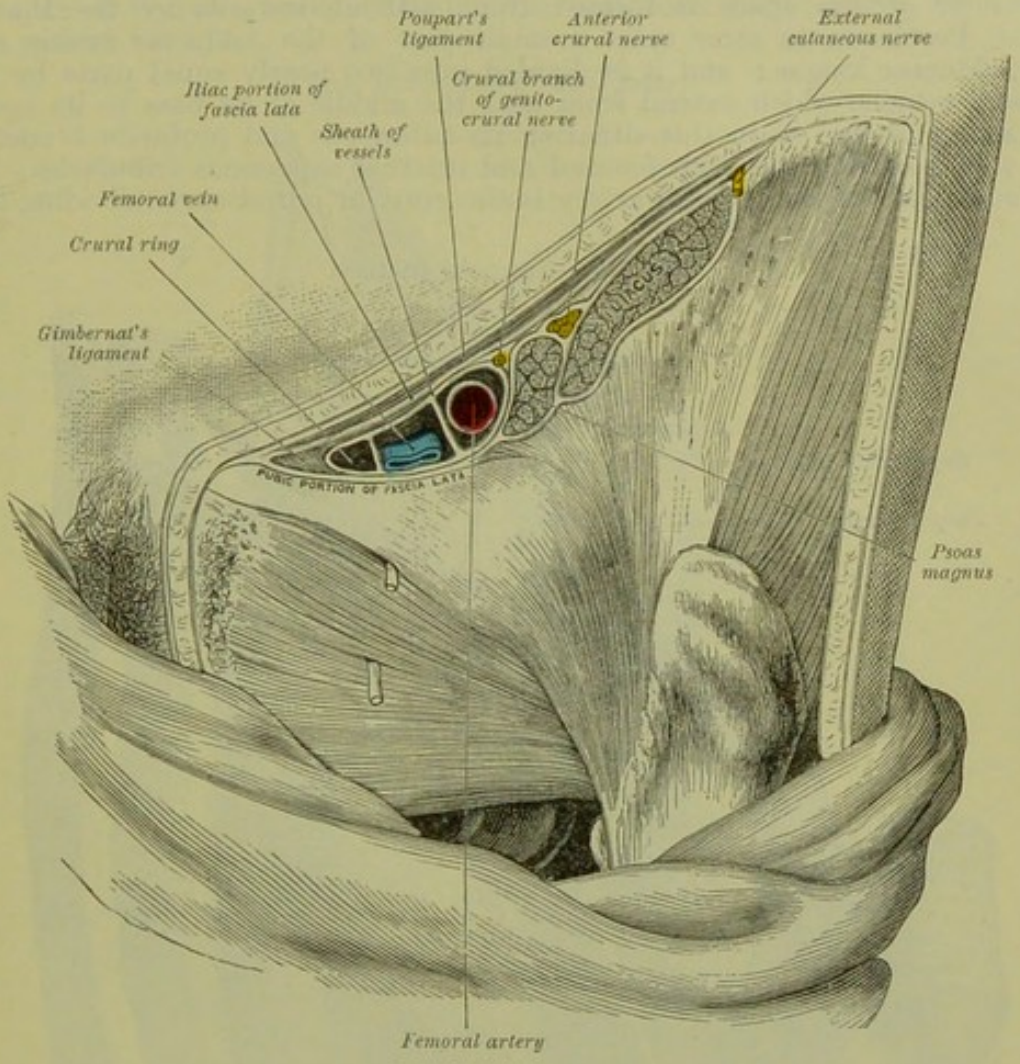

FIG. 616.—The relations of the crural and internal abdominal rings, seen from within the abdomen. Right side.

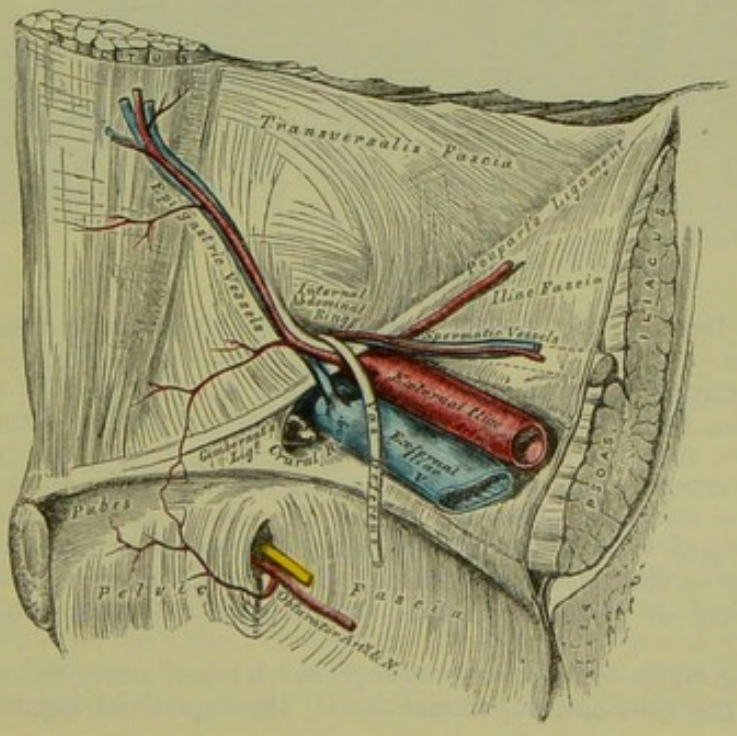

Scarpa's triangle (fig. 617) corresponds to the depression seen immediately below the fold of the groin. Its apex is directed downwards, and the sides are formed externally by the inner margin of the Sartorius, internally by the inner margin of the Adductor longus, and above by Poupart's ligament. The floor of the space is formed from without inwards by the Iliacus, Psoas, Pectineus, in some cases a small part of the Adductor brevis, and the Adductor longus; and it is divided into two nearly equal parts by the femoral vessels, which extend from near the middle of its base to its apex: the artery giving off in this situation its cutaneous and profunda branches, the vein receiving the deep femoral and internal saphenous tributaries. On the outer side of the femoral artery is the anterior crural nerve dividing into

Fig. 617.—Scarpa's triangle.

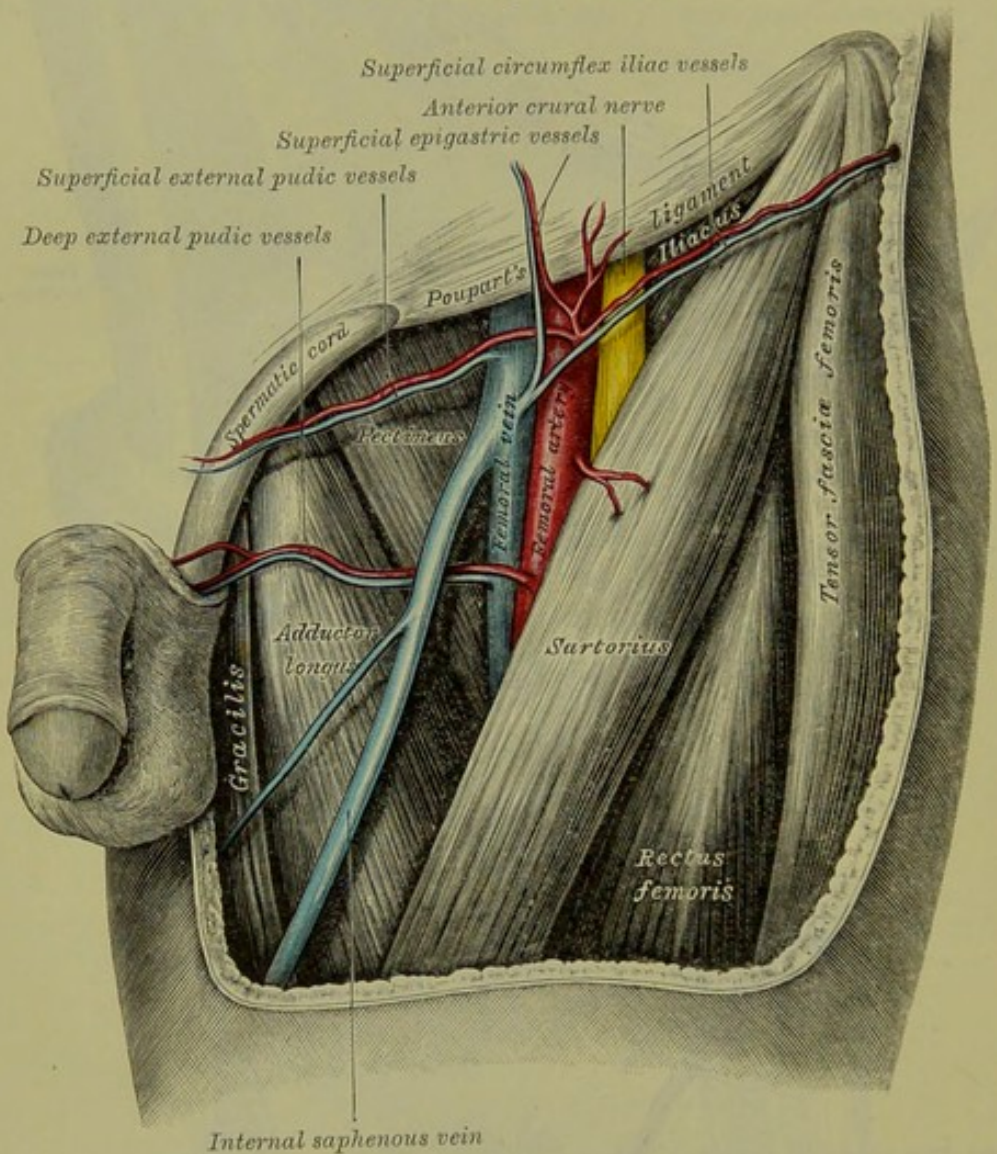

its branches. Besides the vessels and nerves, this space contains some fat and lymphatics.

Hunter's canal is an aponeurotic tunnel in the middle third of the thigh, extending from the apex of Scarpa's triangle to the femoral opening in the Adductor magnus muscle. It is bounded, in front and externally, by the Vastus internus; behind, by the Adductores longus et magnus; and covered in by a strong aponeurosis which extends from the Vastus internus, across the femoral vessels to the Adductores longus et magnus; lying on the aponeurosis is the Sartorius muscle. It contains the femoral artery and vein, the internal or long saphenous nerve, and the nerve to the Vastus internus.

Relations (fig. 617).—In *Scarpa's triangle* the femoral artery is superficial. *In front* of it are the skin and superficial fascia, the superficial inguinal lymphatic

glands, the superficial circumflex iliac vein, the iliac portion of the fascia lata and the anterior part of the femoral sheath. The genital branch of the genito-crural nerve courses for a short distance within the outer compartment of the femoral sheath, and lies at first in front and then on the outer side of the artery. Near the apex of Scarpa's triangle the internal cutaneous nerve crosses the artery from without inwards.

Fig. 618.—The femoral artery.

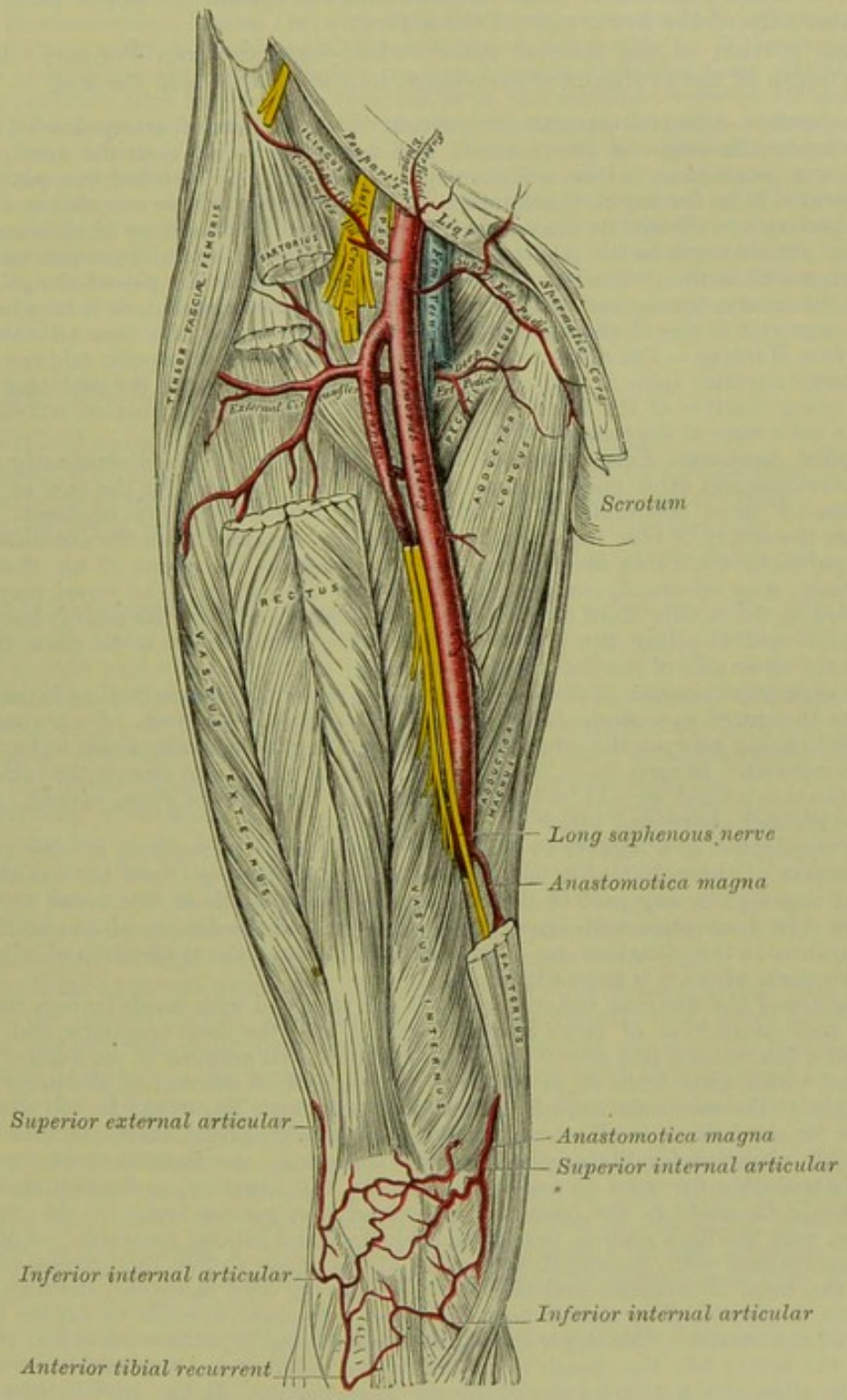

Behind the artery are the posterior part of the femoral sheath, the pubic portion of the fascia lata, the inner part of the tendon of the Psoas, the Pectineus and the Adductor longus. The artery is separated from the capsule of the hip-joint by the tendon of the Psoas, from the Pectineus by the femoral vein and profunda vessels, and from the Adductor longus by the femoral vein. The nerve to the Pectineus passes inwards behind the artery. On the *outer* side of the artery, but separated

from it by some fibres of the Psoas, is the anterior crural nerve. The femoral vein is on the inner side of the upper part of the artery, but is behind the vessel in the lower part of Scarpa's triangle.

In *Hunter's canal* the femoral artery is more deeply situated, being covered by the integument, the superficial and deep fasciæ, the Sartorius and the fibrous roof of the canal; it is crossed from without inwards by the long saphenous nerve. Behind the artery are the Adductores longus et magnus; in front and to its outer side is the Vastus internus. The femoral vein lies behind the upper part, and on the outer side of the lower part of the artery.

That portion of the femoral artery which extends from Poupart's ligament to the origin of the profunda is sometimes named the *common femoral.*

Peculiarities.—Several cases are recorded in which the femoral artery divided into two trunks below the origin of the profunda, and became reunited near the opening in the Adductor magnus, so as to form a single popliteal artery. One occurred in a patient who was operated upon for popliteal aneurysm. A few cases have been recorded in which the femoral artery was absent, its place being supplied by the sciatic artery which accompanied the great sciatic nerve to the popliteal space. The external iliac in these cases was small, and terminated in the profunda. The femoral vein is occasionally placed along the inner side of the artery, throughout the entire extent of Scarpa's triangle; or it may be split so that a large vein is placed on either side of the artery for a greater or lesser distance.

Surface Marking.—The upper two-thirds of a line drawn from a point midway between the anterior superior spine of the ilium and the symphysis pubis to the adductor tubercle on the inner condyle of the femur, with the thigh abducted and rotated outwards, will indicate the course of the femoral artery.

Applied Anatomy.—Compression of the femoral artery, which is constantly requisite in amputations and other operations on the lower limb, and also for the cure of popliteal aneurysm, is most effectually made immediately below Poupart's ligament. In this situation the artery is very superficial, and is merely separated from the ascending ramus of the pubis by the Psoas muscle; so that the surgeon, by means of his thumb or a compressor, may effectually control the circulation through it. The vessel may also be controlled in the middle third of the thigh by placing a pad over the artery, beneath the tourniquet, and directing the pressure from within outwards, so as to press the vessel against the inner side of the shaft of the femur.

The superficial position of the femoral artery in Scarpa's triangle renders it particularly liable to be injured in wounds, stabs, or gunshot injuries in the groin. On account of the close relationship between the artery and vein, the latter vessel is also liable to be wounded in these injuries. In such cases, the artery being compressed as it crosses the ramus of the pubis, the skin wound should be enlarged and the wound in the vessel sought for, and a ligature applied above and below the bleeding point.

The *application of a ligature* to the femoral artery may be required in cases of wound or aneurysm of the popliteal or femoral, or arteries of the leg; and the vessel may be exposed and tied in any part of its course. The great depth of this vessel at its lower part, its close connection with important structures, and the density of its sheath, render the operation in this situation one of greater difficulty than the application of a ligature at its upper part, where it is more superficial.

Ligature of the common femoral artery is not regarded with much favour, on account of the near connection of large branches with it, viz. the deep epigastric and the deep circumflex iliac arising just above Poupart's ligament; on account of the number of small branches which arise from it, in its short course, and on account of the uncertainty of the origin of the profunda femoris, which, if it arise high up, would be too close to the ligature for the formation of a firm coagulum. It would appear, therefore, that the most favourable situation for the application of a ligature to the femoral is at the apex of Scarpa's triangle. In order to reach the artery in this situation, an incision three inches long should be made in the course of the vessel, the patient lying in the recumbent position, with the limb slightly flexed and abducted, and rotated outwards. A large vein is frequently met with, passing in the course of the artery to join the internal saphenous vein; this must be avoided, and the fascia lata having been cautiously divided, and the Sartorius displayed, that muscle must be drawn outwards, in order to expose fully the sheath of the vessels. The finger having been introduced into the wound, and the pulsation of the artery felt, the sheath is opened on the outer side of the vessel to a sufficient extent to allow of the introduction of the aneurysm needle. In this part of the operation the long saphenous nerve and the nerve to the Vastus internus, which are in close relation with the sheath, should be avoided. The aneurysm needle must be carefully introduced and kept close to the artery, to avoid the femoral vein, which lies behind the vessel in this part of its course, and is very closely bound up with it.

To expose the artery in Hunter's canal, an incision between three and four inches in length should be made through the integument, a finger's breadth internal to the line of the artery, the centre of the incision being in the middle of the thigh—i.e. midway between the groin and the knee. The fascia lata having been divided, and the outer

border of the Sartorius exposed, this muscle should be drawn inwards, when the strong fascia which is stretched across from the Adductors to the Vastus internus will be observed, and must be freely divided; the sheath of the vessels is now seen, and must be opened, and the artery secured by passing the aneurysm needle between it and the vein, in the direction from without inwards. In this situation the femoral vein lies on the outer side, and the long saphenous nerve in front of the artery.

It has been seen that the femoral artery occasionally divides into two trunks below the origin of the profunda. If, in the operation for tying the femoral, two vessels be met with, the surgeon should alternately compress each, in order to ascertain which is connected with the aneurysmal tumour, or with the bleeding from the wound, and that one only should be tied which is the source of the pulsation or hæmorrhage. If, however, it be necessary to compress both vessels before the circulation is controlled, both should be tied, as it is probable that they become reunited, as in the instances referred to above.

Collateral Circulation.—After ligature of the femoral artery, the main channels for carrying on the circulation are the anastomoses between—(1) the gluteal and sciatic branches of the internal iliac with the internal and external circumflex and superior perforating branches of the profunda femoris; (2) the obturator branch of the internal iliac with the internal circumflex of the profunda; (3) the internal pudic of the internal iliac with the superficial and deep external pudic of the femoral; (4) the deep circumflex iliac of the external iliac with the external circumflex of the profunda and the superficial circumflex iliac of the femoral; and (5) the sciatic and comes nervi ischiadici of the internal iliac with the perforating branches of the profunda.

Branches.—The branches of the femoral artery are:

Superficial epigastric.		Muscular.
Superficial circumflex iliac.		External circumflex.
Superficial external pudic.	Profunda	Internal circumflex.
Deep external pudic.		Three perforating.
		Anastomotica magna.

The **superficial epigastric** (a. epigastrica superficialis) arises from the front of the femoral artery about half an inch below Poupart's ligament, and, passing through the femoral sheath and the cribriform fascia, turns upwards in front of Poupart's ligament, and ascends between the two layers of the superficial fascia of the abdominal wall nearly as far as the umbilicus. It distributes branches to the superficial inguinal glands, the superficial fascia, and the integument; it anastomoses with branches of the deep epigastric, and with its fellow of the opposite side.

The **superficial circumflex iliac** (a. circumflexa ilium superficialis), the smallest of the cutaneous branches, arises close to the preceding, and, piercing the fascia lata, runs outwards, parallel with Poupart's ligament, as far as the crest of the ilium; it divides into branches which supply the integument of the groin, the superficial fascia, and the superficial inguinal lymphatic glands, anastomosing with the deep circumflex iliac, and with the gluteal and external circumflex arteries.

The **superficial external pudic** (a. pudenda externa superficialis) arises from the inner side of the femoral artery, close to the preceding vessels, and, after piercing the femoral sheath and cribriform fascia, courses inwards, across the spermatic cord (or round ligament in the female), to be distributed to the integument on the lower part of the abdomen, the penis and scrotum in the male, and the labium majus in the female, anastomosing with branches of the internal pudic.

The **deep external pudic** (a. pudenda externa profunda), more deeply seated than the preceding, passes inwards across the Pectineus and Adductor longus muscles; it is covered by the fascia lata, which it pierces at the inner border of the thigh, and is distributed, in the male to the integument of the scrotum and perinæum, in the female to the labium majus; its branches anastomose with those of the superficial perineal artery.

Muscular branches are supplied by the femoral artery to the Sartorius, Vastus internus, and Adductors.

The **profunda** (a. profunda femoris) (fig. 620) is a large vessel arising from the outer and back part of the femoral artery, from one to two inches below Poupart's ligament. At first it lies on the outer side of the femoral artery; it then runs behind it and the femoral vein to the inner side of the femur, and, passing downwards behind the Adductor longus, terminates at the lower third of the thigh in a small branch, which pierces the Adductor magnus, and is distributed on the back of the thigh to the Flexor muscles. The terminal part of the profunda is sometimes named the *fourth perforating artery*.

Relations.—*Behind*, it lies from above downwards upon the Iliacus, Pectineus, Adductor brevis, and Adductor magnus. *In front*, it is separated from the femoral artery by the femoral and profunda veins above, and by the Adductor longus below. On its *outer side*, the origin of the Vastus internus intervenes between it and the femur.

Peculiarities.—This vessel sometimes arises from the inner side, and, more rarely, from the back of the femoral artery; but a more important peculiarity, from a surgical point of view, is that relating to the height at which the vessel arises. In three-fourths of a large number of cases it arose between one and two inches below Poupart's ligament; in a few cases the distance was less than an inch; more rarely, opposite the ligament; and in one case above Poupart's ligament, from the external iliac. Occasionally the distance between the origin of the vessel and Poupart's ligament exceeds two inches.

The profunda gives off the following branches:

External circumflex. Internal circumflex. Three perforating. Muscular.

The **external circumflex** (a. circumflexa femoris lateralis) supplies the muscles on the front of the thigh. It arises from the outer side of the profunda, passes horizontally outwards, between the divisions of the anterior crural nerve, and behind the Sartorius and Rectus femoris, and divides into ascending, transverse, and descending branches.

The *ascending branch* (ramus ascendens) passes upwards, beneath the Tensor fasciæ femoris muscle, to the outer side of the hip, and anastomoses with the terminal branches of the gluteal and deep circumflex iliac arteries.

The *descending branch* (ramus descendens) runs downwards, behind the Rectus, upon the Vastus externus to which it gives offsets; one long branch descends in the muscle as far as the knee, and anastomoses with the superior external articular branch of the popliteal artery. It is accompanied by the branch of the anterior crural nerve to the Vastus externus.

The *transverse branch* (ramus transversus), the smallest, passes outwards over the Crureus, pierces the Vastus externus, and winds round the femur, just below the great trochanter, anastomosing at the back of the thigh with the internal circumflex, sciatic, and superior perforating arteries.

The **internal circumflex** (a. circumflexa femoris medialis), smaller than the external, arises from the inner and posterior aspect of the profunda, and winds round the inner side of the femur, passing first between the Pectineus and Psoas muscles, and then between the Obturator externus and Adductor brevis. At the upper border of the Adductor brevis, it gives off two branches, one of which passes inwards to be distributed to the Adductor muscles, the Gracilis, and Obturator externus, anastomosing with the obturator artery; the other descends beneath the Adductor brevis, to supply it and the Adductor magnus; while the continuation of the vessel passes backwards and divides into an ascending and a transverse branch. The *ascending branch* (ramus profundus) runs obliquely upwards upon the tendon of the Obturator externus and in front of the Quadratus femoris towards the digital fossa, where it anastomoses with twigs from the gluteal and sciatic arteries. The *transverse branch* (ramus superficialis), larger than the ascending, appears between the Quadratus femoris and upper border of the Adductor magnus, anastomosing with the sciatic, external circumflex, and superior perforating arteries (*crucial anastomosis*). Opposite the hip-joint, the artery gives off an articular vessel, which enters the joint beneath the transverse ligament; and, after supplying the adipose tissue, passes along the round ligament to the head of the femur.

The **perforating arteries** (fig. 613), usually three in number, are so named because they perforate the tendon of the Adductor magnus muscle to reach the back of the thigh. They pass backwards close to the linea aspera of the femur under cover of small tendinous arches in the muscle. The first is given off above the Adductor brevis, the second in front of that muscle, and the third immediately below it.

The *first perforating artery* (a. perforans prima) passes backwards between the Pectineus and Adductor brevis (sometimes it perforates the latter); it then pierces the Adductor magnus close to the linea aspera. It gives branches to the Adductor brevis, Adductor magnus, Biceps, and Gluteus maximus muscles, and anastomoses with the sciatic, internal and external circumflex, and middle perforating arteries.

The *second perforating artery* (a. perforans secunda), larger than the first, pierces the tendons of the Adductor brevis and Adductor magnus muscles, and divides into ascending and descending branches, which supply the flexor muscles of the thigh, anastomosing with the first and third perforating. The second artery frequently arises in common with the first. The nutrient artery of the femur (a. nutricia femoris) is usually given off from this branch.

The *third perforating artery* (a. perforans tertia) is given off below the Adductor brevis; it pierces the Adductor magnus, and divides into branches which supply the flexor muscles of the thigh; anastomosing above with the higher perforating arteries, and below with the terminal branches of the profunda and the muscular branches of the popliteal. The nutrient artery of the femur may arise from this branch.

The termination of the profunda artery, already described, is sometimes termed the *fourth perforating artery*.

Numerous **muscular branches** arise from the profunda; some of these end in the Adductor muscles, others pierce the Adductor magnus, give branches to the hamstrings, and anastomose with the internal circumflex artery and with upper muscular branches of the popliteal.

The **anastomotica magna** (a. genu suprema) (fig. 618) arises from the femoral artery just before it passes through the tendinous opening in the Adductor magnus muscle, and immediately divides into a superficial and a deep branch.

The *superficial branch* (ramus saphenus) pierces the aponeurotic covering of Hunter's canal, and accompanies the long saphenous nerve to the inner side of the knee. It passes between the Sartorius and Gracilis muscles, and, piercing the fascia lata, is distributed to the integument of the upper and inner part of the leg, anastomosing with the inferior internal articular artery.

The *deep branch* (ramus musculoarticularis) descends in the substance of the Vastus internus, lying in front of the tendon of the Adductor magnus, to the inner side of the knee, where it anastomoses with the superior internal articular artery and anterior recurrent branch of the anterior tibial. A branch from this vessel crosses outwards above the articular surface of the femur, forming an anastomotic arch with the superior external articular artery, and supplying branches to the knee-joint.

The Popliteal Space (fig. 620)

Boundaries.—The **popliteal space,** or **ham,** is a lozenge-shaped space, at the back part of the knee-joint. Above, it is bounded externally by the Biceps and internally by the Semitendinosus and Semimembranosus; below, it is limited by the outer head of the Gastrocnemius and the Plantaris externally and by the inner head of the Gastrocnemius internally. The floor is formed by the lower part of the posterior surface of the shaft of the femur, the posterior ligament of the knee-joint, the upper end of the tibia, and the fascia covering the Popliteus muscle; the space is covered in by the fascia lata.

Contents.—The popliteal space contains the popliteal vessels and nerves, together with the termination of the external saphenous vein, the lower part of the small sciatic nerve, the articular branch from the obturator nerve, a few small lymphatic glands, and a considerable quantity of loose adipose tissue. The internal popliteal nerve descends in the middle line of the space, lying under the deep fascia and crossing the vessels from without inwards. The external popliteal nerve descends on the outer side of the upper part of the space, close to the tendon of the Biceps muscle. At the bottom of the space are the popliteal vessels, the vein being superficial to the artery and united to it by dense areolar tissue; the vein is a thick-walled vessel, and lies at first to the outer side of the artery, and then crosses it to gain the inner side below; sometimes it is double, the artery lying between two venæ comites, which are usually connected by short transverse branches. The articular branch from the obturator nerve descends upon the artery to supply the knee. The popliteal lymphatic glands, four or five in number, surround the artery: one usually lies superficial to the vessel; another is situated between it and the bone; and the rest are placed on either side of it. Arising from the artery, and passing off from it at right angles, are its articular branches.

Popliteal Artery (figs. 619, 620)

The **popliteal artery** (a. poplitea) is the continuation of the femoral, and courses through the popliteal space. It extends from the opening in the Adductor magnus, at the junction of the middle and lower thirds of the thigh, downwards and outwards to the intercondyloid notch of the femur, and then

Fig. 619.—Side view of the popliteal artery.
(From a preparation in the Museum of the Royal College of Surgeons of England.)

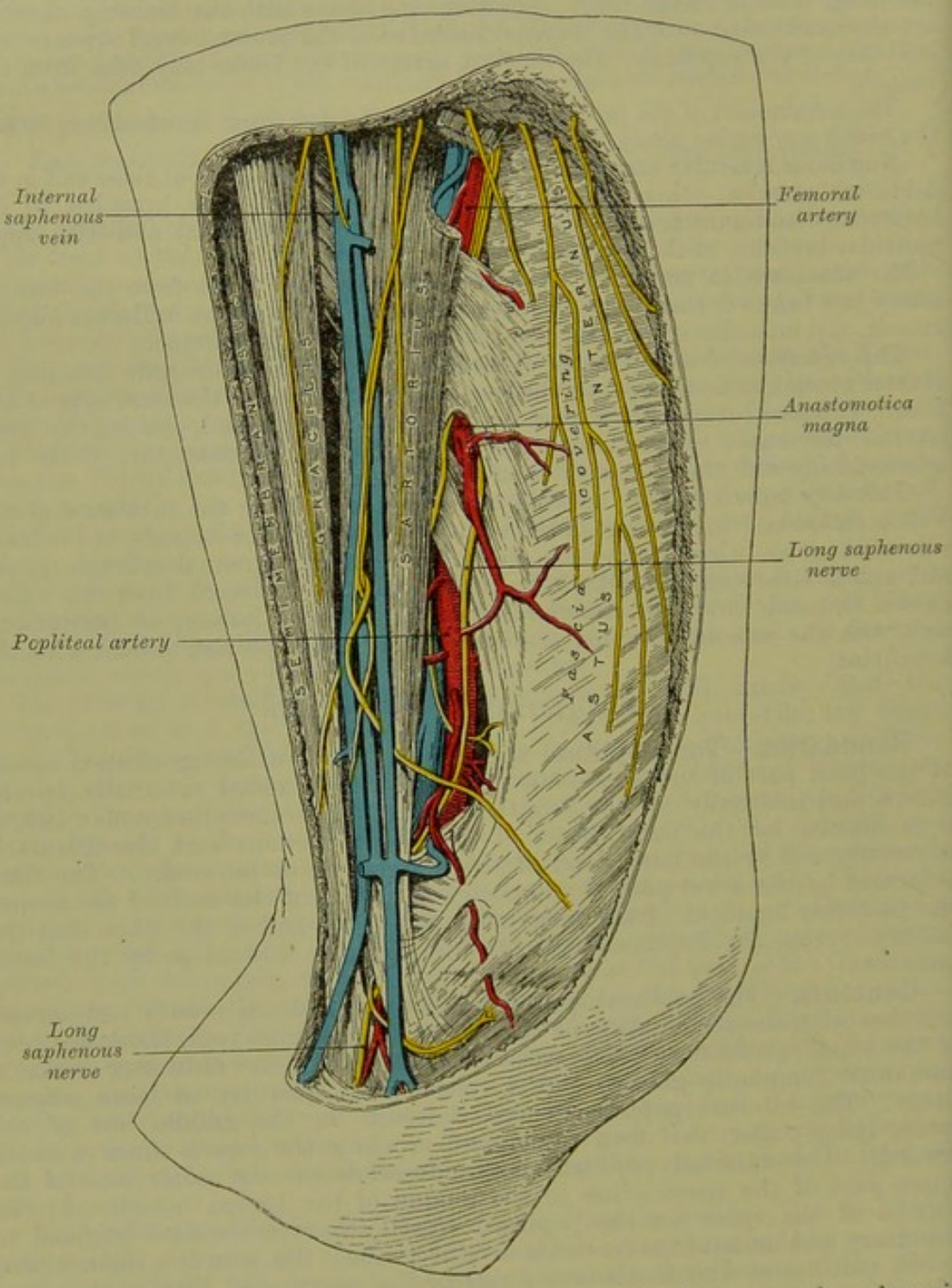

vertically downwards to the lower border of the Popliteus muscle, where it divides into *anterior* and *posterior tibial arteries*.

Relations.—In *front* from above downwards are the popliteal surface of the femur (which is separated from the artery by some fat), the posterior ligament of the knee joint, and the fascia covering the Popliteus. *Behind*, it is overlapped above by the Semimembranosus, and below it is covered by the Gastrocnemius and Plantaris. In the middle part of its course the artery is separated from the integument and fasciæ by a quantity of fat, and is crossed from without inwards by the

internal popliteal nerve and the popliteal vein, the vein being between the nerve and the artery and closely adherent to the latter. On its *outer* side, above, are the Biceps, the internal popliteal nerve, the popliteal vein, and the external condyle of the femur; below, the Plantaris and the outer head of the Gastrocnemius. On its *inner* side, above, are the Semimembranosus and the internal condyle of the femur; below, the internal popliteal nerve, the popliteal vein, and the inner head of the Gastrocnemius. As already stated, the popliteal lymphatic glands, four or five in number, are grouped around the artery.

Peculiarities in point of division.—Occasionally the popliteal artery divides into its terminal branches opposite the knee-joint. The anterior tibial under these circumstances usually passes in front of the Popliteus muscle.

Unusual branches.—The artery sometimes divides into the anterior tibial and peroneal, the posterior tibial being wanting, or very small. Occasionally it divides into three branches, the anterior and posterior tibial, and peroneal.

Surface Marking.—The course of the upper part of the popliteal artery is indicated by a line drawn from the outer border of the Semimembranosus muscle at the junction of the middle and lower thirds of the thigh—that is to say, from a point a little internal to the upper angle of the popliteal space—obliquely downwards to the middle of the popliteal space exactly behind the knee-joint. From this point it passes vertically downwards to the level of a line drawn through the lower part of the tubercle of the tibia.

Applied Anatomy.—The popliteal artery is not infrequently the seat of injury. It may be torn by direct violence, as by the passage of a cart-wheel over the knee, or by hyper-extension of the knee. It may also be lacerated by fracture of the lower part of the shaft of the femur, or by antero-posterior dislocation of the knee-joint. It has been torn in breaking down adhesions in cases of fibrous ankylosis of the knee, and is in danger of being wounded, and in fact has been wounded, in performing Macewen's operation of osteotomy of the lower end of the femur for genu valgum. The popliteal artery is more frequently the seat of aneurysm than any other artery in the body, with the exception of the thoracic aorta. No doubt this is due in a great measure to the amount of movement to which it is subjected, and to the fact that it is supported by loose and lax tissue only, and not by muscles as is the case with most arteries. When the knee is acutely flexed the popliteal artery becomes bent on itself to such an extent as to entirely arrest the circulation through it.

Ligature of the popliteal artery is required in cases of wound of the vessel, but for aneurysm it is preferable to tie the femoral. The popliteal may be tied in the upper or lower part of its course; but in the middle of the ham the operation is attended with considerable difficulty, from the great depth of the artery, and from the extreme degree of tension of the lateral boundaries of the space.

In order to expose the upper part of the vessel, the patient should be placed in the supine position, with the knee flexed and the thigh abducted and rotated outwards, so that it rests on its outer surface; an incision three inches in length, beginning at the junction of the middle and lower thirds of the thigh, is to be made parallel to and immediately behind the tendon of the Adductor magnus, and the skin, superficial and deep fasciæ divided. The tendon of the muscle is thus exposed, and is to be drawn forwards, and the hamstring tendons backwards. A quantity of fatty tissue will now be opened up, in which the artery will be felt pulsating. This is to be separated with the point of a director until the artery is exposed. The vein and nerve will not be seen, as they lie to the outer side of the artery. The sheath is to be opened and the aneurysm needle passed from before backwards, keeping its point close to the artery for fear of injuring the vein. The only structure to avoid in the superficial incision is the long saphenous vein.

To expose the vessel in the lower part of its course, where the artery lies between the two heads of the Gastrocnemius, the patient should be placed in the prone position with the limb extended. An incision should then be made through the integument in the middle line, commencing opposite the bend of the knee-joint, care being taken to avoid the external saphenous vein and nerve. After dividing the deep fascia, and separating some dense cellular tissue, the artery, vein, and nerve will be exposed, between the two heads of the Gastrocnemius. Some muscular branches of the popliteal should be avoided if possible, or, if divided, tied immediately. The leg being now flexed, in order the more effectually to separate the two heads of the Gastrocnemius, the nerve should be drawn inwards and the vein outwards, and the aneurysm needle passed between the artery and vein from without inwards.

Branches.—The branches of the popliteal artery are:

Muscular { Superior.	Superior external articular.
Muscular { Inferior or Sural.	Azygos articular.
Cutaneous.	Inferior internal articular.
Superior internal articular.	Inferior external articular.

The **superior muscular branches**, two or three in number, arise from the upper part of the artery, and are distributed to the lower parts of the Adductor magnus and hamstring muscles, anastomosing with the fourth perforating branch of the profunda.

Fig. 620.—The popliteal, posterior tibial, and peroneal arteries.

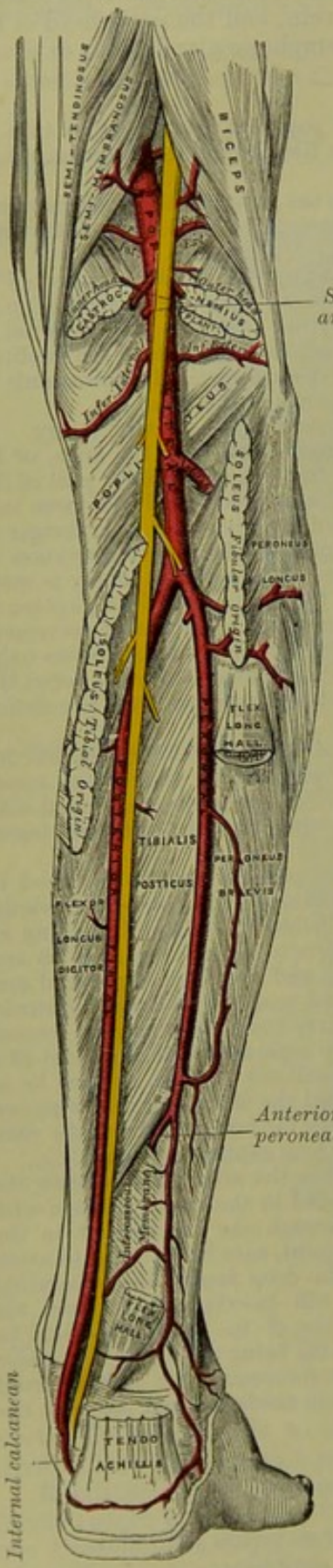

The **inferior muscular** or **sural** (aa. surales) are two large branches, which are distributed to the Gastrocnemius, Soleus, and Plantaris. They arise from the popliteal artery opposite the knee-joint.

The **cutaneous branches** arise either from the popliteal artery or from some of its branches; they descend between the two heads of the Gastrocnemius muscle, and, piercing the deep fascia, are distributed to the integument of the calf. One branch usually accompanies the short, or external, saphenous vein.

The **superior articular arteries**, two in number, arise one on either side of the popliteal, and wind round the femur immediately above its condyles to the front of the knee-joint. The *superior internal articular* (a. genu superior medialis) runs inwards beneath the inner hamstring muscles, to which it supplies branches, above the inner head of the Gastrocnemius, and passes beneath the tendon of the Adductor magnus. It divides into two branches, one of which supplies the Vastus internus, anastomosing with the anastomotica magna and inferior internal articular; the other ramifies close to the surface of the femur, supplying it and the knee-joint, and anastomosing with the superior external articular artery. The superior internal articular artery is frequently of small size, a condition which is associated with an increase in the size of the anastomotica magna. The *superior external articular* (a. genu superior lateralis) passes above the outer condyle, beneath the tendon of the Biceps, and divides into a superficial and a deep branch; the superficial branch supplies the Vastus externus, and anastomoses with the descending branch of the external circumflex and the inferior external articular arteries; the deep branch supplies the lower part of the femur and knee-joint, and forms an anastomotic arch across the front of the bone with the anastomotica magna and the inferior internal articular arteries.

The **azygos articular** (a. genu media) is a small branch, arising opposite the bend of the knee-joint. It pierces the posterior ligament, and supplies the ligaments and synovial membrane in the interior of the articulation.

The **inferior articular arteries**, two in number, arise from the popliteal beneath the Gastrocnemius. The *inferior internal articular* (a. genu inferior medialis) first descends along the upper margin of the Popliteus muscle, to which it gives branches;

it then passes below the inner tuberosity of the tibia, beneath the internal lateral ligament, at the anterior border of which it ascends to the front and inner side of the joint, to supply the head of the tibia and the articulation of the knee, anastomosing with the inferior external articular and superior internal articular arteries. The *inferior external articular* (a. genu inferior lateralis) runs outwards above the head of the fibula to the front of the knee-joint, passing in its course beneath the outer head of the Gastrocnemius, the external lateral ligament, and the tendon of the Biceps muscle. It terminates by dividing into branches, which anastomose with the inferior internal articular artery, the superior external articular artery, and the anterior recurrent branch of the anterior tibial.

Circumpatellar anastomosis (fig. 621).—Around and above the patella, and on the contiguous ends of the femur and tibia, is a large network of vessels forming

Fig. 621.—Circumpatellar anastomosis.

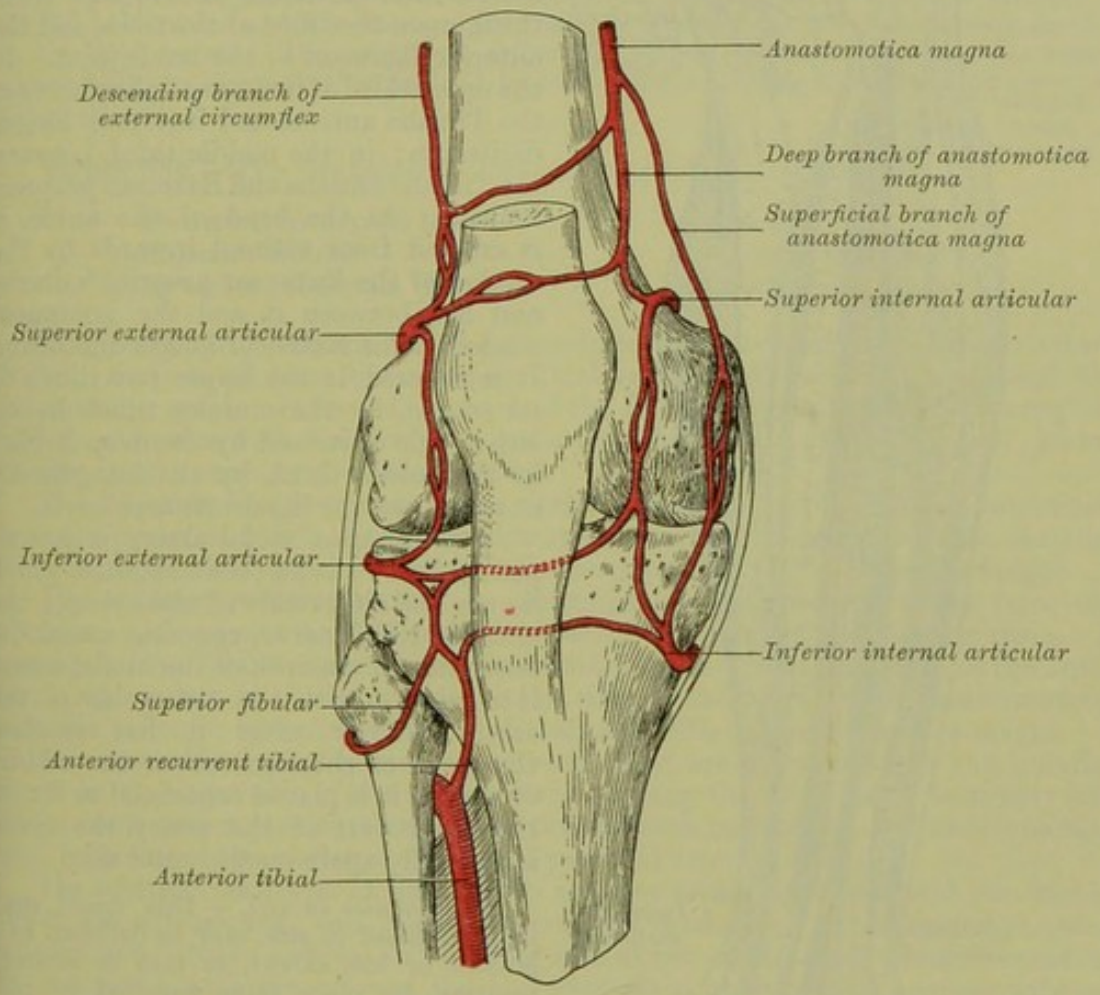

a superficial and a deep plexus. The *superficial plexus* is situated between the fascia and skin round about the patella, and forms three well-defined arches : one, above the upper border of the patella, in the loose connective tissue over the Quadriceps extensor muscle ; the other two, below the level of the patella, are situated in the fat behind the ligamentum patellæ. The *deep plexus*, which forms a close network of vessels, lies on the lower end of the femur and upper end of the tibia around their articular surfaces, and sends numerous offsets into the interior of the joint. The arteries from which this plexus is formed are the two internal and the two external articular branches of the popliteal : the anastomotica magna ; the descending branch of the external circumflex ; and the anterior recurrent branch of the anterior tibial.

Anterior Tibial Artery (fig. 622)

The **anterior tibial artery** (a. tibialis anterior) commences at the bifurcation of the popliteal, at the lower border of the Popliteus muscle, passes forwards between the two heads of the Tibialis posticus, and through the

large oval aperture above the upper border of the interosseous membrane, to the deep part of the front of the leg: it here lies close to the inner side of the neck of the fibula. It then descends on the anterior surface of the interosseous membrane, gradually approaching the tibia; and, at the lower part of the leg, lies on this bone, and then on the anterior ligament of the ankle-joint to the bend of the ankle, where it is more superficial, and becomes the *dorsalis pedis*.

Fig. 622.—Anterior tibial and dorsalis pedis arteries.

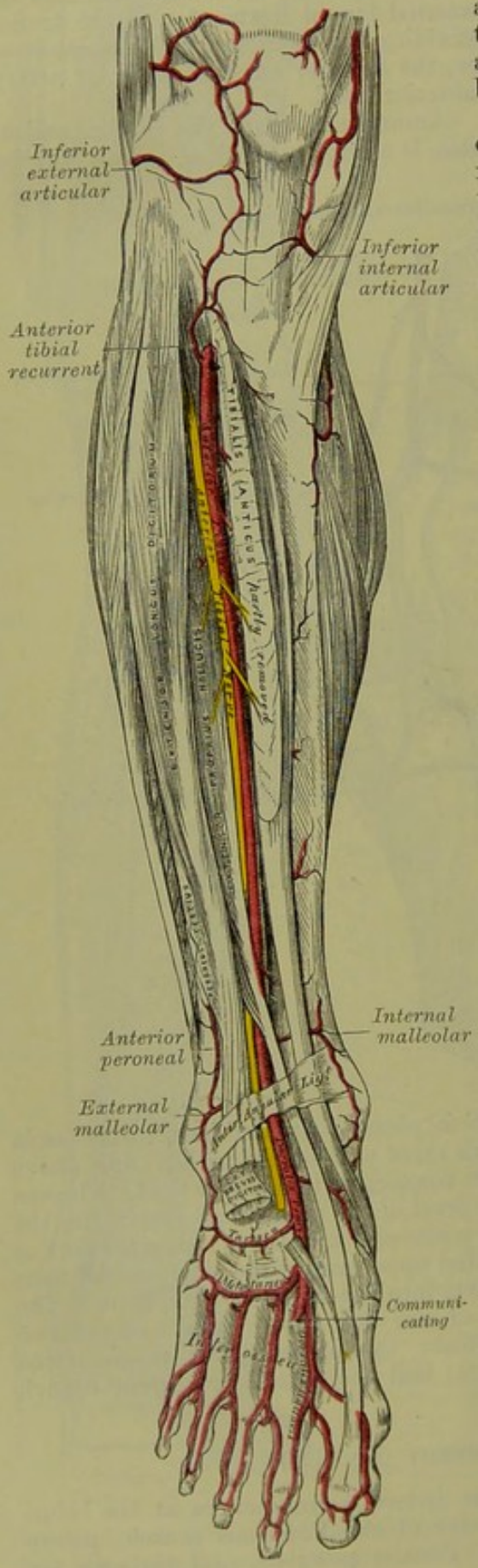

Relations.—In the upper two-thirds of its extent, the anterior tibial artery rests upon the interosseous membrane, to which it is connected by delicate fibrous arches thrown across it; in the lower third, upon the front of the tibia, and the anterior ligament of the ankle-joint. In the upper third of its course, it lies between the Tibialis anticus and Extensor longus digitorum; in the middle third between the Tibialis anticus and Extensor proprius hallucis. At the bend of the ankle, it is crossed from without inwards by the tendon of the Extensor proprius hallucis, and lies between it and the innermost tendon of the Extensor longus digitorum. It is covered, in the upper two-thirds of its course, by the muscles which lie on either side of it, and by the deep fascia; in the lower third, by the integument, anterior annular ligament, and fascia.

The anterior tibial artery is accompanied by two veins (venæ comites) which lie one on either side of the artery; the anterior tibial nerve, coursing round the outer side of the neck of the fibula, comes into relation with the outer side of the artery shortly after it has reached the front of the leg; about the middle of the leg it is placed superficial to it; at the lower part of the artery the nerve is generally again on the outer side.

Peculiarities in size.—This vessel may be diminished in size, may be deficient to a greater or less extent, or may be entirely wanting, its place being supplied by perforating branches from the posterior tibial, or by the anterior division of the peroneal artery.

Course.—The artery occasionally deviates in its course towards the fibular side of the leg, regaining its usual position beneath the annular ligament at the front of the ankle. In two instances the vessel has been found to approach the surface in the middle of the leg, being covered merely by the integument and fascia below that point.

Surface Marking.—Draw a line from the inner side of the head of the fibula to a point midway between the two malleoli. This line from a point an inch and a quarter below the head of the fibula will mark the course of the artery.

Applied Anatomy.—The anterior tibial artery is liable to be injured in fractures of the

lower third of the tibia, on account of its close proximity to the bone. The application of a ligature to the vessel is rarely required, except in cases of wound or for traumatic aneurysm. The operation in the upper third of the leg is attended with great difficulty on account of the depth of the vessel from the surface. An incision about four inches in length is made in the line of the artery to about a hand's breadth below the level of the knee-joint. The skin and superficial structures having been divided and the deep fascia exposed, the wound must be carefully dried, its edges retracted, and the white line separating the Tibialis anticus from the Extensor longus digitorum sought for. When this has been clearly defined, the deep fascia is to be divided in this line, and the Tibialis anticus separated from adjacent muscles with the handle of the scalpel or a director until the interosseous membrane is reached. The foot is to be flexed in order to relax the muscles, and upon drawing them apart the artery will be found lying on the interosseous membrane with the nerve on its outer side or on the top of it. The nerve should be drawn outwards, and the venæ comites separated from the artery and the needle passed around it.

To tie the vessel in the lower third of the leg above the ankle-joint, an incision about three inches in length should be made through the integument between the tendons of the Tibialis anticus and Extensor proprius hallucis muscles, the deep fascia being divided to the same extent. The tendon on either side should be retracted, when the vessel, accompanied by the venæ comites, will be seen lying upon the tibia, with the nerve on the outer side.

Branches.—The branches of the anterior tibial artery are:

Posterior recurrent tibial.	Muscular.
Superior fibular.	Internal malleolar.
Anterior recurrent tibial.	External malleolar.

The **posterior recurrent tibial** (a. recurrens tibialis posterior), an inconstant branch, is given off from the anterior tibial before that vessel passes through the interosseous space. It ascends in front of the Popliteus muscle, which it supplies, and anastomoses with the lower articular branches of the popliteal artery, giving an offset to the superior tibio-fibular joint.

The **superior fibular** is sometimes derived from the anterior tibial, sometimes from the posterior tibial. It passes outwards, round the neck of the fibula, through the Soleus, which it supplies, and ends in the substance of the Peroneus longus.

The **anterior recurrent tibial** (a. recurrens tibialis anterior) arises from the anterior tibial, as soon as that vessel has passed through the interosseous space; it ascends in the Tibialis anticus muscle, ramifies on the front and sides of the knee-joint, and assists in the formation of the circumpatellar plexus by anastomosing with the articular branches of the popliteal, and with the anastomotica magna.

The **muscular branches** are numerous; they are distributed to the muscles which lie on either side of the vessel, some piercing the deep fascia to supply the integument, others passing through the interosseous membrane, and anastomosing with branches of the posterior tibial and peroneal arteries.

The **internal malleolar** (a. malleolaris anterior medialis) arises about two inches above the articulation, and passes beneath the tendons of the Extensor proprius hallucis and Tibialis anticus, to the inner side of the ankle, upon which it ramifies, anastomosing with branches of the posterior tibial and internal plantar arteries and with the internal calcanean from the posterior tibial.

The **external malleolar** (a. malleolaris anterior lateralis) passes beneath the tendons of the Extensor longus digitorum and Peroneus tertius, and supplies the outer side of the ankle, anastomosing with the anterior peroneal artery, and with ascending twigs from the tarsal branch of the dorsalis pedis.

Dorsalis Pedis Artery (fig. 622)

The **dorsalis pedis artery** (a. dorsalis pedis), the continuation of the anterior tibial, passes forwards from the bend of the ankle along the tibial side of the dorsum of the foot to the back part of the first intermetatarsal space, where it divides into two branches, the *dorsalis hallucis* and *communicating*.

Relations.—This vessel, in its course forwards, rests upon the anterior ligament of the ankle-joint, the astragalus, navicular, and middle cuneiform bones, and the ligaments connecting them, being covered by the integument, fascia and anterior annular ligament, and crossed near its termination by the innermost tendon of the Extensor brevis digitorum. On its *tibial side* is the tendon of

the Extensor proprius hallucis; on its *fibular side*, the innermost tendon of the Extensor longus digitorum, and the termination of the anterior tibial nerve. It is accompanied by two veins.

Peculiarities in size.—The dorsal artery of the foot may be larger than usual, to compensate for a deficient plantar artery; or its terminal branches to the toes may be absent, the toes then being supplied by the internal plantar; or its place may be taken altogether by a large anterior peroneal artery.

Position.—This artery frequently curves outwards, lying external to the line between the middle of the ankle and the back part of the first interosseous space.

Surface Marking.—The dorsalis pedis artery is indicated on the surface of the dorsum of the foot by a line drawn from the centre of the space between the two malleoli to the back of the first intermetatarsal space.

Applied Anatomy.—This artery may be tied, by making an incision two inches in length, through the integument, on the fibular side of the tendon of the Extensor proprius hallucis, in the interval between it and the inner border of the short Extensor muscle. The incision should not extend farther forwards than the back part of the first intermetatarsal space, as the artery divides in that situation. The deep fascia being divided to the same extent, the artery will be exposed, the nerve lying upon its outer side.

Branches.—The branches of the dorsalis pedis are:

Tarsal.	Dorsalis hallucis.
Metatarsal—Interosseous.	Communicating.

The **tarsal** (a. tarsea lateralis) arises from the dorsalis pedis, as that vessel crosses the navicular bone; it passes in an arched direction outwards, lying upon the tarsal bones, and covered by the Extensor brevis digitorum; it supplies this muscle and the articulations of the tarsus, and anastomoses with branches from the metatarsal, external malleolar, peroneal, and external plantar arteries.

The **metatarsal** (a. arcuata) arises a little anterior to the preceding; it passes outwards, over the bases of the metatarsal bones, beneath the tendons of the short Extensor, its direction being influenced by its point of origin; and it anastomoses with the tarsal and external plantar arteries. This vessel gives off three *dorsal interosseous arteries* (aa. metatarseæ dorsales), which run forwards upon the outer three Dorsal interossei, and, in the clefts between the toes, divide into two dorsal collateral branches for the adjoining toes. At the back part of each interosseous space these vessels receive the posterior perforating branches from the plantar arch; and at the fore part of each interosseous space they are joined by the anterior perforating branches, from the plantar digital arteries. The outermost interosseous artery gives off a branch which supplies the outer side of the little toe.

The **dorsalis hallucis**, or **first dorsal interosseous artery**, runs forward along the outer border of the first metatarsal bone, and at the cleft between the first and second toes divides into two branches, one of which passes inwards, beneath the tendon of the Extensor proprius hallucis, and is distributed to the inner border of the great toe; the other bifurcates to supply the adjoining sides of the great and second toes.

The **communicating** dips down into the sole of the foot, between the two heads of the First dorsal interosseous muscle, and anastomoses with the termination of the external plantar artery, to complete the plantar arch. It here gives off its plantar digital branch, which is named the *arteria magna hallucis*. This artery passes forwards along the first interosseous space, and, after sending a branch along the inner side of the great toe, bifurcates for the supply of the adjacent sides of the great and second toes.

Posterior Tibial Artery (fig. 620)

The **posterior tibial artery** (a. tibialis posterior) begins at the lower border of the Popliteus muscle, opposite the interval between the tibia and fibula; it extends obliquely downwards, and, as it descends, it approaches the inner side of the leg, lying behind the tibia, and in the lower part of its course is situated midway between the internal malleolus and the tuberosity of the os calcis. Here it divides beneath the origin of the Abductor hallucis into the *internal* and *external plantar* arteries.

Relations.—The posterior tibial artery lies successively upon the Tibialis posticus, the Flexor longus digitorum, the tibia, and the back part of the ankle-joint. It is covered by the deep transverse fascia, which separates it above from the Gastrocnemius and Soleus muscles: at its termination it is covered by the Abductor hallucis muscle. In the lower third of the leg, where it is more superficial, it is covered only by the integument and fascia, and runs parallel with the inner border of the tendo Achillis. It is accompanied by two veins, and by the posterior tibial nerve, which lies at first to the inner side of the artery, but soon crosses it, and is, in the greater part of its course, on its outer side.

Behind the inner malleolus, the tendons and blood-vessels are arranged, under cover of the internal annular ligament, in the following order from within outwards: first, the tendons of the Tibialis posticus and Flexor longus digitorum, lying in the same groove, behind the inner malleolus, the former being internal. External to these is the posterior tibial artery, having a vein on either side; and, still more externally, the posterior tibial nerve. About half an inch nearer the heel is the tendon of the Flexor longus hallucis.

Peculiarities in size.—The posterior tibial is not infrequently smaller than usual, or absent, its place being supplied by a large peroneal artery, which passes inwards at the lower end of the tibia, and either joins the small posterior tibial artery, or continues alone to the sole of the foot.

Surface Marking.—The course of the posterior tibial artery is indicated by a line drawn from a point an inch below the centre of the popliteal space to midway between the tip of the internal malleolus and the centre of the convexity of the heel.

Applied Anatomy.—The application of a ligature to the posterior tibial may be required in cases of wound of the sole of the foot, attended with great hæmorrhage, when the vessel should be tied at the inner ankle. In cases of wound of the posterior tibial, it will be necessary to enlarge the opening so as to expose the vessel at the wounded point, excepting where the vessel is injured by a punctured wound from the front of the leg. In cases of aneurysm from wound of the artery low down, the vessel should be tied in the middle of the leg.

To tie the posterior tibial artery at the ankle, a semilunar incision, convex backwards, should be made through the integument, about two inches and a half in length, midway between the heel and inner ankle, or a little nearer the latter. The subcutaneous cellular tissue having been divided, a strong and dense fascia, the internal annular ligament, is exposed. This ligament is continuous above with the deep fascia of the leg, covers the vessels and nerves, and is intimately adherent to the sheaths of the tendons. This having been cautiously divided upon a director, the sheath of the vessels is exposed, and, being opened, the artery is seen with one of the venæ comites on either side. The aneurysm needle should be passed round the vessel from the heel towards the ankle, in order to avoid the posterior tibial nerve, care at the same time being taken not to include the venæ comites.

The vessel may also be tied in the lower third of the leg by making an incision about three inches in length, parallel with the inner margin of the tendo Achillis. The internal saphenous vein being carefully avoided, the two layers of fascia must be divided upon a director, when the artery is exposed along the outer margin of the Flexor longus digitorum, with one of its venæ comites on either side, and the nerve lying external to it.

Ligature of the posterior tibial in the middle of the leg is a very difficult operation, on account of the great depth of the vessel from the surface. The patient being placed in the recumbent position, the injured limb should rest on its outer side, the knee being partially bent, and the foot extended, so as to relax the muscles of the calf. An incision about four inches in length should then be made through the integument, a finger's breadth behind the inner margin of the tibia, care being taken to avoid the internal saphenous vein. The deep fascia having been divided, the margin of the Gastrocnemius is exposed, and must be drawn aside, and the tibial attachment of the Soleus divided. The artery may now be felt pulsating beneath the deep fascia, about an inch from the margin of the tibia. The fascia having been divided, and the limb placed in such a position as to relax the muscles of the calf as much as possible, the veins should be separated from the artery and the aneurysm needle passed round the vessel from without inwards, so as to avoid wounding the posterior tibial nerve.

Branches.—The branches of the posterior tibial artery are:

Peroneal.	Muscular.
Nutrient.	Communicating.

Internal calcanean.

The **peroneal** (a. peronæa) lies, deeply seated, along the back part of the fibular side of the leg. It arises from the posterior tibial, about an inch below

the lower border of the Popliteus muscle, passes obliquely outwards to the fibula, and then descends along the inner side of that bone, contained in a fibrous canal between the Tibialis posticus and the Flexor longus hallucis, or in the substance of the latter muscle. About two inches above the outer malleolus it divides into two terminal branches, the *anterior* and *posterior peroneal*.

Relations.—This vessel lies at first upon the Tibialis posticus, and then, for the greater part of its course, in a fibrous canal between the origins of the Flexor longus hallucis and Tibialis posticus, covered or surrounded by the fibres of the Flexor longus hallucis. It is covered, in the *upper* part of its course, by the Soleus and deep transverse fascia; *below*, by the Flexor longus hallucis.

Peculiarities in origin.—The peroneal artery may arise three inches below the Popliteus, or from the posterior tibial high up, or even from the popliteal.

Its size is more frequently increased than diminished; and then it either reinforces the posterior tibial by its junction with it, or altogether takes the place of the posterior tibial in the lower part of the leg and foot, the latter vessel only existing as a short muscular branch. In those rare cases where the peroneal artery is smaller than usual, a branch from the posterior tibial supplies its place; and a branch from the anterior tibial compensates for the diminished anterior peroneal artery. In one case the peroneal artery was entirely wanting.

The anterior peroneal is sometimes enlarged, and takes the place of the dorsal artery of the foot.

The branches of the peroneal are:

Muscular.	Communicating.
Nutrient.	Posterior peroneal.
Anterior peroneal.	External calcanean.

Muscular branches.—The peroneal artery, in its course, gives off branches to the Soleus, Tibialis posticus, Flexor longus hallucis, and Peronei muscles.

The *nutrient artery* (a. nutritia fibulæ) supplies the fibula.

The *anterior peroneal* (ramus perforans) pierces the interosseous membrane, about two inches above the outer malleolus, to reach the front of the leg, and, passing down beneath the Peroneus tertius to the outer side of the ankle, ramifies on the front and outer side of the tarsus, anastomosing with the external malleolar and tarsal arteries.

The *communicating* (ramus communicans) is given off from the peroneal about an inch from its lower end, and passes inwards to join the communicating branch of the posterior tibial.

The *posterior peroneal* passes down behind the inferior tibio-fibular articulation to the back of the external malleolus, to terminate in branches which ramify on the outer surface and back of the os calcis, and anastomose with the external malleolar and tarsal arteries.

The *external calcanean* (rami calcanei laterales) are the terminal branches of the posterior peroneal artery; they pass to the outer side of the heel, and communicate with the external malleolar and, on the back of the heel, with the internal calcanean arteries.

The **nutrient** (a. nutritia tibiæ) of the tibia arises from the posterior tibial, near its origin, and after supplying a few muscular branches enters the nutrient canal of that bone, which it traverses obliquely from above downwards. This is the largest nutrient artery of bone in the body.

The **muscular branches** of the posterior tibial are distributed to the Soleus and deep muscles along the back of the leg.

The **communicating branch** (ramus communicans) runs transversely across the back of the tibia, about two inches above its lower end, beneath the Flexor longus hallucis, to join a similar branch of the peroneal.

The **internal calcanean** (rami calcanei mediales) are several large arteries which arise from the posterior tibial just before its division; they are distributed to the fat and integument behind the tendo Achillis and about the heel, and to the muscles on the inner side of the sole, anastomosing with the peroneal and internal malleolar and, on the back of the heel, with the external calcanean arteries.

The **internal plantar** (a. plantaris medialis) (figs. 623 and 624), much smaller than the external, passes forwards along the inner side of the foot. It is at first situated above the Abductor hallucis, and then between it and the Flexor brevis digitorum, both of which it supplies. At the base of the first metatarsal bone, where it is much diminished in size, it passes along the inner border of the great toe, anastomosing with its digital branch. Small superficial digital branches

accompany the digital branches of the internal plantar nerve and join the plantar digital arteries of the three inner spaces.

The **external plantar** (a. plantaris lateralis), much larger than the internal, passes obliquely outwards and forwards to the base of the fifth metatarsal bone. It then turns inwards to the interval between the bases of the first and second metatarsal bones, where it anastomoses with the communicating branch from the dorsalis pedis artery, thus completing the *plantar arch*. As this artery passes outwards, it is first placed between the os calcis and Abductor hallucis,

FIG. 623.—The plantar arteries. Superficial view.

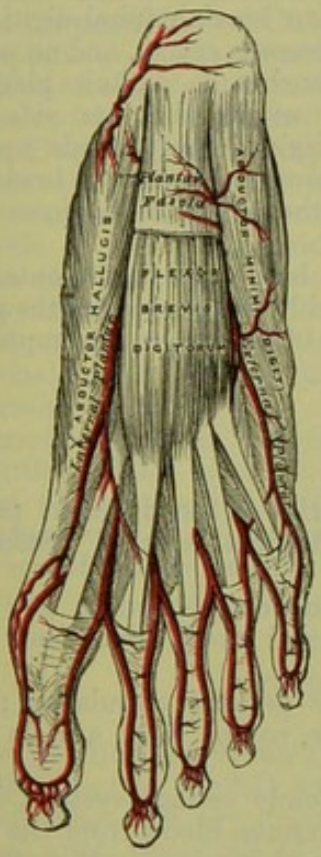

FIG. 624.—The plantar arteries. Deep view.

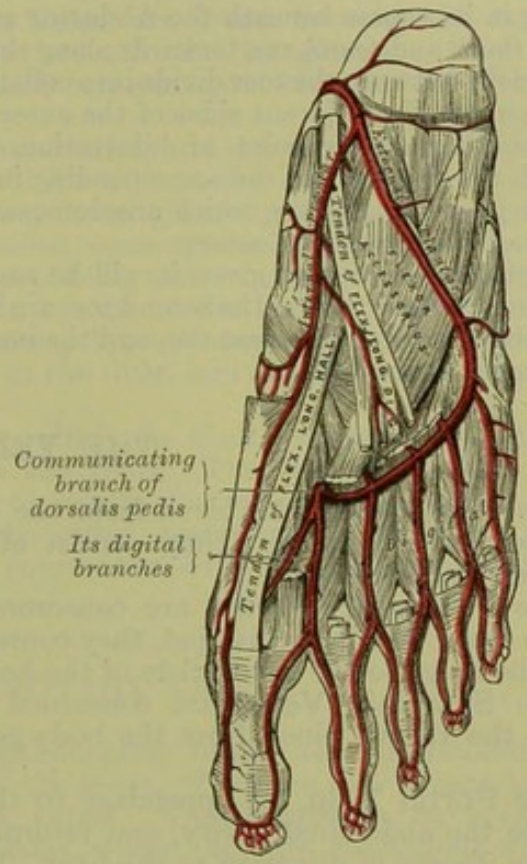

and then between the Flexor brevis digitorum and Flexor accessorius; as it passes forwards to the base of the little toe, it lies more superficially between the Flexor brevis digitorum and Abductor minimi digiti, covered by the deep fascia and integument. The remaining portion of the vessel is deeply situated; it extends from the base of the metatarsal bone of the little toe to the back part of the first interosseous space, and forms the plantar arch; it is convex forwards, lies below the tarsal ends of the second, third, and fourth metatarsal bones and the corresponding Interosseous muscles, and upon the Adductor obliquus hallucis.

Surface Marking.—The course of the internal plantar artery is represented by a line drawn from the mid-point between the tip of the internal malleolus and the centre of the convexity of the heel to the middle of the under surface of the great toe; the external plantar by a line from the same point to within a finger's breadth of the tuberosity of the fifth metatarsal bone. The plantar arch is indicated by a line drawn from this point i.e. a finger's breadth internal to the tuberosity of the fifth metatarsal bone, transversely across the foot to the back of the first interosseous space.

Applied Anatomy.—Wounds of the plantar arch are always serious, on account of the depth of the vessel and the important structures which must be interfered with in an attempt to ligature it. They must be treated on similar lines to those of wounds of the palmar arches (see page 682). Pressure locally, combined with elevation of the limb, may in some cases be sufficient to arrest the bleeding, but this failing an attempt should be made to find the bleeding point and ligature it. Should this prove unsuccessful, it may be necessary to ligature the superficial femoral, as ligature of the anterior and posterior tibial arteries may not be sufficient to control the hæmorrhage, and it is safer and quicker to tie the femoral under the circumstances.

Branches.—The plantar arch, besides distributing numerous branches to the muscles, integument, and fasciæ in the sole, gives off the following branches :

Posterior perforating. Digital—Anterior perforating.

The **posterior perforating** (rami perforantes) are three small branches, which ascend through the back part of the outer three interosseous spaces, between the heads of the Dorsal interosseous muscles, and anastomose with the interosseous branches from the metatarsal artery.

The **digital branches** (aa. metatarseæ plantares) are four in number, and supply the outer three toes and half the second toe. The *first* arises from the outer side of the plantar arch, and is distributed to the outer side of the little toe, passing in its course beneath the Abductor and Flexor brevis minimi digiti. The *second*, *third*, and *fourth* run forwards along the interosseous spaces, and on arriving at the clefts between the toes divide into collateral branches (aa. digitales plantares), which supply the adjacent sides of the outer three toes and the outer side of the second. Near to its point of bifurcation, each digital artery sends upwards, through the fore part of the corresponding interosseous space, a small branch, the *anterior perforating artery*, which anastomoses with the corresponding interosseous branch of the metatarsal artery.

From the description given it will be seen that both sides of the outer three toes, and the outer side of the second toe, are supplied by branches from the plantar arch ; both sides of the great toe, and the inner side of the second, are supplied by the arteria magna hallucis.

THE VEINS

The veins convey the blood from the capillaries of the different parts of the body to the heart. They consist of two distinct sets of vessels, the *pulmonary* and *systemic*.

The **Pulmonary Veins** are concerned in the circulation in the lungs. Unlike other vessels of this kind, they contain arterial blood, which they return from the lungs to the left auricle of the heart.

The **Systemic Veins** are concerned in the general circulation ; they return the venous blood from the body generally, to the right auricle of the heart.

The **Portal Vein,** an appendage to the systemic venous system, is confined to the abdominal cavity, and returns the venous blood from the spleen and the viscera of digestion to the liver. This vessel ramifies in the substance of the liver and breaks up into a minute network of capillaries. From these capillaries the blood is conveyed by the hepatic veins to the inferior vena cava.

The veins, like the arteries, are found in nearly every tissue of the body. They commence by minute plexuses which receive the blood from the capillaries. The branches which have their commencement in these plexuses unite together into trunks, and these, in their passage towards the heart, constantly increase in size as they receive tributaries, or join other veins. The veins are larger and altogether more numerous than the arteries ; hence, the entire capacity of the venous system is much greater than that of the arterial ; the capacity of the pulmonary veins, however, only slightly exceeds that of the pulmonary arteries. Since the combined area of the smaller venous branches is greater than that of the main trunks, the venous system may be compared to a cone, the summit of which corresponds to the heart, its base to the periphery of the body. In form, the veins are cylindrical like the arteries; their walls, however, collapse when the vessels are empty, and the uniformity of their surfaces is interrupted at intervals by slight constrictions, which indicate the existence of valves in their interior. They usually retain, however, the same calibre so long as they receive no branches.

The veins communicate very freely with one another, especially in certain regions of the body ; and this communication exists between the larger trunks as well as between the smaller branches. Thus, between the sinuses of the cranium, and between the veins of the neck, where obstruction would be attended with imminent danger to the cerebral venous system, large and

very frequent anastomoses are found. The same free communication exists between the veins throughout the whole extent of the spinal canal, and between the veins composing the various venous plexuses in the abdomen and pelvis, e.g. the spermatic, uterine, vesical, and prostatic.

Veins have thinner walls than arteries, the difference in thickness being due to the smaller amount of elastic and muscular tissues. The superficial veins usually have thicker coats than the deep veins, and the walls of the veins of the lower limb are thicker than those of the upper.

The minute structure of these vessels has been described in the section on Histology (pages 59 and 60).

The systemic veins are subdivided into three sets, viz. superficial and deep veins, and venous sinuses.

The **Superficial** or **Cutaneous Veins** are found between the layers of the superficial fascia, immediately beneath the integument; they return the blood from these structures, and communicate with the deep veins by perforating the deep fascia.

The **Deep Veins** accompany the arteries, and are usually enclosed in the same sheaths with those vessels. With the smaller arteries—as the radial, ulnar, brachial, tibial, peroneal—they exist generally in pairs, one lying on each side of the vessel, and are called *venæ comites*. The larger arteries—such as the axillary, subclavian, popliteal, and femoral—have usually only one accompanying vein. In certain organs of the body, however, the deep veins do not accompany the arteries; for instance, the veins in the skull and spinal canal, the hepatic veins in the liver, and the larger veins returning blood from the bones.

Venous Sinuses are channels which, in their structure and mode of distribution, differ altogether from the veins. They are found only in the interior of the skull, and consist of canals formed by a separation of the two layers of the dura mater; the outer coat consists of fibrous tissue, the inner of an endothelial layer continuous with the lining membrane of the veins.

THE PULMONARY VEINS

The **pulmonary veins** (venæ pulmonales) return the arterialised blood from the lungs to the left auricle of the heart. They are four in number, two for each lung, and are destitute of valves. They commence in a capillary network upon the walls of the air-sacs, where they are continuous with the capillary ramifications of the pulmonary artery, and, joining together, form one vessel for each lobule. These vessels, uniting successively, form a single trunk for each lobe, three for the right, and two for the left lung. The vein from the middle lobe of the right lung generally unites with that from the upper lobe, so that ultimately two trunks from each lung are formed; they perforate the pericardium and open separately into the upper and back part of the left auricle. Occasionally the three veins on the right side remain separate. Not infrequently, the two left pulmonary veins terminate by a common opening.

Within the lung, the branches of the pulmonary artery are in front, the veins behind, and the bronchi between the two.

At the root of the lung, the upper pulmonary vein lies in front of and a little below the pulmonary artery; the lower is situated below the other structures in the lung root, and on a plane posterior to the upper vein. Behind the pulmonary artery is the bronchus.

Within the pericardium, their anterior surfaces are invested by the serous layer of this membrane.

The right pulmonary veins pass behind the right auricle and superior vena cava; the left in front of the thoracic aorta.

Applied Anatomy.—Thrombosis of larger or smaller branches of the pulmonary veins is common in inflamed areas of the lung, or as a consequence of pressure from tumours, but it does not give rise to any special symptoms.

THE SYSTEMIC VEINS

The **systemic veins** may be arranged into three groups: 1. The cardiac veins. 2. The veins of the head and neck, upper extremity, and thorax, which terminate in the superior vena cava. 3. The veins of the lower extremity, abdomen, and pelvis, which terminate in the inferior vena cava.

CARDIAC VEINS

The **coronary sinus** (sinus coronarius) is a wide venous channel about an inch in length which receives the majority of the veins draining the blood from the substance of the heart. It is situated in the posterior part of the auriculo-ventricular groove, and is covered by muscular fibres from the left auricle. It terminates in the right auricle between the opening of the inferior vena cava and the auriculo-ventricular aperture, its orifice being guarded by a semilunar valve, the *valve of Thebesius*.

Its tributaries are the great, small, and middle cardiac veins, the posterior vein of the left ventricle, and the oblique vein of Marshall, all of which, except the last, are provided with valves at their orifices.

FIG. 625.—Base and postero-inferior surface of heart.

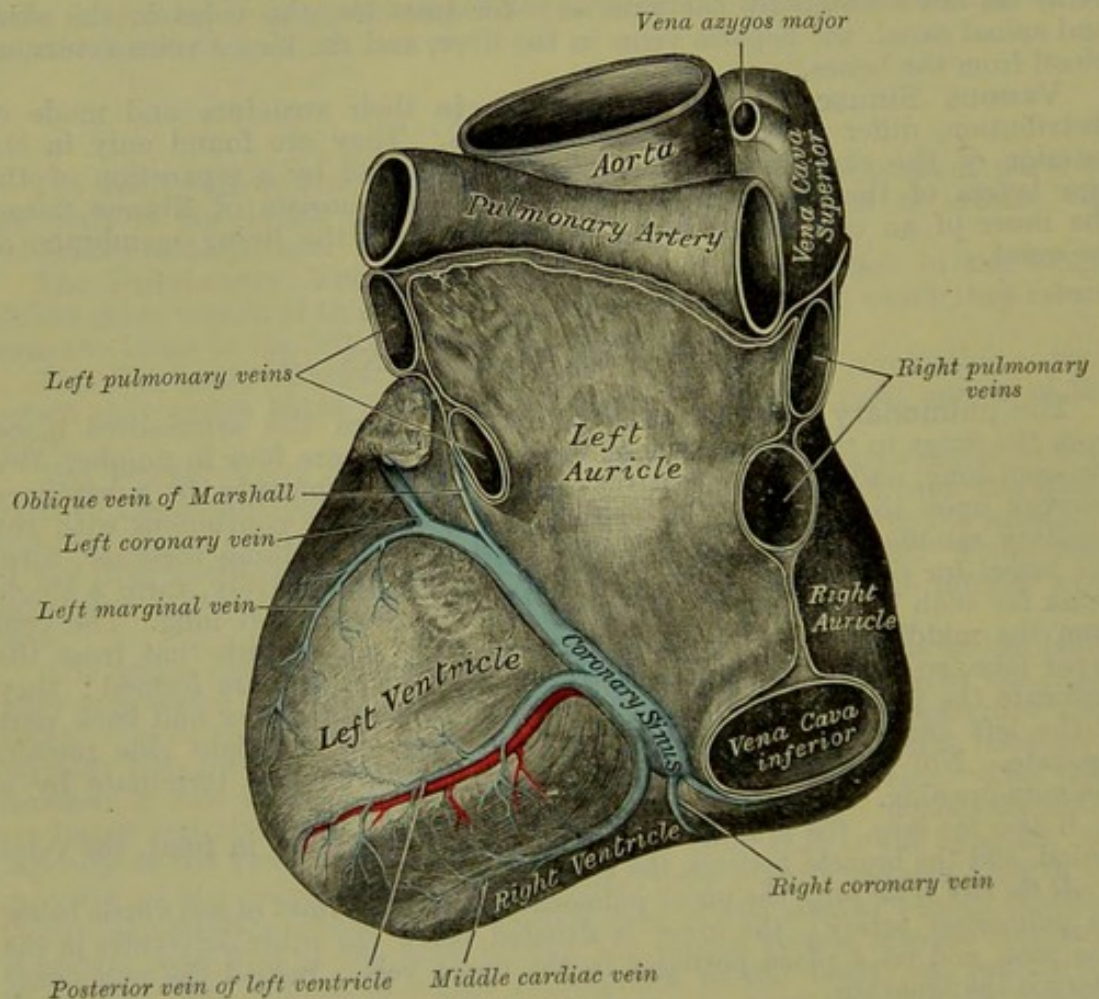

1. The **great cardiac** or **left coronary vein** (v. cordis magna) begins at the apex of the heart and ascends along the anterior interventricular groove to the base of the ventricles. It then curves to the left in the auriculo-ventricular groove to the back of the heart, and opens into the left extremity of the coronary sinus. It receives tributaries from the left auricle and from both ventricles: one of these, the *left marginal vein*, is of considerable size, and ascends along the left margin of the heart.

2. The **small cardiac** or **right coronary vein** (v. cordis parva) runs in the groove between the right auricle and ventricle, and opens into the right extremity

of the coronary sinus. It receives blood from the back of the right auricle and ventricle; its largest tributary, the *right marginal vein*, ascends along the right margin of the heart and joins it in the auriculo-ventricular groove.

3. The **middle cardiac vein** (v. cordis media) commences at the apex of the heart, ascends in the posterior interventricular groove, and ends in the coronary sinus near its right extremity.

4. The **posterior vein of the left ventricle** (v. posterior ventriculi sinistri) ascends on the back of the left ventricle to the coronary sinus, but may end in the great cardiac vein.

5. The **oblique vein of Marshall** (v. obliqua atrii sinistri) is a small vessel which descends obliquely on the back of the left auricle and ends in the coronary sinus near its right extremity; it is continuous above with the *vestigial fold of Marshall*, and the two structures form the remnant of the left Cuverian duct.

The following cardiac veins do not terminate in the coronary sinus: (1) the **anterior cardiac veins** (vv. cordis anteriores), comprising three or four small vessels which collect blood from the front of the right ventricle and open into the right auricle. The right marginal vein frequently opens into the right auricle, and is therefore sometimes regarded as belonging to this group. (2) The **veins of Thebesius** (vv. cordis minimæ), consisting of a number of minute veins which arise in the muscular wall of the heart; the majority open into the auricles, but a few terminate in the ventricles.

VEINS OF THE HEAD AND NECK

The veins of the head and neck may be subdivided into three groups: 1. The veins of the exterior of the head and face. 2. The veins of the neck. 3. The veins of the diploë and the interior of the cranium.

Veins of the Exterior of the Head and Face (fig. 626)

The veins of the exterior of the head and face are:

Frontal.	Superficial temporal.
Supra-orbital.	Internal maxillary.
Angular.	Temporo-maxillary.
Facial.	Posterior auricular.
Occipital.	

The **frontal vein** (v. frontalis) commences on the anterior part of the skull in a venous plexus which communicates with the anterior tributaries of the temporal vein. The veins converge to form a single trunk, which runs downwards near the middle line of the forehead parallel with the vein of the opposite side. The two veins are joined, at the root of the nose, by a transverse branch, called the *nasal arch*, which receives some small veins from the dorsum of the nose. Occasionally the frontal veins join to form a single trunk, which bifurcates at the root of the nose into the two angular veins. At the root of the nose the veins diverge, and, each at the inner angle of the orbit, joins the *supra-orbital vein*, to form the *angular vein*.

The **supra-orbital vein** (v. supraorbitalis) commences on the forehead, communicating with the anterior temporal vein, and runs downwards and inwards, superficial to the Occipito-frontalis muscle; it receives tributaries from the neighbouring structures, and joins the frontal vein at the inner angle of the orbit to form the *angular vein*. Previous to its junction with the frontal vein, it sends through the supra-orbital notch into the orbit a branch which communicates with the ophthalmic vein. As this vessel passes through the notch, it receives a diploic vein from the diploë of the frontal bone, through a foramen at the bottom of the notch.

The **angular vein** (v. angularis), formed by the junction of the frontal and supra-orbital veins, runs obliquely downwards and outwards, on the side of the root of the nose, to the level of the lower margin of the orbit, where it becomes the facial vein. It receives the veins of the ala nasi on its inner side, and the superior palpebral veins on its outer side; it communicates with the ophthalmic vein, thus establishing an important anastomosis between the facial vein and the cavernous sinus.

The **facial vein** (v. facialis anterior) commences at the side of the root of the nose, being a direct continuation of the angular vein. It lies behind the facial artery and follows a less tortuous course. It runs obliquely downwards and outwards, beneath the Zygomaticus major and minor muscles, descends along the anterior border of the Masseter, crosses over the body of the lower jaw, with the facial artery, and passes obliquely outwards and backwards, beneath the Platysma and cervical fascia superficial to the submaxillary gland. It unites with the anterior division of the temporo-maxillary vein to form a large trunk, the *common facial vein* (v. facialis communis), which enters the internal jugular vein.

Fig. 626.—Veins of the head and neck.

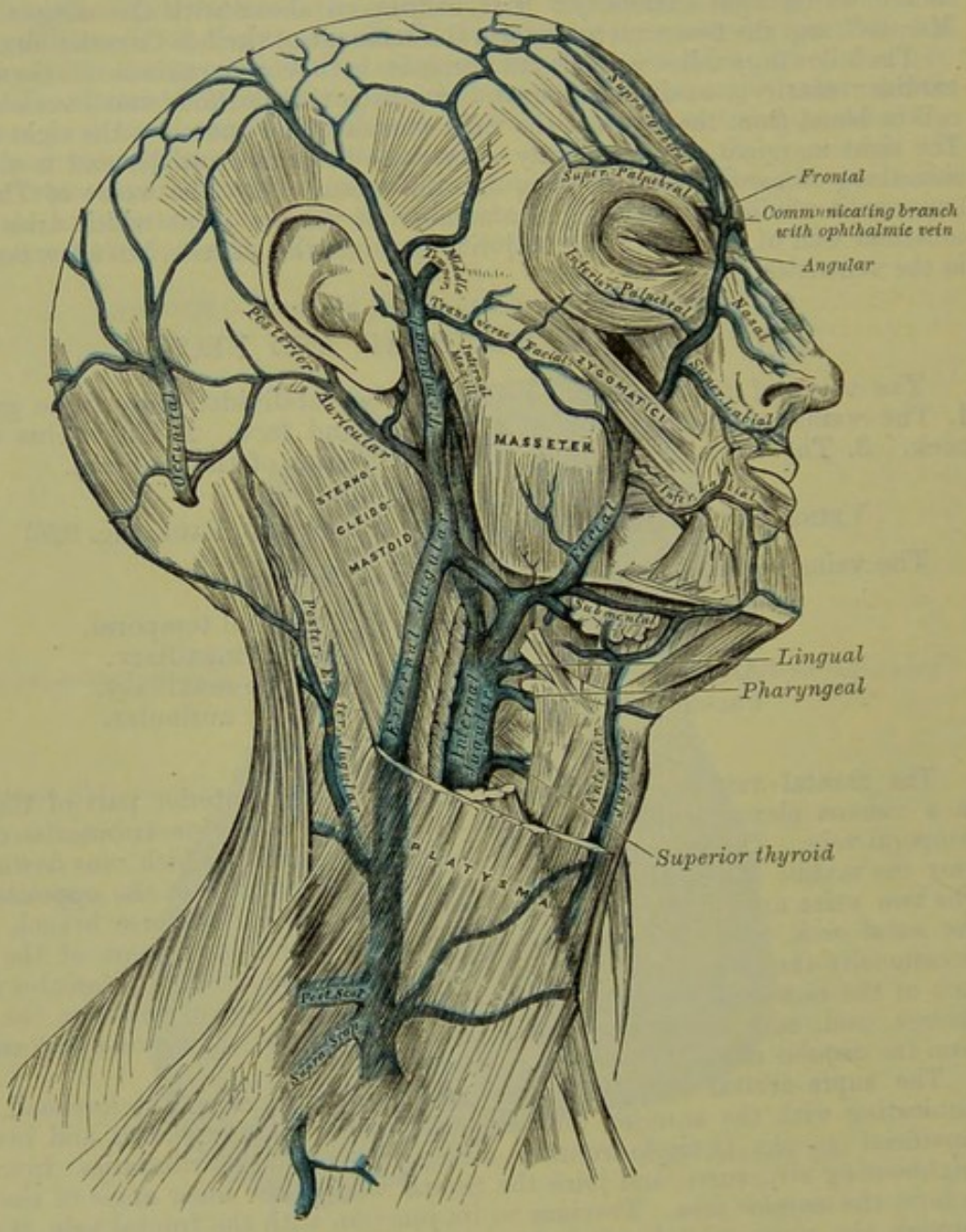

From near its termination a communicating branch often runs down the anterior border of the Sterno-mastoid to join the lower part of the anterior jugular vein.

Tributaries.—The facial vein receives, near the angle of the mouth, a communicating tributary of considerable size, the *deep facial vein*, from the pterygoid plexus. It is also joined by the inferior palpebral, the superior and inferior labial, the buccal and the masseteric veins. Below the jaw it receives the submental; the inferior palatine which returns the blood from the plexus around the tonsil and soft palate; the submaxillary which commences in the submaxillary gland; and, generally, the ranine vein.

Applied Anatomy.—There are some points about the facial vein which render it of great importance in surgery. It is not so flaccid as are most superficial veins, and, in consequence of this, remains more patent when divided. It has, moreover, no valves. It communicates freely with the intracranial circulation, not only at its commencement by the angular and supra-orbital veins which communicate with the ophthalmic vein, a tributary of the cavernous sinus, but also by the deep facial vein, which communicates through the pterygoid plexus with the cavernous sinus by branches which pass through the foramen ovale and foramen lacerum medium (see page 730). These facts have an important bearing upon the surgery of some diseases of the face ; for on account of its patency the facial vein favours septic absorption, and therefore any phlegmonous inflammation of the face following a poisoned wound is liable to set up thrombosis in the facial vein, and detached portions of the clot may give rise to purulent foci in other parts of the body. On account of its communications with the cerebral sinuses, these thrombi are apt to extend upwards into them, and so induce a fatal issue; this has been known to follow facial carbuncle.

The **superficial temporal vein** (v. temporalis superficialis) commences on the side and vertex of the skull in a plexus which communicates with the frontal and supra-orbital veins in front, the corresponding vein of the opposite side, and the posterior auricular and occipital veins behind. From this network anterior and posterior branches arise, and unite above the zygoma to form the trunk of the vein, which is joined in this situation by a large vein, the *middle temporal* (v. temporalis media), from the substance of the Temporal muscle. It then crosses the posterior root of the zygoma, enters the substance of the parotid gland, and unites with the internal maxillary vein to form the temporo-maxillary vein.

Tributaries.—The temporal vein receives in its course some parotid veins, articular veins from the temporo-mandibular joint, anterior auricular veins from the external ear, and a vein of large size, the *transverse facial* (v. transversa faciei), from the side of the face. The middle temporal vein, previous to its junction with the temporal vein, receives the *orbital vein*, which is formed by some external palpebral branches, and passes backwards between the layers of the temporal fascia.

The **pterygoid plexus** (plexus pterygoideus) is of considerable size, and is situated between the Temporal and External pterygoid, and partly between the two Pterygoid muscles. It receives tributaries corresponding with the branches of the internal maxillary artery. Thus it receives the middle meningeal, the deep temporal, the pterygoid, masseteric, buccal, alveolar, some palatine veins, and the inferior dental, and a branch which communicates with the ophthalmic vein through the spheno-maxillary fissure. This plexus communicates very freely with the facial vein ; it also communicates with the cavernous sinus, by branches through the foramen Vesalii, foramen ovale, and foramen lacerum medium, at the base of the skull.

The **internal maxillary vein** (v. maxillaris interna) is a short trunk which accompanies the first part of the internal maxillary artery. It is formed by a confluence of the veins of the pterygoid plexus, and passes backwards between the internal lateral ligament and the neck of the mandible, and unites with the temporal vein to form the temporo-maxillary vein.

The **temporo-maxillary vein** (v. facialis posterior), formed by the union of the temporal and internal maxillary veins, descends in the substance of the parotid gland, superficial to the external carotid artery but beneath the facial nerve, between the ramus of the mandible and the Sterno-mastoid muscle. It divides into two branches, an anterior, which passes inwards to join the facial vein, and a posterior, which is joined by the posterior auricular vein and becomes the external jugular.

The **posterior auricular vein** (v. auricularis posterior) commences upon the side of the head, in a plexus which communicates with the tributaries of the temporal and occipital veins. It descends behind the external ear, and joins the posterior division of the temporo-maxillary vein to form the external jugular. It receives the stylo-mastoid vein, and some tributaries from the back part of the external ear.

The **occipital vein** (v. occipitalis) commences in a plexus at the back part of the vertex of the skull. From the plexus emerges a single vessel, which pierces the cranial attachment of the Trapezius and, dipping into the sub-occipital triangle, joins the deep cervical vein. Occasionally it follows the course of the

occipital artery instead and terminates in the internal jugular; in other instances, it joins the posterior auricular and passes into the external jugular. As it passes across the mastoid portion of the temporal bone, it receives the mastoid vein, and thus establishes a communication with the lateral sinus.

Veins of the Neck (fig. 627)

The veins of the neck, which return the blood from the head and face, are:

External jugular.	Anterior jugular.
Posterior external jugular.	Internal jugular.
Vertebral.	

The **external jugular vein** (v. jugularis externa) receives the greater part of the blood from the exterior of the cranium and deep parts of the face, being formed by the junction of the posterior division of the temporo-maxillary with the posterior auricular vein. It commences in the substance of the parotid gland, on a level with the angle of the mandible, and runs perpendicularly

Fig. 627.—The veins of the neck, viewed from in front. (Spalteholz.)

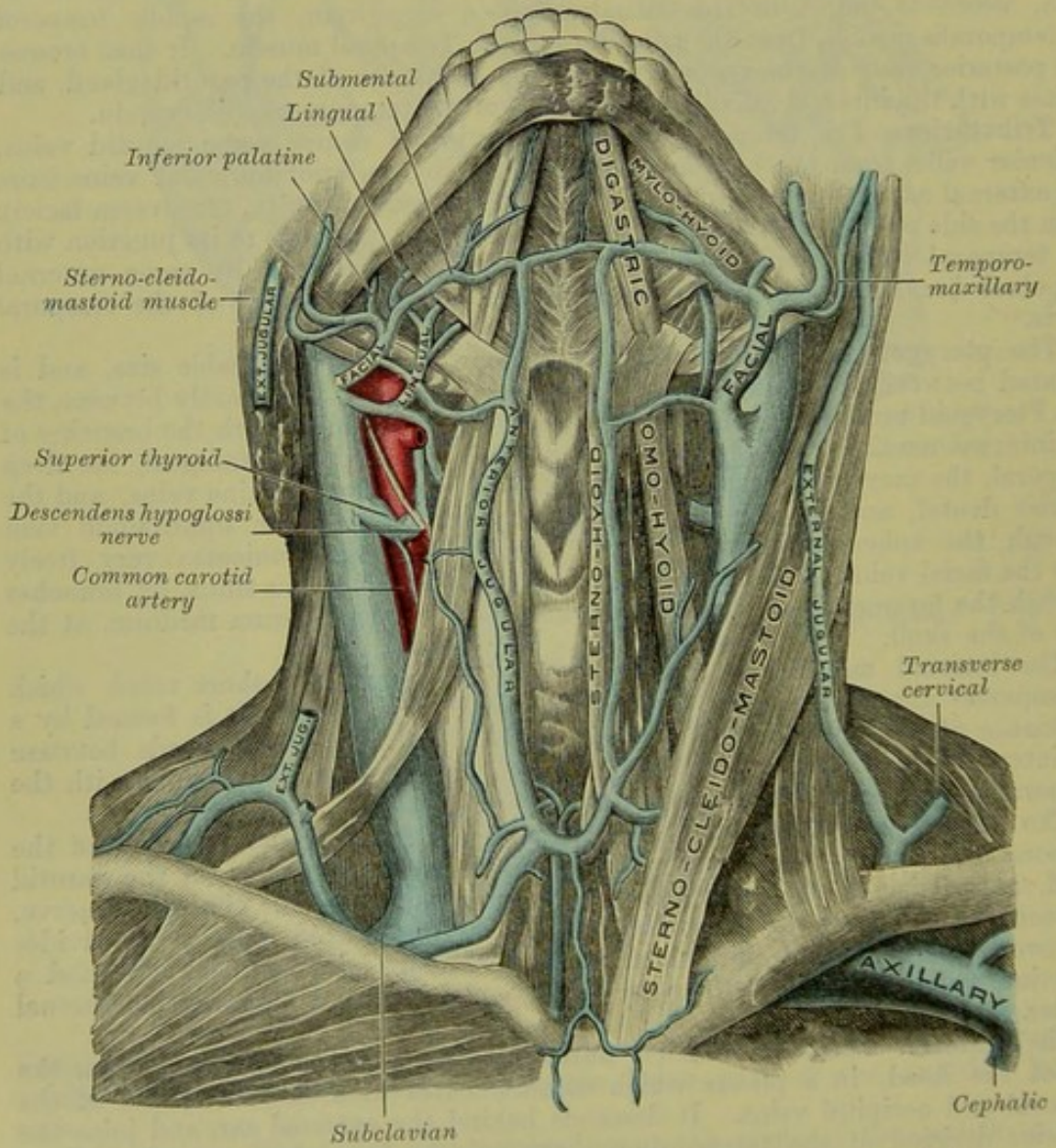

down the neck, in the direction of a line drawn from the angle of the mandible to the middle of the clavicle. In its course it crosses the Sterno-mastoid muscle, and in the subclavian triangle perforates the deep fascia, and terminates in the subclavian vein, on the outer side or in front of the Scalenus anticus muscle. It is separated from the Sterno-mastoid by the investing layer of the deep cervical fascia, and is covered by the Platysma, the superficial fascia,

and the integument; it crosses the superficial cervical nerve, and its upper half runs parallel with the great auricular nerve. The external jugular vein varies in size, bearing an inverse proportion to the other veins of the neck; it is occasionally double. It is provided with two pairs of valves, the lower pair being placed at its entrance into the subclavian vein, the upper pair in most cases about an inch and a half above the clavicle. The portion of vein between the two sets of valves is often dilated, and is termed the *sinus*. These valves do not prevent the regurgitation of the blood, or the passage of injection from below upwards.

Applied Anatomy.—Venesection used formerly to be performed on the external jugular vein, but is now probably never resorted to. The anatomical point to be remembered in performing this operation is to cut across the fibres of the Platysma in opening the vein, so that by their contraction they will expose the orifice in the vein and so allow the flow of blood.

Tributaries.—This vein receives the occipital occasionally, the posterior external jugular, and, near its termination, the transverse cervical, suprascapular, and anterior jugular veins; in the substance of the parotid, a large branch of communication from the internal jugular joins it.

The **posterior external jugular vein** commences in the occipital region and returns the blood from the integument and superficial muscles in the upper and back part of the neck, lying between the Splenius and Trapezius muscles. It runs down the back part of the neck, and opens into the external jugular just below the middle of its course.

The **anterior jugular vein** (v. jugularis anterior) commences near the hyoid bone from the confluence of several superficial veins from the submaxillary region. It descends between the median line and the anterior border of the Sterno-mastoid, and, at the lower part of the neck, passes beneath that muscle to open into the termination of the external jugular, or, in some instances, into the subclavian vein (figs. 626, 627). It varies considerably in size, bearing usually an inverse proportion to the external jugular; most frequently there are two anterior jugulars, a right and left; but sometimes only one. Its tributaries are some laryngeal veins, and occasionally a small thyroid vein. Just above the sternum, the two anterior jugular veins communicate by a transverse trunk, which receives tributaries from the inferior thyroid veins; each also communicates with the internal jugular. There are no valves in this vein.

The **internal jugular vein** (v. jugularis interna) collects the blood from the interior of the cranium, from the superficial parts of the face, and from the neck. It is directly continuous with the lateral sinus, and commences in the posterior compartment of the jugular foramen, at the base of the skull (fig. 636). At its origin it is somewhat dilated, and this dilatation is called the *sinus*, or *bulb* (bulbus venæ jugularis superior). It runs down the side of the neck in a vertical direction, lying at first on the outer side of the internal carotid artery, and then on the outer side of the common carotid, and at the root of the neck unites with the subclavian vein to form the innominate vein. At its commencement it lies upon the Rectus capitis lateralis, behind the internal carotid artery and the nerves passing through the jugular foramen; lower down, the vein and artery lie upon the same plane, the glosso-pharyngeal and hypoglossal nerves passing forwards between them; the pneumogastric descends between and behind them in the same sheath, and the spinal accessory runs obliquely outwards, behind or in front of the vein. At the root of the neck the right internal jugular vein is placed at a little distance from the common carotid artery, and crosses the first part of the subclavian artery, while the left internal jugular vein usually overlaps the common carotid artery. The left vein is usually smaller than the right, and each contains a pair of valves, which are placed about an inch above the termination of the vessel.

Tributaries.—The vein receives in its course the inferior petrosal sinus, the common facial, lingual, pharyngeal, superior and middle thyroid veins, and sometimes the occipital. At its point of junction with the common facial vein it becomes greatly increased in size.

The **inferior petrosal sinus** (sinus petrosus inferior) leaves the skull through the anterior compartment of the jugular foramen, and joins the vein near its commencement.

The **lingual veins** (vv. linguales) commence on the dorsum, sides, and under surface of the tongue, and, passing backwards along the course of the lingual artery and its branches, terminate in the internal jugular. The *ranine vein*, a branch of considerable size, commencing below the tip of the tongue, may join the lingual; generally, however, it passes backwards on the Hyo-glossus muscle in company with the hypoglossal nerve, and joins the facial.

The **pharyngeal veins** (vv. pharyngeæ) begin in the *pharyngeal plexus* on the wall of the pharynx, and, after receiving meningeal tributaries, and the Vidian and spheno-palatine veins, terminate in the internal jugular. They occasionally open into the facial, lingual, or superior thyroid vein.

The **superior thyroid vein** (v. thyreoidea superior) (fig. 628) begins in the substance and on the surface of the thyroid gland, by tributaries corresponding with the branches of the superior thyroid artery, and terminates in the upper part of the internal jugular vein. It receives the superior laryngeal and crico-thyroid veins.

FIG. 628.—The veins of the thyroid body.

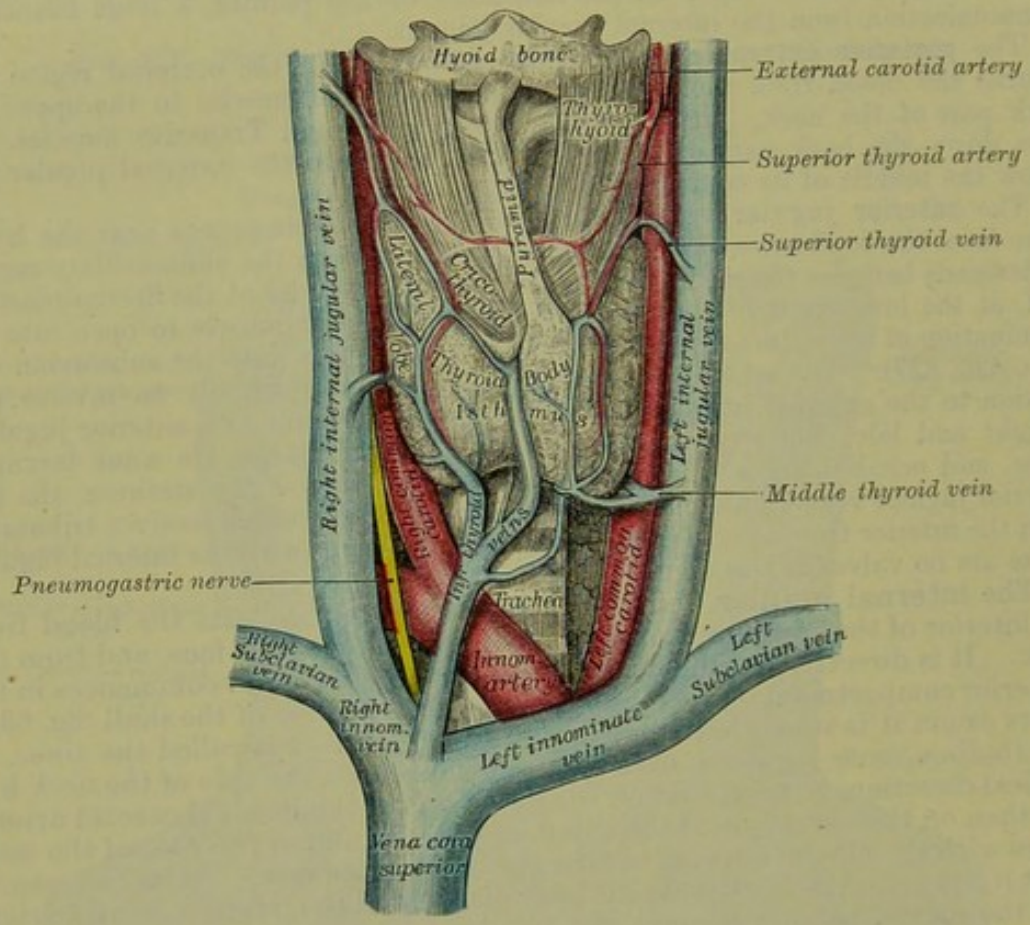

The **middle thyroid vein** (v. thyreoidea media) (fig. 628) collects the blood from the lower part of the lateral lobe of the thyroid gland, and after being joined by some veins from the larynx and trachea, terminates in the lower part of the internal jugular vein.

The **facial** and **occipital veins** have been described above.

Applied Anatomy.—The internal jugular vein requires ligature in cases of septic thrombosis of the lateral sinus from suppuration in the middle ear, in order to prevent septic emboli being carried into the general circulation. This operation has been performed recently in many cases, with the most satisfactory results. The cases are generally those of chronic disease of the middle ear, with discharge of pus which perhaps has existed for many years. The patient is seized with acute septic inflammation, spreading to the mastoid cells, and setting up septic thrombosis of the lateral sinus extending to the internal jugular vein. Such cases are always extremely grave, for there is a danger of a portion of the septic clot being detached and causing septic embolism in the thoracic viscera. If the condition be suspected, the diseased bone should be removed at once from the mastoid process. The sinus is then investigated, and if it be found thrombosed,

the surgeon should proceed to ligature the internal jugular vein, by an incision along the anterior border of the sterno-mastoid, the centre of which is on a level with the greater cornu of the hyoid bone. The vein should be ligatured in two places and divided between. After the vessel has been secured and divided, the lateral sinus is to be thoroughly cleared out, and by removing the ligature from the upper end of the divided vein, all septic clots removed by syringing from the sinus through the vein. If hæmorrhage occur from the distal end of the sinus, it can be arrested by careful plugging with antiseptic gauze.

The internal jugular vein is also surgically important, because it is surrounded by a large number of the deep chain of cervical lymphatic glands; and when these are enlarged in tuberculous or malignant disease, they are apt to become adherent to the vessel, rendering their removal difficult and often dangerous. The proper course to pursue in these cases is to ligature the vessel above and below the glandular mass, and resect the included portion together with the glands.

Cardiac pulsation is often demonstrable in the internal jugular vein at the root of the neck. There are no valves in the innominate veins or superior vena cava; in consequence, the systole of the right auricle causes a wave to pass up these vessels, and when the conditions are favourable this wave appears as a somewhat feeble flicker over the internal jugular vein at the root of the neck, quite distinct from, and just preceding, the more forcible impulse transmitted from the underlying common carotid artery and due to the ventricular systole. This auricular systolic venous impulse is much increased in conditions in which the right auricle is abnormally distended with blood or is hypertrophied, as is often the case in disease of the mitral valves. In Stokes-Adams' disease (p. 611) it is this pulsation which gives evidence of the fact that the auricles are beating faster—often two or three times faster—than the ventricles.

The **vertebral vein** (v. vertebralis) is formed in the suboccipital triangle, from numerous small tributaries which spring from the intraspinal venous plexuses and issue from the spinal canal above the posterior arch of the atlas. They unite with small veins from the deep muscles at the upper and back part of the neck, and form a vessel which passes outwards and enters the foramen in the transverse process of the atlas, and descends, forming a dense plexus around the vertebral artery, in the canal formed by the foramina in the transverse processes of the cervical vertebræ. This plexus unites at the lower part of the neck into a single trunk, which emerges from the foramen in the transverse process of the sixth cervical vertebra, and terminates at the root of the neck in the back part of the innominate vein near its origin, its mouth being guarded by a pair of valves. On the right side, it crosses the first part of the subclavian artery.

Tributaries.—The vertebral vein receives in its course a vein from the inside of the skull through the posterior condyloid foramen; muscular veins, from the muscles in the prevertebral region; posterior-spinal veins, from the back part of the cervical portion of the vertebral column; intra-spinal veins, from the interior of the spinal canal; the anterior and posterior vertebral veins; and close to its termination it is sometimes joined by the first intercostal vein.

The **anterior vertebral vein** commences in a plexus around the transverse processes of the upper cervical vertebræ, descends in company with the ascending cervical artery between the Scalenus anticus and Rectus capitis anticus major muscles, and opens into the vertebral vein just before its termination.

The **posterior vertebral** or **deep cervical vein** (v. cervicalis profunda) accompanies the profunda cervicis artery, lying between the Complexus and Semispinalis colli. It commences in the suboccipital region by communicating branches from the occipital vein and tributaries from the deep muscles at the back of the neck. It receives tributaries from the plexuses around the spinous processes of the cervical vertebræ, and terminates in the lower end of the vertebral vein.

Veins of the Diploë (fig. 629)

The **diploic veins** (venæ diploicæ) occupy channels in the cancellous tissue of the cranial bones.

They are large and exhibit at irregular intervals pouch-like dilatations; their walls are thin, and formed of endothelium resting upon a layer of elastic tissue.

In adult life, so long as the cranial bones are distinct and separable, these veins are confined to the particular bones; but in old age, when the sutures are united, they communicate with each other, and increase in size. They

communicate, in the interior of the cranium, with the meningeal veins and the sinuses of the dura mater; and, on the exterior of the skull, with the veins of the pericranium. They consist of (1) the *frontal* (v. diploica frontalis), which opens into the supra-orbital vein by an aperture in the supra-orbital notch; (2) the *anterior temporal* (v. diploica temporalis anterior), which is confined chiefly to the frontal bone, and opens into one of the deep temporal

Fig. 629.—Veins of the diploë as displayed by the removal of the outer table of the skull.

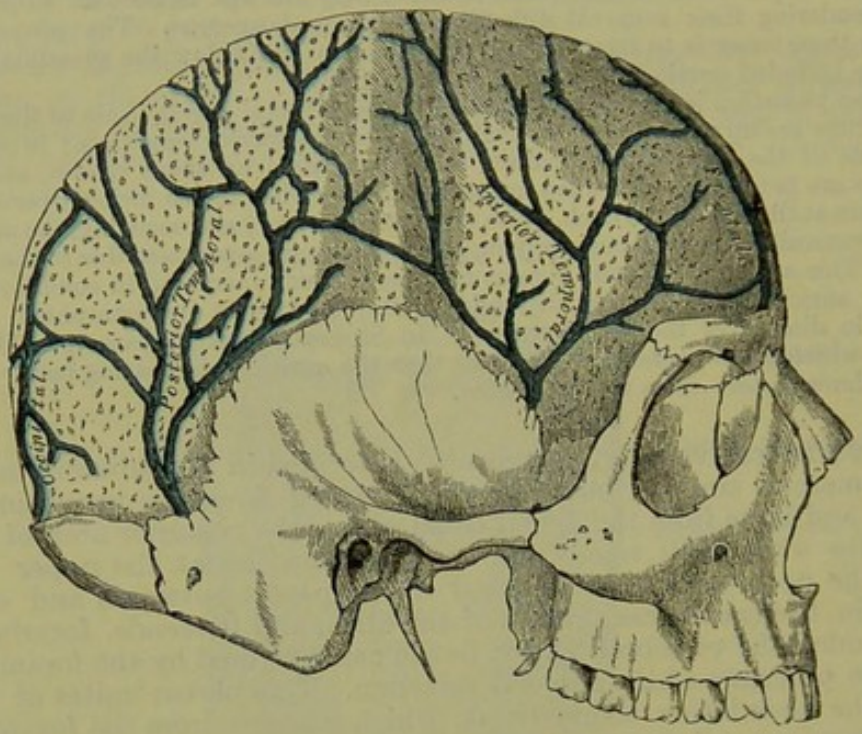

veins, through an aperture in the great wing of the sphenoid; (3) the *posterior temporal* (v. diploica temporalis posterior), which is situated in the parietal bone, and terminates in the lateral sinus, through an aperture at the postero-inferior angle of the parietal bone or through the mastoid foramen; and (4) the *occipital* (v. diploica occipitalis), the largest of the four, which is confined to the occipital bone, and opens either externally into the occipital vein, or internally into the lateral sinus or torcular Herophili.

Veins of the Brain

The veins of the brain (venæ cerebri) possess no valves, and their walls, owing to the absence of muscular tissue, are extremely thin. They pierce the arachnoid membrane, and the inner or meningeal layer of the dura mater, and open into the cranial venous sinuses. They may be divided into two sets, cerebral and cerebellar.

The **cerebral veins** consist of (*a*) the superficial veins which are placed on the surface of the brain, and (*b*) the deep veins which occupy its interior.

The **superficial cerebral veins** ramify upon the surface of the cerebrum, being lodged in the sulci between the convolutions, a few running across the convolutions. They receive tributaries from the cerebral cortex, and are divisible into two sets, superior and inferior.

The **superior cerebral veins** (vv. cerebri superiores), eight to twelve in number on either side, return the blood from the convolutions on the superior surface of the hemisphere; they pass forwards and inwards towards the great longitudinal fissure, where they receive the veins from the median surface of the hemisphere; near their terminations they become invested with tubular sheaths of the arachnoid membrane, and open into the superior longitudinal sinus, in the opposite direction to the course of the current of the blood in the sinus.

The **inferior cerebral veins** (vv. cerebri inferiores) ramify on the lower part of the outer, and on the under, surfaces of the cerebral hemisphere. One of large size, the *middle cerebral* or *superficial Sylvian vein* (vena cerebri media), commences on

the surface of the temporal lobe, and, running along the fissure of Sylvius, opens into the cavernous sinus. Another large vein, the *great anastomotic vein of Trolard*, connects the superior longitudinal and cavernous sinuses, by becoming continuous above with one of the superior cerebral veins, and below by joining the middle cerebral vein. A third, the *posterior anastomotic vein of Labbé*, connects the middle cerebral vein with the lateral sinus by coursing over the temporal lobe. A fourth, the *basilar vein* (v. basalis [Rosenthali]), is formed at the anterior perforated spot by the union of (*a*) a small *anterior cerebral vein* which accompanies the anterior cerebral artery, (*b*) the *deep Sylvian vein* which receives tributaries from the island of Reil and neighbouring convolutions, and runs in the lower part of the Sylvian fissure, and (*c*) the *inferior striate veins* which leave the corpus striatum through the anterior perforated space. The basilar vein passes backwards round the crus cerebri, and ends in the vein of Galen ; it receives tributaries from the interpeduncular space, the descending horn of the lateral ventricle, the uncinate gyrus, and the mid-brain. Small inferior cerebral veins from the under surface of the frontal lobe end in the cavernous sinus; others from the temporal lobe terminate in the superior petrosal and lateral sinuses.

The **deep cerebral veins** (vv. cerebri internæ) are collected into two large trunks, named the *veins of Galen*. Each of these is formed by the union of two veins, the *vena corporis striati* and the *choroid vein* (v. choroidea). They run backwards, parallel with one another, between the layers of the velum interpositum, and beneath the splenium of the corpus callosum, where they unite to form a short trunk, the *vena magna Galeni* (v. cerebri magna), which ends in the anterior extremity of the straight sinus. Just before their union each receives the corresponding basilar vein.

The *vena corporis striati* commences in the groove between the corpus striatum and thalamus, receives numerous veins from both of these parts, and unites behind the anterior pillar of the fornix with the choroid vein, to form one of the venæ Galeni. The *choroid vein* runs along the whole length of the outer border of the choroid plexus, and receives veins from the hippocampus major, the fornix and the corpus callosum.

The **cerebellar veins** are placed on the surface of the cerebellum, and are disposed in two sets, superior and inferior. The *superior cerebellar veins* (vv. cerebelli superiores) pass partly forwards and inwards, across the superior vermis, to terminate in the straight sinus and venæ Galeni, partly outwards to the lateral and superior petrosal sinuses. The *inferior cerebellar veins* (vv. cerebelli inferiores), of large size, terminate in the lateral, superior petrosal, and occipital sinuses.

Sinuses of the Dura Mater

The sinuses of the dura mater (sinus duræ matris) are venous channels which drain the blood from the brain ; they are situated between the two layers of the dura mater and lined by endothelium continuous with that which lines the veins. They are fourteen in number, of which six are single and situated in the middle line ; the other eight are paired, four being placed on either side of the middle line. They may be divided into two groups : (1) a postero-superior group situated at the upper and back part of the skull, and (2) an antero-inferior group at the base of the skull.

The postero-superior group comprises the

Superior longitudinal sinus.	Straight sinus.
Inferior longitudinal sinus.	Two lateral sinuses.
Occipital sinus.	

The **superior longitudinal sinus** (sinus sagittalis superior) (fig. 630) occupies the attached margin of the falx cerebri. Commencing at the foramen cæcum, through which it communicates by a small branch with the veins of the nasal fossæ, it runs from before backwards, grooving the inner surface of the frontal, the adjacent margins of the two parietals, and the superior division of the crucial ridge of the occipital ; near the internal occipital protuberance it deviates to one or other side (usually the right), and is continued as the corresponding lateral sinus. The sinus is triangular in section ; it is narrow in front, and gradually increases in size as it passes backwards. Its inner surface

presents the openings of the superior cerebral veins, which run, for the most part, from behind forwards, and open chiefly at the back part of the sinus, their orifices being concealed by fibrous folds; numerous fibrous bands (*chordæ Willisii*) extend transversely across the inferior angle of the sinus; and, lastly, small openings communicate with *venous lacunæ* in the dura mater, into which small white bodies, the *glandulæ Pacchionii*, project. The

Fig. 630.—Superior longitudinal sinus laid open after removal of the skull-cap. The chordæ Willisii are clearly seen. The parasinoidal sinuses are also well shown; from two of them probes are passed into the superior longitudinal sinus. (Poirier and Charpy.)

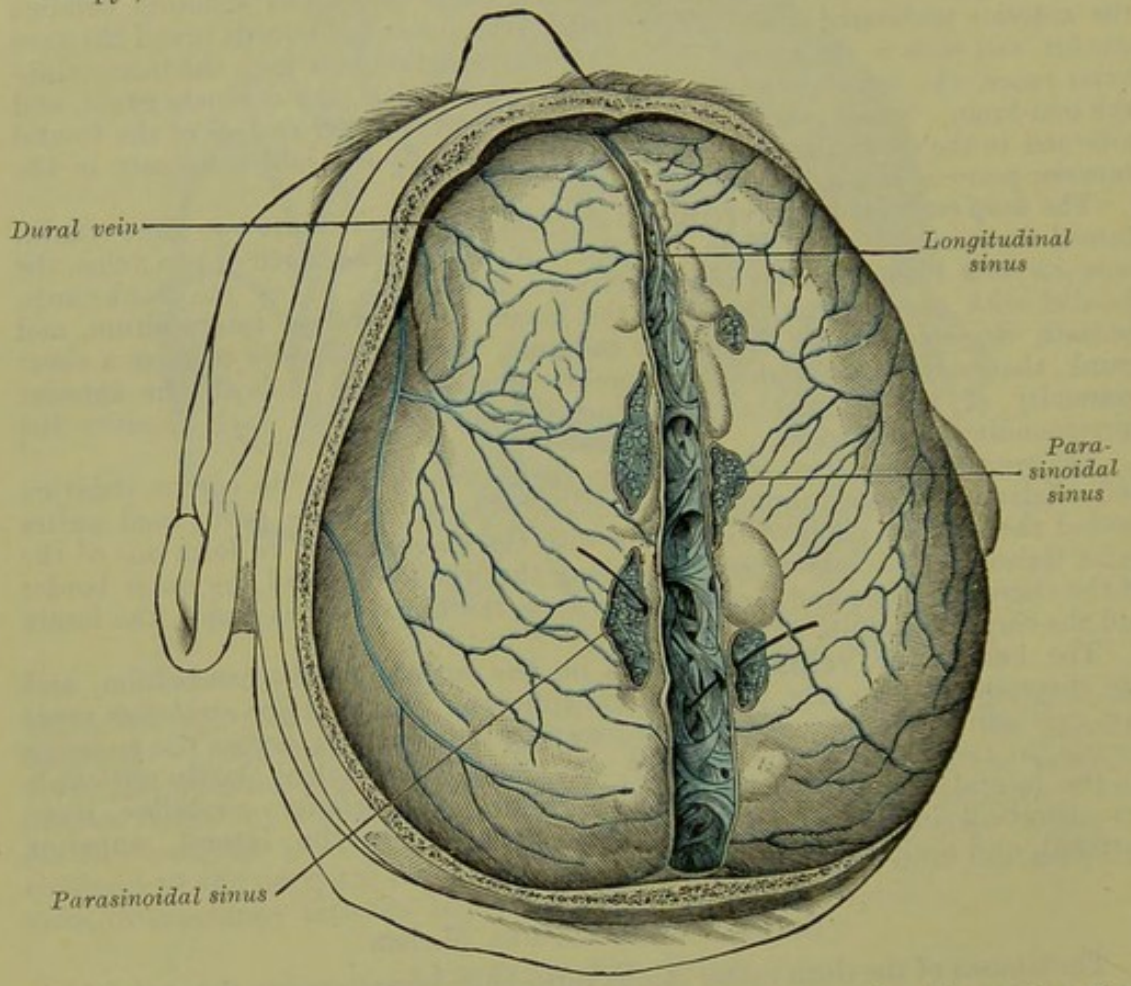

superior longitudinal sinus receives the superior cerebral veins, veins from the diploë and dura mater, and, at the posterior extremity of the sagittal suture, veins from the pericranium, which pass through the parietal foramina.

Applied Anatomy.—The numerous communications which take place between this sinus and the veins of the nose, scalp and diploë, cause it to be frequently the seat of infective thrombosis from suppurative processes in these parts.

The **inferior longitudinal sinus** (sinus sagittalis inferior) (fig. 631) is contained in the posterior half or two-thirds of the free margin of the falx cerebri. It is of a cylindrical form, increases in size as it passes backwards, and terminates in the straight sinus. It receives several veins from the falx cerebri, and occasionally a few from the mesial surface of the hemispheres.

The **straight sinus** (sinus rectus) (figs. 631, 632) is situated at the line of junction of the falx cerebri with the tentorium cerebelli. It is triangular in section, increases in size as it proceeds backwards, and runs obliquely downwards and backwards from the termination of the inferior longitudinal sinus to the lateral sinus of the opposite side to that into which the superior longitudinal sinus is prolonged. Its terminal part communicates by a cross branch with the torcular Herophili. Besides the inferior longitudinal sinus, it receives the vena magna Galeni and the superior cerebellar veins. A few transverse bands cross its interior.

The **lateral sinuses** (figs. 631, 632) are of large size, and commence at the internal occipital protuberance; one, generally the right, being the direct

Fig. 631.—Sagittal section of the skull, showing the sinuses of the dura mater.

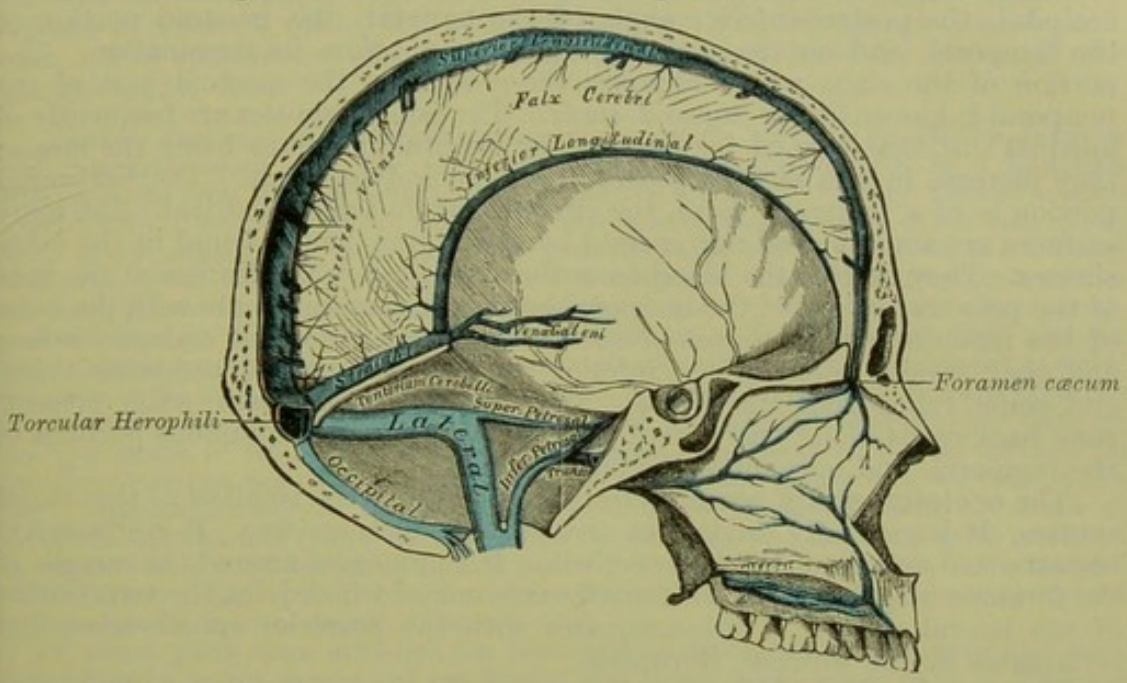

Fig. 632.—Tentorium cerebelli from above.

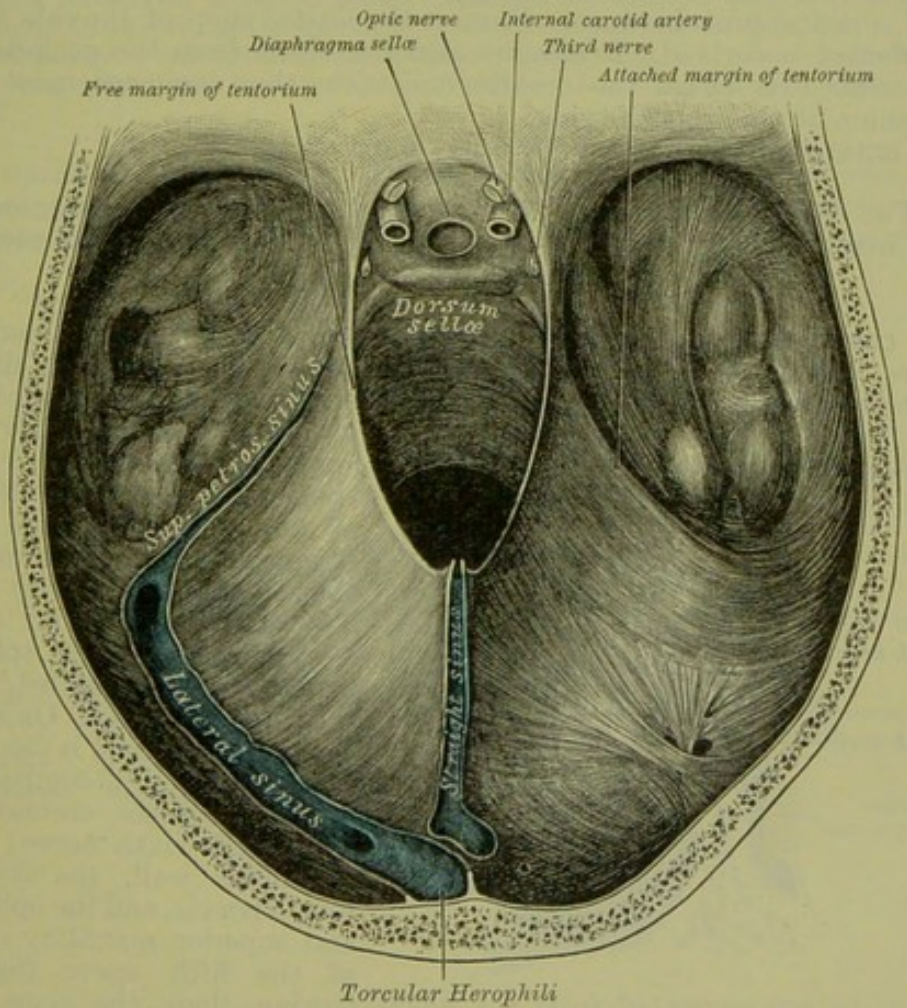

continuation of the superior longitudinal sinus, the other of the straight sinus. Each lateral sinus (sinus transversus) passes outwards and forwards, describing a slight curve with its convexity upwards, to the base of the petrous portion

of the temporal bone, and is situated, in this part of its course, in the attached margin of the tentorium cerebelli; it then leaves the tentorium and curves downwards and inwards to reach the jugular foramen, where it terminates in the internal jugular vein. In its course it rests upon the inner surface of the occipital, the postero-inferior angle of the parietal, the mastoid portion of the temporal, and on the occipital, again, just before its termination. The portion of the sinus which occupies the groove on the mastoid part of the temporal is known as the *sigmoid sinus*. The lateral sinuses are frequently of unequal size, that formed by the superior longitudinal sinus being the larger; they increase in size as they proceed from behind forwards. The horizontal portion is of a prismatic form, the curved portion semicylindrical. The inner surfaces are smooth, and not crossed by the fibrous bands found in the other sinuses. They receive the blood from the superior petrosal sinuses at the base of the petrous portion of the temporal bone; they communicate with the veins of the pericranium by means of the mastoid and condyloid emissary veins; and they receive some of the inferior cerebral and inferior cerebellar veins, and some veins from the diploë. The *petro-squamous sinus*, when present, runs backwards along the junction of the petrous and squamous portions of the temporal, and opens into the lateral sinus.

The **occipital sinus** (sinus occipitalis) (fig. 631) is the smallest of the cranial sinuses. It is generally single, but occasionally there are two. It is situated in the attached margin of the falx cerebelli. It commences around the margin of the foramen magnum by several small veins, one of which joins the termination of the lateral sinus; it communicates with the posterior spinal veins, and terminates in the torcular Herophili.

The *torcular Herophili*, or *confluence of the sinuses* (confluens sinuum) is the term applied to the dilated extremity of the superior longitudinal sinus. It is of irregular form, and is lodged on one side (generally the right) of the internal occipital protuberance. From it the lateral sinus of the side to which it is deflected is derived. It receives also the blood from the occipital sinus, and is connected across the middle line with the commencement of the lateral sinus of the opposite side.

The antero-inferior group of sinuses comprises the

Two cavernous sinuses.
Circular sinus.
Two superior petrosal sinuses.
Two inferior petrosal sinuses.
Basilar sinus.

The **cavernous sinuses** are so named because they present a reticulated structure, due to their being traversed by numerous interlacing filaments. They are of irregular form, larger behind than in front, and are placed one on either side of the body of the sphenoid, extending from the sphenoidal fissure to the apex of the petrous portion of the temporal bone. Each cavernous sinus (sinus cavernosus) receives anteriorly the superior ophthalmic vein through the sphenoidal fissure, and opens behind into the petrosal sinuses. On the inner wall of each sinus is the internal carotid artery, accompanied by filaments of the carotid plexus and by the sixth nerve; and on the outer wall, the third and fourth nerves, and the ophthalmic and superior maxillary divisions of the fifth nerve (fig. 635).

Fig. 633.—Oblique section through the cavernous sinus.

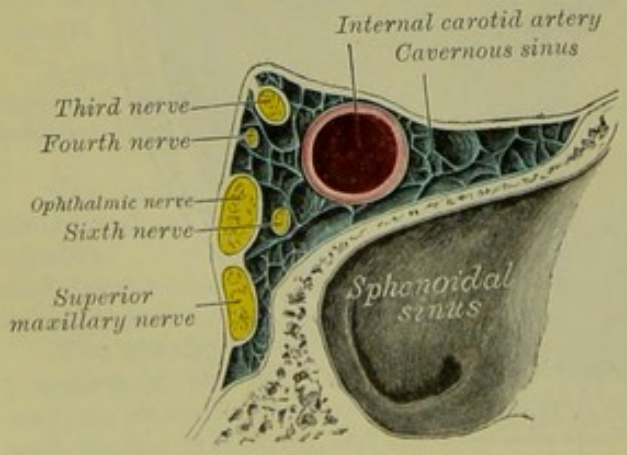

These parts are separated from the blood flowing along the sinus by the lining membrane, which is continuous with the inner coat of the veins. The cavernous sinus receives some of the cerebral veins, and also the small *spheno-parietal sinus* (sinus sphenoparietalis), which extends inwards on the

under aspect of the lesser wing of the sphenoid. It communicates with the lateral sinus by means of the superior petrosal sinus; with the internal jugular vein through the inferior petrosal sinus and through a plexus of veins on the internal carotid artery; with the pterygoid venous plexus through the foramen Vesalii or foramen ovale, and with the angular vein through the ophthalmic vein. The two sinuses also communicate with each other by means of the circular sinus.

Applied Anatomy.—An arterio-venous communication may be established between the cavernous sinus and the internal carotid artery, giving rise to a pulsating tumour in the orbit. These communications may be the result of injury, such as a bullet wound, a stab, or a blow or fall sufficiently severe to cause a fracture of the base of the skull in this situation, or they may occur from the rupture of an aneurysm or a diseased condition of the internal carotid artery. The symptoms are sudden noise and pain in the head, followed by exophthalmos, swelling and congestion of the lids and conjunctivæ, and development of a pulsating tumour at the margin of the orbit, with thrill and the characteristic bruit; accompanying these symptoms there may be impairment of sight, paralysis of the iris and orbital muscles, and pain of varying intensity. In some cases the opposite orbit becomes affected by the passage of the arterial blood into the opposite sinus by means of the circular sinus; or the arterial blood may find its way through the emissary veins (see page 743) into the pterygoid plexus, and thence into the veins of the face. Pulsating tumours of the orbit may also be due to traumatic aneurysm of one of the orbital arteries, and symptoms resembling those of pulsating tumour may be produced by pressure on the ophthalmic vein, as it enters the sinus, by an aneurysm of the internal carotid artery. Ligature of the internal or common carotid artery has been performed in these cases with some degree of success.

Of recent years more attention has been paid to thrombosis of the cavernous sinus than formerly, and it is now well established that caries in the upper parts of the nasal fossæ and suppuration in certain of the accessory sinuses of the nose, are frequently responsible for septic thrombosis of the cavernous sinuses, in exactly the same way as lateral sinus thrombosis is due to septic disease in the mastoid process. Many deaths from meningitis, hitherto unaccounted for, are in reality due to the spread of an infection from an ethmoidal or sphenoidal air cell to the cavernous sinus, and thence to the meninges. It is obvious, therefore, that no case of chronic nasal suppuration should be left untreated.

The **ophthalmic veins** (fig. 634) are two in number, superior and inferior.

The *superior ophthalmic vein* (v. ophthalmica superior) connects the angular vein at the inner angle of the orbit with the cavernous sinus; it pursues the

Fig. 634.—Veins of orbit. (Poirier and Charpy.)

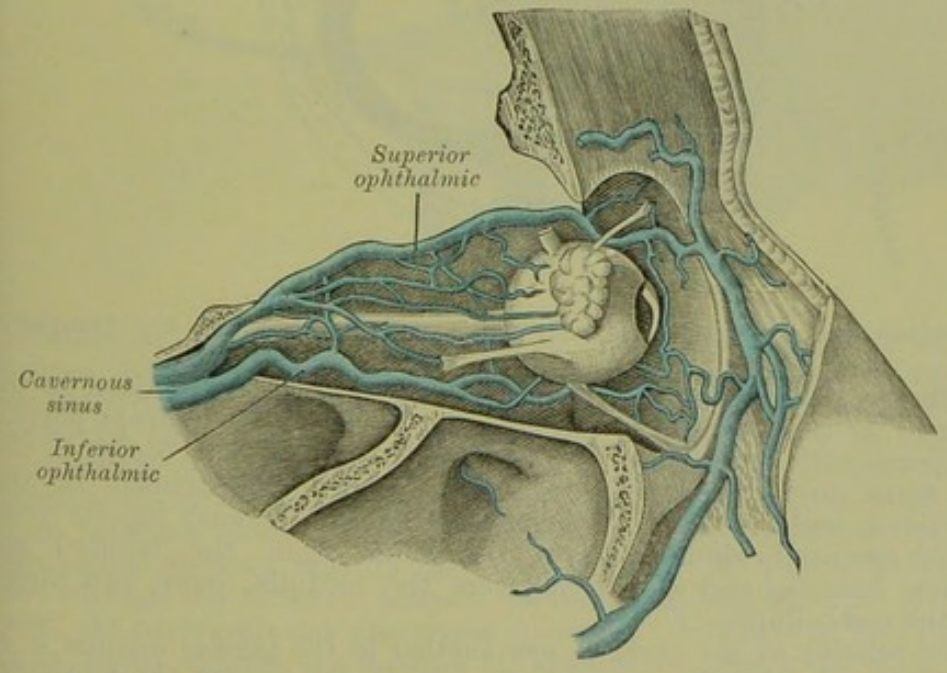

same course as the ophthalmic artery, and receives tributaries corresponding to the branches derived from that vessel. Forming a short single trunk, it passes through the inner extremity of the sphenoidal fissure, and terminates in the cavernous sinus.

The *inferior opthalmic vein* (v. ophthalmica inferior) receives the veins from the floor of the orbit, and either passes out of the orbit through the sphenomaxillary fissure to join the pterygoid plexus of veins; or else, passing backwards through the sphenoidal fissure, it enters the cavernous sinus, either by a separate opening, or more frequently in common with the superior ophthalmic vein.

The **circular sinus** (sinus circularis) (fig. 635) is formed by two transverse vessels, the *anterior* and *posterior intercavernous sinuses*, which connect together the two cavernous sinuses; one passes in front of and the other behind the pituitary body, and thus they form with the cavernous sinuses a venous circle around that body. The anterior one is usually the larger of the two, and one or other is occasionally absent.

The **superior petrosal sinus** (sinus petrosus superior) is situated along the superior border of the petrous portion of the temporal bone, in the attached margin of the tentorium. It is small and narrow, and connects the cavernous and lateral sinuses, opening into the latter as it curves downwards on the inner surface of the mastoid part of the temporal bone. It receives

FIG. 635.—The sinuses at the base of the skull.

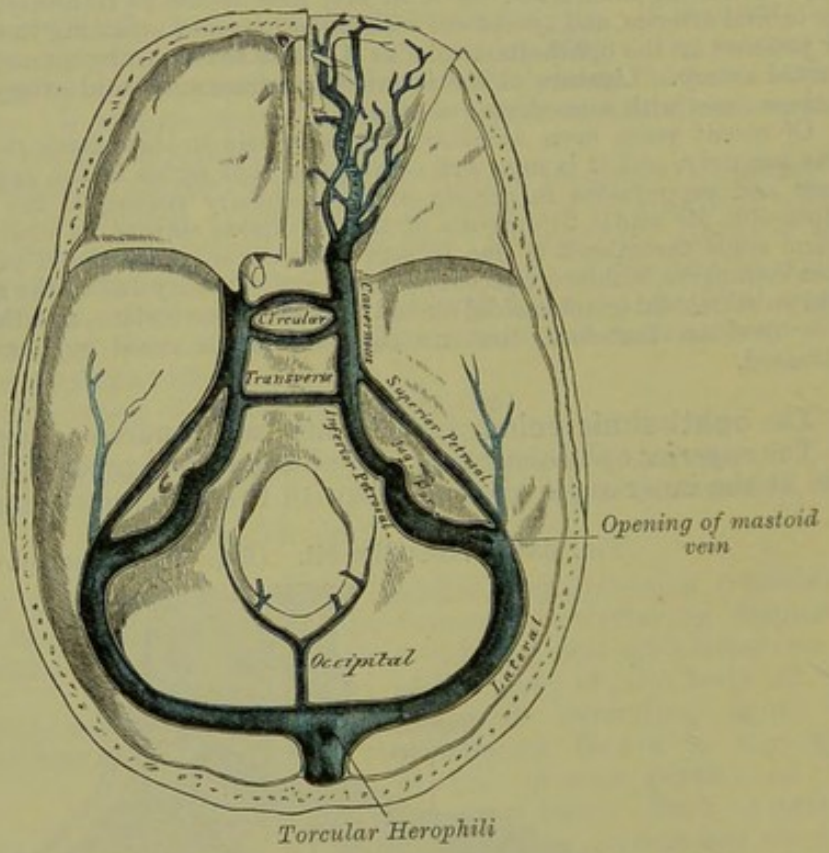

some cerebellar and inferior cerebral veins, and veins from the tympanic cavity.

The **inferior petrosal sinus** (sinus petrosus inferior) is situated in the groove formed by the junction of the posterior border of the petrous portion of the temporal with the basilar process of the occipital. It begins in the cavernous sinus, and, passing through the anterior compartment of the jugular foramen, ends in the commencement of the internal jugular vein. The inferior petrosal sinus receives the veins from the internal ear (vv. auditivæ internæ) and also veins from the medulla, pons, and under surface of the cerebellum.

The exact relation of the parts to one another in the jugular foramen is as follows (fig. 636): the inferior petrosal sinus is in front, with the meningeal branch of the ascending pharyngeal artery, and is directed obliquely downwards and backwards; the lateral sinus is situated at the back part of the foramen with a meningeal branch of the occipital artery, and between the two are the glosso-pharyngeal, pneumogastric, and spinal accessory nerves. These three sets of

structures are divided from each other by two processes of fibrous tissue. The junction of the inferior petrosal sinus with the internal jugular vein takes place superficial to the nerves, so that these latter lie a little internal to the venous channels in the foramen.

The **basilar sinus** (plexus basilaris) consists of several interlacing veins between the layers of the dura mater over the basilar process of the occipital bone, which serve to connect the two inferior petrosal sinuses. They communicate with the anterior spinal veins.

Emissary veins.—The emissary veins are vessels which pass through apertures in the cranial wall and establish communications between the sinuses inside the skull and the veins external to it. Some of these are always present, others only occasionally so. They vary much in size in different individuals. The principal emissary veins are the following. 1. A vein (emissarium mastoideum), almost always present, runs through the mastoid foramen and unites the lateral sinus with the posterior auricular or with the occipital vein. 2. A vein (emissarium

FIG. 636.—Relation of structures in jugular foramen.

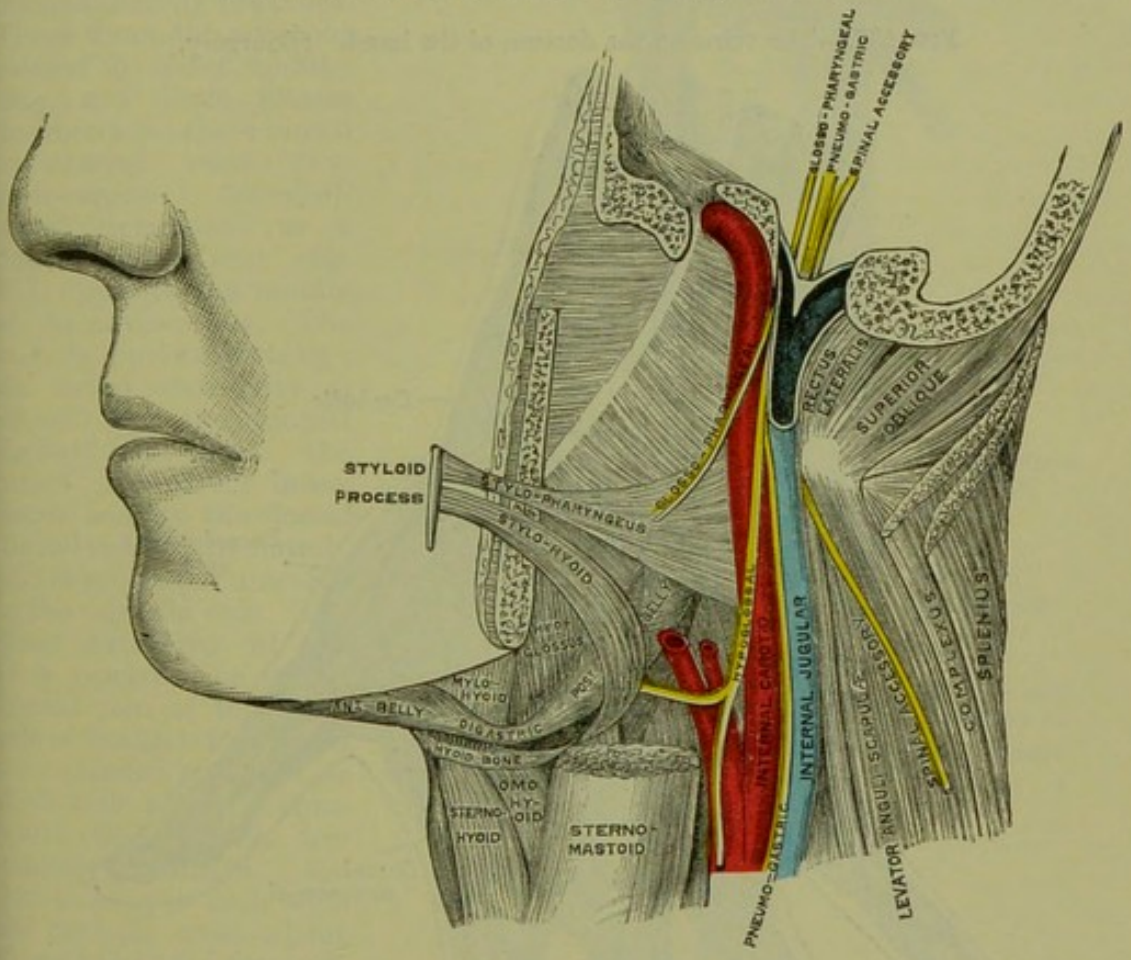

parietale) passes through the parietal foramen and connects the superior longitudinal sinus with the veins of the scalp. 3. A plexus of minute veins (rete canalis hypoglossi) traverses the anterior condyloid foramen and joins the lateral sinus with the vertebral vein and deep veins of the neck. 4. An inconstant vein (emissarium condyloideum) passes through the posterior condyloid foramen and connects the lateral sinus with the deep veins of the neck. 5. A plexus of veins (rete foraminis ovalis) unites the cavernous sinus with the pterygoid and pharyngeal plexuses through the foramen ovale. 6. Two or three small veins run through the foramen lacerum medium and connect the cavernous sinus with the pterygoid and pharyngeal plexuses. 7. There is sometimes a small vein passing through the foramen of Vesalius connecting the same parts. 8. A plexus of veins (plexus venosus caroticus internus) traverses the carotid canal and unites the cavernous sinus with the internal jugular vein. 9. A vein is transmitted through the foramen cæcum and connects the superior longitudinal sinus with the veins of the mucous membrane of the nose.

Applied Anatomy.—These emissary veins together with the other communications between the intra- and extra-cranial circulation are of great importance in surgery. Inflammatory processes commencing on the outside of the skull may travel inwards through them, and lead to osteo-phlebitis of the diploë and inflammation of the membranes of the brain. To this in former days was to be attributed one of the principal dangers of wounds of the scalp.

By means of these emissary veins blood may be abstracted almost directly from the intracranial circulation—e.g. leeches applied behind the ear drain blood almost directly from the lateral sinus, through the mastoid vein. Again, epistaxis in children will frequently relieve severe headache, the blood which flows from the nose being partly derived from the superior longitudinal sinus by means of the vein passing through the foramen cæcum.

VEINS OF THE UPPER EXTREMITY AND THORAX

The veins of the upper extremity are divided into two sets, *superficial* and *deep*.

The **superficial veins** are placed immediately beneath the integument between the two layers of superficial fascia.

FIG. 637.—The veins on the dorsum of the hand. (Bourgery.)

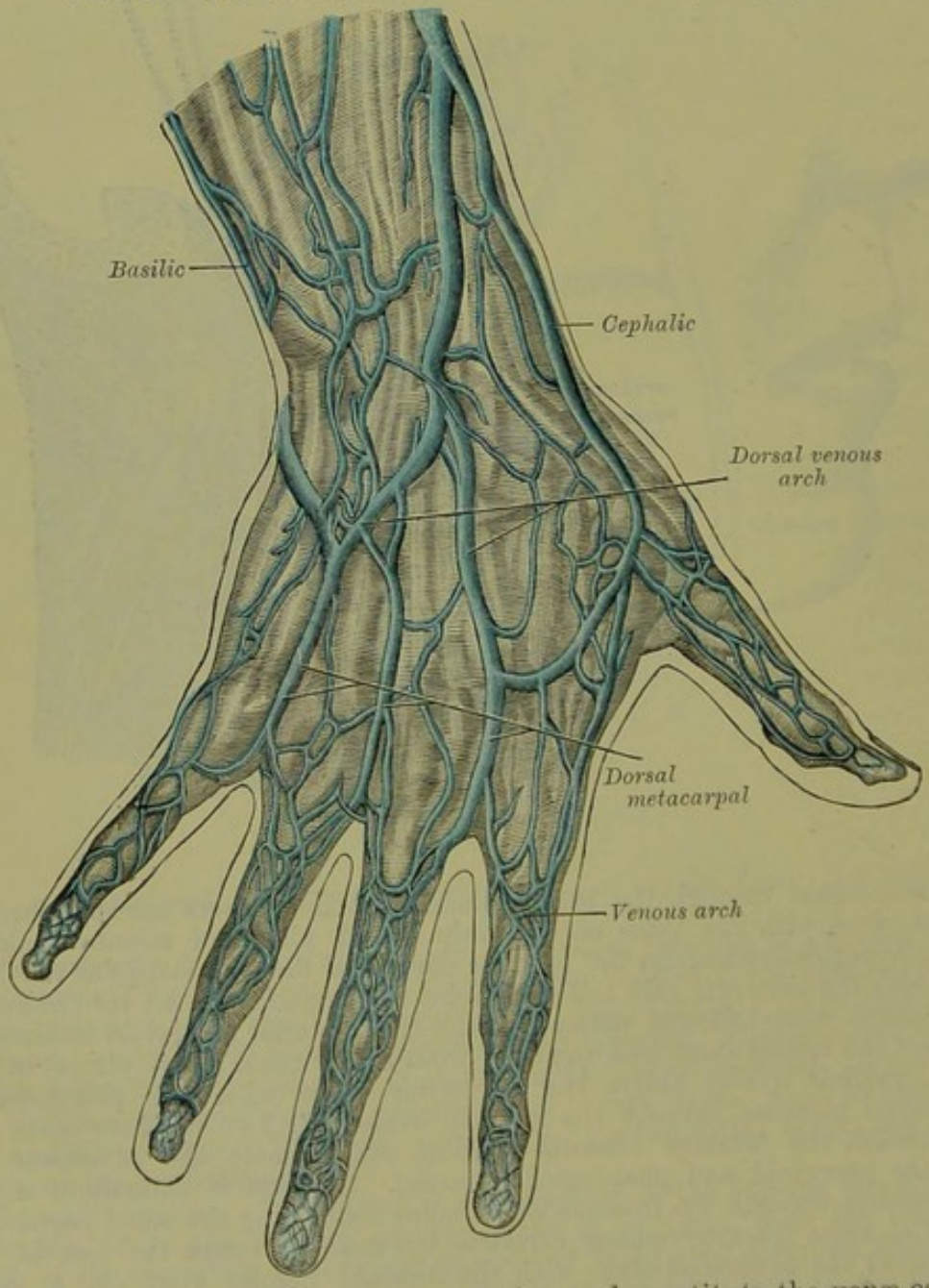

The **deep veins** accompany the arteries, and constitute the venæ comites of those vessels.

Both sets of vessels are provided with valves, which are more numerous in the deep than in the superficial.

The superficial veins of the upper extremity are, the

Digital.
Metacarpal.
Cephalic.
Basilic.
Median.

Digital veins.—The dorsal digital veins pass along the sides of the fingers and are joined to one another by oblique communicating branches. Those from the adjacent sides of the index, middle, ring, and little fingers unite to form three dorsal metacarpal veins (vv. metacarpeæ dorsales), which terminate in a dorsal venous arch (fig. 637) opposite the middle of the metacarpus. The arch is convex distally; its radial extremity is joined by the dorsal digital vein from the radial side of the index finger and by the dorsal digital veins of the thumb, and is prolonged upwards as the cephalic vein. The ulnar extremity of the arch receives the dorsal digital vein of the ulnar side of the little finger and is continued upwards as the basilic vein. A communicating branch frequently connects the dorsal venous arch with the cephalic vein about the middle of the forearm.

The palmar digital veins (vv. digitales volares) on each finger are connected to one another and to the dorsal digital veins by oblique vessels (vv. intercapitulares). They drain into a venous plexus which is situated over the thenar and hypothenar eminences and across the front of the wrist.

Fig. 638.—The superficial veins of the upper extremity.

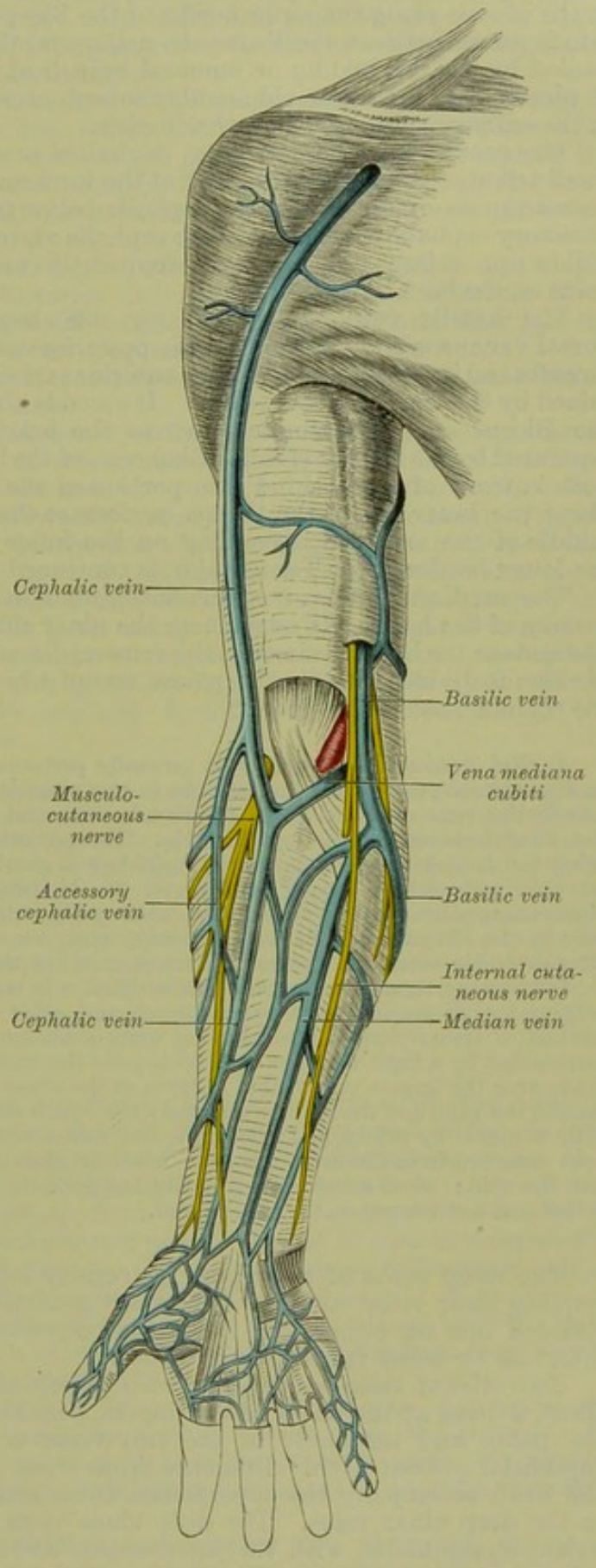

The **cephalic vein** (v. cephalica) (fig. 638) begins in the radial end of the dorsal venous arch and winds upwards round the radial border of the forearm,

receiving tributaries from both surfaces. Below the front of the elbow it gives off the *vena mediana cubiti*, which passes across to join the basilic. It then ascends in front of the elbow in the groove between the Brachio-radialis and the Biceps. It crosses superficial to the musculo-cutaneous nerve and ascends in the groove along the outer border of the Biceps. In the upper third of the arm it passes between the Pectoralis major and the Deltoid, where it is accompanied by the descending or humeral branch of the acromio-thoracic artery. It pierces the costo-coracoid membrane and, crossing the axillary artery, ends in the axillary vein just below the clavicle.

The *accessory cephalic vein* (v. cephalica accessoria) arises either from a small tributary plexus on the back of the forearm or from the ulnar side of the dorsal venous arch ; it joins the cephalic below the elbow. In some cases the accessory cephalic springs from the cephalic above the wrist and joins it again higher up. A large oblique branch frequently connects the basilic and cephalic veins on the back of the forearm.

The **basilic vein** (v. basilica) (fig. 638) begins in the ulnar end of the dorsal venous arch. It runs up the posterior surface of the ulnar side of the forearm and inclines forward to the anterior surface below the elbow, where it is joined by the vena mediana cubiti. It ascends obliquely in the groove between the Biceps and Pronator teres across the brachial artery, from which it is separated by the bicipital fascia ; filaments of the internal cutaneous nerve pass both in front of and behind this portion of the vein. It then runs upwards along the inner side of the Biceps, perforates the deep fascia a little below the middle of the arm and, ascending on the inner side of the brachial artery to the lower border of the Teres major, is continued onwards as the axillary vein.

The **median vein** (v. mediana antibrachii) drains the plexus on the palmar surface of the hand. It ascends on the ulnar side of the front of the forearm and ends in the basilic vein or in the vena mediana cubiti ; in a small proportion of cases it divides into two branches, one of which joins the basilic, the other the cephalic, below the elbow.*

Applied Anatomy.—Venesection is generally performed at the bend of the elbow, and as a matter of practice the largest vein in this situation is commonly selected. This is usually the vena mediana cubiti (median basilic), and there are anatomical advantages and disadvantages in selecting this vein. The advantages are, that in addition to its being the largest vessel and therefore yielding a greater supply of blood, it is the least movable and can be easily steadied on the bicipital fascia on which it rests. The disadvantages are, that it is in close relationship with the brachial artery, separated only by the bicipital fascia ; and formerly, when venesection was frequently practised, arterio-venous aneurysm was no uncommon result of this practice.

Intravenous infusion of normal saline solution is very frequently required in modern surgery for all conditions of severe shock and after profuse hæmorrhages, the older method of transfusion of blood having quite sunk into oblivion. The patient's arm is surrounded by a tight bandage so as to impede the venous return, and a small incision is made over the largest vein visible in front of the elbow ; a double ligature is now passed around the vein, and the lower one is tied ; the vein is then opened and a canula connected with a funnel by tubing and filled with hot saline solution is inserted. The bandage is next removed from the arm, and two, three, or more pints of fluid are allowed to flow into the vein ; when a sufficient quantity has gone in, the upper ligature round the vein is tied and a stitch put in the skin wound.

The **deep veins of the upper extremity** follow the course of the arteries, forming their venæ comites. They are generally arranged in pairs, and are situated one on either side of the corresponding artery, and connected at intervals by short transverse branches.

Two digital veins accompany each artery along the sides of the fingers : these, uniting at the bases of the fingers, pass along the interosseous spaces in the palm, and terminate in the two venæ comites which accompany the superficial palmar arch. Branches from these vessels on the radial side of the hand accompany the superficialis volæ, and on the ulnar side terminate in the deep ulnar veins. The deep ulnar veins, as they pass in front of the wrist, communicate with the interosseous and superficial veins, and, at the

* Consult an article by Berry and Newton, *Anatomischer Anzeiger*, Band xxxiii., December 1908.

elbow, unite with the deep radial veins to form the venæ comites of the brachial artery.

The **interosseous veins** accompany the anterior and posterior interosseous arteries. The anterior interosseous veins commence in front of the wrist, where they communicate with the deep radial and ulnar veins; at the upper part of the forearm they receive the posterior interosseous veins, and terminate in the venæ comites of the ulnar artery.

The **deep palmar veins** accompany the deep palmar arch, being formed by tributaries which follow the ramifications of that vessel. They communicate with the deep ulnar veins at the inner side of the hand, and on the outer side terminate in the venæ comites of the radial artery. At the wrist, they receive a dorsal and a palmar tributary from the thumb, and unite with the venæ comites of the radial artery.

The **brachial veins** (vv. brachiales) are placed one on either side of the brachial artery, receiving tributaries corresponding with the branches given off from that vessel; near the lower margin of the Subscapularis, they join the axillary vein; the inner of the two frequently joins the basilic vein.

These deep veins have numerous anastomoses, not only with each other, but also with the superficial veins.

The **axillary vein** (v. axillaris) is of large size, and is the continuation upwards of the basilic vein. It commences at the lower border of the Teres major, increases in size as it ascends, by receiving tributaries corresponding with the branches of the axillary artery, and terminates immediately beneath the clavicle at the outer border of the first rib, where it becomes the subclavian vein. This vessel is covered in front by the Pectoral muscles and costo-coracoid membrane, and lies on the thoracic side of the axillary artery, which it partially overlaps. Near the lower margin of the Subscapularis it receives the venæ comites of the brachial artery, and, near its termination, the cephalic vein. It is provided with a pair of valves opposite the lower border of the Subscapularis muscle; valves are also found at the terminations of the cephalic and subscapular veins.

Applied Anatomy.—Since the axillary vein is superficial to and larger than the axillary artery, which it overlaps, it is more liable to be wounded than the artery in the operation of extirpation of the axillary glands, especially as these glands, when diseased, are apt to become adherent to it. When it is wounded, there is always a danger of air being drawn into its interior, and death resulting. To avoid wounding the axillary vein in the extirpation of glands from the axilla, it is always advisable to expose the vein as soon as possible; no sharp cutting instruments should be used after the axillary cavity has been freely exposed; and care should be taken to use no undue force in isolating the glands (see page 773). Should the vein be so imbedded in a malignant deposit that the latter cannot be removed without taking away a part of the vein, this must be done after the vessel has been ligatured above and below.

The **subclavian vein** (v. subclavia), the continuation of the axillary, extends from the outer border of the first rib to the inner end of the clavicle, where it unites with the internal jugular to form the innominate vein. It is in relation, in front, with the clavicle and Subclavius muscle; behind and above, with the subclavian artery, from which it is separated internally by the Scalenus anticus muscle and phrenic nerve. Below, it rests in a depression on the first rib and upon the pleura. It is usually provided with a pair of valves, which are situated about an inch from its termination.

The subclavian vein occasionally rises in the neck to a level with the third part of the subclavian artery, and in one or two instances has been seen passing with this vessel behind the Scalenus anticus.

Tributaries.—This vein receives the external jugular vein, sometimes the anterior jugular vein, and occasionally a small branch from the cephalic. At its angle of junction with the internal jugular, the left subclavian vein receives the thoracic duct; while the right subclavian vein receives the right lymphatic duct.

The **innominate** or **brachio-cephalic veins** (vv. anonymæ dextra et sinistra) (fig. 639) are two large trunks, placed one on either side of the root of the neck, and formed by the union of the internal jugular and subclavian veins of the corresponding side.

The **right innominate vein** is a short vessel, an inch in length, which commences at the inner end of the clavicle, and, passing almost vertically downwards, joins with the left innominate vein just below the cartilage of the first rib, close to the right border of the sternum, to form the superior vena cava. It lies superficial and external to the innominate artery; on its right side is the phrenic nerve, and the pleura is here interposed between it and the apex of the lung. This vein, at the angle of junction of the internal jugular with the subclavian, receives the right vertebral vein; and, lower down, the right internal mammary, right inferior thyroid, and sometimes the right superior intercostal veins.

The **left innominate vein,** about two and a half inches in length, and larger than the right, passes from left to right across the upper part and front of the chest, at the same time inclining downwards, to unite with its fellow of the opposite side, and form the *superior vena cava*. It is in relation, in front, with the manubrium sterni, from which it is separated by the Sterno-hyoid and Sterno-thyroid muscles, the thymus gland or its remains, and some loose areolar tissue. Behind it are the three large arteries arising from the arch of the aorta, together with the vagus and phrenic nerves. This vessel is joined by the left vertebral, left internal mammary, left inferior thyroid, and the left superior intercostal veins, and occasionally some thymic and pericardiac veins. There are no valves in the innominate veins.

Peculiarities.—Sometimes the innominate veins open separately into the right auricle; in such cases the right vein takes the ordinary course of the superior vena cava: but the left vein—*left superior vena cava*, as it is termed—after communicating by a small branch with the right one, passes in front of the root of the left lung, and, turning to the back of the heart, receives the cardiac veins, and terminates in the back of the right auricle. This occasional condition in the adult is due to the persistence of the early fœtal condition, and is the normal state of things in birds and some mammalia.

The **internal mammary veins** (vv. mammariæ internæ), two to each internal mammary artery, follow the course of that vessel, and receive tributaries corresponding to its branches. The two veins unite into a single trunk, which terminates in the corresponding innominate vein. The *superior phrenic vein* (i.e. the vein accompanying the arteria comes nervi phrenici) usually opens into the internal mammary vein.

The **inferior thyroid veins** (vv. thyreoideæ inferiores), two, frequently three or four, in number, arise in the venous plexus on the thyroid body, communicating with the middle and superior thyroid veins. They form a plexus in front of the trachea, behind the Sterno-thyroid muscles. From this plexus, a left vein descends and joins the left innominate trunk, and a right vein passes obliquely downwards and outwards across the innominate artery to open into the right innominate vein, just at its junction with the superior vena cava. These veins receive œsophageal, tracheal, and inferior laryngeal veins, and are provided with valves at their termination in the innominate veins.

The **superior intercostal veins** (right and left) drain the blood from two or three of the intercostal spaces below the first. The *right* vein (v. intercostalis suprema dextra) passes downwards and inwards and opens into the vena azygos major; the *left* (v. intercostalis suprema sinistra) runs across the arch of the aorta and opens into the left innominate vein. It usually receives the left bronchial and left superior phrenic vein, and communicates below with the vena azygos minor superior. The vein from the first intercostal space opens directly into the corresponding vertebral or innominate vein.

The **vena cava superior** receives the blood which is conveyed to the heart from the whole of the upper half of the body. It is a short trunk, varying from two inches and a half to three inches in length, formed by the junction of the two innominate veins. It commences immediately below the cartilage of the first rib close to the sternum on the right side, and, descending vertically, enters the pericardium about an inch and a half above the heart, and terminates in the upper part of the right auricle opposite the upper border of the third right costal cartilage. In its course it describes a slight curve, the convexity of which is to the right side.

Relations.—*In front*, it is in relation with the pericardium and the process of cervical fascia which is continuous with that sac; these separate it from the

thymus gland, and from the second and third costal cartilages; *behind*, with the root of the right lung. On its *right side*, it is in relation with the phrenic nerve

FIG. 639.—The venæ cavæ and azygos veins, with their formative branches.

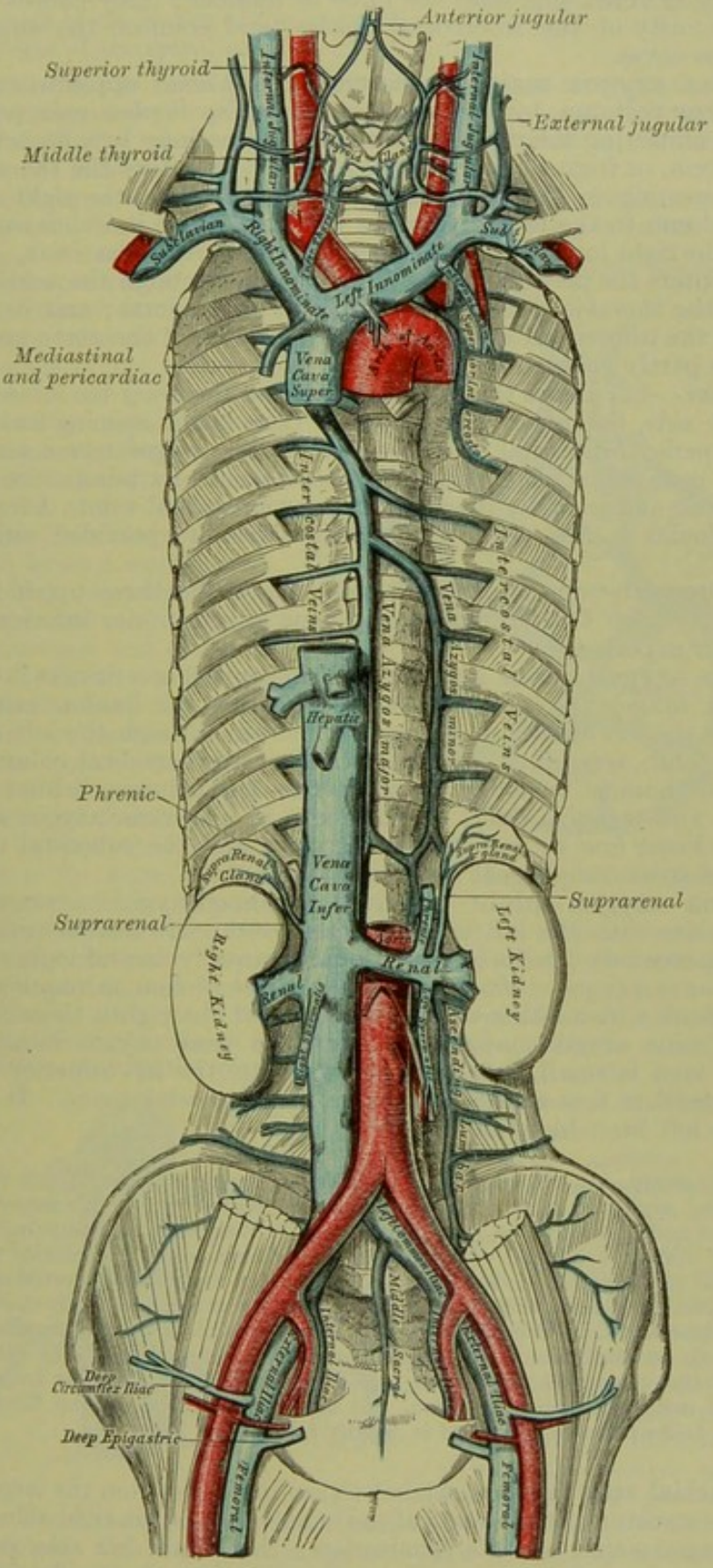

and right pleura; on its *left side*, with the commencement of the innominate artery and the ascending part of the aorta, the latter overlapping it. Just before it

enters the pericardium, it receives the vena azygos major and several small veins from the pericardium and parts in the mediastinum. The portion contained within the pericardium is covered, in front and laterally, by the serous layer of that membrane. The superior vena cava has no valves.

The **azygos veins** (fig. 639) are three in number; they collect the blood from the majority of the intercostal spaces, and connect the superior and inferior venæ cavæ.

The **vena azygos major** (v. azygos) commences opposite the first or second lumbar vertebra, by a branch, the *ascending lumbar vein* (v. lumbalis ascendens) connecting the right lumbar veins; sometimes by a branch from the right renal vein, or from the inferior vena cava. It enters the thorax through the aortic opening in the Diaphragm, and passes along the right side of the vertebral column to the fourth thoracic vertebra, where it arches forward over the root of the right lung, and terminates in the superior vena cava, just before that vessel enters the pericardium. While passing through the aortic opening, it lies with the thoracic duct on the right side of the aorta; and in the thorax it lies upon the intercostal arteries, on the right side of the aorta and thoracic duct, and is partly covered by pleura.

Tributaries.—It receives the subcostal vein and the lower ten intercostal veins of the right side, the upper two or three of these latter opening first of all into the right superior intercostal vein. It receives the azygos minor veins, several œsophageal, mediastinal, and pericardial veins; near its termination, the right bronchial vein; and generally the right superior intercostal vein. A few imperfect valves are found in this vein; but its tributaries are provided with complete valves.

The intercostal veins on the left side, below the three upper intercostal spaces, usually form two trunks, named vena azygos minor inferior and vena azygos minor superior.

The **vena azygos minor inferior** (v. hemiazygos) commences in the lumbar region, by a branch (*ascending lumbar*) connecting the lumbar veins or by a branch from the left renal. It enters the thorax, through the left crus of the Diaphragm, and, ascending on the left side of the vertebral column, as high as the ninth thoracic vertebra, passes across the column, behind the aorta, œsophagus, and thoracic duct, to terminate in the vena azygos major. It receives the lower four or five intercostal veins and the subcostal vein of the left side, and some œsophageal and mediastinal veins.

The **vena azygos minor superior** (v. hemiazygos accessoria) varies inversely in size with the left superior intercostal. It receives veins from the intercostal spaces between the left superior intercostal vein and highest tributary of the left lower azygos. They are usually three or four in number, and join to form a trunk which either crosses the body of the eighth thoracic vertebra to join the vena azygos major or ends in the vena azygos minor superior. When this vein is small, or altogether wanting, the left superior intercostal vein will extend as low as the fifth or sixth intercostal space. It sometimes receives the left bronchial vein.

Applied Anatomy.—In obstruction of the inferior vena cava, the azygos veins are one of the principal means by which the venous circulation is carried on, connecting as they do the superior and inferior venæ cavæ, and communicating with the common iliac veins by the ascending lumbar veins and with many of the tributaries of the inferior vena cava.

Thrombosis of the superior vena cava is oftenest due to pressure exerted on the vessel by an aneurysm or a tumour; it may also occur by propagation of clotting from a tributary peripheral vein. If occlusion of the vessel take place slowly, a collateral venous circulation may be established; the patient will have some œdema with dilatation and congestion of the veins about the head and neck, and may also suffer from attacks of dyspnœa and recurrent pleural effusion. In most cases, however, the blockage of the superior cava takes place rapidly, and is rapidly fatal.

The **bronchial veins** (vv. bronchiales) return the blood from the larger bronchi, and from the structures at the roots of the lungs; that of the right side opens into the vena azygos major, near its termination; that of the left side, into the left superior intercostal vein or vena azygos minor superior. A considerable quantity of the blood which is carried to the lungs through the bronchial arteries is returned to the left side of the heart through the pulmonary veins.

The Spinal Veins (figs. 640, 641)

The spinal veins may be arranged into four groups, viz. :

1. The extra-spinal veins.
2. The intra-spinal veins, between the vertebræ and the dura mater.
3. The veins of the bodies of the vertebræ.
4. The veins of the spinal cord.

1. The **extra-spinal veins** form an anterior and a posterior spinal plexus.

The *anterior spinal plexus* (plexus venosi vertebrales anteriores) is situated on the front of the bodies of the vertebræ, and is best marked in the cervical region. It consists of relatively small vessels, which anastomose with the intraspinal veins and the veins from the bodies of the vertebræ, and open into the deep cervical, intercostal, lumbar, and lateral sacral veins in the respective regions of the vertebral column.

Fig. 640.—Transverse section of a thoracic vertebra, showing the spinal veins.

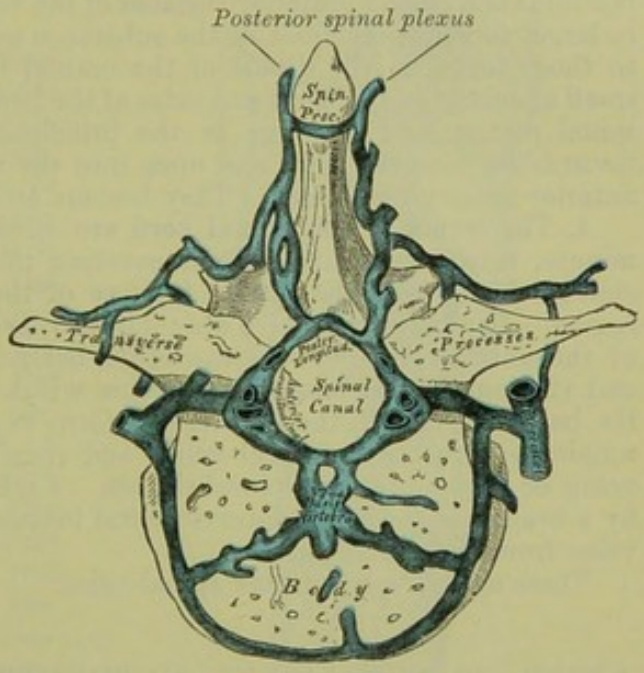

The *posterior spinal plexus* (plexus venosi vertebrales posteriores) receives tributaries from the integument of the back and from the muscles in the vertebral grooves. It forms a complicated network, which surrounds the spinous processes, the laminæ, and the transverse and articular processes of all the vertebræ. It communicates with the intraspinal veins by branches which perforate the ligamenta subflava and others which pass through the intervertebral foramina. It terminates by joining the vertebral veins in the neck, the intercostal veins in the thorax, and the lumbar and sacral veins in the loins and pelvis.

2. The **intra-spinal veins** (vv. spinales internæ) are situated between the dura mater and the vertebræ. They consist of two longitudinal plexuses, one of which runs along the posterior surfaces of the bodies of the vertebræ (*anterior longitudinal spinal veins*); the other (*posterior longitudinal spinal veins*) is placed on the inner or anterior surfaces of the laminæ of the vertebræ.

Fig. 641.—Vertical section of two thoracic vertebræ, showing the spinal veins.

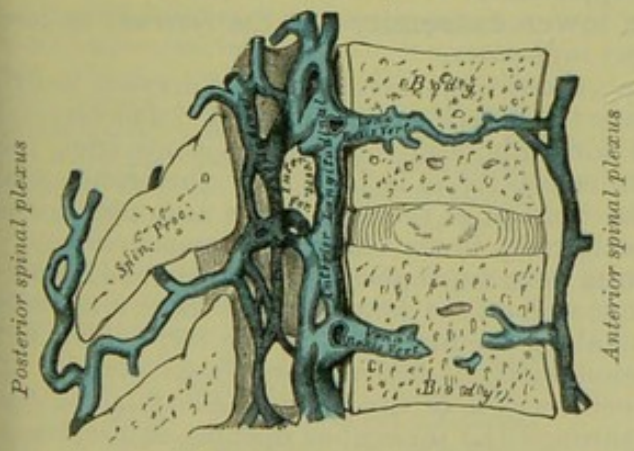

The *anterior longitudinal spinal veins* consist of two large, tortuous veins, which extend from the foramen magnum to the base of the coccyx, being placed one on either side of the posterior surface of the bodies of the vertebræ, along the margin of the posterior common ligament. They communicate through the foramen magnum with the basilar and occipital sinuses, and give off branches which unite above the atlas to form the commencement of the vertebral vein. They also communicate with one another opposite each vertebra by a transverse trunk, which passes beneath the posterior common ligament; these transverse branches receive the *venæ basivertebrales* from the interior of the vertebral bodies. The anterior longitudinal spinal veins are least developed in the cervical and sacral

regions. They are not of uniform size throughout, being alternately enlarged and constricted. At the intervertebral foramina they communicate with the posterior spinal plexus, and with the vertebral veins in the neck, with the intercostal veins in the thoracic region, and with the lumbar and sacral veins in the corresponding regions.

The *posterior longitudinal spinal veins*, smaller than the anterior, are situated one on either side, between the inner surfaces of the laminæ and the dura mater. They communicate (like the anterior), opposite the vertebræ, by transverse trunks; and with the anterior longitudinal veins, by lateral transverse branches, which pass from behind forwards. They join with the posterior spinal plexus by branches which perforate the ligamenta subflava, and communicate through the intervertebral foramina with the vertebral, intercostal, lumbar, and sacral veins.

3. The **veins of the bodies of the vertebræ** (vv. basivertebrales) emerge from the foramina on the posterior surfaces of the vertebral bodies. They are contained in large, tortuous channels in the substance of the bones, similar in every respect to those found in the diploë of the cranial bones. They communicate through small openings on the front and sides of the bodies of the vertebræ with the anterior spinal plexus, and converge to the principal canal which is sometimes double towards its posterior part, and open into the transverse branches which unite the anterior longitudinal veins. They become greatly enlarged in advanced age.

4. The **veins of the spinal cord** are situated in the pia mater and form a minute, tortuous, venous plexus covering the entire surface of the cord. They emerge chiefly from the median furrows of the cord and are largest in the lumbar region. In this plexus there are: (1) two median longitudinal veins, one in front of the anterior fissure, and the other behind the posterior fissure of the cord; and (2) four lateral longitudinal veins which run behind the nerve-roots. Near the base of the skull they unite, and form two or three small trunks, which communicate with the vertebral veins, and then terminate in the inferior cerebellar veins, or in the inferior petrosal sinuses. Each of the spinal nerves is accompanied by a branch as far as the intervertebral foramen; here this branch joins the other veins from the spinal canal.

There are no valves in the spinal veins.

VEINS OF THE LOWER EXTREMITY, ABDOMEN, AND PELVIS

The veins of the lower extremity are subdivided, like those of the upper, into two sets, superficial and deep: the superficial veins are placed beneath the integument, between the two layers of superficial fascia; the deep veins accompany the arteries, and form the venæ comites of those vessels. Both sets of veins are provided with valves, which are more numerous in the deep than in the superficial set. Valves are also more numerous in the veins of the lower than in those of the upper limb.

The **superficial veins of the lower extremity** are the *internal* or *long saphenous*, and the *external* or *short saphenous*.

On the dorsum of the foot is a venous arch (arcus venosus dorsalis pedis), situated in the superficial fascia over the anterior extremities of the metatarsal bones. Its convexity is directed forwards, and receives the veins from the upper surfaces of the toes; at its concavity it is joined by numerous small veins, which form a plexus on the dorsum of the foot. The arch terminates internally in the long saphenous, externally in the short saphenous vein.

The **internal or long saphenous vein** (v. saphena magna) (fig. 642) commences at the inner side of the venous arch on the dorsum of the foot; it ascends in front of the inner malleolus, and along the inner side of the leg, behind the inner margin of the tibia, in relation with the internal saphenous nerve. At the knee, it passes behind the inner condyle of the femur, ascends along the inside of the thigh, and, passing through the saphenous opening in the fascia lata, terminates in the femoral vein about an inch and a half below Poupart's ligament. It receives in its course cutaneous tributaries from the leg and thigh, and at the saphenous opening (fig. 643) the superficial epigastric, superficial circumflex iliac, and superficial external pudic veins. The veins from the inner and back part of the thigh frequently unite to form a large vessel (v. saphena accessoria) which enters the main trunk near the saphenous opening; and

sometimes those on the outer side of the thigh join to form another large vessel; so that occasionally three large veins are seen converging from different parts of the thigh towards the saphenous opening. The internal saphenous vein communicates in the foot with the internal plantar vein; in the leg, with the posterior tibial veins, by branches which perforate the tibial origin of the Soleus muscle, and also with the anterior tibial veins; at the knee, with the articular veins; in the thigh, with the femoral vein by one or more branches. The valves in this vein vary from ten to twenty in number; they are more numerous in the thigh than in the leg.

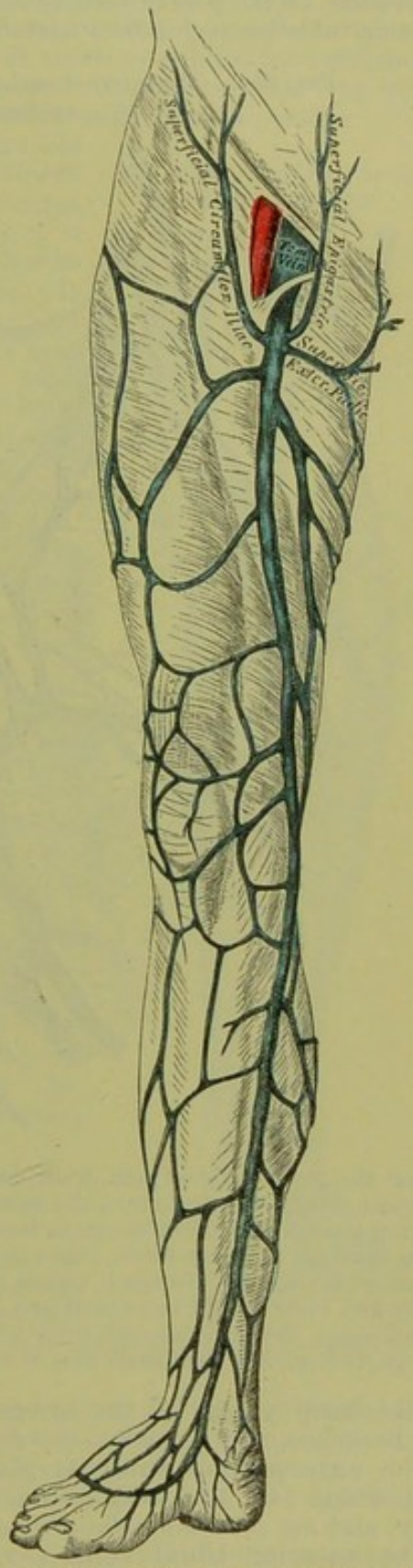

Fig. 642.—The internal or long saphenous vein and its tributaries.

The **external or short saphenous vein** (v. saphena parva) (fig. 644) commences at the outer side of the venous arch on the dorsum of the foot; it ascends behind the outer malleolus, and along the outer border of the tendo Achillis, across which it passes to reach the middle line of the posterior aspect of the leg. Running directly upwards, it perforates the deep fascia in the lower part of the popliteal space, and terminates in the popliteal vein, between the heads of the Gastrocnemius muscle. It receives numerous large tributaries from the back part of the leg, and communicates with the deep veins on the dorsum of the foot, and behind the outer malleolus. Before it perforates the deep fascia, it gives off a communicating branch, which passes upwards and inwards to join the internal saphenous vein. The external saphenous vein contains from nine to twelve valves, one of which is always found near its termination in the popliteal vein. The external saphenous nerve lies close beside this vein.

Applied Anatomy.—A varicose condition of the saphenous veins is more frequently met with than in the other veins of the body, except perhaps the spermatic and hæmorrhoidal veins. The main cause of this is the high blood-pressure, determined chiefly by the erect position, and the length of the column of blood, which has to be propelled in an uphill direction. In normal vessels there is only just sufficient force to perform this task; and in those cases where there is diminished resistance of the walls of the veins, these vessels are liable to dilate and a varicose condition is set up. This diminished resistance may be due to heredity, the vein-walls being congenitally weak, or it may follow inflammatory conditions of the vessels. Increased blood pressure in the veins, caused by any obstacle to the return of the venous blood, such as the pressure of a tumour, or the gravid uterus, or tight gartering, may also produce varix. In the normal condition of the veins, the valves in their interior break up the column of blood into a number of smaller columns, and so to a considerable

extent mitigate the ill effects of the erect position ; but when the dilatation of the veins has reached a certain limit, the valves become incapable of supporting the overlying column of blood, and the pressure is increased, tending to emphasise also the varicose condition. Both the saphenous veins in the leg are accompanied by nerves, the internal saphenous being joined by its companion nerve just below the level of the knee-joint. No doubt much of the pain of varicose veins in the leg is due to this fact.

Operations for the relief of varicose veins are frequently required, portions of the veins being removed after having been ligatured above and below. It is important to note

Fig. 643.—The internal saphenous vein and its tributaries at the saphenous opening.

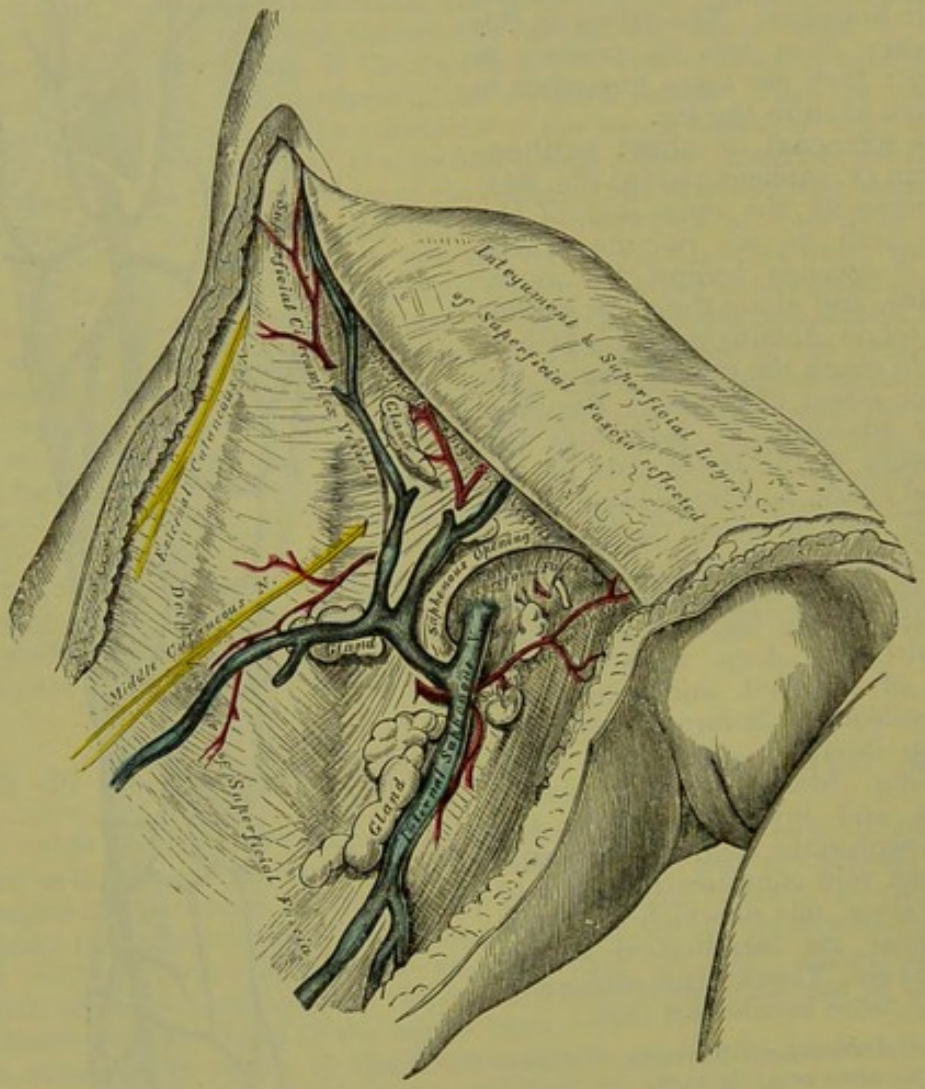

whether the main varicose area drains into the internal or the external saphenous vein—the former condition being much the more common—and to control the venous return by removing a small portion of the main trunk just before it opens into the deep vein by passing through the deep fascia ; thus in most cases a piece should be removed from the internal saphenous just before it passes through the saphenous opening, and in addition the affected veins should be excised just above and just below the level of the knee-joint. In other cases the external saphenous will have to be dealt with immediately below the point where it pierces the fascial roof of the popliteal space.

The **deep veins of the lower extremity** accompany the arteries and their branches, and are called the *venæ comites* of those vessels.

The **external** and **internal plantar veins** unite to form the **posterior tibial veins** (vv. tibiales posteriores), which accompany the posterior tibial artery, and are joined by the *peroneal veins* (vv. peronææ).

The **anterior tibial veins** (vv. tibiales anteriores) are the upward continuations of the venæ comites of the dorsalis pedis artery. They leave the front of the leg by passing between the tibia and fibula, over the interosseous membrane, and form, by their junction with the posterior tibial, the *popliteal* vein.

The valves in the deep veins are very numerous.

The **popliteal vein** (v. poplitea) is formed by the junction of the venæ comites of the anterior and posterior tibial arteries at the lower border of the Popliteus muscle; it ascends through the popliteal space to the tendinous aperture in the Adductor magnus, where it becomes the femoral vein. In the lower part of its course it is placed internal to the artery; between the heads of the Gastrocnemius it is superficial to that vessel; but above the knee-joint, it is close to its outer side. It receives tributaries corresponding to the branches of the popliteal artery, and it also receives the external saphenous vein. The valves in this vein are usually four in number.

The **femoral vein** (v. femoralis) accompanies the femoral artery through the upper two-thirds of the thigh. In the lower part of its course it lies external to the artery; higher up, it is behind it; and at Poupart's ligament, it lies to its inner side, and on the same plane. It receives numerous muscular tributaries, and about an inch and a half below Poupart's ligament it is joined by the profunda femoris: near its termination it is joined by the internal saphenous vein. The valves in the femoral vein are three in number.

Fig. 644.—External or short saphenous vein.

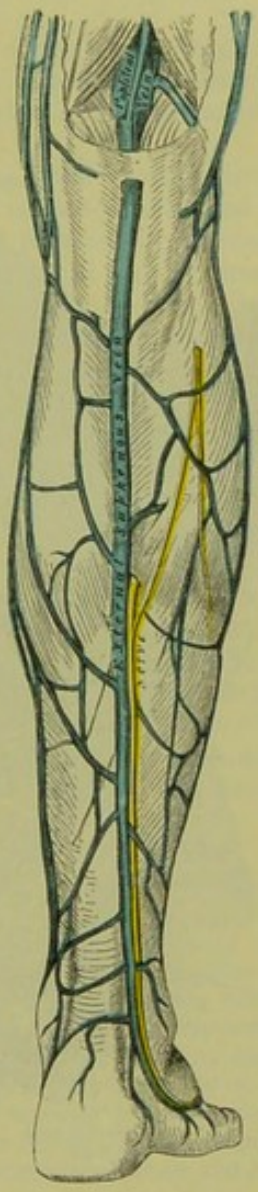

The *profunda femoris vein* (v. profunda femoris) receives tributaries corresponding to the perforating branches of the profunda artery, and through these establishes communications with the popliteal vein below and the sciatic vein above. It also receives the internal and external circumflex veins.

The **external iliac vein** (v. iliaca externa) (fig. 645) commences at the termination of the femoral, beneath Poupart's ligament, and, passing upwards along the brim of the pelvis, terminates opposite the sacro-iliac articulation, by uniting with the internal iliac to form the common iliac vein. On the right side, it lies at first along the inner side of the external iliac artery; but, as it passes upwards, gradually inclines behind it. On the left side, it lies altogether on the inner side of the artery. It receives, immediately above Poupart's ligament, the deep epigastric and deep circumflex iliac veins, and a small pubic vein corresponding to the pubic branch of the obturator artery. It frequently contains one, sometimes two, valves.

Tributaries.—The external iliac vein receives the deep epigastric, deep circumflex iliac, and pubic veins.

The **deep epigastric vein** (v. epigastrica inferior) is formed by the union of the venæ comites of the deep epigastric artery, which communicate above with the superior epigastric vein; it joins the external iliac about half an inch above Poupart's ligament.

The **deep circumflex iliac vein** (v. circumflexa ilium profunda) is formed by the union of the venæ comites of the deep circumflex iliac artery, and joins the external iliac vein about three-quarters of an inch above Poupart's ligament.

The *pubic vein* communicates with the obturator vein in the thyroid foramen, and ascends on the back of the pubis to the external iliac vein.

The **internal iliac vein** (v. hypogastrica) (fig. 645) commences near the upper part of the great sacro-sciatic foramen, passes upwards behind and slightly to the inner side of the internal iliac artery and, at the brim of the pelvis, joins with the external iliac to form the common iliac vein.

Tributaries.—With the exception of the fœtal umbilical vein which passes upwards and backwards from the umbilicus to the liver, and the ilio-lumbar vein which usually joins the common iliac vein, the tributaries of the internal iliac vein correspond with the branches of the internal iliac artery. It receives (*a*) the gluteal, sciatic, internal pudic, and obturator veins, which have their origins outside the pelvis; (*b*) the lateral sacral veins, which lie in front of the sacrum; and (*c*) the middle hæmorrhoidal, vesical, uterine, and vaginal veins, which originate in venous plexuses connected with the pelvic viscera.

1. The **gluteal veins** (vv. glutææ superiores) or venæ comites of the gluteal artery, receive tributaries from the buttock corresponding with the branches of the artery;

Fig. 645.—The veins of the right half of the male pelvis. (Spalteholz.)

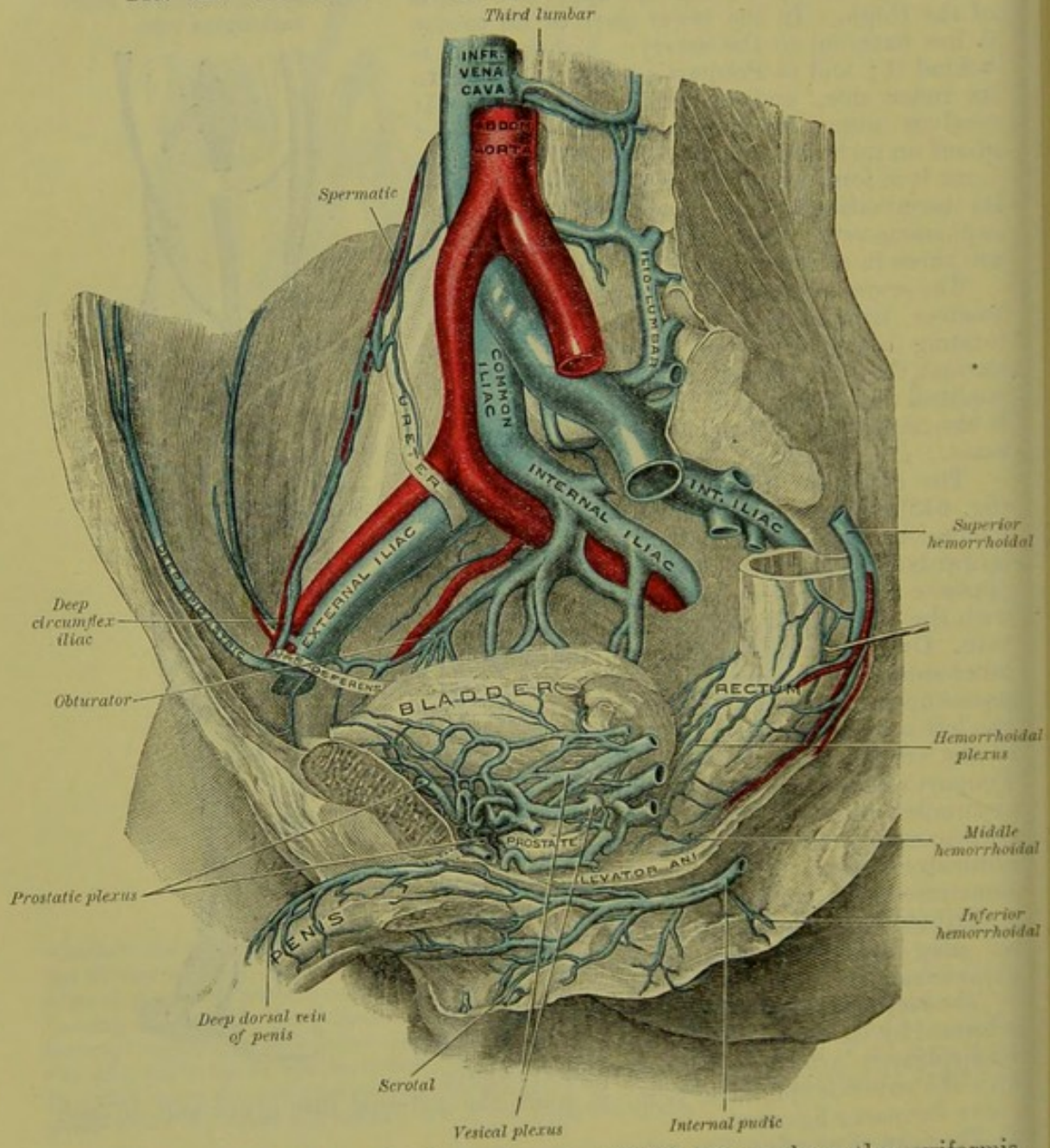

they enter the pelvis through the great sacro-sciatic foramen, above the pyriformis, and frequently unite before ending in the internal iliac vein.

2. The **sciatic veins** (vv. glutææ inferiores) or venæ comites of the sciatic artery begin on the upper part of the back of the thigh, where they anastomose with the internal circumflex and first perforating veins. They enter the pelvis through the lower part of the sacro-sciatic foramen and join to form a single stem which opens into the lower part of the internal iliac vein.

3. The **internal pudic veins** (vv. pudendæ internæ) are the venæ comites of the internal pudic artery. They commence in the veins which issue from the corpus

cavernosum, accompany the internal pudic artery, and unite to form a single vessel, which ends in the internal iliac vein. They receive the veins from the bulb of the urethra, and the superficial perineal and inferior hæmorrhoidal veins (vv. hæmorrhoidales inferiores). The deep dorsal vein of the penis communicates with the internal pudic veins, but ends mainly in the vesico-prostatic venous plexus.

4. The **obturator vein** (v. obturatoria) begins in the upper portion of the adductor region of the thigh and enters the pelvis through the anterior part of the obturator foramen. It runs backwards and upwards on the lateral wall of the pelvis below the obturator artery, and then passes between the ureter and the internal iliac artery, to end in the internal iliac vein.

5. The **lateral sacral veins** (vv. sacrales laterales) accompany the lateral sacral arteries on the anterior surface of the sacrum and terminate in the internal iliac vein.

6. The **middle hæmorrhoidal vein** (v. hæmorrhoidalis media) takes origin in the hæmorrhoidal plexus and receives tributaries from the bladder, prostate gland, and seminal vesicle: it runs outwards on the pelvic surface of the Levator ani to end in the internal iliac vein.

The **hæmorrhoidal plexus** surrounds the rectum, and communicates in front with the vesico-prostatic plexus in the male, and the utero-vaginal plexus in the female. It consists of two parts, an *internal* in the submucosa, and an *external* outside the muscular coat. Below, the internal plexus presents a series of dilated pouches which are arranged in a circle around the tube immediately above the anal orifice and are connected by transverse branches.

The lower part of the external plexus is drained by the inferior hæmorrhoidal veins into the internal pudic; its middle part by the middle hæmorrhoidal vein which joins the internal iliac; and its upper part by the superior hæmorrhoidal vein which forms the commencement of the inferior mesenteric vein, a tributary of the portal vein. A free communication between the portal and systemic venous systems is established through the hæmorrhoidal plexus.

The **vesico-prostatic plexus** surrounds the prostate gland and the neck of the bladder, and lies partly in the fascial sheath of the prostate and partly between the sheath and the capsule of the gland. In front it receives the deep dorsal vein of the penis; behind, it communicates with the hæmorrhoidal and vesical plexuses, and derives tributaries from the vasa deferentia and vesiculæ seminales. It is drained into the internal iliac veins by one or more vessels on either side. The corresponding plexus in the female is named the *vesico-vaginal*.

The **vesical plexus** lies on the muscular coat of the bladder, and is best marked towards the base and sides of the viscus; it drains into the vesico-prostatic plexus.

Applied Anatomy.—The veins of the hæmorrhoidal plexus are apt to become dilated and varicose, and form piles. This is due to several anatomical reasons: the vessels are contained in very loose, lax connective tissue, so that they get less support from surrounding structures than most other veins, and are less capable of resisting increased blood pressure; the condition is favoured by gravitation, being influenced by the erect posture, either sitting or standing, and by the fact that the superior hæmorrhoidal and portal veins have no valves; the veins pass through muscular tissue and are liable to be compressed by its contraction, especially during the act of defæcation; they are affected by every form of portal obstruction.

The prostatic plexus of veins is apt to become congested in many inflammatory conditions in the neighbourhood, such as acute gonorrhœal prostatitis. It is owing to the free communication which exists between this and the middle hæmorrhoidal plexus that great relief can be given by free saline purgation.

Hæmorrhage may be very free from the prostatic plexus after operations on that gland, but can usually be checked by hot fluid irrigation. Septic thrombosis sometimes occurs after operations, and infected emboli may find their way into the general circulation.

The **dorsal veins of the penis** are two in number, a superficial and a deep. The *superficial* vein drains the prepuce and skin of the penis, and, running backwards in the subcutaneous tissue, inclines to the right or left, and opens into the corresponding superficial external pudic vein, a tributary of the internal or long saphenous vein. The *deep* vein receives the blood from the glans penis and corpora cavernosa:

it courses backwards in the middle line between the dorsal arteries, underneath the deep fascia, and near the root of the penis passes between the two parts of the suspensory ligament and then through an aperture between the subpubic ligament and the triangular ligament of the urethra, and divides into two branches, which enter the prostatic plexus. The deep vein also communicates below the symphysis pubis with the internal pudic vein.

The **uterine plexuses** lie along the sides and superior angles of the uterus between the two layers of the broad ligament, and communicate with the ovarian and vaginal plexuses. They are drained by a pair of uterine veins on either side: these arise from the lower part of the plexuses, opposite the os uteri externum, and open into the corresponding internal iliac vein.

The **vaginal plexuses** are placed at the sides of the vagina; they communicate with the uterine, vesical, and hæmorrhoidal plexuses, and are drained by the vaginal veins, one on either side, into the internal iliac veins.

The **common iliac veins** are formed by the union of the external and internal iliac veins in front of the sacro-iliac articulation; passing obliquely upwards towards the right side, they terminate upon the fifth lumbar vertebra, by uniting with each other at an acute angle to form the inferior vena cava. The *right common iliac* (v. iliaca communis dextra) is shorter than the left, nearly vertical in its direction, and ascends behind and then to the outer side of its corresponding artery. The *left common iliac* (v. iliaca communis sinistra), longer than the right and more oblique in its course, is at first situated on the inner side of the corresponding artery, and then behind the right common iliac. Each common iliac receives the ilio-lumbar, and sometimes the lateral sacral veins. The left receives, in addition, the middle sacral vein. No valves are found in these veins.

The **middle sacral veins** accompany the corresponding artery along the front of the sacrum, and join to form a single vein (v. sacralis media), which terminates in the left common iliac vein; sometimes in the angle of junction of the two iliac veins.

Peculiarities.—The left common iliac vein, instead of joining with the right in its usual position, occasionally ascends on the left side of the aorta as high as the kidney, where, after receiving the left renal vein, it crosses over the aorta, and then joins with the right vein to form the vena cava. In these cases, the two common iliacs are connected by a small communicating branch at the spot where they are usually united.*

The **vena cava inferior** (fig. 639) returns to the heart the blood from all the parts below the Diaphragm. It is formed by the junction of the two common iliacs, on the right side of the fifth lumbar vertebra. It passes upwards along the front of the vertebral column, on the right side of the aorta, and, having reached the liver, is contained in a groove on its posterior surface. It then perforates the Diaphragm between the mesial and right portions of its central tendon; it subsequently inclines forwards and inwards for about an inch, and, piercing the fibrous pericardium, passes behind the serous pericardium to open into the lower and back part of the right auricle. In front of its auricular orifice is a semilunar valve, termed the *valve of Eustachius*: this is rudimentary in the adult, but is of large size and exercises an important function in the fœtus.

Relations.—The *abdominal portion* of the inferior vena cava is in relation *in front*, from below upwards, with the mesentery, right spermatic artery, transverse portion of the duodenum, the pancreas, portal vein, and the posterior surface of the liver, which partly and occasionally completely surrounds it; *behind*, with the vertebral column, the right Psoas muscle, the right crus of the Diaphragm, the right renal and lumbar arteries, right semilunar ganglion, and the inner part of the right suprarenal body; on the *right side*, with the right kidney and ureter; on the *left side*, with the aorta.

The *thoracic portion* is only about an inch in length, and is situated partly inside and partly outside the pericardial sac. The *extra-pericardial part* is separated from the right pleura and lung by a fibrous band, named the *right phrenico-pericardiac ligament* of Teutleben. This ligament, often feebly marked, is attached

* See two cases which have been described by Walsham in the *St. Bartholomew's Hospital Reports*, vols. xvi. and xvii.

below to the margin of the vena-caval opening in the Diaphragm, and above to the pericardium in front of and behind the root of the right lung. The *intra-pericardiac part* is very short, and is covered antero-laterally by the serous layer of the pericardium.

Peculiarities.—In position.—This vessel is sometimes placed on the left side of the aorta, as high as the left renal vein, after receiving which it crosses over to its usual position on the right side; or it may be placed altogether on the left side of the aorta, as far upwards as its termination in the heart: in such cases, the abdominal and thoracic viscera, together with the great vessels, are all transposed.

Point of termination.—Occasionally the inferior vena cava joins the right azygos vein, which is then of large size. In such cases, the superior vena cava receives the whole of the blood from the body before transmitting it to the right auricle, except the blood from the hepatic veins, which passes directly into the right auricle.

Applied Anatomy.—Thrombosis of the inferior vena cava is due to much the same causes as that of the superior (see page 750). It usually causes œdema of the legs and back, without ascites; if the renal veins are involved, blood and albumin will often appear in the urine. An extensive collateral venous circulation is soon established by enlargement either of the superficial or of the deep veins, or of both. In the first case the epigastric, the circumflex iliac, the long thoracic, the internal mammary, the intercostals, the external pudic, and the lumbo-vertebral anastomotic veins of Braune effect the communication with the superior cava; in the second, the deep anastomosis is made by the azygos and hemiazygos and the lumbar veins.*

Tributaries.—It receives in its course the following veins:

Lumbar.	Renal.	Inferior phrenic.
Right spermatic, or ovarian.	Suprarenal.	Hepatic.

The **lumbar veins** (vv. lumbales), four in number on each side, collect the blood by dorsal tributaries from the muscles and integument of the loins, and by abdominal tributaries from the walls of the abdomen, where they communicate with the epigastric veins. At the vertebral column, they receive veins from the spinal plexuses, and then pass forwards, round the sides of the bodies of the vertebræ, beneath the Psoas magnus, and terminate in the back part of the inferior cava. The left lumbar veins are longer than the right, and pass behind the aorta. The lumbar veins are connected together by a longitudinal vein which passes in front of the transverse processes of the lumbar vertebræ, and is called the *ascending lumbar*. It forms the most frequent origin of the corresponding vena azygos, and serves to connect the common iliac, ilio-lumbar, lumbar, and azygos veins of its own side of the body.

The **spermatic veins** (vv. spermaticæ) emerge from the back of the testis, and receive tributaries from the epididymis; they unite and form a convoluted plexus, called the *spermatic plexus* (plexus pampiniformis), which constitutes the greater mass of the cord; the vessels composing this plexus are very numerous, and ascend along the cord, in front of the vas deferens. Below the external abdominal ring they unite to form three or four veins, which pass along the inguinal canal, and, entering the abdomen through the internal abdominal ring, coalesce to form two veins, which ascend on the Psoas muscle, behind the peritoneum, lying one on either side of the spermatic artery. These unite to form a single vein, which opens on the right side into the inferior vena cava, at an acute angle; on the left side into the left renal vein, at a right angle. The spermatic veins are provided with valves.† The left spermatic vein passes behind the iliac colon, and is thus exposed to pressure from the contents of that part of the bowel.

Applied Anatomy.—The spermatic veins are very frequently varicose, constituting the condition known as *varicocele*. Though it is quite possible that the originating cause of this affection may be a congenital weakness of the walls of the veins of the pampiniform plexus, still it must be admitted that there are many anatomical reasons why these veins should become varicose: viz. the imperfect support afforded to them by the loose tissue of the scrotum; their great length; their vertical course; their dependent position;

* G. Blumer, in Osler and McCrae's *System of Medicine*, London, 1908, vol. iv.

† Rivington has pointed out that valves are usually found at the orifices of both the right and left spermatic veins. When no valves exist at the opening of the left spermatic vein into the left renal vein, valves are generally present in the left renal vein within a quarter of an inch from the orifice of the spermatic vein.—*Journal of Anatomy and Physiology*, vol. vii. p. 163.

their plexiform arrangement in the scrotum, with their termination in one small vein in the abdomen ; their few and imperfect valves ; and the fact that they may be subjected to pressure in their passage through the abdominal wall. Varicocele almost invariably occurs on the left side, and this has been accounted for by the facts that the left spermatic vein joins the left renal at a right angle ; that it is overlaid by the iliac colon, and that when this portion of the gut is full of fæcal matter, in cases of constipation, its weight impedes the return of the venous blood ; and that the left spermatic veins are somewhat longer than the right.

The operation for the removal of a varicocele consists in making a small incision just over the external abdominal ring and passing an aneurysm needle round the mass of veins, taking care that the vas deferens is not included. The veins are isolated from the vas and ligatured above and below, as high and as low as possible, and the intermediate portion cut away; the divided ends are fixed together with a suture, and the skin wound closed.

The **ovarian veins** (vv. ovaricæ) correspond with the spermatic in the male ; they form a plexus in the broad ligament near the ovary and Fallopian tube, and communicate with the uterine plexus. They terminate in the same way as the spermatic veins in the male. Valves are occasionally found in these veins. Like the uterine veins, they become much enlarged during pregnancy.

The **renal veins** (vv. renales) are of large size, and placed in front of the renal arteries. The left is longer than the right, and passes in front of the aorta, just below the origin of the superior mesenteric artery. It receives the left spermatic, the left inferior phrenic, and, generally, the left suprarenal veins. It opens into the vena cava at a slightly higher level than the right.

The **suprarenal veins** (vv. suprarenales) are two in number : the right terminates in the vena cava ; the left, in the left renal or phrenic vein.

The **inferior phrenic veins** (vv. phrenicæ inferiores) follow the course of the phrenic arteries ; the right ends in the inferior vena cava, the left in the left renal vein.

The **hepatic veins** (vv. hepaticæ) commence in the substance of the liver, in the capillary terminations of the portal vein and hepatic artery, and consist of two groups, upper and lower. The *upper group* is usually made up of three large veins, which converge towards the posterior surface of the liver, and open into the inferior vena cava, while that vessel is situated in the groove on the back part of the liver. The veins of the *lower group* vary in number, and are of small size ; they come from the right and Spigelian lobes. The hepatic veins run singly, and are in direct contact with the hepatic tissue. They are destitute of valves.

Portal System of Veins (fig. 646)

The portal system includes all the veins which drain the blood from the abdominal part of the alimentary canal (with the exception of the lower part of the rectum) and from the spleen, pancreas, and gall bladder. From these viscera the blood is conveyed to the liver by the *portal vein*. In the substance of the liver the portal vein ramifies like an artery and terminates in the *portal capillaries*, from which the blood is conveyed to the inferior vena cava by the hepatic veins. From this it will be seen that the blood of the portal system passes through two sets of capillary vessels, viz. (*a*) the capillaries of the alimentary canal, spleen, pancreas, and gall bladder; and (*b*) the portal capillaries in the substance of the liver. The portal vein and its tributaries are destitute of valves.

The **portal vein** (vena portæ) is about three inches in length, and is formed at the level of the second lumbar vertebra by the junction of the superior mesenteric and splenic veins, the union of these veins taking place in front of the inferior vena cava and behind the neck of the pancreas. It passes upwards behind the first part of the duodenum and then ascends in the right border of the small omentum to the right extremity of the transverse fissure of the liver, where it divides into a right and a left branch, which accompany the corresponding branches of the hepatic artery into the substance of the liver. In the small omentum it is placed behind and between the common bile duct and the hepatic artery, the former lying to the right of the latter. It is surrounded by the hepatic plexus of nerves, and is accompanied by numerous lymphatic vessels and some lymphatic glands. The *right branch* of the portal vein enters

the right lobe of the liver, but before doing so generally receives the cystic vein. The *left branch*, longer but of smaller calibre than the right, crosses the longitudinal fissure, gives branches to the caudate and Spigelian lobes, and then enters the left lobe of the liver. As it crosses the longitudinal fissure it is joined in front by a fibrous cord, the *ligamentum teres* of the liver or *obliterated*

Fig. 646.—Portal vein and its tributaries.

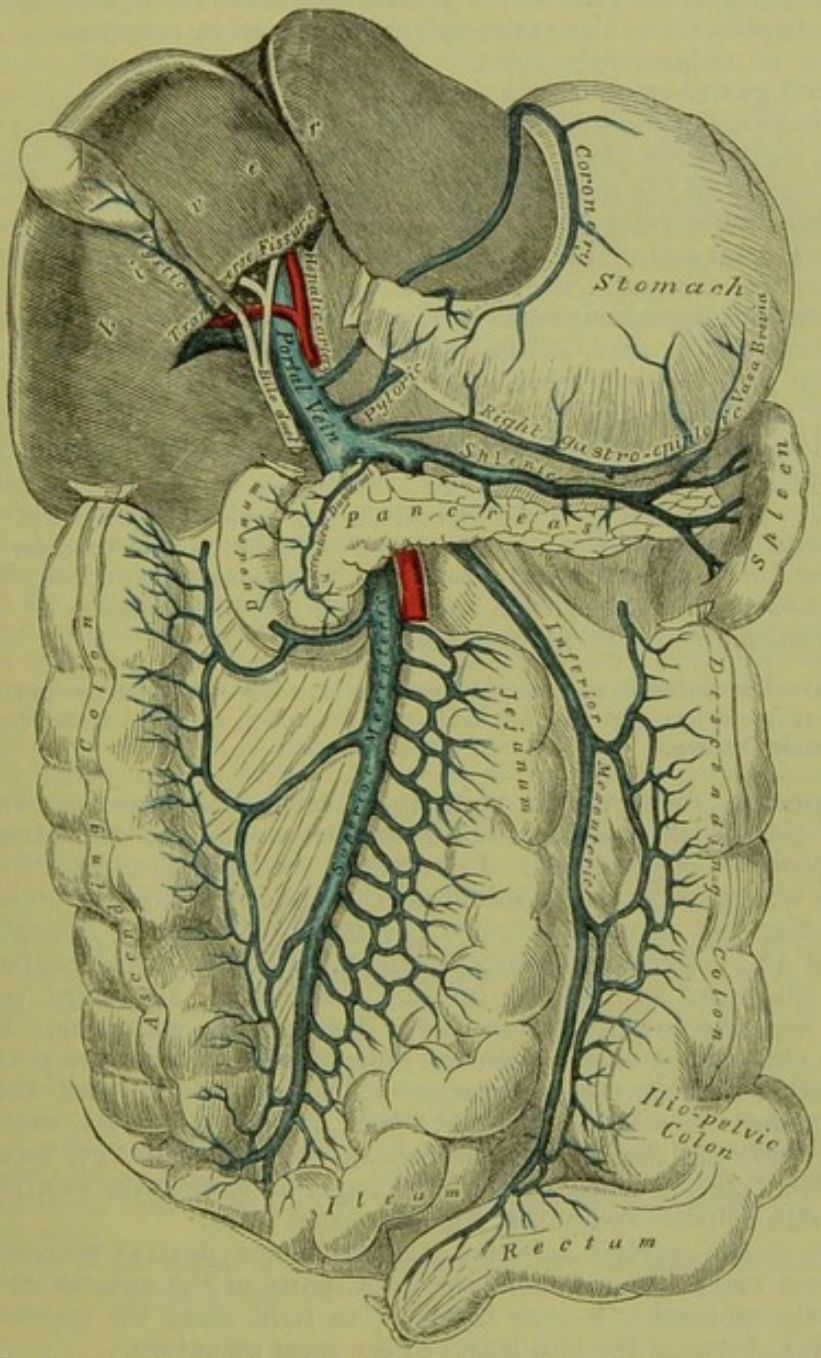

Note.—In this diagram the right gastro-epiploic vein opens into the splenic vein; generally it empties itself into the superior mesenteric, close to its termination.

umbilical vein, and is united to the inferior vena cava by a second fibrous cord, the *ligamentum venosum* or *obliterated ductus venosus*.

The tributaries of the portal vein are:

Splenic.	Pyloric.
Superior mesenteric.	Cystic.
Coronary.	Parumbilical.

The **splenic vein** (v. lienalis) commences by five or six large branches which return the blood from the spleen. These unite to form a single vessel, which passes from left to right, grooving the upper and back part of the

pancreas, below the splenic artery, and terminates behind the neck of the pancreas by uniting at a right angle with the superior mesenteric to form the portal vein. The splenic vein is of large size, but is not tortuous like the artery.

Tributaries.—The splenic vein receives the short gastric veins, the left gastro-epiploic vein, the pancreatic veins, and the inferior mesenteric veins.

(*a*) The **short gastric veins** (vv. gastricæ breves), some four or five in number, drain the fundus and left part of the greater curvature of the stomach, and pass between the two layers of the gastro-splenic omentum to terminate in the splenic vein or in one of its large tributaries.

(*b*) The **left gastro-epiploic vein** (v. gastroepiploica sinistra) receives branches from the anterior and posterior surfaces of the stomach and from the great omentum; it runs from right to left along the greater curvature of the stomach and ends in the commencement of the splenic vein.

(*c*) The **pancreatic veins** (vv. pancreaticæ) consist of several small vessels which drain the body and tail of the pancreas, and open into the trunk of the splenic vein.

(*d*) The **inferior mesenteric vein** (v. mesenterica inferior) returns blood from the rectum, and the pelvic, iliac, and descending parts of the colon. It begins in the rectum as the *superior hæmorrhoidal vein* (v. hæmorrhoidalis superior), which has its origin in the hæmorrhoidal plexus, and through this plexus communicates with the middle and inferior hæmorrhoidal veins. The superior hæmorrhoidal vein leaves the pelvis and crosses the iliac vessels in company with the superior hæmorrhoidal artery, and is continued upwards as the inferior mesenteric vein. This vein lies to the left of the inferior mesenteric artery, and ascends behind the peritoneum and in front of the left Psoas; it then passes behind the body of the pancreas and opens into the splenic vein; sometimes it terminates in the angle of union of the splenic and superior mesenteric veins.

Tributaries.—The inferior mesenteric vein receives the *sigmoid veins* (vv. sigmoideæ) from the ilio-pelvic colon and the *left colic vein* (v. colica sinistra) from the descending colon and splenic flexure.

The **superior mesenteric vein** (v. mesenterica superior) returns the blood from the small intestine, and from the cæcum and the ascending and transverse portions of the colon. It begins in the right iliac fossa by the union of the veins which drain the terminal part of the ilium, the cæcum and vermiform appendix, and ascends between the two layers of the mesentery on the right side of the superior mesenteric artery. In its upward course it passes in front of the right ureter, the inferior vena cava, the third part of the duodenum, and the lower portion of the head of the pancreas. Behind the neck of the pancreas it unites with the splenic vein to form the portal vein.

Tributaries.—Besides the tributaries which correspond with the branches of the superior mesenteric artery: viz. the *veins of the small intestine* (vv. intestinales), the *ileo-colic* (v. ileocolica), the *right colic* (vv. colicæ dextræ) and the *middle colic* (v. colica media), the superior mesenteric vein is joined by the right gastro-epiploic and pancreatico-duodenal veins.

The *right gastro-epiploic vein* (v. gastroepiploica dextra) receives branches from the great omentum and from the lower parts of the anterior and posterior surfaces of the stomach; it runs from left to right along the greater curvature of the stomach, between the two layers of the great omentum.

The *pancreatico-duodenal veins* (vv. pancreaticoduodenales) accompany their corresponding arteries; the lower of the two frequently joins the right gastro-epiploic vein.

The **coronary vein** (v. coronaria ventriculi) derives tributaries from both surfaces of the stomach; it runs from right to left along the lesser curvature of the stomach, between the two layers of the gastro-hepatic omentum, to the œsophageal opening of the stomach, where it receives some œsophageal veins. It then turns backwards and passes from left to right behind the lesser sac of the peritoneum and ends in the portal vein.

The **pyloric vein** (v. pylorica) is of small size, and runs from left to right along the pyloric portion of the lesser curvature of the stomach, between the two layers of the gastro-hepatic omentum, to terminate in the portal vein.

The **cystic vein** (v. cystica) drains the blood from the gall bladder, and, ascending alongside the cystic duct, usually terminates in the right branch of the portal vein.

Parumbilical veins (vv. parumbilicales).—In the course of the ligamentum teres of the liver, and of the urachus, small veins (parumbilical) are found, which establish an anastomosis between the veins of the anterior abdominal wall and the portal and iliac veins. The best marked of these small veins is one which commences at the umbilicus and runs backwards and upwards in, or on the surface of, the ligamentum teres between the layers of the falciform ligament to terminate in the left portal vein.

Applied Anatomy.—Obstruction to the portal vein may produce ascites, and this may arise from many causes: as (1) the pressure of a tumour on the portal vein, such as cancer or hydatid cyst in the liver, enlarged lymphatic glands in the lesser omentum, or cancer of the head of the pancreas ; (2) from cirrhosis of the liver, when the radicles of the portal vein are pressed upon by the contracting fibrous tissue in the portal canals ; (3) from valvular disease of the heart, and back pressure on the hepatic veins, and so on the whole of the circulation through the liver. In this condition the prognosis as regards life and freedom from ascites may be much improved by the establishment of a good collateral venous circulation to relieve the portal obstruction in the liver. This is effected by communications between (*a*) the gastric veins, and the œsophageal veins emptying themselves into the vena azygos minor, which often project as a varicose bunch into the stomach ; (*b*) the veins of the colon and duodenum, and the left renal vein ; (*c*) the accessory portal system of Sappey, branches of which pass in the round and falciform ligaments (particularly the latter) to unite with the epigastric and internal mammary veins, and through the diaphragmatic veins with the azygos ; a single large vein, shown to be a parumbilical vein, may pass from the hilus of the liver by the round ligament to the umbilicus, producing there a bunch of prominent varicose veins known as the *Caput Medusæ* ; (*d*) the veins of Retzius, which connect the intestinal veins with the inferior vena cava and its retroperitoneal branches ; (*e*) the inferior mesenteric veins, and the hæmorrhoidal veins that open into the internal iliacs ; (*f*) very rarely the ductus venosus remains patent, affording a direct connection between the portal vein and the inferior vena cava.

An operation for the relief of portal obstruction on these lines has been advocated by Rutherford Morison and by Talma. It consists in curetting the opposed surfaces of the liver and diaphragm and stitching them together, so as to secure vascular inflammatory adhesions between the two. The great omentum may with advantage be interposed between them, so as to increase the amount of the adhesions, and the spleen has been similarly scraped and sutured to or into the abdominal wall. The operation should not be deferred until the patient is moribund.

Thrombosis of the portal vein, or pylethrombosis, is a very serious event, and is oftenest due to pathological processes causing compression of the vessel or injury to its wall, such as tumours or inflammation about the pylorus, head of the pancreas, or appendix, or to gall-stones or cirrhosis of the liver. If the thrombus is infected with bacteria, as is often the case when it is due to appendicitis, septic or suppurative pylephlebitis results ; this condition is known also as *portal pyæmia*. Fragments of the infected clot break off and are carried away to lodge in the smaller veins in the liver, with the development of multiple abscesses in its substance and a rapidly fatal result. When the thrombus is sterile, the chief signs produced are enlargement of the spleen, recurrent ascites, and the establishment of a collateral venous circulation, the case clinically resembling one of atrophic cirrhosis of the liver.

The symptoms of thrombosis of the mesenteric veins are very much the same as those of embolism of the mesenteric arteries (see p. 694).

THE LYMPHATIC SYSTEM

The lymphatic system includes the lymphatic vessels and lymphatic glands. The lymphatic vessels of the small intestine receive the special designation of *lacteals* or *chyliferous vessels* ; they differ in no respect from the lymphatic vessels generally, excepting that during the process of digestion they contain a milk-white fluid, the *chyle*.

The **lymphatic vessels** are exceedingly delicate, and their coats are so transparent that the fluid they contain is readily seen through them. They retain a nearly uniform size, being interrupted at intervals by constrictions, which give them a knotted or beaded appearance. These constrictions are due to the presence of valves in their interior. Lymphatic vessels have been found in nearly every texture and organ of the body which contains

blood-vessels. Such non-vascular structures as cartilage, the nails, cuticle, and hair have none, but with these exceptions it is probable that eventually all parts will be found to be permeated by these vessels.

The lymphatic vessels are arranged into a superficial and a deep set. On the surface of the body the *superficial* lymphatic vessels are placed immediately beneath the integument, accompanying the superficial veins; they join the deep lymphatic vessels in certain situations by perforating the deep fascia. In the interior of the body they lie in the submucous areolar tissue, throughout the whole length of the gastro-pulmonary and genito-urinary tracts; and in the subserous tissue of the thoracic and abdominal walls. The method of their origin has been described along with the details of their minute anatomy. Here it will be sufficient to say that a plexiform network of minute lymphatic vessels may be found interspersed among the proper elements and blood-vessels of the several tissues; the vessels composing the network, as well as the meshes between them, are much larger than those of the capillary plexus. From these networks small vessels emerge, which pass, either to a neighbouring gland, or to join some larger lymphatic trunk. The *deep* lymphatic vessels, fewer in number, and larger than the superficial, accompany the deep blood-vessels. Their mode of origin is probably similar to that of the superficial vessels. The lymphatic vessels of any part or organ exceed the veins in number, but in size they are much smaller. Their anastomoses also, especially those of the large trunks, are more frequent, and are effected by vessels equal in diameter to those which they connect, the continuous trunks retaining the same diameter.

The **lymphatic glands** are small, solid, glandular bodies, situated in the course of the lymphatic vessels. In size they vary from a hemp-seed to an almond, and their colour, on section, is of a pinkish-grey tint, excepting in the bronchial glands, which in the adult are mottled with black. Each gland is invested by a fibrous capsule, from which prolongations dip into its substance, forming partitions. Before entering a gland a lymphatic or lacteal vessel divides into several small branches, which are named *afferent vessels*. As they enter, their external coat becomes continuous with the capsule of the gland, and the vessels much thinned and consisting only of their internal or endothelial coats pass into the gland, and open into the lymph sinuses. From these sinuses fine branches proceed to form a plexus, the vessels of which unite to form a single *efferent vessel*; this, on emerging from the hilus of the gland, is again invested with an external coat.

Applied Anatomy.—The lymphatic channels and glands draining any infected area of the body are very liable to become infected, with the production of acute or chronic lymphangitis and lymphadenitis. In acute cases the paths of the superficial lymphatics are often marked out on the skin by the appearance over them of the four cardinal signs of inflammation—pain, redness, heat, and swelling—while the glands swell and may suppurate. Chronic inflammation leads to growth and fibrosis of the lymphatics and the connective tissue round them; obstruction to the passage of the lymph results, as the fibrous tissue contracts and causes stenosis or obliteration of the lymphatic channels, and hard œdema of the involved skin and subcutaneous tissues follows (*pachydermia lymphangiectatica*). Chronic lymphangitis, together with the blocking of numerous lymphatic vessels by the escaped ova of the minute parasitic worm *Microfilaria nocturna*, is the cause of elephantiasis, a condition common in the tropics and subtropics, and characterised by enormous enlargement and thickening of the integuments of some part of the body, most frequently of the leg. Tubercular and syphilitic enlargements of the lymphatics and glands are both very commonly met with. Primary tumours of the lymphatics are lymphangioma and endothelioma; the so-called 'congenital cystic hygroma' of the neck, arm, trunk, or thigh, is a cystic lymphangioma. Primary tumours of the lymphatic glands may be innocent (lymphadenoma, myxoma, chondroma) or malignant (lymphosarcoma); cancer is never met with as a primary affection, but is extremely common secondarily to cancer of some other part of the body.

The appearance of secondary malignant deposits or of secondary infection in parts of the body that seem not to be directly associated by any lymphatic connection with the seat of the primary growth or infection has often been observed, and explained as due to 'retrograde transport' of cancer cells or bacteria by a reversed flow of lymph. Weleminsky,* however, believes that the explanation is to be found in the fact that when the infected glands have grown to a certain size they no longer permit the normal flow of lymph through them, and that under these circumstances very delicate lymphatic

* *Berliner klin. Woch.*, 1905, No. 24, p. 743.

connections, whose existence normally remains unsuspected, develop to a surprising extent between groups of lymphatic glands that at first sight appear to be unconnected with one another.

Thoracic Duct

The **thoracic duct** (ductus thoracicus) (fig. 647) conveys the great mass of the lymph and chyle into the blood. It is the common trunk of all the lymphatic vessels of the body, excepting those of the right side of the head, neck, and thorax, and right upper extremity, the right lung, right side of the heart, and the convex surface of the liver. In the adult it varies in length from fifteen to eighteen inches, and extends from the second lumbar vertebra to the root of the neck. It commences in the abdomen by a triangular dilatation, the *receptaculum chyli*, which is situated on the front of the body of the second lumbar vertebra, to the right side of and behind the aorta, by the side of the right crus of the Diaphragm. It enters the thorax through the aortic opening of the Diaphragm, and is then placed in the posterior mediastinum between the aorta and vena azygos major. Here it lies in front of the vertebral column, from which it is separated by the right intercostal arteries, and by the azygos minor veins as they cross the middle line to open into the vena azygos major. Opposite the fifth thoracic vertebra, it inclines towards the left side, enters the superior mediastinum, and ascends behind the arch of the aorta, on the left side of the œsophagus, and behind the first portion of the left subclavian artery, to the upper orifice of the thorax. Opposite the seventh cervical vertebra, it turns outwards in front of the vertebral vein and artery, behind the left common carotid artery and vagus nerve, and then curves downwards over the subclavian artery, and in front of the Scalenus anticus muscle and the phrenic nerve, so as to form an arch; it terminates in the angle of junction of the left subclavian vein with the left internal jugular vein. The thoracic duct, at its commencement, is about equal in diameter to a goose-quill,

Fig. 647.—The thoracic and right lymphatic ducts.

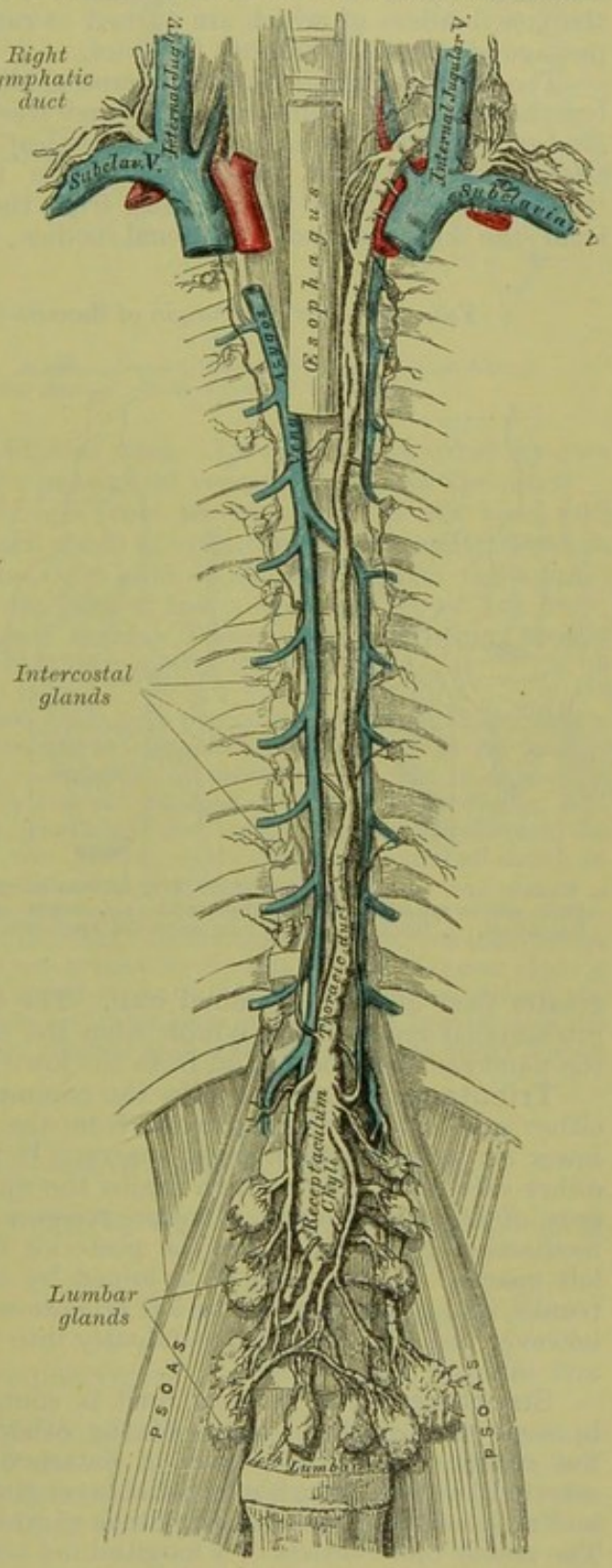

but it diminishes considerably in calibre in the middle of the thorax, and is again dilated just before its termination. It is generally flexuous and constricted at intervals so as to present a varicose appearance. Not infrequently it divides in the middle of its course into two branches of unequal size, which soon reunite, or into several branches which form a plexiform interlacement. It occasionally divides at its upper part into two branches, right and left; the left terminates in the usual manner, while the right opens into the right subclavian vein, in connection with the right lymphatic duct. The thoracic duct has several valves: at its termination it is provided with a pair of valves, the free borders of which are turned towards the vein, so as to prevent the passage of venous blood into the duct.

The **receptaculum chyli** (cisterna chyli) (fig. 648) receives the two lumbar lymphatic trunks, right and left, and the intestinal lymphatic trunk. The *lumbar lymphatic trunks* (trunci lumbales) are formed by the union of the efferent vessels from the lateral aortic lymphatic glands. They receive the lymph from the lower limbs, from the walls and viscera of the pelvis, from the kidneys and suprarenal bodies, and the deep lymphatics of the

Fig. 648.—Modes of origin of thoracic duct. (Poirier and Charpy.)

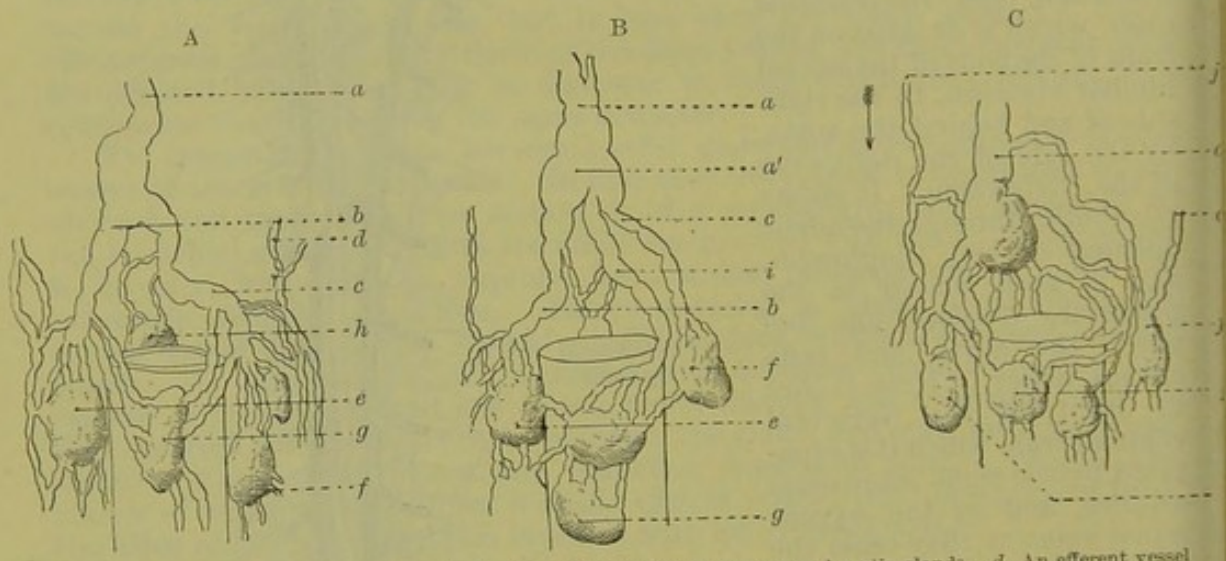

a. Thoracic duct. *a'*. Receptaculum chyli. *b*, *c*. Efferent trunks from lateral aortic glands. *d*. An efferent vessel which pierces the left crus of the diaphragm. *e*, *f*. Lateral aortic glands. *h*. Retro-aortic glands. *i*. Truncus intestinalis. *j*. Descending branch from intercostal lymphatics.

greater part of the abdominal wall. The *intestinal lymphatic trunk* (truncus intestinalis) receives the lymph from the stomach and small intestine, from the pancreas and spleen, and from the lower and front part of the liver.

Tributaries.—Opening into the commencement of the thoracic duct, on either side, is a descending trunk from the posterior intercostal glands of the lower six or seven intercostal spaces. In the thorax the duct is joined, on either side, by a trunk which drains the upper lumbar glands and pierces the crus of the Diaphragm. It also receives the efferents from the posterior mediastinal glands and from the posterior intercostal glands of the upper six left spaces. In the neck it is joined by the *left jugular* and *left subclavian* trunks, and sometimes by the left *broncho-mediastinal* trunk; the last-named, however, usually opens independently into the junction of the left subclavian and internal jugular veins.

Structure.—The thoracic duct is composed of three coats, which differ in some respects from those of the other lymphatic vessels. The *internal coat* consists of a single layer of flattened, lanceolate endothelial cells, with serrated borders; a subendothelial layer similar to that found in the arteries; and an elastic fibrous coat, the fibres of which run in a longitudinal direction. The *middle coat* consists of a longitudinal layer of white connective tissue with elastic fibres, external to which are several laminæ of muscular tissue, the fibres of which are for the most part disposed transversely, but some are oblique or longitudinal, and intermixed with elastic fibres. The *external coat*

is composed of areolar tissue, with elastic fibres and isolated fasciculi of muscular fibres.

The **right lymphatic duct** (ductus lymphaticus dexter) (fig. 649), about half an inch in length, courses along the inner border of the Scalenus anticus at the root of the neck and terminates in the right subclavian vein, at its angle

FIG. 649.—Terminal collecting trunks of right side. (Poirier and Charpy.)

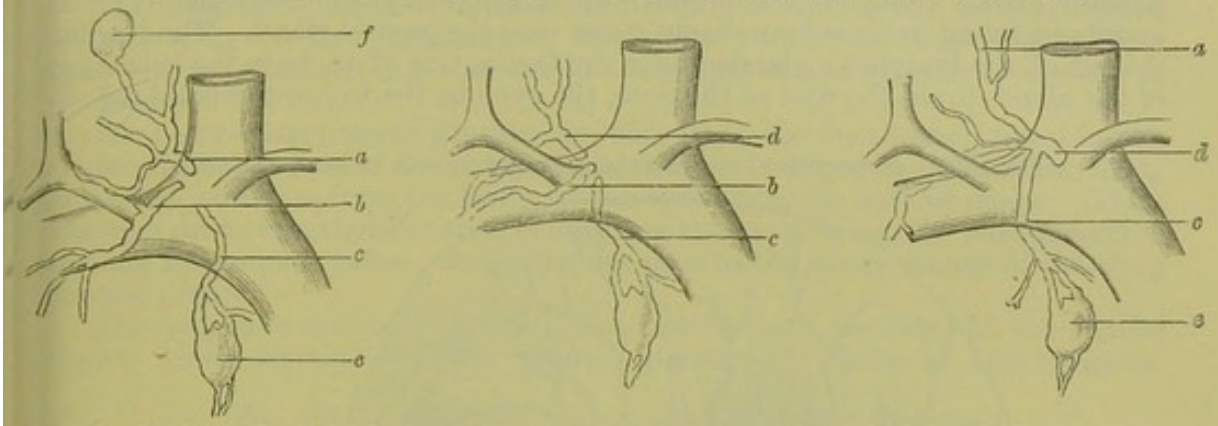

a. Jugular trunk. *b*. Subclavian trunk. *c*. Broncho-mediastinal trunk. *d*. Right lymphatic trunk. *e*. Gland of internal mammary chain. *f*. Gland of deep cervical chain.

of junction with the right internal jugular vein. Its orifice is guarded by two semilunar valves, which prevent the passage of venous blood into the duct.

Tributaries.—It receives the lymph from the right side of the head and neck through the *right jugular trunk*; from the right upper extremity through the *right subclavian trunk*; from the right side of the thorax, the right lung, and right side of the heart, and from part of the convex surface of the liver, through the *right broncho-mediastinal trunk*. These three collecting trunks frequently open separately in the angle of union of the two veins.

Applied Anatomy.—Blockage of the thoracic duct by mature specimens of the minute parasitic worm *Microfilaria nocturna* gives rise to stasis of the chyle, and to its passage in various abnormal directions on its course past the obstruction. The neighbouring abdominal, renal, and pelvic lymphatics become enlarged, varicose, and tortuous, and chyle may make its way into the urine (chyluria), the tunica vaginalis (chylocele), the abdominal cavity (chylous ascites), or the pleural cavity (chylous pleural effusion), in consequence of rupture of some of these distended lymphatic vessels.

The thoracic duct may be secondarily infected in intestinal or pulmonary tuberculosis, and may contain either miliary tubercles, caseating tuberculous masses, or even tuberculous ulcers. It is often the seat of secondary carcinomatous deposits in cases of cancer of some abdominal viscus, becoming infiltrated throughout until it becomes a stiff moniliform rod as thick as a pencil, with multiple stenoses and dilatations of its lumen; in such cases the left supraclavicular glands often become infected and enlarged, while the lungs remain entirely free from secondary growths.

LYMPHATICS OF THE HEAD, FACE, AND NECK

The **lymphatic glands of the head** (fig. 650) are arranged in the following groups:

Occipital.	Facial.
Posterior auricular.	Internal maxillary.
Parotid.	Lingual.
Retro-pharyngeal.	

The **occipital glands** (lymphoglandulæ occipitales), one to three in number, are placed on the back of the head close to the margin of the Trapezius and resting on the insertion of the Complexus. Their afferent vessels drain the occipital region of the scalp, while their efferents pass to the upper glands of the deep cervical group.

The **posterior auricular** or **mastoid glands** (lymphoglandulæ auriculares posteriores), usually two in number, are situated on the mastoid insertion of the Sterno-mastoid. Their afferent vessels drain the posterior part of the

temporo-parietal region, the upper part of the internal surface of the pinna, and the back of the external auditory meatus; their efferents pass to the upper glands of the deep cervical group.

The **parotid glands** (lymphoglandulæ parotideæ) form three groups in relation with the parotid salivary gland, viz. a superficial group, situated over the gland but under the parotid fascia (lymphoglandulæ auriculares anteriores), a deeper group imbedded in the substance of the gland, and a group of subparotid glands lying on the lateral wall of the pharynx. Occasionally small glands are found in the subcutaneous tissue over the parotid gland. The afferent vessels of the lymphatic glands under the fascia, and of those in the substance of the gland, drain the root of the nose, the eyelids, the fronto-temporal region,

Fig. 650.—Superficial lymphatic glands and vessels of head and neck.

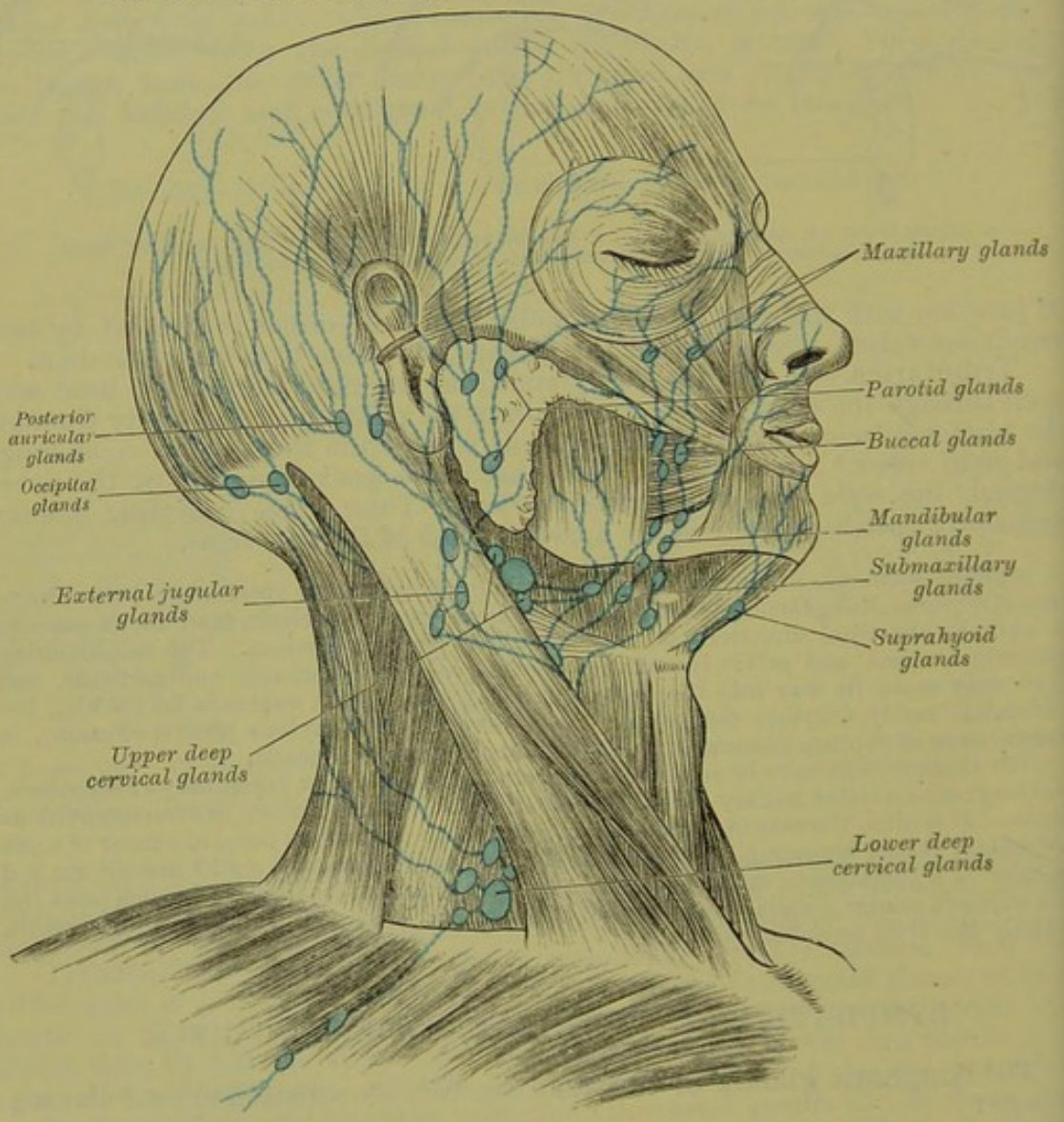

the outer surface of the pinna, the external auditory meatus and the tympanum, possibly also the posterior parts of the palate and of the floor of the nose. The efferents of these glands pass to the upper glands of the deep cervical group. The afferents of the subparotid glands drain the naso-pharynx and posterior part of the nasal fossa; their efferents pass to the upper deep cervical glands.

The **facial glands** (lymphoglandulæ faciales) comprise three groups: (*a*) *maxillary*, scattered over the infra-orbital region from the groove between the nose and cheek to the zygoma; (*b*) *buccal*, one or more placed on the Buccinator opposite the angle of the mouth; (*c*) *mandibular*, on the outer surface of the mandible, in front of the Masseter and in contact with the facial vessels. Their afferent vessels drain the eyelids, the conjunctiva, and the

integument and mucous membrane of the nose and cheek; their efferents pass to the submaxillary glands.

The **internal maxillary glands** (lymphoglandulæ faciales profundæ) are deeply placed beneath the ramus of the mandible, on the outer surface of the External pterygoid, in relation to the internal maxillary artery. Their afferent vessels drain the temporal and zygomatic fossæ and the naso-pharynx; their efferents pass to the upper glands of the deep cervical group.

The **lingual glands** (lymphoglandulæ linguales) are two or three small nodules lying on the Hyo-glossus, and under the Genio-hyoglossus. They form merely glandular sub-stations in the course of the lymphatic vessels of the tongue.

The **retro-pharyngeal glands** (fig. 651) lie in the bucco-pharyngeal fascia, behind the upper part of the pharynx and in front of the arch of the atlas, being separated, however, from the latter by the Rectus capitis anticus major. Their afferents drain an extensive area, comprising the nasal fossæ, the naso-pharynx, and the Eustachian tubes; their efferents pass to the upper glands of the deep cervical group.

The *lymphatic vessels of the scalp* are divisible into (*a*) those of the frontal region, which terminate in the parotid glands; (*b*) those of the temporo-

FIG. 651.—Lymphatics of pharynx. (Poirier and Charpy.)

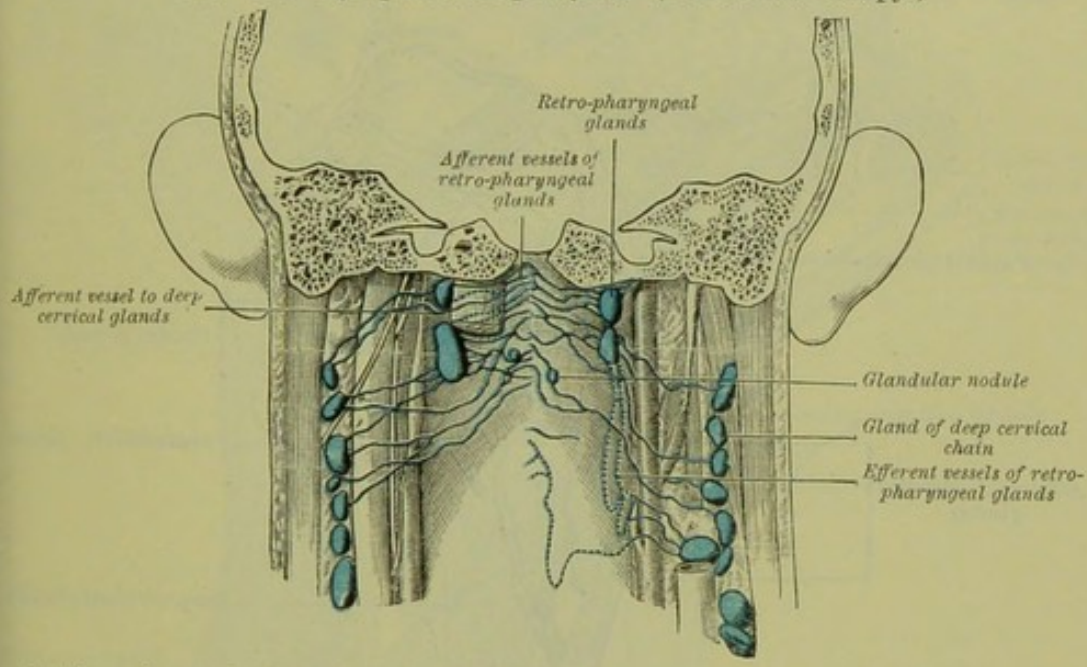

parietal region, which end in the parotid and posterior auricular glands; and (*c*) those of the occipital region, which terminate partly in the occipital glands and partly in a trunk which runs down along the posterior border of the Sterno-mastoid to end in the lower group of deep cervical glands.

The *lymphatic vessels of the pinna and external auditory meatus* are also divisible into three groups: (*a*) an anterior, from the outer surface of the pinna and anterior wall of the meatus to the parotid glands; (*b*) a posterior, from the margin of the pinna, the upper part of its inner surface, the internal surface and posterior wall of the meatus to the posterior auricular and upper deep cervical glands; (*c*) an inferior, from the floor of the meatus and from the lobule to the external jugular and upper deep cervical glands.

The *lymphatic vessels of the face* are more numerous than those of the scalp. Those from the eyelids and conjunctivæ terminate partly in the submaxillary, but mainly in the parotid glands. The vessels from the posterior part of the cheek also pass to the parotid glands, while those from the anterior portion of the cheek, the side of the nose, the upper lip, and the lateral portions of the lower lip terminate in the submaxillary glands. The deeper vessels from the temporal and zygomatic fossæ pass to the internal maxillary and upper deep cervical glands. The deeper vessels of the cheek and lips terminate, like the superficial, in the submaxillary glands. Both superficial and deep vessels of the central part of the lower lip run to the suprahyoid glands.

The *lymphatic vessels of the nasal fossæ* can be injected from the subdural and subarachnoid spaces. Those from the anterior parts of the fossæ communicate with the vessels of the nasal integument and terminate in the submaxillary glands; those from the posterior two-thirds of the fossæ and from the communicating air sinuses pass partly to the retropharyngeal and partly to the upper deep cervical glands.

Lymphatic vessels of the mouth.—The vessels of the gums terminate in the submaxillary glands; those of the hard palate are continuous in front with those of the upper gum, but pass backwards to pierce the Superior constrictor and end in the upper deep cervical and subparotid glands; those of the soft palate pass backwards and outwards, and terminate partly in the retropharyngeal and subparotid, and partly in the upper deep cervical glands. The vessels of the anterior part of the floor of the mouth pass either directly to the lower glands of the upper deep cervical group, or indirectly through the suprahyoid glands; from the rest of the floor of the mouth the vessels terminate in the submaxillary and upper deep cervical glands.

The *lymphatic vessels of the tonsil* pass to the upper deep cervical glands.

Fig. 652.—The lymphatics of the face. (After Küttner.)

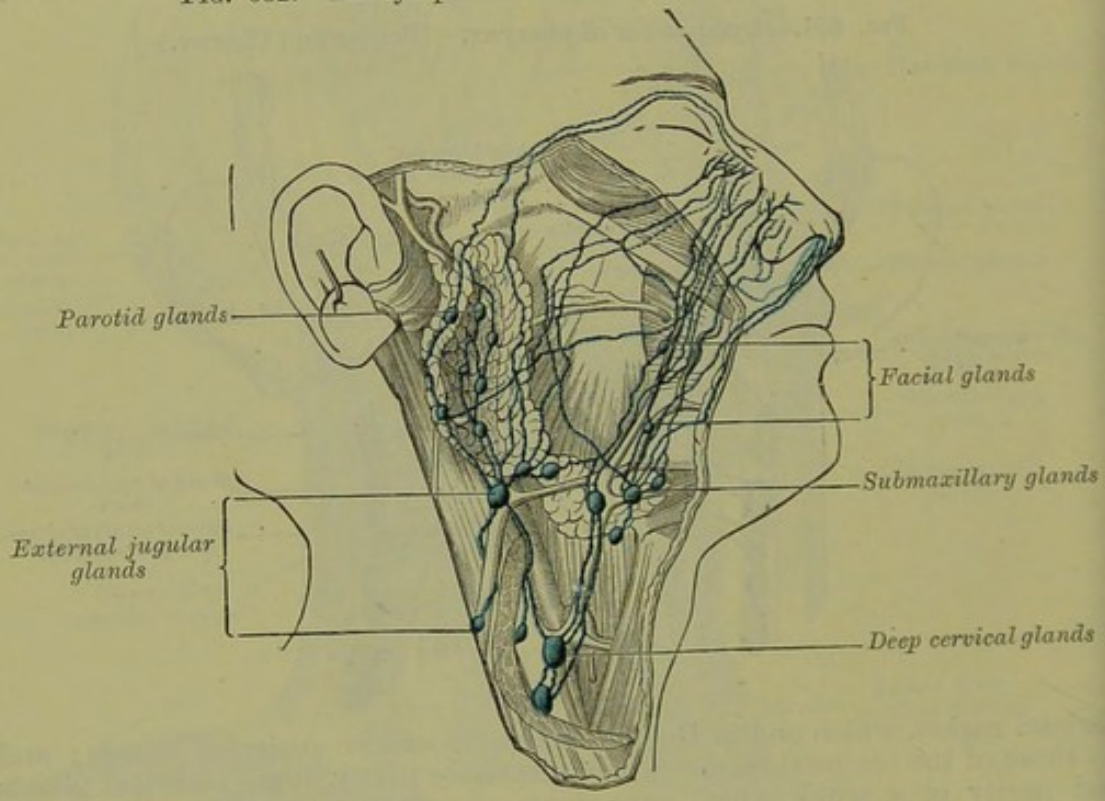

The *lymphatic vessels of the tongue* (fig. 653) are drained chiefly into the deep cervical glands lying between the posterior belly of the Digastric and the posterior belly of the Omo-hyoid; one gland situated at the bifurcation of the common carotid artery is so intimately associated with these vessels that it is known as the *principal gland of the tongue.* The vessels of the tongue have been divided into four groups: (1) apical, from the tip of the tongue to the suprahyoid glands and principal gland of tongue; (2) lateral, from the margin of the tongue—some of these pierce the Mylo-hyoid to terminate in the submaxillary glands, others pass down on the Hyo-glossus to the upper deep cervical; (3) basal, from the region of the circumvallate papillæ to the upper deep cervical glands; and (4) median, a few of which perforate the Mylo-hyoid to reach the submaxillary glands, while the majority turn round the posterior border of the muscle to enter the upper deep cervical glands.

The **lymphatic glands of the neck** include the following groups:

Submaxillary.
Suprahyoid.
External jugular.
Anterior cervical.
Deep cervical.

The **submaxillary glands** (lymphoglandulæ submaxillares) (fig. 652), three to six in number, are placed beneath the body of the mandible in the submaxillary triangle, and rest on the superficial surface of the submaxillary salivary gland. One gland (the *middle gland of Stahr*), which lies on the facial artery as it turns over the mandible, is the most constant of the series. Small lymphatic glands are sometimes found on the deep surface of the submaxillary gland. Their afferents drain the inner canthus of the eye, the cheek, the side of the nose, the upper lip, the outer part of the lower lip, the gums, and the anterior part of the margin of the tongue; efferent vessels from the facial and suprahyoid glands also enter the submaxillary glands. Their efferent vessels pass to the upper glands of the deep cervical group.

FIG. 653.—Lymphatics of the tongue. (Poirier.)

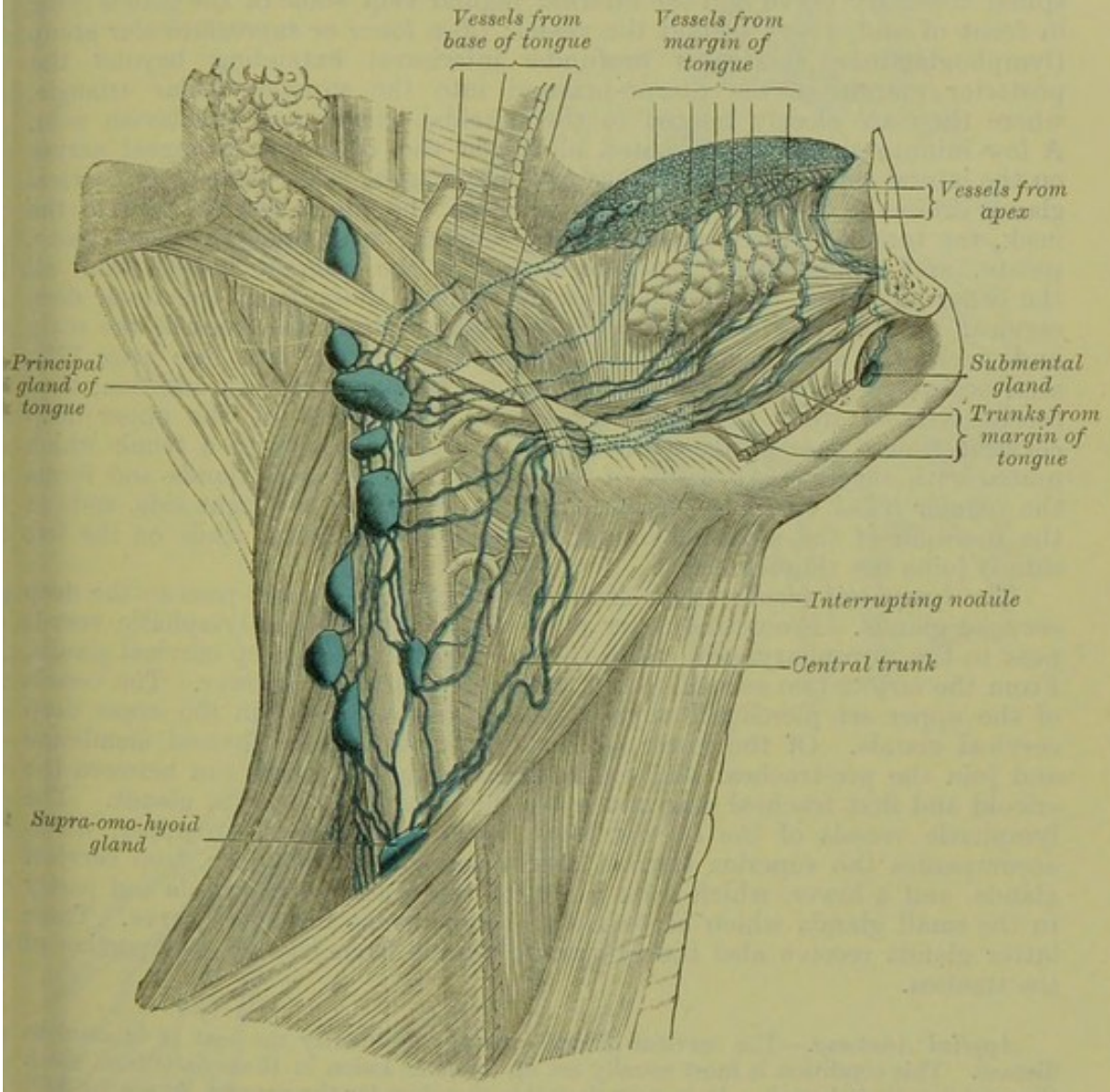

The **suprahyoid** or **submental glands** are situated close to the middle line of the neck between the anterior bellies of the two Digastric muscles. Their afferents drain the central portions of the lower lip and floor of the mouth and the tip of the tongue; their efferents pass partly to the submaxillary glands and partly to a gland of the deep cervical group situated on the internal jugular vein at the level of the cricoid cartilage.

The **external jugular glands** (lymphoglandulæ cervicales superficiales) lie in close relationship with the external jugular vein as it emerges from the parotid gland, and, therefore, superficial to the Sterno-mastoid. Their afferents drain the lower parts of the pinna and parotid region, while their efferents pass round the anterior margin of the Sterno-mastoid to join the upper deep cervical glands.

The **anterior cervical glands** form an irregular and inconstant group on the front of the larynx and trachea. They may be divided into : (*a*) a superficial set, placed on the anterior jugular vein ; (*b*) a deeper set, which is further subdivided into pre-laryngeal, on the crico-thyroid membrane, and pre-tracheal, on the front of the trachea. This deeper set drains the lower part of the larynx, the thyroid body, and the upper part of the trachea ; its efferents pass to the lower glands of the upper deep cervical group.

The **deep cervical glands** (lymphoglandulæ cervicales profundæ) (figs. 650, 653) are numerous and of large size ; they form a chain along the carotid sheath, lying by the side of the pharynx, œsophagus, and trachea, and extending from the base of the skull to the root of the neck. They are usually described in two groups : (1) an *upper* or *substerno-mastoid* group (lymphoglandulæ cervicales profundæ superiores) lying under the Sterno-mastoid in close relation with the spinal accessory nerve and the internal jugular vein, some of the glands lying in front of and others behind the vessel ; (2) a *lower* or *supraclavicular* group (lymphoglandulæ cervicales profundæ inferiores) extending beyond the posterior margin of the Sterno-mastoid into the supraclavicular triangle, where they are closely related to the brachial plexus and subclavian vein. A few minute glands are situated alongside the recurrent laryngeal nerves on the lateral aspects of the trachea and œsophagus. The *upper* deep cervical glands drain the occipital portion of the scalp, the pinna, and the back of the neck, the tongue, larynx, thyroid body, trachea, naso-pharynx, nasal fossæ, palate, and œsophagus. They receive also the efferent vessels from all the other glands of the head and neck, except those from the lower deep cervical group. The *lower* deep cervical glands drain the back of the scalp and neck, the superficial pectoral region, part of the arm (see page 775), and, occasionally, part of the upper surface of the liver. In addition, they receive vessels from the upper group. The efferents of the upper deep cervical glands pass partly to the lower group and partly to a trunk which unites with the efferent trunk of the lower deep cervical glands and forms the *jugular trunk* (truncus jugularis). This trunk, on the right side, ends in the junction of the internal jugular and subclavian veins, while on the left side it joins the thoracic duct.

The *lymphatic vessels of the skin and muscles of the neck* pass to the deep cervical glands. From the upper part of the *pharynx* the lymphatic vessels pass to the retropharyngeal, from the lower part to the deep cervical glands. From the *larynx* two sets of vessels arise, an upper and a lower. The vessels of the upper set pierce the thyro-hyoid membrane and join the upper deep cervical glands. Of the lower set, some pierce the crico-thyroid membrane and join the pre-tracheal and pre-laryngeal glands ; others run between the cricoid and first tracheal ring and enter the lower deep cervical glands. The lymphatic vessels of the *thyroid body* consist of two sets, an upper, which accompanies the superior thyroid artery and enters the upper deep cervical glands, and a lower, which runs partly to the pre-tracheal glands and partly to the small glands which accompany the recurrent laryngeal nerve. These latter glands receive also the lymphatic vessels from the cervical portion of the trachea.

Applied Anatomy.—The cervical glands are very frequently the seat of tuberculous disease. This condition is most usually set up by some lesion in those parts from which they receive their lymph. It is very desirable therefore for the surgeon, in dealing with these cases, to possess a knowledge of the relation of the respective groups of glands to the periphery, while in order to eradicate them by operation a long and difficult dissection may be required.

LYMPHATICS OF THE UPPER EXTREMITY

The **lymphatic glands of the upper extremity** (fig. 654) are divided into two sets, *superficial* and *deep*.

The **superficial lymphatic glands** are few and of small size. One or two are placed above the internal epicondyle of the humerus, near the basilic vein. Their afferents drain the inner three fingers, the inner portion of the hand

and the superficial area over the ulnar side of the forearm; these vessels are, however, in free communication with the other lymphatic vessels of the forearm. Their efferents accompany the basilic vein and join the deeper vessels. One or two glands are found beside the cephalic vein, between the Pectoralis major and Deltoid, immediately below the clavicle. They are situated in the course of the external collecting trunks of the arm.

The **deep lymphatic glands** are chiefly grouped in the axilla, although a few may be found in the forearm, in the course of the radial, ulnar, and

Fig. 654.—The superficial lymphatics of the upper extremity.

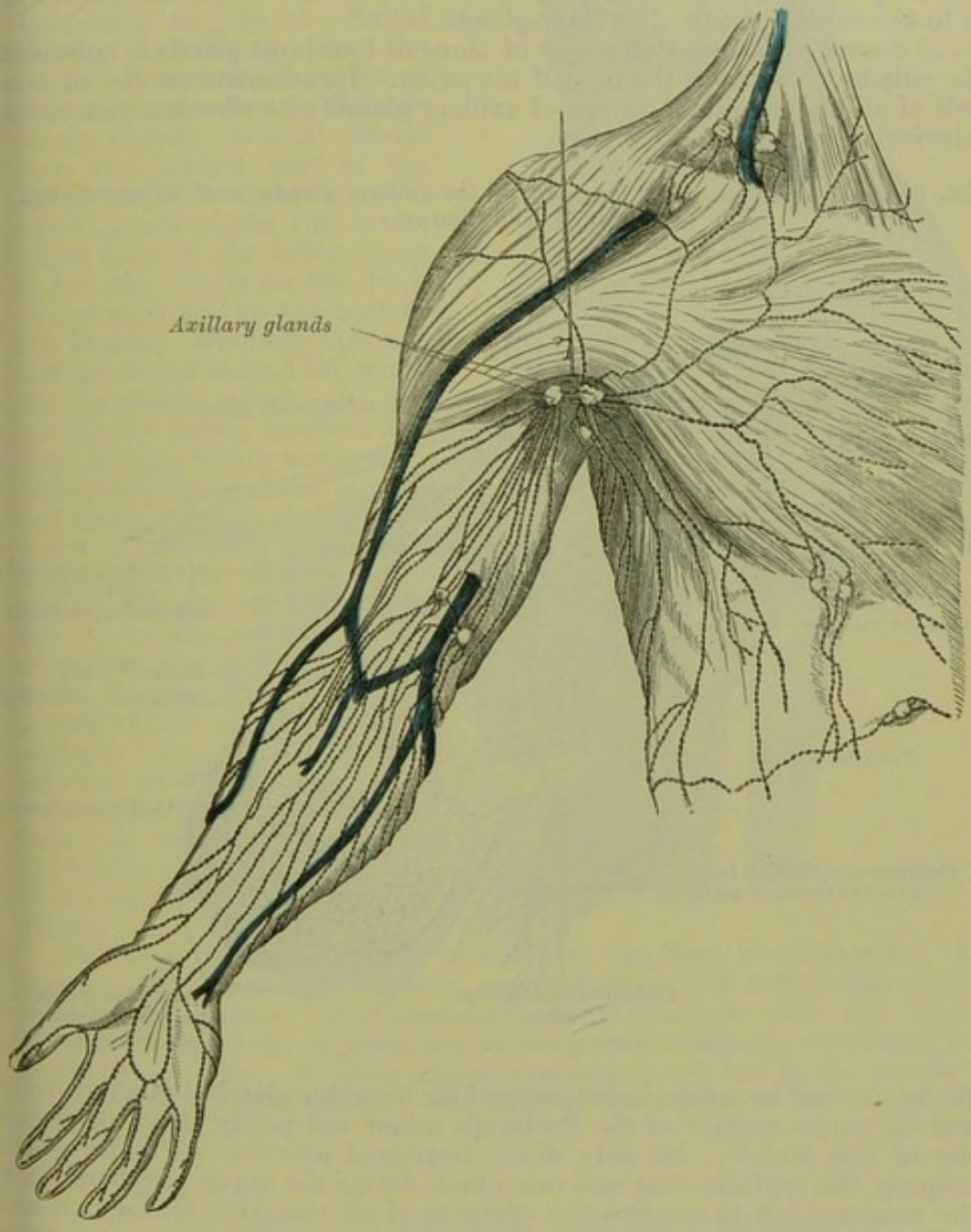

interosseous vessels, and in the arm along the inner side of the middle part of the brachial artery.

The **axillary glands** (lymphoglandulæ axillares) (fig. 655) are of large size, vary from twenty to thirty in number, and may be arranged in the following groups:

1. An *external group* of from four to six glands lies in relation to the inner and posterior aspects of the axillary vein; the afferents of these glands drain the whole arm with the exception of that portion whose vessels accompany the cephalic vein. The efferent vessels pass partly to the central and

subclavicular axillary glands and partly to the lower deep cervical glands.

2. An *anterior* or *pectoral group* consists of four or five glands along the lower border of the Pectoralis minor, in relation with the long thoracic artery. Their afferents drain the skin and muscles of the anterior and lateral thoracic walls, and the mammary gland; their efferents pass partly to the central, and partly to the subclavicular axillary glands.

3. A *posterior* or *subscapular group* of six or seven glands is placed along the lower margin of the posterior wall of the axilla in the course of the subscapular artery. The afferents of this group drain the skin and muscles of the lower part of the neck and of the posterior thoracic wall; their efferents pass to the central group of axillary glands.

4. A *central* or *intermediate group* of three or four large glands is imbedded in the adipose tissue near the base of the axilla. Its afferents are the efferent vessels of all the preceding groups of axillary glands; its efferents pass to the subclavicular group.

Fig. 655.—Lymphatics of the mamma and the axillary glands (semi-diagrammatic). (Poirier and Charpy.)

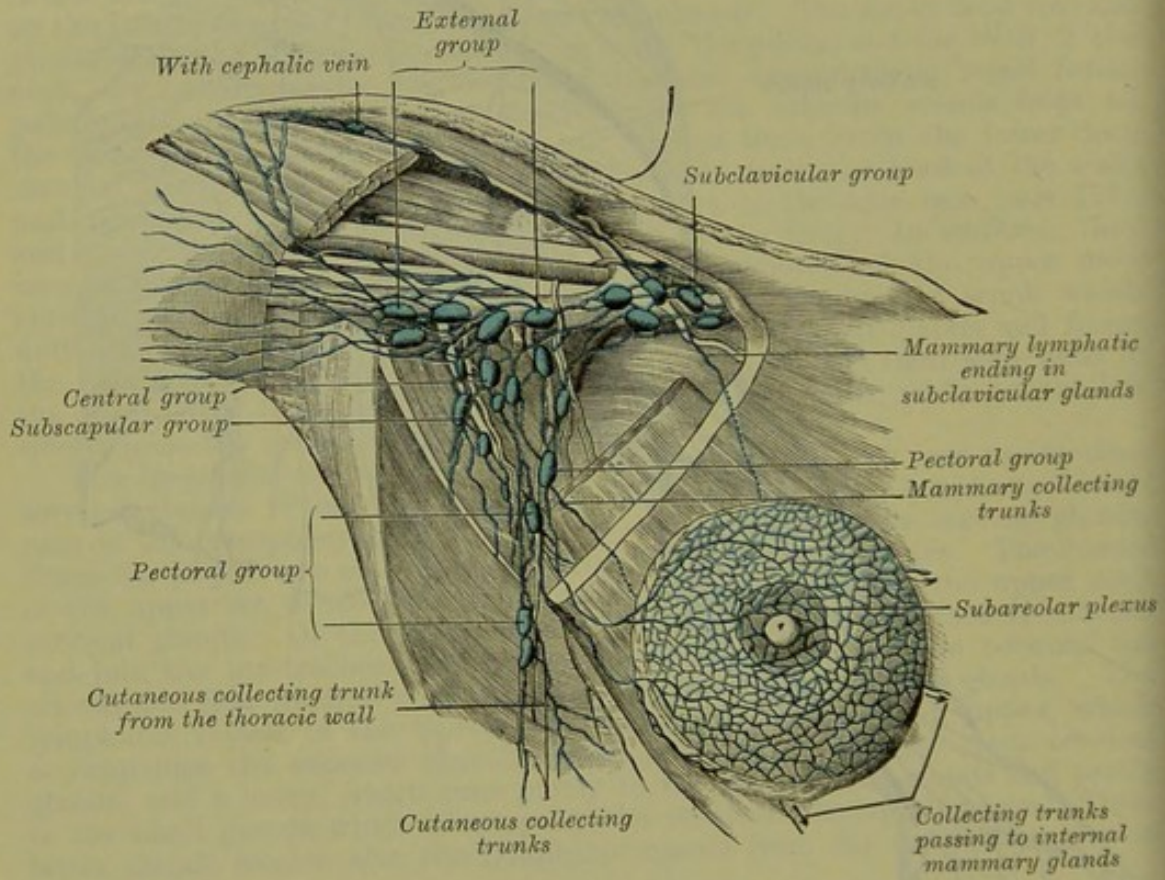

5. An *internal* or *subclavicular group* of six to twelve glands is situated partly behind the upper portion of the Pectoralis minor and partly above the upper border of this muscle. Its only direct territorial afferents are those which accompany the cephalic vein and one which drains the upper peripheral part of the mamma, but it receives the efferents of all the other axillary glands. The efferent vessels of the subclavicular group unite to form a trunk of some size, the *subclavian trunk* (truncus subclavius), which opens either directly into the junction of the internal jugular and subclavian veins or into the jugular lymphatic trunk: on the left side it may terminate in the thoracic duct. A few efferents from the subclavicular glands usually pass to the lower deep cervical glands.

Applied Anatomy.—In malignant disease or infectious processes implicating the upper part of the back and shoulder, the front of the chest and mamma, the upper part of the front and side of the abdomen, or the hand, forearm, and arm, enlargement of the axillary glands is very often found.

The *lymphatic vessels of the upper extremity* are divided into two sets, superficial and deep.

The *superficial lymphatic vessels* (fig. 656) commence in the lymphatic plexus which everywhere pervades the skin; the meshes of the plexus are much finer in the palm and on the flexor aspect of the digits than elsewhere. The digital plexuses are drained by a pair of vessels which run on the lateral aspect of each digit, and incline backwards to reach the dorsum of the hand. From the dense plexus of the palm, vessels pass in different directions, viz. upwards towards the wrist, downwards to join the digital vessels, inwards to join the vessels on the ulnar border of the hand, and outwards to those on the thumb. Several vessels from the central part of the plexus unite to form a trunk, which passes round the metacarpal bone of the index finger to join the vessels on the back of that digit and on the back of the thumb. Running upwards in front of and behind the wrist, the lymphatic vessels are collected into radial, median, and ulnar groups, which accompany respectively the cephalic, median and basilic veins in the forearm. A few of the ulnar lymphatics terminate in the supratrochlear glands, but the majority pass directly to the external group of axillary glands. Some of the radial vessels are collected into a trunk, which ascends with the cephalic vein to the glands between the Pectoralis major and Deltoid; the efferents from this group pass either to the subclavicular axillary glands or to the lower deep cervical glands.

FIG. 656.—Lymphatic vessels of the dorsal surface of the hand. (Sappey.)

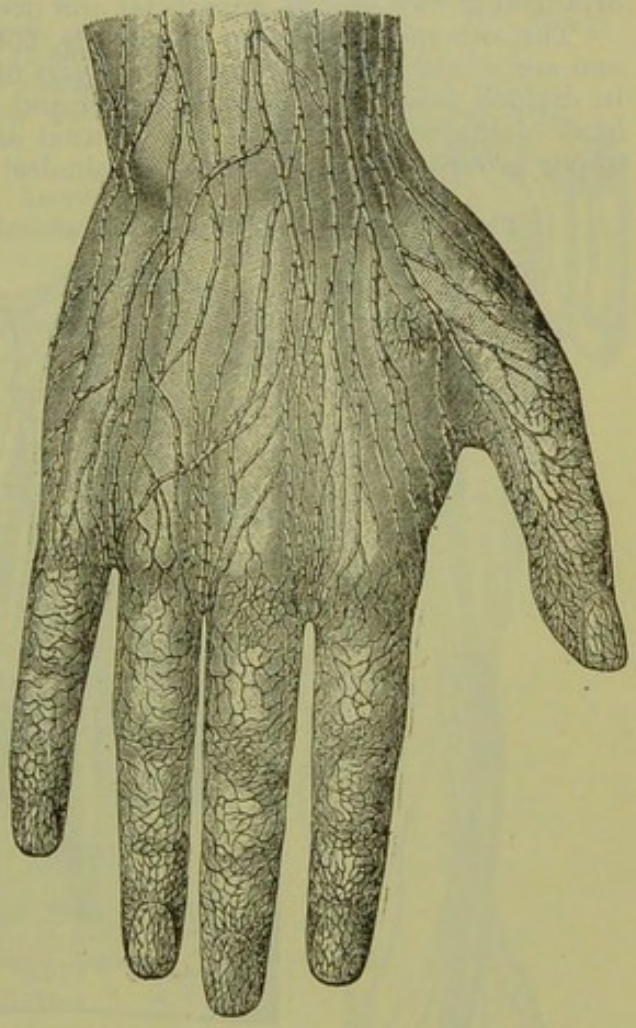

The *deep lymphatic vessels* accompany the deep blood-vessels. In the forearm, they consist of four sets, corresponding with the radial, ulnar, and interosseous arteries; they communicate at intervals with the superficial lymphatics, and some of them end in the glands which are occasionally found beside the arteries. In their course upwards, a few end in the glands which lie upon the brachial artery; but most of them pass to the external group of axillary glands.

LYMPHATICS OF THE LOWER EXTREMITY

The **lymphatic glands of the lower extremity** consist of the anterior tibial gland, and the popliteal and inguinal glands.

The **anterior tibial gland** (lymphoglandula tibialis anterior) is small and inconstant. It lies on the interosseous membrane in relation to the upper part of the anterior tibial vessels, and constitutes a sub-station in the course of the anterior tibial lymphatic trunks.

The **popliteal glands** (lymphoglandulæ popliteæ) (fig. 657), small in size and some six or seven in number, are imbedded in the fat contained in the popliteal space. One lies immediately beneath the popliteal fascia, near the

terminal part of the external saphenous vein, and drains the region from which this vein derives its tributaries. Another is placed between the popliteal artery and the posterior ligament of the knee ; it receives the lymphatic vessels from the knee-joint together with those which accompany the articular arteries. The others lie at the sides of the popliteal vessels, and receive as afferents the trunks which accompany the anterior and posterior tibial vessels. The efferents of the popliteal glands pass almost entirely alongside the femoral vessels to the deep inguinal glands, but a few may accompany the internal saphenous vein, and end in the glands of the superficial inguinal group.

The **inguinal glands** vary from twelve to twenty in number, and are arranged in two groups, superficial and deep.

The *superficial inguinal glands* (fig. 658) lie in front of Scarpa's triangle, and are situated between the two layers of the superficial fascia. They may be divided into two groups, an upper and a lower, by a horizontal line at the level of the termination of the internal saphenous vein. The glands of the upper group (lymphoglandulæ inguinales) form a chain immediately below

Fig. 657.—Lymphatic glands of popliteal space. (Poirier and Charpy.)

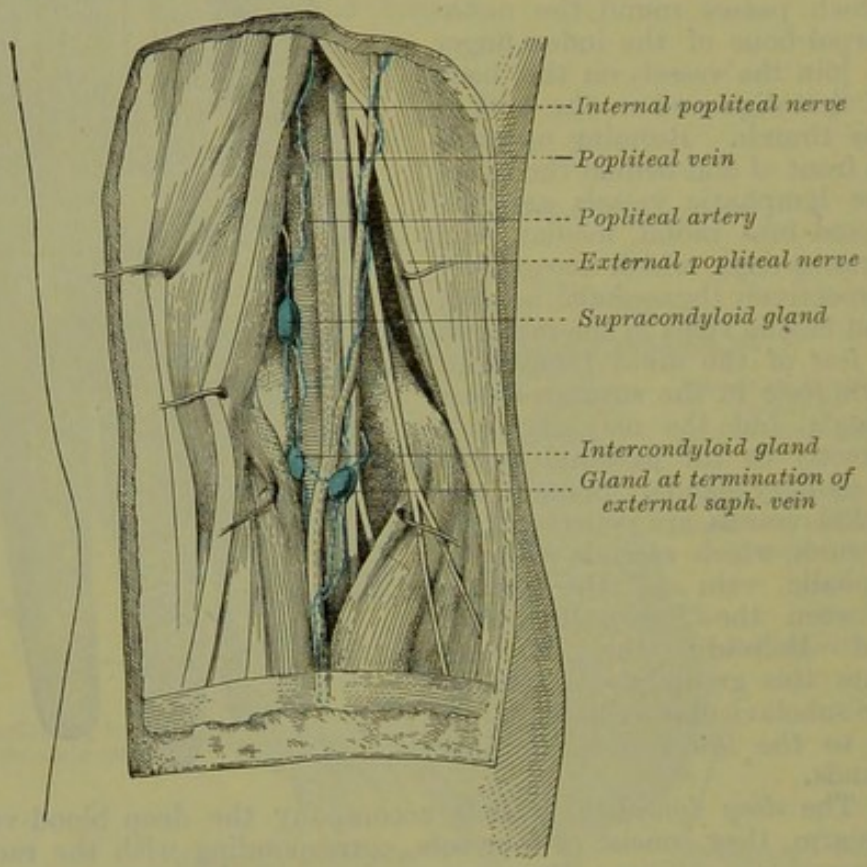

Poupart's ligament. They receive as afferents lymphatic vessels from the integument of the penis, scrotum, perinæum, buttock, and abdominal wall below the level of the umbilicus. The glands of the lower group (lymphoglandulæ subinguinales) are placed on either side of the upper part of the internal saphenous vein, and their afferents consist of the superficial lymphatic vessels of the lower extremity ; they also receive some of the vessels which drain the integument of the penis, scrotum, perinæum, and buttock.

The *deep inguinal glands* (lymphoglandulæ subinguinales profundæ) (fig. 659) vary from one to three in number, and are placed under the fascia lata, on the inner side of the femoral vein. When three are present, the lowest is situated just below the junction of the internal saphenous and femoral veins, the middle in the crural canal, and the highest in the outer part of the crural ring. The middle is the most inconstant of the three, but the highest one, the *gland of Cloquet or Rosenmüller*, is also frequently absent. They receive as afferents the deep lymphatic trunks which accompany the femoral vessels, the lymphatics from the glans penis vel clitoridis, and also some of the efferents from the superficial inguinal glands.

Applied Anatomy.—Inflammation and suppuration of the popliteal glands are most commonly due to a sore on the outer side of the heel.

The inguinal glands frequently become enlarged in diseases implicating the parts from which their lymphatics originate. Thus in malignant or syphilitic affections of the prepuce and penis, or labia majora, in cancer scroti, in abscess in the perinæum, or in similar diseases affecting the integument and superficial structures in those parts, or the sub-umbilical part of the abdominal wall, or the gluteal region, the upper chain of glands is almost invariably enlarged, the lower chain being implicated in diseases affecting the lower limb.

The *lymphatic vessels of the lower extremity* consist of two sets, superficial and deep, and in their distribution correspond closely with the veins.

The *superficial lymphatic vessels* lie in the superficial fascia, and are divisible into two groups: an internal, which follows the course of the internal saphenous vein; and an external, which accompanies the external saphenous. The vessels of the *internal group* are larger and more numerous than those of the external group, and commence on the inner side and dorsum of the foot; they pass both in front of and behind the inner ankle, run up the leg with the internal saphenous vein, pass with it behind the inner condyle of the femur, and accompany it to the groin, where they terminate in the inferior group of superficial inguinal lymphatic glands. The vessels of the *external group* arise from the outer side of the foot; some ascend in front of the leg, and, just below the knee, cross the tibia from without inwards, to join the lymphatics on the inner side of the thigh; others pass behind the outer malleolus, and, accompanying the external saphenous vein, enter the popliteal glands.

The *deep lymphatic vessels* are few in number, and accompany the deep blood-vessels. In the leg, they consist of three sets, the anterior tibial, posterior tibial, and peroneal, which accompany the corresponding blood-vessels, two or three with each artery; they ascend alongside the blood-vessels, and enter the lymphatic glands in the popliteal space.

The deep lymphatic vessels of the gluteal and ischial regions follow the course of the corresponding blood-vessels. Those accompanying the gluteal vessels end in a gland which lies on the intrapelvic portion of the gluteal artery near the upper border of the

FIG. 658.—The superficial lymphatics of the lower extremity.

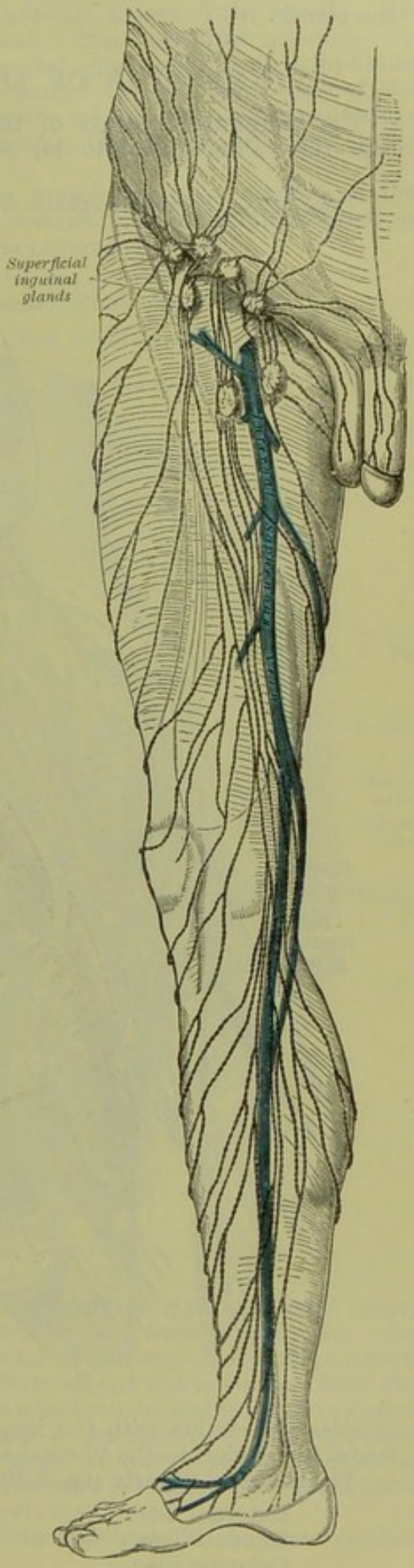

great sacro-sciatic notch. Those following the sciatic vessels traverse one or two small glands which lie below the Pyriformis muscle, and end in the internal iliac glands.

LYMPHATICS OF THE ABDOMEN AND PELVIS

The **lymphatic glands of the abdomen and pelvis** may be divided, from their situations, into (*a*) *parietal*, lying behind the peritoneum and

Fig. 659.—The deep lymphatic vessels and glands of the abdomen and pelvis.

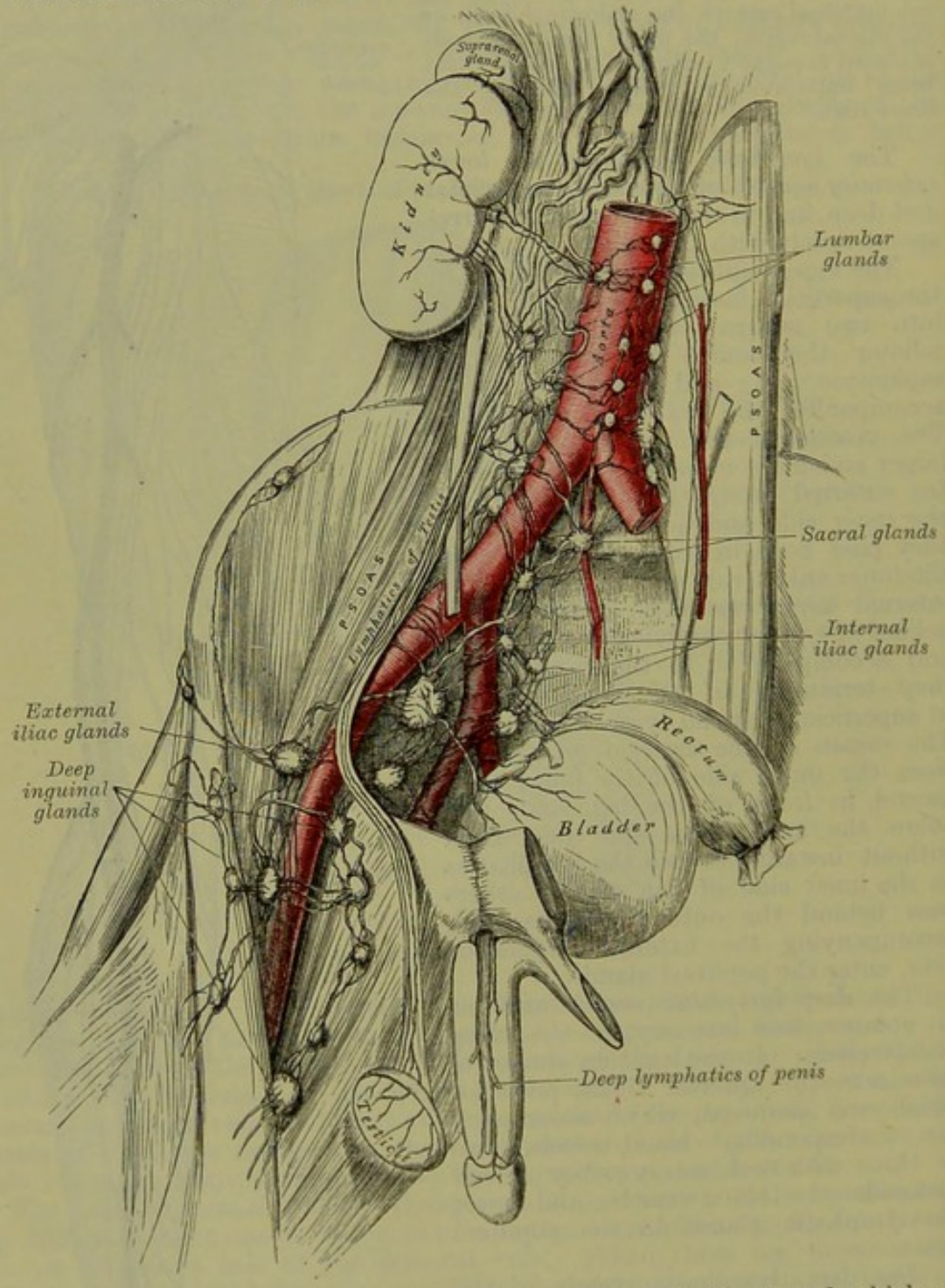

in close association with the larger blood-vessels; and (*b*) *visceral*, which are found in relation to the visceral arteries.

The **parietal glands** (fig. 659) include the following groups:

External iliac.
Internal iliac.
Common iliac.
Lumbar { Lateral aortic. Pre-aortic. Retro-aortic.

The **external iliac glands,** from eight to ten in number, lie along the external iliac vessels. They are arranged in three groups, one on the outer, another on the inner, and a third on the anterior aspect of the vessels; the third group is, however, sometimes absent. Their principal afferents are derived from the superficial and deep inguinal glands, the deep lymphatics of the abdominal wall below the umbilicus and of the adductor region of the thigh, and the lymphatics from the glans penis vel clitoridis, the membranous urethra, the prostate, the base of the bladder, the cervix uteri, and upper part of the vagina.

Small chains of glands are sometimes found along the courses of the deep epigastric and deep circumflex iliac arteries, and an *obturator gland* is occasionally seen on the upper aspect of the obturator foramen.

FIG. 660.—Ilio-pelvic lymphatic glands. (Cunéo and Marcille.)

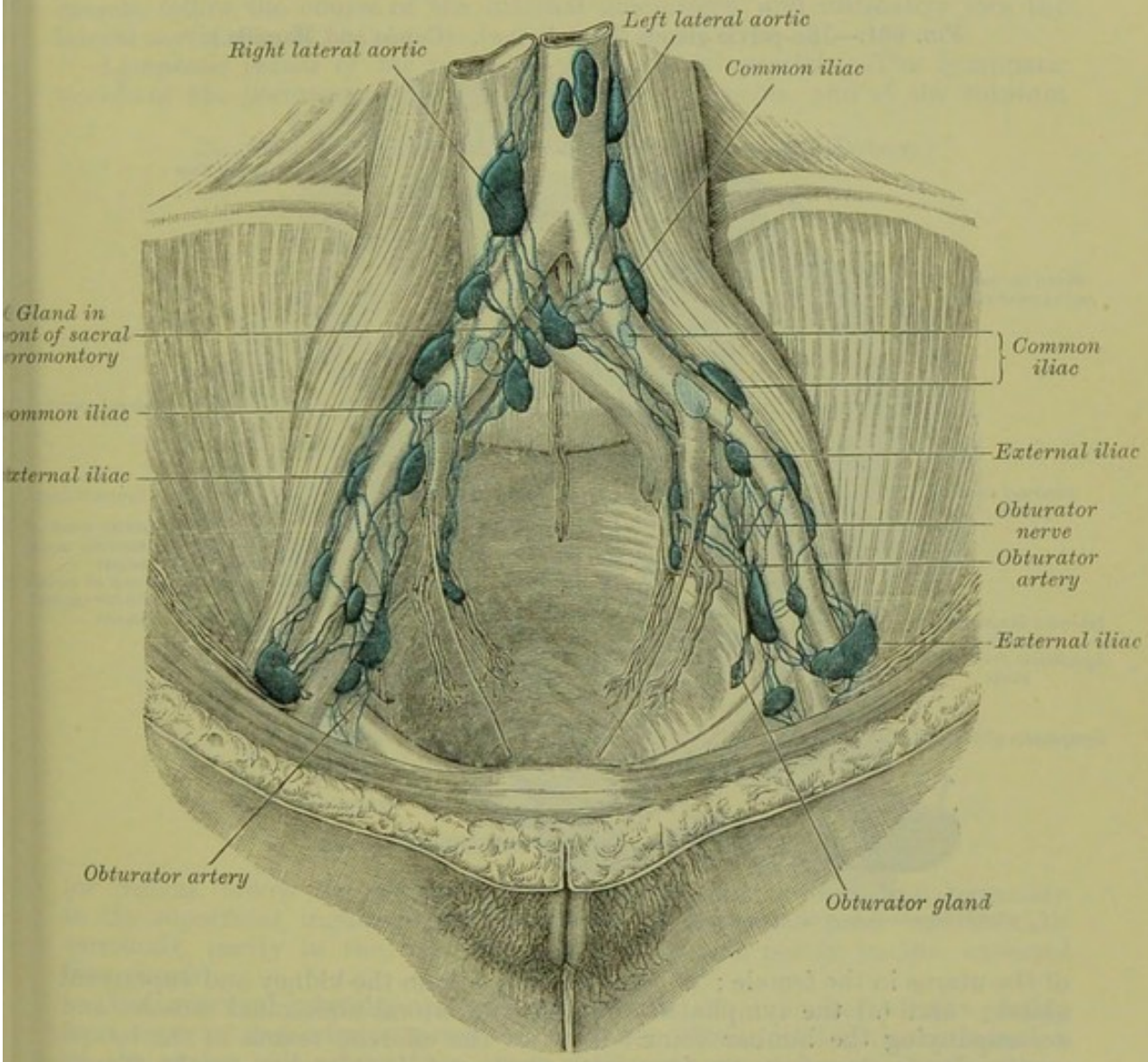

The **internal iliac** or **hypogastric glands** (lymphoglandulæ hypogastricæ) (figs. 660, 661) surround the internal iliac vessels, and receive the lymphatics corresponding to the distribution of the branches of the internal iliac artery: i.e. they receive lymphatics from all the pelvic viscera, from the deeper parts of the perinæum, including the membranous and penile portions of the urethra, and from the buttock and back of the thigh. The *sacral glands* are an isolated set of this group, placed in the concavity of the sacrum, in relation to the middle and lateral sacral arteries; they receive lymphatics from the rectum and posterior wall of the pelvis.

The efferents of the internal iliac group terminate in the common iliac glands.

The **common iliac glands,** four to six in number, are grouped in relation to the lateral and deep aspects of the common iliac artery, one or two being placed below the bifurcation of the aorta, in front of the fifth lumbar vertebra. They drain chiefly the internal and external iliac glands, and their efferents pass to the lateral aortic glands.

The **lumbar glands** (lymphoglandulæ lumbales) are very numerous, and consist of right and left lateral aortic, pre-aortic, and retro-aortic groups.

The *right lateral aortic glands* are situated partly in front of the inferior vena cava, near the termination of the renal vein, and partly behind it on the origin of the Psoas, and on the right crus of the Diaphragm. The *left lateral aortic glands* form a chain on the left side of the abdominal aorta in front of the origin of the Psoas and left crus of the Diaphragm. The glands on either side receive (*a*) the efferents of the common iliac glands, (*b*) the lymphatics from the testicle in the male and from the ovary, Fallopian tube, and body

FIG. 661.—Ilio-pelvic glands (lateral view). (Cunéo and Marcille.)

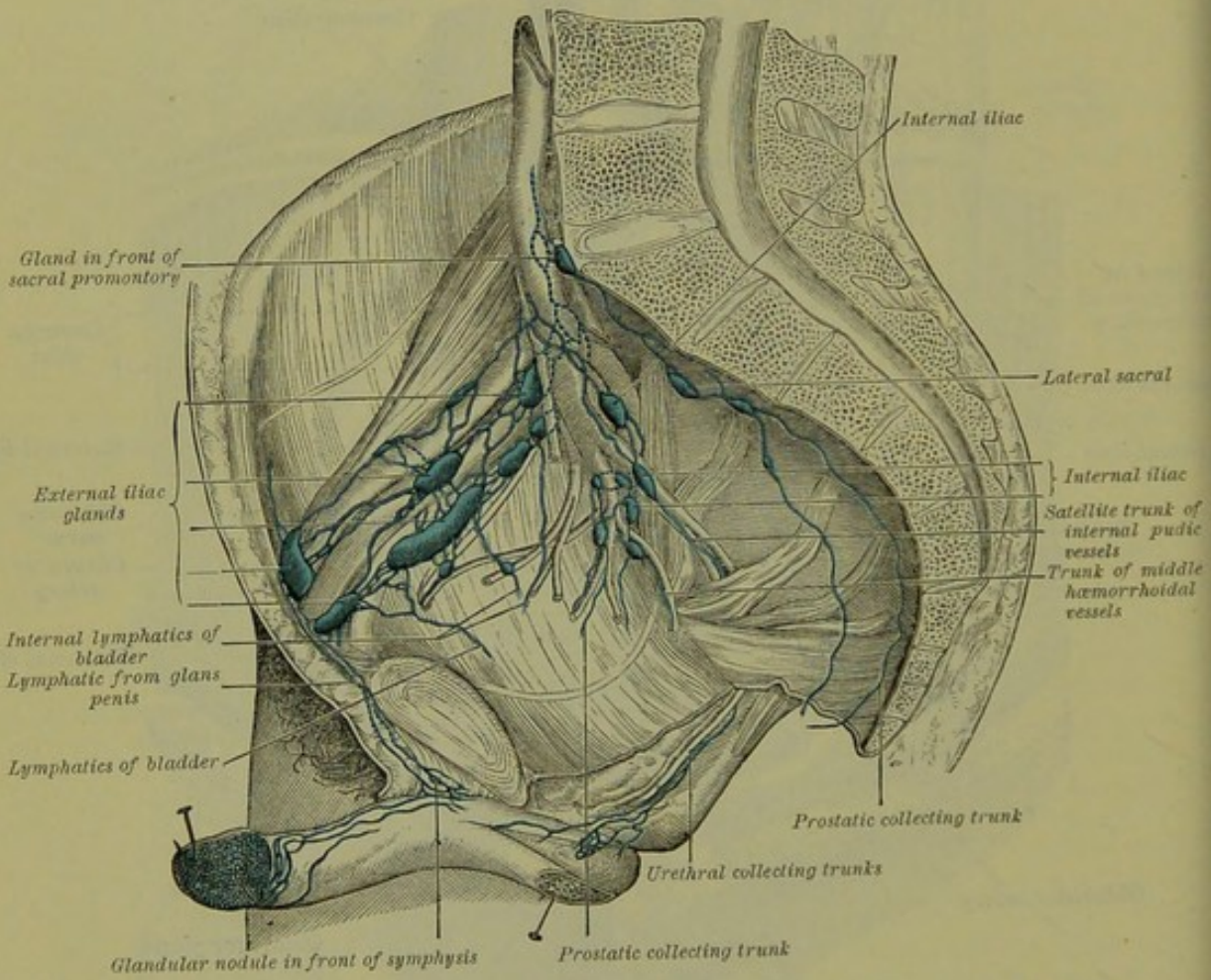

of the uterus in the female ; (*c*) the lymphatics from the kidney and suprarenal gland ; and (*d*) the lymphatics draining the lateral abdominal muscles and accompanying the lumbar veins. Most of the efferent vessels of the lateral aortic glands converge to form the *right and left lumbar trunks* (trunci lumbales) which join the receptaculum chyli, but some enter the pre- and retro-aortic glands, and others pierce the crura of the Diaphragm to join the lower end of the thoracic duct. The *pre-aortic glands* lie in front of the aorta, and may be divided into *cœliac*, *superior mesenteric*, and *inferior mesenteric* groups, arranged around the origins of the corresponding arteries. They receive a few vessels from the lateral aortic glands, but their principal afferents are derived from the viscera supplied by the three arteries with which they are associated. Some of their efferents pass to the retro-aortic glands, but the majority unite to form a common trunk, the *truncus intestinalis*, which enters the receptaculum chyli. The *retro-aortic glands* are placed below the receptaculum chyli, on the bodies of the third and fourth lumbar vertebræ. They

receive lymphatic trunks from the lateral and pre-aortic glands, while their efferents terminate in the receptaculum chyli.

The *lymphatic vessels of the walls of the abdomen and pelvis* may be divided into two sets, superficial and deep.

The *superficial vessels* follow the course of the superficial blood-vessels and converge to the upper group of the superficial inguinal glands. Those derived from the integument of the front of the abdomen below the umbilicus follow the course of the superficial epigastric vessels, and those from the sides of the lumbar part of the abdominal wall pass along the crest of the ilium, with the superficial circumflex iliac vessels. The superficial lymphatic vessels of the gluteal region turn horizontally round the outer side of the buttock, and join the superficial inguinal glands.

The *deep vessels* run alongside the principal blood-vessels. Those of the parietes of the pelvis, which accompany the gluteal, sciatic, and obturator vessels, follow the course of the internal iliac artery, and ultimately join the lateral aortic glands.

Lymphatic vessels of the perinæum and external genitals.—The lymphatic vessels of the perinæum, of the integument of the penis, and of the scrotum

Fig. 662.—Lymphatics of stomach, &c. (Jamieson and Dobson.)

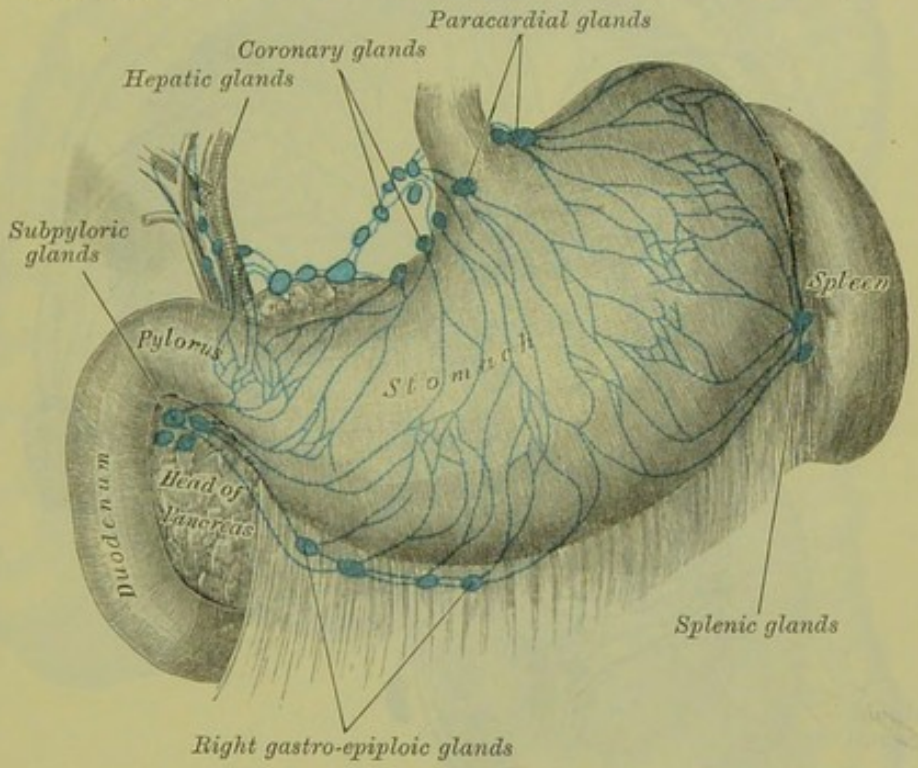

(or vulva), follow the course of the external pudic vessels, and terminate in the superficial inguinal glands. Those of the glans penis vel clitoridis terminate partly in the deep inguinal glands and partly in the external iliac glands.

The **visceral glands** are associated with the branches of the cœliac axis, superior and inferior mesenteric arteries. Those related to the branches of the cœliac axis artery form three chains, coronary, hepatic, and splenic, which accompany the corresponding branches of the artery.

The glands of the **coronary chain** (lymphoglandulæ gastricæ superiores) are divisible into three groups, viz. : (*a*) *upper coronary*, on the stem of the artery ; (*b*) *lower coronary*, accompanying the descending branches of the artery along the cardiac half of the lesser curvature of the stomach, between the two layers of the small omentum ; and (*c*) *paracardial* ' outlying members of the coronary chain, disposed in a manner comparable to a chain of beads around the neck of the stomach ' (Jamieson and Dobson).*

The glands of the coronary chain receive their afferents from the stomach ; their efferents pass to the cœliac group of pre-aortic glands.

* *Lancet*, April 20 and 27, 1907.

The glands of the **hepatic chain** (lymphoglandulæ hepaticæ) (fig. 662) consist of the following groups: (*a*) *hepatic*, on the stem of the hepatic artery, and extending upwards along the common bile-duct, between the two layers of the gastro-hepatic omentum, as far as the transverse fissure of the liver; the *cystic gland*, a member of this group, is placed near the neck of the gall-bladder; (*b*) *subpyloric*, four or five in number, in close relation to the bifurcation of the gastro-duodenal artery, in the angle between the first and second parts of the duodenum; an outlying member of this group is sometimes found above the duodenum on the pyloric artery; (*c*) *right gastro-epiploic* (lymphoglandulæ gastricæ inferiores), four to seven in number, between the two layers of the great omentum, along the pyloric half of the greater curvature of the stomach. The glands of the hepatic chain receive afferents from the stomach, duodenum, liver, gall-bladder, and pancreas; their efferents join the cœliac group of pre-aortic glands.

Fig. 663.—Lymphatics of stomach, &c. The stomach has been turned upwards. (Jamieson and Dobson.)

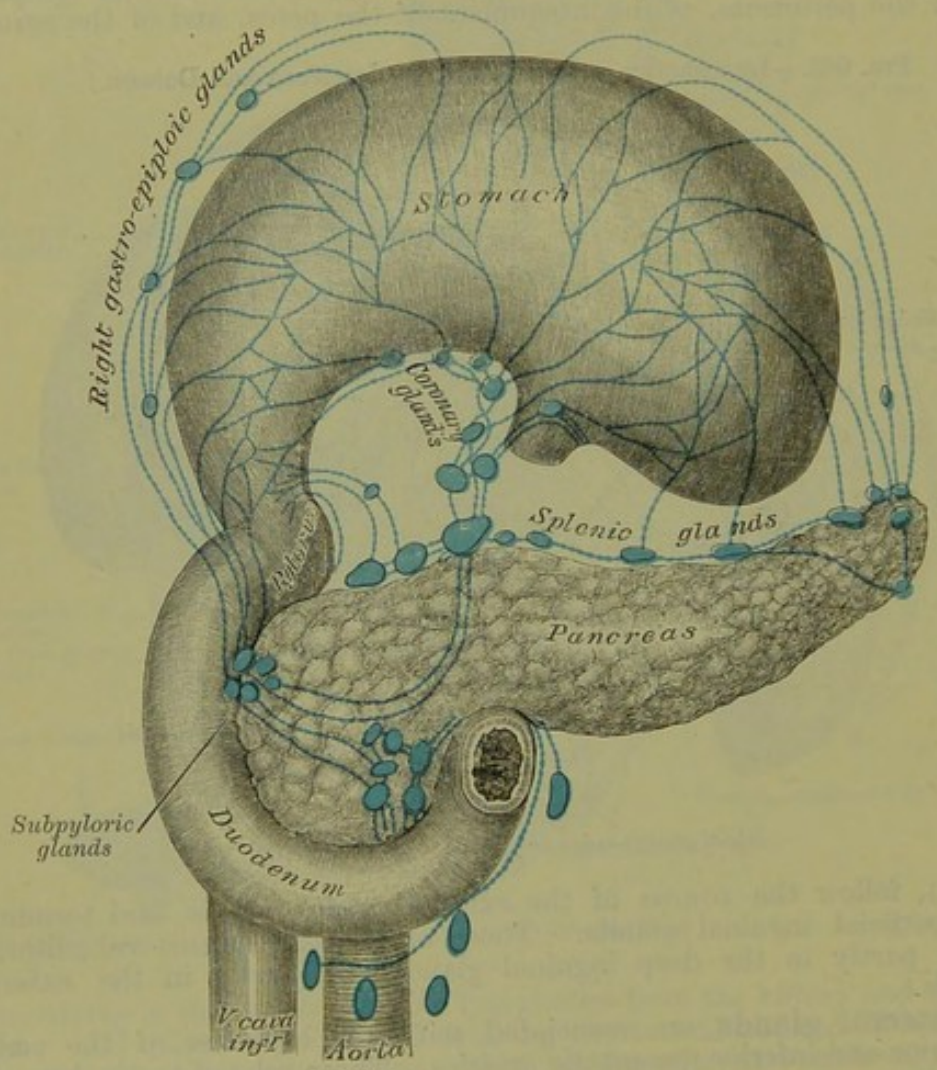

The **splenic glands** (lymphoglandulæ pancreaticolienales) (fig. 663) accompany the splenic artery, and are situated in relation to the posterior surface and upper border of the pancreas; one or two members of this group are found in the gastro-splenic omentum (Jamieson and Dobson, *op. cit.*). Their afferents are derived from the stomach, spleen, and pancreas; their efferents join the cœliac group of pre-aortic glands.

The **superior mesenteric glands** may be divided into three principal groups: mesenteric, ileo-colic, and meso-colic.

The *mesenteric glands* (lymphoglandulæ mesentericæ) (fig. 664) lie between the layers of the mesentery. They vary from one hundred to one hundred and fifty in number, and may be grouped into three sets, viz.: one lying close to the wall of the small intestine, amongst the terminal twigs of the superior

mesenteric artery ; a second, in relation to the loops and primary branches of the vessel ; and a third along the trunk of the artery.

Applied Anatomy.—Enlargement of the mesenteric lymphatic glands is seen in most diseased conditions of the intestinal tract, and is well marked in enteric fever, tuberculous ulceration or malignant growths of the bowel. The enlarged glands can often be palpated through the wall of the abdomen.

The *ileo-colic glands* (fig. 665), from ten to twenty in number, form a chain around the ileo-colic artery, but show a tendency to subdivision into two groups, one near the duodenum and another on the lower part of the trunk of the artery. Where the vessel divides into its terminal branches the chain is broken up into several groups, viz. : (*a*) *ileal*, in relation to the ileal branch of the artery ; (*b*) *anterior ileo-colic*, usually of three glands, in the ileo-colic fold, near the wall

Fig. 664.—Lymphatics of colon. (Jamieson and Dobson.)

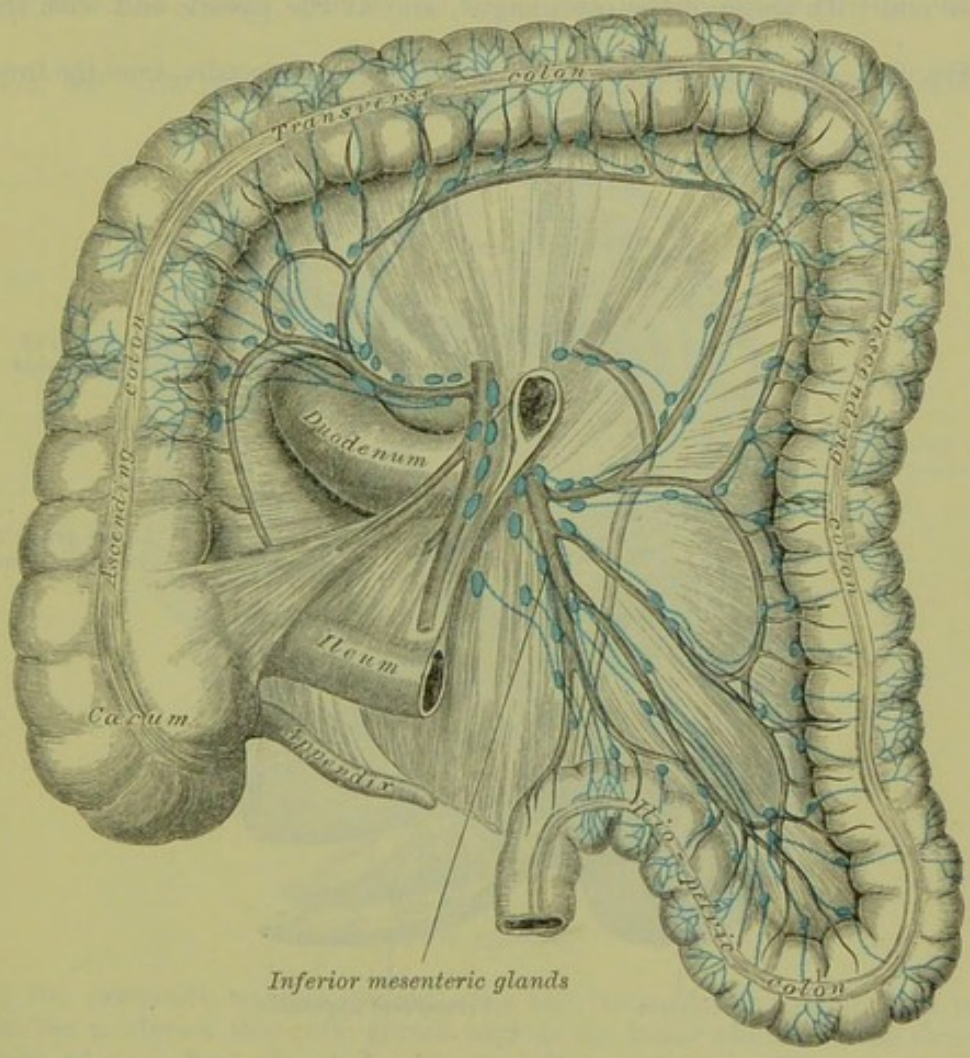

of the cæcum ; (*c*) *posterior ileo-colic*, mostly placed in the angle between the ileum and the colon, but partly lying behind the cæcum at its junction with the ascending colon ; (*d*) *appendicular*, usually a single gland, between the layers of the meso-appendix, near its free edge ; (*e*) *right colic*, along the inner side of the ascending colon.

The *meso-colic glands* are numerous, and lie between the layers of the transverse meso-colon, in close relation to the transverse colon ; they are best developed in the neighbourhood of the hepatic and splenic flexures. One or two small glands are occasionally seen along the trunk of the right colic artery, and others are found in relation to the trunk and branches of the middle colic artery.

The superior mesenteric glands receive afferents from the jejunum, ileum, cæcum, vermiform appendix, and the ascending and transverse parts of the colon ; their efferents pass to the pre-aortic glands.

The **inferior mesenteric glands** (fig. 664) consist of : (*a*) small glands on the branches of the left colic and sigmoid arteries; (*b*) a group in the pelvic mesocolon, around the superior hæmorrhoidal artery; and (*c*) a *pararectal* group in contact with the muscular coat of the rectum. They drain the descending, iliac, and pelvic parts of the colon and the upper part of the rectum ; their efferents pass to the pre-aortic glands.

The *lymphatic vessels of the abdominal and pelvic viscera* consist of : (1) those of the subdiaphragmatic portion of the alimentary canal and its associated glands, the liver and pancreas ; (2) those of the spleen and suprarenal bodies ; (3) those of the urinary organs ; (4) those of the reproductive organs.

(1) The *lymphatic vessels of the subdiaphragmatic portion of the alimentary canal* are situated partly in the mucous membrane and partly in the sero-muscular coats, but as the former system drains into the latter, the two may be considered as one.

The *lymphatic vessels of the stomach* (figs. 662, 663) are continuous at the cardiac end with those of the œsophagus, and at the pyloric end with those of

Fig. 665.—The lymphatics of cæcum and vermiform appendix, from the front. (Jamieson and Dobson.)

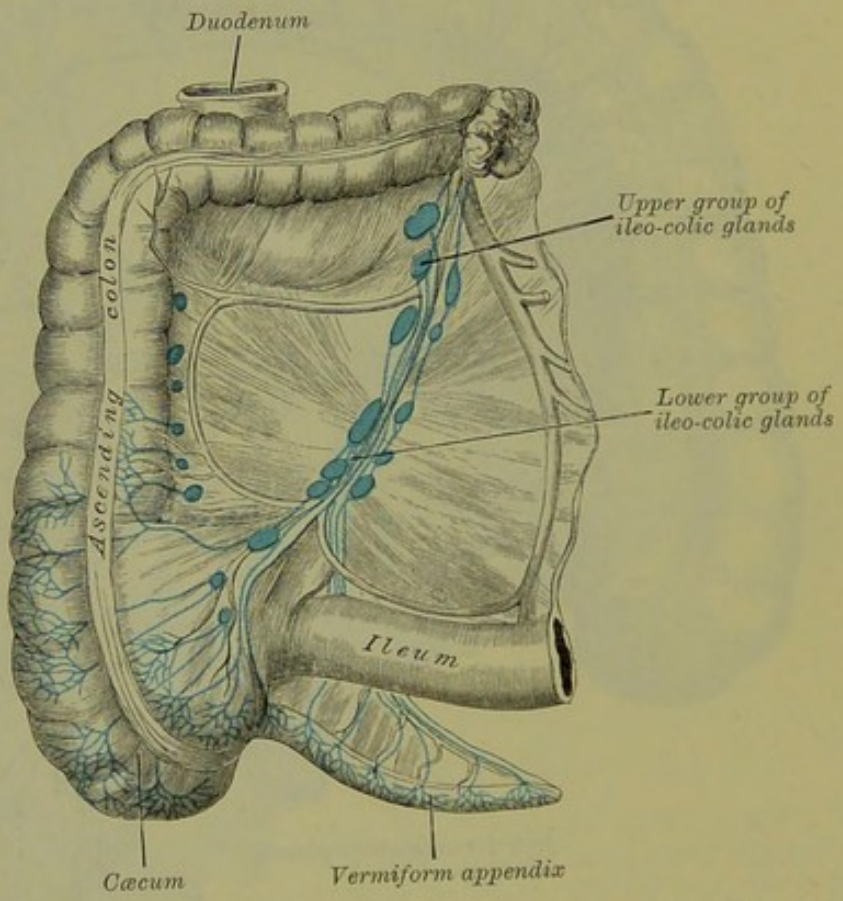

the duodenum. They mainly follow the blood-vessels, and may be arranged in four sets. Those of the first set accompany the branches of the coronary artery, receiving tributaries from a large area on either surface of the stomach, and terminate in the glands of the coronary chain. Those of the second set drain the fundus of the stomach on the left of a line drawn vertically from the œsophagus ; they accompany, more or less closely, the vasa brevia and left gastro-epiploic arteries, and end in the splenic glands. The vessels of the third set drain the right portion of the greater curvature as far as the pyloric canal, and end in the right gastro-epiploic glands, the efferents of which pass to the subpyloric group. Those of the fourth set drain the pyloric canal and pass to the hepatic and subpyloric glands, and to the glands of the coronary chain.

The *lymphatic vessels of the duodenum* consist of an anterior and a posterior set, which open into a series of small *pancreatico-duodenal glands* on the anterior and posterior aspects of the groove between the head of the pancreas and the duodenum. The efferents of these glands run in two directions, upwards to

the hepatic glands and downwards to the pre-aortic glands around the origin of the superior mesenteric artery.

The *lymphatic vessels of the jejunum and ileum* are termed *lacteals*, from the milk-white fluid they contain during intestinal digestion. They run between the layers of the mesentery and enter the mesenteric glands, the efferents of which terminate in the pre-aortic glands.

The *lymphatic vessels of the vermiform appendix and cæcum* (figs. 665, 666) are numerous, since in the wall of the appendix there is a large amount of adenoid tissue. From the body and tail of the appendix eight to fifteen vessels ascend between the layers of the meso-appendix, one or two being interrupted in the appendicular gland. On reaching the stem of the appendicular artery, they unite to form three or four vessels, which end partly in the lower and partly in the upper glands of the ileo-colic chain. The vessels from the root of the appendix and from the cæcum consist of an anterior and a posterior group. The anterior vessels pass in front of the cæcum, and end in the anterior ileo-colic glands, and in the upper and lower glands of the ileo-colic

Fig. 666.—The lymphatics of cæcum and vermiform appendix, from behind. (Jamieson and Dobson.)

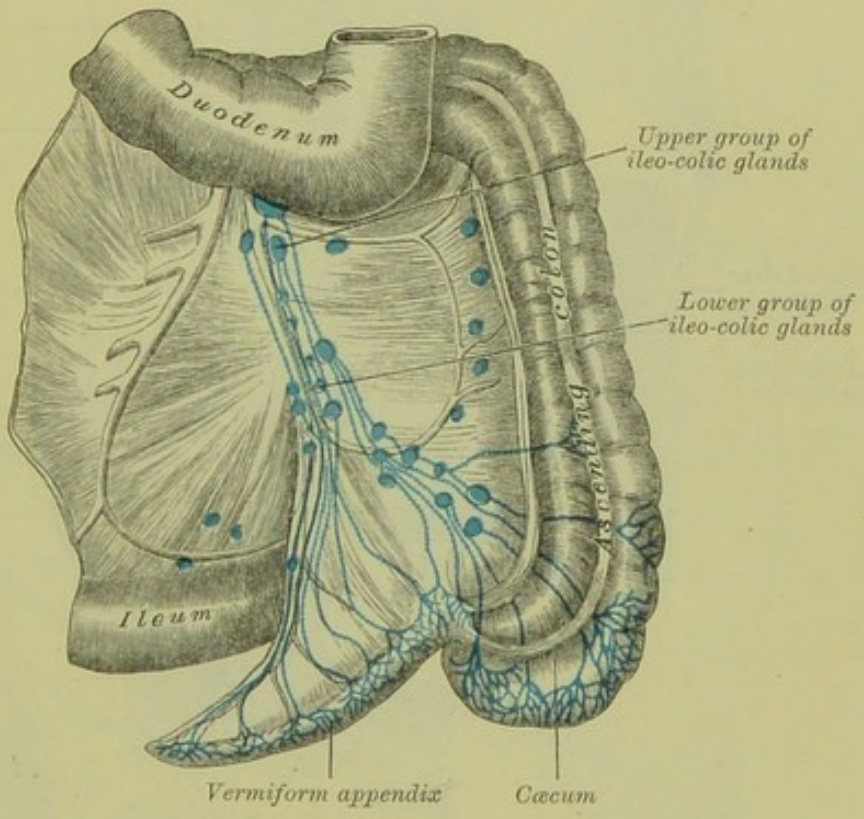

chain; the posterior vessels ascend over the back of the cæcum and terminate in the posterior ileo-colic glands and in the lower glands of the ileo-colic chain.

Lymphatic vessels of the colon.—The lymphatics of the ascending and transverse parts of the colon finally terminate in the mesenteric glands, after traversing the right colic and meso-colic glands. Those of the descending and ilio-pelvic parts of the colon are interrupted by the small glands on the branches of the left colic and sigmoid arteries, and ultimately end in the pre-aortic glands around the origin of the inferior mesenteric artery (fig. 664).

Lymphatic vessels of the anus, anal canal, and rectum.—The lymphatics from the *anus* pass forwards and end with those of the integument of the perinæum and scrotum in the superficial inguinal glands; those from the *anal canal* accompany the middle and inferior hæmorrhoidal arteries, and end in the internal iliac glands; while the vessels from the *rectum* traverse the pararectal glands and pass to those in the pelvic meso-colon; the efferents of the latter terminate in the pre-aortic glands around the origin of the inferior mesenteric artery.

The *lymphatic vessels of the liver* are divisible into two sets, superficial and deep. The former arise in the subperitoneal areolar tissue over the entire surface of the organ, and may be grouped into: (*a*) those on the convex surface, (*b*) those on the inferior surface.

(*a*) On the *convex surface.*—The vessels from the back part of this surface reach their terminal glands by three different routes: the vessels of the middle set, five or six in number, pass through the caval opening in the Diaphragm and end in one or two glands which are situated around the terminal part of the inferior vena cava; a few vessels from the left side pass backwards towards the œsophageal opening, and terminate in the paracardial glands of the coronary chain; the vessels from the right side, one or two in number, run on the abdominal surface of the Diaphragm, and, after crossing its right crus, terminate in the pre-aortic glands which surround the origin of the cœliac axis. From the portions of the right and left lobes adjacent to the falciform ligament, the lymphatic vessels converge to form two trunks, one of

Fig. 667.—Lymphatics of the bladder. (Cunéo and Marcille.)

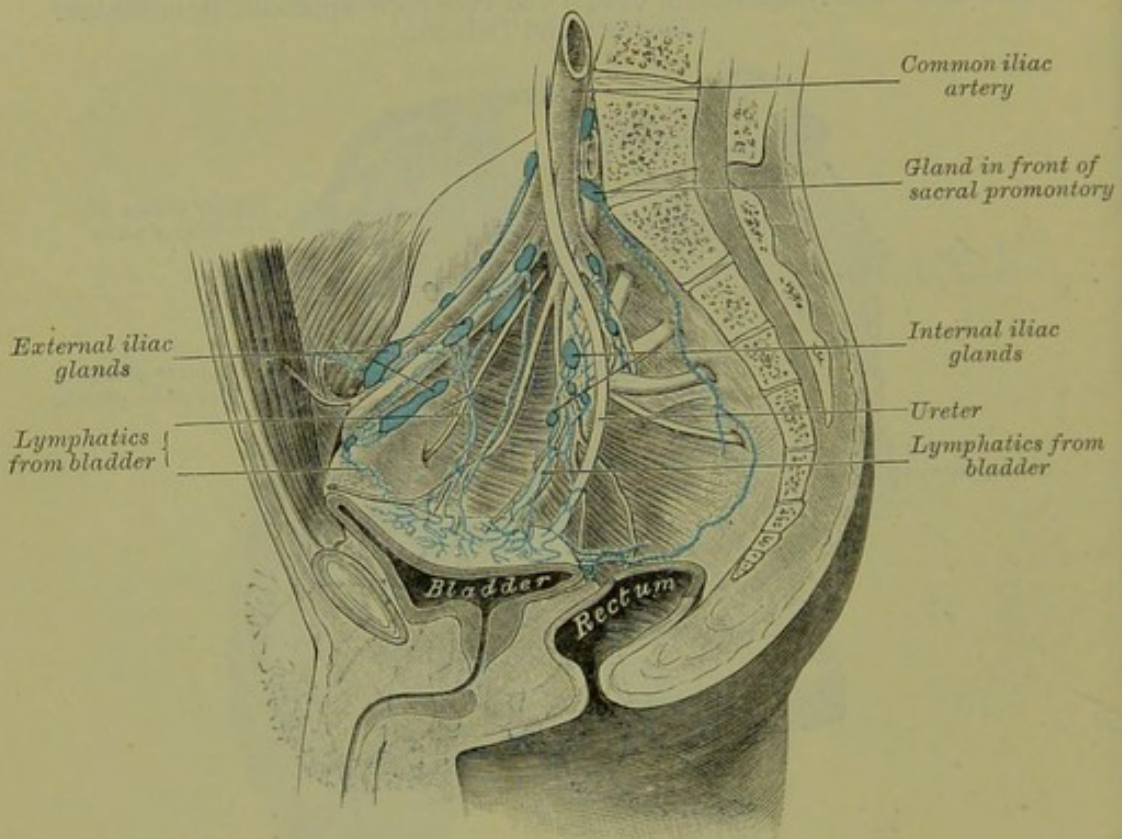

which accompanies the vena cava through the Diaphragm, and ends in the glands around the terminal part of this vessel; the other runs downwards and forwards, and, turning round the anterior sharp margin of the liver, accompanies the upper part of the ligamentum teres, and ends in the upper hepatic glands. From the anterior surface a few additional vessels turn round the anterior sharp margin to reach the upper hepatic glands.

(*b*) On the *inferior surface.*—The vessels from this surface mostly converge to the transverse fissure, and accompany the deep lymphatics emerging from this fissure to the hepatic glands; one or two from the posterior parts of the right and Spigelian lobes accompany the inferior vena cava through the Diaphragm, and end in the glands round the terminal part of this vein.

The deep lymphatics converge to ascending and descending trunks. The ascending trunks accompany the hepatic veins and pass through the Diaphragm to end in the glands round the terminal part of the inferior vena cava. The descending trunks emerge from the transverse fissure, and end in the hepatic glands.

The *lymphatic vessels of the gall-bladder* pass to the hepatic glands in the transverse fissure of the liver; those of the *common bile-duct* to the hepatic glands alongside the duct and into the upper pancreatico-duodenal glands.

The *lymphatic vessels of the pancreas* follow the course of its blood-vessels. Most of them enter the glands of the splenic chain, but some end in the pancreatico-duodenal glands, and others in the pre-aortic glands, near the origin of the superior mesenteric artery.

(2) The *lymphatic vessels of the spleen and suprarenal glands.*

The *lymphatic vessels of the spleen*, both superficial and deep, pass to the splenic glands in the lieno-renal ligament.

Fig. 668.—Lymphatics of the prostate. (Cunéo and Marcille.)

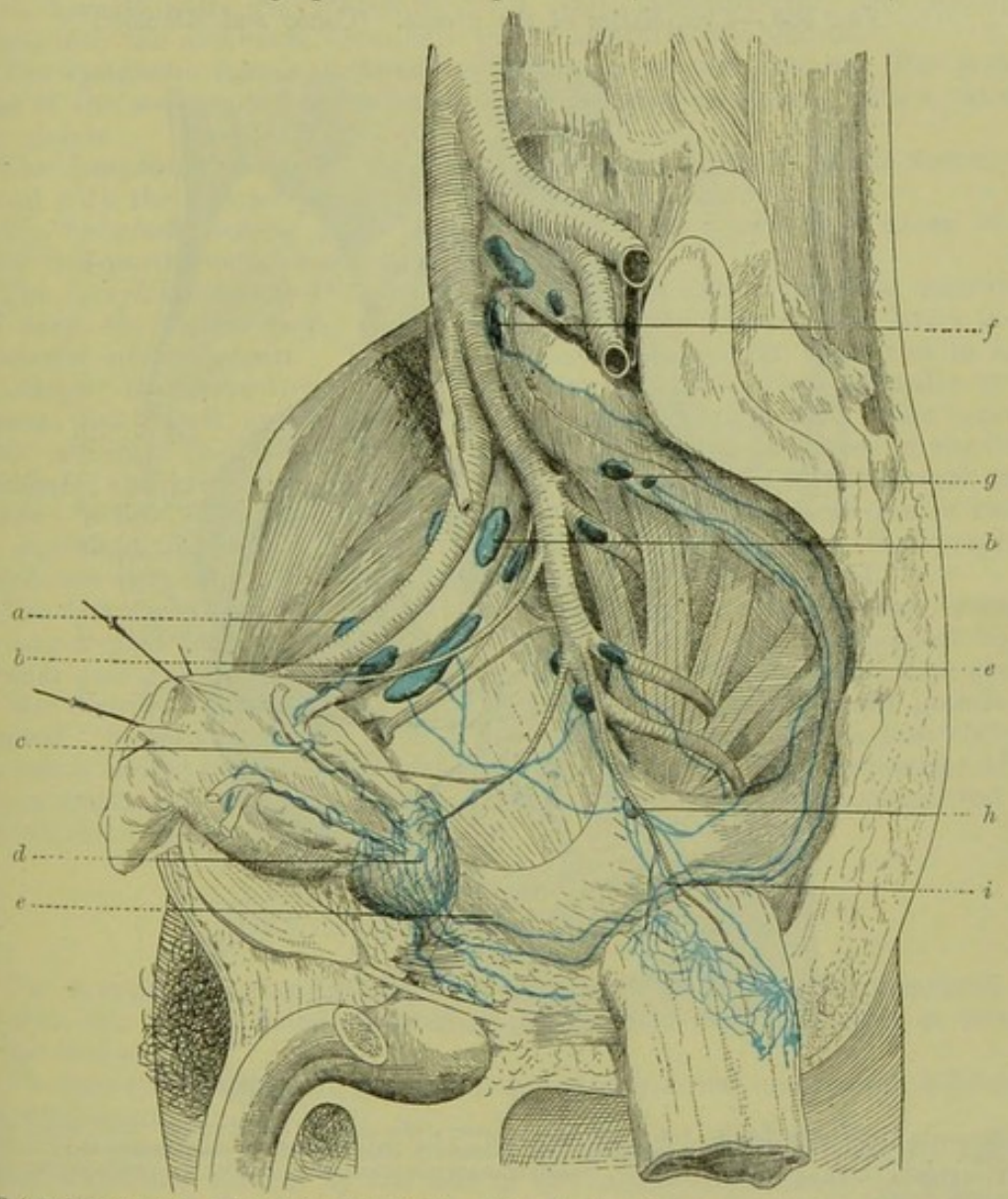

a, b. External iliac glands. *c.* Vessel draining into external iliac glands. *d.* Retro-prostatic lymph-nodes. *e.* Vessels draining into gland on sacral promontory. *f.* Gland in front of sacral promontory. *g.* Lateral sacral glands. *h.* Middle hæmorrhoidal gland. *i.* Middle hæmorrhoidal lymphatic vessels.

The *lymphatic vessels of the suprarenal glands* usually accompany the suprarenal veins, and end in the lateral aortic glands; occasionally some of them pierce the crura of the Diaphragm and terminate in the glands of the posterior mediastinum.

(3) The *lymphatic vessels of the urinary organs.*

The *lymphatic vessels of the kidney* form three plexuses: one in the substance of the kidney, a second beneath its fibrous capsule, and a third in the perinephric fat; the second and third communicate freely with each other.

The vessels from the plexus in the kidney substance converge to form four or five trunks which issue at the hilus. Here they are joined by vessels

from the plexus under the capsule, and, following the course of the renal vein, end in the lateral aortic glands. The perinephric plexus is drained directly into the upper lateral aortic glands.

The *lymphatic vessels of the ureter* run in different directions. Those from its upper portion end partly in the efferent vessels of the kidney and partly in the lateral aortic glands; those from the portion immediately above the pelvic brim are drained into the common iliac glands; while the vessels from the intrapelvic portion of the tube join the efferents from the bladder, or terminate in the internal iliac glands.

The *lymphatic vessels of the bladder* (fig. 667) originate in two plexuses, an intra- and an extra-muscular, it being generally admitted that the mucous

FIG. 669.—Lymphatics of the uterus. (Cunéo and Marcille.)

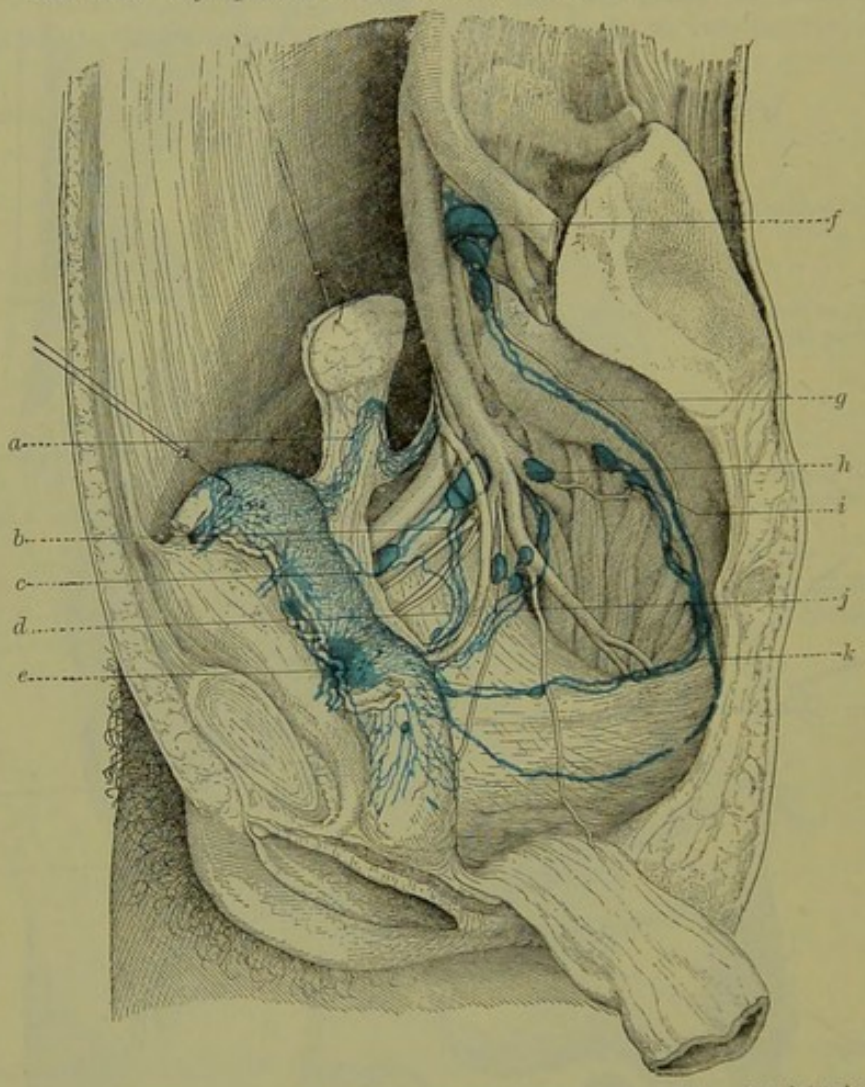

a. Efferents to lateral aortic glands. *b*, *c*, *d*. Efferents to external iliac glands. *e*. Network on lateral aspect of cervix uteri. *f*. Glands in front of sacral promontory. *g*. Efferents to glands in front of sacral promontory. *h*. Internal iliac glands. *i*. Lateral sacral glands. *j*. Vessels draining into internal iliac glands. *k*. Vessels passing to lateral sacral glands.

membrane is devoid of lymphatics.* The efferent vessels are arranged in two groups, one from the anterior and another from the posterior surface of the bladder. The vessels from the *anterior* surface pass to the external iliac glands, but in their course minute glands are situated. These minute glands are arranged in two groups, an *anterior vesical* group, in front of the bladder, and a *lateral vesical*, in relation to the hypogastric artery. The vessels from the *posterior* surface pass to the internal, external, and common iliac glands; those draining the upper part of this surface traverse the lateral vesical glands.

The *lymphatic vessels of the prostate* (fig. 668) terminate chiefly in the

* Some authorities maintain that a plexus of lymphatic vessels does exist in the mucous membrane of the bladder (consult *Médecine opératoire des Voies urinaires*, par J. Albarran, Paris, 1909).

internal iliac and sacral glands, but one trunk from the posterior surface ends in the external iliac glands, and another from the anterior surface joins the vessels which drain the membranous part of the urethra.

Lymphatic vessels of the urethra.—The lymphatics of the *penile* portion of the urethra accompany those of the glans penis, and terminate with them in the deep inguinal and external iliac glands. Those of the *membranous and prostatic* portions, and those of the whole urethra in the female, pass to the internal iliac glands.

(4) *The lymphatic vessels of the reproductive organs.*

The *lymphatic vessels of the testes* consist of two sets, superficial and deep, the former commencing on the surface of the tunica vaginalis, the latter in the epididymis and body of the testis. They form several large trunks, which ascend with the spermatic cord, and, accompanying the spermatic vessels into the abdomen, terminate in the lateral aortic glands.

The *lymphatic vessels of the vas deferens* pass to the external iliac glands; those of the *vesiculæ seminales* partly to the internal and partly to the external iliac glands.

The *lymphatic vessels of the ovary* are similar to those of the testis, and ascend with the ovarian artery to the lateral aortic glands.

The *lymphatic vessels of the Fallopian tube* pass partly with those of the ovary and partly with those of the uterus.

The *lymphatic vessels of the uterus* (fig. 669) consist of two sets, superficial and deep, the former being placed beneath the peritoneum, the latter in the substance of the organ. The lymphatics of the cervix uteri run in three directions: transversely to the external iliac glands, postero-laterally to the internal iliac glands, and posteriorly to the common iliac glands. The majority of the vessels of the body and fundus of the uterus pass outwards in the broad ligaments, and are continued up with the ovarian vessels to the lateral aortic glands; a few, however, run to the external iliac glands, and one or two to the superficial inguinal glands. In the unimpregnated uterus, the lymphatic vessels are very small, but during gestation are greatly enlarged.

The *lymphatic vessels of the vagina* are carried in three directions: those of the upper part to the external iliac glands, those of the middle part to the internal iliac glands, and those of the lower part to the common iliac glands. On the course of those from the middle and lower parts small glands are situated. Some lymphatics from the lower part of the vagina join those of the vulva and pass to the superficial inguinal glands. The lymphatics of the vagina anastomose with those of the cervix uteri, vulva, and rectum, but not with those of the bladder.

LYMPHATICS OF THE THORAX

The **lymphatic glands of the thorax** may be divided into parietal and visceral—the former being situated in the thoracic wall, the latter in relation to the viscera.

The **parietal lymphatic glands** include the internal mammary, intercostal and diaphragmatic glands.

1. The **internal mammary glands** are placed at the anterior extremities of the intercostal spaces, by the side of the internal mammary artery. They derive afferents from the mammary gland, from the deeper structures of the anterior abdominal wall above the level of the umbilicus, from the upper surface of the liver through a small group of glands which lie behind the ensiform cartilage, and from the deeper parts of the anterior portion of the thoracic wall. Their efferents usually unite to form a single trunk on either side; this may open directly into the junction of the internal jugular and subclavian veins, or that of the right side may join the right subclavian trunk, and that of the left the thoracic duct.

2. The **intercostal glands** (lymphoglandulæ intercostales) occupy the posterior parts of the intercostal spaces, in relation to the intercostal vessels. They receive the deep lymphatics from the postero-lateral aspect of the chest; some of these vessels are interrupted by small lateral intercostal glands. The efferents of the glands in the lower four or five spaces unite to form a trunk,

which descends and opens either into the receptaculum chyli or into the commencement of the thoracic duct. The efferents of the glands in the upper spaces of the left side terminate in the thoracic duct; those of the corresponding right spaces, in the right lymphatic duct.

3. The **diaphragmatic glands** lie on the thoracic aspect of the Diaphragm, and consist of three sets, anterior, middle, and posterior.

The *anterior* set consists of (*a*) two or three small glands behind the base of the ensiform cartilage, which receive afferents from the convex surface of the liver, and (*b*) one or two glands on either side near the junction of the seventh rib with its cartilage, which receive lymphatic vessels from the front part of the Diaphragm. The efferent vessels of the anterior set pass to the internal mammary glands.

The *middle* set consists of two or three glands on either side close to where the phrenic nerves enter the Diaphragm. On the right side some of the glands of this group lie within the fibrous sac of the pericardium, on the front of the termination of the inferior vena cava. The afferents of this set are derived from the middle part of the Diaphragm, those on the right side also receiving afferents from the convex surface of the liver. Their efferents pass to the posterior mediastinal glands.

The *posterior* set consists of a few glands situated on the back of the diaphragmatic crura, and connected on the one hand with the lumbar glands and on the other with the posterior mediastinal glands.

The *superficial lymphatic vessels of the thoracic wall* ramify beneath the skin and converge to the axillary glands. Those over the Trapezius and Latissimus dorsi run forwards and unite to form about ten or twelve trunks which end in the subscapular group. Those over the pectoral region, including the vessels from the skin covering the peripheral part of the mamma, run backwards, and those over the Serratus magnus upwards, to the pectoral group. Others near the lateral margin of the sternum pass inwards between the rib cartilages and end in the internal mammary glands, while the vessels of opposite sides anastomose across the front of the sternum. A the few vessels from the upper part of the pectoral region pass upwards over clavicle to the supraclavicular group of cervical glands.

The *lymphatic vessels of the mammary gland* originate in a plexus in the interlobular spaces and on the walls of the galactophorous ducts. Those from the central part of the gland pass to an intricate plexus situated beneath the areola, a plexus which receives also the lymphatics from the skin over the central part of the gland and those from the areola and nipple. Its efferents are collected into two trunks which pass to the pectoral group of axillary glands. The vessels which drain the inner part of the mammary gland pierce the thoracic wall and end in the internal mammary glands, while a vessel has occasionally been seen emerging from the upper part of the gland and, piercing the Pectoralis major, to terminate in the subclavicular glands (fig. 655).

The *deep lymphatic vessels of the thoracic wall* consist of:

1. The lymphatics of the muscles which lie on the ribs: most of these terminate in the axillary glands, but some from the Pectoralis major pass to the internal mammary glands.

2. The intercostal lymphatic vessels which drain the Intercostal muscles and parietal pleura. Those draining the External intercostal muscles run backwards and, after receiving the vessels which accompany the posterior branches of the intercostal arteries, terminate in the posterior intercostal glands. Those of the Internal intercostal muscles and parietal pleura consist of a single trunk in each space. These trunks run forwards in the subpleural tissue and the upper six open separately into the internal mammary glands or into the vessels which unite them: those of the lower spaces unite to form a single trunk which terminates in the lowest of the internal mammary glands.

3. The *lymphatic vessels of the Diaphragm*, which form two plexuses, one on its thoracic and another on its abdominal surface. These plexuses anastomose freely with each other, and are best marked on the parts covered respectively by the pleuræ and peritoneum. That on the thoracic surface communicates with the lymphatics of the costal and mediastinal parts of the pleura, and its efferents consist of three groups: (*a*) anterior, passing to the glands which lie near the junction of the seventh rib with its cartilage; (*b*) middle, to

the glands on the œsophagus and to those around the termination of the inferior vena cava; and (*c*) posterior, to the glands which surround the aorta at the point where this vessel leaves the thoracic cavity.

The plexus on the abdominal surface is composed of fine vessels, and anastomoses with the lymphatics of the liver and, at the periphery of the Diaphragm, with those of the subperitoneal tissue. The efferents from the right half of this plexus terminate partly in a group of glands on the trunk of the corresponding inferior phrenic artery, while others end in the right lateral aortic glands. Those from the left half of the plexus pass to the pre- and lateral aortic glands and to the glands on the terminal portion of the œsophagus.

FIG. 670.—Disposition and relations of the tracheo-bronchial lymphatic glands. (From a figure designed by M. Hallé, and printed in 'La Clinique Médicale,' tome iv.)

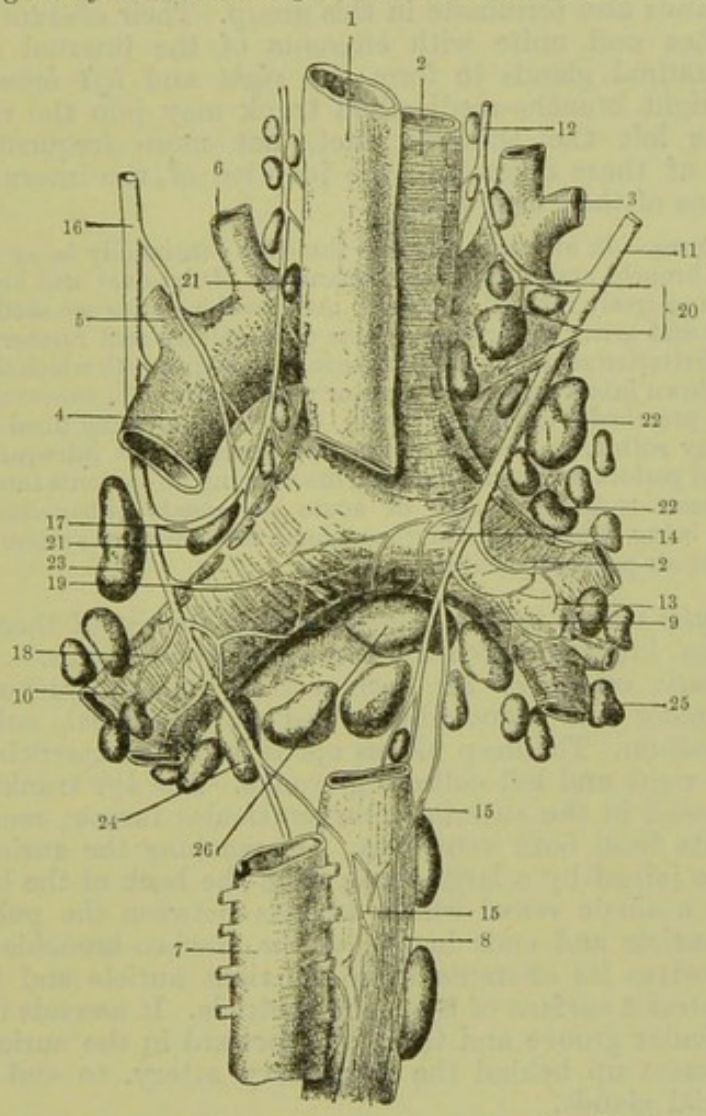

1. Œsophagus. 2. Trachea. 3. Innominate artery. 4. Arch of aorta. 5. Left subclavian artery. 6. Left common carotid artery. 7. Thoracic aorta. 8. Œsophagus. 9. Right bronchus. 10. Left bronchus. 11. Right vagus nerve. 12. Right recurrent laryngeal nerve. 13, 14. Right posterior pulmonary plexus. 15. Œsophageal plexus. 16. Left vagus nerve. 17. Left recurrent laryngeal nerve. 18, 19. Left posterior pulmonary plexus. 20. Glands accompanying right recurrent laryngeal nerve. 21. Glands accompanying left recurrent laryngeal nerve. 22. Right tracheo-bronchial glands. 23. Left tracheo-bronchial glands. 24, 25. Interbronchial glands. 26. Glands below bifurcation of trachea.

The **visceral lymphatic glands** consist of three groups, viz. anterior mediastinal, posterior mediastinal, and tracheo-bronchial.

The **anterior mediastinal glands** (lymphoglandulæ mediastinales anteriores) are placed in the anterior part of the superior mediastinum, in front of the arch of the aorta and in relation to the innominate veins and the large arterial trunks which arise from the aortic arch. They receive afferents from the thymus gland and pericardium, and from the internal mammary glands; their efferents unite with those of the tracheo-bronchial glands, to form the right and left broncho-mediastinal trunks.

The **posterior mediastinal glands** (lymphoglandulæ mediastinales posteriores) lie behind the pericardium in relation to the œsophagus and descending thoracic aorta. Their afferents are derived from the œsophagus, the posterior part of the pericardium, the Diaphragm, and the convex surface of the liver. Their efferents mostly terminate in the thoracic duct, but some join the tracheo-bronchial glands.

The **tracheo-bronchial glands** (fig. 670) form three main groups in relation to the bifurcation of the trachea—one on either side of the trachea above the bronchi, and one in the angle between the bronchi (lymphoglandulæ tracheales) ; other glands, termed *interbronchial* (lymphoglandulæ bronchiales), are found at the points of division of the larger bronchi. The afferents of the tracheo-bronchial glands drain the lungs and bronchi, the thoracic part of the trachea and the heart ; some of the efferents of the posterior mediastinal glands also terminate in this group. Their efferent vessels ascend upon the trachea and unite with efferents of the internal mammary and anterior mediastinal glands to form the *right* and *left broncho-mediastinal trunks*. The right broncho-mediastinal trunk may join the right lymphatic duct, and the left the thoracic duct, but more frequently they open independently of these ducts into the junction of the internal jugular and subclavian veins of their own side.

Applied Anatomy.—In all town-dwellers there are continually being swept into these glands from the bronchi and alveoli large quantities of the dust and black carbonaceous pigment that are so freely inhaled in cities. At first the glands are moderately enlarged, firm, inky black and gritty on section ; later they enlarge still further, often becoming fibrous from the irritation set up by the minute foreign bodies with which they are crammed, and may break down into a soft slimy mass or may calcify. In tuberculosis of the lungs these glands are practically always infected ; they enlarge, being filled with tuberculous deposits that may soften, or become fibrous, or calcify. Not infrequently an enlarged tuberculous gland perforates into a bronchus, discharging its contents into the tube. When this happens there is great danger of acute pulmonary tuberculosis, the infecting gland-substance being rapidly spread throughout the bronchial system by the coughing its presence in the air-passages excites.

The *lymphatic vessels of the thoracic viscera* consist of those of the heart and pericardium, lungs and pleura, thymus, and œsophagus.

The *lymphatic vessels of the heart* consist of two plexuses, (*a*) deep, immediately under the endocardium, and (*b*) superficial, subjacent to the visceral pericardium. The deep plexus opens into the superficial, the efferents of which form right and left collecting trunks. The *left* trunks, two or three in number, ascend in the anterior interventricular furrow, receiving, in their course, afferents from both ventricles. On reaching the auriculo-ventricular furrow they are joined by a large trunk from the back of the heart, and then unite to form a single vessel which ascends between the pulmonary artery and the left auricle and ends in one of the tracheo-bronchial glands. The *right* trunk receives its afferents from the right auricle and from the right border and posterior surface of the right ventricle. It ascends in the posterior auriculo-ventricular groove and then runs forward in the auriculo-ventricular groove, and passes up behind the pulmonary artery, to end in one of the tracheo-bronchial glands.

The *lymphatic vessels of the lungs* originate in two plexuses, a superficial and a deep. The superficial plexus is placed beneath the visceral pleura. The deep accompanies the branches of the pulmonary vessels and the ramifications of the bronchi. In the case of the larger bronchi the deep plexus consists of two networks, one, submucous, beneath the mucous membrane, and another, peribronchial, outside the walls of the bronchi. In the smaller bronchi there is but a single plexus, which extends as far as the bronchioles, but fails to reach the alveoli, in the walls of which there are no traces of lymphatic vessels. The superficial efferents turn round the borders of the lungs and the margins of their fissures, and converge to end in some glands situated at the hilus ; the deep efferents are conducted to the hilus along the pulmonary vessels and bronchi, and end in the tracheo-bronchial glands. Little or no anastomosis occurs between the superficial and deep lymphatics of the lungs, except in the region of the hilus.

The *lymphatic vessels of the pleura* consist of two sets—one in the visceral and another in the parietal part of the membrane. Those of the visceral pleura drain into the superficial efferents of the lung, while the lymphatics of the parietal pleura have three modes of ending, viz. : (*a*) those of the costal portion join the lymphatics of the Internal intercostal muscles and so reach the internal mammary glands ; (*b*) those of the diaphragmatic part are drained by the efferents of the Diaphragm ; while (*c*) those of the mediastinal portion terminate in the posterior mediastinal glands.

The *lymphatic vessels of the thymus gland* terminate in the superior mediastinal, tracheo-bronchial, and internal mammary glands.

The *lymphatic vessels of the œsophagus* form a plexus round that tube, and the collecting vessels from the plexus drain into the posterior mediastinal glands.

NEUROLOGY

THE **Nervous System** is the most complicated and the most highly organised of the various systems which make up the human body. It may be divided into two parts, central and peripheral.

The **central nervous system** consists of (*a*) an upper expanded portion, the *brain*, contained within the cranium, and (*b*) a lower, elongated, nearly cylindrical portion, the *spinal cord*, lodged in the vertebral canal; the two portions are continuous with one another at the level of the upper border of the atlas.

The **peripheral nervous system** consists of a series of nerves by which the central nervous system is connected with the various tissues of the body. For descriptive purposes these nerves may be arranged in two groups, *cerebro-spinal* and *sympathetic*, the arrangement, however, being an arbitrary one, since the two groups are intimately connected and closely intermingled. The cerebro-spinal nerves are forty-three in number on either side—twelve *cranial*, attached to the brain, and thirty-one *spinal*, to the spinal cord. They are associated with the functions of the special and general senses and with the voluntary movements of the body. The sympathetic nerves transmit the impulses which regulate the movements of the viscera, determine the calibre of the blood-vessels and control the phenomena of secretion. In relation with them are two rows of *central ganglia*, situated one on either side of the middle line in front of the vertebral column; these ganglia are intimately connected with the spinal cord and nerves, and are also joined to each other by vertical strands of nerve-fibres so as to constitute a pair of knotted cords, the *gangliated cords of the sympathetic*, which reach from the base of the skull to the coccyx. The sympathetic nerves issuing from the ganglia form three great prevertebral plexuses which supply the thoracic, abdominal, and pelvic viscera; in relation to the walls of these viscera intricate nerve plexuses and numerous *peripheral ganglia* are found.

The nervous system is built up of nervous and non-nervous tissues—the former consisting of nerve-cells and nerve-fibres; the latter, of neuroglia and blood-vessels, together with certain enveloping membranes.

The minute structure of the nervous elements, and of the neuroglia, has been described in the chapter on Histology (pp. 42 to 55); and an outline of the development of the nervous system furnished in that on Embryology (pp. 115 to 128). It may be stated here, however, that, in its earliest condition, the nervous system consists of cells only, and that the nerve-fibres arise as outgrowths from the cells.

The embryonic nerve-cells, or *neuroblasts*, as they are termed, are at first spherical, but soon become pear-shaped, and the attenuated end of each cell grows out to form a slender process, the *axon*, while from the body of the cell other processes, termed *dendrites*, arise. The axon may run for a shorter or longer distance as the axis cylinder of a nerve-fibre, or may break up at once into numerous delicate filaments, as in the Golgi cell, type II. Dendrites and axons are alike conductors of nervous impulses: the former, however, convey them to, the latter from, the nerve-cells; in other words, the dendrites form the paths of reception, the axons those of transmission.

The nerve-cell and its processes collectively constitute what is termed a *neuron*, and Waldeyer formulated the theory that the nervous system is built up of numerous neurons, 'anatomically and genetically independent of

one another.' According to this theory (*neuron theory*) the processes of one neuron only come into contact, and are never in direct continuity, with those of other neurons; while impulses are transmitted from one nerve-cell to another through these points of contact. This theory is based on the following facts, viz.: (1) embryonic nerve-cells or neuroblasts are entirely distinct from one another; (2) when nervous tissues are stained by the Golgi method no continuity is seen even between neighbouring neurons; and (3) when degenerative changes occur in nervous tissue, either as the result of disease or experiment, they never spread from one neuron to another, but are limited to the individual neurons, or groups of neurons, primarily affected. It must, however, be added that within the past few years the validity of the neuron theory has been called in question by certain eminent histologists, who maintain that by the employment of more delicate histological methods, minute fibrils can be followed from one nerve-cell into another.

The Spinal Cord

The **spinal cord** (medulla spinalis) forms the elongated, nearly cylindrical, part of the central nervous system which occupies the upper two-thirds of the vertebral canal. Its average length in the male is about eighteen inches (45 cm.), in the female about seventeen inches (42–43 cm.), while its weight amounts to a little over an ounce. It extends from the level of the upper border of the atlas to that of the lower border of the first, or upper border of the second, lumbar vertebra (fig. 671). Above, it is directly continuous with the hind-brain; below, it ends in a conical extremity, the *conus medullaris*, from the apex of which a delicate filament, the *filum terminale*, is continued downwards as far as the first segment of the coccyx (fig. 672).

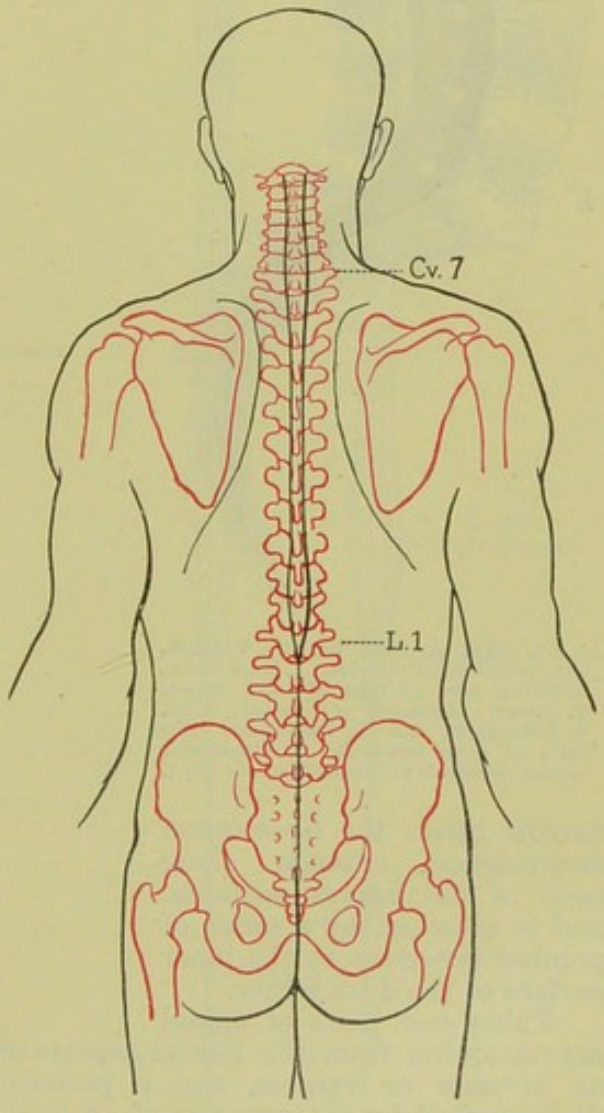

Fig. 671.—Showing the relation of the spinal cord to the dorsal surface of the trunk. The vertebræ, &c., are outlined in red.

The position of the spinal cord varies with the movements of the vertebral column, its lower extremity being drawn slightly upwards when the column is flexed. It also varies at different periods of life: up to the third month of fœtal life the cord is as long as the canal in which it lies, but from this stage onwards the vertebral column elongates more rapidly than the cord, so that by the end of the fifth month the cord terminates at the base of the sacrum, and at birth about the level of the third lumbar vertebra.

The spinal cord does not nearly fill the canal in which it lies, being ensheathed by three protective membranes, separated from each other by two concentric spaces. The three membranes are named from without inwards the dura mater, the arachnoid membrane, and the pia mater. The *dura mater* is a strong, fibrous membrane which forms a wide, tubular sheath around the cord; this sheath extends below the termination of the cord and ends in a pointed *cul de sac* at the level of the lower

border of the second sacral vertebra. The dura mater is separated from the wall of the vertebral canal by a quantity of loose areolar tissue and a plexus of veins, while between it and the subjacent arachnoid membrane is a capillary interval, the *subdural space*, which contains a small quantity of fluid, probably of the nature of lymph. The *arachnoid membrane* is a thin, transparent sheath, separated from the pia mater by a comparatively wide interval, the *subarachnoid space*, which is filled with cerebro-spinal fluid. The *pia mater* closely invests the cord and sends delicate septa into its substance; a narrow band, the *ligamentum denticulatum*, extends along each of its lateral surfaces, and is attached by a series of pointed processes to the inner surface of the dura mater.

Fig. 672.—Sagittal section of spinal canal to show the lower end of the spinal cord and the filum terminale. (Testut.)

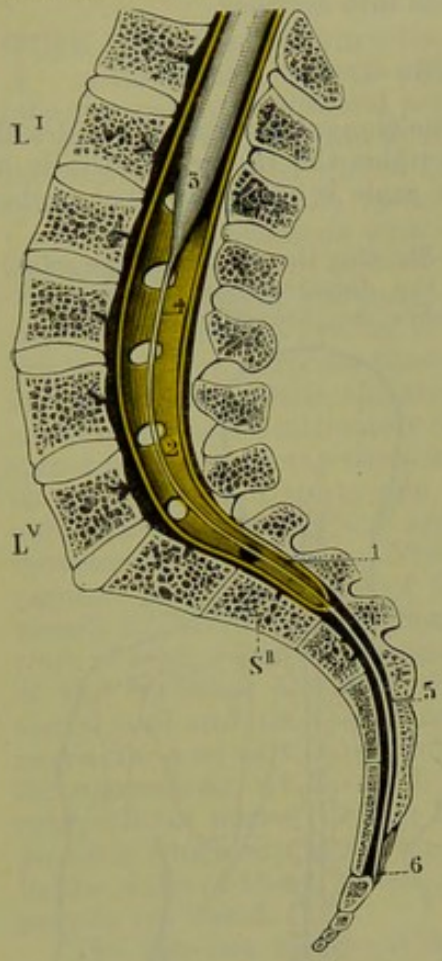

LI, LV. First and fifth lumbar vertebræ. SII. Second sacral vertebra. 1. Dura mater. 2. Lower part of tube of dura mater. 3. Lower extremity of spinal cord. 4, Intra-dural, and 5, Extra-dural portions of filum terminale. 6. Attachment of filum terminale to first segment of coccyx.

Fig. 673.—Cauda equina and filum terminale seen from behind. The dura mater has been opened and spread out, and the arachnoid membrane has been removed.

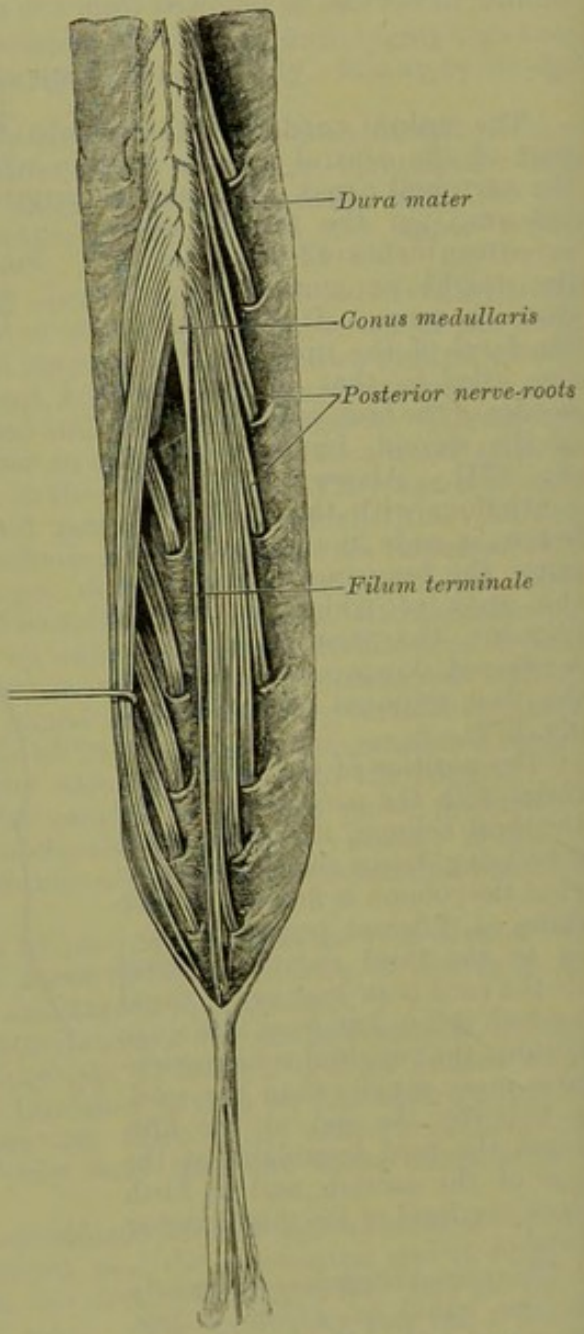

Thirty-one pairs of spinal nerves spring from the lateral aspects of the spinal cord, each nerve having an anterior or ventral, and a posterior or dorsal root, the latter being distinguished by the presence of an oval swelling, the *spinal ganglion*, which contains numerous nerve-cells. Each root consists of several bundles of nerve-fibres, and as these bundles pass inwards to reach the lateral aspect of the cord they diverge from each other so that the attachment of the nerve-root extends for some distance along the side of the cord. The pairs

of spinal nerves are grouped as follows: cervical 8, thoracic 12, lumbar 5, sacral 5, coccygeal 1, and, for convenience of description, the cord is divided into cervical, thoracic, lumbar and sacral regions, corresponding with these different groups of nerves.

Although no trace of transverse segmentation is visible on the surface of the spinal cord it is convenient to regard it as being built up of a series of superimposed *spinal segments* or *neuromeres*, each of which has a length equivalent to the extent of attachment of a pair of spinal nerves. Since the distance between the successive pairs of nerves varies in different parts of the cord, it follows that the spinal segments are of varying lengths; thus, in the cervical region they average about thirteen millimetres, in the mid-thoracic region about twenty-six millimetres, while in the lumbar and sacral regions they diminish rapidly from about fifteen millimetres at the level of the first pair of lumbar nerves to about four millimetres opposite the attachments of the lower sacral nerves.

As a consequence of the unequal rate of growth of the spinal cord and vertebral column, the nerve-roots, which at first passed transversely outwards to reach their respective intervertebral foramina, become more and more oblique in direction from above downwards, so that the lower part of the tubular sheath of dura mater is occupied by the lumbar and sacral nerves, which descend almost vertically to reach their points of exit. From the appearance these nerves present at their attachment to the cord and from their great length they are collectively termed the *cauda equina* (fig. 673).

The *filum terminale* is a delicate filament, about eight inches in length, prolonged downwards from the apex of the conus medullaris. It consists of two parts, an upper and a lower. The upper part, or *filum terminale internum*, measures about six inches in length and reaches as far as the lower border of the second sacral vertebra. It is contained within the tubular sheath of dura

FIG. 674.—Diagrams of the spinal cord.

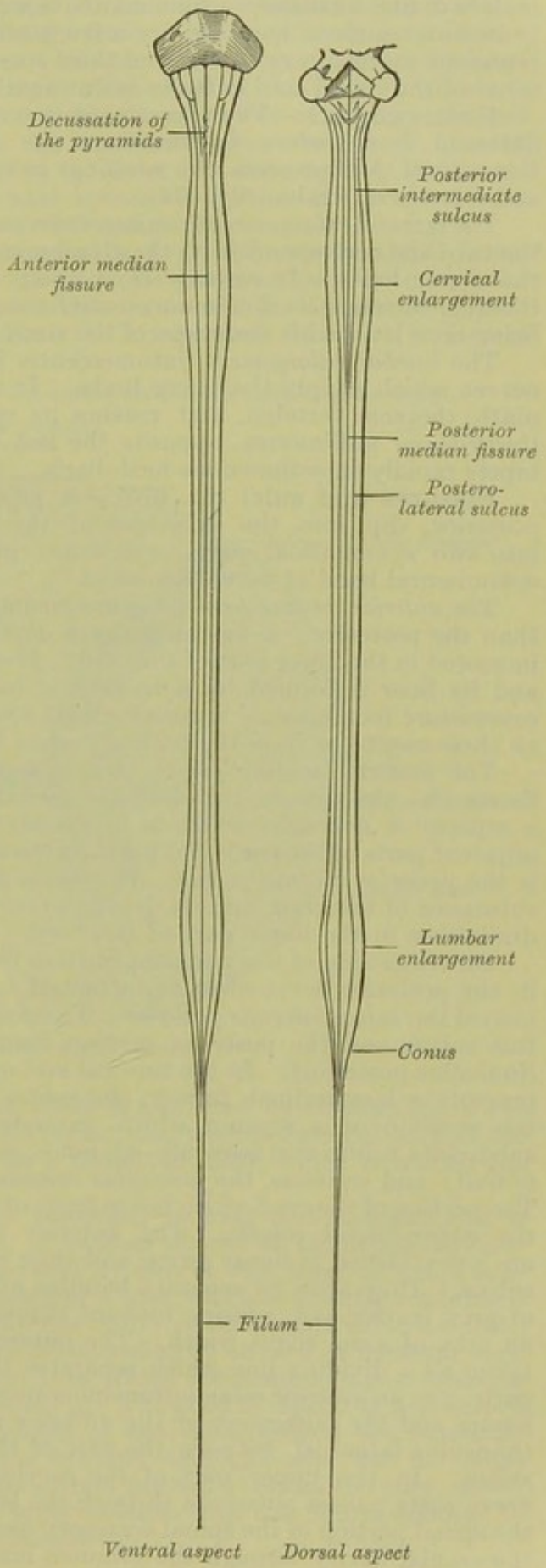

mater, and is surrounded by the nerves forming the cauda equina, from which it can be readily recognised by its bluish-white colour. The lower part, or *filum terminale externum*, is closely invested by, and is adherent to, the dura mater; it extends downwards from the apex of the sheath and is attached to the back of the first segment of the coccyx. The filum terminale consists mainly of fibrous tissue, continuous above with that of the pia mater. Adhering to its outer surface, however, are a few strands of nerve-fibres which probably represent rudimentary second and third coccygeal nerves; further, the central canal of the spinal cord extends downwards into it for two or three inches.

Enlargements.—The spinal cord is not quite cylindrical, being slightly flattened from before backwards; nor is it of uniform circumference throughout, but presents two swellings or enlargements, an upper or cervical, and a lower or lumbar (fig. 674).

The *cervical enlargement* (intumescentia cervicalis) is the more pronounced of the two, and corresponds with the attachments of the large nerves which supply the upper limbs. It extends from about the third cervical to the second thoracic vertebra, its maximum circumference (about thirty-eight millimetres) being on a level with the origin of the sixth pair of cervical nerves.

The *lumbar enlargement* (intumescentia lumbalis) gives attachment to the nerves which supply the lower limbs. It commences about the level of the ninth thoracic vertebra, and reaches its maximum circumference, of about thirty-three millimetres, opposite the last thoracic vertebra, below which it tapers rapidly into the conus medullaris.

Fissures and sulci (fig. 675).—A pair of median fissures, anterior and posterior, dip into the substance of the cord, and incompletely divide it into two symmetrical parts, which are joined across the middle line by a commissural band of nervous matter.

The *anterior median fissure* (fissura mediana anterior) is wider and shallower than the posterior: it has an average depth of three millimetres, but this is increased in the lower part of the cord. It contains a double fold of pia mater, and its floor is formed by a transverse band of white substance, the *white commissure* (commissura anterior alba), which is perforated by blood-vessels on their way to or from the central part of the cord.

The *posterior median fissure* (sulcus medianus posterior) is not an actual fissure like the anterior; it does not contain a fold of pia mater, but merely a septum of neuroglia which is intimately united with the neuroglia in the adjacent parts of the cord, and for this reason it would be more correct to name it the *posterior median septum*. It reaches rather more than halfway into the substance of the cord, and its depth varies from four to six millimetres, but diminishes in the lower part of the cord.

On either side of the posterior median fissure, and at a short distance from it, the posterior nerve-roots are attached to the cord along a vertical furrow named the *sulcus lateralis posterior*. The portion of the cord which lies between this sulcus and the posterior median fissure is named the *posterior column* (funiculus posterior). In the cervical and upper thoracic regions this column presents a longitudinal furrow, the *sulcus intermedius posterior*: this marks the position of a septum which extends into the posterior column and subdivides it into two fasciculi—an inner, named the *fasciculus gracilis* or *tract of Goll*; and an outer, the *fasciculus cuneatus* or *tract of Burdach* (see fig. 681). The portion of the cord which lies in front of the postero-lateral sulcus is termed the *antero-lateral column*. The anterior nerve-roots, unlike the posterior, are not attached in linear series, and their position of exit is not marked by a sulcus. They arise by separate bundles which spring from the anterior horn of grey matter and, passing forward through the white matter, emerge over an area of some slight width. The outermost of these bundles is generally taken as a dividing line which separates the antero-lateral column into two parts, viz. an *anterior column* (funiculus anterior), between the anterior median fissure and the outermost of the anterior nerve-roots; and a *lateral column* (funiculus lateralis), between the exit of these roots and the postero-lateral sulcus. In the upper part of the cervical region of the cord a series of nerve-roots passes outwards through the lateral column; these unite to form the spinal portion of the spinal accessory nerve, which runs upwards and enters the cranial cavity through the foramen magnum.

Internal Structure of the Spinal Cord

On examining a transverse section of the cord (fig. 675) it is seen to consist of grey and white nervous matter, the former being enclosed within the latter.

Grey matter.—The grey matter (substantia grisea) consists of two symmetrical portions, one in each half of the cord : these are joined across the middle line by a transverse band, termed the *grey commissure* (commissura grisea), through which runs a minute canal, the *canalis centralis* of the cord, just visible to the naked eye. Each half of the grey substance is shaped in the form of a comma or crescent, the concavity of which is directed outwards ; and these, together with the intervening grey commissure, present on transverse section the appearance of the letter H. An imaginary line drawn transversely through the central canal serves to divide each crescent into an anterior or ventral, and a posterior or dorsal cornu.

The **anterior cornu** (columna anterior) is directed forwards, and is broad and of a rounded or quadrangular shape. Its posterior part is termed the *base*, and its anterior part the *head*, but these are not differentiated from each other by any well-defined constriction. It is separated from the surface of

Fig. 675.—Transverse section of the spinal cord in the mid-thoracic region.

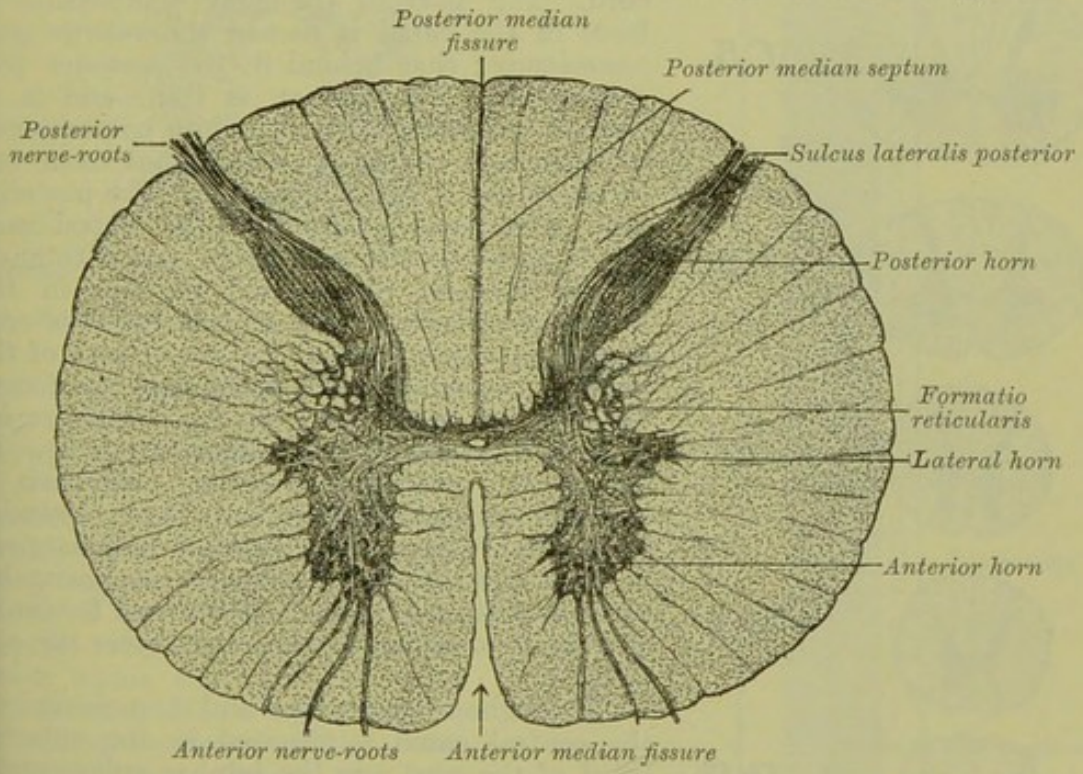

the cord by a layer of white matter which is traversed by the bundles of the anterior nerve-roots. In the thoracic region, the postero-external part of the anterior cornu projects outwards as a triangular field, which is named the **lateral cornu** (columna lateralis).

The **posterior cornu** (columna posterior) is long and slender, and is directed backwards and outwards : it reaches almost as far as the postero-lateral sulcus, from which it is separated by only a thin layer of white substance, the *tract of Lissauer*. It consists of a *base*, which is directly continuous with the corresponding part of the anterior horn ; a *neck* (cervix columnæ post.) or slightly constricted portion, which is succeeded by an oval or fusiform area, termed the *head* (caput columnæ post.), of which the summit (apex columnæ post.) approaches the postero-lateral sulcus. The head is capped by a V-shaped or crescentic mass of translucent, gelatinous neuroglia, termed the *substantia gelatinosa of Rolando*, which contains not only neuroglia-cells, but numerous small nerve-cells. Between the anterior and posterior cornua the grey matter extends as a series of processes for some distance into the lateral column, to form a network called the *formatio reticularis*.

The quantity of grey matter, as well as the form which it assumes on transverse section, varies markedly at different levels. It is small, not only in amount but relatively to the surrounding white substance, in the thoracic region. Its amount is greatly increased in the cervical and lumbar enlargements: in the latter, and especially in the conus medullaris, its proportion to the white matter is greatest (fig. 676). In the cervical region its posterior cornu remains comparatively narrow, while its anterior is broad and expanded; in the thoracic region, both cornua are attenuated, and the lateral horn is evident; in the lumbar enlargement, both cornua are expanded; while in the conus medullaris the grey matter assumes the form of two oval masses, one in each half of the cord, connected together by a broad grey commissure.

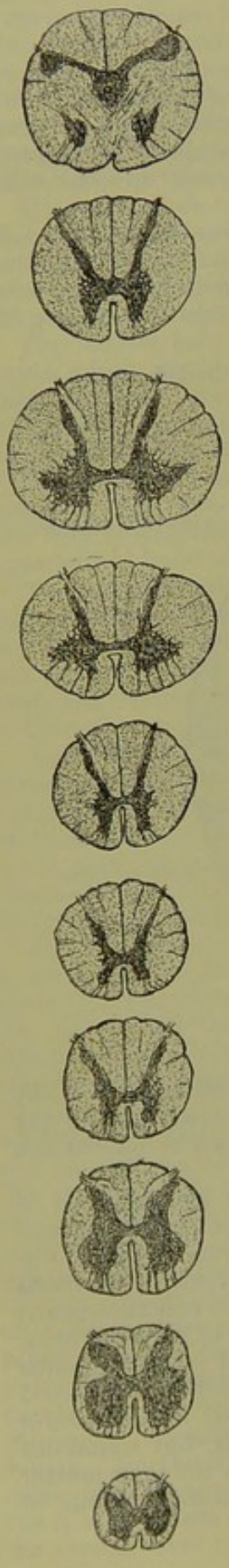

Fig. 676.—Transverse sections of the spinal cord at different levels.

The **central canal** runs in the grey commissure throughout the entire length of the cord. The part of the grey commissure in front of the canal is named the *anterior grey commissure*; that behind it, the *posterior grey commissure*. The former is thin, and is in contact anteriorly with the white commissure: it contains a couple of longitudinal veins, one on either side of the middle line. The posterior grey commissure reaches from the central canal to the posterior median septum, and is thinnest in the thoracic region, and thickest in the conus medullaris. The central canal is continued upwards through the lower part of the medulla oblongata, and opens into the fourth ventricle of the brain; below, it reaches for a short distance into the filum terminale. In the lower part of the conus medullaris it exhibits a fusiform dilatation, the *ventriculus terminalis*;* this has a vertical measurement of from eight to ten millimetres, is triangular on cross section with its base directed forwards, and tends to undergo obliteration after the age of forty.

Throughout the cervical and thoracic regions the central canal is situated in the anterior third of the cord: in the lumbar enlargement it is near the middle, and in the conus medullaris it approaches the posterior surface. It is filled with cerebro-spinal fluid, and is lined by ciliated, columnar epithelium, outside which is an encircling band of gelatinous substance, the *substantia gelatinosa centralis*. This gelatinous substance consists mainly of neuroglia, but contains a few nerve cells and fibres; it is traversed by processes from the deep ends of the columnar ciliated cells which line the central canal (fig. 677).

Structure of the grey matter.—The grey matter consists of neuroglia, together with numerous nerve-cells and nerve-fibres. Throughout the greater part of the grey matter the neuroglia presents the appearance of a sponge-

* *Archiv für micro. Anat.* 1875.

like network, but around the central canal and on the heads of the posterior cornua it consists of the gelatinous substance already referred to (fig. 677). The nerve-cells in the grey matter are multipolar, and vary greatly in size and shape (fig. 678). They consist of: (1) motor cells of large size, which are situated in the anterior horn, and are especially numerous in the cervical and lumbar enlargements; the axons of nearly all these cells pass out to form the anterior nerve-roots, but before leaving the white substance they frequently give off collaterals, which re-enter and ramify in the grey matter.* (2) Cells of small or medium size, whose axons do not emerge from the cord but pass into the white matter; here some assume an

Fig. 677.—Section of central canal of spinal cord, showing ependymal and neuroglial cells. (v. Lenhossek.)

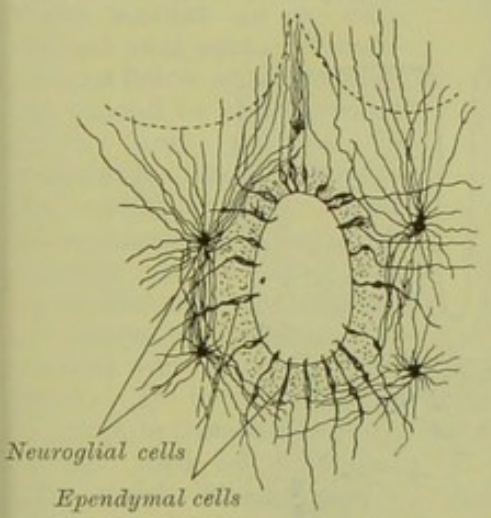

Fig. 678.—Cells of spinal cord. (Poirier.)

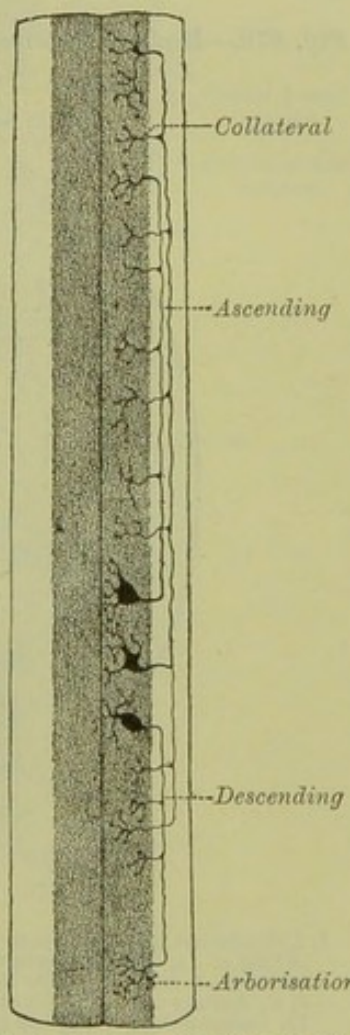

Diagram showing in longitudinal section the intersegmental neurons of the spinal cord. The grey and white parts correspond respectively to the grey and white substance of the spinal cord.

ascending, and others a descending course, but most of them divide in a T-shaped manner into descending and ascending processes. They give off collaterals which enter and ramify in the grey matter, and the terminations of the axons behave in a similar manner. The lengths of these axons vary greatly: some are short and pass only between adjoining segments of the cord, while others are longer and connect more distant segments. These cells and their processes constitute a series of *association* or *intersegmental neurons*, which link together the different parts of the cord. The axons of most of these cells are confined to that side of the cord in which the nerve-cells are situated, but some cross to the opposite side through the anterior commissure, and are termed *crossed commissural fibres*. Some of these latter end directly in the grey matter, while others enter the white matter, in which they ascend or descend for varying distances, before finally terminating in the grey matter. (3) Cells of the type II. of Golgi, limited to the posterior horn, and found in the substantia gelatinosa of Rolando, whose axons are short and entirely confined to the grey matter, in which they break up into numerous fine filaments.

* Lenhossek and Cajal found that in the chick embryo the axons of a few of these nerve-cells passed backwards through the posterior cornu, and emerged as the *motor fibres* of the *posterior nerve-roots*. These fibres are said to control the peristaltic movements of the intestine. Their presence, in man, has not yet been determined.

Most of the nerve-cells are arranged in longitudinal columns, which appear as groups on transverse section (figs. 679, 680).

Nerve-cells in the anterior horn.—The nerve-cells in the anterior horn are arranged in columns of varying length, and appear in groups in successive transverse sections of the cord. The longest of these cell-columns occupies the mesial part of the anterior horn, and is named the *antero-mesial*: it is absent only in the fifth lumbar, the first sacral and the upper part of the second sacral segments (Bruce).* Behind it is a *dorso-mesial* column of small cells, which extends from the second thoracic to the first lumbar segment, and is also present in the first, sixth, and seventh cervical segments.

In the cervical and lumbar enlargements, where the anterior horn is expanded in a lateral direction, the following additional columns are present: viz.: (*a*) *antero-lateral*, in the fourth, fifth, and sixth cervical and the second

FIG. 679.—Mode of distribution of the nerve-cells in the grey matter. (Schematic.) (Testut.)

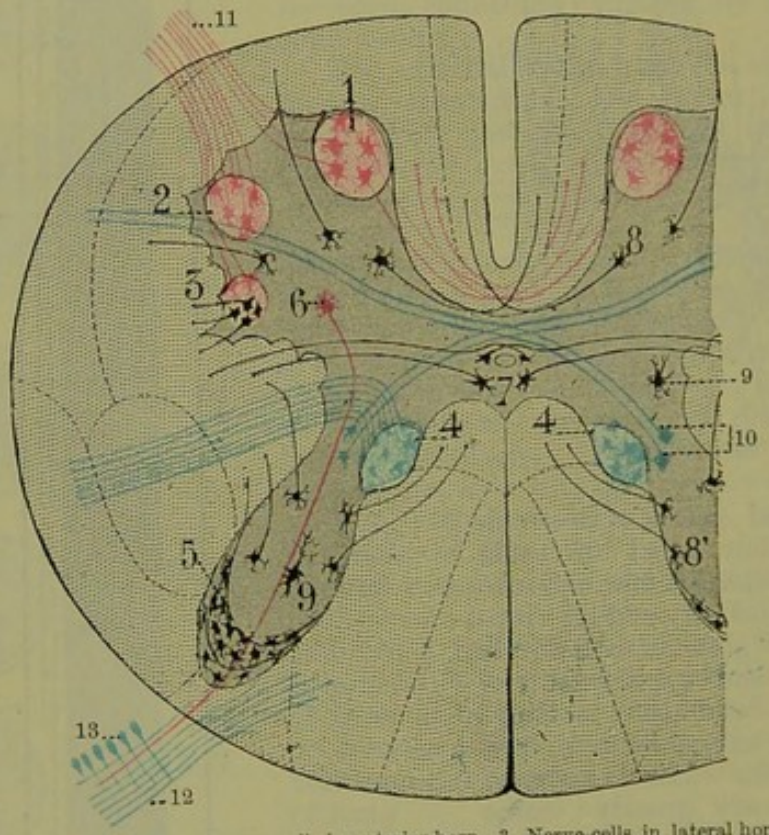

1, 2. Mesial and lateral groups of nerve-cells in anterior horn. 3. Nerve-cells in lateral horn. 4, 4. Column of Clarke. 5. Group of nerve-cells in substantia gelatinosa of Rolando. 6. Nerve-cell of anterior horn, the axon of which is passing into the posterior nerve-root. 7. Cells of substantia gelatinosa centralis. 8, 8'. Solitary cells. 9. Cells of Golgi. 10. Cells of origin of the tract of Gowers. 11. Anterior root. 12. Posterior root. 13. Spinal ganglion.

thoracic segments, and in the lower four lumbar and upper two sacral segments; (*b*) *postero-lateral*, in the lower five cervical, lower four lumbar, and upper three sacral segments; (*c*) *post-postero-lateral*, in the last cervical, first thoracic, and upper three sacral segments; and (*d*) a *central*, in the lower four lumbar and upper two sacral segments. Solitary cells are scattered throughout the base of the anterior horn, the axons of some of which form crossed commissural fibres, while others constitute the motor fibres of the posterior nerve-root. (See footnote, page 801).

Nerve-cells in the lateral horn.—These form a column which is best marked where the lateral horn of grey matter is differentiated, viz. in the thoracic region; but it can be traced throughout the entire length of the cord,† in the form of groups of small cells which are situated in the anterior part of the

* *Topographical Atlas of the Spinal Cord.* 1901.

† According to Bruce and Pirie (*B.M.J.* Nov. 17, 1906) this column extends from the middle of the eighth cervical segment to the lower part of the second lumbar or the upper part of the third lumbar segment.

formatio reticularis. The cells of this column are fusiform or star-shaped, and of a medium size : the axons of some of them pass into the anterior nerve-roots, by which they are carried to the sympathetic nerves ; while those of others pass into the anterior and lateral columns, where they become longitudinal.

Nerve-cells in the posterior horn.—1. The *column of Clarke* (*posterior vesicular column*). — This occupies the inner part of the base of the posterior horn, and appears on transverse section as a well-defined oval area. It commences below at the level of the second or third lumbar nerve, and reaches its maximum size opposite the twelfth thoracic nerve. Above the level of the ninth thoracic nerve its size diminishes, and the column terminates opposite the last cervical or first thoracic nerve. It is represented, however, in the other regions of the cord by scattered cells, which become aggregated to form a *cervical nucleus* opposite the third cervical nerve, and a *sacral nucleus* in the middle and lower part of the sacral region. Its cells are of medium size, and of an oval or pyriform shape ; their axons pass into the peripheral part of the lateral column of the same side, and there ascend, under the name of the *direct* or *ascending cerebellar tract*. 2. *Nerve-cells in the substantia gelatinosa of Rolando.* —These are arranged in three zones : a posterior or marginal zone, composed of large triangular or fusiform cells ; an intermediate zone of small fusiform cells ; and an anterior zone of star-shaped cells. The axons of these cells pass into the lateral and posterior columns, and there assume a vertical course. In the anterior zone some Golgi cells are found whose short axons ramify in the grey matter. 3. *Solitary cells* of varying form and size are scattered throughout the posterior horn. Some of these are grouped to form

FIG. 680.—Transverse sections of the spinal cord at different levels to show the arrangement of the principal cell-columns.

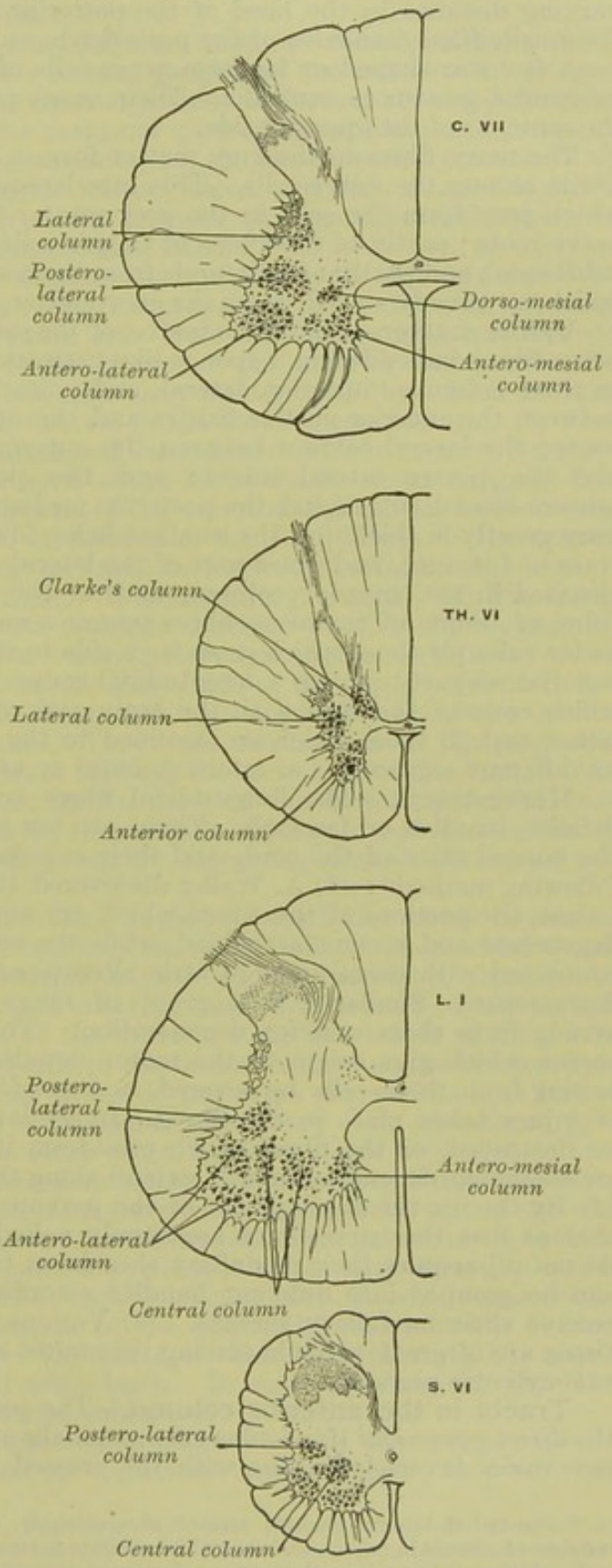

the *posterior basal column* in the base of the posterior horn and on the outer side of Clarke's column. The posterior basal column is well marked in the gorilla (Waldeyer), but is ill-defined in man. The axons of these cells pass partly to the posterior and lateral columns of the same side, and partly through the anterior commissure to the lateral column of the opposite side. Before leaving the grey matter, a considerable number run longitudinally for a varying distance in the head of the posterior horn, forming what is termed the *longitudinal fasciculus* of the posterior horn.

A few star-shaped or fusiform nerve-cells of varying size are found in the substantia gelatinosa centralis. Their axons pass into the lateral column of the same, or of the opposite side.

The nerve-fibres in the grey matter form a dense interlacement of minute fibrils among the nerve-cells. This interlacement is formed partly of axons which pass from the cells in the grey matter to enter the white columns or nerve-roots ; partly of the axons of Golgi's cells which ramify only in the grey substance ; and partly of collaterals from the nerve-fibres in the white columns, which, as already stated, enter the grey matter and ramify within it.

White matter.—The white matter of the spinal cord consists of medullated nerve-fibres imbedded in a sponge-like network of neuroglia, and is arranged in three columns : anterior, lateral, and posterior. The anterior column lies between the anterior median fissure and the outermost of the anterior nerve-roots ; the lateral column between the outermost of the anterior nerve-roots and the postero-lateral sulcus; and the posterior column between the postero-lateral sulcus and the posterior median fissure (fig. 681). The fibres vary greatly in thickness, the smallest being found in the fasciculus gracilis, the tract of Lissauer, and inner part of the lateral column ; while the largest are situated in the anterior column, and in the peripheral part of the lateral column. Some of the nerve-fibres assume a more or less transverse direction, as for example those which cross from side to side in the anterior commissure, but the majority pursue a longitudinal course and are divisible into (1) those which connect the cord with the brain and convey impulses to or from the latter, and (2) those which are confined to the spinal cord and link together its different segments (i.e. intersegmental or association fibres).

Nerve-tracts.—The longitudinal fibres are grouped into more or less definite bundles or fasciculi. These are not recognisable from each other in the normal state of the cord, and their existence has been determined by the following methods : (1) A. Waller discovered that if a bundle of nerve-fibres be cut, the portions of the fibres which are separated from their cells rapidly degenerate and become atrophied, while the cells and the parts of the fibres connected with them undergo little alteration.* This is known as *Wallerian degeneration*. Similarly, if a group of nerve-cells be destroyed, the fibres arising from them undergo degeneration. Thus, if the cells of the cerebral cortex which give origin to the motor impulses be destroyed, or if the fibres arising from these cells be severed, a *descending* degeneration from the seat of injury takes place in the fibres. In the same manner, if a spinal ganglion be destroyed, or the fibres which pass from it into the spinal cord be cut, an *ascending* degeneration will extend along these fibres into the spinal cord. (2) By tracing the development of the nervous system, it has been observed that at first the nerve-fibres are merely naked axis-cylinders, and that they do not all acquire their medullary sheaths at the same time ; hence the fibres can be grouped into different bundles according to the dates at which they receive their medullary sheaths. (3) Various methods of staining nervous tissue are of great value in tracing the course and mode of termination of the axis-cylinder processes.

Tracts in the anterior column.—The principal tract in this column is the *direct pyramidal* (fasciculus corticospinalis anterior), which is usually small, but varies inversely in size with the crossed pyramidal tract. It lies close

* Somewhat later a change, termed *chromatolysis*, takes place in the nerve-cells, and consists of a breaking down and an ultimate disappearance of the Nissl bodies. Further, the body of the cell is swollen, the nucleus displaced towards the periphery, and the part of the axon still attached to the altered cell is diminished in size and somewhat atrophied. Under favourable conditions the cell is capable of reassuming its normal appearance, and its axon may grow again.

to the anterior median fissure, and is present only in the upper part of the cord; gradually diminishing in size as it descends, it terminates about the middle of the thoracic region. It consists of descending fibres which arise from cells in the motor area of the cerebral hemisphere of the same side, and which, as they run downwards in the cord, cross in succession through the white commissure to the opposite side, where they end by arborising around the motor cells in the anterior cornu.

In addition to the direct pyramidal tract there are strands of fibres in the anterior column, which connect certain ganglia in the brain with the grey matter of the spinal cord. The most important of these is the *vestibulo-spinal tract*, which occupies chiefly the marginal part of the column and is mainly derived from the cells of Deiter's nucleus, i.e. the chief terminal nucleus of the vestibular division of the eighth cranial nerve. Of the other descending fibres some pass downwards from the corpora quadrigemina and others are continuous with the posterior longitudinal bundle.

The remaining fibres of the anterior column constitute what is termed the *anterior basis bundle* (fasciculus anterior proprius). It consists of (*a*) longitudinal intersegmental fibres which arise from cells in the grey matter, more especially from those of the mesial group of the anterior horn, and, after a longer or shorter course, re-enter the grey matter; (*b*) fibres from the grey matter of the opposite side, which cross in the anterior commissure; (*c*) fibres arising from cells of the cerebellum and extending down the cord to terminate round the cells of the anterior horn—these fibres constitute an irregular tract disposed in the peripheral portions of the anterior and lateral basis bundles (*descending cerebello-spinal tract of Löwenthal*); and (*d*) fibres of the anterior nerve-roots which run obliquely forwards to reach the surface of the cord.

Tracts in the lateral column.—1. **Descending tracts.**—(*a*) The *crossed pyramidal tract* (fasciculus corticospinalis dorsalis) extends throughout the entire length of the cord, and on transverse section appears as an oval area in front of the posterior horn and on the mesial side of the direct cerebellar tract. It consists of fibres which arise from cells in the motor area of the cerebral hemisphere of the opposite side. They pass downwards in company with those of the direct pyramidal tract through the same side of the brain as that from which they originate, but, unlike those of the direct pyramidal tract, they cross to the opposite side in the medulla oblongata and descend in the lateral column of the cord; they end by arborising around the motor cells in the anterior horn.*

The crossed and direct pyramidal tracts constitute the motor fasciculi of the spinal cord and have their origins in the motor cells of the cerebral cortex. They descend through the internal capsule of the cerebrum, traverse the crus cerebri and pons Varolii and enter the anterior pyramid of the medulla oblongata. In the lower part of the medulla some two-thirds of them cross the middle line and run downwards in the lateral column as the crossed pyramidal tract, while the remaining fibres do not cross the middle line, but are continued into the same side of the cord, where they form the direct pyramidal tract. The fibres of the latter tract, however, have been seen to cross the middle line in the anterior commissure of the cord and thus the motor fibres from one side of the brain ultimately reach the opposite side of the cord. The proportion of fibres which cross in the medulla oblongata is not a constant one and thus the direct and crossed pyramidal tracts vary inversely in size. Sometimes the direct pyramidal tract is absent, and in such cases it may be presumed that the decussation of the pyramidal fibres in the medulla oblongata has been complete. The fibres of these two tracts do not acquire their medullary sheaths until after birth. In some animals the pyramidal fibres are situated in the posterior column of the cord.

(*b*) The *rubro-spinal tract* (tract of Monakow) lies on the ventral aspect of the crossed pyramidal tract and on transverse section appears as a somewhat

* It is probable (Schäfer, *Proc. Physiolog. Soc.* 1899) that the fibres of the direct and crossed pyramidal tracts are not related in this direct manner with the cells of the anterior horn. They terminate by arborising round the cells at the base of the posterior horn and the cells of Clarke's column, which in turn link them to the motor cells in the anterior horn, usually of several segments of the cord. In consequence of these interposed neurons the fibres of the pyramidal tracts correspond not to individual muscles, but to associated groups of muscles.

triangular area. Its fibres descend from the mid-brain, where they have their origin in the red nucleus of the tegmentum of the opposite side.

(*c*) The *tecto-spinal tract* originates in the upper quadrigeminal body of the opposite side, and its fibres are partly intermingled with those of the rubro-spinal tract, and are partly contained in the anterior column.

(*d*) The *olivo-spinal tract* or tract of Helweg arises in the vicinity of the inferior olivary body in the medulla oblongata and is seen only in the cervical region of the cord, where it forms a small triangular area at the periphery of the cord close to the outermost of the anterior nerve-roots. Its exact origin and its mode of ending have not yet been definitely made out.

2. **Ascending tracts.**—(*a*) The *direct cerebellar tract of Flechsig* (tractus spinocerebellaris dorsalis) is situated at the periphery of the posterior part of the lateral column of the cord, and on transverse section appears as a flattened band which extends as far forwards as a line drawn transversely through the central canal. Internally it is in contact with the crossed pyramidal tract,

Fig. 681.—Diagram of the principal tracts in the spinal cord.

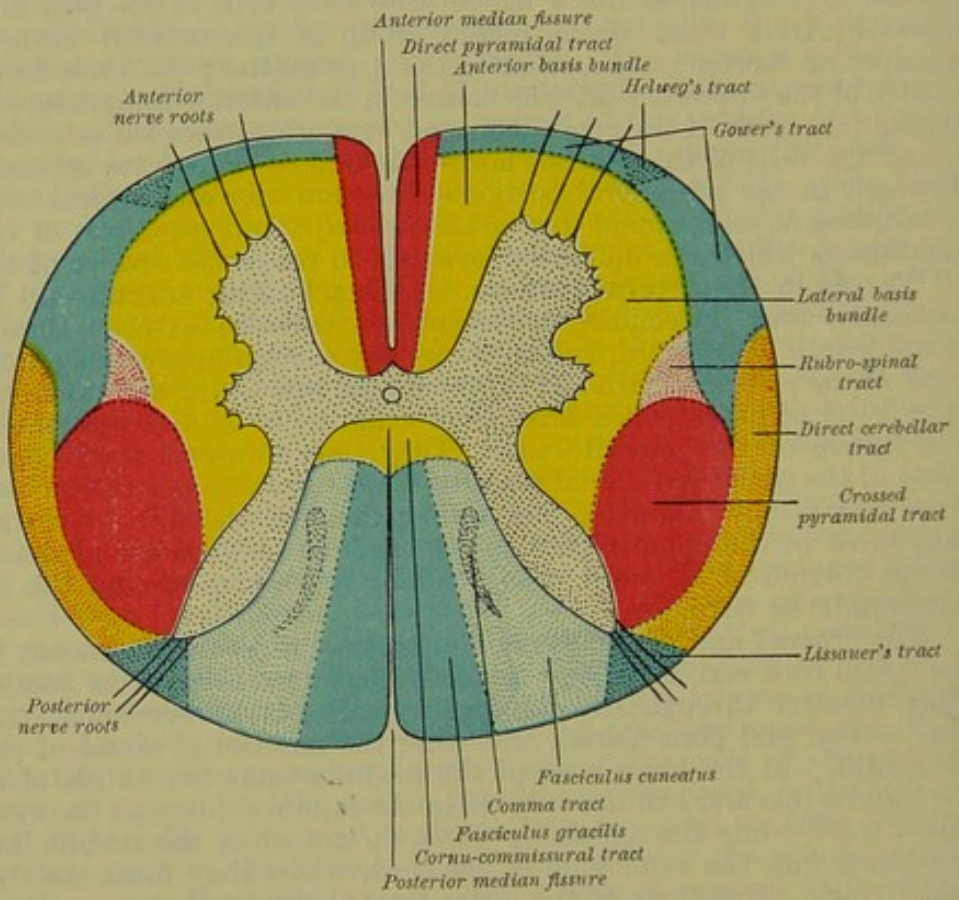

behind, with the tract of Lissauer. It commences below about the level of the second or third lumbar nerve and, increasing in size as it ascends, passes to the cerebellum through the inferior peduncle. Its fibres are generally regarded as being formed by the axons of the cells of Clarke's column; they receive their medullary sheaths about the sixth or seventh month of fœtal life.

(*b*) The *tract of Gowers* (fasciculus anterolateralis superficialis) skirts the periphery of the lateral column in front of the direct cerebellar tract. In transverse section it is shaped somewhat like a comma, the expanded end of which lies in front of the crossed pyramidal tract while the tail reaches forwards into the anterior column. Its fibres come from the opposite side of the cord and cross in the anterior commissure; they are derived from the cells of Clarke's column and from the cells of the posterior horn. The tract of Gowers commences about the level of the third pair of lumbar nerves, and, increasing in size as it ascends, can be followed upwards into the medulla oblongata and pons. It consists of three fasciculi: (1) the *fasciculus spinocerebellaris ventralis*, the largest of the three, which passes to the cerebellum by way of its superior peduncles; (2) the *spino-thalamic tract*, which ends in the thalamus,

and is sometimes termed the *secondary sensory tract*; and (3) the *spino-tectal tract*, which passes to the corpora quadrigemina.

(*c*) The *tract of Lissauer* is a small strand situated in relation to the tip of the posterior horn close to the entrance of the posterior nerve-roots. It consists of fine fibres which do not receive their medullary sheaths until towards the close of fœtal life. It is usually regarded as being formed by some of the fibres of the posterior nerve-root, which ascend for a short distance in the tract and then enter the posterior horn, but since its fibres are myelinated later than those of the posterior nerve-roots, and do not undergo degeneration in locomotor ataxia, they are probably intersegmental in character.

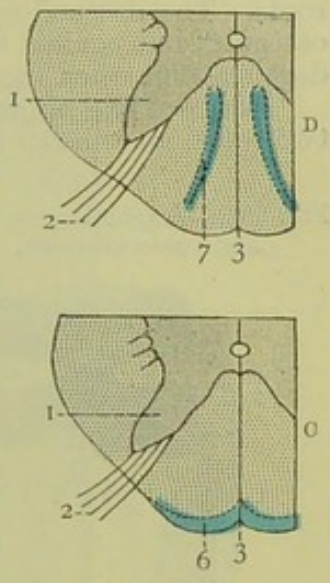

FIG. 682. — Descending fibres in the posterior column, shown at different levels. (Testut.)

A. In the conus medullaris. B. In the lumbar region. C. In the lower thoracic region. D. In the upper thoracic region. 1. Posterior horn. 2. Posterior nerve-roots. 3. Posterior median fissure. 4. Triangular strand. 5. Oval area of Flechsig. 6. Dorsal peripheral band. 7. Descending comma tract.

(*d*) The *lateral basis bundle* constitutes the remainder of the lateral column, and the portion of it which lies next the grey matter is sometimes named the *lateral limiting zone*. It is continuous in front with the anterior basis bundle, and the two together constitute the *antero-lateral ground bundle*. It consists chiefly of intersegmental fibres which arise from cells in the grey matter, and, after a longer or shorter course, re-enter the grey matter and ramify in it. Some of its fibres are, however, continued upwards into the brain under the name of the dorsal or posterior longitudinal fasciculus.

Tracts in the posterior column.—This column comprises two main tracts, viz. the fasciculus gracilis, and the fasciculus cuneatus. These are separated from each other in the cervical and upper thoracic regions by the postero-intermediate septum, and consist mainly of ascending fibres derived from the posterior nerve-roots.

The *fasciculus gracilis* (tract of Goll) is wedge-shaped on transverse section, and lies next the posterior median fissure, its base being at the surface of the cord, and its apex directed towards the posterior grey commissure. It increases in size from below upwards, and consists of long thin fibres derived from the posterior nerve-roots, which ascend as far as the medulla oblongata, where they end in the nucleus gracilis.

The *fasciculus cuneatus* (tract of Burdach) is triangular on transverse section, and lies between the fasciculus gracilis and the posterior cornu, its base corresponding with the surface of the cord. Its fibres, larger than those of the fasciculus gracilis, are mostly derived from the same source, viz. the posterior nerve-roots. Some ascend for only a short distance in the tract, and, entering the grey matter, come into close relationship with the cells of Clarke's column; while others can be traced as far as the medulla oblongata, where they end in the gracile and cuneate nuclei.

Occupying the ventral part of the posterior column is a strand of fibres termed the *cornu-commissural tract*. It is somewhat triangular on transverse section, and occupies the angle between the posterior grey commissure and the posterior cornu. It is best marked in the lumbar region, but can be traced into the thoracic and cervical regions. Its fibres, derived from the cells of the posterior horn, divide into ascending and descending branches which re-enter and ramify in the grey matter. It has been found to preserve its integrity in certain cases of locomotor ataxia.

Descending fibres in the posterior column (fig. 682).—The posterior column contains some descending fibres which occupy different parts of the column at

different levels. In the cervical and upper thoracic regions, they appear as a comma-shaped strand (*descending comma tract* of Schultze) in the outer part of the fasciculus cuneatus, the blunt end of the comma being directed towards the posterior grey commissure; in the lower thoracic region they form a thin band (*dorsal peripheral band*) on the posterior surface of the column; in the lumbar region, they are situated by the side of the posterior median fissure, and here appear on section as a semi-elliptical bundle, which, together with the corresponding bundle of the opposite side, forms the *oval area of Flechsig*; while in the conus medullaris they assume the form of a *triangular strand* in the postero-internal part of the fasciculus gracilis. These descending fibres are mainly intersegmental in character, and derived from cells in the posterior horn, but some may consist of the descending branches of the posterior nerve-roots. The descending comma tract was supposed to belong to the second category, but against this view is the fact that it does not undergo descending degeneration when the posterior nerve-roots are destroyed.

Roots of the spinal nerves.—As already stated, each spinal nerve possesses two roots, an anterior and a posterior, which are attached to the surface of the cord opposite the corresponding horn of grey matter (fig. 683); their fibres become medullated about the fifth month of fœtal life.

Fig. 683.—A spinal nerve with its anterior and posterior roots. (Testut.)

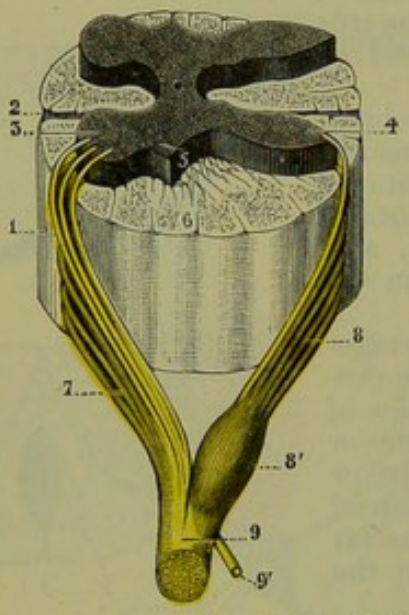

1. A portion of the spinal cord viewed from the left side. 2. Anterior median fissure. 3. Anterior horn. 4. Posterior horn. 5. Lateral horn. 6. Formatio reticularis. 7. Anterior root. 8. Posterior root, with 8', its ganglion. 9. Spinal nerve; 9', its posterior division.

The *anterior nerve-roots* consist of *efferent* fibres, which are the axons of the nerve-cells in the ventral part of the anterior horn. A short distance from their origins, these axons are invested by medullary sheaths and, passing forwards and slightly outwards, emerge on the surface of the cord in two or three irregular rows over an area which measures about three millimetres in width.

The *posterior root* of each spinal nerve comprises some six or eight fasciculi which are attached in linear series along the postero-lateral sulcus. It consists of afferent fibres which arise from the nerve-cells in the spinal ganglia. Each ganglion-cell, at first round or oval, is elongated into two processes, an internal (axon) and an external (dendrite), and so becomes a bipolar nerve-cell. These two processes gradually undergo approximation, and finally arise from a single stem in a T-shaped manner. The internal processes of the ganglion-cells grow into the cord as the posterior roots of the spinal nerves, while the external are directed towards the periphery.

The posterior nerve-root enters the cord in two chief bundles, mesial and lateral. The *mesial* strand passes directly into the fasciculus cuneatus: it consists of coarse fibres, which acquire their medullary sheaths by the fifth month of intra-uterine life. The *lateral* strand is sometimes divided into an intermediate and an external bundle. The intermediate bundle consists of coarse fibres, which enter the gelatinous substance of Rolando; while the external is composed of fine fibres, which assume a longitudinal direction in the tract of Lissauer; the latter do not acquire their medullary sheaths until after birth.

Having entered the cord, all the fibres of the posterior nerve-roots divide into ascending and descending branches, and these in their turn give off collaterals which enter the grey matter (fig. 684). The descending fibres are short, and soon enter the grey matter. The ascending fibres are grouped into long, short, and intermediate: the long fibres ascend in the fasciculus gracilis and fasciculus cuneatus as far as the medulla, where they end by arborising around the cells of the gracile and cuneate nuclei; the short fibres run upwards for a distance

of only five or six millimetres, and enter the grey matter; while the intermediate fibres, after a somewhat longer course, have a similar destination. All the fibres which enter the grey matter end by arborising around its nerve-cells, those of intermediate length being especially associated with the cells of Clarke's column.

The course taken by the fibres of the posterior nerve-roots has been arrived at by dividing the nerve-roots between their ganglia and their entrance into

Fig. 684.—Dorsal roots entering cord and dividing into ascending and descending branches. (Van Gehuchten.)

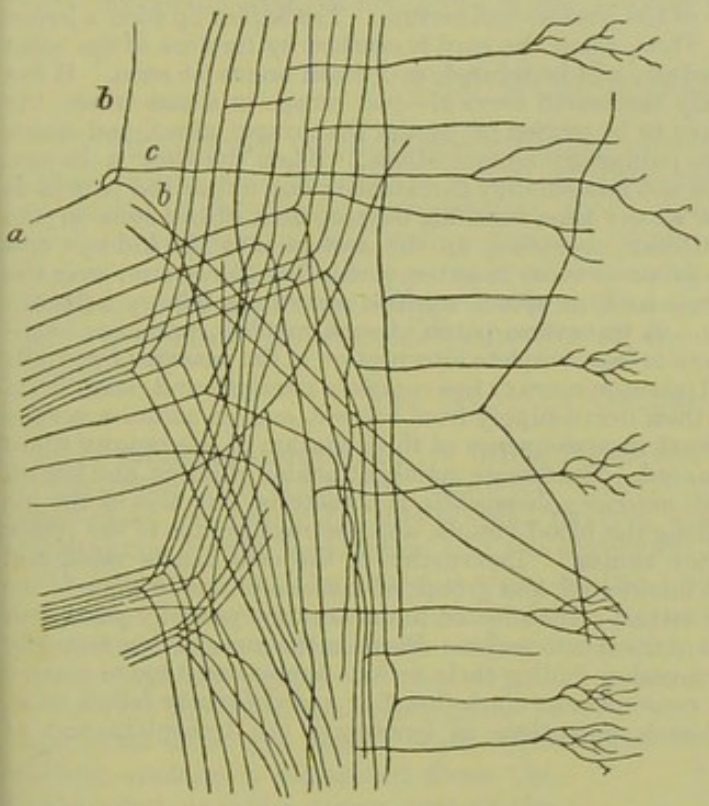

a. Stem-fibre. *b, b*. Ascending and descending limbs of bifurcation. *c*. Collateral arising from stem-fibre.

Fig. 685.—Formation of the fasciculus gracilis. (Poirier.)

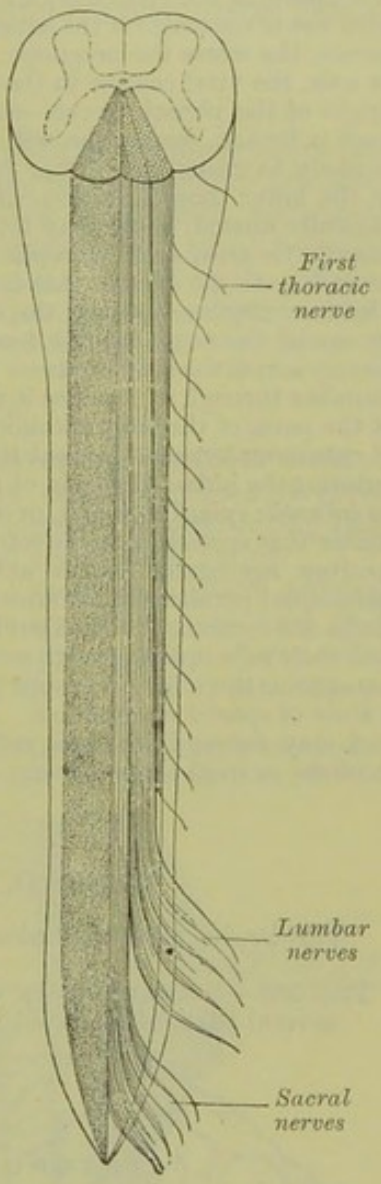

Spinal cord viewed from behind. To the left, the fasciculus gracilis is shaded. To the right, the drawing shows that the fasciculus gracilis is formed by the long fibres of the posterior roots, and that in this tract the sacral nerves lie next the mesial plane, the lumbar to their outer side, and the thoracic still more laterally.

the spinal cord, and by subsequently examining the degenerated areas. It has been determined that the fibres pursue an oblique course upwards, being situated at first in the outer part of the fasciculus cuneatus: higher up, they occupy the middle of this fasciculus, having been displaced inwards by the accession of other entering fibres; while still higher, they pass into, and are continued upwards in, the fasciculus gracilis. The upper cervical fibres do not reach this fasciculus, but are entirely confined to the fasciculus cuneatus. The degeneration method proves that the localisation of these fibres is very precise: the sacral nerves lie in the inner part of the fasciculus gracilis and near its periphery; the lumbar nerves to their outer side; the thoracic nerves still more laterally; while the cervical nerves are confined to the fasciculus cuneatus (fig. 685).

The **development** of the spinal cord is described in the section on Embryology (page 115)

Applied Anatomy.—Several cases have been recorded * in which a local doubling of the spinal cord has taken place. The condition is probably due to some interference with the development of the medullary tube in the embryo; in a few it was associated

* For a complete analysis of these cases consult paper by Bruce, Stuart McDonald, and Pirie, *Review of Neurology and Psychiatry*, Jan. 1906.

with spina bifida, while in one recent case * the two parts were separated by a dermoid tumour. Other *congenital abnormalities* of the spinal cord occur in connection with spina bifida (see page 201), and also in *syringomyelia*. In this latter chronic condition an abnormal proliferation of the spinal neuroglia takes place, generally near the central canal and in the cervical enlargement, and later this mass becomes absorbed, leaving an irregular cavity in its place. This gives rise to a number of interesting signs and symptoms, such as analgesia (or insensitiveness to pain), inability to distinguish between cold and heat, progressive atrophy in the muscles of the hands and arms, trophic changes in the bones and joints, and painless whitlows. Severe *injuries* to the cord may occur in fractures or fracture-dislocations of the vertebral column anywhere above the second lumbar vertebra. If the cord is completely crushed or torn across, total paralysis and anæsthesia of all parts of the body drawing their nerve supply from below the injured spot will follow, with loss of control over the actions of the bladder and rectum. The higher up such a lesion occurs, the worse the prognosis. Thus, when the cord is crushed by fracture of the atlas or axis, the vital centres in the medulla will be injured, and death occurs at once. If the origin of the phrenic nerve—mainly the fourth cervical—just escape in a case where the neck is broken, respiration will have to be carried on by the Diaphragm alone, and death is likely to ensue before long from pulmonary complications. When the back is broken in the lower thoracic region, life is not immediately threatened; but unless the patient is carefully nursed, death may follow at any time from the development of bed-sores in the anæsthetic area, or from septic infection spreading up the ureters into the kidneys and secondary to the cystitis that is so prone to occur in patients who have no control over the bladder. *Inflammation* of the spinal cord, or *spinal myelitis*, sometimes follows influenza or one of the acute specific fevers. A transverse patch of such myelitis extending completely across the cord produces more or less complete interruption of the passage of nervous impulses through it. Hence it will occasion more or less complete paralysis and anæsthesia of the parts of the body obtaining their nerve-supply from below it, and, in addition, a zone of cutaneous hyperæsthesia at its level, in consequence of the irritation of the sensory fibres entering the inflamed region of the cord. The disease mainly attacking children, and known as *infantile spinal paralysis*, or *acute anterior poliomyelitis*, is a bacterial infection of the pia mater that spreads into the cord along the blood-vessels, and destroys groups of the motor neurons aggregated in the anterior cornua. Destruction of the cells causes rapid and permanent paralysis of the muscles innervated, and groups of muscles in one or more of the limbs are commonly picked out for attack. The affected limbs are thus partially paralysed, and their subsequent growth and nutrition both suffer. Further, the muscles that normally antagonise the affected groups of muscles, finding their actions unopposed, tend to assume a state of spastic contraction. In consequence, much dwarfing and deformity follow later, and may demand for their relief such operations as tenotomy, the transplantation of tendons, or even amputation.

THE BRAIN

General Considerations and Divisions

The brain, or encephalon, is contained within the cranium, and constitutes the upper, greatly expanded part of the central nervous system. In its early embryonic condition it consists of three hollow vesicles, termed the *fore-brain*, the *mid-brain*, and the *hind-brain*; and the parts derived from each of these can be recognised in the adult (fig. 686). Thus, in the process of development the wall of the hind-brain (rhombencephalon) undergoes modification to form the medulla oblongata, the pons Varolii, and cerebellum, while its cavity is expanded to form the fourth ventricle. The mid-brain (mesencephalon) forms but a small part of the adult

Fig. 686.—Scheme showing the connections of the several parts of the brain. (After Schwalbe.)

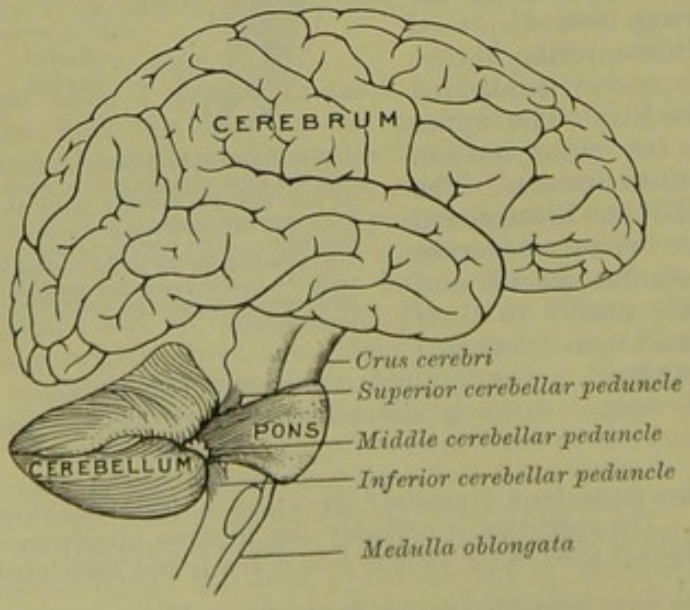

* Harriehausen, *D. Ztschrft. f. Nervenheilk.*, Bd. 36, Hft. 3 and 4, S. 268.

brain : its cavity becomes the aqueduct of Sylvius, which serves as a tubular communication between the third and fourth ventricles ; while its walls are thickened to form the corpora quadrigemina and crura cerebri, which constitute the bond of union of the fore-brain with the hind-brain. The fore-brain undergoes great modification : its anterior part (telencephalon) expands laterally in the form of two hollow vesicles the cavities of which become the lateral ventricles, while the surrounding walls form the cerebral hemispheres and their commissures ; the cavity of the posterior part of the fore-brain (diencephalon) forms the greater part of the third ventricle, and from its walls are developed most of the structures which bound that cavity. Further details regarding these important changes are given in the chapter on Embryology (page 118).

THE HIND-BRAIN

The **hind-brain** or **rhombencephalon** occupies the posterior fossa of the cranial cavity and lies below a fold of dura mater, the tentorium cerebelli. It consists of (*a*) the *myelencephalon*, which comprises the medulla oblongata and the lower part of the fourth ventricle ; (*b*) the *metencephalon*, which includes the pons, cerebellum, and upper part of the fourth ventricle ; and (*c*) the *isthmus rhombencephali*, a constricted portion immediately adjoining the mesencephalon, which comprises the superior peduncles of the cerebellum and the valve of Vieussens.

The Medulla Oblongata

The **medulla oblongata,** or **bulb,** forms the lowest and smallest division of the brain ; its structure, however, is extremely complex, since it gives attachment to many of the cranial nerves, and forms the connecting link between the spinal cord below and the cerebrum and cerebellum above.

It extends from the lower margin of the pons Varolii to a plane passing transversely below the decussation of the pyramids and above the first pair of cervical nerves ; this plane corresponds with the upper border of the atlas behind, and the middle of the odontoid process of the axis in front, and at this level the medulla oblongata is continuous with the spinal cord. Its anterior surface is separated from the basi-occiput and the upper part of the odontoid process of the axis by the membranes of the brain and the occipito-axial ligaments. Its posterior surface is received into the fossa between the hemispheres of the cerebellum, and the upper portion of it forms the lower part of the floor of the fourth ventricle. The vertebral arteries pass upwards and forwards in relation to its lateral aspects ; they then curve forwards on to its anterior surface and unite at the lower border of the pons Varolii to form the basilar artery.

Fig. 687.—Medulla oblongata and pons Varolii. Anterior surface.

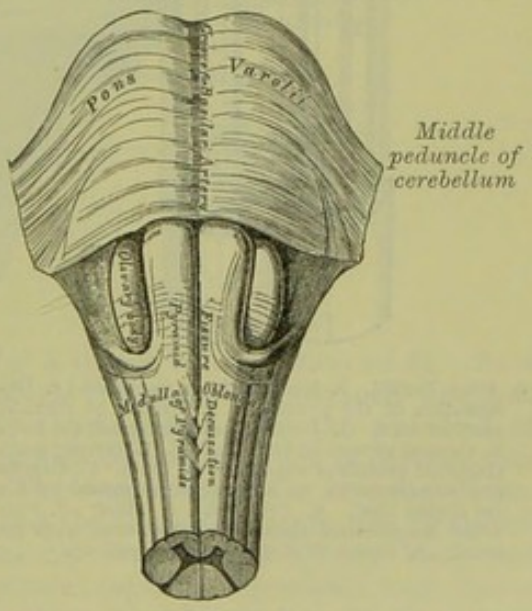

The medulla oblongata (fig. 687) is pyramidal in shape, its broad extremity being directed upwards towards the pons Varolii, while its narrow, lower end is continuous with the spinal cord. It measures rather over an inch in length, a little less than an inch in breadth at its widest part, and about half an inch in thickness ; while it weighs about a quarter of an ounce. The central canal of the spinal cord is prolonged into its lower half, and then opens into the cavity of the fourth ventricle ; and the medulla may therefore be divided into a lower *closed part* containing the central canal, and an upper *open part* corresponding with the lower portion of the fourth ventricle. Its anterior and posterior surfaces are marked by median fissures, which are continuous with the corresponding fissures of the spinal cord.

The **anterior fissure** (fissura mediana anterior) contains a fold of pia mater, and extends along the entire length of the medulla: it terminates at the lower border of the pons Varolii in a small triangular expansion, the *foramen cæcum*. Its lower part is interrupted by bundles of fibres which cross obliquely from one side to the other, and constitute the *pyramidal decussation*. Some fibres, termed the *anterior external arcuate fibres*, emerge from the fissure above this decussation and curve outwards and upwards over the lateral aspect of the medulla.

The **posterior fissure** (fissura mediana posterior) is a narrow groove which exists only in the closed part of the medulla; it becomes gradually shallower from below upwards, and finally terminates about the middle of the medulla, where the central canal of the cord expands into the cavity of the fourth ventricle.

These two fissures divide the closed part of the medulla into symmetrical halves, each half presenting elongated eminences which, on surface view, are continuous with the columns of the cord. In the open part of the medulla the halves are separated by the anterior median fissure, and by a median *raphe* which extends from the bottom of the fissure to the floor of the fourth ventricle. Further, certain of the cranial nerves pass through the substance of the medulla, and are attached to its surface in series with the roots of the spinal nerves; thus, the fibres of the hypoglossal nerve represent the upward continuation of the anterior nerve-roots, and emerge in linear series from a furrow termed the *pre-olivary* or *antero-lateral sulcus* (sulcus lateralis anterior). Similarly, the spinal accessory, vagus, and glosso-pharyngeal nerves correspond with the posterior nerve-roots, and are attached to the bottom of a sulcus named the *postero-lateral sulcus* (sulcus lateralis posterior). Advantage is taken of this arrangement to subdivide each half of the medulla into three areas, anterior, middle, and posterior. Although these three areas appear to be directly continuous with the corresponding columns of the cord, it must be pointed out that they do not necessarily contain the same fibres, since some of the nerve-tracts of the cord terminate in the medulla, while others alter their course in passing through it.

Fig. 688.—Decussation of pyramids. Scheme showing passage of various tracts from cord to medulla. (Testut.)

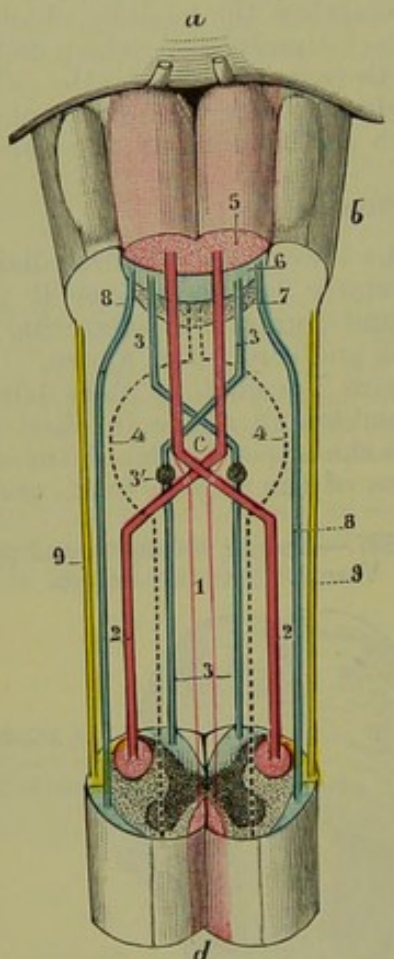

a. Pons Varolii. *b*. Medulla from the front. *c*. Decussation of the pyramids. *d*. Section of cervical part of cord. 1. Direct pyramidal tract (in red). 2. Crossed pyramidal tract (in red). 3. Sensory tract (fasciculi gracilis et cuneatus) (in blue). 3'. Gracile and cuneate nuclei. 4. Antero-lateral ground bundle (in dotted line). 5. Pyramid. 6. Fillet. 7. Posterior longitudinal fasciculus. 8. Gowers' tract (in blue). 9. Direct cerebellar tract (in yellow).

The **anterior area** (fig. 687) is named the **pyramid** (pyramis), and lies between the anterior fissure and the antero-lateral sulcus. Its upper extremity is slightly constricted, and between it and the pons the fibres of the sixth nerve emerge; a little below the pons it becomes enlarged and prominent, and finally tapers into the anterior column of the cord, with which, at first sight, it appears to be directly continuous.

The two pyramids constitute the great motor strands of the medulla, since they contain the motor fibres which pass from the brain to the spinal cord. When these pyramidal fibres are traced downwards, it is found that some two-thirds, or more, of them leave the anterior pyramid in successive bundles, and decussate in the anterior median fissure with corresponding bundles

derived from the opposite pyramid, forming what is termed the *motor or pyramidal decussation* (decussatio pyramidum). Having crossed the middle line, they pass down in the posterior part of the lateral column as the crossed pyramidal tract. The remaining fibres—i.e. those which occupy the outer part of the pyramid—do not cross the middle line, but are carried downwards as the direct pyramidal tract (fig. 688) into the anterior column of the same side.

The greater part of the basis bundle of the anterior column of the cord is continued upwards through the medulla oblongata as a strand, which is termed the *posterior longitudinal fasciculus*.

The **lateral area** (fig. 689) is limited in front by the antero-lateral sulcus and the roots of the hypoglossal nerve, and behind by the postero-lateral sulcus and the roots of the spinal accessory, vagus, and glosso-pharyngeal nerves. Its upper part consists of a prominent oval mass which is named the *olivary body*, while its lower part is of the same width as the lateral column of the

Fig. 689.—Hind- and mid-brains ; postero-lateral view.

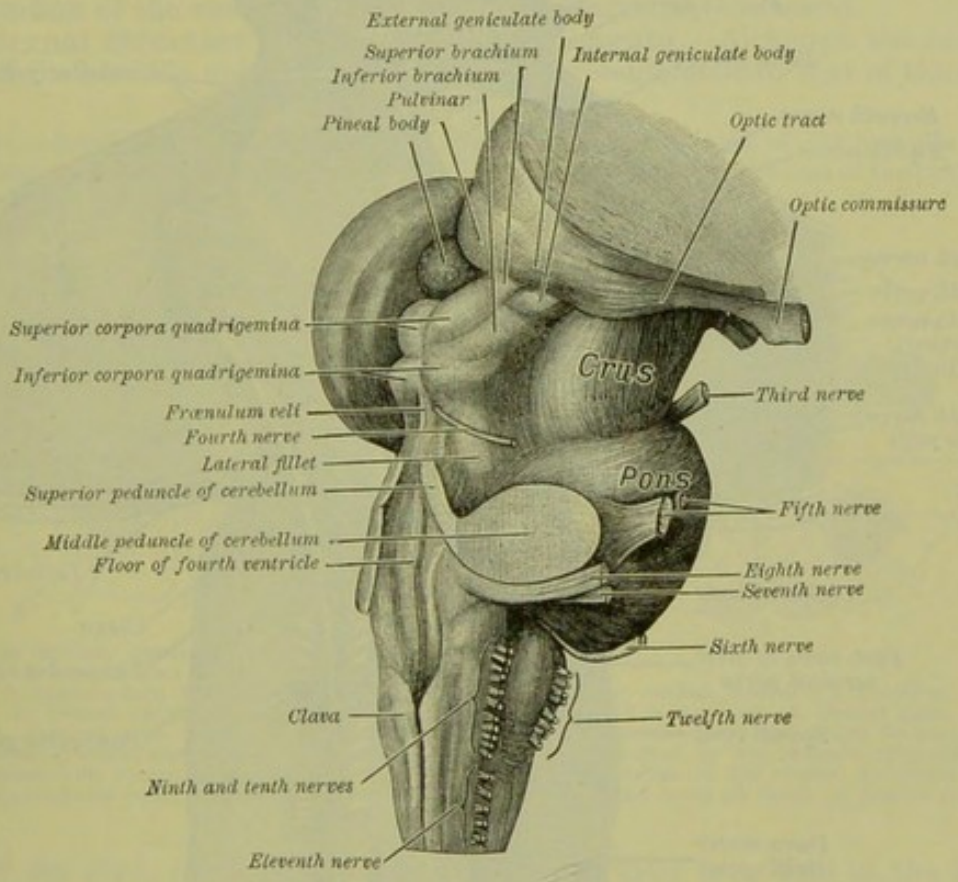

cord, and appears on the surface to be a direct continuation of it. As a matter of fact, only a portion of the lateral column is continued upwards into this area, for the crossed pyramidal tract passes into the pyramid of the opposite side, and the direct or ascending cerebellar tract is carried into the restiform body in the posterior area. The remainder of the lateral column, which consists chiefly of the basis bundle and the tract of Gowers, can be traced into the lateral area. Most of these fibres dip beneath the olivary body and disappear from the surface ; but a small strand remains superficial, and passes up between the olivary body and the postero-lateral sulcus. At the upper end of this strand is a depression or fossa, in which the auditory nerve is seen.

The **olivary body** (oliva) is situated on the outer side of the pyramid, from which it is separated by the antero-lateral or pre-olivary sulcus, and the fibres of the hypoglossal nerve. Behind, it is separated from the postero-lateral sulcus by the small superficial strand of the lateral column already referred to. It measures about half an inch in length, and between its upper end and the pons there is a slight depression to which the roots of the seventh

nerve are attached. The external arcuate fibres wind across the lower part of the pyramid and olivary body to enter the restiform body.

The **posterior area** (fig. 690) lies behind the postero-lateral sulcus and the roots of the spinal accessory, vagus, and the glosso-pharyngeal nerves, and, like the lateral area, is divisible into a lower and an upper portion.

The *lower part* is limited behind by the posterior median fissure, and consists of the *fasciculus gracilis* and the *fasciculus cuneatus*. The fasciculus gracilis is a narrow white band placed parallel to and along the side of the posterior median fissure, and separated from the fasciculus cuneatus by the postero-intermediate furrow and septum. The gracile and cuneate fasciculi are at first vertical in direction; but at the lower part of the floor of the fourth

FIG. 690.—Upper part of spinal cord and hind- and mid-brains; posterior aspect, exposed *in situ*.

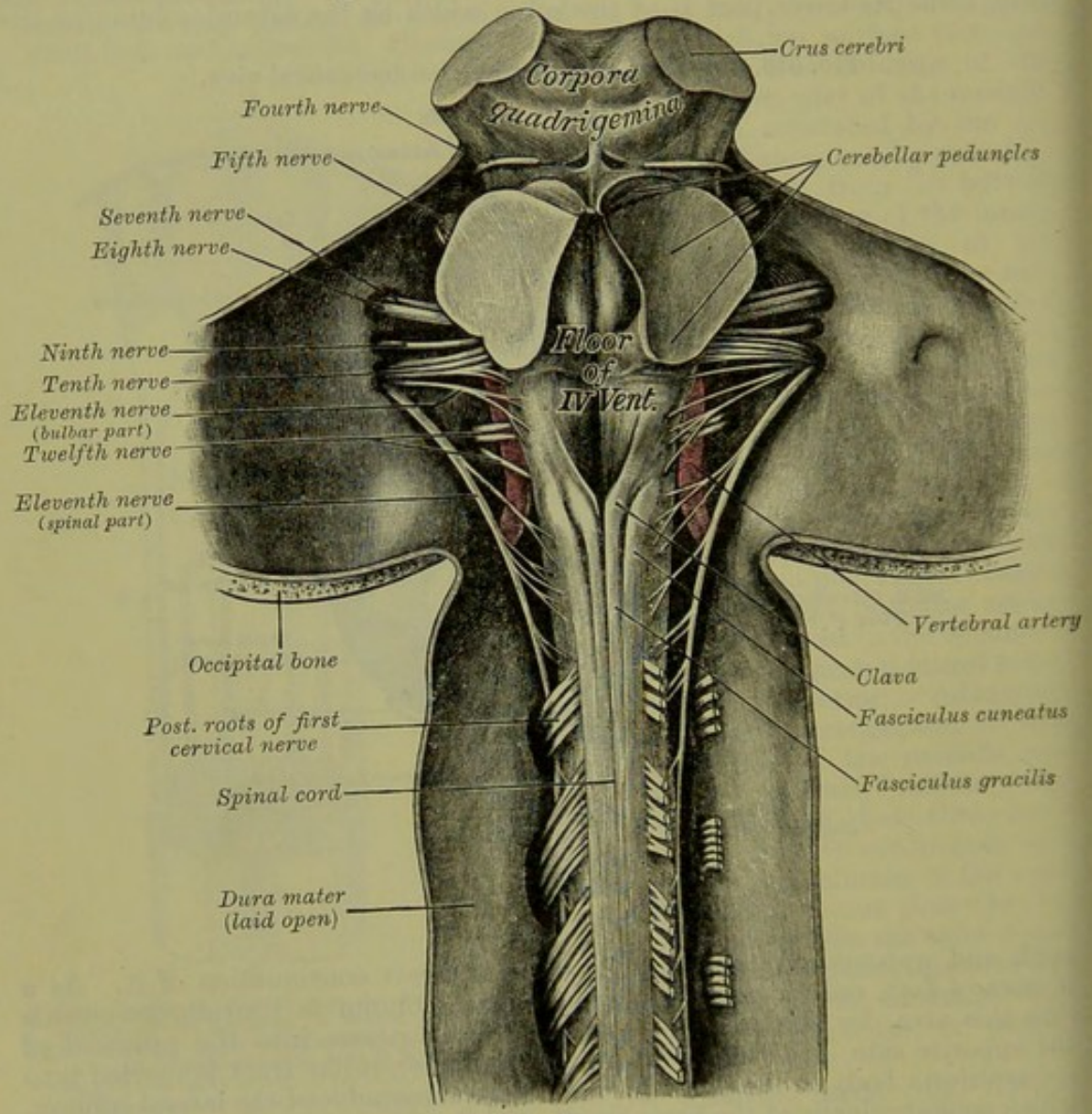

ventricle they diverge from the middle line in a V-shaped manner, and each presents an elongated swelling. That on the fasciculus gracilis is named the *clava*, and is produced by a subjacent nucleus of grey matter, the *nucleus gracilis*; that on the fasciculus cuneatus is termed the *cuneate tubercle*, and is likewise caused by a grey nucleus, named the *nucleus cuneatus*. The fibres of these fasciculi terminate by arborising around the cells in their respective nuclei. A third elevation, termed the *fasciculus of Rolando*, is seen in the lower part of the posterior area of the medulla. It lies on the lateral aspect of the fasciculus cuneatus, and is not represented by a corresponding elevation in the cord. It is produced by the substantia gelatinosa of Rolando, which is separated from the surface of the medulla by a band of nerve-fibres which

form the lower sensory, or spinal, root of the fifth nerve. Narrow below, the fasciculus gradually expands above, and terminates, about half an inch below the pons, in a tubercle, the *tubercle of Rolando*.

The *upper part* of the posterior area of the medulla is occupied by the *restiform body* (*corpus restiforme*), a thick rope-like strand which is situated between the lower part of the floor of the fourth ventricle and the roots of the ninth and tenth nerves. The restiform bodies connect the cord and medulla with the cerebellum, and are named the *inferior peduncles of the cerebellum*. As they pass upwards, they diverge from each other, and assist in forming the lower parts of the lateral boundaries of the fourth ventricle; higher up, they are directed backwards, each passing to the corresponding cerebellar hemisphere. Near where they enter the cerebellum they are crossed by several strands of fibres, which extend inwards over the floor of the fourth ventricle, and are named the *striæ acusticæ*. At first sight the restiform body appears to be formed by the upward continuation of the fasciculus gracilis and fasciculus cuneatus; this, however, is not so, as it is probable that all the fibres of these fasciculi end in the gracile and cuneate nuclei. The constitution of the restiform body will be subsequently discussed.

Internal structure of the medulla oblongata.—Although the external form of the medulla oblongata bears a certain resemblance to that of the upper

FIG. 691.—Section of the medulla through the lower part of the decussation of the pyramids. (Testut.)

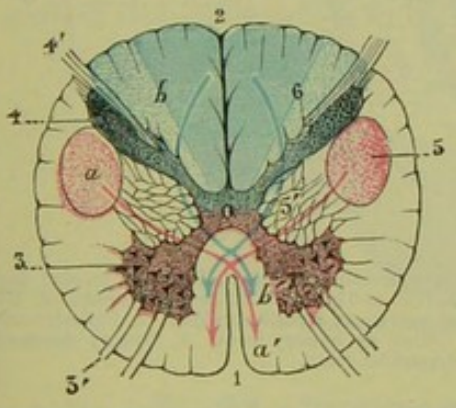

1. Anterior median fissure. 2. Posterior median fissure. 3. Anterior horn (in red), with 3', anterior root. 4. Posterior horn (in blue), with 4', posterior roots. 5. Crossed pyramidal tract. 6. Posterior column. The red arrow, *a*, *a'*, indicates the course the crossed pyramidal tract takes at the level of the decussation of the pyramids; the blue arrow, *b*, *b'*, indicates the course which the sensory fibres take.

FIG. 692.—Section of the medulla at the level of the decussation of the pyramids. (Testut.)

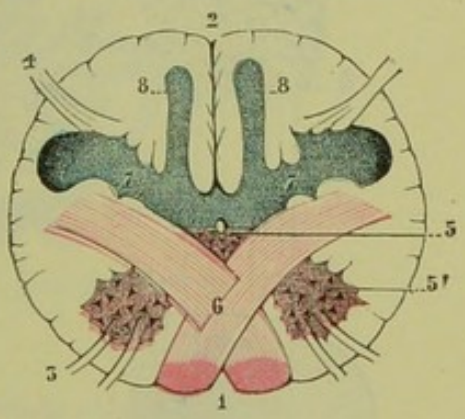

1. Anterior median fissure. 2. Posterior median fissure. 3. Motor roots. 4. Sensory roots. 5. Base of the anterior horn, from which the head (5') has been detached by the crossed pyramidal tract. 6. Decussation of the crossed pyramidal tracts. 7. Posterior horns (in blue). 8. Gracile nucleus.

part of the cord, its internal structure differs widely from that of the latter, and this for the following principal reasons: (1) certain tracts of fibres which extend from the cord to the brain, and *vice versa*, undergo a rearrangement in their passage through the medulla; (2) others which exist in the cord terminate in the medulla; (3) new strands originate in the grey matter of the medulla and pass to different parts of the brain; (4) the grey matter, which in the cord forms a continuous H-shaped column, becomes greatly modified and subdivided in the medulla, in which also new masses of grey matter are added; (5) on account of the opening-out of the central canal of the cord, certain parts of the grey matter, which in the cord were more or less centrally situated, are displayed in the floor of the fourth ventricle; (6) lastly, the medulla is intimately associated with many of the cranial nerves, some arising from, and others terminating in, nuclei within its substance.

The internal structure of the medulla is best studied by examining series of transverse and of longitudinal sections (figs. 695, 696). A short description of the course taken by the principal tracts, and of the arrangement of the grey matter, will now be given.

The pyramidal tracts.—The division of the pyramids of the medulla into direct and crossed pyramidal tracts, and the course of these tracts in the cord,

have already been described. In passing to reach the lateral column of the opposite side, the fibres of the crossed pyramidal tracts extend backwards through the anterior cornua, and the head of each of these horns is separated from its base (figs. 691, 692). The base retains its position in relation to the ventral aspect of the central canal, and, when the latter opens into the fourth ventricle, appears in the floor of that cavity close to the middle line, where it forms the nuclei of the twelfth and sixth nerves; while above the level of the ventricle it exists as the nuclei of the third and fourth nerves in relation to the floor of the aqueduct of Sylvius. The head of the cornu is pushed outwards and forms an elongated column, the *nucleus ambiguus*, which gives origin from below upwards to the bulbar part of the spinal accessory and the motor fibres of the vagus and glosso-pharyngeal, and still higher to the motor fibres of the seventh and fifth nerves.

FIG. 693.—Superior terminations of the posterior tracts of the spinal cord. (Testut.)

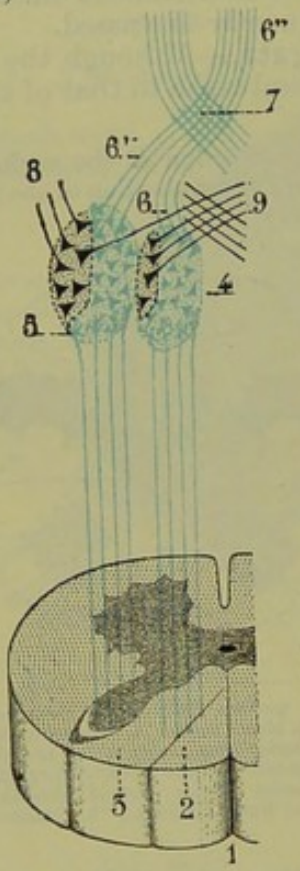

1. Posterior median fissure. 2. Fasciculus gracilis. 3. Fasciculus cuneatus. 4. Gracile nucleus. 5. Cuneate nucleus. 6, 6′, 6″. Sensory fibres forming the fillet. 7. Sensory decussation. 8. Cerebellar fibres uncrossed (in black). 9. Cerebellar fibres crossed (in black).

FIG. 694.—Transverse section passing through the sensory decussation. (Schematic.) (Testut.)

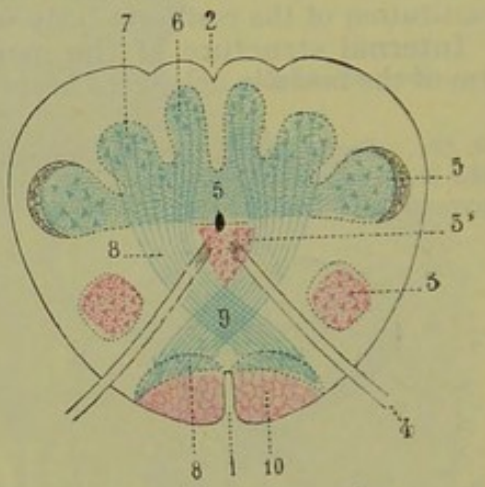

1. Anterior median fissure. 2. Posterior median fissure. 3, 3′. Head and base of anterior horn (in red). 4. Hypoglossal nerve. 6. Gracile nucleus. 7. Cuneate nucleus. 8, 8. Fillet, or sensory tract. 9. Sensory decussation. 10. Pyramidal tract.

The **fasciculus gracilis** and **fasciculus cuneatus** constitute the posterior sensory fasciculi of the spinal cord; they are prolonged upwards into the lower part of the medulla oblongata, where they terminate respectively in the nucleus gracilis and nucleus cuneatus. These two nuclei are continuous, in front, with the central grey matter of the cord, and may be regarded as dorsal projections of this, each being covered superficially by the fibres of the corresponding fasciculus. On transverse section (fig. 694), the nucleus gracilis appears as a single, more or less quadrangular mass, while the nucleus cuneatus consists of two parts: a larger, somewhat triangular, *internal nucleus*, composed of small or medium sized cells, and a smaller *external nucleus* containing large cells.

The fibres of the fasciculus gracilis and fasciculus cuneatus end by arborising around the cells of these nuclei, which therefore may be regarded as the nuclei of termination of the posterior sensory fasciculi (fig. 693). From the cells of the nuclei new fibres take origin, some of which are continued as the posterior external arcuate fibres into the restiform body, and through it to the cerebellum, but most of which pass forwards through the neck of the posterior horn, thus cutting off the head from the base of the horn. Curving forwards and inwards, they decussate in the middle line with the corresponding fibres of the opposite side, and run upwards immediately behind the pyramidal

fibres, as a flattened band, named the *fillet* or *lemniscus*. The decussation of these sensory fibres is situated above that of the motor fibres, and is named the *sensory decussation* or the *decussation of the fillet* (decussatio lemniscorum). The fillet is joined by the spino-thalamic tract or secondary sensory fasciculus

FIG. 695.—Section of the medulla oblongata at about the middle of the olivary body. (Schwalbe.)

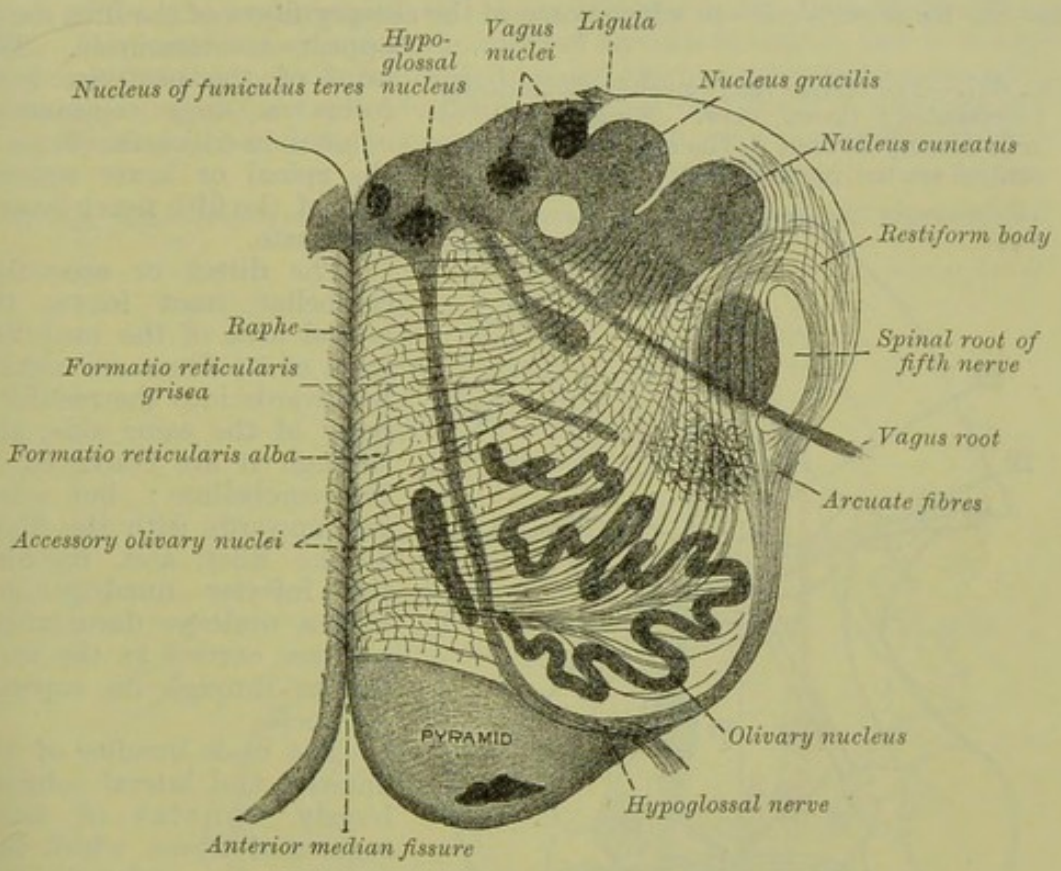

FIG. 696.—Transverse section of medulla oblongata at the middle of the olivary body.

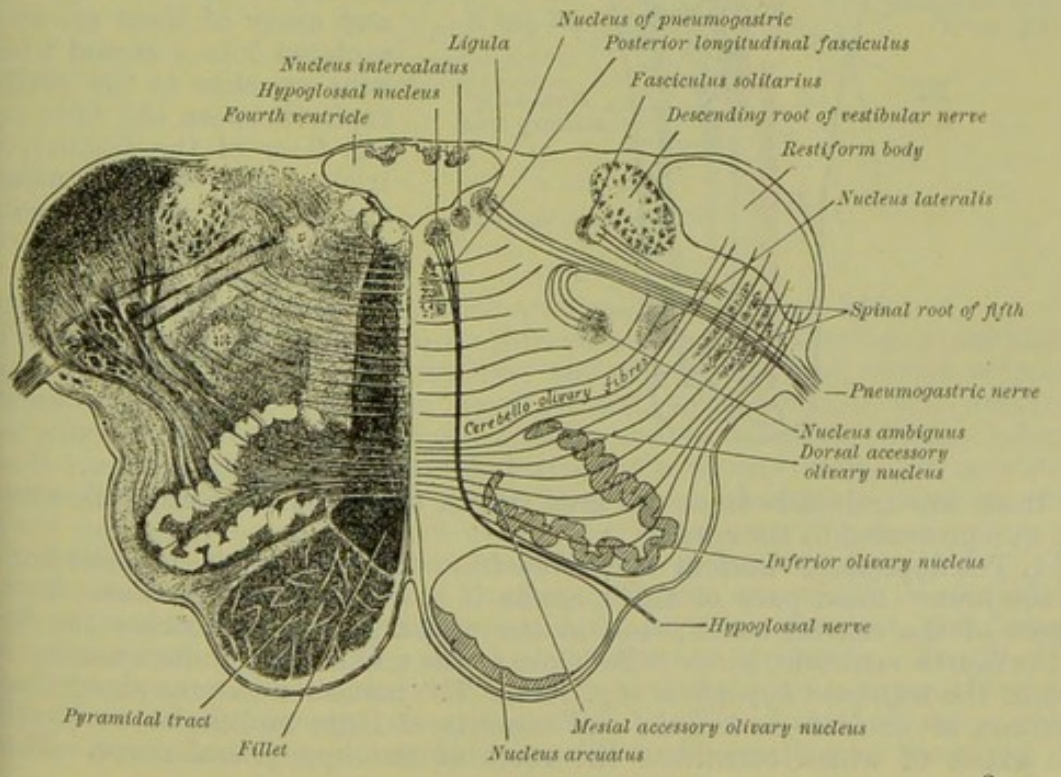

(p. 806), the fibres of which are derived from the cells of the grey matter of the opposite side of the spinal cord.

The base of the posterior horn at first lies on the dorsal aspect of the central canal, but when the latter opens into the fourth ventricle, it appears in the lateral part of the floor of that cavity. It forms the nuclei of termination of the sensory fibres of the vagus and glosso-pharyngeal, and is associated with the vestibular part of the auditory nerve and the sensory root of the seventh nerve (pars intermedia of Wrisberg). Still higher, it forms a mass of pigmented cells—the *locus cæruleus*—in which some of the sensory fibres of the fifth nerve appear to terminate. The head of the posterior horn forms a long continuous column, in which the fibres of the spinal or lower sensory root of the fifth nerve largely terminate.

Fig. 697.—The cranial nerve nuclei schematically represented; dorsal view. Motor nuclei in red; sensory in blue. (The olfactory and optic centres are not represented.)

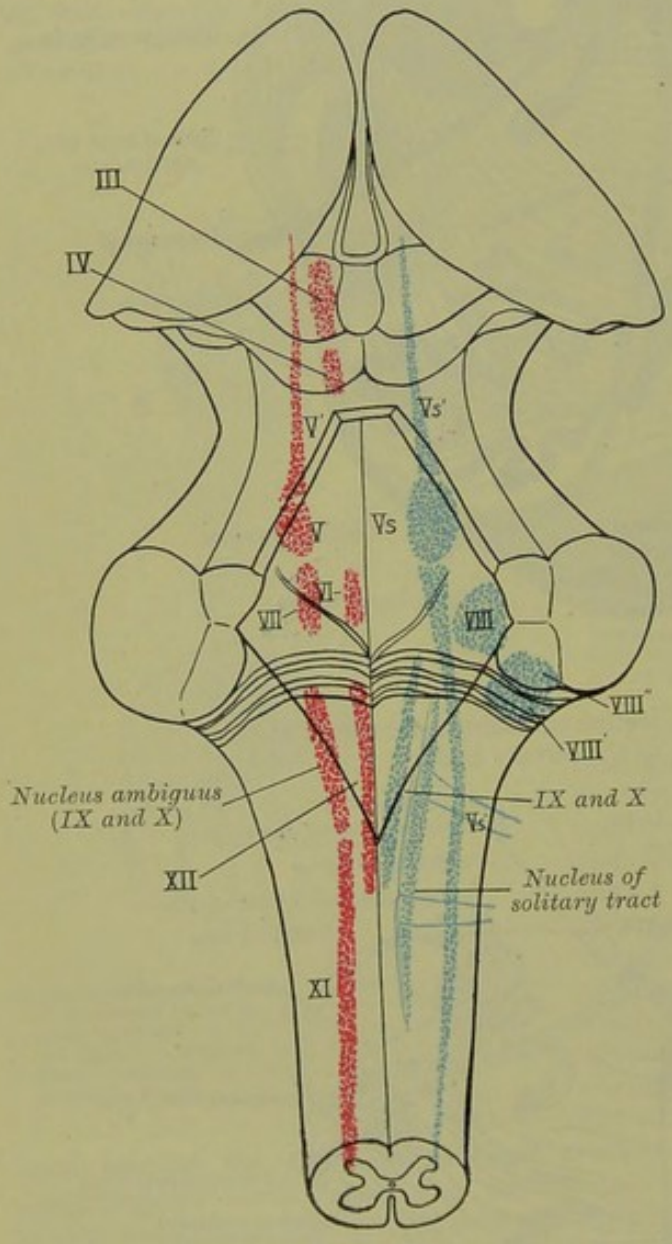

The direct or ascending cerebellar tract leaves the lateral area of the medulla; most of its fibres are carried backwards into the restiform body of the same side, and through it are conveyed to the cerebellum; but some run upwards with the fibres of the fillet, and, reaching the inferior quadrigeminal bodies, undergo decussation, and are carried to the cerebellum through its superior peduncle.

The basis bundles of the anterior and lateral columns largely consist of intersegmental fibres, which link together the different segments of the cord; they assist in forming the formatio reticularis of the medulla, and many of them are accumulated into a strand which runs up close to the median raphe between the fillet and the floor of the fourth ventricle. This strand is named the *dorsal* or *posterior longitudinal fasciculus*, and will be again referred to.

Grey matter of the medulla oblongata (figs. 695, 696).—In addition to the gracile and cuneate nuclei, there are several others which require consideration. Some of these are traceable from the grey matter of the spinal cord, while others are unrepresented in the cord.

1. The *hypoglossal nucleus* is derived from the base of the anterior horn; in the lower closed part of the medulla it is situated on the ventro-lateral aspect of the central canal; but in the upper part it approaches the floor of the fourth ventricle, where it lies close to the middle line, under an eminence named the *trigonum hypoglossi* (fig. 710). The nucleus measures about three-quarters of an inch in length, and consists of large multipolar nerve-cells, the axons of which constitute the roots of the hypoglossal nerve. These

nerve-roots pass forward between the anterior and lateral areas of the medulla, and emerge from the preolivary sulcus.

2. The *motor nucleus* (figs. 697, 698) common to the *glosso-pharyngeal*, *vagus*, and bulbar portion of the *spinal accessory* nerves, is named the *nucleus ambiguus*. It represents the head of the anterior horn, lies deeply in the formatio reticularis grisea, and extends throughout nearly the whole length of the medulla.

3. The *sensory nucleus* (figs. 697, 699), or nucleus of termination of the sensory fibres of the *glosso-pharyngeal* and *vagus*, represents the base of the posterior horn. It measures nearly three-quarters of an inch in length, and in the lower, closed part of the medulla is situated behind the hypoglossal nucleus; whereas in the upper, open part it lies to the outer side of that nucleus, and corresponds to an eminence, named the *trigonum vagi*, in the floor of the fourth ventricle.

FIG. 698.—Nuclei of origin of cranial motor nerves schematically represented; lateral view.

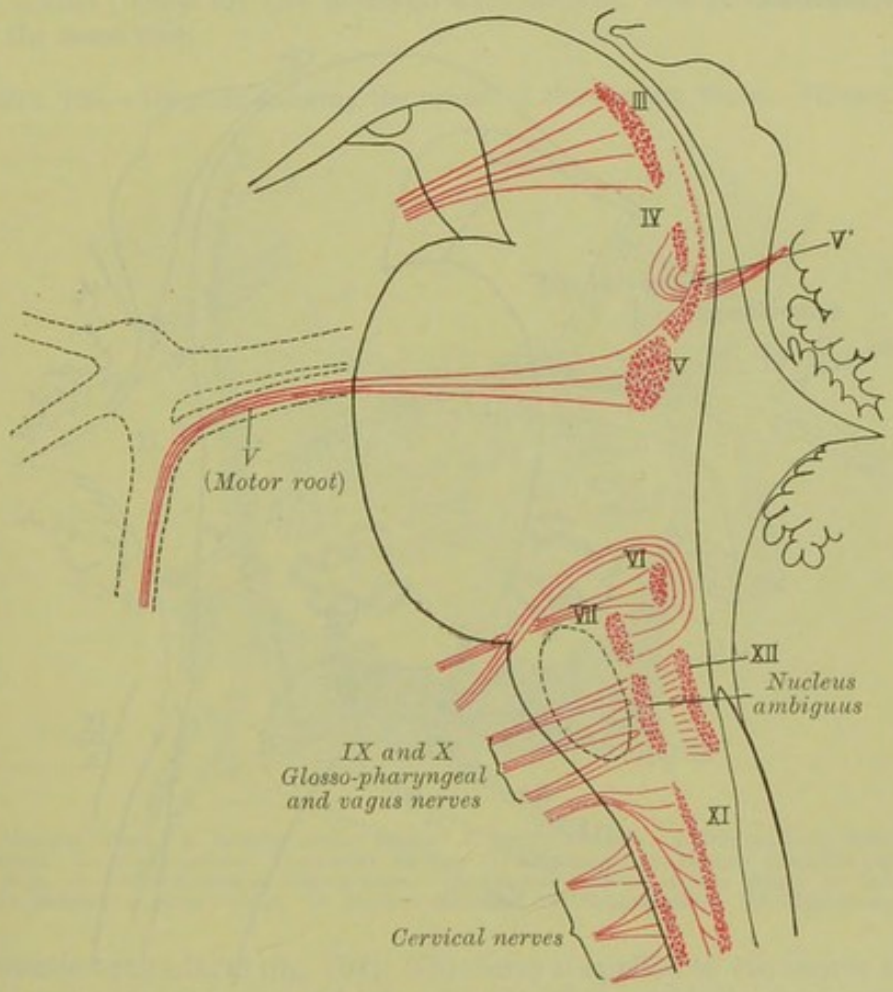

4. The *nuclei of the auditory nerve* are described on page 825.

5. The *olivary nuclei* (fig. 695) are three in number on either side of the middle line, viz. the inferior olivary nucleus, and the mesial and dorsal accessory olivary nuclei; they consist of small, round, yellowish cells and numerous fine nerve-fibres. (*a*) The *inferior olivary nucleus* (nucleus olivaris inferior) is the largest of these, and is situated within the olivary body. It consists of a grey folded lamina arranged in the form of an incomplete capsule, which opens internally by an aperture called the *hilus*, emerging from which are numerous fibres which collectively constitute the *peduncle of the olive*. (*b*) The *mesial accessory olivary nucleus* (nucleus olivaris accessorius medialis) lies between the inferior olivary nucleus and the anterior pyramid, and forms a curved lamina, the concavity of which is directed outwards. The fibres of the hypoglossal nerve, as they traverse the medulla, pass between the mesial accessory and the inferior olivary nuclei. (*c*) The *dorsal accessory olivary nucleus* (nucleus olivaris accessorius dorsalis) is the smallest of the three, and

appears on transverse section as a curved lamina on the dorsal aspect of the inferior olivary nucleus.

The inferior olivary nucleus is connected—(1) with that of the opposite side by fibres which cross through the raphe ; (2) with the anterior horn of the same side of the spinal cord by a strand of fibres termed the *spino-olivary tract* ; (3) with the thalamus of the cerebrum by the *cerebro-olivary tract* which passes through the pons Varolii and tegmentum ; (4) with the opposite cerebellar hemisphere by the *cerebello-olivary tract*, the fibres of which pass across the raphe and turn backwards to enter the deep part of the restiform body. Removal of one cerebellar hemisphere is followed by atrophy of the opposite olivary nucleus.

6. The *nucleus arcuatus* will be described with the anterior external arcuate fibres (page 821).

Fig. 699. — Primary terminal nuclei of the afferent (sensory) cranial nerves schematically represented ; lateral view. The olfactory and optic centres are not represented.

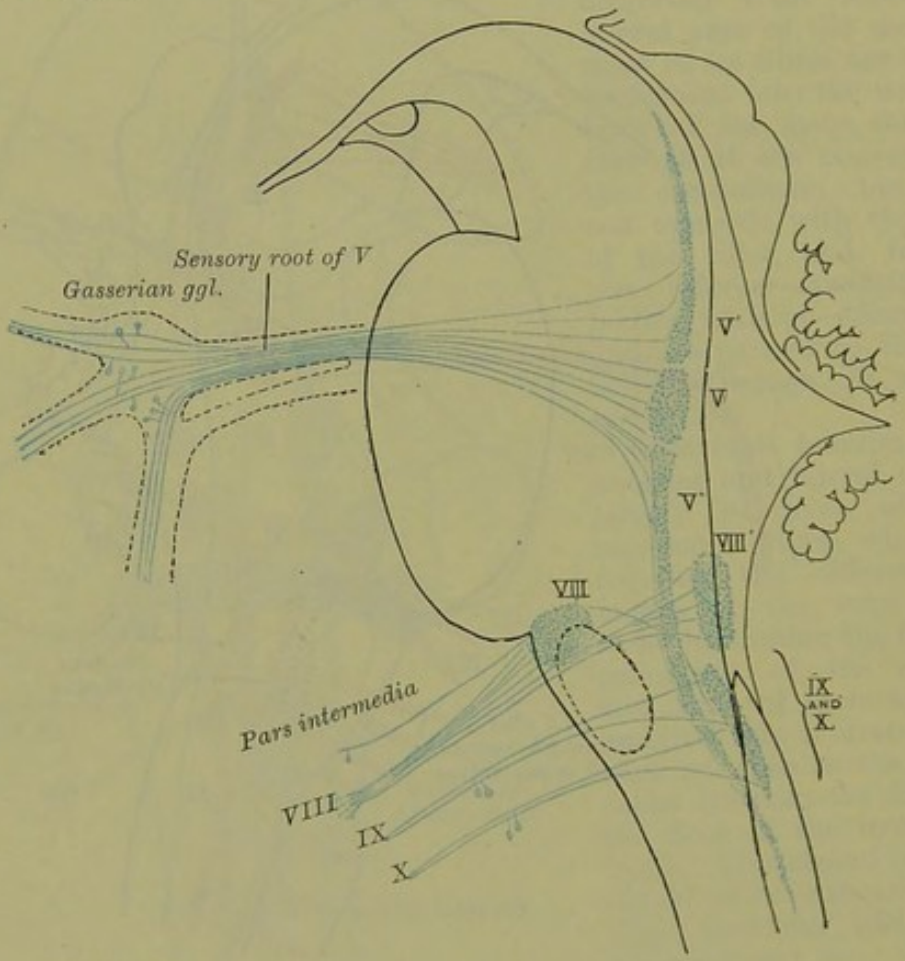

Restiform bodies.—The position of the restiform bodies, or inferior peduncles of the cerebellum, has already been described (page 815). Each restiform body comprises : (1) the direct or ascending cerebellar tract from the lateral column of the cord ; (2) descending cerebellar fibres, many of which are disseminated throughout the peripheral part of the anterior and lateral columns of the cord, while others are conducted to the motor nuclei of the cranial nerves ; and (3) the arcuate fibres (fibræ arcuatæ) which are arranged in three sets, viz. the internal arcuate fibres, and the anterior and posterior external arcuate fibres.

The *internal arcuate fibres* form the deeper and larger part of the restiform body. They decussate in the middle line of the medulla, and having reached the opposite side, terminate partly in the gracile and cuneate nuclei, while many of them enter the hilus of the inferior olivary nucleus, and constitute the cerebello-olivary tract already described (fig. 700).

The *anterior external arcuate fibres* vary as to their prominence in different cases : in some they form an almost continuous layer covering the pyramid and olivary body, while in others they are barely visible on the surface. They arise from the cells of the gracile and cuneate nuclei, and passing forwards through the formatio reticularis, decussate in the middle line. Most of them reach the surface by way of the anterior median fissure, and arch outwards and backwards over the pyramid. Reinforced by others which emerge between the pyramid and olivary body, they pass backwards over the olivary body and lateral area of the medulla, and enter the outer part of the restiform body. They thus connect the cerebellum with the gracile and cuneate nuclei of the opposite side. As the fibres arch across the pyramid, they enclose a small nucleus which lies in front and to the inner side of the pyramid. This is named the *nucleus arcuatus*, and is directly continuous above with the nuclei pontis in the pons Varolii : it contains small fusiform cells, around which some of the arcuate fibres terminate, and from which others arise.

The *posterior external arcuate fibres* also take origin in the gracile and cuneate nuclei ; they do not undergo decussation, but pass to the restiform body of the same side.

Fig. 700.—Diagram showing the course of the arcuate fibres. (Testut.)

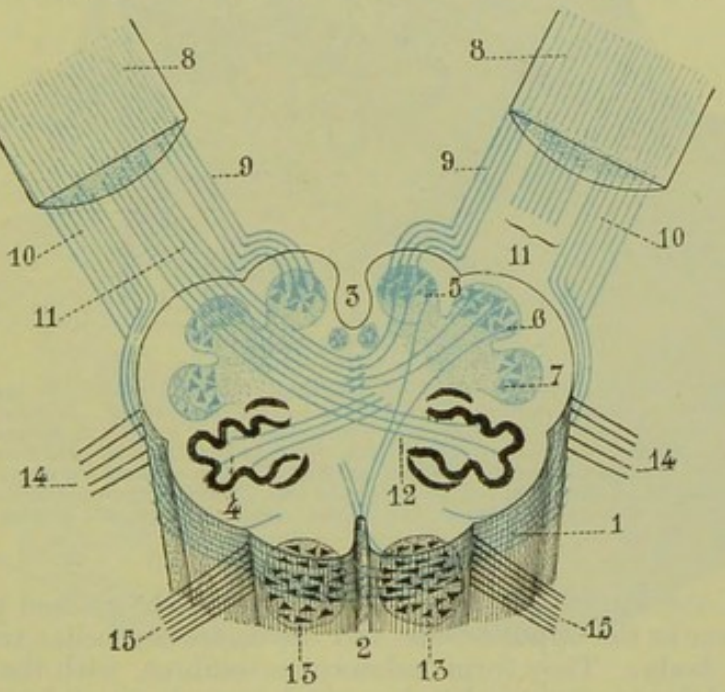

1. Medulla, anterior surface. 2. Anterior median fissure. 3. Fourth ventricle. 4. Olivary body, with the accessory olivary nuclei. 5. Gracile nucleus. 6. Cuneate nucleus. 7. Trigeminal. 8. Inferior cerebellar peduncles, seen from in front. 9. Posterior external arcuate fibres. 10. Anterior external arcuate fibres. 11. Internal arcuate fibres. 12. Peduncle of olivary body. 13. Nucleus arcuatus. 14. Pneumogastric. 15. Hypoglossal.

Formatio reticularis (fig. 701). This term is applied to the coarse reticulum which occupies the anterior and lateral areas of the medulla, and is seen when transverse sections are examined. It is situated behind the pyramid and olivary body, extending laterally as far as the restiform bodies, and dorsally to within a short distance of the floor of the fourth ventricle. The reticulum is caused by the intersection of bundles of fibres running at right angles to each other, some being longitudinal, others more or less transverse in direction. The formatio reticularis presents a different appearance in the anterior area from what it does in the lateral area ; in the former, there is an almost entire absence of nerve-cells, and hence this part is known as the *reticularis alba* ; whereas nerve-cells are numerous in the lateral area, and as a consequence it presents a grey appearance, and is termed the *reticularis grisea*.

In the substance of the formatio reticularis are two small nuclei of grey matter : one is situated near the dorsal aspect of the hilus of the inferior olivary nucleus, and is named the *inferior central nucleus*, or *nucleus of Roller* ; the other lies between the olivary body and the spinal root of the fifth nerve, and is termed the *nucleus lateralis*.

In the reticularis alba the longitudinal fibres form two well-defined strands, viz. : (1) the *fillet*, which lies close to the raphe, immediately behind the fibres of the pyramid ; and (2) the *posterior longitudinal fasciculus*, which is continued upwards from the antero-lateral ground bundle of the spinal cord, and, in the upper part of the medulla, lies between the fillet and the grey matter in the floor of the fourth ventricle. The longitudinal fibres in the reticularis grisea are

Fig. 701.—The formatio reticularis of the medulla, shown by a horizontal section passing through the middle of the olivary body. (Testut.)

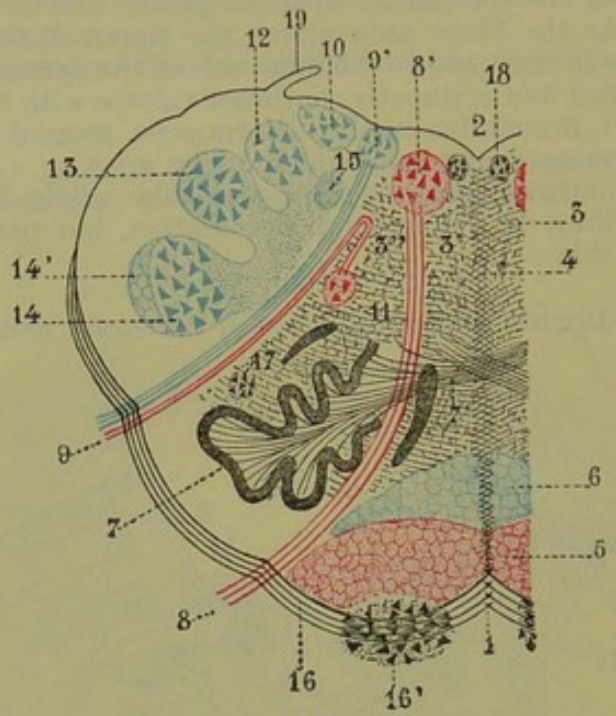

1. Anterior median fissure. 2. Fourth ventricle. 3. Formatio reticularis, with 3', its internal part (reticularis alba), and 3'', its external part (reticularis grisea). 4. Raphe. 5. Pyramid. 6. Fillet. 7. Inferior olivary nucleus with the two accessory olivary nuclei. 8. Hypoglossal nerve, with 8', its nucleus of origin. 9. Vagus nerve, with 9', its nucleus of termination. 10. External dorsal auditory nucleus. 11. Nucleus ambiguus (nucleus of origin of motor fibres of glosso-pharyngeal, vagus, and bulbar portion of spinal accessory). 12. Gracile nucleus. 13. Cuneate nucleus. 14. Head of posterior cornu, with 14', the lower sensory root of fifth nerve. 15. Fasciculus solitarius. 16. Anterior external arcuate fibres, with 16', the nucleus arcuatus. 17. Nucleus lateralis. 18. Nucleus of fasciculus teres. 19. Ligula.

derived from the lateral column of the cord after the crossed pyramidal tract has passed over to the opposite side, and the direct cerebellar tract has entered the restiform body. They form indeterminate fibres, with the exception of a bundle named the *fasciculus solitarius*, which is made up of descending fibres of the vagus and glosso-pharyngeal nerves. The transverse fibres of the formatio reticularis are the arcuate fibres already described (pages 820, 821).

Applied Anatomy.—In *bulbar paralysis*, which is really a special form of a progressive degeneration affecting the whole efferent or motor tract, the disease begins with impairment of the movements of the lips, tongue, pharynx, and larynx, due to degeneration of the motor cells in the nuclei of the medulla. Speech and swallowing become difficult, and the saliva dribbles from the open mouth. Other groups of muscles soon become involved, and death often occurs from 'aspiration pneumonia,' set up by food that has accidentally passed down the trachea.

The Pons

The **pons** (pons Varolii) or fore part of the hind-brain is situated in front of the cerebellum. From its superior surface the crura cerebri emerge, one on either side of the middle line. Curving round each crus, close to the upper surface of the pons, a thin white band, the *tænia pontis*, is frequently seen ; it passes into the cerebellum between the middle and superior peduncles. Behind and below, the pons is continuous with the medulla oblongata, from which it is separated on its ventral surface by a furrow in which the sixth, seventh, and eighth cranial nerves appear.

Its *ventral* or *anterior surface* is very prominent, markedly convex from side to side, less so from above downwards. It consists of transverse fibres arched like a bridge across the middle line, and gathered on either side into a compact mass which forms the middle peduncle of the cerebellum. It rests upon the posterior surface of the basi-sphenoid, and is limited above and below by well-defined borders. It presents, in the middle line, a furrow (*sulcus basilaris*) for the lodgment of the basilar artery; this furrow is bounded on either side by an eminence—the *pyramidal eminence*—caused by the passage of the pyramidal fibres downwards through the substance of the pons. Outside these eminences, near the upper border of the pons, the fifth nerves make their exit, each consisting of a smaller, internal, motor root, and a larger, external, sensory root; a vertical line, drawn on either side immediately outside the fifth nerve, may be taken as the boundary between the ventral surface of the pons and the middle peduncle of the cerebellum.

FIG. 702.—Vertical transverse section of the pons, at its upper part. (Testut.)

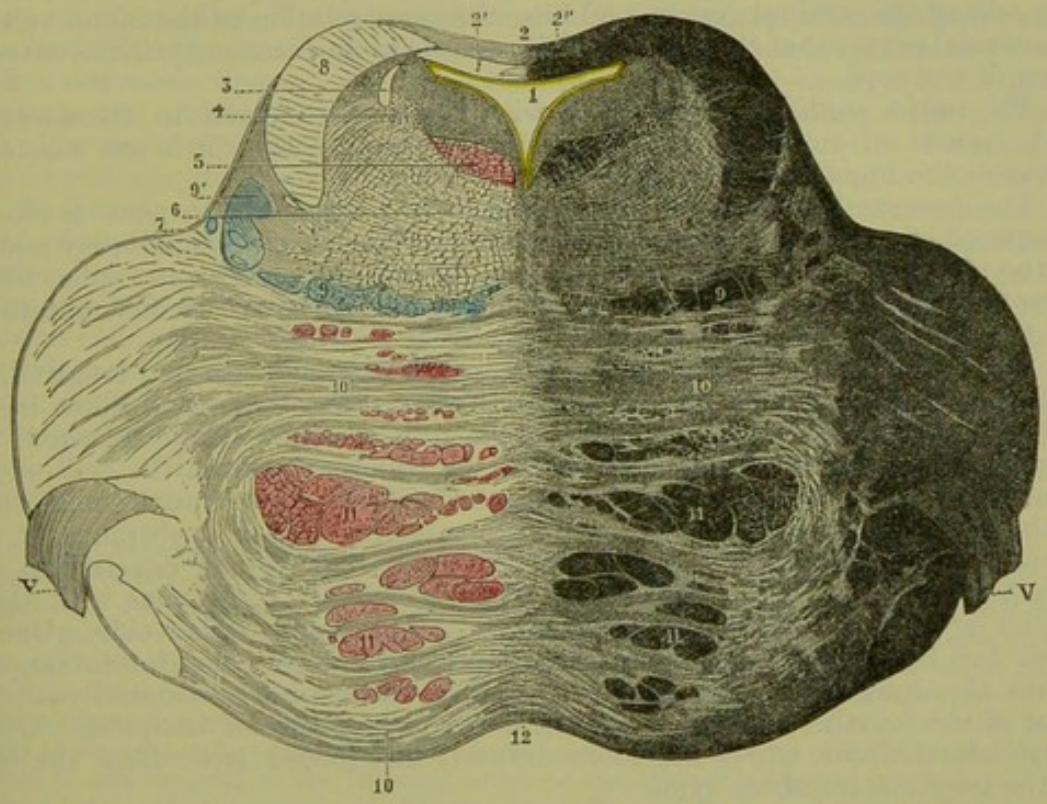

1. Fourth ventricle; its ependyma in yellow. 2. Valve of Vieussens, with 2', its white stratum (superior medullary velum), and 2'', its grey stratum (lingula). 3. Superior or Sylvian root of trigeminal. 4. Nerve-cells associated with this root. 5. Posterior longitudinal fasciculus. 6. Formatio reticularis. 7. Lateral sulcus. 8. Section of superior cerebellar peduncle. 9. Mesial fillet. 9'. Lateral fillet. 10, 10. Transverse fibres of pons. 11, 11. Pyramidal fibres. 12. Raphe. V. Trigeminal.

Its *dorsal* or *posterior surface*, triangular in shape, is hidden by the cerebellum, and is bounded laterally by the superior cerebellar peduncles. It forms the upper part of the floor of the fourth ventricle, with which it will be described.

Structure (fig. 702).—Transverse sections of the pons show that it is composed of two parts which differ from each other in appearance and structure: thus, the ventral portion consists for the most part of fibres arranged in transverse and longitudinal bundles, together with a small amount of grey matter; while the dorsal portion is a continuation of the reticular formation of the medulla oblongata, and is called the tegmental portion, as most of its constituents are continued into the tegmentum of the crus cerebri.

The *ventral part* of the pons (pars basilaris pontis) consists of—(*a*) superficial and deep transverse fibres, (*b*) longitudinal fibres, and (*c*) some small nuclei of grey matter, termed the nuclei pontis.

The *superficial transverse fibres* (fibræ pontis superficiales) constitute a rather thick layer on the ventral surface of the pons, and are collected into a large rounded bundle on either side of the middle line. This bundle, with the addition

of some transverse fibres from the deeper part of the pons, forms the middle peduncle of the corresponding half of the cerebellum.

The *deep transverse fibres* (fibræ pontis profundæ) partly intersect and partly lie on the dorsal aspect of the pyramidal fibres. They course to the lateral border of the pons, and assist the superficial transverse fibres in forming the middle peduncle of the cerebellum. The further connections of the transverse fibres will be discussed with the anatomy of the cerebellum.

The *longitudinal fibres* (fasciculi longitudinales) are derived from the crura cerebri, and enter the upper surface of the pons. They stream downwards on either side of the middle line in larger or smaller bundles, separated from each other by the deeper transverse fibres; these longitudinal bundles cause a forward projection of the superficial transverse fibres, and thus give rise to the pyramidal eminences on the ventral surface. Some of these fibres end in the nuclei pontis, and others, after decussating, in the motor nuclei of the fifth, sixth, seventh, and twelfth nerves; but most of them are carried through the pons, and at its lower surface are collected into the pyramids of the medulla. The fibres which end in the motor nuclei of the cranial nerves are derived from the cells of the cerebral cortex, and bear the same relation to the motor cells of the cranial nerves that the pyramidal fibres bear to the motor cells in the anterior horn of the cord.

The *nuclei pontis* are continuous with the arcuate nuclei in the medulla, and consist of small groups of multipolar nerve-cells which are scattered between the bundles of transverse fibres.

The *tegmental* or *dorsal part* (pars dorsalis pontis) of the pons is chiefly composed of an upward continuation of the reticular formation and grey matter of the medulla. It is subdivided into lateral halves by a median raphe, which however does not extend into the ventral part of the pons, being obliterated by the transverse fibres.

The tegmental portion of the pons consists of transverse and longitudinal fibres, and also contains important grey nuclei. The transverse fibres in the lower part of the pons are collected into a distinct strand, named the *corpus trapezoideum*. This consists of fibres which arise from the cells of the ventral or accessory auditory nucleus, and will be referred to in connection with the cochlear division of the auditory nerve. In the substance of the corpus trapezoideum is a collection of nerve-cells, which constitutes the *trapezoid nucleus*. The longitudinal fibres, which are continuous with those of the medulla, are mostly collected into two bundles on either side. One of these lies between the corpus trapezoideum and the reticular formation, and forms the upward prolongation of the *fillet*; the second is situated near the floor of the fourth ventricle, and is the *posterior longitudinal fasciculus*. Other longitudinal fibres, which are more diffusely distributed, arise from the cells of the grey matter of the pons.

The greater part of the dorsal portion of the pons is a continuation upward of the formatio reticularis of the medulla, and, like it, presents the appearance of a network, in the meshes of which are numerous nerve-cells. Besides these scattered nerve-cells, there are some important masses of grey matter which require mention, viz. the superior olivary nucleus and the nuclei of the fifth, sixth, seventh, and eighth nerves (fig. 697).

1. The *superior olivary nucleus* (nucleus olivaris superior) is a small mass of grey matter situated on the dorsal surface of the outer part of the corpus trapezoideum. Rudimentary in man, but well developed in certain animals, it exhibits the same structure as the inferior olivary nucleus, and is situated immediately above it. Some of the fibres of the corpus trapezoideum end by arborising around the cells of this nucleus, while others arise from these cells.

2. *Nuclei of the fifth nerve.*—The nuclei of the fifth nerve in the pons are two in number: a motor and a sensory. The *motor nucleus* is situated in the upper part of the pons, close under its dorsal surface and along the line of the lateral margin of the fourth ventricle. The axis-cylinder processes of its cells form a portion of the motor root of the fifth nerve: the remaining fibres of the motor root of this nerve are formed by a tract which arises from the grey matter of the floor of the Sylvian aqueduct, and hence is named the *Sylvian* or *mesencephalic root*. The *sensory nucleus* lies external to the motor one, and beneath the superior peduncle of the cerebellum. Some of the sensory fibres

of the fifth nerve terminate in this nucleus ; but the greater number descend, under the name of the lower sensory or spinal root, to end in the substantia gelatinosa of Rolando. The roots, motor and sensory, of the fifth nerve pass through the substance of the pons and emerge near the upper margin of its ventral surface.

3. The *nucleus of the sixth nerve* is a circular mass of grey matter situated close to the floor of the fourth ventricle, above the striæ acusticæ and subjacent to the eminentia teres : it lies a little external to the ascending part of the seventh nerve. The fibres of the sixth nerve pass forward through the entire thickness of the pons on the mesial side of the superior olivary nucleus, and between the outer bundles of the pyramidal fibres, and emerge in the furrow between the lower border of the pons and the pyramid of the medulla.

4. The *nucleus of the seventh nerve* is situated deeply in the reticular formation of the pons, on the dorsal aspect of the superior olivary nucleus, and the roots of the nerve derived from it pursue a remarkably tortuous course in the substance of the pons. At first they pass backwards and inwards until they reach the floor of the fourth ventricle, close to the median groove, where they are collected into a round bundle. This passes upwards and forwards, producing an elevation (fasciculus teres) in the floor of the ventricle, and then takes a sharp bend, and arches outwards through the substance of the pons to emerge at its lower border in the interval between the olivary and restiform bodies of the medulla.

5. The *nuclei of the auditory nerve*.—The auditory nerve consists of a cochlear and a vestibular division. The fibres of the cochlear division end in two nuclei : (*a*) the *lateral cochlear nucleus*, which corresponds to the tuberculum acusticum on the dorso-lateral surface of the restiform body ; and (*b*) the *ventral* or *accessory cochlear nucleus*, which is placed between the two divisions of the nerve, on the ventral aspect of the restiform body. The nuclei in which the vestibular division ends are (*a*) the *dorsal* or *chief vestibular* nucleus, which corresponds to the trigonum acustici in the floor of the fourth ventricle ; the caudal end of this nucleus is sometimes termed the *descending* or *spinal vestibular nucleus* ; (*b*) the *nucleus of Deiters*, consisting of large cells and situated in the lateral angle of the floor of the fourth ventricle ; the dorso-lateral part of this nucleus is sometimes termed the *nucleus of Bechterew*.

Applied Anatomy.—Injury to the pons, such as may occur on the occlusion or rupture of one of its blood-vessels, often gives rise to a special train of symptoms that is almost diagnostic. Pontine lesions are characterised mainly by ' alternate paralyses ' ; that is to say, by paralysis of one of the motor cerebral nerves on one side, and of the limbs on the other side of the body. Thus a hæmorrhage into the lower part of the pons might cause paralysis of the face (' lower segment paralysis ') on the same side, from destruction of the facial nucleus or nerve-root, and paralysis of the arm and leg on the opposite side from injury to the adjacent pyramidal tract. In the same way, paralysis of the External rectus muscle of one eye and of the Internal rectus of the other (' conjugate paralysis ' of the muscles turning the two eyes in one direction) and often paralysis of one side of the face as well, together with palsy of the limbs on the opposite side of the body, may be found when the lesion occurs about the nucleus of the sixth nerve. Hearing is often unaffected in pontine lesions, possibly because the central auditory tract occupies a ventral and external position in the pons.

The Cerebellum

The **cerebellum** constitutes the largest part of the hind-brain. It lies behind the pons Varolii and medulla oblongata, while between its central portion and these structures is the cavity of the fourth ventricle. It rests on the inferior occipital fossæ, while above it is a fold of dura mater, named the tentorium cerebelli, which separates it from the tentorial surface of the cerebrum. It is somewhat oval in form, but constricted mesially and flattened from above downwards, its greatest diameter being from side to side. Its surface is not convoluted like that of the cerebrum, but is traversed by numerous curved furrows or sulci, which vary in depth at different parts, and separate the laminæ of which it is composed.

Lobes of the cerebellum.—The cerebellum consists of three parts, a median and two lateral, which are continuous with each other, and are substantially the same in structure. The median portion is constricted, and is called the *worm* or *vermis*, from the annulated appearance which it presents owing to transverse ridges and furrows upon it; the lateral expanded portions are named the

hemispheres. On the upper surface of the cerebellum the vermis is elevated above the level of the hemispheres, but on the under surface it is sunk almost out of sight in the bottom of a deep depression between them; this depression is called the *vallecula cerebelli*, and lodges the medulla oblongata. The part of the vermis which lies on the upper surface of the cerebellum is named the *superior vermis*; that on the lower surface, the *inferior vermis*. Below and behind, the hemispheres are separated by a deep notch, the *posterior cerebellar notch* (incisura cerebelli posterior), and in front by a broader shallower notch, the *anterior cerebellar notch* (incisura cerebelli anterior). The anterior notch lies close to the pons and upper part of the medulla, and its upper edge encircles the lower pair of corpora quadrigemina and the superior peduncles of the cerebellum. The posterior notch contains the upper part of a fold of dura mater, the falx cerebelli.

The cerebellum is characterised by its laminated or foliated appearance; it is marked by deep, somewhat curved fissures, which lie close together, and extend for a considerable distance into its substance, dividing it into a series of layers or leaves. The largest and deepest fissure is named the *great horizontal fissure* (sulcus horizontalis cerebelli). It commences in front at the pons, and passes horizontally round the free margin of the hemisphere to the middle line behind, and divides the cerebellum into an upper and a lower portion. Several secondary but deep fissures separate the cerebellum into lobes, and these are further subdivided by shallower sulci, which separate the individual folia or laminæ from each other. Upon making sections across the laminæ, it will be seen that the folia, though differing in appearance from the convolutions of the cerebrum, are analogous to them, inasmuch as they consist of a central white substance with a covering or cortex of grey matter.

The cerebellum is connected to the cerebrum, pons, and medulla by three pairs of peduncles: a superior pair connect it with the cerebrum; a middle pair with the pons; and an inferior pair with the medulla.

The **upper surface of the cerebellum** (fig. 703) is elevated in the middle line and sloped towards the circumference, the hemispheres being connected together by the superior vermis, which assumes the form of a raised median ridge, most prominent in front, but not sharply defined from the hemispheres. This surface is traversed by four curved fissures, which extend across its whole width and divide it into five lobes. Although each lobe

Fig. 703.—Upper surface of the cerebellum. (Schäfer.)

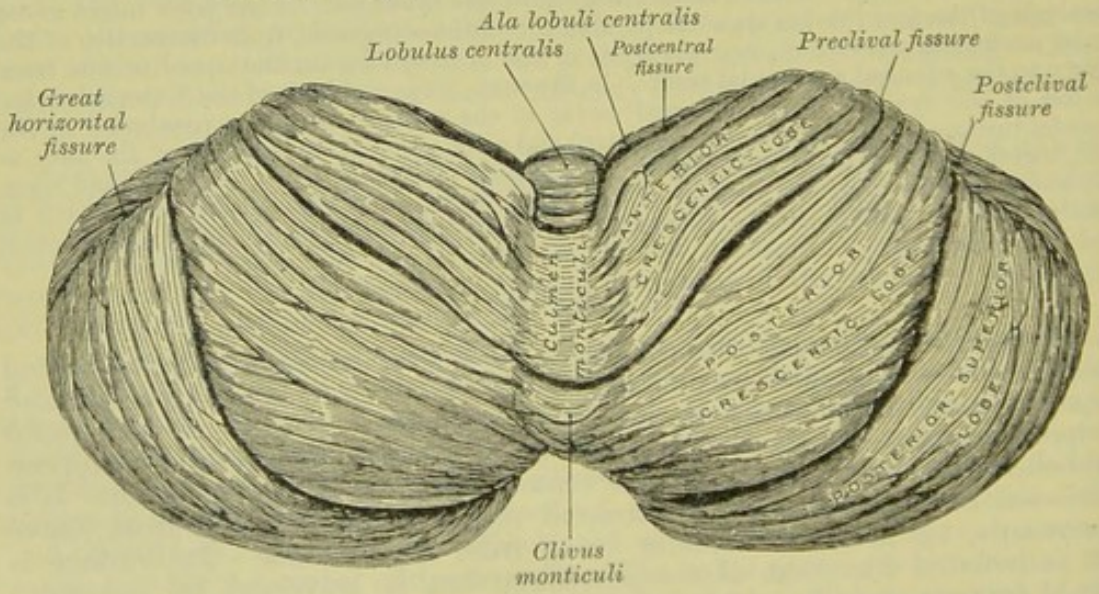

extends continuously from side to side the portion of the lobe in the vermis has received a different name from that in the hemispheres. The five lobes in the vermis are named, from before backwards: (1) the *lingula*, (2) the *lobulus centralis*, (3) the *culmen monticuli*, (4) the *clivus monticuli*, and (5) the *folium cacuminis*; and the corresponding lobes in each hemisphere are termed: (1) the *frænulum*, (2) the *ala lobuli centralis*, (3) the *anterior crescentic*, (4) the *posterior*

crescentic, and (5) the *postero-superior*. The four fissures are named from before backwards, the *precentral*, the *postcentral*, the *preclival*, and the *postclival*. The arrangement of these lobes and fissures will be understood by a reference to the accompanying scheme, in which they are named in order from before backwards.

Hemisphere	*Superior vermis*	*Hemisphere*
Frænulum.	Lingula.	Frænulum.
	Precentral fissure	
Ala lobuli centralis.	Lobulus centralis.	Ala lobuli centralis.
	Postcentral fissure	
Anterior crescentic lobe.	Culmen monticuli.	Anterior crescentic lobe.
	Preclival fissure	
Posterior crescentic lobe.	Clivus monticuli.	Posterior crescentic lobe.
	Postclival fissure	
Postero-superior lobe.	Folium cacuminis.	Postero-superior lobe.

The **lingula** is a small tongue-shaped process, consisting of four or five folia ; it lies in front of the lobulus centralis, and is concealed by it. Anteriorly, it rests on the dorsal surface of the valve of Vieussens, and its white matter is continuous with that of the valve. On either side, the lingula gradually shades off, and is prolonged for only a short distance into the hemispheres, where it forms the **frænulum**. This does not stretch beyond the superior peduncle of the cerebellum, over which it lies.

The **lobulus centralis** is a small square lobe, situated in the anterior notch. It overlaps the lingula, and is in turn partially concealed by the culmen monticuli ; laterally, it extends along the upper and anterior part of each hemisphere, where it forms a wing-like prolongation, the **ala lobuli centralis.**

The **culmen monticuli** is much larger than the two lobes just described, and constitutes, with the succeeding lobe, the bulk of the superior vermis. In front, it partially overlaps and obscures the lobulus centralis ; and behind, it is separated from the clivus by the *preclival fissure*. It forms the most prominent part of the superior vermis, and is marked on its surface by three or four secondary fissures, which divide it into smaller lobules. Laterally, it is continuous with the **anterior crescentic lobes** of the hemispheres, which are separated from the posterior crescentic lobes by the preclival fissure. The culmen monticuli and the two anterior crescentic lobes form the **lobus culminis.**

The **clivus monticuli** is of considerable size, and consists of a group of laminæ which are separated in front from the culmen by the preclival fissure, but appear behind to be almost continuous with the folium cacuminis ; it will be found, however, on careful examination, to be separated from it by a well-defined fissure, the *postclival fissure*. Laterally, this lobe is continued into the hemispheres as the **posterior crescentic lobes,** which are somewhat semilunar in shape, and form, with the anterior crescentic lobes, the greater part of the upper surface of the hemispheres. The two posterior crescentic lobes and the intervening clivus monticuli constitute the **lobus clivi.**

The **folium cacuminis** is a short, narrow, concealed band at the posterior extremity of the vermis, consisting apparently of a single folium, but in reality marked on its upper and under surfaces by secondary fissures. Laterally, it expands in either hemisphere into a considerable lobe, which is semilunar in shape, and is situated at the postero-superior part of the hemisphere, and bounded below by the *great horizontal fissure*. It is named the **postero-superior lobe,** and occupies the posterior third of the upper surface of the hemisphere, forming its rounded postero-lateral border. The postero-superior lobes and the folium cacuminis form the **lobus cacuminis.**

The **under surface of the cerebellum** (figs. 704, 705) presents, in the middle line, the *inferior vermis*, buried in the vallecula, and separated from the hemisphere on either side by a deep groove, the *sulcus valleculæ*. Here, as on the upper surface, there are deep fissures, dividing it into separate segments or

lobes; but the arrangement is more complicated, and the relation of the segments of the vermis to those of the hemisphere is less clearly marked. This surface is divided into four lobes by three main fissures, which, however, are not so regularly disposed as those on the upper surface. The lobes on the vermis are named from before backwards: (1) the *nodule*, (2) the *uvula*, (3) the *pyramid*, and (4) the *tuber valvulæ* or *tuber posticum*. On the hemispheres

Fig. 704.—Under surface of the cerebellum. (Schäfer.)

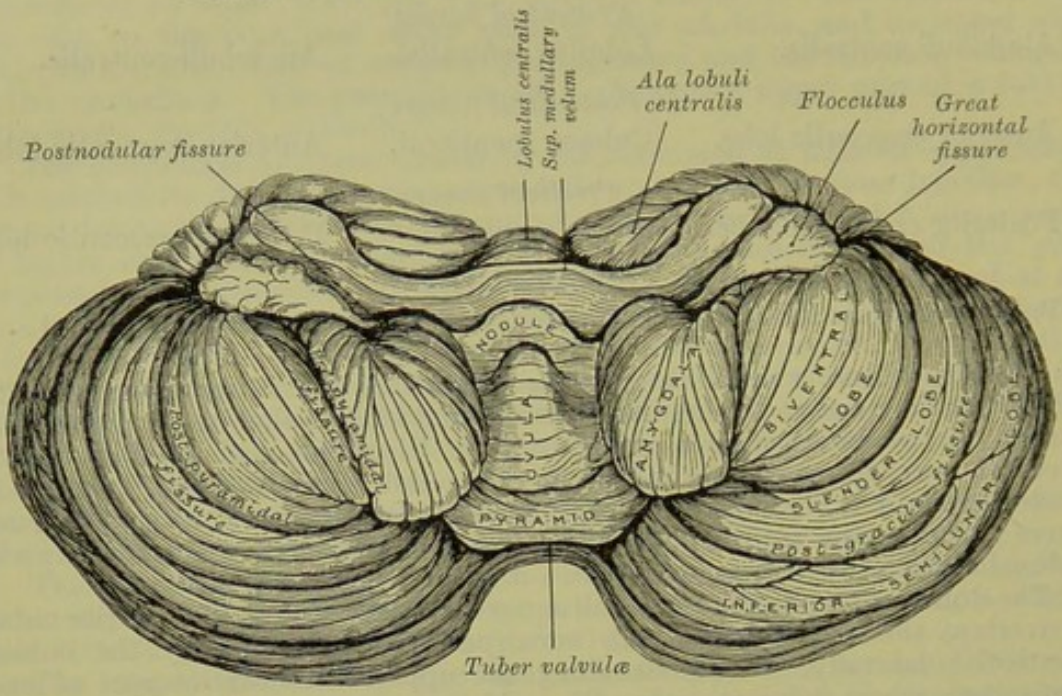

the corresponding lobes are: (1) the *flocculus*, (2) the *amygdala* or *tonsil*, (3) the *biventral* or *digastric lobe*, and (4) the *postero-inferior lobe*, which occupies at least two-thirds of the under surface and is subdivided by a secondary fissure, named the *postgracile fissure*; the anterior of the two subdivisions is named the *slender lobe* (lobus gracilis); and the posterior, the *inferior semilunar*

Fig. 705.—Diagram showing fissures on under surface of the cerebellum.

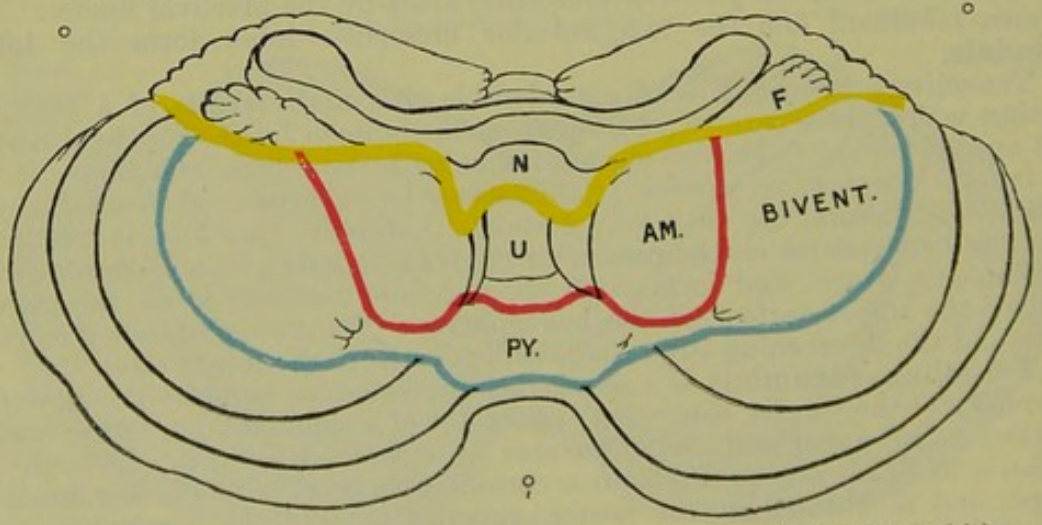

F. Flocculus. N. Nodule. U. Uvula. PY. Pyramid. AM. Amygdala. BIVENT. Biventral lobe.

or *postero-inferior lobe*. The three main fissures are: (1) The *postnodular fissure* which runs transversely across the vermis, separating the nodule in front from the uvula behind. When this fissure reaches the hemispheres, it passes in front of the amygdala, and then crosses between the flocculus in front and the biventral lobe behind, and joins the anterior end of the great horizontal fissure. (2) The *prepyramidal fissure* crosses the vermis between the uvula in

front and the pyramid behind, then curves laterally behind the amygdala, and passes forwards along the outer border of this lobe, between it and the biventral lobe, to join the postnodular fissure. (3) The *postpyramidal fissure* passes across the vermis behind the pyramid and in front of the tuber valvulæ, and, in the hemispheres, courses behind the amygdala and biventral lobes, and then along the outer border of the biventral lobe to the postnodular sulcus. It forms the anterior boundary of the postero-inferior lobe, which, as already stated, is subdivided by the *postgracile fissure*. These fissures and lobes are here arranged, from before backwards, in a schematic form.

Hemisphere	*Inferior vermis*	*Hemisphere*
Flocculus.	Nodule.	Flocculus.
	Postnodular fissure	
Amygdala.	Uvula.	Amygdala.
	Prepyramidal fissure	
Biventral lobe.	Pyramid.	Biventral lobe.
	Postpyramidal fissure	
Lobus gracilis.		Lobus gracilis.
Postgracile fissure.	Tuber valvulæ.	*Postgracile fissure.*
Inferior semilunar lobe.		Inferior semilunar lobe.

The **nodule** and **flocculus.**—The nodule is a distinct prominence, forming the anterior extremity of the inferior vermis. It abuts against the roof of the fourth ventricle, and can only be distinctly seen after the cerebellum has been separated from the medulla and pons. On either side of the nodule is a thin layer of white substance, named the *inferior medullary velum*. It is semilunar in form, its convex border being continuous with the white substance of the cerebellum ; it extends on either side as far as the flocculus, which it connects with the nodule. The flocculus is a prominent, irregular lobule, situated just in front of the biventral lobe, between it and the middle peduncle of the cerebellum. It is subdivided into a few small laminæ, and is connected to the inferior medullary velum by its central white core. The flocculi, together with the inferior medullary velum and nodule, constitute the **lobus noduli.**

The **uvula** and **amygdalæ.**—The uvula forms a considerable portion of the inferior vermis ; it is separated on either side from the amygdala by the *sulcus valleculæ*, at the bottom of which it is connected to the amygdala by a ridge of grey matter, indented on its surface by shallow furrows, and hence called the *furrowed band*. It is marked on its surface by three or four transverse fissures. The amygdalæ, or tonsils, are rounded masses, situated in the lateral hemispheres. Each lies in a deep fossa, termed the *bird's nest* (nidus avis), between the uvula and the biventral lobe. The uvula and tonsils form the **lobus uvulæ.**

The **pyramid** and **biventral lobes** constitute the **lobus pyramidis.** The pyramid is a conical projection, forming the largest prominence of the inferior vermis. It is separated from the hemispheres by the sulcus valleculæ, across which it is connected to the biventral lobe by an indistinct grey band, analogous to the furrowed band already described. The biventral lobe is triangular in shape ; its apex points inwards and backwards, and is joined by the connecting band to the pyramid. The external border is separated from the slender lobe by the postpyramidal fissure. The base is directed forwards, and is on a line with the anterior border of the amygdala, and is separated from the flocculus by the postnodular fissure.

The **tuber valvulæ** and the **postero-inferior lobes** collectively form the **lobus tuberis**. The tuber valvulæ is the most posterior division of the inferior vermis. It is of small size, and laterally spreads out into the large postero-inferior lobes of the hemispheres. These lobes, as stated above, comprise at least two-thirds of the inferior surface of the hemisphere, and are divided into two by the *postgracile fissure*. The anterior part is named the *slender lobe* (lobus gracilis) ; and the posterior, the *inferior semilunar lobe*. Each of them is traversed by a curved fissure ; that in the slender lobe being well marked and termed the *intragracile fissure*.

Internal Structure of the Cerebellum

The cerebellum consists of white and grey matter.

White matter.—If a sagittal section (fig. 706) be made through either hemisphere, the interior will be found to consist of a central stem of white matter, in the interior of which is a grey mass, the *nucleus dentatus*. From the surface of this central stem a series of plates of medullary matter are detached; these are covered with grey matter and form the laminæ. In consequence of the main branches from the central stem dividing and subdividing, the section presents a characteristic appearance, which is named the *arbor vitæ*. If the sagittal section be made through the middle of the vermis, it will be found that the central stem divides into a vertical and a horizontal branch. The *vertical* branch passes upwards to the culmen, where it subdivides freely, one of its ramifications passing forwards and upwards to the central lobe. The *horizontal* branch passes backwards to the folium cacuminis, greatly diminished in size in consequence of having given off large secondary branches: one, from its upper surface, ascends to the clivus; the others descend, and enter the lobes in the inferior vermiform process,

Fig. 706.—Sagittal section of the cerebellum, near the point of junction of the vermis with the hemisphere. (Schäfer.)

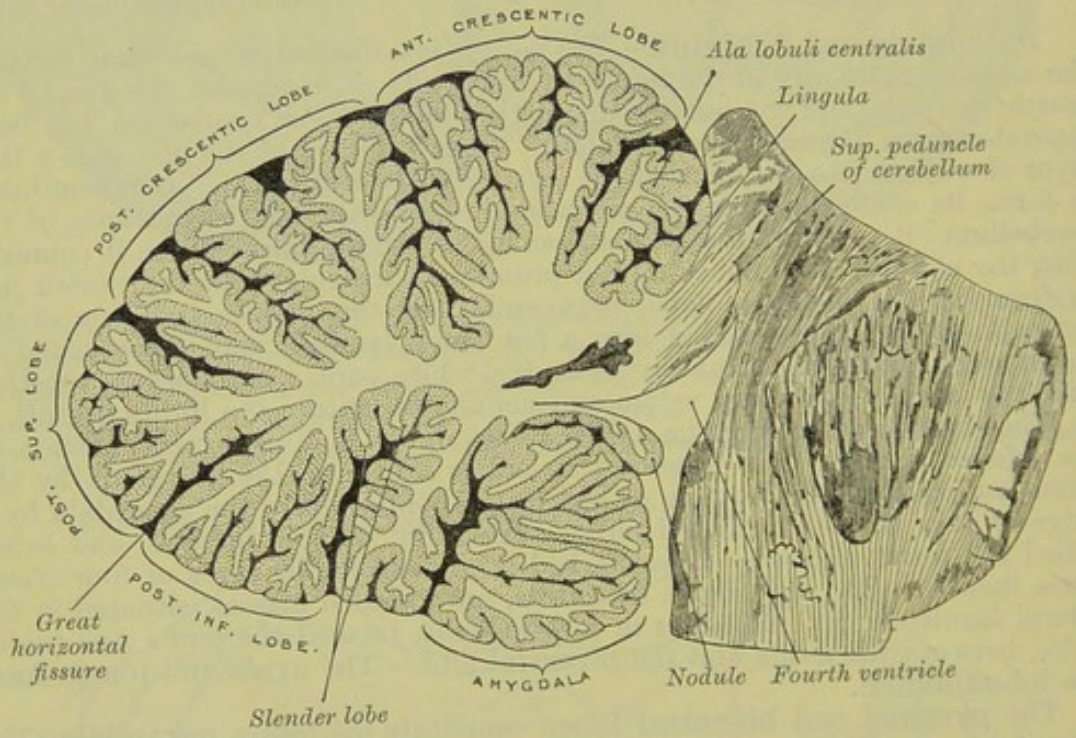

viz. the tuber valvulæ, the pyramid, the uvula, and the nodule. It is not necessary to describe in detail the various divisions of the white matter, as they correspond to the lobes on the surface.

The white matter of the cerebellum includes two sets of nerve-fibres: (1) the *peduncular fibres*, continuous with those of the peduncles of the cerebellum; (2) the fibres proper (*fibræ propriæ*) of the cerebellum itself.

The **peduncles.**—From the anterior part of each hemisphere arise three large processes or peduncles—superior, middle, and inferior—by which the cerebellum is connected with the rest of the brain.

The **superior peduncles** emerge from the upper and mesial part of the white substance of the hemispheres and are placed under cover of the upper part of the cerebellum. They are joined to each other across the middle line by the valve of Vieussens, and can be followed upwards as far as the inferior quadrigeminal bodies, under which they disappear. Below, they form the upper lateral boundaries of the fourth ventricle, but as they ascend they converge on the dorsal aspect of the ventricle and thus assist in roofing it in.

The fibres of the superior peduncle are mainly derived from the cells of the nucleus dentatus, and emerge from the hilus of this nucleus; a few arise

from the cells of the smaller grey nuclei in the cerebellar white substance, and others from the cells of the cerebellar cortex. They are continued upwards beneath the corpora quadrigemina, and the fibres of the two peduncles undergo a complete decussation in front of the Sylvian aqueduct. Having crossed the middle line they divide into ascending and descending groups of fibres, the former ending in the red nucleus, the thalamus, and the nucleus of the third nerve, while the descending fibres can be traced as far as the dorsal part of the pons ; Cajal believes them to be continued into the anterior column of the spinal cord.

As already stated (page 806), the greater part of the tract of Gowers passes to the cerebellum, which it reaches by way of the superior peduncle.

The **middle peduncles** are the largest, and are formed by the transverse fibres of the pons. They enter the cerebellum between the margins of the great horizontal fissure, and their fibres are grouped into two main bundles : one, consisting of the upper transverse fibres of the pons, spreads out in the infero-lateral part of the hemisphere ; the other, comprising the lower transverse fibres of the pons, radiates into the upper part of the hemisphere.

The middle peduncle is composed entirely of centripetal fibres, which arise from the cells of the nuclei pontis of the opposite side and terminate in the cerebellar cortex.

The **inferior peduncles** consist mainly of afferent fibres, and are continuous below with the restiform bodies of the medulla oblongata.* They pass at first upwards and outwards, forming part of the lateral walls of the fourth ventricle, and then bend abruptly backwards to enter the cerebellum between the middle and superior peduncles.

The inferior peduncle contains the following fasciculi : (1) the direct cerebellar tract of the spinal cord, which terminates mainly in the superior vermis ; (2) fibres from the nucleus gracilis and nucleus cuneatus of the same and of the opposite sides ; (3) fibres from the opposite olivary body ; (4) crossed and uncrossed fibres from the reticular formation of the medulla ; (5) vestibular fibres, derived partly from the vestibular division of the auditory nerve and partly from the nuclei in which this division terminates—these fibres occupy the inner segment of the peduncle and divide into ascending and descending groups of fibres ; the ascending fibres partly end in the roof nucleus of the opposite side of the cerebellum ; (6) cerebello-bulbar fibres which come from the opposite roof nucleus and probably from the nucleus dentatus, and are said to end in the nucleus of Deiters and in the formatio reticularis of the medulla oblongata.

The **valve of Vieussens,** or **superior medullary velum,** is a thin, transparent lamina of white matter, which stretches across from one superior peduncle to the other ; on the dorsal surface of its lower half the folia of the lingula are prolonged. It forms, together with the superior peduncles, the roof of the upper part of the fourth ventricle, and is continuous with the central white stem of the cerebellum. It is narrow above, where it passes beneath the corpora quadrigemina, and broader below, at its connection with the white substance of the superior vermis. A slightly elevated ridge, the *frænulum veli*, descends upon the upper part of the valve from between the lower corpora quadrigemina, and on either side of this the fourth nerve emerges.

The **inferior medullary velum** is a thin layer of white substance, which is prolonged from the white centre of the medulla above and on either side of the nodule, and assists in forming a part of the roof of the fourth ventricle. Somewhat semilunar in shape, it is continuous with the white substance of the cerebellum by its convex edge, while its thin concave margin is apparently free. In reality, however, it is continuous with the epithelium of the ventricle, which is prolonged downwards from the inferior medullary velum to the ligulæ.

The two medullary vela are in contact with each other along their line of emergence from the white substance of the cerebellum ; and this line of contact forms the summit of the roof of the fourth ventricle, which, in a vertical section through the cavity, appears as a pointed angle.

* Strictly speaking, each inferior peduncle consists of an inner and an outer segment, the latter of which is the restiform body.

The **fibræ propriæ** of the cerebellum are of two kinds : (1) *commissural fibres*, which cross the middle line to connect the opposite halves of the cerebellum, some at the anterior part, and others at the posterior part of the vermiform process; (2) *arcuate* or *association fibres*, which connect adjacent laminæ with each other.

Grey matter.—The grey matter of the cerebellum is found in two situations : (1) on the surface, forming the cortex ; (2) as independent masses in the interior.

(1) The **grey matter of the cortex** presents a characteristic foliated appearance, due to the series of laminæ which are given off from the central

Fig. 707.—Transverse section of a cerebellar folium. (Diagrammatic, after Cajal and Kölliker.)

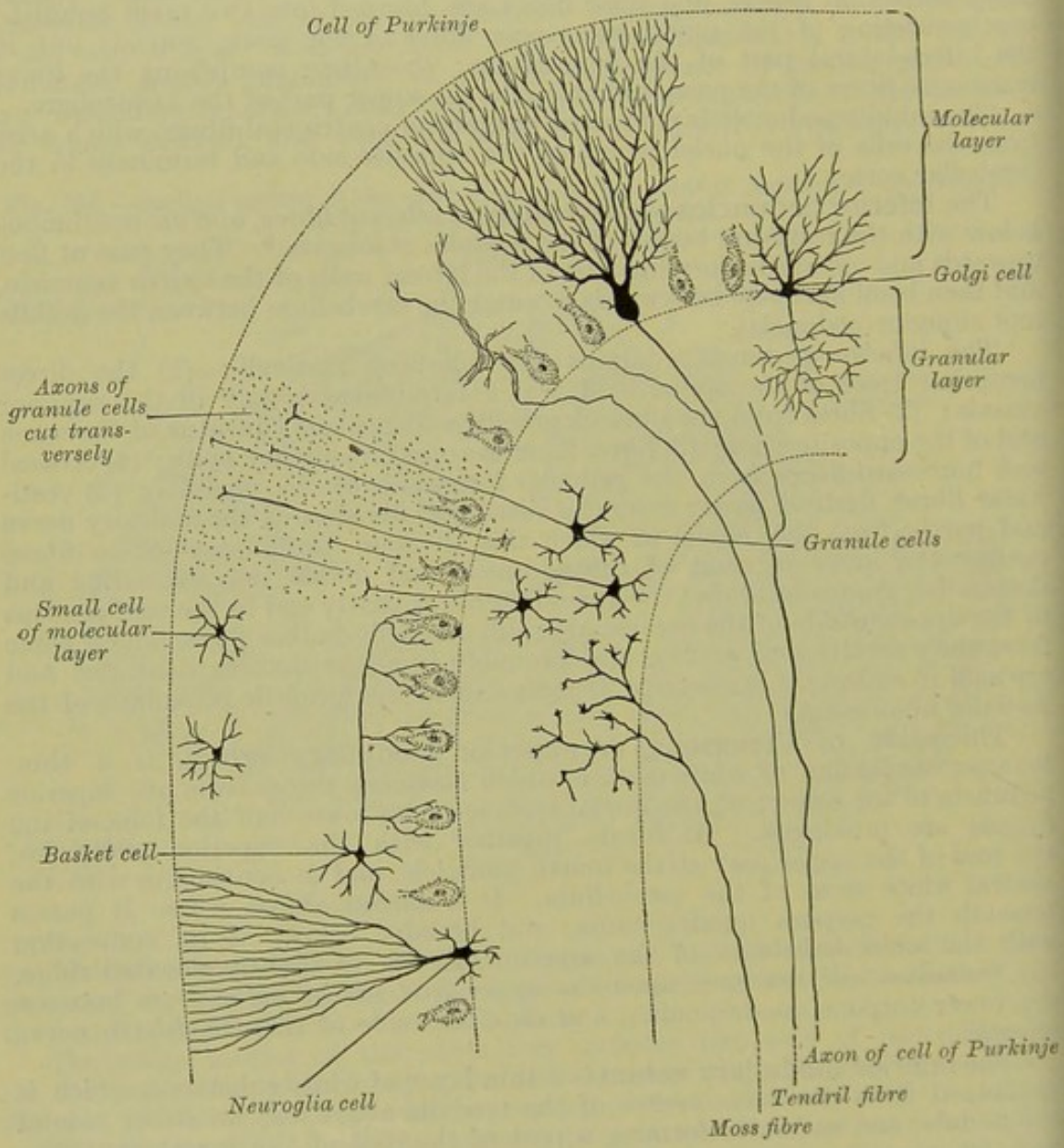

white matter ; these in their turn give off secondary laminæ, which are covered with grey matter. This arrangement gives to the cut surface of the organ a foliated appearance (fig. 706). Externally, the cortex is covered by pia mater ; internally is the medullary centre, consisting mainly of nerve-fibres.

Microscopic appearance of the cortex.—The cortex consists of two distinct layers, viz. an external grey molecular layer, and an internal rust-coloured granular layer. Between the two layers is an incomplete stratum of cells which are characteristic of the cerebellum, viz. the *cells of Purkinje*.

The *external grey* or *molecular layer* (fig. 707) consists of fibres and cells. The nerve-fibres are delicate fibrillæ, and are derived from the following

sources : (*a*) the dendrites and axon-collaterals of Purkinje's cells ; (*b*) fibres from cells in the granular layer ; (*c*) fibres from the central white substance of the cerebellum ; (*d*) fibres derived from cells in the molecular layer itself. In addition to these are other fibres, which have a vertical direction. These are the processes of large neuroglia-cells, situated in the granular layer. They pass outwards to the periphery of the grey matter, where they expand into little conical enlargements which form a sort of limiting membrane beneath the pia mater, analogous to the membrana limitans interna in the retina, formed by the fibres of Müller.

The *cells of the molecular layer* are small, and are arranged in two strata, an outer and an inner. They all possess branched axis-cylinder processes ; those of the inner layer run for some distance horizontally—i.e. parallel with the surface of the folium—giving off collaterals, which pass in a vertical direction towards the cell-bodies of Purkinje's corpuscles, around which they become enlarged, and form a basket-like network. Hence these cells of the inner layer are named *basket-cells*.

The *cells of Purkinje* form a single stratum of large, flask-shaped cells situated at the junction of the molecular and granular layers, their bases resting against the latter ; in fishes and reptiles they are arranged in several layers. The cells are flattened in a direction transverse to the long axis of the folium, and thus appear broad in sections carried across the folium, and fusiform in sections parallel to the long axis of the folium. From the neck of the flask one or more dendrites arise and pass into the molecular layer, where they subdivide and form an extremely rich arborescence, the various subdivisions of the dendrites being covered by lateral spine-like processes. This arborescence is not circular, but, like the cell, is flattened at right angles to the long axis of the folium ; in other words, it does not resemble a round bush, but has been aptly compared by Obersteiner to the branches of a fruit tree trained against a trellis or a wall. Hence, in sections carried across the folium the arborescence is broad and expanded ; whereas in those which are parallel to the long axis of the folium, the arborescence, like the cell itself, is seen in profile, and is limited to a narrow area.

From the bottom of the flask-shaped cell the axon arises ; this passes through the granular layer, and, becoming medullated, is continued as a nerve-fibre in the subjacent white substance. This axon as it passes through the granular layer gives off fine collaterals some of which run back into the molecular layer.

The *internal rust-coloured, granular*, or *nuclear, layer* (fig. 707) is characterised by containing numerous small nerve-cells or granules of a reddish-brown colour, together with many nerve-fibrils. Most of the cells are nearly spherical and provided with short dendrites which spread out in a spider-like manner in the granular layer. Their axons pass outwards into the molecular layer, and, bifurcating at right angles, run horizontally for some distance. In the outer part of the granular layer are some larger cells, of the type termed *Golgi cells*. Their axons undergo frequent division as soon as they leave the nerve-cells, and pass into the granular layer ; while their dendrites ramify chiefly in the molecular layer.

Finally, in the grey matter of the cerebellar cortex, there are fibres which come from the white centre and penetrate the cortex. The cell-origin of these fibres is unknown, though it is believed that it is probably in the grey matter of the spinal cord. Some of these fibres end in the granular layer by dividing into numerous branches, on which are to be seen peculiar moss-like appendages ; hence they have been termed by Ramón y Cajal the *moss-fibres* ; they form an arborescence around the cells of the granular layer. Other fibres derived from the medullary centre can be traced into the molecular layer, where their branches cling around the dendrites of Purkinje's cells, and hence they have been named the *clinging* or *tendril fibres*.

(2) The **independent centres of grey matter** in the cerebellum are four in number on either side : one is of large size, and is known as the nucleus dentatus ; the other three, much smaller, are situated near the middle of the cerebellum, and are known as the nucleus emboliformis, nucleus globosus, and nucleus fastigii.

The *nucleus dentatus* (fig. 708) is situated a little to the inner side of the centre of the stem of the white matter of the hemisphere. It consists of an irregularly folded lamina, of a greyish-yellow colour, containing white fibres, and presenting on its antero-internal aspect an opening, the hilus, from which most of the fibres of the superior cerebellar peduncle emerge.

The *nucleus emboliformis* lies immediately to the inner side of the corpus dentatum, and partly covering its hilus. The *nucleus globosus* is an elongated mass, directed antero-posteriorly, and placed to the inner side of the preceding. The *nucleus fastigii*, or roof nucleus of Stilling, is somewhat larger than the other

Fig. 708.—Sagittal section through right cerebellar hemisphere. The right olivary body has also been cut sagittally.

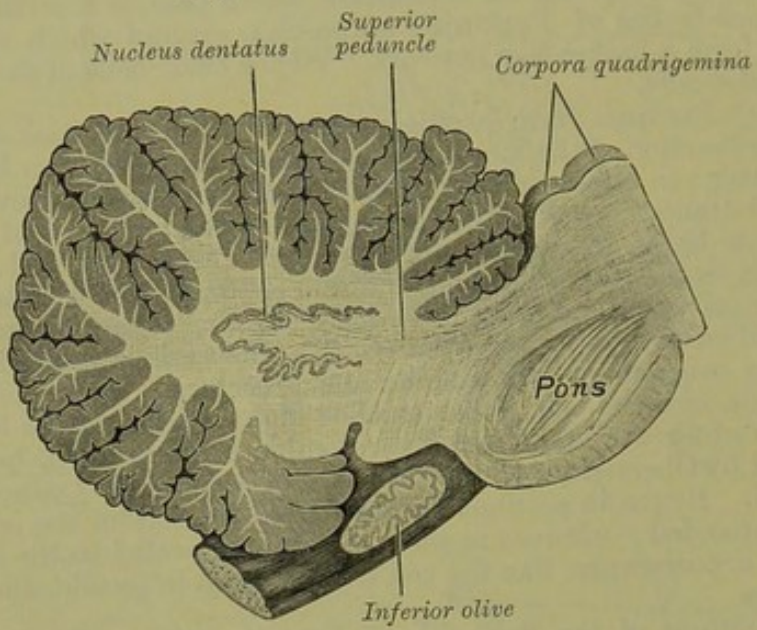

two, and is situated close to the middle line at the anterior end of the superior vermiform process, and immediately over the roof of the fourth ventricle, from which it is separated by a thin layer of white matter.

Weight of the cerebellum.—Its average weight in the male is about 5 oz. 4 drs. It attains its maximum between the twenty-fifth and fortieth years; its increase after the fourteenth year being relatively greater in the female than in the male. The proportion between the cerebellum and cerebrum is, in the male, as 1 to 8·2, and in the female as 1 to 8. In the infant the cerebellum is proportionately much smaller than in the adult, the relation between it and the cerebrum being, according to Cruveilhier, 1 to 20.

Applied Anatomy.—The general functions of the cerebellum in the human economy appear to be the co-ordination of movements and equilibration. The exact functions of its different parts are still quite uncertain, owing to the contradictory nature of the evidence furnished by (1) ablation experiments upon animals, and (2) clinical observations in man of the effects produced by abcesses or tumours affecting different portions of the organ. According to W. A. Turner, 'The following localising symptoms would therefore indicate the presence of a tumour implicating the right cerebellar hemisphere and middle peduncle: deafness in the right ear, unassociated with middle ear complications; an unsteady and uncertain gait, with a tendency to fall more particularly to the right side; coarse nystagmoid oscillations on looking to the right; movements resembling those of disseminated sclerosis on volitional effort of the right arm; an awkward uncertain action of the right leg; a slight increase of the right knee-jerk; and, perhaps, slight blunting of sensibility over the right cornea and side of the face.'

The Fourth Ventricle

The **fourth ventricle** (ventriculus quartus), or cavity of the hind-brain, is situated in front of the cerebellum and behind the pons Varolii and upper half of the medulla oblongata. It is lined by ciliated epithelium, and is continuous below

with the central canal of the medulla oblongata ;* above, it communicates, by means of a passage termed the aqueduct of Sylvius, with the cavity of the third ventricle. It presents four angles, and possesses a roof or dorsal wall, a floor or ventral wall, and lateral boundaries.

Angles.—The *superior angle* is on a level with the upper border of the pons Varolii, and is continuous with the lower end of the aqueduct of Sylvius. The *inferior angle* is on a level with the lower end of the olivary body, and opens into the central canal of the medulla oblongata. Each *lateral angle* corresponds with the point of meeting of the three cerebellar peduncles. A little below the lateral angles, on a level with the striæ acusticæ, the ventricular cavity is prolonged outwards in the form of two narrow passages, one on either side. These are named the *lateral recesses*, and are situated between the restiform bodies and the flocculi, reaching as far as the attachments of the glosso-pharyngeal and vagi nerves.

Lateral boundaries.—The lower part of each lateral boundary is constituted by the clava, the fasciculus cuneatus, and the restiform body ; the upper part by the superior cerebellar peduncle.

FIG. 709.—Scheme of roof of fourth ventricle.

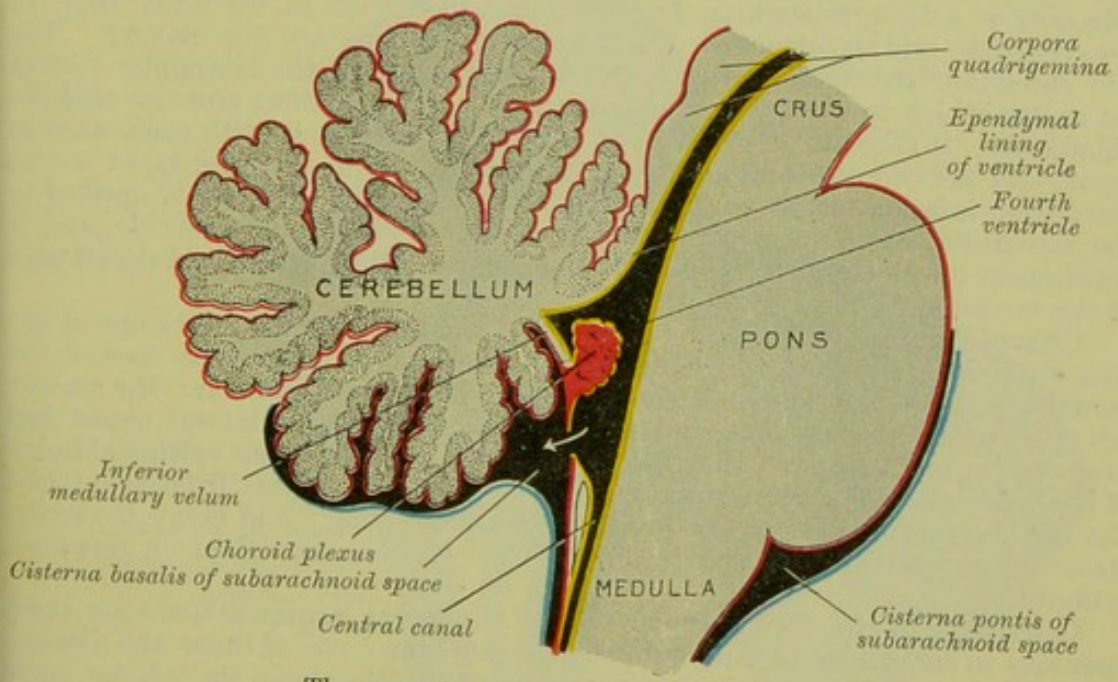

The arrow is in the foramen of Majendie.

Roof or dorsal wall (fig. 709).—The upper portion of the roof is formed by the superior cerebellar peduncles and the valve of Vieussens ; the lower portion, by the inferior medullary velum, the epithelial lining of the ventricle covered by the tela chorioidea inferior, the ligulæ and the obex.

The *superior peduncles*, on emerging from the central white substance of the cerebellum, pass upwards and forwards, forming at first the lateral boundaries of the upper part of the cavity ; but on approaching the inferior quadrigeminal bodies, they converge, and their mesial portions overlap the cavity and form part of its roof,

The *superior medullary velum* (velum medullare anterius) (page 831) fills in the angular interval between the superior peduncles, and is continuous behind with the central white substance of the cerebellum ; it is covered on its dorsal aspect by the lingula of the superior vermis.

The *inferior medullary velum* (velum medullare posterius) (page 831) is continued downwards and forwards from the central white substance of the cerebellum in front of the nodule and amygdalæ, and ends inferiorly in a thin,

* J. T. Wilson (*Journal of Anatomy and Physiology*, vol. xl.) has pointed out that the central canal of the medulla, immediately below its entrance into the fourth ventricle, retains the cleft-like form presented by the fœtal spinal canal, and that it is marked by dorso- and ventro-lateral sulci.

concave, somewhat ragged margin. Below this margin the roof is devoid of nervous matter except in the immediate vicinity of the lower lateral boundaries of the ventricle, where two narrow white bands, the *ligulæ*, appear; these bands meet over the inferior angle of the ventricle in a thin triangular lamina, the *obex*. The non-nervous part of the roof is formed by the *epithelial lining of the ventricle*, which is prolonged downwards as a thin membrane (*membrana tectoria*), from the deep surface of the inferior medullary velum to the corresponding surface of the obex and ligulæ, and thence on to the floor of the ventricular cavity. It is covered and strengthened by a portion of the pia mater, which is named the *tela chorioidea ventriculi quarti*.

The *ligulæ* are two narrow bands of white matter, one on either side, which complete the lower part of the roof of the ventricle. Each consists of an inner vertical and an outer horizontal part. The vertical part is continuous below the obex, and is adherent by its outer border to the clava; the horizontal portion extends transversely outwards across the restiform body, below the striæ acusticæ, and roofs in the lower and posterior part of the lateral recess. It is attached by its lower margin to the restiform body, and partly encloses the choroid plexus, which, however, projects beyond it like a cluster of grapes; and hence this part of the ligula has been termed the *cornucopia* (Bochdalek). The *obex* is a thin, triangular, grey lamina, which roofs in the lower angle of the ventricle and is attached by its lateral margins to the clavæ.* The *tela chorioidea ventriculi quarti* is the name applied to the triangular fold of pia mater which is carried upwards between the cerebellum and the medulla oblongata. It consists of two layers, which are continuous with each other in front, and are more or less adherent throughout. The posterior layer covers the antero-inferior surface of the cerebellum, while the anterior is applied to the structures which form the lower part of the roof of the ventricle, and is continuous inferiorly with the pia mater on the restiform bodies and closed part of the medulla.

Choroid plexuses.—These consist of two highly vascular inflexions of the tela chorioidea inferior, which invaginate the lower part of the roof of the ventricle. Each consists of a vertical and a horizontal portion: the former lies close to the middle line, and the latter passes into the lateral recess and projects beyond its apex; they are everywhere covered by the epithelial lining of the ventricle. The vertical parts of the plexuses are distinct from each other, but the horizontal portions are joined in the middle line; and hence the entire structure presents the form of the letter T, the vertical limb of which, however, is double.

Openings in the roof.—In the roof of the fourth ventricle there are three openings in the pia mater and subjacent epithelium: one of these, the *foramen of Majendie*, is situated in the middle line immediately above the inferior angle of the ventricle; the other two (*foramina of Luschka*, or *foramina of Key and Retzius*) are found at the extremities of the lateral recesses. By means of these three foramina the cavity of the ventricle communicates with the subarachnoid space, and the cerebro-spinal fluid can pass from the ventricle into this space, or *vice versa*.

Floor or ventral wall (fig. 710).—This is rhomboidal in shape, its upper portion being formed by the dorsal surface of the pons Varolii, and its lower by the corresponding surface of the open part of the medulla oblongata. It is covered by a layer of grey matter continuous with the grey matter of the spinal cord; superficial to this is a thin lamina of neuroglia, which constitutes the ependyma of the ventricle and supports a layer of ciliated epithelium. It is traversed by a median sulcus, which divides it into symmetrical halves, and it is crossed at the level of the lateral recesses by a number of white strands, named the *striæ acusticæ*. These form a portion of the cochlear division of the auditory nerve, and vary greatly in different brains as to their direction and prominence; they sweep round the outer aspect of the restiform body, extend inwards on the floor of the ventricle, and disappear by passing into the median

* J. T. Wilson, *op. cit.*, recognises two forms of obex: (*a*) the *true obex*, constituted by a medullary thickening of the roof plate, and (*b*) a *false or membranous obex* where the medullary thickening fails to take place, and where the roof plate is represented only by the ependymal layer clothing the ventral surface of a pial reduplication which forms the main substance of the membranous fold in question.

sulcus. They divide the floor into two triangular areas, an upper and a lower, which correspond, approximately, to the portions of the floor which are formed by the back of the pons and medulla respectively.

Below the striæ acusticæ, at a short distance from the median sulcus, on either side, is a small triangular depression, the *inferior fovea*, the apex of which is directed upwards, while its sides are prolonged downwards as divergent furrows. The inner of these furrows is carried towards the lower angle of the ventricle, the outer towards its lateral wall; and in this manner three small triangular areas are marked off on either side of the middle line. That which lies between the diverging furrows of the fovea is darker in colour than the other two, and is named the *ala cinerea* or *trigonum vagi*; it corresponds with the position of the sensory nuclei of the vagus and glosso-pharyngeal nerves. The base of the trigonum vagi is crossed by a narrow translucent elevation named the *funiculus separans*, between which and the clava is a small tongue-shaped area, the *area postrema*. On section, it is seen that the funiculus separans is formed by a strip of thickened ependyma, and that the area postrema is

FIG. 710.—Floor of fourth ventricle.

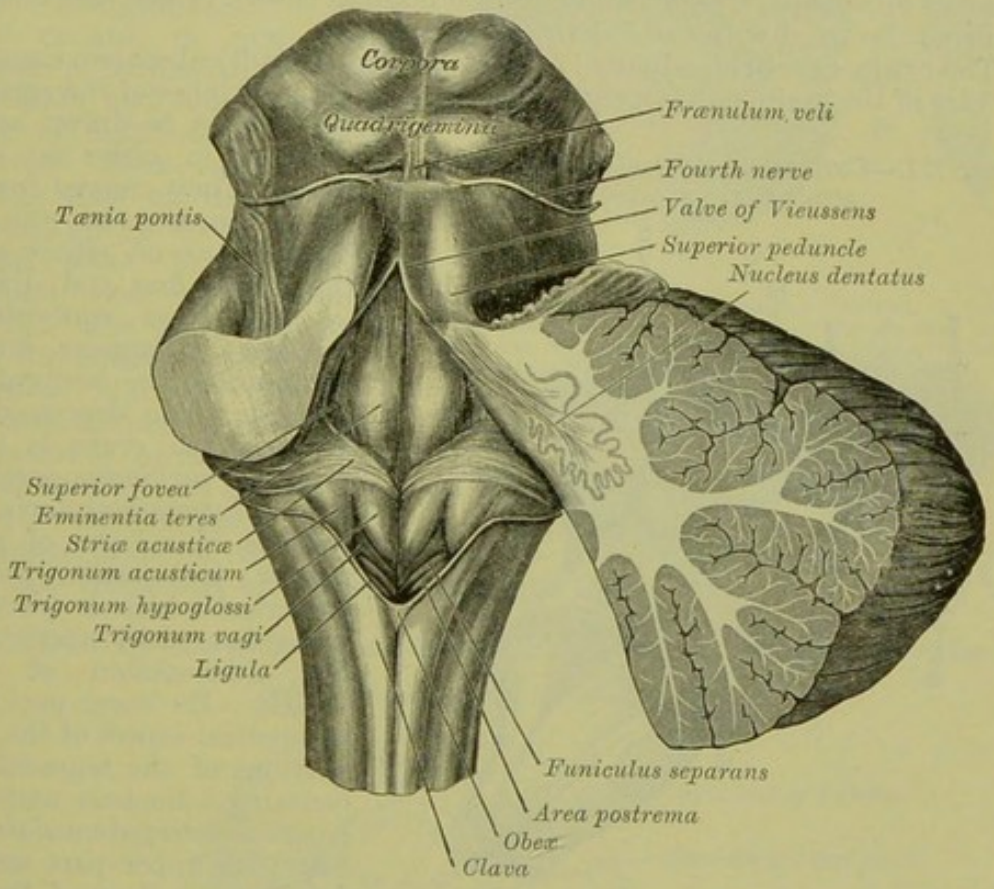

occupied by a loose highly vascular myelospongium, and contains neurons of a moderate size. The area which lies between the inner limb of the fovea and the median sulcus is termed the *trigonum hypoglossi*; its base, directed upwards, is continuous with an elevation, the *eminentia teres*, which lies above the striæ acusticæ; its apex forms with that of the opposite side a pointed elevation, the *calamus scriptorius*. When examined under water with a lens, the trigonum vagi is seen to consist of a mesial and a lateral area separated from one another by a series of oblique furrows; the mesial area corresponds with the ventricular part of the nucleus of the hypoglossal nerve, the lateral with a small-celled nucleus, the *nucleus intercalatus*. The third area, that on the outer side of the fovea inferior, is named the *trigonum acusticum*, and corresponds with one of the chief nuclei of the auditory nerve. Its base is directed upwards, and is continuous with a larger eminence, termed the *eminentia* or *area acustica*, which is crossed by the striæ acusticæ.

In each half of that part of the floor of the ventricle which lies above the striæ acusticæ, a small depression, the *superior fovea*, is seen. Between it and

the median sulcus is an elongated eminence, the *eminentia teres*, which overlies the nucleus of the sixth nerve, and is, in part at least, produced by the ascending portion of the root of the seventh nerve. This eminence becomes less distinct above, while below it is continuous with the trigonum hypoglossi. Outside the superior fovea is the prominence of the *area acustica* (already referred to); and above it is a bluish, depressed spot, the *locus cæruleus*, which owes its colour to an underlying patch of deeply pigmented nerve-cells, termed the *substantia ferruginosa*, in which a part of the sensory root of the fifth nerve terminates.

THE MID-BRAIN

The **mid-brain**, or **mesencephalon** (fig. 711), is the short, constricted portion which connects the pons Varolii and cerebellum with the thalamencephalon and cerebral hemispheres. It is directed upwards and forwards, and consists of: (1) a ventro-lateral portion, composed of a pair of cylindrical bodies, named the *crura cerebri*; (2) a dorsal portion, consisting of four rounded eminences, named the *corpora quadrigemina*; and (3) an intervening passage or tunnel, the *aqueduct of Sylvius*, which represents the original cavity of the mid-brain and connects the third with the fourth ventricle.

The **crura cerebri** (pedunculi cerebri) are two cylindrical masses situated at the base of the brain, and largely hidden by the temporal lobes of the cerebrum, which must be drawn aside or removed in order to expose them. They emerge from the upper surface of the pons Varolii, one on either side of the middle line, and, diverging as they pass upwards and forwards, disappear into the substance of the cerebral hemispheres. The depressed area between the crura is termed the *locus perforatus posticus* or *fossa interpeduncularis*, and consists of a layer of greyish matter (substantia perforata posterior) which is pierced by numerous small apertures for the transmission of blood-vessels. Its lower part lies on the ventral aspect of the mesial portions of the tegmenta, and contains a nucleus named the *ganglion interpedunculare* (page 840); its upper part assists in forming the floor of the third ventricle. The ventral surface of each crus is crossed from within outwards by the superior cerebellar and posterior cerebral arteries; its lateral surface is in relation to the uncinate convolution of the cerebral hemisphere and is crossed from behind forwards by the fourth nerve. Close to its point of disappearance into the cerebral hemisphere, the optic tract winds forwards around its ventro-lateral surface. The inner surface of the crus forms the lateral boundary of the posterior part of a space known as the interpeduncular space, and is marked by a longitudinal furrow, the *oculo-motor sulcus*, from which the roots of the third or oculo-motor nerve emerge. On the outer surface of each crus there is a second longitudinal furrow, termed the *sulcus lateralis*, which is prolonged downwards between the superior and middle cerebellar peduncles. The fibres of the lateral fillet come to the surface in

Fig. 711.—Corpora quadrigemina and corpora geniculata. (Testut.)

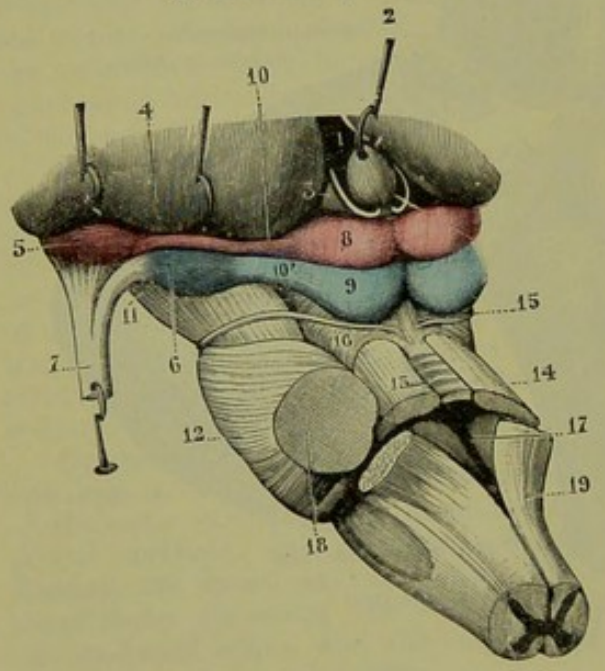

1. Third ventricle. 2. Pineal gland. 3. Habenula. 4. Posterior end of thalamus raised to show: 5. External geniculate body. 6. Internal geniculate body. 7. Optic tract. 8. Superior quadrigeminal body. 9. Inferior quadrigeminal body. 10. Superior brachium. 10'. Inferior brachium. 11. Crus cerebri. 12. Pons. 13. Valve of Vieussens. 14. Superior cerebral peduncle. 15. Fourth nerve. 16. Lateral fillet. 17. Fourth ventricle. 18. Middle peduncle of cerebellum. 19. Inferior peduncle of cerebellum.

this sulcus, and pass backwards and upwards, to disappear under the lower quadrigeminal body.

Structure of the crura cerebri (figs. 713, 714).—On transverse section, each crus is seen to consist of a dorsal and a ventral part, separated by a deeply pigmented lamina of grey matter, termed the *substantia nigra*. The dorsal part is named the *tegmentum*; the ventral, the *crusta* or *pes*; the two crustæ are separated from each other, but the tegmenta are joined in the mesial plane by a forward prolongation of the raphe of the pons Varolii. Laterally, the tegmenta are free, and are constituted by the fibres of the lateral fillet; dorsally, they blend with the corpora quadrigemina.

Fig. 712.—Vertical transverse section through mid-brain. (Schematic.) (Testut.)

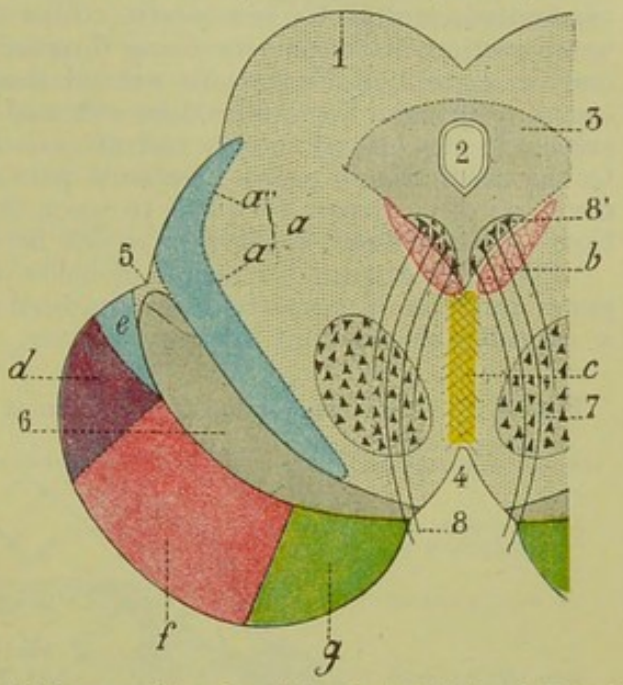

1. Corpora quadrigemina. 2. Aqueduct of Sylvius. 3. Central grey matter of aqueduct. 4. Interpeduncular space. 5. Sulcus lateralis. 6. Substantia nigra. 7. Red nucleus of tegmentum. 8. Third nerve, with 8′, its nucleus of origin. *a*. Fillet (in blue), with *a′*, the mesial or sensory fillet, and *a″*, the lateral or auditory fillet. *b*. Posterior longitudinal fasciculus. *c*. Raphe. *d*. Posterior cortico-protuberantial tract. *e*. Portion of mesial fillet which passes to the lenticular nucleus and island of Reil. *f*. Pyramidal tract (in red). *g*. Geniculate bundle (in green).

The **crusta, or pes** (basis pedunculi) is semilunar on transverse section, and consists almost entirely of longitudinal bundles of efferent fibres, which arise from the cells of the cerebral cortex and are grouped into three principal sets, viz. pyramidal, geniculate, and cortico-pontine (fig. 712). The *pyramidal* fibres occupy the middle three-fifths of the crusta, and are continued downwards through the pons into the pyramid of the medulla. The *geniculate* fibres—so named because they are situated in the knee-shaped bend of the internal capsule—occupy the inner fifth of the crusta, and terminate, after decussating with the corresponding fibres of the

Fig. 713.—Transverse section of mid-brain at level of inferior quadrigeminal bodies.

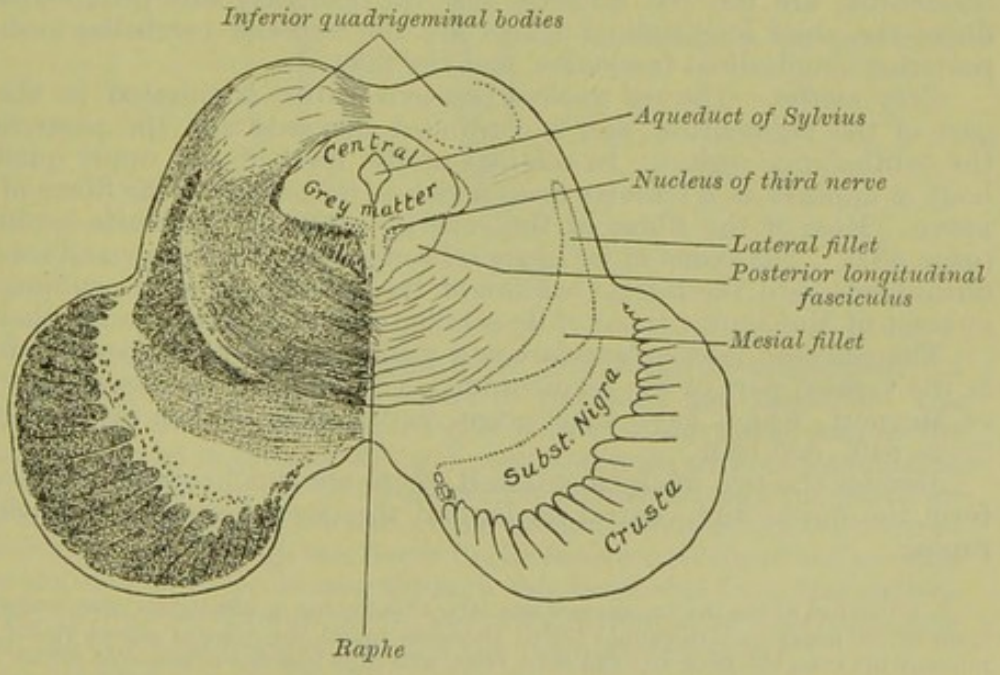

other side, in the motor nuclei of the cranial nerves. The *cortico-pontine* fibres terminate below in the nuclei pontis, and consist of anterior and posterior

groups. The fibres of the posterior group arise in the temporal and occipital lobes, and occupy the outer fifth of the crusta; while those of the anterior group take origin in the frontal lobe, and are disseminated among the pyramidal and geniculate fibres. On the dorsal aspect of the cortico-pontine fibres a strand of the mesial fillet passes up in the crusta.*

The **substantia nigra** is a layer of grey matter containing numerous deeply pigmented, multipolar nerve-cells. Like the crusta, it is semilunar on transverse section, its concavity being directed towards the tegmentum; from its convex aspect, prolongations extend downwards between the fibres of the crusta. Thicker internally than externally, it reaches from the oculo-motor sulcus to the lateral sulcus, and extends from the upper surface of the pons to the subthalamic region; its inner part is traversed by the fibres of the third nerve as these stream forwards to reach the oculo-motor sulcus. The connections of the substantia nigra have not been definitely established.

The **tegmentum** is continuous below with the reticular formation of the pons, and, like it, consists of longitudinal and transverse fibres, together with a considerable amount of grey matter. The principal grey masses of the

FIG. 714.—Transverse section of mid-brain at level of superior quadrigeminal bodies.

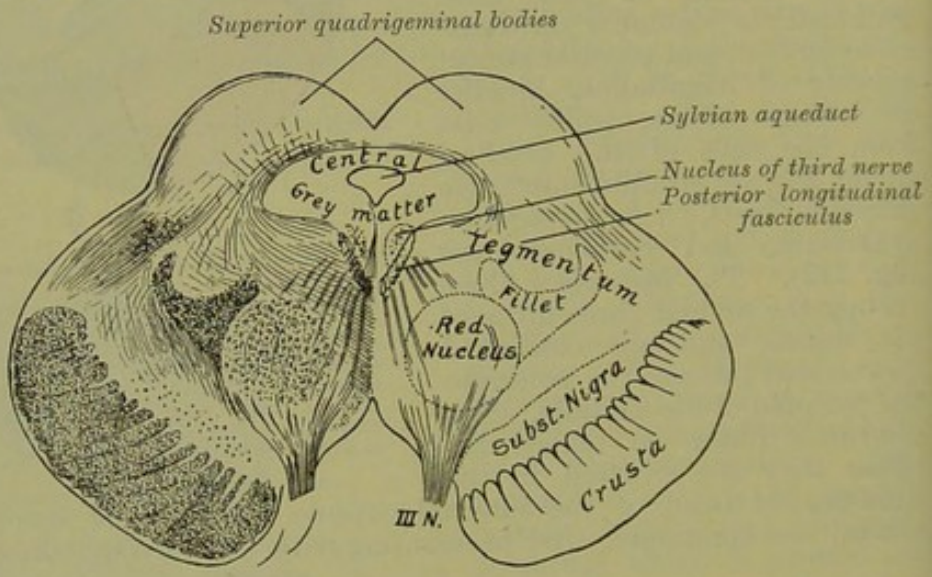

tegmentum are the red nucleus and the ganglion interpedunculare; of its fibres the chief longitudinal tracts are the superior cerebellar peduncle, the posterior longitudinal fasciculus, and the fillet.

Grey matter.—The *red nucleus* (nucleus ruber) is situated in the anterior part of the tegmentum, and is continued upwards into the posterior part of the subthalamic region. In sections at the level of the upper quadrigeminal body it appears as a circular mass which is traversed by the fibres of the third nerve. Most of the fibres of the superior cerebellar peduncle terminate in it (page 831). The axons of its larger cells cross the middle line and are continued downwards into the lateral column of the spinal cord as the rubrospinal tract or tract of Monakow; those of its smaller cells end mainly in the thalamus.

The *ganglion interpedunculare* is a median collection of nerve cells situated in the ventral part of the tegmentum. The fibres of the fasciculus retroflexus of Meynert, which have their origin in the cells of the ganglion habenulæ (page 849), end in it.

Besides the two nuclei mentioned, there are small collections of cells which form the dorsal and ventral nuclei and the central nucleus or nucleus of the raphe.

* A band of fibres, the *tractus peduncularis transversus*, is sometimes seen emerging from in front of the upper quadrigeminal body; it passes round the ventral aspect of the crus about midway between the pons and the optic tract, and dips into the oculomotor sulcus. This band is a constant structure in many mammals, but is only present in about thirty per cent. of human brains. Since it undergoes atrophy after enucleation of the eyeballs, it may be considered as forming a path for visual sensations.

White matter.—(1) The origin and course of the *superior cerebellar peduncle* have already been described (page 830).

(2) The *dorsal* or *posterior longitudinal fasciculus* (fig. 715) is continuous below with the antero-lateral ground-bundle of the spinal cord ; and has been traced by Edinger as far as a nucleus, the *nucleus of the posterior longitudinal fasciculus*, situated in the hypothalamus, immediately in front of the aqueduct of Sylvius. In the medulla oblongata and pons, it runs close to the middle line, near the floor of the fourth ventricle ; in the mid-brain, it is situated on the ventral aspect of the Sylvian aqueduct, below the nuclei of the third and fourth nerves. Its connections are imperfectly known, but it consists largely of ascending and descending intersegmental or association fibres, which connect the various nuclei of the mid- and hind-brains to each other. Many of the descending

FIG. 715.—Scheme of the posterior longitudinal fasciculus ; motor fibres in red, sensory, in blue.

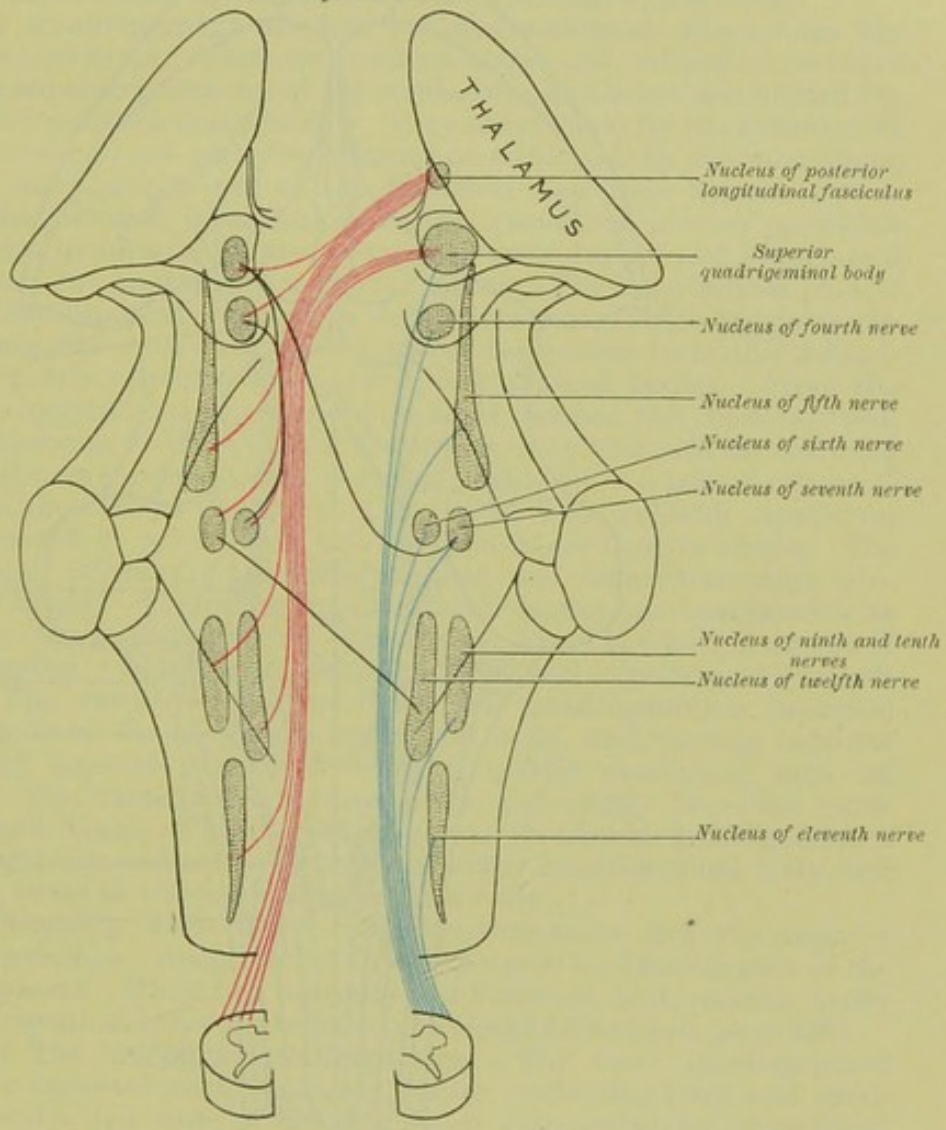

fibres arise in the superior quadrigeminal body, and, after decussating in the middle line, terminate in the motor nuclei of the pons and medulla. The ascending fibres arise from the cells of the grey matter of the upper part of the cord, and from the nuclei in the medulla and pons, and pass, without undergoing decussation, to the higher nuclei. Fibres are also carried through the posterior longitudinal fasciculus from the nucleus of the sixth nerve into the third nerve of the opposite side, and through this nerve to the Internal rectus of the eyeball. Again, fibres are said to be prolonged through this fasciculus from the nucleus of the third nerve into the seventh nerve, and are distributed to the Orbicularis palpebrarum, the Corrugator supercilii, and the Occipito-frontalis.*

* A. Bruce and J. H. Harvey Pirrie, 'On the Origin of the Facial Nerve,' *Review of Neurology and Psychiatry*, vol. vi. No. 12, December 1908, produce weighty evidence against the view that the facial nerve derives fibres from the nucleus of the third nerve.

(3) *The fillet* or *lemniscus* (fig. 716).—The fibres of the fillet have been seen to take origin in the gracile and cuneate nuclei of the medulla oblongata, and to cross to the opposite side in the sensory decussation (page 816). They then pass upwards through the medulla, in which they are situated behind the pyramidal fibres and between the olivary bodies. Here they are joined by the fibres of Gowers' ascending tract, these having already undergone decussation in the spinal cord. As the fillet ascends, it receives additional fibres from the terminal nuclei of the sensory nerves of the opposite side. In the pons, it assumes a flattened, ribbon-like appearance, and is placed on the dorsal aspect of the trapezium. In the mid-brain, its outer part is folded backwards and

FIG. 716.—Scheme showing the course of the fibres of the fillet; mesial fillet in blue, lateral fillet in red.

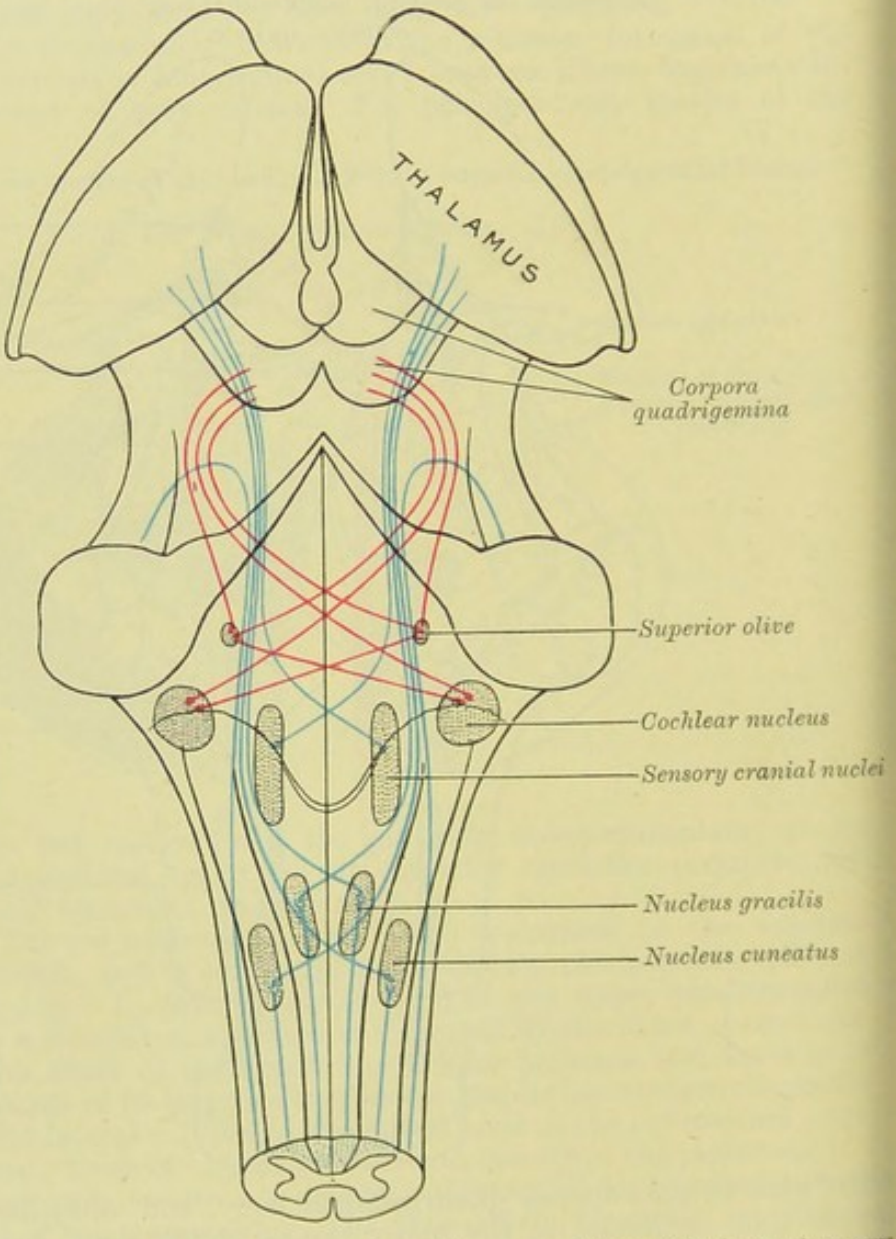

forms nearly a right angle with its mesial portion; and hence it is customary to speak of the fillet as consisting of lateral and mesial parts.

The *lateral fillet* (lemniscus lateralis) has been seen to come to the surface of the mid-brain along its lateral sulcus, and to disappear under the inferior quadrigeminal body. It consists of fibres which are derived from the terminal nuclei of the cochlear division of the auditory nerve, together with others which arise within the superior olive and the trapezoid nucleus. Most of these fibres are crossed, but some are uncrossed. Many of them pass to the inferior quadrigeminal body of the same or opposite side; but others are prolonged to the thalamus, and thence through the posterior part of the internal capsule to the middle and superior temporal convolutions.

The *mesial fillet* (lemniscus medialis) comprises that portion of the fillet which commences in the gracile and cuneate nuclei of the opposite side, and which is joined by Gowers' tract and by fibres from the terminal nuclei of the sensory nerves of the opposite side, excepting the cochlear division of the auditory. In the crus cerebri, a few of its fibres pass upwards in the outer part of the pes or crusta, on the dorsal aspect of the cortico-pontine fibres, and reach the lenticular nucleus and the island of Reil. The greater part of the mesial fillet, on the other hand, is prolonged through the tegmentum, and most of its fibres end in the thalamus; probably some are continued directly through the posterior part of the internal capsule to the cerebral cortex. From the cells of the thalamus a relay of fibres is prolonged to the cerebral cortex.

Besides these three tracts, there are the *tecto-spinal tract* from the upper quadrigeminal body and the *rubro-spinal tract* from the red nucleus; these tracts cross the middle line and are continued downwards into the spinal cord.

The **corpora quadrigemina** are four rounded eminences which form the dorsal part of the mid-brain. They are situated above and in front of the valve of Vieussens and superior peduncles of the cerebellum, and below and behind the third ventricle and posterior commissure. They are covered by the splenium of the corpus callosum, and are partly overlapped on either side by the inner angle, or pulvinar, of the posterior end of the thalamus; on their lateral aspect, under cover of the pulvinar, is an oval eminence, named the *internal geniculate body*. The corpora quadrigemina are arranged in pairs (upper and lower), and are separated from one another by a crucial sulcus. The longitudinal part of this sulcus expands superiorly to form a slight depression which supports the *pineal body*, a cone-like structure which projects backwards from the thalamencephalon and partly obscures the upper quadrigeminal bodies. From the lower end of the longitudinal sulcus, a white band, termed the *frænulum veli*, is prolonged downwards to the valve of Vieussens; on either side of this band the fourth cranial nerve emerges, and passes forwards on the lateral aspect of the crus to reach the base of the brain. The *upper pair* (colliculi superiores) are larger and darker in colour than the lower, and are oval in shape. The *lower pair* (colliculi inferiores) are hemispherical, and somewhat more prominent than the upper. The upper quadrigeminal bodies are associated with the sense of sight, the lower with that of hearing. From the lateral aspect of each of the four bodies, a white band, termed the *brachium*, is prolonged upwards and forwards. The *superior brachium* (brachium quadrigeminum superius) extends outwards from the upper quadrigeminal body, and, passing between the pulvinar and internal geniculate body, is partly continued into an eminence called the external geniculate body, and partly into the outer portion of the optic tract. The *inferior brachium* (brachium quadrigeminum inferius) passes forwards and upwards from the lower quadrigeminal body, and disappears under cover of the internal geniculate body.

In close relationship with the corpora quadrigemina are the *superior peduncles of the cerebellum*, which emerge from the upper and mesial part of the cerebellar hemispheres. They run upwards and forwards, and, passing under the corpora quadrigemina, enter the tegmenta as already described (page 830).

Structure of the corpora quadrigemina.—The *lower* quadrigeminal body consists of a compact nucleus of grey matter containing large and small multipolar nerve-cells, and more or less completely surrounded by white fibres derived from the lateral fillet. Most of these fibres end in the grey nucleus of the same side, but some cross the middle line and terminate in that of the opposite side. From the cells of the grey nucleus, fibres are prolonged through the inferior brachium into the tegmentum of the crus cerebri, and are carried to the optic thalamus and the cortex of the temporal lobe; other fibres cross the middle line and end in the opposite quadrigeminal body.

The *upper* quadrigeminal body is covered by a thin stratum of white fibres, termed the *stratum zonale*, the majority of whose fibres are derived from the optic tract. Beneath this is the *stratum cinereum*, a layer of grey matter which resembles a cap: it is semilunar in shape, thicker in the centre than at the margins, and consists of numerous multipolar nerve-cells, for the most part of small size, imbedded in a fine network of nerve-fibres. Still deeper is the *stratum opticum*, which contains large multipolar nerve-cells, separated by

numerous fine nerve-fibres. Finally, there is the *stratum lemnisci*, which consists of fibres derived partly from the fillet and partly from the cells of the stratum opticum ; interspersed among these fibres are many large multipolar nerve-cells. The two last-named strata are sometimes termed the *grey-white layers*, from the fact that they consist of both grey and white matter. Of the afferent fibres which reach the superior quadrigeminal body, some are derived from the fillet, but the majority have their origin in the retina and are conveyed to it through the superior brachium ; all of them terminate by arborising around the cells of the grey matter. Of the fibres which arise from the cells of the grey matter, some cross the middle line to the opposite quadrigeminal body ; many ascend through the superior brachium, and finally reach the cortex of the occipital lobe of the cerebrum ; while others, after undergoing decussation (the *fountain decussation of Meynert*) form the tecto-spinal tract which descends through the formatio reticularis of the mid-brain, pons, and medulla into the spinal cord, where it is found partly in the anterior column and partly intermingled with the fibres of the rubro-spinal tract.

The corpora quadrigemina are larger in the lower animals than in man. In fishes, reptiles, and birds, they are hollow, and only two in number (corpora bigemina) ; they represent the superior quadrigeminals of mammals, and are frequently termed the optic lobes, because of their intimate connection with the optic tracts.

The **aqueduct of Sylvius** (aquæductus cerebri) is a narrow canal, about fifteen millimetres in length, situated between the corpora quadrigemina and tegmenta, and connecting the third with the fourth ventricle. Its shape, as seen in transverse sections, varies at different levels, being T-shaped below, triangular above, and oval in the middle. The central part is slightly dilated, and was named by Retzius the *ventricle of the mid-brain*. It is lined by ciliated columnar epithelium, and is surrounded by a layer of grey matter named the *central grey matter* (stratum griseum centrale) of the aqueduct : this is continuous below with the grey substance in the floor of the fourth ventricle, and above with that of the third ventricle. Dorsally, it is partly separated from the grey matter of the quadrigeminal bodies by the fibres of the lemniscus ; ventral to it are the posterior longitudinal fasciculus, and the formatio reticularis of the tegmentum. Scattered throughout its grey matter are numerous nerve-cells of various sizes, interlaced by a network of fine fibres. Besides these scattered cells it contains three groups which constitute the nuclei of the third and fourth nerves, and the nucleus of the Sylvian or mesencephalic root of the fifth nerve. The *nucleus of the fifth nerve* extends along the entire length of the aqueduct, and occupies the outer part of the grey substance, while those of the third and fourth are situated in its ventral part. The *nucleus of the third nerve* measures about ten millimetres in length, and lies under the upper quadrigeminal body, beyond which, however, it extends for a short distance into the grey matter of the third ventricle. The *nucleus of the fourth nerve* is small and nearly circular, and is on a level with a plane carried transversely through the upper part of the lower quadrigeminal body.

THE FORE-BRAIN

The **fore-brain** consists of : (1) the *diencephalon* or *inter-brain*, which corresponds in a large measure to the third ventricle and the structures which bound it ; and (2) the *telencephalon*, which comprises the largest part of the brain, viz. the cerebral hemispheres ; these hemispheres are intimately connected with each other across the middle line, and each contains a large cavity, named the lateral ventricle. The lateral ventricles communicate through the foramen of Monro with the third ventricle, but are separated from each other by a mesial septum ; this contains a slit-like cavity, the so-called fifth ventricle, which, however, has no communication with the other brain ventricles.

The Diencephalon

The **diencephalon** or **inter-brain** is connected above and in front with the cerebral hemispheres ; behind with the mid-brain. Its upper surface

is concealed by the corpus callosum, and is covered by a fold of pia mater, named the velum interpositum ; inferiorly it reaches to the base of the brain.

The diencephalon comprises : (1) the thalamencephalon : (2) the pars mamillaria hypothalami ; and (3) the posterior part of the third ventricle. For descriptive purposes, however, it is more convenient to consider the whole of the third ventricle and its boundaries together : this necessitates the inclusion, under this heading, of the pars optica hypothalami and the corresponding part of the third ventricle—structures which properly belong to the telencephalon.

The **thalamencephalon** consists of : (1) the thalamus : (2) the meta-thalamus or corpora geniculata ; and (3) the epithalamus, which comprises the trigonum habenulæ, the pineal body, and the posterior commissure.

FIG. 717.—The third and fourth ventricles.

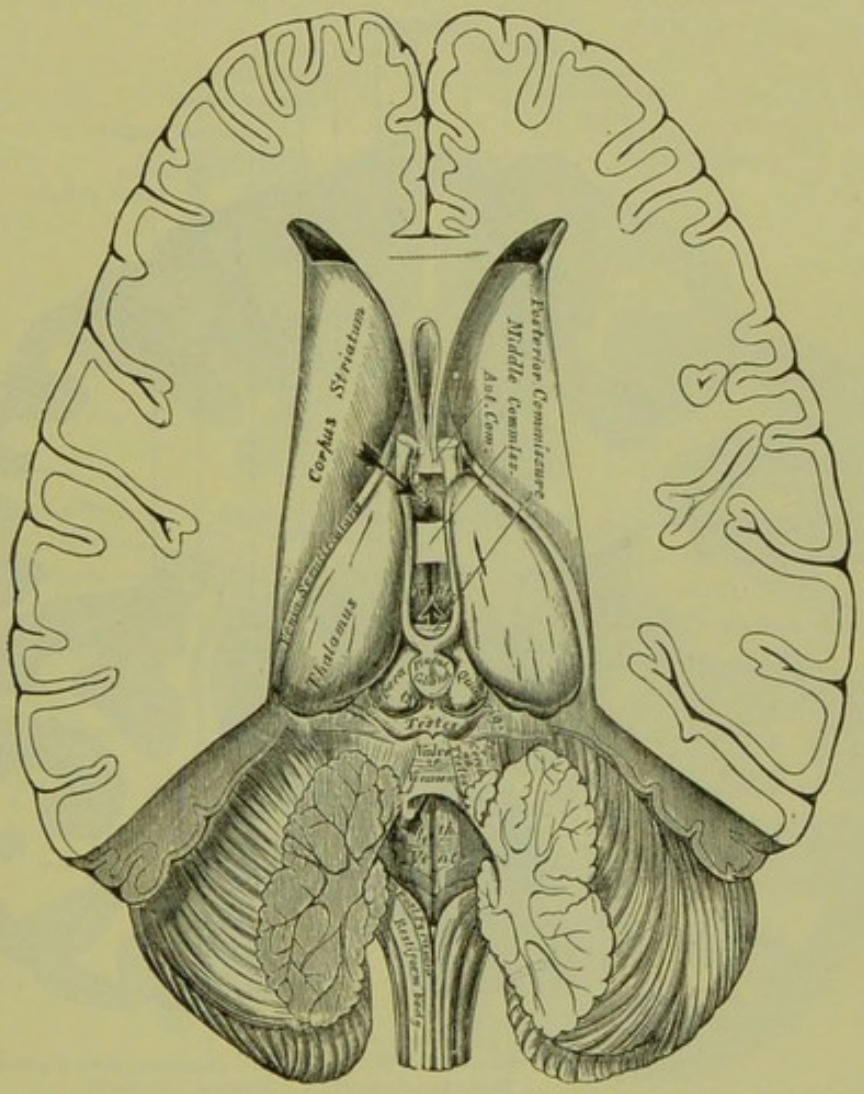

The lower arrow has been placed in the aqueduct of Sylvius ; the upper points to the foramen of Monro.

The **thalami** or **optic thalami** (figs. 717, 718) are two large ovoid masses, situated one on either side of the third ventricle and reaching for some distance behind that cavity. Each measures about an inch and a half in length, and presents two extremities, an anterior and posterior, and four surfaces, superior, inferior, internal, and external.

The *anterior extremity* is narrow, directed forwards and inwards, and lies close to the middle line, where it forms the posterior boundary of the foramen of Monro.

The *posterior extremity* is expanded, directed backwards and outwards, and overlaps the superior quadrigeminal body. Internally, it presents a well-marked angular prominence, the *posterior tubercle* or *pulvinar*, which

is continued externally into an oval swelling, the *external geniculate body*, while beneath the pulvinar, but separated by the superior brachium, is a second oval swelling, the *internal geniculate body*.

The *superior surface* is free, slightly convex, and covered by a layer of white matter, termed the *stratum zonale*. It is separated externally from the caudate nucleus by a white band named the *tænia semicircularis*, and by the *vein of the corpus striatum*. It is divided into an inner and an outer portion by an oblique shallow furrow which runs from behind forwards and inwards and corresponds with the outer margin of the fornix. The part on the outer side of the furrow forms a portion of the floor of the lateral ventricle, and is covered by the epithelial lining of this cavity. The part on the inner side is covered by the velum interpositum, and excluded from the lateral and

Fig. 718.—Coronal section of brain immediately in front of pons.

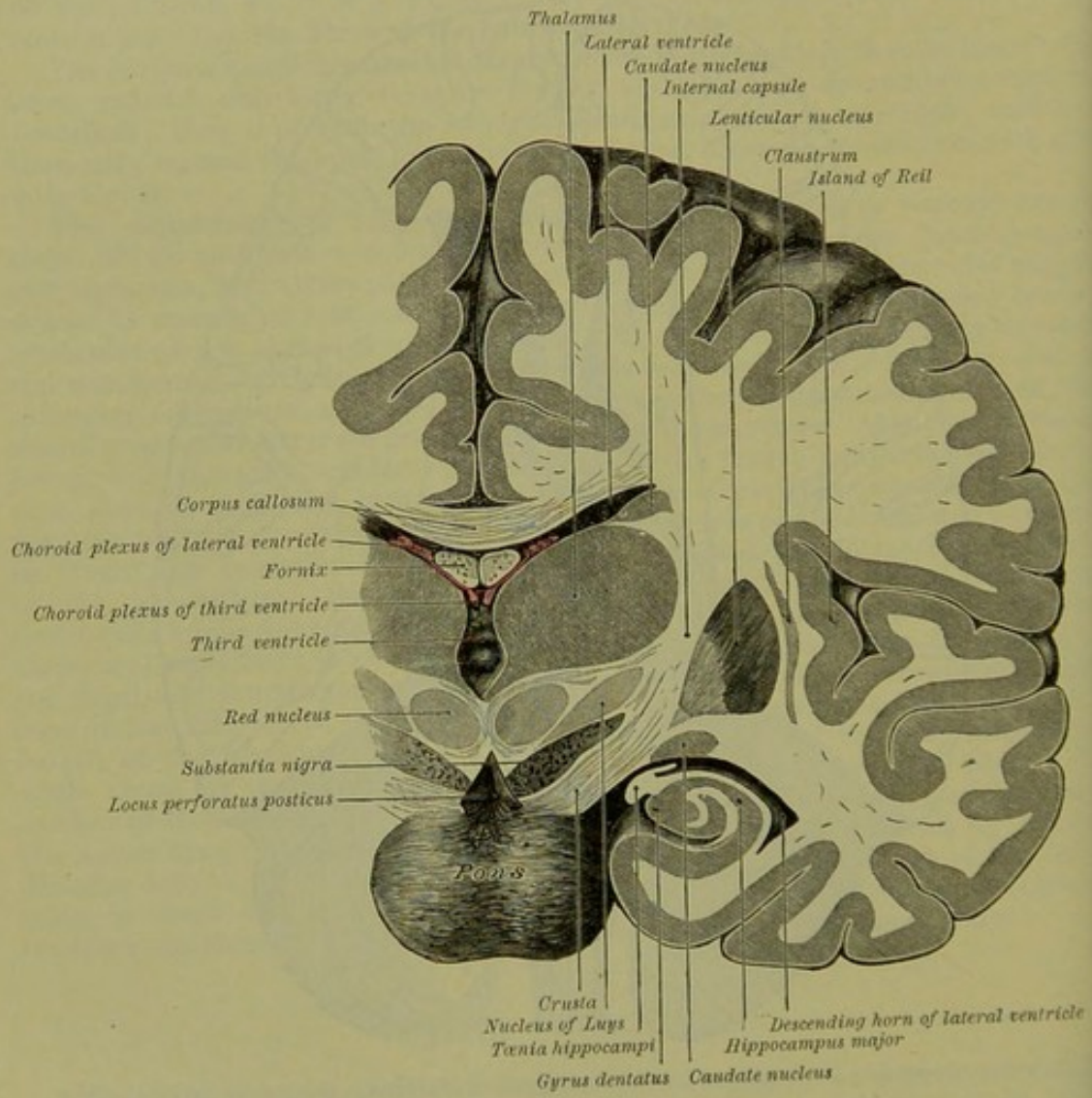

third ventricles, and is therefore destitute of an epithelial covering. In front, it is separated from the internal surface by a salient margin in which are contained the fibres of the stria pinealis, and along which the epithelial lining of the third ventricle is reflected on to the under surface of the velum interpositum. Behind, it is limited internally by a groove, the *sulcus habenulæ*, which intervenes between it and a small triangular area, termed the *trigonum habenulæ*.

The *inferior surface* rests upon and is continuous with the upward prolongation of the tegmentum (*subthalamic tegmental region*), in front of which it is related to the *substantia innominata of Meynert*.

The *internal surface* constitutes the upper part of the lateral wall of the third ventricle, and is connected to the corresponding surface of the opposite

thalamus by a flattened grey band, the *middle* or *grey commissure*. This commissure averages about one-third of an inch in its antero-posterior diameter : it sometimes consists of two parts and occasionally is absent. It contains nerve-cells and nerve-fibres : a few of the latter may cross the middle line, but most of them pass towards the middle line and then curve outwards on the same side.

The *external surface* is in contact with a thick band of white matter which forms the posterior limb of the internal capsule and separates the thalamus from the lenticular nucleus of the corpus striatum.

Structure.—The thalamus consists chiefly of grey matter, but its upper surface is covered by a layer of white matter, named the *stratum zonale*, and its outer surface by a similar layer termed the *external medullary lamina*.

FIG. 719.—Coronal section of brain through middle commissure.

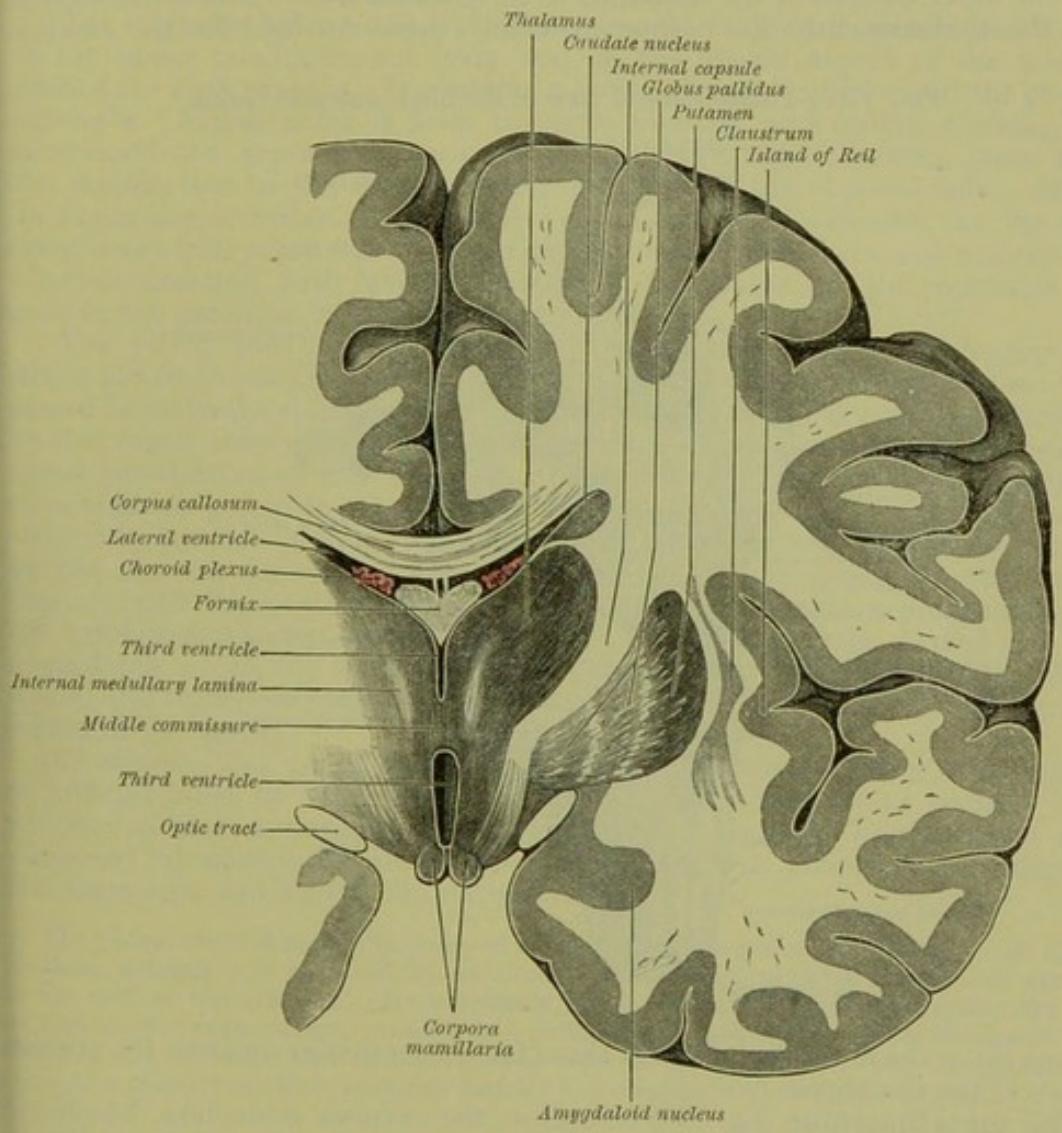

Its grey matter is partially subdivided into three parts—anterior, inner and outer—by a white layer, the *internal medullary lamina*. The anterior part comprises the anterior tubercle, the inner part lies next the lateral wall of the third ventricle, while the outer and largest part is interposed between the internal and external medullary laminæ and includes the pulvinar. The outer part is traversed by numerous fibres which radiate from the thalamus into the internal capsule, and pass through the latter to the cerebral cortex. These three parts are built up of numerous nuclei, the connections of many of which are imperfectly known.

Connections.—The thalamus may be regarded as a large ganglionic mass in which the ascending tracts of the tegmentum and a considerable proportion of the fibres of the optic tract end, and from the cells of which

numerous fibres (thalamo-cortical) take origin, and radiate to almost every part of the cerebral cortex. The fillet, together with the other longitudinal strands of the tegmentum, enters its ventral part: the bundle of Vicq d'Azyr, from the corpus albicans, ends in its anterior tubercle, while many of the fibres of the optic tract terminate in its posterior extremity. The thalamus also receives numerous fibres (cortico-thalamic) from the cells of the cerebral cortex. The fibres which arise from the cells of the thalamus form four principal groups or stalks: (*a*) those of the *anterior stalk* pass through the anterior limb of the internal capsule to the frontal lobe; (*b*) the fibres of the *posterior stalk* or *optic radiations* arise in the pulvinar and are conveyed through the extreme posterior part of the internal capsule to the occipital lobe; (*c*) the fibres of the *inferior stalk* leave the under and mesial surfaces of the thalamus, and pass outwards beneath the lenticular nucleus to end in the temporal lobe and island of Reil; (*d*) those of the *parietal stalk* pass from the outer nucleus of the thalamus to the parietal lobe. Fibres also extend from the thalamus into the corpus striatum—those destined for the caudate

Fig. 720.—Postero-lateral view of the hind- and mid-brains.

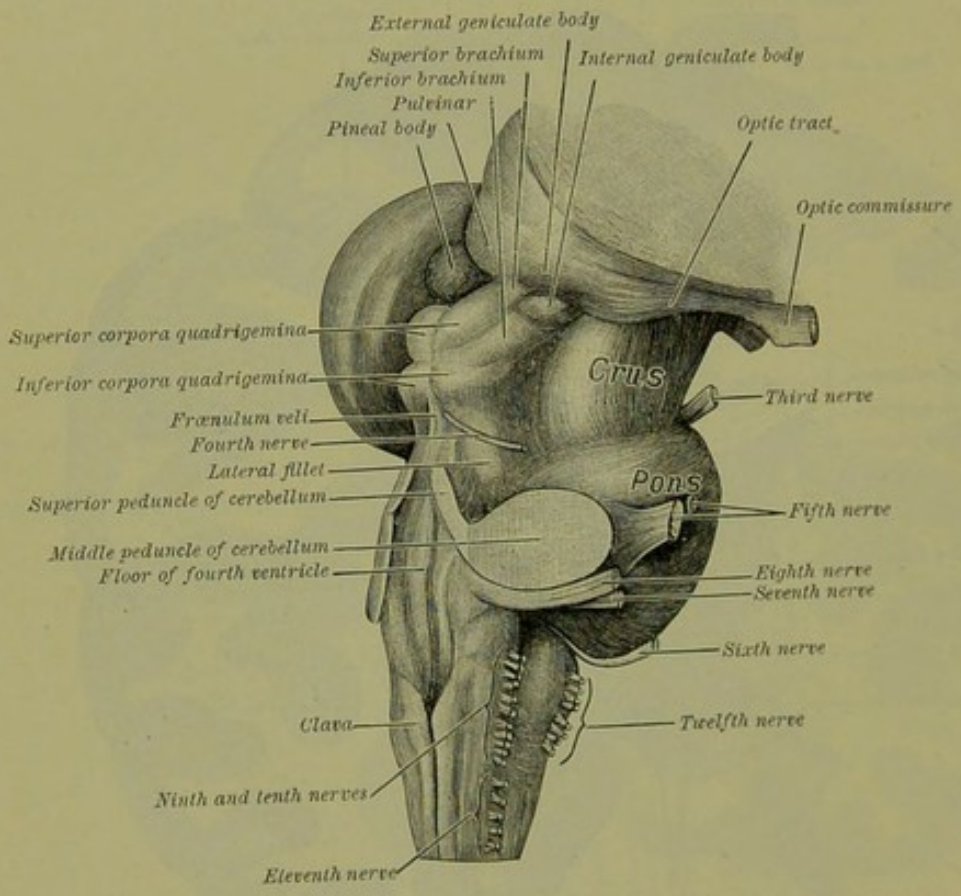

nucleus leave the outer surface, and those for the lenticular nucleus, the inferior surface of the thalamus.

The **metathalamus** (fig. 720) comprises the corpora geniculata, which are two in number—an internal and an external—on each side and have already been referred to in connection with the posterior extremity of the thalamus.

The *internal geniculate body* (corpus geniculatum mediale) lies under cover of the pulvinar of the thalamus and on the lateral aspect of the corpora quadrigemina. Oval in shape, with its long axis directed forwards and outwards, it is lighter in colour and smaller in size than the external. The inferior brachium from the lower quadrigeminal body disappears under cover of it, while from its outer extremity a strand of fibres passes to join the optic tract. Entering it are many acoustic fibres from the lateral fillet. The internal geniculate bodies are connected with one another by the commissure of Gudden, which passes through the posterior part of the optic commissure.

The *external geniculate body* (corpus geniculatum laterale) forms an oval elevation on the outer part of the posterior extremity of the thalamus, and

is connected internally with the upper quadrigeminal body by the superior brachium. It is of a dark colour, and presents a laminated arrangement consisting of alternate layers of grey and white matter. It receives numerous fibres from the optic tract, while other fibres of this tract pass over or through it into the pulvinar. Its cells are large and pigmented; their axons pass to the visual area in the occipital part of the cerebral cortex.

The upper quadrigeminal body, the pulvinar and the external geniculate body receive many fibres from the optic tracts, and are therefore intimately connected with sight, constituting what are termed the *lower visual centres*. Extirpation of the eyes in newly born animals entails an arrest of the development of these centres, but has no effect on the internal geniculate or lower quadrigeminal bodies. Moreover, the latter are well-developed in the mole, an animal in which the upper quadrigeminal body is rudimentary.

The **epithalamus** comprises the trigonum habenulæ, the pineal body, and the posterior commissure.

The *trigonum habenulæ* is a small depressed triangular area situated in front of the upper quadrigeminal body and on the lateral aspect of the posterior part of the stria pinealis. It contains a group of nerve-cells termed the *ganglion habenulæ*. Fibres enter it from the stria pinealis, and others, forming what is termed the *superior commissure* (commissura habenularum), pass across the middle line to the corresponding ganglion of the opposite side. Most of its fibres are, however, directed downwards and form a bundle, the *fasciculus retroflexus* of Meynert, which passes on the mesial side of the red nucleus, and, after decussating with the corresponding fasciculus of the opposite side, ends in the ganglion interpedunculare.

The *pineal body* (corpus pineale) is a small, conical, reddish-grey body which lies in the depression between the upper quadrigeminal bodies. It is placed beneath the splenium of the corpus callosum, but is separated from this by the velum interpositum, the lower layer of which envelops it. It measures about one-third of an inch in length, and its base, directed forwards, is attached by a stalk or peduncle of white matter. The *stalk* of the pineal body divides anteriorly into two laminæ, a dorsal and a ventral, separated from one another by the recessus pinealis of the third ventricle. The ventral lamina is continuous with the posterior commissure; the dorsal lamina is continuous with the commissura habenularum and divides into two strands, named the striæ medullares, which run forwards, one on either side, along the junction of the mesial and upper surfaces of the thalamus to blend in front with the anterior pillars of the fornix.

Structure.—The pineal body is destitute of nervous matter, and consists of follicles lined by epithelium and enveloped by connective tissue. These follicles contain a variable quantity of gritty material named *brain sand*, composed of phosphate and carbonate of calcium, phosphate of magnesia and ammonia, and a little animal matter.

The pineal body is generally believed to be the homologue of the pineal eye of lizards. In these animals it is attached by an elongated stalk and projects through an aperture in the roof of the cranium. Its extremity lies immediately under the epidermis, and, on microscopic examination, presents in a rudimentary fashion structures similar to those found in the eyeball. Recent observations tend to the conclusion that the pineal body arises as a paired structure, probably serially homologous with the paired eyes.

The *posterior commissure* (commissura posterior) is a rounded band of white fibres which stretches across the middle line on the dorsal aspect of the upper end of the Sylvian aqueduct. Its fibres acquire their medullary sheaths early, but their connections have not been definitely determined. Most of them have their origin in a nucleus, the *nucleus of the posterior commissure* or *nucleus of Darkschewitsch*, which lies in the central grey matter of the upper end of the Sylvian aqueduct, in front of the nucleus of the third nerve. Some are probably derived from the posterior part of the thalamus and the superior quadrigeminal body, while others are believed to be continued downwards into the posterior longitudinal bundle.

The **hypothalamus** (fig. 721) includes the subthalamic tegmental region and the structures which form the greater part of the floor of the third

ventricle, viz. the corpora mamillaria, tuber cinereum, infundibulum, pituitary body, and optic commissure.

The *subthalamic tegmental region* consists of the upward continuation of the tegmentum, which lies on the ventro-lateral aspect of the thalamus and separates it from the fibres of the internal capsule. The red nucleus and the substantia nigra are prolonged into its lower part; in front it is continuous with the substantia innominata of Meynert, internally with the grey matter of the floor of the third ventricle.

It consists from above downwards of three strata: (1) *stratum dorsale*, directly applied to the under surface of the thalamus and consisting of fine longitudinal fibres; (2) *zona incerta*, a continuation forwards of the formatio reticularis of the tegmentum; and (3) the *corpus subthalamicum* or *nucleus of Luys*, a brownish mass presenting a lenticular shape on transverse section, and situated on the dorsal aspect of the fibres of the crusta; it is encapsuled

FIG. 721.—Mesial sagittal section of brain. The relations of the pia mater are indicated by the red colour.

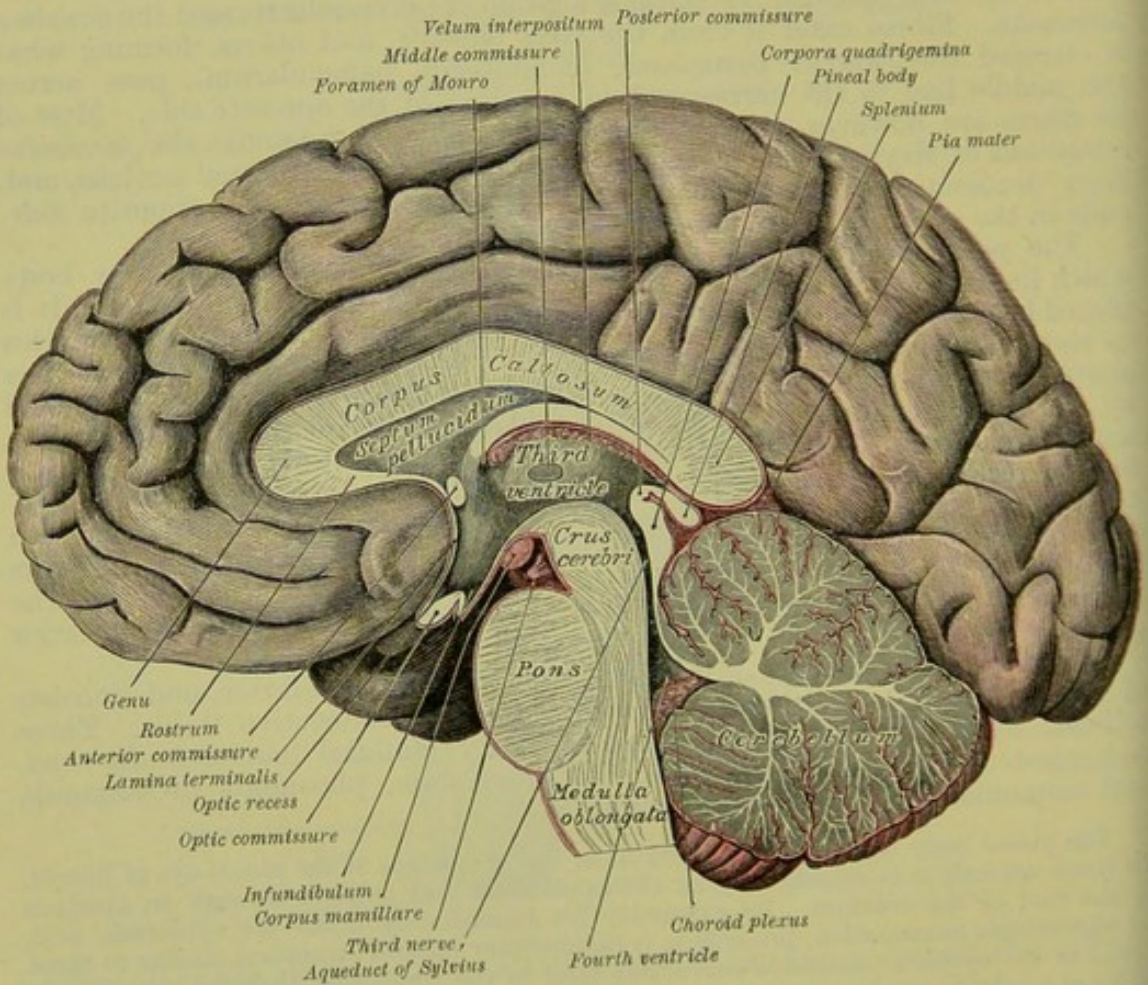

by a lamina of nerve-fibres and contains numerous medium-sized nerve-cells the connections of which are as yet not fully determined.

The *corpora mamillaria* are two round white masses, each about the size of a small pea, which lie side by side below the grey matter of the floor of the third ventricle in front of the locus perforatus posticus. They consist of white matter externally and of grey matter internally, the cells of the latter forming two nuclei, a *mesial* of smaller and a *lateral* of larger cells. The white matter is mainly formed by the fibres of the anterior pillars of the fornix, which descend to the base of the brain and end partly in the corpora mamillaria. From the cells of the grey matter of each mamillary body two fasciculi arise; one, the bundle of Vicq d'Azyr, passes upwards into the anterior nucleus of the thalamus; the other is directed downwards into the tegmentum. Afferent fibres are believed to reach the corpus mamillare from the mesial fillet and from the tegmentum.

The *tuber cinereum* is a hollow eminence of grey matter situated between the corpora mamillaria behind, and the optic commissure in front. Laterally it is continuous with the grey matter of the anterior perforated spaces and anteriorly with a thin lamina, the *lamina terminalis*. From the under surface of the tuber cinereum a hollow conical process, the *infundibulum*, projects downwards and forwards and is attached to the posterior lobe of the pituitary body.

In the lateral part of the tuber cinereum is a nucleus of nerve-cells, the *basal optic nucleus of Meynert*, while close to the cavity of the third ventricle are three additional nuclei.

Between the tuber cinereum and the corpora mamillaria a small elevation, with a corresponding depression in the third ventricle, is sometimes seen. Retzius has named it the *eminentia saccularis*, and regards it as the representative of the saccus vasculosus found in this situation in some of the lower vertebrates.

Fig. 722.—The pituitary body, in position. Shown in sagittal section. (Testut.)

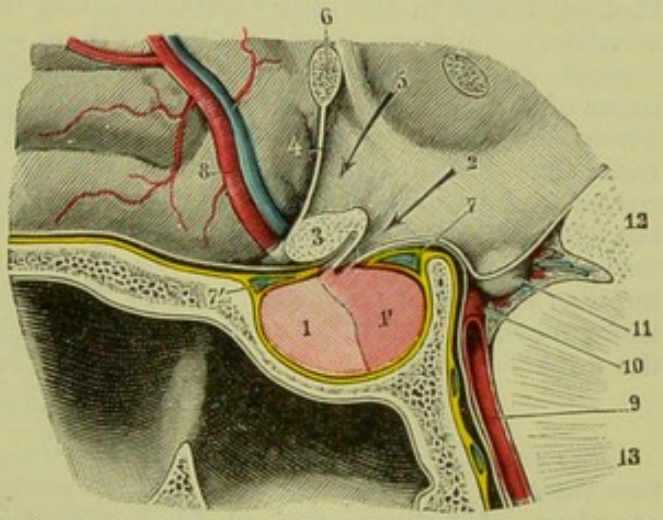

1, 1′. Anterior and posterior lobes of pituitary body. 2. Infundibulum. 3. Optic commissure. 4. Lamina terminalis. 5. Optic recess. 6. Anterior commissure. 7, 7′. Circular sinus. 8. Anterior cerebral artery. 9. Basilar artery. 10. Posterior cerebral artery. 11. Corpus albicans. 12. Crus cerebri. 13. Pons Varolii.

The *pituitary body* (hypophysis) (fig. 722) is a reddish-grey, somewhat oval mass, measuring about half an inch in its transverse, and about one-third of an inch in its antero-posterior diameter. It is attached to the extremity of the infundibulum, and is situated in the pituitary fossa of the sphenoid bone, where it is retained by a circular fold of dura mater, the *diaphragma sellæ*. This fold almost completely roofs in the pituitary fossa, leaving only a small central aperture through which the infundibulum passes.

The pituitary body consists of an anterior and a posterior lobe, which differ from one another in their mode of development and in their structure. The *anterior lobe* is the larger, and is somewhat kidney-shaped, the concavity being directed backwards and embracing the posterior lobe. It is developed from a diverticulum of the ectoderm of the primitive buccal cavity or stomatodæum (see page 155). It is highly vascular, and consists essentially of epithelial cells arranged in cord-like trabeculæ or alveoli, the latter sometimes containing a colloid material similar to that found in the alveoli of the thyroid body. The *posterior lobe* is developed as a downgrowth from the floor of the embryonic brain, and during early fœtal life contains a cavity continuous with that of the third ventricle. This cavity undergoes obliteration and, in the adult, the lobe consists of a reticulum of connective tissue with branched cells, some of which contain pigment. In man this lobe contains no nervous elements, but in certain of the lower vertebrates (e.g. fishes) nervous structures are present, and the lobe is of large size.

Fig. 723.—Course of the fibres in the optic commissure.

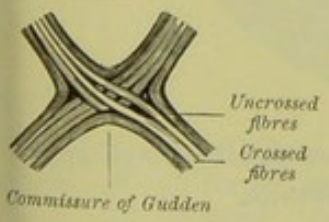

Optic commissure.—The optic commissure consists of a flattened, somewhat quadrilateral band of fibres, which is situated at the junction of the floor and anterior wall of the third ventricle. Most of its fibres have their origin in the retina, and reach it through the optic nerves, which are continuous with its antero-lateral angles. In the commissure, they undergo a partial decussation (fig. 723) : those fibres which come from the nasal or inner half of the retina decussate and enter the optic tract of the opposite side, while the fibres from the temporal or outer half of the retina do not undergo decussation, but pass back

into the optic tract of the same side. Occupying the posterior part of the commissure, however, is a strand of fibres which is not derived from the optic nerves; this constitutes the *commissure of Gudden*, and has already been referred to as forming a connecting link between the internal geniculate bodies.

Optic tracts.—The optic tracts are continued backwards and outwards from the postero-lateral angles of the optic commissure. Each passes between the anterior perforated space and the tuber cinereum, and, winding round the ventro-lateral aspect of the crus cerebri, divides into a mesial and a lateral root. The former comprises the fibres of Gudden's commissure. The lateral root consists mainly of afferent fibres which arise in the retina and undergo partial decussation in the optic commissure, as described; but it also contains a few fine efferent fibres which have their origins in the brain and their terminations in the retina. When traced backwards, the fibres of the lateral root are found to end in the external geniculate body and pulvinar of the optic thalamus, and in the upper quadrigeminal body; and these three structures constitute the *lower visual centres*. Fibres arise from the nerve-cells in these centres, and pass through the hindmost part of the internal capsule, under the name of the *optic radiations*, to the cortex of the occipital lobe of the cerebrum, where the *higher visual centre* is situated. Some of the fibres of the optic radiations take an opposite course, arising from the cells of the occipital cortex and passing to the lower visual centres. Some fibres are detached from the optic tract, and pass through the crus cerebri to the nucleus of the third nerve. These may be regarded as the afferent branches for the Sphincter pupillæ and Ciliary muscles. Other fibres have been described as reaching the cerebellum through its superior peduncles; while others, again, are lost in the pons Varolii.

The Third Ventricle

The **third ventricle** (figs. 717, 721) consists of a median cleft between the two thalami. Behind, it communicates with the fourth ventricle through the aqueduct of Sylvius, and in front with the lateral ventricles through the foramen of Monro. Somewhat triangular in shape, with the apex directed backwards, it presents a roof, a floor, an anterior and a posterior boundary and a pair of lateral walls.

Fig. 724.—Coronal section of lateral and third ventricles. (Diagrammatic.)

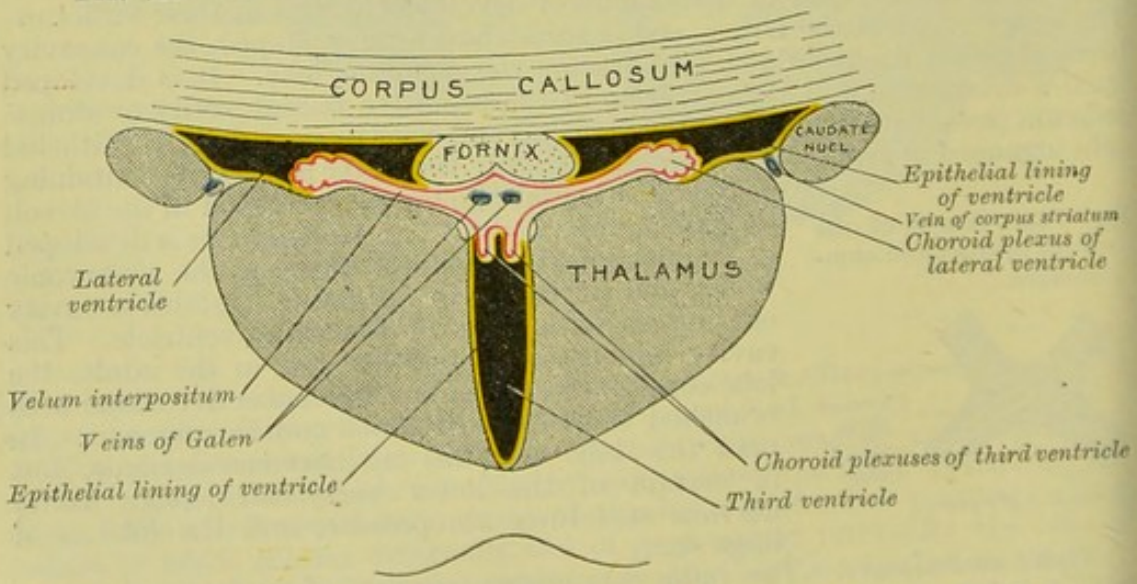

The *roof* (fig. 724) is formed by a layer of epithelium, which stretches between the upper edges of the lateral walls of the cavity and is continuous with the epithelial lining of the ventricle. It is covered by and adherent to a fold of pia mater, named the *velum interpositum*, from the under surface of which a pair of vascular fringed processes, the *choroid plexuses of the third ventricle*, project downwards, one on either side of the middle line, and invaginate the

epithelial roof into the ventricular cavity. When the velum interpositum is reflected, the epithelial roof is torn from its lateral attachments and removed with it, and the cavity of the ventricle is exposed.

The *floor* slopes downwards and forwards and is formed mainly by the structures which constitute the hypothalamus : from before backwards these are, the optic commissure, the tuber cinereum and infundibulum, and the corpora mamillaria. Behind the last, the floor is formed by the locus perforatus posticus and the tegmenta of the crura cerebri. The ventricle is prolonged downwards as a funnel-shaped recess, the *recessus infundibuli*, into the infundibulum, and to the apex of the latter the pituitary body is attached.

The *anterior boundary* is constituted below by the *lamina terminalis*, a thin layer of grey matter which stretches from the upper surface of the optic

FIG. 725.—Base of brain.

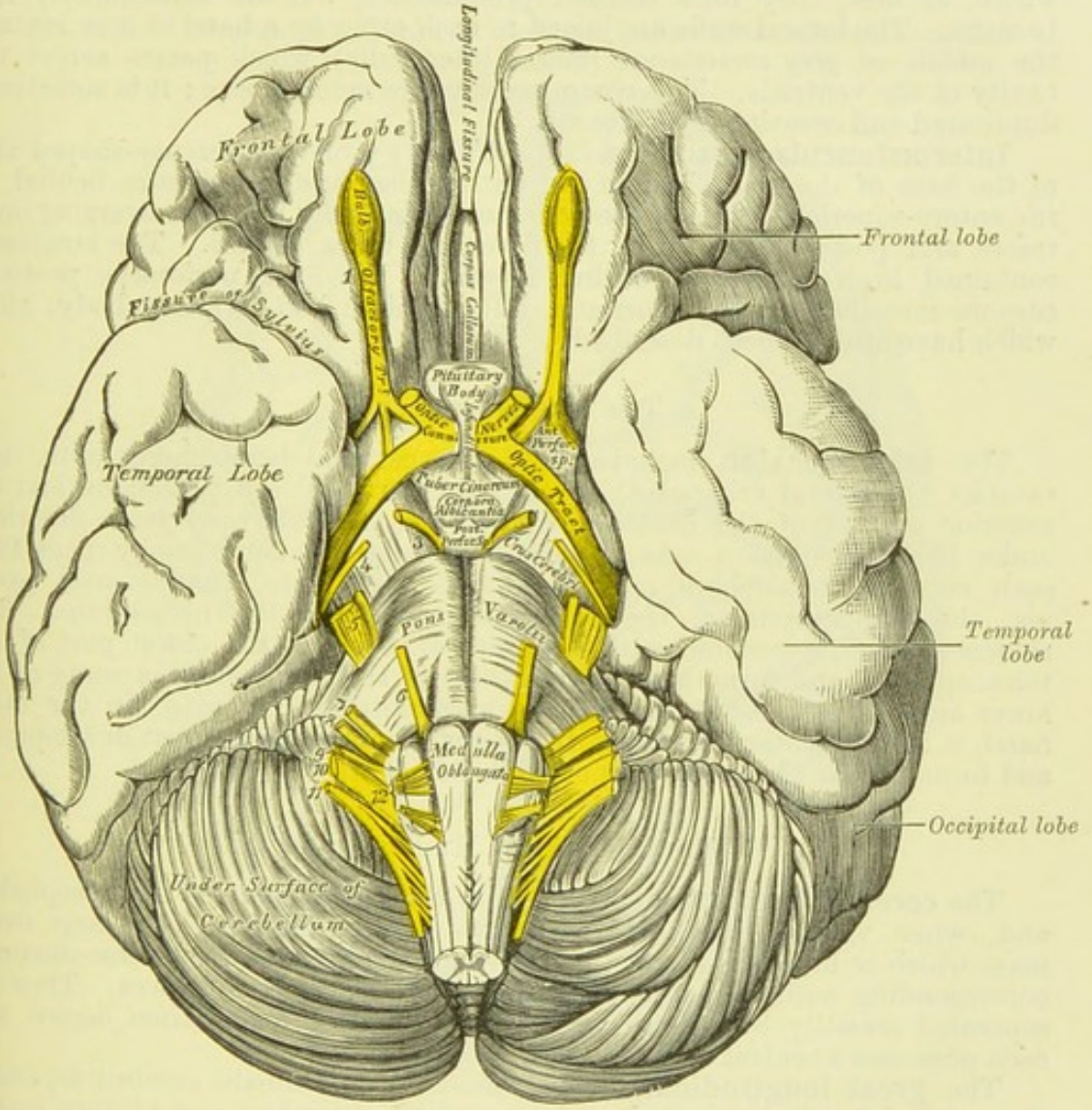

commissure to the rostrum of the corpus callosum, and above by the anterior pillars of the fornix and the anterior commissure. At the junction of the floor and anterior wall, immediately above the optic commissure, the ventricle presents a small angular recess or diverticulum, the *optic* or *supra-optic recess*. Between the anterior pillars of the fornix and above the anterior commissure is a second recess termed the *vulva*. At the junction of the roof and anterior wall of the ventricle, and situated between the thalami behind and the anterior pillars of the fornix in front, is the *foramen of Monro* (foramen interventriculare) through which the third communicates with the lateral ventricles.

The *posterior boundary* is constituted by the pineal body, the posterior commissure and the aqueduct of Sylvius. A small recess, the *recessus pinealis*,

projects into the stalk of the pineal body, whilst in front of and above the pineal body is a second recess, the *recessus suprapinealis*, consisting of a diverticulum of the epithelium which forms the ventricular roof.

Each *lateral wall* consists of an upper portion formed by the inner surface of the anterior two-thirds of the thalamus and a lower consisting of an upward continuation of the grey matter of the ventricular floor. These two parts correspond to the alar and basal laminæ respectively of the lateral wall of the fore-brain vesicle and are separated from each other by a furrow, the *sulcus of Monro*, which extends from the foramen of Monro to the aqueduct of Sylvius (see page 122). The lateral wall is limited above by a delicate band of white fibres, the *stria pinealis*, which runs forwards along the junction of the mesial and upper surfaces of the thalamus to join the corresponding anterior pillar of the fornix. The anterior pillars of the fornix curve downwards in front of the foramen of Monro, and then run in the lateral walls of the ventricle, where, at first, they form distinct prominences, but are subsequently lost to sight. The lateral walls are joined to each other by a band of grey matter, the *middle or grey commissure* (massa intermedia), which passes across the cavity of the ventricle. This commissure varies much in size ; it is sometimes duplicated and occasionally is absent.

Interpeduncular space (fig. 725).—This is a somewhat lozenge-shaped area of the base of the brain, limited in front by the optic commissure, behind by the antero-superior surface of the pons, antero-laterally by the converging optic tracts and postero-laterally by the diverging crura cerebri. The structures contained in it are, from behind forwards, the locus perforatus posticus, corpora mamillaria, tuber cinereum, infundibulum and pituitary body, all of which have already been described.

The Telencephalon

The **telencephalon** includes : (1) the cerebral hemispheres with their cavities, the lateral ventricles ; and (2) the pars optica hypothalami and the anterior portion of the third ventricle, which have already been described under the diencephalon. As stated in the chapter on Embryology (page 124), each cerebral hemisphere may be divided into three fundamental parts, viz. the rhinencephalon, the corpus striatum and the neopallium. The rhinencephalon, associated with the sense of smell, is the oldest part of the telencephalon, and forms almost the whole of the hemisphere in some of the lower animals (e.g. fishes, amphibians, and reptiles). In man, on the other hand, it is rudimentary, whereas the neopallium undergoes great development and forms by far the larger part of the hemisphere.

The Cerebral Hemispheres

The **cerebral hemispheres** constitute the largest part of the encephalon, and, when viewed together from above, assume the form of a large ovoid mass which is broader behind than in front, the greatest transverse diameter corresponding with a line connecting the two parietal eminences. They are separated mesially by a deep cleft, named the *great longitudinal fissure*, and each possesses a central cavity, named the lateral ventricle.

The **great longitudinal fissure** (fissura longitudinalis cerebri) separates the cerebral hemispheres, and contains a sickle-shaped process of dura mater, the falx cerebri. In front and behind, the fissure extends from the upper to the under surfaces of the hemispheres and completely severs them, but its middle portion only separates them for about one-half of their vertical extent ; for at this part they are connected across the middle line by a great central white commissure, the *corpus callosum*.

In a median sagittal section (fig. 721) the cut corpus callosum presents the appearance of a broad, arched band. Its thick posterior end, termed the *splenium*, overlaps the mid-brain, but is separated from it by the velum interpositum and the pineal body. Its anterior curved end, termed the *genu*, gradually tapers into a thinner portion, the *rostrum*, which is continued downwards and backwards in front of the anterior commissure to join the lamina terminalis. Arching backwards from immediately behind the anterior

commissure to the under surface of the splenium is a second white band named the *fornix*: between this and the corpus callosum are the laminæ of the septum pellucidum, enclosing between them the cavity of the so-called fifth ventricle.

Surfaces of the Cerebral Hemispheres

Each hemisphere presents three surfaces: an outer, a mesial, and a lower.

The *outer surface* is convex in adaptation to the concavity of the corresponding half of the vault of the cranium. The *mesial surface* is flat and vertical, and is separated from that of the opposite hemisphere by the great longitudinal fissure and the falx cerebri. The *lower surface* is of an irregular form, and may be divided into three areas: anterior, middle, and posterior. The anterior area, formed by the orbital surface of the frontal lobe, is concave, and rests on the roof of the orbit and nose; the middle area is convex, and

Fig. 726.—Convolutions and sulci on the upper surface of the cerebral hemispheres.

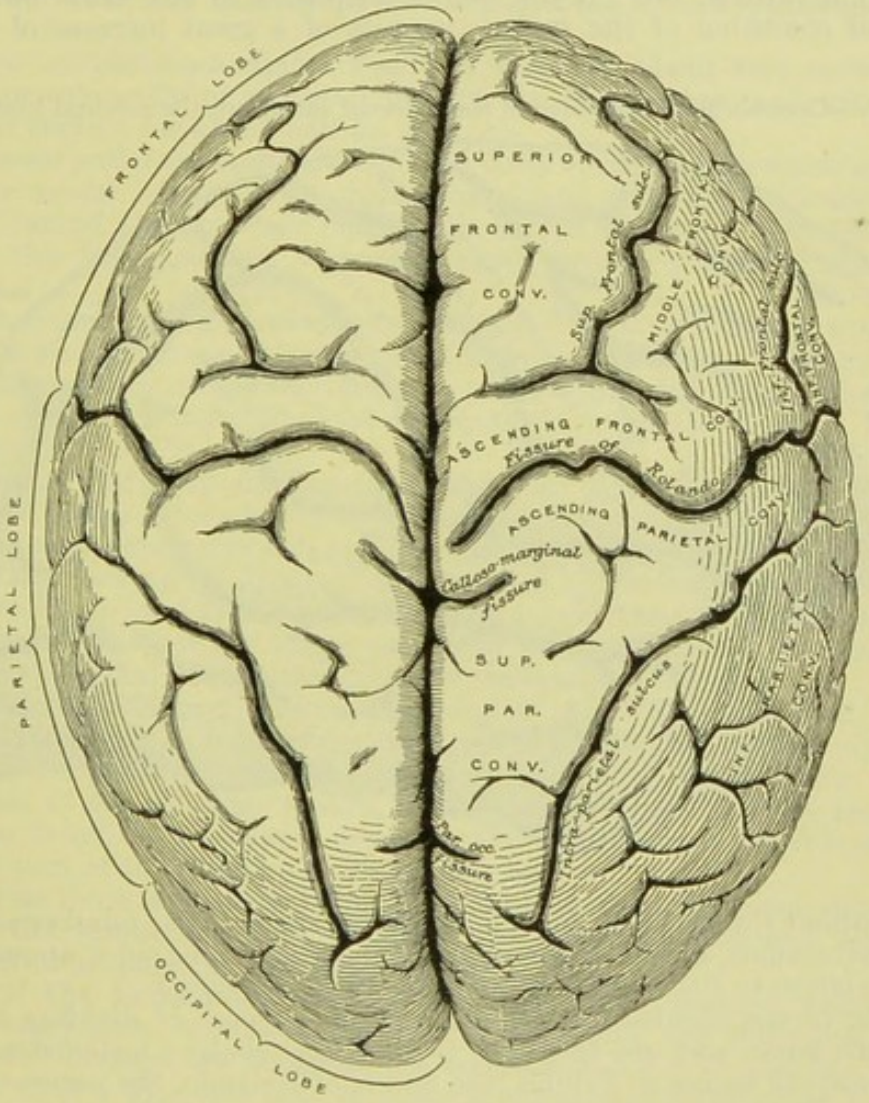

consists of the under surface of the temporal lobe: it is adapted to the corresponding half of the middle cranial fossa. The posterior area is concave, directed inwards as well as downwards, and is named the *tentorial surface*, since it rests upon the tentorium cerebelli, which intervenes between it and the upper surface of the cerebellum.

These three surfaces are separated from each other by the following borders: (a) *supero-mesial*, between the outer and mesial surfaces; (b) *infero-lateral*, between the outer and inferior surfaces; the anterior part of this border separating the outer from the orbital surface, is known as the *superciliary* border; (c) *internal occipital*, separating the mesial and tentorial surfaces; and (d) *internal orbital*, separating the orbital from the mesial surface. The

anterior extremity of the hemisphere is named the *frontal pole*; the posterior, the *occipital pole*; and the anterior end of the temporal lobe, the *temporal pole*. About two inches in front of the occipital pole on the infero-lateral border is an indentation or notch, named the *pre-occipital notch*.

The surfaces of the hemispheres are moulded into a number of irregular eminences, named *convolutions* or *gyri*, and these are separated by clefts or furrows, termed *fissures* or *sulci*. The fissures are of two kinds, *complete* and *incomplete*. The former appear early in fœtal life, are few in number, and are produced by infoldings of the entire thickness of the brain-wall, and give rise to corresponding elevations in the interior of the ventricle. They comprise the hippocampal or dentate fissure, and parts of the calcarine and collateral fissures. The incomplete fissures are very numerous, and only indent the central white substance, without producing any corresponding elevations in the ventricular cavity.

The convolutions and their intervening fissures are fairly constant in their arrangement; at the same time they vary within certain limits, not only in different individuals, but on the two hemispheres of the same brain. The convoluted condition of the surface permits of a great increase of the grey

Fig. 727.—Convolutions and sulci on the external surface of the cerebral hemisphere.

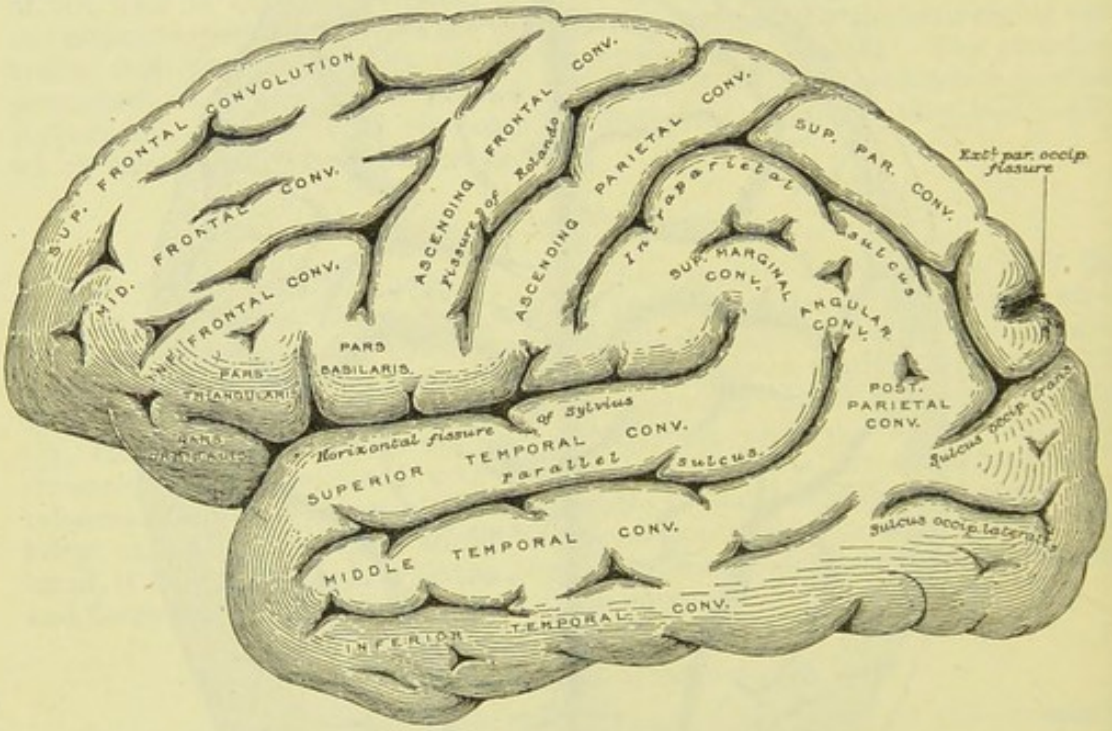

matter without the sacrifice of much additional space. The number and extent of the convolutions, as well as the depth of the intervening sulci, appear to bear a direct relation to the intellectual powers of the individual.

Certain of the fissures are utilised for the purpose of dividing the hemisphere into lobes, and are therefore termed *interlobular*; included under this category are the fissure of Sylvius, the fissure of Rolando, the parieto-occipital, calcarine, calloso-marginal, and collateral fissures, and the sulcus circularis of Reil.

The **fissure of Sylvius** (fissura cerebri lateralis) (fig. 727) constitutes a well-marked cleft on the under and outer surfaces of the hemisphere, and consists of a short stem which divides into three limbs. The *stem* is situated on the base of the brain, and commences at the outer angle of the anterior perforated spot, in a depression named the vallecula Sylvii. From this point it extends outwards between the anterior part of the temporal lobe and the orbital surface of the frontal lobe, and reaches the outer surface of the hemisphere. Here it divides into three limbs: an anterior, an ascending, and a posterior. The *anterior limb* (ramus anterior horizontalis) passes forwards for nearly an inch into the inferior frontal convolution, while the *ascending limb* (ramus anterior

ascendens) extends upwards into the same convolution for about an equal distance. The *posterior limb* (ramus posterior) is the longest; it is carried backwards and slightly upwards for about three inches, and terminates by an upward inflexion in the parietal lobe.

The **fissure of Rolando** (sulcus centralis) (figs. 726, 727) is situated about the middle of the outer surface of the hemisphere, and commences in or near the great longitudinal fissure, a little behind its mid-point. It runs sinuously downwards and forwards, and terminates a little above the posterior limb of the fissure of Sylvius, and about an inch behind the ascending limb of the same fissure. It describes two chief curves: an upper or *superior genu* with its concavity directed forwards, and a lower or *inferior genu* with its concavity directed backwards. The fissure of Rolando forms an angle opening forwards, of about seventy degrees with the mesial plane.

The **parieto-occipital fissure** (fissura parietooccipitalis) (fig. 729).—Only a small part of this fissure is seen on the outer surface of the hemisphere, its chief part being situated on the mesial surface. That on the outer surface is usually named the external, and that on the mesial aspect the internal parieto-occipital fissure.

The *external* parieto-occipital fissure is situated about two inches from the posterior extremity or occipital pole of the hemisphere, and extends on to the outer surface for about half an inch.

The *internal* parieto-occipital fissure runs downwards and forwards as a deep cleft on the mesial surface of the hemisphere, and joins the calcarine fissure below and behind the posterior end of the corpus callosum. On separating the lips of this fissure, it will be seen in most cases to contain a submerged convolution.

The **calcarine fissure** (fissura calcarina) (fig. 729) is situated on the mesial surface of the hemisphere. It begins near the occipital pole in a bifid extremity, and runs almost horizontally forward to a point a little below the splenium of the corpus callosum: it is joined at an acute angle by the internal parieto-occipital fissure.

The **calloso-marginal fissure** (sulcus cinguli) (fig. 729) is situated on the mesial surface of the hemisphere; it commences below the anterior end of the corpus callosum and runs upwards and forwards nearly parallel to the rostrum of this body and, curving in front of the genu, is continued backwards above the corpus callosum, and finally ascends to the upper margin of the hemisphere a short distance behind the upper extremity of the fissure of Rolando. It separates the marginal convolution from the callosal convolution.

The **collateral fissure** (fissura collateralis) (fig. 729) is situated on the tentorial surface of the hemisphere, and extends from near the occipital to within a short distance of the temporal pole. Behind, it lies below and to the outer side of the calcarine fissure, from which it is separated by the gyrus lingualis; in front, it is situated between the hippocampal convolution and the anterior part of the temporo-occipital convolution.

The **sulcus circularis of Reil** (fig. 731) is situated on the lower and lateral surfaces of the hemisphere: it surrounds the island of Reil and separates it from the frontal, parietal and temporal lobes.

Lobes of the hemispheres.—By means of these fissures, assisted by certain arbitrary lines, each hemisphere is divided into the following lobes: the *frontal*, the *parietal*, the *temporal*, the *occipital*, the *limbic*, and the *insula*, or *island of Reil*. The first four of these lobes are named after the bones of the skull with which they are chiefly in relation, but it must be borne in mind that their limits do not correspond accurately with the margins of these bones.

Frontal lobe (lobus frontalis).—On the outer surface of the hemisphere this lobe extends from the frontal pole to the fissure of Rolando, the latter separating it from the parietal lobe. Below, it is limited by the posterior limb of the fissure of Sylvius, which intervenes between it and the temporal lobe. On the mesial surface, it is separated from the limbic lobe by the calloso-marginal fissure; and on the under surface, it is bounded behind by the posterior limb of the Sylvian fissure.

The *outer surface* of the frontal lobe (fig. 727) is traversed by three sulci which divide it into four convolutions: the sulci are named the precentral, and the superior and inferior frontal, while the convolutions are the precentral, and

the superior, middle, and inferior frontal. The *precentral sulcus* runs parallel to the fissure of Rolando, and is usually divided into an upper and a lower part. It forms the anterior limit of a convolution, which lies between it and the fissure of Rolando, and which is called the *precentral convolution.* From it two sulci, the *superior* and *inferior frontal*, run forwards and downwards, and divide the remainder of the outer surface of the lobe into three parallel convolutions, named, respectively, the *superior*, *middle*, and *inferior frontal convolutions.*

The *precentral convolution* (gyrus centralis anterior) is a simple convolution, bounded in front by the precentral sulcus, behind by the fissure of Rolando, and extending from the supero-mesial border of the hemisphere to the posterior limb of the fissure of Sylvius.

The *superior frontal convolution* (gyrus frontalis superior) is situated between the margin of the longitudinal fissure and the superior frontal sulcus.

FIG. 728.—Convolutions and sulci on the under surface of the frontal lobe.

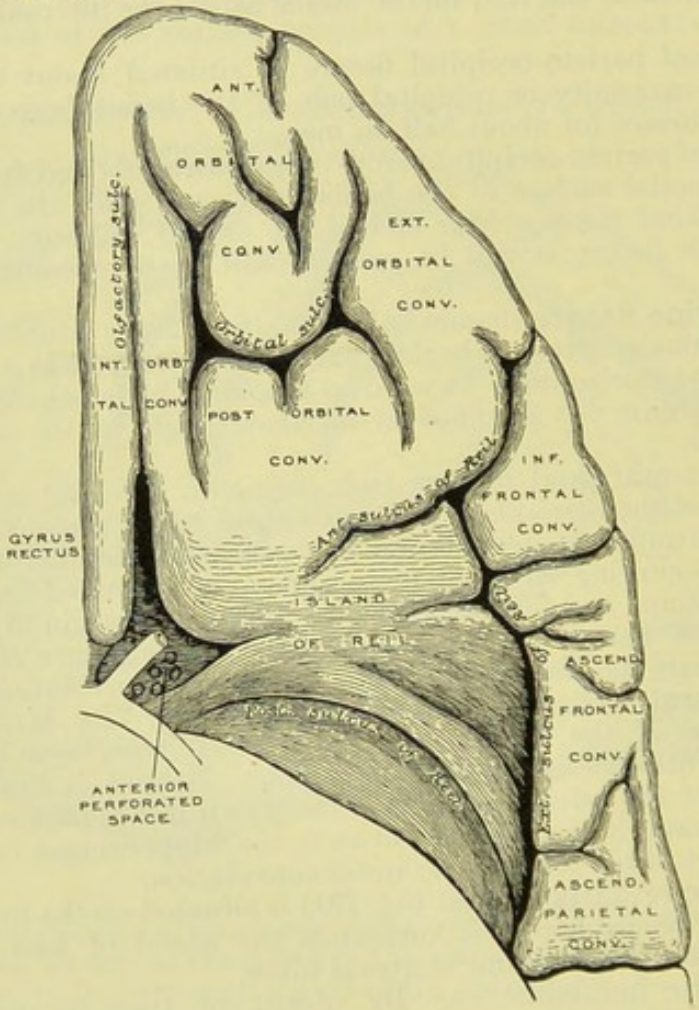

It is continuous on the inner aspect of the hemisphere with the marginal convolution, and on the orbital surface with the internal orbital convolution. It is usually more or less completely subdivided into an upper and a lower part by an antero-posterior sulcus, the *sulcus paramesialis*, which, however, is frequently interrupted by bridging convolutions.

The *middle frontal convolution* (gyrus frontalis medius) is situated between the superior and inferior frontal sulci, and is continuous with the anterior orbital convolution on the lower surface of the hemisphere. It is frequently subdivided into two by a horizontal sulcus which terminates anteriorly in a wide bifurcation, the *sulcus frontalis medius* of Eberstaller.

The *inferior frontal convolution* (gyrus frontalis inferior) is situated below the inferior frontal sulcus, and extends forwards from the lower part of the precentral sulcus; it is continuous with the external and posterior orbital convolutions on the under surface of the lobe. It is subdivided by the anterior

and ascending limbs of the fissure of Sylvius into three parts, viz.: (1) the *pars orbitalis*, below the anterior limb of the fissure; (2) the *pars triangularis* ('cap' of Broca), between the two limbs; and (3) the *pars basilaris*, behind the ascending limb.

The left inferior frontal convolution is, as a rule, more highly developed than the right, and is named the *convolution of Broca*, from the fact that in 1861 Broca discovered that it was the centre for speech.

The *under* or *orbital surface* of the frontal lobe is concave, and rests on the orbital plate of the frontal bone (fig. 728). It is divided into four convolutions (gyri orbitales) by a well-marked H-shaped sulcus, the *sulcus orbitalis*. These are named, from their position, the *internal*, *anterior*, *external*, and *posterior orbital convolutions*. The internal orbital convolution presents a well-marked antero-posterior groove or sulcus, the *sulcus olfactorius*, for the olfactory tract; the portion internal to this is named the *gyrus rectus*, and is continuous with the marginal gyrus on the mesial surface.

The *mesial* or *internal surface* of the frontal lobe is occupied by a single curved convolution, which from its situation is termed the *marginal gyrus* (fig. 729). It commences in front of the anterior perforated space, runs along the margin of the longitudinal fissure on the mesial surface of the orbital

Fig. 729.—Mesial surface of left cerebral hemisphere.

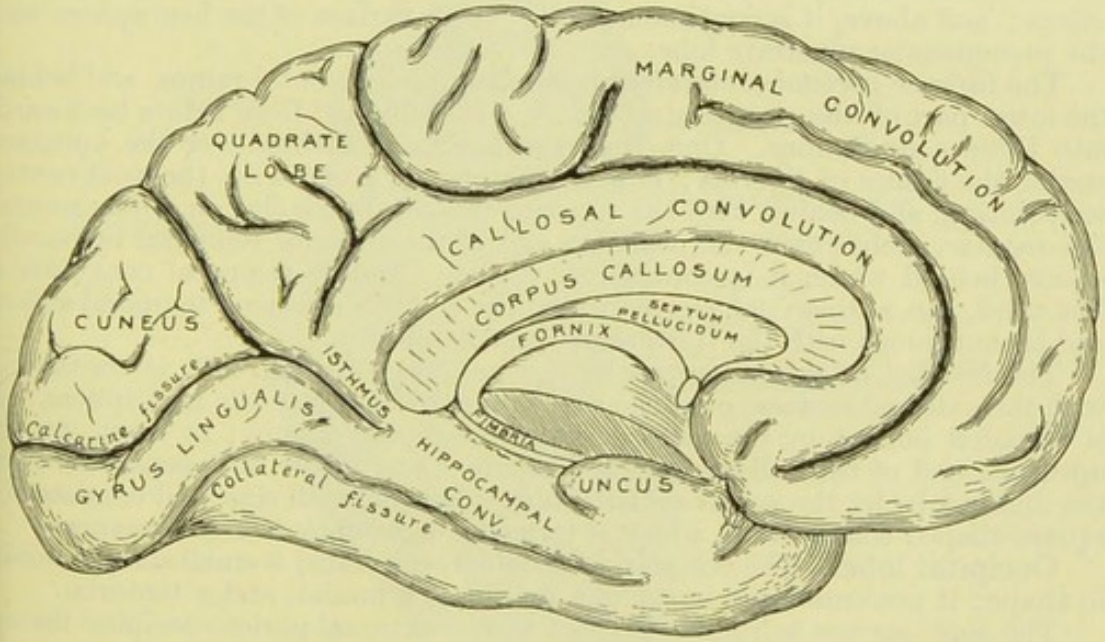

lobe, where it is continuous with the internal orbital convolution; it then ascends, and runs backwards to the point where the calloso-marginal fissure turns upwards to reach the superior border of the hemisphere. The posterior part of this convolution is sometimes marked off by a vertical fissure, and is distinguished as the *paracentral lobule* (lobulus paracentralis), because it is continuous with those convolutions which lie immediately in front of and behind the central fissure or fissure of Rolando.

Parietal lobe.—The parietal lobe (lobus parietalis) forms a part of both the outer and mesial surfaces of the hemisphere. It is separated from the frontal lobe by the fissure of Rolando, but its boundaries below and behind are not so definite. Posteriorly, it is limited by the external parieto-occipital fissure, and by a line carried across the hemisphere from the outer end of this fissure towards the preoccipital notch. Below, it is separated from the temporal lobe by the posterior limb of the fissure of Sylvius, and by a line carried backwards from the horizontal part of this fissure to meet the line passing downwards to the pre-occipital notch.

The *outer surface* of the parietal lobe (fig. 727) is cleft by a well-marked furrow, the *intraparietal sulcus* of Turner, which consists of an oblique and a horizontal portion. The oblique part is named the *sulcus postcentralis*, and commences below, about midway between the lower end of the fissure of Rolando and the

upturned end of the fissure of Sylvius. It runs upwards and backwards, parallel to the fissure of Rolando, and is sometimes divided into an *upper* and a *lower* ramus. It forms the posterior limit of the postcentral convolution.

From about the middle of the postcentral sulcus, or from the upper end of its inferior ramus, the *horizontal portion* of the intraparietal sulcus is carried backwards and slightly upwards on the parietal lobe, and is prolonged, under the name of the *ramus occipitalis*, on to the occipital lobe; here it divides into two parts, which form nearly a right angle with the main stem and constitute the *sulcus occipitalis transversus*. The part of the parietal lobe above the horizontal ramus is named the superior parietal convolution; the part below, the inferior parietal convolution.

The *postcentral convolution* (gyrus centralis posterior) extends from the great longitudinal fissure above to the horizontal limb of the fissure of Sylvius below. It lies parallel with the ascending frontal or precentral convolution, with which it is connected below, and also, sometimes, above, the fissure of Rolando.

The *superior parietal convolution* (lobulus parietalis superior) is bounded in front by the upper part of the postcentral sulcus which lies between it and the postcentral convolution, but it is usually connected with this latter above the upper extremity of the sulcus; behind, it is bounded by the external parieto-occipital fissure, outside the termination of which it is joined to the occipital lobe by a narrow convolution, the *arcus parieto-occipitalis*; below, it is separated from the inferior parietal convolution by the horizontal portion of the intraparietal sulcus; and above, it is continuous on the inner surface of the hemisphere with the precuneus or quadrate lobe.

The *inferior parietal convolution* lies below the horizontal ramus, and behind the lower part of the post-central sulcus. It is divided from before backwards into three convolutions. One, the *supramarginal*, arches over the upturned end of the fissure of Sylvius; it is continuous in front with the post-central convolution, and behind with the superior temporal convolution. The second, the *angular*, arches over the posterior end of the superior temporal or parallel sulcus, behind which it is continuous with the middle temporal convolution. The third, the *postparietal*, curves round the end of the second temporal sulcus, and is continuous with the third temporal convolution.

The *internal* or *mesial surface* of the parietal lobe (fig. 729) is continuous with the external surface, over the supero-mesial border of the hemisphere. It is bounded behind by the internal parieto-occipital fissure; in front, by the upturned end of the calloso-marginal fissure; and below, it is separated from the limbic lobe by the *sulcus subparietalis*. It is of small size, and consists of a square-shaped convolution, which is termed the *quadrate lobe* or *precuneus*.

Occipital lobe.—The occipital lobe (lobus occipitalis) is small and pyramidal in shape; it presents three surfaces: an outer, a mesial, and a tentorial.

The *outer surface* is limited in front by the external parieto-occipital fissure, and by a line carried from the outer end of this fissure to the pre-occipital notch. This surface is traversed by the transverse occipital and the lateral occipital sulci. The *sulcus occipitalis transversus* is continuous with the posterior end of the ramus occipitalis of the intraparietal sulcus, and runs across the upper part of the lobe, a short distance behind the external parieto-occipital fissure. The *sulcus occipitalis lateralis* extends from behind forwards, and divides the outer surface of the occipital lobe into an *upper* and a *lower* convolution, which are continuous in front with the parietal and temporal lobes.*

The *mesial surface* of the occipital lobe is bounded in front by the internal parieto-occipital fissure, and is traversed by the calcarine fissure, which subdivides it into the cuneus and the lingual lobule. The *calcarine fissure* (fissura calcarina) commences near the occipital pole in a bifid extremity; it runs almost horizontally forwards, and ends in the substance of the limbic lobe, a little below the posterior extremity of the corpus callosum. It is joined at an acute angle by the *internal parieto-occipital fissure*, and the wedge-shaped area between the two fissures is named the *cuneus*. The anterior portion of the calcarine fissure gives rise to the prominence of the *hippocampus minor*, or *calcar avis*, in the interior of the lateral ventricle. The *lingual lobule* (gyrus

* Elliot Smith has named the lateral occipital sulcus the *sulcus lunatus*; he regards it as the representative, in the human brain, of the 'Affenspalte' of the brain of the ape.

lingualis) lies between the calcarine fissure and the posterior part of the collateral fissure, and extends, therefore, on to the tentorial surface. Behind, it reaches the occipital pole; in front, it is continued on to the tentorial surface of the temporal lobe, and joins the hippocampal convolution.

The *tentorial surface* of the occipital lobe is limited in front by an imaginary line carried inwards from the pre-occipital notch, and consists of the posterior part of the *occipito-temporal convolution* and the lower part of the *lingual lobule*, which are separated from each other by the posterior segment of the *collateral fissure*.

Temporal lobe.—The temporal lobe (lobus temporalis) presents upper, lower, and tentorial surfaces.

The *upper surface* form the lower limit of the fissure of Sylvius, and overlaps the island of Reil. On opening out the fissure of Sylvius, three or four gyri will be seen springing from the depth of the hinder end of the fissure, and running obliquely forwards and outwards on the posterior part of the upper surface of the first temporal convolution; these are named the *gyri temporales transversi* or *gyri of Heschl* (fig. 730).

FIG. 730.—Section of brain showing upper surface of temporal lobe.

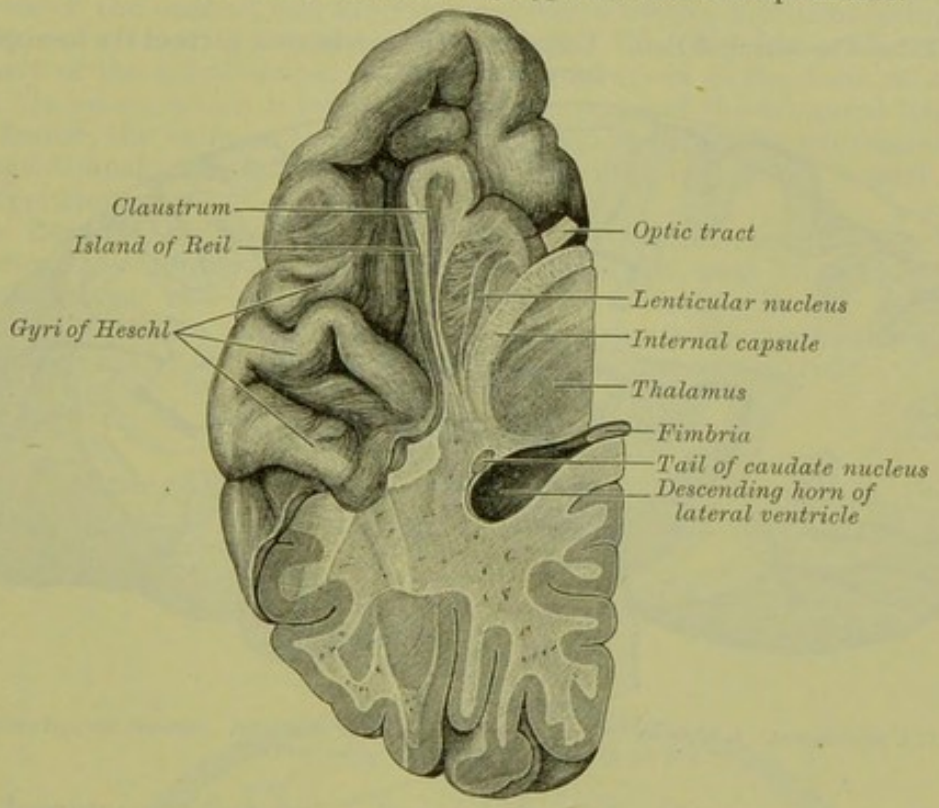

The *outer surface* (fig. 727) is bounded above by the posterior limb of the fissure of Sylvius, and by the imaginary line continued backwards from it; below, it is limited by the infero-lateral border of the hemisphere. It is divided into superior, middle, and inferior convolutions by two sulci, which are termed the first and second temporal sulci. The *first temporal sulcus* (sulcus temporalis superior) runs from before backwards through the temporal lobe, some little distance below, but parallel with, the posterior limb of the fissure of Sylvius; and hence it is often termed the *parallel sulcus*. The *second temporal sulcus* (sulcus temporalis medius) takes the same direction as the first, but is situated at a lower level, and is usually subdivided into two or more parts. The *superior temporal convolution* (gyrus temporalis superior) lies between the posterior limb of the fissure of Sylvius and the parallel sulcus, and is continuous behind with the supra-marginal and angular convolutions. The *middle temporal convolution* (gyrus temporalis medius) is placed between the first and second temporal sulci, and is joined posteriorly with the angular and postparietal convolutions. The *inferior temporal convolution* (gyrus temporalis inferior) is placed below the second temporal sulcus, and is connected behind with the lower occipital convolution; it also extends round the infero-lateral border

on to the tentorial surface, where it is limited by the occipito-temporal sulcus about to be described.

The *tentorial surface* is concave, looks downwards and inwards, and is directly continuous posteriorly with the tentorial surface of the occipital lobe. It is traversed by the *occipito-temporal sulcus* (sulcus temporalis inferior) which extends from near the occipital pole behind, to within a short distance of the temporal pole in front, but is frequently subdivided by bridging gyri. To the outer side of this fissure is the narrow tentorial part of the third temporal convolution, and to its inner side the *occipito-temporal convolution*, which extends from the occipital to the temporal pole. This convolution is limited internally by the collateral fissure, which separates it from the lingual lobule behind and from the hippocampal convolution of the limbic lobe in front.

The **insula**, or **island of Reil** (fig. 731), lies deeply in the Sylvian fissure, and can only be seen when the lips of that fissure are widely separated, since it is overlapped and hidden by the convolutions which bound the fissure. These convolutions are termed the *opercula of the insula* ; they are separated from each other by the three limbs of the Sylvian fissure, and named the orbital, frontal, fronto-parietal, and temporal opercula. The *orbital operculum* lies below the anterior limb of the fissure, the *frontal* between the anterior and ascending

Fig. 731.—The island of Reil. Left side. The overlapping parts of the hemisphere have been removed.

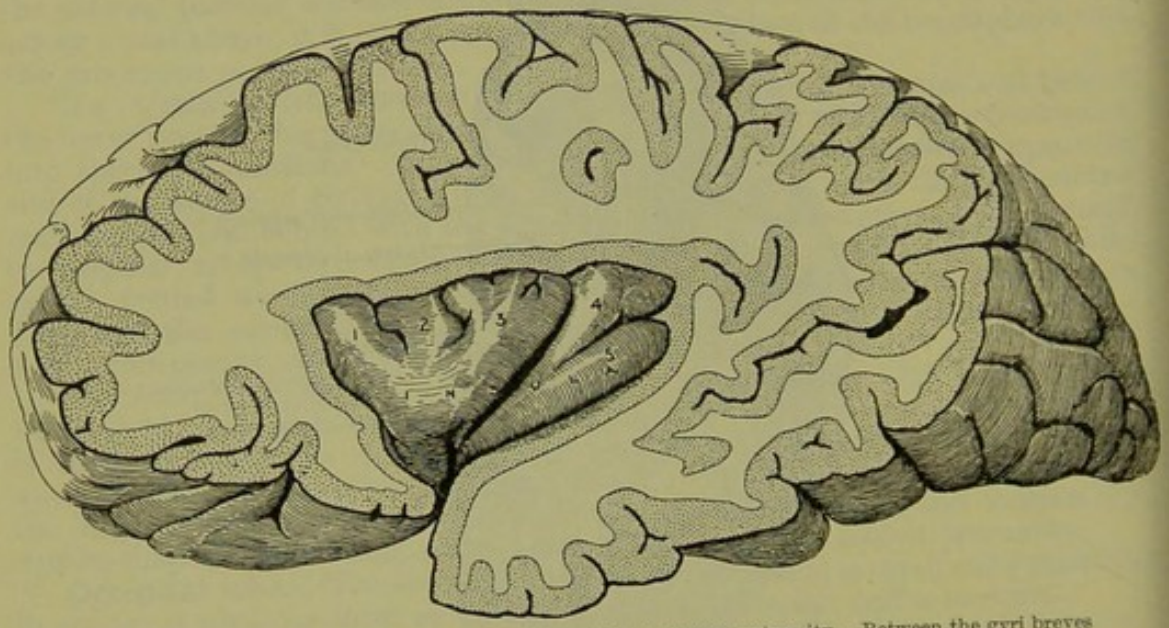

1, 2, 3. Gyri breves. 4, 5. Gyrus longus, bifurcated at its upper extremity. Between the gyri breves and the gyrus longus is seen the sulcus centralis.

limbs, the *fronto-parietal* between the ascending limb and the upturned end of the posterior limb, and the *temporal* below the posterior limb. The frontal operculum is of small size when the anterior and ascending limbs of the fissure of Sylvius arise from a common stem which lies between the orbital and fronto-parietal opercula. The island of Reil is surrounded by a deep *limiting sulcus* (sulcus circularis) which separates it from the frontal, parietal, and temporal lobes. When the opercula have been removed it presents the form of a triangular eminence, the apex of which is directed downwards and inwards towards the anterior perforated space. It is divided into a *precentral* and a *postcentral* lobe by the *sulcus centralis*, which runs backwards and upwards from the apex of the insula. The precentral lobe is further subdivided by shallow sulci into three or four short convolutions, the *gyri breves insulæ*, while the postcentral lobe is named the *gyrus longus insulæ*, and is often bifurcated at its upper extremity. The grey matter of the insula is continuous with that of the different opercula, while its deep surface corresponds with the lenticular nucleus of the corpus striatum.

Limbic lobe (fig. 729).—The term limbic lobe (*grande lobe limbique*) was introduced by Broca in 1878, and under it he included the callosal and hippocampal convolutions, which together arch round the corpus callosum and

the dentate or hippocampal fissure. These he separated on the morphological ground that they are well developed in animals possessing a keen sense of smell (osmatic animals), such as the dog and fox. They were thus regarded as a part of the rhinencephalon, but it is now recognised that they belong to the neopallium ; the callosal convolution is therefore sometimes described as a part of the frontal lobe and the hippocampal convolution as a part of the temporal lobe.

The *callosal convolution* (gyrus cinguli) is an arch-shaped convolution, lying in close relation to the superficial surface of the corpus callosum, from which it is separated by a slit-like fissure, the *callosal fissure*. It commences below the rostrum of the corpus callosum, curves round in front of the genu, extends along the upper surface of the body, and finally turns downwards behind the splenium, where it is connected by a narrow *isthmus* with the gyrus hippocampi. It is separated from the marginal convolution by the calloso-marginal sulcus, and from the quadrate lobe by the subparietal sulcus.

The *hippocampal convolution* (gyrus hippocampi) is bounded above by the hippocampal or dentate fissure, and below by the anterior part of the collateral fissure. Behind, it is continuous superiorly, through the isthmus, with the callosal convolution, and inferiorly with the lingual lobule. Running in the substance of the callosal and hippocampal convolutions, and connecting them together, is a tract of arched fibres, named the *cingulum*. The anterior extremity of the hippocampal convolution is recurved in the form of a hook, named the *uncus*, which is separated from the apex of the temporal lobe by a slight fissure, the *incisura temporalis*. Although superficially continuous with the hippocampal convolution the uncus forms morphologically a part of the rhinencephalon.

The **dentate** or **hippocampal fissure** commences immediately behind the posterior extremity of the corpus callosum, and runs forwards between the hippocampal and dentate convolutions to terminate in the uncus. It is a complete fissure (see page 856), and gives rise to the prominence of the hippocampus major in the descending horn of the lateral ventricle.

Rhinencephalon (fig. 732)

The **rhinencephalon** comprises the olfactory lobe, the uncus, the subcallosal, supracallosal, and dentate gyri, the septum pellucidum, the fornix, and the hippocampus major.

Fig. 732.—Scheme of rhinencephalon.

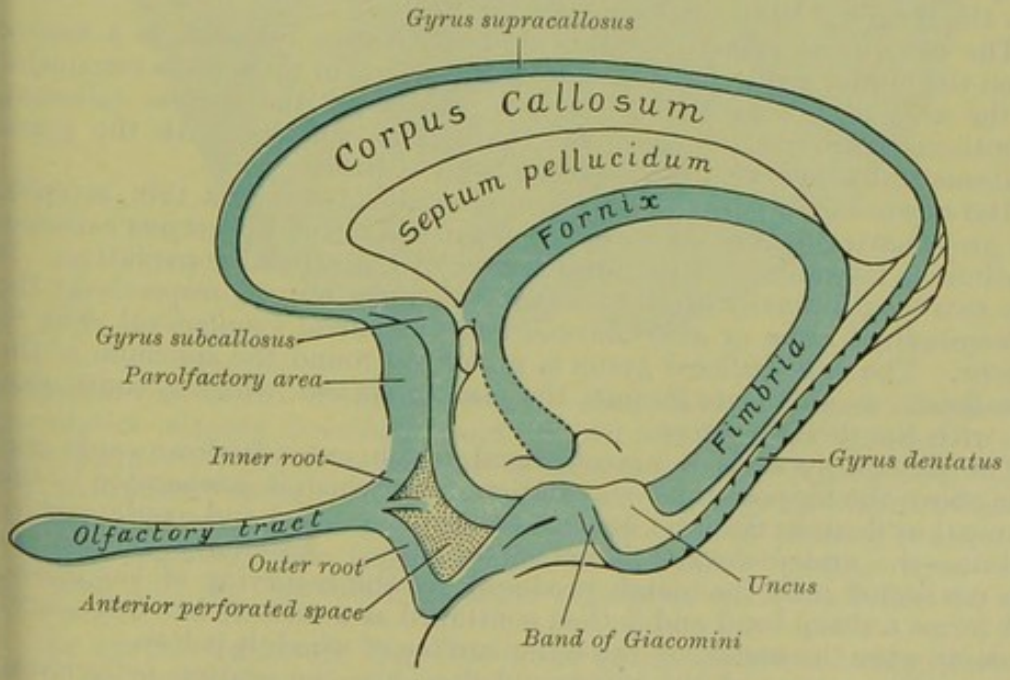

1. The **olfactory lobe** is situated on the under surface of the frontal lobe. In many vertebrates it constitutes a well-marked portion of the hemisphere

and encloses an extension of the anterior horn of the lateral ventricle; but in man and some other mammals it is rudimentary. It consists of the olfactory bulb, the olfactory tract, the trigonum olfactorium, the area of Broca, and the anterior perforated space.

(*a*) The *olfactory bulb* (bulbus olfactorius) is an oval, reddish-grey mass which rests on the cribriform plate of the ethmoid and forms the anterior expanded extremity of the olfactory tract. Its under surface receives the olfactory nerves, which pass upwards through the cribriform plate from the olfactory region of the nose. Its minute structure is described on page 883.

(*b*) The *olfactory tract* (tractus olfactorius) is a narrow white band, triangular on transverse section, the apex being directed upwards. It lies in the olfactory sulcus on the under surface of the frontal lobe, and when traced backwards is seen to divide into two roots, an outer and an inner. The *outer root* is directed across the lateral part of the anterior perforated space and then bends abruptly inwards towards the uncus of the gyrus hippocampi. The *inner root* turns inwards behind Broca's area and ends in the subcallosal gyrus; in some cases a small *middle root* is seen running backwards to the anterior perforated space.

(*c*) The *trigonum olfactorium* is a small triangular area in front of the anterior perforated space. Its apex, directed forwards, occupies the posterior part of the olfactory sulcus, and is brought into view by turning backwards the olfactory tract.

(*d*) The *area of Broca* (parolfactory area) is a small triangular field on the mesial surface of the hemisphere in front of the gyrus subcallosus; it is continuous below with the trigonum olfactorium, and above and in front with the callosal convolution.

(*e*) The *anterior perforated space* is an irregularly quadrilateral area in front of the optic tract and behind the trigonum olfactorium, from which it is separated by the *fissura prima*; internally it is continuous with the lamina terminalis; externally it is bounded by the outer root of the olfactory tract. Its grey matter is continuous above with that of the corpus striatum, and is perforated anteriorly by numerous small blood-vessels. Its posterior part assumes the form of a whitish band, the *diagonal band of Broca*, continued in front into the gyrus subcallosus and behind into the temporal lobe.

2. The **uncus** has already been described (page 863) as the recurved, hook-like portion of the hippocampal convolution.

3. The **subcallosal, supracallosal,** and **dentate gyri** form a rudimentary arch-shaped lamina of grey matter which establishes a circuitous connection between the diagonal band of Broca and the uncus.

(*a*) The *subcallosal gyrus* or peduncle of the corpus callosum is a narrow lamina on the mesial surface of the hemisphere in front of the lamina terminalis, behind the area of Broca, and below the rostrum of the corpus callosum. It is continuous around the genu of the corpus callosum with the gyrus supracallosus and below with the diagonal band of Broca.

(*b*) The *supracallosal gyrus* or *indusium griseum* consists of a thin, atrophic layer of grey matter in contact with the upper surface of the corpus callosum and continuous laterally with the grey matter of the callosal convolution. It contains two longitudinally directed strands of fibres termed respectively the *mesial longitudinal striæ* or *striæ Lancisi* and the *lateral longitudinal striæ* or *tæniæ tectæ*. The supracallosal gyrus is prolonged round the splenium of the corpus callosum as a delicate lamina, the *fasciola cinerea*, which is continuous in front with the dentate gyrus.

(*c*) The *dentate gyrus* is a narrow band which extends downwards and forwards above the hippocampal convolution, from which it is separated by the hippocampal or dentate fissure. Its free margin is notched and overlapped by the fimbria—the *fimbrio-dentate fissure* intervening. Anteriorly the dentate gyrus is continued into the notch produced by the recurving of the uncus, where it forms a sharp bend and is then continued as a delicate band, the *band of Giacomini*, over the uncus, on the outer surface of which it is lost.

The remaining parts of the rhinencephalon, viz. the septum pellucidum, fornix, and hippocampus major, will be described in connection with the lateral ventricle.

Interior of the Cerebral Hemispheres

If the upper part of either hemisphere be removed with a knife, at a level about half an inch above the corpus callosum, the internal white matter will be exposed. It is an oval-shaped centre of white substance surrounded by a narrow convoluted margin of grey matter of almost uniform thickness. The white central mass has been called the *centrum ovale minus*. Its surface is studded with numerous minute red dots (*puncta vasculosa*), produced by the escape of blood from divided blood-vessels ; in inflammation or great congestion of the brain these are very numerous, and of a dark colour. If the remaining portions of the hemispheres be slightly drawn apart a broad band of white substance will be observed, connecting them at the bottom of the longitudinal fissure ; this is the *corpus callosum*. The margins of the hemispheres which

Fig. 733.—Corpus callosum from above.

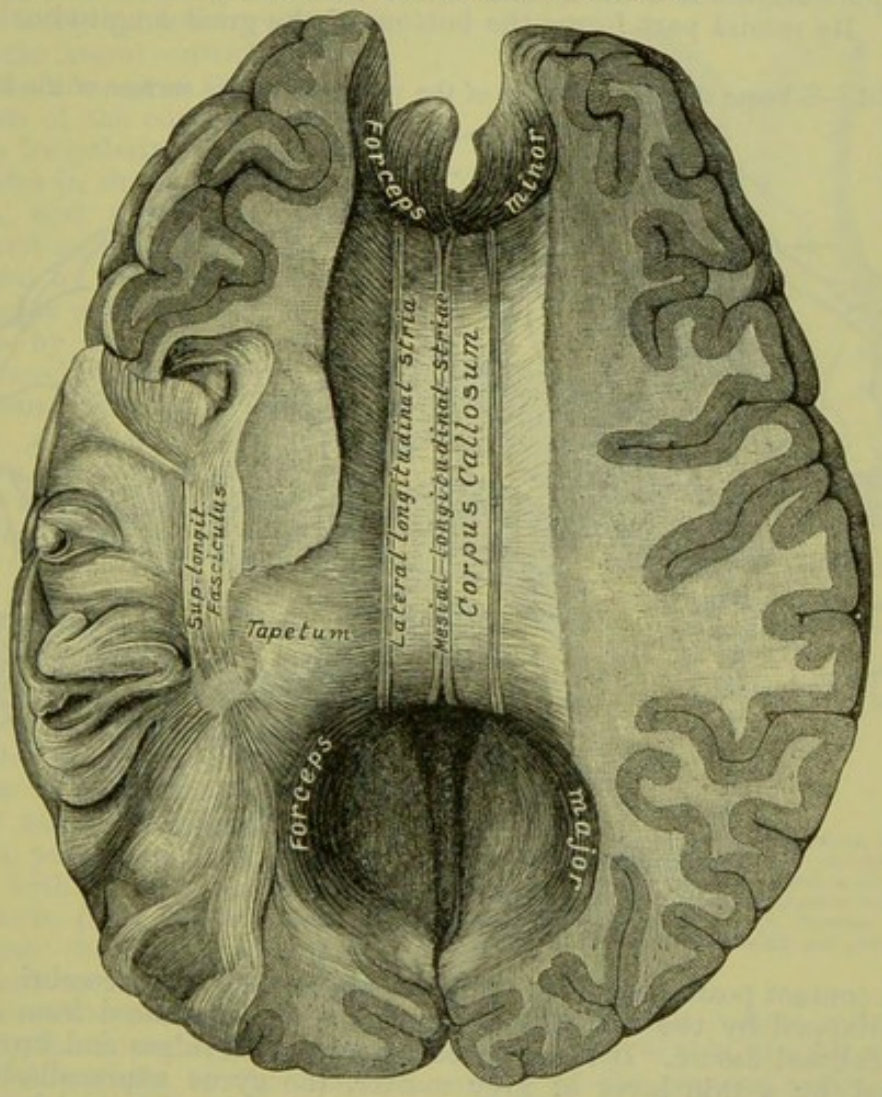

overlap it are called the *labia cerebri*. Each labium is part of the callosal convolution already described ; and the slit-like interval between it and the upper surface of the corpus callosum is termed the *callosal fissure* (fig. 729). If the hemispheres be sliced off to a level with the upper surface of the corpus callosum, the white substance of that structure will be seen connecting the two hemispheres. The large expanse of medullary matter now exposed, surrounded by the convoluted margin of grey substance, is called the *centrum ovale majus*.

The **corpus callosum** (fig. 733) is the great transverse commissure which unites the cerebral hemispheres and roofs in the lateral ventricles. A good conception of its position and size is obtained by examining a mesial section of the brain (fig. 721), when it is seen to form an arched structure about four

inches in length. Its anterior extremity reaches to within about an inch and a half of the frontal pole, and its posterior extremity about two and a half inches from the occipital pole of the hemisphere.

The *anterior extremity* is named the *genu*, and is bent downwards and backwards in front of the septum pellucidum; diminishing rapidly in thickness, it is prolonged backwards, under the name of the *rostrum*, which is connected below with the lamina terminalis. The anterior cerebral arteries are in contact with the under aspect of the rostrum; they then arch over the front of the genu, and are carried backwards above the body of the corpus callosum.

The *posterior extremity* is termed the *splenium*, and constitutes the thickest part of the corpus callosum. It overlaps the velum interpositum and the mid-brain, and terminates in a thick, convex, free border. When a mesial section of the splenium is examined, it is seen that the posterior end of the corpus callosum is acutely bent forwards, the upper and lower parts being applied to each other.

The *upper surface* is convex from before backwards, and is nearly an inch in width. Its mesial part forms the bottom of the great longitudinal fissure,

FIG. 734.—Scheme showing relations of the ventricles to the surface of the brain.

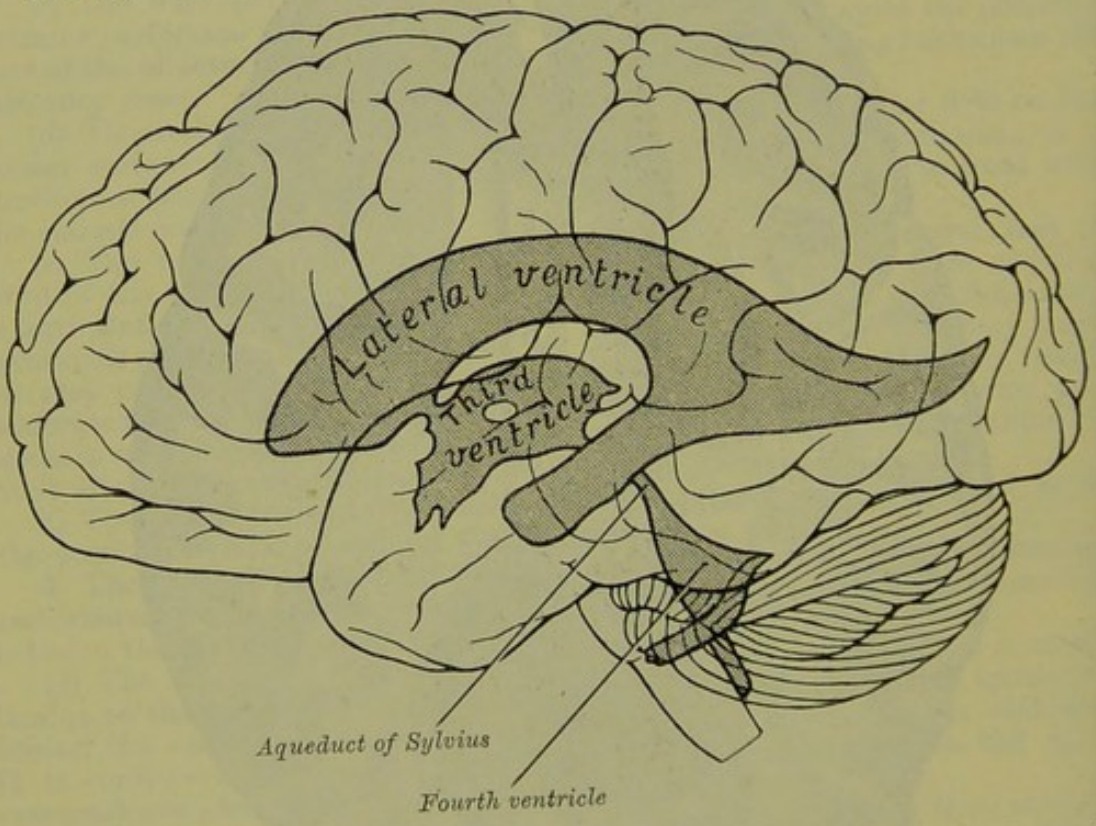

and is in contact posteriorly with the lower border of the falx cerebri. Laterally it is overlapped by the callosal convolution, but is separated from it by the slit-like callosal fissure. It is traversed by numerous ridges and furrows, and is covered by a thin layer of grey matter, the gyrus supracallosus, which exhibits on either side of the middle line the mesial and lateral longitudinal striæ, already described (page 864).

The *lower surface* is concave, and forms on either side of the middle line the roof of the lateral ventricle. Mesially, this surface is attached in front to the septum pellucidum; behind this it is fused with the upper surface of the body of the fornix, while the splenium is in contact with the velum interpositum.

On either side, the fibres of the corpus callosum radiate in the white substance and pass to the various parts of the cerebral cortex. The part of the corpus callosum which curves forwards from the genu into the frontal lobes is called the *forceps minor*. The part which curves backwards from the splenium into the occipital lobes is known as the *forceps major*. Between these two parts is the main body of the fibres which constitute the *tapetum* or *mat*;

this extends laterally on either side into the temporal lobe, and covers in the body of the lateral ventricle.

The lateral ventricles (ventriculi laterales) (fig. 736).—The lateral ventricles, two in number, right and left, are irregular cavities situated in the lower and inner parts of the cerebral hemispheres, one on either side of the middle line. They are separated from each other by a mesial vertical partition, the *septum pellucidum*, but communicate with the third ventricle and indirectly with each other through the *foramen of Monro*. They are lined by a thin, diaphanous membrane, the *ependyma*, which is covered by ciliated epithelium, and moistened by cerebro-spinal fluid, which, even in health, may be secreted in considerable amount. Each lateral ventricle consists of a central cavity or *body*, and three prolongations from it, termed *cornua*. The *anterior* cornu curves forwards and outwards into the frontal lobe; the *posterior* backwards and inwards into the occipital lobe; and the *middle* descends into the temporal lobe.

FIG. 735.—Drawing of a cast of the ventricular cavities viewed from above. (Testut.)

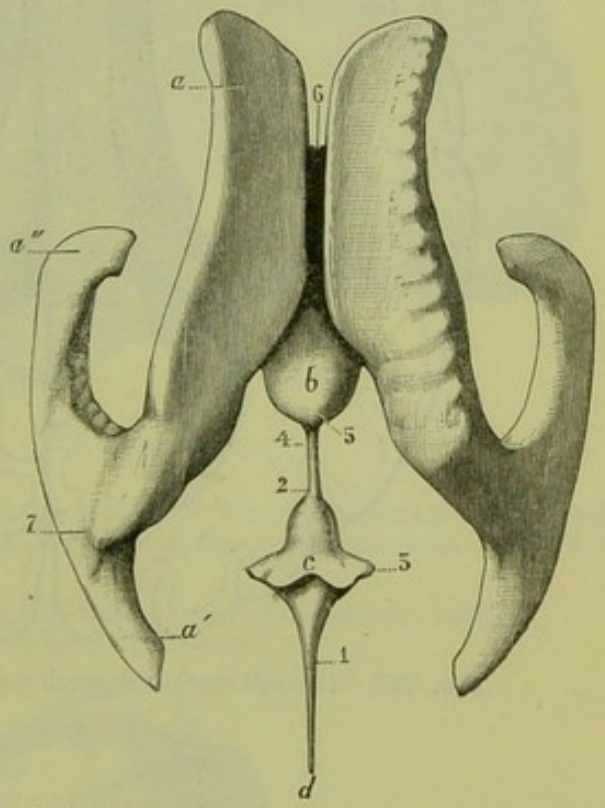

a, *a'*, *a''*. The three horns—anterior, posterior, and middle—of the left lateral ventricle. *b*. Third ventricle. *c*. Fourth ventricle. *d*. Commencement of central canal of cord. 1. Inferior angle of fourth ventricle. 2. Superior angle. 3. Lateral angle. 4. Sylvian aqueduct. 5. Recessus suprapinealis. 6. Vulva. 7. Junction of descending and posterior horns.

The **body** (pars centralis) (fig. 736) of the lateral ventricle extends from the foramen of Monro to the splenium of the corpus callosum. It is an irregularly curved cavity, triangular in shape on transverse section, and presents a roof, a floor, and an inner wall. Its roof is formed by the under surface of the corpus callosum; its floor is formed by the following parts, enumerated in their order of position, from before backwards: the *caudate nucleus of the corpus striatum*, the *tænia semicircularis* and the *vein of the corpus striatum*, the outer portion of the upper surface of the *thalamus*, the *choroid plexus*, and the lateral part of the *fornix*; its inner wall is the posterior part of the septum pellucidum, which separates it from the opposite ventricle, and connects the under surface of the corpus callosum with the fornix.

The **anterior cornu** (cornu anterius) passes forwards and outwards, with a slight inclination downwards, from the foramen of Monro into the frontal lobe, curving round the anterior extremity of the caudate nucleus. It is bounded above by the corpus callosum, and below by the upper surface of the reflected portion of this, the rostrum. It is bounded internally by the anterior portion of the septum pellucidum, and externally by the head of the caudate nucleus of the corpus striatum. Its apex reaches the posterior surface of the genu of the corpus callosum (fig. 741).

The **posterior cornu** (cornu posterius) (figs. 736, 737) passes into the occipital lobe, its direction being backwards and outwards, and then inwards; its concavity is therefore directed inwards. Its roof is formed by the fibres of the corpus callosum passing to the temporal and occipital lobes. On its inner wall is seen a longitudinal eminence, which is an involution of the ventricular wall produced by the calcarine fissure; this is called the *hippocampus minor*, or *calcar avis*. Just above this the forceps major of the corpus callosum, sweeping round to enter the occipital lobe, causes another projection, which is known as the *bulb of the posterior cornu*. The hippocampus minor and bulb of the posterior cornu are extremely variable in their degree of development; in some cases they are ill-defined, in others unusually prominent.

The **middle** or **descending cornu** (cornu inferius) (fig. 738), the largest of the three, traverses the temporal lobe of the brain, forming in its course a

Fig. 736.—Lateral ventricles of the brain.

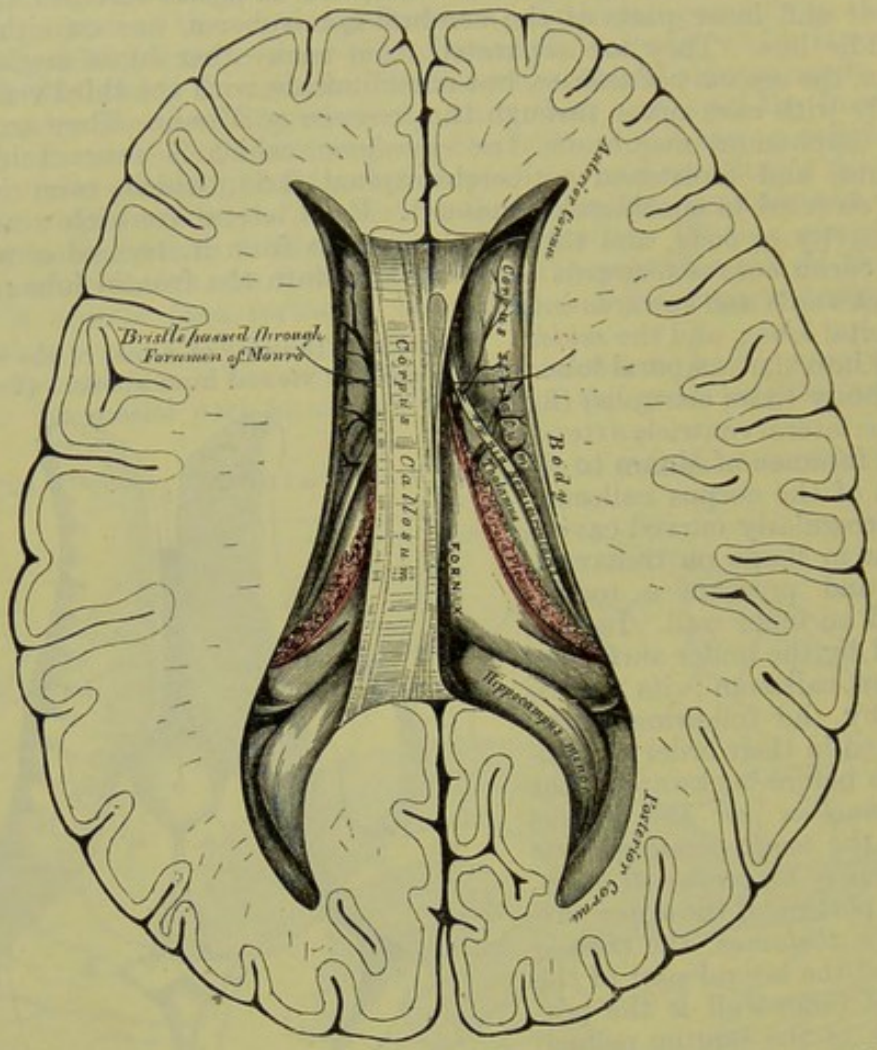

Fig. 737.—Coronal section through posterior cornu of lateral ventricle.

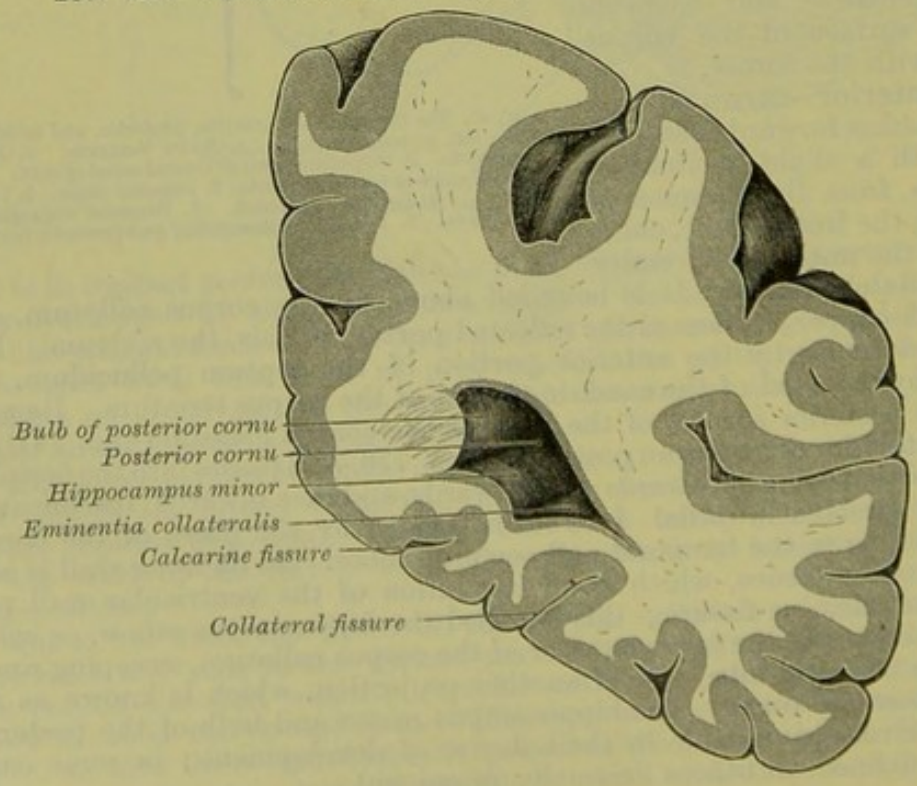

remarkable curve round the back of the thalamus. It passes at first backwards, outwards, and downwards, and then curves forwards, and inwards, to within

Fig. 738.—Posterior and descending cornua of left lateral ventricle exposed from the side.

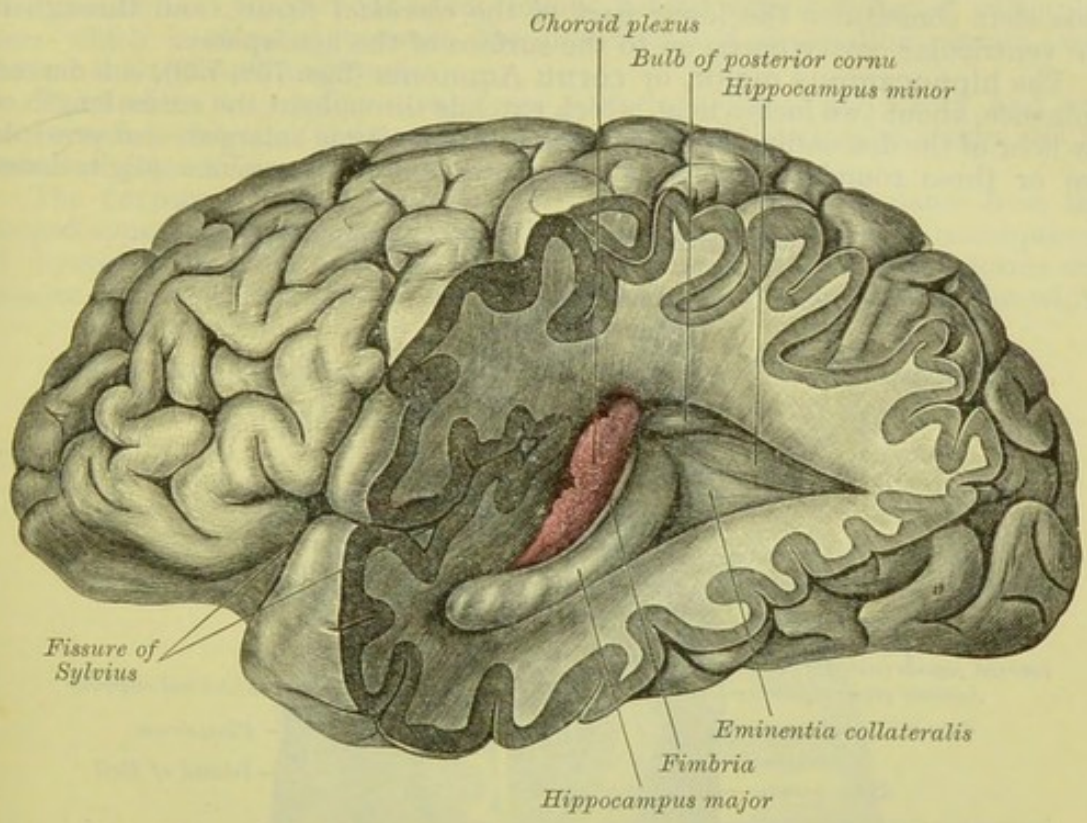

an inch of the apex of the temporal lobe, its direction being fairly well indicated on the surface of the brain by that of the parallel sulcus. Its roof

Fig. 739.—Transverse section of the descending cornu of the lateral ventricle. (From a drawing by F. A. Barton.)

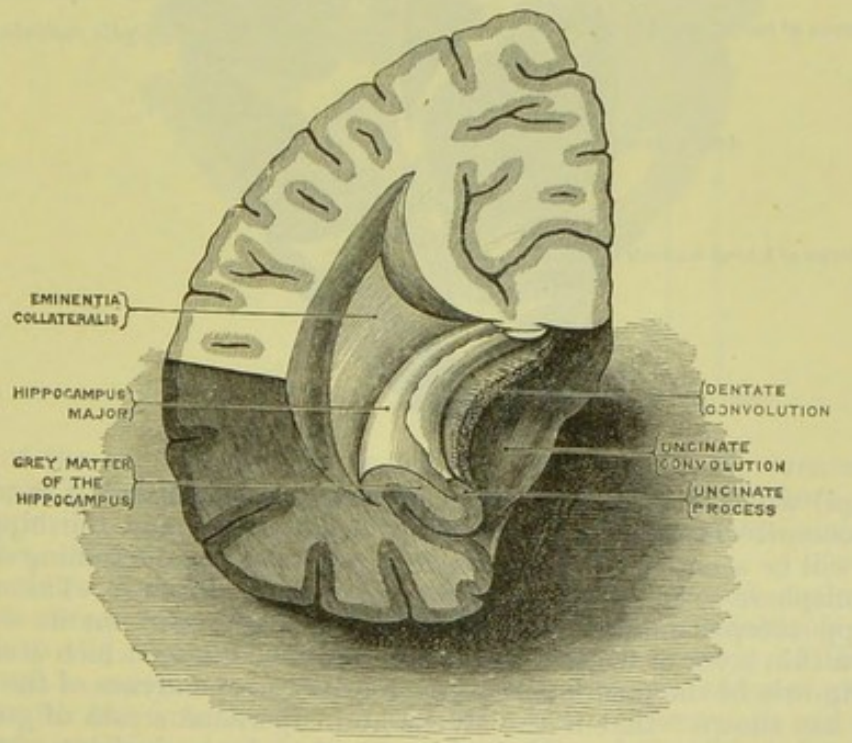

is formed chiefly by the under surface of the tapetum of the corpus callosum, but the tail of the nucleus caudatus, and the tænia semicircularis also extend

forwards in the roof of the descending horn to its extremity, where they end in a mass of grey matter, the *nucleus amygdalæ*. Its floor presents the following parts: the *hippocampus major*, the *fimbria* or *tænia hippocampi*, the *eminentia collateralis*, and the *choroid plexus*. When the choroid plexus is removed, a cleft-like opening is formed along the mesial wall of the descending cornu. This cleft constitutes the lower part of the *choroidal fissure*, and through it the ventricular cavity opens on to the surface of the hemisphere.

The **hippocampus major**, or **cornu Ammonis** (figs. 738, 739), is a curved eminence, about two inches long, which extends throughout the entire length of the floor of the descending horn. Its lower extremity is enlarged, and presents two or three rounded elevations with intervening depressions (digitationes

FIG. 740.—Horizontal section of right cerebral hemisphere.

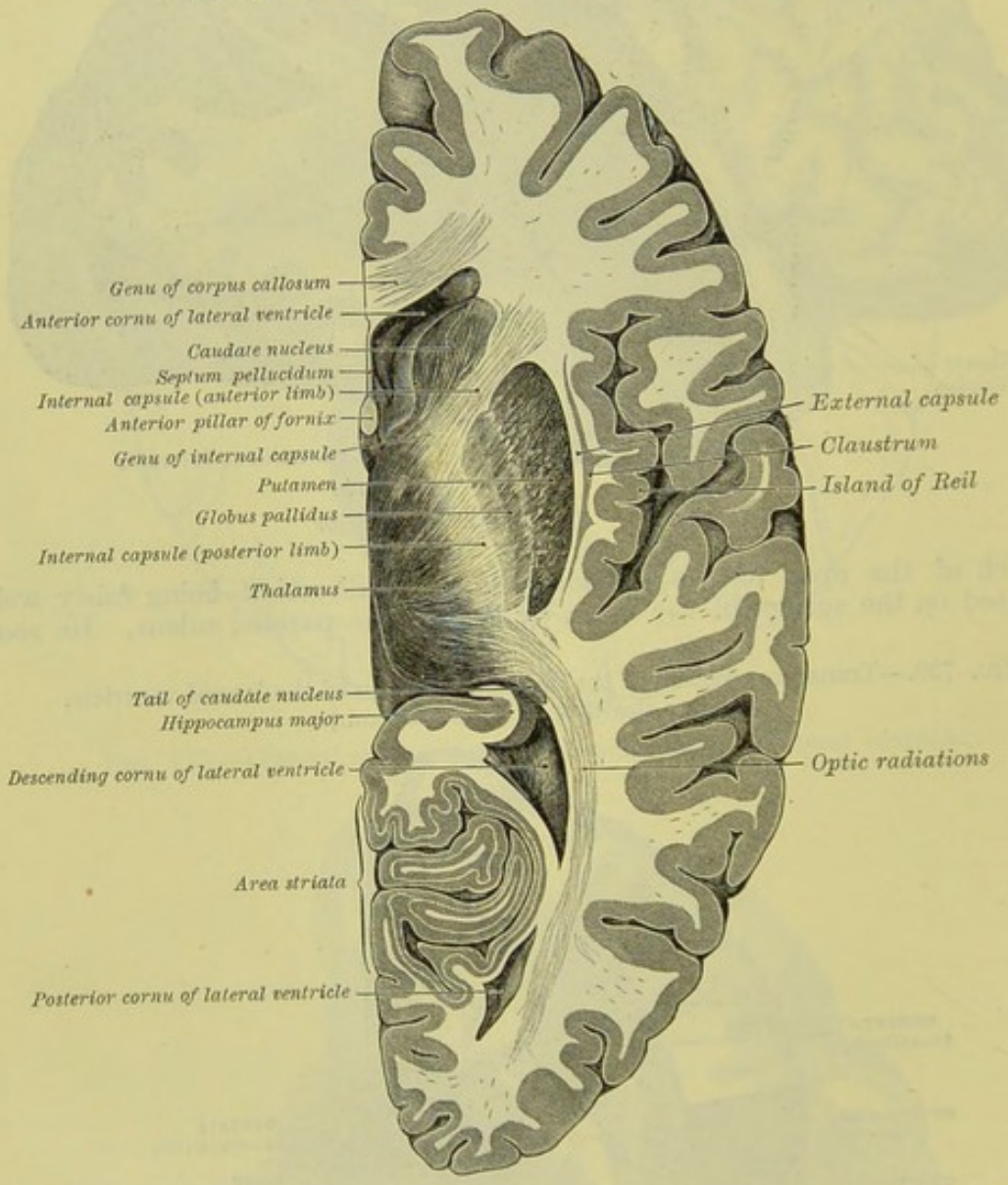

hippocampi) which give it a paw-like appearance, and hence it is named the *pes hippocampi*. If a transverse section be made through the hippocampus major, it will be seen that this eminence is produced by the folding of the wall of the hemisphere to form the dentate or hippocampal fissure. The main mass of the hippocampus major consists of grey matter; but on its ventricular surface is a thin layer of white matter, known as the *alveus*, which is continuous with the fimbria of the fornix and is covered by the ependyma of the ventricle. Macarthy has shown * that if the alveus and superficial strata of grey matter be reflected from the surface of the hippocampus by an incision carried along

* *Journal of Anatomy and Physiology*, vol. xxxiii.

its convexity, the 'core' of the hippocampus, as he terms it, presents, in many cases, a corrugated or crimped appearance.

The **eminentia collateralis** is an elongated eminence lying to the outer side of and parallel with the hippocampus major. It corresponds with the middle part of the collateral fissure, and its size depends on the depth and direction of that furrow. It is continuous behind with a flattened triangular area which is situated between the posterior and descending cornua, and named the *trigonum collaterale*.

The fimbria is a continuation of the posterior pillar of the fornix, and will be discussed with that body; while a description of the choroid plexus will be found on page 877.

The **corpus striatum** (figs. 740, 741, 742) has received its name from the striped appearance which a section of its anterior part presents, in consequence of diverging white fibres being mixed with the grey matter which forms the greater part of its substance. A part of this body is imbedded in the white

FIG. 741.—Coronal section through anterior cornua of lateral ventricles.

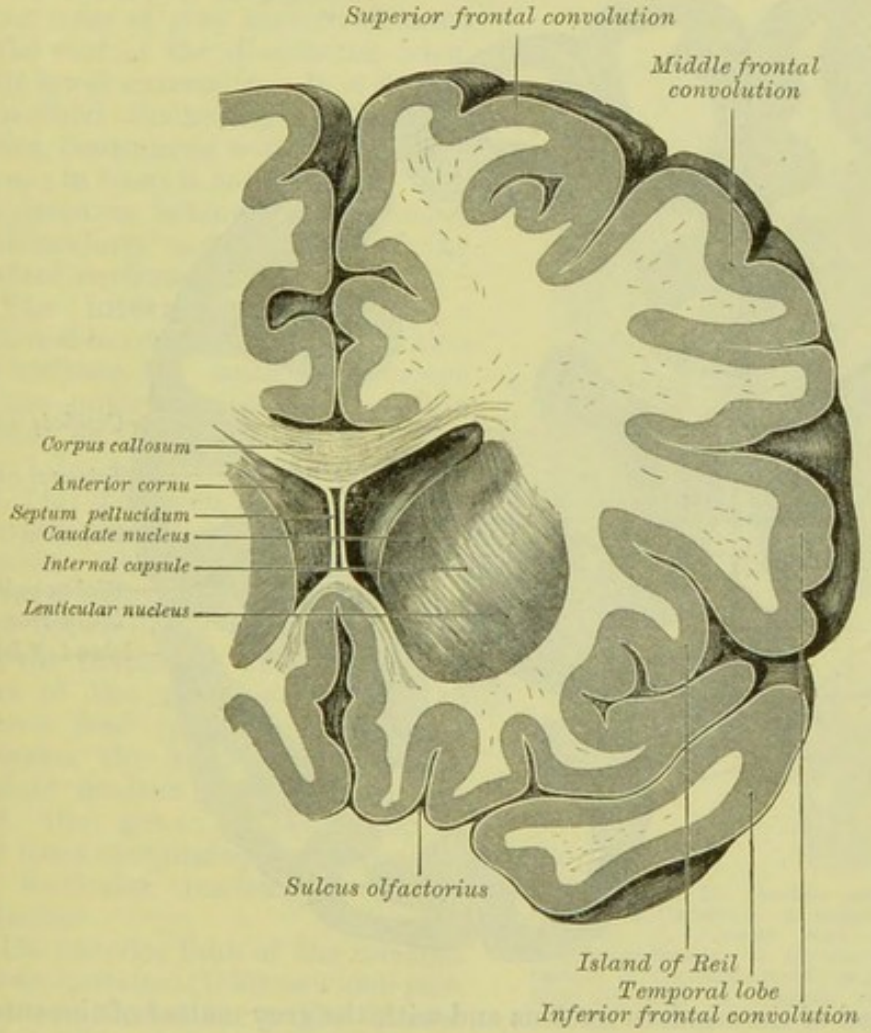

substance of the hemisphere, and is therefore external to the ventricle. It is termed the *extra-ventricular portion*, or the *nucleus lenticularis*; a part, however, is visible in the ventricle, and is named the *intraventricular portion*, or the *nucleus caudatus*.

The **nucleus caudatus** is a pear-shaped, highly arched mass of grey matter; its broad extremity, or *head* (caput nuclei caudati), is directed forwards into the fore-part of the body and anterior cornu of the lateral ventricle, and is continuous with the grey matter of the anterior perforated space and with the anterior end of the lenticular nucleus; its narrow end, or *tail* (cauda nuclei caudati) is directed outwards and backwards on the outer side of the thalamus, from which it is separated by the tænia semicircularis and the vein of the corpus striatum. It is then continued downwards

into the roof of the descending cornu, where it terminates in the *nucleus amygdalæ*, at the apex of the temporal lobe. It is covered by the lining of the ventricle, and crossed by some veins of considerable size. It is separated from the extra-ventricular portion, in the greater part of its extent, by a lamina of white matter, which is called the *internal capsule*, but the two portions of the corpus striatum are united in front (fig. 741).

The **nucleus lenticularis** (nucleus lentiformis), or extra-ventricular portion of the corpus striatum, is placed outside the caudate nucleus and thalamus, and is seen only in sections of the hemisphere. When divided horizontally, it exhibits, to some extent, the appearance of a biconvex lens, while a vertical transverse section of its central part presents a somewhat triangular outline. It does not extend as far forwards or backwards as the nucleus caudatus. It is bounded externally by a lamina of white matter called the *external capsule*, on the outer surface of which is a thin layer of grey matter termed the *claustrum*. Its anterior extremity is continuous with the lower

Fig. 742.—Coronal section of brain through anterior commissure.

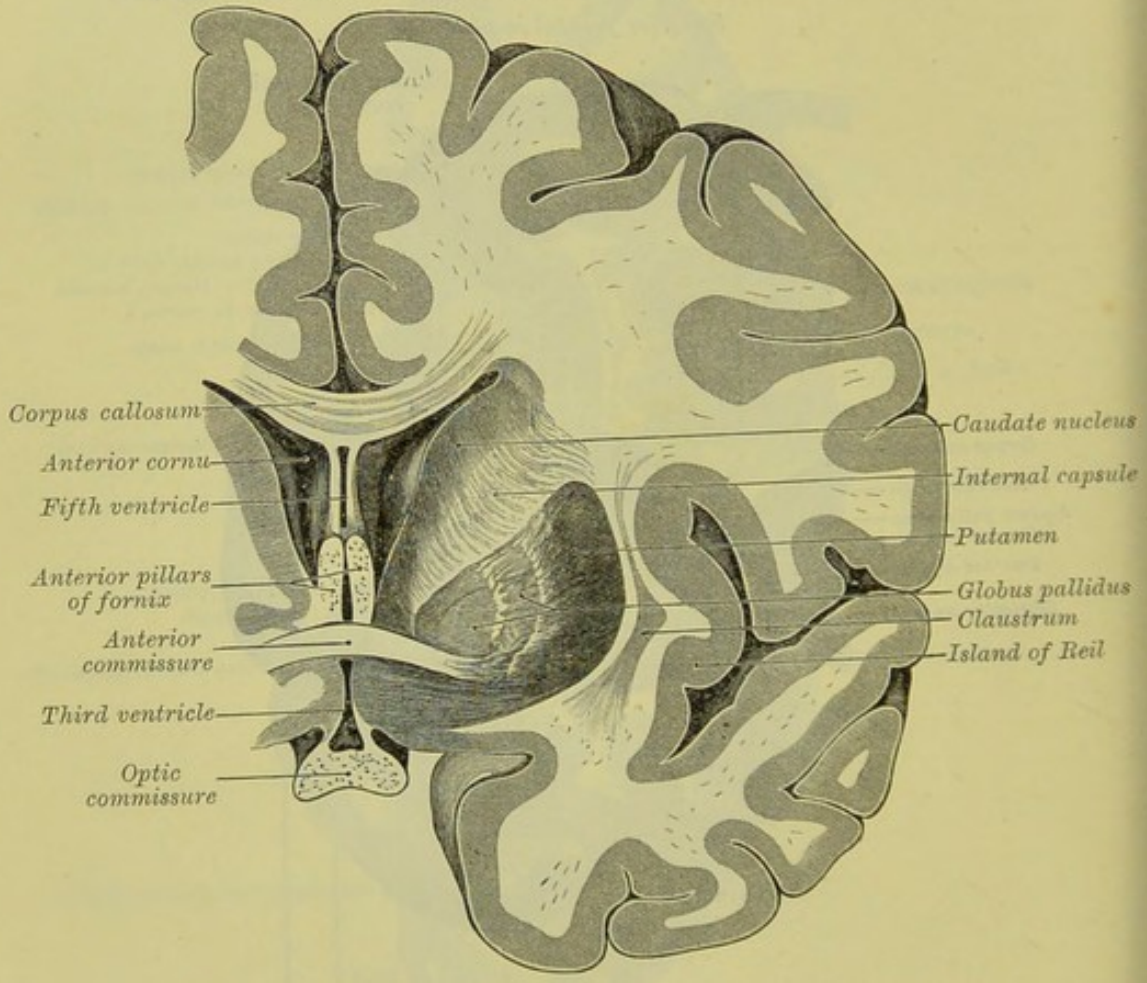

part of the head of the caudate nucleus and with the grey matter of the anterior perforated space.

Upon making a transverse vertical section through the middle of the nucleus lenticularis it is seen to be divided by two white laminæ, the *medullary laminæ*, into three zones. The outermost and largest zone is of a reddish colour, and is known as the *putamen*, while the two inner are paler and of a yellowish tint, and together constitute the *globus pallidus*. All three zones are marked by fine radiating white fibres, which are most distinct in the putamen.

The grey matter of the corpus striatum is traversed by nerve-fibres, some of which are believed to originate in it. The cells are multipolar, both large and small; those of the lenticular nucleus contain yellow pigment. The caudate and lenticular nuclei are not only directly continuous with each other anteriorly, but are connected to each other by numerous fibres. The corpus striatum is also connected: (1) to the cerebral cortex, by what are termed

the *cortico-striate* fibres; (2) to the thalamus, by fibres which pass through the internal capsule, and by a strand named the *ansa lenticularis*; (3) to the crus cerebri, by fibres which leave the lower aspect of the caudate and lenticular nuclei.

The **claustrum** is a thin layer of grey matter, situated on the outer surface of the external capsule. On transverse section it is seen to be triangular, with its apex directed upwards and its base downwards. Its inner surface, which is contiguous to the external capsule, is smooth, but its outer surface presents ridges and furrows which correspond with the convolutions and sulci of the island of Reil, with which it is in close relationship. The claustrum is regarded as a detached portion of the grey matter of the island of Reil, from which it is separated by a layer of white fibres, the *capsula extrema* or *band of Baillarger*. Its cells are small and spindle-shaped, and contain yellow pigment; they are similar to those found in the deepest layer of the cortex.

The **nucleus amygdalæ** is an ovoid mass of grey matter, situated in the roof of the descending horn, at its lower extremity. It is merely a localised thickening of the grey cortex, continuous with that of the uncus; in front it is continuous with the putamen, behind with the tænia semicircularis and the tail of the caudate nucleus.

The **internal capsule** is a flattened band of white fibres, which lies between the lenticular nucleus on the outer side and the caudate nucleus and thalamus on the inner side. In horizontal section (figs. 740, 743) it is seen to be somewhat abruptly curved, with its convexity inwards; the prominence of the curve is called the *genu*, and projects between the caudate nucleus and the thalamus. The portion in front of the genu is termed the *anterior limb* (pars frontalis), and separates the lenticular from the caudate nucleus; the portion behind the genu is the *posterior limb* (pars occipitalis), and separates the lenticular nucleus from the thalamus.

FIG. 743.—Horizontal section of the internal capsule. (Schematic.) (Testut.) Below the horizontal section, there is shown a transverse section of the corresponding crus cerebri.

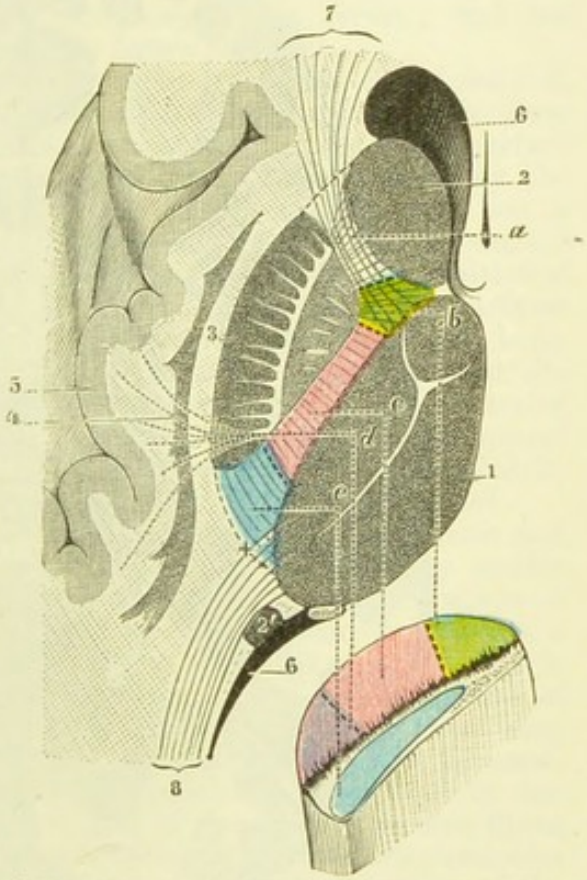

1. Thalamus. 2, 2'. Caudate nucleus. 3. Lenticular nucleus. 4. Claustrum. 5. Island of Reil. 6. Lateral ventricle. 7. Anterior stalk of optic thalamus. 8. Optic radiations. *a*. Anterior segment of internal capsule. *b*. Geniculate bundle (in green). *c*. Pyramidal fibres (in red). *d*. Posterior cortico-pontine fibres. *e*. Fillet.

The anterior limb of the internal capsule contains: (1) fibres which pass from the thalamus to the frontal lobe (cortico-thalamic); (2) fibres connecting the lenticular and caudate nuclei (lenticulo-caudate); (3) fibres connecting the cortex with the corpus striatum (cortico-striate); and (4) fibres passing from the frontal lobe to the nuclei pontis (cortico-pontine). The fibres which occupy the region of the genu are named the *geniculate fibres*; they originate in the motor part of the cerebral cortex, and, after passing downwards in the inner fifth of the crusta, undergo decussation and end in the motor nuclei of the cranial nerves of the opposite side. The anterior two-thirds of the posterior limb contains the *pyramidal fibres*, which arise in the motor area of the cortex and, passing downwards through the middle three-fifths of the crusta, are continued into the pyramids of the medulla. The posterior third of the posterior limb contains: (1) sensory fibres, which are largely derived from the thalamus, but some of which may be continued

upwards from the mesial fillet; (2) the fibres of optic radiation, which pass from the lower visual centres to the cortex of the occipital lobe; (3) auditory fibres, from the lateral fillet to the temporal lobe; and (4) cortico-pontine fibres, which pass from the occipital and temporal lobes to the nuclei pontis.

The fibres of the internal capsule radiate widely as they pass to and from the various parts of the cerebral cortex, forming the *corona radiata* and intermingling with the fibres of the corpus callosum.

The **external capsule** is a lamina of white matter, situated on the outer side of the lenticular nucleus, between it and the claustrum, and continuous with the internal capsule below and behind the lenticular nucleus. It probably contains fibres derived from the thalamus, the anterior white commissure, and the subthalamic region.

Fig. 744.—The fornix and corpus callosum from below. (From a specimen in the Department of Human Anatomy of the University of Oxford.)

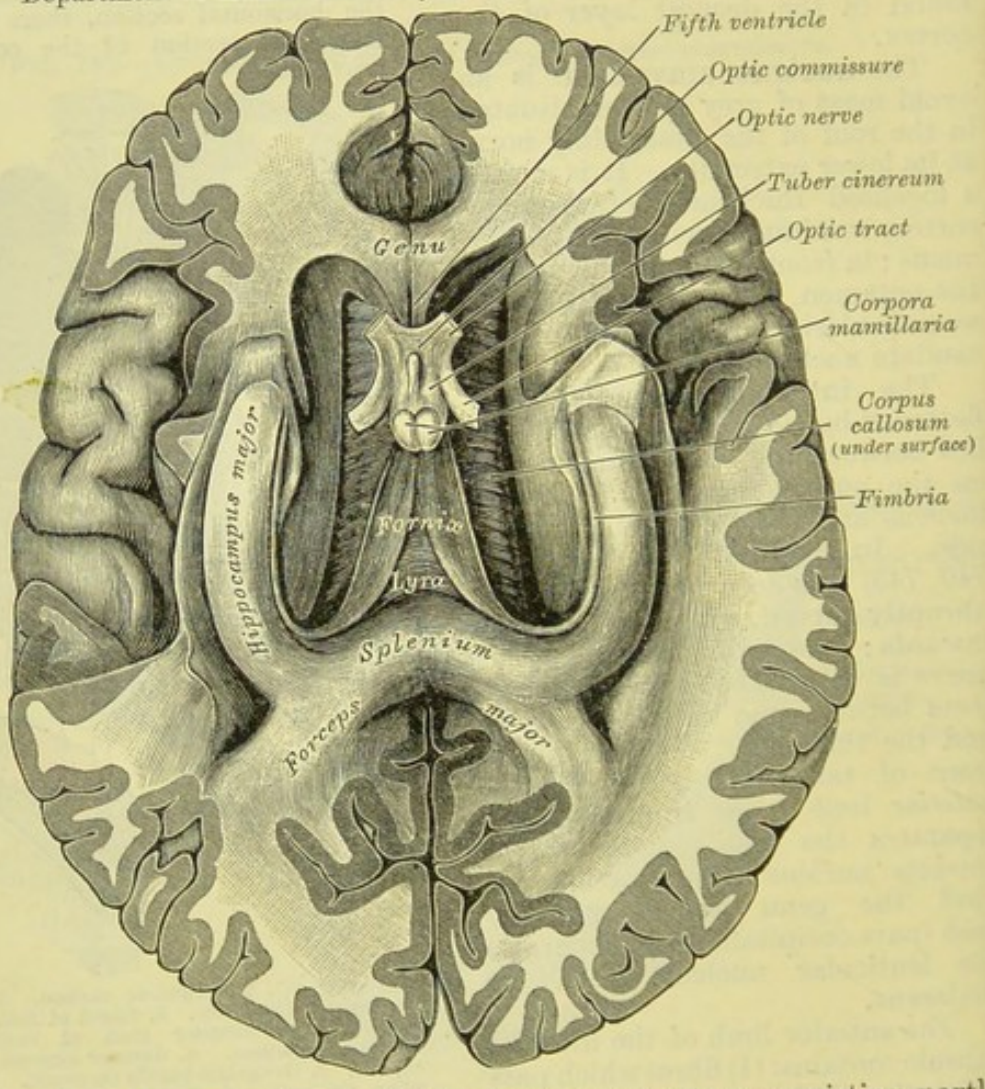

The **substantia innominata of Meynert** is a stratum consisting partly of grey and partly of white matter, which lies below the anterior part of the thalamus and lenticular nucleus. It consists of three layers, superior, middle, and inferior. The *superior* layer is named the *ansa lenticularis*, and its fibres, derived from the medullary lamina of the lenticular nucleus, pass inwards to end in the thalamus and subthalamic region, while others are said to terminate in the tegmentum and red nucleus. The *middle* layer consists of nerve-cells and nerve-fibres: fibres enter it from the parietal lobe through the external capsule, while others are said to connect it with the posterior longitudinal fasciculus. The *lower* layer forms the main part of the inferior stalk of the thalamus, and connects this body with the temporal lobe and the island of Reil.

The **tænia semicircularis** is a narrow, whitish band of medullary substance situated in the depression between the caudate nucleus and the

thalamus. Anteriorly, its fibres are partly continued into the anterior pillar of the fornix; some, however, pass over the anterior commissure to the grey matter between the caudate nucleus and septum pellucidum, while others are said to penetrate the caudate nucleus. Posteriorly, it is continued into the roof of the middle or descending horn of the lateral ventricle, at the extremity of which it enters the *nucleus amygdalæ*. Superficial to it is a large vein, the *vena corporis striati*, which receives numerous tributaries from the corpus striatum and thalamus; it runs forwards to the foramen of Monro and joins with the vein of the choroid plexus to form the corresponding *vena Galeni*. On the surface of the vein of the corpus striatum is a narrow band of white fibres, named the *lamina cornea*.

The **fornix** (figs. 721, 744) is a longitudinal, arch-shaped lamella of white matter, situated below the corpus callosum, with which it is continuous behind, but from which it is separated in front by the septum pellucidum. It may be described as consisting of two symmetrical bands, one for either hemisphere. The two portions are not united to each other in front and behind, but their central parts are joined together in the middle line. The anterior parts are called the *anterior pillars* (*columnæ fornicis*); the intermediate united portions constitute the *body of the fornix*; and the posterior parts are termed the *posterior pillars* (*crura fornicis*).

The *body of the fornix* is triangular, narrow in front, and broad behind. The mesial part of its upper surface is connected to the septum pellucidum in front and to the corpus callosum behind. The lateral portion of this surface forms part of the floor of the lateral ventricle, and is covered by the ventricular epithelium. Its outer edge overlaps the choroid plexuses, and is continuous with the epithelial covering of these structures. The under surface rests upon the velum interpositum, which separates it from the epithelial roof of the third ventricle, and from the inner portions of the upper surfaces of the thalami. When viewed from below the lateral portions of the body of the fornix are seen to be joined by a thin triangular lamina, named the *psalterium* or *lyra*. This lamina contains some transverse fibres which connect the two hippocampi across the middle line and constitute the *hippocampal* commissure. Between the psalterium and the corpus callosum a horizontal cleft, the so-called *ventricle of the fornix* or *ventricle of Verga*, is sometimes found.

The *anterior pillars* arch downwards in front of the foramen of Monro and behind the anterior commissure, and each descends through the grey matter in the lateral wall of the third ventricle to the base of the brain, where it terminates in the corpus albicans. From the cells of the corpus albicans a fasciculus of fibres, termed the *bundle of Vicq d'Azyr*, takes origin and is prolonged into the anterior nucleus of the thalamus. The anterior pillar of the fornix and the bundle of Vicq d'Azyr together form a loop resembling the figure 8, but the continuity of the loop is broken in the corpus albicans. The anterior pillar of the fornix is joined by the stria pinealis and by the superficial fibres of the tænia semicircularis, and is also said to receive fibres from the septum pellucidum. Zuckerkandl describes an *olfactory fasciculus* which becomes detached from the main portion of the anterior pillar of the fornix, and passes downwards in front of the anterior commissure to the base of the brain, where it divides into two bundles, one joining the inner root of the olfactory tract; the other joins the subcallosal gyrus, and through it reaches the hippocampal convolution.

The *posterior pillars* are prolonged backwards from the body of the fornix. They are flattened bands, and at their commencement are intimately connected by their upper surfaces with the under aspect of the corpus callosum. Diverging from one another, each curves round the posterior extremity of the thalamus, and passes downwards and forwards into the descending horn of the lateral ventricle. Here it lies along the concavity of the hippocampus major, on the surface of which some of its fibres are spread out to form the *alveus*, while the remainder are continued as a narrow white band, the *fimbria* or *tænia hippocampi*, which is prolonged into the uncus of the gyrus hippocampi. Its inner edge overlaps the dentate convolution (page 864), from which it is separated by the *fimbrio-dentate fissure*; from its outer margin, which is thin and ragged, the ventricular epithelium is reflected over the choroid plexus as the latter projects into the choroidal fissure.

Foramen of Monro.—Between the anterior pillars of the fornix and the anterior extremities of the thalami, an oval aperture is seen on either side: this is the foramen of Monro and through it the lateral ventricle communicates with the third ventricle. Behind the epithelial lining of the foramen the choroid plexuses of the lateral ventricles are joined across the middle line.

The **anterior commissure** (commissura anterior) is a bundle of white fibres, which connects the two cerebral hemispheres across the middle line, and is placed in front of the anterior pillars of the fornix. On sagittal section it is seen to be oval in shape, its long diameter being vertical in direction and measuring about one-fifth of an inch. Its fibres can be traced outwards and backwards on each side beneath the corpus striatum into the substance of the temporal lobe. It serves in this way to connect the two temporal lobes,

Fig. 745.—The fornix, velum interpositum, and middle or descending cornu of the lateral ventricle.

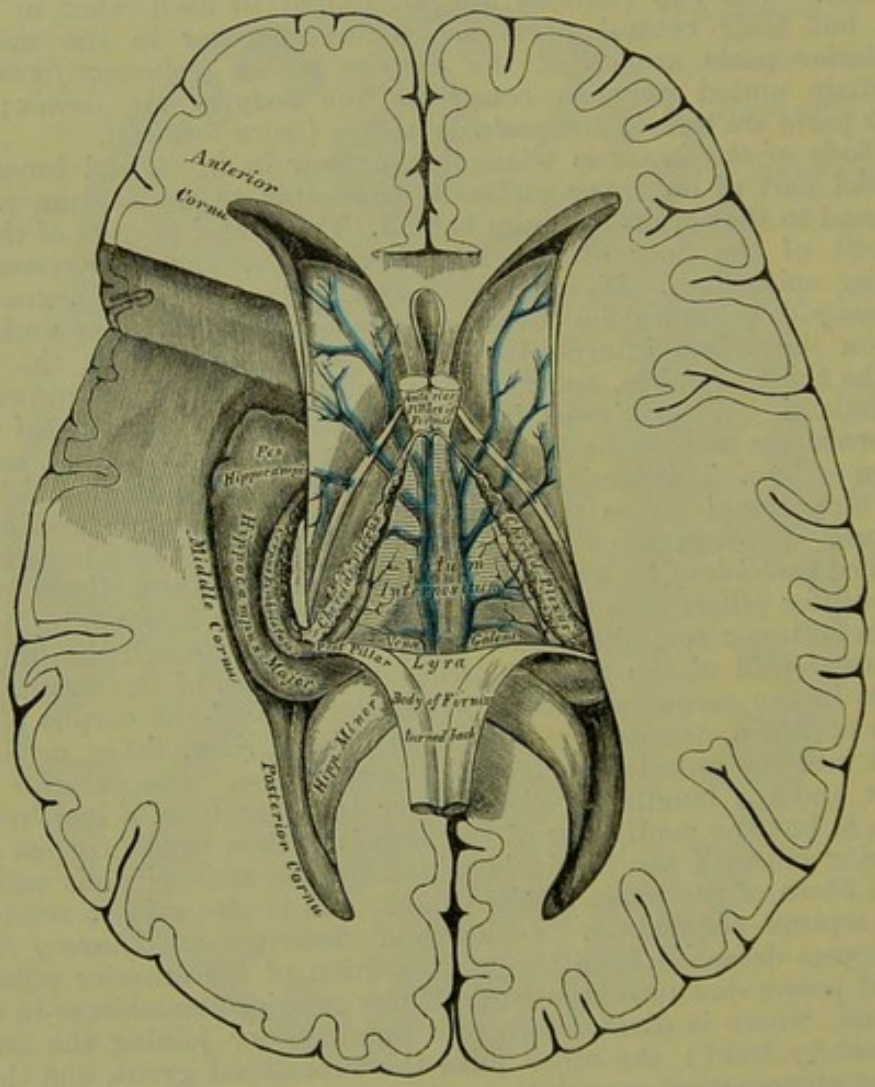

but it also contains fibres from the olfactory tract of the opposite side, the decussation of which in the anterior commissure may serve to explain the condition of crossed anosmia, i.e. a loss of smell in one side of the nose resulting from a lesion in the temporal lobe of the opposite side.

The **septum pellucidum** (*septum lucidum*) is a thin, vertically placed partition. It consists of two distinct laminæ, separated in part of their extent by a narrow chink or interval, the so-called *fifth ventricle*. The outer surface of each lamina is directed towards the body and anterior cornu of the lateral ventricle, and is covered by the ependyma of that cavity, while its mesial surface bounds the cavity of the fifth ventricle. It is a thin, semi-transparent septum, attached, above, to the under surface of the corpus callosum; below, to the anterior part of the fornix behind, and the reflected portion of the corpus callosum in front. It is triangular in form, broad in front and narrow

behind; its inferior angle corresponds with the upper part of the anterior commissure.

The *cavum septi pellucidi* or so-called *fifth ventricle* is generally regarded as part of the great longitudinal fissure, which has become shut off by the union of the hemispheres in the formation of the corpus callosum above and the fornix below. Each half of the septum is therefore formed by the median wall of the hemisphere, and consists of a mesial layer of grey matter, derived from the grey matter of the cortex, and an external layer of white substance continuous with the white matter of the cerebral hemispheres. The fifth ventricle differs from the other ventricles of the brain, inasmuch as it is not developed from the cavity of the cerebral vesicles, is not lined by ciliated epithelium, and does not communicate with the general ventricular cavity.

The **choroid plexus of the lateral ventricle** (plexus chorioideus ventriculi lateralis) (fig. 745) is a highly vascular fringe-like process of pia mater, which appears as if it were contained within the ventricular cavity. The plexus, however, is not actually within the cavity, as it is everywhere covered by a layer of epithelium continuous with the epithelial lining of the ventricle, which therefore shuts it out of the ventricular cavity. It extends from the foramen of Monro, where it is joined with the plexus of the opposite ventricle, to the extremity of the descending horn. The part in relation to the body of

FIG. 746.—Coronal section of descending horn of lateral ventricle. (Diagrammatic.)

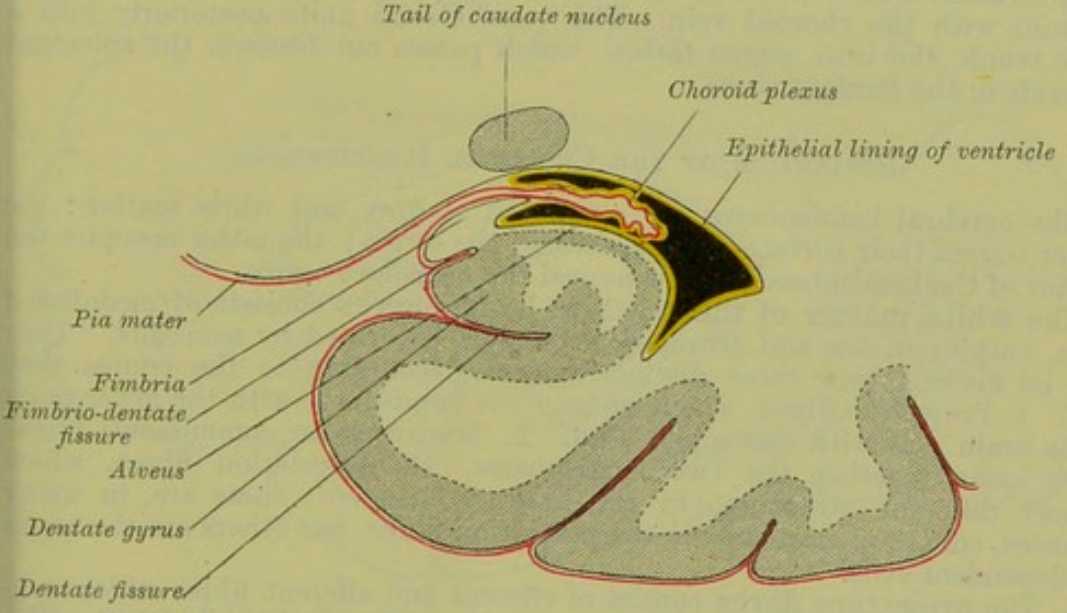

the ventricle forms the vascular fringed margin of a triangular process of pia mater, named the *velum interpositum*, and projects from under cover of the outer edge of the fornix. It lies upon the upper surface of the thalamus, from which the epithelium is reflected over the plexus on to the edge of the fornix. The portion in relation to the descending horn lies in the concavity of the hippocampus major and overlaps the fimbria: from the outer edge of the latter the epithelium is reflected over the plexus on to the roof of the cornu (fig. 746). It consists of minute and highly vascular villous processes, each with an afferent and an efferent vessel. The cells of the epithelium which covers it often contain yellowish fat molecules. The *arteries* of the plexus are: (*a*) the anterior choroidal, a branch of the internal carotid, which enters the plexus at the extremity of the descending horn; and (*b*) the posterior choroidal, one or two small branches of the posterior cerebral, which pass forwards under the splenium. The *veins* of the choroid plexus unite to form a prominent vein, which courses from behind forwards to the foramen of Monro and joins with the vein of the corpus striatum to form the corresponding vein of Galen.

When the choroid plexus is pulled away, the continuity of the epithelium which covers it, with that which lines the ventricle, is severed, and a cleft-like space is produced. This is named the *choroidal fissure*; like the plexus, it extends from the foramen of Monro to the extremity of the descending horn.

The upper part of this fissure, i.e. the part nearest the foramen of Monro, is situated between the lateral edge of the fornix and the upper surface of the thalamus; further back, at the beginning of the descending horn, it is between the commencement of the fimbria and the posterior end of the thalamus, while in the descending horn it lies between the fimbria in the floor and the tænia semicircularis in the roof of the cornu: through this part of the fissure the descending horn opens on to the tentorial surface of the hemisphere.

The **velum interpositum, or tela chorioidea ventriculi tertii** (fig. 745), is a double fold of pia mater, triangular in shape, which lies beneath the fornix. The lateral portions of its lower surface rest upon the thalami, while its mesial portion is in contact with the epithelial roof of the third ventricle. Its apex is situated at the foramen of Monro; its base corresponds with the splenium of the corpus callosum, and occupies the interval between that structure above and the corpora quadrigemina and pineal body below. This interval, together with the lower portions of the choroidal fissures, is sometimes spoken of as the *great transverse fissure* of the brain. At its base the two layers of the velum separate from each other, and are continuous with the pia mater investing the brain in this region. Each of its lateral margins is modified to form the highly vascular fringed structure which constitutes the choroid plexus of the lateral ventricle. It is supplied by the anterior and posterior choroidal arteries already described. The veins of the velum interpositum are named the *venæ Galeni*; they are two in number, and run backwards between its layers, each being formed at the foramen of Monro by the union of the vein of the corpus striatum with the choroid vein. The venæ Galeni unite posteriorly into a single trunk, the *vena magna Galeni*, which passes out beneath the splenium and ends in the straight sinus.

Structure of the Cerebral Hemispheres

The cerebral hemispheres are composed of grey and white matter: the former covers their surfaces, and is termed the *cortex*; the latter occupies the interior of the hemispheres, and is named the *medullary centre*.

The **white matter of the cerebral hemispheres** consists of medullated fibres, varying in size and arranged in bundles, separated by neuroglia. They may be divided into three distinct systems, according to the course they take. 1. Projection fibres, which connect the hemisphere with the lower parts of the brain and with the spinal cord. 2. Transverse or commissural fibres, which unite together the two hemispheres. 3. Association fibres, which connect different structures in the same hemisphere; these are, in many instances, collateral branches of the projection fibres, but others are the axons of independent cells.

1. The **projection fibres** consist of efferent and afferent fibres which connect the cortex with the lower parts of the brain and with the spinal cord. The principal efferent strands are: (1) the motor tract, which occupies the genu and anterior two-thirds of the posterior limb of the internal capsule, and consists of (*a*) the geniculate fibres, which decussate and end in the motor nuclei of the cranial nerves of the opposite side; and (*b*) the pyramidal fibres, which are prolonged through the pyramid of the medulla into the spinal cord: (2) the cortico-pontine fibres, which end in the nuclei pontis. The chief afferent fibres are: (1) those fibres of the fillet which are not interrupted in the thalamus; (2) those fibres of the superior cerebellar peduncles which are not interrupted in the red nucleus and thalamus; (3) the numerous fibres which arise within the thalamus, and pass through its stalks to the different parts of the cortex (page 848); (4) the optic and acoustic fibres, the former passing to the occipital, the latter to the temporal lobe.

2. The **transverse or commissural fibres** connect the two hemispheres. They include: (*a*) the transverse fibres of the corpus callosum, (*b*) the anterior commissure, (*c*) the posterior commissure, and (*d*) the lyra; they have already been described.

3. **Association fibres** (fig. 747).—These connect different parts of the same hemisphere, and are of two kinds: (1) those which unite adjacent convolutions, *short association fibres*; (2) those which pass between more distant parts, *long association fibres*.

The *short association fibres* are situated immediately beneath the grey substance of the cortex of the hemispheres, and connect together adjacent convolutions.

The *long association fibres* include the following : (*a*) the uncinate fasciculus ; (*b*) the cingulum ; (*c*) the superior longitudinal fasciculus ; (*d*) the inferior longitudinal fasciculus ; (*e*) the perpendicular fasciculus ; (*f*) the occipito-frontal fasciculus ; and (*g*) the fornix.

(*a*) The *uncinate fasciculus* passes across the bottom of the Sylvian fissure, and connects the convolutions of the frontal lobe with the anterior end of the temporal lobe.

(*b*) The *cingulum* is a band of white matter which is contained within the callosal convolution. Commencing in front at the anterior perforated space, it passes forwards and upwards parallel with the rostrum, winds round the genu, runs in the convolution from before backwards, immediately above the corpus callosum, turns round its posterior extremity, and passes into the gyrus hippocampi, in the anterior extremity of which it ends.

(*c*) The *superior longitudinal fasciculus* consists of fibres which pass backwards from the frontal lobe above the lenticular nucleus and island of

Fig. 747.—Diagram showing principal systems of association fibres in the cerebrum.

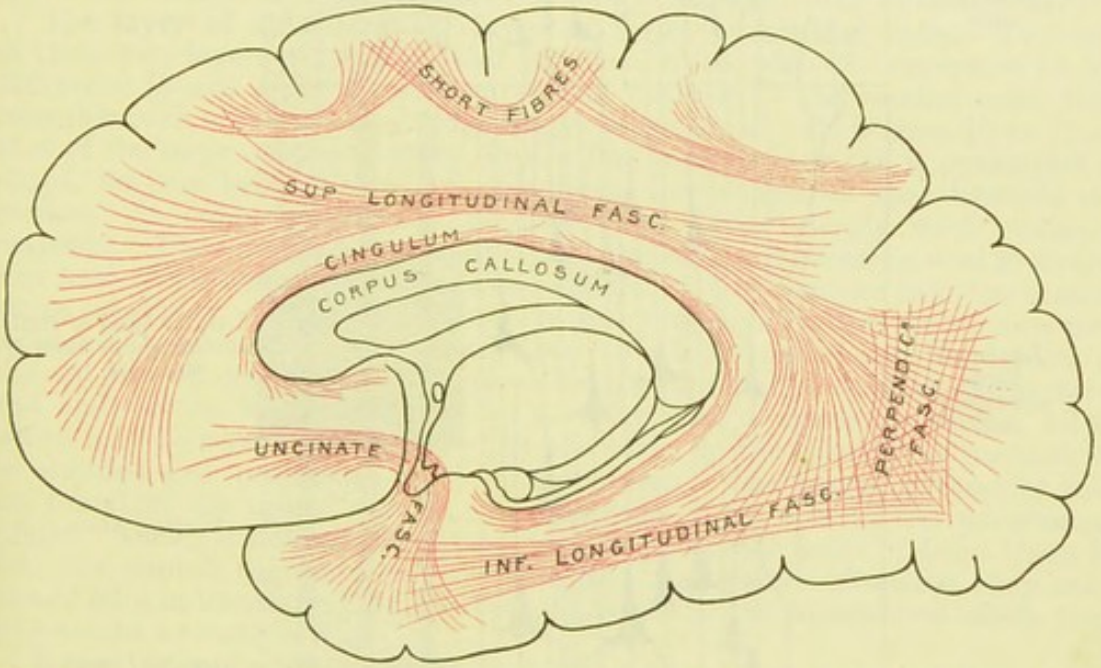

Reil ; some of these terminate in the occipital lobe, while others pass downwards and forwards into the temporal lobe.

(*d*) The *inferior longitudinal fasciculus* is a collection of fibres which connect the temporal and occipital lobes, running along the outer wall of the descending and posterior cornua of the lateral ventricle.

(*e*) The *perpendicular fasciculus* runs vertically through the front part of the occipital lobe, and connects the inferior parietal lobule with the fourth temporal convolution.

(*f*) The *occipito-frontal fasciculus* passes backwards from the frontal lobe, along the outer border of the caudate nucleus, and on the mesial aspect of the corona radiata, and its fibres radiate in a fan-like manner and pass into the occipital and temporal lobes on the outer aspect of the posterior and descending cornua. Déjerine regards the fibres of the tapetum as being derived from this fasciculus, and not from the corpus callosum.

(*g*) The *fornix* connects the hippocampal convolution with the corpus albicans, and, by means of the bundle of Vicq d'Azyr, with the thalamus (see page 875). Through the fibres of the lyra it probably also unites the opposite hippocampal convolutions.

The **grey matter of the hemisphere** is divided into : (1) that of the cerebral cortex, and (2) that of the nucleus caudatus, the nucleus lenticularis, the claustrum, and the nucleus amygdalæ.

Structure of the Cerebral Cortex (fig. 748)

The cerebral cortex differs in its thickness and in its minute structure in different parts of the hemisphere. For instance, it is thinner in the occipital region than in the pre- and postcentral gyri, and it is also much thinner at the bottom of the sulci than on the top of the convolutions. Again, the minute structure of the precentral differs from that of the postcentral gyrus, and areas

Fig. 748.—Cerebral cortex. (Poirier.) To the left, the groups of cells; to the right, the systems of fibres. Quite to the left of the figure a sensory nerve-fibre is shown.

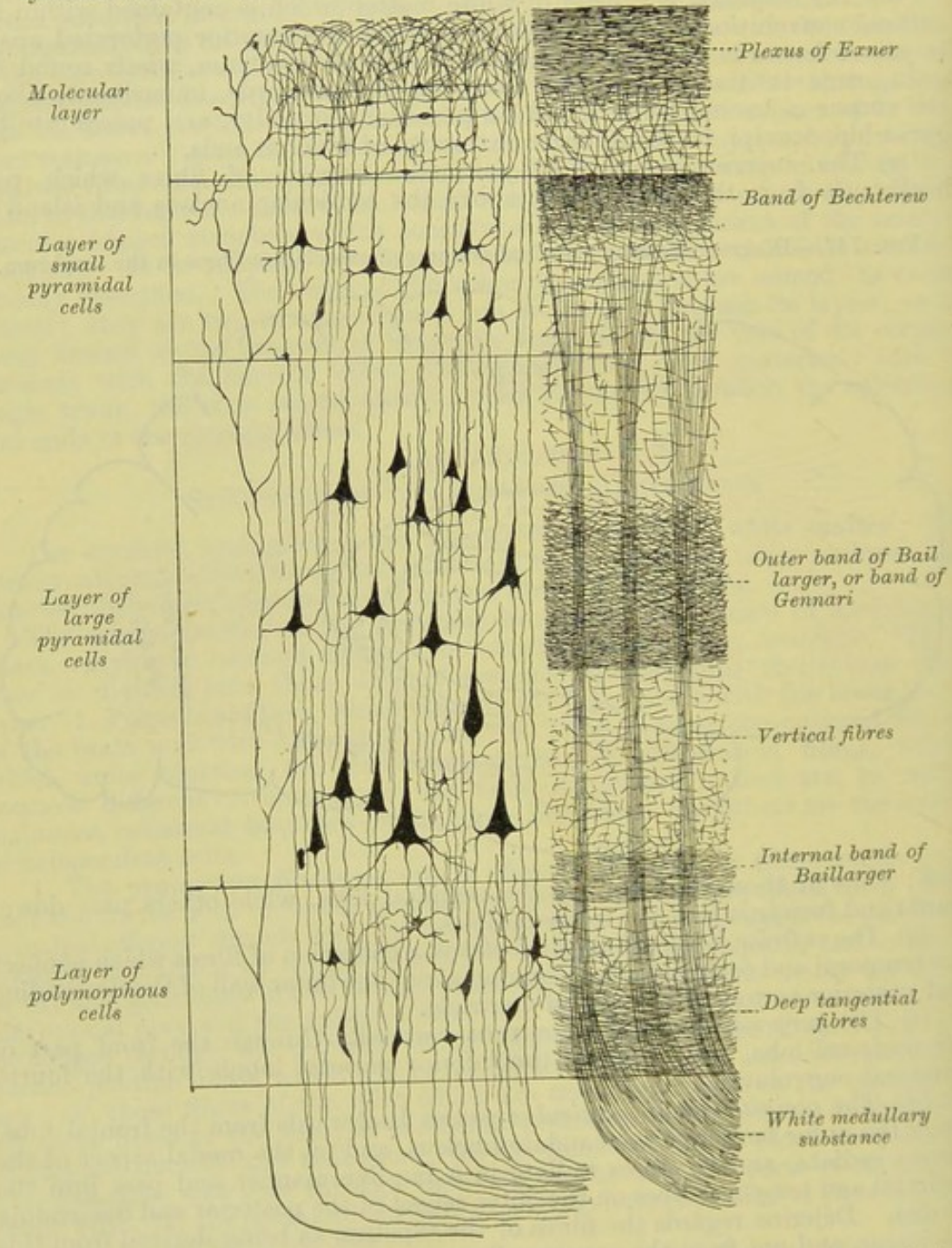

possessing a specialised type of cortex can be mapped out in the occipital lobe.

On examining a section through the cortex with a lens, it is seen to consist of alternating white and grey layers thus disposed from the surface inwards: (1) a thin layer of white substance; (2) a layer of grey substance; (3) a second layer of white substance (outer band of Baillarger or band of Gennari); (4) a second grey layer; (5) a third white layer (inner band of

Baillarger) ; (6) a third grey layer, which rests on the medullary substance of the convolution.

The cortex is made up of nerve-cells which vary in size and shape, and of nerve-fibres which are either medullated or naked axis-cylinders, imbedded in a matrix of neuroglia.

Nerve-cells.—According to Cajal, whose description is now generally accepted, the nerve-cells are arranged in four layers, named from the surface inwards as follows ; (1) the molecular layer, (2) the layer of small pyramidal cells, (3) the layer of large pyramidal cells, (4) the layer of polymorphous cells.

The molecular layer.—In this layer the cells are polygonal, triangular, or fusiform in shape. Each polygonal cell gives off some four or five dendrites, while its axon may arise directly from the cell or from one of its dendrites. The axons and dendrites of these cells ramify in the molecular layer. Each triangular cell gives off two or three dendrites, from one of which the axon arises, the dendrites and the axon ramifying in the molecular layer. The fusiform cells are placed with their long axes parallel to the surface and are mostly bipolar, each pole being prolonged into a dendrite, which runs horizontally for some distance and furnishes ascending branches. Their axons, two or three in number, arise from the dendrites, and, like them, take a horizontal course, giving off numerous ascending collaterals. The distribution of the axons and dendrites of all three sets of cells is limited to the molecular layer.

The layer of small and the layer of large pyramidal cells.—The cells in these two layers may be studied together, since, with the exception of the difference in size and the more superficial position of the smaller cells, they resemble each other. The average length of the small cells is from 10 to 15 μ ; that of the large cells from 20 to 30 μ. The body of each cell is pyramidal in shape, its base being directed to the deeper parts and its apex towards the surface. It contains granular pigment, and stains deeply with ordinary reagents. The nucleus is nucleolated, of large size, and round or oval in shape. The base of the cell gives off the axis-cylinder, and this passes into the central white substance, giving off collaterals in its course, and is distributed as a projection, commissural, or association fibre. Both the apical and basal parts of the cell give off dendrites. The apical dendrite is directed towards the surface, and ends in the molecular layer by dividing into numerous branches, all of which may be seen, when prepared by the silver or methylene-blue method, to be studded with projecting bristle-like processes. The largest pyramidal cells are found in the upper part of the precentral gyrus and in the paracentral lobule. These, which are often arranged in groups or nests of from three to five, are named the *giant-cells of Betz*. In the former situation they may exceed 50 μ in length and 40 μ in breadth, while in the paracentral lobule they may attain a length of 65 μ.

Layer of polymorphous cells.—The cells in this layer, as their name implies, are very irregular in contour ; they may be fusiform, oval, triangular, or star-shaped. Their dendrites are directed outwards, towards, but do not reach, the molecular layer ; their axons pass into the subjacent white matter.

There are two other kinds of cells in the cerebral cortex, but their axons pass in a direction opposite to that of the pyramidal and polymorphous cells, among which they lie. They are : (*a*) the *cells of Golgi*, the axons of which do not become medullated, but divide, immediately after their origins, into a large number of branches, which are directed towards the surface of the cortex ; (*b*) the *cells of Martinotti*, which are chiefly found in the polymorphous layer. Their dendrites are short, and may have an ascending or descending course, while their axons pass out into the molecular layer and form an extensive horizontal arborisation.

Nerve-fibres.—These fill up a large part of the intervals between the cells, and may be medullated or non-medullated—the latter comprising the axons of the smallest pyramidal cells and the cells of Golgi. In their direction the fibres may be either transverse (tangential or horizontal) or vertical (radial). The *tangential fibres* run parallel to the surface of the hemisphere, intersecting the vertical fibres at a right angle. They constitute several strata, of which the following are the most important : (1) a stratum of white fibres covering the superficial aspect of the molecular layer (plexus of Exner) ; (2) the band of Bechterew, which is situated in the outer part of the layer of small

pyramidal cells ; (3) the external band of Baillarger (band of Gennari or band of Vicq d'Azyr), which runs through the layer of large pyramidal cells ; (4) the internal band of Baillarger, which intervenes between the layer of large pyramidal cells and the polymorphous layer ; (5) the deep tangential fibres which lie in the lower part of the polymorphous layer. According to Cajal, the transverse fibres consist of (*a*) the collaterals of the pyramidal and polymorphous cells and of the cells of Martinotti ; (*b*) the arborisations of the axons of Golgi's cells ; (*c*) the collaterals and terminal arborisations of the projection, commissural, or association fibres. *The vertical fibres.*—Some of these, viz. the axons of the pyramidal and polymorphous cells, are directed towards the central white matter, while others, the terminations of the projection, commissural, or association fibres, pass outwards to end in the cortex. The axons of the cells of Martinotti are also ascending fibres.

Special Types of Cerebral Cortex

It has been already pointed out that the minute structure of the cortex differs in different regions of the hemisphere ; and A. W. Campbell * has endeavoured to prove, as the result of an exhaustive examination of a series of human and anthropoid brains, 'that there exists a direct correlation between physiological function and histological structure.' The principal regions where the 'typical' structure is departed from will now be referred to.

1. In the calcarine fissure and the convolutions bounding it, the inner band of Baillarger is absent, while the band of Gennari is of considerable thickness, and forms a characteristic feature of this region of the cortex. If a section be examined microscopically, an additional layer is seen to be interpolated between the molecular layer and the layer of small pyramidal cells. This extra layer consists of two or three strata of fusiform cells, the long axes of which are at right angles to the surface. Each cell gives off two dendrites, external and internal, from the latter of which the axon arises and passes into the white central substance. In the layer of small pyramidal cells, fusiform cells, identical with the above, are seen, as well as ovoid or star-like cells with ascending axons (cells of Martinotti). This is the *visual area* of the cortex, and it has been shown by J. S. Bolton † that in old-standing cases of optic atrophy the thickness of Gennari's band is reduced by nearly 50 per cent.

A. W. Campbell says : 'Histologically, two distinct types of cortex can be made out in the occipital lobe. The first of these coats the walls and bounding convolutions of the calcarine fissure, and is distinguished by the well-known line of Gennari or Vicq d'Azyr ; the second area forms an investing zone a centimetre or more broad around the first, and is characterised by a remarkable wealth of fibres, as well as by curious pyriform cells of large size richly stocked with chromophilic elements—cells which seem to have escaped the observation of Ramón y Cajal, Bolton, and others who have worked at this region. As to the functions of these two regions there is abundant evidence, anatomical, embryological, and pathological, to show that the first or calcarine area is that to which visual sensations primarily pass, and we are gradually obtaining proof to the effect that the second investing area is constituted for the interpretation and further elaboration of these sensations. These areas therefore deserve the names *visuo-sensory* and *visuo-psychic*.'

2. The precentral gyrus is characterised by the presence of the giant-cells of Betz and by 'a wealth of nerve-fibres immeasurably superior to that of any other part' (Campbell), and in these respects differs from the postcentral gyrus. These two gyri, together with the paracentral lobule, have long been regarded as containing the 'motor areas' of the hemisphere ; but Sherrington and Grünbaum have shown ‡ that in the chimpanzee the motor area never extends on to the free face of the postcentral convolution, but 'occupies unbrokenly the whole length of the precentral convolution, and in most cases the greater part or the whole of its width. It extends into the depth of the Rolandic fissure, occupying the anterior wall, and in some places the floor, and in some extending even into the deeper part of the posterior wall of the fissure.'

* *Histological Studies on the Localisation of Cerebral Function*, Cambridge University Press.
† *Phil. Trans. of Royal Society*, Series B, vol. cxciii. p. 165.
‡ *Transactions of the Pathological Society of London*, vol. liii.

3. In the hippocampus major the molecular layer is very thick and contains a large number of Golgi cells. It has been divided into three strata: (*a*) s. convolutum or s. granulosum, containing many tangential fibres; (*b*) s. lacunosum, presenting numerous lymphatic or vascular spaces; (*c*) s. radiatum, exhibiting a rich plexus of fibrils. The two layers of pyramidal cells are condensed into one, and the cells are mostly of large size. The axons of the cells in the polymorphous layer may run in an ascending, a descending, or a horizontal direction. Between the polymorphous layer and the ventricular ependyma is the white substance of the alveus.

4. In the rudimentary dentate convolution the molecular layer contains some pyramidal cells, while the layer of pyramidal cells is almost entirely represented by small ovoid cells.

5. The olfactory bulb.—In many of the lower animals this contains a cavity which communicates through the hollow olfactory stalk with the lateral ventricle. In man the original cavity is filled up by neuroglia and its wall becomes thickened, but much more so on its ventral than on its dorsal aspect. Its dorsal part contains a small amount of grey and white matter, but it is scanty and ill defined. A section through the ventral part (fig. 749) shows it to consist of the following layers from without inwards: (1) A layer of olfactory

FIG. 749.—Coronal section of olfactory bulb. (Schwalbe.)

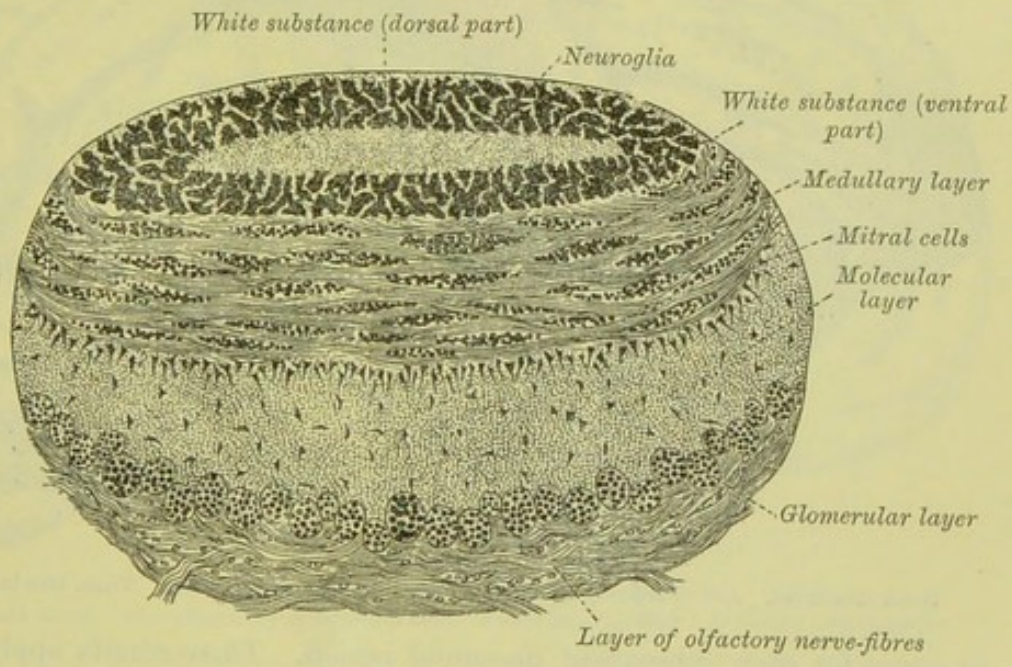

nerve-fibres, which are the non-medullated axons prolonged from the olfactory cells of the nose, and which reach the bulb by passing through the cribriform plate of the ethmoid bone. At first they cover the bulb, and then penetrate it to end by forming synapses with the dendrites of the mitral cells, presently to be described. (2) *Glomerular layer.*—This contains numerous spheroidal reticulated enlargements, termed *glomeruli*, which are produced by the branching and arborisation of the processes of the olfactory nerve-fibres with the descending dendrite of the mitral cells. (3) *Molecular layer.*—This is formed of a matrix of neuroglia, imbedded in which are the *mitral cells.* These cells are pyramidal in shape, and the basal part of each gives off a thick dendrite which descends into the glomerular layer, where it arborises as indicated above, and others which interlace with similar dendrites of neighbouring mitral cells. The axons pass through the next layer into the white matter of the bulb, from which, after becoming bent on themselves at a right angle, they are continued into the olfactory tract. (4) *Nerve-fibre layer.*—This lies next the central core of neuroglia, and its fibres consist of the axons or afferent processes of the mitral cells which are passing to the brain; some efferent fibres are, however, also present, and terminate in the molecular layer, but nothing is known as to their exact origin.

Weight of the encephalon.—The average weight of the brain, in the adult male, is 49½ oz., or a little more than 3 lb. avoirdupois; that of the female, 44 oz.; the average difference between the two being from 5 to 6 oz. The prevailing weight of the brain, in the male, ranges between 46 oz. and 53 oz.; and, in the female, between 41 oz. and 47 oz. In the male, the maximum weight out of 278 cases was 65 oz. and the minimum weight 34 oz. The maximum weight of the adult female brain, out of 191 cases, was 56 oz., and the minimum weight 31 oz. According to Luschka, the average weight of a man's brain is 1,424 grammes (about 45 oz.), of a woman's 1,272 grammes (about 41 oz.); and according to Krause, 1,570 grammes (about 48½ oz.) for the male, and 1,350 grammes (about 43 oz.) for the female. It appears that the weight of the brain increases rapidly up to the seventh year, more slowly to between sixteen and twenty, and still more slowly to between thirty and forty, when it reaches its maximum. As age further advances and the mental faculties decline, the brain diminishes slowly in weight, to the extent of about

FIG. 750.—Areas of localisation on outer surface of hemisphere.

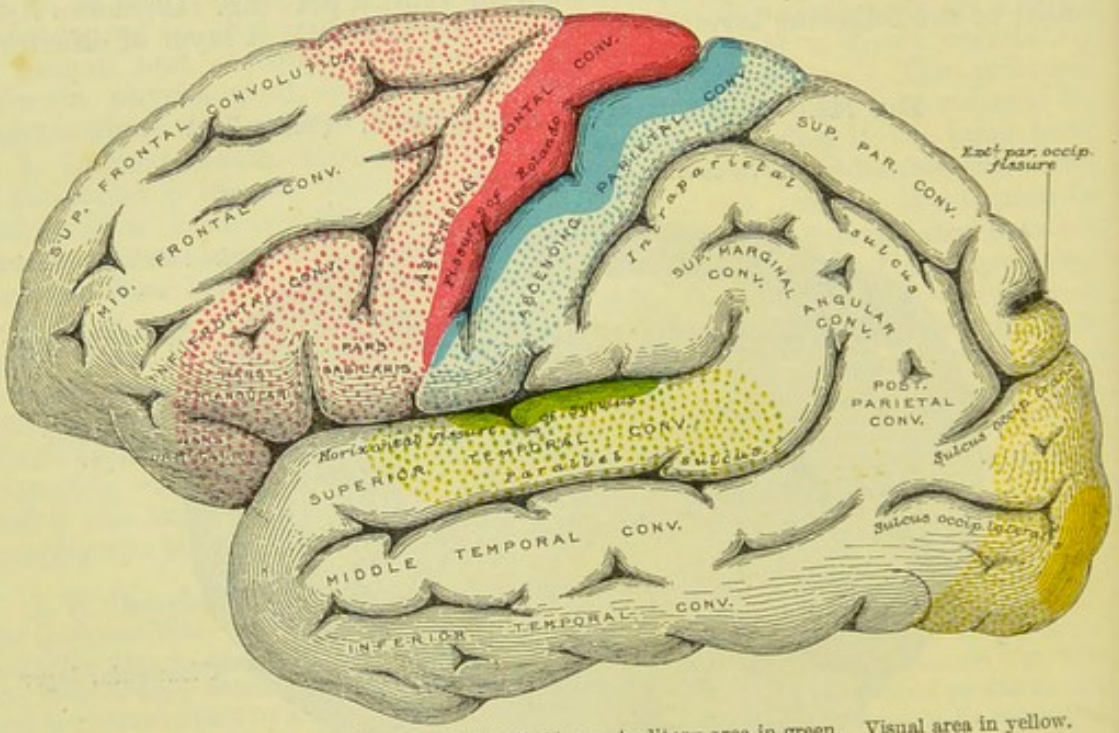

Motor area in red. Area of ordinary sensation in blue. Auditory area in green. Visual area in yellow.

an ounce for each subsequent decennial period. These results apply alike to both sexes.

The size of the brain was formerly said to bear a general relation to the intellectual capacity of the individual. Cuvier's brain weighed rather more than 64 oz., that of the late Dr. Abercrombie 63 oz., and that of Dupuytren 62½ oz. But these facts are by no means conclusive, and it is well known that these weights have been equalled by the brains of persons who never displayed any remarkable intellect. Haldennan, of Cincinnati, has recorded the case of a mulatto, aged 45, whose brain weighed 68⅜ oz.; he had been a slave, and was never regarded as particularly intelligent; he was illiterate, but is said to have been reserved, meditative, and economical. Ensor, district medical officer at Port Elizabeth, reports that the brain of Carey, the Irish informer, weighed 61 oz. On the other hand, the brain of an idiot seldom weighs more than 23 oz. M. Nikiforoff has published an article on the subject of the weight of brains in the 'Novosti.' According to him, the weight of the brain has no influence whatever on the mental faculties. It ought to be remembered that the significance of the weight of the brain should depend upon the proportion it bears to the dimensions of the whole body and to the age of the individual. It is equally important to know what was the cause of death, for long illness or old age exhausts the brain. To define the real degree of development of the brain, it is therefore necessary to have a knowledge of

the condition of the whole body; and, as this is usually lacking, the mere record of weight possesses little significance.

The human brain is heavier than that of any of the lower animals, except the elephant and whale. The brain of the former weighs from eight to ten pounds; and that of a whale, in a specimen seventy-five feet long, weighed rather more than five pounds.

Cerebral Localisation.—Physiological and pathological research have now gone far to prove that a considerable part of the surface of the brain may be mapped out into a series of more or less definite areas, each of which is intimately connected with some well-defined function.

The chief areas are indicated in figs. 750 and 751.

Motor areas.—The motor area occupies the precentral and frontal gyri and the paracentral lobule. The centres for the lower limb are located on the uppermost part of the precentral gyrus and its continuation on to the paracentral lobule; those for the trunk are on the upper portion, and those for the upper limb on the middle portion of the precentral gyrus. The facial centres are situated on the lower part of the precentral gyrus, those for the tongue, larynx, muscles of mastication, and pharynx on the frontal opercula, while those for the head and neck occupy the posterior end of the mid-frontal region.

FIG. 751.—Areas of localisation on inner surface of hemisphere.

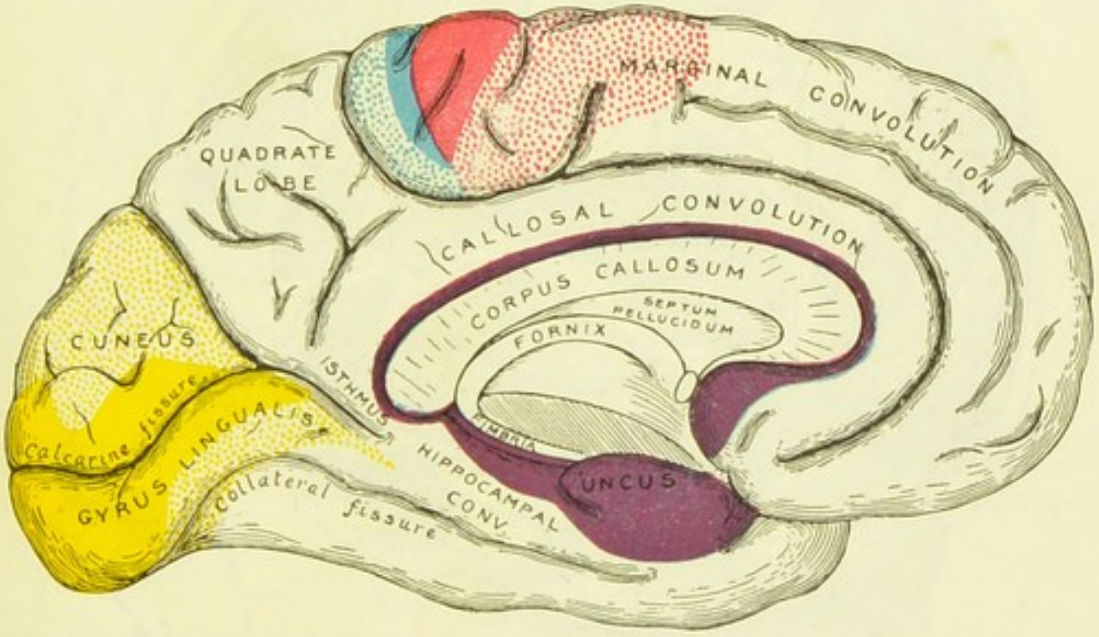

Motor area in red. Area of ordinary sensation in blue. Visual area in yellow. Olfactory area in purple.

Sensory areas.—Tactile and temperature senses are located on the postcentral gyrus, while the sense of form and solidity is on the superior parietal gyrus and precuneus. With regard to the special senses, the area for the sense of taste is probably related to the uncus and hippocampal gyrus. The auditory area occupies the middle third of the superior temporal gyrus and the adjacent gyri in the Sylvian fissure; the visual area, the calcarine fissure and cuneus; the olfactory area, the rhinencephalon. As special centres of much importance may be noted: the emissive centre for speech on the left inferior frontal and precentral gyri; the auditory receptive centre on the marginal and superior temporal gyri, and the visual receptive centre on the angular gyrus.

Cerebral Topography.—The relation of the principal fissures and convolutions of the cerebrum to the outer surface of the scalp has been the subject of much investigation, and many systems have been devised by which one may localise these parts from an examination of the external surface of the head (fig. 752).

These plans can only be regarded as approximately correct for several reasons: in the first place, because the relations of the convolutions and sulci to the surface vary in different individuals; secondly, because the surface area of the scalp is greater than the surface area of the brain, so that lines drawn on the one cannot correspond exactly to sulci or convolutions on the other; and thirdly, because the sulci and convolutions in two individuals are never precisely alike. Nevertheless, the principal fissures and convolutions can be mapped out with sufficient accuracy for all practical purposes, so that any particular convolution can be exposed by removing with the trephine a certain portion of the skull.

The various landmarks on the outside of the skull, which can be easily felt, and which serve as indications of the position of the parts beneath, have been already referred to (see page 280), but there are certain other points or landmarks which require alluding to, in order to facilitate the description of the relation of the fissures and convolutions of the brain to the external surface of the skull.

A line drawn horizontally backwards from the middle of the infra-orbital margin, through the centre of the outlet of the external auditory meatus, will represent what is known as *Reid's base-line*. A spot on this base-line in the hollow between the tragus of the ear and the condyle of the mandible is known as the *pre-auricular point*.

The longitudinal fissure.—This corresponds to a line drawn from the nasion to the inion.

The Sylvian fissure.—In order to mark out this fissure, a point must be defined by carrying horizontally backwards a line for $1\frac{3}{8}$ of an inch (thirty-five millimetres) from the

Fig. 752.—Drawing of a cast by Cunningham to illustrate the relations of the brain to the skull.

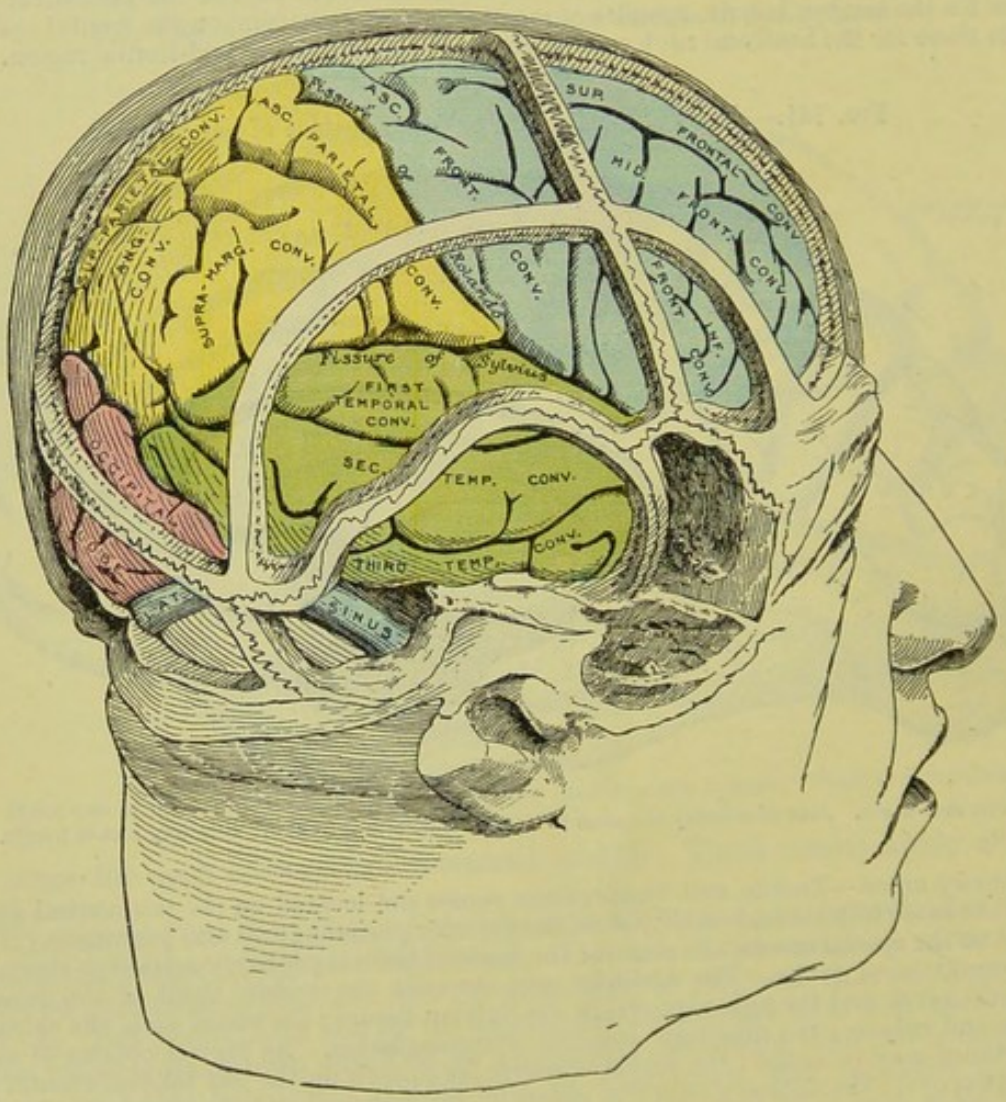

external angular process of the frontal bone, and from the posterior extremity of this line a vertical line upwards for half an inch (twelve millimetres); the upper end of this second line is the point in question, and is known as the *Sylvian point*. It marks the spot where the Sylvian fissure divides. Another and simple plan of defining the Sylvian point has been devised by E. H. Taylor. He divides the distance between the nasion and inion into four equal parts, and draws one line from the junction of the third and fourth parts, reckoning from before backwards, to the external angular process of the frontal bone; and a second line, from the junction of the first and second segments to the centre of the external auditory meatus. The Sylvian point will be the spot where these two lines cross one another, and the first line from this point onwards will lie over the posterior limb of the fissure of Sylvius. The *Sylvian line*—that is to say, the line on the surface of the skull which lies over the posterior limb of the fissure of Sylvius—is usually marked out by drawing a line from the Sylvian point to the lower part of the parietal

eminence. The ascending limb of the fissure of Sylvius may be marked out by drawing a line upwards, at right angles to the Sylvian line, for nearly an inch (two centimetres); and the horizontal limb by a line of the same length, drawn horizontally forwards from the same point.

The fissure of Rolando.—Thane defines this fissure by taking the centre of a line between the nasion and the inion and fixes the *superior Rolandic point* at half an inch behind this. The *inferior Rolandic point* is defined by drawing a line at right angles to the base-line of Reid, from the pre-auricular point to the Sylvian line; this it meets about an inch from the Sylvian point. By joining these two points, the *Rolandic line*, which overlies the fissure of Rolando, is mapped out. It forms an angle opening forwards, of about seventy degrees with the median line. Reid has devised another plan for mapping out this fissure. He draws two perpendicular lines from the base-line to the top of the head; one from the pre-auricular point, and the other from the posterior border of the mastoid process at its root. A line drawn from the upper extremity of the posterior

FIG. 753.—Relations of the brain and middle meningeal artery to the surface of the skull.

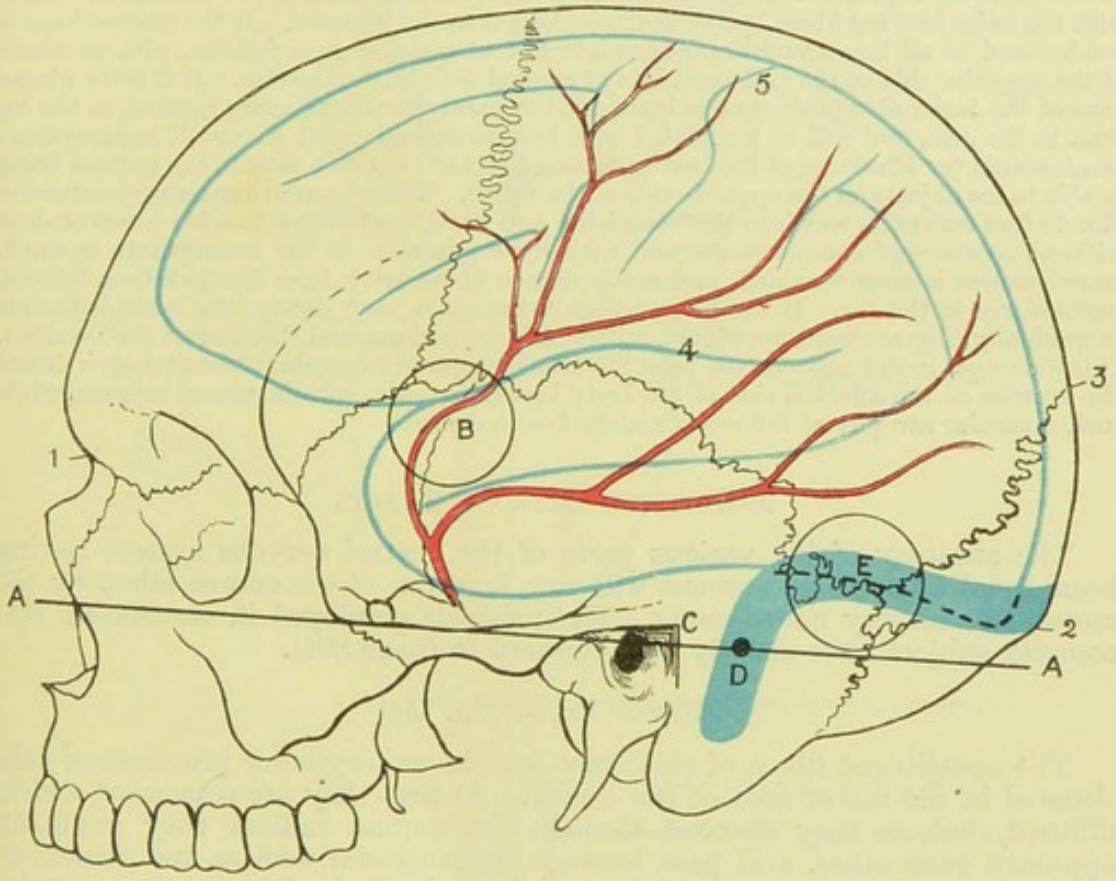

1, Nasion; 2, Inion; 3, Lambda; 4, Fissure of Sylvius; 5, Fissure of Rolando. AA, Reid's base line; B, Point for trephining the anterior branch of the middle meningeal artery; C, Suprameatal triangle; D, Sigmoid bend of the lateral sinus; E, Point for trephining over the straight portion of the lateral sinus, exposing dura mater of both cerebrum and cerebellum. Outline of cerebral hemisphere indicated in blue; course of middle meningeal artery in red.

line to the point where the Sylvian line crosses the anterior one would indicate the position of the fissure of Rolando.

The *external parieto-occipital fissure* runs outwards at right angles to the great longitudinal fissure for about an inch, from a point one-fifth of an inch in front of the lambda (posterior fontanelle). Reid states that if the posterior limb of the fissure of Sylvius be continued backwards to the sagittal suture, the last inch of this line will indicate the position of the sulcus.

The *precentral* and *postcentral sulci* are situated three-fifths of an inch in front of and behind the Rolandic fissure respectively; they are nearly parallel with this fissure, and extend as low as the Sylvian line.

The *superior frontal fissure* may be mapped out by drawing a line from the junction of the upper and middle third of the precentral sulcus, in a direction parallel with the longitudinal fissure, to a point midway between the middle line of the forehead and the temporal ridge, an inch and a half above the supra-orbital notch.

The *inferior frontal fissure* follows the course of the superior temporal ridge, commencing at the junction of the middle and lower thirds of the precentral sulcus.

The *intraparietal fissure* begins on a level with the junction of the middle and lower third of the fissure of Rolando, on a line carried across the head from the back of the root of one auricle to that of the other. After passing upwards, it curves backwards, lying parallel to the longitudinal fissure, midway between it and the parietal eminence; it then curves downwards to end midway between the lambda and the parietal eminence.

The *lateral ventricles* may be circumscribed, according to Poirier, by describing a quadrilateral figure on the side of the head. The upper limit is a horizontal line drawn two inches above and parallel with the zygoma: this defines the roof of the ventricular cavity. The lower limit is a second horizontal line drawn half an inch above the zygoma: this indicates the level of the extremity of the descending horn of the ventricle. Two vertical lines—one drawn through the junction of the anterior and middle thirds of the zygomatic arch, and the other two inches behind the tip of the mastoid process—indicate the extent of the anterior horn in front and the posterior horn behind.

Applied Anatomy.—The *internal capsule* is of great interest to the clinician because it is so often the seat of hæmorrhage (from the lenticulo-striate and lenticulo-optic arteries, Charcot's 'arteries of cerebral hæmorrhage'), or of thrombosis, in patients whose vessels are weakened by old age or disease. A 'stroke,' or 'apoplexy' is the result; blood is effused from the ruptured vessel and tears up the surrounding brain tissue, and also interferes with the neighbouring fibres by the compression set up by its mass. If the hæmorrhage is sudden and at all large, rapid and complete loss of consciousness follows, with paralysis of the opposite side of the body and loss of control over the sphincters. If it is the hinder part of the internal capsule that is involved, the paralysis will be more marked in the leg than in the arm, and will be associated with hemianæsthesia, and also with homonymous hemianopsia (or blindness of the corresponding halves of the two retinæ, the patient being unable to see objects on the opposite side of the body). If the hæmorrhage is very extensive blood often makes its way into the ventricles, and death may follow in a few hours or days without recovery of consciousness, and with hyperpyrexia. If the hæmorrhage is small, consciousness is soon regained, and a fair degree of recovery from the paralysis follows, particularly in the leg. If the hæmorrhage takes place very slowly, the hemiplegia sets in gradually (ingravescent apoplexy), with headache and gradual clouding of the faculties. It is the upper motor neuron (see page 889) that is injured in cerebral hæmorrhage; hence the muscles on the affected side of the body become spastic, with increased reflexes, while such muscular atrophy as follows is mainly due to disuse.

Motor and Sensory Tracts

The anatomy of the various parts of the central nervous system having been described, a short account will now be given of the course taken by the motor and sensory nerve-tracts. The methods employed in elucidating this complex subject have already been referred to (page 804).

Motor Tract (fig. 754)

The constituent fibres of this tract are the axis-cylinder processes of cells situated in the motor area of the cortex. At first they are somewhat widely diffused, but as they descend through the corona radiata they gradually approach each other, and pass between the lenticular nucleus and thalamus, in the genu and anterior two-thirds of the posterior limb of the internal capsule; those which occupy the genu are named the geniculate fibres, while the remainder constitute the pyramidal fibres. Proceeding downwards they enter the crusta or pes of the crus cerebri, the pyramidal fibres occupying the middle three-fifths, and the geniculate fibres the innermost fifth of this structure. The geniculate fibres then decussate in the middle line with the corresponding fibres of the opposite side, and end by arborising around the cells of the motor nuclei of the cranial nerves. The pyramidal fibres are continued downwards into the anterior pyramids of the medulla, and the transit of the fibres from the medulla is effected by two paths. The fibres nearest to the anterior median fissure cross the middle line, forming the *decussation of the pyramids*, and descend in the opposite side of the cord, as the indirect or crossed pyramidal tract. Throughout the length of the spinal cord fibres from this column pass into the grey matter, to terminate by ramifying around the cells of the anterior horn. The more laterally placed portion of the motor tract does not decussate in the medulla, but descends as the direct or uncrossed pyramidal tract; these fibres, however, end in the anterior grey horn of the opposite side of the spinal cord by passing across in the anterior white commissure. There is considerable variation in the extent to which decussation takes place in the medulla, the commonest condition being that in which about two-thirds or

three-fourths of the fibres decussate in the medulla and the remainder in the cord.

The axons of the motor cells in the anterior horn pass out as the fibres of the anterior roots of the spinal nerves, along which the impulses are conducted to the muscles of the trunk and limbs.

From this it will be seen that all the fibres of the motor tract pass to the nuclei of the motor nerves on the opposite side of the brain or cord, a fact

FIG. 754.—The motor tract. (Modified from Poirier.)

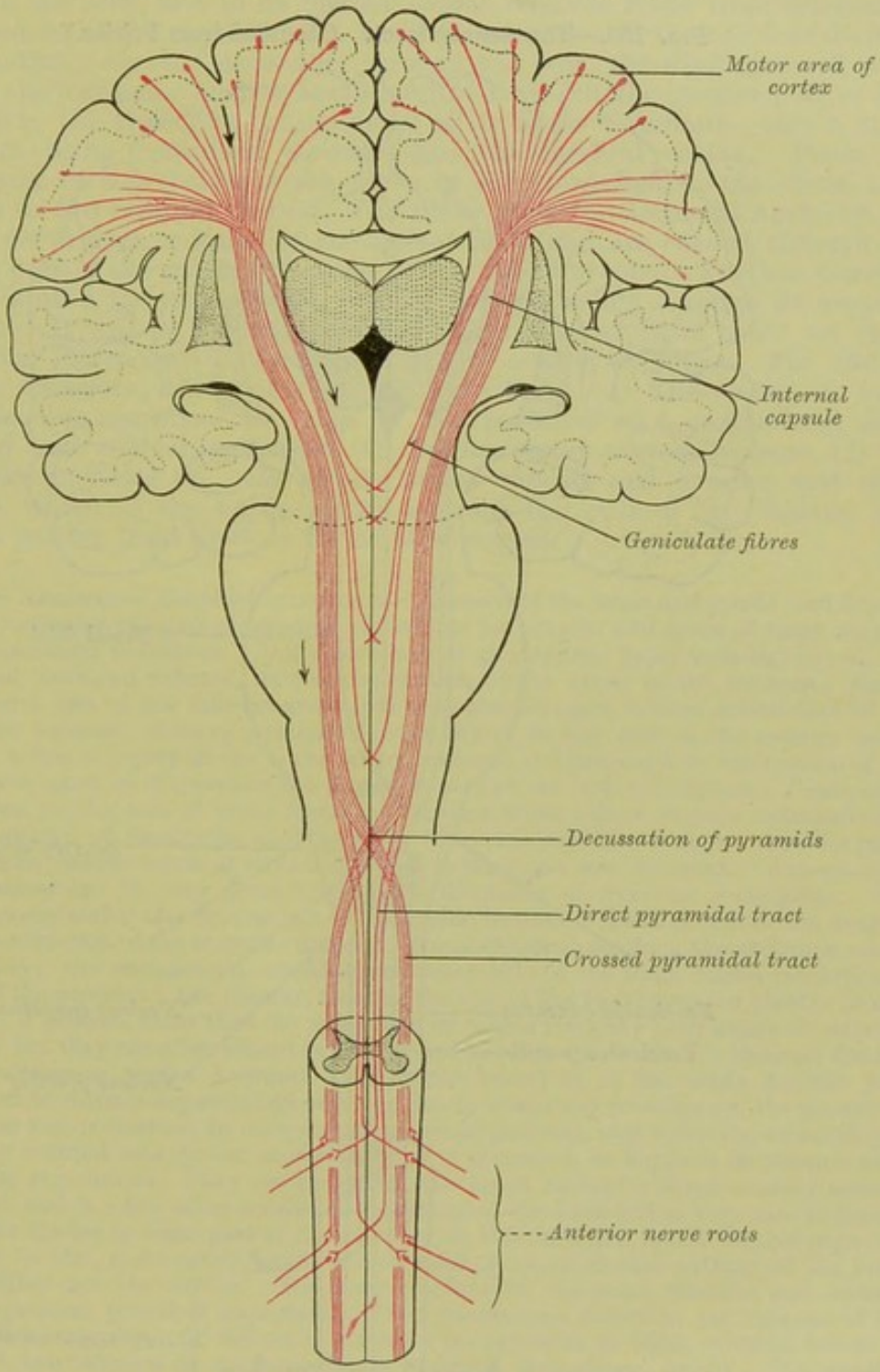

which explains why a lesion involving the motor area of one side causes paralysis of the muscles of the opposite side of the body. Further, it will be seen that there is a break in the continuity of the motor chain: in the case of the cranial nerves this break occurs in the nuclei of these nerves; and in the case of the spinal nerves, in the anterior horn of grey matter. For clinical purposes it is convenient to emphasise this break and divide the motor tract into two portions: (1) a series of *upper motor neurons* which comprises the motor cells in the

cortex and their descending fibres down to the nuclei of the motor nerves; (2) a series of *lower motor neurons* which includes the cells of the nuclei of the motor cranial nerves or the cells of the anterior horns of the cord and their axis-cylinder processes to the periphery.*

Sensory Tract (fig. 755)

Sensory impulses are conveyed to the spinal cord through the posterior roots of the spinal nerves. On entering the cord these root-fibres divide into

Fig. 755.—The sensory tract. (Modified from Poirier.)

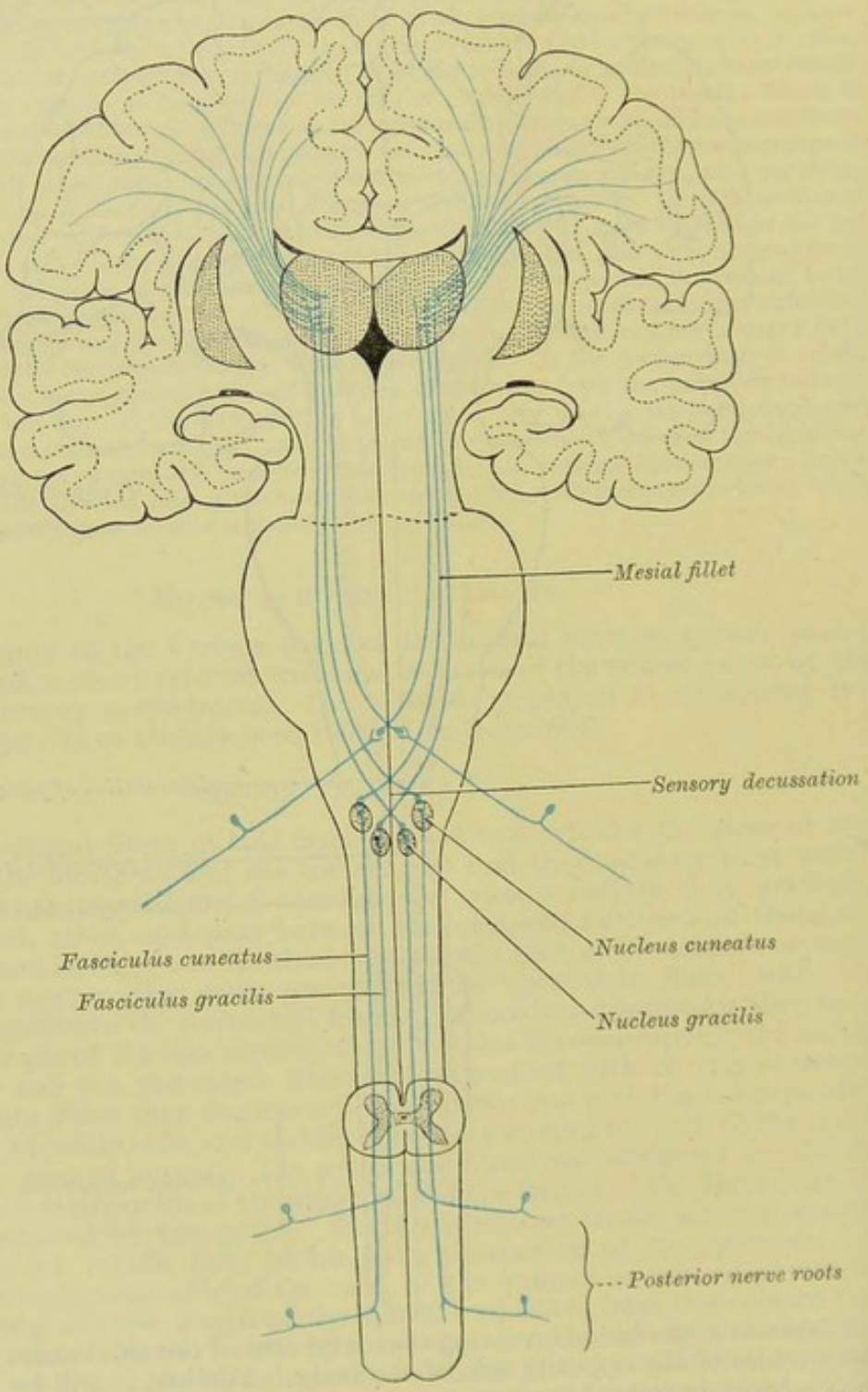

descending and ascending branches; the former soon enter the grey matter: of the latter some end in the grey matter after a longer or shorter course, while

* As already mentioned (footnote, page 805) a neuron in the posterior horn of the cord is probably interposed between each upper and lower motor neuron.

others are continued directly into the posterior columns of the cord, where they form the fasciculus gracilis and fasciculus cuneatus. From the cells of the posterior horn, fibres arise which cross the middle line and ascend in the peripheral part of the lateral column as the tract of Gowers. Certain observers maintain that some of the sensory fibres ascend in the anterior column. The fibres of the fasciculus gracilis and fasciculus cuneatus end by arborising around the cells of the gracile and cuneate nuclei, and from these cells the fibres of the mesial fillet take origin and cross to the opposite side in the *sensory decussation*. The mesial fillet is then joined by the fibres of Gowers' tract, which have already crossed in the cord, and in its further course receives fibres from the cranial sensory nuclei of the opposite side, with the exception of the cochlear division of the auditory nerve. Ascending through the crus, the fillet gives off some fibres to the lenticular nucleus and island of Reil, but the greater part of it is carried into the thalamus, where most of its fibres terminate—only a small proportion being continued directly into the cerebral cortex. From the grey matter of the thalamus the fibres of the third link in the chain arise and pass to the cerebral cortex. The fibres from the terminal nuclei of the cochlear nerve pass upwards in the lateral fillet, and are carried through the posterior part of the internal capsule to the temporal lobe. Further, Gowers' tract gives off a fasciculus which reaches the cerebellum through its superior peduncles. It will be evident, therefore, that in most cases there are three cell-stations interposed in the course of the sensory impulses. For clinical purposes, therefore, three neurons are described. (1) The series of *lower sensory neurons* comprises the cells of the posterior root ganglia and their peripheral and central processes. Of the *two upper sensory neurons*, (2) the lower series includes the cells of the nuclei cuneati and graciles and their processes, while (3) the upper group contains the cells of the thalami and the fibres passing from these to the cerebral cortex.

Applied Anatomy.—The chief symptoms of diseases of the brain and spinal cord depend upon the particular systems of neurons picked out for attack, and some of them may be briefly summarised as follows. *Motor paralysis* of the *spastic* type, with rigidity of the muscles and increased reflexes, follows destruction of the upper motor neurons; *flaccid* paralysis, with loss of the reflexes and rapid muscular atrophy, follows destruction of the lower motor neuron. *Sensory paralysis* follows injury to any part of the sensory path; in tabes it is due to injury of the lower sensory neuron, in hemiplegia to destruction of the upper sensory axon as it traverses the posterior part of the internal capsule. *Dissociation of sensations*, or the loss of some forms of sensation while others remain unimpaired, is seen in a number of conditions such as tabes or syringomyelia; it shows that the paths through which various forms of sensation travel to the brain are different. *Abnormalities of reflex actions* are of very great help in the diagnosis of nervous complaints. The numerous *superficial* or *skin reflexes* (*e.g.* the scapular, irritation of the skin over the scapula produces contraction of the scapular muscles; the abdominal, stroking the abdomen causes its retraction; the cremasteric, stroking the inner side of the thigh causes retraction of that side of the scrotum; the plantar, tickling the sole of the foot brings on plantar flexion of the toes), if present, show that the reflex arcs on whose integrity their existence depends are intact; but they are often absent in health, and so cannot be trusted to indicate disease. The *deep reflexes* or *tendon reactions*, such as the knee-jerk or the tendo Achillis jerk, are increased in chronic degeneration of, or gradually increasing pressure on, the pyramidal fibres (upper motor neuron), in nervous or hysterical patients, and when the irritability of the anterior cornual cells (lower motor neuron) is increased, as happens in tetanus or in poisoning by strychnine. They are lost when the lower motor or lower sensory neurons are diseased, and in a few other conditions; absence of the knee-jerk is very rare in health, and suggests disease in some part of its reflex arc, in the third and fourth lumbar segments of the cord, or else, more rarely, grave intracranial or spinal disease cutting off the lower from the higher nervous centres. The *organic reflexes* of the pupil, bladder, and rectum, are of the greatest practical importance. The commonest defect in the reflexes of the pupil is reflex iridoplegia, or failure to contract on exposure to light, without failure to contract on convergence or accommodation ('Argyll Robertson' pupil). The pupil is also contracted (miosis), and may or may not dilate when the skin of the neck is pinched (the cilio-spinal reflex). Micturition is a spinal reflex much under the control of the brain; if the centre for micturition in the second sacral segment is destroyed the sphincter and the walls of the bladder are paralysed, the bladder becomes distended with urine, and incontinence from overflow results. If this centre escapes injury but is cut off more or less completely from impulses descending to it from above, there will be more or less interference with micturition. This varies in degree from the 'precipitate micturition' of tabetic patients, who must perforce hurry to pass water the moment the impulse seizes them, to the

state of 'reflex incontinence,' when the bladder automatically empties itself from time to time, almost without the patient's knowledge. Defæcation is a very similar spinal reflex, and is liable to very similar disorders of function.

The *upper motor neuron* (page 889) is affected in hemiplegia, the *lower motor neuron* (page 890) in infantile spinal paralysis; both these systems of neurons are diseased together in the somewhat rare disorders known as amyotrophic lateral sclerosis and progressive muscular atrophy. The chief symptom here is wasting and weakness in certain groups of muscles; the palsy will be flaccid, with loss of the reflexes, or spastic, with increased reflexes, according as the degeneration mainly involves the lower or the upper motor neuron. The sphincters are affected only in the later stages of these diseases.

Pathological changes in the *lower sensory neuron* are the cause of tabes dorsalis or locomotor ataxy, which occurs almost entirely in adults who have had syphilis. In the early or pre-ataxic stage the patient may exhibit the Argyll-Robertson pupil (page 891), and loss of the knee-jerks, and complain of sharp, stabbing pains ('lightning pains') in the limbs, difficult or precipitate micturition, and sometimes of severe and painful attacks of indigestion (gastric crises). In the second or ataxic stage, coming on perhaps years later, he will complain, in addition, of interference with his powers of getting about and turning, although his muscular strength is well preserved. He is unable to stand steady with his eyes shut or in the dark, his gait becomes exaggerated and stamping in character, he has to use a stout stick to walk with, and he may suffer from painful crises in various parts of the body. Control over the sphincters is further weakened, and on examination there will be found marked inco-ordination of the limbs, zones of anæsthesia about the trunk or down the limbs, and marked analgesia (or insensitiveness to pain) when pressure is applied to the bones, tendons, trachea, tongue, eyeballs, mammæ, and testes.* The ataxy progresses till the third or bed-ridden stage is reached; control over the sphincters is still further lost, and the patient is likely to die of intercurrent disease or of general paralysis of the insane.

No nervous disease is recognised as dependent upon degeneration of either or both of the two *upper sensory neurons*.

MENINGES OF THE BRAIN AND SPINAL CORD

The brain and spinal cord are enclosed within three membranes. These are named from without inwards: the dura mater, the arachnoid membrane, and the pia mater.

The Dura Mater

The **dura mater** is a thick and dense inelastic membrane, which forms an external covering for the brain and spinal cord. The portion which encloses the brain differs in several essential particulars from that which surrounds the spinal cord, and therefore it is necessary to describe them separately; but at the same time it must be distinctly understood that the two form one complete membrane, and are continuous with each other at the foramen magnum.

The **cranial dura mater** lines the interior of the skull, and serves the twofold purpose of an internal periosteum to the bones, and a membrane for the protection of the brain. It is composed of two layers closely connected together, except in certain situations, where, as already described (page 737), they separate to form sinuses for the passage of venous blood. Upon the outer surface of the cranial dura mater, in the situation of the longitudinal sinus, may be seen numerous small whitish bodies, the *glandulæ Pacchionii*. Its outer surface is rough and fibrillated, and adheres closely to the inner surface of the bones, the adhesion being most marked opposite the sutures and at the base of the skull. Its inner surface is smooth and lined by a layer of endothelium. It sends inwards four processes which divide the cavity of the skull into a series of freely communicating compartments, for the lodgment and protection of the different parts of the brain; and it is prolonged to the outer surface of the skull, through the various foramina which exist at the base, and thus becomes continuous with the pericranium; its fibrous layer forms sheaths for the nerves which pass through these apertures. At the base of the skull, it sends a fibrous prolongation into the foramen cæcum; it sends a series of tubular prolongations round the filaments of the olfactory nerves as they pass through the cribriform plate, and another round the nasal nerve as it passes through the nasal slit; a prolongation is also continued

* J. Grasset, *Le Tabes, Maladie de la Sensibilité profonde:* Montpellier, 1909.

through the sphenoidal fissure into the orbit, and another is carried into the same cavity through the optic foramen, forming a sheath for the optic nerve, which is continued as far as the eyeball. In the posterior fossa it sends a process into the internal auditory meatus, ensheathing the facial and auditory nerves; another through the jugular foramen, forming a sheath for the structures which pass through this opening; and a third through the anterior condyloid foramen. Around the margin of the foramen magnum it is closely adherent to the bone, and is continuous with the spinal dura mater.

Processes.—The processes of the cranial dura mater, which project into the cavity of the skull, are formed by reduplications of the inner or meningeal layer of the membrane, and are four in number: the falx cerebri, the tentorium cerebelli, the falx cerebelli, and the diaphragma sellæ.

The *falx cerebri*, so named from its sickle-like form, is a strong, arched process which descends vertically in the longitudinal fissure between the hemispheres of the brain. It is narrow in front, where it is attached to the crista galli of the ethmoid; and broad behind, where it is connected with the upper surface of the tentorium cerebelli. Its upper margin is convex, and attached to the inner surface of the skull in the middle line, as far back as the internal occipital protuberance; it contains the superior longitudinal sinus. Its lower margin is free, concave, and presents a sharp curved edge, which contains the inferior longitudinal sinus.

The *tentorium cerebelli* (fig. 756) is an arched lamina of dura mater, elevated in the middle, and inclining downwards towards the circum-

FIG. 756.—Tentorium cerebelli seen from above.

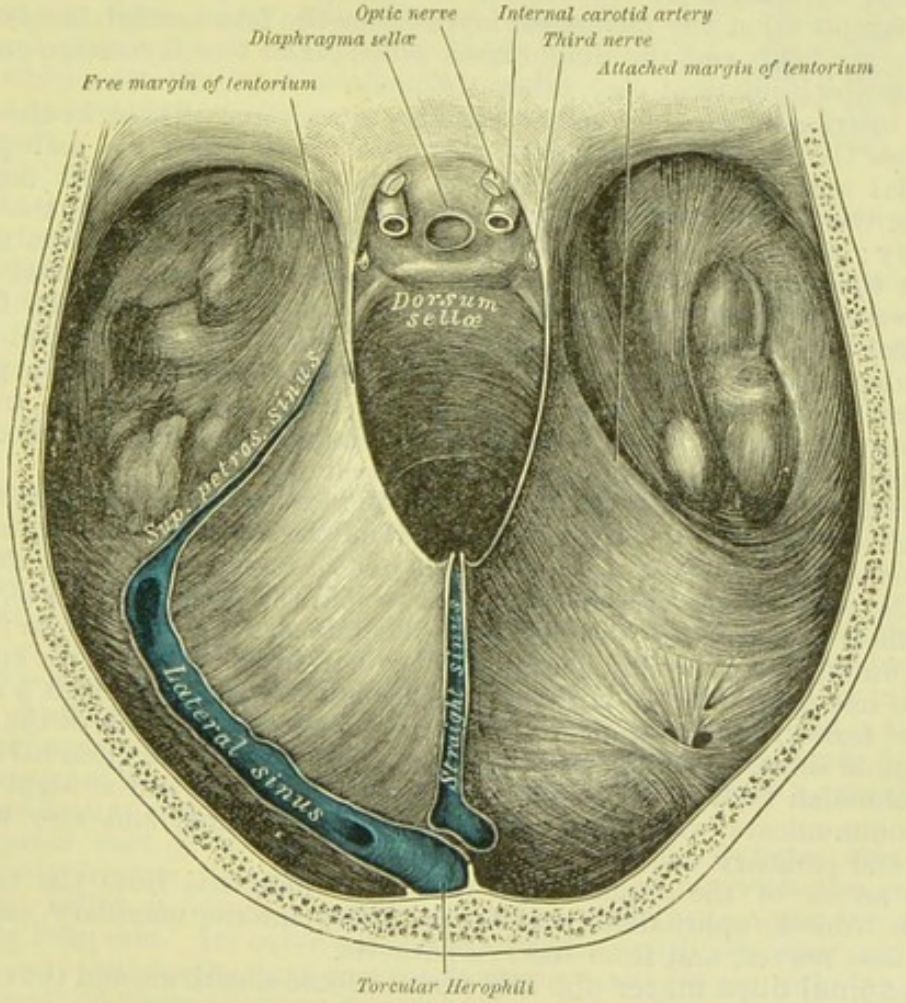

ference. It covers the upper surface of the cerebellum, and supports the occipital lobes of the brain. Its anterior border is free and concave, and bounds a large oval opening, the *incisura tentorii*, for the transmission of the crura cerebri. It is attached, behind, by its convex border to the transverse ridges upon the inner surface of the occipital bone,

and there encloses the lateral sinuses; in front, to the superior margin of the petrous portion of the temporal bone on either side, enclosing the superior petrosal sinuses, and at the apex of this bone the free or anterior border and the attached or external border meet, and, crossing one another, are continued forwards to be fixed to the anterior and posterior clinoid processes respectively. To the middle line of its upper surface the posterior border of the falx cerebri is attached, the straight sinus being placed at their line of junction.

The *falx cerebelli* is a small triangular process of dura mater, received into the indentation between the two lateral lobes of the cerebellum behind. Its base is attached, above, to the under and back part of the tentorium; its posterior margin, to the lower division of the vertical crest on the inner surface of the occipital bone. As it descends, it sometimes divides into two smaller folds, which are lost on the sides of the foramen magnum.

The *diaphragma sellæ* is a small circular horizontal fold, which constitutes a roof for the sella turcica. This almost completely covers the pituitary body, presenting merely a small central opening for the infundibulum to pass through.

Structure.—The cranial dura mater consists of white fibrous tissue, with connective-tissue cells and elastic fibres arranged in flattened laminæ which are imperfectly separated by lacunar spaces and blood-vessels into two layers, *endosteal* and *meningeal*. The *endosteal layer* is the internal periosteum for the cranial bones, and contains the blood-vessels for their supply. At the margin of the foramen magnum it is continuous with the periosteum lining the spinal canal. The *meningeal* or *supporting layer* is lined on its inner surface by a layer of nucleated endothelium, similar to that found on serous membranes: these cells were formerly regarded as belonging to the arachnoid membrane. By its reduplication the meningeal layer forms the falx cerebri, the tentorium and falx cerebelli, and the diaphragma sellæ. The two layers are connected by fibres which intersect each other obliquely.

The *arteries* of the dura mater are very numerous. Those in the anterior fossa are the anterior meningeal branches of the anterior and posterior ethmoidal and internal carotid, and a branch from the middle meningeal. Those in the middle fossa are the middle and small meningeal of the internal maxillary; a branch from the ascending pharyngeal, which enters the skull through the foramen lacerum medium; branches from the internal carotid, and a recurrent branch from the lachrymal. Those in the posterior fossa are meningeal branches from the occipital, one of which enters the skull through the jugular foramen, and the other through the mastoid foramen; the posterior meningeal from the vertebral; occasional meningeal branches from the ascending pharyngeal, which enter the skull through the jugular and condyloid foramina; and a branch from the middle meningeal.

The *veins* which return the blood from the cranial dura mater anastomose with the diploic veins. They terminate in the various sinuses, with the exception of the two which accompany the middle meningeal artery; these pass out of the skull at the foramen spinosum to join the pterygoid plexus, through which their contents are drained into the internal maxillary vein; above, they communicate with the superior longitudinal sinus. Many of the meningeal veins do not open directly into the sinuses, but indirectly through a series of ampullæ, termed *venous lacunæ*. These are found on either side of the superior longitudinal sinus, especially near its middle portion, and are often invaginated by Pacchionian bodies; they also exist near the lateral and straight sinuses. They communicate with the underlying cerebral veins, and also with the diploic and emissary veins.

The *nerves* of the cranial dura mater are filaments from the Gasserian ganglion, from the ophthalmic, superior maxillary, inferior maxillary, vagus, and hypoglossal nerves, and from the sympathetic.

The **spinal dura mater** (fig. 757) forms a loose sheath around the cord, and represents only the inner or meningeal layer of the cranial dura mater; the outer or endosteal layer ceases at the foramen magnum, its place being taken by the periosteum lining the spinal canal. The dura mater is separated from the bony walls of the spinal canal by a space, the *epidural space*, which contains a quantity of loose areolar tissue and a plexus of veins; the situation of these veins between the dura mater of the cord and the periosteum of the vertebræ

corresponds therefore to that of the cranial sinuses between the meningeal and endosteal layers of the cranial dura mater. It is attached to the circumference of the foramen magnum, and to the second and third cervical vertebræ; it is also connected to the posterior common ligament, especially near the lower end of the spinal canal, by fibrous slips; it extends below as far as the lower border of the second sacral vertebra, where its cavity terminates; below this level it closely invests the filum terminale and descends to the back of the coccyx, where it blends with the periosteum. The sheath of dura mater is much larger than is necessary for the accommodation of its contents, and its size is greater in the cervical and lumbar regions than in the thoracic. Its inner surface is smooth. On each side may be seen the double openings which transmit the two roots of the corresponding spinal nerve, the dura mater being continued in the form of tubular prolongations on them as they pass through the intervertebral foramina. These prolongations are short in the upper part of the spine, but gradually become longer below, forming a number of tubes of fibrous membrane, which enclose the lower spinal nerves and are contained in the spinal canal.

Fig. 757.—The spinal cord and its membranes.

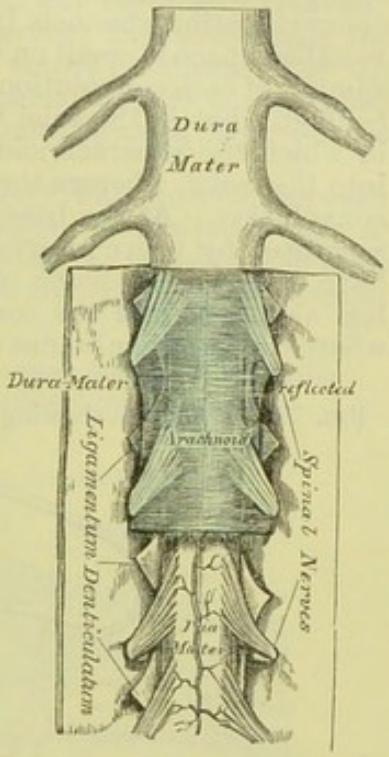

Structure.—The spinal dura mater resembles in structure the meningeal or supporting layer of the cranial dura mater, consisting of white fibrous and elastic tissue arranged in bands or lamellæ which, for the most part, are parallel with one another and have a longitudinal arrangement. Its internal surface is covered by a layer of endothelium, which gives this surface its smooth appearance. It is sparingly supplied with blood-vessels, and some few nerves have been traced into it.

Subdural space.—The dura mater is separated from the arachnoid by a potential space, the *subdural space*. The two membranes are, in fact, in contact with each other, except where they are separated by a minute quantity of fluid, which just serves to keep the two opposing surfaces moist.

The Arachnoid Membrane

The **arachnoid membrane** is a delicate membrane which envelops both the brain and cord, lying between the pia mater internally and the dura mater externally.

The *cranial part of the arachnoid* invests the brain loosely, and does not dip into the sulci between the convolutions, nor into the fissures, with the exception of the longitudinal fissure. On the upper surface of the cerebrum the arachnoid is thin and transparent, and may be easily demonstrated by injecting a stream of air beneath it. At the base of the brain the arachnoid is thicker, and slightly opaque towards the central part where it extends across between the two temporal lobes in front of the pons Varolii, so as to leave a considerable interval between it and the brain.

The *spinal part of the arachnoid* is a thin, delicate, tubular membrane which loosely invests the cord. Above, it is continuous with the cerebral arachnoid; below, it widens out and invests the cauda equina and the nerves proceeding from this. Its outer surface is in contact with the inner surface of the dura mater, but for the most part the membranes are not connected together, though here and there they may be joined together by isolated connective-tissue trabeculæ, which are most numerous on the posterior surface of the cord. The space between the two membranes is the *subdural space*.

The arachnoid membrane surrounds the nerves which arise from the brain and spinal cord, and encloses them in loose sheaths as far as their points of exit from the skull and spinal canal.

Structure.—The arachnoid consists of bundles of white fibrous and elastic tissue intimately blended together. Its outer surface is covered with a layer of endothelium. Vessels of considerable size, but few in number, and, according to Bochdalek, a rich plexus of nerves derived from the motor division of the fifth, the facial, and the spinal accessory nerves, are found in the arachnoid.

The **subarachnoid space** is the interval between the arachnoid and pia mater. It is not, properly speaking, a *space*, for it is occupied everywhere by a spongy tissue consisting of trabeculæ of delicate connective tissue, and intercommunicating channels in which the subarachnoid fluid is contained. This so-called space is small on the surface of the hemispheres of the brain ; on the summit of each convolution the pia mater and arachnoid membrane are in close contact ; but in the sulci between the convolutions, triangular spaces are left, in which the subarachnoid trabecular tissue is found, for the pia mater dips into the sulci, whereas the arachnoid bridges across them from convolution to convolution. At the base of the brain, in certain situations, the arachnoid is separated by wider intervals from the pia mater, forming larger spaces, which have received the name of *cisternæ*, and in these the subarachnoid tissue is less abundant and the communicating channels larger than in those regions where the two membranes are more closely approximated.

Fig. 758.—Diagram showing the positions of the three principal subarachnoid cisternæ.

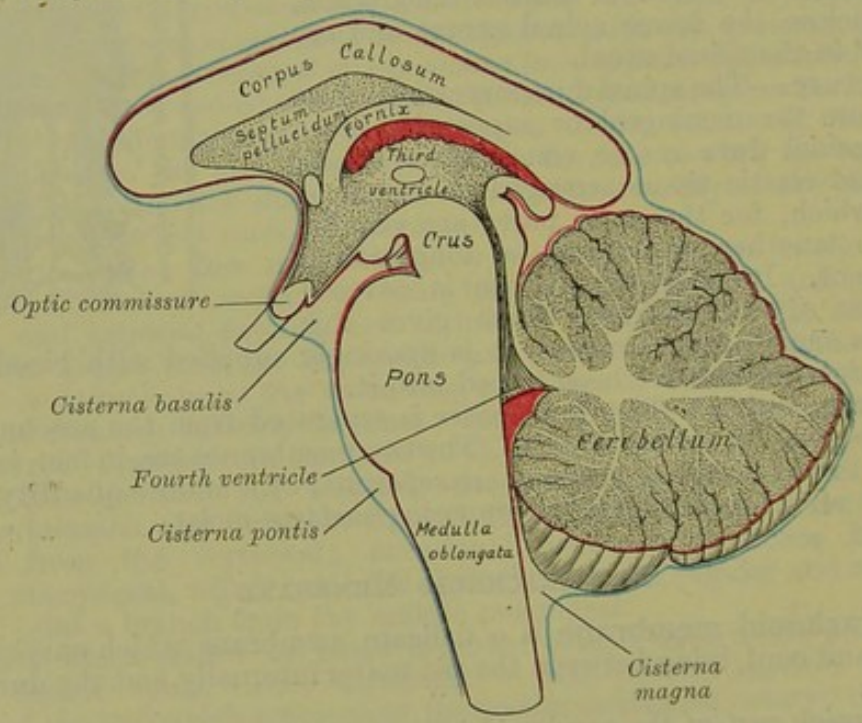

The three principal spaces have been named the *cisterna magna*, the *cisterna pontis*, and the *cisterna basalis* (fig. 758) ; but it should be clearly understood that these spaces communicate freely with each other. The *cisterna magna* is a space, triangular on sagittal section, caused by the arachnoid bridging over the interval between the medulla and the under surfaces of the hemispheres of the cerebellum ; it is continuous with the subarachnoid space of the cord at the level of the foramen magnum. The *cisterna pontis* is a considerable interval between the pia mater and the arachnoid on the ventral aspect of the pons Varolii. It contains the basilar artery, and is continuous behind with the subarachnoid space of the spinal cord, and with the cisterna magna ; and in front of the pons with the cisterna basalis. The *cisterna basalis* is a wide interval left between the pia mater and the arachnoid, where the latter membrane extends across between the two temporal lobes. It encloses the crura cerebri and the structures contained in the interpeduncular space, and contains the circle of Willis. In front, the cisterna basalis extends forwards on to the upper surface of the corpus callosum, for the arachnoid stretches across from one cerebral hemisphere to the other immediately beneath the free border of the falx cerebri, and thus leaves a space

in which the anterior cerebral arteries are contained. Again, another space is formed in front of either temporal lobe by the arachnoid bridging across the fissure of Sylvius without dipping down to the bottom of the fissure. This space is a prolongation from the cisterna basalis, and contains the middle cerebral artery. The subarachnoid space communicates with the general ventricular cavity of the brain by three openings : one of these, the *foramen of Majendie*, is in the middle line at the inferior boundary of the fourth ventricle ; the other two are at the extremities of the lateral recesses of the fourth ventricle, behind the upper roots of the glosso-pharyngeal nerves ; they are named the *foramina of Key and Retzius* or *of Luschka*. It is stated by Meckel that the lateral ventricles also communicate with the subarachnoid space at the apices of their descending horns. There is no direct communication between the subdural and subarachnoid spaces.

The spinal part of the subarachnoid space is a very wide interval between the arachnoid membrane and the pia mater, and is largest at the lower part of the spinal canal, where the arachnoid membrane encloses the nerves which form the cauda equina. Superiorly, it is continuous with the cranial subarachnoid

FIG. 759.—Diagrammatic representation of a section across the top of the skull, showing the membranes of the brain, &c. (Modified from Testut.)

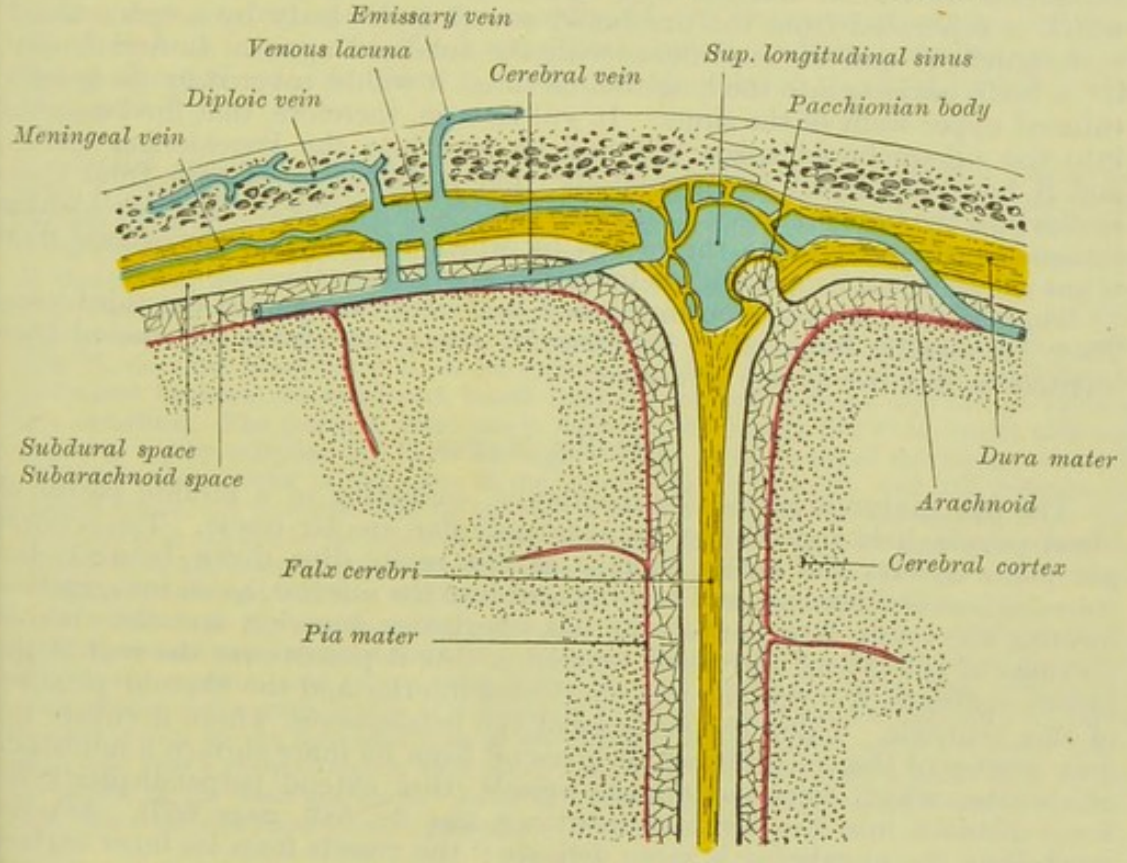

space, through which it communicates with the general ventricular cavity of the brain, by means of the openings, in the roof of the fourth ventricle (*foramen of Majendie* and *foramina of Key and Retzius*). It is partially divided by a longitudinal membranous septum, the *septum posticum*, which serves to connect the arachnoid with the pia mater, opposite the posterior median fissure of the spinal cord, and forms a partition, which is incomplete and cribriform above, but more perfect in the thoracic region ; it consists of bundles of white fibrous tissue interlacing with each other. Each of these divisions of the spinal subarachnoid space is further subdivided by the *ligamenta denticulata*, which will be described with the pia mater.

The cerebro-spinal fluid fills up the subarachnoid space. In the spine it is so abundant as to completely fill up the whole of the space included in the dura mater. It is a clear limpid fluid, having a saltish taste, and a slightly alkaline reaction. According to Lassaigne, it consists of 98·5 parts of water, the remaining 1·5 per cent. being solid matters, animal and saline. It varies in

quantity, being most abundant in old persons, and is quickly secreted. Its chief use is probably to afford mechanical protection to the nervous centres, and to prevent the effects of concussions communicated from without.

The **glandulæ Pacchionii**, or **arachnoid villi** (fig. 759), are small, fleshy-looking elevations, usually collected into clusters of variable size, which may be seen upon the outer surface of the dura mater, in the vicinity of the superior longitudinal sinus, and in some other situations. Little pits or depressions will be found on the corresponding parts of the calvarium, into which these elevations are received. Upon laying open the superior longitudinal sinus, villi will be found protruding into its interior. They are not glandular in structure, but, according to Luschka, are enlarged normal villi of the arachnoid. On each side of the sinus, and communicating with it, are large venous spaces, named *lacunæ laterales*, situated in the dura mater, and into these the villi project. As they grow they push the thinned dura mater before them, and cause absorption of the bone from pressure, and so produce the pits or depressions on the inner wall of the calvarium. A Pacchionian body consists of the following parts: 1. In the interior is a core of subarachnoid tissue, which is continuous with the meshwork of the general subarachnoid tissue through a narrow pedicle, by which the Pacchionian body is attached to the arachnoid. 2. Around this tissue is a layer of arachnoid membrane, which limits and encloses the subarachnoid tissue. 3. Outside this, again, is the thinned wall of the lacuna, which is separated from the arachnoid covering the body by a space which corresponds to and is continuous with the subdural space. 4. And finally, if the body projects into the longitudinal sinus, it will be covered by the greatly thinned upper walls of the sinus. It will be seen, therefore, that fluid injected into the subarachnoid space will find its way into the Pacchionian bodies, and it has been found experimentally that it passes by osmosis from these bodies into the venous sinuses into which these bodies project. The Pacchionian bodies are supposed to be the means by which excess of cerebro-spinal fluid is got rid of, when its quantity is increased above normal.

These bodies are not seen in infancy, and very rarely until the third year. They are usually found after the seventh year; and from this period they increase in number as age advances.

The Pia Mater

The **pia mater** is a vascular membrane, consisting of a minute plexus of blood-vessels, held together by an extremely fine areolar tissue. The *cerebral pia mater* invests the entire surface of the brain, dips down between the convolutions and laminæ, and is prolonged into the interior, as an invagination forming the velum interpositum or tela chorioidea superior, and the choroid plexuses of the lateral and third ventricles. As it passes over the roof of the fourth ventricle, it forms the tela chorioidea inferior and the choroid plexuses of this ventricle. Upon the surfaces of the hemispheres, where it covers the grey matter of the convolutions, it gives off from its inner surface a multitude of sheaths, which surround minute vessels, that extend perpendicularly for some distance into the cerebral substance (see fig. 589, page 653). On the cerebellum the membrane is more delicate; the vessels from its inner surface are shorter, and its relations to the cortex are not so intimate.

The *spinal pia mater* is thicker, firmer, and less vascular than that of the brain: this is due to the fact that it consists of two layers, the outer or additional one being composed of bundles of connective-tissue fibres, arranged for the most part longitudinally. Between the layers are cleft-like spaces which communicate with the subarachnoid space, and a number of blood-vessels which are enclosed in perivascular lymphatic sheaths. The spinal pia mater covers the entire surface of the cord, and is very intimately adherent to it; in front it sends a process backwards into the anterior fissure. A longitudinal fibrous band, called by Haller the *linea splendens*, extends along the middle line of the anterior surface; and a somewhat similar band, the *ligamentum denticulatum*, is situated on either side. At the point where the cord terminates, the pia mater becomes contracted and is continued down as a long, slender filament (*filum terminale*), which descends through the centre of the mass of nerves forming the cauda equina. It blends with the dura mater at the

level of the lower border of the second sacral vertebra, and extends downwards as far as the base of the coccyx, where it blends with the periosteum. It assists in maintaining the cord in its position during the movements of the trunk, and is, from this circumstance, called the *central ligament of the cord.*

The pia mater of both the brain and the spinal cord forms sheaths for the nerves as they emerge from the central nervous matter. This sheath is closely connected with the nerve, and blends with its common membranous investment.

The **ligamentum denticulatum** (figs. 757, 760) is a narrow fibrous band situated on either side of the spinal cord throughout its entire length, and separating the anterior from the posterior roots of the spinal nerves. It has received its name from the serrated appearance which it presents. Its inner border is continuous with the pia mater at the side of the cord. Its outer border presents a series of triangular tooth-like processes, the points of which are fixed at intervals to the dura mater. These processes are twenty-one in number, on either side, the first being attached to the dura mater, opposite the margin of the foramen magnum, between the vertebral artery and the hypoglossal nerve ; and the last near the lower end of the cord. Its function is to support the cord in the fluid by which it is surrounded.

FIG. 760.—Transverse section of the spinal cord and its membranes.

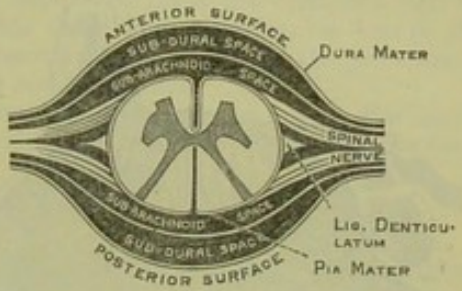

Applied Anatomy.—Evidence of great value in the diagnosis of meningitis may sometimes be obtained by puncturing the membranes of the cord and withdrawing some of the cerebro-spinal fluid ; moreover the operation of lumbar puncture is in many cases curative, under the supposition that the draining of some of the cerebro-spinal fluid relieves the patient by diminishing the intracranial pressure. The operation is performed by inserting a trocar, of the smallest size, between the laminæ of the third and fourth, or of the fourth and fifth lumbar vertebræ, through the ligamentum subflavum. The spinal cord, even of a child at birth, does not reach below the third lumbar vertebra, and therefore the canal may be punctured between the third and fourth lumbar vertebræ without any risk of injuring this structure. The point of puncture is indicated by laying the child on its side and dropping a perpendicular line from the highest point of the crest of the ilium ; this will cross the upper border of the spine of the fourth lumbar vertebra, and will indicate the level at which the trocar should be inserted a little to one side of the middle line. The puncture may require to be repeated more than once, and the greatest precaution must be taken not to allow septic infection of the meninges. If there be any appreciable increase of pressure, the fluid will flow through the trocar with the greatest freedom.

In addition to the constitutional signs and symptoms of fever, *acute spinal meningitis* exhibits certain characteristic features. Pain and tenderness to pressure along the spinal column are common, and so are pains in the limbs or round the trunk from irritation of the posterior nerve-roots by the inflammatory products. Irritation of the anterior nerve-roots is shown by the increased tone of the muscles, which may go on to the point where they pass into a state of spasm with much increased reflexes ; this is often seen in the retraction of the head and neck. Later in the disease the reflexes are often lost, when, also, the urine and fæces may be passed involuntarily.

CRANIAL NERVES (NERVI CEREBRALES)

There are twelve pairs of cranial nerves ; they are attached to the brain and are transmitted through foramina in the base of the cranium. Taken in their order, from before backwards, the different pairs are named as follows :

1st. Olfactory.
2nd. Optic.
3rd. Motor oculi.
4th. Trochlear (Pathetic).
5th. Trifacial (Trigeminus).
6th. Abducent.
7th. Facial.
8th. Auditory.
9th. Glosso-pharyngeal.
10th. Pneumogastric or Vagus.
11th. Spinal accessory.
12th. Hypoglossal.

The area of attachment of a cranial nerve to the surface of the brain is termed its *superficial* or *apparent origin.* The fibres of the nerve can, in all

cases, be traced into the substance of the brain to a special centre of grey matter, termed the *nucleus*. The motor or efferent cranial nerves arise from groups of nerve-cells situated within the brain, and such groups of cells constitute their *nuclei of origin*. The sensory or afferent cranial nerves arise outside the brain from groups of nerve-cells or ganglia derived from the neural crest or ganglion ridge, and situated on the trunks of the nerves ; these ganglia must therefore be looked upon as their *nuclei of origin*. The central processes of these ganglion-cells grow into the brain, and there end by arborising around the cells of certain nuclei or collections of nerve-cells, which are termed their *nuclei of termination*. The nuclei of origin of the motor nerves and the nuclei of termination of the sensory nerves are brought into relationship with the cerebral cortex, the former through the geniculate bundle of the internal capsule, the latter through the fillet. The geniculate fibres arise from the cells of the motor area of the cortex, and, after crossing the middle line, end by arborising around the cells of the nuclei of origin of the motor nerves. On the other hand, fibres arise from the cells of the nuclei of termination of the sensory nerves, and after crossing the opposite side, join the fillet, and thus connect these nuclei, directly or indirectly, with the cerebral cortex. As already stated in the chapter on Embryology (page 127), the cranial nerves, with the exception of the first and second, are developed in a similar manner to the spinal nerves.

Fig. 761.—Nerves of septum of nose. Right side.

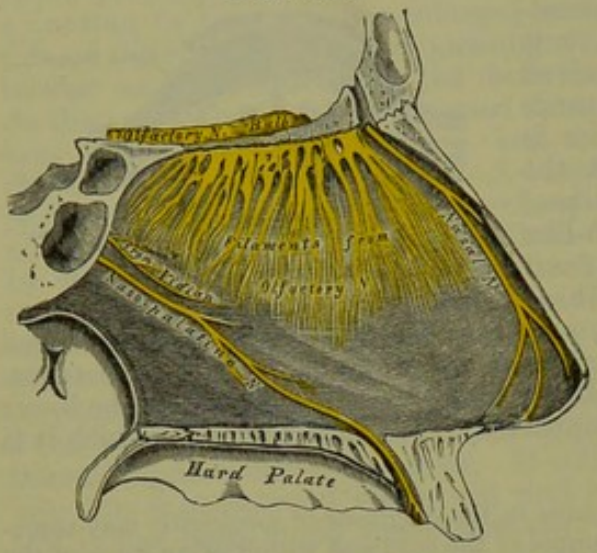

First Nerve (fig. 761)

The **Olfactory nerves** (nn. olfactorii) are the nerves of smell, and are distributed to the mucous membrane of the olfactory region of the nose : this

Fig. 762.—Plan of olfactory neurons.

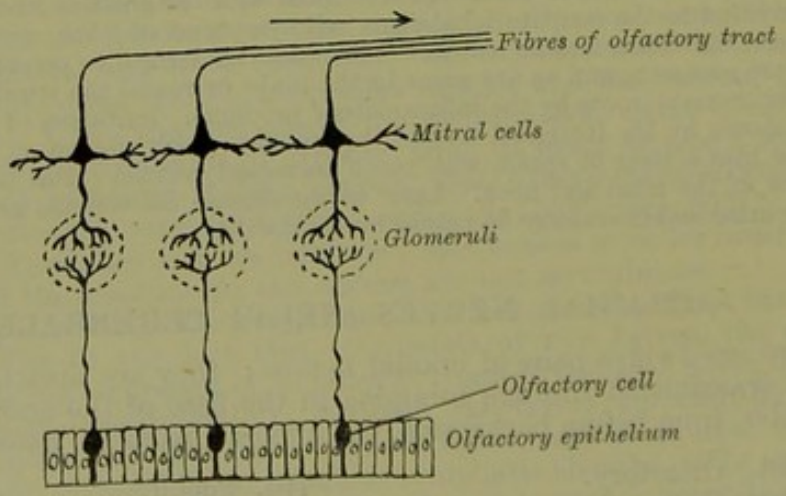

region comprises the superior turbinated process of the ethmoid, and the corresponding part of the nasal septum. The nerves originate from the central or deep processes of the olfactory cells of the nasal mucous membrane. They form a plexiform network in the mucous membrane, and are then collected into about twenty branches, which pierce the cribriform plate of the ethmoid bone in two groups, an outer and an inner, and terminate in the glomeruli of the olfactory bulb (figs. 749 and 762). Each branch receives tubular sheaths

from the dura mater and pia mater, the former being lost in the periosteum of the nose, the latter in the neurilemma of the nerve.

The olfactory nerves differ in structure from other nerves in being composed exclusively of non-medullated fibres. They consist of axis-cylinders with distinct nucleated sheaths, in which there are, however, fewer nuclei than are found in ordinary non-medullated nerve-fibres.

The olfactory centre in the cortex is generally associated with the rhinencephalon (p. 863).

Applied Anatomy.—In severe injuries to the head involving the anterior fossa of the base of the skull, the olfactory bulb may become separated from the olfactory nerves, thus producing loss of smell (*anosmia*), and with this there is a considerable loss in the sense of taste, since much of the perfection of the sense of taste is due to the substances being also odorous, and simultaneously exciting the sense of smell.

Anosmia often occurs after influenza or other acute infection of the nose. *Parosmia*, or a perversion of the sense of smell, may occur in lesions of the cortical olfactory centres, or in insanity.

Second Nerve (fig. 763)

The **Second** or **Optic nerve** (n. opticus), the nerve of sight, is distributed exclusively to the eyeball. The nerves of opposite sides are connected together at the commissure, and from the back of the commissure they may be traced to the brain, under the name of the *optic tracts*.

The *optic tract*, at its connection with the brain, is divided into two bands, external and internal. The *external* band is the larger; it arises from the external geniculate body and from the pulvinar of the thalamus, and is partly continuous with the brachium of the upper quadrigeminal body. The *internal* band curves round the crusta, and ends in the internal geniculate body; its fibres are merely commissural, forming Gudden's commissure. From these origins the tract winds obliquely across the under surface of the crus cerebri in the form of a flattened band, and is attached to the crus by its anterior margin. It then assumes a cylindrical form, and, as it passes forwards, is connected with the tuber cinereum and lamina terminalis. It finally joins with the tract of the opposite side to form the *optic commissure*.

Fig. 763.—The left optic nerve and optic tracts.

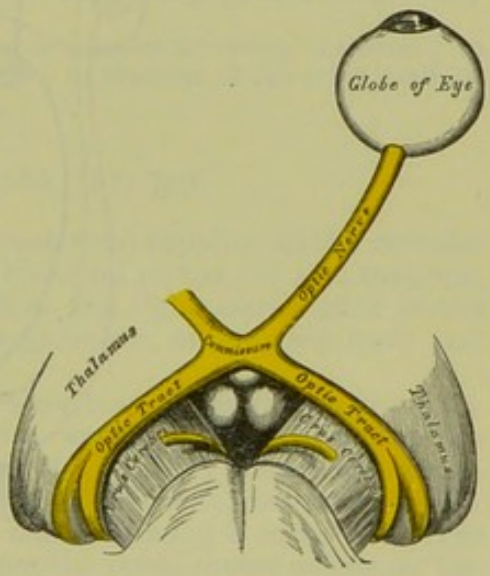

The *optic commissure* or *chiasma*, somewhat quadrilateral in form, rests upon the olivary eminence and on the anterior part of the diaphragma sellæ, being bounded above, by the lamina terminalis; behind, by the tuber cinereum; on either side, by the anterior perforated space. Within the commissure, the optic nerves of the two sides undergo a partial decussation. The fibres which form the inner margin of each tract and posterior part of the commissure have no connection with the optic nerves. They simply pass across the commissure from one hemisphere of the brain to the other, and connect the internal geniculate bodies of the two sides. They are known as the *commissure of Gudden*. The remaining and principal part of the commissure consists of two sets of fibres, crossed and uncrossed. The *crossed*, which are the more numerous, occupy the central part of the commissure, and pass from the optic nerve of one side to the optic tract of the other, decussating in the commissure with similar fibres of the opposite optic nerve. The *uncrossed* fibres occupy the outer part of the chiasma, and pass from the nerve of one side to the tract of the same side.*

The great majority of the fibres of the optic nerve (fig. 764) consist of the afferent axons of nerve-cells in the retina; a few, however, are efferent fibres, and grow out from the brain. They become medullated during the last month of

* A specimen of congenital absence of the optic commissure is to be found in the Museum of the Westminster Hospital. See also Henle, *Nervenlehre*, p. 393, ed. 2.

fœtal life. The afferent fibres end in arborisations around the cells in the external geniculate body, pulvinar, and upper quadrigeminal body, which constitute the *lower visual centres*. From these nuclei other fibres are prolonged to the *cortical visual centre*, which, according to most observers, is situated in the cuneus, and in the neighbourhood of the calcarine fissure.

Some fibres are detached from the optic tract, and pass through the crus cerebri to the nucleus of the third nerve. These fibres are small, and may be regarded as afferent branches for the Sphincter pupillæ and Ciliary muscles. Other fibres pass to the cerebellum through its superior peduncles, while others, again, are lost in the pons.

Fig. 764.—Scheme showing central connections of the optic nerve and optic tract.

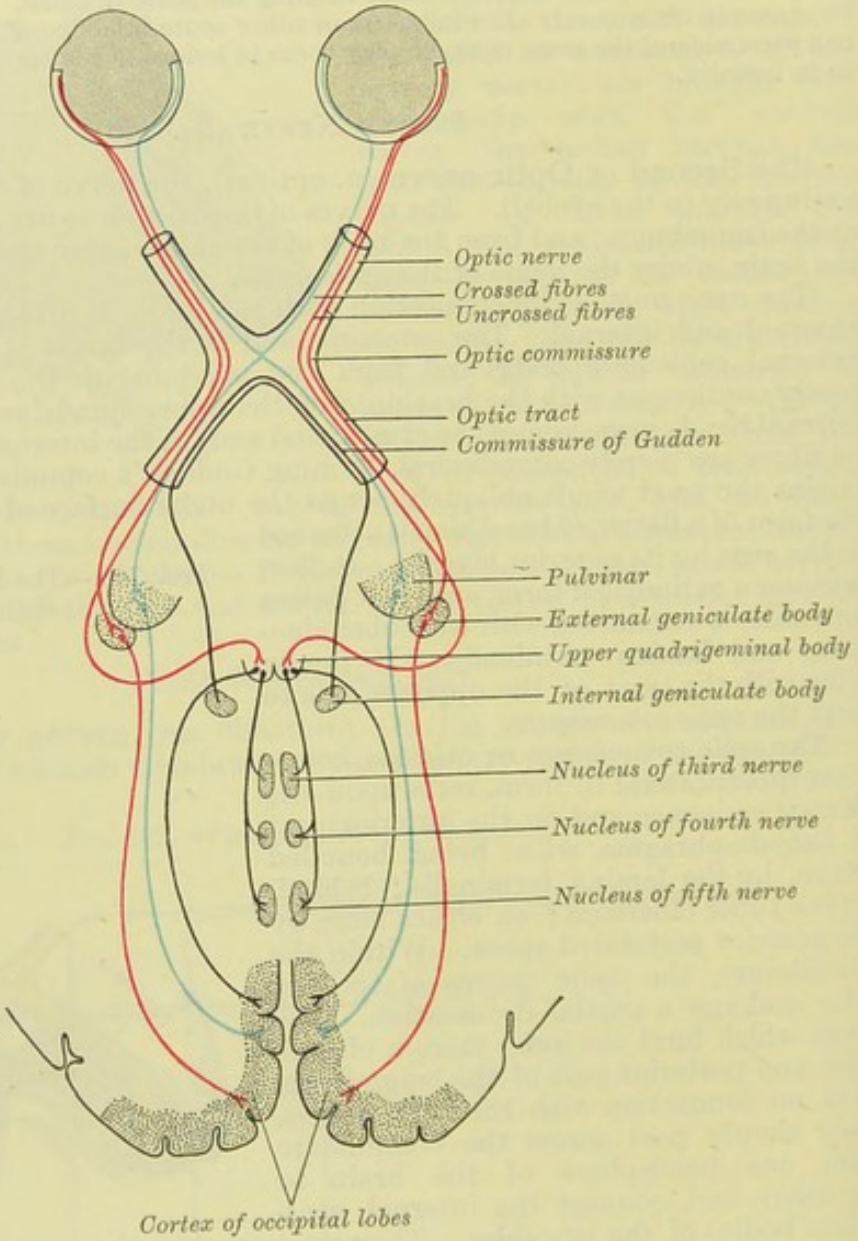

The *optic nerves* arise from the fore part of the commissure, and, diverging from one another, each becomes rounded in form and firm in texture, and is enclosed in a sheath derived from the pia mater and arachnoid. As the nerve passes through the corresponding optic foramen, it receives a sheath from the dura mater; and as it enters the orbit this sheath divides into two layers, one of which becomes continuous with the periosteum of the orbit; the other forms the proper sheath of the nerve, and surrounds it as far as the sclera. The nerve passes forwards and outwards through the cavity of the orbit, pierces the sclera and the choroid coat at the back part of the eyeball, about one-eighth of an inch to the nasal side of its centre, and expands into the internal layer of the retina. A small artery, the *arteria centralis retinæ*,

perforates the optic nerve a little behind the globe, and runs along its interior in a tubular canal of fibrous tissue. It supplies the inner surface of the retina, and is accompanied by corresponding veins. The retina is described with the anatomy of the eyeball.

Applied Anatomy.—The optic nerve is peculiarly liable to become the seat of neuritis or undergo atrophy in affections of the central nervous system, and as a rule the pathological relationship between the two affections is exceedingly difficult to trace. There are, however, certain points in connection with the anatomy of this nerve which tend to throw light upon the frequent association of these affections with intracranial disease. (1) From its mode of development, and from its structure, the optic nerve must be regarded as a prolongation of the brain-substance, rather than as an ordinary cerebro-spinal nerve. (2) As it passes from the brain it receives sheaths from the three cerebral membranes, a perineural sheath from the pia mater, an intermediate sheath from the arachnoid, and an outer sheath from the dura mater, which is also connected with the periosteum as it passes through the optic foramen. These sheaths are separated from each other by spaces which communicate with the subdural and subarachnoid spaces respectively. The innermost or perineural sheath sends a process around the arteria centralis retinæ into the interior of the nerve, and enters intimately into its structure. Thus inflammatory affections of the meninges or of the brain may readily extend along these spaces, or along the interstitial connective tissue in the nerve.

The course of the fibres in the optic commissure has an important pathological bearing, and has been the subject of much controversy. Microscopic examination, experiments, and pathology all seem to point to the fact that there is a partial decussation of the fibres, each optic tract supplying the corresponding half of each eye, so that the right tract supplies the right half of each eye, and the left tract the left half of each eye. At the same time Charcot believes, and his view has met with general acceptation, that the fibres which do not decussate at the optic commissure have already decussated in the corpora quadrigemina, so that the lesion of the cerebral centre of one side causes complete blindness of the opposite eye, because both sets of decussating fibres are destroyed ; whereas if one tract, say the right, be destroyed by disease, there will be blindness of the right half of both retinæ.

An antero-posterior section through the commissure would divide the decussating fibres, and would therefore produce blindness of the inner half of each eye ; while a section at the margin of the side of the optic commissure would produce blindness of the external half of the retina of the same side. An early symptom of tumour-growth in the pituitary body would be pressure on the commissure.

The optic nerve may also be affected in injuries or diseases involving the orbit ; in fractures of the anterior fossa of the base of the skull ; in tumours of the orbit itself, or those invading this cavity from neighbouring parts.

Third Nerve (figs. 765, 766, 767, 769)

The **Third** or **Motor oculi nerve** (n. oculomotorius) supplies all the muscles of the orbit, except the Superior oblique and External rectus ; it also supplies, through its connection with the ciliary ganglion, the Sphincter muscle of the iris and the Ciliary muscle. It is a rather large nerve, of rounded form and firm texture.

The fibres of the third nerve arise from a nucleus which lies in the grey matter of the floor of the aqueduct of Sylvius and extends in front of the aqueduct for a short distance into the floor of the third ventricle. From their nucleus of origin the fibres pass forwards through the tegmentum, the red nucleus and the inner part of the substantia nigra, forming a series of curves with their convexity outwards, and emerge from the oculo-motor sulcus on the inner side of the crus cerebri.

The nucleus of the oculo-motor nerve does not consist of a continuous column of cells, but is broken up into a number of smaller nuclei, which may be arranged in two groups, anterior and posterior. Those of the posterior group are six in number, five of which are symmetrical on the two sides of the middle line, while the sixth is centrally placed and is common to the nerves of both sides. The anterior group consists of two nuclei, an antero-internal and an antero-external (fig. 765).

The nucleus of the third nerve is said to give fibres to the seventh nerve, which probably supply the Orbicularis palpebrarum, Corrugator supercilii, and anterior belly of the Occipito-frontalis.* It is also connected with the nuclei

* See footnote, p. 841.

of the fourth and sixth nerves, with the cerebellum, upper quadrigeminal body and cortex of the occipital lobe of the cerebrum.

Fig. 765.—Figure showing the different groups of cells, which constitute, according to Perlia, the nucleus of origin of the motor oculi nerve. (Testut.)

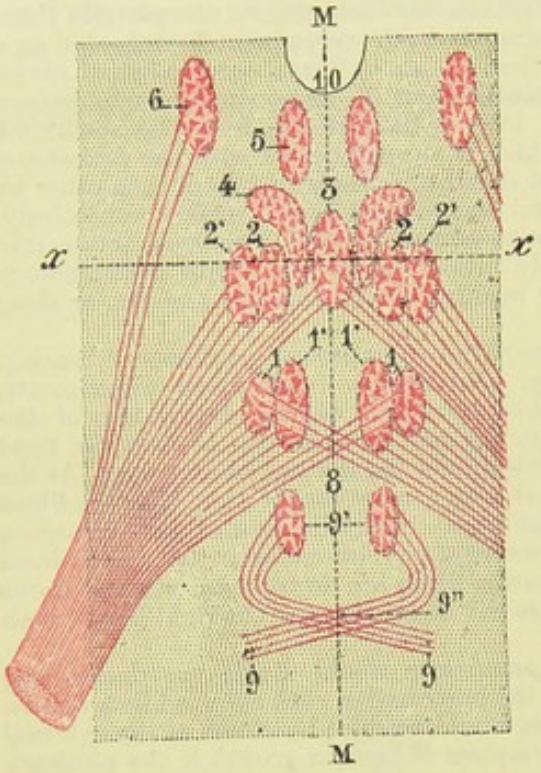

1. Posterior dorsal nucleus. 1'. Posterior ventral nucleus. 2. Anterior dorsal nucleus. 2'. Anterior ventral nucleus. 3. Central nucleus. 4. Nucleus of Edinger and Westphal. 5. Antero-internal nucleus. 6. Antero-external nucleus. 8. Crossed fibres. 9. Trochlear nerve, with 9', its nucleus of origin, and 9", its decussation. 10. Third ventricle. M, M. Median line.

The nucleus of the third nerve, considered from a physiological standpoint, can be subdivided into several smaller groups of cells, each group controlling a particular muscle. The nerves to the different muscles appear to take their origin from behind forwards, as follows: Inferior oblique, Inferior rectus, Superior rectus, Levator palpebræ, and Internal rectus; while from the anterior end of the nucleus the fibres for accommodation and for the Sphincter pupillæ take their origin.

On emerging from the brain, the nerve is invested with a sheath of pia mater, and enclosed in a prolongation from the arachnoid. It passes between the superior cerebellar and posterior cerebral arteries, and then pierces the dura mater in front of and external to the posterior clinoid process, passing between the free and attached borders of the tentorium, which are prolonged forwards to be connected with the anterior and posterior clinoid processes of the sphenoid bone. It passes along the outer wall of the cavernous sinus, above the other orbital nerves, receiving in its course one or two filaments from the cavernous plexus of the sympathetic, and a communicating branch from the first division of the fifth. It then divides into two branches, which enter the orbit through the sphenoidal fissure, between the two heads of the External rectus muscle. On passing

Fig. 766.—Plan of the motor oculi nerve. (After Flower.)

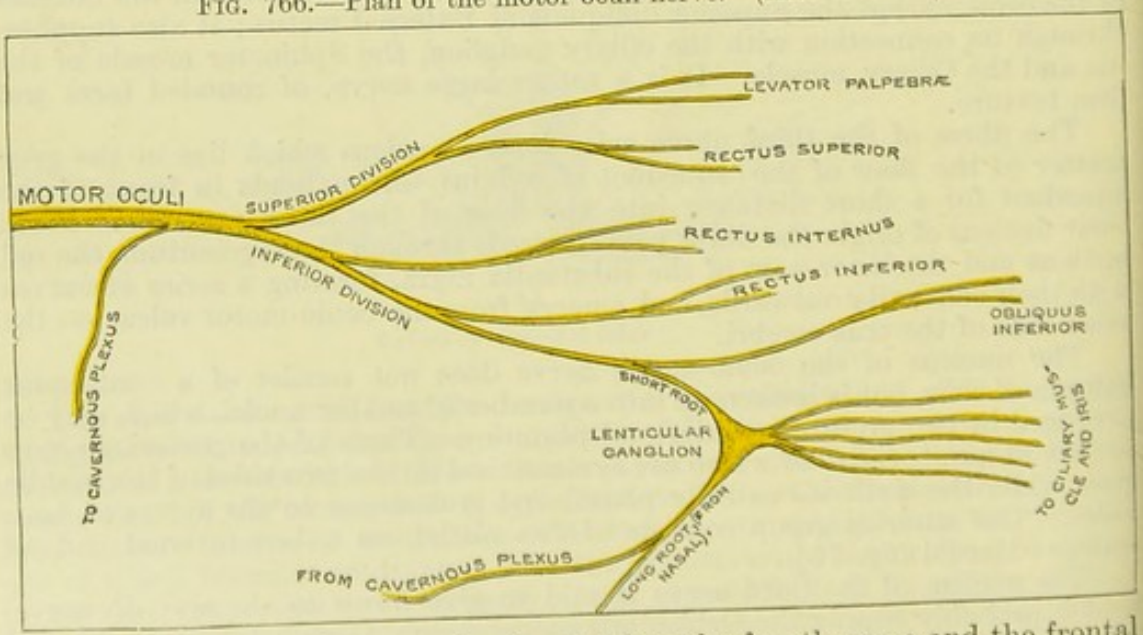

through the fissure, the nerve is placed below the fourth nerve and the frontal and lachrymal branches of the ophthalmic nerve, while the nasal nerve is placed between its two divisions.

The *superior division* (ramus superior), the smaller, passes inwards over the optic nerve, and supplies the Superior rectus and Levator palpebræ. The *inferior division* (ramus inferior), the larger, divides into three branches. One passes beneath the optic nerve to the Internal rectus ; another, to the Inferior rectus ; and the third, the longest of the three, runs forwards between the Inferior and External recti to the Inferior oblique. From this latter a short thick branch (radix brevis ganglii ciliaris) is given off to the lower part of the lenticular ganglion, and forms its inferior root. All these branches enter the muscles on their ocular surfaces, with the exception of the nerve to the Inferior oblique, which enters the muscle at its posterior border.

Applied Anatomy.—Paralysis of the third nerve may be the result of many causes, such as cerebral disease ; or conditions causing pressure on the cavernous sinus ; or periostitis of the bones entering into the formation of the sphenoidal fissure. It results, when complete, in (1) ptosis, or drooping of the upper eyelid, in consequence of the Levator palpebræ being paralysed ; (2) external strabismus, on account of the unopposed action of the External rectus and Superior oblique muscles, which are not supplied by the third nerve and are therefore not paralysed ; (3) dilation of the pupil, because the sphincter fibres of the iris are paralysed ; (4) loss of power of accommodation and of contraction on exposure to light, as the Sphincter pupillæ, the Ciliary muscle, and the Internal rectus are paralysed ; (5) slight prominence of the eyeball, owing to most of its muscles being relaxed ; (6) the patient will complain most of the diplopia, or double vision that occurs, the false image being higher than the true, and the separation of the two images increasing with movements inwards. Occasionally paralysis may affect only a part of the nerve—that is to say, there may be, for example, a dilated and fixed pupil, with ptosis, but no other signs. Irritation of the nerve causes spasm of one or other of the muscles supplied by it ; thus, there may be internal strabismus from spasm of the Internal rectus ; accommodation for near objects only, from spasm of the Ciliary muscle ; or miosis (contraction of the pupil) from irritation of the Sphincter of the pupil.

The third nerve is particularly liable to become involved in a syphilitic periarteritis as it leaves the base of the brain, when passing between the posterior cerebral and superior cerebellar arteries ; associated with locomotor ataxia various partial or complete paralyses of the nerve are often seen.

Fig. 767.—Nerves of the orbit. Seen from above.

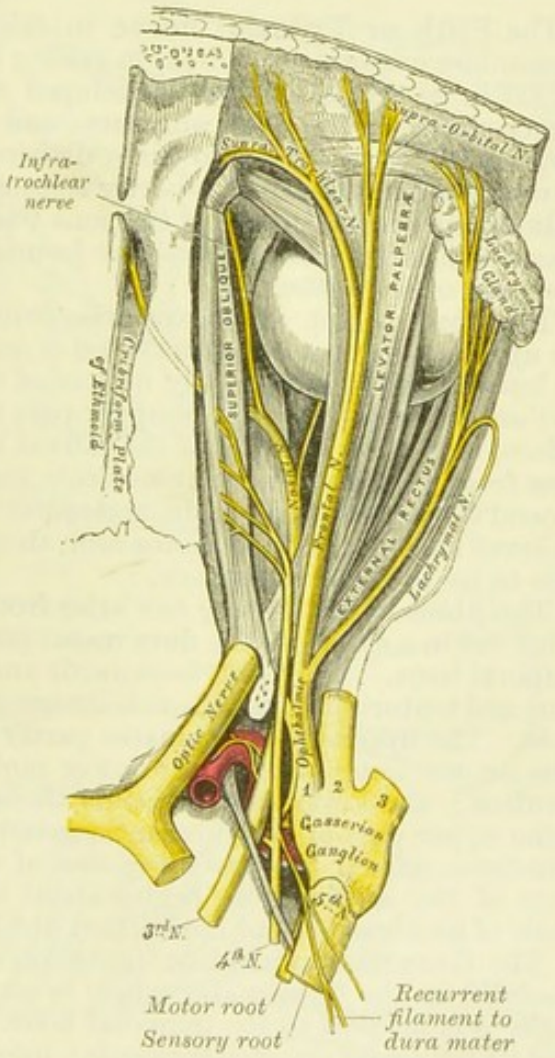

Fourth Nerve (fig. 767)

The **Fourth** or **Trochlear nerve** (n. trochlearis), the smallest of the cranial nerves, supplies the Superior oblique muscle of the eyeball.

It arises from a nucleus situated in the floor of the Sylvian aqueduct, opposite the upper part of the lower quadrigeminal body. From its origin the nerve runs outwards and downwards through the tegmentum, and then turns backwards and inwards into the upper part of the valve of Vieussens. Here it decussates with the corresponding nerve of the opposite side and emerges from the surface of the valve at the side of the frænulum veli, immediately behind the lower quadrigeminal body.

Emerging from the valve of Vieussens, the nerve is directed outwards across the superior peduncle of the cerebellum, and then winds forwards round the outer side of the crus cerebri, immediately above the pons Varolii, pierces the dura mater in the free border of the tentorium cerebelli, just behind, and external to, the posterior clinoid process, and passes forwards in the outer wall of the cavernous sinus, between the third nerve and the ophthalmic division of the fifth. It crosses the third nerve, and enters the orbit through the sphenoidal fissure. It now becomes the highest of all the nerves, and lies at the inner extremity of the fissure internal to the frontal nerve. In the orbit it passes inwards, above the origin of the Levator palpebræ, and finally enters the orbital surface of the Superior oblique.

Branches of communication.—In the outer wall of the cavernous sinus the fourth nerve forms communications with the ophthalmic division of the fifth and with the cavernous plexus of the sympathetic. In the sphenoidal fissure it occasionally gives off a branch to the lachrymal nerve. *Branches of distribution.*—It gives off a recurrent branch, which passes backwards between the layers of the tentorium, dividing into two or three filaments which may be traced as far back as the wall of the lateral sinus.

Applied Anatomy.—When the fourth nerve is paralysed there is loss of function in the Superior oblique, so that the patient is unable to turn his eye downwards and outwards. Should the patient attempt to do this, the eye of the affected side is twisted inwards, producing diplopia or double vision. Single vision exists in the whole of the field so long as the eyes look above the horizontal plane, but diplopia occurs on looking downwards. To counteract this the patient holds his head forwards, and also inclines it to the sound side.

Fifth Nerve

The **Fifth** or **Trifacial nerve** (n. trigeminus) is the largest cranial nerve. It resembles a spinal nerve : (1) in arising by two roots, a motor and a sensory ; and (2) in having a ganglion developed on its sensory root. It is the great sensory nerve of the head and face, and the motor nerve of the muscles of mastication. It divides into three divisions, the first and second of which are entirely sensory, the third is partly sensory and partly motor.

It emerges from the side of the pons Varolii, near its upper border, by a small *motor* and a large *sensory* root—the former being situated in front and to the inner side of the latter.

The fibres of the *motor root* arise from two nuclei, an upper and a lower. The *upper nucleus* consists of a strand of cells which occupies the whole length of the lateral portion of the grey matter of the Sylvian aqueduct. The *lower* or *chief nucleus* is situated in the upper part of the pons Varolii, close to its dorsal surface, and along the line of the lateral margin of the fourth ventricle. The fibres from the upper nucleus constitute the *mesencephalic* or *Sylvian root* : they descend through the mid-brain, and, entering the pons, join with the fibres from the lower nucleus ; and the motor root, thus formed, passes forwards through the pons to its point of emergence.

The fibres of the *sensory root* arise from the cells of the Gasserian ganglion which lies in a cavity of the dura mater near the apex of the petrous part of the temporal bone. They pass backwards and inwards below the superior petrosal sinus and tentorium cerebelli, and, entering the pons, divide into upper and lower roots. The upper root terminates partly in a nucleus which is situated in the pons on the outer side of the lower motor nucleus, and partly in the locus cœruleus ; the lower root descends through the pons and medulla, and ends in the upper part of the substantia gelatinosa of Rolando. This lower root is sometimes named the *ascending root* of the fifth nerve. Medullation of the fibres of the sensory root begins about the fifth month of fœtal life, but the whole of its fibres are not medullated until the third month after birth.

The **Gasserian ganglion** (ganglion semilunare) occupies a cavity (*cavum Meckelii*) in the dura mater which is situated on a depression near the apex of the petrous part of the temporal bone. It is somewhat crescentic in shape, with its convexity directed forwards ; internally it is in relation with the internal carotid artery and the posterior part of the cavernous sinus. The motor root runs forwards and outwards in front and to the inner side of the sensory root, and then passes below the ganglion without having any connection with it;

Fig. 768.—Plan of the fifth cranial nerve. (After Flower.)

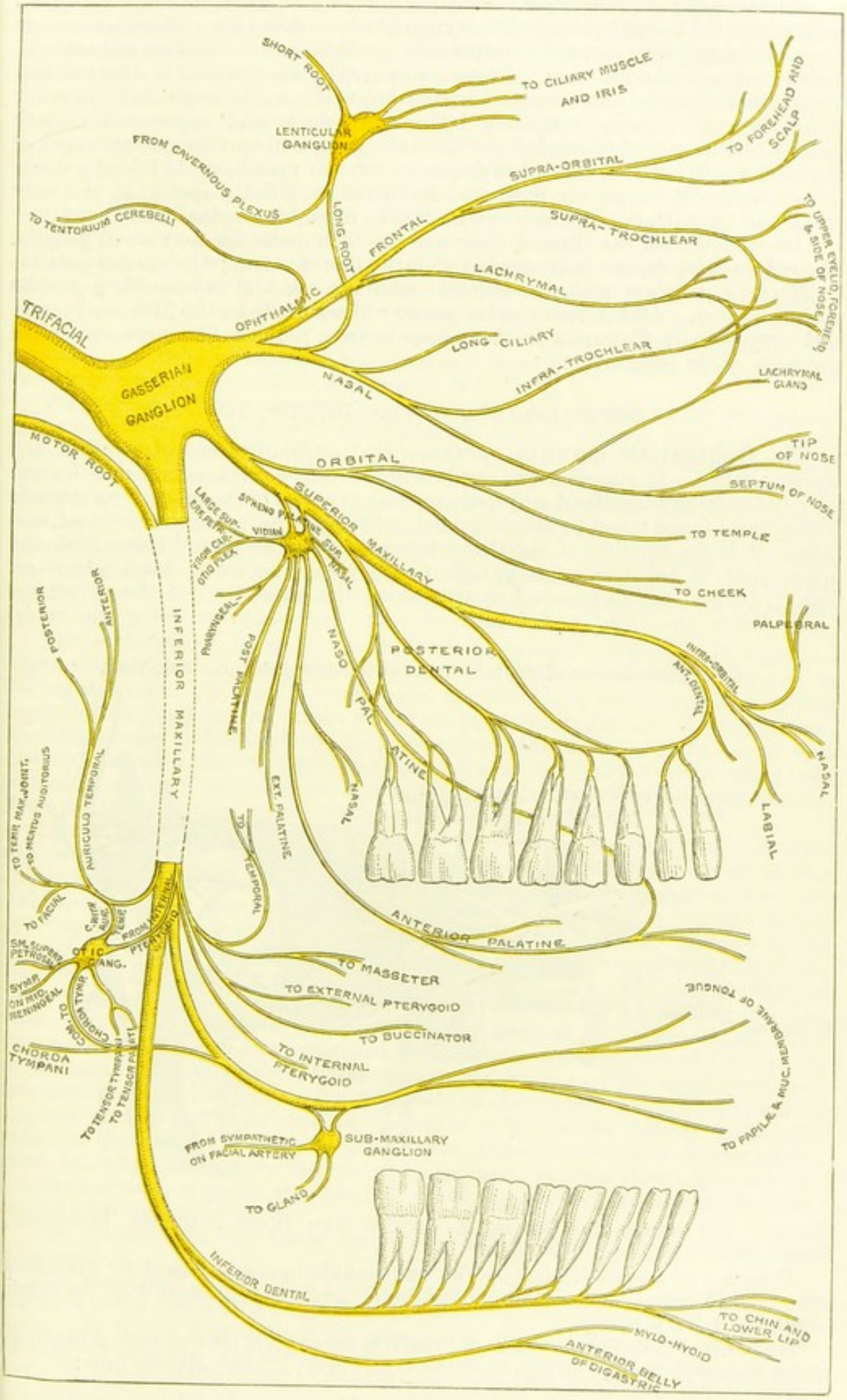

it leaves the skull through the foramen ovale, and, immediately below this foramen, joins the inferior maxillary nerve. Besides the motor root, the large superficial petrosal nerve lies underneath the ganglion.

Branches of communication.—This ganglion receives, on its inner side, filaments from the carotid plexus of the sympathetic. *Branches of distribution.*—It gives off minute branches to the tentorium cerebelli, and to the dura mater in the middle fossa of the cranium. From its convex border, which is directed forwards and outwards, three large branches proceed, viz. *the ophthalmic, superior maxillary*, and *inferior maxillary*. The ophthalmic and superior maxillary consist exclusively of fibres derived from the ganglion, and are solely nerves of common sensation. The third division, or inferior maxillary, is joined outside the cranium by the motor root, and is, therefore, strictly speaking, the only portion of the fifth nerve which can be said to resemble a spinal nerve.

Associated with the three divisions of the fifth nerve are four small ganglia. The *ophthalmic ganglion* is connected with the first division ; the *spheno-palatine* or *Meckel's ganglion* with the second ; and the *otic* and *submaxillary ganglia* with the third. All the four receive sensory filaments from the fifth, and motor and sympathetic filaments from various sources ; these filaments are called the *roots of the ganglia*.

Ophthalmic Nerve (figs. 767, 768, 769)

The **Ophthalmic nerve** (n. ophthalmicus), or first division of the fifth, is a sensory nerve. It supplies sensory branches to the cornea, ciliary muscle, and iris ; to the lachrymal gland and conjunctiva ; to a part of the mucous membrane of the nasal fossæ ; and to the integument of the eyelids, eyebrow, forehead, and nose. It is the smallest of the three divisions of the fifth, and arises from the upper part of the Gasserian ganglion as a short, flattened band, about an inch in length, which passes forwards along the outer wall of the cavernous sinus, below the third and fourth nerves ; just before entering the orbit,

Fig. 769.—Nerves of the orbit and ophthalmic ganglion. Side view.

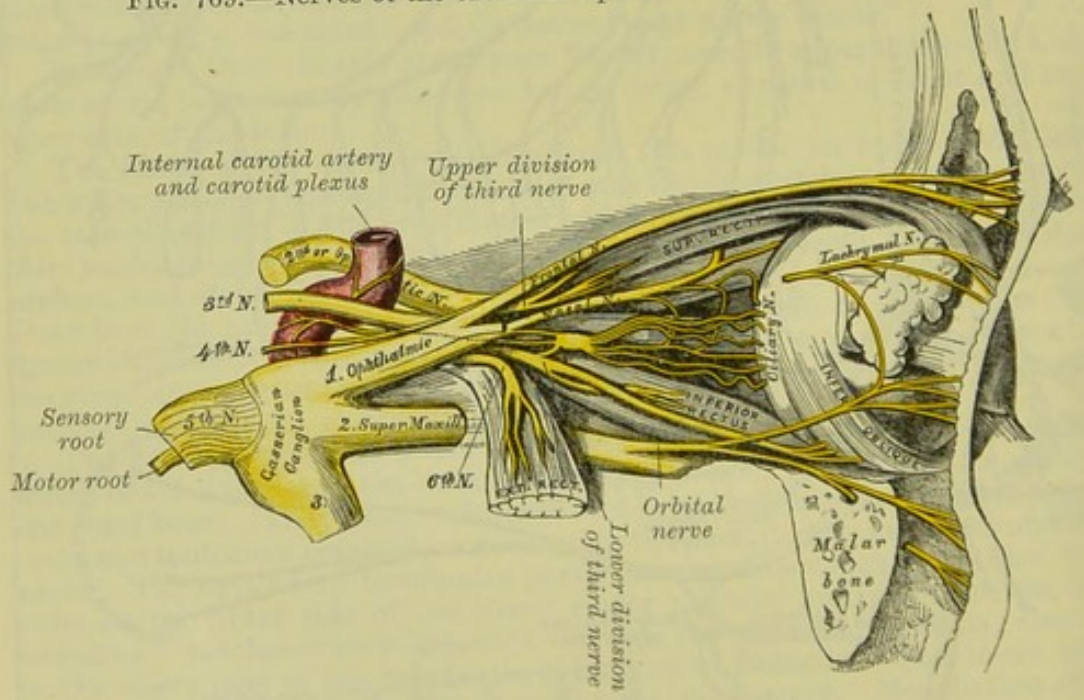

through the sphenoidal fissure, it divides into three branches, *lachrymal*, *frontal*, and *nasal*.

Branches of communication.—The ophthalmic nerve is joined by filaments from the cavernous plexus of the sympathetic, and communicates with the third, fourth, and sixth nerves.

Branches of distribution.—The ophthalmic nerve gives off a recurrent filament which passes between the layers of the tentorium : it then divides into :

Lachrymal. Frontal. Nasal.

The **lachrymal nerve** (n. lacrimalis) is the smallest of the three branches of the ophthalmic. It sometimes receives a filament from the fourth nerve, but this is possibly derived from the branch of communication which passes from the ophthalmic to the fourth. It passes forward in a separate tube of dura mater, and enters the orbit through the narrowest part of the sphenoidal fissure. In the orbit it runs along the upper border of the External rectus muscle, with the lachrymal artery, and communicates with the temporo-malar branch of the superior maxillary. It enters the lachrymal gland and gives off several filaments, which supply the gland and the conjunctiva. Finally it pierces the superior palpebral ligament, and terminates in the integument of the upper eyelid, joining with filaments of the facial nerve. The lachrymal nerve is occasionally absent, and in such cases its place is taken by the temporal branch of the superior maxillary. Sometimes the latter branch is absent, and a continuation of the lachrymal is substituted for it.

The **frontal nerve** (n. frontalis) is the largest division of the ophthalmic, and may be regarded, both from its size and direction, as the continuation of the nerve. It enters the orbit through the sphenoidal fissure, and runs forwards along the middle line, between the Levator palpebræ and the periosteum. Midway between the apex and base of the orbit it divides into two branches, supratrochlear and supraorbital.

The *supratrochlear nerve* (n. supratrochlearis), the smaller of the two, passes inwards, above the pulley of the Superior oblique muscle, and gives off a descending filament, which joins with the infratrochlear branch of the nasal nerve. It then escapes from the orbit between the pulley of the Superior oblique and the supraorbital foramen, curves up on to the forehead close to the bone, ascends beneath the Corrugator supercilii and Occipito-frontalis muscles, and dividing into branches, which pierce these muscles, it supplies the integument of the lower part of the forehead on either side of the middle line and sends filaments to the conjunctiva and skin of the upper eyelid.

The *supraorbital nerve* (n. supraorbitalis) passes forwards through the supraorbital foramen, and gives off, in this situation, palpebral filaments to the upper eyelid. It then ascends upon the forehead, and terminates in two branches, an inner and an outer, which supply the integument of the cranium, reaching nearly as far back as the parieto-occipital suture. They are at first situated beneath the Occipito-frontalis, the inner branch perforating the frontal portion of the muscle, the outer branch its tendinous aponeurosis. From its two branches, small twigs pass to the pericranium.

The **nasal nerve** (n. nasociliaris) is intermediate in size between the frontal and lachrymal, and is more deeply placed than the other branches of the ophthalmic. It enters the orbit between the two heads of the External rectus, and runs obliquely inwards across the optic nerve, beneath the Superior rectus and Superior oblique muscles, to the inner wall of the orbit. Here it passes through the anterior ethmoidal foramen, and, entering the cavity of the cranium, traverses a shallow groove on the front part of the cribriform plate of the ethmoid bone, and runs down, through the slit by the side of the crista galli, into the nose, where it divides into two branches, an internal and an external. The *internal branch* supplies the mucous membrane near the fore part of the septum of the nose. The *external branch* descends in a groove on the inner surface of the nasal bone, and supplies a few filaments to the mucous membrane covering the fore part of the outer wall of the nares as far as the inferior turbinated bone; it then leaves the cavity of the nose, between the lower border of the nasal bone and the upper lateral cartilage, and, passing down beneath the Compressor nasi, supplies the integument of the ala and the tip of the nose, joining with the facial nerve.

The branches of the nasal nerve are, the *ganglionic*, *long ciliary*, and *infratrochlear*.

The *ganglionic branch* (radix longa ganglii ciliaris), about half an inch in length, usually arises from the nasal between the two heads of the External rectus. It passes forwards on the outer side of the optic nerve, and enters the postero-superior angle of the ciliary ganglion, forming its superior or long root. It is sometimes joined by a filament from the cavernous plexus of the sympathetic, or from the superior division of the third nerve.

The *long ciliary nerves* (nn. ciliares longi), two or three in number, are given off from the nasal, as it crosses the optic nerve. They accompany the short ciliary nerves from the ciliary ganglion, pierce the posterior part of the sclerotic, and running forwards between it and the choroid, are distributed to the Ciliary muscle, iris, and cornea.

The *infratrochlear nerve* (n. infratrochlearis) is given off just before the nasal nerve enters the anterior ethmoidal foramen. It runs forwards along the upper border of the Internal rectus, and is joined, near the pulley of the Superior oblique, by a filament from the supratrochlear nerve. It then passes to the inner angle of the eye, and supplies the integument of the eyelids and side of the nose, the conjunctiva, lachrymal sac, and caruncula lacrimalis.

Ophthalmic Ganglion (figs. 766, 769)

The **ophthalmic** or **lenticular ganglion** (ganglion ciliare) is a small, quadrangular, flattened ganglion, of a reddish-grey colour, and about the size

Fig. 770.—Distribution of the second and third divisions of the fifth nerve, and submaxillary ganglion.

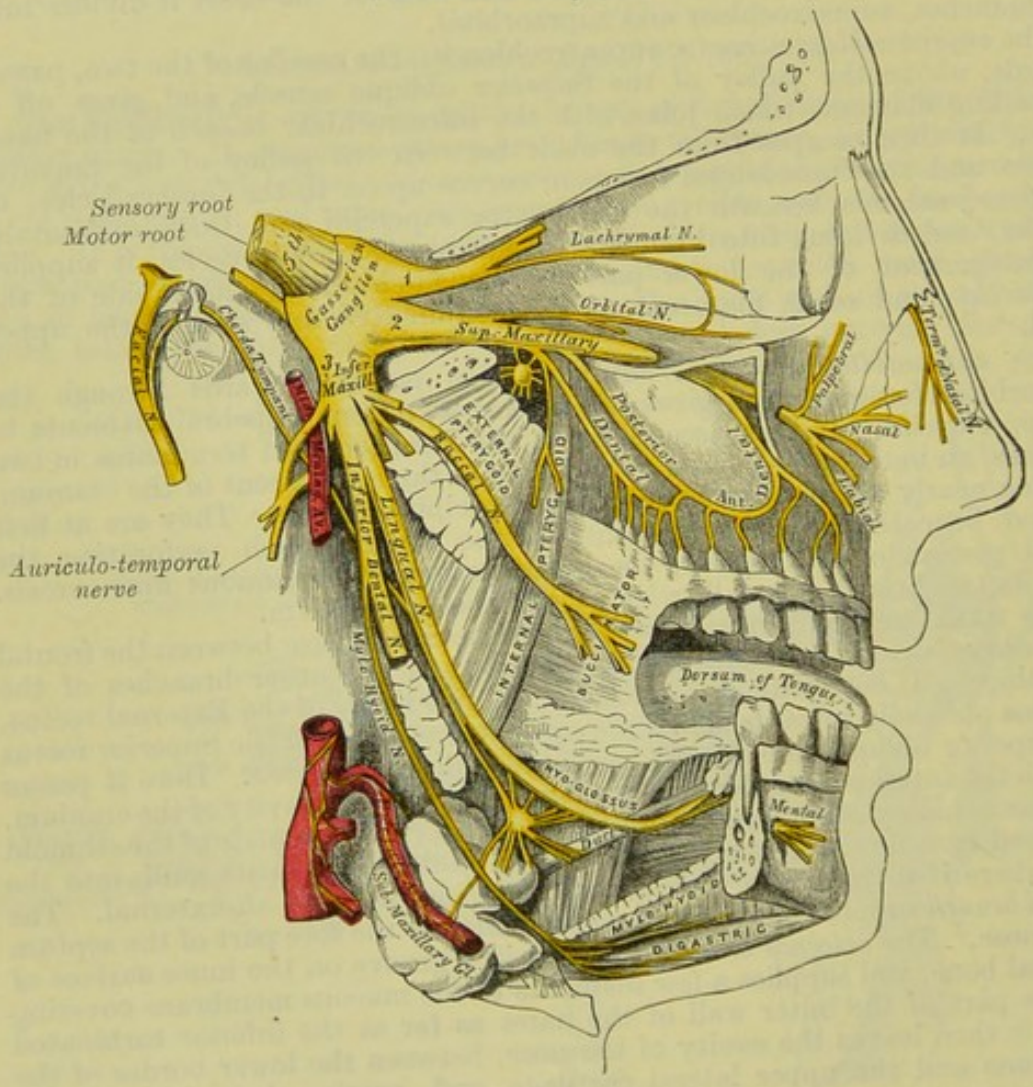

of a pin's head, situated at the back part of the orbit, in some loose fat between the optic nerve and the External rectus muscle, lying generally on the outer side of the ophthalmic artery.

Its *branches of communication*, or *roots*, are three, all of which enter its posterior border. One, the long or sensory root, is derived from the nasal branch of the ophthalmic, and joins its postero-superior angle. The second, the short or motor root, is a short, thick nerve, occasionally divided into two parts, which is derived from the branch of the third nerve to the Inferior oblique muscle, and is connected with the postero-inferior angle of the ganglion. The third, the

sympathetic root, is a slender filament from the cavernous plexus of the sympathetic. This is frequently blended with the long root, though it sometimes passes to the ganglion separately. According to Tiedemann, this ganglion receives a filament of communication from the spheno-palatine ganglion.

Its *branches of distribution* are the short ciliary nerves (nn. ciliares breves). These are delicate filaments, from six to ten in number, which arise from the fore part of the ganglion in two bundles connected with its superior and inferior angles; the lower bundle is the larger. They run forwards with the ciliary arteries in a wavy course, one set above and the other below the optic nerve, and are accompanied by the long ciliary nerves from the nasal. They pierce the sclera at the back part of the globe, pass forwards in delicate grooves on its inner surface, and are distributed to the Ciliary muscle, iris, and cornea. Tiedemann has described one small branch as penetrating the optic nerve with the arteria centralis retinæ.

Superior Maxillary Nerve (fig. 770)

The **Superior maxillary nerve** (n. maxillaris), or second division of the fifth, is a sensory nerve. It is intermediate, both in position and size, between the ophthalmic and inferior maxillary. It commences at the middle of the Gasserian ganglion as a flattened plexiform band, and, passing horizontally forwards, it leaves the skull through the foramen rotundum, where it becomes more cylindrical in form, and firmer in texture. It then crosses the spheno-maxillary fossa, inclines outwards on the back of the maxilla, and enters the orbit through the spheno-maxillary fissure; it traverses the infraorbital groove and canal in the floor of the orbit, and appears upon the face at the infraorbital foramen.* At its termination, the nerve lies beneath the Levator labii superioris muscle, and divides into a leash of branches which spread out upon the side of the nose, the lower eyelid, and the upper lip, joining with filaments of the facial nerve.

Branches of distribution.—The branches of this nerve may be divided into four groups, according as they are given off in the cranium, in the spheno-maxillary fossa, in the infraorbital canal, or on the face.

In the cranium	Meningeal.
In the spheno-maxillary fossa	Orbital or temporo-malar. Spheno-palatine. Posterior superior dental.
In the infraorbital canal	Middle superior dental. Anterior superior dental.
On the face	Palpebral. Nasal. Labial.

The **meningeal branch** (n. meningeus medius) is given off from the nerve directly after its origin from the Gasserian ganglion; it accompanies the middle meningeal artery and supplies the dura mater.

The **orbital** or **temporo-malar branch** (n. zygomaticus) arises in the spheno-maxillary fossa, enters the orbit by the spheno-maxillary fissure, and divides at the back of that cavity into two branches, temporal and malar.

The *temporal branch* (ramus zygomaticotemporalis) runs along the outer wall of the orbit in a groove in the malar bone, receives a branch of communication from the lachrymal, and, passing through a foramen in the malar bone, enters the temporal fossa. It ascends between the bone, and substance of the Temporal muscle, pierces the temporal fascia about an inch above the zygoma, and is distributed to the integument covering the temple and side of the forehead, communicating with the facial nerve and with the auriculo-temporal branch of the inferior maxillary. As it pierces the temporal fascia, it gives off a slender twig, which runs between the two layers of the fascia to the outer angle of the orbit.

The *malar branch* (ramus zygomaticofacialis) passes along the external inferior angle of the orbit, emerges upon the face through a foramen in the

* After it enters the infraorbital canal, the nerve is frequently called the *infraorbital*.

malar bone, and, perforating the Orbicularis palpebrarum muscle, supplies the skin on the prominence of the cheek. It joins with the facial nerve and with the palpebral branches of the superior maxillary.

The **spheno-palatine branches,** two in number, descend to the spheno-palatine ganglion.

The **posterior superior dental branches** (rami alveolares superiores posteriores) arise from the trunk of the nerve just as it is about to enter the infraorbital groove; they are generally two in number, but sometimes arise by a single trunk, and immediately divide and pass downwards on the tuberosity of the maxilla. They give off several twigs to the gums and neighbouring parts of the mucous membrane of the cheek. They then enter the posterior dental canals on the zygomatic surface of the maxilla, and, passing from behind forwards in the substance of the bone, communicate with the middle dental nerve, and give off branches to the lining membrane of the antrum and three twigs to each molar tooth. These twigs enter the foramina at the apices of the fangs, and supply the pulp.

The **middle superior dental branch** (ramus alveolaris superior medius) is given off from the superior maxillary nerve in the back part of the infraorbital canal, and runs downwards and forwards in a special canal in the outer wall of the antrum to supply the two biscupid teeth. It forms a plexus (plexus dentalis superior) with the posterior and anterior dental branches.

At its point of communication with the posterior branch is a slight thickening which has received the name of the *ganglion of Valentin*; and at its point of communication with the anterior branch is a second enlargement, which is called the *ganglion of Bochdalek*. Neither of these is a true ganglion.

The **anterior superior dental branch** (ramus alveolaris superior anterior), of considerable size, is given off from the superior maxillary nerve just before its exit from the infraorbital foramen; it enters a special canal in the anterior wall of the antrum, and divides into a series of branches which supply the incisor and canine teeth. It communicates with the middle dental nerve, and gives off a *nasal branch*, which passes through a minute canal into the nasal fossa, and supplies the mucous membrane of the fore part of the inferior meatus and the floor of this cavity, communicating with the nasal branches from Meckel's ganglion.

The **palpebral branches** (rami palpebrales inferiores) pass upwards beneath the Orbicularis palpebrarum. They supply the integument and conjunctiva of the lower eyelid, joining at the outer angle of the orbit with the facial nerve and malar branch of the orbital.

The **nasal branches** (rami nasales externi) pass inwards; they supply the integument of the side of the nose, and join with the nasal branch of the ophthalmic.

The **labial branches** (rami labiales superiores), the largest and most numerous, descend beneath the Levator labii superioris, and are distributed to the integument of the upper lip, the mucous membrane of the mouth, and labial glands.

All these branches are joined, immediately beneath the orbit, by filaments from the facial nerve, forming an intricate plexus, the *infraorbital*.

Spheno-palatine Ganglion (fig. 771)

The **spheno-palatine ganglion** (ganglion sphenopalatinum), or ganglion of Meckel, the largest of the ganglia associated with the branches of the fifth nerve, is deeply placed in the spheno-maxillary fossa, close to the spheno-palatine foramen. It is triangular or heart-shaped, of a reddish-grey colour, and is situated just below the superior maxillary nerve as it crosses the fossa.

Branches of communication.—Like the other ganglia of the fifth nerve, the spheno-palatine possesses a motor, a sensory, and a sympathetic root. Its *sensory root* is derived from the superior maxillary nerve through its two spheno-palatine branches. These branches of the nerve, given off in the spheno-maxillary fossa, descend to the ganglion. Their fibres, for the most part, pass in front of the ganglion, as they proceed to their destination, in the palate and nasal fossa, and are not incorporated in the ganglionic mass; some few of the fibres, however,

enter the ganglion, constituting its sensory root. Its *motor root* is probably derived from the facial nerve through the large superficial petrosal nerve but this nerve consists chiefly of sensory fibres, and its *sympathetic root*, from the carotid plexus, through the large deep petrosal nerve. These two nerves join together to form a single nerve, the *Vidian*, before their entrance into the ganglion.

The *large superficial petrosal branch* (n. petrosus superficialis major) is given off from the geniculate ganglion of the facial nerve in the aqueductus Fallopii; it passes through the hiatus Fallopii, enters the cranial cavity, and runs forwards contained in a groove on the anterior surface of the petrous portion of the temporal bone, lying beneath the dura mater. It then enters the cartilaginous substance which fills in the foramen lacerum medium, and joining with the large deep petrosal branch forms the Vidian nerve.

The *large deep petrosal branch* (n. petrosus profundus) is given off from the carotid plexus, and runs through the carotid canal on the outer side of the internal carotid artery. It then enters the cartilaginous substance which fills in the foramen lacerum medium, and joins with the large superficial petrosal nerve to form the Vidian.

FIG. 771.—The spheno-palatine ganglion and its branches.

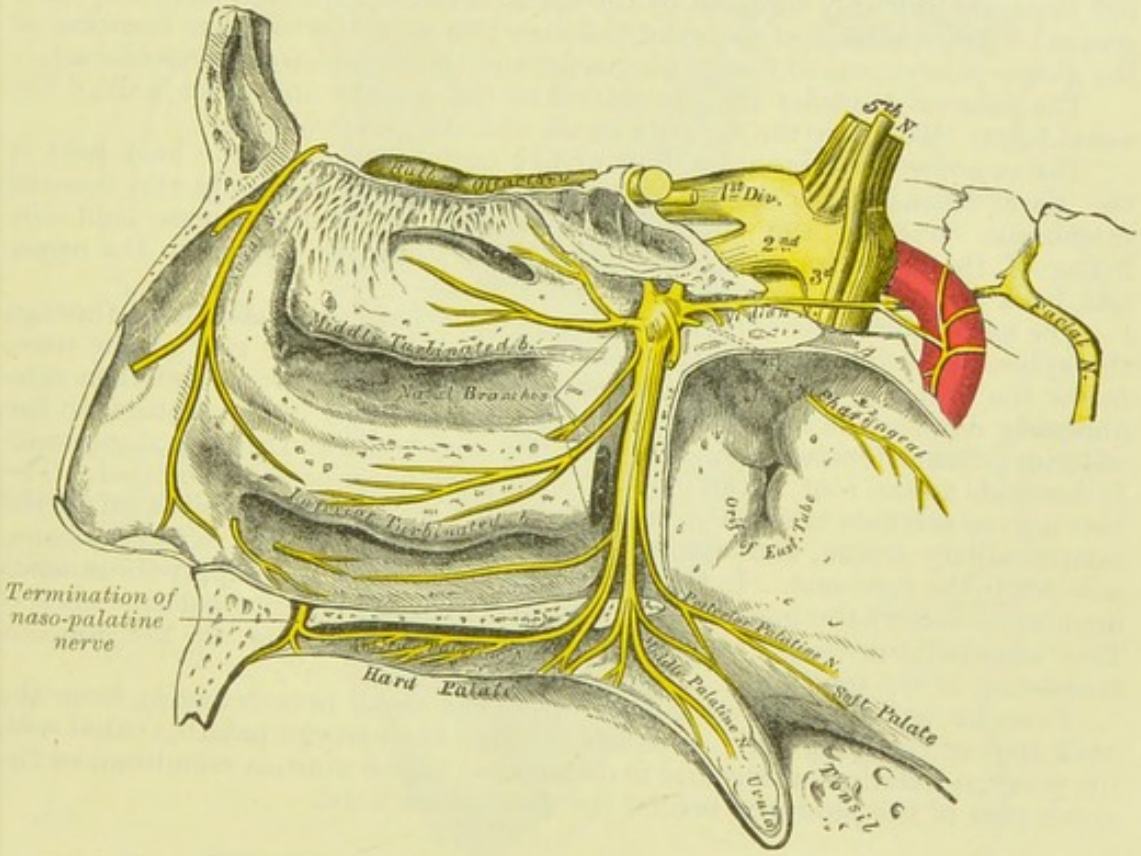

The *Vidian nerve* (n. canalis pterygoidei), formed by the junction of the two preceding nerves in the cartilaginous substance which fills in the middle lacerated foramen, passes forwards, through the Vidian canal, with the artery of the same name, and is joined by a small ascending branch, the *sphenoidal branch*, from the otic ganglion. Finally, it enters the spheno-maxillary fossa, and joins the posterior angle of Meckel's ganglion.

Branches of distribution.—These are divisible into four groups, viz. *ascending* branches, which pass to the orbit; *descending*, to the palate; *internal*, to the nose; and *posterior*, to the nasopharynx.

The *ascending branches* (rami orbitales) are two or three delicate filaments, which enter the orbit by the spheno-maxillary fissure, and supply the periosteum. According to Luschka, some filaments pass through foramina in the suture between the os planum of the ethmoid and frontal bone to supply the mucous membrane of the posterior ethmoidal and sphenoidal sinuses.

The *descending* or *palatine branches* (nn. palatini) are distributed to the roof of the mouth, soft palate, tonsil, and lining membrane of the nose. They are

almost a direct continuation of the spheno-palatine branches of the superior maxillary nerve, and are three in number : anterior, middle, and posterior.

The *anterior palatine nerve* (n. palatinus anterior) descends through the posterior palatine canal, emerges upon the hard palate at the posterior palatine foramen, and passes forwards in a groove in the hard palate, nearly as far as the incisor teeth. It supplies the gums, the mucous membrane and glands of the hard palate, and communicates in front with the termination of the naso-palatine nerve. While in the posterior palatine canal, it gives off *inferior nasal branches*, which enter the nose through openings in the palate bone, and ramify over the inferior turbinated bone and middle and inferior meatuses ; and, at its exit from the canal, a palatine branch is distributed to both surfaces of the soft palate.

The *middle palatine nerve* (n. palatinus medius) descends, through one of the accessory palatine canals, distributing branches to the uvula, tonsil, and soft palate. It is occasionally wanting.

The *posterior palatine nerve* (n. palatinus posterior) descends through the posterior palatine canal, and emerges by a separate opening behind the posterior palatine foramen. It supplies the soft palate, tonsil, and uvula, and was formerly believed to supply the Levator palati and Azygos uvulæ muscles, but these are probably supplied by the spinal accessory through the pharyngeal plexus. The middle and posterior palatine join with the tonsillar branches of the glosso-pharyngeal to form a plexus around the tonsil (*circulus tonsillaris*).

The *internal branches* are distributed to the septum and outer wall of the nasal fossa. They are the superior nasal and the naso-palatine.

The *superior nasal branches*, four or five in number, enter the back part of the nasal fossa by the spheno-palatine foramen. They supply the mucous membrane covering the superior and middle turbinated bones, and the lining of the posterior ethmoidal cells, a few being prolonged to the upper and back part of the septum.

The *naso-palatine nerve* (n. nasopalatinus) also enters the nasal fossa through the spheno-palatine foramen ; it passes inwards across the roof of the nose, below the orifice of the sphenoidal sinus to reach the septum, and then runs obliquely downwards and forwards along the lower part of the septum, to the anterior palatine foramen, lying between the periosteum and mucous membrane. It descends to the roof of the mouth through the anterior palatine canal. The two nerves are here contained in separate and distinct canals, situated in the intermaxillary suture, and termed the *foramina of Scarpa*, the left nerve being anterior to the right one. In the mouth, they become united, supply the mucous membrane behind the incisor teeth, and join with the anterior palatine nerves. The naso-palatine nerve furnishes a few small filaments to the mucous membrane of the septum.

Posterior branch.—The *pharyngeal nerve* is a small branch arising from the back part of the ganglion. It passes through the pterygo-palatine canal with the pterygo-palatine artery, and is distributed to the mucous membrane of the upper part of the pharynx, behind the Eustachian tube.

Inferior Maxillary Nerve (figs. 768, 770, 772)

The **Inferior maxillary nerve** (n. mandibularis) distributes branches to the teeth and gums of the lower jaw, the integument of the temple and external ear, the lower part of the face and lower lip, and the muscles of mastication; it also supplies a large branch to the tongue. It is the largest of the three divisions of the fifth, and is made up of two roots : a large or sensory root proceeding from the inferior angle of the Gasserian ganglion ; and a small or motor root, which passes beneath the ganglion, and unites with the sensory root, just after its exit from the skull through the foramen ovale. Immediately beneath the base of the skull, the nerve divides into two trunks, anterior and posterior. Previous to its division, the primary trunk gives off from its inner side a recurrent (meningeal) branch, and the nerve to the Internal pterygoid.

The **recurrent branch** (n. spinosus) is given off directly after its exit from the foramen ovale. It passes backwards into the skull through the foramen spinosum with the middle meningeal artery. It divides into two branches, anterior and posterior, which accompany the main divisions of the artery

and supply the dura mater. The posterior branch also supplies the mucous lining of the mastoid cells. The anterior branch communicates with the meningeal branch of the superior maxillary nerve.

The nerve to the **internal pterygoid** (n. pterygoideus internus), given off from the inferior maxillary before it divides, is intimately connected at its origin with the otic ganglion. It is a slender branch, which passes inwards and enters the deep surface of the Internal pterygoid.

The *anterior* and smaller division, which receives nearly the whole of the motor root, divides into branches which supply the muscles of mastication and the skin and mucous membrane of the cheek. They are the masseteric, deep temporal, long buccal, and external pterygoid.

The **masseteric branch** (n. massetericus) passes outwards, above the External pterygoid, in front of the temporo-mandibular articulation, and behind

Fig. 772.—The External pterygoid muscle and the branches of the inferior maxillary nerve in relation to it.

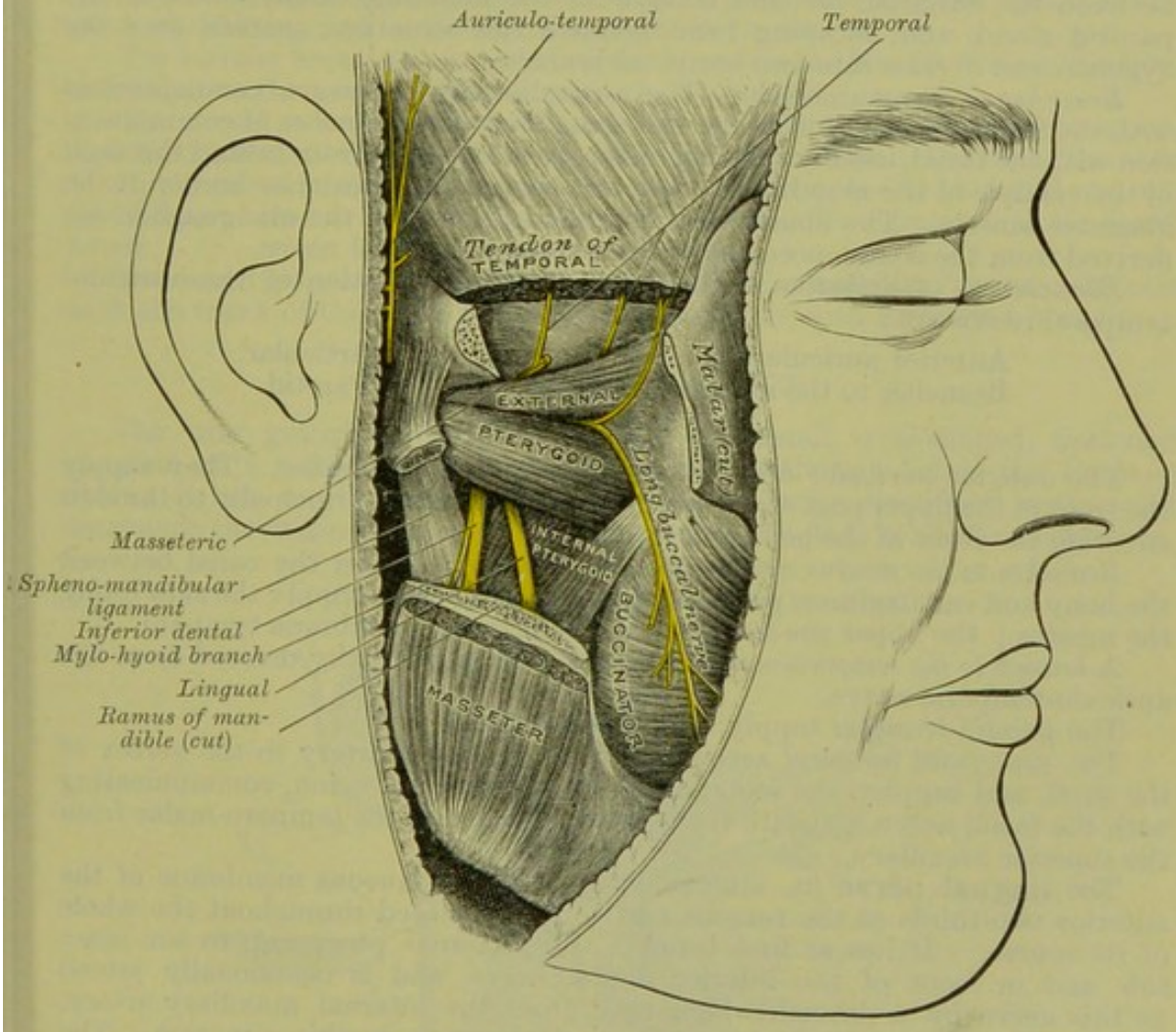

the tendon of the Temporal; it crosses the sigmoid notch with the masseteric artery, to the deep surface of the Masseter, in which it ramifies nearly as far as its anterior border. It gives a filament to the temporo-mandibular joint.

The **deep temporal branches** (nn. temporales profundi) are two in number, anterior and posterior. They pass above the upper border of the External pterygoid and enter the deep surface of the Temporal. The *posterior branch*, of small size, is placed at the back of the temporal fossa. It sometimes arises in common with the masseteric branch. The *anterior branch* is frequently given off with the buccal nerve, and then turns upwards over the upper head of the External pterygoid. Frequently a third branch (*middle deep temporal*) is present.

The **long buccal branch** (n. buccinatorius) passes forwards between the two heads of the External pterygoid, and downwards beneath or through

the fibres of the Temporal; it emerges from under the anterior border of the Masseter, ramifies on the surface of the Buccinator, and unites with the buccal branches of the facial nerve. It gives a branch to the External pterygoid during its passage through that muscle, and may give off the anterior deep temporal nerve. The long buccal branch supplies the integument over the Buccinator muscle, and the mucous membrane lining its inner surface.

The nerve to the **external pterygoid** (n. pterygoideus externus) frequently arises in conjunction with the long buccal, but it may be given off separately from the anterior trunk of the nerve. It enters the muscle on its inner surface.

The *posterior* and larger division of the inferior maxillary nerve is for the most part sensory, but receives a few filaments from the motor root. It divides into three branches: auriculo-temporal, lingual, and inferior dental.

The **auriculo-temporal nerve** (n. auriculotemporalis) generally arises by two roots, between which the middle meningeal artery passes. It runs backwards beneath the External pterygoid muscle to the inner side of the neck of the mandible. It then turns upwards with the temporal artery, between the external ear and condyle of the mandible, under cover of the parotid gland, and, escaping from beneath this structure, ascends over the zygoma, and divides into two temporal branches.

Branches of communication.—The auriculo-temporal nerve communicates with the facial nerve and with the otic ganglion. The branches of communication with the facial, usually two in number, pass forwards, from behind the neck of the condyle of the mandible, to join this nerve at the posterior border of the Masseter muscle. The filaments of communication with the otic ganglion are derived from the commencement of the auriculo-temporal nerve.

Branches of distribution.—The branches of distribution of the auriculo-temporal nerve are:

Anterior auricular.
Branches to the meatus auditorius.
Superficial temporal.
Articular.
Parotid.

The *anterior auricular branches* are usually two in number. They supply the front of the upper part of the pinna, being distributed principally to the skin covering the front of the helix and tragus.

Branches to the meatus auditorius, two in number, enter the canal between the bony and cartilaginous portions of the meatus. They supply the skin lining the meatus; the upper one sending a filament to the membrana tympani.

A *branch to the temporo-mandibular articulation* is usually derived from the auriculo-temporal nerve.

The *parotid branches* supply the parotid gland.

The *superficial temporal* accompanies the temporal artery to the vertex of the skull, and supplies the integument of the temporal region, communicating with the facial nerve, and with the temporal branch of the temporo-malar from the superior maxillary.

The **lingual nerve** (n. lingualis) supplies the mucous membrane of the anterior two-thirds of the tongue, and is deeply placed throughout the whole of its course. It lies at first beneath the External pterygoid, to the inner side and in front of the inferior dental nerve, and is occasionally joined to this nerve by a branch which may cross the internal maxillary artery. The chorda tympani also joins it at an acute angle in this situation. The nerve then passes between the Internal pterygoid muscle and the inner side of the ramus of the mandible, and crosses obliquely to the side of the tongue over the Superior constrictor and Stylo-glossus, and then between the Hyo-glossus and deep part of the submaxillary gland; it finally runs across Wharton's duct, and along the tongue to its tip, lying immediately beneath the mucous membrane.

The *branches of communication* are with the facial (through the chorda tympani), the inferior dental and hypoglossal nerves, and the submaxillary ganglion. The branches to the submaxillary ganglion are two or three in number; those connected with the hypoglossal nerve form a plexus at the anterior margin of the Hyo-glossus.

The *branches of distribution* supply the mucous membrane of the mouth, the gums, the sublingual gland, and the mucous membrane of the anterior

two-thirds of the tongue ; the terminal filaments communicate, at the tip of the tongue, with the hypoglossal nerve.

The **inferior dental nerve** (n. alveolaris inferior) is the largest of the three branches of the inferior maxillary nerve. It passes downwards with the inferior dental artery, at first beneath the External pterygoid muscle, and then between the internal lateral ligament and the ramus of the mandible to the dental foramen. It then passes forwards in the inferior dental canal, lying beneath the teeth, as far as the mental foramen, where it divides into two terminal branches, incisive and mental.

The branches of the inferior dental are the mylo-hyoid, dental, incisive, and mental.

The *mylo-hyoid nerve* (n. mylohyoideus) is derived from the inferior dental just as that nerve is about to enter the dental foramen. It descends in a groove on the inner surface of the ramus of the mandible, and reaching the under surface of the Mylo-hyoid supplies this muscle and the anterior belly of the Digastric.

The *dental branches* supply the molar and biscupid teeth. They correspond in number to the fangs of those teeth ; each nerve entering the orifice at the point of the fang, and supplying the pulp of the tooth.

The *incisive branch* is continued onwards within the bone to the middle line, and supplies the canine and incisor teeth.

The *mental nerve* (n. mentalis) emerges from the bone at the mental foramen, and divides beneath the Depressor anguli oris into three branches ; one descends to supply the skin of the chin, and two ascend to supply the skin and mucous membrane of the lower lip. These branches communicate freely with the facial nerve.

Two small ganglia are connected with the inferior maxillary nerve : the otic with the trunk of the nerve ; and the submaxillary with its lingual branch.

Otic Ganglion (fig. 773)

The **otic ganglion** (ganglion oticum) is a small, oval-shaped, flattened ganglion of a reddish-grey colour, situated immediately below the foramen ovale ; it lies on the inner surface of the inferior maxillary nerve, and surrounds the origin of the internal pterygoid nerve. It is in relation, *externally*,

Fig. 773.—The otic ganglion and its branches.

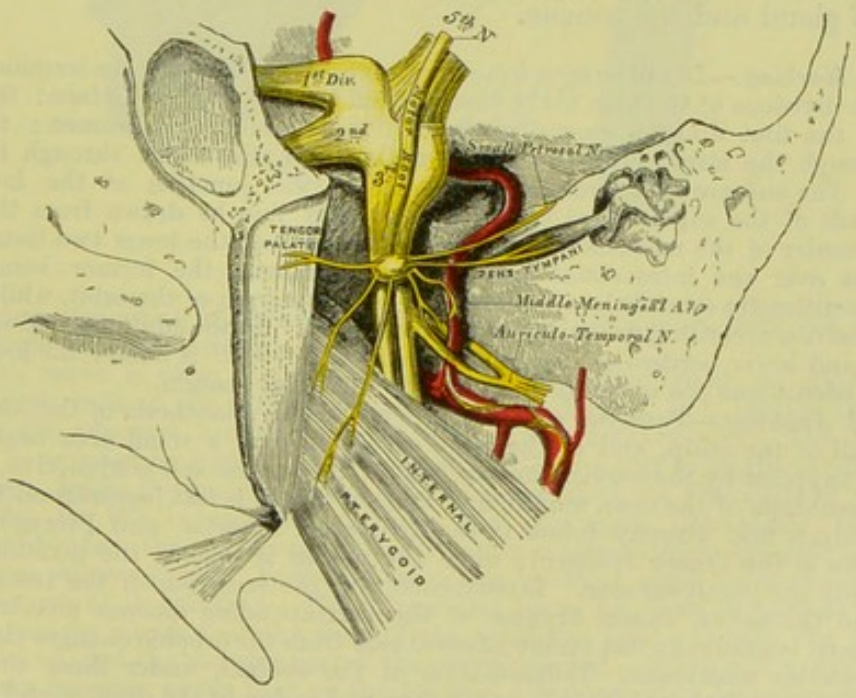

with the trunk of the inferior maxillary nerve, at the point where the motor root joins the sensory portion ; *internally*, with the cartilaginous part of the Eustachian tube, and the origin of the Tensor palati muscle ; *behind*, with the middle meningeal artery.

Branches of communication.—It is connected by two or three short delicate filaments with the internal pterygoid branch of the inferior maxillary nerve, from which it may obtain a motor, and possibly also a sensory root. It communicates with the glosso-pharyngeal and facial nerves, through the small superficial petrosal nerve continued from the tympanic plexus, and through this communication it probably receives a sensory root from the glosso-pharyngeal and a motor root from the facial; its communication with the sympathetic is effected by a filament from the plexus surrounding the middle meningeal artery. The ganglion also communicates with the auriculo-temporal nerve by a branch which is probably derived from the glosso-pharyngeal, and which passes to the ganglion, and then through it and the auriculo-temporal nerve to the parotid gland. A slender filament (*sphenoidal*) ascends from it to the Vidian nerve, and a small branch communicates with the chorda tympani.

Its *branches of distribution* are, a filament to the Tensor tympani, and one to the Tensor palati. The former passes backwards, on the outer side of the Eustachian tube; the latter arises from the ganglion, near the origin of the internal pterygoid nerve, and passes forwards. The fibres of these nerves are, however, mainly derived from the nerve to the Internal pterygoid.

Submaxillary Ganglion (fig. 770)

The **submaxillary ganglion** (ganglion submaxillare) is of small size and is fusiform in shape. It is situated above the deep portion of the submaxillary gland, on the Hyo-glossus muscle, near the posterior border of the Mylo-hyoid, and is connected by filaments with the lower border of the lingual nerve.

Branches of communication.—This ganglion is suspended from the lingual nerve by two filaments which join the front and back parts of the ganglion. It also receives a branch from the chorda tympani nerve, and communicates with the sympathetic by filaments from the sympathetic plexus around the facial artery.

Branches of distribution.—These are five or six in number; they arise from the lower part of the ganglion, and supply the mucous membrane of the mouth and Wharton's duct, some being lost in the submaxillary gland. The branch of communication from the lingual to the fore part of the ganglion is by some regarded as a branch of distribution, through which filaments of the chorda tympani pass from the ganglion to the nerve, and by it are conveyed to the sublingual gland and the tongue.

Surface Marking.—It will be seen from the above description that the terminal branches of the three divisions of the fifth nerve emerge from foramina on to the face: the terminal branch of the first division emerging through the supraorbital foramen; that of the second through the infraorbital foramen; and that of the third through the mental foramen. The supraorbital foramen is situated at the junction of the internal and middle thirds of the supraorbital arch. If a straight line be drawn from this point to the lower border of the mandible, so that it passes between the lower two bicuspid teeth, it will pass over the infraorbital and mental foramina; the former being situated about one centimetre (two-fifths of an inch) below the margin of the orbit, while the latter varies in position according to the age of the individual. In the adult it is midway between the upper and lower borders of the mandible; in the child it is nearer the lower border, and in the edentulous jaw of old age it is close to the upper margin.

Applied Anatomy.—Paralysis of the fifth nerve causes anæsthesia of the corresponding anterior half of the scalp, and of the face, excepting over a small area near the angle of the jaw supplied by the cervical nerves, and of the cornea and conjunctiva, and of the mucous membrane of the nose, mouth, and tongue. Taste is lost (*ageusia*) on the affected side. Paralysis and atrophy follow in the Temporal, Masseter, and Pterygoid muscles, possibly also in the Tensor tympani; when the mouth is opened the mandible is thrust over towards the paralysed side. Interference with the secretion of the tears, the nasal mucus, and the saliva, causes dryness of the corresponding mucous membranes. The sense of smell is gradually lost on the affected side from the trophic changes that follow in the Schneiderian membrane. Inflammation of the eyeball, under these circumstances known as neuroparalytic ophthalmia, is not rare, and is due to the dryness and insensitiveness of the conjunctiva; it is not a 'trophic' phenomenon, but depends on the occurrence and neglect of traumatic inflammation in the anæsthetic eye.

Fifth nerve reflexes.—Pains referred to various branches of the fifth cranial nerve are of very frequent occurrence, and should always lead to a careful examination in order to discover a local cause. As a general rule the diffusion of pain over the various branches

of the nerve is at first confined to one only of the main divisions, and the search for the causative lesion should always commence with a thorough examination of all those parts which are supplied by that division ; although in severe cases pain may radiate over the branches of the other main divisions. The commonest example of this condition is the neuralgia which is so often associated with dental caries—here, although the tooth itself may not appear to be painful, the most distressing referred pains may be experienced, and these are at once relieved by treatment directed to the affected tooth.

Many other examples of ' fifth nerve ' reflexes could be quoted, but it will be sufficient to mention the more common ones. Dealing with the ophthalmic division, severe supra-orbital pain is commonly associated with acute glaucoma or with disease of the frontal or ethmoidal air-cells. Malignant growths or empyema of the maxillary antrum, or unhealthy conditions about the inferior turbinateds or the septum of the nose, are often found giving rise to ' second division ' neuralgia, and should be always looked for in the absence of dental disease in the maxilla.

It is on the third division, however, that some of the most striking reflexes are seen. It is quite common to meet with patients who complain of pain in the ear, in whom there is no sign of aural disease, and the cause is usually to be found in a carious tooth in the mandible. Moreover, with an ulcer or cancer of the tongue, often the first pain to be

FIG. 774.—Diagram showing cutaneous areas of face and scalp.

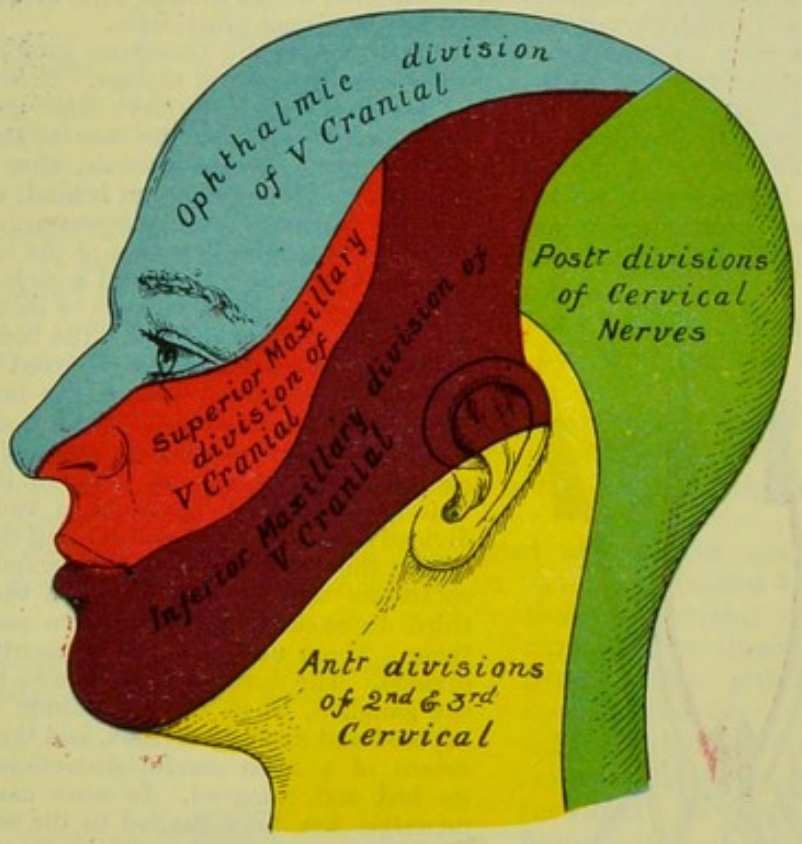

experienced is one which radiates to the ear and temporal fossa, over the distribution of the auriculo-temporal nerve.

The fifth nerve is often the seat of severe neuralgia for which no local cause can be discovered; each of the three divisions has been divided, or a portion of the nerve excised, for this affection, usually, however, with only temporary relief. The supraorbital nerve may be exposed by making an incision an inch and a half in length along the supra-orbital margin, below the eyebrow which is to be drawn upwards, the centre of the incision corresponding to the supraorbital notch. The skin and Orbicularis palpebrarum having been divided, the nerve can be easily found emerging from the notch, and lying in some loose cellular tissue. It should be drawn up by a blunt hook and divided, or, better, a portion of it removed. The infraorbital nerve has been divided at its exit by an incision on the cheek ; or the floor of the orbit has been exposed, the infraorbital canal opened up, and the anterior part of the nerve resected ; or the whole nerve, together with Meckel's ganglion as far back as the foramen rotundum may be removed, but even then a return of the neuralgia in some other branches of the fifth nerve is the rule rather than the exception. The operation is performed as follows : the superior maxillary bone is first exposed by a T-shaped incision, one limb passing along the lower margin of the orbit, the other from the centre of this vertically down the cheek to the angle of the mouth. The nerve is to be found, divided, and a piece of silk tied to it as a guide.

A small trephine (half-inch) is applied to the bone, below, but including the infraorbital foramen, and the antrum opened. The trephine is then applied to the posterior wall of the antrum, and the spheno-maxillary fossa exposed. The infraorbital canal is opened up from below, and the nerve drawn down into the trephine hole, it being held on the stretch by means of the piece of silk; it is severed with fine curved scissors as near the foramen rotundum as possible, any branches coming off from the ganglion being also divided. The inferior dental nerve can be reached by a transverse incision over the ramus of the jaw placed so as to avoid injury to the facial nerve; the Masseter muscle having been divided, a small trephine is applied to the ramus immediately beneath the masseteric notch, and, when the bone has been removed, the nerve is found lying on the Internal pterygoid just as it enters the inferior dental canal, and it can here be resected.

The lingual (gustatory) nerve is occasionally divided with the view of relieving the pain in cancerous disease of the tongue. This may be done in that part of its course where it lies below and behind the last molar tooth. If a line be drawn from the middle of the crown of the last molar tooth to the angle of the jaw it will cross the nerve, which lies about half an inch behind the tooth, parallel to the bulging alveolar ridge on the inner side of the body of the bone. The tongue should be pulled forwards and over to the opposite side, when the nerve can be seen standing out as a firm cord under the mucous membrane by the side of the tongue, and can be easily seized with a sharp hook and divided or a portion excised. This is a simple enough operation on the cadaver, but when the disease is extensive and has extended to the floor of the mouth, as is generally the case when division of a nerve is required, the operation is not practicable.

In severe cases of neuralgia of the fifth nerve, the Gasserian ganglion has been removed in whole or in part with a considerable measure of success. Rose was the first to perform this operation; and he reached the ganglion by trephining the base of the skull in the position of the foramen ovale, after dividing the zygomatic arch, in front and behind, and turning it and the Masseter muscle downwards, and cutting through the coronoid process of the lower jaw, and turning it and the Temporal muscle upwards. A more efficient method appears to be that known as the Krause-Hartley method. The bone forming the temporal fossa having been removed to a sufficient extent, the temporal lobe of the brain, with the dura mater, is gradually raised from the middle fossa, until the foramen spinosum, with the middle meningeal artery passing through it, is exposed. This vessel is to be ligatured in two places, and divided between the ligatures; and then by further raising the temporal lobe, the foramina ovale and rotundum will be exposed, with the second and third divisions of the fifth nerve passing through them. These nerves are to be clearly defined and divided. The dura mater is then to be raised from the ganglion, when the ophthalmic nerve will be exposed and must be divided, and the ganglion, by means of a little careful dissection, raised from its bed and removed. In some cases where the neuralgia has been limited to the second division of the nerve an intracranial resection of that division alone has been performed with great success. In other cases where the disease has not affected the ophthalmic division, resection of the outer half of the ganglion only, with the superior and inferior maxillary nerves, has been performed, thus leaving the sensory nerve supply to the cornea intact. The motor root is usually resected with the third division of the nerve, leading to complete paralysis of the muscles of mastication on that side.

FIG. 775.—Figure showing the mode of innervation of the Internal and External recti muscles of the eye (after Duval and Laborde). (Testut.)

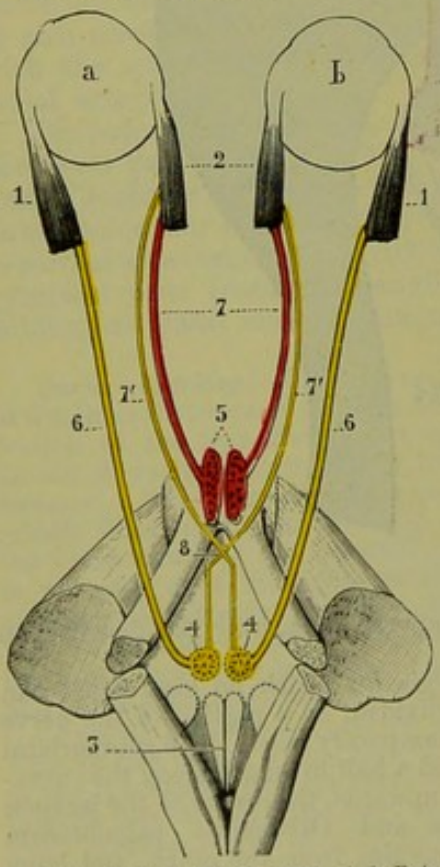

a. Left eyeball. *b*. Right eyeball. 1, 1. External rectus muscle. 2. Internal rectus muscle. 3. Floor of fourth ventricle. 4. Nucleus of sixth nerve. 5. Nucleus of third nerve. 6. Sixth nerve. 7. Nerve to Internal rectus arising from the nucleus of the third nerve of the same side. 7'. Nerve to the Internal rectus of the other side arising from the opposite nucleus. 8. Decussation of the fibres of sixth nerve to Internal recti.

SIXTH NERVE (figs. 769, 775)

The **Sixth nerve** (n. abducens) supplies the External rectus muscle of the eyeball.

Its fibres arise from a small nucleus situated in the upper part of the floor of the fourth ventricle, close to the middle line and beneath the eminentia teres. They pass downwards and forwards through the pons, and emerge in the furrow

between the lower border of the pons and the upper end of the pyramid of the medulla oblongata.

From the nucleus of the sixth nerve, fibres pass through the posterior longitudinal bundle to the oculo-motor nerve of the opposite side, along which they are carried to the Internal rectus muscle. The External rectus of one eye and the Internal rectus of the other may therefore be said to receive their nerves from the same nucleus—a factor of great importance in connection with the conjugate movements of the eyeball, and one that may explain certain paralytic phenomena of the Recti, which are often associated with lesions in the pons.

Fig. 776.—Oblique section through the right cavernous sinus.

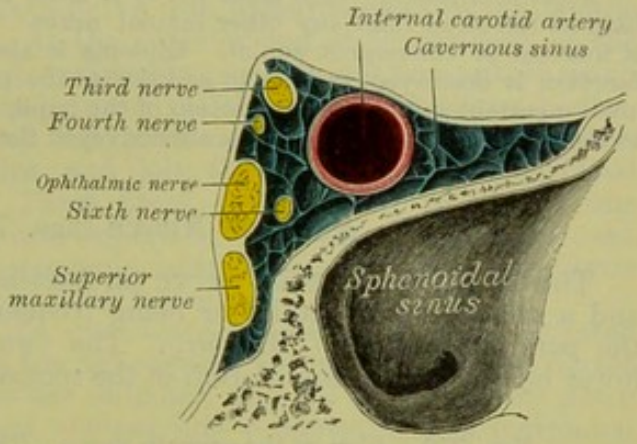

The nerve pierces the dura mater on the basilar surface of the sphenoid bone, runs through a notch immediately below the posterior clinoid process, and enters the cavernous sinus. It passes forwards through the sinus, lying on the outer side of the internal carotid artery. It enters the orbit through the sphenoidal fissure, and lies above the ophthalmic vein, from which it is separated by a lamina of dura mater. It then passes between the two heads of the External rectus, and is distributed to that muscle on its ocular surface.

Branches of communication.—The sixth nerve is joined by several filaments from the carotid and cavernous plexuses, and by one from the ophthalmic nerve.

The sixth nerve, together with the third, fourth, and the ophthalmic division of the fifth, as they pass to the orbit, bear a certain relation to each other in the cavernous sinus, at the sphenoidal fissure, and in the cavity of the orbit, which will now be described.

In the *cavernous sinus* (fig. 776), the third and fourth nerves and the ophthalmic division of the fifth are placed on the outer wall of the sinus, in their numerical order, both from above downwards, and from within outwards. The sixth nerve lies at the outer side of the internal carotid artery. As these nerves pass forwards to the sphenoidal fissure, the third and fifth nerves become divided into branches, and the sixth approaches the rest; so that their relative position becomes considerably changed.

Fig. 777.—Relations of structures passing through the sphenoidal fissure.

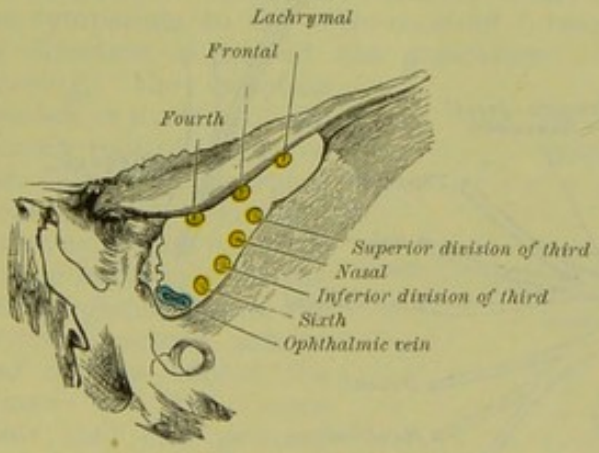

In the *sphenoidal fissure* (fig. 777), the fourth nerve, and the frontal and lachrymal divisions of the ophthalmic lie in this order from within outwards upon the same plane; they enter the cavity of the orbit above the muscles. The remaining nerves enter the orbit between the two heads of the External rectus. The superior division of the third is the highest of these; beneath this lies the nasal branch of the ophthalmic; then the inferior division of the third; and the sixth lowest of all.

In the *orbit*, the fourth, and the frontal and lachrymal divisions of the ophthalmic lie on the same plane immediately beneath the periosteum, the

fourth nerve being internal and resting on the Superior oblique, the frontal resting on the Levator palpebræ, and the lachrymal on the External rectus. The superior division of the third nerve lies immediately beneath the Superior rectus, while the nasal branch of the ophthalmic crosses the optic nerve to reach the inner side of the orbit. Beneath these is the optic nerve, surrounded in front by the ciliary nerves, and having the lenticular ganglion on its outer side, between it and the External rectus. Below the optic nerve are the inferior division of the third, and the sixth, the latter lying on the outer side of the orbit.

Applied Anatomy.—The sixth nerve is more frequently involved in fractures of the base of the skull than any other cranial nerve. The result of paralysis of this nerve is internal or convergent squint. Diplopia is also present. When injured so that its function is destroyed, there is, in addition to the paralysis of the External rectus muscle, often a certain amount of contraction of the pupil, because some of the sympathetic fibres to the radiating muscle of the iris are conveyed through this nerve.

Seventh Nerve (figs. 778, 779, 780)

The **Seventh** or **Facial nerve** (n. facialis), like the fifth, consists of a motor and a sensory part, the latter being frequently described under the name of the *pars intermedia of Wrisberg*. The two parts emerge separately at the lower border of the pons Varolii in the recess between the olivary and restiform

Fig. 778.—Plan of the seventh nerve. The course of the sensory fibres is represented by the blue lines.

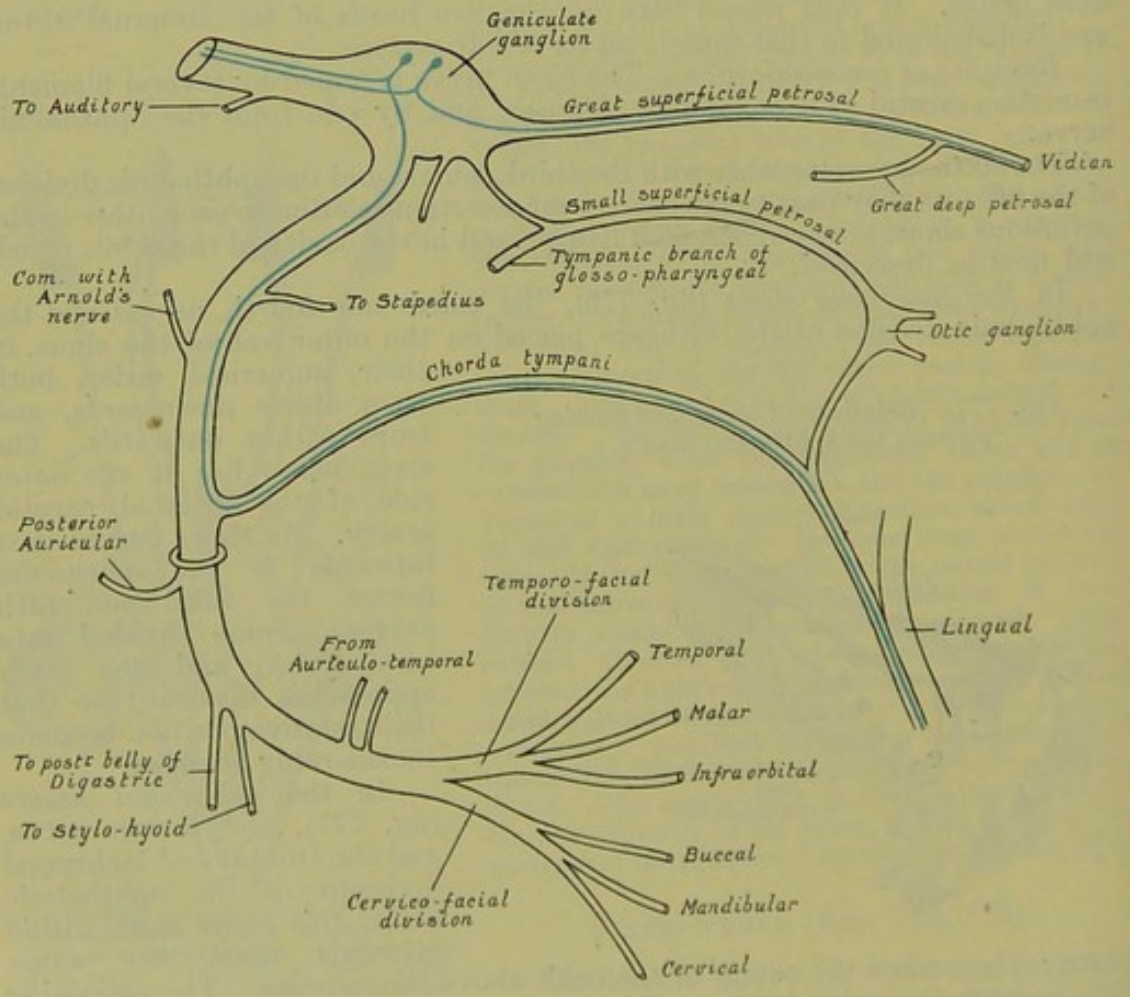

bodies, the motor part being the more internal; immediately to the outer side of the sensory part is the auditory nerve.

The motor part supplies the muscles of the face, scalp and pinna, the Buccinator and Platysma, the Stylo-hyoid and posterior belly of the Digastric, and the Stapedius muscle of the tympanic cavity; it also contains some fibres

which constitute the vasodilator nerves of the submaxillary and sublingual glands, and are conveyed to these glands through the chorda tympani. The sensory part contains the fibres of taste for the anterior two-thirds of the tongue.

The *motor* root takes origin from a nucleus which lies deeply in the reticular formation of the lower part of the pons Varolii. This nucleus is situated above the nucleus ambiguus, behind the superior olive, and internal to the lower sensory root of the fifth nerve. From this origin the fibres pursue a curved course in the substance of the pons. They first pass backwards and inwards towards the floor of the fourth ventricle, and, reaching the posterior extremity of the nucleus of the sixth nerve, run upwards close to the middle line beneath the eminentia teres. At the anterior end of the nucleus of the sixth nerve they make a second bend, and run downwards and forwards through the pons to their point of emergence between the olivary and restiform bodies.

Some fibres from the nucleus of the third nerve are said to descend in the posterior longitudinal fasciculus and join the motor root of the facial nerve before it leaves the pons. These fibres are believed to supply the Orbicularis palpebrarum, Corrugator supercilii, and anterior belly of the Occipito-frontalis, since these muscles have been observed to escape paralysis in lesions of the motor nucleus of the facial nerve.*

The *sensory* root arises from the geniculate ganglion, which is situated on the genu of the facial nerve in the aqueductus Fallopii, behind the hiatus Fallopii. The cells of this ganglion are unipolar, and the single process given off from each divides in a T-shaped manner into a central and a peripheral branch. The central branches run inwards, and, leaving the trunk of the facial nerve in the internal auditory meatus, form the sensory root; the peripheral branches are continued into the chorda tympani and great superficial petrosal nerves. Entering the brain at the lower border of the pons between the motor root internally and the auditory nerve externally, the fibres of the sensory root pass into the substance of the medulla and terminate in the upper part of the nucleus of the glosso-pharyngeal and in the fasciculus solitarius.

From their superficial attachments to the brain, the two roots of the facial nerve pass outwards and forwards with the auditory nerve to the internal auditory meatus. In the meatus the motor root lies in a groove on the upper and anterior surface of the auditory nerve, the sensory root being placed between the two.

At the bottom of the meatus, the facial nerve enters the aqueductus Fallopii, and follows the course of that canal through the petrous portion of the temporal bone, to its termination at the stylo-mastoid foramen. It is at first directed outwards between the cochlea and vestibule towards the inner wall of the tympanum; it then bends suddenly backwards and arches downwards behind the tympanum to the stylo-mastoid foramen. The point where it changes its direction is named the *geniculum*; it presents a reddish gangliform swelling, the *ganglion geniculi*, or nucleus of the sensory root of the nerve (fig. 779). On emerging from the stylo-mastoid foramen, it runs forwards in the substance of the parotid gland, crosses the external carotid artery, and divides behind the ramus of the mandible into two primary branches, *temporo-facial* and *cervico-facial*, from which numerous offsets are distributed over the side of the head, face, and upper part of the neck, supplying the superficial muscles in these regions. As the primary branches and their offsets diverge from each other, they present somewhat the appearance of a bird's foot or claws; hence the name of *pes anserinus* is given to the divisions of the facial nerve in and near the parotid gland.

FIG. 779.—The course and connections of the facial nerve in the temporal bone.

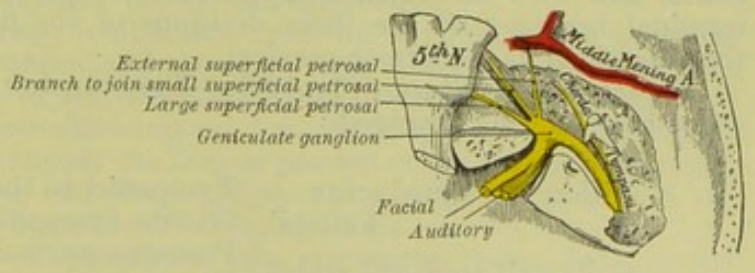

* See footnote, page 841.

Branches of communication.—The communications of the facial nerve may be arranged as follows :

In the internal auditory meatus	With the auditory nerve.
At the geniculate ganglion	With Meckel's ganglion by the large superficial petrosal nerve.
	With the otic ganglion by a branch which joins the small superficial petrosal nerve.
	With the sympathetic on the middle meningeal by the external superficial petrosal nerve.
In the Fallopian aqueduct	With the auricular branch of the pneumogastric.
At its exit from the stylo-mastoid foramen	With the glosso-pharyngeal.
	,, ,, pneumogastric.
	,, ,, great auricular.
	,, ,, auriculo-temporal.
Behind the ear	With the small occipital.
On the face	With the three divisions of the fifth.
In the neck	With the superficial cervical.

In the internal auditory meatus some minute filaments pass from the pars intermedia and from the facial to the auditory nerve.

The *large superficial petrosal nerve* arises from the geniculate ganglion, and consists chiefly of sensory branches which are distributed to the mucous membrane of the soft palate ; but it probably also contains a few motor fibres which form the motor root of Meckel's ganglion. It passes forwards through the hiatus Fallopii, and runs in a groove on the anterior surface of the petrous portion of the temporal bone beneath the Gasserian ganglion, to the foramen lacerum medium. It receives a twig from the tympanic plexus, and in the foramen is joined by the great deep petrosal, from the sympathetic plexus on the internal carotid artery, to form the Vidian nerve. This nerve passes forwards through the Vidian canal and ends in Meckel's ganglion. The geniculate ganglion is connected with the otic ganglion, by a branch which joins the small superficial petrosal nerve, and also with the sympathetic filaments accompanying the middle meningeal artery, by the external petrosal (Bidder). From the ganglion, according to Arnold, a twig is sent back to the auditory nerve. Just before the facial nerve emerges from the stylo-mastoid foramen, it generally receives a twig of communication from the auricular branch of the pneumogastric.

After its exit from the stylo-mastoid foramen, the facial sends a twig to the glosso-pharyngeal, and communicates with the auricular branch of the pneumogastric, with the great auricular branch of the cervical plexus, with the auriculo-temporal branch of the inferior maxillary nerve in the parotid gland, and with the small occipital behind the ear ; on the face with the terminal branches of the three divisions of the fifth, and in the neck with the superficial or transverse cervical.

Branches of distribution (fig. 780).—The branches of distribution of the facial nerve may be thus arranged :

Within the aqueductus Fallopii	Tympanic, to the Stapedius muscle.	
	Chorda tympani.	
At its exit from the stylo-mastoid foramen	Posterior auricular.	
	Digastric.	
	Stylo-hyoid.	
On the face	Temporo-facial	Temporal.
		Malar.
		Infraorbital.
	Cervico-facial	Buccal.
		Mandibular.
		Cervical.

The **tympanic branch** arises from the nerve opposite the pyramid; it passes through a small canal in the pyramid, and supplies the Stapedius muscle.

The **chorda tympani** is given off from the facial as it passes vertically downwards at the back of the tympanum, about a quarter of an inch before its exit from the stylo-mastoid foramen. It runs from below upwards and forwards in a distinct canal, and enters the cavity of the tympanum, through an aperture (*iter chordæ posterius*) on its posterior wall, close to the inner aspect of the posterior border of the membrana tympani and on a level with the upper end of the handle of the malleus, and becomes invested with mucous membrane. It traverses the cavity of the tympanum, between the fibrous and mucous layers of the membrana tympani, crosses over the handle of the malleus, and emerges from the cavity through a foramen situated at the inner end of the Glaserian fissure, and named the *iter chordæ anterius*, or *canal of Huguier*. It then descends between the two Pterygoid muscles on the inner aspect of the spine of the sphenoid, which it sometimes grooves, and joins, at an acute angle, the posterior border of the lingual nerve. It receives a few efferent fibres from the motor root; these enter the submaxillary ganglion, and through it are distributed to the submaxillary and sublingual glands; the majority of its fibres are afferent and continued onwards through the muscular substance of the tongue to the mucous membrane covering its anterior two-thirds; they constitute the nerve of taste for this portion of the tongue. Before joining the lingual nerve the chorda tympani receives a small communicating branch from the otic ganglion.

The **posterior auricular nerve** (n. auricularis posterior) arises close to the stylo-mastoid foramen, and passes upwards in front of the mastoid process; here it is joined by a filament from the auricular branch of the pneumogastric, and communicates with the mastoid branch of the great auricular, and with the small occipital. As it ascends between the meatus and mastoid process it divides into auricular and occipital branches. The *auricular branch* supplies the Retrahens auriculam and the small intrinsic muscles on the cranial surface of the pinna. The *occipital branch*, the larger, passes backwards along the superior curved line of the occipital bone, and supplies the occipital portion of the Occipito-frontalis.

The **digastric branch** (ramus digastricus) arises close to the stylo-mastoid foramen; it divides into several filaments, which supply the posterior belly of the Digastric; one of these perforates that muscle to join the glossopharyngeal nerve.

The **stylo-hyoid branch** (ramus stylohyoideus) frequently arises in conjunction with that to the posterior belly of the Digastric; it is long and slender, and passes inwards to enter the Stylo-hyoid about its middle.

The **temporo-facial division**, the larger of the two terminal branches, runs upwards and forwards through the parotid gland, crosses the external carotid artery and temporo-maxillary vein, and passes over the neck of the condyle of the mandible, being connected in this situation with the auriculo-temporal branch of the inferior maxillary nerve. It breaks up into branches, which are distributed over the temple and upper part of the face; these are grouped into three sets: temporal, malar, and infraorbital.

The *temporal branches* (rami temporales) cross the zygoma to the temporal region, supplying the Attrahens and Attollens auriculam muscles, and join with the temporal branch of the temporo-malar, a branch of the superior maxillary, and with the auriculo-temporal branch of the inferior maxillary. The more anterior branches supply the frontal portion of the Occipito-frontalis, the Orbicularis palpebrarum, and the Corrugator supercilii, and join with the supraorbital and lachrymal branches of the ophthalmic.

The *malar branches* (rami zygomatici) run across the malar bone to the outer angle of the orbit, where they supply the Orbicularis palpebrarum, and join with filaments from the lachrymal nerve and the malar branch of the superior maxillary nerve.

The *infraorbital branches* (rami infraorbitales), of larger size than the rest, pass horizontally forwards to be distributed between the lower margin of the orbit and the mouth. The *superficial branches* run beneath the skin and above the superficial muscles of the face which they supply: some branches are distributed to the Pyramidalis nasi, joining at the inner angle of the orbit

with the infratrochlear and nasal branches of the ophthalmic. The *deep branches* pass beneath the Zygomatici and the Levator labii superioris, supplying them and the Levator anguli oris, and form a plexus (*infraorbital*) by joining with the infraorbital branch of the superior maxillary nerve and the buccal branches of the cervico-facial. These branches also supply the Levator labii superioris alæque nasi and the small muscles of the nose.

The **cervico-facial division** passes obliquely downwards and forwards through the parotid gland, across the external carotid artery. In this situation it is joined by branches from the great auricular nerve. Opposite the angle of the mandible it divides into branches which are distributed on the

FIG. 780.—The nerves of the scalp, face, and side of neck.

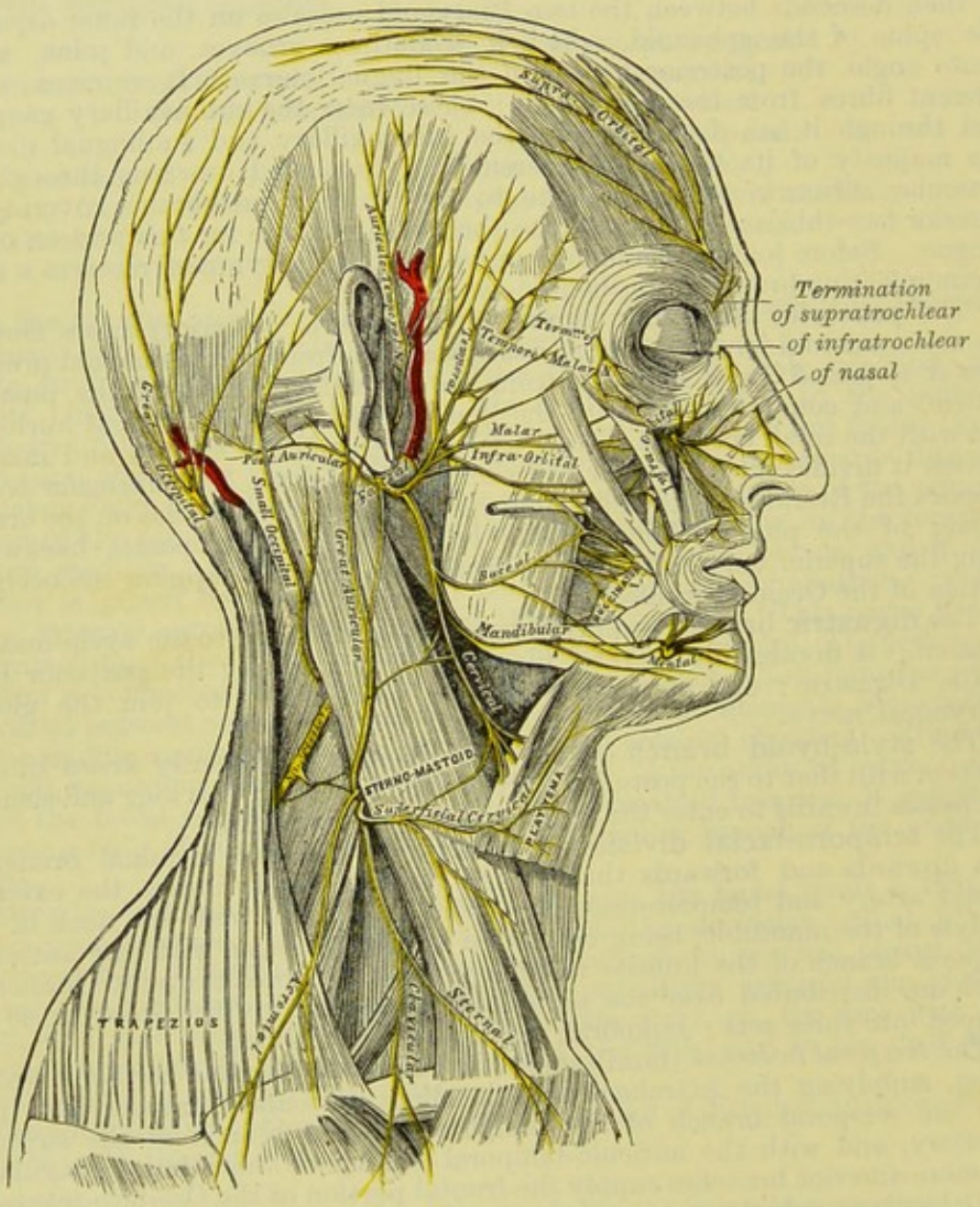

lower half of the face and upper part of the neck. These may be grouped into three sets : buccal, mandibular, and cervical.

The *buccal branches* (rami buccales) cross the Masseter. They supply the Buccinator and Orbicularis oris, and join with the infraorbital branches of the temporo-facial division of the nerve, and with filaments of the long buccal branch of the inferior maxillary nerve.

The *mandibular branch* (ramus marginalis mandibulæ) passes forwards beneath the Platysma and Depressor anguli oris, supplying the muscles of the lower lip and chin, and communicating with the mental branch of the inferior dental nerve.

The *cervical branch* (ramus colli) runs forwards beneath the Platysma, and forms a series of arches across the side of the neck over the suprahyoid region. One of the branches descends vertically to join with the superficial cervical nerve from the cervical plexus ; others supply the Platysma.

Applied Anatomy.—Facial palsy is commonly unilateral, and may be either : (1) *peripheral*, from lesion of the facial nerve ; (2) *nuclear*, from destruction of the facial nucleus ; or (3) *central, cerebral*, or *supranuclear*, from injury in the brain to the fibres passing from the cortex through the internal capsule to the facial nucleus, or from injury to the face-area of the motor cortex itself. In supranuclear facial paralysis, which is usually part of a hemiplegia, it is the lower part of the face that is chiefly affected, while the forehead can be freely wrinkled on the palsied side, the eye can be closed fairly well, and the eyeball is not rolled up under the upper lid ; emotional movements of the face are much better executed than voluntary ; and the electrical reactions of the muscles on the affected side are not altered. If the paralysis is due to lesion of the facial nucleus, the Orbicularis oris escapes, as the nuclear origin of the nerve to this muscle seems to be connected with that of the tongue-nerves ; otherwise the symptoms are identical with those of the common peripheral facial palsy, of which several types may be distinguished according to the point in its course at which the facial nerve is injured. If the lesion occurs (*a*) in the pons, facial paralysis is produced as in (*d*) below ; taste and hearing are not affected, but the sixth nerve also will be paralysed because the fibres of the facial nerve loop round its nucleus in the pons. When the nerve is paralysed (*b*) in the petrous bone, in addition to the paralysis of the muscles of expression, there is loss of taste in the anterior part of the tongue, and the patient is unable to recognise the difference between bitters and sweets, acids and salines, from involvement of the chorda tympani. The mouth is dry, because the salivary glands are not secreting ; and the sense of hearing is affected from paralysis of the Stapedius. When the cause of the paralysis is (*c*) fracture of the base of the skull, the auditory and petrosal nerves are usually involved. But by far the commonest cause of facial palsy is (*d*) exposure of the nerve to cold or injury at or after its exit from the stylomastoid foramen (Bell's paralysis). In these cases the face looks asymmetrical even when at rest, and more so in the old than in the young. The affected side of the face and forehead remains motionless when voluntary or emotional movement is attempted. The lines on the forehead are smoothed out, the eye can be shut only by hand, tears fail to enter the lachrymal puncta because they are no longer in contact with the conjunctiva, the conjunctival reflex is absent, and efforts to close the eye merely cause the eyeball to roll upwards until the cornea lies under the upper lid. The tip of the nose is drawn over towards the sound side ; the naso-labial fold is partially obliterated on the affected side, and the ala nasi does not move properly on respiration. The lips remain in contact on the paralysed side, and cannot be put together for whistling ; when a smile is attempted the angle of the mouth is drawn up on the unaffected side ; on the affected side the lips remain nearly closed, and the mouth assumes a characteristic triangular form. During mastication food accumulates in the cheek, from paralysis of the Buccinator, and dribbles or is pushed out from between the paralysed lips. On protrusion the tongue seems to be thrust over towards the palsied side, but verification of its position by reference to the incisor teeth will show that this is not really so. The Platysma and the muscles of the pinna are paralysed ; in severe cases the articulation of labials is impaired. The electrical reactions of the affected muscles are altered (reaction of degeneration), and the degree to which this alteration has taken place after a week or ten days gives a valuable guide to the prognosis. Most cases of Bell's palsy recover completely.

The facial nerve is at fault in cases of so-called 'histrionic spasm,' which consists in an almost constant and uncontrollable twitching of some or all of the muscles of the face. This twitching is sometimes so severe as to cause great discomfort and annoyance to the patient, and to interfere with sleep, and for its relief the facial nerve has been stretched. The operation is performed by making an incision behind the ear, from the root of the mastoid process to the angle of the jaw. The parotid is turned forwards and the dissection carried along the anterior border of the Sterno-mastoid muscle and mastoid process, until the upper border of the posterior belly of the Digastric is found. The nerve is parallel to this on about the level of the middle of the mastoid process. When found, the nerve must be stretched by passing a blunt hook beneath it and pulling it forwards and outwards. Too great force must not be used, for fear of permanent injury to the nerve.

Eighth Nerve

The **Eighth or Auditory nerve** (n. acusticus) is the special nerve of the sense of hearing, being distributed exclusively to the internal ear. It consists of two sets of fibres, which, although differing in their central connections, are both concerned in the transmission of afferent impulses from the internal ear to the medulla and pons, and from there, by means of new fibres which arise from collections of grey matter in these structures, to the cerebrum and cerebellum.

One set of fibres forms the vestibular root of the nerve, and arises from the cells in the ganglion of Scarpa which is situated in the internal auditory meatus; the other set constitutes the cochlear root, and takes origin from the cells in the ganglion spirale or ganglion of Corti, which occupies the spiral canal of the cochlea. Both of these ganglia consist of bipolar nerve-cells; one process from each of the cells passes inwards to the brain, the other outwards to the internal ear. At its connection with the brain the eighth nerve occupies the groove between the pons and medulla, where it is situated between the restiform body which is behind, and the seventh nerve which is in front.

Vestibular root (radix vestibularis) (fig. 781).—The fibres of this root enter the medulla to the inner side of those of the cochlear root, and pass between the restiform body which is to their outer side, and the inferior sensory root of the fifth which lies to their inner side. They then divide into an ascending and a descending set. The fibres of the latter end by arborising round the cells of the *internal nucleus*, which is situated in the *trigonum acusticum* in the floor of the fourth ventricle. The ascending fibres either end in the same manner or in the *external nucleus*, which is situated to the outer side of the trigonum acusticum and farther from the ventricular floor. It is described as consisting of two parts, an inner, the *nucleus of Deiters*, and an outer, the *nucleus of Bechterew*. Some of the axons of the cells of the external nucleus, and possibly also of the internal nucleus, are continued upwards through the restiform body to the roof nuclei of the opposite side of the cerebellum, to which also other fibres of the vestibular root are prolonged without interruption in the nuclei of the medulla. A second set of fibres from the internal and external nuclei end partly in the tegmentum, while the remainder ascend in the posterior longitudinal bundle to arborise around the cells of the nuclei of the oculo-motor nerve.

Fig. 781.—Terminal nuclei of the vestibular root of the auditory nerve, with their upper connections. (Schematic.) (Testut.)

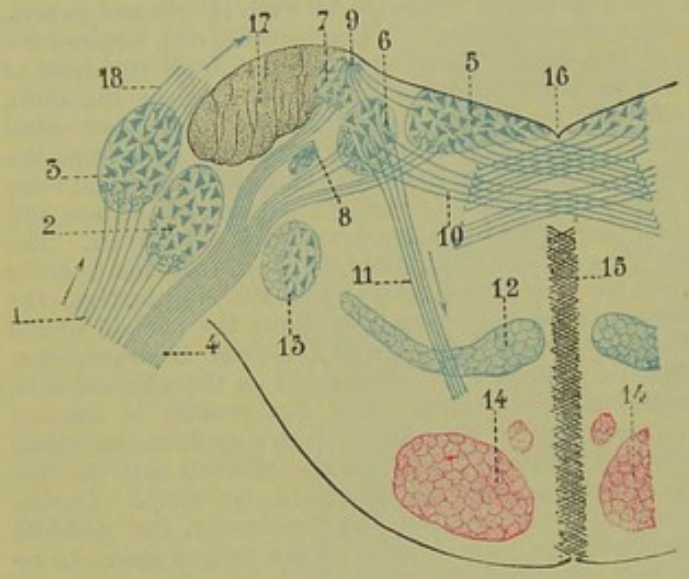

1. Posterior or cochlear root, with its two nuclei. 2. Accessory nucleus. 3. Tuberculum acusticum. 4. Anterior or vestibular root. 5. Internal nucleus. 6. Nucleus of Deiters. 7. Nucleus of Bechterew. 8. Inferior or descending root of auditory. 9. Ascending cerebellar fibres. 10. Fibres going to raphe. 11. Fibres taking an oblique course. 12. Fillet. 13. Inferior sensory root of trigeminal. 14. Pyramidal tract. 15. Raphe. 16. Fourth ventricle. 17. Restiform body. 18. Origin of striæ acusticæ.

Cochlear root (radix cochlearis) (fig. 782).—This part of the nerve is placed external to the vestibular root. Its fibres end in two nuclei, one of which, the *accessory nucleus*, lies immediately in front of the restiform body; the other, the *tuberculum acusticum*, somewhat to its outer side.

The striæ acusticæ, or medullary striæ, are the axons of the cells of the tuberculum acusticum. They pass backwards and inwards over the restiform body, and across the floor of the fourth ventricle towards the middle line. Here they dip into the substance of the pons, to end around the cells of the *superior olives* of both sides. There are, however, other fibres, and these are both direct and crossed, which do not arborise around the tegmental nuclei, but pass into the lateral fillet. The cells of the accessory nucleus give origin to fibres which pass transversely in the pons and constitute the trapezium. Of the trapezoid fibres some terminate around the cells of the superior olive or of the *trapezoid nucleus* (which lies ventral to the olive) of the same or opposite side, while others, crossed or uncrossed, pass directly into the lateral fillet.

If the further connections of the cochlear nerve of one side, say the left, be considered, it is found that they lie to the outer side of the main sensory tract, the fillet, and are therefore termed the *lateral fillet*. The fibres comprising the

left lateral fillet arise in the superior olive and trapezoid nucleus of the same or opposite side, while others are the uninterrupted fibres already alluded to, and these are either crossed or uncrossed, the former being the axons of the cells of the right accessory nucleus or of the cells of the right tuberculum acusticum, while the latter are derived from the same cells of the left side. In the upper part of the lateral fillet there is a collection of nerve-cells, the *nucleus of the lateral fillet*, around the cells of which some of the fibres arborise and from the cells of which axons originate to continue upwards the tract of the lateral fillet. The ultimate ending of the left lateral fillet is partly in the opposite internal geniculate body, and partly in both inferior quadrigeminal bodies. From the cells of these bodies new fibres arise which ascend in the posterior limb of the internal capsule to reach the posterior three-fifths of the first left temporal convolution and the transverse temporal gyri of Heschl.

FIG. 782.—Terminal nuclei of the cochlear root of the auditory nerve, with their upper connections. (Schematic.) (Testut.)

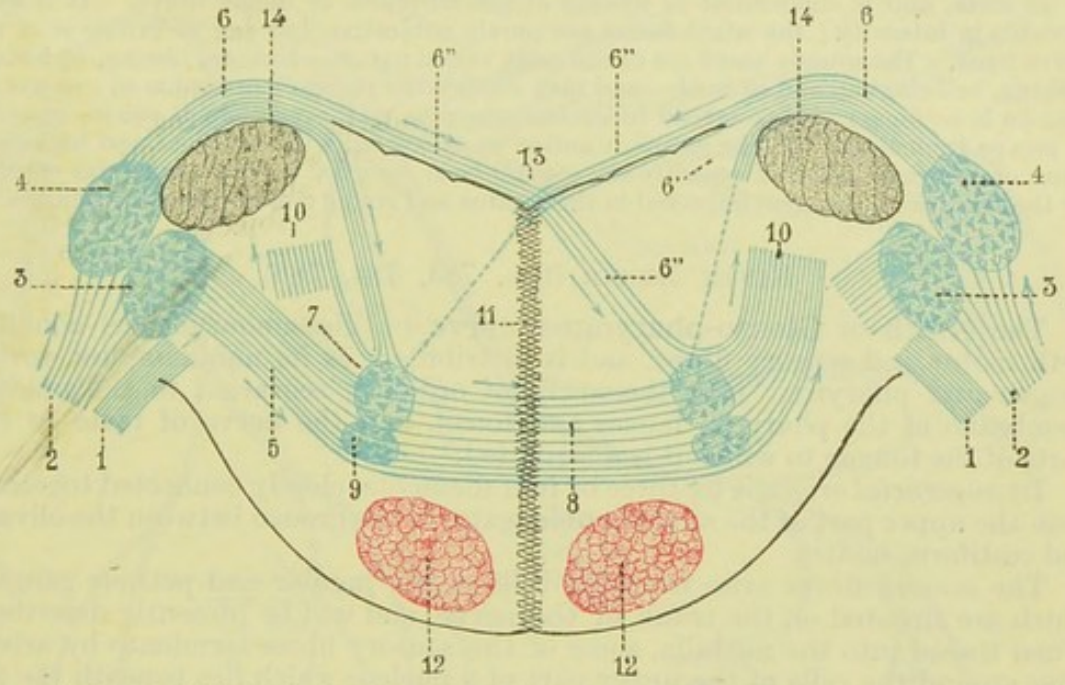

The vestibular root with its terminal nuclei and their efferent fibres have been suppressed. On the other hand, in order not to obscure the trapezoid body, the efferent fibres of the terminal nuclei on the right side have been resected in a considerable portion of their extent. The trapezoid body, therefore, shows only one-half of its fibres, viz. those which come from the left.

1. Anterior or vestibular root of the auditory, divided at its entrance into the bulb. 2. Posterior or cochlear root. 3. Accessory nucleus of auditory nerve. 4. Tuberculum acusticum. 5. Efferent fibres of accessory nucleus. 6. Efferent fibres of tuberculum acusticum, forming the striæ acusticæ, with 6', their direct bundle going to the superior olivary body of the same side; 6", their decussating bundles going to the superior olivary body of the opposite side. 7. Superior olivary body. 8. Trapezoid body. 9. Trapezoid nucleus. 10. Central acoustic tract (lateral fillet). 11. Raphe. 12. Pyramidal tract. 13. Fourth ventricle. 14. Restiform body.

The auditory nerve contains a few efferent fibres which arise in the quadrigeminal bodies, the nucleus of the lateral fillet, the trapezoid nucleus, and superior olive.

The auditory nerve after leaving the medulla passes forwards across the posterior border of the middle peduncle of the cerebellum, in company with the facial nerve, from which it is partially separated by the auditory artery. It then enters the internal auditory meatus with the facial nerve. At the bottom of the meatus it receives one or two filaments from the facial nerve, and then divides into its two branches, *cochlear* and *vestibular*. The auditory nerve is soft in texture, and is destitute of neurilemma; its distribution will be described with the anatomy of the ear.

Applied Anatomy.—The auditory nerve is frequently injured, together with the facial nerve, in fractures of the middle fossa of the base of the skull implicating the internal auditory meatus. The nerve may be either torn across, producing permanent deafness, or it may be bruised or pressed upon by extravasated blood or inflammatory exudation, when the deafness will in all probability be temporary. The nerve may also be injured by violent blows on the head without any fracture of the bones of the skull taking place,

and deafness may arise from loud explosions from dynamite, &c., probably from some lesion of this nerve, which is more liable to be injured than the other cranial nerves on account of its structure. 'Nerve deafness' as contrasted with deafness due to changes in the middle ear or meatus, is suggested if (1) a sounding tuning-fork placed on the middle line of the head is heard better (Weber's test) by the unaffected ear; or if (2) the sounding tuning-fork is heard longer when held before the affected ear (= air conduction) than when it is stood on the corresponding mastoid (= bone conduction, Rinne's test); or if (3) the sounding tuning-fork applied to the vertex or mastoid is heard less well when the air in the meatus is compressed by the use of a Siegle's speculum (Gellé's test); or if (4) the tuning-fork placed on the mastoid is heard for a shorter time than its sound is perceptible to a normal individual (= evidence that bone conduction is diminished, Schwabach's test). It must be remembered that all these tests are liable to anomalies and exceptions, and are no longer applicable to old people. If, however, concordant results are yielded by the tests of Weber, Rinne, and Gellé, Bezold's 'triad of symptoms,' nerve-deafness rather than deafness due to disease of the conducting structures is rendered highly probable.

Tinnitus aurium, or the hearing of sounds in the ear that have no objective cause outside the body, is said to be present in as many as sixty per cent. of cases of ear disease of all sorts, and is commonest in disease of the labyrinth or of the nerve. It is very variable in intensity; the worst forms are purely subjective and due to irritation of the nerve itself. The sounds heard are of the most varied nature—buzzing, hissing, whistling, rushing, bell-ringing, and so forth—and may occupy the patient's attention so completely that he is no longer able to attend to his business; he may even commit suicide in order to escape from them. In the insane, tinnitus is associated with delusions and hallucinations of hearing; cases of insanity have even been recorded in which cure was effected by the removal of cerumen impacted in the meatus and giving rise to persistent tinnitus.

Ninth Nerve (figs. 783, 784, 786)

The **Ninth** or **Glosso-pharyngeal nerve** (n. glossopharyngeus) contains both motor and sensory fibres, and is distributed, as its name implies, to the tongue and pharynx. It is the nerve of ordinary sensation to the mucous membrane of the pharynx, fauces and tonsil, and the nerve of taste to the parts of the tongue to which it is distributed.

Its *superficial origin* is by three or four filaments, closely connected together, from the upper part of the medulla oblongata, in the groove between the olivary and restiform bodies.

The *sensory* fibres arise from the cells of the jugular and petrous ganglia, which are situated on the trunk of the nerve, and will be presently described. When traced into the medulla, some of the sensory fibres terminate by arborising around the cells of the upper part of a nucleus which lies beneath the ala cinerea in the lower part of the floor of the fourth ventricle. Many of the fibres, however, contribute to form a strand, named the *fasciculus solitarius*, which descends in the medulla. Associated with this strand are numerous nerve-cells, around which the fibres of the fasciculus terminate.

The *motor* fibres take origin from the cells of the *nucleus ambiguus*, which lies some distance from the lower part of the floor of the fourth ventricle in the lateral area of the medulla and is continuous below with the anterior grey cornu of the spinal cord. From this nucleus the fibres are first directed backwards, and then they bend forwards and outwards to join the fibres of the sensory root. The nucleus ambiguus gives origin to the motor branches of the glosso-pharyngeal and vagus, and to the bulbar part of the spinal accessory.

From its superficial origin, the glosso-pharyngeal nerve passes outwards across the flocculus, and leaves the skull at the central part of the jugular foramen, in a separate sheath of the dura mater, external to and in front of the pneumogastric and spinal accessory nerves (fig. 636). In its passage through the jugular foramen, it grooves the lower border of the petrous portion of the temporal bone; and, at its exit from the skull, passes forwards between the jugular vein and internal carotid artery; it descends in front of the latter vessel, and beneath the styloid process and the muscles connected with it, to the lower border of the Stylo-pharyngeus. The nerve now curves inwards, forming an arch on the side of the neck and lying upon the Stylo-pharyngeus and Middle constrictor of the pharynx. It then passes under cover of the Hyo-glossus, and is finally distributed to the mucous membrane of the fauces and base of the tongue, and the mucous glands of the mouth and tonsil.

Fig. 783.—Plan of the glosso-pharyngeal, pneumogastric, and spinal accessory nerves. (After Flower.)

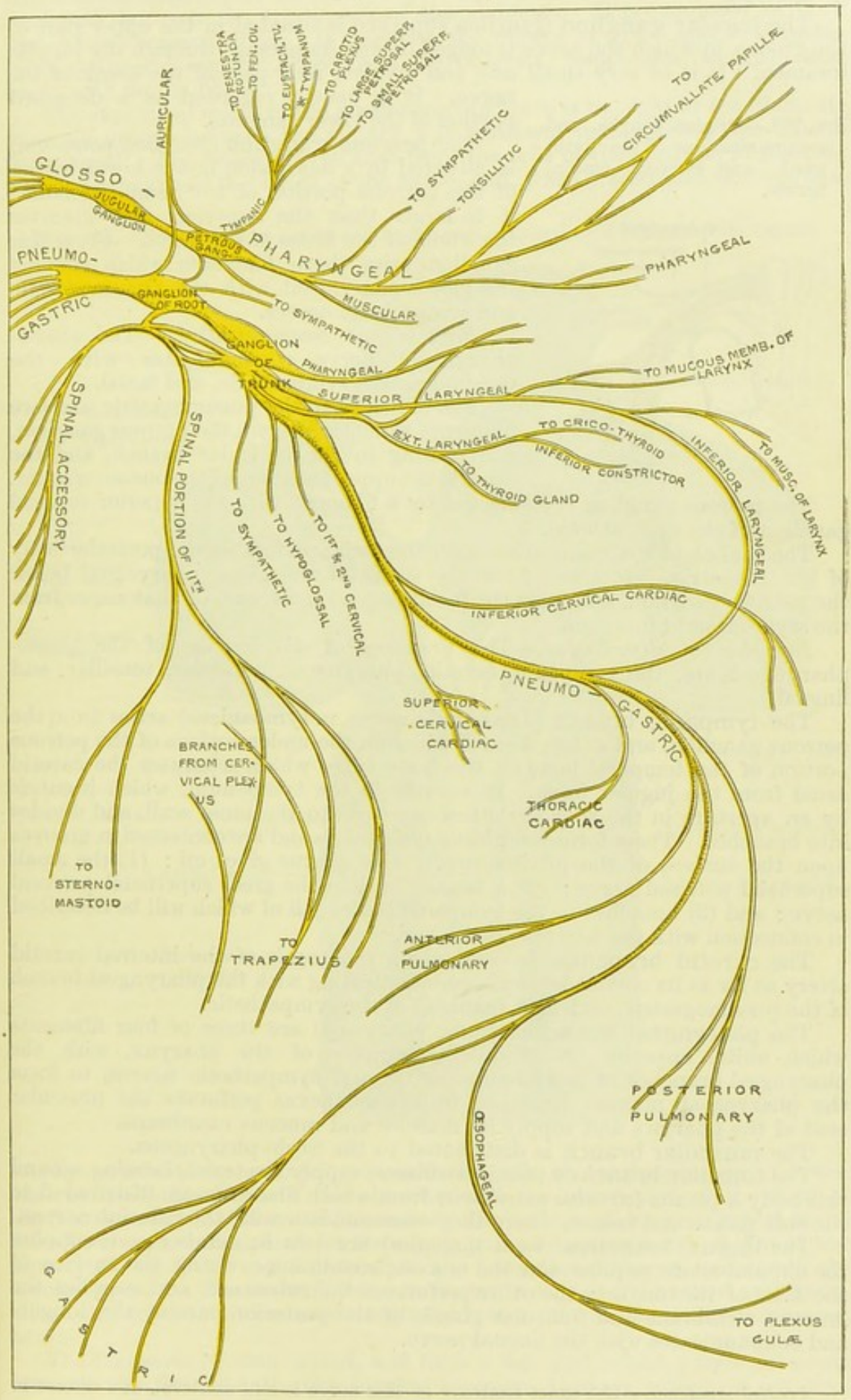

In passing through the jugular foramen, the nerve presents, in succession, two gangliform enlargements (fig. 784). The superior, the smaller, is called the *jugular ganglion*; the inferior and larger, the *petrous ganglion*, or the *ganglion of Andersch*.

The **jugular ganglion** (ganglion superius) is situated in the upper part of the groove in which the nerve is lodged during its passage through the jugular foramen. It is of very small size, and involves only part of the trunk of the nerve. It is usually regarded as a detached portion of the lower ganglion.

FIG. 784.—Origins, ganglia, and communications of the ninth, tenth, and eleventh cranial nerves.

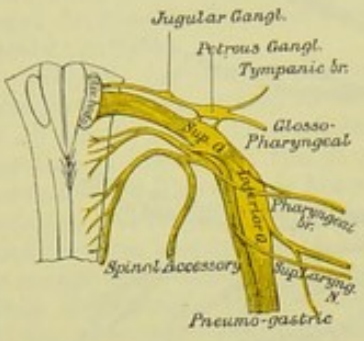

The **petrous ganglion** (ganglion petrosum) is situated in a depression in the lower border of the petrous portion of the temporal bone; it is larger than the superior, and involves the whole of the fibres of the nerve. From this ganglion arise those filaments which connect the glosso-pharyngeal with the pneumogastric and sympathetic nerves.

Branches of communication.—The glosso-pharyngeal nerve communicates with the pneumogastric, sympathetic, and facial.

The branches to the pneumogastric are two filaments which arise from the petrous ganglion, one passing to the auricular branch, and the other to the upper ganglion, of the pneumogastric.

The petrous ganglion is connected by a filament with the superior cervical ganglion of the sympathetic.

The branch of communication with the facial perforates the posterior belly of the Digastric. It arises from the trunk of the glosso-pharyngeal below the petrous ganglion, and joins the facial just after the exit of that nerve from the stylo-mastoid foramen.

Branches of distribution.—The branches of distribution of the glosso-pharyngeal are, the tympanic, carotid, pharyngeal, muscular, tonsillar, and lingual.

The **tympanic branch** (Jacobson's nerve, n. tympanicus) arises from the petrous ganglion, and enters a small canal on the under surface of the petrous portion of the temporal bone on the bony ridge which separates the carotid canal from the jugular fossa. It ascends to the tympanum, which it enters by an aperture in the floor of that cavity close to the inner wall, and divides into branches. These form the *plexus tympanicus* and are contained in grooves upon the surface of the promontory. This plexus gives off: (1) the small superficial petrosal nerve; (2) a branch to join the great superficial petrosal nerve; and (3) branches to the tympanic cavity, all of which will be described in connection with the anatomy of the ear.

The **carotid branches** descend along the trunk of the internal carotid artery as far as its commencement, communicating with the pharyngeal branch of the pneumogastric, and with branches of the sympathetic.

The **pharyngeal branches** (rami pharyngei) are three or four filaments which unite, opposite the Middle constrictor of the pharynx, with the pharyngeal branches of the pneumogastric and sympathetic nerves, to form the pharyngeal plexus; branches from this plexus perforate the muscular coat of the pharynx and supply its muscles and mucous membrane.

The **muscular branch** is distributed to the Stylo-pharyngeus.

The **tonsillar branches** (rami tonsillares) supply the tonsil, forming around this body a plexus (*circulus tonsillaris*) from which filaments are distributed to the soft palate and fauces, where they communicate with the palatine nerves.

The **lingual branches** (rami linguales) are two in number: one supplies the circumvallate papillæ and the mucous membrane covering the surface of the base of the tongue; the other perforates the substance, and supplies the mucous membrane and follicular glands of the posterior part of the tongue, and communicates with the lingual nerve.

Applied Anatomy.—The exact anatomy of this nerve is still doubtful, and disease in it alone cannot usually be diagnosed.

Tenth Nerve (figs. 783, 785, 786)

The **Tenth** or **Pneumogastric nerve** (n. vagus) has a more extensive distribution than any of the other cranial nerves, since it passes through the neck and thorax to the upper part of the abdomen. It is composed of both motor and sensory fibres. It supplies the organs of voice and respiration with motor and sensory fibres; and the pharynx, œsophagus, stomach, and heart with motor fibres.

The *superficial origin* of the pneumogastric nerve is by eight or ten filaments from the groove between the olivary and restiform bodies, below the glosso-pharyngeal. The *sensory* fibres arise from the cells of the ganglion of the root and the ganglion of the trunk of the nerve, and, when traced into the medulla,

Fig. 785.—Mid- and hind-brains and upper part of spinal cord exposed from behind.

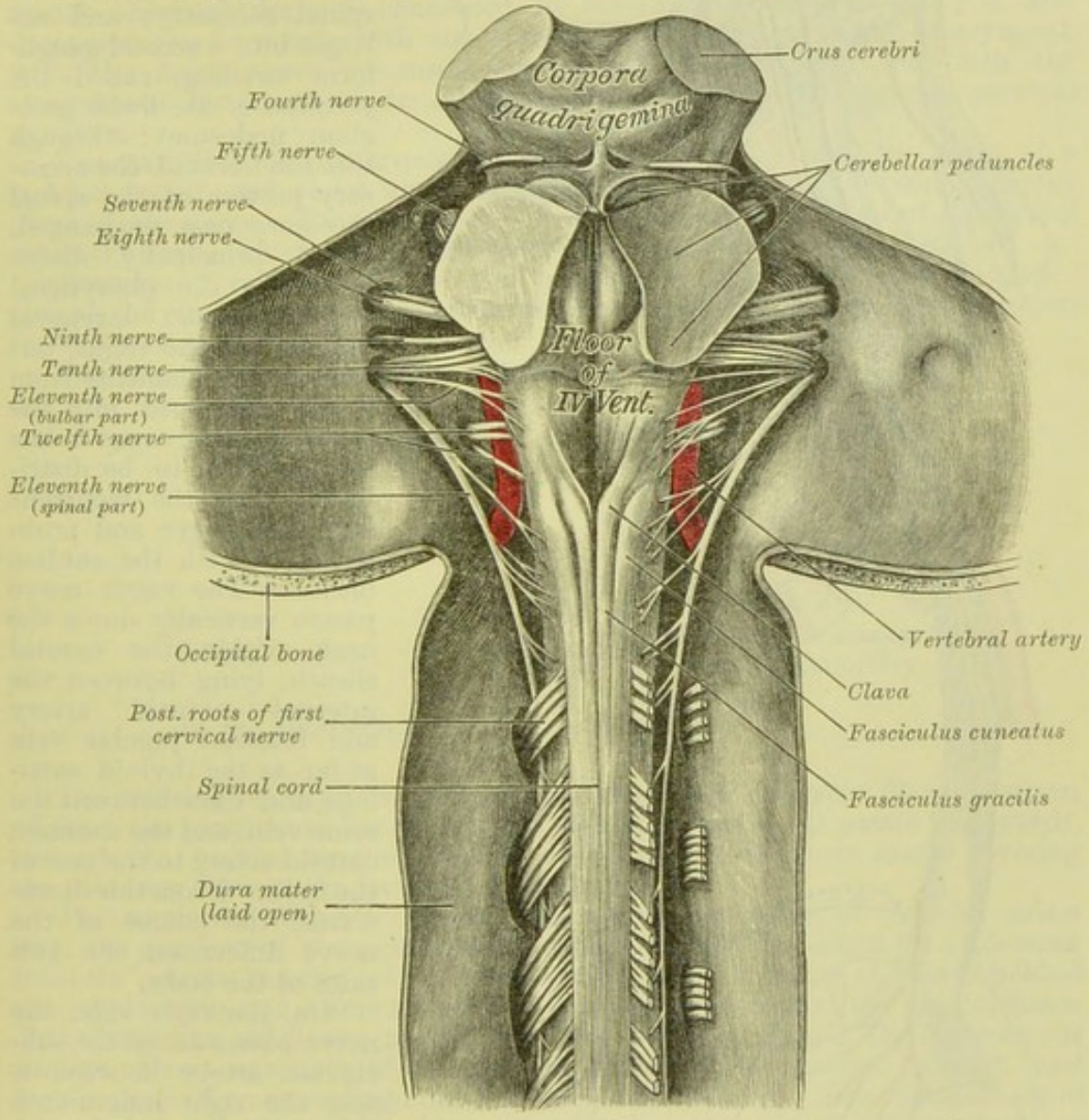

mostly terminate by arborising around the cells of the inferior part of the nucleus which lies beneath the ala cinerea in the lower part of the floor of the fourth ventricle. Some of the sensory fibres of the glosso-pharyngeal nerve have been seen to terminate in the upper part of this nucleus. A few of the sensory fibres of the vagus descend in the fasciculus solitarius and terminate around its cells. The *motor* fibres arise from the cells of the nucleus ambiguus, already referred to in connection with the motor root of the glosso-pharyngeal nerve.

The filaments become united, and form a flat cord, which passes outwards beneath the flocculus to the jugular foramen, through which it emerges from the cranium. In passing through this opening, the pneumogastric is

accompanied by the spinal accessory, and is contained in the same sheath of dura mater with it, a membranous septum separating them from the glosso-pharyngeal which lies in front (fig. 636). The nerve in this situation presents a well-marked ganglionic enlargement, which is called the *ganglion of the root* (ganglion jugulare); to it the accessory part of the spinal accessory nerve is connected by one or two filaments. After its exit from the jugular foramen the nerve is joined by the accessory portion of the spinal accessory, and enlarges into a second ganglifform swelling, called the *ganglion of the trunk* (ganglion nodosum); through this the fibres of the accessory portion of the spinal accessory pass unchanged, being principally distributed to the pharyngeal and superior laryngeal branches of the vagus, but some of the filaments from it are continued into the trunk of the vagus below the ganglion, to be distributed with the recurrent laryngeal nerve and probably also with the cardiac nerves. The vagus nerve passes vertically down the neck within the carotid sheath, lying between the internal carotid artery and internal jugular vein as far as the thyroid cartilage, and then between the same vein and the common carotid artery to the root of the neck. From this downwards, the course of the nerve differs on the two sides of the body.

Fig. 786.—Course and distribution of the ninth, tenth, and eleventh cranial nerves.

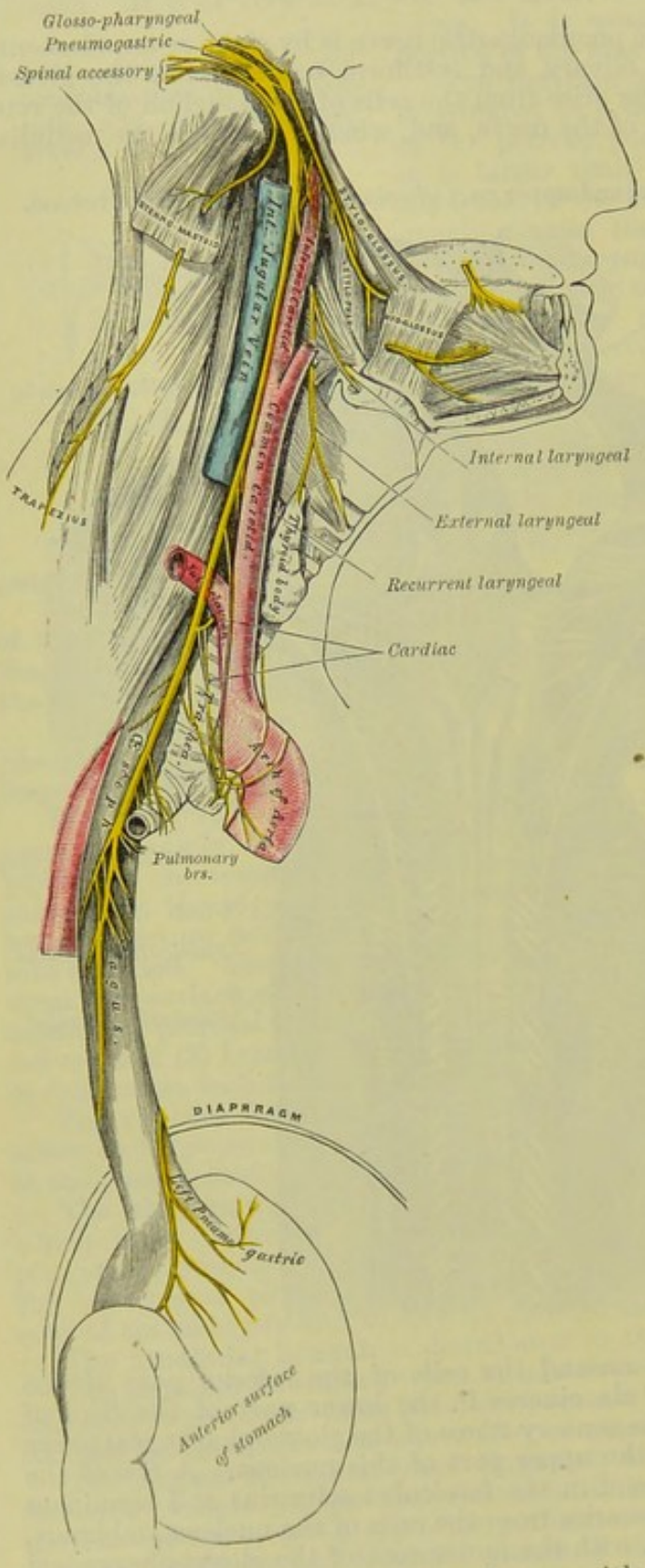

On the *right side*, the nerve passes across the subclavian artery between it and the right innominate vein, and descends by the side of the trachea to the back part of the root of the lung, where it spreads out in a plexiform network (*posterior pulmonary plexus*). From the lower part of this two cords descend on the œsophagus, and divide to form, with branches from the opposite nerve, the œsophageal plexus (*plexus gulæ*). Below, these branches are collected into a single cord, which runs along the back part of the œsophagus, enters the abdomen, and is distributed to the posterior surface of the stomach,

joining the left side of the solar plexus, and sending filaments to the splenic plexus and a considerable branch to the cœliac plexus.

On the *left side*, the pneumogastric nerve enters the chest between the left carotid and subclavian arteries, behind the left innominate vein. It crosses the arch of the aorta, and descends behind the root of the left lung, forming the *posterior pulmonary plexus*. From this it runs along the anterior surface of the œsophagus, where it unites with the nerve of the right side in forming the *plexus gulæ*, and is continued to the stomach, distributing branches over its anterior surface; some of these extend over the fundus, and others along the lesser curvature. Filaments from these branches enter the gastro-hepatic omentum, and join the hepatic plexus.

The **ganglion of the root** is of a greyish colour, spherical in form, about one sixth of an inch in diameter.

Branches of communication.—To this ganglion the accessory portion of the spinal accessory nerve is connected by several delicate filaments; it also communicates by a twig with the petrous ganglion of the glosso-pharyngeal, with the facial nerve by means of its auricular branch, and with the sympathetic by means of an ascending filament from the superior cervical ganglion.

The **ganglion of the trunk** is a plexiform cord, cylindrical in form, of a reddish colour, and about an inch in length; it involves the whole of the fibres of the nerve. Passing through it is the accessory portion of the spinal accessory nerve, which blends with the pneumogastric below the ganglion.

Branches of communication.—This ganglion is connected with the hypoglossal, the superior cervical ganglion of the sympathetic, and the loop between the first and second cervical nerves.

Branches of distribution.—The branches of the pneumogastric are:

In the jugular fossa	Meningeal. Auricular.
In the neck	Pharyngeal. Superior laryngeal. Recurrent laryngeal. Cervical cardiac.
In the thorax	Thoracic cardiac. Anterior pulmonary. Posterior pulmonary. Œsophageal.
In the abdomen	Gastric.

The **meningeal branch** (ramus meningeus) is a recurrent filament given off from the ganglion of the root in the jugular foramen. It passes backwards, through the jugular foramen, and is distributed to the dura mater covering the posterior fossa of the base of the skull.

The **auricular branch** (ramus auricularis), or nerve of Arnold, arises from the ganglion of the root, and is joined soon after its origin by a filament from the petrous ganglion of the glosso-pharyngeal; it passes outwards behind the jugular vein, and enters a small canal on the outer wall of the jugular fossa. Traversing the substance of the temporal bone, it crosses the aqueductus Fallopii about one-sixth of an inch above the stylo-mastoid foramen, and here it gives off an ascending branch which joins the facial. The continuation of the nerve reaches the surface by passing through the auricular fissure between the mastoid process and the tympanic plate, and divides into two branches, one of which communicates with the posterior auricular nerve, while the other supplies the integument at the back part of the pinna and the posterior part of the external auditory meatus.

The **pharyngeal branch** (ramus pharyngeus), the principal motor nerve of the pharynx, arises from the upper part of the ganglion of the trunk. It consists principally of filaments from the accessory portion of the spinal accessory; it passes across the internal carotid artery to the upper border of the Middle constrictor, where it divides into numerous filaments, which join with those from the glosso-pharyngeal, sympathetic, and external laryngeal to form the *pharyngeal plexus*. From the plexus, branches are distributed to

the muscles and mucous membrane of the pharynx and the muscles of the soft palate, except the Tensor palati. A minute filament descends and joins the hypoglossal nerve as it winds round the occipital artery.

The **superior laryngeal nerve** (n. laryngeus superior) is larger than the preceding, and arises from the middle of the ganglion of the trunk. In its course it receives a branch from the superior cervical ganglion of the sympathetic. It descends, by the side of the pharynx, behind the internal carotid artery, and divides into two branches, the external and internal laryngeal.

The *external laryngeal branch* (ramus externus), the smaller, descends on the larynx, beneath the Sterno-thyroid, to supply the Crico-thyroid muscle. It gives branches to the pharyngeal plexus and the Inferior constrictor, and communicates with the superior cardiac nerve, behind the common carotid artery.

The *internal laryngeal branch* (ramus internus) descends to the thyro-hyoid membrane, pierces it in company with the superior laryngeal artery, and is distributed to the mucous membrane of the larynx. A small branch communicates with the recurrent laryngeal nerve. Of the branches to the mucous membrane some are distributed to the epiglottis, the base of the tongue, and the epiglottic glands; while others pass backwards, in the aryteno-epiglottic fold, to supply the mucous membrane surrounding the superior orifice of the larynx, and that lining the cavity of the larynx as low down as the vocal cord. The filament which joins with the recurrent laryngeal descends beneath the mucous membrane on the inner surface of the thyroid cartilage, where the two nerves become united.

The **inferior or recurrent laryngeal nerve** (n. recurrens), so called from its reflected course, is the motor nerve of the larynx. It arises, on the *right* side, in front of the subclavian artery; winds from before backwards round that vessel, and ascends obliquely to the side of the trachea behind the common carotid, and either in front of or behind the inferior thyroid artery. On the *left* side, it arises in front of the arch of the aorta, and winds from before backwards below the aorta at the point where the obliterated ductus arteriosus is attached, and then ascends to the side of the trachea. The nerve on either side ascends in the groove between the trachea and œsophagus, passes under the lower border of the Inferior constrictor muscle to enter the larynx behind the articulation of the inferior cornu of the thyroid cartilage with the cricoid, and is distributed to all the muscles of the larynx, excepting the Crico-thyroid. It communicates with the superior laryngeal nerve, and gives off a few filaments to the mucous membrane of the lower part of the larynx.

The recurrent laryngeal, as it hooks round the subclavian artery or aorta, gives off several cardiac filaments, which unite with the cardiac branches from the pneumogastric and sympathetic. As it ascends in the neck it gives off œsophageal branches, more numerous on the left than on the right side, which supply the mucous membrane and muscular coat of the œsophagus; tracheal branches to the mucous membrane and muscular fibres of the trachea; and some pharyngeal filaments to the Inferior constrictor of the pharynx.

The **cervical cardiac branches** (rami cardiaci superiores), two or three in number, arise from the pneumogastric, at the upper and lower parts of the neck.

The *superior branches* are small, and communicate with the cardiac branches of the sympathetic. They can be traced to the great or deep cardiac plexus.

The *inferior branch* arises at the lower part of the neck, just above the first rib. That from the right vagus passes in front or by the side of the innominate artery, and communicates with one of the cardiac nerves proceeding to the great or deep cardiac plexus; that from the left runs down across the left side of the arch of the aorta, and joins the superficial cardiac plexus.

The **thoracic cardiac branches** (rami cardiaci inferiores), on the right side, arise from the trunk of the pneumogastric as it lies by the side of the trachea, and from its recurrent laryngeal branch; but on the left side from the recurrent nerve only; passing inwards, they end in the deep cardiac plexus.

The **anterior pulmonary branches** (rami bronchiales anteriores), two or three in number, and of small size, are distributed on the anterior surface of the root of the lung. They join with filaments from the sympathetic, and form the *anterior pulmonary plexus* (plexus pulmonalis anterior).

The **posterior pulmonary branches** (rami bronchiales posteriores), more numerous and larger than the anterior, are distributed on the posterior surface of the root of the lung ; they are joined by filaments from the third and fourth (sometimes also from the first and second) thoracic ganglia of the sympathetic, and form the *posterior pulmonary plexus* (plexus pulmonalis posterior). Branches from this plexus accompany the ramifications of the bronchi through the substance of the lung.

The **œsophageal branches** (rami œsophagei) are given off from the pneumogastric both above and below the pulmonary branches. The lower are more numerous and larger than the upper. They form, together with branches from the opposite nerve, the *œsophageal plexus*. From this plexus filaments are distributed to the back of the pericardium.

The **gastric branches** (rami gastrici) are the terminal filaments of the pneumogastric nerve. The nerve on the right side is distributed to the posterior surface of the stomach, and joins the left side of the cœliac plexus and the splenic plexus. The nerve on the left side is distributed over the anterior surface of the stomach, and along the lesser curvature. It unites with branches of the right nerve and with the sympathetic, some filaments passing through the lesser omentum to the hepatic plexus.

Applied Anatomy.—The trunk of the pneumogastric is rarely injured, but the functions of the nerve may be interfered with by damage to its nucleus of origin in the medulla ; by thickening or growth from the meninges or bones, or aneurysm of the basilar artery, before its exit from the skull ; injuries such as gunshot or punctured wounds in the neck, or injuries during such operations as ligature of the carotid artery, removal of tuberculous glands or other deep-seated tumours. The pneumogastric may also be compressed by aneurysms of the carotid artery, and its deep origin becomes affected in bulbar paralysis. The symptoms produced by paralysis of the nerve are palpitation, with increased frequency of the pulse, constant vomiting, slowing of the respiration, and a sensation of suffocation.

' Reflexes ' on the branches of the vagus are not at all uncommonly met with. The ' ear cough ' is perhaps one of the commonest, where a plug of wax in the auditory meatus may by irritating the filaments of Arnold's nerve be responsible for a persistent cough. Syringing the external auditory meatus frequently produces cough, and, in children, vomiting is not uncommon as the result of such a procedure ; moreover, in people with weak hearts, syringing the ear has been responsible for a sudden fatal syncope, by reflex irritation of the cardiac branches. Another very common example is the persistent cough which is frequently due to enlarged bronchial glands in children, the irritation of which is referred to the superior laryngeal filaments.

The anatomy of the laryngeal nerves is of considerable importance in considering some of the morbid conditions of the larynx. When the peripheral terminations of the superior laryngeal nerve are irritated by some foreign body passing over them, reflex spasm of the glottis is the result. When its trunk is pressed upon by, for instance, a goitre or an aneurysm of the upper part of the carotid, there is a peculiar dry, brassy cough. When the nerve is paralysed, there is anæsthesia of the mucous membrane of the larynx, so that foreign bodies can readily enter the cavity, and, as the nerve also supplies the Cricothyroid muscle, the vocal cords cannot be made tense, and the voice is deep and hoarse. Paralysis may be the result of bulbar paralysis ; may be a sequel to diphtheria, when both nerves are usually involved ; or it may, though less commonly, be caused by the pressure of tumours or aneurysms, when the paralysis is generally unilateral. Irritation of the recurrent or inferior laryngeal nerves produces spasm of the muscles of the larynx. When both these recurrent nerves are paralysed, the vocal cords are motionless, in the so-called ' cadaveric position '—that is to say, in the position in which they are found in ordinary tranquil respiration ; neither closed as in phonation, nor open as in deep inspiratory efforts. When one recurrent nerve is paralysed, the cord of the same side is motionless, while the opposite one crosses the middle line to accommodate itself to the affected one ; hence phonation is present, but the voice is altered and weak in timbre. The nerves may be paralysed in bulbar paralysis or after diphtheria, when the paralysis usually affects both sides ; or they may be affected by the pressure of aneurysms of the aorta, innominate, or subclavian arteries ; by mediastinal tumours ; by gummata ; or by cancer of the upper part of the œsophagus, when the paralysis is often unilateral. Paralysis of the adductor muscles of the larynx on both sides is quite common, and is usually functional in nature. The voice is reduced to a whisper, but the power of coughing is preserved.

Eleventh Nerve (figs. 783, 785, 786)

The **Eleventh or Spinal Accessory nerve** (n. accessorius) consists of two parts : one, the accessory part to the vagus, and the other the spinal portion.

The **bulbar or accessory part** is the smaller of the two. Its fibres arise from the cells of the *nucleus ambiguus* and emerge as four or five delicate filaments from the side of the medulla, below the roots of the vagus. It passes outwards to the jugular foramen, where it interchanges fibres with the spinal portion or becomes united to it for a short distance ; it is also connected, in the foramen, with the ganglion of the root of the vagus by one or two filaments. It then passes through the foramen, and becoming again separated from the spinal portion it is continued over the surface of the ganglion of the trunk of the vagus, being adherent to its surface, and is distributed principally to the pharyngeal and superior laryngeal branches of the pneumogastric. Through the pharyngeal branch it probably supplies the Azygos uvulæ and Levator palati muscles (see page 486). Some few filaments from it are continued into the trunk of the vagus

FIG. 787.—Plan of the hypoglossal nerve.

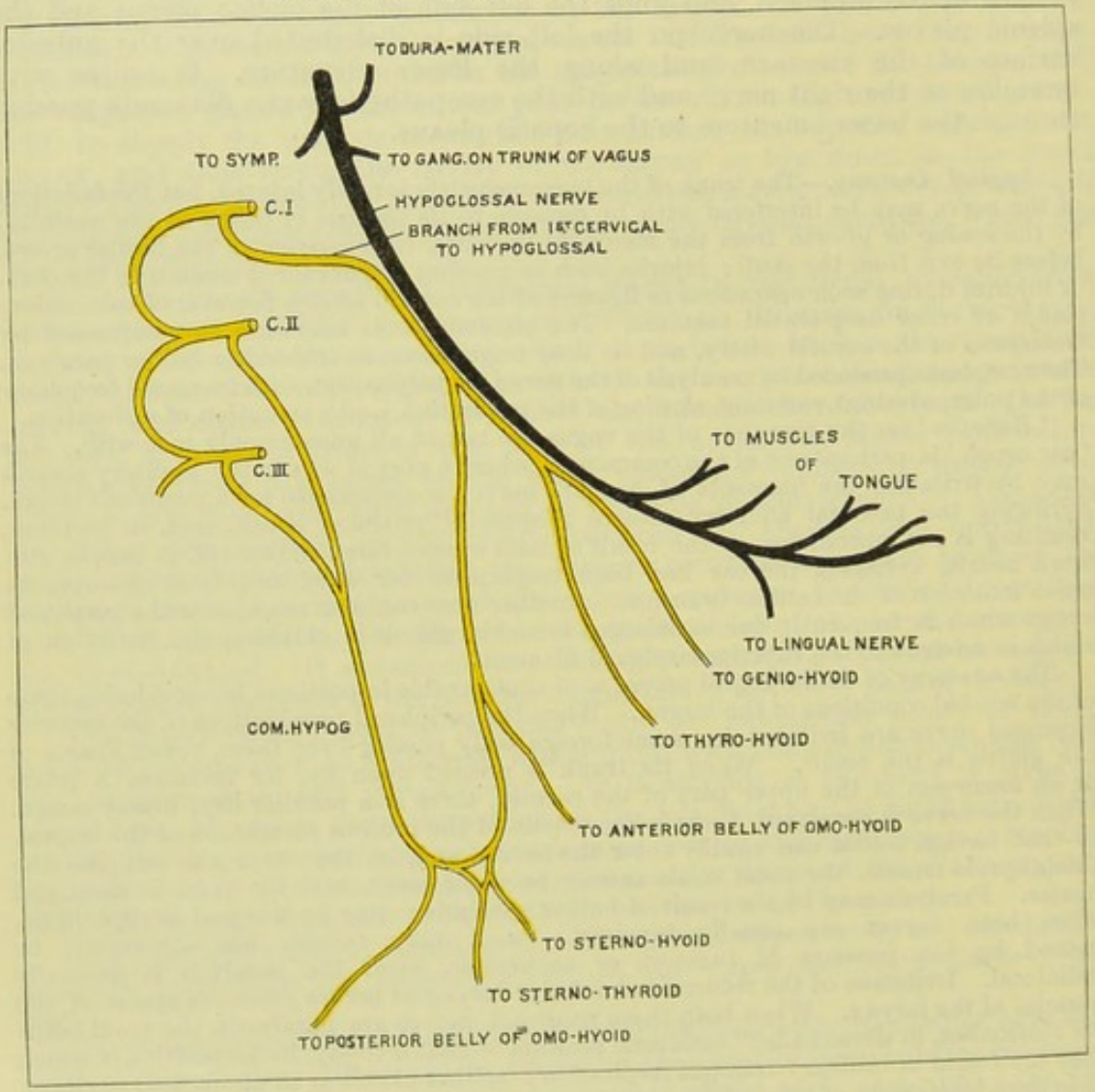

below the ganglion, to be distributed with the recurrent laryngeal nerve and probably also with the cardiac nerves.

The **spinal portion** is firm in texture, and its fibres arise from the motor cells in the outer part of the anterior horn of the grey matter of the spinal cord as low as the fifth cervical nerve. Passing outwards and backwards through the lateral white column of the cord, they emerge on its surface and unite to form a single trunk, which ascends between the ligamentum denticulatum and the posterior roots of the spinal nerves, enters the skull through the foramen magnum, and is then directed outwards to the jugular foramen, through which it passes, lying in the same sheath of dura mater as the pneumogastric, but separated from it by a fold of the arachnoid. In the jugular foramen, it receives one or two filaments from the accessory portion, or else joins it for a short distance and then separates from it again. At its exit from the jugular

foramen, it runs backwards, either in front of or behind the internal jugular vein, and descends obliquely behind the Digastric and Stylo-hyoid muscles to the upper part of the Sterno-mastoid. It pierces this muscle, and passes obliquely across the posterior triangle, to terminate in the deep surface of the Trapezius. During its passage through the Sterno-mastoid it gives several branches to the muscle, and joins in its substance with branches from the second cervical. In the posterior triangle it joins with the second and third cervical nerves, while beneath the Trapezius it forms a plexus with the third and fourth cervical nerves, and from this plexus fibres are distributed to the muscle.

Applied Anatomy.—The functions of the spinal accessory nerve may be interfered with either by central changes ; or at its exit from the skull, by fractures running across the jugular foramen ; or in the neck, by inflamed lymphatic glands, &c. The acute wry neck in children is most commonly due to inflamed or suppurating glands, and rapidly subsides with appropriate treatment. Central irritation causes clonic spasm of the Sterno-mastoid and Trapezius muscles, or, as it is termed, spasmodic torticollis. In cases of this affection in which all previous palliative treatment has failed, and the spasms are so severe as to undermine the patient's health, division or excision of a portion of the spinal accessory nerve has been resorted to. This must be done from the anterior border of the Sterno-mastoid muscle. The operation consists in making an incision, three inches in length, from the apex of the mastoid process along the anterior border of the muscle, which is defined and pulled backwards, so as to stretch the nerve, which is then to be sought for beneath the Digastric muscle, about two inches below the apex of the mastoid process. Unfortunately, the operation does not yield a satisfactory or permanent cure, as the spasms tend to recur after an interval, either in the same muscles or in other groups of neck muscles.

In cases where extensive dissections are undertaken for enlarged glands in the posterior triangle of the neck, it is essential that this nerve should be at once sought for and isolated from the mass of inflamed glands so as to maintain its continuity, as otherwise it would be very liable to be divided, with resulting paralysis of the Trapezius.

Twelfth Nerve (figs. 785, 787, 788)

The **Twelfth** or **Hypoglossal nerve** (n. hypoglossus) is the motor nerve of the tongue.

Its fibres arise from the cells of the *hypoglossal nucleus*, which is an upward prolongation of the base of the anterior horn of grey matter of the cord. This nucleus is about three-quarters of an inch in length, and its upper part corresponds with the *trigonum hypoglossi*, which is situated close to the middle line in the lower half of the floor of the fourth ventricle. The lower part of the nucleus extends downwards into the closed part of the medulla, and there lies in relation to the ventro-lateral aspect of the central canal. The fibres run forwards through the entire thickness of the medulla, between its anterior and lateral areas, and emerge in the pre-olivary sulcus between the pyramid and the olivary body.

The filaments of this nerve are collected into two bundles, which perforate the dura mater separately, opposite the anterior condyloid foramen, and unite together after their passage through it. In those cases in which the anterior condyloid foramen in the occipital bone is double, these two portions of the nerve are separated by the small piece of bone which divides the foramen. The nerve descends almost vertically to a point corresponding with the angle of the jaw. It is at first deeply seated beneath the internal carotid artery and internal jugular vein, and intimately connected with the pneumogastric nerve ; it then passes forwards between the vein and artery, and lower down in the neck becomes superficial below the Digastric muscle. The nerve then loops round the occipital artery, and crosses the external carotid and lingual below the tendon of the Digastric. It passes beneath the tendon of the Digastric, the Stylo-hyoid, and the Mylo-hyoid muscles, lying between the last-named muscle and the Hyo-glossus, and communicates at the anterior border of the Hyo-glossus with the lingual nerve ; it is then continued forwards in the fibres of the Genio-hyo-glossus muscle as far as the tip of the tongue, distributing branches to its muscular substance.

Branches of communication.—The branches of communication are, with the

Pneumogastric.	First and second cervical nerves.
Sympathetic.	Lingual.

The communication with the pneumogastric takes place close to the exit of the nerve from the skull, numerous filaments passing between the hypoglossal and the ganglion of the trunk of the pneumogastric through the mass of connective tissue which unites the two nerves. It also communicates with the pharyngeal plexus by a minute filament as it winds round the occipital artery.

The communication with the sympathetic takes place opposite the atlas by branches derived from the superior cervical ganglion, and in the same situation the nerve is joined by a filament derived from the loop connecting the first two cervical nerves.

The communication with the lingual takes place near the anterior border of the Hyo-glossus muscle by numerous filaments which ascend upon it.

FIG. 788.—Hypoglossal nerve, cervical plexus, and their branches.

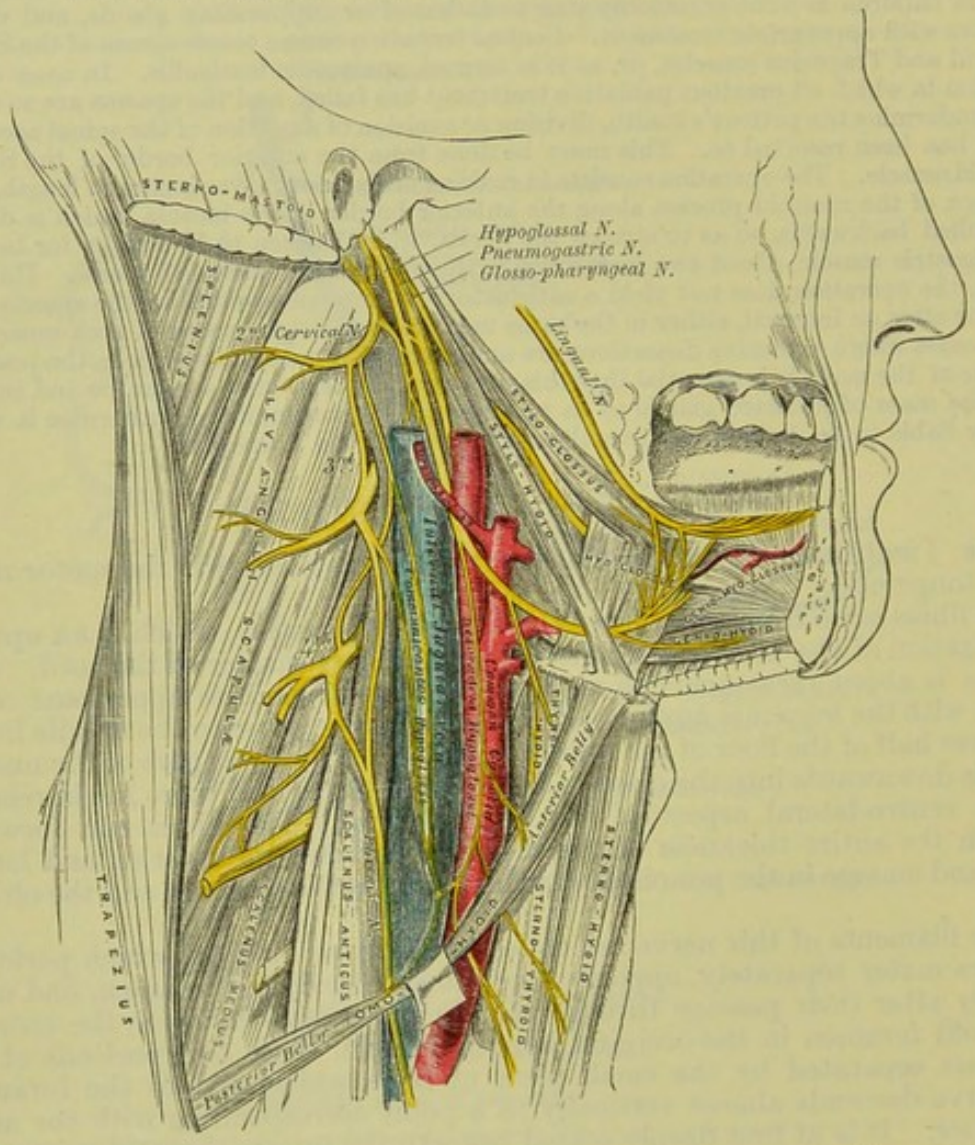

Branches of distribution.—The branches of distribution are, the

Meningeal.
Descendens hypoglossi.
Thyro-hyoid.
Muscular.

Of these branches, the meningeal, descendens hypoglossi, thyro-hyoid, and the muscular branch to the Genio-hyoid, are probably derived mainly from the branch which passes from the loop between the first and second cervical to join the hypoglossal (fig. 787).

Meningeal branches.—As the hypoglossal nerve passes through the anterior condyloid foramen it gives off, according to Luschka, several filaments to the dura mater in the posterior fossa of the base of the skull.

The **descendens hypoglossi** (ramus descendens) is a long slender branch, which quits the hypoglossal where it turns round the occipital artery. It

descends in front of the sheath of the carotid vessels, giving off a branch to the anterior belly of the Omo-hyoid, and then joins the descendens cervicis (ramus communicans hypoglossi) from the second and third cervical nerves, just below the middle of the neck, to form a loop, the *ansa hypoglossi*. From the convexity of this loop branches pass to supply the Sterno-hyoid, the Sterno-thyroid, and the posterior belly of the Omo-hyoid. According to Arnold, another filament descends in front of the vessels into the chest, and joins the cardiac and phrenic nerves.

The **thyro-hyoid branch** (ramus thyreohyoideus) arises from the hypoglossal near the posterior border of the Hyo-glossus ; it runs obliquely across the great cornu of the hyoid bone, and supplies the Thyro-hyoid muscle.

The **muscular branches** are distributed to the Stylo-glossus, Hyo-glossus, Genio-hyoid, and Genio-hyo-glossus muscles. At the under surface of the tongue numerous slender branches pass upwards into the substance of the organ to supply its intrinsic muscles.

Applied Anatomy.—The hypoglossal nerve is an important guide in the operation of ligature of the lingual artery (see page 631). It runs forwards on the Hyo-glossus just above the great cornu of the hyoid bone, and forms the upper boundary of the triangular space in which the artery is to be sought for by cutting through the fibres of the Hyo-glossus. In cases where it has been injured on one side of the neck, or in some cases of bulbar paralysis, unilateral paralysis, together with hemiatrophy of the tongue, is the result ; the tongue, when protruded, being directed to the paralysed side owing to the unopposed action of the Genio-hyo-glossus of the opposite side. On retraction, the wasted and paralysed side of the tongue rises up higher than the other. The larynx may deviate towards the sound side on swallowing, from the unilateral paralysis of the depressors of the hyoid bone. If the paralysis is bilateral, the tongue lies motionless in the mouth, while articulation and mastication are much interfered with.

THE SPINAL NERVES (NERVI SPINALES)

The **spinal nerves** spring from the spinal cord, and are transmitted through the intervertebral foramina. They number thirty-one pairs, which are grouped as follows :

Cervical, 8 ;
Thoracic, 12 ;
Lumbar, 5 ;
Sacral, 5 ;
Coccygeal, 1.

The *first cervical nerve* emerges from the vertebral canal between the occipital bone and the atlas, and is therefore called the *suboccipital nerve* (n. suboccipitalis) ; the eighth issues between the seventh cervical and first thoracic vertebræ.

Nerve roots.—Each nerve is attached to the spinal cord by two roots, an anterior or ventral, and a posterior or dorsal, the latter being characterised by the presence of a ganglion, the *spinal ganglion*.

The **anterior root** (radix anterior) emerges from the anterior surface of the cord as a number of rootlets or fasciculi (fila radicularia), which coalesce to form two bundles near the intervertebral foramen.

The **posterior root** (radix posterior) is larger than the anterior owing to the greater size and number of its fasciculi ; these are attached along the postero-lateral furrow of the spinal cord and unite to form two bundles which join the spinal ganglion. The posterior root of the first cervical nerve is exceptional in that it is smaller than the anterior ; it is occasionally wanting.

The **spinal ganglia** (ganglia spinalia) are collections of nerve cells on the posterior roots of the spinal nerves. Each ganglion is oval in shape, reddish in colour, and its size bears a proportion to that of the nerve root on which it is situated ; it is bifid internally where it is joined by the two bundles of the posterior nerve root. The ganglia are usually placed in the intervertebral foramina, immediately outside the points where the nerve roots perforate the dura mater, but there are exceptions to this rule ; thus the ganglia of the first and second cervical nerves lie on the neural arches of the atlas and axis respectively, those of the sacral nerves are inside the vertebral canal, while

that on the posterior root of the coccygeal nerve is placed within the sheath of dura mater.

Structure.—The ganglia consist chiefly of unipolar nerve cells, and from these the fibres of the posterior root take origin—the single process of each cell dividing after a short course into a central fibre which enters the spinal cord and a peripheral fibre which runs outwards into the spinal nerve. Two other forms of cells are, however, present, viz. : (*a*) the cells of Dogiel, whose axons

FIG. 789.—Distribution of cutaneous nerves.

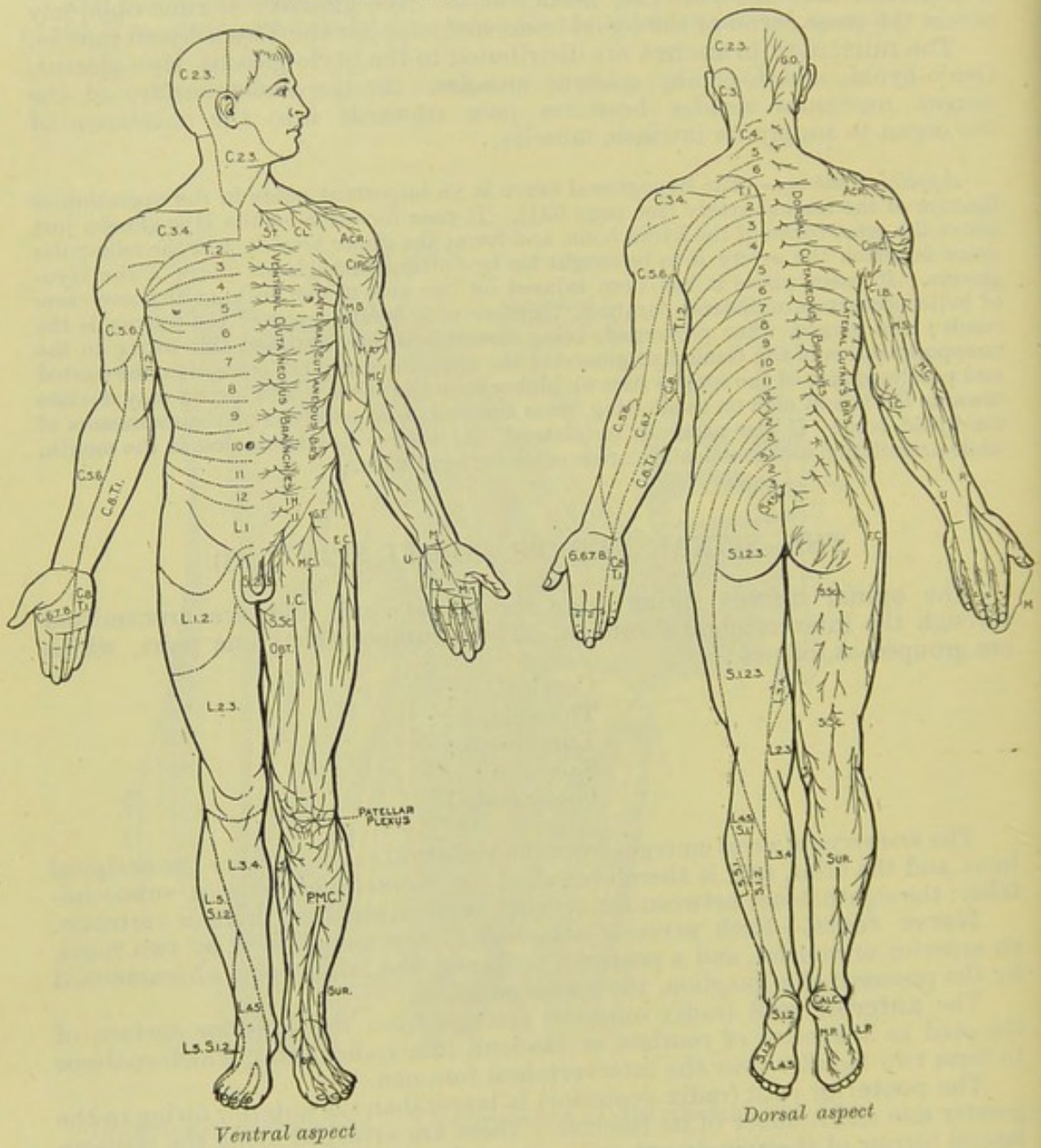

ramify close to the cell (type II. of Golgi), and are distributed entirely within the ganglion; and (*b*) multipolar cells similar to those found in the sympathetic ganglia.

The ganglion of the first cervical nerve may be absent, while small *aberrant ganglia* consisting of groups of nerve cells are sometimes found on the posterior roots between the spinal ganglia and the cord.

Each nerve root receives a covering from the pia mater, and is loosely invested by the arachnoid membrane, the latter being prolonged as far as the points where the roots pierce the dura mater. The two roots pierce the dura mater separately, each receiving a sheath from this membrane; where the

roots join to form the spinal nerve this sheath is continuous with the epineurium of the nerve.

Size and direction.—The roots of the upper four *cervical* nerves are small, those of the lower four are large. The posterior roots of the cervical nerves bear a proportion to the anterior of three to one, which is greater than in the other regions; their individual filaments are also larger than those of the anterior roots. The posterior root of the first cervical is an exception to this rule, being smaller than the anterior root; in eight per cent. of cases it is wanting. The roots of the first and second cervical nerves are short, and run nearly horizontally outwards to their points of exit from the vertebral canal. From the second to the eighth cervical they are directed obliquely downwards and outwards, the obliquity and length of the roots successively increasing; the distance, however, between the level of attachment of any of these roots to the cord and the points of exit of the corresponding nerves never exceeds the depth of one vertebra.

The roots of the *thoracic* nerves, with the exception of the first, are of small size, and the posterior only slightly exceed the anterior in thickness. They increase successively in length, from above downwards, and in the lower part of the thoracic region descend in contact with the cord for a distance equal to the height of at least two vertebræ before they emerge from the vertebral canal.

The roots of the lower *lumbar* and upper *sacral* nerves are the largest, and their individual filaments the most numerous of all the spinal nerves, while the roots of the *coccygeal* nerve are the smallest.

The roots of the lumbar, sacral, and coccygeal nerves run vertically downwards to their respective exits, and as the spinal cord ends near the lower border of the first lumbar vertebra it follows that the length of the successive roots must rapidly increase. As already mentioned (page 797), the term *cauda equina* is applied to this collection of nerve roots.

From the description given it will be seen that the largest nerve roots, and consequently the largest spinal nerves, are attached to the cervical and lumbar swellings of the cord; these nerves are distributed to the upper and lower limbs.

Points of emergence.—The following table, after Macalister, shows the relations which the places of attachment of the nerves to the cord present to the bodies and spinous processes of the vertebræ:

Level of body of	No. of Nerve	Level of tip of spine of	Level of body of	No. of Nerve	Level of tip of spine of
C. 1	C. 1	—	T. 8	T. 9	7 T.
2	2	—	9	10	8 T.
	3	1 C.	10	11	9 T.
3	4	2 C.	—	12	10 T.
4	5	3 C.	11	L. 1	11 T.
5	6	4 C.	—	2	—
6	7	5 C.	12	3	
—	8	6 C.	—	4	12 T.
7	T. 1	7 C.		5	—
T. 1	2	1 T.		S. 1	
2	3	—	L. 1	2	
3	4	2 T.		3	
4	5	3 T.		4	1 L.
5	6	4 T.	—	5	
6	7	5 T.	—	C. 1	
7	8	6 T.	L. 2	—	—

Connections with sympathetic. — Immediately beyond the spinal ganglion, the anterior and posterior nerve roots unite to form the *spinal* nerve which emerges through the intervertebral foramen. Each spinal nerve receives a branch (*grey ramus communicans*) from the adjacent ganglion of the sympathetic cord, while all the thoracic, and the first and second lumbar nerves each

contribute a branch (*white ramus communicans*) to the adjoining sympathetic ganglion. The second, third, and fourth sacral nerves also supply white rami; these branches, however, are not connected with the ganglia of the sympathetic cord, but run directly into the pelvic plexuses of the sympathetic.

Structure.—Each typical spinal nerve contains fibres belonging to two systems, viz. the somatic, and the sympathetic or splanchnic, as well as fibres connecting these systems with each other.

1. The **somatic** fibres are efferent and afferent. The *efferent* fibres originate in the cells of the anterior horn of the spinal cord, and run outwards through the anterior nerve roots to the spinal nerve. They convey impulses to the voluntary muscles, and are continuous from their origin to their peripheral distribution. The *afferent* fibres convey impressions inwards from the skin, &c., and originate in the unipolar nerve cells of the spinal ganglia. The single processes of these cells divide into peripheral and central fibres, and the latter enter the spinal cord through the posterior nerve roots. Many of them are

Fig. 790.—Scheme showing structure of a typical spinal nerve.

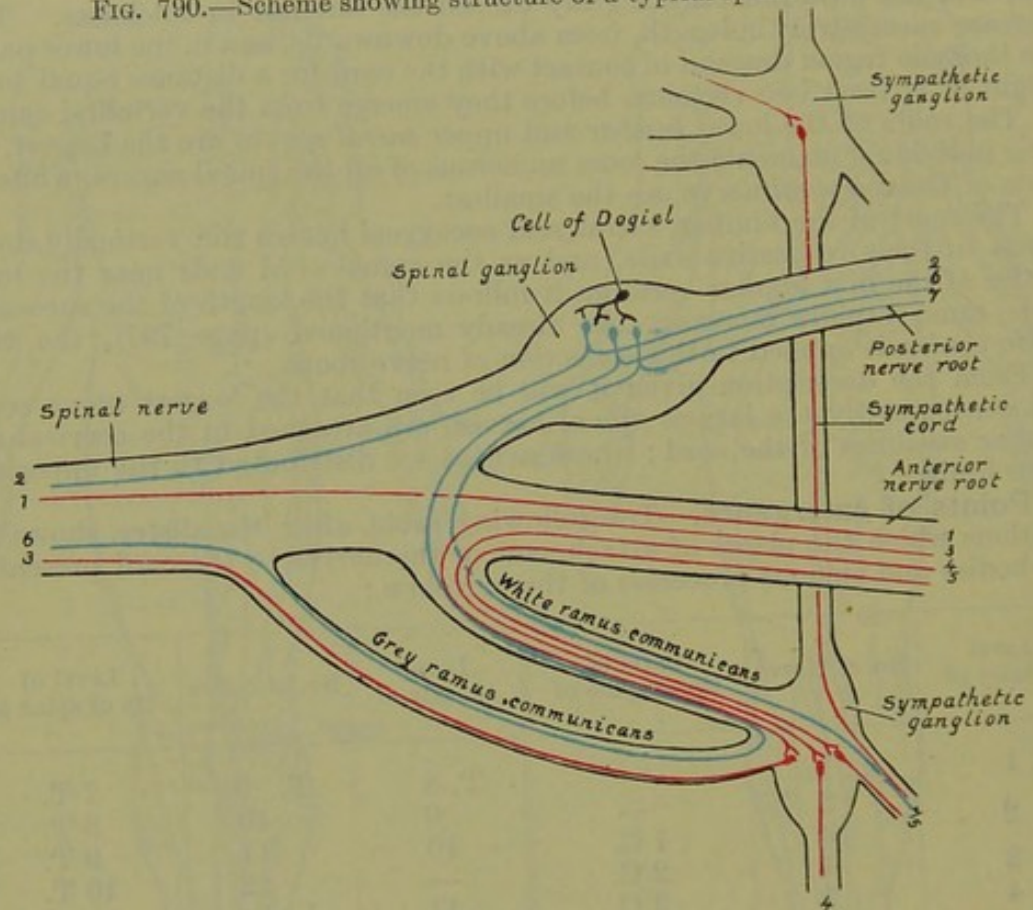

1. Somatic efferent. 2. Somatic afferent. 3, 4, 5. Splanchnic efferent. 6, 7. Splanchnic afferent.

continued up the cord to the medulla oblongata, where they end in the nucleus gracilis and nucleus cuneatus, but some form synapses round efferent neurons in the same or opposite side of the cord, completing in this way reflex arcs.

2. The **sympathetic** fibres are also efferent and afferent. The *efferent* fibres originate in the lateral horn of the spinal cord and are conveyed through the anterior nerve root and the white ramus communicans to the corresponding ganglion of the sympathetic chain; here they may end by forming synapses around its cells, or may run through the ganglion to end in another of the chain ganglia or in a more distally placed ganglion in one of the sympathetic plexuses. In all cases they terminate by forming synapses around other nerve cells. From the cells of the chain ganglia other fibres take origin; some of these run inwards through the grey rami communicantes to join the spinal nerves, along which they are carried to the blood-vessels of the trunk and limbs,* while others pass

* It is generally stated that the sympathetic fibres which run in the spinal nerves are distributed to the Arrectores pilorum muscles and the glands of the skin, but the evidence is not conclusive.

to the viscera, either directly or after interruption in one of the distal ganglia. The *afferent* fibres are derived partly from the unipolar cells (type I.) and partly from the multipolar cells (type III.) of the spinal ganglia. Their peripheral processes are carried outwards through the white rami communicantes, and after passing through one or more sympathetic ganglia (but always without interruption in them) finally terminate in the tissues of the viscera. The central processes of the unipolar cells enter the spinal cord through the posterior nerve root and form synapses around either somatic or sympathetic efferent neurons, thus completing reflex arcs. The dendrites of the multipolar nerve cells form synapses around the cells of type II. (cells of Dogiel) in the spinal ganglia, and by this path the original impulse is transferred from the sympathetic to the somatic system, through which it is conveyed to the sensorium.

Divisions.—After emerging from the intervertebral foramen, each spinal nerve gives off a small *recurrent branch* (ramus meningeus) which re-enters the spinal canal through the intervertebral foramen and supplies the vertebræ and their ligaments, and the blood-vessels of the spinal cord and its membranes. It then splits into a posterior or dorsal, and an anterior or ventral division, each division containing fibres from both nerve roots.

POSTERIOR PRIMARY DIVISIONS OF THE SPINAL NERVES

The **posterior primary divisions** are as a rule smaller than the anterior. They are directed backwards and, with the exceptions of those of the first cervical, the fourth and fifth sacral, and the coccygeal, divide into internal and external branches (rami mediales et laterales) for the supply of the muscles and skin of the posterior part of the trunk.

Cervical Nerves

The **posterior division of the first cervical or suboccipital nerve** is larger than the anterior division, and emerges above the posterior arch of the atlas and beneath the vertebral artery. It enters the suboccipital triangle and supplies the muscles which bound this space, viz. the Rectus capitis posticus major, the Obliquus superior, and the Obliquus inferior; it gives branches also to the Rectus capitis posticus minor and the Complexus. A filament from the branch to the Obliquus inferior joins the second cervical nerve.

The nerve also occasionally gives off a cutaneous branch which accompanies the occipital artery to the scalp, and communicates with the great and small occipital nerves.

The **posterior division of the second cervical nerve** is much larger than the anterior division, and is the greatest of all the posterior cervical divisions. It emerges between the posterior arch of the atlas and the lamina of the axis, below the Inferior oblique. It supplies a twig to this muscle, receives a communicating filament from the first cervical, and then divides into a large internal and a small external branch.

The *internal* branch, called from its size the *great occipital nerve* (n. occipitalis major) ascends obliquely inwards between the Obliquus inferior and the Complexus, and pierces the latter muscle and the Trapezius near their attachments to the occipital bone. It is now joined by a filament from the posterior division of the third cervical and, ascending on the back of the head with the occipital artery, divides into branches which communicate with the small occipital nerve and supply the skin of the scalp as far forward as the vertex of the skull. It gives off muscular branches to the Complexus, and occasionally a twig to the back of the pinna. The *external* branch supplies filaments to the Splenius, Trachelo-mastoid and Complexus, and is often joined by the corresponding branch of the third cervical.

The **posterior division of the third cervical** is intermediate in size between those of the second and fourth. Its *internal* branch runs between the Complexus and Semispinalis, and piercing the Splenius and Trapezius, ends in the skin. While under the Trapezius it gives off a branch called the *third*

occipital nerve (n. occipitalis tertius) which pierces the Trapezius and ends in the skin of the lower part of the back of the head. It lies to the inner side of the great occipital and communicates with it. The *external* branch often joins that of the second.

The posterior division of the suboccipital, and the inner branches of the posterior primary divisions of the second and third cervical nerves are sometimes joined by communicating loops to form the *posterior cervical plexus* (Cruveilhier) (fig. 791).

The **posterior divisions of the lower five cervical nerves** divide into internal and external branches. The *internal* branches of the fourth

Fig. 791.—Plan of the posterior divisions of the upper cervical nerves.

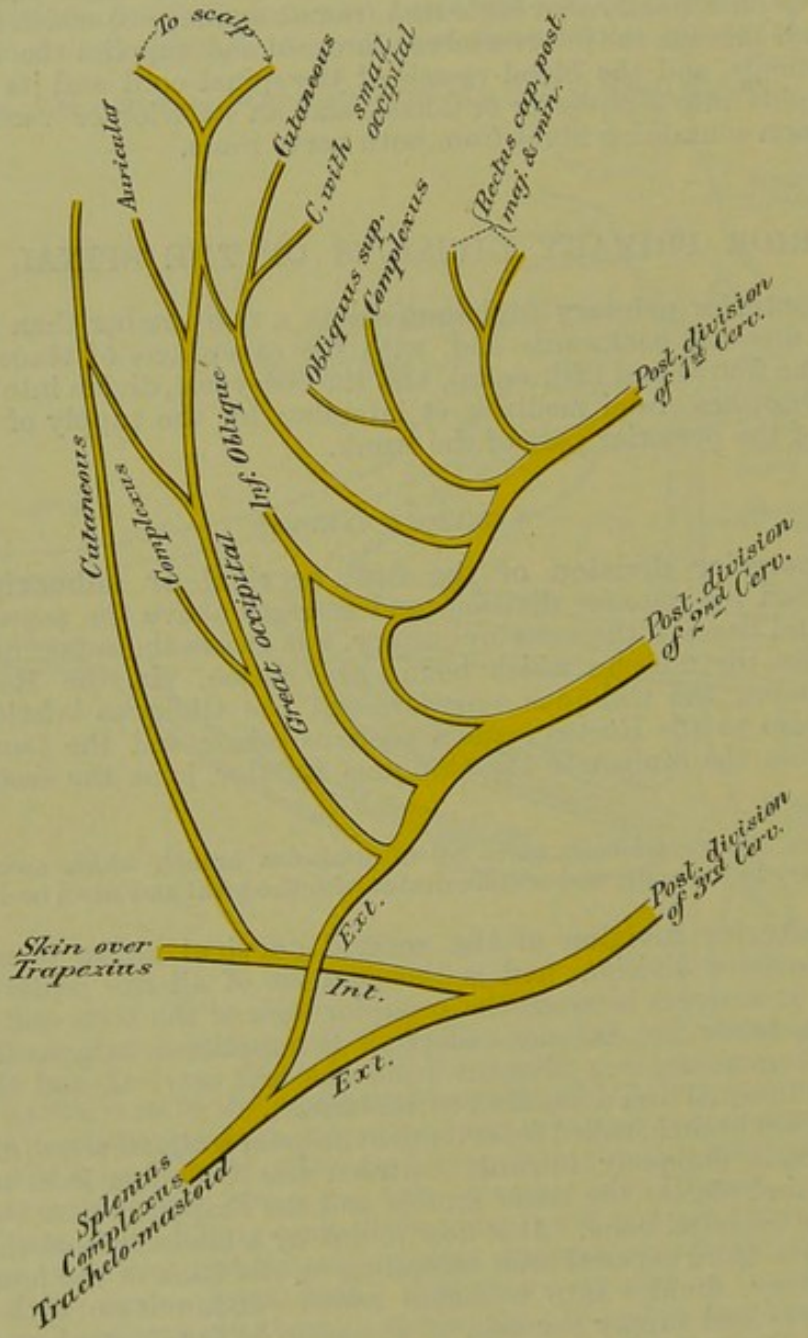

and fifth run between the Semispinalis and Complexus, and, having reached the spinous processes, pierce the Splenius and Trapezius to end in the skin. Sometimes the internal branch of the fifth fails to reach the skin. The internal branches of the lower three nerves are small, and end in the Semispinalis, Multifidus spinæ, Complexus and Interspinales. The *external* branches of the lower five nerves supply the Cervicalis ascendens, Transversalis colli, and Trachelo-mastoid.

FIG. 792.—Superficial and deep distribution of the posterior divisions of the spinal nerves (after Hirschfeld and Leveillé). On the left side the cutaneous branches are represented lying on the superficial layer of muscles. On the right side the superficial muscles have been removed, the Splenius capitis and Complexus divided in the neck, and the Erector spinæ divided and partly removed in the back, so as to expose the posterior divisions of the spinal nerves near their origin.

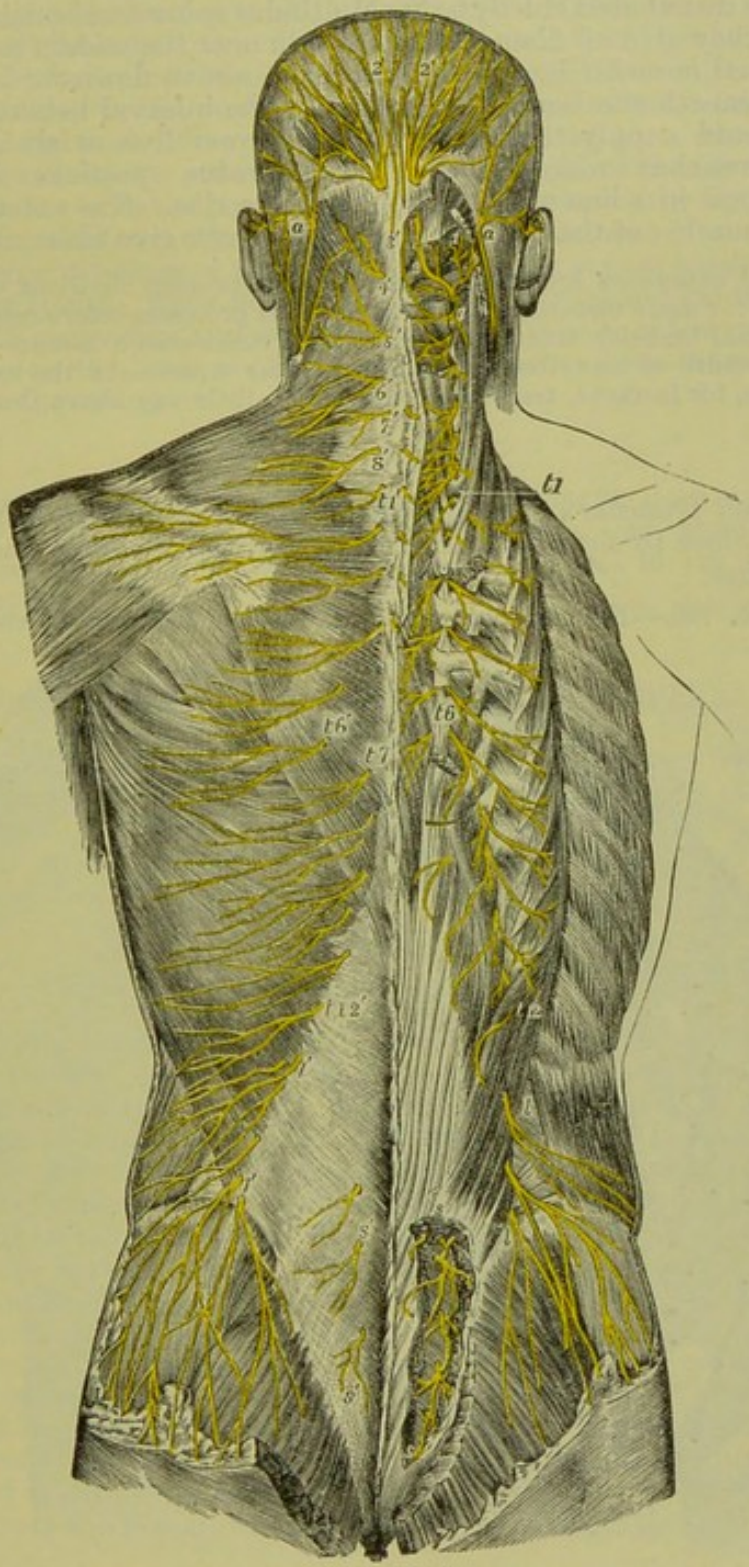

a, *a*. Small occipital nerve from the cervical plexus. 1. External muscular branches of the first cervical nerve, and union by a loop with the second. 2. Placed on the Rectus capitis posticus major muscle, marks the great occipital nerve (2'), passing round the short muscles and piercing the Complexus: the external branch is seen to the outside. 3. External branch from the posterior division of the third nerve. 3'. Its internal branch, sometimes called the third occipital. 4' to 8'. The internal branches of the several corresponding nerves on the left side. The external branches of these nerves, proceeding to muscles, are displayed on the right side. *t* 1 to *t* 6 and thence to *t* 12. External muscular branches of the posterior divisions of the 12 thoracic nerves on the right side. *t* 1' to *t* 6'. The internal cutaneous branches of the six upper thoracic nerves on the left side. *t* 7' to *t* 12'. Cutaneous twigs from the external branches of the six lower thoracic nerves. *l*, *l*. External branches from the posterior divisions of several lumbar nerves on the right side, piercing the muscles, the lower descending over the gluteal region. *l'*, *l'*. The same, more superficially, on the left side. *s*, *s*. The issue and union by loops of the posterior divisions of four sacral nerves on the right side. *s'*, *s'*. Some of those distributed to the skin on the left side.

Thoracic Nerves (fig. 792)

The *internal* branches of the **posterior divisions of the upper six thoracic nerves** run inwards between the Semispinalis dorsi and Multifidus spinæ, which they supply; they then pierce the Rhomboidei and Trapezius and reach the skin by the sides of the spinous processes. The internal branches of the **lower six** are distributed chiefly to the Multifidus spinæ and Longissimus dorsi; occasionally they give off filaments to the skin near the middle line.

The *external branches* increase in size from above downwards. They run through or beneath the Longissimus dorsi to the interval between it and the Ilio-costalis, and supply these muscles; the lower five or six also give off cutaneous branches which pierce the Serratus posticus inferior and Latissimus dorsi in a line with the angles of the ribs. The external branches of a variable number of the upper thoracic nerves also give filaments to the skin.

The internal cutaneous branches of the posterior primary divisions of the thoracic nerves descend for some distance close to the spinous processes before reaching the skin, while the external branches travel downwards for a considerable distance—it may be as much as the breadth of four ribs—before they become superficial; the branch from the twelfth thoracic, for instance, reaches the skin only a little way above the iliac crest.*

Lumbar Nerves

The *internal branches* of the **posterior divisions of the lumbar nerves** pass inwards close to the articular processes of the vertebræ and end in the Multifidus spinæ.

Fig. 793.—The posterior primary divisions of the sacral nerves.

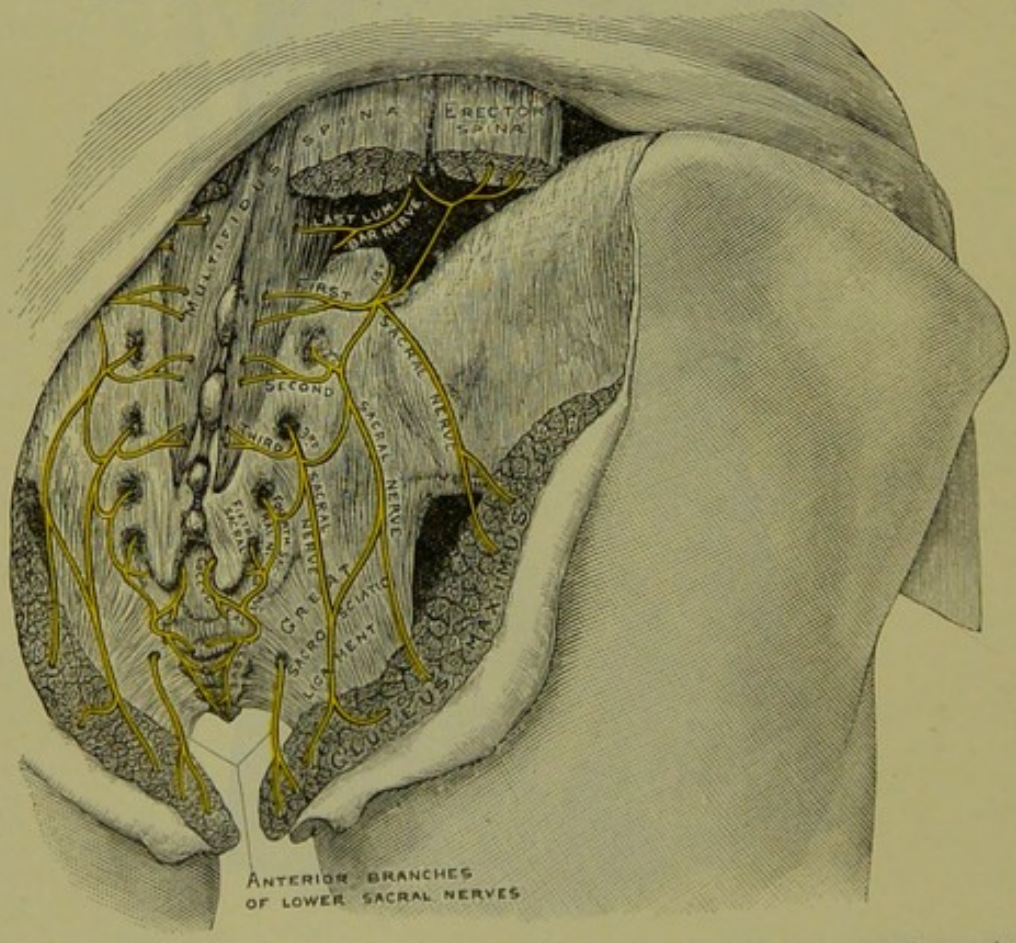

The *external branches* supply the Erector Spinæ. The upper three give off cutaneous nerves which pierce the aponeurosis of the Latissimus dorsi at the outer border of the Erector spinæ and descend across the posterior part of the iliac crest to the skin of the buttock, some of their twigs running as far as the level of the great trochanter.

* Consult in this connection an article on the cutaneous branches of the posterior primary divisions of the spinal nerves, by H. M. Johnston, *Journal of Anatomy and Physiology*, vol. xliii.

Sacral Nerves

The **posterior divisions of the sacral nerves** (fig. 793) are small, and diminish in size from above downwards; they emerge, except the last, through the posterior sacral foramina. The *upper three* are covered at their points of exit by the Multifidus spinæ, and divide into internal and external branches.

The *internal* branches are small, and end in the Multifidus spinæ.

The *external* branches join with one another and with the last lumbar and fourth sacral to form loops on the posterior surface of the sacrum. From these loops branches run to the posterior surface of the great sacro-sciatic ligament and form a second series of loops under the Gluteus maximus. From this second series cutaneous branches, two or three in number, pierce the Gluteus maximus along a line drawn from the posterior superior iliac spine to the tip of the coccyx; they supply the skin over the posterior part of the buttock.

The posterior divisions of the *lower two* sacral nerves are small and lie below the Multifidus spinæ. They do not divide into internal and external branches, but unite with each other and with the posterior division of the coccygeal nerve to form loops on the back of the sacrum; filaments from these loops supply the skin over the coccyx.

Coccygeal Nerve

The **posterior division of the coccygeal nerve** does not divide into an internal and an external branch, but receives, as already stated, a communicating branch from the last sacral; it is lost in the skin over the back of the coccyx.

ANTERIOR PRIMARY DIVISIONS OF THE SPINAL NERVES

The **anterior primary divisions of the spinal nerves** (rami anteriores) supply the antero-lateral parts of the trunk, and the limbs; they are for the most part larger than the posterior divisions. In the thoracic region they run independently of one another, but in the cervical, lumbar, and sacral regions they unite near their origins to form plexuses.

CERVICAL NERVES (NN. CERVICALES)

The **anterior primary divisions of the cervical nerves,** with the exception of the first, pass outwards between the anterior and posterior Intertransverse muscles, lying on the grooved upper surfaces of the transverse processes, and emerge between the muscles attached to the anterior and posterior tubercles of these. The *anterior primary division of the first or suboccipital nerve* issues from the vertebral canal above the posterior arch of the atlas and runs forwards round the lateral aspect of its superior articular process, internal to the vertebral artery. In most cases it descends internal to and in front of the Rectus lateralis, but in some cases it pierces the muscle.

The anterior primary divisions of the *upper four cervical nerves* unite to form the *cervical plexus*, and each receives a grey ramus communicans from the superior cervical ganglion of the sympathetic cord. Those of the *lower four cervical*, together with the greater part of the first thoracic, form the *brachial plexus*. They each receive a grey ramus communicans, those for the fifth and sixth being derived from the middle, and those for the seventh and eighth from the lowest, cervical ganglion of the sympathetic.

Cervical Plexus (Plexus Cervicalis)

The **cervical plexus** (fig. 794) is formed by the anterior primary divisions of the upper four cervical nerves; each nerve, except the first, divides into an upper and a lower branch, and the branches unite to form three loops. It is situated opposite the upper four cervical vertebræ, in front of the Levator anguli scapulæ and Scalenus medius, and covered by the Sterno-mastoid.

Its branches are divided into two groups, *superficial* and *deep*, and are here

given in tabular form; the figures following the names indicate the nerves from which the different branches take origin:

Superficial	Ascending	Small occipital		2, C.
		Great auricular		2, 3, C.
	Transverse	Superficial or transverse cervical		2, 3, C.
	Descending or Supraclavicular	Sternal, Clavicular, Acromial		3, 4, C.
Deep	Internal — Communicating	With hypoglossal		1, 2, C.
		,, vagus		1, 2, C.
		,, sympathetic		1, 2, 3, 4, C.
	Internal — Muscular	Rectus lateralis		1, C.
		Anterior recti		1, 2, C.
		Communicantes hypoglossi		2, 3, C.
		Phrenic		3, 4, 5, C.
	External — Communicating	with Spinal accessory		2, 3, 4, C.
	External — Muscular	Sterno-mastoid		2, C.
		Trapezius		3, 4, C.
		Levator anguli scapulæ		3, 4, C.
		Scalenus medius		3, 4, C.

Superficial Branches of the Cervical Plexus (fig. 795)

The **small occipital** (n. occipitalis minor) arises from the second cervical nerve, sometimes also from the third; it curves round the posterior border of the Sterno-mastoid, and ascends along the posterior border of the muscle. Near the cranium it perforates the deep fascia, and is continued upwards along the side of the head behind the ear, supplying the integument and communicating with the great occipital, the great auricular, and the posterior auricular branch of the facial. The small occipital varies in size, and is sometimes duplicated.

It gives off an *auricular branch*, which supplies the integument of the upper and back part of the auricle, communicating with the mastoid branch of the great auricular. This branch is occasionally derived from the great occipital nerve.

The **great auricular** (n. auricularis magnus) is the largest of the ascending branches. It arises from the second and third cervical nerves, winds round the posterior border of the Sterno-mastoid, and, after perforating the deep fascia, ascends upon that muscle beneath the Platysma to the parotid gland, where it divides into facial, auricular, and mastoid branches.

The *facial branches* are distributed to the integument of the face over the parotid gland; others penetrate the substance of the gland, and communicate with the facial nerve.

The *auricular branches* ascend to supply the integument of the back of the pinna, except at its upper part, communicating with the auricular branches of the facial and pneumogastric nerves. A filament pierces the pinna to reach its outer surface, where it is distributed to the lobule and lower part of the concha.

The *mastoid branch* communicates with the small occipital and with the posterior auricular branch of the facial, and is distributed to the integument behind the ear.

The **superficial** or **transverse cervical** (n. cutaneus colli) arises from the second and third cervical nerves, turns round the posterior border of the Sterno-mastoid about its middle, and, passing obliquely forwards beneath the external jugular vein to the anterior border of the muscle, perforates the deep cervical fascia, and divides beneath the Platysma into two branches, which are distributed to the antero-lateral parts of the neck.

The *ascending branch* gives a filament which accompanies the external jugular vein; it then passes upwards to the submaxillary region, and divides into branches, some of which form a plexus with the cervical branches of the facial

nerve beneath the Platysma; others pierce that muscle, and are distributed to the integument of the upper half of the neck, at its fore part, as high as the chin.

The *descending branch* (occasionally represented by two or more filaments) pierces the Platysma, and is distributed to the integument of the side and front of the neck, as low as the sternum.

The **descending or supraclavicular nerves** (nn. supraclaviculares) arise from the third and fourth cervical nerves: emerging beneath the posterior border of the Sterno-mastoid, they descend in the posterior triangle of the neck beneath the Platysma and deep cervical fascia. Near the clavicle they

Fig. 794.—Plan of cervical plexus.

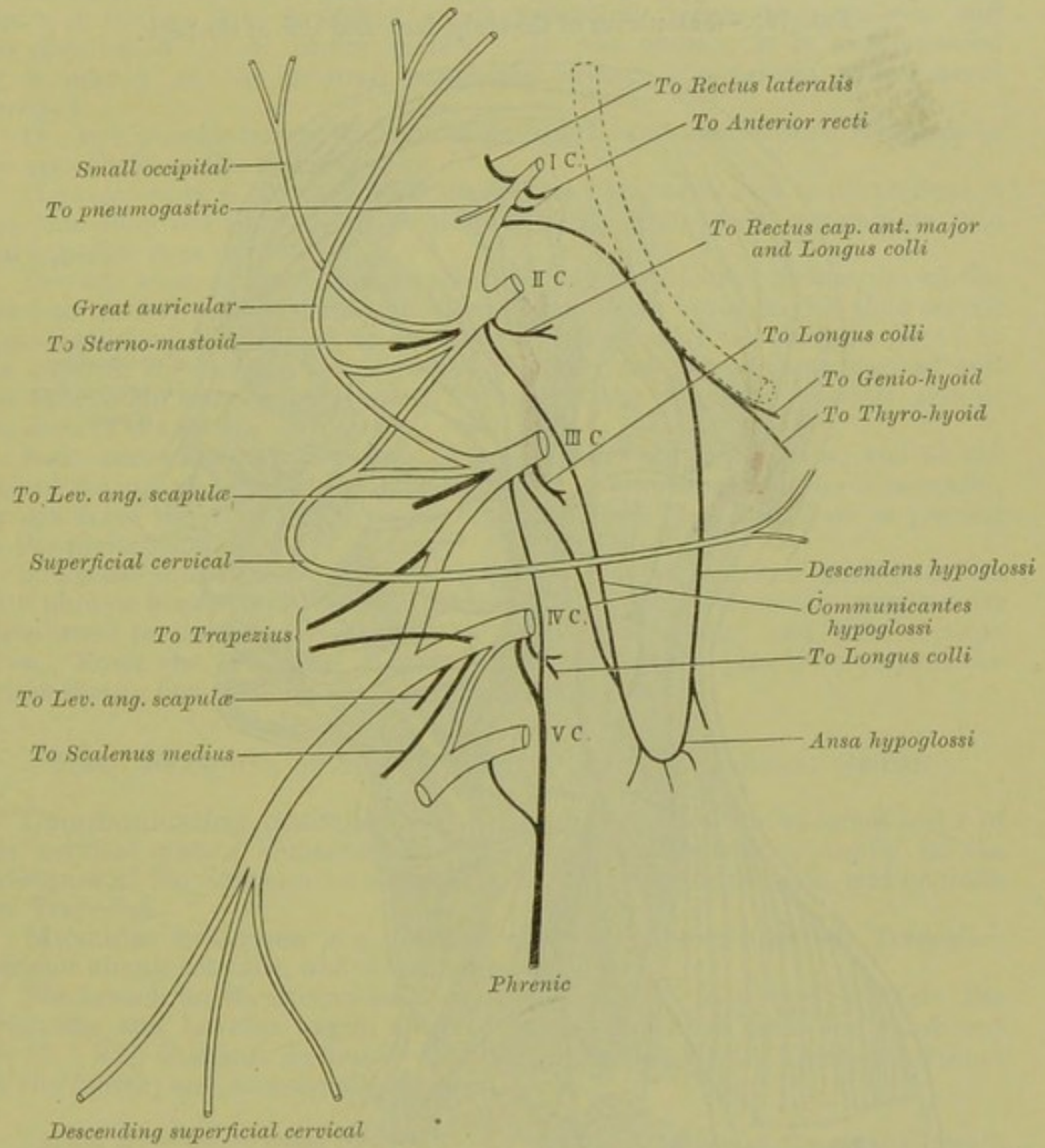

perforate the fascia and Platysma to become cutaneous, and are arranged, according to their position, into three groups.

The *inner* or *sternal branches* (nn. supraclaviculares anteriores) cross obliquely over the external jugular vein and the clavicular and sternal attachments of the Sterno-mastoid, and supply the integument as far as the median line. They furnish one or two filaments to the sterno-clavicular joint.

The *middle* or *clavicular branches* (nn. supraclaviculares medii) cross the clavicle, and supply the integument over the Pectoral and Deltoid muscles, communicating with the cutaneous branches of the upper intercostal nerves.

The *external* or *acromial branches* (nn. supraclaviculares posteriores) pass obliquely across the outer surface of the Trapezius and the acromion, and supply the integument of the upper and back part of the shoulder.

Deep Branches of the Cervical Plexus. Internal Series

The **communicating branches** consist of several filaments, which pass from the loop between the first and second cervical nerves to the pneumogastric, hypoglossal, and sympathetic. The branch to the hypoglossal ultimately leaves that nerve as a series of branches, viz. the descendens hypoglossi, the nerve to the Thyro-hyoid and the nerve to the Genio-hyoid (see page 940). A communicating branch also passes from the fourth to the fifth cervical, while each of the first four cervical nerves receives a grey ramus communicans from the superior cervical ganglion of the sympathetic.

Fig. 795.—The nerves of the scalp, face, and side of the neck.

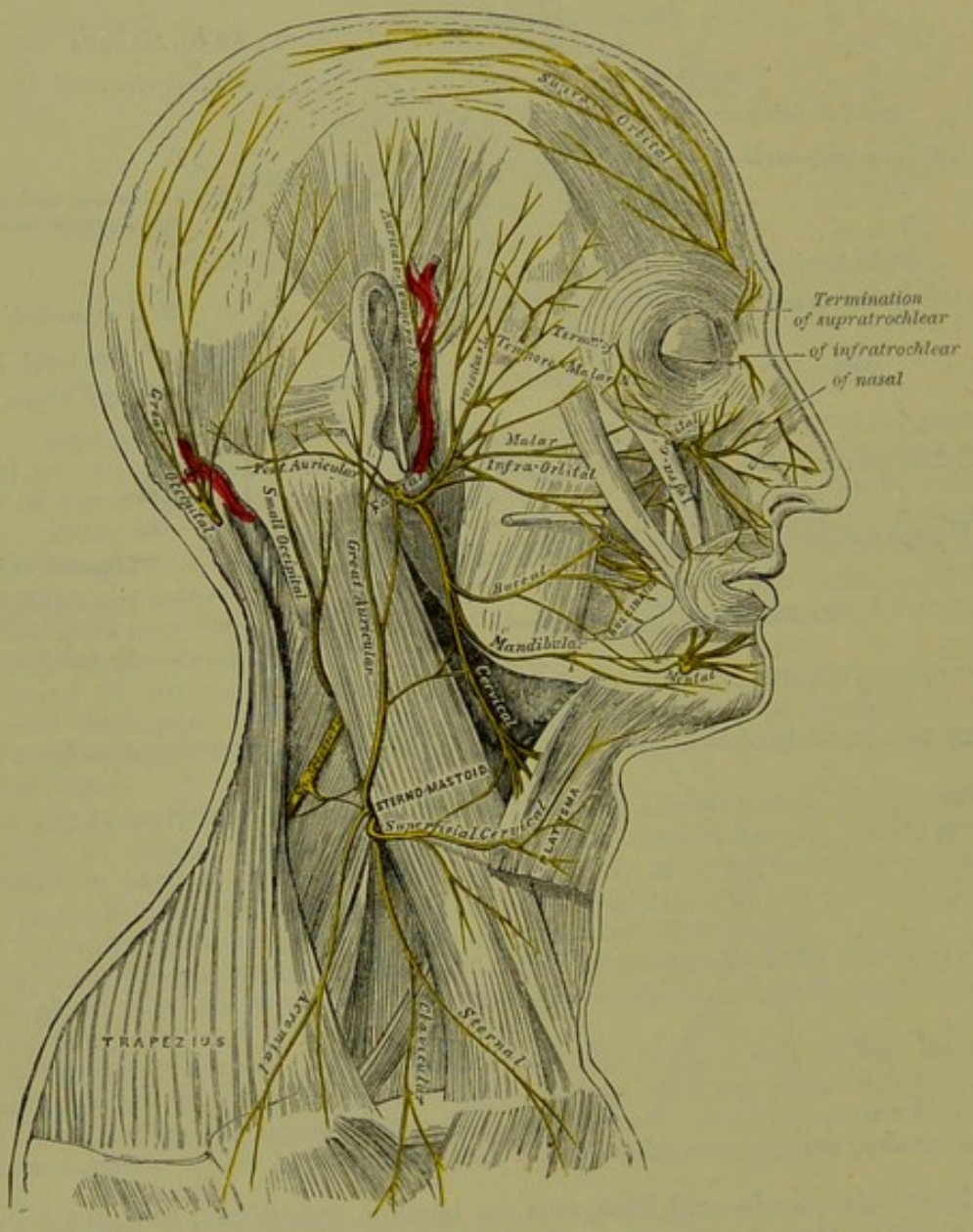

Muscular branches supply the Anterior recti and Rectus lateralis muscles; they proceed from the first cervical nerve, and from the loop formed between it and the second.

The **communicantes hypoglossi** (fig. 794) consist usually of two filaments, one derived from the second, and the other from the third cervical. These filaments usually join to form the *descendens cervicis*, which passes downwards on the outer side of the internal jugular vein, crosses in front of the vein a little below the middle of the neck, and forms a loop (*ansa hypoglossi*) with the descendens hypoglossi in front of the sheath of the carotid vessels (see page 941). Occasionally, the loop is formed within the sheath.

The **phrenic** (n. phrenicus), or *internal respiratory nerve of Bell*, arises chiefly from the fourth cervical nerve, but receives a filament from the third and a branch from the fifth ; the fibres from the fifth nerve occasionally come through the nerve to the Subclavius. It descends to the root of the neck, running obliquely across the front of the Scalenus anticus, and beneath the Sterno-mastoid, the posterior belly of the Omo-hyoid, and the transversalis colli and suprascapular vessels. It next passes over the first part of the subclavian artery, between it and the subclavian vein, and, as it enters the chest, crosses the internal mammary artery near its origin. Within the chest, it descends nearly vertically in front of the root of the lung, and then between the pericardium and the mediastinal portion of the pleura, to the Diaphragm, where it divides into branches, which separately pierce that muscle, and are distributed to its under surface. In the thorax it is accompanied by a branch of the internal mammary artery, the arteria comes nervi phrenici.

The two phrenic nerves differ in their length, and also in their relations at the upper part of the thorax.

The *right nerve* is situated more deeply, and is shorter and more vertical in direction than the left ; it lies on the outer side of the right innominate vein and superior vena cava.

The *left nerve* is rather longer than the right, from the inclination of the heart to the left side, and from the Diaphragm being lower on this than on the opposite side. At the root of the neck it is crossed by the thoracic duct ; in the superior mediastinum it is placed between the left common carotid and left subclavian arteries, and crosses in front of the vagus on the left side of the arch of the aorta.

Each nerve supplies filaments to the pericardium and pleura, and at the root of the neck is joined by a filament from the sympathetic, and, occasionally, by one from the ansa hypoglossi. Branches have been described as passing to the peritoneum.

From the *right nerve*, one or two filaments pass to join in a small ganglion with phrenic branches of the solar plexus ; and branches from this ganglion are distributed to the hepatic plexus, the suprarenal capsule, and inferior vena cava. From the *left nerve*, filaments pass to join the phrenic plexus of the sympathetic, but without any ganglionic enlargement.

Deep Branches of the Cervical Plexus. External Series

Communicating branches.—The deep branches of the external series of the cervical plexus communicate with the spinal accessory nerve, in the substance of the Sterno-mastoid muscle, in the posterior triangle, and beneath the Trapezius.

Muscular branches are distributed to the Sterno-mastoid, Trapezius, Levator anguli scapulæ, and Scalenus medius.

The branch for the Sterno-mastoid is derived from the second cervical ; the Trapezius and Levator anguli scapulæ receive branches from the third and fourth. The Scalenus medius is supplied sometimes by the third, sometimes by the fourth, and occasionally by both nerves.

Applied Anatomy. — Pains referred to the terminal branches of the cervical plexus are not uncommon in caries of the cervical spine, where pain may be felt radiating over the occiput, if the disease is situated high up in the spine.

The Brachial Plexus (Plexus Brachialis)

The **brachial plexus** (fig. 796) is formed by the union of the anterior primary divisions of the lower four cervical nerves and the greater part of the anterior primary division of the first thoracic nerve ; a fasciculus from the fourth cervical nerve usually contributes and frequently one from the second thoracic nerve. It extends from the lower part of the side of the neck to the axilla. The nerves which form the plexus are nearly equal in size, but their mode of communication is subject to some variation, so that no one plan can be given as applying

to every case. The following is, however, the most constant arrangement. The fifth and sixth cervical unite soon after their exit from the intervertebral foramina to form a common trunk. The eighth cervical and first thoracic also unite to form one trunk, while the seventh cervical runs out alone. Three trunks are thus formed, an upper one, formed by the junction of the fifth and sixth cervical nerves; a middle one, consisting of the seventh cervical nerve; and a lower one, formed by the junction of the eighth cervical and first thoracic nerves. As they pass beneath the clavicle, each of these three trunks divides into two divisions, an *anterior* and a *posterior*.* The anterior divisions of the upper

Fig. 796.—Plan of brachial plexus.

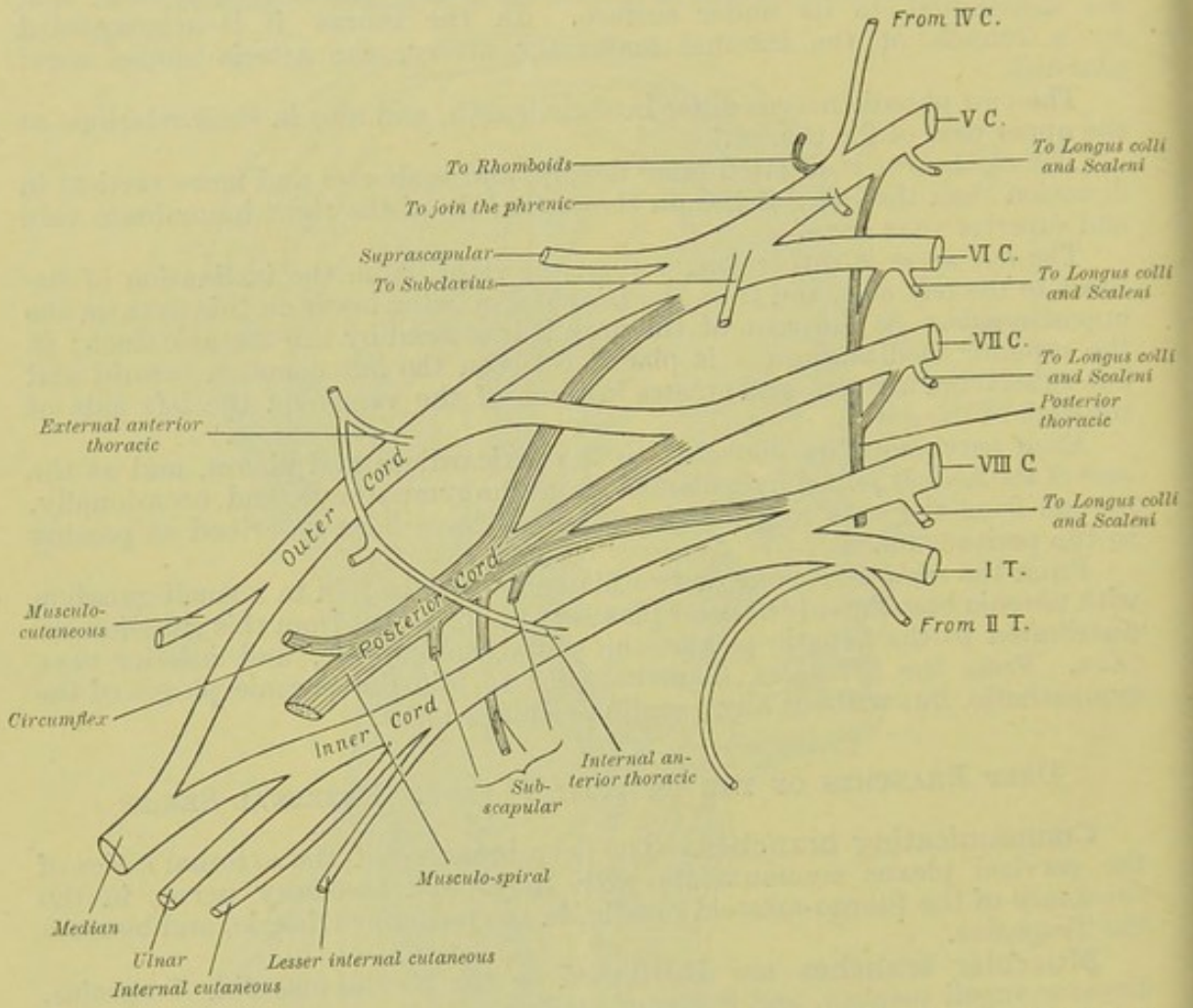

and middle trunks then unite to form a cord, which is situated on the outer side of the middle part of the axillary artery, and is called the *outer cord* of the brachial plexus. The anterior division of the lower trunk passes down on the inner side of the axillary artery in the middle of the axilla, and forms the *inner cord* of the brachial plexus. The posterior divisions of all three trunks unite to form the *posterior cord* of the brachial plexus, which is situated behind the second portion of the axillary artery.

Relations.—*In the neck*, the brachial plexus lies in the posterior triangle, being covered by the skin, Platysma, and deep fascia: it is crossed by the descending superficial cervical nerves, the posterior belly of the Omo-hyoid, the external jugular vein, and the Transversalis colli artery. When the posterior scapular artery arises from the third part of the subclavian, it usually passes between the roots of the plexus. The plexus emerges from between the Anterior and Middle scalenus muscles; its upper part lies above the third part of the subclavian artery, while the trunk formed by the union of the eighth cervical and first thoracic is placed behind the artery; it next passes behind the clavicle,

* The posterior division of the lower trunk is very much smaller than the others, and is frequently derived entirely from the eighth cervical nerve.

the Subclavius muscle and suprascapular vessels, and lies upon the first serration of the Serratus magnus, and the Subscapularis. *In the axilla* it is placed on the outer side of the first portion of the axillary artery ; it surrounds the second part of the artery, one cord lying upon the outer side of that vessel, one on the inner side, and one behind it ; and at the lower part of the axillary space gives off its terminal branches to the upper extremity.

Branches of communication.—The brachial plexus communicates with the cervical plexus by a branch from the fourth to the fifth nerve, and with the phrenic nerve by a branch from the fifth cervical, which joins that nerve on the Scalenus anticus. Close to their exit from the intervertebral foramina the fifth and sixth cervical nerves are joined by filaments from the middle cervical ganglion of the sympathetic, the seventh and eighth cervical by twigs from the inferior ganglion, and the first thoracic nerve by a branch from the first thoracic ganglion.

Branches of distribution.—The branches of the brachial plexus may be arranged into two groups, viz. those given off above and those below the clavicle.

Supraclavicular Branches

Communicating	with phrenic	5 C.
	with sympathetic	5, 6, 7, 8 C, 1 T.
Muscular to	Rhomboids (posterior scapular)	5 C.
	Supraspinatus, Infraspinatus (suprascapular)	5, 6 C.
	Subclavius	5, 6 C.
	Serratus magnus (posterior thoracic)	5, 6, 7 C.
	Longus colli	5, 6, 7, 8 C.
	Scaleni	5, 6, 7, 8 C.

The **communicating branch** with the phrenic is derived from the fifth cervical nerve or from the loop between the fifth and sixth ; it joins the phrenic on the Scalenus anticus. The communications with the sympathetic have already been referred to.

The unnamed **muscular branches** supply the Longus colli, Scaleni, and Subclavius. Those for the Longus colli and Scaleni arise from the four lower cervical nerves at their exit from the intervertebral foramina.

The nerve to the Subclavius is a small filament, which arises from the fifth cervical at its point of junction with the sixth nerve ; it descends in front of the third part of the subclavian artery and the lower trunk of the plexus, to the muscle, and is usually connected by a filament with the phrenic nerve.

The **posterior scapular** (n. dorsalis scapulæ), or nerve to the Rhomboids, arises from the fifth cervical, pierces the Scalenus medius, and passes beneath the Levator anguli scapulæ, which it occasionally supplies, to the Rhomboid muscles.

The **posterior thoracic** (n. thoracalis longus), or *external respiratory of Bell* (fig. 801) supplies the Serratus magnus, and is remarkable for the length of its course. It usually arises by three roots from the fifth, sixth, and seventh cervical nerves ; but the root from the seventh nerve may be absent. The roots from the fifth and sixth nerves pierce the Scalenus medius, while that from the seventh nerve emerges from in front of the muscle. The nerve passes down behind the brachial plexus and the axillary vessels, resting on the outer surface of the Serratus magnus. It extends along the side of the chest to the lower border of that muscle, supplying filaments to each of its digitations.

The **suprascapular** (n. suprascapularis) (fig. 802) arises from the trunk formed by the fifth and sixth cervical nerves ; running obliquely outwards beneath the Trapezius and the Omo-hyoid, it enters the supraspinous fossa through the suprascapular notch, below the transverse or suprascapular ligament; it then passes beneath the Supraspinatus muscle, and curves round the external border of the spine of the scapula to the infraspinous fossa. In the supraspinous fossa it gives off two branches to the Supraspinatus muscle, and an articular filament to the shoulder-joint ; and in the infraspinous fossa it gives off two branches to the Infraspinatus muscle, besides some filaments to the shoulder-joint and scapula.

Infraclavicular Branches

The infraclavicular branches are derived from the three cords of the brachial plexus. The fasciculi of which they are composed may be traced through the plexus to the spinal nerves from which they originate. They are as follows:

Outer cord	Musculo-cutaneous	5, 6 C.
	External anterior thoracic	5, 6, 7 C.
	Outer head of median	6, 7 C.
Inner cord	Internal anterior thoracic	8 C, 1 T.
	Internal cutaneous	8 C, 1 T.
	Lesser internal cutaneous	(8 C) 1 T.
	Ulnar	8 C, 1 T.
	Inner head of median	8 C, 1 T.
Posterior cord	Upper subscapular	5, 6 C.
	Middle ,,	5, 6, 7 C.
	Lower ,,	5, 6 C.
	Circumflex	5, 6 C.
	Musculo-spiral	(5) 6, 7, 8 C (1 T).

These branches may be arranged according to the regions they supply:

To the chest	Internal and external anterior thoracic.
To the shoulder	Subscapulars.
	Circumflex.
To the arm, forearm, and hand	Musculo-cutaneous.
	Internal cutaneous.
	Lesser internal cutaneous.
	Median.
	Ulnar.
	Musculo-spiral.

The **anterior thoracic nerves** (nn. thoracales anteriores) (fig. 801), two in number, supply the Pectoral muscles.

The *external anterior thoracic*, the larger of the two, arises from the outer cord of the brachial plexus, through which its fibres may be traced to the fifth, sixth, and seventh cervical nerves. It passes inwards, across the axillary artery and vein, pierces the costo-coracoid membrane, and is distributed to the under surface of the Pectoralis major. It sends down a communicating filament which joins the internal nerve, and forms with it a loop in front of the first part of the axillary artery.

The *internal anterior thoracic* arises from the inner cord, and through it from the eighth cervical and first thoracic. It passes behind the first part of the axillary artery, curves forwards between the axillary artery and vein, and joins with the filament from the external nerve. It then passes to the under surface of the Pectoralis minor muscle, where it divides into a number of branches, which supply the muscle. Some two or three branches pass through the muscle to supply the Pectoralis major.

The **subscapular nerves** (nn. subscapulares), three in number, supply the Subscapularis, Teres major, and Latissimus dorsi muscles. The fasciculi of which they are composed may be traced to the fifth, sixth, and seventh cervical nerves.

The *upper* or *short subscapular*, the smallest, enters the upper part of the Subscapularis muscle; this nerve is frequently represented by two branches.

The *lower subscapular* enters the axillary border of the Subscapularis, and terminates in the Teres major. The latter muscle is sometimes supplied by a separate branch.

The *middle* or *long subscapular*, the largest of the three, follows the course of the subscapular artery, along the posterior wall of the axilla to the Latissimus dorsi, in which it may be traced as far as the lower border of the muscle.

The **circumflex** (n. axillaris) (fig. 802) supplies some of the muscles and part of the integument of the shoulder, and gives a branch to the shoulder-joint. It arises from the posterior cord of the brachial plexus, in common

with the musculo-spiral nerve, and its fibres may be traced through the posterior cord to the fifth and sixth cervical nerves. It is at first placed behind the axillary artery, between it and the Subscapularis muscle, and passes downwards and outwards to the lower border of that muscle. It then winds backwards, in company with the posterior circumflex artery, through a quadrilateral space bounded above by the Subscapularis, below by the Teres major, internally by the long head of the Triceps, and externally by the surgical neck of the humerus, and divides into two branches.

The *upper branch* winds round the surgical neck of the humerus, beneath the Deltoid, with the posterior circumflex vessels, as far as the anterior border of that muscle, supplying it, and giving off cutaneous branches, which pierce the muscle and ramify in the integument covering its lower part.

The *lower branch*, at its origin, distributes filaments to the Teres minor and the back part of the Deltoid. Upon the filament to the former muscle an oval enlargement usually exists. The nerve then pierces the deep fascia, and supplies the integument over the lower two-thirds of the posterior part of the Deltoid, as well as that covering the long head of the Triceps.

The circumflex nerve, before its division, gives off an articular filament which enters the shoulder-joint below the Subscapularis.

Fig. 797.—Cutaneous nerves of right upper extremity. Anterior view.

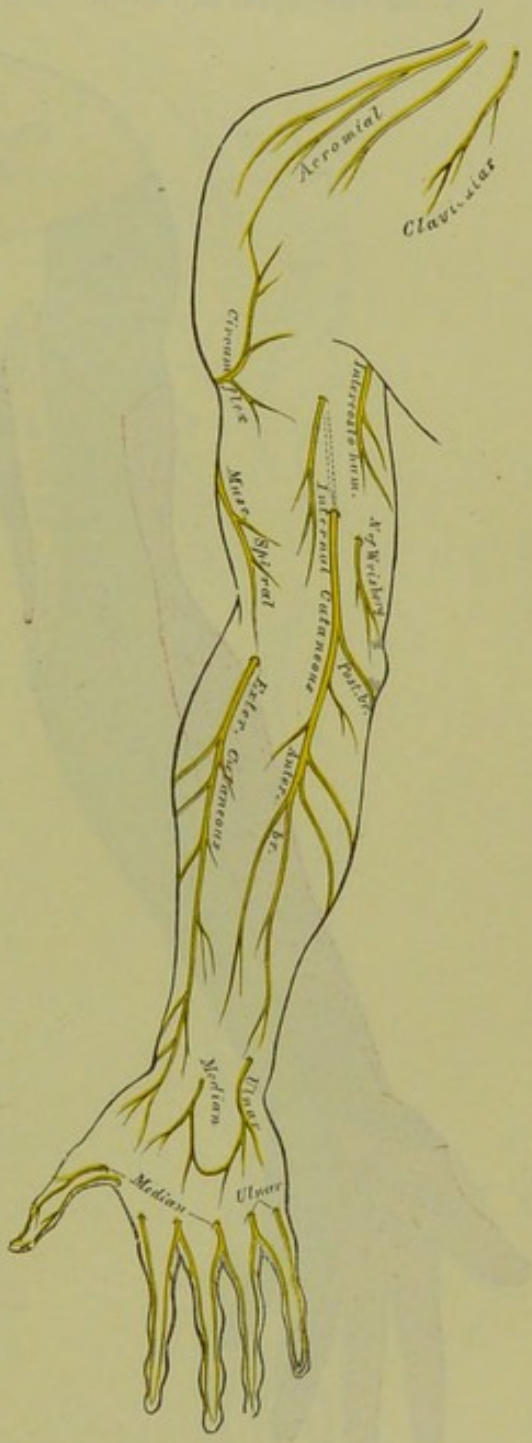

The **musculo-cutaneous** (n. musculocutaneus) (fig. 801) arises from the outer cord of the brachial plexus, opposite the lower border of the Pectoralis minor, its fibres being derived from the fifth and sixth cervical nerves. It perforates the Coraco-brachialis muscle and passes obliquely between the Biceps and Brachialis anticus, to the outer side of the arm; a little above the elbow it becomes cutaneous by perforating the deep fascia on the outer side of the tendon of the Biceps. In its course through the arm it supplies the Coraco-brachialis, Biceps, and the greater part of the Brachialis anticus. The branch to the Coraco-brachialis is given off from the nerve close to its origin, and in some instances, especially in early life, as a separate filament from the outer cord of the plexus; it is derived from the seventh nerve, and is by some anatomists regarded as a separate nerve, more or less closely incorporated with the musculo-cutaneous. The branches to the Biceps and Brachialis anticus are given off after the musculo-cutaneous has pierced the Coraco-brachialis. The nerve also sends a small branch to the bone, which enters the nutrient foramen with the accompanying artery, while the branch supplying the Brachialis anticus gives a filament to the elbow joint.

The cutaneous portion of the nerve (n. cutaneus antibrachii lateralis) passes behind the median cephalic vein, and divides, opposite the elbow-joint, into an anterior and a posterior branch.

The *anterior branch* descends along the radial border of the forearm to the wrist, and supplies the integument over the outer half of its anterior surface. At the wrist-joint it is placed in front of the radial artery, and some filaments, piercing the deep fascia, accompany that vessel to the back of the wrist, and supply the carpus. The nerve then passes downwards to the ball of the thumb, where it terminates in cutaneous filaments. It communicates with a branch from the radial nerve, and with the palmar cutaneous branch of the median.

The *posterior branch* passes downwards, along the back part of the radial side of the forearm, to the wrist. It supplies the integument of the lower two-thirds of the forearm, communicating with the radial nerve and the external cutaneous branch of the musculo-spiral.

The musculo-cutaneous nerve presents frequent irregularities. It may adhere for some distance to the median and then pass outwards, beneath the Biceps, instead of through the Coraco-brachialis. Frequently some of the fibres of the median run for some distance in the musculo-cutaneous and then leave it to join their proper trunk. Less frequently the reverse is the case, and the median sends a branch to join the musculo-cutaneous. Instead of piercing the Coraco-brachialis the nerve may pass under it or through the Biceps. Occasionally it gives a filament to the Pronator teres, and it has been seen to supply the back of the thumb when the radial nerve was absent.

FIG. 798.—Segmental distribution of the cutaneous nerves of the right upper extremity. Anterior view.

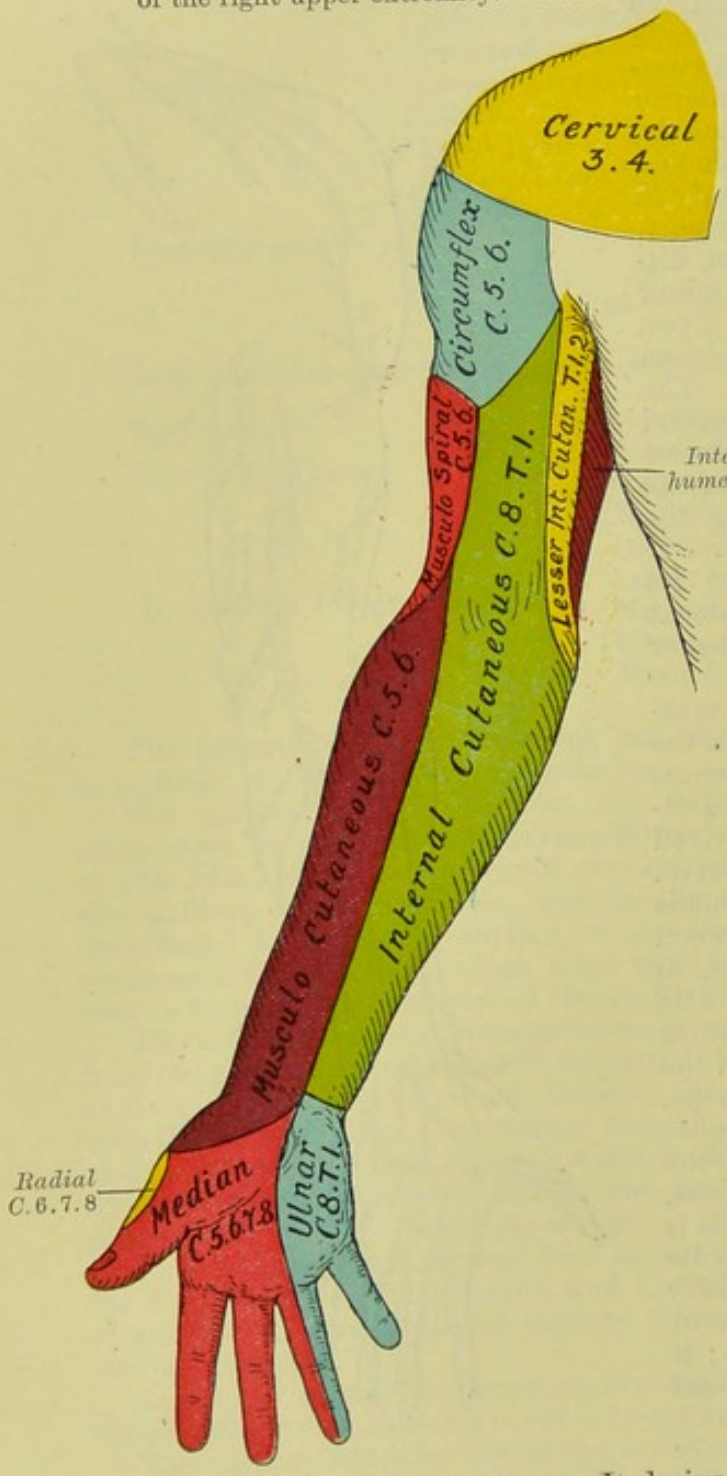

The **internal cutaneous** (n. cutaneus antibrachii medialis) (fig. 801) arises from the inner cord in common with the ulnar and internal head of the median, and, at its commencement, lies on the inner side of the axillary artery. It derives its fibres from the eighth cervical and first thoracic nerves. It gives off, near the axilla, a filament, which pierces the fascia and supplies the integument covering the Biceps muscle, nearly as far as the elbow. This filament lies a little external to the common trunk, from which it arises. The nerve then passes down the inner side of the arm on the inner side of the brachial artery, pierces the deep fascia with the basilic vein, about the middle of the upper arm, and, becoming cutaneous, divides into two branches, an anterior and a posterior.

The *anterior branch*, the larger of the two, passes usually in front of, but occasionally behind, the median basilic vein. It then descends on the anterior surface of the ulnar side of the forearm, distributing filaments to the integument as far as the wrist, and communicating with the palmar cutaneous branch of the ulnar nerve.

The *posterior branch* passes obliquely downwards on the inner side of the basilic vein, in front of the internal epicondyle of the humerus, to the back of the forearm, and descends on the posterior surface of its ulnar side as far as the wrist, distributing filaments to the integument. It communicates with the lesser internal cutaneous, the lower external cutaneous branch of the musculo-spiral, and the dorsal branch of the ulnar nerve.

FIG. 799.—Cutaneous nerves of right upper extremity. Posterior view.

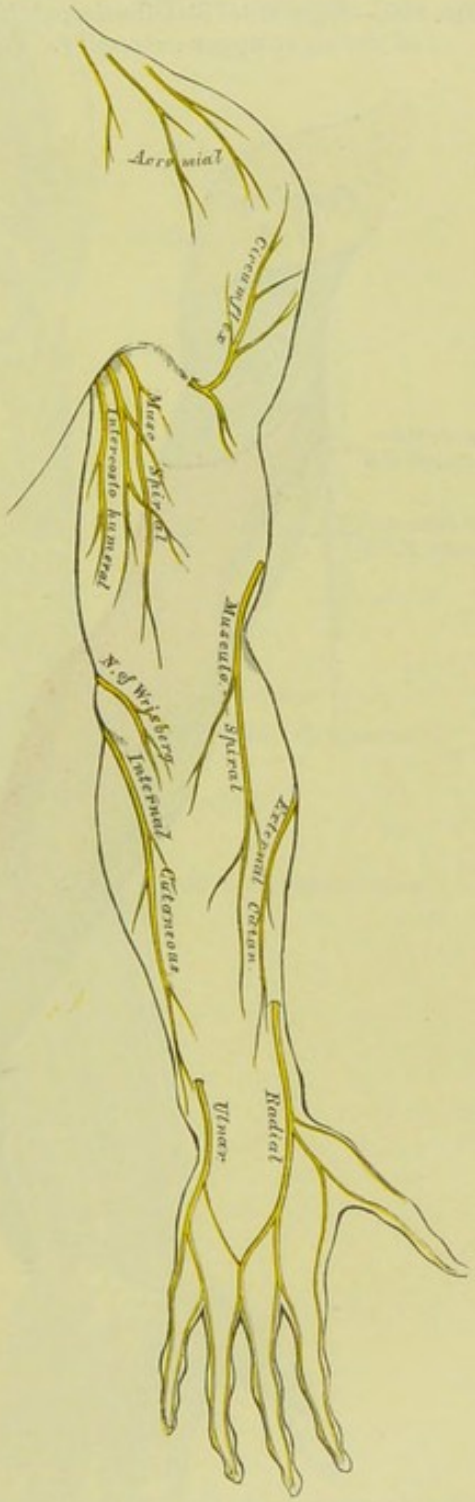

The **lesser internal cutaneous** (n. cutaneus brachii medialis), or nerve of Wrisberg, is distributed to the integument on the inner side of the arm (fig. 801). It is the smallest of the branches of the brachial plexus, and arising from the inner cord receives its fibres from the first thoracic nerve, and sometimes from the eighth cervical. It passes through the axillary space, at first lying behind, and then on the inner side of the axillary vein, and communicates with the intercosto-humeral nerve (lateral cutaneous branch of the second thoracic). It descends along the inner side of the brachial artery to the middle of the arm, where it pierces the deep fascia, and is distributed to the integument of the back part of the lower third of the arm, extending as far as the elbow, where some filaments are lost in the integument in front of the inner epicondyle, and others over the olecranon. It communicates with the posterior branch of the internal cutaneous nerve.

In some cases the nerve of Wrisberg and intercosto-humeral are connected by two or three filaments, which form a plexus at the back part of the axilla. In other cases, the intercosto-humeral is of large size, and takes the place of the nerve of Wrisberg, receiving merely a filament of communication from the brachial plexus, which represents the latter nerve; in a few cases, this filament is wanting.

The **median** (n. medianus) (fig. 801) extends along the middle of the arm and forearm to the hand. It arises by two roots, one from the outer and one from the inner cord of the brachial plexus; these embrace the lower part of the axillary artery, uniting either in front or on the outer side of that vessel. Its fibres are derived from the sixth, seventh, and eighth cervical and first thoracic nerves. As it descends through the arm, it lies at first on the outer side of the brachial artery, crosses that vessel in the middle of its course, usually in front of, but occasionally behind it, and lies on its inner side

at the bend of the elbow, where it is situated beneath the bicipital fascia, and is separated from the elbow-joint by the Brachialis anticus. *In the forearm* it passes between the two heads of the Pronator teres and crosses the ulnar artery, but is separated from this vessel by the deep head of the Pronator teres. It descends beneath the Flexor sublimis digitorum, lying on the Flexor profundus digitorum, to within two inches above the anterior annular ligament of the wrist; here it becomes more superficial, and is situated between the tendons of the Flexor sublimis digitorum and Flexor carpi radialis. In this situation it lies beneath, and rather to the radial side of, the tendon of the Palmaris longus, and is covered by the integument and fascia. It then passes beneath the anterior annular ligament into the palm of the hand. In its course through the forearm it is accompanied by a branch of the anterior interosseous artery.

FIG. 800.—Segmental distribution of the cutaneous nerves of the right upper extremity. Posterior view.

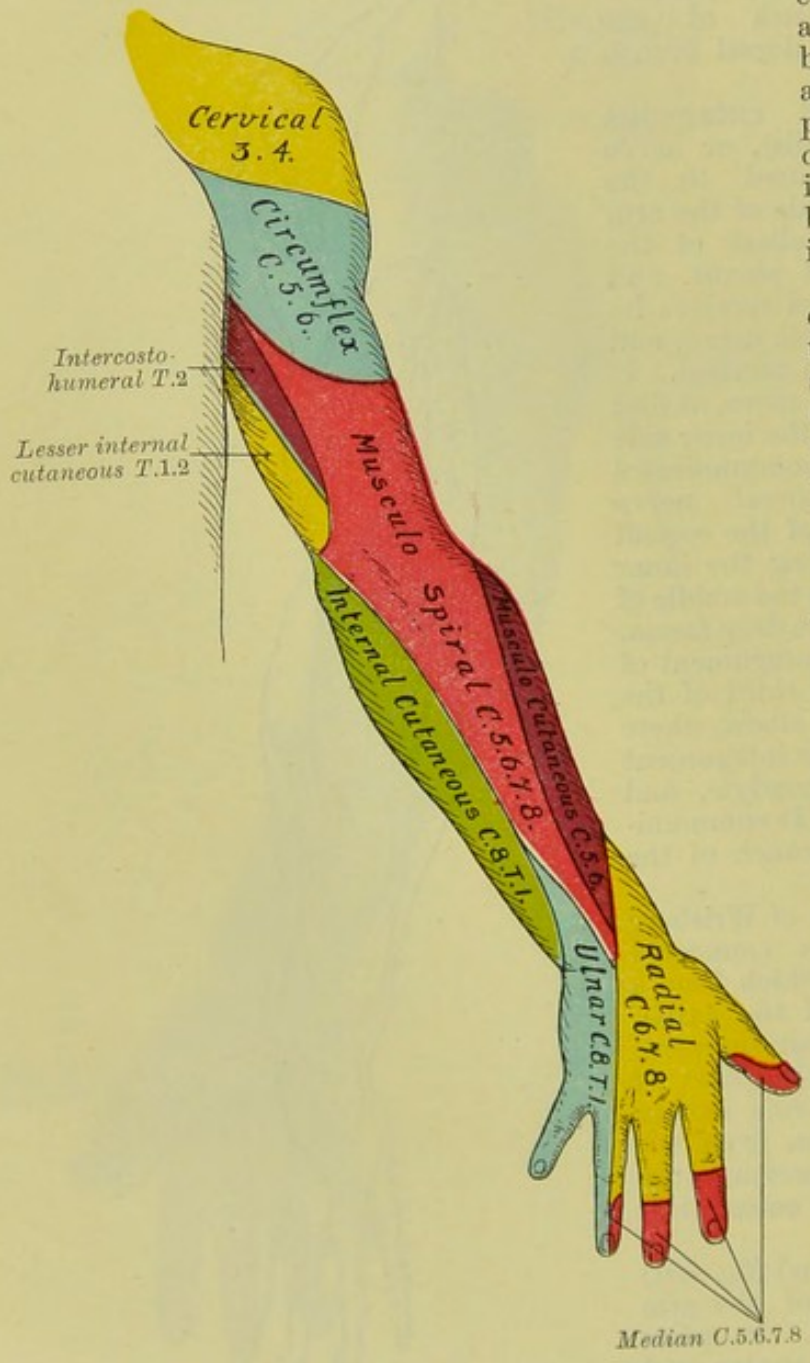

Branches. — With the exception of the nerve to the Pronator teres, which sometimes arises above the elbow-joint, the median nerve gives off no branches in the arm. As it passes in front of the elbow, it supplies one or two articular twigs to the joint. *In the forearm* its branches are, muscular, anterior interosseous, and palmar cutaneous.

The *muscular branches* are derived from the nerve near the elbow and supply all the superficial muscles on the front of the forearm, except the Flexor carpi ulnaris.

The *anterior interosseous* (n. interosseus antibrachii volaris) supplies the deep muscles on the front of the forearm, except the inner half of the Flexor profundus digitorum. It accompanies the anterior interosseous artery along the interosseous membrane, in the interval between the Flexor longus pollicis and Flexor profundus digitorum, supplying the whole of the former and the outer half of the latter, and terminates below in the Pronator quadratus and wrist-joint.

The *palmar cutaneous branch* (ramus cutaneus palmaris) arises from the median nerve at the lower part of the forearm. It pierces the fascia above the annular ligament, and, descending over that ligament, divides into two branches; the outer supplies the skin over the ball of the thumb, and communicates with the anterior cutaneous branch of the musculo-cutaneous

nerve; the inner supplies the integument of the palm of the hand, communicating with the palmar cutaneous branch of the ulnar.

FIG. 801.—Nerves of the left upper extremity.

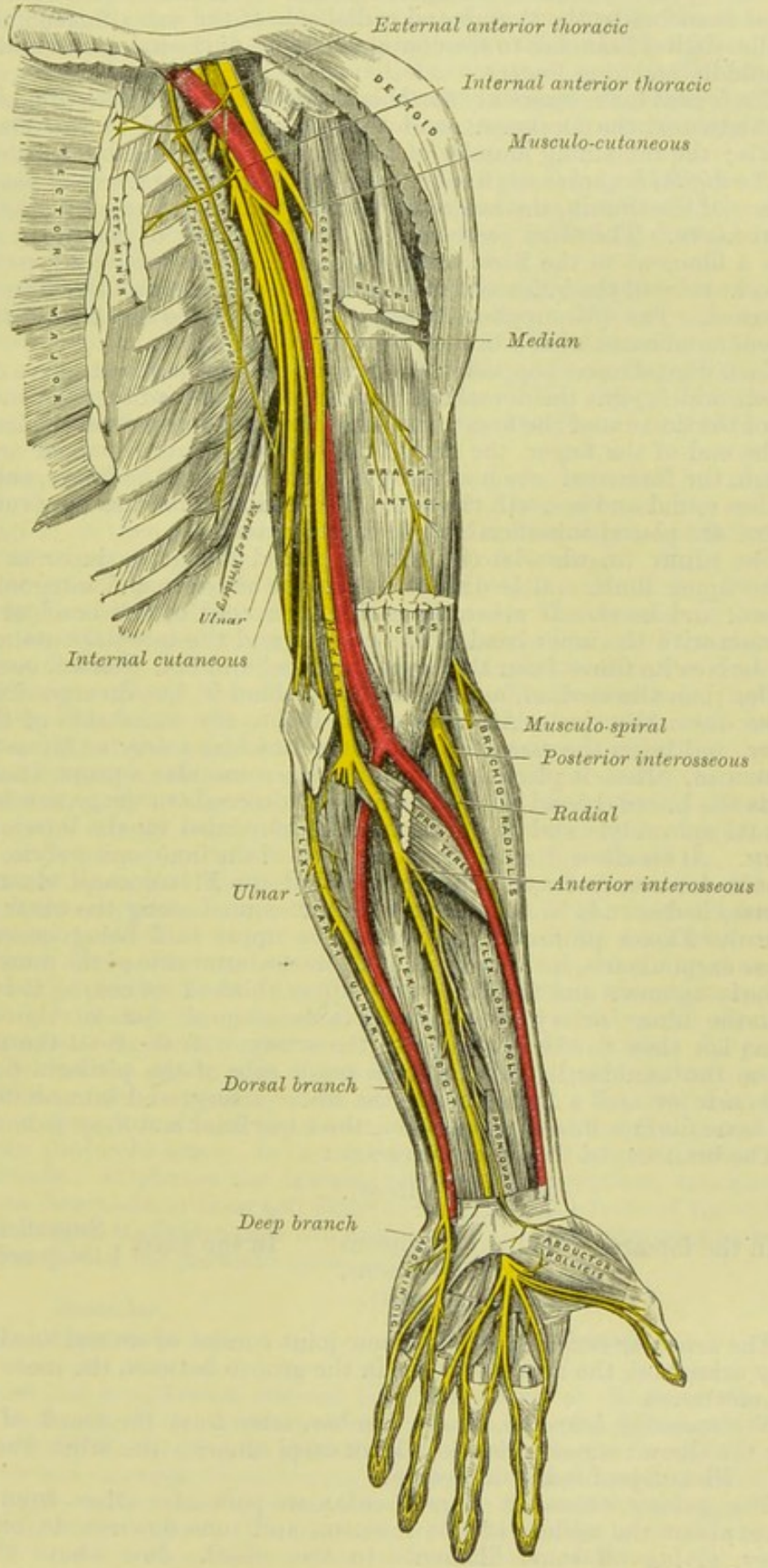

In the palm of the hand, the median nerve is covered by the integument and palmar fascia, and crossed by the superficial palmar arch. It rests upon the tendons of the Flexor muscles. In this situation it becomes enlarged, somewhat flattened, of a reddish colour, and divides into two branches. Of these, the *external* supplies a muscular branch to some of the muscles of the thumb, and digital branches to the thumb and radial side of the index finger; the *internal* supplies digital branches to the contiguous sides of the index and middle, and of the middle and ring fingers.

The *branch to the muscles of the thumb* is a short nerve, which divides to supply the Abductor, the Opponens, and the superficial head of the Flexor brevis pollicis; the remaining muscles of this group are supplied by the ulnar nerve.

The *digital branches* are five in number. The *first* and *second* pass along the borders of the thumb, the external branch communicating with branches of the radial nerve. The *third* passes along the radial side of the index finger, and gives a filament to the First lumbrical. The *fourth* subdivides to supply the adjacent sides of the index and middle fingers, and sends a branch to the Second lumbrical. The *fifth* supplies the adjacent sides of the middle and ring fingers, and communicates with a branch from the ulnar nerve.

Each digital nerve, opposite the base of the first phalanx, gives off a dorsal branch, which joins the dorsal digital nerve from the radial, and runs along the side of the dorsum of the finger, to end in the integument over the last phalanx. At the end of the finger, the digital nerve divides into a palmar and a dorsal branch, the former of which supplies the extremity of the finger, and the latter ramifies round and beneath the nail. The digital nerves, as they run along the fingers, are placed superficial to the digital arteries.

The **ulnar** (n. ulnaris) (fig. 801) is placed along the inner or ulnar side of the upper limb, and is distributed to the muscles and integument of the forearm and hand. It arises from the inner cord of the brachial plexus, in common with the inner head of the median and the internal cutaneous nerve, and derives its fibres from the eighth cervical and first thoracic nerves. It is smaller than the median, and lies at first behind it, but diverges from it in its course down the arm. At its origin it lies to the inner side of the axillary artery, and bears the same relation to the brachial artery as far as the middle of the arm. Here it pierces the internal intermuscular septum, runs obliquely across the internal head of the Triceps, and descends to the groove between the internal epicondyle and the olecranon, accompanied by the inferior profunda artery. *At the elbow*, it rests upon the back of the inner epicondyle, and passes into the forearm between the two heads of the Flexor carpi ulnaris. *In the forearm*, it descends in a perfectly straight course along the ulnar side, lying upon the Flexor profundus digitorum, its upper half being covered by the Flexor carpi ulnaris, its lower half lying on the outer side of the muscle, covered by the integument and fascia. In the upper third of its course, it is separated from the ulnar artery by a considerable interval, but in the rest of its extent lies close to the inner side of the artery. *At the wrist* the ulnar nerve crosses the annular ligament on the outer side of the pisiform bone, to the inner side of and a little behind the ulnar artery, and immediately beyond this bone divides into two branches, the superficial and deep palmar.

The branches of the ulnar nerve are:

In the forearm	Articular (elbow). Muscular. Palmar cutaneous. Dorsal cutaneous. Articular (wrist).	In the hand	Superficial palmar. Deep palmar.

The *articular branches* to the elbow-joint consist of several small filaments. They arise from the nerve as it lies in the groove between the inner epicondyle and olecranon.

The *muscular branches*, two in number, arise from the trunk of the nerve near the elbow: one supplies the Flexor carpi ulnaris; the other, the inner half of the Flexor profundus digitorum.

The *palmar cutaneous* (ramus cutaneus palmaris) arises from the ulnar nerve about the middle of the forearm, and runs downwards, on the ulnar artery, giving off some filaments to the vessel. Just above the annular

ligament, it perforates the deep fascia and ends in the integument of the palm, communicating with the palmar branch of the median nerve.

The *dorsal cutaneous branch* (ramus dorsalis manus) arises about two inches above the wrist; it passes backwards beneath the Flexor carpi ulnaris, perforates the deep fascia, and, running along the ulnar side of the back of the wrist and hand, divides into branches: one of these supplies the inner side of the little finger; a second supplies the adjacent sides of the little and ring fingers; a third joins the branch of the radial nerve which supplies the adjoining sides of the middle and ring fingers, and assists in supplying them; a fourth is distributed to the metacarpal region of the hand, communicating with a branch of the radial nerve.

On the little finger the dorsal digital branches extend only as far as the base of the terminal phalanx, and on the ring finger as far as the base of the second phalanx; the more distal parts of these digits are supplied by dorsal branches derived from the palmar digital branches of the ulnar.

The *superficial palmar branch* (ramus superficialis) supplies the Palmaris brevis, and the integument on the inner side of the hand, and terminates in two digital branches, which are distributed, one to the ulnar side of the little finger, the other to the adjoining sides of the little and ring fingers, the latter communicating with a branch from the median. The digital branches are distributed to the fingers in the same manner as the digital branches of the median.

The *deep palmar branch* (ramus profundus), accompanied by the deep branch of the ulnar artery, passes between the Abductor and Flexor brevis minimi digiti; it then perforates the Opponens minimi digiti and follows the course of the deep palmar arch beneath the flexor tendons. At its origin it supplies the muscles of the little finger. As it crosses the deep part of the hand, it supplies all the Interossei and the two inner Lumbricales; it ends by supplying the Adductores transversus et obliquus pollicis and the inner head of the Flexor brevis pollicis. It also sends articular filaments to the wrist-joint.

It will be remembered that the inner part of the Flexor profundus digitorum is supplied by the ulnar nerve; the two inner Lumbricales, which are connected with the tendons of this part of the muscle, are therefore supplied by the same nerve. In like manner the outer part of the Flexor profundus and the two outer Lumbricales are supplied by the median nerve. Brooks stated that in twelve instances out of twenty-one he found that the Third lumbrical received a twig from the median nerve, in addition to its branch from the ulnar.

The **musculo-spiral** (n. radialis) (fig. 802), the largest branch of the brachial plexus, supplies the muscles of the back part of the arm and forearm, and the integument of the same parts, as well as that of the back of the hand. It arises from the posterior cord of the brachial plexus, of which it may be regarded as the continuation. Its fibres are derived from the sixth, seventh, and eighth cervical nerves, and sometimes also from the fifth cervical and first thoracic nerves. At its commencement it is placed first behind the axillary and then behind the upper part of the brachial artery, passing down in front of the tendons of the Latissimus dorsi and Teres major. It winds round from the inner to the outer side of the humerus in the musculo-spiral groove with the superior profunda artery, between the internal and external heads of the Triceps muscle. It pierces the external intermuscular septum, and descends between the Brachialis anticus and Brachio-radialis to the front of the external epicondyle, where it divides into the radial and posterior interosseous nerves.

The branches of the musculo-spiral nerve are:

Muscular.	Radial.
Cutaneous.	Posterior interosseous.

The *muscular branches* are derived from the nerve, at the inner side, back part, and outer side of the arm respectively; they supply the Triceps, Anconeus, Brachio-radialis, Extensor carpi radialis longior, and Brachialis anticus.

The internal muscular branches supply the inner and middle heads of the Triceps muscle. That to the inner head of the Triceps is a long, slender filament, which lies close to the ulnar nerve as far as the lower third of the arm, and is therefore frequently spoken of as the *ulnar collateral*.

The posterior muscular branch, of large size, arises from the nerve in the groove between the Triceps and the humerus. It divides into branches, which supply the inner and outer heads of the Triceps and the Anconeus muscles. The branch for the latter muscle is a long, slender filament, which descends in the substance of the inner head of the Triceps to the Anconeus.

Fig. 802.—The suprascapular, circumflex, and musculo-spiral nerves.

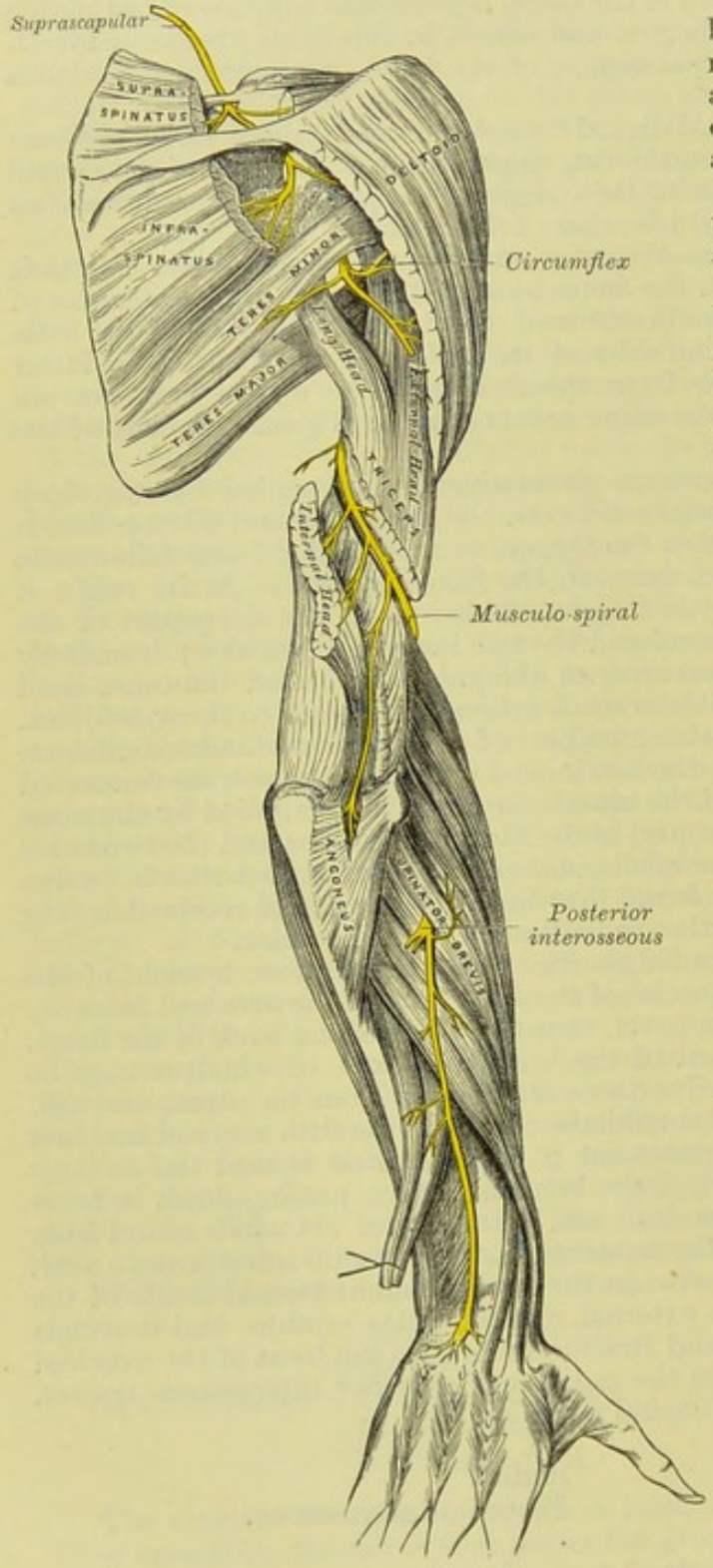

The external muscular branches supply the Brachio-radialis, Extensor carpi radialis longior, and (usually) the outer part of the Brachialis anticus.

The *cutaneous branches* are three in number, one internal and two external.

The internal cutaneous branch arises in the axillary space, with the inner muscular branch. It is of small size, and passes through the axilla to the inner side of the arm, supplying the integument on its posterior aspect nearly as far as the olecranon. In its course it crosses beneath the intercosto-humeral, with which it communicates.

The two external cutaneous branches perforate the outer head of the Triceps at its attachment to the humerus. The *upper* and smaller one passes to the front of the elbow, lying close to the cephalic vein, and supplies the integument of the lower half of the arm on its anterior aspect. The *lower* branch pierces the deep fascia below the insertion of the Deltoid, and passes down along the outer side of the arm and elbow, and then along the back part of the radial side of the forearm to the wrist, supplying the integument in its course, and joining, near its termination, with the posterior cutaneous branch of the musculo-cutaneous nerve.

The **radial** (ramus superficialis n. radialis) passes along the front of the radial side of the forearm to the commencement of its lower third. It lies at first a little to the outer side of the radial artery, concealed beneath the Brachio-radialis. In the middle third of the forearm, it lies beneath the same muscle, in close relation with the outer side of the artery. It quits the artery about three inches above the wrist, passes beneath the tendon of the Brachio-radialis, and, piercing the deep fascia at the outer border of the forearm, divides into two branches.

The external branch, the smaller of the two, supplies the integument of the radial side and ball of the thumb, joining with the anterior branch of the musculo-cutaneous nerve.

The internal branch communicates, above the wrist, with the posterior cutaneous branch from the musculo-cutaneous, and, on the back of the hand, with the dorsal cutaneous branch of the ulnar nerve. It then divides into four digital nerves, which are distributed as follows : the first supplies the ulnar side of the thumb ; the second, the radial side of the index finger ; the third, the adjoining sides of the index and middle fingers ; and the fourth, the adjacent borders of the middle and ring fingers.* The latter nerve communicates with a filament from the dorsal branch of the ulnar nerve.

The **posterior interosseous** (n. interosseus antibrachii dorsalis) winds to the back of the forearm round the outer side of the radius, passes between the two planes of fibres of the Supinator brevis, and is prolonged downwards between the superficial and deep layer of muscles, to the middle of the forearm. Considerably diminished in size, it descends on the interosseous membrane, beneath the Extensor longus pollicis, to the back of the carpus, where it presents a gangliform enlargement from which filaments are distributed to the ligaments and articulations of the carpus. It supplies all the muscles on the radial side and posterior aspect of the forearm, excepting the Anconeus, Brachio-radialis, and Extensor carpi radialis longior.

Applied Anatomy.—The brachial plexus may be injured by falls from a height on to the side of the head and shoulder, whereby the nerves of the plexus are violently stretched ; the fifth cervical nerve sustains the greatest amount of injury, and the subsequent paralysis may be confined to the muscles supplied by this nerve, viz. the Deltoid, Biceps, Brachialis anticus, and Brachio-radialis, with sometimes the Supra- and Infra-spinatus and the Supinator brevis. The position of the limb, under such conditions, is characteristic : the arm hangs by the side and is rotated inwards ; the forearm is extended and pronated. The arm cannot be raised from the side ; all power of flexion of the elbow is lost, as is also supination of the forearm. This is known as Erb's paralysis, and a very similar condition is occasionally met with in new-born children, either from injury to the fifth nerve from the pressure of forceps used in effecting delivery, or from traction of the head in breech presentations. A second variety of partial palsy of the brachial plexus is known as the Klumpke paralysis. In this it is the eighth cervical and first thoracic nerves that are injured, either before or after they have joined to form the lower trunk. Atrophy follows in the intrinsic muscles of the hand, and in the flexors of the fingers and wrists ; the thenar and hypothenar eminences waste and flatten ; the fingers cannot be spread out or approximated, on account of the paralysis of the Interossei, and become clawed. The injury to the nerves may follow direct violence, or a gunshot wound.

The brachial plexus may also be injured by violent traction on the arm, or by efforts at reducing a dislocation of the shoulder-joint ; and the amount of paralysis will depend upon the amount of injury to the constituent nerves. When the entire plexus is involved, the whole of the upper extremity will be paralysed and anæsthetic. In these cases the injury appears to be rather a tearing away of the roots of the nerves from their origin in the spinal cord, than a solution of continuity in the nerves themselves. The brachial plexus in the axilla is often damaged from the pressure of a crutch, producing the condition known as 'crutch paralysis.' In these cases the musculo-spiral seems most frequently to be the nerve chiefly implicated ; the ulnar nerve suffers next in frequency. The median and musculo-spiral nerves often suffer from 'sleep palsies,' paralysis from pressure coming on while the patient is profoundly asleep under the influence of alcohol or some narcotic.

Paralysis of the *posterior thoracic nerve* throws the Serratus magnus out of action, and may occur in porters in whom the nerve is exposed to injury in the shoulder as it crosses the posterior triangle of the neck. The lower angle of the scapula is drawn inwards towards the middle line, by the unopposed action of the Rhomboids and Levator anguli scapulæ, and tends to project out backwards when the arm is held horizontally forwards. The arm cannot be raised above the horizontal unless the lower angle of the scapula is pushed outwards for the patient.

The *circumflex nerve*, on account of its course round the surgical neck of the humerus, is liable to be torn in fractures of this part of the bone, and in dislocations of the shoulder-joint ; paralysis of the Deltoid, anæsthesia of the skin covering that muscle, and the formation of adhesions in the shoulder-joint in consequence of injury to its trophic nerves, result. According to Erb, inflammation of the shoulder-joint is liable to be followed by a neuritis of this nerve from extension of the inflammation to it. Paralysis

* According to Hutchinson, the digital nerve to the thumb reaches only as high as the root of the nail: the one to the forefinger as high as the middle of the second phalanx: and the one to the middle and ring fingers not higher than the first phalangeal joint.—*London Hos. Gaz.* vol. iii. p. 319.

of the Deltoid renders abduction of the arm to the horizontal level impossible. The associated paralysis of the Teres minor is not easily demonstrated.

Hilton takes the circumflex nerve as an illustration of a law which he lays down, that 'the same trunks of nerves whose branches supply the groups of muscles moving a joint, furnish also a distribution of nerves to the skin over the insertions of the same muscles, and the interior of the joint receives its nerves from the same source.' In this way he explains the fact that an inflamed joint becomes rigid.

The *median nerve* is liable to injury in wounds of the forearm. When it is paralysed, there is loss of flexion of the second phalanges of all the fingers, and of the terminal phalanges of the index and middle fingers. Flexion of the terminal phalanges of the ring and little fingers is effected by that portion of the Flexor profundus digitorum which is supplied by the ulnar nerve. There is power to flex the proximal phalanges through the Interossei. The thumb cannot be flexed or opposed, and is maintained in a position of extension and adduction. There is loss in the power of pronating the forearm; the Brachio-radialis has the power of bringing the forearm into a position of mid-pronation, but beyond this no further pronation can be effected. The wrist can be flexed, if the hand is first adducted, by the action of the Flexor carpi ulnaris. There is loss or impairment of sensation on the palmar surfaces of the thumb, index, middle, and outer half of ring fingers, and on the dorsal surfaces of the same fingers over the last two phalanges; except in the thumb, where the loss of sensation would be limited to the back of the last phalanx. In old cases the unopposed action of the Interossei produces backward dislocation of the interphalangeal joints. The thumb is extended and adducted to the index, cannot be flexed or abducted, and cannot be apposed to any one of the fingers; in consequence an 'ape-like' hand is produced. In order to expose the median nerve, for the purpose of uniting the divided ends, supposing the injury to be just above the wrist, an incision should be made along the radial side of the tendon of the Palmaris longus, which serves as a guide to the nerve.

The *ulnar nerve* is also liable to be injured in wounds of the forearm. When paralysed, there is impaired power of ulnar flexion, and upon an attempt being made to flex the wrist, the hand is drawn to the radial side from paralysis of the Flexor carpi ulnaris: there is inability to spread out the fingers from paralysis of the Interossei, and for the same reason the fingers, especially the ring and little fingers, cannot be flexed at the meta-carpo-phalangeal joints or extended at the interphalangeal joints, and the hand assumes a claw shape from the action of the opposing muscles; there is loss of power of flexion in the little and ring fingers; and there is inability to adduct the thumb. The muscles of the hypothenar eminence become wasted. Sensation is lost, or impaired, in the skin supplied by the nerve. In order to expose the nerve in the lower part of the forearm, an incision should be made along the outer border of the tendon of the Flexor carpi ulnaris, and the nerve will be found lying on the ulnar side of the ulnar artery.

The *musculo-spiral nerve* is probably more frequently injured than any other nerve of the upper extremity. In consequence of its close relationship to the humerus, as it lies in the musculo-spiral groove, it is often torn or injured in fractures of this bone, or subsequently involved in the callus that may be thrown out around a fracture, and thus pressed upon and its functions interfered with. It is also liable to be contused against the bone by kicks or blows, or to be divided by wounds of the arm. When paralysed, the hand is flexed at the wrist and lies flaccid. This is known as *wrist-drop*. The fingers are also flexed, and on an attempt being made to extend them, the last two phalanges only will be extended, through the action of the Interossei; the first phalanges remaining flexed. There is no power of extending the wrist. Supination is completely lost when the forearm is extended on the arm, but is possible to a certain extent if the forearm be flexed so as to allow of the action of the Biceps. The power of extension of the forearm is lost on account of paralysis of the Triceps, if the injury to the nerve has taken place near its origin. In cases due to pressure, sensation is hardly affected; severe injury to the nerve occasions anæsthesia over the area supplied by the radial nerve, and, if the lesion be high up, on the outer side of the upper arm and the back of the forearm (external and internal cutaneous branches) as well.

The nerve is best exposed by making an incision along the inner border of the Brachio-radialis, just above the level of the elbow-joint. The skin and superficial structures are to be divided and the deep fascia exposed. The white line in this structure indicating the border of the muscle is to be defined, and the deep fascia divided in this line. By now raising the Brachio-radialis, the nerve will be found lying between it and the Brachialis anticus. The muscles supplied by the posterior interosseous branch of the musculo-spiral nerve are also particularly liable to be affected in chronic lead poisoning.

THORACIC NERVES (NN. THORACALES)

The **anterior primary divisions of the thoracic nerves** are twelve in number on either side. Eleven of them are situated between the ribs, and are therefore termed *intercostal*; the twelfth lies below the last rib. Each nerve is connected

with the adjoining ganglion of the sympathetic by one or two filaments. The intercostal nerves are distributed chiefly to the parietes of the thorax and abdomen, and differ from the anterior divisions of the other spinal nerves, in that each pursues an independent course, i.e. there is no plexus formation. The first two nerves supply fibres to the upper limb in addition to their thoracic branches; the next four are limited in their distribution to the parietes of the thorax; the five lower supply the parietes of the chest and abdomen. The twelfth thoracic is distributed to the abdominal wall and the skin of the buttock.

The **first thoracic nerve.**—The anterior division of the first thoracic nerve divides into two branches; one, the larger, leaves the thorax in front of the neck of the first rib, and enters into the formation of the brachial plexus; the other and smaller branch runs along the first intercostal space, forming the *first intercostal nerve*, and terminates on the front of the chest, by forming the first anterior cutaneous nerve of the thorax. Occasionally this anterior cutaneous branch is wanting. The first intercostal nerve as a rule gives off no lateral cutaneous branch; but sometimes a small branch is given off, to communicate with the intercosto-humeral. It frequently receives a connecting twig from the second thoracic nerve, which passes upwards over the neck of the second rib.

The **upper thoracic nerves.**—The anterior divisions of the second, third, fourth, fifth, and sixth thoracic nerves, and the small branch from the first thoracic, are confined to the parietes of the thorax, and are named *thoracic intercostal nerves*. They pass forwards (fig. 803) in the intercostal spaces below the intercostal vessels. At the back of the chest they lie between the pleura and the posterior intercostal membranes, but soon pierce the latter and run between the two planes of Intercostal muscles as far as the middle of the rib. They then enter the substance of the Internal intercostal muscles, and, running

FIG. 803.—Diagram of the course and branches of a typical intercostal nerve.

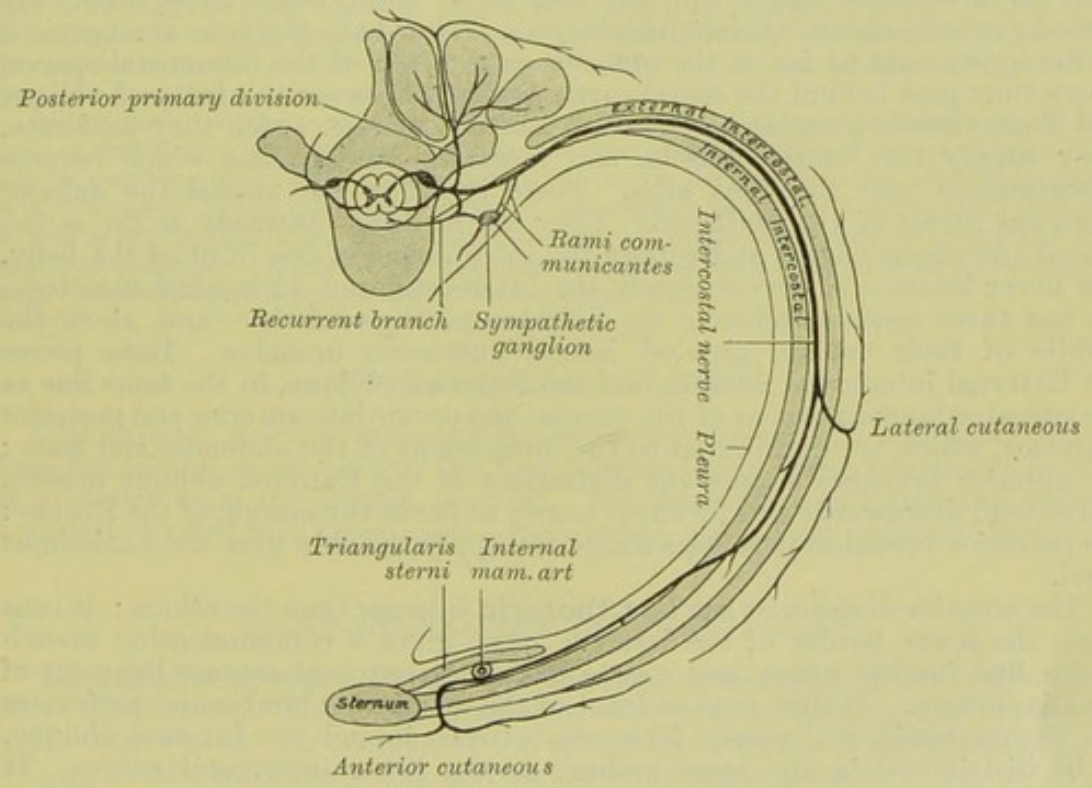

amidst their fibres as far as the costal cartilages, they gain the inner surfaces of the muscles and lie between them and the pleura. Near the sternum, they cross in front of the internal mammary artery and Triangularis sterni muscle, pierce the Internal intercostal muscles, the anterior intercostal membranes, and Pectoralis major muscle, and supply the integument of the front of the chest and over the mammary gland, forming the anterior cutaneous nerves (rami cutanei anteriores) of the thorax; the branch from the second nerve is joined with the supraclavicular nerves of the cervical plexus.

Branches.—Numerous slender muscular filaments supply the Intercostals, the Infracostales, the Levatores costarum, the Serratus posticus superior, and the Triangularis sterni muscles. At the front of the chest some of these branches cross the costal cartilages from one intercostal space to another.

Lateral cutaneous nerves (rami cutanei laterales).—These are derived from the intercostal nerves, midway between the vertebræ and sternum; they pierce the External intercostal and Serratus magnus muscles, and divide into anterior and posterior branches.

The *anterior branches* (rami anteriores) are reflected forwards to the side and the fore part of the chest, supplying the integument of the chest and mamma; those of the fifth and sixth nerves supply the upper digitations of the External oblique.

The *posterior branches* (rami posteriores) are reflected backwards, to supply the integument over the scapula and over the Latissimus dorsi.

The lateral cutaneous branch of the second intercostal nerve is of large size, and does not divide, like the other nerves, into an anterior and a posterior branch. It is named, from its origin and distribution, the *intercosto-humeral* nerve (n. intercostobrachialis) (fig. 801). It pierces the External intercostal muscle and the Serratus magnus, crosses the axilla to the inner side of the arm, and joins with a filament from the nerve of Wrisberg. It then pierces the fascia, and supplies the skin of the upper half of the inner and back part of the arm, communicating with the internal cutaneous branch of the musculo-spiral nerve. The size of this nerve is in inverse proportion to the size of the other cutaneous nerves, especially the nerve of Wrisberg. A second intercosto-humeral nerve is frequently given off from the third intercostal. It supplies filaments to the armpit and inner side of the arm.

The **lower thoracic nerves.**—The anterior divisions of the seventh, eighth, ninth, tenth, and eleventh thoracic nerves are continued anteriorly from the intercostal spaces into the abdominal wall; hence these nerves are named *thoracico-abdominal intercostal nerves.* They have the same arrangement as the upper ones as far as the anterior extremities of the intercostal spaces, where they pass behind the costal cartilages, and between the Internal oblique and Transversalis muscles, to the sheath of the Rectus, which they perforate. They supply the Rectus muscle, and terminate in branches which become subcutaneous near the linea alba. These branches are named the *anterior cutaneous nerves* of the abdomen. They are directed outwards as far as the lateral cutaneous nerves and supply the integument of the front of the belly. The lower intercostal nerves supply the Intercostal and Abdominal muscles—the last three send branches to the Serratus posticus inferior—and, about the middle of their course, give off lateral cutaneous branches. These pierce the External intercostal muscles and the External oblique, in the same line as the lateral cutaneous nerves of the thorax, and divide into anterior and posterior branches, which are distributed to the integument of the abdomen and back; the anterior branches supply the digitations of the External oblique muscle, and extend downwards and forwards nearly as far as the margin of the Rectus: the posterior branches pass backwards to supply the skin over the Latissimus dorsi.

The anterior division of the **last thoracic** is larger than the others; it runs along the lower border of the last rib, often gives a communicating branch to the first lumbar nerve, and passes under the external arcuate ligament of the Diaphragm. It then runs in front of the Quadratus lumborum, perforates the Transversalis, and passes forwards between it and the Internal oblique, to be distributed in the same manner as the lower intercostal nerves. It communicates with the ilio-hypogastric branch of the lumbar plexus, and gives a branch to the Pyramidalis muscle.

The *lateral cutaneous branch of the last thoracic* is remarkable for its large size. It does not divide into an anterior and a posterior branch like the lateral cutaneous branches of the intercostal nerves, but perforates the Internal and External oblique muscles, passes downwards over the crest of the ilium in front of the iliac branch of the ilio-hypogastric (fig. 811), and is distributed to the integument of the front part of the gluteal region, some of its filaments extending as low down as the trochanter major.

Applied Anatomy.—The lower seven thoracic nerves and the ilio-hypogastric from the first lumbar nerve supply the skin of the abdominal wall. They run downwards and inwards fairly equidistant from each other. The sixth and seventh supply the skin over the ' pit of the stomach ' ; the eighth corresponds to about the position of the middle linea transversa ; the tenth to the umbilicus ; and the ilio-hypogastric supplies the skin over the pubis and external abdominal ring. In many diseases affecting the nerve-trunks at or near their origins, the pain is referred to their peripheral terminations. Thus, in Pott's disease of the spine, children will often be brought to the surgeon suffering from pain in the belly. This is due to the fact that the nerves are irritated at the seat of disease as they issue from the spinal canal. When the irritation is confined to a single pair of nerves, the sensation complained of is often a feeling of constriction, as if a cord were tied round the abdomen, and in these cases the situation of the sense of constriction may serve to localise the disease in the spinal column. In other cases where the bone disease is more extensive, and two or more nerves are involved, a more general, diffused pain in the abdomen is felt.

Again, it must be borne in mind that the same nerves which supply the skin of the abdomen supply also the planes of muscle which constitute the greater part of the abdominal wall. Hence, it follows that any irritation applied to the peripheral terminations of the cutaneous branches in the skin of the abdomen is immediately followed by reflex contraction of the abdominal muscles. The supply of both muscles and skin from the same source is of importance in protecting the abdominal viscera from injury. A blow on the abdomen, even of a severe character, will do no injury to the viscera if the muscles are in a condition of firm contraction ; whereas in cases where the muscles have been taken unawares, and the blow has been struck while they were in a state of rest, an injury insufficient to produce any lesion of the abdominal wall has been attended with rupture of some of the abdominal contents. The importance, therefore, of immediate reflex contraction upon the receipt of an injury cannot be over-estimated, and the intimate association of the cutaneous and muscular fibres in the same nerve produces a much more rapid response on the part of the muscles to any peripheral stimulation of the cutaneous filaments than would be the case if the two sets of fibres were derived from independent sources.

Again, the nerves supplying the abdominal muscles and skin, derived from the lower intercostal nerves, are intimately connected with the sympathetic supplying the abdominal viscera through the lower thoracic ganglia from which the splanchnic nerves are derived. In consequence of this, in laceration of the abdominal viscera and in acute peritonitis, the muscles of the belly wall become firmly contracted, and thus as far as possible preserve the abdominal contents in a condition of rest.

Inflammation of the ganglia on one or more of any of the posterior nerve-roots is the cause of *shingles* * or herpes zoster, in which there is a painful eruption of groups of cutaneous vesicles corresponding to the distribution of the nerves derived from the affected ganglia. It is commonest in the intercostal nerves ; the eruption is often preceded and followed, as well as accompanied, by girdle pains, and in old people these may be prolonged and serious in character. Herpes is the analogue on the sensory side to anterior poliomyelitis (page 810) on the motor side of the nervous system.

LUMBO-SACRAL PLEXUS

The anterior primary divisions of the lumbar, sacral and coccygeal nerves form the lumbo-sacral plexus, the first lumbar nerve being frequently joined by a branch from the twelfth thoracic. For descriptive purposes this plexus is usually divided into three parts—the lumbar, sacral and pudendal plexuses.

LUMBAR NERVES (NN. LUMBALES)

The **anterior primary divisions of the lumbar nerves** increase in size from above downwards. They are joined, near their origins, by *grey rami communicantes* from the lumbar ganglia of the sympathetic cord. These rami consist of long, slender branches which accompany the lumbar arteries round the sides of the vertebral bodies, beneath the Psoas magnus. Their arrangement is somewhat irregular : one ganglion may give rami to two lumbar nerves, or one lumbar nerve may receive rami from two ganglia. The first and second, and sometimes the third and fourth lumbar nerves are each connected with the lumbar part of the sympathetic cord by a *white ramus communicans*. The nerves pass obliquely outwards behind the Psoas magnus, or between its fasciculi, distributing filaments to it and the Quadratus lumborum. The first

* From Lat. *cingulum*, a belt.

three and the greater part of the fourth are connected together in this situation by anastomotic loops, and form the *lumbar plexus*. The smaller part of the fourth joins with the fifth to form the *lumbo-sacral cord* (truncus lumbosacralis), which assists in the formation of the sacral plexus. The fourth nerve is named the *nervus furcalis*, from the fact that it is subdivided between the two plexuses.*

Lumbar Plexus (Plexus lumbalis)

The **lumbar plexus** (fig. 804) is formed by the loops of communication between the anterior divisions of the first three and the greater part of the fourth lumbar nerves. The plexus is narrow above, and the first lumbar often receives a branch from the last thoracic nerve; it is broad below, where it is joined to the sacral plexus by the lumbo-sacral cord. It is situated in the posterior part of the Psoas magnus, in front of the transverse processes of the lumbar vertebræ.

Fig. 804.—Plan of lumbar plexus.

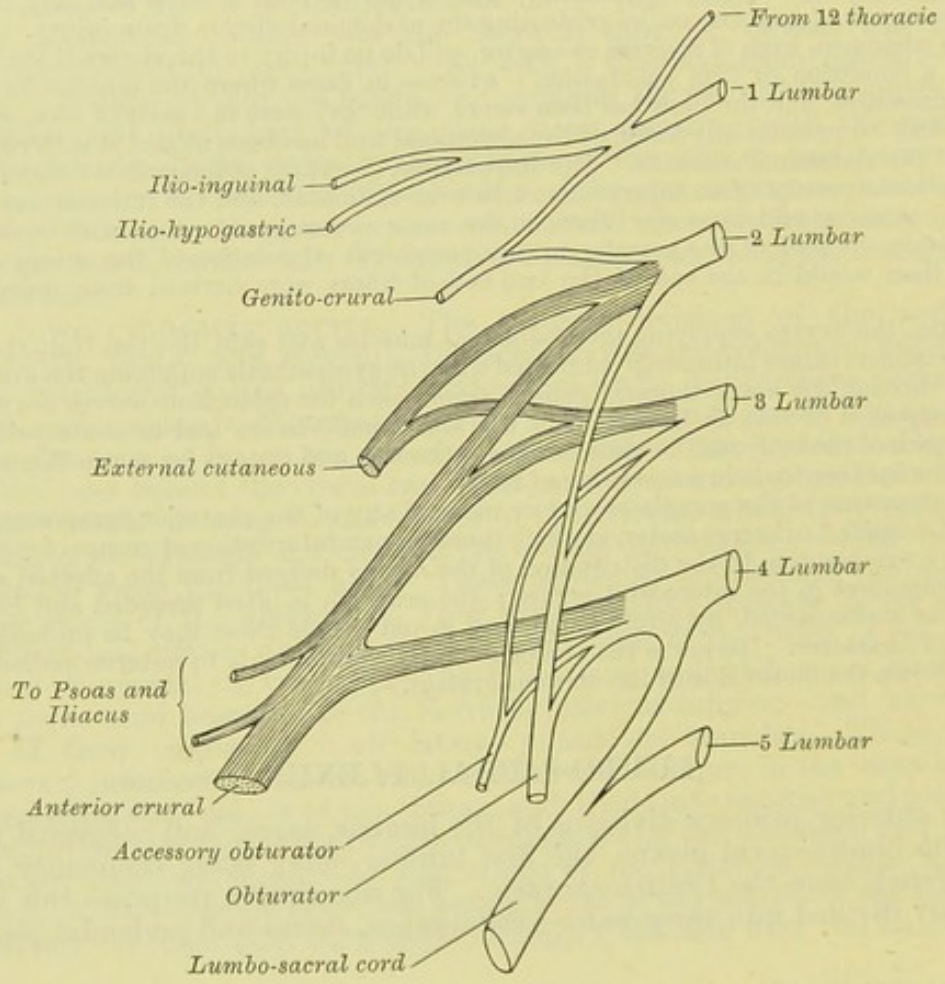

The mode in which the plexus is arranged varies in different subjects. It differs from the brachial plexus in not forming an intricate interlacement, but the several nerves of distribution arise from one or more of the spinal nerves, somewhat in the following manner: the first lumbar nerve frequently receives a twig from the last thoracic, and divides into an upper and lower branch; the upper and larger branch subdivides into the ilio-hypogastric and ilio-inguinal; the lower and smaller branch unites with a branch of the second lumbar to form

* In most cases the fourth lumbar is the *nervus furcalis*; but this arrangement is frequently departed from. The third is occasionally the lowest nerve which enters the lumbar plexus, giving at the same time some fibres to the sacral plexus, and thus forming the nervus furcalis; or both the third and fourth may be furcal nerves. When this occurs, the plexus is termed *high* or *pre-fixed*. More frequently the fifth nerve is divided between the lumbar and sacral plexuses, and constitutes the nervus furcalis; and when this takes place, the plexus is distinguished as a *low* or *post-fixed* plexus. These variations necessarily produce corresponding modifications in the sacral plexus.

the genito-crural nerve. The remainder of the second nerve, and the third and fourth nerves, divide into ventral and dorsal divisions. The ventral division of the second unites with the ventral divisions of the third and fourth nerves to form the obturator nerve. The dorsal divisions of the second and third nerves divide into two branches, a smaller branch from each uniting to form the external cutaneous nerve, and a larger branch from each joining with the dorsal division of the fourth lumbar nerve to form the anterior

Fig. 805.—The lumbar plexus and its branches.

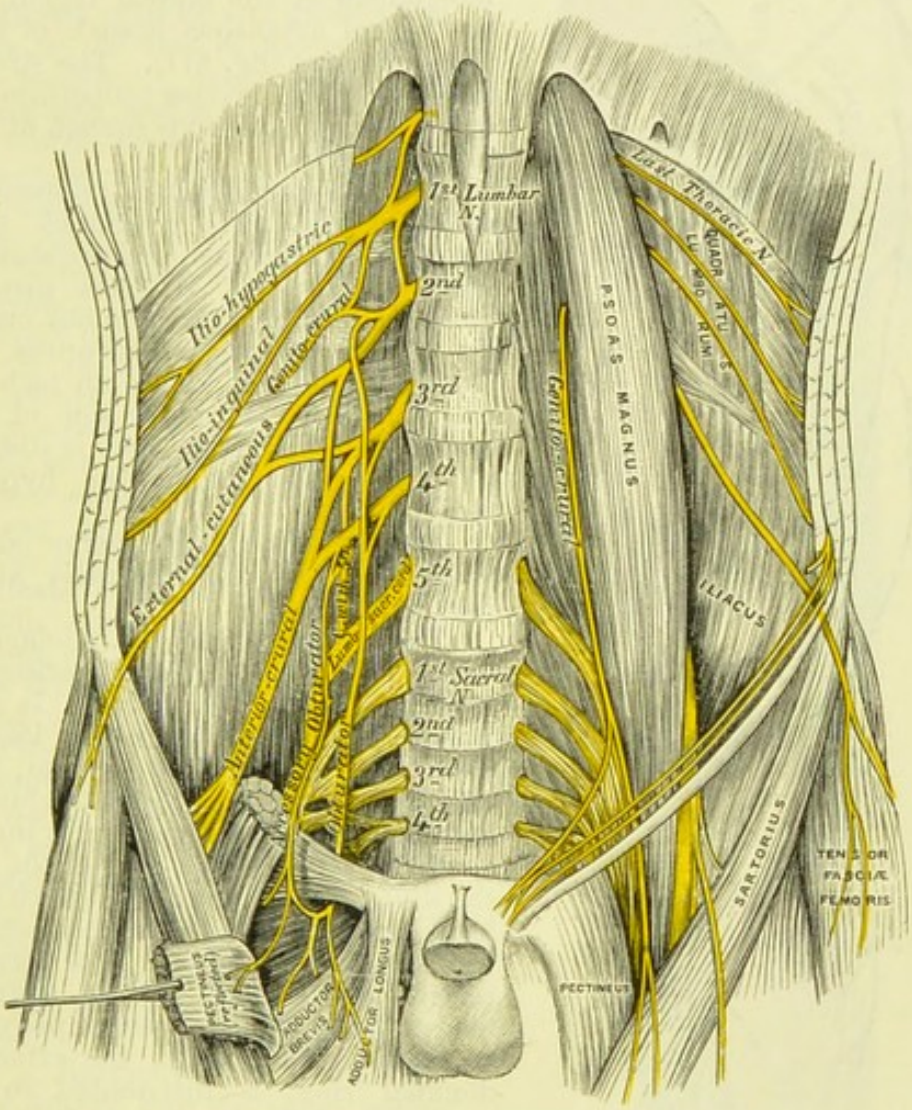

crural nerve. The accessory obturator, when it exists, is formed by the union of two small branches given off from the third and fourth nerves.

The branches of the lumbar plexus may therefore be arranged as follows :

Ilio-hypogastric	1 L.
Ilio-inguinal	1 L.
Genito-crural	1, 2 L.
	Dorsal divisions.
External cutaneous	2, 3, L.
Anterior crural	2, 3, 4 L.
	Ventral divisions.
Obturator	2, 3, 4 L.
Accessory obturator	3, 4 L.

The **ilio-hypogastric** (n. iliohypogastricus) arises from the first lumbar nerve. It emerges from the outer border of the Psoas muscle at its upper

part, and crosses obliquely in front of the Quadratus lumborum to the crest of the ilium. It then perforates the Transversalis muscle at its posterior part, near the crest of the ilium, and divides between it and the Internal oblique into two branches, iliac and hypogastric.

Fig. 806.—Cutaneous nerves of lower extremity. Front view.

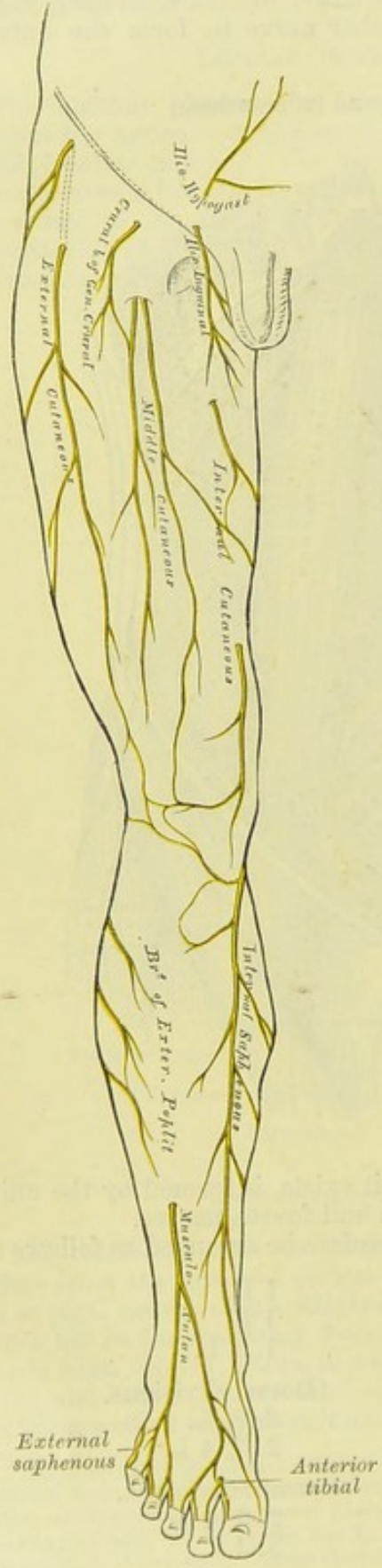

The *iliac branch* (ramus cutaneus lateralis) pierces the Internal and External oblique muscles immediately above the crest of the ilium, and is distributed to the integument of the gluteal region, behind the lateral cutaneous branch of the last thoracic nerve (fig. 811). The size of the nerve bears an inverse proportion to that of the lateral cutaneous branch of the last thoracic nerve.

The *hypogastric branch* (ramus cutaneus anterior) (fig. 806) continues onwards between the Internal oblique and Transversalis muscles. It then pierces the Internal oblique, and becomes cutaneous by perforating the aponeurosis of the External oblique, about an inch above, and a little to the outer side of the external abdominal ring, and is distributed to the integument of the hypogastric region.

The ilio-hypogastric nerve communicates with the last thoracic and ilio-inguinal nerves.

The **ilio-inguinal** (n. ilioinguinalis), smaller than the preceding, arises with it from the first lumbar nerve. It emerges from the outer border of the Psoas just below the ilio-hypogastric, and, passing obliquely across the Quadratus lumborum and Iliacus muscles, perforates the Transversalis, near the fore part of the crest of the ilium, and communicates with the ilio-hypogastric nerve between that muscle and the Internal oblique. The nerve then pierces the Internal oblique, distributing filaments to it, and, accompanying the spermatic cord through the external abdominal ring, is distributed to the integument of the upper and inner part of the thigh, to the skin over the root of the penis and upper part of the scrotum in the male, and to the skin covering the mons Veneris and labium majus in the female. The size of this nerve is in inverse proportion to that of the ilio-hypogastric. Occasionally it is very small, and ends by joining the ilio-hypogastric; in such cases, a branch from the ilio-hypogastric takes the place of the ilio-inguinal, or the latter nerve may be altogether absent.

The **genito-crural** (n. genitofemoralis) arises from the first and second lumbar nerves. It passes obliquely through the substance of the Psoas, and emerges from its inner border, close to the vertebral column, opposite the disc between the third and fourth lumbar vertebræ; it then descends on the

surface of the Psoas muscle, under cover of the peritoneum, and divides into a genital and a crural branch. Occasionally the two branches emerge separately through the substance of the Psoas.

The *genital branch* (n. spermaticus externus) passes outwards on the Psoas magnus, and pierces the fascia transversalis, or passes through the internal abdominal ring ; it then descends along the back part of the spermatic cord to the scrotum, supplies, in the male, the Cremaster muscle, and gives a few filaments to the skin of the scrotum. In the female, it accompanies the round ligament, and is lost upon it.

The *crural branch* (n. lumboinguinalis) descends on the external iliac artery, sending a few filaments round it, and, passing beneath Poupart's ligament to the thigh, enters the sheath of the femoral vessels, lying superficial and a little external to the femoral artery. It pierces the anterior layer of the sheath of the vessels, and, becoming superficial by passing through the fascia lata, it supplies the skin of the anterior aspect of the thigh as far as midway between the pelvis and knee. On the front of the thigh it communicates with the outer branch of the middle cutaneous nerve, derived from the anterior crural.

A few filaments from this nerve may be traced on to the femoral artery ; they are derived from the nerve as it passes beneath Poupart's ligament.

The **external cutaneous** (n. cutaneus femoris lateralis) arises from the second and third lumbar nerves. It emerges from the outer border of the Psoas muscle about its middle, and crosses the Iliacus muscle obliquely, towards the anterior superior spine of the ilium. It then passes under Poupart's ligament and over the Sartorius muscle into the thigh, where it divides into two branches, an anterior and a posterior.

The *anterior branch* descends in an aponeurotic canal formed in the fascia lata, becomes superficial about four inches below Poupart's ligament, and divides into branches which are distributed to the integument along the anterior and outer part of the thigh, as far down as the knee. The terminal filaments of this nerve frequently communicate with the middle and internal cutaneous, and with the patellar branch of the long saphenous, forming with them the *patellar plexus*.

The *posterior branch* pierces the fascia lata, and subdivides into

FIG. 807. — Segmental distribution of cutaneous nerves of right lower extremity. Front view.

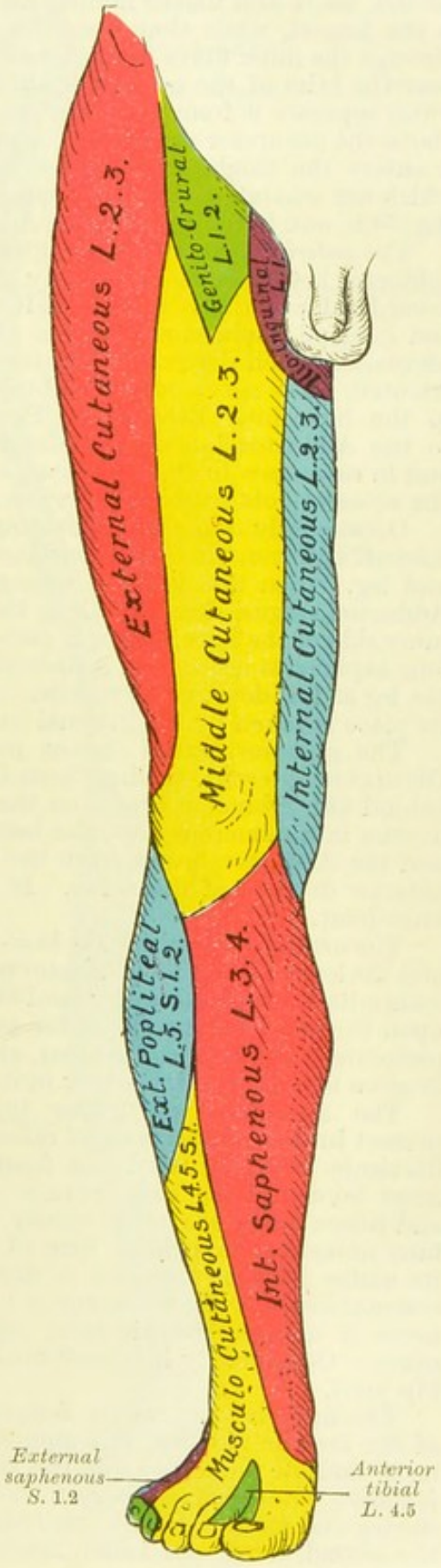

filaments which pass backwards across the outer and posterior surface of the thigh, supplying the integument from the level of the great trochanter to the middle of the thigh.

The **obturator** (n. obturatorius) supplies the Obturator externus and the Adductor muscles of the thigh, the articulations of the hip and knee, and occasionally part of the integument of the thigh and leg. It arises from the second, third, and fourth lumbar nerves. Of these, the branch from the third is the largest, while that from the second is often very small. It descends through the inner fibres of the Psoas muscle, and emerges from its inner border near the brim of the pelvis; it then passes behind the external iliac vessels which separate it from the ureter, and runs along the lateral wall of the pelvis, above the obturator vessels, to the upper part of the obturator foramen. Here it enters the thigh, and divides into an anterior and a posterior branch, which are separated at first by some of the fibres of the Obturator externus (fig. 545), and lower down by the Adductor brevis.

The *anterior branch* (ramus anterior) (fig. 808) passes down in front of the Adductor brevis, being covered by the Pectineus and Adductor longus; at the lower border of the latter muscle it communicates with the internal cutaneous and internal saphenous branches of the anterior crural, forming a kind of plexus. It then descends upon the femoral artery, to which it is finally distributed. The nerve, near the obturator foramen, gives off an articular branch to the hip-joint. Behind the Pectineus, it distributes muscular branches to the Adductor longus and Gracilis, and usually to the Adductor brevis, and in rare cases to the Pectineus, and receives a communicating branch from the accessory obturator nerve when that nerve is present.

Occasionally the communicating branch to the internal cutaneous and internal saphenous nerves is continued down, as a cutaneous branch, to the thigh and leg. When this is so, it emerges from beneath the lower border of the Adductor longus, descends along the posterior margin of the Sartorius to the inner side of the knee, where it pierces the deep fascia, communicates with the long saphenous nerve, and is distributed to the integument of the inner side of the leg as low down as its middle. When this communicating branch is small, its place is taken by the internal cutaneous nerve.

The *posterior branch* (ramus posterior) pierces the anterior part of the Obturator externus, sending branches to supply this muscle; it then passes behind the Adductor brevis on the front of the Adductor magnus, where it divides into numerous muscular branches, which supply the Adductor magnus, and the Adductor brevis when the latter does not receive a branch from the anterior division of the nerve. It also gives off an articular filament to the knee-joint.

The *articular branch for the knee-joint* is sometimes absent; it either perforates the lower part of the Adductor magnus, or passes through the opening which transmits the femoral artery, and enters the popliteal space; it then descends upon the popliteal artery, as far as the back part of the knee-joint, where it perforates the posterior ligament, and is distributed to the synovial membrane. It gives filaments to the artery in its course.

The **accessory obturator** (n. obturatorius accessorius) (fig. 805) is present in about 29 per cent. of cases. It is of small size, and arises by separate filaments from the third and fourth lumbar nerves. It descends along the inner border of the Psoas muscle, crosses the ascending ramus of the pubis, and passes under the outer border of the Pectineus muscle, where it divides into numerous branches. One of these supplies the Pectineus, penetrating its under surface; another is distributed to the hip-joint; while a third communicates with the anterior branch of the obturator nerve. When this nerve is absent, the hip-joint receives two branches from the obturator nerve. Occasionally it is very small and becomes lost in the capsule of the hip-joint.

The **anterior crural** (n. femoralis) (figs. 805, 808) is the largest branch of the lumbar plexus. It supplies muscular branches to the Iliacus, Pectineus, and all the muscles on the front of the thigh, except the Tensor fasciæ femoris; cutaneous filaments to the front and inner side of the thigh, and to the leg and foot; and articular branches to the hip and knee. It arises from the second, third, and fourth lumbar nerves. It descends through the fibres

of the Psoas, emerging from the muscle at the lower part of its outer border, and passes down between it and the Iliacus behind the fascia iliaca; it then runs beneath Poupart's ligament, into the thigh, where it becomes somewhat flattened, and divides into an anterior and a posterior part. Under Poupart's ligament, it is separated from the femoral artery by a portion of the Psoas.

Within the abdomen the anterior crural nerve gives off from its outer side some small branches to the Iliacus, and a branch to the femoral artery, which is distributed upon the upper part of that vessel. The origin of this branch varies: it occasionally arises higher than usual, or it may arise lower down in the thigh.

In the thigh the following branches are given off:

From the Anterior Division

Middle cutaneous.
Internal cutaneous.
Muscular.

From the Posterior Division

Long saphenous.
Muscular.
Articular.

The *middle cutaneous nerve* (fig. 806) pierces the fascia lata (and generally the Sartorius) about three inches below Poupart's ligament, and divides into two branches (rami cutanei anteriores) which descend in immediate proximity along the fore part of the thigh, to supply the integument as low as the front of the knee. Here they communicate with the internal cutaneous nerve and the patellar branch of the internal saphenous, to form the patellar plexus. In the upper part of the thigh the outer division of the middle cutaneous communicates with the crural branch of the genito-crural nerve.

The *internal cutaneous nerve* passes obliquely across the upper part of the

Fig. 808.—Nerves of the right lower extremity. Front view.

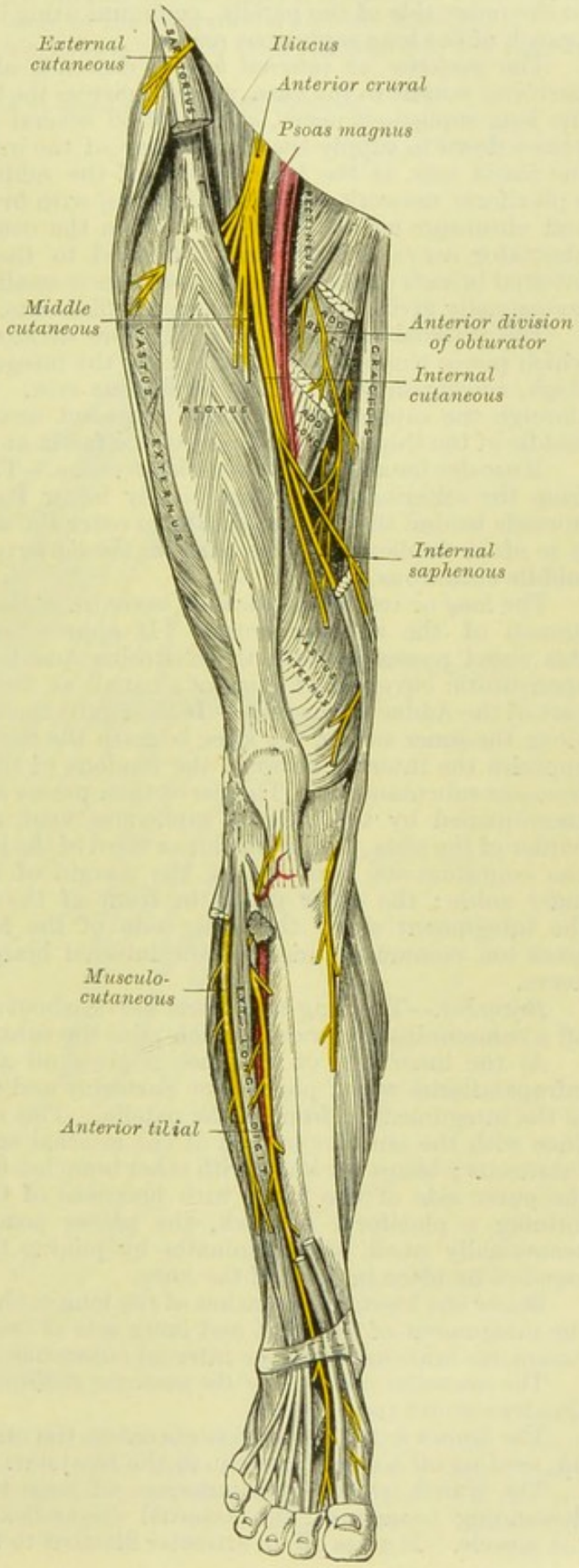

sheath of the femoral artery, and divides in front, or at the inner side of that vessel, into two branches, an anterior and a posterior or internal.

The *anterior branch* runs downwards on the Sartorius, perforates the fascia lata at the lower third of the thigh, and divides into two branches : one supplies the integument as low down as the inner side of the knee ; the other crosses to the outer side of the patella, communicating in its course with the patellar branch of the long saphenous nerve.

The *posterior* or *internal branch* descends along the inner border of the Sartorius muscle to the knee, where it pierces the fascia lata, communicates with the long saphenous nerve, and gives off several cutaneous branches. It then passes down to supply the integument of the inner side of the leg. Beneath the fascia lata, at the lower border of the Adductor longus, it joins to form a plexiform network (*subsartorial plexus*) with branches of the long saphenous and obturator nerves (fig. 808). When the communicating branch from the obturator nerve is large and continued to the integument of the leg, the internal branch of the internal cutaneous is small, and terminates in the plexus, occasionally giving off a few cutaneous filaments.

The internal cutaneous nerve, before dividing, gives off a few filaments, which pierce the fascia lata, to supply the integument of the inner side of the thigh, accompanying the long saphenous vein. One of these filaments passes through the saphenous opening ; a second becomes subcutaneous about the middle of the thigh ; a third pierces the fascia at its lower third.

Muscular branches of the anterior division.—The *nerve to the Pectineus* arises from the anterior crural immediately below Poupart's ligament, and passes inwards behind the femoral sheath to enter the anterior surface of the muscle ; it is often duplicated. The *nerve to the Sartorius* arises in common with the middle cutaneous.

The *long* or *internal saphenous nerve* (n. saphenus) is the largest cutaneous branch of the anterior crural. It approaches the femoral artery where this vessel passes beneath the Sartorius, and lies in front of it, beneath the aponeurotic covering of Hunter's canal, as far as the opening in the lower part of the Adductor magnus. It then quits the artery, and descends vertically along the inner side of the knee beneath the Sartorius, pierces the fascia lata, opposite the interval between the tendons of the Sartorius and Gracilis, and becomes subcutaneous. The nerve then passes along the inner side of the leg, accompanied by the internal saphenous vein, descends behind the internal border of the tibia, and, at the lower third of the leg, divides into two branches : one continues its course along the margin of the tibia, terminating at the inner ankle ; the other passes in front of the ankle, and is distributed to the integument along the inner side of the foot, as far as the ball of the great toe, communicating with the internal branch of the musculo-cutaneous nerve.

Branches.—The long saphenous nerve, about the middle of the thigh, gives off a communicating branch which joins the subsartorial plexus.

At the inner side of the knee it gives off a large *patellar branch* (ramus infrapatellaris) which pierces the Sartorius and fascia lata, and is distributed to the integument in front of the patella. This nerve communicates above the knee with the anterior branch of the internal cutaneous and with the middle cutaneous ; below the knee, with other branches of the long saphenous ; and, on the outer side of the joint, with branches of the external cutaneous nerve, forming a plexiform network, the *plexus patellæ*. The patellar branch is occasionally small, and terminates by joining the internal cutaneous, which supplies its place in front of the knee.

Below the knee, the branches of the long saphenous nerve are distributed to the integument of the front and inner side of the leg, communicating with the cutaneous branches from the internal cutaneous, or from the obturator nerve.

The *muscular branches of the posterior division* supply the four parts of the Quadriceps extensor muscle.

The *branch to the Rectus femoris* enters the under surface of the muscle high up, sending off a small filament to the hip-joint.

The *branch to the Vastus externus*, of large size, follows the course of the descending branch of the external circumflex artery to the lower part of the muscle. It gives off an articular filament to the knee-joint.

The *branch to the Vastus internus* is a long filament running down on the outer side of the femoral vessels in company with the internal saphenous nerve. It enters the muscle about its middle, and gives off a filament, which can usually be traced downwards, on the surface of the muscle, to the knee-joint.

The *branches to the Crureus* are two or three in number, and enter the muscle on its anterior surface about the middle of the thigh ; a filament from one of these descends through the muscle to the Subcrureus and the knee-joint.

The *articular branch to the hip-joint* is derived from the nerve to the Rectus.

FIG. 809.—Plan of sacral and pudendal plexuses.

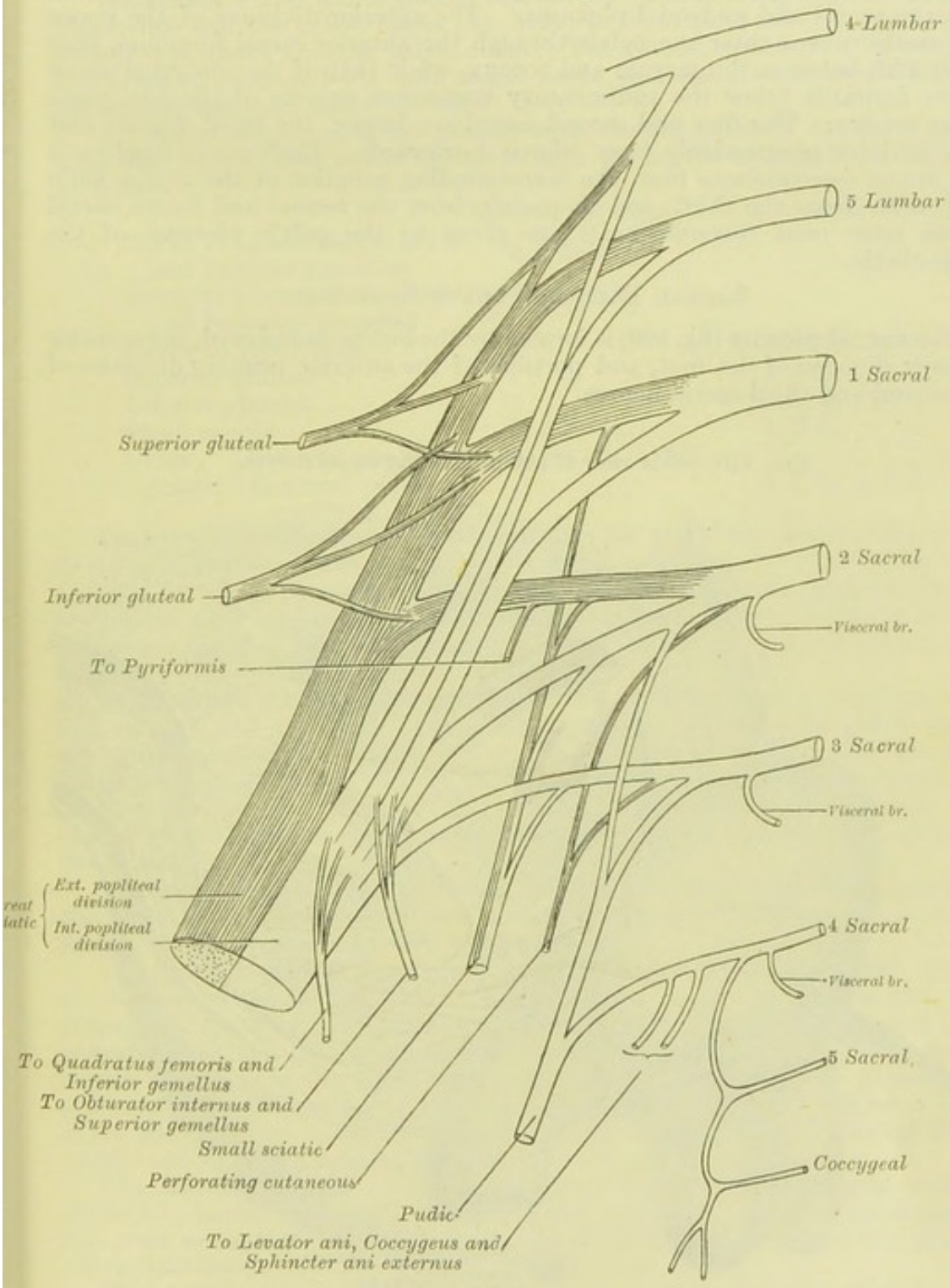

The *articular branches to the knee-joint* are three in number. One, a long, slender filament, is derived from the nerve to the Vastus externus ; it penetrates the capsular ligament of the joint on its anterior aspect. Another is derived from the nerve to the Vastus internus. It can usually be traced downwards

on the surface of this muscle to near the joint ; it then penetrates the muscular fibres, and accompanies the deep branch of the anastomotica magna artery, pierces the capsular ligament of the joint on its inner side, and supplies the synovial membrane. The third branch is derived from the nerve to the Crureus.

SACRAL AND COCCYGEAL NERVES (NN. SACRALES ET COCCYGEUS)

The **anterior primary divisions of the sacral and coccygeal nerves** form the sacral and pudendal plexuses. The anterior divisions of the upper four sacral nerves enter the pelvis through the anterior sacral foramina, that of the fifth between the sacrum and coccyx, while that of the coccygeal nerve curves forwards below the rudimentary transverse process of the first piece of the coccyx. The first and second sacral are large ; the third, fourth, and fifth diminish progressively from above downwards. Each nerve receives a *grey ramus communicans* from the corresponding ganglion of the sympathetic cord, while from the third, and frequently from the second and fourth sacral nerves *white rami communicantes* are given to the pelvic plexuses of the sympathetic.

Sacral Plexus (Plexus Sacralis)

The **sacral plexus** (fig. 809) is formed by the lumbo-sacral cord, the anterior primary division of the first, and portions of the anterior primary divisions of the second and third sacral nerves.

Fig. 810.—Side view of pelvis, showing sacral nerves.

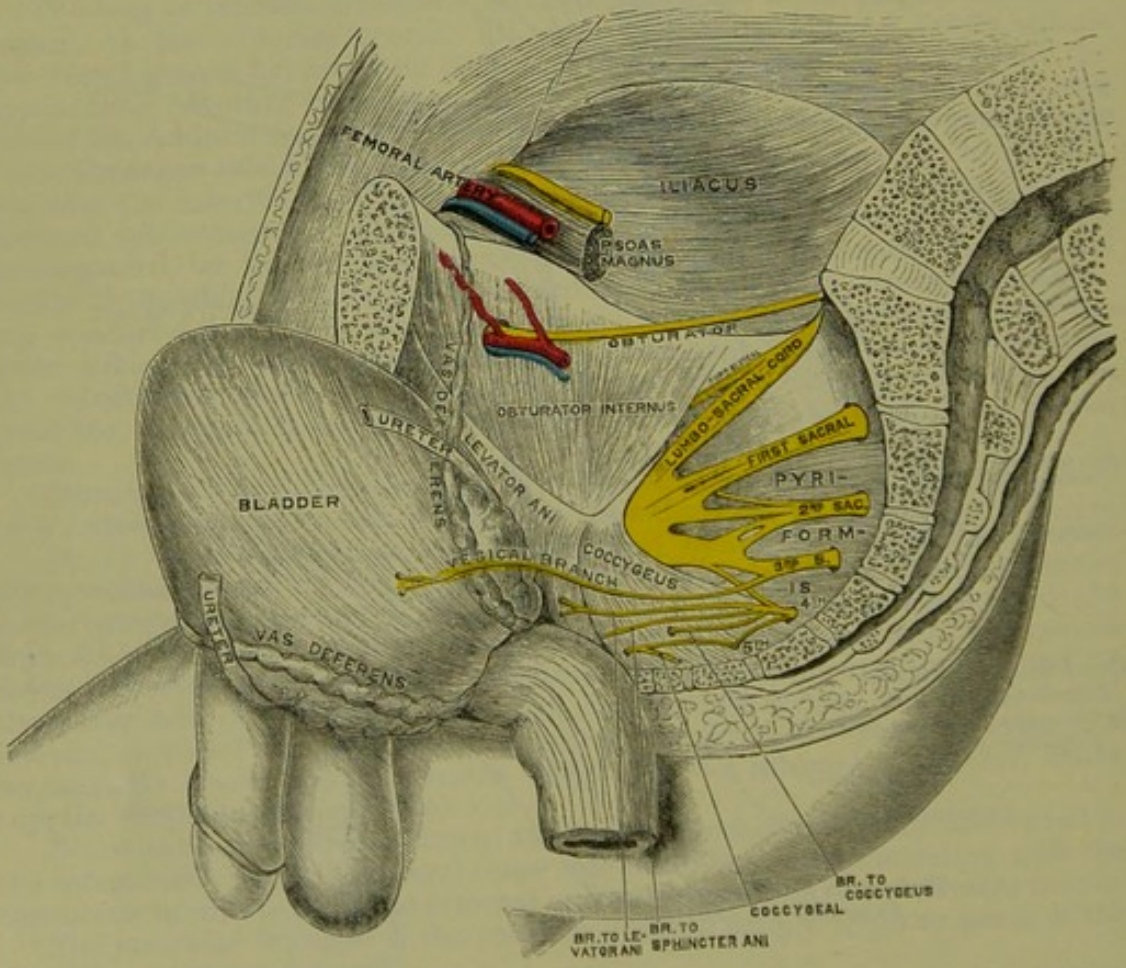

The lumbo-sacral cord comprises the whole of the anterior primary division of the fifth and a part of that of the fourth lumbar nerves ; it appears at the inner margin of the Psoas magnus and runs downwards over the pelvic brim to join the first sacral nerve. The third sacral nerve divides into an upper and

a lower branch, the former entering the sacral and the latter the pudendal plexus.

The nerves forming the sacral plexus converge towards the lower part of the great sacro-sciatic foramen, and unite to form a flattened band, from the anterior and posterior surfaces of which several branches arise. The band itself is continued as the great sciatic nerve, which splits on the back of the thigh into the internal and external popliteal nerves; these two nerves sometimes arise separately from the plexus, and in all cases their independence can be shown by dissection.

Relations.—The sacral plexus lies on the back of the pelvis between the Pyriformis and the pelvic fascia (fig. 810); in front of it are the internal iliac vessels, the ureter and the pelvic colon. The gluteal vessels run between the lumbo-sacral cord and the first sacral nerve, and the sciatic vessels between the second and third sacral nerves.

All the nerves entering the plexus, with the exception of the third sacral, split into ventral and dorsal divisions, and the nerves arising from these are as follows:

	Ventral divisions.	Dorsal divisions.
Nerve to Quadratus femoris and Inferior gemellus	4, 5 L, 1 S.	
Nerve to Obturator internus and Superior gemellus	5 L, 1, 2 S.	
Nerve to Pyriformis		(1) 2 S.
Superior gluteal		4, 5 L, 1 S.
Inferior gluteal		5 L, 1, 2 S.
Small sciatic	2, 3 S	1, 2 S.
Great sciatic: Internal popliteal	4, 5 L, 1, 2, 3 S.	
Great sciatic: External popliteal		4, 5 L, 1, 2 S.

The **nerve to the Quadratus femoris and Inferior gemellus** arises from the ventral divisions of the fourth and fifth lumbar and first sacral nerves: it leaves the pelvis through the great sacro-sciatic foramen, below the Pyriformis, and runs down in front of the great sciatic nerve, the Gemelli and the tendon of the Obturator internus, and enters the anterior surfaces of the muscles; it gives an articular branch to the hip-joint.

The **nerve to the Obturator internus** arises from the ventral divisions of the fifth lumbar and first and second sacral nerves: it leaves the pelvis through the great sacro-sciatic foramen below the Pyriformis muscle, crosses the ischial spine, re-enters the pelvis through the small sacro-sciatic foramen, and ends, after entering the pelvic surface of the muscle, in the Obturator internus. The branch to the Gemellus superior enters the upper part of the posterior surface of the muscle.

The **nerve to the Pyriformis** arises from the dorsal division of the second, or the dorsal divisions of the first and second, sacral nerves, and enters the anterior surface of the muscle: this nerve may be double.

The **superior gluteal** (n. glutæus superior) arises from the dorsal divisions of the fourth and fifth lumbar and first sacral nerves: it leaves the pelvis through the great sacro-sciatic foramen above the Pyriformis, accompanied by the gluteal vessels, and divides into a superior and an inferior branch. The *superior* branch accompanies the upper branch of the deep division of the gluteal artery and ends in the Gluteus minimus. The *inferior* branch runs with the lower branch of the gluteal artery across the Gluteus minimus; it gives filaments to the Gluteus medius and Gluteus minimus, and ends in the Tensor fasciæ femoris.

The **inferior gluteal** (n. glutæus inferior) arises from the dorsal divisions of the fifth lumbar and first and second sacral nerves: it leaves the pelvis through the great sacro-sciatic foramen, below the Pyriformis, and divides into branches which enter the deep surface of the Gluteus maximus.

The **small sciatic** (n. cutaneus femoris posterior) is distributed to the skin of the perinæum and posterior surface of the thigh and leg. It arises partly from the ventral and partly from the dorsal divisions of the first, second, and third sacral nerves, and issues from the pelvis through the great sacro-sciatic foramen below the Pyriformis. It then descends beneath the Gluteus maximus with the sciatic artery, and runs down the back of the thigh beneath

the fascia lata, and over the long head of the Biceps to the back of the knee: here it pierces the fascia and accompanies the external saphenous vein to about the middle of the back of the leg, its terminal twigs communicating with the external saphenous nerve.

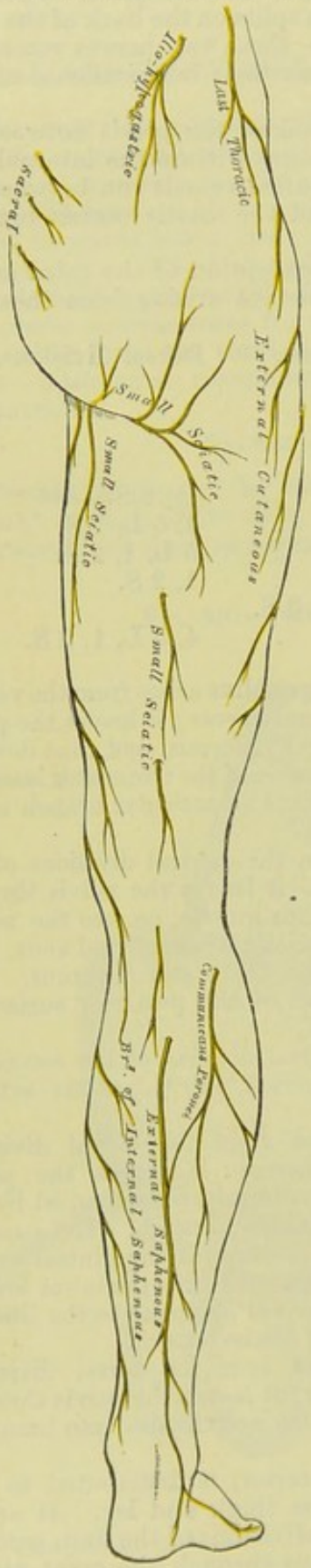

FIG. 811.—Cutaneous nerves of right lower extremity. Posterior view.

Its branches are all cutaneous, and are grouped as follows: gluteal, perineal, and femoral.

The *gluteal branches*, three or four in number, turn upwards round the lower border of the Gluteus maximus, and supply the skin covering the lower and outer part of that muscle.

The *perineal branches* (rami perineales) are distributed to the skin at the upper and inner side of the thigh. One branch, longer than the rest, the *inferior pudendal*, curves forwards below and in front of the ischial tuberosity, pierces the fascia lata, and runs forwards beneath the superficial fascia of the perinæum to the skin of the scrotum in the male, and of the labium majus in the female. It communicates with the inferior hæmorrhoidal and superficial perinæal nerves.

The *femoral branches* consist of numerous filaments derived from both sides of the nerve, and are distributed to the skin covering the back and inner side of the thigh, the popliteal space, and the upper part of the back of the leg.

The **great sciatic** (n. ischiadicus) (fig. 813) supplies nearly the whole of the integument of the leg, the muscles of the back of the thigh, and those of the leg and foot. It is the largest nerve in the body, measuring three-quarters of an inch in breadth, and is the continuation of the flattened band of the sacral plexus. It passes out of the pelvis through the great sacro-sciatic foramen, below the Pyriformis muscle. It descends between the great trochanter of the femur and the tuberosity of the ischium, along the back part of the thigh to about its lower third, where it divides into two large branches, the *internal* and *external popliteal nerves*. This division may take place at any point between the sacral plexus and the lower third of the thigh. When it occurs at the plexus, the external popliteal nerve usually pierces the Pyriformis.

As the nerve descends along the back of the thigh, it rests upon the posterior surface of the ischium, the nerve to the Quadratus femoris, and the external rotator muscles of the thigh, in company with the small sciatic nerve and artery, and is covered by the Gluteus maximus; lower down, it lies upon the Adductor magnus, and is covered by the long head of the Biceps.

The *branches* of the nerve, before its division, are articular and muscular.

The *articular branches* arise from the upper part of the nerve; they supply the hip-joint, perforating the posterior part of its fibrous capsule. These branches are sometimes derived from the sacral plexus.

The *muscular branches* are distributed to the flexors of the leg: viz. the Biceps, Semitendinosus, and Semimembranosus, and to the Adductor magnus. The nerve to the short head of the Biceps comes from the external popliteal part of the great sciatic, while the other muscular branches arise from the internal popliteal portion, as may be seen in those cases where the two popliteal nerves emerge separately on the buttock.

The **internal popliteal** (n. tibialis), the larger of the two terminal branches of the great sciatic, arises from the anterior branches of the last two lumbar and first three sacral nerves. It descends along the back part of the thigh, through the middle of the popliteal space, to the lower part of the Popliteus muscle, where it passes with the popliteal artery beneath the arch of the Soleus, and becomes the posterior tibial. It is overlapped by the hamstring muscles above, and then becomes more superficial, and lies to the outer side of, and some distance from, the popliteal vessels; opposite the knee-joint, it is in close relation with the vessels, and crosses to the inner side of the artery. Below, it is overlapped by the Gastrocnemius.

The branches of this nerve are, articular, muscular, and a cutaneous branch, the ~~*communicans tibialis*~~ nervus suralis.

The *articular branches*, usually three in number, supply the knee-joint; two of these accompany the superior and inferior internal articular arteries; and a third, the azygos articular artery.

The *muscular branches*, four or five in number, arise from the nerve as it lies between the two heads of the Gastrocnemius muscle; they supply that muscle, and the Plantaris, Soleus, and Popliteus. The branch which supplies the Popliteus turns round the lower border and is distributed to the deep surface of the muscle.

The *communicans tibialis* (n. cutaneus suræ medialis) descends between the two heads of the Gastrocnemius muscle, and, about the middle of the back of the leg, pierces the deep fascia, and joins a communicating branch (*communicans peronei*) from the external popliteal nerve to form the external, or short, saphenous nerve (fig. 811).

The *external saphenous* (n. suralis), formed by the communicating branches of the internal and external popliteal nerves, passes downwards and outwards near the outer margin of the tendo Achillis, lying close to

FIG. 812.—Segmental distribution of the cutaneous nerves of the right lower extremity. Posterior view.

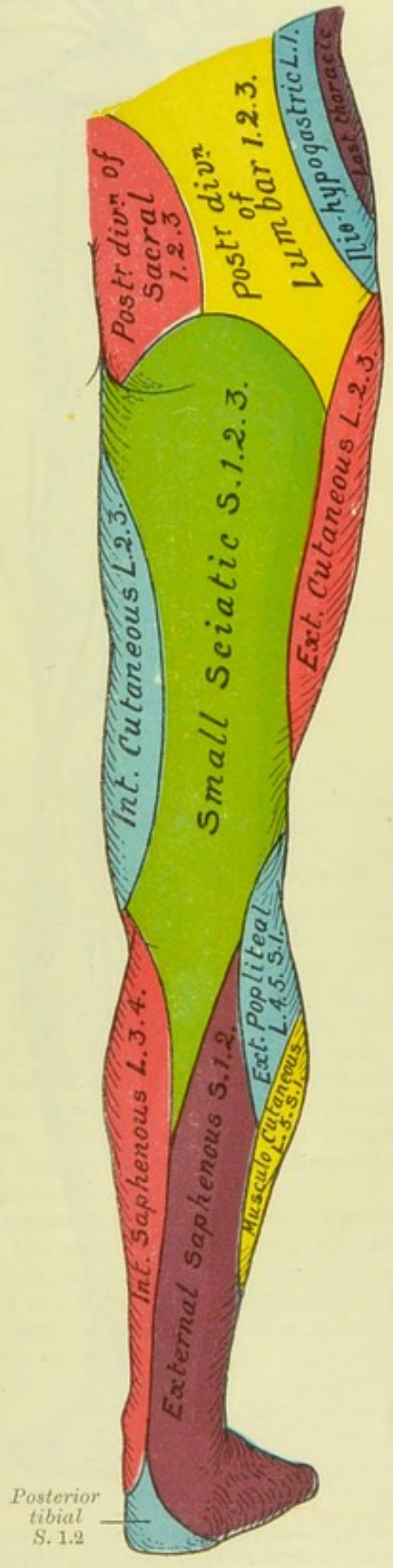

Fig. 813.—Nerves of the right lower extremity.* Posterior view.

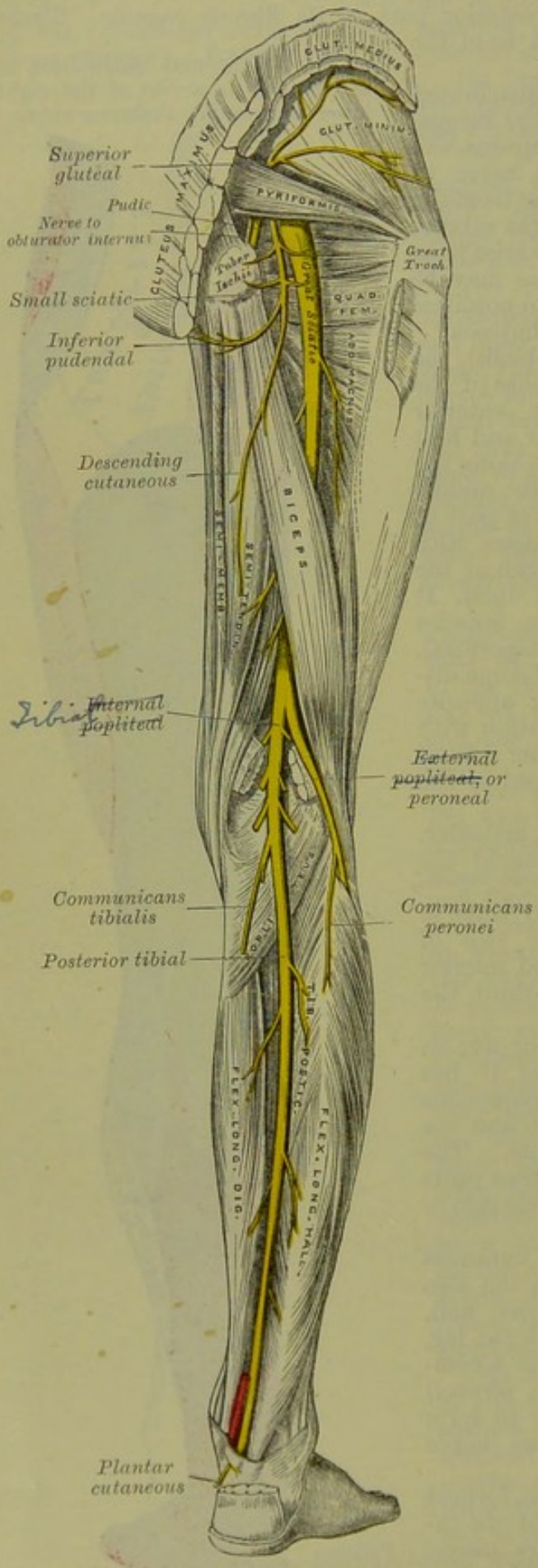

the external saphenous vein, to the interval between the external malleolus and the os calcis. It winds round the outer malleolus, and is distributed to the integument along the outer side of the foot and little toe, communicating on the dorsum of the foot with the musculo-cutaneous nerve. In the leg, its branches communicate with those of the small sciatic.

The **posterior tibial** (fig. 813), the direct continuation of the internal popliteal nerve, commences at the lower border of the Popliteus muscle, and passes along the back part of the leg with the posterior tibial vessels to the interval between the inner malleolus and the heel, where it divides beneath the internal annular ligament of the ankle into the *internal* and *external plantar nerves*. It lies upon the deep muscles of the leg, and is covered in the upper part by the muscles of the calf, lower down by the skin and the superficial and deep fasciæ. In the upper part of its course, it lies to the inner side of the posterior tibial artery; but it soon crosses that vessel, and lies to its outer side as far as the ankle. In the lower third of the leg, it is placed parallel with the inner margin of the tendo Achillis.

The *branches of the posterior tibial nerve* are muscular, internal calcanean, and articular.

The *muscular branches* arise either separately or by a common trunk from the upper part of the nerve. They supply the Soleus, Tibialis posticus, Flexor longus digitorum, and Flexor longus hallucis muscles; the branch to the last muscle accompanies the peroneal artery. The branch from the posterior tibial nerve to the Soleus enters the deep surface of the muscle, while that from the internal popliteal enters the superficial surface.

The *internal calcanean branch* (ramus calcaneus medialis) perforates the internal annular ligament, and supplies the integument of the heel and inner side of the sole of the foot.

* N.B.—In this diagram the communicans tibialis and communicans peronei are not in their normal position. They have been displaced by the removal of the superficial muscles.

The *articular branch* is given off just above the bifurcation of the nerve, and supplies the ankle-joint.

The **internal plantar** (n. plantaris medialis) (fig. 814), the larger of the two terminal branches of the posterior tibial, accompanies the internal plantar artery along the inner side of the foot. From its origin at the inner ankle it passes beneath the Abductor hallucis, and then forwards between this muscle and the Flexor brevis digitorum; it divides opposite the bases of the metatarsal bones into four digital branches, and communicates with the external plantar nerve.

Fig. 814.—The plantar nerves.

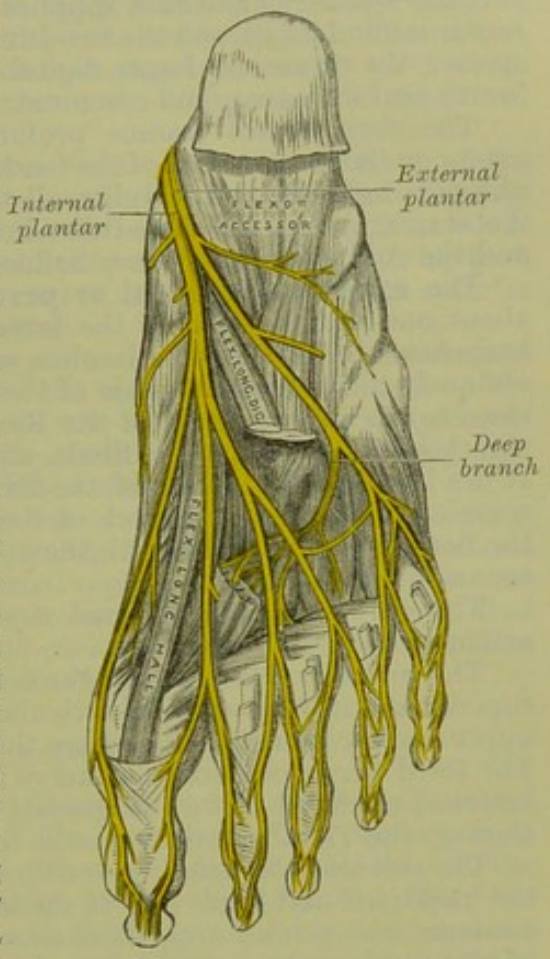

Branches.—In its course, the internal plantar nerve gives off *cutaneous branches*, which pierce the plantar fascia, and supply the integument of the sole of the foot; *muscular branches*, which supply the Abductor hallucis and Flexor brevis digitorum; *articular branches* to the articulations of the tarsus and metatarsus; and *four digital branches*. The first (innermost) branch becomes cutaneous about the middle of the sole, between the Abductor hallucis and Flexor brevis digitorum; the three outer branches pass between the divisions of the plantar fascia in the clefts between the toes. They are distributed in the following manner: the *first* supplies the inner border of the great toe, and sends a filament to the Flexor brevis hallucis muscle; the *second* bifurcates, to supply the adjacent sides of the great and second toes, sending a filament to the First lumbricalis; * the *third digital branch* supplies the adjacent sides of the second and third toes; the *fourth* supplies the corresponding sides of the third and fourth toes, and receives a communicating branch from the external plantar nerve. Each digital nerve gives off cutaneous and articular filaments; and opposite the last phalanx sends a dorsal branch, which supplies the structures around the nail, the continuation of the nerve being distributed to the ball of the toe. It will be observed that these digital branches are precisely similar in their distribution to those of the median nerve in the hand.

Fig. 815.—Cutaneous distribution of plantar nerves.

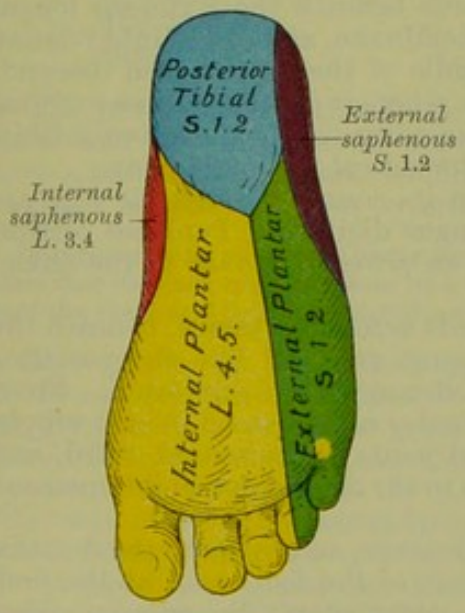

The **external plantar** (n. plantaris lateralis), the smaller of the two, completes the nervous supply to the structures of the sole of the foot, being distributed to the little toe and outer half of the fourth, as well as to most of the deep muscles, its distribution being similar to that of the ulnar in the hand. It passes obliquely forwards with the external plantar artery to the outer side of the foot, lying between the Flexor brevis digitorum and Flexor accessorius; and, in the interval between the former muscle and the Abductor

* Consult article by Brooks, *Journal of Anat. and Physiol.*, vol. xxi.

minimi digiti, divides into a superficial and a deep branch. Before its division, it supplies the Flexor accessorius and Abductor minimi digiti.

The *superficial branch* (ramus superficialis) separates into two digital nerves : one, the smaller of the two, supplies the outer side of the little toe, the Flexor brevis minimi digiti, and the two Interosseous muscles of the fourth metatarsal space ; the other and larger digital branch supplies the adjoining sides of the fourth and fifth toes, and communicates with the internal plantar nerve.

The *deep branch* (ramus profundus) accompanies the external plantar artery on the deep surface of the tendons of the Flexor muscles and the Adductor obliquus hallucis, and supplies all the Interossei (except those in the fourth metatarsal space), the three outer Lumbricales, the Adductor obliquus hallucis, and the Adductor transversus hallucis.

The **external popliteal** or **peroneal** (n. peronæus communis) (fig. 813), about one-half the size of the internal popliteal, is derived from the dorsal branches of the last two lumbar and first two sacral nerves. It descends obliquely along the outer side of the popliteal space to the head of the fibula, close to the inner margin of the Biceps muscle. It is easily felt beneath the skin behind the head of the fibula, at the inner side of the tendon of the Biceps. It lies between the tendon of the Biceps and outer head of the Gastrocnemius muscle, winds round the neck of the fibula, between the Peroneus longus and the bone, and divides beneath the muscle into the anterior tibial and musculo-cutaneous nerves.

The *branches of the external popliteal nerve*, previous to its division, are articular and cutaneous.

The *articular branches* are three in number ; two of these accompany the superior and inferior external articular arteries to the outer side of the knee. The upper one occasionally arises from the great sciatic nerve before its bifurcation. The third (*recurrent*) articular nerve is given off at the point of division of the external popliteal nerve ; it ascends with the anterior recurrent tibial artery through the Tibialis anticus muscle to the front of the knee, which it supplies.

The *cutaneous branches*, two or three in number, supply the integument along the back part and outer side of the leg ; one of these, larger than the rest, the *communicans peronei* (ramus anastomoticus peronæus), arises near the head of the fibula, crosses the external head of the Gastrocnemius to the middle of the leg, and joins with the communicans tibialis to form the external saphenous. The communicans peronei is occasionally continued down as a separate branch as far as the heel.

The **anterior tibial** (n. peronæus profundus) (fig. 808) commences at the bifurcation of the peroneal nerve, between the fibula and upper part of the Peroneus longus, passes obliquely forwards beneath the Extensor longus digitorum to the fore part of the interosseus membrane, and comes into relation with the anterior tibial artery above the middle of the leg ; it then descends with the artery to the front of the ankle-joint, where it divides into an external and an internal branch. It lies at first on the outer side of the anterior tibial artery, then in front of it, and again on its outer side at the ankle-joint.

The *branches of the anterior tibial nerve*, in its course through the leg, are *muscular* to the Tibialis anticus, Extensor longus digitorum, Peroneus tertius, and Extensor proprius hallucis muscles, and an *articular branch* to the ankle-joint.

The *external terminal branch* passes outwards across the tarsus, beneath the Extensor brevis digitorum, and, having become enlarged like the posterior interosseus nerve at the wrist, supplies the Extensor brevis digitorum. From the enlargement three minute *interosseous branches* are given off, which supply the tarsal joints and the metatarso-phalangeal joints of the second, third, and fourth toes. The first of these sends a filament to the Second dorsal interosseous muscle.

The *internal branch*, the continuation of the nerve, accompanies the dorsalis pedis artery along the inner side of the dorsum of the foot, and, at the first interosseous space, divides into two branches, which supply the adjacent sides of the great and second toes, communicating with the innermost branch of the musculo-cutaneous nerve. Before it divides it gives off to the first space an *interosseous branch* which supplies the metatarso-phalangeal joint of the great toe and sends a filament to the First dorsal interosseous muscle.

The **musculo-cutaneous** (n. peronæus superficialis) (fig. 808) supplies the muscles on the fibular side of the leg, and the integument over the greater part of the dorsum of the foot. It passes forwards between the Peronei and the Extensor longus digitorum, pierces the deep fascia at the lower third of the leg, on its front and outer side, and divides into two branches. This nerve, in its course between the muscles, gives off muscular branches to the Peronei longus and brevis, and cutaneous filaments to the integument of the lower part of the leg.

The *internal branch of the musculo-cutaneous nerve* passes in front of the ankle-joint, and divides into two branches, one of which supplies the inner side of the great toe, the other, the adjacent sides of the second and third toes. It also supplies the integument of the inner ankle and inner side of the foot, communicating with the internal saphenous nerve, and joining with the anterior tibial nerve, between the great and second toes.

The *external branch*, the smaller, passes along the outer side of the dorsum of the foot, and divides into two branches, the inner being distributed to the contiguous sides of the third and fourth toes, the outer to the opposed sides of the fourth and fifth toes. It also supplies the integument of the outer ankle and outer side of the foot, communicating with the short saphenous nerve.

The branches of the musculo-cutaneous nerve supply all the toes excepting the outer side of the little toe, and the adjoining sides of the great and second toes, the former being supplied by the external saphenous, and the latter by the internal branch of the anterior tibial. It frequently happens, however, that some of the outer branches of the musculo-cutaneous are absent, their places being then taken by branches of the external saphenous nerve.

Pudendal Plexus (Plexus Pudendus)

The **pudendal plexus** (fig. 809) is not sharply marked off from the sacral plexus, and as a consequence some of the branches which spring from it may arise in conjunction with those of the sacral plexus. It lies on the posterior wall of the pelvis, and is usually formed by branches from the anterior primary divisions of the second and third sacral nerves, the whole of the anterior primary divisions of the fourth and fifth sacral nerves and the coccygeal nerve.

It gives off the following branches :

Perforating cutaneous	2, 3 S.
Pudic	2, 3, 4 S.
Visceral	3, 4 S.
Muscular	4, S.
Ano-coccygeal	4, 5, S. and Cocc.

The **perforating cutaneous** usually arises from the posterior surface of the second and third sacral nerves. It pierces the lower part of the great sacro-sciatic ligament, and winding round the inferior border of the Gluteus maximus supplies the skin covering the inner and lower parts of that muscle.

The perforating cutaneous nerve may arise from the pudic or it may be absent : in the latter case its place may be taken by a branch from the small sciatic nerve or by a branch from the third and fourth, or fourth and fifth, sacral nerves.

The **pudic** (n. pudendus) derives its fibres from the ventral branches of the second, third, and fourth sacral nerves. It leaves the pelvis, below the Pyriformis, through the great sacro-sciatic foramen. It then crosses the spine of the ischium, and re-enters the pelvis through the small sacro-sciatic foramen. It accompanies the pudic vessels upwards and forwards along the outer wall of the ischio-rectal fossa, being contained in a sheath of the obturator fascia, termed *Alcock's canal*, and divides into two terminal branches, viz. the perineal nerve, and the dorsal nerve of the penis or clitoris. Before its division it gives off the inferior hæmorrhoidal nerve.

The *inferior hæmorrhoidal nerve* is occasionally derived separately from the sacral plexus. It passes across the ischio-rectal fossa, with its accompanying vessels, towards the lower end of the rectum, and is distributed to the Sphincter ani externus and to the integument round the anus. Branches of this nerve

communicate with the inferior pudendal and superficial perineal nerves at the fore part of the perinæum.

The *perineal nerve*, the inferior and larger of the two terminal branches of the pudic, is situated below the pudic artery. It accompanies the superficial perineal artery in the perinæum and divides into cutaneous and muscular branches.

The cutaneous branches (superficial perineal) are two in number, posterior and anterior. The *posterior* or *external branch* pierces the base of the triangular ligament of the urethra, and passes forwards along the outer side of the urethral triangle in company with the superficial perineal artery ; it is distributed to the skin of the scrotum. It communicates with the inferior hæmorrhoidal, the inferior pudendal, and the other superficial perineal nerve. The *anterior* or *internal branch* also pierces the base of the triangular ligament, and passes forwards nearer to the middle line, to be distributed to the inner and back part of the scrotum. Both these nerves supply the labium majus in the female.

The muscular branches are distributed to the Transversus perinæi, Accelerator urinæ, Erector penis, and Compressor urethræ. A distinct branch given off from the nerve to the Accelerator urinæ, pierces this muscle, and supplies the corpus spongiosum, ending in the mucous membrane of the urethra. This is the *nerve to the bulb*.

The *dorsal nerve of the penis* is the deepest division of the pudic nerve ; it accompanies the pudic artery along the ramus of the ischium ; it then runs forwards along the inner margin of the ramus of the pubis, between the superficial and deep layers of the triangular ligament. Piercing the superficial layer it gives a branch to the corpus cavernosum, and passes forwards, in company with the dorsal artery of the penis, between the layers of the suspensory ligament, on to the dorsum of the penis, along which it is carried as far as the glans on which it ends.

In the female the dorsal nerve is very small, and supplies the clitoris.

The **visceral branches** arise from the third and fourth, and sometimes from the second, sacral nerves and are distributed to the bladder and rectum and, in the female, to the vagina ; they communicate with the pelvic plexuses of the sympathetic.

The **muscular branches** are derived from the fourth sacral, and supply the Levator ani, Coccygeus, and Sphincter ani externus. The branches to the Levator ani and Coccygeus enter their pelvic surfaces ; that to the Sphincter ani externus (perineal branch) reaches the ischio-rectal fossa by piercing the Coccygeus or by passing between it and the Levator ani. Cutaneous filaments from this branch supply the skin between the anus and the coccyx.

Ano-coccygeal branches (nn. anicoccygei).—The fifth sacral nerve receives a communicating filament from the fourth, and unites with the coccygeal nerve to form what is known as the *coccygeal plexus* (plexus coccygeus). From this plexus the ano-coccygeal nerves take origin : they consist of a few fine filaments which pierce the great sacro-sciatic ligament to supply the skin in the region of the coccyx.

Applied Anatomy.—The lumbar plexus passes through the Psoas magnus, and therefore in psoas abscess any or all of its branches may be irritated, causing severe pain in the part to which the irritated nerves are distributed. The genito-~~crural~~ nerve is the one which is most frequently implicated. This nerve is also of importance as it is concerned in one of the principal superficial reflexes employed in the investigation of diseases of the spinal cord. If the skin over the inner side of the thigh just below Poupart's ligament, the part supplied by the crural branch of the genito-~~crural~~ nerve, be gently tickled in a male child, the testicle will be noticed to be drawn upwards, through the action of the Cremaster muscle, supplied by the genital branch of the same nerve. The same result may sometimes be noticed in adults, and can almost always be produced by severe stimulation. This reflex, when present, shows that the portion of the cord from which the first and second lumbar nerves are derived is in a normal condition.

The anterior crural nerve is in danger of being injured in fractures of the true pelvis, since the fracture most commonly takes place through the ascending ramus of the pubis, at or near the point where this nerve crosses the bone. It is also liable to be injured in fractures and dislocations of the femur, and is likely to be pressed upon, and its functions impaired, by some tumours growing in the pelvis. Moreover, on account of its superficial position, it is exposed to injury in wounds and stabs in the groin. It is also likely to be affected in cases of infantile paralysis. When this nerve is paralysed, the patient is

unable to flex his hip completely, on account of the paralysis of the Iliacus; or to extend the knee on the thigh, on account of paralysis of the Quadriceps extensor cruris; there is complete paralysis of the Sartorius, and partial paralysis of the Pectineus. There is loss of sensation down the front and inner side of the thigh, except in that part supplied by the crural branch of the genito-crural, and by the ilio-inguinal. There is also loss of sensation down the inner side of the leg and foot as far as the ball of the great toe.

The obturator nerve is rarely paralysed alone, but occasionally in association with the anterior crural. The principal interest attached to it is in connection with its supply to the knee; pain in the knee being symptomatic of many diseases in which the trunk of this nerve, or one of its branches, is irritated. Thus it is well known that in the earlier stages of hip-joint disease the patient does not complain of pain in that articulation, but on the inner side of the knee, or in the knee-joint itself, both these articulations being supplied by the obturator nerve, the final distribution of the nerve being to the knee-joint. Again, the same thing occurs in sacro-iliac disease: pain is complained of in the knee-joint, or on its inner side. The obturator nerve is in close relationship with the sacro-iliac articulation, passing over it, and, according to some anatomists, distributing filaments to it. Further, in cancer of the ilio-pelvic colon, and even in cases where masses of hardened fæces are impacted in this portion of the gut, pain is complained of in the knee. The left obturator nerve lies beneath the pelvic colon, and is readily pressed upon and irritated when disease exists in this part of the intestine. Finally, pain in the knee forms an important diagnostic sign in obturator hernia. The hernial protrusion as it passes out through the opening in the obturator membrane presses upon the nerve and causes pain in the parts supplied by its peripheral filaments. When the obturator nerve is paralysed, the patient is unable to press his knees together or to cross one leg over the other, on account of paralysis of the Adductor muscles. Rotation outwards of the thigh is impaired from paralysis of the Obturator externus. Sometimes there is loss of sensation in the upper half of the inner side of the thigh.

The great sciatic nerve is liable to be pressed upon by various forms of pelvic tumour, giving rise to pain along its trunk, to which the term sciatica is applied. Tumours growing from the pelvic viscera, especially advanced cancer of the rectum, aneurysms of some of the branches of the internal iliac artery, calculus in the bladder when of large size, accumulation of fæces in the rectum, may all cause pressure on the nerve inside the pelvis, and give rise to sciatica. Outside the pelvis violent movements of the hip-joint, exostoses or other tumours growing from the margin of the sacro-sciatic foramen, may also give rise to the same condition. Most cases of sciatica, however, are due to neuritis of the sciatic nerve from exposure to cold, and it occurs more often in men than in women, in the latter half of life, and often in association with rheumatism, gout, or diabetes mellitus. The inflamed nerve is often sensitive to pressure, particularly in certain 'tender spots' (e.g. near the posterior iliac spine, at the sciatic notch, about the middle of the back of the thigh, in the popliteal space, below the head of the fibula, behind the malleoli, on the dorsum of the foot), and pain is felt whenever extension of the leg is attempted, and the nerve is stretched. Paralysis of the sciatic nerve is rarely complete; when the lesion occurs high up there is palsy of the Biceps, Semimembranosus, and Semitendinosus, and of the muscles below the knee. If the lesion be lower down, there is loss of motion in all the muscles below the knee, and loss of sensation in the same situation, except the upper half of the back of the leg, which is supplied by the small sciatic, and in the upper half of the inner side of the leg, when the communicating branch of the obturator is large (see page 974). Lesions of the external popliteal nerve cause paralysis of the Tibialis anticus, the Peronei, the long Extensors of the toes, and the short Extensor on the dorsum of the foot. 'Foot-drop' follows, dorsal flexion of the toes and abduction of the foot becoming impossible. Later on talipes results, largely by the action of gravity and by the weight of the superincumbent bedclothes when the patient lies in bed.

The great sciatic nerve has been frequently cut down upon and stretched, or has been acupunctured, for the relief of sciatica. In order to define it on the surface, a point is taken at the junction of the middle and lower thirds of a line stretching from the posterior superior spine of the ilium to the outer part of the tuber ischii, and a line drawn from this to the middle of the upper part of the popliteal space. The line must be slightly curved with its convexity outwards, and as it passes downwards to the lower border of the Gluteus maximus is slightly nearer to the tuber ischii than to the great trochanter, as it crosses a line drawn between these two points. The operation of stretching the sciatic nerve is performed by making an incision over the course of the nerve about the centre of the thigh. The skin, superficial structures, and deep fascia having been divided, the interval between the inner and outer hamstrings is to be defined, and these muscles pulled inwards and outwards respectively with retractors. The nerve will be found a little to the inner side of the Biceps. It is to be separated from the surrounding structures, hooked up with the finger, and stretched by steady and continuous traction for two or three minutes. The sciatic nerve may also be stretched by what is known as the 'dry' plan. The patient is laid on his back, the foot is extended, the leg flexed on the thigh, and the thigh strongly flexed on the abdomen. While the thigh is maintained in this position, the leg is forcibly extended to its full extent, and the foot as fully flexed on the leg.

The position of the external popliteal, close behind the tendon of the Biceps on the outer side of the ham, should be remembered in subcutaneous division of the tendon. After the tendon is divided, a cord often rises up close beside it, which might be mistaken for a small undivided portion of the tendon, and the surgeon might be tempted to reintroduce his knife and cut it. This must never be done, as the cord is the external popliteal nerve, which becomes prominent as soon as the tendon is divided. Where this nerve winds round the neck of the fibula, it is also liable to be severed accidentally if its exact situation is not kept in mind, and especial care must be used when dealing with sinuses leading down to carious bone in this situation. Section of the nerve results in complete 'foot-drop' from paralysis of the anterior tibial group of muscles and inversion of the foot from the unopposed action of the Tibialis posticus, the Peronei being paralysed, together with anæsthesia of the parts supplied by the nerve, and, owing to loss of nutrition, the limb frequently becomes blue and cold, and may develop 'trophic' sores.

THE SYMPATHETIC NERVES

The **sympathetic nerves** (fig. 816) are distributed to the viscera and blood-vessels * and are intimately connected with the spinal and certain of the cranial nerves. They are characterised by the presence of numerous ganglia which may be divided into three groups, central, collateral, and terminal.

The *central* ganglia are arranged in two vertical rows, one on either side of the middle line, situated partly in front and partly at the sides of the vertebral column. Each ganglion is joined by intervening nervous trunks to adjacent ganglia so that two chains or cords are formed, the *gangliated cords of the sympathetic*. The *collateral* ganglia are found in connection with three great *prevertebral plexuses*, placed within the thorax, abdomen, and pelvis respectively, while the *terminal* ganglia are located in the walls of the viscera.†

The **gangliated cords** (trunci sympathici) extend from the base of the skull to the coccyx. The cranial end of each is continued upwards through the carotid canal into the skull, and forms a plexus on the internal carotid artery; the lower ends of the two cords converge and end in a single ganglion, the *ganglion impar*, placed in front of the coccyx. The ganglia of each cord are distinguished as cervical, thoracic, lumbar, and sacral, and, except in the neck, they closely correspond in number to the vertebræ. They are arranged thus:

Cervical portion	3 ganglia
Thoracic ,,	12 ,,
Lumbar ,,	4 ,,
Sacral ,,	4 or 5 ,,

In the neck the ganglia lie in front of the transverse processes of the vertebræ; in the thoracic region in front of the heads of the ribs; in the lumbar region on the sides of the vertebral bodies; and in the sacral region in front of the sacrum.

Connections with the spinal nerves.—Communications are established between the sympathetic and spinal nerves through what are known as the *grey* and *white rami communicantes* (fig. 790); the grey rami conveying sympathetic fibres into the spinal nerves and the white rami transmitting spinal fibres into the sympathetic. Each spinal nerve receives a grey ramus communicans from the gangliated cord of the sympathetic, but white rami are not supplied by all the spinal nerves. The white rami are derived from the first thoracic to the first lumbar nerves inclusive, while the visceral branches which run from the second, third, and fourth sacral nerves directly to the pelvic plexuses of the sympathetic belong to this category. The fibres which reach the sympathetic through the white rami communicantes are *medullated*; those which spring from the cells of the sympathetic ganglia are almost entirely non-medullated. The sympathetic nerves consist of efferent and afferent fibres, the origin and course of which are described on pages 944, 945.

* See footnote, p. 944.

† The ciliary, spheno-palatine, otic, and submaxillary ganglia, already described in connection with the fifth cranial nerve, may be regarded as belonging to the sympathetic.

The **three great gangliated plexuses** are situated in front of the spine in the thoracic, abdominal, and pelvic regions, and are named, respectively, the

FIG. 816.—The right sympathetic chain and its connections with the thoracic, abdominal, and pelvic plexuses. (After Schwalbe.)

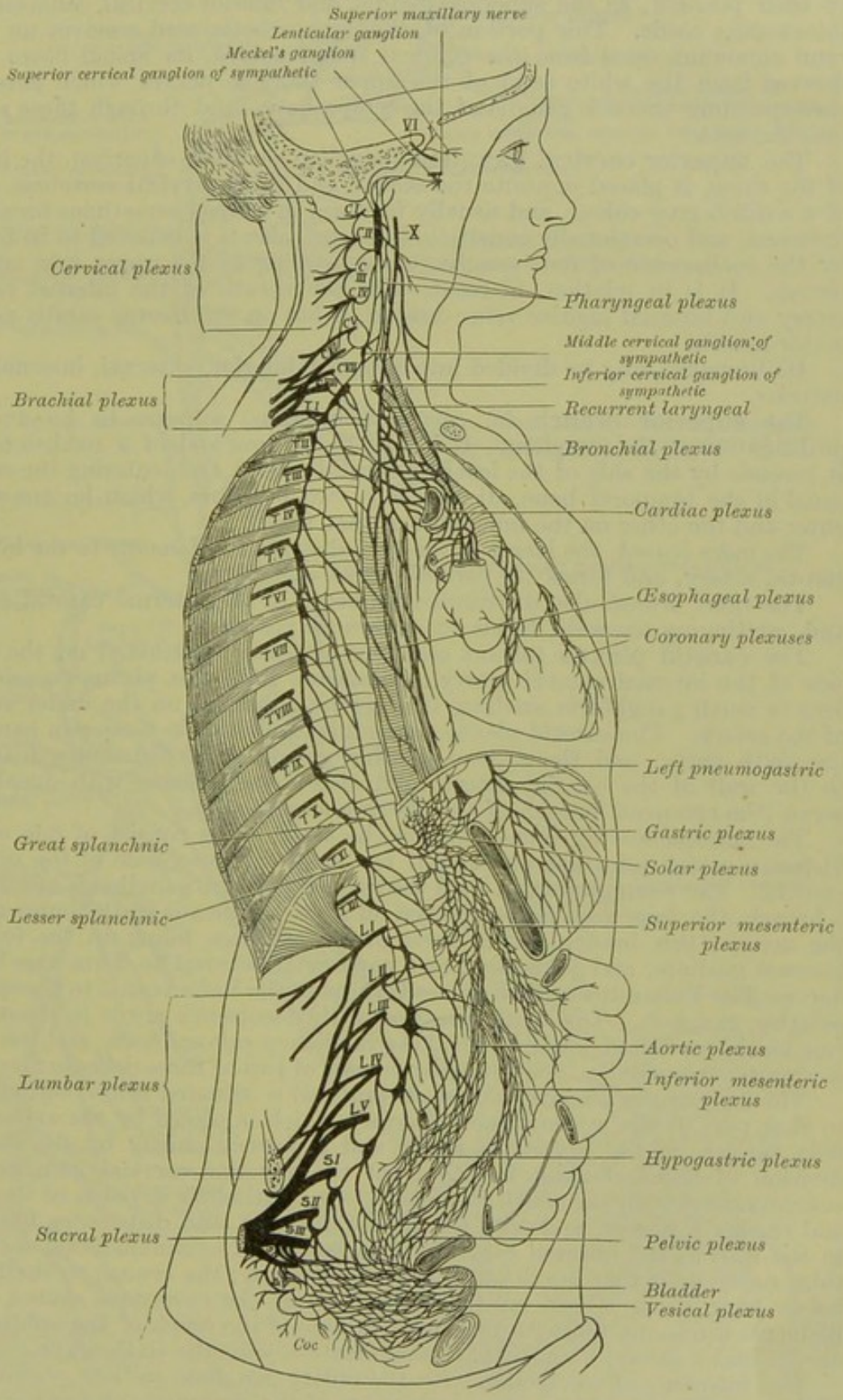

cardiac, the *solar* or *epigastric*, and the *hypogastric plexuses*. They consist of collections of nerves and ganglia ; the nerves being derived from the gangliated cords and from the cerebro-spinal nerves. They distribute branches to the viscera.

Cervico-cephalic Portion of the Gangliated Cord (fig. 817)

The cervico-cephalic portion of each gangliated cord (pars cephalica et cervicalis s. sympathici) consists of three ganglia, distinguished, according to their position, as the superior, middle, and inferior cervical, connected by intervening cords. This portion of the sympathetic cord receives no white rami communicantes from the cervical spinal nerves, its spinal fibres being derived from the white rami of the upper thoracic nerves, which enter the corresponding thoracic ganglia of the sympathetic, and through these ascend into the neck.

The **superior cervical ganglion** (ganglion cervicale superius), the largest of the three, is placed opposite the second and third cervical vertebræ. It is of a reddish-grey colour, and usually fusiform in shape ; sometimes broad and flattened, and occasionally constricted at intervals ; it is believed to be formed by the coalescence of four ganglia, corresponding to the upper four cervical nerves. It is in relation, in front, with the sheath of the internal carotid artery and internal jugular vein ; behind, it lies on the Rectus capitis anticus major muscle.

Its branches may be divided into superior, inferior, external, internal, and anterior.

The **superior branch** (n. caroticus internus) appears to be a direct prolongation of the ganglion. It is soft in texture, and of a reddish colour. It ascends by the side of the internal carotid artery, and, entering the carotid canal in the temporal bone, divides into two branches, which lie one on the outer and the other on the inner side of that vessel.

The *outer branch*, the larger of the two, distributes filaments to the internal carotid artery, and forms the *carotid plexus*.

The *inner branch* also distributes filaments to the internal carotid artery, and, continuing onwards, forms the *cavernous plexus*.

The **carotid plexus** (plexus caroticus internus) is situated on the outer side of the internal carotid artery. Filaments from this plexus occasionally form a small gangliform swelling (the *carotid ganglion*) on the under surface of the artery. The carotid plexus communicates with the Gasserian ganglion, the sixth nerve, and the spheno-palatine ganglion ; it distributes filaments to the wall of the carotid artery, and also communicates with Jacobson's nerve (the tympanic branch of the glosso-pharyngeal).

The communicating branches with the sixth nerve consist of one or two filaments which join that nerve as it lies upon the outer side of the internal carotid. The communication with the spheno-palatine ganglion is effected by a branch, the *large deep petrosal*, given off from the plexus on the outer side of the artery ; this branch passes through the cartilage filling up the foramen lacerum medium, and joins the great superficial petrosal to form the Vidian nerve. The Vidian nerve then proceeds through the Vidian canal to the spheno-palatine ganglion. The communication with Jacobson's nerve is effected by two branches, one of which is called the *small deep petrosal nerve*, and the other the *carotico-tympanic* ; the latter may consist of two or three delicate filaments.

The **cavernous plexus** (plexus cavernosus) is situated below and internal to that part of the internal carotid artery which is placed by the side of the sella turcica, in the cavernous sinus, and is formed chiefly by the internal division of the ascending branch from the superior cervical ganglion. It communicates with the third, the fourth, the ophthalmic division of the fifth, and the sixth nerves, and with the ciliary ganglion, and distributes filaments to the wall of the internal carotid. The branch of communication with the third nerve joins that nerve at its point of division ; the branch to the fourth nerve joins it as it lies on the outer wall of the cavernous sinus ; other filaments are connected with the under surface of the trunk of the ophthalmic nerve ; and a second filament of communication joins the sixth nerve.

The filaments of connection with the ciliary ganglion (radices sympathicæ ganglii ciliaris) arise from the anterior part of the cavernous plexus and enter the orbit through the sphenoidal fissure ; they may join the nasal branch of the ophthalmic nerve, or be continued forwards as a separate branch.

The terminal filaments from the carotid and cavernous plexuses are prolonged along the internal carotid, forming plexuses which entwine round

FIG. 817.—Plan of the cervico-cephalic portion of the sympathetic. (After Flower.)

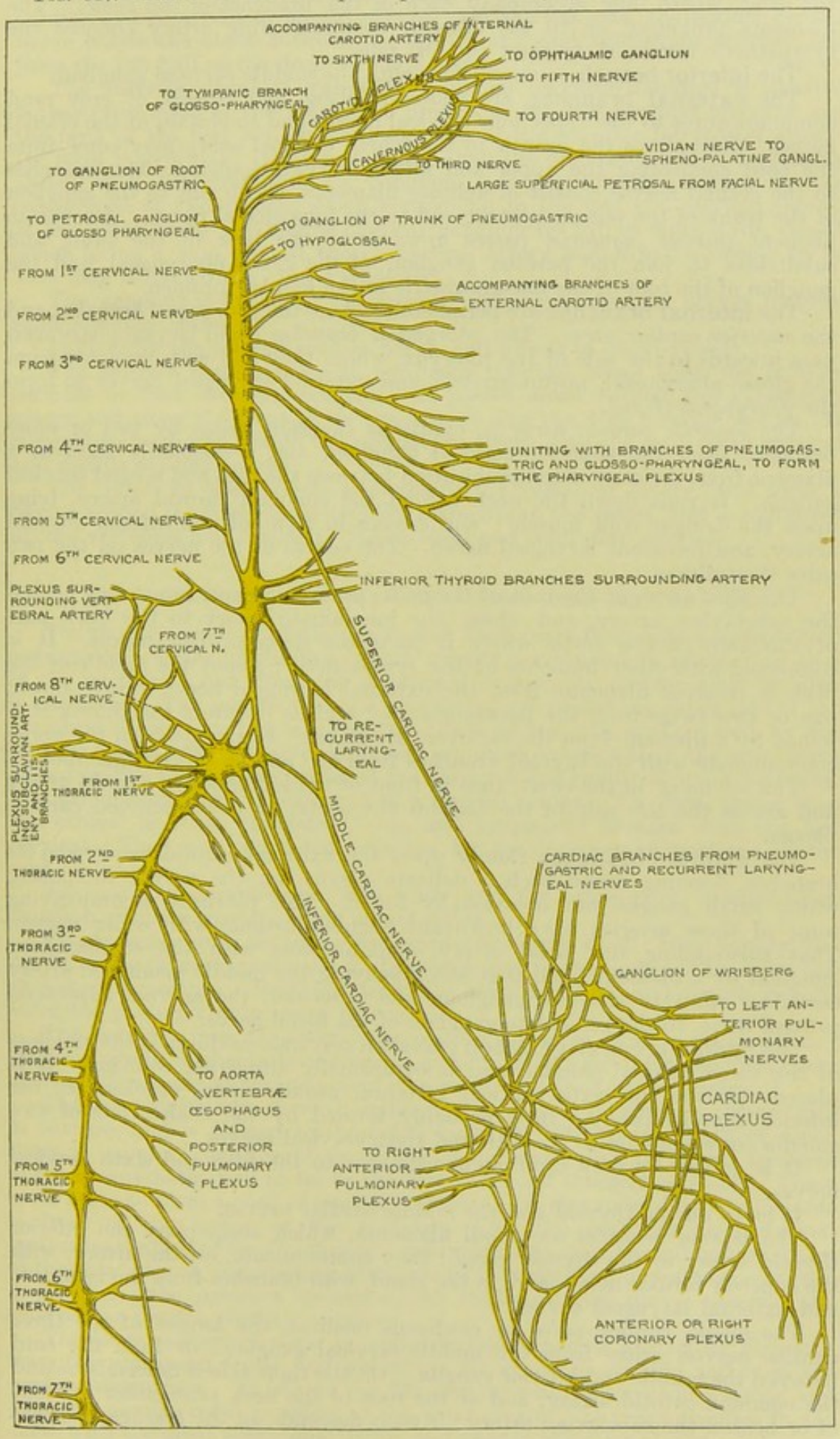

the anterior and middle cerebral arteries and the ophthalmic artery : along the former vessels, they may be traced to the pia mater ; along the latter, into the orbit, where they accompany each of the branches of the vessel. The filaments prolonged on to the anterior communicating artery connect the sympathetic nerves of the right and left sides.

The **inferior branch** communicates with the middle cervical ganglion.

The **external branches** are communicating, and consist of grey rami communicantes to the upper four cervical nerves and to certain of the cranial nerves. Sometimes the branch to the fourth cervical nerve may come from the cord connecting the upper and middle cervical ganglia. The branches to the cranial nerves consist of delicate filaments, which run to the ganglion of the trunk of the pneumogastric, and to the hypoglossal nerve. A separate filament (*nervus jugularis*) passes upwards to the base of the skull, and subdivides to join the petrous ganglion of the glosso-pharyngeal, and the ganglion of the root of the pneumogastric in the jugular foramen.

The **internal branches** are peripheral, and are the *pharyngeal branches*, and the *superior cardiac nerve*. The *pharyngeal branches* (rami laryngopharyngei) pass inwards to the side of the pharynx, where they join with branches from the glosso-pharyngeal, pneumogastric, and external laryngeal nerves to form the *pharyngeal plexus*.

The *superior cardiac nerve* (n. cardiacus superior) arises by two or more branches from the superior cervical ganglion, and occasionally receives a filament from the cord of communication between the first and second cervical ganglia. It runs down the neck behind the common carotid artery, lying upon the Longus colli muscle ; and crosses in front of the inferior thyroid artery, and recurrent laryngeal nerve. The course of the nerves on the two sides then differs.

The *right nerve*, at the root of the neck, passes either in front of or behind the subclavian artery, and along the innominate artery to the back part of the arch of the aorta, where it joins the deep cardiac plexus. It is connected with other branches of the sympathetic ; about the middle of the neck it receives filaments from the external laryngeal nerve ; lower down, one or two twigs from the pneumogastric ; and as it enters the thorax it is joined by a filament from the recurrent laryngeal. Filaments from the nerve communicate with the thyroid branches from the middle cervical ganglion.

The *left nerve*, in the chest, runs in front of the left common carotid artery and across the left side of the arch of the aorta, to the superficial cardiac plexus.

The **anterior branches** ramify upon the external carotid artery and its branches, forming round each a delicate plexus, on the nerves composing which small ganglia are occasionally found. The plexuses accompanying some of these arteries have important communications with other nerves. That surrounding the facial artery communicates with the submaxillary ganglion by a filament ; and that accompanying the middle meningeal artery sends an offset to the otic ganglion, and a second, the *external superficial petrosal nerve*, to the geniculate ganglion of the facial nerve.

The **middle cervical ganglion** (ganglion cervicale medium) is the smallest of the three cervical ganglia, and is occasionally altogether wanting. It is placed opposite the sixth cervical vertebra, usually upon, or close to, the inferior thyroid artery. It is probably formed by the coalescence of two ganglia corresponding to the fifth and sixth cervical nerves.

It is joined by grey rami communicantes to the fifth and sixth cervical nerves.

It gives off the thyroid and the middle cardiac nerves.

The *thyroid branches* are small filaments, which accompany the inferior thyroid artery to the thyroid gland ; they communicate, on the artery, with the superior cardiac nerve, and, in the gland, with branches from the recurrent and external laryngeal nerves.

The *middle cardiac nerve* (n. cardiacus medius), the largest of the three cardiac nerves, arises from the middle cervical ganglion, or from the cord between the middle and inferior ganglia. On the right side it descends behind the common carotid artery, and at the root of the neck runs either in front of or behind the subclavian artery ; it then descends on the trachea, receives

a few filaments from the recurrent laryngeal nerve, and joins the right half of the deep cardiac plexus. In the neck, it communicates with the superior cardiac and recurrent laryngeal nerves. On the left side, the middle cardiac nerve enters the chest between the left carotid and subclavian arteries, and joins the left half of the deep cardiac plexus.

The **inferior cervical ganglion** (ganglion cervicale inferius) is situated between the base of the transverse process of the last cervical vertebra and the neck of the first rib, on the inner side of the superior intercostal artery. Its form is irregular ; it is larger in size than the preceding, and is frequently joined with the first thoracic ganglion. It is probably formed by the coalescence of two ganglia which correspond to the last two cervical nerves. It is connected to the middle cervical ganglion by two or more cords, one of which forms a loop around the subclavian artery and supplies offsets to it. This loop is named the *ansa Vieussenii*.

The ganglion is joined to the seventh and eighth cervical nerves by grey rami communicantes.

It gives off the inferior cardiac nerve, and offsets to blood-vessels.

The *inferior cardiac nerve* (n. cardiacus inferior) arises from the inferior cervical or first thoracic ganglion. It passes down behind the subclavian artery and along the front of the trachea, to join the deep cardiac plexus. It communicates freely behind the subclavian artery with the recurrent laryngeal and middle cardiac nerves.

The *offsets to blood-vessels* accompany the vertebral artery, and form a plexus around it ; this plexus supplies filaments to the vessel, and is continued up the vertebral and basilar to the cerebral and cerebellar arteries.

Thoracic Portion of the Gangliated Cord (figs. 816, 818)

The thoracic portion of the gangliated cord (pars thoracalis s. sympathici) consists of a series of ganglia, which usually correspond in number to that of the vertebræ ; but, from the occasional coalescence of two, their number is uncertain. The ganglia (ganglia thoracalia) are placed on either side of the vertebral column, resting against the heads of the ribs, and covered by the pleura costalis ; the last two, however, are more anterior than the rest, being placed on the sides of the bodies of the eleventh and twelfth thoracic vertebræ. The ganglia are small in size, and of a greyish colour. The first, larger than the others, is of an elongated form, and frequently blended with the last cervical. They are connected together by the intervening portions of the cord.

Two rami communicantes, one white and the other grey, connect each ganglion with its corresponding spinal nerve.

The *branches from the upper five ganglia* are very small ; they supply filaments to the thoracic aorta and its branches, and to the bodies of the vertebræ and their ligaments. Branches from the second, third, and fourth ganglia enter the posterior pulmonary plexus.

The *branches from the lower seven ganglia* are large, and white in colour ; they distribute filaments to the aorta, and unite to form the three splanchnic nerves. These are named the *great*, the *lesser*, and the *least splanchnic*.

The *great splanchnic nerve* (n. splanchnicus major) is white in colour, firm in texture, and is formed by branches from the fifth to the ninth or tenth thoracic ganglia ; but the fibres in the higher roots may be traced upwards in the sympathetic cord as far as the first or second thoracic ganglion. These roots unite to form a cord of considerable size. It descends obliquely inwards in front of the bodies of the vertebræ along the posterior mediastinum, perforates the crus of the Diaphragm, and terminates in the semilunar ganglion of the solar plexus, distributing filaments to the renal and suprarenal plexuses. A ganglion (the *ganglion splanchnicum*) exists on this nerve opposite the eleventh or twelfth thoracic vertebra.

The *lesser splanchnic nerve* (n. splanchnicus minor) is formed by filaments from the ninth and tenth, and sometimes the eleventh ganglia, and from the cord between them. It pierces the Diaphragm with the preceding nerve, and joins the aortico-renal ganglion of the solar plexus. It communicates in the chest with the great splanchnic nerve, and ends in the solar plexus.

The *least splanchnic nerve* (n. splanchnicus imus) arises from the last thoracic ganglion, and, piercing the Diaphragm, terminates in the renal plexus. It occasionally communicates with the preceding nerve.

A striking analogy exists between the splanchnic and the cardiac nerves. The cardiac nerves are three in number; they arise from all three cervical

Fig. 818.—Thoracic portion of the gangliated cord. Right side.

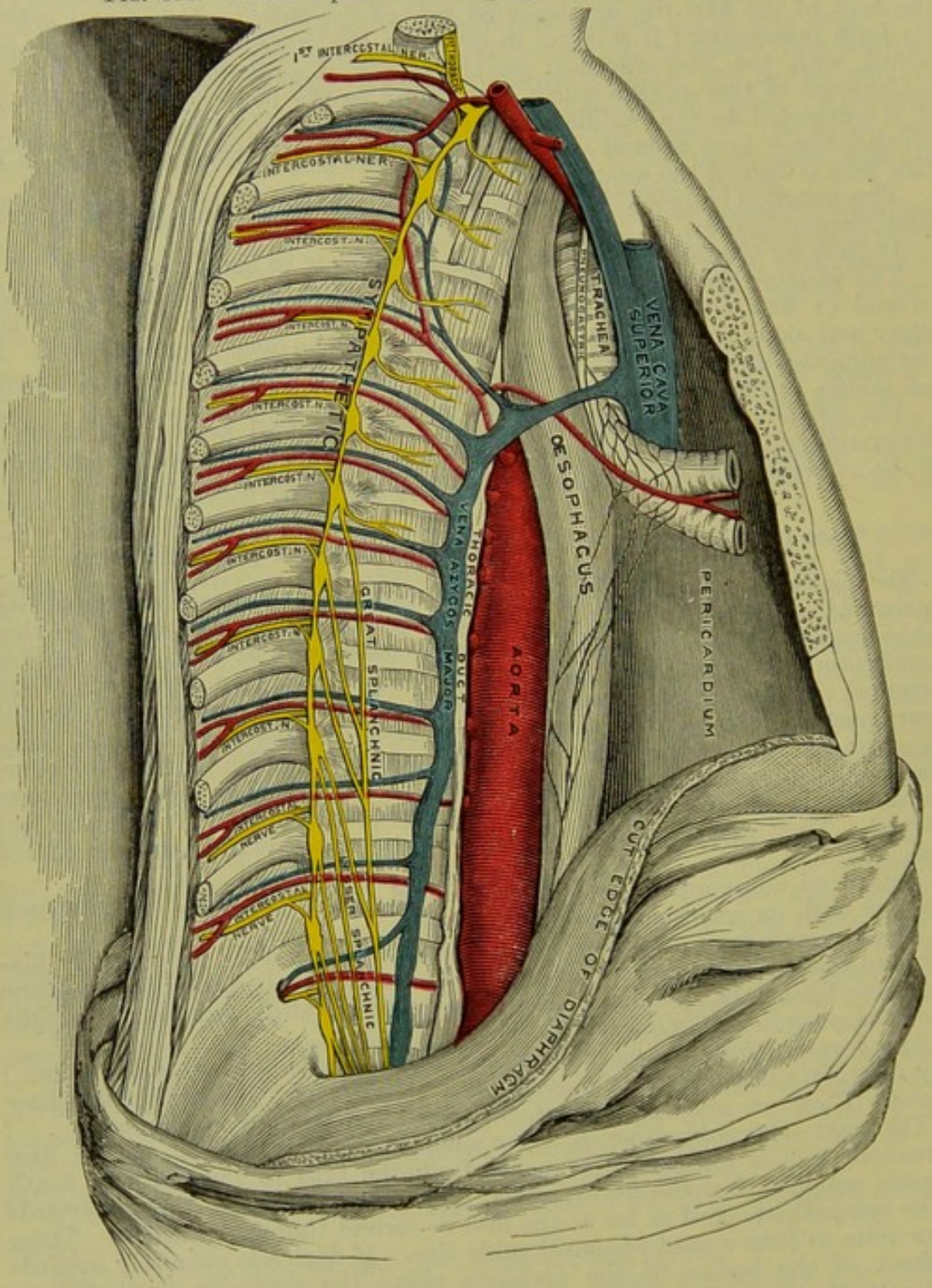

ganglia, and are distributed to a large and important organ in the thoracic cavity. The splanchnic nerves, also three in number, are connected probably with all the thoracic ganglia, and are distributed to important organs in the abdominal cavity.

Lumbar Portion of the Gangliated Cord (fig. 819)

The lumbar portion of the gangliated cord (pars abdominalis s. sympathici) is situated in front of the vertebral column, along the inner margin of the Psoas

magnus. It consists usually of four ganglia (ganglia lumbalia), connected together by interganglionic cords. It is continuous above with the thoracic portion beneath the internal arcuate ligament of the Diaphragm, and below

FIG. 819.—Lumbar portion of the gangliated cord, with the solar and hypogastric plexuses. (After Henle.)

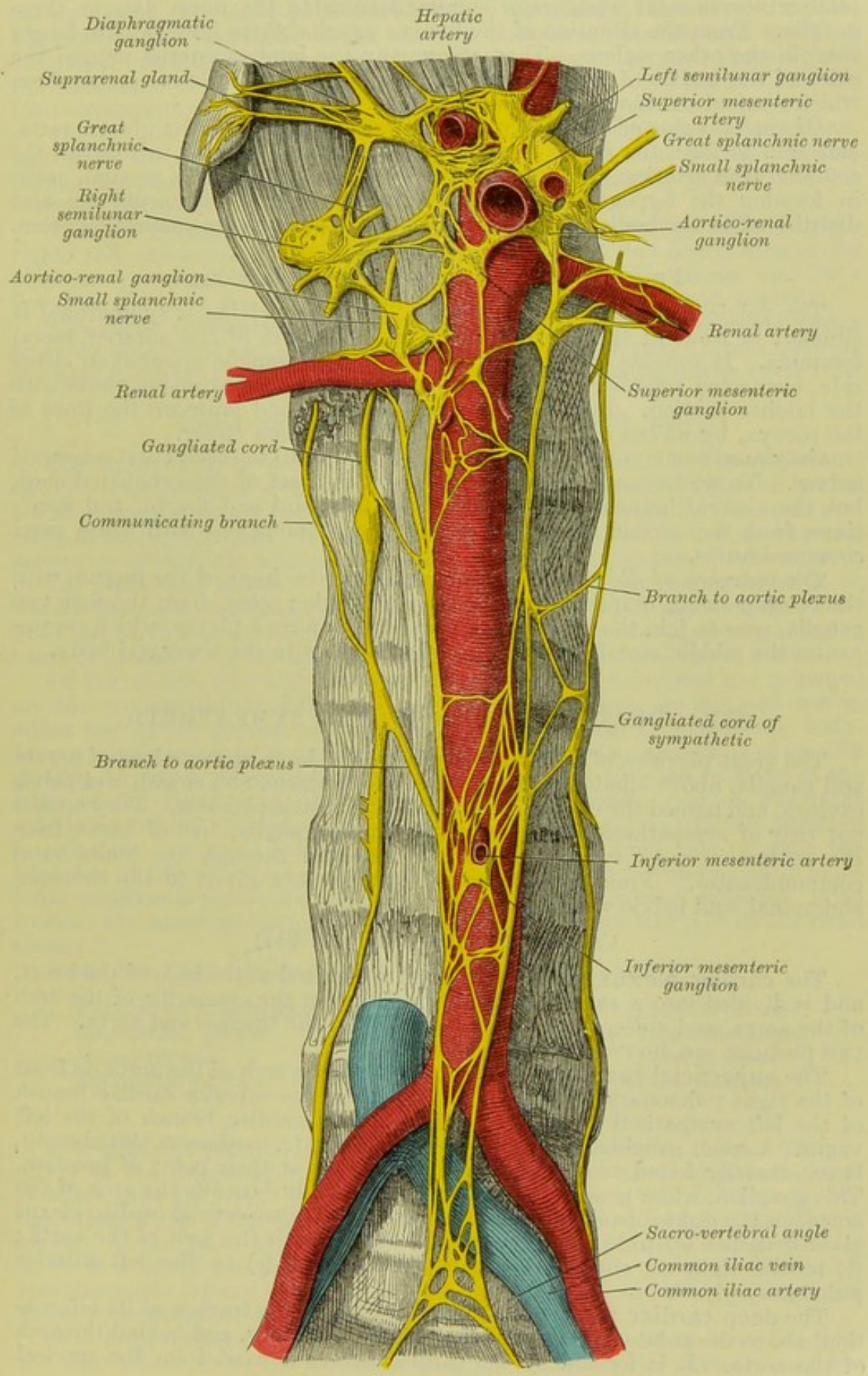

with the sacral portion behind the common iliac artery. The ganglia are of small size, and placed much nearer the median line than are the thoracic ganglia.

Grey rami communicantes connect all the ganglia with the lumbar spinal nerves. There may be two from each ganglion, but the arrangement is not so uniform as in other regions. The first and second, and sometimes the third, lumbar nerves send white rami communicantes to the upper two or three ganglia. From the situation of the lumbar ganglia, these branches are longer than in the other regions. They accompany the lumbar arteries around the sides of the bodies of the vertebræ, passing beneath the fibrous arches from which some of the fibres of the Psoas arise.

Of the *branches of distribution*, some pass inwards, in front of the aorta, and help to form the aortic plexus. Other branches descend in front of the common iliac arteries, and, joining over the promontory of the sacrum, assist in forming the hypogastric plexus. Numerous delicate filaments are also distributed to the bodies of the vertebræ, and the ligaments connecting them.

Pelvic Portion of the Gangliated Cord

The pelvic portion of the gangliated cord (pars pelvina s. sympathici) is situated in front of the sacrum, along the inner side of the anterior sacral foramina. It consists of four or five small ganglia (ganglia sacralia) on either side, connected together by interganglionic cords, and continuous above with the lumbar portion. Below, these cords converge and unite on the front of the coccyx, by means of a small ganglion, the *ganglion impar*.

Grey rami communicantes pass from the ganglia to the sacral and coccygeal nerves. No white rami communicantes join this part of the gangliated cord, but the visceral branches which arise from the third and fourth, and sometimes from the second, sacral are regarded as homologous with white rami communicantes.

The *branches of distribution* communicate on the front of the sacrum with the corresponding branches from the opposite side; some, from the first two ganglia, pass to join the pelvic plexus, and others form a plexus, which accompanies the middle sacral artery and sends filaments to the coccygeal body.

THE GREAT PLEXUSES OF THE SYMPATHETIC

The great plexuses of the sympathetic are the large aggregations of nerves and ganglia, above alluded to, situated in the thoracic, abdominal, and pelvic cavities, and named the cardiac, solar, and hypogastric plexuses. They consist not only of sympathetic fibres derived from the ganglia, but of fibres from the central nervous system, which are conveyed through the white rami communicantes. From the plexuses branches are given to the thoracic, abdominal, and pelvic viscera.

Cardiac Plexus (figs. 816, 817)

The **cardiac plexus** (plexus cardiacus) is situated at the base of the heart, and is divided into a *superficial part*, which lies in the concavity of the arch of the aorta, and a *deep part*, which lies between the trachea and aorta. The two plexuses are, however, closely connected.

The **superficial cardiac plexus** lies beneath the arch of the aorta, in front of the right pulmonary artery. It is formed by the superior cardiac branch of the left sympathetic and the inferior cervical cardiac branch of the left vagus. A small ganglion, the *ganglion of Wrisberg* (g. cardiacum [Wrisbergi]), is occasionally found connected with these nerves at their point of junction. This ganglion, when present, is situated immediately beneath the arch of the aorta, on the right side of the ductus arteriosus. The superficial cardiac plexus gives branches (*a*) to the deep cardiac plexus beneath the arch of the aorta; (*b*) to the right or anterior coronary plexus; and (*c*) to the left anterior pulmonary plexus.

The **deep cardiac plexus** is situated in front of the trachea at its bifurcation, above the point of division of the pulmonary artery, and behind the arch of the aorta. It is formed by the cardiac nerves derived from the cervical

ganglia of the sympathetic, and the cardiac branches of the recurrent laryngeal and vagus. The only cardiac nerves which do not enter into the formation of this plexus are the superior cardiac branch of the left sympathetic, and the inferior cervical cardiac branch from the left vagus, which pass to the superficial plexus.

The branches from the *right side* of this plexus pass, some in front of, and others behind, the right pulmonary artery ; the former, the more numerous, transmit a few filaments to the anterior pulmonary plexus, and are then continued onwards to form part of the right coronary plexus ; those behind the pulmonary artery distribute a few filaments to the right auricle, and are then continued onwards to form part of the left coronary plexus.

The *left side* of the plexus is connected with the superficial cardiac plexus, and gives filaments to the left auricle of the heart, and to the anterior pulmonary plexus, and is then continued to form the greater part of the left coronary plexus.

The **left coronary plexus** (plexus coronarius posterior) is larger than the right, and accompanies the left coronary artery ; it is chiefly formed by filaments prolonged from the left side of the deep cardiac plexus, and by a few from the right side. It gives branches to the left auricle and ventricle.

The **right coronary plexus** (plexus coronarius anterior) is formed partly from the superficial and partly from the deep cardiac plexus. It accompanies the right coronary artery, and gives branches to the right auricle and ventricle.

Epigastric or Solar Plexus (figs. 819, 820)

The **epigastric** or **solar plexus** supplies the viscera in the abdominal cavity. It consists of a great network of nerves and ganglia situated behind the stomach and lesser sac of the peritoneum, and in front of the aorta and crura of the Diaphragm. It surrounds the cœliac axis and root of the superior mesenteric artery, extending downwards as low as the pancreas, and outwards to the suprarenal glands. This plexus, and the ganglia connected with it, receive the great and small splanchnic nerves of both sides, and some filaments from the right vagus. It distributes filaments, which accompany, under the name of plexuses, all the branches from the front of the abdominal aorta.

Of the ganglia of which the solar plexus is partly composed the principal are the two **semilunar ganglia** (ganglia cœliaca), which are situated one on either side of the plexus, and are the largest peripheral ganglia in the body. They are large irregular gangliform masses, formed by the aggregation of smaller ganglia, having interspaces between them. They are situated in front of the crura of the Diaphragm, close to the suprarenal glands, that on the right side lying behind the inferior vena cava. The upper part of each ganglion is joined by the great splanchnic nerve, and to the inner side of each the branches of the solar plexus are connected. The lower portion of each semilunar ganglion is segmented off, and is named the *aortico-renal ganglion*. This receives the lesser splanchnic nerve, and gives off the greater part of the renal plexus.

From the epigastric or solar plexus are derived the following :

Phrenic or Diaphragmatic plexus.
Suprarenal plexus.
Renal plexus.
Spermatic plexus.
Cœliac plexus { Gastric plexus. / Hepatic plexus. / Splenic plexus.
Superior mesenteric plexus.
Aortic plexus.

The **phrenic plexus** (plexus phrenicus) accompanies the inferior phrenic artery to the Diaphragm, some filaments passing to the suprarenal gland. It arises from the upper part of the semilunar ganglion, and is larger on the right than on the left side. It receives one or two branches from the phrenic nerve. At the point of junction of the right phrenic plexus with the phrenic nerve is a small ganglion (*ganglion phrenicum*). This ganglion distributes branches to the inferior vena cava, the suprarenal gland, and the hepatic plexus. There is no ganglion on the left side.

The **suprarenal plexus** (plexus suprarenalis) is formed by branches from the solar plexus, from the semilunar ganglion, and from the phrenic and great

splanchnic nerves, a ganglion being formed at the point of junction with the latter nerve. The plexus supplies the suprarenal gland, being distributed chiefly to its medullary portion ; its branches are remarkable for their large size in comparison with that of the organ they supply.

The **renal plexus** (plexus renalis) is formed by filaments from the solar plexus, the lower part of the semilunar ganglion (aortico-renal ganglion), and the aortic plexus. It is joined also by the smallest splanchnic nerve. The nerves from these sources, fifteen or twenty in number, have numerous ganglia developed upon them. They accompany the branches of the renal

Fig. 820.—The semilunar ganglia with the sympathetic plexuses of the abdominal viscera radiating from the ganglia. (From Toldt's 'Atlas,' published by Messrs. Rebman, Ltd., London.)

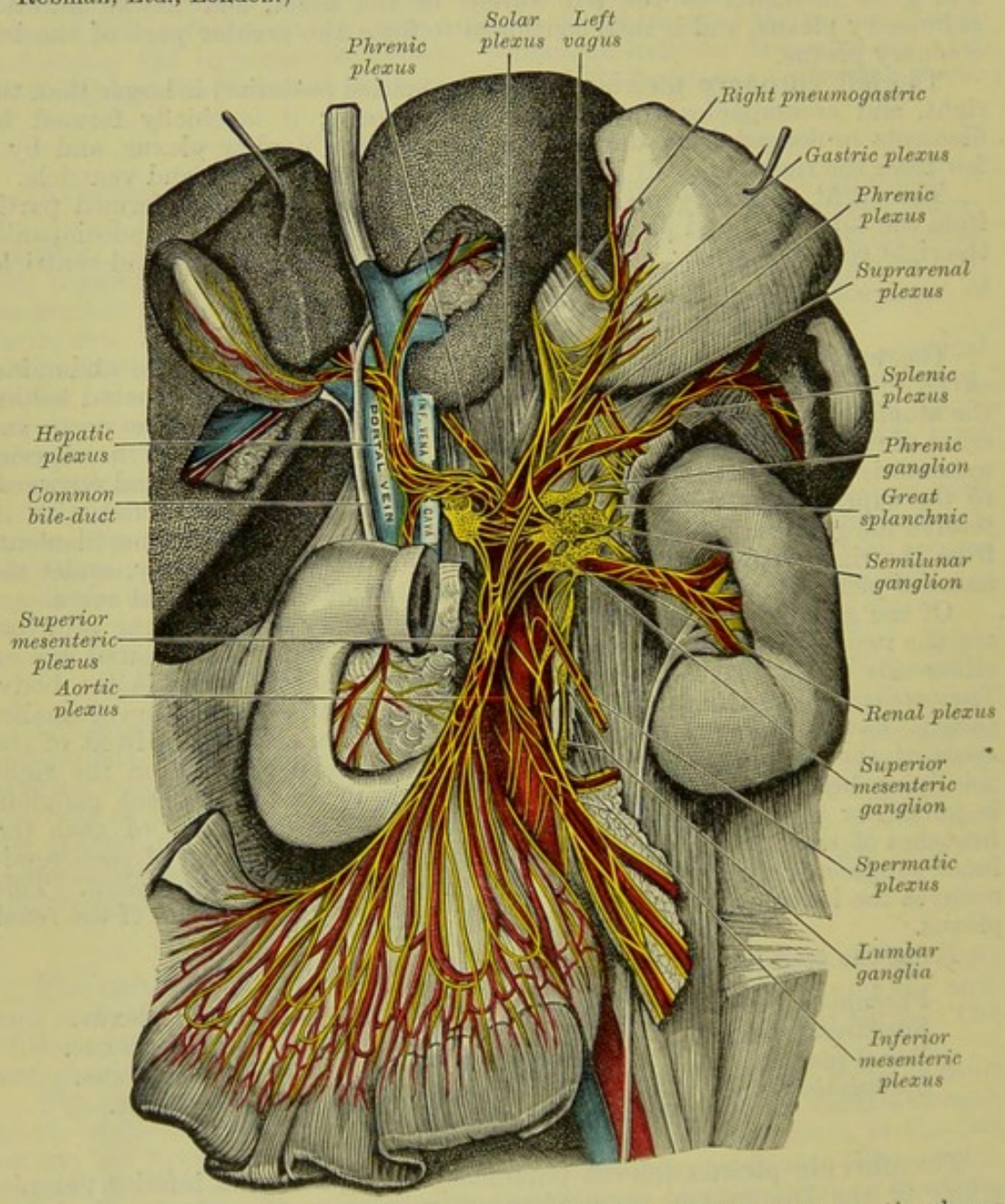

artery into the kidney ; some filaments are distributed to the spermatic plexus and, on the right side, to the inferior vena cava.

The **spermatic plexus** (plexus spermaticus) is derived from the renal plexus, receiving branches from the aortic plexus. It accompanies the spermatic vessels to the testis.

Applied Anatomy.—The intimate connection which exists between the renal and spermatic plexuses serves to explain the very frequent symptom in renal calculus, of pain which is referred to the body of the testicle.

In the female, the **ovarian plexus** (plexus ovaricus) arises like the spermatic plexus, and is distributed to the ovary, and fundus of the uterus.

The **cœliac plexus** (plexus cœliacus), of large size, is a direct continuation from the solar plexus : it surrounds the cœliac axis, and subdivides into the gastric, hepatic, and splenic plexuses. It receives branches from the lesser splanchnic nerves, and, on the left side, a filament from the right vagus.

The *gastric* or *coronary plexus* (plexus gastricus superior) accompanies the gastric artery along the lesser curvature of the stomach, and joins with branches from the left vagus.

The *hepatic plexus* (plexus hepaticus), the largest offset from the cœliac plexus, receives filaments from the left vagus and right phrenic nerves. It accompanies the hepatic artery, ramifying upon its branches, and upon those of the portal vein in the substance of the liver.

Branches from this plexus accompany all the divisions of the hepatic artery. Thus there is a *pyloric plexus* on the pyloric branch of the hepatic, which joins with the gastric plexus and vagi nerves. There is also a *gastro-duodenal plexus*, subdividing into the *pancreatico-duodenal plexus*, which accompanies the superior pancreatico-duodenal artery, to supply the pancreas and duodenum, and joins with branches from the mesenteric plexus ; and the *gastro-epiploic plexus*, which accompanies the right gastro-epiploic artery along the greater curvature of the stomach, and unites with branches from the splenic plexus. A *cystic plexus*, which supplies the gall-bladder, also arises from the hepatic plexus, near the liver.

The *splenic plexus* (plexus lienalis) is formed by branches from the cœliac plexus, the left semilunar ganglia, and from the right vagus nerve. It accompanies the splenic artery and its branches to the substance of the spleen, giving off, in its course, filaments to the pancreas (*pancreatic plexus*), and the *left gastro-epiploic plexus*, which accompanies the left gastro-epiploic artery along the greater curvature of the stomach.

The **superior mesenteric plexus** (plexus mesentericus superior) is a continuation of the lower part of the solar plexus, receiving a branch from the junction of the right vagus nerve with the cœliac plexus. It surrounds the superior mesenteric artery, accompanies it into the mesentery, and divides into a number of secondary plexuses, which are distributed to all the parts supplied by the artery, viz. pancreatic branches to the pancreas ; intestinal branches to the small intestine ; and ileo-colic, right colic, and middle colic branches, which supply the corresponding parts of the great intestine. The nerves composing this plexus are white in colour and firm in texture ; in the upper part of the plexus close to the origin of the superior mesenteric artery is a ganglion (*ganglion mesentericum superius*).

The **aortic plexus** (plexus aorticus abdominalis) is formed by branches derived, on either side, from the solar plexus and the semilunar ganglia, and receives filaments from some of the lumbar ganglia. It is situated upon the sides and front of the aorta, between the origins of the superior and inferior mesenteric arteries. From this plexus arise part of the spermatic, the inferior mesenteric, and the hypogastric plexuses ; it also distributes filaments to the inferior vena cava.

The **inferior mesenteric plexus** (plexus mesentericus inferior) is derived chiefly from the left side of the aortic plexus. It surrounds the inferior mesenteric artery, and divides into a number of secondary plexuses, which are distributed to all the parts supplied by the artery, viz. the *left colic* and *sigmoid plexuses*, which supply the descending and ilio-pelvic parts of the colon ; and the *superior hæmorrhoidal plexus* (plexus hæmorrhoidalis superior) which supplies the rectum and joins in the pelvis with branches from the pelvic plexuses.

Hypogastric Plexus (fig. 816)

The **hypogastric plexus** (plexus hypogastricus) is situated in front of the promontory of the sacrum, between the two common iliac arteries, and is formed by the union of numerous filaments, which descend on either side from the aortic plexus, and from the lumbar ganglia. This plexus contains no evident ganglia ; it bifurcates, below, into two lateral portions which form the *pelvic plexuses*.

Pelvic Plexuses (fig. 816)

The **pelvic plexuses** supply the viscera of the pelvic cavity, and are situated at the sides of the rectum in the male, and at the sides of the rectum and vagina in the female. They are formed on either side by a continuation of the hypogastric plexus, by the visceral branches from the second, third, and fourth sacral nerves, and by a few filaments from the first two sacral ganglia. At the points of junction of these nerves small ganglia are found. From these plexuses numerous branches are distributed to the viscera of the pelvis. They accompany the branches of the internal iliac artery.

The **middle hæmorrhoidal plexus** (plexus hæmorrhoidalis medius) arises from the upper part of the pelvic plexus. It supplies the rectum, and joins with branches of the superior hæmorrhoidal plexus.

The **vesical plexus** (plexus vesicalis) arises from the fore-part of the pelvic plexus. The nerves composing it are numerous, and contain a large proportion of spinal nerve-fibres. They accompany the vesical arteries, and are distributed to the side and base of the bladder. Numerous filaments also pass to the vesicula seminalis and vas deferens; those accompanying the vas deferens join, on the spermatic cord, with branches from the spermatic plexus.

The **prostatic plexus** (plexus prostaticus) is continued from the lower part of the pelvic plexus. The nerves composing it are of large size. They are distributed to the prostate gland, vesiculæ seminales, and erectile structure of the penis. The nerves supplying the erectile structure of the penis consist of two sets, the small and large cavernous nerves, which arise from the fore-part of the prostatic plexus, and, after joining with branches from the internal pudic nerve, pass forwards beneath the pubic arch.

The *small cavernous nerves* (nn. cavernosi penis minores) perforate the fibrous covering of the penis, near its root.

The *large cavernous nerve* (n. cavernosus penis major) passes forwards along the dorsum of the penis, joins with the dorsal nerve of the penis, and is distributed to the corpora cavernosa and corpus spongiosum.

The **vaginal plexus** (plexus vaginalis) arises from the lower part of the pelvic plexus. It is distributed to the walls of the vagina, to the erectile tissue of the vestibule, and to the clitoris. The nerves composing this plexus contain, like the vesical, a large proportion of spinal nerve-fibres.

The **uterine plexus** (plexus uterinus) accompanies the uterine artery to the side of the uterus, between the layers of the broad ligament; it communicates with the ovarian plexus.

Applied Anatomy.—Little is known as to the connection between the numerous microscopical alterations (pigmentation, atrophy, hæmorrhage, fibrosis) that have been described in the sympathetic nervous system, and the functional changes that ensue therefrom. Grosser lesions due to stabs, bullet-wounds, or the pressure of new growths, may cause either irritative or paralytic symptoms. In *paralysis* of the cervical sympathetic on one side, the pupil is small and does not dilate when shaded or on the instillation of cocaine, although it contracts still further when brightly illuminated; it also loses the cilio-spinal reflex, failing to dilate when the skin of the neck is pinched. The palpebral fissure narrows from paralysis of the involuntary muscle of the eyelid, and the eyeball sinks backwards into the orbit—enophthalmus—either from paralysis of Müller's orbital muscle which closes the spheno-maxillary fissure, or from wasting of the intra-orbital fat. The superficial vessels of the face and scalp are at first dilated, but later they contract. Anidrosis, or absence of sweating, is often noted on the affected side. *Irritation* of the cervical sympathetic produces signs mainly the converse of those described above. We have no definite knowledge of the signs and symptoms that follow lesions of the thoracic or abdominal sympathetic systems. It is likely, however, that a number of nervous disorders characterised by persistent vascular disturbances, such as dilatation of the vessels with throbbing, flushing, sweating, and localised œdema, or contraction of the vessels with pallor, chilliness, pain, and malnutrition of the affected parts, are due to implication of the sympathetic nervous system. It is possible, too, that the rare condition of *progressive facial hemiatrophy*, coming on between the ages of ten and twenty, and producing marked unilateral shrinkage of all the tissues of the face, is primarily an affection of the sympathetic.

ORGANS OF SPECIAL SENSE

THE organs of the senses (organa sensuum) are five in number : viz. those of Touch, of Taste, of Smell, of Sight, and of Hearing. The skin, which is the principal seat of the sense of touch, has been described in the section on Histology. The remaining four are the organs of special sense.

ORGANS OF TASTE

The peripheral organs of the sense of taste consist of certain flask-shaped groups of modified epithelial cells termed *taste-buds*, which are found on the tongue and adjacent parts. They occupy nests in the stratified epithelium, and are present in large numbers on the sides of the circumvallate papillæ (fig. 821), and to a less extent on their opposed walls. They are also found on the fungiform papillæ over the back part and sides of the tongue, and in the general epithelial covering of the same areas. They are very plentiful over the fimbriæ linguæ, and are also present on the under aspect of the soft palate, and on the posterior surface of the epiglottis.

FIG. 821.—Section of part of the papilla foliata of a rabbit. (Magnified.)

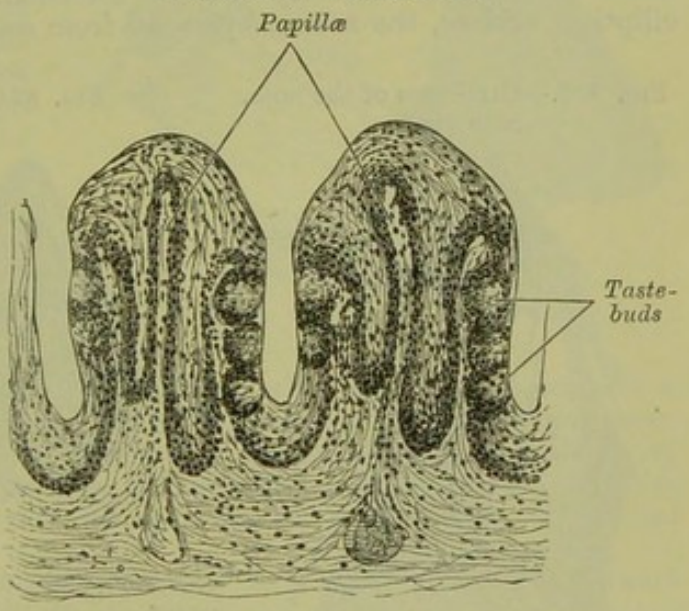

Structure.—Each taste-bud is flask-like in shape (fig. 822), its broad base resting on the corium, and its neck opening by an orifice, the *gustatory pore*, between the cells of the epithelium. The bud is formed by two kinds of cells : supporting cells and gustatory cells. The *supporting cells* are mostly arranged like the staves of a cask, and form an outer envelope for the bud. Some, however, are found in the interior of the bud between the gustatory cells. The *gustatory cells* occupy the central portion of the bud ; they are spindle-shaped, and each possesses a large spherical nucleus near the middle of the cell. The peripheral end of the cell terminates at the gustatory pore in a fine hair-like filament, the *gustatory hair*. The central process passes towards the deep extremity of the bud, and there ends

FIG. 822.—Taste-bud, highly magnified.

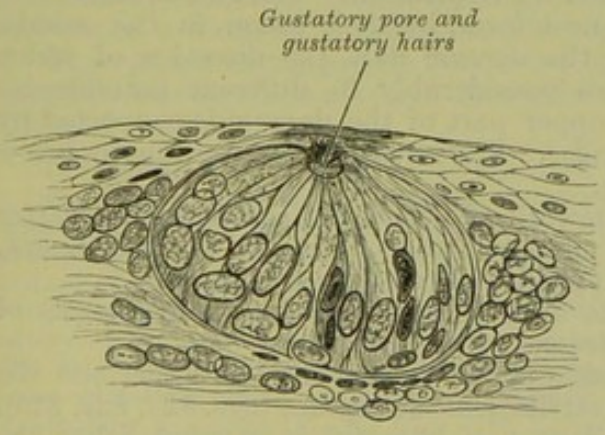

in a single or bifurcated varicose filament, which was formerly supposed to be continuous with the terminal fibril of a nerve ; the investigations of Lenhossék and others would seem to prove, however, that this is not so, but that the nerve-fibrils after losing their medullary sheaths enter the taste-bud, and terminate in fine extremities between the gustatory cells. Other nerve-fibrils may be seen ramifying between the supporting cells and terminating in fine extremities ; these, however, are believed to be nerves of ordinary sensation and not gustatory.

Nerves of taste.—The chorda tympani nerve, derived from the sensory root of the facial, is generally regarded as the nerve of taste for the anterior two-thirds of the tongue ; the nerve for the posterior third is the glosso-pharyngeal.

THE NOSE

The nose is the peripheral organ of the sense of smell : by means of the peculiar properties of its nerves, it protects the lungs from the inhalation of deleterious gases, and assists the organ of taste in discriminating the properties of food.

The organ of smell consists of two parts : an external, the *outer nose*, which projects from the centre of the face ; and an internal, the *cavum nasi*, which is divided by a septum into *right* and *left nasal fossæ*.

The **outer nose** (nasus externus) is pyramidal in form, and its upper angle or *root* is connected directly with the forehead. Its *base* is perforated by two elliptical orifices, the *nares*, separated from each other by an antero-posterior

Fig. 823.—Cartilages of the nose. Side view.

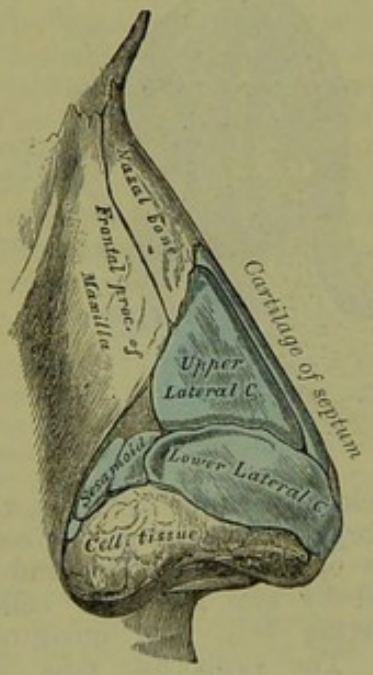

Fig. 824.—Cartilages of the nose, seen from below.

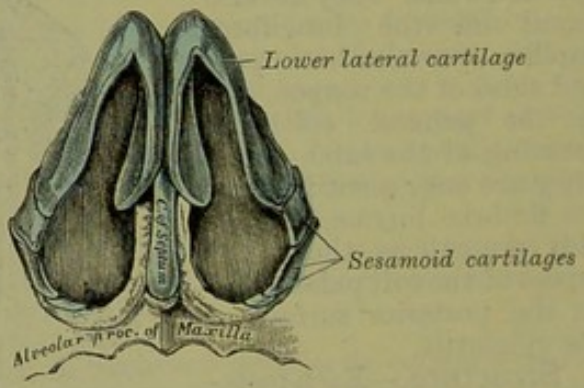

septum, the *columna*. The margins of the nares are provided with a number of stiff hairs, or *vibrissæ*, which arrest the passage of foreign substances carried with the current of air intended for respiration. The lateral surfaces of the nose form, by their union in the middle line, the *dorsum nasi*, the direction of which varies considerably in different individuals ; the upper part of the dorsum is supported by the nasal bones, and is named the *bridge*. The lateral surface terminates below in a rounded eminence, the *ala nasi*.

The nose is composed of a framework of bones and cartilages, the latter being slightly acted upon by certain muscles. It is covered by the integument, lined by mucous membrane, and supplied with vessels and nerves.

The *bony framework* occupies the upper part of the organ ; it consists of the nasal bones, and the frontal processes of the maxillæ.

The *cartilaginous framework* consists of five pieces, the two upper and the two lower lateral cartilages, and the cartilage of the septum (figs. 823, 824, 825).

The *upper lateral cartilage* (cartilago nasi lateralis) is situated below the free margin of the nasal bone, and is flattened, and triangular in shape. Its anterior margin is thicker than the posterior, and is continuous above with the

cartilage of the septum, but separated from it below by a narrow fissure. Its posterior margin is attached to the nasal bone and the frontal process of the maxilla. Its inferior margin is connected by fibrous tissue with the lower lateral cartilage ; one surface is turned outwards, the other inwards towards the nasal cavity.

The *lower lateral cartilage* (cartilago alaris major) is a thin, flexible plate, situated immediately below the preceding, bent upon itself in such a manner as to form the inner and outer walls of the naris of its own side. The portion which forms the inner wall (*crus mediale*) is thicker than the rest, and loosely connected with the corresponding portion of the opposite cartilage, to form a part of the columna ; the opposed inferior borders form, with the thickened integument and subjacent tissue, the septum mobile nasi. The part which forms the outer wall (*crus laterale*) is curved to correspond with the ala of the nose ; it is oval and flattened, narrow behind, where it is connected with the frontal process of the maxilla by a tough fibrous membrane, in which are found three or four small cartilaginous plates, the *cartilagines alares minores*. Above, it is connected by fibrous tissue to the upper lateral cartilage and front part of the cartilage of the septum ; below, it falls short of the margin of the nostril, the ala being completed by fatty and fibrous tissue covered by skin. In front, the lower lateral cartilages are separated by a notch which corresponds with the point of the nose.

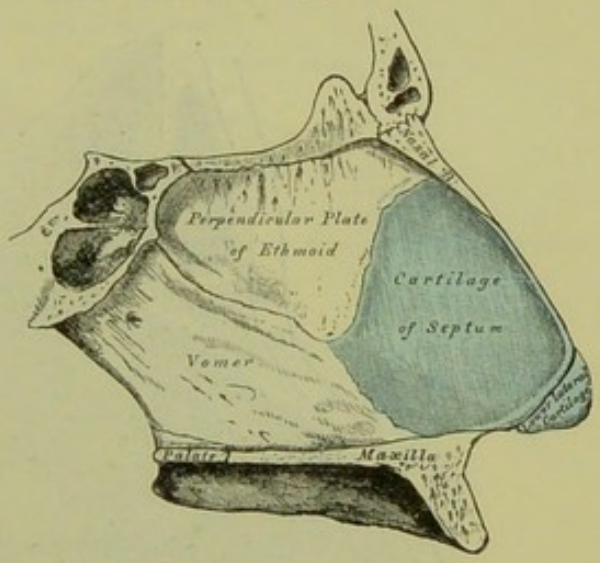

FIG. 825.—Bones and cartilages of septum of nose. Right side.

The *cartilage of the septum* (cartilago septi nasi) is somewhat quadrilateral in form, thicker at its margins than at its centre, and completes the separation between the nasal fossæ in front. Its anterior margin, thickest above, is connected with the nasal bones, and is continuous with the anterior margins of the two upper lateral cartilages ; below, it is connected to the inner portions of the lower lateral cartilages by fibrous tissue. Its posterior margin is connected with the perpendicular plate of the ethmoid ; its inferior margin with the vomer and the palatal processes of the maxillæ.

It may be prolonged backwards (especially in children) for some distance between the vomer and perpendicular plate of the ethmoid, forming what is termed the *processus sphenoidalis*. The septal cartilage does not reach as far as the lowest part of the nasal septum. This is formed by the inner portions of the lower lateral cartilages and by the skin ; it is freely movable, and hence is termed the *septum mobile nasi*.

The various cartilages are connected to each other, and to the bones, by a tough fibrous membrane, which allows the utmost facility of movement between them.

The *muscles of the nose* have been described on pages 463, 464.

The *integument* covering the dorsum and sides of the nose is thin, and loosely connected with the subjacent parts ; but where it forms the tip and the alæ of the nose it is thicker and more firmly adherent, and is furnished with a large number of sebaceous follicles, the orifices of which are usually very distinct.

The *arteries of the outer nose* are the lateralis nasi from the facial, and the inferior artery of the septum from the superior coronary, which supply the alæ and septum ; the sides and dorsum being supplied from the nasal branch of the ophthalmic and the infra-orbital branch of the internal maxillary. The *veins* terminate in the facial and ophthalmic.

The *nerves* for the muscles of the nose are derived from the facial, while the skin receives branches from the infra-trochlear and nasal branches of the ophthalmic, and from the infra-orbital.

Nasal fossæ.—The nasal fossæ are two irregular cavities situated one on either side of the mesial plane. They open in front through the nares, and communicate behind through the choanæ with the naso-pharynx. The *nares* are somewhat pear-shaped apertures, each measuring about one inch antero-posteriorly and half an inch transversely at its widest part. The *choanæ* are two oval openings which are smaller in the living or recent subject than in the skeleton, because they are narrowed by the mucous membrane. Each measures an inch in the vertical, and half an inch in the transverse direction in a well-developed adult skull.

For the description of the bony boundaries of the nasal fossæ, see page 275.

Inside the aperture of the nostril is a slight dilatation, the *vestibule* (vestibulum nasi), bounded externally by the ala and outer plate of the lower lateral cartilage, and internally by the mesial plate of the same cartilage. It is lined by skin, and contains hairs and sebaceous glands, and extends as a small pouch, the *ventricle*, towards the point of the nose. The fossa, above

Fig. 826.—Outer wall of nasal fossa.

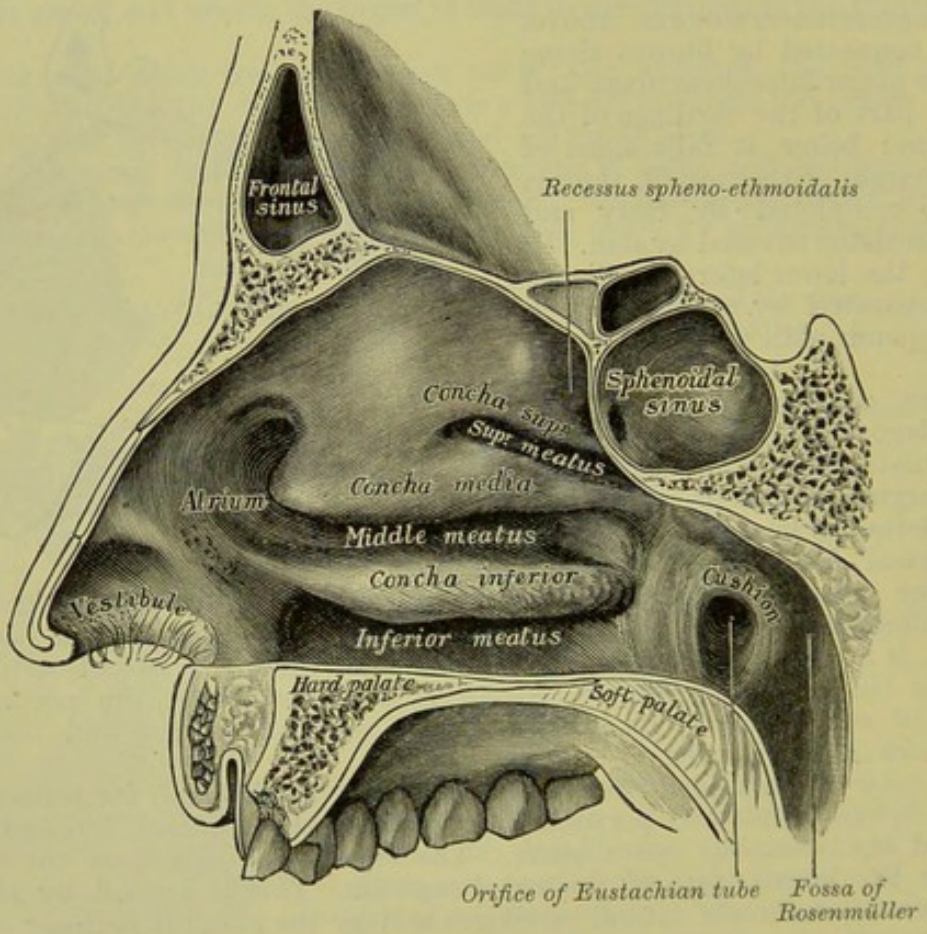

and behind the vestibule, is divided into two parts: an *olfactory* portion (regio olfactoria), consisting of the superior turbinated process and the opposed part of the septum, and a *respiratory* portion (regio respiratoria), which comprises the rest of the fossa.

Outer wall (figs. 826, 827).—The sphenoidal air-sinus opens into the recessus spheno-ethmoidalis, a narrow recess above the superior turbinated process. The posterior ethmoidal cells open into the front and upper part of the superior meatus. On raising or cutting away the middle turbinated bone the outer wall of the middle meatus is fully exposed, and presents (1) a rounded elevation, the *bulla ethmoidalis*, opening on or immediately above which are the orifices of the middle ethmoidal cells; (2) a deep, narrow, curved groove, in front of the bulla ethmoidalis, termed the *hiatus semilunaris*, into the lower part of which the antrum of Highmore opens, the orifice being placed near the roof of the antrum. The middle meatus is prolonged, above and in front, into the *infundibulum*; this leads into the frontal sinus, and into it the anterior

ethmoidal cells open. The anterior extremity of the meatus is continued into a depressed area, lying above the vestibule and named the *atrium meatus medii*. The *nasal duct* opens into the anterior part of the inferior meatus, the opening being overlapped sometimes by a fold of mucous membrane.

Inner wall (fig. 825).—The inner wall or septum is frequently more or less deflected from the mesial plane, thus lessening the size of one fossa and increasing that of the other. Ridges or spurs of bone growing outwards from the septum are also sometimes present. Immediately over the incisive foramen at the lower edge of the cartilage of the septum a depression, the *naso-palatine recess*, may be seen. In the septum close to this recess a minute orifice may be discerned : it leads backwards into a blind pouch, the rudimentary *organ of Jacobson* (organon vomeronasale), which is supported by a strip of cartilage, the *cartilage of Jacobson* (cartilago vomeronasalis). This organ is well-developed in many of the lower animals, where it apparently plays a part in the sense of smell,

Fig. 827.—Outer wall of nasal fossa ; the turbinated processes of the ethmoid and the inferior turbinated bone have been removed.

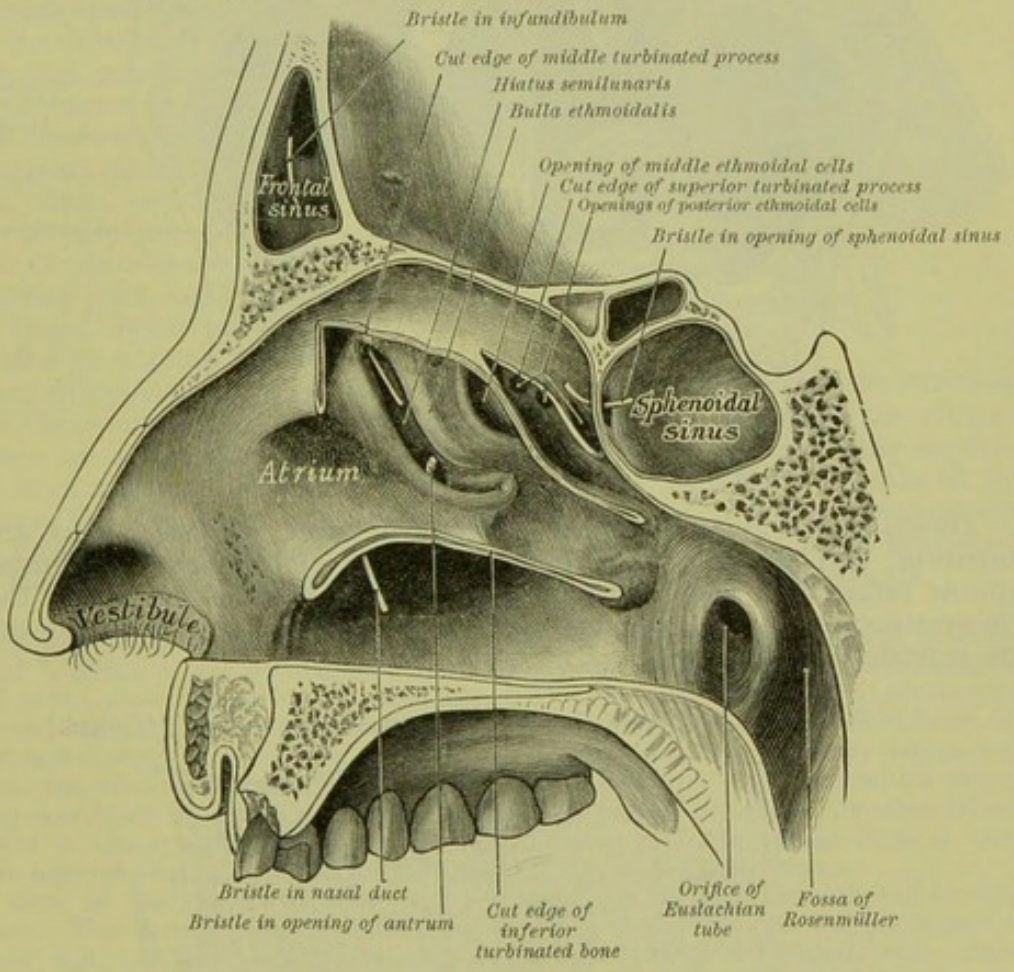

since it is supplied by twigs of the olfactory nerve and lined by epithelium similar to that which lines the olfactory region of the nose.

The *mucous membrane* lining the nasal fossæ is sometimes called the *Schneiderian membrane*, from Schneider,* who first showed that the nasal secretion proceeded from the mucous membrane, and not, as was formerly imagined, from the brain. It is intimately adherent to the periosteum or perichondrium over which it lies. It is continuous with the skin through the anterior nares, and with the mucous membrane of the naso-pharynx through the posterior nares. From the nasal fossæ its continuity with the conjunctiva may be traced, through the nasal duct and lachrymal canals ; and with the frontal, ethmoidal, and sphenoidal sinuses, and the antrum of Highmore, through the several openings in the meatuses. The mucous membrane is thickest, and most vascular, over the turbinated bones and processes. It is

* Conrad Victor Schneider, 1614–1680, Professor of Anatomy at Wittemberg.

also thick over the septum; but it is very thin in the meatuses and on the floor of the nasal fossæ. Where it lines the various sinuses it is thin and pale.

Fig. 828.—Coronal section of nasal fossæ.

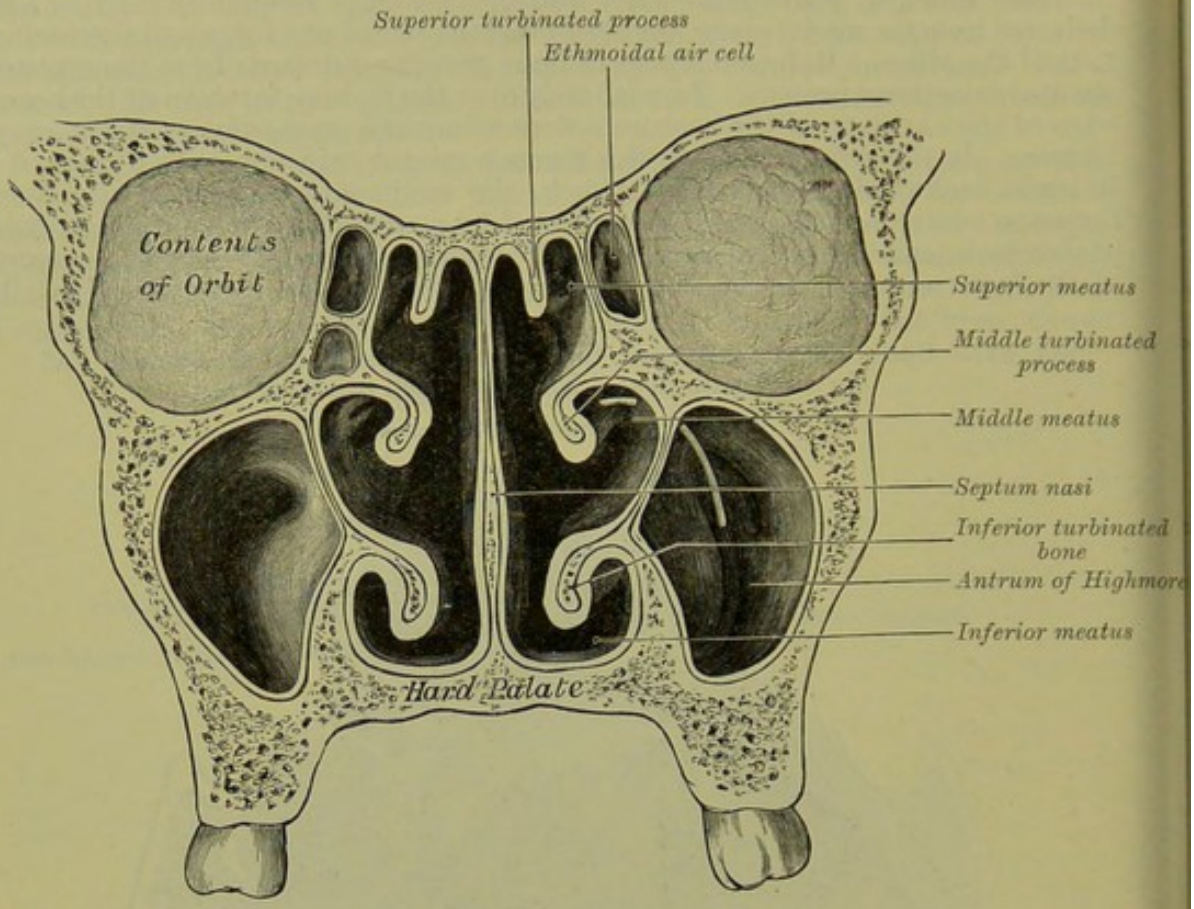

Owing to the great thickness of this membrane, the nasal fossæ are much narrower, and the middle turbinated process and inferior turbinated bone appear larger and more prominent than in the skeleton. From the same circumstance, also, the various apertures communicating with the meatuses are considerably narrowed.

Fig. 829.—Section of the olfactory mucous membrane. (Cadiat.)

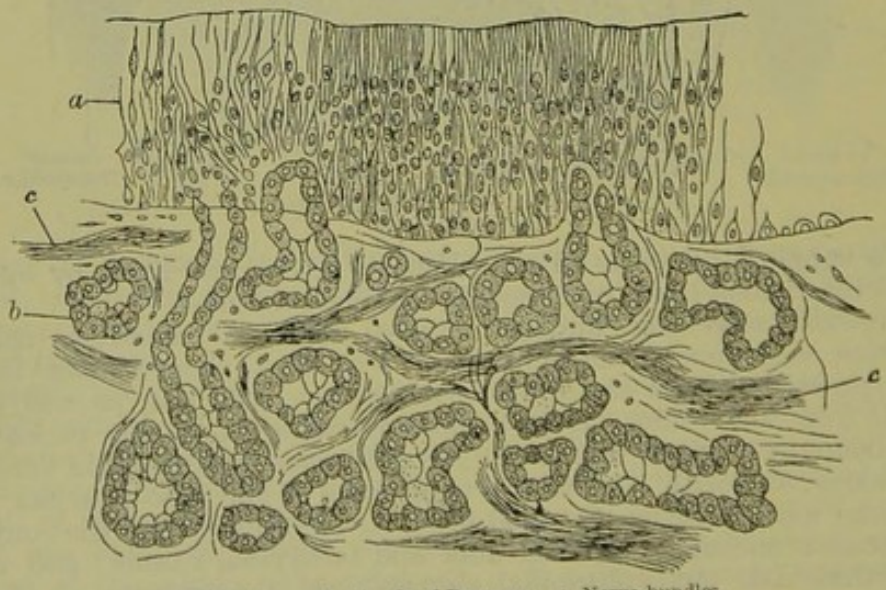

a. Epithelium. b. Glands of Bowman. c. Nerve-bundles.

Structure of the mucous membrane (fig. 829).—The epithelium covering the mucous membrane differs in its character according to the functions of the part

of the nose in which it is found. In the *respiratory region* it is columnar and ciliated. Interspersed among the columnar cells are goblet or mucin cells, while between their bases are found smaller pyramidal cells. Beneath the epithelium and its basement membrane is a fibrous layer infiltrated with lymph-corpuscles, so as to form in many parts a diffuse adenoid tissue, and under this a nearly continuous layer of smaller and larger glands, some mucous and some serous, the ducts of which open upon the surface. In the *olfactory region* the mucous membrane is yellowish in colour and the epithelial cells are columnar and non-ciliated; they are of two kinds, supporting cells and olfactory cells. The *supporting cells* contain oval nuclei, which are situated in the deeper parts of the cells and constitute the zone of oval nuclei; the outer part of the cell is columnar, and contains granules of yellow pigment, while its deeper portion is prolonged as a delicate process which ramifies and communicates with similar processes from neighbouring cells, so as to form a network in the mucous membrane. Lying between these central processes of the supporting cells are a number of spindle-shaped cells, the *olfactory cells*, each consisting of a large spherical nucleus surrounded by a small amount of granular protoplasm, and possessing two processes, one of which runs outwards between the columnar epithelial cells, and projects on the surface of the mucous membrane as a fine, hair-like process, the *olfactory hair*; the other or deep process runs inwards, is frequently beaded, and is continuous with one of the filaments of the olfactory nerve. Beneath the epithelium, and extending through the thickness of the mucous membrane, is a layer of tubular, often branched, glands, the *glands of Bowman*, identical in structure with serous glands.

Fig. 830.—Nerves of septum of nose. Right side.

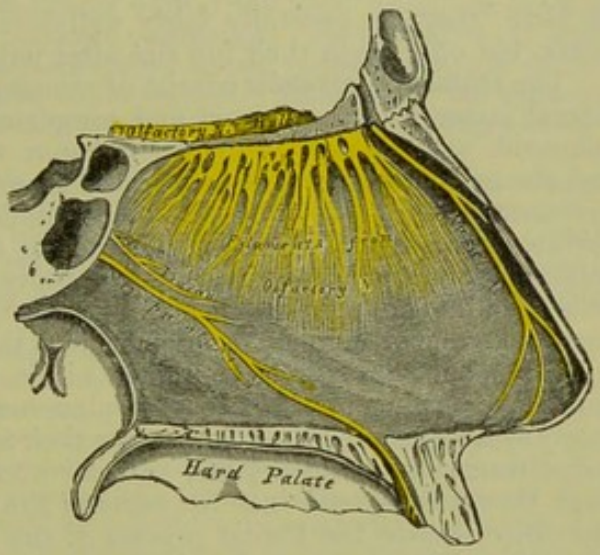

Vessels and Nerves.—The *arteries* of the nasal fossæ are the anterior and posterior ethmoidal branches of the ophthalmic, which supply the ethmoidal cells, frontal sinuses, and roof of the nose; the spheno-palatine branch of the internal maxillary, which supplies the mucous membrane covering the turbinated processes and inferior turbinated bone, the meatuses and septum; the inferior artery of the septum, from the superior coronary of the facial; the infra-orbital and alveolar branches of the internal maxillary, which supply the lining membrane of the antrum; and the pterygo-palatine branch of the same artery, distributed to the sphenoidal sinus. The ramifications of these vessels form a close plexiform network, beneath and in the substance of the mucous membrane.

The *veins* of the nasal fossæ form a close cavernous network beneath the mucous membrane. This cavernous appearance is especially well marked over the lower part of the septum and over the middle turbinated process and inferior turbinated bone. Some of the veins open into the spheno-palatine vein; others join the facial vein; some accompany the ethmoidal arteries, and terminate in the ophthalmic vein; and, lastly, a few communicate with the veins in the interior of the skull, through the foramina in the cribriform plate of the ethmoid bone, and the foramen cæcum.

The *lymphatics* have already been described (page 770).

The *nerves* of ordinary sensation are, the nasal branch of the ophthalmic, filaments from the anterior dental branch of the superior maxillary, the Vidian, the naso-palatine, the large or anterior palatine, and nasal branches of Meckel's ganglion.

The nasal branch of the ophthalmic distributes filaments to the fore-part of the septum and outer wall of the nasal fossæ. Filaments from the anterior dental branch of the superior maxillary supply the inferior meatus and inferior turbinated bone. The Vidian nerve supplies the upper and back part of the septum, and superior spongy bone; and the upper nasal branches from the spheno-palatine ganglion have a similar distribution. The naso-palatine nerve supplies the middle of the septum. The large, or anterior palatine, nerve supplies the lower nasal branches to the middle turbinated process and inferior turbinated bone.

The *olfactory*, the special nerve of the sense of smell, is distributed to the olfactory region.

Accessory Sinuses of the Nose (figs. 826, 827, 828)

The **accessory sinuses or air-cells of the nose** are the frontal, ethmoidal, sphenoidal and maxillary; they vary in size and form in different individuals, and are lined by mucous membrane directly continuous with that of the nasal fossæ.

The **frontal sinuses**, situated behind the superciliary ridges, are rarely symmetrical, and the septum between them frequently deviates to one or other side of the middle line. Their average measurements are as follows: height, 1¼ in.; breadth, 1 in.; depth from before backwards, 1 in. Each opens into the anterior part of the corresponding middle meatus of the nose through the infundibulum which traverses the anterior part of the lateral mass of the ethmoid. Absent at birth, they are generally fairly well-developed between the ninth and twelfth years, but only reach their full size after puberty.

The **ethmoidal air-cells** consist of numerous thin-walled cavities situated in the lateral masses of the ethmoid and completed by the frontal, maxilla, lachrymal, sphenoid, and palate. They lie between the upper parts of the nasal fossæ and the orbits, and are separated from these cavities by thin bony laminæ. They are arranged in three groups, anterior, middle, and posterior. The anterior and middle groups open into the middle meatus of the nose, the former by way of the infundibulum, the latter directly on or above the bulla ethmoidalis. The posterior cells open into the superior meatus under cover of the superior turbinated process; sometimes one or more of them opens into the sphenoidal sinus.

The **sphenoidal sinuses** contained within the body of the sphenoid vary in size and shape; owing to the lateral displacement of the intervening septum they are rarely symmetrical. The following are their average measurements: vertical height ⅞ in.; transverse breadth ¾ in.; antero-posterior depth ⅞ in. When exceptionally large they may extend into the roots of the pterygoid processes or greater wings, and may invade the basilar process of the occipital. Each sinus communicates with the recessus spheno-ethmoidalis by means of an aperture in the upper part of its anterior wall. Their development does not begin until about the eighth year.

The **maxillary sinus** or **antrum of Highmore**, the largest of the accessory sinuses of the nose, is a pyramidal cavity in the body of the maxilla. Its base is formed by the outer wall of the nasal fossa, and its apex extends into the zygomatic process. Its roof or orbital wall is frequently ridged by the infra-orbital canal, while its floor is formed by the alveolar process and is usually on a level with the floor of the nose; projecting into the latter are several conical elevations corresponding with the roots of the first and second molar teeth, and in some cases the floor is perforated by one or more of these roots. The size of the sinus varies in different skulls, and even on the two sides of the same skull. The following measurements are those of an average-sized antrum: vertical height opposite the first molar tooth 1½ in.; transverse breadth 1 in.; antero-posterior depth 1¼ in. In the antero-superior part of its base is an opening through which it communicates with the lower part of the hiatus semilunaris; a second orifice is frequently seen in, or immediately behind, the hiatus. The maxillary antrum appears as a shallow groove on the inner surface of the bone about the fourth month of fœtal life, but does not reach its full size until after the second dentition.*

Applied Anatomy.—Instances of congenital deformity of the nose are occasionally met with, such as complete absence of the outer nose, an aperture only being present; or perfect development on one side, and suppression or malformation on the other. Deformities which have been acquired are much more common, such as flattening of the nose, the result of syphilitic necrosis; or imperfect development of the nasal bones in cases of congenital syphilis; or a lateral deviation of the nose may result from fracture.

The skin over the alæ and tip of the nose is thick and closely adherent to subjacent parts; inflammation of this part is therefore very painful, on account of the tension. It is largely supplied with blood, and, the circulation here being terminal, vascular engorgement is liable to occur, especially in women at the menopause, and in both sexes from disorders of digestion, exposure to cold, &c. The skin of the nose also contains a large number of sebaceous follicles, and these, as the result of intemperance, are apt to become affected and the nose reddened, congested, and irregularly swollen. To this the term 'grog-blossom' is popularly applied. In some of these cases there is enormous hypertrophy of the skin and subcutaneous tissues. Epithelioma and rodent ulcer may attack

* The various measurements of the accessory sinuses of the nose given above are quoted from Aldren Turner's *Accessory Sinuses of the Nose.*

the nose, the latter being the more common of the two. Lupus and syphilitic ulceration frequently affect the nose, and may destroy the whole of the cartilaginous portion. In fact, lupus vulgaris begins more frequently on the ala of the nose than in any other situation.

To examine the nasal cavities, the head should be thrown back and the nose drawn upwards, the parts being dilated by some form of speculum. The posterior nares can be explored by reflected light from the mouth, through which they can be illuminated. The examination is very difficult to carry out, and, as a rule, sufficient information regarding the presence of foreign bodies or tumours in the naso-pharynx can be obtained by the introduction of the finger behind the soft palate through the mouth. The septum of the nose may be displaced or may deviate from the middle line ; this may be the result of an injury or of some congenital defect. Sometimes the deviation may be so great that the septum may come into contact with the outer wall of the nasal fossa, and may even become adherent to it, thus producing complete obstruction. Perforation of the septum is not an uncommon affection, and may arise from several causes : syphilitic or tuberculous ulceration, blood-tumour or abscess of the septum. When small, the perforation may cause a peculiar whistling sound during respiration. When large, it may lead to the falling in of the bridge of the nose.

Epistaxis is a very common affection in children. It is rarely of much consequence, and will almost always subside without treatment ; but in the more violent hæmorrhages of later life it may be necessary to plug the posterior nares. In performing this operation it is desirable to remember the size of the posterior nares. A ready method of regulating the bulk of the plug to fit the opening is to make it of the same size as the terminal phalanx of the thumb of the patient to be operated on.

Foreign bodies, such as boot-buttons, are frequently inserted into the nostrils by children, and require some care in removal, as unskilled attempts only result in pushing the foreign body further into the nasal fossa. Bodies which remain in the nose for any length of time set up ulceration of the mucous membrane, sometimes spreading to the bone, and a profuse purulent discharge results. A condition of unilateral nasal discharge in a child is always suggestive of the presence of a foreign body. The removal of such objects is best effected by giving the child an anæsthetic, opening the mouth with a gag, and placing the left forefinger in the naso-pharynx, so as to prevent the escape of the body into the air-passages ; the foreign body is then removed through the anterior naris by a suitable scoop or forceps manipulated by the right hand.

Enlargement of the mucous membrane covering the inferior turbinated bone or middle turbinated process is a very frequent accompaniment of chronic nasal catarrh. In old-standing cases the bones themselves may become enlarged, constituting the 'hypertrophied turbinals' which are so often the cause of nasal obstruction. In the case of the inferior turbinated the anterior or posterior extremity is usually more especially affected, giving rise to a reddened mass of tissue often confused with a nasal polypus ; the appearances, however, are totally different, as the true nasal polypi appear as glistening greyish-white bodies between the turbinates. Turbinal hypertrophy can be temporarily reduced to a great extent by the local application of cocaine, and if the reduction by this means is to practically the normal condition, then treatment by application of the galvano-cautery will be sufficient ; otherwise the enlarged portion of the bone or bones will require removal by a wire snare after the attachment to the lateral wall of the nasal fossa has been freed, by special nasal scissors, in the case of enlargement of the anterior end, and by the spoke-shave when the posterior end is enlarged. It is highly inadvisable to remove more than is necessary, as too free removal results in a dry condition of the air-passages, which conduces to a chronic dry pharyngitis and laryngitis.

Nasal polypi are of frequent occurrence ; in the common gelatinous form they spring from the outer wall of the nasal fossa and project down between the turbinateds, giving rise to obstructed nasal respiration. They are always accompanied by purulent discharge, and are due in all instances to small areas of carious bone in the region of the *bulla ethmoidalis*, or about the ethmoidal or sphenoidal air-cells. They appear as glistening greyish-white bodies swinging on a pedicle, and the larger ones can be encircled with a cold wire snare and thus removed ; usually, however, after the extirpation of the larger ones has been carried out, numerous small polypi can be seen springing from the region of their bases, and cauterisation of such affected areas must be thoroughly carried out if a recurrence of the trouble is to be avoided. In bad cases a free curetting of the ethmoidal air-cells may be called for after removal of the middle turbinated process. Fibrous polypi are also more rarely met with, and these are of the nature of new growths ; they most frequently spring from the base of the skull behind the posterior nares and form pedunculated tumours occupying the naso-pharynx. Malignant polypi also occur, most commonly originating in the antrum and projecting through its inner wall into the nasal fossa ; for such cases removal of the maxilla offers the only hope of cure.

Suppuration in the accessory nasal sinuses is of frequent occurrence, and in connection with this it is advisable that the student should recollect the situations at which the various sinuses normally communicate with the nasal fossæ : thus one finds they fall into two main groups : the anterior, opening into the middle meatus and draining the maxillary

antrum, the frontal sinus and the anterior ethmoidal air-cells, the two latter *via* the infundibulum; and the posterior group, opening into the superior meatus and sphenoethmoidal recess and draining the posterior ethmoidal and sphenoidal air-cells. Suppuration in the anterior group is the more common, and the pus can be seen running down over the anterior end of the inferior turbinated, whereas in the case of the posterior group, the pus does not come forwards, but runs back into the naso-pharynx over the posterior end of the middle turbinated process. Again, it is of importance to notice that the middle meatus is of such a form that pus running down the infundibulum from the frontal sinus is directed by the groove beneath the bulla ethmoidalis straight into the ostium of the maxillary antrum. So that the latter sinus may, in some cases, act as a secondary reservoir for pus discharged from the frontal sinus. All the accessory sinuses can be and are infected from the nasal fossa, but it should be noted that in the case of one sinus, viz. the maxillary antrum, the infection is frequently conveyed in another way, and that is from the teeth. This sinus is the one most frequently the seat of chronic suppuration and it often requires drainage. This drainage can be carried out by drilling a hole through the alveolus after removal of a tooth, preferably the first molar, or by gouging away the facial aspect of the maxilla, after having reflected the gum by incision of the mucous membrane, or by removing bone from the outer wall of the inferior meatus of the nose. Simple drainage, however, is not usually sufficient, and more extensive operations have often to be performed.

THE EYE

The eyeball (bulbus oculi) is contained in the cavity of the orbit. In this situation it is protected from injury, while its position is such as to ensure an extensive range of sight; it is additionally protected in front by several appendages, such as the eyebrow, eyelids, &c.

FIG. 831.—The right eye in sagittal section, showing the capsule of Tenon (semi-diagrammatic). (Testut.)

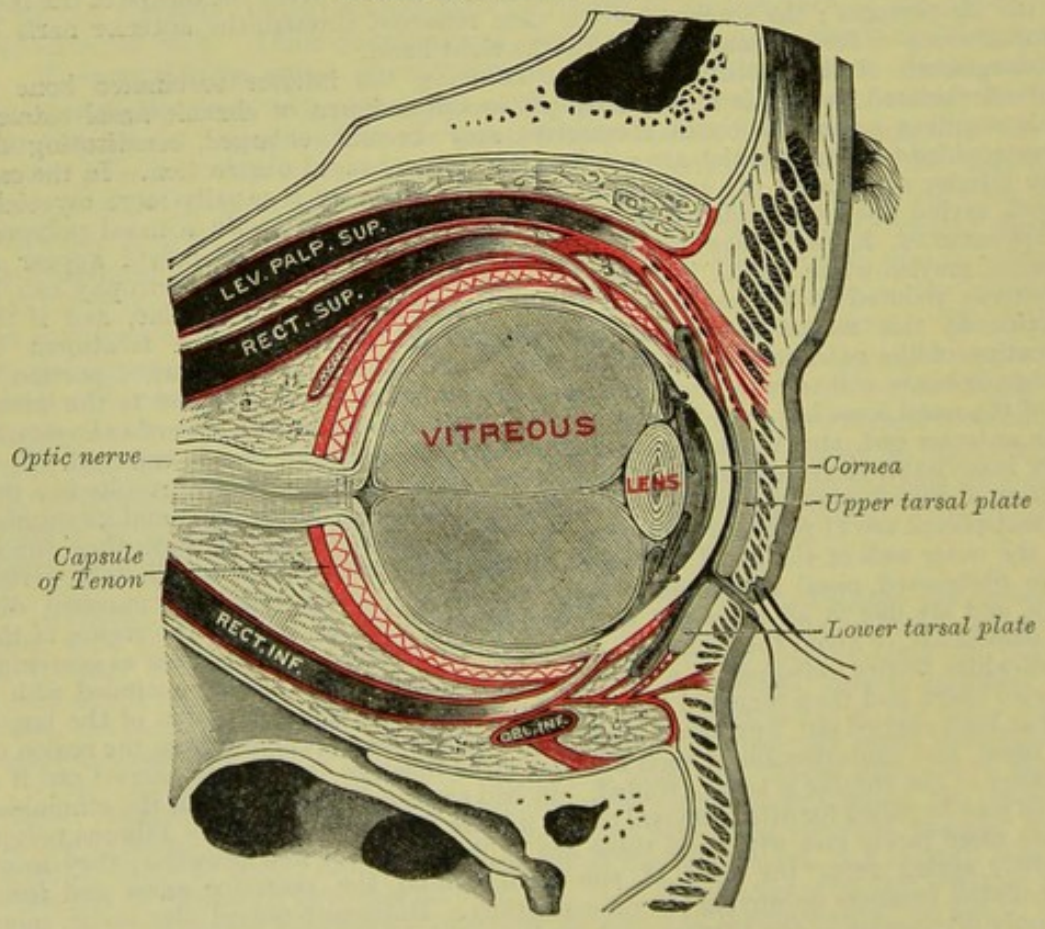

The eyeball is imbedded in the fat of the orbit, but is surrounded by a thin membranous sac, the *capsule of Tenon*, which isolates it, so as to allow of free movement.

The **capsule of Tenon** (fascia bulbi) (fig. 831) is a thin membrane which envelops the eyeball from the optic nerve to the ciliary region, separating it

from the orbital fat and forming a socket in which it plays. Its inner surface is smooth, and is separated from the outer surface of the sclera by the *periscleral lymph-space*. This lymph-space is continuous with the subdural and subarachnoid spaces, and is traversed by delicate bands of connective tissue which extend between the capsule and the sclera. The capsule is perforated behind by the ciliary vessels and nerves and by the optic nerve, being continuous with the sheath of the latter. In front it blends with the ocular conjunctiva, and with it is attached to the ciliary region of the eyeball. It is perforated by the tendons of the ocular muscles, and is reflected backwards on each as a tubular sheath. The sheath of the Superior oblique is carried as far as the fibrous pulley of that muscle; that on the Inferior oblique reaches as far as the floor of the orbit, to which it gives off a slip. The sheaths on the Recti are gradually lost in the perimysium, but they give off important expansions. The expansion from the Superior rectus blends with the tendon of the Levator palpebræ; that of the Inferior rectus is attached to the inferior tarsal plate. These two Recti, therefore, will exercise some influence on the movements of the eyelids. The expansions from the sheaths of the Internal and External recti are strong, especially that from the latter muscle, and are attached to the lachrymal and malar bones respectively. As they probably check the action of these two Recti they have been named the *internal* and *external check ligaments*.

Lockwood has described a thickening of the lower part of the capsule of Tenon, which he has named the *suspensory ligament of the eye*. It is slung like a hammock below the eyeball, being expanded in the centre, and narrow at its extremities which are attached to the malar and lachrymal bones respectively.*

The eyeball is composed of segments of two spheres of different sizes. The anterior segment is one of a small sphere; it is transparent, and forms about one-sixth of the eyeball. It is more prominent than the posterior segment, which is one of a larger sphere, and is opaque, and forms about five-sixths of the globe. The term *anterior pole* is applied to the central point of the anterior curvature of the eyeball, and that of *posterior pole* to the central point of its posterior curvature; a line joining the two poles forms the *axis optica*. The axes of the eyeballs are nearly parallel, and therefore do not correspond to the axes of the orbits, which are directed forwards and outwards. The optic nerves follow the direction of the axes of the orbits, and are therefore not parallel; each enters its eyeball about 1 mm. below and 3 mm. to the inner or nasal side of the posterior pole. The eyeball measures rather more in its transverse and antero-posterior diameters than in its vertical diameter, the former amounting to about 24 mm., the latter to about 23·5 mm.; in the female all three diameters are rather less than in the male. At birth the eyeball has a diameter of about 17·5 mm., while at puberty it measures from 20 to 21 mm.

The eyeball is composed of three tunics, and of three refracting media.

Tunics of the Eye (fig. 832)

From without inwards the three tunics are: (1) A fibrous tunic (tunica fibrosa oculi), consisting of the *sclera* behind and the *cornea* in front; (2) a vascular pigmented tunic (tunica vasculosa oculi), comprising, from behind forwards, the *choroid*, *ciliary body*, and *iris*; and (3) a nervous tunic, the *retina*.

I. The Sclera and Cornea

The sclera and cornea (fig. 832) form the external tunic of the eyeball; they are essentially fibrous in structure, the sclera being opaque, and forming the posterior five-sixths of the surface of the globe; the cornea forms the remaining sixth, and is transparent.

The **sclera** has received its name from its extreme density and hardness; it is a firm, unyielding, fibrous membrane, serving to maintain the form of the globe. It is much thicker behind than in front. Its *external surface* is of a white colour, and is in contact with the inner surface of the capsule of Tenon; it is quite smooth, except at the points where the Recti and Obliqui

* See a paper by C. B. Lockwood, *Journal of Anatomy and Physiology*, vol. xx. part i. p. 1.

are inserted into it, and its anterior part is covered by the conjunctival membrane: hence the whiteness and brilliancy of the front of the eyeball. Its *inner surface* is stained of a brown colour and marked by grooves, in which are lodged the ciliary nerves and vessels; it is separated from the outer surface of the choroid by an extensive lymph-space (*spatium perichorioideale*) which is traversed by an exceedingly fine cellular tissue, the *lamina suprachorioidea*. Behind, it is pierced by the optic nerve, and is continuous through the fibrous sheath of this nerve with the dura mater. At the point where the optic nerve passes through the sclera, the tunic forms a thin cribriform lamina, the *lamina cribrosa scleræ*; the minute orifices in this lamina serve for the transmission of the nervous filaments, and the fibrous septa dividing them from one another are continuous with the membranous processes which separate the bundles of nerve-fibres. One of these openings, larger than the rest, occupies the centre of the lamella; it transmits the central artery and vein of the retina. Around the cribriform lamella are numerous small apertures for the transmission of the ciliary vessels and nerves, and about midway between

Fig. 832.—Horizontal section of the eyeball.

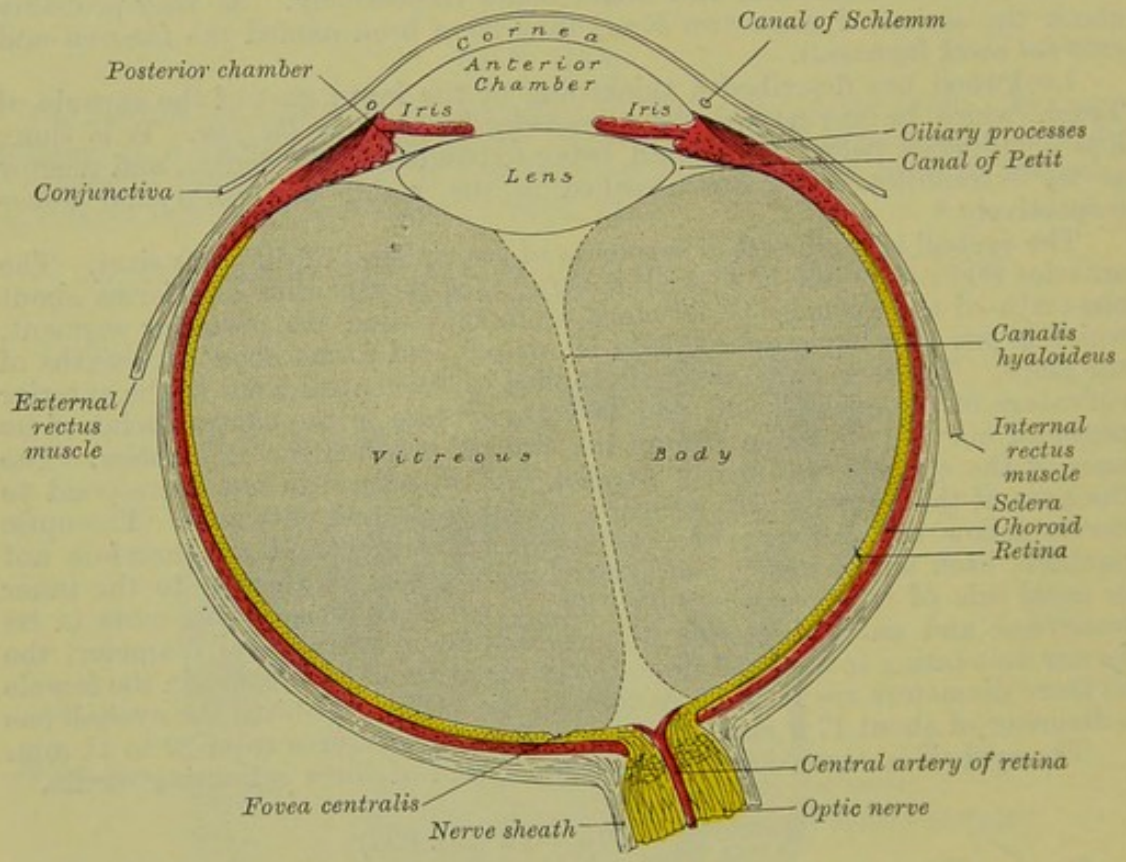

the margin of the cornea and the entrance of the optic nerve are four or five large apertures, for the transmission of veins (*venæ vorticosæ*). In front, the fibrous tissue of the sclera is directly continuous with that of the cornea, but the opaque sclera slightly overlaps the outer surface of the transparent cornea.

Structure.—The sclera is formed of white fibrous tissue intermixed with fine elastic fibres, and of flattened connective-tissue corpuscles, some of which are pigmented, contained in cell-spaces between the fibres. The fibres are aggregated into bundles, which are arranged chiefly in a longitudinal direction. Its *vessels* are not numerous, the capillaries being of small size, uniting at long and wide intervals. Its *nerves* are derived from the ciliary nerves, but their exact mode of ending is not known.

The **cornea** is the projecting transparent part of the external tunic of the eyeball, and forms the anterior sixth of the surface of the globe. It is almost circular in outline, occasionally a little broader in the transverse than in the vertical direction. It is convex anteriorly, and projects forwards from the sclera in the same manner that a watch-glass does from its case. Its degree of curvature varies in different individuals, and in the same individual at different

periods of life, being more pronounced in youth than in advanced life. The cornea is dense and of uniform thickness throughout; its posterior surface is perfectly circular in outline, and exceeds the anterior surface slightly in extent, from the latter being overlapped by the tissue of the sclera.

Structure (fig. 833).—The cornea consists from before backwards of the four following layers, viz.: (1) a layer of stratified epithelium, continuous with that of the conjunctiva; (2) the *substantia propria*; (3) a homogeneous elastic lamina; and (4) a layer of endothelium.

The *stratified epithelium* (epithelium corneæ) covering the front of the cornea consists of several layers of cells. The cells of the deepest layer are columnar;

Fig. 833.—Vertical section of human cornea from near the margin. (Waldeyer.) Magnified.



1. Epithelium. 2. Anterior homogeneous lamina. 3. Substantia propria. 4. Posterior homogeneous (elastic) lamina. 5. Endothelium of the anterior chamber. *a*. Oblique fibres in the anterior layer of the substantia propria. *b*. Lamellæ the fibres of which are cut across, producing a dotted appearance. *c*. Corneal corpuscles appearing fusiform in section. *d*. Lamellæ the fibres of which are cut longitudinally. *e*. Transition to the sclera, with more distinct fibrillation, and surmounted by a thicker epithelium. *f*. Small blood-vessels cut across near the margin of the cornea.

then follow two or three layers of polyhedral cells, the majority of which present finger-like processes (i.e. prickle-cells) similar to those found in the cuticle. Lastly, there are three or four layers of scaly epithelium, with flattened nuclei.

The *substantia propria* is fibrous, tough, unyielding, perfectly transparent, and continuous with the sclera. It is composed of about sixty flattened lamellæ, superimposed one on another. These lamellæ are made up of bundles

of modified connective tissue, the fibres of which are directly continuous with the fibres of the sclera. The fibres of each lamella are for the most part parallel with one another, but at right angles to those of adjacent lamellæ. Fibres, however, frequently pass from one lamella to the next.

The lamellæ are connected with each other by an interstitial cement-substance, in which are spaces, the *corneal spaces*. These are stellate in shape and have numerous offsets, by which they communicate with each other. Each contains a cell, the *corneal corpuscle*, resembling in form the space in which it is lodged, but not entirely filling it.

Immediately beneath the conjunctival epithelium, the cornea proper presents certain characteristics which have led some anatomists to regard it as a distinct membrane, and it has been named the *lamina elastica anterior of Bowman*. It differs, however, from the lamina elastica posterior, in presenting evidence of fibrillar structure, and in not having the same tendency to curl inwards, or to undergo fracture, when detached from the other layers of the cornea. It consists of extremely closely interwoven fibrils, similar to those found in the substantia propria, but contains no corneal corpuscles. It may be regarded as a part of the proper tissue of the cornea.

The *lamina elastica posterior* (*membrane of Descemet or Demours*) covers the posterior surface of the substantia propria, and consists of an elastic, transparent homogeneous membrane, of extreme thinness, which is not rendered opaque by either water, alcohol, or acids. It is very brittle, but its most remarkable properties are its extreme elasticity, and the tendency which it presents to curl up, or roll upon itself, with the attached surface innermost, when separated from the proper substance of the cornea. Its use appears to be 'to preserve the requisite permanent correct curvature of the flaccid cornea proper' (Jacob).

At the margin of the cornea the lamina elastica posterior breaks up into fibres which form a reticular structure at the outer angle of the anterior chamber, the intervals between the fibres forming small cavernous spaces, the *spaces of Fontana* (spatia anguli iridis). These spaces communicate with a circular canal in the substance of the sclera close to its junction with the cornea. This is the *canal of Schlemm* (sinus venosus scleræ) ; it communicates internally with the anterior chamber through the spaces of Fontana, and externally with the scleral veins. Some of the fibres of this reticulated structure are continued into the substance of the iris, forming the *ligamentum pectinatum iridis* ; while others are connected with the fore-part of the sclera and choroid.

The *layer of endothelium* (endothelium cameræ anterioris) covers the posterior surface of the elastic lamina, is reflected on to the front of the iris, and also lines the spaces of Fontana. It consists of a single stratum of polygonal, flattened, nucleated cells, similar to those lining other serous cavities.

Vessels and Nerves.—The cornea is a non-vascular structure, the capillary vessels terminating in loops at its circumference. Lymphatic vessels have not as yet been demonstrated in it, but are represented by the channels in which the bundles of nerves run ; these are lined by an endothelium. The nerves are numerous and are derived from the ciliary nerves. They form an *annular plexus* around the periphery of the cornea, from which fibres enter the substantia propria. They lose their medullary sheaths and ramify throughout its substance in a delicate network, and their terminal filaments form a firm and closer plexus on the surface of the cornea proper, beneath the epithelium. This is termed the *sub-epithelial plexus*, and from it fibrils are given off which ramify between the epithelial cells, forming an *intra-epithelial plexus*.

II. The Vascular and Pigmented Tunic (figs. 832, 834, 835.)

The middle tunic of the eye is formed from behind forwards by the choroid, the ciliary body, and the iris.

The choroid invests the posterior five-sixths of the globe, and extends as far forwards as the ora serrata of the retina. The ciliary body connects the choroid to the circumference of the iris. The iris is a circular diaphragm behind the cornea, and presents in its centre a rounded aperture, the *pupil*.

The **choroid** (chorioidea) is a thin, highly vascular membrane, of a dark brown or chocolate colour, which invests the posterior five-sixths of the globe ; it is pierced behind by the optic nerve, and in this situation is firmly adherent

to the sclera. It is thicker behind than in front. Externally, it is loosely connected by the lamina fusca with the inner surface of the sclera. Its inner surface is attached to the pigmented layer of the retina.

Structure.—The choroid consists mainly of a dense capillary plexus, and of small arteries and veins carrying blood to and returning it from this plexus. On its external surface, i.e. the surface next the sclera, is a thin membrane, the *lamina suprachorioidea*, composed of delicate non-vascular lamellæ—each lamella consisting of a network of fine elastic fibres among which are branched pigment-cells. The spaces between the lamellæ are lined by endothelium, and open freely into the perichoroidal lymph-space, which, in its turn, communicates with the periscleral space by the perforations in the sclera through which the vessels and nerves are transmitted.

Fig. 834.—The choroid and iris. (Enlarged.)

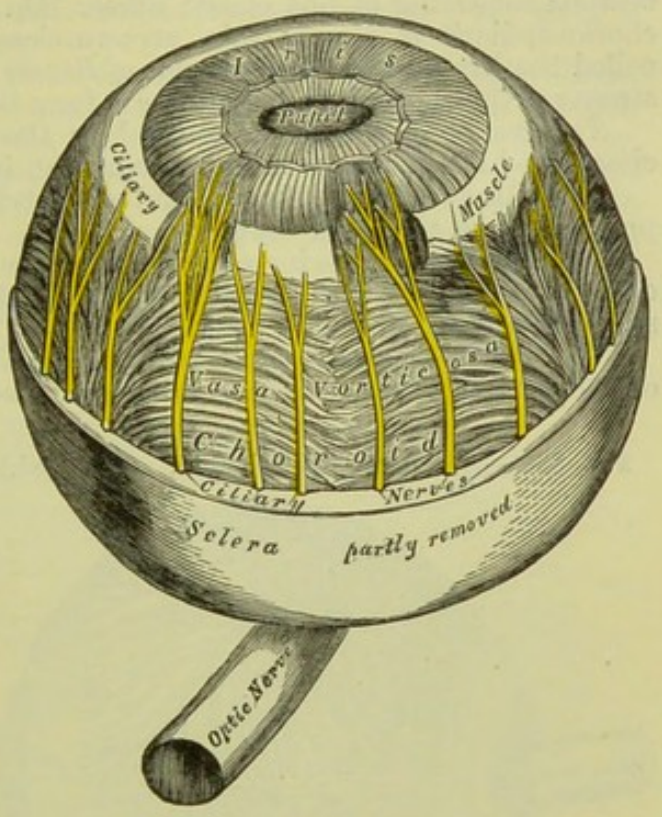

Internal to this lamina is the *choroid proper*, and in consequence of the small arteries and veins being arranged on the outer surface of the capillary network, it is customary to describe this as consisting of two layers: an outer, composed of small arteries and veins, with pigment-cells interspersed between them; and an inner, consisting of a capillary plexus. The *outer layer* or *lamina vasculosa* consists, in part, of the larger branches of the short ciliary arteries which run forwards between the veins, before they bend inwards to terminate in the capillaries, but is formed principally of veins,

Fig. 835.—The arteries of the choroid and iris.
The greater part of the sclera has been removed. (Enlarged.)

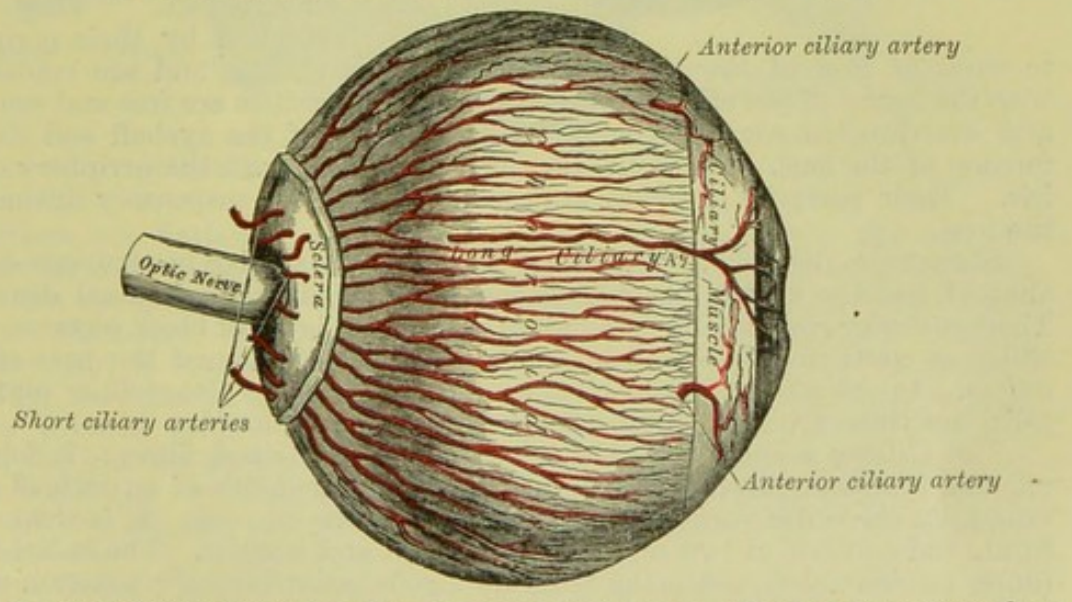

named, from their arrangement, the *venæ vorticosæ*. They converge to four or five equidistant trunks, which pierce the sclera midway between the margin of the cornea and the entrance of the optic nerve. Interspersed between the vessels are dark star-shaped pigment-cells, the processes of which, communicating

with those of neighbouring cells, form a delicate network or stroma, which, towards the inner surface of the choroid, loses its pigmentary character. The *inner layer* or *lamina choriocapillaris* consists of an exceedingly fine capillary plexus, formed by the short ciliary vessels; the network is closer, and finer in the posterior than in the anterior part of the choroid. About half an inch behind the cornea its meshes become larger, and are continuous with those of the ciliary processes. These two laminæ are connected by a *stratum intermedium* consisting of fine elastic fibres. On the inner surface of the lamina choriocapillaris is a very thin, structureless, or faintly fibrous membrane, called the *lamina basalis* (*membrane of Bruch*); it is closely connected with the stroma of the choroid, and separates it from the pigmentary layer of the retina.

Tapetum.—This name is applied to the outer and posterior part of the choroid, which in many animals presents an iridescent appearance.

The **ciliary body** (corpus ciliare) comprises the orbiculus ciliaris, the ciliary processes, and the Ciliary muscle.

The *orbiculus ciliaris* is a zone of about one-sixth of an inch (4 mm.) in width, directly continuous with the anterior part of the choroid; it presents numerous ridges arranged in a radial manner.

The *ciliary processes* (processus ciliares) are formed by the inward folding of the various layers of the choroid (i.e. the choroid proper and the lamina basalis), and are received between corresponding foldings of the suspensory ligament of the lens, thus establishing a connection between the choroid and inner tunic of the eye. They are arranged in a circle, and form a sort of frill behind the iris, round the margin of the lens. They vary from sixty to eighty in number, lie side by side, and may be divided into large and small; the former are about one-tenth of an inch (2·5 mm.) in length, and the latter, consisting of about one-third of the entire number, are situated in the spaces between them, but without regular arrangement. They are attached by their periphery to three or four of the ridges of the orbiculus ciliaris, and are continuous with the layers of the choroid: their opposite extremities are free and rounded, and are directed towards the posterior chamber of the eyeball and circumference of the lens. In front, they are continuous with the periphery of the iris. Their posterior surfaces are connected with the suspensory ligament of the lens.

Fig. 836.—The veins of the choroid. (Enlarged.)

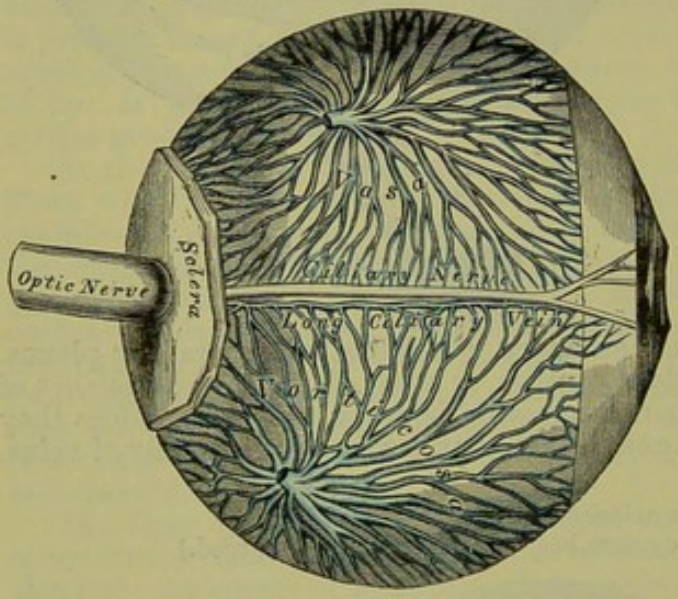

Structure (fig. 837).—The ciliary processes are similar in structure to the choroid, but the vessels are larger, and have chiefly a longitudinal direction. Their posterior surfaces are covered by a bilaminar layer of black pigment-cells, which is continued forwards from the retina, and is named the *pars ciliaris retinæ*. In the stroma of the ciliary processes there are also stellate pigment-cells, but these are not so numerous as in the choroid itself.

The *Ciliary muscle* (m. ciliaris) consists of unstriped fibres: it forms a greyish, semitransparent, circular band, about one-eighth of an inch (3 mm.) broad, on the outer surface of the fore-part of the choroid. It is thickest in front, and consists of two sets of fibres, *radial* and *circular*. The radial fibres (fibræ meridionales), much the more numerous, arise from the junction of the cornea and sclera, and from the ligamentum pectinatum iridis; they run backwards, and are attached to the ciliary processes and orbiculus ciliaris. One bundle, according to Waldeyer, is continued backwards to be inserted into the sclera. The circular fibres (fibræ circulares) are internal to the radiating

ones and to some extent unconnected with them, and have a circular course around the attachment of the iris. They are sometimes called the *ring muscle* of Müller, and were formerly described as the ciliary ligament. They are well developed in hypermetropic, but are rudimentary or absent in myopic eyes. The Ciliary muscle is the chief agent in accommodation, i.e. in adjusting the eye to the vision of near objects. When it contracts, it draws forwards the ciliary processes, relaxes the suspensory ligament of the lens, and thus allows the anterior surface of the lens to become more convex; the pupil is at the same time slightly contracted.

The **iris** has received its name from its various colours in different individuals. It is a thin, circular, contractile disc, suspended in the aqueous humour between the cornea and lens, and perforated a little to the nasal side of its centre by a circular aperture, the *pupil* (pupilla), for the transmission of light. By its periphery it is continuous with the ciliary body, and is also connected with the posterior elastic lamina of the cornea by means of the pectinate ligament;

FIG. 837.—Section of the eye, showing the relations of the cornea, sclera, and iris, together with the Ciliary muscle and the spaces of Fontana near the angle of the anterior chamber. (Waldeyer.)

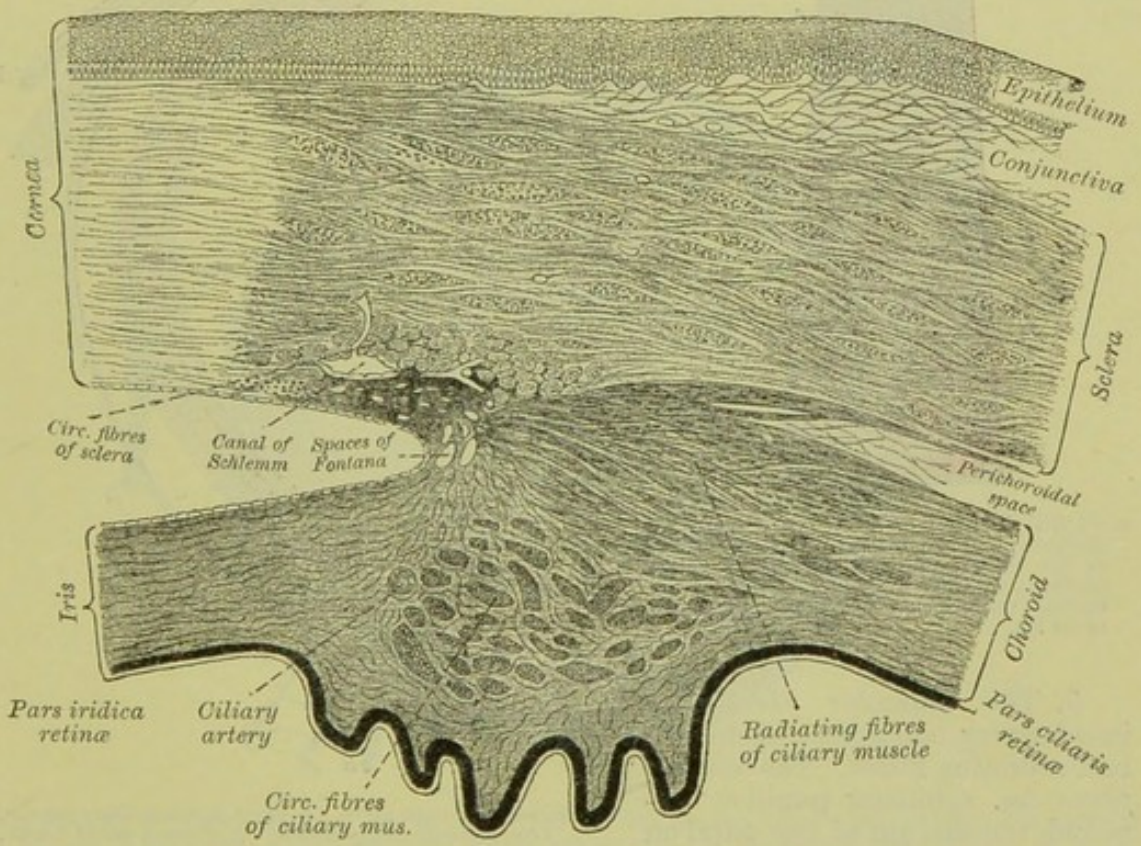

its surfaces are flattened, and look forwards and backwards, the anterior towards the cornea, the posterior towards the ciliary processes and lens. The iris divides the space between the front of the lens and the back of the cornea into two chambers—anterior and posterior. The *anterior chamber* (camera oculi anterior) is bounded in front by the posterior surface of the cornea; behind by the front of the iris and the central part of the lens. The *posterior chamber* (camera oculi posterior) is a narrow chink between the peripheral part of the iris, the suspensory ligament of the lens and the ciliary processes. In the adult the two chambers communicate through the pupil, but in the fœtus of the seventh month, when the pupil is closed by the *membrana pupillaris*, the two chambers are quite separate.

Structure.—The iris is composed of the following structures:

1. In front is a layer of flattened endothelial cells placed on a delicate hyaline basement-membrane. This layer is continuous with the epithelial layer covering the membrane of Descemet, and in men with dark-coloured irides the cells contain pigment-granules.

2. *Stroma.*—The stroma iridis consists of fibres and cells. The former are made up of delicate bundles of fibrous tissue, of which some few fibres have a circular direction at the circumference of the iris; but the chief mass consists of fibres radiating towards the pupil. They form, by their interlacement, delicate meshes, in which the vessels and nerves are contained. Interspersed between the bundles of connective tissue are numerous branched cells with fine processes. In dark eyes many of them contain pigment-granules, but in blue eyes and the pink eyes of albinos they are unpigmented.

FIG. 838.—Vessels of the choroid, ciliary processes, and iris of a child. (Arnold.) Magnified 10 times.

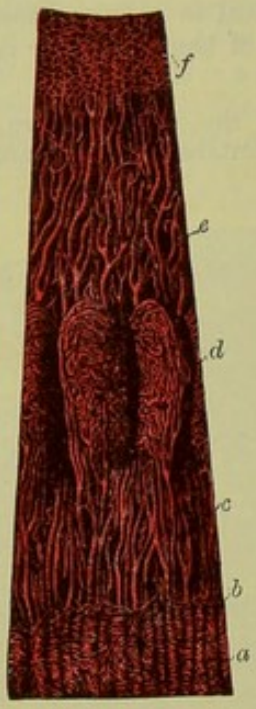

a. Capillary network of the posterior part of the choroid, ending at *b*, the ora serrata. *c*. Arteries of the corona ciliaris, supplying the ciliary processes, *d*, and passing into the iris, *e*. *f*. The capillary network close to the pupillary margin of the iris.

FIG. 839.—Diagrammatic representation of the course of the vessels in the eye. Horizontal section. (Leber.) Arteries and capillaries red; veins blue.

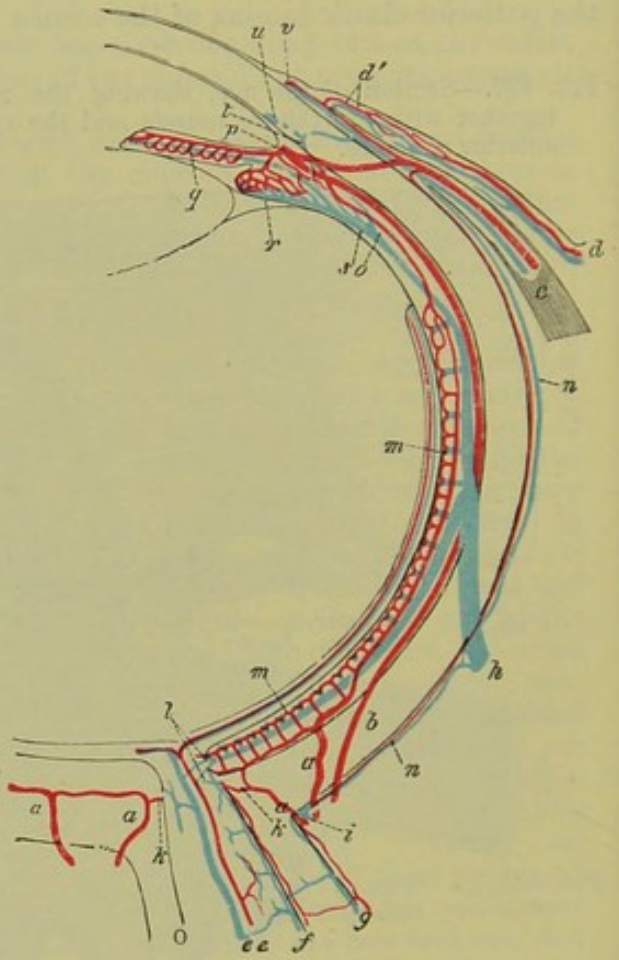

O. Entrance of optic nerve. *a*. Short posterior ciliary arteries. *b*. Long posterior ciliary arteries. *c*. Anterior ciliary vessels. *d*. Posterior conjunctival vessels. *d'*. Anterior conjunctival vessels. *e*. Central vessels of the retina. *f*. Vessels of the inner sheath of the optic nerve. *g*. Vessels of the outer sheath. *h*. Vorticose vein. *i*. Short posterior ciliary vein. *k*. Branches of the short posterior ciliary arteries to the optic nerve. *l*. Anastomosis of choroidal vessels with those of optic nerve. *m*. Chorio-capillaris. *n*. Episcleral vessels. *o*. Recurrent artery of the choroid. *p*. Circulus iridis major (in section). *q*. Vessels of iris. *r*. Vessels of ciliary process. *s*. Branch from ciliary muscle to vorticose vein. *t*. Branch from ciliary muscle to anterior ciliary vein. *u*. Canal of Schlemm. *v*. Capillary loop at margin of cornea.

3. The *muscular fibres* are involuntary, and consist of circular and radiating fibres. The *circular fibres* (m. sphincter pupillæ) surround the margin of the pupil on the posterior surface of the iris, like a sphincter, forming a narrow band about one-thirtieth of an inch (1 mm.) in width; those near the free margin are closely aggregated; those more external, somewhat separated, form incomplete circles. The *radiating fibres* (m. dilatator pupillæ) converge from the circumference towards the centre, and blend with the circular fibres near the margin of the pupil. These fibres are regarded by some as elastic, not muscular.

4. The posterior surface (facies posterior) of the iris is of a deep purple tint, being covered by two layers of pigmented columnar epithelium, continuous at the periphery of the iris with the pars ciliaris retinæ. This pigmented epithelium is named the *pars iridica retinæ* or, from the resemblance of its colour to that of a ripe grape, the *uvea*.

The colour of the iris is produced by the reflection of light from dark pigment-cells underlying a translucent tissue, and is therefore determined by the amount of the pigment and its distribution throughout the texture of the iris. The number and the situation of the pigment-cells differ in different irides. In the albino pigment is absent. In the various shades of blue eyes the pigment-cells are confined to the posterior surface of the iris, whereas in grey, brown, and black eyes pigment is found also in the cells of the stroma and in those of the epithelial layer on the front of the iris.

Vessels and Nerves.—The *arteries of the iris* are derived from the long and anterior ciliary arteries, and from the vessels of the ciliary processes (see page 648). The long ciliary arteries, two in number, having reached the attached margin of the iris, divide each into an upper and lower branch; these anastomose with corresponding branches from the opposite side and thus encircle the iris; into this vascular zone (*circulus arteriosus major*) the anterior ciliary arteries pour their blood. From this zone vessels converge to the free margin of the iris, and there communicate by branches from one to another to form a second zone (*circulus arteriosus minor*) (figs. 838 and 840).

FIG. 840.—The iris, viewed from in front, with its great and small arterial circles. (Testut.)

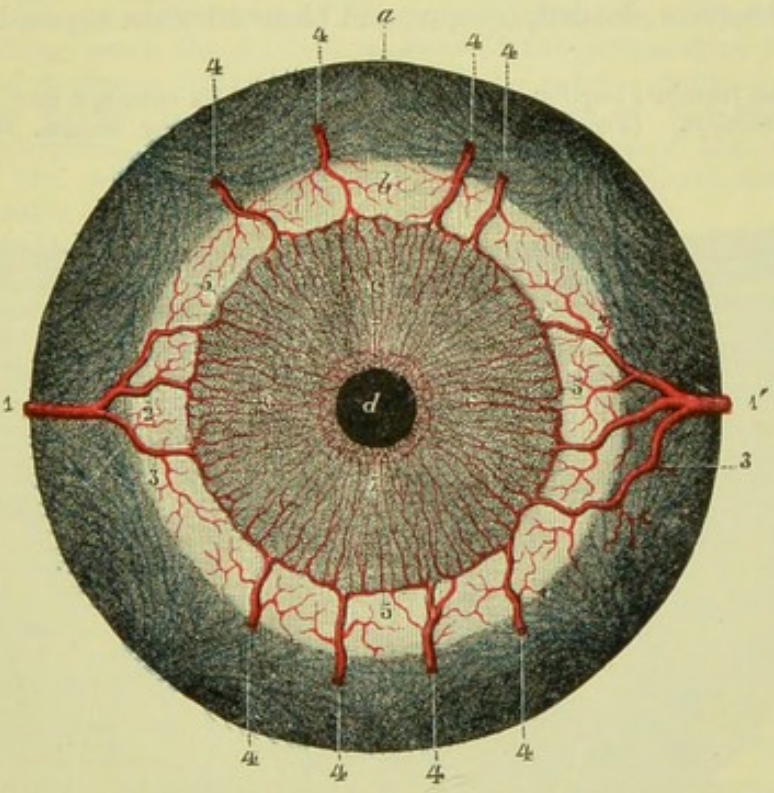

a. Choroid. *b*. Ciliary muscle. *c*. Iris. *d*. Pupil. 1 and 1′. The two long ciliary arteries, with 2, their ascending branch of bifurcation; 3, their descending branch of bifurcation. 4. The anterior ciliary arteries. 5. Circulus major; 6, its branches radiating through the iris. 7. Circulus minor around the pupil.

The *nerves of the choroid and iris* are derived from the ciliary branches of the lenticular ganglion, and the long ciliary from the nasal branch of the ophthalmic division of the fifth. They pierce the sclera around the entrance of the optic nerve, run forwards in the perichoroidal space, and supply the blood-vessels of the choroid. After reaching the iris they form a plexus around its attached margin; from this are derived non-medullated fibres which terminate in the circular and radiating muscular fibres. Their exact mode of termination has not been ascertained. Other fibres from the plexus terminate in a network on the anterior surface of the iris. The fibres derived from the motor root of the lenticular ganglion (third nerve) supply the circular fibres, while those derived from the sympathetic supply the radiating fibres.

Membrana pupillaris.—In the fœtus, the pupil is closed by a delicate vascular membrane, the *membrana pupillaris*, which divides the space in which the iris is suspended into two distinct chambers. This membrane contains numerous minute vessels, continued from the margin of the iris to those on the front part of the capsule of the lens. These vessels have a looped arrangement,

and converge towards each other without anastomosing. Between the seventh and eighth month the membrane begins to disappear by absorption from the centre towards the circumference, and at birth only a few fragments are present ; in exceptional cases it may persist.

III. The Retina

The **retina** is a delicate nervous membrane, upon the surface of which the images of external objects are received. Its outer surface is in contact with the choroid ; its inner with the vitreous body. Behind, it is continuous with the optic nerve ; it gradually diminishes in thickness from behind forwards, and extends nearly as far as the ciliary body, where it appears to terminate in a jagged margin, the *ora serrata*. Here the nervous tissues of the retina end, but a thin prolongation of the membrane extends forwards over the back of the ciliary processes and iris, forming the *pars ciliaris retinæ* and *pars iridica retinæ* already referred to. This forward prolongation consists of the pigmentary layer of the retina together with a stratum of columnar epithelium. The retina is soft, semitransparent, and of a purple tint in the fresh state, owing to the presence of a colouring material named *rhodopsin* or *visual purple* ; but it soon becomes clouded, opaque, and bleached when exposed to sunlight.

Fig. 841.—The terminal portion of the optic nerve and its entrance into the eyeball, in horizontal section. (From Toldt's 'Atlas,' published by Messrs. Rebman, Ltd., London.)

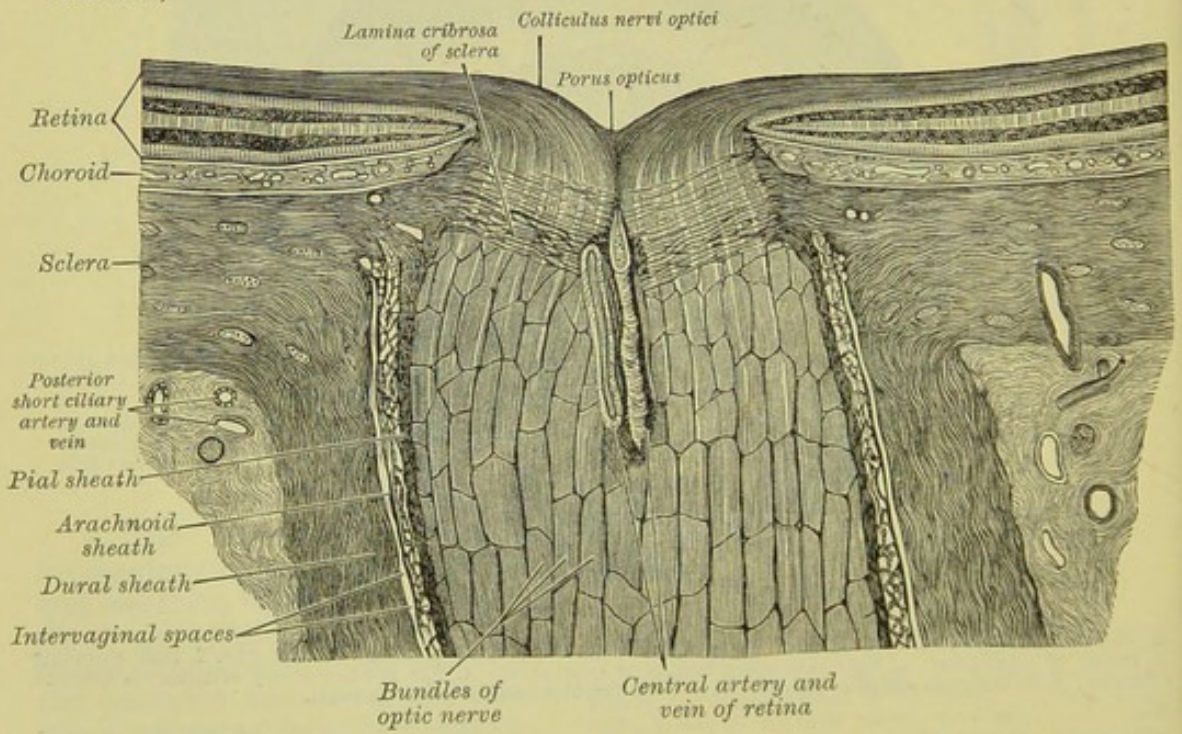

Exactly in the centre of the posterior part of the retina, corresponding to the axis of the eye, and at a point in which the sense of vision is most perfect, is an oval yellowish area, the *yellow spot* (macula lutea) ; in the spot is a central depression, the *fovea centralis*. At the fovea centralis the retina is exceedingly thin, and the dark colour of the choroid is distinctly seen through it. It exists only in man, the quadrumana, and some saurian reptiles. About one eighth of an inch (3 mm.) to the inner side, and about 1 mm. below the level of the yellow spot, is the point of entrance of the optic nerve (*porus opticus* or *optic disc*), the circumference of which is slightly raised so as to form an eminence (*colliculus nervi optici*) (fig. 841) ; the arteria centralis retinæ pierces its centre. This is the only part of the surface of the retina from which the power of vision is absent, and is termed the ' blind spot.'

Structure (figs. 842, 843).—The retina is exceedingly complex, and, when examined microscopically by means of sections made perpendicularly to its

surface, is found to consist of ten layers, named from within outwards as follows :

1. Membrana limitans interna.
2. Layer of nerve-fibres (stratum opticum).
3. Ganglionic layer, consisting of nerve-cells.
4. Inner plexiform layer.
5. Inner nuclear layer, or layer of inner granules.
6. Outer plexiform layer.
7. Outer nuclear layer, or layer of outer granules.
8. Membrana limitans externa.
9. Jacob's membrane (layer of rods and cones).
10. Pigmented layer (tapetum nigrum).

1. The *membrana limitans interna* is the innermost layer, and is in contact with the hyaloid membrane of the vitreous body. It is derived from the supporting framework of the retina, with which it will be described.

2. The *layer of nerve-fibres* is formed by the expansion of the optic nerve, the fibres of which pass through all the layers of the retina, except the membrana limitans interna. As the nerve passes through the lamina cribrosa scleræ, its fibres lose their medullary sheaths and are continued onwards through the choroid and retina as simple axis cylinders. When these non-medullated fibres reach the internal surface of the retina they radiate from their point of entrance over the surface of the retina, grouped in bundles, and in many places arranged in plexuses. Most of the fibres in this layer are centripetal, and are the direct continuations of the axis-cylinder processes of the cells of the next layer, but a few of them are centrifugal and run through this and the next succeeding layer to ramify in the inner molecular and inner nuclear layers, where they terminate in enlarged extremities (fig. 843). The layer of nerve-fibres is thickest near the optic nerve disc, gradually diminishing towards the ora serrata.

FIG. 842.—Section of retina. (Magnified.)

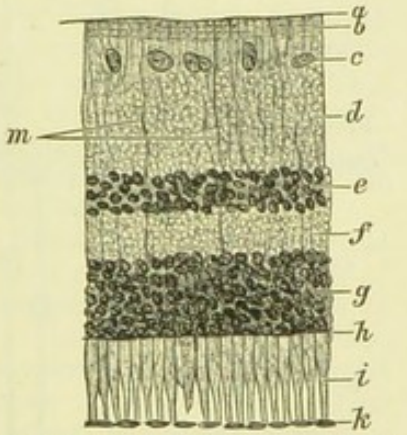

a. Membrana limitans interna. *b*. Layer of nerve-fibres. *c*. Ganglionic layer. *d*. Inner plexiform layer. *e*. Inner nuclear layer. *f*. Outer plexiform layer. *g*. Outer nuclear layer. *h*. Membrana limitans externa. *i*. Layer of rods and cones. *k*. Pigmented layer. *m*. Fibres of Müller.

3. The *ganglionic layer* consists of a single layer of large ganglion-cells, except in the macula lutea, where there are several strata. The cells are somewhat flask-shaped ; the rounded internal surface of each resting on the preceding layer, and sending off an axon which is prolonged as a nerve-fibre into the fibrous layer. From the opposite extremity numerous dendrites extend into the inner plexiform layer, where they branch and form flattened arborisations at different levels (fig. 843). The ganglion-cells vary much in size, and the dendrites of the smaller ones as a rule arborise in the inner plexiform layer as soon as they enter it ; while those of the larger cells ramify close to the inner nuclear layer.

4. The *inner plexiform layer* is made up of a dense reticulum of minute fibrils, formed by the interlacement of the dendrites of the ganglion-cells with those of the cells of the inner nuclear layer, immediately to be described. Within the reticulum formed by these fibrils a few branched spongioblasts are sometimes imbedded.

5. The *inner nuclear layer* or *layer of inner granules* is made up of a number of closely packed cells, of which there are three varieties, viz. bipolar cells, horizontal cells and amacrine cells.

The *bipolar cells* are by far the most numerous, and are round or oval in shape, each cell being prolonged into an inner and an outer process. They are divisible into rod-bipolars and cone-bipolars. The inner processes of the *rod-bipolars* run through the inner plexiform layer and arborise around the bodies of the cells of the ganglionic layer ; their outer processes end in tufts of fibrils around the button-like ends of a number of rod-fibres. The inner processes of

the *cone-bipolars* ramify in the inner plexiform layer in contact with the dendrites of the ganglionic cells.

The *horizontal cells* lie in the outer part of the inner nuclear layer and possess somewhat flattened cell bodies. Their dendrites divide into numerous branches in the outer plexiform layer while their axons run horizontally for some distance and finally ramify in the same layer.

The *amacrine cells* are placed in the inner part of the inner nuclear layer, and are so named because they have not yet been shown to possess axis-cylinder processes. Their dendrites undergo extensive ramification in the inner plexiform layer.

6. The *outer plexiform layer* is much thinner than the inner plexiform layer ; but, like it, consists of a dense network of minute fibrils derived from the processes of the horizontal cells of the preceding layer, and the outer processes of the bipolar cells, which ramify in it, forming arborisations around the ends of the rod-fibres and with the branched foot-plates of the cone-fibres.

7. *The outer nuclear layer* or *layer of outer granules.*—Like the inner nuclear layer, this layer contains several strata of clear oval nuclear bodies ; they are

FIG. 843.—Plan of retinal neurons. (After Cajal.)

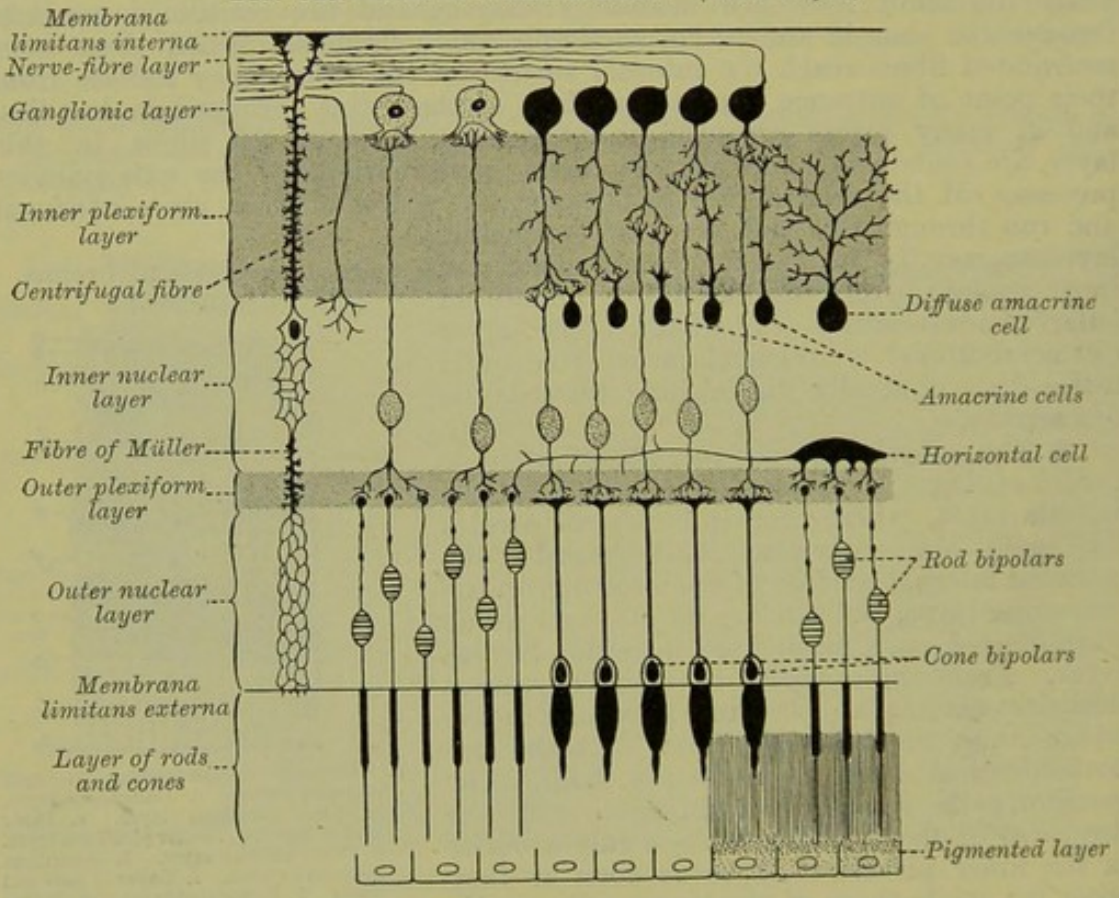

of two kinds, and on account of their being respectively connected with the rods and cones of Jacob's membrane, are named rod-granules and cone-granules. The *rod-granules* are much the more numerous, and are placed at different levels throughout the layer. Their nuclei present a peculiar cross-striped appearance, and prolonged from either extremity of the cell is a fine process : the outer process is continuous with a single rod of Jacob's membrane ; the inner passes inwards towards the outer plexiform layer and terminates in an enlarged extremity, and is imbedded in the tuft into which the outer processes of the rod-bipolars break up. In its course it presents numerous varicosities. The *cone-granules*, fewer in number than the rod-granules, are placed close to the membrana limitans externa, through which they are continuous with the cones of Jacob's membrane. They do not present any cross striping, but contain a pyriform nucleus, which almost completely fills the cell. From the inner extremity of the granule a thick process passes inwards to the outer plexiform layer, where it expands into a pyramidal enlargement or foot-plate, from which are given

off numerous fine fibrils, which come in contact with the outer processes of the cone-bipolars.

8. *The membrana limitans externa.*—This layer, like the membrana limitans interna, is derived from the supporting framework of the retina, with which it will be described.

9. *Jacob's membrane* (*layer of rods and cones*).—The elements which compose this layer are of two kinds, *rods* and *cones*, the former being much more numerous than the latter. The *rods* are of nearly uniform size, and are arranged perpendicularly to the surface. Each rod consists of two segments, an outer and inner, of about equal lengths. The segments differ from each other as regards refraction and in their behaviour with colouring reagents, the inner segment becoming stained by carmine, iodine, &c., the outer segment remaining unstained with these reagents, but staining yellowish-brown with osmic acid. The outer segment is marked by transverse striæ, and tends to break up into a number of thin discs superimposed on one another. It also exhibits faint longitudinal markings. The inner segment at its deeper part where it is joined to the outer process of the rod-granule, is indistinctly granular; its more superficial part presents a longitudinal striation, being composed of fine, bright, highly refracting fibrils. The visual purple or rhodopsin is found only in the outer segments.

The *cones* are conical or flask-shaped, their broad ends resting upon the membrana limitans externa, the narrow pointed extremity being turned to the choroid. Like the rods, each is made up of two segments, outer and inner; the outer segment is a short conical process, which, like the outer segment of the rod, exhibits transverse striæ. The inner segment resembles the inner segment of the rods in structure, presenting a superficial striated and deep granular part, but differs from it in size and shape, being bulged out laterally and flask-shaped. The chemical and optical characters of the two portions are identical with those of the rods.

10. *The pigmented layer.*—The most external layer of the retina, formerly regarded as a part of the choroid, consists of a single layer of hexagonal epithelial cells, loaded with pigment-granules. They are smooth externally, where they are in contact with the choroid, but internally they are prolonged into fine, straight processes, which extend between the rods, this being especially the case when the eye is exposed to light. In the eyes of albinos, the cells of the pigmented layer are present, but they contain no colouring matter.

Supporting framework of the retina.—Almost all these layers of the retina are connected together by a supporting framework, formed by the *fibres of Müller*, or *radiating fibres*, from which the membranæ limitans interna et externa are derived. These fibres stretch between the two limiting layers, 'as columns between a floor and a ceiling,' and pass through all the nervous layers, except Jacob's membrane. Each commences on the inner surface of the retina by an expanded, often forked, base, which sometimes contains a spheroidal body, staining deeply with hæmatoxylin, the edges of the bases of adjoining fibres being united to form the membrana limitans interna. As they pass through the nerve-fibre and ganglionic layers they give off few lateral branches; in the inner nuclear layer they give off numerous lateral processes for the support of the inner granules, while in the outer nuclear layer they form a network around the rod- and cone-fibrils, and unite to form the external limiting membrane at the bases of the rods and cones. In the inner nuclear layer each fibre of Müller presents a clear oval nucleus, which is sometimes situated at the side of, sometimes altogether within, the fibre.

Macula lutea and fovea centralis.—The structure of the retina at the yellow spot presents some modifications. In the macula lutea: (1) the nerve-fibres are wanting as a continuous layer; (2) the ganglionic layer consists of several strata of cells, instead of a single layer; (3) in Jacob's membrane there are no rods, but only cones, and these are longer and narrower than in other parts; and (4) in the outer nuclear layer there are only cone-fibres, which are very long and arranged in curved lines. At the fovea centralis the only parts which exist are (1) the cones of Jacob's membrane; (2) the outer nuclear layer, the cone-fibres of which are almost horizontal in direction; (3) an exceedingly thin inner plexiform layer; (4) the pigmented layer, which is thicker and its pigment more pronounced than elsewhere. The colour of the macula seems to

imbue all the layers except Jacob's membrane ; it is of a rich yellow, deepest towards the centre, and does not appear to be due to pigment-cells, but is simply a staining of the constituent parts.

At the ora serrata the nervous layers of the retina terminate abruptly, and the retina is continued onwards as a single layer of columnar cells covered by the pigmented layer. This prolongation is known as the *pars ciliaris retinæ*, and can be traced forwards from the ciliary processes on to the back of the iris, where it is termed the *pars iridica retinæ* or *uvea*.

From the description given of the nervous elements of the retina it will be seen that there is no direct continuity between the structures which form its different layers except between the ganglionic and nerve-fibre layers, the majority of the nerve-fibres being formed of the axons of the ganglionic cells. In the inner plexiform layer the dendrites of the ganglionic layer interlace with those of the cells of the inner nuclear layer, while in the outer plexiform layer a like synapsis occurs between the processes of the inner granules and the rod and cone elements.

The *arteria centralis retinæ* (fig. 844) and its accompanying vein pierce the optic nerve, and enter the globe of the eye through the porus opticus. The artery immediately bifurcates into an upper and a lower branch, and each of these again divides into an inner or nasal and an outer or temporal branch, which at first run between the hyaloid membrane and the nervous layer ; but they soon enter the latter, and pass forwards, dividing dichotomously. From these branches a minute capillary plexus is given off, which does not extend beyond

Fig. 844.—The arteria centralis retinæ, yellow spot, &c. ; the anterior half of the eyeball has been removed. (Enlarged.)

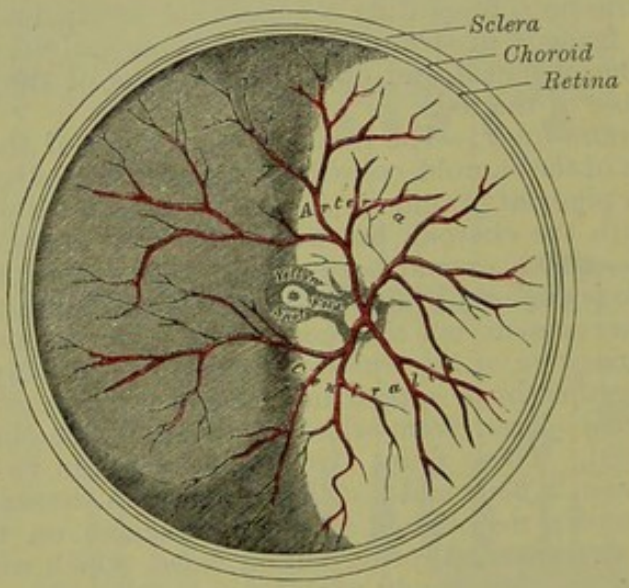

the inner nuclear layer. The macula receives small twigs from the temporal branches and others directly from the central artery ; these do not, however, reach as far as the fovea centralis, which has no blood-vessels. The branches of the arteria centralis retinæ do not anastomose with each other—in other words they are terminal arteries. In the fœtus, a small vessel passes forwards as a continuation of the arteria centralis retinæ through the vitreous humour, to the posterior surface of the capsule of the lens.

Refracting Media

The refracting media are three, viz. :

Aqueous humour. Vitreous body. Crystalline lens.

I. Aqueous Humour

The **aqueous humour** fills the anterior and posterior chambers of the eyeball. It is small in quantity (scarcely exceeding, according to Petit, four or five grains in weight) and has an alkaline reaction ; it consists mainly of water, less than one-fiftieth of its weight being solid matter, chiefly chloride of sodium.

II. Vitreous Body

The **vitreous body** (corpus vitreum) forms about four-fifths of the globe of the eye. It fills the concavity of the retina, and is hollowed in front, forming a deep concavity, the *fossa hyaloidea*, for the reception of the lens. It is perfectly transparent, of the consistence of thin jelly, and is composed of an albuminous fluid enclosed in a delicate transparent membrane, the *membrana hyaloidea*. It has been supposed, by Hannover, that from its inner surface numerous thin lamellæ are prolonged inwards in a radiating manner, forming spaces in which the fluid is contained. In the adult, these lamellæ cannot be detected even after careful microscopic examination in the fresh state, but in preparations hardened in weak chromic acid it is possible to make out a distinct lamellation at the periphery of the body; and in the fœtus a peculiar fibrous texture pervades the mass, the fibres joining at numerous points, and presenting minute nuclear granules at their point of junction. In the centre of the vitreous humour, running from the entrance of the optic nerve to the posterior surface of the lens, is a canal, the *canalis hyaloideus*, filled with fluid and lined by a prolongation of the hyaloid membrane. This canal, in the embryonic vitreous body, conveyed the minute vessel from the central artery of the retina to the back of the lens. The fluid from the vitreous body is nearly pure water; it contains, however, some salts, and a little albumen.

The *membrana hyaloidea* encloses the whole of the vitreous body. In front of the ora serrata it is thickened by the accession of radial fibres and is termed the *zonule of Zinn* or *zonula ciliaris*. Here it presents a series of radially arranged furrows, in which the ciliary processes are accommodated and to which they adhere, as is shown by the fact that when they are removed some of their pigment remains attached to the zonule. The zonule of Zinn splits into two layers, one of which is thin and lines the fossa hyaloidea, the other is named the *suspensory ligament of the lens*; it is thicker, and passes over the ciliary body to be attached to the capsule of the lens a short distance in front of its equator. Scattered and delicate fibres are also attached to the region of the equator itself. This ligament retains the lens in position, and is relaxed by the contraction of the radial fibres of the Ciliary muscle, so that the lens is allowed to become more convex. Behind the suspensory ligament there is a sacculated canal, the *canal of Petit*, which encircles the equator of the lens and which can be easily inflated through a fine blowpipe inserted under the suspensory ligament.

No vessels penetrate the vitreous body; so that its nutrition must be carried on by the vessels of the retina and ciliary processes, situated upon its exterior.

III. Crystalline Lens

The **crystalline lens** (lens crystallina), enclosed in its capsule, is situated immediately behind the iris, in front of the vitreous body, and encircled by the ciliary processes, which slightly overlap its margin.

The *capsule of the lens* (capsula lentis) is a transparent structureless membrane which closely surrounds the lens, and is thicker in front than behind. It is brittle but highly elastic, and when ruptured the edges roll up with the outer surface innermost. It rests, behind, in the fossa hyaloidea in the fore-part of the vitreous body; in front, it is in contact with the free border of the iris, but recedes from it at the circumference, thus forming the posterior chamber of the eye; it is retained in its position chiefly by the suspensory ligament of the lens, already described.

Fig. 845.—The crystalline lens, hardened and divided. (Enlarged.)

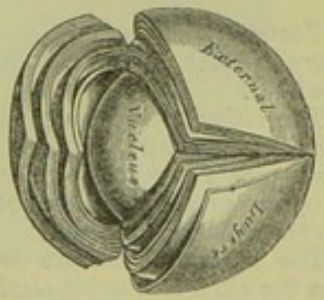

The *lens* is a transparent biconvex body, the convexity of its anterior being less than that of its posterior surface. The central points of these surfaces are termed respectively the *anterior* and *posterior poles*. A line connecting the poles constitutes the *axis* of the lens (axis lentis), while the marginal circumference is termed the *equator* (æquator lentis).

Structure.—The lens is made up of an outer, soft part (substantia corticalis) and a central, firm part (nucleus lentis) (fig. 845). Faint lines (radii lentis) radiate from the poles to the equator. In the adult there may be six or more of these lines, but in the fœtus they are only three in number and diverge from each other at angles of 120 degrees (fig. 846). On the anterior surface one line ascends vertically and the other two diverge downwards and outwards. On the posterior surface one ray descends vertically and the other two diverge upwards. They correspond with the free edges of an equal number of septa composed of an amorphous substance, which dip into the substance of the lens. When the lens has been hardened it is seen to consist of a series of concentrically arranged laminæ, each of which is interrupted at the septa referred to. Each lamina is built up of a number of hexagonal, ribbon-like fibres (fibræ lentis) the edges of which are more or less serrated—the serrations fitting between those of neighbouring fibres, while the ends of the fibres come into apposition at the septa. The fibres run in a curved manner from the septa on the anterior surface to those on the posterior surface. No fibres pass from pole to pole; they are arranged in such a way that those which commence near the pole on one aspect of the lens terminate near the peripheral extremity of the plane on the

FIG. 846.—Diagram to show the direction and arrangement of the radiating lines on the front and back of the fœtal lens. A. From the front. B. From the back.

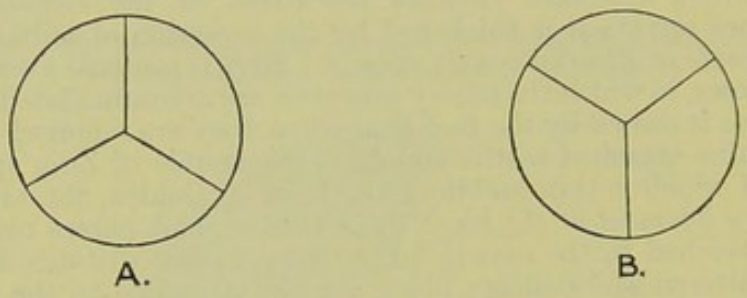

other, and *vice versa*. The fibres of the outer layers of the lens are nucleated, and together form a layer (nuclear layer) on the surface of the lens, most distinct towards its circumference. The anterior surface of the lens is covered by a layer of transparent, columnar, nucleated cells (epithelium lentis). At the equator the cells become elongated, and their gradual transition into lens fibres can be traced (fig. 847).

In the fœtus, the lens is nearly spherical, and has a slightly reddish tint; it is not perfectly transparent, and is so soft as to break down readily on the slightest pressure. A small branch from the arteria centralis retinæ runs forwards, as already mentioned, through the vitreous body to the posterior part of the capsule of the lens, where its branches radiate and form a plexiform network, which covers its surface, and they are continuous round the margin of the capsule with the vessels of the pupillary membrane, and with those of the iris.

In the adult, the posterior surface is more convex than the anterior; it is colourless, transparent, firm in texture, and devoid of vessels.

In old age it becomes flattened on both surfaces, slightly opaque, of an amber tint, and increased in density.

Vessels and Nerves.—The *arteries of the globe of the eye* are the short, long, and anterior ciliary arteries, and the arteria centralis retinæ. They have been already described (see page 648).

The *ciliary veins* are seen on the outer surface of the choroid, and are named, from their arrangement, the *venæ vorticosæ*. They converge to four or five equidistant trunks which pierce the sclera midway between the margin of the cornea and the entrance of the optic nerve. Another set of veins accompanies the anterior ciliary arteries and opens into the ophthalmic vein.

The *ciliary nerves* are derived from the nasal branch of the ophthalmic nerve and from the ciliary or ophthalmic ganglion.

Applied Anatomy.—From a surgical point of view the cornea may be regarded as consisting of three layers: (1) an external epithelial layer, developed from the ectoderm, and continuous with the epithelial covering of the rest of the body, so that its lesions resemble those of the epidermis; (2) the cornea proper, derived from the

mesoderm, and associated in its diseases with the fibro-vascular structures of the body; and (3) the posterior elastic layer with its endothelium, also derived from the mesoderm and having the characters of a serous membrane, so that inflammation of it resembles inflammation of the other serous and synovial membranes of the body.

The cornea contains no blood-vessels except at its periphery, where numerous delicate loops, derived from the anterior ciliary arteries, may be demonstrated on its anterior surface. The rest of the cornea is nourished by lymph, which gains access to the proper substance of the cornea and the posterior layer through the spaces of Fontana. This lack of a direct blood-supply renders the cornea very apt to inflame in the cachectic and ill-nourished. In cases of *granular lids*, there is a peculiar affection of the cornea, called *pannus*, in which the anterior layers of the cornea become vascularised, and a rich network of blood-vessels may be seen upon it; and in interstitial keratitis new vessels extend into the cornea, giving it a pinkish hue to which the term 'salmon patch' is applied. The cornea is richly supplied with nerves, derived from the ciliary, which enter the cornea through the fore-part of the sclera and form plexuses in the stroma, terminating between the epithelial cells by free ends or in corpuscles. In cases of glaucoma the ciliary nerves may be pressed upon as they course between the choroid and sclera, and the cornea becomes anæsthetic.

The sclera has very few blood-vessels and nerves. The blood-vessels are derived from the anterior ciliary, and form an open plexus in its substance. As they approach the corneal margin the arrangement is peculiar. Some branches pass through the sclera to the ciliary body; others become superficial and lie in the episcleral tissue, and form arches, by anastomosing with each other some little distance behind the corneal margin. From these arches numerous straight vessels are given off, which run forwards to the cornea, forming its marginal plexus. In inflammation of the sclera and episcleral tissue these vessels become conspicuous, and form a pinkish zone of straight vessels radiating from the corneal margin, commonly known as the *zone of ciliary injection*. In inflammation of the iris and ciliary body this zone is present, since the sclera speedily becomes involved when these structures are inflamed. But in inflammation of the cornea the sclera is seldom much affected, though the two are structurally continuous. This would appear to be due to the fact, that the nutrition of the cornea is derived from a different source than that of the sclera. The sclera may be ruptured subcutaneously without any laceration of the conjunctiva and the rupture usually occurs near the corneal margin, where the tunic is thinnest. It may be complicated with lesions of adjacent parts—laceration of the choroid, retina, iris, or suspensory ligament of the lens—and is then often attended with hæmorrhage into the anterior chamber, which masks the nature of the injury. In some cases the lens has escaped through the rent in the sclera and has been found under the conjunctiva. Wounds of the sclera are always dangerous, and are often followed by inflammation, suppuration, and by sympathetic ophthalmia.

FIG. 847. — Section through the margin of the lens, showing the transition of the epithelium into the lens-fibres. (Babuchin.)

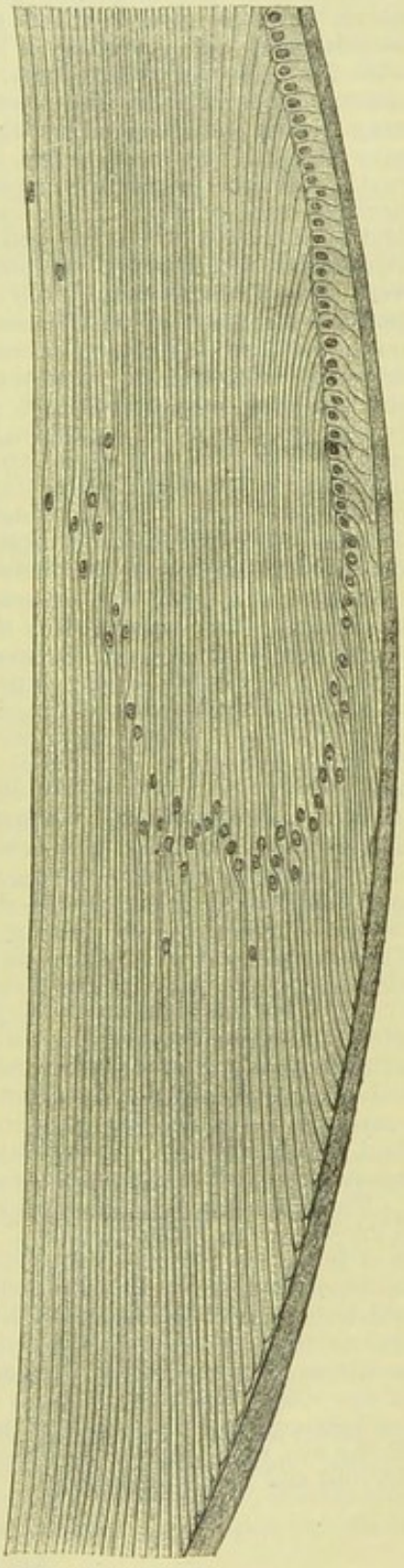

One of the functions of the choroid is to provide nutrition for the retina, and to convey vessels and nerves to the ciliary body and iris. Inflammation of the choroid is therefore followed by grave disturbances in the nutrition of the retina, and is attended with early interference with vision. Its diseases bear a considerable analogy to those which affect

the skin, and it is one of the places from which melanotic sarcomata may grow. These tumours contain a large amount of pigment in their cells, and originate only in those parts where pigment is naturally present.

The iris may be absent, either in part or altogether as a congenital condition, and in some instances the pupillary membrane may remain persistent, though it is rarely complete. Again, the iris may be the seat of a malformation, termed *coloboma*, which consists in a deficiency or cleft, clearly due in a great number of cases to an arrest in development. In these cases it is found at the lower aspect, extending directly downwards from the pupil, and the gap frequently extends through the choroid to the entrance of the optic nerve. In some rarer cases the gap is found in other parts of the iris, and is not then associated with any deficiency of the choroid. Wounds of the iris, especially if complicated with injury to the ciliary body, may be followed by serious consequences. If septic matter is introduced, and a suppurative inflammation is set up, complete loss of vision may result; and, what is perhaps of greater consequence, similar inflammatory changes may be set up in the sound eye, from spreading of the infective process through the connective tissue surrounding the optic nerve to the commissure, and thence down the opposite nerve to the sound eye. The iris is abundantly supplied with blood-vessels and nerves, and is very prone to become inflamed, and when inflamed, in consequence of the intimate relationship which exists between the vessels of the iris and choroid, this latter tunic is very liable to participate in the inflammation. The iris is covered with epithelium, and partakes of the character of a serous membrane, and, like these structures, is apt to pour out a plastic exudation, when inflamed, and contract adhesions, either to the cornea in front (*synechia anterior*), or to the capsule of the lens behind (*synechia posterior*). In iritis the lens may become involved, and the condition known as secondary cataract may be set up. Tumours occasionally commence in the iris; of these, cysts, which are usually congenital, and sarcomatous tumours, are the most common. Gummata are not infrequently found in this situation. In some forms of injury of the eyeball, as from the impact of a spent shot, the rebound of a twig, or a blow with a whip, the iris may be detached from the Ciliary muscle, the amount of detachment varying from the slightest degree to separation of the whole iris from its ciliary connection.

The retina, with the exception of its pigment layer and its vessels, is perfectly transparent when examined by the ophthalmoscope, so that its diseased conditions are recognised by its loss of transparency. In retinitis, for instance, there is more or less dense and extensive opacity of its structure, and not infrequently extravasations of blood into its substance. Hæmorrhages may also take place into the retina, from rupture of a blood-vessel without inflammation. The retina may become displaced from effusion of serum between it and the choroid, or by blows on the eyeball, or may occur without apparent cause in progressive myopia, and in this case the ophthalmoscope shows an opaque, tremulous cloud. Glioma, a form of sarcoma, and essentially a disease of early life, is occasionally met with in connection with the retina.

The lens has no blood-vessels, nerves, or connective tissue in its structure, and therefore is not subject to those morbid changes to which tissues containing these structures are liable. It does, however, present certain morbid or abnormal conditions of various kinds. Thus, variations in shape, and displacements, are among its congenital defects. Opacities may occur from injury, senile changes, or malnutrition. These opacities give rise to *cataract*, of which the senile variety is the most common. They vary as to the part of the lens in which the opacity commences, and are classified accordingly, as nuclear, cortical, lamellar, anterior and posterior polar. Senile changes may take place in the lens, impairing its elasticity and rendering it harder than in youth, so that it loses its power of altering its curvature to suit the requirements of near vision. This condition is known as *presbyopia*. And, finally, the lens may be dislocated or displaced by blows upon the eyeball; and its relations to surrounding structures altered by adhesions or the pressure of new growths.

There are two particular regions of the eye which require special notice: one of these is known as the 'filtration area,' and the other as the 'dangerous area.' The *filtration area* is the circumcorneal zone immediately in front of the iris. Here are situated the cavernous spaces of Fontana, which communicate with the canal of Schlemm through which the chief transudation of fluid from the eye is believed to take place. If any obstruction to this transudation occur, increased intra-ocular tension is set up, and the disease known as *glaucoma* results. The *dangerous area of the eye* is the region in the neighbourhood of the ciliary body, and wounds or injuries in this situation are peculiarly dangerous; for inflammation of the ciliary body is apt to spread to many of the other structures of the eye, especially to the iris and choroid, which are intimately connected with it by nervous and vascular supplies.

Appendages of the Eye

The appendages of the eye (organa oculi accessoria) include the eyebrows, the eyelids, the conjunctiva, and the lachrymal apparatus, viz. the lachrymal gland, the lachrymal sac, and the nasal duct.

The **eyebrows** (supercilia) are two arched eminences of integument, which surmount the upper circumference of the orbit on either side, and support numerous short, thick hairs, directed obliquely on the surface. In structure, the eyebrows consist of thickened integument, connected beneath with the Orbicularis palpebrarum, Corrugator supercilii, and Occipito-frontalis muscles. These muscles serve, by their action on this part, to control to a certain extent the amount of light admitted into the eye.

The **eyelids** (palpebræ) are two thin, movable folds, placed in front of the eye, protecting it from injury by their closure. The upper lid is the larger, and the more movable of the two, and is furnished with an elevator muscle, the Levator palpebræ superioris. When the eyelids are open, an elliptical space (*rima palpebrarum*) is left between their margins, the angles of which correspond to the junctions of the upper and lower lids, and are called *canthi*.

Fig. 848.—Vertical section through the upper eyelid. (After Waldeyer.)

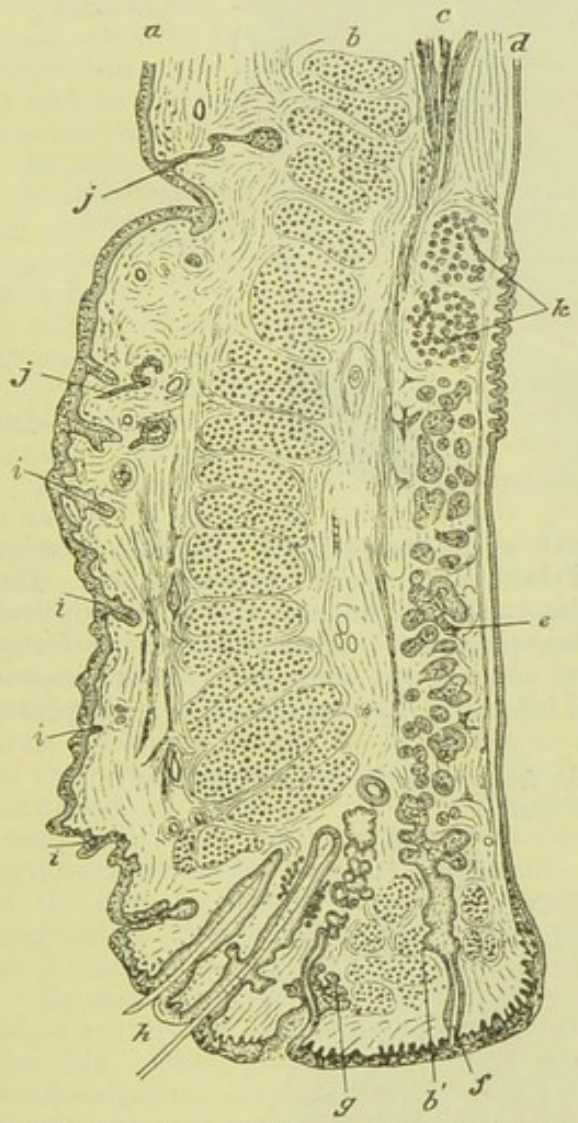

a. Skin. *b*. Orbicularis palpebrarum. *b'*. Marginal fasciculus of Orbicularis (ciliary bundle). *c*. Levator palpebræ. *d*. Conjunctiva. *e*. Tarsal plate. *f*. Meibomian gland. *g*. Sebaceous gland. *h*. Eyelashes. *i*. Small hairs of skin. *j*. Sweat-glands. *k*. Posterior tarsal glands.

The *outer canthus* (commissura palpebrarum lateralis) is more acute than the inner, and the lids here lie in close contact with the globe: but the *inner canthus* (commissura palpebrarum medialis) is prolonged for a short distance inwards towards the nose, and the two lids are separated by a triangular space, the *lacus lacrimalis*. At the basal angles of the lacus lacrimalis, on the margin of each eyelid, is a small conical elevation, the *lachrymal papilla*, the apex of which is pierced by a small orifice, the *punctum lacrimale*, the commencement of the lachrymal canal.

The *eyelashes* (*cilia*) are attached to the free edges of the eyelids; they are short, thick, curved hairs, arranged in a double or triple row at the margin of the lids: those of the upper lid, more numerous and longer than those of the lower, curve upwards; those of the lower lid curve downwards, so that they do not interlace in closing the lids. Near the attachment of the eyelashes are the openings of a number of glands, *glands of Moll*, arranged in several rows close to the free margin of the lid. They are regarded as enlarged and modified sweat-glands.

Structure of the eyelids.—The eyelids are composed of the following structures taken in their order from without inwards: integument, areolar tissue, fibres of the Orbicularis muscle, tarsal plate and its ligament, Meibomian glands and conjunctiva. The upper lid has, in addition, the aponeurosis of the Levator palpebræ (fig. 848).

The *integument* is extremely thin, and continuous at the margins of the lids with the conjunctiva.

The *subcutaneous areolar tissue* is very lax and delicate, seldom contains any fat, and is extremely liable to serous infiltration.

The *palpebral fibres of the Orbicularis muscle* are thin, pale in colour, and possess an involuntary action.

The *tarsal plates* (fig. 849) are two thin elongated plates of dense connective tissue, about an inch in length. They are placed one in each lid, and contribute to its form and support. The *superior tarsal plate* (tarsus superior), the larger, is of a semilunar form, about one-third of an inch in breadth at the centre,

Fig. 849.—The tarsal plates and their ligaments. Right eye; front view. (Testut.)

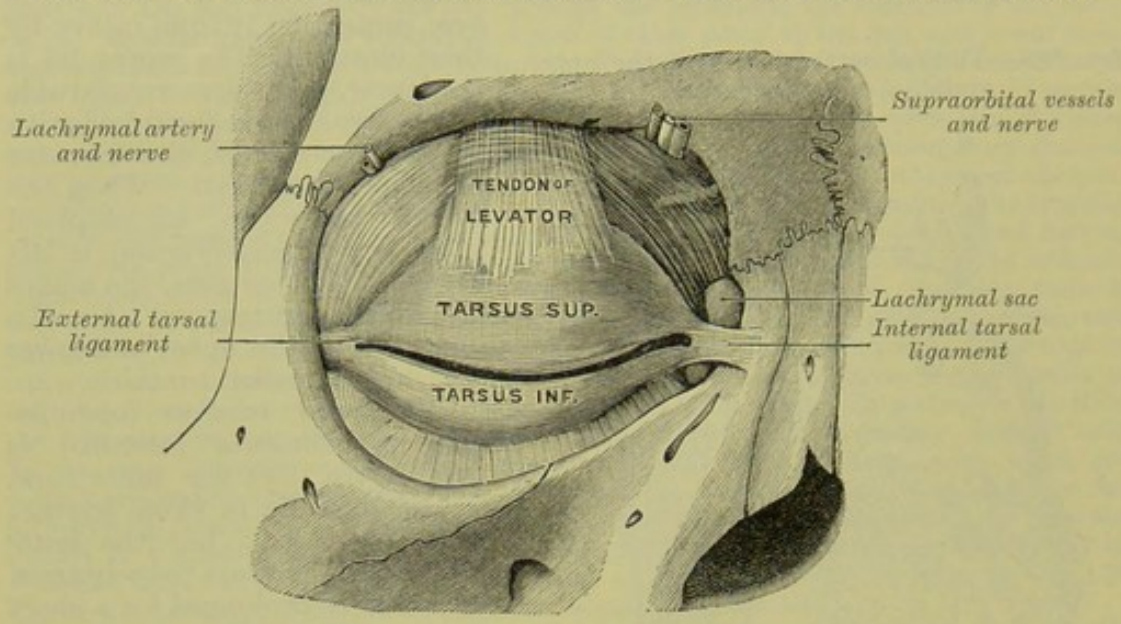

and gradually narrowing towards each of its extremities. To the anterior surface of this plate the aponeurosis of the Levator palpebræ is attached. The *inferior tarsal plate* (tarsus inferior), the smaller, is thinner, and of an elliptical form. The *free* or *ciliary margins* of these plates are thick, and present perfectly straight edges. The *attached* or *orbital margins* are connected to the circumference of the orbit by the superior and inferior palpebral ligaments. The *outer*

Fig. 850.—The Meibomian glands, &c., seen from the inner surface of the eyelids.

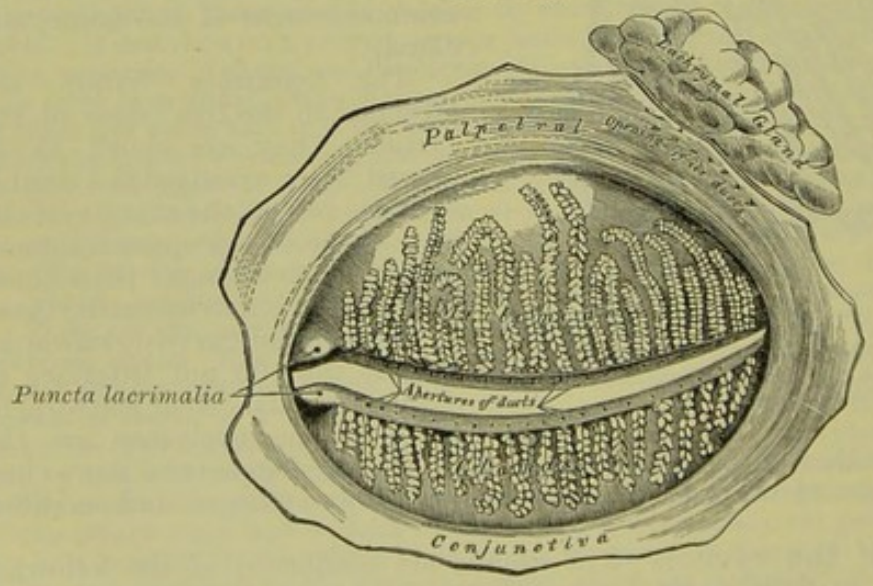

angles are attached to the malar bone by the external tarsal ligament. The *inner angles* of the two plates end at the lacus lacrimalis, and are attached to the frontal process of the maxilla by the internal tarsal ligament or tendo oculi.

The *palpebral* ligaments are membranous expansions situated one in each lid, and attached marginally to the edge of the orbit, where they are continuous with the periosteum. The superior ligament blends with the tendon of the Levator palpebræ and the superior tarsal plate, the inferior with the inferior

tarsal plate. Externally the two ligaments fuse to form the external tarsal ligament, just referred to ; internally they are much thinner and, becoming separated from the internal tarsal ligament, are fixed to the lachrymal bone immediately behind the lachrymal sac. Together, the ligaments form an incomplete septum, the *septum orbitale*, which is perforated by the vessels and nerves which pass from the orbital cavity to the face and scalp.

The *Meibomian glands* (glandulæ tarsales) (fig. 850) are situated upon the inner surfaces of the eyelids, between the tarsal plates and conjunctiva, and may be distinctly seen through the mucous membrane on everting the eyelids, presenting an appearance like parallel strings of pearls. They are about thirty in number in the upper eyelid, and somewhat fewer in the lower. They are imbedded in grooves in the inner surfaces of the tarsal plates, and correspond in length with the breadth of each plate ; they are, consequently, longer in the upper than in the lower eyelid. Their ducts open on the free margins of the lids by minute foramina which correspond in number to the follicles. The use of their secretion is to prevent adhesion of the lids.

Structure.—These glands are a variety of the cutaneous sebaceous glands, each consisting of a single straight tube or follicle, having a cæcal termination, and with numerous small lateral diverticula opening into it. The tubes are supported by a basement membrane, and are lined at their mouths by stratified epithelium ; the deeper parts of the tubes and the lateral offshoots are lined by a layer of polyhedral cells. They are thus identical in structure with the sebaceous glands.

The **conjunctiva** is the mucous membrane of the eye. It lines the inner surfaces of the eyelids, and is reflected over the fore-part of the sclera and cornea. In each of these situations its structure presents some peculiarities.

The *palpebral portion* is thick, opaque, highly vascular, and covered with numerous papillæ, its deeper parts presenting a considerable amount of lymphoid tissue. At the margins of the lids it becomes continuous with the lining membrane of the ducts of the Meibomian glands, and, through the lachrymal canals, with the lining membrane of the lachrymal sac and nasal duct. At the outer angle of the upper lid the lachrymal ducts open on its free surface ; and at the inner angle of the eye it forms a semilunar fold, the *plica semilunaris*. The line of reflection of the conjunctiva from the upper lid on to the eyeball is named the *fornix conjunctivæ superior* and that from the lower lid the *fornix conjunctivæ inferior*. Upon the *sclera* the conjunctiva is loosely connected to the globe ; it becomes thinner, loses its papillary structure, is transparent, and only slightly vascular in health. Upon the *cornea*, the conjunctiva consists only of epithelium, constituting the stratified epithelium of the cornea, already described (see page 1013). *Lymphatics* arise in the conjunctiva in a delicate zone around the cornea, from which the vessels run to the ocular conjunctiva.

In and near the fornices, but more plentiful in the upper than in the lower lid, a number of convoluted tubular glands open on the surface of the conjunctiva. Other glands, analogous to lymphoid follicles, and called by Henle *trachoma glands*, are found in the conjunctiva, and, according to Strohmeyer, are chiefly situated near the inner canthus of the eye. They were first described by Brush, in his description of Peyer's patches of the small intestine, as ' identical structures existing in the under eyelid of the ox.'

The *caruncula lacrimalis* is a small, reddish, conical-shaped body, situated at the inner canthus of the eye, and filling up the *lacus lacrimalis*. It consists of a small island of skin containing sebaceous and sweat glands, and is the source of the whitish secretion which constantly collects at the inner angle of the eye. A few slender hairs are attached to its surface. On the outer side of the caruncula is a slight semilunar fold of mucous membrane, the concavity of which is directed towards the cornea ; it is called the *plica semilunaris*. Müller found smooth muscular fibres in this fold, and in some of the domesticated animals a thin plate of cartilage has been discovered. This structure is considered to be the rudiment of the third eyelid in birds, the *membrana nictitans*.

The nerves in the conjunctiva are numerous and form rich plexuses. According to Krause they terminate in a peculiar form of tactile corpuscle, which he terms ' terminal bulb.'

Lachrymal Apparatus (fig. 851)

The lachrymal apparatus (apparatus lacrimalis) consists of the lachrymal gland which secretes the tears, and its excretory ducts which convey the fluid to the surface of the eye ; the fluid is carried away by the lachrymal canals into the lachrymal sac, and along the nasal duct into the cavity of the nose.

The **lachrymal gland** is lodged in the lachrymal fossa, on the inner side of the external angular process of the frontal bone. It is of an oval form, about the size and shape of an almond, and consists of an upper and a lower portion. The upper portion (*glandula lacrimalis superior*) is connected to the periosteum of the orbit by a few fibrous bands, and rests upon the Superior and External recti, which separate it from the globe of the eye. The lower part (*glandula lacrimalis inferior*) is separated from the upper by a fibrous septum, and projects into the back part of the upper eyelid, where its deep surface is related to the conjunctiva. The ducts of the gland, from six to twelve in number, run obliquely beneath the mucous membrane for a short distance, and, separating from each other, open by a series of minute orifices on the upper and outer half of the conjunctiva, near the superior fornix. These orifices are arranged in a row, so as to disperse the secretion over the surface of the membrane.

Fig. 851.—The lachrymal apparatus. Right side.

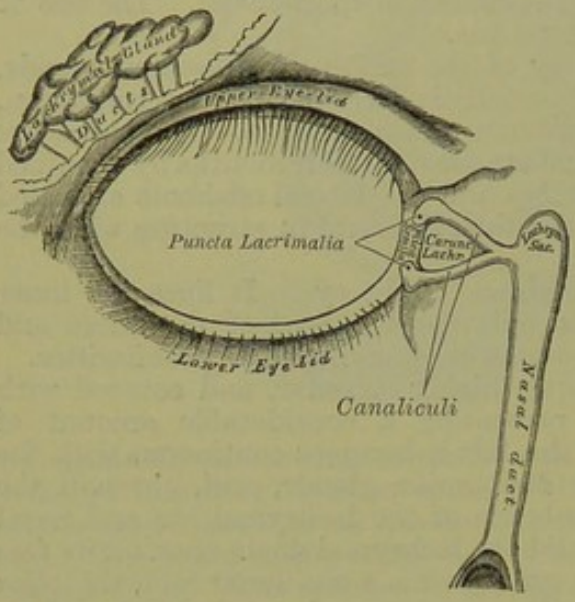

Structure of the lachrymal gland (fig. 852).—In structure and general appearance the lachrymal resembles the serous salivary glands (page 1112). In the recent state the cells are so crowded with granules that their limits can hardly be defined. They contain oval nuclei, and the cell protoplasm is finely fibrillated.

The **lachrymal canals** (ductus lacrimales) commence at the minute orifices, *puncta lacrimalia*, on the summit of small conical elevations, the *papillæ lacrimales*, seen on the margins of the lids, at the outer extremity of the lacus lacrimalis. The *superior canal*, the smaller and shorter of the two, at first ascends, and then bends at an acute angle, and passes inwards and downwards to the lachrymal sac. The *inferior canal* at first descends, and then passes almost horizontally inwards to the lachrymal sac. They are dense and elastic in structure and are dilated into *ampullæ* at their angles. The mucous membrane is covered with stratified scaly epithelium, placed on a basement membrane. Outside the latter is a layer of striped muscle, continuous with the Tensor tarsi ; at the bases of the lachrymal papillæ the fibres of this layer are circularly arranged and form a kind of sphincter.

Fig. 852.—Alveoli of lachrymal gland.

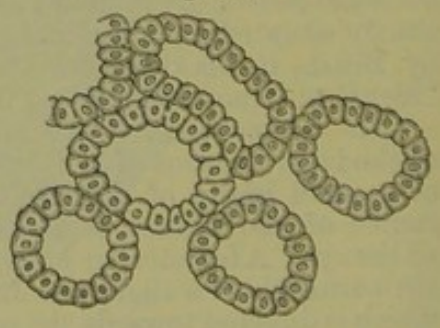

The **lachrymal sac** (saccus lacrimalis) is the upper dilated extremity of the nasal duct, and is lodged in a deep groove formed by the lachrymal bone and frontal process of the maxilla. It is oval in form, its upper extremity being closed in and rounded, while below, it is continued into the nasal duct. It is covered by a fibrous expansion derived from the tendo oculi, and on its deep surface it is crossed by the Tensor tarsi muscle (Horner's muscle, page 460), which is attached to the ridge on the lachrymal bone.

Structure.—The lachrymal sac consists of a fibrous elastic coat, lined internally by mucous membrane: the latter being continuous, through the lachrymal canals, with the mucous lining of the conjunctiva, and through the nasal duct with the mucous membrane of the nose.

The **nasal duct** (ductus nasolacrimalis) is a membranous canal, about three-quarters of an inch in length, which extends from the lower part of the lachrymal sac to the inferior meatus of the nose, where it terminates by a somewhat expanded orifice, provided with an imperfect valve, the *plica lacrimalis* (*Hasneri*), formed by a fold of the mucous membrane. It is contained in an osseous canal, formed by the maxilla, the lachrymal, and the inferior turbinated, is narrower in the middle than at either extremity, and takes a direction downwards, backwards, and a little outwards. It is lined by mucous membrane which is continuous below with that of the nose. This membrane in the lachrymal sac and nasal duct is covered with columnar epithelium as in the nose; this epithelium is in places ciliated.

Surface Form.—The palpebral fissure, or opening between the eyelids, is elliptical in shape, and differs in size in different individuals and in different races of mankind. In the Mongolian races, for instance, the opening is very small, merely a narrow fissure, and this makes the eye appear small in these races, whereas the size of the eyeball is relatively very constant. The normal form of the fissure is oblique, in a direction upwards and outwards, so that the outer angle is on a slightly higher level than the inner. This is exaggerated in the Mongolian races, in whom, owing to the upward projection of the malar bone and the shortness of the external angular process of the frontal bone, the tarsal plate of the upper lid is raised at its outer part, and gives a very oblique direction to the palpebral fissure. When the eyes are directed forwards, as in ordinary vision, the upper part of the cornea is covered by the upper lid, and the lower margin of the cornea corresponds to the level of the lower lid, so that about the lower three-fourths of the cornea are exposed under ordinary circumstances.

On the margins of the lids, about a quarter of an inch from the inner canthus, are two small openings, the *puncta lacrimalia*, the commencement of the lachrymal canals. They are best seen by everting the eyelids. In the natural condition they are in contact with the conjunctiva of the eyeball, and are maintained in this position by the Tensor tarsi muscle, so that the tears running over the surface of the globe easily find their way into the lachrymal canals. The position of the lachrymal sac into which the canals open is indicated by a little tubercle (page 282), which is plainly to be felt on the lower margin of the orbit. The lachrymal sac lies immediately above and to the inner side of this tubercle, and a knife passed through the skin in this situation would open the cavity. The position of the lachrymal sac may also be indicated by the tendo oculi, or internal tarsal ligament. If both lids be drawn outwards so as to tighten the skin at the inner angle, a prominent cord will be seen beneath the tightened skin. This is the *tendo oculi*, which lies directly over the lachrymal sac, bisecting it, and thus forming a useful guide to its situation. A knife entered immediately beneath the tense cord would open the lower part of the sac. A probe introduced through this opening can be readily passed downwards, through the duct into the inferior meatus of the nose. The direction of the duct is downwards, outwards, and backwards, and this course should be borne in mind in passing the probe, otherwise the point may be driven through the thin bony walls of the canal. A convenient plan is to direct the probe in such a manner, that if it were pushed onwards it would strike the first molar tooth of the mandible on the same side of the head. In other words, the surgeon standing in front of his patient should carry in his mind the position of the first molar tooth, and should push his probe onwards as if he desired to reach this structure.

Beneath the internal angular process of the frontal bone, the pulley of the Superior oblique can be plainly felt by pushing the finger backwards between the upper and inner angle of the eye and the roof of the orbit; passing backwards and outwards from this pulley the tendon can be felt for a short distance.

Applied Anatomy.—The eyelids are composed of various tissues, and consequently are liable to a variety of diseases. The skin which covers them is exceedingly thin and delicate, and is supported on a quantity of loose areolar subcutaneous tissue, which contains no fat. In consequence of this it is very freely movable, and is liable to be drawn down by the contraction of neighbouring cicatrices, and thus produce an eversion of the lid, known as *ectropion*. Inversion of the lids (*entropion*) from spasm of the Orbicularis palpebrarum or from chronic inflammation of the palpebral conjunctiva may also occur. The eyelids are richly supplied with blood, and are often the seat of vascular growths, such as nævi. Rodent ulcer frequently commences about the inner canthus. The loose cellular tissue beneath the skin is liable to become extensively infiltrated either with blood or inflammatory products, producing very great swelling. Even from very slight injuries to this tissue, the extravasation of blood may be so great as to produce considerable swelling of the lids and complete closure of the eye, and the same is the case

when inflammatory products are poured out. The follicles of the eyelashes, or the sebaceous glands associated with these follicles may, be the seat of inflammation, constituting the ordinary 'sty.' The Meibomian glands are affected in the so-called 'tarsal tumour': the tumour, according to some, being caused by the retained secretion of these glands; by others it is believed to be a neoplasm connected with the gland. The ciliary follicles are liable to become inflamed, constituting the disease known as *blepharitis ciliaris* or 'blear eye.' Irregular or disorderly growth of the eyelashes not infrequently occurs; some of them being turned towards the eyeball and producing inflammation and ulceration of the cornea, and possibly eventually complete destruction of the eye. The Orbicularis palpebrarum may be the seat of spasm, either in the form of slight quivering of the lids; or repeated twitchings, most commonly due to errors of refraction in children; or more continuous spasm, due to some irritation of the fifth or seventh cranial nerve. The Orbicularis may be paralysed, generally associated with paralysis of the other facial muscles. Under these circumstances the patient is unable to close the lids, and, if he attempts to do so, rolls the eyeball upwards under the upper lid. The tears overflow from displacement of the lower lid, and the conjunctiva and cornea, being constantly exposed and the patient being unable to wink, become irritated from dust and foreign bodies. Ptosis, or dropping of the upper eyelid, may be congenital, or may be due to paralysis of the Levator palpebræ superioris, in which case there will probably be other symptoms of implication of the third nerve. The eyelids may be the seat of bruises, wounds, or burns. Following burns, adhesion of the margins of the lids to each other, or adhesion of the lids to the globe, may take place. The eyelids are sometimes the seat of emphysema, after fracture of some of the thin bones forming the inner wall of the orbit. If shortly after such an injury the patient blows his nose, air is forced from the nostril through the lacerated structures into the connective tissue of the eyelids, which suddenly swell up and present the peculiar crackling characteristic of this affection.

Foreign bodies frequently get into the conjunctival sac and cause great pain, especially if they come in contact with the corneal surface, during the movements of the lid and the eye on each other. The conjunctiva is often involved in severe injuries of the eyeball, but is seldom ruptured alone; the most common form of injury to the conjunctiva alone is from a burn, either from fire, strong acids, or lime. In these cases union is liable to take place between the eyelid and the eyeball. The conjunctiva is often the seat of inflammation arising from many different causes, and the arrangement of the conjunctival vessels should be remembered as affording a means of diagnosis between this condition and injection of the sclera, which is present in inflammation of the deeper structures of the globe. The inflamed conjunctiva is bright red; the vessels are large and tortuous, and greatest at the circumference, shading off towards the corneal margin; they anastomose freely and form a dense network, and they can be emptied or displaced by gentle pressure. Inflammation of the underlying sclera, ciliary body, or iris, is a far more serious condition; the injection is in the deeper vessels of the eye, and as seen through the sclera presents a diffuse and dull purplish or violet zone of circumcorneal discoloration.

The lachrymal gland is occasionally, though rarely, the seat of inflammation, either acute or chronic; it is also sometimes the seat of tumours, benign or malignant, and for these may require removal. This may be done by an incision through the skin, just below the eyebrow; and the gland, being invested with a special capsule of its own, may be isolated and removed, without opening the general cavity of the orbit. The canaliculi may be obstructed, either as a congenital defect, or by some foreign body, as an eyelash or a dacryolith, causing the tears to run over the cheek. The canaliculi may also become occluded as a result of burns or injury; overflow of the tears may in addition result from deviation of the puncta, or from chronic inflammation of the lachrymal sac. This latter condition is set up by some obstruction to the nasal duct, frequently occurring in tuberculous subjects. In consequence of this the tears and mucus accumulate in the lachrymal sac, distending it. Suppuration in the lachrymal sac is sometimes met with; this may be the sequel of a chronic inflammation; or may occur after some of the eruptive fevers, in cases where the lachrymal passages were previously quite healthy. It may lead to lachrymal fistula from an abscess forming in the sac, which bursts or is opened on the surface; and this condition is often seen in badly nourished, tuberculous children.

THE EAR

The organ of hearing (organon auditus) is divisible into three parts: the external ear, the middle ear or tympanum, and the internal ear or labyrinth.

The External Ear

The **external ear** consists of the expanded portion named the *pinna* or *auricula*, and the *auditory canal* or *meatus*. The former serves to collect the vibrations of the air by which sound is produced; the latter conducts those vibrations to the tympanum.

The **pinna** or **auricula** (fig. 853) is of an ovoid form, with its larger end directed upwards. Its outer surface is irregularly concave, directed slightly forwards, and presents numerous eminences and depressions to which names have been assigned. Thus the external prominent rim of the auricle is called the *helix*. Where the helix turns downwards behind, a small tubercle, the *tubercle of Darwin* (tuberculum auriculæ) is frequently seen. This tubercle is very evident about the sixth month of fœtal life ; at this stage the human pinna has a close resemblance to that of some of the adult monkeys. Another curved prominence, parallel with and in front of the helix, is called the *antihelix* ; this divides above into two crura, which enclose a triangular depression, the *fossa of the antihelix* (*fossa triangularis*). The narrow curved depression between the helix and the antihelix is called the *fossa of the helix* (*scapha*) ; the antihelix describes a curve round a deep, capacious cavity, the *concha auriculæ*, which is partially divided into two parts by the *crus helicis* or the commencement of the helix ; the upper part is termed the *cymba conchæ*, the lower part the *cavum conchæ*. In front of the concha, and projecting backwards over the meatus, is a small pointed eminence, the *tragus* : so called from its being generally covered on its under surface with a tuft of hair, resembling a goat's beard. Opposite the tragus, and separated from it by a deep notch (*incisura intertragica*), is a small tubercle, the *antitragus*. Below this is the *lobule* (lobulus auriculæ), composed of tough areolar and adipose tissues, and wanting the firmness and elasticity of the rest of the pinna.

Fig. 853.—The pinna, or auricle. Outer surface.

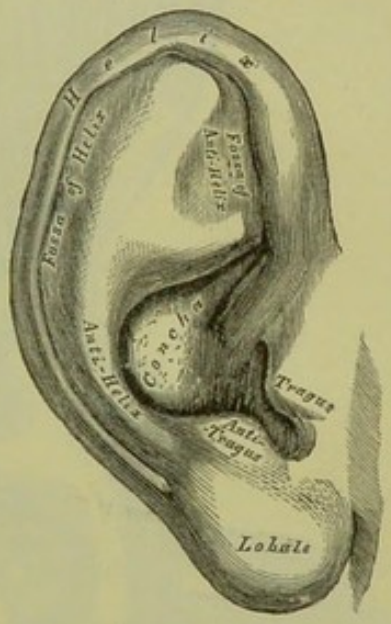

The cranial surface of the pinna presents elevations which correspond to the depressions on its outer surface and after which they are named, e.g. eminentia conchæ, eminentia triangularis, &c.

Structure of the pinna.—The pinna is composed of a thin plate of yellow fibro-cartilage, covered with integument, and connected to the surrounding

Fig. 854.—Cranial surface of cartilage of right pinna.

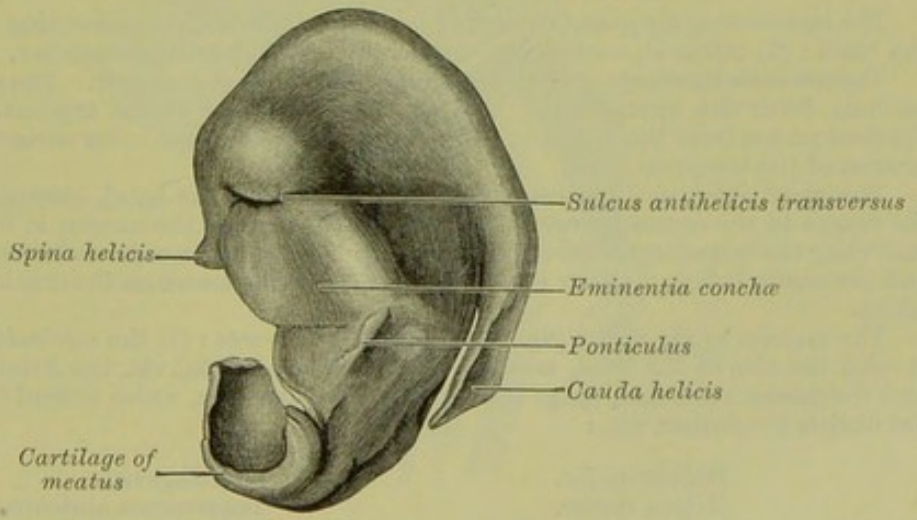

parts by the extrinsic ligaments and muscles ; and to the commencement of the external auditory canal by fibrous tissue.

The *integument* is thin, closely adherent to the cartilage, and covered with hairs furnished with sebaceous glands which are most numerous in the concha and scaphoid fossa. The hairs are most numerous and largest on the tragus and antitragus.

The *cartilage of the pinna* (cartilago auriculæ) (figs. 854, 855) consists of one single piece; it gives form to this part of the ear, and upon its surface are found all the eminences and depressions above described. It does not enter into the construction of all parts of the auricle; thus it does not form a constituent part of the lobule; it is deficient, also, between the tragus and beginning of the helix, the gap being filled up by dense fibrous tissue. At the front part of the pinna, where the helix bends upwards, is a small projection of cartilage, called the *spina helicis*, while the lower part of the helix is prolonged downwards as a tail-like process, the *cauda helicis*; this is separated from the antihelix by a fissure, the *fissura antitragohelicina*. The cranial aspect of the cartilage exhibits a transverse furrow, the *sulcus antihelicis transversus*, which corresponds with the inferior crus of the antihelix and separates the prominence produced by the concha from that caused by the fossa triangularis. The eminentia conchæ is crossed by a vertical ridge (*ponticulus*) which gives attachment to the Retrahens auriculam muscle. The cartilage of the pinna presents several intervals or fissures in its substance, which partially separate the different parts. The fissure of the helix is a short vertical slit, situated at the forepart of the pinna. Another fissure, the fissure of the tragus, is seen upon the anterior surface of the tragus. The cartilage of the pinna is of that form which is known as yellow fibro-cartilage.

Fig. 855.—The muscles of the pinna.

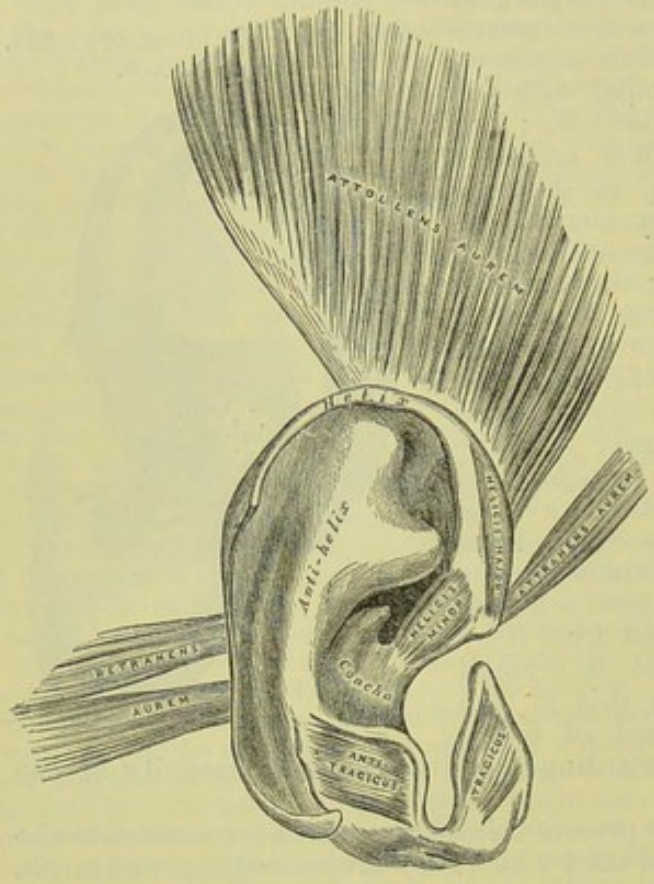

The *ligaments of the pinna* consist of two sets: (1) extrinsic, connecting it to the side of the head; (2) intrinsic, connecting various parts of its cartilage together.

The *extrinsic ligaments* are two in number, anterior and posterior. The *anterior ligament* extends from the spina helicis and tragus to the root of the zygoma. The *posterior ligament* passes from the posterior surface of the concha to the outer surface of the mastoid process of the temporal bone.

The chief *intrinsic ligaments* are: (*a*) a strong fibrous band, stretching across from the tragus to the commencement of the helix, completing the meatus in front, and partly encircling the boundary of the concha; and (*b*) a band which extends between the antihelix and the cauda helicis. Other less important bands are found on the cranial surface of the pinna.

The *muscles of the pinna* (fig. 855) consist of two sets: (1) the *extrinsic*, which connect it with the side of the head, moving the pinna as a whole, viz. the Attollens, Attrahens, and Retrahens auriculam (page 459); and (2) the *intrinsic*, which extend from one part of the auricle to another, viz.:

Helicis major.	Antitragicus.
Helicis minor.	Transversus auriculæ.
Tragicus.	Obliquus auriculæ.

The *Helicis major* is a narrow vertical band of muscular fibres, situated upon the anterior margin of the helix. It arises below, from the crus helicis, and is inserted into the anterior border of the helix, just where it is about to curve backwards.

The *Helicis minor* is an oblique fasciculus, which covers the crus helicis.

The *Tragicus* is a short, flattened vertical band of muscular fibres situated upon the outer surface of the tragus.

The *Antitragicus* arises from the outer part of the antitragus: its fibres are inserted into the cauda helicis and antihelix. This muscle is usually very distinct.

The *Transversus auriculæ* is placed on the cranial surface of the pinna. It consists of scattered fibres, partly tendinous and partly muscular, extending from the convexity of the concha to the prominence corresponding with the groove of the helix.

Fig. 856.—A front view of the organ of hearing. Right side.

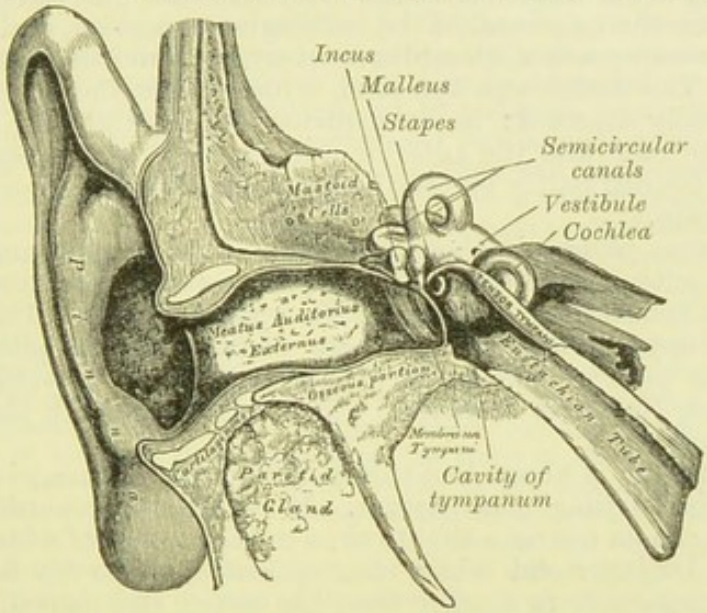

The *Obliquus auriculæ* consists of a few fibres extending from the upper and back part of the concha to the convexity immediately above it.

The *arteries of the pinna* are the posterior auricular from the external carotid, the anterior auricular from the temporal, and an auricular branch from the occipital artery.

The *veins* accompany the corresponding arteries.

Fig. 857.—Horizontal section through left ear; upper half of section.

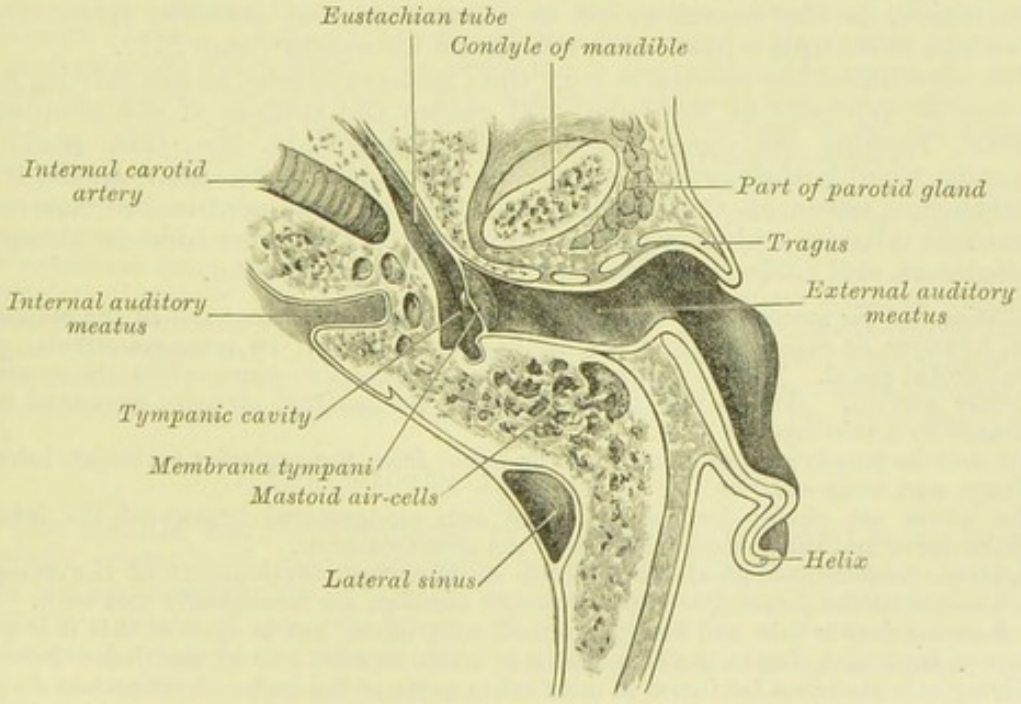

The *nerves* are: the great auricular, from the cervical plexus; the auricular branch of the pneumogastric; the auriculo-temporal branch of the inferior maxillary nerve; the small occipital from the cervical plexus, and the great occipital or internal branch of the posterior primary division of the second cervical nerve. The muscles of the pinna are supplied by the facial nerve.

The **auditory canal** (meatus acusticus externus) extends from the bottom of the concha to the membrana tympani (figs. 856, 857). It is about an inch and

a half in length if measured from the tragus; from the bottom of the concha its length is about an inch. It forms a sort of S-shaped curve, and is directed at first inwards, forwards, and slightly upwards (*pars externa*); it then passes inwards and backwards (*pars media*), and lastly is carried inwards, forwards, and slightly downwards (*pars interna*). It forms an oval cylindrical canal, the greatest diameter being in the vertical direction at the external orifice, but nearly in the horizontal direction at the tympanic end. It presents two constrictions, one near the inner end of the cartilaginous portion, and another, the *isthmus*, in the osseous portion, about three-quarters of an inch from the bottom of the concha. The membrana tympani, which closes the inner end of the meatus, is obliquely directed; in consequence of this the floor of the canal is longer than the roof, and the anterior wall longer than the posterior. The auditory canal is formed partly by cartilage and membrane, and partly by bone, and is lined by skin.

The *cartilaginous portion* is about one-third of an inch (8 mm.) in length; it is continuous with the cartilage of the pinna, and firmly attached to the circumference of the auditory process of the temporal bone. The cartilage is deficient at its upper and back part, its place being supplied by fibrous membrane. This part of the canal is rendered freely movable by two or three deep fissures (*incisuræ Santorini*) which extend through the cartilage in a vertical direction.

The *osseous portion* is about two-thirds of an inch (16 mm.) in length, and narrower than the cartilaginous portion. It is directed inwards and a little forwards, forming in its course a slight curve the convexity of which is upwards and backwards. Its inner end, which communicates, in the dry bone, with the cavity of the tympanum, is smaller than the outer, and sloped, the anterior wall projecting beyond the posterior for about one-sixth of an inch; it is marked, except at its upper part, by a narrow groove, the *sulcus tympanicus*, in which the circumference of the membrana tympani is attached. Its outer end is dilated and rough in the greater part of its circumference, for the attachment of the cartilage of the pinna. Its transverse section is oval, the greatest diameter being from above downwards and backwards. The front and lower parts of this canal are formed by a curved plate of bone, the tympanic plate, which, in the fœtus, exists as a separate ring (*annulus tympanicus*), incomplete at its upper part. See section on Osteology (page 231).

The *skin* lining the meatus is very thin, adheres closely to the cartilaginous and osseous portions of the tube, and covers the surface of the membrana tympani, forming its outer layer. After maceration, the thin pouch of epidermis, when withdrawn, preserves the form of the meatus. In the thick subcutaneous tissue of the cartilaginous part of the meatus are numerous ceruminous glands, which secrete the ear-wax. They resemble in structure sweat-glands, and their ducts open on the surface of the skin.

Relations of the meatus.—In front of the osseous part is the condyle of the mandible, which, however, is separated from the cartilaginous part by the retro-mandibular part of the parotid gland. The movements of the jaw influence to some extent the lumen of this latter portion. Behind the osseous part are the mastoid air-cells, separated from the meatus by a thin layer of bone.

The *arteries* supplying the meatus are branches from the posterior auricular, internal maxillary, and temporal.

The *nerves* are chiefly derived from the auriculo-temporal branch of the inferior maxillary nerve and the auricular branch of the pneumogastric.

Applied Anatomy.—Malformations, such as imperfect development of the external parts, absence of the meatus, or supernumerary auricles, are occasionally met with. The skin of the auricle is thin and richly supplied with blood, but in spite of this it is often the seat of frost-bite, due to the fact that it is much exposed to cold, and lacks the usual underlying subcutaneous fat found in most other parts of the body. A collection of blood is sometimes found between the cartilage and perichondrium (*hæmatoma auris*), usually the result of traumatism, but not necessarily due to this cause. It is said to occur most frequently in the ears of the insane. Keloid sometimes grows in the auricle around the puncture made for earrings, and epithelioma occasionally affects this part. Deposits of urate of soda are often met with in the pinna in gouty subjects.

The external auditory meatus can be most satisfactorily examined by light reflected down a funnel-shaped speculum; by gently moving the latter in different directions the whole of the canal and membrana tympani can be brought into view. In using this instrument, it is advisable that the pinna should be drawn upwards, backwards, and a

little outwards, so as to render the canal as straight as possible. The points to be noted are, the presence of wax or foreign bodies ; the size of the canal ; and the condition of the membrana tympani. Accumulation of wax is often a cause of deafness, and may give rise to very serious consequences, such as ulceration of the membrane, and it is best removed by syringing. Foreign bodies are not infrequently introduced into the ear by children, and, when situated in the first portion of the canal, may be removed with tolerable facility by means of a minute hook or loop of fine wire, aided by reflected light ; but when they have slipped beyond the narrow middle part of the meatus, their removal is in no wise easy, and attempts to effect it, in inexperienced hands, may be followed by destruction of the membrana tympani and possibly the contents of the tympanum. The calibre of the external auditory canal may be narrowed by inflammation of its lining membrane, running on to suppuration ; by periostitis ; by polypi ; or by exostoses.

At the point of junction of the osseous and cartilaginous portions an obtuse angle, which projects into the tube at its antero-inferior wall, is formed. This produces a sort of constriction in this situation, and renders it a narrow portion of the canal—an important point to be borne in mind in connection with the presence of foreign bodies in the ears. The cartilaginous is connected to the bony part by fibrous tissue which renders the outer part of the tube very movable, and therefore by drawing the pinna upwards and backwards the canal is rendered almost straight. At the external orifice are a few short, crisp hairs, which serve to prevent the entrance of small particles of dust, or flies and other insects. In the external auditory meatus the secretion of the ceruminous glands serves to catch any small particles which may find their way into the canal, and prevent their reaching the membrana tympani, where their presence might excite irritation. The shortness of the canal in children should be borne in mind in introducing the aural speculum, so that it be not pushed in too far, at the risk of injuring the membrana tympani ; indeed, even in the adult the speculum should never be introduced beyond the constriction which marks the junction of the osseous and cartilaginous portions, and thus assist the operator in obtaining, by the aid of reflected light, a good view of the membrana tympani. Just in front of the membrane is a well-marked depression, situated on the floor of the canal, and bounded by a somewhat prominent ridge ; in this foreign bodies may become lodged. By aid of the speculum, combined with traction of the auricle upwards and backwards, the greater part of the membrana tympani is rendered visible. It is a pearly-grey membrane, slightly glistening in the adult, placed obliquely, so as to form with the floor of the meatus a very acute angle (about fifty-five degrees), while with the roof it forms an obtuse angle. At birth it is more horizontal, situated in almost the same plane as the base of the skull. About midway between the anterior and posterior margins of the membrane, and extending from the centre obliquely upwards, is a reddish-yellow streak ; this is the handle of the malleus, which is inserted into the membrane. At the upper part of this streak, close to the roof of the meatus, a little white, rounded prominence is plainly to be seen ; this is the processus brevis of the malleus, projecting against the membrane. The membrana tympani does not present a plane surface ; on the contrary, its centre is drawn inwards, on account of its connection with the handle of the malleus, and thus the external surface is rendered concave.

The connections of the nerves of the meatus explain the fact of the occurrence, in cases of irritation of the meatus, of constant coughing and sneezing, from implication of the pneumogastric, and the vomiting which may follow syringing the ears of children, and the occasional heart failure similarly induced in elderly people. No doubt also the association of earache with toothache or with cancer of the tongue is due to implication of the inferior maxillary, a branch of the fifth, which supplies also the teeth and the tongue. The upper half of the membrana tympani is much more richly supplied with blood than the lower half. For this reason, and also to avoid the chorda tympani nerve and ossicles, incisions through the membrane should be made at the lower and posterior part.

The Middle Ear, or Tympanum

The **middle ear,** or **tympanic cavity** (cavum tympani) is an irregular laterally compressed cavity, situated within the temporal bone. It is filled with air, and communicates with the naso-pharynx by the Eustachian tube. It contains a chain of movable bones, which connect its outer to its inner wall, and serve to convey the vibrations communicated to the membrana tympani across the cavity to the internal ear.

The tympanic cavity consists of two parts : the *atrium* or *tympanic cavity proper*, opposite the tympanic membrane, and the *attic* or *recessus epitympanicus*, above the level of the upper part of the membrane ; the latter contains the upper half of the malleus and the greater part of the incus. Including the attic the vertical and antero-posterior diameters of the tympanic cavity each measures about fifteen millimetres. From without inwards it measures about six millimetres above and four millimetres below ; opposite the centre of the tympanic membrane it is only about two millimetres. It is bounded

externally by the membrana tympani and meatus; internally, by the outer wall of the internal ear; it communicates, behind, with the mastoid antrum and through it with the mastoid cells, and in front with the Eustachian tube.

The **roof** (paries tegmentalis) is broad, flattened, and formed of a thin plate of bone (*tegmen tympani*), which separates the cranial and tympanic cavities. It is situated on the anterior surface of the petrous portion of the temporal bone close to its angle of junction with the squamous portion of the same bone, and is prolonged backwards so as to roof in the mastoid antrum; it is also carried forwards to cover in the canal for the Tensor tympani muscle. Its outer edge corresponds with the remains of the petro-squamous suture.

The **floor** (paries jugularis) is narrow, and is separated by a thin plate of bone (*fundus tympani*) from the jugular fossa. It presents, near the inner wall, a small aperture for the passage of Jacobson's nerve.

The **outer wall** (paries membranacea) is formed mainly by the membrana tympani, partly by the ring of bone into which this membrane is inserted.

FIG. 858.—Coronal section of right temporal bone.

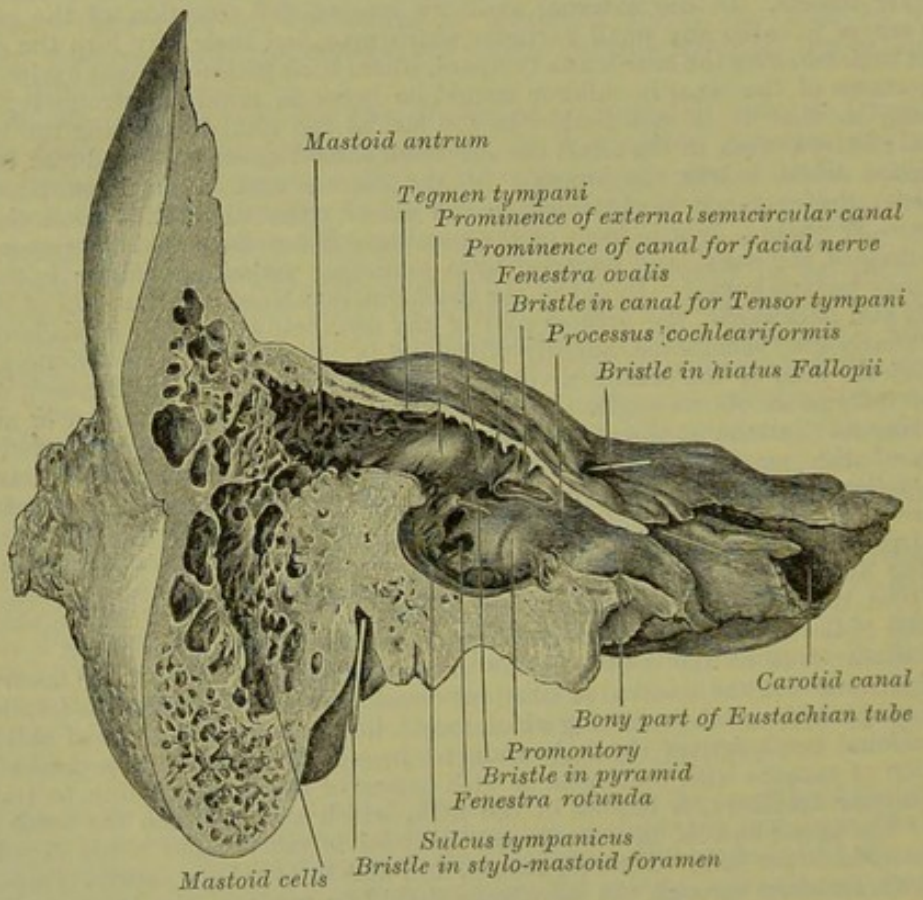

This ring of bone is incomplete at its upper part, forming a notch (*incisura Rivini*), close to which are three small apertures: the iter chordæ posterius, the Glaserian fissure, and the iter chordæ anterius.

The *iter chordæ posterius* (apertura tympanica canaliculi chordæ) is situated in the angle of junction between the posterior and outer walls of the tympanum, immediately behind the membrana tympani and on a level with the upper end of the handle of the malleus; it leads into a minute canal, which descends in front of the aquæductus Fallopii, and terminates in that canal near the stylo-mastoid foramen. Through it the chorda tympani nerve enters the tympanum.

The *Glaserian fissure* (fissura petrotympanica) opens just above and in front of the ring of bone into which the membrana tympani is inserted; in this situation it is a mere slit about a line in length. It lodges the long process and anterior ligament of the malleus, and gives passage to the tympanic branch of the internal maxillary artery.

The *iter chordæ anterius* (*canal of Huguier*) is placed at the inner end of the Glaserian fissure; through it the chorda tympani nerve leaves the tympanum.

The **inner wall** (paries labyrinthica) (fig. 858) is vertical in direction, and looks directly outwards. It presents for examination the following parts :

Fenestra ovalis.	Promontorium.
Fenestra rotunda.	Prominentia canalis facialis.

The *fenestra ovalis* (fenestra vestibuli) is a reniform opening leading from the tympanum into the vestibule of the internal ear ; its long diameter is directed horizontally, and its convex border is upwards. In the recent state it is occupied by the base of the stapes, the circumference of which is fixed by the annular ligament to the margin of the foramen.

The *fenestra rotunda* (fenestra cochleæ) is situated below and a little behind the fenestra ovalis, from which it is separated by a rounded elevation, the *promontorium*. It is placed at the bottom of a funnel-shaped depression and, in the macerated bone, leads into the cochlea of the internal ear ; it is closed in the recent state by a membrane (*membrana tympani secundaria*) which is concave towards the tympanum, convex towards the cochlea. This membrane consists of three layers : an external, or mucous, derived from the mucous lining of the tympanum ; an internal from the lining membrane of the cochlea ; and an intermediate, or fibrous layer.

The *promontorium* is a rounded hollow prominence, formed by the projection outwards of the first turn of the cochlea ; it is placed between the fenestræ, and is furrowed on its surface by three small grooves, which lodge branches of the tympanic plexus. A minute spicule of bone frequently connects the promontorium to the pyramid.

The *prominentia canalis facialis* indicates the position of the bony canal (aquæductus Fallopii), in which the facial nerve is contained ; this canal traverses the inner wall of the tympanum above the fenestra ovalis, and behind that opening curves nearly vertically downwards along the posterior wall.

The **posterior wall** (paries mastoidea) is wider above than below, and presents for examination the

Opening of the antrum.	Pyramid.	Fossa incudis.

The *opening of the antrum* is a large irregular aperture, which extends backwards from the epitympanic recess and leads into a considerable air space, the *mastoid antrum* (antrum tympanicum) (see page 226). The antrum communicates with large irregular cavities contained in the interior of the mastoid process, the *mastoid air-cells* (cellulæ mastoideæ). These cavities vary considerably in number, size, and form ; they are lined by mucous membrane, continuous with that lining the cavity of the tympanum. On the inner wall of the opening into the antrum is a rounded eminence, situated above and behind the eminence of the aquæductus Fallopii ; it corresponds with the position of the ampullated extremities of the superior and external semicircular canals.

The *pyramid* (eminentia pyramidalis) is a conical eminence, situated immediately behind the fenestra ovalis, and in front of the vertical portion of the Fallopian aqueduct ; it is hollow in the interior, and contains the Stapedius muscle ; its summit projects forwards towards the fenestra ovalis, and presents a small aperture which transmits the tendon of the muscle. The cavity in the pyramid is prolonged downwards and backwards in front of the aquæductus Fallopii, and communicates with it by a minute canal which transmits a twig from the facial nerve to the Stapedius muscle.

The *fossa incudis* is a small depression which is situated in the lower and back part of the epitympanic recess, and lodges the short process of the incus.

The **anterior wall** (paries carotica) is wider above than below ; it corresponds with the carotid canal, from which it is separated by a thin plate of bone perforated by the tympanic branch of the internal carotid artery, and by a communicating branch which connects the sympathetic plexus on the internal carotid artery with the tympanic plexus on the promontory. At the upper part of the anterior wall are the orifice of the canal for the Tensor tympani and the orifice of the Eustachian tube, separated from each other by a thin horizontal plate of bone, the *processus cochleariformis* (septum canalis musculotubarii). These canals run from the tympanum forwards, inwards, and a little downwards, to the retiring angle between the squamous and petrous portions of the temporal bone.

The *canal for the Tensor tympani* (semicanalis m. tensoris tympani) is the superior and the smaller of the two; it is cylindrical and lies beneath the forward prolongation of the tegmen tympani. It extends on to the inner wall of the tympanum and ends immediately above the fenestra ovalis. The processus cochleariformis passes backwards below this part of the canal, forming its outer wall and floor; it expands above the anterior extremity of the fenestra ovalis and terminates by curving outwards so as to form a pulley over which the tendon passes.

The *Eustachian tube* (tuba auditiva) is the channel through which the tympanum communicates with the naso-pharynx. Its length is an inch and a half (36 mm.), and its direction is downwards, forwards, and inwards, forming an angle of about forty-five degrees with the sagittal plane and one of from thirty to forty degrees with the horizontal plane. It is formed partly of bone, partly of cartilage and fibrous tissue.

Fig. 859.—The membrana tympani viewed from within. (Testut.)

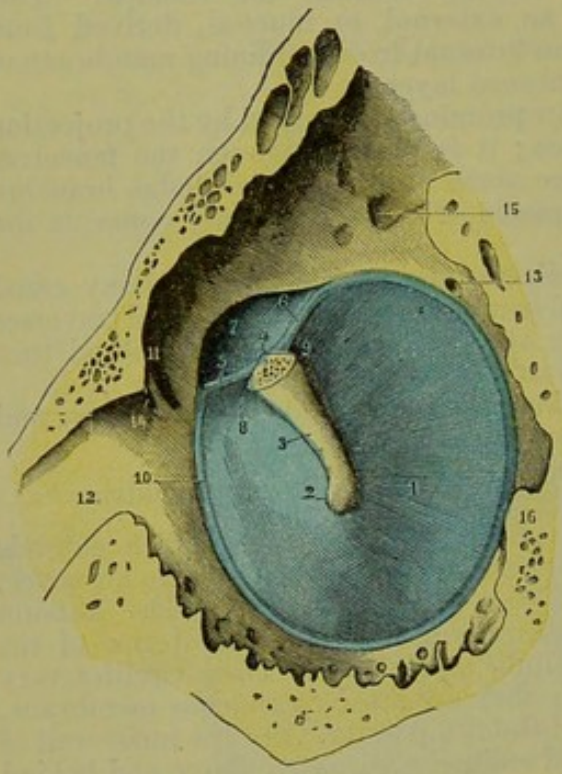

The malleus has been resected immediately beyond its processus brevis, in order to show the malleolar folds and the membrane of Shrapnell.

1. Membrana tympani. 2. Umbo or navel. 3. Handle of the malleus. 4. Processus brevis. 5. Anterior malleolar fold. 6. Posterior malleolar fold. 7. Membrane of Shrapnell. 8. Anterior pouch of Tröltsch. 9. Posterior pouch of Tröltsch. 10. Fibro-cartilaginous ring. 11. Glaserian fissure. 12. Eustachian tube. 13. Iter chordæ posterius. 14. Iter chordæ anterius. 15. Fossa incudis for short process of the incus. 16. Prominentia styloidea.

The *osseous portion* (pars ossea tubæ auditivæ) is about half an inch in length. It commences in the anterior wall of the tympanum, below the processus cochleariformis, and, gradually narrowing, terminates at the angle of junction of the petrous and squamous portions of the temporal bone, its extremity presenting a jagged margin which serves for the attachment of the cartilaginous portion.

The *cartilaginous portion* (pars cartilaginea tubæ auditivæ), about an inch in length, is formed of a triangular plate of elastic fibro-cartilage, the apex of which is attached to the margin of the inner extremity of the osseous canal, while its base lies directly under the mucous membrane of the naso-pharynx, where it forms an elevation or cushion behind the pharyngeal orifice of the tube. The upper edge of the cartilage is curled upon itself, being bent outwards so as to present on transverse section the appearance of a hook; a groove or furrow is thus produced, which opens below and externally, and this part of the canal is completed by fibrous membrane. The cartilage lies in a groove between the petrous temporal and the greater wing of the sphenoid; this groove ends opposite the middle of the internal pterygoid plate. The cartilaginous and bony portions of the tube are not in the same plane, the former inclining downwards a little more than the latter. The diameter of the tube is not uniform throughout, being greatest at the pharyngeal orifice, least at the junction of the bony and cartilaginous portions, and again expanding as it approaches the tympanic cavity; the narrowest part of the tube is termed the *isthmus*. The position and relations of the pharyngeal orifice are described with the naso-pharynx. The mucous membrane of the tube is continuous in front with that of the naso-pharynx and behind with that of the tympanic cavity; it is covered with ciliated epithelium and is thin in the osseous portion, while in the cartilaginous portion it contains many mucous glands and near the pharyngeal orifice a considerable amount of adenoid tissue, which has been named by Gerlach the *tube-tonsil*. The tube is opened during deglutition by the Salpingo-pharyngeus and Dilatator

tubæ. The latter arises from the hook of the cartilage and from the membranous part of the tube, and blends below with the Tensor palati.

The **membrana tympani** (fig. 859) separates the cavity of the tympanum from the bottom of the external meatus. It is a thin, semi-transparent membrane, nearly oval in form, somewhat broader above than below, and directed very obliquely downwards and inwards so as to form an angle of about fifty-five degrees with the floor of the meatus. Its longest diameter is directed from above and behind, downwards and forwards, and measures from nine to ten millimetres; its shortest diameter measures from eight to nine millimetres. The greater part of its circumference is thickened to form an annular ring which is fixed in a groove, the *sulcus tympanicus*, at the inner extremity of the meatus. This sulcus is deficient superiorly at the incisure or notch of Rivinus. From the extremities of this notch two bands, the *anterior* and *posterior malleolar folds*, are prolonged to the short process of the malleus. The small, somewhat triangular part of the membrane situated above these folds is lax and thin, and is named the *pars flaccida* of Shrapnell; in it a small orifice is sometimes seen. The handle of the malleus is firmly attached to the inner aspect of the membrane as far as its centre, which it draws inwards towards the cavity of the tympanum. The outer surface of the membrane is thus concave, and the most depressed part of this concavity is named the *umbo* (umbo membranæ tympani).

Structure.—The membrana tympani is composed of three layers, an external (cuticular), a middle (fibrous), and an internal (mucous). The *cuticular* layer (stratum cutaneum) is derived from the integument lining the meatus. The fibrous layer consists of two strata, an external (stratum radiatum) of *radial fibres*, which diverge from the handle of the malleus, and an internal (stratum circulare) of *circular fibres*, which are plentiful around the circumference but sparse and scattered near the centre of the membrane. Branched or *dendritic* fibres, as pointed out by Grüber, are also present, especially in the posterior half of the membrane.

[*Vessels and Nerves.*—The *arteries* of the membrana tympani are derived from the deep auricular branch of the internal maxillary, which ramifies beneath the cuticular layer: and from the stylo-mastoid branch of the posterior auricular, and tympanic branch of the internal maxillary, which are distributed on the mucous surface. The superficial *veins* open into the external jugular; those on the mucous surface drain partly into the lateral sinus and veins of the dura mater, and partly into a plexus on the Eustachian tube. The membrane receives its *nerve supply* from the auriculo-temporal branch of the inferior maxillary, the auricular branch of the vagus, and the tympanic branch of the glosso-pharyngeal.

Ossicles of the Tympanum (Ossicula auditus)

The tympanic cavity contains a chain of three movable bones, the *malleus*, *incus*, and *stapes*. The first is attached to the membrana tympani, the last to the circumference of the fenestra ovalis, the incus being placed between the two, and connected to both by delicate articulations.

The **Malleus** (fig. 860), so named from its fancied resemblance to a hammer, consists of a head, neck, and three processes, viz. the handle or manubrium, the processus gracilis, and the processus brevis.

The *head* (capitulum mallei) is the large upper extremity of the bone; it is oval in shape, and articulates posteriorly with the incus, being free in the rest of its extent. The facet for articulation with the incus is constricted near the middle, and consists of an upper larger, and lower lesser part, which form nearly a right angle with each other. Opposite the constriction the lower margin of the facet projects in the form of a process, the *cog-tooth* or *spur* of the malleus.

The *neck* (collum mallei) is the narrow contracted part just beneath the head; below it, is a prominence, to which the various processes are attached.

The *handle* (manubrium mallei) is connected by its outer margin with the membrana tympani. It is directed downwards, inwards, and backwards; it decreases in size towards its free extremity, which is curved slightly forwards, and flattened from within outwards. On the inner side, near its upper end, is a slight projection, into which the tendon of the Tensor tympani is inserted.

The *processus gracilis* (processus anterior [Folii]) is a delicate process,

which springs from the eminence below the neck and is directed forwards and outwards to the Glaserian fissure, to which it is connected by ligamentous fibres. In the fœtus this is the longest process of the malleus, and is in direct continuity with the cartilage of Meckel.

The *processus brevis* (processus lateralis) is a slight conical projection, which springs from the root of the manubrium ; it is directed outwards, and is attached to the upper part of the tympanic membrane and, by means of the anterior and posterior malleolar folds, to the extremities of the notch of Rivinus.

Fig. 860.—Left malleus. A. From behind. B. From within.

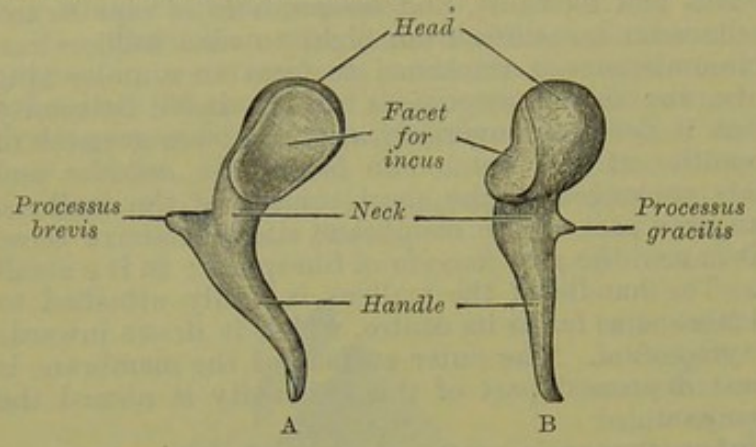

The **Incus** (fig. 861) has received its name from its supposed resemblance to an anvil, but it is more like a bicuspid tooth, with two roots, which differ in length, and are widely separated from each other. It consists of a body and two processes.

The *body* (corpus incudis) is somewhat quadrilateral but compressed laterally. On its anterior surface is a deeply concavo-convex facet, which articulates with the head of the malleus.

The two processes diverge from one another nearly at right angles.

The *short process* (crus breve) is somewhat conical in shape, projects almost horizontally backwards, and is attached to a depression, the *fossa incudis*, in the lower and back part of the epitympanic recess.

Fig. 861.—Left incus. A. From within. B. From the front.

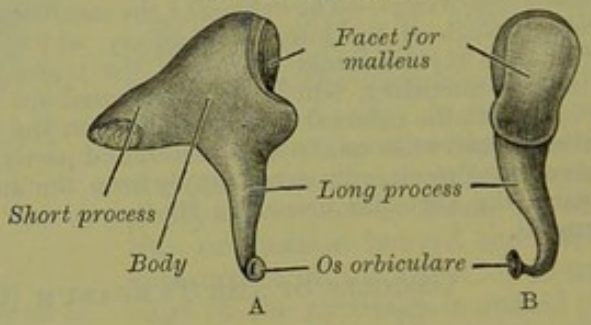

The *long process* (crus longum), longer and more slender than the preceding, descends nearly vertically behind and parallel to the handle of the malleus, and, bending inwards, terminates in a rounded globular projection, the *os orbiculare* or *lenticular process*, which is tipped with cartilage, and articulates with the head of the stapes. In the fœtus the os orbiculare exists as a separate bone.

The **Stapes** (fig. 862), so called from its close resemblance to a stirrup, consists of a head, neck, two crura, and a base.

Fig. 862.—A. Left stapes. B. Foot-plate of stapes from within.

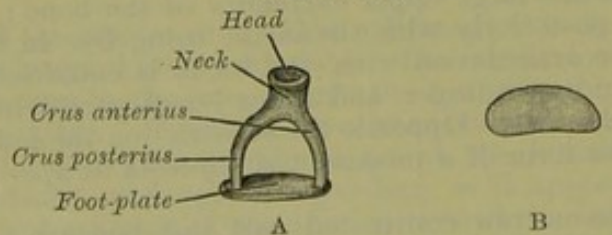

The *head* (capitulum stapedis) presents a depression, tipped with cartilage, which articulates with the os orbiculare.

The *neck* (collum stapedis), the constricted part of the bone succeeding the head, receives the insertion of the Stapedius muscle.

The *two crura* (crus anterius et crus posterius) diverge from the neck and are connected at their extremities by a flattened oval-shaped plate (*the base*), which forms the foot-plate of the stirrup and is fixed to the margin of the fenestra ovalis by ligamentous fibres. Of the two crura the anterior is shorter and less curved than the posterior.

Ligaments of the Ossicula.—These small bones are connected with each other, and with the walls of the tympanum, by ligaments, and moved by small muscles. The articular surfaces of the malleus and incus, and the orbicular process of the incus and head of the stapes, are covered with cartilage and connected together by delicate capsular ligaments, lined by synovial membrane. The ligaments connecting the ossicula with the walls of the tympanum are five in number: three for the malleus, one for the incus, and one for the stapes.

The *anterior ligament of the malleus* (lig. mallei anterius) was formerly described as a muscle (*Laxator tympani*). It is now, however, believed by most observers to consist of ligamentous fibres only. It is attached by one extremity to the neck of the malleus, just above the processus gracilis, and by the other to the anterior wall of the tympanum, close to the Glaserian fissure, some of its fibres being prolonged through the fissure to reach the spine of the sphenoid.

The *superior ligament of the malleus* (lig. mallei superius) is a delicate, round bundle of fibres which descends perpendicularly from the roof of the epitympanic recess to the head of the malleus.

The *external ligament of the malleus* (lig. mallei lateralis) is a triangular plane of fibres passing from the posterior part of the notch in the tympanic ring (*incisura Rivini*) to the head of the malleus.

The *posterior ligament of the incus* (lig. incudis posterius) is a short, thick, ligamentous band which connects the extremity of the short process of the incus to the fossa incudis in the epitympanic recess.

The vestibular surface and the circumference of the foot of the stapes are covered with hyaline cartilage; that encircling the base is attached to the margin of the fenestra ovalis by a fibrous ring, the *annular ligament of the stapes* (lig. annulare baseos stapedis).

A *superior ligament of the incus* (lig. incudis superius) has been described, but it is little more than a fold of mucous membrane.

The **muscles of the tympanum** are two:

Tensor tympani. Stapedius.

The *Tensor tympani*, the larger, is contained in the bony canal above the osseous portion of the Eustachian tube, from which it is separated by the processus cochleariformis. It arises from the cartilaginous portion of the Eustachian tube and the adjoining part of the greater wing of the sphenoid, as well as from the osseous canal in which it is contained. Passing backwards through the canal, it terminates in a slender tendon which enters the tympanum, makes a sharp bend outward round the extremity of the processus cochleariformis, and is inserted into the handle of the malleus, near its root. It is supplied by a branch from the otic ganglion.

The *Stapedius* arises from the side of a conical cavity, hollowed out of the interior of the pyramid; its tendon emerges from the orifice at the apex of the pyramid, and, passing forwards, is inserted into the posterior surface of the neck of the stapes. Its surface is aponeurotic, its interior fleshy; and its tendon occasionally contains a slender bony spine, which is constant in some mammalia. It is supplied by a branch of the facial nerve.

Actions.—The Tensor tympani draws the membrana tympani inwards, and thus increases its tension. The Stapedius draws the head of the stapes backwards, and thus causes the base of the bone to rotate on a vertical axis drawn through its own centre; the back part of the base is pressed inwards towards the vestibule, while the fore part is drawn from it. It probably compresses the contents of the vestibule.

The **mucous membrane of the tympanic cavity** is continuous with that of the pharynx, through the Eustachian tube. It invests the ossicles, and the muscles and nerves contained in the tympanic cavity; forms the internal layer of the membrana tympani, and the outer layer of the membrana tympani secundaria, and is reflected into the mastoid antrum and cells, which it lines throughout. It forms several vascular folds, which extend from the walls of the tympanum to the ossicles; of these one descends from the roof of the tympanum to the head of the malleus and upper margin of the body of the incus, a second invests the Stapedius muscle: other folds invest the chorda

tympani nerve and the Tensor tympani muscle. These folds separate off pouch-like cavities, and give the interior of the tympanum a somewhat honeycomb appearance. One of these pouches is well marked, viz. the *pouch of Prussak*, which lies between the neck of the malleus and the membrana flaccida. Two other folds may be mentioned : they are formed by the mucous membrane which envelops the chorda tympani nerve and are situated, one in front of, and the other behind the handle of the malleus ; they are named the *anterior* and *posterior recesses of Tröltsch*. In the tympanum this membrane is pale, thin, slightly vascular and covered for the most part with columnar ciliated epithelium, but over the pyramid, ossicula, and membrana tympani it possesses a flattened non-ciliated epithelium. In the antrum and mastoid cells its epithelium is also non-ciliated. In the osseous portion of the Eustachian tube the membrane is thin ; but in the cartilaginous portion it is very thick, highly vascular, and provided with numerous mucous glands ; the epithelium which lines the tube is columnar and ciliated.

Vessels and Nerves.—The *arteries* are six in number. Two of them are larger than the rest, viz. the tympanic branch of the internal maxillary, which supplies the membrana tympani ; and the stylo-mastoid branch of the posterior auricular, which supplies the back part of the tympanum and mastoid cells. The smaller arteries are—the petrosal branch of the middle meningeal, which enters through the hiatus Fallopii ; a branch from the ascending pharyngeal and another from the Vidian, which accompany the Eustachian tube ; and the tympanic branch from the internal carotid, given off in the carotid canal and perforating the thin anterior wall of the tympanum. The *veins* terminate in the pterygoid plexus, the superior petrosal sinus, and the middle meningeal vein. The *nerves* constitute the tympanic plexus, which ramifies upon the surface of the promontory. The plexus is formed by (1) the tympanic branch of the glosso-pharyngeal ; (2) the small deep petrosal nerve ; (3) the small superficial petrosal nerve ; and (4) a branch which joins the great superficial petrosal.

The *tympanic branch of the glosso-pharyngeal* (Jacobson's nerve) enters the tympanic cavity by an aperture in its floor close to the inner wall, and divides into branches which ramify on the promontory and enter into the formation of the plexus. The *small deep petrosal nerve* from the carotid plexus of the sympathetic passes through the wall of the carotid canal, and joins the branches of Jacobson's nerve. The branch to the great superficial petrosal passes through an opening on the inner wall, in front of the fenestra ovalis. The *small superficial petrosal nerve*, from the otic ganglion, passes backwards through a foramen in the middle fossa of the base of the skull (sometimes the foramen ovale), and enters the anterior surface of the petrous bone through a small aperture, situated external to the hiatus Fallopii ; it courses downwards through the bone, past the geniculate ganglion of the facial nerve, receiving a connecting filament from it, and enters the tympanic cavity, where it communicates with Jacobson's nerve, and assists in forming the tympanic plexus.

The *branches of distribution* of the tympanic plexus are supplied to the mucous membrane of the tympanic cavity ; a branch passes to the fenestra ovalis, another to the fenestra rotunda, and a third to the Eustachian tube. The small superficial petrosal may be looked upon as the continuation of the nerve of Jacobson through the plexus to the otic ganglion.

In addition to the tympanic plexus there are the nerves supplying the muscles. The Tensor tympani is supplied by a branch from the third division of the fifth through the otic ganglion, and the Stapedius by the tympanic branch of the facial.

The *chorda tympani* nerve crosses the tympanic cavity. It is given off from the sensory part of the facial, about a quarter of an inch before the nerve emerges from the stylo-mastoid foramen. It runs from below upwards and forwards in a canal, and enters the tympanic cavity through the *iter chordæ posterius*, already described (page 1040), and becomes invested with mucous membrane. It traverses the tympanic cavity, crossing internal to the membrana tympani and over the upper part of the handle of the malleus to the anterior wall, where it emerges through the *iter chordæ anterius*, or *canal of Huguier*.

Applied Anatomy.—The tympanic cavity is very frequently the seat of disease both suppurative and non-suppurative, and in practically every case the inflammation spreads upwards from the nose or throat along the Eustachian tube. The anatomy of the tympanic cavity is of the very greatest practical importance as regards its relations to other parts. Its roof is formed by a thin plate of bone which, with the dura mater, is all that separates it from the temporal lobe of the brain ; its floor is situated immediately above the jugular fossa behind, and the carotid canal in front ; its posterior wall presents the opening of the mastoid antrum, and on its anterior wall is the opening of the Eustachian tube. Acute inflammatory troubles spreading up to the tympanum by the latter tube are usually associated with so much inflammatory swelling of the mucous membrane of the Eustachian tube as to occlude it, and thus the products of inflammation are pent up in the tympanic cavity and directly involve the mastoid antrum. Under such circumstances

the only means of escape for the products is by rupture of the tympanic membrane, which usually occurs spontaneously and is followed by a free discharge of pus and relief to the acute pain which exists in these cases. Should the swelling of the walls of the Eustachian tube then subside, the normal drainage of the cavity will be established and the perforation in the drum will heal, but if not—as is often the case because the opening of the tube may be occluded by adenoid growths in the naso-pharynx or other cause—the pus will continue to accumulate in the middle ear and will overflow through the perforation as a chronic otorrhœa. In the course of time the disease spreads beyond the mucous membrane to the walls of the tympanic cavity, to the ossicles, or to the bone of the mastoid process, and when this has occurred the condition is incurable except by the removal of the carious bone. Further severe intracranial complications are at this time often produced owing to purulent material being retained; thus an abscess may form between the bone and dura mater, (*a*) about the roof of the tympanum, and immediately beneath the dura covering the temporal lobe, or (*b*) between the deep aspect of the mastoid process and the sigmoid bend of the lateral sinus, possibly extending widely and surrounding the sinus. In this latter type of case, thrombosis of the lateral sinus readily occurs, and the clot being also infected tends to disintegrate and be carried into the general circulation, particles often becoming lodged in the capillaries of the lungs and setting up abscesses therein. Pyæmia from lateral sinus thrombosis is probably more common than from any other focus of origin. In addition, bone disease of the tympanum or mastoid antrum may be associated with severe and fatal septic meningitis, or with the formation of abscess in the encephalon, the most common sites being the temporal lobe and the hemisphere of the cerebellum.

Less serious, but more common, is the formation of a subperiosteal mastoid abscess with great swelling behind the ear, and protrusion outwards of the auricle; such a condition demands an early incision down through all the structures, including the periosteum, over the whole length of the mastoid process, and then it will frequently be found that the underlying bone is carious or that a track leads through the bone into the mastoid antrum. In such conditions extensive operations for the removal of bone are often required. In many cases of chronic bone disease in the tympanic cavity the facial nerve becomes exposed as it lies in the aqueduct of Fallopius, and an inflammatory process is set up in the nerve, leading to facial paralysis of the infranuclear type (see page 927). In other cases localised areas of bone disease, most often in the region of the attic, form the points from which aural polypi grow, and the ear polypus, like the nasal polypus, must be considered to have originated in a spot of carious bone, the removal of which is necessary if a cure is to be established. Fractures of the middle fossa of the base of the skull almost invariably involve the tympanic roof, and are accompanied by a rupture of the drum or fracture through the roof of the bony meatus. They are associated with profuse continued bleeding from the ear, and, if the dura has also been lacerated, with discharge of copious amounts of cerebro-spinal fluid. Here the avoidance of infection from the outside is of the utmost importance, as should it occur septic meningitis must inevitably follow with a fatal issue.

Of the non-suppurative conditions which affect the middle ear, chronic catarrh, leading to sclerosis of the whole of the tympanic contents, is again due to spread of inflammation from some nasal or pharyngeal condition. The progress is very slow, but leads to ever-increasing deafness—this deafness in the first instance is in no way connected with any defect in the auditory nerve, and this can be shown by the fact that the hearing by bone conduction over the mastoid process remains normal. In chronic non-suppurative otitis, media treatment must be especially directed towards placing the nose and pharynx in a healthy condition; when this has been accomplished, the aural condition often improves of itself; if not, however, improvement may be induced by forcing air up the Eustachian tube by means of the Politzer bag, or directly into the orifice of the tube by means of the Eustachian catheter.

Internal Ear, or Labyrinth

The **internal ear** (auris interna) is the essential part of the organ of hearing, receiving the ultimate distribution of the auditory nerve. It is called the **labyrinth**, from the complexity of its shape, and consists of two parts: the *osseous labyrinth*, a series of cavities channelled out of the substance of the petrous bone, and the *membranous labyrinth*, the latter being contained within the former.

The Osseous Labyrinth (fig. 863)

The **osseous labyrinth** (labyrinthus osseus) consists of three parts: the *vestibule*, *semicircular canals*, and *cochlea*. These are cavities hollowed out of the substance of the bone, and lined by periosteum; they contain a clear fluid, the perilymph, in which the membranous labyrinth is situated.

The **vestibule** (vestibulum) is the central part of the internal ear, and is situated on the inner side of the tympanum, behind the cochlea, and in

front of the semicircular canals. It is somewhat ovoid in shape, flattened from within outwards, and measures about one-fifth of an inch from before backwards, the same from above downwards, and about one-eighth of an inch from without inwards. On its *outer* or *tympanic wall* is the fenestra ovalis, closed, in the recent state, by the base of the stapes and annular ligament. On its *inner wall*, at the fore part, is a small circular depression, the *recessus sphæricus*, which is perforated, at its anterior and inferior part, by several minute holes (*macula cribrosa media*) for the passage of filaments of the auditory nerve to the saccule; and behind this depression is an oblique ridge, the *crista vestibuli*, the anterior end of which is named the *pyramid* (pyramis vestibuli). This ridge bifurcates below to enclose a small depression, the *fossa cochlearis*, which is perforated by a number of holes for the passage of filaments of the auditory nerve which supply the posterior end of the ductus cochlearis. At the hinder part of the inner wall is the orifice of the *aquæductus vestibuli*, which extends to the posterior surface of the petrous portion of the temporal bone. It transmits a small vein, and contains a tubular prolongation of the membranous labyrinth, the *ductus endolymphaticus*, which ends in a *cul-de-sac* between the layers of the dura mater within the cranial cavity. On

Fig. 863.—The osseous labyrinth laid open. (Enlarged.)

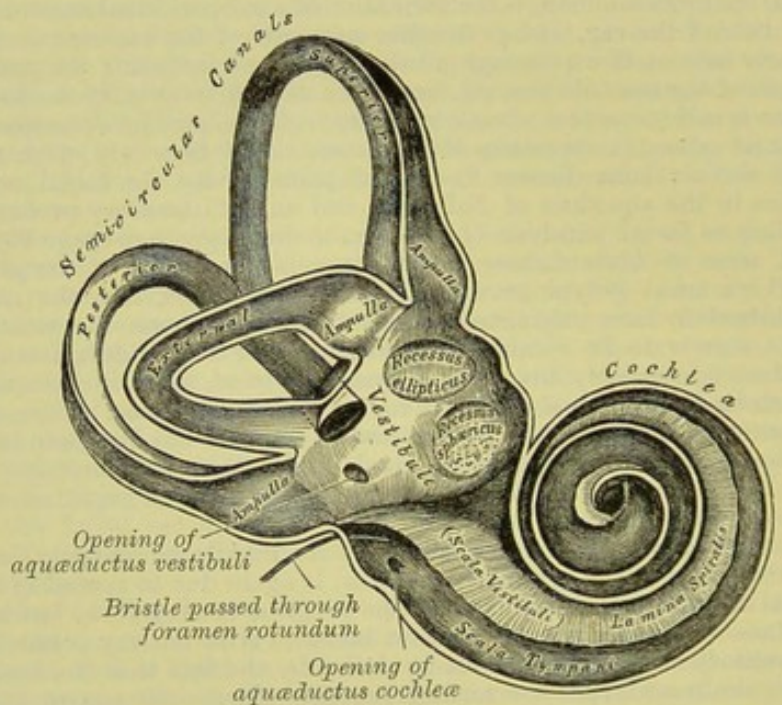

the *upper wall* or *roof* is a transversely oval depression, the *recessus ellipticus*, separated from the recessus sphæricus by the crista vestibuli already mentioned. The pyramid and adjoining part of the recessus ellipticus are perforated by a number of holes (*macula cribrosa superior*). The apertures in the pyramid transmit the nerves to the utricle; those in the recessus ellipticus the nerves to the ampullæ of the superior and external semicircular canals. *Behind*, the semicircular canals open into the vestibule by five orifices. In *front* is an elliptical opening, which communicates with the scala vestibuli of the cochlea.

The **bony semicircular canals** (canales semicirculares ossei) are situated above and behind the vestibule. They are of unequal length, compressed from side to side, and each describes the greater part of a circle. Each measures about ·8 mm. in diameter, and presents a dilatation at one end, called the *ampulla*, which measures more than twice the diameter of the tube. They open into the vestibule by five orifices, one of the apertures being common to two of the canals.

The *superior semicircular canal* (canalis semicircularis superior), 15 to 20 mm. in length, is vertical in direction, and is placed transversely to the long axis of the petrous portion of the temporal bone, on the anterior surface of which

its arch forms a round projection. It describes about two-thirds of a circle. Its outer extremity is ampullated, and opens into the upper part of the vestibule; the opposite end joins with the upper part of the posterior canal to form the *crus commune*, which opens into the upper and inner part of the vestibule.

The *posterior semicircular canal* (canalis semicircularis posterior), also vertical, is directed backwards, nearly parallel to the posterior surface of the petrous bone; it is the longest of the three, measuring from 18 to 22 mm.; its lower or ampullated end opens into the lower and back part of the vestibule, its opposite opens into the crus commune already mentioned.

The *external* or *horizontal canal* (canalis semicircularis lateralis) is the shortest of the three. It measures from 12 to 15 mm., and its arch is directed horizontally outwards and backwards; thus each semicircular canal stands at right angles to the other two. Its ampullated end corresponds to the upper and outer angle of the vestibule, just above the fenestra ovalis, where it opens close to the ampullary end of the superior canal; its opposite end opens by a distinct orifice at the upper and back part of the vestibule. 'The external canal of one ear is very nearly in the same plane as that of the other; while the superior canal of one ear is nearly parallel to the posterior canal of the other.' *

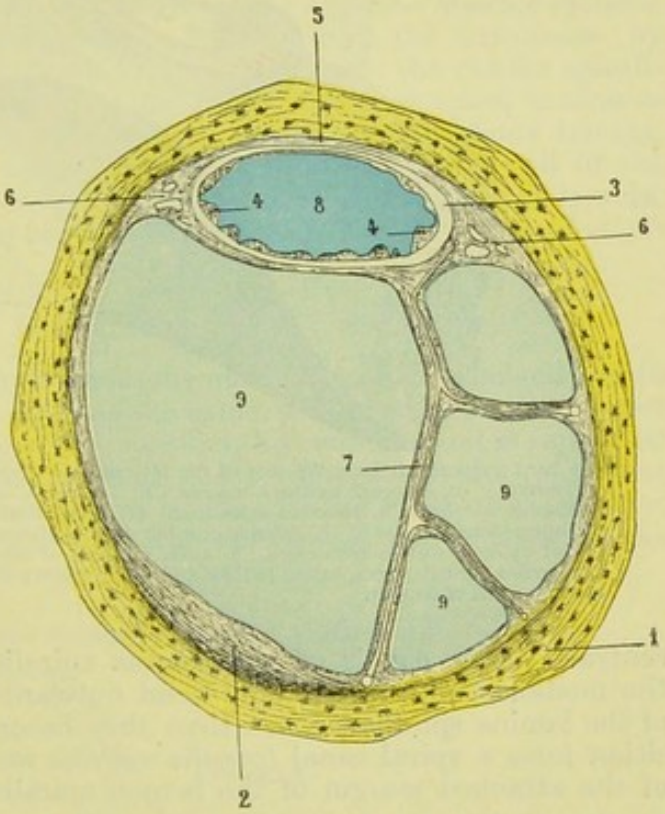

Fig. 864.—Transverse section of a human semicircular canal (after Rüdinger). (Testut.)

1. Bony semicircular canal. 2. Periosteum. 3. Membranous semicircular canal, with 4, papilliform processes on its internal surface. 5. Connective tissue binding the membranous canal to the periosteum. 6, 6. Fibrous bands uniting the free surface of the membranous canal to the periosteum. 7. Vessels. 8. Endolymphatic space. 9, 9. Perilymphatic space.

The **cochlea** (figs. 865, 866) bears some resemblance to a common snail-shell; it forms the anterior part of the labyrinth, is conical in form, and placed almost horizontally in front of the vestibule; its apex (cupula) is directed forwards and outwards, with a slight inclination downwards, towards the upper and front part of the inner wall of the tympanum; its base (basis cochleæ) corresponds with the bottom of the internal auditory meatus, and is perforated by numerous apertures for the passage of the cochlear division of the auditory nerve. It measures about 5 mm. from base to apex, and its breadth across the base is somewhat greater (about 9 mm.). It consists of a conical-shaped central axis, the *modiolus*; of a canal, the inner wall of which is formed by the central axis, wound spirally around it for two turns and three-quarters, from the base to the apex; and of a delicate lamina (the *lamina spiralis ossea*) which projects from the modiolus, and, following the windings of the canal, partially subdivides it into two. In the recent state a membrane, the *membrana basilaris*, stretches from the free border of this lamina to the outer wall of the bony cochlea and completely separates the canal into two passages, which, however, communicate with each other at the apex of the modiolus by a small opening, named the *helicotrema*.

The *modiolus* is the central axis or pillar of the cochlea. It is conical in form, and extends from the base to the apex of the cochlea. Its base (basis

* Crum Brown, *Journal of Anatomy and Physiology*, vol. viii.

modioli) is broad, and appears at the bottom of the internal auditory meatus, where it corresponds with the area cochleæ ; it is perforated by numerous orifices, which transmit filaments of the cochlear division of the auditory nerve ; the nerves for the first turn and a half pass through the foramina of the tractus spiralis foraminosus ; those for the apical, turn through the foramen

Fig. 865.—The cochlea and vestibule, viewed from above. (Testut.)

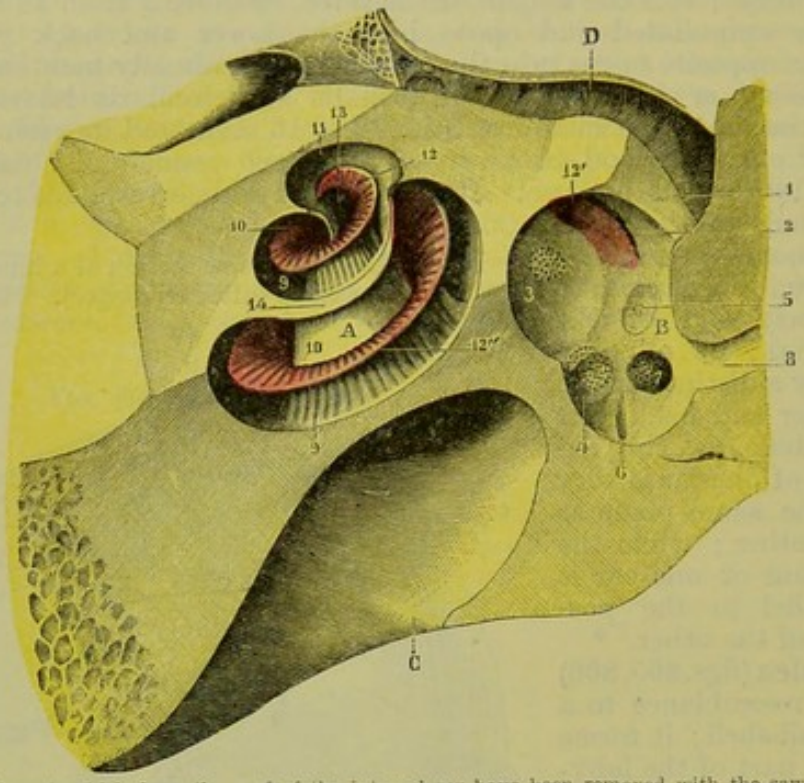

All the hard parts which form the roof of the internal ear have been removed with the saw. A. Cochlea. B. Vestibule. C. Internal auditory meatus. D. Tympanic cavity. 1. Lower border of fenestra ovalis. 2. Fissura vestibuli. 3. Recessus sphæricus. 4. Recessus ellipticus. 5. Fossa cochlearis. 6. Orifice of the aquæductus vestibuli. 7. Inferior opening of the posterior semicircular canal. 8. Non-ampullated end of external semicircular canal. 9. Scala tympani of the cochlea. 10. Scala vestibuli. 11. Cupula. 12. Lamina spiralis ossea, with 12′, its vestibular origin ; 12″, its external border. 13. Helicotrema. 14. Bony wall of cochlea.

centrale. The canals of the tractus spiralis foraminosus pass up through the modiolus and successively bend outwards to reach the attached margin of the lamina spiralis ossea. Here they become enlarged, and by their apposition form a spiral canal (*canalis spiralis modioli*), which follows the course of the attached margin of the lamina spiralis ossea and lodges the ganglion

Fig. 866.—The cochlea laid open. (Enlarged.)

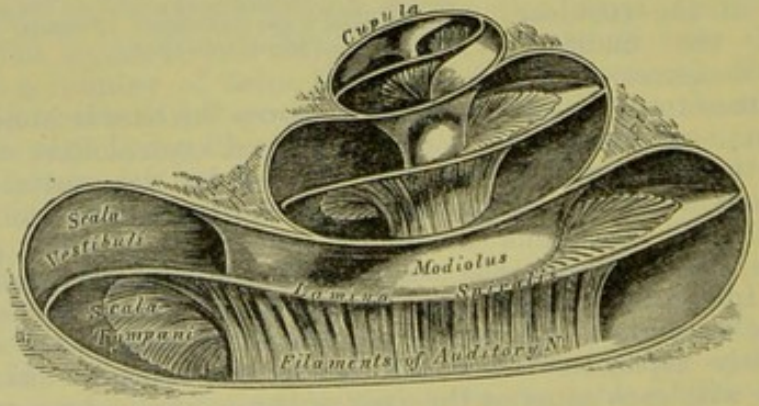

spirale (*ganglion of Corti*). The foramen centrale is continued into a canal which runs up the middle of the modiolus to its apex. The modiolus diminishes rapidly in size in the second and succeeding coil.

The bony canal of the cochlea takes two turns and three-quarters round the modiolus. It is a little over an inch in length (about 30 mm.) and

diminishes gradually in size from the base to the summit, where it terminates in the *cupula*, which forms the apex of the cochlea. The commencement of this canal is about the tenth of an inch in diameter; it diverges from the modiolus towards the tympanum and vestibule, and presents three openings. One, the *fenestra rotunda*, communicates with the tympanum—in the recent state this aperture is closed by a membrane, the *membrana tympani secundaria*; another, of an elliptical form, opens into the vestibule. The third is the aperture of the aqueductus cochleæ, leading to a minute funnel-shaped canal, which opens on the basilar surface of the petrous bone and transmits a small vein, and also forms a communication between the subarachnoid space of the skull and the scala tympani.

The *lamina spiralis ossea* is a bony shelf or ledge which projects outwards from the modiolus into the interior of the spiral canal, and, like the canal, takes two and three-quarter turns round the modiolus. It reaches about halfway towards the outer wall of the spiral tube, and partially divides its cavity into two passages or scalæ, of which the upper is named the *scala vestibuli*, while the lower is termed the *scala tympani*. Near the summit of the cochlea the lamina terminates in a hook-shaped process, the *hamulus laminæ spiralis*, which assists in forming the boundary of a small opening, the *helicotrema*, by which the two scalæ communicate with each other. From the canalis spiralis modioli numerous canals pass outwards through the osseous spiral lamina as far as its free edge. In the lower part of the first turn a second bony lamina, the *lamina spiralis secundaria*, projects inwards from the outer wall of the bony tube; it does not, however, reach the primary osseous spiral lamina, so that if viewed from the vestibule a narrow fissure, the *fissura vestibuli*, is seen between them.

The Membranous Labyrinth (figs. 867, 868, 869)

The **membranous labyrinth** (labyrinthus membranaceus) is lodged within the bony cavities just described, and has the same general form as the cavities in which it is contained; it is, however, considerably smaller, and is separated from the bony walls by a quantity of fluid, the *perilymph*. It does not float loosely in this fluid, but in certain places is fixed to the walls of the cavity. The membranous labyrinth contains fluid, the *endolymph*, and on its walls the ramifications of the auditory nerve are distributed.

Fig. 867.—The membranous labyrinth. (Enlarged.)

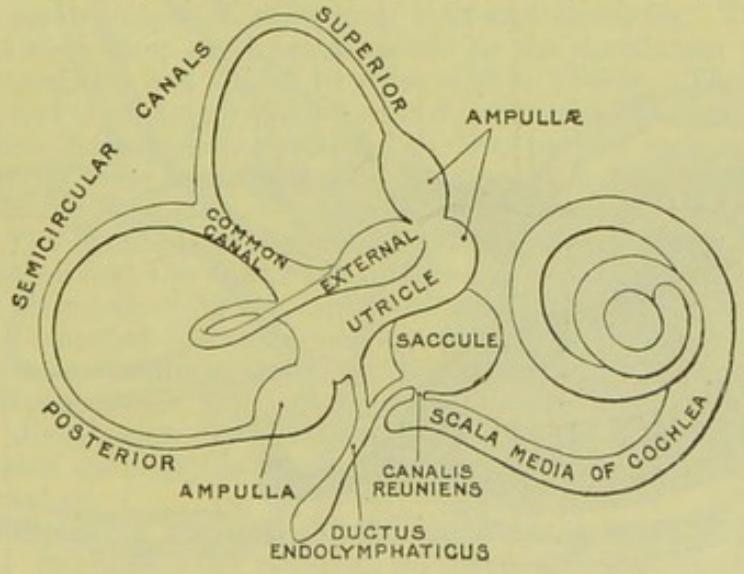

Within the osseous vestibule the membranous labyrinth does not quite preserve the form of the bony cavity, but presents two membranous sacs, the *utricle* and the *saccule*.

The **utricle** (utriculus), the larger of the two, is of an oblong form, compressed laterally, and occupies the upper and back part of the vestibule, lying in contact with the recessus ellipticus and the part below it. That portion which is lodged in the recess forms a sort of pouch or *cul-de-sac*, the floor

and anterior wall of which are much thicker than elsewhere, and form the *macula acustica utriculi*, which receives the utricular filaments of the auditory

FIG. 868.—Right human membranous labyrinth, removed from its bony enclosure and viewed from the antero-lateral aspect. (G. Retzius.)

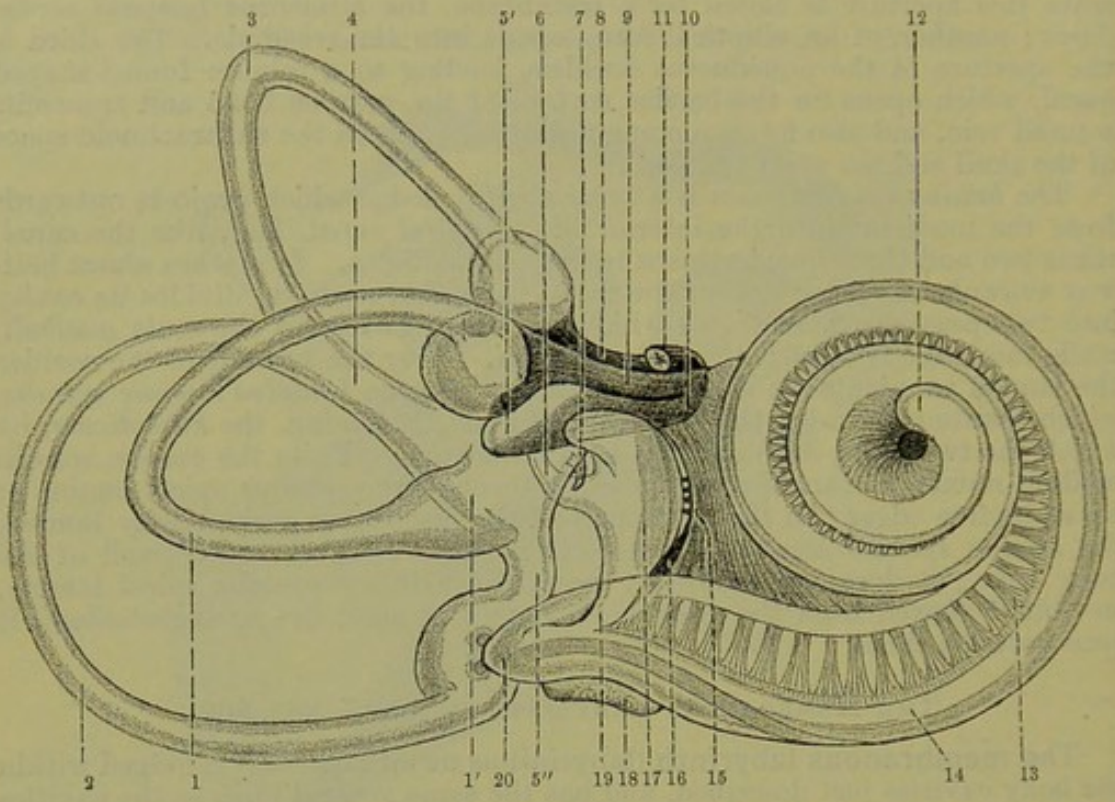

FIG. 869.—The same from the postero-mesial aspect. (G. Retzius.)

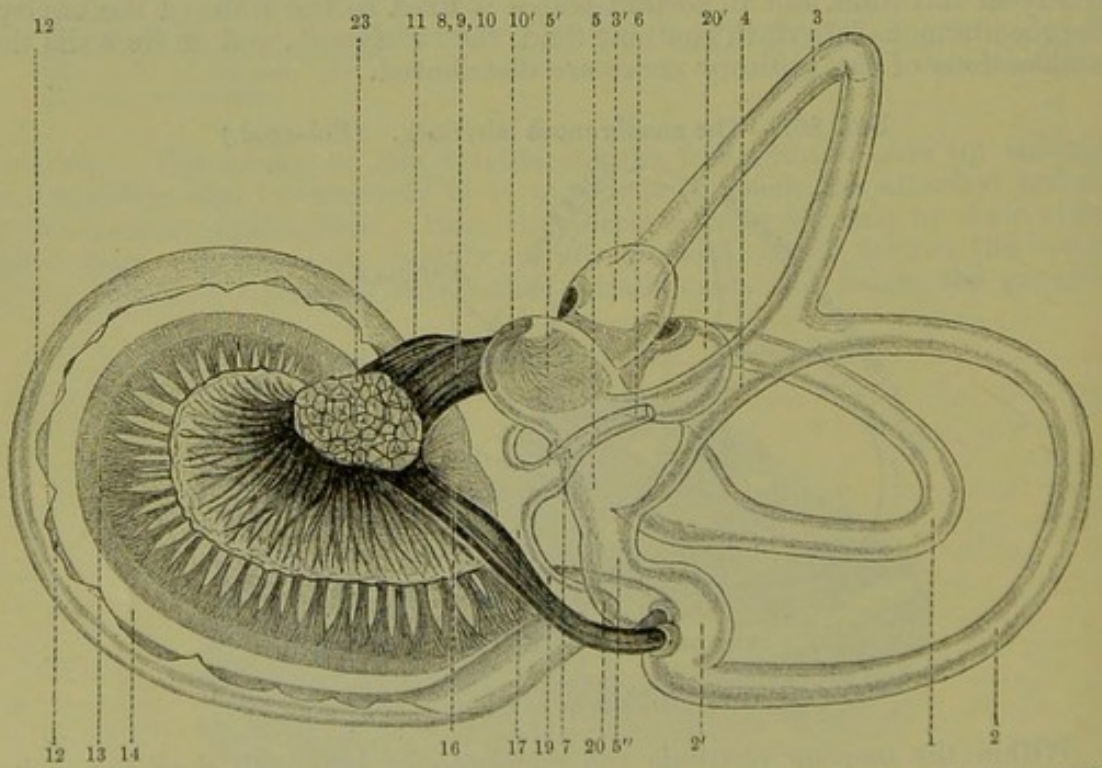

1. External semicircular canal; 1′, its ampulla. 2. Posterior canal; 2′, its ampulla. 3. Superior canal; 3′, its ampulla. 4. Conjoined limb of superior and posterior canals (sinus utriculi superior). 5. Utricle. 5′. Recessus utriculi. 5″. Sinus utriculi posterior. 6. Ductus endolymphaticus. 7. Canalis utriculo-sacccularis. 8. Nerve to ampulla of superior canal. 9. Nerve to ampulla of external canal. 10. Nerve to recessus utriculi (in fig. 868, the three branches appear conjoined). 10′. Ending of nerve in recessus utriculi. 11. Facial nerve. 12. Lagena cochleæ. 13. Nerve of cochlea within spiral lamina. 14. Basilar membrane. 15. Nerve-fibres to macula of saccule. 16. Nerve to ampulla of posterior canal. 17. Saccule. 18. Secondary membrane of tympanum. 19. Canalis reuniens. 20. Blind ending of cochlear canal in vestibule. 23. Section of the seventh and eighth nerves within internal auditory meatus (the separation between them is not apparent in the section).

nerve and has attached to its internal surface a layer of calcareous particles (otoliths). The cavity of the utricle communicates behind with the membranous semicircular canals by five orifices. From its anterior wall is given off a small canal, the *ductus utriculosaccularis*, which opens into the ductus endolymphaticus.

The **saccule** (sacculus) is the smaller of the two vestibular sacs ; it is globular in form, and lies in the recessus sphæricus near the opening of the scala vestibuli of the cochlea. Its anterior part exhibits an oval thickening, the *macula acustica sacculi*, to which are distributed the saccular filaments of the auditory nerve. Its cavity does not directly communicate with that of the utricle. From the posterior wall is given off a canal, the *ductus endolymphaticus* ; this duct is joined by the ductus utriculo-saccularis, and then passes along the aquæductus vestibuli and ends in a blind pouch (saccus endolymphaticus) on the posterior surface of the petrous portion of the temporal bone, where it is in contact with the dura mater. From the lower part of the saccule a short tube, the *canalis reuniens* of Hensen, passes downwards and outwards to open into the ductus cochlearis near its vestibular extremity (fig. 867).

The **membranous semicircular canals** (ductus semicirculares) (fig. 864) are about one-fourth of the diameter of the osseous canals, but in number, shape, and general form they are precisely similar, and each presents at one end an ampulla (ampulla membranacea). They open by five orifices into the utricle, one opening being common to the inner end of the superior and the upper end of the posterior canal. In the ampullæ the wall is thickened, and projects into the cavity as a fiddle-shaped, transversely placed elevation, the *septum transversum*, in which the nerves end.

The utricle, saccule, and membranous canals are held in position by numerous fibrous bands which stretch across the space between them and the bony walls.

Structure.—The walls of the utricle, saccule, and semicircular canals consist of three layers. The *outer layer* is a loose and flocculent structure, apparently composed of ordinary fibrous tissue, containing blood-vessels and some pigment-cells. The *middle layer*, thicker and more transparent, forms a homogeneous membrana propria, and presents on its internal surface, especially in the semicircular canals, numerous papilliform projections, which, on the addition of acetic acid, exhibit an appearance of longitudinal fibrillation and elongated nuclei. The *inner layer* is formed of polygonal nucleated epithelial cells. In the maculæ of the utricle and saccule, and in the transverse septa of the ampullæ of the canals, the middle coat is thickened and the epithelium is columnar, and consists of *supporting cells* and *hair-cells*. The former are fusiform, and their deep ends are attached to the membrana propria, while their free extremities are united to form a thin cuticle. The hair-cells are flask-shaped, and their deep, rounded ends do not reach the membrana propria, but lie between the supporting cells. The deep part of each contains a large nucleus, while its more superficial part is granular and pigmented. The free end is surmounted by a long, tapering, hair-like filament, which projects into the cavity. The filaments of the auditory nerve enter these parts, and having pierced the outer and the thickened middle layers, they lose their medullary sheaths, and their axis cylinders ramify between the hair-cells.

Two small rounded bodies termed *otoconia* (otoliths), and consisting of a mass of minute crystalline grains of carbonate of lime, held together in a mesh of delicate fibrous tissue, are contained in the walls of the utricle and saccule opposite the distribution of the nerves. According to Bowman, a calcareous material is also sparingly scattered in the cells lining the ampullæ of the semicircular canals.

The **membranous cochlea, ductus cochlearis,** or **scala media** consists of a spirally arranged tube enclosed in the bony canal of the cochlea and lying along its outer wall.

As already stated, the osseous spiral lamina extends only part of the distance between the modiolus and the outer bony wall of the cochlea, while a membrane, the *membrana basilaris*, stretches from its free edge to the outer wall of the cochlea, and completes the roof of the scala tympani (fig. 870). A second and more delicate membrane, the *membrane of Reissner* (membrana vestibularis) extends from the thickened periosteum covering the lamina

spiralis ossea to the outer wall of the cochlea, to which it is attached at some little distance from the outer edge of the membrana basilaris. A canal is thus shut off between the scala tympani below and the scala vestibuli above; this is the *membranous canal of the cochlea*, *ductus cochlearis*, or *scala media*. It is triangular on transverse section, its roof being formed by the membrane of Reissner, its outer wall by the periosteum which lines the bony canal, and

Fig. 870.—Floor of scala media, showing the organ of Corti, &c.

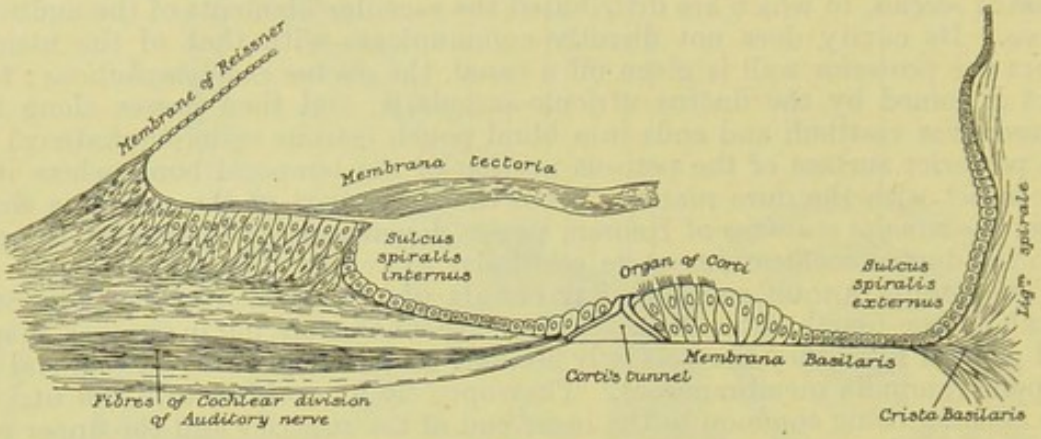

its floor by the membrana basilaris and the outer part of the lamina spiralis ossea. On the membrana basilaris is placed the organ of Corti. Reissner's membrane is thin and homogeneous, and is covered on its upper and under surfaces by a layer of epithelium. The periosteum, supporting the outer wall of the ductus cochlearis, is greatly thickened and altered in character, forming what is called the *ligamentum spirale*. It projects inwards below as a triangular

Fig. 871.—The lamina reticularis and subjacent structures. (Schematic.) (Testut.)

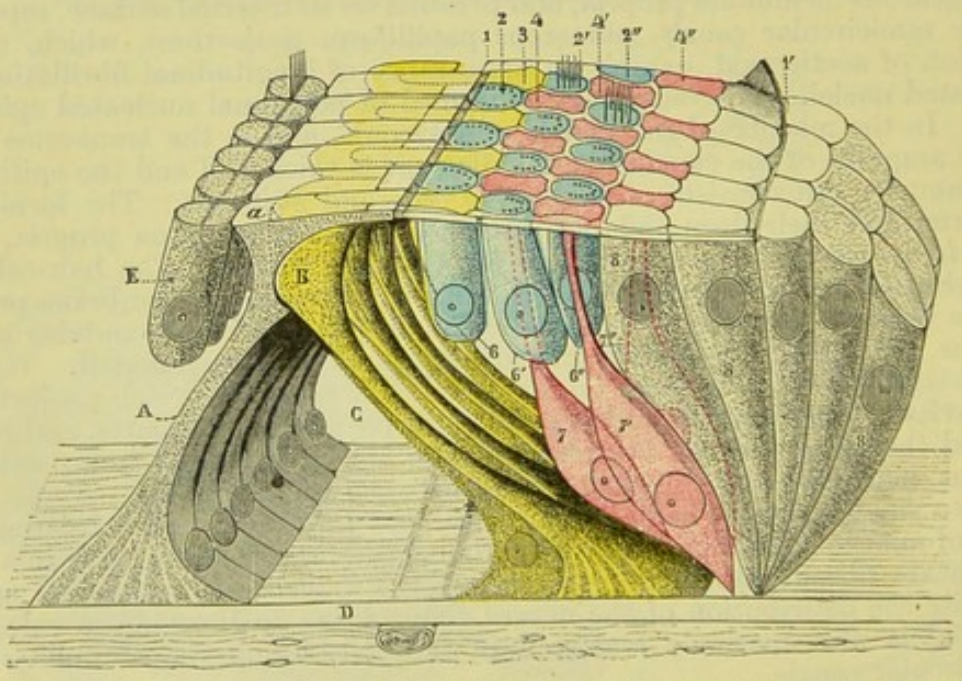

A. Internal pillar of Corti, with *a*, its plate. B. External pillar (in yellow). C. Tunnel of Corti. D. Membrana basilaris. E. Inner hair-cells. 1, 1'. Internal and external borders of the membrana reticularis. 2, 2', 2''. The three rows of circular holes (in blue). 3. First row of phalanges (in yellow). 4, 4', 4''. Second, third, and fourth rows of phalanges (in red). 6, 6', 6''. The three rows of outer hair-cells (in blue). 7, 7', 7''. Cells of Deiters. 8. Cells of Claudius.

prominence, the *crista basilaris*, which gives attachment to the outer edge of the membrana basilaris, and immediately above which is a concavity, the *sulcus spiralis externus*. The upper portion of the ligamentum spirale contains numerous capillary loops and small blood-vessels, and forms what is termed the *stria vascularis*.

The lamina spiralis ossea (fig. 872) consists of two plates of bone extending outwards ; between these are the canals for the transmission of the filaments of the auditory nerve. On the upper plate of that part of the osseous spiral lamina which is outside Reissner's membrane the periosteum is thickened to form the *limbus laminæ spiralis*, and this terminates externally in a concavity, the *sulcus spiralis internus*, which presents, on section, the form of the letter C ; the upper part of the letter, formed by the overhanging extremity of the limbus, is named the *labium vestibulare* ; the lower part, prolonged and tapering, is called the *labium tympanicum*, and is perforated by numerous foramina (*foramina nervosa*) for the passage of the cochlear nerves. Externally, the labium tympanicum is continuous with the membrana basilaris. The upper surface of the labium vestibulare is intersected at right angles by a number of furrows, between which are numerous elevations ; these present the appearance of teeth along the free surface and margin of the labium, and have been named by Huschke the *auditory teeth*. The limbus is covered by a layer of what appears to be squamous epithelium, but the deeper parts of the cells with their contained nuclei occupy the intervals between the

Fig. 872.—Limbus laminæ spiralis and membrana basilaris. (Schematic.) (Testut.)

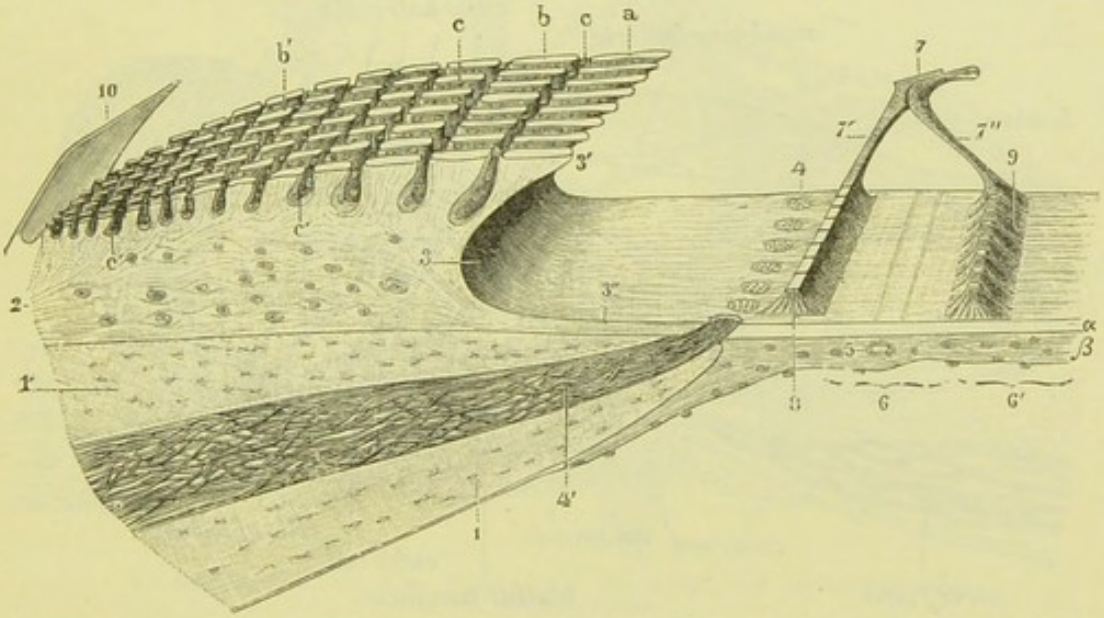

1, 1'. Upper and lower lamellæ of the lamina spiralis ossea. 2. Limbus laminæ spiralis, with *a*, the teeth of the first row ; *b*, *b'*, the auditory teeth of the other rows ; *c*, *c'*, the interdental grooves and the cells which are lodged in them. 3. Sulcus spiralis internus, with 3', its labium vestibulare, and 3'', its labium tympanicum. 4. Foramina nervosa, giving passage to the nerves from the ganglion spirale or ganglion of Corti. 5. Vas spirale. 6. Zona arcuata, and 6', zona pectinata of the basilar membrane, with *α*, its hyaline layer, *β*, its connective-tissue layer. 7. Arch of Corti, with 7', its inner rod, and 7'', its outer rod. 8. Feet of the internal rods, from which the cells are removed. 9. Feet of the external rods. 10. Membrane of Reissner, at its origin.

elevations and between the auditory teeth. This layer is continuous on the one hand with that which lines the sulcus spiralis internus, and on the other with that which covers the under aspect of Reissner's membrane. The basilar membrane may be divided into two areas, inner and outer. The inner is thin, and is named the *zona arcuata* : it supports the organ of Corti. The outer is thicker and striated, and is termed the *zona pectinata*. The under surface of the membrane is covered by a layer of vascular connective tissue. One of the vessels in this tissue is somewhat larger than the rest, and is named the *vas spirale* ; it lies below Corti's tunnel.

Organ of Corti (organon spirale).—This organ (figs. 871, 873) is situated upon the inner part of the membrana basilaris, and appears at first sight as a papilla, winding spirally throughout the whole length of the ductus cochlearis, from which circumstance it has been designated the *papilla spiralis*. More accurately viewed, it is seen to be composed of a remarkable arrangement of cells, which may be likened to the keyboard of a pianoforte. Of these cells, the central ones are rodlike bodies, and are called the inner and outer *rods of Corti*. Their bases are expanded and placed on the basilar membrane, at some little distance from each other, while their intermediate portions are

inclined towards each other, so that the rods meet at their opposite extremities, and form a series of arches roofing over a minute tunnel, the *tunnel of Corti*, between them and the basilar membrane ; this tunnel ascends spirally through the whole length of the cochlea.

The *inner rods*, some 6,000 in number, rest by means of expanded foot-plates on the basilar membrane, close to the labium tympanicum ; they project obliquely upwards and outwards, and terminate above in expanded extremities, each of which resembles in shape the upper end of the ulna, with its sigmoid cavity, coronoid and olecranon processes. On the outer side of the rod, in the angle formed between it and the basilar membrane, is a nucleated mass of protoplasm ; while on the inner side is a row of epithelial cells (*inner hair-cells*), each surmounted by a brush of fine, stiff, hair-like processes. On the inner side of these cells are two or three rows of columnar supporting cells, which are continuous with the cubical cells lining the sulcus spiralis internus.

The *outer rods*, numbering about 4,000, also rest by broad foot-plates on the basilar membrane ; they incline upwards and inwards, and the upper extremity of each resembles the head and bill of a swan ; the back of the head

Fig. 873.—Section through the organ of Corti. Magnified. (G. Retzius.)

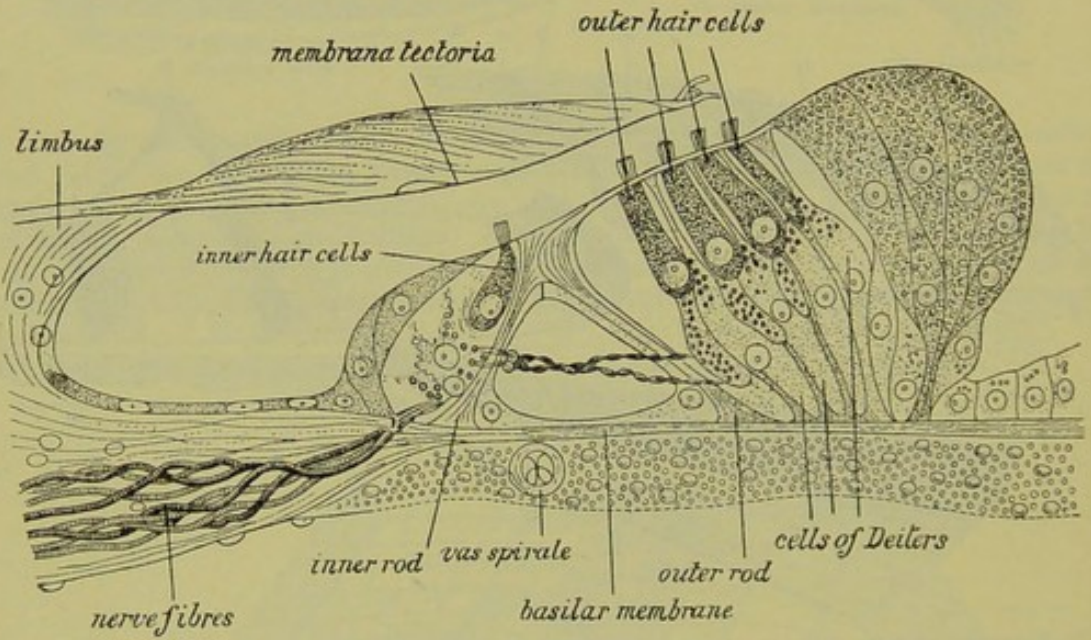

fitting into the concavity—the analogue of the sigmoid cavity—of one or more of the internal rods, and the bill projecting outwards as a phalangeal process of the membrana reticularis, presently to be described.

In the head of the outer rod is an oval portion where the fibres of which the rod appears to be composed are deficient ; it stains more deeply with carmine than the rest of the rod. At the base of the rod, on its internal side —that is to say, in the angle formed by the rod with the basilar membrane —is a similar protoplasmic mass to that found on the outer side of the base of the inner rod ; these masses of protoplasm are probably the undifferentiated portions of the cells from which the rods are developed. External to the outer rod are three or four successive rows of epithelial cells, more elongated than those found on the internal side of the inner rod, but, like them, furnished with minute hairs or cilia. These are termed the *outer hair-cells*, in contra-distinction to the *inner hair-cells* above referred to. The outer hair-cells number about 12,000, the inner about 3,500.

The *hair-cells* are somewhat oval in shape ; their free extremities are on a level with the heads of Corti's rods, and from each some twenty fine hairlets project and are arranged in the form of a crescent, the concavity of which opens inwards. The deep ends of the cells are rounded and contain large nuclei : they reach only as far as the middle of Corti's rods, and are in contact with the ramifications of the nervous filaments. Between the rows of the outer hair-cells are rows of supporting cells, called the *cells of Deiters* ; their expanded bases are planted on the basilar membrane, while the opposite end of each

presents a clubbed extremity or *phalangeal* process. Immediately to the outer side of Deiters' cells are some five or six rows of columnar cells, the *supporting cells of Hensen*. Their bases are narrow, while their upper parts are expanded and form a rounded elevation on the floor of the ductus cochlearis. The columnar cells lying outside Hensen's cells are termed the *cells of Claudius*. A space is seen between the outer rods of Corti and the adjacent hair-cells ; this is called the *space of Nuel*.

The *lamina reticularis* or *membrane of Kölliker* is a delicate framework perforated by rounded holes. It extends from the heads of the outer rods of Corti to the external row of the outer hair-cells, and is formed by several rows of 'minute fiddle-shaped cuticular structures,' called *phalanges*, between which are circular apertures containing the free ends of the hair-cells. The innermost row of phalanges consists of the phalangeal processes of the outer rods of Corti ; the outer rows are formed by the modified free ends of Deiters' cells.

FIG. 874.—Longitudinal section of the cochlea, showing the relations of the scalæ, the ganglion spirale, &c.

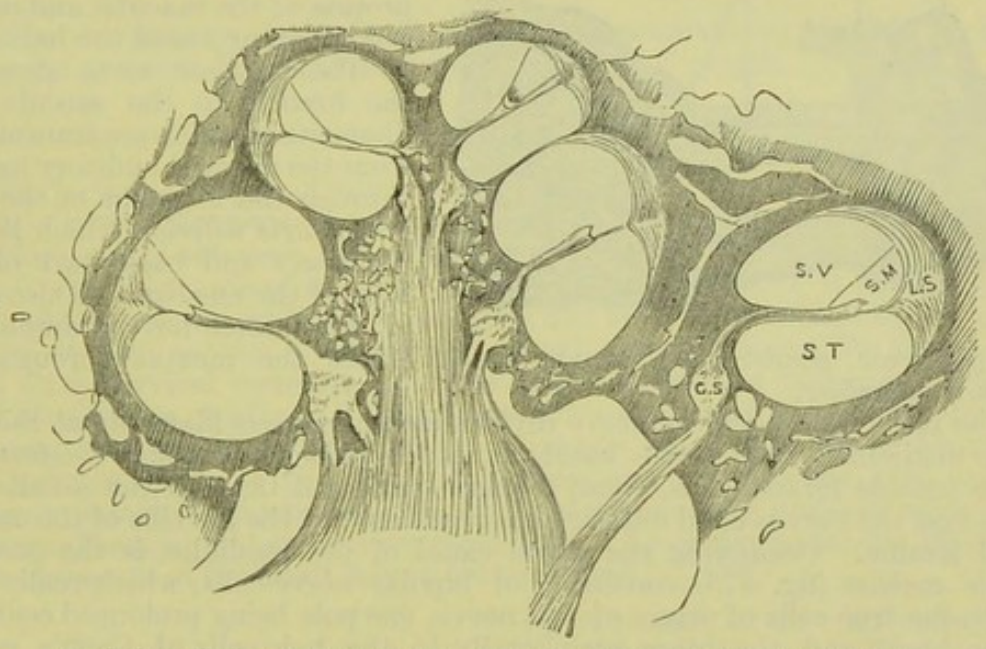

S.V. Scala vestibuli. S.T. Scala tympani. S.M. Scala media. L.S. Ligamentum spirale. G.S. Ganglion spirale.

Covering over these structures, but not touching them, is the *membrana tectoria*, or membrane of Corti, which is attached to the limbus laminæ spiralis close to the inner edge of the membrane of Reissner. It is thin near its inner margin, and overlies the auditory teeth of Huschke. Its outer half is thick, and along its lower edge, opposite the inner hair-cells, is a clear band, named *Hensen's stripe*. Externally, the membrane becomes much thinner, and is attached to the outer row of Deiters' cells (Retzius).

The *osseous labyrinth* is lined by an exceedingly thin fibro-serous membrane, analogous to a periosteum, from its close adhesion to the inner surfaces of these cavities, and performing the office of a serous membrane by its free surface. It lines the vestibule, and from this cavity is continued into the semicircular canals and the scala vestibuli of the cochlea, and through the helicotrema into the scala tympani. A delicate tubular process is prolonged along the aqueduct of the vestibule to the inner surface of the dura mater. This membrane is continued across the fenestra ovalis and rotunda, and consequently has no communication with the lining membrane of the tympanum. Its attached surface is rough and fibrous, and closely adherent to the bone ; its free surface is smooth and pale, covered with a layer of epithelium, and secretes a thin, limpid fluid, the *perilymph*.

The ductus cochlearis or scala media is closed above and below. The upper blind extremity is termed the *lagena*, and is attached to the cupula at the upper part of the helicotrema ; the lower end is lodged in the recessus cochlearis of the vestibule. Near this blind extremity, the scala media receives

the *canalis reuniens of Hensen* (fig. 867), a very delicate canal, by which the ductus cochlearis is brought into continuity with the saccule.

The **auditory nerve,** the special nerve of the sense of hearing, divides, at the bottom of the internal auditory meatus, into two branches, the cochlear and vestibular.

The *vestibular nerve*, the posterior of the two, presents, as it lies in the internal auditory meatus, a ganglion, the *ganglion of Scarpa*, the cells of which constitute the real origin of the nerve ; it divides into three branches, which pass through minute openings at the upper and back part of the bottom of the meatus (*area vestibularis superior*), and, entering the vestibule, are distributed to the utricle and to the ampullæ of the external and superior semicircular canals.

The nervous filaments enter the ampullary enlargements opposite the septum transversum, and arborise around the hair-cells. In the utricle and saccule the nerve-fibres pierce the membrana propria of the maculæ, and end in arborisations round the hair-cells.

Fig. 875.—Part of the cochlear division of the auditory nerve, highly magnified. (Henle.)

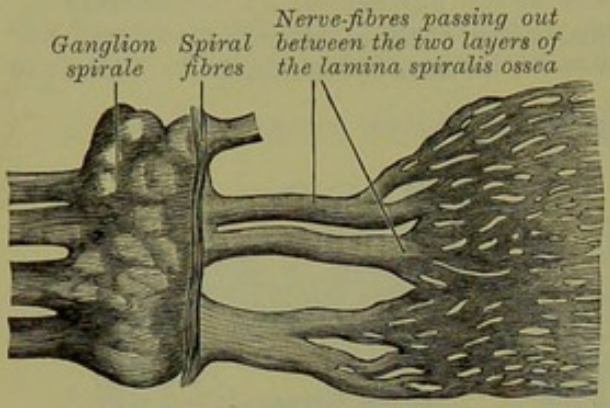

The *cochlear nerve* gives off the branch to the saccule, the filaments of which are transmitted from the internal auditory meatus through the foramina of the *area vestibularis inferior*, which lies at the lower and back part of the floor of the meatus. It also gives off the branch for the ampulla of the posterior semicircular canal, which leaves the meatus through the *foramen singulare.*

The rest of the cochlear nerve divides into numerous filaments at the base of the modiolus ; those for the basal and middle coils pass through the foramina in the tractus foraminosus, those for the apical coil through the canalis centralis, and the nerves bend outwards to pass between the lamellæ of the osseous spiral lamina. Occupying the spiral canal of the modiolus is the *ganglion spirale cochleæ* (fig. 875), consisting of bipolar nerve-cells, which really constitute the true cells of origin of this nerve, one pole being prolonged centrally to the brain and the other peripherally to the hair-cells of Corti's organ. Reaching the outer edge of the osseous spiral lamina, they pass through the foramina in the labium tympanicum ; some end by arborising around the bases of the inner hair-cells, while others pass between Corti's rods and through the tunnel, to terminate in a similar manner in relation to the outer hair-cells.

Vessels.—The *arteries of the labyrinth* are the internal auditory, from the basilar, and the stylo-mastoid, from the posterior auricular. The internal auditory divides at the bottom of the internal meatus into two branches : cochlear and vestibular. The cochlear branch subdivides into twelve or fourteen twigs, which traverse the canals in the modiolus, and are distributed, in the form of a capillary network, in the lamina spiralis and basilar membrane. The vestibular branches accompany the nerves, and are distributed, in the form of a minute capillary network, in the substance of the membranous labyrinth.

The *veins* (auditory) of the vestibule and semicircular canals accompany the arteries, and, receiving those of the cochlea at the base of the modiolus, terminate in the posterior part of the superior petrosal sinus or in the lateral sinus.

Applied Anatomy.—The diseased conditions which may be found in the internal ear usually result from the spread of a suppurative process from the middle ear—thus in chronic suppuration of the latter, destruction of the internal ear may take place, with necrosis of parts of the cochlea or vestibule. Such cases will be associated with 'nerve deafness,' and the disease may spread by means of the sheaths of the facial and auditory nerves into the posterior fossa of the skull.

Hæmorrhage occasionally occurs into the labyrinth in certain blood disorders, resulting in complete 'nerve deafness,' and such conditions may be associated with symptoms known as 'Menière's disease,' vertigo, giddiness, and tinnitus. Nerve deafness is diagnosed when all 'bone-conduction' of sound is lost, and is most commonly seen in patients suffering from congenital syphilis, many deaf-mutes being the subjects of this condition.

SPLANCHNOLOGY

UNDER this heading are included the respiratory, digestive and uro-genital organs, and the ductless glands.

RESPIRATORY ORGANS

The respiratory organs (apparatus respiratorius) consist of the larynx or organ of voice, the trachea, bronchi, lungs and pleuræ.

The Larynx

The larynx, or organ of voice, is placed at the upper part of the air-passage. It is situated between the trachea and base of the tongue, at the upper and fore part of the neck, where it forms a considerable projection in the middle line. On either side of it lie the great vessels of the neck; it forms the lower part of the anterior wall of the pharynx, and is covered behind by the mucous lining of that cavity. Its vertical extent corresponds to the fourth, fifth, and sixth cervical vertebræ, but it is placed somewhat higher in the female and also during childhood. In infants between six and twelve months of age Symington found that the tip of the epiglottis was a little above the level of the cartilage between the odontoid process and body of the axis, and that between infancy and adult life the larynx descends for a distance equal to two vertebral bodies and two intervertebral discs. According to Sappey the average measurements of the adult larynx are as follows:

	In males	In females
Length	44 mm.	36 mm.
Transverse diameter . . .	43 ,,	41 ,,
Antero-posterior diameter . .	36 ,,	26 ,,
Circumference	136 ,,	112 ,,

Until puberty the larynx of the male and that of the female differ little in size. In the female its further increase at puberty is only slight, whereas in the male it is great; all the cartilages are enlarged and the thyroid becomes prominent in the middle line of the neck, while the length of the glottis is nearly doubled.

The larynx is broad above, where it presents the form of a triangular box, flattened behind and at the sides, and bounded in front by a prominent vertical ridge. Below, it is narrow and cylindrical. It is composed of cartilages, which are connected together by ligaments and moved by numerous muscles. It is lined by mucous membrane which is continuous above with that of the pharynx and below with that of the trachea.

The **cartilages of the larynx** (cartilagines laryngis) (fig. 876) are nine in number, three single, and three paired, as follows:

Thyroid.	Two Arytenoid.
Cricoid.	Two Cornicula laryngis.
Epiglottis.	Two Cuneiform.

The **thyroid cartilage** (cartilago thyreoidea) is the largest cartilage of the larynx. It consists of two alæ or laminæ the anterior borders of which are fused with each other at a right angle in the middle line of the neck, and

form a subcutaneous projection named the *pomum Adami* (prominentia laryngea). This prominence is most distinct at its upper part, and is larger in the male than in the female. Immediately above it the alæ are separated by a V-shaped notch, the *thyroid notch* (incisura thyreoidea superior). The alæ are irregularly quadrilateral in shape, their posterior angles being prolonged into processes termed the *superior* and *inferior cornua*.

The *outer surface* of each ala presents an *oblique ridge* (linea obliqua) which runs downwards and forwards from a tubercle situated near the root of the superior cornu, to another on the lower border. This ridge gives attachment to the Sterno-thyroid and Thyro-hyoid, and from the portion of cartilage included between it and the posterior border a part of the Inferior constrictor muscle takes origin.

Fig. 876.—The cartilages of the larynx. Posterior view.

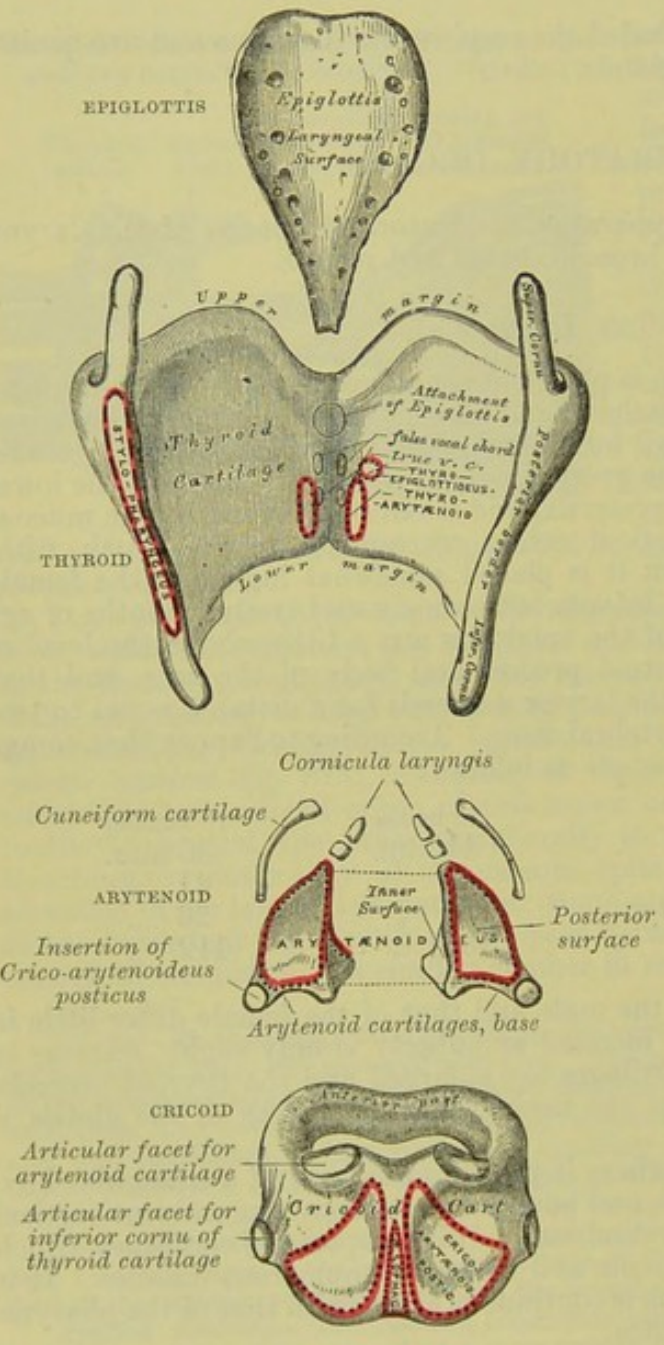

The *inner surface* is smooth; above and behind, it is slightly concave and covered by mucous membrane. In front, in the receding angle formed by the junction of the alæ, are attached the epiglottis, the true and false vocal cords, the Thyro-arytenoideus and Thyro-epiglottideus muscles, and the thyro-epiglottic ligament.

The *upper border* is concave behind and convex in front; it gives attachment to the corresponding half of the thyro-hyoid membrane.

The *lower border* is concave behind, and nearly straight in front, the two parts being separated by the inferior tubercle. A small part of it in and near the median line is connected to the cricoid cartilage by the middle portion of the crico-thyroid membrane.

The *posterior border*, thick and rounded, receives the insertions of the Stylo-pharyngeus and Palato-pharyngeus muscles. It terminates above, in the superior cornu, and below, in the inferior cornu. The *superior cornu* (cornu superius) is long and narrow, directed upwards, backwards, and inwards, and ends in a conical extremity, which gives attachment to the lateral thyro-hyoid ligament. The *inferior cornu* (cornu inferius) is short and thick; it is directed downwards, with a slight inclination forwards and inwards, and presents, on its inner surface, a small oval articular facet for articulation with the side of the cricoid cartilage.

During infancy the alæ of the thyroid cartilage are joined to each other by a narrow, lozenge-shaped strip, named the *intrathyroid cartilage*. This strip extends from the upper to the lower border of the cartilage in the middle

line, and is distinguished from the alæ by being more transparent and more flexible.

The **cricoid cartilage** (cartilago cricoidea) is so called from its resemblance to a signet ring. It is smaller, but thicker and stronger than the thyroid cartilage, and forms the lower and back part of the wall of the larynx. It consists of two parts : a quadrate portion, situated behind, and a narrow ring or arch, one-fourth or one-fifth of the depth of the posterior part, situated in front. The posterior square portion rapidly narrows at the sides of the cartilage, at the expense of the upper border, into the anterior portion.

The *posterior portion* is very deep and broad, and measures from above downwards about an inch (2 to 3 cm.) ; it presents, on its posterior surface, in the middle line, a vertical ridge for the attachment of the longitudinal fibres of the œsophagus ; and on either side of this a broad depression for the Crico-arytenoideus posticus muscle.

The *anterior portion* is narrow and convex, and measures vertically about one-fourth or one-fifth of an inch (7 to 5 mm.) ; it affords attachment externally in front and at the sides to the Crico-thyroid muscles, and behind, to part of the Inferior constrictor.

At the junction of the posterior quadrate portion with the rest of the cartilage is a small round articular eminence on either side, for articulation with the inferior cornu of the thyroid cartilage.

The *lower border* of the cricoid cartilage is horizontal, and connected to the upper ring of the trachea by a fibrous membrane.

The *upper border* is directed obliquely upwards and backwards, owing to the great depth of the posterior surface. It gives attachment, in front, to the middle portion of the crico-thyroid membrane ; at the sides, to the lateral portions of the same membrane and to the Crico-arytenoideus lateralis muscles ; behind, it presents, in the middle, a shallow notch, and on either side of this is a smooth, oval, convex surface, directed upwards and outwards, for articulation with the base of an arytenoid cartilage.

The *inner surface* of the cricoid cartilage is smooth, and lined by mucous membrane.

The **arytenoid cartilages** (cartilagines arytænoideæ) are two in number, and situated at the upper border of the cricoid cartilage, at the back of the larynx. Each cartilage is pyramidal in form, and presents for examination three surfaces, a base, and an apex.

The *posterior surface* is triangular, smooth, concave, and gives attachment to the Arytenoideus muscle.

The *antero-external surface* is somewhat convex and rough. It presents rather below its centre a transverse ridge, to the inner extremity of which is attached the false vocal cord ; to the outer part, as well as to the surfaces above and below it, the Thyro-arytenoideus muscle is inserted.

The *internal surface* is narrow, smooth, and flattened, covered by mucous membrane, and forms the lateral boundary of the respiratory part of the glottis.

The *base* of each cartilage is broad, and presents a concave smooth surface, for articulation with the cricoid cartilage. Two of its angles require special mention :- the *external*, which is short, rounded, and prominent, projects backwards and outwards, and is termed the *processus muscularis* ; it gives insertion to the Crico-arytenoideus posticus behind, and to the Crico-arytenoideus lateralis in front. The *anterior angle*, also prominent, but more pointed, projects horizontally forwards, and gives attachment to the true vocal cord. This angle is called the *processus vocalis*.

The *apex* of each cartilage is pointed, curved backwards and inwards, and surmounted by a small conical, cartilaginous nodule, the *corniculum laryngis*.

The **cornicula laryngis** or **cartilages of Santorini** (cartilagines corniculatæ) are two small conical nodules, consisting of yellow elastic cartilage, which articulate with the summits of the arytenoid cartilages and serve to prolong them backwards and inwards. They are situated in the posterior parts of the aryteno-epiglottic folds of mucous membrane, and are sometimes united to the arytenoid cartilages.

The **cuneiform cartilages** or **cartilages of Wrisberg** (cartilagines cuneiformes) are two small, elongated pieces of yellow elastic cartilage, placed one on either side, in the aryteno-epiglottic fold, where they give rise to small

whitish elevations on the inner surface of the mucous membrane, just in front of the arytenoid cartilages.

The **epiglottis** is a thin lamella of fibro-cartilage, of a yellowish colour, shaped like a leaf, and projecting behind the tongue, in front of the superior opening of the larynx. The projecting extremity is broad and rounded; the attached part or apex is long, narrow, and connected to the receding angle between the two alæ of the thyroid cartilage, just below the median notch, by a ligamentous band, the *thyro-epiglottic ligament* (lig. thyreoepiglotticum). The lower part of its anterior surface is connected to the upper border of the body of the hyoid bone by an elastic ligamentous band, the *hyo-epiglottic ligament*.

The *anterior* or *lingual surface* is curved forwards towards the tongue, and covered on its upper, free part by mucous membrane which is reflected on to the sides and base of the organ, forming a median and two lateral folds, the

Fig. 877.—The ligaments of the larynx. Antero-lateral view.

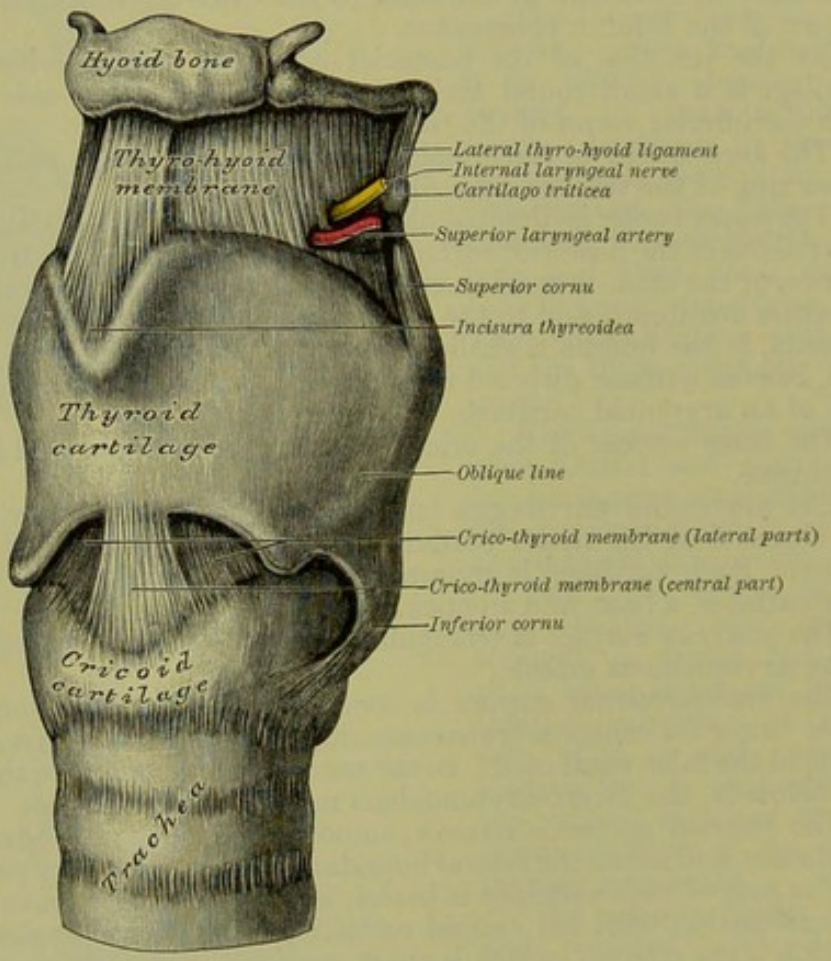

glosso-epiglottic folds; the lateral folds are partly attached to the wall of the pharynx. The depressions between the epiglottis and the base of the tongue, on either side of the median fold, are named the *valleculæ*. The lower part of the anterior surface lies behind the hyoid bone, the thyro-hyoid membrane, and upper part of the thyroid cartilage, but is separated from these structures by a mass of fatty tissue.

The *posterior* or *laryngeal surface* is smooth, concave from side to side, concavo-convex from above downwards; its lower part projects backwards as an elevation, the *tubercle* or *cushion* (tuberculum epiglotticum). When the mucous membrane is removed, the surface of the cartilage is seen to be indented by a number of small pits, in which mucous glands are lodged. To its sides the aryteno-epiglottic folds are attached.

Structure.—The cornicula laryngis and cuneiform cartilages, the epiglottis, and the apices of the arytenoids at first consist of hyaline cartilage, but later elastic fibres grow in from the perichondrium, and eventually they are converted into yellow fibro-cartilage,

which shows little tendency to calcification. The thyroid, cricoid, and the greater part of the arytenoids consist of hyaline cartilage, and become more or less ossified as age advances. Ossification commences about the twenty-fifth year in the thyroid cartilage, and somewhat later in the cricoid and arytenoids; by the sixty-fifth year these cartilages may be completely converted into bone.

Ligaments.—The ligaments of the larynx (figs. 877, 878) are *extrinsic*, i.e. those connecting the thyroid cartilage and epiglottis with the hyoid bone, and the cricoid cartilage with the trachea; and *intrinsic*, those which connect the several cartilages of the larynx to each other.

Extrinsic ligaments.—The ligaments connecting the thyroid cartilage with the hyoid bone are three in number—the thyro-hyoid membrane, and the two lateral thyro-hyoid ligaments.

The *thyro-hyoid membrane* (membrana hyothyreoidea) is a broad, fibro-elastic, membranous layer, attached below to the upper border of the thyroid cartilage, and above to the upper margin of the posterior surface of the body and greater cornua of the hyoid bone, thus passing behind the posterior surface

FIG. 878.—Ligaments of the larynx. Posterior view.

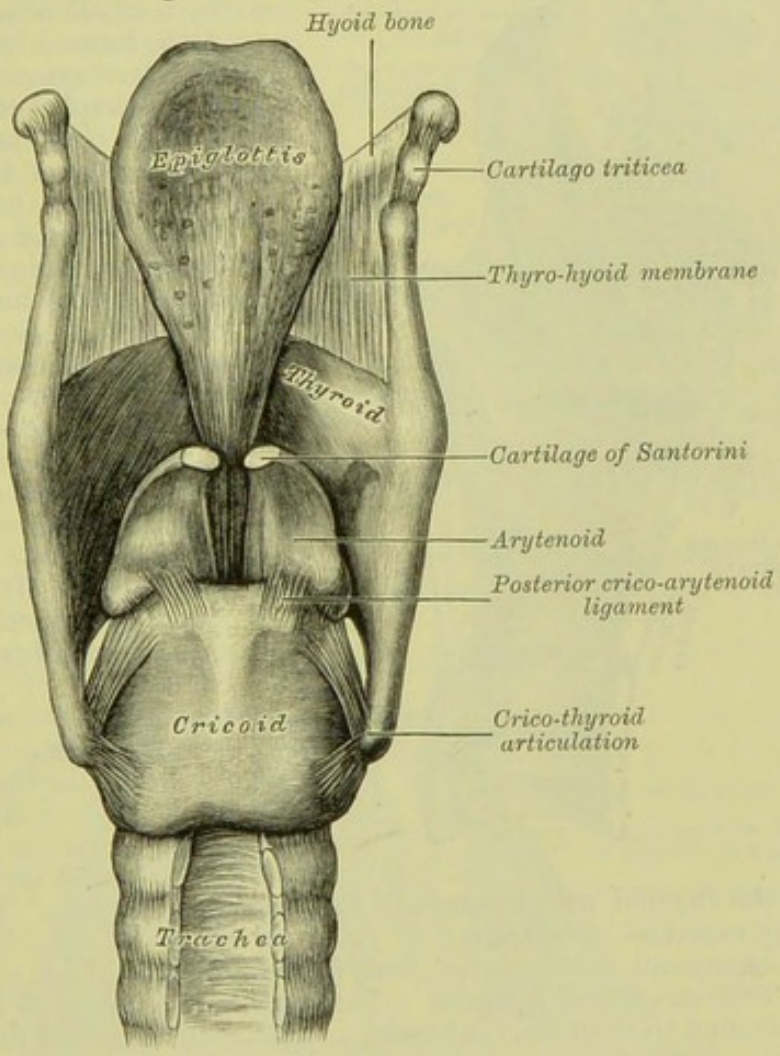

of the body of the hyoid, and being separated from it by a synovial bursa, which facilitates the upward movement of the larynx during deglutition. It is thicker in the middle line than at either side, and is pierced, in the latter situation, by the superior laryngeal vessels and the internal laryngeal nerve. Its anterior surface is in relation with the Thyro-hyoid, Sterno-hyoid, and Omo-hyoid muscles, and with the body of the hyoid bone.

The *lateral thyro-hyoid ligament* (lig. hyothyreoideum laterale) is a round elastic cord, which passes between the superior cornu of the ala of the thyroid cartilage and the extremity of the greater cornu of the hyoid bone. A small cartilaginous nodule (*cartilago triticea*), sometimes bony, is frequently found in it.

The ligament connecting the epiglottis with the hyoid bone is the *hyo-epiglottic*. In addition to this extrinsic ligament, the epiglottis is connected to the tongue by the three glosso-epiglottic folds of mucous membrane, which may also be considered as extrinsic ligaments of the epiglottis.

The *hyo-epiglottic ligament* (lig. hyoepiglotticum) is an elastic band, which extends from the anterior surface of the epiglottis to the upper border of the body of the hyoid bone.

Intrinsic ligaments.—The ligaments connecting the thyroid cartilage to the cricoid are three in number—the crico-thyroid membrane, and the capsular ligaments.

The *crico-thyroid membrane* is composed mainly of yellow elastic tissue. It consists of three parts, a central, triangular portion and two lateral portions. The *central* part (lig. cricothyreoideum medium) is thick and strong, narrow above and broad below. It connects together the contiguous margins of the thyroid and cricoid cartilages. It is convex, concealed on either side by the Crico-thyroideus, but subcutaneous in the middle line; it is crossed horizontally by a small anastomotic arterial arch, formed by the junction of the two crico-thyroid arteries. The *lateral* portions are thinner and lie close under the mucous membrane of the larynx; they extend from the superior border of the cricoid cartilage to the inferior margin of the true vocal cords, with which they are continuous. These cords may therefore be regarded as the free borders of the lateral portions of the crico-thyroid membrane; they extend from the vocal processes of the arytenoid cartilages to the receding angle of the thyroid cartilage near its centre. The lateral portions are lined internally by mucous membrane, and covered externally by the Crico-arytenoideus lateralis and Thyro-arytenoideus muscles.

FIG. 879.—Sagittal section of the larynx and upper part of the trachea.

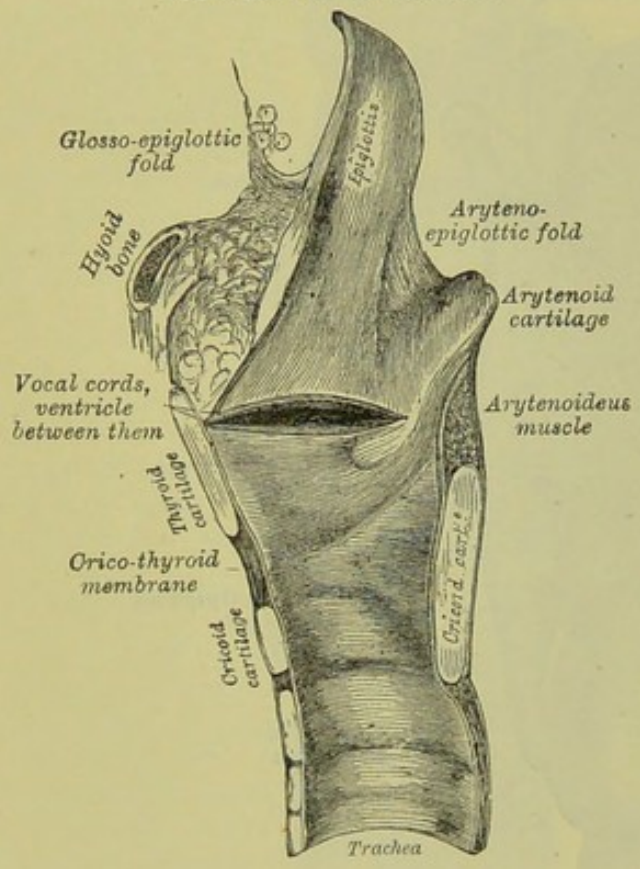

A *capsular ligament*, strengthened posteriorly by a well-marked fibrous band, encloses the articulation of the inferior cornu of the thyroid with the cricoid cartilage on each side. The articulation is lined by synovial membrane.

Each arytenoid cartilage is connected to the cricoid by a *capsular* and a *posterior crico-arytenoid ligament*. The *capsular ligament* is thin and loose, and is attached to the margins of the articular surfaces, and lined by synovial membrane. The *posterior crico-arytenoid ligament* (lig. cricoarytænoideum posterius) extends from the cricoid to the inner and back part of the base of the arytenoid.

The *thyro-epiglottic ligament* (lig. thyreoepiglotticum) is a long, slender, elastic cord which connects the apex of the epiglottis with the receding angle of the thyroid cartilage, immediately beneath the median notch, above the attachment of the vocal cords.

The *crico-tracheal ligament* (lig. cricotracheale) connects the cricoid cartilage with the first ring of the trachea. It resembles the fibrous membrane which connects the cartilaginous rings of the trachea to each other.

Movements.—The articulation between the inferior cornu of the thyroid cartilage and the cricoid cartilage on either side is a diarthrodial one, and

permits of rotatory and gliding movements. The rotatory movement is one in which the inferior cornua of the thyroid cartilage rotate upon the cricoid cartilage around an axis passing transversely through both joints. The gliding movement consists in a limited shifting of the cricoid on the thyroid in different directions.

The articulation between the arytenoid cartilages and the cricoid is also a diarthrodial one, and permits of two varieties of movement: one a rotation of the arytenoid on a vertical axis, whereby the vocal process is moved outwards or inwards, and the opening of the rima glottidis increased or diminished; the other is a gliding movement, and allows the arytenoid cartilages to approach or recede from each other; from the direction and slope of the articular surfaces outward gliding is accompanied by a forward and downward movement. The two movements of gliding and rotation are associated, the gliding inwards being connected with inward rotation, and the gliding outwards with outward rotation. The posterior crico-arytenoid ligaments limit the forward movement of the arytenoid cartilages on the cricoid.

Fig. 880.—Coronal section of larynx and upper part of trachea.

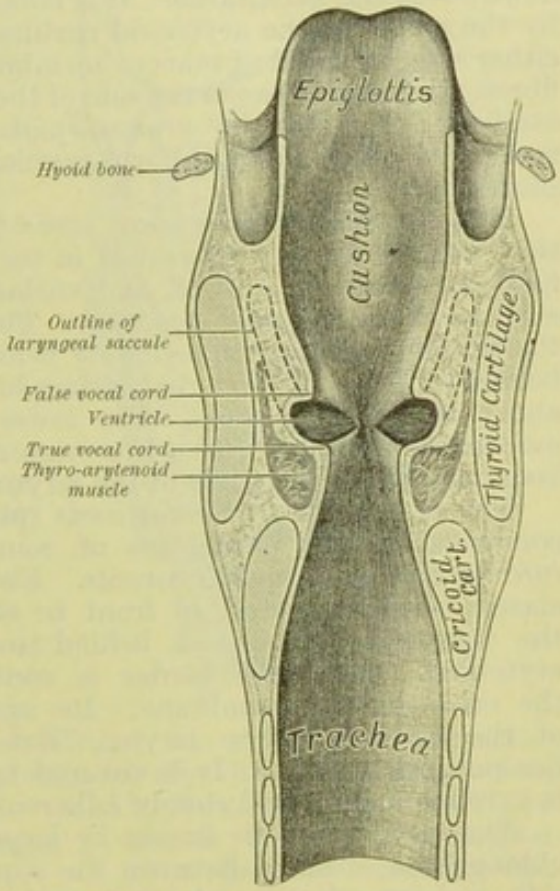

Interior of the larynx (figs. 879, 880).—The *cavity of the larynx* (cavum laryngis) extends from its superior aperture to the lower border of the cricoid cartilage. It is divided into two parts by the projection inwards of the true vocal cords, between which is a narrow triangular fissure or chink, the *rima glottidis*. The portion of the cavity of the larynx above the true

Fig. 881.—Larynx, viewed from above. (Testut.)

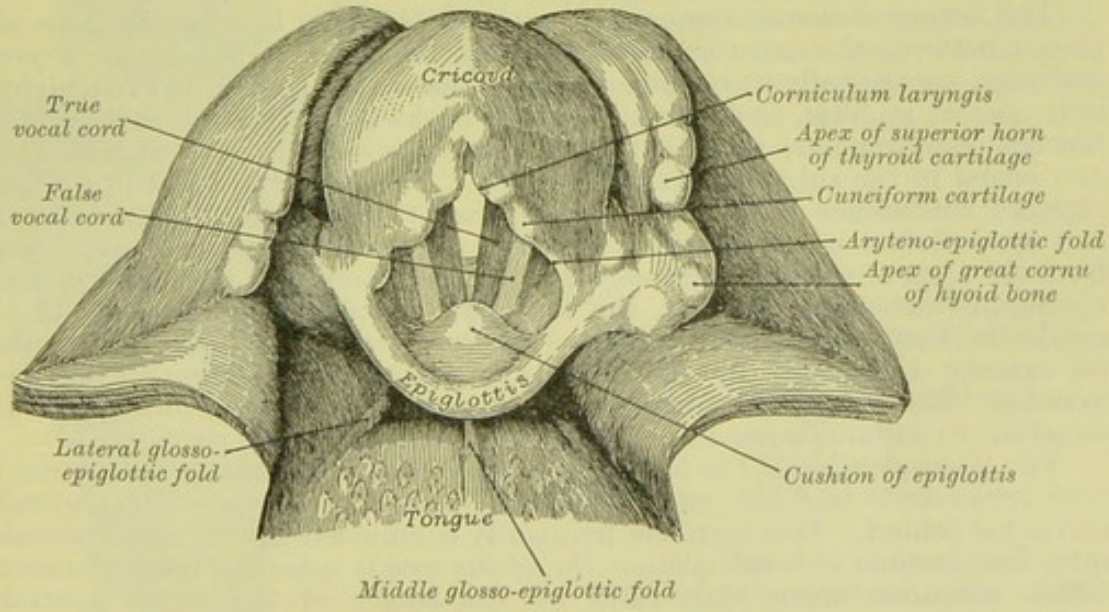

vocal cords, sometimes called the *vestibule* (vestibulum laryngis), is wide and triangular in shape, its base or anterior wall presenting, however, about its centre the backward projection of the cushion of the epiglottis. It contains

the false vocal cords, and between these and the true vocal cords are the ventricles of the larynx. The portion below the true vocal cords is at first of an elliptical form, but lower down it widens out, assumes a circular form, and is continuous with the tube of the trachea.

The *superior aperture of the larynx* (aditus laryngis) (fig. 881) is a triangular or cordiform opening, wide in front, narrow behind, and sloping obliquely downwards and backwards. It is bounded, in front, by the epiglottis; behind, by the apices of the arytenoid cartilages and the cornicula laryngis; and on either side, by a fold of mucous membrane, enclosing ligamentous and muscular fibres, stretched between the side of the epiglottis and the apex of the arytenoid cartilage; this is the *aryteno-epiglottic fold* (plica aryepiglottica), on the margin of which the cuneiform cartilage forms a more or less distinct whitish prominence.

The *superior* or *false vocal cords* (plicæ ventriculares), so called because they are not directly concerned in the production of the voice, are two thick folds of mucous membrane, each enclosing a narrow band of fibrous tissue, the *superior thyro-arytenoid ligament*. This is attached in front to the angle of the thyroid cartilage immediately below the attachment of the epiglottis, and behind to the antero-external surface of the arytenoid cartilage, a short distance above the vocal process. The lower border of this ligament, enclosed in mucous membrane, forms a free crescentic margin, which constitutes the upper boundary of the ventricle of the larynx.

The *inferior* or *true vocal cords* (plicæ vocales), so called from their being concerned in the production of sound, are two strong bands, named the *inferior thyro-arytenoid ligaments*. Each ligament consists of a band of yellow elastic tissue, attached in front to the depression between the two alæ of the thyroid cartilage, and behind to the vocal process of the base of the arytenoid. Its lower border is continuous with the thin lateral part of the crico-thyroid membrane. Its upper border forms the lower boundary of the ventricle of the larynx. Externally the Thyro-arytenoideus muscle lies parallel with it. It is covered internally by mucous membrane, which is extremely thin, and closely adherent to its surface.

The *ventricle of the larynx* or *laryngeal sinus* (ventriculus laryngis) is an oblong fossa, situated between the superior and inferior vocal cords on either side, and extending nearly their entire length. The fossa is bounded, above, by the free crescentic edge of the false vocal cord; below by the straight margin of the true vocal cord; externally, by the mucous membrane covering the corresponding Thyro-arytenoideus muscle. The anterior part of the ventricle leads up by a narrow opening into a cæcal pouch of mucous membrane of variable size, called the laryngeal saccule.

The *laryngeal saccule* (appendix ventriculi laryngis) is a membranous sac, placed between the superior vocal cord and the inner surface of the thyroid cartilage, occasionally extending as far as its upper border or even higher; it is conical in form, and curved slightly backwards. On the surface of its mucous membrane are the openings of sixty or seventy mucous glands, which are lodged in the submucous areolar tissue. This sac is enclosed in a fibrous capsule, continuous below with the superior thyro-arytenoid ligament: its laryngeal surface is covered by a few delicate muscular fasciculi, which arise from the apex of the arytenoid cartilage and become lost in the fold of mucous membrane extending between the arytenoid cartilage and the side of the epiglottis (they were named by Hilton the *compressor sacculi laryngis*); while its exterior is covered by the Thyro-arytenoideus and Thyro-epiglottideus muscles. These muscles compress the laryngeal saccule, and express the secretion it contains upon the vocal cords to lubricate their surfaces.

The *rima glottidis* is the elongated fissure or chink between the inferior or true vocal cords in front, and the bases and vocal processes of the arytenoid cartilages behind. It is therefore frequently subdivided into a larger anterior inter-ligamentous or *vocal* portion, the *glottis vocalis* (pars intramembranacea), which measures about three-fifths of the length of the entire aperture, and a posterior intercartilaginous or *respiratory* part, the *glottis respiratoria* (pars intercartilaginea). Posteriorly it is limited by the mucous membrane passing between the arytenoid cartilages. The rima glottidis is the narrowest part of the cavity of the larynx, and its level corresponds with the bases of the

arytenoid cartilages. Its length, in the male, measures rather less than an inch (23 mm.); in the female it is shorter by 5 or 6 mm. The width and shape of the rima glottidis vary with the movements of the vocal cords and arytenoid cartilages during respiration and phonation. In the condition of rest, i.e. when these structures are uninfluenced by muscular action, as in quiet respiration, the glottis vocalis is triangular, with its apex in front and its base behind—the latter being represented by a line, about 8 mm. long, connecting the anterior extremities of the vocal processes, while the inner surfaces of the arytenoids are parallel to each other, and hence the glottis respiratoria is rectangular. During extreme adduction of the cords, as in the emission of a high note, the glottis vocalis is reduced to a linear slit by the apposition of the cords, while the glottis respiratoria is triangular, its apex corresponding to the anterior extremities of the vocal processes of the arytenoids, which are approximated by the inward rotation of the cartilages. Conversely in extreme abduction of the cords, as in forced inspiration, the arytenoids and their vocal processes are rotated outwards, and the glottis respiratoria is triangular in shape but with its apex directed backwards. In this condition the entire glottis is somewhat lozenge-shaped, the sides of the glottis vocalis diverging from before backwards, those of the glottis respiratoria diverging from behind forwards—the widest part of the aperture corresponding with the attachments of the cords to the vocal processes.

Fig. 882.—Side view of the larynx, showing muscular attachments.

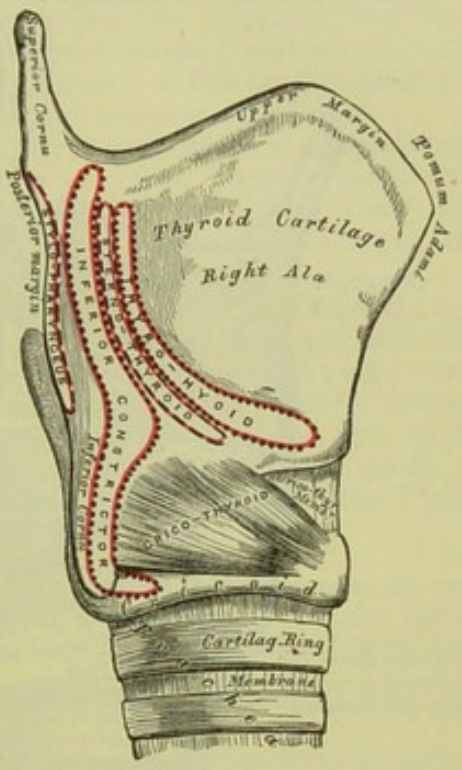

Fig. 883.—Muscles of larynx. Posterior view.

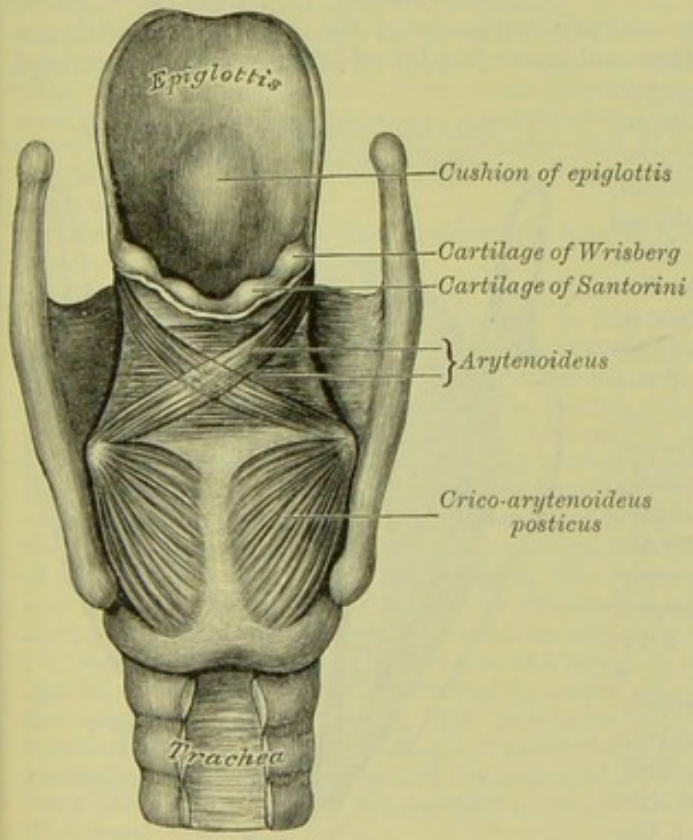

Muscles.—The muscles of the larynx are *extrinsic*, passing between the larynx and parts around—these have been described in the section on Myology; and *intrinsic*, confined entirely to the larynx.

The intrinsic muscles are:

Crico-thyroideus.
Crico-arytenoideus posticus.
Crico-arytenoideus lateralis.
Arytenoideus.
Thyro-arytenoideus.

The *Crico-thyroideus* (m. cricothyreoideus) (fig. 882) is triangular in form, and situated at the fore part and side of the cricoid cartilage. It arises from the front and lateral part of the cricoid cartilage; its fibres diverge, passing obliquely upwards and

outwards, to be inserted into the lower border of the ala of the thyroid cartilage, and the anterior border of the inferior cornu.

Fig. 884.—Muscles of larynx. Side view. Right ala of thyroid cartilage removed.

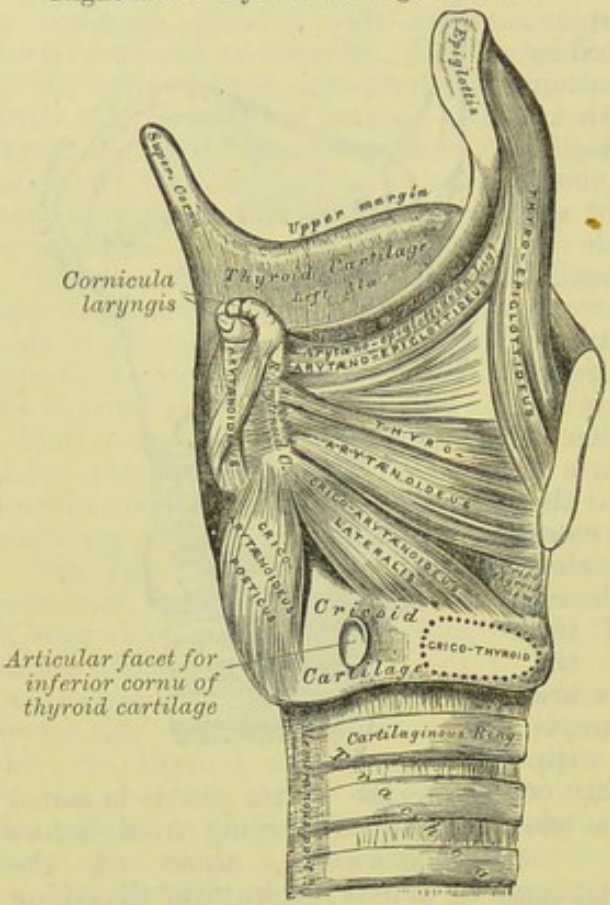

The inner borders of the two muscles are separated in the middle line by a triangular interval, occupied by the central part of the crico-thyroid membrane.

The *Crico-arytenoideus posticus* (m. cricoarytænoideus posterior) (fig. 883) arises from the broad depression on the corresponding half of the posterior surface of the cricoid cartilage; its fibres run upwards and outwards, and converge to be inserted into the posterior surface of the muscular process at the base of the arytenoid cartilage. The uppermost fibres are nearly horizontal, the middle oblique, and the lowest almost vertical.

The *Crico-arytenoideus lateralis* (m. cricoarytænoideus lateralis) (fig. 884) is smaller than the preceding, and of an oblong form. It arises from the upper border of the side of the cricoid cartilage, and, passing obliquely upwards and backwards, is inserted into the front of the muscular process of the arytenoid cartilage.

The *Arytenoideus* (m. arytænoideus) (fig. 883) is a single muscle, filling up the posterior concave surfaces of the arytenoid cartilages. It arises from the posterior surface and outer border of one arytenoid cartilage, and is inserted into the corresponding parts of the opposite cartilage. It consists of three planes of fibres, two oblique and one transverse. The *oblique fibres* (m. arytænoideus obliquus), the more superficial, form two fasciculi, which pass from the base of one cartilage to the apex of the opposite one, and which therefore cross each other like the limbs of the letter X. The *transverse fibres* (m. arytænoideus transversus), the deeper and more numerous, pass transversely across between the two cartilages. A few of the oblique fibres are continued round the outer margin of the cartilage, and are prolonged into the aryteno-epiglottic fold. They are sometimes described as a separate muscle, the *Aryepiglotticus*.

Fig. 885.—Interior of the larynx, seen from above. (Enlarged.)

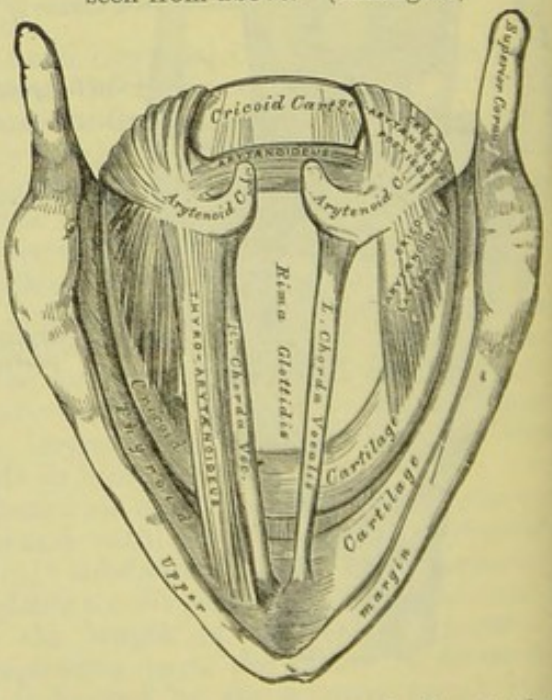

The *Thyro-arytenoideus* (m. thyreo-arytænoideus) (figs. 880, 884, 885) is a broad, flat muscle, which lies parallel with the outer side of the true vocal cord and supports the wall of the ventricle. It arises in front from the lower half of the receding angle of the thyroid cartilage, and from the crico-thyroid membrane.

Its fibres pass backwards and outwards, to be inserted into the base and anterior surface of the arytenoid cartilage. This muscle consists of two fasciculi, an inner and an outer.* The *inner portion* (m. vocalis) is a triangular band which is inserted into the vocal process of the arytenoid cartilage, and into the adjacent portion of its anterior surface; it lies parallel with the true vocal cord, to which it is adherent. The *outer portion* (m. thyreoarytænoideus externus), the thinner, is inserted into the anterior surface and outer border of the arytenoid cartilage above the preceding fibres; it lies on the outer side of the laryngeal saccule, immediately beneath the mucous membrane.

A considerable number of the fibres of the Thyro-arytenoideus are prolonged into the aryteno-epiglottic fold, where some of them become lost, while others are continued forwards to the margin of the epiglottis. They have received a distinctive name, *Thyro-epiglotticus* (m. thyreoepiglotticus), and are sometimes described as a separate muscle.

Actions.—In considering the actions of the muscles of the larynx, they may be conveniently divided into two groups, viz.: 1. Those which open and close the glottis. 2. Those which regulate the degree of tension of the vocal cords.

1. The muscles which open the glottis are the Crico-arytenoidei postici; and those which close it are the Crico-arytenoidei laterales and the Arytenoideus. 2. The muscles which regulate the tension of the vocal cords are the Crico-thyroidei, which elongate and render them tense; and the Thyro-arytenoidei, which relax and shorten them.

The *Posterior crico-arytenoid muscles* separate the vocal cords, and, consequently, open the glottis, by rotating the arytenoid cartilages outwards around a vertical axis passing through the crico-arytenoid joints; so that their vocal processes and the vocal cords attached to them become widely separated.

The *Lateral crico-arytenoid muscles* close the glottis, by rotating the arytenoid cartilages inwards, so as to approximate their vocal processes.

The *Arytenoid muscle* approximates the arytenoid cartilages, and thus closes the opening of the glottis, especially at its back part.

The *Crico-thyroid muscles* produce tension and elongation of the vocal cords by drawing down the lower border of the thyroid cartilage and slightly advancing its inferior cornua; the distance between the vocal processes and the angle of the thyroid is thus increased, and the cords are consequently elongated.

The *Thyro-arytenoid muscles*, consisting of two parts having different attachments and different directions, are rather complicated as regards their action. Their main use is to draw the arytenoid cartilages forwards towards the thyroid, and thus shorten and relax the vocal cords. But, owing to the connection of the inner portion with the vocal cord, this part, if acting separately, is supposed to modify its elasticity and tension, and the outer portion, being inserted into the outer part of the anterior surface of the arytenoid cartilage, may rotate it inwards, and thus narrow the rima glottidis by bringing the two cords together.

The manner in which the superior aperture of the larynx is closed during deglutition is referred to on page 486.

Mucous Membrane.—The mucous membrane of the larynx is continuous above with that lining the mouth and pharynx, and is prolonged through the trachea and bronchi into the lungs. It lines the posterior surface and the upper part of the anterior surface of the epiglottis, to which it is closely adherent, and forms the aryteno-epiglottic folds which bound the superior aperture of the larynx. It lines the whole of the cavity of the larynx; forms, by its reduplication, the chief part of the superior, or false vocal cord; and, from the ventricle, is continued into the laryngeal saccule. It is then reflected over the true vocal cords, where it is thin, and very intimately adherent; covers the inner surface of the crico-thyroid membrane and cricoid cartilage; and is ultimately continuous with the lining membrane of the trachea. The upper part of the anterior surface and the upper half of the posterior surface of the epiglottis, the upper part of the aryteno-epiglottic folds, and the true vocal cords are covered by stratified squamous epithelium; all the rest of the laryngeal mucous membrane is covered by columnar ciliated cells.

Glands.—The mucous membrane of the larynx is furnished with numerous muciparous glands, the orifices of which are found in nearly every part; they are very plentiful upon the epiglottis, being lodged in little pits in its substance; they are also found in large numbers along the posterior margin of the aryteno-epiglottic fold, in front of the arytenoid cartilages, where they are termed the *arytenoid glands*. They exist also in large numbers upon the inner surface of the sacculus laryngis. None are found on the free edges of the true vocal cords.

* Henle describes these two portions as separate muscles, under the names of External and Internal thyro-arytenoids.

Vessels and Nerves.—The *arteries of the larynx* are the laryngeal branches derived from the superior and inferior thyroid. The *veins* accompany the arteries: those accompanying the superior laryngeal artery join the superior thyroid vein which opens into the internal jugular vein; while those accompanying the inferior laryngeal artery join the inferior thyroid vein which opens into the innominate vein. The *lymphatics* consist of two sets, superior and inferior. The former accompany the superior laryngeal artery and pierce the thyro-hyoid membrane, to terminate in the glands situated near the bifurcation of the common carotid artery. Of the latter, some pass through the crico-thyroid membrane and open into a gland lying in front of that membrane or in front of the upper part of the trachea, while others pass to the deep cervical glands and to the glands which accompany the inferior thyroid artery. The *nerves* are derived from the internal and external laryngeal branches of the superior laryngeal nerve, from the inferior or recurrent laryngeal, and from the sympathetic. The internal laryngeal nerve is almost entirely sensory, but some motor filaments are said to be carried by it to the Arytenoideus muscle. It divides into a branch which is distributed to both surfaces of the epiglottis, a second to the aryteno-epiglottic fold, and a third, the largest, which supplies the mucous membrane over the back of the larynx and communicates with the recurrent laryngeal. The external laryngeal nerve supplies the Crico-thyroideus muscle. The recurrent laryngeal passes upwards under the lower border of the Inferior constrictor, and enters the larynx between the cricoid and thyroid cartilages. It supplies all the muscles of the larynx except the Crico-thyroideus, and perhaps a part of the Arytenoideus. The sensory branches of the laryngeal nerves form subepithelial plexuses, from which fibres pass to end between the cells covering the mucous membrane.

Over the posterior surface of the epiglottis, in the aryteno-epiglottic folds, and less regularly in some other parts, taste-buds, similar to those in the tongue, are found.

The Trachea and Bronchi (fig. 886)

The **trachea,** or **windpipe,** is a cartilaginous and membranous tube, which extends from the lower part of the larynx, on a level with the sixth cervical vertebra, to the upper border of the fifth thoracic vertebra, where it divides into the two bronchi, one for each lung. The trachea is nearly but not quite cylindrical, being flattened posteriorly; it measures about four inches and a half (11 cm.) in length; its diameter, from side to side, is from three-quarters of an inch to an inch (19 to 25 mm.), being always greater in the male than in the female.

Relations.—The anterior surface of the trachea is convex, and covered, *in the neck*, from above downwards, by the isthmus of the thyroid gland, the inferior thyroid veins, the arteria thyreoidea ima (when that vessel exists), the Sterno-thyroid and Sterno-hyoid muscles, the cervical fascia, and, more superficially, by the anastomosing branches between the anterior jugular veins; *in the thorax*, it is covered from before backwards by the first piece of the sternum, the remains of the thymus gland, the left innominate vein, the arch of the aorta, the innominate and left common carotid arteries, and the deep cardiac plexus. Posteriorly it is in relation with the œsophagus; laterally, *in the neck*, it is in relation with the common carotid arteries, the lateral lobes of the thyroid gland, the inferior thyroid arteries, and the recurrent laryngeal nerves; *in the thorax*, it lies in the upper part of the interpleural space (superior mediastinum), and is in relation on the right side to the pleura and right vagus, and near the root of the neck to the innominate artery; on its left side are the recurrent laryngeal nerve, the aortic arch, and the left common carotid and subclavian arteries.

The **right bronchus** (bronchus dexter), wider, shorter, and more vertical in direction than the left, is about an inch in length, and enters the right lung nearly opposite the fifth thoracic vertebra. The vena azygos major arches over it from behind; and the right pulmonary artery lies below and then in front of it. About three-quarters of an inch from its commencement it gives off a branch to the upper lobe of the right lung. This is termed the *eparterial branch* (ramus bronchialis eparterialis), because it is given off above the right pulmonary artery. The bronchus now passes below the artery, and is known as the *hyparterial branch* (ramus bronchialis hyparterialis); it divides into two branches for the middle and lower lobes.

The **left bronchus** (bronchus sinister) is smaller and longer than the right, being nearly two inches in length. It enters the root of the left lung opposite the sixth thoracic vertebra, about an inch lower than the right bronchus. It passes beneath the arch of the aorta, crosses in front of the œsophagus, the thoracic duct, and the descending aorta, and has the left

pulmonary artery lying at first above, and then in front of it. The left bronchus has no eparterial branch, and therefore it has been supposed by some that there is no upper lobe to the left lung, but that the so-called upper lobe corresponds to the middle lobe of the right lung.

The further subdivision of the bronchi will be considered with the anatomy of the lung.

If a transverse section be made across the trachea a short distance above its point of bifurcation, and a bird's-eye view taken of its interior (fig. 887),

FIG. 886.—Front view of cartilages of larynx, trachea, and bronchi.

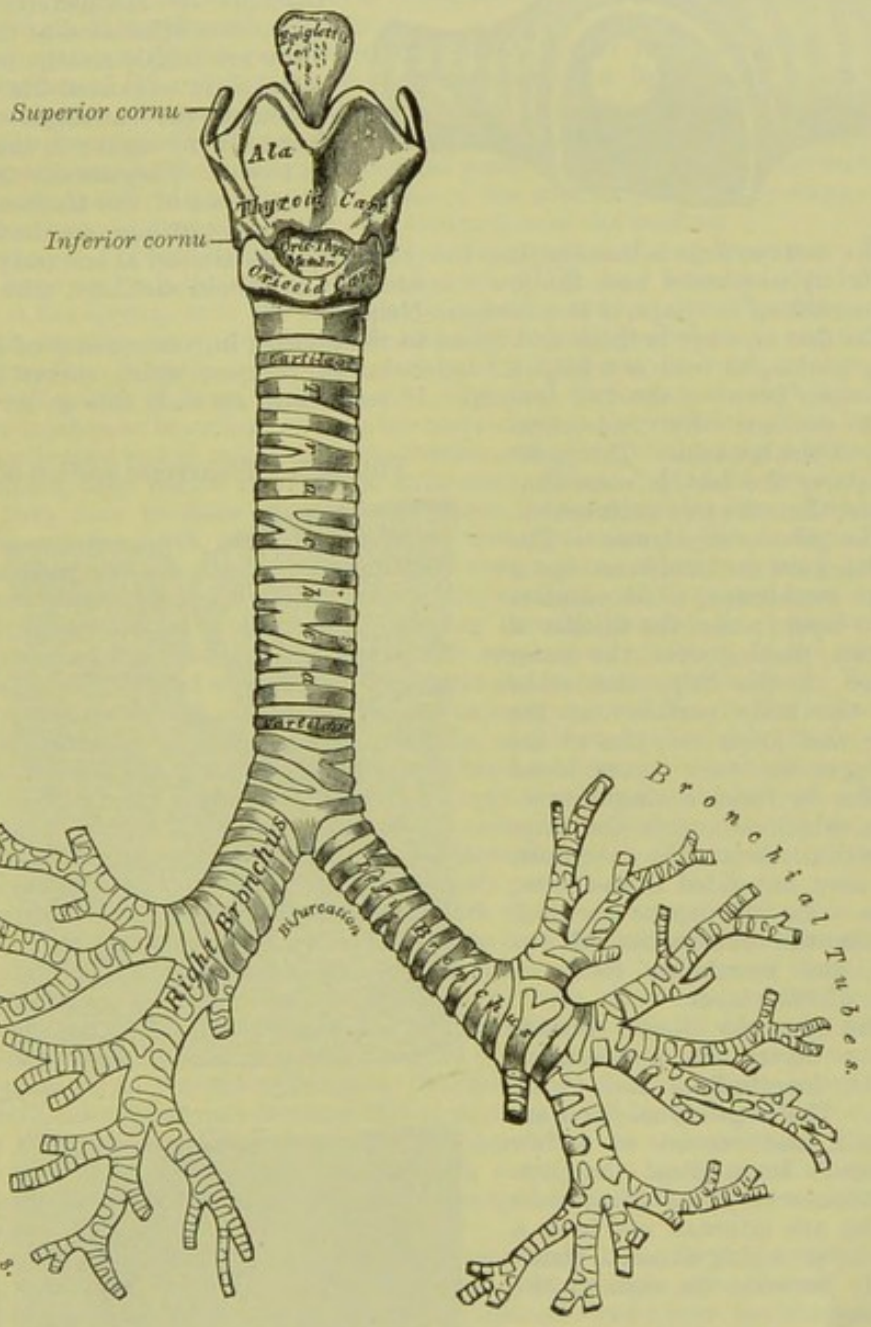

the septum placed at the bottom of the trachea and separating the two bronchi will be seen to occupy the left of the median line, and the right bronchus appears to be a more direct continuation of the trachea than the left, so that any solid body dropping into the trachea would naturally be directed towards the right bronchus. This tendency is aided by the larger size of the right tube as compared with its fellow. This fact serves to explain why a foreign body in the trachea more frequently falls into the right bronchus.*

* Reigel asserts that the entry of a foreign body into the *left* bronchus is by no means so infrequent as is generally supposed. See also *Med.-Chir. Trans.* vol. lxxi. p. 121.

Structure (fig. 888).—The trachea is composed of imperfect rings of hyaline cartilage, fibrous tissue, muscular fibres, mucous membrane, and glands.

The *cartilages* vary from sixteen to twenty in number: each forms an imperfect ring, which occupies the anterior two-thirds or so of the circumference of the trachea, being deficient behind, where the tube is completed by fibrous tissue and unstriped muscular fibres. The cartilages are placed horizontally above each other, separated by narrow intervals. They measure about 4 mm. in depth, and 1 mm. in thickness. Their outer surfaces are flattened, but internally they are convex, from being thicker in the middle than at the margins. Two or more of the cartilages often unite, partially or completely, and they are sometimes bifurcated at their extremities. They are highly elastic, but may become calcified in advanced life. In the right bronchus the cartilages vary in number from six to eight; in the left, from nine to twelve. They are shorter and narrower than those of the trachea. The peculiar tracheal cartilages are the first and the last.

Fig. 887.—Transverse section of the trachea, just above its bifurcation, with a bird's-eye view of the interior.

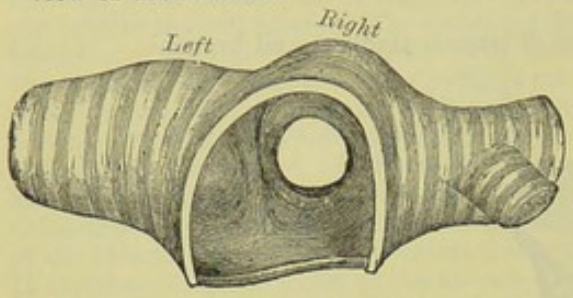

The *first cartilage* is broader than the rest, and often divided at one end; it is connected by fibrous membrane with the lower border of the cricoid cartilage, with which, or with the succeeding cartilage, it is sometimes blended.

The *last cartilage* is thick and broad in the middle, in consequence of its lower border being prolonged into a triangular hook-shaped process, which curves downwards and backwards between the two bronchi. It terminates on each side in an imperfect ring, which encloses the commencement of the bronchi. The cartilage above the last is somewhat broader than the rest at its centre.

The *fibrous membrane*. — The cartilages are enclosed in an elastic fibrous membrane, which consists of two layers; one, the thicker of the two, passing over the outer surface of the ring, the other over the inner surface: at the upper and lower margins of the cartilages the two layers blend together to form a single membrane, which connects the rings one with another. They are thus, as it were, imbedded in the membrane. In the space behind, between the extremities of the rings, the membrane forms a single distinct layer.

The *muscular tissue* consists of two layers of non-striated muscle, longitudinal and transverse. The *longitudinal fibres* are external, and consist of a few scattered longitudinal bundles. The *transverse fibres* (Trachealis muscle) are internal, and form a thin layer which extends transversely between the ends of the cartilages.

Fig. 888.—Transverse section of trachea.

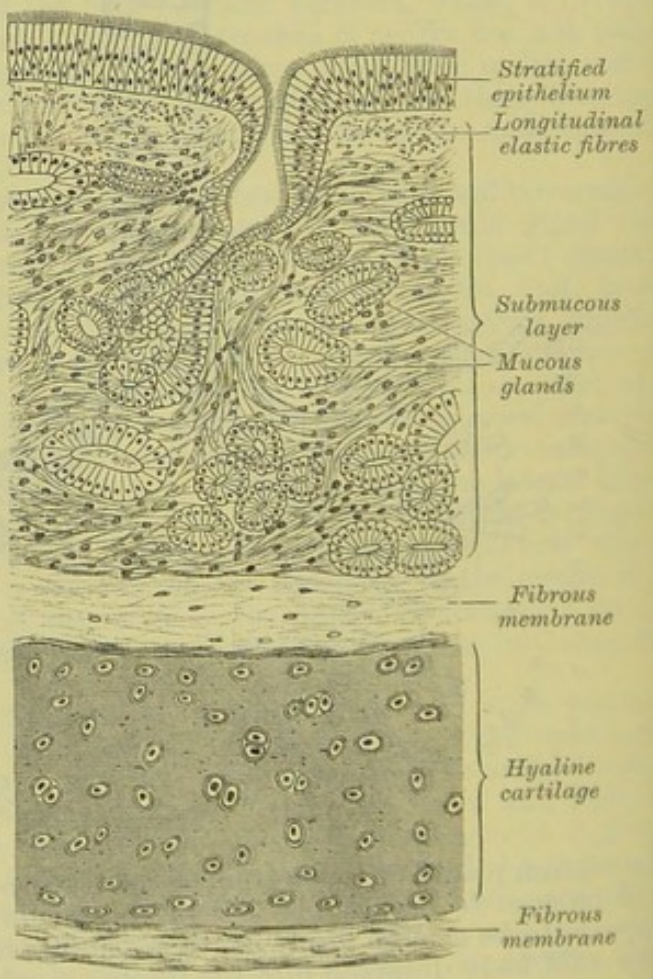

Mucous membrane. — The mucous membrane is continuous above with that of the larynx, and below with that of the bronchi. It consists of areolar and lymphoid tissue, and presents a well-marked basement-membrane, supporting a stratified epithelium, the outer layer of which is columnar and ciliated, while the inner layers are composed of oval or rounded cells. Beneath the basement-membrane there is a distinct layer of longitudinal elastic fibres with a small amount of intervening areolar tissue. The submucous layer is composed of a loose mesh-work of connective tissue, containing large blood-vessels, nerves, and mucous glands; the ducts of the latter pierce the overlying layers and open on the surface.

Vessels and Nerves.—The trachea is supplied with blood by the inferior thyroid *arteries*. The *veins* terminate in the thyroid venous plexus. The *nerves* are derived from the pneumogastric and its recurrent branches, and from the sympathetic.

Surface Form.—In the middle line of the neck, some of the cartilages of the larynx can be readily distinguished. In the receding angle below the chin, the hyoid bone can easily be made out (see page 261), and a finger's breadth below it is the pomum Adami, the prominence between the upper borders of the two alæ of the thyroid cartilage. About an inch below this, in the middle line, is a depression corresponding to the crico-thyroid space, in which the operation of laryngotomy is performed. This depression is bounded below by a prominent arch, the anterior part of the cricoid cartilage, below which the trachea can be felt, though it is only in the emaciated that the separate rings can be distinguished. The lower part of the trachea is not easily made out, for as it descends in the neck it takes a deeper position. The level of the vocal cords corresponds to the middle of the anterior margin of the thyroid cartilage.

With the laryngoscope the following structures can be seen: the base of the tongue, and the upper surface of the epiglottis, with the glosso-epiglottic ligaments; the superior aperture of the larynx, bounded on either side by the aryteno-epiglottic folds, in which may be seen two rounded eminences, corresponding to the cornicula and cuneiform cartilages. Beneath these lie the false and true vocal cords with the ventricle between them. Still deeper are seen the cricoid cartilage and some of the anterior parts of the rings of the trachea, and sometimes, in deep inspiration, the bifurcation of the trachea.

Applied Anatomy.—Foreign bodies often find their way into the air-passages. These may consist of large soft substances, as pieces of meat, which may become lodged in the upper aperture of the larynx, or in the rima glottidis, and cause speedy suffocation unless rapidly got rid of, or unless an opening is made into the air-passages below, so as to enable the patient to breathe. Smaller bodies, frequently of a hard nature, such as cherry or plum stones, small pieces of bone, buttons, &c., may find their way through the rima glottidis into the trachea or bronchus, or may become lodged in the ventricle of the larynx. The dangers then depend not so much upon the mechanical obstruction as upon the spasm of the glottis which they excite from reflex irritation. When lodged in the ventricle of the larynx, they may produce very few symptoms, beyond sudden loss of voice or alteration in the voice sounds immediately after the inhalation of the foreign body. When, however, they are situated in the trachea, they are constantly striking against the vocal cords during expiratory efforts, and produce attacks of dyspnœa from spasm of the glottis. When lodged in the bronchus, they usually become fixed there, and, occluding the lumen of the tube, cause a loss of the respiratory murmur on the affected side, and may subsequently lead to purulent bronchitis and gangrene of the lung. Foreign bodies in the air-passages should always be removed as soon as possible. In the less urgent cases a thorough examination of the pharynx, larynx, and bronchi should be made, using one or another of the modern forms of laryngoscope, tracheoscope, or bronchoscope; when discovered, the foreign body should be removed by appropriately shaped forceps. In the cases where urgent dyspnœa is produced and death seems imminent from asphyxia, after digital examination of the back of the throat and inversion with shaking of the patient have failed to give relief, tracheotomy should be rapidly performed.

Beneath the mucous membrane of the upper part of the air-passages there is a considerable amount of submucous tissue, which is liable to become much swollen from effusion in inflammatory affections, constituting the condition known as 'œdema of the glottis.' This effusion does not extend below the level of the vocal cords, on account of the fact that the mucous membrane is closely adherent to these structures without the intervention of any submucous tissue. So that, in cases of œdema of the glottis, in which it is necessary to open the air-passages to prevent suffocation, the operation of laryngotomy is sufficient. Laryngeal or glottidean œdema may be secondary to some local inflammatory affection, such as acute septic laryngitis, syphilitic laryngeal perichondritis, or to malignant disease. Or the œdema may be passive (non-inflammatory), consequent upon renal or cardiac mischief, angioneurotic œdema, or, in unusually susceptible persons, the administration of potassium iodide.

Chronic laryngitis is an inflammation of the mucous glands of the larynx, which occurs in those who speak much in public, and is known as 'clergyman's sore throat.' It is due to the dryness induced by the large amount of cold air drawn into the air-passages during prolonged speaking, which excites increased activity of the mucous glands to keep the parts moist, and this eventually terminates in inflammation of these structures.

Ulceration of the larynx may occur from syphilis, either as a superficial ulceration, or from the softening of a gumma; from tuberculous disease (laryngeal phthisis), or from malignant disease (epithelioma).

The air-passages may be opened in three different situations: by a vertical incision through the centre of the thyroid cartilage (*thyrotomy*); through the crico-thyroid membrane (*laryngotomy*), or in some part of the trachea (*tracheotomy*).

Thyrotomy is usually performed for the purpose of removing growths from the vocal cords or for extracting foreign bodies from the ventricle of the larynx. A median incision

is made from the upper border of the body of the hyoid bone to the lower border of the cricoid cartilage, and is carried through the subcutaneous tissues and deep fascia between the margins of the Sterno-hyoid muscles. An incision is then made in the crico-thyroid membrane, and one blade of a stout, sharp-pointed pair of scissors is introduced beneath the lower border of the thyroid cartilage, and this structure is divided from below upwards. Great care must be taken to cut exactly in the middle line to avoid wounding the vocal cords. If the two halves of the cartilage are now drawn apart, a very good view of the interior of the larynx will be obtained.

Laryngotomy is anatomically a simple operation: it can readily be performed, and should be employed in those cases where the air-passages require opening in an emergency for the relief of some sudden obstruction to respiration. The crico-thyroid membrane is very superficial, being covered only in the middle line by the skin, superficial fascia, and the deep fascia. On either side of the middle line it is also covered by the Sterno-hyoid and Sterno-thyroid muscles, which diverge from each other at their upper parts, leaving a slight interval between them. On these muscles rest the anterior jugular veins. The only vessel of any importance in connection with this operation is the crico-thyroid artery, which crosses the crico-thyroid membrane, and may be wounded, but rarely gives rise to any trouble. The operation is performed thus: the head being thrown back and steadied by an assistant, the finger is passed over the front of the neck, and the crico-thyroid depression felt for. A vertical incision is then made through the skin in the middle line over this spot, and carried down through the fascia until the crico-thyroid membrane is exposed. A cross-cut is then made through the membrane, close to the upper border of the cricoid cartilage, so as to avoid, if possible, the crico-thyroid artery, and a laryngotomy tube inserted. It has been recommended, as a more rapid way of performing the operation, to make a transverse instead of a longitudinal cut through the superficial structures, and thus to open at once the air-passages. It will be seen, however, that in operating in this way the anterior jugular veins are in danger of being wounded.

Tracheotomy may be performed either above or below the isthmus of the thyroid body, or this structure may be divided and the trachea opened behind it.

From the relations already described it must be evident that the trachea can be more readily opened above than below the isthmus of the thyroid body.

Tracheotomy above the isthmus is performed thus: the patient should, if possible, be laid on his back on a table in a good light. A pillow is to be placed under the shoulders and the head thrown back and steadied by an assistant. The surgeon standing on the right side of his patient makes an incision from an inch and a half to two inches in length in the median line of the neck from the top of the cricoid cartilage. The incision must be made exactly in the middle line so as to avoid the anterior jugular veins, and after the superficial structures have been divided, the interval between the Sterno-hyoid muscles must be found, the raphe divided, and the muscles drawn apart. The lower border of the cricoid cartilage must now be felt for, and the upper part of the trachea exposed from this point downwards in the middle line. Bose has recommended that the layer of fascia in front of the trachea should be divided transversely at the level of the lower border of the cricoid cartilage, and, having been seized with a pair of forceps, pressed downwards with the handle of the scalpel. By this means the isthmus of the thyroid gland is depressed and is saved from all danger of being wounded, and the trachea cleanly exposed. The trachea is now transfixed with a sharp hook and drawn forwards in order to steady it, and is then opened by inserting the knife into it and dividing the upper two or three rings by cutting upwards. If the trachea is to be opened beneath the isthmus, the incision must be made from a little below the cricoid cartilage to the top of the sternum.

In the child the trachea is smaller, more deeply placed, and more movable than in the adult. In fat or short-necked people, or in those in whom the muscles of the neck are prominently developed, the trachea is more deeply placed than in the opposite conditions.

A portion of the larynx or the whole of it may be removed for malignant disease. The results which have been obtained from the removal of the whole of it have not been very satisfactory, and the cases in which the operation is justifiable are very few. It may be removed by a median incision through the soft parts, freeing the cartilages from the muscles and other structures in front, separating the larynx from the trachea below, and dissecting off the deeper structure from below upwards.

The Pleuræ

Each lung is invested by an exceedingly delicate serous membrane, the **pleura,** which encloses the organ as far as its root, and is then reflected on to the pericardium, chest-wall, and Diaphragm. The portion of the serous membrane investing the surface of the lung and dipping into the fissures between its lobes, is called the *visceral layer of the pleura* (pleura pulmonalis); while that which lines the inner surface of the chest and covers the Diaphragm

and pericardium, is called the *parietal layer of the pleura* (pleura parietalis). The space between these two layers is called the *cavity of the pleura* (cavum pleuræ), but it must be borne in mind that in the healthy condition the two layers are in contact and that there is no real cavity. When the lung becomes collapsed a separation of it from the wall of the chest takes place and a cavity appears. Each pleura is a shut sac, one occupying the right, the other the left half of the thorax ; and they are perfectly separate from each other. The two pleuræ do not meet in the middle of the chest, excepting anteriorly opposite the second and third pieces of the sternum. The space left between them contains all the thoracic viscera excepting the lungs, and is named the *mediastinum*.

Different portions of the parietal pleura have received special names which indicate their position : thus, that portion which lines the inner surfaces of the ribs and Intercostal muscles is the *costal pleura* (pleura costalis) ; that which

FIG. 889.—Front view of chest, showing relations of pleuræ and lungs to the chest-wall. The blue lines indicate the lines of the reflection of the pleuræ ; the red, the outlines of the lungs and their fissures.

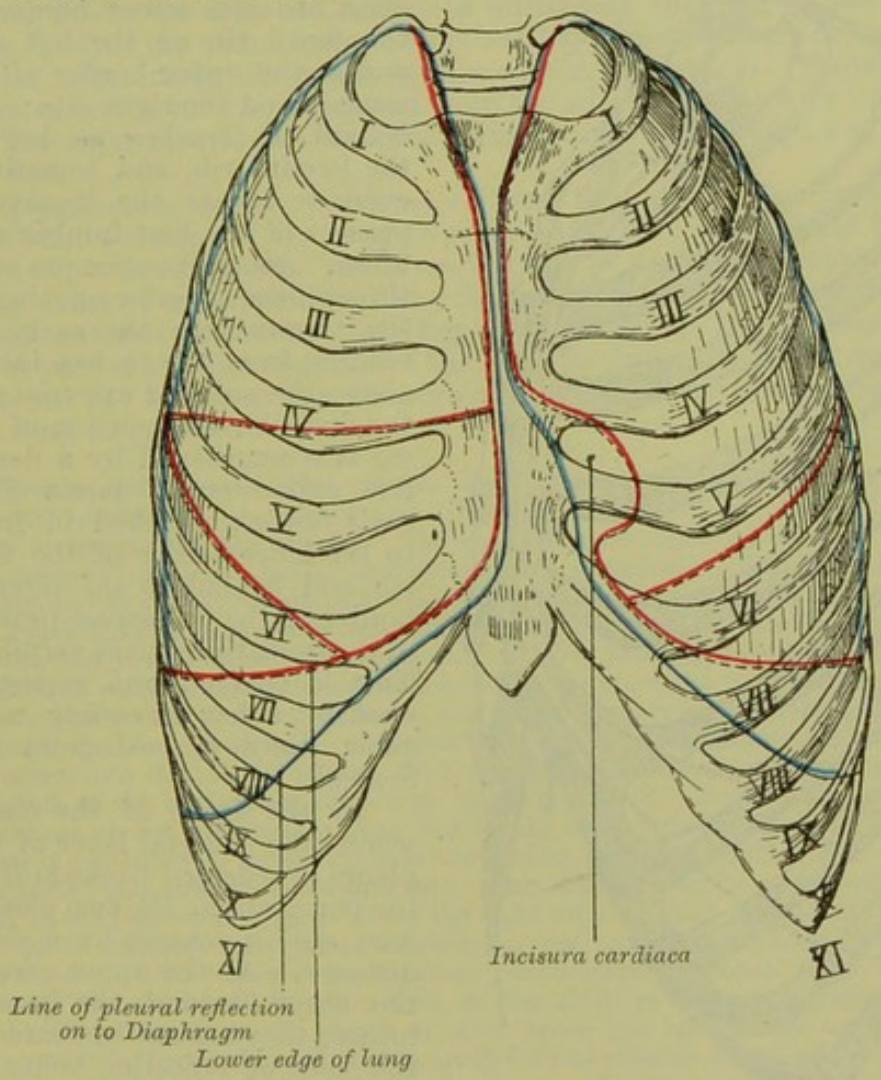

coats the convex surface of the Diaphragm is the *diaphragmatic pleura* (pleura diaphragmatica) ; that which rises into the neck, over the summit of the lung, is the *cervical pleura* (cupula pleuræ) ; and that which is applied to the adjacent structures in the mediastinum is the *mediastinal pleura* (pleura mediastinalis).

Reflections of the pleura (figs. 889, 890).—Commencing at the sternum, the pleura passes outwards, lines the costal cartilages, the inner surfaces of the ribs and Intercostal muscles, and at the back part of the thorax passes over the gangliated cord of the sympathetic and its branches, and is reflected upon the sides of the bodies of the vertebræ, where it is separated by a narrow interval, the *posterior mediastinum* (cavum mediastinale posterius), from the opposite pleura. From the vertebral column the pleura passes to the side of

the pericardium, which it covers to a slight extent; it then covers the back part of the root of the lung, from the lower border of which a triangular sheet descends vertically by the side of the posterior mediastinum to the Diaphragm. This sheet is the posterior layer of a wide fold, known as the broad ligament of the lung (*ligamentum pulmonale* or *ligamentum latum pulmonis*). From the posterior aspect of the lung root, the pleura may be traced over the convex surface of the lung, the summit and base, and also over the sides of the fissures between the lobes, on to its inner surface and the front part of its root; it is continued from the lower margin of the root as the anterior layer of the broad ligament, and from this it is reflected on to the pericardium, and from it to the back of the sternum. *Below*, it covers the upper surface of the Diaphragm, and extends, in front, as low as the costal cartilage of the seventh rib; at the side of the chest, to the lower border of the tenth rib on the left side and to the upper border of the same rib on the right side; and behind, it reaches as low as the twelfth rib, and sometimes even as low as the transverse process of the first lumbar vertebra. *Above*, its apex projects, through the superior opening of the thorax into the neck, extending from one to two inches above the anterior extremity of the first rib; this portion of the sac is strengthened by a dome-like expansion of fascia (*Sibson's fascia*), attached in front to the inner border of the first rib, and behind to the anterior border of the transverse process of the seventh cervical vertebra. This is covered and strengthened by a few spreading muscular fibres derived from the Scaleni.

Fig. 890.—Lateral view of chest, showing relations of right pleura and lung to the chest-wall. The blue line indicates the line of pleural reflection; the red lines, the outline of the lung and its fissures.

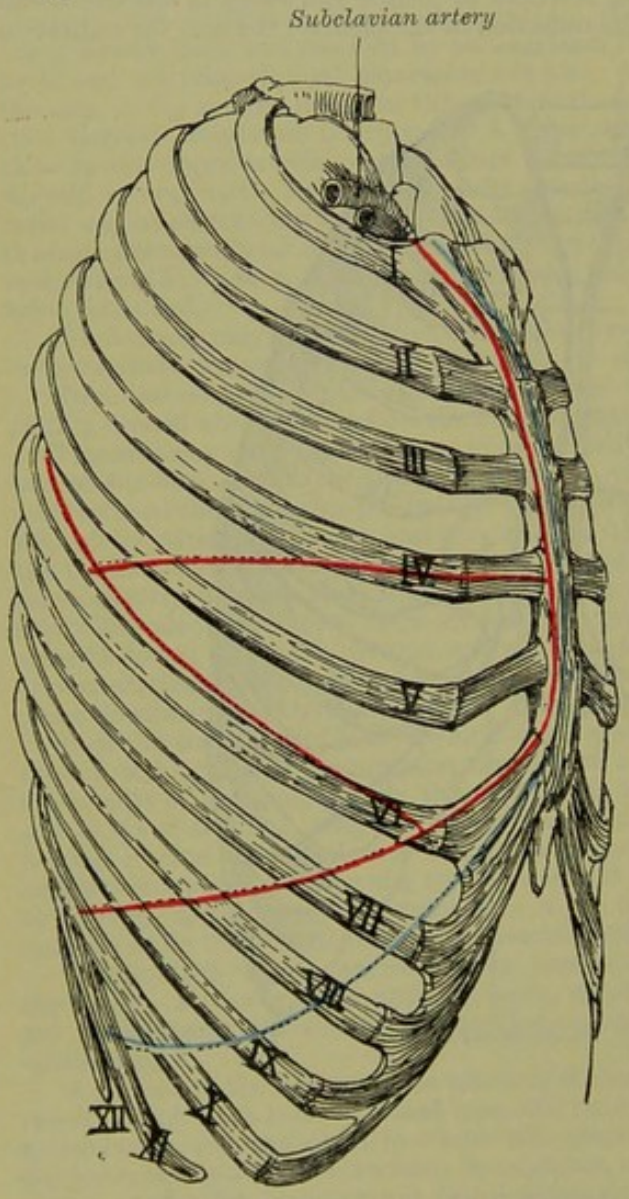

In the front of the chest, where the parietal layer of the pleura is reflected backwards to the pericardium, the two pleural sacs are in contact for a short distance. At the upper part of the chest, behind the manubrium, they are not in contact; the point of reflection being represented by a line drawn from the sterno-clavicular articulation to the mid-point of the junction of the manubrium with the body of the sternum. From this point the two pleuræ descend in close contact to the level of the fourth costal cartilages, and the line of reflection on the right side is continued downwards in nearly a straight line to the lower end of the gladiolus, and then turns outwards, while on the left side the line of reflection diverges outwards and is continued downwards, close to the left border of the sternum, as far as the sixth costal cartilage. The inferior limit of the pleura is on a considerably lower level than the corresponding limit of the lung, but does not extend to the attachment of the Diaphragm, so that below the line of reflection of the pleura from the chest-

wall on to the Diaphragm the latter is in direct contact with the rib cartilages and the Internal intercostal muscles. Moreover, in ordinary inspiration the thin margin of the base of the lung does not extend as low as the line of the pleural reflection, with the result that the costal and diaphragmatic pleuræ are here in contact, the narrow slit between the two being termed the *sinus phrenicocostalis*. A similar condition exists behind the sternum and rib cartilages, where the anterior thin margin of the lung falls short of the line of pleural reflection, and where the slit-like cavity between the two layers of pleura forms what is sometimes called the *sinus costomediastinalis*.

The line along which the right pleura is reflected from the chest-wall to the Diaphragm starts in front, immediately below the seventh costo-sternal joint, and runs downwards and backwards behind the seventh costal cartilage so as to cross the tenth rib in the mid-axillary line, from which it is prolonged to the twelfth dorsal spine. The reflection of the left pleura follows at first the ascending part of the sixth costal cartilage, and in the rest of its course is slightly lower than that of the right side.

The free surface of the pleura is smooth, polished, and moistened by a serous fluid ; its attached surface is intimately adherent to the surface of the lung, and to the pulmonary vessels as they emerge from the pericardium ; it is also adherent to the upper surface of the Diaphragm : throughout the rest of its extent it may be separated from the adjacent parts with extreme facility.

The right pleural sac is shorter, wider, and reaches higher in the neck than the left.

Ligamentum latum pulmonis.—From the above description it will be seen that the root of the lung is covered in front and behind by pleura, and that at its lower border the investing layers come into contact. Here they form a sort of mesenteric fold, the *ligamentum latum pulmonis* (lig. pulmonale), which extends as far as the Diaphragm between the pericardium and the lower part of the inner surface of the lung, having a free falciform border below, between the lung and the Diaphragm. It serves to retain the lower part of the lung in position.

Vessels and Nerves.—The *arteries of the pleura* are derived from the intercostal, internal mammary, musculo-phrenic, thymic, pericardiac, and bronchial vessels. The *veins* correspond to the arteries. The *lymphatics* are described on page 793. The *nerves* are derived from the phrenic and sympathetic (Luschka). Kölliker states that nerves accompany the ramifications of the bronchial arteries in the pleura pulmonalis.

Applied Anatomy.—Acute inflammation of the pleura, or *pleurisy*, may be either dry or wet, and, if wet, either serous or purulent. *Dry pleurisy* is common in pneumonia, and is often an early manifestation of tuberculosis. It gives rise to much pain, and to friction sounds due to the scraping to and fro over one another of the inflamed and roughened parietal and visceral pleuræ. *Wet pleurisy* occurs if the inflammation causes the effusion of serum into the pleural cavity. The two pleural layers are now separated by the fluid effusion, so the friction sounds are no longer produced. Room is found for the fluid by shrinkage of the supernatant lung due to the retraction of its elastic tissue, and later, when the quantity of serum exceeds about three pints, by shifting over of the heart and unaffected lung towards the sound side. This shifting may be so extensive that the apex beat of the heart comes to lie under the right nipple. Any pleural effusion that is large enough to embarrass respiration seriously, or has remained unabsorbed for two or three weeks, should be removed by tapping (paracentesis thoracis). The trocar is pushed through the chest-wall into the fluid, in the sixth or seventh intercostal space in the mid-axillary line, or in the eighth or ninth space just outside the angle of the scapula. Aspiration is then performed, and as much fluid as possible drawn off: it must be stopped, however, if the patient shows signs of collapse, or if fits of coughing occur and threaten to wound the expanding lung against the sharp end of the trocar. Non-inflammatory or passive effusion into the pleura, called *hydrothorax*, is often seen in the later stages of chronic renal or cardiac disease, and demands treatment on lines similar to the above.

Purulent pleural effusion, or *empyema*, often occurs after such diseases as pneumonia or measles. This condition requires drainage of the cavity, which usually necessitates excision of a portion of a rib. An incision is made down to the seventh or eighth rib in the mid- or posterior axillary line and the periosteum is incised, and separated from the shaft of the rib, carrying with it the structures in the subcostal groove. With bone-cutting forceps about one and a half or two inches of the rib are separated and removed, and the underlying pleura is incised. The pus having been evacuated, a large drainage tube is inserted into the cavity. The pleura should never be irrigated, as sudden death has followed this proceeding, and great care should be taken to prevent the tube from slipping into the cavity, an occurrence which is far from uncommon.

Pneumothorax, or the presence of gas in the pleural cavity, is a common terminal event in tuberculosis of the lungs; less often it is due to trauma—rupture of the lung, for example, when the chest is crushed, or tearing of the lung tissue by the sharp projecting end of a broken rib. Air escapes from the lung into the pleural cavity; the elastic tissue of the lung at once contracts, and finally that organ shrinks away to a dark rounded mass the size of a fist, lying close against the vertebral column. The symptoms of pneumothorax are often very severe; cyanosis, intense dyspnœa, great pain on the affected side, and cardiac failure. Their severity is increased by the fact that the blood-vessels of the collapsed lung offer less resistance to the circulation of the blood than do those of the other lung. Not only, therefore, does the sound lung suddenly have to take over the work—the aeration of the blood—normally performed by both lungs, but it has to do so at the moment when the circulation of blood through it is partially short-circuited by the collapsed lung. If the patient survives for a few days, empyema often complicates the pneumothorax, setting up the condition called *pyopneumothorax*.

In operations upon the kidney, it must be borne in mind that the pleura usually extends below the level of the inner portion of the last rib, and may therefore be opened in these operations, especially when the last rib is removed in order to give more room.

The Mediastinum

The **mediastinum** is the space left in and near the median line of the chest by the non-apposition of the two pleuræ. It extends from the sternum in front to the vertebral column behind, and contains all the thoracic viscera excepting the lungs. The mediastinum may be divided for purposes of description into two parts: an upper portion, above the upper level of the pericardium, which is named the *superior mediastinum* (Struthers); and a lower portion, below the upper level of the pericardium. This lower portion is again subdivided

Fig. 891.—A transverse section of the thorax, showing the relative position of the viscera, and the reflections of the pleuræ.

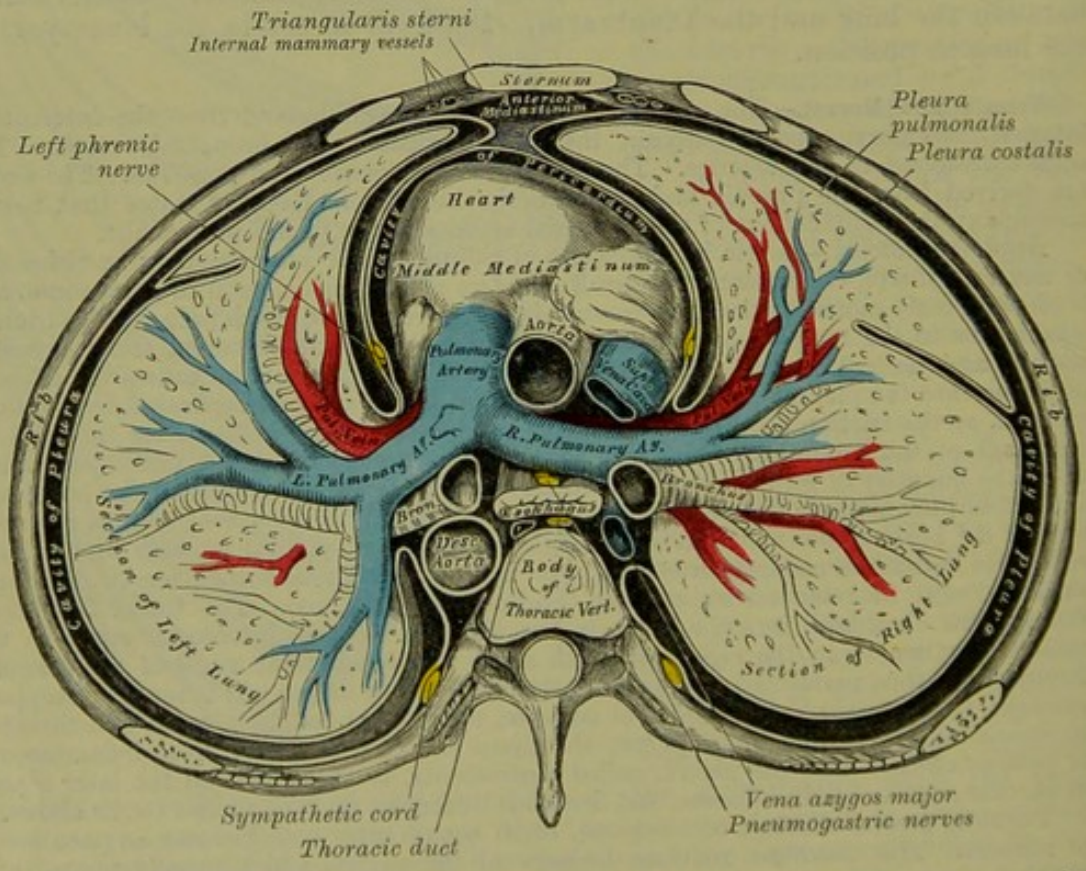

into three parts, viz. that which is in front of the pericardium, the *anterior mediastinum*; that which contains the pericardium and its contents, the *middle mediastinum*; and that which is behind the pericardium, the *posterior mediastinum* (fig. 891).

The **superior mediastinum** (fig. 892) is that portion of the interpleural space which lies between the manubrium sterni in front and the upper thoracic vertebræ behind. It is bounded below by a plane passing backwards from the

junction of the manubrium and gladiolus sterni to the lower part of the body of the fourth thoracic vertebra, and laterally by the pleuræ. It contains the origins of the Sterno-hyoid and Sterno-thyroid muscles and the lower ends of the Longus colli muscles; the arch of the aorta; the innominate artery and the thoracic portions of the left common carotid and the subclavian arteries; the innominate veins and the upper half of the superior vena cava; the left superior intercostal vein; the pneumogastric, cardiac, phrenic, and left recurrent laryngeal nerves; the trachea, œsophagus, and thoracic duct; the remains of the thymus gland, and some lymphatic glands.

The **anterior mediastinum** is bounded in front by the sternum, laterally by the pleuræ, and behind by the pericardium. It is narrow above, but widens out a little below, and, owing to the oblique course taken by the left pleura, it is directed from above downwards and to the left. Its anterior wall is formed by the left Triangularis sterni muscle and the fifth, sixth, and seventh left costal cartilages. It contains a quantity of loose areolar tissue, some

Fig. 892.—Transverse section through the upper margin of the second thoracic vertebra. (Braune.)

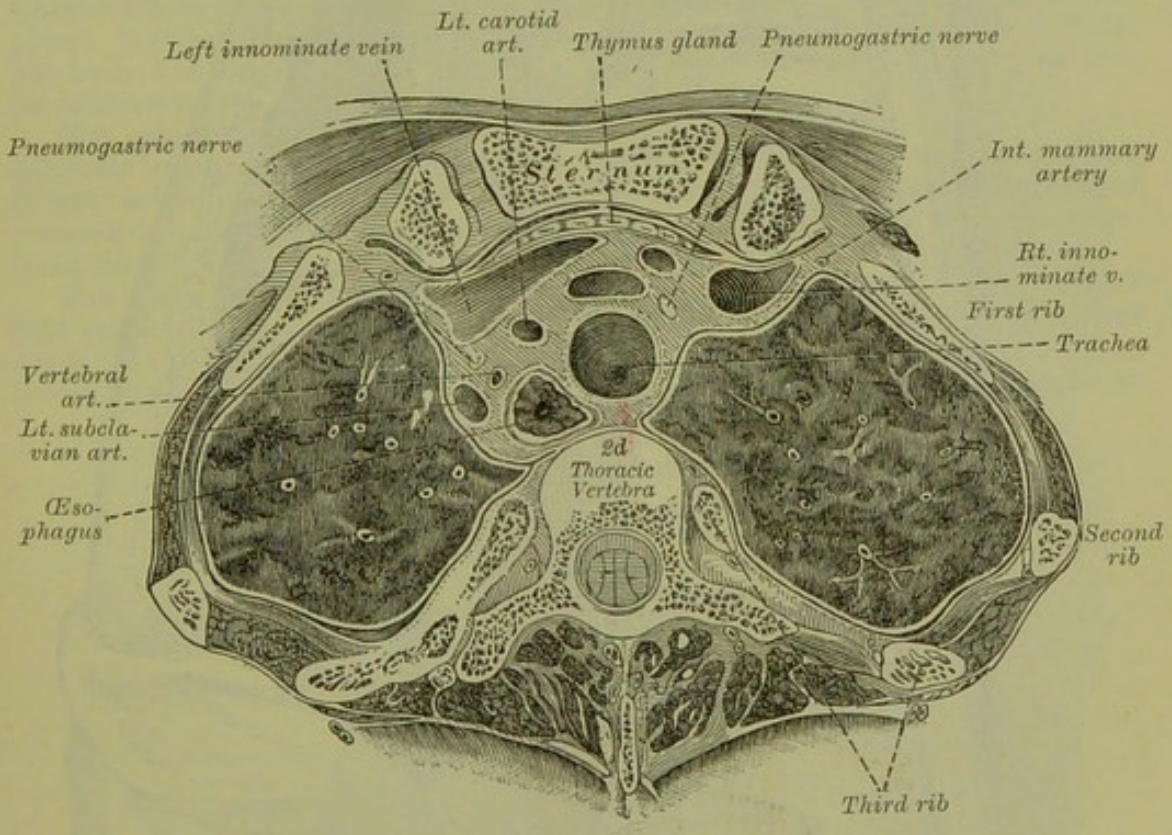

lymphatic vessels which ascend from the convex surface of the liver, two or three lymphatic glands (anterior mediastinal glands), and the small mediastinal branches of the internal mammary artery.

The **middle mediastinum** is the broadest part of the interpleural space. It contains the heart enclosed in the pericardium, the ascending aorta, the lower half of the superior vena cava with the vena azygos major opening into it, the bifurcation of the trachea and the two bronchi, the pulmonary artery dividing into its two branches, the right and left pulmonary veins, the phrenic nerves, and some bronchial lymphatic glands.

The **posterior mediastinum** (fig. 893) is an irregular triangular space running parallel with the vertebral column; it is bounded in front by the pericardium above, and by the posterior surface of the Diaphragm below, behind by the vertebral column from the lower border of the fourth to the twelfth thoracic vertebra, and on either side by the pleura. It contains the descending thoracic aorta, the venæ azygos major and minor, the pneumogastric and splanchnic nerves, the œsophagus, the thoracic duct, and some lymphatic glands.

Applied Anatomy.—Primary tumours of the mediastinum are usually lymphoma or lymphosarcoma arising from the thymus or from the bronchial or posterior mediastinal lymph-glands: sarcomata, dermoid cysts, and embryomata, occur more rarely. These tumours give rise to pain, deformity of the chest, and symptoms of pressure on the various nerves, blood-vessels, air-passages, lymphatics, and on the œsophagus, as these various structures pass through the thorax. They may produce physical signs very much like those of an aortic aneurysm, so that diagnosis between the two is often difficult. The

FIG. 893.—The posterior mediastinum.

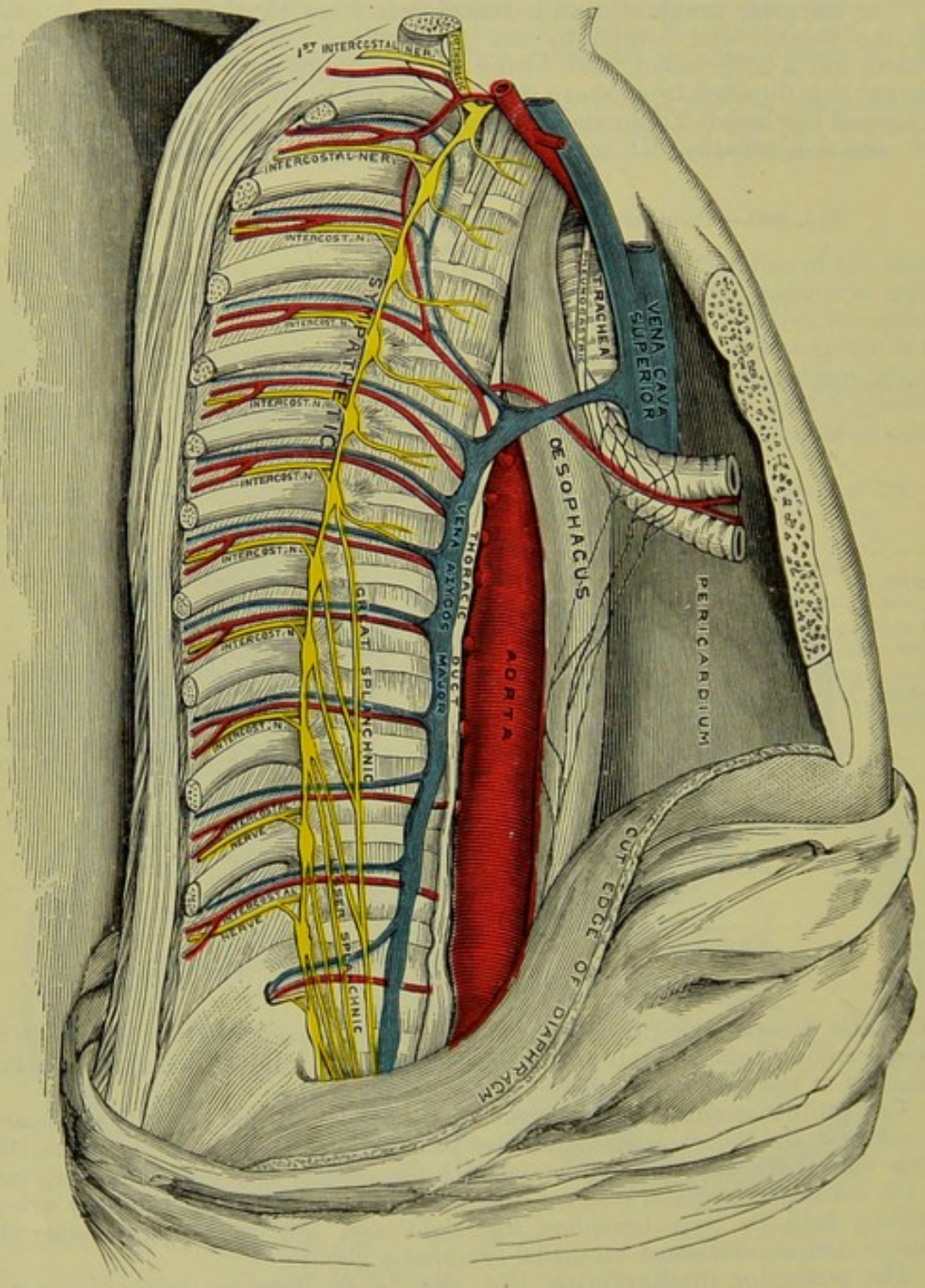

prognosis is bad, life usually ending within a few months or a year of the onset of the symptoms.

Inflammation of the mediastinum due to wounds, or to the spread of inflammation from adjacent parts (e.g. the œsophagus, the pericardium) is sometimes acute, leading to abscess-formation. A more chronic form associated with adhesions and inflammation of the pericardium—the so-called chronic adhesive mediastino-pericarditis—gives rise to obscure symptoms suggesting gradual heart-failure, and leads to death slowly but surely.

The Lungs

The **lungs** (pulmones) are the essential organs of respiration; they are two in number, placed one on either side of the chest, and separated from each other by the heart and other contents of the mediastinum. Each lung is conical in shape, and presents for examination an apex, a base, two borders, and two surfaces.

The *apex* (apex pulmonis) is rounded, and extends into the root of the neck, reaching from an inch to an inch and a half above the level of the anterior end of the first rib. A furrow produced by the subclavian artery as it curves outwards in front of the pleura runs upwards and outwards immediately below the apex.

The *base* (basis pulmonis) is broad, concave, and rests upon the convex surface of the Diaphragm, which separates the right lung from the right lobe of the liver, and the left lung from the left lobe of the liver, the stomach, and spleen. Since the Diaphragm extends higher on the right than on the left side, it follows that the concavity on the base of the right lung is deeper than that on the left. Laterally and behind, the base is bounded by a thin, sharp margin which projects for some distance into the phrenico-costal sinus of the pleura, between the lower ribs and the costal attachment of the Diaphragm. The base of the lung descends during inspiration and ascends during expiration; its relation to the chest-wall is indicated in figs. 889 and 890.

The *external* or *costal surface* (facies costalis) is smooth, convex, of considerable extent, and corresponds to the form of the cavity of the chest, being deeper behind than in front. It is in contact with the costal pleura, and presents in a hardened specimen slight grooves corresponding with the overlying ribs.

The *inner* or *mediastinal surface* (facies mediastinalis) is in contact with that portion of the pleura which forms the lateral boundary of the mediastinal space. It presents a deep concavity which accommodates the pericardial sac; this is larger and deeper on the left than on the right lung, on account of the heart

Fig. 894.—Mediastinal surface of right lung.

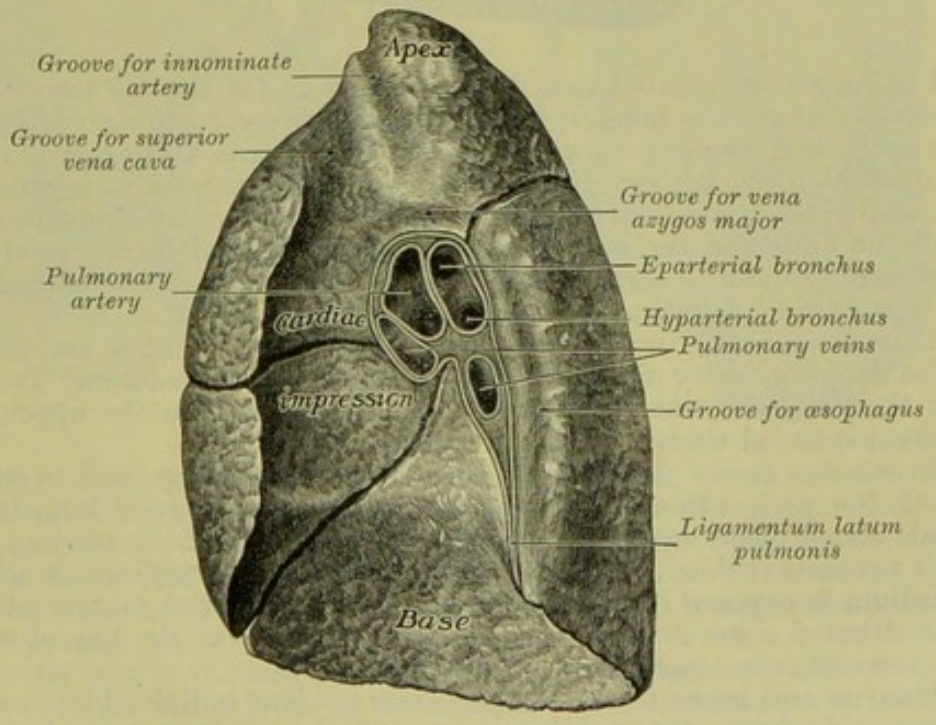

projecting farther to the left than to the right side of the mesial plane. Above and behind this concavity is a triangular depression named the *hilus* (hilus pulmonis), where the structures which form the root of the lung enter and leave the viscus. These structures are invested by pleural membrane, which, below the hilus, forms the ligamentum latum pulmonis. On the *right* lung (fig. 894), immediately above the hilus, is an arched furrow which

accommodates the vena azygos major; while running upwards, and then arching outwards some little distance below the apex, is a wide groove for the superior vena cava and right innominate vein, and behind this, nearer the apex, is a second furrow for the innominate artery. Along the back part of the inner surface is a vertical groove for the œsophagus; this groove becomes less distinct below, owing to the inclination of the lower part of the œsophagus to the left of the middle line. In front and to the right of the lower part of the œsophageal groove, the inner surface is applied to the pleural covering of the right and posterior aspects of the thoracic part of the inferior vena cava—this

Fig. 895.—Mediastinal surface of left lung.

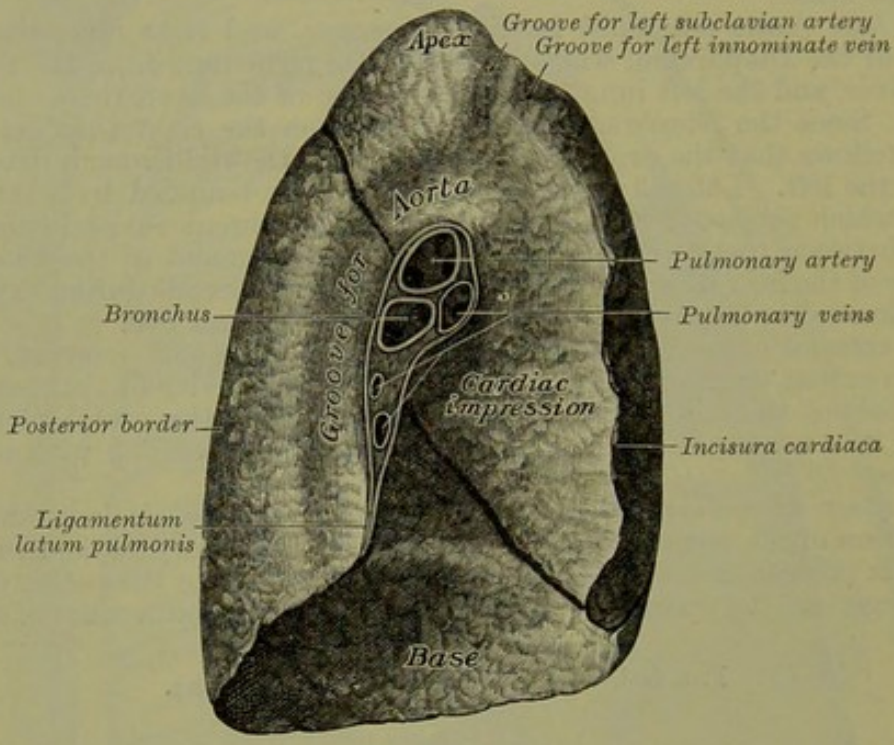

vessel being accommodated in a deep concavity. On the *left* lung (fig. 895), immediately above the hilus, is a well-marked curved furrow produced by the aortic arch, and running upwards from this towards the apex is a groove accommodating the left subclavian artery; a slight impression in front of the latter and close to the margin of the lung lodges the left innominate vein. Behind the hilus and pericardial depression is a vertical furrow produced by the descending thoracic aorta, and in front of this, near the base of the lung, the lower part of the œsophagus causes a shallow depression.

The *posterior border* (margo posterior) is broad and rounded, and is received into the deep concavity on either side of the vertebral column. It is much longer than the anterior border, and projects, below, into the upper part of the phrenico-costal sinus.

The *anterior border* (margo anterior) is thin and sharp, and overlaps the front of the pericardium. The anterior border of the *right* lung is almost vertical, and projects into the costo-mediastinal sinus of the pleura; that of the *left* presents, below, an angular notch, the *incisura cardiaca*, in which the pericardium is exposed. Opposite this notch the anterior margin of the left lung is situated some little distance to the outer side of the line of reflection of the corresponding part of the pleura.

Fissures and lobes of the lungs.—The *left lung* is divided into two lobes, an upper and a lower, by an *oblique fissure*, which extends from the outer to the inner surface of the lung both above and below the hilus. As seen on the surface, this fissure commences on the inner aspect of the lung at the upper and posterior part of the hilus, and runs backwards and upwards to the posterior border, which it crosses at a point about two and a half inches below the apex. It then extends downwards and forwards over the outer surface, and reaches the lower border a little behind its anterior extremity, and its further course can

be followed upwards and backwards across the inner surface as far as the lower part of the hilus. The *upper lobe* (lobus superior) lies above and in front of this fissure, and includes the apex, the anterior border, and a considerable part of the outer surface and the greater part of the inner surface of the lung. The *lower lobe* (lobus inferior), the larger of the two, is situated below and behind the fissure, and comprises almost the whole of the base, a large portion of the outer surface, and the greater part of the posterior border.

The *right lung* is divided into three lobes, upper, middle, and lower, by an oblique and a horizontal fissure. The *oblique fissure* separates the lower from the middle and upper lobes, and corresponds closely with the fissure in the left lung. Its direction is, however, more vertical, and it cuts the lower border about three inches behind its anterior extremity. The *horizontal fissure* separates the upper from the middle lobe. It begins in the oblique fissure near the posterior border of the lung, and, running horizontally forwards, cuts

FIG. 896.—Front view of heart and lungs.

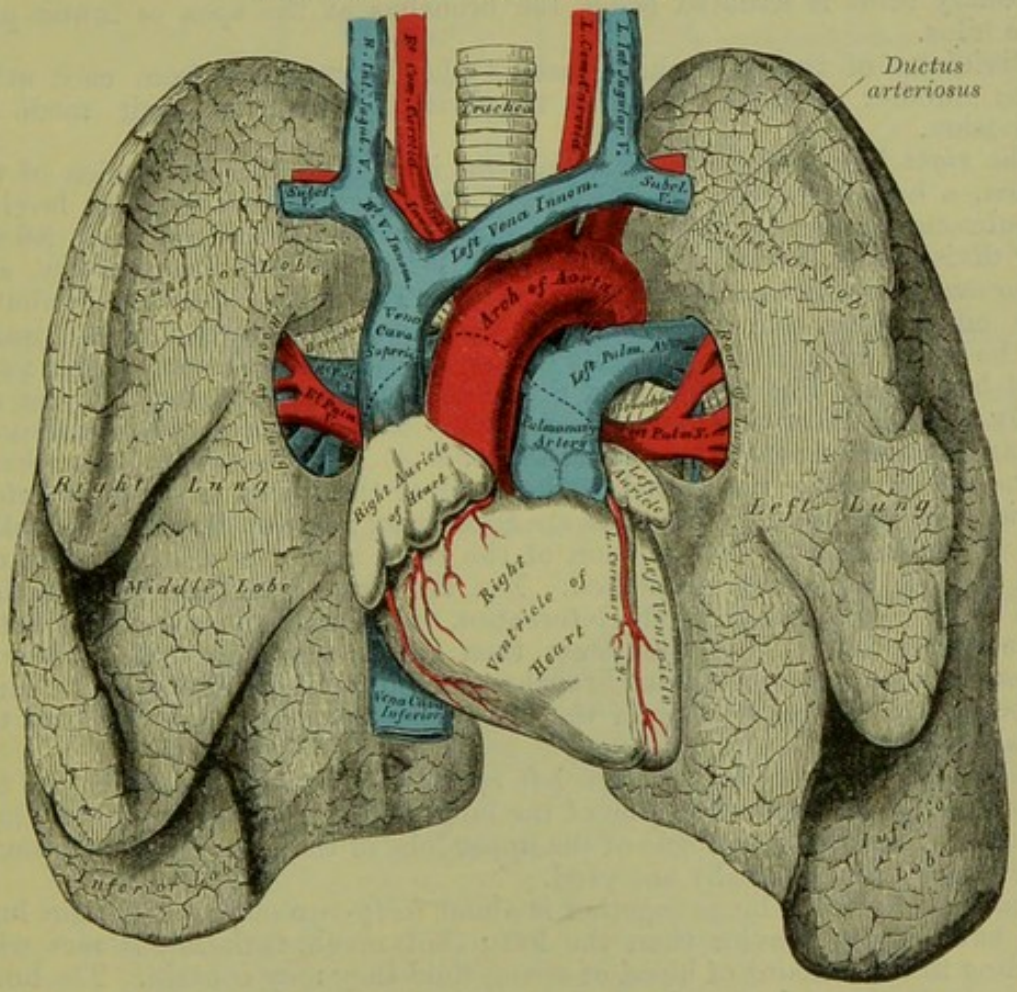

the anterior border on a level with the sternal end of the fourth costal cartilage; on the inner surface it may be traced backwards to the hilus. The *middle lobe* (lobus medius), the smallest of the lobes of the right lung, lies between the horizontal fissure and the lower part of the oblique fissure; it is wedge-shaped, and includes the lower part of the anterior border and the anterior part of the base of the lung.

The *right lung* is the larger and heavier; it is broader than the *left*, owing to the inclination of the heart to the left side; it is also shorter by an inch, in consequence of the Diaphragm rising higher on the right side to accommodate the liver.

The **root of the lung** (radix pulmonis).—A little above the middle of the inner surface of each lung, and nearer its posterior than its anterior border, is its root, by which the lung is connected to the heart and the trachea. The root is formed by the bronchus, the pulmonary artery, the pulmonary veins, the bronchial arteries and veins, the pulmonary plexuses of nerves, lymphatics,

bronchial glands, and areolar tissue, all of which are enclosed by a reflection of the pleura. The root of the right lung lies behind the superior vena cava and part of the right auricle, and below the vena azygos major. That of the left lung passes beneath the arch of the aorta and in front of the descending aorta; the phrenic nerve, with its accompanying artery and vein, and the anterior pulmonary plexus, lie in front of each, and the pneumogastric and posterior pulmonary plexus behind each; below each is the ligamentum latum pulmonis.

The chief structures composing the root of each lung are arranged in a similar manner from before backwards on both sides, viz. the upper of the two pulmonary veins in front; the pulmonary artery in the middle; and the bronchus, together with the bronchial vessels, behind. From above downwards, on the two sides, their arrangement differs, thus:

On the right side their position is—eparterial bronchus, pulmonary artery, hyparterial bronchus, pulmonary veins; but on the left side their position is—pulmonary artery, bronchus, pulmonary veins. The lower of the two pulmonary veins is situated below the bronchus at the apex or lowest part of the hilus.

Divisions of the bronchi.—Just as the lungs differ from each other in the number of their lobes, so the bronchi differ in their mode of subdivision.

The *right* bronchus gives off, about an inch from the bifurcation of the trachea, a branch for the upper lobe. This branch arises above the level of the pulmonary artery, and is therefore named the *eparterial bronchus*. All the other divisions of the main stem come off below the pulmonary artery, and consequently are termed *hyparterial bronchi*. The first of these is distributed to the middle lobe, and the main tube then passes downwards and backwards into the lower lobe, giving off in its course a series of large ventral and small dorsal branches. The ventral and dorsal branches arise alternately, and are usually eight in number—four of each kind. The branch to the middle lobe is regarded as the first of the ventral series.

The *left* bronchus passes below the level of the pulmonary artery before it divides, and hence all its branches are *hyparterial*; it may therefore be looked upon as equivalent to that portion of the right bronchus which lies on the distal side of its eparterial branch. The first branch of the left bronchus arises about two inches from the bifurcation of the trachea, and is distributed to the upper lobe. The main stem then enters the lower lobe, where it divides into ventral and dorsal branches similar to those in the right lung. The branch to the upper lobe of the left lung is regarded as the first of the ventral series.

Aeby regarded the absence of a left eparterial bronchus as indicating the absence of the corresponding lobe of the lung, and considered the middle lobe of the right lung the homologue of the upper lobe of the left. His conclusions, however, are not universally accepted.

The *weight* of both lungs together is about forty-two ounces, the right lung being two ounces heavier than the left; but much variation is met with according to the amount of blood or serous fluid they may contain. The lungs are heavier in the male than in the female, their proportion to the body being, in the former, as 1 to 37, in the latter as 1 to 43.

The *colour* of the lungs at birth is a pinkish-white; in adult life it is a dark slaty-grey, mottled in patches; and as age advances, this mottling assumes a black colour. The colouring matter consists of granules of a carbonaceous substance deposited in the areolar tissue near the surface of the organ. It increases in quantity as age advances, and is more abundant in males than in females. The posterior border of the lung is usually darker than the anterior.

The *surface* of the lung is smooth, shining, and marked out into numerous polyhedral areas, indicating the lobules of the organ: each of these areas is crossed by numerous lighter lines.

The *substance* of the lung is of a light, porous, spongy texture; it floats in water, and crepitates when handled, owing to the presence of air in the air-sacs; it is also highly elastic; hence the retracted state of these organs when they are removed from the closed cavity of the thorax.

Structure.—The lungs are composed of an external serous coat, a subserous areolar tissue, and the pulmonary substance or parenchyma.

The *serous coat* is the visceral layer of the pleura ; it is thin, transparent, and invests the entire organ as far as the root.

FIG. 897.—Section of lung tissue.

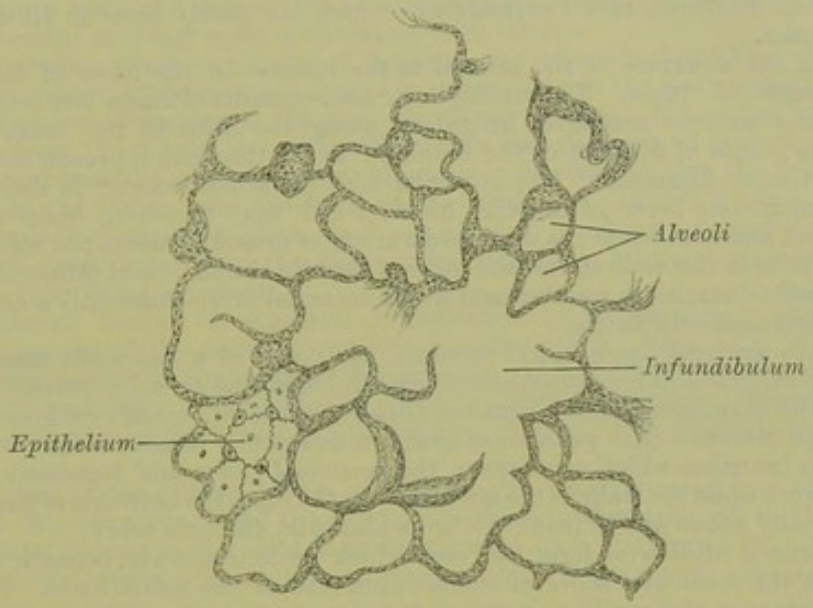

The *subserous areolar tissue* contains a large proportion of elastic fibres ; it invests the entire surface of the lung, and extends inwards between the lobules.

The *parenchyma* is composed of lobules which, although closely connected together by an interlobular areolar tissue, are quite distinct from one another, and may be teased asunder without much difficulty in the fœtus. The lobules vary in size : those on the

FIG. 898.—Section of a portion of an atelectic lung of kitten.

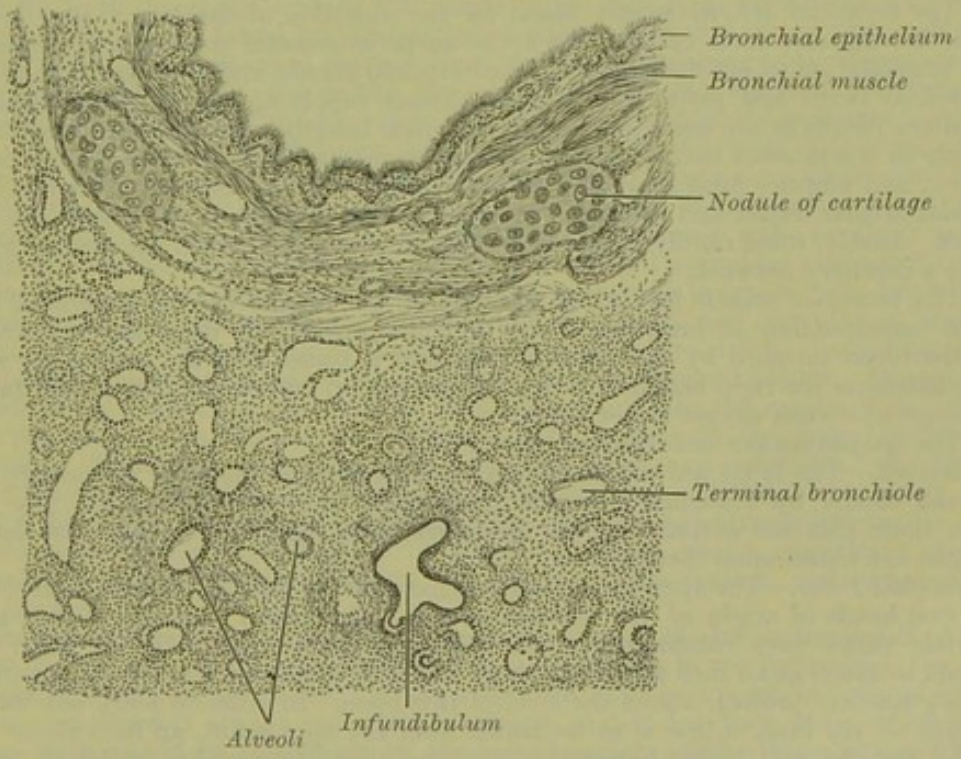

surface are large, of pyramidal form, the base turned towards the surface ; those in the interior smaller, and of various forms. Each lobule is composed of one of the ramifications of a bronchial tube and its terminal air-cells, and of the ramifications of the pulmonary and bronchial vessels, lymphatics, and nerves ; all of these structures being connected together by areolar tissue.

The primary branches of the *bronchus*, upon entering the substance of the lung, divide and subdivide into smaller tubes throughout the entire organ. Each of the smaller subdivisions of the bronchus enters a pulmonary lobule, and is termed an *intralobular bronchus*. This gives off collateral branches and then bifurcates about the centre of the lobule; these bifurcations divide at right angles to the previous plane of division and the process is repeated until a large number of ultimate bronchi (*bronchioles*) are formed. Each bronchiole now becomes enlarged, and is termed the *atrium* or *alveolar passage*; from it are given off, on all sides, ramifications, called *infundibula*, which are closely beset in all directions by *alveoli* or *air-sacs*.

Changes in the structure of the bronchi in the lungs.—In the lobes of the lungs the following changes take place. The *cartilages* are not segments of rings, but consist of small oval or angular patches scattered irregularly along the sides of the tube, being most distinct at the points of division of the bronchi; as the bronchi approach their terminations the cartilages disappear. The muscular coat (*bronchial muscle*) is disposed in the form of a continuous layer of annular fibres, which may be traced upon the smallest bronchial tubes, and consists of the unstriped variety of muscular tissue; at the termination of the bronchioles in the atria the muscle forms a definite circular band (Miller). The layers of epithelial cells diminish in number and in the terminal bronchioles only a single layer of non-ciliated flattened cells exists.

The air-sacs are small polyhedral recesses, composed of a basement membrane surrounded by a few involuntary muscular and elastic fibres, and lined by flattened squamous epithelium, with sinuous outlines; between these cells are seen small oval granular cells.

Vessels and Nerves.—The *pulmonary artery* conveys the venous blood to the lungs; it divides into branches which accompany the bronchial tubes and terminate in a dense capillary network upon the walls of the air-sacs. In the lung, the branches of the pulmonary artery are usually above and in front of a bronchial tube, the vein below.

The *pulmonary capillaries* form plexuses which lie immediately beneath the mucous membrane, in the walls and septa of the air-sacs, and of the infundibula. In the septa between the air-sacs the capillary network forms a single layer. The capillaries form a very minute network, the meshes of which are smaller than the vessels themselves; their walls are also exceedingly thin. The arteries of neighbouring lobules are independent of each other, but the veins freely anastomose.

The *pulmonary veins* commence in the pulmonary capillaries, the radicles coalescing into larger branches which run through the substance of the lung, independently of the minute arteries and bronchi. After freely communicating with other branches they form large vessels, which ultimately come into relation with the arteries and bronchial tubes, and accompany them to the hilus of the organ. Finally they open into the left auricle of the heart, conveying oxygenated blood to be distributed to all parts of the body by the aorta.

The *bronchial arteries* supply blood for the nutrition of the lung; they are derived from the thoracic aorta or from the upper aortic intercostal arteries, and, accompanying the bronchial tubes, are distributed to the bronchial glands, and upon the walls of the larger bronchial tubes and pulmonary vessels. Those supplying the bronchial tubes form a capillary plexus in the muscular coat, from which branches are given off to form a second plexus in the mucous coat. This plexus communicates with branches of the pulmonary artery, and empties itself into the pulmonary veins. Others are distributed in the interlobular areolar tissue, and terminate partly in the deep, partly in the superficial, bronchial veins. Lastly, some ramify upon the surface of the lung, beneath the pleura, where they form a capillary network.

The *bronchial vein* is formed at the root of the lung, receiving superficial and deep veins corresponding to branches of the bronchial artery. It does not, however, receive all the blood supplied by the artery, as some of it passes into the pulmonary veins. It terminates on the right side in the vena azygos major, and on the left side in the superior intercostal or vena azygos minor superior.

The *lymphatics* are described on page 792.

Nerves.—The lungs are supplied from the anterior and posterior pulmonary plexuses, formed chiefly by branches from the sympathetic and pneumogastric. The filaments from these plexuses accompany the bronchial tubes, upon which they are lost. Small ganglia are found upon these nerves.

Surface Form.—The apex of the lung is situated in the neck, behind the interval between the two heads of origin of the Sterno-mastoid. The height to which it rises above the clavicle varies very considerably, but is generally about an inch. It may, however, extend as much as an inch and a half or an inch and three-quarters, or, on the other hand, it may scarcely project, above the level of this bone. In order to mark out the anterior margin of the lung, a line is to be drawn from the apex point, an inch above the level of the clavicle, and rather nearer the posterior than the anterior border of the Sterno-mastoid muscle, downwards and inwards across the sterno-clavicular articulation and manubrium sterni until it meets, or almost meets, its fellow of the other side at the level of the articulation of the manubrium and gladiolus. From this point the two lines are to be drawn downwards, rather to the left of the mesial line but close to it, as far as the level of the articulation of the fourth costal cartilages with the sternum. From here the two lines diverge, the left at first passing outwards with a slight inclination down-

wards, and then taking a bend downwards with a slight inclination outwards to the apex of the heart, and thence to the sixth costo-chondral articulation. The direction of the anterior border of this part of the left lung is denoted with sufficient accuracy by a curved line, with its convexity directed upwards and outwards from the articulation of the fourth right costal cartilage of the sternum to the fifth intercostal space, an inch and a half below, and three-quarters of an inch internal to the left nipple. The continuation of the anterior border of the right lung is marked by a prolongation of its line from the level of the fourth costal cartilages vertically downwards as far as the sixth, when it slopes off along the line of the sixth costal cartilage to its articulation with the rib.

After expiration the lower border of the lung may be marked out by a slightly curved line, with its convexity downwards, from the articulation of the sixth costal cartilage with its rib to the spinous process of the tenth thoracic vertebra. If vertical lines are drawn downwards from the nipple, the mid-axillary line, and the apex of the scapula, while the arms are raised from the sides, they should intersect this convex line, the first at the sixth, the second at the eighth, and the third at the tenth rib. It will thus be seen that the pleura extends farther down than the lung, so that it may be wounded, and a wound pass through both layers into the Diaphragm, and even injure the abdominal viscera, without the lung being involved.

The posterior border of the lung is indicated by a line drawn from the level of the spinous process of the seventh cervical vertebra, down either side of the vertebral column, corresponding to the costo-vertebral joints as low as the spinous process of the tenth thoracic vertebra. The trachea bifurcates opposite the spinous process of the fourth thoracic vertebra, and from this point the two bronchi are directed downwards and outwards.

The position of the oblique fissure in each lung may be indicated by a line drawn from the second thoracic spine round the side of the chest to the sixth rib in the nipple line. The horizontal fissure in the right lung is indicated by a line drawn from the preceding, where it bisects the mid-axillary line, to the junction of the fourth costal cartilage with the sternum.

Applied Anatomy.—The lungs may be wounded or torn in three ways: (1) by compression of the chest, without any injury to the ribs; (2) by a fractured rib penetrating the lung; (3) by stabs, gunshot wounds, &c.

The first form, where the lung is ruptured by external compression without any fracture of the ribs, is very rare, and usually occurs in young children, and affects the root of the lung, i.e. the most fixed part, and thus, implicating the great vessels, is frequently fatal. It would seem *a priori* a most unusual injury, and its exact mode of causation is difficult to interpret.

In the second variety, when the wound in the lung is produced by the penetration of a broken rib, both the pleura costalis and pleura pulmonalis must necessarily be injured, and consequently the air taken into the wounded air-sacs may find its way through these wounds into the cellular tissue of the parietes of the chest, producing *surgical* emphysema. This it may do without collecting in the pleural cavity; the two layers of the pleura are so intimately in contact that the air passes straight through from the wounded lung into the subcutaneous tissue. Emphysema constitutes therefore the most important sign of injury to the lung in cases of fracture of the ribs. Pneumothorax, or air in the pleural cavity, is much more likely to occur in injuries of the third variety—that is to say, from external wounds, from stabs, gunshot injuries, and such like—in which case air passes either from the wound of the lung or from the external wound into the cavity of the pleura during the respiratory movements. In these cases there is generally no emphysema of the subcutaneous tissue unless the external wound is small and valvular, so that the air is drawn into the wound during inspiration, and then forced into the cellular tissue around during expiration because it cannot escape from the external wound. Occasionally in wounds of the parietes of the chest no air finds its way into the cavity of the pleura, because the lung at the time of the accident protrudes through the wound and blocks the opening. This takes place where the wound is large, and constitutes one form of *hernia* of the lung. Another form of hernia of the lung occurs, though very rarely, after wounds of the chest-wall, when the wound has healed and the cicatrix subsequently yields from the pressure of the viscus behind. It forms a globular, elastic, crepitating swelling, which enlarges during expiratory efforts, falls in during inspiration, and disappears on holding the breath.

An incision into the lung is occasionally required in cases of abscess the result of pneumonia or the presence of a foreign body, and from an abscess in the liver which has made its way through the Diaphragm into the lung substance, and also in cases of hydatid disease. In these cases there is always risk of hæmorrhage, and it has been recommended that the lung tissue should be penetrated by the actual cautery, rather than with the knife. Unless adhesions have formed between the two layers of the pleura, the pleural cavity must necessarily be opened, and there is the further risk of pneumothorax, and possibly of septic infection. It is therefore advisable to suture the lung to the opening in the thoracic wall, and wait for adhesions to form before perforating the lung.

The routine methods of physical examination—inspection, palpation, percussion, and auscultation—are nowhere more important than they are in the diagnosis of diseases of

the lungs. It is essential, too, that in every case the two sides of the chest should be compared with one another, and that the wide variations that may be met with under normal conditions in different persons and at different ages should be kept in mind when the chest is being examined. On *inspection* the thorax will be seen to be enlarged and barrel-shaped in emphysema, in which the volume of the lungs is increased by dilatation of their alveoli, or in an acute attack of asthma, or when a large pleural effusion or mediastinal tumour is present. The chest-wall will be flattened or sunken, on the other hand, over an area of lung that has collapsed or become fibrosed, as often happens in chronic pulmonary tuberculosis. The respiratory movements of the chest-wall will be lessened, or even absent, over a part or the whole of the affected side in such acute disorders as pleurisy, pneumonia, or pleural effusion, or in more chronic disease where the underlying lung is fibrosed, or is crushed to one side by a mediastinal tumour ; and by the use of the *x*-rays a corresponding loss of movement or displacement of the Diaphragm on the affected side can often be observed. Under normal conditions the intercostal spaces are a little depressed ; but they may be obliterated or even bulging on that side when a large effusion or new growth fills up one of the pleural cavities.

On *palpation* the hand can be used to verify the eye's impressions as to the degree of movement on respiration of any part of the chest-wall. The facility with which the vibrations produced by the voice are conducted from the larynx by the underlying lung to the hand (in the form of *vocal fremitus*) can also be tested. The vocal fremitus is commonly much increased over the consolidated area in pneumonia or in fibrosis of the lung, and much diminished over a pleural effusion when the lung is pushed up by the fluid towards the top of the pleural cavity. It is also diminished, but to a less extent, in emphysema, and in bronchitis when the bronchi are blocked by secretion. In bronchitis the bubbling of the secretion in the tubes can often be felt by a hand placed on the chest-wall as the patient breathes; and in chronic pleurisy the friction of the two roughened pleural surfaces against one another can sometimes be felt in the same way.

On *percussion*, the normal resonance of the pulmonary tissue is found to be increased in emphysema, and in pneumothorax (page 1078) this hyper-resonance may be still further increased. The resonance is lessened in any condition causing collapse or solidification of the lung-tissue, or when its place is taken by fluid (pleural effusion) or some solid growth (mediastinal tumour). Thus dulness on percussion at the bases of the lungs is common in the hypostatic congestion of the bases seen in heart-failure ; dulness at the right base is often due to compression of the lung by enlargement of the liver ; some dulness at the apex of a lung is frequently met with in tuberculosis of that part, before the disease has progressed very far. Complete dulness over one side of the chest, back and front alike, except at the apex, is common when a large pleural effusion has taken the lung's place. Von Korányi, Grocco, and others, have drawn attention to a triangular patch of dulness along the vertebral column (the paravertebral triangle of dulness) on the unaffected side in pleural effusion ; this triangle of dulness is said to be absent in other conditions causing loss of pulmonary resonance on percussion, and is due to shifting over of the contents of the posterior mediastinum towards the sound side. The apex of this triangle is in the middle line at the upper level of the fluid effusion ; its base, some two to four inches in length, runs horizontally outwards from the middle line at the level where the pulmonary resonance normally comes to an end.

On *auscultation* of the lungs, both in health and disease, the variety of sounds to be heard is very great. It is impossible to give adequate consideration to them here, and for further information reference should be made to the text-books dealing with the subject.*

ORGANS OF DIGESTION

The apparatus for the digestion of the food (apparatus digestorius) consists of the alimentary canal and of certain accessory organs.

The **alimentary canal** is a musculo-membranous tube, about thirty feet in length, extending from the mouth to the anus, and lined throughout its entire extent by mucous membrane. It has received different names in the various parts of its course : at its commencement is the *mouth*, where provision is made for the mechanical division of the food (*mastication*), and for its admixture with a fluid secreted by the salivary glands (*insalivation*) ; beyond this are the organs of deglutition, the *pharynx* and the *œsophagus*, which convey the food into the *stomach* in which the principal chemical changes occur, and in which the reduction and solution of the food take place ; the stomach is followed by the *small intestine*, which is divided for purposes of description into three parts, the *duodenum*, the *jejunum*, and *ileum*, and in which the

* See especially *Auscultation and Percussion*, by Samuel Gee. Edit. 5, 1906. Smith, Elder & Co.

nutritive principles of the food are separated and absorbed ; finally the small intestine terminates in the *large intestine*, which is made up of *cæcum*, *colon*, *rectum*, and *anal canal*, the last terminating on the surface of the body at the *anus*. The *accessory organs* are the *teeth*, for purposes of mastication ; the three pairs of *salivary glands*—the *parotid*, *submaxillary*, and *sublingual*—the secretion from which mixes with the food in the mouth and converts it into a bolus and acts chemically on one of its constituents ; the *liver* and *pancreas*, two large glands in the abdomen, the secretions of which, in addition to that of numerous minute glands in the walls of the alimentary canal, assist in the process of digestion.

Alimentary Canal

Mouth.
Pharynx.
Œsophagus.
Stomach.
Small intestine { Duodenum. Jejunum. Ileum.
Large intestine { Cæcum. Colon. Rectum. Anal canal.

Accessory Organs

Teeth.
Salivary glands { Parotid. Submaxillary. Sublingual.
Liver.
Pancreas.

The Mouth

The **mouth** (cavum oris) is placed at the commencement of the alimentary canal (fig. 899) ; it is a nearly oval-shaped cavity, in which the mastication of the food takes place. It consists of two parts : an outer, smaller portion, the vestibule (vestibulum oris), and an inner, larger part, the cavity proper of the mouth (cavum oris proprium).

The *vestibulum oris* is a slit-like space, bounded in front and laterally by the lips and cheeks ; behind and internally by the gums and teeth. It communicates with the surface of the body by the *aperture of the mouth*. Above and below, it is limited by the reflection of the mucous membrane from the lips and cheeks to the gum covering the upper and lower alveolar arch respectively. It receives the secretion from the parotid glands, and communicates, when the jaws are closed, with the cavum oris by an aperture on either side behind the wisdom teeth, and by narrow clefts between opposing teeth.

The *cavum oris proprium* is bounded laterally and in front by the alveolar arches with their contained teeth ; behind, it communicates with the pharynx by a constricted aperture termed the *isthmus faucium*. It is roofed in by the hard and soft palates, while the greater part of the floor is formed by the tongue, the remainder being completed by the reflection of the mucous membrane from the sides and under surface of the tongue to the gum lining the inner aspect of the mandible. It receives the secretion from the submaxillary and sublingual glands.

The *mucous membrane* lining the mouth is continuous with the integument at the free margin of the lips, and with the mucous lining of the pharynx behind ; it is of a rose-pink tinge during life, and very thick where it overlies the hard parts bounding the cavity. It is covered by stratified epithelium.

The **lips** (labia oris) are two fleshy folds which surround the orifice of the mouth (rima oris), formed externally of integument and internally of mucous membrane, between which are found the Orbicularis oris muscle, the coronary vessels, some nerves, areolar tissue, and fat, and numerous small labial glands. The inner surface of each lip is connected in the middle line to the gum of the corresponding jaw by a fold of mucous membrane, the *frenulum*—the upper being the larger of the two.

The *labial glands* are situated between the mucous membrane and the Orbicularis oris, round the orifice of the mouth. They are circular in form, and about the size of small peas ; their ducts opening by minute orifices upon the mucous membrane. In structure they resemble the salivary glands.

The **cheeks** (buccæ) form the sides of the face, and are continuous in front with the lips. They are composed externally of integument; internally

FIG. 899.—Sagittal section of nose, mouth, pharynx, and larynx.

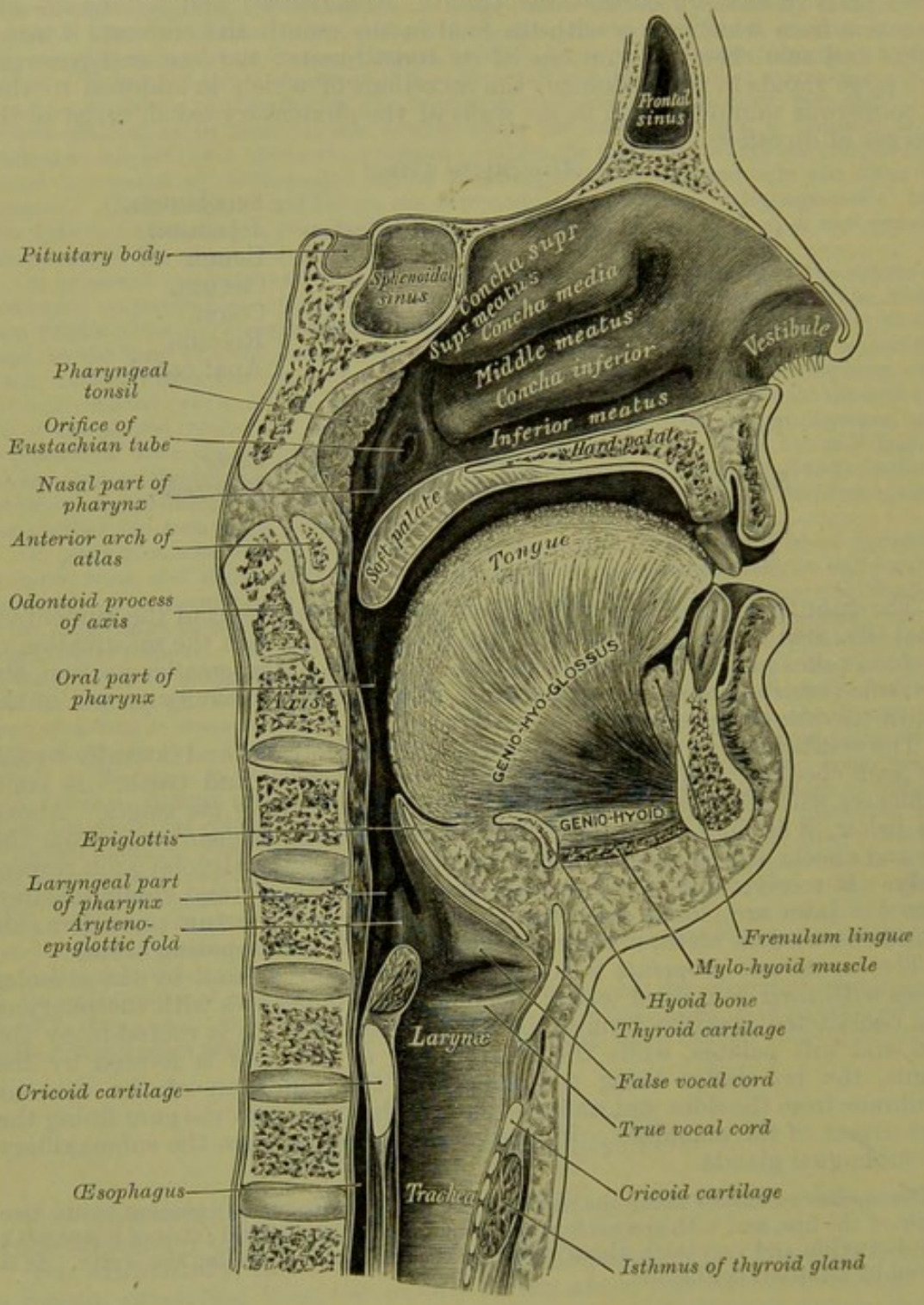

of mucous membrane; and between the two of a muscular stratum, besides a large quantity of fat, areolar tissue, vessels, nerves, and buccal glands.

The *mucous membrane* lining the cheek is reflected above and below upon the gums, and is continuous behind with the lining membrane of the soft palate. Opposite the second molar tooth of the upper jaw is a papilla, the summit of which presents the aperture of the duct of the parotid gland. The principal muscle of the cheek is the Buccinator; but numerous other muscles enter into its formation, viz. the Zygomatici, Risorius, and Platysma.

The *buccal glands* are placed between the mucous membrane and Buccinator muscle: they are similar in structure to the labial glands, but smaller. About five of larger size than the rest are placed between the Masseter and Buccinator muscles around the distal

extremity of Stenson's duct; their ducts open in the mouth opposite the last molar tooth. They are called *molar glands*.

The **gums** (gingivæ) are composed of a dense fibrous tissue, closely connected to the periosteum of the alveolar processes, and surrounding the necks of the teeth. They are covered by smooth and vascular mucous membrane, which is remarkable for its limited sensibility. Around the necks of the teeth this membrane presents numerous fine papillæ, and is reflected into the alveoli, where it is continuous with the periosteal membrane lining these cavities.

Applied Anatomy.—The gums are occasionally the seat of considerable hypertrophy, forming a lobulated vascular fold growing up in front and behind the teeth, so as almost to bury them. They may also become swollen and congested, bleeding freely, and often becoming ulcerated. The condition is known as *spongy gums*, and may occur in scurvy, in stomatitis and dyspepsia, in ill-fed tuberculous children, and from the administration of mercury; the gums are very tender, mastication is painful, and there is often considerable fœtor. The margin of the gum presents an interrupted blue line in cases of lead-poisoning. The collection of tartar, which consists of the secretion from the gums, mixed with fragments of food and salivary salts, may give rise to a condition known as *pyorrhœa alveolaris*, which is an inflammatory condition of the gums, followed by the gradual absorption of the alveolus and the falling out of the teeth. Fibrous tumours (epulis), myeloid growths and epitheliomata are met with in the gums.

The **palate** (palatum) forms the roof of the mouth: it consists of two portions, the hard palate in front, the soft palate behind.

The **hard palate** (palatum durum) is bounded in front and at the sides by the alveolar arches and gums; behind, it is continuous with the soft palate. It is covered by a dense structure formed by the periosteum and mucous membrane of the mouth, which are intimately adherent. Along the middle line is a linear ridge or raphe (raphe palati), which terminates anteriorly in a small papilla corresponding with the inferior opening of the anterior palatine fossa. On either side and in front of the raphe the mucous membrane is thick, pale in colour, and corrugated; behind, it is thin, smooth, and of a deeper colour: it is covered with squamous epithelium, and furnished with numerous glands (palatal glands), which lie between the mucous membrane and the surface of the bone.

The **soft palate** (palatum molle) is a movable fold, suspended from the posterior border of the hard palate, and forming an incomplete septum between the mouth and pharynx. It consists of a fold of mucous membrane enclosing muscular fibres, an aponeurosis, vessels, nerves, adenoid tissue, and mucous glands. When occupying its usual position (i.e. relaxed and pendent) its anterior surface is concave, continuous with the roof of the mouth, and marked by a median ridge or raphe, which indicates its original separation into two lateral halves. Its posterior surface is convex, and continuous with the mucous membrane covering the floor of the nasal fossæ. Its upper border is attached to the posterior margin of the hard palate, and its sides are blended with the pharynx. Its lower border is free.

Hanging from the middle of its lower border is a small, conical, pendulous process, the *uvula* (uvula palatina); and arching outwards and downwards from the base of the uvula on either side are two curved folds of mucous membrane, containing muscular fibres, called the *arches* or *pillars of the soft palate* or *pillars of the fauces*.

The *anterior pillar* (arcus glossopalatinus) on either side runs downwards, outwards, and forwards to the side of the base of the tongue, and is formed by the projection of the Palato-glossus muscle, covered by mucous membrane.

The *posterior pillar* (arcus pharyngopalatinus) is larger and projects farther inwards than the anterior; it runs downwards, outwards, and backwards to the side of the pharynx, and is formed by the projection of the Palato-pharyngeus muscle, covered by mucous membrane. The anterior and posterior pillars are separated below by a triangular interval, in which the tonsil is lodged.

The aperture by which the mouth communicates with the pharynx is called the *isthmus faucium*. It is bounded, above, by the soft palate; below,

by the dorsum of the tongue ; and on either side, by the anterior pillar of the fauces.

The *aponeurosis of the soft palate* is a thin but firm fibrous layer attached above to the posterior border of the hard palate, and becoming thinner towards the free margin of the soft palate. Laterally, it is continuous with the pharyngeal aponeurosis. It forms the framework of the soft palate, and is joined by the tendons of the Tensor palati muscles.

The *muscles of the soft palate* are five on each side : the Levator palati, Tensor palati, Azygos uvulæ, Palato-glossus, and Palato-pharyngeus (see pages 484, 485). The following is the relative position of the structures in a dissection of the soft palate from the posterior or pharyngeal to the anterior or oral surface. Immediately beneath the mucous membrane is a thin stratum of muscular fibres, the posterior fasciculus of the Palato-pharyngeus muscle, joining with its fellow of the opposite side in the middle line. Beneath this is the Azygos uvulæ, consisting of two rounded fleshy fasciculi which are in contact with each other in the median line of the soft palate. Next comes the aponeurosis of the Levator palati joining with that of the muscle of the opposite side in the middle line. Fourthly, is the anterior fasciculus of the Palato-pharyngeus, thicker than the posterior, and separating the Levator palati from the next muscle, the Tensor palati. This muscle terminates in a tendon which, after winding round the hamular process, expands into a broad aponeurosis in the soft palate, anterior to the other muscles which have been enumerated. Finally there is a thin muscular stratum, the Palato-glossus muscle, placed in front of the aponeurosis of the Tensor palati, and separated from the oral mucous membrane by glands and adenoid tissue.

The *mucous membrane of the soft palate* is thin, and covered with squamous epithelium on both surfaces, excepting near the orifice of the Eustachian tube, where it is columnar and ciliated.* Beneath the mucous membrane on the oral surface of the soft palate is a considerable amount of adenoid tissue. The palatine glands form a continuous layer on its posterior surface and round the uvula.

Vessels and Nerves.—The *arteries* supplying the palate are the descending palatine branch of the internal maxillary, the ascending palatine branch of the facial, and the palatine branch of the ascending pharyngeal. The *veins* terminate chiefly in the pterygoid and tonsillar plexuses. The *lymphatic vessels* pass to the deep cervical glands. The *motor nerves* are chiefly derived from the pharyngeal plexus, the Tensor palati, however, receiving a special branch from the otic ganglion. The *sensory* filaments are derived from the descending palatine and naso-palatine nerves and from the glosso-pharyngeal.

Applied Anatomy.—The occurrence of a congenital cleft in the palate has been already referred to as a defect in development (page 285). Acquired perforations of the palate are almost invariably the result of the breaking down of syphilitic gummata. The ensuing ulceration may continue until practically the whole palate, both hard and soft, has been destroyed. Tumours of the palate, both innocent and malignant, are occasionally seen.

Paralysis of the soft palate often occurs after diphtheria. It gives rise to a change in the voice, which becomes nasal, and to the regurgitation of fluids down the nose when their swallowing is attempted. On inspection, the palate is seen to hang flaccid and motionless when phonation or deglutition are attempted ; it is also anæsthetic.

The Teeth (Dentes) (figs. 900 to 903)

The human subject is provided with two sets of teeth, which make their appearance at different periods of life. Those of the first set appear in childhood, and are called the *temporary*, *deciduous*, or *milk teeth*. Those of the second set, which also appear at an early period, continue until old age, and are named *permanent*.

The *temporary teeth* are twenty in number : four incisors, two canines, and four molars, in each jaw.

The *permanent teeth* are thirty-two in number : four incisors, two canines, four bicuspids, and six molars, in each jaw.

* According to Klein, the mucous membrane on the nasal surface of the soft palate in the fœtus is covered throughout by columnar ciliated epithelium, which subsequently becomes squamous ; some anatomists state that it is covered with columnar ciliated epithelium, except at its free margin, throughout life.

The dental formulæ may be represented as follows :

Temporary Teeth

	mol.	can.	in.	in.	can.	mol.	
Upper jaw . .	2	1	2	2	1	2	} Total 20
Lower jaw . .	2	1	2	2	1	2	

Permanent Teeth

	mol.	bic.	can.	in.	in.	can.	bic.	mol.	
Upper jaw .	3	2	1	2	2	1	2	3	} Total 32
Lower jaw .	3	2	1	2	2	1	2	3	

General characters.—Each tooth consists of three portions : the *crown*, or *body* (corona dentis), projecting above the gum ; the *root* (radix dentis), consisting of one or more *fangs*, entirely concealed within the alveolus ; and the *neck* (collum dentis), the constricted portion between the crown and root.

The *roots of the teeth* are firmly implanted within the alveoli ; these depressions are lined with periosteum which is reflected on to the tooth at the point of the fang, and covers it as far as the neck. At the margin of the alveolus, the periosteum becomes continuous with the fibrous structure of the gums.

FIG. 900.—Permanent teeth of upper jaw, seen from below.

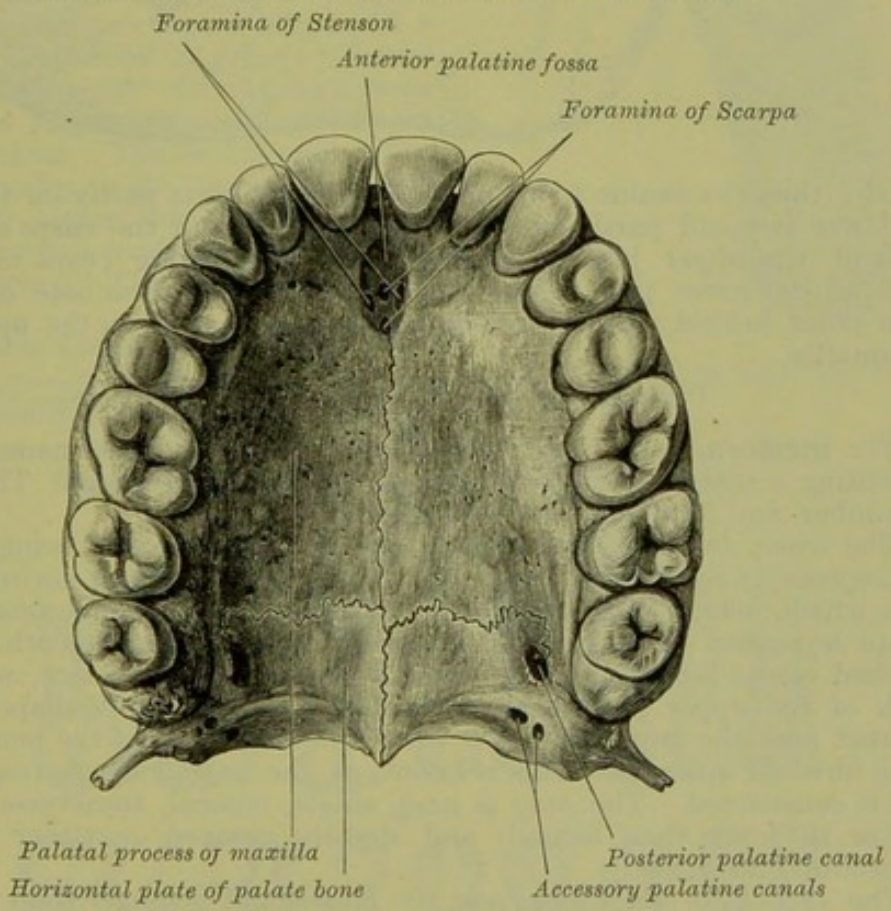

In consequence of the curve of the dental arch, such terms as anterior, posterior, internal, and external, as applied to the teeth, are misleading and confusing. Special terms are therefore applied to the different surfaces of a tooth : that surface which is directed towards the lips or cheek is known as the *labial* surface (facies labialis) ; that which is directed towards the tongue is described as the *lingual* surface (facies lingualis) ; that surface which is directed towards the mesial line, supposing the teeth were arranged in a straight line outwards from the central incisor, is known as the *proximal* surface ; while that which is directed away from the mesial line is called the *distal* surface.

The teeth in the maxillæ form a larger arch than those in the mandible, so that they slightly overlap those of the mandible both in front and at the sides in the normal condition. Since the upper central incisors are wider than the lower, the other teeth in the upper jaw are thrown somewhat distally, and the two sets do not quite correspond to each other when the mouth is

Fig. 901.—Side views of the teeth and jaws. (Cryer.)

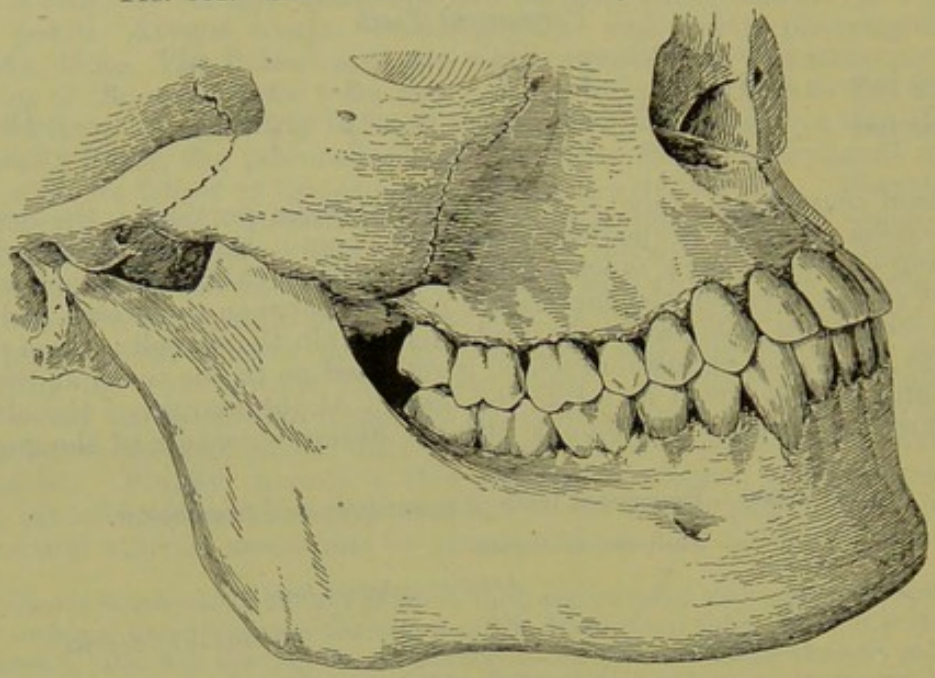

closed : thus the canine tooth of the upper jaw rests partly on the canine of the lower jaw and partly on the first premolar, and the cusps of the molar teeth of the upper jaw lie behind the corresponding cusps of the molar teeth of the lower jaw. The two series, however, terminate at nearly the same point behind ; this is mainly because the molars in the upper jaw are the smaller.

Permanent Teeth (Dentes permanentes)

The **incisors,** or cutting teeth (dentes incisivi), are so named from their presenting a sharp cutting edge, adapted for biting the food. They are eight in number, and form the four front teeth in each jaw.

The *crown* is directed vertically, and is chisel-shaped, being bevelled at the expense of its lingual surface, so as to present a sharp horizontal cutting edge, which, before being subjected to attrition, presents three small prominent points separated by two slight notches. It is convex, smooth, and highly polished on its labial surface ; concave on its lingual surface, where, in the teeth of the upper jaw, it is frequently marked by a V-shaped eminence, situated near the gum, the apex, where the two arms of the eminence meet, being directed upwards. This is known as the *basal ridge* or *cingulum*. The *neck* is constricted. The *fang* is long, single, conical, transversely flattened, thicker in front than behind, and slightly grooved on either side in the longitudinal direction.

The *incisors of the upper jaw* are larger and stronger than those of the lower jaw. They are directed obliquely downwards and forwards. The two central ones are larger than the two lateral, and their roots are more rounded.

The *incisors of the lower jaw* are smaller than those of the upper jaw : the two central ones are smaller than the two lateral, and are the smallest of all the incisor teeth. They are placed vertically and are somewhat bevelled in front, where they have been worn down by contact with the overlapping edge of the upper teeth. The cingulum is absent.

The **canine teeth** (dentes canini) are four in number, two in the upper, and two in the lower jaw ; one being placed distally to each lateral incisor. They are larger and stronger than the incisors, and their fangs sink deeply into the jaws, and cause well-marked prominences upon the surface.

The *crown* is large and conical, very convex on its labial surface, a little hollowed and uneven on its lingual surface, and tapering to a blunted point or cusp, which projects beyond the level of the other teeth. The *root* is single, but longer and thicker than that of the incisors, conical in form, compressed laterally, and marked by a slight groove on each side.

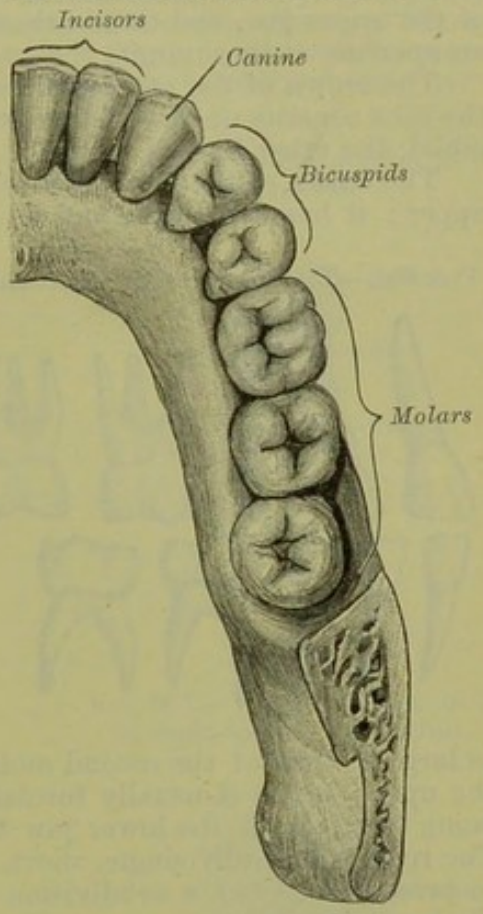

Fig. 902.—Permanent teeth of right half of mandible seen from above.

The *upper canine teeth* (popularly called *eye-teeth*) are larger and longer than the lower, and situated a little distally to them. They usually present a distinct basal ridge.

The *lower canine teeth* are placed mesially to the upper, so that their summits correspond to the interval between the upper canine teeth and the neighbouring incisors on each side.

The **bicuspid teeth** or **premolars** (dentes premolares) are eight in number: four in each jaw, two being placed distally to each of the canine teeth. They are smaller and shorter than the canines.

The *crown* is compressed proximodistally, and surmounted by two pyramidal eminences or cusps, a labial and a lingual, separated by a groove; hence their name, *bicuspid*. Of the two cusps the labial is larger and more prominent than the lingual. The *neck* is oval. The *root* is generally single, compressed, and presents on either side a deep groove, which indicates a tendency in the root to become double. The apex is generally bifid.

The *upper bicuspids* are larger, and present a greater tendency to the division of their roots than the lower; this is especially marked in the first upper bicuspid.

Fig. 903.—Permanent teeth. Right side. (Burchard.)

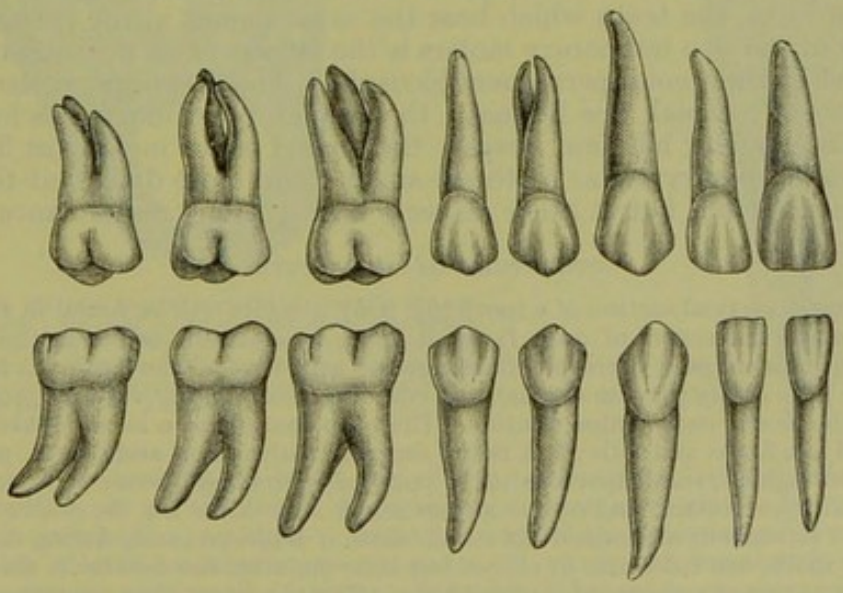

The **molar teeth** (dentes molares) are the largest of the permanent set, and are adapted from the great breadth of their crowns for grinding and pounding the food. They are twelve in number: six in each jaw, three being placed distally to each of the second bicuspids.

The *crown* is nearly cubical in form, convex on its labial and lingual surfaces, flattened on its proximal and distal aspects; the upper surface is surmounted by four or five tubercles, or cusps (four in the upper, five in the lower molars), separated from each other by a crucial depression; hence the molars are sometimes termed *multicuspids*. The *neck* is distinct, large, and rounded. The *root* is subdivided into two or three fangs: three in the teeth of the upper jaw, and two in those of the lower. Each of these fangs presents an aperture at its summit.

The crown of the *first molar tooth* in the *upper jaw* has usually four cusps; the root consists of three fangs, widely separated from one another, two being labial, the other lingual.

The crown of the *first molar tooth* in the *lower jaw* is larger than that of the upper; it has five cusps, and its root consists of two fangs, one being placed proximally, the other distally: they are both compressed from before backwards, and grooved on their contiguous faces, indicating a tendency to division.

Fig. 904.—Temporary teeth. Left side.

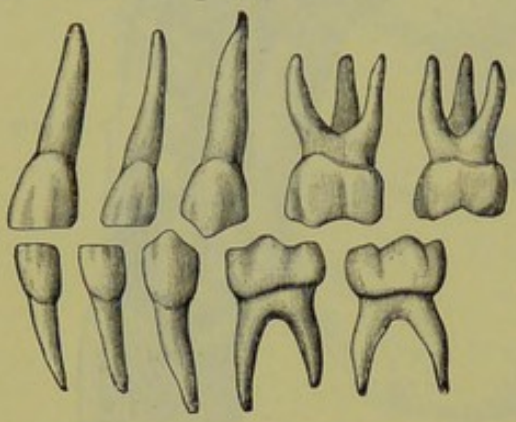

The *second molar* is a little smaller than the first. The crown has three or four cusps in the upper, and usually five in the lower jaw. The root has three fangs in the upper jaw, and two in the lower, the characters of which are similar to those of the preceding tooth.

The *third molar tooth* is called the *wisdom-tooth* or *dens sapientiæ* (dens serotinus), from its late appearance through the gum. Its crown is nearly as large as that of the second molar, but is smaller than that of the first. In the upper jaw it is usually furnished with three cusps, the two lingual ones being blended; in the lower jaw there are five cusps as in the other molars. The root is generally single, short, conical, slightly curved, and grooved so as to present traces of a subdivision into three fangs in the upper, and two in the lower jaw.

Temporary Teeth (Dentes decidui) (fig. 904)

The **temporary,** or **milk teeth,** are smaller than, but, generally speaking, resemble in form, the teeth which bear the same names in the permanent set. The hinder of the two temporary molars is the largest of all the milk teeth, and is succeeded by the second permanent bicuspid. The first upper molar has only three cusps—two labial, one lingual; the second upper molar has four cusps. The first lower molar has four cusps; the second lower molar has five. The fangs of the temporary molar teeth are smaller and more divergent than those of the permanent set, but in other respects bear a strong resemblance to them.

Structure of the Teeth

On making a vertical section of a tooth (fig. 905), a cavity will be found in the interior of the crown and the centre of each fang; it opens by a minute orifice at the extremity of the latter. In shape it corresponds somewhat with that of the tooth; it forms what is called the *pulp cavity* (cavum dentis), and contains a soft, highly vascular, and sensitive substance, the *dental pulp* (pulpa dentis). The pulp consists of a loose connective tissue consisting of fine fibres and cells; it is richly supplied with vessels and nerves, which enter the cavity through the small aperture at the point of each fang. Some of the cells of the pulp permeate the matrix, and others are arranged as a layer on the wall of the pulp cavity. The latter cells are named the *odontoblasts of Waldeyer*, and, during the development of the tooth, are columnar in shape, but later on, after the dentine is fully formed, they become flattened and resemble osteoblasts. They have two fine processes, the outer one passing into a dental tubule, the inner being continuous with the processes of the connective-tissue cells of the pulp matrix.

The solid portion of the tooth consists of (1) the *ivory* or *dentine*, which forms the bulk of the tooth; (2) the *enamel*, which covers the exposed part of the crown; and (3) a thin layer, the *cement* or *crusta petrosa*, which is disposed on the surface of the fang.

The *ivory*, or *dentine* (substantia eburnea) (fig. 907), forms the principal mass of a tooth ; in its central part is the cavity enclosing the pulp. It is a modification of osseous tissue, from which it differs, however, in structure. On microscopic examination it is seen to consist of a number of minute wavy and branching tubes, the *dentinal tubules*, imbedded in a dense homogeneous substance, the *matrix*.

The *dentinal tubules* (canaliculi dentales) (fig. 908) are placed parallel with one another, and open at their inner ends into the pulp cavity. In their course to the periphery they present two or three curves, and are twisted on themselves in a spiral direction. These tubes vary in direction : thus in a tooth of the mandible they are vertical in the upper portion of the crown, becoming oblique and then horizontal in the neck and upper part

Fig. 905.—Vertical section of a tooth *in situ*. (15 diameters.)

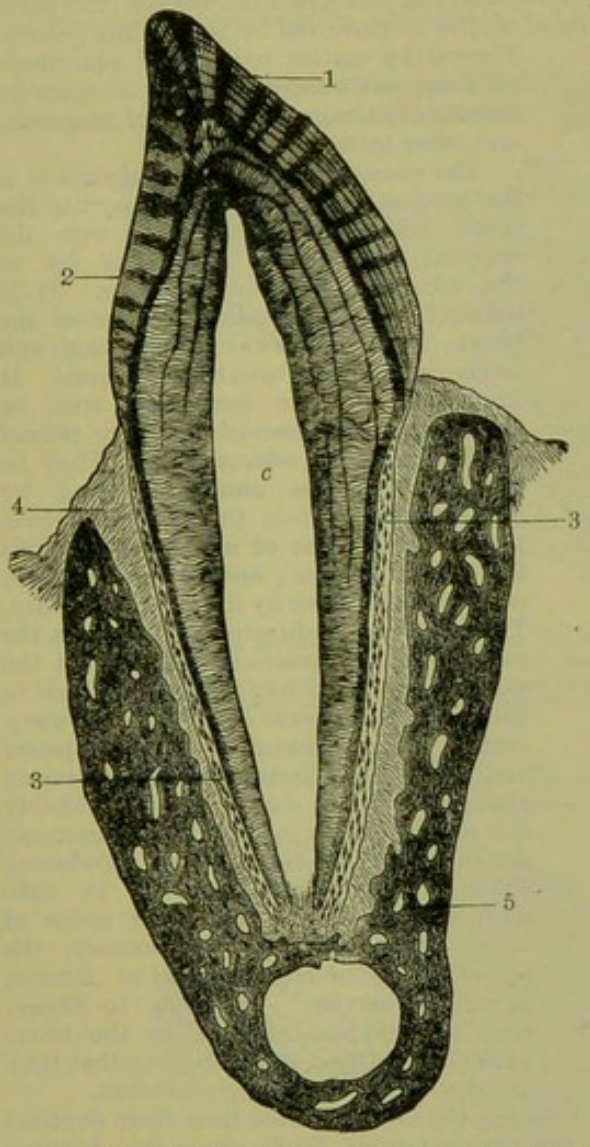

c is placed in the pulp cavity, opposite the cervix or neck of the tooth ; the part above it is the crown, that below is the root (fang). 1. Enamel with radial and concentric markings. 2. Dentine with tubules and incremental lines. 3. Cement or crusta petrosa, with bone corpuscles. 4. Dental periosteum. 5. Mandible.

Fig. 906.—Vertical section of a molar tooth.

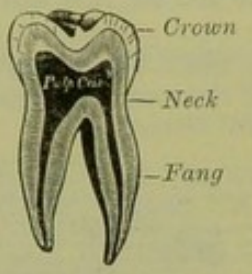

Fig. 907.—Vertical section of a bicuspid tooth. (Magnified.)

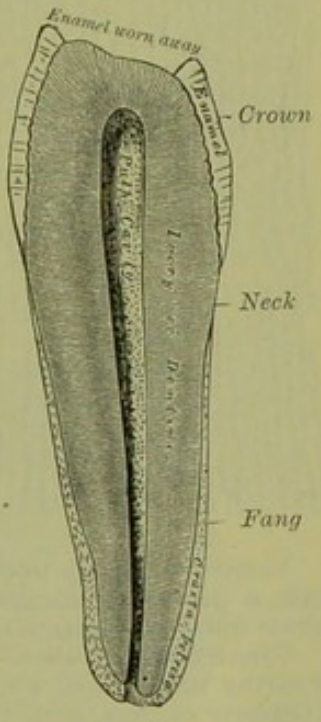

of the root, while towards the lower part of the root they are inclined downwards. In their course they divide and subdivide dichotomously, so as to give to the cut surface of the dentine a striated appearance. From the sides of the tubes, especially in the fang, ramifications of extreme minuteness are given off, which join together in loops in the matrix, or terminate in small dilatations, from which branches are given off. Near the periphery of the dentine, the finer ramifications of the tubules terminate imperceptibly by free ends. The dentinal tubules have comparatively thick walls, consisting, in addition to the intertubular tissue, of an elastic homogeneous membrane, the *dentinal sheath of Neumann*, which resists the action of acids ; they contain slender cylindrical prolongations of the odontoblasts, first described by Tomes, and named *Tomes's fibres* or *dentinal fibres*.

The *matrix* is translucent, and contains the chief part of the earthy matter of the dentine. In it are a number of fine fibrils, which are continuous with the fibrils of the dental pulp. After the earthy matter has been removed by steeping a tooth in weak acid, the animal basis remaining may be torn into laminæ which run parallel with the pulp cavity, across the direction of the tubes. A section of dry dentine often displays a series of somewhat parallel lines—the *incremental lines of Salter*. These lines are composed of imperfectly calcified dentine arranged in layers. In consequence of the imperfection in the calcifying process, little irregular cavities are left, termed *interglobular spaces* (spatia interglobularia). Normally a series of these spaces is found towards the outer surface of the dentine, where they form a layer, which is sometimes known as the *granular layer* (fig. 907). They have received their name from the fact that they are surrounded by minute nodules or globules of dentine. Other curved lines may be seen parallel to the surface. These are the *lines of Schreger*, and are due to the optical effect of simultaneous curvature of the dentinal fibres.

Chemical Composition.—According to Berzelius and von Bibra, dentine consists of 28 parts of animal and 72 of earthy matter. The animal matter is converted by boiling into gelatin. The earthy matter consists of phosphate of lime, carbonate of lime, a trace of fluoride of calcium, phosphate of magnesia, and other salts.

FIG. 908.—Transverse section of a portion of the root of a canine tooth. (Magnified 300 diameters.)

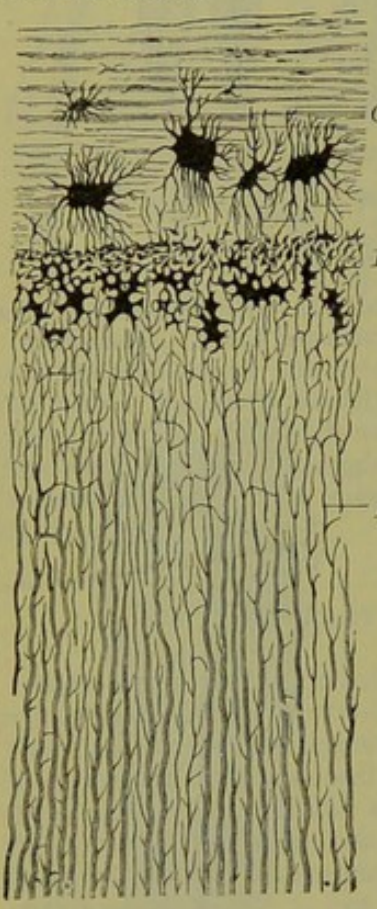

The *enamel* (substantia adamantina) is the hardest and most compact part of the tooth, and forms a thin crust over the exposed part of the crown, as far as the commencement of the fang. It is thickest on the grinding surface of the crown, until worn away by attrition, and becomes thinner towards the neck. It consists of minute hexagonal rods or columns termed *enamel fibres* or *enamel prisms* (prismata adamantina). They lie parallel with one another, resting by one extremity upon the dentine, which presents a number of minute depressions for their reception; and forming the free surface of the crown by the other extremity. The columns are directed vertically on the summit of the crown, horizontally at the sides; they are about $\frac{1}{5500}$ of an inch in diameter, and pursue a more or less wavy course. Each column is a six-sided prism and presents numerous dark transverse shadings; these shadings are probably due to the manner in which the columns are developed in successive stages, producing shallow constrictions, as will be subsequently explained. Another series of lines, having a brown appearance, the *parallel striæ* or *coloured lines of Retzius*, is seen on section. According to Ebner, they are produced by air in the interprismatic spaces; others believe that they are the result of true pigmentation.

Numerous minute interstices intervene between the enamel fibres near their dentinal ends, a provision calculated to allow of the permeation of fluids from the dentinal tubule into the substance of the enamel.

Chemical Composition.—According to von Bibra, enamel consists of 96·5 per cent. of earthy matter, and 3·5 per cent. of animal matter.* The earthy matter consists of phosphate of lime, with traces of fluoride of calcium, carbonate of lime, phosphate of magnesia, and other salts.

The *crusta petrosa*, or *cement* (substantia ossea), is disposed as a thin layer on the roots of the teeth, from the termination of the enamel to the apex of the fang, where it is usually very thick. In structure and chemical composition it resembles bone. It contains, sparingly, the lacunæ and canaliculi which characterise true bone; the lacunæ placed near the surface have the canaliculi radiating from the side of the lacunæ towards the periodontal membrane; and those more deeply placed join with the adjacent dental tubules. In the thicker portions of the crusta petrosa, the lamellæ and Haversian canals peculiar to bone are also found.

* Tomes disputes this, and says that enamel is an inorganic substance, and that what has been regarded as organic matter is in reality merely water in combination with the salts.

As age advances, the cement increases in thickness, and gives rise to those bony growths, or exostoses, so common in the teeth of the aged; the pulp cavity also becomes partially filled up by a hard substance, intermediate in structure between dentine and bone (*osteo-dentine*, Owen; *secondary dentine*, Tomes). It appears to be formed by a slow conversion of the dental pulp, which shrinks, or even disappears.

Development of the Teeth (figs. 909 to 912)

In describing the development of the teeth, the mode of formation of the temporary or milk teeth must first be considered, and then that of the permanent series.

Development of the temporary teeth.—The development of these teeth begins at a very early period of fœtal life—about the sixth week. It commences as a thickening of the epithelium along the line of the future jaw, the thickening being due to a rapid multiplication of the more deeply situated epithelial cells. As the cells multiply they extend into the subjacent mesoderm, and thus form a semicircular ridge or strand of cells imbedded

Fig. 909.—Sagittal section through the first lower temporary molar of a human embryo 30 mm. long. (Röse.) $\frac{100}{1}$.

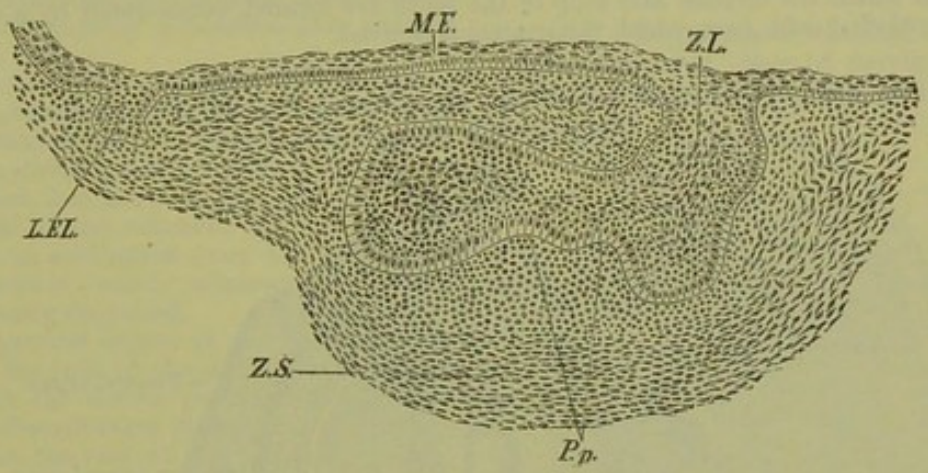

L.E.L., labio-dental lamina, here separated from and well in advance of the dental lamina; *Z.L.*, placed over the shallow dental furrow, points to the dental lamina, which is spread out below to form the enamel germ of the future tooth; *P.p.*, bicuspidate papilla, capped by the enamel germ; *Z.S.*, condensed tissue forming dental sac; *M.E.*, mouth-epithelium.

Fig. 910.—Similar section through the canine tooth of an embryo 40 mm. long. (Röse.) $\frac{100}{1}$.

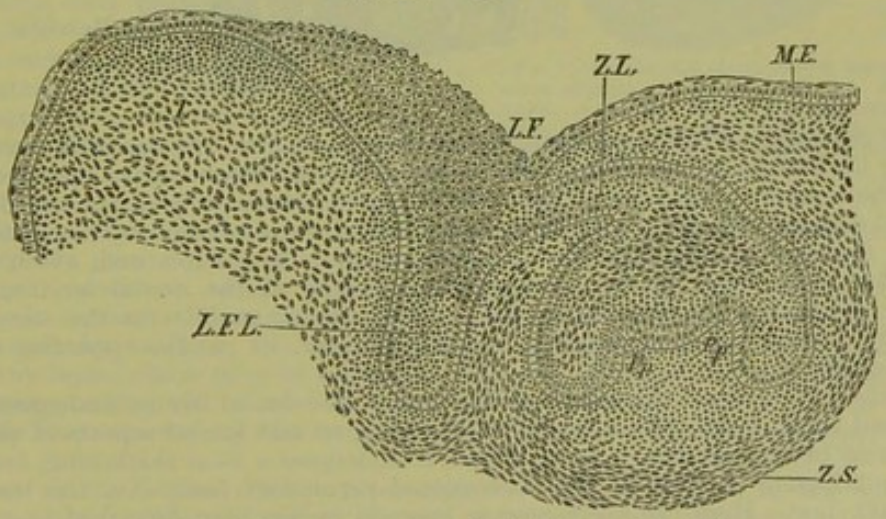

L.F., labio-dental furrow. The other lettering as in fig. 909.

in mesoderm. About the seventh week a longitudinal splitting or cleavage of this strand of cells takes place, and it becomes divided into two strands; the separation begins in front and extends laterally: the process occupying four or five weeks. Of the two strands thus formed, the *outer* or *labial* forms the future labio-dental furrow, and is therefore termed the *labio-dental lamina*; while the other, the *inner* or *lingual*, is the ridge of cells in connection with which the teeth, both temporary and permanent, are developed. Hence it is known as the *dental lamina* or *common dental germ*. It forms a flat band of cells, which

grows into the substance of the embryonic jaw, at first horizontally inwards, and then, as the teeth develop, vertically, i.e. upwards in the upper jaw, and downwards in the lower jaw. While still maintaining a horizontal direction, it has two edges; one, the *attached edge*, which is continuous with the epithelium lining the mouth; the other, the *free edge*, projecting inwards, and imbedded in the mesodermal tissue of the embryonic jaw. Along its line of attachment to the buccal epithelium is a shallow groove, the *dental furrow*.

About the ninth week the dental lamina begins to develop enlargements along its free border. These are ten in number in each jaw, and each corresponds to a future milk tooth. They consist of masses of epithelial cells; and the cells of the deeper part—that is, the part farthest from the margin of the jaw—increase rapidly and spread out in all directions. Each mass thus comes to assume a club shape, connected with the general epithelial lining of the mouth by a narrow neck, embraced by mesoderm. They are now known as *special dental germs*. After a time the lower expanded portion inclines outwards, so as to form an angle with the superficial constricted portion, which is sometimes known as the *neck* of the special dental germ. About the tenth week the mesodermal tissue beneath these special dental germs becomes differentiated into papillæ; these grow upwards, and come in contact with the epithelial cells of the special dental germs, which become folded over them like a hood or cap. There is, then, at this stage a papilla (or papillæ) which has already begun to assume somewhat the shape of the crown of the future tooth, and from which the dentine and pulp of the tooth are formed, surmounted by a dome or cap of epithelial cells, from which the enamel is derived.

FIG. 911.—Vertical section of the mandible of an early human fœtus. (Magnified 25 diameters.)

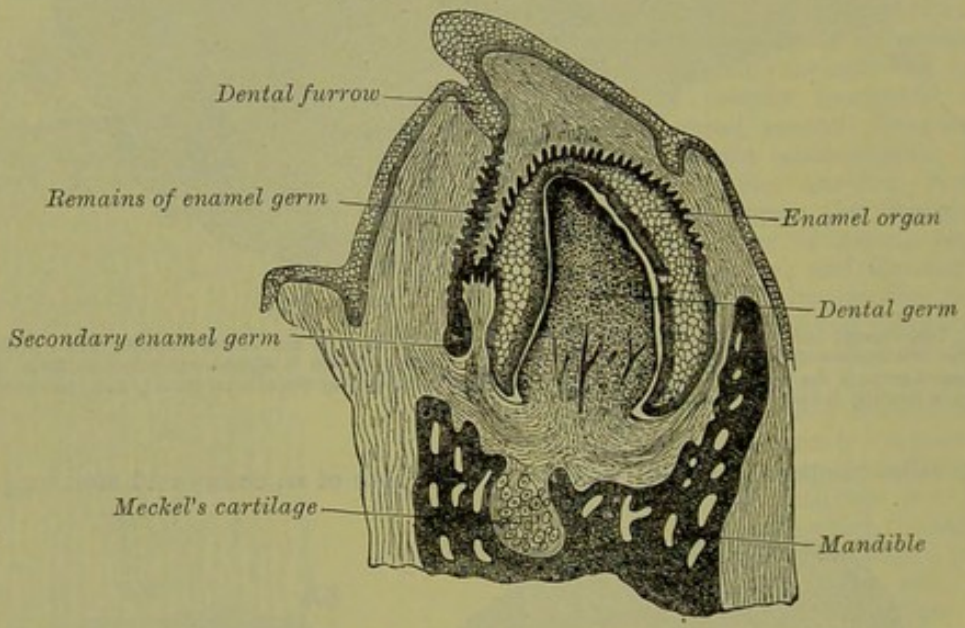

In the meantime, while these changes have been going on, the dental lamina has been extending backwards behind the special dental germ corresponding to the second molar tooth of the temporary set, and at about the seventeenth week it presents an enlargement, the special dental germ, for the first permanent molar, soon followed by the formation of a papilla in the mesodermal tissue for the same tooth. This is followed, about the sixth month after birth, by a further extension backwards of the dental lamina, with the formation of another enlargement and its corresponding papilla for the second molar. And finally the process is repeated for the third molar, its papilla appearing about the fifth year of life.

After the formation of the special dental germs, the dental lamina undergoes atrophic changes and becomes cribriform, except on the lingual and lateral aspects of each of the special germs of the temporary teeth, where it undergoes a local thickening, forming the special dental germ of each of the successional permanent teeth—i.e. the ten anterior ones in each jaw. Here the same process goes on as has been described in connection with those of the milk teeth: that is, they recede into the substance of the gum behind the germs of the temporary teeth. As they recede they become club-shaped, form an expansion at their distal extremity, and finally meet a papilla, which has been formed in the mesoderm, just in the same manner as was the case in the temporary teeth. The apex of the papilla indents the dental germ, which encloses it, and, forming a cap for it, becomes converted into the enamel, while the papilla forms the dentine and pulp of the permanent tooth.

The special dental germs consist at first of rounded or polyhedral epithelial cells; after the formation of the papillæ, these cells undergo a differentiation into three classes.

Those which are in immediate contact with the papilla become elongated, and form a layer of well-marked columnar epithelium coating the papilla. They are the cells which form the enamel fibres, and are therefore termed *enamel cells* or *adamantoblasts*. The cells of the outer layer of the special dental germ, which are in contact with the inner surface of the dental sac, presently to be described, are much shorter, cubical in form, and are named the *external enamel epithelium*. All the intermediate round cells of the dental germ between these two layers undergo a peculiar change. They become stellate in shape and develop processes, which unite to form a network into which fluid is secreted; this has the appearance of a jelly, and to it the name of enamel pulp is given. This transformed special dental germ is now known under the name of *enamel organ*.

While these changes are going on, a sac is formed around each enamel organ from the surrounding mesodermal tissue. This is known as the *dental sac*, and is a vascular membrane of connective tissue. It grows up from below, and thus encloses the whole tooth germ; as it grows it causes the neck of the enamel organ to atrophy and disappear; so that all communication between the enamel organ and the superficial epithelium is cut off. At this stage there are vascular papillæ surmounted by inverted caps of epithelial cells, the whole being surrounded by membranous sacs. The cap consists of an internal layer of cells—the enamel cells or adamantoblasts—in contact with the papilla; of an external layer of cells—the external enamel epithelium—lining the interior of the dental sac; and of an intermediate mass of stellate cells, with anastomosing processes—the enamel pulp (fig. 912).

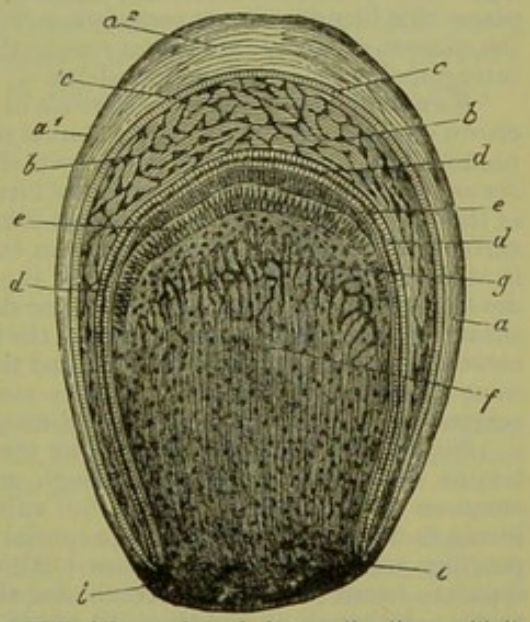

Fig. 912.—Dental sac of a human embryo at an advanced stage of development. Partly diagrammatic.

a. Wall of the sac, formed of connective tissue, with its outer stratum, *a'*, and its inner, *a*. *b*. Enamel organ. *c*. The external enamel epithelium. *d*. The enamel cells. *e*. Dentine cells. *f*. Dental papilla. *g*, *i*. Transition of the wall of the follicle into the tissue of the dental germ.

Formation of the enamel.—The enamel is formed exclusively from the enamel cells or adamantoblasts of the special dental germ, either by direct calcification of the columnar cells, which become elongated into the hexagonal rods of the enamel; or, as is believed by some, as a secretion from the adamantoblasts, within which calcareous matter is subsequently deposited.

The process begins at the apex of each cusp, at the ends of the enamel cells, in contact with the dental papilla. Here a fine globular deposit takes place, being apparently shed from the end of the adamantoblasts. It is known by the name of *enamel droplet*, and resembles keratin in its resistance to the action of mineral acids. This droplet then calcifies and forms the first layer of the enamel; a second droplet now appears and calcifies, and so on; successive droplets of keratin-like material are shed from the adamantoblasts and form successive layers of enamel, the adamantoblasts gradually receding as each layer is produced, until at the termination of the process they have almost disappeared. The intermediate cells of the enamel pulp atrophy and disappear, so that the newly formed calcified material and the external enamel epithelium come into apposition. This latter layer, however, soon disappears on the emergence of the tooth beyond the gum. After its disappearance the crown of the tooth is still covered by a distinct membrane, which remains persistent for some time. This is known as the *cuticula dentis*, or *Nasmyth's membrane*, and is believed to be the last-formed layer of enamel derived from the adamantoblasts, which has not become calcified. It forms a horny layer, which may be separated from the subjacent calcified mass by the action of strong acids. It is marked by the hexagonal impressions of the enamel prisms, and, when stained by nitrate of silver, shows the characteristic appearance of epithelium.

Formation of the dentine.—While these changes are taking place in the epithelium to form the enamel, contemporaneous changes occurring in the differentiated mesoderm of the dental papillæ result in the formation of the dentine. As before stated, the first germs of the dentine are the papillæ, corresponding in number to the teeth, formed from the soft mesodermal tissue which bounds the depressions containing the special enamel germs. The papillæ grow upwards into the enamel germs and become covered by them, both being enclosed in a vascular connective tissue, the dental sac, in the manner above described. Each papilla then constitutes the formative pulp from which the dentine and permanent pulp are developed; it consists of rounded cells, and is very vascular, and soon begins to assume the shape of the future tooth. The next step is the appearance of the *odontoblasts*, which have a relation to the development of the teeth similar to that of

the osteoblasts to the formation of bone. They are formed from the cells of the periphery of the papilla—that is to say, from the cells in immediate contact with the adamantoblasts of the special dental germ. These cells become elongated ; one end of the elongated cell resting against the epithelium of the special dental germs, the other being tapered and often branched. By the direct transformation of the peripheral ends of these cells, or by a secretion from them, a layer of uncalcified matrix is formed which caps the cusp or cusps, if there are more than one, of the papillæ. In this matrix islets of calcification make their appearance, and coalescing give rise to a continuous layer of calcified material which covers each cusp and constitutes the first layer of dentine. The odontoblasts, having thus formed the first layer, retire towards the centre of the papilla, and as they do so produce successive layers of dentine from their peripheral extremities—that is to say, they form the dentinal matrix in which calcification subsequently takes place. As they thus recede from the periphery of the papilla, they leave behind them filamentous processes of cell protoplasm, provided with finer side processes ; these are surrounded by calcified material, and thus form the dentinal tubules, and, by their side branches, the anastomosing tubules, whereby the dentinal tubules communicate : the processes of protoplasm contained within them, constitute the dentinal fibres (Tomes's fibres) which, as mentioned above, are found within the tubules. In this way the entire thickness of the dentine is developed, each tubule being completed throughout its whole length by a single odontoblast. The central part of the papilla does not undergo calcification, but persists as the pulp of the tooth. In this process of formation of dentine it has been shown that an uncalcified matrix is first developed, and that in this matrix islets of calcification appear which subsequently blend together to form a cap to each cusp : in like manner successive layers are produced, which ultimately become blended with each other. In certain places this blending is not complete, portions of the matrix remaining uncalcified between the successive layers ; this gives rise, in the macerated tooth, to little spaces, which are the interglobular spaces alluded to above.

Formation of the cement.—The root of the tooth begins to be formed shortly before the crown emerges through the gum, but is not completed until some time afterwards. It is produced by a downgrowth of the epithelium of the dental germ, which extends almost as far as the situation of the apex of the future fang, and determines the form of this portion of the tooth. This fold of epithelium is known as the *epithelial sheath*, and on its papillary surface odontoblasts appear, which in turn form dentine, so that the dentine formation is identical in the crown and root of the tooth. After the dentine of the root has been developed, the vascular tissues of the dental sac begin to break through the epithelial sheath, and spread over the surface of the fang as a layer of bone-forming material. In this osteoblasts make their appearance, and the process of ossification goes on in identically the same manner as in the ordinary intra-membranous ossification of bone. In this way the cement is formed, and consists of ordinary bone, containing canaliculi and lacunæ.

Formation of the alveoli.—About the fourteenth week of embryonic life the dental lamina becomes enclosed in a trough or groove of mesodermal tissue, which at first is common to all the dental germs, but subsequently becomes divided by bony septa into loculi, each loculus containing the special dental germ of a temporary tooth and its corresponding permanent tooth. After birth each cavity becomes subdivided, so as to form separate loculi (the future alveoli) for the milk tooth and its corresponding permanent tooth. Although at one time the whole of the growing tooth is contained in the cavity of the alveolus, the latter never completely encloses it, since there is always an aperture over the top of the crown filled by soft tissue, by which the dental sac is connected with the surface of the gum, and which in the permanent teeth is called the *gubernaculum dentis*.

Development of the permanent teeth.—The permanent teeth as regards their development may be divided into two sets : (1) those which replace the temporary teeth, and which, like them, are ten in number in each jaw ; these are the *successional permanent teeth* ; and (2) those which have no temporary predecessors, but are superadded distal to the temporary dental series. These are three in number on either side in each jaw, and are termed *superadded permanent teeth*. They are the three molars of the permanent set, the molars of the temporary set being replaced by the premolars or bicuspids of the permanent set. The development of the successional permanent teeth—the ten anterior ones in either jaw—has already been indicated. During their development the permanent teeth, enclosed in their sacs, come to be placed on the lingual side of the temporary teeth and more distant from the margin of the future gum, and, as already stated, are separated from them by bony partitions. As the crown of the permanent tooth grows, absorption of these bony partitions and of the fang of the temporary tooth takes place, through the agency of *osteoclasts*, which appear at this time, and finally nothing but the crown of the temporary tooth remains. This is shed or removed, and the permanent tooth takes its place.

The superadded permanent teeth are developed in the manner already described, by extensions backward of the posterior part of the dental lamina in each jaw.

Eruption.—When the calcification of the different tissues of the tooth is sufficiently advanced to enable it to bear the pressure to which it will be

afterwards subjected, eruption takes place, the tooth making its way through the gum. The gum is absorbed by the pressure of the crown of the tooth against it, which is itself pressed up by the increasing size of the fang. At the same time the septa between the dental sacs, at first fibrous in structure, ossify, and constitute the alveoli ; these firmly embrace the necks of the teeth, and afford them a solid basis of support.

The eruption of the temporary teeth commences at the seventh month after birth, and is completed about the end of the second year, those of the lower jaw preceding those of the upper.

The following, according to C. S. Tomes, are the most usual times of eruption :

Lower central incisors	6 to 9 months.
Upper incisors	8 to 10 months.
Lower lateral incisors and first molars	15 to 21 months.
Canines	16 to 20 months.
Second molars	20 to 24 months.

Calcification of the permanent teeth proceeds in the following order in the lower jaw (in the upper jaw it takes place a little later) : the first molar, soon after birth ; the central and lateral incisors, and the canine, about six months after birth ; the bicuspids, at the second year, or a little later ; the second molar, about the end of the second year ; the third molar, about the twelfth year.

The eruption of the permanent teeth takes place at the following periods, the teeth of the lower jaw preceding those of the upper by a short interval :

First molars	6th year.
Two central incisors	7th year.
Two lateral incisors	8th year.
First bicuspids	9th year.
Second bicuspids	10th year.
Canines	11th to 12th year.
Second molars	12th to 13th year.
' Wisdom ' teeth	17th to 25th year.

Towards the sixth year, before the shedding of the temporary teeth begins, there are twenty-four teeth in each jaw, viz. the ten temporary teeth and the crowns of all the permanent teeth except the third molars.

Applied Anatomy. — As a consequence of local irritation or of chronic digestive disturbances occurring during their eruption, both the temporary and the permanent teeth may show defective development or irregular transverse furrowing and erosions ; this is particularly the case with the incisors. Quite distinct from, and much less common than this, is a characteristic malformation of the two upper central permanent incisors seen in patients with inherited syphilis, and first described by Hutchinson. Here there is a crescentic notch in the anterior surface and at the cutting edge of the tooth, which is peg-shaped, stunted, and often also set obliquely in the gum, pointing either inwards or outwards. Numerous forms of innocent *tumour* arising from the teeth, or from their constituent layers, have been described under the general name of *odontoma*. *Injection* of the pulp of a tooth by bacteria gaining access thereto in consequence of dental caries gives rise to the common and very painful *alveolar abscess* ; starting in the apical space between the root of the tooth and its alveolar socket, the pus from such an abscess may make its way into the antrum, or burst through the hard palate or cheek. A more superficial abscess forming between the root of a tooth and the gum is known as a *gum-boil.*

The Tongue

The **tongue** is the principal organ of the sense of taste, and is an important organ of speech ; it also assists in the mastication and deglutition of the food. It is situated in the floor of the mouth, within the curve of the body of the mandible.

Its *base*, or *root* (radix linguæ), is directed backwards, and connected with the hyoid bone by the Hyo-glossi and Genio-hyo-glossi muscles and the hyo-glossal membrane ; with the epiglottis by three folds (*glosso-epiglottic*) of mucous membrane ; with the soft palate by means of the anterior pillars of the fauces ; and with the pharynx by the Superior constrictors and the

mucous membrane. Its *apex* (apex linguæ), thin and narrow, is directed forwards against the inner surfaces of the lower incisor teeth. Its *under surface* (facies inferior) is connected with the mandible by the Genio-hyo-glossus muscles ; from its sides, the mucous membrane is reflected to the inner surface of the gums ; and from its under surface on to the floor of the mouth, where, in the middle line, it is elevated into a distinct vertical fold, the *frenulum linguæ*. To the outer side of the frenulum is a slight fold of the mucous membrane, the *plica fimbriata*, the free edge of which exhibits a series of fringe-like processes.

The tip of the tongue, part of the under surface, its sides, and dorsum are free.

The *dorsum* of the tongue (dorsum linguæ) (fig. 913) is convex, marked along the middle line by a furrow (sulcus medianus), which divides it into symmetrical

Fig. 913.—Upper surface of the tongue.

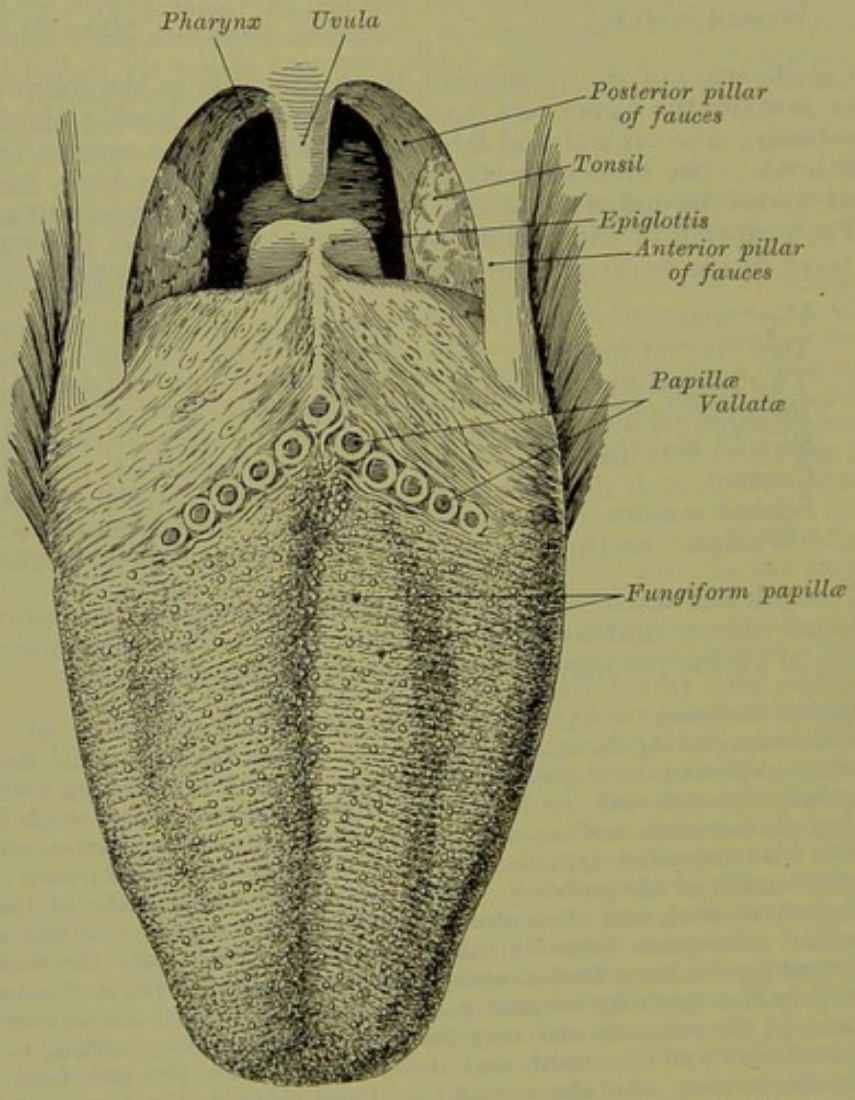

halves ; this furrow terminates behind, about an inch from the base of the organ, in a depression, the *foramen cæcum*, from which a shallow groove, the *sulcus terminalis*, runs outwards and forwards on either side to the lateral margin of the tongue. The part of the dorsum of the tongue in front of this groove, forming about two-thirds of its surface, looks upwards, and is rough and covered with papillæ ; the posterior third looks backwards, and is smoother, and contains numerous muciparous glands and lymphoid follicles. The foramen cæcum is the remains of the upper part of the *thyroglossal duct* or diverticulum, from which the median rudiment of the thyroid gland is developed ; the pyramidal lobe of the thyroid gland indicates the position of the lower part of the duct.

The papillæ of the tongue (papillæ linguæ) (fig. 914).—These are papillary projections of the corium. They are thickly distributed over the anterior

two-thirds of its upper surface, giving to it its characteristic roughness. The varieties of papillæ met with are the papillæ vallatæ, papillæ fungiformes, papillæ filiformes, and papillæ simplices.

The *papillæ vallatæ* are of large size, and vary from eight to twelve in number. They are situated on the dorsum of the tongue immediately in front of the foramen cæcum and sulcus terminalis, forming a row on either side; the two rows run backwards and inwards, and meet in the middle line, like the limbs of the letter V inverted. Each papilla consists of a projection of mucous membrane from $\frac{1}{20}$ to $\frac{1}{12}$ of an inch wide, attached to the bottom of a circular depression of the mucous membrane; the papilla is shaped like a truncated cone; the smaller end being directed downwards and attached to the tongue, the broader part or base projecting a little above the surface of the tongue and being studded with numerous small secondary papillæ and covered by stratified squamous epithelium. The cup-shaped depression forms a kind of fossa round the papilla, and the mucous membrane outside the fossa forms a circular elevation, named the wall (vallum).

The *papillæ fungiformes*, more numerous than the preceding, are found chiefly at the sides and apex, but are scattered irregularly and sparingly over the dorsum. They are easily recognised, among the other papillæ, by their large size, rounded eminences, and deep red colour. They are narrow at their attachment to the tongue, but broad and rounded at their free extremities, and covered with secondary papillæ.

FIG. 914.—The three kinds of papillæ. (Magnified.)

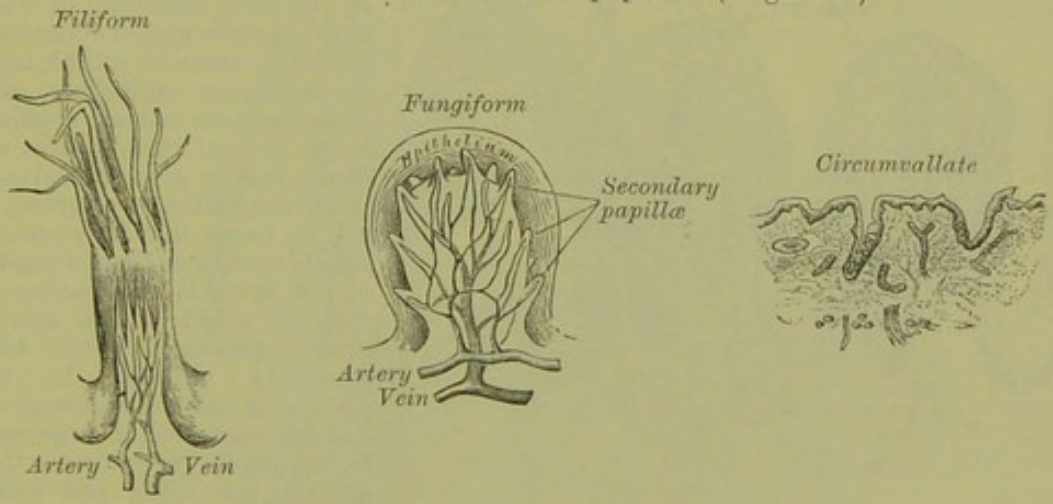

The *papillæ filiformes* cover the anterior two-thirds of the dorsum of the tongue. They are very minute, more or less conical or filiform in shape, and arranged in lines parallel with the two rows of the papillæ circumvallatæ; excepting at the apex of the organ, where their direction is transverse. Projecting from their apices are numerous filiform processes, or secondary papillæ; these are of a whitish tint, owing to the thickness and density of the epithelium of which they are composed, and which has here undergone a peculiar modification, the cells having become cornified and elongated into dense, imbricated, brush-like processes. They contain also a number of elastic fibres, which render them firmer and more elastic than the papillæ of mucous membrane generally.

Simple papillæ, similar to those of the skin, cover the whole of the mucous membrane of the tongue, as well as the larger papillæ. They consist of closely set microscopic elevations of the corium, containing a papillary loop, covered by a layer of epithelium.

Structure of the tongue.—The tongue is partly invested by mucous membrane and a submucous fibrous layer. It consists of symmetrical halves, separated from each other in the middle line by a fibrous septum (septum linguæ). Each half is composed of muscular fibres arranged in various directions (page 480), containing much interposed fat, and supplied by vessels and nerves.

The mucous membrane differs in different parts. That covering the under surface of the organ is thin, smooth, and identical in structure with that lining the rest of the

oral cavity. The mucous membrane of the dorsum of the tongue behind the foramen cæcum and sulcus terminalis is thick and freely movable over the subjacent parts. It contains a large number of lymphoid follicles, which together constitute what is sometimes termed the *lingual tonsil* (tonsilla lingualis). Each follicle forms a rounded eminence, the centre of which is perforated by a minute orifice leading into a funnel-shaped cavity or recess; around this recess are grouped numerous oval or rounded nodules of lymphoid tissue, each enveloped by a capsule derived from the submucosa, while opening into the bottom of the recesses are also seen the ducts of mucous glands. The mucous membrane on the anterior part of the dorsum of the tongue is thin, intimately adherent to the muscular tissue, and presents numerous minute surface eminences, the *papillæ* of the tongue. It consists of a layer of connective tissue, the *corium* or *mucosa*, covered with epithelium.

The epithelium is of the scaly variety, like that of the epidermis, but is much thinner than that of the skin: the intervals between the large papillæ are not filled up by it, but each papilla has a separate investment from root to summit. The deepest cells may sometimes be detached as a separate layer, corresponding to the rete mucosum, but they never contain colouring matter.

The *corium* consists of a dense felt-work of fibrous connective tissue, with numerous elastic fibres, firmly connected with the fibrous tissue forming the septa between the muscular bundles of the tongue. It contains the ramifications of the numerous vessels and nerves from which the papillæ are supplied, large plexuses of lymphatic vessels, and the glands of the tongue.

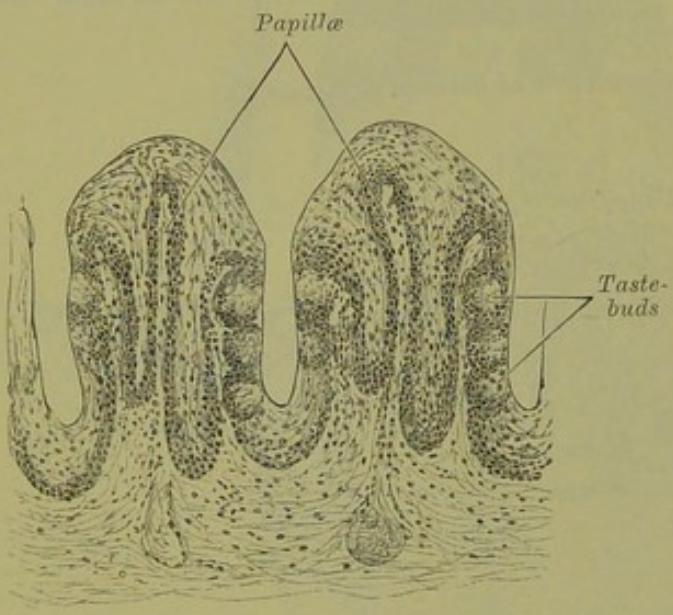

Fig. 915.—Section of papilla foliata of a rabbit. (Magnified.)

Structure of the papillæ (fig. 915).—The papillæ apparently resemble in structure those of the cutis, consisting of cone-shaped projections of connective tissue, covered with a thick layer of squamous epithelium, and containing one or more capillary loops, among which nerves are distributed in great abundance. If the epithelium be removed, it will be found that they are not simple elevations like the papillæ of the skin, for the surface of each is studded with minute conical processes which form secondary papillæ. In the papillæ circumvallatæ, the nerves are numerous and of large size; in the papillæ fungiformes they are also numerous, and terminate in a plexiform network, from which brush-like branches proceed; in the papillæ filiformes, their mode of termination is uncertain.

Glands of the tongue.—The tongue is provided with mucous and serous glands.

The *mucous glands* are similar in structure to the labial and buccal glands. They are found especially at the back part behind the circumvallate papillæ, but are also present at the apex and marginal parts. In this connection the glands of Blandin or Nuhn require special notice. They are situated on the under surface of the apex of the tongue, one on either side of the frenulum, where they are covered by a fasciculus of muscular fibres derived from the Stylo-glossus and Inferior lingualis. They are from half an inch to nearly an inch long, and about the third of an inch broad, and each opens by three or four ducts on the under surface of the apex (fig. 916).

The *serous glands* occur only at the back of the tongue in the neighbourhood of the taste-buds, their ducts opening for the most part into the fossæ of the circumvallate papillæ. These glands are racemose, the duct branching into several minute ducts, which terminate in alveoli, lined by a single layer of more or less columnar epithelium. Their secretion is of a watery nature, and probably assists in the distribution of the substance to be tasted over the taste area. (Ebner.)

The *fibrous septum* consists of a vertical layer of fibrous tissue, extending throughout the entire length of the middle line of the tongue, from the base to the apex, though not quite reaching the dorsum. It is thicker behind than in front, and occasionally contains a small fibro-cartilage, about a quarter of an inch in length. It is well displayed by making a vertical section across the organ.

The *hyoglossal membrane* is a strong fibrous lamina, which connects the under surface of the base of the tongue to the body of the hyoid bone. This membrane receives, in front, some of the fibres of the Genio-hyo-glossus muscles.

Muscles.—The muscular fibres of the tongue run in various directions. These fibres are divided into two sets, extrinsic and intrinsic, which have already been described (pages 479 to 482).

Vessels and Nerves.—The main artery of the tongue is the lingual branch of the external carotid, but the facial and ascending pharyngeal also give branches to it. The *veins* open into the internal jugular.

The *lymphatics of the tongue* have been described on page 770.

The *nerves of the tongue* are: (1) the lingual branch of the third division of the fifth, which is distributed to the papillæ at the fore-part and sides of the tongue, and forms the nerve of ordinary sensibility for its anterior two-thirds; (2) the chorda tympani branch of the facial nerve, which runs in the sheath of the lingual, and is generally regarded as the nerve of taste for the anterior two-thirds; this nerve is a continuation of the sensory root of the facial (pars intermedia of Wrisberg); (3) the lingual branch of the glosso-pharyngeal, which is distributed to the mucous membrane at the base and sides of the tongue, and to the papillæ vallatæ, and which supplies both sensory and gustatory filaments to this region; (4) the hypoglossal nerve, which is the motor nerve to the muscular substance of the tongue; (5) the superior laryngeal, which sends some fine branches to the root near the epiglottis.

FIG. 916.—Under surface of tongue, showing position and relations of glands of Blandin or Nuhn. (From a preparation in the Museum of the Royal College of Surgeons of England.)

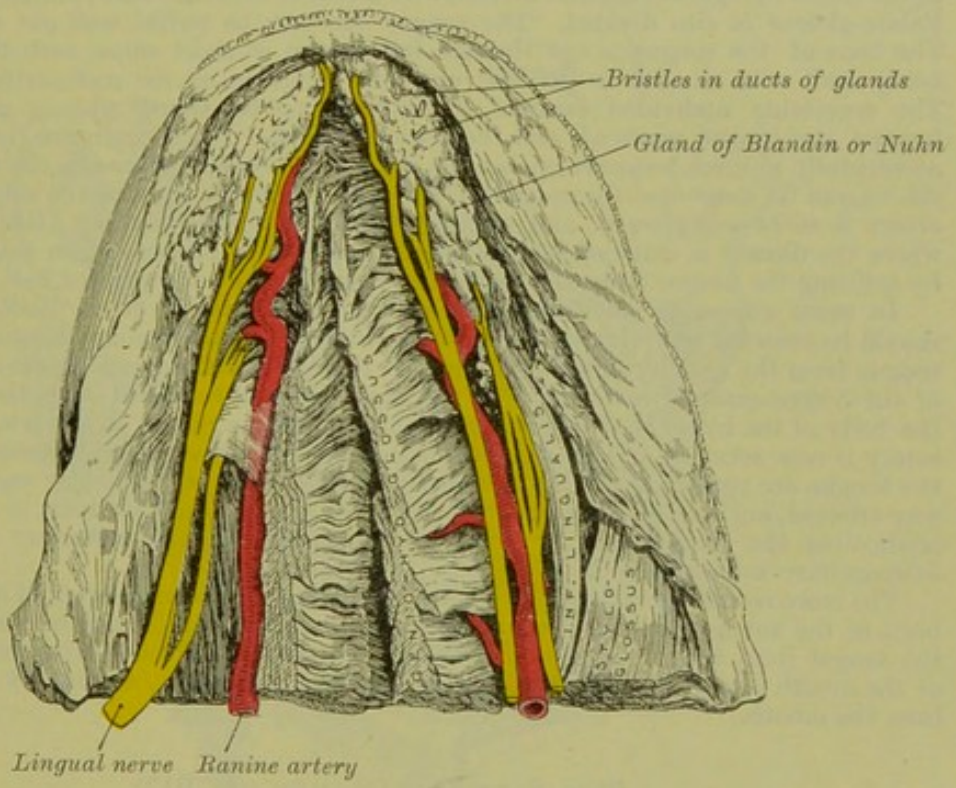

Applied Anatomy.—The diseases to which the tongue is liable are numerous, and any or all of the structures of which it is composed—muscles, connective tissue, mucous membrane, glands, vessels, nerves, and lymphatics—may be the seat of morbid changes. It is not often the seat of congenital defects, though a few cases of vertical cleft have been recorded, and it is occasionally, though much more rarely than is commonly supposed, the seat of 'tongue tie,' from shortness of the frenulum.

There is one condition which may be regarded as congenital, the so-called macroglossia, though sometimes it does not evidence itself until a year or two after birth. This is an enlargement of the tongue which is due primarily to a dilatation of the lymph-channels and a greatly increased development of the lymphatic tissue throughout the organ. This is often aggravated by inflammatory changes induced by injury or exposure, and the tongue may assume enormous dimensions and hang out of the mouth, giving the child an imbecile expression. The treatment consists in excising a V-shaped portion and bringing the cut surfaces together with deeply placed sutures.

Acute inflammation of the tongue, which may be caused by injury and the introduction of some septic or irritating matter, is attended by great swelling from infiltration of its connective tissue, which is in considerable quantity. This renders the patient incapable of swallowing or speaking, and may seriously impede respiration. It may run on to suppuration, and the formation of an acute abscess.

In all ages the mucous membrane of the tongue has received much sedulous consideration in disease, and it is certain that the amount and the distribution of the 'fur' with which it may be covered often give valuable help in diagnosis. The fur consists of proliferating or desquamated epithelium, bound up with inspissated mucus, the débris of food, and bacteria of all sorts. The mucous membrane of the tongue may become chronically inflamed, and presents different appearances in the various stages of the disease, to which the terms leucoplakia and psoriasis linguæ have been given. They are usually the result of syphilis.

The tongue, being very vascular, is often the seat of nævoid growths, and these have a tendency to increase rapidly.

The tongue is frequently the seat of ulceration, which may arise from many causes, as from the irritation of jagged teeth, dyspepsia, tuberculosis, syphilis, and cancer. Of these the cancerous ulcer is the most important and also the most common. The variety is the squamous epithelioma, which soon develops into an ulcer with an indurated edge. It causes great pain, which speedily extends to all parts supplied with sensation by the fifth nerve, especially to the region of the ear (auriculo-temporal branch).

Cancer of the tongue may necessitate removal of a part or the whole of the organ, and many different methods have been adopted for its excision. It may be removed from the mouth by the écraseur or the scissors. Probably the better method is by the scissors, usually known as Whitehead's method. The mouth is widely opened with a gag, the tongue transfixed with a stout silk ligature, by which to hold and make traction on it; the reflection of mucous membrane from the tongue to the jaw, and the insertion of the Genio-hyo-glossus are first divided with a pair of curved, blunt-pointed scissors. The Palato-glossus is also divided. The tongue can now be pulled well out of the mouth. The base of the tongue is cut through by a series of short snips, each bleeding vessel being dealt with as soon as divided, until the situation of the main artery is reached. The remaining undivided portion of tissue is to be seized with a pair of Wells' forceps, the tongue removed, and the vessel secured. In the event of the artery being accidentally injured, hæmorrhage can be at once controlled by passing the forefinger over the tongue till it touches the epiglottis, and then turning it towards the side on which the artery is to be compressed, and pushing it forcibly against the jaw (Heath). In cases where the disease is confined to one side of the tongue, this operation may be modified by splitting the tongue down the centre and removing only the affected half.

In cases where the submaxillary lymphatic glands are involved, Kocher's operation should be resorted to. Having performed a preliminary tracheotomy, Kocher removes the tongue from the neck by an incision from near the lobule of the ear, down the anterior border of the Sterno-mastoid to the level of the great cornu of the hyoid bone, then forwards to the body of the hyoid bone, and upwards to near the symphysis of the jaw. The lingual artery is now secured, and by a careful dissection the submaxillary lymphatic glands and the tongue are removed. If the lymphatic glands in the submaxillary region are in any way affected, an extensive dissection of these will be required if there is any chance of eradicating the disease, and for this purpose it will be found necessary to remove the submaxillary salivary gland.

The more recent operations aim at, first, clearing the neck thoroughly of affected glands, both in the submaxillary region and along the carotid sheath, and secondly removal of the tongue from within the mouth, leaving if possible the mucous membrane of the floor of the mouth intact, so as to avoid soiling the large wound in the neck by the discharges from the mouth.

The Salivary Glands (fig. 917)

The principal salivary glands communicating with the mouth, and pouring their secretion into its cavity, are the parotid, submaxillary, and sublingual.

Parotid gland.—The parotid gland (gl. parotis) is the largest of the three salivary glands, varying in weight from half an ounce to an ounce. It lies upon the side of the face, immediately below and in front of the external ear. The main portion of the gland is superficial, somewhat flattened and quadrilateral in form, and is placed between the ramus of the mandible in front and the mastoid process and Sterno-mastoid muscle behind, overlapping, however, both boundaries. Above, it is limited by the zygoma; below, it extends to about the level of a line joining the tip of the mastoid process to the angle of the jaw. The remainder of the gland is wedge-shaped, and extends deeply inwards towards the pharyngeal wall.

The gland is enclosed within a capsule continuous with the deep cervical fascia; the layer covering the outer surface is dense and closely adherent to the gland; a portion of the fascia, attached to the styloid process and the angle of the mandible, is thickened to form the stylo-mandibular ligament which intervenes between the parotid and submaxillary glands.

The *anterior surface* of the gland is moulded on the posterior border of the ramus of the mandible, clothed by the Internal pterygoid and Masseter muscles. The inner lip of the groove dips, for a short distance, between the two Pterygoid muscles, while the outer lip extends for some distance over the superficial surface of the Masseter ; a small portion of this lip immediately below the zygoma is usually detached, and is named the *socia parotidis*.

The *outer* or *superficial surface*, slightly lobulated, is covered by the integument, the superficial fascia containing the facial branches of the great auricular nerve and some small lymphatic glands, and the fascia which forms the capsule of the gland.

The *inner* or *deep surface* extends inwards by means of two processes, one of which lies on the styloid process and the styloid group of muscles and projects under the mastoid process and Sterno-mastoid muscle ; the other is situated in front of the styloid process, and passes into the posterior part of the glenoid fossa behind the temporo-mandibular joint. The deep surface is in contact with the internal and external carotid arteries, the internal jugular vein, and the vagus and glosso-pharyngeal nerves.

Fig. 917.—The salivary glands.

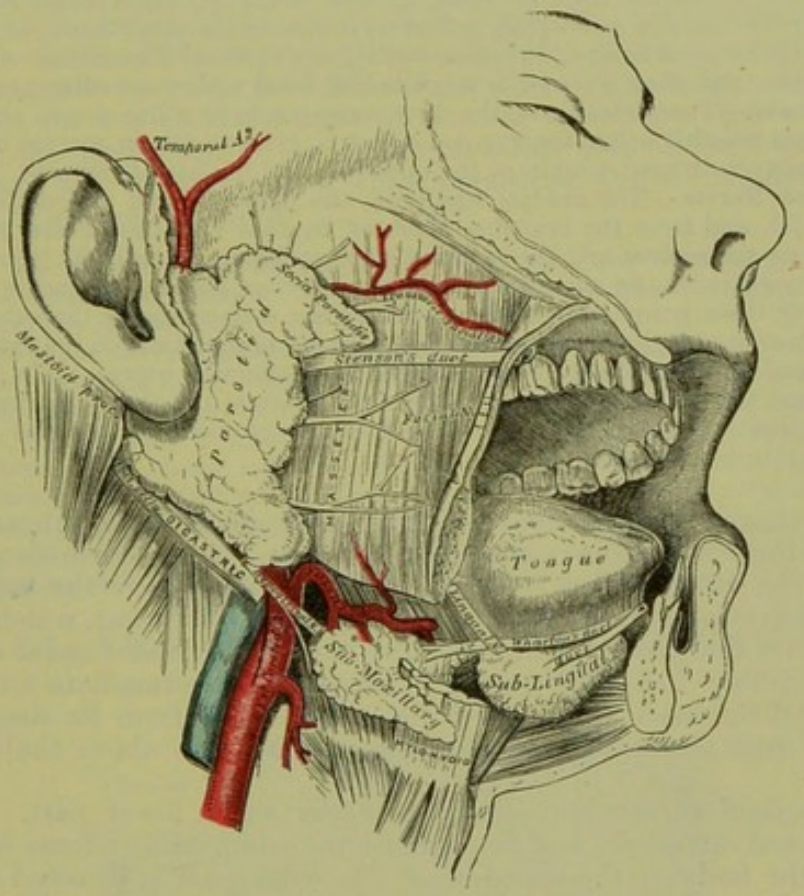

The *anterior border* lies on the superficial surface of the Masseter ; the *posterior* abuts on the external auditory meatus and the mastoid process, and overlaps the anterior edge of the Sterno-mastoid. The *superior* border is in contact with the zygomatic arch, and the *inferior* overlaps the posterior belly of the Digastric. The *inner border*, at the junction of the anterior and inner surfaces, is separated from the pharyngeal wall by some loose connective tissue.

Structures within the gland.—The external carotid artery lies at first on the deep surface, and then in the substance of the gland. The artery gives off its posterior auricular branch which emerges from the gland behind ; it then divides into its terminal branches, the internal maxillary and superficial temporal ; the former runs inwards behind the neck of the mandible ; the latter runs upwards across the zygoma and gives off its transverse facial branch which emerges from the front of the gland. Superficial to the arteries are the temporal and internal maxillary veins, uniting to form the

temporo-maxillary vein; in the lower part of the gland this vein splits into anterior and posterior divisions. The anterior division emerges from the gland to join the facial vein; the posterior unites in the gland with the posterior auricular to form the external jugular vein. On a still more superficial plane is the facial nerve, the branches of which emerge at the upper and anterior borders of the gland. Branches of the great auricular nerve pierce the gland to join the facial, while the auriculo-temporal branch of the inferior maxillary nerve issues from the upper part of the gland.

The **duct of the parotid gland**, or **Stenson's duct** (ductus parotideus), is about two inches and a half in length. It commences by numerous branches from the anterior part of the gland, crosses the Masseter muscle, and at its anterior border turns inwards nearly at a right angle and passes into the substance of the Buccinator muscle, which it pierces; it then runs for a short distance obliquely forwards between the Buccinator and mucous membrane of the mouth, and opens upon the inner surface of the cheek by a small orifice, opposite the second molar tooth of the upper jaw. While crossing the Masseter it receives the duct of *socia parotidis*; in this position it has the transverse facial artery above it and some branches of the facial nerve below it.

Structure.—The parotid duct is dense, its wall being of considerable thickness; its canal is about the size of a crow-quill, but at its orifice on the inner aspect of the cheek its lumen is greatly reduced in size. It consists of a thick external fibrous coat which contains contractile fibres, and of an internal or mucous coat lined with short columnar epithelium.

Surface Form.—The direction of the duct corresponds to a line drawn across the face about a finger's breadth below the zygoma—that is, from the lower margin of the concha to midway between the red margin of the upper lip and the ala of the nose.

Vessels and Nerves.—The *arteries* supplying the parotid gland are derived from the external carotid, and from the branches given off by that vessel in or near its substance. The *veins* empty themselves into the external jugular, through some of its tributaries. The *lymphatics* terminate in the superficial and deep cervical glands, passing in their course through two or three lymphatic glands, placed on the surface and in the substance of the parotid. The *nerves* are derived from the plexus of the sympathetic on the external carotid artery, the facial, the auriculo-temporal, and the great auricular nerves. It is probable that the branch from the auriculo-temporal nerve is derived from the glosso-pharyngeal through the otic ganglion. At all events, in some of the lower animals this has been proved experimentally to be the case.

Submaxillary gland.—The submaxillary gland (gl. submaxillaris) is irregular in form and about the size of a walnut. A considerable part of it is situated in the submaxillary triangle, reaching forwards to the anterior belly of the Digastric and backwards to the stylo-hyoid ligament, which intervenes between it and the parotid gland. Above, it extends under cover of the body of the mandible; below, it usually overlaps the intermediate tendon of the Digastric and the insertion of the Stylo-hyoid, while from its deep surface a tongue-like *deep process* extends forwards and inwards above the Mylo-hyoid muscle.

Its *superficial surface* consists of an upper and a lower part. The *upper part* is directed outwards, and lies against the submaxillary fossa on the inner surface of the body of the mandible. The *lower part* is directed downwards and outwards, and is covered by the skin, superficial fascia, Platysma, and deep cervical fascia; it is crossed by the facial vein and by filaments of the facial nerve; in contact with it, near the mandible, are the submaxillary lymphatic glands.

The *deep surface* is in relation with the Mylo-hyoid, Hyo-glossus, Stylo-glossus, Stylo-hyoid, and posterior belly of the Digastric; in contact with it are the mylo-hyoid nerve and the mylo-hyoid and submental vessels.

The facial artery is imbedded in a groove in the posterior border of the gland.

The *deep process* of the gland extends forwards and inwards between the Mylo-hyoid below and externally, and the Hyo-glossus and Stylo-glossus internally; above it, is the lingual nerve; below it, the hypoglossal nerve and the ranine vein.

The **duct of the submaxillary gland**, or **Wharton's duct** (ductus submaxillaris) is about two inches in length, and its wall is much thinner than that of the parotid duct. It begins by numerous branches from the

deep surface of the gland, and runs forwards and inwards between the Mylo-hyoid and the Hyo-glossus and Genio-hyo-glossus muscles, then between the sublingual gland and the Genio-hyo-glossus, and opens by a narrow orifice on the summit of a small papilla, at the side of the frenulum linguæ. On the Hyo-glossus muscle it lies between the lingual and hypoglossal nerves, but at the anterior border of the muscle it is crossed by the lingual nerve.

Vessels and Nerves.—The *arteries* supplying the submaxillary gland are branches of the facial and lingual. Its *veins* follow the course of the arteries. The *nerves* are derived from the submaxillary ganglion, through which it receives filaments from the chorda tympani of the facial and lingual branch of the inferior maxillary, sometimes from the mylo-hyoid branch of the inferior dental, and from the sympathetic.

Sublingual gland.—The sublingual gland (gl. sublingualis) is the smallest of the salivary glands. It is situated beneath the mucous membrane of the floor of the mouth, at the side of the frenulum linguæ, in contact with the inner surface of the lower jaw, close to the symphysis. It is narrow, flattened, shaped somewhat like an almond, and weighs about a drachm. It is in relation, *above*, with the mucous membrane ; *below*, with the Mylo-hyoid muscle ; *in front*, with the mandible, and its fellow of the opposite side ; *behind*, with the deep part of the submaxillary gland ; and *internally*, with the Genio-hyo-glossus, from which it is separated by the lingual nerve and Wharton's duct. Its excretory ducts (*ducts of Rivinus*) are from eight to twenty in number ; some join Wharton's duct ; others open separately into the mouth, on the elevated crest of mucous membrane (*plica sublingualis*), caused by the projection of the gland, on either side of the frenulum linguæ. One or more join to form a tube, which opens into the Whartonian duct : this is called the *duct of Bartholin*.

Vessels and Nerves.—The sublingual gland is supplied with blood from the sublingual and submental arteries. Its nerves are derived from the lingual, the chorda tympani, and the sympathetic.

Structure of the salivary glands.—The salivary glands are compound racemose glands, consisting of numerous lobes, which are made up of smaller lobules, connected together by dense areolar tissue, vessels, and ducts. Each lobule consists of the ramifications of a single duct, the branches terminating in dilated ends or alveoli on which the capillaries are distributed. The alveoli are enclosed by a basement-membrane, which is continuous with the membrana propria of the duct. It presents a peculiar reticulated structure, and consists of a network of branched and flattened nucleated cells.

The alveoli of the salivary glands are of two kinds, which differ in the appearance of their secreting cells, in their size, and in the nature of their secretion. (1) The mucous

FIG. 918.—A highly magnified section of the submaxillary gland of the dog, stained with carmine. (Kölliker.)

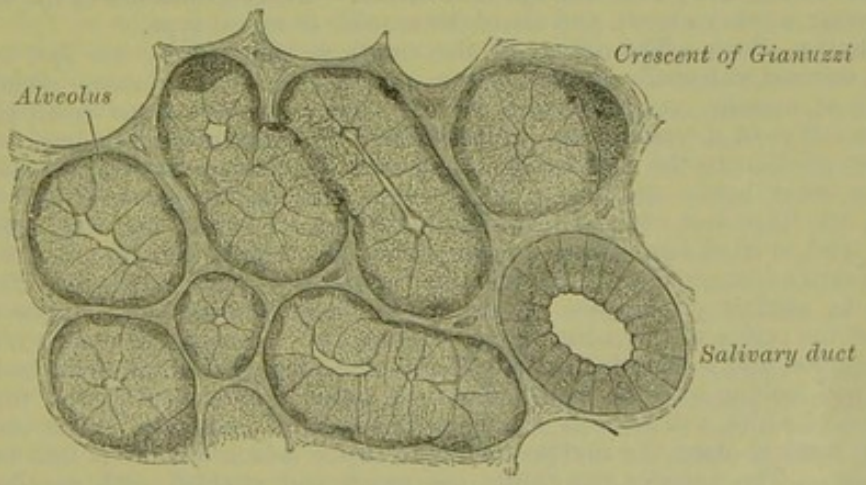

variety secretes a viscid fluid, which contains mucin ; (2) the serous variety secretes a thinner and more watery fluid. The sublingual gland consists of mucous, the parotid of serous alveoli. The submaxillary contains both mucous and serous alveoli, the latter, however, preponderating.

The cells in the *mucous alveoli* are spheroidal in shape, glassy and transparent. The nucleus is usually situated near the basement-membrane, and is flattened. The cells contain a quantity of mucinogen, to which their clear, transparent appearance is due.

In some alveoli are seen peculiar crescentic bodies, lying between the cells and the membrana propria. They are termed the *crescents of Gianuzzi*, or the *demilunes of Heidenhain* (fig. 918), and are composed of polyhedral granular cells, which Heidenhain regards as young epithelial cells destined to supply the place of those salivary cells which have undergone disintegration. This view, however, is not accepted by Klein.

In the *serous alveoli* the cells almost completely fill the cavity, so that there is hardly any lumen perceptible; they contain granules imbedded in a closely reticulated protoplasm (fig. 919).

The ducts are lined at their origins by epithelium which differs little from the pavement type. As the ducts enlarge, the epithelial cells change to the columnar type, and the part of the cell next the basement-membrane is finely striated. The lobules of the salivary glands are richly supplied with blood-vessels which form a dense network in the inter-alveolar spaces. Fine plexuses of nerves are also found in the interlobular tissue. The nerve-fibrils pierce the basement-membrane of the alveoli, and end in branched varicose filaments between the secreting cells. In the hilus of the submaxillary gland there is a collection of nerve-cells termed *Langley's ganglion*.

Mucous glands.—Besides the salivary glands proper, numerous other glands are found in the mouth. Many of these glands are found at the posterior part of the dorsum of the tongue, behind the circumvallate papillæ, and also along its margins as far forwards as the

FIG. 919.—Section of a serous salivary gland.

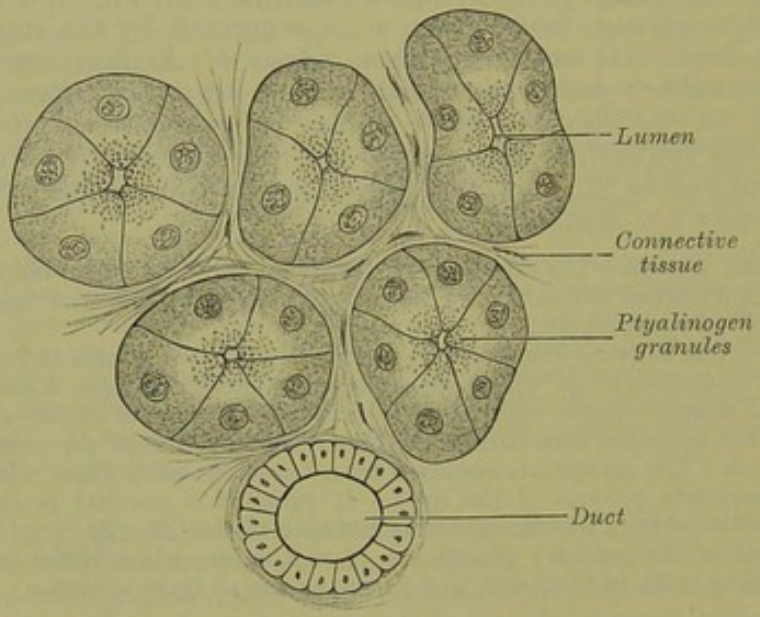

apex. Others lie around and in the tonsil between its crypts, and large numbers are present in the soft palate, the lips and cheeks. These glands are of the same structure as the larger salivary glands, and are of the mucous or mixed type.

Surface Form.—The orifice of the mouth is bounded by the lips, two thick, fleshy folds covered externally by integument and internally by mucous membrane, and consisting of muscles, vessels, nerves, areolar tissue, and numerous small glands. The size of the orifice of the mouth varies considerably in different individuals, but seems to bear a close relation to the size and prominence of the teeth. Its corners usually correspond to the outer border of the canine teeth. In the Mongolian tribes, where the front teeth are large and inclined forward, the mouth is large; and this, combined with the thick and everted lips, which appear to be associated with prominent teeth, gives to the Negro's face much of the peculiarity by which it is characterised. The smaller teeth, and the slighter prominence of the alveolar arch of the more highly civilised races, render the orifice of the mouth much smaller, and thus a small mouth is an indication of intelligence, and is regarded as an evidence of the higher civilisation of the individual.

Upon looking into the mouth, the first thing to be noted is the tongue, the upper surface of which will be seen occupying the floor of the cavity. This surface is convex, and is marked along the middle line by a raphe, which divides it into two symmetrical portions. The anterior two-thirds are rough and studded with papillæ; the posterior third, smooth and tuberculated, is covered by numerous glands which project from the surface. Upon raising the tongue, the mucous membrane which invests its upper surface may be traced over its sides on to its under surface, from which it is reflected over the floor of the mouth on to the inner surface of the mandible, a part of which it covers. As it passes over the borders of the tongue it changes its character, becoming thin and smooth, and losing the papillæ which are to be seen on the upper surface. In the middle line the mucous membrane on the under surface of the tip of the tongue forms a distinct

fold, the *frenulum linguæ*, by which this organ is connected to the symphysis menti. Occasionally it is found that this frenulum is rather shorter than natural, and, acting as a bridle, prevents the complete protrusion of the tongue. When this condition exists and an attempt is made to protrude the organ, the tip will be seen to remain buried in the floor of the mouth, and the dorsum of the tongue is rendered very convex, and more or less extruded from the mouth ; at the same time a deep furrow will be noticed to appear in the middle line of the anterior part of the dorsum. Sometimes, a little external to the frenulum, the ranine vein may be seen immediately beneath the mucous membrane. The corresponding artery, being more deeply placed, does not come into view, nor can its pulsation be felt with the finger. On either side of the frenulum, in the floor of the mouth, is a longitudinal elevation or ridge, produced by the projection of the sublingual gland, which lies immediately beneath the mucous membrane. Close to the attachment of the frenulum to the tip of the tongue may be seen on either side the slit-like orifice of Wharton's duct, into which a fine probe may be passed without much difficulty. In the middle line, both of the upper and lower lip, small folds of mucous membrane pass from the lip to the bone, constituting the *frenula* ; these are not so large as the frenulum linguæ. By pulling outwards the angle of the mouth the mucous membrane lining the cheeks can be seen, and on it may be perceived a little papilla which marks the position of the orifice of Stenson's duct—the duct of the parotid gland. The exact position of the orifice of the duct is opposite the second molar tooth of the upper jaw. The introduction of a probe into this duct is attended with considerable difficulty.

At the back of the mouth is seen the *isthmus of the fauces*, or, as it is popularly called, 'the throat' : this is the space between the pillars of the fauces on either side, and is the means by which the mouth communicates with the pharynx. Above, it is bounded by the soft palate, the anterior surface of which is concave and covered with mucous membrane which is continuous with that lining the roof of the mouth. Projecting downwards from the middle of its lower border is a conical projection, the *uvula*. On either side of the isthmus of the fauces are the anterior and posterior pillars, formed by the Palato-glossus and Palato-pharyngeus muscles respectively, covered by mucous membrane. Between the two pillars on either side is situated the tonsil.

When the mouth is wide open a prominent tense fold of mucous membrane may be seen and felt extending upwards and backwards from the position of the fang of the last molar tooth to the posterior part of the hard palate. This is caused by the pterygo-mandibular ligament which is attached by one extremity to the apex of the internal pterygoid plate, and by the other to the posterior extremity of the mylo-hyoid ridge of the lower jaw. It intervenes between the Buccinator and the Superior constrictor of the pharynx. The fang of the last molar tooth indicates the position of the lingual (gustatory) nerve, where it is easily accessible, and can with readiness be divided in cases of cancer of the tongue (see page 920). On the inner side of the last molar tooth one can feel the hamular process of the internal pterygoid plate of the sphenoid bone, around which the tendon of the Tensor palati plays. About one-third of an inch in front of the hamular process and the same distance directly inwards from the last molar tooth is the situation of the opening of the posterior palatine canal, through which emerges the posterior or descending palatine branch of the internal maxillary artery, and one of the descending palatine nerves from Meckel's ganglion. The exact position of the opening on the subject may be ascertained by driving a needle through the tissues of the palate in this situation, when it will be at once felt to enter the canal. The artery emerging from the opening runs forwards in a groove in the bone, just internal to the alveolar border of the hard palate, and may be wounded in the operation for the cure of cleft palate. Under these circumstances the palatine canal may require plugging. By introducing the finger into the mouth the anterior border of the coronoid process of the jaw can be felt, and is especially prominent when the jaw is dislocated. By throwing the head well back a considerable portion of the posterior wall of the pharynx may be seen through the isthmus faucium, and on introducing the finger the anterior surface of the bodies of the upper cervical vertebræ may be felt immediately beneath the thin muscular stratum forming the wall of the pharynx. The finger can be hooked round the posterior border of the soft palate, and, by turning it forwards, the posterior nares, separated by the septum, can be felt, or the presence of any adenoid or other growths in the naso-pharynx ascertained.

Applied Anatomy.—The parotid glands, and much less often the other salivary glands, are liable to an acute infectious inflammation, known in the case of the parotid as *mumps*. The affected glands swell up, becoming tense, tender, and painful ; much pain is felt when swallowing or mastication is attempted, and salivation may or may not occur. The inflammation goes down after a few days ; suppuration in the affected glands is very rare.

The Pharynx

The **pharynx** is that part of the alimentary canal which is placed behind the nose, mouth, and larynx. It is a musculo-membranous tube, somewhat conical in form, with the base upwards, and the apex downwards, extending

from the under surface of the skull to the level of the cricoid cartilage in front, and that of the sixth cervical vertebra behind.

The cavity of the pharynx (cavum pharyngis) is about five inches in length, and broader in the transverse than in the antero-posterior diameter. Its greatest breadth is immediately below the base of the skull, where it projects on either side, behind the orifice of the Eustachian tube, as a recess termed the fossa of Rosenmüller; its narrowest point is at its termination in the œsophagus. It is limited, *above*, by the body of the sphenoid and basilar process of the occipital bone; *below*, it is continuous with the œsophagus; *posteriorly*, it is connected by loose areolar tissue with the cervical portion of the vertebral column, and the Longus colli and Rectus capitis anticus muscles; *anteriorly*, it is incomplete, and is attached in succession to the internal pterygoid plate, pterygo-mandibular ligament, mandible, tongue, hyoid bone, and thyroid and cricoid cartilages; *laterally*, it is connected to the styloid processes and their muscles, and is in contact with the common and internal carotid arteries, the internal jugular veins, and the glosso-pharyngeal, pneumogastric, hypoglossal, and sympathetic nerves, and above with a small part of the Internal pterygoid muscles. Seven openings communicate with it, viz. the two posterior nares, the two Eustachian tubes, the mouth, the larynx, and the œsophagus. The cavity of the pharynx may be subdivided from above downwards into three parts: nasal, oral, and laryngeal (fig. 899).

The *nasal part*, or naso-pharynx (pars nasalis), lies behind the nose and above the level of the soft palate: it differs from the two lower parts of the tube in that its cavity always remains patent. In front it communicates through the choanæ with the nasal fossæ. On its lateral wall is the *pharyngeal orifice of the Eustachian tube* (ostium pharyngeum tubæ), somewhat triangular in shape, and bounded behind by a firm prominence, the *cushion* (torus tubarius), caused by the inner extremity of the cartilage of the tube which elevates the mucous membrane. A vertical fold of mucous membrane, the *plica salpingopharyngea*, stretches from the lower part of the cushion; it contains the Salpingo-pharyngeus muscle. A second and smaller fold, the *plica salpingopalatina*, stretches from the upper part of the cushion to the palate. Behind the orifice of the Eustachian tube is a deep recess, the *fossa of Rosenmüller* (recessus pharyngeus), which represents the remains of the upper part of the second visceral cleft. On the posterior wall is a prominence, best marked in childhood, produced by a mass of lymphoid tissue, which is known as the *pharyngeal tonsil* (tonsilla pharyngea). Above the pharyngeal tonsil, in the middle line, an irregular flask-shaped depression of the mucous membrane is sometimes seen extending up as far as the basilar process of the occipital bone. It is known as the *bursa pharyngea*, and was regarded by Luschka as the remains of the diverticulum which is concerned in the development of the anterior lobe of the pituitary body. Some anatomists believe it to be connected with the formation of the pharyngeal tonsil.

Fig. 920.—Section of tonsil.

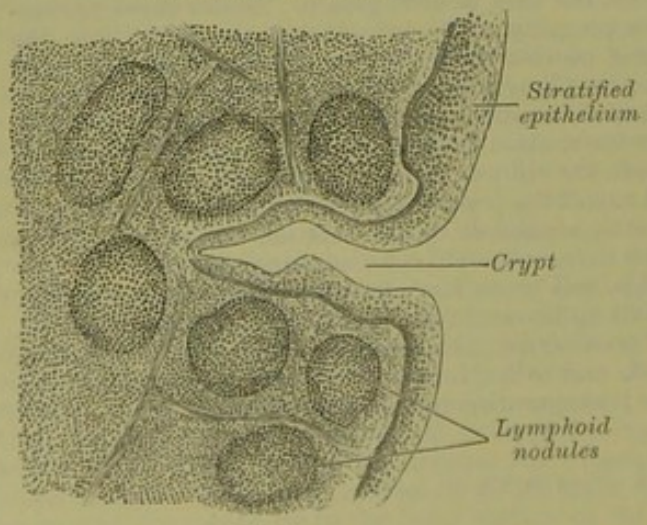

The *oral part* (pars oralis) reaches from the soft palate to the level of the hyoid bone. It opens anteriorly, through the isthmus faucium, into the mouth, while in its lateral wall, between the two pillars of the fauces, is the tonsil.

The **tonsils** (tonsillæ palatinæ) are two prominent bodies situated one on either side between the anterior and posterior pillars of the fauces. They are of a rounded form, and vary considerably in size in different individuals. A recess, the *fossa supratonsillaris*, may be seen, directed upwards and backwards, above the tonsil. His regards this as the remains of the lower

part of the second visceral cleft. It is covered by a fold of mucous membrane termed the *plica triangularis*. *Externally* the tonsil is in relation with the inner surface of the Superior constrictor, to the outer side of which are the ascending palatine and tonsillar arteries and the Internal pterygoid muscle. The internal carotid artery lies behind and to the outer side of the tonsil, and nearly an inch (twenty to twenty-five millimetres) distant from it. The outer surface of the tonsil corresponds in position to the angle of the mandible. Its *inner surface* presents from twelve to fifteen orifices, leading into small crypts or recesses, from which numerous follicles branch out into the substance of the gland (fig. 920). These follicles are lined by a continuation of the mucous membrane of the pharynx, covered with epithelium ; around each follicle is a layer of closed capsules consisting of adenoid tissue imbedded in the submucous tissue. Surrounding each follicle is a close plexus of lymphatics, from which the lymphatic vessels pass to the deep cervical glands in the neighbourhood of the greater cornu of the hyoid bone, behind and below the angle of the mandible ; these glands frequently become enlarged in affections of the tonsils.

The tonsils form part of a circular band of adenoid tissue which guards the opening into the digestive and respiratory tubes. The anterior part of the ring is formed by the submucous adenoid collections on the posterior part of the tongue ; the lateral portions consist of the tonsils and the adenoid collections in the vicinity of the Eustachian tubes, while the ring is completed behind by the pharyngeal tonsil on the posterior wall of the pharynx. In the intervals between these main masses are smaller collections of adenoid tissue.

Vessels and Nerves.—The *arteries* supplying the tonsil are the dorsalis linguæ from the lingual, the ascending palatine and tonsillar from the facial, the ascending pharyngeal from the external carotid, the descending palatine branch of the internal maxillary, and a twig from the small meningeal.

The *veins* terminate in the tonsillar plexus, on the outer side of the tonsil.

The *nerves* are derived from Meckel's ganglion, and from the glosso-pharyngeal.

Applied Anatomy.—The tonsils can be easily inspected by instructing the patient to throw the head back and open his mouth widely ; the tongue at the same time being depressed by a spatula or tongue-depressor. The normal tonsil should not project beyond the plane of the anterior pillar of the fauces. They are prone to become enlarged, especially in tuberculous children ; and when much increased in size they cause great trouble, owing to obstruction to respiration and deglutition. The tonsils may be the seat of acute inflammation, which may run on to suppuration, requiring evacuation of the pus. The incision into the tonsil should always be made from in front backwards and inwards. Another form of acute inflammation of the tonsil is follicular tonsillitis, due to the lodgment of micro-organisms in the crypts of the tonsil. The removal of an enlarged tonsil is, as a rule, a very simple operation, and is not usually attended with much hæmorrhage, unless the patient is suffering from hæmophilia. The tonsil may be the seat of malignant growth, either an epithelioma or a lymphosarcoma.

The *laryngeal part* of the pharynx (pars laryngea) reaches from the hyoid bone to the lower border of the cricoid cartilage, where it is continuous with the œsophagus. In front it presents the triangular aperture of the larynx, the base of which is directed forwards and is formed by the epiglottis, while its lateral boundaries are constituted by the aryteno-epiglottic folds. On either side of the laryngeal orifice is a recess, termed the *sinus pyriformis* ; it is bounded internally by the aryteno-epiglottic fold, externally by the thyroid cartilage and thyro-hyoid membrane.

Structure.—The pharynx is composed of three coats : mucous, fibrous, and muscular.

The *pharyngeal aponeurosis*, or *fibrous coat*, is situated between the mucous and muscular layers. It is thick above where the muscular fibres are wanting, and is firmly connected to the basilar process of the occipital and petrous portions of the temporal bones. As it descends it diminishes in thickness, and is gradually lost. It is strengthened posteriorly by a strong fibrous band, which is attached above to the pharyngeal spine on the under surface of the basilar portion of the occipital bone, and passes downwards, forming a median raphe, which gives attachment to the Constrictor muscles of the pharynx.

The *mucous coat* is continuous with that lining the Eustachian tubes, the nasal fossæ, the mouth, and the larynx. In the naso-pharynx it is covered by columnar ciliated epithelium ; in the buccal and laryngeal portions the epithelium is stratified. Beneath the mucous membrane are found racemose mucous glands ; they are especially numerous at the upper part of the pharynx around the orifices of the Eustachian tubes.

The *muscular coat* has been already described (pages 482 to 484).

Applied Anatomy.—Hypertrophy of the lymphatic tissue in the naso-pharynx, commonly known as 'adenoids,' is a frequent cause of mouth-breathing and all its attendant disadvantages and dangers in children. It entails a proneness to inflammation of all parts of the air-passages and of the Eustachian tubes, and leads to deformed development of the palate and dental arch. In many cases adenoids tend to atrophy about the age of puberty, by which time their presence is likely to have caused permanent injury to the health and development of the patient. No certain remedy for adenoids exists excepting operation.

The pharynx is sometimes the seat of a pouch-like dilatation of its walls, in which the food collects when the patient swallows. A cure is effected by removing the diverticulum and accurately suturing the opening in the pharynx which has been made. The internal carotid artery is in close relation with the pharynx, so that its pulsations can be felt through the mouth. It has been occasionally wounded by sharp-pointed instruments, introduced into the mouth and thrust through the wall of the pharynx. In aneurysm of this vessel in the neck, the tumour necessarily bulges into the pharynx, as this is the direction in which it meets with the least resistance, nothing lying between the vessel and the mucous membrane except the thin Constrictor muscle, whereas on the outer side there are the dense cervical fascia, the muscles descending from the styloid process, and the margin of the Sterno-mastoid.

The mucous membrane of the pharynx is very vascular, and is often the seat of inflammation, frequently of a septic character, since the numerous recesses are prone to lodge micro-organisms. And, in addition, owing to its exposed situation, the mucous membrane is liable to be irritated by agents introduced during inspiration. The inflammation may be attended with serious consequences: it may extend up the Eustachian tube and involve the middle ear; it may spread to the entrance of the larynx, causing œdema and seriously interfering with respiration; or, invading the lymphatics, it may spread to the loose areolar tissue surrounding the pharyngeal wall, and may extend far and wide, sometimes into the posterior mediastinum along the œsophagus. Abscess may form in the connective tissue behind the pharynx, between it and the vertebral column, constituting what is known as *retro-pharyngeal abscess.* This is most commonly due to caries of the cervical vertebræ; but may also be caused by suppuration of a lymphatic gland, which is situated in this position opposite the axis, and which receives lymphatics from the nasal fossæ; by a gumma; or by acute pharyngitis. In these cases the pus may be easily evacuated by incision with a guarded bistoury, through the mouth, but, for aseptic reasons, it is desirable that the abscess should be opened from the neck. In some instances this is perfectly easy: the abscess can be felt bulging at the side of the neck, and merely requires an incision for its relief; but this is not always so, and then an incision should be made along the posterior border of the Sterno-mastoid and the deep fascia divided. A director is now to be inserted into the wound, the forefinger of the left hand being introduced into the mouth and pressure made upon the swelling. This acts as a guide, and the director is to be pushed onwards until pus appears in the groove. A pair of sinus forceps is now inserted along the director and the opening into the cavity dilated.

Abscess also occurs in children, underneath the mucous membrane, between it and the pharyngeal aponeurosis. The condition usually arises from a peritonsillar inflammation, which spreads backwards. In some cases an enormous swelling may form, which pushes forwards the soft palate and gives rise to respiratory obstruction. In such the abscess should be opened through the mouth with the child in the inverted position, so as to prevent the first gush of pus from entering the superior opening of the larynx.

Foreign bodies not infrequently become lodged in the pharynx, and most usually at its termination at about the level of the cricoid cartilage, just beyond the reach of the finger, as the distance from the arch of the teeth to the commencement of the œsophagus is about six inches.

The Œsophagus

The **œsophagus,** or **gullet,** is a muscular canal, about nine or ten inches in length, extending from the pharynx to the stomach. It commences at the upper border of the cricoid cartilage, opposite the sixth cervical vertebra, descends along the front of the vertebral column, through the posterior mediastinum, passes through the Diaphragm, and, entering the abdomen, terminates at the cardiac orifice of the stomach, opposite the eleventh thoracic vertebra. The general direction of the œsophagus is vertical; but it presents two slight curves in its course. At its commencement it is placed in the median line; but it inclines to the left side as far as the root of the neck, gradually passes to the middle line again at the level of the fifth thoracic vertebra, and finally deviates to the left as it passes forwards to the œsophageal opening of the Diaphragm. The œsophagus also presents antero-posterior flexures corresponding to the curvatures of the cervical and thoracic

portions of the vertebral column. It is the narrowest part of the alimentary canal, and is most contracted at its commencement, and at the point where it passes through the Diaphragm.

Relations.—The *cervical portion* (pars cervicalis) of the œsophagus is in relation, *in front*, with the trachea ; and at the lower part of the neck, where it projects to the left side, with the thyroid gland ; *behind*, it rests upon the vertebral column and Longus colli muscles ; *on either side* it is in relation with the common carotid artery (especially the left, as it inclines to that side), and part of the lateral lobe of the thyroid gland ; the recurrent laryngeal nerves ascend between it and the trachea ; to its left side is the thoracic duct.

The *thoracic portion* (pars thoracalis) of the œsophagus is at first situated a little to the left of the median line ; it passes behind the aortic arch, separated from it by the trachea, and descends in the posterior mediastinum, along the right side of the aorta, then runs in front and a little to the left of the aorta, and enters the abdomen through the Diaphragm at the level of the tenth thoracic vertebra. Just before it perforates the Diaphragm it presents a distinct dilatation or *bulb*. It is in relation, *in front*, with the trachea, the left bronchus, the pericardium, and the Diaphragm ; *behind*, it rests upon the vertebral column, the Longus colli muscles, the right intercostal arteries, the thoracic duct, and azygos minor veins ; and below, near the Diaphragm, upon the front of the aorta. On its *left* side, in the superior mediastinum, are the terminal part of the arch of the aorta, the left subclavian artery, the thoracic duct, and left pleura, while running upwards in the angle between it and the trachea is the left recurrent laryngeal nerve ; below, it is in relation with the descending thoracic aorta. On its *right* side are the right pleura, and the vena azygos major which it overlaps. The pneumogastric nerves descend in close contact with it, the right nerve passing down behind, and the left nerve in front of it ; the two nerves uniting to form a plexus (the *plexus gulæ*) around the tube.

In the lower part of the posterior mediastinum the thoracic duct lies to the right side of the œsophagus ; higher up, it is placed behind it, and, crossing about the level of the fourth thoracic vertebra, is continued upwards on its left side.

The *abdominal portion* (pars abdominalis) of the œsophagus lies in the œsophageal groove on the posterior surface of the left lobe of the liver. It measures about half an inch in length, and its front and left aspects only are covered by peritoneal membrane. It is somewhat conical with its base applied to the upper orifice of the stomach, and is known as the *antrum cardiacum*.

Fig. 921.—Section of œsophagus.

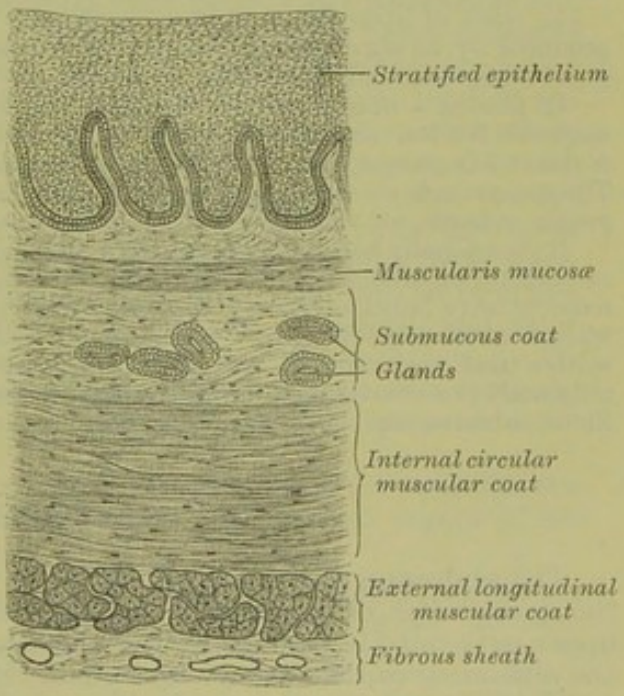

Structure (fig. 921).—The œsophagus has three coats: an external or muscular ; a middle or areolar ; and an internal or mucous coat.

The *muscular coat* is composed of two planes of considerable thickness : an external longitudinal and an internal circular.

The *longitudinal fibres* are arranged, at the commencement of the tube, in three fasciculi : one in front, which is attached to the vertical ridge on the posterior surface of the cricoid cartilage ; and one at either side, which is continuous with the muscular fibres of the pharynx : as they descend they blend together, and form a uniform layer, which covers the outer surface of the tube.

Accessory slips of muscular fibres pass between the œsophagus and the left pleura, where the latter covers the thoracic aorta, or the root of the left bronchus, or the back of the pericardium.

The *circular fibres* are continuous above with the Inferior constrictor; their direction is transverse at the upper and lower parts of the tube, but oblique in the central part.

The muscular fibres in the upper part of the œsophagus are of a red colour, and consist chiefly of the striped variety; but below, they consist for the most part of involuntary fibres.

The *areolar* or *submucous coat* connects loosely the mucous and muscular coats.

The *mucous coat* is thick, of a reddish colour above, and pale below. It is disposed in longitudinal folds, which disappear on distension of the tube. Its surface is studded with minute papillæ, and it is covered throughout with a thick layer of stratified pavement epithelium. Beneath the mucous membrane, between it and the areolar coat, is a layer of longitudinally arranged non-striped muscular fibres. This is the *muscularis mucosæ*. At the commencement of the œsophagus it is absent, or only represented by a few scattered bundles; lower down it forms a considerable stratum.

The *œsophageal glands* are small compound racemose glands of the mucous type: they are lodged in the submucous tissue, and each opens upon the surface by a long excretory duct.

Vessels and Nerves.—The arteries supplying the œsophagus are derived from the inferior thyroid branch of the thyroid axis of the subclavian, from the descending thoracic aorta, from the gastric branch of the cœliac axis, and from the left inferior phrenic of the abdominal aorta. They have for the most part a longitudinal direction.

The nerves are derived from the pneumogastric and from the sympathetic; they form a plexus, in which are groups of ganglion-cells, between the two layers of the muscular coats, and also a second plexus in the submucous tissue.

Applied Anatomy.—The œsophagus may be obstructed by foreign bodies, and also by changes in its coats producing stricture, or by pressure on it from without of new growths or aneurysm, &c. The different forms of stricture are: (1) the fibrous, due to cicatrisation following destruction of tissue, the result of swallowing boiling or corrosive fluids—here dilatation of the stricture may be carried out; and (2) malignant, usually epitheliomatous in its nature. This may be situated either at the upper end of the tube, opposite the cricoid cartilage, or at its lower end at the cardiac orifice, but is most commonly found at that part of the tube where it is crossed by the left bronchus. In these cases, if the patient is losing weight from insufficient nourishment, the operation of gastrostomy may be performed in order to avoid death from starvation; death, however, most commonly occurs from ulceration of the growth into the mediastinum or air-passages. In cases of stricture of the œsophagus it may be necessary to dilate the canal by a bougie, when it is of importance that the direction of the œsophagus and its relations to surrounding parts should be remembered. In cases of malignant disease of the œsophagus, where its tissues have become softened from infiltration of the growth, the greatest care is requisite in directing the bougie through the strictured part, as a false passage may easily be made, and the instrument may pass into the mediastinum or into one or other pleural cavity, or even into the pericardium.

In cases of obstruction of the œsophagus, and consequent symptoms of stricture, produced by an aneurysm of some part of the aorta pressing upon this tube, the passage of a bougie could only hasten the fatal issue.

In passing a bougie the left forefinger should be introduced into the mouth, and the epiglottis felt for, care being taken not to throw the head too far backwards. The bougie is then to be passed beyond the finger until it touches the posterior wall of the pharynx. The patient is now asked to swallow, and at the moment of swallowing the bougie is passed gently onwards, all violence being carefully avoided.

It occasionally happens that a foreign body becomes impacted in the œsophagus, which can neither be brought upwards nor moved downwards. When all ordinary means for its removal have failed, excision is the only resource. This, of course, can only be performed when it is not very low down. If the foreign body is allowed to remain, extensive inflammation and ulceration of the œsophagus may ensue. In one case the foreign body ultimately penetrated the intervertebral substance, and destroyed life by inflammation of the membranes and substance of the cord.

THE ABDOMEN

The **abdomen** is the largest cavity in the body. It is of an oval shape, the extremities of the oval being directed upwards and downwards. The upper extremity is formed by the Diaphragm which extends as a dome over the abdomen, so that the cavity extends high into the bony thorax, reaching on the right side, in the nipple line, to the upper border of the fifth rib; on the left side it falls below this level by about an inch. The lower extremity is formed by the structures which clothe the inner surface of the bony pelvis, principally the Levatores ani and Coccygei muscles on either side. These muscles are sometimes termed the *Diaphragm of the pelvis*. The cavity is wider above than below, and measures more in the vertical than in the

transverse diameter. In order to facilitate description, it is artificially divided into two parts : an upper and larger part, the *abdomen proper* ; and a lower and smaller part, the *pelvis*. These two cavities are not separated from each other, but the limit between them is marked by the brim of the true pelvis.

The **abdomen proper** differs from the other great cavities of the body in being bounded for the most part by muscles and fasciæ, so that it can vary in capacity and shape according to the condition of the viscera which it contains ; but, in addition to this, the abdomen varies in form and extent with age and sex. In the adult male, with moderate distension of the viscera, it is oval or barrel-shaped, but at the same time flattened from before backwards. In the adult female, with a fully developed pelvis, it is conical with the apex above, and in young children it is conical with the apex below.

It is bounded *in front* and *at the sides* by the lower ribs, the abdominal muscles, and the iliac fossæ ; *behind* by the vertebral column and the Psoas and Quadratus lumborum muscles ; *above* by the Diaphragm ; *below* by the plane of the brim of the pelvis. The muscles forming the boundaries of the cavity are lined upon their inner surfaces by a layer of fascia, differently named according to the part it covers.

The abdomen contains the greater part of the alimentary canal ; some of the accessory organs to digestion, viz. the liver and pancreas ; the spleen, the kidneys, and suprarenal glands. Most of these structures, as well as the wall of the cavity in which they are contained, are more or less covered by an extensive and complicated serous membrane, the *peritoneum*.

The *apertures* found in the walls of the abdomen, for the transmission of structures to or from it, are, the *umbilicus* (in the fœtus), for the transmission of the umbilical vessels ; the *caval opening* in the Diaphragm, for the transmission of the inferior vena cava ; the *aortic opening*, for the passage of the aorta, vena azygos major, and thoracic duct ; and the *œsophageal opening*, for the œsophagus and pneumogastric nerves. *Below*, there are two apertures on either side : one for the passage of the femoral vessels, and the other for the transmission of the spermatic cord in the male, and the round ligament in the female.

Regions.—For convenience of description of the viscera, as well as of reference to the morbid conditions of the contained parts, the abdomen is artificially divided into nine regions by imaginary planes, two horizontal and two sagittal, passing through the cavity, the edges of the planes being indicated by lines drawn on the surface of the body. Of the horizontal planes the upper or *infracostal* is indicated by a line encircling the body at the level of the lowest points of the tenth costal cartilages, the lower by a line carried round the trunk at the level of the highest points of the iliac crests as seen from the front. The latter is the *intertubercular plane* of Cunningham, who has pointed out* that its level corresponds with the prominent and easily defined tubercle on the iliac crest about two inches behind the anterior superior iliac spine. By means of these imaginary planes the abdomen is divided into three zones, which are named from above downwards the *subcostal*, *umbilical*, and *hypogastric* zones. Each of these is further subdivided into three regions by the two sagittal planes, which are indicated on the surface by lines drawn vertically through points halfway between the anterior superior iliac spines and the symphysis pubis.†

The middle region of the upper zone is called the *epigastric* ; and the two lateral regions, the *right* and *left hypochondriac*. The central region of the

* *Journal of Anatomy and Physiology*, vol. xxvii.

† Anatomists are far from agreed as to the best method of subdividing the abdominal cavity, but that given above is the one which is generally adopted in this country. Addison,[1] in a careful analysis of the abdominal viscera in a large number of subjects, adopts the following lines: (1) a median, from the symphysis pubis to the ensiform cartilage ; (2) two lateral lines each drawn vertically through a point midway between the anterior superior iliac spine and the symphysis pubis ; (3) an upper transverse line halfway between the symphysis pubis and the suprasternal notch ; and (4) a lower transverse line midway between the last and the upper border of the symphysis pubis. The upper transverse line corresponds with what he has termed the *transpyloric plane*, from the fact that in most cases this plane cuts through the pylorus.

[1] *Journal of Anatomy and Physiology*, vols. xxxiii., xxxiv., xxxv.

Fig. 922.—Front view of the thoracic and abdominal viscera.

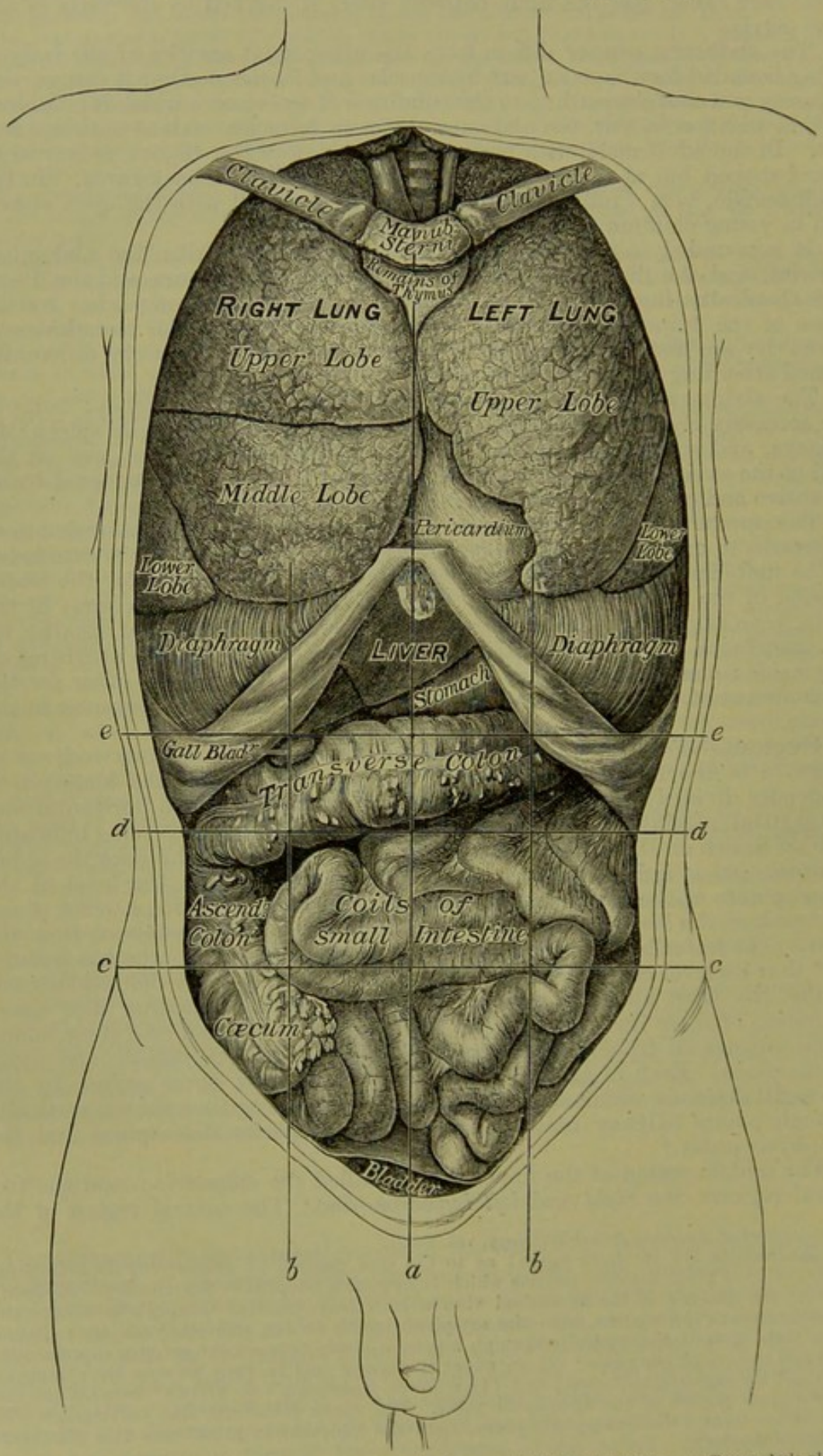

a. Mesial plane. *b b*. Lateral planes. *c c*. Intertubercular plane. *d d*. Infracostal plane. *e e*. Transpyloric plane.

middle zone is the *umbilical*; and the two lateral regions, the *right* and *left lumbar*. The middle region of the lower zone is the *hypogastric* or *pubic region*; and the lateral regions are the *right* and *left iliac* or *inguinal* (fig. 922).

The **pelvis** is that portion of the abdominal cavity which lies below and behind a plane passing through the promontory of the sacrum, the ilio-pectineal lines, and the pubic crests. It is bounded behind by the sacrum, coccyx, Pyriformis muscles, and the sacro-sciatic ligaments; in front and laterally by the pubes and ischia and Obturator internus muscles; above it communicates with the abdomen proper; below it is closed by the Levatores ani and Coccygei muscles and the triangular ligament. The pelvis contains the bladder, the pelvic colon, a few coils of the small intestine, and some of the generative organs.

When the anterior abdominal wall is removed, the viscera are partly exposed as follows: above and to the right side is the liver, situated chiefly under the shelter of the right ribs and their cartilages, but extending across the middle line and reaching for some distance below the level of the ensiform cartilage. To the left of the liver is the stomach, from the lower border of which an apron-like fold of peritoneum, the *great omentum*, descends for a varying distance, and obscures, to a greater or lesser extent, the other viscera. Below it, however, some of the coils of the small intestine can generally be seen, while in the right and left iliac regions respectively the cæcum and the iliac colon are partly exposed. The bladder occupies the anterior part of the pelvis, and, if distended, will project above the symphysis pubis; the rectum lies in the concavity of the sacrum, but is usually obscured by the coils of the small intestine. The pelvic colon lies between the rectum and the bladder.

If the stomach is followed from left to right it will be found to be continuous with the first part of the small intestine, or duodenum, the point of continuity being marked by a thickened ring which indicates the position of the pyloric valve. The duodenum passes towards the under surface of the liver, and then, curving downwards, is lost to sight. If, however, the great omentum be thrown upwards over the chest, the terminal part of the duodenum will be observed passing across the vertebral column towards the left side, where it becomes continuous with the coils of the jejunum and ileum. These measure some twenty feet in length, and if followed downwards will be seen to end in the right iliac fossa by opening into the cæcum or commencement of the large intestine. From the cæcum the large intestine takes an arched course, passing at first upwards on the right side, then across the middle line and downwards on the left side, and forming respectively the ascending, transverse, and descending parts of the colon. In the left iliac region and pelvis it assumes the form of a loop, the ilio-pelvic colon or sigmoid flexure, and terminates in the rectum.

The spleen lies behind the stomach in the left hypochondriac region, and may be in part exposed by pulling the stomach over towards the right side.

The glistening appearance of the deep surface of the abdominal wall and of the exposed viscera is due to the fact that the former is lined, and the latter more or less completely covered, by a serous membrane, the *peritoneum*.

The Peritoneum

The peritoneum is the largest serous membrane in the body, and consists, in the male, of a closed sac, a part of which is applied against the abdominal parietes, while the remainder is reflected over the contained viscera. In the female the peritoneum is not a closed sac, since the free extremities of the Fallopian tubes open directly into the peritoneal cavity. The part which lines the parietes is named the *parietal* portion of the peritoneum; that which is reflected over the contained viscera constitutes the *visceral* portion of the peritoneum. The *free surface* of the membrane is smooth, covered by a layer of flattened endothelium, and lubricated by a small quantity of serous fluid. Hence the viscera can glide freely against the wall of the cavity or upon one another with the least possible amount of friction. The *attached surface* is rough, being connected to the viscera and inner surface of the parietes by means of areolar tissue, termed the *subserous areolar tissue*.

The parietal portion is loosely connected with the fascial lining of the abdomen and pelvis, but is more closely adherent to the under surface of the Diaphragm and also in the middle line of the abdomen.

The space between the parietal and visceral layers of the peritoneum is named the *peritoneal cavity*; but it must be remembered that under normal conditions this cavity is a potential one, since the parietal and visceral layers are in contact. The peritoneal 'cavity' is subdivided into a *greater* and a *lesser sac*, which communicate through the foramen of Winslow (foramen epiploicum). The greater sac is opened when the abdominal wall is cut through; the lesser is situated behind the stomach and adjoining structures, and may be regarded as a diverticulum from the greater sac.

The peritoneum differs from the other serous membranes of the body in presenting a much more complex arrangement, and one which can only be clearly understood by following the changes which take place in the alimentary

FIG. 923.—Vertical disposition of the peritoneum.

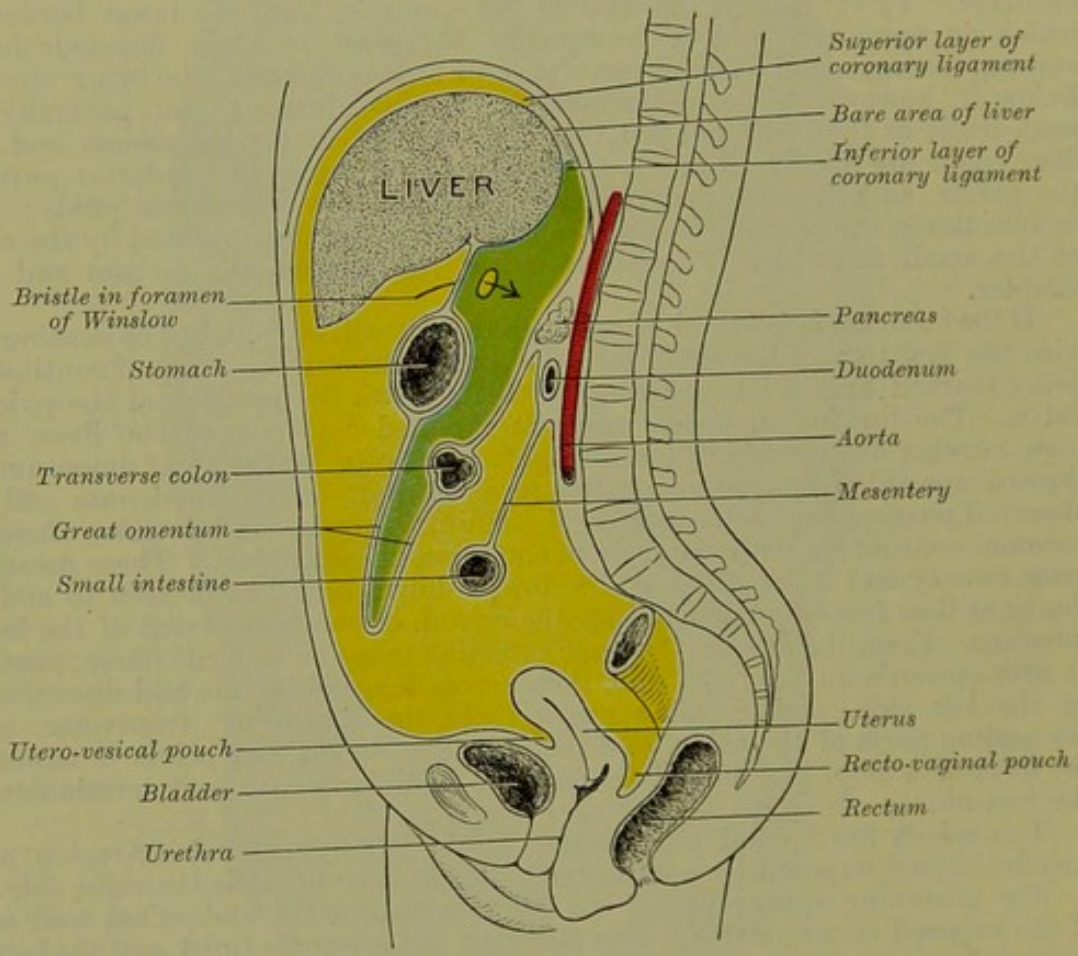

canal during its development; the student therefore is advised to preface his study of the peritoneum by reviewing the chapter dealing with this subject in the section on Embryology (page 150).

To trace the membrane from one viscus to another, and from the viscera to the parietes, it is necessary to follow its continuity in the vertical and horizontal directions, and it will be found simpler to describe the two sacs separately.

Vertical disposition of the greater sac (fig. 923).—It is convenient to trace the greater sac from the back of the abdominal wall at the level of the umbilicus. On following the peritoneum upwards from this level it is seen to be reflected around a fibrous cord, the *ligamentum teres*, or *obliterated umbilical vein*, which reaches from the umbilicus to the under surface of the liver. This reflection forms a somewhat triangular fold, the *falciform* or *suspensory ligament of the liver*, attaching the upper and anterior surfaces of the liver to the Diaphragm and abdominal wall. With the exception of the line of attachment of this ligament the peritoneum covers the whole of the under

surface of the anterior part of the Diaphragm, and is continued from it on to the upper surface of the right lobe of the liver as the *superior layer of the coronary ligament*, and on to the upper surface of the left lobe as the *superior layer of the left lateral ligament* of the liver. Covering the upper and anterior surfaces of the liver, it is continued round its sharp margin on to the under surface, where it presents the following relations: (*a*) It covers the under surface of the right lobe and is reflected from the back part of this on to the upper extremity of the right kidney, forming in this situation the *inferior layer of the coronary ligament*; from the kidney it is carried downwards to the duodenum and hepatic flexure of the colon and inwards to the inferior vena cava, where it is continuous with the posterior wall of the lesser sac. Between the two layers of the coronary ligament there is a large triangular surface of the liver devoid of peritoneal covering: this

FIG. 924.—Posterior view of the anterior abdominal wall in its lower half. The peritoneum is in place, and the various cords are shining through. (After Joessel.)

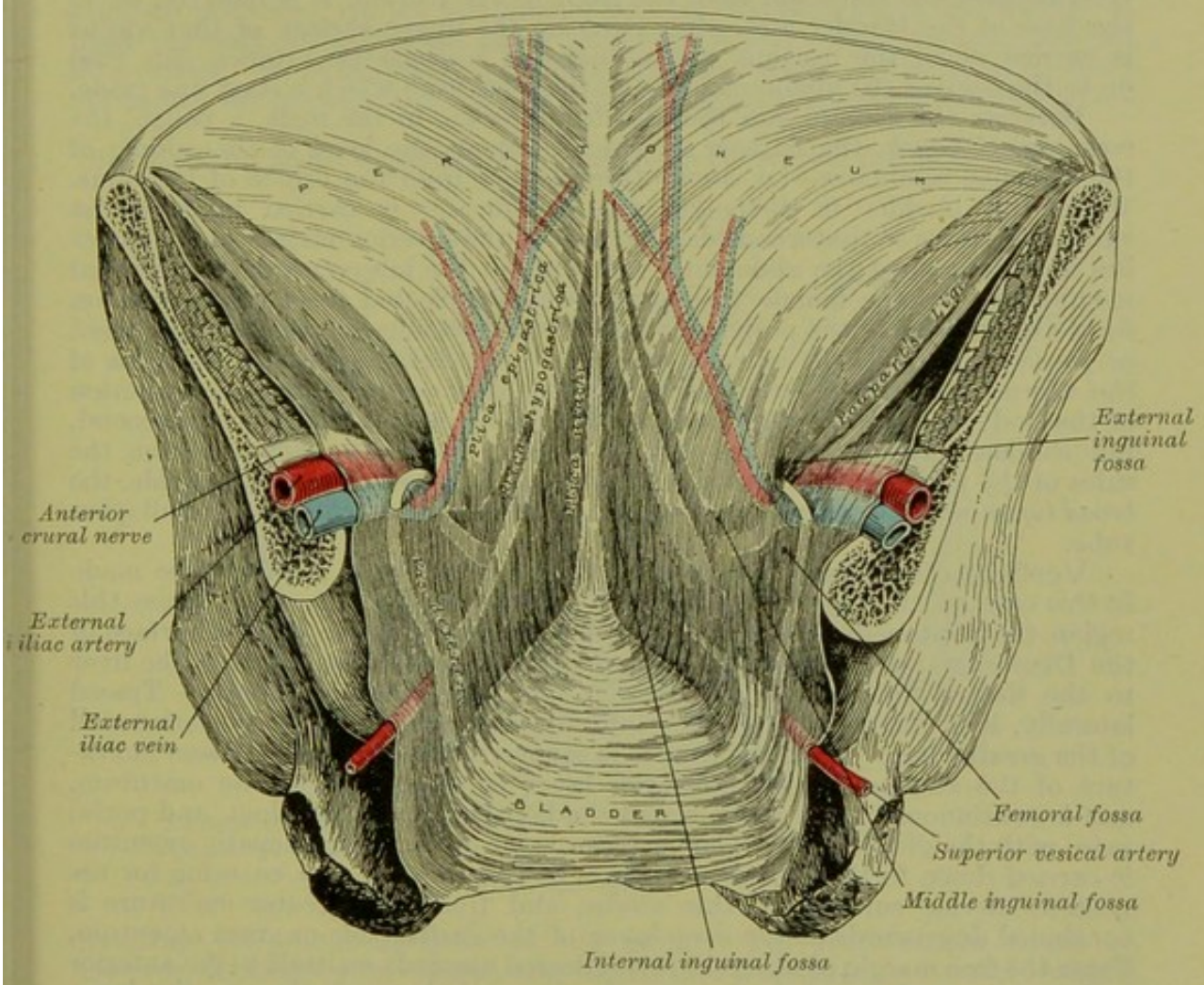

is named the *bare area* of the liver, and is attached to the Diaphragm by areolar tissue. Towards the right margin of the liver the two layers of the coronary ligament gradually approach each other, and ultimately fuse to form a small triangular fold connecting the right lobe of the liver to the Diaphragm, and named the *right lateral ligament* of the liver. The apex of the triangular bare area corresponds with the point of meeting of the two layers of the coronary ligament, its base with the fossa for the inferior vena cava. (*b*) It covers the lower surface of the quadrate lobe, the under and lateral surfaces of the gall-bladder, and the under surface and posterior border of the left lobe; it is then reflected from the upper surface of the liver to the Diaphragm as the *inferior layer of the left lateral ligament*, and from the transverse fissure and fissure for the ductus venosus to the lesser curvature of the stomach as the anterior layer of the *gastro-hepatic*, or

small, omentum. If this layer of the small omentum be followed to the right it will be found to turn round the hepatic artery, bile-duct, and portal vein, and become continuous with the anterior wall of the lesser sac, forming a free folded edge of peritoneum. Traced downwards, it covers the antero-superior surface of the stomach and the commencement of the duodenum, and is carried down from the greater curvature of the stomach into a large free fold, known as the *gastro-colic* or *great omentum.* Reaching the free margin of this fold, it is reflected upwards to cover the under and posterior surfaces of the transverse colon, and thence to the posterior abdominal wall as the inferior layer of the *transverse mesocolon.* It reaches the abdominal wall at the upper border of the third part of the duodenum, and is then carried down on the superior mesenteric vessels to the small intestine as the anterior layer of the *mesentery.* It encircles the intestine, and subsequently may be traced, as the posterior layer of the mesentery, upwards and backwards to the abdominal wall. From this it sweeps down over the aorta into the pelvis, where it invests the pelvic colon, its reduplication forming the *pelvic mesocolon.* Leaving first the sides and then the front of the rectum, it is reflected on to the base of the bladder and, after covering the upper surface of that viscus is carried along the urachus and obliterated hypogastric arteries (fig. 924) on to the back of the abdominal wall to the level from which a start was made.

Between the rectum and the bladder it forms, in the male, a pouch, the *recto-vesical pouch*, the bottom of which is about the level of the middle of the vesiculæ seminales—i.e. about three inches from the orifice of the anus. When the bladder is distended, the peritoneum is carried up with the expanded viscus so that a considerable part of the anterior surface of the latter lies directly against the abdominal wall without the intervention of peritoneal membrane. In the female the peritoneum is reflected from the rectum on to the upper part of the posterior vaginal wall, forming the *recto-vaginal pouch* or *pouch of Douglas.* It is continued over the posterior surface and fundus of the uterus on to its anterior surface, which it covers as far as the junction of the body and cervix uteri, and then to the bladder, forming here a second, but shallower, pouch, the *utero-vesical pouch.* It is also reflected from the sides of the uterus to the lateral walls of the pelvis as two expanded folds, the *broad ligaments of the uterus*, in the free margin of each of which is the Fallopian tube.

Vertical disposition of the lesser sac (fig. 923).—A start may be made in this case on the posterior abdominal wall above the pancreas. From this region the peritoneum may be followed upwards on to the inferior surface of the Diaphragm, and thence on to the Spigelian and caudate lobes of the liver to the fissure for the ductus venosus and the transverse fissure. Traced laterally, it is continuous over the inferior vena cava with the posterior wall of the greater sac. From the liver it is carried downwards to the lesser curvature of the stomach as the posterior layer of the gastro-hepatic omentum, and is continuous on the right, round the hepatic artery, bile-duct, and portal vein, with the greater sac. The posterior layer of the gastro-hepatic omentum is carried down to the greater curvature of the stomach as a covering for the postero-inferior surface of this viscus, and from the greater curvature is continued downwards as the deep layer of the gastro-colic or great omentum. From the free margin of this fold it is reflected upwards on itself to the anterior and superior surfaces of the transverse colon, and thence as the superior layer of the transverse meso-colon to the upper border of the third part of the duodenum, from which it may be followed over the front of the pancreas to the level from which a start was made. It will be seen that the loop formed by the wall of the lesser sac below the transverse colon follows, and is closely applied to, the deep surface of that formed by the greater sac, and that the great omentum or large fold of peritoneum which hangs in front of the small intestine therefore consists of four layers, two anterior and two posterior, separated by the potential cavity of the lesser sac.

Horizontal disposition of the peritoneum.—Below the transverse colon the arrangement is simple, as it includes only the greater sac; above the level of the transverse colon it is more complicated on account of the existence of the two sacs. Below the transverse colon it may be considered in the two regions, viz. in the pelvis and in the abdomen proper.

(1) *In the pelvis.*—The peritoneum here follows closely the surfaces of the pelvic viscera and the inequalities of the pelvic walls, and presents important differences in the two sexes. (*a*) *In the male* it encircles the pelvic colon, from which it is reflected to the posterior wall of the pelvis as a fold, the *pelvic mesocolon.* It then leaves the sides and, finally, the front of the rectum, and is continued on to the bladder; on either side of the rectum it forms a fossa, the *pararectal fossa*, which varies in size with the distension of the rectum. In front of the rectum the peritoneum forms the recto-vesical pouch, which is limited laterally by peritoneal folds extending from the sides of the bladder to the rectum and sacrum. These folds are known from their position as the *recto-vesical* or *sacro-genital folds.* The peritoneum of the anterior pelvic wall covers the superior surface of the bladder, and on either side of this viscus forms a depression, termed the *paravesical fossa*, and limited externally by the fold of peritoneum covering the vas deferens. The size of this fossa is dependent on the state of distension of the bladder; when the bladder is empty, a variable fold of peritoneum, the *plica vesicalis transversa*, divides the fossa into two portions. On the peritoneum between the paravesical and pararectal fossæ the only elevations are those produced by the ureters and the internal iliac vessels. (*b*) *In the female*, pararectal and paravesical fossæ similar to those in the male are present: the outer limit of the paravesical fossa is the peritoneum

Fig. 925.—Horizontal disposition of the peritoneum in the lower part of the abdomen.

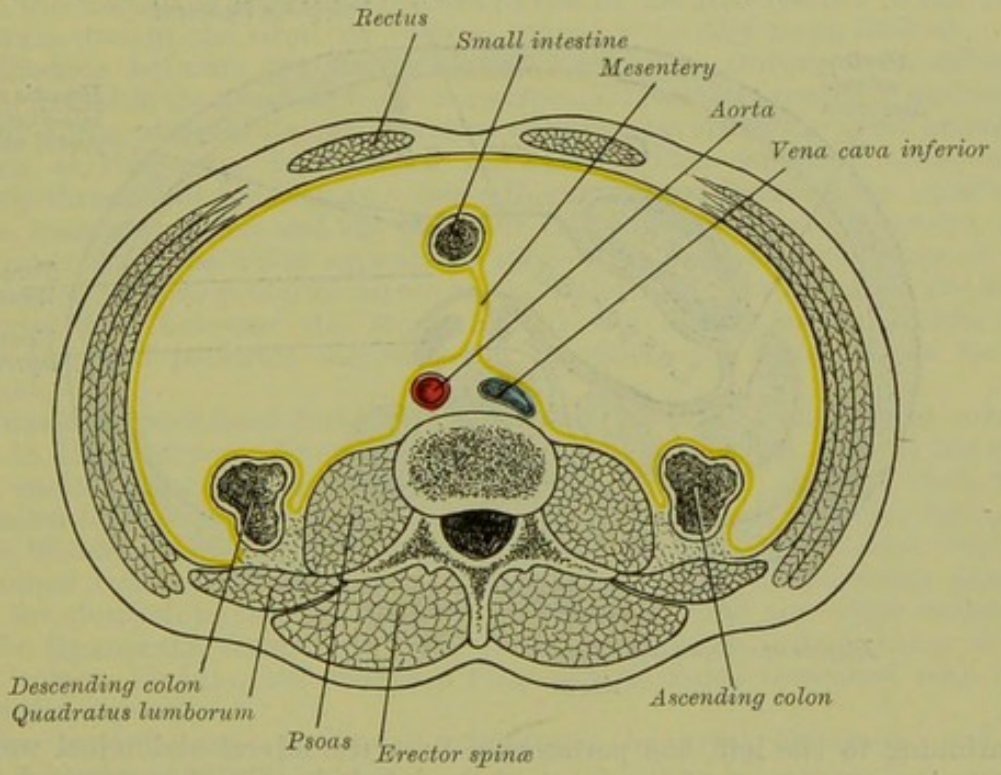

investing the round ligament of the uterus. The recto-vesical pouch is, however, divided by the uterus and vagina into a small anterior utero-vesical and a large, deep, posterior recto-vaginal pouch. The sacro-genital folds form the margins of the latter, and are continued on to the back of the uterus to form a transverse fold, the *torus uterinus.* The *broad ligaments* extend from the sides of the uterus to the lateral walls of the pelvis; they contain in their free margins the Fallopian tubes, and in their posterior layers the ovaries. Below, the broad ligaments are continuous with the peritoneum on the lateral walls of the pelvis. On the lateral pelvic wall behind the attachment of the broad ligament, in the angle between the elevations produced by the diverging internal and external iliac vessels, is a slight fossa, the *ovarian fossa*, in which the ovary normally lies.

(2) *In the lower abdomen* (fig. 925).—Starting from the linea alba, below the level of the transverse colon, and tracing the continuity of the peritoneum in a horizontal direction to the right, the membrane covers the inner surface of the abdominal wall almost as far as the outer border of the Quadratus lumborum;

it encloses the cæcum and vermiform appendix, and is reflected over the sides and front of the ascending colon ; it may then be traced over the Psoas muscle and inferior vena cava towards the middle line, whence it passes along the mesenteric vessels to invest the small intestine, and back again to the large vessels in front of the vertebral column, forming the *mesentery*, between the layers of which are contained the mesenteric blood-vessels, lacteals, and glands. It is then continued over the left Psoas muscle ; it covers the sides and front of the descending colon, and, reaching the abdominal wall, is carried on it to the middle line.

(3) *In the upper abdomen* (fig. 926).—Above the transverse colon the peritoneum can be traced, forming the greater and lesser sacs, and the communication of the two sacs with one another through the foramen of Winslow can be demonstrated.

(*a*) *Greater sac.*—Commencing on the posterior abdominal wall at the inferior vena cava, the membrane may be followed to the right over the front of the upper part of the right kidney on to the antero-lateral abdominal wall. From the middle of the anterior wall a backwardly directed fold encircles the obliterated umbilical vein and forms the falciform ligament of the liver.

FIG. 926.—Horizontal disposition of the peritoneum in the upper part of the abdomen.

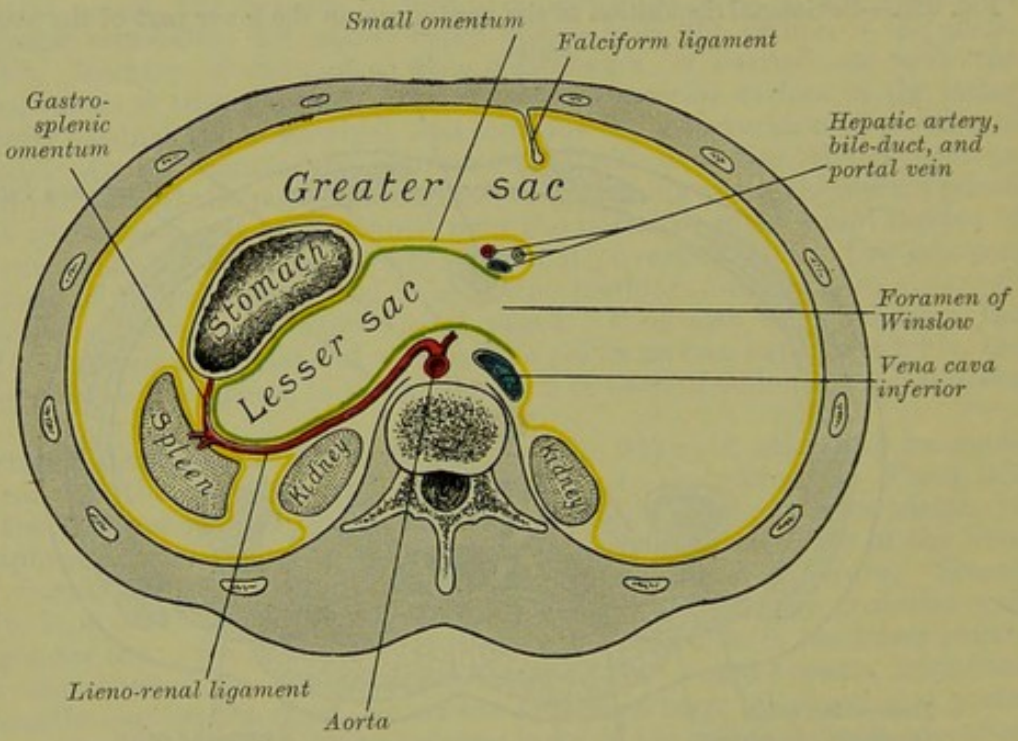

Continuing to the left, the peritoneum lines the lateral abdominal wall and covers the outer part of the front of the left kidney, and is reflected to the posterior border of the hilus of the spleen as the posterior layer of the *lieno-renal ligament*. It can then be traced over the surface of the spleen to the front of the hilus, and thence to the cardiac extremity of the stomach as the anterior layer of the *gastro-splenic omentum*. It covers the antero-superior surfaces of the stomach and first part of the duodenum, and extends up from the lesser curvature of the stomach to the liver, the latter portion forming the anterior layer of the gastro-hepatic omentum.

(*b*) *Lesser sac.*—On the posterior abdominal wall the peritoneum of the greater sac is continuous with that of the lesser sac in front of the inferior vena cava. Starting from here, the lesser sac may be traced across the aorta and over the inner part of the front of the left kidney to the hilus of the spleen as the anterior layer of the lieno-renal ligament. From the spleen it is reflected to the stomach as the posterior layer of the gastro-splenic omentum. It covers the postero-inferior surfaces of the stomach and commencement of the duodenum, and from the lesser curvature of the stomach extends upwards to the liver as the posterior layer of the gastro-hepatic omentum ; the right

margin of this layer is continuous round the hepatic artery, bile-duct, and portal vein, with the wall of the greater sac.

Foramen of Winslow.—The foramen of Winslow is the passage of communication between the greater and lesser sacs. It is bounded *in front* by the free border of the gastro-hepatic omentum, with the common bile-duct, hepatic artery, and portal vein between its two layers; *behind* by the peritoneum covering the inferior vena cava; *above* by the peritoneum on the caudate lobe of the liver, and *below* by the peritoneum covering the commencement of the duodenum and the hepatic artery, the latter passing forwards below the foramen before ascending between the two layers of the gastro-hepatic omentum.

The *boundaries of the lesser sac* will now be evident. It is bounded *in front*, from above downwards, by the Spigelian lobe of the liver, the gastro-hepatic omentum, the stomach, and the anterior two layers of the great omentum. *Behind*, it is limited, from below upwards, by the two posterior layers of the great omentum, the transverse colon, and the ascending layer of the transverse mesocolon, the upper surface of the pancreas, the left suprarenal gland, and the upper end of the left kidney. To the right of the œsophageal opening of the stomach it is formed by that part of the Diaphragm which supports the Spigelian lobe of the liver. Laterally, the lesser sac extends from the foramen of Winslow to the spleen, where it is limited by the lieno-renal ligament and the gastro-splenic omentum.

In the fœtus the lesser sac reaches as low as the free margin of the great omentum, but in the adult its vertical extent is usually more limited owing to adhesions between the layers of the omentum. During a considerable part of fœtal life the transverse colon is suspended from the posterior abdominal wall by a mesentery of its own, the two posterior layers of the great omentum passing at this stage in front of the colon. This condition occasionally persists throughout life, but as a rule adhesion occurs between the mesentery of the transverse colon and the posterior layer of the great omentum, with the result that the colon appears to receive its peritoneal covering by the splitting of the two posterior layers of the latter fold. In the adult the lesser sac intervenes between the stomach and the structures on which that viscus lies, and performs therefore the functions of a serous bursa for the stomach.

Numerous peritoneal folds extend between the various organs or connect them to the parietes. They serve to hold them in position, and, at the same time, enclose the vessels and nerves proceeding to them. Some of these folds are called *ligaments*, such as the ligaments of the liver and the false ligaments of the bladder. Others, which connect certain parts of the intestine with the abdominal wall, constitute the *mesenteries*; and lastly, those which proceed from the stomach to certain viscera in its neighbourhood are called *omenta*.

The **ligaments**, formed by folds of the peritoneum, include those of the liver, spleen, bladder, and uterus. They will be found described with their respective organs.

The **omenta** are: the small omentum, the great omentum, and the gastro-splenic omentum.

The *small* or *gastro-hepatic omentum* (omentum minus) is the duplicature which extends between the liver and the lesser curvature of the stomach. It is extremely thin, and is continuous with the two layers of peritoneum which cover respectively the antero-superior and postero-inferior surfaces of the stomach. When these two layers reach the lesser curvature of the stomach, they join together and ascend as a double fold to the transverse fissure of the liver; to the left of this fissure the fold is attached to the bottom of the fissure of the ductus venosus, along which it is carried to the Diaphragm, where the two layers separate to embrace the end of the œsophagus. At the right border the two layers are continuous, and form a free margin which constitutes the anterior boundary of the foramen of Winslow. Between the two layers, close to this free margin, are the hepatic artery, the common bile-duct, the portal vein, lymphatics, and the hepatic plexus of nerves—all these structures being enclosed in loose areolar tissue, called *Glisson's capsule*. Between the layers, where they are attached to the stomach, run the gastric artery and the pyloric branch of the hepatic artery.

The *great* or *gastro-colic omentum* (omentum majus) is the largest peritoneal fold. It consists of a double sheet of peritoneum, folded on itself so that it is made up of four layers. The two layers which descend from the stomach pass in front of the small intestines, sometimes as low down as the pelvis; they then turn upon themselves, and ascend again as far as the transverse colon, where they separate and enclose that part of the intestine. These individual layers may be easily demonstrated in the young subject, but in the adult they are more or less inseparably blended. The left border of the

FIG. 927.—Diagram devised by Delépine to show the lines along which the peritoneum leaves the wall of the abdomen to invest the viscera.

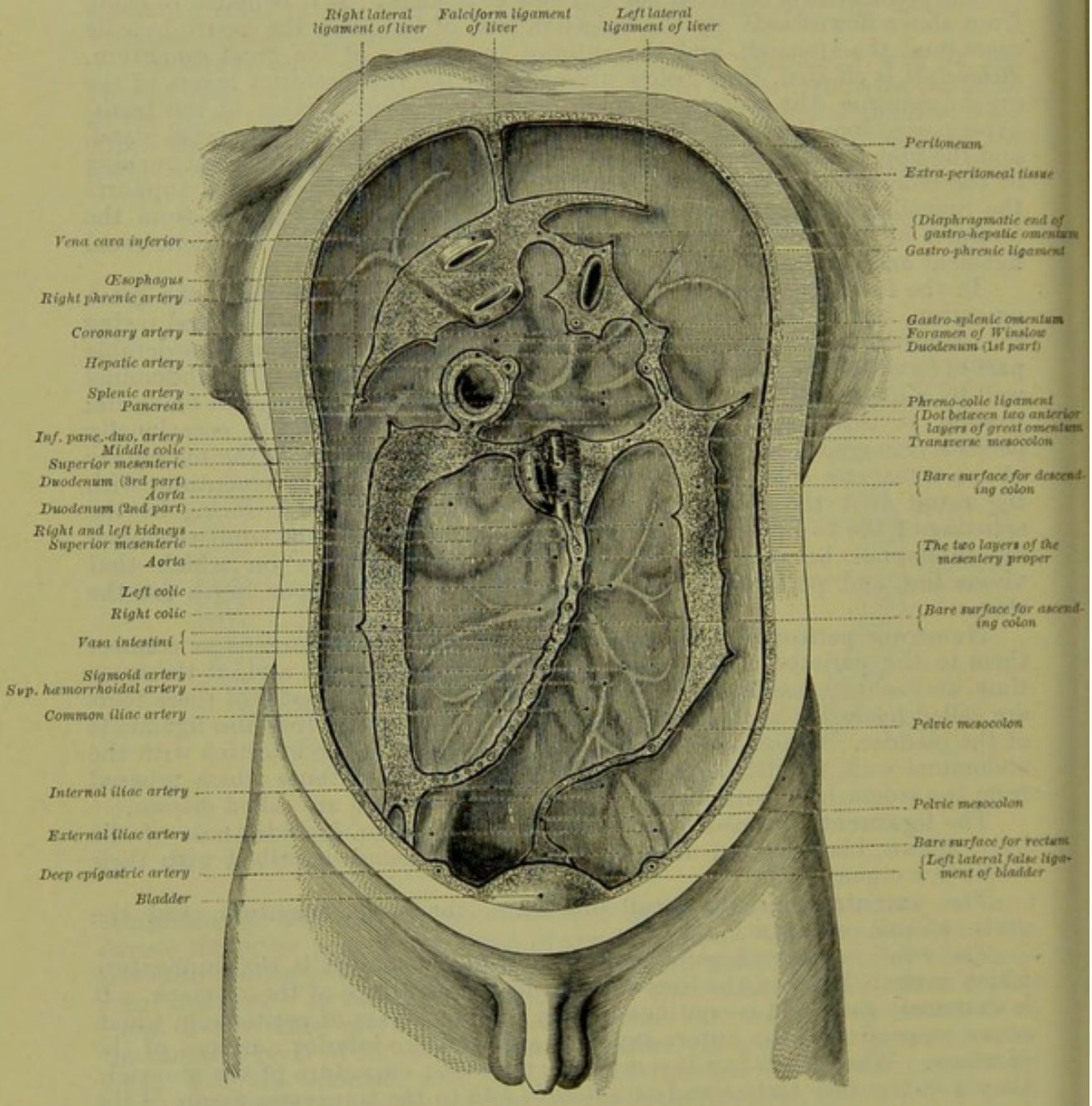

great omentum is continuous with the gastro-splenic omentum; its right border extends as far only as the duodenum. The great omentum is usually thin, presents a cribriform appearance, and always contains some adipose tissue, which in fat people accumulates in considerable quantity. Between its two anterior layers is the anastomosis between the right and left gastro-epiploic arteries.

The *gastro-splenic omentum* (lig. gastrolienale) is the fold which connects the margins of the hilus of the spleen to the stomach, being continuous by its lower border with the great omentum. It contains the vasa brevia.

The **mesenteries** are : the mesentery proper, the transverse mesocolon, and the pelvic mesocolon. In addition to these there are sometimes present an ascending and a descending mesocolon.

The *mesentery proper* (mesenterium) is the broad, fan-shaped fold of peritoneum which connects the convolutions of the jejunum and ileum with the posterior wall of the abdomen. Its *root*—the part connected with the structures in front of the vertebral column—is narrow, about six inches in length, and is directed obliquely from the duodeno-jejunal flexure at the left side of the second lumbar vertebra to the right iliac fossa (fig. 927). Its intestinal border is about twenty feet in length ; and here the two layers separate to enclose the intestine, and form its peritoneal coat. Its breadth, between its vertebral and intestinal borders, is about eight inches. Its *upper border* is continuous with the under surface of the transverse mesocolon : its *lower border*, with the peritoneum covering the cæcum and ascending colon. It serves to retain the small intestines in their position, and contains between its layers the rami intestini tenuis of the superior mesenteric artery, with their accompanying veins and plexuses of nerves, the lacteal vessels, and mesenteric glands.

In most cases the peritoneum covers only the front and sides of the ascending and descending parts of the colon. Sometimes, however, these are surrounded by the serous membrane and attached to the posterior abdominal wall by an ascending and a descending mesocolon respectively. At the place where the transverse colon turns downwards to form the descending colon, a fold of peritoneum is continued to the Diaphragm opposite the tenth and eleventh ribs. This is the *phreno-colic ligament* ; it passes below the spleen, and serves to support this organ, and therefore it has received the name of *sustentaculum lienis*.

The *transverse mesocolon* (mesocolon transversum) is a broad fold, which connects the transverse colon to the posterior wall of the abdomen. It is continuous with the two posterior layers of the great omentum, which, after separating to surround the transverse colon, join behind it, and are continued backwards to the spine, where they diverge in front of the anterior border of the pancreas. This fold contains between its layers the vessels which supply the transverse colon.

The *pelvic mesocolon* is the fold of peritoneum which retains the pelvic colon in connection with the pelvic wall. Its line of attachment forms a V-shaped curve, the apex of the curve being placed about the point of division of the left common iliac artery. The curve begins on the inner side of the left Psoas, and runs upwards and backwards to the apex, from which it bends sharply downwards and inwards, and ends in the mesial plane at the level of the third sacral vertebra. Between the two layers of this fold run the sigmoid and superior hæmorrhoidal vessels.

The *appendices epiploicæ* are small pouches of the peritoneum filled with fat and situated along the colon and upper part of the rectum. They are chiefly appended to the transverse colon.

Retro-peritoneal fossæ.—In certain parts of the abdominal cavity there are recesses of peritoneum forming *culs-de-sac* or pouches, which are of surgical interest in connection with the possibility of the occurrence of retro-peritoneal hernia. One of these is the lesser sac of the peritoneum, which may be regarded as a recess of peritoneum through the foramen of Winslow, in which a hernia may take place, but there are several others, of smaller size, which require mention.

These recesses or fossæ may be divided into three groups, viz. : 1, the duodenal fossæ ; 2, the circumcæcal fossæ ; and 3, the intersigmoid fossa.

1. *Duodenal fossæ* (figs. 928, 929).—Moynihan has described no less than nine fossæ as occurring in the neighbourhood of the duodenum. Three of these are fairly constant, and are the only ones which require mention. (*a*) The *inferior duodenal fossa* is the most constant of all the peritoneal fossæ in this region, being present in from 70 to 75 per cent. of cases. It is situated opposite the third lumbar vertebra on the left side of the ascending portion of the duodenum. Its opening is directed upwards, and is bounded by a thin sharp fold of peritoneum with a concave margin, called the *inferior duodenal fold*. The tip of the index finger introduced into the fossa under the fold passes

some little distance behind the ascending or fourth portion of the duodenum. (*b*) The *superior duodenal fossa* is the next most constant pouch or recess, being present in from 40 to 50 per cent. of cases. It often coexists with the inferior one, and its orifice looks downwards, in the opposite direction to the

Fig. 928.—Superior and inferior duodenal fossæ. (Poirier and Charpy.)

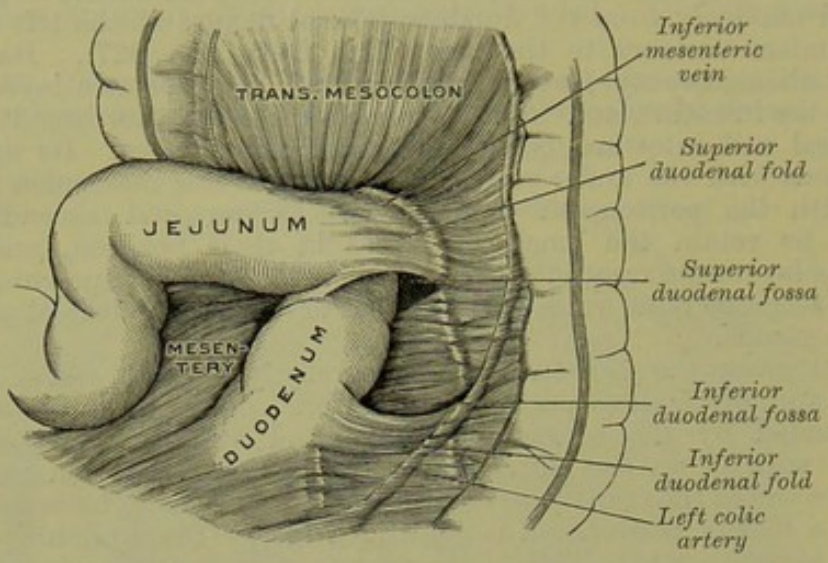

preceding fossa. It lies to the left of the ascending portion of the duodenum. It is bounded by the free edge of the *superior duodenal fold*, which presents a semilunar margin; to the right it is blended with the peritoneum covering the ascending duodenum, and to the left with the peritoneum covering the

Fig. 929.—Duodeno-jejunal fossa. (Poirier and Charpy.)

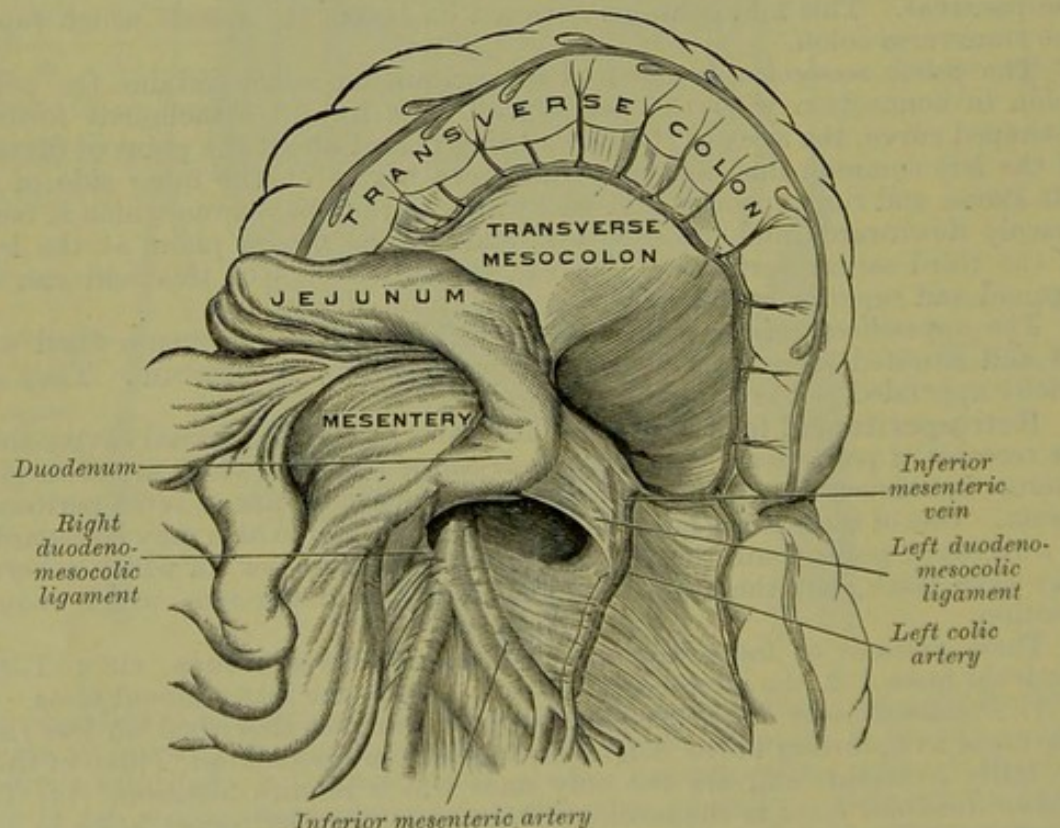

peri-nephric tissues. The fossa is bounded in front by the superior duodenal fold; behind by the second lumbar vertebra; to the right by the duodenum. Its depth is two centimetres, and it terminates in the angle formed by the left renal vein crossing the aorta. This fossa is of importance, as it is in

relation with the inferior mesenteric vein: that is to say, the vein almost always corresponds to the line of union of the superior duodenal fold with the posterior parietal peritoneum. (*c*) The *duodeno-jejunal fossa* can be seen by pulling the jejunum downwards and to the right, after the transverse colon has been pulled upwards. It will appear as an almost circular opening, looking downwards and to the right, and bounded by two free borders or folds of peritoneum, the *duodeno-mesocolic ligaments*. The opening admits the little finger into the fossa, to the depth of from two to three centimetres. The fossa is bounded above by the pancreas, to the right by the aorta, and to the left by the kidney; beneath is the left renal vein. The fossa exists in from 15 to 20 per cent. of cases, and has never yet been found in conjunction with any other form of duodenal fossa.

Fig. 930.—Ileo-colic fossa. (Poirier and Charpy.)

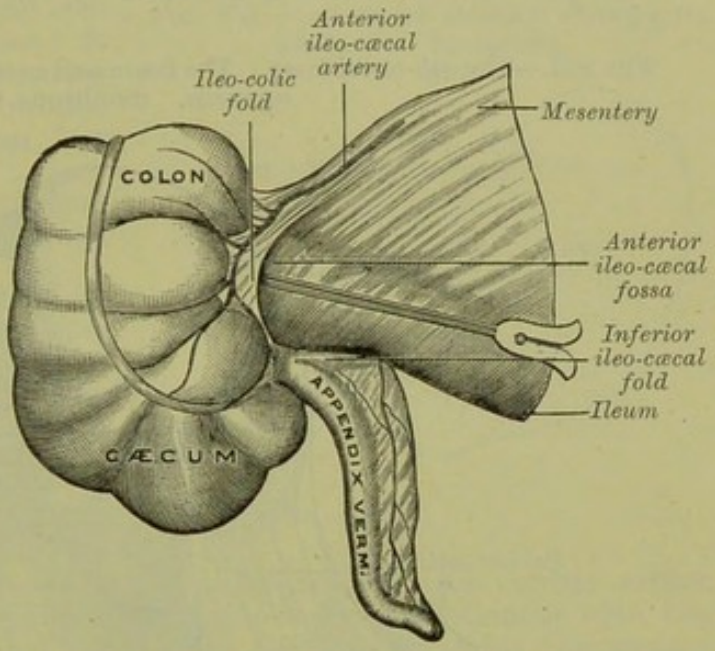

2. *Circumcæcal fossæ* (figs. 930, 931, 932).—There are at least three pouches or recesses termed *circumcæcal fossæ* to be found in the neighbourhood of the cæcum. (*a*) The *ileo-colic fossa* (superior ileo-cæcal) is formed by a fold of peritoneum, the ileo-colic fold, arching over the branch of the ileo-colic artery which supplies the ileo-colic junction. The fossa is a narrow chink situated

Fig. 931.—Ileo-cæcal fossa. The cæcum and ascending colon have been drawn outwards and downwards, the ileum upwards and backwards, and the appendix downwards. (Poirier and Charpy.)

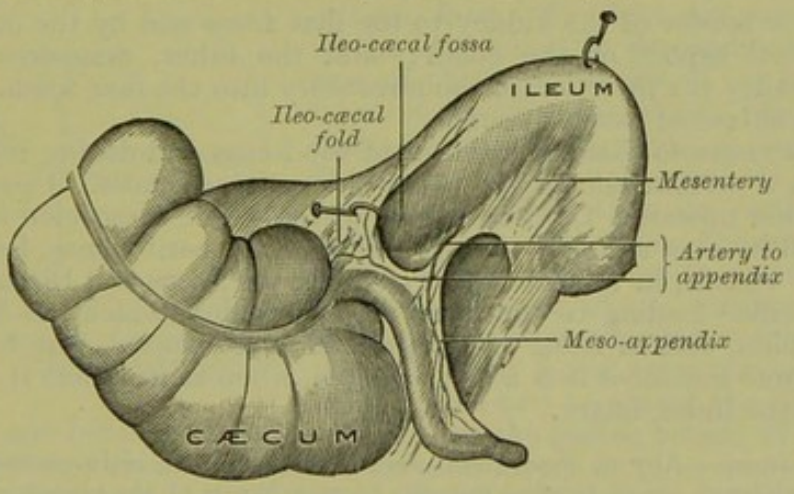

between the ileo-colic fold in front, and the mesentery of the small intestine, the ileum, and the small portion of the cæcum behind. (*b*) The *ileo-cæcal fossa* (inferior ileo-cæcal) is situated behind the angle of junction of the ileum and cæcum. It is formed by a fold of peritoneum (the ileo-cæcal fold or bloodless fold of Treves), the upper border of which is attached to the ileum, opposite its mesenteric attachment, while the lower border, passing over the ileo-cæcal junction, joins the mesentery of the appendix, and sometimes the appendix itself; hence this fold has been called the ileo-appendicular. Between this fold and the mesentery of the vermiform

appendix is the ileo-cæcal fossa. It is bounded above by the posterior surface of the ileum and the mesentery; in front and below by the ileo-cæcal fold, and behind by the upper part of the mesentery of the appendix. (c) The *subcæcal fossa* (retro-cæcal) is situated immediately behind the cæcum, which has to be raised to bring it into view. It varies much in size and extent. In some cases it is sufficiently large to admit the index finger, and extends upwards behind the ascending colon in the direction of the kidney: in others it is merely a shallow depression. It is bounded and formed by two folds: one, the *parieto-colic*, which is attached by one edge to the abdominal wall

Fig. 932.—The sub-cæcal fossa. The ileum and cæcum are drawn backwards and upwards. (Souligoux.)

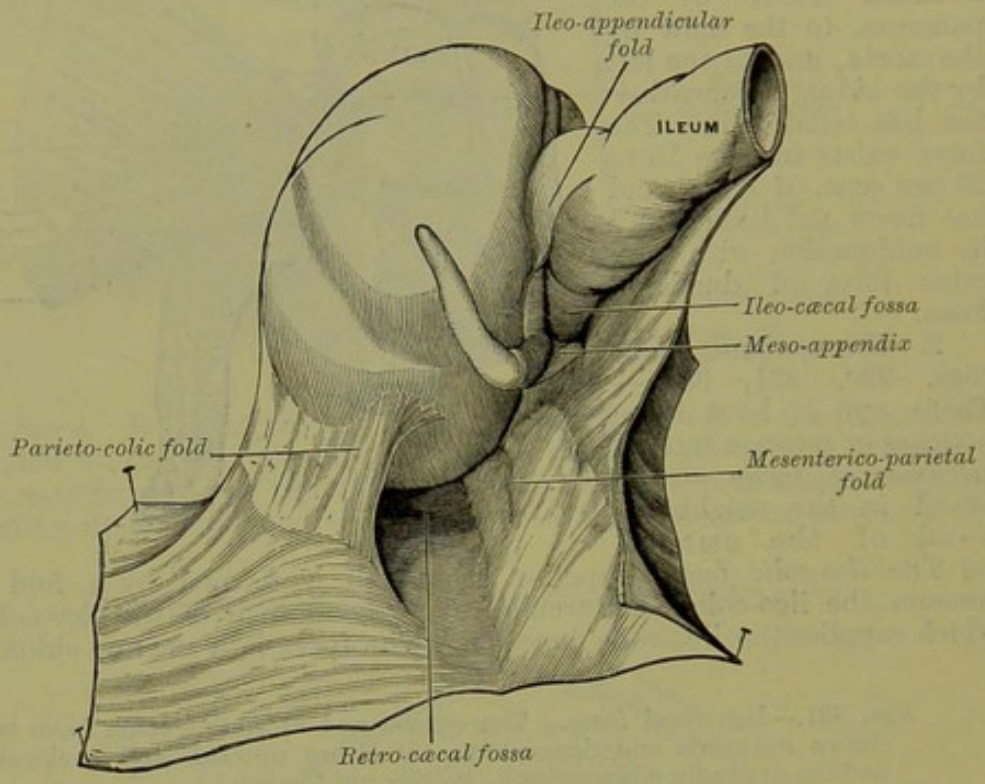

from the lower border of the kidney to the iliac fossa and by the other to the postero-external aspect of the colon; and the other, *mesenterico-parietal*, which is in reality the insertion of the mesentery into the iliac fossa. In some instances the subcæcal fossa is double.

3. The *intersigmoid fossa* is constant in the fœtus and during infancy, but disappears in a certain percentage of cases as age advances. Upon drawing the pelvic colon upwards, the left surface of the pelvic mesocolon is exposed, and on it will be seen a funnel-shaped recess of the peritoneum, lying on the external iliac vessels, in the interspace between the Psoas and Iliacus muscles. This is the orifice leading to the fossa intersigmoidea, which lies behind the pelvic mesocolon, and in front of the parietal peritoneum. The fossa varies in size; in some instances it is a mere dimple, whereas in others it will admit the whole of the index finger.

Applied Anatomy.—Any of these fossæ may be the site of a retro-peritoneal hernia. The circumcæcal fossæ are of especial interest, because hernia of the vermiform appendix frequently takes place into one of them, and it may there become strangulated. The presence of these pouches also explains the course which pus has been known to take in cases of perforation of the appendix, where it travels upwards behind the ascending colon as far as the Diaphragm.*

The Stomach

The **stomach** is the most dilated part of the alimentary canal, and is situated between the end of the œsophagus and the beginning of the small

* On the anatomy of these fossæ, see the *Arris and Gale Lectures* by Moynihan, 1899.

intestine. It lies more or less horizontally in the epigastric, umbilical, and left hypochondriac regions of the abdomen, and occupies a recess bounded by the upper abdominal viscera, and completed in front and on the left side by the anterior abdominal wall and the Diaphragm.

The *shape and position* of the stomach are so greatly modified by changes within itself and in the surrounding viscera that no one form can be described as typical. The chief modifications are determined by (1) the amount of the stomach contents, (2) the stage which the digestive process has reached, (3) the degree of development of the gastric musculature, and (4) the condition of the adjacent intestines. It is, however, possible by comparing a series of stomachs to determine certain markings more or less common to all.

Fig. 933.—Outline of stomach showing its anatomical landmarks.

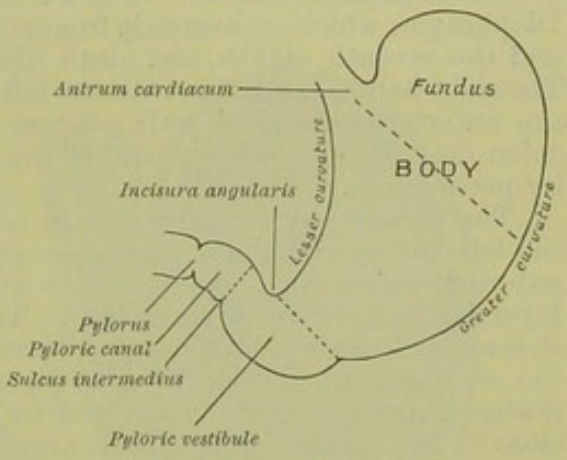

The stomach presents two openings, two borders or curvatures, and two surfaces.

Openings. — The opening by which the œsophagus communicates with the stomach is known as the *cardiac orifice*, and is situated on the left of the middle line at the level of the tenth thoracic vertebra. The short intra-abdominal portion of the œsophagus (*antrum cardiacum*) is conical in shape and curved sharply to the left, the base of the cone being continuous with the cardiac orifice of the stomach. The right margin of the œsophagus is continuous with the lesser curvature of the stomach, while the left margin joins the greater curvature at an acute angle, termed the *incisura cardiaca*.

The *pyloric orifice* communicates with the duodenum, and its position is usually indicated on the surface of the stomach by a circular groove, the *duodeno-pyloric constriction*. This orifice lies to the right of the middle line at the level of the upper border of the first lumbar vertebra.

Fig. 934. — Outline of stomach at an early stage of gastric digestion.

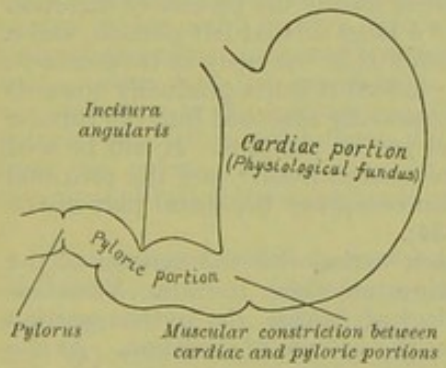

Curvatures. — The *lesser curvature*, extending between the cardiac and pyloric orifices, forms the right or posterior border of the stomach. It descends as a continuation of the right margin of the œsophagus in front of the left crus of the Diaphragm, and then, turning to the right, it crosses the first lumbar vertebra and ends at the pylorus. Nearer its pyloric than its cardiac end is a well-marked notch, the *incisura angularis*, which varies somewhat in position with the state of distension of the viscus ; it serves to separate the stomach into a right and a left portion. The lesser curvature gives attachment to the two layers of the gastro-hepatic omentum, and between these two layers are the gastric branch of the coronary artery and the pyloric branch of the hepatic artery.

The *greater curvature* is directed mainly forwards, and is four or five times as long as the lesser curvature. Starting from the cardiac orifice at the incisura cardiaca, it forms an arch backwards, upwards, and to the left ; the highest point of the convexity is on a level with the sixth left costal cartilage. From this level it may be followed downwards and forwards, with a slight convexity to the left as low as the cartilage of the ninth rib ; it then turns to the right, to end at the pylorus. Directly opposite the incisura angularis of the lesser curvature the greater curvature presents a dilatation, the *pyloric vestibule*, which is limited on the right by a slight groove, the *sulcus intermedius* ; this sulcus is about an inch from the duodeno-pyloric constriction.

The portion between the sulcus intermedius and the duodeno-pyloric constriction is termed the *pyloric canal*. At its commencement the greater curvature is covered by peritoneum continuous with that covering the front of the organ. The left part of the curvature gives attachment to the gastro-splenic omentum, while to its anterior portion are attached the two layers of the great omentum, separated from each other by the gastro-epiploic vessels.

Surfaces.—When the stomach is in the contracted condition, its surfaces are directed upwards and downwards respectively, but when the viscus is distended they are directed forwards and backwards. They may therefore be described as antero-superior and postero-inferior.

Antero-superior surface.—The left half of this surface is in contact with the Diaphragm, which separates it from the base of the left lung, the pericardium, and the seventh, eighth, and ninth ribs and intercostal spaces of the left side. The right half is in relation with the left and quadrate lobes of the liver and with the anterior abdominal wall. When the stomach is empty, the transverse colon may lie on the front part of this surface. The whole surface is covered by peritoneum.

The *postero-inferior surface* is in relation with the Diaphragm, the spleen, the left suprarenal gland, the upper part of the front of the left kidney, the anterior surface of the pancreas, the splenic flexure of the colon, and the upper layer of the transverse mesocolon. These structures form a shallow bed, the *stomach bed*, on which the viscus rests. The transverse mesocolon separates the stomach from the duodeno-jejunal flexure and small intestine. The postero-inferior surface is covered by peritoneum, except over a small area close to the cardiac orifice ; this area is limited by the lines of attachment of the *gastro-phrenic ligament*, and lies in apposition with the Diaphragm, and frequently the upper portion of the left suprarenal gland.

Component parts of the stomach.—The stomach is capable of subdivision into distinctive parts, and the divisions may be made on either anatomical or physiological grounds.

Anatomical subdivisions.—A plane passing through the incisura angularis on the lesser curvature and the left limit of the opposed dilatation (pyloric vestibule) on the greater curvature divides the stomach into a left portion or *body* and a right or *pyloric* portion. The left portion of the body is known as the *fundus*, and is marked off from the remainder of the body by a plane passing through the cardiac orifice and a point on the greater curvature directly opposite. The pyloric portion is divided into a right part, the *pyloric canal*, and a left, the *pyloric vestibule*, by a plane through the sulcus intermedius at right angles to the long axis of this portion (fig. 933).

Physiological subdivisions.—If the stomach be examined during the process of digestion it will be found divided by a muscular constriction into a large dilated left portion, and a narrow contracted tubular right portion. The constriction is in the body of the stomach, and does not follow any of the anatomical landmarks; indeed it shifts gradually towards the left as digestion progresses, i.e. more of the body is gradually absorbed into the tubular part. These two portions are known as the *fundus* and *pyloric* portions. It will be seen therefore that the physiological fundus includes the anatomical fundus and the proximal part of the body, while the physiological pyloric portion comprises the distal part of the body, the pyloric vestibule and the pyloric canal (fig. 934).

Position of the stomach.—The position of the stomach varies with the amount of the stomach contents and with the condition of the intestines on which it rests. Variation in the amount of its contents affects only the physiological fundus, the pyloric portion remaining in a more or less contracted condition during the process of digestion. As the stomach fills it tends to expand forwards and downwards in the direction of least resistance, but when this is interfered with by a distended condition of the colon or intestines the fundus presses upwards on the liver and Diaphragm and gives rise to the feelings of oppression and palpitation complained of in such cases. His * and Cunningham † have shown by hardening the viscera *in situ* that the contracted stomach has a sickle shape, the fundus looking directly backwards. The surfaces are directed upwards and downwards, the upper surface having, however, a gradual downward slope to the right. The greater curvature is in front and at a slightly higher level than the lesser.

The position of the full stomach depends, as already indicated, on the state of the intestines ; when these are empty the fundus expands vertically and also forwards, the pylorus is displaced towards the right, and the whole organ assumes an oblique position, so that

* *Archiv für Anatomie und Physiologie, anat. Abth.*, 1903.
† *Transactions of the Royal Society of Edinburgh*, vol. xlv. part i.

its surfaces are directed more forwards and backwards. The lowest part of the stomach is at the pyloric vestibule, which reaches to the region of the umbilicus. Where the intestines interfere with the downward expansion of the fundus the stomach retains the horizontal position which is characteristic of the contracted viscus.

Examination of the stomach during life by *x*-rays has confirmed these findings, and has demonstrated that, in the erect posture, the full stomach usually presents a hook-like appearance, the long axis of the physiological fundus being directed downwards, inwards, and forwards towards the umbilicus, while the pyloric portion curves upwards to the duodeno-pyloric junction.

Interior of the stomach.—When examined after death, the stomach is usually fixed at some temporary stage of the digestive process. A common form is that shown in fig. 935. If the viscus be laid open by a section through the plane of its two curvatures, it is seen to

Fig. 935.—Interior of the stomach.

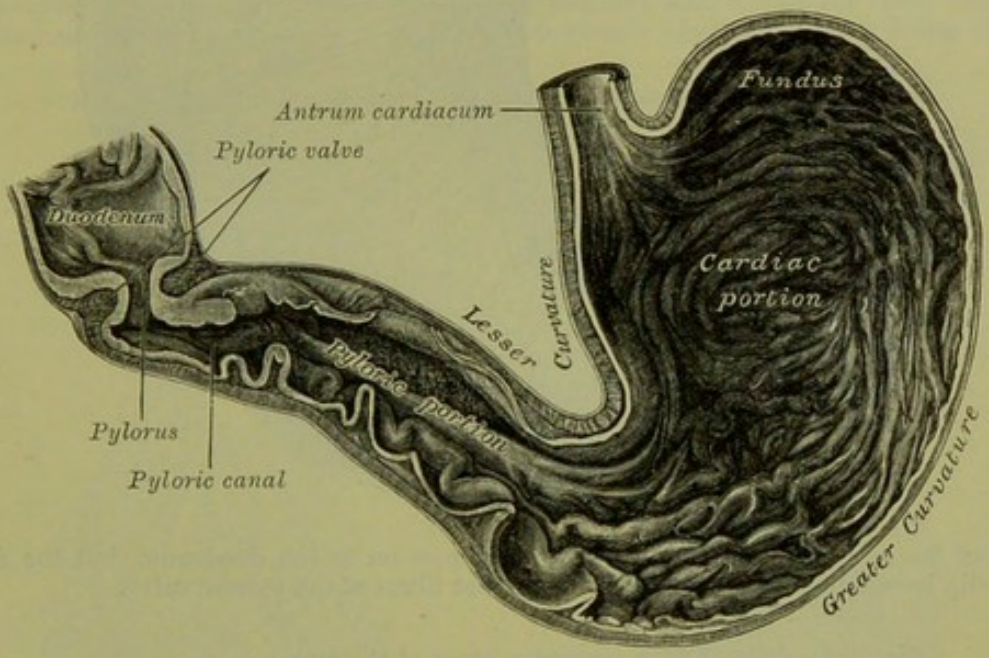

consist of two segments : (*a*) a large globular portion on the left and (*b*) a narrow tubular part on the right. These correspond to the physiological subdivisions of fundus and pyloric portions already described, and are separated by a constriction which indents the body and greater curvature, but does not involve the lesser curvature. To the left of the cardiac orifice is the incisura cardiaca : the projection of this notch into the cavity of the stomach increases as the organ distends, and has been supposed to act as a valve preventing regurgitation into the œsophagus. In the pyloric portion are seen : (*a*) the elevation corresponding to the incisura angularis, and (*b*) the circular projection from the duodeno-pyloric constriction which forms the pyloric valve. The separation of the pyloric vestibule from the pyloric canal is scarcely indicated, but the manner in which the pylorus is invaginated into the duodenum is evident.

The *pyloric valve* is formed by a reduplication of the mucous membrane of the stomach, containing numerous circular muscular fibres, which are aggregated into a thick ring. Some of the deeper longitudinal fibres turn in and interlace with the circular fibres of the valve.

Structure.—The wall of the stomach consists of four coats : serous, muscular, areolar, and mucous, together with vessels and nerves.

The *serous coat* is derived from the peritoneum, and covers the entire surface of the organ, excepting along the greater and lesser curvatures, at the points of attachment of the greater and lesser omenta ; here the two layers of peritoneum leave a small triangular space, along which the nutrient vessels and nerves pass. On the posterior surface of the stomach, close to the cardiac orifice, there is also a small area uncovered by peritoneum, where the organ is in contact with the under surface of the Diaphragm.

The *muscular coat* (figs. 936, 937) is situated immediately beneath the serous covering, to which it is closely connected. It consists of three sets of fibres : longitudinal, circular, and oblique.

The *longitudinal fibres* are the most superficial, and are arranged in two sets. The first set consists of fibres continuous with the longitudinal fibres of the œsophagus ; they radiate in a stellate manner from the cardiac orifice and are practically all lost before the pyloric

portion is reached. The second set commences on the body of the stomach and passes to the right, its fibres becoming more thickly distributed as they approach the pylorus.

Fig. 936.—The longitudinal and circular muscular fibres of the stomach, viewed from above and in front. (Spalteholz.)

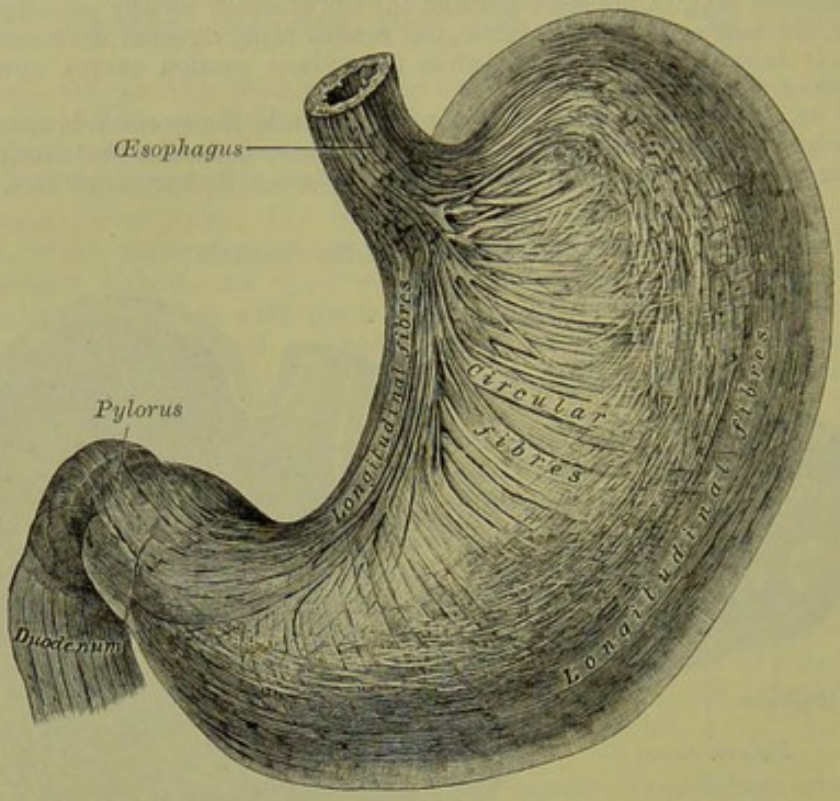

Some of the more superficial fibres of this set pass on to the duodenum, but the deeper fibres dip inwards and interlace with the circular fibres of the pyloric valve.

Fig. 937.—The oblique muscular fibres of the stomach, viewed from above and in front. (Spalteholz.)

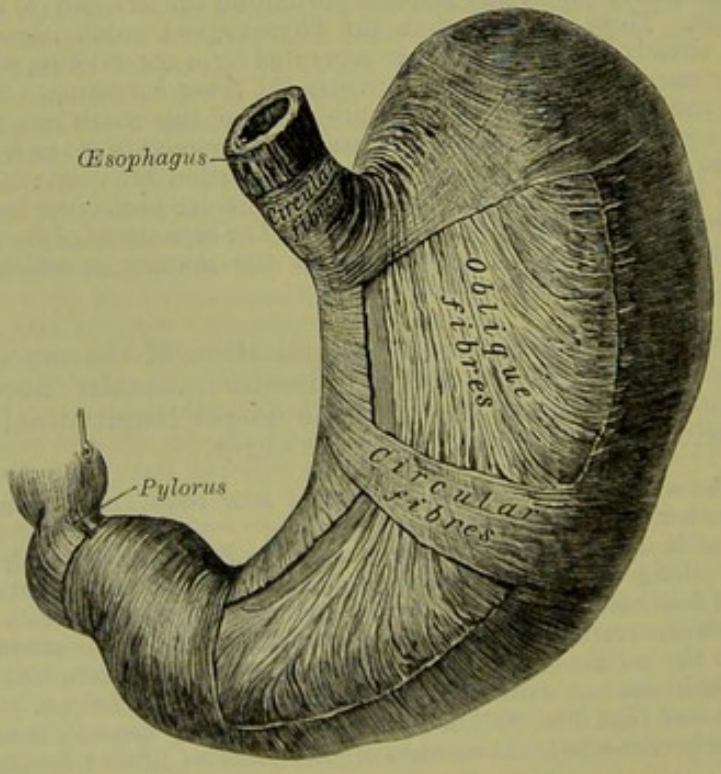

The *circular fibres* form a uniform layer over the whole extent of the stomach beneath the longitudinal fibres. At the pylorus they are most abundant, and are aggregated into a circular ring, which projects into the lumen, and forms, with the fold of mucous membrane

covering its surface, the *pyloric valve*. They are continuous with the circular fibres of the œsophagus, but are sharply marked off from the circular fibres of the duodenum.

The *oblique fibres* are limited chiefly to the cardiac end of the stomach, where they are disposed as a thick uniform layer, covering both surfaces, some passing obliquely from left to right, others from right to left, round the cardiac end.

The *areolar* or *submucous coat* consists of a loose, areolar tissue, connecting the mucous and muscular layers.

The *mucous membrane* is thick and its surface is smooth, soft, and velvety. In the fresh state it is of a pinkish tinge at the pyloric end, and of a red or reddish-brown colour over the rest of its surface. In infancy it is of a brighter hue, the vascular redness being more marked. It is thin at the cardiac extremity, but thicker towards the pylorus. During the contracted state of the organ it is thrown into numerous plaits or rugæ, which, for the most part, have a longitudinal direction, and are most marked towards the lesser end of the stomach, and along the greater curvature (fig. 935). These folds are entirely obliterated when the organ becomes distended.

Structure of the Mucous Membrane.—When examined with a lens, the inner surface of the mucous membrane presents a peculiar honeycomb appearance from being covered

FIG. 938.—Pyloric gland.

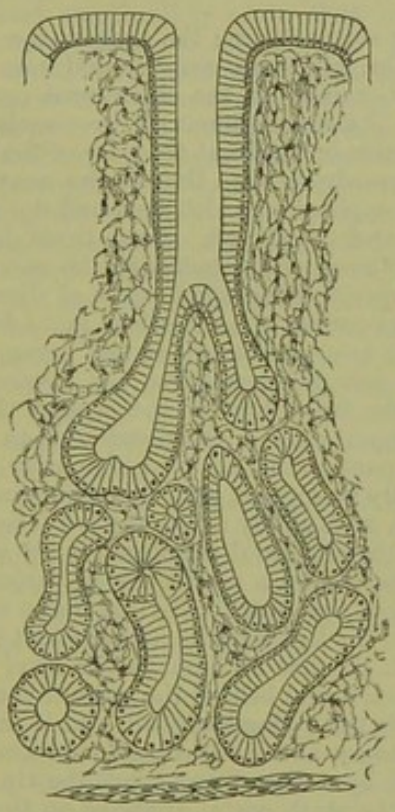

FIG. 939.—Cardiac gland.

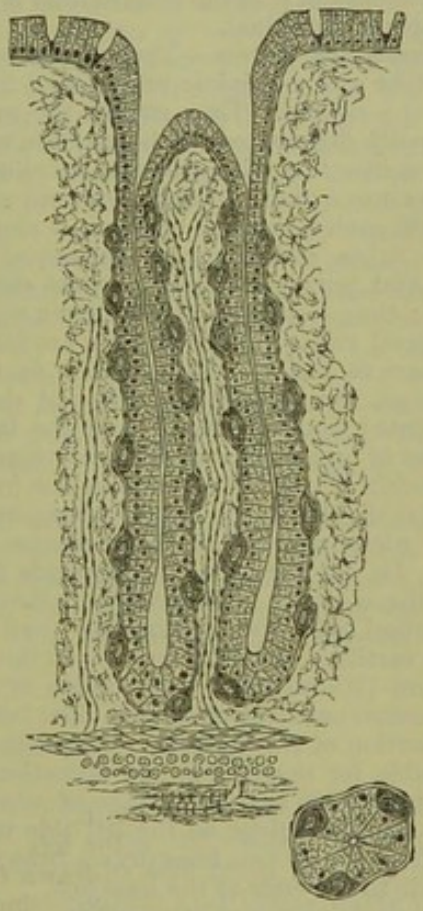

with small shallow depressions or alveoli, of a polygonal or hexagonal form, which vary from $\frac{1}{100}$ to $\frac{2}{100}$ of an inch in diameter, and are separated by slightly elevated ridges. In the bottom of the alveoli are seen the orifices of minute tubes, the *gastric glands*, which are situated perpendicularly side by side throughout the entire substance of the mucous membrane. The surface of the mucous membrane of the stomach is covered by a single layer of columnar epithelium ; it lines the alveoli, and also for a certain distance the mouths of the gastric glands. This epithelium commences very abruptly at the cardiac orifice, where the cells suddenly change in character from the stratified epithelium of the œsophagus.

The gastric glands are of two kinds, (*a*) *pyloric* and (*b*) *cardiac* or *oxyntic glands*. They are both tubular in character, and are formed of a delicate basement-membrane, lined by epithelium ; the basement-membrane consists of flattened transparent endothelial cells. The *pyloric glands* (fig. 938) are most numerous at the pyloric end of the stomach, and from this fact have received their name. They consist of two or three short closed tubes opening into a common duct or mouth, the external orifice of which is situated at the bottom of an alveolus. These tubes are wavy, and are about equal in length to the duct. The tubes and duct are lined throughout with epithelium, the duct being lined by columnar cells, continuous with the epithelium lining the surface of the mucous

membrane of the stomach, the tubes with shorter and more cubical cells which are finely granular. The *cardiac glands* (fig. 939) are found all over the surface of the stomach, but occur most numerously at the cardiac end. Like the pyloric glands they consist of a duct, into which open two or more closed tubes. The duct, however, in these glands is shorter than in the other variety, sometimes not amounting to more than one-sixth of the whole length of the gland; it is lined throughout by columnar epithelium. At the point where the terminal tubes open into the duct, and which is termed the neck, the epithelium alters, and consists of short columnar or polyhedral, granular cells, which almost fill the tube, so that the lumen becomes suddenly constricted, and is continued down as a very fine channel. They are known as the *chief* or *central* cells of the glands. Between these cells and the basement-membrane, larger oval cells, which stain deeply with eosin, are found; these cells are studded throughout the tube at intervals, giving it a beaded or varicose appearance. These are known as the *parietal* or *oxyntic* cells. Between the glands the mucous membrane consists of a connective-tissue framework, with lymphoid tissue. In places, this latter tissue, especially in early life, is collected into little masses, which to a certain extent resemble the solitary glands of the intestine, and are termed the *lenticular* glands of the stomach. They are not, however, so distinctly circumscribed as the solitary glands. Beneath the mucous membrane, and between it and the submucous coat, is a thin stratum of involuntary muscular fibre (*muscularis mucosæ*), which in some parts consists only of a single longitudinal layer; in others of two layers, an inner circular, and an outer longitudinal.

Vessels and Nerves.—The arteries supplying the stomach are: the gastric, the pyloric and right gastro-epiploic branches of the hepatic, the left gastro-epiploic and vasa brevia from the splenic. They supply the muscular coat, ramify in the submucous coat, and are finally distributed to the mucous membrane. The arrangement of the vessels in the mucous membrane is somewhat peculiar. The arteries break up at the base of the gastric tubules into a plexus of fine capillaries which run upwards between the tubules, anastomosing with each other, and ending in a plexus of larger capillaries, which surround the mouths of the tubes, and also form hexagonal meshes around the alveoli. From these the *veins* arise, and pursue a straight course downwards, between the tubules, to the submucous tissue; they terminate either in the splenic and superior mesenteric veins, or directly in the portal vein. The *lymphatics* are numerous: they consist of a superficial and a deep set, and pass to the lymphatic glands found along the two curvatures of the organ. The *nerves* are the terminal branches of the right and left pneumogastric, the former being distributed upon the back, and the latter upon the front part of the organ. A great number of branches from the solar plexus of the sympathetic are also distributed to it.

Surface Form.—The stomach lies for the most part in the left hypochondriac region, but also slightly in the epigastric region, and is partly in contact with the abdominal wall, partly under cover of the lower ribs on the left side, and partly under the left lobe of the liver. Its cardiac orifice corresponds to the seventh left costal cartilage, about an inch from the sternum. The pyloric orifice would be pierced by a needle passed through the abdominal wall, five centimetres (two inches) below the junction of the right seventh costal cartilage with the sternum, to the disc between the last thoracic and the first lumbar vertebra (Macalister). The fundus of the stomach reaches as high as the level of the sixth costal cartilage of the left side, being a little below and behind the apex of the heart. The portion of the stomach which is in contact with the abdominal wall, and is therefore accessible for opening in the operations of gastrotomy and gastrostomy, is represented by a triangular space, the base of which is formed by a line drawn from the tip of the tenth costal cartilage on the left side to the tip of the ninth costal cartilage on the right, and the sides by two lines drawn from the extremity of the eighth costal cartilage on the left side to the ends of the base line.

Applied Anatomy.—Operations on the stomach are frequently performed. By 'gastrotomy' is meant an incision into the stomach for the removal of a foreign body, the opening being immediately afterwards closed—in contradistinction to 'gastrostomy' the making of a more or less permanent fistulous opening. *Gastrotomy* is probably best performed by an incision in the linea alba, especially if the foreign body be large, by a cut from the ensiform cartilage to the umbilicus; but may be performed by an incision over the foreign body itself, where this can be felt, or by one of the incisions for gastrostomy mentioned below. The peritoneal cavity is opened, and the point at which the stomach is to be incised decided upon. This portion is then brought out of the abdominal wound, and sponges are carefully packed round it. The stomach is now opened by a transverse incision and the foreign body extracted. The wound in the stomach is then closed by Lembert's sutures, i.e. by sutures passed through the peritoneal and muscular coats in such a way that the peritoneal surfaces on each side of the wound are brought into apposition. In *gastrostomy* the incision is commenced opposite the eighth left intercostal space, two inches from the median line, and carried downwards for three inches. By this incision the fibres of the Rectus muscle are exposed, and these are separated in the same line. The posterior layer of the sheath, the Transversalis muscle and fascia, and the peritoneum are then divided, and the peritoneal cavity opened. The anterior wall of the stomach is now seized and drawn out of the wound, and a silk suture passed through its muscular and serous coats at the point selected for opening the viscus. This is held by an assistant so that a

long conical diverticulum of the stomach protrudes from the external wound, and the parietal peritoneum and the posterior layer of the sheath of the Rectus are sutured to it. A second incision is made through the skin, over the margin of the costal cartilage, above and a little to the outer side of the first incision. A track is made under the skin through the subcutaneous tissue from the one opening to the other, and the diverticulum of the stomach is drawn along this track by means of the suture inserted into it, so that its apex appears at the second opening. A small perforation is now made into the stomach through this protruding apex, and its margins are carefully and accurately sutured to the edge of the external wound. The remainder of this incision and the whole of the first incision are then closed in the ordinary way and the wound dressed.

In cases of gastric ulcer perforation sometimes takes place, and this was formerly regarded as an almost fatal complication. In the present day, by opening the abdomen and closing the perforation, which is generally situated on the anterior surface of the stomach, a considerable number of cases are cured, provided the operation is done not longer than twelve or fifteen hours after the perforation has taken place. The opening is best closed by bringing the peritoneal surfaces on either side into apposition by means of Lembert's sutures.

Excision of the pylorus has occasionally been performed, but the results of this operation are by no means favourable, and, in cases of cancer of the pylorus, before operative proceedings are undertaken, the tumour has become so fixed and has so far implicated surrounding parts that removal of the pylorus is impossible and gastro-enterostomy has to be substituted. The object of this operation is to make a fistulous communication between the stomach, on the cardiac side of the disease, and the small intestine, as high up as is possible. In cases of cancer of the stomach involving other parts than the pylorus, the question of removing the whole or greater part of the stomach has to be considered. This operation has been performed by Schlatter and others with success.

Hypertrophy and spasm of the circumferential muscular coat of the pylorus coming on during the first few weeks or months of life, and somewhat erroneously described as *congenital hypertrophic stenosis of the pylorus*, is a rare but serious disorder of infancy. It is characterised by abdominal pains and obstinate vomiting coming on after food has been given, and gastric peristalsis can be observed by inspection of the child's epigastrium after it has been fed and before vomiting has occurred. Progressive wasting for want of nourishment, and death from exhaustion, tend to ensue. Treatment should be by washing out the stomach, and the administration at frequent intervals of small quantities of easily digested food, so as to minimise irritation of the gastric mucous membrane. Surgical interference — pyloroplasty or pylorectomy — entailing a severe operation, gives less favourable results.

The stomach is seldom ruptured from external violence, on account of its protected position. If it occurs, it is when the organ is distended with food. The stomach is sometimes injured in gunshot wounds. There is intense shock and severe pain, localised at first at the seat of the injury, but soon radiating over the whole abdomen. The treatment consists in opening the peritoneal cavity, clearing away all the extruded contents of the stomach, and repairing the rent.

The Small Intestine (Intestinum tenue)

The **small intestine** is a convoluted tube, extending from the pylorus to the ileo-cæcal valve, where it terminates in the large intestine. It is about twenty feet in length,* and gradually diminishes in size from its commencement to its termination. It is contained in the central and lower parts of the abdominal cavity, and is surrounded above and at the sides by the large intestine; a portion of it extends below the brim of the pelvis and lies in front of the rectum. It is in relation, in front, with the great omentum and abdominal parietes, and is connected to the vertebral column by a fold of peritoneum, the mesentery. The small intestine is divisible into three portions: the duodenum, the jejunum, and ileum.

The **duodenum** (figs. 940, 970) has received its name from being about equal in length to the breadth of twelve fingers (ten inches). It is the shortest, the widest, and the most fixed part of the small intestine, and has no mesentery, being only partially covered by peritoneum. Its course presents a remarkable curve, somewhat of the shape of an imperfect circle, so that its termination is not far removed from its starting-point.

* Treves states that, in one hundred cases, the average length of the small intestine in the adult male was 22 feet 6 inches, and in the adult female 23 feet 4 inches; but that it varies very much, the extremes in the male being 31 feet 10 inches in one case, and 15 feet 6 inches in another, a difference of over 15 feet. He states that he has convinced himself that the length of the bowel is independent, in the adult, of age, height, and weight.

In the adult the course of the duodenum is as follows: commencing at the pylorus it passes backwards, upwards, and to the right, beneath the quadrate lobe of the liver to the neck of the gall-bladder, varying slightly in direction

FIG. 940.—Relations of duodenum, pancreas, and spleen.
(From a cast by Birmingham.*)

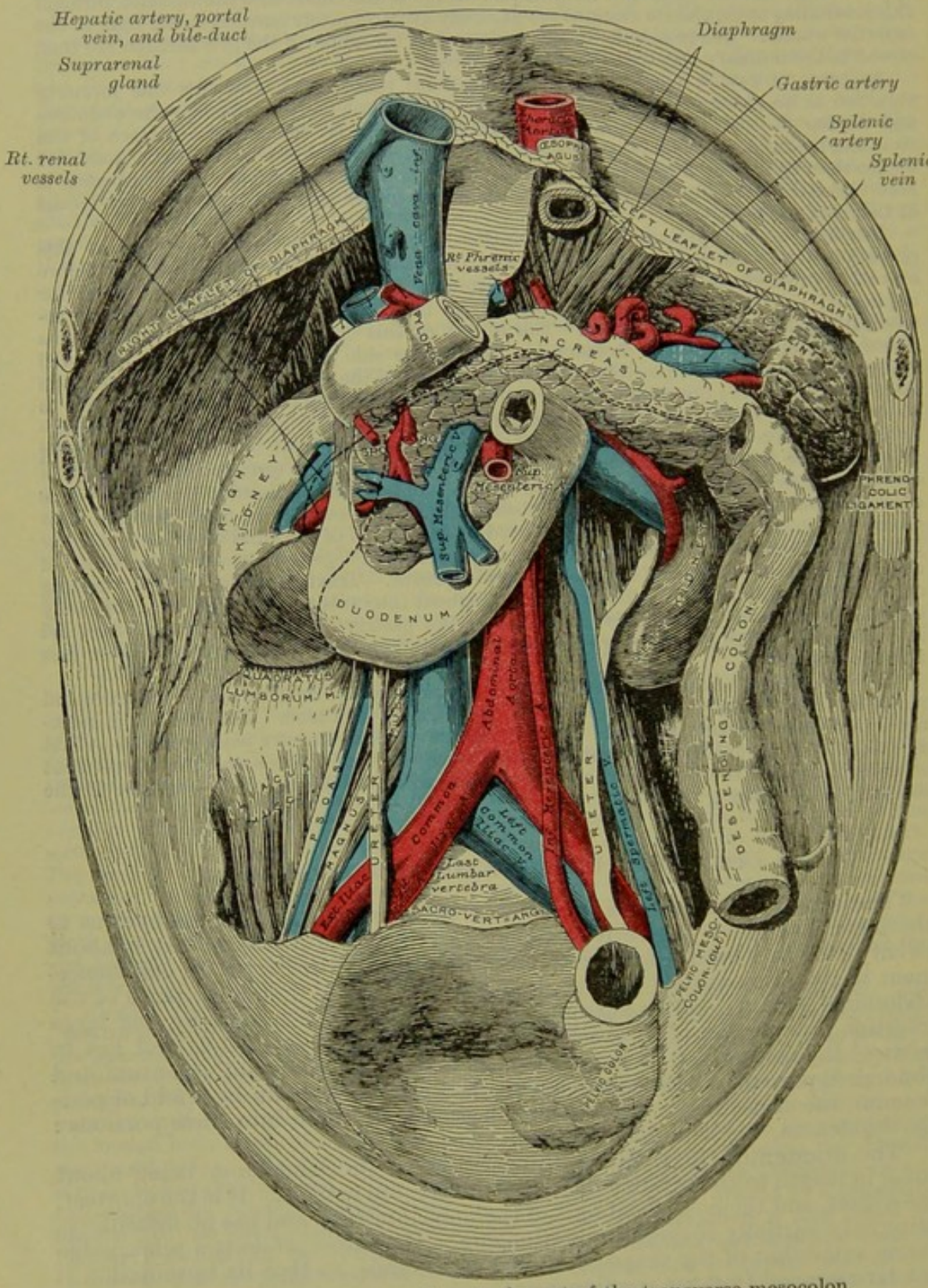

The dotted lines represent the attachment of the transverse mesocolon.

according to the degree of distension of the stomach: it then takes a sharp curve and descends along the right margin of the head of the pancreas, for a variable distance, generally to the level of the upper border of the body of the

* In the subject from which the cast was taken the left kidney was lower than normal.

fourth lumbar vertebra. It now takes a second bend, and passes from right to left across the vertebral column, having a slight inclination upwards ; and on the left side of the vertebral column it ascends for about an inch, and then terminates opposite the second lumbar vertebra in the jejunum. As it unites with the jejunum it turns abruptly forwards, forming the *duodeno-jejunal flexure*. From the above description it will be seen that the duodenum may be divided into four portions : superior, descending, transverse, and ascending.

Relations.—The first or *superior portion* is about two inches in length. Beginning at the pylorus, it ends at the neck of the gall-bladder. It is the most movable of the four portions. It is almost completely covered by peritoneum derived from the two layers of the lesser omentum, but a small part of its posterior surface near the neck of the gall-bladder and the inferior vena cava is uncovered. It is in such close relation with the gall-bladder that it is usually found to be stained by bile after death, especially on its anterior surface. It is in relation above and in front with the quadrate lobe of the liver and the gall-bladder ; behind with the gastro-duodenal artery, the

FIG. 941.—Interior of a portion of the duodenum, showing bile papilla.

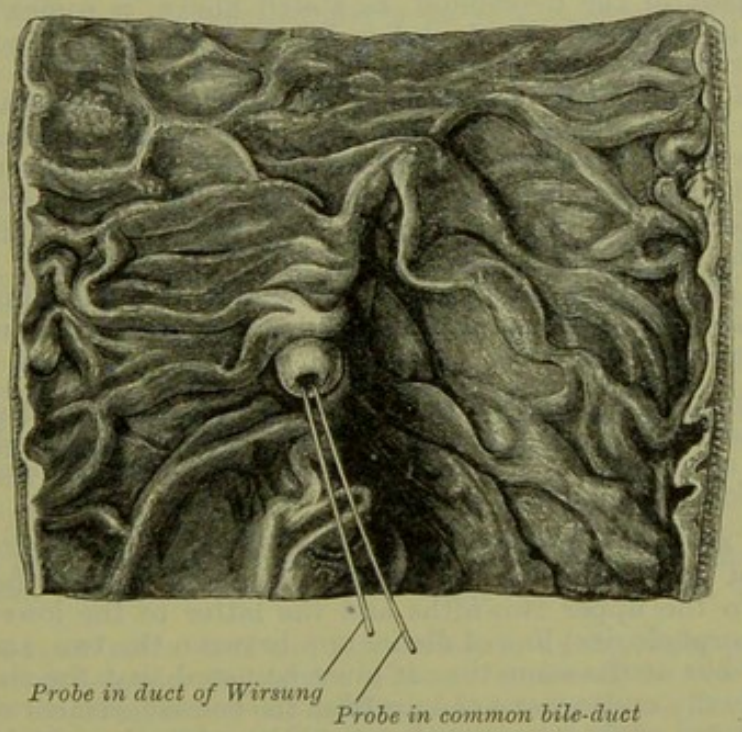

common bile-duct, and the portal vein ; and below with the head and neck of the pancreas.

The second or *descending portion* is between three and four inches in length, and extends from the neck of the gall-bladder on a level with the first lumbar vertebra along the right side of the vertebral column as low as the upper border of the body of the fourth lumbar vertebra. It is crossed in its middle third by the transverse colon, the posterior surface of which is uncovered by peritoneum and is connected to the duodenum by a small quantity of connective tissue. The portions of the descending part of the duodenum above and below this interspace are named the supra- and infra-colic portions, and are covered in front by peritoneum ; the infra-colic part is covered by the right leaf of the mesentery. Posteriorly the descending portion of the duodenum is not covered by peritoneum. It is in relation, in front, with the transverse colon, and above this with the liver ; behind, with the inner part of the right kidney to which it is connected by loose areolar tissue, the renal vessels, the vena cava inferior, and the Psoas magnus below ; at its inner side is the head of the pancreas, and the common bile-duct ; to its outer side is the hepatic flexure of the colon. The common bile-duct and the pancreatic duct perforate the inner side of this portion of the intestine obliquely, some three or four inches below the pylorus (fig. 941). The relations of the second part of the duodenum to the right kidney present considerable variations.

The third or *transverse portion* (pre-aortic portion) is from two to three inches in length. It commences at the right side of the upper border of the fourth lumbar vertebra and passes from right to left, with a slight inclination upwards, in front of the great vessels and crura of the Diaphragm, and ends in the fourth portion in front of the abdominal aorta. It is crossed by the superior mesenteric vessels and the mesentery. Its front surface is covered by peritoneum, except near the middle line, where it is crossed by the superior mesenteric vessels. Its posterior surface is uncovered by peritoneum, except towards its left extremity, where the posterior layer of the mesentery may sometimes be found covering it to a variable extent. This surface rests upon the right crus of the Diaphragm, the vena cava inferior, and the aorta. The upper surface is in relation with the head of the pancreas.

The fourth or *ascending portion* of the duodenum is about an inch in length. It ascends on the left side of the aorta, as far as the level of the upper border of the second lumbar vertebra, where it turns abruptly forwards to become the jejunum, forming the *duodeno-jejunal flexure*. It lies in front of the left Psoas muscle and left renal vessels, and is covered in front, and partly at the sides, by peritoneum continuous with the left portion of the mesentery.

The first part of the duodenum, as stated above, is somewhat movable, but the rest is practically fixed, and is bound down to neighbouring viscera and the posterior abdominal wall by the peritoneum. In addition to this, the fourth part of the duodenum and the duodeno-jejunal flexure are fixed by a structure to which the name of *musculus suspensorius duodeni* has been given. This structure commences in the connective tissue around the cœliac axis and left crus of the Diaphragm, and passes downwards to be inserted into the superior border of the duodeno-jejunal curve and a part of the ascending duodenum, and from this it is continued into the mesentery. It possesses, according to Treitz, plain muscular fibres mixed with the fibrous tissue of which it is principally made up. It is of little importance as a muscle, but acts as a suspensory ligament.

Vessels and Nerves.—The *arteries* supplying the duodenum are the pyloric and superior pancreatico-duodenal branches of the hepatic, and the inferior pancreatico-duodenal branch of the superior mesenteric. The *veins* terminate in the splenic and superior mesenteric. The *nerves* are derived from the solar plexus.

Jejunum and ileum.—The remainder of the small intestine from the termination of the duodenum is named *jejunum* and *ileum*; the former term being given to the upper two-fifths and the latter to the lower three-fifths. There is no morphological line of distinction between the two, and the division is arbitrary; but at the same time it must be noted that the character of the intestine gradually undergoes a change from the commencement of the jejunum to the termination of the ileum, so that a portion of the bowel taken from these two situations would present characteristic and marked differences. These are briefly as follows.

The *jejunum* (intestinum jejunum) is wider, its diameter being about an inch and a half, and is thicker, more vascular, and of a deeper colour than the ileum, so that a given length weighs more. Its valvulæ conniventes are large and thickly set, and its villi are larger than in the ileum. The glands of Peyer are almost absent in the upper part of the jejunum, and in the lower part are less frequently found than in the ileum, and are smaller and tend to assume a circular form. By grasping the jejunum between the finger and thumb the valvulæ conniventes can be felt through the walls of the gut; these being absent in the lower part of the ileum, it is possible in this way to distinguish the upper from the lower part of the small intestine.

The *ileum* (intestinum ileum) is narrow, its diameter being an inch and a quarter, and its coats thinner and less vascular than those of the jejunum. It possesses but few valvulæ conniventes, and they are small and disappear entirely towards its lower end, but Peyer's patches are larger and more numerous. The jejunum for the most part occupies the umbilical and left iliac regions, while the ileum occupies chiefly the umbilical, hypogastric, right iliac, and pelvic regions. Its terminal part usually lies in the pelvis, from which it ascends over the right iliac vessels and Psoas muscle; it ends in the right iliac fossa by opening into the inner side of the commencement of the

large intestine. The jejunum and ileum are attached to the posterior abdominal wall by an extensive fold of peritoneum, the *mesentery*, which allows the freest motion, so that each coil can accommodate itself to changes in form and position. The mesentery is fan-shaped; its posterior border or root, about six inches in length, is attached to the posterior abdominal wall from the left side of the body of the second lumbar vertebra to the right iliac fossa, crossing successively the third part of the duodenum, the aorta, the inferior vena cava, the ureter, and right Psoas muscle (fig. 927). Its breadth between its vertebral and intestinal borders is about eight inches, and is greater in the middle than at its upper and lower extremities. According to Lockwood it tends to increase in breadth as age advances. Between the two layers of which it is composed are contained blood-vessels, nerves, lacteals, and lymphatic glands, together with a variable amount of fat.

Meckel's diverticulum.—This consists of a pouch which projects from the lower part of the ileum in about 2 per cent. of subjects. Its average position is about three feet above the ileo-cæcal valve, and its average length about two inches. Its calibre is generally similar to that of the ileum, and its blind extremity may be free or may be connected with the abdominal wall or with some other portion of the intestine by a fibrous band. It represents the remains of the proximal part of the vitelline or omphalo-mesenteric duct, the duct of communication between the yolk sac and the alimentary canal in early fœtal life.

Structure.—The wall of the small intestine is composed of four coats: serous, muscular, areolar, and mucous.

The *serous coat* is derived from the peritoneum. The first or ascending portion of the duodenum is almost completely surrounded by this membrane near its pyloric end, but is only covered in front at the other extremity; the second or descending portion is covered by it in front, except where it is carried off by the transverse colon; and the third or transverse portion lies behind the peritoneum, which passes over it, without being closely incorporated with the other coats of this part of the intestine, and is separated from it in and near the middle line by the superior mesenteric vessels. The remaining portion of the small intestine is surrounded by the peritoneum, excepting along its attached or mesenteric border; here a space is left for the vessels and nerves to pass to the gut.

The *muscular coat* consists of two layers of fibres, an external, longitudinal, and an internal, circular layer. The *longitudinal fibres* are thinly scattered over the surface of the intestine, and are more distinct along its free border. The *circular fibres* form a thick, uniform layer, and are composed of plain muscle-cells of considerable length. The muscular coat is thicker at the upper than at the lower part of the small intestine.

The *areolar* or *submucous coat* connects together the mucous and muscular layers. It consists of loose, filamentous areolar tissue containing blood-vessels, lymphatics, and nerves.

The *mucous membrane* is thick and highly vascular at the upper part of the small intestine, but somewhat paler and thinner below. It consists of the following structures: next the areolar or submucous coat is a layer of longitudinal unstriped muscular fibres, the *muscularis mucosæ*; internal to this is a quantity of retiform tissue, enclosing in its meshes lymph-corpuscles, and in which the blood-vessels and nerves ramify; lastly, a basement-membrane, supporting a single layer of epithelial cells, which throughout the intestines are columnar in character. The cells are granular in appearance, and each possesses a clear oval nucleus. At their superficial or unattached ends they present a distinct layer of highly refracting material, marked by vertical striæ (the *striated border*).

The mucous membrane presents for examination the following structures, contained within it or belonging to it:

Valvulæ conniventes.	Glands	Duodenal glands.
Villi.		Solitary glands.
Simple follicles.		Peyer's or agminated glands.

The **valvulæ conniventes** or valves of Kerkring (plicæ circulares) are large folds or valvular flaps projecting into the lumen of the bowel. They are composed of reduplications or folds of the mucous membrane, the two layers of the fold being bound together by submucous tissue; unlike the folds in the stomach, they are permanent, and are not obliterated when the intestine is distended. The majority extend transversely across the cylinder of the intestine for about one-half or two-thirds of its circumference, but some form complete circles, and others have a spiral direction; the latter usually extend a little more than once round the bowel, but occasionally two or three times. The larger folds are about one-third of an inch in depth at their broadest part; but the greater number are of smaller size. The larger and smaller folds alternate with each other. They are not found at the commencement of the duodenum, but begin to appear about one or two inches beyond the pylorus. In the lower part of the descending portion, below the point where the bile and pancreatic

ducts enter the intestine, they are very large and closely approximated. In the transverse portion of the duodenum and upper half of the jejunum they are large and numerous, but from this point, down to the middle of the ileum, they diminish considerably in size. In the lower part of the ileum they almost entirely disappear; hence the comparative thinness of this portion of the intestine, as compared with the duodenum and jejunum. The valvulæ conniventes retard the passage of the food along the intestines, and afford an increased surface for absorption.

The villi (villi intestinales) are highly vascular processes, projecting from the mucous membrane of the small intestine throughout its whole extent, and giving to its surface a velvety appearance. They are largest and most numerous in the duodenum and jejunum, and become fewer and smaller in the ileum.

Structure of the villi (figs. 942, 943).—The essential parts of a villus are: the lacteal vessel, the blood-vessels, the epithelium, the basement-membrane, and muscular tissue of the mucosa, all being supported and held together by retiform lymphoid tissue.

FIG. 942.—Diagrammatic section of a villus. (Watney.)

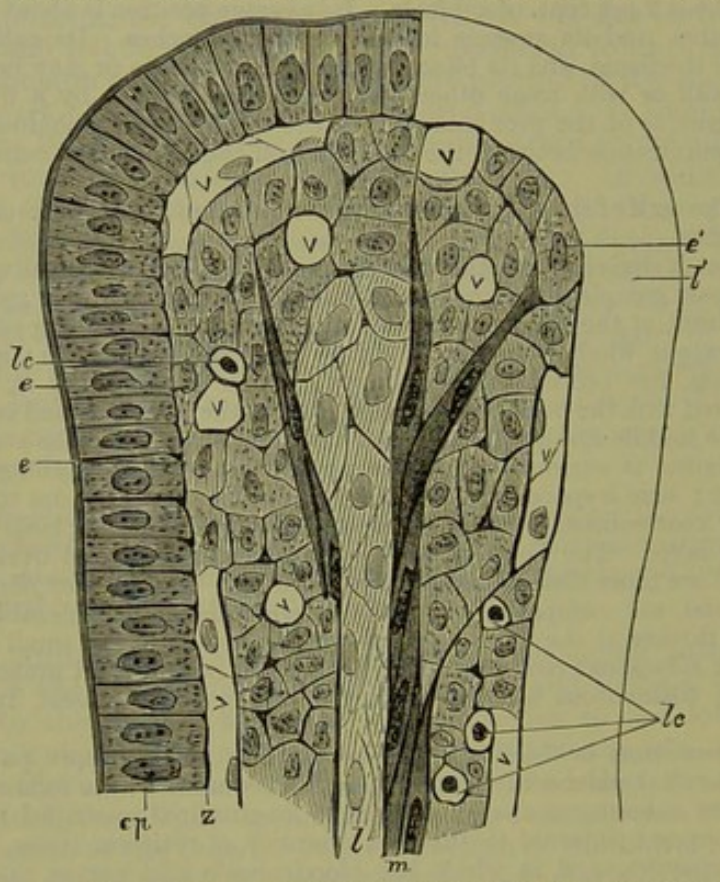

ep. Epithelium only partially shaded in. *l.* Central chyle-vessel: the cells forming the vessel have been less shaded to distinguish them from the cells of the parenchyma of the villus. *m.* Muscle-fibres running up by the side of the chyle-vessel. It will be noticed that each muscle-fibre is surrounded by the reticulum, and by this reticulum the muscles are attached to the cells forming the membrana propria, as at *e'*, or to the reticulum of the villus. *lc.* Lymph-corpuscles, marked by a spherical nucleus and a clear zone of protoplasm. *l'.* Upper limit of the chyle-vessel. *e*, *e*, *e'*. Cells forming the membrana propria. It will be seen that there is hardly any difference between the cells of the parenchyma, the endothelium of the *upper* part of the chyle-vessel, and the cells of the membrana propria. v. Blood-vessels. *z.* Dark line at the base of the epithelium formed by the reticulum. It will be seen that the reticulum penetrates between all the other elements of the villus. The reticulum contains thickenings or 'nodal points.' The diagram shows that the cells of the upper part of the villus are larger and contain a larger zone of protoplasm than those of the lower part. The cells of the upper part of the chyle-vessel differ somewhat from those of the lower part, in that they more nearly resemble the cells of the parenchyma.

These structures are arranged in the following manner. Situated in the centre of the villus is the lacteal, terminating near the summit in a blind extremity; running along this vessel are unstriped muscular fibres; surrounding it is a plexus of capillary vessels, the whole being enclosed by a basement-membrane, and covered by columnar epithelium. Those structures which are contained within the basement-membrane—namely, the lacteal, the muscular tissue, and the blood-vessels—are surrounded and enclosed by a delicate reticulum which forms the matrix of the villus, and in the meshes of which are found large flattened cells, each with an oval nucleus, and, in smaller numbers, lymph-corpuscles. Nerve-fibres are contained within the villi; they form ramifications throughout the reticulum.

The *lacteals* are in some cases double, and in some animals multiple. Situated in the axis of the villi, they commence by dilated cæcal extremities near to, but not quite at, the

summit of the villus. The walls are composed of a single layer of endothelial cells, the interstitial substance between the cells being continuous with the reticulum of the matrix.

FIG. 943.—Villi of small intestine. (Cadiat.)

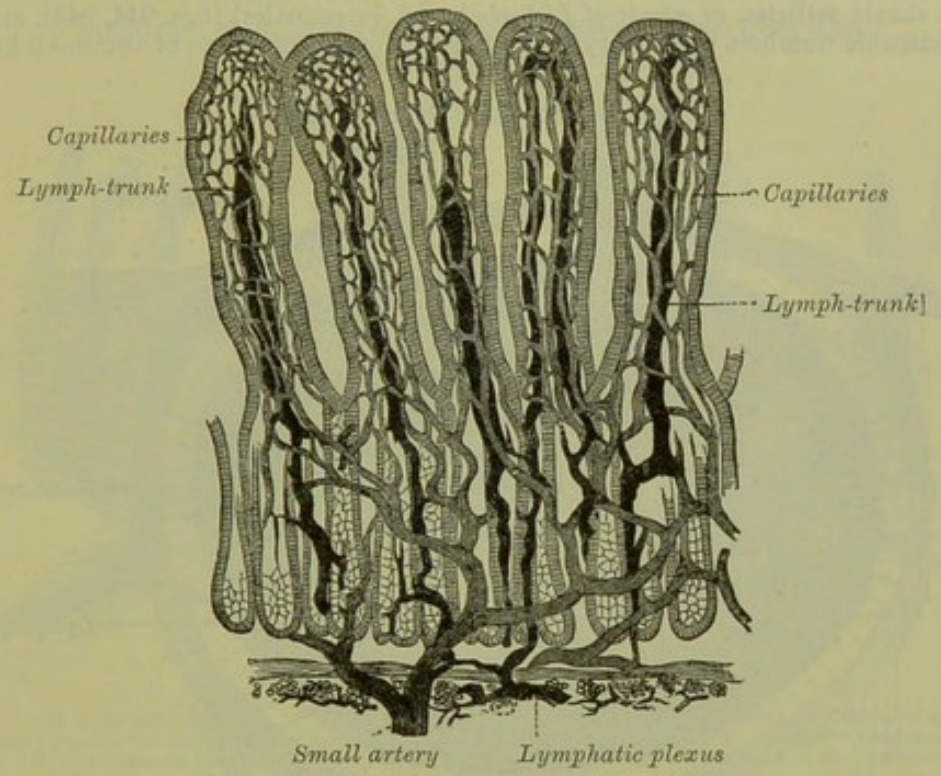

FIG. 944.—Longitudinal section of crypts of Lieberkühn. Goblet-cells seen among the columnar epithelial cells. (Klein and Noble Smith.)

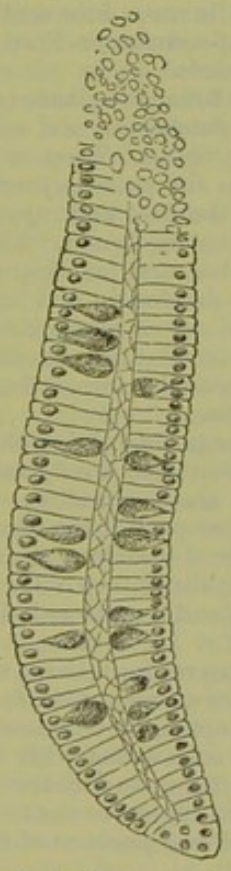

FIG. 945.—Transverse section of crypts of Lieberkühn. (Klein and Noble Smith.)

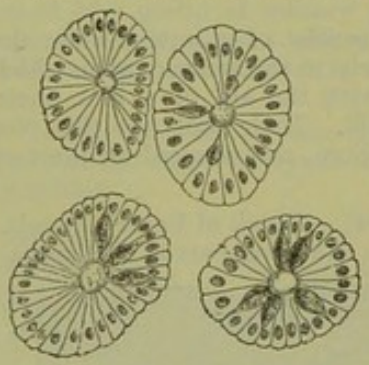

The *muscular fibres* are derived from the muscularis mucosæ, and are arranged in longitudinal bundles around the lacteal vessel, extending from the base to the summit of the villus, and giving off, laterally, individual muscle-cells, which are enclosed by the reticulum, and by it are attached to the basement-membrane.

The *blood-vessels* form a plexus between the lacteal and the basement-membrane, and are enclosed in the reticular tissue. In the interstices of the capillary plexus are contained the cells of the villus.

These structures are surrounded by the basement-membrane, which is made up of a stratum of endothelial cells, and upon this is placed a layer of columnar epithelium. The reticulum of the matrix is continuous through the basement-membrane (that is, through the interstitial substance between the individual endothelial cells) with the interstitial cement-substance of the columnar cells on the surface of the villus. Thus we are enabled to trace a direct continuity between the interior of the lacteal and the surface of

the villus by means of the reticular tissue, and it is along this path that the chyle passes in the process of absorption by the villi. That is to say, it passes first of all into the columnar epithelial cells, and, escaping from them, is carried into the reticulum of the villus, and thence into the central lacteal.

The **simple follicles**, or *crypts of Lieberkühn* (gl. intestinales) (figs. 944, 945), are found in considerable numbers over every part of the mucous membrane of the small intestine.

FIG. 946.—Lymphoid nodule.

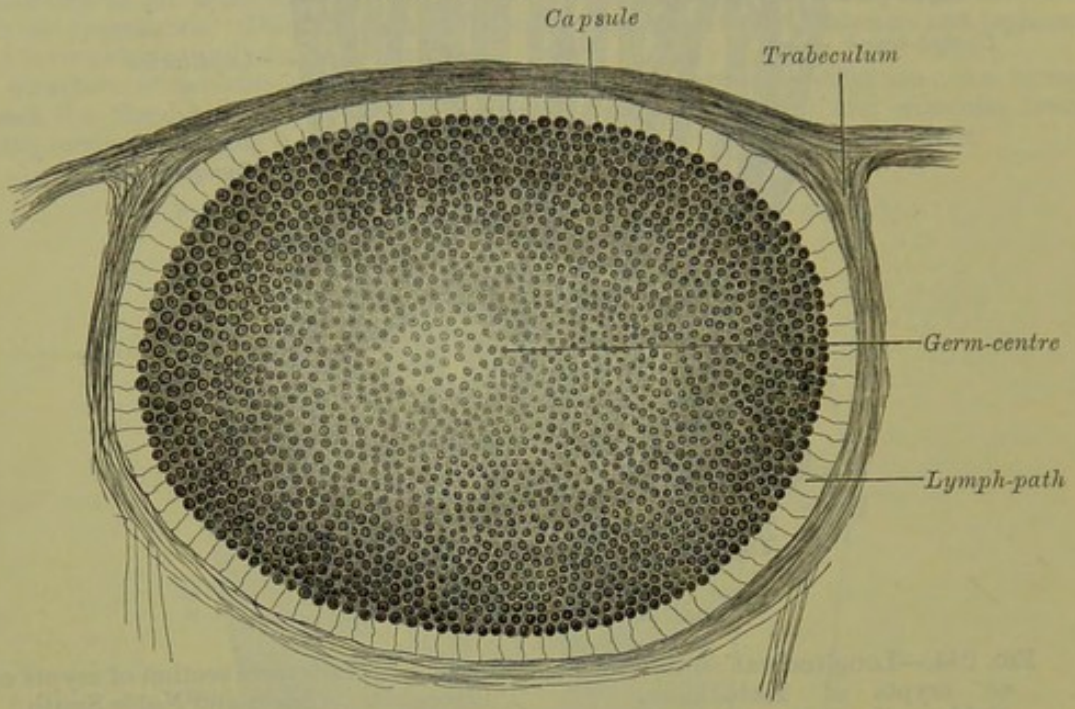

They consist of minute tubular depressions of the mucous membrane, arranged perpendicularly to the surface, upon which they open by small circular apertures. They may be seen with the aid of a lens, their orifices appearing as minute dots scattered between the villi. Their walls are thin, consisting of a basement-membrane lined by columnar epithelium, and covered on their exterior by capillary vessels.

FIG. 947.—Patch of Peyer's glands. From the lower part of the ileum.

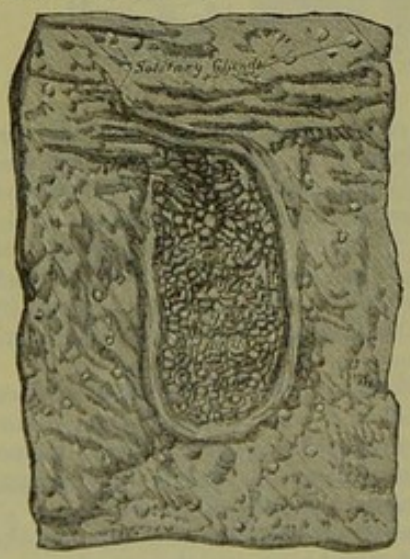

The **duodenal** or **Brunner's glands** (gl. duodenales) are limited to the duodenum, and are found in the submucous areolar tissue. They are largest and most numerous near the pylorus, forming an almost complete layer in the first and upper half of the second portions of the duodenum. They then begin to diminish in number, and practically disappear at the junction of the duodenum and jejunum. They are small compound acino-tubular glands, consisting of a number of alveoli lined by short columnar epithelium and opening by a single duct on the inner surface of the intestine.

The **solitary glands** (noduli lymphatici solitarii) (fig. 946) are found scattered throughout the mucous membrane of the small intestine, but are most numerous in the lower part of the ileum. They are small, round, lymphoid nodules; their free surfaces are covered with rudimentary villi, except at the summit, and each gland is surrounded by the openings of the follicles of Lieberkühn. Each consists of a dense interlacing retiform tissue closely packed with lymph-corpuscles, and permeated with an abundant capillary network. The interspaces of the retiform tissue are continuous with larger lymph-spaces which surround the gland, through which they communicate with the lacteal system. They are situated partly in the submucous tissue, partly in the mucous membrane, where they form slight projections of its epithelial layer, after having penetrated the muscularis mucosæ.

Peyer's glands (noduli lymphatici aggregati) (figs. 947 to 949) may be regarded as aggregations of solitary glands forming circular or oval patches, from twenty to thirty in number, and varying in length from half an inch to four inches. They are largest and

most numerous in the ileum. In the lower part of the jejunum they are small, circular, and few in number. They are occasionally seen in the duodenum. They are placed lengthwise in the intestine, and are situated in the portion of the tube most distant from

FIG. 948.—Vertical section of one of Peyer's patches from man, injected through its lymphatic canals.

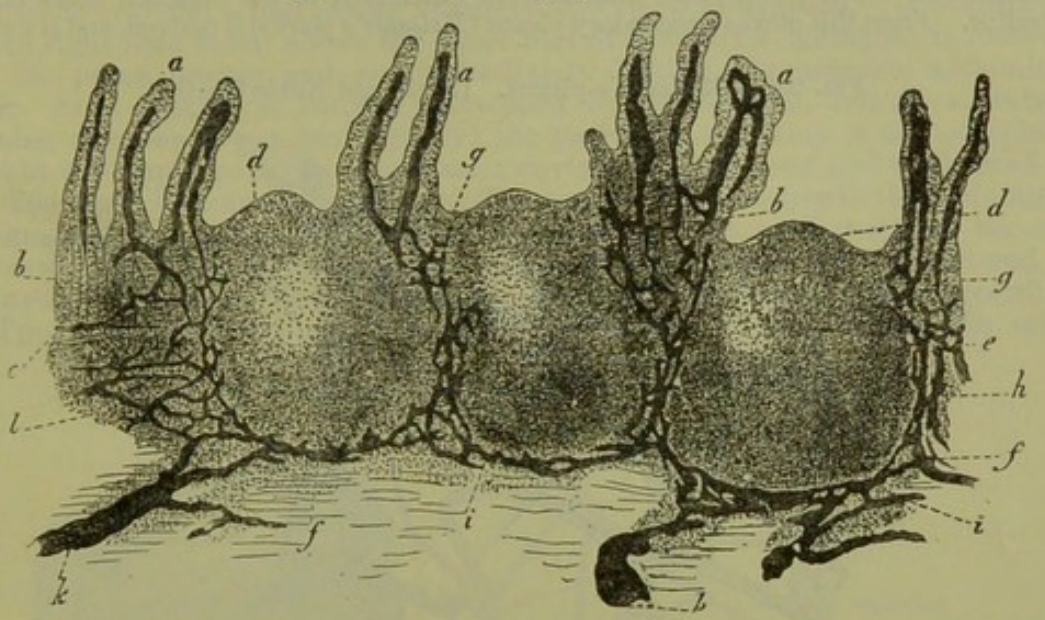

a. Villi with their chyle-passages. *b*. Follicles of Lieberkühn. *c*. Muscularis mucosæ. *d*. Cupula or apex of solitary glands. *e*. Mesial zone of glands. *f*. Base of glands. *g*. Points of exit of the chyle-passages from the villi, and entrance into the true mucous membrane. *h*. Retiform arrangement of the lymphatics in the mesial zone. *i*. Course of the latter at the base of the glands. *k*. Confluence of the lymphatics opening into the vessels of the submucous tissue. *l*. Follicular tissue of the latter.

the attachment of the mesentery. Each patch is formed of a group of solitary glands covered with mucous membrane, but the patches do not, as a rule, possess villi on their free surfaces. They are best marked in the young subject, become indistinct in middle age, and sometimes disappear altogether in advanced life. They are freely supplied with blood-vessels, which form an abundant plexus around each follicle and give off fine branches which permeate the lymphoid tissue in the interior of the follicle. The lymphatic plexuses are especially abundant around these patches (fig. 948).

FIG. 949.—Transverse section through the equatorial plane of three of Peyer's follicles from the rabbit.

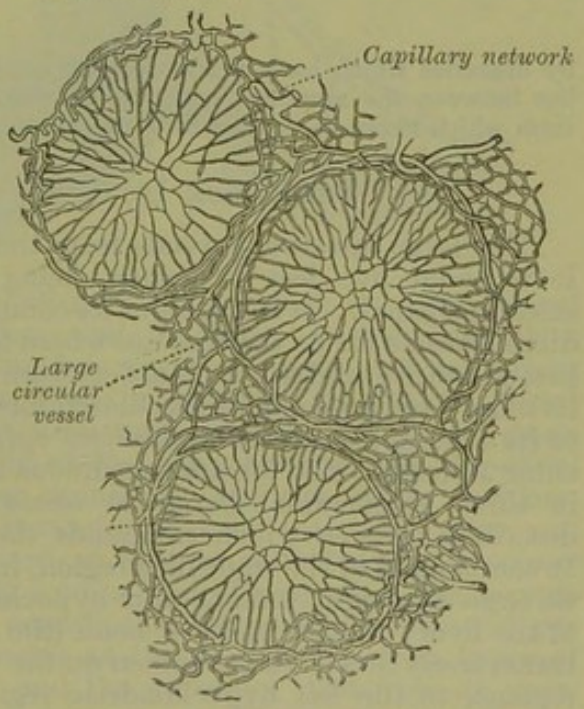

Vessels and Nerves.—The jejunum and ileum are supplied by the superior mesenteric artery, the branches of which, having reached the attached border of the bowel, run between the serous and muscular coats, with frequent inosculations to the free border, where they also anastomose with other branches running round the opposite surface of the gut. From these vessels numerous branches are given off, which pierce the muscular coat, supplying it and forming an intricate plexus in the submucous tissue. From this plexus minute vessels pass to the glands and villi of the mucous membrane. The veins have a similar course and arrangement to the arteries. The *lymphatics* of the small intestine (lacteals) are arranged in two sets, those of the mucous membrane and those of the muscular coat. The lymphatics of the villi commence in these structures in the manner described above, and form an intricate plexus in the mucous and submucous tissue, being joined by the lymphatics from the lymph-spaces at the bases of the solitary glands, and from this pass to larger vessels at the mesenteric border of the gut. The lymphatics of the muscular coat are situated to a great extent between the two layers of muscular fibres, where they form a

close plexus, and throughout their course communicate freely with the lymphatics from the mucous membrane, and empty themselves in the same manner into the origins of the lacteal vessels at the attached border of the gut.

The *nerves of the small intestines* are derived from the plexuses of sympathetic nerves around the superior mesenteric artery. From this source they run to a plexus of nerves and ganglia situated between the circular and longitudinal muscular fibres (*Auerbach's plexus*), from which the nervous branches are distributed to the muscular coats of the intestine. From this plexus a secondary plexus (*Meissner's plexus*) is derived, and is formed

Fig. 950.—Meissner's plexus. (Klein and Noble Smith.)

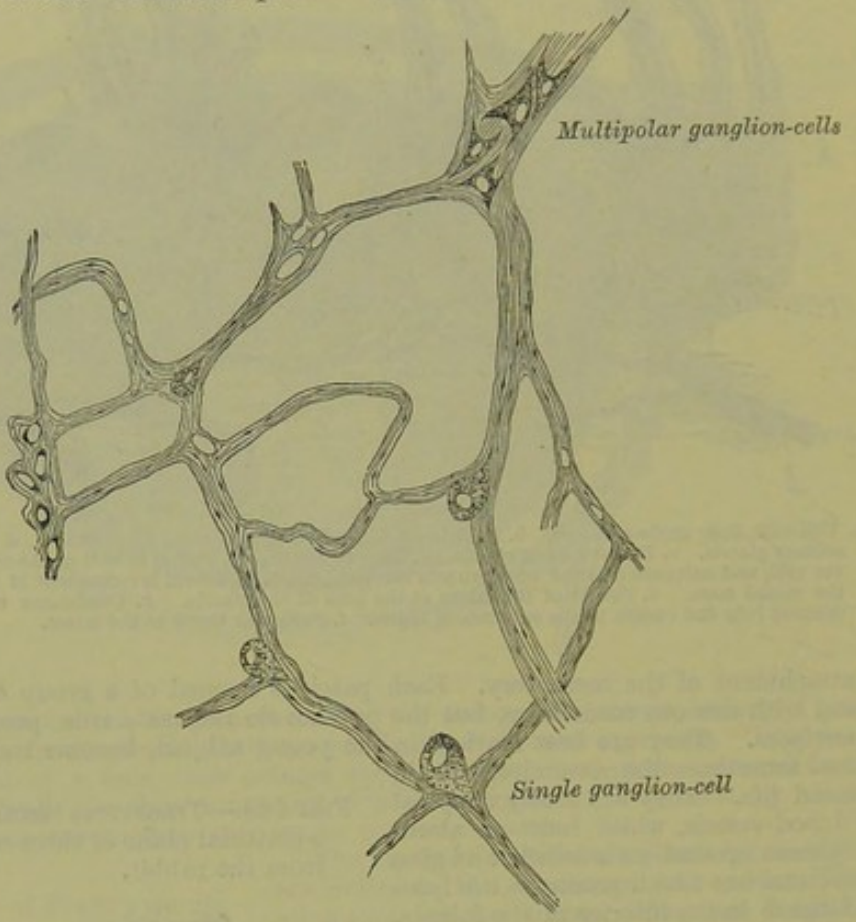

by branches which have perforated the circular muscular fibres (fig. 950). This plexus lies between the muscular and mucous coats of the intestine; it also contains ganglia from which nerve-fibres pass to the muscularis mucosæ and to the mucous membrane.

The Large Intestine (Intestinum crassum)

The large intestine extends from the termination of the ileum to the anus. It is about five feet in length, being one-fifth of the whole extent of the intestinal canal. It is largest at its commencement at the cæcum, and gradually diminishes as far as the rectum, where there is a dilatation of considerable size just above the anal canal. It differs from the small intestine in its greater calibre, its more fixed position, its sacculated form, and in possessing certain appendages to its external coat, the *appendices epiploicæ*. Further, its longitudinal muscular fibres do not form a continuous layer around the gut, but are arranged in three longitudinal bands or *tæniæ*. The large intestine, in its course, describes an arch which surrounds the convolutions of the small intestine. It commences in the right iliac region, in a dilated part, the *cæcum*. It ascends through the right lumbar and hypochondriac regions to the under surface of the liver; it here takes a bend (the *hepatic flexure*) to the left, and passes transversely across the abdomen on the confines of the epigastric and umbilical regions, to the left hypochondriac region; it then bends again (the *splenic flexure*), and descends through the left lumbar region to the left iliac fossa, where it becomes convoluted, and forms the *sigmoid flexure*; finally it enters the pelvis, and descends along its posterior wall to the anus. The large intestine is divided into the cæcum, colon, rectum, and anal canal.

The **cæcum** (intestinum cæcum), the commencement of the large intestine, is the large blind pouch situated below the ileo-cæcal valve (fig. 951). Its blind end is directed downwards, and its open end upwards, communicating directly with the colon, of which this blind pouch appears to be the beginning or head, and hence the old name of *caput cæcum coli* was applied to it. Its size is variously estimated by different authors, but on an average it may be said to be two and a half inches in length and three in breadth. It is situated in the right iliac fossa, above the outer half of Poupart's ligament : it rests on the Ilio-psoas muscle and lies immediately behind the anterior abdominal wall. As a rule, it is entirely enveloped by peritoneum, but in a certain number of cases (5 per cent., Berry) the peritoneal covering is not complete, so that the upper part of the posterior surface is uncovered and connected to the iliac fascia by connective tissue. The cæcum lies quite free in the abdominal cavity and enjoys a considerable amount of movement, so that it may become herniated down the right inguinal canal, and has occasionally been found in an inguinal hernia on the left side. The cæcum varies in shape, but, according to Treves, in man it may be classified under one of four types. In early

Fig. 951.—The cæcum and appendix, with their arteries.

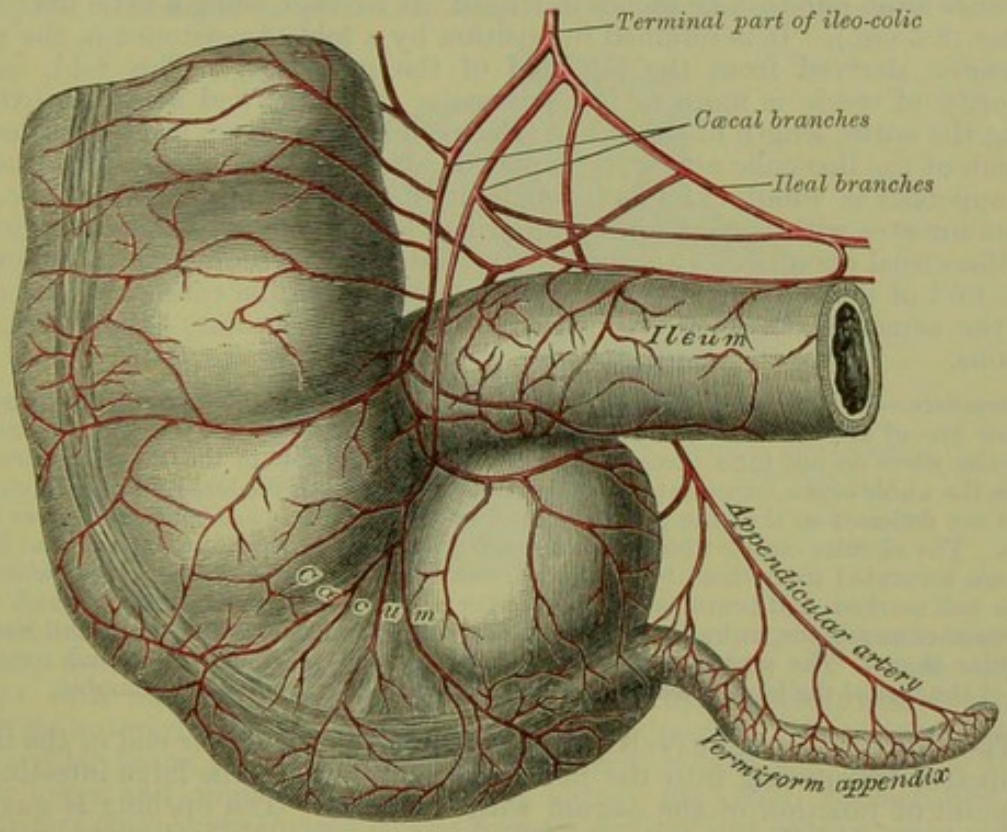

fœtal life it is short, conical, and broad at the base, with its apex turned upwards and inwards towards the ileo-cæcal junction. It then resembles the cæcum of some monkeys, e.g. mangabey monkey. As the fœtus grows the cæcum increases in length more than in breadth, so that it forms a longer tube than in the primitive form and without the broad base, but with the same inclination inwards of the apex towards the ileo-cæcal junction. This form is seen in other monkeys : e.g. the spider monkey. As development goes on, the lower part of the tube ceases to grow and the upper part becomes greatly increased, so that at birth there is a narrow tube, the vermiform appendix, hanging from a conical projection, the cæcum. This is the infantile form, and as it persists throughout life in about 2 per cent. of cases, it is regarded by Treves as the *first* of his four types of human cæca. The cæcum is conical and the appendix rises from its apex. The three longitudinal bands start from the appendix and are equidistant from each other. In the *second* type, the conical cæcum has become quadrate by the growing out of a saccule on either side of the anterior longitudinal band. These saccules are of equal size, and the appendix arises from between them,

instead of from the apex of a cone. This type is found in about 3 per cent. of cases. The *third* type is the normal type of man. Here the two saccules, which in the second type were uniform, have grown at unequal rates: the right with greater rapidity than the left. In consequence of this an apparently new apex has been formed by the growing downwards of the right saccule, and the original apex, with the appendix attached, is pushed over to the left towards the ileo-cæcal junction. The three longitudinal bands still start from the base of the appendix, but they are now no longer equidistant from each other, because the right saccule has grown between the anterior and postero-external bands, pushing them over to the left. This type occurs in about 90 per cent. of cases. The *fourth* type is merely an exaggerated condition of the third; the right saccule is still larger, and at the same time the left saccule has become atrophied, so that the original apex of the cæcum, with the appendix, is close to the ileo-cæcal junction, and the anterior band courses inwards to the same situation. This type is present in about 4 per cent. of cases.

The **vermiform appendix** (processus vermiformis) is a long, narrow, worm-shaped tube, which starts from what was originally the apex of the cæcum, and may pass in several directions: upwards behind the cæcum; to the left behind the ileum and mesentery; or downwards into the true pelvis. It varies from one to nine inches in length, its average being a little over three inches (8·3 cm.). It is retained in position by a fold of peritoneum, the *meso-appendix*, derived from the left leaf of the mesentery. This fold, in the majority of cases, is more or less triangular in shape, and as a rule extends along the entire length of the tube. Between its two layers lies a considerable branch of the ileo-colic artery, the appendicular artery (fig. 951). The canal of the appendix is small, extends throughout the whole length of the tube, and communicates with the cæcum by an orifice which is placed below and behind the ileo-cæcal opening. It is sometimes guarded by a semilunar valve formed by a fold of mucous membrane, but this is by no means constant. Its coats are the same as those of the intestine: serous, muscular, submucous, and mucous.

Structure.—The *serous* coat forms a complete investment for the tube, except along the narrow line of attachment of its mesentery in its proximal two-thirds. The *longitudinal muscular fibres* do not form three bands as in the greater part of the large intestine, but invest the whole organ, except at one or two points where both the longitudinal and circular fibres are deficient so that the peritoneal and submucous coats are contiguous over small areas. The circular muscle fibres form a much thicker layer than the longitudinal fibres, and are separated from them by a small amount of connective tissue. The *submucous coat* is well marked, and contains a large number of masses of lymphoid tissue which cause the mucous membrane to bulge into the lumen and so render the latter of small size and irregular shape. The *mucous membrane* is lined by columnar epithelium and resembles that of the rest of the large intestine, but the simple follicles are fewer in number.

The **ileo-cæcal valve** (valvula coli) (fig. 952).—The lower end of the ileum terminates by opening into the inner and back part of the large intestine, at the point of junction of the cæcum with the colon. The opening is guarded by a valve, consisting of two segments, an upper or colic and lower or cæcal, which project into the lumen of the large intestine. If the intestine has been inflated and dried, the segments are of a semilunar shape. The upper one, nearly horizontal in direction, is attached by its convex border to the line of junction of the ileum with the colon; the lower segment, which is longer and more concave, is attached to the line of junction of the ileum with the cæcum. At the ends of the aperture the two segments of the valve coalesce, and are continued as narrow membranous ridges around the canal for a short distance, forming the *frenula* or *retinacula* of the valve. The left or anterior end of the aperture is rounded; the right or posterior is narrow and pointed. In the fresh condition, or in specimens which have been hardened *in situ*, the segments project as thick cushion-like folds into the lumen of the large gut, while the opening between them may present the appearance of a slit or may be somewhat oval in shape.

Each segment of the valve is formed by a reduplication of the mucous membrane and of the circular muscular fibres of the intestine, the longitudinal fibres and peritoneum being continued uninterruptedly across from one portion of the intestine to the other. When these are divided or removed, the ileum

may be drawn outwards, and all traces of the valve will be lost, the ileum appearing to open into the large intestine by a funnel-shaped orifice of large size.

The surface of each segment of the valve directed towards the ileum is covered with villi, and presents the characteristic structure of the mucous membrane of the small intestine ; while that turned towards the large intestine is destitute of villi, and marked with the orifices of the numerous tubular glands peculiar to the mucous membrane of the large intestine. These differences in structure continue as far as the free margin of the valve.

When the cæcum is distended, the margins of the opening are approximated so as to prevent any reflux into the ileum. This is believed to be due to tension or stretching of the retinacula of the valve.

The **colon** is divided into five parts : the ascending, transverse, descending, iliac, and pelvic.

The **ascending colon** (colon ascendens) is smaller in calibre than the cæcum, with which it is continuous. It passes upwards, from its commencement at the cæcum, opposite the ileo-cæcal valve, to the under surface of the right lobe of the liver, on the right of the gall-bladder, where it is lodged in a shallow

FIG. 952.—Interior of the cæcum and lower end of colon, showing ileo-cæcal valve.

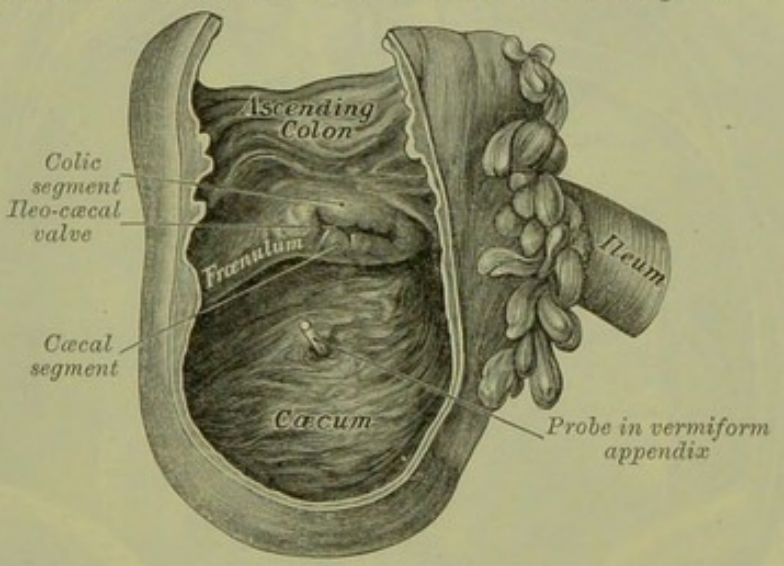

depression, the impressio colica ; here it bends abruptly forwards and to the left, forming the *hepatic flexure* (flexura coli dextra). It is retained in contact with the posterior wall of the abdomen by the peritoneum, which covers its anterior surface and sides, its posterior surface being connected by loose areolar tissue with the Quadratus lumborum muscle, and with the front of the lower and outer part of the right kidney (fig. 953). Sometimes the peritoneum completely invests it, and forms a distinct but narrow mesocolon.* It is in relation, in front, with the convolutions of the ileum and the abdominal parietes.

The **transverse colon** (colon transversum), the longest and most movable part of the colon, passes transversely from the right hypochondriac region across the abdomen, opposite the confines of the epigastric and umbilical zones, into the left hypochondriac region, where it curves downwards beneath the lower end of the spleen, forming the *splenic flexure* (flexura coli sinistra). In its course it describes an arch, the concavity of which is directed backwards and a little upwards. It is almost completely invested by peritoneum, and is connected to the posterior abdominal wall by a large and wide duplicature

* Treves states that, after a careful examination of one hundred subjects, he found that in fifty-two there was neither an ascending nor a descending mesocolon. In twenty-two there was a descending mesocolon, but no trace of a corresponding fold on the other side. In fourteen subjects there was a mesocolon to both the ascending and the descending segments of the bowel ; while in the remaining twelve there was an ascending mesocolon, but no corresponding fold on the left side. It follows, therefore, that in performing lumbar colotomy a mesocolon may be expected upon the left side in 36 per cent. of all cases, and on the right in 26 per cent.—*The Anatomy of the Intestinal Canal and Peritoneum in Man*, 1885, p. 55.

of that membrane, the *transverse mesocolon*. It is in relation, by its upper surface, with the liver and gall-bladder, the great curvature of the stomach, and the lower end of the spleen ; by its under surface, with the small intestines ;

Fig. 953.—Diagram of the relations of the large intestine and kidneys, from behind.

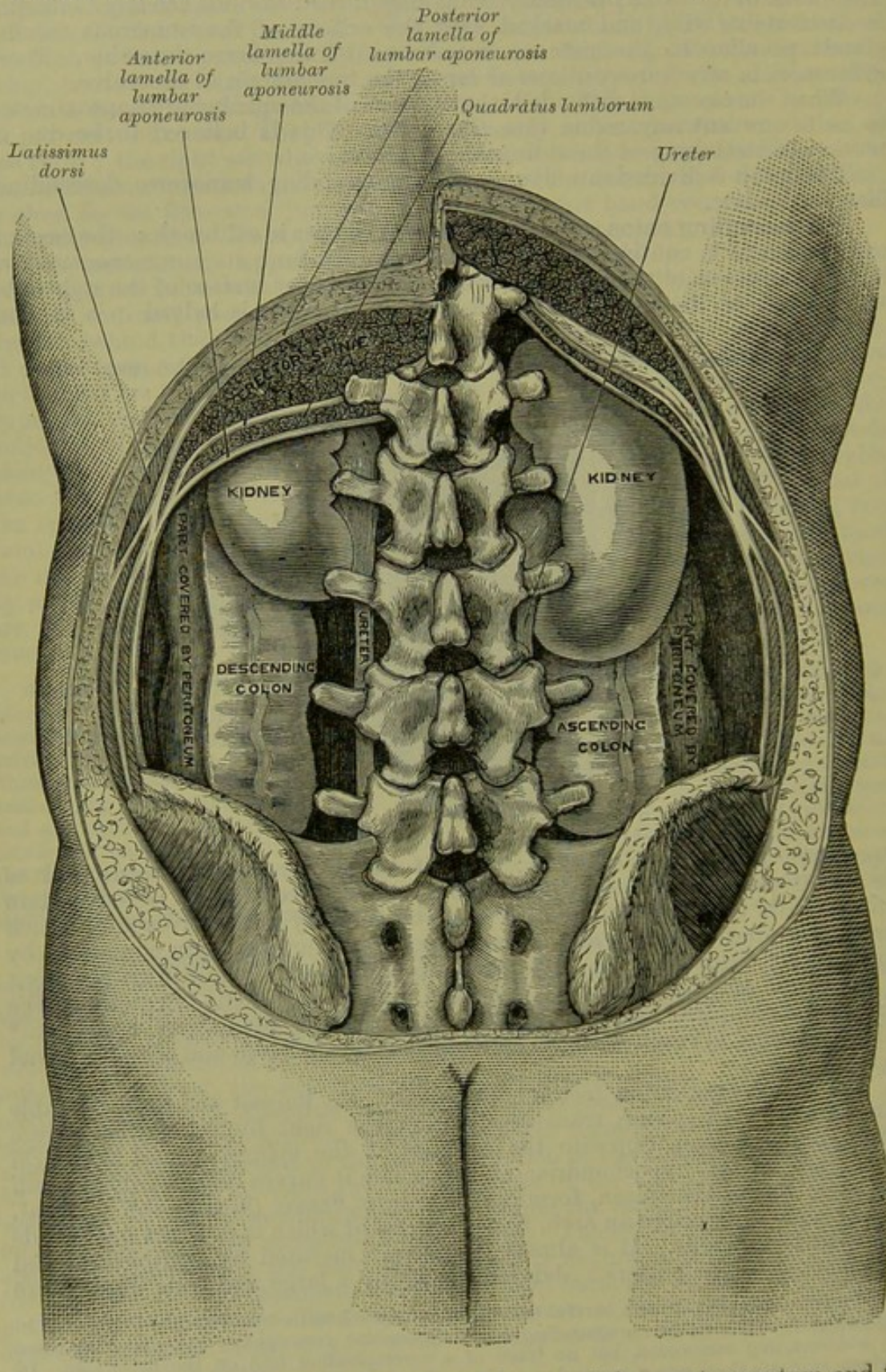

by its anterior surface, with the anterior layers of the great omentum and the abdominal parietes ; its posterior surface is in relation from right to left with the second portion of the duodenum, the head of the pancreas, and some of the convolutions of the jejunum and ileum.

The *splenic flexure* (flexura coli sinistra) is situated at the junction of the transverse and descending parts of the colon, and is in relation with the lower end of the spleen and the tail of the pancreas. It lies at a higher level than, and on a plane posterior to, the hepatic flexure, and is attached to the Diaphragm, opposite the tenth and eleventh ribs, by a peritoneal fold, named the *phrenocolic* or *costocolic ligament*, which assists in supporting the lower end of the spleen (see page 1129).

The **descending colon** (colon descendens) passes downwards through the left hypochondriac and lumbar regions along the outer border of the left kidney. At the lower end of the kidney it turns inwards towards the outer border of the Psoas muscle, along which it descends to the crest of the ilium, where it terminates in the iliac colon. It is retained in position by the peritoneum, which covers its anterior surface and sides, its posterior surface being connected by areolar tissue with the outer border of the left kidney, and with the Quadratus lumborum muscle (fig. 953). It is smaller in calibre and

FIG. 954.—Ilio-pelvic colon and rectum seen from the front, after removal of pubic bones and bladder.

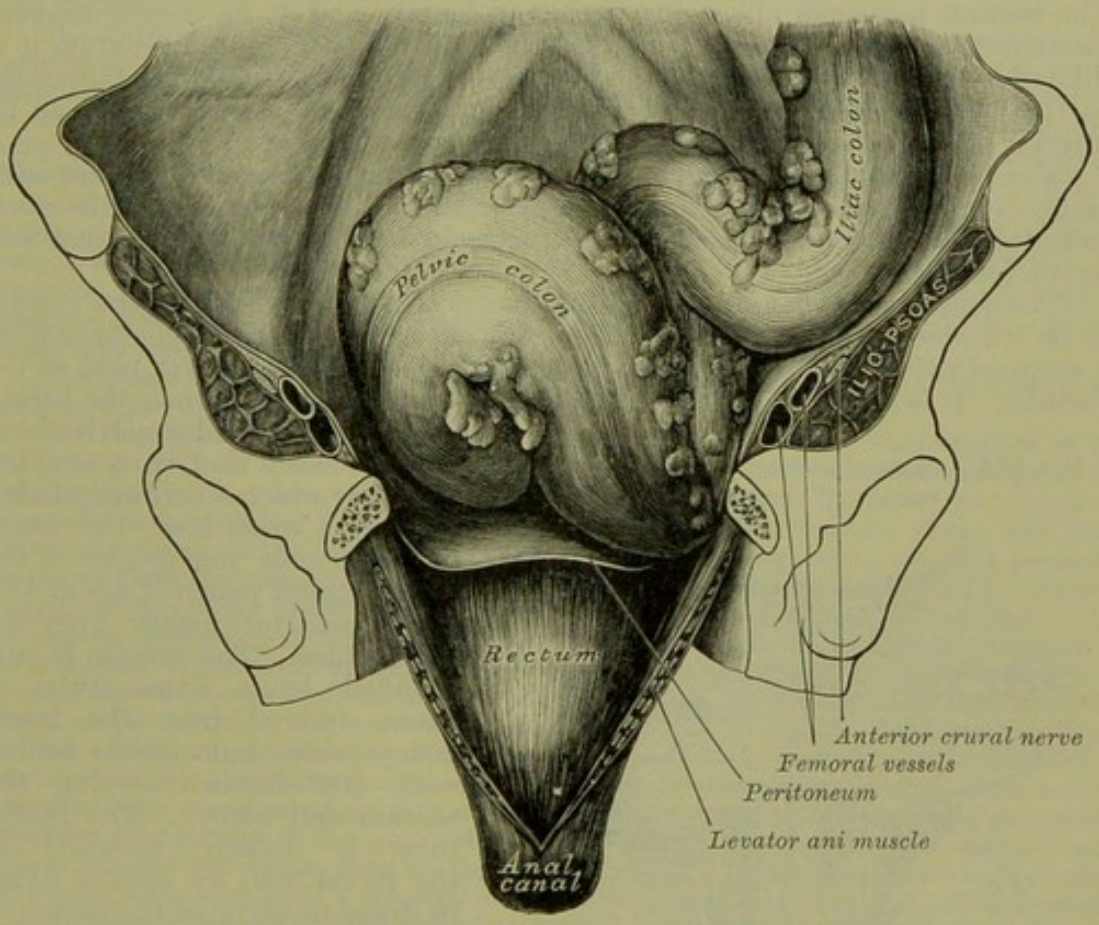

more deeply placed than the ascending colon, and is more frequently covered with peritoneum on its posterior surface than the ascending colon (Treves).

The **iliac colon** (fig. 954) is situated in the left iliac fossa, and measures about five or six inches in length. It begins at the level of the iliac crest, where it is continuous with the descending colon, and ends in the pelvic colon at the brim of the pelvis. It curves downwards and inwards in front of the Iliacus and Psoas, and, as a rule, is covered by peritoneum on its sides and anterior surface only.

The **pelvic colon** (fig. 954) forms a loop which averages about sixteen inches in length, and normally lies within the pelvis, but on account of its freedom of movement it is liable to be displaced into the abdominal cavity. It begins at the brim of the pelvis, where it is continuous with the pelvic colon, and passes transversely across the front of the sacrum to the right side of the pelvis ; it then curves on itself and turns towards the left to reach the middle line at the level of the third piece of the sacrum, where it bends downwards and ends

in the rectum. It is completely surrounded by peritoneum, which forms a mesentery (pelvic mesocolon) : the mesentery diminishes in length from the centre towards the ends of the loop, where it disappears, so that the loop is fixed at its junctions with the iliac colon and rectum, but enjoys a considerable range of movement in its central portion.

Relations of the pelvic colon.—*Behind* the pelvic colon are the external iliac vessels, the left Pyriformis muscle, and left sacral plexus of nerves ; in *front*, it is separated from the bladder in the male, and the uterus in the female, by some coils of the small intestine.

The **rectum** is continuous above with the pelvic colon, whilst below it ends in the anal canal. From its origin at the level of the third sacral vertebra it passes downwards, lying in the sacro-coccygeal curve, and extends for about an inch in front of, and a little below, the tip of the coccyx, as far as the apex of the prostate gland. It then bends sharply backwards into the anal canal. It therefore presents two antero-posterior curves : an upper, with its convexity backwards, and a lower, with its convexity forwards. Two lateral curves are also described, one to the right opposite the junction of the third and fourth sacral vertebræ, and the other to the left, opposite the left sacro-coccygeal articulation ; they are, however, of little importance. The rectum measures about five inches in length, and at its commencement its calibre is similar to that of the pelvic colon, but near its termination it is dilated to form the *rectal ampulla*. The rectum has no sacculations comparable to those of the colon, but a sacculated condition, due to the presence in its interior of valves (shortly to be described) is sometimes seen.

The peritoneum is related to the upper two-thirds of the rectum, covering at first its front and sides, but lower down its front only ; from the latter it is reflected on to the seminal vesicles in the male and the posterior vaginal wall in the female.

The level at which the peritoneum leaves the anterior wall of the rectum to be reflected on to the viscus in front of it is of considerable importance from a surgical point of view, in connection with removal of the lower part of the rectum. It is higher in the male than in the female. In the former the height of the recto-vesical pouch is about three inches : that is to say, the height to which an ordinary index finger can reach from the anus. In the female the height of the recto-vaginal pouch is about two and a quarter inches from the anal orifice. The rectum is surrounded by a dense tube of fascia derived from the fascia endopelvina, but fused behind with the fascia covering the sacrum and coccyx. The fascial tube is loosely attached to the rectal wall by areolar tissue in order to allow of distension of the viscus.

FIG. 955.—Coronal section through the anal canal. (Symington.)

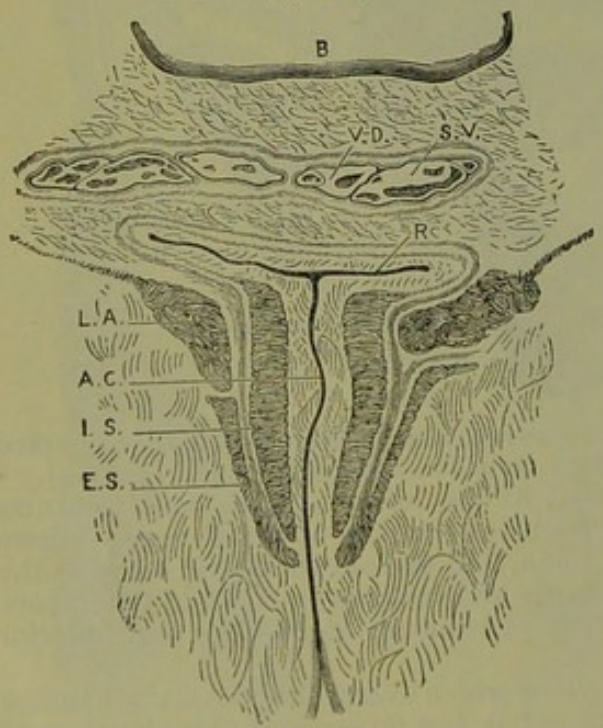

B. Cavity of bladder. V.D. Vas deferens. S.V. Seminal vesicle. R. Second part of rectum. A.C. Anal canal. L.A. Levator ani. I.S. Internal sphincter. E.S. External sphincter.

Relations of the rectum.—The upper part of the rectum is in relation, *behind*, with the superior hæmorrhoidal vessels, the left Pyriformis muscle, and left sacral plexus of nerves, which separate it from the anterior surfaces of the sacral vertebræ ; in its lower part it lies directly on the sacrum, coccyx, and Levatores ani, a dense fascia alone intervening ; *in front*, it is separated above, in the male, from the posterior surface of the bladder ; in the female, from the posterior surface of the uterus and its appendages, by some

convolutions of the small intestine, and frequently by the pelvic colon ; *below*, in the male, it is in relation with the triangular portion of the base of the bladder, the vesiculæ seminales, and vasa deferentia, and more anteriorly with the posterior surface of the prostate ; in the female, with the posterior wall of the vagina.

The **anal canal** (fig. 955) or terminal portion of the large intestine begins at the level of the apex of the prostate, is directed downwards and backwards, and ends at the anus. It forms an angle with the lower part of the rectum, and measures from an inch to an inch and a half in length. It has no peritoneal covering, but is invested by the Sphincter ani internus, supported by the Levatores ani, and surrounded at its termination by the Sphincter ani externus. In the empty condition it presents the appearance of an antero-posterior longitudinal slit. Behind it, is a mass of muscular and fibrous tissue, the *ano-coccygeal body* (Symington) ; in front of it, in the male, are the membranous portion and bulb of the urethra, and the base of the triangular ligament ; and in the female it is separated from the lower end of the vagina by a mass of muscular and fibrous tissue, named the *perineal body*.

Structure of the colon.—The large intestine has four coats : serous, muscular, areolar, and mucous.

The *serous coat* is derived from the peritoneum, and invests the different portions of the large intestine to a variable extent. The cæcum is completely covered by the serous membrane, except in about 5 per cent. of cases where the upper part of the posterior surface is uncovered. The ascending, descending, and iliac parts of the colon are usually covered only in front and at the sides ; a variable amount of the posterior surface is uncovered.* The transverse colon is almost completely invested, the parts corresponding to the attachment of the great omentum and transverse mesocolon being alone excepted. The pelvic colon is entirely surrounded. The rectum is covered above on its anterior surface and sides ; below, on its anterior aspect only ; the anal canal is entirely devoid of any serous covering. In the course of the colon the peritoneal coat is thrown into a number of small pouches filled with fat, called *appendices epiploicæ*. They are most numerous on the transverse colon.

The *muscular coat* consists of an external longitudinal, and an internal circular, layer of non-striped muscular fibres.

The *longitudinal fibres* do not form a continuous layer over the whole surface of the large intestine. In the cæcum and colon they are especially collected into three flat longitudinal bands (*tæniæ coli*), each of about half an inch in width. The vermiform appendix is surrounded by a uniform layer of longitudinal muscular fibres, and these bands commence at the attachment of the appendix to the cæcum ; one, the posterior, is placed along the attached border of the intestine ; the anterior, the largest, corresponds along the arch of the colon to the attachment of the great omentum, but is in front in the ascending, descending and iliac parts of the colon, and in the pelvic colon ; the third, or lateral band, is found on the inner side of the ascending and descending parts of the colon, and on the under aspect of the transverse colon. These bands are shorter than the other coats of the intestine, and serve to produce the sacculi which are characteristic of the cæcum and colon ; accordingly, when they are dissected off, the tube can be lengthened, and its sacculated character becomes lost. In the pelvic colon the longitudinal fibres become more scattered ; and round the rectum they spread out and form a layer, which completely encircles this portion of the gut, but is thicker on the anterior and posterior surfaces, where it forms two bands, than on the lateral surfaces. In addition, two bands of plain muscular tissue arise from the second and third coccygeal vertebræ, and pass downwards and forwards to blend with the longitudinal muscular fibres on the posterior wall of the anal canal. These are known as the *recto-coccygeal* muscles.

The *circular fibres* form a thin layer over the cæcum and colon, being especially accumulated in the intervals between the sacculi ; in the rectum they form a thick layer, and in the anal canal they become numerous, and constitute the Internal sphincter.

The *areolar coat* connects the muscular and mucous layers closely together.

The *mucous membrane*, in the cæcum and colon, is pale, smooth, destitute of villi, and raised into numerous crescentic folds which correspond to the intervals between the sacculi. In the rectum it is thicker, of a darker colour, more vascular, and connected loosely to the muscular coat, as in the œsophagus. When the lower part of the rectum is contracted, its mucous membrane is thrown into a number of folds, which are longitudinal in direction and are effaced by the distension of the gut. Besides these there are certain permanent horizontal folds, of a semilunar shape, known as Houston's valves (fig. 956).† They are usually three in number ; sometimes a fourth is found, and occasionally only two are present. One is situated near the commencement of the rectum, on the right side ; a second extends

* See footnote, p. 1151.

† *Dublin Hosp. Reports*, vol. v. p. 163.

inwards from the left side of the tube, opposite the middle of the sacrum; a third, the largest and most constant, projects backwards from the fore part of the rectum, opposite the base of the bladder. When a fourth is present, it is situated nearly an inch above the anus on the left and posterior wall of the tube. These folds are about half an inch in width, and contain some of the circular fibres of the gut. In the empty state of the intestines they overlap each other, as Houston remarks, so effectually as to require considerable manœuvring to conduct a bougie or the finger along to the canal of the intestine. Their use seems to be, 'to support the weight of fæcal matter, and prevent its urging towards the anus, where its presence always excites a sensation demanding its discharge.' *

The lumen of the anal canal presents, in its upper half, a number of vertical folds, produced by an infolding of the mucous membrane and some of the muscular tissue. They are known as the *columns of Morgagni* (fig. 956), and are separated from one another by furrows, which terminate below in small valve-like folds, termed *anal valves*, which join together the lower ends of the columns of Morgagni.

As in the small intestine, the mucous membrane consists of: a muscular layer, the muscularis mucosæ; a quantity of retiform tissue in which the vessels ramify; a basement-membrane and epithelium which is of the columnar variety, and exactly resembles the epithelium found in the small intestine. The mucous membrane of the large intestine presents for examination simple follicles and solitary glands.

Fig. 956.—Coronal section of rectum and anal canal.

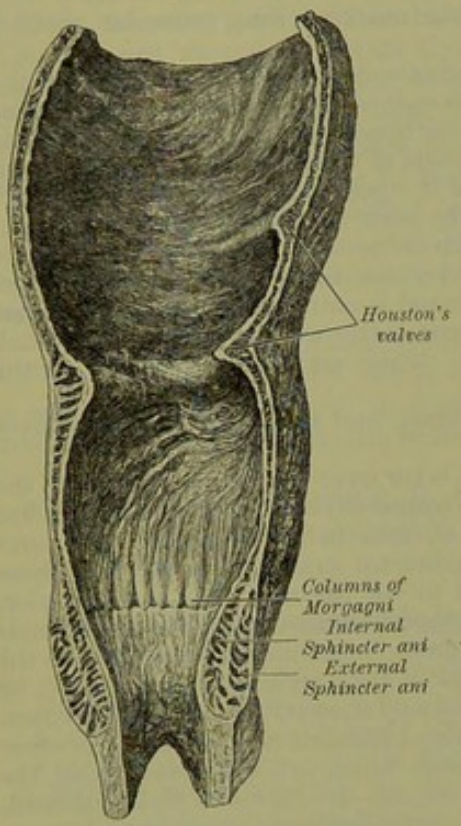

Fig. 957.—Transverse section of large intestine.

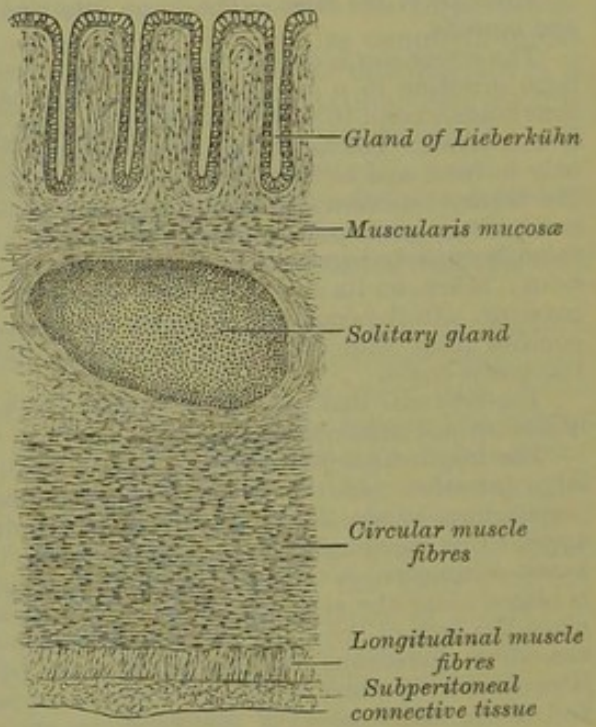

The *simple follicles* (glands of Lieberkühn) are minute tubular prolongations of the mucous membrane arranged perpendicularly, side by side, over its entire surface; they are longer, more numerous, and placed in much closer apposition than those of the small intestine; and they open by minute rounded orifices upon the surface, giving it a cribriform appearance. Each gland is lined by short columnar epithelium and contains numerous goblet cells.

The *solitary glands* (fig. 957) of the large intestine are most abundant in the cæcum and vermiform appendix, but are irregularly scattered also over the rest of the intestine. They are similar to those of the small intestine.

Vessels and Nerves.—The *arteries* supplying the colon are derived from the colic and sigmoid branches of the mesenteric arteries. They give off large branches, which ramify between and supply the muscular coats, and after dividing into small vessels in the submucous tissue, pass to the mucous membrane. The rectum is supplied by the superior

* Paterson (The form of the rectum, *Journal of Anatomy and Physiology*, vol. xliii.) utilises the third fold for the purpose of dividing the rectum into an upper and a lower portion; he considers the latter 'to be just as much a duct as the narrower anal canal below,' and maintains that, under normal conditions, it does not contain fæces except during the act of defæcation.

hæmorrhoidal branch of the inferior mesenteric, and the anal canal by the middle hæmorrhoidal from the internal iliac, and the inferior hæmorrhoidal from the pudic artery. The superior hæmorrhoidal, the continuation of the superior mesenteric, divides into two branches, which run down either side of the rectum to within about five inches of the anus; they here split up into about six branches, which pierce the muscular coat and descend between it and the mucous membrane in a longitudinal direction, parallel with each other as far as the Internal sphincter, where they anastomose with the other hæmorrhoidal arteries and form a series of loops around the anus. The *veins* of the rectum commence in a plexus of vessels which surrounds the anal canal. In the vessels forming this plexus are small saccular dilatations just within the margin of the anus; from the plexus about six vessels of considerable size are given off. These ascend between the muscular and mucous coats for about five inches, running parallel to each other; they then pierce the muscular coat, and, by their union, form a single trunk, the superior hæmorrhoidal vein. This arrangement is termed the *hæmorrhoidal plexus*; it communicates with the tributaries of the middle and inferior hæmorrhoidal veins, at its commencement, and thus a communication is established between the systemic and portal circulations. The *nerves* are derived from the sympathetic plexuses around the branches of the superior and inferior mesenteric arteries. They are distributed in a similar way to those found in the small intestine.

The *lymphatics* of the large intestine are described on page 785.

Surface Relations.—The coils of the small intestine occupy the front of the abdomen, below the transverse colon, and are covered more or less completely by the great omentum. For the most part the coils of the jejunum occupy the left side of the abdominal cavity, i.e. the left lumbar and iliac regions and the left half of the umbilical region; while the coils of the ilium are situated to the right, in the right lumbar and iliac regions, in the right half of the umbilical region, and also in the hypogastric region. The cæcum is situated in the right iliac region. Its position varies slightly, but the mid-point of a line drawn from the anterior superior spinous process of the ilium to the symphysis pubis will about mark the middle of its lower border. It is comparatively superficial. From it the ascending colon passes upwards through the right lumbar and hypochondriac regions, and becomes more deeply situated as it ascends to the hepatic flexure, which is deeply placed under cover of the liver. The transverse colon crosses the belly transversely on the confines of the umbilical and epigastric regions; its lower border being on a level slightly above the umbilicus, its upper border just below the greater curvature of the stomach.* The splenic flexure of the colon is situated behind the stomach in the left hypochondrium, and is on a higher level than the hepatic flexure. The descending colon is deeply seated, passing down through the left hypochondriac and lumbar regions to the sigmoid flexure, which is situated in the left iliac region and can be felt in thin persons, with relaxed abdominal walls, rolling under the fingers when empty, and when distended forming a distinct tumour. The position of the base of the vermiform appendix is indicated by a point an inch and a half from the right anterior superior spinous process of the ilium, in a line drawn from this process to the umbilicus. This is known as *McBurney's spot.* Another mode of defining the position of the base of the appendix is to draw a line between the anterior superior iliac spines, marking the point where this line intersects the right semilunar line.

Peristalsis of the coils of the small intestine can be observed in some persons with extremely thin abdominal walls, when some degree of constipation exists; it is, however, of great importance as a diagnostic sign of chronic intestinal obstruction, and when such is suspected, should be always looked for. Owing to the resistance offered to the passage of the bowel contents for some period, hypertrophy of the muscular coats of the intestine takes place, and the peristaltic movements of the distended gut may become distinctly visible through the normal thickness of abdominal wall.

In cases of obstruction near the ileo-cæcal junction the distension of the small intestine gives rise to a marked prominence of the central portion of the abdomen, whereas if the obstruction be low down in the large gut, the whole course of the colon may be seen mapped out, thus giving rise to distension in the flanks and transversely about the level of the umbilicus. Thus valuable information as to the seat of the obstruction may often be obtained from simple inspection of the abdomen. Great distension of the intestines also occurs in peritonitis and in typhoid fever.

Upon introducing the finger into the male rectum, the membranous portion of the urethra can be felt exactly in the middle line if an instrument has been introduced into the bladder; above this the prostate gland can be recognised by its shape and hardness and any enlargement detected; behind the prostate the fluctuating wall of the bladder when full can be felt, and if thought desirable, can be tapped in this situation; on either side of and behind the prostate the vesicula seminalis can be readily felt, especially if enlarged by tuberculous disease. Behind, the coccyx is to be felt; and on the mucous membrane one or two of Houston's folds. The ischio-rectal fossa can be explored on either side, with a view to

* The transverse colon frequently sags downwards, especially in those affected with chronic constipation; when the abdomen is opened it is not unusual to find the upper border of the colon distinctly below the umbilicus, and in some cases the convexity of this portion of the large intestine reaches the pelvic brim.

ascertaining the presence of deep-seated collections of pus. Finally, it will be noted that the finger is firmly gripped by the Sphincter for about an inch up the bowel.

Applied Anatomy.—The small intestines are much exposed to injury, but, in consequence of their elasticity and the ease with which one coil glides over another, they are not so frequently ruptured as would otherwise be the case. Any part of the small intestine may be ruptured, but probably the most common situation is the transverse duodenum, on account of its being more fixed than other portions of the bowel, and because it is situated in front of the bodies of the vertebræ, so that if this portion of the intestine is struck by a sharp blow, as from the kick of a horse, it is unable to glide out of the way, but is compressed against the bone and so lacerated. Wounds of the intestine sometimes occur. If the wound is a small puncture, under, it is said, three lines in length, no extravasation of the contents of the bowel takes place; the mucous membrane becomes everted and plugs the little opening. The small intestine, and most frequently the ileum, may become strangulated by internal bands, or through apertures, normal or abnormal. The bands may be formed in several different ways: they may be old peritoneal adhesions from previous attacks of peritonitis; or an adherent omentum from the same cause; or the band may be formed by Meckel's diverticulum, which has contracted adhesions at its distal extremity; or it may be the result of the abnormal attachment of some normal structure, as the adhesion of two appendices epiploicæ, or an adherent vermiform appendix or Fallopian tube. Intussusception, most commonly an invagination of the small intestine into the large, may take place; it may attain great size, and it is not uncommon in these cases to find the ileo-cæcal valve projecting from the anus. Stricture, the impaction of foreign bodies, and twisting of the gut (*volvulus*) may also lead to intestinal obstruction.

Resection of a portion of the intestine may be required in cases of gangrene; for the removal of new growth in the bowel; in dealing with artificial anus; and in cases of rupture. The operation is termed *enterectomy*, and is performed as follows: the abdomen having been opened and the amount of bowel requiring removal having been determined upon, the intestine must be clamped on either side of this portion in order to prevent the escape of any of its contents during the operation. The portion of the bowel is then separated above and below by means of scissors. If the portion resected is small, it may be simply removed from the mesentery at its attachment, and the bleeding vessels tied; but if it be large it will be necessary to take away a triangular piece of the mesentery, and, having secured the vessels, suture the cut edges of this structure together. In doing this, care must be taken not to leave any intestine projecting beyond the line of the section of mesentery, as gangrene is very likely to occur in the projecting part if this is done. The surgeon then proceeds to unite the cut ends of the bowel together by what is termed end-to-end anastomosis. There are many ways of doing this, which may be divided into two classes, one where the anastomosis is made by means of some mechanical appliance, such as Murphy's button, or one of the forms of decalcified bone bobbin; and the other, where the operation is performed by suturing the ends of the bowel in such a manner that the peritoneum covering the two divided ends is brought into contact, so that speedy union may ensue.

The vermiform appendix is very liable to become inflamed, because it contains a relatively large amount of lymphoid tissue which is prone to bacterial infection. In many cases the inflammation is set up by the impaction in it of a solid mass of fæces or a foreign body, or by the inspissation of its mucous secretion in catarrhal conditions. The inflammation may result in ulceration and perforation, or if very acute in gangrene of the appendix. These conditions generally require immediate operative interference, and in chronic cases with recurring attacks of inflammation it is generally advisable to remove this diverticulum of the bowel. In incising the abdominal wall for this operation, the muscles should be split in the direction of their fibres rather than cut across in order to prevent subsequent weakening of the abdominal parietes and the occurrence of a ventral hernia. After the appendix has been removed it is better to suture the planes of the abdominal wall separately.

In external hernia the ileum is the portion of bowel most frequently herniated. When a part of the large intestine is involved it is usually the cæcum, and this may occur even on the left side. In some few cases the vermiform appendix has been the part implicated in strangulated hernia.

Chronic ulcer of the duodenum is sometimes met with, probably produced by the same causes as chronic ulcer of the stomach. It may perforate and set up a rapidly fatal peritonitis, or it may open into one of the large duodenal vessels and cause death from hæmorrhage. An acute ulcer sometimes, but rarely, follows extensive burns of the skin.

The calibre of the large intestine gradually diminishes from the cæcum, which has the greatest diameter of any part of the bowel, to the point of junction of the pelvic colon with the rectum. At or a little below this point stricture most commonly occurs, and diminishes in frequency as one proceeds upwards to the cæcum. When distended by some obstruction low down, the outline of the large intestine can be defined throughout nearly the whole of its course—all, in fact, except the hepatic and splenic flexures, which are more deeply placed; the distension is most obvious in the flanks and on the front of the abdomen just above the umbilicus. The cæcum, however, is the portion of the bowel

which becomes most distended. It may assume enormous dimensions, and has been known to give way from the distension, causing fatal peritonitis. The hepatic flexure and the right extremity of the transverse colon are in close relationship with the liver, and abscess of this viscus sometimes bursts into the gut in this situation. The gall-bladder may become adherent to the colon, and gall-stones may find their way through into it and may become impacted or may be discharged per anum. The mobility of the pelvic colon renders it more liable to become the seat of a volvulus or twist than any other part of the intestine. It generally occurs in patients who have been the subjects of habitual constipation, and in whom, therefore, the mesocolon is elongated. The gut at this part, being loaded with fæces, falls over the part below, and so gives rise to the twist.

Hernia.—The two chief sites at which external hernia may take place are the inguinal region and the crural canal. The description of the inguinal canal and its relations will be found on page 1205 and that of the crural canal on pages 708 and 709. Some points in regard to the disposition of the peritoneum in these regions may, however, be recapitulated here.

Between the upper margin of the front of the pelvis and the umbilicus, the peritoneum, when viewed from behind, will be seen to be raised into five folds, with intervening depressions, by more or less prominent bands which converge to the umbilicus (fig. 924). The urachus, situated in the middle line, is covered by a fold of peritoneum known as the *plica urachi*. On either side of this a fold of peritoneum round the obliterated hypogastric artery forms the *plica hypogastrica*. To either side of these three cords is the deep epigastric artery covered by the *plica epigastrica*. Between these raised folds are depressions constituting the so-called fossæ. The most internal, between the plica urachi and plica hypogastrica, is known as the *internal inguinal fossa* (fovea supravesicalis). The middle one is situated between the plica hypogastrica and plica epigastrica, and is termed the *middle inguinal fossa* (fovea inguinalis mesialis). The external one is external to the plica epigastrica, and is known as the *external inguinal fossa* (fovea inguinalis lateralis). Occasionally the deep epigastric artery corresponds in position to the obliterated hypogastric artery, and then there is but one fold on each side of the middle line. In the usual position of the parts, the floor of the external inguinal fossa corresponds to the internal abdominal ring, and into this fossa an oblique inguinal hernia descends. To the inner side of the plica epigastrica are the two internal fossæ, and through either of these a direct hernia may descend. The whole of the space between the deep epigastric artery, the margin of the Rectus, and Poupart's ligament, is known as Hesselbach's triangle. Below the level of Poupart's ligament is a small depression corresponding to the position of the crural ring. It is known as the *femoral fossa*, and into it a femoral hernia descends.

Inguinal hernia.—Inguinal hernia is that form of protrusion which makes its way through the abdomen in the inguinal region. There are two principal varieties of it: external or oblique, and internal or direct.

In *oblique inguinal hernia* the intestine escapes from the abdominal cavity at the internal ring, pushing before it a pouch of peritoneum which forms the hernial sac. As it enters the inguinal canal it receives an investment from the extra-peritoneal tissue and is enclosed in the infundibuliform fascia. In passing along the inguinal canal it displaces upwards the arched fibres of the Transversalis and Internal oblique, and receives a covering of Cremaster muscle and cremasteric fascia. It then passes along the front of the spermatic cord and escapes from the inguinal canal at the external ring, becoming invested by intercolumnar fascia. Lastly it descends into the scrotum, receiving coverings from the superficial fascia and the integument.

The seat of stricture in oblique inguinal hernia is at either the external or internal abdominal ring; most frequently in the latter situation. If it is situated at the external ring, the division of a few fibres at one point of the circumference is all that is necessary for the replacement of the hernia. If at the internal ring, it is necessary to divide the aponeurosis of the External oblique so as to lay open the inguinal canal; in dividing the aponeurosis the incision should be directed parallel to Poupart's ligament, and the constriction at the internal ring should then be divided directly upwards.

When the intestine passes along the inguinal canal and escapes from the external ring into the scrotum, it is called *complete* oblique inguinal or *scrotal* hernia. If the intestine does not escape from the external ring, but is retained in the inguinal canal, it is called *incomplete* inguinal hernia or *bubonocele*. In each of these cases the coverings which invest it will depend upon the extent to which it descends in the inguinal canal.

There are some other varieties of oblique inguinal hernia (fig. 958) depending upon congenital defects in the processus vaginalis, the pouch of peritoneum which precedes the descent of the testis. Normally this pouch is closed before birth, closure commencing at two points, viz. at the internal abdominal ring and at the top of the epididymis, and gradually extending until the whole of the intervening portion is converted into a fibrous cord. From failure in the completion of this process, variations in the relation of the hernial protrusion to the testis and tunica vaginalis are produced; these constitute distinct varieties of inguinal hernia, viz. congenital, infantile, encysted, and hernia of the funicular process.

Where the processus vaginalis remains patent throughout, the cavity of the tunica vaginalis communicates directly with that of the peritoneum. The intestine descends along this pouch into the cavity of the tunica vaginalis which constitutes the sac of the

FIG. 958.—Varieties of oblique inguinal hernia.

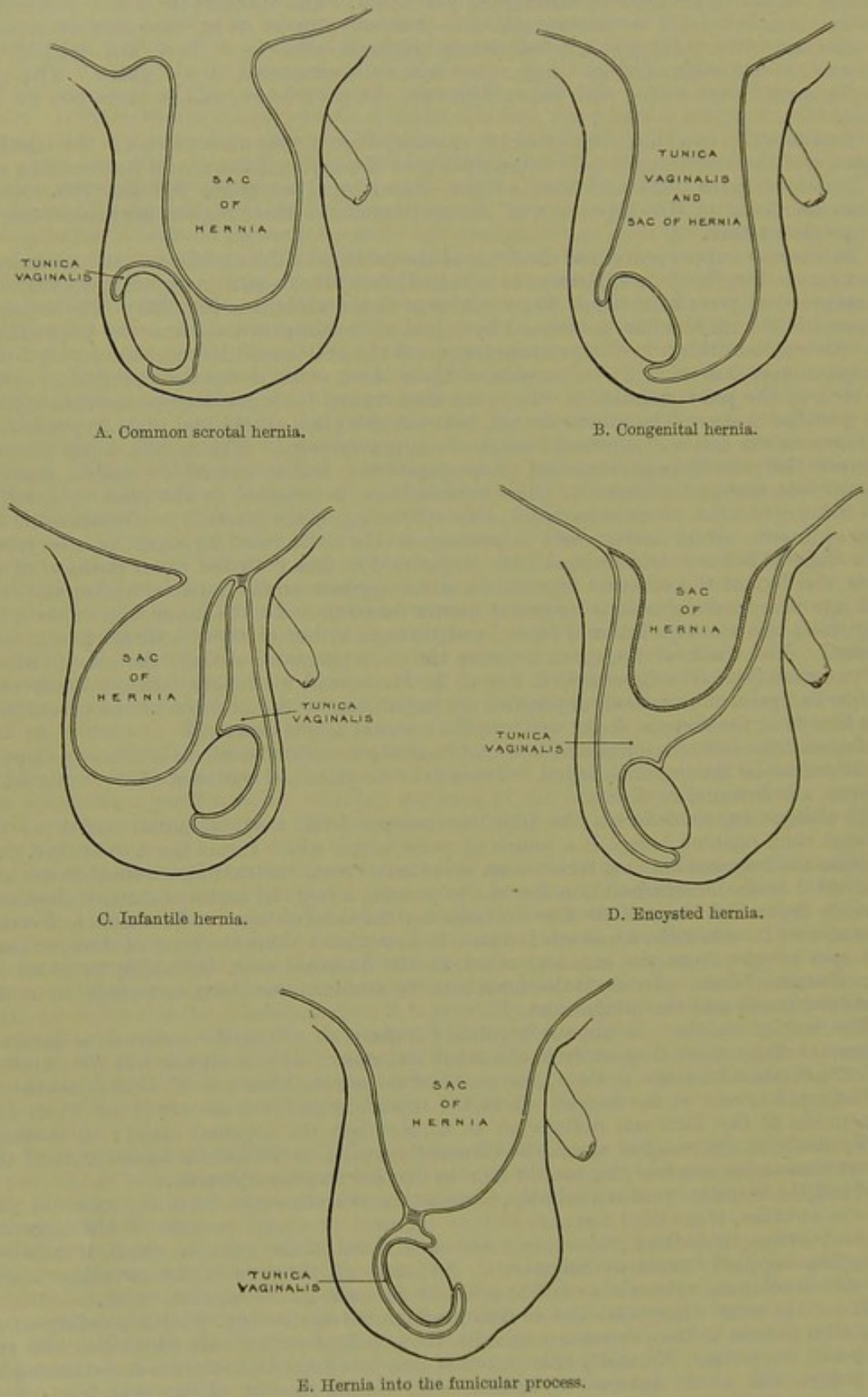

A. Common scrotal hernia.

B. Congenital hernia.

C. Infantile hernia.

D. Encysted hernia.

E. Hernia into the funicular process.

hernia, and the gut lies in contact with the testis. Though this form of hernia is termed *congenital*, the term does not imply that the hernia existed at birth, but merely that a condition is present which may allow of the descent of the hernia at any moment. As a matter of fact, congenital herniæ frequently do not appear till adult life.

Where the processus vaginalis is occluded at the internal ring only and remains patent throughout the rest of its extent two varieties of oblique inguinal hernia may be produced, viz. infantile and encysted herniæ. In the *infantile* form (fig. 958, C) the bowel presses upon the peritoneum in the immediate neighbourhood of the septum and causes it to yield and form a sac which descends behind the tunica vaginalis; so that in front of the bowel there are three layers of peritoneum, the two layers of the tunica vaginalis and its own sac. In the *encysted* form (fig. 958, D) pressure at the occluded spot causes the septum to yield and form a sac which projects into the tunica vaginalis, forming thus a sac within a sac, so that in front of the bowel there are two layers of peritoneum, one from the tunica vaginalis, and one from its own sac.

Where the processus vaginalis is occluded at the lower point only, i.e. just above the testis, the intestine descends into the pouch of peritoneum as far as the testis, but is prevented from entering the sac of the tunica vaginalis by the septum which has formed between it and the pouch. This is known as *hernia into the funicular process*; it resembles the congenital form except that instead of enveloping the testis it lies above it.

In *direct inguinal hernia* the protrusion makes its way through some part of Hesselbach's triangle, either through (*a*) the outer part, where only extra-peritoneal tissue and transversalis fascia intervene between the peritoneum and the aponeurosis of the External oblique; or through (*b*) the conjoined tendon which stretches across the inner two-thirds of the triangle between the artery and the middle line. In the former the hernial protrusion escapes from the abdomen on the outer side of the conjoined tendon, pushes before it the peritoneum, extra-peritoneal tissue and transversalis fascia, and enters the inguinal canal. It passes along nearly the whole length of the canal and finally emerges from the external ring, receiving an investment from the intercolumnar fascia. The coverings of this form of hernia are similar to those of the oblique form, except that a portion derived from the general layer of transversalis fascia replaces the infundibuliform fascia.

In the second form, which is the more frequent, the hernia is either forced through the fibres of the conjoined tendon, or the tendon is gradually distended in front of it so as to form a complete investment for it. The intestine then enters the lower end of the inguinal canal, escapes at the external ring, lying on the inner side of the cord, and receives additional coverings from the intercolumnar fascia, the superficial fascia and the integument. The coverings of this form therefore differ from those of the oblique form in that the conjoined tendon is substituted for the cremaster, and the infundibuliform fascia is replaced by a portion of the general layer of the transversalis fascia.

The seat of stricture in both varieties of direct hernia is usually found either at the neck of the sac or at the external ring. In that form which perforates the conjoined tendon it not infrequently occurs at the edges of the fissure through which the gut passes. In all cases of inguinal hernia, whether direct or oblique, it is proper to divide the stricture directly upwards; by cutting in this direction the incision is made parallel to the deep epigastric artery—external to it in the oblique variety, internal to it in the direct form of hernia; all chance of wounding the vessel is thus avoided. Direct inguinal hernia is of much less frequent occurrence than oblique, and is found more often in men than in women. The main differences in position between it and the oblique form are: (*a*) it is placed over the pubis and not in the course of the inguinal canal; (*b*) the deep epigastric artery runs on the outer or iliac side of the neck of the sac; and (*c*) the spermatic cord lies along its external and posterior sides, not directly behind it as in oblique inguinal hernia.

Femoral hernia.—In femoral hernia the protrusion of the intestine takes place through the crural ring. As already described (page 708), this ring is closed by the septum crurale, a partition of modified extra-peritoneal tissue; it is therefore a weak spot in the abdominal wall, and especially in the female, where the ring is larger and where profound changes are produced in the tissues of the abdomen by pregnancy. Femoral hernia is therefore more common in women than in men.

When a portion of intestine is forced through the crural ring, it carries before it a pouch of peritoneum, which forms the hernial sac. It receives an investment from the extra-peritoneal tissue or septum crurale, and descends along the crural canal, or inner compartment of the sheath of the femoral vessels, as far as the saphenous opening; at this point it changes its course, being prevented from extending farther down the sheath on account of the narrowing of the latter, and its close contact with the vessels, and also the close attachment of the superficial fascia and femoral sheath to the lower part of the circumference of the saphenous opening. The tumour is consequently directed forwards, pushing before it the cribriform fascia, and then curves upwards over Poupart's ligament and the lower part of the External oblique, being covered by the superficial fascia and integument. While the hernia is contained in the crural canal it is usually of small size, owing to the resisting nature of the surrounding parts, but when it escapes from the saphenous opening into the loose areolar tissue of the groin it becomes considerably enlarged. The direction taken by a femoral hernia in its descent is at first downwards, then forwards and upwards; in the application of taxis for the reduction of a femoral hernia therefore, pressure should be directed in the reverse order.

The coverings of a femoral hernia from within outwards are: peritoneum, septum crurale, femoral sheath, cribriform fascia, superficial fascia, and integument. Sir Astley

Cooper has described an investment for femoral hernia under the name of *fascia propria*, lying immediately external to the peritoneal sac but frequently separated from it by some adipose tissue. Surgically it is important to remember the frequent existence of this layer on account of the ease with which an inexperienced operator may mistake the fascia for the peritoneal sac and the contained fat for omentum, as there is often a great excess of subperitoneal fatty tissue enclosed in the 'fascia propria.' In many cases it resembles a fatty tumour, but on further dissection the true hernial sac will be found in the centre of the mass of fat. The fascia propria is merely modified extra-peritoneal tissue which has been thickened to form a membranous sheet by the pressure of the hernia.

When the intestine descends along the femoral canal only as far as the saphenous opening the condition is known as *incomplete* femoral hernia. The small size of the protrusion in this form of hernia, on account of the firm and resisting nature of the canal in which it is contained, renders it an exceedingly dangerous variety of the disease, from the extreme difficulty of detecting the existence of the swelling, especially in corpulent subjects. The coverings of an incomplete femoral hernia would be from without inwards: integument, superficial fascia, superior falciform process of fascia lata, femoral sheath, septum crurale and peritoneum.

The seat of stricture of a femoral hernia varies: it may be in the peritoneum at the neck of the hernial sac; in the greater number of cases it is at the point of junction of the superior falciform process with the free edge of Gimbernat's ligament; or it may be at the margin of the saphenous opening. The stricture should in every case be divided in a direction upwards and inwards for a distance of about one-sixth to one-quarter of an inch. All vessels or other structures of importance in relation to the neck of the sac will thus be avoided.

The spine of the pubis forms an important landmark in serving to differentiate the inguinal from the femoral variety of hernia. The inguinal protrusion is above and to the inner side of the spine, while the femoral is below and to its outer side.

There are several details of practical interest in connection with the mesentery which merit notice. 1. The depth of the mesentery—that is to say, the distance from its parietal to its intestinal attachment—is normally less than eight inches, generally nearer six or seven; but under certain abnormal conditions it may become elongated, and this would appear to favour the occurrence of hernia of the intestine. 2. Not only may the depth of the mesentery be increased, but its point of attachment to the posterior abdominal wall may yield, and descend over the lumbar vertebræ. This condition, which is known under the name of *enteroptosis*, usually occurs in women who have borne many children, and is attended with general relaxation of the abdominal parietes. It produces a characteristic appearance, the abdomen being prominent and pendulous below, while above, it is flattened and constricted. 3. Holes are sometimes present in the mesentery, and these may be congenital, or may be the result of injury. They are of practical importance, since a knuckle of intestine may become herniated into one of them, causing acute strangulation. 4. The lymphatic glands contained between the two layers of the mesentery are frequently the seat of tuberculous deposit, especially in children.

The surgical anatomy of the rectum is of considerable importance. There may be congenital malformations due to arrest of, or imperfection in, development. Thus, there may be no proctodœal invagination (see page 161), and consequently a complete absence of the anus; or the hind-gut may be imperfectly developed, and there may be an absence of the rectum, though the anus is developed; or the ectodermal invagination may not communicate with the termination of the hind-gut from want of solution of continuity in the septum which in early fœtal life exists between the two. The mucous membrane is thick and but loosely connected to the muscular coat beneath, and thus favours prolapse, especially in children. The vessels of the rectum are arranged, as mentioned above, longitudinally, and are contained in the loose cellular tissue between the mucous and muscular coats, and receive no support from surrounding tissues, and this favours varicosity. Moreover, the veins, after running upwards in a longitudinal direction for about five inches in the submucous tissue, pierce the muscular coats, and are liable to become constricted at this spot by the contraction of the muscular wall of the gut. In addition to this there are no valves in the superior hæmorrhoidal veins, and the vessels of the rectum are placed in a dependent position, and are liable to be pressed upon and obstructed by hardened fæces. The anatomical arrangement, therefore, of the hæmorrhoidal vessels explains the great tendency to the occurrence of piles. The presence of the Sphincter ani externus is of surgical importance, since it is the constant contraction of this muscle which prevents an ischio-rectal abscess from healing, and causes it to become a fistula. Also the reflex contraction of this muscle is the cause of the severe pain complained of in fissure of the anus. The relations of the peritoneum to the bowel are of importance in connection with the operation of removal of the rectum for malignant disease. This membrane gradually leaves the rectum as it descends into the pelvis; first leaving its posterior surface, then the sides, and then the anterior surface, to become reflected, in the male on to the posterior wall of the bladder, forming the recto-vesical pouch, and in the female on to the posterior wall of the vagina, forming Douglas's pouch. The recto-vesical pouch of peritoneum extends to within three inches from the anus. Within recent years much more extensive operations

have been done for the removal of cancer of the rectum, and in these the peritoneal cavity has necessarily been opened. If, in these cases, the opening is plugged with antiseptic gauze until the operation is completed and then the edges of the wound in the peritoneum are accurately brought together with sutures, no evil result appears to follow. For cases of cancer of the rectum which are too low to be reached by abdominal section, and too high to be removed by the perinæum, Kraske has devised an operation which goes by his name. The patient is placed on his right side and an incision is made from the last piece of the sacrum to the anus. The soft parts are now separated from the back of the sides of the sacrum and coccyx, and the greater and lesser sacro-sciatic ligaments are separated. The coccyx is removed, and if necessary a small piece of the sacrum, and the edges of the wound being now forcibly drawn outwards, a considerable length of the rectum is brought into view, and the diseased portion can be removed, leaving the anal portion of the gut, if healthy. The two divided ends of the gut can sometimes be approximated and sutured together, the posterior part being left open for drainage.

The colon frequently requires opening in cases of intestinal obstruction, and by some surgeons this operation is performed in cases of cancer of the rectum as soon as the disease is recognised, in the hope that the symptoms may be relieved by removing the irritation produced by the passage of fæcal matter over the diseased surface. The operation of colostomy may be performed either in the inguinal or lumbar region; but inguinal colostomy has in the present day entirely superseded the lumbar operation. The main reason for preferring this operation is that a spur-shaped process of the mesocolon can be formed, which prevents any fæcal matter finding its way past the artificial anus, and the greater ease in maintaining cleanliness. The pelvic colon being entirely surrounded by peritoneum, a coil can be drawn out of the wound and opened, leaving the attachment of the mesocolon to form a spur, much as it does in an artificial anus caused by sloughing of the intestine after a strangulated hernia, and this prevents any fæcal matter finding its way from the gut above the opening into that below. The operation is performed by making an incision two or three inches in length from a point one inch internal to the anterior superior spinous process of the ilium, parallel to Poupart's ligament. The various muscular layers are cut through, and the peritoneum opened; the pelvic colon is now sought for, pulled out of the wound, and fixed by passing a needle threaded with carbolised silk first through the mesocolon close to the gut, and then through the abdominal wall. The wound is dressed, and about the second day the protruding coil of intestine is opened.

The loose connective tissue round the rectum is occasionally the site of an abscess, the active focus of which, however, may be located elsewhere. This form of abscess may be described as the *superior pelvic-rectal*; it is placed above the pelvic diaphragm but beneath the peritoneum. The acute variety is generally due to ulceration or perforation of the bowel (possibly produced by a foreign body) above the level of attachment of the Levator ani. The abscess may also occur above a stricture (simple or malignant) of the rectum; occasionally it arises from suppuration around the prostate, and more rarely follows abscess of the vesiculæ seminales. Chronic abscesses also appear in the same region either from caries of the anterior surface of the sacrum or from caseation of the presacral lymphatic glands, whilst in other cases an abscess finds its way down into the pelvis from disease of the anterior surfaces of the bodies of the lumbar vertebræ.

The Liver

The **liver** (hepar) is the largest gland in the body, and is situated in the upper and right parts of the abdominal cavity, occupying almost the whole of the right hypochondrium, the greater part of the epigastrium, and not uncommonly extending into the left hypochondrium as far as the mammary line. In the male it weighs from fifty to sixty ounces, in the female from forty to fifty. It is relatively much larger in the fœtus than in the adult, constituting, in the former, about one-eighteenth, and in the latter, about one thirty-sixth of the entire body weight. Its greatest transverse measurement is from eight to nine inches. Vertically, near its lateral or right surface, it measures about six or seven inches, while its greatest antero-posterior diameter is on a level with the upper end of the right kidney, and is from four to five inches. Opposite the vertebral column its measurement from before backwards is reduced to about three inches. Its consistence is that of a soft solid; it is, however, friable and easily lacerated; its colour is a dark reddish-brown, and its specific gravity is 1·05.

To obtain a correct idea of its shape it must be hardened *in situ*, and it will then be seen to present the appearance of a wedge, the base of which is directed to the right and the thin edge towards the left. Symington describes its shape as that 'of a right-angled triangular prism with the right angle rounded off.'

Surfaces.—The liver possesses five surfaces, viz. superior, inferior, anterior, posterior, and lateral. A sharp, well-defined margin divides the inferior from the anterior and lateral surfaces, but the other surfaces are separated from one another by thick, rounded borders. The superior and anterior surfaces are attached to the Diaphragm and anterior abdominal wall by a triangular or falciform fold of peritoneum, the *suspensory* or *falciform ligament*, in the free margin of which is a rounded cord, the *ligamentum teres* or obliterated umbilical vein. The line of attachment of the falciform ligament divides the liver into two parts, termed the right and left lobes, the right being much the larger. The inferior and posterior surfaces are divided into five lobes by five fissures, which are arranged in the form of the letter H. The left limb of the H marks on these surfaces the division of the liver into right and left lobes; it is known as the *longitudinal fissure*, and consists of two parts, viz. the *umbilical fissure* in front and the *fissure for the ductus venosus* behind. The right limb of the H is formed in front by the *fissure or fossa for the gall-bladder*, and behind by the *fissure for the inferior vena cava*; these two fissures are separated from one another by a band of liver-substance, termed the *caudate lobe*. The bar connecting the two limbs

Fig. 959.—The liver. Superior and anterior surfaces. (Slightly modified from His' model.)

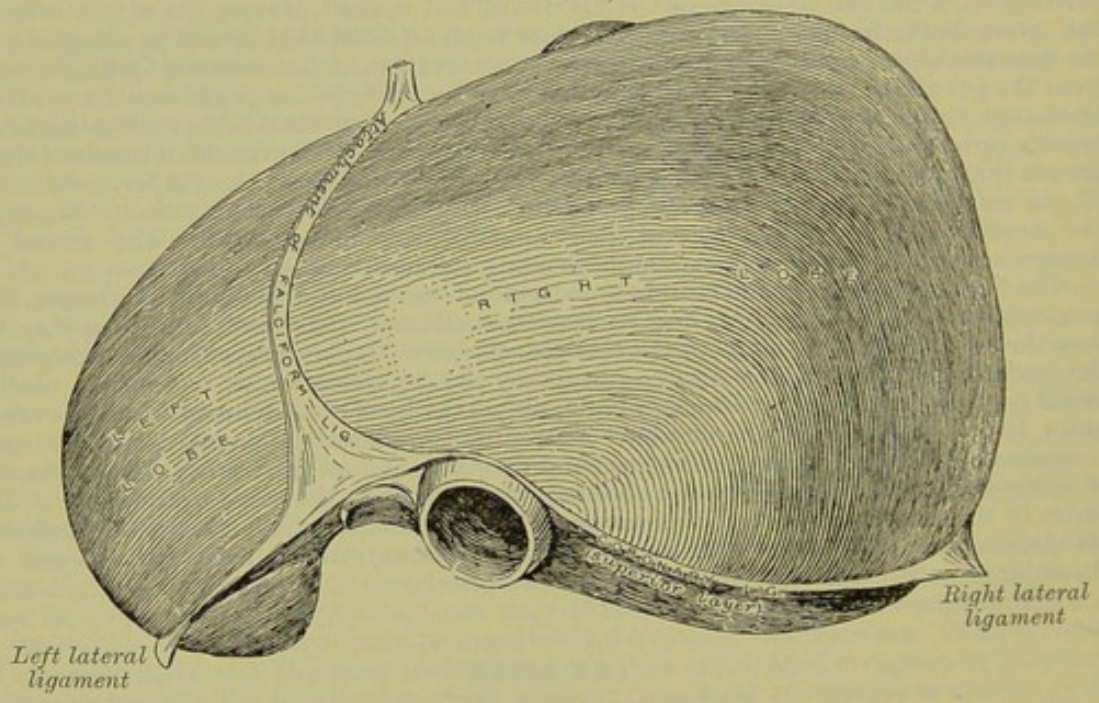

of the H is the *transverse* or *portal fissure*; in front of it is the *quadrate lobe*, behind it the *Spigelian lobe*.

The *superior surface* (fig. 959) comprises a part of both lobes, and, as a whole, is convex, and fits under the vault of the Diaphragm; its central part, however, presents a shallow depression, which corresponds with the position of the pericardium on the upper surface of the Diaphragm. It is separated from the anterior, posterior, and lateral surfaces by thick, rounded borders. Its left extremity is separated from the under surface by a prominent sharp margin. Except along the lines of attachment of the falciform ligament it is completely covered by peritoneum.

The *anterior surface* is large, triangular in shape, and comprises also a part of both lobes. It is directed forwards, and the greater part of it is in contact with the Diaphragm, which separates it on the right from the sixth to the tenth ribs and their cartilages, and on the left from the seventh and eighth costal cartilages. In the middle line it lies behind the ensiform cartilage, and in the angle between the diverging rib cartilages of opposite sides is in contact with the abdominal wall. It is separated from the inferior surface by a sharp margin, and from the superior and lateral surfaces by thick rounded borders. It is completely covered by peritoneum except along the line of attachment of the falciform ligament.

The *lateral* or *right surface* is covered by peritoneum, and is convex from before backwards and slightly so from above downwards. It is directed towards the right side, forming the base of the wedge, and lies against the lateral portion of the Diaphragm, which separates it from the lower part of the pleura and lung, outside which are the right costal arches from the seventh to the eleventh inclusive.

The *inferior* or *visceral surface* (figs. 960, 961) is uneven, concave, directed downwards, backwards, and to the left, and is in relation with the stomach and duodenum, the hepatic flexure of the colon, and the right kidney and suprarenal gland. The surface is almost completely invested by peritoneum; the only parts where this covering is absent are where the gall-bladder is attached to the liver, and at the transverse fissure where the two layers of the lesser omentum are separated from each other by the blood-vessels and ducts of the viscus. The inferior surface of the left lobe presents behind and to the left an impression (impressio cardiaca) where it is moulded over the cardiac part of the stomach, and to the right of this a rounded eminence, the *tuber omentale*, which fits into the concavity of the lesser curvature of the stomach

FIG. 960.—The liver. Inferior surface. (Drawn from His' model.)

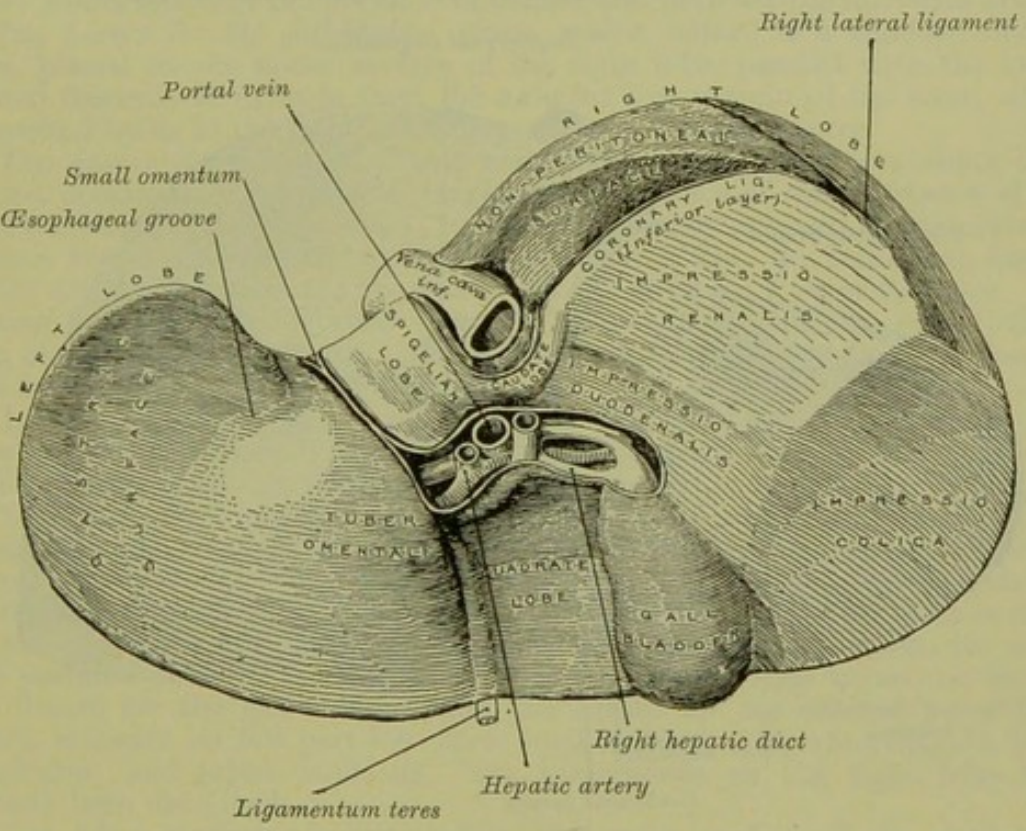

and lies in front of the anterior layer of the lesser omentum. The under surface of the right lobe is divided into two unequal portions by a fossa, the *fossa vesicalis* (fossa vesicæ felleæ), which lodges the gall-bladder; the portion to the left, the smaller of the two, is the *quadrate lobe*, and is in relation with the pyloric end of the stomach and the first portion of the duodenum. The portion of the under surface of the right lobe to the right of the fossa vesicalis presents two shallow impressions, one situated behind the other, the two being separated by a ridge. The anterior of these two impressions, the *impressio colica*, is produced by the hepatic flexure of the colon; the posterior, the *impressio renalis*, is occupied by the upper part of the right kidney and lower part of the right suprarenal gland. To the inner side of the renal impression is a third and slightly marked impression, lying between it and the neck of the gall-bladder. This is caused by the second portion of the duodenum, and is known as the *impressio duodenalis*. Just in front of the inferior vena cava is a narrow strip of liver tissue, the *caudate lobe*, which connects the right inferior angle of the Spigelian lobe to the under surface of the right lobe. It forms the upper boundary of the foramen of Winslow.

The *posterior surface* (fig. 961) is rounded and broad behind the right lobe, but narrow on the left. Over a large part of its extent it is not covered by peritoneum; this uncovered portion is about three inches broad at its widest part, and is in direct contact with the Diaphragm. It is marked off from the upper surface by the line of reflection of the upper or anterior layer of the coronary ligament, and from the under surface by the line of reflection of the lower layer of the coronary ligament. The central part of the posterior surface presents a deep concavity which is moulded on the vertebral column and crura of the Diaphragm. To the right of this the inferior vena cava is lodged in an indentation in the liver substance, lying between the uncovered area and the Spigelian lobe. Close to the right of this indentation and immediately above the renal impression is a small triangular depressed area (*impressio suprarenalis*), the greater part of which is devoid of peritoneum; it lodges the right suprarenal gland. To the left of the inferior vena cava is the *Spigelian lobe*, which lies between the fissure for the vena cava and the fissure for the ductus venosus. Its lower end projects and forms part of the posterior boundary of the transverse fissure; on the right, it is connected with the

Fig. 961.—The liver. Posterior surface. (Drawn from His' model.)

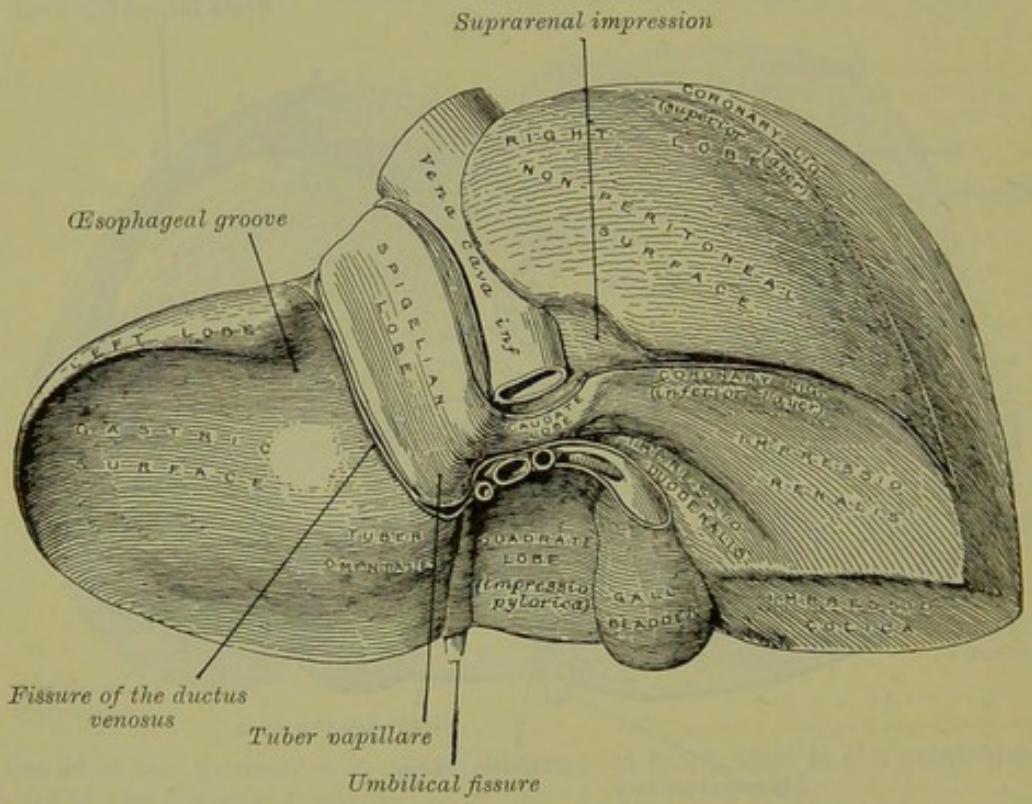

under surface of the right lobe of the liver by the caudate lobe, and on the left it presents a tubercle, the *tuber papillare*. Its posterior surface rests upon the Diaphragm, being separated from it merely by the upper part of the lesser sac of the peritoneum. To the left of the fissure for the ductus venosus is a groove in which lies the antrum cardiacum of the œsophagus.

The *inferior border* is thin and sharp, and marked opposite the attachment of the falciform ligament by a deep notch, the *umbilical notch*, and opposite the cartilage of the ninth rib by a second notch for the fundus of the gall-bladder. In adult males this border generally corresponds with the lower margin of the thorax in the right nipple line; but in women and children it usually projects below the ribs.

The *left extremity of the liver* is thin and flattened from above downwards.

Fissures (fig. 961).—As already described, five fissures are seen upon the under and posterior surfaces of the liver. They are, the umbilical fissure and the fissure for the ductus venosus, forming together the longitudinal fissure; the transverse fissure; the fissure for the gall-bladder; and the fissure for the inferior vena cava.

The *longitudinal fissure* (fossa sagittalis sinistra) is a deep groove, which extends from the notch on the anterior margin of the liver to the upper border of the posterior surface of the organ; it separates the right and left lobes. The transverse fissure joins it, at right angles, and divides it into two parts. The anterior part, or *umbilical fissure* (fossa venæ umbilicalis), lodges the umbilical vein in the fœtus, and its remains (the ligamentum teres) in the adult; it lies between the quadrate lobe and the left lobe of the liver, and is often partially bridged over by a prolongation of the hepatic substance, the *pons hepatis*. The posterior part, or *fissure for the ductus venosus* (fossa ductus venosi), lies between the left lobe and the lobe of Spigelius; it lodges in the fœtus the ductus venosus, and in the adult a slender fibrous cord (lig. venosum), the obliterated remains of that vessel.

The *transverse* or *portal fissure* (porta hepatis) is a short but deep fissure, about two inches in length, extending transversely across the under surface of the left portion of the right lobe, nearer its posterior surface than its anterior border. It joins nearly at right angles with the longitudinal fissure, and separates the quadrate lobe in front from the caudate and Spigelian lobes behind. It transmits the portal vein, the hepatic artery and nerves, and the hepatic duct and lymphatics. The hepatic duct lies in front and to the right, the hepatic artery to the left, and the portal vein behind and between the duct and artery.

The *fissure for the gall-bladder* (fossa vesicæ felleæ) is a shallow, oblong fossa, placed on the under surface of the right lobe, parallel with the longitudinal fissure. It extends from the anterior free margin of the liver, which is notched by it, to the right extremity of the transverse fissure.

The *fissure for the inferior vena cava* (fossa venæ cavæ) is a short deep fissure, occasionally a complete canal, in consequence of the substance of the liver surrounding the vena cava. It extends obliquely upwards on the posterior surface from the lobus caudatus which separates it from the transverse fissure, and is situated between the Spigelian lobe and the bare area of the liver. On slitting open the inferior vena cava the orifices of the hepatic veins will be seen opening into this vessel at its upper part, after perforating the floor of this fissure.

Lobes.—The lobes of the liver, like the ligaments and fissures, are five in number—the right lobe, the left lobe, the lobus quadratus, the lobus Spigelii, and the lobus caudatus, the last three being merely parts of the right lobe.

The *right lobe* is much larger than the left; the proportion between them being as six to one. It occupies the right hypochondrium, and is separated from the left lobe on its upper and anterior surfaces by the falciform ligament; on its under and posterior surfaces by the longitudinal fissure; and in front by the umbilical notch. It is of a somewhat quadrilateral form, its under and posterior surfaces being marked by three fissures: the transverse fissure, the fissure for the gall-bladder, and the fissure for the inferior vena cava, which separate its left part into three smaller lobes: the lobus Spigelii, lobus quadratus, and lobus caudatus. The impressions on the right lobe have already been described.

The *lobus quadratus* is situated on the under surface of the right lobe, bounded in front by the inferior margin of the liver; behind by the transverse fissure; on the right, by the fossa for the gall-bladder; and on the left, by the umbilical fissure. It is oblong in shape, its antero-posterior diameter being greater than its transverse.

The *lobus Spigelii* is situated upon the posterior surface of the right lobe of the liver, opposite the tenth and eleventh thoracic vertebræ. It is bounded, below, by the transverse fissure; on the right, by the fissure for the inferior vena cava; and, on the left, by the fissure for the ductus venosus. It looks backwards, being nearly vertical in position; it is longer from above downwards than from side to side, and is somewhat concave in the transverse direction.

The *lobus caudatus*, or tailed lobe, is a small elevation of the hepatic substance extending obliquely outwards, from the lower extremity of the lobus Spigelii to the under surface of the right lobe. It is situated behind the transverse fissure, and separates the fissure for the gall-bladder from the commencement of the fissure for the inferior vena cava.

The *left lobe* is smaller and more flattened than the right. It is situated in the epigastric and left hypochondriac regions. Its upper surface is slightly

convex and is moulded on to the Diaphragm ; its under surface presents the *gastric impression* and *omental tuberosity*, already referred to.

Ligaments.—The liver is connected to the under surface of the Diaphragm and to the anterior wall of the abdomen by five ligaments, four of which are peritoneal folds ; the fifth is a round, fibrous cord, resulting from the obliteration of the umbilical vein. These ligaments are the falciform, coronary, two lateral, and round. It is also attached to the lesser curvature of the stomach by the gastro-hepatic or small omentum (see page 1123).

The *falciform ligament* (lig. falciforme hepatis) is a broad and thin antero-posterior peritoneal fold, falciform in shape, its base being directed downwards and backwards, its apex upwards and backwards. It is attached by one margin to the under surface of the Diaphragm, and the posterior surface of the sheath of the right Rectus muscle as low down as the umbilicus ; by its hepatic margin it extends from the notch on the anterior margin of the liver, as far back as the posterior surface. It is composed of two layers of peritoneum closely united together. Its base or free edge contains the round ligament between its layers.

The *coronary ligament* (lig. coronarium hepatis) consists of an upper and a lower layer. The *upper layer* is formed by the reflection of the peritoneum from the upper margin of the bare area of the liver to the under surface of the Diaphragm, and is continuous with the right layer of the falciform ligament. The *lower layer* is reflected from the lower margin of the bare area on to the right kidney and suprarenal gland.

The *lateral ligaments*, two in number, right and left, are triangular in shape. The *right lateral ligament* (lig. triangulare dextrum) is situated at the right extremity of the bare area, and is a small fold which passes to the Diaphragm, being formed by the apposition of the upper and lower layers of the coronary ligament. The *left lateral ligament* (lig. triangulare sinistrum) is a fold of some considerable size, which connects the posterior part of the upper surface of the left lobe to the Diaphragm ; its anterior layer is continuous with the left layer of the falciform ligament.

The *round ligament* (lig. teres hepatis) is a fibrous cord resulting from the obliteration of the umbilical vein. It ascends from the umbilicus, in the free margin of the falciform ligament, to the notch in the anterior border of the liver, from which it may be traced along the longitudinal fissure on the inferior surface of the liver ; on the posterior surface it is continued upwards as the obliterated ductus venosus (lig. venosum) as far as the inferior vena cava.

Vessels and Nerves.—The vessels connected with the liver are, the hepatic artery, the portal vein, and the hepatic veins.

The *hepatic artery* and *portal vein*, accompanied by numerous nerves, ascend to the transverse fissure, between the layers of the gastro-hepatic omentum. The *bile-duct* and lymphatic vessels descend from the transverse fissure between the layers of the same omentum. The relative positions of the three structures are as follows: the bile-duct lies to the right, the hepatic artery to the left, and the portal vein behind and between the other two. They are enveloped in a loose areolar tissue, the *capsule of Glisson*, which accompanies the vessels in their course through the portal canals, in the interior of the organ.

The *hepatic veins* convey the blood from the liver, and are described on page 760. They have very little cellular investment, and what there is binds their parietes closely to the walls of the canals through which they run ; so that, on section of the organ, they remain widely open and are solitary, and may be easily distinguished from the branches of the portal vein, which are more or less collapsed, and always accompanied by an artery and duct.

The *lymphatics* of the liver are described on page 786.

The *nerves* of the liver, derived from the left pneumogastric and sympathetic, enter at the transverse fissure and accompany the vessels and ducts to the interlobular spaces. Here, according to Korolkow, the medullated fibres are distributed almost exclusively to the coats of the blood-vessels ; while the non-medullated enter the lobules and ramify between the cells.

Structure of the Liver.—The substance of the liver is composed of lobules, held together by an extremely fine areolar tissue, in which ramify the portal vein, hepatic ducts, hepatic artery, hepatic veins, lymphatics, and nerves ; the whole being invested by a serous and a fibrous coat.

The *serous coat* is derived from the peritoneum, and invests the greater part of the surface of the organ. It is intimately adherent to the fibrous coat.

The *fibrous coat* lies beneath the serous investment, and covers the entire surface of the organ. It is difficult of demonstration, excepting where the serous coat is deficient. At the transverse fissure it is continuous with the capsule of Glisson, and, on the surface of the organ, with the areolar tissue separating the lobules.

The *lobules* (figs. 962, 963) form the chief mass of the hepatic substance; they may be seen either on the surface of the organ, or by making a section through the gland, as small

Fig. 962.—Longitudinal section of an hepatic vein. (After Kiernan.)

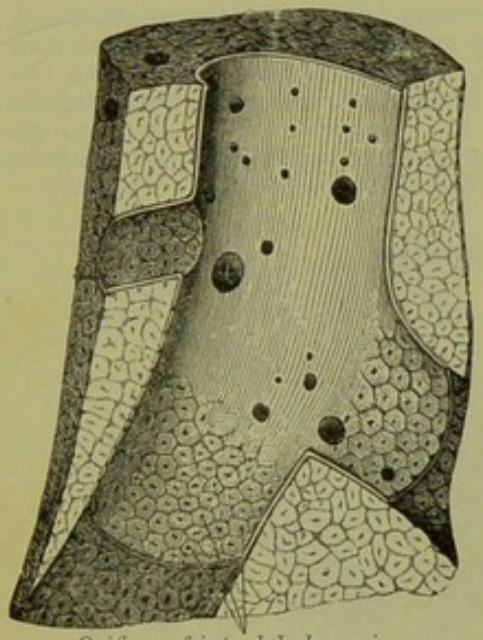

Fig. 963.—Longitudinal section of a small portal vein and canal. (After Kiernan.)

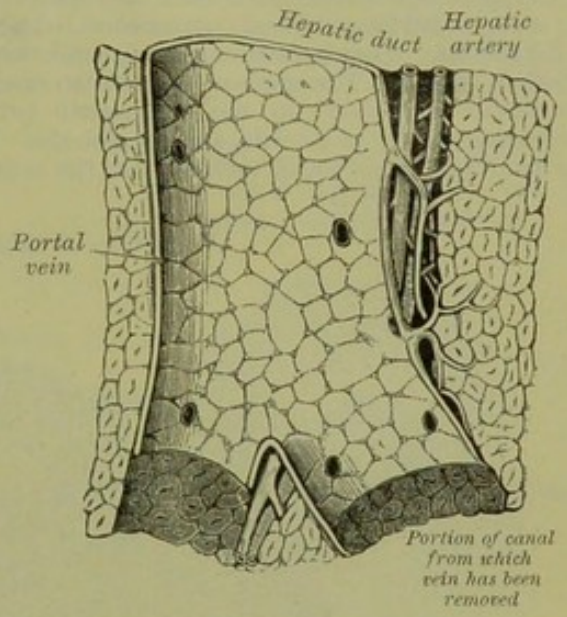

granular bodies, about the size of a millet seed, measuring from one-twentieth to one-tenth of an inch in diameter. In the human subject their outlines are very irregular; but in some of the lower animals (for example, the pig) they are well defined, and, when divided transversely, have polygonal outlines. The bases of the lobules are clustered round the smallest radicles (*sublobular*) of the hepatic veins, to which each is connected by means of a small branch which issues from the centre of the lobule (*intralobular*). The remaining part of the

Fig. 964.—Horizontal section of liver (dog).

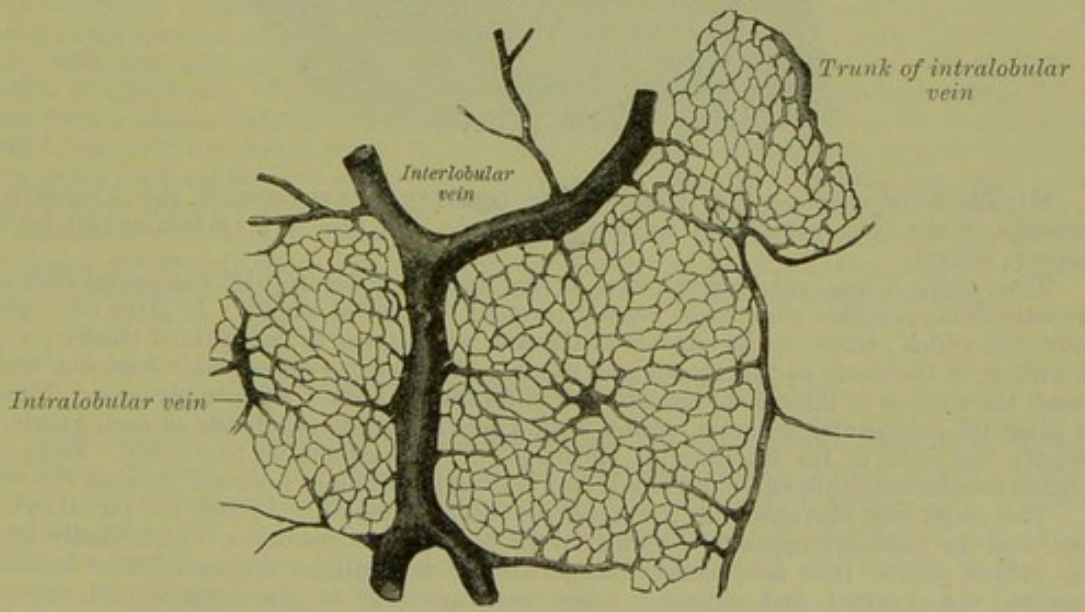

surface of each lobule is imperfectly isolated from the surrounding lobules by a thin stratum of areolar tissue, in which is contained a plexus of vessels (the *interlobular plexus*) and ducts. In some animals, as the pig, the lobules are completely isolated from one another by the interlobular areolar tissue.

If one of the sublobular veins be laid open, the bases of the lobules may be seen through the thin wall of the vein on which they rest, arranged in a form resembling a tesselated

pavement, the centre of each polygonal space presenting a minute aperture, the mouth of an intralobular vein (fig. 962).

Microscopic appearance (fig. 965).—Each lobule consists of a mass of cells (*hepatic cells*), surrounded by a dense capillary plexus, composed of vessels which penetrate from the circumference to the centre of the lobule, and terminate in the *intralobular vein*, which runs through its centre, to open at its base into one of the *sublobular veins*. Between the cells are also the minute bile capillaries. Therefore, in the lobule there are all the essentials of a secreting gland; that is to say: (1) *cells*, by which the secretion is formed; (2) *blood-vessels*, in close relation with the cells, containing the blood from which the secretion is derived; (3) *ducts*, by which the secretion, when formed, is carried away.

(1) The *hepatic cells* are more or less spheroidal in form; but may be rounded, flattened, or many-sided from mutual compression. They vary in size from $\frac{1}{1000}$ to $\frac{1}{2000}$ of an inch in diameter. They consist of a honeycomb network, and contain one or sometimes two distinct nuclei. The nucleus contains an intranuclear network and one or two refractile nucleoli. Imbedded in the honeycomb network are numerous yellow particles, the colouring-matter of the bile, and fat globules. The cells adhere together by their surfaces so as to form rows, which radiate from the centre to the circumference of the lobules.*

FIG. 965.—A single liver lobule.

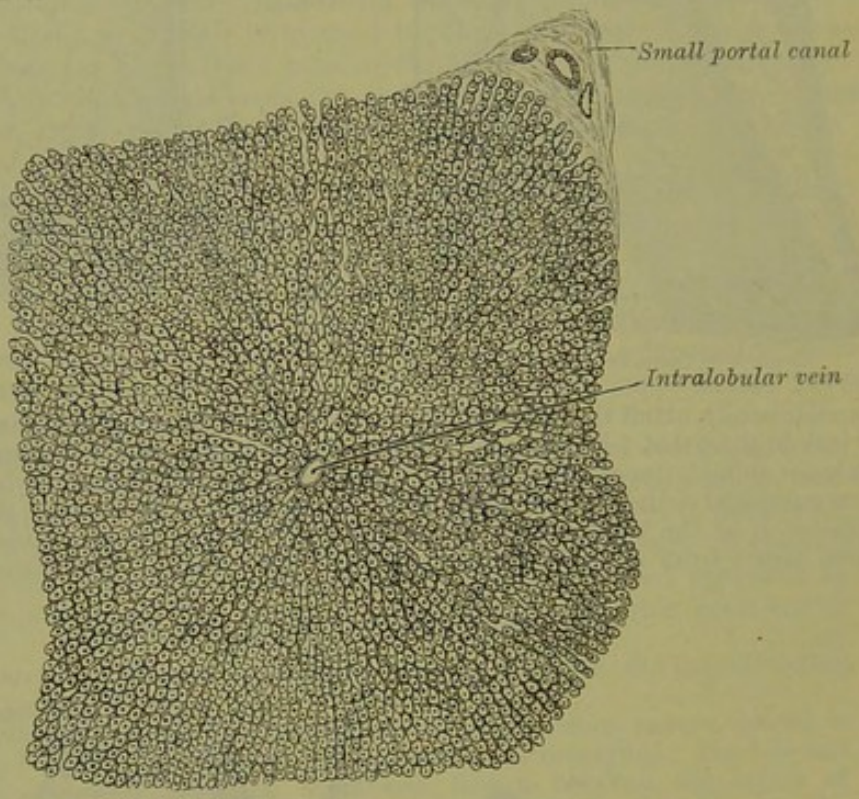

(2) *The blood-vessels.*—The blood in the capillary plexus around the liver-cells is brought to the liver principally by the portal vein, but also to a certain extent by the hepatic artery.

The *hepatic artery*, entering the liver at the transverse fissure with the portal vein and hepatic duct, ramifies with these vessels through the portal canals. It gives off *vaginal branches*, which ramify in the capsule of Glisson, and appear to be destined chiefly for the nutrition of the coats of the vessels and ducts. It also gives off *capsular branches*, which reach the surface of the organ, terminating in its fibrous coat in stellate plexuses. Finally it gives off *interlobular branches*, which form a plexus on the outer side of each lobule, to supply the walls of the interlobular veins and the accompanying bile-ducts. From this plexus lobular branches enter the lobule and end in the capillary network between the cells.

The *portal vein* also enters at the transverse fissure, and runs through the portal canals, enclosed in Glisson's capsule, dividing in its course into branches, which finally break up into a plexus (the *interlobular plexus*) in the interlobular spaces. These branches receive the vaginal and capsular veins, corresponding to the vaginal and capsular branches of the hepatic artery (fig. 963). Thus it will be seen that all the blood carried to

* Delépine states that there are evidences of the arrangement of these cells in the form of columns, which form tubes with narrow lumina branching from terminal bile-ducts. This branching is evidenced by a divergence of the columns from lines extending between adjacent portal vessels. The columns of cells group round terminal bile-ducts and not round the so-called intralobular veins.—*Lancet*, 1895, vol. i. p. 1254.

the liver by the portal vein and hepatic artery finds its way into the interlobular plexus. From this plexus the blood is carried into the lobule by fine branches which converge from the circumference to the centre of the lobule, and are connected by transverse branches (fig. 964). In the interstices of the network of vessels thus formed are situated the liver-cells; and here it is that, the blood being brought into intimate connection with the liver-cells, the bile is secreted. Arrived at the centre of the lobule, all these minute vessels empty themselves into one vein, of considerable size, which runs down the centre of the lobule from apex to base, and is called the *intralobular vein*. At the base of the lobule this vein opens directly into the *sublobular vein*, with which the lobule is connected. The sublobular veins unite to form larger and larger trunks, and end at last in the hepatic veins, which converge to form three large trunks which open into the inferior vena cava, while that vessel is situated in the fissure appropriated to it at the back of the liver.

(3) *The bile-ducts.*—Several views have prevailed as to the mode of origin of the hepatic ducts; it seems, however, to be generally believed that they commence by little passages

Fig. 966.—Section of liver.

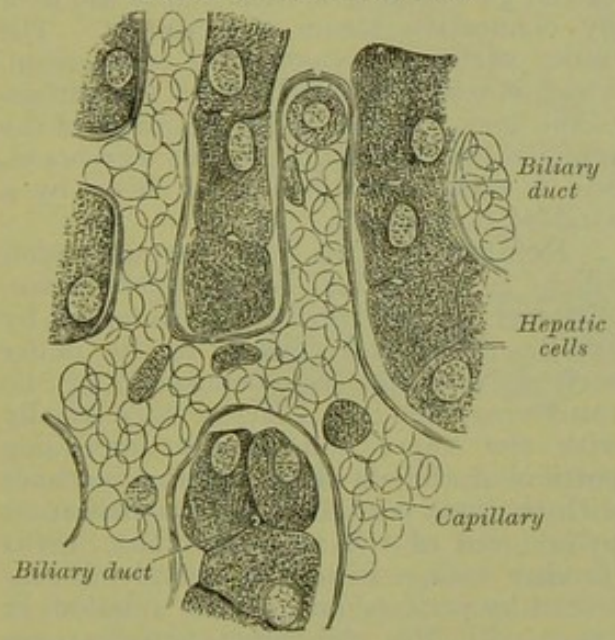

Fig. 967.—A transverse section of a small portal canal and its vessels. (After Kiernan.)

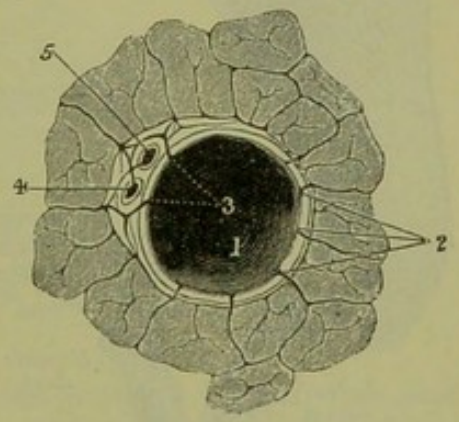

1. Portal vein. 2. Interlobular branches. 3. Vaginal branches. 4. Hepatic duct. 5. Hepatic artery.

which are formed between the cells, and which have been termed *intercellular biliary passages* or *bile capillaries*, although some authorities maintain that they have an intracellular origin. These passages are merely little channels or spaces left between the contiguous surfaces of two cells, or in the angle where three or more liver-cells meet (fig. 966), and they are always separated from the blood capillaries by at least half the width of a liver-cell. The channels thus formed radiate to the circumference of the lobule, and form a plexus (*interlobular*) between the lobules. From this plexus ducts are derived which pass into the portal canals, become enclosed in Glisson's capsule, and, accompanying the portal vein and hepatic artery (fig. 967), join with other ducts to form two main trunks, which leave the liver at the transverse fissure, and by their union form the *hepatic duct*.

Structure of the ducts.—The walls of the biliary ducts consist of a connective-tissue coat, in which are muscle-cells, arranged both circularly and longitudinally, and an epithelial layer, consisting of short columnar cells resting on a distinct basement-membrane.

Excretory Apparatus of the Liver

The excretory apparatus of the liver consists of (1) the *hepatic duct*, formed, as we have seen, by the junction of the two main ducts, which pass out of the liver at the transverse fissure; (2) the *gall-bladder*, which serves as a reservoir for the bile; (3) the *cystic duct*, or the duct of the gall-bladder; and (4) the *common bile-duct*, formed by the junction of the hepatic and cystic ducts.

The **hepatic duct.**—Two main trunks of nearly equal size issue from the liver at the transverse fissure, one from the right, the other from the left lobe; these unite to form the hepatic duct (ductus hepaticus), which then passes downwards and to the right for about an inch and a half, between the layers of the lesser omentum, where it is joined at an acute angle by the cystic duct, and so forms the common bile-duct (ductus choledochus). The hepatic duct is accompanied by the hepatic artery and portal vein.

The **gall-bladder** (vesica fellea) (fig. 968) is a conical or pear-shaped musculo-membranous sac, lodged in a fossa on the under surface of the right lobe of the liver, and extending from near the right extremity of the transverse fissure to the anterior border of the organ. It is from three to four inches in length, one inch in breadth at its widest part, and holds from eight to ten drachms. It is divided into a fundus, body, and neck. The *fundus*, or broad extremity, is directed downwards, forwards, and to the right, and projects beyond the anterior border of the liver; the *body* and *neck* lie in the fossa vesicalis, and are directed upwards and backwards to the left. The upper surface of the gall-bladder is attached to the liver by connective tissue and vessels. The under surface is covered by peritoneum, which is reflected on to it from the surface of the liver. Occasionally the whole of the organ is invested by the serous membrane, and is then connected to the liver by a kind of mesentery.

Fig. 968.—The gall-bladder and bile-ducts laid open. (Spalteholz.)

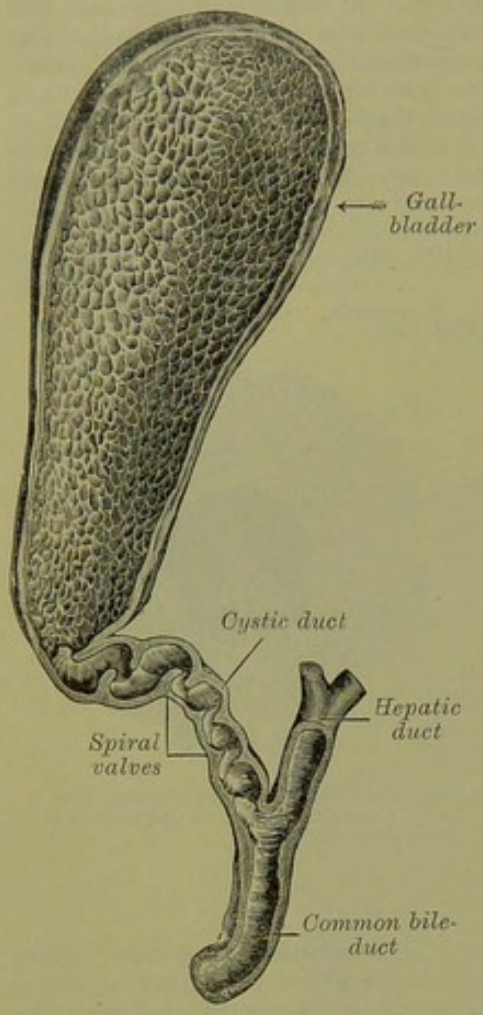

Relations.—The *body* (corpus vesicæ felleæ) is in relation, by its upper surface, with the liver, to which it is connected by areolar tissue and vessels; by its under surface, with the commencement of the transverse colon; and farther back usually with the upper end of the descending portion of the duodenum, but sometimes with the first portion of the duodenum or pyloric end of the stomach. The *fundus* (fundus vesicæ felleæ) is completely invested by peritoneum; it is in relation, in front, with the abdominal parietes, immediately below the ninth costal cartilage; behind with the transverse arch of the colon. The *neck* (collum vesicæ felleæ) is narrow, and curves upon itself like the letter S; at its point of connection with the cystic duct it presents a well-marked constriction.

Structure (fig. 969).—The gall-bladder consists of three coats: serous, fibrous and muscular, and mucous.

The *external* or *serous coat* is derived from the peritoneum; it completely invests the fundus, but covers the body and neck only on their under surfaces.

The *fibro-muscular coat*, a thin but strong layer forming the framework of the sac, consists of dense fibrous tissue, which interlaces in all directions, and is mixed with plain muscular fibres, disposed chiefly in a longitudinal direction, a few running transversely.

The *internal* or *mucous coat* is loosely connected with the fibrous layer. It is generally of a yellowish-brown colour, and is elevated into minute rugæ. Opposite the neck of the gall-bladder the mucous membrane projects inwards in the form of oblique ridges or folds, forming a sort of spiral valve (valvula spiralis).

The mucous membrane is continuous through the hepatic duct with the mucous membrane lining the ducts of the liver, and through the common bile-duct with the mucous membrane of the alimentary canal. It is covered with columnar epithelium, and secretes mucin; in some animals it secretes a nucleo-protein instead of mucin.

The **cystic duct** (ductus cysticus), about an inch and a half in length, runs backwards, downwards, and to the left from the neck of the gall-bladder, and joins the hepatic duct to form the common bile-duct. The mucous membrane lining its interior is thrown into a series of crescentic folds, from five to twelve in number, similar to those found in the neck of the gall-bladder. They project into the duct in regular succession, and are directed obliquely round

the tube, presenting much the appearance of a continuous spiral valve. When the duct is distended, the spaces between the folds are dilated, so as to give to its exterior a twisted appearance.

The **common bile-duct** (ductus choledochus) is formed by the junction of the cystic and hepatic ducts; it is about three inches in length, and of the diameter of a goose-quill.

It descends along the right border of the lesser omentum behind the first portion of the duodenum, in front of the portal vein, and to the right of

FIG. 969.—Transverse section of gall-bladder.

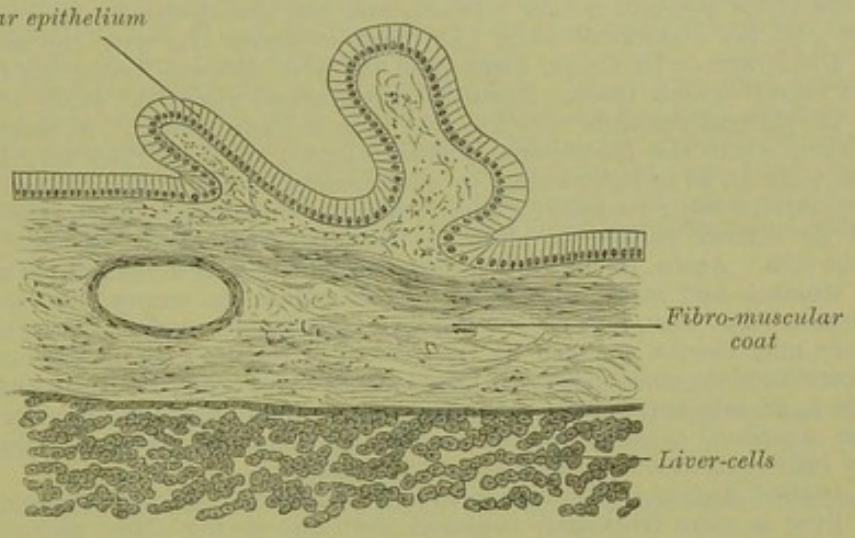

the hepatic artery; it then passes between the head of the pancreas and descending portion of the duodenum, and, running for a short distance along the right side of the terminal part of the pancreatic duct, passes with it, obliquely between the mucous and muscular coats. The two ducts unite and open by a common orifice upon the summit of a papilla, situated at the inner side of the descending portion of the duodenum, a little below its middle and about three or four inches from the pylorus (fig. 941). The short tube formed by the union of the two ducts is dilated into an ampulla, the *ampulla of Vater*.

Structure.—The coats of the large biliary ducts are an external or fibrous, and an internal or mucous. The fibrous coat is composed of strong fibro-areolar tissue, with a certain amount of muscular tissue, arranged, for the most part, in a circular manner around the duct. The mucous coat is continuous with the lining membrane of the hepatic ducts and gall-bladder, and also with that of the duodenum; and, like the mucous membrane of these structures, its epithelium is of the columnar variety. It is provided with numerous mucous glands, which are lobulated and open by minute orifices scattered irregularly in the larger ducts.

Surface Relations.—The liver is situated mainly in the right hypochondriac and the epigastric regions, and is moulded to the dome of the Diaphragm. In the greater part of its extent it lies under cover of the lower ribs and their cartilages, but in the epigastric region it comes in contact with the abdominal wall, in the subcostal angle. The *upper limit of the right lobe of the liver* may be defined in the middle line by the junction of the meso-sternum with the ensiform cartilage; on the right side the line must be carried upwards as far as the fifth rib cartilage in the line of the nipple, and then downwards to reach the seventh rib at the side of the chest. The *upper limit of the left lobe* may be defined by continuing this line to the left, with an inclination downwards, to a point about two inches to the left of the sternum on a level with the sixth left costal cartilage. The *lower limit of the liver* may be indicated by a line drawn half an inch below the lower border of the thorax on the right side, as far as the ninth right costal cartilage, and thence obliquely upwards across the subcostal angle to the eighth left costal cartilage. A slightly curved line with its convexity to the left from this point, i.e. the eighth left costal cartilage, to the termination of the line indicating the upper limit, will denote the left margin of the liver. Birmingham teaches that the limits of the normal liver may be marked out on the surface of the body in the following manner. Take three points: 1, half an inch below the right nipple; 2, half an inch below the tip of the tenth rib; and 3, one inch below the left nipple. Join 1 and 3 by a line slightly convex upwards; join 1 and 2 by a line

slightly convex outwards, and 2 and 3 by a line slightly convex downwards. The fundus of the gall-bladder approaches the surface behind the anterior extremity of the ninth costal cartilage, close to the outer margin of the right Rectus muscle.

It must be remembered that the liver is subject to considerable alterations in position, and the student should make himself acquainted with the different circumstances under which this occurs, as they are of importance in determining the existence of enlargement or other diseases of the organ.

The position of the liver varies according to the posture of the body. In the erect position in the adult male, the edge of the liver projects about half an inch below the lower edge of the right costal cartilages, and its anterior border can often be felt in this situation if the abdominal wall is thin. In the supine position the liver gravitates backwards, and recedes above the lower margin of the ribs, and cannot then be detected by the finger. In the prone position it falls forward, and can then generally be felt in a patient with loose and lax abdominal walls. Its position varies also with the ascent or descent of the Diaphragm. In a deep inspiration the liver descends below the ribs; in expiration it is raised behind them. Again, in emphysema, where the lungs are voluminous and the Diaphragm descends very low, the liver is pushed down: in some other diseases, as phthisis, where the Diaphragm is much arched, the liver rises very high up. Pressure from without, as in tight-lacing, by compressing the lower part of the chest, displaces the liver considerably; its anterior edge frequently extending as low as the crest of the ilium; and its convex surface is often at the same time deeply indented from the pressure of the ribs. Again, its position varies greatly according to the greater or less distension of the stomach and intestines. When the intestines are empty, the liver descends in the abdomen; but when they are distended, it is pushed upwards. Its relations to surrounding organs may also be changed by the growth of tumours, or by collections of fluid in the thoracic or abdominal cavities. Ptosis of the liver, or hepatoptosis, from abnormal laxity of its ligaments and failure of the support it usually receives from the subjacent viscera, is an occasional cause of various nervous and gastro-intestinal disturbances. It has been very fully described by Glénard and his pupils.

Applied Anatomy.—On account of its large size, its fixed position, and its friability, the liver is more frequently ruptured than any of the other abdominal viscera. The rupture may vary from a slight scratch to an extensive and complete laceration of its substance, dividing it into two parts. Sometimes an internal rupture, without laceration of the peritoneal covering, takes place, and such injuries are most susceptible of repair; but small tears of the surface may also heal; when, however, the laceration is extensive, death usually takes place from hæmorrhage, on account of the fact that the hepatic veins are contained in rigid canals in the liver-substance and are unable to contract, and are moreover unprovided with valves. The liver may also be torn by the end of a broken rib perforating the Diaphragm. It may be injured by stabs or other punctured wounds, and when these are inflicted through the chest-wall the pleural and peritoneal cavities may both be opened up, and both lung and liver wounded. In cases of wound of the liver from the front, hernia of a part of this viscus may take place, but generally can be easily replaced. In cases of laceration of the liver, when there is evidence that bleeding is going on, the abdomen must be opened, the laceration sought for, and the bleeding arrested. This may be done temporarily by introducing the forefinger into the foramen of Winslow and placing the thumb on the gastro-hepatic omentum, and compressing the hepatic artery and portal vein between the two. Any bleeding points can then be seen and tied, and the margins of the laceration, if small, brought together and sutured by means of a blunt curved needle passed from one side of the wound to the other. All sutures must be passed before any are tied, and this must be done with the greatest gentleness, as the liver substance is very friable. When the laceration is extensive it must be packed with gauze, the end of which is allowed to hang out of the external wound.

Abscess of the liver is of not infrequent occurrence. The so-called *tropical abscess* is due to absorption from the intestine of the amœba of dysentery, which reaches the liver through the portal system and causes the formation of a large chronic abscess; this may open in many different ways on account of the relations of the liver to other organs. Thus it has been known to burst into the lungs when the pus is coughed up, or into the stomach when the pus is vomited; it may burst into the colon, or duodenum; or, by perforating the Diaphragm, it may empty itself into the pleural cavity. It often makes its way forwards, and points on the anterior abdominal wall, and finally it may burst into the peritoneal or pericardial cavities. Abscesses of the liver frequently require opening, and this must be done by an incision in the abdominal wall, in the thoracic wall, or in the lumbar region, according to the direction in which the abscess is tracking. The incision through the abdominal wall is to be preferred when possible. The abdominal wall is incised over the swelling, and, unless the peritoneum is adherent, gauze is packed all round the exposed liver surface and the abscess opened, and a large drainage tube inserted. Hydatid cysts are more often found in the liver than in any of the other viscera. The reason of this is not far to seek. The embryo of the egg of the tænia echinococcus, being liberated in the stomach by the disintegration of its shell, bores its way through the gastric walls and usually enters a blood-vessel, and is carried by the blood-stream to the hepatic capillaries,

where its onward course is arrested, and where it undergoes development into the fully formed hydatid.

The gall-bladder may become distended in cases of obstruction of its duct or the common bile-duct, or from a collection of gall-stones in its interior, thus forming a large tumour. The swelling is pear-shaped, and projects downwards and forwards to the umbilicus. It moves with respiration, since it is attached to the liver. To relieve this condition, the gall-bladder must be opened (*cholecystotomy*) and the gall-stones removed. The operation is performed by an incision, two or three inches long, through the outer part of the right Rectus muscle, commencing at the costal margin. The peritoneal cavity is opened, and, the tumour having been found, gauze is packed round it to protect the peritoneal cavity, and it is aspirated. When the contained fluid has been evacuated the flaccid bladder is drawn out of the abdominal wound and its wall incised; any gall-stones in the bladder are now removed and the interior of the sac sponged dry. If the case is one of obstruction of the duct, an attempt must be made to dislodge the stone by manipulation through the wall of the duct; or it may be crushed from without by the fingers or carefully padded forceps. If this does not succeed, the safest plan is to incise the duct, extract the stone, and close the incision by fine sutures in two layers. After all obstruction has been removed, the edges of the incision in the gall-bladder may be sutured to the anterior sheath of the Rectus and a fistulous communication established between the gall-bladder and the exterior; this fistulous opening usually closes in the course of a few weeks. The gall-bladder may be completely removed if it be quite certain that no cause for biliary obstruction remain: this is also done for primary malignant growth of the viscus.

The Pancreas

The **pancreas** is a compound racemose gland, analogous in its structure to the salivary glands, though softer and less compactly arranged than those

Fig. 970.—The duodenum and pancreas.
The liver has been lifted up and the greater part of the stomach removed. (Testut.)

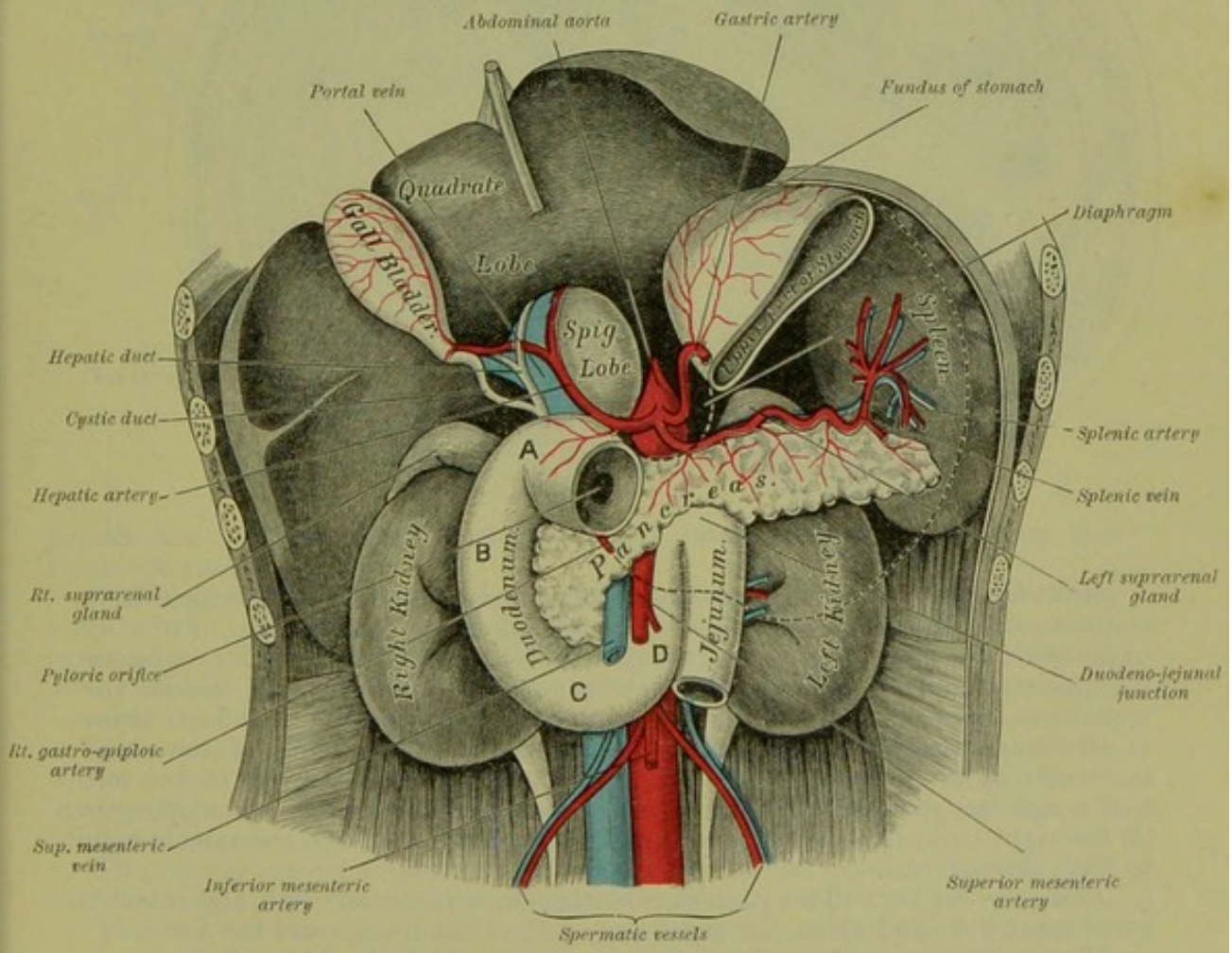

A, B, C, D. The four portions of the duodenum.

organs. It is long and irregularly prismatic in shape; its right extremity, being broad, is called the *head*, and is connected to the main portion of the

organ, or *body*, by a slight constriction, the *neck*; while its left extremity gradually tapers to form the *tail*. It is situated transversely across the posterior wall of the abdomen, at the back of the epigastric and left hypochondriac regions. Its length varies from five to six inches, and its weight from two to three and a half ounces.

Relations (figs. 970, 971, 972).—The **head** (caput pancreatis) is flattened from before backwards, and is lodged within the curve of the duodenum. Its upper border is in contact with the first part of the duodenum and its lower overlaps the third part; its right and left borders overlap in front, and insinuate themselves behind, the second and fourth parts of the duodenum respectively. The angle of junction of the lower and left lateral borders forms a prolongation, termed the *processus uncinatus*. In the groove between the duodenum and the right lateral and lower borders in front are the anastomosing superior and inferior pancreatico-duodenal arteries; the common bile-duct descends behind, along the right border, to its termination in the second part of the duodenum.

Fig. 971.—Transverse section through the middle of the first lumbar vertebra, showing the relations of the pancreas. (Braune.)

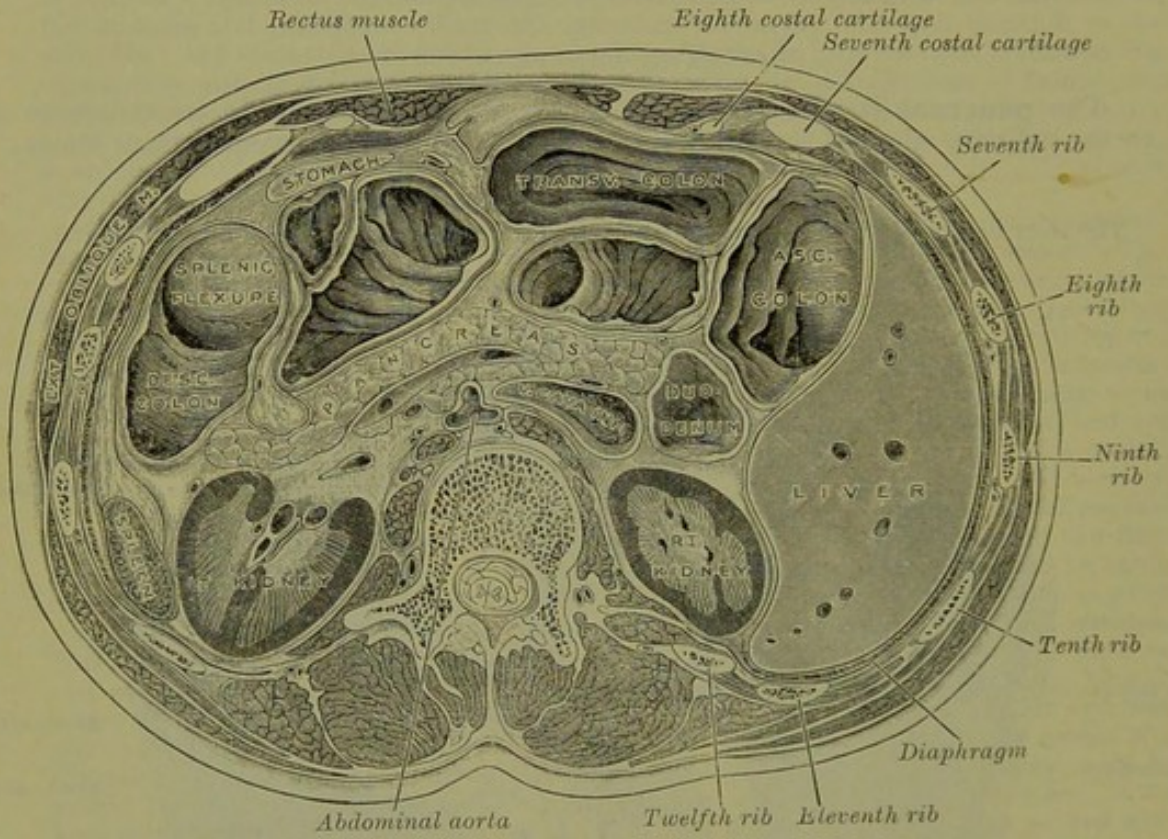

Anterior surface.—The greater part of the right half of this surface is in contact with the transverse colon, only areolar tissue intervening. From its upper part the *neck* originates, its right limit being marked by a groove for the gastro-duodenal artery. The lower part of the right half, below the transverse colon, is covered by peritoneum continuous with the inferior layer of the transverse mesocolon, and is in contact with the coils of the small intestine. The superior mesenteric artery passes down in front of the left half across the processus uncinatus; the superior mesenteric vein runs upwards on the right side of the artery and, behind the neck, joins with the splenic vein to form the portal vein.

Posterior surface.—The posterior surface is in relation with the inferior vena cava, the renal veins, the right crus of the Diaphragm, and the aorta.

The **neck** springs from the right upper portion of the front of the head. It is about an inch in length, and is directed at first upwards and forwards, and then upwards and to the left to join the body; it is somewhat flattened from above downwards and backwards. Its antero-superior surface supports the

pylorus ; its postero-inferior surface is in relation with the commencement of the portal vein ; on the right it is grooved by the gastro-duodenal artery.

The **body** (corpus pancreatis) is somewhat prismatic in shape, and has three surfaces : anterior, posterior, and inferior.

The *anterior surface* (facies anterior) is somewhat concave, and is directed forwards and upwards : it is covered by the postero-inferior surface of the stomach which rests upon it, the two organs being separated by the lesser sac of the peritoneum. Where it joins the neck there is a well-marked prominence, the *tuber omentale*, which abuts against the posterior surface of the small omentum.

The *posterior surface* (facies posterior) is devoid of peritoneum, and is in contact with the aorta, the splenic vein, the left kidney and its vessels, the left suprarenal gland, the origin of the superior mesenteric artery, and the crura of the Diaphragm.

The *inferior surface* (facies inferior) is narrow on the right but broader on the left, and is covered by peritoneum ; it lies upon the duodeno-jejunal

FIG. 972.—The pancreas and duodenum from behind. (Drawn from His' model.)

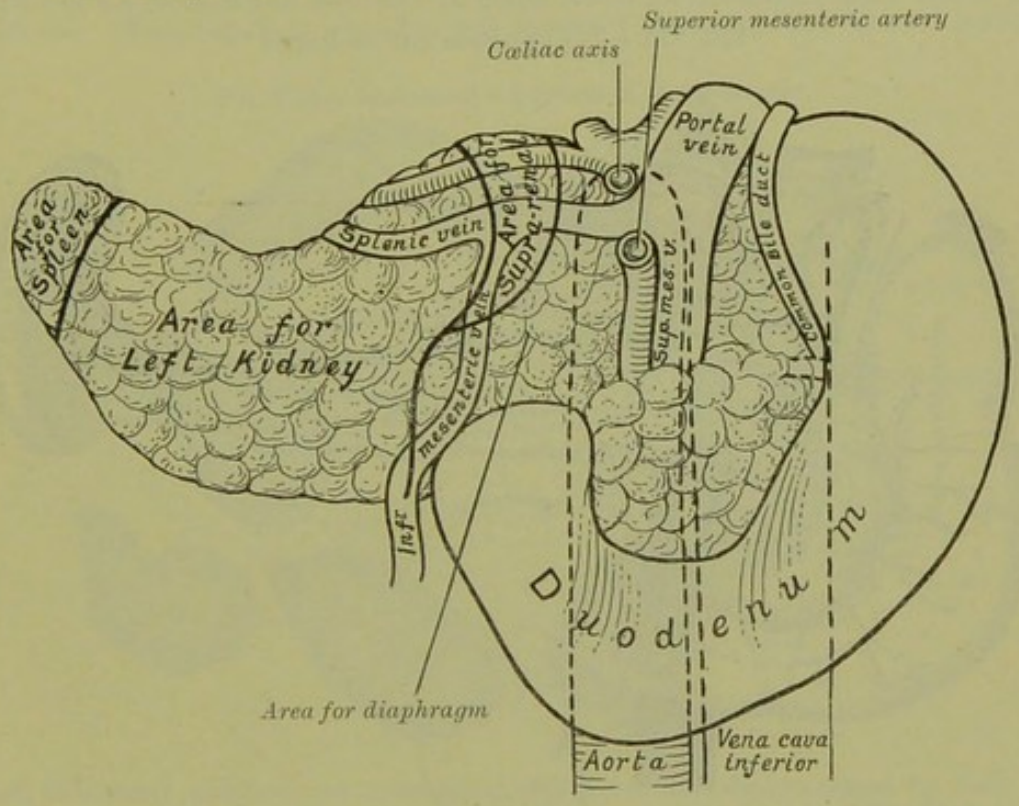

flexure and on some coils of the jejunum ; its left extremity rests on the splenic flexure of the colon.

The *superior border* (margo superior) is blunt and flat to the right ; narrow and sharp to the left, near the tail. It commences on the right in the omental tuberosity, and is in relation with the cœliac axis, from which the hepatic artery courses to the right just above the gland, while the splenic artery runs towards the left in a groove along this border.

The *anterior border* (margo anterior) separates the anterior from the inferior surface, and along this border the two layers of the transverse mesocolon diverge from one another : one passing upwards over the anterior surface, the other backwards over the inferior surface.

The *inferior border* separates the posterior from the inferior surface ; the superior mesenteric vessels emerge under its right extremity.

The **tail** (cauda pancreatis) is narrow ; it extends to the left as far as the lower part of the gastric surface of the spleen, and it is in contact with the splenic flexure of the colon.

Birmingham describes the body of the pancreas as projecting forwards as a prominent ridge into the abdominal cavity and forming a sort of shelf on

which the stomach lies. He says: 'The portion of the pancreas to the left of the middle line has a very considerable antero-posterior thickness; as a result the anterior surface is of considerable extent; it looks strongly upwards, and forms a large and important part of the shelf. As the pancreas extends to the left towards the spleen it crosses the upper part of the kidney, and is so moulded on to it that the top of the kidney forms an extension inwards and backwards of the upper surface of the pancreas and extends the bed in this direction. On the other hand, the extremity of the pancreas comes in contact with the spleen in such a way that the plane of its upper surface runs with little interruption upwards and backwards into the concave gastric surface of the spleen, which completes the bed behind and to the left, and, running upwards, forms a partial cap for the wide end of the stomach.' *

The **pancreatic duct** or **canal of Wirsung** (ductus pancreaticus) extends transversely from left to right through the substance of the pancreas (fig. 973). It commences by the junction of the small ducts of the lobules situated in the tail of the pancreas, and, running from left to right through the body, it receives the ducts of the various lobules composing the gland. Considerably augmented in size, it reaches the neck, and turning downwards, backwards, and to the

Fig. 973.—The pancreas and its ducts.

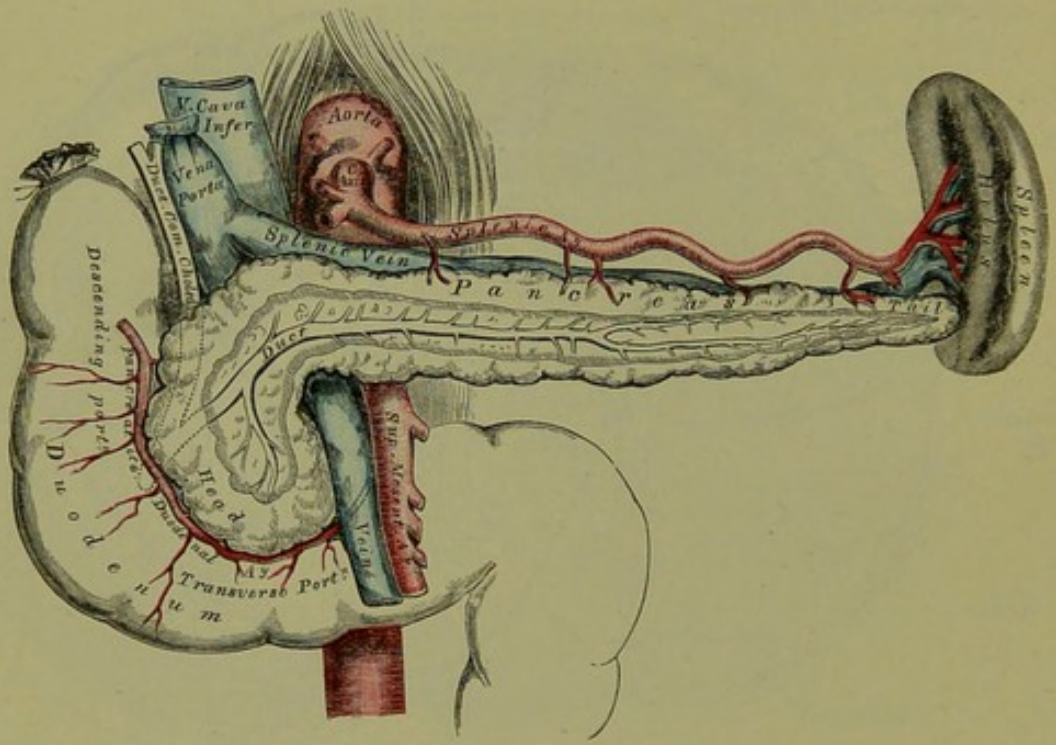

right, it comes into relation with the common bile-duct, which lies to its right side; leaving the head of the gland, it passes very obliquely through the mucous and muscular coats of the duodenum, and terminates by an orifice common to it and the common bile-duct upon the summit of an elevated papilla, situated at the inner side of the descending portion of the duodenum, three or four inches below the pylorus (fig. 941).

Sometimes the pancreatic duct and the common bile-duct open separately into the duodenum. Frequently there is an accessory duct, which is given off from the canal of Wirsung in the neck of the pancreas and passes horizontally to the right to open into the duodenum about an inch above the orifice of the main duct. It receives the ducts from the lower part of the head, and is known as the *ductus pancreaticus accessorius* or *ductus Santorini*.

The pancreatic duct, near the duodenum, is about the size of an ordinary quill: its walls are thin, consisting of two coats, an external fibrous and an internal mucous; the latter is smooth, and furnished near its termination with a few scattered follicles.

* *Journal of Anatomy and Physiology*, vol. xxxi. pt. 1, p. 102.

Structure (fig. 974).—In structure, the pancreas resembles the salivary glands. It differs from them, however, in certain particulars, and is looser and softer in its texture. It is not enclosed in a distinct capsule, but is surrounded by areolar tissue, which dips into its interior, and connects together the various lobules of which it is composed. Each lobule, like the lobules of the salivary glands, consists of one of the ultimate ramifications of the main duct, terminating in a number of cæcal pouches or alveoli, which are tubular and somewhat convoluted. The minute ducts connected with the alveoli are narrow and lined with flattened cells. The alveoli are almost completely filled with secreting cells, so that scarcely any lumen is visible. In some animals those cells which occupy the centre of the alveolus are spindle-shaped, and are known as the *centro-acinar cells of Langerhans*. The true secreting cells which line the wall of the alveolus are very characteristic. They are columnar in shape and present two zones: an outer one, clear and finely striated next the basement-membrane, and an inner granular one next the lumen. During activity the granular zone gradually diminishes in size, and when exhausted is only seen as a small area surrounding the lumen. During the resting stages it gradually increases until it fills nearly three-fourths of the cell. In some of the secreting cells of the pancreas is a spherical mass, staining more easily than the rest of the cell; this is termed the *paranucleus*, and is believed to be an extension from the nucleus. The connective tissue between the alveoli presents in certain parts collections of cells, which are termed *inter-alveolar cell-islets*, or islands of Langerhans. The cells stain lightly and are more or less polyhedral in shape, forming a network in which ramify many capillaries. These cell-islets were formerly supposed to secrete an 'internal secretion'

Fig. 974.—Section of a portion of the pancreas.

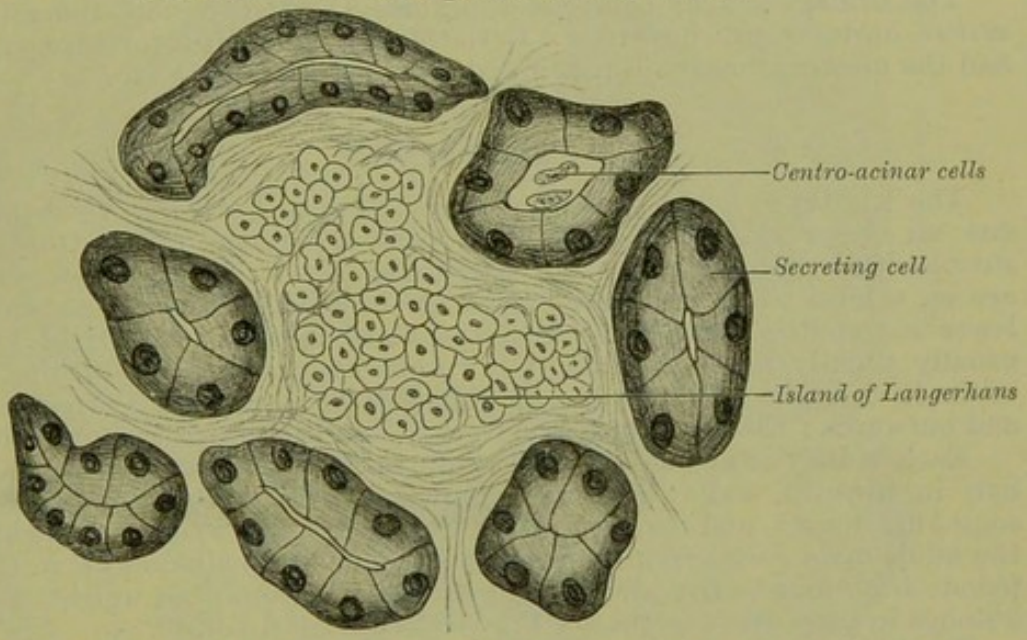

which influenced carbohydrate metabolism, but have been demonstrated by Dale to be alveoli in a stage of exhaustion, which after a time become re-converted into fresh alveoli.

Vessels and Nerves.—The *arteries of the pancreas* are derived from the splenic, and the pancreatico-duodenal branches of the hepatic and superior mesenteric. Its *veins* open into the splenic and superior mesenteric veins. Its *lymphatics* are described on page 787. Its *nerves* are filaments from the splenic plexus.

Surface Relations.—The pancreas lies in front of the second lumbar vertebra, and can sometimes be felt, in emaciated subjects, when the stomach and colon are empty, by making deep pressure in the middle line about three inches above the umbilicus.

Applied Anatomy.—Inflammation of the pancreas has of late years received considerable attention. It appears to be due to infection of the pancreatic ducts by micro-organisms from the duodenum in cases of gastro-duodenal catarrh, or from the biliary passages in which a gall-stone is lodged. Acute cases usually terminate fatally and are frequently of the hæmorrhagic type; chronic inflammation of the pancreas produces few symptoms of disease unless it is extensive, when attacks of abdominal pain, loss of appetite, progressive weakness and wasting, and the passage of whitish fatty motions, are likely to follow. Extensive fibrosis of the pancreas is also one of the commonest lesions found post-mortem in cases of diabetes mellitus. Cysts of the pancreas are sometimes met with. They may be the result of traumatism, when they generally contain blood, or they may be due to retention from obstruction of a duct, or from pressure on the main duct by a gall-stone. They may attain a large size, and cause symptoms by pressing on the stomach, Diaphragm, or common bile-duct. They generally push their way forwards between the stomach and transverse colon, and may then be felt as a definite tumour in

the middle line of the upper part of the abdomen. The tumour is fixed and does not move with respiration. The treatment consists in opening the abdomen in the middle line, incising the cyst, evacuating its contents, and fixing its walls to the deeper layers of the abdominal wall. Drainage in the left loin, just below the last rib, can sometimes be established. When they are situated in the tail of the pancreas they may be removed. The pancreas is often the seat of cancer; this usually affects the head, and therefore speedily involves the common bile-duct, leading to persistent jaundice; or it may press upon the portal vein, causing ascites, or involve the stomach, causing pyloric obstruction. It has been said that the pancreas is the only abdominal viscus which has never been found in a hernial protrusion; but even this organ has been found, in company with other viscera, in rare cases of diaphragmatic hernia.

UROGENITAL ORGANS

The urogenital organs (apparatus urogenitalis) consist of (*a*) the urinary organs for the secretion and discharge of the urine and (*b*) the genital organs, which are concerned with the process of reproduction.

THE URINARY ORGANS

The urinary organs comprise the *kidneys*, which secrete the urine; the *ureters*, or ducts, which convey it to the *bladder*, where it is for a time retained; and the *urethra*, through which it is discharged from the body.

The Kidneys

The **kidneys** (renes) are situated in the posterior part of the abdomen, one on either side of the vertebral column, behind the peritoneum, and surrounded by a mass of fat and loose areolar tissue. Their upper extremities are on a level with the upper border of the twelfth thoracic vertebra, their lower extremities on a level with the third lumbar. The right kidney is usually slightly lower than the left, probably on account of the vicinity of the liver. The long axis of each kidney is directed from above downwards and outwards; the transverse axis from within backwards and outwards.

Each kidney is about four and a half inches in length, two to two and a half in breadth, and rather more than one inch in thickness. The left is somewhat longer, and narrower, than the right. The weight of the kidney in the adult male varies from four and a half ounces to six ounces, in the adult female from four to five and a half ounces. The combined weight of the two kidneys in proportion to that of the body is about 1 to 240.

The kidney has a characteristic form, and presents for examination two surfaces, two borders, and an upper and lower extremity.

Relations (figs. 975, 976, 977).—The *anterior surface* (facies anterior) of each kidney is convex, and looks forwards and outwards. Its relations to adjacent viscera differ so completely on the two sides that separate descriptions are necessary.

(*a*) *Anterior surface of right kidney.*—A narrow portion at the upper extremity is in relation with the suprarenal gland. Immediately below this a large area, involving about three-fourths of the surface, lies in the renal impression on the inferior surface of the liver, and a narrow but somewhat variable area near the inner border is in contact with the second part of the duodenum. The lower part of the anterior surface is in contact externally with the hepatic flexure of the colon, and internally with the small intestine. The areas in relation with the liver and intestine are covered by peritoneum; the suprarenal, duodenal, and colic areas are devoid of peritoneum.

(*b*) *Anterior surface of left kidney.*—A small area along the upper part of the inner border is in relation with the suprarenal gland, and close to the outer border is a narrow strip in contact with the renal impression on the spleen. A broad, somewhat quadrilateral field, about the middle of the anterior surface, marks the site of contact with the body of the pancreas, on the deep surface of which are the splenic vessels. Above this is a small

triangular portion, between the suprarenal and splenic areas, in contact with the postero-inferior surface of the stomach. Below the pancreatic area the outer part is in relation with the splenic flexure of the colon, the inner with the small intestine. The area in contact with the stomach is covered by the peritoneum of the lesser sac, while that in relation to the small intestine is covered by the peritoneum of the greater sac; behind the latter are some branches of the left colic vessels.

The *posterior surface* (facies posterior) of each kidney is directed backwards and inwards. It is entirely devoid of peritoneal covering, and imbedded in areolar and fatty tissue. It lies upon the Diaphragm, the external and internal arcuate ligaments, the Psoas muscle, the anterior layer of the lumbar

Fig. 975.—The relations of the kidneys, from behind.

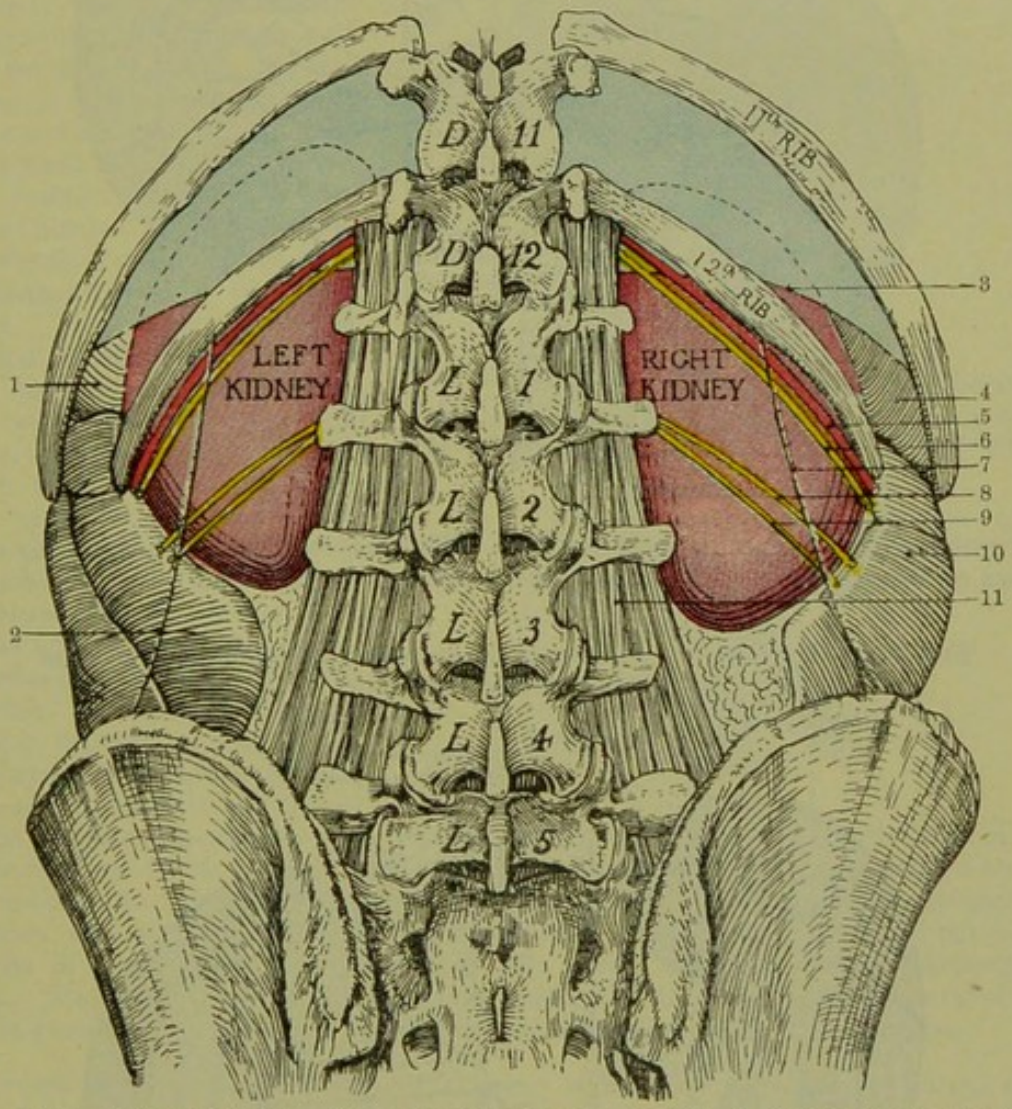

1. Spleen. 2. Descending colon. 3. Line of pleural reflection. 4. Liver. 5. Subcostal artery. 6. Last thoracic nerve. 7. Line indicating outer edge of Quadratus lumborum. 8. Ilio-inguinal nerve. 9. Ilio-hypogastric nerve. 10. Ascending colon. 11. Psoas.

aponeurosis (which separates it from the Quadratus lumborum), and the tendon of the Transversalis muscle, one or two of the upper lumbar arteries, and the last thoracic, ilio-hypogastric, and ilio-inguinal nerves. The right kidney rests upon the twelfth rib, the left usually on the eleventh and twelfth. The Diaphragm separates the kidney from the pleura, which dips down to form the phrenico-costal sinus, but frequently the muscular fibres of the Diaphragm are defective or absent over a triangular area immediately above the external arcuate ligament, and when this is the case the perinephric areolar tissue is in actual contact with the diaphragmatic pleura.

The *external border* (margo lateralis) is convex, and is directed outwards and backwards, towards the postero-lateral wall of the abdomen. On the left side it is in contact, at its upper part, with the spleen.

The *internal border* (margo medialis) is concave in the centre and convex towards either extremity; it is directed forwards and a little downwards. Its central part presents a deep longitudinal fissure, bounded by prominent

Fig. 976.—The anterior surfaces of the kidneys, showing the areas of contact of neighbouring viscera.

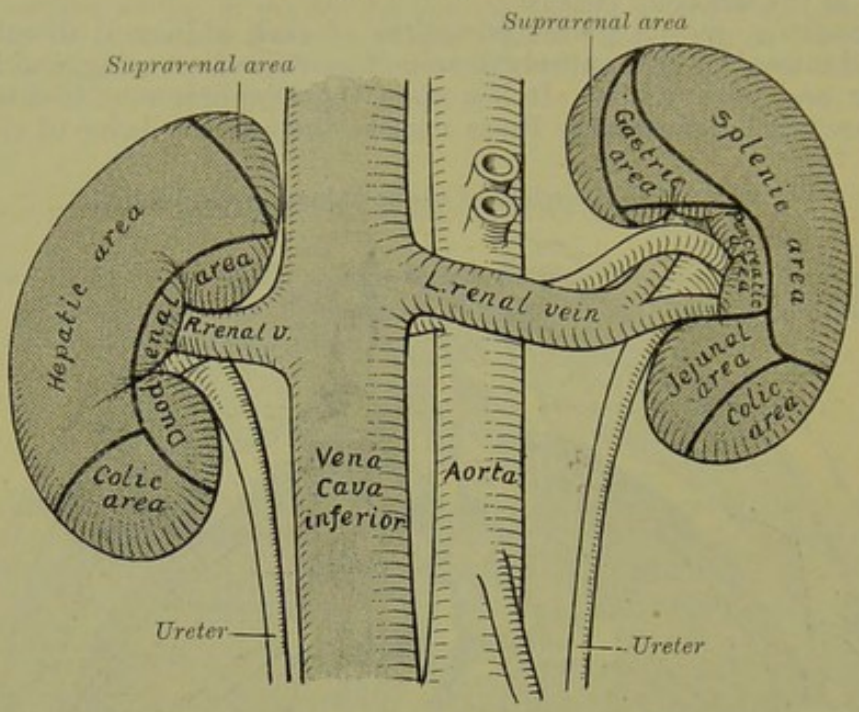

overhanging anterior and posterior lips. This fissure is named the *hilus*, and allows of the transmission of the vessels, nerves, and ureter.

Fig. 977.—The posterior surfaces of the kidneys, showing areas of relation to the parietes.

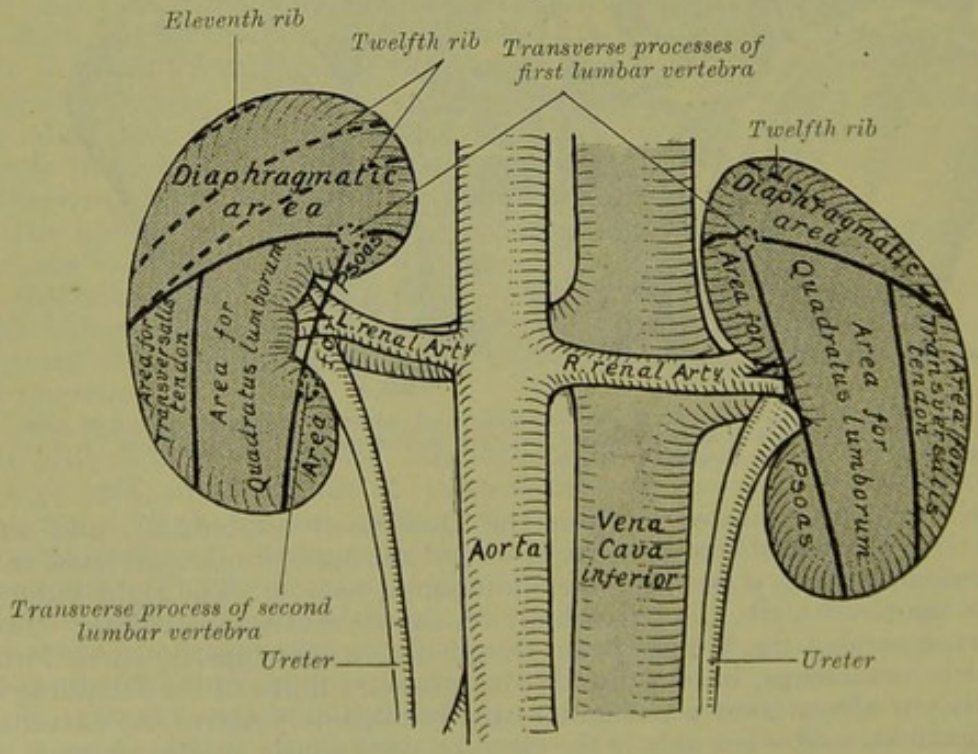

The *superior extremity* (extremitas superior), directed slightly inwards as well as upwards, is thick and rounded, and is surmounted by the suprarenal gland, which covers also a small portion of the anterior surface.

The *inferior extremity* (extremitas inferior), directed a little outwards as well as downwards, is smaller and thinner than the superior. It extends to within two inches of the crest of the ilium.

The relative position of the main structures in the hilus is as follows : the vein is in front, the artery in the middle, and the ureter behind and directed downwards. Frequently, however, branches of both artery and vein are placed behind the ureter.

Fixation of the kidney (figs. 978, 979).—The kidney and its vessels are imbedded in a mass of fatty tissue, termed the *capsula adiposa*, which is thickest at the margin of the kidney and is prolonged through the hilus into the renal sinus. The kidney and the capsula adiposa are enclosed in a sheath of fibrous tissue continuous with the subperitoneal fascia, and named the *fascia renalis*. At the outer border of the kidney the fascia renalis splits into an anterior and a posterior layer. The anterior layer is carried inwards in front of the kidney and its vessels, and is continuous over the aorta with the corresponding layer of the opposite side. The posterior layer extends inwards behind the kidney and blends with the fascia on the Quadratus lumborum and Psoas and through this fascia is attached to the vertebral column. At the upper margin of the suprarenal gland the two layers of the fascia renalis fuse, and unite with the fascia of the Diaphragm ; below they remain separate, and are gradually lost in the subperitoneal fascia of the iliac fossa. The fascia renalis is connected to the fibrous capsule of the kidney by numerous trabeculæ, which traverse the capsula adiposa, and are strongest near the lower end of the organ. Behind the fascia renalis is a considerable quantity of fat, which constitutes the *paranephric body*. The kidney is held in position partly through the attachments of the fascia renalis and partly by the apposition of the neighbouring viscera.

FIG. 978.—Sagittal section through posterior abdominal wall, showing the relations of the capsule of the kidney. (After Gerota.)

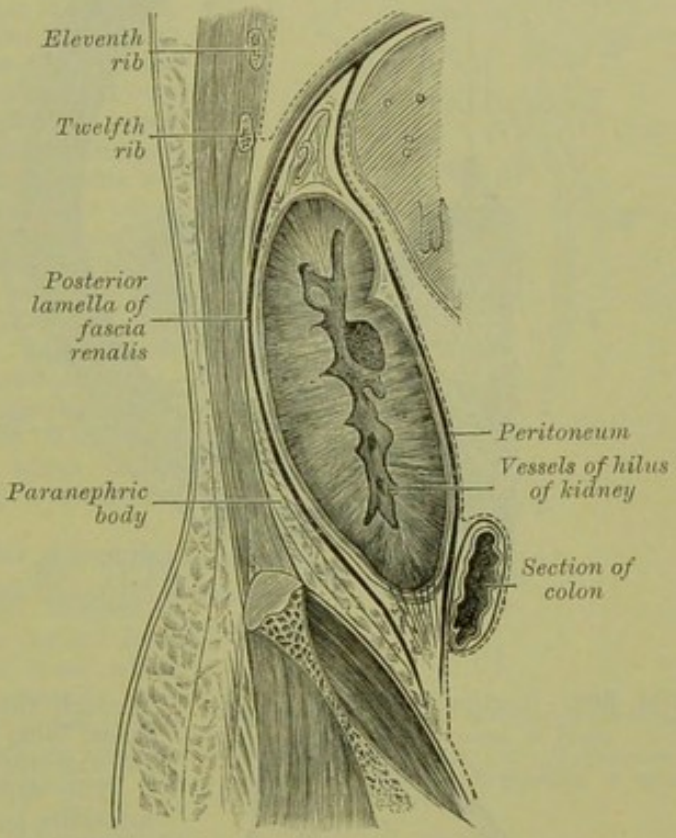

General structure of the kidney.—The kidney is invested by a capsule of fibrous tissue (tunica fibrosa), which forms a firm, smooth covering to the organ. The capsule can be easily stripped off, but in doing so, numerous fine processes of connective tissue and small blood-vessels are torn through. Beneath this coat, a thin wide-meshed network of unstriped muscular fibre forms an incomplete covering to the organ. When the capsule is stripped off, the surface of the kidney is found to be smooth and even, and of a deep red colour. In infants, fissures extending for some depth may be seen on the surface of the organ, a remnant of the lobular construction of the gland. The kidney is dense in texture, but is easily lacerable by mechanical force. If a vertical section of the kidney be made from its convex to its concave border, and the loose tissue and fat removed from around the vessels and the excretory duct it will be seen that the kidney consists of a central cavity surrounded at all parts but one by the proper kidney-substance (fig. 980). This central cavity is called the *renal sinus*, and is lined by a prolongation of the capsule, which is continued round the lips of the hilus. Through the hilus the blood-vessels of the kidney and its excretory duct pass, and therefore these structures, upon entering or leaving the kidney, are contained within the sinus. The excretory duct or *ureter* begins by several short truncated branches termed *calyces* or *infundibula* (calyces renales), which unite to form two or three short tubes ; these in turn expand into a wide funnel-shaped sac named

the *pelvis of the kidney* (pelvis renalis), from the neck of which the ureter issues. The calyces and pelvis lie within the sinus; the blood-vessels of the kidney, after passing

Fig. 979.—Transverse section, showing the relations of the capsule of the kidney. (After Gerota.)

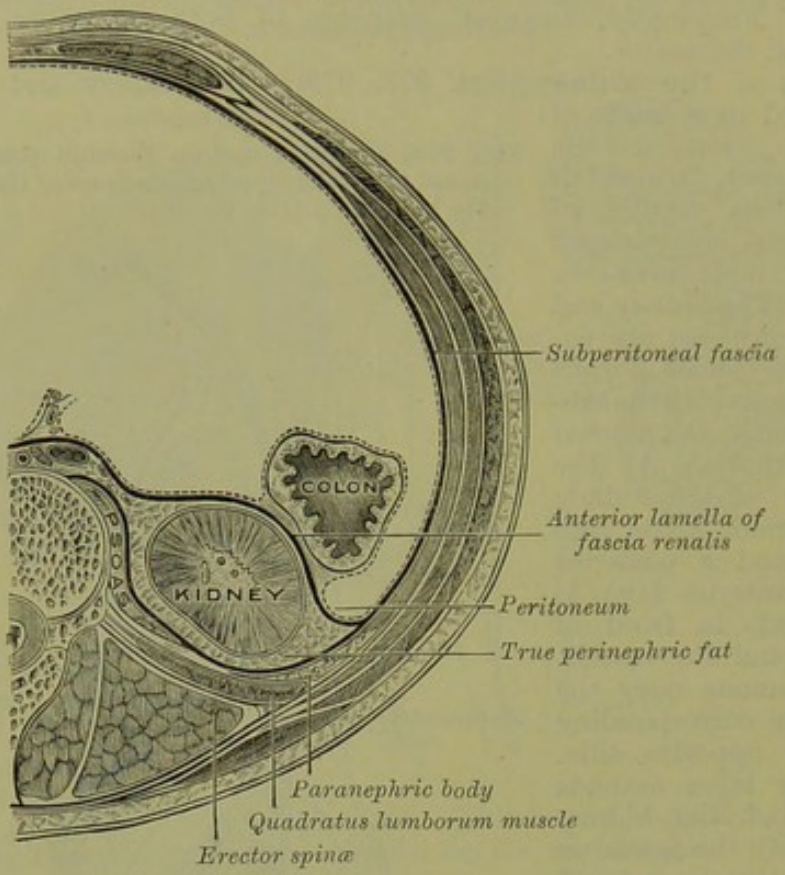

Fig. 980.—Vertical section of kidney.

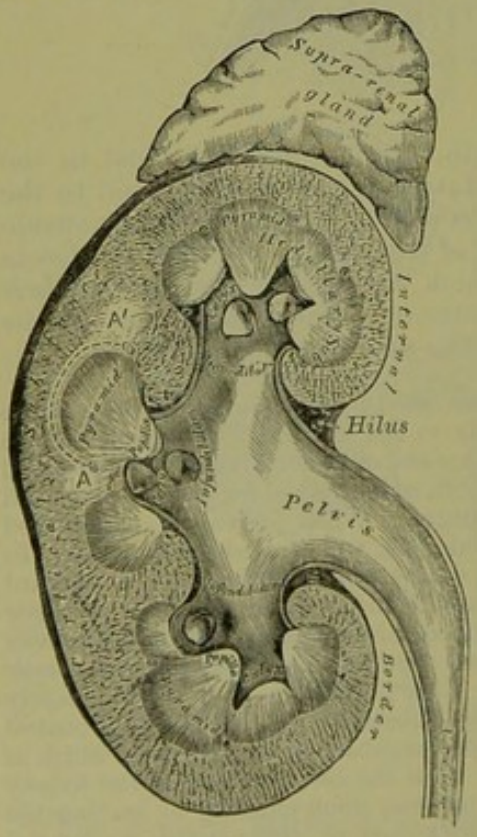

through the hilus, are also contained in the sinus, lying between its lining membrane and the excretory apparatus.

The kidney is composed of an internal *medullary* and an external *cortical* portion.

The *medullary portion* (substantia medullaris) consists of a series of red-coloured striated conical masses, termed the *medullary pyramids* or *pyramids of Malpighi* (pyramides renales), the bases of which are directed towards the circumference of the kidney, while their apices converge towards the renal sinus, where they form prominent papillæ (*papillæ renales*) projecting into the interior of the calyces; each calyx receives from one to three papillæ.

The *cortical portion* (substantia corticalis) is reddish-brown in colour and soft and granular in consistence. It lies immediately beneath the capsule, arches over the bases of the pyramids, and dips in between adjacent pyramids towards the renal sinus. The parts dipping in between the pyramids are named the *cortical columns* (columnæ renales [Bertini]), while the portions which connect the cortical columns to each other and intervene between the bases of the pyramids and the capsule are called the *cortical arches* (indicated between A and A′ in fig. 980). If the cortex be examined with a lens, it will be seen to consist of a series of lighter-coloured, conical areas, termed *medullary rays* (pars radiata) and a darker-coloured intervening substance, which from the complexity of its structure is named the *labyrinth* (pars convoluta). The medullary rays gradually taper towards the circumference

of the kidney, and consist of a series of outward prolongations from the base of each medullary pyramid.

The *cortical* and *medullary* parts, so dissimilar in appearance, are very similar in structure, being made up of urinary tubes and blood-vessels, united and bound together by a connecting stroma.

Fig. 981.—Plan of uriniferous tubes.

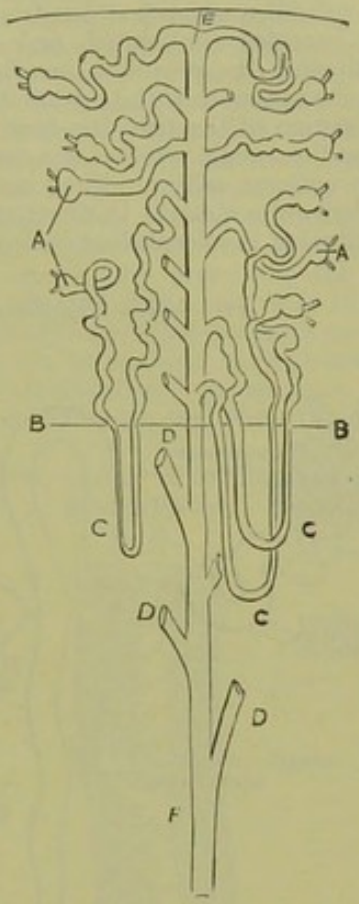

A A. Malpighian bodies. B B. Margin of medullary structure. C C C. Loops of Henle. D D D. Straight tubes cut off. E. Commencing straight tubes. F. Termination of straight tube.

Minute Anatomy.—The *tubuli uriniferi* (tubuli renales), of which the kidney is for the most part made up, commence in the cortical portion of the kidney, and after pursuing a very circuitous course through the cortical and medullary parts, finally terminate at the apices of the medullary pyramids by open mouths (fig. 981), so that the fluid which they contain is emptied, through the calyces, into the pelvis of the kidney. If the surface of one of the papillæ be examined with a lens, it will be seen to be studded over with minute openings, the orifices of the tubuli uriniferi, from sixteen to twenty in number, and if pressure be made on a fresh kidney, urine will be seen to exude from these orifices. The tubuli uriniferi commence in the labyrinth and cortical columns of the kidney as the *Malpighian bodies*, which are small rounded masses of a deep red colour, varying in size, but of an average of about $\frac{1}{12}$ of an inch in diameter. Each of these little bodies is composed of two parts: a central glomerulus of vessels, called a *Malpighian tuft*; and a membranous envelope, the *Malpighian capsule*, or *capsule of Bowman*, which is the small pouch-like commencement of a uriniferous tubule.

The *Malpighian tuft*, or vascular glomerulus, is a network of convoluted capillary blood-vessels, held together by scanty connective tissue. This capillary network is derived from a small arterial twig, the *afferent vessel*, which pierces the wall of the capsule, generally at a point opposite to that at which the latter is connected with the tube; and the resulting vein, the *efferent vessel*, emerges from the capsule at the same point. The afferent vessel is usually the larger of the two (fig. 982). The *Malpighian*, or *Bowman's capsule*, which surrounds the glomerulus, is formed of a hyaline membrane, supported by a small amount of connective tissue, which is continuous with the connective tissue of the tube. It is lined on its inner surface by a layer of squamous epithelial cells,

Fig. 982.—Minute structure of kidney.

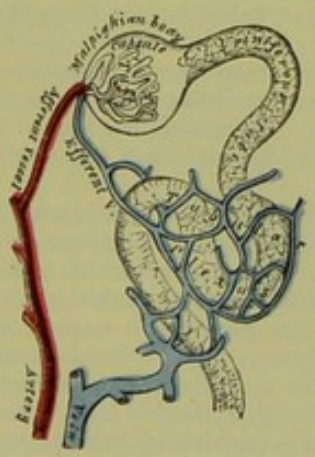

Fig. 983.—Malpighian body.

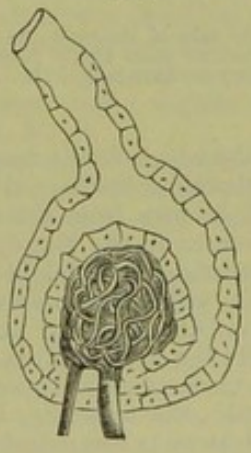

which are reflected from the lining membrane on to the glomerulus, at the point of entrance or exit of the afferent and efferent vessels. The whole surface of the glomerulus is covered with a continuous layer of the same cells, on a delicate supporting membrane (fig. 983). Thus between the glomerulus and the capsule a space is left, forming a cavity lined by a

continuous layer of squamous cells; this cavity varies in size according to the state of secretion and the amount of fluid present in it. In the fœtus and young subject the cells are polyhedral or even columnar.

The *tubuli uriniferi*, commencing in the Malpighian bodies, present, during their course, many changes in shape and direction, and are contained partly in the medullary and partly in the cortical portions of the organ. At their junction with the Malpighian capsule they exhibit a somewhat constricted portion, which is termed the *neck*. Beyond this the tube becomes convoluted, and pursues a considerable course in the cortical structure constituting the *proximal convoluted tube*. After a time the convolutions disappear, and the tube approaches the medullary portion of the kidney in a more or less spiral manner; this section of the tube has been called the *spiral tube*. Throughout this portion of their course the tubuli uriniferi are contained entirely in the cortical structure, and present a fairly uniform calibre. They now enter the medullary portion, suddenly become much smaller, quite straight in direction, and dip down for a variable depth into the pyramids, constituting the *descending limb of Henle's loop*. Bending on themselves, they form what is termed the *loop of Henle*, and re-ascending, they become suddenly enlarged and again spiral in direction, forming the *ascending limb of Henle's loop*, and re-enter the cortical structure. This portion of the tube does not present a uniform calibre, but becomes narrower as it ascends, and is irregular in outline. As a narrow tube it enters the cortex and ascends for a short distance, when it again becomes dilated, irregular, and angular. This section is termed the *zig-zag tubule*; it terminates in a convoluted tube, which exactly resembles the proximal convoluted tubule, and is called the *distal convoluted tubule*. This again terminates in a narrow *junctional tube*, which enters the straight or collecting tube.

Fig. 984.—Uriniferous tube.

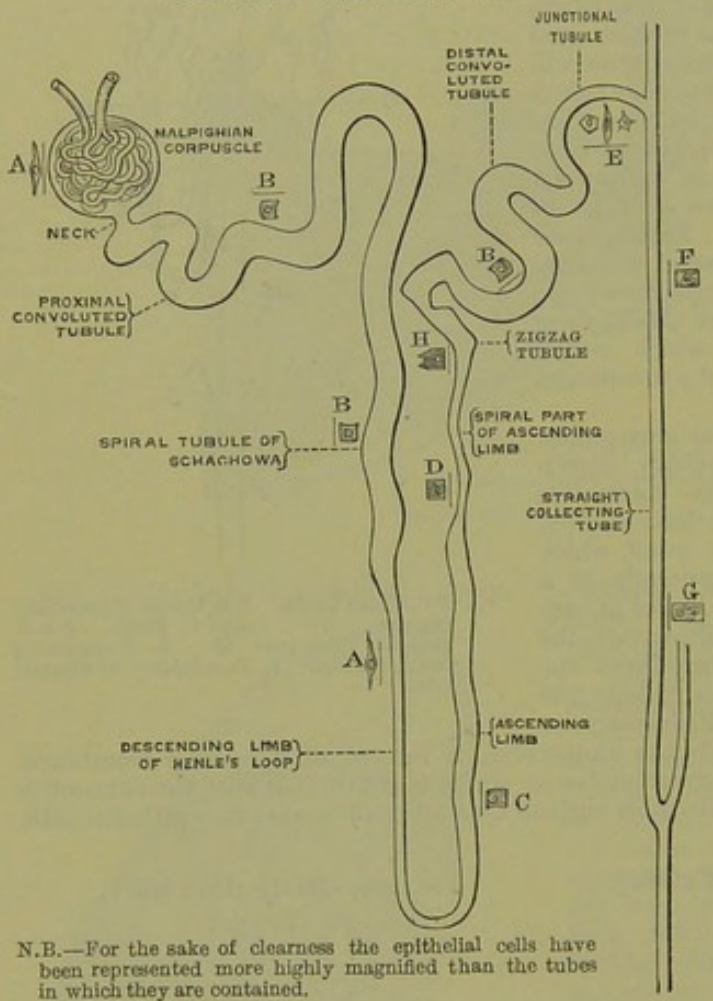

N.B.—For the sake of clearness the epithelial cells have been represented more highly magnified than the tubes in which they are contained.

The *straight* or *collecting tubes* commence in the medullary rays of the cortex, where they receive the curved extremities of the distal convoluted tubules. They unite at short intervals with one another, the resulting tubes presenting a considerable increase in calibre, so that a series of comparatively large tubes passes from the bases of the medullary rays into the medullary pyramids. In the medulla the tubes of each pyramid converge to join a central tube which finally opens on the summit of one of the papillæ; the contents of the tube are therefore discharged into one of the calyces.

It will be seen from the above description that the tubes are continuous from their commencement in the Malpighian bodies to their termination at the orifices on the apices of the pyramids of Malpighi; and that the urine, the secretion of which commences in the capsule, will find its way through these tubes into the calyces of the kidney, and so into the ureter. Commencing at the capsule, the tube first presents a narrow constricted portion, (1) the neck. (2) It forms a wide convoluted tube, the *proximal convoluted tube*. (3) It becomes spiral, the *spiral tubule*. (4) It enters the medullary structure as a narrow, straight tube, the *descending limb of Henle's loop*. (5) It forms *Henle's loop*, and, becoming dilated, it ascends somewhat spirally, and, gradually diminishing in calibre, again enters the cortical structure, the *ascending limb of Henle's loop*. (6) It now becomes irregular and angular in outline, the *zig-zag tubule*. (7) It then becomes convoluted, the *distal convoluted tubule*. (8) Diminishing in size, it forms a curve, the *junctional tubule*. (9) Finally it joins a straight tube, the *straight collecting tube*, which is continued downwards through the medullary substance to open at the apex of a pyramid.

Structure of the tubuli uriniferi.—The tubuli uriniferi consist of basement-membrane lined with epithelium. The epithelium varies considerably in different sections of the uriniferous tubes. In the neck the epithelium is continuous with that lining the Malpighian capsule, and like it consists of flattened cells each containing an oval nucleus (fig. 984, A). In the proximal convoluted tubule and the spiral tubule the epithelium is polyhedral in shape, the sides of the cells not being straight, but interlocking with each other, and in some animals so fused together that it is impossible to make out the lines of junction. In the human kidney the cells often present an angular projection of the surface next the basement-membrane. These cells are made up of more or less rod-like fibres, which rest by one extremity on the basement-membrane, while the other projects towards the lumen of the tube. This gives to the cells the appearance of distinct striation (Heidenhain) (fig. 984, B). In the descending limb of Henle's loop the epithelium resembles that found in the Malpighian capsule and the commencement of the tube, consisting of flat, clear epithelial plates, each with an oval nucleus (figs. 984, A; 985). In the ascending limb, on the other hand, the cells partake more of the character of those described as existing in the proximal convoluted tubule, being polyhedral in shape, and presenting the same appearance of striation. The nucleus, however, is not situated in the centre of the cell, but near the lumen (fig. 984, C). After the ascending limb of Henle's loop becomes narrower upon entering the cortical structure, the striation appears to be confined to the outer part of the cell; at all events it is much more distinct in this situation; the nucleus, which appears flattened and angular, being still situated near the lumen (fig. 984, D). In the

FIG. 985.*—Longitudinal section of Henle's descending limb.

a. Membrana propria.
b. Epithelium.

FIG. 986.—Longitudinal section of straight tube.

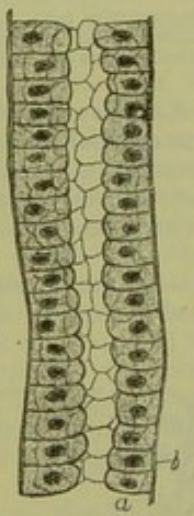

a. Cylindrical or cubical epithelium.
b. Membrana propria.

irregular tubule, the cells undergo a still further change, becoming very angular, and presenting thick bright rods or markings, which render the striation much more distinct than in any other section of the urinary tubules (fig. 984, H). In the distal convoluted tubule the epithelium appears to be somewhat similar to that which has been described as existing in the proximal convoluted tubule, but presents a peculiar refractive appearance (fig. 984, B). In the junctional tubule, just before its entrance into the straight collecting tube, the epithelium varies greatly as regards the shape of the cells, some being angular with short processes, others spindle-shaped, others polyhedral (fig. 984, E).

In the straight tube the epithelium is more or less columnar: in its papillary portion the cells are distinctly columnar and transparent (fig. 986); but as the tube approaches the cortex the cells are less uniform in shape: some are polyhedral, and others angular with short processes (fig. 984, F and G).

The **renal blood-vessels.**—The kidney is plentifully supplied with blood by the renal artery, a large offset of the abdominal aorta. Before it enters the kidney, each artery divides into four or five branches; at the hilus these branches lie between the renal vein and ureter, the vein being in front, the ureter behind; one branch usually lies behind the ureter. Each vessel gives off some small branches to the suprarenal glands, to the ureter, and to the surrounding cellular tissue and muscles. Frequently a second renal artery, termed the *inferior renal*, is given off from the abdominal aorta at a lower level, and supplies the lower portion of the kidney, whilst occasionally an additional artery enters the upper part of the kidney. The branches of the renal artery, while in the sinus, give off a few twigs for the nutrition of the surrounding tissues, and terminate in the *arteriæ propriæ renales*, which enter the kidney proper in the columns of Bertin. Two of these

* From the *Handbook for the Physiological Laboratory*.

pass to each medullary pyramid, and run along its sides for its entire length, giving off, as they advance, the afferent vessels of the Malpighian bodies in the columns. Having arrived at the bases of the pyramids, they form arterial arches or arcades which lie between the bases of the pyramids and the cortical arches, and break up into two distinct sets of branches devoted to the supply of the remaining portions of the kidney.

FIG. 987.—Transverse section of pyramidal substance of kidney of pig, the blood-vessels of which are injected.

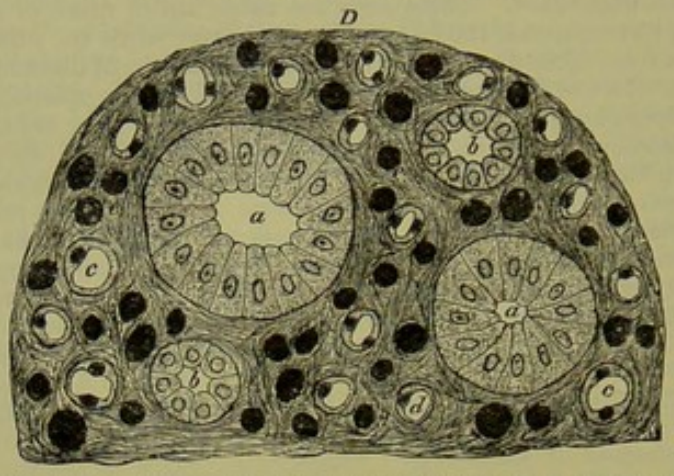

a. Large collecting tube, cut across, lined with cylindrical epithelium. *b*. Branch of collecting tube, cut across, lined with epithelium with shorter cylinders. *c*, *d*. Henle's loops cut across. *e*. Blood-vessels cut across. D. Connective-tissue ground-substance.

The *first set*, the *interlobular arteries* (figs. 988, 989, B), are given off at right angles from the side of the arterial arcade looking towards the cortical substance, and pass directly outwards between the medullary rays to reach the fibrous capsule, where they terminate in the capillary network of this part. These vessels do not anastomose with each other, but form what are called *end-arteries*. In their outward course they give off lateral branches;

FIG. 988.—Diagrammatic sketch of the blood-vessels of the kidney.

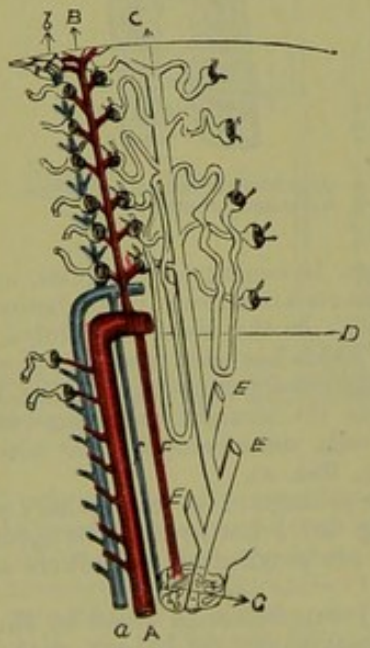

FIG. 989.—A portion of fig. 988 enlarged. (The references are the same.)

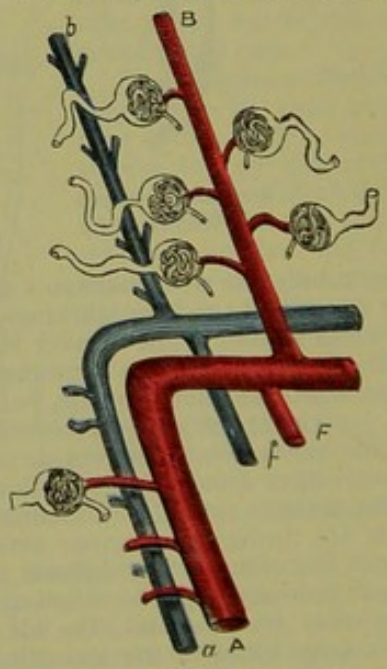

A *a*. Proper renal artery and vein, the former giving off the renal afferents, the latter receiving the renal efferents. B *b*. Interlobular artery and vein, the latter commencing from the stellate veins, and receiving branches from the plexus around the tubuli contorti, the former giving off renal afferents. C. Straight tube, surrounded by tubuli contorti, with which it communicates, as more fully shown in fig. 981. D. Margin of medullary substance. E E E. Receiving tubes, cut off. F *f*. Arteriolæ et venæ rectæ, the latter arising from (G) the plexus at the medullary apex.

these are the *afferent vessels* for the Malpighian bodies (see page 1185); they pierce the capsule, and end in the Malpighian tufts. From each tuft the corresponding *efferent vessel* arises, and, having made its egress from the capsule near to the point where the afferent vessel enters, breaks up into a number of branches, which form a dense *plexus* around the adjacent urinary tubes (fig. 990).

The *second set of branches* from the arterial arcades supply the medullary pyramids, which they enter at their bases ; and, passing straight through their substance to their apices, terminate in the venous plexuses found in that situation. They are called the *arteriæ rectæ* (figs. 988, 989, F).

The *renal veins* arise from three sources, viz. the veins beneath the capsule, the plexuses around the convoluted tubules in the cortical arches, and the plexuses situated at the apices of the pyramids of Malpighi. The veins beneath the capsule (*venæ stellatæ*) are stellate in arrangement, and are derived from the capillary network, into which the terminal branches of the interlobular arteries break up. These join to form the *venæ interlobulares*, which pass inwards between the medullary rays, receive branches from the plexuses around the convoluted tubules, and, having arrived at the bases of the Malpighian pyramids, join with the venæ rectæ, next to be described (figs. 988, 989, *b*).

The *venæ rectæ* are branches from the plexuses at the apices of the medullary pyramids, formed by the terminations of the arteriæ rectæ. They run outwards in a straight course between the tubes of the medullary structure, and joining, as above stated, the venæ interlobulares, form venous arcades ; these in turn unite and form veins which pass along the sides of the pyramids (figs. 988, 989, F).

These vessels, *venæ propriæ renales*, accompany the arteries of the same name, running along the entire length of the sides of the pyramids ; and, having received in their course the efferent vessels from the Malpighian bodies in the adjacent cortical structure, quit the kidney substance to enter the sinus. In this cavity they join the corresponding veins from the other pyramids to form the *renal vein*, which emerges from the kidney at the hilus and opens into the inferior vena cava ; the left vein is longer than the right, and crosses in front of the abdominal aorta.

FIG. 990.—Diagrammatic representation of the blood-vessels in the substance of the cortex of the kidney. (From Ludwig, in Stricker's 'Handbook.')

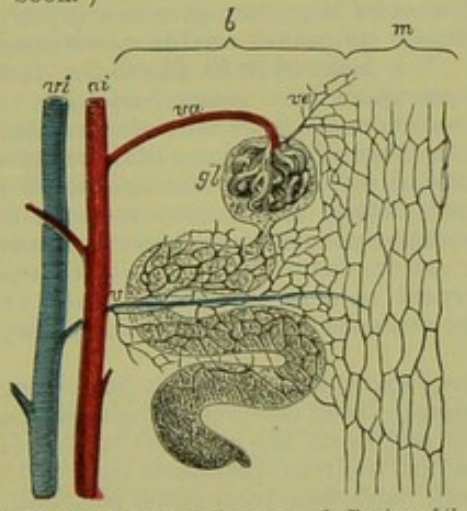

m. Region of the medullary ray. *b*. Region of the tortuous portion of the tubules. *ai*. Arteria interlobularis. *vi*. Vena interlobularis. *va*. Vas afferens. *gl*. Glomerulus. *ve*. Vas efferens. *v*. Venous twig of the interlobularis.

Nerves of the kidney.—The nerves of the kidney, although small, are about fifteen in number. They have small ganglia developed upon them, and are derived from the renal plexus, which is formed by branches from the solar plexus, the lower and outer part of the semilunar ganglion and aortic plexus, and from the lesser and smallest splanchnic nerves. They communicate with the spermatic plexus, a circumstance which may explain the occurrence of pain in the testicle in affections of the kidney. So far as they have been traced, they seem to accompany the renal artery and its branches, but their exact mode of termination is not known.

The *lymphatics* of the kidney are described on pages 787, 788.

Connective tissue, or *intertubular stroma*.—Although the tubules and vessels are closely packed, a small amount of connective tissue, continuous with the capsule, binds them firmly together. This tissue was first described by Goodsir, and subsequently by Bowman. Ludwig and Zawarykin have observed distinct fibres passing around the Malpighian bodies ; and Henle has seen them between the straight tubes composing the medullary structure.

Surface Marking.—The kidneys, being situated at the back part of the abdominal cavity and deeply placed, cannot be felt unless enlarged or misplaced. The greater part of each kidney lies in the epigastric region, i.e. internal to the mid-Poupart plane, but a small part is situated outside this plane, viz. in the hypochondriac region. The lower end of the left kidney is usually on a level with the subcostal plane : that of the right extends for about half an inch below this plane. The left is somewhat higher than the right. According to Morris, the position of the kidney may be thus defined : *Anteriorly*. '1. A horizontal line through the umbilicus is below the lower edge of each kidney. 2. A vertical line carried upwards to the costal arch from the middle of Poupart's ligament has one-third of the kidney to its outer side, and two-thirds to its inner side, i.e. between this line and the median line of the body.' In adopting these lines it must be borne in mind that the axes of the kidneys are not vertical, but oblique, and if continued upwards would meet about the ninth thoracic vertebra. *Posteriorly*. The upper end of the left kidney would be defined by a line drawn horizontally outwards from the spinous processes of the eleventh thoracic vertebra, and its lower end by a point two inches above the iliac crest. The right kidney would be half to three-quarters of an inch lower. Morris lays down the following rules for indicating the position of the kidney on the posterior surface of the body : 1. A line parallel with, and one inch from the vertebral column between the lower edge of the tip of the spinous process

of the eleventh thoracic vertebra, and the lower edge of the spinous process of the third lumbar vertebra. 2. A line from the top of this first line outwards at right angles to it for two and three-quarter inches. 3. A line from the lower end of the first transversely outwards for two and three-quarter inches. 4. A line parallel to the first and connecting the outer extremities of the second and third lines just described.

The hilus of the kidney lies about two inches from the middle line of the back at the level of the spinous process of the first lumbar vertebra.

Applied Anatomy.—Malformations of the kidney are not uncommon. There may be an entire absence of one kidney, but, according to Morris, the number of these cases is 'excessively small': or there may be congenital atrophy of one kidney, when the kidney is very small, but usually healthy in structure. These cases are of great importance, and must be duly taken into account when nephrectomy is contemplated. A more common malformation is where the two kidneys are fused together. They may be joined together only at their lower ends by means of a thick mass of renal tissue, so as to form a horse-shoe-shaped body, or they may be completely united, forming a disc-like kidney, from which two ureters descend into the bladder. These fused kidneys are generally situated in the middle line of the abdomen, but may be misplaced as well. In some mammals (e.g. ox and bear) the kidney consists of a number of distinct lobules; this lobulated condition is characteristic of the kidney of the human fœtus, and traces of it may persist in the adult. Sometimes the pelvis is duplicated, while a double ureter is not very uncommon. In some rare instances a third kidney may be present.

One or both kidneys may be misplaced as a congenital condition, and remain fixed in this abnormal position. They are then very often misshapen. They may be situated higher, though this is very uncommon, or lower than normal or removed farther from the vertebral column than usual; or they may be displaced into the iliac fossa, over the sacro-iliac joint, on to the promontory of the sacrum, or into the pelvis between the rectum and bladder or by the side of the uterus. In these latter cases they may give rise to very serious trouble. The kidney may also be misplaced as a congenital condition, but may not be fixed; it is then known as a *floating kidney*. It is believed to be due to the fact that the kidney is completely enveloped by peritoneum which then passes backwards to the vertebral column as a double layer, forming a mesonephron which permits of movement taking place. The kidney may also be misplaced as an acquired condition; in these cases the kidney is mobile in the tissues by which it is surrounded, moving with the capsule in the perinephric tissues. This condition is known as *movable kidney*, and is more common in the female than in the male. It occurs in badly nourished people, or in those who have become emaciated from any cause. It must not be confounded with the *floating kidney*, which is a congenital condition due to the development of a mesonephron. The two conditions cannot, however, be distinguished until the abdomen is opened or the kidney explored from the loin.

Injuries of the kidney are generally due to some severe crushing force, as from being run over by a heavy waggon or cart, or from the abdomen being compressed between the buffers of two railway carriages. When a laceration occurs on the posterior surface of the organ, infiltration of blood and urine takes place into the retro-peritoneal connective tissue; this is often followed by suppuration, and death may ensue from septic poisoning. When the laceration is in front, the peritoneum may be torn and extravasation of blood and urine take place into the peritoneal cavity. Death may occur from hæmorrhage or peritonitis. Occasionally, when rupture involves the pelvis of the kidney or the commencement of the ureter, this duct may become blocked, and hydronephrosis follow. Sometimes the kidney may be bruised by blows in the loin, or by being compressed between the lower ribs and the ilium when the body is violently bent forwards. This is followed by a little transient hæmaturia, which, however, speedily passes off.

The loose cellular tissue around the kidney may be the seat of suppuration, constituting *perinephric abscess*. This may be due to injury, to disease of the kidney itself, or to extension of inflammation from neighbouring parts. The abscess tends to point externally in the groin or loin.

Tumours of the kidney, of which perhaps sarcoma, in children, is the most common, may be recognised by their position; by the resonant colon lying in front of them; and by their rounded outline not presenting a notched anterior margin like the spleen, with which they are most likely to be confounded.

The *hypernephroma*, a benign or malignant tumour arising from the suprarenal gland, or from suprarenal 'rests' or inclusions in the cortex or medulla of the kidney, is not infrequent. When occurring in children it is often associated with precocious growth of the body generally and of the hair and sexual organs in particular. Arising, as it often does, in the kidney, a hypernephroma may be indistinguishable from a true renal tumour so far as the physical signs and symptoms go; it is really, however, a tumour of the suprarenal gland substance.

The examination of the kidney should be bimanual; that is to say, one hand should be placed in the flank and firm pressure made forwards; while the other hand is buried in the abdominal wall, over the situation of the organ. Manipulation of the kidney frequently produces a peculiar sickening sensation, with sometimes faintness.

The kidney may require exposure for exploration or the evacuation of pus (nephrotomy); it may be incised for the removal of stone (nephro-lithotomy); it may be sutured when movable or floating (nephrorrhaphy); or it may be removed (nephrectomy). It may be exposed either by a lumbar or an abdominal incision; except in cases of very large tumours, a lumbar incision is best, as it has the advantages of not opening the peritoneum, and of affording admirable drainage. An oblique incision should be made, starting at the outer border of the Erector spinæ, half an inch below the last rib and directed downwards and forwards towards a point an inch in front of the anterior superior spine of the ilium. The structures divided are the skin, the superficial fascia with the cutaneous nerves, the deep fascia, the posterior border of the External oblique muscle of the abdomen, and the outer border of the Latissimus dorsi; the Internal oblique and the posterior aponeurosis of the Transversalis muscle; the outer border of the Quadratus lumborum; the deep layer of the lumbar aponeurosis, and the transversalis fascia. The fatty tissue around the kidney is now exposed to view, and must be separated by the fingers, or a director, in order to reach the kidney. The operations of *nephro-lithotomy*, for the removal of calculi from the kidney, and *nephrotomy*, or incision of the kidney for abscess, &c., are generally performed by the lumbar incision. This route is also generally chosen for *nephrectomy*. The abdominal operation is best performed by an incision through the outer part of the Rectus on the side of the kidney to be removed; the kidney is then reached from the outer side of the colon, ascending or descending, as the case may be, and the vessels of the colon are not interfered with. The incision commencing just below the costal arch is made of varying length, according to the size of the kidney. The abdominal cavity is opened. The intestines are drawn inwards and the peritoneum over the kidney to the outer side of the colon incised, so that the fingers can be introduced behind the peritoneum. The kidney must now be enucleated, and the vessels firmly ligatured and divided with the ureter, the latter being tied, or if thought necessary stitched to the edge of the wound. The particular advantage of the abdominal operation is that the condition of the other kidney can be ascertained by manual examination, before the removal of the diseased kidney is finally decided upon.

Nephrorrhaphy is the name given to the operation for fixing a movable kidney. The kidney is reached by the lumbar incision, and its posterior surface denuded of its fatty capsule. Three stitches of medium thickness are passed through the transversalis fascia and muscles and through the cortical portion of the kidney, securing a good hold of it. When these sutures are tied, the kidney is tightly anchored in position; cases which are seen sometimes afterwards seem however to show that it does not always remain fixed.

The Ureters

The **ureters** are the two tubes which convey the urine from the kidneys to the bladder. Each commences within the sinus of the corresponding kidney as a number of short cup-shaped tubes, termed *calyces* or *infundibula*, which encircle the *renal papillæ*. Since a single calyx may enclose more than one papilla the calyces are generally fewer in number than the pyramids—the former varying from seven to thirteen, the latter from eight to eighteen. The calyces join to form two or three short tubes, and these unite to form a funnel-shaped dilatation, wide above and narrow below, named the **pelvis of the kidney**, which is situated behind the renal vessels and lies partly inside and partly outside the renal sinus. It is usually placed on a level with the spinous process of the first lumbar vertebra.

The **ureter proper** measures from ten to twelve inches in length, and is a thick-walled narrow cylindrical tube which is directly continuous near the lower end of the kidney with the tapering extremity of the pelvis. It runs downwards and inwards in front of the Psoas muscle and, entering the pelvic cavity, finally opens into the base of the bladder.

The *abdominal part* (pars abdominalis) lies behind the peritoneum on the inner part of the Psoas muscle, and is crossed obliquely by the spermatic vessels. It enters the pelvic cavity by crossing either the termination of the common, or the commencement of the external, iliac vessels.

At its origin the *right* ureter is usually covered by the second part of the duodenum, and in its course downwards lies to the right of the inferior vena cava, and is crossed by the right colic artery, while near the pelvic brim it passes behind the lower part of the mesentery and the terminal part of the ileum. The *left* ureter is crossed by the left colic artery, and near the brim of the pelvis passes behind the pelvic colon and its mesentery.

The *pelvic part* (pars pelvina) runs at first downwards on the lateral wall of the pelvic cavity under cover of the peritoneum, lying in front of the internal

Abdom. Part — {Cov.d at origin by 2nd Pt. of Duod. (Rt. Ureter)
{Crossed by Rt. or left Colic & Spermatic Art.
Pelvic Part {Crosses Ext. Iliac vessels. lies in front of Int. Iliac Vessels.

iliac vessels and on the inner side of the obliterated hypogastric artery and the obturator nerve and vessels. Opposite the lower part of the great sacro-sciatic foramen it inclines inwards behind the vas deferens (which crosses to its inner side) and reaches the base of the bladder, where it is situated in front of the upper end of the seminal vesicle and at a distance of about two inches from the opposite ureter. Finally, the ureters run obliquely for about three-quarters of an inch through the wall of the bladder and open by slit-like apertures into the cavity of the viscus at the lateral angles of the trigone. When the bladder is distended the openings of the ureters are about two inches apart, but when it is empty and contracted the distance between them is diminished by one-half. Owing to their oblique course through the coats of the bladder, their upper and lower walls become closely applied to each other when the viscus is distended, and, acting as valves, prevent regurgitation of urine from the bladder.

In the *female*, the ureter forms, as it lies in relation to the wall of the pelvis, the posterior boundary of a shallow depression named the *fossa ovarii*, in which the ovary is situated. It then runs inwards and forwards on the lateral aspect of the cervix uteri and upper part of the vagina to reach the base of the bladder. In this part of its course it is accompanied for about an inch by the uterine artery, which then crosses in front of the ureter and ascends between the two layers of the broad ligament. The ureter is distant about three-quarters of an inch from the lateral aspect of the neck of the uterus.

The ureter is sometimes duplicated, and the two tubes may remain distinct as far as the base of the bladder. On rare occasions they open separately into the bladder cavity.

Structure (fig. 991).—The ureter is composed of three coats: fibrous, muscular, and mucous.

The *fibrous coat* is continuous at one end with the capsule of the kidney on the floor of the sinus; while at the other it is lost in the fibrous structure of the bladder.

In the pelvis of the kidney the *muscular coat* consists of two layers, longitudinal and circular: the longitudinal fibres become lost upon the sides of the papillæ at the extremities of the calyces; the circular fibres may be traced surrounding the medullary structure in the same situation. In the ureter proper the muscular fibres are very distinct, and are arranged in three layers: an external longitudinal, a middle circular, and an internal, less distinct than the other two, but having a general longitudinal direction. According to Kölliker this internal layer is found only in the neighbourhood of the bladder.

Fig. 991.—Transverse section of ureter.

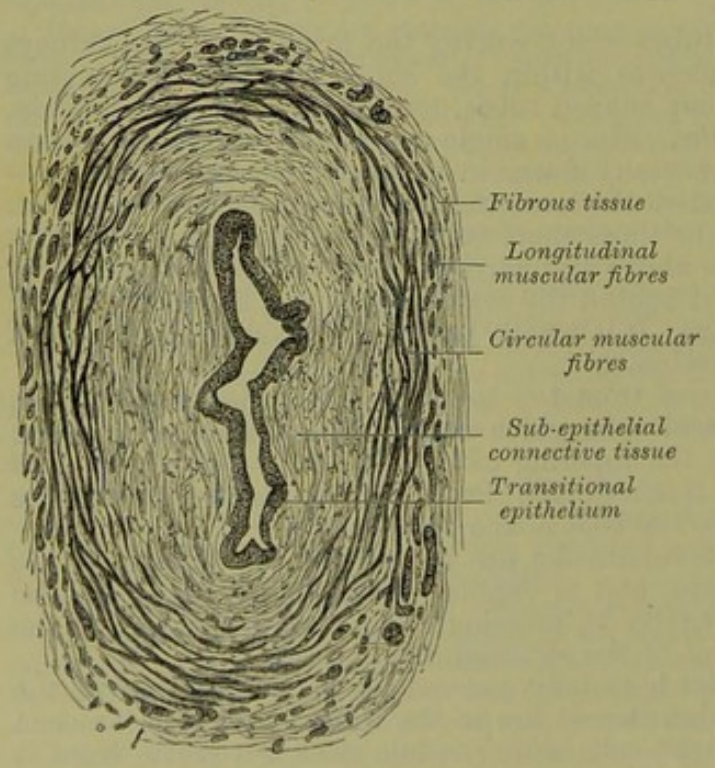

The *mucous coat* is smooth, and presents a few longitudinal folds which become effaced by distension. It is continuous with the mucous membrane of the bladder below, while it is prolonged over the papillæ of the kidney above. Its epithelium is of a transitional character, and resembles that found in the bladder (see fig. 996, page 1197). It consists of several layers of cells, of which the innermost — that is to say, the cells in contact with the urine—are quadrilateral in shape, with concavities on their deep surfaces into which the rounded ends of the cells of the second layer fit. These, the intermediate cells, more or less resemble columnar epithelium, and are pear-shaped, with rounded internal extremities which fit into the concavities of the cells of the first layer, and narrow external extremities which are wedged in between the cells of the third layer. The external or third layer

consists of conical or oval cells varying in number in different parts, and presenting processes which extend down into the basement-membrane. Beneath the epithelium, and separating it from the muscular coats, is a dense layer of fibrous tissue containing many elastic fibres.

The *arteries* supplying the ureter are branches from the renal, spermatic, internal iliac, and inferior vesical.

The *nerves* are derived from the inferior mesenteric, spermatic, and pelvic plexuses.

Applied Anatomy.—Rupture of the ureter is not a common accident, but occasionally occurs. If it be torn completely across, the urine collects in the retro-peritoneal tissues; if it be not completely divided, the lumen of the tube may become strictured and hydronephrosis or pyonephrosis result. The ureter may be accidentally wounded in some pelvic operations, such as removal of the uterus; if this should happen the divided ends must be sutured together, or failing to accomplish this an attempt may be made to implant the upper end into the bladder or rectum. If this cannot be carried out the only alternative is to remove the kidney immediately.

Stones not uncommonly become impacted in the ureter. These may occur at any part, but most commonly either at the point where the tube is crossing the pelvic brim or at the termination, where it is passing obliquely through the muscular wall of the bladder. In the former case, an incision with its centre opposite, and one inch internal to, the anterior superior spine of the ilium dividing all the structures down to the peritoneum, enables the operator to reach the ureter by pushing the unopened peritoneum inwards; the stone can then be felt in the ureter, the wall of which is incised, and the stone extracted, free drainage being provided for the escaping urine. When the stone is impacted at the vesical end of the tube a preliminary incision into the bladder is required, and by scratching through the mucous membrane overlying it the calculus can be removed.

The Bladder (fig. 992)

The **bladder** (vesica urinaria) is a musculo-membranous sac which acts as a reservoir for the urine; and as its size, position, and relations vary according

Fig. 992.—Median sagittal section of male pelvis.

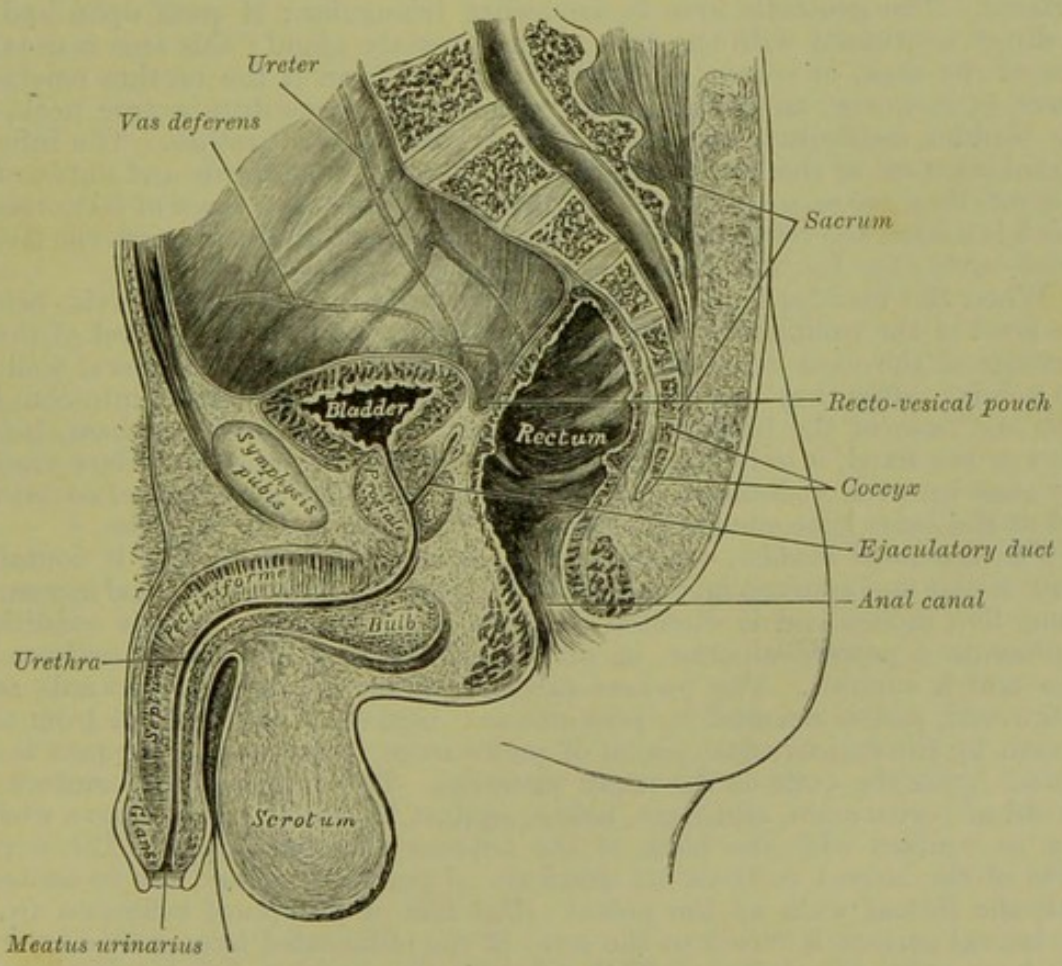

to the amount of fluid it contains, it is necessary to study it as it appears (*a*) when empty, and (*b*) when distended. In both conditions the position of

the bladder varies with the condition of the rectum, being pushed upw and forwards when the rectum is distended.

The empty bladder.—When hardened *in situ*, the empty bladder has form of a flattened tetrahedron, with its apex tilted forwards. It pres a base, an apex, a superior and an inferior surface. The *base* is triangula shape, and is directed downwards and backwards towards the rectum, f which it is separated by the recto-vesical fascia, the vesiculæ seminales, the terminal portions of the vasa deferentia. The *apex* is directed forwa towards the upper part of the symphysis pubis, and from it a fibrous cor continued upwards on the back of the anterior abdominal wall to the umbilic This cord is named the *urachus*, and represents the fibrous remains of the int abdominal part of the fœtal allantois (see page 175). The peritoneum carried by it from the apex of the bladder on to the abdominal wall to fo what is termed the anterior or superior false ligament of the bladder. T *superior surface* is triangular, bounded on either side by a lateral border wh separates it from the inferior surface, and behind by a posterior bord represented by a line joining the two ureters, which intervenes between and the base. The lateral borders extend from the ureters to the bladd apex, and from them the peritoneum is carried to the walls of the pelvis the lateral false ligaments of the bladder. On either side of the bladder t peritoneum shows a depression, which is named the *paravesical fossa*. T superior surface is directed upwards, is covered by peritoneum, and is in relati with the pelvic colon and some of the coils of the small intestine. When t bladder is empty and firmly contracted, this surface is convex and the later and posterior borders are rounded; whereas if the bladder be relaxed it concave, and the interior of the viscus, as seen in a vertical mesial sectio presents the appearance of a V-shaped slit with a shorter posterior and a longe anterior limb—the apex of the V corresponding with the orifice of the urethra The *inferior* surface is directed downwards and is uncovered by peritoneum It may be divided into a posterior or prostatic area and two infero-latera surfaces. The prostatic area is somewhat triangular: it rests upon and i in direct continuity with the base of the prostate gland; this area is usuall named the *neck*, or *cervix*, of the bladder, and from it the urethra emerges There is, however, no tapering part which would constitute a true neck, a the bladder suddenly contracts to the opening of the urethra. The infero lateral portions of the inferior surface are directed downwards and outwards in front, they are separated from the symphysis pubis by a mass of fatty tissue which is named the *retro-pubic pad*; behind, they are in contact with the fascia which covers the Levatores ani and Obturator internus muscles.

When the bladder is empty it is placed entirely within the pelvis, below the level of the obliterated hypogastric arteries, and below the level of those portions of the vasa deferentia which are in contact with the lateral wall of the pelvis; after they cross the ureters the vasa deferentia come into contact with the base of the bladder. As the viscus becomes filled, its base, being more or less fixed, is only slightly depressed; while its superior surface gradually rises into the abdominal cavity, carrying with it its peritoneal covering, and at the same time rounding off the posterior and lateral borders.

The distended bladder.—When the bladder is moderately full it contains about a pint and assumes an oval form; the long diameter of the oval measures about five inches and is directed upwards and forwards. In this condition it presents a postero-superior, an antero-inferior, and two lateral surfaces, a base and a summit. The postero-superior surface is directed upwards and backwards, and is covered by peritoneum: behind, it is separated from the rectum by the recto-vesical pouch of peritoneum, while its anterior part is in contact with the coils of the small intestine. The antero-inferior surface is devoid of peritoneum, and rests, below, against the pubic bones, above which it is in contact with the back of the anterior abdominal wall. The lower parts of the lateral surfaces are destitute of peritoneum, and are in contact with the lateral walls of the pelvis. The line of peritoneal reflection from the lateral surface is raised to the level of the obliterated hypogastric artery. The base or fundus undergoes little alteration in position, being only slightly lowered. It exhibits, however, a narrow triangular area, which is separated from the rectum merely by the recto-vesical fascia. This area is bounded

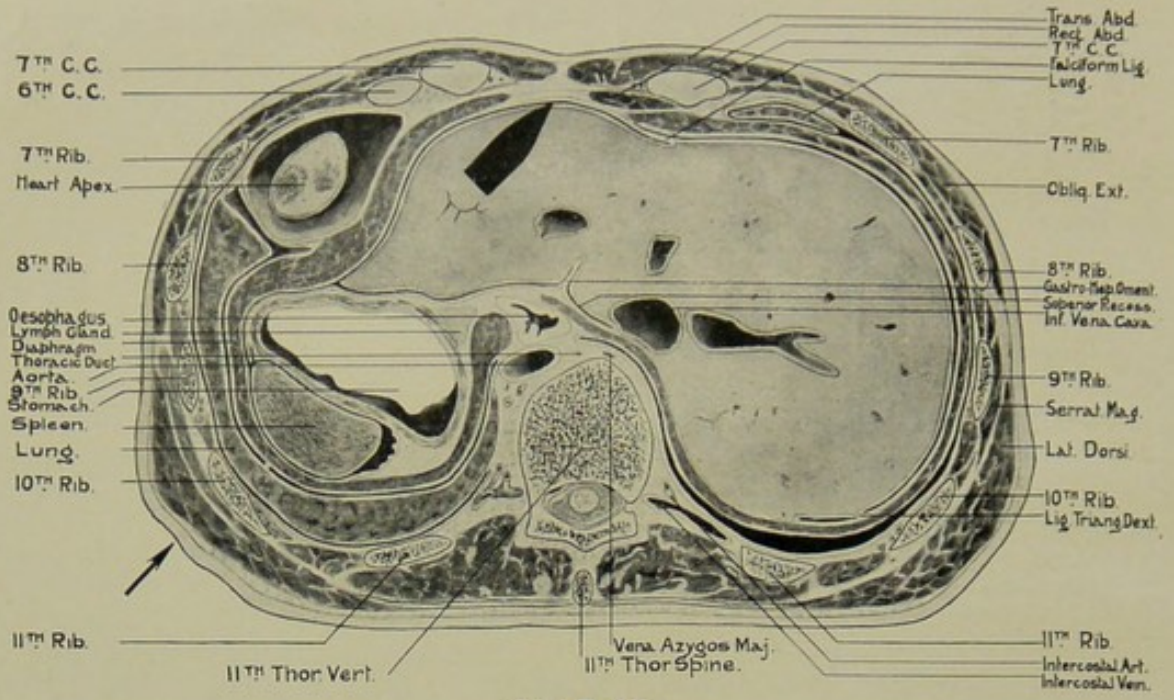

SLAB IX.

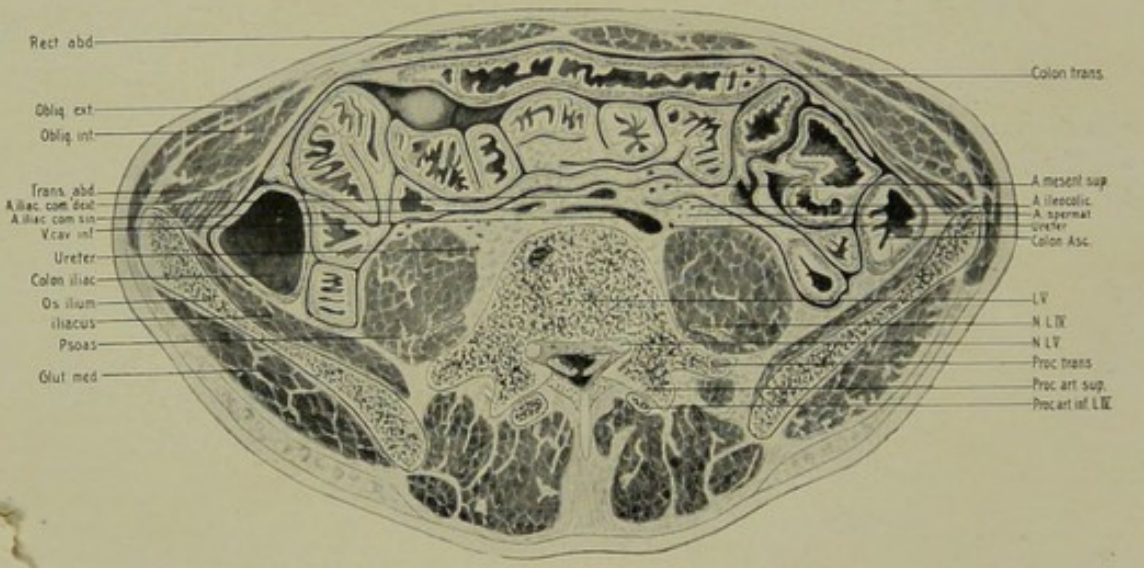

SLAB XVI.

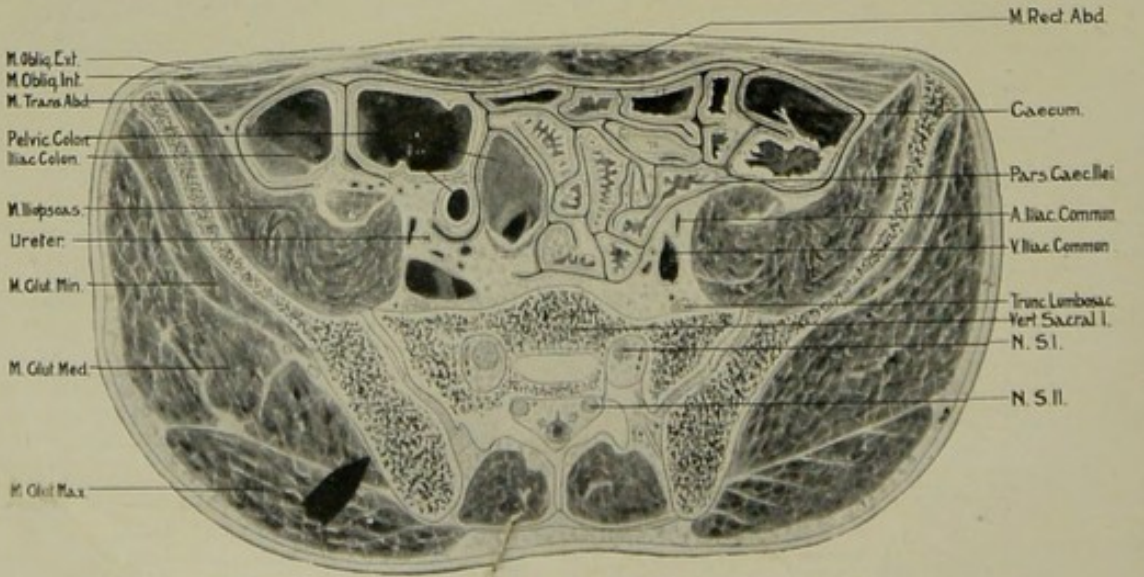

SLAB XVIII.

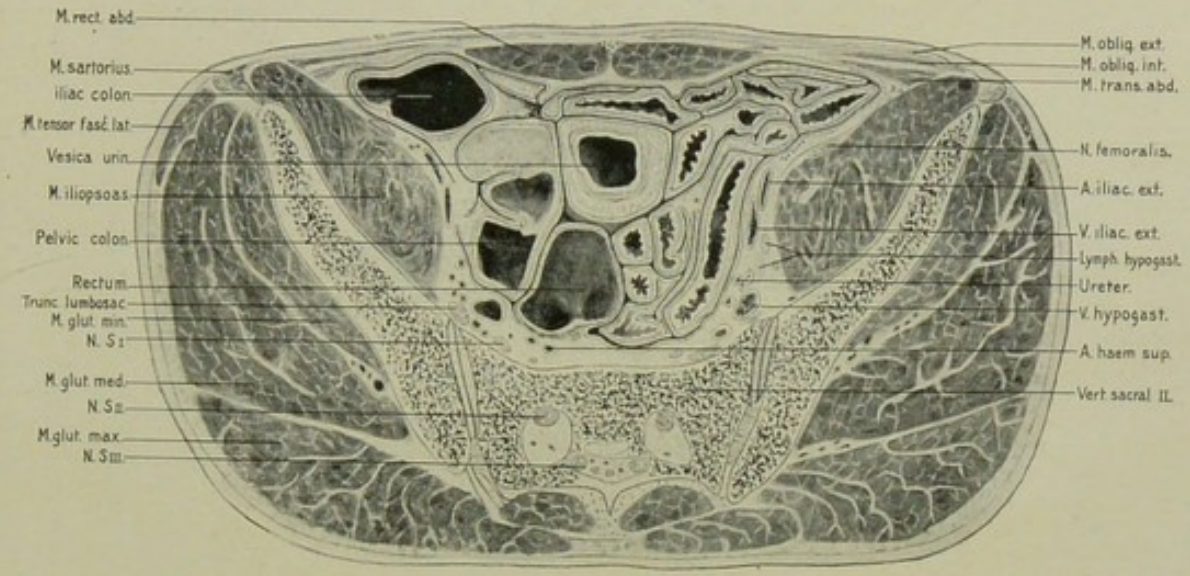

SLAB XIX.

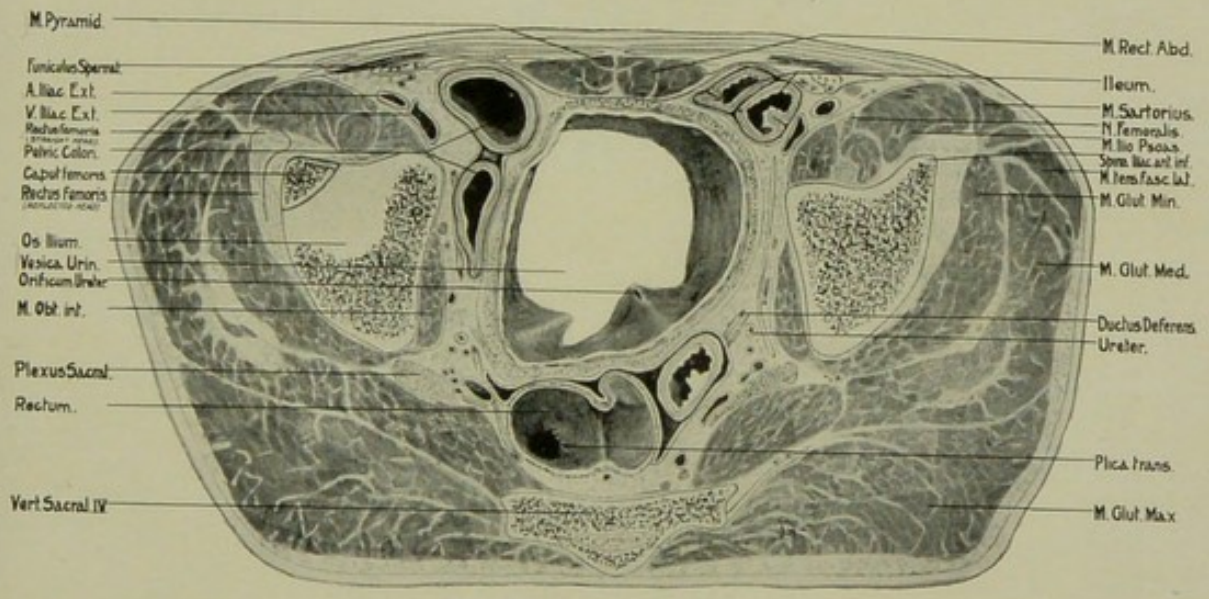

SLAB XX.

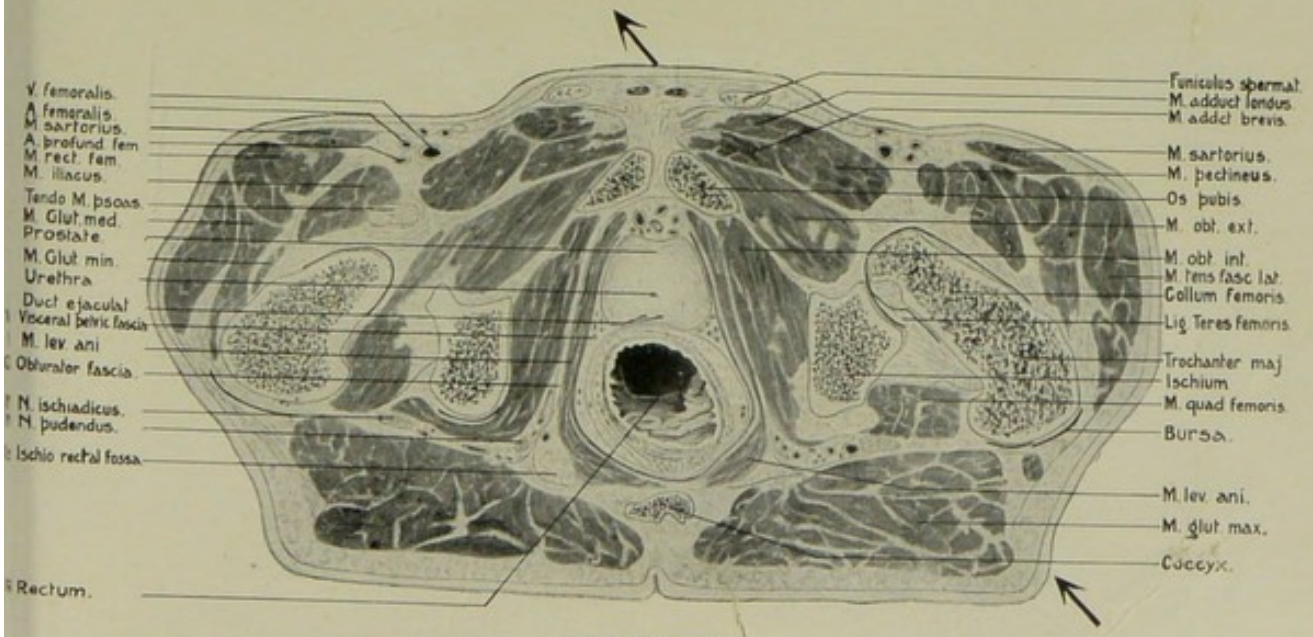

SLAB XXII.

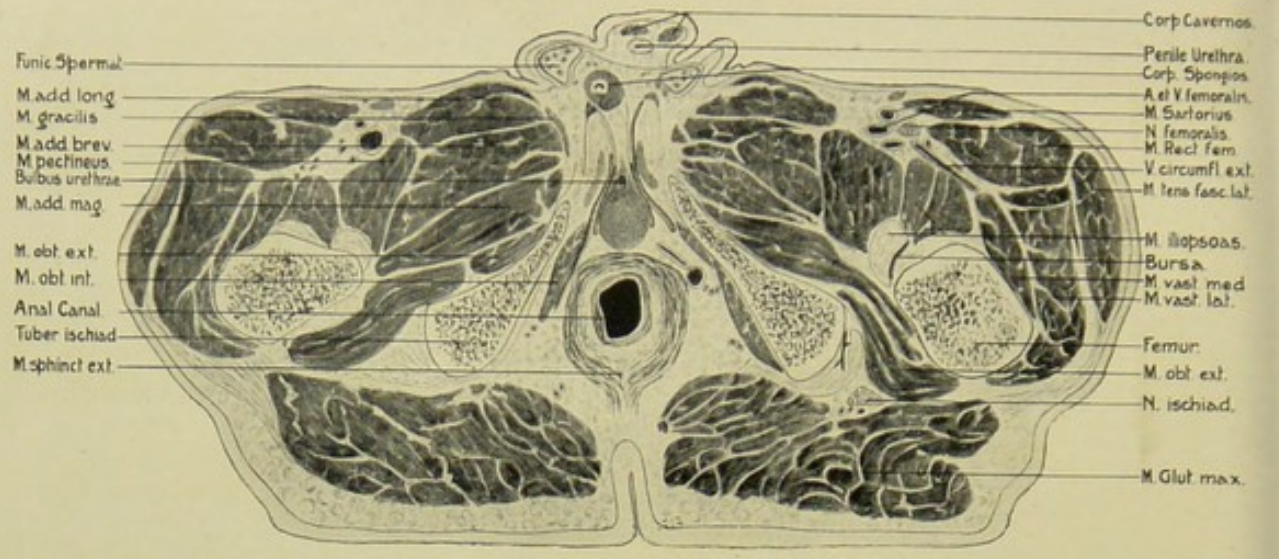

SLAB XXIII.

For remaining sections see Quain's Splanchnology.

	FIG.
SLAB X.	309
„ XI.	310
„ XII.	311
„ XIII.	317
„ XIV.	314
„ XV.	315
„ XVII.	316
„ XXI.	318

below by the prostate, above by the recto-vesical fold of peritoneum, and laterally by the vasa deferentia. The vasa deferentia frequently come in contact with each other above the prostate, and under such circumstances the lower part of the triangular area is obliterated. The line of reflection of the peritoneum from the rectum to the bladder appears to undergo little or no

Fig. 993.—Sagittal section through the pelvis of a newly born male child.

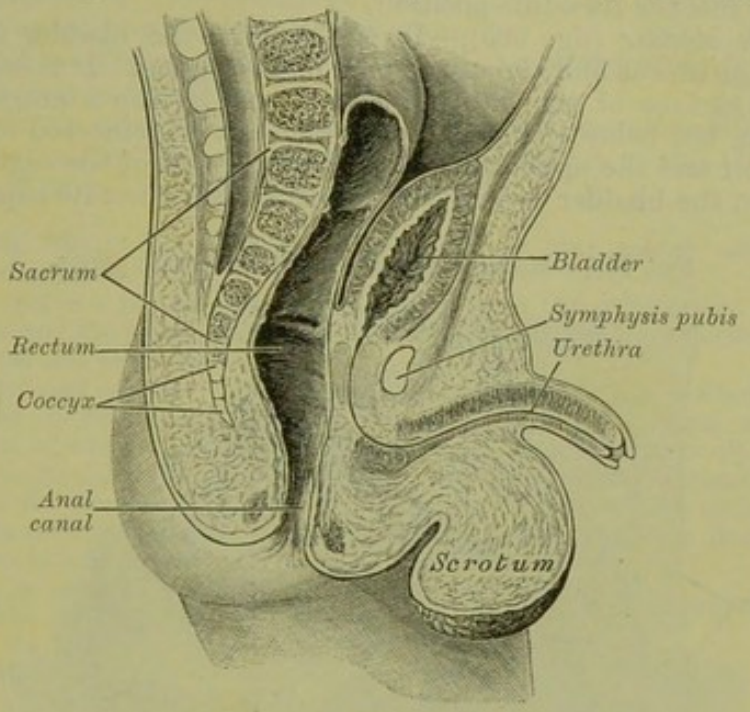

change when the latter is distended ; it is situated about four inches from the anus. The summit is directed upwards and forwards above the point of attachment of the urachus, and hence the peritoneum, which follows the urachus, forms a pouch of varying depth between the summit of the bladder and the anterior abdominal wall.

Fig. 994.—Sagittal section through the pelvis of a newly born female child.

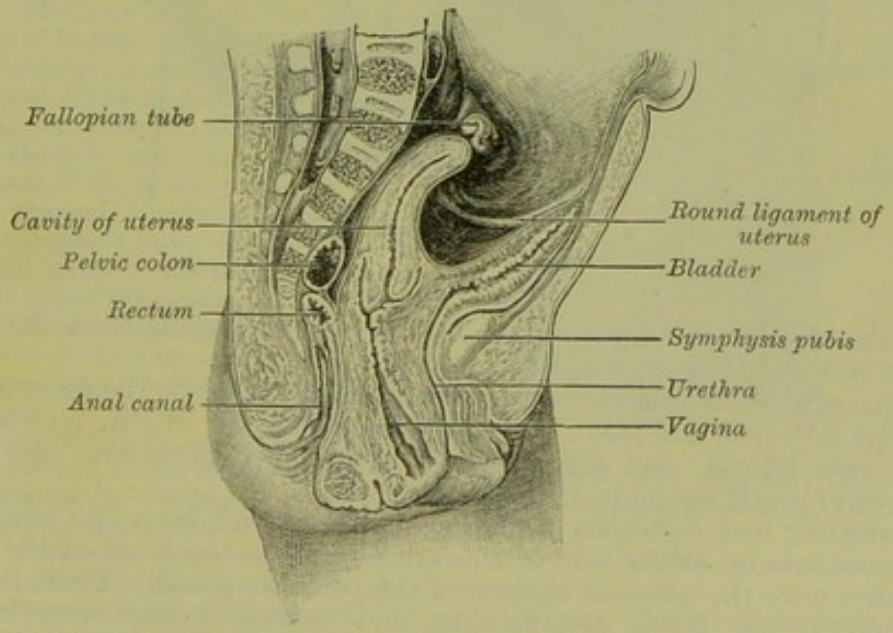

The bladder in the child (figs. 993, 994).—In the new-born child the urethral orifice of the bladder is at the level of the upper border of the symphysis pubis ; the bladder therefore lies relatively at a much higher level in the infant than in the adult. Its anterior surface is 'in contact with about the lower two-thirds of that part of the abdominal wall which lies between

the symphysis pubis and the umbilicus' (Symington).* Its posterior surface is clothed with peritoneum as far as the level of the orifice of the urethra. Although the bladder of the infant is usually described as an abdominal organ, Symington has pointed out that only about one-half of it lies above the plane of the pelvic inlet. Disse maintains that the urethral orifice sinks rapidly during the first three years, and then more slowly until the ninth year, after which it remains stationary until puberty, when it again slowly descends and reaches its adult position.

The female bladder (fig. 995).—In the female, the bladder is in relation behind with the uterus and the upper part of the vagina. It is separated from the anterior surface of the body of the uterus by the utero-vesical pouch of peritoneum, but below the level of this pouch it is connected to the front of the cervix uteri and the upper part of the anterior wall of the vagina by areolar tissue. When the bladder is empty the uterus rests upon its superior surface.

FIG. 995.—Median sagittal section of female pelvis.

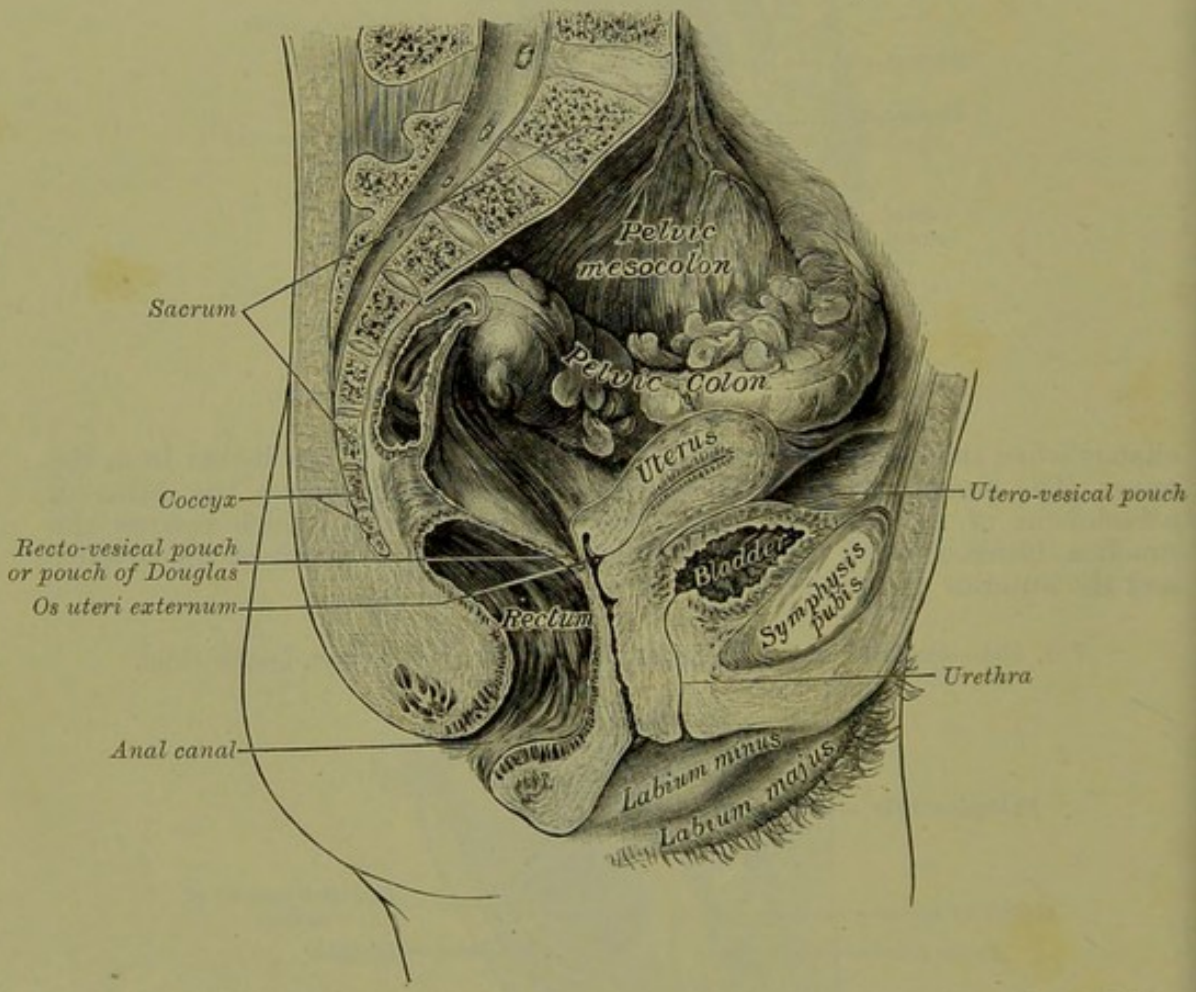

The female bladder is said by some to be more capacious than that of the male, but probably the opposite is the case.

Ligaments.—The bladder is retained in its place by ligaments, which are divided into true and false. The true ligaments are five in number: two anterior, two lateral, and the urachus. The false ligaments, also five in number, are formed by folds of the peritoneum.

The *anterior true ligaments* (pubo-prostatic) extend from the back of the pubic bones, one on either side of the symphysis, to the front of the neck of the bladder, over the anterior surface of the prostate gland. These ligaments are formed by the fascia endopelvina, and contain a few muscular fibres prolonged from the bladder.

The *lateral true ligaments*, also formed by the fascia endopelvina, are broader and thinner than the preceding. They are attached to the lateral parts of the prostate, and to the sides of the base of the bladder.

* *The Anatomy of the child.*

The *urachus* is the fibro-muscular cord already mentioned, extending between the summit of the bladder and the umbilicus. It is broad below, at its attachment to the bladder, and becomes narrower as it ascends.

The *false ligaments of the bladder* are two posterior, two lateral, and one anterior or superior.

The *two posterior* ligaments form the sacro-genital folds, already described (page 1124); they pass forwards from the sides of the rectum to the posterior and lateral aspects of the vesiculæ seminales, and form the lateral boundaries of the recto-vesical pouch of the peritoneum.

The *two lateral ligaments* are reflections of the peritoneum, from the lateral walls of the pelvis to the sides of the bladder.

The *anterior* or *superior ligament* (ligamentum suspensorium) is the fold of peritoneum extending from the summit of the bladder to the abdominal wall. It is carried off from the bladder by the urachus.

Structure (fig. 996).—The bladder is composed of four coats: serous, muscular, submucous, and mucous.

The *serous coat* is a partial one, and is derived from the peritoneum. It invests the superior surface and the upper parts of the lateral surfaces, and is reflected from these on to the abdominal and pelvic walls.

The *muscular coat* consists of three layers of unstriped muscular fibres: an external layer, composed of fibres having for the most part a longitudinal arrangement; a middle layer, in which the fibres are arranged, more or less, in a circular manner; and an internal layer, in which the fibres have a general longitudinal arrangement.

The *fibres of the external longitudinal layer* arise from the posterior surface of the body of the pubis in both sexes (*musculi pubo-vesicales*), and in the male from the adjacent part of the prostate gland and its capsule. They pass, in a more or less longitudinal manner, up the anterior surface of the bladder, over its apex, and then descend along its posterior surface to its base, where they become attached to the prostate in the male, and to the front of the vagina in the female. At the sides of the bladder the fibres are arranged obliquely and intersect one another. This layer has been named the *Detrusor urinæ muscle*.

Fig. 996.—Vertical section of bladder.

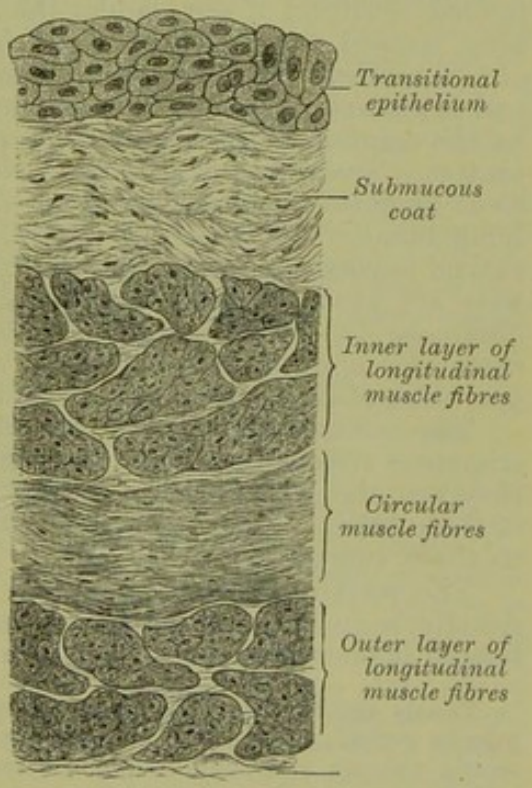

The *fibres of the middle circular layer* are very thinly and irregularly scattered on the body of the organ, and, although to some extent placed transversely to the long axis of the bladder, are for the most part arranged obliquely. Towards the lower part of the bladder, round the neck and commencement of the urethra, they are disposed in a thick circular layer, forming the *Sphincter vesicæ*, which is continuous with the muscular fibres of the prostate gland.

The *internal longitudinal layer* is thin, and its fasciculi have a reticular arrangement, but with a tendency to assume for the most part a longitudinal direction.

Two bands of oblique fibres, originating behind the orifices of the ureters, converge to the back part of the prostate gland, and are inserted by means of a fibrous process, into the middle lobe of that organ. They are the *muscles of the ureters*, described by Sir C. Bell, who supposed that during the contraction of the bladder they serve to retain the oblique direction of the ureters, and so prevent the reflux of the urine into them.

The *submucous coat* consists of a layer of areolar tissue, connecting together the muscular and mucous coats, and intimately united to the latter.

The *mucous coat* is thin, smooth, and of a pale rose colour. It is continuous above through the ureters with the lining membrane of the uriniferous tubes, and below with that of the urethra. It is connected loosely to the muscular coat by a layer of areolar tissue, and is therefore thrown into folds or *rugæ* when the bladder is empty. Over the trigonum vesicæ the mucous membrane is closely attached to the muscular coat, and is not thrown into folds, but is smooth and flat. The epithelium covering it is of the transitional variety, consisting of a superficial layer of polyhedral flattened cells, each with one, two,

or three nuclei; beneath these is a stratum of large club-shaped cells, with their narrow extremities directed downwards and wedged in between smaller spindle-shaped cells,

Fig. 997.—Superficial layer of the epithelium of the bladder. Composed of polyhedral cells of various sizes, each with one, two, or three nuclei. (Klein and Noble Smith.)

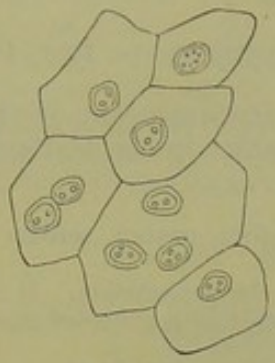

Fig. 998.—Deep layers of the epithelium of the bladder, showing large club-shaped cells above, and smaller, more spindle-shaped cells below, each with an oval nucleus. (Klein and Noble Smith.)

containing oval nuclei (figs. 997, 998). There are no true glands in the mucous membrane of the bladder, though certain mucous follicles which exist, especially near the neck of the bladder, have been regarded as such.

Interior of the bladder.—The mucous membrane lining the bladder is, over the greater part of the viscus, loosely attached to the muscular coat, and appears wrinkled or folded when the bladder is contracted: in the distended condition of the bladder the folds are effaced. Over a small triangular area, termed the *trigonum vesicæ*, immediately above and behind the orifice of the urethra, the mucous membrane is firmly bound to the muscular coat, and is always smooth. The anterior angle of the trigonum vesicæ is formed by the opening of the urethra: its postero-lateral angles by the orifices of the ureters. Stretching behind the latter openings is a slightly curved ridge, the *torus uretericus*, forming the base of the trigone and produced by an underlying bundle of non-striped muscular fibres. The lateral parts of this ridge extend beyond the openings of the ureters, and are named the *plicæ uretericæ*; they are produced by the terminal portions of the ureters as they traverse obliquely the bladder-wall. When the bladder is illuminated the torus uretericus appears as a pale band and forms an important guide during the operation of introducing a catheter into the ureter.

The *orifices of the ureters* are placed at the postero-lateral angles of the trigonum vesicæ, and are usually slit-like in form. In the contracted bladder they are about an inch apart and about the same distance from the orifice of the urethra; in the distended viscus these measurements may be increased to about two inches.

The *urethral orifice* is placed at the apex of the trigonum vesicæ, and is usually somewhat crescentic in form; the mucous membrane immediately behind it presents a slight elevation, named the *uvula vesicæ*.

Vessels and Nerves.—The *arteries* supplying the bladder are the superior, middle, and inferior vesical, derived from the anterior trunk of the internal iliac. The obturator and sciatic arteries also supply small visceral branches to the bladder, and in the female additional branches are derived from the uterine and vaginal arteries.

The *veins* form a complicated plexus round the neck, sides, and base of the bladder, and terminate in the internal iliac veins.

The *lymphatics* are described on page 788.

The *nerves* are derived from the pelvic plexuses of the sympathetic and from the third and fourth sacral nerves; the former supplying the upper part of the organ, the latter its base and neck. According to F. Darwin, the sympathetic fibres have ganglia connected with them, which send branches to the vessels and muscular coat.

Surface Form.—The surface form of the bladder varies with its degree of distension and under other circumstances. In the young child it is represented by a conical figure, the apex of which, even when the viscus is empty, is situated in the hypogastric region, above the level of the symphysis pubis. In the adult, when the bladder is empty, its apex does not reach above the level of the upper border of the symphysis pubis, and the

whole organ is situated in the pelvis ; the neck, in the male, corresponding to a line drawn horizontally backwards through the symphysis, a little below its middle. As the bladder becomes distended it gradually rises out of the pelvis into the abdomen, and forms a swelling in the hypogastric region, which is perceptible to the hand, as well as to percussion. In extreme distension it reaches into the umbilical region. Under these circumstances the lower part of its anterior surface, for a distance of about two inches above the symphysis pubis, is closely applied to the abdominal wall, without the intervention of peritoneum, so that it can be tapped by an opening in the middle line just above the symphysis pubis, without any fear of wounding the serous membrane. When the rectum is distended, the prostatic portion of the urethra is elongated and the bladder lifted out of the pelvis and the peritoneum pushed upwards.

When distended the bladder can be felt in the male, from the rectum, behind the prostate, and fluctuation can be perceived by a bimanual examination, one finger being introduced into the rectum and the distended bladder tapped on the front of the abdomen with the finger of the other hand. This portion of the bladder—that is, the portion felt in the rectum by the finger—is also uncovered by peritoneum, and the bladder may here be punctured from the rectum, in the middle line, without risk of wounding the serous membrane.

Applied Anatomy.—A defect of development, in which the bladder is implicated, is known under the name of *extroversion of the bladder*. In this condition the lower part of the abdominal wall and the anterior wall of the bladder are wanting, so that the posterior surface of the bladder presents on the abdominal surface, and is pushed forwards by the pressure of the viscera within the abdomen, forming a red vascular tumour on which the openings of the ureters are visible. The penis, except the glans, is rudimentary and is cleft on its dorsal surface, exposing the floor of the urethra, a condition known as *epispadias*. The pelvic bones are also arrested in development (see page 331).

The bladder may be ruptured by violence applied to the abdominal wall, when the viscus is distended, without any injury to the bony pelvis, or it may be torn in cases of fracture of the pelvis. The rupture may be either intraperitoneal or extraperitoneal : that is, may implicate the superior surface of the bladder in the former case, or one of the other surfaces in the latter. Until recently intraperitoneal rupture was uniformly fatal, but now abdominal section and suturing the rent with Lembert's suture is resorted to, with a very considerable amount of success. The sutures are inserted only through the peritoneal and muscular coats in such a way as to bring the serous surfaces at the margins of the wound into apposition, and one is inserted just beyond each end of the wound. The bladder should be tested as to whether it is water-tight before closing the external incision.

The muscular coat of the bladder undergoes hypertrophy in cases in which there is any obstruction to the flow of urine. Under these circumstances the bundles of which the muscular coat consists become much increased in size, and, interlacing in all directions, give rise to what is known as the *fasciculated bladder*. Between these muscular bundles the mucous membrane may bulge out, forming sacculi, constituting the *sacculated bladder*, and in these little pouches phosphatic concretions may collect, forming *encysted calculi*. The mucous membrane is very loosely attached, except over the trigone, to allow of the distension of the viscus.

Various forms of tumour have been found springing from the wall of the bladder. The commonest innocent tumour is the villous papilloma. Of the malignant tumours, epithelioma is the most common, but sarcoma is occasionally found in the bladder of children.

In doubtful cases the cystoscope proves a valuable aid in diagnosis. This instrument consists of a tube in which is fixed a small electric light, the wires of which run through the shaft of the instrument. Upon introducing this down the urethra, the bladder can be examined with the eye, and a villous growth or other tumour, a calculus, or an ulcer can be detected ; or the orifices of the ureters can be examined, and renal hæmaturia diagnosed, and it can be definitely settled from which kidney the blood comes. Again, the presence of minute tuberculous ulceration near the mouth of the ureter on the affected side may establish the diagnosis, not only of tuberculous kidney, but also of the side in which the disease is located. Caspar has utilised the cystoscope in catheterising the ureter, by causing a groove to be made on one side of the shaft of the instrument, along which a fine bougie can be passed. The mouth of the ureter is first found by the surgeon, and the bougie then projected into the field of vision and guided directly into the opening.

Puncture of the bladder may be performed either above the symphysis pubis or through the rectum, in both cases without wounding the peritoneum. The former plan is generally to be preferred, since in puncture by the rectum a permanent fistula may be left from abscess forming between the rectum and the bladder ; or pelvic cellulitis may be set up ; moreover, it is exceedingly inconvenient to keep a canula in the rectum. In some cases, in performing this operation the recto-vesical pouch of peritoneum has been wounded, inducing fatal peritonitis. Puncture through the rectum, therefore, has been almost completely abandoned in favour of the suprapubic route.

Access to the bladder, for the purpose of removing calculi or an enlarged prostate, is almost always effected by the suprapubic route, the old perineal operation being now rarely resorted to. In the female, owing to the shortness of the urethra, and its ready

dilatability, calculi and foreign bodies and new growths, when of small size, may be removed by the urethral route.

Suprapubic cystotomy is performed by first injecting ten or twelve ounces of some weak antiseptic fluid into the bladder. Then, with or without distending the rectum, a vertical median incision, from three to four inches in length, is made in the hypogastric region immediately above the symphysis, and extended between the Pyramidales and Recti muscles until the transversalis fascia is reached. This is divided and some fatty tissue exposed (space of Retzius). Upon separating this, the anterior surface of the bladder will be exposed and will be recognised by its muscular fibres. A needle should be passed through its coats on either side of the spot selected for the opening, and two long pieces of silk inserted. The bladder is incised between these stays, which are held by an assistant and form a useful guide to the opening in the bladder when the fluid has escaped.

It is important that the bladder should be emptied by catheter as a routine measure in women, prior to operations on the lower part of the abdomen or pelvis. Neglect of this precaution has, not uncommonly, led to that viscus being opened by accident. Women especially are apt to acquire an atonic distension of the bladder, and the fact that some quantity of urine has been passed immediately before operation is no guarantee that the viscus is not distended. If the accident should occur, the bladder wall must be carefully sutured before the peritoneum is opened.

The Male Urethra

The **male urethra** (urethra virilis) extends from the neck of the bladder to the meatus urinarius at the end of the penis. It presents a double curve in the ordinary relaxed state of the penis (fig. 992). Its length varies from seven to eight inches ; and it is divided into three portions, the *prostatic*, *membranous*, and *spongy*, the structure and relations of which are essentially different. Except during the passage of the urine or semen, the urethra is a mere transverse cleft or slit, with its upper and under surfaces in contact. At the meatus urinarius the slit is vertical, and in the prostatic portion somewhat arched.

The **prostatic portion** (pars prostatica) (figs. 992, 999), the widest and most dilatable part of the canal, is about an inch and a quarter in length. It runs almost vertically through the prostate gland, from its base to its apex, lying nearer its anterior than its posterior surface ; the form of the canal is spindle-shaped, being wider in the middle than at either extremity, and narrowest below, where it joins the membranous portion. A transverse section of the canal as it lies in the prostate is horseshoe-shaped, the convexity being directed forwards, since the direction of the canal is nearly vertical.

Upon the posterior wall or floor is a narrow longitudinal ridge, the *verumontanum*, or *caput gallinaginis* (crista urethralis), formed by an elevation of the mucous membrane and its subjacent tissue. It is from 15 to 17 mm. in length, and about 3 mm. in height, and contains, according to Kobelt, muscular and erectile tissues. When distended, it may serve to prevent the passage of the semen backwards into the bladder. On either side of the verumontanum is a slightly depressed fossa, the *prostatic sinus*, the floor of which is perforated by numerous apertures, the *orifices of the prostatic ducts* from the lateral lobes of the prostate gland ; the ducts of the middle lobe open behind the verumontanum. At the fore-part of the verumontanum, in the middle line, is a depression, the *sinus pocularis* (utriculus prostaticus), upon or within the margins of which are the slit-like openings of the ejaculatory ducts. The sinus pocularis forms a *cul-de-sac* about a quarter of an inch in length, which runs upwards and backwards in the substance of the prostate behind the middle lobe ; its prominent anterior wall partly forms the verumontanum. Its walls are composed of fibrous tissue, muscular fibres, and mucous membrane, and numerous small glands open on its inner surface. It has been called by Weber, who discovered it, the *uterus masculinus*, from its being developed from the united lower ends of the atrophied Müllerian ducts, and therefore homologous with the uterus and vagina in the female.

The **membranous portion** (pars membranacea) (figs. 992, 999) extends between the apex of the prostate and the bulb of the corpus spongiosum. It is the narrowest part of the canal (excepting the meatus), and measures three-quarters of an inch along its upper, but only half an inch along its lower surface, in consequence of the bulb projecting backwards beneath it. Its anterior concave surface is placed about an inch below and behind the pubic

arch, from which it is separated by the dorsal vessels and nerves of the penis, and some muscular fibres. Its posterior convex surface is separated from the rectum by a triangular space, which constitutes the perinæum. The membranous portion of the urethra lies between the inferior and superior layers of the triangular ligament. As it pierces the inferior layer, the fibres around the opening are prolonged over the tube. It is surrounded by the Compressor urethræ muscle.

Fig. 999.—The male urethra, laid open on its anterior (upper) surface. (Testut.)

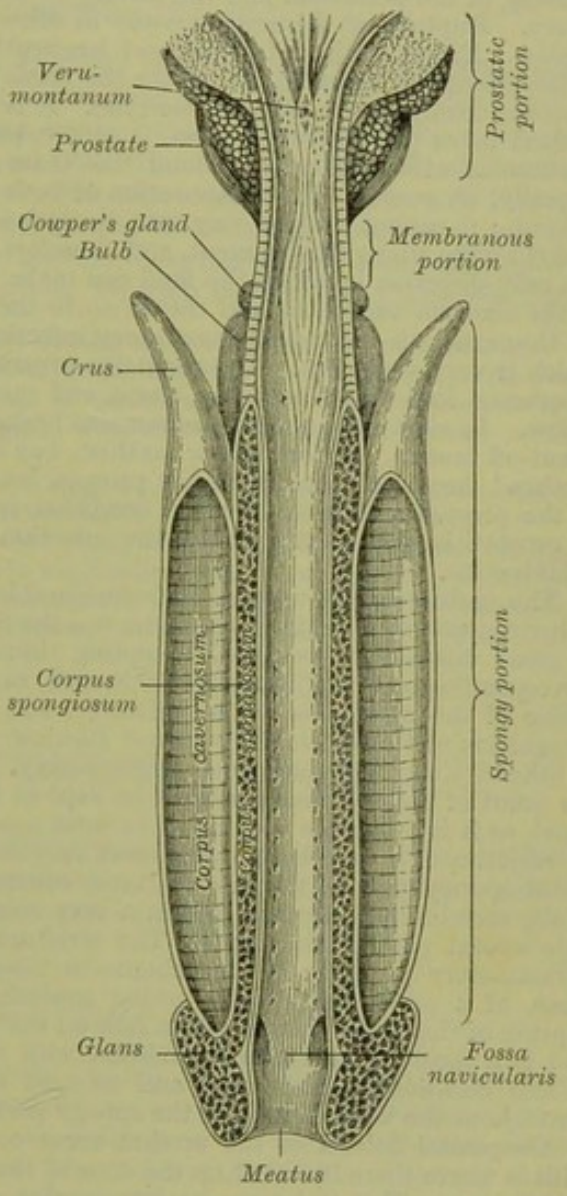

The **spongy portion** (pars cavernosa) (figs. 992, 999) is the longest part of the urethra, and is contained in the corpus spongiosum. It is about six inches in length, and extends from the termination of the membranous portion to the meatus urinarius. Commencing just below the triangular ligament, it passes forwards for a short distance ; and then, in the flaccid condition of the penis, it bends downwards and forwards. It is narrow, and of uniform size in the body of the penis, measuring about a quarter of an inch in diameter ; it is dilated behind, within the bulb, and again anteriorly within the glans penis, where it forms the *fossa navicularis urethræ*.

The *bulbous portion* is a name sometimes given to the posterior part of the spongy portion contained within the bulb.

The *meatus urinarius* (orificium urethræ externum) is the most contracted part of the urethra ; it is a vertical slit, about a quarter of an inch in length, bounded on each side by two small labia.

The inner surface of the lining membrane of the urethra, especially on the floor of the spongy portion, presents the orifices of numerous mucous glands and follicles situated in the submucous tissue, and named the *glands of Littré*. Besides these there are a number of small pit-like recesses, or *lacunæ*, of varying sizes. Their orifices are directed forwards, so that they may easily intercept the point of a catheter in its passage along the canal. One of these lacunæ, larger than the rest, is situated on the upper surface of the fossa navicularis ; it is called the *lacuna magna*. Into the bulbous portion are found opening the ducts of Cowper's glands.

Structure.—The urethra is composed of mucous membrane, supported by a submucous tissue which connects it with the various structures through which it passes.

The *mucous coat* forms part of the genito-urinary mucous membrane. It is continuous with the mucous membrane of the bladder, ureters, and kidneys ; externally, with the integument covering the glans penis ; and is prolonged into the ducts of the glands which open into the urethra, viz. Cowper's glands and the prostate gland ; and into the vasa deferentia and vesiculæ seminales, through the ejaculatory ducts. In the spongy and membranous portions the mucous membrane is arranged in longitudinal folds when the

tube is empty. Small papillæ are found upon it, near the orifice; in the upper two-thirds its epithelial lining is of the transitional variety; it then becomes columnar in shape until near the meatus, where it is squamous and stratified.

The *submucous tissue* consists of a vascular erectile layer; outside this is a layer of unstriped muscular fibres, arranged in a circular direction, which separates the mucous membrane and submucous tissue from the tissue of the corpus spongiosum.

Applied Anatomy.—The urethra may be ruptured by the patient falling astride of any hard substance and striking his perinæum, so that the urethra is crushed against the pubic arch. Bleeding will at once take place from the urethra, and this, together with the bruising in the perinæum and the history of the accident, will point to the nature of the injury. Rupture of the urethra is due in other cases to the perforation of a periurethral abscess. Extravasation of urine most frequently takes place into the perinæum in front of the triangular ligament, i.e. under the fascia of Colles. Both these layers of fascia are attached firmly to the ischio-pubic rami. It is clear, therefore, that when extravasation of fluid takes place between them, it cannot pass backwards, because the two layers are continuous with each other around the Transversus perinæi muscles; it cannot extend laterally, on account of the connection of both these layers to the rami of the pubis and ischium; it cannot find its way into the pelvis, because the opening into this cavity is closed by the triangular ligament, and, therefore, so long as these two layers remain intact, the only direction in which the fluid can make its way is forwards into the areolar tissue of the scrotum and penis, and thence on to the anterior wall of the abdomen.

Gonorrhœa is an acute inflammatory infection of the mucous membrane of the urethra which is very prevalent. The causative organisms (gonococci) pass through the mucous membrane into the submucous tissue, and most serious complications and results may follow. In most cases the disease remains limited to the part of the urethra in front of the 'shut-off muscle,' or Compressor urethræ, but in some (about 10 per cent.) the 'posterior urethra' becomes involved in the process, leading to an inflammation of the openings of the prostatic follicles. Such a condition is apt to continue as a very chronic form of prostatitis, and in many cases the infection will spread along the vas, giving rise to epididymitis.

The anatomy of the urethra is of considerable importance in connection with the passage of instruments into the bladder. Otis was the first to point out that the urethra is capable of great dilatability, so that, excepting through the external meatus, an instrument corresponding to 18 English gauge (29 French) can usually be passed without damage. The orifice of the urethra is not so dilatable, and therefore frequently requires slitting. A recognition of this dilatability caused Bigelow to very considerably modify the operation of lithotrity and introduce that of litholapaxy. In passing catheters, especially fine ones, the point of the instrument should be kept as far as possible along the upper wall of the canal, as it is otherwise very liable to enter one of the lacunæ.

Stricture of the urethra is a disease of very common occurrence, and is generally situated in the spongy part of the urethra, most commonly in the bulbous portion, just in front of the membranous urethra, but in a very considerable number of cases in the penile or ante-scrotal part of the canal. The stricture usually results from the contraction of inflammatory products in the submucous tissue, the result, in the vast majority of all cases, of a prolonged gleet following gonorrhœa. Urethral stricture, however, follows rupture of that tube resulting from falls on the perinæum, and in this variety is very dense, and is a most unsatisfactory condition with regard to treatment. Congenital stricture is also occasionally met with, and in such cases multiple strictures may be present throughout the whole length of the spongy portion.

Congenital defects of the urethra occur occasionally. The one most frequently met with is where there is a cleft on the floor of the urethra owing to an arrest of union in the middle line. This is known as *hypospadias*, and the cleft may vary in extent. The simplest and by far the most common form is where the deficiency is confined to the glans penis. The urethra ends at the point where the extremity of the prepuce joins the body of the penis, in a small valve-like opening. The prepuce is also cleft on its under surface and forms a sort of hood over the glans. There is a depression on the glans in the position of the normal meatus. This condition produces no disability and requires no treatment. In more severe cases the penile portion of the urethra is cleft throughout its entire length, and the opening of the urethra is at the point of junction of the penis and scrotum. The under surface of the penis in the middle line presents a furrow lined by a moist mucous membrane, on either side of which is often more or less dense fibrous tissue stretching from the glans to the opening of the urethra, which prevents complete erection taking place. Great discomfort is induced during micturition, and connection is impossible. The condition may be remedied by a series of plastic operations. The worst form of this condition is where the urethra is deficient as far back as the perinæum, and the scrotum is cleft. The penis is small and bound down between the two halves of the scrotum, so as to resemble an hypertrophied clitoris. The testes are often retained. The condition of parts, therefore, very much resembles the external organs of generation of the female, and many children the victims of this malformation have been brought up as girls. The halves of the scrotum, deficient of testes, resemble the labia, the cleft between them looks like the

orifice of the vagina, and the diminutive penis is taken for an enlarged clitoris. There is no remedy for this condition.

A much more uncommon form of malformation is where there is an apparent deficiency of the upper wall of the urethra ; this is named *epispadias*. The deficiency may vary in extent ; when it is complete the condition is associated with extroversion of the bladder (see page 1199). In less extensive cases, where there is no extroversion, there is an infundibuliform opening into the bladder. The penis is usually dwarfed and turned upwards, so that the glans lies over the opening.

The Female Urethra (fig. 995)

The **female urethra** (urethra muliebris) is a narrow membranous canal, about an inch and a half in length, extending from the neck of the bladder to the meatus urinarius. It is placed behind the symphysis pubis, imbedded in the anterior wall of the vagina, and its direction is obliquely downwards and forwards ; it is slightly curved with the concavity directed forwards and upwards. Its diameter when undilated is about a quarter of an inch. It perforates the triangular ligament, and its external orifice is situated directly in front of the vaginal opening and about an inch behind the glans clitoridis.

Structure.—The urethra consists of three coats : muscular, erectile, and mucous.

The *muscular coat* is continuous with that of the bladder ; it extends the whole length of the tube, and consists of circular fibres. In addition to this, between the two layers of the triangular ligament, the female urethra is surrounded by the Compressor urethræ, as in the male.

A *thin layer of spongy erectile tissue*, containing a plexus of large veins, intermixed with bundles of unstriped muscular fibres, lies immediately beneath the mucous coat.

The *mucous coat* is pale ; it is continuous externally with that of the vulva, and internally with that of the bladder, and is thrown into longitudinal folds, one of which, placed along the floor of the canal, resembles the verumontanum in the male urethra. It is lined by stratified epithelium, which becomes transitional near the bladder. Its external orifice is surrounded by a few mucous follicles.

MALE REPRODUCTIVE ORGANS

The male reproductive organs (organa genitalia virilia) include the *testes*, the *vasa deferentia*, the *vesiculæ seminales*, the *ejaculatory ducts*, and the *penis*, together with the following accessory structures, viz. the *prostate gland* and *Cowper's glands*.

The Testes and their Coverings (fig. 1000)

The **testes** are two glandular organs, which secrete the semen ; they are situated in the scrotum, being suspended by the spermatic cords. At an early period of fœtal life the testes are contained in the abdominal cavity, behind the peritoneum. Before birth they descend to the inguinal canal, along which they pass with the spermatic cord, and, emerging at the external abdominal ring, they descend into the scrotum, becoming invested in their course by coverings derived from the serous, muscular, and fibrous layers of the abdominal parietes, as well as by the scrotum.

The **coverings of the testes** are, the

Skin Dartos	Scrotum.	Cremasteric fascia. Infundibuliform fascia.
Intercolumnar fascia.		Tunica vaginalis.

The **scrotum** is a cutaneous pouch which contains the testes and parts of the spermatic cords. It is divided on its surface into two lateral portions by a ridge, or *raphe* (raphe scroti), which is continued forwards to the under surface of the penis, and backwards along the middle line of the perinæum to the anus. Of these two lateral portions the left is longer than the right, to correspond with the greater length of the left spermatic cord. Its external aspect varies under different circumstances : thus, under the influence of warmth, and in old and debilitated persons, it becomes elongated and flaccid ; but, under

the influence of cold, and in the young and robust, it is short, corrugated, and closely applied to the testes.

The scrotum consists of two layers, the integument and the dartos.

The **integument** is very thin, of a brownish colour, and generally thrown into folds or rugæ. It is provided with sebaceous follicles, the secretion of which has a peculiar odour, and is beset with thinly scattered, crisp hairs, the roots of which are seen through the skin.

The **dartos** (tunica dartos) is a thin layer of non-striped muscular fibres, and is continuous, around the base of the scrotum, with the two layers of the superficial fascia of the groin and of the perinæum, and sends inwards a septum, *septum scroti*, which divides the scrotal pouch into two cavities for the testes, the septum extending between the raphe and the under surface of the penis, as far as its root.

FIG. 1000.—Transverse section through the left side of the scrotum and the left testicle. The sac of the tunica vaginalis is represented in a distended condition. (Diagrammatic.) (Delépine.)

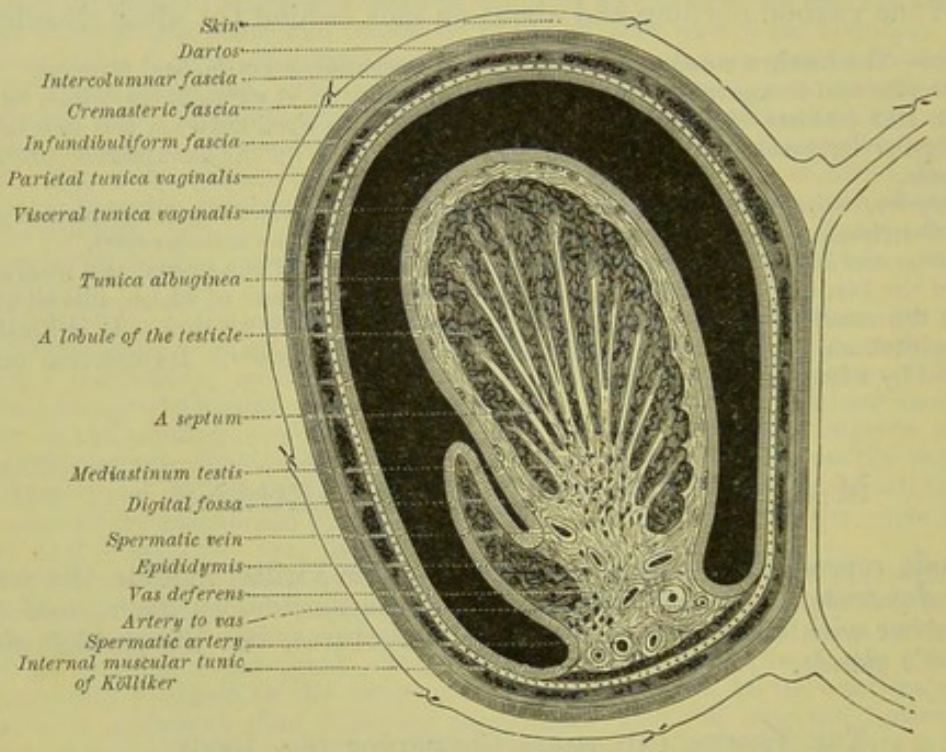

The dartos is closely united to the skin externally, but connected with the subjacent parts by delicate areolar tissue, upon which it glides with the greatest facility.

The **intercolumnar fascia** is a thin membrane, prolonged downwards around the surface of the cord and testis (see page 509). It is separated from the dartos by loose areolar tissue.

The **cremasteric fascia** consists of scattered bundles of muscular fibres (*Cremaster muscle*), connected together into a continuous covering by intermediate areolar tissue (see page 511).

The **infundibuliform fascia** is a thin layer, which loosely invests the cord; it is a continuation downwards of the fascia transversalis (see page 515).

The **tunica vaginalis** is described with the testis.

Vessels and Nerves.—The *arteries* supplying the coverings of the testes are: the superficial and deep external pudic branches of the femoral, the superficial perineal branch of the internal pudic, and the cremasteric branch from the deep epigastric. The *veins* follow the course of the corresponding arteries. The *lymphatics* terminate in the inguinal glands. The *nerves* are the ilio-inguinal and genito-crural branches of the lumbar plexus, the two superficial perineal branches of the internal pudic nerve, and the inferior pudendal branch of the small sciatic nerve.

The **inguinal** or **spermatic canal** (canalis inguinalis) contains the spermatic cord in the male, and the round ligament in the female. It is an

oblique canal, about an inch and a half in length, directed downwards and inwards, and placed parallel with, and a little above, Poupart's ligament. It commences, above, at the internal or deep abdominal ring, which is the point where the cord enters the inguinal canal; and terminates, below, at the external or superficial ring. It is bounded, *in front*, by the integument and superficial fascia, by the aponeurosis of the External oblique throughout its whole length, and by the Internal oblique for its outer third; *behind*, by the triangular fascia, the conjoined tendon of the Internal oblique and Transversalis, the transversalis fascia, and the subperitoneal fat and peritoneum; *above*, by the arched fibres of the Internal oblique and Transversalis; *below*, by the union of the transversalis fascia with Poupart's ligament.

The **spermatic cord** (funiculus spermaticus) extends from the internal or deep abdominal ring, where the structures of which it is composed converge, to the back part of the testicle. In the abdominal wall the cord passes obliquely along the inguinal canal, lying at first beneath the Internal oblique, and upon the fascia transversalis; but nearer the pubis, it rests upon Poupart's ligament, having the aponeurosis of the External oblique in front of it, and the conjoined tendon behind it. It then escapes at the external ring, and descends nearly vertically into the scrotum. The left cord is rather longer than the right, consequently the left testis hangs somewhat lower than its fellow.

Structure of the spermatic cord.—The spermatic cord is composed of arteries, veins, lymphatics, nerves, and the excretory duct of the testicle. These structures are connected together by areolar tissue, and invested by the layers brought down by the testis in its descent.

The *arteries of the cord* are: the spermatic, from the aorta; the artery of the vas deferens, from the superior vesical; and the cremasteric, from the deep epigastric.

The *spermatic artery*, a branch of the abdominal aorta, escapes from the abdomen at the internal or deep abdominal ring, and accompanies the other constituents of the spermatic cord along the inguinal canal and through the external abdominal ring into the scrotum. It then descends to the testis, and, becoming tortuous, divides into several branches, two or three of which accompany the vas deferens and supply the epididymis, anastomosing with the artery of the vas deferens: the others supply the substance of the testis.

The *cremasteric artery* is a branch of the deep epigastric artery. It accompanies the spermatic cord and supplies the Cremaster muscle and other coverings of the cord, anastomosing with the spermatic artery.

The *artery of the vas deferens*, a branch of the superior vesical, is a long slender vessel, which accompanies the vas deferens, ramifying upon the coats of that duct, and anastomosing with the spermatic artery near the testis.

The *spermatic veins* emerge from the back of the testis, and receive tributaries from the epididymis: they unite and form a convoluted plexus (*plexus pampiniformis*), which forms the chief mass of the cord; the vessels composing this plexus are very numerous, and ascend along the cord in front of the vas deferens; below the external or superficial abdominal ring they unite to form three or four veins, which pass along the inguinal canal, and, entering the abdomen through the internal or deep abdominal ring, coalesce to form two veins. These again unite to form a single vein, which opens on the right side into the inferior vena cava, at an acute angle, and on the left side into the renal vein, at a right angle.

The *lymphatic vessels* terminate in the lumbar glands.

The *nerves* are the spermatic plexus from the sympathetic, joined by filaments from the pelvic plexus which accompany the artery of the vas deferens.

Applied Anatomy.—The scrotum forms an admirable covering for the protection of the testes. These bodies, lying suspended and loose in the cavity of the scrotum and surrounded by serous membrane, are capable of great mobility, and can therefore easily slip about within the scrotum, and thus avoid injuries from blows or squeezes. The skin of the scrotum is very elastic and capable of great distension, and on account of the looseness and amount of subcutaneous tissue, the scrotum becomes greatly enlarged in cases of œdema, to which this part is especially liable as a result of its dependent position. The scrotum is occasionally the seat of epithelioma; this is no doubt due to the rugæ on its surface, which favour the lodgment of dirt, and this, producing irritation, is the exciting cause of the disease, which is especially common in chimney-sweeps from the lodgment of soot. The disease is very much less common than it used to be; this is probably due to the better hygienic conditions of the working classes. The scrotum is also the part most frequently affected by elephantiasis.

On account of the looseness of the subcutaneous tissue, large extravasations of blood may take place from very slight injuries. It is therefore generally recommended never to apply leeches to the scrotum, since they may lead to ecchymosis, but rather to puncture one or more of the superficial veins of the scrotum in cases where local

blood-letting from this part is judged to be desirable. The muscular fibre in the dartos causes contraction and considerable diminution in the size of a wound of the scrotum, as after the operation of castration, and is of assistance in keeping the edges together, and covering the exposed parts.

The **testes** are suspended in the scrotum by the spermatic cords, the left testis hanging somewhat lower than its fellow. The average dimensions of the testis are from one and a half to two inches in length, an inch in breadth, and an inch and a quarter in the antero-posterior diameter; its weight varies from six to eight drachms. Each testis is of an oval form (fig. 1001), compressed laterally, and having an oblique position in the scrotum; the upper extremity is directed forwards and a little outwards; the lower, backwards and a little inwards; the anterior convex border looks forwards and downwards; the posterior or straight border, to which the cord is attached, backwards and upwards.

Fig. 1001.—The testis *in situ*, the tunica vaginalis having been laid open.

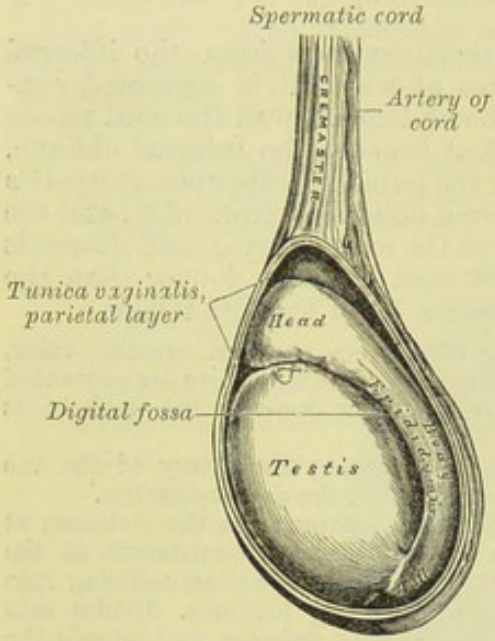

The anterior border and lateral surfaces, as well as both extremities of the organ, are convex, free, smooth, and invested by the visceral layer of the tunica vaginalis. The posterior border, to which the cord is attached, receives only a partial investment from that membrane. Lying upon the outer edge of this posterior border is a long, narrow, flattened body, named, from its relation to the testis, the *epididymis*. It consists of a central portion, or *body* (corpus); an upper enlarged extremity, the *globus major*, or head (caput); and a lower pointed extremity, the *globus minor*, or tail (cauda), which is continuous with the vas deferens or duct of the testis. The globus major is intimately connected with the upper end of the testis by means of the efferent ducts of the gland; the globus minor is connected with the lower end by cellular tissue, and a reflection of the tunica vaginalis. The outer surface and upper and lower ends of the epididymis are free and covered by the serous membrane; the body is also completely invested by it, excepting along its posterior border; whilst between the body and the testis is a pouch, named the *digital fossa* (sinus epididymidis). The epididymis is connected to the back of the testis by a fold of the serous membrane. Attached to the upper end of the testis, close to the globus major, are two small pedunculated bodies. One of them is pear-shaped, and attached by its narrow stalk, the other is small and sessile; they are believed to be the remains of the upper extremity of the Müllerian duct (page 170), and are termed the *hydatids of Morgagni*; some observers, however, regard the stalked hydatid as being a rudiment of the pronephros.

The testis is invested by three tunics: the tunica vaginalis, tunica albuginea, and tunica vasculosa.

The **tunica vaginalis** is the serous covering of the testis. It is a pouch of serous membrane, derived from the peritoneum during the descent of the testis, in the fœtus, from the abdomen into the scrotum. After its descent, that portion of the pouch which extends from the internal ring to near the upper part of the gland becomes obliterated; the lower portion remains as a shut sac, which invests the outer surface of the testis, and is reflected on to the internal surface of the scrotum; hence it may be described as consisting of a visceral and parietal portion.

The *visceral portion* (lamina visceralis) covers the greater part of the testis and epididymis, connecting the latter to the testis by means of a distinct fold. From the posterior border of the gland it is reflected on to the internal surface of the scrotum.

The *parietal portion* (lamina parietalis) is far more extensive than the visceral portion, extending upwards for some distance in front and on the inner side of the cord, and reaching below the testis. The inner surface of the tunica vaginalis is free, smooth, and covered by a layer of endothelial cells. The interval between the visceral and parietal layers of this membrane constitutes the cavity of the tunica vaginalis.

The obliterated portion of the pouch may generally be seen as a fibro-cellular thread lying in the loose areolar tissue around the spermatic cord; sometimes this may be traced as a distinct band from the upper end of the inguinal canal, where it is connected with the peritoneum, down to the tunica vaginalis; sometimes it gradually becomes lost on the spermatic cord. Occasionally no trace of it can be detected. In some cases it happens that the pouch of peritoneum does not become obliterated, but the sac of the peritoneum communicates with the tunica vaginalis. This may give rise to one of the varieties of oblique inguinal hernia (page 1159). In other cases the pouch may contract, but not become entirely obliterated; it then forms a minute canal leading from the peritoneum to the tunica vaginalis.

The **tunica albuginea** is the fibrous covering of the testis. It is a dense membrane, of a bluish-white colour, composed of bundles of white fibrous tissue which interlace in every direction. Its outer surface is covered by the tunica vaginalis, except at the points of attachment of the epididymis to the testis, and along its posterior border, where the spermatic vessels enter the gland. Its inner surface is applied to the tunica vasculosa over the glandular substance of the testis, and, at its posterior border, is reflected into the interior of the gland, forming an incomplete vertical septum, called the *mediastinum testis* (*corpus Highmori*).

The *mediastinum testis* extends from the upper, nearly to the lower extremity of the gland, and is wider above than below. From the front and sides of this septum numerous slender fibrous cords and imperfect septa (*trabeculæ*) are given off, which radiate towards the surface of the organ, and are attached to the inner surface of the tunica albuginea. They therefore divide the interior of the organ into a number of incomplete spaces which are somewhat cone-shaped, being broad at their bases at the surface of the gland, and becoming narrower as they converge to the mediastinum. The mediastinum supports the vessels and ducts of the testis in their passage to and from the substance of the gland.

The **tunica vasculosa** is the vascular layer of the testis, consisting of a plexus of blood-vessels, held together by delicate areolar tissue. It covers the inner surface of the tunica albuginea and the different septa in the interior of the gland, and therefore forms an internal investment to all the spaces of which the gland is composed.

Structure.—The glandular structure of the testis consists of numerous lobules (*lobuli testis*). Their number, in a single testis, is estimated by Berres at 250, and by Krause at 400. They differ in size according to their position, those in the middle of the gland being larger and longer. The lobules are conical in shape, the base being directed towards the circumference of the organ, the apex towards the mediastinum. Each lobule is contained in one of the intervals between the fibrous cords and the vascular processes which extend between the mediastinum testis and the tunica albuginea, and consists of from one to three, or more, minute convoluted tubes, the *tubuli seminiferi*. The tubes may be separately unravelled, by careful dissection under water, and may be seen to commence either by free cæcal ends or by anastomotic loops. The total number of tubes is estimated by Lauth at 840, and their average length two feet and a quarter. Their diameter varies from $\frac{1}{200}$ to $\frac{1}{120}$ of an inch. The tubuli are pale in colour in early life, but in old age they acquire a deep yellow tinge, from containing much fatty matter. Each tube consists of a basement layer, formed of epithelioid cells united edge to edge, outside which are other layers of flattened cells arranged in interrupted laminæ, which give to the tube an appearance of striation in cross-section. The cells of the outer layers gradually pass into the interstitial tissue. Within the basement-membrane are epithelial cells arranged in several irregular layers, which are not always clearly separated, but which may be arranged in three different groups (fig. 1002). Among these cells may be seen the *spermatozoa* in different stages of development. 1. Lining the basement-membrane and forming the outer zone is a layer of cubical cells, with small nuclei; these are known as the *lining cells* or *spermatogonia*. The nucleus of some of them may be seen to be in process of indirect division (*karyokinesis*, page 4), and in consequence of this daughter cells are formed, which constitute the second zone. 2. Within this first layer is to be seen a number of larger polyhedral cells, with clear

nuclei, arranged in two or three layers; these are the *intermediate cells* or *spermatocytes*. Most of these cells are in a condition of karyokinetic division, and the cells which result

FIG. 1002.—Transverse section of a seminiferous tubule.

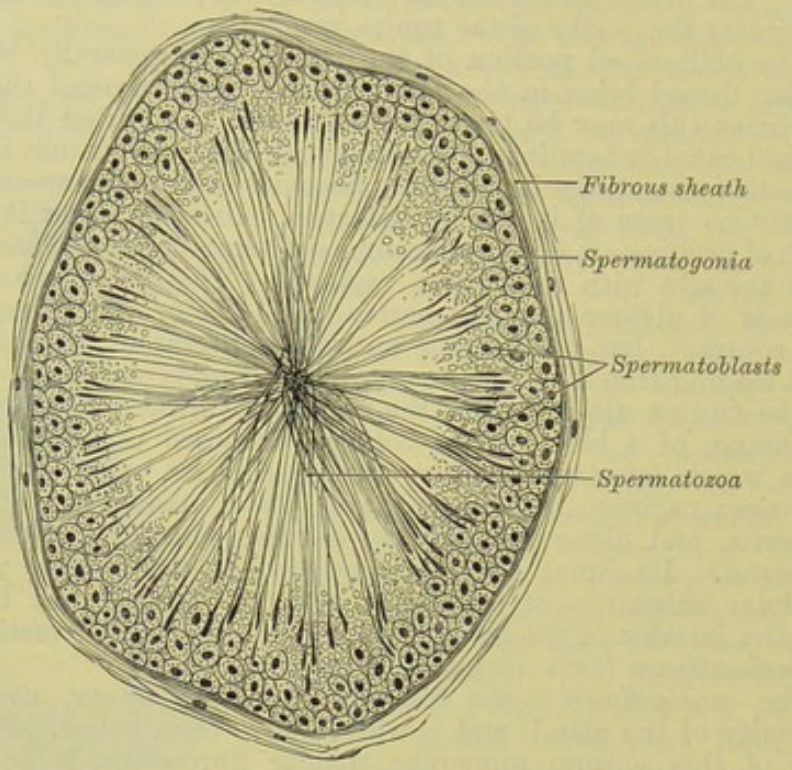

from this division form those of the next layer, the *spermatoblasts* or *spermatids*. 3. The third layer of cells consists of the spermatoblasts or spermatids, and each of these, without further subdivision, becomes a *spermatozoon*. They are ill-defined granular masses of protoplasm, of an elongated form, with a nucleus, which becomes the head of the future spermatozoon. In addition to these three layers of cells others are seen, which are termed the *supporting cells*, or *cells of Sertoli*. They are elongated and columnar, and project inwards from the basement-membrane towards the lumen of the tube. They give off numerous lateral branches, which form a reticulum for the support of the three groups of cells just described. As development of the spermatozoa proceeds the latter group themselves around the inner extremities of the supporting cells. The nuclear portion of the spermatozoon, which is partly imbedded in the supporting cell, is differentiated to form the head of the spermatozoon, while the cell protoplasm becomes lengthened out to form the middle piece and tail, the latter projecting into the lumen of the tube. Ultimately the heads are liberated and the spermatozoa are set free. The structure of the spermatozoa is described on page 81.

FIG. 1003.—Vertical section of the testicle, to show the arrangement of the ducts.

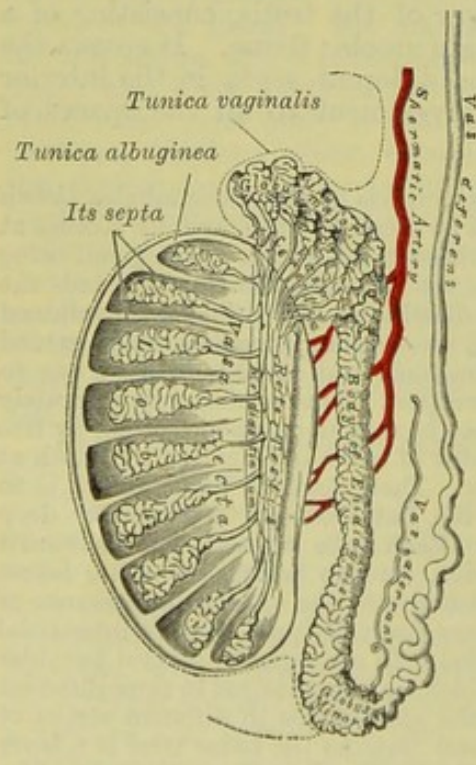

In the apices of the lobules, the tubuli become less convoluted, assume a nearly straight course, and unite together to form from twenty to thirty larger ducts, of about $\frac{1}{150}$ of an inch in diameter, and these, from their straight course, are called *vasa recta* (fig. 1003).

The *vasa recta* (tubuli recti) enter the fibrous tissue of the mediastinum, and pass upwards and backwards, forming, in their ascent, a close network of anastomosing tubes which are merely channels in the fibrous stroma, lined by flattened epithelium, and having no proper walls; this constitutes the *rete testis*. At the upper end of the mediastinum,

the vessels of the rete testis terminate in from twelve to fifteen or twenty ducts, the *vasa efferentia* (ductuli efferentes testis); they perforate the tunica albuginea, and carry the seminal fluid from the testis to the epididymis. Their course is at first straight; they then become enlarged, and exceedingly convoluted, and form a series of conical masses, the *coni vasculosi*, which together constitute the globus major of the epididymis. Each cone consists of a single convoluted duct, from six to eight inches in length, the diameter of which gradually decreases from the testis to the epididymis. Opposite the bases of the cones the efferent vessels open at narrow intervals into a single duct, which constitutes, by its complex convolutions, the body and globus minor of the epididymis. When the convolutions of this tube are unravelled, it measures upwards of twenty feet in length; it increases in diameter and thickness as it approaches the vas deferens. The convolutions are held together by fine areolar tissue, and by bands of fibrous tissue.

The vasa recta have very thin walls; like the channels of the rete testis they are lined by a single layer of flattened epithelium. The vasa efferentia and the tube of the epididymis have walls of considerable thickness, on account of the presence in them of muscular tissue, which is principally arranged in a circular manner. These tubes are lined by columnar ciliated epithelium.

Applied Anatomy.—The testis, developed in the lumbar region, may be arrested or delayed in its transit to the scrotum. It may be retained in the abdomen; or it may be arrested at the internal abdominal ring, or in the inguinal canal; or it may just pass out of the external ring without finding its way to the bottom of the scrotum. When retained in the abdomen it gives rise to no symptoms, other than the absence of the testis from the scrotum; but when it is retained in the inguinal canal it is subjected to pressure and may become inflamed and painful. The testis when first formed is believed to be normal, but if retained it undergoes degenerative changes and becomes functionally useless; so that a man in whom both testes are retained (*anorchism*) is sterile, though he may not be impotent. The absence of one testicle is termed *monorchism*. When a testis is retained in the inguinal canal it is often complicated with a congenital hernia, the funicular process of the peritoneum not being obliterated. In addition to the cases above described, where there is some arrest in the descent of the testis, this organ may descend through the inguinal canal, but may miss the scrotum and assume some abnormal position. The most common form is where the testis, emerging at the external abdominal ring, slips down between the scrotum and thigh and comes to rest in the perinæum. This is known as *perineal ectopia testis*. With all varieties of abnormality in the position of the testis, it is very common to find concurrently a congenital hernia, or, if a hernia be not actually present, the funicular process is usually patent, and almost invariably so if the testis is in the inguinal canal.

The testis, finally reaching the scrotum, may occupy an abnormal position in it. It may be inverted, so that its posterior or attached border is directed forwards and the tunica vaginalis is situated behind. Should a hydrocele occur, and tapping be resorted to, the trocar may be thrust into the testis, if the operation is performed in the ordinary way, and care is not taken beforehand to ascertain the position of the gland.

A number of instances of torsion of the spermatic cord, resulting in acute strangulation of the testis, have been recorded. In some it has been attributed to a strain or twist, and in several patients the condition has been associated with a late descent of the organ. Symptoms of this condition closely simulate those of a strangulated hernia. In consequence of the torsion the circulation is partly arrested and the organ swells and becomes acutely painful, and the condition may be accompanied with shock and vomiting. Gangrene of the testis, however, rarely follows, and the condition, if left without operation, ends in atrophy of the organ. Torsion of the body of the testis also sometimes occurs within the tunica vaginalis in those cases in which a persistent mesorchium is present.

Fluid collections of a serous character are very frequently found in the scrotum. To these the term *hydrocele* is applied. The most common form is the ordinary *vaginal hydrocele*, in which the fluid is contained in the sac of the tunica vaginalis, which is separated, in its normal condition, from the peritoneal cavity by the whole extent of the inguinal canal. In another form, the *congenital hydrocele*, the fluid is in the sac of the tunica vaginalis, but this cavity communicates with the general peritoneal cavity, its tubular process remaining pervious. A third variety, known as an *infantile hydrocele*, occurs in those cases where the tubular process becomes obliterated only at its upper part, at or near the internal abdominal ring. It resembles the vaginal hydrocele, except as regards its shape, the collection of fluid extending up the cord into the inguinal canal. Fourthly, the funicular process may become obliterated both at the internal ring and above the epididymis, leaving a central unobliterated portion, which may become distended with fluid, giving rise to a condition known as the *encysted hydrocele of the cord*.

Encysted hydrocele of the epididymis or *spermatocele* is the name given to a cyst usually found in connection with the globus major of the epididymis. Among its contents are found, in many instances, a varying number of spermatozoa, and it is probably a retention cyst of one of the tubules.

The testis frequently requires removal for malignant disease; in tuberculous disease; in cases of large *hernia testis*, and in some instances of incompletely descended or misplaced

testes. The operation of castration was formerly performed for enlargement of the prostate, but has now been entirely abandoned in favour of the direct operation on the enlarged prostate. Castration is in most cases best carried out by the 'high' operation, an incision being made through the skin and fascia in the region of the external abdominal ring. The testis, with its deeper coverings, is then pushed up into the wound and separated from the scrotal tissues. The cord is then isolated, and an aneurysm needle, armed with a ligature, passed through it, as high as it is thought necessary, and the cord tied and divided. In cases of malignant and tuberculous disease, it is desirable to open the inguinal canal and tie the cord as near the internal abdominal ring as possible. When removing the testis in this manner the tunica vaginalis is not opened and its folds of reflection to the scrotal tissues do not need division. The whole of the tunica vaginalis is thus removed with the cord and its coverings.

Acute inflammation of the testis, or *orchitis*, is common in gonorrhœa; a chronic fibrosing form of orchitis is frequent in syphilis, and leads to skrinkage and hardening of the testis. In tabes dorsalis the testis often becomes quite insensitive to pressure, which, in the healthy adult, readily produces a severe and peculiar sickening sensation.

Vas Deferens

The **vas deferens** (ductus deferens), the excretory duct of the testis, is the continuation of the canal of the epididymis. Commencing at the lower part of the globus minor, it is at first very tortuous, but gradually becoming less twisted it ascends along the posterior border of the testis and inner side of the epididymis, and along the back part of the spermatic cord, through the inguinal canal to the internal or deep abdominal ring. From the ring it curves round the outer side of the deep epigastric artery, and ascends for about an inch in front of the external iliac artery. It is next directed backwards and slightly downwards, and, crossing the external iliac vessels obliquely, enters the pelvic cavity, where it lies between the peritoneal membrane and the lateral wall of the pelvis, and passes on the inner side of the obliterated hypogastric artery and the obturator nerve and vessels. It then crosses in front of the ureter, and, reaching the inner side of this tube, bends to form an acute angle, and runs inwards and slightly forwards between the base of the bladder and the upper end of the seminal vesicle. Reaching the inner side of the seminal vesicle, it is directed downwards and inwards in contact with it, gradually approaching the vas of the opposite side. Here it lies between the base of the bladder and the rectum, where it is enclosed, together with the seminal vesicle, in a sheath derived from the recto-vesical portion of the fascia endopelvina. Lastly, it is directed downwards to the base of the prostate, where it becomes greatly narrowed, and is joined at an acute angle by the duct of the seminal vesicle to form the ejaculatory duct, which traverses the prostate gland behind its middle lobe and opens into the prostatic portion of the urethra, close to the sinus pocularis. The vas deferens presents a hard and cord-like sensation to the fingers, and is of cylindrical form; its walls are dense, and its canal is extremely small. At the base of the bladder it becomes enlarged and tortuous, and this portion is termed the *ampulla*. A small triangular area of the base of the bladder, between the *vasa deferentia laterally and the bottom of the recto-vesical pouch of peritoneum above, is in contact with the rectum.

* ductī deferentēs

Structure.—The vas deferens consists of three coats: (1) an external or areolar coat; (2) a muscular coat, which in the greater part of the tube consists of two layers of unstriped muscular fibre: an outer, longitudinal in direction, and an inner, circular; but in addition to these, at the commencement of the vas deferens, there is a third layer, consisting of longitudinal fibres, placed internal to the circular stratum, between it and the mucous membrane; (3) an internal, or mucous coat, which is pale, and arranged in longitudinal folds. The mucous coat is lined by columnar epithelium which is non-ciliated throughout the greater part of the tube; a variable portion of the testicular end of the tube is lined by two strata of columnar cells and the cells of the superficial layer are ciliated.

A long narrow tube, the *vas aberrans of Haller*, is occasionally found connected with the lower part of the canal of the epididymis, or with the commencement of the vas deferens. It extends up into the cord for about two or three inches, where it terminates by a blind extremity, which is sometimes bifurcated. Its length varies from an inch and a half to fourteen inches, and it may become dilated towards its extremity; more commonly it retains the same diameter throughout. Its structure is similar to that of the vas deferens. Occasionally it is found unconnected with the epididymis.

Organ of Giraldès.—This term is applied to a small collection of convoluted tubules, situated in front of the lower part of the cord above the globus major of the epididymis. These tubes are lined with columnar ciliated epithelium, and probably represent the remains of a part of the Wolffian body.

Vesiculæ Seminales (fig. 1004)

The **vesiculæ seminales** are two lobulated membranous pouches, placed between the base of the bladder and the rectum, serving as reservoirs for the semen, and secreting a fluid to be added to the secretion of the testes. Each sac is somewhat pyramidal in form, the broad end being directed backwards, upwards and outwards. It measures usually about two and a half inches in length, but varies in size, not only in different individuals, but also in the same individual on the two sides. The *anterior surface* is in contact with the base of the bladder, extending from near the termination of the ureter to the base of the prostate gland. The *posterior surface* rests upon the rectum, from which it is separated by the recto-vesical fascia. Their *upper extremities* diverge from each other, and are separated from the bladder by the vas deferens

Fig. 1004.—Base of the bladder with the vesiculæ seminales.

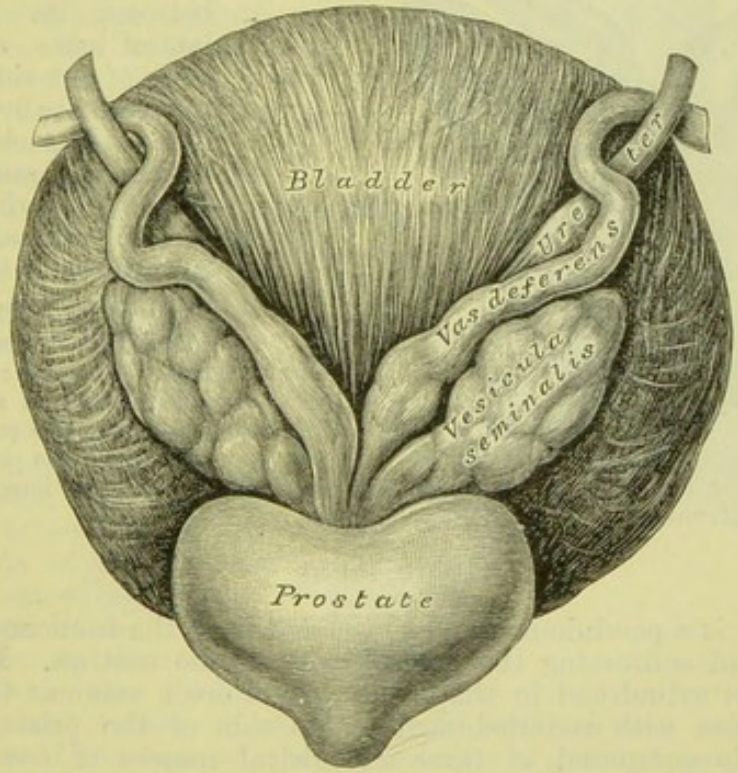

and the lower end of the ureter, and are partly covered by peritoneum. Their *lower extremities* are pointed, and converge towards the base of the prostate gland, where each joins with the corresponding vas deferens to form the ejaculatory duct. Along the inner margin of each vesicle runs the enlarged and tortuous vas deferens.

Each vesicle consists of a single tube, coiled upon itself, and giving off several irregular cæcal diverticula ; the separate coils, as well as the diverticula, are connected together by fibrous tissue. When uncoiled, the tube is about the diameter of a quill, and varies in length from four to six inches ; it terminates posteriorly in a *cul-de-sac* ; its anterior extremity becomes constricted into a narrow straight duct, which joins with the corresponding vas deferens to form the ejaculatory duct.

Structure.—The vesiculæ seminales are composed of three coats : an *external* or *areolar coat* ; a *middle* or *muscular coat*, thinner than in the vas deferens and arranged in two layers, an outer longitudinal and inner circular ; an *internal* or *mucous coat*, which is pale, of a whitish-brown colour, and presents a delicate reticular structure. The epithelium is columnar, and, in the diverticula, goblet-cells are present, the secretion of which increases the bulk of the seminal fluid.

Vessels and Nerves.—The *arteries* supplying the vesiculæ seminales are derived from the middle and inferior vesical, and middle hæmorrhoidal. The veins and lymphatics accompany the arteries. The nerves are derived from the pelvic plexuses.

Applied Anatomy.—The vesiculæ seminales are often the seat of an extension of the disease in cases of tuberculosis of the testis, and should always be examined from the rectum, before deciding to perform castration in this affection. They also become affected in chronic posterior urethritis of gonorrhœal origin.

Ejaculatory Ducts (fig. 1005)

The **ejaculatory ducts** are two in number, one on either side of the middle line. Each is formed by the union of the duct from the vesicula seminalis with the vas deferens, and is about three-quarters of an inch in length. They commence at the base of the prostate, and run forwards and downwards between its middle and lateral lobes, and along the sides of the sinus pocularis, to terminate by separate slit-like orifices close to or just within the margins of the sinus. The ducts diminish in size, and also converge, towards their terminations.

Fig. 1005.—Vesiculæ seminales and ampullæ of vasa deferentia, seen from the front. The anterior walls of the left ampulla, left seminal vesicle, and prostatic urethra have been cut away.

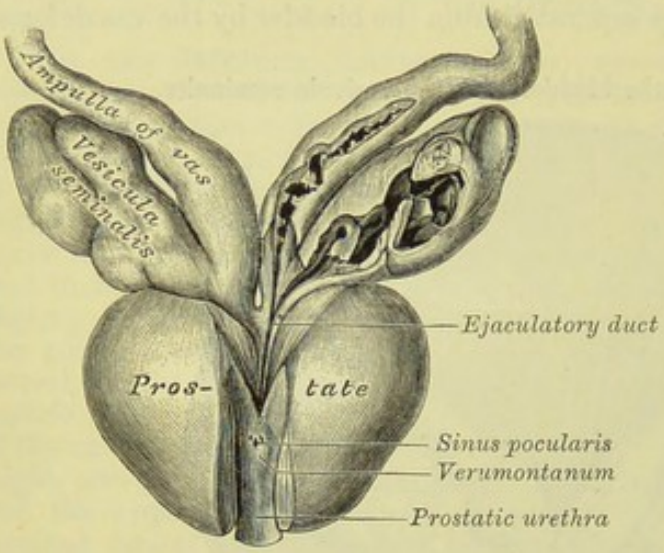

Structure.—The coats of the ejaculatory ducts are extremely thin. They are: an *outer fibrous layer*, which is almost entirely lost after the entrance of the ducts into the prostate; a *layer of muscular fibres*, consisting of an outer thin circular, and an inner longitudinal, layer; and *mucous membrane*.

The Penis

The **penis** is a pendulous organ suspended from the front and sides of the pubic arch and containing the greater part of the urethra. In the flaccid condition it is cylindrical in shape, but when erect assumes the form of a triangular prism with rounded angles, one side of the prism forming the dorsum. It is composed of three cylindrical masses of cavernous tissue bound together by fibrous tissue and covered with skin. Two of the masses are lateral, and are known as the *corpora cavernosa*; the third is median, and is termed the *corpus spongiosum* (figs. 1006, 1007).

The **corpora cavernosa** (corpora cavernosa penis) form the greater part of the substance of the penis. For their anterior three-fourths they lie in intimate apposition with one another, but behind they diverge in the form of two tapering processes, known as the *crura*, which are firmly connected to the rami of the pubic arch. Traced from behind forwards, each crus commences by a blunt-pointed process in front of the tuberosity of the ischium. Just before it meets its fellow it presents a slight enlargement, named by Kobelt the *bulb of the corpus cavernosum*. Beyond this point the crus undergoes a constriction and merges into the corpus cavernosum proper, which retains a uniform diameter to its anterior end. Each corpus cavernosum terminates abruptly in a rounded extremity some distance from the point of the penis.

The corpora cavernosa are surrounded by a strong fibrous envelope consisting of superficial and deep fibres. The superficial fibres are longitudinal in direction, and form a single tube which encloses both corpora; the deep fibres are arranged circularly round each corpus, and form by their junction

in the mesial plane a partition or septum (septum penis). This is thick and complete behind, but is imperfect in front, where it consists of a series of vertical bands arranged like the teeth of a comb; it is therefore named the *septum pectiniforme*.

FIG. 1006.—The constituent cavernous cylinders of the penis. The glans and anterior part of the corpus spongiosum are detached from the corpora cavernosa and turned to one side.

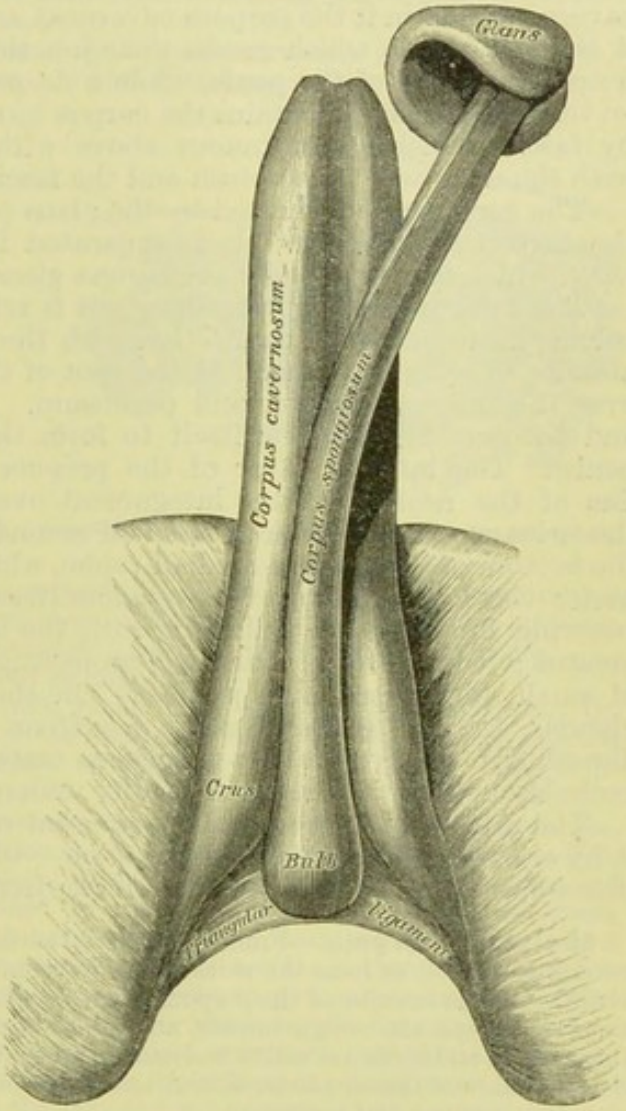

The **corpus spongiosum** (corpus cavernosum urethræ) contains the urethra. Behind, it is expanded to form the urethral bulb (bulbus urethræ), and lies in apposition with the superficial layer of the triangular ligament, from which it receives a fibrous investment. The urethra enters the bulb nearer to the upper than to the lower surface. On the latter there is a depressed median raphe (sulcus bulbi), from which a thin fibrous septum projects into the substance of the bulb and divides it imperfectly into two lateral lobes or *hemispheres*.

The portion of the corpus spongiosum in front of the bulb lies in a groove on the under surface of the conjoined corpora cavernosa. It is cylindrical in form and tapers slightly from behind forwards. Its anterior extremity is expanded in the form of an obtuse cone, flattened from above downwards. This expansion, termed the *glans penis*, is moulded on the rounded ends of the corpora cavernosa, extending further on their upper than on their lower surfaces. At the summit of the glans is the slit-like vertical urethral orifice or meatus (orificium urethræ externum). The circumference of the base of the glans forms a rounded projecting border, the *corona glandis*, overhanging a deep sulcus (sulcus retroglandularis), behind which is the *neck* (collum penis) of the penis.

FIG. 1007.—Transverse section of the penis.

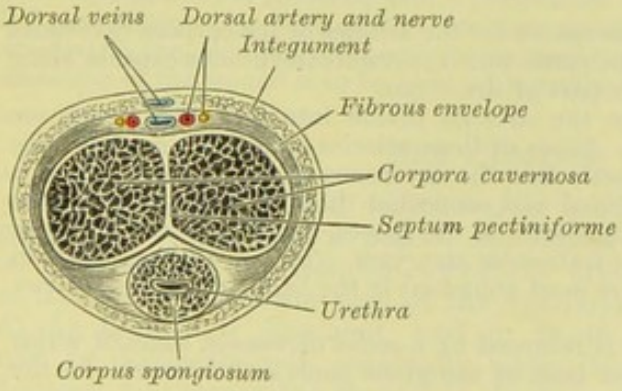

For descriptive purposes it is convenient to divide the penis into three regions: the root, the body, and the extremity.

The **root** (radix penis) of the penis is triradiate in form, consisting of the diverging crura, one on either side, and the mesial bulb of the corpus spongiosum. Each crus is covered by the Erector penis, while the bulb is surrounded by the Ejaculator urinæ. The root of the penis lies in the perinæum between the superficial layer of the triangular ligament and the fascia of Colles. In addition to being attached to the pubic rami and triangular ligament, it is bound to the

front of the symphysis pubis by the *suspensory ligament* (lig. suspensorium penis). The upper fibres of this ligament pass downwards from the lower end of the linea alba, and the lower fibres from the symphysis pubis; together they form a strong fibrous band, which extends to the upper surface of the root, where it splits into two fasciculi and blends with the fascial sheath of the organ.

The **body** (corpus penis) extends from the root to the ends of the corpora cavernosa, and in it the corpora cavernosa are intimately bound to one another. A shallow groove which marks their junction on the upper surface lodges the deep dorsal vein of the penis, while a deeper and wider groove between them on the under surface contains the corpus spongiosum. The body is ensheathed by fascia, which is continuous above with the fascia of Scarpa, and below with the dartos of the scrotum and the fascia of Colles.

The **extremity** is formed by the glans penis, the expanded anterior end of the corpus spongiosum. It is separated from the body by the constricted neck, which is overhung by the corona glandis.

The integument covering the penis is remarkable for its thinness, its dark colour, its looseness of connection with the deeper parts of the organ and its absence of adipose tissue. At the root of the penis it is continuous with that over the pubes, scrotum, and perinæum. At the neck it leaves the surface and becomes folded upon itself to form the *prepuce* or *foreskin* (præputium penis). The internal layer of the prepuce is directly continuous, along the line of the neck, with the integument over the glans. Immediately behind the urinary meatus it forms a small secondary reduplication, attached along the bottom of a depressed median raphe, which extends from the meatus to the neck; this fold is termed the *frenulum* (frenulum præputii). The integument covering the glans is continuous with the urethral mucous membrane at the meatus; it is devoid of hairs, but projecting from its free surface are a number of small, highly sensitive papillæ. On the corona and neck numerous small glands, the *glandulæ Tysonii odoriferæ* (glandulæ præputii) have been described.* They secrete a sebaceous material of very peculiar odour, which probably contains casein, and readily undergoes decomposition.

The prepuce covers a variable amount of the glans, and is separated from it by a potential sac—the *preputial sac*—which presents two shallow recesses (fossæ frenuli), one on either side of the frenulum.

Structure of the penis.—From the internal surface of the fibrous envelope of the corpora cavernosa as well as from the sides of the septum, numerous bands or cords are given off, which cross the interior of the corpora cavernosa in all directions, subdividing them into a number of separate compartments, and giving the entire structure a spongy appearance. These bands and cords are called *trabeculæ* (trabeculæ corporum cavernosorum), and consist of white fibrous tissue, elastic fibres, and plain muscular fibres. In them are contained numerous arteries and nerves.

The component fibres which form the trabeculæ are larger and stronger round the circumference than at the centres of the corpora cavernosa; they are also thicker behind than in front. The interspaces (cavernous spaces), on the contrary, are larger at the centre than at the circumference, their long diameters being directed transversely. They are filled with blood, and are lined by a layer of flattened cells similar to the endothelial lining of veins.

The arteries bringing the blood to these spaces are the arteries of the corpora cavernosa and branches from the dorsal arteries of the penis, which perforate the fibrous capsule, along the upper surface, especially near the fore-part of the organ.

On entering the cavernous structure the arteries divide into branches, which are supported and enclosed by the trabeculæ. Some of these arteries terminate in a capillary network, the branches of which open directly into the cavernous spaces; others assume a tendril-like appearance, and form convoluted and somewhat dilated vessels, which were named by Müller *helicine arteries*. They project into the spaces, and from them are given off small capillary branches to supply the trabecular structure. They are bound down in the spaces by fine fibrous processes, and are most abundant in the back part of the corpora cavernosa (fig. 1008).

The blood from the cavernous spaces is returned by a series of vessels, some of which emerge in considerable numbers from the base of the glans penis and converge on the

* Stieda (*Comptes-rendus du XII Congrès International de Médecine*, Moscow, 1897) asserts that Tyson's glands are never found on the corona glandis, and that what have hitherto been mistaken for glands are really large papillæ.

dorsum of the organ to form the deep dorsal vein; others pass out on the upper surface of the corpora cavernosa and join the same vein; some emerge from the under surface of the corpora cavernosa and, receiving branches from the corpus spongiosum, wind round the sides of the penis to terminate in the deep dorsal vein; but the greater number pass out at the root of the penis and join the prostatic plexus.

The fibrous envelope of the corpus spongiosum is thinner, whiter in colour, and more elastic than that of the corpora cavernosa. The trabeculæ are more delicate, nearly uniform in size, and the meshes between them smaller than in the corpora cavernosa:

FIG. 1008.—From the peripheral portion of the corpus cavernosum penis under a low magnifying power. (Copied from Langer.)

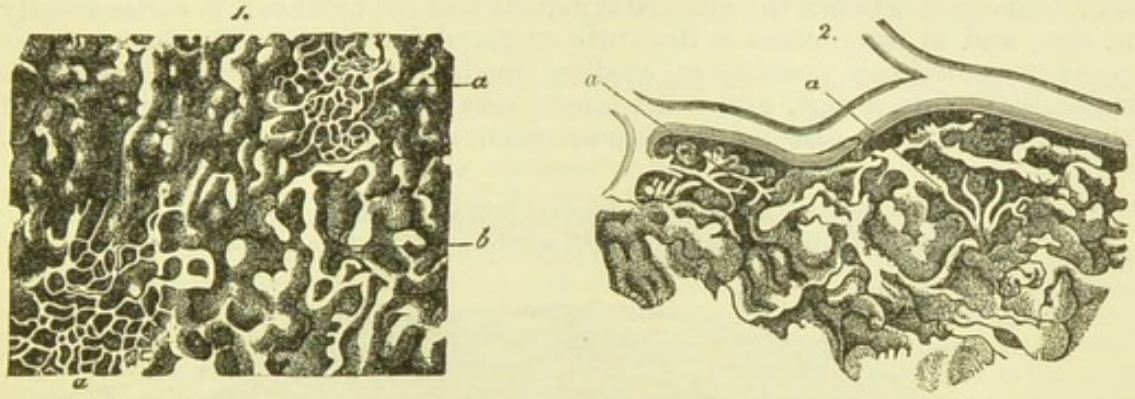

1. *a*. Capillary network. *b*. Cavernous spaces. 2. Connection of the arterial twigs (*a*) with the cavernous spaces.

their long diameters, for the most part, corresponding with that of the penis. The external envelope or outer coat of the corpus spongiosum is formed partly of unstriped muscular fibre, and a layer of the same tissue immediately surrounds the canal of the urethra.

The *lymphatics of the penis* are described on page 789.

The *nerves* are derived from the internal pudic nerve and the pelvic plexuses. On the glans and bulb some filaments of the cutaneous nerves have Pacinian bodies connected with them, and, according to Krause, many of them terminate in peculiar end-bulbs (see page 50).

Applied Anatomy.—The penis occasionally requires removal for malignant disease. Usually, removal of the ante-scrotal portion is all that is necessary, but sometimes it is requisite to remove the whole organ from its attachment to the rami of the pubes and ischia. The former operation is performed by cutting through the corpora cavernosa from the dorsum, and then separating the corpus spongiosum from them, dividing it at a level nearer the glans penis. The mucous membrane of the urethra is then slit up, and the edges of the flap attached to the external skin, in order to prevent contraction of the orifice, which might otherwise take place. The vessels which require ligature are the two dorsal arteries of the penis, the arteries of the corpora cavernosa, and the artery of the septum. When the entire organ requires removal, the patient is placed in the lithotomy position, and an incision is made through the skin and subcutaneous tissue round the root of the penis, and carried down through the median line of the scrotum as far as the perinæum. The two halves of the scrotum are then separated from each other, and a catheter having been introduced into the bladder as a guide, the spongy portion of the urethra below the triangular ligament is separated from the corpora cavernosa and divided, the catheter having been withdrawn. The suspensory ligament is now severed and the rura separated from the bone with a periosteum scraper, and the whole penis removed. The membranous portion of the urethra, which has not been removed, is now to be attached to the skin at the posterior extremity of the incision in the perinæum. The remainder of the wound is to be brought together, free drainage being provided for.

THE PROSTATE GLAND

The **prostate gland** (prostate) is a firm, partly glandular and partly muscular body, which is placed immediately below the neck of the bladder and around the commencement of the urethra. It is situated in the pelvic cavity, below the lower part of the symphysis pubis, above the superior layer of the triangular ligament, and in front of the rectum, through which it may be distinctly felt, especially when enlarged. It is about the size of a chestnut and somewhat conical in shape, and presents for examination a base, an apex, an anterior, a posterior, and two lateral surfaces.

The *base* (basis prostatæ) is directed upwards, and is applied to the under surface of the bladder. The greater part of this surface is directly continuous

with the bladder wall: the urethra penetrates it nearer its anterior than its posterior border.

The *apex* (apex prostatæ) is directed downwards, and is in contact with the deep layer of the triangular ligament.

The *posterior surface* (facies posterior) is flattened from side to side and convex from above downwards; it rests on the rectum, and is distant about an inch and a half from the anus. Near its upper border there is a depression through which the two common ejaculatory ducts enter the prostate. This depression serves to divide the posterior surface into a lower larger and an upper smaller part. The upper smaller part constitutes the *middle lobe* of the prostate and intervenes between the ejaculatory ducts and the urethra; it varies greatly in size, and in some cases is destitute of glandular tissue. The lower larger portion sometimes presents a shallow median furrow, which imperfectly separates it into a *right* and a *left lateral* lobe: these form the main mass of the gland and are directly continuous with each other behind the urethra.

FIG. 1009.—Transverse section of normal prostate through the middle of the verumontanum, from a subject aged nineteen years. (Taylor.)

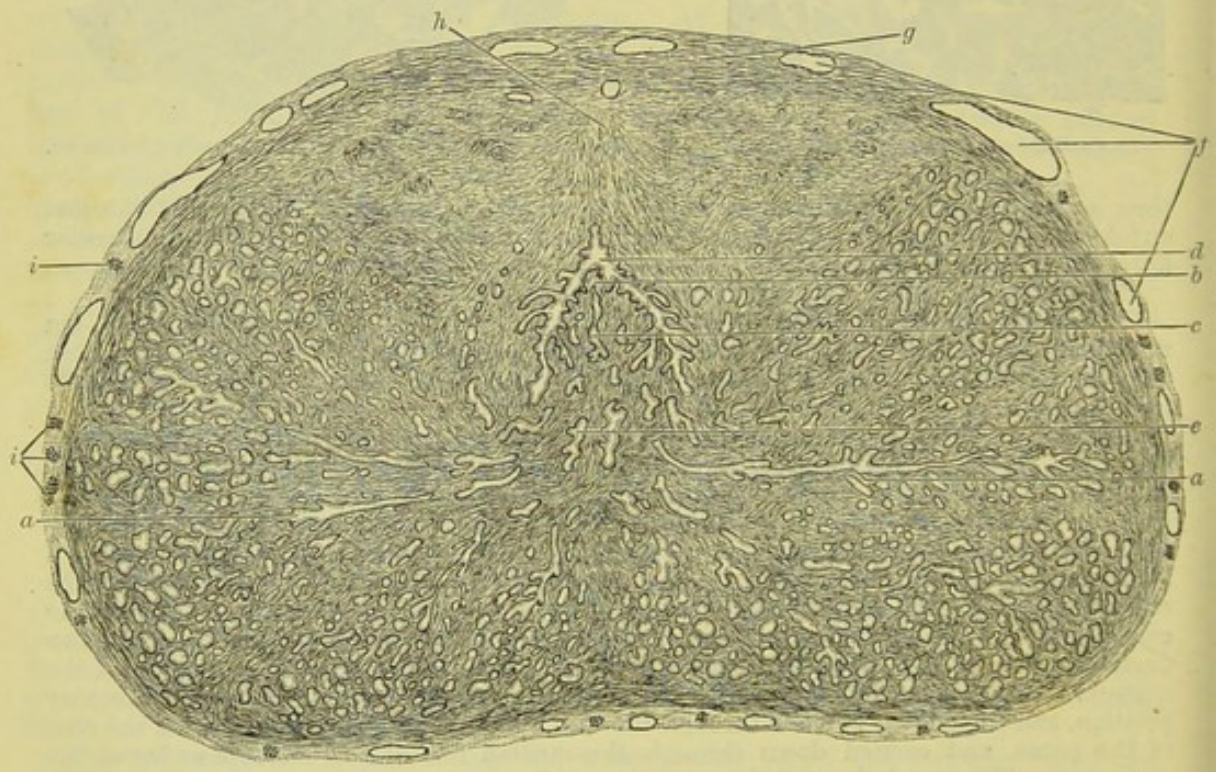

a, longitudinal section of ducts leading from the lobules of the prostatic glands; *b*, verumontanum; *c*, sinus pocularis; *d*, urethra; *e*, ejaculatory ducts; *f*, arteries, veins, and venous sinuses in sheath of prostate; *g*, nerve trunks in sheath; *h*, point of origin of fibro-muscular bands encircling urethra; *i*, zone of striated voluntary muscle on superior surface.

In front of the urethra they are connected by a band which is named the *anterior commissure*: this consists of the same tissues as the capsule and is devoid of glandular substance.

The *anterior surface* (facies anterior) measures about an inch from above downwards, but is narrow and convex from side to side. It is placed about three-quarters of an inch behind the pubic symphysis, from which it is separated by a plexus of veins and a quantity of loose fat. It is connected to the pubic bone on either side by the pubo-prostatic ligaments. The urethra emerges from this surface a little above and in front of the apex of the gland.

The *lateral surfaces* (facies laterales) are prominent, and are covered by the anterior portions of the Levatores ani muscles, which are, however, separated from the gland by a plexus of veins.

The prostate measures about an inch and a half transversely at the base, three-quarters of an inch in its antero-posterior diameter, and an inch and a quarter in its vertical diameter. Its weight is about four and a half drachms. It is held in its position by the anterior ligaments of the bladder (*pubo-*

prostatic) ; by the deep layer of the triangular ligament, which invests the commencement of the membranous portion of the urethra and prostate gland; and by the anterior portions of the Levatores ani muscles, which pass backwards from the pubis and embrace the sides of the prostate. These portions of the Levatores ani, from the support they afford to the prostate, are named the *Levatores prostatæ*.

The prostate gland is perforated by the urethra and the ejaculatory ducts. The urethra usually lies along the junction of its anterior with its middle third. The ejaculatory ducts pass obliquely downwards and forwards through the posterior part of the prostate, and open into the prostatic portion of the urethra.

Structure.—The prostate is immediately enveloped by a thin but firm fibrous capsule, distinct from that derived from the fascia endopelvina, and separated from it by a plexus of veins. This capsule is firmly adherent to the prostate and is structurally continuous with the stroma of the gland, being composed of the same tissues, viz. non-striped muscle and fibrous tissue. The substance of the prostate is of a pale reddish-grey colour, of great density, and not easily torn. It consists of glandular substance and muscular tissue.

The *muscular tissue*, according to Kölliker, constitutes the proper stroma of the prostate ; the connective tissue being very scanty, and simply forming, between the muscular fibres, thin trabeculæ, in which the vessels and nerves of the gland ramify. The muscular tissue is arranged as follows : immediately beneath the fibrous capsule is a dense layer, which forms an investing sheath for the gland ; secondly, around the urethra, as it lies in the prostate, is another dense layer of circular fibres, continuous above with the internal layer of the muscular coat of the bladder, and below blending with the fibres surrounding the membranous portion of the urethra. Between these two layers strong bands of muscular tissue, which decussate freely, form meshes in which the glandular structure of the organ is imbedded. In that part of the gland which is situated in front of the urethra the muscular tissue is especially dense, and there is here little or no gland tissue ; while in that part which is behind the urethra the muscular tissue presents a wide-meshed structure, which is densest at the base of the gland—that is, near the bladder—becoming looser and more sponge-like towards the apex of the organ.

The *glandular substance* is composed of numerous follicular pouches, opening into elongated canals, which join to form from twelve to twenty small excretory ducts. The follicles are connected together by areolar tissue, supported by prolongations from the fibrous capsule and muscular stroma, and enclosed in a delicate capillary plexus. The epithelium which lines the canals and the terminal vesicles is of the columnar variety. The prostatic ducts open into the floor of the prostatic portion of the urethra, and are lined by two layers of epithelium, the inner layer consisting of columnar and the outer of small cubical cells.

Vessels and Nerves.—The *arteries* supplying the prostate are derived from the internal pudic, vesical, and hæmorrhoidal. Its veins form a plexus around the sides and base of the gland ; they receive in front the dorsal vein of the penis, and terminate in the internal iliac veins. The *nerves* are derived from the pelvic plexus.

Applied Anatomy.—By means of the finger introduced into the rectum, the surgeon detects enlargement or other disease of the prostate; he can feel the apex of the gland, which is the guide to Cock's operation for stricture; he is enabled also by the same means to direct the point of a catheter, when its introduction is attended with difficulty either from injury or disease of the membranous or prostatic portions of the urethra. When the finger is introduced into the bowel, the surgeon may, in some cases, especially in boys, learn the position, as well as the size, of a calculus in the bladder ; and in the operation for its removal, if, as is not infrequently the case, it should be lodged behind an enlarged prostate, it may be displaced from its position by pressing upwards the base of the bladder from the rectum. The prostate gland is occasionally the seat of suppuration, due to either gonorrhœa or tuberculous disease. The gland is enveloped in a dense unyielding capsule, which determines the course of the abscess, and also explains the great pain which is present in the acute form of the disease. The abscess most frequently bursts into the urethra, the direction in which there is least resistance, but may burst into the rectum, or more rarely in the perinæum. In advanced life the prostate sometimes becomes considerably enlarged and projects into the bladder so as to impede the passage of the urine. According to Messer's researches, conducted at Greenwich Hospital, it would seem that such obstruction exists in 20 per cent. of all men over sixty years of age. In some cases the condition affects principally the lateral lobes, which may undergo considerable enlargement without causing much inconvenience. In other cases it would seem that the middle lobe enlarges most, and even a small enlargement of this lobe may act injuriously, by forming a sort of valve over the urethral orifice, preventing the passage of the urine ; and the more the patient strains, the more completely will it block the opening into the urethra. In consequence of the enlargement of the prostate, a pouch is formed at the base of the bladder behind the projection, in which urine collects, and cannot be entirely expelled. It becomes decomposed

and ammoniacal, and leads to cystitis. For this condition *prostatectomy* is sometimes done. The bladder is opened by an incision above the symphysis pubis, the mucous membrane of the post-prostatic pouch is scratched through, and the finger is then introduced into the space between the true capsule of the prostate and outer capsule formed by the fascia endopelvina. Separation in this plane is then carried out below and laterally until the apex of the gland is reached. The whole of the work is done with the finger, which is gradually swept round the sides until the anterior surface is reached and freed. The gland is then, by traction, displaced into the bladder and removed, usually carrying with it the greater portion of the mucous membrane of the prostatic urethra. Hæmorrhage, which may be considerable at times, is checked by hot irrigations, and the bladder is temporarily drained. Very satisfactory results have followed this operation.

The prostate can be reached from the perinæum, and in some cases the enlarged gland has been removed by this route, but the perineal approach is not usually employed except in the case of abscess of or about the gland.

Cowper's Glands

Cowper's glands (glandulæ bulbo-urethrales) are two small, rounded, and somewhat lobulated bodies, of a yellow colour, about the size of peas, placed behind the membranous portion of the urethra, between the two layers of the triangular ligament. They lie close above the bulb, and are enclosed by the transverse fibres of the Compressor urethræ muscle. Their existence is said to be constant : they gradually diminish in size as age advances.

The excretory duct of each gland, nearly an inch in length, passes obliquely forwards beneath the mucous membrane, and opens by a minute orifice on the floor of the bulbous portion of the urethra.

Structure—Each gland is made up of several lobules, held together by a fibrous investment. Each lobule consists of a number of acini, lined by columnar epithelial cells, opening into one duct, which joins with the ducts of other lobules outside the gland to form the single excretory duct.

FEMALE REPRODUCTIVE ORGANS

The female reproductive organs (organa genitalia muliebria) consist of an internal and an external group. The *internal organs* are situated within the pelvis, and consist of the ovaries, the Fallopian tubes, the uterus, and the vagina. The *external organs* are placed below the triangular ligament of the urethra and below and in front of the pubic arch. They comprise the mons Veneris, the labia majora et minora, the clitoris, the bulbus vestibuli, and the glands of Bartholin.

The Ovaries

The **ovaries** are homologous with the testes in the male. They are two nodular bodies, situated one on either side of the uterus in relation to the lateral wall of the pelvis, and attached to the back of the broad ligament of the uterus, behind and below the Fallopian tubes (fig. 1010). The ovaries are of a greyish-pink colour, and present either a smooth or a puckered uneven surface. They are each about an inch and a half in length, three-quarters of an inch in width, and about a third of an inch in thickness, and weigh from one to two drachms. Each ovary (ovarium) presents an outer and an inner surface, an upper and a lower extremity, and an anterior and a posterior border. It lies in a shallow depression, named the *fossa ovarii*, on the lateral wall of the pelvis ; this fossa is bounded above by the external iliac vessels, in front by the obliterated hypogastric artery, and behind by the ureter. The exact position of the ovary has been the subject of considerable difference of opinion, and the description here given applies to the ovary of the nulliparous woman. The ovary becomes displaced during the first pregnancy, and probably never again returns to its original position. In the erect posture the long axis of the ovary is vertical. The *upper* or *tubal* extremity is near the external iliac vein ; to it is attached the ovarian fimbria of the Fallopian tube and a fold of peritoneum, the *suspensory ligament of the ovary*, which is directed upwards over the iliac vessels and contains the ovarian vessels. The *lower* or *uterine*

end is directed downwards towards the pelvic floor; it is usually narrower than the upper, and is attached to the lateral angle of the uterus, immediately behind the Fallopian tube, by a rounded cord termed the *ligament of the ovary*, which lies within the broad ligament and contains some non-striped

FIG. 1010.—Uterus and right broad ligament, seen from behind. The broad ligament has been spread out and the ovary drawn downwards.

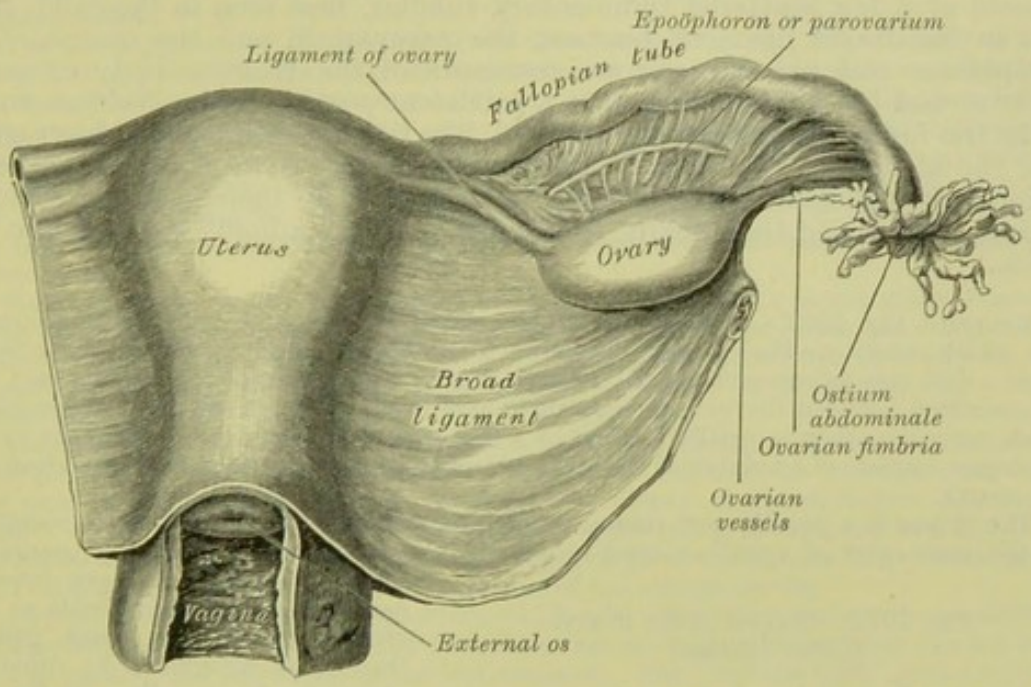

muscular fibres. The *outer* surface is in contact with the parietal peritoneum, which lines the fossa ovarii; the *inner* surface is to a large extent covered by the fimbriated extremity of the Fallopian tube. The *anterior* or *straight* border is directed towards the obliterated hypogastric artery, and is attached to the back of the broad ligament by a short fold named the *mes-*

FIG. 1011.—Adult ovary, epoöphoron, and Fallopian tube. (From Farre, after Kobelt.)

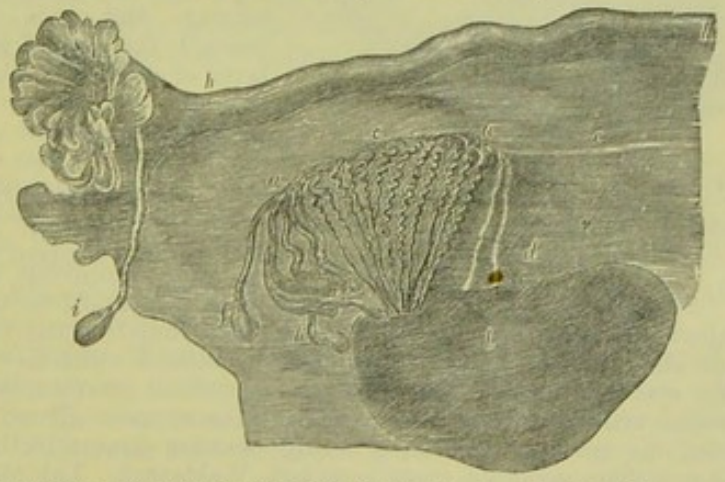

a, *a*. Epoöphoron formed from the upper part of the Wolffian body. *b*. Remains of the uppermost tubes sometimes forming hydatids. *c*. Middle set of tubes. *d*. Some lower atrophied tubes. *e*. Atrophied remains of the Wolffian duct. *f*. The terminal bulb or hydatid. *h*. The Fallopian tube. *i*. Hydatid attached to the extremity. *l*. The ovary.

ovarium. Between the two layers of this fold the blood-vessels and nerves pass to reach the hilus of the ovary. The *posterior* or *convex* border is free, and is directed towards the ureter. The Fallopian tube arches over the ovary, running upwards in relation to its anterior border, then curving over its upper or tubal pole, and finally passing downwards on its posterior border and inner surface.

Epoöphoron and paroöphoron (figs. 1010, 1011).—Lying in the broad ligament, between the ovary and the Fallopian tube, is the *epoöphoron* or *parovarium*, also called the *organ of Rosenmüller*. This consists of a few closed convoluted tubes, lined with epithelium, which converge towards the ovary at one end and at the other are united by a longitudinal tube, the *duct of Gärtner*. In the human female this duct terminates in a bulbous enlargement; in the cow it attains a greater development and opens into the vagina. The *paroöphoron* consists of a few scattered rudimentary tubules, best seen in the child, situated in the broad ligament between the parovarium and the uterus. The epoöphoron and paroöphoron are remnants of the Wolffian body or mesonephros, and the duct of Gärtner is a persistent portion of the Wolffian duct.

In the fœtus, the ovaries are situated, like the testes, in the lumbar region, near the kidneys. They may be distinguished from those bodies at an early period by their elongated and flattened form, and by their position, which is at first oblique and then nearly transverse. They gradually descend into the pelvis.

Structure (fig. 1012).—The surface of the ovary is covered by a layer of columnar cells which constitute the *germinal epithelium of Waldeyer*. This epithelium gives to the ovary a dull grey colour as compared with the shining smoothness of the peritoneum; and the transition between the pavement epithelium of the peritoneum and the columnar cells which cover the ovary is usually marked by a line around the anterior border of the ovary. The ovary consists of a number of Graafian follicles imbedded in the meshes of a stroma or framework.

The *stroma* is a peculiar soft tissue, abundantly supplied with blood-vessels, consisting for the most part of spindle-shaped cells with a small amount of ordinary connective tissue. These cells have been regarded by some anatomists as unstriped muscle-cells, which, indeed, they most resemble; by others as connective-tissue cells. On the surface of the organ this tissue is much condensed, and forms a layer (*tunica albuginea*) composed of short connective-tissue fibres, with fusiform cells between them.

FIG. 1012.—Section of the ovary. (After Schrön.)

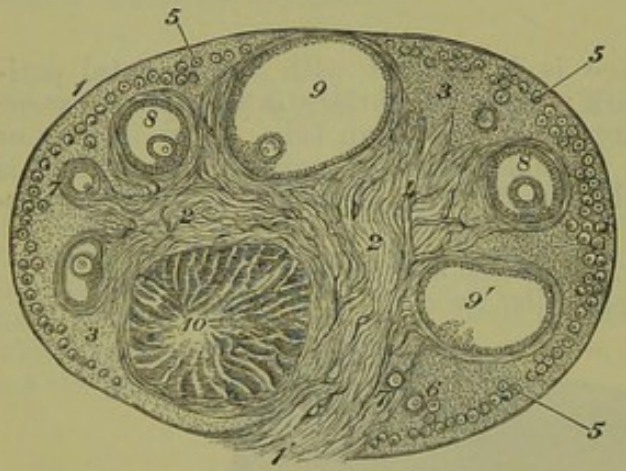

1. Outer covering. 1′. Attached border. 2. Central stroma. 3. Peripheral stroma. 4. Blood-vessels. 5. Graafian follicles in their earliest stage. 6, 7, 8. More advanced follicles. 9. An almost mature follicle. 9′. Follicle from which the ovum has escaped. 10. Corpus luteum.

Graafian follicles.—Upon making a section of an ovary, numerous round transparent vesicles of various sizes are to be seen; they are the Graafian follicles, or ovisacs containing the ova. Immediately beneath the superficial covering is a layer of stroma, in which are a large number of minute vesicles, of uniform size, about $\frac{1}{100}$ of an inch in diameter. These are the follicles in their earliest condition, and the layer where they are found has been termed the *cortical layer*. They are especially numerous in the ovary of the young child. After puberty, and during the whole of the child-bearing period, large and mature, or almost mature, Graafian follicles are also found in the cortical layer in small numbers, and also 'corpora lutea,' the remains of follicles which have burst and are undergoing atrophy and absorption. Beneath this superficial stratum, other large and more mature follicles are found imbedded in the ovarian stroma. These increase in size as they recede from the surface towards a highly vascular stroma in the centre of the organ, termed the *medullary substance* (*zona vasculosa*, Waldeyer). This stroma forms the tissue of the hilus by which the ovary is attached, and through which the blood-vessels enter: it does not contain any Graafian follicles.

The larger Graafian follicles consist of an external fibro-vascular coat, connected with the surrounding stroma of the ovary by a network of blood-vessels; and an internal coat, named the *ovicapsule*, which is lined by a layer of nucleated cells, called the *membrana granulosa*. In that part of the mature Graafian follicle which is nearest the surface of the ovary, the cells of the membrana granulosa are connected into a mass which projects into the cavity of the follicle. This is termed the *discus proligerus*, and in it the ovum is imbedded.* The follicle contains a transparent albuminous fluid.

* For a description of the ovum, see page 78.

The ova are usually regarded as being formed from the germinal epithelium on the surface of the ovary. This becomes thickened, and in it are seen some cells which are larger and more rounded than the rest: these are termed the *primordial ova*. The germinal epithelium grows downwards in the form of tubes or columns, termed the *egg tubes* of Pflüger, into the ovarian stroma, which grows outwards between the tubes, and ultimately cuts them off from the germinal epithelium. These tubes are further subdivided into rounded *nests* or groups, each containing a primordial ovum which undergoes further development and growth while the surrounding cells of the nest form the epithelium of the Graafian follicle.

The development and maturation of the Graafian follicles and ova continue uninterruptedly from puberty to the end of the fruitful period of woman's life, while their formation commences before birth. Before puberty the ovaries are small, the Graafian follicles contained in them are disposed in a comparatively thick layer in the cortical substance; here they present the appearance of a large number of minute closed vesicles, constituting the early condition of the Graafian follicles; many, however, never attain full development, but shrink and disappear. At puberty the ovaries enlarge and become more vascular, the Graafian follicles are developed in greater abundance, and their ova are capable of fecundation.

Discharge of the ovum.—The Graafian follicles, after attaining a certain stage of development, gradually approach the surface of the ovary and burst; the ovum and fluid contents of the follicle are liberated on the exterior of the ovary, and carried into the Fallopian tube by peritoneal currents set up by the movements of the cilia covering the mucous membrane of the fimbriæ.

Vessels and Nerves.—The *arteries* of the ovaries and Fallopian tubes are the ovarian from the aorta. Each enters the attached border, or hilus, of the corresponding ovary. The *veins* emerge from the hilus in the form of a plexus, the *pampiniform plexus*; the ovarian vein is formed from this plexus, and leaves the pelvis in company with the artery. The *nerves* are derived from the hypogastric or pelvic plexus, and from the ovarian plexus, the Fallopian tube receiving a branch from one of the uterine nerves.

Applied Anatomy.—The inflammations which affect the ovary are merely an extension of those from the tube. Ovarian new formations are of common occurrence, and are either solid or cystic; the former being the less common. The '*ovarian cysts*' in the majority of cases are cystadenomata which may assume enormous dimensions; in rarer instances they form from the tubules at the hilus of the ovary or those of the organ of Rosenmüller; in other instances a clear watery cyst forms between the layers of the broad ligament. An ovarian cyst, once diagnosed, should always be removed, as it is liable to become affected by suppuration, torsion of its pedicle, or other serious complications. The operation for its removal, badly termed *ovariotomy*, consists in opening the abdomen, and reducing the size of the cyst when large by tapping it before its withdrawal from the abdomen; the pedicle is then clamped with a large forceps, and the cyst is cut free. This pedicle must then be transfixed and securely ligatured by an interlocking ligature, which will not slip off. The pedicle consists of an elongated part of the broad ligament, including the Fallopian tube and ovarian artery, and a great number of large veins. Ovariotomy for a simple uncomplicated cyst presents no special difficulties, but, in cases where there are old adhesions implicating the small intestines, it may present very great difficulties.

The Fallopian Tubes (figs. 1010, 1013)

The **Fallopian tubes,** or **oviducts,** convey the ova from the ovaries to the cavity of the uterus. They are two in number, one on either side, situated in the upper margin of the broad ligament, and extending from either superior angle of the uterus to the side of the pelvis. Each tube is about four inches in length; and is described as consisting of three portions: (1) the *isthmus*, or inner constricted third; (2) the *ampulla*, or outer dilated portion, which curves over the ovary; and (3) the *infundibulum*, with its *ostium abdominale*, surrounded by *fimbriæ*, one of which, the *fimbria ovarica*, is attached to the ovary. The Fallopian tube is directed outwards as far as the lower or uterine pole of the ovary, and then ascends along the anterior border of the ovary to the upper or tubal pole, over which it arches; finally it turns downwards and ends in relation to the posterior border and inner surface of the ovary. The uterine opening is minute, and will only admit a fine bristle; the abdominal opening is somewhat larger. In connection with the fimbriæ of the Fallopian tube, or with the broad ligament close to them, there are frequently one or more small pedunculated vesicles. These are termed the *hydatids of Morgagni*.

Structure.—The Fallopian tube consists of three coats: serous, muscular, and mucous. The *external* or *serous coat* is peritoneal. The *middle* or *muscular coat* consists of

an external longitudinal and an internal circular layer of non-striped muscular fibres continuous with those of the uterus. The *internal* or *mucous coat* is continuous with the mucous lining of the uterus, and, at the free extremity of the tube, with the peritoneum. It is thrown into longitudinal folds, which in the outer, larger part of the tube, or ampulla, are much more extensive than in the narrow canal of the isthmus. The lining epithelium is columnar and ciliated. This form of epithelium is also found on the inner surface of the fimbriæ; while on the outer or serous surfaces of these processes the epithelium gradually merges into the endothelium of the peritoneum.

Applied Anatomy.—The majority of the diseases of the Fallopian tube are due to infections which have spread by way of the vagina and uterus, and the disease often does not stop at the Fallopian tube, but passes on to the peritoneum, giving rise to acute general peritonitis, or a localised condition termed *perimetritis* that may be acute or chronic. Perimetritis is often followed by various painful conditions, which are due to the peritoneal adhesions resulting from the inflammation of the serous membrane, and which persist throughout life. Tubal inflammation (*salpingitis*) is usually the result of an infection either by the gonococcus or by septic organisms implanted at the time of labour or abortion. In many cases the fimbriated ends of the tubes become closed by adhesions, pus collects in the tubes, and a *pyosalpinx* results.

Fertilisation of the ovum has been stated (page 83) to occur in the tube, and the fertilised ovum is then normally passed on into the uterus; the ovum, however, may segment whilst it is still in the Fallopian tube, giving rise to the commonest variety of *ectopic gestation*. In such cases the amnion and chorion are formed, but a true decidua is never present; and the gestation usually terminates by extrusion of the ovum through the abdominal ostium, although it is not uncommon for the tube to rupture into the peritoneal cavity, this being accompanied by severe hæmorrhage, and needing surgical interference.

The Uterus (figs. 1010, 1013, 1014)

The **uterus**, or **womb**, is a hollow, thick-walled, muscular organ situated deeply in the pelvic cavity between the bladder and rectum. Into its upper part the Fallopian tubes open, one on either side, while below, its cavity communicates with that of the vagina. When the ova are discharged from

Fig. 1013.—Female pelvis and its contents, seen from above and in front.

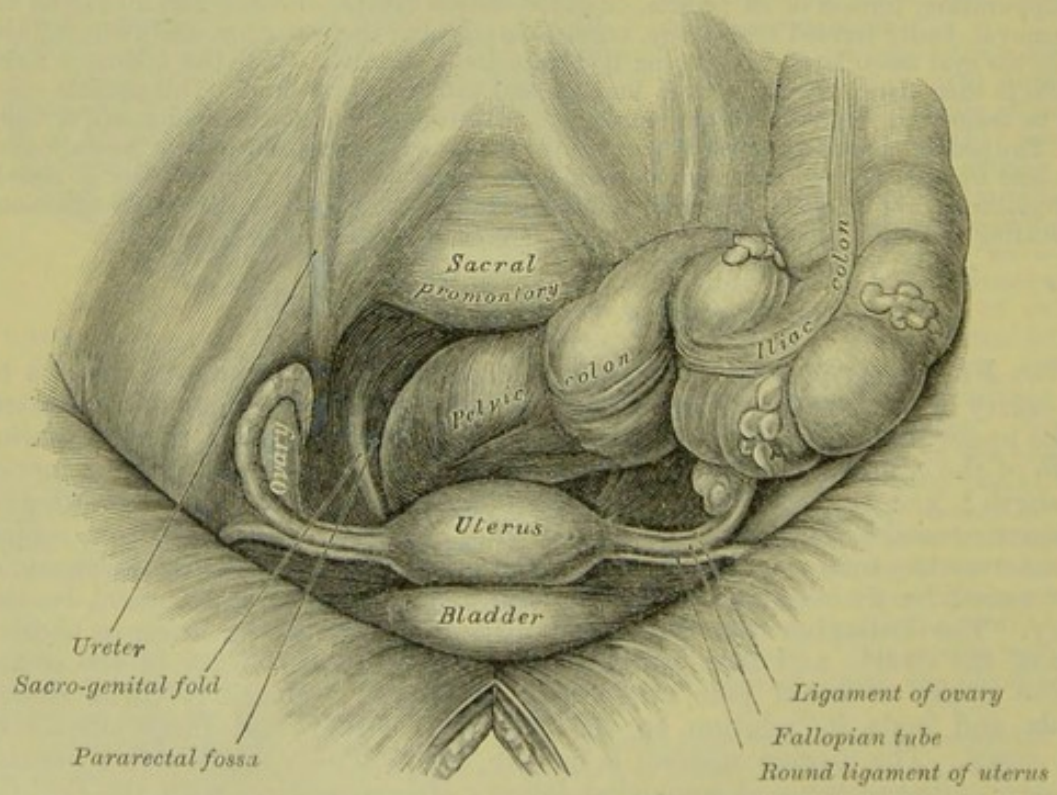

the ovaries they are carried to the uterine cavity through the Fallopian tubes. If an ovum be fertilised it imbeds itself in the uterine wall and is normally retained in the uterus until pre-natal development is completed, the uterus undergoing changes in size and structure to accommodate itself to the needs of the growing embryo (see page 97). After parturition the uterus returns

almost to its former condition, but certain traces of its enlargement remain. It is necessary therefore to describe as the type-form the adult virgin uterus, and then to consider the modifications which are effected as a result of pregnancy.

In the virgin state the uterus is flattened antero-posteriorly and is pyriform in shape, with the apex directed downwards and backwards. It lies between the bladder in front and the pelvic colon and rectum behind, and is completely within the pelvis, so that its base is below the level of the pelvic brim. Its upper part is suspended by the broad and the round ligaments, while its lower portion is imbedded in the fibrous tissue of the pelvis.

The long axis of the uterus usually lies approximately in the axis of the pelvic brim, but as the organ is freely movable its position varies with the state of distension of the bladder and rectum. Except when much displaced by a fully distended bladder, it forms an angle with the vagina, since the axis of the vagina corresponds to the axes of the cavity and outlet of the pelvis.

FIG. 1014.—Median sagittal section of female pelvis.

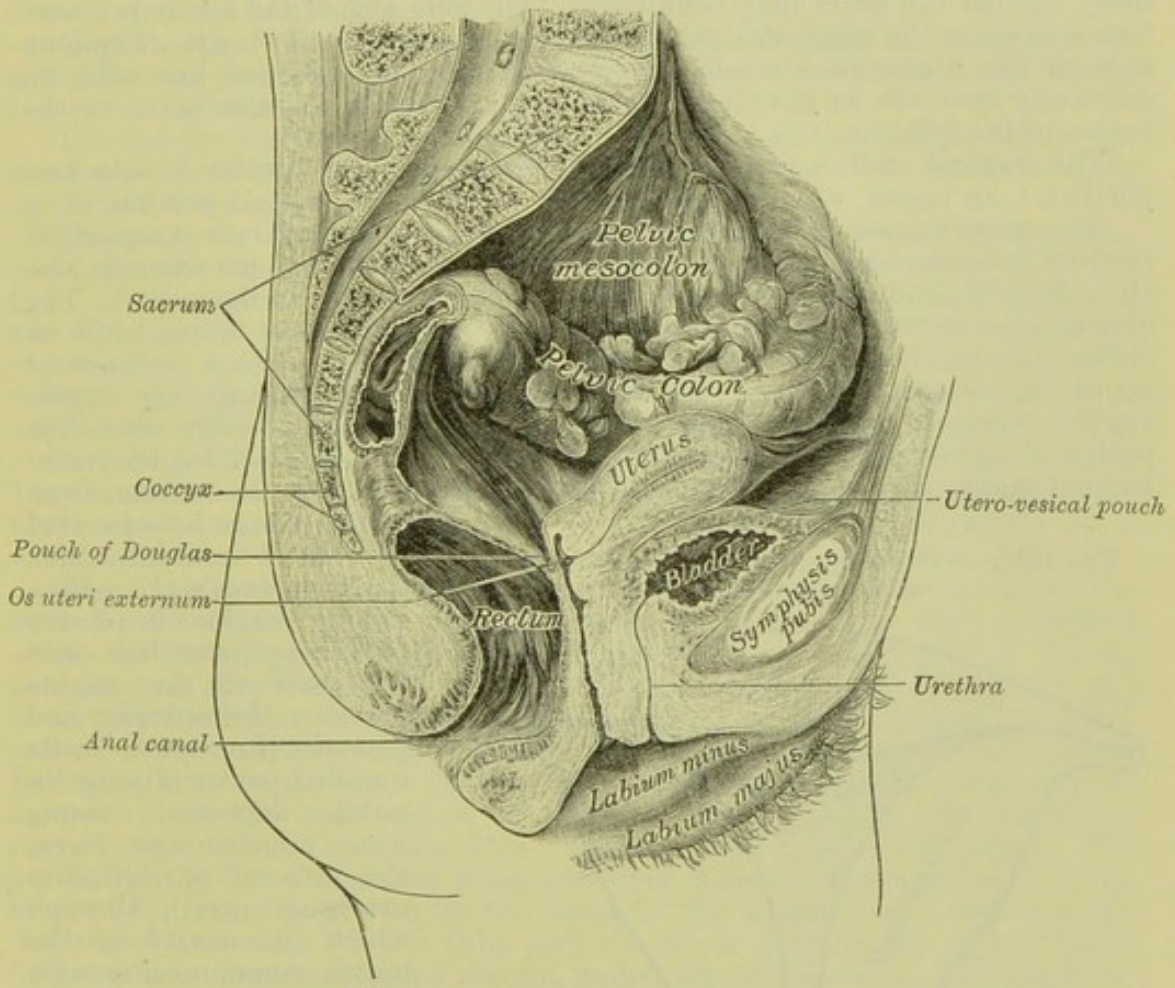

The uterus measures about three inches in length, two inches in breadth at its upper part, and nearly an inch in thickness ; it weighs from an ounce to an ounce and a half. It is divisible into two portions. On the surface, about midway between the apex and base, is a slight constriction, known as the *isthmus* (isthmus uteri), and corresponding to this in the interior is a narrowing of the uterine cavity, the *internal os* (orificium internum uteri). The portion above the isthmus is termed the *body*, and that below, the *cervix*. The part of the body which lies above a plane passing through the points of entrance of the Fallopian tubes is known as the *fundus* (fundus uteri).

Body (corpus uteri).—The body gradually narrows from the fundus to the isthmus.

The *anterior surface* (facies vesicalis) is flattened and covered by peritoneum, which is reflected on to the bladder to form the utero-vesical pouch. The surface lies in apposition with the bladder.

The *posterior surface* (facies intestinalis) is convex transversely, and is covered by peritoneum, which is continued down on to the cervix and vagina.

It is in relation with the pelvic colon, from which it is usually separated by some coils of small intestine.

The *superior surface* is part of the fundus. It is slightly convex in all directions, and covered by peritoneum continuous with that on the anterior and posterior surfaces. On it rest some coils of small intestine, and occasionally the distended pelvic colon.

The *lateral margins* (margines laterales) are slightly convex. At the upper end of each the Fallopian tube pierces the uterine wall. Below and in front of this point the round ligament of the uterus is attached, while behind it, is the attachment of the ligament of the ovary. These three structures lie within a fold of peritoneum which is reflected from the margin of the uterus to the wall of the pelvis, and is named the broad ligament.

Cervix (cervix uteri).—The cervix is the lower constricted segment of the uterus. It is somewhat conical in shape, with its truncated apex directed downwards and backwards, but is slightly wider in the middle than either above or below. Owing to its relationships, it is less freely movable than the body, so that the latter may bend on it. The long axis of the cervix is therefore seldom in the same straight line as the long axis of the body. The long axis of the uterus as a whole presents the form of a curved line with its concavity forwards, or in extreme cases may present an angular bend at the region of the isthmus.

The vaginal wall is attached round the cervix, and divides it into two portions: an upper, supravaginal portion, and a lower, vaginal portion.

The *supravaginal portion* (portio supravaginalis) of the cervix is separated *in front* from the bladder by fibrous tissue (*parametrium*), which extends also on to its *sides* and outwards between the layers of the broad ligaments. The uterine arteries reach the margins of the cervix in this fibrous tissue, while on either side the ureter runs downwards and forwards in it at a distance of about three-quarters of an inch from the cervix. *Posteriorly*, the supravaginal cervix is covered by peritoneum, which is prolonged below on to the posterior vaginal wall, whence it is reflected on to the rectum, forming the recto-vaginal pouch or pouch of Douglas. It is in relation with the rectum, from which it may be separated by coils of small intestine.

FIG. 1015.—Vertical transverse section of uterus and upper part of vagina.

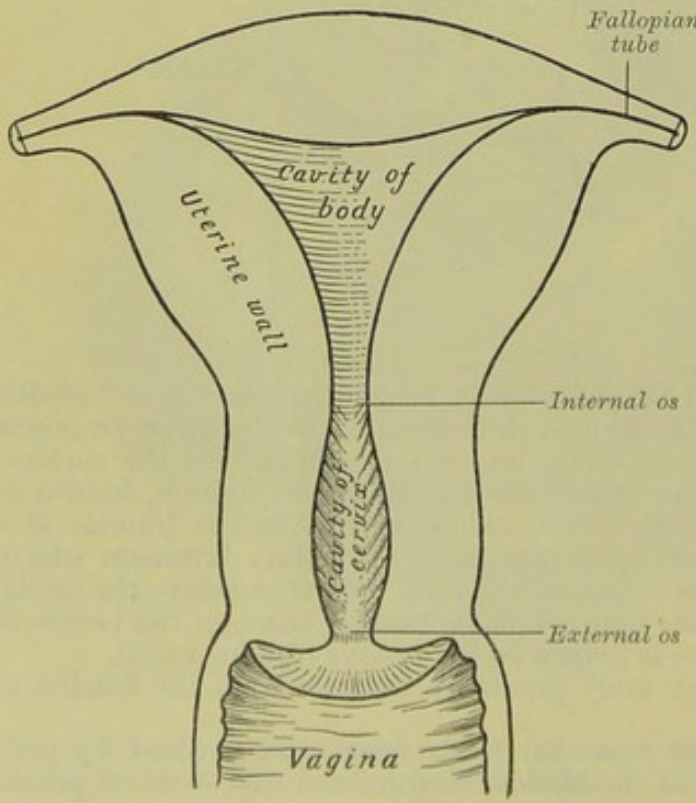

The *vaginal portion* (portio vaginalis) of the cervix projects free into the roof of the vagina between the anterior and posterior fornices. On its rounded extremity is a small, depressed, somewhat circular aperture, the *external os* (orificium externum uteri), through which the cavity of the cervix communicates with that of the vagina. The external os is bounded by two lips, an anterior (labium anterius cervicis) and a posterior (labium posterius cervicis), of which the anterior is the shorter and thicker, although, on account of the slope of the cervix, it projects lower than the posterior. Normally both lips are in contact with the posterior vaginal wall.

Interior of the uterus (fig. 1015).—The cavity of the uterus is small in comparison with the size of the organ.

The **cavity of the body** is a mere slit, flattened antero-posteriorly. It is triangular in shape, the base being formed by the internal surface of the fundus between the uterine orifices of the Fallopian tubes, the apex by the internal os through which the cavity of the body communicates with the cavity of the cervix.

The **cavity of the cervix** (canalis cervicis uteri) is somewhat fusiform, flattened from before backwards, and broader at the middle than at either extremity. It communicates above through the internal os with the cavity of the body, and below through the external os with the vaginal cavity. The wall of the canal presents an anterior and a posterior longitudinal ridge, from each of which proceed a number of small oblique columns, giving the appearance of branches from the stem of a tree; to this arrangement the name *arbor vitæ uterina* is applied. The longitudinal ridges are not exactly opposed, but fit against one another so as to close the cervical canal.

The total length of the uterine cavity from the external os to the fundus is about two and a half inches.

Ligaments.—The ligaments of the uterus are eight in number: one anterior; one posterior; two lateral or broad; two utero-sacral; and, lastly, two round ligaments.

The *anterior ligament* consists of the utero-vesical fold of peritoneum, which is reflected on to the bladder from the front of the uterus, at the junction of the cervix and body.

The *posterior ligament* consists of the recto-vaginal fold of peritoneum, which is reflected from the back of the upper fourth of the vagina on to the front of the rectum. It forms the bottom of a deep pouch called *Douglas's pouch*, which is bounded in front by the posterior wall of the uterus, the supravaginal cervix, and the upper fourth of the vagina; behind, by the rectum; and laterally by two crescentic folds of peritoneum which pass backwards from the cervix uteri on either side of the rectum to the posterior wall of the pelvis. These folds are named the *sacro-genital*, or *recto-uterine folds*. They contain a considerable amount of fibrous tissue and non-striped muscular fibres which are attached to the front of the sacrum and constitute the *utero-sacral ligaments*.

The *two lateral* or *broad ligaments* pass from the sides of the uterus to the lateral walls of the pelvis. Together with the uterus they form a septum across the female pelvis, which divides that cavity into two portions. In the anterior part is contained the bladder; in the posterior part, the rectum, and in certain conditions some coils of the small intestine and a part of the pelvic colon. Between the two layers of each broad ligament are contained: (1) the Fallopian tube superiorly; (2) the round ligament; (3) the ovary and its ligament; (4) the parovarium, or organ of Rosenmüller; (5) connective tissue; (6) unstriped muscular fibre; and (7) blood-vessels and nerves. The portion of the broad ligament which stretches from the Fallopian tube to the level of the ovary is known by the name of the *mesosalpinx*. Between the fimbriated extremity of the tube and the lower attachment of the broad ligament is a concave rounded margin, called the *infundibulo-pelvic ligament*.

The *round ligaments* are two flattened bands between four and five inches in length, situated between the layers of the broad ligament in front of and below the Fallopian tubes. Commencing on either side at the superior angle of the uterus, this ligament is directed forwards, upwards, and outwards over the pelvic brim. It then passes through the internal abdominal ring and along the inguinal canal to the labium majus, in which it becomes lost. The round ligament consists principally of muscular tissue, prolonged from the uterus; also of some fibrous and areolar tissue, besides blood-vessels and nerves, enclosed in a duplicature of peritoneum, which, in the fœtus, is prolonged in the form of a tubular process for a short distance into the inguinal canal. This process is called the *canal of Nuck*. It is generally obliterated in the adult, but sometimes remains pervious even in advanced life. It is analogous to the processus vaginalis which precedes the descent of the testis.

In addition to the ligaments just described, there is a band named the *ligamentum transversalis colli* (Mackenrodt) on either side of the cervix uteri. It is attached to the lateral aspect of the cervix uteri and to the vault and lateral fornix of the vagina, and is

continuous externally with the fibrous tissue which surrounds the pelvic blood-vessels. (Consult a note on the lateral fixation of the uterus by Ella G. A. Ovenden, 'Journal of Anatomy and Physiology,' vol. xli., part iv., p. 308.)

The form, size, and situation of the uterus vary at different periods of life and under different circumstances.

In the fœtus the uterus is contained in the abdominal cavity, projecting beyond the brim of the pelvis (fig. 1017). The cervix is considerably larger than the body.

At puberty the uterus is pyriform in shape, and weighs from eight to ten drachms. It has descended into the pelvis, the fundus being just below the level of the brim of this cavity. The arbor vitæ is distinct, and extends to the upper part of the cavity of the organ.

The position of the uterus in the adult is liable to considerable variation, depending chiefly on the condition of the bladder and rectum. When the bladder is empty the entire uterus is directed forwards, and is at the same time bent on itself at the junction of the body and cervix, so that the body lies upon the bladder. As the latter fills, the uterus gradually becomes more and more erect, until with a fully distended bladder the fundus may be directed backwards towards the sacrum.

Fig. 1016.—The arteries of the internal organs of generation of the female, seen from behind. (After Hyrtl.)

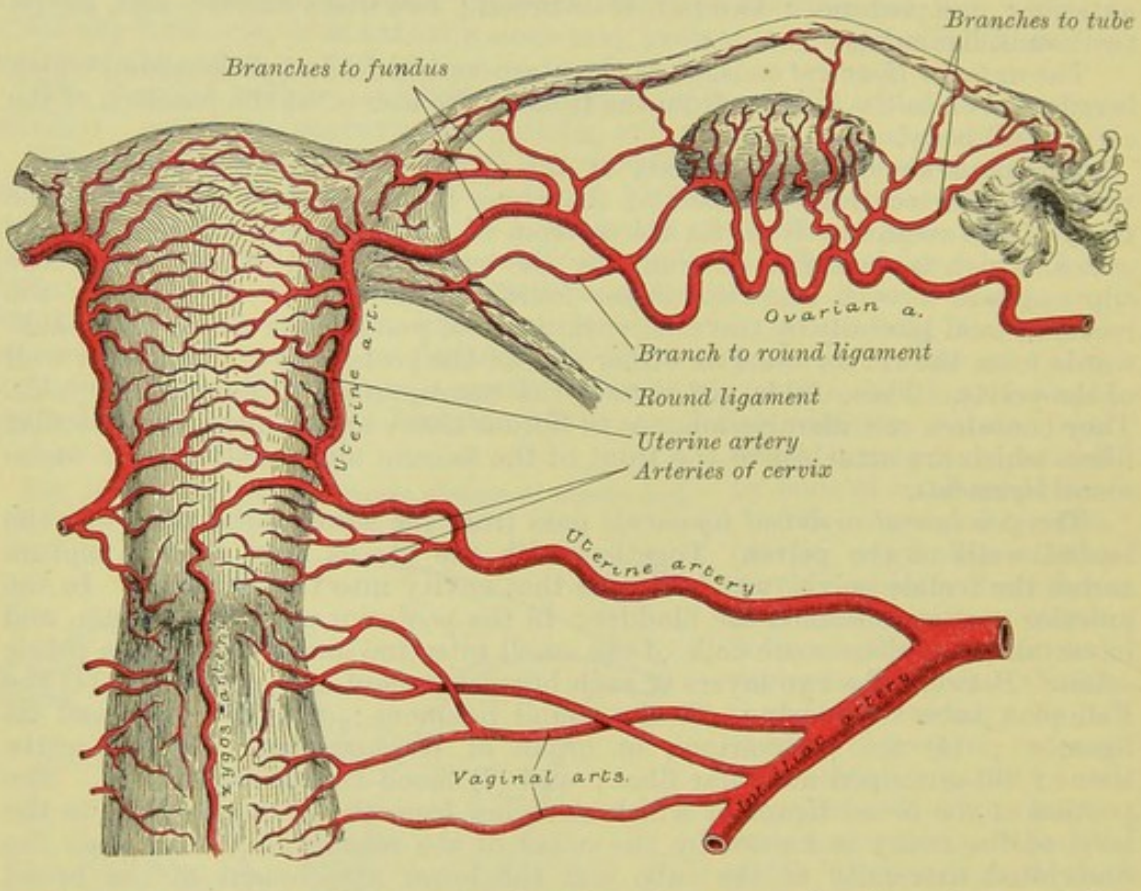

During menstruation the organ is enlarged, and more vascular, its surfaces rounder; the os externum is rounded, its labia swollen, and the lining membrane of the body thickened, softer, and of a darker colour. According to Sir J. Williams, at each recurrence of menstruation, a molecular disintegration of the mucous membrane takes place, which leads to its complete removal, only the bases of the glands imbedded in the muscle being left. At the cessation of menstruation, by a proliferation of the remaining structures, a fresh mucous membrane is formed.

During pregnancy the uterus becomes enormously enlarged, and in the eighth month reaches the epigastric region. The increase in size is partly due to growth of pre-existing muscle, and partly to development of new fibres.

After parturition the uterus nearly regains its usual size, weighing about an ounce and a half; but its cavity is larger than in the virgin state, its vessels are tortuous, and its muscular layers are more defined; the external orifice is more marked, and its edges present one or more fissures.

In old age the uterus becomes atrophied, and paler and denser in texture; a more distinct constriction separates the body and cervix. The ostium internum is frequently, and the ostium externum occasionally, obliterated, while the labia almost entirely disappear.

Structure.—The uterus is composed of three coats: an external or serous coat, a middle or muscular coat, and an internal or mucous coat.

The *serous coat* is derived from the peritoneum ; it invests the fundus and the whole of the posterior surface of the uterus ; but covers the anterior surface only as far as the junction of the body and cervix. In the lower fourth of the posterior surface the peritoneum, though covering the uterus, is not closely connected with it, being separated from it by a layer of loose cellular tissue and some large veins.

The *muscular coat* forms the chief bulk of the substance of the uterus. In the virgin it is dense, firm, of a greyish colour, and cuts almost like cartilage. It is thick opposite the middle of the body and fundus, and thin at the orifices of the Fallopian tubes. It consists of bundles of unstriped muscular fibres, disposed in layers, intermixed with areolar tissue, blood-vessels, lymphatic vessels, and nerves. During pregnancy the muscular tissue becomes more prominently developed, and is disposed in three layers : external, middle, and internal.

The external layer, placed beneath the peritoneum, is disposed as a thin plane on the anterior and posterior surfaces. It consists of fibres which pass transversely across the fundus, and, converging at each superior angle of the uterus, are continued on to the Fallopian tube, the round ligament, and the ligament of the ovary : some passing at each side into the broad ligament, and others running backwards from the cervix into the sacro-uterine ligaments. The middle layer of fibres, which is thickest, presents no regularity in its arrangement, being disposed longitudinally, obliquely, and transversely. It contains most blood-vessels. The internal or deep layer consists of circular fibres arranged in the form of two hollow cones, the apices of which surround the orifices of the Fallopian

FIG. 1017.—Sagittal section through the pelvis of a newly born female child.

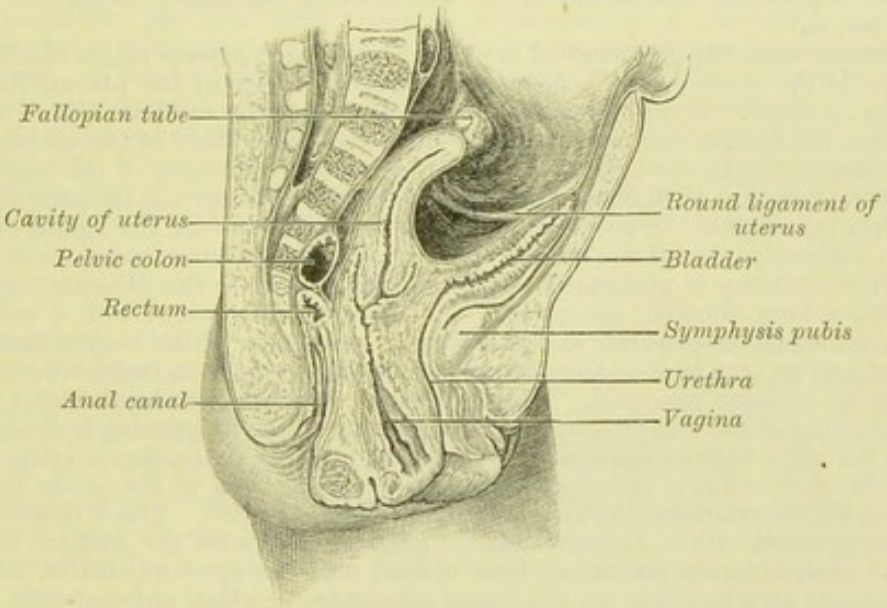

tubes, their bases intermingling with one another on the middle of the body of the uterus. At the internal os these circular fibres form a distinct sphincter.

The *mucous membrane* is thin, smooth, and closely adherent to the subjacent tissue. It is continuous, through the fimbriated extremity of the Fallopian tubes, with the peritoneum ; and, through the os uteri, with the lining of the vagina.

In the body of the uterus the mucous membrane is smooth, soft, of a pale red colour, lined by columnar ciliated epithelium, and presents, when viewed with a lens, the orifices of numerous tubular follicles, arranged perpendicularly to the surface. It is unprovided with any submucosa, but is intimately connected with the innermost layer of the muscular coat, which by some anatomists is regarded as the muscularis mucosæ. The structure of the corium differs from that of ordinary mucous membranes, and consists of an embryonic nucleated and highly cellular form of connective tissue in which run numerous large lymphatics. In it are the tube-like *uterine glands*, which are of small size in the unimpregnated uterus, but shortly after impregnation become enlarged and elongated, presenting a contorted or waved appearance (see page 97). They consist of a delicate membrane, lined by an epithelium, which becomes ciliated towards the orifices.

In the cervix the mucous membrane is sharply differentiated from that of the uterine cavity. It is thrown into numerous oblique ridges, which diverge from an anterior and posterior longitudinal raphe, presenting an appearance which has received the name of *arbor vitæ*. In the upper two-thirds of the canal, the mucous membrane is provided with numerous deep glandular follicles, which secrete a clear viscid alkaline mucus ; and, in addition, extending through the whole length of the canal is a variable number of little cysts, presumably follicles which have become occluded and distended with retained

secretion. They are called the *ovula Nabothi*. The mucous membrane covering the lower half of the cervical canal presents numerous papillæ. The epithelium of the upper two-thirds is cylindrical and ciliated, but below this it loses its cilia, and gradually changes to squamous epithelium close to the external os. On the vaginal surface of the cervix the epithelium is similar to that lining the vagina, viz. stratified squamous.

Vessels and Nerves.—The *arteries* of the uterus are the uterine, from the internal iliac; and the ovarian, from the abdominal aorta (fig. 1016). They are remarkable for their tortuous course in the substance of the organ, and for their frequent anastomoses. The termination of the ovarian artery meets the termination of the uterine artery, and forms an anastomotic trunk from which branches are given off to supply the uterus, their disposition being, as shown by Sir John Williams, circular. The *veins* are of large size, and correspond with the arteries. They terminate in the uterine plexuses. In the impregnated uterus the arteries carry the blood to, and the veins convey it away from, the maternal blood-sinuses of the placenta (see page 100). The *lymphatics* are described on page 789. The *nerves* are derived from the hypogastric and ovarian plexuses, and from the third and fourth sacral nerves.

Applied Anatomy.—A certain amount of anteversion and retroversion can take place without the condition being regarded as pathological, but when the degree of flexion becomes considerable it must be regarded as a morbid condition. This is especially true of retroversion and retroflexion. The former is a falling back of the whole uterus, so that the cervix points upwards towards the pubes, and the latter is a bending backwards of the body, the cervix remaining in its normal position. The two conditions are usually combined. Prolapse of the uterus is another common infirmity. The organ sinks to an abnormally low level in the pelvis, and sometimes protrudes beyond the vulva. This is due to the supporting mechanism of the uterus being insufficient to sustain the strain thrown upon it.

The uterus may require removal in cases of malignant disease or for fibroid tumours. Carcinoma is the most common form of malignant disease of the uterus, though cases of sarcoma do occur. It may show itself either as a columnar carcinoma or as a squamous carcinoma; the former commencing either in the cervix or body of the uterus, the latter always commencing in the epithelial cells of the mucous covering of the vaginal surface of the cervix. Cancer of the body or of the cervix may be treated in the early stage, before fixation has taken place, by removal of the uterus, either through the vagina or by means of abdominal section, but if the body be much enlarged the former operation is impossible. Vaginal hysterectomy is performed by placing the patient in the lithotomy position and introducing a large duckbill speculum. The cervix is then seized with a volsellum and pulled down as far as possible, and the mucous membrane of the vagina incised around the cervix and as near to it as the disease will allow, especially in front, where the ureters are in danger of being wounded. Douglas's pouch is then opened sufficiently to allow of the introduction of the two forefingers, by means of which the opening is dilated laterally as far as the sacro-uterine ligaments. A somewhat similar proceeding is adopted in front, but here the bladder has to be separated from the anterior wall of the uterus for about an inch before the vesico-uterine fold of peritoneum can be reached. This is done by carefully burrowing upwards with a director and stripping the tissues off the anterior uterine wall. When the vesico-uterine pouch has been opened and the aperture dilated laterally, the uterus remains attached only by the broad ligaments, in which are contained the vessels that supply the uterus. Before division of the ligaments, these vessels have to be dealt with. The forefinger of the left hand is introduced into Douglas's pouch, and an aneurysm needle, armed with a long silk ligature, is inserted into the vesico-uterine pouch, and is pushed through the broad ligament about an inch above its lower level and at some distance from the uterus. One end of the ligature is now pulled through the anterior opening, and in this way we have the lowest inch of the broad ligament, in which is contained the uterine artery (fig. 1016), enclosed in a ligature. This is tied tightly, and the operation is repeated on the other side. The broad ligament is then divided on either side, between the ligature and the uterus, to the extent to which it has been constricted. By traction on the volsellum which grasps the cervix, the uterus can be pulled considerably further down in the vagina, and a second inch of the broad ligament is treated in a similar way. This second ligature will embrace the pampiniform plexus of veins, and, when the broad ligament has been divided on either side, it will be found that a third ligature can be made to pass over the Fallopian tube and top of the broad ligament, after the uterus has been dragged down as far as possible. After the third ligature has been tied and the structures between it and the uterus divided, this organ will be freed from all its connections and can be removed from the vagina. The third ligature will contain the ovarian artery, between the ovary and the uterine cornu, as it lies below the Fallopian tube. The vagina is then sponged out and lightly dressed with gauze; no sutures being used.

In the treatment of uterine fibroids which require operative interference, removal of the whole of the uterus together with the tumours through an abdominal incision gives the most satisfactory results; for, if the tumour is large, its size acts as a barrier to its safe delivery through the pelvis and genital passages. After the abdomen has been opened the uterine vessels are secured and the broad ligaments divided in a manner similar to that

employed in vaginal hysterectomy, except that the proceeding is commenced from above. When the first two ligatures have been tied, and the broad ligament divided, it will be found that the uterus can be raised out of the pelvis. A transverse incision is now made through the peritoneum, where it is reflected from the anterior surface of the uterus on to the back of the bladder, and the serous membrane peeled from the surface of the uterus until the vagina is reached. The anterior wall of this canal is then cut across. The uterus is now turned forwards and the peritoneum at the bottom of Douglas's pouch incised transversely, and the posterior wall of the vagina cut across, until it meets the incision on the anterior wall. The uterus is now almost free, and is held only by the lower part of the broad ligament on either side, containing the uterine artery. A third ligature is made to encircle this as close to the uterus as possible, the position of the ureter being always kept in mind, and, after having been tied, the structures are divided between the ligature and the uterus. The organ can now be removed. The vagina is plugged with gauze, and the external wound closed in the usual way. The vagina acts as a drain, and therefore the opening into it is not sutured.

Inflammation of the cellular tissue surrounding the cervix occasionally takes place. Laceration of the cervix by instruments or by the fœtal head frequently occurs, opening up the cellular planes and so exposing them to any infection that may be present. An inflammatory mass forms in the cellular tissue between the layers of the broad ligament or of the utero-sacral ligaments, and the condition is termed pelvic cellulitis, or *parametritis*. This condition is usually confined to one side of the pelvis, forming a large inflammatory mass which pushes the uterus over to the opposite side. It does not always remain localised, however, but may spread widely, surrounding the rectum or the neck of the bladder, or mounting into the iliac fossa, or even to the perinephric cellular tissue. The condition may resolve or an abscess may form. In the former condition the cicatrisation of the inflammatory products often produces displacements of the uterus towards the affected side of the pelvis, or stricture of the rectum when that viscus has been surrounded by the process. When suppuration ensues, the pus may burst into the bladder, vagina, or rectum, or it may present above Poupart's ligament, or it may mount to the anterior abdominal wall in front of the bladder or to the posterior abdominal wall between the iliac crest and last rib. The abscess may, moreover, make its way into the buttock by passing out of the pelvis through the great sacro-sciatic foramen, or it may pass down between the fibres of the Levator ani and appear as a secondary ischio-rectal abscess.

The Vagina (fig. 1014)

The **vagina** extends from the vestibule to the uterus, and is situated behind the bladder and in front of the rectum; it is directed upwards and backwards, its axis forming with that of the uterus an angle of over 90°, opening forwards. Its walls are ordinarily in contact, and the usual shape of its lower part on transverse section is that of an H, the transverse limb being slightly curved forwards or backwards, while the lateral limbs are somewhat convex towards the median line; its middle part has the appearance of a transverse slit. Its length is two and a half to three inches along its anterior wall, and three and a half inches along its posterior wall. It is constricted at its commencement, dilated in the middle, and narrowed near its uterine extremity; it surrounds the vaginal portion of the cervix uteri, a short distance from the os, its attachment extending higher up on the posterior than on the anterior wall of the uterus. To the recess behind the cervix the term *posterior fornix* is applied, while the smaller recess in front is termed *anterior fornix*.

The *anterior surface* of the vagina is in relation with the base of the bladder, and with the urethra. Its *posterior surface* is connected for the middle two fourths of its extent to the anterior wall of the rectum, the upper fourth being separated from that tube by the recto-vaginal pouch of peritoneum, or pouch of Douglas. The lower fourth is separated from the anal canal by the perinæum. Its sides are enclosed between the Levatores ani muscles. As the terminal portions of the ureters pass forwards and inwards to reach the base of the bladder, they run one on either side of the lateral aspect of the upper part of the vagina.

Structure.—The vagina consists of an internal mucous lining, and a muscular coat, separated by a layer of erectile tissue.

The *mucous membrane* is continuous above with that lining the uterus. Its inner surface presents two longitudinal ridges, one on its anterior and one on its posterior wall. These ridges are called the *columns of the vagina*, and from them numerous transverse ridges or rugæ extend outwards on either side. These rugæ are divided by furrows of variable depth, giving to the mucous membrane the appearance of being studded over with conical projections or papillæ; they are most numerous near the orifice of the vagina, especially in females before parturition. The epithelium covering the mucous membrane

is of the stratified squamous variety. The submucous tissue is very loose, and contains numerous large veins, which by their anastomoses form a plexus, together with smooth muscular fibres derived from the muscular coat; it is regarded by Gussenbauer as an erectile tissue. It contains a number of mucous crypts, but no true glands.

The *muscular coat* consists of two layers: an external longitudinal, which is by far the stronger, and an internal circular layer. The longitudinal fibres are continuous with the superficial muscular fibres of the uterus. The strongest fasciculi are those attached to the recto-vesical fascia on each side. The two layers are not distinctly separable from each other, but are connected by oblique decussating fasciculi, which pass from the one layer to the other. In addition to this, the vagina at its lower end is surrounded by a band of striped muscular fibres, the *Sphincter vaginæ* (see page 526).

External to the muscular coat is a layer of connective tissue, containing a large plexus of blood-vessels.

The *erectile tissue* consists of a layer of loose connective tissue, situated between the mucous membrane and the muscular coat; imbedded in it is a plexus of large veins, and numerous bundles of unstriped muscular fibres, derived from the circular muscular layer. The arrangement of the veins is similar to that found in other erectile tissues.

External Organs (fig. 1018)

The **external genital organs of the female** are: the mons Veneris, the labia majora et minora, the clitoris, the bulbus vestibuli, and the glands of Bartholin. The term *vulva* or *pudendum* (pudendum muliebre), as generally applied, includes all these parts.

Fig. 1018.—External genital organs of female. The labia minora have been drawn apart.

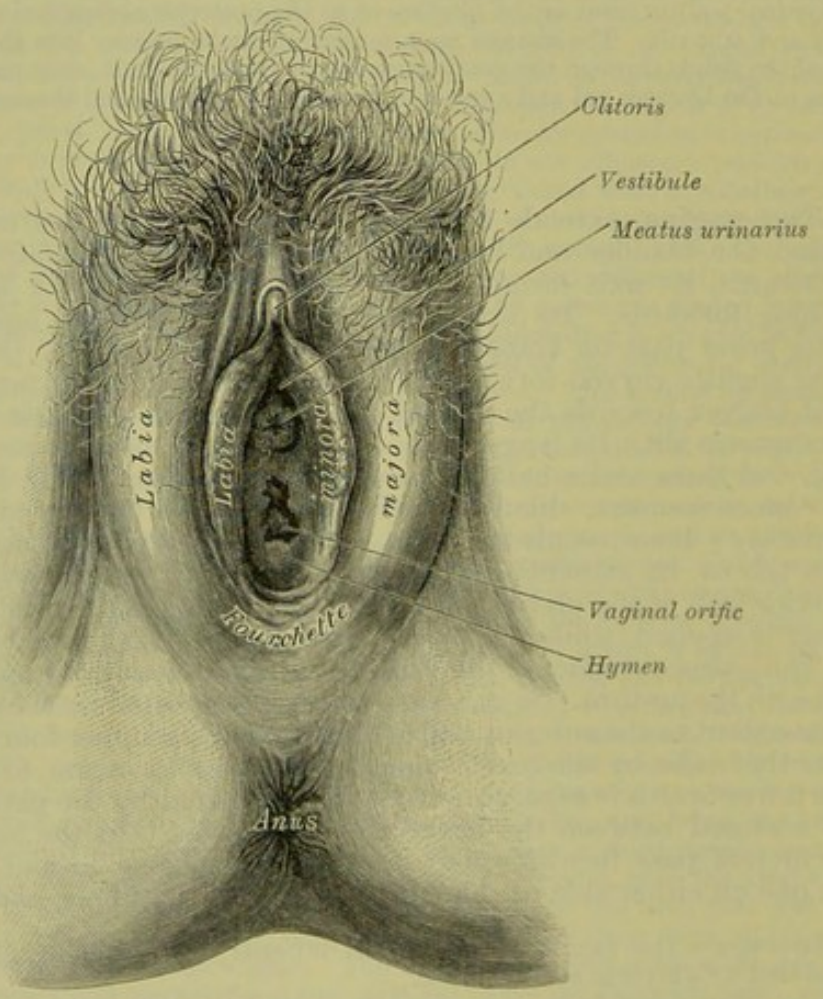

The **mons Veneris** is the rounded eminence in front of the pubic symphysis, formed by a collection of fatty tissue beneath the integument. It becomes covered with hair at the time of puberty.

The **labia majora** (labia majora pudendi) are two prominent longitudinal cutaneous folds which extend downwards and backwards from the mons

Veneris and form the lateral boundaries of a fissure or cleft, the *urogenital cleft* (rima pudendi) into which the vagina and urethra open. Each labium has two surfaces, an outer, pigmented and covered with strong, crisp hairs; and an inner, smooth and beset with large sebaceous follicles. Between the two there is a considerable quantity of areolar tissue, fat, and a tissue resembling the dartos of the scrotum, besides vessels, nerves, and glands. The labia are thicker in front, where they form by their meeting the *anterior commissure* (commissura labiorum anterior). Posteriorly they are not really joined, but appear to become lost in the neighbouring integument, terminating close to, and nearly parallel with, each other. Together with the connecting skin between them, they form the *posterior commissure* (commissura labiorum posterior), or posterior boundary of the vulval orifice. The interval between the posterior commissure and the anus, from an inch to an inch and a quarter in length, constitutes the perinæum. The labia majora correspond to the scrotum in the male.

The **labia minora,** or **nymphæ** (labia minora pudendi), are two small cutaneous folds, situated within the labia majora, and extending from the clitoris obliquely downwards, outwards, and backwards for about an inch and a half on each side of the orifice of the vagina, between which and the labia majora they are lost; in the virgin the posterior ends of the labia minora are usually joined across the middle line by a fold of skin, named the *fourchette* (frenulum labiorum pudendi). Anteriorly, each labium minus divides into two portions: the upper division passes above the clitoris to meet its fellow of the opposite side, forming a fold which overhangs the glans clitoridis and is named the *præputium clitoridis*; the lower division passes beneath the clitoris and becomes united to its under surface, forming, with its fellow of the opposite side, the *frenulum clitoridis*. On the internal surfaces of the labia minora are numerous sebaceous follicles.

The **clitoris** is an erectile structure, homologous with the penis. It is situated beneath the anterior commissure, partially hidden between the anterior extremities of the labia minora. It consists of two corpora cavernosa, composed of erectile tissue enclosed in a dense layer of fibrous membrane, united together along their inner surfaces by an incomplete fibrous pectiniform septum; these are connected to the rami of the pubis and ischium on either side by a crus; the free extremity, or *glans clitoridis*, is a small rounded tubercle, consisting of spongy erectile tissue, and highly sensitive. The clitoris is provided, like the penis, with a suspensory ligament, and with two small muscles, the Erectores clitoridis, which are inserted into the crura of the clitoris.

The **vestibule.**—The cleft between the labia minora and behind the glans clitoridis is named the *vestibule* (vestibulum vaginæ): in it are seen the urethral and vaginal orifices and the openings of the ducts of Bartholin's glands.

The **urethral orifice** (orificium urethræ externum) is placed about an inch behind the glans clitoridis and immediately in front of that of the vagina; it usually assumes the form of a short, sagittal cleft with slightly raised margins.

The **vaginal orifice** (orificium vaginæ) is a mesial slit below and behind the opening of the urethra; its size varies inversely with the degree of development of the *hymen*.

The **hymen** is a thin fold of mucous membrane situated at the orifice of the vagina; the inner surfaces of the fold are normally in contact with each other, and the vaginal orifice appears as a cleft between them. The hymen varies much in shape. When stretched, its commonest form is that of a ring, generally broadest posteriorly; sometimes it is represented by a semilunar fold, with its concave margin turned towards the pubes. Occasionally it is cribriform, or its free margin forms a membranous fringe. It may be entirely absent, or may form a complete septum across the lower end of the vagina; the latter condition is known as an imperforate hymen. It may persist after copulation, so that it cannot be considered as a test of virginity. When the hymen has been ruptured, small rounded elevations known as the *carunculæ hymeneales* are found as its remains. Between the hymen and the fourchette is a shallow depression, named the *fossa navicularis*.

The **bulbus vestibuli** is the homologue of the bulb and adjoining part of the corpus spongiosum of the male, and consists of two elongated masses

of erectile tissue, placed one on either side of the vaginal orifice and united to each other in front by a narrow median band termed the *pars intermedia*. Each lateral mass measures a little over an inch in length. Their posterior ends are expanded and are in contact with the glands of Bartholin; their anterior ends are tapered and joined to one another by the pars intermedia; their deep surfaces are in contact with the triangular ligament; superficially they are covered by the Bulbo-cavernosus muscle.

The **glands of Bartholin** (glandulæ vestibulares majores) are the homologues of Cowper's glands in the male. They consist of two small, roundish bodies of a reddish-yellow colour, situated one on either side of the vaginal orifice in contact with the posterior end of each lateral mass of the bulbus vestibuli. Each gland opens by means of a duct, about three-quarters of an inch in length, immediately external to the hymen, in the groove between it and the labium minus.

Mammary Glands

The **mammæ**, or breasts, secrete the milk, and are accessory glands of the generative system. They exist in the male as well as in the female; but in the former only in the rudimentary state, unless their growth is excited by peculiar circumstances. In the female they are two large hemispherical eminences lying within the superficial fascia and situated towards the lateral aspects of the pectoral region; they correspond to the intervals between the second and sixth ribs, and extend from the side of the sternum to near the mid-axillary line. Their weight and dimensions differ at different periods of life, and in different individuals. Before puberty they are of small size, but enlarge as the generative organs become more completely developed.

Fig. 1019.—Dissection of the lower half of the female breast during the period of lactation. (Luschka.)

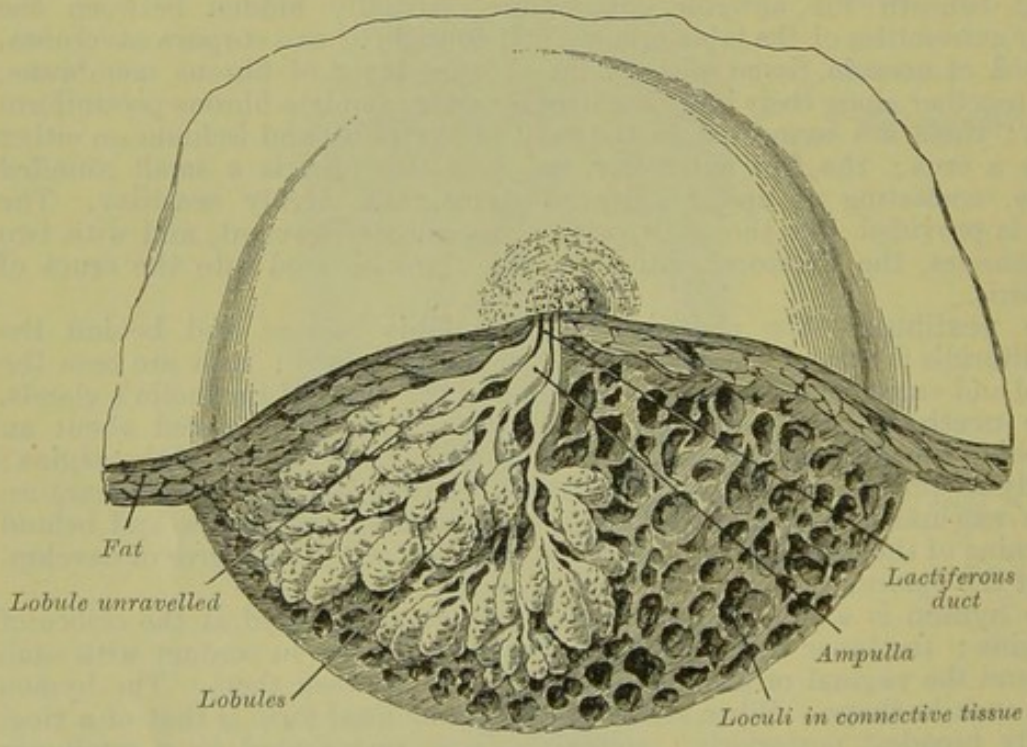

They increase during pregnancy, and especially after delivery, and become atrophied in old age. The left mamma is generally a little larger than the right. The base of each is nearly circular, flattened, or slightly concave, and has its long diameter directed upwards and outwards towards the axilla; it is separated from the fascia covering the Pectoralis major and Serratus magnus muscles by loose connective tissue. The outer surface of the mamma is convex, and presents, just below the centre, a small conical prominence, the nipple.

The **nipple** (papilla mammæ) is a cylindrical or conical eminence, capable of undergoing a sort of erection from mechanical excitement, a change mainly

due to the contraction of its muscular fibres. It is of a pink or brownish hue, its surface wrinkled and provided with papillæ; and it is perforated by from fifteen to twenty orifices, the apertures of the lactiferous ducts. The surface of the nipple is dark-coloured, and surrounded by an *areola* having a coloured tint. In the virgin the areola is of a delicate rosy hue; about the second month after impregnation it enlarges and acquires a darker tinge, which increases as pregnancy advances, becoming in some cases of a dark brown, or even black colour. This colour diminishes as soon as lactation is over, but is never entirely lost throughout life. These changes in the colour of the areola are of importance in forming a conclusion in a case of suspected first pregnancy. Near the base of the nipple, and upon the surface of the areola, are numerous large sebaceous glands (*glands of Montgomery*), which become much enlarged during lactation, and present the appearance of small tubercles beneath the skin. These glands secrete a peculiar fatty substance, which serves as a protection to the integument of the nipple during the act of sucking. The nipple consists of numerous vessels, intermixed with plain muscular fibres, which are principally arranged in a circular manner around the base: some few fibres radiating from base to apex. The nipple and areola are closely attached to the skin.

Structure (figs. 1019, 1020).—The mamma consists of gland-tissue; of fibrous tissue, connecting its lobes; and of fatty tissue in the intervals between the lobes. The gland-tissue, when freed from fibrous tissue and fat, is of a pale reddish colour, firm in texture, flattened from before backwards and thicker in the centre than at the circumference. The anterior surface of the mamma presents numerous irregular processes which project towards the skin and are joined to it by bands of connective tissue. It consists of numerous lobes, and these are composed of lobules, connected together by areolar tissue, blood-vessels, and ducts. The smallest lobules consist of a cluster of rounded alveoli, which open into the smallest branches of the lactiferous ducts; these ducts unite to form larger ducts, and these terminate in a single canal, corresponding with one of the chief subdivisions of the gland. The number of excretory ducts varies from fifteen to twenty; they are termed the *tubuli lactiferi*. They converge towards the areola, beneath which they form dilatations, or *ampullæ*, which serve as reservoirs for the milk, and, at the base of the nipple, become contracted, and pursue a straight course to its summit, perforating it by separate orifices considerably narrower than the ducts themselves. The ducts are composed of areolar tissue containing longitudinal and transverse elastic fibres; muscular fibres are entirely absent; they are lined by columnar epithelium resting on a basement-membrane. The epithelium of the mammary gland differs according to the state of activity of the organ. In the gland of a woman who is not pregnant or suckling, the alveoli are very small and solid, being filled with a mass of granular polyhedral cells. During pregnancy the alveoli enlarge, and the cells undergo rapid multiplication. At the commencement of lactation, the cells in the centre of the alveolus undergo fatty degeneration, and are eliminated in the first milk, as *colostrum corpuscles*. The peripheral cells of the alveolus remain, and form a single layer of granular, short columnar cells, with spherical nuclei, lining the basement-membrane.* The cells, during the state of activity of the gland, are capable of forming, in their interior, oil-globules, which are then ejected into the lumen of the alveolus, and constitute the milk-globules.

FIG. 1020.—Transverse section of portion of mammary gland.

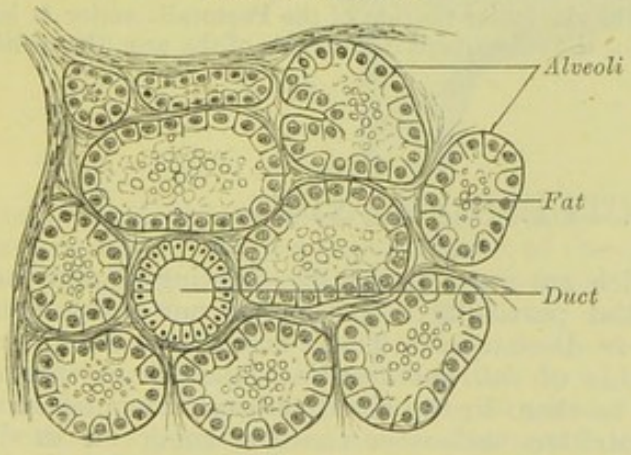

The *fibrous tissue* invests the entire surface of the breast, and sends down septa between its lobes, connecting them together.

The *fatty tissue* covers the surface of the gland, and occupies the interval between its lobes. It usually exists in considerable abundance, and determines the form and size of the gland. There is no fat immediately beneath the areola and nipple.

* According to Lacroix and Benda, there is a thin layer of non-striped muscle between the basement-membrane and the secreting cells.

Vessels and Nerves.—The *arteries* supplying the mammæ are derived from the thoracic branches of the axillary, the intercostals, and the internal mammary. The *veins* describe an anastomotic circle round the base of the nipple, called by Haller the *circulus venosus*. From this, large branches transmit the blood to the circumference of the gland, and end in the axillary and internal mammary veins. The *lymphatics* are described on page 790. The *nerves* are derived from the anterior and lateral cutaneous nerves of the thorax.

Applied Anatomy.—The ducts descending from the nipple radiate through the gland, and when an incision is made into the breast the scalpel should be directed radially, from the centre to the periphery, so that it may not pass across the ducts. A milk duct may become obstructed and distended, forming a tumour known as a *galactocele*. *Abscess* frequently occurs about the breast, and most often in women who are lactating, especially those who have cracks or fissures about the nipple. The abscess may lie between the septa, in the breast-tissue itself; or it may lie beneath the skin by the side of the nipple and superficial to the breast; or it may form beneath it, between the breast and the deep fascia. Free incision, radiating from the nipple, is required in such cases.

Cystic formation of many different kinds is commonly seen in the mamma: in some cases it is due to dilatation of the larger ducts or of the lymph spaces throughout the gland; in others the cysts occur in new growths of the mamma, or as the result of obstruction of the smaller ducts by chronic inflammatory processes.

Malignant growths are seen more often in the breast than in any other organ; they are of great variety, but the commonest is the spheroidal-celled cancer, the cells of which are intermingled with a varying amount of fibrous tissue. A hard contracting tumour-mass results, which drags on the fibrous septa between the lobes so that fixation or retraction of the nipple ensues, and sooner or later the malignant infiltration invades the surrounding breast-tissues, the skin, the deep fascia and Pectorals, and even the chest wall and pleura. The lymphatic glands beneath the Pectorals and those situated towards the apex of the axilla become early involved with secondary malignant deposit, and later the supraclavicular glands enlarge. In other cases the mediastinal glands may be involved, when the disease is situated on the inner side of the nipple.

The operation for removal of a breast affected with malignant disease should be an extensive procedure, with the object of extirpating all fascial planes and lymphatic structures that may be infected. The incision commences below, over the upper part of the sheath of the Rectus, encloses the mamma by an ellipse, and is then continued on towards the apex of the axilla. The skin is reflected on both sides of the incision; anteriorly, till the sternum is reached, and posteriorly to the posterior boundary of the axilla. The origin of the sternal portion of the Pectoralis major is then divided and turned backwards. The Pectoralis minor is next seen, and its origin is then divided in a similar manner. The whole of the muscular and fascial planes of the front of the chest are thus separated *en masse*, carrying with them the mamma and the skin covering it. The insertions of the two Pectorals have next to be divided, and finally the axillary lymphatic glands and fat are removed from the axillary vessels in one piece with the mass of tissue already detached. This is done by first freely exposing the whole length of the axillary vein and then, with a blunt instrument, peeling the structures off the vein from above downwards, from the point where they are crossed by the Subclavius muscle to the lower border of the axilla. In this part of the operation many branches of both vein and artery require ligature. The only thing which then remains to be divided is the deep fascia along the posterior axillary wall. The wound is then closed, drainage is provided, and firm pressure is applied with the dressings. It will be noted that the clavicular portion of the Pectoralis major is left intact, as it is of considerable service for the subsequent movements of the arm, the utility of which is but slightly impaired.

THE DUCTLESS GLANDS

There are certain organs which are very similar to secreting glands, but differ from them in one essential particular, viz. they do not possess any ducts by which their secretion is discharged. These organs are known as *ductless glands*. They are capable of *internal secretion*—that is to say, of forming, from materials brought to them in the blood, substances which have a certain influence upon the nutritive and other changes going on in the body. This secretion is carried into the blood-stream, either directly by the veins or indirectly through the medium of the lymphatics.

These glands include the thyroid and the parathyroids, the thymus, the spleen, the suprarenal glands, and the small carotid and coccygeal bodies, which will be described in this section. They also include the lymphatic glands, which have already been described in the section on Angiology; and the pineal gland and pituitary body described in the section on Neurology.

The Thyroid Body (fig. 1021)

The **thyroid body** is a highly vascular organ, situated at the front and sides of the neck ; it consists of two lateral lobes connected across the middle line by a narrow transverse portion, the *isthmus*.

The weight of the thyroid body is somewhat variable, but is usually about one ounce. It is slightly heavier in the female, in whom it becomes enlarged during menstruation and pregnancy.

The lobes are conical in shape, the apex of each being directed upwards and outwards as far as the junction of the middle with the lower third of the thyroid cartilage ; the base looks downwards, and is on a level with the fifth or sixth tracheal ring. Each lobe is about two inches in length ; its greatest width is about an inch and a quarter, and its thickness about three-quarters of an inch.

The *external* or *superficial surface* is convex, and covered by the skin, the superficial and deep fasciæ, the Sterno-mastoid, the anterior belly of the

Fig. 1021.—The thyroid gland and its relations.

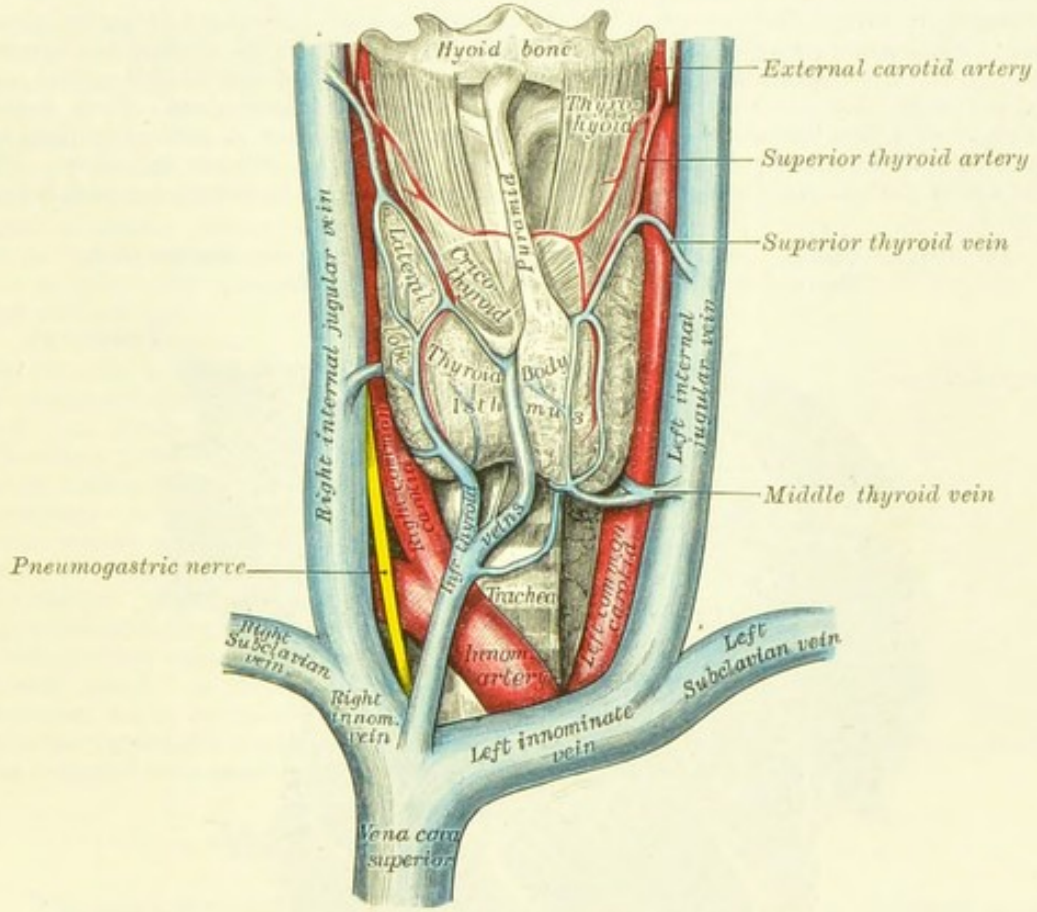

Omo-hyoid, the Sterno-hyoid and Sterno-thyroid muscles, and beneath the last muscle by the pre-tracheal layer of the deep fascia, which forms a capsule for the gland. The *deep* or *internal surface* is moulded over the underlying structures, viz. the thyroid and cricoid cartilages, the trachea, the Inferior constrictor and posterior part of the Crico-thyroid muscles, the œsophagus (particularly on the left side of the neck), the superior and inferior thyroid arteries, and the recurrent laryngeal nerves. The *anterior border* is thin, and inclines obliquely from above downwards and inwards towards the middle line of the neck, while the *posterior border* is thick and overlaps the common carotid artery.

The *isthmus* connects together the lower thirds of the two lateral lobes ; it measures about half an inch in breadth, and the same in depth, and usually covers the second and third rings of the trachea. Its situation and size present, however, many variations, and this must be remembered in performing tracheotomy. In the middle line of the neck it is covered by the skin and

fascia, and close to the middle line, on either side, by the Sterno-hyoid. Across its upper border runs a branch of the superior thyroid artery; at its lower border are the inferior thyroid veins. Sometimes the isthmus is altogether wanting.

A third lobe, of conical shape, called the *pyramid*, frequently arises from the upper part of the isthmus, or from the adjacent portion of either lobe, but most commonly the left, and ascends as high as the hyoid bone. It is occasionally quite detached, or may be divided into two or more parts.

A fibrous or muscular band is sometimes found attached, above, to the body of the hyoid bone, and below to the isthmus of the gland, or its pyramidal process. When muscular, it is termed the *Levator glandulæ thyreoideæ*.

Small detached portions of thyroid tissue are sometimes found in the vicinity of the lateral lobes or above the isthmus; they are called *accessory thyroids*.

Structure.—The thyroid body is invested by a thin capsule of connective tissue, which projects into its substance and imperfectly divides it into masses of irregular form and size. When the organ is cut into, it is of a brownish-red colour, and is seen to be made up of a number of closed vesicles, containing a yellow glairy fluid, and separated from each other by intermediate connective tissue.

According to Baber, the vesicles of the thyroid of the adult animal are generally closed cavities; but in some young animals (e.g. young dogs) the vesicles are more or less tubular and branched. This appearance he supposes to be due to the mode of growth of the gland, and merely indicating that an increase in the number of vesicles is taking place. Each vesicle is composed of a fine basement-membrane, lined by a single layer of cubical epithelium, surrounding a large lumen; between the epithelial cells exists a delicate reticulum. The vesicles are of various sizes and shapes, and contain as a normal product a viscid, homo-

FIG. 1022.—Minute structure of thyroid. From a transverse section of the thyroid of a dog. (Semi-diagrammatic.) (Baber.)

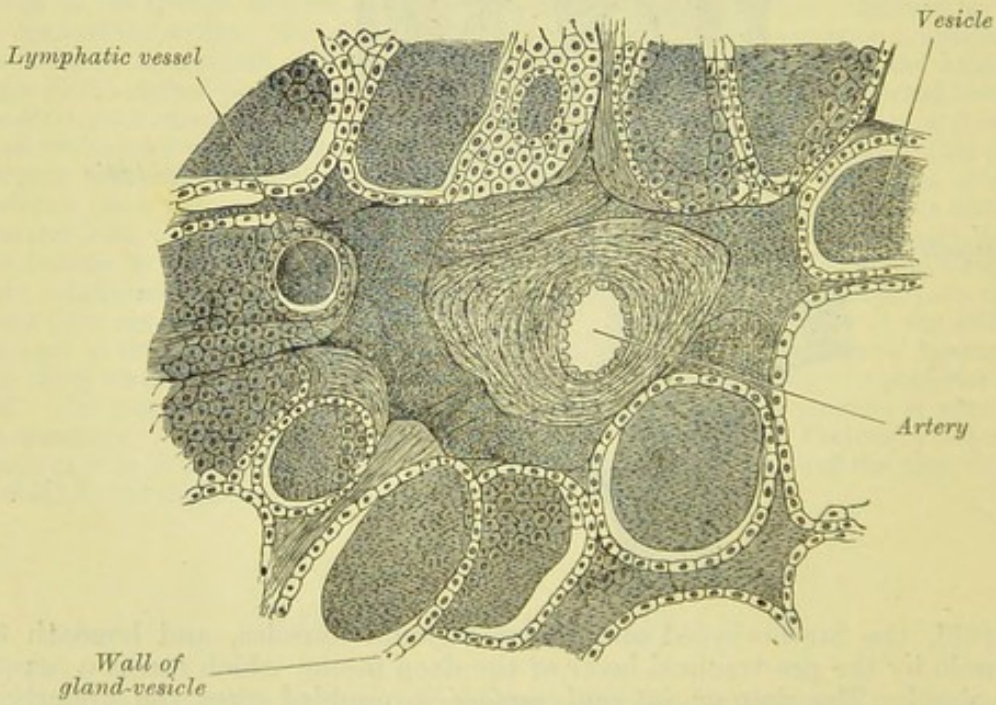

geneous, semi-fluid, slightly yellowish, colloid material; red corpuscles are found in it in various stages of disintegration and decolorisation, the yellow tinge being probably due to the hæmoglobin, which is thus set free from the coloured corpuscles. The colloid material contains an iodine compound, *thyroidin*, readily stained by eosin. It passes out between the cubical cells and is absorbed into the blood or lymph.

The capillary blood-vessels form a dense plexus in the connective tissue around the vesicles, between the epithelium of the vesicles and the endothelium of the lymphatics, which surround a greater or smaller part of the circumference of the vesicle. The lymphatic vessels run in the interlobular connective tissue, not uncommonly surrounding the arteries which they accompany, and communicate with a network in the capsule of the gland.

Vessels and Nerves.—The *arteries* supplying the thyroid are the superior and inferior thyroid, and sometimes an additional branch (thyreoidea media or ima) from the innomi-

nate artery or the arch of the aorta, which ascends upon the front of the trachea. The arteries are remarkable for their large size and frequent anastomoses. The *veins* form a plexus on the surface of the gland and on the front of the trachea; from this plexus the superior, middle, and inferior thyroid veins arise; the superior and middle terminate in the internal jugular, the inferior in the innominate vein. The *lymphatics* are numerous, of large size, and end in the thoracic and right lymphatic ducts. The *nerves* are derived from the middle and inferior cervical ganglia of the sympathetic.

Applied Anatomy.—An enlargement of the thyroid gland is called a goitre. The swelling may take the form of a diffuse hypertrophy of the whole gland, giving rise to the *parenchymatous goitre*, this being mainly due to the hypertrophy of the thyroid follicles themselves; in other cases a *fibroid* form of goitre is produced owing to the increase in the interstitial connective tissue; in others, again, the vascular changes may preponderate, and many large pulsating vessels may be present. Much more commonly, however, the enlargement is due to adenomatous new growth in the substance of the thyroid; these tumours are always innocent, and tend to destroy life only by pressure on the air passages. A single tumour is the rule, but in some instances a very large number may be present. They tend to show marked mucoid degeneration, and so become converted into cyst-adenomata, and finally into what appear to be simple cysts. These tumours may attain an enormous size and may involve practically the whole gland. Malignant tumour-growth also, more rarely, attacks the organ.

When, in spite of treatment, a goitre continues to grow, and especially when there are commencing symptoms of tracheal pressure, operative interference becomes necessary. This is not difficult, if an encapsuled tumour is to be dealt with, provided the anatomical layers covering it are remembered. In such a case it is necessary to make an incision suited to the size and situation of the tumour, and having divided the deep cervical fascia, to retract the Sterno-mastoid or divide it if necessary. The Sterno-hyoid and Sterno-thyroid muscles next require division, or in some cases their fibres may be separated and drawn asunder, and beneath is found the ensheathing capsule derived from the pre-tracheal fascia; this requires division, and exposes the true capsule of the thyroid gland. In the case of an adenoma or cyst, this true capsule then needs incision before the tumour can be effectually shelled out, and this is usually accomplished with very little hæmorrhage, and without any of the main vessels of the gland requiring ligature.

Partial extirpation of the thyroid, viz. the removal of one lateral lobe with division of the isthmus, may be required in cases of parenchymatous goitre, and possibly in early cases of malignant disease. It is a more radical proceeding, and carries with it a much greater risk from hæmorrhage; there is also a danger of wounding the recurrent laryngeal nerve. The whole gland must never be removed, as such a procedure is followed by the development of myxœdema. In hemi-thyroidectomy a free incision is indicated—dividing muscles, if necessary—to expose the true gland capsule, but at the same time avoiding injury to the large vessels which lie beneath it. The superior and inferior pedicles containing the respective thyroid arteries are then isolated and clamped on either side and divided between the clamps. The half gland is then turned over towards the middle line, and the isthmus ligatured and divided. Some venous bleeding is apt to occur from connections with the tracheal veins, and must be stopped. The pedicles are then securely ligatured and the wound closed. In dealing with the inferior thyroid artery, the position of the recurrent laryngeal nerve must be borne in mind, so as not to ligature or divide it. Temporary aphonia not uncommonly follows from bruising of the nerve, and if nothing more serious has occurred soon passes off.

The Parathyroid Glands

The **parathyroid glands** are small brownish-red bodies, situated near the thyroid gland, but differing from it in structure, being composed of masses of cells arranged in a more or less columnar fashion with numerous intervening capillaries. They measure on an average about a quarter of an inch in length, and from a sixth to an eighth of an inch in breadth, and usually present the appearance of flattened oval discs. They are divided, according to their situation, into *superior* and *inferior*. The superior, usually two in number, are the more constant in position, and are situated, one on either side, at the level of the lower border of the cricoid cartilage, behind the junction of the pharynx and œsophagus, and in front of the prevertebral fascia. The inferior, also usually two in number, may be applied to the lower edge of the lateral lobe, or placed at some little distance below the thyroid body, or found in relation to one of the inferior thyroid veins.*

In man, they number four as a rule; fewer than four were found in less

* Consult an article 'Concerning the Parathyroid Glands,' by D. A. Welsh, *Journal of Anatomy and Physiology*, vol. xxxii.

than 1 per cent. of over a thousand persons (Pepere *), but more than four in over 33 per cent. of 122 bodies examined by Civalleri. In addition, numerous minute islands of parathyroid tissue may be found scattered in the connective tissue and fat of the neck round the parathyroid glands proper, and quite distinct from them.

Structure.—Microscopically the parathyroids show great variety in structure. Masses of gland cells, gland cells in networks, columns, or alveoli, and in follicles containing a colloid secretion, all occur normally. In addition, the amount and disposition of the fat, blood-vessels, and fibrous tissue all vary widely, not only in different parathyroids, but even in different parts of the same parathyroid gland.

Applied Anatomy.—No doubt the parathyroid glands produce an internal secretion essential to the well-being of the human economy; but it is still a matter of dispute what symptoms of disease are produced by their removal and suppression of their secretion. Pepere believes that they show signs of exceptional activity during pregnancy, and that parathyroid insufficiency is a main factor in the production of tetany in infants and adults, of eclampsia, and of certain sorts of fits.

The Thymus Gland (fig. 1023)

The **thymus gland** is a temporary organ, attaining its full size at the end of the second year, when it ceases to grow, and gradually dwindles, until at puberty it has almost disappeared. If examined when its growth is most active, it will be found to consist of two lateral lobes placed in close contact along the middle line, situated partly in the thorax, partly in the neck, and extending from the fourth costal cartilage upwards, as high as the lower border of the thyroid gland. It is covered by the sternum, and by the origins of the Sterno-hyoid and Sterno-thyroid muscles. Below, it rests upon the

Fig. 1023.—The thymus gland of a full-time fœtus, exposed *in situ*.

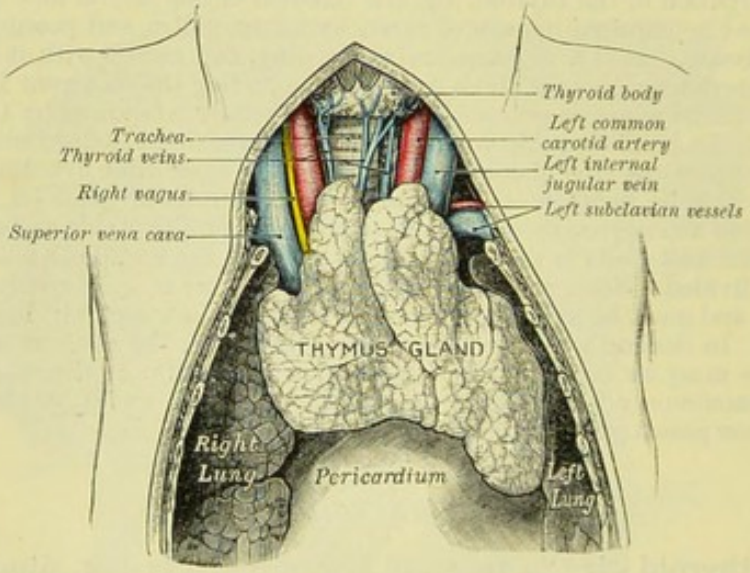

pericardium, being separated from the arch of the aorta and great vessels by a layer of fascia. In the neck it lies on the front and sides of the trachea, behind the Sterno-hyoid and Sterno-thyroid muscles. The two lobes generally differ in size; they are occasionally united, so as to form a single mass; and sometimes separated by an intermediate lobe. The thymus is of a pinkish-grey colour, soft, and lobulated on its surfaces. It is about two inches in length, one and a half in breadth below, and about three or four lines in thickness. At birth it weighs about half an ounce.

Structure.—Each lateral lobe is composed of numerous lobules held together by delicate areolar tissue; the entire gland being enclosed in an investing capsule of a similar but denser structure. The primary lobules vary in size from that of a pin's head to that of a small pea, and are made up of a number of small nodules or follicles, which are irregular in shape and are more or less fused together, especially towards the interior of the gland. Each follicle consists of a medullary and a cortical portion, and these differ in many essential

* Consult *Le Ghiandole paratiroidee*, by A. Pepere, Turin, 1906.

particulars from each other. The *cortical portion* is mainly composed of lymphoid cells, supported by a delicate reticulum. In addition to this reticulum, of which only traces are found in the medullary portion, there is also a network of finely branched cells, which is continuous with a similar network in the medullary portion. This network forms an adventitia to the blood-vessels. In the *medullary portion* there are but few lymphoid cells, but there are, especially towards the centre, granular cells and concentric corpuscles. The granular cells are rounded or flask-shaped masses, attached (often by fibrillated extremities) to blood-vessels and to newly formed connective tissue. The concentric corpuscles are composed of a central mass, consisting of one or more granular cells, and of a capsule which is formed of epithelioid cells ; these latter are continuous with the branched cells forming the network mentioned above.

FIG. 1024.—Minute structure of thymus gland. Follicle of injected thymus from calf, four days old, slightly diagrammatic, magnified about 50 diameters. The large vessels are disposed in two rings, one of which surrounds the follicle, the other lies just within the margin of the medulla. (Watney.)

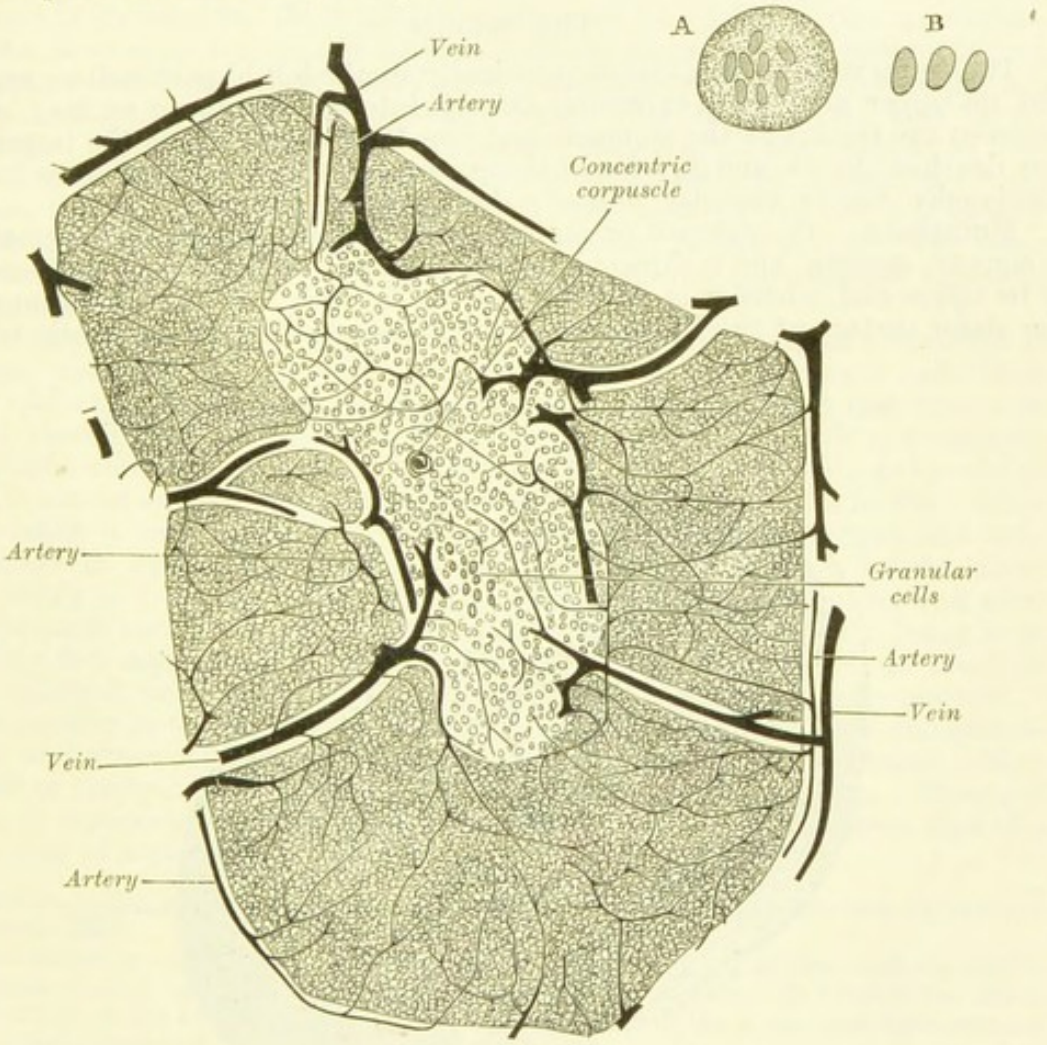

A and B. From thymus of camel, examined without addition of any reagent. Magnified about 400 diameters. A. Large colourless cell, containing small oval masses of hæmoglobin. Similar cells are found in the lymph-glands, spleen, and medulla of bone. B. Coloured blood-corpuscles.

Each follicle is surrounded by a capillary plexus, from which vessels pass into the interior, and radiate from the periphery towards the centre, forming a second zone just within the margin of the medullary portion. In the centre of the medulla there are very few vessels, and they are of minute size.

Watney has made the important observation that hæmoglobin is found in the thymus, either in cysts or in cells situated near to, or forming part of, the concentric corpuscles. This hæmoglobin occurs as granules or as circular masses exactly resembling coloured blood-corpuscles. He has also discovered, in the lymph issuing from the thymus, similar cells to those found in the gland, and, like them, containing hæmoglobin in the form of either granules or masses. From these facts he arrives at the conclusion that the thymus is one source of the coloured blood-corpuscles.

Vessels and Nerves.—The *arteries* supplying the thymus are derived from the internal mammary, and from the superior and inferior thyroid. The *veins* terminate in the left

innominate vein, and in the thyroid veins. The *lymphatics* are described on page 793. The *nerves* are exceedingly minute ; they are derived from the pneumogastric and sympathetic. Branches from the descendens hypoglossi and phrenic reach the investing capsule, but do not penetrate into the substance of the gland.

Applied Anatomy.—Sudden death—'thymus death'—with heart-failure, and with or without acute respiratory embarrassment, has been recorded in a number of infants and children in whom the thymus gland was considerably enlarged and the lymphatic tissues throughout the body showed general hypertrophy, but who showed no other evidence of disease. Such deaths have often occurred during the administration of anæsthetics, particularly chloroform. How far the enlarged thymus was responsible for the death of these patients, and, if it was responsible, how far its action was mechanical, are points that have been much disputed. Short of producing this sudden death, it appears that thymic enlargement may cause attacks of respiratory stridor, or noisy and difficult breathing, and spasmodic attacks of asthma—'thymic asthma'—which may be frequently repeated and may even result in death. Primary tumours of the thymus are rare forms of mediastinal new growth, and are usually dermoids or lymphosarcomas.

The Spleen

The **spleen** (lien) is situated principally in the left hypochondriac region, but its upper and inner extremity extends into the epigastric region ; it lies between the fundus of the stomach and the Diaphragm. It is the largest of the ductless glands, and is of an oblong, flattened form, soft, of very friable consistence, highly vascular, and of a dark purplish colour.

Relations.—The *external* or *diaphragmatic surface* (facies diaphragmatica) is convex, smooth, and is directed upwards, backwards, and to the left, except at its upper end, where it is directed slightly inwards. It is in relation with the under surface of the Diaphragm, which separates it from the ninth, tenth,

Fig. 1025.—The spleen, showing its gastric and renal surfaces.

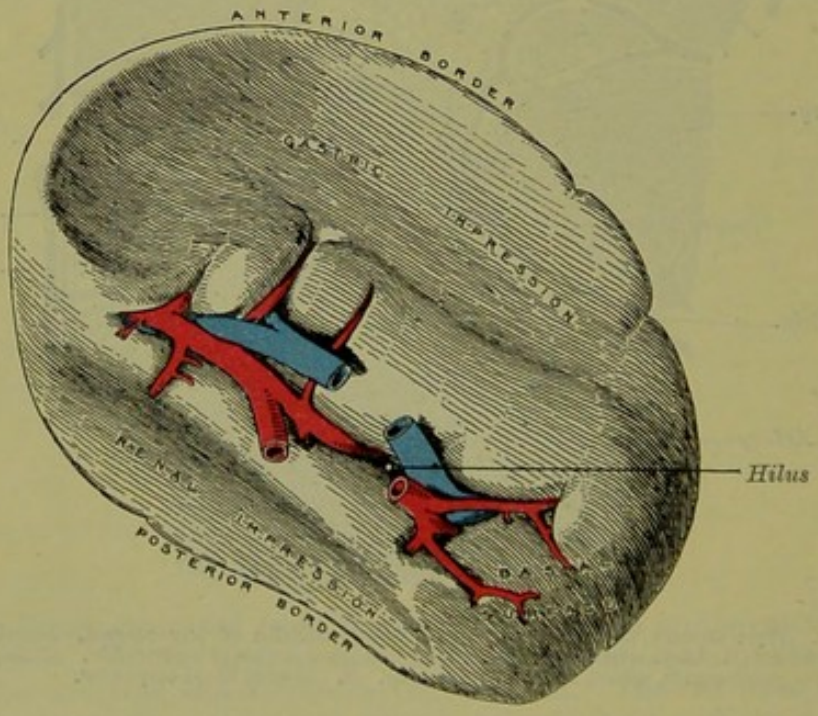

and eleventh ribs of the left side, and the intervening lower border of the left lung and pleura.

The *internal surface* is divided by a ridge into an anterior or gastric, and a posterior or renal portion.

The *gastric surface* (facies gastrica), which is directed forwards and inwards, is broad and concave, and is in contact with the posterior wall of the fundus of the stomach ; and below this with the tail of the pancreas. It presents near its inner border a long fissure, termed the hilus. This is pierced by several irregular apertures, for the entrance and exit of vessels and nerves.

The *renal surface* (facies renalis) is directed inwards and downwards. It is somewhat flattened, is considerably narrower than the gastric surface, and

is in relation with the upper part of the outer surface of the left kidney and occasionally with the left suprarenal gland.

The *upper end* is directed inwards, towards the vertebral column, where it lies on a level with the eleventh thoracic vertebra. The *lower end*, sometimes termed the *basal surface*, is flat, triangular in shape, and rests upon the splenic flexure of the colon and the phreno-colic ligament, and is generally in contact with the tail of the pancreas. The *anterior* border is free, sharp, and thin, and is often notched, especially below; it separates the diaphragmatic from the gastric surface. The *posterior* border, more rounded and blunter than the anterior, separates the renal from the diaphragmatic surface; it corresponds to the lower border of the eleventh rib and lies between the Diaphragm and left kidney. The *internal* border or intermediate margin is the ridge which separates the renal and gastric surfaces. The *inferior* border separates the diaphragmatic from the basal surface.

The spleen is almost entirely surrounded by peritoneum, which is firmly adherent to its capsule. It is held in position by two folds of this membrane. One, the *lieno-renal ligament*, is derived from the layers of peritoneum forming the greater and lesser sacs, where they come into contact between the left kidney and the spleen; the splenic vessels pass between its two layers (fig. 926). The other fold, the *gastro-splenic omentum*, is also formed of two layers, derived from the greater and lesser sacs respectively, where they meet between the spleen and stomach (fig. 926); the vasa brevia and left gastro-epiploic branches of the splenic artery run between its two layers. The lower end or basal surface of the spleen is supported by the phreno-colic ligament (see page 1129).

The size and weight of the spleen are liable to very extreme variations at different periods of life, in different individuals, and in the same individual under different conditions. *In the adult*, it is usually about five inches in length, three inches in breadth, and an inch or an inch and a half in thickness, and weighs about seven ounces. *At birth*, its weight, in proportion to the entire body, is almost equal to what is observed in the adult, being as 1 to 350: while in the adult it varies from 1 to 320 and 400. *In old age*, the organ not only diminishes in weight, but decreases considerably in proportion to the entire body, being as 1 to 700. The size of the spleen is increased during and after digestion, and varies according to the state of nutrition of the body, being large in highly fed, and small in starved animals. In malarial fever it becomes much enlarged, weighing occasionally even from eighteen to twenty pounds.

Frequently in the neighbourhood of the spleen, and especially in the gastro-splenic and great omenta, small nodules of splenic tissue may be found, either isolated or connected to the spleen by thin bands of splenic tissue. They are known as *supernumerary* or *accessory spleens*. They vary in size from that of a pea to that of a plum.

Structure.—The spleen is invested by two coats: an external serous and an internal fibro-elastic coat.

The *external* or *serous coat* is derived from the peritoneum; it is thin, smooth, and in the human subject intimately adherent to the fibro-elastic coat. It invests the entire organ, except at the hilus and along the lines of reflection of the lieno-renal ligament and gastro-splenic omentum.

The *fibro-elastic coat* invests the organ, and at the hilus is reflected inwards upon the vessels in the form of sheaths. From these sheaths, as well as from the inner surface of the fibro-elastic coat, numerous small fibrous bands, *trabeculæ* (fig. 1026), are given off in all directions; these uniting, constitute the framework of the spleen. The spleen therefore consists of a number of small spaces or *areolæ*, formed by the trabeculæ; in these areolæ is contained the *splenic pulp*.

The fibro-elastic coat, the sheaths of the vessels, and the trabeculæ, are composed of white, and yellow elastic, fibrous tissues, the latter predominating. It is owing to the presence of the elastic tissue that the spleen possesses a considerable amount of elasticity, which allows of the very great variations in size that it presents under certain circumstances. In addition to these constituents of this tunic, there is found in man a small amount of non-striped muscular fibre; and in some mammalia (e.g. dog, pig, and cat) a large amount, so that the trabeculæ appear to consist chiefly of muscular tissue.

The *splenic pulp* is a soft mass of a dark reddish-brown colour, resembling grumous blood; it consists of a number of branching cells and of an intercellular substance. The cells are connective-tissue corpuscles, and are termed the *sustentacular* or *supporting cells of the pulp*. The processes of these cells communicate with each other, thus forming a

delicate reticulated tissue in the interior of the areolæ, so that each areola may be considered to be divided into a number of smaller spaces by the junction of the processes of the branching corpuscles. These secondary spaces are full of blood, in which, however, the white corpuscles are found to be in larger proportion than they are in ordinary blood. Large rounded cells, termed *splenic cells*, are also seen; these are capable of amœboid movement, and often contain pigment and red blood-corpuscles in their interior. The sustentacular cells are either small uni-nucleated, or large multi-nucleated cells; they do not stain deeply with carmine, and in this respect differ from the cells of the Malpighian bodies, but like these cells they exhibit amœboid movements. In many of them may be seen deep red or reddish-yellow granules of various sizes, also blood-corpuscles in all stages of disintegration. Klein has pointed out that sometimes these cells, in the young spleen, contain proliferating nuclei; that is to say, the nucleus is of large size, and presents a number of knob-like projections, as if small nuclei were budding from it by a process of gemmation. This observation is of importance, as it may explain one possible source of the colourless blood-corpuscles.

Blood-vessels of the spleen.—The splenic artery is remarkable for its large size in proportion to the size of the organ, and also for its tortuous course. It divides into six or more branches, which enter the hilus of the spleen and ramify throughout its substance (fig. 1027), receiving sheaths from an involution of the external fibrous tissue. Similar sheaths also invest the nerves and veins.

FIG. 1026.—Transverse section of the spleen, showing the trabecular tissue and the splenic vein and its tributaries.

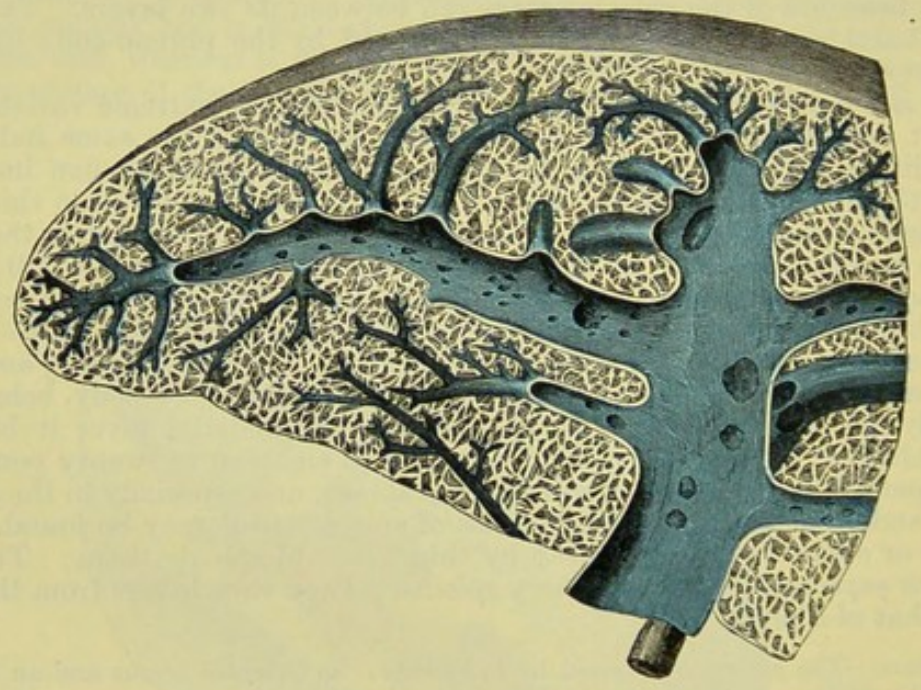

Each branch runs in the transverse axis of the organ, from within outwards, diminishing in size during its transit, and giving off in its passage smaller branches, some of which pass to the anterior, others to the posterior part. These ultimately leave the trabecular sheaths, and terminate in the proper substance of the spleen in small tufts or pencils of minute arterioles, which open into the interstices of the reticulum formed by the branched sustentacular cells. Each of the larger branches of the artery supplies chiefly that region of the organ in which the branch ramifies, having no anastomosis with the majority of the other branches.

The *arterioles*, supported by the minute trabeculæ, traverse the pulp in all directions in bundles of straight vessels. Their external coats, on leaving the trabecular sheaths, consist of ordinary connective tissue, but they gradually undergo a transformation, become much thickened, and converted into adenoid material.* This change is effected by the conversion of the connective tissue into adenoid tissue; the bundles of connective tissue becoming looser and their fibrils more delicate, and containing in their interstices an abundance of lymph-corpuscles (W. Müller).

The altered coat of the arterioles, consisting of adenoid tissue, presents here and there thickenings of a spheroidal shape, the *Malpighian bodies of the spleen*. These bodies vary

* According to Klein, it is the sheath of the small vessel which undergoes this transformation, and forms a 'solid mass of adenoid tissue which surrounds the vessel like a cylindrical sheath.'—*Atlas of Histology*, p. 424.

in size from about $\frac{1}{100}$ of an inch to $\frac{1}{25}$ of an inch in diameter. They are merely local expansions or hyperplasiæ of the adenoid tissue of which the external coat of the smaller arteries of the spleen is formed. They are most frequently found surrounding the arteriole, which thus seems to tunnel them, but occasionally they grow from one side of the vessel only, and present the appearance of a sessile bud growing from the arterial wall. Klein, however, denies this, and says it is incorrect to describe the Malpighian bodies as isolated

FIG. 1027.—Transverse section of the human spleen, showing the distribution of the splenic artery and its branches.

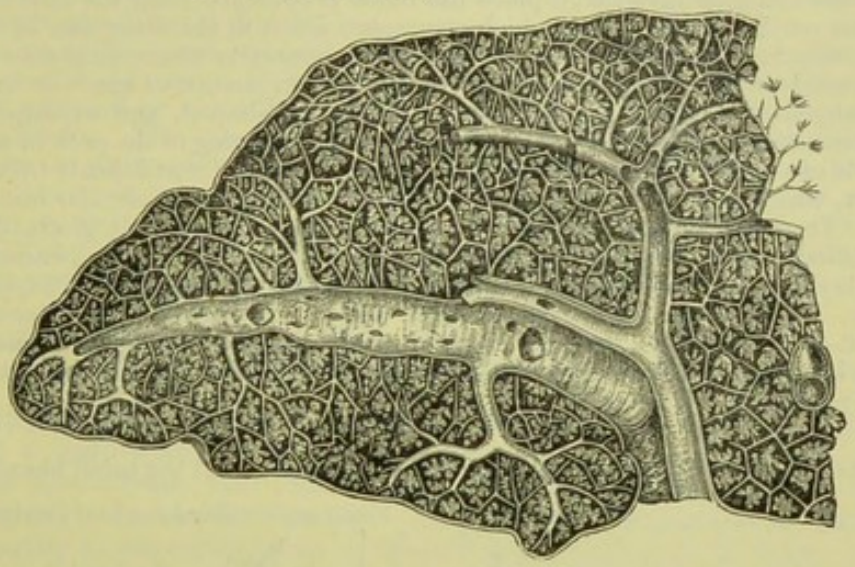

masses of adenoid tissue, that they are always formed around an artery, though there is generally a greater amount on one side than on the other, and that, therefore, in transverse sections, the artery, in the majority of cases, is found in an eccentric position. These bodies are visible to the naked eye on the surface of a fresh section of the organ, appearing as minute dots of a semi-opaque whitish colour in the dark substance of the pulp. In

FIG. 1028.—Transverse section of a portion of the spleen.

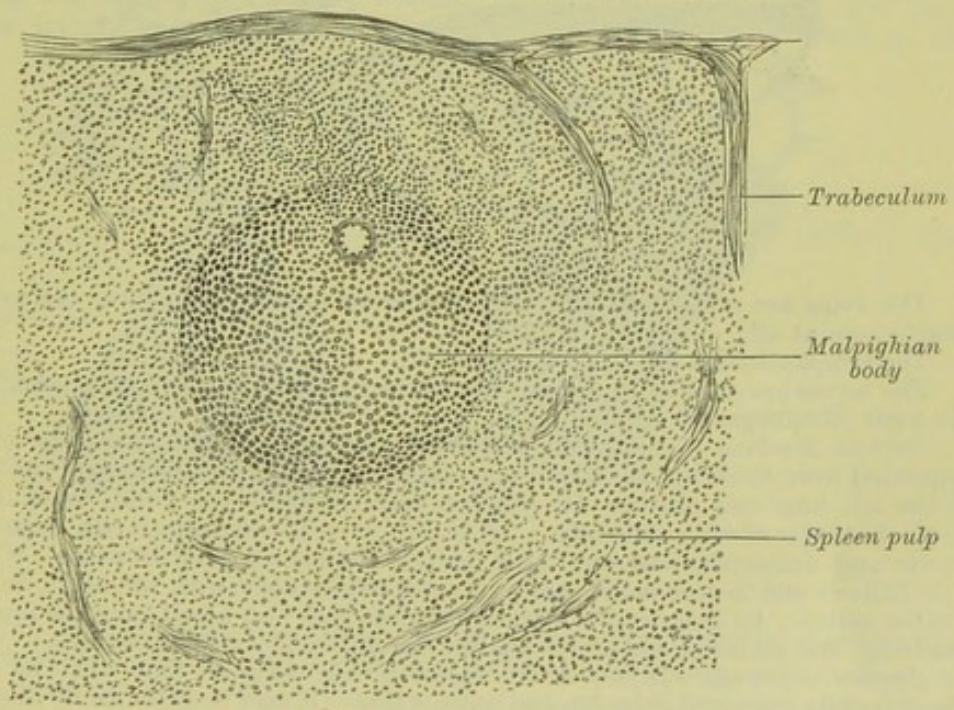

minute structure they resemble the adenoid tissue of lymphatic glands, consisting of a delicate reticulum, in the meshes of which lie ordinary lymphoid cells (fig. 1028).

The reticulum of the tissue is made up of extremely fine fibrils, and is comparatively open in the centre of the corpuscle, becoming closer at its periphery. The cells which it encloses, like the supporting cells of the pulp, are possessed of amœboid movements, but when treated with carmine become deeply stained, and can be easily distinguished from those of the pulp.

The arterioles terminate in capillaries, which traverse the pulp in all directions; their walls become much attenuated, lose their tubular character, and the cells of the adenoid tissue of which they are composed become altered, presenting a branched appearance, and acquiring processes which are directly connected with the processes of the sustentacular cells of the pulp (fig. 1029). In this manner the capillary vessels terminate, and the blood flowing through them finds its way into the interstices of the reticulated tissue formed by the branched connective-tissue corpuscles of the splenic pulp. Thus the blood passing through the spleen is brought into intimate relation with the elements of the pulp, and no doubt undergoes important changes.

After these changes have taken place the blood is collected from the interstices of the tissue by the rootlets of the veins, which commence much in the same way as the arteries terminate. Where a vein is about to commence, the connective-tissue corpuscles of the pulp arrange themselves in rows, in such a way as to form an elongated space or sinus. They become changed in shape, being elongated and spindle-shaped, and overlap each other at their extremities. They thus form a sort of endothelial lining of the path or sinus, which is the radicle of a vein. On the outer surface of these cells are seen delicate transverse lines or markings, which are due to minute elastic fibrillæ arranged in a circular manner around the sinus. Thus the channel obtains an external investment, and gradually becomes converted into a small vein, which after a time attains a coat of ordinary connective tissue, lined by a layer of fusiform epithelial cells which are continuous with the supporting cells of the pulp. The smaller veins unite to form larger ones; these do not accompany the arteries, but soon enter the trabecular sheaths of the capsule, and by their junction form six or more branches, which emerge from the hilus, and, uniting, constitute the splenic vein, the largest radicle of the portal vein.

FIG. 1029.—Section of the spleen, showing the termination of the small blood-vessels.

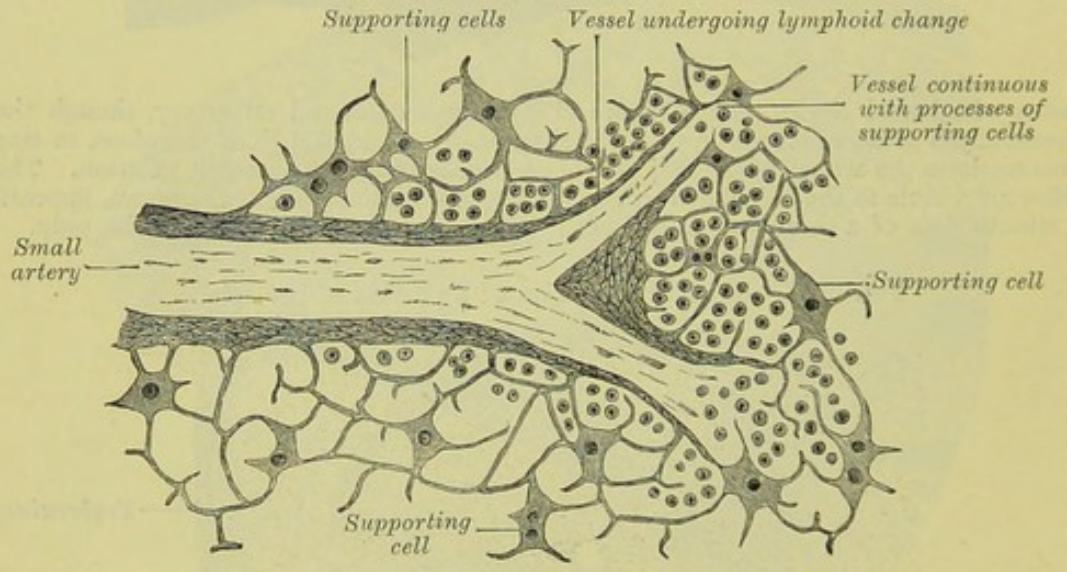

The veins are remarkable for their numerous anastomoses, while the arteries hardly anastomose at all.

The lymphatics are described on page 787.

The *nerves* are derived from branches of the right and left semilunar ganglia, and from the right pneumogastric nerve.

Surface Marking.—The spleen is situated under cover of the ribs of the left side, being separated from them by the Diaphragm, and above by a small portion of the lower margin of the left lung and pleura. Its position corresponds to the ninth, tenth, and eleventh ribs. It is placed very obliquely. 'It is oblique in two directions, viz. from above downwards and outwards, and also from above downwards and forwards' (Cunningham). 'Its highest and lowest points are on a level respectively with the ninth dorsal and first lumbar spines; its inner end is distant about an inch and a half from the median plane of the body, and its outer end about reaches the mid-axillary line' (Quain).

Applied Anatomy.—Injury of the spleen is less common than that of the liver, on account of its protected situation and connections. It may be ruptured by direct or indirect violence; torn by a broken rib; or injured by a punctured or gunshot wound. When the organ is enlarged, the chance of rupture is increased. The great risk is hæmorrhage, owing to the vascularity of the organ, and the absence of a proper system of capillaries. The injury is not, however, necessarily fatal, and this would appear to be due, in a great measure, to the contractile power of the capsule, which narrows the wound and prevents the escape of blood. In cases where the diagnosis is clear, and the symptoms indicate danger to life, laparotomy must be performed, and if the hæmorrhage cannot be stayed by ordinary surgical methods, the spleen must be removed.

The spleen may become enormously enlarged in certain diseased conditions, such as ague, leukæmia, syphilis, valvular disease of the heart, or without any obtainable history of previous disease. It may also become enlarged in lymphadenoma, as a part of a general blood-disease. In these cases the tumour may fill a considerable part of the abdomen and extend into the pelvis, and may be mistaken for ovarian or uterine new growth.

The spleen is sometimes the seat of cystic tumours, especially hydatids, and of abscess. These cases require treatment by incision and drainage; and in abscess great care must be taken, if there are no adhesions between the spleen and abdominal wall, to prevent the escape of any of the pus into the peritoneal cavity. If possible the operation should be performed in two stages. Sarcoma and carcinoma are occasionally found in the spleen, but very rarely as a primary disease.

Extirpation of the spleen has been performed for wounds or injuries, in floating spleen, in simple hypertrophy, and in leukæmic enlargement; but in the last condition the operation is now regarded as unjustifiable, as every case in which it has been performed has terminated fatally. The incision is best made in the left semilunar line; the spleen is isolated from its surroundings, and the pedicle transfixed and ligatured in two portions, before the tumour is turned out of the abdominal cavity, if possible, so as to avoid any traction on the pedicle, which may cause tearing of the splenic vein. Care must be taken in applying the ligature not to include the tail of the pancreas, and in lifting out the organ to avoid rupturing the capsule.

Suprarenal Glands

The **suprarenal glands** (glandulæ suprarenales) are two small flattened bodies of a yellowish colour, situated at the back part of the abdomen, behind the peritoneum, and immediately above and in front of the upper end of each kidney; hence their name. The right one is somewhat triangular in shape, bearing a resemblance to a cocked hat; the left is more semilunar, usually larger and placed at a higher level than the right. They vary in size in different individuals, being sometimes so small as to be scarcely detected: their usual size is from an inch and a quarter to nearly two inches in length, rather less in width, and from two to three lines in thickness. Their average weight is from one to one and a half drachms each.

Relations.—The relations of the suprarenal glands differ on the two sides of the body.

The *right suprarenal* is situated behind the inferior vena cava and right lobe of the liver, and in front of the Diaphragm and upper end of the

Fig. 1030.—Suprarenal glands viewed from the front.

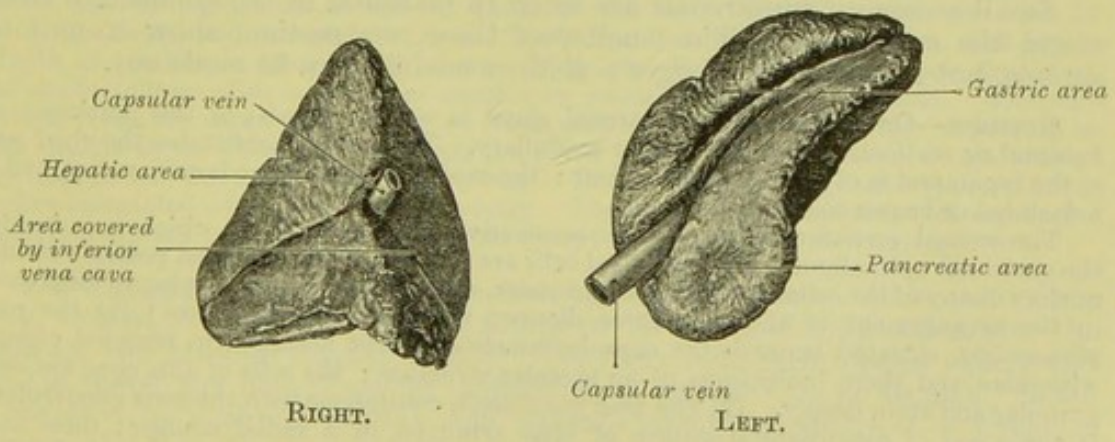

right kidney. It is roughly triangular in shape; its base, directed downwards, is in contact with the inner and anterior aspects of the upper end of the right kidney. It presents two surfaces for examination, an anterior and a posterior. The *anterior surface* looks forwards and outwards, and has two areas: an inner, narrow and non-peritoneal, which lies behind the inferior vena cava; and an outer, somewhat triangular, in contact with the liver. The upper part of this surface is devoid of peritoneum, and is in relation with the bare area of the liver near its lower and inner angle, while its inferior portion is covered by peritoneum, reflected on to it from the inferior layer of the coronary ligament. A little below the apex, and near the anterior border of the gland,

is a short furrow termed the hilus, from which the suprarenal vein emerges to join the inferior vena cava. The *posterior surface* is divided into upper and lower parts by a curved ridge : the upper, slightly convex, rests upon the Diaphragm ; the lower, concave, is in contact with the upper end and the adjacent part of the anterior surface of the kidney.

The *left suprarenal*, slightly larger than the right, is crescentic in shape, its concavity being adapted to the inner border of the upper part of the left kidney. It presents an inner border which is convex, and an outer which is concave ; its upper border is narrow, and its lower rounded. Its *anterior surface* has two areas : an upper one, covered by the peritoneum forming the lesser sac, which separates it from the cardiac end of the stomach and sometimes from the superior extremity of the spleen ; and a lower one, which is in

FIG. 1031.—Suprarenal glands viewed from behind.

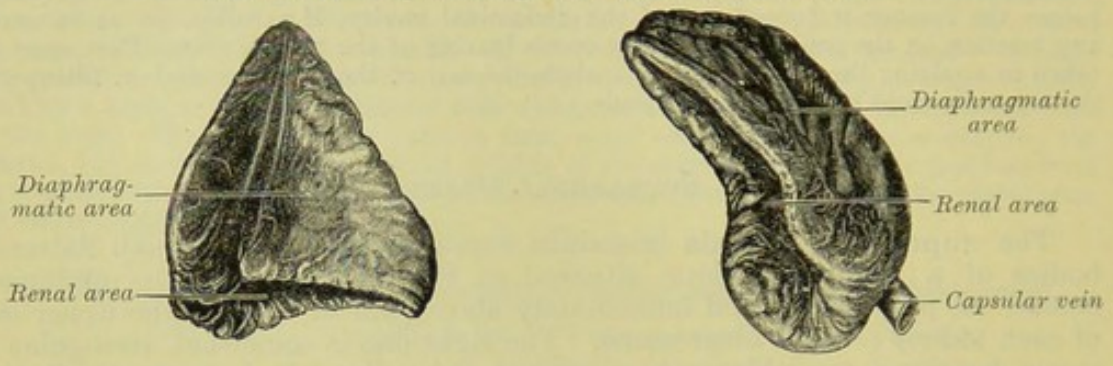

RIGHT. LEFT.

contact with the pancreas and splenic artery, and is therefore not covered by the peritoneum. On the anterior surface, near its lower end, is a furrow or hilus, directed downwards and forwards, from which the suprarenal vein emerges. Its *posterior surface* presents a vertical ridge, which divides it into two areas ; the outer area rests on the kidney, the inner and smaller, on the left crus of the Diaphragm.

The surface of the suprarenal gland is surrounded by areolar tissue containing much fat, and closely invested by a thin fibrous capsule, which is difficult to remove on account of the numerous fibrous processes and vessels entering the organ through the furrows on its anterior surface and base.

Small accessory suprarenals are often to be found in the connective tissue round the suprarenals. The smaller of these, on section, show a uniform surface, but in some of the larger a distinct medulla can be made out.

Structure.—On section, the suprarenal gland is seen to consist of two portions : an external or cortical, and an internal or medullary. The former constitutes the chief part of the organ and is of a deep yellow colour ; the medullary substance is soft, pulpy, and of a dark red or brown colour.

The *cortical portion* consists of a fine connective-tissue network, in which is imbedded the glandular epithelium. The epithelial cells are polyhedral in shape and possess rounded nuclei ; many of the cells contain coarse granules, others fat globules. Owing to differences in the arrangement of the cells three distinct zones can be made out : (1) the *zona glomerulosa*, situated beneath the capsule, consists of cells arranged in rounded groups, with here and there indications of an alveolar structure ; the cells of this zone are very granular and stain deeply. (2) The *zona fasciculata*, continuous with the zona glomerulosa, is composed of quadrilateral groups of cells arranged in a radial manner; these cells contain finer granules and in many instances fat globules. (3) The *zona reticularis*, in contact with the medulla, consists of cylindrical masses of cells irregularly arranged ; these cells often contain pigment granules which give this zone a darker appearance than the rest of the cortex.

The *medullary portion* is extremely vascular, and is composed of a loose meshwork of connective tissue surrounding a large plexus of veins and containing non-striped muscular fibres. In addition to the veins, multi-nucleated masses of protoplasm are scattered throughout the medulla as well as many irregular-shaped cells containing pigment. The cell-protoplasm has an especial affinity for chromic salts, which stain it a brown colour. Such cells are therefore termed *chromaffin cells*. This portion of the gland is richly supplied with non-medullated nerve-fibres, and here and there sympathetic ganglia are found.

Vessels and Nerves.—The *arteries* supplying the suprarenal glands are numerous and of comparatively large size; they are derived from the aorta, the inferior phrenic, and the renal. They subdivide into minute branches previous to entering the cortical part of the gland, where they break up into capillaries which end in the venous plexus of the medullary portion.

The *suprarenal vein* returns the blood from the medullary venous plexus and receives several branches from the cortical substance; it emerges from the hilus of the gland and on the right side opens into the inferior vena cava, on the left into the renal vein.

The *lymphatics* terminate in the lumbar glands.

The *nerves* are exceedingly numerous, and are derived from the solar and renal plexuses, and, according to Bergmann, from the phrenic and pneumogastric nerves. They enter the lower and inner part of the capsule, traverse the cortex, and terminate around the cells of the medulla. They have numerous small ganglia developed upon them, from which circumstance the organ has been conjectured to have some function in connection with the sympathetic nervous system.

FIG. 1032.—Section of a part of a suprarenal gland. (Magnified.)

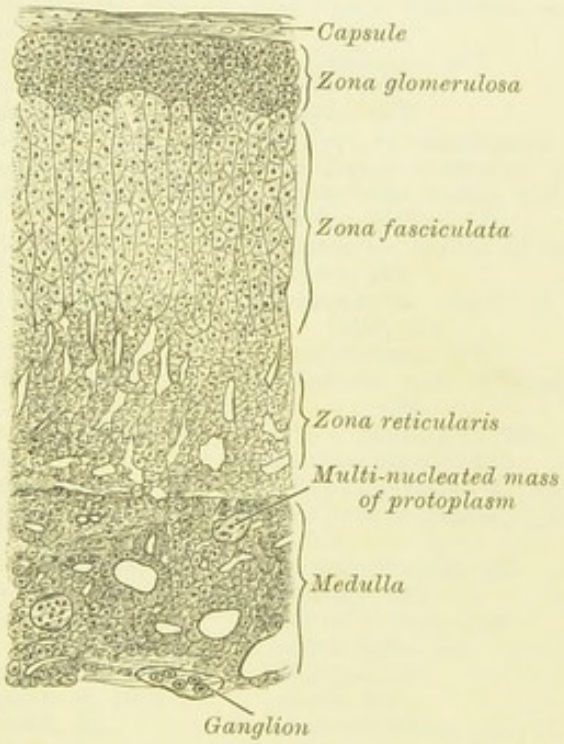

Applied Anatomy.—The suprarenal *cortex* is derived from the cœlomic epithelium of the Wolffian ridge, and is connected with the sexual glands; it is related to growth and development in some way, and is often found to be hypertrophied in patients with chronic kidney disease and high blood-pressure. The *medulla*, on the other hand, is neuro-ectodermal in origin, and closely connected with the sympathetic nervous system. It supplies the body with an internal secretion called *adrenalin*, that tends to raise the blood-pressure by stimulating the vaso-constrictor fibres of the sympathetic. When the suprarenal medulla is destroyed by tuberculosis, to which the glands are prone, or by the pressure of a new growth, the secretion of adrenalin becomes inadequate, and Addison's disease develops. Patients with Addison's disease become pigmented in various parts of the body, possibly from irritation of the sympathetic, and complain of great weakness, lack of energy, nausea, and severe attacks of vomiting. Their blood-pressure is low, the whole nervous system is depressed, and death follows after a period of months or years, usually from asthenia. Tumours derived from the suprarenal itself, or from misplaced suprarenal 'rests' occurring in such organs as the kidney or liver, may be either benign or malignant, and are classed together under the name 'hypernephroma.' In children the malignant hypernephroma is often associated with obesity and precocity. The benign hypernephroma, or suprarenal adenoma, appears to produce no symptoms except those due to its slow enlargement.

The **carotid bodies**, two in number, are situated one on either side of the neck, behind the common carotid artery at its point of bifurcation into the external and internal carotid trunks. They are reddish-brown in colour and oval in shape, the long diameter measuring about one-fifth of an inch. Each is invested by a fibrous capsule and consists largely of spherical or irregular masses of cells—the masses being more or less isolated from one another by septa which extend inwards from the deep surface of the capsule. The cells are polyhedral in shape, and each contains a large nucleus imbedded in finely granular protoplasm which is stained yellow by chromic salts. Numerous nerve-fibres, derived from the sympathetic plexus on the carotid artery, are distributed throughout the organ, and a network of large capillaries ramifies amongst the cells.

The **coccygeal body** or *gland of Luschka* is placed in front of, or immediately below, the tip of the coccyx. It is about the size of a millet-seed and is irregularly oval in shape; several smaller nodules are found around or near the main mass. It consists of irregular masses of round or polyhedral cells,

the cells of each mass being grouped around a dilated capillary vessel. Each cell contains a large round or oval nucleus, the protoplasm surrounding which is clear and is not stained by chromic salts.*

Besides the ductless glands mentioned, reference may be made to a pair of small bodies, the **aortic bodies of Zuckerkandl**. These are found in the embryo and persist until shortly after birth; they lie one on either side of the abdominal aorta close to the origin of the superior mesenteric artery. They consist essentially of masses of polygonal or cuboidal, chromaffin, cells imbedded in a wide-meshed capillary plexus.

* Consult the following article: 'Über die Menschliche Steissdrüse,' von J. W. Thomson Walker, *Archiv für mikroskopische Anatomie und Entwickelungsgeschichte*, Band 64. 1904.

INDEX

Abdomen, 1118
  apertures in walls of, 1119
  boundaries of, 1118
  fascia of, 506
  lymphatic glands of, 778
  muscles of, 506
  regions of, 1119
Abdominal aorta, 685
    applied anatomy of, 687
    branches of, 687
    surface marking of, 687
  muscles, 506
  ring, external, 508
    internal, 516
  viscera, lymphatic vessels of, 784
    position of, 1056
  wall, lymphatic vessels of, 781
Abdomino-thoracic arch, 212
Abductor hallucis muscle, 588
  indicis muscle, 557
  longus pollicis muscle, 549
  minimi digiti muscle, (hand) 556, (foot) 589
  pollicis muscle, 554
Aberrant duct of testis, 1210
Accelerator urinæ muscle, 524
Accessorius ad ilio-costalem muscle, 496
  pedis muscle, 589
Accessory obturator nerve, 974
  olivary nuclei, 819
  palatine canals, 252
  processes, 191
  pudic artery, 701
  sinuses of nose, 1008
    applied anatomy of, 1008
  spleens, 1241
  thyroids, 1236
Acetabuli, fossa, 326
  os, 327
Acetabulum, 325
Achromatic spindle, 4
Achromatin, 4
Acromial end of clavicle, 288
  region, muscles of, 533
Acromio-clavicular joint, 401
    applied anatomy of, 403
    surface form of, 403
Acromio-thoracic artery, 670
Acromion process, 292
Actions of Muscles. *See each Group of Muscles*
Adamantoblasts, 1101
Adductor brevis muscle, 571
  longus muscle, 571
  magnus muscle, 572
  obliquus hallucis muscle, 591
    pollicis muscle, 554
Adductor transversus hallucis muscle, 591
    pollicis muscle, 555
  tubercle, 336
Adenoid tissue, 20
Adipose tissue, 17
    development of, 18
Adminiculum lineæ albæ, 514
Adrenalin, 1247
Afferent nerves, 49
  vessels of kidney, 1185
After-birth, 101
Agger nasi, 245
Air-cells of nose, 1008
Ala cinerea, 837
  lobuli centralis, 827
  nasi, 1002
Alæ of sacrum, 194
  of vomer, 254
Alar lamina, 117
  processes of ethmoid, 238
  thoracic artery, 670
Alcock, canal of, 518
Alimentary canal, 1088
    development of, 150
    subdivisions of, 1088
Allantoic vessels, 94
Allantois, 94
Alveolar arch, 245
  artery, 639
  point, 279
  process, 245
Alveoli, formation of, 1102
  of mandible, 256
  of maxilla, 245
  of stomach, 1137
Alveus, 870, 875
Amacrine cells of retina, 1022
Amnion, 93
  false, 94
Amniotic cavity, 94
    primitive, 86
  ectoderm, 94
  fold, 93
Amphiarthrosis, 369
Ampulla of vas deferens, 1210
  of Fallopian tube, 1221
  of rectum, 1154
  of Vater, 1173
Ampullæ of semicircular canals, 1048
  of tubuli lactiferi, 1233
Amygdalæ of cerebellum, 829
Anal canal, 1155
  columns of Morgagni of, 1156
  development of, 160
Anal canal, lymphatic vessels of, 785
    membrane, 161
  fascia, 518
  valves, 1156
Anaphase of karyokinesis, 5
Anastomosis of arteries, 617
  around elbow-joint, 674
  circumpatellar, 719
Anastomotic branch of sciatic artery, 704
Anastomotica magna of brachial, 674
    of femoral, 715
Anatomical neck of humerus, 296
      fracture of, 300
Anconeus muscle, 547
Andersch, ganglion of, 932
Aneurysms of abdominal aorta, 687
  of arch of aorta, 622
Angiology, 597
Angle of Ludwig, 204
  of mandible, 257
  of pubis, 325
  of rib, 208
  sacro-vertebral, 191
  subscapular, 289
Angular artery, 633
  convolution, 860
  movement, 370
  process, external, 221
    internal, 221
  vein, 729
Angulus Ludovici, 204
Animal cell, 3
Ankle-joint, 440
  applied anatomy of, 444
  relations of tendons and vessels to, 442
  surface form of, 443
Annular ligament of ankle, anterior, 586
      external, 587
      internal, 587
    of radius and ulna, 413
    of wrist, anterior, 550
      posterior, 551
Annulus fibrosus, 374
  ovalis, 605
Ano-coccygeal body, 1155
  nerves, 986
  raphe, 520
Ansa hypoglossi, 941, 952
  lenticularis, 873, 874
  Vieussenii, 993
Anterior annular ligament of ankle, 586
    of wrist, 550

Anterior basis bundle, 805
cerebral artery, 648
cervical lymphatic glands, 772
chamber of eye, 1017
columns of spinal cord, 804
commissure of brain, 876
of prostate, 1216
common ligament, 373
cornu of lateral ventricle, 867
of spinal cord, 800
crescentic lobe, 827
crural nerve, 974
dental canal, 243
ethmoidal cells, 239
fontanelle, 277
fossa of skull, 271
internal frontal arteries, 648
interosseous nerve, 960
jugular vein, 733
median fissure of medulla, 812
of spinal cord, 798
mediastinum, 1079
nasal spine, 246
nerve roots, 808, 941
palatine fossa, 246, 262
perforated space, 864
primary divisions of cervical nerves, 949
of lumbar nerves, 969
of sacral and coccygeal, 978
of spinal nerves, 949
of thoracic nerves, 966
pulmonary plexus, 936
thoracic nerves, 956
tibial artery, 719
nerve, 984
triangle of neck, 640
Antero-lateral ganglionic arteries, 650
ground bundle, 807
Antero-median ganglionic arteries, 648
Anticlinal vertebra, 188*n*
Anticubital fossa, 672
Antihelix, 1035
fossa of, 1035
Antitragicus muscle, 1037
Antitragus, 1035
Antrum cardiacum, 1117, 1133
of Highmore, 244, 1008
mastoid, 226
opening of, 1041
Anus, 1089
development of, 161
lymphatic vessels of, 785
Aorta, 619
abdominal, 685
applied anatomy of, 687
branches of, 687
arch of, 620
applied anatomy of, 622
branches of, 623
peculiarities of, 622
of branches of, 623
ascending, 619
descending, 682
development of, 142
great sinus of, 619
thoracic, 682
applied anatomy of, 684
branches of, 684
Aortæ, dorsal, 136, 142
Aortæ, primitive, 135
ventral, 136
Aortic arches, 141
bodies of Zuckerkandl, 1248
isthmus, 143
lymphatic glands, 780
opening of diaphragm, 503
of heart, 609
plexus, 999
semilunar valves, 609
septum, 140
vestibule, 609
Aortico-renal ganglion, 997
Aperture, anterior nasal, 277
superior, of larynx, 1066
Apertures in walls of abdomen, 1119
Aponeuroses, 455
epicranial, 458
of external oblique, 506
lumbar, 493
palatine, 484
pharyngeal, 1115
of soft palate, 1092
Appendages of eye, 1028
applied anatomy of, 1033
of embryo, 92
of skin, 67
Appendices epiploicæ, 1129
Appendicular artery, 692
Appendix of left auricle, 608
of right auricle, 604
lymphatic vessels of, 785
vermiform, 1150
xiphoid, 204
Applied Anatomy—
of abdominal aorta, 687
of abducent nerve, 922
of acromio-clavicular joint, 403
of adductor longus muscle, 573
of ankle-joint, 444
of anterior tibial artery, 720
of arch of aorta, 622
of arteries, 617
of ascending pharyngeal artery, 636
of auditory nerve, 929
of auriculo-ventricular bundle, 611
of axilla, 666
of axillary artery, 668
fascia, 529
glands, 774
vein, 747
of azygos veins, 750
of biceps of arm, 583
of bladder, 1199
of bone, 34
of bones of forearm, 308
of foot, 363
of hand, 320
of leg, 349
of pelvis, 331
of skull, 282
of brachial artery, 672
plexus, 965
of brain, 891
of branches of internal iliac artery, 705
of carpal bones, 320
of cavernous sinus, 741
of cerebellum, 834
Applied Anatomy (*cont.*)
of cervical fascia, 474
glands, 772
plexus, 953
ribs, 210
of clavicle, 289
of common carotid artery, 627
iliac artery, 697
of coronary arteries, 620
of deep epigastric artery, 707
of deltoid muscle, 534
of descending aorta, 684
palatine artery, 640
of dorsalis pedis artery, 722
of eighth nerve, 929
of elbow-joint, 412
of eleventh nerve, 939
of emissary veins, 744
of Eustachian tube, 1046
of extensor tendons of fingers, 549
of external carotid artery, 629
ear, 1038
iliac artery, 705
jugular vein, 733
of eye, 1026
of eyelids, 1033
of facial artery, 633
nerve, 927
vein, 731
of Fallopian tube, 1222
of fascia of axilla, 529
of Psoas and Iliacus, 565
of femoral artery, 712
hernia, 1161
of femur, 340
of fibula, 349
of fifth nerve, 918
of fingers, 553
of first nerve, 901
of flexor sheaths of fingers, 553
of foot, bones of, 363
of forearm, bones of, 308
of fourth nerve, 906
of gall-bladder, 1175
of glosso-pharyngeal nerve, 932
of gluteal artery, 705
of hæmorrhoidal venous plexus, 757
of hamstring tendons, 575
of hand, bones of, 320
of heart, 613
of hip-joint, 428
of humerus, 300
of hyoid bone, 261
of hypoglossal nerve, 941
of iliac fascia, 565
of inferior calcaneo-navicular ligament, 447
vena cava, 759
of inguinal glands, 777
hernia, 1159
of innominate artery, 624
of intercostal arteries, 685
nerves, 969
of internal capsule, 888
carotid artery, 645
ear, 1058

Applied Anatomy (*cont.*)
of internal iliac artery, 698
jugular vein, 734
mammary artery, 665
pudic artery, 705
of intervertebral discs, 375
of intestines, 1158
of ischio-rectal fossa, 522
of kidneys, 1190
of knee-joint, 438
of labyrinth, 1058
of lachrymal apparatus, 1034
of laryngeal nerves, 937
of laryngo-tracheal region, 1073
of larynx, 1073
of leg, bones of, 349
of lingual artery, 631
of liver, 1174
of lumbar plexus, 986
of lungs, 1087
of lymphatic system, 764
of mammary glands, 1234
of mastoid antrum, 226
of mediastinum, 1080
of medulla oblongata, 822
of meninges, 899
of mesenteric arteries, 694
lymphatic glands, 783
of metacarpal bones, 320
of metatarsal bones, 364
of metatarso-phalangeal joint of great toe, 452
of middle ear, 1046
meningeal artery, 638
of motor-oculi nerve, 905
of muscles, 454
of eyeball, 463
of lower extremity, 595
of soft palate, 486
of upper extremity, 560
of vertebral column, 500
of musculo-spiral nerve, 966
of nasal fossæ, 1008
of ninth nerve, 931
of nose, 1008
of œsophagus, 1118
of olfactory nerve, 901
of optic nerve, 903
of ovaries, 1221
of palate, 1092
muscles of, 486
of palmar arches, 682
fascia, 553
of pancreas, 1179
of parametrium, 1229
of parathyroid glands, 1238
of patella, 343
of pelvis, 331
of penis, 1215
of pericardium, 600
of peritoneal fossæ, 1132
of peroneal or external popliteal nerve, 988
of phalanges of hand, 320
of foot, 364
of pharynx, 1116
of pigment, 36
of plantar arch, 725
Applied Anatomy (*cont.*)
of pleura, 1077
of pons, 825
of pneumogastric nerve, 937
of popliteal artery, 717
lymphatic glands, 777
of portal system of veins, 763
of posterior tibial artery, 723
of pronator teres muscle, 540
of prostate gland, 1217
of prostatic venous plexus, 757
of psoas magnus muscle, 566
of pulmonary artery, 619
veins, 727
of radial artery, 676
of radius, 308
of recti muscles of eye, 463
of rectus femoris muscle, 570
of ribs, 212
of salivary glands, 1113
of saphenous veins, 753
of scalp, 458
of scapula, 294
of sciatic artery, 705
nerve (great), 987
of second nerve, 903
of serratus magnus muscle, 533
of seventh nerve, 927
of sheath of psoas muscle, 566
of shoulder-joint, 407
of sixth nerve, 922
of skull, 282
of spermatic veins, 759
of spinal accessory nerve, 939
arteries, 660
cord, 809
of spleen, 1244
of splenic artery, 690
of sterno-clavicular joint, 401
of sterno-mastoid muscle, 475
of sternum, 212
of stomach, 1138
of subclavian artery, 657
of superior radio-ulnar joint, 413
thyroid artery, 630
vena cava, 750
of suprarenal glands, 1247
of sympathetic nerves, 1000
of synovial membrane, 367
sheaths of tendons of wrist, 553
of tarsal bones, 363
joints, 449
of teeth, 1103
of temporal artery, 636
of temporo-mandibular joint, 385
of tendons of leg and foot, 586
of tenth nerve, 937
of testis, 1209
Applied Anatomy (*cont.*)
of third nerve, 905
of thoracic aorta, 684
duct, 767
nerves, 969
of thorax, 212
of thymus, 1240
of thyroid body, 1237
of tibia, 349
of tongue, 482
of tonsils, 1115
of trachea, 1074
of tracheo-bronchial glands, 792
of triceps, 539
of trifacial nerve, 918
of trochlear nerve, 906
of twelfth nerve, 941
of tympanic cavity, 1046
of ulna, 308
of ulnar artery, 679
of ureter, 1193
of urethra, 1202
of uterus, 1228
of vagus, 937
of veins in front of elbow, 746
of vena mediani cubiti, 746
of vertebral column, 201
joints, 382
of vesiculæ seminales, 1212
of wrist-joint, 417
Aquæductus cochleæ, 228, 1051
Fallopii, 228
Sylvii, 844
vestibuli, 228, 1048
Aqueous humour, 1024
Arachnoid membrane, 895
cisternæ, 896
villi, 898
Arantii, corpora, 607
Arbor vitæ of cerebellum, 830
uterinæ, 1225
Arch, alveolar, 245
of aorta, 620
applied anatomy of, 622
branches of, 623
peculiarities of, 622
axillary, 490
crural, deep, 516, 708
palmar, deep, 676
superficial, 681
plantar, 725
posterior carpal, 681
of pubis, 329
of a vertebra, 183
zygomatic, 266
Arches, aortic (fœtal), 141
branchial or visceral, 107
of foot, 452
of soft palate, 1091
Arcuate fibres, anterior external, 821
internal, 820
posterior external, 821
ligaments, 502
nucleus, 821
Arcus parieto-occipitalis, 860
Area acustica, 837
anterior, of medulla, 812
of Broca, 864
bucco-pharyngeal, 687
cribrosa media, 227
superior, 227
embryonic, 86

Area, extra-embryonic, 86
facialis, 228
lateral, of medulla, 813
olfactory, 110
oval, of Flechsig, 808
pericardial, 87
posterior, of medulla, 814
postrema, 837
proamniotic, 87
vestibularis inferior, 1058
superior, 1058
Areas of Cohnheim, 38
motor, of cerebral cortex, 885
sensory, of cerebral cortex, 885
Areola of breast, 1233
Areolæ of bone, primary, 32
secondary, 32
Areolar tissue, 16
Arm, muscles of, 533
bones of, 286
fascia of, 533
lymphatic glands of, 772
lymphatics of, 775
veins of, 744
Arnold's nerve, 935
Arrectores pilorum, 70
Arteria centralis retinæ, 648, 1024
hyaloidea, 131
magna hallucis, 722
princeps cervicis, 634
Arteriæ propriæ renales, 1187
receptaculi, 646
rectæ, 1189
Arterial mesocardium, 600
Arteries, *Histology of*, 55
anastomoses of, 617
applied anatomy of, 617
development of, 141
distribution of, 617
mode of division, 617
of origin of branches, 617
nerves of, 57
sheaths of, 56
structure of, 55
subdivision of, 617
systemic, 617
Arteries or Artery, *Descriptive Anatomy of*, 617
accessory pudic, 701
acromio-thoracic, 670
alar thoracic, 670
alveolar, 639
anastomotic branch of sciatic, 704
anastomotica magna, of brachial, 674
of femoral, 715
angular, 633
anterior cerebral, 648
choroidal, 652
ciliary, 648
circumflex, 671
communicating, 648
dental, 640
inferior cerebellar, 661
intercostal, 665
internal frontal, 648
spinal, 660
tibial, 719
antero-lateral ganglionic, 650
antero-median ganglionic, 648
aorta, 619
abdominal, 685
Arteries or Artery (*cont.*)
aorta, arch of, 620
ascending, 619
descending, 682
thoracic, 682
appendicular, 692
articular, of knee, 718
ascending cervical, 662
frontal, 651
parietal, 651
pharyngeal, 636
auditory, 661
auricular, anterior, 636
deep, 638
of occipital, 634
posterior, 635
right, of heart, 620
axillary, 667
azygos, of knee, 718
basilar, 661
brachial, 671
brachio-cephalic, 623
bronchial, 684
buccal, 639
of bulb, 703
bulbar, 661
cæcal, of ileo-colic, 692
calcanean, external, 724
internal, 724
carotid, common, 625
external, 628
internal, 643
carpal, anterior radial, 677
posterior radial, 677
anterior ulnar, 681
posterior ulnar, 681
carpal arch, anterior, 677
posterior, 677, 681
central, of retina, 648
cerebellar, anterior inferior, 661
posterior inferior, 661
superior, 661
cerebral, 648, 650, 661
of cerebral hæmorrhage, 651
cervical, ascending, 662
princeps, 634
profunda, 665
superficial, 663
transverse, 662
choroidal, anterior, 652
posterior, 661
ciliary, 648
circle of Willis, 652
circumflex, of arm, 670, 671
iliac, deep, 707
superficial, 713
external, of thigh, 714
internal, of thigh, 714
coccygeal branch of sciatic, 704
cochlear, 1058
cœliac axis, 688
colic, left, 693
middle, 692
right, 692
comes nervi ischiadici, 704
mediani, 681
phrenici, 663
common carotid, 625
iliac, 696
communicating, of anterior cerebral, 648
of dorsalis pedis, 722
of posterior cerebral, 652
coronary, of heart, 620
Arteries or Artery (*cont.*)
coronary of lip, 633
of stomach, 688
of corpus cavernosum, 703
cremasteric, 706
crico-thyroid, 630
cystic, 690
deep auricular, 638
branch of ulnar, 681
cervical, 665
circumflex iliac, 707
epigastric, 706
external pudic, 713
palmar arch, 676
temporal, 639
dental, anterior, 640
inferior, 639
posterior, 639
descending aorta, 682
coronary, 620
palatine, 640
digital, palmar, 681
plantar, 726
of ulnar, 681
dorsal, of penis, 703
dorsales linguæ, 630
dorsalis hallucis, 722
indicis, 677
pedis, 721
pollicis, 677
scapulæ, 670
epigastric, deep, 706
superficial, 713
superior, 665
ethmoidal, 647
external carotid, 628
circumflex, 714
iliac, 705
maxillary, 631
plantar, 725
pudic, deep, 713
superficial, 713
facial, 631
transverse, 636
femoral, 707
frontal, 648
ganglionic, antero-lateral, 650
antero-median, 648
postero-lateral, 661
postero-median, 661
Gasserian, 646
gastric, 688
gastro-duodenal, 689
gastro-epiploic, right, 690
left, 690
gluteal, 704
hæmorrhoidal, inferior, 701
middle, 699
superior, 694
helicine, 1214
hepatic, 688
hypogastric, in fœtus, 614
ileal of ileo-colic, 692
ileo-colic, 692
iliac, common, 696
external, 705
internal, 698
ilio-lumbar, 704
inferior articular of knee, 718
cerebellar, anterior, 661
posterior, 661
dental, 639
external frontal, 651
hæmorrhoidal, 701
internal frontal, 648
labial, 633

Arteries or Artery (*cont.*)
inferior laryngeal, 662
mesenteric, 693
pancreatico-duodenal, 691
profunda, 674
thyroid, 662
infrahyoid, 629
infraorbital, 639
innominate, 623
intercostal, 684
anterior, 665
superior, 665
interlobular, of kidney, 1188
internal auditory, 661, 1058
carotid, 643
iliac, 698
mammary, 663
maxillary, 637
plantar, 724
pudic, 701
interosseous, of foot, 722
of hand, 677, 678
ulnar, 680
intestini tenuis, 691
labial, inferior, 633
of labyrinth, 1058
lachrymal, 647
lateral nasal, 633
sacral, 704
lingual, 630
long ciliary, 648
thoracic, 670
of lower extremity 707
lumbar, 695
magna hallucis, 722
malar, 647
malleolar, 721
mammary, internal, 663
marginal, 620
masseteric, 639
mastoid, 635
maxillary, external, 631
internal, 637
mediastinal, from aorta, 684
from internal mammary, 664
meningeal, anterior, 646
middle, 638
from occipital, 634
from pharyngeal, 636
small, 639
from vertebral, 660
mesenteric, inferior, 693
superior, 690
metatarsal, 722
middle cerebral, 650
hæmorrhoidal, 699
internal frontal, 648
meningeal, 638
sacral, 696
musculo-phrenic, 665
mylo-hyoid, 639
nasal, of ophthalmic, 648
of nasal septum, inferior, 633
naso-palatine, 640
nutrient, of femur, 715
of fibula, 724
of humerus, 674
of tibia, 724
obturator, 700
occipital, 634
œsophageal of inferior thyroid, 662
of aorta, 684
ophthalmic, 647

Arteries or Artery (*cont.*)
ovarian, 695
palatine, ascending, 632
descending, 640
of pharyngeal, 635
palmar arch, deep, 676
superficial, 681
interosseous, 678
palpebral, 647
pancreatic, of splenic, 690
pancreatico-duodenal, inferior, 691
superior, 690
parieto-temporal, 652
perforating, of foot, 726
of hand, 678
of internal mammary, 665
of thigh, 714
pericardiac, 664, 684
perineal, superficial, 701
transverse, 702
peroneal, 723
anterior, 724
posterior, 724
pharyngeal, ascending, 635
phrenic, inferior, 695
superior, 685
pituitary, 646
plantar, 724, 725
popliteal, 716
posterior auricular, 635
cerebral, 661
circumflex, 670
communicating, 652
dental, 639
inferior cerebellar, 661
internal frontal, 649
meningeal, from vertebral, 660
scapular, 663
tibial, 722
prevertebral, 635
princeps cervicis, 634
pollicis, 677
profunda, of arm, inferior, 674
superior, 673
cervicis, 665
femoris, 713
of ulnar, 681
pterygoid, 639
pterygo-palatine, 640
pudic, deep external, 713
internal, in female, 703
in male, 701
superficial external, 703
pulmonary, 618
pyloric, 689
radial, 675
recurrent, 677
carpal, 677
radialis indicis, 678
ranine, 631
recurrent interosseous, 681
of hand, 678
radial, 677
tibial, anterior, 721
posterior, 721
ulnar, anterior, 679
posterior, 679
renal, 694
inferior, 1187
sacral, lateral, 704
middle, 696
scapular, posterior, 663
sciatic, 703

Arteries or Artery (*cont.*)
short ciliary, 648
sigmoid, 693
small meningeal, 639
spermatic, 694
spheno-palatine, 640
spinal, anterior, 660
posterior, 660
splenic, 690
sternal, 664
sterno-mastoid, 630, 634
stylo-mastoid, 635
subclavian, 654
subcostal, 685
sublingual, 630
submaxillary, 633
submental, 633
subscapular, 670
superficial cervical, 663
circumflex iliac, 713
epigastric, 713
external pudic, 713
palmar arch, 681
perineal, 701
temporal, 636
superficialis volæ, 677
superior articular of knee, 718
cerebellar, 661
epigastric, 665
fibular, 721
hæmorrhoidal, 694
intercostal, 665
laryngeal, 630
mesenteric, 690
phrenic, 685
profunda, 673
thoracic, 669
thyroid, 629
supra-acromial, 662
suprahyoid, 630
supraorbital, 647
suprarenal, 694
suprascapular, 662
suprasternal, 662
sural, 719
tarsal, 722
temporal, anterior, 636
deep, 639
middle, 636
of middle cerebral, 652
posterior, 636
superficial, 636
thoracic, acromio-, 670
alar, 670
aorta, 682
long, 670
superior, 669
thyreoidea ima, 624
thyroid axis, 662
inferior, 662
superior, 629
tibial, anterior, 719
posterior, 722
recurrent, 721
tonsillar, 633
transverse cervical, 662
coronary, 620
facial, 636
of the trunk, 682
tympanic, from internal carotid, 646
from internal maxillary, 638
ulnar, 678
recurrent, anterior, 679

Arteries or Artery (*cont.*)
ulnar, recurrent, posterior, 679
umbilical, in fœtus, 614
of upper extremity, 654
uterine, 699
vaginal, 700
of vas deferens, 699
vasa aberrantia, of arm, 672
brevia, 690
intestini tenuis, 691
vertebral, 659
vesical, inferior, 699
middle, 699
superior, 699
vestibular, 1001
Vidian, of internal maxillary, 640
of ophthalmic, 646
Arthrodia, 370
Articular arteries from popliteal, 718
cartilage, 22
end bulbs, 50
lamella of bone, 366
processes of vertebræ, 183
synovial membranes, 367
Articulations, 366
acromio-clavicular, 401
ankle, 440
astragalo-navicular, 445
atlanto-axial, 377
calcaneo-astragaloid, 444
calcaneo-cuboid, 446
calcaneo-navicular, 447
carpal, 416
carpo-metacarpal, 420
chondro-sternal, 388
classification of, 368
coccygeal, 396
condyloid, 370
costo-central, 386
costo-chondral, 390
costo-transverse, 386
costo-vertebral, 385
cuboideo-navicular, 448
cuneo-cuboid, 448
cuneo-navicular, 447
elbow, 409
hip, 423
immovable, 368
intercentral, 373
intercuneiform, 448
intermetacarpal, 422
intermetatarsal, 450
interneural, 375
interphalangeal, 242, 451
intertarsal, 444
knee, 430
of larynx, 1063
metacarpo-phalangeal, 422
metatarso-phalangeal, 451
mixed, 369
movable, 369
movements of, 370
occipito-atlantal, 380
occipito-axial, 382
of pelvis, 393
with vertebral column, 392
pubic, 396
radio-carpal, 415
radio-ulnar, inferior, 414
superior, 413
by reciprocal reception, 370
sacro-coccygeal, 396
sacro-iliac, 393
Articulations (*cont.*)
sacro-vertebral, 392
shoulder, 404
sterno-clavicular, 399
of sternum, 390
tarsal, 444
tarso-metatarsal, 449
temporo-mandibular, 382
tibio-fibular, inferior, 440
middle, 439
superior, 439
of trunk, 372
of vertebral column, 372
with cranium, 380
with pelvis, 392
wrist, 415
Aryepiglotticus, 1068
Aryteno-epiglottic folds, 1066
Arytenoid cartilages, 1061
glands, 1069
muscle, 1068
Ascending aorta, 619
cervical artery, 662
colon, 1151
frontal artery, 651
lumbar vein, 759
palatine artery, 632
pharyngeal artery, 635
applied anatomy of, 636
Association fibres of cerebral hemispheres, 878
neurons, 801
Asterion, 279
Astragalo-navicular ligament, 445
Astragalus, 353
ossification of, 362
Atlanto-axial articulation, 377
Atlas, 185
development of, 103
ossification of, 196
Atrium of bronchi, 1086
of nasal fossa, 1005
of tympanic cavity, 1039
Attic or epitympanic recess, 226, 1039
Attollens auriculam muscle, 459
Attraction particle, or centrosome, 4
sphere, or centrosphere, 4
Attrahens auriculam muscle, 459
Auditory artery, 661
canal, 1037
meatus, external, 230, 1037
development of, 134
lymphatic vessels of, 769
relations of, 1038
internal, 227
nerve, 927, 1058
applied anatomy of, 929
nuclei, 825
ossicles, development of, 134
process, external, 229
teeth, of Huschke, 1055
veins, 1058
vesicle, 133
Auerbach's plexus, 1148
Auricle of heart, appendix of, 680
principal cavity of, 608
primitive, 139
left, 608
right, 604
Auricle of heart, right, openings in, 604
sinus venosus of, 604
valves in, 604
Auricula of ear, 1035
cartilage of, 1036
ligaments of, 1036
muscles of, 1036
vessels and nerves of, 1036
Auricular artery, anterior, 636
deep, 638
of occipital, 634
posterior, 635
canal, 139
fissure, 228
nerve, anterior, 916
great, 950
posterior, from facial, 925
of vagus, 935
point, 279
surface of ilium, 322
of sacrum, 193
vein, posterior, 731
Auriculo-temporal nerve, 916
Auriculo-ventricular bundle of His, 611
groove of heart, 602
opening, left, 609
right, 606
Auscultation, triangle of, 492
Axes of pelvis, 329
Axial filament of spermatozoön, 82
Axilla, 666
applied anatomy of, 666
fascia of, 529
lymphatic glands of, 773
Axillary arch, 490
artery, 667
applied anatomy of, 668
branches of, 669
surface marking of, 668
lymphatic glands, 773
vein, 747
applied anatomy of, 747
Axis, cerebro-spinal, 763
cœliac, 688
optica, 1011
vertebra, 186
development of, 104
ossification of, 196
thyroid, 662
Axis-cylinder of nerve-fibre, 45
process, 44
of Purkinje, 45
Axon of nerve-cells, 44
Azygos arteries of vagina, 700
artery, articular, 718
uvulæ muscle, 484
veins, 750

Back, muscles of, fifth layer, 497
first layer, 489
fourth layer, 494
second layer, 492
third layer, 493
Baillarger, band of, 873
inner, 880
outer, 880
Balbiani, body of, 79
Ball-and-socket joint, 370
Band of Baillarger, 873
inner, 880
outer, 880
of Bechterew, 881

Band of Gennari, 880
of Giacomini, 864
ilio-tibial, 567
moderator, 607
of Vicq d'Azyr, 882
Bare area of liver, 1123
Bartholin, duct of, 1111
glands of, 1232
Basal column, posterior, 804
knobs of Engelmann, 14
lamina, 117
optic nucleus of Meynert, 851
plate of decidua, 100
ridge, or cingulum of tooth, 1094
Base of sacrum, 193
of skull, inferior surface, 262
upper surface, 271
Basement membranes, 20
Basi-hyal of hyoid bone, 260
Basilar artery, 661
groove, 217
process, 216
Basilic vein, 746
Basion, 279
Basket cells of cerebellum, 833
Bauhin, valve of, 1083
Bechterew, band of, 881
nucleus of, 825
Bell, external respiratory nerve of, 955
Bend of elbow, 672
Betz, giant cells of, 881
Biceps flexor cruris muscle, 577
flexor cubiti muscle, 537
Bicipital fascia, 538
groove, 295
ridges, 295
tuberosity, 306
Bicuspid teeth, 1095
valve, 609
Bigelow, Y-shaped ligament of, 425
Bile ducts, 1171, 1172
structure of, 1171
Bipolar cells of retina, 1021
Bird's nest of cerebellum, 829
Biventer cervicis muscle, 497
Biventral lobes, 829
BLADDER, 1193
applied anatomy of, 1199
in child, 1195
development of, 175
distended, 1194
empty, 1194
female, 1196
interior of, 1198
ligaments of, 1196
lymphatic vessels of, 788
structure of, 1197
surface form of, 1198
trigone of, 1198
vessels and nerves of, 1196
Blandin, glands of, 1106
Blastodermic vesicle, 85
Blastopore, 86
BLOOD, *General Composition of*, 7
circulation of, in adult, 597
in fœtus, 135, 614
coagulation of, 10
corpuscles, 7
crystals, 11
development of, 135
plasma of, 10
platelets, 9
Blood-corpuscles, origin of, 9, 135
Blood-islands, 135
Blood-sinuses, maternal, 99
Blood-vessels of brain, 652
Bochdalek, cornucopia of, 836
ganglion of, 912
Bodies, aortic, of Zuckerkandl, 1248
Malpighian, of kidney, 1185
of spleen, 1242
Pacchionian, 898
polar, 80
Body, ano-coccygeal, 1155
of Balbiani, 79
carotid, 1247
coccygeal, 1247
of lateral ventricle, 867
olivary, 813
of penis, 1214
perineal, 1155
of stomach, 1134
restiform, 815
thyroid, 1235
of a tooth, 1093
of the uterus, 1223
of a vertebra, 183
vitreous, 1025
Body-cavity or cœlom, 91
Body-stalk of mesoderm, 95
BONE, *Histology of*, 24
animal constituent of, 29
articular lamella of, 366
canaliculi of, 29
cancellous tissue of, 24
cells, 29
chemical composition of, 29
compact tissue of, 24
development of, 30
diploë of, 182
earthy constituent of, 30
eminences and depressions of, 182
Haversian canals of, 27
systems of, 27
lacunæ of, 29
lamellæ of, 28
lymphatics of, 27
marrow of, 25
medullary canal of, 181
membrane of, 25
nerves of, 27
ossification of, 30
perforating fibres of, 28
periosteum of, 25
vessels of, 26
Bones, classes of, viz. long, flat, mixed or irregular, short, 181
number of, in the body, 181
BONES OR BONE, *Descriptive Anatomy of*, 181
of arm, 286
astragalus, 353
atlas, 185
axis, 186
carpal, 311
clavicle, 286
coccyx, 194
cranial, 214
cuboid, 354
cuneiform, of carpus, 312
of tarsus, 356
of ear, 1043
ethmoid, 238
BONES OR BONE (*cont.*)
facial, 241
femur, 332
fibula, 347
of foot, 349
frontal, 220
of hand, 311
humerus, 295
hyoid, 260
ilium, 320
incus, 1044
inferior maxillary, 255
turbinated, 253
innominate, 320
interparietal, 217
ischium, 323
lachrymal, 247
of leg, 320
lesser lachrymal, 248
malar, 248
malleus, 1043
mandible, 255
maxilla, 242
maxillary, inferior, 255
superior, 242
metacarpal, 315
metatarsal, 358
nasal, 241
of nose, outer, 1002
navicular, 356
occipital, 214
orbicular, 1044
os calcis, 349
magnum, 314
palate, 250
parietal, 218
patella, 341
pelvic, 327
phalanges of foot, 361
of hand, 318
pisiform, 313
pubis, 324
radius, 306
ribs, 206
sacrum, 191
scaphoid, 311
scapula, 288
semilunar, 312
sesamoid, 364
sphenoid, 232
sphenoidal turbinated, 236
stapes, 1044
sternum, 203
superior maxillary, 242
tarsal, 349
temporal, 223
tibia, 343
trapezium, 313
trapezoid, 313
triquetral, 240
turbinated, inferior, 253
sphenoidal, 236
ulna, 301
unciform, 314
vertebra prominens, 187
vertebræ, cervical, 184
lumbar, 190
thoracic, or dorsal, 187
vomer, 254
Wormian, 240
zygomatic, 248
Bowman, glands of, 1007
lamina elastica anterior of, 1014
sarcous elements of, 35
Bowman's capsule, 1185

Brachia of corpora quadrigemina, 843
Brachial artery, 671
applied anatomy of, 672
branches of, 673
peculiarities of, 672
surface marking of, 672
plexus, 953
applied anatomy of, 965
veins, 747
Brachialis anticus muscle, 538
Brachio-cephalic veins, 747
Brachio-radialis muscle, 545
Brain, *Histology of*, 47
development of, 118
divisions of, 810
hemispheres of, 854
lobes of, 857
meninges of, 892
veins of, 736
weight of, 884
Brain-sand, 849
Breasts, 1232
development of, 115
Bregma, 279
Bregmatic fontanelle, 277
Bridge of nose, 1002
Brim of pelvis, 327
Broad ligaments of uterus, 1225
formation of, 1124
Broca, area of, 864
convolution of, 859
diagonal band of, 864
limbic lobe of, 862
Bronchi, left, 1070
changes in structure of, in lung, 1086
divisions of, 1084
right, 1070
Bronchial arteries, 684
veins, 750
Broncho-mediastinal trunk, left, 792
right, 792
Bruch, membrane of, 1016
Brunner's glands, 1146
Bryant's triangle, 428
Buccal arteries, 639
glands, 1090
lymphatic glands, 768
nerve of facial, 926
long, of inferior maxillary, 915
Buccinator muscle, 467
Bucco-pharyngeal area, 87
fascia, 473
Bulb, or medulla oblongata, 811
artery of, 703
of corpus cavernosum, 1212
spongiosum, 1213
of internal jugular vein, 733
of œsophagus, 1117
olfactory, 864, 883
of the posterior horn, 867
Bulbar arteries, 661
portion of spinal accessory nerve, 938
Bulbous portion of urethra, 1201
Bulbus cordis, 137
vestibuli, 1231
Bulla ethmoidalis, 276, 1004
Bundle of Vicq d'Azyr, 850, 875
oval, 117
Burdach's tract, 807
Burns' space, 473
Bursa omentalis, 158
pharyngea, 1114
Bursæ of knee, 435
of Gluteus maximus, 574
mucosæ, 367
of shoulder, 405
synoviæ, 367
Bursal synovial membranes, 367

Cæcal arteries, 692
Cæcum, 1149
lymphatic vessels of, 785
Calamus scriptorius, 837
Calcanean arteries, external, 724
internal, 724
facets, 354
nerve, internal, 982
Calcaneo-astragaloid ligaments, 444
Calcaneo-cuboid ligaments, 446
Calcaneo-navicular ligaments, 447
Calcar avis, 860, 867
femorale, 339
Calcarine fissure, 857
Callosal convolution, 863
fissure, 863
Calloso-marginal fissure, 857
Calyces of kidney, 1183
Camper, fascia of, 506
Canaliculi of bone, 29
Canalis centralis cochleæ, 227
hyaloideus, 131, 1025
reuniens of Hensen, 1053
spiralis modioli, 1050
Canals or Canal—
accessory palatine, 252
Alcock's, 518
alimentary, 1088
for Arnold's nerve, 228
auditory, 1037
carotid, 228
cranio-pharyngeal, 155, 237
crural, 708
dental anterior, 243
inferior, 257
middle, 243
posterior, 242
ethmoidal, 222
Haversian, of bone, 27
of Huguier, 224, 1040
Hunter's, 710
infraorbital, 243
inguinal or spermatic, 1204
for Jacobson's nerve, 228
lachrymal, 1032
malar, 248
neural, 89
neurenteric, 89
of Nuck, 175, 1225
palatine, accessory, 252
anterior, 246
posterior, 244, 251
of Petit, 1025
pterygo-palatine, 236
of Schlemm, 1014
semicircular, bony, 1048
membranous, 1053
Canals or Canal (*cont.*)
spermatic, 1204
of spinal cord, 800
spiral of modiolus, 1050
for tensor tympani muscle, 229, 1042
vertebral, 200
Vidian, 236
of Wirsung, 1178
Cancellous tissue of bone, 24
Canine eminence, 242
fossa, 242
teeth, 1094
Canthi of eyelids, 1029
Cap of Broca, 859
Capillaries, 57
structure of, 58
Capitellum of humerus, 298
Capsula adiposa of kidney, 1183
extrema of brain, 873
Capsule of Bowman, 1185
of brain, external, 874
internal, 873
fibrous of kidney, 1183
of Glisson, 1168
of lens, 1025
of Tenon, 1010
Caput cæcum coli, 1149
gallinaginis, 1200
Cardiac cycle, 612
ganglion of Wrisberg, 996
glands of stomach, 1138
lymphatics, 792
muscular tissue, 41
nerves from pneumogastric, 936
from sympathetic, 992, 993
orifice of stomach, 1133
plexuses of nerves, 996
veins, 728
Cardinal veins, fœtal, 146
Carotico-clinoid foramen, 235
ligament, 237
Carotico-tympanic nerve, 990
Carotid arch, 142
artery, common, 625
applied anatomy of, 627
branches of (occasional), 627
peculiarities of, 626
surface marking of, 627
external, 628
applied anatomy of, 629
branches of, 629
surface marking of, 629
internal, 643
applied anatomy, 645
branches of, 646
peculiarities of, 645
body, 626, 1247
canal, 228
ganglion, 990
groove, 233
nerves from glosso-pharyngeal, 932
plexus, 990
triangle, inferior, 641
superior, 641
tubercle, 185
Carpal arch, anterior, 677
posterior, 681
arteries, from radial, 677
from ulnar, 681
bones, 311
ligaments, 417

Carpo - metacarpal articulations, 420
Carpus, 311
applied anatomy of, 320
articulations of, 417
ossification of, 319
surface form of, 319
Cartilage, *Histology of*, 21
articular, 22
cellular, 21
costal, 22
cricoid, 1061
of ear, 1036
ensiform, 204
of epiglottis, 1062
epiphysial, 31
ethmo-vomerine, 255
hyaline, 21
intrathyroid, 1060
of Jacobson, 1005
permanent, 21
of the pinna, 1036
of septum of nose, 1003
temporary, 21
thyroid, 1059
white fibro-, 23
xiphoid, 204
yellow elastic, 24
Cartilage cells, 22
lacunæ, 22
Cartilages, arytenoid, 1061
of bronchi, 1086
costal, 211
cuneiform, 1061
of larynx, 1059
Meckel's, 108, 258
of the nose, 1002
parachordal, 106
of Santorini, 1061
semilunar of knee, 434
of trachea, 1072
of Wrisberg, 1061
Cartilagines alares minores, 1003
Cartilaginous ear capsule, 106
vertebral column, 103
Cartilago triticea, 1063
Caruncula lacrimalis, 1031
Carunculæ hymeneales, 1231
Cauda equina, 797
helicis, 1036
Caudal fold of embryo, 92
Caudate nucleus, 871
Cava, inferior, 758
peculiarities, 759
superior, 748
Cavernous nerves of penis, 1000
plexus, 990
sinuses, 740
applied anatomy of, 741
nerves in, 921
Cavity, amniotic, 93
body, or cœlom, 91
cotyloid, 325
glenoid, 292
of larynx, 1065
of pelvis, 328
peritoneal, 1122
sigmoid, of radius, 307
greater, of ulna, 304
lesser, of ulna, 304
of thorax, 598
tympanic, 1039
of uterus, 1224
Cavum conchæ, 1035
Meckelii, 906
Cavum oris proprium, 1089
septi pellucidi, 877
Cell, animal, 3
definition of, 3
division of, direct, 7
indirect, 4
nucleus of, 4
reproduction of, 4
structure of, 3
Cell-mass, inner, of ovum, 85
intermediate, 90
Cell-wall, 7
Cells of bone, 29
centro-acinar, of Langerhans, 1179
chalice, 13
chromaffin, 1246
of Claudius, 1057
of Deiters, 1056
of Dogiel, 942
enamel, 1101
ethmoidal, 239
fat, 17
germinal, 115
giant, 26
of Betz, 881
goblet, 13
of Golgi, 881
gustatory, 1001
of Martinotti, 881
mastoid, 226
nerve, 44
nerve-epithelium, 52
olfactory, 1007
prickle, 15
of Purkinje, 833
of Sertoli, 1208
of spinal ganglia, 942
splenic, 1242
supporting, of Hensen, 1057
wandering, 16
Cellular cartilage, 21
Cement, intercellular, 4
of teeth, 1098
formation of, 1102
Central canal of cord, 800
ganglionic system of arteries, 653
grey matter of aqueduct of Sylvius, 844
ligament of cord, 899
tendinous point of perinæum, 524
tendon of diaphragm, 503
Centre, higher visual, 852
of ossification, 31
Centres of ossification, number of, 33
lower visual, 852
Centrifugal nerve-fibres, 49
Centripetal nerve-fibres, 49
Centro-acinar cells of Langerhans, 1179
Centrosome, 4
bodies of spermatozoön, 82
of ovum, 79
Centrosphere, 4
Centrum ovale majus, 865
minus, 865
of vertebra, 183
Cephalic flexure of embryonic brain, 119
fold of embryo, 92
vein, 745
accessory, 746
Cerato-hyal of hyoid bone, 261
Cerebellar arteries, anterior inferior, 661
posterior inferior, 661
superior, 661
direct tract, 806
notches, 826
veins, 737
Cerebello-olivary tract, 820
Cerebellum, 825
applied anatomy of, 834
development of, 120
fibræ propriæ of, 832
great horizontal fissure of, 826
grey matter of, 832
hemispheres of, 826
laminæ of, 832
lobes of, 825
nucleus dentatus, 834
peduncles of, 830, 831
structure of, 830
under surface of, 827
upper surface of, 826
vermis of, 826
weight of, 834
white matter of, 830
Cerebral arteries, anterior, 648
middle, 650
posterior, 661
cortex, nerve-cells of, 881
nerve-fibres of, 881
special types of, 882
structure of, 880
hemispheres, 854
association fibres of, 878
borders of, 855
commissural fibres of, 878
convolutions, 856
development of, 124
fissures of, 856
grey matter of, 879
gyri of, 856
interior of, 865
lobes of, 857
localisation of, 885
poles of, 856
projection fibres of, 878
structure of, 878
sulci of, 856
surfaces of, 855
transverse fibres of, 878
white matter of, 878
topography, 885
veins, 736, 737
ventricles, 834, 852, 867
vesicles, 118
Cerebro-olivary tract, 820
Cerebro-spinal fluid, 897
Ceruminous glands, 1038
Cervical artery, ascending, 662
superficial, 663
transverse, 662
enlargement of spinal cord, 798
fascia, 471
ganglion, inferior, 993
middle, 992
superior, 990
lymphatic glands, anterior, 772
deep, 772
applied anatomy of, 772
nerve, superficial or transverse, 950
of facial, 927
nerves, 945

Cervical nerves, anterior divisions of, 949
posterior divisions of, 945
cardiac, 936
plexus, 949
deep branches of, 953
posterior, 946
superficial branches of, 950
rib, 187
applied anatomy of, 210
vertebræ, 184
Cervicalis ascendens muscle, 496
Cervicis princeps artery, 634
profunda artery, 665
Cervico-cephalic portion of sympathetic cord, 990
Cervico-facial nerve, 926
Cervix uteri, 1224
Chalice cells, 13
Chambers of the eye, 1017
Chassaignac's tubercle, 184
Check ligaments, 382
of eye, 1011
Cheeks, structure of, 1090
Chest, applied anatomy of, 212
surface form of, 211
Chiasma, or optic commissure, 901
Choanæ, 277, 1004
Cholesterin, 7
Chondrin, 24
Chondro-cranium, 105
Chondro-glossus muscle, 480
Chondro-mucoid, 24
Chondro-sternal ligaments, 388
Chondro-xiphoid ligament, 390
Chorda tympani nerve, 925
Chordæ tendineæ, of left ventricle, 608
of right ventricle, 606
Willisii, 738
Chordal furrow, 89
portion of base of skull, 106
Chorion, 97
frondosum, 97
læve, 97
Chorionic villi, 97
Choroid, 1014
development of, 133
plexus of fourth ventricle, 836
of lateral ventricle, 877
of third ventricle, 852
vein of brain, 737
Choroidal arteries, anterior, 652
posterior, 661
fissure, 129, 877
Chromaffin cells, 1246
Chromatin, 4
Chromatolysis, 45
Chromoplasm, 4
Chromosomes, 5
Chyle, 12, 763
Chyliferous vessels, 763
Cilia, or eyelashes, 1029
Ciliary arteries, 648
body, 1016
muscle, 1016
nerves, long, 910
short, 911
processes of eye, 1016
Ciliated epithelium, 13
Cingulum, 863, 879
of teeth, 1094
Circle of Willis, 652
Circular sinus, 742
Circulation of blood in adult, 597
in fœtus, 614
Circulus major of iris, 648
minor, 648
tonsillaris, 932
venosus of mamma, 1234
Circumcæcal fossæ, 1131
Circumduction, 370
Circumferential fibro-cartilage, 24
Circumflex artery of arm, anterior, 671
posterior, 672
artery of thigh, external, 714
internal, 714
iliac artery, deep, 707
superficial, 713
vein, deep, 755
superficial, 752
nerve, 956
Circumpatellar anastomosis, 719
Cisterna basalis, 896
magna, 896
pontis, 896
Cisternæ of arachnoid, 896
Clarke's column, 803
Classification of joints, 368
Claudius, cells of, 1057
Claustrum, 873
Clava of fasciculus gracilis, 814
Clavicle, 286
applied anatomy of, 289
ossification of, 288
peculiarities in sexes, 288
structure of, 288
surface form of, 288
Clavi-pectoral fascia, 667
Cleft palate, 285
Clefts, visceral, 107
Clinging fibres of cerebellum, 833
Clinoid processes, anterior, 235
middle, 232
posterior, 232
Clitoridis, præputium, 1231
Clitoris, 1231
frenulum of, 1231
muscles of, 527
Clivus, 233
monticuli of cerebellum, 827
Cloaca, ectodermal, 161
entodermal, 161
Cloacal membrane, 161
Cloquet, lymphatic gland of, 776
Clot, 10
Coagulation of blood, 10
Coccygeal artery, 704
body, 1247
nerve, anterior primary divisions of, 978
posterior primary divisions of, 949
plexus, 986
Coccygeus muscle, 521
Coccyx, 194
ossification of, 198
Cochlea, 1049
aqueduct of, 228
canalis spiralis of, 1050
cupula of, 1049
hamulus laminæ spiralis of, 1051
helicotrema, 1051
Cochlea, lamina spiralis of, 1051
lamina spiralis secundaria, 1051
membranous canal of, 1053
modiolus of, 1049
nerves of, 1058
scalæ of, 1051
veins of, 1058
Cochlear artery, 1058
nerve, 928, 1058
Cochlear nuclei, 825
root of eighth nerve, 928
Cochleariform process, 229, 1041
Cœliac axis, 688
plexus, 999
Cœlom, 91
Cog-tooth of malleus, 1043
Cohnheim, areas of, 38
Colic, left, 693
middle, 692
right, 692
Colic arteries of ileo-colic, 692
Collateral circulation. *See* Applied Anatomy of each artery
eminence, 871
fissure, 857
intercostal artery, 685
Collecting tubes of kidney, 1186
Colles, fascia of, 506, 523
Colliculus nervi optici, 1020
Colon, 1151
ascending, 1151
descending, 1152
hepatic flexure, 1151
iliac, 1153
lymphatic vessels of, 785
pelvic, 1153
splenic flexure of, 1153
Colostrum corpuscles, 1233
Coloured lines of Retzius, 1018
Coloured or red corpuscles, 7
Colourless corpuscles, 8
Column, vertebral, 182, 198
Columna nasi, 1002
Columnæ carneæ of left ventricle, 609
of right ventricle, 607
Columnar epithelium, 13
Columns of external abdominal ring, 508
of Morgagni, 1156
of spinal cord, 798
of vagina, 1229
Comes nervi ischiadici, 704
nervi mediani, 681
nervi phrenici, 663
Comma tract, descending, 801
Commissural fibres of brain, 878
Commissure of brain, anterior, 127, 876
middle or soft, 122
posterior, 123
superior, 849
of Gudden, 901
of labia majora, anterior, 1231
posterior, 1231
optic, 851, 901
of prostate, anterior, 1216
of spinal cord, grey, 800
white, 800

Common bile duct, 1173
lymphatics of, 787
carotid artery, 625
iliac artery, 696
glands, 780
veins, 758
ligaments of vertebræ, 373
Communicans peronei nerve, 984
tibialis nerve, 981
Communicantes hypoglossi nerve, 952
Communicating artery of brain, anterior, 648
posterior, 652
from dorsalis pedis, 722
Compact tissue of bone, 24
Comparison of bones of hand and foot, 362
Complexus muscle, 497
Compressor naris muscle, 464
narium minor muscle, 464
urethræ muscle, 526
in female, 528
Concha, 1035
cavum conchæ, 1035
cymba conchæ, 1035
Condylar process of mandible, 257
Condyles of femur, 337
mandible, 257
Condyloid articulations, 370
foramina, 216
fossa, 216
Cone of attraction of ovum, 83
Cone-bipolars of retina, 1021
Cone-granules of retina, 1022
Cones of retina, 1023
Confluence of the sinuses, 740
Congenital fissures in cranium, 240
hernia, 1160
Coni vasculosi, 1209
Conjoined tendon of internal oblique and transversalis muscles, 512
Conjunctiva, 1031
Connecting fibro-cartilages, 24
Connective tissues, 15
development of, 21
lymphatics of, 21
nerves of, 21
vessels of, 21
Connective-tissue corpuscles, 15
Connective tissue of kidney, 1189
extra-peritoneal, 516
Conoid ligament, 402
tubercle, 287
Constrictor muscle, inferior, 482
isthmi faucium muscle, 479
muscle, middle, 483
superior, 483
urethræ muscle, in female, 528
in male, 526
Contractile fibre-cells, 41
Conus arteriosus, 606
medullaris, 795
Convoluted tubes of kidney, 1186
tubular gland, 75
Convolution of Broca, 859
Convolutions, angular, 860
Convolutions, ascending frontal or precentral, 858
parietal or postcentral, 860
callosal, 863
of cerebrum, topography of, 885
cuneus, 860
dentate, 864
frontal, 858
of Heschl, 861
hippocampal, 863
inferior parietal, 860
marginal, 859
occipital, 861
occipito-temporal, 861, 862
orbital, 859
parietal, 860
postcentral, 860
postparietal, 860
precentral, 858
precuneus, 860
quadrate, 860
superior parietal, 860
supramarginal, 860
temporal, 861
Cooper, ligament of, 510
Coraco-acromial ligament, 403
Coraco-brachialis muscle, 537
Coraco-clavicular ligament, 402
Coraco-humeral ligament, 404
Coracoid process, 293
Cord, spermatic, 1205
spinal, 795
umbilical, 95
Corium of mucous membrane, 74
of skin, 66
Cornea, 1012
Corneal corpuscles, 1014
spaces, 1014
Cornicula laryngis, 1061
Cornua of the coccyx, 195
of the hyoid bone, 261
of the lateral ventricles, 867
of the sacrum, 192
of the spinal cord, 799
of the thyroid cartilage, 1060
Cornu Ammonis, 870
Cornu-commissural tract, 807
Cornucopia of Bochdalek, 836
Corona glandis, 1213
radiata of brain, 874
of ovum, 79
Coronal suture, 219
Coronary arteries of heart, 620
peculiarities of, 620
of lip, 633
artery of stomach, 688
ligament of liver, 1123
ligaments of knee, 434
lymphatic glands, 781
plexuses, 997
sinus, 728
opening of, 604
vein of stomach, 762
veins of heart, 728
Coronoid fossa, 298
process of mandible, 257
of ulna, 301
Corpora Arantii, 607
cavernosa clitoridis, 1231
penis, 1212
bulbs of, 1212
crura of, 1212
geniculata, 848
Corpora mamillaria, 850
quadrigemina, 843
brachia of, 843
structure of, 843
Corpus callosum, 865
development of, 127
genu of, 866
rostrum of, 866
splenium of, 866
cavernosum, artery of, 703
Highmori, 1207
spongiosum, 1213
striatum, 124, 871
vein of, 737
subthalamicum, 850
trapezoideum, 824
Corpuscles, coloured, 7
colourless, 7
development of, 135
origin of, 9
colostrum, 1233
connective-tissue, 15
genital, 50
of Herbst, 51
Pacinian, 51
tactile, 50
of Vater, 51*n*
Corrugator cutis ani muscle, 522
supercilii muscle, 460
Cortex of cerebellum, 832
of cerebrum, 880
of kidney, 1184
of suprarenal glands, 1246
Corti, ganglion of, 1050
organ of, 1055
rods of, 1056
tunnel of, 1056
Cortical arches, 1184
arterial system of brain, 654
columns, 1184
visual centre, 882
Cortico-pontine fibres of crusta, 839
Cortico-striate fibres, 873
Costal cartilages, 22, 211
articulation with ribs, 390
process, 184
Costo-central articulation, 386
Costo-chondral articulation, 390
Costo-clavicular ligament, 400
Costo-coracoid ligament, 531
membrane, 530
Costo-mediastinal sinus, 1077
Costo-transverse articulations, 386
Costo-vertebral articulations, 385
Cotyloid cavity, 325
ligament, 425
notch, 326
Coverings of direct inguinal hernia, 1161
of femoral hernia, 1161
of oblique inguinal hernia, 1159
of testes, 1203
Cowper's glands, 1218
Cranial bones, 214
fossæ, 271
nerves, 899
development of, 127
eighth pair, 927
eleventh, 937
fifth, 906

Cranial nerves, first, 900
fourth, 905
ninth, 930
second, 901
seventh, 922
sixth, 920
tenth, 933
third, 903
twelfth, 939
Craniology, 278
Cranio-pharyngeal canal, 115, 237
Cranium, 213
bones of, 214
congenital fissures in, 240
development of, 105
Cremaster muscle, 511
Cremasteric artery, 706
fascia, 512
Crescentic lobe, anterior, 827
posterior, 827
Crescents of Gianuzzi, 1112
Crest, frontal, 221
of ilium, 323
incisor, 246
infratemporal, 234
lachrymal, 248
nasal, 246
of nasal bone, 242
neural, 89
obturator, 325
occipital, 215
internal, 216
of pubis, 325
of spine of scapula, 291
supramastoid, 223
of tibia, 344
turbinated, of maxilla, 244, 245
of palate, 251
Cribriform fascia, 566
plate of ethmoid, 238
Crico-arytenoid ligament, posterior, 1064
Crico-arytenoideus lateralis muscle, 1068
posticus muscle, 1068
Crico-thyroid artery, 630
membrane, 1064
muscle, 1067
Crico-tracheal ligament, 1064
Cricoid cartilage, 1061
Crista basilaris, 1054
falciformis, 227
galli, 238
lacrimalis, 245
sphenoidalis, 233
terminalis of His, 138, 604
vestibuli, 1048
Crossed commissural fibres, 801
pyramidal tract, 805
Crown of a tooth, 1093
Crucial anastomosis, 704, 714
ligaments of knee, 432
ridge of occipital, 215
Cruciform ligament, 378
Crura cerebri, 838
structure of, 839
of clitoris, 1231
of corpora cavernosa, 1212
of diaphragm, 502
fornicis, 875
of penis, 1212
of stapes, 1044
Crural arch, deep, 516, 708
canal, 708
Crural nerve, anterior, 974
ring, 708
septum, 708
Crureus muscle, 569
Crus commune of semicircular canals, 1049
helicis, 1035
laterale, 1003
mediale, 1003
penis, 1212
superior and inferior, of transverse ligament, 378
Crusta or pes, 839
petrosa of teeth, 1098
Crypts of Lieberkühn, 1146
Crystalline lens, 1025
development of, 129
Crystals, blood, 11
Cuboid bone, 355
Cuboideo-navicular articulation, 448
Culmen monticuli of cerebellum, 827
Cuneate fasciculus, 807
nucleus, 814
tubercle, 814
Cuneiform bone, external, of foot, 358
internal, of foot, 356
middle, of foot, 357
of hand, 312
cartilages, 1061
Cuneo-cuboid articulation, 448
Cuneo-navicular articulation, 447
Cuneus, 860
Cupula of cochlea, 1051
Curvatures of stomach, 1133
Curved lines of ilium, 320, 321
of occipital, 214
Curves of the vertebral column, 198
Cushion of epiglottis, 1062
of Eustachian tube, 1114
Cusps of bicuspid valve, 609
of tricuspid valve, 606
Cutaneous nerve of thigh, external, 973
internal, 975
middle, 975
Cuticle of skin, 64
Cuticula dentis, 1101
Cutis plate, 102
vera, 66
Cuvier, ducts of, 146
Cycle, cardiac, 612
Cylindrical epithelium, 13
Cymba conchæ, 1035
Cystic artery, 690
duct, 1172
plexus of nerves, 999
vein, 763
Cytoblast, 86
Cytoplasm, 3

Dacryon, 279
Dangerous area of eyeball, 1028
Dartos, 1204
Darwin, tubercle of, 1035
Daughter chromosomes, 5
skeins, 5
Decidua, 97
basalis, 99
capsularis, 98
placentalis, 99
Decidua vera, 99
Decidual cells, 98
Decussation of fillet, 817
of optic nerves, 901
of pyramids, 813
Deep abdominal ring, 516
auricular artery, 638
cervical lymphatic glands, 772
crural arch, 516
epigastric artery, 706
vein, 755
external pudic artery, 713
palmar arch, 676
fascia, 552
temporal artery, 639
nerves, 915
transverse fascia of leg, 583
Degeneration, Wallerian, 46, 804
Deglutition, 486
Deiters, cells of, 1056
nucleus of, 825
Delimitation of embryo, 91
Deltoid ligament, 441
muscle, 534
tubercle, 287
tuberosity, 298
Demilunes of Heidenhain, 1112
Demours, membrane of, 1014
Dendrites, 794
Dendrons of nerve-cells, 45
Dens sapientiæ, 1096
Dental artery, anterior, 640
inferior, 639
posterior, 639
canal, anterior, 243
inferior, 257
middle, 243
posterior, 242
furrow, 1100
germ, common, 1099
special, 1100
lamina, 1099
nerves, inferior, 917
superior, 912
pulp, 1096
sacs, 1101
Dentate gyrus, 864
fissure, 863
Dentinal tubules, 1097
fibres, 1097
sheath of Neumann, 1097
Dentine, 1097
formation of, 1101
secondary, 1099
Depressions for Pacchionian bodies, 218, 221
Depressor alæ nasi muscle, 464
anguli oris muscle, 466
labii inferioris muscle, 466
Dermal bones, 107
Dermatoma, 102
Dermic coat of hair follicle, 69
Dermis, or true skin, 66
Descemet, membrane of, 1014
Descendens hypoglossi nerve, 940
Descending aorta, 682
cerebello-spinal tract, 805
colon, 1153
comma tract, 808
cornu of lateral ventricle, 868
palatine artery, 640
Descent of testis, 173
Detrusor urinæ muscle, 1197

Deutoplasm, 79
Development of adipose tissue, 18
alimentary canal and its appendages, 150
arteries, 141
atlas, 103
axis, 104
bone, 30
brain, 118
connective tissue, 21
cranial nerves, 127
cranium, 105
Diaphragm, 167
ear, 133
ethmoid, 107
external organs of generation, 175
eye, 128
face, 110
frontal bone, 107
generative organs, 167
glands of skin, 114
heart, 137
hyoid bone, 108
joints, 114
kidney, 174
limbs, 113
liver, 164
lymphatics, 149
mammæ, 115
mouth, 151
muscle fibres, 42
muscles, 114
nerve cells and fibres, 47
nervous system, 115
nose, 110
ovaries, 172
palate, 111
pancreas, 165
parietes, 102
pericardium, 150
permanent teeth, 1102
pharynx, 155
pituitary body, 155
pleuræ, 167
prostate, 175
respiratory organs, 166
ribs, 104
salivary glands, 153
sense organs, 115
skeleton, 102
skin, 114
skull, 105
spinal cord, 115
spleen, 166
sternum, 104
suprarenal glands, 169
temporary teeth, 1099
testis, 173
thymus gland, 154
thyroid body, 154
tongue, 153
tonsils, 154
urethra, 175
urinary bladder, 175
organs, 167
vascular system, 135
veins, 145
vertebral column, 102
visceral arches, 107
vomer, 112
Diagonal band of Broca, 864
Diaphragm, 501
development of, 167
lymphatics, vessels of, 790
Diaphragm, pelvic, 517
trefoil tendon of, 503
Diaphragma sellæ, 894
urogenitale, 525
Diaphragmatic lymphatic glands, 790
Diaphysis, 33
Diarthrosis, 369
Diaster, 5
Diencephalon, 122, 844
Digastric fossa, 225
muscle, 477
nerve, from facial, 925
triangle, 642
Digestion, organs of, 1088
Digital arteries from palmar arch, 681
of anterior tibial, 984
of external plantar, 984
of internal plantar, 983
fossa of epididymis, 1206
fossa of femur, 334
nerves of musculo-cutaneous, 985
of median, 962
of radial, 965
of ulnar, 963
sheaths of fingers, 552
of toes, 589
veins of hand, 745
Dilatator naris anterior, 464
posterior, 464
pupillæ muscle, 1018
tubæ, 1043
Diploë, 182
veins of, 735
Direct cerebellar tract of cord, 806
inguinal hernia, 1161
course of, 1161
coverings of, 1161
pyramidal tract, 804
Discharge of ovum, 1221
Disc, interpubic, 397
Discs, intervertebral, 374
Discus proligerus, 1220
Dispirem or daughter skeins, 5
Distal convoluted tubule, 1186
Diverticulum, Meckel's, 93, 1143
Division of bronchi, 1084
of cells, 4
direct, 7
indirect, 4
Dobie's line, 38
Dogiel, cells of, 942
Dorsal artery of penis, 703
auditory nucleus, 825
lamina, 117
longitudinal fasciculus, 841
nerve of penis, 986
peripheral band, 808
veins of penis, 757
vertebræ, 187
peculiar, 188
Dorsales pollicis arteries, 677
Dorsalis hallucis artery, 722
indicis, 677
linguæ, 630
pedis, 721
applied anatomy of, 722
branches of, 722
peculiarities of, 722
surface marking of, 722
scapulæ, 670
Dorso-epitrochlearis muscle, 492
Dorsum ilii, 320
of scapula, 289
sellæ, 232
Douglas, pouch of, 1225
semilunar fold of, 513
Ductless glands, 1234
aortic bodies of Zuckerkandl, 1248
carotid bodies, 1247
coccygeal body, 1247
parathyroids, 1237
spleen, 1240
suprarenals, 1245
thymus, 1238
thyroid, 1235
Ducts or Duct—
accessory pancreatic, 1178
of Bartholin, 1111
common bile duct, 1173
of Cowper's glands, 1218
of Cuvier, 146
cystic, 1172
ejaculatory, 1212
of Gärtner, 1220
hepatic, 1171
lactiferous, 1233
of liver, 1171
lymphatic, right, 767
Müllerian, 170
nasal, 1033
pancreatic, 1178
parotid, 1110
perinephric, 168
prostatic, orifices of, 1200
of Rivinus, 1111
Stenson's, 1100
sublingual, 1111
submaxillary, 1110
thoracic, 765
thyroglossal, 154
vitelline, 93
Wharton's, 1110
of Wirsung, 1178
Wolffian, 168
Ductus arteriosus, 614
how obliterated in fœtus, 616
choledochus, 1173
cochlearis, 1053
endolymphaticus, 133, 1053
pancreaticus accessorius, 1178
Santorini, 1178
utriculo-saccularis, 1053
venosus, 146, 614
development of, 146
fissure for, 1167
Duodenal fold, inferior, 1129
superior, 1130
fossa, inferior, 1129
superior, 1130
glands, 1146
Duodeno-jejunal flexure, 1142
fossa, 1131
Duodeno-mesocolic ligaments, 1131
Duodeno-pyloric constriction, 1133
Duodenum, 1139
first portion, 1141
second portion, 1141
third portion, 1142
fourth portion, 1142
lymphatic vessels of, 784

Duodenum, vessels and nerves of, 1142
Dura mater, 892
arteries of, 894
cranial, 892
endosteal layer of, 894
meningeal layer of, 894
nerves of, 894
processes of, 893
spinal, 894
structure of, 894, 895
veins of, 894

Ear, 1034
arteries of, 1037, 1043, 1058
auditory canal, 1037
applied anatomy of, 1038
cochlea, 1049
development of, 133
external, 1034
internal, or labyrinth, 1047
meatus acusticus externus, 1037
middle or tympanum, 1039
membranous labyrinth, 1051
muscles of pinna, 1036
of tympanum, 1045
osseous labyrinth, 1047
ossicles of tympanum, 1043
pinna or auricle of, 1035
semicircular canals, 1048
tympanum, or middle ear, 1039
applied anatomy of, 1046
vessels and nerves of, 1046
vestibule, 1047
Ectoderm, 87
amniotic, 94
embryonic, 86
primitive, 85
Ectodermal cloaca, 161
Efferent nerves, 49
Egg-tubes of Pflüger, 1221
Eighth cranial nerve, 927
applied anatomy of, 929
nuclei of, 825
Ejaculator urinæ, 524
Ejaculatory ducts, 1212
Elastic cartilage, 24
lamina of cornea, 1014
tissue, yellow, 19
Elastin, 19
Elbow, bend of, 672
joint, 409
anastomoses around, 674
applied anatomy of, 412
surface form of, 411
vessels and nerves of, 410, 411
Eleidin, 66
Eleventh cranial nerve, 937
applied anatomy of, 939
Embryo, delimitation of, 91
membranes and appendages of, 92
Embryonic area, 86
ectoderm, 86
pole, 15
Eminence, canine, 242
frontal, 220
hypothenar, 550
ilio-pectineal, 323
parietal, 218
pyramidal, of pons, 823
thenar, 550
Eminences and depressions of bones, 182
Eminentia acustica, 837
arcuata, 227
articularis, 223
collateralis, 871
cruciata, 215
saccularis, 851
teres, 838
Emissary veins, 743
Enamel cells, 1101
droplet, 1101
epithelium, 1101
organ, 1101
prisms or fibres, 1098
of teeth, 1098
formation of, 1101
Enarthrosis, 370
Encephalon, 810
weight of, 884
End-bulbs of Krause, 50
articular, 50
End-piece of spermatozoön, 82
End-plates, motor, of Kühne, 53
Endings of Ruffini, 50
Endocardial cushions, 139
Endocardium, 609
Endognathion, 285
Endolymph, 1051
Endomysium, 37
Endoneurium, 48
Endoskeleton, 181
Endosteal layer of dura mater, 894
Endothelium, 13
Ensiform process, 204
Entoderm, 86, 88
Entodermal cloaca, 161
Eosinophil corpuscles, 8
Eparterial branch of bronchus, 1070
Ependyma, 867
Ependymal layer, 116
Epicardium, 600
Epicondyles of humerus, 299
Epicranial aponeurosis, 458
Epidermic coat of hair follicle, 69
Epidermis, development of, 114
structure of, 64
Epididymis, 1206
development of, 169
Epigastric artery, deep, 706
applied anatomy of, 707
peculiarities, 707
superficial, 713
superior, 665
fossa, 212
plexus, 997
region, 1119
vein, deep, 755
superficial, 752
Epiglottis, 1062
Epihyal, 478
Epimysium, 36
Epineurium, 47
Epiotic centre of temporal bone, 231
Epiphysial cartilage, 31
Epiphysis, 33
Epistropheus, 186
Epithalamus, 123, 849
fasciculus retroflexus of Meynert, 849
Epithalamus, ganglion habenulæ, 849
pineal body, 849
homologies of, 849
stalk of, 849
structure of, 849
posterior commissure, 849
nucleus of, 849
superior commissure, 849
trigonum habenulæ, 849
Epithelial cells, 12
Epithelium, 12
ciliated, 13
columnar, 13
cylindrical, 13
enamel, 1101
germinal, of Waldeyer, 172, 1220
pavement, 12
simple, 12
spheroidal or glandular, 13
stratified, 14
of cornea, 1013
transitional, 15
Epitympanic recess, 226, 1039
Eponychium, 68
Epoöphoron, 169, 1220
Equator of lens, 1025
Erector clitoridis muscle, 527
penis muscle, 524
spinæ muscle, 495
Eruption of the teeth, 1102
Erythroblasts, 10, 26
Erythrocytes, 7
Ethmo-vomerine cartilage, 255
Ethmoid bone, 238
articulations of, 240
cribriform plate of, 238
development of, 107
lateral masses of, 239
os planum of, 239
ossification of, 240
perpendicular plate of, 239
uncinate process of, 239
Ethmoidal arteries, 647
canal, anterior, 222
posterior, 222
cells, 239, 1008
notch, 222
plate, 106
process of inferior turbinated, 253
spine, 232
Eustachian tube, 1042
cushion of, 1114
isthmus of, 1042
pharyngeal orifice of, 1114
tonsil of, 1042
valve, 605
in fœtal heart, 614
Exner, plexus of, 881
Exognathion, 285
Exoskeleton, 181
Extensor brevis digitorum muscle, 587
brevis pollicis, 549
carpi radialis brevior muscle 545
longior, 545
ulnaris, 547
coccygis, 498
communis digitorum (hand), 546
indicis, 549
longus digitorum (foot), 580
pollicis, 549

Extensor minimi digiti, 547
ossis metacarpi pollicis, 549
proprius hallucis, 580
External abdominal ring, 508
annular ligament, 587
capsule of brain, 874
carotid artery, 628
cutaneous nerve, 973
iliac artery, 705
lymphatic glands, 779
vein, 755
jugular vein, 732
maxillary artery, 631
medullary lamina, 847
organs of generation, development of, 175
female, 1230
lymphatic vessels of, 781
os uteri, 1224
plantar artery, 725
nerve, 983
popliteal nerve, 984
pterygoid plate, 236
respiratory nerve of Bell, 955
saphenous nerve, 981
vein, 753
spermatic fascia, 509
sphincter ani, 494
Extra-embryonic area, 86
Extra-peritoneal connective tissue, 516
Extra-spinal veins, 751
Extremities, 286
bones of the lower, 320
upper, 286
Extremity of penis, 1214
Extrinsic muscles of tongue, 480
Eye, 1010
appendages of, 1028
applied anatomy of, 1026
aqueous humour, 1024
capsule of Tenon, 1010
chambers of, 1017
choroid, 1014
ciliary body, 1016
muscle, 1016
processes, 1016
conjunctiva, 1031
cornea, 1012
crystalline lens, 1025
development of, 128
hyaloid membrane, 1025
iris, 1017
membrana hyaloidea, 1025
pupillaris, 1019
orbiculus ciliaris, 1016
pupil, 1017
refracting media, 1024
retina, 1020
sclera, 1011
tunics of, 1011
uvea, 1018
vascular and pigmented tunic, 1014
vessels and nerves of globe of, 1026
vitreous body, 1025
Eyeball, muscles of, 462
Eyebrows, 1029
Eyelashes, 1029
Eyelids, 1029
development of, 133
Meibomian glands of, 1031
muscles of, 459
palpebral ligaments of, 1030
structure of, 1029
Eyelids, tarsal plates of, 1030
Eye-teeth, 1095

Face, arteries of, 631
bones of, 241
development of, 110
lymphatics of, 769
muscles of, 456
Facial artery, 631
applied anatomy of, 633
peculiarities of, 633
transverse, 636
bones, 241
nerve, 922
vein, 730
applied anatomy of, 731
common, 730
deep, 730
transverse, 731
Falciform ligament of liver, 1168
of pelvis, 395
process of fascia lata, 568
Fallopian tubes, 1221
applied anatomy of, 1222
development of, 170
fimbriated extremity of, 1221
lymphatic vessels of, 789
structure of, 1221
False ligaments of bladder, 1197
pelvis, 327
ribs, 206
vocal cords, 1066
Falx cerebelli, 894
cerebri, 893
Fangs of teeth, 1093
Fascia, anal, 518
axillaris, 529
of arm, 533
of back, 489
bicipital, 538
bucco-pharyngeal, 473
of Camper, 506
cervical, deep, 472
superficial, 471
clavi-pectoral, 667
of Colles, 506, 523
of cranial region, 456
cremasteric, 512
cribriform, 566
deep, 455
dorsal, of foot, 587
endopelvina, 519
of forearm, 539
general description of, 455
of hand, 550
iliac, 564
infraspinata, 536
infundibuliform, 516
intercolumnar, 509
intercostal, 500
ischio-rectal, 521
lata, 566
falciform process of, 568
iliac portion, 568
pubic portion, 568
of leg, 579
deep transverse, 583
lumbar, 493
of mamma, 529
masseteric, 467
of Obturator internus, 517
Fascia (*cont.*)
of orbit, 463
palmar, 552
parotid, 473
pelvic, 517
of pelvic diaphragm, 518
plantar, 587
pretracheal, 473
prevertebral, 473
propria of femoral hernia, 1162
of psoas and iliacus, 564
of pyriformis, 518
of Quadratus lumborum, 517
rectal, 519
recto-vesical, 519
renalis, 1183
of Scarpa, 506
semilunar, 538
spermatic, external, 509
subscapularis, 534
superficial, 455
supraspinata, 535
temporal, 468
of thigh, 566
of thoracic region, 528
transversalis, 515
triangular, 510
vertebral, 493
vesical, 519
Fasciæ, general description of, 455
Fasciculus cuneatus, 807, 816
gracilis, 807, 816
inferior longitudinal, 879
occipito-frontal, 879
perpendicular, 879
posterior longitudinal, 841
retroflexus of Meynert, 849
of Rolando, 814
solitarius, 822
spino-cerebellaris ventralis, 806
superior longitudinal, 879
Fasciola cinerea, 864
Fat, 17
cells, 17
Fauces, isthmus of, 1091
pillars of, 1091
Female Reproductive Organs—
bulbus vestibuli, 1231
carunculæ hymeneales, 1231
clitoris, 1231
development of, 167
fossa navicularis, 1231
fourchette, 1231
glands of Bartholin, 1232
hymen, 1231
labia majora, 1230
minora, 1231
mons Veneris, 1230
nymphæ, 1231
uterus, 1222
vagina, 1229
vestibule, 1231
Femoral artery, 707
applied anatomy of, 712
branches of, 713
common, 712
peculiarities of, 712
surface marking of, 712
hernia, 1161
region, muscles of anterior, 566
internal, 571

Femoral region, posterior, 577
sheath, 707
spur, 339
vein, 755
Femur, 332
applied anatomy of, 340
articulations of, 339
condyles of, 337
head of, 332
neck of, 332
ossification of, 339
structure of, 338
surface form of, 340
trochanters of, 333
Fenestra ovalis, 1041
rotunda, 1041
Fenestrated membrane of Henle, 55
Fertilisation of ovum, 83
Fibræ propriæ of cerebellum, 832
Fibre-cells, contractile, 41
Fibres, arcuate, 820
dentinal, 1097
intercolumnar, 509
of Müller, 1023
of muscles, 37
of nerves, 45
of Purkinje, 42
of Remak, 47
of Tomes, 1097
Fibrillæ, termination of nerves in, 49
Fibrin, 10
ferment, 10
Fibrinogen, 10
Fibro-cartilage, 23
connecting, circumferential, and stratiform, 24
interarticular, 23
yellow, 24
Fibro-cartilages—
acromio-clavicular, 402
intervertebral, 374
of knee, 434
pubic, 397
radio-ulnar, 414
sacro-coccygeal, 396
sterno-clavicular, 400
temporo-mandibular, 383
Fibro-serous membranes, 72
Fibrous cartilage, 23
pericardium, 599
rings of heart, 610
tissue, white, 18
Fibula, 347
applied anatomy of, 349
articulations of, 348
ossification of, 348
surface form of, 348
Fibular artery, superior, 721
region, muscles of, 565
Fifth cranial nerve, 906
applied anatomy of, 918
nuclei of, 824, 844
surface marking of, 918
ventricle of brain, 877
Filiform papillæ of the tongue, 1105
Fillet, 842
lateral, 842
mesial, 843
Filtration area of eyeball, 1028
Filum terminale of cord, 797
Fimbria or tænia hippocampi, 875
ovarica, 1221
Fimbriæ of Fallopian tube, 1221
Fimbrio-dentate fissure, 864
First nerve, 900
applied anatomy of, 901
Fission of cells, 7
Fissura antitragohelicina, 1036
petro-occipitalis, 264
petro-squamosa, 264
petro-tympanica, 1040
prima of cerebellum, 121
of rhinencephalon, 864
secunda of cerebellum, 121
vestibuli, 1051
Fissure, auricular, 228
choroidal, 129
for ductus venosus, 1167
Glaserian, 224
longitudinal of liver, 1167
transverse, 1167
portal, 1167
pterygo-maxillary, 268
spheno-maxillary, 267
sphenoidal, 235
of spinal cord, 798
umbilical, 1167
for vena cava, 1167
Fissures of cerebellum, 827, 828
great horizontal, 826
intragracile, 829
postcentral, 827
postclival, 827
postgracile, 829
postnodular, 828
postpyramidal, 829
precentral, 827
preclival, 827
prepyramidal, 828
of cerebrum, 856
calcarine, 857, 860
callosal, 863
calloso-marginal, 857
collateral, 857
dentate, 863
fimbrio-dentate, 864
great longitudinal, 854
hippocampal, 863
parieto-occipital, 857, 869
Rolando, 857
Sylvius, 856
transverse, 878
of the cerebellum (embryonic), 120
of the cerebrum (embryonic), 126
congenital (of skull), 240
of the lung, 1082
of the medulla, 812
of the spinal cord, 798
Fixation muscles, 454
of the kidney, 1183
Flat bones, 181
Flechsig, oval area of, 808
tract of, 806
Flexor accessorius muscle, 589
brevis digitorum, 588
hallucis, 590
minimi digiti of foot, 591
of hand, 556
pollicis, 554
carpi radialis, 540
ulnaris, 541
Flexor longus digitorum, 583
hallucis, 583
pollicis, 544
profundus digitorum, 543
sublimis digitorum, 541
Flexure, hepatic, 1151
splenic, 1151
Flexures of embryonic brain, cephalic, 119
cervical, 119
pontine, 119
Floating ribs, 207
Flocculus, 829
Floor plate, 115
Fluid, cerebro-spinal, 897
Fluids, nutritive, 7
Fœtus, circulation in, 614
Eustachian valve in, 614
foramen ovale in, 140
vascular system in, peculiarities, 614
Fold of Douglas, 513
vestigial, of pericardium, 600
Folds, amniotic, 93
aryteno-epiglottic, 1066
caudal and cephalic, 92
genital, inner, 176
outer or labio-scrotal, 175
glosso-epiglottic, 1062
recto-uterine, 1225
recto-vesical, or sacro-genital, 1125
Folium cacuminis, 827
Follicle of hair, 68
simple, of intestine, 1146
Follicles, Graafian, 1220
Fontana, spaces of, 1014
Fontanelles, 277
Foot, arches of, 452
arteries of, 721, 724, 725
bones of, 349
applied anatomy of, 363
ossification of, 362
surface form of, 363
dorsum, fascia of, 587
muscles of, 587
ligaments of, 444
sole of, fascia of, 587
muscles of, 589
Foramen cæcum of frontal bone, 221
of medulla oblongata, 812
of tongue, 154, 1104
carotico-clinoid, 235
condyloid, anterior, 216
posterior, 216
dental, inferior, 256
of Huschke, 230
incisor, 246
infraorbital, 242
intervertebral, 183
jugular, 264
lacerum medium, 264
magnum, 217
of Majendie, 836, 897
mastoid, 225
mental, 255
of Monro, 876
development of, 122
obturator, 326
optic, 232
ovale of heart, 140, 614
of sphenoid, 234
palatine, accessory, 252
posterior, 252

Foramen, parietal, 218
rotundum, 234
sacro-sciatic, 395, 396
singulare, 227
spheno-palatine, 252
spinosum, 234
sternal, 204
stylomastoid, 228
supraorbital, 221
supratrochlear, 299
thyroid, 326
transversarium, 184
vertebral, 183
Vesalii, 234
of Winslow, 158, 1127
Foramina of Diaphragm, 503
ethmoidal, 270
intervertebral, 183
of Key and Retzius, 836, 837
of Luschka, 836, 897
malar, 248
nervosa, 1055
olfactory, 238
sacral, 191
of scarpa, 246
of Stenson, 246
Thebesii, 604
Forceps, major, 866
minor, 866
Forearm, bones of, 301
fascia of, 539
muscles of, 539
Forebrain, 122, 844
Foregut, 150
Foreskin, 1214
Form of embryo at different stages, 177
Formatio reticularis alba, 821
of cord, 799
grisea, 821
of medulla, 821
Formation, hippocampal, 126
Formative yolk, 79
Fornices of vagina, 1229
Fornix of brain, 875
body of, 875
development of, 127
pillars of, 875
conjunctivæ, 1031
Fossa acetabuli, 326
anticubital, 672
of antihelix, 1035
canine, 242
cochlearis, 1048
condyloidea, 216
coronoidea, 298
digastric, 225
digital, of epididymis, 1206
of femur, 334
duodenal, inferior, 1129
superior, 1130
duodeno-jejunal, 1131
femoral, 709
glenoid, 224
of helix, 1035
hyaloidea, 1025
ileo-cæcal, 1131
ileo-colic, 1131
iliac, 322
incisive, 242
incudis, 1041
infraspinous, 289
infratemporal, 267
interpeduncularis, 838
intersigmoid, 1132
Fossa, ischio-rectal, 522
jugular, 228
lachrymal, 221, 245
navicularis of urethra, 1201
of vulva, 1231
occipital, 215
olecranon, 298
ovalis, 605
ovarii, 1218
palatine, anterior, 246
pararectal, 1125
paravesical, 1125
pituitary, 232
pterygoid, 236
radialis, 298
retrocæcal, 1132
of Rosenmüller, 1114
scapha, 1035
scaphoidea, 236
of skull, anterior, 271
middle, 273
posterior, 274
spheno-maxillary, 268
subarcuata, 228
subcæcal, 1132
sublingual, 256
submaxillary, 256
subscapular, 289
supraspinous, 289
supratonsillaris, 1114
Sylvian, 126
temporal, 266
triangularis, 1035
trochanteric, 334
zygomatic, 267
Fossæ, nasal, 275, 1004
retroperitoneal, 1129
of skull, 271
Fountain decussation of Meynert, 844
Fourchette, 1231
Fourth cranial nerve, 905
applied anatomy of, 906
ventricle, 834
Fovea centralis retinæ, 1023
inferior of fourth ventricle, 837
inguinalis lateralis, 1159
mesialis, 1159
superior of fourth ventricle, 837
supravesicalis, 1159
trochlearis, 221
Fracture of acromion process, 560
of clavicle, 560
of femur above condyles, 595
below trochanters, 595
of fibula, with dislocation of tibia, 596
of humerus, shaft of, 561
surgical neck, 561
of neck of femur, 595
of olecranon process, 562
of patella, 595
of pelvis, 332
Pott's, 596
of radius, 562
lower end of, 563
shaft of, 562
and ulna, 562
of ribs, 212
of skull, 282
of sternum, 212
of tibia, shaft of, 595
of ulna, shaft of, 562
Frenula of ileo-cæcal valve, 1150
of lips, 1089
Frenulum of cerebellum, 827
clitoridis, 1231
linguæ, 1104
præputii, 1214
veli, 831
Frontal artery, 648
bone, 220
articulations of, 223
ossification of, 223
structure of, 223
convolutions, 857
crest, 221
eminence, 220
lobe, 857
nerve, 909
operculum, 862
sinuses, 222, 1008
suture, 220
vein, 729
Fronto-ethmoidal suture, 272
Fronto-malar suture, 265
Fronto-maxillary suture, 271
Fronto-nasal process, 110
Fronto-parietal operculum, 862
Fronto-sphenoidal process of malar, 248
Fundus of stomach, 1134
tympani, 1040
of uterus, 1223
Fungiform papillæ of tongue, 1105
Funicular process, 173
Funiculus of nerve, 47
separans, 837
Furcalis, nervus, 970
Furcula, 154
Furrow, chordal, 89
dental, 1100
iliac, 331
sternal, 211
Furrowed band of cerebellum, 829

Galen, veins of, 737
Gall-bladder, 1172
applied anatomy of, 1175
fissure for, 1167
lymphatic vessels of, 787
structure of, 1172
Gangliated cord of sympathetic, 988
cervico-cephalic portion, 990
lumbar portion, 994
pelvic portion, 996
thoracic portion, 993
Ganglion or Ganglia, *Histology of*, 53
of Andersch, 932
aortic-renal, 997
of Bochdalek, 912
cardiac, 996
carotid, 990
cervical, inferior, 993
middle, 992
superior, 990
diaphragmatic, 997
on facial nerve, 923
of fifth nerve, 908
Gasserian, 906
geniculi, 923
of glosso-pharyngeal, 932
habenulæ, 849
impar, 996

Ganglion or Ganglia (*cont.*)
interpedunculare, 840
jugular, 932
Langley's, 1112
lenticular, 910
lumbar, 995
Meckel's, 912
mesenteric, 999
ophthalmic, 910
otic, 917
petrous, 932
phrenicum, 997
of pneumogastric, 935
of root of vagus, 935
sacral, 996
of Scarpa, 1058
semilunar, of abdomen, 997
spheno-palatine, 912
spinal, 941
spirale cochleæ, 1058
splanchnicum, 993
submaxillary, 918
suprarenal, 998
thoracic, 993
of trunk of vagus, 935
of Valentin, 912
of Wrisberg, 996
Ganglion ridge or neural crest, 89, 118
Ganglionic branch of nasal nerve, 909
arteries, antero-lateral, 650
antero-median, 648
postero-lateral, 661
postero-median, 661
layer of retina, 1021
Gärtner, duct of, 169, 1220
Gasserian ganglion, 906
depression for, 227
artery, 646
Gastric arteries (vasa brevia), 690
artery, 688
glands, 1137
nerves from vagus, 937
plexus, 999
veins, short, 762
Gastrocnemius muscle, 581
Gastro-colic omentum, 1128
Gastro-duodenal artery, 689
plexus, 999
Gastro-epiploic plexus, 999
veins, 762
Gastro-epiploic artery, right, 690
left, 690
vein, left, 762
Gastro-hepatic omentum, 1127
Gastro-phrenic ligament, 1134
Gastro-splenic omentum, 1128
Gemellus inferior muscle, 576
superior muscle, 576
Gemmation of cells, 7
Generative Organs, development of, 167
female, 1218
male, 1203
Geniculate bodies, 848
fibres of crusta, 839
of internal capsule, 873
Geniculum of facial nerve, 923
Genio-hyo-glossus muscle, 479
Genio-hyoid muscle, 479
Genital cord, 170
corpuscles, 50
folds, inner, 176
Genital folds, outer, 175
gland, 170
groove, 176
ridge, 170
tubercle, 175
Genito-crural nerve, 972
Gennari, band of, 880, 882
Genu of corpus callosum, 866
of internal capsule, 873
Gerlach, tube-tonsil of, 1042
Germ, common dental, 1099
special dental, 1100
Germ-centres, 63
Germinal cells, 115
epithelium of Waldeyer, 172, 1220
path, 173
spot, 78
vesicle, 79
Giacomini, band of, 864
Giant-cells, 26
of Betz, 881
Gianuzzi, crescents of, 1112
Gimbernat's ligament, 510
Ginglymus, 369
Giraldès, organ of, 169, 1211
Girdle, pelvic, 286
shoulder, 286
Glabella of frontal bone, 220
Gladiolus, 204
Gland or Glands—
arytenoid, 1069
of Bartholin, 1232
of Blandin, 1106
of Bowman, 1007
Brunner's, 1146
buccal, 1090
ceruminous, 1038
Cowper's, 1218
ductless, 1234
duodenal, 1146
gastric, 1137
genital, 170
labial, 1089
lachrymal, 1032
of larynx, 1069
lingual, 1106
of Littré, 1201
of Luschka, 1247
lymphatic, 61
mammary, 1232
Meibomian, 1031
molar, 1091
of Moll, 1029
of Montgomery, 1233
of Nuhn, 1106
œsophageal, 1118
palatal, 1091
parathyroid, 1237
parotid, 1118
Peyer's, 1146
prostate, 1215
salivary, 1108
sebaceous, 71
secreting, 74
racemose or saccular, 75
simple, 74
tubular, 74
compound, 75
convoluted, 75
solitary, 1146
spleen, 1240
sublingual, 1111
submaxillary, 1110
sudoriferous, 71
suprarenal, 1245
Gland or Glands (*cont.*)
sweat, 71
thymus, 1238
thyroid, 1235
of tongue, 1106
of Tyson, 1214
uterine, 1227
Glandulæ Pacchioni, 898
Tysonii odoriferæ, 1214
Glandular epithelium, 13
Glans clitoridis, 1231
penis, 1213
Glaserian fissure, 224, 1040
Gleno-humeral ligaments, 404
Glenoid cavity, 292
fossa, 224
ligament of Cruveilhier, 422, 451
of shoulder, 405
Gliding movement, 370
Glisson's capsule, 1168
Globular processes of His, 111
Globus major of epididymis, 1206
minor, 1206
pallidus of lenticular nucleus, 872
Glosso-epiglottic folds, 1062
Glosso-pharyngeal nerve, 930
applied anatomy of, 932
Glottis respiratoria, 1066
rima of, 1066
vocalis, 1066
Gluteal artery, 704
nerve, inferior, 979
superior, 979
region, muscles of, 573
ridge, 336
veins, 756
Gluteus maximus muscle, 573
medius muscle, 574
minimus muscle, 575
Goblet cells, 13
Golgi, cells of, 881
organ of, 52
Goll, tract of, 807
Gomphosis, 368
Gonion, 279
Gowers, tract of, 806
Graafian follicles, 1220
structure of, 1220
Gracile nucleus, 814
Gracilis muscle, 571
Grande lobe limbique of Broca, 862
Grandry, tactile corpuscles of, 50
Granular or rust-coloured layer of cerebellar cortex, 833
layer of dentine, 1098
Granule cells, 15
Great auricular nerve, 950
horizontal fissure, 826
longitudinal fissure, 854
occipital nerve, 945
omentum, 1128
sacro-sciatic foramen, 394
sciatic nerve, 980
sinus of aorta, 619
transverse fissure, 878
Greater curvature of stomach, 1133
wings of sphenoid, 234
Grey commissure of spinal cord, 800
of third ventricle, 854

Grey matter of cerebellum, 832
of cerebral hemispheres, 879
of medulla oblongata, 818
of spinal cord, 799, 800
Grey or gelatinous nerve-fibres, 47
Groove, auriculo-ventricular, 602
bicipital, 295
carotid, 233
infraorbital, 243
interauricular, 602
interventricular, 602
lachrymal, 244
musculo-spiral, 297
mylo-hyoid, 256
nasal, 242
neural, 89
occipital, 255
optic, 232
primitive, 86
subclavian, 288
subcostal, 208
vertebral, 200
Grooves, interventricular, 602
Ground bundle, antero-lateral, 807
Gubernaculum dentis, 1102
testis, 173
Gudden, commissure of, 901
Gums, 1091
Gustatory cells, 1101
hair, 1001
pore, 1001
Gyri, or convolutions of brain, 856
breves insulæ, 862
of Heschl, 861
Gyrus dentatus, 864
hippocampi, 863
longus insulæ, 862
marginal, 859
rectus, 859
subcallosal, 864
supracallosal, 864
temporalis transversi, 861

Hæmatoidin crystals, 11
Hæmin crystals, 11
Hæmoglobin, 7
crystals, 11
Hæmorrhoidal artery, inferior, 701
middle, 699
superior, 694
nerve, inferior, 985
plexus of nerves, 999, 1000
vein, inferior, 762
middle, 757
venous plexus, 757
applied anatomy of, 757
Hair-cells of internal ear, 1056
Hairs, 68
cuticle of, 70
follicles of, 68
gustatory, 1001
olfactory, 1007
shaft of, 70
structure of, 68
Haller, vas aberrans of, 1210
Hallucis magna artery, 722
Ham, region of the, 715
Hamstring tendons, applied anatomy of, 578
Hamular process of lachrymal, 248
of sphenoid, 236
Hamulus laminæ spiralis, 1051
Hand, arteries of, 681
bones of, 311
fascia of, 550
muscles of, 550
nerves of, from median, 962
from radial, 965
from ulnar, 962, 963
surface form of, 319, 559
veins of, 745
Hard palate, 1091
Harrison's sulcus, 213
Hasner, plica lacrimalis of, 1033
Haversian canals of bone, 27
systems of bone, 27
Head, arteries of, 625
lymphatics of, 767
muscles of, 456
veins of, 729
Head-cap of spermatozoön, 81
Head-kidney, 168
Heart, 601
applied anatomy of, 613
arteries of, 611, 620
component parts of, 602
development of, 137
endocardium, 609
fibres of the auricles, 610
of the ventricles, 611
fibrous rings of, 610
infundibulum of, 606
left auricle, 608
ventricle, 608
lymphatic vessels of, 792
muscular fibres of, 610
structure of, 41
nerves of, 612, 936, 996
position of, 601
right auricle, 604
ventricle, 606
septum ventriculorum, 609
size and weight, 602
structure of, 609
surface marking of, 612
veins of, 612
Heidenhain, demilunes of, 1112
Helicine arteries, 1214
Helicis major muscle, 1036
minor muscle, 1036
Helicotrema of cochlea, 1049, 1051
Helix, 1035
fossa of, 1035
muscles of, 1036
spine of, 1036
Hemispheres of cerebellum, 826
development of, 120
of cerebrum, 854
development of, 124
Henle, ligament of, 513
loop of, 1186
Henle's layer of hair-follicle, 70
Hensen, canalis reuniens of, 1053
lines of, 39
supporting cells of, 1057
Hensen's stripe, 1057
Hepatic artery, 688
cells, 1170
cylinders, 164
duct, 1171
lymphatic glands, 782
Hepatic plexus, 999
veins, 760
Herbst, corpuscles of, 51
Hernia, congenital, 1160
direct inguinal, 1161
encysted, 1161
femoral, 1161
into funicular process, 1161
infantile, 1161
inguinal, 1159
oblique inguinal, 1159
scrotal, 1159
Herophilus, torcular of, 740
Heschl, gyri of, 861
Hesselbach, ligament of, 513
triangle of, 1159
Hiatus Fallopii, 227
semilunaris, 276, 1004
Higher visual centres, 852
Highmore, antrum of, 244, 1008
Hilus of kidney, 1182
of lung, 1081
of spleen, 1240
Hind-brain, 119, 811
Hind-gut, 150
Hinge-joint, 369
Hip-joint, 243
applied anatomy of, 428
muscles in relation with, 426
surface form of, 428
Hippocampal convolution, 863
fissure, 863
formation, 126
Hippocampus major, 870
minor, 867
His, auriculo-ventricular bundle of, 611
sulcus terminalis of, 604
Horizontal cells of retina, 1022
fissure, great, 826
plate of palate, 250
Horner's muscle, 460
Houston's valves of rectum, 1155
Howship's lacunæ, 26
Huguier, canal of, 224, 1040
Humerus, 295
applied anatomy of, 300
articulations of, 300
head of, 295
neck of, 295
nutrient artery of, 674
ossification of, 299
structure of, 299
surface form of, 300
tuberosities of, greater, 295
lesser, 295
Humour, aqueous, 1024
Hunter's canal, 710
Huschke, auditory teeth of, 1055
foramen of, 230
Huxley's layer of hair-follicle, 70
Hyaline cartilage, 21
cell, 8
Hyaloid membrane of eye, 1025
Hyaloplasm, 3
Hydatids of Morgagni, 168, 1206, 1221
Hymen, 1231
Hyo-epiglottic ligament, 1064
Hyo-glossal membrane, 1106
Hyo-glossus muscle, 480
Hyoid arch (fœtal), 108
bone, 260

Hyoid bone, cornua of, 261
ossification of, 261
muscles of infrahyoid region, 476
of suprahyoid region, 477
Hyparterial bronchi, 1084
Hypochondriac regions, 1119
Hypochordal bar, 103
Hypogastric arteries in fœtus, 614
how obliterated, 616
lymphatic glands, 779
plexus, 999
zone, 1119
Hypoglossal nerve, 939
applied anatomy of, 941
nucleus of, 818
Hypothalami, pars mamillaria, 123
pars optica, 123
Hypothalamus, 849
corpora mamillaria, 850
infundibulum, 851
optic commissure, 851
pituitary body, 851
subthalamic tegmental region, 850
corpus subthalamicum, 850
nucleus of Luys, 850
stratum dorsale, 850
zona incerta, 850
tuber cinereum, 851
Hypothenar eminence, 550

Ileo-cæcal fossa, 1131
valve, 1150
Ileo-colic artery, 692
fossa, 1131
Ileum, 1142
lymphatic vessels of, 785
Iliac arteries, common, 696
applied anatomy of, 697
peculiarities of, 696
surface marking of, 697
external, 705
applied anatomy of, 705
surface marking of, 705
internal, 698
applied anatomy of, 705
at birth, 698
peculiarity in the fœtus, 698
colon, 1153
fascia, 564
fossa, 322
furrow, 331
lymphatic glands, 779, 780
portion of fascia lata, 568
region, muscles of, 564
spines, 323
veins, common, 758
peculiarities of, 758
external, 755
internal, 755
Iliacus muscle, 565
fascia of, 564
Ilio-coccygeus muscle, 521
Ilio-costalis muscle, 496
Ilio-femoral ligament, 425
Ilio-hypogastric nerve, 971
Ilio-inguinal nerve, 972
Ilio-lumbar artery, 704
ligament, 393
vein, 758
Ilio-pectineal eminence, 323
Ilio-pectineal ligament, 564
Ilio-sacralis muscle, 521
Ilio-tibial band, 567
Ilio-trochanteric ligament, 425
Ilium, 320
crest of, 323
dorsum of, 320
spines of, 323
tubercular point of, 323
Immovable articulations, 368
Impressio cardiaca, 1165
colica, 1165
duodenalis, 1165
renalis, 1165
suprarenalis, 1166
Impression, rhomboid, 288
Incisive bone, 246
fossa, 242
Incisor crest, 246
teeth, 1094
Incisura angularis, 1133
cardiaca, 1133
cerebelli anterior, 826
posterior, 826
intertragica, 1035
parietalis, 225
Rivini, 1040
temporalis, 863
tentorii, 893
Incisuræ Santorini, 1038
Incremental lines of Salter, 1098
Incus, 1044
development of, 134
ligaments of, 1045
Index, cephalic or breadth, 279
gnathic or alveolar, 280
nasal, 280
orbital, 279
vertical or height, 279
Indusium griseum, 864
Infantile hernia, 1161
Inferior carotid trangle, 641
central nucleus, 821
coronary artery, 633
dental artery, 639
canal, 257
nerve, 917
external frontal artery, 650
fovea of fourth ventricle, 837
hæmorrhoidal artery, 701
internal frontal artery, 648
labial artery, 633
laryngeal artery, 662
nerve, 936
longitudinal fasciculus, 879
maxillary nerve, 914
meatus of nose, 276
medullary velum, 829, 831
mesenteric artery, 639
glands, 784
vein, 762
phrenic artery, 695
profunda artery, 674
thyroid artery, 662
veins, 748
turbinated bone, 253
articulations of, 254
ethmoidal process of, 253
lachrymal process of, 253
maxillary process of, 254
ossification of, 254
vena cava, 758
development of, 146
opening of, 604
Infracostal muscles, 501
Infracostal plane, 1119
Infraglenoid tubercle, 292
Infrahyoid artery, 292
Infraorbital artery, 639
branches of facial, 925
canal, 243
foramen, 242
groove, 243
nerve, 911*n*
plexus of nerves, 912, 926
Infrapatellar pad of fat, 431
Infraspinatus muscle, 536
Infraspinous fascia, 536
fossa, 289
Infrasternal notch, 212
Infratemporal crest, 234
fossa, 267
Infratrochlear nerve, 910
Infundibula of kidney, 1183
Infundibuliform fascia, 516
Infundibulo-pelvic ligament, 1225
Infundibulum of brain, 851
of Fallopian tube, 1221
of heart, 606
of nasal fossa, 1004
Inguinal canal, 1204
glands, deep, 776
applied anatomy of, 777
superficial, 776
hernia, 1159
Inion, 279
Inlet of pelvis, 327
Innominate artery, 623
applied anatomy of, 624
peculiarities of, 624
bone, 320
articulations of, 327
ossification of, 326
veins, 747, 748
peculiarities of, 748
Insertion of muscles, 454
Insula, 862
Interalveolar cell-islets, 1179
Interarticular chondro-sternal ligaments, 389
costo-central ligaments, 386
fibro-cartilage, 23
of acromio-clavicular joint, 402
of knee, 434
of radio-ulnar joint, 414
of sterno-clavicular joint, 400
of temporo-mandibular joint, 383
ligament of rib, 386
Interauricular groove, 602
Inter-brain, 844
Intercavernous sinuses, 742
Intercellular biliary passages, 1171
Intercentral articulations, 373
Interchondral ligaments, 390
Interclavicular ligament, 400
Interclinoid ligament, 237
Intercolumnar fascia, 509
fibres, 509
Intercondyloid notch, 337
Intercostal arteries, 684
anterior, 665
superior, 665
fasciæ, 500
lymphatic glands, 789
membranes, 500
muscles, 500

Intercostal nerves, 966
spaces, 207
veins, 750
superior, 748
Intercosto-humeral nerves, 968
Intercuneiform articulations, 448
Interglobular spaces, 1098
Interior of bladder, 1198
of larynx, 1065
of uterus, 1223
Interlobular arteries of kidney, 1188
biliary plexus, 1171
Intermediate cell-mass, 90
Intermetacarpal articulations, 422
Intermetatarsal articulations, 450
Intermuscular septa, 456
of arm, 537
of thigh, 567
Internal abdominal ring, 516
annular ligament, 587
calcanean nerve, 982
capsule of brain, 873
carotid artery, 643
cutaneous nerve, 958
ear, 1047
iliac lymphatic glands, 779
vein, 755
jugular vein, 733
mammary artery, 663
branches of, 638
glands, 789
veins, 748
maxillary artery, 637
branches of, 638
medullary lamina, 847
oblique muscle, 510
occipital crest, 216
os uteri, 1223
plantar artery, 725
nerve, 983
popliteal nerve, 981
pterygoid plate, 236
pudic nerve, 701
saphenous nerve, 976
vein, 752
secretion, 76
sphincter of anus, 523
Interneural articulations, 375
Internodal segments of nerves, 46
Interossei muscles, dorsal, of foot, 591
of hand, 557
palmar, 557
plantar, 591
Interosseous arteries of hand, 677, 678
of foot, 722
of forearm, 680
recurrent, 681
Interosseous membrane of forearm, 414
of leg, 439
nerve, anterior, 960
posterior, 965
veins of forearm, 747
Interparietal bone, 217
Interpeduncular space, 854
Interphalangeal articulations, 423, 451
Interpubic disc, 397
Intersegmental neurons, 801
Intersigmoid fossa, 1132
Interspinales muscles, 498
Interspinous ligaments, 376
Intersternal ligaments, 390
Intertarsal articulations, 444
Intertransversales muscles, 498
laterales, 498
mediales, 498
Intertransverse ligaments, 376
Intertrochanteric line, anterior, 334
posterior, 335
Intertubercular plane, 1119
Intertubular stroma of kidney, 1189
Interventricular grooves, 602
septum, 609
Intervertebral discs, 374
foramina, 183
notches, 183
Intervillous spaces, 99
Intestine, applied anatomy of, 1158
development of, 155
large, 1148
coats of, 1155
lymphatics of, 784
small, 1139
coats of, 1143
surface relations of, 1157
vessels and nerves of, 1147
Intracartilaginous ossification, 31
Intraepithelial plexus of cornea, 1014
Intragracile fissure, 829
Intrajugular process, 216
Intralobular veins, 1169
Intramembranous ossification, 30
Intranuclear network, 4
Intraparietal sulcus, 859
Intraspinal veins, 751
Intrathyroid cartilage, 1060
Intrinsic muscles of tongue, 480
Involuntary muscle, 40
Iris, 1017
Irregular bones, 182
Ischio-capsular ligament, 424
Ischio-rectal fascia, 521
fossa, 522
applied anatomy of, 522
Ischium, 323
body of, 323
ramus of, 324
spine of, 323
tuberosity of, 324
Island of Reil, 862
convolutions of, 862
development of, 126
limiting sulcus of, 862
Islands of Langerhans, 1179
Isthmus, aortic, 621
of auditory canal, 1038
of Fallopian tube, 1221
faucium, 1091
of limbic lobe, 863
of thyroid gland, 1235
rhombencephali, 119
Iterchordæ anterius, 1040
chordæ posterius, 1040
Ivory of tooth, 1097

Jacob's membrane, 1023
Jacobson, cartilage of, 1005
foramen for nerve of, 228
nerve of, 932, 1046
organ of, 112, 1005
Jaw, lower, *See* Mandible
upper. *See* Maxilla
Jejunum, 1142
lymphatic vessels of, 785
Jelly of Wharton, 19
Joint. *See* Syndesmology
Jugular foramen, 264
fossa, 228
ganglion, 932
lymphatic glands, 771
process, 216
vein, anterior, 733
external, 732
applied anatomy of, 733
internal, 733
applied anatomy of, 734
posterior external, 733
primitive, 146
sinus or bulb, 733
surface, 228
Jugum sphenoidale, 237
Junctional tube, 1186

Karyokinesis, 4
Karyomitosis, 4
Karyoplasm, 79
Keratin, 14
Kerkring, valves of, 1143
Key and Retzius, foramina of, 836, 897
Kidneys, 1180
applied anatomy of, 1190
calyces of, 1183
cortical substance of, 1184
development of, 174
fascia renalis, 1183
fixation of, 1183
hilus of, 1182
infundibula of, 1183
lymphatic vessels of, 787
Malpighian bodies of, 1185
tufts of, 1185
medullary substance of, 1184
minute anatomy of, 1185
nerves of, 1189
paranephric body, 1183
pelvis of, 1184, 1191
renal artery, 694, 1187
sinus, 1183
surface marking of, 1189
tubuli uriniferi, 1185
veins of, 1189
weight and dimensions of, 1180
Knee-joint, 430
applied anatomy of, 438
bursæ of, 435
surface form of, 438
Kölliker, membrane of, 1057
Krause, end-bulbs of, 50
membrane of, 38
Kühne, motor end plate of, 53

Labbé, posterior anastomotic vein of, 737
Labia cerebri, 865
majora, 1230
minora, 1231
Labial artery, 633

Labial glands, 1089
nerves from superior maxillary, 912
Labio-dental strand, 1099
Labium tympanicum, 1055
vestibulare, 1055
Labyrinth, membranous, 1051
arteries of, 1058
osseous, 1047
Lachrymal apparatus, 1032
applied anatomy of, 1033
development of, 133
artery, 647
bone, 247
articulations of, 248
lesser, 248
ossification of, 248
canals, 1032
ampullæ of, 1032
caruncula, 1031
crest, 248
fossa, 221, 245
gland, 1032
inferior part, 1032
superior part, 1032
groove, 244
nerve, 909
notch, 243
papilla, 1029, 1032
process of inferior turbinated bone, 253
puncta, 1032
sac, 1032
tubercle, 245
Lacteals, 763
Lactiferous ducts, 1233
Lacuna magna, 1201
Lacunæ of bone, 27
Howship's, 26
laterales, 898
of urethra, 1201
Lacus lacrimalis, 1029
Lagena, 1057
Lambda, 219
Lambdoid suture, 217
Lamella of bone, articular, 366
Lamellæ of bone, 28
circumferential, 27
interstitial, 27
primary, 27
secondary, 27
Lamellar cells, 15
Lamina basalis, 1016
chorio-capillaris, 1016
cornea of corpus striatum, 875
cribrosa, 227
scleræ, 1012
dental, 1099
dorsal or alar, 117
elastica anterior of cornea, 1014
posterior of cornea, 1014
reticularis, 1057
spiralis ossea of cochlea, 1051
spiralis secundaria, 1051
suprachorioidea, 1012, 1015
terminalis, 122, 851
vasculosa, 1015
ventral or basal, 117
of the vertebræ, 183
Laminæ, nasal (fœtal), 111
Lancisi, striæ of, 864
Langerhans, centro-acinar cells of, 1179
islands of, 1179
Langhans, layer of, 86
Langley's ganglion, 1112
Lantermann, segments of, 46
Lanugo (fœtal hairs), 115
Large cavernous nerve, 1000
deep petrosal nerve, 913
intestine, 1148
cæcum, 1149
colon, 1151
ileo-cæcal valve, 1150
rectum, 1154
superficial petrosal nerve, 913, 924
Laryngeal artery, inferior, 662
superior, 630
nerve, external, 936
inferior, 936
internal, 936
recurrent, 936
superior, 936
saccule, 1166
sinus, 1066
Laryngotomy, 1074
Larynx, 1059
actions of muscles of, 1069
applied anatomy of, 1073
arteries of, 1070
cartilages of, 1059
cavity of, 1065
glands of, 1069
ligaments of, 1063
lymphatic vessels of, 772
mucous membrane of, 1069
muscles of, 1067
nerves of, 1070
rima glottidis of, 1066
superior aperture of, 1066
surface form of, 1073
veins of, 1070
ventricle of, 1066
vestibule of, 1065
vocal cords of, false, 1066
true, 1066
Lateral area of medulla, 813
basis bundle, 807
cornua of spinal cord, 799
nerve-cells in, 802
ligaments of liver, 1168
limiting zone, 807
longitudinal striæ, 864
mass of ethmoid, 239
mesoderm, 90
nasal artery, 633
processes, 110
occipital sulcus, 860
recesses of fourth ventricle, 835
sacral arteries, 704
sinuses of brain, 739
ventricles of brain, 867
Latissimus dorsi muscle, 490
Layer of Langhans, 86
of rods and cones, 1023
Layers of cerebral cortex, 880
Lecithin, 7
Left lobe of liver, 1167
Leg, bones of, 320
fascia of, 579
deep transverse, 583
muscles of, 579
back of, 581
front of, 579
Lemniscus, 842
Lens, crystalline, 1025
capsule of, 1025
Lens, changes produced in, by age, 1026
development of, 131
equator of, 1025
poles of, 1025
structure of, 1026
suspensory ligament of, 1025
vascular capsule of, 131
vesicle, 128
Lenticular ganglion, 910
nucleus, 872
process of incus, 1044
Lesser curvature of stomach, 1133
internal cutaneous nerve, 959
lachrymal bone, 248
omentum, 1127
sac of peritoneum, 1126
boundaries of, 1127
wings of sphenoid, 235
Leucocytes, 8
development of, 10
Levator anguli oris, 464
scapulæ, 492
ani, 519
glandulæ thyreoideæ, 1236
labii inferioris, 466
superioris, 464
alæque nasi, 464
menti, 466
palati, 484
palpebræ, 461
prostatæ, 520
Levatores costarum, 501
Lieberkühn, crypts of, 1146
Lieno-renal ligament, 1126
Ligament or Ligaments—
acromio-clavicular, inferior, 401
superior, 400
alar of knee, 434
of ankle, anterior, 441
lateral, 441
annular, of ankle, 586
external, 587
internal, 587
of radius, 413
of wrist, anterior, 550
posterior, 551
arcuate, 502
astragalo-navicular, 445
atlanto-axial, anterior, 377
posterior, 378
of bladder, false, 1197
true, 1196
broad ligaments of uterus, 1225
calcaneo - astragaloid, anterior, 444
external, 444
internal, 444
interosseous, 445
posterior, 445
calcaneo-cuboid, internal, 446
long, 446
short, 446
superior, 446
calcaneo-navicular, inferior, 447
superior, 447
capsular, *see* Individual Joints
carotico-clinoid, 237
carpo - metacarpal, dorsal, 420

Ligament or Ligaments (*cont.*)
carpo-metacarpal, interosseous, 421
palmar, 421
of carpus, 418
central, of spinal cord, 899
cheek, 382
of eye, 1011
chondro-sternal, anterior, 388
posterior, 389
chondro-xiphoid, 390
common vertebral, anterior, 373
posterior, 373
conoid, 402
of Cooper, 510
coraco-acromial, 403
coraco-clavicular, 402
coraco-humeral, 404
coronary, of knee, 434
of liver, 1123
costo-clavicular, 400
costo-coracoid, 531
costo-transverse, 387
costo-vertebral, or stellate, 386
cotyloid, 425
crico-arytenoid, 1064
crico-tracheal, 1064
crucial, of knee, 432
cruciform, 378
cuboideo-navicular, 448
cuneo-cuboid, 448
cuneo-navicular, 447
deltoid, 441
of elbow, 409
anterior, 409
external lateral, 410
internal lateral, 410
posterior, 409
falciform, of liver, 1122
of pelvis, 395
gastro-phrenic, 1134
Gimbernat's, 510
gleno-humeral, 404
glenoid, 405
of Henle, 513
of Hesselbach, 513
of hip, 423
hyo-epiglottic, 1064
ilio-femoral, 425
ilio-lumbar, 393
ilio-pectineal, 564
ilio-trochanteric, 425
of incus, 1045
infundibulo-pelvic, 1225
interarticular, of ribs, 386
interchondral, 390
interclavicular, 400
interclinoid, 237
intercuneiform, 448
intermetacarpal, 422
intermetatarsal, 450
interphalangeal, 423, 451
interspinous, 376
intersternal, 390
intertarsal, 444
intertransverse, 376
ischio-capsular, 424
of knee, 430
of larynx, 1063
lateral patellar, 430
left lateral of liver, 1168
lieno-renal, 1126
long plantar, 446
lumbo-sacral, 393
of malleus, 1045
metacarpo-phalangeal, 422
metatarso-phalangeal, 451
mucosum, of knee, 434
nuchæ, 376
oblique, 414
sacro-iliac, 394
occipito-atlantal, anterior, 380
lateral, 381
posterior, 380
occipito-axial, 382
odontoid, 382
orbicular, 413
of ovary, 1219
palpebral, 1030
of patella, lateral, 430
of pelvis, 393
phrenico-pericardiac, 758
phreno-colic, 1153
of the pinna, 1036
plantar, 446
posterior, of knee, 431
Poupart's, 509
pterygo-mandibular, 467
pterygo-spinous, 237
pubic, anterior, 396
posterior, 397
superior, 397
pubo-femoral, 424
pubo-prostatic, 1196
quadrate, 413
radio-carpal, 415
of radio-ulnar joint, inferior, 414
middle, 413
superior, 413
rhomboid, 400
right lateral of liver, 1168
round, of hip, 425
of liver, 1168
of uterus, 1225
sacro-coccygeal, 396
sacro-iliac, anterior, 394
sacro-sciatic, great, 394
small, 395
sacro-vertebral, 392
of scapula, 403
of shoulder, 404
spheno-mandibular, 382
spino-glenoid, 404
spring, 447
stellate, 386
sterno-clavicular, anterior, 400
posterior, 400
sterno-pericardiac, 600
of sternum, 390
structure of, 366
stylo-hyoid, 478
stylo-mandibular, 384
subpubic, 397
superficial transverse, of fingers, 553
suprascapular, 403
supraspinous, 375
suspensory of axilla, 529
of eye, 1011
of lens, 1025
of liver, 1122
of mamma, 529
of ovary, 1218
of penis, 1214
sutural, 368
synovial, 367
tarsal, of eyelids, 460
tarso-metatarsal, 449
of tarsus, 444
teres, of hip, 425
thyro-arytenoid, 1066
thyro-epiglottic, 1064
thyro-hyoid, lateral, 1063
tibio-fibular, 439
transversalis colli uteri, 1225
transverse, of ankle, 440
of atlas, 378
of hip, 426
humeral, 405
of knee, 434
metacarpal, 422
metatarsal, 450
of scapula, 403
trapezoid, 402
triangular, of urethra, 525, 527
utero-sacral, 1225
of uterus, 1225
of vertebræ, 372
of Winslow, 431
of Wrisberg, 434
of wrist, anterior, 416
lateral external, 416
internal, 416
posterior, 416
Y-shaped of Bigelow, 425
of Zinn, 462
Ligamenta alaria, 434
brevia, 544
longa, 544
subflava, 375
suspensoria of mamma, 529
Ligamentous action of muscles, 372
Ligamentum apicis dentis, 382
arcuatum externum, 502
internum, 502
medium, 503
arteriosum, 619
denticulatum, 899
latum pulmonis, 1077
mucosum, 434
nuchæ, 376
patellæ, 431
pectinatum iridis, 1014
posticum Winslowii, 431
spirale, 1054
teres, 425, 1168
Ligature of arteries, *see* each Artery
Ligulæ, 836
Limbic lobe, 862
Limbs, bones of the, 286
development of, 113
Limbus laminæ spiralis, 1055
Limiting zone, lateral, 807
Line or lines—
coloured, of Retzius, 1098
curved, of ilium, 320
of occipital, 214
incremental of Salter, 1098
intertrochanteric, 334
Nélaton's, 428
oblique of fibula, 347
of mandible, external, 255
internal, 256
of radius, 306
of tibia, 344
of Schreger, 1098

Line or lines (*cont.*)
spiral of femur, 334
Linea alba, 514
aspera, 335
ilio-pectinea, 322
intercondyloidea, 337
quadrata, 335
splendens, 898
suprema, 214
Lineæ semilunares, 514
transversæ of abdomen, 513
Lingual artery, 630
applied anatomy of, 631
branches of glosso-pharyngeal nerve, 932
lobule, 860
nerve, 916
strand, 1099
tonsil, 1105
veins, 734
Lingualis muscle, inferior, 482
superior, 481
transverse, 481
vertical, 481
Lingula of cerebellum, 827
of mandible, 256
of sphenoid, 233
Lips, 1089
arteries of, 633
Liquor amnii, 94
sanguinis, 10
Lissauer, tract of, 807
Littré, glands of, 1201
Liver, 1163
applied anatomy of, 1174
bile ducts of, 1171
development of, 164
fissures of, 1166
hepatic artery, 688, 1168
cells, 1170
duct, 1171
veins, 760, 1168
ligaments of, 1168
lobes of, 1167
lobules of, 1169
lymphatic vessels of, 786
microscopic appearance of, 1170
nerves of, 1168
portal vein, 760
situation, size, and weight, 1163
structure of, 1168
surface relations of, 1173
surfaces of, 1164
vessels of, 1168
Lobes of cerebral hemisphere, 857
cuneus, 860
frontal, 857
insula, or island of Reil, 862
limbic, 862
occipital, 860
olfactory, 863
parietal, 859
precuneus, 860
quadrate, 860
temporal, 861
Lobes of cerebellum, 825
of liver, 1167
of lung, 1082
of prostate, 1216
of thymus, 1238
of thyroid, 1235
Lobule of the ear, 1035
Lobule, lingual, 860
paracentral, 859
Lobules of liver, 1169
of lung, 1085
Lobuli testes, 1207
Lobulus centralis, 827
Lobus cacuminis, 827
caudatus, 1167
clivi, 827
culminis, 827
gracilis, 829
noduli, 829
pyramidis, 829
quadratus, 1167
Spigelii, 1167
tuberis, 829
uvulæ, 829
Localisation, cerebral, 885
Lockwood, superior tendon of, 462
Locus cæruleus, 838
perforatus anticus, 864
posticus, 838
Long bones, 181
buccal nerve, 915
ciliary nerve, 910
saphenous nerve, 976
saphenous vein, 752
thoracic artery, 670
Longissimus dorsi muscle, 496
Longitudinal fasciculus, inferior, 879
perpendicular, 879
posterior, 841
superior, 879
fissure of brain, 854
of liver, 1167
sinus of brain, inferior, 738
superior, 737
striæ, lateral, 864
mesial, 864
Longus colli muscle, 487
Loop of Henle, 1186
Lowenthal, tract of, 805
Lower extremity, arteries of, 707
articulations of, 423
bones of, 320
fasciæ of, 563
lymphatic vessels of, 777
muscles of, 563
surface form of, 593
nerves of, 970
veins of, 752
Lower visual centres, 852
Lower, tubercle of, 605
Ludwig, angle of, 204
Lumbar arteries, 695
enlargement of spinal cord, 798
fascia or aponeurosis, 493
ganglia of sympathetic, 995
lymphatic glands, 780
nerves, anterior divisions of, 969
posterior divisions of, 948
plexus of nerves, 970
portion of sympathetic cord, 994
applied anatomy of, 986
regions of abdomen, 1121
vein, ascending, 759
veins, 759
vertebræ, 190
ossification of, 197
Lumbo-sacral cord, 970
ligament, 393
plexus, 959
Lumbricales muscles of foot, 590
of hand, 556
Lung-buds, 166
Lungs, 1081
air-sacs of, 1086
applied anatomy of, 1087
capillaries of, 1086
development, 166
lobes and fissures of, 1082
lobules of, 1086
lymphatic vessels of, 792
nerves of, 1086
root of, 1083
structure of, 1085
surface marking of, 1086
weight, colour, &c., 1084
Lunulæ of nails, 68
of semilunar valves, 607
Luschka, foramina of, 836, 897
gland of, 1247
Luys, nucleus of, 850
Lymph, 11
capillaries, 11
path or sinus, 62
sacs (fœtal), 149
Lymphatic duct, right, 766
Lymphatic glands of abdomen, 778
aortic, 780
applied anatomy of, 764
auricular, posterior, 767
axillary, 773
bronchial, 792
buccal, 768
cervical, anterior, 772
deep, 772
applied anatomy of, 772
Cloquet, gland of, 776
coronary, 781
diaphragmatic, 790
facial, 768
of head, 767
histology of, 61
hypogastric, 779
iliac, common, 780
external, 779
internal, 779
inguinal, 776
applied anatomy of, 777
intercostal, 789
jugular, external, 771
lingual, 769
of lower extremity, 775
lumbar, 780
mammary, internal, 789
mandibular, 768
mastoid, 767
maxillary, 768
internal, 769
mediastinal, anterior, 791
posterior, 792
mesenteric, 782, 784
of neck, 770
obturator, 779
occipital, 757
pancreatico-duodenal, 784
pararectal, 784
parotid, 768
of pelvis, 778
popliteal, 775

Lymphatic glands, principal gland of tongue, 770
retro-pharyngeal, 769
of Rosenmüller, 776
sacral, 779
of small intestine, 760
splenic, 782
Stahr, middle gland of, 771
of stomach, 759
submaxillary, 771
submental, 771
suprahyoid, 771
of thorax, 789
tibial, anterior, 775
tracheo-bronchial, 792
of upper extremity, 772
Lymphatic vessels of abdominal viscera, 784
of abdominal wall, 781
of anal canal, 785
of anus, 785
of appendix, 785
applied anatomy of, 764
of bladder, 788
broncho - mediastinal trunk, left, 766
right, 767
of cæcum, 785
of clitoris, 781
of colon, 785
of common bile-duct, 787
of diaphragm, 790
of duodenum, 784
of external genitals, 781
of face, 769
of Fallopian tubes, 789
of gall-bladder, 787
of gluteal region, 777
of head, 769
of heart, 792
histology of, 60
of ileum, 785
intestinal trunk, 766
of jejunum, 785
jugular trunk, left, 766
right, 767
of kidneys, 787
of labia, 781
lacteals, 763
of large intestine, 785
of larynx, 772
of liver, 786
of lower extremity, 777
lumbar trunks, 766
of lung, 792
of mammary gland, 790
of mouth, 770
of nasal fossæ, 770
of neck, 772
of nymphæ, 781
of œsophagus, 793
of ovary, 789
of pancreas, 787
of pelvis, 781, 784
of penis, 789
of perinæum, 781
of pharynx, 772
of pinna, 769
of pleura, 793
of prostate, 788
of rectum, 785
of reproductive organs, 789
of scalp, 769
of scrotum, 781
of small intestine, 785
Lymphatic vessels of spleen, 787
of stomach, 784
subclavian trunk, left, 766
right, 767
of suprarenal glands, 787
of testes, 789
of thoracic viscera, 792
of thoracic wall, 790
of thyroid body, 772
of tongue, 770
of tonsil, 770
of upper extremity, 775
of ureter, 788
of urethra, 789
of urinary organs, 787
of uterus, 789
of vagina, 789
of vas deferens, 789
of vermiform appendix, 785
of vesiculæ seminales, 789
Lymphocyte, 8
Lymphoid tissue, 20
Lyra of fornix, 875

McBurney's spot, 1157
Macula acustica sacculi, 1053
utriculi, 1052
cribrosa media, 1048
superior, 1048
lutea, 1023
Majendie, foramen of, 836, 897
Malar artery, 647
bone, 248
articulations of, 250
foramina of, 248
fronto-sphenoidal process of, 248
maxillary process of, 250
orbital process of, 248
ossification of, 250
temporal process of, 250
tubercle, 248
canals, 248
nerves, from facial, 925
from temporo-malar, 911
process of maxilla, 245
Male urethra, 1200
Malleolar arteries, external and internal, 721
folds, anterior and posterior, 1043
Malleolus, external, 348
internal, 345
Malleus, 1043
development of, 134
ligaments of, 1045
Malo-maxillary suture, 271
Malpighi, pyramids of, 1184
Malpighian bodies of kidney, 1185
bodies of spleen, 1242
capsules, 1185
tufts, 1185
Mamillary process, 191
Mammæ, 1232
applied anatomy of, 1234
development of, 115
lymphatic vessels of, 790
nipple of, 1232
structure of, 1233
vessels and nerves of, 1234
Mammary artery, internal, 663
glands, 1232
lymphatic vessels of, 790
veins, internal, 748
Mandible, 255
articulations of, 260
body of, 255
changes in, due to age, 260
condylar process of, 257
coronoid process of, 257
ossification of, 258
ramus of, 256
Mandibular arch, 108
nerve, 927
Mantle layer, 116
Manubrium mallei, 1043
of sternum, 204
Margin, supraorbital, 221
Marginal gyrus, 859
layer or veil, 116
Marrow of bone, 25
red, 26
yellow, 25
Marshall, vestigial fold of, 148, 600
Martinotti, cells of, 881
Masseter muscle, 468
Masseteric artery, 639
fascia, 467
nerve, 915
Mastoid antrum, 226
opening of, 1041
cells, 226, 1041
foramen, 225
portion of temporal bone, 225
process, 225
Mat or tapetum, 866
Maternal blood-sinuses, 99
Matrix of nail, 68
of tooth, 1098
Maturation of ovum, 79
Maxilla, 242
articulations of, 247
changes in, due to age, 247
ossification of, 247
Maxillary artery, external, 631
internal, 637
bone, inferior, 255
superior, 242
nerve, inferior, 914
superior, 911
process of inferior turbinated, 254
of malar bone, 250
of palate bone, 252
processes of fœtus, 111
sinus, 244, 1008
tuberosity, 242
vein, internal, 731
Meatus acusticus internus, 227
externus, 230, 1037
applied anatomy of, 1038
urinarius, 1201
Meatuses of the nose, 276
Mechanism of pelvis, 397
of respiration, 505
of thorax, 391
Meckel's cartilage, 108, 258
diverticulum, 93
ganglion, 912
Media, refracting of eye, 1024
Median nerve, 959
vein, 746
Mediastinal arteries, from internal mammary, 664
lymphatic glands, anterior, 791
posterior, 792
subpleural plexus, 665

Mediastinum, 1078
anterior, 1079
applied anatomy of, 1080
middle, 1079
posterior, 1079
superior, 1078
testis, 1207
Medio-tarsal joint, 443, 447
Medulla Oblongata, 811
applied anatomy of, 822
arcuate fibres of, 830
areas of, 812, 813, 814
development of, 119
fasciculus cuneatus of, 816
gracilis of, 816
of Rolando, 815
fissures of, 812
formatio reticularis of, 821
grey matter of, 818
lateral area, 813
olivary body of, 813
posterior area of, 814
pyramids of, 812, 815
raphe of, 812
restiform bodies of, 815
structure of, 815
Medulla of hair, 70
Medullary artery of bone, 26
canal of bone, 25
formation of, 33
centre of hemispheres of brain, 878
folds, 88
lamina, external, 847
internal, 847
laminæ of nucleus lenticularis, 872
membrane of bone, 25
portion of kidney, 1184
of suprarenal glands, 1246
segments of nerves, 46
sheath of nerve-fibres, 46
spaces of bone, 29
velum, inferior, 829, 831
superior, 831
Medullated nerve-fibres, 45
Meibomian glands, 1031
Meissner's plexus, 1148
tactile corpuscles, 50
Melanin, 36
Membrana basilaris, 1049, 1055
granulosa of Graafian follicle, 1220
hyaloidea, 1025
limitans externa of retina, 1021
interna of retina, 1023
nictitans, 1031
propria, 17
pupillaris, 131, 1019
sacciformis, 415
tectoria, 836
tympani, 1043
structure of, 1043
secundaria, 1041
Membrane, arachnoid, 895
of Bruch, 1016
of Corti, 1057
costo-coracoid, 530
crico-thyroid, 1064
of Descemet, 1014
external limiting, 1023
fenestrated, 55
hyaloid, 1025
Membrane, hyoglossal, 1106
intercostal, 500
internal limiting, 1021
interosseous, of forearm, 414
of leg, 439
Jacob's, 1023
of Kölliker, 1057
of Krause, 38
medullary of bone, 25
of Nasmyth, 1101
nuclear, 4
obturator, 575
pupillary, 1019
of Reissner, 1053
Schneiderian, 1005
thyro-hyoid, 1063
vitelline, 83
Membranes—
basement, 20
of brain and spinal cord, 892
of embryo, 92
mucous, 73
serous, 72
synovial, 73, 367
Membranous primordial cranium, 105
canal of cochlea, 1053
labyrinth, 1051
portion of urethra, 1200
semicircular canals, 1053
vertebral column, 103
Meningeal artery, from ascending pharyngeal, 636
anterior, from internal carotid, 646
middle, from internal maxillary, 638
from occipital, 634
posterior, from vertebral, 659
small, from internal maxillary, 639
layer of dura mater, 894
nerves from hypoglossal, 940
from superior maxillary, 911
Meninges of brain and spinal cord, 892
Menisci, 369
Mental foramen, 255
nerve, 917
point, 279
protuberance, 255
tubercles, 255
Mesencephalic root of fifth nerve, 906
Mesencephalon, 121, 838
Mesenteric artery, inferior, 693
superior, 690
lymphatic glands, 782, 784
plexuses of nerves, 999
vein, inferior, 762
superior, 762
Mesenterico-parietal fold, 1065
Mesenteries, 1129
development of, 158
meso-appendix, 1150
pelvic mesocolon, 1129
transverse mesocolon, 1129
Mesentery proper, 1129
Mesial fillet, 843
longitudinal striæ, 864
Meso-appendix, 1150
Mesoblast, 87
Mesocardium, arterial, 600
venous, 600
Mesocolon, fœtal, 158
pelvic, 1129
transverse, 1129
Mesoderm, 88
formation of, 87
lateral, 90
paraxial, 90
Mesodermic somites, 91
Mesogastrium, dorsal, 158
ventral, 157
Mesognathion, 285
Mesonephros, 168
Mesorchium, 172
Mesosalpinx, 1225
Mesosternum, 203
Mesovarium, 172, 1219
Metacarpal artery, 664
bones, 315
applied anatomy of, 320
articulations of, 317
common characters of, 315
ossification of, 319
peculiar characters of, 316
Metacarpo-phalangeal articulations, 422
Metacarpus, 315
Metanephros, 174
Metaphase of karyokinesis, 5
Metasternum, 203
Metatarsal artery, 722
bones, 358
common characters of, 358
peculiar characters of, 359
Metatarso-phalangeal articulations, 451
Metatarsus, 358
ossification of, 362
Metathalamus, 122, 848
Metencephalon, 119
Metopic suture, 220
Meynert, basal optic nucleus of, 851
fasciculus retroflexus of, 849
fountain decussation of, 844
substantia innominata of, 874
Microcytes, 7
Micropyle, 79
Mid-brain, 121, 838
ventricle of, 844
Mid-carpal joint, 418
Mid-gut, 150
Middle cerebral artery, 650
cervical ganglion, 992
clinoid processes, 232
commissure, 854
cornu of lateral ventricle, 868
ear, or tympanum, 1039
fossa of skull, 273
frontal convolution, 858
hæmorrhoidal artery, 699
internal frontal artery, 648
meatus of nasal fossa, 276
mediastinum, 1079
meningeal artery, 638
odontoid ligament, 382
sacral artery, 696
veins, 785
Milk teeth, 1096
Mitochondrial sheath, 82
Mitral cells, 883
valve, 609
Mixed articulations, 369
Moderator band, 607
Modiolus of cochlea, 1049

Molar glands, 1091
teeth, 1095
Molecular layer of cortex of cerebellum, 832
of cerebrum, 881
Moll, glands of, 1029
Monakow, tract of, 805
Monaster, or mother star, 5
Monro, foramen of, 122, 876
sulcus of, 122, 854
Mons Veneris, 1230
Montgomery, glands of, 1233
Morgagni, hydatid of, 168, 1206, 1221
columns of, 1156
sinus of, 483
Morula, 84
Moss-fibres, 833
Mother star, or monaster, 5
Motor areas of cerebral cortex, 885
decussation, 813
end-plates, 53
nerves, 53
oculi nerve, 903
applied anatomy of, 905
tract, 888
Mouth, 1089
development of, 151
lymphatics of, 770
mucous membrane of, 1090
Movable articulations, 369
Movement admitted in joints, 370
Mucigen, 13
Mucous glands of tongue, 1106
membrane, 73
tissue, 19
Mucus, 73
Müller, fibres of, 1023
ring muscle of, 1017
Müllerian ducts, 170
eminence, 170
Multicuspid teeth, 1096
Multifidus spinæ muscle, 497
Muscle or Muscles, *Histology of*, 36
applied anatomy of, 454
arrangement of fibres of, 37
bipenniform, 453
blood-vessels of, 40
cardiac, 41
columns, 38
derivation of names, 453
development of, 42, 114
fasciculi of, 36
fibres of, 36
fixation, 454
form of, 453
fusiform, 453
insertion of, 454
involuntary, 40
lymphatics of, 40
meaning of the terms 'origin' and 'insertion,' 454
mode of connection of, with bone, cartilage, skin, &c., 454
nerves of, 40
origin of, 454
penniform, 453
plates, 102
quadrilateral, 453
rhomboidal, 453
sarcous elements of, 39
sheath of, 37
Muscle or Muscles (*cont.*)
skeletal, 36
striped, 36
structure of, 36
synergic, 454
tendons of, 455
triangular, 453
unstriped, 40
voluntary, 36
Muscle or Muscles, *Descriptive Anatomy* —
of abdomen, 506
abductor hallucis, 588
indicis, 557
minimi digiti (foot), 589
(hand), 556
pollicis, 549
accelerator urinæ, 524
accessorius ad ilio-costalem, 496
pedis, 589
adductor brevis, 571
longus, 571
magnus, 572
obliquus hallucis, 591
pollicis, 554
transversus hallucis, 591
pollicis, 555
anconeus, 547
antitragicus, 1037
aryepiglotticus, 1068
arytenoideus, 1068
attollens auriculam, 459
attrahens auriculam, 459
axillary arch, 490
azygos uvulæ, 484
biceps, of arm, 537
of thigh, 577
biventer cervicis, 497
brachialis anticus, 538
brachio-radialis, 545
buccinator, 467
cervicalis ascendens, 496
chondro-glossus, 480
ciliary, of eye, 1016
coccygeus, 521
complexus, 497
compressor naris, 464
narium minor, 464
urethræ, in female, 528
in male, 526
constrictor isthmi faucium, 479*n*
pharyngis inferior, 482
medius, 483
superior, 483
coraco-brachialis, 537
corrugator cutis ani, 522
supercilii, 461
cremaster, 511
crico-arytenoideus lateralis, 1068
posticus, 1068
crico-thyroideus, 1067
crureus, 569
deltoid, 534
depressor alæ nasi, 464
anguli oris, 466
labii inferioris, 466
detrusor urinæ, 1197
diaphragm, 501
digastric, 477
dilatator naris, anterior, 464
posterior, 464
tubæ, 1042
dorso-epitrochlearis, 492
Muscle or Muscles (*cont.*)
ejaculator urinæ, 524
erector clitoridis, 527
penis, 524
spinæ, 495
extensor brevis digitorum, 587
pollicis, 548
carpi radialis brevior, 545
longior, 545
ulnaris, 547
coccygis, 498
communis digitorum, 546
indicis, 549
longus digitorum, 580
pollicis, 549
minimi digiti, 547
ossis metacarpi pollicis, 548
proprius hallucis, 580
external sphincter ani, 522
of face, 456
of femoral region, anterior, 566
internal, 571
posterior, 577
of fibular region, 585
flexor accessorius, 589
brevis digitorum, 588
hallucis, 590
minimi digiti, of foot, 591
of hand, 556
pollicis, 554
carpi radialis, 540
ulnaris, 541
longus digitorum, 583
hallucis, 583
pollicis, 544
profundus digitorum, 543
sublimis digitorum, 541
frontalis 457
gastrocnemius, 581
gemellus inferior, 576
superior, 576
genio-hyo-glossus, 479
genio-hyoid, 479
gluteus maximus, 573
medius, 574
minimus, 575
gracilis, 571
of hand, 550
of head and face, 456
helicis major, 1036
minor, 1036
Horner's, 460
hyo-glossus, 480
of iliac region, 564
iliacus, 565
ilio-coccygeus, 521
ilio-costalis, 496
ilio-sacralis, 521
incisivus inferior, 467
superior, 467
infracostal, 501
infraspinatus, 536
intercostal, 500
internal sphincter ani, 523
interossei, of foot, 591
of hand, 556
interspinales, 498
intertransversales, 498
of larynx, 1067
latissimus dorsi, 490
of leg, 579
levator anguli oris, 464
scapulæ, 492

Muscle or Muscles (*cont.*)
levator ani, 519
glandulæ thyreoideæ, 1236
labii inferioris, 466
superioris, 464
alæque nasi, 464
menti, 466
palati, 484
palpebræ, 461
prostatæ, 520
levatores costarum, 501
lingualis, 481
longissimus dorsi, 496
longus colli, 487
lumbricales, of foot, 590
of hand, 556
masseter, 468
multifidus spinæ, 497
musculus accessorius ad ilio-costalem, 496
mylo-hyoid, 478
obliquus abdominis externus, 506
internus, 510
auriculæ, 1037
capitis inferior, 498
superior, 498
oculi inferior, 462
superior, 462
obturator externus, 576
internus, 575
occipitalis, 457
occipito-frontalis, 456
omo-hyoid, 476
opponens minimi digiti, 556
pollicis, 554
orbicularis oris, 466
palpebrarum, 459
of palate, 484
palato-glossus, 485
palato-pharyngeus, 485
palmaris brevis, 556
longus, 541
pectineus, 571
pectoralis major, 529
minor, 531
of perinæum, 521
peroneus brevis, 585
longus, 585
tertius, 580
pharyngo-glossus, 480
of pharynx, 482
of pinna, 1036
plantaris, 582
platysma, 471
popliteus, 583
pronator quadratus, 544
teres, 540
psoas magnus, 564
parvus, 565
pterygoid, external, 469
internal, 470
pubo-coccygeus, 521
pubo-rectalis, 521
pyramidalis abdominis, 514
nasi, 463
pyriformis, 575
quadratus femoris, 576
lumborum, 517
menti, 466
quadriceps extensor cruris, 568
recto-coccygeal, 1155
rectus abdominis, 513
capitis anticus major, 486
minor, 486

Muscle or Muscles (*cont.*)
rectus capitis lateralis, 486
posticus major, 498
minor, 498
externus, inferior, internus, and superior of eyeball, 462
femoris, 569
retrahens auriculam, 459
rhomboideus major, 492
minor, 492
risorius, 467
rotatores spinæ, 497
salpingo-pharyngeus, 485
sartorius, 568
scalenus anticus, 488
medius, 488
posticus, 488
semimembranosus, 578
semispinalis colli, 497
dorsi, 497
semitendinosus, 578
serratus magnus, 532
posticus, inferior, 493
superior, 493
of sole of foot, 587
first layer, 588
fourth layer, 591
second layer, 589
third layer, 590
soleus, 582
sphincter ani, externus, 522
internus, 523
recti, 521
vaginæ, 526
vesicæ, 1197
spinalis colli, 497
dorsi, 496
splenius, 494
capitis, 494
colli, 494
stapedius, 1045
sterno-cleido-mastoid, 475
sterno-hyoid, 476
sterno-thyroid, 476
stylo-glossus, 480
stylo-hyoid, 478
stylo-pharyngeus, 484
subanconeus, 539
subclavius, 532
subcrureus, 570
subscapularis, 534
supinator brevis, 547
longus, 545
supraspinatus, 536
temporal, 469
tensor fasciæ femoris, 568
palati, 484
tarsi, 460
tympani, 1045
teres major, 536
minor, 536
of thigh, 566
thyro-arytenoideus, 1068
thyro-epiglotticus, 1069
thyro-hyoid, 476
tibialis anticus, 580
posticus, 584
of tongue, 479
trachealis, 1072
trachelo-mastoid, 496
tragicus, 1036
transversalis abdominis, 512
cervicis, 496
transversus auriculæ, 1037
perinæi, in male, 524

Muscle or Muscles (*cont.*)
transversus perinæi, in female, 526
trapezius, 490
triangularis sterni, 501
triceps extensor cubiti, 538
of tympanum, 1045
of ureters, 1197
vastus externus, 569
internus, 569
zygomaticus major, 464
minor, 465
Muscles of expression, 470
of pelvic outlet, 521
Muscular fibres of heart, 41, 610
process of arytenoid, 1061
substance of tongue, 480
tissue, 36
triangle of neck, 641
Muscularis mucosæ, 74
Musculi papillares of left ventricle, 609
of right ventricle, 607
pectinati of left auricle, 608
of right auricle, 604
pubo-vesicalis, 1197
Musculo-cutaneous nerve of arm, 957
of leg, 985
Musculo-phrenic artery, 665
Musculo-spiral groove, 297
nerve, 963
Musculus accessorius ad ilio-costalem, 496
incisivus inferior, 467
superior, 467
naso-labialis, 467
suspensorius duodeni, 1142
Myelencephalon, 119, 811
Myelocytes, 26
Myeloplaxes, 26
Myelospongium, 115
Mylo-hyoid artery, 639
groove, 256
muscle, 478
nerve, 917
ridge, 256
Myocardium, 609
Myocœl, 91
Myology, 453
Myotome, 102

Nails, 67
lunula of, 68
matrix of, 68
Nares, anterior, 1002
posterior, 277
Nasal aperture, anterior, 277
artery, lateral, 633
of ophthalmic, 648
bones, 241
articulations of, 242
ossification of, 242
cartilages, 1002
crest, 242, 246
duct, 1033
fossæ, 275, 1004
applied anatomy of, 1008
arteries of, 1007
lymphatic vessels of, 770
mucous membrane of, 1006
nerves of, 1007
veins of, 1007
vestibule of, 1004

Nasal groove, 242
laminæ (fœtal), 111
nerve, 909
nerves from Meckel's ganglion, 912
notch of frontal, 221
of maxilla, 242
process, 221
processes of fœtus, 110
septum, 275
spine, 221
anterior, 242
posterior, 251
Nasion, 279
Nasmyth's membrane, 1101
Naso-labialis muscle, 467
Naso-palatine nerve, 914
artery, 640
recess, 1005
Naso-pharynx, 1114
Navicular bone of foot, 356
Neck, lymphatic glands of, 770
lymphatic vessels of, 772
muscles of, 471
of tooth, 1093
triangles of, 640
veins of, 732
Nélaton's line, 428
Neopallium, 125
Nerve-cells, 44
of cerebellar cortex, 833
of cerebral cortex, 881
of spinal cord, 802
Nerve-epithelium cells, 52
Nerve-fibres, 45
medullated, 45
non-medullated, 47
of cerebral cortex, 881
Nerve-roots, anterior, 941
posterior, 941
Nerve-tracts of cord, 804
Nerves, *Histology of*, 42
cerebro-spinal, 47
development of, 47, 118
endoneurium of, 48
epineurium of, 47
fasciculi of, 47
funiculi of, 47
origins of, 49
perineurium of, 48
plexus of, 48
sheath of, 47
spinal, roots of, 941
sympathetic, 49
terminations of, 49
vessels of, 48
Nerves or Nerve, *Descriptive Anatomy of:*
abducent, 920
accessory obturator, 974
ano-coccygeal, 986
anterior crural, 974
interosseous, 960
superior dental, 912
thoracic, 956
tibial, 984
Arnold's, 935
auditory, 927, 1058
auricular, great, 950
posterior, 925
of auriculo-temporal, 916
of vagus, 935
auriculo-temporal, 916
of brachial plexus, 953
buccal, long, 915
Nerves or Nerve (*cont.*)
buccal of facial, 926
calcanean, internal, 982
cardiac, cervical, of vagus, 936
of sympathetic, 992, 993
thoracic, of vagus, 936
carotico-tympanic, 990
cavernous, of penis, 1000
cervical, anterior primary divisions of, 949
cardiac, 936
of facial, 927
posterior primary divisions of, 945
superficial or transverse, 950
cochlear, 1058
cervico-facial, 926
chorda tympani, 925
ciliary, long, 910
short, 911
circumflex, 956
coccygeal, anterior primary division of, 978
posterior primary division of, 949
cochlear, 928, 1058
communicans peronei, 984
tibialis, 981
communicantes hypoglossi, 952
cranial, 899
crural, anterior, 974
deep palmar, of ulnar, 963
temporal, 915
dental, anterior superior, 912
inferior, 917
middle superior, 912
posterior inferior, 912
descendens hypoglossi, 940
digastric, from facial, 925
digital, of median, 962
of radial, 965
of ulnar, 963
of anterior tibial, 984
of external plantar, 984
of internal plantar, 983
of musculo-cutaneous, 985
dorsal, of penis, 986
of dura mater, 894
eighth cranial, 927
eleventh cranial, 937
external cutaneous of thigh, 973
plantar, 983
popliteal, 984
respiratory, of Bell, 955
saphenous, 981
facial, 922
fifth cranial, 906
first cranial, 900
fourth cranial, 905
frontal, 909
ganglionic branch of nasal, 909
gastric branches of vagus, 937
genito-crural, 972
glosso-pharyngeal, 930
gluteal, inferior, 979
superior, 979
great auricular, 950
occipital, 945
sciatic, 980
splanchnic, 993
Nerves or Nerve (*cont.*)
hæmorrhoidal, inferior, 985
of heart, 936, 992, 993
hepatic, 999
hypoglossal, 939
ilio-hypogastric, 971
ilio-inguinal, 972
incisive, 917
inferior dental, 917
gluteal, 979
hæmorrhoidal, 985
maxillary, 914
infraorbital, 911*n*
of facial, 925
infratrochlear, 910
internal cutaneous, of arm, 958
lesser, 959
of thigh, 975
calcanean, 982
plantar, 983
popliteal, 981
intercostal, 966
intercosto-humeral, 968
interosseous, anterior, 960
posterior, 965
Jacobson's, 932
labial, 912
of labyrinth, 1058
lachrymal, 909
large deep petrosal, 913
superficial petrosal, 913
laryngeal, external, 936
inferior, 936
internal, 936
recurrent, 936
superior, 936
least splanchnic, 994
lesser splanchnic, 993
lingual, of fifth, 916
of glosso-pharyngeal, 932
long buccal, 915
ciliary, 910
saphenous, 976
lumbar, anterior primary divisions of, 969
posterior primary divisions of, 948
lumbo-sacral cord, 978
malar branch of facial, 925
of temporo-malar, 911
mandibular, of facial, 926
masseteric, 915
maxillary, inferior, 914
superior, 911
median, 959
meningeal, of hypoglossal, 940
of superior maxillary, 911
mental, 917
middle cardiac, 992
cutaneous, 975
superior dental, 912
motor-oculi, 903
musculo-cutaneous, of arm, 957
of leg, 985
musculo-spiral, 963
mylo-hyoid, 917
nasal, of ophthalmic, 909
from Meckel's ganglion, 914
of superior maxillary, 912
naso-palatine, 914
ninth cranial, 930
obturator, 974

Nerves or Nerve (*cont.*)
obturator, accessory, 974
occipital, great, 945
small, 950
of third cervical, 945
œsophageal, 937
olfactory, 900
ophthalmic, 908
optic, 901
orbital, their relation, in cavernous sinus, 921
in orbit, 921
in sphenoidal fissure, 921
of superior maxillary, 911
palatine, anterior or large, 914
middle, 914
posterior, 914
palmar cutaneous, of median, 960
of ulnar, 962
palpebral, 912
pars intermedia of Wrisberg, 922
perforating cutaneous, 985
perineal, 986
superficial, 986
peroneal, 984
petrosal, deep, large, 913, 990
small, 990
superficial, external, 992
large, 913
small, 1046
pharyngeal, of glosso-pharyngeal, 932
of Meckel's ganglion, 914
of pneumogastric, 935
of sympathetic, 992
phrenic, 953
plantar, external, 983
internal, 983
pneumogastric, 933
popliteal, external, 984
internal, 981
posterior auricular, 925
scapular, 955
superior dental, 912
tibial, 982
pterygoid, 915, 916
pudendal, inferior, 980
pudic, 985
pulmonary, from vagus, 936, 937
radial, 964
rami communicantes, 943
recurrent laryngeal, 936
of inferior maxillary, 914
respiratory, external, 955
to rhomboids, 955
roots, 941
sacral, 978
plexus, 978
saphenous, long or internal, 976
short or external, 981
sciatic, great, 980
small, 979
second cranial, 901
seventh cranial, 922
short ciliary, 911
sixth cranial, 920
small occipital, 950
spheno-palatine, 912
Nerves or Nerve (*cont.*)
spinal, 941
anterior primary divisions of, 949
posterior primary divisions of, 945
spinal accessory, 937
splanchnic, great, 993
least, 994
lesser, 993
stylo-hyoid of facial, 925
to subclavius, 955
suboccipital, 945, 949
subscapular, 956
superficial cervical, 950
superior cardiac, 992
gluteal, 979
laryngeal, 936
maxillary, 911
nasal, 914
supraclavicular, 951
supraorbital, 909
suprascapular, 955
supratrochlear, 909
sympathetic, 988
of taste, 1002
temporal, of auriculo-temporal, 916
deep, 915
of facial, 925
middle, 915
of temporo-malar, 911
temporo-facial, 925
temporo-malar, 911
tenth cranial, 933
third cranial, 903
thoracic, anterior primary divisions of, 966
posterior primary divisions of, 948
external anterior, 956
internal anterior, 956
thyro-hyoid, 941
thyroid, 992
tibial, anterior, 984
posterior, 982
of tongue, 1107
tonsillar, 932
transverse cervical, 950
trifacial, 906
trochlear, 905
twelfth cranial, 939
tympanic, of facial, 925
of glosso-pharyngeal, 932
ulnar, 962
collateral, 963
uterine, 1000
vaginal, 1000
vagus, 933
vestibular, 1058
Vidian, 913
of Wrisberg, 959
Nervi-nervorum, 48
Nervous system, development of, 115
description of, 794
Nervous Tissue, *Histology of*, 42
Nervus furcalis, 970
jugularis, 992
Neumann, dentinal sheath of, 1097
Neural arch, 183
canal, 89
crest, 89
folds, 88
Neural groove, 88
tube, 88
Neurenteric canal, 89
Neurilemma, 46
Neuroblasts, 47, 115, 794
Neurocentral synchondrosis, 195
Neuroglia, 43
of cord, 800
Neurokeratin, 46
Neurology, 794
Neuromeres, 797
Neuro-muscular spindles, 52
Neuron theory, 54, 794
Neurons, 794
Neuro-tendinous spindles, 52
Nidus avis cerebelli, 829
Ninth nerve, 930
Nipple, 1232
Nissl's granules, 45
Nodes of Ranvier, 46
Nodule of cerebellum, 829
Non-medullated nerve-fibres, 45
Normæ of skull—
basalis, 262
frontalis, 268
lateralis, 265
occipitalis, 268
verticalis, 261
Normoblasts, 26
Nose, 1002
accessory sinuses of, 1008
applied anatomy of, 1008
arteries of, 1003
cartilage of septum of, 1003
development of, 110
fossæ of, 275
lateral cartilages of, 1002
mucous membrane of, 1006
muscles of, 463
nerves of, 1003
outer, 1002
veins of, 1003
Notch, cotyloid, 326
ethmoidal, 222
intercondyloid, 337
lachrymal, 243
nasal, 221
popliteal, 344
presternal, 204
pterygoid, 236
sacro-sciatic, great, 324
small, 324
sigmoid, 258
spheno-palatine, 252
supraorbital, 221
suprascapular, 292
suprasternal, 489
thyroid, 1060
Notches, cerebellar, 826
intervertebral, 183
Notochord, 89
Nuck, canal of, 174, 1225
Nuclear layers of retina, 1021, 1022
membrane, 4
substance, 4
Nucleated sheath of Schwann, 46
Nuclei of auditory nerve, 825, 928
cochlear, 825
of cranial nerves, 900
of fifth nerve, 824, 844
of glosso-pharyngeal and vagus nerves, 819

Nuclei, olivary, 819
of origin of motor nerves, 900
pontis, 824
of sensory nerves, 900
of termination of sensory nerves, 900
of third nerve, 903
vestibular, 825
Nuclein, 4
Nucleoli, 4
pseudo-, 4
true, 4
Nucleo-protein, 7
Nucleus ambiguus, 819
amygdalæ, 873
arcuatus, 821
of Bechterew, 825
caudatus, 871
of a cell, 4
of Darkschewitsch, 849
of Deiters, 825
dentatus of cerebellum, 834
emboliformis, 834
of the facial nerve, 825
fastigii, 834
of the fourth nerve, 844
globosus, 834
inferior central, 821
intercalatus, 837
lateralis, 821
lenticularis, 872
lentis, 1026
of Luys, 850
olivary, accessory, 819
inferior, 819
of posterior commissure, 849
longitudinal fasciculus, 841
pulposus, 374
red, 840
resting, 5
of Roller, 821
roof, of Stilling, 834
segmentation, first, 84
of the seventh nerve, 825
of the sixth nerve, 825
of the spinal accessory nerve, 819
superior olivary, 824
trapezoid, 824
of the twelfth nerve, 818
of vagus, 819, 933
Nuel, space of, 1057
Nuhn, glands of, 1106
Nutrient artery of bone, 26
Nutritive fluids, 7
yolk, 79
Nymphæ, 1231

Obelion, 279
Obex, 836
Oblique inguinal hernia, 1159
coverings of, 1159
ligament, 414
line of the fibula, 347
of mandible, 255, 256
of radius, 306
of tibia, 344
ridge of clavicle, 287
of ulna, 304
sinus of pericardium, 600
Obliquus abdominis externus, 506
internus, 510
auriculæ, 1037
Obliquus capitis, inferior, 498
superior, 498
oculi, inferior, 462
superior, 462
Obturator artery, 700
peculiarities of, 700
relation of, to crural ring, 700
externus muscle, 576
foramen, 326
internus muscle, 575
fascia of, 517
lymphatic gland, 779
membrane, 575
nerve, 974
accessory, 974
vein, 757
Occipital artery, 634
bone, 214
articulations of, 217
ossification of, 217
structure of, 217
convolutions, 860
crests, 215, 216
fissure, transverse, 860
fossæ, 215
groove, 225
lobe, 860
lymphatic glands, 767
nerve, great, 945
small, 950
point, 279
protuberance, external, 214
internal, 215
sinus, 740
sulcus, lateral, 860
transverse, 860
triangle of neck, 640
vein, 731
Occipito-atlantal articulation, 380
Occipito-axial articulation, 382
Occipito-frontal fasciculus, 879
Occipito-frontalis muscle, 456
Occipito-mastoid suture, 274
Occipito-temporal convolution, 861
Oculo-motor sulcus, 838
Oculo-nasal sulcus, 111
Odontoblasts, 1101
Odontoid ligaments, 382
process of axis, 186
Œsophageal arteries, 662, 684
glands, 1118
nerves, 937
opening in diaphragm, 503
plexus, 937
Œsophagus, 1116
applied anatomy of, 1118
lymphatic vessels of, 793
structure of, 1117
Olecranon fossa, 298
process, 301
Olfactory areas, 110
bulb, 864
structure of, 883
cells, 1007
fasciculus, 875
foramina, 238
hairs, 1007
lobe, 863
nerves, 900
applied anatomy of, 901
development of, 128
pits, 110
sulcus, 859
Olfactory tract, 864
Olivary bodies of medulla oblongata, 813
eminence, 232
nucleus, dorsal accessory, 819
inferior, 819
mesial accessory, 819
superior, 824
peduncle, 819
Olive, peduncle of, 819
Omentum, gastro-colic, 1127
gastro-hepatic, 1128
gastro-splenic, 1128
great, 1128
small, 1127
Omo-hyoid muscle, 476
Ontogeny, 77
Oöcytes, primary, 78
secondary, 80
Oögonia, 78
Opening of aorta in left ventricle, 609
aortic, in diaphragm, 503
caval, in diaphragm, 503
of coronary sinus, 604
of inferior cava, 604
left auriculo-ventricular, 609
œsophageal, in diaphragm, 503
of pulmonary artery, 606
veins, 608
right auriculo-ventricular, 606
saphenous, 568
of superior cava, 604
of thorax, lower, 598
upper, 598
Opercula of the insula, 862
Ophryon, 279
Ophthalmic artery, 647
ganglion, 910
nerve, 908
vein, 741
Opisthion, 279
Opisthotic centre of temporal bone, 231
Opponens minimi digiti muscle, 556
pollicis muscle, 554
Optic axis, 1011
chiasma, 851, 901
commissure, 851, 901
cup, 128
disc, 1020
foramen, 232
groove, 232
nerve, 901
applied anatomy of, 903
radiations, 848, 852
recess, 853
stalks, 122
thalamus, 845
tracts, 852, 901
vesicle, 122
Ora serrata, 1024
Orbicular ligament, 413
Orbicularis oris muscle, 466
palpebrarum muscle, 459
Orbiculus ciliaris, 1016
Orbit, 270
muscles of, 461
relation of nerves in, 921
Orbital convolutions, 859
fascia, 463
nerve, 911
operculum, 862

Orbital plates, 221
process of malar, 248
of palate, 252
sulcus, 859
Orbitalis muscle, 463
Orbito-sphenoids, 235
Organ of Corti, 1055
enamel, 1101
of Giraldès, 169, 1211
of Golgi, 52
of hearing, 1034
of Rosenmüller, 169, 1220
of sight, 1010
of smell, 1002
Organs of digestion, 1088
external genital, of female, 1230
of Jacobson, 112, 1005
reproductive, of female, 1218
of male, 1203
respiratory, 1059
of special sense, 1001
of taste, 1001
Orifice, auriculo-ventricular, right, 606
left, 609
cardiac, of stomach, 1133
pharyngeal of Eustachian tube, 1114
pyloric, of stomach, 1133
urethral, 1198
vaginal, 1231
Orifices of ureters, 1198
Origin of lymphatics, 61
of muscles, 454
of nerves, 49
Os acetabuli, 327
calcis, 349
ossification of, 362
cordis, 610
incisivum, 246
innominatum, 320
linguæ, 260
magnum, 314
orbiculare of incus, 1044
planum of ethmoid, 239
trigonum, 355
uteri externus, 1224
internus, 1223
Ossa cranii, 214
faciei, 241
triquetra, 240
Ossicles of tympanum, 1043
development of, 134
ligaments of, 1045
Ossification, intracartilaginous, 31
intramembranous, 30
Ossification of atlas, 196—
axis, 196
clavicle, 288
coccyx, 198
ethmoid, 240
femur, 339
fibula, 349
foot, 362
frontal, 223
hand, 319
humerus, 299
hyoid, 261
inferior turbinated, 254
lachrymal, 248
lumbar vertebræ, 197
malar, 250
mandible, 258
maxilla, 247
Ossification, nasal, 242
occipital, 217
os innominatum, 326
palate, 253
parietal, 219
patella, 342
radius, 307
ribs, 210
sacrum, 197
scapula, 294
seventh cervical vertebra, 197
sphenoid, 236
sternum, 206
temporal, 230
tibia, 346
ulna, 305
vertebral column, 195
vomer, 255
Osteoblasts, 25
Osteoclasts, 26
Osteodentine, 1099
Osteogenetic fibres, 30
Osteology, 181
Ostium abdominale of Fallopian tube, 1221
primum of heart, 139
secundum of heart, 140
Otic ganglion, 917
vesicle, 133
Otoconia or otoliths, 1053
Outlet of pelvis, 329
Ova, primitive, 172
Oval area of Flechsig, 808
bundle, 117
Ovarian arteries, 695
fossa, 1125, 1218
plexus of nerves, 999
veins, 760
Ovaries, 1218
development of, 172
Graafian follicles of, 1220
ligaments of, 1218, 1219
lymphatic vessels of, 789
stroma of, 1220
tunica albuginea of, 1220
vessels and nerves of, 1221
Ovicapsule of Graafian follicle, 1220
Oviducts, 1221
Ovula Nabothi, 1228
Ovum, 3, 78
coverings of, 79
discharge of, 1221
fertilisation of, 83
germinal spot of, 78
vesicle of, 79
maturation of, 79
segmentation of, 84
structure of, 78
yolk of, 79
zona pellucida of, 79
Oxyntic cells, 1138
glands, 1138

Pacchionian depressions, 218, 221
bodies, 898
Pacinian corpuscles, 51
Pad, retropubic, 1194
Palatal processes of fœtus, 111
process of maxilla, 245
Palate, arches of, 1091
bone, 250
articulations of, 253
Palate bone, horizontal plate of, 250
orbital process of, 252
ossification of, 253
sphenoidal process of, 252
vertical plate of, 251
development of, 111
hard, 1091
muscles of, 484
soft, 1091
Palatine aponeurosis, 484
artery, ascending, 632
of ascending pharyngeal, 636
descending, 640
canal, posterior, 244, 251
accessory, 252
fossa, anterior, 246
nerves, 913
veins, inferior, 730
Palato-glossus muscle, 485
Palato-pharyngeus, 485
Palmar arch, deep, 676
superficial, 681
surface marking of, 682
cutaneous nerve, of median, 960
of ulnar, 962
fascia, 552
interossei arteries, 678
nerve, deep, of ulnar, 963
superficial, 963
veins, deep, 747
Palmaris brevis muscle, 556
longus muscle, 541
Palpebræ, 1029
Palpebral arteries, 647
ligaments, 1030
muscles, 459
nerves from superior maxillary, 912
veins, inferior, 730
superior, 729
Pampiniform plexus of veins, 759
Pancreas, 1175
applied anatomy of, 1179
development of, 165
lymphatic vessels of, 787
structure of, 1179
surface relations of, 1179
vessels and nerves of, 1179
Pancreatic arteries, 690
duct, 1178
accessory, 1178
plexus of nerves, 999
veins, 762
Pancreatica magna artery, 690
Pancreatico-duodenal artery, inferior, 691
superior, 690
lymphatic glands, 784
plexus of nerves, 999
Papilla spiralis, 1055
Papillæ lacrimales, 1032
of kidney, 1184
of skin, 67
of tongue, 1104
of tooth, 1100
Papillary layer of skin, 67
Paracentral lobule, 859
Parachordal cartilages, 106
Paralinin, 4
Parallel striæ of Retzius, 1098
sulcus, 861
Paramastoid process, 216

Paranephric body, 1183
Paranucleus, 1179
Paraplasm, 4
Pararectal lymphatic glands, 784
fossa, 1125
Parathyroid glands, 1237
development of, 155
Paravesical fossa, 1125
Paraxial mesoderm, 90
Parietal bone, 218
articulations of, 220
development of, 107
eminence, 218
foramen, 218
ossification of, 219
cells of gastric glands, 1138
lobe, 859
convolutions of, 860
veins, 146
Parieto-colic fold, 1132
Parieto-mastoid suture, 266
Parieto-occipital fissure, 857
Parieto-temporal artery, 652
Parolfactory area, 864
Paroöphoron, 169, 1220
Parotid duct, 1110
fascia, 473
gland, 1108
accessory portion of, 1109
applied anatomy of, 1113
nerves of, 1110
structure of, 1109
vessels of, 1110
lymphatic glands, 768
Parovarium, 1220
Pars basalis, 859
ciliaris retinæ, 1016, 1020
externa, interna, et media of auditory canal, 1038
flaccida of membrana tympani, 1043
intermedia of Wrisberg, 922
iridica retinæ, 1018, 1020
laryngea of pharynx, 1115
mamillaria hypothalami, 123
membranacea septi, 609
nasalis of pharynx, 1114
optica hypothalami, 123
oralis of pharynx, 1114
orbitalis, 859
triangularis, 859
Parumbilical veins, 763
Patella, 341
applied anatomy of, 343
articulations of, 342
movements of, 437
ossification of, 342
structure of, 342
surface form of, 342
Patellar ligaments, 430
plexus, 973
Pavement epithelium, 12
Pectineus muscle, 571
Pectiniform septum, 1213
Pectoralis major, 529
minor, 531
Peculiar thoracic vertebræ, 188
Peculiarities of fœtal heart, 148
Pedicles of a vertebra, 183
Peduncles of cerebellum, 830, 831
of the olive, 819
Pelvic colon, 1153
diaphragm, 517
Pelvic diaphragm, fascia of, 517
fascia, 517
girdle, 286
mesocolon, 1129
plexuses, 1000
portion of sympathetic cord, 996
Pelvis, 327, 1121
applied anatomy of, 331
arteries of, 698
articulations of, 393
axes of, 329
boundaries of, 327
brim of, 327
cavity of, 328
false, 327
in fœtus, 331
inlet of, 327
of kidney, 1191
ligaments of, 369
lymphatic glands of, 778
vessels of, 781
male and female, differences between, 329
mechanism of, 397
outlet of, 329
position of, 329
surface form of, 331
true, 327
Penis, 1212
applied anatomy of, 1215
body of, 1214
corona glandis, 1213
corpora cavernosa, 1212
corpus spongiosum, 1213
crura of, 1212
dorsal artery of, 703
veins of, 757
extremity of, 1214
glans, 1213
nerves of, 986
prepuce or foreskin of, 1214
root of, 1213
septum pectiniforme of, 1213
structure of, 1214
suspensory ligament, 1214
Penniform muscle, 453
Perforated space, anterior, 864
posterior, 838
Perforating arteries, of hand, 678
from internal mammary, 665
from plantar, 726
from profunda, 714
cutaneous nerve, 985
fibres of Sharpey, 29
Perforator of spermatozoön, 81
Pericardiac arteries, 664, 684
Pericardial area, 87
Pericardium, applied anatomy of, 600
development of, 150
diverticula of, 600
fibrous, 599
nerves of, 600
oblique sinus of, 600
relations of, 598
serous, 600
structure of, 599
transverse sinus of, 600
vessels of, 600
vestigial fold of, 600
Perichondrium, 21
Perilymph, 1051, 1057
Perimysium, 36
Perinæum, boundaries of, 521
central tendinous point of, 524
lymphatic vessels of, 781
muscles of, 521
Perineal artery, superficial, 701
transverse, 702
body, 1155
branch of fourth sacral nerve, 986
nerve, 986
superficial, 986
Perineurium, 48
Periosteum, 25
internal, 25
Peripheral end-bulbs, 50
organs, 49
termination of nerves, 49
Perisclerotic lymph space, 1011
Peritoneal cavity, 1122
Peritoneum, attached surface of, 1121
foramen of Winslow, 1127
free surface of, 1121
greater sac of, 1122
horizontal disposition of, in lower abdomen, 1125
in upper abdomen, 1126
in pelvis, 1125
lesser sac of, 1122
ligaments, 1127
mesenteries, 1129
omenta, 1127
parietal portion of, 1121
vertical disposition of greater sac, 1122
of lesser sac, 1124
visceral portion of, 1121
Permanent cartilage, 21
teeth, 1094
development of, 1102
Peroneal artery, 723
peculiarities of, 724
anterior, 724
posterior, 724
nerve, 984
septa, 579
tubercle, 352
Peroneus brevis muscle, 585
longus muscle, 585
tertius muscle, 580
Perpendicular fasciculus, 879
line of ulna, 304
plate of ethmoid, 239
Pes anserinus, 923
or crusta of crus cerebri, 839
hippocampi, 870
Petit, canal of, 1025
triangle of, 492
Petro-mastoid portion of temporal bone, 225
Petro-occipital suture, 274
Petro-squamous sinus, 740
suture, 227
Petrosal nerve, large superficial, 913, 924
large deep, 913
small superficial, 1046
process, 233
sinus, inferior, 742
superior, 742
Petrous ganglion, 932
portion of temporal bone, 227
Peyer's glands, 1146
Pflüger, egg tubes of, 1221

Phalanges of cochlea, 1057
of foot, 361
ossification of, 362
of hand, 318
ossification of, 319
Pharyngeal aponeurosis, 1115
artery, ascending, 636
nerve, from external laryngeal, 936
from glosso-pharyngeal, 932
from Meckel's ganglion, 914
from sympathetic, 992
from vagus, 935
orifice of Eustachian tube, 1114
plexus of nerves, 992
septum, 151
tonsil, 1114
tubercle, 217
veins, 734
Pharyngo-glossus muscle, 484
Pharynx, 1113
aponeurosis of, 1115
applied anatomy of, 1116
development of, 155
lymphatic vessels of, 772
mucous membrane of, 1115
muscles of, 482
Philtrum, 467
Phrenic artery, superior, 685
inferior, 695
nerve, 953
plexus of nerves, 997
vein, superior, 748
inferior, 760
Phrenico-costal sinus, 1077
Phrenico-pericardiac ligament of Teutleben, 758
Phreno-colic ligament, 1153
Phylogeny, 77
Pia mater, 898
Pigment, 35
of iris, 1018
of skin, 66
Pigmentary layer of retina, 1023
Pigmented connective-tissue cells, 35
epithelial cells, 35
Pillars of external abdominal ring, 508
of fauces, 1091
Pineal body, 849
development of, 123
striæ of, 854
structure of, 849
eye of lizards, 849
recess, 123
Pinna, 1034
development of, 134
ligaments of, 1036
lymphatic vessels of, 769
muscles of, 1036
nerves of, 1057
vessels of, 1037
Pisiform bone, 313
Piso-metacarpal ligament, 418
Piso-uncinate ligament, 418
Pit of the stomach, 212
Pits, olfactory, 110
Pituitary body, 851
arteries of, 646
development of, 155
lobes of, 851
Pituitary fossa, 232
Pivot-joint, 370
Placenta, 99
circulation through, 101, 614
cotyledons of, 101
fœtal, 99
maternal, 100
separation of, 101
Placental circulation, 101, 614
Plane, infracostal, 1119
intertubercular, 1119
transpyloric, 1119*n*
Plantar arch, 725
artery, external, 725
internal, 724
fascia, 587
ligaments, 446
nerve, external, 983
internal, 983
veins, external, 754
internal, 754
Plantaris muscle, 582
Planum nuchale, 215
occipitale, 214
Plasma, 10
cells, 15
Plasmodioblast, 86
Plate or plates—
cribriform, 238
ethmoidal, 106
perpendicular, 239
pterygoid, 236
tarsal, 1030
Platelets of blood, 9
Platysma, 471
Pleura, 1074
applied anatomy of, 1077
cervical, 1075
costalis, 1075
development of, 167
diaphragmatic, 1075
lymphatic vessels of, 793
mediastinal, 1075
pulmonalis, 1075
reflections of, traced, 1075
vessels and nerves of, 1077
Plexiform layers of retina, 1021, 1022
Plexus of Nerves, 48
aortic, 999
brachial, 953
cardiac, 996
carotid, 990
cavernous, 990
cervical, 949
posterior, 946
coccygeal, 986
cœliac, 999
of cornea, intraepithelial, 1014
subepithelial, 1014
coronary, 997
cystic, 999
epigastric or solar, 997
of Exner, 881
gastric, 999
gastro-duodenal, 999
gastro-epiploic, 999
hæmorrhoidal, inferior, 1000
superior, 999
hepatic, 999
hypogastric, 999
infraorbital, 912, 926
lumbar, 970
lumbo-sacral, 969
mesenteric, inferior, 999
Plexus of Nerves (*cont.*)
mesenteric, superior, 999
œsophageal, 937
ovarian, 999
pancreatic, 999
pancreatico-duodenal, 999
patellar, 973
pelvic, 1000
pharyngeal, 992
phrenic, 997
prostatic, 1000
pudendal, 985
pulmonary, 936, 937
pyloric, 999
renal, 998
sacral, 978
solar, 997
spermatic, 998
splenic, 999
subsartorial, 976
superficial cardiac, 996
suprarenal, 997
tonsillar, 932
tympanic, 1046
uterine, 1000
vaginal, 1000
vesical, 1000
Plica epigastrica, 1159
fimbriata of tongue, 1104
gubernatrix, 173
hypogastrica, 1159
lacrimalis of Hasner, 1033
salpingo-palatina, 1114
salpingo-pharyngea, 1114
semilunaris, 1031
triangularis, 1115
urachi, 1159
vascularis, 173
vesicalis transversa, 1125
Plicæ uretericæ, 1198
Pneumogastric nerve, 933
applied anatomy of, 937
Polar bodies, 80
Poles of eye, 1011
of lens, 1025
Polymorphonuclear leucocytes, 8
Polyspermy, 84
Pomum Adami, 1060
Pons hepatis, 1167
Varolii, 822
applied anatomy of, 825
development of, 120
structure of, 823
Ponticulus of pinna, 1036
Pontine flexure of embryonic brain, 119
Popliteal artery, 716
applied anatomy of, 717
branches of, 717
peculiarities of, 717
surface marking of, 717
lymphatic glands, 775
nerve, external, 984
internal, 981
notch, 344
space, 715
surface of femur, 336
vein, 755
Popliteus muscle, 583
Pore, gustatory, 1001
Portal canals, 1168
fissure, 1167
vein, 760
applied anatomy of, 763
development of, 145

Porus opticus, 1020
Post-allantoic gut, 162
Post-anal gut, 162
Post-branchial bodies, 155
Post-central fissure, 827
  lobe of insula, 862
  sulcus, 859
Post-clival fissure, 827
Post-glenoid process, 224
Post-gracile fissure, 829
Post-nodular fissure, 828
Post-parietal convolution, 860
Post-pyramidal fissure, 829
Post-sphenoid part of sphenoid, 237
Posterior annular ligament, 551
  auricular artery, 635
  basal column, 804
  cervical plexus, 946
  chamber of eye, 1017
  choroidal artery, 661
  clinoid process, 232
  commissure of brain, 840
    nucleus of, 849
  common ligament, 373
  communicating artery, 652
  cornu of lateral ventricle, 867
  crescentic lobe, 827
  inferior cerebellar artery, 661
  internal frontal artery, 649
  interosseous artery, 681
    nerve, 965
  longitudinal fasciculus, 841
  median fissure of cord, 798
    of medulla, 812
  mediastinum, 1079
  nerve root, 941
  perforated space, 838
  primary divisions of cervical nerves, 945
    of coccygeal nerve, 949
    of lumbar nerves, 948
    of sacral nerves, 949
    of thoracic nerves, 948
  pulmonary plexus, 937
  scapular artery, 663
    nerve, 955
  thoracic nerve, 955
  tibial artery, 722
    nerve, 982
  triangle of neck, 643
  vesicular column, 803
Postero-inferior lobe, 829
Postero-lateral ganglionic arteries, 661
Postero-median ganglionic arteries, 661
Postero-superior lobe, 827
Pott's fracture, 596
Pouch of Douglas, 1124, 1225
  of Prussak, 1046
  of Rathke, 155
  recto-vaginal, 1124
  recto-vesical, 1124
Poupart's ligament, 509
Præputium clitoridis, 1231
Preauricular point, 281
Precentral convolution, 858
  fissure, 827
  sulcus, 858
Prechordal portion of base of fœtal skull, 106
Preclival fissure, 827
Precuneus, of brain, 860
Premaxilla, 246
Premolar teeth, 1095
Preolivary sulcus, 812
Prepatellar bursa, 570
Prepuce, 1214
  of clitoris, 1231
  development of, 177
Prepyramidal fissure, 828
Presphenoid part of sphenoid, 237
Presternal notch, 204
Presternum, 203
Pretracheal fascia, 473
Prevertebral arteries, 636
  fascia, 473
Prickle cells, 15, 65
Primary areolæ of bone, 32
  cephalic flexure, 119
  cerebral vesicles, 89
  oöcytes, 78
  spermatocytes, 82
Primitive alimentary canal, 92
  amniotic cavity, 86
  aortæ, 135
  aortic stem, 140
  auricle, 139
  ectoderm, 85
  fibrillæ of Schultze, 46
  groove, 86
  jugular veins, 146
  ova, 172
  segments, 91
  sheath of nerve-fibre, 46
  sperm-cells, 173
  streak, 86
  ventricle of heart, 140
  vertebral bow, 103
Primordial cranium, 105
  ova, 1221
Princeps cervicis artery, 634
  pollicis artery, 677
Proamnion, 87
Processes or Process—
  accessory, 191
  acromion, 292
  alar, 238
  alveolar, 245
  angular, external, 221
    internal, 221
  articular, of vertebræ, 183
  basilar, 216
  ciliary, 1016
  clinoid, anterior, 235
    middle, 232
    posterior, 232
  cochleariform, 229
  condylar, of mandible, 257
  coracoid, 293
  coronoid, of mandible, 257
    of ulna, 301
  costal, 184
  of dura mater, 893
  ensiform, 204
  ethmoidal, of inferior turbinated, 253
  external auditory, 229
  frontal, of maxilla, 245
  fronto-nasal, 110
  fronto-sphenoidal, 248
  funicular, 173*n*
  globular, of His, 111
  hamular, of lachrymal, 248
    of sphenoid, 236
  jugular, 228
  lachrymal, of inferior turbinated bone, 253
  lateral nasal, 110
Processes or Process (*cont.*)
  malar, 245
  mamillary, 191
  mastoid, 225
  maxillary, of fœtus, 111
    of inferior turbinated, 254
    of malar bone, 250
    of palate bone, 252
  nasal, of frontal bone, 221
    of maxilla, 245
  odontoid, of axis, 186
  olecranon, 301
  orbital, of malar, 248
    of palate, 252
  palatal, of fœtus, 111
    of maxilla, 245
  paramastoid, 216
  petrosal, 233
  post-glenoid, 224
  pterygoid, of sphenoid, 236
  sphenoidal, of palate, 242
  spinous, of ilium, 323
    of sphenoid, 234
    of tibia, 343
    of vertebræ, 183
  styloid, of fibula, 347
    of radius, 307
    of temporal, 230
    of ulna, 305
  temporal, of malar, 250
  transverse, of vertebræ, 183
  turbinal, of lachrymal, 248
  turbinated, of ethmoid, 240
  unciform, 314
  uncinate, of ethmoid, 239
  vaginal, of sphenoid, 236
    of temporal, 228
  zygomatic, of maxilla, 245
    of temporal, 223
Processus brevis of malleus, 1044
  cochleariformis, 229, 1041
  gracilis of malleus, 1043
  intrajugularis, 216
  jugularis, 216
  muscularis, of arytenoid, 1061
  pyramidalis, of palate bone, 252
  sphenoidalis, 1003
  tubarius, 236
  uncinatus, of ethmoid, 239
  vocalis, of arytenoid, 1061
Proctodœum, 161
Profunda cervicis artery, 665
  femoris artery, 713
    vein, 755
  artery, inferior, 674
    superior, 673
  of ulnar, 681
Projection fibres of hemispheres, 878
Prominentia canalis facialis, 1041
Promontory of tympanum, 1041
Pronator teres muscle, 540
  quadratus muscle, 544
  ridge, 304
Pronephric duct, 168
Pronephros, 168
Pronucleus, female, 81
  male, 84
Prootic centre of temporal bone, 230
Prophase of karyokinesis, 5

Prostate gland, 1215
applied anatomy of, 1217
development of, 175
lobes of, 1216
lymphatic vessels of, 788
vessels and nerves of, 1217
Prostatic ducts, orifices of, 1200
plexus of nerves, 1000
portion of urethra, 1200
sinus, 1200
Prosthion, 279
Protoplasm, 3
Protoplasmic process of nerve-cells, 45
Protovertebral somites, 91
Protuberance, mental, 255
occipital, external, 214
internal, 215
Proximal convoluted tube, 1186
Prussak, pouch of, 1046
Psalterium, 875
Pseudo-nucleoli, 4
Pseudopodium, 9
Pseudostomata of serous membranes, 73
Psoas magnus muscle, 564
applied anatomy of, 565
parvus muscle, 565
Pterion, 279
ossicle, 240
Pterygoid arteries, 639
fossa of sphenoid, 236
muscles, 469
nerves, 915, 916
notch, 236
plates, 236
plexus of vein, 731
processes of sphenoid, 236
tubercle, 236
Pterygo-mandibular ligament, 467
Pterygo-maxillary fissure, 268
Pterygo-palatine artery, 640
canal, 236
sulcus, 236
Pterygo-spinous ligament, 237
Pubic arch, 329
ligaments, 396
portion of fascia lata, 568
spine, 325
Pubis, 324
angle of, 325
body of, 324
crest of, 325
rami of, 325
spine of, 325
symphysis of, 396
Pubo-coccygeus muscle, 521
Pubo-femoral ligament, 424
Pubo-prostatic ligaments, 1196
Pubo-rectalis muscle, 521
Pudendal plexus, 985
Pudendum, 1230
Pudic artery, accessory, 701
deep external, 713
internal, in male, 701
peculiarities of, 701
in female, 703
superficial external, 713
nerve, 985
vein, internal, 756
Pulmonary artery, 618
opening of, in right ventricle, 606
nerves from vagus, 936, 937
Pulmonary valves, 607
veins, 727
openings of, in left auricle, 608
Pulp, dental, of teeth, 1096
of spleen, 1241
Pulp-cavity of teeth, 1096
Pulvinar of thalamus, 845
Puncta lacrimalia, 1032
vasculosa, 865
Pupil, 1017
Pupillary membrane, 131, 1019
Purkinje, cells of, 833
fibres of, 42
Putamen, 872
Pyloric artery, 689
canal, 1134
glands, 1137
orifice of stomach, 1133
plexus, 999
portion of stomach, 1134
valve, 1135
vein, 762
vestibule, 1133
Pylorus, 1133
Pyramid of cerebellum, 829
of thyroid gland, 1236
of tympanum, 1041
of vestibule, 1048
Pyramidal cells of cerebral cortex, 881
eminence of pons, 823
fibres of crusta, 839
of internal capsule, 873
tracts, 815
Pyramidalis muscle, 514
nasi muscle, 463
Pyramids of Malpighi, 1184
of medulla, 812
decussation of, 813
Pyriformis muscle, 575
fascia of, 518

Quadrate lobe, 860
Quadratus femoris muscle, 576
lumborum muscle, 517
fascia covering, 517
menti muscle, 466
tubercle of, 335
Quadriceps extensor cruris muscle, 568
Quadrigeminal bodies, 843

Racemose glands, 75
Radial artery, 675
applied anatomy of, 676
branches of, 677
peculiarities of, 676
surface marking of, 676
fossa, 298
head of humerus, 298
nerve, 964
recurrent artery, 677
region, muscles of, 545
Radialis indicis artery, 678
Radiating fibres of retina, 1023
Radio-carpal articulation, 415
applied anatomy of, 417
surface form of, 417
Radio-ulnar articulations, inferior, 414
middle, 414
superior, 413
region, anterior, muscles of, 540
Radius, 306
applied anatomy of, 308
articulations of, 307
grooves in lower end of, 307
oblique line of, 306
ossification of, 307
sigmoid cavity of, 307
surface form of, 308
tuberosity of, 306
Rami communicantes, 943
of the ischium, 324
of the mandible, 256
of the pubis, 325
Ramus occipitalis, 860
Ranine artery, 631
vein, 730
Ranvier, nodes of, 46
Raphe, ano-coccygeal, 520
of medulla, 812
of palate, 1091
of scrotum, 1203
Rathke, pouch of, 155
Receptaculum chyli, 766
Recess, epitympanic, 226
naso-palatine, 1005
optic, 853
pineal, 853
spheno-ethmoidal, 276
supraoptic, 853
Recesses of Tröltsch, 1046
Recessus ellipticus, 1048
epitympanicus, 1039
labyrinthi, 133
pinealis, 123
sphæricus, 1048
suprapinealis, 854
Reciprocal reception, articulations by, 370
Rectal ampulla, 1154
fascia, 519
Recto-coccygeal muscles, 1155
Recto-uterine folds, 1225
Recto-vesical fascia, 519
folds, 1125
pouch, 1124
Rectum, 1154
ampulla of, 1154
development of, 160
Houston's valves of, 1155
lymphatic vessels of, 785
relations of, 1154
surgical anatomy of, 1162
Rectus abdominis, 513
sheath of, 513
capitis anticus major, 486
minor, 486
lateralis, 486
posticus major, 498
minor, 498
external, inferior, internal, and superior of eyeball, 462
femoris muscle, 569
Recurrent artery, radial, 677
tibial, anterior, 721
posterior, 721
ulnar, anterior, 679
posterior, 679
laryngeal nerve, 936
nerve of inferior maxillary, 914
Recurrent branches from deep palmar arch, 678
interosseous artery, 681
Red corpuscles, 7
nucleus, 840

Reflections of pleuræ, 1075
Refracting media of eye, 1024
Region—
abdominal, muscles of, 506
acromial, muscles of, 533
auricular, 458
back, muscles of, 489
cervical, superficial, muscles of, 461
cranial, 456
epigastric, 1119
femoral, muscles and fasciæ of, anterior, 566
internal, 571
posterior, 544
fibular, 575
foot, dorsal region of, 587
plantar region of, 587
gluteal, muscles of, 573
hand, muscles and fasciæ of, 550
humeral, anterior, 536
posterior, 538
hypochondriac, 1119
hypogastric, 1121
iliac, muscles and fasciæ of, 564
infrahyoid, 476
inguinal, 1121
intermandibular, muscles of, 466
ischio-rectal, muscles and fasciæ of, 521
lingual, muscles of, 479
mandibular, muscles of, 466
maxillary, muscles of, 464
nasal, muscles of, 463
orbital, muscles of, 461
palatal, muscles of, 484
palpebral, muscles of, 459
pelvis, muscles and fasciæ of, 517
perinæum, muscles and fasciæ of, 521
pharyngeal, muscles of, 482
popliteal space, 715
pterygo-mandibular, muscles of, 469
radial, muscles of, 540
radio-ulnar, anterior, muscles of, 540
posterior, 545
scapular, anterior, muscles of, 354
posterior, 535
Scarpa's triangle, 710
suprahyoid, muscles of, 477
temporo-mandibular, muscles of, 467
thoracic region, anterior, muscles and fasciæ of, 528
lateral, muscles and fasciæ of, 532
thorax, muscles and fasciæ of, 500
tibio-fibular, anterior, muscles of, 579
posterior, 581
umbilical, 1121
urogenital region in male, muscles and fasciæ of, 523
in female, muscles and fasciæ of, 526
Region (*cont.*)
vertebral, anterior, muscles of, 486
lateral, 488
Regions of abdomen, 1119
Reil, island of, 862
convolutions of, 862
sulcus circularis of, 857
Renal afferent vessels, 1185, 1188
artery, 694
inferior, 1187
efferent vessels, 1185, 1188
plexus, 998
veins, 760
Reproductive organs, female, 1218
male, 1203
Respiration, mechanism of, 505
organs of, 1059
Respiratory nerve of Bell, external, 955
organs, development of, 166
Restiform bodies of medulla, 815
Resting nuclei, 5
Rete mucosum of skin, 64
testis, 1208
Reticular lamina of Kölliker, 1057
layer of skin, 67
tissue, 19
Reticularis alba, 821
grisea, 821
Retiform tissue, 19
Retina, 1021
central artery of, 1024
development of, 129
fovea centralis of, 1023
layers of, 1021
macula lutea of, 1023
membrana limitans interna, 1021
externa, 1023
ora serrata of, 1020
structure of, 1020
supporting framework of, 1023
Retinacula of hip-joint, 424
of ileo-cæcal valve, 1150
Retrahens auriculam muscle, 459
Retro-peritoneal fossæ, 1129
circumcæcal, 1131
duodenal, 1129
intersigmoid, 1132
Retro-pharyngeal space, 473
Retro-pubic pad, 1194
Retzius, coloured lines of, 1098
Rhinencephalon, 124, 863
Rhodopsin, or visual purple, 36, 1020
Rhombencephalon, 119, 811
Rhombic lip, 120
Rhomboid impression, 288
ligament, 400
Rhomboideus major, 492
minor, 492
Rhomboids, nerve to, 955
Ribs, 206
angles of, 208
applied anatomy of, 212
development of, 104
heads of, 207
ligaments of, 385
necks of, 207
Ribs, ossification of, 210
peculiar, 209
structure of, 210
tubercles of, 208
Ridge, bicipital, 295
ganglion, 89, 118
gluteal, 336
mylo-hyoid, 256
pronator, 304
superciliary, 220
temporal, 221, 223
trapezoid or oblique, 287
Right lobe of liver, 1167
Rima glottidis, 1066
palpebrarum, 1029
Ring, abdominal, external, 508
internal, 516
crural, 708
muscle of Müller, 1017
tympanic, 231
Rings, fibrous, of heart, 610
Risorius muscle, 467
Rivinus, ducts of, 1110
incisure of, 1040
Rod-bipolars of retina, 1021
Rod-granules of retina, 1022
Rods of Corti, 1055
of retina, 1023
Rolando, fasciculus of, 814
fissure of, 857
substantia gelatinosa of, 799
tubercle of, 815
Roller, nucleus of, 821
Roof nucleus of Stilling, 834
plate, 115
Root of lung, 1083
of penis, 1213
of tooth, 1093
Root-sheath of hair, 69
Roots of spinal nerves, 808
of zygomatic process, 223
Rosenmüller, lymphatic gland of, 776
fossa of, 1114
organ of, 169, 1220
Rostrum of corpus callosum, 866
sphenoidale, 234
Rotation, 371
Rotatores spinæ muscles, 497
Round ligament of liver, 1168
of uterus, 1225
Ruffini's endings, 50
Rust-coloured layer of cerebellar cortex, 833

Sac, lachrymal, 1032
greater, of peritoneum, 1122
lesser, of peritoneum, 1124
Saccular glands, 74, 75
Saccule of vestibule, 1053
laryngeal, 1066
Sacral arteries, lateral, 704
artery, middle, 696
canal, 193
cornua, 192
foramina, 191
ganglia, 996
groove, 192
lymphatic glands, 779
nerves, anterior primary divisions of, 978
posterior primary divisions of, 949
nucleus of spinal cord, 803

Sacral plexus, 978
applied anatomy of, 986
veins, lateral, 757
middle, 758
peculiarities of, 758
Sacro-coccygeal ligaments, 396
Sacro-genital folds, 1125, 1225
Sacro-iliac articulation, 393
ligaments, 394
Sacro-sciatic foramen, great, 395
small, 396
ligament, great, 394
small, 395
notch, great, 324
small, 324
Sacro-vertebral angle, 191
Sacrum, 191
articulations of, 194
ossification of, 197
structure of, 194
variations of, 194
Sacs, dental, 1101
Saddle joint, 370
Sagittal sulcus, 215, 218, 221
suture, 219
Salivary glands, 1108
development of, 153
parotid, 1108
structure of, 1111
sublingual, 111
submaxillary, 1110
Salpingo-pharyngeus muscle, 485
Salter, incremental lines of, 1098
Santorini, cartilages of, 1061
duct of, 165, 1178
Saphenous nerve, long or internal, 976
external, 981
opening, 568
vein, applied anatomy of, 753
external or short, 753
internal or long, 752
Sarcolemma, 37
Sarcomere, 39
Sarcoplasm, 38
Sarcostyles, 38
Sarcous elements of muscle, 39
Sartorius muscle, 568
Scala media of cochlea, 1053
tympani, 1051
vestibuli, 1051
Scalene tubercle, 210
Scalenus anticus, 488
medius, 488
posticus, 488
Scalp, lymphatic vessels of, 769
Scaphoid bone (hand), 311
(foot), 356
fossa of sphenoid, 236
Scapula, 289
applied anatomy of, 294
articulations of, 294
dorsum of, 289
glenoid cavity of, 292
head of, 292
ligaments of, 403
ossification of, 294
spine of, 290
surface form of, 294
venter of, 289
Scapular artery, posterior, 663
nerve, posterior, 955
Scapular notch, great, 292
region, anterior, muscles of, 534
posterior, 535
Scarf-skin, 64
Scarpa, fascia of, 506
foramina of, 246
ganglion of, 1058
Scarpa's triangle, 710
Schindylesis, 368
Schlemm, canal of, 1014
Schneiderian membrane, 1005
Schreger, lines of, 1098
Schultze, descending comma tract of, 808
primitive fibrillæ of, 46
Schwann, nucleated sheath of, 46
white substance of, 46
Sciatic artery, 703
nerve, great, 980
applied anatomy of, 987
small, 979
veins, 756
Sclera, 1011
development of, 133
structure of, 1012
Scleratogenous layer, 103
Sclerotome, 102
Scrobiculus cordis, 212
Scrotum, 1203
applied anatomy of, 1205
dartos of, 1204
development of, 177
septum of, 1204
vessels and nerves of, 1204
Sebaceous glands, 71
Second cranial nerve, 901
applied anatomy of, 903
Secondary areolæ of bone, 32
oöcytes, 80
sensory tract, 807
spermatocytes, 82
Secreting glands, 74
Secretion, internal, 76
Segment, internodal, 46
of Lantermann, 46
medullary, 46
Segmentation of cells, 7
of ovum, 84
nucleus, first, 84
Segments, primitive, 91
spinal, 797
Sella turcica, 232
Semicircular canals, bony, 1048
membranous, 1053
structure of, 1053
Semilunar bone, 312
fascia, 538
fibro-cartilages of knee, 434
fold of Douglas, 513
ganglion of abdomen, 997
lobe, inferior, of cerebellum, 829
Semimembranosus muscle, 578
Seminal vesicles, 1211
Semispinalis muscle, 497
Semitendinosus muscle, 578
Senses, organs of special, 1001
development of, 115
Sensory tract, 890
decussation, 817
epithelium cells, 52
nerves, 49, 885
Septum, aortic, 140
auricularum, 597
Septum crurale, 708
inferius, 140
intermedium, 139
interventricular, 609
linguæ, 1105
lucidum, 876
mobile nasi, 1003
of nose, 275
orbitale, 1031
pectiniforme, 1213
pellucidum, 876
pharyngeal, 151
postero-median, of spinal cord, 798
posticum, 897
primum, 139
secundum, 140
spurium, 138
of tongue, 1105
transversum, 157
of semicircular canals, 1053
ventriculorum, 609
Serosa, or false amnion, 94
Serous glands of tongue, 1106
membranes, 72
pericardium, 600
Serratus magnus, 532
posticus inferior, 493
superior, 493
Sertoli, cells of, 1208
Serum, 11
albumen, 10
globulin, 10
Sesamoid bones, 364
Seventh cranial nerve, 922
applied anatomy of, 927
nucleus of, 825
Shaft of a bone, its structure, 181
of a hair, 70
Sheath of arteries, 56
dentinal, of Neumann, 1097
digital, of fingers, 552
of toes, 589
femoral, 707
mitochondrial, 82
of muscles, 36
of nerves, 46
of rectus muscle, 513
synovial, 367
Shin, 344
Short bones, 181
saphenous vein, 753
Shoulder, muscles of, 533
girdle, 286
joint, 404
applied anatomy of, 407
bursæ of, 405
surface form of, 407
vessels and nerves of, 406
Shrapnell, pars flaccida of, 1043
Sigmoid artery, 693
cavity of radius, 307
greater, of ulna, 304
lesser, of ulna, 304
notch of mandible, 258
sinus, 740
Simple epithelium, 12
papillæ of tongue, 1105
Sinus, aortic, 619
basilar, 743
circular, 742
coronary, 728
costo-mediastinal, 1077

Sinus of external jugular vein, 733
great, of aorta, 619
of internal jugular vein, 733
of kidney, 1183
laryngeal, 1066
longitudinal, inferior, 738
superior, 737
of Morgagni, 483
oblique, of pericardium, 600
petro-squamous, 740
phrenico-costalis, 1077
pocularis, 1200
præcervicalis, 109
prostatic, 1200
pyriformis, 1115
rhomboidalis, 89
spheno-parietal, 740
tarsi, 352
transverse, of pericardium, 600
venosus, 138, 604
scleræ, 1014
Sinuses, accessory of nose, 1008
cavernous, 740
cranial, 221*n*
of dura mater, 737
frontal, 222, 1008
intercavernous, 742
lateral, 739
maxillary, 244, 1008
occipital, 740
petrosal, inferior, 742
superior, 742
petro-squamous, 740
sigmoid, 740
sphenoidal, 233, 1008
spheno-parietal, 740
straight, 738
of Valsalva, aortic, 609
pulmonary, 607
Sixth cranial nerve, 920
applied anatomy of, 922
nucleus of, 825
Skein, or spirem, 5
Skeletal muscles, 36
Skeleton, 181
development of, 102
Skin, *Histology of*, 64
appendages of, 67
arteries of, 67
corium of, 66
cuticle of, 64
derma, or true skin, 66
development of, 114
epidermis of, 64
furrows of, 64
hairs, 68
muscular fibres of, 70
nails, 67
nerves of, 67
papillary layer of, 67
rete mucosum of, 64
reticular layer of, 67
sebaceous glands of, 71
sudoriferous or sweat glands of, 71
tactile corpuscles of, 50
vessels of, 67
Skull, 213
applied anatomy of, 282
base of, external surface, 262
internal surface, 271
development of, 105
differences in, due to age, 277
exterior of, 261
Skull (*cont.*)
fossa of, anterior, 271
middle, 273
posterior, 274
from above, 261
behind, 268
below, 262
in front, 268
in profile, 265
interior of, 271
normæ of, 261
sexual differences in, 278
surface form of, 280
tables of, 182
vitreous table of, 182
Skull-cap, interior of, 271
Slender lobe of cerebellum, 829
Small cavernous nerve, 1000
intestine, 1139
areolar or submucous coat of, 1143
duodenal glands of, 1146
duodenum, 1139
ileum, 1142
jejunum, 1142
lymphatic vessels of, 785
mucous membrane of, 1143
muscular coat of, 1143
Peyer's glands of, 1146
serous coat of, 1143
solitary glands of, 1146
valvulæ conniventes of, 1143
vessels and nerves of, 1147
villi of, 1144
occipital nerve, 950
sciatic nerve, 979
Smell, organ of, 1002
Socia parotidis, 1109
Soft palate, 1091
aponeurosis of, 1092
arches or pillars of, 1091
muscles of, 1092
parts, development of, 114
Solar plexus, 997
Sole of foot, muscles of, first layer, 588
fourth layer, 591
second layer, 589
third layer, 590
Soleus muscle, 582
Solitary cells, 803
glands, 1146
Somatic fibres of spinal nerves, 944
layer of mesoderm, 91
Somatopleure, 91
Somites, protovertebral, 91
Space, anterior perforated, 864
of Burns, 473
intercostal, 207
interpeduncular, 854
of Nuel, 1057
popliteal, 715
posterior perforated, 838
retropharyngeal, 473
of Retzius, 1200
subarachnoid, 896
subdural, 895
suprasternal, 473
Spaces of Fontana, 1014
interglobular, 1098
Spatium perichorioideale, 1012
Special sense, organs of, 1001
types of cerebral cortex, 882
Spermatic Artery, 694
canal, 1204
cord, 1205
arteries of, 1205
lymphatics of, 1205
nerves of, 1205
veins of, 1205
fascia, external, 509
plexus of nerves, 998
applied anatomy of, 998
of veins, 759
structure of, 1205
veins, 759
applied anatomy of, 759
Spermatids, 82, 1208
Spermatoblasts, 1208
Spermatocytes, 82, 1208
Spermatogonia, 82, 1207
Spermatozoön, 81
body of, 82
formation of, 1208
head of, 81
neck of, 82
perforator of, 81
tail of, 82
Spheno-ethmoidal recess, 276, 1004
suture, 272
Spheno-frontal suture, 272
Sphenoid bone, 232
articulations of, 238
body of, 232
development of, 107
greater wings of, 234
lesser wings of, 235
ossification of, 236
pterygoid processes of, 236
rostrum of, 234
spinous processes of, 234
vaginal processes of, 236
Sphenoidal fissure, 235
structures in, 921
process of palate, 252
sinuses, 233, 1008
turbinated bones, 236
Spheno-malar suture, 266
Spheno-mandibular ligament, 382
Spheno-maxillary fissure, 267
fossa, 268
Spheno-palatine artery, 640
foramen, 252
ganglion, 912
nerves, 912
notch, 252
Spheno-parietal sinus, 740
suture, 266, 273
Spheno-petrosal suture, 266, 273
Spheno-squamosal suture, 266, 273
Spheroidal epithelium, 13
Sphincter ani externus, 522
internus, 523
muscle of bladder, 1199
of vagina, 526
pupillæ, 1018
recti muscle, 521
Spina bifida, 201
helicis, 1036
vestibuli, 139
Spinal accessory nerve, 937
applied anatomy of, 939
bulbar part of, 938
nucleus of, 819
spinal part of, 938

Spinal arteries, 660
canal, 200
column, 182
SPINAL CORD, 795
applied anatomy of, 809
central canal of, 800
columns of, 798
development of, 115
distribution of nerve-cells in, 802
enlargements of, 798
fissures of, 798
fœtal peculiarity of, 795
ganglia, 941
structure of, 942
grey commissure of, 800
matter of, 799
ligamentum denticulatum of, 898
meninges of, 892
applied anatomy of, 899
nerve-tracts in, 804
neuroglia of, 800
sulci of, 798
white commissure of, 800
matter of, 804
veins of, 752
Spinal nerves, 941
anterior primary divisions of, 949
arrangement into groups, 941
connections with sympathetic, 943
development of, 118
divisions of, 945
points of emergence of, 943
posterior primary divisions of, 945
roots of, 808, 941
size and direction, 943
structure of, 944
segments, 797
veins, 751
longitudinal, anterior, 751
posterior, 752
plexuses of, 751
Spinalis colli muscle, 497
dorsi muscle, 496
Spindle, achromatic, 4
aortic, 621
neuro-muscular, 52
neuro-tendinous, 52
Spine or spines, ethmoidal, 232
genial, 256
of ilium, 323
of ischium, 323
mental, 256
nasal, 221
anterior, 242
posterior, 251
of pubis, 325
of scapula, 290
sphenoidal, 234
suprameatal, 230
of tibia, 343
Spino-glenoid ligament, 404
Spino-olivary tract, 820
Spino-tectal tract, 807
Spino-thalamic tract, 806
Spinous process of vertebræ, 183
Spiral canal of cochlea, 1050
line of femur, 334
thread of spermatozoön, 82
tubes of kidney, 1186
Spirem or skein, 5
Splanchnic layer of mesoderm, 91
fibres of spinal nerves, 944
nerve, greater, 993
least, 994
lesser, 993
Splanchnology, 1059
Splanchnopleure, 91
SPLEEN, 1240
applied anatomy of, 1244
blood-vessels of, 1242
development of, 166
lymphatic vessels of, 787
Malpighian bodies of, 1242
relations of, 1240
size and weight, 1241
structure of, 1241
surface marking of, 1244
Spleens, accessory, 1241
Splenial centre of ossification, 258
Splenic artery, 690
distribution of, 1242
flexure of colon, 1153
lymphatic glands, 782
plexus, 999
vein, 761
Splenium of corpus callosum, 866
Splenius muscle, 494
Spongioblasts, 115
Spongioplasm, 3
Spongy portion of urethra, 1201
Spring ligament, 447
Spur of malleus, 1043
Squamous portion of temporal bone, 223
suture, 266
Stahr, middle gland of, 771
Stalks of thalamus—
anterior, 848
inferior, 848
parietal, 848
posterior, 848
Stapedius muscle, 1045
Stapes, 1044
annular ligament of, 1045
development of, 134
Stellate ligament, 386
veins of kidney, 1189
Stenson, foramina of, 246
Stenson's duct, 1110
Stephanion, 279
Sternal end of clavicle, 288
foramen, 204
furrow, 211
Sternebræ, 203
Sterno-clavicular articulation, 399
applied anatomy of, 401
surface form of, 401
Sterno-hyoid muscle, 476
Sterno-mastoid artery, 630, 634
muscle, 475
Sterno-pericardiac ligaments, 599
Sterno-thyroid muscle, 476
Sternum, 203
articulations of, 206
development of, 104
ligaments of, 390
ossification of, 206
structure of, 206
Stilling, roof nucleus of, 834
STOMACH, 1132
alveoli of, 1137
anatomical subdivisions of, 1134
applied anatomy of, 1138
areolar or submucous coat of, 1137
bed, 1134
body of, 1134
cardiac glands of, 1138
orifice of, 1133
component parts of, 1134
curvatures of, 1133
development of, 155
fundus of, 1134
incisura angularis of, 1133
interior of, 1135
lymphatic vessels of, 784
mucous membrane of, 1137
muscular coat of, 1135
orifices of, 1133
physiological subdivisions of, 1134
position of, 1134
pyloric canal of, 1134
glands of, 1137
orifice of, 1133
vestibule of, 1133
pylorus, 1135
serous coat of, 1135
shape and position of, 1133
structure of, 1135
sulcus intermedius of, 1133
surface form of, 1138
surfaces of, 1134
vessels and nerves of, 1138
Stomatodœum, 151
Straight sinus, 738
tubes of kidney, 1186
Strand, labio-dental, 1099
lingual, 1099
Strands, lateral and mesial, of posterior nerve-root, 808
Stratified epithelium, 14
Stratiform fibro-cartilage, 24
Stratum cinereum, 843
compactum of decidua, 98
corneum, 66
dorsale, 850
germinativum, 65
granulosum, 65
intermedium of choroid, 1016
lemnisci, 844
lucidum, 66
Malpighii, 65
opticum, 843
spongiosum, 98
zonale, 843
Streak, primitive, 86
Stria pinealis, 854
vascularis, 1054
Striæ acusticæ, 836
gravidarum, 516
Lancisi, 864
longitudinales, 864
Striate veins, inferior, 737
Stripe of Hensen, 1057
Striped muscle, 36
Stroma of iris, 1018
of ovary, 1220
intertubular, of kidney, 1189
Stylo-glossus muscle, 480
Stylo-hyoid ligament, 478
muscle, 478
nerve, from facial, 925

Stylo-mandibular ligament, 384
Stylo-mastoid artery, 636
foramen, 228
vein, 732
Stylo-pharyngeus muscle, 484
Styloid process of fibula, 347
of radius, 307
of temporal bone, 230
of ulna, 305
Subanconeus muscle, 539
Subarachnoid space, 896
Subcallosal gyrus, 864
Subcardinal veins, 146
Subclavian arteries, 654
applied anatomy of, 657
branches of, 659
first part of left, 655
of right, 654
peculiarities of, 656
second portion of, 656
surface form of, 656
third portion of, 656
groove, 288
triangle, 643
vein, 747
Subclavius muscle, 532
nerve to, 955
Subcostal angle, 208
artery, 685
zone, 1119
Subcrureus muscle, 570
Subdural space, 895
Subepithelial plexus of cornea, 1014
Sublingual artery, 630
fossa, 256
gland, 1111
vessels and nerves of, 1111
Sublobular veins, 1169
Submaxillary artery, 633
fossa, 256
ganglion, 918
gland, 1110
vessels and nerves of, 1111
lymphatic glands, 771
triangle, 642
vein, 730
Submental artery, 633
vein, 730
Submucous tissue, 74
Subnasal point, 279
Suboccipital nerve, 945
triangle, 499
Subparietal sulcus, 860
Subperitoneal connective tissue, 516
Subpleural mediastinal plexus, 665
Subpubic ligament, 397
Subsartorial plexus, 976
Subscapular angle, 289
artery, 670
fascia, 534
fossa, 289
nerves, 956
Subscapularis muscle, 534
Subserous areolar tissue, 1121
Substantia corticalis, 1026
ferruginosa, 838
gelatinosa centralis, 800
of Rolando, 799
nerve-cells in, 803
innominata of Meynert, 874
nigra, 840
propria of cornea, 1013
Subthalamic tegmental region, 850
Suctorial pad, 467
Sudoriferous glands, 71
Sulci of cerebral hemisphere, 856
of spinal cord, 798
Sulcus, antero-lateral of medulla, 812
antihelicis transversus, 1036
basilaris, 823
centralis of insula, 862
circularis of Reil, 857
frontal, inferior, 858
superior, 858
intermedius of stomach, 1133
intraparietal, 859
lateralis, 838
lunatus, 860*n*
of Monro, 122, 854
occipitalis lateralis, 860
transversus, 860
occipito-temporal, 862
oculo-motor, 838
oculo-nasal, 111
olfactorius, 859
orbitalis, 859
parallel, 861
postcentral, 850
postero-lateral of medulla, 812
precentral, 858
preolivary, 812
pterygopalatinus, 236
sagittalis, 215, 218, 221
sigmoideus, 226
spiralis externus, 1054
internus, 1055
subparietalis, 860
tali, 353
temporal, first, 861
second, 861
terminalis of right auricle, 604
of tongue, 1104
tubæ, 235
tympanicus, 1038, 1043
valleculæ, 827
Supercilia, 1029
Superciliary ridge, 220
Superficial abdominal ring, 508
cervical artery, 663
nerve, 950
circumflex iliac artery, 713
epigastric artery, 713
external pudic artery, 713
palmar arch, 681
perineal artery, 701
temporal artery, 636
applied anatomy of, 636
vein, 731
transverse ligament of fingers, 553
Superficialis volæ artery, 677
Superior aperture of larynx, 1066
carotid triangle, 641
commissure of brain, 849
coronary artery, 633
epigastric artery, 665
fovea of fourth ventricle, 837
laryngeal artery, 630
nerve, 936
ligament of incus, 1045
of malleus, 1045
Superior longitudinal fasciculus, 879
maxillary bone, 242
nerve, 911
meatus, 276
mediastinum, 1079
medullary velum, 831
mesenteric artery, 690
lymphatic glands, 782
olivary nucleus, 824
phrenic vein, 748
profunda artery, 673
thoracic artery, 669
thyroid artery, 629
turbinated crest of maxilla, 245
of palate bone, 251
vena cava, 748
development of, 148
opening of, 604
vocal cords, 1066
Supernumerary spleens, 1241
Supinator brevis muscle, 547
longus muscle, 545
Supporting cells of Hensen, 1057
framework of retina, 1023
Supracallosal gyrus, 864
Supraclavicular nerves, 951
Supracondylar process, 298*n*
ridge, external, 297
internal, 297
Supraglenoid tubercle, 292
Suprahyoid lymphatic glands, 771
artery, 630
triangle, 642
Supramarginal convolution, 860
Supramastoid crest, 223
Suprameatal spine, 230
triangle, 224
Supraoptic recess, 853
Supraorbital artery, 647
foramen, 221
margin, 221
nerve, 909
notch, 221
vein, 729
Suprarenal arteries, 694
glands, 1245
development of, 169
lymphatic vessels of, 787
structure of, 1246
plexus, 997
veins, 760
Suprascapular artery, 662
ligament, 403
nerve, 955
notch, 292
Supraspinatus muscle, 536
Supraspinous fascia, 535
fossa, 289
ligaments, 375
Suprasternal notch, 489
space, 473
Supratrochlear foramen, 299
nerve, 909
Sural arteries, 718
Surface Form or Marking—
of abdominal aorta, 687
of acromio-clavicular joint, 403
of ankle-joint, 443
of anterior tibial artery, 720

Surface Form or Marking (*cont.*)
of axillary artery, 668
of bladder, 1198
of bones of foot, 363
of pelvis, 331
of skull, 280
of thorax, 211
of wrist and hand, 319
of brachial artery, 672
of brain, 885
of clavicle, 288
of common carotid artery, 627
iliac artery, 697
of dorsalis pedis artery, 723
of elbow, 411
of external carotid artery, 629
iliac artery, 705
plantar artery, 725
of femoral artery, 712
of femur, 340
of fibula, 348
of fifth cranial nerve, 918
of fissures of brain, 886
of gall bladder, 1174
of gluteal artery, 705
of heart, 612
of hip-joint, 428
of humerus, 300
of hyoid bone, 261
of inferior radio-ulnar joint, 415
of internal pudic arteries, 705
plantar artery, 725
of intestines, 1157
of joints of fingers, 423
of foot, 451
of kidney, 1189
of knee-joint, 438
of larynx, 1073
of liver, 1173
of lungs, 1086
of mouth, 1112
of muscles of abdomen, 516
of back, 499
of head and face, 470
of lower extremity, 593
of neck, 488
of upper extremity, 558
of palmar arches, 682
of palpebral fissure, 1033
of pancreas, 1179
of patella, 342
of pelvis, 331
of plantar arch, 725
of popliteal artery, 717
of posterior tibial artery, 723
of radial artery, 676
of radius, 308
of sacro-iliac joint, 394
of scapula, 294
of sciatic artery, 705
of shoulder-joint, 407
of skull, 280
of spleen, 1244
of sterno-clavicular joint, 401
of sterno-mastoid, 475
Surface Form or Marking (*cont.*)
of stomach, 1138
of subclavian artery, 656
of superior radio-ulnar joint, 413
of tarsus and foot, 363
of temporo-mandibular joint, 385
of thorax, 211
of tibia, 346
of trachea, 1073
of ulna, 305
of ulnar artery, 679
of ventricles of brain, 888
of vertebral column, 200
of wrist and hand, 319
of wrist-joint, 417
Suspensory ligament of axilla, 529
of eye, 1011
of lens, 1025
of ovary, 1218
of penis, 1214
Sustentacular cells of spleen, 1241
Sustentaculum tali, 353
Sutura, 368
dentata, 368
harmonia, 368
limbosa, 368
notha, 368
serrata, 368
squamosa, 368
vera, 368
Sutural ligament, 368
Suture, coronal, 219
frontal, 220
fronto-ethmoidal, 272
fronto-malar, 265
fronto-maxillary, 271
interparietal, 219
lambdoid, 217
malo-maxillary, 271
metopic, 220
occipito-mastoid, 274
parieto-mastoid, 266
petro-occipital, 274
petro-squamous, 227
sagittal, 219
spheno-ethmoidal, 272
spheno-frontal, 266
spheno-malar, 266
spheno-parietal, 266
spheno-petrosal, 273
spheno-squamosal, 266
squamous, 266
zygomatico-temporal, 265
Sweat-glands, 71
Sylvian fossa, 126
root of fifth nerve, 906
vein, deep, 737
superficial, 736
Sylvius, aqueduct of, 844
fissure of, 856
Sympathetic Nerves, 49, 988
connections with spinal nerves, 988
fibres of spinal nerves, 944
system, applied anatomy of, 1000
gangliated cords of, 988
cervico-cephalic portion, 990
lumbar portion, 994
pelvic portion, 995
Sympathetic system, gangliated thoracic portion, 993
plexuses, 996
cardiac, 996
epigastric, 997
hypogastric, 999
pelvic, 1000
solar, 997
Symphysis, 369
menti, 255
pubis, 396
Synarthrosis, 368
Synchondrosis, 369
neurocentral, 195
Syncytium, 86
Syndesmology, 366
Syndesmosis, 369
Synergic muscles, 454
Synovia, 73, 367
Synovial ligaments, 367
sheaths, 367
of flexor tendons (hand), 551
Synovial Membrane, 73, 367
articular, 367
bursal, 367
vaginal, 367
See also Individual Joints
System, Haversian, 27
Systemic circulation, 597
veins, 728

Tables of the skull, 182
Tactile corpuscles of Grandry, 50
of Wagner and Meissner, 50
Tænia hippocampi, 875
pontis, 822
semicircularis, 874
Tæniæ of muscular coat of large intestine, 1148
tectæ, 864
Tangential fibres of cerebral cortex, 881
Tapetum of choroid, 1016
of corpus callosum, 866
Tarsal artery, 722
bones, 349
ligaments of eyelids, 460
plates of eyelids, 1030
Tarsi, sinus, 352
Tarso-metatarsal articulations, 449
Tarsus, 349
applied anatomy of, 363
articulations of, 444
ossification of, 362
surface form of, 363
synovial membranes of, 450
Taste, nerves of, 1002
organs of, 1001
Taste-buds, 1001
Teeth, 1092
applied anatomy of, 1103
bicuspid, 1095
body of, 1093
canine, 1094
cement of, 1098
crown of, 1093
crusta petrosa of, 1098
dentinal tubules of, 1097
dentine of, 1097
development of, 1099
enamel of, 1098

Teeth (*cont.*)
eruption of, 1102
eye, 1095
fang of, 1093
general characters of, 1093
incisors, 1094
ivory of, 1097
milk, 1096
molar, 1095
multicuspid, 1095
neck of, 1093
permanent, 1094
premolars, 1095
pulp-cavity of, 1096
root of, 1093
structure of, 1096
temporary, 1096
wisdom, 1096
Tegmen tympani, 226, 1040
Tegmental part of pons, 824
Tegmentum of crus cerebri, 840
Tela chorioidea ventriculi quarti, 836
tertii, 878
Telencephalon, 123, 854
Telophase of karyokinesis, 5
Temporal artery, anterior, 636
deep, 639
middle, 636
posterior, 636
superficial, 636
bone, 223
articulations of, 232
development of, 106
mastoid portion, 225
ossification of, 230
petrous portion of, 227
squamous portion of, 223
structure of, 230
branch of temporo-malar nerve, 911
convolutions, 861
fascia, 468
fossa, 266
lines, 218, 221
lobe, 861
muscle, 469
nerves of auriculo-temporal, 916
deep, 915
of facial, 925
operculum, 862
ridge, 221, 223
sulci, 861
vein, superficial, 731
Temporary teeth, 1096
Temporo-facial nerve, 925
Temporo-malar nerve, 911
Temporo-mandibular articulation, 382
applied anatomy of, 385
surface form of, 385
Temporo-maxillary vein, 731
Tendo Achillis, 582
oculi, 460
Tendon, central, of diaphragm, 503
conjoined, of internal oblique and transversalis, 512
structure of, 455
superior, of Lockwood, 462
Tendons on back of wrist, relations of, 551
Tendril fibres of cerebellum, 833
Tenon, capsule of, 1010
Tensor fasciæ femoris muscle, 568
palati muscle, 484
tarsi muscle, 460
tympani muscle, 1045
canal for, 229, 1042
Tenth cranial nerve, 933
surgical anatomy of, 937
Tentorium cerebelli, 893
Teres major muscle, 536
minor muscle, 536
Terminations of lymphatics, 61
of nerves, 49
Testes, 1203, 1206
applied anatomy of, 1209
coni vasculosi of, 1209
coverings of, 1203
descent of, 173
development of, 173
gubernaculum testis, 173
lobules of, 1207
lymphatic vessels of, 789
mediastinum testis, 1207
mode of descent, 173
rete testis, 1208
structure of, 1207
tubuli seminiferi of, 1207
tunica albuginea, 1207
vaginalis, 1206
vasculosa, 1207
vas deferens of, 1210
vasa efferentia of, 1209
vasa recta of, 1208
Thalamencephalon, 845
Thalamus, 122, 845
anterior extremity of, 845
connections of, 848
posterior extremity of, 845
stalks of, 848
structure of, 847
surfaces of, 845, 846
Thebesius, veins of, 729
foramina of, 604
valve of, 605, 728
Thenar eminence, 550
Thigh, fascia lata of, 566
muscles of back of, 577
of front of, 566
superficial fascia, 566
Third cranial nerve, 905
applied anatomy of, 905
ventricle of the brain, 852
choroid plexuses of, 852
Thoracic aorta, 682
applied anatomy of, 684
artery, acromio-, 670
alar, 670
long, 670
superior, 669
duct, 149, 765
applied anatomy of, 767
portion of gangliated cord, 993
nerves, anterior primary divisions of, 966
posterior primary divisions of, 948
applied anatomy of, 969
region, muscles and fascia of anterior, 528
lateral, 532
vertebræ, 187
Thorax, *General Description of*, 598
bones of, 202
boundaries of, 202
Thorax (*cont.*)
cavity of, 598
lower opening of, 202, 598
lymphatic glands of, 789
vessels of, 790, 792
mechanism of, 391
muscles of, 500
parts passing through upper opening of, 598
lower opening of, 598
surface form of, 211
upper opening of, 202, 598
Thrombogen, 10
Thrombokinase, 10
Thumb, carpo-metacarpal articulation of, 420
muscles of, 548, 554
Thymus gland, 1238
applied anatomy of, 1240
development of, 154
lymphatic vessels of, 793
structure of, 1238
vessels and nerves of, 1239
Thyreoidea ima artery, 624
Thyro-arytenoid ligaments, 1066
Thyro-arytenoideus muscle, 1068
Thyro-epiglottic ligament, 1064
muscle, 1069
Thyro-glossal duct, 154
Thyro-hyal of hyoid bone, 261
Thyro-hyoid arch of fœtus, 108
ligaments, lateral, 1063
membrane, 1063
muscle, 476
nerve, 941
Thyroid artery, inferior, 662
superior, 629
applied anatomy of, 630
axis, 662
body, 1235
applied anatomy of, 1237
development of, 154
isthmus of, 1235
lobes of, 1235
lymphatic vessels of, 772
pyramid of, 1236
structure of, 1236
vessels and nerves of, 1236
branches of sympathetic, 992
cartilage, 1059
foramen, 326
notch, 1060
veins, inferior, 748
middle, 734
superior, 734
Thyroidin, 1236
Thyroids, accessory, 1236
Tibia, 343
applied anatomy of, 349
articulations of, 346
crest of, 343
nutrient artery of, 714
ossification of, 346
spine of, 343
surface form of, 346
tubercle of, 344
tuberosities, 343
Tibial artery, anterior, 719
applied anatomy of, 720
branches of, 721
peculiarities of, 720
surface marking of, 720
posterior, 722
applied anatomy of, 723

Tibial artery, posterior, branches of, 723
peculiarities of, 723
surface marking of, 723
lymphatic gland, 775
nerve, anterior, 984
posterior, 982
surfaces of femur, 337
veins, 754
Tibialis anticus muscle, 580
posticus muscle, 584
Tibio-fibular articulations, 439
region, anterior, muscles of, 579
posterior, 581
Tissue, adenoid, 20
adipose, 17
areolar, 16
connective, 15
lymphoid, 20
mucous, 19
muscular, 36
nervous, 42
reticular, 19
retiform, 19
submucous, 74
white fibrous, 18
yellow elastic, 19
Tomes' fibres, 1097
Tongue, 1103
applied anatomy of, 1107
arteries of, 1107
development of, 153
fibrous septum of, 1105
frenulum of, 1104
glands of, 1106
lymphatic vessels of, 770
mucous membrane of, 1105
muscles of, 480
nerves of, 1107
papillæ of, 1104
principal lymphatic gland of, 770
structure of, 1105
Tonsil, lingual, 1106
pharyngeal, 1114
Tonsillar artery, 633
nerves, 932
Tonsils, 1114
applied anatomy of, 1115
development of, 154
lymphatic vessels of, 770
nerves of, 1115
structure of, 1115
vessels of, 1115
Topography, cerebral, 885
Torcular Herophili, 216, 740
Torus uretericus, 1198
uterinus, 1125
Trabeculæ cranii, 106
of spleen, 1241
of testis, 1207
Trachea, 1070
applied anatomy of, 1073
structure of, 1072
vessels and nerves of, 1073
Trachealis muscle, 1072
Trachelo-mastoid muscle, 496
Tracheo-bronchial glands, 792
Tracheotomy, 1074
Trachoma glands, 1031
Tract, anterior basis bundle, 805
of Burdach, 807
cerebello-olivary, 820
cerebro-olivary, 820
Tract, cornu-commissural, 807
crossed pyramidal, 805
descending cerebello-spinal, 805
comma, 808
direct cerebellar, 806
pyramidal, 804
dorsal peripheral band, 808
of Goll, 807
of Gowers, 806
lateral basis bundle, 807
of Lissauer, 807
of Lowenthal, 805
motor, 888
olfactory, 864
olivo-spinal, 806
optic, 901
rubro-spinal, 805
secondary sensory, 807
sensory, 890
spino-olivary, 820
spino-tectal, 807
spino-thalamic, 806
vestibulo-spinal, 119
Tractus solitarius, 805
spiralis foraminosus, 227, 1050
Tragicus muscle, 1036
Tragus, 1035
Transitional epithelium, 15
Transpyloric plane, 1119
Transversalis abdominis muscle, 512
cervicis muscle, 496
fascia, 515
Transverse arteries of basilar, 661
cervical artery, 662
nerve, 950
colon, 1151
facial artery, 636
vein, 731
fibres of hemispheres, 878
fissure of brain, 878
of liver, 1167
humeral ligament, 405
ligament of ankle, 440
of atlas, 378
of hip, 426
of knee, 434
metacarpal, 422
metatarsal, 450
of scapula, 403
superficial, of fingers, 553
tibio-fibular, 440
mesocolon, 1129
occipital sulcus, 860
process of a vertebra, 183
sinus of pericardium, 600
temporal gyri, 861
Transversus auriculæ muscle, 1037
perinæi muscle, in female, 526
in male, 526
Trapezium, 313
Trapezius muscle, 490
Trapezoid, 313
ligament, 402
nucleus, 824
Triangle of auscultation, 492
Bryant's, 428
digastric, 642
of Hesselbach, 1159
inferior carotid, 641
muscular, 641
Triangle of neck, anterior, 640
posterior, 643
occipital, 643
of Petit, 492
Scarpa's, 710
subclavian, 643
submaxillary, 642
suboccipital, 499
superior carotid, 641
suprahyoid, 642
suprameatal, 224
Triangular fascia of abdomen, 510
ligament, 525, 527
Triangularis menti muscle, 466
sterni muscle, 501
Triceps extensor cubiti muscle, 538
Tricuspid valve, 606
Trifacial or trigeminus nerve, 906
applied anatomy of, 919
nuclei of, 906
surface marking of, 918
Trigonum acusticum, 837
collaterale, 871
habenulæ, 849
hypoglossi, 837
olfactorium, 864
vagi, 837
vesicæ, 1198
Trilaminar blastoderm, 87
Trochanter, great, 333
small, 334
tertius, 336
Trochanteric fossa, 334
Trochlea of femur, 337
of humerus, 298
Trochlear nerve, 905
applied anatomy of, 905
Trochoid joint, 370
Trolard, anastomotic vein of, 737
Tröltsch, recess of, 1046
Trophoblast, 85
True ligaments of bladder, 1196
nucleoli, 4
pelvis, 327
ribs, 206
vocal cords, 1066
Trunk, arteries of, 682
articulations of, 372
muscles and fasciæ of, 489
Tube, Eustachian, 1042
Fallopian, 1221
neural, 89
tonsil, 1042
Tuber cinereum, 851
omentale, 1165
papillare, 1166
valvulæ of cerebellum, 829
Tubercle, adductor, 336
carotid or Chassaignac's, 184
conoid, 287
cuneate, 814
of Darwin, 1035
deltoid, 287
of epiglottis, 1062
of femur, 334
of hyoid bone, 260
infraglenoid, 292
lachrymal, 245
of Lower, 605
malar, 248
mental, 255
of navicular, 356

Tubercle for odontoid ligament, 216
peroneal, 353
pharyngeal, 217
pterygoid, 236
of the Quadratus, 334
of rib, 208
of Rolando, 815
scalene, 210
supraglenoid, 292
of the tibia, 344
of ulna, 301
of zygoma, 224
Tuberculum acusticum, 825
anterius, 184
caroticum, 185
impar, 153
jugulare, 216
posterius, 184
Tuberosities of femur, 337
of humerus,
greater, 295
lesser, 295
of tibia, 343
Tuberosity, bicipital, 306
deltoid, 298
of ischium, 324
maxillary, 242
of palate bone, 252
of scaphoid, 311
Tubular membrane of nerves, 48
glands, 74
Tubules, dentinal, 1097
Tubuli lactiferi, 1233
seminiferi, 1207
uriniferi, 1185
Tuft, Malpighian, 1185
Tunica adventitia, 56
albuginea of ovary, 1220
of testis, 1207
elastica externa, 56
intima of arteries, 55
media, 56
vaginalis, 1206
development of, 173
vasculosa testis, 1207
Tunnel of Corti, 1056
Turbinal process, 248
Turbinated bone, inferior, 253
sphenoidal, 236
crest, inferior, 244, 251
superior, 245, 251
processes, 240
Turner, intraparietal sulcus of, 859
Twelfth cranial nerve, 939
applied anatomy of, 941
Tympanic artery, from ascending pharyngeal, 635
from internal carotid, 646
from internal maxillary, 638
nerve (Jacobson's), 932
of facial, 925
plate, 229
ring, 231
Tympanic cavity, 1037
anterior wall of, 1041
applied anatomy of, 1046
arteries of, 1043
atrium of, 1039
inner wall of, 1041
membrane, 1043
structure of, 1043
mucous membrane, 1045
Tympanum, muscles of, 1045
nerves of, 1046
ossicles of, 1043
outer wall of, 1040
posterior wall of, 1041
recessus epitympanicus of, 1039
roof of, 1040
tegmen tympani of, 1040
veins of, 1046
Tyson's glands, 1214

Ulna, 301
applied anatomy of, 308
articulations of, 305
coronoid process of, 301
olecranon process of, 301
ossification of, 305
sigmoid cavities of, 304
structure of, 305
styloid process of, 305
surface form of, 305
tubercle of, 301
Ulnar artery, 678
applied anatomy of, 679
branches of, 679
peculiarities of, 679
recurrent, anterior, 679
posterior, 679
surface marking of, 679
collateral branch of musculospiral, 963
nerve, 962
Umbilical arteries in fœtus, 100, 614
how obliterated, 616
cord, 95
fissure of liver, 1167
notch of liver, 1166
veins, 100, 145
zone, 1119
Umbilicus, 514
Umbo of membrana tympani, 1043
Unciform bone, 314
Uncinate fasciculus, 879
Uncus, 863
Ungual phalanges, 361
Unstriped muscle, 40
Upper extremity, arteries of, 654
applied anatomy of, 560
articulations of, 399
bones of, 286
lymphatics of, 772
muscles and fasciæ of, 528
nerves of, 953
surface form of muscles of, 558
veins of, 744
Urachus, 95
Ureters, 1191
arteries of, 1193
lymphatic vessels of, 788
muscles of, 1197
nerves of, 1193
structure of, 1192
Urethra, development of, 175
male, 1200
applied anatomy of, 1202
bulbous portion of, 1201
caput gallinaginis of, 1200
lymphatic vessels of, 789
membranous portion of, 1200
Urethra, male, prostatic portion of, 1200
sinus pocularis of, 1200
spongy portion of, 1201
structure of, 1201
verumontanum of, 1129
female, 1203
Urethral bulb, 1213
Urinary organs, 1180
development of, 169
lymphatic vessels of, 787
Urogenital cleft, 1231
organs, 1180
Uterine arteries, 699
glands, 1227
plexus of nerves, 1000
plexuses of veins, 758
Uterus, 1222
applied anatomy of, 1228
arbor vitæ of, 1225
body of, 1223
broad ligaments of, 1225
cavity of, 1224
cervix of, 1224
development of, 170
in fœtus, 1226
ligaments of, 1225
lymphatic vessels of, 789
masculinus, or sinus pocularis, 170, 1200
during menstruation, 1226
in old age, 1226
after parturition, 1226
during pregnancy, 1226
at puberty, 1226
round ligaments of, 1225
shape and position of, 1223
structure of, 1226
vessels and nerves of, 1228
virgin state of, 1223
Utricle of vestibule, 1051
Uvea, 1018
Uvula of cerebellum, 829
of throat, 1091
vesicæ, 1198

Vagina, 1229
columns of, 1229
fornices of, 1229
lymphatic vessels of, 789
structure of, 1229
Vaginal arteries, 700
orifice, 1231
plexus of nerves, 1000
plexuses of veins, 758
process of temporal bone, 228
processes of sphenoid bone, 236
synovial membranes, 367
Vagus nerve, 932
ganglion of root of, 935
of trunk of, 935
nuclei of, 819, 933, 934
Valentin, ganglion of, 912
Vallecula of cerebellum, 826
Valleculæ of tongue, 1062
Valsalva, sinuses of, 607, 609
Valve, aortic, 609
coronary, 605
Eustachian, 605
of Hasner, 1033
ileo-cæcal, 1150
of Kerkring, 1143
mitral, or bicuspid, 609
pulmonary, 607

Valve, Thebesian, 605, 728
tricuspid, 606
of Vieussens, 831
Valves, anal, 1156
of lymphatics, 61
in right auricle, 604
of veins, 60
Valvulæ conniventes, 1143
Vas aberrans of Haller, 1210
deferens, 1210
ampulla of, 1210
lymphatic vessels of, 789
structure of, 1210
spirale, 1055
Vasa aberrantia, from brachial artery, 672
afferentia of lymphatic glands, 764
brevia arteries, 690
efferentia of lymphatic glands, 764
of testis, 1209
intestini tenuis arteries, 691
recta of testis, 1208
vasorum of arteries, 56
of veins, 60
Vascular area of yolk-sac, 93
capsule of lens, 131
system, *Histology of*, 55
changes in, at birth, 616
peculiarities in fœtus, 614
Vastus externus muscle, 569
internus muscle, 569
Vater, ampulla of, 1173
corpuscles of, 51*n*
Veins, *Histology of*, 59
anastomoses of, 717
coats of, 59
development of, 145
muscular tissue of, 60
plexuses of, 726
size, form, &c., 726
structure of, 59
valves of, 60
vessels and nerves of, 60
visceral, 145
Veins or Vein, *Descriptive Anatomy of*, 726
of abdomen, 752
anastomotic, of Labbé, 737
of Trolard, 737
angular, 729
auditory, 1058
auricular, posterior, 731
axillary, 747
azygos minor inferior, 750
superior, 750
major, 750
basilar, 737
basilic, 746
basivertebral, 752
brachial, 747
brachio-cephalic or innominate, 747
of brain, 736
bronchial, 750
cardiac, 728, 729
cardinal, 146
cava, inferior, 758
superior, 748
cephalic, 745
accessory, 746
cerebellar, 737
cerebral, 736
anterior, 737
deep, 737
Veins or Vein (*cont.*)
cerebral inferior, 736
middle, 736
superficial, 736
superior, 736
cervical, deep, 735
choroid, of brain, 737
circumflex iliac, deep, 755
superficial, 752
common facial, 730
coronary, of stomach, 762
of corpus striatum, 737
cystic, 763
deep, or venæ comites, 727, 746
cerebral, 737
cervical, 735
facial, 730
digital, of hand, 745
of diploë, 735
dorsal of penis, 757
emissary, 743
applied anatomy of, 744
epigastric, deep, 755
extraspinal, 751
facial, 730
common, 730
deep, 730
transverse, 731
femoral, 755
of fingers, 745
frontal, 729
of Galen, 737
gastric, short, 762
gastro-epiploic, left, 762
right, 762
gluteal, 756
hæmorrhoidal, inferior, 757
middle, 757
superior, 757
of hand, 745
of head and neck, 729
hepatic, 760
iliac, common, 758
external, 755
internal, 755
ilio-lumbar, 758
inferior cava, 758
innominate, 747, 748
intercostal, superior, 748
interlobular, of kidney, 1189
of liver, 1170
interosseous, of forearm, 747
intralobular, of liver, 1169
intraspinal, 751
jugular, anterior, 733
external, 732
posterior, 733
internal, 733
of Labbé, posterior anastomotic, 737
labial, 730
lateral sacral, 758
lingual, 734
of lower extremity, 752
lumbar, 759
ascending, 759
mammary, internal, 748
masseteric, 730
maxillary, internal, 731
median, 746
mediana cubiti, 746
mesenteric, inferior, 762
superior, 762
of neck, 732
oblique, of Marshall, 729
Veins or Vein (*cont.*)
obturator, 757
occipital, 731
ophthalmic, superior, 741
inferior, 742
orbital, 731
ovarian, 760
palmar, deep, 747
palpebral, inferior, 730
superior, 729
pancreatico-duodenal, 762
parumbilical, 763
of pelvis, 752
penis, dorsal of, 757
peroneal, 754
pharyngeal, 734
phrenic, inferior, 760
plantar, 754
popliteal, 755
portal, 760
applied anatomy of, 763
profunda femoris, 755
pterygoid plexus, 731
pudic, external, 752
internal, 756
pulmonary, 727
pyloric, 762
ranine, 730, 734
renal, 760
sacral, lateral, 757
middle, 758
saphenous, external, or short, 753
internal, or long, 752
applied anatomy of, 753
sciatic, 756
spermatic, 759
spinal, 751
plexus, anterior, 751
posterior, 751
veins, longitudinal, 751
of spinal cord, 752
splenic, 761
striate, inferior, 737
stylo-mastoid, 731
subcardinal, 146
subclavian, 747
sublobular, 1169
submaxillary, 730
submental, 730
superficial, 727
supraorbital, 729
suprarenal, 760
suprascapular, 733
Sylvian, deep, 737
superficial, 736
systemic, 726
temporal, superficial, 731
middle, 731
temporo-maxillary, 731
of thorax, 744
thyroid, inferior, 748
middle, 734
superior, 734
tibial, 754
transverse cervical, 733
facial, 731
Trolard, great anastomotic of, 737
umbilical, 100, 145
of upper extremity, 744
uterine plexuses, 758
vaginal plexuses, 758
of liver, 1170
vertebral, 735
anterior, 735

Veins or Vein (*cont.*)
vertebral, posterior, 735
vesical plexus, 757
vesico-prostatic plexus, 757
Vidian, 722
vitelline, 136, 145
Veins, plexuses of, ovarian, 760, 1221
pampiniform, 759, 1206, 1221
pharyngeal, 734
pterygoid, 731
spermatic, 759, 1205
uterine, 758
vaginal, 758
vesico-prostatic, 757
Velum interpositum, 878
medullary, inferior, 829, 831
superior, 831
Vena caval opening in diaphragm, 503
capitis lateralis, 148
cava, inferior, 759
applied anatomy of, 759
development of, 146
fissure for, 1167
peculiarities of, 759
superior, 748
development of, 148
Galeni, 737, 878
magna Galeni, 878
Venæ comites, 727
hepaticæ advehentes, 145
revehentes, 145
interlobulares of kidney, 1189
propriæ renales, 1189
rectæ of kidney, 1189
Thebesii, or minimæ cordis, 729
vorticosæ, 1015
Venesection, 746
Venous lacunæ of dura mater, 894
sinuses of dura mater, 737
mesocardium, 600
Ventral aorta, 136
auditory nucleus, 781
lamina, 117
Ventricle of fornix, 875
of nasal fossa, 1004
of Verga, 875
Ventricles of brain—
fifth, 876
fourth, 834
lateral, 867
third, 852
of heart—
left, 608
primitive, 140
right, 606
of larynx, 1066
Ventriculus terminalis of spinal cord, 800
Verga, ventricle of, 875
Vermicular motion, 45
Vermiform appendix, 1150
Vermis of cerebellum, inferior, 826
superior, 826
Vernix caseosa, 115
Vertebra prominens, 187
ossification of, 197
Vertebræ, 182
anticlinal, 188*n*
cervical, 184
Vertebræ, development of, 102
dorsal or thoracic, 187
general characters of, 183
ligaments of, 373
lumbar, 190
ossification of, 195
sacral and coccygeal, 191
structure of, 183
thoracic or dorsal, 187
Vertebral artery, 659
bow, primitive, 103
canal, 200
column, 182, 198
articulation of, 372
cartilaginous, 103
development of, 102
membranous, 103
ossification of, 195
surface form of, 200
fascia, 493
foramen, 183
groove, 200
ligaments, 373
region, muscles of, anterior, 486
lateral, 488
veins, 735
Vertical plate of palate bone, 251
Verumontanum, 1200
Vesical artery, inferior, 699
middle, 699
superior, 699
fascia, 519
plexus of nerves, 1000
of veins, 757
Vesicle, blastodermic, 85
germinal, 79
optic, 122
otic, 133
Vesicles, cerebral, 89
Vesico-prostatic plexus of veins, 757
Vesiculæ seminales, 1211
lymphatic vessels of, 789
structure of, 1211
vessels and nerves of, 1212
Vesicular column, posterior, of Clarke, 803
Vestibular artery, 1058
nerve, 1058
nuclei of, 825
root of eighth nerve, 928
Vestibule, aortic, 609
of internal ear, 1047
aqueduct of, 1048
fissure of, 1051
of larynx, 1066
of nasal fossa, 1004
of vagina, 1231
Vestibulo-spinal tract, 805
Vestibulum oris, 1089
Vestigial fold of pericardium, 600
Vicq d'Azyr, band of, 882
bundle of, 850–875
Vidian artery from internal maxillary, 640
canal, 236
nerve, 913
Vieussens, ansa of, 993
valve of, 831
Villi of intestine, 1144
arachnoid, 898
of the chorion, 97
Vincula accessoria, 544
Visceral arches, 107
clefts, 107
veins, 145
Visual area of cortex, 885
centres, higher, 852
lower, 852
purple, 36
Visuo-psychic area, 882
Visuo-sensory area, 882
Vitelline circulation, 93, 136
duct, 93
fluid, 92
membrane, 83
veins, 136, 145
Vitellus, 79
Vitreous body of the eye, 1025
development of, 132
table of the skull, 182
Vocal cords, inferior or true, 1066
superior or false, 1066
process of arytenoid, 1061
Voice, organs of, 1059
Voluntary muscles, 36
Vomer, 254
alæ of, 254
articulations of, 255
ossification of, 255
Vulva, 1231
development of, 176
of third ventricle, 853

Wagner, tactile corpuscles of, 50
Waldeyer, germinal epithelium of, 172, 1220
Wallerian degeneration, 46, 804
Wandering cells, 16
Weight of organs. *See* Individual Organs
Wharton's duct, 1110
White fibro-cartilage, 23
fibrous tissue, 18
line of pelvic fascia, 519
matter of cord, 804
of cerebellum, 830
of cerebral hemispheres, 878
nervous, 43
of Schwann, 46
Willis, circle of, 652
Winslow, foramen of, 158, 1127
ligament of, 431
Wirsung, canal of, 1178
Wisdom teeth, 1096
Wolffian body, 168
duct, 168
tubules, 168
Womb, 1222
Worm or vermis, 826
Wormian bones, 240
Wrisberg, cartilages of, 1061
ganglion of, 996
ligament of, 434
nerve of, 959
pars intermedia of, 922
Wrist-joint, 415
applied anatomy of, 417
surface form of, 417
Wry-neck, 475

Xiphoid appendix, 204

Y-shaped cartilage of acetabulum, 327
Y-shaped ligament, 425

Yellow elastic tissue, 19
cartilage, 24
spot of retina, 1020
Yolk, 79
formative, 79
nutritive, 79
Yolk-sac, 92
Yolk-stalk, 156

Zigzag tubule, 1186
Zinn, ligament of, 462
zonule of, 1025
Zona arcuata, 1055
fasciculata, 1246
glomerulosa, 1246
incerta, 850
orbicularis, 424
pectinata, 1055
pellucida, 79
reticularis, 1246
striata, 79
vasculosa, 1220
Zones of abdomen, 1119
Zonula ciliaris, 1025
Zonule of Zinn, 1025
Zygomatic arch, 266
bone, 248
fossa, 267
process of maxilla, 245
temporal, 223
tubercle, 224
Zygomatico-temporal suture, 265
Zygomaticus major muscle, 464
minor muscle, 465
Zuckerkandl, aortic bodies of, 1248

Foramina in Base of Skull.

Foramen Coecum transmits Vein to Supr. Longit. Sinus
Optic Foramen " Optic N. & Opthalmic Artery
Sphenoidal ~~Sinus~~ Fissure " 3rd, 4th, & opthalmic divs. of 5th N. & 6th N.
& orbital branch of mid. meningeal Art.
Foramen Ovale " 3rd. div. of 5th N. & small " "
" Rotundum " 2nd " " " "
" Spinosum " Middle meningeal Art. & Veins
" Lacerum Medium " Intnl. Carotid Art. & plexus of sym. meningeal br. of Asc. Phar.
Carotid Canal transmits Intnl. Carot. Art. into Cranium
Stylo-Mastoid Foramen transmits Facial N. & Stylo-Mastoid A.
Antr. Condyloid Foramen " Hypoglossal N.

PRINTED BY
SPOTTISWOODE AND CO. LTD., LONDON
COLCHESTER AND ETON

A LIST OF WORKS ON MEDICINE, SURGERY AND GENERAL SCIENCE

CONTENTS

	PAGE
ANATOMY	3
BACTERIOLOGY	18
BIOLOGY	13
CHEMISTRY	20
HEALTH AND HYGIENE	16
INDEX	2
MEDICINE	3
MISCELLANEOUS	10
MONOGRAPHS ON BIOCHEMISTRY	24
OPTICS	19
PHOTOGRAPHY	19
PHYSIOLOGY	13
PROCEEDINGS OF THE ROYAL SOCIETY OF MEDICINE	12
SURGERY	3
TEXT-BOOKS OF PHYSICAL CHEMISTRY	23
VETERINARY MEDICINE	12
ZOOLOGY	13

LONGMANS GREEN & CO.

39 PATERNOSTER ROW LONDON E C.

FOURTH AVE. & THIRTIETH ST. NEW YORK

8 HORNBY ROAD BOMBAY

303 BOWBAZAR STREET CALCUTTA

1910

INDEX.

PAGE

Abney's Photography 19
Aikin's The Voice 10
Armitage's A History of Chemistry 20
Armstrong's Simple Carbohydrates and the Glucosides 24
Arrhenius's Text-book of Electro-Chemistry 20
——— Theories of Chemistry 20
Ashby's Health in the Nursery 16
——— Notes on Physiology 13
——— and Wright's The Diseases of Children 3
Baly's Spectroscopy 19, 23
Barnett's Making of the Body... 13
Bayliss' Nature of Enzyme Action 24
Beddard's Elementary Practical Zoology ... 13
Bell's Principles of Gynæcology 4
Bennett's Abdominal Hernia 3
——— On the Use of Massage 3
——— On Varix: Its Causes and Treatment 3
——— Recurrent Effusion into the Knee-Joint after Injury 3
——— Treatment of Simple Fractures ... 3
——— Varicose Veins 3
Bidgood's Practical Elementary Biology ... 13
Bose's Comparative Electro-Physiology ... 13
——— Plant Response 13
——— Response in Living and Non-Living 13
Brodie's Essentials of Physiology 13
Bull's Hints to Mothers... 16
——— Maternal Management of Children ... 16
Bunge's Organic Chemistry for Medical Students 20
Butterworth's Manual of Household Work 16
Cabot's Clinical Examination of the Blood... 4
Campbell's Practical Motherhood 16
Chapman's The Foraminifera 13
Charities Register and Digest 10
Cheyne and Burghard's Manual of Surgical Treatment 4
Coats' Manual of Pathology 5
Colyer's Dental Surgery and Pathology ... 5
Cooke's Aphorisms in Applied Anatomy ... 5
——— Tablets of Anatomy 5
Corfield's Laws of Health 16
Creighton's Economics of the Household ... 16
Crookes' Methods in Chemical Analysis ... 20
Curtis' Practical Bacteriology 18
Dakin's Handbook of Midwifery 5
Desch's Metallography 23
Dickson's The Bone Marrow 5
Donnan's Thermodynamics 23
Drude's Theory of Optics 19
Ellis' Outlines of Bacteriology... 18
Findlay's Phase Rule and its Application ... 23
——— Practical Physical Chemistry 20
Fitzwygram's Horses and Stables 12
Frankland's Bacteria in Daily Life 18
Friend's Theory of Valency 23
Furneaux's Human Physiology 14
——— Practical Hygiene 16
Gaskell's The Origin of the Vertebrates ... 10
Glazebrook's Physical Optics 19
Goadby's Mycology of the Mouth 18
Godfrey's Elementary Chemistry 20
Goodsall and Miles' Diseases of the Anus and Rectum 6
Gray's Anatomy, Descriptive and Applied ... 6
Halliburton's The Essentials of Chemical Physiology 14
Hanson's and Dodgson's Intermediate Course of Laboratory Work in Chemistry 20
Harden's Alcoholic Fermentation 24
Hardy's Colloids 24
Hare's The Food Factor in Disease 6
Hayes' Training and Horse Management ... 12
Hobart's Medical Language of St. Luke ... 10
Hopf's Human Species 10
Hopkins' Development and Present Position of Biological Chemistry 24
Hudson and Gosse's The Rotifera 14
Influence of Heredity on Disease 6
Inquiry into the Phenomena attending Death by Drowning 11
James's Ball Games and Breathing Exercises 16
Kidd's Urinary Surgery 7
King's College Hospital Cooking Recipes ... 11
Klöcker's Fermentation Organisms 18
Leathes' The Fats 24
Lehfeldt's Electro-Chemistry 23
Ling's The Polysaccharides 24
Lloyd and Bigelow's Teaching of Biology ... 14
Luff's Text-book of Forensic Medicine ... 7
Macalister's Systematic Zoology of the Vertebrate Animals 14

PAGE

Macalister's Zoology of the Invertebrate Animals 14
——— Vertebrate Animals ... 14
Macdougall's Elementary Plant Physiology 14
——— Text-book of Plant Physiology ... 14
Marshall's Physiology of Reproduction ... 15
Mees' Atlas of Absorption Spectra 19
Mellor's Chemical Statics and Dynamics ... 23
Mendeléeff's Principles of Chemistry ... 20
Meyer's Outlines of Theoretical Chemistry 20
Monographs on Biochemistry 24
Moon's Relation of Medicine to Philosophy 11
Moore's Elementary Physiology 15
Morgan's Animal Biology 15
Muir's Course of Practical Chemistry ... 20
Newth's Chemical Lecture Experiments ... 21
——— Elementary Practical Chemistry ... 21
——— Manual of Chemical Analysis... ... 21
——— Smaller Chemical Analysis 21
——— Text-book of Inorganic Chemistry... 21
Notter and Firth's Hygiene 17
——— Practical Domestic Hygiene 17
Osborne's Vegetable Proteins... 24
Ostwald's Principles of Chemistry 21
Paget's Memoirs and Letters 11
Perkin's Methods of Electro-Chemistry ... 21
——— Qualitative Chemical Analysis ... 21
Pettigrew's Design in Nature 11
Plimmer's Constitution of the Proteins ... 24
———Physiological Chemistry 21
Pollok's Practical Spectographic Analysis 19, 23
Poole's Cookery for the Diabetic 11
Poore's Colonial and Camp Sanitation ... 17
——— Essays on Rural Hygiene 17
——— The Dwelling House 17
——— The Earth in Relation to Contagia ... 17
Porter's Sanitary Law 17
——— School Hygiene 17
Price and Twiss' Organic Chemistry 21
Probyn-Williams' The Administration of Anaesthetics 7
Proceedings of the Royal Society of Medicine 12
Quain's Dictionary of Medicine 7
——— Elements of Anatomy (10th Edition)... 8
——— (11th Edition)... 9
Radcliffe and Sinnatt's Practical Organic Chemistry 21
Raffety's Science of Radio Activity 11
Reynolds' Experimental Chemistry 21
Robinson's Health of our Children in the Colonies 17
Schäfer's Essentials of Histology 9
——— Practical Physiology 15
Schryver's Characters of the Proteins ... 24
Sheppard and Mees' Photographic Process... 19
Sheppard's Actinochemistry 23
Smiles' Chemical Constitutions and Physical Properties 23
Smith and Hall's Teaching of Chemistry and Physics in Secondary School ... 21
——— Handbook for Midwives 9
Steel's Diseases of the Ox 12
Stevenson's Wounds in War 9
Stewart's Physical and Inorganic Chemistry 22
——— Recent Advances in Organic Chemistry 22
——— Stereochemistry 23
Sutherland-Gower's Cleanliness *versus* Corruption... 11
Symington and Rankin's Atlas of Skiagrams 10
Text-Books of Physical Chemistry 23
Thomsen's Thermochemistry 23
Thornton's Elementary Biology 15
——— Practical Physiology 15
——— Human Physiology 15
Thorpe's Dictionary of Applied Chemistry... 22
Tilden's Chemical Philosophy 22
——— Practical Chemistry 22
——— Progress of Scientific Chemistry ... 22
Vaccine Therapy 10
Vanderpoel's Colour Problems 19
Watt's Dictionary of Chemistry 22
Webbs' The State and the Doctor 11
West's How to Nurse Sick Children... ... 17
Weston's Detection of Carbon Compounds... 22
Whiteley's Chemical Calculations 22
——— Organic Chemistry 22
Williams' Rhinology 10
Wilsmore's Electro-Chemistry 23
Wright's Optical Projection 19
Youatt's The Dog 12
——— The Horse... 12
Young's Stoichiometry 23

MEDICINE, SURGERY, ANATOMY, ETC.

ASHBY AND WRIGHT. THE DISEASES OF CHILDREN, MEDICAL AND SURGICAL. By HENRY ASHBY, M.D. Lond., F.R.C.P., late Physician to the Manchester Children's Hospital; and G. A. WRIGHT, B.A., M.B. Oxon., F.R.C.S. Eng., Surgeon to the Manchester Royal Infirmary; Consulting Surgeon to the Manchester Children's Hospital. With 15 Plates (1 Coloured) and 241 Illustrations in the Text. Fifth Edition. Thoroughly Revised, 1905. 8vo, 21*s.* net.

BENNETT.—*WORKS by Sir WILLIAM H. BENNETT, K.C.V.O., F.R.C.S., Surgeon to St. George's Hospital.*

RECURRENT EFFUSION INTO THE KNEE-JOINT AFTER INJURY, WITH ESPECIAL REFERENCE TO INTERNAL DERANGEMENT, COMMONLY CALLED SLIPPED CARTILAGE: an Analysis of 750 Cases. A Clinical Lecture delivered at St. George's Hospital. With 13 Illustrations. 8vo, 3*s.* 6*d.*

CLINICAL LECTURES ON VARICOSE VEINS OF THE LOWER EXTREMITIES. With 3 Plates. 8vo, 6*s.*

CLINICAL LECTURES ON ABDOMINAL HERNIA: chiefly in relation to Treatment, including the Radical Cure. With 12 Diagrams in the Text. 8vo, 8*s.* 6*d.*

ON VARIX, ITS CAUSES AND TREATMENT, WITH ESPECIAL REFERENCE TO THROMBOSIS. 8vo, 3*s.* 6*d.*

LECTURE ON THE USE OF MASSAGE AND EARLY MOVEMENTS IN RECENT FRACTURES AND OTHER COMMON SURGICAL INJURIES: SPRAINS AND THEIR CONSEQUENCES: RIGIDITY OF THE SPINE, AND THE MANAGEMENT OF STIFF JOINTS GENERALLY. With 23 Illustrations. 8vo, 6*s.*

THE PRESENT POSITION OF THE TREATMENT OF SIMPLE FRACTURES OF THE LIMBS: an Address delivered to the British Medical Association. To which is appended a Summary of the Opinions and Practice of about 300 Surgeons. 8vo, 2*s.* 6*d.*

MEDICINE, SURGERY, ANATOMY, ETC.—*continued.*

BELL. THE PRINCIPLES OF GYNÆCOLOGY. By W. BLAIR BELL, B.S., M.D., Assistant Gynæcological Surgeon, Royal Infirmary, Liverpool. With 6 Coloured Plates (4 by H. K. MAXWELL) and over 350 other Illustrations. 8vo, 21*s.* net.

A concise, yet complete account of the development, anatomy and physiology of the female genital organs. The methods of physical examination are fully described. The diseases of the special organs and the allied morbid conditions are discussed, special attention being paid to the pathology which is illustrated by numerous photomicrographs and drawings of actual specimens, each of which is carefully described.

CABOT. A GUIDE TO THE CLINICAL EXAMINATION OF THE BLOOD FOR DIAGNOSTIC PURPOSES. By RICHARD C. CABOT, M.D., Physician to Out-Patients, Massachusetts General Hospital. With 3 Coloured Plates and 28 Illus. in Text. 8vo, 16*s.*

CHEYNE AND BURGHARD. A MANUAL OF SURGICAL TREATMENT. By Sir W. WATSON CHEYNE, Bart., C.B., M.B., F.R.C.S., F.R.S., D.Sc., Professor of Clinical Surgery in King's College, London; Surgeon to King's College Hospital, and the Children's Hospital, Paddington Green, etc.; and F. F. BURGHARD, M.D. and M.S. Lond., F.R.C.S., Teacher of Practical Surgery in King's College, London; Surgeon to King's College Hospital, and the Children's Hospital, Paddington Green, etc.

PART I. The treatment of General Surgical Diseases, including inflammation, suppuration, ulceration, gangrene, wounds and their complications, infective diseases and tumours; the administration of anæsthetics. With 66 Illustrations. Royal 8vo, 9*s.* net.

PART II. The treatment of the Surgical Affections of the Tissues, including the skin and subcutaneous tissues, the nails, the lymphatic vessels and glands, the fasciæ, bursæ, muscles, tendons and tendon-sheaths, nerves, arteries and veins; deformities. With 141 Illustrations. Royal 8vo, 12*s.* net.

PART III. The treatment of the Surgical Affections of the Bones. Amputations. With 100 Illustrations. Royal 8vo, 10*s.* 6*d.* net.

PART IV. The treatment of the Surgical Affections of the Joints (including excisions) and the spine. With 138 Illustrations. Royal 8vo, 12*s.* net.

PART V. The treatment of the Surgical Affections of the head, face, jaws, lips, larynx and trachea; and the Intrinsic Diseases of the nose, ear and larynx, by H. LAMBERT LACK, M.D. (Lond.), F.R.C.S., Surgeon to the Hospital for Diseases of the Throat, Golden Square, and to the Throat and Ear Department, the Children's Hospital, Paddington Green. With 145 Illustrations. Royal 8vo, 15*s.* net.

PART VI.—Section 1. The Surgical Affections of the tongue and floor of the mouth, the pharynx, neck, œsophagus, stomach and intestines. With an Appendix on the Examination of the Blood in Surgical Condition. By W. ESTE EMERY, M.D., D.Sc. (Lond.). With 124 Illustrations. Royal 8vo, 15*s.* net.

Section 2. The Surgical Affections of the rectum, the liver, pancreas and spleen, and genito-urinary organs, the breast and the thorax. With 113 Illustrations. Royal 8vo, 18*s.* net.

MEDICINE, SURGERY, ANATOMY, ETC.—*continued.*

COATS. A MANUAL OF PATHOLOGY. By JOSEPH COATS, M.D., late Professor of Pathology in the University of Glasgow. Fifth Edition, 1903. Revised throughout and Edited by LEWIS R. SUTHERLAND, M.D., Professor of Pathology, University of St. Andrews. With 729 Illustrations and 2 Coloured Plates. 8vo, 28*s.* net.

COLYER. DENTAL SURGERY AND PATHOLOGY. By J. F. COLYER, L.R.C.P., M.R.C.S., L.D.S., Dental Surgeon to Charing Cross Hospital and the Royal Dental Hospital. Being the Third Edition of "Diseases and Injuries of the Teeth," by MORTON SMALE and J. P. COLYER. With Illustrations. 8vo. 25*s.* net.

COOKE.—*WORKS by THOMAS COOKE, F.R.C.S. Eng., B.A., B.Sc., M.D. Paris, late Senior Assistant Surgeon to the Westminster Hospital.*

TABLETS OF ANATOMY. Being a Synopsis of demonstrations given in the Westminster Hospital Medical School. Eleventh Edition in three Parts, thoroughly brought up to date, and with over 700 Illustrations from all the best sources, British and Foreign. Post 4to. Part I. The Bones, 7*s.* 6*d.* net; Part II. Limbs, Abdomen, Pelvis, 10*s.* 6*d.* net; Part III. Head and Neck, Thorax, Brain, 10*s.* 6*d.* net.

APHORISMS IN APPLIED ANATOMY AND OPERATIVE SURGERY. Including 100 Typical *viva voce* Questions on Surface Marking, etc. Crown 8vo, 3*s.* 6*d.*

DAKIN. A HANDBOOK OF MIDWIFERY. By WILLIAM RADFORD DAKIN, M.D., F.R.C.P., Obstetric Physician and Lecturer on Midwifery at St. George's Hospital, Examiner in Midwifery and Diseases of Women on the Conjoint Board of the Royal Colleges of Physicians and Surgeons in England, etc. With 400 Illustrations. Large crown 8vo, 18*s.*

DICKSON. THE BONE-MARROW: a Cytological Study. Forming an Introduction to the Normal and Pathological Histology of the Tissue, more especially with regard to Blood Formation, Blood Destruction, etc. Together with a short account of the Reactions and Degenerations of the Tissue in Disease. By W. E. CARNEGIE DICKSON, M.D., B.Sc. Edin., F.R.C.P. Edin., Lecturer on Pathological Bacteriology and Senior Assistant to the Professor of Pathology in the University of Edinburgh; Assistant Pathologist to the Edinburgh Royal Infirmary. With 12 Coloured Plates and 51 Micro-Photographs by Richard Muir. Medium 4to, £2 2*s.* net.

MEDICINE, SURGERY, ANATOMY, ETC.—*continued.*

GOODSALL AND MILES. DISEASES OF THE ANUS AND RECTUM. By D. H. GOODSALL, F.R.C.S., late Senior Surgeon Metropolitan Hospital, Senior Surgeon St. Mark's Hospital; and W. ERNEST MILES, F.R.C.S., Assistant Surgeon to the Cancer Hospital, Surgeon (out-patients) to the Gordon Hospital, etc. (In Two Parts).

PART I.—Anatomy of the Ano-rectal Region—General Diagnosis—Abscess—Ano-rectal Fistula—Recto-urethral, Recto-vesical and Recto-vaginal Fistulæ—Sinus over the Sacro-coccygeal Articulation—Fissure—Hæmorrhoids (External and Internal). With 91 Illustrations. 8vo, 7*s.* 6*d.* net.

PART II.—Prolapse of the Rectum—Invagination of the Rectum—Ulceration—Stricture of the Anus and of the Rectum—Malignant Growths of the Anus and Rectum—Benign Tumours of the Anus and Rectum—Foreign Bodies in the Rectum—Pruritus Ani—Syphilis of the Anus and Rectum. With 44 Illustrations. 8vo, 6*s.* net.

GRAY. ANATOMY, DESCRIPTIVE AND APPLIED. By HENRY GRAY, F.R.S., late Lecturer on Anatomy at St. George's Hospital Medical School. Seventeenth Edition. Edited by ROBERT HOWDEN, M.A., M.B., C.M., Professor of Anatomy in the University of Durham. Notes on Applied Anatomy, revised by A. J. JEX-BLAKE, M.A., M.B., M.R.C.P., Assistant Physician to St. George's Hospital; and W. FEDDE FEDDEN, M.S., F.R.C.S., Assistant Surgeon and Lecturer on Surgical Anatomy, St. George's Hospital. With 1,032 Illustrations. Royal 8vo, 32*s.* net.

HARE. THE FOOD FACTOR IN DISEASE: Being an investigation into the humoral causation, meaning, mechanism and rational treatment, preventive and curative, of the Paroxysmal Neuroses (migraine, asthma, angina pectoris, epilepsy, etc.), bilious attacks, gout, catarrhal and other affections, high blood-pressure, circulatory, renal and other degenerations. By FRANCIS HARE, M.D., late Consulting Physician to the Brisbane General Hospital; Visiting Physician at the Diamantina Hospital for Chronic Diseases, Brisbane; Inspector-General of Hospitals for Queensland. 2 vols. Medium 8vo, 30*s.* net.

INFLUENCE OF HEREDITY ON DISEASE (THE), WITH SPECIAL REFERENCE TO TUBERCULOSIS, CANCER, AND DISEASES OF THE NERVOUS SYSTEM. A Discussion opened by SIR WILLIAM S. CHURCH, Bt., K.C.B., M.D., SIR WILLIAM R. GOWERS, M.D., F.R.S. (Diseases of the Nervous System), ARTHUR LATHAM, M.D. (Tuberculosis), and E. F. BASHFORD, M.D. (Cancer). [From the Proceedings of the Royal Society of Medicine, 1909, Vol. II., No. 3.] 4to, 4*s.* 6*d.* net.

MEDICINE, SURGERY, ANATOMY, ETC.—*continued.*

KIDD. URINARY SURGERY: A REVIEW. By FRANK KIDD, M.B., B.C. (Cantab.), F.R.C.S., Assistant Surgeon to the London Hospital. 8vo, 7*s.* 6*d.* net.

LUFF. TEXT-BOOK OF FORENSIC MEDICINE AND TOXICOLOGY. By ARTHUR P. LUFF, M.D., B.Sc. Lond., Physician in Charge of Out-Patients and Lecturer on Medical Jurisprudence and Toxicology in St. Mary's Hospital; Examiner in Forensic Medicine in the University of London; External Examiner in Forensic Medicine in the Victoria University; Official Analyst to the Home Office. With 13 full-page Plates (1 in colours) and 33 Illustrations in the Text. 2 vols., Crown 8vo, 24*s.*

PROBYN-WILLIAMS. A PRACTICAL GUIDE TO THE ADMINISTRATION OF ANAESTHETICS. By R. J. PROBYN-WILLIAMS, M.D., Senior Anaesthetist and Instructor in Anaesthetics at the London Hospital, etc. With 44 Illustrations. Crown 8vo, 4*s.* 6*d.* net.

QUAIN. QUAIN'S (SIR RICHARD) DICTIONARY OF MEDICINE. By Various Writers. Edited by H. MONTAGUE MURRAY, M.D., F.R.C.P., Joint Lecturer on Medicine, Charing Cross Medical School, and Physician to Charing Cross Hospital, and to the Victoria Hospital for Children, Chelsea; Examiner in Medicine to the University of London. Assisted by JOHN HAROLD, M.B., B.Ch., B.A.O., Physician to St. John's and St. Elizabeth's Hospital, and Demonstrator of Medicine at Charing Cross Medical School, and W. CECIL BOSANQUET, M.A., M.D., F.R.C.P., Assistant Physician, Charing Cross Hospital, etc. Third and Cheaper Edition, largely Rewritten, and Revised throughout. With 21 Plates (14 in Colour) and numerous Illustrations in the Text. 8vo, 21*s.* net.. buckram.

MEDICINE, SURGERY, ANATOMY, ETC.—*continued.*

QUAIN. QUAIN'S (JONES) ELEMENTS OF ANATOMY. The TENTH EDITION. Edited by EDWARD ALBERT SCHÄFER, M.D., Sc.D., F.R.S., Professor of Physiology and Histology in the University of Edinburgh; and GEORGE DANCER THANE, Professor of Anatomy in University College, London.

*** The several parts of this work form COMPLETE TEXT-BOOKS OF THEIR RESPECTIVE SUBJECTS. They can be obtained separately as follows:—

VOL. I., PART I. EMBRYOLOGY. By E. A. SCHÄFER, M.D., Sc.D., F.R.S. With 200 Illustrations. Royal 8vo, 9*s.*

VOL. I., PART II. GENERAL ANATOMY OR HISTOLOGY. By E. A. SCHÄFER, M.D., Sc.D., F.R.S. With 491 Illustrations. Royal 8vo, 12*s.* 6*d.*

VOL. II., PART I. OSTEOLOGY—ARTHROLOGY. By G. D. THANE. With 224 Illustrations. Royal 8vo, 11*s.*

VOL. II., PART II. MYOLOGY—ANGEIOLOGY. By G. D. THANE. With 199 Illustrations. Royal 8vo, 16*s.*

VOL. III., Part I. THE SPINAL CORD AND BRAIN. By E. A. SCHÄFER, F.R.S. With 139 Illustrations. Royal 8vo, 12*s.* 6*d.*

VOL. III., PART II. THE NERVES. By G. D. THANE. With 102 Illustrations. Royal 8vo, 9*s.*

VOL. III., PART III. THE ORGANS OF THE SENSES. By E. A. SCHÄFER, F.R.S. With 178 Illustrations. Royal 8vo, 9*s.*

VOL. III., PART IV. SPLANCHNOLOGY. By E. A. SCHÄFER, F.R.S., and JOHNSON SYMINGTON, M.D. With 337 Illustrations. Royal 8vo, 16*s.*

APPENDIX. SUPERFICIAL AND SURGICAL ANATOMY. By Professor G. D. THANE and Professor R. J. GODLEE, M.S. With 29 Illustrations. Royal 8vo, 6*s.* 6*d.*

MEDICINE, SURGERY, ANATOMY, ETC.—*continued.*

QUAIN. QUAIN'S ELEMENTS OF ANATOMY. The ELEVENTH EDITION. Edited by EDWARD ALBERT SCHÄFER, F.R.S., Professor of Physiology and Histology in the University of Edinburgh; JOHNSON SYMINGTON, M.D., F.R.S., Professor of Anatomy in Queen's College, Belfast; and THOMAS HASTIE BRYCE, M.A., M.D., Regius Professor of Anatomy in the University of Glasgow.

IN FOUR VOLUMES. Royal 8vo.

VOL. I. EMBRYOLOGY. By T. H. BRYCE, M.A., M.D. Illustrated by more than 300 Engravings, many of which are coloured. 10*s.* 6*d.* net.

VOL. III. NEUROLOGY. By E. A. SCHÄFER and J. SYMINGTON.

Part I. Containing the General Structure of the Nervous System and the Structure of the Brain and Spinal Cord. With 361 Illustrations, many of which are coloured. 15*s.* net.

Part II. Containing the Descriptive Anatomy of the Peripheral Nerves and of the Organs of Special Sense. With 321 Illustrations, many of which are coloured. 15*s.* net.

*** *The other Volumes are in preparation.*

This work has been completely re-edited and brought up to date. The volumes will comprise respectively Embryology; General and Visceral Anatomy; the Nervous System and Sense Organs; and the Bones, Ligaments, Muscles, and Blood-vessels. Each volume will be complete in itself, and will serve as a text-book for the particular subject or subjects with which it deals. Thus the first volume is intended to form a complete text-book of Human Embryology, the second a text-book of Histology and Visceral Anatomy, the third a text-book of Neurology, the fourth dealing with the systems which are not included in the second and third volumes.

SCHÄFER. THE ESSENTIALS OF HISTOLOGY: Descriptive and Practical. By E. A. SCHÄFER, M.D., Sc.D., F.R.S., Professor of Physiology and Histology in the University of Edinburgh. With 645 Illustrations some of which are Coloured. Eighth Edition Enlarged, 1910. 8vo, 10*s.* 6*d.* net.

SMITH. THE HANDBOOK FOR MIDWIVES. By HENRY FLY SMITH, B.A., M.B., Oxon., M.R.C.S. Second Edition. With 41 Woodcuts. Crown 8vo, 5*s.*

STEVENSON. WOUNDS IN WAR: The Mechanism of their Production and their Treatment. By Colonel W. F. STEVENSON, C.B., K.H.S., R.A.M.C., B.A., M.B., M.Ch. Dublin University; late Surgeon-General and Professor of Military Surgery, Royal Army Medical College, London. With 137 Illustrations. 8vo, 16*s.* net.

MEDICINE, SURGERY, ANATOMY, ETC.—*continued.*

VACCINE THERAPY; ITS ADMINISTRATION, VALUE, AND LIMITATIONS: a Discussion held by the Royal Society of Medicine. Opening Address by Sir ALMROTH WRIGHT, M.D., F.R.S., with Contributions by Dr. W. HALE WHITE, Dr. WILLIAM BULLOCH, Sir WILLIAM LEISHMAN, Dr. KINGSTON FOWLER, Dr. ARTHUR LATHAM, and many others. 8vo, 4*s.* 6*d.* net.

SYMINGTON AND RANKIN. AN ATLAS OF SKIAGRAMS, ILLUSTRATING THE DEVELOPMENT OF THE TEETH. With Explanatory Text. By JOHNSON SYMINGTON, M.D., F.R.S., Professor of Anatomy, Queen's College, Belfast; and J. C. RANKIN, M.D., Physician in charge of the Electrical Department, Royal Victoria Hospital, Belfast. With 12 Plates. Demy 4to. 10*s.* 6*d.* net.

WILLIAMS. RHINOLOGY: a Text-book of Diseases of the Nose and the Nasal Accessory Sinuses. By PATRICK WATSON WILLIAMS, M.D. (London). With 3 Coloured Plates and 44 Black and White Plates (of which 26 are Stereoscopic) and 140 Illustrations in the Text. 8vo, 12*s.* 6*d.* net. With Stereoscope, 15*s.* net.

MISCELLANEOUS.

ANNUAL CHARITIES REGISTER AND DIGEST: being a Classified Register of Charities in or available for the Metropolis, together with a Digest of Information respecting the Legal, Voluntary, and other Means for the Prevention and Relief of Distress and the Improvement of the Condition of the Poor. With an elaborate Index, and an Introduction, "How to Help Cases of Distress". By C. S. LOCH, Secretary to the Council of the Charity Organisation Society, London. 8vo, 5*s.* net.

GASKELL. THE ORIGIN OF VERTEBRATES. By WALTER H. GASKELL, M.A., M.D. (Camb.), LL.D. (Edinburgh and McGill Univ., Montreal), F.R.S., Fellow of Trinity Hall and University Lecturer in Physiology, Cambridge. With 168 Illustrations. 8vo, 21*s.* net.

HOBART. THE MEDICAL LANGUAGE OF ST. LUKE. By the Rev. WILLIAM KIRK HOBART, LL.D. 8vo, 16*s.*

HOPF. THE HUMAN SPECIES: CONSIDERED FROM THE STANDPOINTS OF COMPARATIVE ANATOMY, PHYSIOLOGY, PATHOLOGY AND BACTERIOLOGY. By Dr. LUDWIG HOPF. Authorised English Translation. With 7 Plates and 217 Illustrations in the Text. 8vo, 10*s.* 6*d.* net.

MISCELLANEOUS—*continued.*

INQUIRY (AN) INTO THE PHENOMENA ATTENDING DEATH BY DROWNING AND THE MEANS OF PROMOTING RESUSCITATION IN THE APPARENTLY DROWNED. Report of a Committee appointed by the Royal Medical and Chirurgical Society. With 2 Diagrams and 26 Plates. 8vo, 5*s.* net.

KING'S COLLEGE HOSPITAL BOOK OF COOKING RECIPES: being a Collection of Recipes contributed by Friends of the Hospital and Published in aid of the Fund for the Removal of King's College Hospital to South London. Crown 8vo, 1*s.* net.

MOON. THE RELATION OF MEDICINE TO PHILOSOPHY. By R. O. MOON, M.A., M.D. (Oxon.), F.R.C.P., Physician to the National Hospital for Diseases of the Heart, etc. Crown 8vo, 4*s.* 6*d.* net.

PAGET. MEMOIRS AND LETTERS OF SIR JAMES PAGET, Bart., F.R.S., Sergeant-Surgeon to Her late Majesty Queen Victoria. Edited by STEPHEN PAGET, F.R.C.S. With Portrait. 8vo, 6*s.* net.

PETTIGREW. DESIGN IN NATURE: Illustrated by Spiral and other Arrangements in the Inorganic and Organic Kingdoms as exemplified in Matter, Force, Life, Growth, Rhythms, etc., especially in Crystals, Plants, and Animals. With Examples selected from the Reproductive, Alimentary, Respiratory, Circulatory, Nervous, Muscular, Osseous, Locomotory, and other Systems of Animals. By J. BELL PETTIGREW, M.D., LL.D., F.R.S., F.R.C.P.; Laureate of the Institute of France; late Chandos Professor of Anatomy and Medicine in the University, St. Andrews; Fellow of the Royal Botanical, Medico-Chirurgical, Royal Medical, Literary and Philosophical, Harveian and other Societies. Illustrated by nearly 2,000 Figures, largely original and from nature. In 3 vols. 4to. 63*s.* net.

POOLE. COOKERY FOR THE DIABETIC. By W. H. and Mrs. POOLE. With Preface by Dr. PAVY. Fcap. 8vo, 2*s.* 6*d.*

RAFFETY. AN INTRODUCTION TO THE SCIENCE OF RADIO-ACTIVITY. By CHARLES W. RAFFETY. With 27 Illustrations. Crown 8vo. 4*s.* 6*d.* net.

SUTHERLAND-GOWER. CLEANLINESS *VERSUS* CORRUPTION. By Lord RONALD SUTHERLAND-GOWER. With 11 Illustrations. Crown 8vo, paper covers, 6*d.*

A plea for the more general adoption of cremation for human bodies.

WEBB. THE STATE AND THE DOCTOR. By SIDNEY and BEATRICE WEBB. 8vo, 6*s.* net.

THE PROCEEDINGS OF THE ROYAL SOCIETY OF MEDICINE.

The Royal Society of Medicine was formed in June, 1907, *by the amalgamation of the following London Medical Societies :—*

The Royal Medical and Chirurgical Society.
The Pathological Society.
The Epidemiological Society.
The Odontological Society of Great Britain.
The Obstetrical Society.
The Clinical Society.
The Dermatological Society.
The British Gynæcological Society.
The Neurological Society.
The British Laryngological, Rhinological, and Otological Association.
The Laryngological Society.
The Dermatological Society of Great Britain and Ireland.
The Otological Society of the United Kingdom.
The British Electro-therapeutic Society.
The Therapeutical Society.

The "Proceedings" of the Royal Society of Medicine are published monthly from November to July inclusive. The numbers contain the papers of, and the discussions read at each of the Sections during the previous month, and are so arranged that each Section can, if desired, be detached and bound separately at the end of the year.

The Annual Subscription is **£3 3s. net,** *which may be paid through any bookseller.*

The price of each monthly number is **7s. 6d. net.**

VETERINARY MEDICINE, ETC.

FITZWYGRAM. HORSES AND STABLES. By Lieutenant-General Sir F. FITZWYGRAM, Bart. With 56 pages of Illustrations. 8vo, 3*s.* net.

HAYES. TRAINING AND HORSE MANAGEMENT IN INDIA. With Hindustanee Vocabulary. By M. HORACE HAYES, F.R.C.V.S. (late Captain, "The Buffs"). With Portrait. Crown 8vo, 8*s.* net.

STEEL. A TREATISE ON THE DISEASES OF THE OX; being a Manual of Bovine Pathology. Especially adapted for the use of Veterinary Practitioners and Students. By JOHN HENRY STEEL, F.R.C.V.S., F.Z.S., A.V.D., late Professor of Veterinary Science and Principal of Bombay Veterinary College. With 2 Plates and 117 Woodcuts. 8vo, 15*s.*

YOUATT.—*WORKS by WILLIAM YOUATT.*

THE HORSE. Revised and Enlarged by W. WATSON, M.R.C.V.S. With 52 Wood Engravings. 8vo, 7*s.* 6*d.*

THE DOG. Revised and Enlarged. With 33 Wood Engravings. 8vo, 6*s.*

PHYSIOLOGY, BIOLOGY, ZOOLOGY, ETC.

ASHBY. NOTES ON PHYSIOLOGY FOR THE USE OF STUDENTS PREPARING FOR EXAMINATION. By HENRY ASHBY, M.D. (Lond.), F.R.C.P., late Physician to the General Hospital for Sick Children, Manchester; Lecturer and Examiner in Diseases of Children in the Victoria University. Revised by HUGH T. ASHBY, B.A., M.B., B.C. (Camb.), M.R.C.P. (Lond.). With 147 Illustrations. Crown 8vo, 5*s.*

BARNETT. THE MAKING OF THE BODY: a Children's Book on Anatomy and Physiology. By Mrs. S. A. BARNETT. With 113 Illustrations. Crown 8vo, 1*s.* 9*d.*

BEDDARD. ELEMENTARY PRACTICAL ZOOLOGY. By FRANK E. BEDDARD, M.A. (Oxon.). With 93 Illustrations. Crown 8vo, 2*s.* 6*d.*

BIDGOOD. A COURSE OF PRACTICAL ELEMENTARY BIOLOGY. By JOHN BIDGOOD, B.Sc., F.L.S. With 226 Illustrations. Crown 8vo, 4*s.* 6*d.*

BOSE.—*WORKS by JAGADIS CHUNDER BOSE, M.A. (Cantab.), D.Sc. (Lond.), Professor, Presidency College, Calcutta.*

RESPONSE IN THE LIVING AND NON-LIVING. With 117 Illustrations. 8vo, 10*s.* 6*d.*

PLANT RESPONSE AS A MEANS OF PHYSIOLOGICAL INVESTIGATION. With 278 Illustrations. 8vo, 21*s.*

COMPARATIVE ELECTRO-PHYSIOLOGY: A PHYSICO-PHYSIOLOGICAL STUDY. With 406 Illustrations and Classified List of 321 new Experiments. 8vo, 15*s.* net.

BRODIE. THE ESSENTIALS OF EXPERIMENTAL PHYSIOLOGY. For the use of Students. By T. G. BRODIE, M.D., Lecturer on Physiology, St. Thomas's Hospital Medical School. With 2 Plates and 177 Illustrations in the Text. Crown 8vo, 6*s.* 6*d.*

CHAPMAN. THE FORAMINIFERA: an Introduction to the Study of the Protozoa. By FREDERICK CHAPMAN, A.L.S., F.R.M.S. With 14 Plates and 42 Illustrations in the Text. 8vo, 9*s.* net.

PHYSIOLOGY, BIOLOGY, ZOOLOGY, ETC.—*continued.*

FURNEAUX. HUMAN PHYSIOLOGY. By W. FURNEAUX, F.R.G.S. With 223 Illustrations. Crown 8vo, 2*s.* 6*d.*

HALLIBURTON. THE ESSENTIALS OF CHEMICAL PHYSIOLOGY. For the Use of Students. By W. D. HALLIBURTON, LL.D., M.D., F.R.S., F.R.C.P., Professor of Physiology in King's College, London. With 71 Illustrations. 8vo, 4*s.* 6*d.* net.

HUDSON AND GOSSE. THE ROTIFERA OR "WHEEL ANIMALCULES". By C. T. HUDSON, LL.D., and P. H. GOSSE, F.R.S. With 30 Coloured and 4 Uncoloured Plates. In 6 Parts. 4to, price 10*s.* 6*d.* each; Supplement, 12*s.* 6*d.* Complete in Two Volumes, with Supplement, 4to, £4 4*s.*

*** The Plates in the Supplement contain figures of almost all the Foreign Species, as well as of the British Species, that have been discovered since the original publication of Vols. I. and II.

LLOYD AND BIGELOW. THE TEACHING OF BIOLOGY IN THE SECONDARY SCHOOL. By FRANCIS E. LLOYD, A.M., and MAURICE A. BIGELOW, Ph.D., Professors in Teachers' College, Columbia University. Crown 8vo, 6*s.* net.

MACALISTER.—*WORKS by ALEXANDER MACALISTER, M.D.*

AN INTRODUCTION TO THE SYSTEMATIC ZOOLOGY AND MORPHOLOGY OF VERTEBRATE ANIMALS. With 41 Diagrams. 8vo, 10*s.* 6*d.*

ZOOLOGY OF THE INVERTEBRATE ANIMALS. With 77 Diagrams. Fcp. 8vo, 1*s.* 6*d.*

ZOOLOGY OF THE VERTEBRATE ANIMALS. With 59 Diagrams. Fcp. 8vo, 1*s.* 6*d.*

MACDOUGALL.—*WORKS by DANIEL TREMBLY MACDOUGALL, Ph.D.*

TEXT-BOOK OF PLANT PHYSIOLOGY. With 159 Illustrations. 8vo, 7*s.* 6*d.* net.

ELEMENTARY PLANT PHYSIOLOGY. With 108 Illustrations. Crown 8vo, 3*s.*

PHYSIOLOGY, BIOLOGY, ZOOLOGY, ETC.—*continued.*

MARSHALL. THE PHYSIOLOGY OF REPRODUCTION. By FRANCIS H. A. MARSHALL, M.A. (Cantab.), D.Sc. (Edin.), Fellow of Christ's College, Cambridge, and University Lecturer in Agricultnral Physiology. With Preface by Professor E. A. SCHÄFER, Sc.D., LL.D., F.R.S., and Contributions by WILLIAM CRAMER, Ph.D., D Sc., and JAMES LOCHHEAD, M.A., M.D., B.Sc., F.R.C.S.E. With 154 Illustrations. 8vo, 21*s.* net.

MOORE. ELEMENTARY PHYSIOLOGY AND ANATOMY. By BENJAMIN MOORE, D.Sc., Professor of Bio-Chemistry in the University of Liverpool. With 125 Illustrations. Crown 8vo, 3*s.* 6*d.*

MORGAN. ANIMAL BIOLOGY. An Elementary Text-Book. By C. LLOYD MORGAN, F.R.S., Principal of University College, Bristol. With numerous Illustrations. Crown 8vo, 8*s.* 6*d.*

SCHÄFER. DIRECTIONS FOR CLASS WORK IN PRACTICAL PHYSIOLOGY: Elementary Physiology of Muscle and Nerve and of the Vascular and Nervous Systems. By E. A. SCHÄFER, LL.D., F.R.S., Professor of Physiology in the University of Edinburgh. With 48 Diagrams. 8vo, 3*s.* net.

THORNTON.—*WORKS by JOHN THORNTON, M.A.*

HUMAN PHYSIOLOGY. With 284 Illustrations, some of which are Coloured. Crown 8vo, 6*s.*

ELEMENTARY BIOLOGY, Descriptive and Experimental. With numerous Illustrations. Crown 8vo, 3*s.* 6*d.*

ELEMENTARY PRACTICAL PHYSIOLOGY. With 178 Illustrations (6 of which are Coloured). Crown 8vo, 3*s.* 6*d.*

HEALTH AND HYGIENE, ETC.

ASHBY. HEALTH IN THE NURSERY. By HENRY ASHBY, M.D., F.R.C.P., Physician to the General Hospital for Sick Children, Manchester; Lecturer and Examiner in Diseases of Children in the Victoria University. With 25 Illustrations. Crown 8vo, 3*s.* net.

CAMPBELL. PRACTICAL MOTHERHOOD. By HELEN Y. CAMPBELL, L.R.C.P. and S. (Edin.); L.F.P. and S. (Glas.). 8vo, 7*s.* 6*d.*

BULL.—*WORKS by THOMAS BULL, M.D. Thoroughly Revised by ROBERT W. PARKER, M.R.C.S. Eng.*

HINTS TO MOTHERS ON THE MANAGEMENT OF THEIR HEALTH DURING THE PERIOD OF PREGNANCY, AND HINTS ON NURSING. Fcp. 8vo, sewed, 1*s.* 6*d.*; cloth, gilt edges, 2*s.* net.

THE MATERNAL MANAGEMENT OF CHILDREN IN HEALTH AND DISEASE. Fcp. 8vo, sewed, 1*s.* 6*d.*; cloth, gilt edges, 2*s.* net.

BUTTERWORTH. MANUAL OF HOUSEHOLD WORK AND MANAGEMENT. By ANNIE BUTTERWORTH. Crown 8vo, 2*s.* 6*d.*

CORFIELD. THE LAWS OF HEALTH. By W. H. CORFIELD, M.A., M.D. Fcp. 8vo, 1*s.* 6*d.*

CREIGHTON. THE ECONOMICS OF THE HOUSEHOLD. Six Lectures given at the London School of Economics during the Winter of 1906. By LOUISE CREIGHTON. Crown 8vo, 1*s.* 4*d.*

FURNEAUX. ELEMENTARY PRACTICAL HYGIENE. Section I. By WILLIAM S. FURNEAUX. With 146 Illustrations. Crown 8vo, 2*s.* 6*d.*

JAMES. BALL GAMES AND BREATHING EXERCISES. By ALICE R. JAMES. With Preface by HARRY CAMPBELL, M.D., B.S. (London), F.R.C.P. With 17 Illustrations. Crown 8vo, 1*s.* 6*d.*

HEALTH AND HYGIENE, ETC.—*continued.*

NOTTER AND FIRTH.—*WORKS by J. LANE NOTTER, M.A., M.D., and R. H. FIRTH, F.R.C.S.*

HYGIENE. With 99 Illustrations. Crown 8vo, 4*s.* 6*d.*

PRACTICAL DOMESTIC HYGIENE. With 84 Illustrations. Crown 8vo, 2*s.* 6*d.*

POORE.—*WORKS by GEORGE VIVIAN POORE, M.D., F.R.C.P.*

THE EARTH IN RELATION TO THE PRESERVATION AND DESTRUCTION OF CONTAGIA: being the Milroy Lectures delivered at the Royal College of Physicians in 1899, together with other Papers on Sanitation. 13 Illustrations. Crown 8vo, 5*s.*

ESSAYS ON RURAL HYGIENE. With 12 Illustrations. Crown 8vo, 6*s.* 6*d.*

THE DWELLING HOUSE. With 36 Illustrations. Crown 8vo, 3*s.* 6*d.*

COLONIAL AND CAMP SANITATION. With 11 Illustrations. Crown 8vo, 2*s.* net.

PORTER.—*WORKS by CHARLES PORTER, M.D., B.Sc., M.R.C.P.*

SCHOOL HYGIENE AND THE LAWS OF HEALTH: a Text-Book for Teachers and Students in Training. With 121 Illustrations. Crown 8vo, 3*s.* 6*d.*

SANITARY LAW IN QUESTION AND ANSWER. For the use of Students of Public Health. Crown 8vo, 2*s.* 6*d.* net.

This book is primarily intended to assist candidates for Diplomas in Public Health and the certificates of the various examining bodies granting qualifications to Sanitary Inspectors, in their study of the Sanitary Laws of England and Wales. As many of the queries in the book are such as have to be dealt with almost daily in practice, the volume should prove of value also to those already in the Public Health Service, as a reference book and guide to Sanitary Legislation.

ROBINSON. THE HEALTH OF OUR CHILDREN IN THE COLONIES: a Book for Mothers. By LILIAN AUSTEN ROBINSON, M.D. Crown 8vo, 2*s.* 6*d.* net.

WEST. HOW TO NURSE SICK CHILDREN. By CHARLES WEST, M.D., Founder of and late Physician to the Hospital for Sick Children, Great Ormond Street, London. With Preface by GEORGE F. STILL, M.D., Physician to the Hospital for Sick Children, Great Ormond Street. Crown 8vo, 1*s.* net.

BACTERIOLOGY, ETC.

CURTIS. THE ESSENTIALS OF PRACTICAL BACTERIOLOGY: an Elementary Laboratory Work for Students and Practitioners. By H. J. CURTIS, B.S. and M.D. Lond., F.R.C.S., formerly Surgeon to the North-Eastern Hospital for Children; Assistant Surgeon, Royal Hospital for Children and Women, Waterloo Road; Surgical Registrar and Assistant to the Professor of Pathology, University College, London. With 133 Illustrations. 8vo, 9*s*.

ELLIS. OUTLINES OF BACTERIOLOGY (Technical and Agricultural). By DAVID ELLIS, Ph.D. (Marburg), D.Sc. (London), F.R.S.E., Lecturer in Bacteriology and Botany to the Glasgow and West of Scotland Technical College, Glasgow. With 134 Illustrations. 8vo, 7*s*. 6*d*. net.

FRANKLAND. BACTERIA IN DAILY LIFE. By Mrs. PERCY FRANKLAND, F.R.M.S. Crown 8vo, 5*s*. net.

GOADBY. THE MYCOLOGY OF THE MOUTH: A TEXT-BOOK OF ORAL BACTERIA. By KENNETH W. GOADBY, L.D.S. Eng., D.P.H. Camb., L.R.C.P., M.R.C.S., Bacteriologist and Lecturer on Bacteriology, National Dental Hospital, etc. With 82 Illustrations. 8vo, 8*s*. 6*d*. net.

KLÖCKER. FERMENTATION ORGANISMS. A Laboratory Handbook. By ALB. KLÖCKER, Assistant in the Carlsberg Laboratory, Copenhagen. Translated from the German by G. E. ALLAN, B.Sc., Lecturer in the University of Birmingham, and J. H. MILLAR, F.I.C., formerly Lecturer in the British School of Malting and Brewing, and revised by the Author. With 146 Illustrations. 8vo, 12*s*. net.

OPTICS, PHOTOGRAPHY, ETC.

ABNEY. A TREATISE ON PHOTOGRAPHY. By Sir WILLIAM DE WIVELESLIE ABNEY, K.C.B., F.R.S. With 134 Illustrations. Crown 8vo, 5*s*.

BALY. SPECTROSCOPY. By E. C. C. BALY, F.I.C., Professor of Chemistry in the University of Liverpool. With 163 Illustrations. Crown 8vo, 10*s*. 6*d*.

DRUDE. THE THEORY OF OPTICS. By PAUL DRUDE, Professor of Physics at the University of Giessen. Translated from the German by C. RIBORG MANN and ROBERT A. MILLIKAN, Professors of Physics at the University of Chicago. With 110 Diagrams. 8vo, 15*s*. net.

GLAZEBROOK. PHYSICAL OPTICS. By R. T. GLAZEBROOK, M.A., F.R.S. With 183 Woodcuts of Apparatus, etc. Crown 8vo, 6*s*.

MEES. AN ATLAS OF ABSORPTION SPECTRA. By C. E. KENNETH MEES, D.Sc. Crown 8vo, 6*s*. net.

POLLOK. PRACTICAL SPECTROGRAPHIC ANALYSIS. By J. H. POLLOK, D.Sc. Crown 8vo.

SHEPPARD AND MEES. INVESTIGATION ON THE THEORY OF THE PHOTOGRAPHIC PROCESS. By S. E. SHEPPARD, D.Sc. (Lond.), 1851 Exhibition Scholar of University College, London, and C. E. KENNETH MEES, D.Sc. (Lond.). With 65 Illustrations and Diagrams. Crown 8vo, 6*s*. 6*d*. net.

VANDERPOEL. COLOUR PROBLEMS: A Practical Manual for the Lay Student of Colour. By EMILY NOYES VANDERPOEL. With 117 Plates in Colour. Square 8vo, 21*s*. net.

WRIGHT. OPTICAL PROJECTION: A Treatise on the Use of the Lantern in Exhibition and Scientific Demonstration. By LEWIS WRIGHT, Author of "Light: a Course of Experimental Optics". With 243 Illustrations. Crown 8vo, 6*s*.

CHEMISTRY, ETC.

ARMITAGE. A HISTORY OF CHEMISTRY.
By F. P. ARMITAGE, M.A., F.C.S. Crown 8vo, 6*s*.

ARRHENIUS.—*WORKS by SVANTE ARRHENIUS, Director of the Nobel Institute, Stockholm.*

THEORIES OF CHEMISTRY: being Lectures delivered at the University of California, in Berkeley. Edited by T. SLATER PRICE, D.Sc., Ph.D., F.I.C. 8vo, 5*s*. 6*d*. net.

A TEXT-BOOK OF ELECTRO-CHEMISTRY. Translated from the German Edition by JOHN McCRAE, Ph.D. With 58 Illustrations. 8vo, 9*s*. 6*d*. net.

BUNGE. TEXT-BOOK OF ORGANIC CHEMISTRY FOR MEDICAL STUDENTS. By Dr. G. VON BUNGE, Professor of Physiology in the University of Basel. Translated by R. H. ADERS PLIMMER, D.Sc. 8vo, 6*s*. net.

CROOKES. SELECT METHODS IN CHEMICAL ANALYSIS (chiefly inorganic). By Sir W. CROOKES, O.M., F.R.S. With 68 Illustrations. 8vo, 21*s*. net.

FINDLAY. PRACTICAL PHYSICAL CHEMISTRY By ALEX. FINDLAY, M.A., Ph.D., D.Sc. With 92 Illustrations. Crown 8vo, 4*s*. 6*d*.

GODFREY. ELEMENTARY CHEMISTRY. By HOLLIS GODFREY, Head of the Department of Science, Girls' High School of Practical Arts, Boston, Mass. With numerous Illustrations. Crown 8vo, 4*s*. 6*d*. net.

HANSON AND DODGSON. AN INTERMEDIATE COURSE OF LABORATORY WORK IN CHEMISTRY. By EDWARD KENNETH HANSON, M.A. (Cant.), F.I.C., Teachers' Diploma (Lond.); Lecturer in Chemistry, University College, Reading; Lecturer to the Cambridge University Local Lecture Syndicate, and JOHN WALLIS DODGSON, B.Sc. (Lond.); Director of Evening Classes and Lecturer in Chemistry, University College, Reading. With Illustrations. 8vo, 3*s*. 6*d*.

MENDELEEFF. THE PRINCIPLES OF CHEMISTRY. By D. MENDELÉEFF. Translated from the Russian (Seventh Edition) by GEORGE KAMENSKY, A.R.S.M., and Edited by THOMAS H. POPE, B.Sc., F.I.C. With 110 Illustrations. 2 vols. 8vo, 32*s*. net.

MEYER. OUTLINES OF THEORETICAL CHEMISTRY. By LOTHAR MEYER. Translated by Professors P. PHILLIPS BEDSON, D.Sc., and W. CARLETON WILLIAMS, B.Sc. 8vo, 9*s*.

MUIR. A COURSE OF PRACTICAL CHEMISTRY.
By M. M. PATTISON MUIR, M.A., F.R.S.E.
Part I. Elementary. Cr. 8vo, 4*s*. 6*d*. Part II. Intermediate. Cr. 8vo, 4*s*. 6*d*.

CHEMISTRY, ETC.—*continued.*

NEWTH.—*WORKS by G. S. NEWTH, F.I.C., F.C.S.*

CHEMICAL LECTURE EXPERIMENTS. With 230 Illustrations. Crown 8vo, 6*s.*

MANUAL OF CHEMICAL ANALYSIS, QUALITATIVE AND QUANTITATIVE. With 102 Illustrations. Crown 8vo, 6*s.* 6*d.*

SMALLER CHEMICAL ANALYSIS. Crown 8vo, 2*s.*

A TEXT-BOOK OF INORGANIC CHEMISTRY. With 15 Illustrations. Crown 8vo, 6*s.* 6*d.*

ELEMENTARY PRACTICAL CHEMISTRY. With 108 Illustrations and 254 Experiments. Crown 8vo, 2*s.* 6*d.*

OSTWALD. THE FUNDAMENTAL PRINCIPLES OF CHEMISTRY. An Introduction to all Text-Books of Chemistry. By WILHELM OSTWALD. Authorised Translation by HARRY W. MORSE. 8vo, 7*s.* 6*d.* net.

PERKIN.—*WORKS by F. MOLLWO PERKIN, Ph.D.*

QUALITATIVE CHEMICAL ANALYSIS (ORGANIC AND INORGANIC). With 16 Illustrations and Spectrum Plate. 8vo, 4*s.* 6*d.*

PRACTICAL METHODS OF ELECTRO-CHEMISTRY. 8vo, 6*s.* net.

PLIMMER. PRACTICAL PHYSIOLOGICAL CHEMISTRY. By R. H. ADERS PLIMMER, D.Sc., Assistant Professor of Physiological Chemistry, University College, London. With Coloured Plate of Aboorp. tion Spectra and 49 Illustrations in the Text. Royal 8vo, 6*s.* net.

PRICE AND TWISS. A COURSE OF PRACTICAL ORGANIC CHEMISTRY. By T. SLATER PRICE, D.Sc., Ph.D., F.I.C., Head of the Chemical Department of the Birmingham Municipal Technical School, and D. F. TWISS, M.Sc., A.I.C., Lecturer in Chemistry at the Birmingham Municipal Technical School. 8vo, 3*s.* 6*d.*

RADCLIFFE AND SINNATT. A SYSTEMATIC COURSE OF PRACTICAL ORGANIC CHEMISTRY. By LIONEL GUY RADCLIFFE, F.C.S. With the assistance of FRANK STURDY SINNATT, F.C.S. 8vo, 4*s.* 6*d.*

REYNOLDS. EXPERIMENTAL CHEMISTRY for Junior Students. By J. EMERSON REYNOLDS, M.D., F.R.S. Fcap. 8vo, with numerous Illustrations.

PART I.—*Introductory*, 1*s.* 6*d.* PART III.—*Metals and Allied Bodies*, 3*s.* 6*d.*
PART II.—*Non-Metals*, 2*s.* 6*d.* PART IV.—*Chemistry of Carbon Compounds*, 4*s.*

SMITH AND HALL. THE TEACHING OF CHEMISTRY AND PHYSICS IN THE SECONDARY SCHOOL. By ALEXANDER SMITH, B.Sc., Ph.D., Associate Professor of Chemistry in the University of Chicago, and EDWIN H. HALL, Ph.D., Professor of Physics in Harvard University. With 21 Woodcuts, Bibliographies, and Index. Crown 8vo, 6*s.* net.

CHEMISTRY, ETC.—*continued.*

STEWART.—*WORKS by A. W. STEWART, D.Sc.*

RECENT ADVANCES IN ORGANIC CHEMISTRY. With an Introduction by J. NORMAN COLLIE, Ph.D., LL.D., F.R.S., Professor of Organic Chemistry in University College, London. 8vo, 7*s.* 6*d.*

RECENT ADVANCES IN PHYSICAL AND INORGANIC CHEMISTRY. With an Introduction by Sir WILLIAM RAMSAY, K.C.B., F.R.S. 8vo, 7*s.* 6*d.* net.

THORPE. A DICTIONARY OF APPLIED CHEMISTRY. By Sir T. E. THORPE, C.B., D.Sc. Vict., Ph.D., F.R.S. Assisted by Eminent Contributors. 3 vols. 8vo. Vols. I. and II., £2 2*s.* each (Postage, 3*s.* 4*d.*); Vol. III., £3 3*s.*

TILDEN.—*Works by Sir WILLIAM A. TILDEN, D.Sc. London, F.R.S.*

A SHORT HISTORY OF THE PROGRESS OF SCIENTIFIC CHEMISTRY IN OUR OWN TIMES. Crown 8vo, 5*s.* net.

INTRODUCTION TO THE STUDY OF CHEMICAL PHILOSOPHY. The Principles of Theoretical and Systematic Chemistry. With 5 Illustrations. Crown 8vo, 5*s.* With ANSWERS to Problems. Crown 8vo, 5*s.* 6*d.*

PRACTICAL CHEMISTRY. The Principles of Qualitative Analysis. Fcp. 8vo, 1*s.* 6*d.*

WATTS' DICTIONARY OF CHEMISTRY. Revised and entirely Re-written by H. FORSTER MORLEY, M.A., D.Sc., Fellow of, and lately Assistant-Professor of Chemistry in, University College, London; and M. M. PATTISON MUIR, M.A., F.R.S.E. Assisted by Eminent Contributors. 4 vols. 8vo, £5 net.

WESTON. A SCHEME FOR THE DETECTION OF THE MORE COMMON CLASSES OF CARBON COMPOUNDS. By FRANK E. WESTON, B.Sc., London (First Class Honours), F.C.S., Lecturer in Chemistry at the Polytechnic, Regent Street, W. 8vo, 2*s.*

WHITELEY.—*WORKS by R. L. Whiteley, F.I.C., Principal of the Municipal Science School, West Bromwich.*

CHEMICAL CALCULATIONS. With Explanatory Notes, Problems, and Answers, specially adapted for use in Colleges and Science Schools. With a Preface by Professor F. CLOWES, D.Sc. (Lond.), F.I.C. Crown 8vo, 2*s.*

ORGANIC CHEMISTRY: the Fatty Compounds. With 45 Illustrations. Crown 8vo, 3*s.* 6*d.*

TEXT-BOOKS OF PHYSICAL CHEMISTRY.

Edited by Sir WILLIAM RAMSAY, K.C.B., F.R.S., D.Sc.

Crown 8vo.

STOICHIOMETRY. By SYDNEY YOUNG, D.Sc., F.R.S., Professor o Chemistry in the University of Dublin; together with AN INTRODUCTION TO THE STUDY OF PHYSICAL CHEMISTRY, by Sir WILLIAM RAMSAY, K.C.B., F.R.S., Editor of the Series. 7*s.* 6*d.*

CHEMICAL STATICS AND DYNAMICS, INCLUDING THE THEORIES OF CHEMICAL CHANGE, CATALYSIS, AND EXPLOSIONS. By J. W. MELLOR, D.Sc., B.Sc. 7*s.* 6*d.*

THE PHASE RULE AND ITS APPLICATIONS. By ALEX. FINDLAY, M.A., Ph.D., D.Sc., Lecturer and Demonstrator in Chemistry, University of Birmingham. With 134 Figures in the Text. 5*s.*

SPECTROSCOPY. By E. C. C. BALY, F.I.C., Professor of Chemistry in the University of Liverpool. With 163 Illustrations. 10*s.* 6*d.*

THERMOCHEMISTRY. By JULIUS THOMSEN, Emeritus Professor of Chemistry in the University of Copenhagen. Translated by KATHARINE A. BURKE, B.Sc. (Lond.), Assistant in the Department of Chemistry, University College, London. 9*s.*

ELECTRO-CHEMISTRY. PART I.—GENERAL THEORY. By R. A. LEHFELDT, D.Sc., Transvaal University College, Johannesburg. Including a Chapter on the Relation of Chemical Constitution to Conductivity, by T. S. MOORE, B.A., B.Sc., Lecturer in the University of Birmingham. 5*s.*

ELECTRO-CHEMISTRY. PART II.—APPLICATIONS TO ELECTROLYSIS, PRIMARY AND SECONDARY BATTERIES, ETC. By N. T. M. WILSMORE, D.Sc. [*In preparation.*

STEREOCHEMISTRY. By A. W. STEWART, D.Sc., Carnegie Research Fellow of University College, London. With 87 Illustrations. 10*s.* 6*d.*

THE THEORY OF VALENCY. By J. NEWTON FRIEND, Ph.D. (Würz), D.Sc. (Birmingham). 5*s.*

METALLOGRAPHY. By CECIL H. DESCH, D.Sc. (Lond.), Ph.D. (Wurzb.); Graham Young Lecturer in Metallurgical Chemistry in the University of Glasgow. With 14 Plates and 108 Diagrams in the Text. 9*s.*

THE RELATIONS BETWEEN CHEMICAL CONSTITUTION AND SOME PHYSICAL PROPERTIES. By SAMUEL SMILES, D.Sc., Fellow of University College, and Assistant Professor of Organic Chemistry at University College, London University. 14*s.*

THERMODYNAMICS. By F. G. DONNAN, M.A., Ph.D. [*In preparation.*

ACTINOCHEMISTRY. By S. E. SHEPPARD, D.Sc. [*In preparation.*

PRACTICAL SPECTROGRAPHIC ANALYSIS. By J. H. POLLOK, D.Sc. [*In preparation.*

MONOGRAPHS ON BIOCHEMISTRY.

Edited by R. H. ADERS PLIMMER, D.Sc., and F. GOWLAND HOPKINS, D.Sc., F.R.S.

Royal 8vo.

In these volumes an attempt is being made to make the subject of Biochemistry more accessible by issuing a series of monographs upon the various chapters of the subject, each independent of and yet dependent upon the others, so that from time to time, as new material and the demand therefor necessitate, a new edition of each monograph can be issued without reissuing the whole series. The expenses of publication and the expense to the purchaser will thus be diminished, and by a moderate outlay it will be possible to obtain a full account of any particular subject as nearly current as possible.

THE DEVELOPMENT AND PRESENT POSITION OF BIOLOGICAL CHEMISTRY. By F. GOWLAND HOPKINS, M.A., M.B., D.Sc., F.R.S., Prælector in Biochemistry in the University of Cambridge. [*In preparation.*

THE NATURE OF ENZYME ACTION. By W. M. BAYLISS, D.Sc., F.R.S., Assistant Professor of Physiology, University College, London. 3*s.* net.

THE CHEMICAL CONSTITUTION OF THE PROTEINS. By R. H. ADERS PLIMMER, D.Sc., Teacher of Chemistry at University College, London. In 2 Parts. Part 1, 3*s.* net; Part 2, 2*s.* 6*d.* net.

THE GENERAL CHARACTERS OF THE PROTEINS. By S. B. SCHRYVER, D.Sc., Ph.D., Lecturer on Physiological Chemistry, University College, London. 2*s.* 6*d.* net.

THE VEGETABLE PROTEINS. By THOMAS B. OSBORNE, Ph.D., Research Chemist in the Connecticut Agricultural Experiment Station, New Haven, Connecticut; Research Associate of the Carnegie Institution of Washington, D.C. 3*s.* 6*d.* net.

THE SIMPLE CARBOHYDRATES AND THE GLUCOSIDES. By E. FRANKLAND ARMSTRONG, D.Sc., Ph.D., Associate of the City and Guilds of London Institute. 3*s.* 6*d.* net.

THE FATS. By J. B. LEATHES, D.Sc., Professor of Chemical Pathology in the University of Toronto. 4*s.* net. [*In the press.*

THE POLYSACCHARIDES. By ARTHUR R. LING, F.I.C. [*In preparation.*

COLLOIDS. By W. B. HARDY, M.A., F.R.S. [*In preparation.*

ALCOHOLIC FERMENTATION. By H. HARDEN, D.Sc., F.R.S. [*In preparation.*

H.—5,000—A. U. P.—X/1910.

Connections of Lumbo Dorsal Fascia

Trans. Fasc.

Peritoneum

10.5.69
SL.