

Catalogue of the anatomical and pathological preparations of Dr. William Hunter; prepared by J.H. Teacher.

Contributors

Hunterian Museum (University of Glasgow)
Teacher, John H. (John Hammond), 1869-1930
Royal College of Physicians of London

Publication/Creation

Glasgow : James MacLehose & Sons, 1900.

Persistent URL

<https://wellcomecollection.org/works/tjhyce9q>

Provider

Royal College of Physicians

License and attribution

This material has been provided by Royal College of Physicians, London. The original may be consulted at Royal College of Physicians, London.
Conditions of use: it is possible this item is protected by copyright and/or related rights. You are free to use this item in any way that is permitted by the copyright and related rights legislation that applies to your use. For other uses you need to obtain permission from the rights-holder(s).



Wellcome Collection
183 Euston Road
London NW1 2BE UK
T +44 (0)20 7611 8722
E library@wellcomecollection.org
<https://wellcomecollection.org>

Catalogue of the
Anatomical and Pathological
Preparations of
Dr. William Hunter


In the Hunterian Museum, University of Glasgow

By JOHN H. TEACHER


VOL. I

Glasgow
James MacLehose and Sons
Publishers to the University
1900

105. e.



Catalogue of the
Anatomical and Pathological Preparations
of Dr. William Hunter









PHILIP PIERCE.

ADAM, 1801.

William Hunter.





Catalogue of the
Anatomical and Pathological
Preparations of
Dr. William Hunter

In the Hunterian Museum, University of Glasgow

Catalogue prepared by
JOHN H. TEACHER, M.A., M.B., C.M.

and published at the cost of the
Bellahouston Trustees



VOL. I.



Glasgow
James MacLehose and Sons
Publishers to the University

ROYAL COLLEGE OF PHYSICIANS	
LIBRARY	
CLASS	61(569.538)
ACCN.	29119
SOURCE	
DATE	

GLASGOW : PRINTED AT THE UNIVERSITY PRESS
BY ROBERT MACLEHOSE AND CO.

When the Bellahouston Trustees offered a liberal contribution towards the better arrangement and cataloguing of the Hunterian Anatomical and Pathological Preparations, the University were fortunate in having one of its own graduates well qualified and willing to undertake the task. Dr. J. H. Teacher entered zealously on the work, and, carefully instructing himself as to the methods pursued in the Royal Colleges of Surgeons in Edinburgh and London, began the re-arrangement of the series. Under his direction the preparations were remounted, and the bones carefully exhibited in glass jars. It was not a light task, as will be seen from the numbers given in his Introduction; for he had not only to verify the brief description given in the earlier Catalogue, but he had to search for the many scattered references to the preparations in William Hunter's published writings and unpublished manuscripts.

How he has accomplished the work will be judged by those who visit the collection and compare it with the Catalogue. But I may be permitted to say that, having followed the work closely, I can bear testimony to the extreme care and scrupulous accuracy with which every specimen has been studied and shown to the best advantage. The chapters introductory to the various sections are a valuable contribution to the history of opinion, and a vindication of William Hunter's claims, too long neglected or misunderstood, to rank as an observer of high merit and a physiologist of remarkable perspicacity, as a leader in anatomical speculation, as he had been a pioneer in anatomical teaching.

The price at which the Catalogue is available to the students permits all to possess it, and thus to extend their anatomical and pathological knowledge by the study of the finest specimens illustrating the progress of Hunter's researches.

The merits of the Catalogue are Dr. Teacher's. If any errors are found, I must take the censure of overlooking them during the passage of the work through the press.

The microscopic specimens are preserved in the Museum, and are available for study by those desirous of learning all that may be known regarding the preparations from which they were taken.

A word is due to W. Kinghorn for the admirable manner in which, under Dr. Teacher's directions, he has done the work of remounting.

The Bellahouston Trustees have earned the gratitude of the University, and will, I hope and believe, have reason to be satisfied with the outcome of their wise liberality.

J. YOUNG,
Keeper.

*Hunterian Museum,
December, 1899.*

PREFACE.

DR. W. HUNTER in his will left it a charge to his trustees to prepare, or to cause to be prepared, catalogues of the whole museum, or to revise and complete such catalogues as had been already prepared or were in course of preparation. He had himself prepared a catalogue of the greater part of the anatomical and pathological collection; two copies of this were transmitted to Glasgow with the museum. These are in two thick folio volumes, for the most part neatly written in the same handwriting; the one "seems to be a literal transcript of the other, preserving faithfully the most palpable mistakes." The writer was a good penman, but not technically instructed; the text abounds in errors in the spelling of scientific terms, and even of common words. These errors are in many cases such as an ill-educated amanuensis might commit in writing to dictation; but there are others the work of an ignorant copyist. As many of these errors occur in both copies, it appears as if both had been copied from another MS.; indeed, earlier catalogues still exist in the museum. It seems, therefore, that this is the last edition of a work gradually compiled during the forty years occupied by the formation of the museum. There is no certainty as to who the amanuensis was.

The one volume is new and fresh both internally and externally; the other is old and worn by use. The older copy contains alterations and corrections of descriptions, and many additional descriptions interlined, all in Hunter's handwriting; apparently it was the copy used by Dr. Hunter himself. The interlined descriptions have been added to the newer copy by being written on slips of paper and pasted in at their proper places; the handwriting of these slips has not been identified. The corrections in the matter of the text are not numerous; of merely clerical errors there are no corrections in

either copy. The correctness of additions made by Hunter contrasts strongly with the incorrectness of the parts written by the amanuensis. In the newer-looking copy there are twenty-seven descriptions which are not given in the other. These are in the writing of the amanuensis. Hunter's interlineations contain one date—in the description of preparation CC. 106*a* (now No. 45.75)—“from a woman in the dissecting-room, 1782.” The description of preparation P.23 (now No. 35.18) bears the words “beautiful 1777: yellow fades apace 1778.” A group of specimens, O.42*a* (No. 33.46) and the following, is headed “added 1779.” Also DD.14 was “Cut off, 1780”; these descriptions, in the handwriting of the amanuensis, are in their proper places, and continuous with the rest of the text. The bulk of the MS. was, therefore, prepared between 1778 and 1782, and the corrections and additions presumably were continued up to Hunter's death on March 30th, 1783; there are none of later date. The MS. catalogue was clearly the work of William Hunter, and has been made use of as his in the preparation of the present catalogue. Others seem to have contributed to it, no doubt under his supervision. There are descriptions in the first person singular which may be referred to Hunter; others which speak of “Dr. Hunter” were the work of those whose aid he obtained.

The University authorities did not at first print the MS. The general guide to the museum prepared in 1813 by Captain Laskey probably delayed action. But in this only a few descriptions are quoted in full from the MS., and other preparations are referred to briefly; for medical students it was of small utility.

In 1841 a catalogue in 290 closely-printed 8vo pages was printed by George Richardson, then University printer. The certificate by Dr. Hunter's trustees, copied from the title-page of one of the MSS., prefixed is as follows:—

“The following catalogue is, to the best of our knowledge and belief, a true catalogue of the Anatomical Preparations left by the late Dr. William Hunter.

G. FORDYCE.

DAVID PITCAIRN.

W. COMBE.”¹

There is no indication who supervised the printing of this volume, but its relation to the original MSS. is set forth in the “Advertise-

¹ Should be Charles Combe, but the signature “Ch” might easily be read “W.”

ment" as follows: "The catalogue of the Anatomical Preparations in the Hunterian Museum, now published for the use of the medical students of the University and of scientific visitors, comprises all the Wet Preparations at present in the collection, and many of the Dry Preparations; but the great majority of the latter not being exhibited, chiefly from want of room and of suitable cabinets, it has been deemed superfluous in the meantime to publish a description of them.

"The catalogue has been printed from one of the two manuscript catalogues transmitted to the University by the trustees of Dr. Hunter.

"These catalogues abound with errors of every kind, rendering the descriptions obscure and sometimes quite unintelligible. In rectifying these errors the collation of the manuscript catalogues was, for the most part, of little use, as the one seems to be a literal transcript of the other, preserving faithfully the most palpable mistakes. A careful comparison of the preparations themselves, with the descriptions given of them, was found to be the only means by which the true meaning could be ascertained. Wherever it was possible the exact words of the original have been retained. Most frequently an alteration in the structure of the sentences was sufficient to restore the sense, but in many instances a change in the words themselves was quite indispensable. In such cases, if any doubt remained as to the true meaning, a reference has been given to the MSS., or a note of interrogation added; or if any interpolation had been required, the interpolated words are included within brackets.

"There are many preparations in the collection of which no description is given in either of the manuscript catalogues. Of some of these a short description has been supplied. They are all marked as "not described," although there can be no doubt that a more careful examination will serve to identify many of them with preparations now supposed to be amissing.

"As many of the casts included in the section RR. correspond exactly to plates in Dr. Hunter's *Anatomy of the Gravid Uterus*, and very imperfectly or not at all to any of the descriptions in the manuscript catalogues, it has been deemed advisable to substitute for the latter the descriptions given in the published work, indicating at the same time the plates to which the casts appear to correspond. A similar reference has also been given to the only wet preparation delineated in the same work. It has been

judiciously suggested that references should likewise be given to the plates published by Dr. Baillie, of which upwards of a hundred are taken from the preparations in the Hunterian collection, but this suggestion came too late to be acted upon on the present occasion.

"It is only necessary to remark further that several sections of the catalogue were printed at an earlier period than the rest of it, and, with the exception of the mere correction of the press, under different superintendence. The important labour of determining the correspondence between the several preparations included in these sections, and the descriptions put into the hands of the printer not having been performed with a sufficient degree of care, some preparations have been wrong described and others not described at all, while some descriptions have been printed to which no preparation corresponds. These errors, which must prove embarrassing to the student, were, unfortunately, not discovered till the press was too far advanced to admit of their being corrected. Of these, therefore, and of any similar errors which, notwithstanding the care with which they have been guarded against, may be found in the succeeding sections, the correction must be reserved for the next edition of the catalogue.—Glasgow College, 1st November, 1841."

The volume is a faithful reproduction of the MSS., the descriptions of missing preparations being omitted. The corrections and alterations are not extensive, and the editing seems to have been chiefly concerned with spelling and punctuation: whoever did it, there was not much trouble taken; there are very few additions; of the few references to Hunter's published works the only one to a wet preparation is wrong.

The volume was sold at a shilling, and constituted a sort of perpetual admission ticket to the museum.

Examination of the MSS. shows that they had been checked with the preparations twice—(1) probably when the trustees handed them over to Baillie and Cruikshank, who, under Hunter's will, had the use of the museum for thirty years before it came to Glasgow, and (2) when the printed catalogue was made: at the former date nearly all the preparations were present.

Naturally the first step in the recataloguing and overhauling of the collection was to investigate thoroughly its condition, and find out what required to be done. This implied the determination of the presence or absence of all preparations described in the catalogue,

their condition, their correspondence with the old descriptions and consideration of how far these were adequate, and whether or no the arrangement of the collection was satisfactory. To effect this two copies of the printed catalogue were taken, cut up, and the separated descriptions pasted on sheets. Each preparation was then examined individually, so far as could be done without opening the jars, and compared with its old description, and notes made on the sheets as found necessary; these sheets were again checked at later stages of the work. These papers, with various general statements and tables which were prepared, are preserved in the museum, and form a full and accurate record of the condition of the collection in 1894.

The author of the new catalogue also visited London to study what had been done by the Royal College of Surgeons with the very similar collection of John Hunter. He has here much pleasure in acknowledging the extreme courtesy and kindness of the conservator and other officials of the College, and recording his appreciation of the trouble they took to give him all information, not to speak of practical instruction, which seemed likely to be of use to him in his work. The museums of Guy's, St. Bartholomew's, and St. George's Hospitals, and of Cambridge University, were also visited.

The collection consisted in 1894 of (1) 2607 jar preparations, of which 2250 are mounted in spirit, 254 in turpentine, and 103 dry; (2) 19 large plaster of Paris casts; (3) 410 dry bones illustrating injuries and diseases of bone; and (4) 348 calculi and concretions, all of which were supposed to be Hunterian. Only the jar preparations and the casts were catalogued individually. In regard to the diseased dry bones the MSS. contain the following:—"The collection of diseased bones is so extensive that it would require nearly as much time and labour to describe each bone particularly as has been bestowed on all the other parts of the catalogue taken together. We shall not therefore attempt it, but mention only the number of specimens and general circumstances, so as to be able to ascertain sufficiently to Glasgow this part of the Collection." Then follows an enumeration of the specimens interspersed with a number of general observations, few of which could be brought into relation with any particular specimen. All of this was reproduced without comment, additions, or omissions in the old printed catalogue. The calculi and concretions were dealt with in like manner.

The jar preparations and casts were arranged on shelves in the order of the old catalogue; the dry bones were stored in a large

glazed case, and were not available for examination by visitors, and the calculi and concretions were classified and displayed in two large show-cases, where they still remain.

There were also in the same room, but kept apart from the Hunterian preparations, some hundreds of jar specimens, a number of which, chiefly monstrosities, belong to the present Keeper, about 100 came from the collection of the late Professor Allen Thomson, and the remainder from the collection of his predecessor, Professor Jeffray. There was no catalogue of these specimens, but there were notes on some of the jars. They were carefully examined, and the best of them incorporated with the Hunterian collection; but they are carefully distinguished from it both on the jars and in the catalogue.

He who undertakes the overhauling and recataloguing of an old anatomical collection, especially one of such historical interest as that of William Hunter, has a difficult and delicate task. As to the handling of specimens the difficulty is less, for there is no reason why, with proper care, and taking advantage of the experience of other museums, any harm should come to the preparations by taking them out for examination and remounting them.

But in the recataloguing, which in this case meant so great additions and so much rearrangement that this is rather a new catalogue than a second edition of the old one, there is more room for hesitation, more opportunity for error. On the one hand the words of the maker of the specimens are entitled to respect as such; and, on the other hand, it cannot be denied that descriptions written more than a hundred years ago may have become somewhat unintelligible, especially if they contain references to physiological or pathological theories which have been modified or abandoned. The specimens *are not* out of date; the old descriptions may be. But such descriptions may possess a historical interest. Also the description written by the man who made the preparation is apt to be truer than that written by a stranger. As might be anticipated from the accuracy and scientific caution which characterize the published works of William Hunter, very few of the descriptions in the MSS., judged by the standard of our present knowledge, can be said to contain actual errors; but many are obscure, and many more are insufficient. In many parts the old catalogue is a mere list, and not descriptive. In a few cases the statements in the catalogue appear contradictory to the published opinions of William Hunter; this, as a rule, turns out to be the fault of the obscurity of the descriptions in the catalogue, which are then naturally passed over in favour of

what appears in his published works. Wherever it was possible to retain the old description it has been retained, and explanations and amplifications added to it if thought necessary. All such extracts appear as quotations, with the following exception—names of the animals from which the specimens were obtained were always taken from the old catalogue; so invariable was this rule that it was deemed unnecessary to indicate that fact by quotation marks. It is to be understood that all quotations in the descriptions of Hunterian specimens, unless the contrary be specified, are taken from the old catalogue. In addition, many of the new descriptions are really paraphrases of old ones, which were neither sufficiently clear to be satisfactory for quotation, nor of such importance that they absolutely required it; this, of course, is not in any way indicated, but can easily be ascertained by reference to the old catalogue, either MS. or printed. In the very few instances in which, from examination of the specimen, a doubt was felt as to the correctness of the statement in the old catalogue, a note to that effect was made in the new description. It is hoped that in this way all that was valuable in the old catalogue has been transferred to the new one.

There are also many quotations which are not from the old catalogue. The references to the sources of these are given along with them, and a table of the principal works referred to is given at the end of the book. All the published writings of William Hunter, unpublished papers in the museum, students' notes of his lectures, the works of John Hunter, Hewson, Cruikshank, Matthew Baillie, numerous contemporary papers in the *Transactions of the Royal Society* and elsewhere, especially in six volumes entitled *Medical Observations and Inquiries*, by a Society of Physicians in London, of which William Hunter was a leading member, were searched for references to specimens in the museum. In this way a number of valuable descriptions and clinical histories were obtained. The specimens were identified sometimes from descriptions, sometimes from plates. The greatest care was taken to ensure accuracy, no record being accepted except on the very strongest evidence that it applied to the specimen under consideration. Further, apart from identification of actual preparations, passages which seemed to apply well to certain preparations or groups of preparations were freely quoted from the works of William Hunter. These add greatly not only to the interest of the catalogue, but also to its clearness and instructiveness. It is believed that the new catalogue will therefore be found to give really a much better and fairer

impression of the opinions of William Hunter, and of the extent and wonderful accuracy of his knowledge, than the old one. The connection of the collection with these works is discussed in the Introduction.

In the arrangement of the collection great changes have been made. The old catalogue of the jar preparations was divided into 42 series, each named with a letter of the alphabet (series A, series B, etc., and after series Z, series AA, series BB, etc.), and the numbers of the specimens began afresh with each series. Each series contained specimens illustrating both normal and pathological anatomy—usually the anatomical ones first and then the pathological, but frequently they were mixed up together. A few of the series were arranged somewhat after the order in which the subjects they illustrate were treated in William Hunter's lectures or published papers: but even these required rearrangement. The division into series also, though on an anatomical basis, was not satisfactory. It was therefore decided to make a completely new arrangement, the only part of the old plan which was retained being the recommencement of the numbers with each series.

In the first place the anatomical preparations were separated from the pathological. Then a division of them into classes was made on the usual physiological basis, *e.g.* Class I., *The Skeleton and Organs of Motion*; Class II., *The Circulatory System*, and so on, as will be seen in the table of contents. Each class was then divided on the same principles into a number of series, and corresponding to each anatomical series there was formed a pathological series, which was placed immediately after it. There are a few exceptions to this rule of alternate series, *e.g.* where from the large number of morbid specimens of bones two series were made—(1) *Injuries* and (2) *Diseases of Bones*; and where there was no pathological series to correspond, *e.g.*, to the series *Glands* and series "*Incubated Egg*". From the small number of specimens available in some of the classes the subdivision into series has not been carried very far—not nearly so far as in the great collection of the Royal College of Surgeons of England—and no general pathological series has been made. It is impossible in any arrangement to avoid the overlapping of series, or to avoid separating preparations which on various grounds it would be advisable to keep together. To obviate the inconvenience arising from these causes, numerous cross references have been given under the descriptions of specimens which it is desirable to compare with others in other parts of the collection.

For the internal order of the anatomical series a standard text book of anatomy, viz. Gray's, was taken, and the preparations arranged to illustrate it, so far as they are capable of doing so. This arrangement agrees very well with the way in which the subject is treated in William Hunter's Lectures, which, indeed, as the prototype of modern courses of anatomy in Britain, are probably the germ out of which the modern text-book of anatomy has developed.

The plan of arrangement of the pathological series is substantially that which Mr. Charles W. Cathcart, F.R.C.S.E., has described and applied in the first volume of the *Catalogue of the Museum of the Royal College of Surgeons of Edinburgh*. The specimens in each series are arranged in five groups, with headings, as follows :

- I. Congenital Abnormalities.
- II. Injuries.
- III. Preparations illustrating alterations due to conditions, local or general, affecting Nutrition.
- IV. Changes due to Inflammatory Diseases.
- V. Tumours.

Speaking generally, this plan was found to produce a satisfactory basis for arranging every series except *Internal Parasites*, *Monstrosities*, *Calculi and Concretions*, and part of the series dealing with *Pathological Conditions complicating Pregnancy*. The scheme of arrangement is given in full in the table of contents which appears at the beginning of each series, and is indicated right through the series, the beginning of each group being indicated by its Roman numeral and heading in capital letters. To this there are a few exceptions—series in which there were so few specimens that it was not detailed. Perhaps, with a view to the growth of the collection, this may be a defect in the catalogue, but as the scheme is implied in the order of these series it will probably be as easy to find the proper place for new specimens in them as it will certainly be in those in which the scheme is given at length. It was considered advisable to divide one or two of the series into sections, *e.g.* Series 11, *Diseases of the Heart and Blood-Vessels*, which was divided into Section I., *Heart and Pericardium*, and Section II., *Arteries and Veins*; and each section was arranged according to the usual plan. The specimens were too few to make two separate series.

Group I. comprises all those minor defects and malformations of congenital origin which are so limited in extent as not to warrant placing the subject of them in the category of a monstrosity.

Group II., *Injuries*, requires little explanation. Operation wounds, the phenomena of repair of injuries, and the results of operation would as a rule be included in this group. Some of the complications of injuries and operations, however, such as the results of septic infection (*e.g.* osteomyelitis following amputation), are preferably placed in Group IV. as results of inflammatory disease; also, in Series 9, *Injuries and Diseases of Limbs as a whole*, a special group has been made apart from injuries to illustrate the anatomy of stumps and the results of excision of joints.

Group III. is more difficult to define. Such conditions as atrophy from old age, disuse, or cutting off of nerve supply; or as hypertrophy from increased muscular exertion, such as the hypertrophy of the heart in renal disease, fall naturally into the group of "alterations due to local or general affections of nutrition." So also do the degenerations, such as amyloid disease, calcareous infiltration of arteries, osteomalakia, etc. But besides such conditions the group has had to be extended and made to serve as a convenient receptacle for specimens relating to diseases regarding which it must be said that the cause of them is obscure, and that they cannot in the present state of our knowledge be placed in either Group IV. or Group V.; *e.g.* hypertrophy of the prostate, rickets and atheroma.

In defining Group IV., *Changes due to Inflammatory Disease*, the difficulty is the difficulty of defining inflammatory disease. The solution of it is thus expressed by Mr. Cathcart:—¹"The view of inflammation which underlies the classification here adopted, is that enunciated by Lister ² in 1858, and emphasized afterwards by Cohnheim, Burdon Sanderson, and others, namely, that inflammation is not so much a disease in itself as a consequence of interference with the vitality of the tissues. Causation of inflammation has therefore been chosen as the basis of primary subdivision, and the modes of interference with vitality, or causes of inflammation are thus the distinguishing features of the larger groups. Although it is difficult to conceive how much we may still have to learn on this subject, the knowledge acquired in recent years seems sufficient to justify the plan adopted, even should it require to be afterwards modified. As it stands this plan carries with it at least two distinct advantages. Museum specimens are by its means arranged in accordance with present clinical and pathological knowledge. This is obvious, but in addition the confusion which has so frequently arisen from a 'cross classifica-

¹ *Catalogue of the Museum of the R. C. S. (Ed.)*, vol. i., preface, p. x.

² *Philosophical Transactions*, 1858.

tion' has been avoided. Such headings as 'Necrosis,' 'Periostitis,' and 'Syphilis,' are commonly used as co-ordinate yet distinct subdivisions of bone disease; but as the first indicates result, the second locality, and the third causation, the groups are not mutually exclusive, and uncertainty and confusion are the necessary consequence." Result and locality have been used in a few instances as secondary means of subdivision within the larger groups formed upon the basis of causation where specimens happened to be numerous, as under diseases of bones and diseases of joints. The group, then, includes all changes the result of reaction against irritants, except the direct results of violence, gross foreign bodies, or poisons; it includes therefore specimens from the specific fevers, suppurative diseases, and the specific new formations such as tuberculosis and syphilis.

Group V. has been split up into the clinical divisions, Innocent Tumours and Malignant Tumours; and then further subdivided principally according to the microscopic structure. The clinical histories, where any at all was available, were of the briefest description, and rarely of much assistance in forming a diagnosis. The microscopic examination, as might well be expected from the age of the specimens, was often unsatisfactory. In some cases it was necessary to fall back on the naked eye appearances and the statement of the old catalogue as to the nature of the tumour. On the whole, it is surprising how much light the microscopic examination of specimens which have been from 150 to 120 years in spirit was able to give as to their nature. The results of these examinations were entered in a note-book, which is referred to in the catalogue as "MS. Notes, J. H. T."

The specimens within the groups are arranged in the natural order of the sequence of events; first the early stages of the affection, then the more advanced, and lastly the processes of repair. As in the old arrangement, wet and dry specimens are not separated from one another. Each specimen is designated by its series number and its number within the series, the former appearing first in large black type, and the latter immediately after it in a smaller type; and following that each specimen is provided with a title in bold type indicating briefly the nature of the specimen and the principal points, anatomical or pathological, which it illustrates, after the plan of the late Sir George Murray Humphry's *Catalogue of the Cambridge University Museum*, which is now being adopted in so many other museums. Then follows in small type an indication of its source;

in the case of the Hunterian specimens the word "Hunterian," with the old series letter and the number in the series (or simply "Hunterian" for the uncatalogued specimens), and in the case of others the name of the donor and the date, or "Jeffray Collection," or "From Dr. Allen Thomson's Collection," as the case might be. The old Hunterian numbers, fortunately, were cut on the jars with a diamond; this excellent means of ensuring their survival has been continued wherever a broken or unsuitable jar has had to be replaced, by cutting it on the new jar; but the new numbers are not so attached. After the title comes the description of the specimen, commencing with a brief statement of what it is and how it has been prepared and mounted. The majority of the specimens are mounted in 10 O.P. spirit (methyated but non-mineralized); therefore where the nature of the mountant is not specified, this is to be understood as the medium. The description or clinical history follows, without the distinction of a new paragraph. The history, where there happens to be any, is placed before the description; last of all follow any remarks which may have appeared to the author to be necessary or desirable. Where no clinical history is given it is to be understood that none was available to the author of the present catalogue. In some parts of the collection there were a considerable number of specimens which, either from deterioration through time or from original defects, were unsatisfactory, and it was considered that the series would be clearer and easier to study without these. They were therefore weeded out, and carefully laid aside lest at any time they should be wanted again.

In addition to the cataloguing there was the overhauling of the collection. Considering how long a time has elapsed since the collection was formed it is surprising in what good preservation most of the preparations are. It shows that wet preparations well mounted and sealed are practically everlasting. Many of them, however, obviously required remounting, and many others, which appeared to be in good order, turned out on close investigation to be in an unsatisfactory condition; many, of course, required to be taken out of the jars for examination. It was therefore judged necessary, though it was a very large and very serious piece of work, to overhaul and remount the whole. This has been done, except in the case of a few, which having perfect covers and clear spirit, or being peculiarly delicate objects to interfere with, it was deemed well to let alone in the meantime. These remain to-day as Hunter left them; they are interesting mementoes of the old style of mounting.

The remounting has greatly improved the appearance of the preparations, and accidents, even of the most trifling description, were very few indeed. Experiments were made on specimens which there was reason to fear were spoilt beyond redemption, but it was marvellous how some dim and dirty specimens revived in the fresh spirit, and proved to be beautiful injections well worth exhibition.

Besides the additions from the old collections already mentioned, a number of valuable and interesting preparations have been received from practitioners, which help to fill the gaps in the series. These are acknowledged by the donor's name being set down beside the title of the specimen. Not the least valuable feature of these new specimens is that the donors have kindly furnished histories of them. It is to be hoped that the good practice of presenting interesting preparations (both anatomical and pathological) to the museum will be continued; gaps are shown here and there in the catalogue which invite contributions of this kind.

The compilation of the whole catalogue was supervised by Professor Young. In the earlier part of the work the late Professor Coats was frequently consulted about specimens, but his illness unfortunately deprived the latter parts of the catalogue of this assistance.



INTRODUCTION.

A CATALOGUE of that part of the Museum of Dr. William Hunter, which more than any other was the work of his own hands, would be incomplete did it not contain some account of its origin and growth, of the purposes for which it was used by its maker, and of the circumstances under which it came into the possession of the University of Glasgow. The intrinsic value and interest of the collection are very great, and it is, moreover, of very high interest historically from the fame of its founder, and its relationship to one of the greatest movements in the history of the medical profession in England.

The fame of William Hunter is firmly established, yet it has not always been rightly appreciated on what that fame rests. The tendency has been to remember only one side of his work. William Hunter is generally known in the medical profession as an obstetrician. According to the late Dr. Matthews Duncan, he "certainly was one of the greatest that has ever flourished in this country or in any other." He was celebrated as a teacher of midwifery and a reformer of the practice of midwifery, and his name has been kept "constantly before the profession as the founder of the science of obstetrics" by his great work, *The Anatomy of the Human Gravid Uterus, Exhibited in Figures*. That he has other claims upon the admiration and gratitude of posterity has not been so well remembered. His scientific work was in reality almost entirely on anatomical lines even in obstetrics. As Dr. Matthews Duncan has well said, "We know from his own mouth that it was as an anatomist that he claimed eminence and expected fame; and although his reputation has latterly become too exclusively obstetrical, it has not even in this respect been too highly exalted. Yet it is necessary, with a view to justice, to point out that his

obstetrical fame is chiefly anatomical, and that his greatest claim on our admiration and gratitude arises from his anatomical work and influence."¹

Of William Hunter's printed works undoubtedly the most important is the one already alluded to. It embodies his greatest discoveries; it has been characterized by Waldeyer,² so lately as 1886, as containing "the foundations of our present knowledge of the anatomical relations of the membranes and the gravid uterus"; it is still the foremost work of its kind in this department of anatomy; compared with it his other works are of minor consequence, yet they make contributions to anatomy, physiology, and pathology, as well as to the practice of medicine and surgery that would of themselves have given him a very considerable reputation. Further, he was the founder, the organizer, in every way the leading figure of the school of anatomy of which Sir Charles Bell wrote in 1812,³ the school "founded by the Hunters has made all the anatomists of the present day at home and abroad." It was through this school of anatomy even more than through his writings that his great influence made itself felt.

In 1828, the condition of anatomy in Britain at that time and previously, especially as to the difficulty—"whether arising out of the state of the law or an adverse feeling on the part of the people"—of obtaining subjects for dissection, the manner in which they were obtained, and "the evil consequences thence ensuing as well to the sciences of medicine and surgery as to all who study, teach, and practise them, and eventually to the members of the whole community," was the subject of an enquiry by a select committee of the House of Commons;⁴ and the evidence taken by that committee and the report which they issued are the most reliable sources of information regarding these matters.

The importance of anatomy and the principle that the government of this country ought to protect anatomists and supply materials for the teaching of it, were recognized by a statute of Henry VIII.; but long before the beginning of the eighteenth century the provisions

¹ Harveian Oration, by Dr. Matthews Duncan, *Edinburgh Medical Journal*, No. cclii., June, 1876, p. 1070.

² *Biographisches Lexikon der Aertzte*, Gurlt and Hirsch, Vienna and Leipzig, 1886, s.v. William Hunter.

³ *Letters of Sir Charles Bell*, p. 197, 8vo, London, 1870.

⁴ Report from the Select Committee on Anatomy, 1828, printed for the House of Commons.

of that statute, though slightly amplified by Acts of Elizabeth and James I., had become wholly insufficient owing to the progress of the science. These statutes granted to certain medical corporations for dissection a few bodies of criminals who had been executed, and gave protection to the demonstrations which were given upon these bodies to the members of the corporations and their apprentices. But these "public anatomies" were not sufficient for those members of the profession who properly appreciated the value of anatomical knowledge and desired to improve it, and consequently "private anatomies" were held, the material for which had to be obtained by the anatomist as best he could. The "private anatomies" at first were objected to by the corporations, who were jealous of any infringement of their legal rights, but gradually they came to be tolerated, and early in the eighteenth century had developed into somewhat imperfect courses of public lectures by private teachers. How imperfect they were may be learnt from William Hunter's *Introductory Lectures*,¹ and from various other sources. The only course which Hunter attended in London, "which was by far the most reputable that was given here," was that of Dr. Frank Nicholls, who "professed to teach anatomy, physiology, and the general principles of pathology and midwifery in thirty-nine lectures"; and "Mr. Nourse of St. Bartholomew's embraced *totam rem anatomicam* in twenty-three lectures."² Nicholls used only two bodies in his course. Of dissection by the students there was hardly any, since the lecturers could with difficulty procure only as many bodies as were absolutely necessary for the public demonstrations of the principal and well-known parts of the body. "Hence it is that the students never learn the practical part, and therefore never become anatomists; and the teachers themselves can hardly make improvements, because they cannot have subjects for private experiments and enquiries."

On the continent the position of anatomy was far better, as bodies for dissection were legally provided; and the facilities which English students found abroad, and the great advances which they saw had been made in consequence thereof, had also stimulated the

¹ "*Introductory Lectures*, delivered by Dr. William Hunter, to his last Course of Anatomical Lectures, at his Theatre in Windmill Street: as they were left corrected for the press by himself." Published by his Trustees. London, 4to, 1784.

² Ottery's *Life of John Hunter*, p. 4, Palmer's Edition of *Hunter's Works*, vol. i., London, 8vo, 1835.

taste for anatomy and the desire for better opportunities of prosecuting it at home.

To quote the report of the Select Committee,¹ "The reformation of this antiquated and imperfect system took place, in this country, in the year 1746, when Dr. William Hunter, having a singular enthusiasm for the science, established complete courses of anatomical lectures, and opened a regular school for dissection. The reform thus introduced was complete, and its author exulted before his death in having raised and diffused such a spirit for dissection that he should leave behind him many better anatomists than himself." Hunter's course extended over four months, and consisted of about a hundred meetings. "Some people," he said in 1783, "thought even my former courses too long; why? they had been used to see a course of anatomy finished in thirty or forty lectures; and therefore imagined that, when it took up nearly four months, it must be unnecessarily minute and prolix. But let them reflect how imperfect such courses were; let them recollect that they never saw the human brain or nerves, nor the human lymphatic system, nor the gravid uterus and its contents; let them recollect that there were few parts of the body which they understood thoroughly after attending even repeated courses of this kind, and then they will see that there was great room for improvement, and own that an opportunity of attending a more complete course of anatomical lectures must be a national advantage."² However it may have been before, it is certain that Hunter now managed to provide ample material for the practice of dissection by his students.³

The immediate consequences of this reformation of the teaching of anatomy were vast improvements in all branches of medical science and practice and the creation of such an enthusiasm for practical anatomy, and of such an appreciation of its value, that it came to be recognized by the authorities entrusted with the conferring of diplomas as an indispensable part of medical education, and to be practised on such a scale by "his immediate pupils and their successors" that Government was forced to legislate further for its regulation and protection. The Anatomy Act of 1832, which followed the report of the Select Committee, and under which, with but little modification, anatomists now work, may be fairly regarded

¹ Report from the Select Committee on Anatomy: *vide ante*.

² *Introd. Lectures*, p. 100.

³ In 1756 William Hunter had about 100 students (*Supplement to Medical Commentaries*, p. 20). How many he had later is not known.

as the result in a great measure of Hunter's devotion to the science and singular success in teaching it, and infusing his pupils with his own ardour for it. In a work of Dr. Matthew Baillie,¹ which is quoted with approval in the evidence taken by the Committee, it is written that "if anatomy be more generally or more perfectly known; if surgery has received any improvements from it, it is to be attributed in a great measure to the spirit of this single man": and Baillie did no more than voice the general feeling of men of science in his day.²

It was in connection with his school of anatomy that the museum which William Hunter bequeathed to Glasgow University originated. William Hunter's connection with Glasgow was a close one. His father was the proprietor and tenant of the farm of Long Calderwood, near East Kilbride (about eight miles by road from Glasgow Cross), and his mother was the daughter of Mr. John Paul, the treasurer of the city of Glasgow. William, their seventh child, was born at Long Calderwood on the 23rd of May, 1718. At the age of thirteen and a half he became a student in the Faculty of Arts in Glasgow University, obtained a bursary, and studied for five years. "His father had designed him for the Church, but the idea of subscribing to articles of faith was so repugnant to the liberal mode of thinking that he had already adopted, that he felt an insuperable aversion to theological pursuits. In this state of mind he happened

¹ *Lectures and Observations on Medicine*, 8vo, London, 1825, p. 71.

² America is also particularly indebted to William Hunter, as is shown by the following extract from a letter which is preserved in the Museum. It is addressed to Dr. Hunter, physician-extraordinary to Her Majesty, London, by W. Shippen, Jun., from Philadelphia, under date Nov. 5th, 1765:—"I am much pleased to hear you still continue to bless mankind by your very entertaining and improving lectures; to them I am indebted for the small attainments I have made in anatomy, and the credit I gain in that way in the American world; am now preparing for my fourth course of anatomy, Dr. Morgan for his first course of materia medica. We have introduced the study of [word torn away] into our college, and hope every day to see our plan extended, and who knows but it may be even a college of physic? Such a hope would raise the jealousy of some teachers of medicine in Brittain (*sic*), but I know your benevolent heart too well to doubt of your being pleased to hear that divine science was cultivated in this and every part of the world. I am sure, too, you will be particularly pleased to know that your own sons are engaged in the glorious attempt in America; may the genius of Hunter be ever with us to ensure success." William Shippen was one of the founders of the University of Pennsylvania; his course of anatomy was the first ever given in Philadelphia.

to become acquainted with Dr. Cullen, the present [1783] celebrated professor at Edinburgh, who was then [1736] just established in practice at Hamilton, under the patronage of the Duke of Hamilton. Dr. Cullen's conversation soon determined him to lay aside all thoughts of the Church and devote himself to the profession of physic."¹

In 1737 he went to reside with Cullen at Hamilton, to assist him in his practice, more probably as apprentice than as partner, since Cullen was considerably his senior, and had already been qualified, as qualification went then, for several years before he started practice there.² With him Hunter spent three years, which he afterwards described as the happiest in his life, commencing his medical education in what was then the usual way. In November, 1740, with a view to completing his education, he proceeded to Edinburgh, where, besides other studies, he attended the anatomy course of the first Alexander Monro; and in the summer of 1741 went on by sea to London, provided with letters of introduction to a number of Scotsmen settled there, among whom were Smellie and James Douglas. At that time there was certainly an understanding that he should return to Hamilton and enter into partnership with Cullen,

¹ From *An Account of the Life and Writings of the Late William Hunter, M.D., etc.*, by Samuel Foart Simmons, M.D., F.R.S., p. 2. London, 8vo, 1783.

² The above statement requires explanation. Cullen, in point of fact, had no medical qualification till 1740. He attended Arts classes in the University of Glasgow, and served an apprenticeship to Mr. John Paisley, an active member of the Faculty of Physicians and Surgeons of Glasgow, in that city before the year 1729. Towards the end of that year he went to London, where, after an examination (held by what body is not known to the writer), he obtained an appointment as surgeon on a merchant ship during a voyage to the West Indies. About the beginning of 1732 he returned to Scotland, and practised near Shotts for two years. During the winter sessions of 1734-35 and 1735-36 he attended medical classes at the University of Edinburgh. In 1736 he settled in practice in Hamilton, putting himself thereby within the territorial jurisdiction of the Faculty of Physicians and Surgeons of Glasgow. In the same year he underwent a part of his examination for admission as a member of that Corporation, but it would appear that he did not submit himself for the remaining part. In September, 1740, he received the degree of Doctor of Medicine from the University of Glasgow, and in 1744 he presented his diploma as Doctor to the Faculty of Physicians and Surgeons, whereupon he was admitted as a "freeman member of the Faculty." He was elected *Praeses* of that Corporation in 1747, and was continued in that office during the following year. It is evident that the reason why he did not complete his examination in the Faculty was his intention to enter it as a physician by presentation of his University diploma, to obtain which he was doubtless then making preparations. Compare note 2 on p. xxvii.

Hunter to take up the surgical part of the work, while Cullen devoted himself to the medical part. But he very early abandoned that idea. For a few weeks he resided with Smellie, who had reached London about two years earlier, and then Dr. James Douglas took him into his family as tutor to his son, and "as an assistant in his dissection room and in the surgery."¹ Douglas became much attached to his clever young assistant, and his kind offers of help appear to have been the principal influence that turned Hunter from his earlier plans, and led him to seek a career in London. The change did not interfere with his friendship with Cullen, who, it seems probable, already had it in his own mind to seek a wider sphere for his energies in Glasgow, into which he moved in 1744. The correspondence published in Thomson's *Life of Cullen* shows how intimate this life-long friendship was, and the high regard they had for one another.²

James Douglas was one of the leading practitioners of midwifery in London, and one of the most accomplished anatomists of the day. He is alluded to in Freind's *History of Physick* as "the first who has given us any true idea of the peritoneum." His name is always associated with it as the first describer of "Douglas's pouch." When Hunter came to him he was engaged upon the preparation of an atlas of the anatomy of the bones, the copper plates for which, to the number of 68, were finished before his death. The work was never published; the plates and a volume of proofs are preserved in the Hunterian Museum. It would have been a valuable addition to the literature of osteology.

While with Douglas, Hunter was also studying surgery in St.

¹ The intimacy of Hunter's relations with Douglas and his family is shown in the letters published in Mr. Stephen Paget's recent *Life of John Hunter* (Masters of Medicine Series: London, 1897). Latterly he seems to have acted as a sort of guardian to the family. The last survivor of them died in 1755; *vide* Simmons, *op. cit.*, p. 8. Douglas's papers, drawings, and plates passed into Hunter's possession, and are preserved in the Hunterian Museum.

² *Life of Cullen*, by John Thomson, M.D., Edinburgh and London, 1832 and 1859, 2 vols., 8vo. Cullen may be regarded as the real founder of the Glasgow School of Medicine. The University of Glasgow had the power of conferring medical degrees long before Cullen's time, but the existence of the medical school as a teaching institution was little more than nominal till his appointment to the chair of medicine in 1747. *Vide Memorials of the Faculty of Physicians and Surgeons of Glasgow*, by Alex. Duncan, B.A., LL.D., Librarian to the Faculty, 1896; and the *University of Glasgow, Old and New*, by Professor Stewart, D.D., 1891.

George's Hospital under Dr. James Wilkie, and anatomy under Dr. Frank Nicholls. He also attended "a course of lectures on experimental philosophy by Dr. Desaguliers." "Of these means of improvement he did not fail to make a proper use. He soon became expert in dissection, and Dr. Douglas was at the expense of having several of his preparations engraved. But before many months had elapsed he had the misfortune to lose this excellent friend." "Dr. Douglas died on the first of April, 1742, in his 67th year, leaving a widow and two children." "This event, the probability of which his father had pointed out to him, does not seem to have retarded his progress. Such a loss, and at so critical a period, would probably have destroyed the hopes of a man of less abilities and industry than he possessed. But he seems by this time to have had a consciousness of the superiority of his talents, and he who feels himself equal to great things will not easily be dismayed."¹ He continued working as hard as ever, and in 1743 his first paper, "Of the Structure and Diseases of Articulating Cartilages, by William Hunter, Surgeon," appeared in the *Transactions of the Royal Society*.² The paper is a very interesting one, and was a solid contribution to the knowledge not only of the anatomy but also of the pathology of the joints; it and the fine series of preparations on which it was founded, show that already he was a competent anatomist and a skilful dissector and injector. In accordance with the last wishes of James Douglas, Hunter continued to live with the family and to act as tutor to the son, who was supposed to be studying medicine, and in 1743 accompanied him to Paris for further study. Young Douglas was very dissipated, and would do nothing, but Hunter himself made good use of his opportunities. An interesting memento of this tour—a manuscript in Hunter's writing—is preserved in the museum, it is entitled, "An Abstract of the most remarkable things in Mr. Ferrein's course of Anatomical Lectures, read in 1743-1744." Ferrein was anatomist in the Royal Academy of Sciences in Paris, and Professor of Medicine and Surgery in the Royal College of France.³ According to the

¹ Simmons, *op. cit.*, p. 8.

² *Phil. Trans.*, vol. xliii., p. 514. The identical preparation showing the structure of the cartilages, which was figured, still survives. Some of the injected joints are very fine. They form part of series 2, Anatomy of the Joints.

³ He was the author of many monographs on medical subjects, some of which are referred to in Hunter's notes of his lectures. His name remains in the "pyramids of Ferrein" in the kidney.

Biographie Medicale, "he is to be regarded as one of the greatest anatomists of last century." The notes begin with Lecture IV.—"Nov. 19th, N.S."—which was "Of Bones." The last which is dated was on 26th March, 1744, and there are several after that which are not dated. The course therefore lasted at least five months, and consisted of about one hundred lectures. William Hunter's attitude towards the lectures is decidedly critical. He had done work that entitled him to criticise. He has taken very full notes of many of the lectures, but a considerable number of them he dismisses with the remark that "they contained nothing new." He had reason to differ from his master in regard to the articular cartilages, and to judge by the papers he published within the next few years, he found many other points open to criticism and correction. Possibly, just as Smellie was disappointed with the French teaching of midwifery, so Hunter may have been disappointed with the French teaching of anatomy, considering the reputation of the anatomists, and the facilities which they enjoyed.

At the same time this course must have proved invaluable to him. It was infinitely superior to anything he could get at home. The advertisement of his lectures¹ mentions specially that "gentlemen may have the opportunity of learning the art of dissecting, during the whole winter season, in the same manner as at Paris."

Even before this trip to Paris it is certain that he aimed at becoming a teacher of anatomy. In a letter of September 17th, 1743, he writes of accepting a partnership in a practice of a certain Dr. Owen, son-in-law of Dr. John Douglas, who had "died about two months ago," "as the only way to settle in my darling London, to give lectures," and though he does not here specify what the subject of the lectures was to be, there is no doubt it was anatomy.² There is also a letter to Cullen in May, 1746, saying, "among many other things that take up my time at present, I labour most at a compendious system of anatomy and physiology, which will be necessary to be before me in the winter, should I at last enter upon my old scheme."³

The same year saw his ambition realized. In the same volume

¹ Quoted in *Two Great Scotsmen*, Glasgow, 1893, p. 33, by George R. Mather, M.D.; and in Paget's *John Hunter*, p. 24.

² Paget's *John Hunter*, p. 42. The letter is dated simply Sept. 17th. John Douglas was a brother of Hunter's friend, James Douglas. He died on June 25th, 1743. *Dict. of Nat. Biography*.

³ Thomson's *Cullen*, vol. i., p. 22.

with M. Ferrein's lectures there is a set of "notes on a course of Chyrurgical operations performed before the Society of Navel (*sic*) Surgeons, by Sam Sharpe of Guy's Hospital, March, 1746," taken by Hunter. It seems not improbable that the attendance on this course, and the writing of the "compendious system of anatomy and physiology," were both undertaken with the probability of succeeding Sharpe in the post of lecturer. For in the following autumn, when Mr. Sharpe found himself so busy in practice that he could not continue the lectures, the Society asked William Hunter to take his place. According to Simmons, "he is said to have experienced much solicitude when he began to speak in public," but anyhow he proved so satisfactory to the members of the Society that they asked him to give in addition a course of anatomy lectures. These were equally successful. Thus started his career as a teacher of anatomy. Simmons¹ has well said that, "as he had it in contemplation to teach anatomy, his attention was directed principally to this object; and it deserves to be mentioned, as an additional mark of his prudence, that he did not precipitately engage in this attempt, but spent several years in acquiring such a degree of knowledge and such a collection of preparations as might ensure him success."

These anatomical preparations were the nucleus of his museum. Years after, when he was the most successful practitioner of midwifery in London, he extended the plan of his museum, and collected anything and everything that might add to its usefulness in the diffusion of knowledge and culture. The prudence with which he commenced it is equalled only by the boldness and at the same time the shrewdness with which he went ahead with his plans. The great value that the museum, the expenses of which were paid as he went along out of his professional income,² ultimately attained, proves that he possessed an uncommon degree of business capacity and enterprise.

The school at first was located in Covent Garden, then in Jermyn Street, and finally, in 1771, was removed to a building which he had erected specially for the purpose—the Great Windmill Street School of Anatomy. Up to the time of his starting to teach anatomy his

¹ *Op. cit.*, p. 10.

² This fact and the amount of these expenses on *one department* of the museum are well shown by Mr. George Macdonald, M.A., in the introduction to the *Stevenson Catalogue of Greek Coins in the Hunterian Collection*, p. xxii., Glasgow, 1899.

success in practice can hardly have been very great, for he told one of his pupils that the fees he received at the commencement of the course (some seventy guineas) "was a larger sum than he had ever been master of before"; but success was beginning, the tide had turned in his favour, and he took it at the flood. So far his inclinations and opportunities seem to have led him in the direction of becoming a surgeon, but soon after this a change appears. He was admitted a member of the Corporation of Surgeons in 1747. In 1748 he was appointed one of the "Surgeons-accoucheur" to the Middlesex Hospital,¹ and in 1749 to the British Lying-in Hospital, with the latter of which he was connected for many years. These appointments greatly assisted in bringing him forward in his profession, and also directed him rather towards midwifery and what is now called gynaecology, "in which he was recommended by several of the most eminent surgeons of that time, who respected his anatomical talents and wished to encourage him." Probably, too, he had picked up some of Douglas's midwifery practice. Besides the retirement of several of the leading obstetricians within the next few years opened up to him great opportunities in this line, and gave him enough to do without trying to cultivate surgery, in which there were many able men, such as Percival Pott, Caesar Hawkins, Sharpe, and Bromfield. According to Simmons, "he had always an aversion to surgery," and Matthew Baillie says "he very much disliked all operations which might give pain."² Yet his earlier papers show a strong surgical bent, and his lectures and the preparations in the collection show that he did a certain amount of gynaecological operating.

In 1750 he received the degree of Doctor of Medicine from Glasgow University.

In 1751 he was admitted to the membership of the Faculty of Physicians and Surgeons of Glasgow. The entry in the minute book is as follows: "4th March, 1751, the Faculty in full form ordain a diploma to be made out in favours of Doctor Hunter of London as an honorary member, and the same to be transmitted

¹The authority for this statement is Simmons, *op. cit.*, p. 14. There is no mention of it in *Wilson's History of the Middlesex Hospital*, but that institution is pleased to regard him as a former member of its staff. "If this were so—and at the most he could not have held office for more than a few months—it would be gratifying to think that in his case, as in that of many others in after years, the Middlesex Hospital supplied the first step on the ladder of fame." *The Middlesex Hospital Journal*, vol. ii., No. 8, p. 90, 1898.

²*Op. cit.*, p. 75.

to him by the *Praeses* and Visitor." This was the second occasion on which the power of conferring honorary degrees was exercised by the Faculty; it remained in abeyance for many years afterwards.

In 1756 he left the Corporation of Surgeons and joined the College of Physicians, for which he was fined by the former body. Soon he was recognized as the leading teacher of anatomy, pathologist, and practitioner of midwifery in London. In 1762 he was called to attend Queen Charlotte in her first confinement, and in 1764 he was made physician extraordinary to Her Majesty, an appointment which finally established his position as a physician and an accoucheur.¹

In 1768 he was appointed by King George III. professor of anatomy to the Royal Academy, then newly founded, with his friend Sir Joshua Reynolds as president, "an office on which he conferred celebrity by the zeal and ability with which he discharged its difficult and onerous duties."² There are a few fragments of his lectures to the Academy in the museum.

Simmons remarks that "although by these incidents he was established in the practice of midwifery, it is well known that, in proportion as his reputation increased, his opinion was eagerly sought after in all cases where any light concerning the seat or nature of the disease could be expected from an intimate knowledge of anatomy." His practice became one of the largest ever known in London. It is a wonder that he had the time and energy for anything else.

The form of the anatomical collection was determined by Hunter's courses of anatomy, and the researches to which it was related. The researches account for the strength of particular series or departments of the collection; the extent of such a series as the *Anatomy of the Lymphatic System* or of the *Gravid Uterus*, for example, is only to be understood when its relations to his works are considered. On the other hand, every series bears the impress of having been designed for the purpose of teaching anatomy as the term was understood in Hunter's time, and every preparation illustrates some point to which he was wont to refer in his lectures.

Details as to the dates at which preparations were made, and by

¹ William Hunter's holograph account of his attendance upon Queen Charlotte is preserved in the Hunterian Museum. We have given a brief description of this in an article in the *Glasgow Medical Journal*, July, 1899, under the title of "William Hunter, Anatomist."

² Munk's *Roll of the Royal College of Physicians of England*, vol. i.

whose hands, are obtained from his own catalogue of the collection, and, in greater measure, from the works of himself and of others who contributed so largely to its upbuilding.

William Hunter possessed in a remarkable degree the power of inspiring others with his own enthusiasm, and of engaging able men to work under his direction. The work of these assistants he scrupulously and generously acknowledged in his writings.¹ It is indeed easier to tell what is the work of his assistants' hands than what is the work of his own.

Of the "competent stock of preparations" which William Hunter had before he commenced teaching, very few are traceable. Doubtless Douglas had some, and doubtless these passed into Hunter's hands along with the plates and papers. One or two of the dry bones, in fact, can be identified with the plates. A few preparations that belonged to Cheselden have also been recognized. (*Vide* Index of Names.) The preparations of the joints connected with Hunter's paper on the Articular Cartilages have already been referred to; they are the earliest preparations that can be definitely identified as the work of his own hands.

Although his collection of preparations would seem to have been a considerable one, even before he began to teach anatomy, its greatest growth took place after that event. Most of the preparations, of which the history can be traced, date from after 1746. This is quite what might be expected. Only after the establishment of the course of anatomy would he realize what was required for its illustration, and only then would he obtain a sufficient supply of bodies for the making of numerous preparations. Moreover, till success in practice came the means to meet the expense of forming a large museum were not forthcoming, and success in practice came along with the growth of his reputation as an anatomist and pathologist.

In 1743 he first realized the leading fact as to the nature of the connection between the mother and the foetus in the placenta; and before 1746 he had also arrived at his ideas of the anatomical relations of the lymphatics to the arteries and veins, principally from the result of injections. Altogether, there is abundant evidence

¹ *The Dictionary of National Biography* (Article, John Hunter) states, in reference to the dispute between him and John Hunter, that "there is no doubt that . . . he regarded discoveries made in his dissecting room as his own." It is a pity that so unkind and at the same time so inaccurate a statement should have got into a work which is apt to be accepted as authoritative.

from his writings and from Simmons' statements that in the five years before 1746 he was constantly engaged in dissection, injection, and experiment; laying, at the same time, the foundations of his power as an anatomist and of his museum. The art of injecting—filling the vessels, whether blood-vessels, lymphatics, or ducts, with some fluid which would bring them clearly into view, either as an experiment in itself or as a preliminary to dissection—was one of the principal methods by which the sciences of anatomy and physiology were then being advanced; the injection apparatus and fluids being to the anatomists of those days what the microtome and stains have been to the anatomists of the last thirty years. The art received considerable improvements at the hands of William Hunter. Most of the anatomical preparations in the collection are injected, and their beauty and fineness attest the excellence to which he had brought the art.

One can hardly speak of any period of Hunter's life as the years of his greatest activity either in research or in the formation of the museum. Research and collecting went on constantly from 1741 to 1783. The most important of his works were written between 1750 and 1774, but he left much unfinished, some of which was published after his death. Part of this dates from before 1774, but certainly a good deal of it was of later date.

The MS. catalogue of the anatomical and pathological preparations transmitted to Glasgow with the museum by his trustees, was written for the most part between 1778 and 1780, but this was only the last edition of the work, which had grown up along with the museum; earlier catalogues exist in the museum. The bulk of it is in the handwriting of an amanuensis, but in one of the copies there are numerous later additions interlined in William Hunter's writing. The latest date—the only one in the interlineations—is 1782. Clearly the museum work and the researches were continued, as were his lectures, on to the end of his life. He was only 64 when he died.

In 1748 there were two events that were of great moment to the museum. The one was a second tour on the Continent, which included a visit to Albinus, the famous Dutch anatomist, whose "admirable injections, as he [Hunter] afterwards told Dr. Cullen, inspired him with a strong emulation to excel in that elegant and curious branch of anatomy."¹ The other was the arrival in

¹ Simmons, *op. cit.*, p. 13.

London of John Hunter, a fortnight before the commencement of the autumn course. John Hunter was then twenty years old; he was quite untrained to any craft or profession, and therefore perhaps was all the better suited for an assistant. He attended the lectures and worked in the dissecting room under the eyes of his brother and of Mr. Symons, the assistant. "Mr. Symons, of Exeter, surgeon, attended my first course of lectures in 1746, and the following three courses, and likewise assisted me in the dissections."¹ In 1749 Mr. Symons left to start practice in Exeter, and John Hunter was promoted to his place. Already his brother had recognized his ability and value as an assistant. John took charge of obtaining and preparing the bodies, and doing the bulk of the dissections for the lectures, and the making of preparations. He also looked after the students in the dissecting room, and occasionally lectured when William happened to be engaged. William was thus able to reserve his energies for the lecturing, for his own particular researches, and for his practice, which was the financial backing of the school of anatomy and the museum. The expenses of these were borne solely by himself. In 1758 he proposed to take John into partnership, giving him a share of the profits, and John was to deliver part of the course, but the proposal was never carried out, whether from John's aversion to lecturing, or from his health failing about that time, is uncertain. Together they worked at various researches. William's published works and lectures abound in references to the assistance he received from his brother, of whose industry and abilities he was evidently very proud. He records that John helped him in most of the dissections connected with his great work on the *Gravid Uterus*, and most of the many researches in which John at this time engaged were either undertaken under William's direction, or independently but at his suggestion. Two of these researches were published at length for him by William in his *Medical Commentaries*, and several others are referred to in the same work. This was John's first appearance as an author. A great deal of the first part of John Hunter's *Natural History of the Human Teeth* also dates from this period, as most of the preparations figured in the plates attached to that work, and which still exist, are in William's museum.² Of

¹ *Medical Commentaries*, p. 8.

² *The Natural History of the Human Teeth*, part 1, appeared first in 1771. It forms part of vol. ii. of Palmer's edition of John Hunter's *Works*, London, 8vo, 1835.

course all preparations made by John during these years were made at William's expense, and remained his property.

From 1743 to 1756 William Hunter printed nothing. After 1756 come in rapid succession a number of short papers and one elaborate work of a very strange kind, entitled *Medical Commentaries*. The preceding thirteen years were very busy ones in the way of research, and many discoveries resulted, which were communicated as they were made to his class. He deemed it better that his students should get the benefit of the new knowledge at once than wait till he should have time to publish it. Naturally others who were engaged in similar work made the same discoveries, but they published them, in some cases certainly knowing that Hunter had taught them publicly for years, yet wilfully ignoring him. Thence arose fierce controversy as to priority of discovery. The full title of the work which contains Hunter's side of these disputes is—"Medical Commentaries, part 1, containing a plain and direct answer to Professor Monro, jun., interspersed with remarks on the structure, functions, and diseases of several parts of the human body."¹ The book abounds in references to dissections and experiments made during those years, with minute details as to the dates at which they were made, and it therefore throws a great deal of light on Hunter's occupations and the formation of certain parts of the anatomical museum. Unfortunately the history of the controversies is also detailed at great length, the anatomy being "interspersed" through it. Consequently the *Commentaries* are most wearisome reading. What is of value in them from the scientific point of view, apart from their historical interest, is buried in a vast dust heap of argument and abuse of his opponents. His opponents' writings are just as bad or worse. Fortunately no other of his works appears in like form. In justice to him it may be said that he had the right side in the quarrel; he proved his contention as to priority, and that his opponents should have recognized his work in their writings. Such appears to have been the feeling among his contemporaries.²

¹ *Medical Commentaries*, 4to, London, 1762. Supplement, 1764; second edition, 1787. The controversies were with the Monros of Edinburgh and Percival Pott. Vide *Observations, Anatomical and Physiological*, by Alexander Monro, jun., pamphlet, 8vo, Edin. 1758, and also the same author's *Treatise on the Brain*, and Pott's *Treatise on Ruptures*, second edition, London, 1763. Mr. S. Paget has given a fair account of the controversies in his *Life of John Hunter*, pp. 56 et seq. Hunter's *Commentaries*, it is well known, were revised for him by Smollet.

² "I believe, I may assert, that the sentiments of the great majority of men

The quarrel with the Monros became public in 1757, but the *Commentaries* did not appear till 1762. In the meantime he published a number of papers upon matters concerning which he had no quarrel with any one.

In 1754 he became a member of the *Society of Physicians*, the precursor of the *London Medical Society*. The members of the society were accustomed to meet for the discussion of cases, and the reading of papers which it was designed to publish afterwards. The papers were to be as far as possible narrations of facts and observations; "hypothetical disquisitions, points of controversy, numerous and needless quotations, in short, whatever has rather a tendency to show the parts and erudition of the writer than to advance medical knowledge, will be suppressed." The communications were made by the members, and were received also from friends of members all over the world. In 1756 the society published the first volume of its transactions under the title, *Medical Observations and Inquiries*. In all six volumes were issued, and most of William Hunter's short papers appeared in them. He seems to have been a leading member of the society, as a very large proportion of the communications were made through him, and the publications ceased after his death.¹ Frequently the papers were accompanied by preparations, anatomical or pathological, many of which were presented "to Dr. Hunter's most valuable and magnificent museum."² They came from all parts of the United Kingdom, and a few even from America. Several of the papers are classics in medical literature, and the preparations connected with them are proportionately interesting—*vide* Index of Names. William Hunter's contribution to the first volume of *Medical Observations and Inquiries*³ is a very good account of the various kinds of aneurisms, their symptoms, pathology, and treatment. It also contains the first notice of one of his discoveries—the aneurismal varix and varicose aneurism, or arterio-venous aneurism,—the con-

of science were in favour of the former" (Hunter). Bostock's *Physiology*, third edition, London, 8vo, 1836, p. 610.

¹ Several of these papers of William Hunter were reprinted after his death in various works, but the only collected edition of them which I know of is one mentioned in the *Bibliographisches Lexikon der Aertzte*. A number of his papers from *Medical Observations and Inquiries* and *Philosophical Transactions* were translated into German and published in 1784-85 in two volumes, 8vo, by C. G. Kuhn, at Leipzig. I have not seen these volumes.—J.H.T.

² *Medical Observations and Inquiries*, vol. vi., p. 100.

³ "The history of an aneurism of the aorta, with some remarks on aneurisms in general," *Medical Observations and Inquiries*, vol. i., p. 323.

ditions which result when a communication is established between an artery and an adjacent vein in consequence usually of a wound. Wounding the artery in blood-letting at the bend of the elbow was a not very uncommon accident, and cases of arterio-venous aneurism must have occurred from time to time, but the condition had quite escaped notice till William Hunter recognised its nature and described it. He gave a full account of its pathology and treatment in a second paper in 1761, and further notes in 1770.¹ Plaster of Paris casts were taken from several cases, but neither they nor any specimen of the aneurism are now in the museum. His account of the condition is clear, full, and accurate; it contains practically all that is known about it now. The series of ordinary aneurisms is a considerable one.

In 1757 he also wrote ² an account of a case of extreme emphysema, due to injury of the lungs by broken ribs, successfully treated by minute punctures of the skin to let the air out, and to this was appended a long paper on the structure and diseases of the cellular membrane, as the connective tissues were then termed. It is a remarkable paper in several ways. It bears evidence of a great amount of experiment and wide observation. The most important points as to the connective tissues were the demonstration—(1) that they were not to be regarded as the inorganic basis of our organized and vascular solids (as Haller supposed), but they were in themselves active vascular tissues capable of increase and decay in every part; and (2) that the fat is lodged in cells or bags peculiar to itself, and not merely in the interstices of the tissues like the water of an anasarca, as was commonly supposed. The functions of the epidermis were described, and the sweat ducts were demonstrated in a set of preparations, which are still in the collection; two of these are identified with the figures which accompany the paper. It also dealt with the growth of new blood-vessels into fibrinous exudations; the treatment of abscesses and empyema, pointing out the necessity of early operative interference in many cases; further remarks on emphysema; cattle plague; and tumours of the ovary and broad ligament. He had a very fair knowledge of the natural history of ovarian and allied tumours, and of the signs, symptoms, and complications to which they give rise. He did not, as has been stated, advocate ovariectomy. That, he says, had been done by others, but he decidedly goes

¹ *Medical Observations and Inquiries*, vol. ii., p. 390, and vol. iv., p. 385.

² "The history of an emphysema," *Medical Observations and Inquiries*, vol. ii., p. 17.

against it, pointing out the difficulties and dangers on anatomical grounds that were bound to attend it, *e.g.*, the difficulty of knowing beforehand if there were adhesions. If operation were to be done, he advised the trocar and cannula, but he thought, from what he had seen both in the living and in the dead body, that "a patient will have the best chance of living longest under it [the disease] who does the least to get rid of it." His attitude towards the major operation, artificial anaesthesia being unknown and sepsis the rule after operations, was certainly a wise one.

There are, besides, in the same volume papers on necrosis of bone¹ and on the symphysis pubis.² All of these papers are represented in the museum by numerous preparations. The originals of the illustrations are for the most part readily identified. Nothing more by him appeared in *Medical Observations and Inquiries* till 1770.

There are many investigations referred to in the *Medical Commentaries* which have left their marks on the museum, but the most interesting were those on congenital hernia and the lymphatics. William Hunter had recognized the nature and origin of congenital hernia, and to demonstrate exactly how it was produced, he set John to work at an inquiry into the descent of the testicles in the foetus. This John carried out with the most complete success. His paper was illustrated by three plates taken from dissections, which now form a series of preparations among the most beautiful in William Hunter's museum. It was a first-rate piece of work.³

The most important part of the *Commentaries* is that which relates to the Lymphatic System. His own discoveries in this system William Hunter regarded, and was accustomed to describe, as the "greatest discovery, both in physiology and pathology, that anatomy has suggested since the discovery of the circulation." Very valuable his work certainly was, but he seems to have overestimated the extent to which he was a discoverer; he had been anticipated to a greater extent than he was inclined to allow, and part of his discovery turns out to be really an error. He claimed to have proved "that the lymphatic vessels are the

¹ "An account of a diseased tibia," *Medical Observations and Inquiries*, vol. ii., p. 303.

² "A singular case of separation of the ossa pubis," *ibid.*, p. 321.

³ This paper and an account of some "experiments on absorption by veins" were reprinted in *Observations on some parts of the Animal Economy*, which was first issued in 1786, and forms vol. iv. of Palmer's edition of *John Hunter's Works*. London, 8vo, 1837.

absorbing vessels all over the body; that they are the same as the lacteals; that these altogether, with the thoracic duct, constitute one great and general system, dispersed through the whole body for absorption; that this system *only* does absorb, and not the veins; that it serves to take up and convey whatever is to make or to be mixed with the blood, from the skin, from the intestinal canal, and from all the internal cavities and surfaces whatever." This great work, he says, he effected with the help of his pupils, John Hunter, Hewson, and Cruikshank.¹ The lymphatic vessels were discovered long before Hunter's time, and the lacteals—the lymphatics of the intestines—were regarded as absorbent vessels rising from the internal surfaces of the intestines, and carrying the products of digestion into the blood by way of the thoracic duct. Absorption was also allowed to occur from all surfaces and cavities of the body, but it was supposed to be done by open orifices of certain veins, which were termed inhalent vessels. The similarity in structure of the lymphatics to the lacteals had been noted, and it had been suggested that they too were absorbents; but the generally accepted opinions as to the functions of these vessels and their relations to the blood-vessels were decidedly vague and unsatisfactory. Though it was allowed that some of them might have an independent origin like the lacteals, many of them were only continuations of certain fine branches of the arteries—exhalent vessels; and whereas some of them ran into the thoracic duct like the lacteals, others were the inhalent vessels and ended directly in the veins. William Hunter's account² of their anatomical relations was a very great improvement and was quite what is now believed. From his observations of the phenomena of injections he was convinced that the arteries and veins formed a closed system of tubes. Whereas it was commonly supposed that the lymphatics could be injected by injecting the arteries, he believed that the arteries terminated in the veins alone "by continuity of canal," and proved that it was only when some of these vessels burst (as commonly happened in injecting), and extravasation occurred into the interstices of the tissues, that the injection mass entered the lymphatics. Also, when a fluid such as mercury was injected into the connective tissues, it readily passed into the lymphatics, but not into the veins. On these anatomical grounds, and from the similarity of

¹ *Introductory Lectures*, pp. 58-61. ² *Medical Commentaries*, pp. 5-6 and 40.

the lymphatics to the lacteals, and from the fact, which he first explained, that the path by which morbid poisons absorbed from ulcers, abrasions, or tumours entered the blood was through the lymphatics (as was demonstrated by the red inflamed streaks following the course of these vessels and the involvement of the nearest lymphatic glands), he argued that they and the glands were a complete system in themselves distinct from the blood-vascular system, but supplementary to it, inasmuch as they returned all the lymph and everything else that they absorbed to the veins by way of the thoracic duct. The fluid (lymph) which moistened all the cavities of the body, and which formed what he called "the interstitial fluid" of the tissues, he believed to escape from the blood-vessels, not by exhalent orifices ("exhalent arteries") which nobody could demonstrate, but "as a transudation of the thinner parts of our fluids from their (the vessel walls) not being quite close in their texture"; transudation meaning practically filtration under pressure. So far he was substantially right; but the rest of the theory, viz. that the lymphatics were the only means by which absorption was performed, was wrong. Inhalent orifices of veins could not be demonstrated; "that the lymphatic veins are a system of absorbents has been proved; that the sanguiferous veins are furnished with inhalent branches for the same purpose has been supposed; but Nature would hardly form two systems for the same operation. Such a supposition is inconsistent with the simplicity, uniformity, and perfection of her works."¹ Such was his argument. To prove it John Hunter, at William's suggestion, performed some experiments on living animals, which proved that the lacteals did absorb from the intestines, and were supposed to prove that the veins did not. But the premises of these experiments were defective; the experiments themselves were not sufficiently exhaustive. That they were not absolutely conclusive William Hunter allowed. "If we except poisons, other matters absorbed into the body cannot be traced so as to say whether they are absorbed and conveyed into the mass of blood through the lymphatics or through the veins, as mercury or oil of turpentine. But if we take poisons which stimulate the passages [*e.g.*, "the venereal poison" or poison from a septic wound] through which they are conveyed into the body as they go along, and thus enable us to trace them, we shall find they are conveyed by the lymphatics,

¹ *Commentaries*, p. 96, footnote.

and it is natural to suppose that they are absorbed through the same passages as matters not poisonous."¹ How such substances as mercury could be absorbed into the blood-vessels against the supposed force which "strained" the lymph out of them was inconceivable to him. The phenomena of osmosis, if they do not explain it all, at least make it comprehensible, but they and the influence of the activity of the living cells were discoveries undreamt of till many years after Hunter. When, about 70 years later, his great theory was overturned, the old theory of exhalent arteries and inhalent veins, which no one could demonstrate, and the existence of which William Hunter declined to admit, was revived, only to be dropped again in due course. One of the greatest objections urged (by Monro) against the theory that the lymphatics were the only absorbents was that they did not exist in birds, reptiles, or fishes; and it then became necessary to demonstrate their existence in those orders of animals. This was accomplished in William Hunter's school of anatomy.

John's health broke down soon after he made his experiments on absorption, and he appears never to have made any more of importance, but he discovered the lymphatic vessels in birds and in a crocodile. In 1759 he had pneumonia, and after that he was threatened with consumption. Finally, in 1761, he went abroad with the army, and his connection with his brother's school and museum came to an end.

His place was taken by another of William's pupils, viz. William Hewson, a physiologist of great ability. Hewson at first was assistant, but after a time he was taken into partnership, receiving a share of the profits of the school, and giving a considerable number of the lectures.² Hewson continued the study of the lymphatics with great success. His papers, describing them in birds, reptiles, and fishes, were presented to the Royal Society by William Hunter in 1768 and 1769, and he received the Copley gold medal awarded to the person who, in the opinion of the president and council, had, within the year 1769, "contributed most to the advancement of science and useful knowledge." He also published

¹ MS. Lectures of William Hunter in the library of the Royal College of Surgeons of England, 42, c. 28, p. 104.

² In 1846 the Sydenham Society published a complete edition of Hewson's works, with a biographical introduction, under the editorship of George Gulliver, F.R.S. Information as to him is obtained principally from that volume and from Hunter's writings, and from the various biographies of the Hunters.

in 1774 a description of the distribution of the lymphatics in the human body more complete than had ever been given before. Nearly all the work connected with these papers was done in William Hunter's dissecting rooms. The papers were illustrated by a series of most beautiful injected preparations, which under the terms of the partnership became the property of William Hunter. Most of the beautiful preparations of the lymphatics in the turtle and fishes, which now form a large part of Series 12, *Anatomy of the Lymphatic System*, are undoubtedly the work of Hewson's hands. There is also in the museum a set of dissections of the organ of hearing in fish, which appears to have been made by Hewson. Hewson's partnership with William Hunter ended in 1771 in a quarrel, which seems to have been originated principally about the possession of preparations; at least no reason besides that is given in the biography included in Gulliver's edition of his works. All preparations made in the school were made at Hunter's expense, and, according to Hunter's view of their agreement, they were his property, whereas Hewson claimed that, as a partner in the school, he had the right to make preparations for himself, provided the interests of Dr. Hunter and the lectures did not suffer thereby. The quarrel was submitted to the arbitration of Benjamin Franklin, who was an intimate friend of both, and he decided in favour of Hunter. The partnership was dissolved soon afterwards, and Hewson started a school of his own, which succeeded so well that before the end of the first course he had "more than half the number of pupils that he and Dr. Hunter had when in partnership." He unfortunately fell a victim to a dissection wound in 1774, aged only 34.

"From the manner in which Dr. Hunter¹ and Mr. Hewson² wrote of each other, it is pleasing to suppose that they did not finally retain any acrimonious feeling from the disagreement which had led to their separation." After the settlement of the dispute Hunter handed over a number of preparations to Hewson, and possibly some of them came back among those that he bought when Hewson's collection, along with that of Magnus Falconar,³ was sold in 1778; but most of Hewson's preparations now in the museum never left it.

¹ *Introductory Lectures*, p. 60.

² *On the Lymphatic System*, p. 166, in Gulliver's edition.

³ Magnus Falconar was a very promising young anatomist, a pupil of Hewson, and his successor in his school. He was married to Hewson's sister. He most faithfully edited his friend's unpublished writings. He died of consumption at the age of 24. Several preparations in the Hunterian Museum were "bought at Falconar's sale."

The work of Hewson was for a time strangely neglected, but its great merits are now fully appreciated. In addition to his work on the lymphatic system he was one of the first to shed light upon the nature of the coagulation of the blood and that everlasting puzzle, the function of the spleen. He was also celebrated as a microscopist. He recognized the true shape of the human red corpuscle, and described the "central particle" of those of birds, reptiles, and fishes, which is now known as the nucleus. He discovered the white corpuscles of the blood and lymph, and noted their similarity. Most of the experiments still performed to demonstrate to students the characters of the red corpuscles, and many of those which show the composition of blood plasma were devised by Hewson. William Hunter's microscope is preserved in the museum. Its highest combination of lens and eyepiece is about equal in magnifying power to the ordinary low power combination supplied to students of histology nowadays (*e.g.*, ocular of 6 magnifying power with objective 18 mm.), but vastly inferior in efficiency. Probably Hewson's was very similar. That he should have discovered so much with it must fill us with wonder and admiration for his *visus eruditus*. His microscopic preparations are in the Royal College of Surgeons of England. Hewson's discoveries greatly helped to establish Hunter's theory that the lymphatics were the only absorbents.

After the retiral of Hewson, Hunter applied to the College of Glasgow for some one to succeed him, and William Cumberland Cruikshank, a student and a graduate of Glasgow University, was recommended. He arrived in London in 1771, and was appointed to the care of the museum, library, and dissecting-room. After a few years he was taken into a partnership which lasted till Hunter's death. Under their agreement all the preparations he made became the property of Hunter, just as in the case of Hewson. He continued the investigation of the lymphatic system. Hunter referred to him as follows¹:—"And last of all, Mr. Cruikshank, whom I also bred to anatomy, and took into my house upon the same plan, with the opportunities which he has had in this place, and by being particularly attentive to the lymphatic system, at my desire, has traced the ramifications of that system in almost every part of the body; and from his dissections figures have been made, which, with what I had before, will enable us to publish (we hope in a little time) a full account of the whole system, illustrated by accurate engravings." When Hunter died the work was still unfinished, but Cruikshank

¹ *Introductory Lectures*, p. 61.

finished it; it is the work on which his reputation mainly rests.¹ In the introduction he says:—"In consequence of Dr. Hunter's death this business has now fallen on me. I should have had no small share in it if he had lived; for I had made almost all the preparations from which the drawings were made, and from which the description would then have been and now is taken." "In the present publication we have many reasons to regret the loss of Dr. Hunter. It has so happened that we shall be able to derive no advantage to it from his fortune, which has been otherwise disposed of. The work, from this circumstance, cannot appear at present with the number of plates it would have done had he lived to publish it himself. We have also sustained considerable loss in being deprived of his extreme accuracy, good taste, and unwearied perseverance." Nevertheless the work was at the time the most complete account of the lymphatics that had ever been published. It was the summing-up of all the work that William Hunter and Cruikshank did upon that system. "Almost all the injections from which the drawings were made are still preserved in Windmill Street;" and, of course, are now in Glasgow University. The wet ones are still in perfect preservation; the dried dissections injected with mercury, as such always do, have long since decayed and become useless.

In addition to the preparations of the lymphatics, Cruikshank made many contributions to the museum that are worth mentioning. His paper on the structure of the skin and on insensible perspiration² was illustrated by preparations which are almost all there. Further, those which form Series 47 have been identified with a series of experimental dissections on the subject of generation which "were made upon rabbits, at the expense of Dr. William Hunter, in 1778."³

Moreover, there are also three preparations which have a curious and interesting history. Dr. Robert Kennedy, in the course of his researches upon the regeneration of nerves,⁴ identified one of them

¹ *The Anatomy of the Absorbing Vessels of the Human Body.* By William Cruikshank. London, 1786, 4to; 2nd edition, 1790. It was translated into French, German, and Italian.

² *Experiments on the Insensible Perspiration of the Human Body, showing its Affinity to Respiration.* 8vo. London, 1795. It had already appeared in imperfect form along with some other matters in 1778.

³ *The Experiments on Generation* appeared in *Phil. Trans.* in 1797, vol. lxxxvii., p. 197.

⁴ "On the Regeneration of Nerves," by Robert Kennedy, M.A., B.Sc., M.D., Glasgow, *Phil. Trans.*, vol. 188 (1897), p. 257.

with the illustration in Cruikshank's paper, "Experiments on the Nerves, particularly their Reproduction, and on the Spinal Marrow of Living Animals," published in *Philosophical Transactions* in 1794. The experiments, however, were communicated to the Royal Society in 1776, and this is Cruikshank's account of what happened:¹ "These experiments were made for another purpose, by which I discovered the independence of the heart's motion on its nerves, as well as the reunion after division, and the regeneration after loss of substance in the nerves themselves. I wrote a paper on this subject a long time since, which the late Mr. John Hunter, to whose memory and talents I am always proud to pay my tribute, presented to the Royal Society, but it was not then printed; I think Mr. Hunter gave me for a reason, that it controverted some of Haller's opinions, who was a particular friend of Sir John Pringle, then President of the Royal Society. Another gentleman has lately made experiments on the same subject, and has also presented them to the Royal Society. Upon hearing these read at the Society, Mr. Home,² with that intelligence of anatomical subjects that distinguishes his character, and the school he was bred in, remembered my experiments, though made nearly twenty years ago. The present President of the Royal Society, who, fortunately for mankind, prefers the promulgation of science to Haller or any other man, on being made acquainted with this circumstance, has caused the paper on these experiments to be printed in the *Philosophical Transactions* for 1794."

On Hunter's death it was found that Cruikshank was co-heir with Hunter's nephew, Matthew Baillie, to the use of the museum for thirty years. Thereafter, till his death in 1800, he was the senior member of the Great Windmill Street School of Anatomy.³

Besides those already mentioned, another member of the Hunterian school devoted particular attention to the lymphatic system—this was John Sheldon, F.R.S. He improved the methods of injecting the vessels, and began a description of them, of which only one part was published.⁴ He was a pupil of William Hunter and Hewson. He was a devoted admirer of the latter, and was probably one of the

¹ Given in a footnote to the paper on *Insensible Perspiration*, p. 88.

² Sir Everard Home, John Hunter's brother-in-law.

³ *Life of Cruikshank*, Pettigrew's *Medical Portrait Gallery*, vol. iii., and *Dict. of Nat. Biography*.

⁴ *History of the Absorbent System*. London, 1784, 4to. *Vide Dict. of Nat. Biography* (article, John Sheldon).

pupils who left Hunter when they split. He returned to him "as assistant in anatomy after the death of Hewson." In 1777 he started a school of anatomy on his own account. He succeeded William Hunter as professor of anatomy in the Royal Academy in 1782.

But the best part of the anatomical museum is the obstetric collection. This comprises over four hundred preparations, anatomical and pathological, which represent all that is permanent of the material foundations of the works on which chiefly rests the fame of William Hunter, viz. "his immortal work, *The Anatomy of the Human Gravid Uterus exhibited in Figures*," which, in the words of the late Dr. Matthews Duncan, "is one of the stable foundations of the science and art of midwifery, and cannot fail, in all future ages, to be as valuable and useful as it is now," and the little incomplete volume, *Anatomical Description of the Human Gravid Uterus*, left unfinished, and published after his death by Matthew Baillie, which was intended for a systematic description of the parts figured in the greater work, and an exposition of the physiology of these structures. The merits of these works are universally acknowledged. They contain the foundations of our present knowledge of the anatomical relations of the gravid uterus, and of the anatomy of the decidua, placenta, and foetal membranes. In particular, the nature, origin, and anatomical relations of the decidua are here described and figured as well as they are now or can be. His discoveries in this part of the subject Matthews Duncan, about forty years ago, characterized as "all true and containing all the truth," a statement which, even now, requires hardly any qualification. He carried the knowledge of these structures up to a point beyond which no advance could be made until the advent of the new science of histology. That has added an infinity of details which were beyond the reach of the means of research at Hunter's command, but has found little to correct in the descriptions which he wrote 120 years ago. "The more this great work on the anatomy of the gravid uterus is studied, the more extraordinary and unparalleled will its accuracy be found in every particular."¹

Most of the illustrations and descriptions in these works can still be verified by reference to the original preparations from which they

¹ *Researches in Obstetrics*. Edinburgh, 8vo, 1868, p. 223. The essays collected "after more or less of change" into this volume were published separately, for the most part in the *Edinburgh Medical Journal*, between 1855 and 1867.

were taken. Like all great works on scientific subjects, they were the fruit of many years of patient observation and experiment. In 1741 Hunter, as we have seen, became associated, first with Smellie, and then with James Douglas. These two share the credit of directing Hunter into this line of work. Smellie's obstetric works are on other lines than Hunter's, and are not less famous.¹ Douglas' researches on the anatomy of the gravid uterus never reached publication; among his plates in the Hunterian Museum there are several on this subject, which are of considerable merit, though not to be compared with Hunter's. The work begun under Douglas only reached publication in 1774—over thirty years later.

"Anatomy," he says, in the preface to the engravings, "has, at least, kept pace in improvement with other branches of natural knowledge. Many of the moderns, through much labour and patience, as well as ingenuity and judgment, have thrown considerable lights upon the structure and operations of the human body; and they have, particularly by engravings, made the study of that art, in which humanity is so much interested, both more easy and pleasant. Most of the principal parts of anatomy have, in this manner, been successfully illustrated. "One part, however, and that the most curious, and certainly not the least important of all, the pregnant womb, had not been treated by anatomists with proportionable success. Let it not, however, be objected to them that they neglected what in fact it was rarely in their power to cultivate. Few or none of the anatomists had met with a sufficient number of subjects, either for investigating or demonstrating the principal circumstances of utero-gestation in the human species. But let what cannot be praised in others be passed over in silence. With respect to the present undertaking, in the year 1751² the author met with the first favourable opportunity of examining, in the human species, what before he had been studying in brutes. A woman died suddenly when very near the

¹ *Vide Life of Dr. William Smellie*, by Professor John Glaister, M.D. Glasgow, 1894, 8vo. Also *Dr. Smellie and Dr. William Hunter*, by Professor John Young, M.D., Keeper of the Hunterian Museum, *Brit. Med. Jour.*, Aug. 29, 1896. The original drawings for Smellie's *Anatomical Tables* are preserved in the Hunterian Museum. They are in red chalk, and many of them signed J. Van Rymsdyk. How they came there is not known. They are beautifully executed.

² This is the date given in the preface; in the description of the first plate 1750 is the date given. The original sketches are also dated 1750, which, without doubt, is the correct date.

end of her pregnancy: the body was procured before any sensible putrefaction had begun; the season of the year was favourable to dissection; the injection of the blood-vessels proved successful; a very able painter in this way was found; every part was examined in the most public manner, and the truth thereby well authenticated." In the course of some months ten plates were finished, which he proposed to publish forthwith, but other material coming to hand he resolved to wait. "He foresaw that, in the course of some years, by diligence he might procure in this great city so many opportunities of studying the gravid uterus, as to be enabled to make up a tolerable system; and to exhibit, by figures, all the principal changes that happen in the nine months of utero-gestation. Such is the work which at length is offered to the public. The execution of it has indeed taken up more time than what was at first expected, but it gives the author no small satisfaction to reflect that the delay of publication has contributed not a little to the value of the work."¹

All the original drawings used in the atlas of the Gravid Uterus are preserved in the Hunterian Museum. They are nearly all done in red chalk; for the most part they are by Van Rymsdyk; a few by other artists. The copper-plates are the work of various celebrated engravers—two are by Sir Robert Strange. From the drawings the dates of 27 out of the 34 plates can be certainly determined, and from the nature of the plates these dates tell when the work was done. The drawing of the large dissections had to be made within a few days of obtaining the subjects, for Hunter did "not allow the artist to paint from memory or imagination, but only from immediate observation." Even the smaller figures, which are still represented by preparations in the museum, must have been done principally when they were fresh, for minute details are shown, which were necessarily obscured in converting the dissections into permanent preparations.

Ten of the plates are taken from the 1750 case (Nos. I.-X.); one is dated 1754 (No. XV.). No. XXVI. from another source is

¹ Hunter's *Gravid Uterus* appeared in 1774. The plates were accompanied by descriptive text in English and Latin, which obviated the necessity for translation. It was an elephant folio, printed by Baskerville of Birmingham.

In 1815 a second edition was printed by Messrs. Cox, of the Borough, London, who had bought the copyright from Matthew Baillie. In 1851 a third edition was issued by the Sydenham Society, folio, the plates being doubled. The whole work was also copied full size in Caldani's *Icones Anatomicae*, vol. iii., Venice, 1810.

found to be of the same date, which make twelve certainly in this period of 4 years. Plates Nos. XVI.-XX., XXIII.-XXIV., XXVII.-XXVIII., and part of XXIX. date from 1764; Nos. XI.-XII., XXV., and the rest of XXIX. from 1765; No. XIV. from 1766. Three drawings are dated 1770, and one 1772, all of which are in Plate XXXIV. Of the undated plates Nos. XIII., XXI., XXII., and XXXII., from their style seem to belong to the early period of the work, viz. 1750 to 1754. Writing in 1764¹ he mentions that "sixteen plates were finished . . . several years ago," a statement which lends probability to the above opinion as to the date of these four. Nos. XXX. and XXXI. probably belong to the middle period, 1764-66; and No. XXXIII. to the last, the style and subjects of the figures in that plate being exactly like those of Plate XXXIV., the date of which, in part at least, was 1770-1772.

There was thus a long break after 1754 in which little was added to the work; then under date of March 15th, 1764, he writes: "At last, on the 11th of February, I was so fortunate as to meet with a gravid uterus, to which, from that time, all the hours have been dedicated which have been at my disposal. I have been busy in injecting, dissecting, preserving, and showing it, and in planning and superintending drawings and plaister casts of it, neither of which can possibly be finished for some time."² The year 1766 saw the work nearly complete.

The first ten plates are represented in the museum by a number of plaster of Paris casts. These were taken actually from the same subject, and show the same stages of the dissection as certain of the drawings; they were subsequently coloured after nature. "The whole of them are exactly nature herself, and almost as good as the fresh subject. We have a good many of them to help us on; they are most useful, especially where it is so difficult to get a subject of this kind to explain upon in a course of lectures."³ No preparations can with certainty be identified with these, except that from which the last figure of Plate X. (a supplementary one from another case) was taken; some of Nos. 22 to 23 of Series 48 may have been from the same uterus, as the injection corresponds to that described in the plates. Then there are seventeen preparations which represent the foundations of twenty out of the remaining twenty-four plates. Naturally the preparations are now seen

¹ *Medical Commentaries*, Supplement, p. 33.

² *Ibid.*, p. 32.

³ *Midwifery Lectures*, MS., R.C.S., Eng., 42, c. 31, p. 1.

in the last stage of the dissections. The figures show, in some cases, the whole preparation, in others only particular parts of them. Some preparations appear in several different views. In all, the seventeen represent twenty-eight figures.

For the teaching of the anatomy, apart from microscopic anatomy, of the gravid uterus and membranes, and the general principles of placental structure and physiology, a better series of preparations could not be desired; and to the microscopic study of these organs they form the best possible introduction.

The wonderful fulness and accuracy of William Hunter's descriptions of the anatomy of the gravid uterus and of the physiology of pregnancy is now admitted; but it was not always so. The story of how they were discredited, overwhelmed by the errors of other investigators, and how they were revived sixty years or so later, is a most interesting and curious chapter in the history of science. It is to be found in full detail in the powerful essays of the late Dr. Matthews Duncan, who constituted himself the guardian of William Hunter's scientific reputation. "Numerous authors," he wrote in 1858,¹ "in our own day, especially E. H. Weber, Sharpey, and Coste, have acquired a harvest of fame for re-discovering and proclaiming what we have shown that William Hunter demonstrated and described in 1775, and that not casually and carelessly, as if he had stumbled unexpectedly on truth, but carefully and with reiteration." "No sooner do we leave the guidance of William Hunter, than we fall into a long-continued tissue of errors, of blunders, and of misrepresentations. I am not aware of any instance of such retrogression from truth to untruth, from clearness and simplicity to doubts and confusion, in the history of any science continuously pursued by men of zeal and ability; and, in the present instance, the heart is touched with a feeling akin to pain, when we reflect that the leaders in this unfortunate direction were the nearest relatives of William Hunter—viz., John, his brother and his pupil, and Matthew Baillie, his nephew; for both of whom, it is fortunate that, in other quarters, there is an ample reserve of well-won fame."

In 1780 John Hunter communicated to the Royal Society a paper "on the Structure of the Placenta," in which he laid claim to certain discoveries which had for years been ascribed to his brother. The account which he gave of their discovery was,

¹ *Edinburgh Med. Jour.*, Feb., 1858, reprinted in *Researches in Obstetrics*, p. 226.

that, one day in 1754, along with Dr. Mackenzie, Smellie's assistant, he had dissected a gravid uterus at term, the arteries and veins of which had been unusually successfully injected by Dr. Mackenzie. In the dissection, he stated, he observed certain appearances which he supposed to be new. He completed the dissection, and made the parts into preparations.¹ In the evening, full of the new discoveries, he came and described them to his brother, who at first treated him and them "with gentle raillery," then went and saw the preparations, and was convinced of their truth. But, subsequently, when he described the discoveries in his writings he neglected to state how they were made.

In virtue, then, of that one dissection John Hunter considered himself "as having a just claim to the discovery of the structure of the placenta and its communication with the uterus, together with the use arising from such structure and communication [viz. the nature of the connection between the mother and the foetus], and of having first demonstrated the vascularity of the spongy chorion." Spongy chorion was the old name of the structure for which William Hunter, to get rid of confusion, invented the name decidua, which it still bears.

In the story of the dissection John Hunter laid claim to the most important anatomical discoveries, which William Hunter had already published as his own in the engravings of the *Anatomy of the Gravid Uterus*; and in the rest of the paper he, on the one hand, forestalled his brother in the publication of the physiological discoveries which form the very pith and marrow of the *Anatomical Description of the Gravid Uterus* (which he had long promised, but had not yet been able to complete), claiming them as his own; and, on the other, controverted certain of his brother's most cherished opinions.

In reply William wrote to the Royal Society protesting against John's claims, and pointing out that in regard to the connection between the mother and the foetus the doctrine had already been printed thirteen or fourteen years before in Haller's *Physiology* as his, and by him communicated to Haller; and that for many years past he had treated of it in his lectures as his own. "In the third place," he added, "occasionally in what I have printed, and in my lectures, I hope I have not overlooked opportunities of doing justice to Mr. Hunter's great merits, and of acknowledging that he has been an excellent assistant to me in this and in many other pursuits. By doing so, I always felt an inward gratification (shall I call it?) or

¹ Not identifiable.

pride. I have given him all the little anatomical knowledge that I could communicate, and put him into the very best situation that I could for becoming what the society has, for some time, known him to be. May it be presumed, then, that I stand possessed of the discovery in question till proofs shall be brought to dispossess me. I shall most willingly submit to the pleasure of the society. If they signify an unwillingness that this emulation (shall I call it?) should go on, I shall acquiesce and be silent. If curiosity, justice, or the laws and practice of the society should incline the council to seek out and determine upon the merits, I shall be equally ready to obey their commands. And if it should appear reasonable to them, I would first beg to know the grounds of Mr. Hunter's claim, as I am too well acquainted with his abilities not to think that he must be able to support his claim by something that I am ignorant of. And if I should receive that satisfaction, I shall immediately show that I am more tenacious of truth than even of anatomical discoveries. But if that information should not alter my thoughts on the question, I shall show to the satisfaction of the society, if I can at all judge of my employments and pursuits, that my pretensions arise out of a long series of observations and experiments made with a view to the discovery in question; that it was not a random conjecture, a lucky thought, or accidental occasion, but a persevering pursuit for twelve or thirteen years at least, the progress of which was always publicly known here, and admits of the most circumstantial proof."¹ John replied by reasserting the truth of his story, and offering to share the credit of the discoveries. "Reflection on the famous judgment of Solomon will not tend to confirm the long-delayed claims of John."² Of the two accounts of the circumstances of the discovery that of William certainly seems the more probable. The society refused to admit the paper to the *Transactions*, as the facts had already been printed, and also declined to enter into the controversy, which there ended so far as the principals were concerned, but the quarrel remained. Apparently it was mended when John, three years later, asked to be admitted to the care of his brother in his last illness; but William did not alter the will by which everything he owned was left away from John.

In 1786 John published the paper which was the cause of all the trouble,³ and therein inaugurated the errors which were destined to

¹ Ottley's *Life of John Hunter*, vol. i. of *Works*, Palmer's edition, p. 77.

² Duncan, *Researches in Obstetrics*, p. 230.

³ In *Observations on the Animal Oeconomy*, *Works*, Palmer's edition, vol. iv.

supplant the correct views of William Hunter. How they also came to be attributed to the latter is a cruel instance of the irony of circumstances. At his death the carefully corrected MS. of the *Anatomical Description of the Human Gravid Uterus*, now preserved in the Hunterian Museum, passed, still incomplete, into the hands of Matthew Baillie. The description of the decidua and placenta in the earliest stages of pregnancy, and the manner in which the ovum becomes implanted in the uterus, presented difficulties to William Hunter, many of which still present themselves to us; and at the point where these subjects were to be taken up his MS. stops. His observations at the time he wrote went back no earlier than the third month for the gravid uterus in the dead body, and the sixth week in miscarriages. He was therefore unable to describe how and when the decidua was formed, and how the ovum becomes enclosed in the decidua reflexa. "We cannot get women and open them—one at two days and another at six days after they were pregnant to examine."¹ As to the nature and anatomical arrangements of the decidua he had no difficulty; Plate XXXIV. of his great work is plainness itself on these points. The lectures of 1775 agree with what appears in the atlas of 1774, and with his own parts of the MS.; also, it is plain from the MS. catalogue of his collection, and from his latest writing—"The Introductory Lectures to his last course of lectures"—that he never changed the opinion expressed in his earlier works that it was the uterine mucous membrane modified to meet the peculiar conditions of pregnancy. "The gravid uterus," he says, "is a subject likewise, which has afforded me opportunities of making considerable improvements; particularly one very important discovery; viz. that the internal membrane of the uterus, which I have named decidua, constitutes the exterior part of the secundines, or after-birth; and separates from the rest of the uterus every time that a woman either bears a child or suffers a miscarriage. This discovery includes another, to wit, that the placenta is partly made up of an excrescence from the uterus itself. These discoveries are of the utmost consequence, both in the physiological question about the connection between the mother and child; and likewise in explaining the phenomena of births and abortions, as well as in regulating our practice."²

¹ *Lectures*. MS., R.C.S., Eng., 42, c. 31, p. 69.

² *Introd. Lects.*, p. 61. All the principal passages from the authentic works, and the clearest one from the lectures are quoted in the present *Catalogue of the Anatomical and Pathological Preparations of Dr. William Hunter*, Series 48.

Baillie did not at first realize the value of the MS. that had come into his hands, and it was not until 1794 that he published it. Then he states in his preface, "What appeared to be wanting, I have attempted with much diffidence to add,' a resolution as unfortunate for obstetric anatomy as it was ill-advised in him."¹ John Hunter in his paper had described the decidua as originating as an exudation of lymph (fibrinous exudation) from the vessels of the uterus due to the stimulus of impregnation; the ovum pushed itself into the middle of this lymph, and became attached to it; the lymph continued to be a living part for the time, and the vessels of the uterus ramified upon it, or, where the vessels of the foetus form the placenta, passed through it and opened into the cellular substance of the placenta. In a note he compared this process to the encapsulation of a foreign body in the tissues.

To William Hunter's MS. these erroneous views are added in Baillie's handwriting. In the published work, the opinion as to the nature of the decidua appears as if it had actually been that of William Hunter, and accordingly it has commonly been attributed to him as a later view. The theory as to the enclosure of the ovum in the decidua has also been attributed to him, though it is clear that it was only the view of Baillie or of John Hunter. Adherence to the erroneous views of John Hunter vitiate all that was written on these subjects for about half a century, and many were the ingenious theories raised to meet the numerous difficulties to which these views gave rise. To Coste² belongs the credit of finally re-establishing the correct teaching of William Hunter; even he, however, attributes John Hunter's description of the decidua to William as his later, but less correct views.

How much foundation there was for the claims of John it is impossible now to say, but the probability is that William's acknowledgment that he assisted him in most of the dissections was quite sufficient, and that nearly all the credit of the discoveries belonged to William.

Where the brothers are in agreement, the descriptions of William are far superior in clearness and detail. Moreover, the vascularity of

¹ Matthews Duncan, *op. cit.*, p. 227.

² *Histoire du Développement des Corps Organisés*, Paris, 1847, 8vo, p. 212 (Atlas, large folio). Coste's note is highly appreciative of William Hunter's work, and very fair to him. The above erroneous theory he does not attribute to him, but to later physiologists. He does not mention John Hunter or Baillie.

the decidua from the uterus, the mode of termination of the arteries and veins of the uterus in the placenta, the fact that the injection from them had passed into natural cavities among the foetal vessels yet had not passed into those foetal vessels, are all demonstrated clearly in the illustrations which were made by William Hunter in 1750, and it is unreasonable to suppose that they were figured then, yet only understood in 1754. John's absurdly meagre quotations from his brother's lectures of 1755, intended to show that even then the latter did not understand the placenta, prove nothing.

As to the absence of communication between the circulation of the mother and that of the foetus, the main fact that nothing can pass from the one to the other "except by rupture or transudation," became known to William Hunter many years earlier. His account of the discovery is as follows; it is added to the MS. of the "Anatomical Description of the Gravid Uterus" as a note which, in point of time, was clearly written later than the body of the text, perhaps after the quarrel with John, and intended as an answer to him, but of that there is no definite proof: "The first time (in the year 1743) that I injected the vein of the navel-string, while the placenta adhered to the uterus, in separating these two parts, it was evident that the injection had nowhere passed further than the placenta, except at one place where a small convoluted vessel (no doubt an artery) was traced, distinctly filled with wax, some little way into the substance of the uterus; but upon examination it was evident that there was extravasation in that part of the placenta, and by many trials I know that water, or any fluid fit for transudation, thrown into the umbilical arteries or veins, readily gets into the cellular cavities of the placenta, and thence into the vessels, especially the veins of the uterus."¹ The placenta he described as composed of two parts intimately blended, the one uterine, being the decidua, the other foetal, being formed by the prolongations of the branchings of the vessels of the umbilical cord. These two elements he was able to separate in the placentae of many of the lower animals; also, however finely he might inject the vessels of the uterus, those of the umbilical cord always "remained uninjected." "It was this appearance," he says (in his lectures of 1775), "in the cat and bitch that first led me into the apprehension that the human placenta was the same. I thought this a long time, but I never cared to assert it openly till within these few years."² This was, he admitted, not altogether a new

¹Dr. Edward Rigby's edition, p. 39, 1843. ²MS. R. C. S., Eng., 42, c. 31, p. 37.

discovery; with respect to animals, "this was the opinion of Needham,¹ that it was made of two sorts of vessels, the one uterine, the other foetal, both blended together, but he does not assign any reason for it, or say that it was distinctly so in the human body." Harvey also clearly states that there was no mixing of the two bloods.² But the actual anatomical proof of these facts was wanting, and William Hunter supplied it. In his earlier days the prevailing opinion was that "the red blood passes by continuity of canal from the uterus into the blood-vessels of the foetus," circulates through its body and returns again to the mother. Strange to say, the holders of this opinion also thought that the foetus was nourished by swallowing the liquor amnii. Hunter finally and conclusively proved the reverse, and established correct notions as to the nutrition of the foetus *in utero*. "From all I can make out by injections and every other way I shall certainly conclude that the red blood does not pass from the mother to the child. I no more doubt this than I do that the blood does not pass from the hen to the chick."³

Concerning the nutrition of the foetus, he held that "the child is entirely nourished by the navel string." As to how this was effected he had difficulties. "For my part I think all this is done by absorption, and the navel-string and its branches are like the roots of a [the] child which are bathed in the blood and the juices of the mother, which they absorb and take up and carry to the child; and no doubt what is redundant in the child is returned to the mother."⁴

As to what he meant by absorption in this connection, there is no clear passage that can be quoted; he thought there might be "some kind of vessels with valves that when juices get in a little way

¹ *De Formato Foetu*. Walter Needham, 12mo, London, 1667.

² *De Generatione Animalium*. London, 1651.

³ In favour of the other view, Hunter was accustomed to tell his students there were many cases on record of mothers having bled to death by the navel string, and of foetuses found bloodless through a flooding that had destroyed the mother. "Thus it is asserted, but they are deceived . . . there is no believing these things unless they come from a man of great accuracy and delicacy. He should be accurate in his observations and faithful in his narratives. These qualifications do not combine among philosophers and learned men once in one hundred times; most philosophers, most great men, most anatomists, and most other men of eminence lie like the devil." Plain speaking for a professor addressing his class! *Midwifery Lectures*. MS. 42, c. 31, in the library of the R.C.S., Eng., pp. 96-97.

⁴ *Midwifery Lectures*. MS. R.C.S., Eng., 42, c. 31, pp. 98 and 100. The simile of the hen and the chick may have been borrowed from Harvey. That of the placenta as the root of the child, John Hunter gave as his own in 1780.

they cannot return back again; but then these do not run on and terminate as others in the large vessels or veins adjoining." In fact, he could not explain how the interchanges took place; his difficulties are referred to in an earlier part of this introduction. On the structure of the human placenta he is not absolutely in accordance with the views generally accepted at present. He regarded it as made up of the foetal vessels, and a spongy substance between them full of cells in which the maternal blood circulated. This substance he saw as white uninjected processes of connective tissue between the foetal vessels, and he regarded it as formed by the decidua which sent minute processes into every part of the placenta right to the outer surface of the chorionic membrane which forms its inner limit. These placental cells, which are now called the intervillous spaces, it is clear, he regarded as special blood-cells, which he compared to those of the *corpus spongiosum penis*, and not merely as the interstices of the connective tissue, though Rigby, in the notes to his edition of the *Description of the Gravid Uterus*, attributes that view to him. Nor can it be supposed that he regarded the maternal blood in them as extravasated. Microscopic sections show that, from the second month at least, there are not processes of decidua such as he described throughout the placenta; there is connective tissue between the foetal vessels, but it is that of the chorionic villi. He was right in describing the placenta as a compound organ inasmuch as the decidua is maternal; how far he was right in describing a maternal element all through it depends on a refinement which it is impossible he could ever have contemplated, viz. the nature of the epithelium of the chorionic villi—whether it is all foetal or partly maternal, partly foetal, is a question that remains for the future to settle.

The extent of William Hunter's investigation of the comparative anatomy of the placenta is not shown in any of his works; he never published it in detail. His references to it show that his knowledge was accurate and of considerable extent. The descriptions in the MS. catalogue are very meagre, and do no more than confirm the above impression. As to the beauty and instructiveness of the preparations there can be only one opinion: they give a clearer idea of the principles of placental anatomy than can be obtained in any other way. There are preparations from the sow, mare, sheep, cow, cat, bitch, and rabbit, for the most part injected and dissected, and of a foetus and placenta from the sloth, which, however, is neither injected nor dissected. The

little that he wrote about them and the style of his references show that he studied them principally for the sake of the light they threw on the structure of the human placenta; most of his studies of comparative anatomy being directed to the improvement of human anatomy. "The structure of some parts may be so delicate, or involved in the human species, as to be undiscoverable; yet in another species the structure of those very parts may be apparent. Accordingly, many things have been first discovered in comparative anatomy, and were afterwards found out in the human body. Even monsters, and all uncommon and all diseased animal productions are useful in anatomical enquiries; as the mechanism or texture which is concealed in the ordinary fashion of parts, may be obvious in a preternatural composition. And it may be said that Nature, in thus varying and multiplying her productions, has hung out a train of lights that guide us through her labyrinth."

Among the comparative anatomy preparations there are several of the allantois. It is not recognizable in any of the human preparations, and for this reason William Hunter denied its existence altogether in the human subject. There were plenty of descriptions of the human allantois current in his time, but these were either erroneous observations or were wholly imaginary. Indeed it was unlikely that, with the means at his command, he should have recognised the little tubular diverticulum which represents it. He made no attempt to describe the development of the embryo, perhaps wisely. The earliest conception figured in the atlas is at the fifth week, and the embryo is little more than outlined; but in the collection there is a beautiful little preparation of a conception which cannot have been much more than three weeks old, and which is probably the one referred to in the preface to that work. "Even since the last plate was finished he had an opportunity of making a drawing of a younger embryo than he had before seen," and he promised to offer to the public a description of it and also of "a very curious case"—"a conception in the Fallopian tube," "probably in the way of a supplemental plate or with the anatomical description of the gravid uterus which he proposes to publish at full length." He never carried out this scheme, and there is no detailed description of either of these cases, nor sketches of the embryo in the museum. The embryo and placenta from the extra-uterine case are the original of the illustration in Quain's *Anatomy* "after Allen Thomson," tenth

edition, vol. I., pt. i., p. 104, fig. 124. Professor Thomson sketched it for the seventh edition, 1867, in which it appeared as fig. 603.

There are a few other papers which must be mentioned on account of their connection with the museum and for their general interest.

The wet preparation which figures in the well-known portrait of William Hunter by Sir Joshua Reynolds is of special beauty and interest. It is a dissection of a finely injected gravid uterus in the fifth month from a case of retroversion of that organ. This condition seems to have been observed, but certainly was not properly described or properly understood till Hunter's investigation in 1754 of the very case from which this preparation was obtained. He described the condition and the symptoms and mode of treating it in his lectures thereafter, and prepared a plate of it for his atlas. Circumstances, however, bringing it to his knowledge that the condition was not yet so widely known as it deserved to be, and that lives had been lost which might have been saved had his observations been better known, he published a full account of them as a separate paper in vol. iv. of *Medical Observations and Inquiries* in 1770. The plate is No. XXVI. in the *Atlas of Anatomy of the Gravid Uterus*.

After his death there also appeared three papers in vol. vi. of the same prints, two of which were frequently referred to by his contemporaries and reprinted in various works, and are still well worth reading.¹

The third was on *Three cases of Mal-conformation in the Heart*, but no preparations relating to those cases now remain in the museum. The malformation was stenosis of the pulmonary artery with defect of the interventricular septum, and the condition to which it gave rise was congenital cyanosis or *morbus coeruleus*. His description of the appearance of the victims of this condition has become classical, and his explanation of the cause of the cyanosis, which gives the disease its name, though not the whole truth, is part of it, and is correct so far as it goes. But, surely

¹ Dr. Hingston Fox in his *Oration before the Hunterian Society* (printed in their *Transactions*) in 1897 has given a very interesting account of all three papers. The first is *The successful cure of a severe disorder of the stomach by milk taken in small quantities at once*. The second is *On the uncertainty of the signs of Murder in the case of Bastard Children*; it has been very highly praised by Sir Benjamin Brodie, *vide* p. lxvii. The reference to the third is given in the text.

William Hunter was peculiarly unfortunate in having theories wrongly fathered upon him. The now discredited hypothesis that the cyanosis was due to the mixing of the blood of the right and left ventricles from the imperfection of the septum has been attributed to him ever since 1855 at least. His writings show no trace of any such opinion. He attributed the cyanosis to "the want of the full effect of respiration on the blood," of which, from the malformation, only a part passed through the lungs.¹

Purchase did not bulk largely in the formation of this part of the museum. Besides the preparations bought at Falconar's sale, Hunter (apparently about 1778) purchased for £200 the collection of Dr. Francis Sandys, formerly a practitioner and a teacher of anatomy in London, which was rich in injected preparations and dissections of the eye, but none of the preparations from it can be identified.² Hunter mentions him as the inventor of the method of rendering preparations translucent by means of turpentine; a kind of preparation of which there are many examples in the collection. He also mentions him as having discovered the membrana pupillaris, and as having possessed preparations of it; there are several examples of this in the museum, but they may be Hunter's own, as he records that he succeeded in injecting it himself.³

In the list of his unpublished works Simmons⁴ mentions that William Hunter "had long been employed in collecting and arranging materials for a history of the various concretions that are formed in the human body." He had "nearly completed that part of it which relates to urinary and biliary concretions, and prepared a number of illustrations for it before his death." No MS. connected with this work can be found beyond a number of short notes regarding various specimens, but there are 21 plates (with proofs) containing a large number of figures, nearly all taken from the calculi and concretions, of which there are several hundred, in his collection. The notes are utilized in the present catalogue, and references are given to the figures, which are very well executed and accurate engravings. The original sketches, for the most part in red chalk, by Van Rymsdyk, are also in the museum.

¹ This historical error has at last been corrected by Dr. Laurence Humphry in Clifford Allbutt's *System of Medicine*, 1898, vol. v., p. 722.

² Simmons, p. 14, is the authority for this purchase. He does not give the date.

³ *Medical Commentaries*, p. 62.

⁴ *Op. cit.*, p. 50.

To return now to the lectures, which were the *raison d'être* of the collection, and which determined its general shape.

Regarding William Hunter's teaching we know a good deal: (1) from tradition—he was the most celebrated teacher of anatomy of his day in Britain; (2) from the two *Introductory Lectures* already referred to, which he left corrected for the press, and which were published the year after his death; and (3) from students' notes of his lectures, of which there are several good sets in existence in various libraries.

The first introductory lecture is taken up with a concise history of anatomy, and some remarks on recent advances in science. In the second he discusses the subject-matter of anatomy, the practical importance of the science to medicine and surgery, and details the plan of his lectures. We have here, in fact, an account in his own words of what he intended his anatomical teaching to be, and how he proposed to carry out his intentions. Incidentally the lectures throw a great deal of light on the condition of anatomy and anatomical teaching in Britain in his day and earlier; their accuracy is testified by the use made of them in the report of the Select Committee on Anatomy. They are truly philosophic and at the same time practical introductory lectures.

The students' notes supply details of the scope and character of his teaching, the way he used the anatomical museum, and (perhaps in a not very reliable way) his opinions on subjects not treated in his published works. In writing the catalogue everything that might throw light on the source or purpose of preparations was of interest, and naturally the reports of his lectures, as well as his printed works, were investigated in search of information. The best notes of them in the library of the Royal College of Surgeons of England, with the kind permission of the Council of the College, were copied for the University; they proved most useful to the author of the catalogue.¹ The notes read like verbatim reports; probably they were taken in shorthand and re-written; comparison

¹Several sets of notes were examined, and, to a certain extent collated. There are no less than seven sets in the College of Surgeons, but some of them are very brief notes, and several are incomplete. The excellent set copied for Glasgow University was made up from three different ones. The anatomy lectures from No. 42, c. 28-29; the midwifery from No. 42, c. 31; the operative surgery and one or two other short parts from No. 42, c. 25, which is not so perfect as the other two, but was the only one that contained these lectures. There is a good set in the Royal College of Physicians of England, and an excellent set in the Royal College of Physicians, Edinburgh.

of parts of them with his printed works shows that they are fairly accurate reports—uncommonly good for students' notes. That such good sets of notes should exist is not surprising, for the notes of these lectures were treasured by their owners as valuable books of reference through all their lives. Good sets of them were passed from hand to hand among those who could not actually attend the lectures, and were frequently copied. Hunter desired his students to attend two courses, which they were able to do in one winter, and during the first to take no notes; "his [the student] business is, first of all, to get clear ideas of everything. His eyes and ears are to be employed in that service only. He is first to understand; let him remember as he can." In the second, he should take careful notes and re-write them afterwards. Many students (we know from *Medical Commentaries*) actually attended course after course for two, or even three, winters, and were thus able to get their notes very complete.¹ To describe Hunter's courses as anatomy lectures conveys a very inadequate idea of what they were. They embraced anatomy, physiology, and pathology, and also courses of operative surgery and midwifery. The autumn course of 1775 (MS. No. 42, c. 25) consisted of 112 meetings, which is probably about the average, and extended over about three and a half months. The lectures were given daily, Saturdays as well as week days, and extra evening lectures had to be added to make up this number in that brief time. William Hunter delivered most of the day lectures himself; it was a regular engagement with him; but the evening lectures, and certain of the day ones were left to his partner, who also had to lecture if "the Doctor" happened to be called away on urgent business, or were indisposed. Of the 112 lectures, 2 were the introductory ones; 80 were devoted to what was included under the term anatomy; 15 were on operative surgery; 3 on the making of preparations and embalming (a subject to which William Hunter had devoted a good deal of attention); and the remaining 12 on midwifery, about half of them being anatomical. The importance of these courses can hardly be over-estimated; with the exception of chemistry and materia medica, they were the whole of what may be described as the science part of a medical curriculum in those days. The meetings lasted two hours, which some people thought too long, but there was "useful

¹ *Medical Commentaries*, p. 8, *et seq.* It was from notes taken in shorthand and re-written that John Hunter's surgery lectures were printed. *Works*, Palmer's edition, vol. i.

business enough for two hours a day," and the diligent student seldom tired, for they were not merely lectures, but largely demonstrations, being illustrated by dissections of the fresh subject, supplemented by permanent preparations from the museum. The notes in many places have a scrappy character and other indications that the lecturer was demonstrating upon the body and commenting upon what he showed, and in some of the sets of notes there are lists of the preparations exhibited. "In explaining the structure of parts, if a teacher would be of real service, he must take care not merely to describe, but to show or demonstrate every part. What the student acquires in this way is solid knowledge arising from the information of his own senses; thence his ideas are clear and make a lasting impression on his memory. It is therefore necessary for giving a complete course of anatomy to provide a number of fresh subjects, and to have a competent stock of anatomical preparations." He was very careful that preparations should not supplant the fresh subject. They "should not be used as substitutes for a body; but supplementally, to demonstrate such circumstances clearly as are intricate, confused, or invisible in the fresh subject. And a demonstrator who makes fine preparations should be very much upon his guard; otherwise he will be apt to make an abuse of preparations; he will insensibly contract a partiality to that in which he excels; the elegance of preparations is delusive with students; and the more they are used there will be less expense and trouble with fresh subjects." Properly used, he had no doubt as to their usefulness, and "they serve two purposes chiefly, to wit, the preservation of uncommon things, and the preservation of such things as required considerable labour to anatomize them so as to show their structure distinctly. Of the first sort are the pregnant uterus, diseases, parts of singular conformation, etc. Of the second class are preparations of the ear, the eye, and in general, such as show the very fine and delicate parts of the body, which we call the minutiae of anatomy." Wet preparations he preferred to dry, "because they are more like nature." The preparations were handed round the class, and students were requested to handle them carefully, and on no account by pressing or bending to try their strength or texture. "With all possible care they are constantly wearing out or growing the worse for use. Many of them are the result of patient labour and not easily restored; many of them are such rarities as are not to be recoverable when lost by any pains that can be taken."

So far as they go the anatomy lectures are excellent, and it is surprising how far they do go, and how accurate they are when judged by the standard of to-day.

With the anatomy was incorporated a "sketch" of the physiology of the parts just demonstrated. First "the structure of the parts, and the known phenomena as *data*," then "briefly, the most prevailing opinions or hypotheses, with the principal arguments that have been brought either to support or to overturn them." Thirdly, "in some instances to give our own opinion with caution and reserve; but more generally to leave your judgments free, that enquiry and improvement may go on."¹ "Lest I should be thought too short in the physiological part, I would beg leave to observe that, as far as it is yet known, or has been explained by Haller and the best of the moderns, it may be easily acquired by a student without a master, provided the student is acquainted with philosophy and chemistry, and is an expert and ready anatomist; for with these qualifications he can read any physiological book, and can understand it as fast as he reads."

Too much time, he thought, was spent on physiological speculations. "In our branch, those teachers who take but little pains to demonstrate the parts of the body with precision and clearness, but study to captivate young minds with ingenious speculation, will not leave a reputation that will outlive them half a century. When they cease from their labours, their labours are buried with them. There never was a man, perhaps, more followed and admired in physiology than Boerhaave. I remember the veneration he was held in; and now, in the space of forty years, his physiology is—it shocks me to think in what a light it appears."²

He had no hesitation in "avowing great ignorance in many of the most considerable questions relating to animal operations; such as sensation, motion, respiration, digestion, generation, etc.," or in telling his students of his own mistakes.

After the physiology come observations on pathology, chiefly morbid anatomy and narrations of cases—a part of the lectures on the value of which Hunter laid particular stress. Some of the references to cases it is possible to connect with specimens in the museum.

"The more we know of our fabrick, the more reason we have to believe that if our senses were more acute, and our judgment more enlarged, we should be able to trace many springs of life,

¹ *Introd. Lects.*, p. 97.

² *Introductory Lectures*, p. 98.

which are now hidden from us; by the same sagacity we should discover the true causes and nature of diseases, and thereby be enabled to restore the health of many who are now, from our more confined knowledge, said to labour under incurable diseases. By such an intimate acquaintance with the economy of our bodies, we should discover even the seeds of diseases, and destroy them before they had taken root in the constitution."

Finally, his aims in teaching anatomy are summed up in the two following paragraphs.¹ "Anatomical lectures being intended to serve as a solid foundation for two such important arts as medicine and surgery, a teacher cannot take too much pains to render them useful; and if he is limited in time it will require more particular care that the most essential things be well explained. And with that view he must be satisfied with touching more lightly such things as are of less importance and even to pass over many things of little use, though perhaps curious, for in the study of nature there is no end if we give way to curiosity."

"With this view of my situation in life, I have always studied, and shall continue my endeavours, to employ the time that is given up to anatomical studies as usefully to the student as I can possibly make it. And therefore shall never aim at showing what I know, but labour to show, and describe, as clearly as possible what they ought to know. This plan rejects all declamation, all parade, all wrangling, all subtlety. To make a show, to appear learned and ingenious in natural knowledge, may flatter vanity; to know facts, to separate them from suppositions, to range and connect them, to make them plain to ordinary capacities, and, above all, to point out the useful application is, in my opinion, much more laudable, and shall be the object of my ambitions."

From tradition we have ample testimony that he carried out the purpose expressed in these words. Perhaps the best expression of it is to be found in Sir Benjamin Brodie's Hunterian Oration in 1837.² "I am not aware that there is anyone present of such an age as to remember what William Hunter was as an anatomical teacher. But tradition supplies the place of memory; and I have, in the early part of my life, so frequently heard him spoken of in that capacity by older persons, that it seems to me almost as if I had been myself his pupil. He is reported to have been at

¹ *Introductory Lectures*, p. 98.

² *Works*, collected edition, by Charles Hawkins, 1865, vol. i., p. 443.

once simple and profound; minute in his anatomical demonstrations, yet the very reverse of dry and tedious. Subjects, which were uninteresting in themselves, were rendered interesting by the liveliness of his descriptions, and the more important points were illustrated by the relation of cases and the introduction of appropriate anecdotes, which, while they relieved the painful effort of attention, served to impress his lessons on the mind in such a manner that they could never be effaced. His paper on the structure of the cartilages of joints, published in the *Philosophical Transactions* for the year 1743 (at which time he was only 25 years of age, and in which he anticipated all that Bichât wrote sixty years afterwards respecting the structure and arrangement of the synovial membranes), and his illustrations of the gravid uterus, sufficiently show how correct he was in matters of detail, and at the same time how comprehensive were his general views. But we have evidence that his lectures possessed merits of a higher order than these. His paper on the 'Uncertainty of the Signs of Murder in the Case of Bastard Children,' published in one of the volumes [sixth] of the *Medical Observations and Inquiries*, seems to have been little else than a transcript of a part of one of his lectures; and it is impossible to peruse it without being struck, not only with the intellectual penetration, the great good sense, and the power of argument, which is there displayed, but also of the indications which it affords of a humane, charitable, and even of a tender disposition. If we may venture, from this specimen, to form our judgment as to his other lectures, their tendency must have been to improve his pupils with respect to their moral qualities, fully as much as with respect to their professional attainments."

For the teaching of practical anatomy William Hunter seems to have secured an abundant supply of bodies in spite of the difficulties and dangers with which the getting of them was beset. Fordyce, afterwards one of his trustees, stated in a letter to Cullen,¹ that when he was a student under Hunter he dissected three bodies. Dissection could hardly have been so thorough as it is now, for the means of preserving the bodies were very imperfect, and even in winter they were of little use after eight or ten days. But, since the students had few classes, perhaps even none except anatomy, they probably gave up most of their time to dissection when they obtained a subject. Probably, too, some time was spent in practising

¹ Thomson's *Cullen*, vol. i., p. 124.

operations. Hunter used to advise the student not to dissect till he had first attended a complete course of demonstrations. "Otherwise," said he, "he will be so much at a loss in his work, and receive so little instruction or satisfaction, that at best it will be so much time almost thrown away. It may even create disgust to a study from which he ought to receive pleasure and advantage. But when once he is prepared for this part of his education he cannot dissect too much." Besides that, he should frequent the dissecting-room, where he "will see the preparatory dissection for every lecture; which will make the lecture itself much more intelligible, and fix it deeper in the mind; he will see all the principal parts dissected over and over again; whatever he finds he does not understand, there is such a number of bodies dissected in succession that he will at any time have an opportunity of attending to that particular object, and of getting it explained to him; he will see all the operations of surgery performed and explained again and again, and he will see the practice of all the arts of making preparations."¹

With respect to procuring bodies for dissection the introductory lectures conclude with the following significant remarks:² "In a country where liberty disposes the people to licentiousness and outrage, and where anatomists are not legally supplied with dead bodies, particular care should be taken to avoid giving offence to the populace, or to the prejudices of our neighbours. Therefore it is to be hoped that you will be upon your guard; and, out of doors, speak with caution of what may be passing here, especially with respect to dead bodies." This question of dead bodies was the great difficulty of the anatomist. The principal means by which these were obtained was disinterment. The sinister figure of the "resurrection man" first appeared about the beginning of the 18th century, and up to the passing of the Anatomy Act, he remained almost the sole purveyor of bodies for dissection. At first, a sufficient supply of them was easily obtained; the resurrection men were "circumspect in their proceedings, detection was rare, the offence was little noticed by the public, and was scarcely regarded as penal." But there was a feeling against it; and Hunter foresaw that as dissection came to be more generally practised the desecration of graves would become more frequent and more notorious, the feeling would grow stronger, and with it the vigilance of the law would increase. And so it proved. In his day popular violence was more to be feared than the law; prosecutions even of the actual resurrec-

¹ *Introd. Lects.*, p. 109.

² *Ibid.*, p. 113.

tionists were rarely undertaken, and were still more rarely of any effect. But, in 1788 (only five years after his death), the exhumation of dead bodies was decreed a misdemeanour. Still it went on. Other schools besides that of William Hunter arose, and the demand for bodies became greater at the same time as the difficulty of getting them increased. Their value as a marketable commodity rose, the exhumators grew more unscrupulous and desperate, and the public odium against them more bitter. At last, in 1828, the receiving of stolen bodies was decreed a misdemeanour. Under that decision there was scarcely a teacher or student of medicine in Great Britain who was not liable to prosecution.¹

In 1763, being then in the height of his powers and reputation as an anatomist, William Hunter presented a memorial to the government, in which he proposed a plan for establishing a permanent school of anatomy on the basis of his courses, under royal protection. "Scarce any science or art," runs the memorial, "requires the protection of a prince more than anatomy, as well on account of its great use to mankind, as because it is persecuted by the prejudices, both natural and religious, of the multitude in all nations. Its usefulness indeed is generally allowed; yet the degree and extent of its benefit is known only to the few. It is the only solid foundation of medicine. It is to the physician and surgeon what geometry is to the astronomer. It discovers and ascertains truth; overturns superstition and vulgar error; and checks the enthusiasm of theorists and of sects in medicine, to whom perhaps more of the human species have fallen a sacrifice, than to the sword itself or pestilence. It is likewise, or at least might be, made of considerable use in sculpture and painting."

In spite of all difficulties, he had raised London to the position of one of the best schools of anatomy in Europe, but he foresaw that "without some public and permanent foundation, anatomy, and everything that depends upon it, must sink again to its former state. It will be taught only by young men, as an introduction to business; the name of lecturer, in newspapers, and in private conversation, never failing to give a man some degree of credit. But such young teachers will generally be very indifferently qualified when they begin; and when they have acquired some

¹ *Vide the Report of the Select Committee, and The Diary of a Resurrectionist by the late James Blake Bailey, 8vo, London, 1896. The decision of 1828 was in the case Rex v. Davies and others. Appendix to the Report of the Select Committee, p. 147.*

ability from experience, that is, when they are just become fit for teaching, they will generally leave it off. They will always find their labour better rewarded (in the vulgar sense of reward), by following the practice of physic or surgery, than by reading lectures. So it has been, in fact; and thence, though we have had many professors, or teachers, in this great town, we have not had one Winslow, Morgagni, or Albinus: nor can it be expected that a Briton should be able to do, in a few years, what is done by the labour of a long life in other countries: especially too, when we consider that there is no provision made by our government for supplying him with subjects, and that in other countries this article is amply provided for.”¹

More than two years before this Dr. Hunter had felt himself under the necessity of lessening his work, and had proposed giving up his lectures, but he was so strongly urged to continue them, that, after reflection, he decided to continue them for life, “even if he should be obliged to drop a part of his more lucrative employments. He conceived that a man may do infinitely more good to the public by teaching his art than by practising it. The good effects of the latter must centre in the advantage of the few individuals under his care as patients; but the influence of a teacher extends itself to the whole nation, and descends to posterity. With these intentions towards mankind, and with a desire of gaining what the best men have ever esteemed the highest reward, he begs that the Earl of Bute, who knows well the force of such motives, would recommend him to the King’s favour, that he may better execute his plan of giving lectures during his life, and perpetuate a succession of public teachers of anatomy, under the royal protection. What he at present wishes is this: to be allowed a proper piece of ground, that he may forthwith lay out six, or even seven, thousand pounds in erecting a building fit for the purpose, under any condition that may be agreeable to the king.”

He promised whenever the building was complete to hand it over to the public; and he also offered to endow it with his library, which had already cost him between three and four thousand pounds, and his preparations, which were “of more worth to the public because they are things that cannot be bought.”² But the government would not “venture openly to patronize” dissection, and eventually his proposal received “a silent refusal.”

¹ *Introductory Lectures*, Petition to the King, p. 119.

² *Ibid.*, p. 121.

His disappointment at this treatment of his disinterested offer was very great. He thought of leaving London, and even wrote to Cullen proposing that they should start a new and independent school of medicine in Glasgow. "You have been ill-used at Edinburgh as I have been at London. Could you make a sacrifice of the few more guineas you would receive by practice at Edinburgh, and join with me to raise a school of physic upon a noble plan at Glasgow? I would propose to give all my museum and library, and build a theatre at my own expense; and I should ask nothing for teaching but the credit of doing it with reputation. You and Black and I, with those we could choose, I think could not fail of making our neighbours stare."¹

What reception Cullen gave the proposal is not known; the plan went no further: perhaps the great burst of research in 1764-65 helped Hunter to forget his disappointment. Besides that, London, he knew, was "the only place for such a school, because a sufficient number of dead bodies cannot be procured in any other part of Great Britain"; and in London his scheme was eventually carried out by his own energy and perseverance, and with his own capital.

In 1770 he moved into the house in Great Windmill Street which he built for the purpose, with dissecting-room, lecture theatre, and a fine museum hall. There he lived, conducting his enormous practice, lecturing, working in his dissecting-room, and building up his museum on an extended plan—embracing objects of art, archaeology, natural history, geology, mineralogy—till his death. His museum became more than a museum for a medical school; he made it a University museum. On the 20th of March, 1783, after having been confined to bed for some days through illness, in spite of the protestations of his friends, he rose and attempted to give the introductory lecture to the operative surgery part of his course. Before the end of the lecture he fainted and was carried to bed, from which he never rose again. He died on the 30th of March, in his 65th year.

After his death it was found that, by a will dated July 27th, 1781, he had left his museum and £8000 to Glasgow University, but with the condition attached that it was to remain in London for the use of his partner Cruikshank and his nephew Matthew Baillie for thirty years.

¹ Thomson's *Cullen*, vol. i., p. 150.

Matthew Baillie¹ was the only surviving son of James Baillie, minister of Shotts, Bothwell, and Hamilton successively, and afterwards Professor of Divinity in Glasgow University, and of William Hunter's sister Dorothea. He was born at the manse of Shotts on the 27th of October, 1761. He entered Glasgow University in 1774 as an arts student. Three years later, although his inclinations were rather towards divinity or the bar, he chose medicine as his profession on account of the prospects offered by his connection with the Hunters. His father had died in 1778. As he desired to take an English degree in medicine, he applied for and obtained in 1779 a Snell Exhibition to Oxford. In the spring of the same year he proceeded thither by way of London, where he was to meet his uncle William, and discuss his future line of action. To William Hunter he became as a son.² "He spent the whole of his time after the first year with William Hunter, except during the 'terms,' which amounted to only a few weeks annually." In two years from the commencement of his medical studies he began to assist in the teaching in the Great Windmill Street School. He held the Snell Exhibition, which was worth £120 per annum, for the full period (as it was then) of ten years. At Oxford he graduated B.A. in 1783, M.A. in 1786, M.B. in 1786, and M.D. in 1789.

Besides the interest in the museum, William Hunter left him about £100 a year, and the family estate at Long Calderwood. The latter he immediately gave up to John Hunter. It returned to him in after years, and is still owned by his descendants.

Glasgow University showed its appreciation of the value of its legacy by trying to persuade Matthew Baillie to give it up at once in return for a consideration. The professor of anatomy at that time was William Hamilton (father of the great metaphysician), who had been a student under Hunter, and who had charge of his dissecting-room a few years earlier, before his appointment to the University. But Baillie had his own views about the museum, and stated them with decision, as follows:³

LETTER TO R. BARCLAY, ESQ.

Dear Sir,—I scarce think it is proper for me to be at this

¹ These particulars are taken principally from the biography in Wardrop's edition of his works, 8vo, London, 1824, vol. i., and from the records of Glasgow University.

² William Hunter never married.

³ The Hunter-Baillie MS., vol. i., *Dr. M. Baillie*, p. 10 et seq. Published by kind permission of Miss H. Hunter-Baillie.

meeting, but you have here written down everything I have to say about this business.

1st. I will cheerfully give up to the College of Glasgow, providing the executors and Mr. Cruikshank give their consent, every article in the museum except the anatomical preparations, the few pictures in the house, and a few professional books in the bedroom, for what impartial judges shall reckon a proper consideration.

2nd. The anatomical preparations cannot be given up, because I cannot live without lectures, because my success in life will probably depend upon lectures, and because part of Mr. Cruikshank's support is derived from lectures, with whom I have entered into a written agreement.

3rd. If Glasgow insist upon it, I shall give up the pictures and the few books, rather than that measures in contemplation having so proper an object should not take place.¹

Under those circumstances I shall with the greatest pleasure give up the collection to Glasgow, and I wish most heartily the scheme may meet with no interruption from any party concerned. You know I believe my reasons for not wishing to be present at this meeting. My situation with the executors makes it proper that the scheme should be proposed to me as well as to them, and that I should not of myself make any bargain with Glasgow, which cannot be valid without their consent.

Whenever it is proposed by mutual friends I shall agree to it most willingly.—I am, dear sir,

Yours sincerely,

M. BAILLIE.

(Copy. No date.)

But the University evidently wanted the anatomical preparations. On the other hand, Combe, the author of the catalogue of Hunter's collection of coins, and one of the trustees, desired to keep the medals in London, and tried to raise a subscription to buy them from Glasgow, for which an Act of Parliament would also have been necessary. The correspondence seems to indicate that there was some disposition to disregard Matthew Baillie in the matter. So far as is known, it closes with a letter from which the following is an extract. It is supposed to have been addressed to Dr. Fordyce, another of the trustees.

“I own I was much surprised, and have not yet ceased to wonder

¹ It is not known what this object was.

at the proposal made to Mr. Combe in your first letter. It was proposed in that letter that, in order to induce Glasgow to part with the medals for a price *greater* than their *value*, the other parts of the collection should be given up to them.

"In this proposal, which was general, the anatomical preparations were included. To give up which implies giving up two-thirds of my present income, one-third of Mr. Cruikshank's income, and likewise all the probable chance of my success in life. I think it might have occurred as you knew my fortune exactly, and had some tolerable idea of Mr. C.'s situation, that this sacrifice was too much to be expected.

"I thought you had a better opinion of me than to suppose I should wish to sit down as an idle gentleman upon £100 and afterwards £200 per annum. But, since this is not the case, I should wish you to believe that my ambition is to spend an active and, I hope, a serviceable life; and that I intend to pursue those means which have been put in my power.

"I really could have wished you had not made this proposal, or that now you could make it bear another construction. You have now heard what I have thought and felt upon this subject. It seemed right that I should not conceal it from you."

The upshot was that the whole museum remained in London in the meantime. Baillie, it appears,¹ "had so little besides [the family estate which he gave to John Hunter] that he would have been obliged to leave London, if his lectures had not been successful, but they were a complete success, and from that time his reputation was established as a first-rate lecturer." Two years after Hunter's death he assumed his full place as partner with Cruikshank, and gave his first course of anatomy lectures. At the age of twenty-two he essayed to fill the place of one of the most celebrated teachers of the age; a bold step, but justified by success.

Baillie's reputation rests chiefly on his work as a pathologist. His work on the *Morbid Anatomy of the Human Body* was the first systematic treatise on pathology in the English language. It went through six editions between 1793 and 1824, and was for about fifty years the standard work on the subject. It was accompanied by an Atlas of *Engravings of Morbid Anatomy* (folio), the first fasciculus of which appeared in 1799. Of the 207 figures in it, 114 were taken from preparations in William Hunter's museum. Most of these have

¹ From a note by his daughter, Mrs. Milligan, in Miss Baillie's copy of his life (from Wardrop's edition) and *Lectures and Observations* (*vide ante*), p. 14.

been identified, and references to the engravings are given in the catalogue. The majority of the other figures were from his own collection, now the property of the Royal College of Physicians of London, and from that of John Hunter.

Even before his first work was published Matthew Baillie had begun to succeed in practice, a success that grew so rapidly that he began to have little time for anatomy. In 1787 he was appointed physician to St. George's Hospital. In 1799 he retired from teaching altogether. His practice, almost entirely consulting, became so large that he did but little scientific work after the age of forty; but his practice was founded on the science to which he had devoted his earlier years. He is a most brilliant example of the truth of William Hunter's saying: "Were I to guess at the most probable future improvements in physic I should say that they would arise from a more general and more accurate examination of diseases after death. And were I to place a man of proper talents in the most direct road for becoming truly *great* in his profession, I would choose a good practical anatomist, and put him into a large hospital to attend the *sick* and dissect the dead."¹

After Baillie retired, Cruikshank² arranged to continue the teaching with the assistance of his son-in-law, Leigh Thomas, afterwards president of the College of Surgeons, and of James Wilson, one of Hunter's last pupils. But he died suddenly in 1800. Wilson, who is referred to by the late Sir Benjamin Brodie³ as "*facile princeps* among the London anatomists of that day," became virtually head of the school.

Baillie, in 1802, had intimated to Glasgow University that he was now ready to give up the museum to that institution whenever it had a building fit to receive it. In the meantime Wilson had the use of the collection, and knowing that he was soon to lose it, he made most strenuous efforts to make a substitute for it, in which he was most successful.

In 1807 the building was pronounced ready, and the transfer⁴ of the collection began. It was two years after before it was fairly settled in Glasgow.

¹ *Introd. Lectures*, p. 73.

² After Hunter's death Cruikshank made a collection for himself, largely with the assistance of Wilson, which, on his death, was bought by the Russian Government and taken to St. Petersburg. A few of the preparations are figured in Baillie's *Engravings*.

³ Thomson's *Life of Cullen*, p. 741, note x.

⁴ It was sent from London by sea.

The subsequent history of William Hunter's school of anatomy may be told briefly, although it deserves a longer notice than can be given here.¹ Leigh Thomas soon retired, and was succeeded by Benjamin Brodie. Under Wilson and Brodie the traditions of the school were worthily maintained. Many rival schools had sprung up, but it still retained its place as the leading one. One of these had more pupils, according to Brodie, because the lectures there were more suited to the capacity of the average student; Wilson's were on too high a scientific plane for them.

In 1808 Wilson bought out Baillie for £4000, believing that the College of Physicians intended to take over the school. They did not, however, and in 1812 Wilson, to get rid of some of the responsibilities he had undertaken, resolved to sell the school. Brodie could not afford to buy it, nor did he care for so large a venture, and it was sold to Sir Charles Bell. The purchase included Wilson's collection, which was incorporated with that of the purchaser.

Brodie continued to lecture in surgery for some years, then the lectures in that subject were given by John Shaw, Bell's brother-in-law. Wilson having reserved the right of lecturing, the anatomy lectures were divided between him and Bell (the latter giving the greater number) till his death in 1821. Four years later, Bell sold his whole collection to the Royal College of Surgeons of Edinburgh, of whose museum it forms the foundation; and in 1826, he accepted the chair of anatomy in the New London University (now University College).

The Great Windmill Street School was carried on for a few years longer by Herbert Mayo, Caesar Hawkins, and others. In 1830 King's College was opened, and Mayo accepted the chair of anatomy there. The building being not quite fit for the teaching of anatomy, he continued to conduct his class in the old school. During 1831, most of his collection and apparatus was transferred to King's College.

The era of the private schools of anatomy was drawing to a close, and that of the greater schools in the colleges and large hospitals had commenced. The Great Windmill Street School was finally closed about 1833. It had done its work.

It is to be feared that the museum in Glasgow University was not

¹ *Vide* Letter of the late Sir Benjamin Brodie in vol. ii. of Thomson's *Cullen*, note x., p. 739, *re* the Windmill Street School of Anatomy; also Mr. D'Arcy Power's article in the *Brit. Med. Jour.*, 1895, ii., p. 1388.

put to as much use as it might have been ; but, in William Hunter's own words, "let what cannot be praised be passed over in silence." The anatomical preparations were used a great deal in the teaching of anatomy, and there is reason to believe that many well-known anatomical plates were founded on them. It is far from exhausted yet as a source of inspiration.

But it needs to be extended and kept going. Preparations of the nature of those of the founder do not bulk so largely in the teaching of anatomy as they once did, but they have their sphere. The majority of them, used as he directed they should be used, are as valuable now as they ever were. The interpretation of the appearances which they show may change ; they themselves are so "exactly nature herself" that they can never get out of date. A better foundation for a great anatomical and pathological museum could not be desired.

1871

1. The first of the year was a very cold one, and the weather was very disagreeable. The wind was very strong, and the rain was very much.

2. The second of the year was a very warm one, and the weather was very pleasant. The wind was very light, and the rain was very little.

3. The third of the year was a very cold one, and the weather was very disagreeable. The wind was very strong, and the rain was very much.

4. The fourth of the year was a very warm one, and the weather was very pleasant. The wind was very light, and the rain was very little.

5. The fifth of the year was a very cold one, and the weather was very disagreeable. The wind was very strong, and the rain was very much.

6. The sixth of the year was a very warm one, and the weather was very pleasant. The wind was very light, and the rain was very little.

7. The seventh of the year was a very cold one, and the weather was very disagreeable. The wind was very strong, and the rain was very much.

8. The eighth of the year was a very warm one, and the weather was very pleasant. The wind was very light, and the rain was very little.

9. The ninth of the year was a very cold one, and the weather was very disagreeable. The wind was very strong, and the rain was very much.

10. The tenth of the year was a very warm one, and the weather was very pleasant. The wind was very light, and the rain was very little.

CONTENTS OF VOLUME I.

Supplementary to the following Table there is, at the beginning of each series, an analysis showing what it contains. The plan of these analyses is described in the Preface.

	PAGE
PREFACE,	vii
INTRODUCTION,	xxi

CLASS I. THE SKELETON AND ORGANS OF MOTION.

Series	1. The Structure and Development of the Bones,	1
,,	2. Anatomy of the Joints,	31
,,	3. Injuries of Bone,	40
,,	4. Injuries of Joints,	73
,,	5. Diseases of Bone,	75
,,	6. Diseases of Joints,	143
,,	7. Anatomy of Muscles, Tendons, Bursae, Fasciae, and Connective Tissue,	184
,,	8. Injuries and Diseases of Muscles, Tendons, Bursae, Fasciae, and Connective Tissue,	189
,,	9. Injuries and Diseases affecting Limbs as a Whole,	191

CLASS II. THE CIRCULATORY SYSTEM.

Series	10. The Blood and the Anatomy of the Heart, Arteries, and Veins,	197
,,	11. Injuries and Diseases of the Heart, Pericardium, and Blood-vessels,	209
,,	12. Anatomy of the Lymphatic System,	235
,,	13. Injuries and Diseases of Lymphatic Vessels and Glands,	267
,,	14. Anatomy of Glands,	270
,,	15. Anatomy of the Spleen,	275
,,	16. Injuries and Diseases of the Spleen,	277

CLASS III. THE RESPIRATORY SYSTEM.

	PAGE
Series 17. Anatomy of the Respiratory System,	279
„ 18. Injuries and Diseases of the Respiratory System,	294

CLASS IV. THE DUCTLESS GLANDS.

Series 19. Anatomy of the Thyroid and Thymus Glands and Supra-renal Capsule,	306
„ 20. Injuries and Diseases of the Thyroid and Thymus Glands and Suprarenal Capsule,	309

CLASS V. THE NERVOUS SYSTEM AND ORGANS OF THE SENSES.

Series 21. Anatomy of the Nervous System,	311
„ 22. Injuries and Diseases of the Nervous System,	330
„ 23. Anatomy of the Eye and its Appendages,	344
„ 24. Injuries and Diseases of the Eye and its Appendages,	362
„ 25. Anatomy of the Ear,	363
„ 26. Injuries and Diseases of the Ear,	375

CLASS VI. THE TEGUMENTARY SYSTEM.

Series 27. Anatomy of the Skin, Epidermal Appendages, and the subcutaneous Areolar and Adipose Tissues,	377
„ 28. Injuries and Diseases of the Skin and Appendages,	390

SERIES 1.

THE STRUCTURE AND DEVELOPMENT OF THE BONES.

A. STRUCTURE AND DEVELOPMENT OF BONES IN GENERAL.

<i>Structure and Varieties of Bones,</i>	1-10
<i>Bones of the Skull,</i>	11-16
<i>Periosteum, Blood-vessels, and Marrow of Bones,</i>	17-42
<i>Growth and Development of Bone,</i>	43-57

B. DEVELOPMENT OF THE SKELETON AND PARTICULAR BONES.

<i>The Whole Skeleton,</i>	58-61
<i>The Skull,</i>	62-72
<i>The Hyoid Bone,</i>	73, 74
<i>The Spine,</i>	75-87
<i>The Thorax,</i>	88-100
<i>The Upper Limb,</i>	101-124
<i>The Pelvis and Lower Limb,</i>	125-161

This and the succeeding series include the whole of the old series, I. Bones, K. Periosteum, L. Cartilage, M. Ligament, and N. Osteogeny.

The arrangement within those series, with the exception of K, was not satisfactory, and it was thought best to make a complete rearrangement; treating bone and cartilage and the soft tissues immediately connected therewith in one series, and joints and the structures entering into them in a second series. In this arrangement some specimens belonging to L have been placed in Series No. 1, and others in Series No. 2.

The new order, it is expected, will be found more convenient, and further, it accords much better with that of William Hunter's Anatomy Lectures than did the old order.

Both series are rather incomplete. There were several adult skeletons and a collection of bones from a young adult to show the fully formed epiphyses, but they are no longer in the museum. These, and the numerous preparations of joints which might with advantage be added, it is hoped to supply in the future.

A. STRUCTURE OF BONES IN GENERAL.

Structure and Varieties of Bones.

1.1. The Inorganic Portion of Bone. *J. H. T. 1897.*

Lower end and parts of the shaft of a human femur from which the organic portions have been burnt away. Where the roasting has been complete the bone is white like a piece of limestone; where it has been incomplete the charred remains of organic matter give it a black colour. The compact outer layer of the bone has split in various directions, showing the internal cancellous tissue. The removal of the organic matter renders the porosity of every part of the bone clearly visible. Dry.

1.2. Organic Portion of Bone. *Hunterian. N. 133.*

Two ribs injected red and decalcified by steeping in dilute acid. The result is to leave the organic matrix—a flexible porous tissue preserving the shape of the original bone—what Dr. Hunter terms in his Lectures (MS. R.C.S. Eng., 42. c. 28, p. 196) “the skeleton of a bone; that is, the vascular part of a bone deprived of its earthy matter.” The one is split and partly teased to show its fibrous structure, and the other is tied in a knot to show its toughness and flexibility.

This specimen corresponds to I, No. 9, of the original MS. catalogue. It was supposed to be amissing, and is therefore not described in the 1840 catalogue.

1.3. Shaft of a Long Bone. *Hunterian. I. 3.*

Portion of the shaft of a femur, divided longitudinally, macerated by being “long exposed to the weather.” Shows the hollow

cylindrical shaft of compact bone, and the "great medullary cavity," which is occupied in parts by a network of fine bony fibres. For the bone marrow which fills the space and the interstices of the cancellous bone, see No. 42 of this series. Dry.

1.4. Structure of the Ends of Long Bones. *J. H. T. 1897.*

Anterior portion of the lower third of a human femur, macerated by boiling. Shows the shaft as in the preceding, the compact walls thinning and the medullary cavity becoming more filled with the network of bony fibres down to the end, which is composed entirely of cancellous tissue encased in a thin shell of firm bone on the sides and over the articular surface. The plates of the cancellous tissue run in regular parallel lines perpendicular to the articular surface, with numerous cross plates at irregular intervals. The compact bone being porous, the difference between it and the cancellous is only of degree, the spaces being larger in the latter. Dry.

1.5. Cancellous End of Long Bone. *Hunterian. I. 3a.*

Transverse section of the head of the tibia and fibula, showing the same as the preceding. Macerated and dried.

1.6. Cancellous End of Long Bone. *Hunterian. I. 3b.*

Section of the same tibia immediately below the preceding. Dry.

1.7. Cancellous End of Long Bone. *Hunterian. I. 3b.*

Transverse section of the same tibia immediately below the preceding. These three sections are in series from above downwards, and they show the gradual increase in the shell of compact bone, and the decrease of the cancellous tissue till it disappears, leaving the marrow cavity as in Nos. 3 and 4. Dry.

1.8. Structure of Head and Neck of Femur. *J. H. T. 1897.*

Head and neck of a femur sawn longitudinally, and macerated by boiling, showing the arrangement of the compact and cancellous bone to meet the strains to which it is subjected.

In the upper part of the shaft the fibres of the cancellous tissue rising from the firm outer wall pass obliquely upward, forming a

series of Gothic arches extending to the top of the shaft. From the lower part of the convexity of the upper arch and lower wall of the neck rises a distinct series of strong plates, which run obliquely to the base of the head and neighbouring part of the upper wall of the neck. Crossing those obliquely is a second set of fibres running nearly parallel to the upper border of the neck.

The epiphysial line is well marked. Osseous plates run from it in more or less regular lines perpendicular to the articular surface. In the great trochanter the cancellous tissue is irregular. Dry.

1. 9. Structure of a Short Bone.

Hunterian. N. 133a.

A portion of one of the tarsal bones showing that it is composed, like the heads of the long bones, of a mass of cancellous tissue enclosed in a thin shell of compact bone. Injected red and macerated.

1. 10. Structure of a Flat Bone.

J. H. T. 1897.

Section of the occipital bone, macerated and dried, showing the inner and outer tables of compact bone and the intervening layer of cancellous bone,—the diploe. Dry.

The Bones of the Skull.

1. 11. The Occipital Bone.

Hunterian. I. 13.

An occipital bone "made transparent in an acid," dried and varnished, showing the distribution and extent of the diploe. The tables of solid bone are clear like horn; the spaces of the diploe, being filled with air, appear by reflected light as a network of coarse white lines. By transmitted light they can be very well seen in the thinner parts of the bone as clear streaks. Dry.

1. 12. The Parietal Bone.

Hunterian. I. 11a.

A similar preparation of the parietal bone showing the distribution of the diploe. There are also seen several large vascular channels rising out of the cancellous areas and running towards the sutures, where they are usually connected through foramina with the vessels of the dura mater. Dry.

1.13. The Frontal Bone.*Hunterian. I. 14.*

Lower part of the frontal bone, injected red, cleared with acid, dried and mounted in turpentine. Shows a large amount of highly vascular diploe in the thick supra-orbital ridges and external angular process, and a small amount in the thin orbital plates. From the abundance of blood-vessels it is of a fine red colour; a beautiful preparation.

1.14. The Sutures of the Skull Bones.*Hunterian. I. 15.*

Half calvarium, "injected red, made transparent in an acid, dried and varnished," showing the spaces of the diploe of the different bones continuous at the sutures.

1.15. The Sphenoid Bone.*Hunterian. I. 10.*

"The sphenoid bone, injected red, and semi-transparent from having been steeped in an acid." The soft parts, including the medulla of its cancellous basilar portion, have also been very perfectly removed. It is mounted in the usual way, in spirit, which does not clear it to anything like the extent that turpentine does. Shows the various surfaces for articulation with the surrounding bones.

1.16. The Ethmoid Bone.*Hunterian. I. 11.*

A similar preparation of the ethmoid bone. It hangs by the crista galli, on either side of which are seen the horizontal or cribriform plates, perforated for the passage of the olfactory nerves. On either side are the lateral masses built up of thin plates of bone enclosing air cells. Below are seen the middle turbinate bones, the curled continuations of the internal plates of the lateral masses, and the perpendicular plate which forms the upper part of the nasal septum.

Bones of Face. See Series 29, Teeth; and 17, Nose and Mouth.

The Periosteum, Blood-vessels, and Marrow of Bones.

1.17. The Periosteum.*Hunterian. K. 1.*

"The half of a tibia, sawn lengthways, from a young lad: the periosteum is turned off on one side from top to bottom, and is

seen covering epiphysis as well as body of the bone. It is a white, shining, pretty thick membrane." Also shows the epiphyses and epiphysial layers of cartilage.

1. 18. Periosteum and Ligaments of Sternum and Ribs.

Hunterian. K. 2.

"The fibres of the ligaments between the ends of the ribs and sternum, diffusing themselves over the sternum, and forming periosteum." This and the four succeeding specimens were intended by Dr. Hunter to show the continuity of ligaments and tendons with the periosteum, and their similarity in structure; the chief difference being the superior vascularity of periosteum, which has, "besides its own proper vessels, a vast number of vessels going to the bones distributed upon it." (Lectures, p. 198, MS. R.C.S.Eng., 42. c. 28).

1. 19. Periosteum and Interosseous Ligament. *Hunterian. K. 3.*

"The periosteum investing the radius and ulna in a young subject, continued to form the interosseous ligament."

1. 20. Periosteum and Interosseous Ligament.

Hunterian. K. 3a.

"A similar preparation as regards the interosseous ligament between tibia and fibula."

1. 21. Blood-vessels of Periosteum.

Hunterian. K. 5.

"Tibia and fibula of a young subject; shows the vessels of periosteum injected red; shows periosteum forming also the interosseous ligament, and a portion of it turned down about the middle of the tibia shows its thickness."

1. 22. Blood-vessels of the Periosteum.

Hunterian. K. 5.

"The middle or body of the thigh bone in a child. Periosteum, removed through nearly its whole length on the forepart, shows it of nearly equal thickness, adhering very firmly to the bone; and the arteries injected red show it very vascular." Part of it is dissected so as to appear to be "made up of several laminae."

1. 23. Blood-vessels of the Periosteum. *Hunterian. K. 7a.*

Portion of a thigh bone, injected red similar to the preceding.

1. 24. Blood-vessels of the Periosteum and Bone.

Hunterian. K. 8.

"The tibia of a child; the injected periosteum is turned down all the way, except where one stratum has remained about the middle. It shows the inside of periosteum exceedingly vascular, with a number of red points, opposite to which, in the bone, are seen the torn ends of small vessels entering the bone."

1. 25. Blood-vessels of the Periosteum. *Hunterian. K. 9.*

"The tibia, fibula, and interosseous ligament, in a child, highly injected red, and showing periosteum very vascular; the arteries appear to run a considerable way on the surface of periosteum before they enter the bone." "So we have brought out the periosteum to little more than an expansion of the tendons and ligaments." "I believe one of the uses of the periosteum may be to give the tendons and ligaments a better hold than if merely their internal fibres ran into the bones. But this membrane is continued over these parts of bones where there are no tendons or ligaments inserted, for vessels are entering the surface of bones everywhere. Now, if these vessels had gone directly from the superjacent moving parts into the surface of the hard bone, they would have been cut through every time these parts moved, but the periosteum is an immovable fleshy medium, through which the vessels run in a gradual course to enter the substance of the bones." (Lectures, p. 200, MS. R.C.S.Eng., 42. c. 28.) Dried and mounted in turpentine.

1. 26. Vascularity of the Pericranium. *Hunterian. K. 10.*

"The parietal bone of a child injected red, showing pericranium to be periosteum in every respect." The red has degenerated to a dark slate colour, probably from impurity of the vermilion.

1. 27. Pericranium. *Hunterian. K. 11.*

"One of the frontal bones injected red, showing pericranium made up of strata."

1. 28. Pericranium and Dura Mater. *Hunterian. K. 12.*

"A portion of the parietal bone, injected red; pericranium is turned off on one side and dura mater on the other; they both appear to adhere very firmly to the bone and to be very vascular; the vessels of the bone run a great way under the pericranium before they enter the bone." The dura mater acts to the bones of the skull as an internal periosteum.

1. 29. Fibrous Structure of the Periosteum. *Hunterian. K. 16.*

"The lower end of tibia and fibula: periosteum so prepared as to show that it consists of short laminae, like scales of fishes, etc.—not one continued fibre from one end of the bone to the other. (Dr. H.)"

1. 30. Fibres of the Periosteum. *Hunterian. K. 17.*

A portion of the thigh bone showing the deeper seated fibres of the periosteum running longitudinally.

1. 31. Perichondrium. *Hunterian. L. 9.*

"The first rib from an adult; the periosteum turned off from the long portion appears to be continued into perichondrium, which is also turned off from the cartilaginous extremity." To show the identity of periosteum and perichondrium.

1. 32. The Perichondrium. *Hunterian. L. 10.*

"The thigh bone of a very young child suspended by the perichondrium which covered the external condyle." Intended to show the identity of periosteum and the perichondrium enveloping the cartilaginous parts of young bones. Injected red.

1. 33. Blood-vessels of Perichondrium. *Hunterian. L. 11.*

"Two carpal bones, injected red, from a very young subject; the periosteum appears exceedingly vascular." There is a large centre of ossification in each bone. In turpentine.

1. 34. Vascularity of Perichondrium. *Hunterian. L. 12.*

"A patella with its inserted tendon from the vasti, etc.; it shows the perichondrium on the inner surface of the patella, near the edges exceedingly vascular; arteries injected red."

1. 35. The Vascularity of Bone. *Hunterian. I. 17.*

A transverse section of a bone, highly injected red, showing the above. "When everything but the bony substance has been consumed by being some time underground, or properly burnt, even the compact part examined with a glass appears full of pores, and bony substance is vascular; hard as it is; full of vessels." Compare No. 1. 1.

"In the living animal when the bone is laid bare and scraped, haemorrhage from it is inconsiderable; but by injections we prove bony substance to have a great number of arteries, and consequently we presume corresponding veins, and hence bony substance is not only nourished in every part, but may decay in every part, and there is no part of bony substance that may not be thoroughly changed by disease. We must not therefore consider bony substance as a dead extraneous body, like a piece of wood, put in to support the soft parts, but it is a living part and liable to diseases as well as the other parts." (Lectures, p. 118, MS. R.C.S.Eng., 42. c. 28.) The cancellous tissue containing the marrow appears very highly vascular. Dried and mounted in turpentine.

1. 36. Vascularity of Bone. *Jeffray Collection, No. 20.*

Longitudinal section of the upper third of a humerus rather imperfectly injected red, showing the above. The visible blood-vessels in the solid bone are but few in number. Compare No. 1. 40. Mounted in turpentine.

1. 37. Vascularity of Young Bone. *Hunterian. I. 18.*

Frontal bone of a foetus highly injected red. It is composed of radially disposed spicules of bone with spaces between, which are occupied by the osteogenic tissues. Though stripped of both pericranium and dura mater it appears throughout of a bright vermilion colour, being evidently extremely vascular.

1. 38. Vascularity of Young Bone. *Hunterian. I. 19.*

Parietal bone of a foetus injected red, similar to the preceding.

1. 39. Vascularity of Cranial Bone.*Hunterian. I. 13.*

Occipital bone injected red, stripped of periosteum, decalcified and cleared in turpentine. Blood-vessels visible in all parts of it, but most abundant where the diploe is abundant, and in the cancellous basilar and articular processes. These parts by reflected light are of a bright vermilion colour, which shows the richness of their blood supply.

1. 40. Vascularity of the Vault of the Cranium.*Hunterian. I. 26.*

"The upper part of the cranium injected red to considerable minuteness with the pericranium, which is at one part reflected upwards: from an adult." Most of the vessels are in the pericranium. Decalcified and cleared in turpentine.

1. 41. Vascularity of the Vault of the Skull. *Jeffray Collection.*

Upper part of the cranium of a child, with the dura mater and pericranium, finely injected red, showing the richness of the blood supply of these parts.

1. 42. The Bone Marrow.*Hunterian. I. 20.*

Longitudinal section of the upper half of the tibia of an adolescent subject, finely injected red, showing the disposition of the marrow in the medullary cavity and cancellous tissue. Also the vascularity of it and of the cancellous and compact bone.

"We are certain that the compact substance of bones has not only vessels going in every part from its external surface, but we also know that in most bones there is a pretty large branch of a vessel" (the nutrient artery) "enters at one hole, which goes chiefly to the cancelli and marrow, but also gives branches to the compact substance of bone ramifying from withinwards." (Lectures, p. 192, MS. R.C.S.Eng., 42. c. 28.)

*Growth and Development of Bone.***1. 43. Epiphysis of Long Bones.***Hunterian. N. 24.*

"The tibia of a child from which the epiphysis at each end is half pulled off, to give an idea of epiphysis."

1. 44. Cartilaginous Epiphysis.*Hunterian. L. 8a.*

Head and neck of a femur from a young subject, injected red and sliced longitudinally, showing the highly vascular growing bone and the avascular temporary cartilage composing the epiphyses, from which develop the head, neck, and trochanters. There are a few channels in the cartilage which would carry visible vessels when ossification commenced ; compare succeeding specimens.

1. 45. Ossification in Cartilage.*Hunterian. N. 38.*

"A longitudinal section of the tibia and ends of the fibula, with the patella, from a child at nine months, injected red." In the centre of the cartilaginous head of the tibia is a centre of ossification, about the size of a hemp seed, composed of highly vascular cancellous bone. The cartilage of the epiphyses and patella, except for a few blood-vessels running in channels here and there through it, is avascular, contrasting strongly with the highly vascular centre of ossification and growing ends of the shafts.

1. 46. Ossification in Cartilage.*Hunterian. N. 10.*

A patella, dried and mounted in turpentine, showing in the centre an irregular nodule of bone about the size of a pea.

1. 47. Ossification in Cartilage.*Hunterian. N. 78a.*

"The scapula of a slink calf, pretty much advanced, or not far from birth : the basis of the scapula for about an inch is still cartilage ; the basis of the bony part is most vascular, as if the principal formation of bone was in that part, and the arteries, which are injected red, are seen elongating from it into the cartilaginous base for one-eighth of an inch at least : they are of large size, and perpendicular to the base or in the same line ; some of them seem to communicate with others at their extremities, which are suddenly interrupted, and look as if they had been cut off there as they went out to the perichondrium." A slink calf is commonly understood to be a calf which has never sucked ; here it simply means a foetal calf.

1. 48. Ossification in Cartilage.*Hunterian. N. 78b.*

The fellow of the preceding, dried and mounted in turpentine. Being transparent it shows the ramifications of the arteries in the bone. There are two large ones running from the neck towards the base, one under the spine, the other near the posterior edge.

1. 49. Vascularity of Young Bone. *Hunterian. N. 107a.*

Shaft of metacarpal "of the same calf," highly injected red. The whole bone appears very vascular, but especially the upper end where the epiphysis has been pulled off.

1. 50. Blood-vessels entering Cartilaginous Epiphysis. *Hunterian. N. 107b.*

The lower end of the same bone as the preceding with the epiphysis pulled off and sliced transversely, showing a large centre of ossification.

"In the cut-off extremity of the lower end the vessels which were passing from the bone into the cartilaginous epiphysis are seen large or floating, as cut off or torn through in separating the epiphysis." A considerable number of vessels remain in the corresponding surface of the epiphysis.

1. 51. Ossification in Cartilage. *Hunterian. N. 107c.*

Foot of a slink calf injected red, and a slice cut off one side, showing "the ossifications injected in the centre of cartilages of the metatarsal bone," and phalanges.

1. 52. Ossification in Cartilage. *Hunterian. N. 107f.*

Similar to the preceding. The cuticle removed showing the cutis vera extremely vascular.

1. 53. Ossification in Cartilage. *Hunterian. N. 107g.*

Similar to the preceding.

1. 54. Ossification in Cartilage. *Hunterian. N. 107h.*

Similar to the preceding.

1. 55. Ossification in Membrane. *Hunterian. N. 121.*

Parietal bone "of a foetus at five months," "macerated, showing that it is formed in radiating fibres, which centre around this point, which afterwards becomes the parietal eminence." See also Nos. 1. 61, *et seq.*

1.56. Ossification in Membrane.*Hunterian.*

A parietal and the two halves of a frontal bone of a foetus, injected red, dried and mounted in turpentine, showing the radial arrangement of the osseous fibres, and the high vascularity of developing bone.

1.57. First appearance of Ossification.*Hunterian. RR. 298.*

An embryo about 32 mm. long from the top of the head to the end of the buttocks, probably early in the third month, showing a very early stage of ossification. Mounted as usual in spirit, it is remarkably transparent, and shows the ossifications clearly. There are centres in the clavicles (where they are largest, and extend fully, half of the length of the bones), humerus, radius, and ulna, femur, tibia, upper and lower jaw. The vertebral column is unossified, except for two narrow streaks in the lumbar region, which look like the commencement. There is also a faint trace of ossification in the occipital bone.

B. DEVELOPMENT OF THE SKELETON AND PARTICULAR BONES.*The Whole Skeleton.***1.58. Skeleton of a "Foetus at 3 months."***Hunterian. N. 135.*

Cleaned, dried, and mounted in turpentine. Very imperfect.

1.59. Skeleton of a "Foetus at 3½ months."*Hunterian. N. 136.*

A very small skeleton for three and a half months. It is beautifully dissected, and shows the amount of osseous material laid down at this period. The shafts of all the long bones are osseous, the epiphyses apparently all entirely cartilaginous. In most of the vertebrae there are three centres of ossification: one in the body and one in each lamina. Vault of skull and lower jaw absent.

1.60. Skeleton of a Foetus at about 6 months.*Hunterian. N. 141.*

(Not described.) Injected red, the soft parts, except the ligaments, carefully removed, dried, and mounted in turpentine.

1.61. Skeleton of a "Foetus at 7 months."*Hunterian. N. 140.*

The soft parts, except the ligaments, have been carefully removed. Being mounted in spirit without drying, the cartilaginous parts have retained their natural shape and translucency. There is no sign of ossification in the epiphyses of the long bones, nor in the sternum. The skeleton is well shaped and also very completely preserved. The sutures of the vault of the cranium are all membranous.

*The Skull.***1.62. Frontal Bone of a Foetus at about 3 months.***Hunterian. N. 113a.*

"The os frontis of a foetus within the third month." One half only, macerated, dried, and stuck on a black card. A beautiful little specimen. Shows the process of ossification in membrane, in radiating lines of bone. The supra-orbital ridge appears to be the centre, it is in the thickest and most densely ossified area. Dry.

1.63. Frontal Bone of a Foetus "at about 3 months."*Hunterian. N. 114.*

A similar preparation. On the card there are also part of a temporal bone of like age and two small portions of young membranous bone.

1.64. Frontal Bone "of a Foetus at 7 months."*Hunterian. N. 124.*

Half of the above injected red.

1.65. Parietal Bone "of a Foetus within the third month."*Hunterian. N. 114a.*

Macerated so that only the bony part remains, which is seen to consist of radiating trabeculae. Mounted dry on a black card.

1.66. Parietal Bone from a Foetus at 3 months.*Hunterian. N. 115.*

A similar preparation "from the other side of the same foetus." Mounted dry on a black card.

1.67. Parietal Bone "of a Foetus at 7 months."*Hunterian. N. 123.*

Injected red and dried.

1.68. Parietal Bones "of a Foetus at 7 months."*Hunterian. N. 125 (?).*

Injected red, macerated, dried, and mounted in turpentine.

1.69. The Temporal Bone of a very young Foetus.*Hunterian. N. 70.*

Mounted dry on blue paper. Shows the bony ring of the tympanic membrane already ossified. Compare succeeding specimens.

1.70. Petrous Bone of a Foetus "at 4 months."*Hunterian. N. 72.*

A considerable amount of bone is already formed around the semicircular canals, vestibule, and base of cochlea. The canals are opened and marked by bristles passed through them into the vestibule. Compare Series 24, Anatomy of the Ear.

1.71. Temporal Bone of a Foetus "at 3½ months."*Hunterian. N. 73.*

"Os temporis, bony circle and membrani tympani, with malleus and incus, at 3½ months; the long leg of incus and centre of the head of the malleus is bone; everything else of these last is cartilage."

The petrous portion has been removed. The tympanic ring is already osseous. Its posterior end not yet united with the squamous portion. The membrana is remarkably large compared with the temporal bone. Hung against blue paper.

1.72. Temporal Bone and Ossicles of a Foetus "at 4 months."*Hunterian. N. 74.*

A similar preparation injected red, dried and mounted in turpentine. Showing also the stapes. Ossification has commenced in it. Compare specimens in Series 24, Anatomy of the Ear.

*Hyoid Bone.***1. 73. Five Hyoid Bones "at different ages."***Hunterian. N. 131.*

Showing the centres of ossification in each, which are injected black. The black has faded, but the osseous portions are readily distinguishable. The smallest is entirely cartilaginous.

1. 74. "Hyoid Bone, and Laryngeal Cartilages of a Child."*Hunterian. N. 77.*

Showing three centres of ossification, one for the body and one for each greater cornu. The lesser cornua are only small pieces of cartilage.

*Development of the Vertebral Column.***1. 75. Vertebral Column of a Foetus at about 4 months.***Hunterian. N. 54.*

There is a centre of ossification in the body and in each lamina of the vertebrae. The spine and transverse processes and most of the body are of cartilage. The last sacral and all the coccygeal vertebrae are entirely cartilage.

1. 76. The Vertebral Column of a Foetus at "about 4 months."*Hunterian. N. 54a.*

A little older and larger than the preceding. Ossification is in much the same stage. The centres are much better shown, the bone being coloured black, "by some solution of a metal, probably."

1. 77. Longitudinal Section of the Bodies of a Vertebral Column at about 5 months.*Hunterian. N. 55.*

Injected red. The centres of ossification and the points at which the nutrient vessels enter the vertebrae are picked out by the injection. The section shows mostly the centres for the bodies, here and there also portions of the centres for the laminae.

1. 78. The Vertebral Column of a Foetus of about 6 months.*Hunterian. N. 56.*

The ossifications are coloured green. The lateral centres are seen to have extended to the corners of the bodies of the vertebrae.

1. 79. Centres of Ossification in the Vertebrae.*Hunterian. N. 57.*

"The longitudinal half of four vertebrae of the neck." "The ossified body of one of the vertebrae is half turned out of its bed of cartilage, like a kernel from a nutshell, in another it is entirely removed, and in a third it remains *in situ*."

1. 80. Ossification of Sacrum in a "Child of 1 month."*Hunterian. N. 58.*

A longitudinal section of the bodies of the sacrum, last lumbar vertebrae, and coccyx, showing the development of the first-mentioned from five distinct centres of ossification, representing five vertebral bodies, which afterwards become fused into one bone. The five masses of cartilage containing the centres of ossification are separated by distinct interarticular fibro-cartilages, similar to those of other articulations of the spine, but narrower and with less of a central soft pulp. The cartilage at the anterior and posterior edges of the articulations also appears to have more of the hyaline and less of the fibrous character than that at the corresponding point in the joint between the last lumbar vertebra and the sacrum. The coccyx is composed of three cartilaginous vertebral bodies in which no ossification has yet appeared. Compare No. 1. 87. It is finely injected red.

1. 81. Vertebral Column from a "Child at Birth."*Hunterian. N. 58a.*

Carefully dissected. The bodies are ossified to a considerable extent; the centres in the laminae have extended forwards into the bodies and backwards into the arches till they almost meet. The anterior centre of the atlas is not visible. The first and second sacral vertebrae present five centres, one for the body, one for each lamina, and one for each lateral mass.

1. 82. Right Half of the Vertebral Column "of a Child of 7 or 8 months."*Hunterian. N. 58a.c.*

Dissected and divided longitudinally. Shows the centre in the body of the axis, and the separate centre for the odontoid process.

Also the centre in the anterior arch of the atlas just beginning to be visible. The bodies of the vertebrae are almost completely osseous. Shows also the intervertebral articulations. Compare Series 2, Joints.

1. 83. Left Half of the Vertebral Column "of a Child of 7 or 8 months."

Hunterian. N. 58a.d.

The other half of the preceding.

1. 84. The Vertebral Column "of a Child of 7 or 8 months."

Hunterian. N. 58a.b.

Carefully dissected.

1. 85. The Vertebral Column of a Child "at 1 year old."

Hunterian. N. 58b.

Considerably larger than at birth. The centre for the anterior arch of the atlas is now quite distinct; ossification more advanced but still limited to the same centres; and the union of the laminae of the two sides to one another much firmer than at birth; it seems to be still cartilaginous in most.

1. 86. The Vertebral Column of a "Child at 2 years old."

Hunterian. N. 58c.

Ossification has advanced very much further. The centres of the bodies and laminae much more extensive. The epiphyses of the transverse and spinous processes are cartilaginous. The cartilage at the line of junction of the body and the laminae is narrower. The arches of the laminae are completed by bone. A number of the epiphyses of the transverse processes have been broken off. The neural arches of the sacrum are mostly incomplete. Beautifully dissected, every scrap of periosteum and the capsules of the articulations removed.

1. 87. Os Sacrum of a Child "between 2 and 3 years old."

Hunterian. N. 145.

Beautifully dissected. "Showing the progress of ossification and especially that the spinous processes of the os sacrum are not yet formed." The centre of ossification of the lateral mass of the first vertebra is large and separated from the body only by a thin plate of cartilage.

1. 88. "Spine, Ribs, and Sternum of a Foetus just 3 months old." *Hunterian. N. 52.*

A careful dissection of the above, showing the commencement of ossification. It has commenced in the usual three centres of the vertebrae. It has not begun in the sternum, or heads of ribs. The shafts of the ribs are ossified. With the exception of the first (the joint between the manubrium and the gladiolus) the lines of segmentation of the sternum are not marked.

1. 89. "Skeleton of the Thorax of a Foetus between 3 and 4 months old." *Hunterian. N. 53.*

"Divided into two equal parts, and on blue paper: everything in the spine, except the spinal processes, seems completely ossified; the ossifications are at three different points in each vertebra, viz. in the body of the vertebra, and on each side of the foramen medullae spinalis." Having been dried, the still cartilaginous parts between the ossific centres do not appear clearly.

1. 90. "Sternum and Ribs of a Foetus about 3 months old." *Hunterian. N. 59.*

Dissected. No trace of ossification in the sternum, though the shafts of the ribs are bone.

1. 91. Sternum from a Foetus of "about 4 months." *Hunterian. N. 60a.*

Shows the usual mode of ossification just begun. The four upper centres like pin-heads are quite distinct, the place where the fifth is to be is just suggested, the sixth, that for the xiphoid process, appears much later. In turpentine.

1. 92. Sternum of a Foetus at 8 months. *Hunterian. N. 61c.*

Divided into two thin slices, and mounted on mica. Showing five large centres of ossification, the usual number.

1. 93. Typical Ossification of Sternum. *Hunterian. N. 64.*

"Sternum with cartilages of the ribs and intercostal muscles, the perichondrium also left on; shows five globular ossifications in a line under each other; the whole very vascular, injected red." In turpentine.

1. 94. Sternum, with Three Centres of Ossification.*Hunterian. N. 61a.*

Sternum of a foetus of about 8 months, with only three centres of ossification formed ; all in the gladiolus.

1. 95. Sternum, with Four Centres of Ossification.*Hunterian. N. 63.*

A sternum and costal cartilages sliced showing the above. Injected red.

1. 96. Sternum, with Four Centres of Ossification.*Hunterian. N. 61b.*

In turpentine.

1. 97. Sternum, showing Seven Centres of Ossification.*Hunterian. N. 61 (1).*

The manubrium and first segment of the gladiolus contain one each, the second and third of the gladiolus two each, placed side by side, and the seventh is in the fourth segment. Compare next specimen.

1. 98. Sternum, with Seven Centres of Ossification.*Hunterian. N. 61 (2).*

A slice of the preceding, mounted in turpentine. The smaller centres more distinct. These two were formerly mounted together but unsatisfactorily.

1. 99. Sternum, with Eight Centres of Ossification, and double Ensiform Process.*Hunterian. N. 62.*

The arrangement is similar to the last, but there is a very small extra centre in the lower part of the fourth segment of the gladiolus below the normal one.

1. 100. Sternum, with Eight Centres of Ossification.*Hunterian. N. 65.*

A sternum and ribs. The manubrium and two upper segments have one centre each, and the two lower five between them. This abnormal arrangement is sometimes associated with cleft sternum : the xiphoid in this case forms a loop, in the preceding it is double.

*Development of the Upper Limbs.***1.101. Scapulae from very young Foetuses.***Hunterian. N. 78.*

"Three scapulae on blue paper; the uppermost supposed at two months, the second at ten weeks, and the third certainly at twelve." Even in the smallest there is already ossification.

1.102. Right Upper Extremity "of a Foetus at 3 months."*Hunterian. N. 79.*

The bones of the above, carefully dissected, dried, and on blue paper. The ossification is well advanced in all the shafts, even in the phalanges. The epiphyses are shrivelled up. Compare next specimen.

1.103. Left Upper Extremity "of a Foetus at 3 months."*Hunterian. N. 80.*

The fellow of the preceding. Being mounted in spirit the epiphyses are well preserved. None of them nor of the carpal bones show centres of ossification.

1.104. Left Upper Extremity of a Foetus "between 3 and 4 months."*Hunterian. N. 83.*

Similar to the preceding. The scapula wanting.

1.105. Left Upper Extremity of a Foetus "at 4 months."*Hunterian. N. 84.*

A very perfect skeleton, all the soft parts except the ligaments cleanly dissected away. Showing all the centres of ossification from the clavicle and scapula to the last phalanges; none in the epiphyses yet.

1.106. Right Upper Extremity of a Foetus "at 4 months."*Hunterian. N. 85.*

Fellow of the preceding, dried and mounted in turpentine. Too much cleared and the epiphyses shrivelled.

- 1.107. Right Upper Extremity of a Foetus "at 5½ months."**
Hunterian. N. 86.

Ossification in much the same stage.

- 1.108. Right Upper Extremity of a Foetus "at about 5½ months."**
Hunterian.

Similar to the preceding. (Not numbered nor described.)

- 1.109. Right Scapula of a Foetus "at 6 months."**
Hunterian. N. 87.

The cartilage is now comparatively small in amount, but only one osseous centre (that from which the whole body has been formed) has appeared.

- 1.110. Humerus, Radius, and Ulna of a Foetus "at 9 months."**
Hunterian. N. 91.

Appear to be very small for their age. The shafts of the bones well developed, but still no ossification in the epiphyses.

- 1.111. Scapula, Clavicle, and Humerus of a Foetus "at 7½ months."**
Hunterian. N. 92.

Injected red.

- 1.112. Humerus, Radius, and Ulna of a Foetus "at 9 months."**
Hunterian. N. 93.

- 1.113. Humerus, Radius, and Ulna of a Foetus "at 9 months."**
Hunterian. N. 94.

- 1.114. Humerus "of a Child about 2 years old."**
Hunterian. N. 26.

Broken so as to show both ends. There is a centre of ossification about the size of a pea in the upper, and a smaller one in the lower epiphysis. This must be very nearly the first appearance of ossification in these epiphyses. Injected red and in turpentine.

1. 115. Lower End of Humerus at about 5 years.*Hunterian. N. 27.*

Shows the large centre for the radial head and a small one for the internal condyle, which usually appears just about this age.

1. 116. The Lower End of the Humerus at 5 or 6 years.*Hunterian. N. 28.*

Injected red; showing ossification rather further advanced. The epiphysis for the internal epicondyle absent. Four cm. above the internal condyle there is a little curved bony process five mm. long projecting from the internal border of the shaft downwards and inwards and slightly forwards. It is a fairly common anomaly, and is analogous to the supra-condyloid foramen of certain lower animals.

1. 117. Bones of Forearm and Hand of a Child "at 12 months."*Hunterian. N. 96.***1. 118. Upper Ends of Ulna and Radius about 5th year.***Hunterian. N. 30.*

A large centre of ossification in the head of the radius, but none in the olecranon. In turpentine.

1. 119. The Lower Ends of the Ulna and Radius about the 5th year.*Hunterian. N. 31.*

A large ossification in the epiphysis of the radius, a very small one in that of the ulna. In turpentine.

1. 120. Scaphoid, Semilunar, and Cuneiform Bones "from a subject about 4 years old."*Hunterian. N. 49.*

Injected red and in turpentine. Shows each bone ossifying from a single centre, that in the scaphoid being very small.

1. 121. Bones of Hand from a Foetus "at 6½ months."*Hunterian. N. 90.*

Cleaned, dried, and mounted on blue paper.

1. 122. Bones of Hand from a Foetus "at 6½ months."*Hunterian. N. 89.*

The fellow of the preceding. In spirit.

1. 123. Ossification of the Bones of the Hand.*Hunterian. N. 95.*

The bones of the thumb and fingers, with their metacarpals "at 12 months," carefully dissected and hung side by side. Shows the ossified shafts and cartilaginous ends, of which last only some ossify from independent centres, as will be seen in the next specimen.

1. 124. Ossification of the Finger Bones. *Hunterian. N. 45.*

Longitudinal section of the finger of an adolescent subject, showing the ossification of the metacarpals by a centre for the shaft and a centre for the digital head, and of the phalanges by a centre for the shaft and a centre for the base of each. Injected red.

Development of the Bones of the Lower Limbs.

1. 125. The Lower Extremity of a Foetus, "at 3 months."*Hunterian. N. 97.*

The bones of the above, carefully cleaned, dried, and mounted on blue paper. Shows the body of the ilium and the shafts of the long bones and metatarsals and some phalanges of the toes ossified. The pubis, ischium, and heads of the long bones, and the tarsal bones are cartilage. The cartilage is shrunken. Dry.

1. 126. The Lower Extremity of a Foetus "at 3 months."*Hunterian. N. 98.*

"The fellow of the preceding," mounted in spirit, showing the cartilages much better than the former.

1. 127. The Lower Limb of a Foetus "at 3½ months."*Hunterian. N. 102.*

Similar to the preceding, and showing the same, but more clearly. Also a small centre of ossification has appeared in the ischium.

1.128. Lower Limb of a Foetus "about 3 months" old.*Hunterian. N. 101a.*

A similar specimen, the bony parts stained green. Os innominatum absent.

1.129. The Lower Limb "of a Foetus at 4 months."*Hunterian. N. 103.*

The bones of the above, cleaned, dried, and mounted in turpentine. The cartilages very much shrunken.

1.130. The Lower Limb "of a Foetus at 4 months."*Hunterian. N. 104.*

Similar to the preceding, but being in spirit the cartilages are well preserved and very transparent. The ossification in the ischium is of considerable size.

1.131. The Femur and Leg Bones "from a Foetus at 4½ months."*Hunterian. N. 104a.*

Similar to the preceding but larger.

1.132. The Femur and Leg Bones from a Foetus "at 9 months."*Hunterian. N. 108.*

The bones are more shapely and firmer, but there are no more centres of ossification than at three months. In spirit.

1.133. The Innominate Bones "at Birth."*Hunterian. N. 66.*

There are three centres of ossification, one each for ilium, ischium, and pubis, and their position indicates the manner in which all three enter into the formation of the acetabulum. In the left the ossification of the ischium is visible in the floor of the acetabulum, which is, however, almost wholly cartilaginous.

1.134. The Innominate Bones "at Birth."*Hunterian. N. 66a.*

Similar to the preceding.

1. 135. Ossification of the Innominate Bone "at Birth."*Hunterian. N. 67.*

An innominate bone, finely injected red, and sliced in various directions to show the interior of the flattened spongy bones which form the os innominatum. The spicules of bone in the ilium radiate from a centre near the neck of the bone. Portions of the sacrum are also present.

1. 136. Innominate Bone and Femur "at 12 months."*Hunterian. N. 110.*

Beautifully cleaned and injected red.

1. 137. Innominate Bones "between 2 and 3 years."*Hunterian. N. 145.*

The two innominate bones corresponding to the sacrum No. 87, beautifully cleansed of the soft tissues, showing the three primary ossifications considerably developed. That of the ischium appears in the floor of the acetabulum in a considerable area corresponding with the cotyloid notch and depression for the attachment of the ligamentum teres. That of the ilium has also appeared in the floor of the acetabulum. The cartilage separating the three ossifications as seen from the outside is now reduced to a Y-shaped piece with fairly thick limbs.

1. 138. The Innominate Bone and Femur "at 12 months."*Hunterian. N. 110a.*

Similar to the preceding, but not injected. The upper and lower epiphyses of the femur are split longitudinally showing their shape and extent and that there is as yet no centre of ossification in the former, but a small one in the latter. From the condition of the epiphyses and size of the bones the "12 months" probably means the third month of extra-uterine life. Compare the next specimen.

1. 139. Ossification of the Epiphyses of the Femur.*Hunterian. N. 32a.*

Femur of a child of about a year, injected red, divided longitudinally and the anterior portion dried* and mounted in turpentine. The

cartilages have shrunk considerably. A single centre of ossification is seen in both epiphyses, that in the lower being the larger. Comparing it with the preceding, note how the bone of the shaft has extended up into the neck and the position of the centre of ossification in the articular head. Compare No. 1. 44.

1. 140. Femur of a Child about 2 years old. *Hunterian. N. 34.*

Injected red, broken almost in two, dried and mounted in turpentine, showing a centre of ossification in the epiphysis at each end of the bone.

1. 141. Femur of a Child about 2 years old. *Hunterian. N. 35.*

A similar femur showing the centre of ossification in the upper epiphysis. In turpentine.

1. 142. Ossification of Upper End of Femur.

Hunterian. N. 37a.

The upper end of the femur "from a young person" (over 6 years old at least). Injected red and in turpentine. The head of the bone is divided vertically and one half removed, showing the epiphysis forming the articular head only. The bone of the shaft has formed the whole of the neck and intertrochanteric region. There is a distinct centre of ossification for the great trochanter, which is enclosed in a thin cartilage. The bone is sawn nearly through at the level of the lesser trochanter and bent to show its internal cancellated structure. The bone composing the head is seen to be of similar structure. Compare No. 1. 8.

1. 143. Lower End of the Femur at about 6 years.

Hunterian. N. 36.

Shows the lower epiphysis almost entirely osseous, but covered all over by cartilage and with the epiphysial line well marked. The cancellated structure of the end of the shaft is seen in the section.

1. 144. Lower End of Femur of a Young Adult.

Hunterian. N. 37.

The posterior half of the above, divided longitudinally. The epiphysial line well marked and the head covered with cartilage all round, showing that growth was not complete. Injected red.

1.145. Patella at "about two years." *Hunterian. N. 2.*

The patella with part of the quadriceps muscle, and upper ends of tibia and fibula. Injected red, dried, and mounted in turpentine. The patella is entirely cartilaginous. Numerous blood-vessels course through its substance, and the blood supply of its periosteum is abundant.

1.146. The Patella "of a Child at 4 or 5 years." *Hunterian. N. 3.*

A similar preparation with part of the femur also, injected red and in turpentine. The patella is still entirely cartilaginous. There are large centres of ossification in the epiphyses of the femur and tibia. The femur hangs lowest. The ligamentum mucosum attached to the femur and the pads of fat are well shown.

1.147. The Patella at about 7 years. *Hunterian. N. 14.*

Patella from a child supposed to be about 7 years old, dried and mounted in turpentine, showing the centre of ossification about the size of a pea.

1.148. Bones of Knee-joint at about 7 years. *Hunterian. N. 14.*

The ends of the femur and tibia with the knee-joint opened, from a child of about 7 or 8 years, injected red and in turpentine. The patella contains a knob of bone about the same size as that in the previous specimen. The heads of the bones are ossified to a large extent; they are enveloped all round in cartilage.

1.149. Patella at about 9 years. *Hunterian. N. 9a.*

A similar preparation in which the ends of the femur and tibia are much smaller, but the centre of ossification in the patella is considerably larger. In turpentine.

1.150. Ossification of the Patella at 10 years. *Hunterian. N. 9b.*

A similar preparation considerably larger, perhaps at ten years, the centre of ossification about half the size of the patella.

1. 151. Ossification of the Patella. *Hunterian. N. 22.*

An ossifying patella about 2.3 cm. in diameter divided from side to side. There is a considerable amount of cartilage round the bony centre, which is about 2 cm. across. In structure it is cancellated bone, slightly denser where it borders on the cartilage.

1. 152. Ossification of the Patella. *Hunterian. N. 20.*

A patella nearly fully ossified, about 2.7 cm. in diameter. Injected red and in turpentine. It is split from back to front, and resembles the previous specimen but there is less cartilage.

1. 153. Patella from an Adult; fully Ossified.*Hunterian. N. 21.*

Injected red and in turpentine. The articular cartilage is not perfectly cleared.

1. 154. Ossification of Head of Tibia. *Hunterian. N. 40.*

The head of the tibia, injected red and sliced horizontally into three sections, showing the ossification in the centre of the cartilage. Compare No. 1. 45.

1. 155. Tibia and Fibula at about 2 years. *Hunterian. N. 43.*

Injected red, broken almost in two, dried and mounted in turpentine, showing the centres of ossification in the epiphyses of the tibia, but none in those of the fibula.

1. 156. Tibia and Fibula at about 2 years. *Hunterian. N. 42.*

Similar to the preceding. Not broken. Injected red and in turpentine.

1. 157. Ossification in Heads of Tibia and Fibula.*Hunterian. N. 41.*

Heads of tibia and fibula from a considerably older subject, showing the epiphyses nearly all bone. Injected red and in turpentine.

1.158. Lower End of the Tibia "from a Boy."*Hunterian. N. 44.*

Longitudinal section of the above showing the epiphysial line and the epiphysis all bone, but completely surrounded with cartilage showing that the growth was not completed.

1.159. The Bones of the Foot at 12 months.*Hunterian. N. 111.*

The tibia, fibula, patella, and foot "at 12 months" showing ossification proceeding in the calcaneus, astragalus, and the shafts of all the metatarsals and phalanges. Centres are not visible, even by transmitted light, in the cuboid, scaphoid, and cuneiform bones. Injected red.

1.160. Ossification in the Os Calcis.*Hunterian. N. 50.*

The os calcis "of a child" sliced longitudinally. Shows a single round centre of ossification. At a much later stage there is an epiphysis for its posterior extremity.

1.161. Ossification in the Toes.*Hunterian. N. 46.*

Section of the bones of the great toe and external cuneiform "from a youth" showing that the bases of the metacarpals and phalanges are epiphyses.

SERIES 2.

ANATOMY OF THE JOINTS.

A. STRUCTURE OF JOINTS IN GENERAL.

<i>The Articular Cartilages,</i>	1-2
<i>Blood-vessels of Joints,</i>	3-7

B. PARTICULAR JOINTS.

<i>Articulations of the Vertebrae,</i>	8-14
<i>Temporo-Maxillary,</i>	15
<i>Of the Upper Limb,</i>	16-17
<i>Of the Lower Limb,</i>	18-30

A. STRUCTURE OF JOINTS IN GENERAL.

Articular Cartilages, Synovial Membranes, and Ligaments.

2. 1. Structure of the Articular Cartilages. *Hunterian. L. 1.*

"The inner surface of the patella; its cartilaginous covering, by long maceration in water, has its fibres unravelled; some of these are dug out to show that the fibres of cartilage are perpendicular to the end of the bone they cover." An engraving of this specimen is used to illustrate the paper in *Philosophical Transactions for 1742-43*, Vol. XLII., p. 514, "Of the Structure and Diseases of Articulating Cartilages, by William Hunter, Surgeon," from which the following is a quotation:

"An articulating cartilage is an elastic substance uniformly compact, of a white colour and somewhat diaphanous, having a smooth polished surface covered with a membrane; harder and more brittle than a ligament, softer and more pliable than a bone."

"When an articulating cartilage is well prepared it feels soft, yields to the touch, but restores itself to the former equality of surface when the pressure is taken off. This surface when viewed through a glass appears like a piece of velvet. If we endeavour to peel the cartilage off in lamellae, we find it impracticable; but if we use a certain degree of force, it separates from the bone in small parcels; and we never find the edge of the remaining part oblique, but always perpendicular to the subjacent surface of the bone. If we view this edge through a glass, it appears like the edge of velvet, a mass of short and nearly parallel fibres rising from the bone, and terminating at the external surface of the cartilage; and the bone itself is planned out into small circular dimples, where the little bundles of the cartilaginous fibres were fixed. Thus we may compare the texture of a cartilage to the pile of velvet, its fibres rising up from the bone as the silky threads of that rise from the woven cloth or basis. In both substances the short threads sink and bend in waves upon being compressed; but, by the power of elasticity, recover their perpendicular bearing as soon as they are no longer subjected to a compressing force. If another comparison was necessary, we might instance the flower of any corymbiferous plant, where the flosculi and stamina represent the little bundles of cartilaginous fibres, and the calyx, upon which they are planted, bears analogy to the bone."

"Now these perpendicular fibres make the greatest part of the cartilaginous substance; but without doubt there are likewise transverse fibrils which connect them, and make the whole a solid body, though these last are not so easily seen, because, being very tender, they are destroyed in preparing the cartilage."

2.2. Structure of Articular Cartilage. Perichondrium.

Hunterian. L. 2.

"A portion of the lower end of the humerus, sawn through its cartilaginous covering, to show the same as No. 1." Rather, the bone has been sawn and then the cartilage broken, when it is seen that it splits perpendicularly to the head of the bone, and in the edge is seen the fibrous structure described in the preceding. The ends of the vertical fibres are seen to be covered by a thin sheet of cartilage in which no fibrillation is visible. This has been torn up from them in places, and projects from the broken edge as a distinct membrane. To quote from William Hunter's paper mentioned above, "We are told by anatomists that cartilages are covered with a membrane

named perichondrium. If they mean the cartilages of the ribs, larynx, ear, etc. there, indeed, such a membrane is very conspicuous; but the perichondrium of the smooth articulating cartilages is so fine and firmly braced upon the surface, that there is room to doubt whether it has been often demonstrated or rightly understood. This membrane I have raised in pretty large pieces after macerating; and find it to be a continuation of that fine smooth membrane that lines the capsular ligament, folded over the end of the bone where the ligament is inserted. On the neck of the bone, or between the insertion of the ligament and the border of the cartilage, it is very conspicuous, and may be pulled up with a pair of pincers; but where it covers the cartilage, it coheres to it so closely that it is not to be traced in the recent subject without great care and delicacy. In this particular it resembles that membrane which is common to the eyelids and forepart of the eyeball, and which is loosely connected with the albuginea, but strongly attached to the cornea."

"From this description it is plain that every joint is invested with a membrane which forms a complete bag, and gives a covering to everything within the articulation in the same manner as the peritoneum invests not only the parieties, but the contents of the abdomen." The specimen is injected red.

2.3. The Blood-vessels of an Articulation. *Hunterian. L. 3.*

Lower end of the femur, with the patella, semilunar cartilages, and adjacent portions of the synovial membrane, injected red. The bone, tendons, and synovial membrane all appear vascular, but the articular cartilages completely avascular. "The blood-vessels are so small that they do not admit the red globules of the blood, so that they remained in a great measure unknown, till the art of filling the vascular system with a liquid wax brought them to light. Nor even by this method are we able in adult subjects to demonstrate the vessels of the true cartilaginous substance; the fat, glands, and ligaments shall be red with injected vessels, while not one coloured speck appears upon the cartilage itself. In very young subjects, after a very subtle injection, they are very obvious; and I have found their course to be as follows: All round the neck of the bone there are a great number of arteries and veins, which ramify into smaller branches, and communicate with one another by frequent anastomoses, like those of the mesentery. This might be called the *Circulus Articuli Vasculosus*, the vascular border of the joint. The small branches divide into still smaller ones upon the adjoining sur-

face in their progress towards the centre of the cartilage. We are very seldom able to trace them into its substance, because they terminate abruptly at the edge of the cartilage, like the vessels on the Albuginea Oculi, when they come to the cornea. The larger vessels which compose the vascular circle plunge in by a great number of small holes, and disperse themselves into branches between the cartilage and bone. From these again there arises a crop of small short twigs that shoot towards the outer surface; and whether they serve for nourishing only, or if they pour out a dewy fluid, I shall not pretend to determine. However that be, I cannot help observing, that the distribution of the blood-vessels to the articulating cartilages is very peculiar, and seems calculated for obviating great inconveniences. Had they run on the outer surface, the pressure and motion of the two cartilages must infallibly have occasioned obstructions, inflammations, etc., which would soon have rendered our motions painful, and at last have deprived us of them. But by creeping round the cartilaginous brim, where there is little friction, or under the cartilage, where there is none, they are perfectly well defended from such accidents." In his *Medical Commentaries*, p. 53, William Hunter remarks about the above passage: "In that little essay I advanced that the vessels of the articulating cartilages pass, secure from friction and pressure, between the gristle and the bone. This appearance I saw distinctly in several injected joints; but afterwards I found out that the vessels which I had seen did not belong to the superficial cartilaginous crust which remains in the adult, but to what lies immediately under it, in growing animals, before the ossification is complete." These vessels, nevertheless, are to all intents and purposes the nutrient vessels of the cartilage, as it is they that bring the blood into its neighbourhood.

2. 4. Blood-vessels of an Articulation. *Hunterian. L. 13.*

A knee-joint injected red, rather coarsely and laid open, showing the vascularity of the synovial membrane and fatty pads which fill the crevices of the articulation. Also the avascularity of the articular cartilages.

2. 5. Vascularity of Synovial Membrane. *Hunterian. L. 5.*

The first rank of bones of the carpus from an injected arm, showing the synovial fringes bright red, while the cartilages are pure white.

2. 6. Vascularity of Synovial Membrane. *Hunterian. L. 6.*

A finger from an injected hand, the articulations laid open before, to show the same things as the preceding. Injected as usual with vermilion.

2. 7. Vascularity of Synovial Membranes. *Hunterian. L. 15.*

Lower ends of the tibia and fibula showing the articular surfaces of the ankle; the synovial fringes and adjacent soft parts beautifully injected red, while the avascular articular cartilages remain pure white.

B. PARTICULAR JOINTS.**2. 8. The Intervertebral Substance.** *Hunterian. M. 1.*

"A lumbar vertebra, with two of the intervertebral substances, showing that substance half an inch thick. It is made up externally of the same kind of white silver-coloured fibres as tendon, which decussate one another in many places."

2. 9. The Intervertebral Substance. *Hunterian. M. 1a.*

A section of "a lumbar vertebra from the sea-cow" (Dugong) showing the external firm fibrous, and the central soft gelatinous substances composing the above.

2. 10. The Intervertebral Substance. *Hunterian. M. 2.*

Lumbar vertebra "from the sea-cow," showing on one end of the body the intervertebral substance as in the preceding, and on the other the intervertebral disc of cartilage. In the adult human subject this disc behaves as an epiphysis, ossifies and becomes incorporated with the body of the vertebra.

2. 11. The Intervertebral Substances. *Hunterian. M. 3.*

"The spine of a young child, showing that the intervertebral substance is thinnest in the neck, and becomes gradually thicker to the upper end of the sacrum; shows also the external decussating ligamentous fibres of these substances the whole way."

2.12. The Ligaments of the Vertebral Column.*Hunterian. M. 14.*

"The lumbar vertebrae from an adult, with their connecting ligaments; a bit of stick is passed through the canal for the passage of the cauda equina, with a view to stretch the intervertebral ligaments, and render visible a yellow elastic ligament passing between the spinal processes of the vertebrae and serving the purpose of assisting to maintain the spine constantly erected."

2.13. The Ligamentum Nuchae; Ostrich. *Hunterian. M. 15a.*

"Eight vertebrae of the neck, from the ostrich, showing a strong pyramidal elastic ligament passing through a canal in the spinal processes, and serving to sustain the head in the stooping posture of the animal, also to bring it up again." Corresponds to the inter-spinous ligaments, which, in the human neck, are very weak and not elastic.

2.14. The Atlo-Axial Articulation. *Hunterian. M. 16a.*

The atlas and axis "from a sea-cow," dissected, showing the strong transverse ligaments round the neck of the odontoid processes, confining it in the hollow of the anterior arch of the atlas.

2.15. The Temporo-Maxillary Articulation.*Hunterian. M. 8.*

Dissection of the above. The cavity of the joint is opened on the inner side to show the interarticular fibro-cartilage and "the thickness and extent of the capsular ligament."

2.16. The Shoulder-joint.*Hunterian. M. 9.*

"The joint of the shoulder laid open, showing the thickness and extent of the capsular ligament; from a lad." The humerus, scapula, clavicle, and the ligaments are carefully dissected, showing also the relation of the head of the humerus to the glenoid facet, and of the tendon of the biceps to the joint as it passes through the upper part of the capsular ligament. The claviculo-acromial joint is also opened. Bristles indicate the claviculo-coracoid, conoid, and trapezoid ligaments, and the supra-scapular notch.

2.17. Vertical Section of the Shoulder-joint.*Hunterian. M. 10.*

"A perpendicular section through this joint, from an adult, showing the thickness and extent of the capsular ligament, also the large sacculus mucosus (bursa) under the deltoid muscle."

2.18. The Symphysis Pubis.*Hunterian. M. 4.*

"A perpendicular section of the superior ends of the ossa pubis so as to look upon the symphysis; this joint consists of two fibro-cartilaginous surfaces, and transverse ligamentous fibres passing from one to the other; about the middle there is sometimes a discontinuation of these transverse fibres, and a kind of cartilaginous pulp only, as between the vertebrae, and sometimes a cavity with synovia." There is a slight indication of one here. Compare No. 1. 21. Shows the great thickness of the superior and inferior ligaments.

2.19. The Symphysis Pubis "from a Maid."*Hunterian. M. 4a.*

Divided into three pieces by vertical section; shows the wide sub-pubic angle characteristic of the female pelvis. This specimen is represented in the plate connected with "Some Remarks on the Symphysis Pubis," by William Hunter (*Med. Obs. and Inq.*, Vol. II., p. 333, Plate 1, fig. 3), and is described as "a vertical section of the ossa pubis in a female subject that had not been with child."

2.20. The Symphysis Pubis.*Hunterian. M. 5.*

Divided into three horizontal sections, showing the thickness of the anterior and posterior ligaments.

2.21. The Symphysis Pubis.*Hunterian. M. 6.*

Transverse section of the above showing a distinct synovial cavity; upper half. "A horizontal section of the symphysis of the ossa pubis in a subject who died of a fever in childbed." Figured in *Med. Obs. and Inq.*, Vol. II., Plate 1, fig. 4; William Hunter notes that "in lying-in women there is, sometimes at least, a cavity in the symphysis of the ossa pubis."

2. 22. The Symphysis Pubis.*Hunterian. M. 7.*

The lower part of the preceding.

2. 23. The Hip-joint.*Hunterian. M. 11.*

Right hip-joint of an adult opened in front and the capsule turned down, showing the relation of the head of the bone to the acetabulum and the extent and thickness of the capsular ligament. The capsular ligament is attached near the root of the neck, and the synovial membrane is seen reflected at this point. The whole head and almost the whole neck is therefore within the joint cavity. The neck is clothed with a very strong fibrous sheath.

2. 24. The Hip-joint.*Hunterian. M. 11a.*

Right hip-joint laid open behind and the head of the bone dislocated to show the interior of the acetabulum and the ligamentum teres. The capsule is much thinner than in front.

2. 25. The Knee-joint.*Hunterian. M. 11b.*

Left knee injected, dissected, flexed, and opened in front to show the interior of the joint. The injection is very fine, and gives a good idea of the vascularity of the synovial membranes and the avascularity of the articular cartilages. The ligamentum mucosum is seen passing from the fatty pads below the ligamentum patellae to be attached between the condyles of the femur.

2. 26. The Knee-joint.*Hunterian. M. 11c.*

Dissection of the left knee-joint, opened and semiflexed, showing the semilunar fibro-cartilages and the crucial ligaments. The anterior or external crucial ligament, which is tightened during extension, is seen rising from in front of the spine of the tibia joined with the anterior end of the external semilunar fibro-cartilage; it passes backwards, outwards, and upwards to be attached well back upon the inside of the external condyle of the femur. The posterior or internal, which is tightened during flexion, is also seen rising behind the spine of the tibia joined with the posterior end of the external semilunar fibro-cartilage, and running upwards, forwards, and inwards to be attached to the outer and forepart of the internal condyle of the femur. This is seen best behind. The superior tibia-fibular articulation is also laid open. Injected red.

2. 27. The Semilunar Fibro-cartilages. *Hunterian. L. 4.*

The semilunar fibro-cartilages from a left knee-joint, injected red, hung by a thread passed through the loop of the external one. The attachment to the tibia is marked by a thin slice of bone and cartilage. Between the ends of the external cartilage lies the cut attachment of the anterior crucial ligament. That of the posterior crucial ligament is seen beside the posterior end of the same cartilage. Compare preceding specimen.

2. 28. Ligamentum Patellae and Supra-patellar Bursa. *Hunterian. M. 13b.*

"A fine preparation of the tendon of the vasti and ligament of the patella, the patella itself, and part of the head of the tibia, injected red; the sacculus mucosus above the patella very conspicuous, also the tendinous fibres continued over the patella to form ligament." Injection very imperfect.

2. 29. The Ligamentum Patellae. *Hunterian. M. 13.*

The patella, ligamentum patellae, and its insertion into the spine of the tibia; similar to the preceding.

2. 30. The Ligamentum Patellae. *Hunterian. M. 13a.*

A similiar preparation, finely injected red.

SERIES 3.

INJURIES OF BONE.

For Repair of Fracture, see below Nos. 10, 35, 42, 43, 54, 55, 56, 87, 90, 97, 98.

For Mal-union of Fracture, see below Nos. 28, 41, 43, 59, 61, 63, 64, 69, 70, 83, 84, 86, 93.

For Non-union of Fracture, see below Nos. 45, 66, 72, 81, and Series 5 (under Septic Diseases of Bone).

<i>Fractures of Skull and Face Bones,</i>	1-2
„ <i>Vertebral Column,</i>	3
„ <i>Ribs and Sternum,</i>	4-13
„ <i>Clavicle,</i>	14-22
„ <i>Scapula,</i>	23-25
„ <i>Humerus,</i>	26-39
„ <i>Radius and Ulna,</i>	40-43
„ <i>Bones of Hand,</i>	
„ <i>Pelvis,</i>	44
„ <i>Femur,</i>	45-70
„ <i>Patella,</i>	71-73
„ <i>Tibia and Fibula,</i>	74-100
„ <i>Bones of Foot,</i>	
<i>Gunshot Injuries of Bone,</i>	101
<i>Comparative Pathology,</i>	102-109

3.1. Healed Fracture of the Frontal and Nasal Bones opening the Frontal Sinuses. *Hunterian.*

Part of a cranium macerated, showing the above. The injury has been caused by violence acting in a downward as well as a backward direction. It has fractured the outer table only, laying open the

frontal sinuses; the fragment of frontal bone has been driven downwards and backwards between the eyes, carrying with it the bridge of the nose, after fracturing the left nasal bone and the nasal processes of the left superior maxilla. Union has occurred in this position, so that the cavity of the frontal sinuses lies bare in front, and the bridge of the nose is very greatly flattened. There is no fissuring of the orbital plates. The edges of the fragments are rounded off, showing that the fracture was old.

3.2. Depressed Fracture of the Skull.

Presented by R. J. Marshall, M.D., 1896.

Portion of the vault of the cranium macerated and dried, showing on the outside an oval depression about 2.5 cm. in diameter. The outer table is cracked round the edge of the depression and splintered; the fragments slope down to the centre, which is a small punched-out piece about 6 mm. in diameter, lying 7 mm. below the level of the surrounding bone. The inner table is driven in and splintered over a slightly larger area than the depression of the outer.

From a patient in the mines of Rio Tinto, Southern Spain, who was struck by a falling piece of mineral, and died in the Rio Tinto Company's Hospital shortly afterwards.

3.3. Fracture of the Twelfth Dorsal and First Lumbar Vertebrae with Dislocation.

Hunterian.

The six lower dorsal, the lumbar vertebrae, and the sacrum showing the above. Cleaned and dried. In the absence of a history the nature of the violence which produced the fracture is unknown, but it appears that the upper part of the column has been driven forward, breaking off and carrying with it the right pedicle, lamina, superior articular process, and an edge of bone all round the front of the body of the first lumbar vertebra; while at the same time the arch of the twelfth dorsal has snapped through its pedicles, and is displaced upwards and backwards. The spinous process of the first lumbar is also broken. The displacement is so great that the anterior edge of the first lumbar corresponds with the posterior edge of the body of the last dorsal vertebra. The posterior edge of the body of the first lumbar is about 1 cm. from the lower edge of the arch of the last dorsal, which has been thrown up by the interlocking articular processes. The spinal cord by this means may

have been partly saved, but it is more probable that it was severely crushed and stretched if not completely severed.

3.4. Ankylosis of the First and Second Ribs, probably after Fracture. *Hunterian.*

The first and second ribs of the left side macerated and dried. The fusion commences at a point corresponding with the double origin of the first head of serratus magnus. About an inch in front of this the bony bridge and the second rib have been very thin, and have been broken away in the line of the intercostal space and also for about 2 cm. of the line of the second rib. In front of this gap a band of bone, about the thickness of the ribs, comes down from the first and supports the anterior end of the second rib, acting apparently as the real shaft of the bone. The articular head of the sternal end of the first rib is expanded and irregular as if from chronic osteo-arthritis.

3.5. United Fracture of the Ribs. *Hunterian.*

The second, third, and fourth ribs macerated and dried, illustrating the above. All the three ribs have been fractured at the posterior, and the two lower at the anterior angles as well. There has been considerable displacement, the posterior fragments projecting and overlapping the anterior: consequently the new formation of bone is considerable. The danger of injury to the lungs from such displacement is obvious.

3.6. United Fractures of the Ribs. *Hunterian.*

Two lower ribs macerated and dried, illustrating fracture at the posterior angle. The displacement is similar to that in the preceding. The posterior fragment in the one projects downwards; in the other, rather upwards as well as outwards.

3.7. United Fractures of the Ribs at the Posterior Angle. *Hunterian.*

Two of the floating ribs, tenth and eleventh apparently, macerated and dried, illustrating the above. In both there is considerable thickening. In one there seems to have been no displacement; in the other, the posterior fragment has been driven upwards and inwards.

3.8. United Fractures of the Ribs at the Anterior Angle.*Hunterian.*

Two lower ribs macerated and dried, illustrating the above. There is almost no displacement of the fragments, but a considerable mass of callus shows the seat of fracture. What displacement there is has been of the end of the posterior fragment inwards. From the appearance of the callus the fractures are very old, and probably a certain amount of distortion has been rectified in the natural processes of repair.

3.9. United Fracture of the Ribs at the Anterior Angle.*Hunterian.*

A lower rib macerated, illustrating the above. The fracture must have been of very old standing. The continuity of the fragments is perfectly restored. Only a slight thickening without distortion shows the seat of fracture.

3.10. Recent United Fracture of the Ribs.*Hunterian.*

A tenth rib macerated and dried, illustrating the above. The fracture is at the posterior angle, and on the outer surface the callus has been partly dissected away showing the projecting edge of the posterior fragment. On the upper and inner surface is a mass of spongy sub-periosteal new bone, in some parts fully 5 mm. thick, and extending 2 cm. along the length of the bone. Several large foramina for blood-vessels appear in the mass of callus. Anterior to this is another swelling as if from a former fracture.

3.11. United Fracture of Two Ribs with Ankylosis between them.*Hunterian.*

Two lower ribs macerated and dried, illustrating the above. Both ribs have been fractured about the middle and at the anterior angles, and have united with slight deformity. In addition, a bridge of bone 3 cm. broad by 5 mm. thick has formed at the posterior fracture, firmly uniting the bones to one another. The bridge of new bone is tunnelled on the outside for the intercostal artery and nerve of the upper rib. The intercostal space is about the normal width. The part of the lower rib anterior to the fracture at the angle is wanting.

3.12. United Fracture of Two Ribs with Ankylosis.*Hunterian.*

Parts of two lower ribs macerated and dried, illustrating the above. The fracture has been about the anterior angle, and there is very little thickening or deformity; but between the bones is developed an osseous bridge, 1 cm. wide and 4 mm. thick, firmly uniting them.

3.13. United Fracture of Rib at the Middle.*Hunterian.*

Lower rib macerated and dried, illustrating the above. The bone has healed with considerable thickening, but no deformity.

3.14. Normal Clavicle for Comparison with the succeeding Fractures.*Hunterian.*

Right clavicle macerated and dried.

3.15. United Fracture of the Sternal End of the Clavicle.*Hunterian.*

Left clavicle macerated and dried, illustrating the above. The fracture has been about an inch from the sternal end of the bone, and has apparently passed obliquely from above and behind, downwards, forwards, and inwards, implicating the sterno-clavicular articulation, and that with the first costal cartilage. There is very little callus on the upper and posterior surfaces, and there is almost no elevation or depression of either fragment, but there has been considerable displacement in the antero-posterior direction, so that the curve of the inner half of the bone is almost abolished. In front and below there is a large irregular mass of new bone, from which a section has been sawn out about the middle, showing its cancellous structure. The old shaft appears in the bottom of the cut.

3.16. United Fracture of the Clavicle near the Sternal End.*Hunterian.*

Left clavicle macerated and dried, illustrating the above. The fracture has occurred in the inner half of the clavicle, running in a very oblique direction from near the middle of the bone forwards and inwards to about 2 cm. from the sterno-clavicular articulation. There has been considerable forward displacement of the inner

end of the outer fragment, and overlapping of the two ends. Union has taken place with formation of a large amount of new bone. The inner fragment has also tilted up considerably.

3.17. United Fracture of the Clavicle about the Middle.

Hunterian.

A smallish right clavicle macerated and dried, illustrating the above. The fracture has united with the characteristic elevation of the outer end of the inner fragment and increase of the natural curve. The bone is quite smooth and very little thickened at the seat of fracture.

3.18. United Fracture of the Clavicle about the Middle.

Hunterian.

Right clavicle macerated and dried, illustrating the above. The fracture has united with little thickening, but the inner fragment has been tilted up, the ends have overlapped, and there was probably a good deal of shortening.

3.19. United Fracture of the Clavicle at Junction of Inner and Middle Thirds.

Hunterian.

Left clavicle macerated and dried, illustrating the above. The fracture has united with considerable deformity, the inner fragment being tilted up and projecting markedly above the outer.

3.20. United Fracture of the Clavicle at the Middle.

Hunterian.

Right clavicle macerated and dried, illustrating the above. The fracture has united with the characteristic projection upwards of the inner fragment, and increase of the natural curvature forwards. Probably not much shortening.

3.21. United Fracture of the Clavicle near the Acromial End.

Hunterian.

Left clavicle macerated and dried, illustrating the above. The fracture has been about 3 to 4 cm. from the acromion, just about the conoid and trapezoid ligaments. There is almost no thickening of the bone, and the deformity amounts only to a slight increase of the curvature backwards, and slight depression of the outer fragment.

3. 22. United Fracture of the Clavicle near the Acromial End.*Hunterian.*

Right clavicle macerated and dried, illustrating the above. The fracture has been just internal to the conoid and trapezoid ligaments. There is little thickening, the curve is considerably increased in a backward direction, and the outer fragment lies a little below the level of the inner.

3. 23. Normal Right Scapula.*Hunterian.*

For comparison with the succeeding fractures; macerated and dried.

3. 24. United Fracture of the Body of the Scapula.*Hunterian.*

Left scapula macerated and dried, illustrating the above. The fracture has passed from just below the glenoid facet horizontally across the bone a little below the spine. Being very old and well healed, it cannot be traced to the posterior border, but a little hollow in that edge indicates about where it passed. Union has resulted with a deep fossa between the lower fragment and the spine, and a knob of bone projecting below the glenoid facet as if it had been detached by the accident. The glenoid facet is not involved. The detached lower part of the body has been slightly rotated, carrying the lower angle forward.

3. 25. United Comminuted Fracture of the Body of the Scapula.*Hunterian.*

Left scapula macerated and dried, illustrating the above. There has been comminution of the whole of the bone below the spine, and union has occurred with marked deformity and with several holes in the infra-spinous fossa. The fracture, rising from just below the glenoid facet, runs across about 2 cm. below the spine, then upwards, splitting the base of the spine at the posterior edge.

The whole lower fragment has been carried upwards and forwards, and rotated in the same direction. There is a sharp prominence just below the neck, where the lower fragment has overlapped the upper, and the posterior edge dips into a deep bay below the spine, and then trends much farther forward than in the normal bone.

The anterior border, instead of trending backwards from the glenoid facet, runs down to the lower angle almost in line with the articular surface. A split has also passed longitudinally from the transverse fracture down to the inferior angle. A straight edge applied to the lips of the glenoid facet cuts off about 1.5 cm. (about half an inch) of the angle of the scapula, which must be displaced forwards 8 or 9 cm.

3. 26. Normal Humerus.

Hunterian.

Right humerus macerated and dried, for comparison with the fractures.

3. 27. Recently United Fracture of the Surgical Neck of the Humerus. Impacted. Intra-capsular.

Hunterian.

Right humerus macerated and dried, showing the above. The fracture has been just below the level of the tuberosities. The upper end of the shaft has been driven upwards, forwards, and inwards into the cancellated head, its firm edges crushing the spongy bone, and destroying part of the articulating surface in front. The head is displaced considerably backwards and outwards relatively to the axis of the shaft, and rotated backwards. There has been no fracture of the tuberosities, which have gone with the head. The callus has a spongy texture, and the edges of the lower fragment are quite sharp, showing that the fracture is recent.

3. 28. United Fracture of the Surgical Neck of the Humerus: False Joint.

Hunterian. LL. 15a.

Anterior section, longitudinal, of the head of the left humerus and scapula, most of the soft parts having been removed. Of the scapula there is only a small portion of the glenoid facet and the coracoid process. There has been a transverse fracture about the surgical neck, passing upwards and inwards to about the lower edge of the articular surface. The cavity of the shoulder-joint is partly filled up with fibrous tissue extending from the edges over the articular surfaces. The ends of the fragments have consolidated, the marrow cavity in the lower being closed with bone, and a false joint formed between them. From the position of the fracture it

might be a separation of the epiphysis. In the absence of a history, a rather unsatisfactory specimen. The description in the MSS., which certainly does not apply to the specimen in the jar now, was: "Diseased joint: foot from Battersea: looks like a fracture. (Case Mr. Hewson's)."

3.29. United Fracture of the Humerus about the Surgical Neck.

Hunterian.

Left humerus macerated and dried, showing the above. The fracture has passed rather below the surgical neck. The lower end of the upper fragment has been thrown forward, and the lower fragment drawn upwards, inwards, and forwards. Union has been accomplished with very little thickening, but with a considerable bend forwards at the seat of the injury.

3.30. Very old United Fracture in the Upper Third of the Humerus, above the Insertion of the Deltoid.

Hunterian.

Left humerus minus the head, probably from a grave, illustrating the above. The fracture has passed 2 or 3 cm. lower than in the last. It is of such old standing that its line cannot now be traced. There is a considerable bend outwards and forwards, the upper fragment having been abducted by the muscles inserted into the great tuberosity, while the teres major and latissimus dorsi have not been able to draw the lower fragment inwards, and it has been drawn upwards and forwards by the deltoid, biceps, and coracobrachialis. Consequently the fracture has united with the bone curved as if by too big a pad in the axilla.

3.31. United Fracture below the Insertion of the Deltoid.

Hunterian.

Left humerus macerated and dried, illustrating the above. The fracture has passed from above and inside, downwards, outwards, and forwards. It has healed with a moderate amount of thickening and only slight deformity, due to abduction of the upper fragment by the deltoid, and slight overlapping of the oblique ends. Shortening must have been very slight, and there is no interference with the musculo-spiral groove. A very good union.

**3. 32. United Fracture of the Humerus above the Middle.
Very oblique. Shortening and Inversion.**

Hunterian.

Left humerus macerated and dried, illustrating the above. The fracture in this case has passed higher and more obliquely than in the last, from above and behind downwards and forwards. There is very considerable overlapping of the fragments, and abduction of the upper. They are firmly welded together side by side. The marrow cavity of the lower is pressed against the side of the upper: in the upper it is sealed with bone. The line of fracture has passed a little outside the musculo-spiral groove, and probably did not interfere with the nerve. On placing the humerus beside a normal bone, there is seen to be considerable inversion of the lower end.

**3. 33. United Fracture of the Humerus below the Insertion
of the Deltoid. Complex.**

Hunterian.

Right humerus macerated and dried, illustrating the above. The fracture is rather complex. The upper fragment appears to be split obliquely from about the centre of the shaft downwards and outwards to a point about the middle of the outer side. The outer fragment being abducted, its point projects there considerably. There has also been a fracture passing from the outside obliquely downwards and inwards completely across the shaft. The triangular portion to the inside between the two fissures appears not to have been separated from the upper fragment, as it is not out of line with the inside of the shaft above, but to have been partly broken and bent slightly inwards, and the lower fragment has been drawn up like a wedge between the two points of the upper. The bone is now fairly straight and well mended without a very great deal of thickening. The upper fracture runs dangerously near the musculo-spiral groove.

**3. 34. United Transverse Fracture at the Insertion of the
Deltoid.**

Hunterian.

Right humerus macerated and dried, illustrating the above. The lower end of the upper fragment projects slightly outwards and forwards, otherwise the outside of the bone is smooth, but on the inside there is a mass of spongy callus, making a thickening of the bone considerably larger than a walnut; it hardly extends far enough outwards to have interfered with the musculo-spiral nerve.

3. 35. United Fracture at the Level of the Insertion of the Deltoid.*Hunterian. LL. 38.*

Posterior section of the left humerus, injected red, decalcified, dried, and mounted in turpentine, showing the process of repair at a late period. There has been slight abduction of the upper fragment, displacing its lower end about 1 cm. to the outside of the lower fragment. The dense bony walls of the shaft have been restored and the projections rounded off with rather solid cancellous bone. There are denser strata on the outside and where the remains of the old solid walls of the bone lay. The medullary cavity is occupied for about 4 cm. in the neighbourhood of the fracture by vascular open cancellous bone; it is nearly restored in the centre. The process of union has advanced so far that the exact line of fracture is not visible, but the solid ends of the fragments can be traced for a certain distance into the cancellous callus. It appears to be the half of No. 769 in the Pathological Series of the Museum of the Royal College of Surgeons, England.

3. 36. United Fracture of the Lower Part of the Shaft.*Hunterian.*

Right humerus macerated and dried, illustrating the above. The fracture has passed from above and outside obliquely downwards and inwards, and the lower fragment is behind and outside of the upper, overlapping it considerably; the bone is slightly bent backwards, and considerably thickened and shortened.

3. 37. United Fracture of the Humerus in the Lower Third.*Hunterian.*

Right humerus macerated and dried, illustrating the above. The fracture has passed nearly transversely. The lower fragment has been drawn up considerably on the outside of the upper, and has united with it at an open angle, so as to raise the internal condyle considerably above the external.

3. 38. United Fracture in the Lower Third of the Humerus.*Hunterian.*

Right humerus macerated and dried, illustrating the above. The bone has been fractured about two inches above the elbow, and also

about two inches higher up. The middle fragment is not very badly displaced, but the lower is rotated so that its upper end has overlapped on the outside the lower end of the middle fragment, the broken surface of which has united with its inner side; the trochlear surface is consequently turned slightly inwards.

3. 39. Recent Fracture of the Humerus of a "Child about the First Year." *Hunterian. LL. 8.*

Longitudinal section of a humerus fractured about the middle, injected red, the soft parts removed down to the periosteum, dried and mounted in turpentine. The ends of the fragments are quite sharp, and there is no trace of bony union. The medullary cavity is occupied by vascular tissue, which passes between the fragments on one side. On the outside, splicing the fragments together, there is a thick mass of soft vascular callus—provisional callus. The outer layer of this is more vascular than the inner layers, and looks rather like the old periosteum. Compare No. 3. 43.

3. 40. Fracture at the Middle of the Radius united with Ankylosis to the Ulna. *Hunterian.*

Left radius and ulna macerated and dried, illustrating the above. The radius has been fractured rather below the middle of the shaft obliquely and probably with some splintering, though the injury is so old that the actual lines of fracture are no longer traceable. The upper fragment lies in a plane in front of and to the outside of the lower, so that they are united with a good deal of deformity. In addition, from rather above the seat of fracture for about 5 cm. downwards, the two bones are firmly united by a bridge of bone about 1 cm. thick. The interosseous space above and below is about 6 mm. wide. Below the seat of fracture is another small bridge of bone. The ulna appears not to have been fractured; its lower end is absent, but this is a post-mortem accident. The ankylosis is absolute. It has occurred with the forearm in a position midway between pronation and supination. The bone is covered with fine shallow cracks; it had probably been buried for some time. It is figured in Cheselden's "*Osteographia*," Plate XLV., fig 4, as "Ankylosis of the Cubit from a Fracture," with the ulna whole.

3. 41. United Fracture of the Lower End of the Radius.*Hunterian.*

Left radius macerated and dried, illustrating the above. From a very small adult. The fracture has been about 4 cm. (about quarter of the length of the bone) above the lower end; there has been considerable backward displacement, and the fragments have been allowed to unite in this position: a bad union.

3. 42. Recent United Fracture of the Ulna. Lower Third.*Hunterian.*

Right ulna macerated, illustrating the above. The fracture is united by a considerable mass of spongy bony callus, in which the ends of the fragments can be seen still quite sharp.

3. 43. Recent Fracture of both Bones of the Forearm at the Middle.*Hunterian. LL. 50.*

Longitudinal section of radius and ulna from a young subject, injected red, and cleared of soft parts down to the periosteum, illustrating the process of repair and the evil results of bandaging the forearm in such an injury. The bones have been drawn together so as to obliterate the interosseous space, which would very quickly interfere with all movements of rotation. The fractures are transverse, that of the radius a little above that of the ulna. The fragments are spliced together by considerable spindle-shaped masses of callus, which in section can be seen to be partly bone and partly cartilage. The new bone fills the marrow cavities, and constitutes the greater part of the spindle-shaped thickenings on the outside of the shafts. Between the splinters the callus is chiefly cartilaginous. (Compare No. 3. 39.) About the lower epiphysial lines there is some expansion of the bone, as if the patient had suffered from rickets; the lines are too regular for rickets to have been active at the time the specimen was obtained.

Fractures of the Bones of the Hand.

Specimens wanted.

3. 44. United Fracture of the Crest of the Ilium.*Hunterian.*

Right innominate bone macerated and dried, illustrating the above. The fracture has extended from the middle of the crest

downwards and forwards to the anterior inferior spine, and has united with considerable thickening in its lower and anterior part, but with a hole in the thin part of the ilium and a notch in the crest. Looking from the front the lower fragment seems impacted in the upper, the firm outer layers of which have been thereby driven apart. The upper fragment is thrown considerably downwards and forwards.

3. 45. Intra-capsular Fracture of the Neck of the Femur.
Chronic Osteo-Arthritis. False Joint at Seat of
Fracture. *Hunterian.*

Head of a right femur macerated and dried, illustrating the above. The articular head of the bone is wanting, having possibly been left attached to the pelvis. The neck is very short, and its end is hollowed out into a sort of articular cavity. Round the edges of this the bone is polished and eburnated, and in the middle the cancellated bone is condensed. The lip of this cup is extended by new bone-formation. The top of the great trochanter and the anterior intertrochanteric line are covered by bony tubercles, the result of chronic osteo-arthritis.

3. 46. Intra-capsular Fracture of Femur. Non-union. Dis-
appearance of Neck of Femur. *Hunterian.*

Left femur macerated and dried, showing the above. The neck of the bone has disappeared, its place being marked by a slight hollow with a few osteophytic outgrowths around it on the inner aspect of the upper end of the shaft. The cancellous bone in the floor of this has become exceedingly dense, but is not polished like in the preceding. Probably this was a very old-standing fracture. The head of the bone is, of course, absent.

3. 47. United Extra-capsular Fracture of the Neck of the
Femur, with great Deformity and Extensive New
Formation of Bone. *Hunterian.*

Right femur macerated and dried, illustrating the above. The fracture has been very complex, and attended by great displacement of the fragments; it has healed, with very extensive new formation of bone, in a mass about the upper end of the femur measuring

17 × 10 × 4.5 cm. The original lesions seem to have been a driving downwards and outwards of the head and neck of the femur between the trochanters, splitting off a fragment which includes the posterior half of the great trochanter, the lesser trochanter, and a splinter of shaft about 12 cm. long, and probably producing some splitting of the anterior part of the great trochanter also. The head of the bone has gone outwards with this posterior (upper) fragment, and the lower fragment being drawn up, it lies with its corona almost in line with the inner border of the shaft, and distinctly below the level of the great trochanter. The neck is united to the mass of new bone enveloping the upper end of the lower fragment. It is decidedly shorter than normal. There must have been considerable shortening of the limb. The head of the bone is turned slightly forwards. It is overhung in front by a large nodular mass of new-formed spongy bone.

3. 48. United Impacted Extra-capsular Fracture of the Neck of the Femur. *Hunterian.*

Left femur macerated and dried, illustrating the above. As in the preceding case the neck of the femur has been driven into the cancellated bone of the trochanters, splitting the greater and displacing the posterior half of it. The fissure meets the intertrochanteric line above the lesser trochanter, which is not at all affected. The head of the bone is below the level of the trochanter, and turned backwards, so that the limb must have been slightly shortened and everted, though, as a whole, the deformity is but slight. There is little new bone, but the great trochanter is widened antero-posteriorly.

3. 49. United Fracture of the Femur in the Upper Third. Absence of the Head and Neck, and Formation of a new Articular Surface on the Inner Side of the Trochanters. *Hunterian.*

Right femur, probably from a grave, illustrating the above. The lower end is wanting. The fracture has passed from above and before obliquely downwards and backwards, and union has occurred with the shaft drawn up outside and overlapping the upper fragment considerably. A mass of cancellous bone corresponding to the outer and upper part of the great trochanter has been rotted away, leaving

a ragged gap overhung on the inner side by a ridge of firm bone. This ridge is the upper edge of a nearly flat surface, which looks upwards, backwards, and inwards. This surface, which measures 6.5 cm. vertically by 5.5 cm. horizontally, comprises the inner side of the great and the little trochanters, and from its density and polished appearance has formed one surface of an articulation. Compare the next specimen, in which the fracture has passed through much the same part of the femur.

3.50. United Complex Fracture of the Upper Third of the Femur. Splitting of the Great Trochanter.

Hunterian.

Right femur macerated and dried, illustrating the above. An oblique fracture with splitting of the upper fragment. There have thus been three fragments: one including the head, neck, and anterior half of the great trochanter with about 8 cm. of the front of the shaft; a second including the rest of the great and the lesser trochanter and a splinter of shaft, in all about 15 cm. long; the third, the lowest, meets the first, which is considerably tilted forwards, at a very open angle, which is subtended by the second fragment, the space between the three being filled up by new bone. The split extends to the top of the great trochanter, but the fragments have been prevented from separating above, presumably by the strong fibrous tissue over them. There has been considerable eversion of the lower end of the bone.

3.51. United Fracture of the Femur at the Junction of the Upper and Middle Thirds. Inversion of the Limb.

Hunterian.

Right femur macerated and dried, showing the above. A fracture oblique from above downwards, outwards, and backwards, with the upper fragment everted and lying in front and outside of the lower, united to it at a very open angle. The inversion of the lower fragment is very marked, and must have involved a very serious deformity of the limb. Such a deformity might be produced by the lower part of the limb being kept with the foot vertical, while the upper fragment has been rotated outwards and abducted by the action of the obturator externus, quadratus femoris, gluteus maximus, and psoas and iliacus muscles.

3. 52. United Fracture at the Junction of the Upper and Middle Thirds of the Femur. Eversion of Limb.

Hunterian.

Left femur macerated and dried, showing the above. This contrasts with the last in the upper fragment being to the inside and in front of the lower, which is distinctly everted. The femur is bent inwards at the seat of fracture.

3. 53. United Fracture of the Femur at the Middle. Riding of the Fragments.

Hunterian.

Right femur macerated and dried, showing the above. The fracture is very strongly united, but the upper fragment is tilted forwards, and the lower lies behind, external to, and overlapping it. There must have been considerable shortening, and the inner condyle is higher than the outer, but there is neither eversion nor inversion of the lower fragment.

3. 54. United Fracture of the Femur about the Middle. Vascularity of Callus.

Hunterian. LL. 6.

Section of a left femur injected red, decalcified, dried, and mounted in turpentine, illustrating the above. The upper fragment has been riding over the front of the lower to the extent of fully 4 cm., and union has been effected by a large mass of callus. This is of irregularly rounded shape and fairly smooth on the outside, showing that the fracture was already of considerable age. On the cut surface there appears a marrow cavity of triangular shape in the callus between the ends. The lower fragment is cut obliquely. The upper has its marrow cavity closed by a thin shell of bone. The whole is very vascular.

3. 55. Vascularity of Callus.

Hunterian. LL. 10.

Upper portion of the other section of the preceding, the uniting mass of callus cut through. In turpentine.

3. 56. Section of a United Fracture of the Shaft of the Femur.

Hunterian. LL. 7.

Injected red and mounted in turpentine. The fracture has been very similar to the last, but union has been very much further advanced. The section passes longitudinally through the upper

and obliquely across the lower fragment, cutting three thick walls of dense bone—two external and the third between the fragments. The lines of fracture are not traceable, all the irregularity being smoothed over by the new bone. The ends of the medullary cavity are closed. The new bone is not distinguishable from the old, and there is no appearance of an abnormal number of blood-vessels in it. An advanced stage of repair.

3.57. United Fracture of the Middle of the Femur.

Hunterian.

Left femur, probably from a grave, illustrating the above. The shaft is bent inwards, and there is slight riding of the ends. From a young subject. The cancellous ends are full of adipocere.

3.58. United Complex Fracture of the Femur about the Middle. Marked Bending outwards of the Shaft.

Hunterian.

Left femur macerated and dried, showing the above. The upper fragment has been splintered, one or possibly more chips being detached and lying obliquely between it and the lower. The fracture has evidently been of very old date; and whatever amount of callus may have been thrown out at the time, there is now very little thickening—little more than filling up of the angles between the fragments. All the corners are smoothly rounded off, and the medullary cavity closed with dense bone.

3.59. Badly United Fracture of the Femur about the Middle. Outward Distortion of the Shaft. Inversion of Lower End.

Hunterian.

Left femur, probably from a grave, illustrating the above. The bone is very light, and its articular ends are broken. The fragments are strongly united, but with great deformity. The ends ride considerably, and there must have been a good deal of shortening.

3.60. United Fracture of the Femur about the Middle. Marked Eversion.

Hunterian.

Left femur macerated and dried, showing the above. There has been slight riding, probably due to obliquity of the fracture, and a little bending outwards of the shaft. The union is firm, and

there is not much thickening of the bone, but the lower end is everted to an extent which must have very seriously interfered with locomotion.

3. 61. United Complex Fracture of the Femur about the Middle. Very Bad Eversion. *Hunterian.*

Right femur macerated and dried, illustrating the above. There has been considerable splintering of the bone in various directions, mostly oblique. The fracture has united very strongly, the fragments being all soldered solidly together by the callus. The lower end of the bone is so much everted as to look almost directly outwards, which must have greatly impaired the usefulness of the limb.

3. 62. United Oblique Fracture of the Femur about the Middle. Slight Inversion. *Hunterian.*

Right femur macerated and dried, showing the above. A graveyard specimen. Good firm union with little deformity.

3. 63. Badly United Fracture of the Femur about the Middle. Marked Riding and Shortening. *Hunterian.*

Left femur macerated and dried, showing the above. The fragments overlap about 3 inches, and the upper has been displaced very much in front of the lower. They are united firmly by a large mass of callus. There is slight inversion of the lower end. There must have been 14 or 15 cm. of shortening, and great lameness resulting therefrom.

3. 64. Badly United Fracture of the Femur about the Middle. Marked Shortening and Inversion. *Hunterian.*

Right femur macerated and dried, showing the above. The deformity is like that in the last specimen, but not so bad. There is a large hole in the callus, but the union is quite firm and strong.

3. 65. United Transverse Fracture of the Femur below the Middle. Riding of the Upper Fragment in Front of the Lower. *Hunterian.*

Left femur macerated and dried, showing the above. The upper fragment overrides the lower fully 5 cm., and there must have been considerable shortening and lameness. The medullary cavities are closed by cancellous bone with a thin dense outer shell.

3. 66. Ununited Fracture of the Femur about the Middle. False Joint. *Hunterian. LL. 13.*

Part of a femur, the muscles dissected off to show the above, "From a Sailor (Greenwich Hospital)." The fracture appears to have passed from above obliquely backwards and downwards, and the lower fragment has been drawn up in front of and rather external to the upper, the two crossing one another at an open angle with the points directed backwards. Union not having taken place, the two bones have formed a false joint, so that "he walked as if he had three joints in the thigh bone." The false joint has been laid open, showing that it consisted of a firm capsular ligament keeping the bones in apposition, a synovial membrane, and fibro-cartilaginous surfaces on the opposed sides of the fragments, which glided over one another. New formation of bone had closed the medullary cavities and also thrown out a buttress on the lower fragment, which increased its articular surface.

3. 67. United Complex Fracture of the Femur below the Middle. *Hunterian.*

Right femur macerated and dried, illustrating the above. A longitudinal splinter has been detached on the inner side, and lies obliquely from the upper, which overrides slightly, to the lower. The space between the upper and lower, about 2 cm. wide, is filled up by a large mass of callus binding them firmly together. The shaft is irregular and greatly increased in thickness, but the position of the lower end is very good.

3. 68. United Fracture of the Femur in the Lower Third. Very Oblique. *Hunterian.*

Left femur macerated and dried, showing the above. The fracture has passed from behind and above very obliquely down-

wards and forwards, running into the articular surface of the knee-joint. The lower fragment is tilted backwards, so that its upper end is about 3 cm. from the back of the upper fragment. This gap is filled up by an irregular mass of bone, closing the medullary cavity of the lower fragment. Below this mass a large gap leads into the medullary cavity of the upper fragment. The position is very good and the union strong. It does not appear as if the movement of the joint would have been impaired by the injury to the edge of the articular surface.

3. 69. United Fracture of Lower End of Femur involving the Knee-joint. Probably Compound. Suppuration in Fracture and Knee-joint. Ankylosis. *Hunterian.*

Portions of femur and tibia and patella macerated and dried, illustrating the above. The fracture, which from the smoothness of the callus was a very old one, had passed somewhat obliquely from behind forwards and downwards through the lower third of the femur, involving the upper border of the articular surface of the knee-joint. The lower fragment was tilted backwards, and the upper, which was displaced very much forwards, had probably pierced the skin just above the patella. The fragments are united by a thick curved pillar of bone rising from the top of the lower to the back of the upper. From the point of the upper a spur of bone passes down to the patella, which in turn is firmly ankylosed to the articular surface of the front of the lower fragment. From either condyle of the femur there passes to the tibia a thick strong bar of bone, oval in section, being compressed laterally. Between these there is a large hole, about 4 cm. by 2.5 cm., which extends upwards and downwards into the cancellous heads of the bones. The thigh and leg have formed an angle of about 135° with one another—the limb bent forward.

3. 70. United Fracture of the Femur in the Lower Third. Probably Compound. Suppuration. Destruction of Knee-joint. Ankylosis. *Hunterian.*

Part of femur and tibia macerated and dried, illustrating the above. This specimen resembles the last, being a fracture in the lower third passing obliquely from behind and above downwards and forwards; probably the sharp end of the upper fragment, being

driven forwards through the skin, provided an entrance for pyogenic organisms. The knee-joint has not been involved primarily, but the osteomyelitis has extended down the lower fragment into it. The joint has ankylosed by bone. As in the preceding a couple of bars pass between the condyles of the femur and the head of the tibia, with a gap between which represents the cavity of the joint. The fracture has been comparatively recent, and the bone uniting the fragments is rough and porous; the cancellated tissue of the ends of the femur and tibia is very open, and the outer firm layer, where it has not been destroyed in maceration, is very thin and full of large pores (rarefying osteitis). The inner condyle is united to the tibia by a broad bar of this same spongy bone; the outer seems to have been still incompletely fused with the tibia. Between the fragments of the femur is a considerable cavity, which probably contained a sequestrum.

3.71. Transverse Fracture of the Patella. Firm Fibrous Union.

Hunterian. LL. 18.

Patella with quadriceps tendon, ligamentum patellae, and head of tibia, sawn longitudinally showing the above. Before section the patella could be felt to be in two fragments, separated on the front by a depression about 2 cm. wide. Behind they are close together, and the line of fracture is marked by a row of fibrous tags. They are set at an angle of about 165° to one another. Very slight flexion at the seat of fracture was all the movement possible, the union being almost as firm as if it were osseous. On section the fragments are seen to be united by a wedge of very dense fibrous tissue, its base (in front as indicated above) measuring 2 cm., its apex behind about 5 mm., and its thickness from back to front fully 1.5 cm. The fractured surfaces are covered with a thin irregular shell of dense bone, to which the fibrous wedge is attached. A very strong union.

3.72. Ununited Transverse Fracture of the Patella. Fibrous Connection with the Fragments widely separated.

Hunterian. LL. 20.

Patella with portions of the tibia and tendon of quadriceps, showing the above. The upper fragment is 6.5 cm. above the lower, and connected with it by a fibrous band rather thinner

than the ligamentum patellae. This band just below the upper fragment was connected with the articular surface of the femur by an adhesion about 2 cm. long, which prevented full extension of the leg, but did not interfere with flexion. The usefulness of the limb must have been much impaired. The inner surface of the upper fragment is ulcerated in consequence of pressure on the femur. Compare next specimen.

3.73. Erosion of Femur by Fragment of Fractured Patella.

Hunterian. LL. 24.

Lower end of femur corresponding to the previous specimen, showing a ragged surface 4.5 cm. by 2.5 cm., where by pressure and rubbing of the upper fragment of the patella the soft parts and periosteum have been destroyed and even the surface of the bone slightly eroded. In the position of semiflexion these two specimens fit into one another exactly. In this position the adhesion between the patella and the femur, which is marked with a piece of black bristle, was not quite tense; but it was evident that it must have prevented extension of the leg beyond a position about 30° short of the straight line.

**3.74. Old United Fracture of the Tibia. Upper Third.
Comminuted. Necrosis of Splinters.**

Hunterian.

Right tibia and fibula macerated and dried, showing the above. Apparently of very old standing, the lines of fracture being quite obliterated. It was probably compound, due to direct violence, and comminuted. It was situated in the upper half, principally in the upper third, of the tibia. It is strongly mended by a thick mass of new bone, very dense, but with very large holes for the blood-vessels, and perforated by six cloacae, in none of which does there now remain any sequestrum. The head of the tibia is twisted inwards, the internal tuberosity being much lower than the external. The edges of the articular surface are lipped with osseous outgrowths, the result of chronic osteo-arthritis. The upper tibio-fibular articulation is completely ankylosed. Opposite the seat of fracture the two shafts are united by a thick buttress of bone, and the shaft of the fibula lower down is thickened and roughened by sub-periosteal new bone-formation.

**3. 75. Comminuted Fracture of Head of Tibia and Fibula.
Suppuration. Penetration of Anterior Tibial Artery.**

Jeffray Collection.

Parts of right tibia and fibula, with adjoining soft parts injected and dissected. No history. This would seem to be a case of compound fracture, possibly gun-shot, of the leg about 5 cm. below the knee. About 2.5 cm. of the shaft of the fibula just below the head is wanting; about 7.5 cm. of the bone below the gap is bare and eroded. The tibia can be seen to have been considerably comminuted; the lower fragment is displaced forwards, and on its outer side the periosteum is thickened and raised from the bone. Between the tibia and fibula is a space, from the smoothness of its walls resembling an abscess cavity, at the upper part of which is seen the anterior tibial artery opened for about 1 cm. just after it leaves the popliteal. The hole in the artery is marked by a piece of wood. Shows a fracture complicated by injury of a large blood-vessel.

3. 76. Badly United Fracture of Tibia. Upper Third.

Hunterian.

Right tibia, head absent, macerated and dried, showing the above. The upper fragment sticks out badly to the inner side. It has been fairly recent, probably compound, and followed by osteitis extending up and down the whole length of the bone. There does not appear to have been any necrosis. The osteitis was in the stage of rarefaction of bone: the callus uniting the fragments is very porous.

**3. 77. Old Fracture at Junction of Upper and Middle Thirds
of Tibia.**

Hunterian.

Right tibia macerated and dried, showing the above. There is a very marked bend backwards at the junction of the upper and middle thirds with a certain amount of irregularity behind, which suggests an old fracture with backward projection of the upper fragment. The line of the anterior edge of the tibia is absolutely unbroken, and the grain of the bone suggests bending rather than breaking; possibly an incomplete fracture; very old standing.

3. 78. United Fracture of Tibia low down and Fibula higher up, i.e. by Indirect Violence. *Hunterian.*

Right tibia, fibula and astragalus macerated and dried, showing the above. The tibia is fractured at the junction of the lower and middle thirds, the fibula just below the head. Very well united, though the upper fragment of the tibia projects somewhat on the inner side.

3. 79. Very Old and Well-united Fracture of the Tibia low down and of the Fibula higher up, i.e. by Indirect Violence. *Hunterian.*

Tibia and fibula macerated and dried, showing the above. Similar to the last, but the fracture of the tibia is rather lower down. Both bones are roughened by osteitis.

3. 80. Old United Fracture of Tibia and Fibula, by Indirect Violence. *Hunterian.*

Tibia and fibula macerated and dried, showing the above. The position of the fractures is the same as in the two foregoing specimens. Both bones are covered with irregular projections due to osteitis of long standing. Both bones show considerable overlapping of the fragments; the lower ones are carried backwards and outwards, and the foot must have gone with them. On the tibia is an osseous elevation, which probably underlay an ulcer. The irritation and congestion connected with the ulcer may have been the cause of the general irregular development of new bone.

3. 81. Ununited Fracture of Tibia with United Fracture of Fibula. Septic Osteitis. *Hunterian.*

The specimen consists of the greater part of the fibula and the lower fragment of the tibia, macerated and dried, and both incomplete. The fracture has probably been compound, with suppuration, resulting in amputation some weeks later, as the fibula has been sawn above. The fibula has mended well at both fractures, and the lower end of the tibia is ankylosed to it. The fragment of the tibia is sheathed with spongy new bone, and its upper edges are rounded and show no sign of having been united to its upper fragment; the medullary cavity is closed by bone.

3. 82. Badly United Fracture of Both Bones at the Junction of the Lower and Middle Thirds. *Hunterian.*

Left tibia and part of fibula macerated and dried, showing the above. The bones are broken at the same point, a form of fracture usually the result of direct violence. The lower fragment, with which the foot must have gone, is displaced outwards. The two bones have become ankylosed; the lower part of fibula is wanting.

3. 83. Badly United Fracture of the Tibia and Fibula at the Junction of the Lower and Middle Thirds, with a second Fracture into the Ankle-joint. *Hunterian.*

Lower half of the right tibia and fibula macerated, dried, and divided by longitudinal section, showing the above. The upper fractures have passed from above and behind downwards, inwards, and forwards. The lower fractures are splittings of the ends of both bones into the ankle-joint. All the fractures are united very strongly, but in bad position. The section shows the obliteration of the medullary cavity by strong solid bone. There is considerable irregularity of the articular surface of the ankle, due partly to the fracture, partly to consecutive inflammation of the joint. The bones are ankylosed at both seats of fracture. The foot must have been considerably everted, and the joint of little or no use.

3. 84. Badly United Fracture of the Tibia and Fibula at the Junction of the Lower and Middle Thirds. *Hunterian.*

Left tibia and fibula macerated and dried, showing the above. The foot has been set very badly displaced forwards. The upper end of the lower fragment of the tibia is lodged in the interosseous space, overlapping the upper considerably and meeting it at a considerable angle. The three fragments are firmly united. The lower end of the upper fragment of the fibula is rounded and its medullary cavity closed; it had not united with the lower fragment, which has unfortunately been lost. The usefulness of the leg must have been much impaired. Figured in Cheselden's *Osteographia*, Plate LIV., fig. 1, as "Tibia and Fibula joyned by a Callus."

3. 85. United Fracture of the Tibia and Fibula in the Lower Third. Ankylosis. *Hunterian.*

Tibia and part of fibula, from a grave, showing the above. Evidently a very old fracture, and strongly mended, with ankylosis of the bones, and the foot somewhat displaced in an outward direction.

3. 86. Fracture of Tibia and Fibula at the Junction of the Middle and Lower Thirds. United in bad position. *Hunterian.*

Right tibia with a splinter of the fibula, from a grave, showing the above. Both ends are imperfect. There is an extremely bad projection of the lower fragment in front of the upper. The medullary cavities have been closed by bone. The fibula, with the exception of a small detached splinter ankylosed to the upper fragment, is absent.

3. 87. United Fracture of the Tibia at the Junction of the Lower and Middle Thirds. Process of Repair. *Hunterian.*

Section of the lower half of the tibia, macerated and dried, showing the above. The fracture has been an oblique one, with overlapping of the ends. The medullary cavities are closed by cancellous tissue, but a new one is apparently being opened up by re-absorption of the internal new bone.

3. 88. Old United Fracture of the Tibia in the Lower Third. *Hunterian.*

Right tibia macerated and dried, perhaps from a graveyard, showing the above. A strong union in good position.

3. 89. United Fracture of the Tibia in the Lower Third. *Hunterian.*

Left tibia, probably from a grave, showing the above. A very good union, but with a considerable lump on the front of the shin. There is a square hole very like a pick mark on the head of the bone.

3.90. Fracture of the Tibia in the Lower Third, united in good position. *Hunterian.*

Left tibia macerated and dried, showing the above. The line of the bone is well preserved; there is only a little bending backwards of the lower fragment; no projection of either, and very little thickening.

3.91. United Fracture of the Lower End of the Tibia into the Ankle-joint. Osteo-arthritis *Hunterian.*

Left tibia and fibula macerated and dried, showing the above. The fracture has been a splitting of the lower end of the tibia from the joint, such as might be caused by landing heavily on the feet. A considerable fragment has been split off from the outer and posterior edge of the articular head of the tibia, and driven up between the two bones. Inflammation of the bone and joint has followed, the articular head has been more or less destroyed, and the astragalus has formed a new bed for itself about 1.5 cm. above its former position. Part of the old surface can be seen beside the internal malleolus, which seems to have been fractured also. The joint is widened by an abundant formation of new bone, which has soldered the fragments of the tibia and the fibula into one solid mass. The new formation of bone, consequent upon the osteitis, extends about half-way up both tibia and fibula. On the front of the former there is a round flat elevation of bone, which was probably formed below an ulcer.

3.92. United Fracture of the Tibia and Fibula involving the Ankle-joint. *Hunterian.*

Left tibia and fibula macerated and dried, showing the above. A fairly old fracture, but the lines of it are still recognizable by the porosity of the new bone covering them. The fracture of the tibia suggests impaction of the shaft into the lower end by a blow on the heel. It has been driven like a wedge into the cancellous head, splitting it into three fragments, which can be traced projecting slightly, one outwards, another inwards, and the third in front. The last is detached by a crack extending across the articular surface near its anterior edge. The outer border of the articular surface has been thrust up considerably above the inner. The fibula has been broken through its lower

end, and the fragments carried forwards and upwards, along with the fragments of the tibia. All the fragments of both bones are ankylosed together. The joint is distinctly widened by the mass of new bone between the fragments of the tibia and fibula.

3. 93. Fracture of the Lower End of the Tibia united, with marked Eversion of the Foot. *Hunterian.*

Right tibia, lower end imperfect, from a grave, illustrating the above. The fracture, in which the fibula was doubtless included, has passed about 5 cm. above the joint, obliquely from without inwards, probably, so far as can be judged in the imperfect condition of the specimen, without involving the ankle-joint, and the lower fragments are displaced outwards about 3 cm. In this position it has united. The foot must have been very badly everted.

3. 94. Pott's Fracture. Comparatively recent. Not united. *Hunterian.*

Right tibia and fibula macerated and dried, showing the above. The internal malleolus of the tibia is split off, and the fibula broken obliquely from behind downwards and forwards about 4 cm. above the tip of the external malleolus. There is some osseous callus about the fractures, but the fragments have separated in maceration.

3. 95. United Pott's Fracture. Osteo-arthritis. *Hunterian.*

Right tibia and fibula macerated and dried, showing the above. The tip of the internal malleolus, and the fibula about $2\frac{1}{2}$ cm. above the tip of the external malleolus, have been broken and displaced outwards along with the foot. In this position union has taken place. There has been an osteo-arthritis with new bone-formation about the tibio-fibular and ankle-joints. There is no ankylosis, but there is a certain amount of interlocking of the osseous processes in the former joint.

3. 96. United Fracture of the Fibula in the Lower Third, with Ankylosis to the Tibia. *Hunterian.*

Left tibia and fibula macerated and dried, showing the above. Probably a "Pott's," with tearing of the internal lateral ligament instead of fracture of the internal malleolus. Well united.

3. 97. Recent Fracture of the Tibia. Process of Repair.*Hunterian. LL. 53.*

Inner section of the left tibia showing the above. Shows the ends of the fragments enclosed in a thick mass of soft tissue—provisional callus—of periosteal origin. There is similar soft tissue between the ends of the fragments.

3. 98. Comparatively Recent Fracture of the Fibula. Process of Repair.*Hunterian. LL. 39.*

Longitudinal section of fibula illustrating the above. The fracture, which has been transverse, was probably between two and three weeks old when the specimen was obtained. The ends are in close apposition, with the line of fracture quite distinct; the edges are sharp, but the surfaces of the shaft are not very distinct, owing to the presence of the bony callus on the outside. This is about 3 mm. thick at its thickest point (opposite the fracture), making a spindle-shaped swelling, which acts like a splint to the fragments. The medullary cavity is occupied by a plug of fairly dense osseous callus, extending only about 1 cm. up and down.

3. 99. United Fractures of the Fibula.*Hunterian.*

A group of seven fibulae macerated and dried, illustrating the different seats of fractures of this bone, ranging from just below the head down to 6 or 7 cm. from the lower end, which is the usual seat in a Pott's fracture.

3. 100. Comparatively Recent United Fracture of the Fibula about the Middle. Riding of the Fragments.*Hunterian.*

Portion of left fibula macerated and dried, showing the above. The fracture has passed nearly transversely. The fragments meet at an angle of about 10° off the straight, the upper end of the lower fragment lying in front and outside of the upper, and overlapping it about 2 cm. The medullary cavity is not closed.

B. GUNSHOT INJURIES OF BONE.

3. 101. Encapsulation of Bullet in Bone and Fibrous Tissue.*Hunterian.*

A round leaden musket-ball enclosed in a thin capsule of bone and fibrous tissue, cut in two, showing the above. The bone is a circular disc of rather larger diameter than the ball, covering one side (about a fourth) of it, and is continued at its edges into the fibrous capsule which envelops the remainder. The bone is from 2 to 4 mm. thick, porous and rather rough on the outside as if it had been attached to some osseous surface, which, however, could not be found in the collection.

C. COMPARATIVE PATHOLOGY SPECIMENS.

3. 102. United Fracture at the Middle of the Femur of a Gorilla.*Skeleton presented by John White, M.D., 1865.*

Articulated skeleton in case in large hall of the Museum. The fracture has passed obliquely from without downwards, inwards, and rather forwards. The lower fragment is bent and rotated slightly inwards. The bones ride very little, and strong union has occurred with very little osseous formation and comparatively little shortening and deformity. Contrast this with the succeeding specimens. The animal was not full-grown, as the epiphyses are all quite distinct; the lower one of the fractured bone is amissing.

3. 103. United Fracture of Radius and Ulna, "from a Sow." Ankylosis of the two Bones.*Hunterian.*

Left radius and ulna macerated and dried, illustrating the above. Union has been effected by a huge mass of dense-looking bone, which has fused the four fragments of the two bones into a single piece. The line of the limb has been fairly well maintained.

3. 104. Old Fracture of the Pelvis and Neck of the Femur in a Quadraped.*Hunterian.*

Pelvis and several vertebrae macerated and dried, illustrating the above. The symphysis pubis has been broken away, and the

ends are rounded off, showing that this is not an accident of preparation. The right ischium has also been broken across, and has united again. The right acetabulum is filled up by an irregular mass of bone, part of the outer surface of which is eburnated and polished by friction of another fragment; probably a case of intra-capsular fracture of the neck of the femur with non-union and formation of a false joint.

3.105. Old United Fracture of the Femur of a Quadruped.

Hunterian.

Left femur macerated, dried, and divided longitudinally, showing the above. The fracture is old, and the bone is smooth and polished. The fragments have overlapped to such a degree that the bone must have been shortened by about a third. Union has been effected by coalescence of the opposed outer surfaces, and by the masses of bone closing the medullary cavities. The medullary cavities of the two fragments are quite distinct; they are very wide, and the walls of the bones very thin. Half of the upper epiphysis is absent, the bones being from a young animal.

3.106. Old United Fracture of the Femur of a Quadruped.

Hunterian.

Right femur macerated and dried, showing the above. The fracture has passed from above and in front obliquely downwards and backwards, and the upper fragment is tilted forwards, meeting the lower at an open angle. The two ends are firmly united in a thick mass of bone, which gives evidence on its sides of a slight degree of overlapping of the fragments.

3.107. Recent Fracture of the Femur in a Quadruped.

Not united.

Hunterian.

The two fragments of the femur of some quadruped, macerated, dried, and mounted together on a piece of wood. They have been riding over one another, and were probably united by recent callus, which, being not fully developed, has allowed them to separate in maceration, just as the upper epiphysis has separated through the animal having been young. There has been extensive irregular

outgrowth of bone from both fragments, the rough surfaces of which interlocked, and had doubtless produced a certain degree of union, which time would have consolidated.

3.108. United Fracture of the Tibia of an Antelope.

Hunterian.

Right tibia with the lower bones and hoof, macerated and dried, showing the above. That this is a fairly recent fracture is evident from the porosity and irregularity of the new bone. There is very marked riding of the ends, which are embedded in and firmly united by a mass of new-formed bone of a diameter fully three times that of the normal shaft—an extensive osseous new formation characteristic of healing fractures not kept at rest and in good position.

3.109. Old United Fracture of the Tibia and Fibula, "from a Sow."

Hunterian.

Left tibia and fibula macerated and dried, showing the above. In this fracture also there has been considerable riding and doubtless movement, too, so the point of union is much thicker than the rest of the bone. The mass of callus has, however, in the course of time, become dense and smooth and much reduced in size. The fibula is incorporated with the tibia at the seat of fracture.

SERIES 4.

INJURIES OF JOINTS.

4.1. Old Unreduced Subcoracoid Dislocation of the Humerus. Formation of False Joint. *Hunterian.*

Right scapula and humerus macerated and dried, illustrating the above. There is a cord from the humerus to the acromion, which allows the bones to come into apposition with the back of the head of the humerus, resting on a facet formed by new bony outgrowth on the neck of the scapula below the coracoid process. The articular surface of the humerus is increased by bony outgrowth round the posterior edge of the head, in a manner which adapts it to the new facet on the scapula. The edges of the glenoid facet are rounded as if by atrophy, and the anterior edge is ground down by the movements of the displaced bone. The dislocation must have been of very long duration, and the new joint must have allowed a fair amount of movement. From a subject which was being used for operations on the dead body. Vide *Med. Obs. and Inq.*, Vol. II., p. 351, Plate III., fig. 3.

4.2. Humerus from an Old Unreduced Dislocation backwards. *Hunterian.*

Right humerus macerated and dried, showing the face of the head, which looks forwards and inwards, worn down to a flat eburnated surface, which was probably a new articular facet corresponding to the dorsum of the scapula.

4.3. Unreduced Dislocation of the Thumb at the Metacarpophalangeal Joint. *Hunterian. LL. 35.*

Dissection of "a thumb, dislocated from its first bone, which had never been reduced, but allowed to remain. The cartilaginous

ends are quite covered over with a membranous substance, which, however, is loose, as it covers the central parts." Dislocation has been backwards and outwards.

4. 4. Unreduced Dislocation of the Femur; Facet for New Joint. *Hunterian.*

Right ilium (femur absent) macerated and dried. Appears to have been a case of dislocation of the head of the femur on to the dorsum of the ilium, where a new osseous socket has been in process of formation. The acetabulum is partly filled up, and its edges atrophied.

4. 5. Atrophy and Filling-up of the Acetabulum consequent on Absence of the Head of the Femur. *Hunterian.*

There is no history of the case, and there is no sign of the head of the bone having rested elsewhere on the ilium; but the filling-up and atrophy of the edges of the acetabulum resemble what is seen in the previous specimen. Possibly the sequel of amputation at the hip.

SERIES 5.

DISEASES OF BONE.

I. CONGENITAL DEFECTS AND MALFORMATIONS, . . .	1
II. CHANGES PRODUCED BY CONDITIONS AFFECTING THE NUTRITION OF BONE.	
<i>Atrophy of Bone</i> ,	2-4
<i>Rickets</i> ,	5-30
<i>Osteomalacia</i> ,	31-39
III. CHANGES DUE TO INFLAMMATORY DISEASES.	
<i>Osteitis in general</i> ,	40-43
<i>Changes of Bone due to Inflammation of neighbouring Soft Parts</i> ,	44
<i>Inflammation of Bone produced by Pus-forming Organisms—</i>	
(A) <i>Acute Suppurative (Infective) Osteomyelitis</i> ,	45-82
(B) <i>Invasion of Bones by Ulcers</i> ,	83-85
(C) <i>Septic Inflammations of Bone secondary to Wounds</i> ,	86-112
<i>Tuberculosis of Bone</i> ,	113-116 and in Series 6
<i>Changes due to Syphilis—</i>	
<i>Skull</i> ,	117-124
<i>Limbs</i> ,	125-165
IV. TUMOURS OF BONE.	
<i>Simple Tumours of Bones—Osteomata, Chondromata</i> ,	166-172
<i>Malignant Tumours of Bones—Sarcomata, Carcinomata</i> ,	173-190
V. CHANGES DUE TO VARIOUS LOCAL CONDITIONS,	191

In the Hunterian MSS. and old printed Catalogue there is no particular description of the dry diseased bones. The following descriptions, and also those of dry specimens in the next Series, are therefore, for the most part, entirely new. See Preface.

I. ABNORMALITIES IN GROWTH OR DEVELOPMENT.

5.1. Bones of the Leg and Foot of a Dwarf. *Hunterian.*

Macerated, dried, and articulated. The history of the bones is not known. From the fact that there is no trace remaining of the epiphysial lines it is evident that they were taken from an adult, though the tibia is only 17.5 cm. long. The foot is large in proportion to the leg bones. The normal curves and ridges are exaggerated, but not in a manner suggestive of rickets. The long bones are dense and polished on the surface.

II. CHANGES PRODUCED BY CONDITIONS AFFECTING THE NUTRITION OF BONE.

(1) *Atrophies of Bone.*

5.2. Atrophy of Bone. *Hunterian.*

A tibia macerated, dried, and divided longitudinally, showing the above. The Haversian canals of the dense wall of the shaft are increased in size till they resemble the spaces of the cancellous tissue. This has occurred especially inside, producing the appearance of an increase in the cancellated bone and consequent thinning of the outer dense shell. The cancellous tissue of the ends also appears unduly porous. Compare Rarefying Osteitis, Nos. 5.40 and 5.45 to 5.51.

5.3. Normal Structure of a Long Bone. *Hunterian.*

A femur macerated, dried, and divided longitudinally, showing the appearance and the relative amount of the dense and cancellous tissue in a normal bone; for comparison with the preceding and other diseased bones.

5.4. Senile Changes in the Femur.*Hunterian.*

Right femur macerated and dried, illustrating the above. The bone is very light; externally more porous than normal. Compare the preceding. The natural curve forwards of the shaft is exaggerated. The head of the bone reaches above the level of the top of the great trochanter, the neck being set at a decidedly less open angle to the shaft, and being also shorter than in the normal bone.

(2) *Alterations due to Conditions apparently Constitutional,
but more or less Obscure.*

(A) RICKETS.

5.5. Distortion of the Sternum due to Rickets.*Hunterian.*

Sternum macerated and dried, showing the above. The body of the sternum is convex forwards and considerably wider than normal. From an old subject.

5.6. Distortion of the Sternum due to Rickets.*Hunterian.*

Sternum macerated and dried, showing the above. Similar to the preceding.

5.7. Distortion of the Sternum due to Rickets.*Hunterian.*

Sternum and costal cartilages cleaned, dried, and varnished, showing the above. There is slight anterior convexity of the body, and the manubrium and the xiphoid process are both bent strongly backwards.

5.8. Distortion of the Femur due to Rickets.*Hunterian.*

Right femur of a young subject macerated and dried, showing the above. The chief deformity is a curve markedly forwards and slightly outwards in the upper and middle thirds. The ends show little or no thickening. The bone is unduly porous. There has been a great increase of the bony ridge of the linea aspera, so as to fill up the concavity of the curve. The shaft accordingly appears flattened from side to side, measuring only 1.2 cm. in that diameter, but 2.5 in the direction of the curve; it is doubtful if there is any actual flattening.

5. 9. Distortion of the Femur due to Rickets. *Hunterian.*

Left femur of a young subject macerated and dried, showing the above. There is a marked curve forwards; from side to side it is straight. Like the preceding the shaft presents an appearance of flattening due to filling up of the concavity of the curve. It is also rather porous, and there is some swelling and irregularity about the lower epiphysial line.

5. 10. Distortion of the Femur due to Rickets; slight. *Hunterian.*

Left femur of an adult macerated and dried, showing the above. There is curvature and lateral flattening in the upper and middle thirds, and slight elongation of the internal condyle. The bone is solid and heavy, and the concavity of the curve is filled up by increase of the ridge of the linea aspera as in the preceding.

5. 11. Distortion of the Femur due to Rickets. *Hunterian.*

Right femur of an adult macerated and dried, showing the above. There is slight curvature forwards and outwards in the upper and middle thirds. The bone is slightly flattened in front, producing a somewhat triangular shape of the shaft.

Specimens 10 to 17 show the deformity long after the disease has been cured, and the curvatures of the shafts and thickenings of the ends of the bones have been more or less remedied by nature. Compare Tibiae, Nos. 5. 22 to 5. 27, and Fibulae, Nos. 5. 28 and 5. 29.

5. 12. Distortion of the Femur due to Rickets. *Hunterian.*

Right femur of an adult macerated and dried, showing the above. There is slight anterior convexity with lateral flattening of the shaft, and increase of the linea aspera, especially about the middle.

5. 13. Distortion of the Femur due to Rickets. *Hunterian.*

Right femur of an adult macerated and dried, showing the above. There is convexity outwards and forwards with flattening in a direction not quite antero-posterior, but a little oblique from before outwards, *i.e.* at right angles to the plane of the curve, which is slightly forwards as well as outwards.

5.14. Distortion of the Femur due to Rickets. *Hunterian.*

Left femur of an adult macerated and dried, showing the above. Similar to the foregoing.

5.15. Distortion of the Femur due to Rickets. *Hunterian.*

Left femur of an adult macerated and dried, showing the above. The distortion in this specimen is inwards and very slightly forwards, with slight flattening at right angles to the plane of the curve. This specimen is thinner than most rickety femora.

5.16. Distortion of the Femur due to Rickets. *Hunterian.*

Right femur of an adult macerated and dried, showing the above. The curvature is in the lower half of the bone, inwards and forwards. The inner condyle is not elongated, but there was probably slight genu valgum from the curvature of the shaft. There is slight enlargement at the epiphysial line.

5.17. Distortion of the Femur due to Rickets. *Hunterian.*

Left femur of an adult macerated and dried, showing the above. There is marked convexity forwards, especially in the lower third, causing a degree of deformity which must have been inconvenient. The articular surface of the condyles is turned considerably backwards.

5.18. Distortion of the Femur due to Rickets. Inward Curve of Shaft and Elongation of Internal Condyle. *Hunterian.*

Left femur of an adult macerated and dried, showing the condition which especially gives rise to genu valgum. The shaft as a whole is curved forwards and inwards. Towards its lower end especially it is flattened in an obliquely antero-posterior direction. The elongation of the internal condyle is very striking, and along with the curvature must have produced very decided genu valgum.

5.19. Distortion of the Tibia due to Rickets. *Hunterian.*

Tibia of a young subject, epiphyses wanting, macerated and dried, showing the above. The specimen shows marked bending forwards,

especially about the junction of the lower and middle thirds. The bone is fairly heavy, being abnormally thick for its length, very porous on its surface, and rather swollen at the ends.

5.20. Distortion of the Tibia due to Rickets. *Hunterian.*

Right tibia, probably from a grave, illustrating the above. It is very markedly bent forwards. On the outer side is a rough raised facet-like mark, as if the fibula had pressed on it, giving rise to some inflammation and formation of new bone. This bone is figured in Cheselden's *Osteographia*, Plate LII., fig. 3, as "The Tibia of a man who had had the Rickets."

5.21. Distortion of the Tibia and Fibula due to Rickets. *Hunterian.*

Right tibia and fibula, probably from a grave, showing the above. There has been complete osseous ankylosis of the upper tibio-fibular articulation, cause unknown; the fibula has subsequently been broken off at the neck. The tibia is bent forwards and inwards and the fibula has followed it, and has also flattened out into a sort of boomerang shape, which is very striking. Compare No. 5.30.

5.22. Distortion of the Tibia due to Rickets. *Hunterian.*

Left tibia, macerated and dried, showing a slight curvature forwards. A very thick heavy bone, showing on its surface traces of chronic inflammation.

5.23. Distortion of the Tibia and Fibula due to Rickets. *Hunterian.*

Right tibia and fibula macerated and dried, showing the above. The degree of deformity is slight. The tibia is bent inwards and forwards chiefly about the middle and upper thirds; the fibula rather lower down. The latter is also flattened in a manner resembling Nos. 5.20 and 5.30, but to a much less degree.

5.24. Distortion of the Tibia due to Rickets. *Hunterian.*

Left tibia macerated and dried, showing the above. The bone is very thick and heavy, and bent forwards and outwards and markedly flattened laterally.

5. 25. Distortion of the Tibia due to Rickets. *Hunterian.*

Right tibia macerated and dried, showing a slight curvature forwards and inwards with lateral flattening.

5. 26. Distortion of the Tibia due to Rickets. *Hunterian.*

Left tibia macerated and dried, showing the above. In this and the two following there is a bending inwards and a very striking antero-posterior flattening, most marked in the upper third.

5. 27. Distortion of the Tibia due to Rickets. *Hunterian.*

Left tibia macerated and dried, showing the above. Similar to the foregoing, but more striking. The flattening extends nearly the whole length of the shaft. There is a small projecting bony spine on the inner edge of the head, which is probably an ossification of part of the internal lateral ligament of the knee-joint.

5. 28. Distortion of the Tibia due to Rickets. *Hunterian.*

Left tibia, probably from a grave, showing the above. Similar to the preceding. The greatest curve is about the middle. There is also a slight bend backwards.

5. 29. Distortion of the Fibula due to Rickets. *Hunterian.*

Left fibula macerated and dried, showing the above. A very long bone. The deformity of the subject must have been very slight.

5. 30. Distortion of the Fibula due to Rickets. *Hunterian.*

Right fibula macerated and dried. A very good example of the "boomerang-like" distortion. Compare No. 5. 21. The bone takes a decided bend inwards about the middle, while the ends above and below are nearly straight. At the bend, and for some distance above and below, it is broad and flat like a boomerang.

(B) OSTEOMALACIA.

5. 31. Deformity of the Humerus due to Osteomalacia.*Hunterian. LL. 1.*

Posterior half of the left humerus, dissected, of "a man who died at Wapping, with remarkable softness of the bones." This and the three succeeding specimens are from a case described under the title, "A Remarkable Case of the Softness of the Bones, by Mr. Henry Thomson, Surgeon to the London Hospital," in Vol. V. of *Med. Obs. and Inq.*, p. 259, from which the following account is taken: "James Stevenson, a shoemaker in Wapping, aet. 33, five feet seven inches high, enjoyed a good state of health till about the year 1766, when he was seized with violent pains in his knees and feet, and was tormented with a headache, which came on at irregular periods." These pains were supposed to be rheumatic. Shortly afterwards he injured his shoulder by a fall, and was unable to move it for several months. In November 1768 he hurt his right thigh, and was confined to bed for a week, and was afterwards unable to walk without assistance. In December of the same year, while being helped up stairs, he struck the toe of his right foot on the edge of the step, and instantly cried out that his thigh was broken. He was confined to bed with great pain, and the leg was shortened and crooked. A fracture of the femur was diagnosed, and splints were applied. The pain continued, but slightly less violent than before. On removing the splints, five weeks later, and moving the leg, the surgeon "was surprised to find the thigh-bone yield, and fall in about a hand's-breadth above the knee," as if there were a fracture, but without any crepitus. The leg bent and broke the same way; and, on examining the tibia, he found a remarkable softness and yielding of the bone, as if it contained fluid. The fractures were attended with very little additional pain. An incision was made over the tibia, and the bone was found to be pliant and yielding, being "only about the solidity and thickness of the rind of cheese." The medullary cavity was filled with a "dusky red or liver-coloured flesh, devoid of sensibility, and from which the osseous covering had been removed without the least haemorrhage; in short, it appeared to me an unorganized mass, similar to the flesh-like substance or coagulum which may be formed on a stick or feather by stirring fresh-drawn blood in a basin." The left leg and thigh lost their straightness in the same way; and as the deformity increased, he lost all power of motion. Throughout he continued to

suffer pain in the bones, which was greatly increased when he was moved. His appetite remained good. "His urine for the first two years generally deposited a whitish sediment, which, upon evaporation, became like mortar." He grew gradually weaker, and died on the 18th of February, 1775.

On sectio, by Mr. Thomson assisted by Dr. Hunter, every bone in the body was found to have lost its hardness, being easily cut with a scalpel. The internal organs all appeared healthy. The articular cartilages preserved their normal colour and smoothness. The muscles, especially in the lower extremities, were exceedingly pale, "and it would scarcely have been possible to have traced them by dissection, from their contortion and adhesion to each other."

In the old catalogue the specimen was described as follows: "The cavity of the bone is much enlarged, and was full of oil mixed with blood; no appearance of cancellae, but cross-bridges or septa here and there. The two extremities are less altered than the other parts; the cortical part thin as paper and as soft as bees-wax almost."

5.32. Osteomalacia of the Femur. *Hunterian. LL. 2.*

Posterior section of the left femur. From the same case as the preceding. The middle of the shaft is soft and limp as if nothing were left but periosteum.

5.33. Osteomalacia of the Tibia and Fibula. *Hunterian. LL. 3.*

Posterior(?) section of the left tibia and fibula from the same case.

5.34. Osteomalacia of the Ilium. *Hunterian. LL. 5.*

A portion of the ilium from the same case filled with the altered marrow. Obscured by a deposit of fatty matter.

5.35. Osteomalacia of the Humerus. *Hunterian.*

Posterior section of the right humerus, probably from the same case, macerated and dried, showing the above. The shell of the bone is extremely porous and thin. Here and there are plates of bone which are still of a solid texture. The cancellous tissue has nearly all disappeared.

5. 36. Osteomalacia of the Humerus. *Hunterian. LL. 4.*

Left humerus from an adult, "case unknown," showing the above. The bone is bent in several different ways, and is soft, though not altered to such an extreme degree as the tibia and femur of the previous case.

5. 37. Distortion of the Thorax due to an Abnormal Softness of the Bones. *Hunterian.*

The three lower cervical and all the dorsal vertebrae with the ribs, except the three lowest on the right and the lowest on the left, partly macerated, cleaned, and dried, showing the above. The deformity consists in (1) kyphosis, affecting chiefly the upper dorsal region, and consequent narrowing of the intercostal spaces reducing the vertical depth of the chest; (2) falling in of the ribs anterior to the angles, so as to decrease the width but to increase the antero-posterior depth of the chest and project the sternum forwards; (3) curving of the sternum with the concavity forwards, slight; (4) the chest as a whole is twisted so that the left side is larger than the right. The lateral flattening looks as if the patient had lain chiefly on his side during the course of the disease. The bones are abnormally light and flexible, the cancellous tissue being increased at the expense of the solid. Between the angles and the insertions of the serratus magnus on the ribs there are healed fractures—of sixth, seventh, and eighth on the right, and of the fifth, sixth, seventh, and eighth on the left. Several of the ribs on the left side show also ununited fractures, but whether vital or post mortem cannot be determined; there is no trace of repair about them. Several of the ribs of the right side show, mostly in their anterior parts, partial fractures like what is produced on bending a quill. There is no thickening of the ends of the ribs like in rickets, nor is the deformity that which occurs in that disease. The condition of the bones is more like osteomalacia. There is neither history nor former description of the specimen.

(C) COMPARATIVE PATHOLOGY.

5. 38. Bending of the Bones of a Monkey dying of Pulmonary Tuberculosis. Recent Fracture.

Presented by Professor Young.

Articulated skeleton of a small monkey, which had been long in captivity and was the subject of advanced phthisis. About 24 hours

before its death, which was artificially hastened, it was attacked by another monkey, which chewed its left arm off about the upper third of the humerus. The upper fragment remains, and shows the irregular jagged edges characteristic of a recent fracture; there are no teeth marks. Most of the long bones show an abnormal bending, usually most marked towards one end,—which is the upper in the humeri and tibiae, lower in the radii, ulnae, femora, and fibulae. At and around the seats of curvature the bones are thickened and porous—a periosteal formation of new bone. The affected areas are all in the diaphyses. The epiphysis of the right radius seems also to be enlarged. Apparently a sort of rickets.

5.39. Rickets in a Monkey.

Andersonian Collection.

Skeleton, articulated, of a monkey, history unknown. A young animal; the epiphyses not being united to the diaphyses. All the bones, including those of the cranium and vertebral column, appear unduly porous. All the long bones are thickened and more or less curved in an abnormal manner, the direction of the curves, as in rickets of human beings, corresponding to the direction of the strains on the limbs. The epiphysial lines are very markedly irregular.

III. INFLAMMATORY CHANGES IN BONE.

(1) *Specimens illustrative of Osteitis in General.*

5.40. Rarefying Osteitis.

Hunterian.

Part of an ulna divided in longitudinal section, to show the above. Macerated and dried. The outer shell of the bone, which should be dense and firm, is extremely porous like cancellous bone. Internally the bone is of very similar structure. Here and there, amid the rarefied tissue, are larger trabeculae—remains of the old dense shell. The marrow cavity has been encroached upon by new cancellous bone. Probably from a case of acute suppurative osteomyelitis. The cavities in the interior of the bone were probably abscesses.

5.41. Condensing Osteitis about an Old Fracture.

Hunterian.

The lower part of a fibula, divided longitudinally, macerated and dried, showing the above. The fracture had long been healed. The

medullary cavity is filled by bone which has been cancellated, but is now almost solid. The seat of fracture forms a node-like enlargement, the surface of which presents a worm-eaten appearance as if it had formed the base of an ulcer, the presence of which would keep up irritation and consequent inflammatory action in the neighbouring bone. The old shaft can be distinguished from the new-formed bone by being in most places a little denser.

5. 42. Chronic Osteomyelitis of the Fibula. Enlargement and Condensation. *Hunterian.*

Left fibula macerated and dried, showing the results of the above. Divided longitudinally. The whole bone from end to end is greatly thickened and roughened by periosteal new-formation of bone. Its surface is in some parts porous as if this had been still in progress; in others it is dense. The section shows almost complete abolition of the medullary cavity by new-formed cancellous tissue of somewhat dense texture. The walls of the bone are very thick and dense. Here and there a portion of the old shaft is recognizable, but for the most part it is indistinguishable from the new bone. An example of condensing osteitis or osteosclerosis. The cause is unknown. Probably it was long standing ulceration of the neighbouring soft parts, possibly complicated by syphilis.

5. 43. Chronic Osteomyelitis of the Femur. Great Enlargement and Condensation. *Hunterian.*

Right femur macerated, dried, and divided longitudinally in its lower half, showing the above. From the middle down to the lower epiphysis the shaft of the femur is greatly enlarged by periosteal new-formation of bone. Its external surface is very rough and irregular; porous, yet fairly dense. In section the new bone is seen to be formed on the outside of the old shaft, whose walls can be traced by their greater density and by their having a longitudinal grain, whereas the new bone is irregular. The latter presents the appearance of a very dense cancellous tissue, having been originally of fine spongy texture, but the trabeculae having been greatly increased in thickness at the expense of the spaces—osteosclerosis. The medullary cavity is filled with cancellated bone of very open texture, with a great deal of adipocere in its meshes. It has also expanded by a process of rarefaction and absorption of the inner

layers of the old dense shaft, which in the lower third of its length is quite thin, and, getting still thinner, finally disappears near the lower end, where the rarefying osteitis has passed clean through it and invaded the new-formed dense bone outside. The history of the bone is unknown. The cause of the condition was probably a very chronic suppurative osteomyelitis.

5. 43a. Chronic Osteomyelitis of Femur.

Hunterian.

Anterior section of the preceding bone.

(2) *Changes of Bone due to Inflammation of the neighbouring Soft Parts.*

5. 44. Osseous Outgrowths on Fibula associated with Chronic Ulcer.

Hunterian.

Head of right fibula macerated and dried, illustrating the above. The history of the specimen is unknown; but it is covered with bony outgrowths, especially along the lines of attachment of the interosseous membranes and muscles, very similar to what is seen in cases of chronic ulcer of the leg. It has been catalogued accordingly after comparison with specimens of known antecedents in other collections.

(3) *Inflammation of Bone produced by Pus-forming Organisms.*

(A) WHERE THE ORGANISMS HAVE REACHED THE BONE THROUGH THE CIRCULATION: ACUTE SUPPURATIVE (INFECTIVE) OSTEO-MYELITIS AND PERIOSTITIS.

(a) *Where the Destructive Process is advancing.*

5. 45. Acute Suppurative Osteomyelitis of Upper End of the Tibia. Rarefaction.

Hunterian.

Left tibia macerated and dried. An example of juxta-epiphysal osteomyelitis, the chief seat of the disease being in the neighbourhood of the epiphysis, which is absent, possibly having been detached in maceration, but very probably by the disease. The disease has

extended downwards through about the upper third of the diaphysis. The dense walls of the shaft are opened out and rendered porous, parts of the cancellous head, including a considerable portion of the epiphysial surface, are quite destroyed. There has been some periosteal new-formation of bone on the shaft and round the sides of the head. The new bone is porous, of close texture, and of a greyish colour. It is readily distinguishable from the old bone, which is white and has a worm-eaten appearance, the Haversian canals having been opened out into wide spaces by the inflammatory process. A septic form of caries.

**5. 46. Acute Suppurative Osteomyelitis: Juxta-Epiphysial.
Rarefaction.** *Hunterian.*

Lower half of a femur macerated and dried, the epiphysis absent. Very similar to the preceding. The fine Haversian canals of the dense bone have been opened out into wide irregular spaces, and the cancellous head partly destroyed. On the shaft a layer of new bone has been formed under the periosteum.

**5. 47. Acute Suppurative Osteomyelitis: Juxta-Epiphysial.
Rarefaction.** *Hunterian.*

Lower half of tibia and fibula macerated and dried. The seat of the disease in both is the cancellous tissue near the epiphysial line. All round both bones in this region the outer shell has been opened up and destroyed. This rarefaction has extended some little way up the shaft, but below it stops abruptly, leaving the outer shell of the articular head as a sharp uneven edge under which it has burrowed along the epiphysial line. There is some periosteal new bone on the outside of the shaft. Compare next specimen.

**5. 48. Acute Suppurative Osteomyelitis: Juxta-Epiphysial.
Rarefaction.** *Hunterian.*

Lower end of tibia macerated and dried. A specimen very similar to the preceding, divided longitudinally to show the manner in which the carious process has eaten in beneath the shell of the epiphysis and along the epiphysial line. The disease is almost entirely in the shaft, which is rarefied more or less for about 3 cm. above the epiphysial line, but on the posterior side it has crossed this line and destroyed part of the cancellous tissue of the epiphysis also. At the

outer side there has been some condensing osteitis of the cancellous tissue of the epiphysis. On the inside, part of the articular surface is destroyed; possibly, however, this is the result of the maceration. The seat of the disease in this specimen is a very common one for tubercle, but the manner of spreading up the shaft is more like the result of inflammation due to pyogenic microbes.

5.49. Acute Suppurative Osteomyelitis. Rarefaction.
Periosteal New-formation of Bone. *Hunterian.*

Lower portion of a femur macerated and dried. A very irregular fragment of bone, but showing very well the formation of a complete new case of bone on the outside of the old shaft. The centre of the specimen is a large cavity with fairly smooth walls having very little cancellous tissue projecting from them; probably an abscess cavity. This is open below where the epiphysial surface has been destroyed, and on the side where there has been some destruction of the shaft. In a cut surface at the edge of this latter opening, and on the transverse section of the bone above, there is shown very beautifully the old shaft with its outline quite distinct, but its dense walls rarefied to a shell of coarsely cancellated bone. On the outer surface of this is a layer of very similar new-formed porous bone. The new bone is of closer texture—the cancelli smaller, and the trabeculae thinner and less regular than in the old. It is roughly tuberculated on the outside. Compare No. 5.43. The disease may have been tubercular; but if so, septic organisms have probably also been present.

5.50. Acute Suppurative Osteomyelitis: Juxta-Epiphysial.
Rarefaction and Necrosis. *Hunterian.*

Lower half of femur, epiphysis absent, macerated and dried. The epiphysis has probably been detached by the disease. In the epiphysial surface of the end of the shaft there are several cavities containing small sequestra not quite detached. These are sclerosed. The cancellous tissue of the head as a whole seems also to have been in a condition of condensing osteitis. The sides of the head and the front of the shaft are covered by a layer of periosteal new bone. The back shows a large area, occupying the popliteal space and part of the outer side, most of which is smooth white old bone; the rest round about this is rarefied and eroded to a considerable degree. The smooth bone is a large superficial sequestrum which was in process of separation by absorption of the living bone around it.

**5. 51. Acute Suppurative Osteomyelitis and Periostitis.
Necrosis and Rarefaction. Sequestrum in process
of Separation.** *Hunterian.*

Upper portion of tibia, epiphysis absent, macerated and dried. An irregular fragment of an extremely diseased bone. The epiphysial surface of the diaphysis is gone, and the cancellous bone further opened out and eroded in various places. The denser portion of the shaft has been eaten out in all directions by granulations both externally and in the marrow cavity. On the one side is a large white sequestrum recognizable as the inner surface of the shin. This sequestrum extends the whole thickness of the shaft in to the medulla. Around it at one or two points there is some new bone formed between the periosteum and portions of the old shaft which had not necrosed. The other side shows a large area of this new bone, and above it a fairly solid piece of the old shaft which had not died. On the latter are several thin flat sequestra, which show that the outer layer of bone connected with the periosteum has died and exfoliated, while the deeper connected with the bone marrow has survived.

**5. 52. Acute Suppurative Periostitis and Osteomyelitis.
Necrosis.** *Hunterian.*

A portion probably of the same bone as the preceding, showing on one side a large irregularly eroded sequestrum connected with other smaller sequestra extending all round the medullary cavity. It is only partially separated from the rarefied non-necrosed bone. On the other side the sequestra are thinner and internal, abutting on the medullary cavity. Outside the latter sequestra a layer of periosteal new bone has been formed for about half way round the shaft.

**5. 53. Acute Suppurative Periostitis and Osteomyelitis.
Necrosis.** *Hunterian.*

A tibia macerated and dried, showing a large irregular sequestrum of dense bone in process of separation. The sequestrum includes the whole diameter of the shaft. To the inside the groove of separation is completed. Above and below it is only partially formed, and even the line where separation would have eventually occurred is for the most part indefinite. One portion of the

sequestrum shows the smooth surface of the old shaft; the rest is eaten out into bays and hollows by granulations proceeding from the periosteum or from surviving superficial layers of bone. A new case of bone has been in process of formation around it, but it is still very soft and porous, and has mostly been broken away in preparation. The whole bone was in two pieces, broken through the sequestrum, which shows that its ends were still firmly attached to the surviving parts of the diaphysis. There has been more of osteomyelitis than of periostitis about the case.

5. 54. Acute Suppurative Osteomyelitis. Necrosis.

Hunterian.

Portion of a tibia macerated and dried, showing a large sequestrum in process of separation. The sequestrum in this case is irregular all over, showing that the disease was mostly in the deeper parts of the bone. It extends all round the medullary cavity and nearly the whole length of the diaphysis, stopping short of either epiphysial line. It is partly surrounded by a case of new bone, in which the surviving superficial layers of the old shaft (considerably rarefied) are readily distinguishable from the more finely porous new bone outside. The grain of the old bone is longitudinal; that of the new bone is mainly perpendicular to the surface of the shaft.

5. 55. Acute Suppurative Osteomyelitis. Sequestrum separated.

Hunterian.

A tibia, upper end incomplete, macerated and dried, showing a large sequestrum completely loose and partially invested in a new case of bone, which is recognizable as composed partly of the old shaft, partly of new periosteal bone developed on its surface. A considerable part of the sequestrum shows the old surface of the bone, and over the region of this there has been very little new bone-formation from the periosteum, contrasting strongly with the amount which has occurred where there was surviving old bone. The sequestrum in parts extends all round the medullary cavity. The inflammation has not extended the length of the lower epiphysial line. The new bone is formed in irregular lumps, the grain of which is more or less perpendicular to the shaft. The old bone shows a longitudinal grain, and is more regular.

(b) *Where Regenerative Processes after Separation of Necrosed Portions have advanced some Distance.*

5.56. Acute Suppurative Osteomyelitis. Destruction and Separation of Epiphysis. Necrosis of whole Diaphysis. Partial Formation of New Shaft around Sequestrum. *From Dr. Allen Thomson's Collection.*

A tibia from an adolescent subject, macerated and dried, showing the above. The sequestrum includes almost the whole length and circumference of the shaft. The disease has extended into the lower epiphysis (mount lower end up), almost destroying it and involving the tibio-fibular and ankle joints. The sequestrum is enclosed in a case of new irregular porous bone which has formed around it, and would have prevented its discharge. This case is imperfect opposite where the whole thickness of the shaft has necrosed, and best formed where part has survived. In the latter region the new shaft is fairly well developed, and the rarefied remains of the old shaft can be recognized lining its interior and forming a foundation to it; here the new bone has clearly been developed between the periosteum and the living old bone. Where no old bone has survived, the new case has formed chiefly, but not entirely, by sprouting laterally from the living old bone; but there is a fairly strong band of new bone right up along one face of the sequestrum where, from its appearance to the naked eye, the periosteum has been stripped clean from its surface without any bone adhering; at this place the new bone must have been formed from the deep layer of the periosteum. The upper epiphysis has not been affected. The periosteal new bone is present in a thin layer right up to the epiphysial line. Compare history of specimen, No. 5.73.

5.57. Acute Suppurative Osteomyelitis. Destruction of Epiphysis. Necrosis of whole Diaphysis. Partial Formation of New Shaft. *Hunterian. LL. 55.*

An adult tibia macerated, cleaned, and mounted in spirit, showing the above. There is an enormous sequestrum including the whole length and nearly the whole circumference of the diaphysis. Only on the inner side is the old surface of the bone present, and there it is black and charred, probably, to judge from the accounts in the medical literature of the eighteenth century, by application of the actual cautery, a proceeding which William Hunter very rightly held

to be of very little service, as the cauterization only produced exfoliation of as much tissue as it killed, and that was only the superficial layers, whereas the disease generally extended through and through the bone, and therefore some of it was certain to be left behind. (*Lectures*, p. 165, MS. R.C.S.Eng., 42, c. 28.) The whole sequestrum is loose; it is enclosed in a thick tuberculated case of new bone, which has preserved the length and, to a less degree, the form of the bone. As in the preceding, it is thickest and strongest where the outer layers of the wall of the bone have not shared in the necrosis. The principal gaps in the new shell are opposite to and extending for some little distance around the areas where the cautery was applied. The epiphyses have not been detached, as in the preceding young bone, but both have been invaded by the disease. The lower with its articular surfaces has been almost completely destroyed. The upper is rarefied, excavated, and contains sequestra, and there is some erosion around the edges of the outer articular surface; the knee-joint was therefore probably in a state of suppuration also. It is obvious that an operation on the new case of bone would have been necessary for the liberation of the sequestrum.

5.58. Acute Suppurative Osteomyelitis. Necrosis. Formation of New Shaft.

Hunterian.

Lower portion of a tibia macerated and dried, showing the above. The disease has affected chiefly the lower half of the shaft, but has extended into the epiphysis also. There are a number of small thin dense sequestra enclosed in the new case of very open porous bone. Several cavities higher up on the front of the shin are widely opened, and the sequestra have fallen out. Shows the characters of recently formed new periosteal bone, detached sequestra, and the cloacae through which the pus escaped.

5.59. Acute Suppurative Osteomyelitis. Regeneration of Shaft by Periosteal New-formation of Bone.

Hunterian,

An ulna macerated and dried, which from end to end appears to consist of new-formed spongy bone. In the lower third is a hole through it which probably contained a sequestrum. At this point it is bent slightly. At several other points there are cloacae within which can be seen rarefied and apparently necrosed bone. There is

no solid white sequestrum like in the preceding. It looks more like a caries of the whole inside of the bone leading to new-formation all over the exterior. The shaft is thickened, but its form is fairly well preserved.

5. 60. Acute Suppurative Osteomyelitis. Limited Necrosis. Formation of New Bone.

Hunterian.

Right femur macerated and dried, showing the above. A transverse section has been cut out of the middle of the diseased area. From the surgical neck to below the middle of the bone there has been necrosis of about one-third of the circumference of the shaft and separation of a thin sequestrum of the outer layer of the dense wall. The section shows the cavity in which the sequestrum lay, separated from the medullary cavity by a thin shell of fairly dense bone, and overlaid externally by a very thick mass of porous new bone. The outline of the old shaft is distinct behind and a little way round the sequestrum cavity at one side, showing that in parts at least the necrosis did not reach the surface of the shaft. Behind, where there has been no necrosis, the surface is covered with a thin crust of new bone. The thickening of the femur is very considerable. About the middle of the diseased area there is a cloaca through which the sequestrum is visible.

(c) Restoration of Bones after Separation of Necrosed Portions.

5. 61. Acute Suppurative Osteomyelitis. Multiple Sequestra. Formation of Thick Strong New Shaft.

Hunterian.

One half of a tibia, divided longitudinally, macerated and dried, showing the above. The middle region of the shaft, from about 3 cm. from either epiphysial line, is a thick pillar of dense externally tuberculated bone pierced here and there by about a dozen cloacae. These lead into cavities which can be seen in the cut surface. Most of the sequestra have fallen out. Those that remain are thin and small. In front the line of the old shaft is traceable, though the new bone is of hardly different texture. The place of the old medullary cavity is occupied by sclerosed cancellous new bone. The posterior wall is composed of dense bone fully 1.5 cm. thick, not quite as solid as the normal dense shaft and of irregular structure, the pores

running in all directions, mostly across, so that it has not the longitudinal grain of the original bone.

5.62. Acute Suppurative Osteomyelitis. Necrosis. Restoration of Shaft of Tibia by New-formation of Bone. *Hunterian.*

Right tibia macerated and dried, showing the above. There has apparently been necrosis of the greater part of the middle two-thirds of the diaphysis. The bone has been restored by formation of a thick column of new bone, in which are still visible the cavities in which the sequestra lay and the cloacae by which they escaped. The old medullary cavity has been filled up with cancellous bone. The length of the bone has probably been completely preserved and also its form, though with considerable thickening and increased weight.

5.63. Acute Suppurative Osteomyelitis. Restoration of Shaft of Humerus after Separation of Necrosed Portions. *Hunterian.*

Left humerus of a young adult, macerated and dried (perhaps a graveyard specimen), showing a stage in the process of repair more advanced than in the preceding. The necrosis has extended nearly the whole length of the shaft. It has been restored with a great deal of thickening. There are numerous cloacae leading to cavities in many of which sequestra are still enclosed, having been prevented from escaping by the new-formed bone around them. The new bone is denser and less rough than in the preceding specimen.

5.64. Acute Suppurative Osteomyelitis. Repair after Necrosis and Separation of the Sequestrum. Abscess in the Head of the Bone. *Hunterian.*

Right humerus, from a grave, showing the above. The disease has resulted in necrosis of the upper third of the shaft. The sequestrum has disappeared, but the cavity and the cloaca remain, and the shaft around them is considerably thickened. It has evidently been an old affection, as the new bone is very dense and fairly smooth. The head is imperfect, and there is a hole in it which looks like an abscess cavity; the bone round it is rarefied, and the disease was probably in a more active stage than in the sequestrum cavity below, with which it has a communication.

*(d) Involvement of Joints and other Complications.***5. 65. Acute Suppurative Osteomyelitis of Tibia and Fibula, of very old standing. Process of Restoration in the Diaphysis. Destruction of the Knee and Ankle Joints.** *Hunterian.*

Right tibia and fibula of a young adult, partly macerated, cleaned and dried, showing the above. The shaft contains a number of cavities from most of which the sequestra have disappeared. In one there is a small sequestrum and the dried-up remains of the granulation tissue which lined it. The bone round them is thickened and dense, and sprouting into the cloacae, showing an advanced stage of repair. On the other hand, the disease in the upper epiphysis of the tibia seems to have been actively advancing; it has excavated it in all directions, and almost totally destroyed it and its articular surfaces. There is some sclerosis of the cancellous tissue around the abscess cavities, showing that it is of fairly old standing too. At the lower end of the tibia and fibula there has also been disease of the epiphysis; the articular surfaces are not destroyed, but that of the tibia has been driven up on the outer side in consequence of collapse of the supporting cancellous bone.

5. 66. Acute Suppurative Osteomyelitis. Restoration after Necrosis and Separation of Sequestra. Yielding and Bending of the New Shaft. *Hunterian.*

A left tibia, probably from a grave, showing the above. It is greatly thickened, and contains numerous sequestrum cavities from which the sequestra have disappeared. The disease has been very extensive in the upper third, and here the new case has yielded and bent considerably outwards and forwards. The outer articular surface of the head is higher than the inner, having been supported by the fibula.

5. 67. Acute Suppurative Osteomyelitis. Restoration of Bone after Necrosis and Separation of Sequestra. *Hunterian. LL. 41.*

Shaft of a long bone (tibia?) cleaned and in spirit, showing the above. The specimen consists of a thick rough shaft of new-formed bone perforated by cloacae and enclosing sequestra. The new-formed bone is old and fairly dense.

5.68. Acute Suppurative Osteomyelitis. Necrosis. Extensive and Irregular Formation of New Bone round Sequestra. *Hunterian. LL. 40.*

A large very irregular mass of porous new bone formed around the necrosed shaft of a femur, macerated and mounted in spirit. The rarefied condition of the new bone suggests that the shaft had been restored, but that the disease was still active and attacking the new bone. The epiphyses had been detached. The irritation which gave rise to such an amount of new bone-formation must have been of very long duration.

(e) Results of Operation in Acute Suppurative Osteomyelitis.

5.69. Acute Suppurative Osteomyelitis. Trephining the Medullary Cavity. *Hunterian.*

Left tibia macerated and dried, greatly thickened in its lower two-thirds by periosteal new-formation. The disease seems to have been chiefly in the interior of the bone, and there are several small cloacae leading into it, in which, however, no sequestra are visible. On the shin are two trephine marks, about 2 cm. in diameter, with sharp edges, showing that they had been made no long time before the removal of the bone from the living body. The one disc of bone remains firmly fixed. The other had been removed, and a portion of the adjacent bone had broken away with it—this one had opened an abscess in the medulla.

5.70. Acute Suppurative Osteomyelitis. Necrosis. Trephining the Medullary Cavity. *Hunterian.*

Shaft of a long bone, probably tibia, macerated and dried, showing great thickening by periosteal new-formation, necrosis and separation of a number of sequestra, and six trephine holes of about 2 cm. diameter in a row down one side of the bone, opening the sequestrum and medullary cavities. There are also several cloacae. The thickness of the new bone drilled through shows that trephining was performed at a very late stage of the disease. The cut edges are slightly rounded off, showing that the bone remained in the living body some time after the operation.

5.71. Acute Suppurative Osteomyelitis. Drilling the Sequestrum. *Hunterian.*

Lower portion of a tibia macerated and dried. About the middle is a large ulcerated depression in the internal surface of the bone with a sequestrum in process of separation in its centre. The sequestrum is blackened as if by the cautery, and perforated in numerous places by a fine drill—operations formerly used to encourage and hasten exfoliation. The bone all round it and through to the other side is rarefied—septic caries. On the less diseased surfaces of the diaphysis there is a thin crust of periosteal bone. Probably the leg was amputated below the knee after various methods of persuading the sequestrum to come away had been tried unsuccessfully and probably with the result of extending the osteomyelitis. Compare, under Nos. 5.57 and 5.76, William Hunter's opinion of these proceedings.

5.72. Osteomyelitis. Gouging the Bone. *Hunterian.*

Left tibia macerated and dried. A large heavy bone greatly sclerosed and thickened by periosteal new-formation. About the middle is a circular hollow about 3.5 cm. in diameter and 1 cm. deep, the edges of which have decidedly the appearance of having been cut with a gouge. On one side they are dense, and have been rounded off by the vital action of the tissues; on the other they are rarefied by a process of septic caries. The floor of the hollow communicates with the medullary cavity. Continuous with the lower border is another shallower depression with rarefied carious floor. The history is unknown. Probably the bone was thickened and enlarged by chronic osteomyelitis and subject to deep-seated pains, for the relief of which it was gouged, and septic caries in the vicinity of the wound resulted. The enlargement has a very old chronic appearance; the lower part of it resembles a syphilitic node.

5.73. Acute Suppurative Osteomyelitis. Gouging of Bone. Septic Osteitis round Wound. *Hunterian.*

Lower two-thirds of a right tibia macerated and dried. The bone is enlarged and dense, evidently the result of suppurative osteomyelitis of very old standing. There is a large cavity (no longer containing sequestra) with one large cloaca behind and two large ones in front. The walls of the first are of dense bone, and its edges have a natural definite appearance. Of the other two, the lower has rounded spongy

edges; the upper is much wider, and has its edges sloping gently inwards from the borders of the bone, as if it had been made artificially. Around both the surface of the new bone is rarefied, and partly covered by a thin layer of more porous bone of still later formation, probably the result of a new osteitis consequent on operative interference, which in those days almost inevitably meant fresh inoculation with septic organisms. Compare Osteitis the result of septic organisms introduced through Wounds, Nos. 5. 86, *et seq.*

(f) *Sequestra from Cases of Acute Suppurative Osteomyelitis.*

5.74. Acute Suppurative Osteomyelitis. Sequestrum comprising whole Circumference of Diaphysis of Femur. Restoration of Limb without Deformity or Loss of Power. *Hunterian.*

A large sequestrum dried, of which the following account is taken from *Med. Obs. and Inq.*, Vol. II., p. 299, *et seq.* ("A Remarkable Separation of part of the Thigh Bone," by Dr. Alex. Mackenzie of Mountmill. Read July 14, 1760, by William Hunter): "The bone herewith sent is seven inches and a half of the thigh bone of William Baxter, at this time miller in the mill of Unthank, in the parish of Duffus, in the shire of Elgin, who, when a boy of thirteen years old, got a blow on his thigh at school, of which he at first hardly complained; but in a few months he began to have pain in that thigh; it inflamed, swelled, and appeared to have matter in it.

"The parents being poor, no surgeon was called, and the boy was allowed to linger for a great while. At length the matter made its way through the skin by a small opening on the interior part of the thigh, about three inches above the joint of the knee, and continued spueing out large quantities of thin sanies matter for eighteen or twenty months.

"At length the hole in the skin enlarged, and the point of a bone began to appear very sharp and rough, which hurt him much when anything caught hold of it, as his breeches often did; for it is to be observed that the boy, for the most part, continued walking to school with no other assistance than a stick in his hand. After two and a half years' distress, as he lay abed one morning, he felt the bone looser and farther without the skin than ordinary; upon which he gave it a strong pull, and brought away this very bone: a pretty large haemorrhage ensued, but the wound in the thigh healed in a very short time; and he has never since found the least inconvenience.

"I, being told this singular case by Archibald Dunbar, Esq., of Thunderton, on whose estate this miller lives, sent for him and examined this thigh narrowly and found it as firm as the other; the only difference I could discover was that it is somewhat thicker and a little more curved, but no remarkable tightness or compactness of the muscles, nor any unnatural cohesion of them to the bone, come in place of the former; only at the opening from which the bone was drawn there is a large and very firm cicatrix: he walks with so little a halt that it is barely perceptible.

"I am not sure but this may be a singular case—to me I own it is—nor do I remember of meeting with any history like it in any author I have read. Portions of the tibia being brought away are frequent; but here there was no second bone to resist the contractile powers of the muscles, while the old bone was loose at both ends. This is not a splinter of a bone, but a large portion of its whole circumference, undisfigured except at its two extremities, where it is eat away and destroyed by the disease. Considering how many of the muscles of the thigh are inserted into, and some of the leg have their rise from, the *linea aspera*, is it not wonderful how the patient could perform any of the motions of the thigh and leg during the disease? for it is very certain that he walked most of the time a great distance to school, and even now that he should have as compleat an use of that thigh and leg as of the other.

"On the whole it is obvious that the cure was all the work of nature and time; and may not it serve as a caution to surgeons not to be too precipitate in amputating limbs?"

The sequestrum is figured at the end of the volume (Plate I., fig. 1). It is followed by "An account of a Diseased Tibia, as a supplement to the last article" (by William Hunter, M.D. Read April 20, 1761), the specimen connected with which is unfortunately not in the collection. In the latter case (it was not under Hunter's care) a new shaft had been formed round the sequestrum, enclosing it so completely "that though it was quite loose, it could not be thrown out"; therefore he points out that, while the one case shows that "in Surgery we should trust a great deal to nature," yet, on the other hand, "art may sometimes cure a disease, which would get the better of nature." "So that in surgery, as in physick, there will always be a field for the exercise of judgment." In the latter case part of the new bone would have had to be cut away to let the sequestrum out; the limb was amputated! The patient recovered.

5.75. Acute Suppurative Osteomyelitis. Sequestrum of almost the whole Diaphysis of Femur. *Hunterian.*

Dried. The upper end and most of the surface is irregularly eroded. The lower end is rarefied as if there had been inflammation for some time prior to necrosis. The sequestrum must have extended almost from epiphysis to epiphysis, and at nearly all points it includes practically the whole circumference of the bone. The medullary cavity is quite devoid of cancellous tissue. From a young subject.

5.76. Sequestrum after Acute Suppurative Osteomyelitis. *Hunterian.*

A considerable portion of the solid shell of the tibia with a little cancellous tissue inside. Dried. The front and inner aspect shows the natural surface of the bone charred in places, probably by application of the actual cautery with the intention of assisting the process of exfoliation. "As far as the power of caustic reaches so far do the parts become dead, and then the sound parts adjoining to them inflame, suppurate, and cast them off as a slough." (*Lectures*, p. 253, MS. R.C.S.Eng., 42, c. 28.) Compare No. 5.57.

5.77. Sequestrum after Acute Suppurative Osteomyelitis. *Hunterian.*

A large portion of the internal and external surfaces and anterior edge of a tibia, showing the usual characters of a sequestrum. Also blackened, probably by the application of the actual cautery.

5.78. Sequestra after Acute Suppurative Osteomyelitis. *Hunterian.*

Two specimens of the above, showing the usual characters of sequestra of dense bone. The larger includes the whole circumference of the shaft of a femur. The other is small and blackened, probably by application of the actual cautery.

5.79. Sequestrum after Acute Suppurative Osteomyelitis of the Clavicle. *Hunterian.*

A sequestrum of the dense wall of the clavicle of a young subject, comprising in the middle the whole circumference of the bone and the long irregular tapered ends extending almost its whole length.

5. 80. Sequestrum after Acute Suppurative Osteomyelitis of the Inferior Maxilla. *Hunterian.*

A large sequestrum of almost one half of the above, including the articular head. For the most part the bone shows the characteristic pitted or eroded appearance, but here and there on the body and over the articular process the original surface of the bone is present. There are also one or two rarefied areas, as if inflammation had produced some changes in that way before the necrosis occurred. Most of the teeth had been absent, and their sockets filled up.

5. 81. Sequestrum after Acute Suppurative Osteomyelitis. Trephine Holes. *Hunterian.*

A considerable sequestrum of the front of the tibia, showing two trephine holes and a smaller drilled hole. One of the former had reached the medullary cavity. Compare 5. 69 and 5. 70.

5. 82. Sequestrum after Acute Suppurative Osteomyelitis. Trephine Marks. *Hunterian.*

A considerable sequestrum, 14 cm. long, of almost the entire circumference of the tibia for part of its length, showing on the inner anterior surface several superficial trephine marks and other cuts.

(B) INFLAMMATION OF BONE DUE TO PUS-FORMING ORGANISMS WHICH HAVE REACHED IT THROUGH WOUNDS OF THE ADJACENT SOFT PARTS.

(a) *Disease of Bone Secondary to Ulcers.*

5. 83. Osteitis due to an Ulcer invading the Bone. New-Formation followed by Rarefaction. *Hunterian.*

Lower two-thirds of tibia and fibula macerated and dried. The inner surface of the lower third of the tibia and the outer surface of the corresponding part of the fibula are covered with a flat sharply-defined crust of porous bone. These crusts are fully 5 mm. thick. They are slightly hollowed on the surface; the raised edges are of roughly circular outline and slightly overhang the adjacent sound bone and interosseous space. In position and shape these

bony plateaux correspond with the common position and shape of chronic ulcers extending round the lower part of the leg. They have rarefied and irregularly eroded surfaces, as if the ulcerative process had extended into and were destroying them. There has been some periosteal new-formation of bone on the surfaces of the shafts above and below, from the irritation due to the presence of the ulcer. There is no history of the specimen, but it has been compared with specimens in other museums, which are known to have been associated with ulcers.

5.84. Invasion of the Tibia and Fibula by an Ulcer of the Leg. *Hunterian.*

Tibia and fibula macerated and dried, illustrating the above. The middle of the tibia is about half eaten through by caries, probably of septic origin, and due to an ulcer which has invaded the bone. The floor of the carious area is mostly composed of new-formed spongy, irregular bone, but also shows portions of dense bone which had been formed in the medullary cavity, and were being destroyed again by rarefying osteitis. The ulcerative process has extended to the fibula, which shows a rarefied carious area in front. The two bones are ankylosed together by irregular processes of dense bone, which have shot out across the interosseous space in the vicinity of the ulcer. They are also thickened, irregular, and condensed above and below. From the patchiness of the new bone on the fibula there was probably a syphilitic element in the case.

5.85. Osteomyelitis the result of Invasion of the Tibia by an Ulcer. Rarefaction. *Hunterian.*

Lower part of a very large tibia, sawn across near the upper end, macerated and dried. The whole bone is greatly thickened and very heavy. On the inner surface, about the junction of the lower and middle third, is a node-like swelling which was probably the base of an ulcer. This is rarefied and deeply eroded in various places. Just above the internal malleolus are two cloacae leading into a cavity which extends some way up the bone. From these two places all around, up the bone, the whole thickness of the shaft, and down into the ankle-joint, the tibia is eroded and opened out by a rarefying osteomyelitis. Whether this is the result of the ulcer invading the bone or of an acute suppurative osteomyelitis connected with juxta-

epiphysial abscess is unknown. The leg was probably amputated below the knee on account of the acute disease, which, from the shape and appearance of the bone, had supervened on an old standing osteosclerosis.

(C) DISEASES OF BONE IN CONNECTION WITH WOUNDS WHICH HAVE
BECOME SEPTIC: SEPTIC OR INFECTIVE OSTEOMYELITIS.

(a) *The disease advancing.*

**5. 86. Septic Osteomyelitis after Compound Fracture. Rare-
fying Osteitis.** *Hunterian. LL. 42.*

Longitudinal section of part of a bone, probably the femur, coarsely injected red. The lower end of the specimen presents the appearance of a fracture. Small portions of the point seem to be necrosed and undergoing separation. For a considerable way up, the dense bone of the shaft is irregularly rarefied.

5. 87. Septic Periostitis and Osteomyelitis of Scapula.

Hunterian.

A whole right scapula macerated and dried, illustrating the above. It is encased in an irregular shell of porous new-formed bone, broken here and there, allowing the old bone to be seen. It is not necrosed, but has been in a condition of rarefying osteomyelitis. The glenoid facet is destroyed, and at one side of it there is a small hollow like an abscess cavity. The new-formation is greatest around the neck, probably the sequel of amputation or disease of the shoulder-joint gone septic.

5. 88. Septic Osteomyelitis after Amputation. *Hunterian.*

Portion of a femur macerated and dried, showing the above. The end of the stump is enlarged slightly by periosteal new-formation; but the chief change is in the shape of rarefaction of the old dense wall of the bone; this extends a considerable way up the shaft.

**5. 89. Septic Osteomyelitis after Amputation. Rarefaction.
Necrosis.** *Hunterian.*

Portion of a tibia, probably from a grave, illustrating the above. Like the preceding, it shows some thickening of the end by periosteal

new-formation of porous bone, and the effects of osteomyelitis in the stage of rarefaction extending a long way up the shaft. It is partly divided in longitudinal section to show the rarefaction of the old dense wall and the separation of a sequestrum of very much rarefied cancellous tissue.

5. 90. Osteomyelitis after Compound Fracture. Sclerosis of Bone. *Hunterian.*

A fragment of a long bone macerated and dried, showing the above. The line of fracture has been very oblique. The medullary cavity of the fragment is obliterated by dense bone. On the oblique surface lies a smaller piece of bone, firmly attached though considerably undermined all round, as if it were a sequestrum undergoing separation. It is dense bone, as if a condensing osteitis had preceded necrosis. There are two holes drilled in it. Compare 5. 69 and 5. 70.

5. 91. Septic Osteomyelitis after Compound Fracture. Extensive Necrosis. *Hunterian.*

Tibia and lower part of fibula macerated and dried. They have been fractured a little below the middle, probably by direct violence, with some comminution. The wound has gone septic, and large portions of bone above and below have necrosed, and were in process of separation by rarefying osteitis. The grooves of separation of the sequestra are well marked. There is but little trace of inflammation except in their immediate vicinity. There is a little periosteal new-formation on the living side of the grooves of separation. Upper part of the fibula amissing.

5. 92. Septic Osteomyelitis after Compound Fracture. Necrosis. Amputation. *Hunterian.*

Lower two-thirds of a femur macerated and dried. From a young subject; the epiphysis absent. About the middle of the specimen there is a transverse fracture with slight comminution. The ends above and below have undergone necrosis, and the grooves of separation are well marked about 2 cm. on either side of the break. There is some periosteal new-formation of bone both above and below, but very little extension of the destructive processes

from the immediate vicinity of the fracture. The portion has been sawn off about 10 cm. above the break, probably amputation. So far as can be judged from the appearances of the bone, the case would have done very well had nature been allowed to go on with the separation of the necrosed fragments and the ordinary processes of repair after they had been got rid of.

5.93. Septic Osteomyelitis after Amputation. Necrosis.
Hunterian.

Upper half of an ulna macerated and dried, showing the above. A small annular sequestrum is in process of separation by rarefying osteitis above it. The amount of the disease is slight. There is a little periosteal new-formation on the shaft for about 3 cm. above the end.

5.94. Septic Osteomyelitis after Amputation. Necrosis.
Hunterian.

Portion of a femur macerated and dried, showing the above. There is a small annular sequestrum of dense bone in process of separation from the end of the stump. The line of separation is well marked. There is a little new bone-formation above it. Perhaps a re-amputation.

5.95. Septic Osteomyelitis after Amputation. Necrosis and Septic Caries.
Hunterian.

About 7 cm. of the middle of the diaphysis of a femur macerated, dried, and divided longitudinally, showing the above. The front of the solid wall of the bone is rarefied, and considerably eroded—septic caries. Round the rest of the circumference of the bone a large sequestrum seems to be separating. Superficially there is a groove of separation, above which, on the front and one side, there is a portion of living bone with periosteal new-formation on its surface; but the other side is all sequestrum, and neither externally nor in the cut surface is the limit of the necrosis visible. Probably this specimen was from a re-amputation, which, it is evident, cannot have got rid of all the disease.

**5.96. Septic Osteomyelitis after Amputation. Extensive
Rarefaction and Necrosis of Stump. *Hunterian.***

The greater part of a femur macerated and dried, illustrating the above. There is an annular sequestrum (part in front broken off and lost) of about 1 cm. of the dense shaft nearly separated, but above that there is more or less rarefaction of the shaft extending up to the anatomical neck, most advanced in front, but quite evident behind and inside also. The specimen was probably obtained on the death of the patient from pyaemia or exhaustion. There is no trace of periosteal new-formation of bone; probably an acute case.

**5.97. Septic Osteomyelitis after Amputation. Extensive
Necrosis of Stump. *Hunterian.***

Upper two-thirds of a femur macerated and dried, illustrating the above. The specimen shows an enormous sequestrum extending from the end of the stump to the surgical neck. The process of separation is far advanced, and the groove well marked. Above it there has been rarefaction, and some periosteal new-formation. Probably obtained after the death of the patient from pyaemia or exhaustion by long continued suppuration.

**5.98. Septic Osteomyelitis after Amputation. Necrosis
and Separation of Small Sequestrum.**

Hunterian. LL. 52.

"A portion of the thigh bone from an old soldier, where the leg had been amputated above the knee. There is a considerable thickening from ossification at the end of the stump, and a small piece of bone is exfoliating." The sequestrum, which had doubtless acted as a source of irritation for a long period, is almost separated. After this had occurred there would probably have been sound healing, as the bone above appears tolerably healthy.

**5.99. Septic Osteomyelitis after Amputation. Extensive
Necrosis. Formation of New Shaft around Se-
questrum. *Hunterian. LL. 59.***

Portion of bone from a stump, cleaned and mounted in spirit, showing the above. There is a large quite loose sequestrum,

consisting of about 17 cm. of the shaft of a long bone (femur?), which has evidently necrosed from the sawn surface up to the epiphysial line above. Around it is a fairly complete shell of new bone formed by the periosteum, thickest about the extremity. It is pierced by several cloacae, and partly broken down to show the sequestrum. There is neither history nor description. Probably it was obtained on the death of the patient from pyaemia or exhaustion by long continued suppuration.

5.100. Septic Osteomyelitis after Amputation. Enlargement of End of Stump of Bone. *Hunterian.*

Short portion of a tibia macerated and dried, showing the above. In the upper (sawn) surface is seen a circle of the old dense shell of bone enclosed in a sheath of new periosteal bone from 3 mm. to nearly 1 cm. in thickness. There is about 3 cm. of shaft of this new bone, then a rounded knob of similar new bone forming the end of the stump. The lower surface of this is eroded, and more open than that of the shaft. The medullary cavity is open and partly filled with adipocere. The old dense shell is partly rarefied, partly dense, and does not appear to be necrosed. The enlargement is the result of long continued inflammation.

5.101. Septic Osteomyelitis after Amputation. Necrosis. Enlargement of End of Stump in consequence of Irritation by Sequestra. *Hunterian.*

A large rounded mass of spongy bone similar to the preceding. In the sawn surface can be seen the outline of the old shaft, the dense shell very much rarefied. There are also cavities containing sequestra, and opening by cloacae on the end and one side of the mass.

5.102. Septic Osteomyelitis after Compound Fracture. Separation of Sequestrum. *Hunterian.*

Lower portion of the tibia, showing a large sequestrum, the upper end of which shows the sharp edges characteristic of a fracture. The lower end is enclosed in a sheath of new-formed bone; it is loose, and on removal shows the irregularly eroded ends characteristic of a sequestrum.

5.103. Septic Osteomyelitis after Compound Fracture. Necrosis. Union around the Sequestra. *Hunterian.*

Fibula macerated and dried, showing the above. It has been fractured about the middle with considerable comminution, and was probably compound. A large splinter has necrosed, but callus has been thrown out all around from the other fragments, reuniting the bone and shutting in the sequestrum, which is movable but not removable.

5.104. Septic Osteomyelitis after Compound Fracture. Comminution. Multiple Necrosis. Union with great Thickening around the Sequestra. *Hunterian.*

Portion of a femur, probably from a grave. There has been a fracture about the middle, comminuted and compound, followed by the entrance of septic organisms and osteomyelitis, and periostitis. Numerous sequestra have separated, and a very thick new case of porous bone has been formed around them by the periosteum, shutting them in and at the same time healing the fracture with a great deal of deformity. Towards the upper end, part of the new case has been scraped away, showing the rarefied old wall within it.

5.105. Septic Osteomyelitis after Compound Comminuted Fracture. Necrosis. Union around the Sequestra. *Hunterian.*

Tibia macerated and dried, showing the above. There is a very bad deformity, the lower fragment riding in front of and to the outside of the upper, while lying loose between the two is a third fragment which had died. The two principal fragments are thickened by periostitic new-formation of bone, and are united by a thick bridge behind the sequestrum. In front they are not united. A part of the surface adjacent to the break is eroded, as if it had formed the base of a chronic ulcer.

5.106. Sequestrum from Septic Osteomyelitis after Compound Fracture. *Hunterian.*

A large sequestrum, probably of the femur, dried. The lower end has the sharp edges characteristic of fracture, and for about 3 cm. its exterior has the smooth surface of the old shaft. Above, it is eroded, and even perforated by the action of the granulations

which effected its separation from the living tissues. Its upper part has a sawn surface as if an amputation had been performed, the saw cut passing below the upper limit of the necrosis. No history.

5.107. Sequestra from Septic Osteomyelitis after Compound Fracture. *Hunterian.*

Three sequestra of dense bone, dried, similar to the preceding.

5.108. Sequestrum from Septic Osteomyelitis after Amputation. *Hunterian.*

A large portion of a long bone, including the greater part of the cancellous head, but not the epiphysis, dried. There is only a small portion of the old surface of the shaft preserved; the rest is eroded in the usual manner, the cancellous tissue, which seems to have undergone considerable sclerosis before its death, in like fashion to the dense bone.

5.109. Sequestrum from Septic Osteomyelitis after Amputation. *Hunterian.*

A portion of the dense shell of a long bone dried. The sawn surface has necrosed in its entirety. Above, the sequestrum tapers away, getting thinner and more scooped out by the granulations till it ends in a thin jagged edge. As usual it is considerably longer on the one side than on the other.

5.110. Sequestrum from Septic Osteomyelitis after Amputation. *Hunterian.*

A sequestrum, apparently of the fibula, dried, similar to the preceding.

5.111. Sequestrum from Septic Osteomyelitis after Amputation. *Hunterian.*

A sequestrum, probably from the tibia, dried. It consists of about 6 cm. of nearly the whole circumference of the shaft of the bone and about half of the dense wall where it is expanding into the head, with a considerable amount of the cancellous tissue inside it.

*(b) Repair in Bones after Septic Wounds.***5.112. Healing with Ankylosis after a Fracture into the Ankle-joint complicated by Septic Arthritis and Osteomyelitis.** *Hunterian.*

Tibia and fibula with part of the skeleton of the foot, in which there are recognizable portions of the astragalus, os calcis, and the smaller bones down to the bases of the metatarsals, all fused together into an irregular mass of spongy bone. There is no history; but there has evidently been a fracture, probably a compound "Pott's," opening the ankle-joint. The only break now recognizable is that of the fibula, situated 3 or 4 cm. above its lower end. The foot has been carried outwards to a marked degree as in that fracture. While still in this position inflammation has set in, resulting in the destruction of the ankle and adjacent tarsal joints and ankylosis of the various bones. There are traces of periosteal new-formation for a short distance up the shafts of the tibia and fibula. The specimen has the appearance of being from a grave; the cancellous bone composing the greater part of the os calcis and malleoli of the tibia and fibula has rotted away.

(4) Tuberculosis of Bone.

Most of the specimens in the collection illustrating the results of disease of bone due to the tubercle bacillus by itself or in association with pus-forming organisms will be found in Series 6, Diseases of the Joints, under the headings Tubercular Disease of the Bones and Joints, and Tubercular Disease of the Spine.

5.113. Rarefying Osteitis. Caries. Tubercular (?) and Septic. *Hunterian.*

Lower portion of a tibia macerated and dried, illustrating the above. The epiphysis absent. The cancellous lower end of the bone has been hollowed out as if by an abscess, which has destroyed the epiphysial surface almost completely. It opens above by a rounded orifice on the front of the bone. The walls all around and for some distance up the shaft are greatly rarefied. Externally, they are covered with a crust of spongy periosteal new bone, which is especially abundant around the cloaca. In the dry bone it is im-

possible to be certain as to the nature of the disease; probably it was a tubercular abscess in the end of the bone with subsequent septic osteomyelitis. The specimen is placed here as an example of caries.

5.114. Rarefying Osteomyelitis. Caries. Tubercular and Septic. *Hunterian.*

Lower portion of a tibia macerated and dried, illustrating the above. The cancellous end of the bone presents an eroded rarefied appearance as if it had been riddled with tubercular granulations. On the outside there is a considerable crust of periosteal new bone, indicating that septic infection had also been present. Introduced as an example of caries.

5.115. Abscess in Bone. Osteosclerosis. *Hunterian.*

Lower portion of a femur, divided longitudinally, macerated and dried. In the lower third of the diaphysis there is an irregular elongated cavity extending from about 3 cm. above the epiphysial line upwards for about 5 cm. The bone around it is widely cancellous. There are several small incompletely detached sequestra here and there. The cavity opens by a narrow round orifice on the front of the bone near its upper end. The cancellous head of the bone as a whole is very considerable sclerosed, and the marrow cavity above is filled with a decidedly dense porous bone. The outer walls are thickened and condensed behind, but rather rarefied in front. Externally, there has been some periosteal new bone-formation. An old standing disease evidently, and whether septic or tubercular it is now impossible to say. Probably a chronic tubercular affection originally, to which septic organisms have obtained access on the formation and opening of an abscess in the soft tissues over the orifice of the cloaca. The bone is that of an adult.

5.116. Abscess of Bone. Probably Tubercular followed by Septic Osteomyelitis. Involvement and Destruction of Knee-joint. *Hunterian.*

Lower portion of femur—a longitudinal section, including the external condyle, removed from about half of one side to show the

interior of the bone—macerated and dried. From the epiphysial line an elongated irregular cavity extends for a distance of about 12 cm. up the centre of the bone, to open by a rounded orifice on the inside. Its walls are of fairly firm cancellous bone. There are also several smaller cavities which open independently in other directions. The outside of the shaft is covered with rough periosteal new bone, which is fairly dense, and the medullary cavity is blocked above by bone—in some parts cancellous, but mostly dense—evidently new-formations of considerable age. The smaller section of the bone has an extremely irregular eroded appearance externally, and in the hollows lie numerous partly detached sequestra. The articular surfaces have mostly been destroyed. Several small abscess cavities have opened upon them. Probably a chronic tubercular disease with abscesses which had burst and let in pyogenic organisms.

(5) *Inflammation of Bone due to Syphilis.*

(A) OF THE CRANIAL BONES.

5. 117. Syphilitic Disease of the Skull. Extensive Necrosis. *Hunterian.*

A cranium macerated and dried, showing the above. The chief seat of the disease has been the frontal region. Practically the whole frontal bone, with the exception of the orbital plates and the portions of the inner table at the back of the frontal sinuses, after being deeply eroded almost all over its outer surface, has necrosed and become an enormous sequestrum. The groove of separation is cut completely through to the inside, except a bridge of bone about 2 cm. wide, which still connects it with the right parietal; but for this and some interlocking angles here and there, it is free. The groove follows the coronal sutures. Below, on the right, the disease has passed over into the great wing of the sphenoid, part of which is included in the sequestrum; also into the malar bone, which has been detached as a sequestrum and lost. In front it runs along the supra-orbital ridge and down round the nasal processes. The right orbital plate and external angular process of the superior maxilla are considerably rarefied. The rarefying osteitis, with patches of erosion of the outer table (syphilitic caries), extends all over both parietals and the upper part of the occipital bone.

5.118. Syphilitic Disease of the Skull.*Hunterian.*

The vertical plate of the frontal bone, which is divided into two halves by a frontal suture, macerated and dried, illustrating the above. There are numerous irregular erosions of the outer table into the diploe, and on the right through the inner table also. Most of these have cleanly cut edges, showing that the process of ulceration was advancing. Others have rounded edges, as if healing had commenced. The whole bone is thickened, and very heavy from filling up of the spaces of the diploe with new dense bony matter. This specimen is figured in Matthew Baillie's *Engravings*, Fasc. X., Plate II., fig. 1, as a representation of "the effects which venereal disease commonly produces upon the bones of the cranium." This is a comparatively rare occurrence nowadays.

5.119. Sequestra separated by Syphilitic Disease of the Skull.*Hunterian.*

Two sequestra from different cases cleaned and dried. The larger is an irregularly ovoid portion of the vault of a cranium, measuring 14 by 9 cm. It resembles the sequestrum in No. 5.117, but is denser and less eroded on the surface. A considerable area of it includes the whole thickness of the skull; the rest is irregularly scooped out internally and externally, and here and there perforated, by the granulations which effected its separation from the living bone. The other sequestrum is similar, but much smaller. It is much more rarefied and eroded, and consists almost entirely of external table and diploe.

5.120. Syphilitic Disease of the Skull. Sequestra in Process of Separation.*Hunterian.*

A cranium macerated and dried, showing the above. The vault is perforated clean through by five holes, of circular shape, from 1.5 to 3 cm. in diameter, almost certainly the result of syphilis. The holes are slightly wider in the outer than in the inner table, and widest of all in the diploe. The bones as a whole are thickened, and the diploe sclerosed. Two of the holes in the frontal bone have coalesced. Beside these is an area showing the manner in which these are formed—inflammation, then necrosis of a circular patch of bone, which is separated by rarefying osteitis round about. In the posterior region of the right parietal is a circular patch of rarefied bone

without any sequestrum, and near the lambdoid suture one of the perforations shows the process of extension—about 5 mm. outside the edge of the hole all round there is a circular trench cutting off a ring of bone the whole thickness of the vault; internally the groove of separation is still incomplete—just a ring of rarefaction.

5.121. Extensive Destruction of the Vault of the Skull by Syphilis. *Hunterian.*

A skull cap macerated and dried, illustrating the above. There is an enormous nearly square gap, measuring 9 cm. by 7 cm., mostly in the left parietal bone but extending slightly into the right, clean through the skull; due doubtless to the separation of a large sequestrum. The gap in the inner table is as large as that in the outer. The whole thickness of the bones for some little distance around the edges is rarefied and eroded by granulations in a peculiar manner, producing a worm-eaten appearance.

In the right parietal, just outside the edge of the large gap, there is a small irregularly rounded hole about 1 cm. in diameter, with its edges rarefied and eroded in the same peculiar manner for about 1.5 cm. all round. There is another similar small perforation and part of a larger eroded patch in the frontal bone. The latter has been cut across in the preparation of the specimen, but it looks as if it must have extended down to about the supra-orbital ridge. There has been slight periosteal new-formation of bone around the diseased areas outside the line of advancing rarefaction. There is no history, but it is almost certainly syphilitic.

5.122. Syphilitic Disease of the Skull. Healing after Separation of Sequestrum. *Hunterian.*

A cranium macerated and dried, illustrating the above. In the frontal bone, extending from the coronal suture almost to the supra-orbital ridges and nearly the whole breadth of the forehead, is an excavation of irregular shape, measuring about 9 by 7 cm., its edges shelving down all round towards the centre, where there is a perforation into the cranial cavity of irregular rhomboid shape, measuring 7 by 3.5 cm. The borders of this excavation are dense bone, the spaces of the diploe being obliterated by condensing osteitis. The excavation appears to be just what would result from the separation of a sequestrum like No. 5. 119, in which a large area of the outer

table and diploe with a much smaller area of inner table had necrosed and been cast off, and then the adjacent living bone healed with condensation and thickening and a permanent hole into the cranium. There is a smaller similar excavation in the left supra-orbital ridge.

5.123. Syphilitic Disease of the Skull. Healing after Separation of Sequestrum. *Hunterian.*

A cranium macerated and dried, illustrating the above. There is an excavation and perforation similar to that in the preceding specimen, produced by the separation as a sequestrum of nearly the whole left half and part of the right half of the frontal bone. The inner table is the one of which least had been destroyed. There is some excavation of the remainder of the frontal bone, as if superficial exfoliation had taken place; and corresponding to this there is a considerable thickening by periosteal formation of new bone on the inner table, in consequence of inflammation spreading through from the outside.

5.124. Syphilitic Disease of the Skull. Healing after Separation of Sequestrum. *Hunterian.*

A skull cap macerated and dried, illustrating the above. There has been separation of a very large sequestrum (mostly of the outer table) over the vertex, including about half of both parietal bones and small areas of the frontal and occipital. The area of superficial necrosis measures 13 cm. in the sagittal by 13 cm. in the transverse direction, and is of roughly circular outline. In the centre the sequestrum has included the whole thickness of the vault, and there is a gap of rhomboid shape, 6.5 cm. in the line of the sagittal suture and 5 cm. transversely. The excavated areas, both superficial and deep, are almost symmetrical on the two sides of the sagittal suture. The osseous floor and edges of it are rather porous, healing being not so far advanced as in the preceding. There is no thickening of the skull.

(B) SYPHILITIC DISEASE OF THE REST OF THE SKELETON.

The history of the following bones is unknown, but they have been found to present appearances similar to those of undoubtedly syphilitic bones in other museums, and they are catalogued accordingly.

- (1) *Changes in the form of Periostitic New-formation of Bone or a more or less general Enlargement and Condensation.*

5.125. Syphilitic Enlargement of the Humerus. *Hunterian.*

A rather small right humerus macerated and dried, showing slight thickening of the lower third by a thin rather patchy crust of periosteal new bone. The old solid shell under the crust slightly more porous than normally. Probably syphilitic.

5.126. Syphilitic Enlargement of the Humerus. *Hunterian.*

A small left humerus macerated and dried, showing a node of fairly dense periosteal bone about the middle. Probably syphilitic.

5.127. General Enlargement of the Humerus. **Probably Syphilitic.** *Hunterian.*

A large humerus macerated and dried, showing the above. The whole bone is considerably enlarged and heavier than normal, and its surface from end to end is rough and irregular, its appearance suggesting periostitic thickening of old standing. It is more porous than a normal shaft. Probably syphilitic.

5.128. Syphilitic Node on Radius. *Hunterian.*

A radius macerated and dried. For about 6 cm. the inner half of the circumference of the middle of the shaft is covered with a fairly thick crust of porous periosteal new bone, making a spindle-shaped swelling. Probably a syphilitic node.

5.129. Syphilitic Enlargement of Radius and Ulna. **Early Stage.** *Hunterian.*

Right radius and ulna macerated and dried, showing the above. The middle of the radius is enclosed in a sheath of porous new bone, making a spindle shaped swelling extending about two-thirds of its length. Part of the new crust and the underlying old dense shell seems to be undergoing rarefaction and re-absorption. The ulna is covered from the lower third up to the end of the olecranon with a similar crust of bone, thickest above the middle and on the posterior surface. The articular surfaces of the head of the

ulna are eroded. The eroded bone in some parts has a rounded-off slightly condensed appearance, as if healing were in progress. The whole condition, arthritis included, was probably syphilitic. Compare the shape of the ulna with that of the succeeding enlarged and dense bones.

5.130. Syphilitic Enlargement of Radius and Ulna.

Hunterian.

A large radius and ulna macerated and dried, showing the above. Both bones are considerably enlarged by periosteal formation around them of new bone, which is fairly dense and evidently of considerable age. The enlargement extends on the ulna from near the lower end up to the tip of the olecranon. It is most marked in the middle and upper portions. In the radius, on the other hand, the upper third is almost unaffected; while the lower two-thirds are as much thickened as the upper parts of the ulna. The new bone is not of uniform texture, parts being white and dense; other parts full of pores, like that on the preceding specimen. Compare the preceding and succeeding specimens. Probably syphilitic.

5.131. Syphilitic Enlargement and Condensation of the Radius and Ulna.

Hunterian.

A radius and ulna macerated and dried. They are greatly thickened and very heavy; their surface white and for the most part smooth. The distribution of the thickening is similar to that described in the preceding, affecting all but the lower end in the ulna, and all but the upper end in the radius. It is greatest on the posterior side of the ulna, increasing its curvature in that direction, and in the radius all round the middle. Comparing it with the two preceding specimens, it seems to be a later stage of a similar condition—a thickening by chronic periostitis followed by sclerosis of the new bone. Probably of syphilitic origin.

5.132. Syphilitic Enlargement of the Radius. *Hunterian.*

A radius macerated and dried, very similar to the preceding—being greatly enlarged with the exception of the upper end and two or three centimetres of the shaft, but having a surface not quite so smooth and condensed. The lower half has been sawn in two.

longitudinally. The cut surfaces show the medullary cavity filled with a rather dense cancellous tissue. The old dense shell is traceable, though mostly removed by a process of rarefaction which has extended from within through it even out into the dense new bone, so that the compact outer shell is not much thicker than it would be in a normal radius. The bone is very much increased in weight as well as size.

5.133. Syphilitic Enlargement of the Ulna. *Hunterian.*

An ulna macerated and dried. Thickened and condensed in like fashion to No. 5. 130 by chronic inflammation. Probably syphilitic. The new bone is fairly porous.

5.134. Syphilitic Enlargement of the Ulna. *Hunterian.*

An ulna macerated and dried. Enlarged in the same manner as the preceding, and very much condensed, having a white smooth surface like that of No. 5. 131. Very heavy.

5.135. Syphilitic Enlargement of the Femur. *Hunterian.*

Right femur, probably from a grave, showing a slight thickening of the lower two-thirds of the diaphysis by a thin layer of porous periosteal new bone. The crust has been broken in front, where it happens to be thickest, showing the underlying dense shell slightly rarefied. The new-formation is rather patchy in its distribution in the upper parts. The result of a fairly recent periostitis, which was very probably of syphilitic origin.

5.136. Syphilitic Enlargement of the Femur. *Hunterian.*

Left femur macerated and dried. About one-third of the shaft in the upper part of the lower half is encased nearly all round in a thin crust of periosteal new bone, which is fairly dense, showing that it is a formation of rather old standing. Very like the preceding, and probably also of syphilitic origin.

5.137. Syphilitic Enlargement of the Tibia. *Hunterian.*

Right tibia macerated and dried. Nearly the whole bone is covered with a thin and very patchily distributed crust of porous

bone of fairly open texture. The result of a not very recent periostitis ; probably of syphilitic origin.

5. 138. Syphilitic Enlargement of the Tibia. *Hunterian.*

Left tibia, probably from a grave. The lower half, more particularly on its inner subcutaneous side and towards the lower end, covered with an irregular fairly thick crust of porous periosteal new bone. Probably the result of a syphilitic periostitis.

5. 139. Syphilitic Enlargement of the Tibia. *Hunterian.*

Portion of a right tibia, probably from a grave. The lower half of the inner subcutaneous surface covered with a thin crust of porous periosteal new bone. This is broken away in places, showing the old shell somewhat rarefied. Probably syphilitic.

5. 140. Syphilitic Enlargement of the Tibia. *Hunterian.*

Portion of a left tibia macerated and dried. The inner surface of the lower third is covered by a node-like enlargement in the form of a crust of very spongy bone. Most of this is broken away, showing the rarefied surface of the old shell.

5. 141. Syphilitic Enlargement of the Tibia. *Hunterian.*

A right tibia, probably from a grave, showing in the middle third of the shaft a spindle-shaped thickening composed of periosteal new-formed bone. This extends all round the shaft, but is much thicker and more extensive on the outer and posterior than on the inner subcutaneous side. Its surface is irregular. Its texture is fairly close, showing that it was not of recent formation. Probably syphilitic.

5. 142. Syphilitic Enlargement of the Tibia. *Hunterian.*

A large right tibia, probably from a grave, showing an old periosteal node of the middle of the shaft. The thickening is mostly on the posterior and inner surfaces. The new bone is considerably condensed, and its surface fairly smooth. Probably syphilitic.

5.143. Syphilitic Enlargement of the Tibia. *Hunterian.*

Lower half of a tibia macerated and dried, showing the above. An old standing enlargement. The inner surface shows two node-like swellings, and appears to be also thickened as a whole and made unduly convex. The surface of the upper node is porous as if it were being re-absorbed—perhaps being invaded by an ulcer. Probably syphilitic.

5.144. Syphilitic Enlargement of the Tibia. *Hunterian.*

Upper two-thirds of a tibia macerated and dried, showing a node-like thickening of about one-third of the inner (subcutaneous) surface. It is of old standing, dense, and fairly smooth. The grain of the new bone is unusually regular, and runs longitudinally. Probably syphilitic.

5.145. Syphilitic Enlargement of the Tibia. Marked Condensation. *Hunterian.*

Upper part of a tibia, probably from a grave, showing a node-like swelling which must have been of old standing, as its surface is as smooth and dense as that of the original shell. A section of it placed alongside shows the almost complete filling up of the medullary cavity with very dense bone. It is just possible to trace the outline of the old shell by its being of slightly lighter colour than the new bone. Probably an old syphilitic node, though it might be the result of a chronic periostitis from a blow.

5.146. Structure of a Syphilitic Enlargement of the Tibia.

Hunterian. LL. 36.

“A longitudinal section of the tibia, on which a large node, probably venereal, was formed. The leg had been injected, and the bone afterwards steeped in an acid.” It is beautifully transparent, being mounted in turpentine. The new-formed bone is seen on both sides of the section, readily recognizable between the old shell and the vascular periosteum. The old shell has a decidedly longitudinal grain; the new bone has rather the appearance of having been formed in lumps perpendicular to the surface of the shaft. Compare No. 5. 57 in particular and other specimens. The medullary

cavity in the neighbourhood of the node is filled up with widely cancellous bone, which is decidedly vascular. "The node resembles much the callus of bone (about a fracture), and is also evidently vascular."

5.147. Syphilitic Enlargement of the Tibia. *Hunterian.*

Lower portion of the tibia macerated and dried, showing the above. Its surface nearly all over is composed of rough new bone, dense but with abundant channels for blood-vessels. It has been sawn longitudinally to show, as in the preceding, the new bone formed on the exterior of the old; chiefly over the crest and on the inner and outer surfaces. There has also been new-formation of cancellous bone internally, narrowing the medullary cavity. Where the new bone is thickest, there has been a rarefying osteitis of the old dense shell, converting it into cancellous bone. The old shell is traceable in front only, about the upper and lower ends. Probably syphilitic.

5.148. Syphilitic Enlargement of the Tibia. *Hunterian.*

A large tibia macerated and dried, showing considerable thickening of the shaft, mostly on the back, by old chronic periostitis. Probably syphilitic. Near the lower end behind there is also a patch of recently-formed new bone.

5.149. Syphilitic Enlargement of the Tibia. *Hunterian.*

A large tibia and fibula macerated and dried. A very good pair for the preceding, and showing a very similar enlargement—on the tibia, mostly behind and in the lower half; on the fibula, pretty well all round its lower two-thirds. A patch near the lower end is of more recent date. Probably syphilitic.

5.150. Syphilitic Enlargement of the Tibia and Fibula.

Hunterian.

A tibia and fibula macerated and dried, showing a condition very similar to the preceding, but the enlargement is considerably greater and also more general. The new bone is firm and smooth,

but very porous. A little below the middle of the inner surface and crest of the tibia is a node-like swelling with distinct raised borders, which probably underlay an ulcer. Its surface is slightly more porous than the surrounding bone, but not ulcerated. Probably syphilitic.

5.151. Syphilitic Enlargement of the Fibula. *Hunterian.*

A fibula macerated and dried. The middle two-thirds of the shaft is covered with a thin crust of periosteal new bone. Probably syphilitic.

5.152. Syphilitic (Ulcer ?) Enlargement of Fibula.

Hunterian.

Portion of a fibula macerated, dried, and divided longitudinally. It is considerably thickened from end to end. The periosteal new bone has been formed very irregularly, giving to most of its surface a rough tuberculated appearance, but leaving almost unaltered patches of the old surface here and there. It is an old standing condition; the new bone is mostly dense. In the cut surface the old shell is, for the most part, distinguishable from the new bone. Here and there it has been considerably eroded from within. The condition was probably of syphilitic origin, complicated by ulcers, the irritation from which would increase the inflammation and new-formation of bone.

5.153. Syphilitic Enlargement of the Fibula. *Hunterian.*

Fibula from a very tall person, macerated and dried, showing considerably enlargement. Probably syphilitic.

5.154. Syphilitic Enlargement of the Fibula. *Hunterian.*

Fibula from a tall person, macerated and dried, showing the lower half of its shaft about doubled in diameter in consequence of periostitis. Probably syphilitic.

5.155. Syphilitic Enlargement of the Fibula. *Hunterian.*

A fibula macerated and dried, showing a great enlargement of the lower part of its shaft similar to that in the preceding, but in an

earlier stage. The new bone is rough and very porous, and there are a number of holes in its surface, as if there had been small necroses. Probably syphilitic.

5. 156. Syphilitic Enlargement of the Fibula. *Hunterian.*

Fibula macerated and dried, showing the above. The new-formed bone is so old and dense that it is not distinguishable from the old. The enlargement is general and pretty considerable. Probably syphilitic. Compare No. 5. 152, which this bone decidedly resembles.

5. 157. Syphilitic Enlargement of the Fibula. Rickets (?). *Hunterian.*

A fibula macerated and dried, greatly thickened by periosteal new bone about the middle, where it is also bent forwards into a shape similar to the rickety fibulae. See Nos. 5. 21, 23, 29, and 30. Probably a syphilitic thickening of a bone deformed by a previous, perhaps very old, attack of rickets.

5. 158. Syphilitic Enlargement of the Fibula. *Hunterian.*

Portion of a fibula macerated and dried, showing the above; of old standing. At the lower end there has also been an osteitis of a later date, and in the rarefying stage, destroying the lower end. The articular surface is eroded to a considerable extent. Above this there is a thin crust of recent periosteal new bone. The nature of this cannot be made out now; possibly septic inflammation from a wound or ulcer.

5. 159. Syphilitic (?) Enlargement of the Tibia and Fibula. *Hunterian.*

Lower portion of the tibia and fibula, probably from a grave, showing a very great enlargement of the latter, with very little alteration of the former. The fibula is almost as large as the tibia. The new-formed bone is smooth over most of the outer surface; rough elsewhere, especially along the lines of attachment of fasciae and ligaments. Possibly syphilitic, but possibly due to an ulcer or even elephantiasis.

(C) CHANGES IN THE BONES DUE TO INFLAMMATION, PROBABLY
SYPHILITIC IN ORIGIN, COMPLICATED BY SEPSIS.

**5.160. Syphilitic (?) Disease of the Tibia, and Invasion by
Septic Rarefying Osteitis.** *Hunterian.*

Lower portion of a tibia macerated and dried, illustrating the above. About the junction of the lower and middle thirds on the inner (subcutaneous) surface there is a deep erosion, apparently the result of an advancing osteitis—a septic caries. Round this erosion two layers of bone are recognizable: (1) a recent periosteal crust, all but the borders of which is eaten away; revealing (2) a deeper layer of porous periosteal bone rising up like the sloping edge of a node above and below the erosion, which had destroyed the central parts of it, and had laid bare and was eroding the original shaft. Probably this was a node of syphilitic origin which had been cut down on, a proceeding which William Hunter advised, saying that you “would thus bring on a suppuration which seldom fails of resolving them.” (*Lectures*, p. 202, MS. R.C.S.Eng., 42, c. 28.)

**5.161. Syphilitic Enlargement of the Tibia, followed by
Septic Osteitis.** *Hunterian.*

Tibia, probably from a grave, the articular ends to a great extent destroyed. The middle third of the shaft presents a spindle-shaped swelling composed of a crust of new bone formed upon its crest and inner and outer surfaces. Towards the borders of the node the new-formed bone is fairly dense, evidently not recent. Over this are patches of a very thin recent formation. Towards the middle the greater part of the old new-formed bone is rarefied, undermined, and in places broken down by a new inflammatory process, which was probably septic, and possibly the result of cutting down on the node. Compare the preceding. Where the new crust is broken, the old shell of the bone is visible, also greatly rarefied and eroded—caries, probably septic, of the node and underlying old shell.

**5.162. Syphilitic (?) Enlargement of the Tibia. Invasion
by Ulcer.** *Hunterian.*

Portion of a tibia macerated and dried. The lower fourth of the bone, from the tip of the malleolus, is covered on its inner

side by a node-like swelling of very porous bone. The edges of the swelling, especially the posterior, are somewhat raised, suggesting that it was the base of an ulcer. The sponginess of its surface suggests that the ulcer was invading it. The surface of the whole shaft of the bone appears abnormally porous. Possibly syphilitic, but might be the result of an ulcer from other causes, such as a blow.

5.163. Syphilitic Node on a Bone deformed by Rickets.
Invasion by an Ulcer. *Hunterian.*

Portion of a tibia macerated and dried. The bone is thick and heavy, and has a considerable bend forwards, doubtless the result of old rickets. The middle third of the front and sides of the bone is occupied by a large prominent node; probably syphilitic. An oval patch with raised edges in the middle of this presents a rough rarefied surface: it has evidently been the base of an ulcer which was beginning to invade the bone. The rest of the node round about this is of densish bone, evidently of considerable age.

5.164. Syphilitic Enlargement of the Tibia. Invasion by an Ulcer. *Hunterian.*

A tibia, probably from a grave. The whole shaft is covered more or less with irregular periostitic outgrowths; dense and old. In addition there is a spindle-shaped enlargement of the middle of the bone; old and probably of syphilitic origin. On the front and inner side of this is an area bounded by slightly raised edges, measuring 11.5 cm. by 5 cm., the surface of which is rarefied and eroded in the manner characteristic of invasion by a chronic ulcer. The irregular periostitic outgrowths are probably the result of irritation of the periosteum by the neighbouring ulcer.

Comparative Anatomy Specimen.

5.165. Node on the Metatarsus of a Quadruped.

Hunterian.

Metatarsal bone of a quadruped macerated and dried, described in the former printed catalogue as "an excellent specimen of a node on the tibia of a quadruped." It is a circumscribed oval new-formation, about 5 by 4 cm. in diameter, and about 1 cm. high, placed on one side of the bone. It is composed of somewhat porous new-formed

bone, slightly rarefied on the surface, and with a small cavity scooped out in its centre. Possibly the result of irritation of the periosteum by some chronic ulcerative process in the overlying soft parts. It is almost needless to say that it is not syphilitic.

IV. TUMOURS OF THE BONES.

(1) *Osseous and Cartilaginous Tumours of Bone: Osteomata and Exostoses.*

5.166. Osteoma (Ossifying Chondroma) of Fibula.

Hunterian.

Section of a large tumour enveloping the upper two-thirds of a fibula. History unknown. The tumour is egg shaped, the broad end upwards, and slightly flattened on the top. It measures 24 by 15 cm. Externally it is enclosed in a fibrous sheath like periosteum. Numerous large blood-vessels, coarsely injected red, run over it. In the cut surface the shaft, head, and upper epiphysial line of the fibula, where they have been traversed by the cut, are distinctly recognizable. The lower epiphysis is also sliced to show the line there also cartilaginous. The top of the growth rises 1.5 cm. above the top of the fibula, 3 cm. above the epiphysial line. The bulk of the tumour is composed of bone, rising in irregular masses from the surface of the shaft. Throughout the tumour, as in normal bone, there are strands of soft fibrous tissue, in which, here and there, blood-vessels appear. Towards the outside the bone becomes more irregular, and the gaps between the osseous processes are filled up with cartilage. This is found all round the exterior of the mass in a layer which varies greatly in thickness—in some places thin, in others extending in irregular masses between the trabeculae of bone for 2 or 3 cm. Microscopically, a section shows irregular masses of cartilage with strands of fibrous tissue between them, and occasional portions of bone embedded in and presumably developing from the cartilage. It is too much degenerated to show details of structure. (MS. Notes, J. H. T., p. 7.)

5.167. Cancellous Osteomata of Femur, Tibia, and Fibula.

Hunterian.

Lower half of a femur with the whole of the tibia and fibula macerated and dried, showing the above. The specimens are very imperfect, the friable cancellous tissue of the ends of the bones and

of the tumours being a good deal broken in places. The lower end of the femur, as a whole, seems to be enlarged. Rising from the inner and posterior side, about 7 cm. above the surface of the condyle, is a rounded irregular mass of cancellous bone, 8 cm. in diameter, and projecting fully 9 cm. Around the base, where it is somewhat constricted, it has a smooth shell of dense bone like that of the normal cancellous head. The rest, the greater part, of the surface is tuberculated, and, where still unbroken, covered with a thin shell of fairly dense porous bone like that bordering upon an epiphysial cartilage; from what is known of such tumours it may fairly be assumed that those parts were sheathed with cartilage, like the osseous tissue in the preceding specimen. Above the outer condyle projects a similar much smaller tumour. To the outside of this is a broken surface of open cancellous bone, probably the base of a third tumour. Above is a spine like an ossified tendon. In front, just above the edge of the articular surface, is another large broken surface with raised borders of smooth dense bone, clearly the site of a fourth tumour; the base is fully as large as that of the first mentioned tumour. From the inside of the tibia, about 2.5 cm. below the articular surface, rises yet another tumour similar to the first. It measures 7 cm. vertically by 5 cm. across, and projects 5 cm. The head of the fibula is expanded and ankylosed to the tibia by a mass of similar cancellous bone. The lower ends of the two bones are also expanded and fused together for a distance of about 6 cm. in a considerable mass of similar bone.

5. 168. Exostosis of the Humerus.

Hunterian.

A humerus macerated and dried, showing the above. The tumour consists of a globular mass, about the size of a marble, of open cancellous bone set on a somewhat narrowed base. Its apex is porous, and was probably covered with cartilage. It rises from the back of the humerus, rather to its outer side, about the middle. There is a rising of the dense bone from above downwards, from which the tumour is continued for about 2 cm. backwards and downwards, overhanging its base below for a distance of about 1 cm. A groove, like the musculo-spiral, runs above and to the outside of it; but below and to the inside is a deep groove beneath the overhanging portion, which probably transmitted the nerve or superior profunda artery, and over the lower shoulder of the tumour, close to this, is a second somewhat similar groove. It appears to be related to the origin of the outer rather than of the inner head of the triceps.

5. 169. Exostosis of the Femur.*Hunterian.*

Right femur, probably from a grave. In the region of the origin of the crureus muscle there projects forwards and downwards a large mass of bone. Its sides have a firm shell pierced by numerous foramina for blood-vessels; it is porous on the anterior surface, which, in the fresh state, was probably covered with cartilage. The base of the tumour measures 9 cm. longitudinally by 5 cm. across. It is considerably wider than the shaft, and projects about 3 cm. forwards. Below, it is continued in a thick spur, overhanging its base about 4 cm. See also *Séries 8, Diseases of Muscles, Tendons, etc.*

*Comparative Pathology of Osteoma.***5. 170. Osteoma of the Canon Bones of a Horse.** *Hunterian.*

Lower portion of the canon bone and first phalanx of the fore-leg of a horse enveloped in a large and very irregular mass of dense bone. Macerated, dried, and divided longitudinally. The growth appears to have arisen in two portions from the two sides and back of the long bones, and from the two sesamoid bones connected with the joint. The sawing of the bones has allowed the two masses to separate. The smaller is connected with the one half of the phalanx and the corresponding sesamoid bone; it is distinct from that of the other side, and has no trace of saw cut on it. It has also been free from the canon bone altogether. The mass of the other side is much larger, and almost completely envelops the other sesamoid and halves of the canon bone and phalanx, ankylosing them all together. The saw has cut off portions of it, which, along with one half of the canon bone, have been lost; the cut surfaces show very dense irregular bone. The outer surface looks like that of a very coarse sponge—irregularly nodulated, full of large foramina, and the surface of the individual nodules full of finer pores. It was probably growing at the periphery. When the two portions are placed in apposition, the mass is of oval shape, and measures 20 cm. long by 11 cm. broad and 35 cm. in circumference.

5. 171. Osteomata of Sternum of Natatorial Bird.*Presented by Professor Young, 1897.*

Sternum, probably of a wild duck, macerated and dried, showing

the above. On either side of the carina, in the angle between it and the body of the sternum, near the posterior end, is an oval mass of smooth dense bone. The larger measures 21 by 12 by 10 mm.; and the smaller, 16 by 10 by 7 mm. They rise from both body and carina exactly opposite one another. On the deep surface of the bone in the middle line, corresponding to their bases, is a single circular tumour of similar character, 14 mm. in diameter, and projecting 5 mm. inwards. Near the anterior end of the sternum there is another small nodule on the inner surface, also exactly in the middle line. There are four shot holes in the body of the sternum.

5. 172. Large Osteoma of the Vertebral Column of Codfish.

Presented by Professor Young, 1897.

Three of the dorsal vertebrae from a codfish (which had been boiled), cleaned and dried. On the left side of the spinous processes is a large mass of bone, of globular shape, filling up the angle between them and the lateral processes, and with a smaller projection which envelops one of the latter, and passes between the other two about half way across the front of the bodies. The tumour seems to spring chiefly from the side of the body and lamina of the middle one of the three vertebrae. A small outgrowth projects some way into the vertebral canal, and must have compressed the cord. The main mass is slightly flattened radially to the vertebral column. It measures 7 cm. longitudinally, 7 cm. transversely, and stands out 5.5 cm. from its base. It is composed of very closely set spicules of bone radiating from its base; this bone is similar in character to that composing the skeleton of the fish, if anything rather harder and more dense, and very heavy. The surface of the growth looks somewhat like the capitulum of a daisy, a resemblance heightened by its having a yellow colour due to dried particles of the soft tissue entangled between the ends of the spicules.

5. 172a. Osteoma of Vertebral Column of Codfish.

Presented by Mrs. J. R. Robertson, Glasgow, 1898.

Tail portion of the vertebral column of a large codfish, showing a tumour similar to the preceding, about the size of a

marble, growing from the side of the body of one of the vertebrae.

5.172b. Hyperostosis of Vertebrae in Haddock.

Presented by Robert Mason, Esq., 1889.

Vertebral column of a haddock cleaned and dried. The bodies of fifteen of the vertebrae of the tail portion are expanded to three or four times their normal size. The expansion is quite regular, and apparently osseous. There is no interference with the canal of either dorsal or ventral arches.

(b) *Sarcomata of Bone.*

(A) CENTRAL.

5.173. Large Central Sarcoma of the Humerus.

Jeffray Collection.

A large tumour, involving about the upper two-thirds of the shaft and head of the humerus, overlying soft parts removed, except a few muscles which are stretched and spread out upon it. The large arteries have been injected red and dissected; the circumflex is much elongated. The tumour forms a large carrot-shaped mass, about 10 cm. in diameter near the top, and tapering downwards to the unaffected portion of the shaft. The articular surface of the head projects from one side on a level with the top. Its cartilage is intact, but it is hollowed out to a mere shell. There are several large holes in the tumour, through which the contents, which have evidently been very soft, have escaped, leaving the outer shell, which is clearly the expanded shaft of the bone. Its walls are 1 to 2 cm. thick, and composed of soft tumour tissue, mixed with a good deal of bone in irregular spicules and plates. It had been stuffed to preserve its shape while hardening. There is no history. Microscopically, it is clearly a sarcoma; although the tissue is extremely degenerated. (MS. Notes, J.H.T., p. 9.)

5.174. Central Sarcoma of Radius.

Jeffray Collection.

Portions of the humerus, radius and ulna, and soft parts dissected to show an oval tumour which has expanded the upper third of the

shaft of the radius. The articular head appears to be intact. The tumour is cut open in front. It consists of a very soft friable tissue permeated with spicules of bone. Microscopically, it is a round or short spindle-celled sarcoma. (MS. Notes, J.H.T., p. 10.) The arteries are coarsely injected red. A number of points of injection mass are visible in the cut surface of the tumour.

5.175. Central Sarcoma of the Head of the Fibula.

Hunterian.

Tibia and fibula macerated and dried. The head and upper third of the shaft of the latter is expanded into a globular shell about 12 cm. in diameter. The back of the tumour has been removed, showing the cavity, from which all the soft contents have disappeared in preparation. The wall of the shell is of porous bone, externally fairly smooth, but internally very irregular; it is fenestrated in some parts, in others fully 1 cm. in thickness. In front there is a deep groove, as if the expansion of the bone had been limited by a tendon, fascia, or large nerve. The tumour is united to the surface of the tibia by bone; the latter bone has, however, no part in it. The specimen is undoubtedly the skeleton of a tumour similar to No. 5.173. There is no history, but it is mentioned in the old catalogue as a "spina ventosa."

5.176. Large Sarcoma of the Femur. Central(?).

Hunterian.

Lower portion of the femur, the head absent, broken off apparently just below the trochanters, macerated and dried. In front of the upper third of the shaft is a large very imperfect shell of porous bone, similar to that shown in the preceding, evidently the outer parts of a sarcoma of the bone. It appears to have been of globular shape, and about 17 cm. in diameter. The upper portion of the shell of the tumour, with nearly all of the part of the shaft from which it sprung, is absent; but the upper end of the fragment, to which it is still attached, has evidently been part of its seat, as it is slightly expanded and its medullary cavity enlarged. The growth appears to have been of central origin. A length of about 8 cm. of the shaft is overlapped by the tumour, but not involved in it; it is slightly rarefied. Mentioned in the old catalogue as a "spina ventosa."

(B) PERIOSTEAL SARCOMATA OF BONE.

5.177. Periosteal Sarcoma (?) of Femur. *Hunterian.*

Section of the lower two-thirds of a femur, from an adolescent subject, partly macerated and dried. A spindle-shaped thickening, consisting principally of radiating spicules of bone, extends from the middle of the shaft down into the condyle. The old dense shell is considerably eroded and rarefied. The medullary cavity is filled with a fine cancellous bone, which was probably tumour tissue. Histological evidence is of course wanting, but from the naked-eye appearances it is probable that it was a periosteal sarcoma.

5.178. Periosteal Sarcoma (Osteosarcoma ?) of the Fibula.*Hunterian.*

Fibula of a young adult, macerated and dried. The upper third, 11 cm., of the shaft and the head to the edge of the articular surface is enveloped in a mass of irregular spongy bone, about 10 cm. in its largest diameter. Probably the skeleton of an ossifying periosteal sarcoma, possibly, however, of an osteoma (ossifying chondroma), like No. 5. 166. The fibula below the growth is thickened as if by chronic periostitis.

5.179. Periosteal Sarcoma (?) of Femur. *Hunterian.*

Lower portion of a femur, probably from a grave. The lower part of the shaft is considerably expanded. Its surface consists of a mass of irregularly radiate coarse fibres and plates of bone. The lower end is broken away, showing the medullary cavity considerably enlarged at the expense of the old shell, of which no trace remains. Probably the skeleton of a periosteal sarcoma which has also been growing inside the bone.

5.180. Periosteal Sarcoma (?) of the Tibia. *Hunterian.*

A tibia from a young adult, macerated and dried (mounted upside down). The upper half of the diaphysis and the sides of the epiphysis, and also a smaller completely distinct area of the former near the lower end, are enveloped in fusiform masses of fine asbestos-like

radiating spicules of bone. The growth is much more developed on the diaphysis than on the epiphysis. Both the epiphyses had been detached in preparation. The greatest thickness of the upper mass is 8 cm; of the lower, about 4 cm. Probably the skeleton of a periosteal sarcoma.

For sarcoma in the lungs secondary to sarcoma in the limbs, see Series 18, Diseases of the Respiratory System, No. 38.

5.180a. Sarcoma (?) of the Skull.

Hunterian.

Cranium with the right side of the vault removed to show the interior. Nearly the whole of the left side of the vault, from the root of the nose to the borders of the occipital bone, and from the vertex almost to the meatus auditorius externus, has been replaced by an irregular growth of plates and spicules of bone, which formed the osseous framework of a large tumour. Probably it was sarcomatous growth, originating from the bone.

The following account of the case and specimen is taken from *Med. Obs. and Inq.*, Vol. V., p. 187, *et seq.*, "An Account of a Singular Caries of the Skull, by Mr. Jonathan Wathen." The specimen was readily identified with the illustration, though it is now imperfect, several parts of the tumour having been broken off and lost. "Aug. 25, 1772, William Halsey, of Barnet, Hertfordshire, aged twenty-eight, asked my advice concerning a disorder in his head. I found the teguments of the cranium on the left side exceedingly distended from the top of the head to his ear, and from thence forwards and downwards parallel to the ala nasi, in form of a pouch, entirely covering and closing up the left eye. The upper and most prominent part of the swelling appeared pale, white, and shining from the great distension of the skin; the surrounding, variegated, pale, red, yellow, and the cutaneous veins enlarged and discoloured, as in the *carcinoma*. Notwithstanding the magnitude and frightful aspect of this tumor, he never had felt any pain or uneasiness from the first, except some little prickings and dartings when his head was bent forward, or inclined to either side. The substance of the tumor, as perceptible to the touch, was unequally solid, like that of an occult cancer, and its greatest thickness about three inches on the upper part of the os frontis, where it was most prominent. As he had always a good state of health, and never had received an injury of any kind on his head,

no cause could be assigned for it. Having requested the favour of Dr. Hunter's inspection, his opinion was that the disorder was within the skull, as well as without, and that the bone was exceedingly diseased; but he thought the most singular circumstance was, that he had no pain in his head. The first intimation he had of it was about two years ago, when he perceived a swelling on the posterior part of the left parietal bone, about the size of a pigeon's egg; for as it gave him no uneasiness, he had hardly taken notice of it before, whereupon asking advice, and some topical applications having been prescribed without effect, and having no great inconvenience, he neglected it for a year and a half, when another swelling began upon the superior part of the left side of the os frontis; he was then admitted into St. Bartholomew's Hospital, where he remained a fortnight; but as the real state of the case was obscure, and no indication presented itself, he returned into the country, visiting the hospital occasionally for three months, during which time the swellings increased very fast, and approached very near to each other, but as yet were separated by a depression of the skin. Some were for making an incision to the bone, but the majority being against it, he was discharged." The surgeons at St. George's Hospital also refused to operate. In three weeks the swellings had become blended, and shortly afterwards, when Mr. Wathen was examining him, "he fell into a fit with convulsions, which soon went off." "As there was no doubt but that the skull was exceedingly diseased, nor any hopes of relief, much less of a cure, to be obtained without a separation of the morbid part, I resolved to lay the supposed caries bare, without which an exfoliation could not be expected." This was attempted by means of "common caustic" and arsenical bougies for fear of haemorrhage. The result was suppuration and the separation of large sloughs of soft tissues filled with bony spicules. After some weeks of this treatment, "he now frequently complained of violent pain in the skull, and had several little attacks of fever, the pulse was remarkably small and quick, and a kind of stupor and delirium hung upon him for some days. . . . Once he had a fit whilst he was dressing, and was somewhat convulsed, but it soon went off, and he mended so much in a few days that he said he was as well as ever." He lived several months longer, and died, apparently of exhaustion, on March 9, 1773. In the left hemisphere of the brain were found two abscesses corresponding to the two largest slough holes, "through both of which the dura mater had protruded itself." The dura mater was attached to the bones "by means of a fungus resembling that

which occupied the external surface, and appeared to arise from every part of the bone that had been diseased. The dura mater separated from the fungus without tearing any of it away."

(c) *Carcinomata in Bone secondary to Tumours in other parts of the Body.*

(1) IN THE CRANIAL BONES.

5.181. Large Secondary (?) Carcinomatous Tumour of the Skull, involving Dura Mater and pressing on the Brain.

Hunterian. EE. 27.

"A soft pulpy tumour, which had formed a bed for itself on the upper surface of the brain, large enough to admit a child's fist, made its way through the top of the skull, and rose above the surface of the frontal and parietal bones for more than 2 inches in height and 4 or 5 in breadth." This and the following specimen have been identified as portions of the same tumour. Comparison of the two shows that the present specimen consists of about half of the tumour, with portions of the adjacent bone and dura mater. The bone, and tumour connected with it, has been again divided vertically, and one portion of it removed to show the underlying dura mater and its tumour mass. The cranial bone is expanded from a thickness of 5 mm. to a thickness of 40 mm. by tumour tissue, which at its edge seems to be separating the inner and the outer tables, at the same time infiltrating them and also causing formation of new bone in connection with both. For this, see also next specimen. Outside the line of irregular new bone derived from the outer table is a layer of pulpy tumour tissue, fairly dense, which appears to be thickened and infiltrated pericranium; it is 15 mm. thick in the middle, and at the edge of the affected bone thin and continuous with the unaltered pericranium. Where the portion of tumour of bone has been removed, the dura mater is seen to be infiltrated with tumour tissue. In the cut surface of the edge, the dura mater is seen to be expanded and split into two layers, its thickness increasing from the normal at the edge of the infiltration up to about 10 mm. Inside the inner of these layers, and continuous with it, is the mass of tumour, very soft and loose textured, which is described above as having "formed a bed for itself on the upper surface of the brain." It is

of semi-globular shape, largely composed of coarse fibres running perpendicular to the surface of the dura mater, and sheathed with a fine soft membrane, pia mater, to judge from the number of vessels hanging from it. Here and there are fragments, apparently of brain tissue, which have doubtless adhered through being involved by processes of the growth. Microscopically, it consists of masses of cells (very badly preserved), lying in the spaces of a well-developed fibrous stroma; clearly carcinoma, probably a secondary infection of the marrow in the diploe. No details of structure, sufficient to ally it to any of the organs commonly the seat of such tumours, can be made out. (MS. Notes, J.H.T., p. 34.) It is figured in Matthew Baillie's *Engravings*, Fasc. X., Plate V., fig. 1, but the description gives no additional information.

5.182. Bony Framework of a Carcinoma of the Skull.

Hunterian.

A portion of the vault of the cranium macerated and dried. It has been recognized as the other portion of the preceding. Rising, symmetrically to the middle line, from the parietal and temporal bones is a semi-globular mass of osseous trabeculae, mostly running vertical to the surface of the cranium, with wide cancelli between. In the cut surface, this is seen to consist of an outer layer, in which the plates are much thicker, and which appears to be an expansion of, and new formation from, the outer table. Inside this layer the spicules of bone are finer, and the centre, which in the other specimen does not contain any bone, is now an empty space open to the interior of the skull. Round the edges inside, there has been a slight amount of a similar expansion of the inner table. Rarefaction of both tables and diploe extends some little way outside the circle of actual tumour. It measures 8.5 cm. in diameter by about 3 cm. in height.

5.183. Secondary (?) Carcinomatous Tumour of the Skull. Pressing on Brain.

Hunterian. EE. 27b.

"A portion of the skull, dura mater, and posterior lobe of the cerebrum from an old gentlewoman, aged about seventy. A tumour rose gradually on the occiput. She consulted me about two years before. It appeared to me to be a swelling of the bone itself;

at least it felt as hard as bone, and was smooth, rising from its extreme boundary, as in swellings of bone. It gave her no uneasiness, and I advised doing nothing. Her friends desired me to examine it after death. She had continued well till within a short time of her death, when she became gradually sleepy, and more and more insensible till she died, after two or three days of total insensibility. It was a case similar to that of Hoquet's (Series 43, No. 62, Carcinoma of Testicle), and of the old man in Monmouth Street, and the case by Mr. Wathen" (*vide* No. 5. 180a). The tumour is somewhat similar in appearance to the preceding, but there is no expansion or new-formation of the bone, which has simply disappeared and been replaced by tumour tissue. The line of it is traceable in the tumour, which seems to have grown inwards and outwards from it. The growth is covered with pericranium externally, and by dura mater internally, except in parts where it has passed through it, and projects inwards as a number of soft naked fungations. Microscopically, it consists of a well-formed fibrous stroma, containing an abundance of nests of epithelial cells. A carcinoma, almost certainly secondary, but to what it is impossible to say. There is no bone in it; the hardness was probably due to tension. (MS. Notes, J.H.T., p. 35.)

**5. 184. Carcinomatous (?) Tumours of the Skull. Probably
Secondary. *Hunterian.***

A skull macerated and dried, showing a number of excrescences and erosions, probably the result of secondary cancerous infection of the diploe. It is figured in Matthew Baillie's *Engravings*, Fasc. X., Pl. I., fig. 1, and is described as follows: "In this plate are represented two diseases of the cranium. The one consists of bony excrescences which assume a sort of oval form. They are composed of bony spicula resembling crystallizations, which grow from the outer, and also from the inner, surface of the cranium. The original bone of the cranium at these places is absorbed and in this disease a double process would appear to be going on at the same time, viz. the absorption of the original bone, and the formation of the new bone in the shape of spicula or crystals. Of the nature of this disease nothing is accurately known, but it has been sometimes regarded as cancerous." In the light of our present knowledge, it may be said, with much probability, that the disease is the result of carcinoma, which had become dis-

seminated throughout the body, giving rise to secondary tumours in the bone marrow. Part of the occipital bone has been removed to show the spicules of bone growing inwards. Many of the external spicules have been rubbed off since the publication of Matthew Baillie's work in 1799.

5.185. Secondary Carcinoma (?) in the Ilium. *Hunterian.*

Left ilium macerated and dried, illustrating the above. A growth, probably carcinomatous, has eaten out a circular hole in the blade of the ilium. It has destroyed the cancellous tissue and the dense shell towards the iliac fossa. The external shell is also thinned, rarefied, and eaten away in places. There has been some periosteal new-formation on the bone around and over the surfaces of the growth.

5.186. Secondary Carcinoma of Rib. *Hunterian. RR. 430.*

A portion of two ribs dissected, and one of them which contains the tumour, divided longitudinally. For a length of about 9 cm. the osseous shaft of the rib has been entirely destroyed, and its place taken by a fusiform tumour. This is smooth externally, being enclosed in periosteum. In the cut surface it consists of a network of fibrous tissue with fairly wide spaces. There is no bone in the tumour, though the line of the rib is faintly indicated in the arrangement of the fibrous stroma. Microscopically, it is a carcinoma, consisting of wide fibrous meshes lined with epithelium set in large circles like ducts. Probably secondary to a carcinoma of stomach or bowel. (MS. Notes, J.H.T., p. 6.) Not described in the old catalogue.

5.187. Secondary Carcinoma of Tibia. Fracture.

Hunterian. LL. 56.

Tibia and fibula injected red, and the soft parts removed down to the periosteum. There has been fracture of both bones (tibia in lower, fibula in the upper third, as if by indirect violence), which had long been healed. In the upper third of the tibia there is a considerable swelling within the periosteum, which is a cyst with rather thick fleshy and highly vascular walls; the cavity seems to run round the shaft of the bone, which is fractured. The ends of the fragments are rarefied and eroded. On microscopic examination of

a portion of the wall and tissue inside it, the growth was recognized, though much degenerated, as being a carcinoma. The tumour was probably secondary to a carcinoma elsewhere, and the fracture was evidently due to the weakening of the bone by it. (MS. Notes. J.H.T., p. 5.) Not described in the old catalogue.

5.188. Secondary Epithelioma in the Femur.

Hunterian. LL. 57.

Left femur, all the soft parts down to the periosteum removed, showing a globular tumour about the size of a foetal head at term, enveloping the shaft just below the trochanters. It is enclosed within the periosteum, and is of fairly soft fleshy consistence. On the inside an incision has been made down to the bone, showing that a considerable portion of the shaft has been replaced by tumour, and that fracture has resulted from the weakening of the shaft. The end of the fragment is filled with tumour tissue and its shell thinned. Microscopically, though the tissue is much degenerated, there is recognizable a fibrous stroma with its meshes filled with cells, which in places are compressed into masses resembling the laminated capsules of an epithelioma of the skin. (MS. Notes, J.H.T., p. 8.) Not described in the old catalogue.

(d) Tumours of the Jaws.

5.189. Enormous Fungating Sarcoma of the Superior Maxilla.

The head and neck, apparently of a young subject, the back of the cranium and brain removed, injected red, showing the above. History unknown. In the front view almost the whole face is hidden behind a great fleshy tumour, most of the surface of which is ulcerated and of a patchy red and white colour, due to the injection. It seems to have arisen in the right maxillary region, doubtless within the antrum. The right cheek is bulged out laterally, and the right eye pushed forwards and upwards almost on to the supra-orbital ridge. The left eye is overhung and closed by the tumour, and pushed somewhat to the left. The nose and whole upper lip are infiltrated by the growth, and enormously expanded. The root of the former is involved in tumour up to the forehead. The point is flattened out and unrecognizable, but the nostrils and edges of the alae are recognizable low

down on the side of the tumour near the angle between it and the left cheek. The fungation measures 14 cm. across, 13 cm. vertically, and projects 9 cm. from the line of the face. The growth has shoved down the palate, but has not invaded the cavity of the mouth nor of the cranium. Microscopically, it is a spindle-celled sarcoma. (MS. Notes, J.H.T., p. 20.)

5.190. Carcinoma of the Superior Maxilla.

Hunterian. GG. 55.

The left side of a head cut off by sagittal section passing through the forehead, anterior fossa of the skull, cavity of nose, and roof of mouth, just to the right of the falx cerebri and septum nasi, and by a transverse section falling behind the angle of the jaw and great wing of the sphenoid, but in front of the ear and posterior wall of the pharynx; lower jaw and septum of nose afterwards removed. Described in the old catalogue as "showing polypous excrescences everywhere in the cavity of the nose, destroying the bones even of the orbit and the eye itself, and forming a tumour externally on the cheek." The left nostril is filled with tumour masses, upon which in the middle of the nose and hanging into the naso-pharynx, are several apparently innocent mucous polypi. It has not appeared in the cranial cavity nor in the mouth. Microscopically, a portion taken from the large fungating mass on the cheek, though badly preserved, shows the structure of a carcinoma. It probably originated in the antrum. (MS. Notes, J.H.T., p. 57.)

V. ALTERATIONS IN THE BONES FROM VARIOUS LOCAL CAUSES.

5.191. Skull of a Gymnast with Depressed Base.

From Dr Allen Thomson's Collection.

The first three vertebrae and skull, the vault and lower jaw removed, macerated and dried. On the left side is written, "Cardowny, Gymnast (depressed base)." An extensive region of the base around the condyles is considerably pressed upwards. The alteration in position has affected the condyloid and basilar portions of the occipital bone, and the petrous portions of the temporal bones. All of these have been more or less raised. The elevation has been greater and more extensive on the right than on the left; the right condyle is at least 1 cm. higher than the left, its three

supporting arches being very strikingly elongated. The right condyle is rotated inwards, so that its longitudinal axis (produced forwards) meets the corresponding axis of the left condyle fully 8 mm. to the left of the median line. The elevation extends back on the right almost to the inferior curved line, at which region the displaced and the normal portions of bone make an angle so sharp as to suggest that there had once been a fracture. On the left there is only a slight increase of the natural curve of the bone. The petrous bones appear to be bent and the apices raised, and also to be rotated on their axes so as to raise the posterior borders. The alterations probably occurred while the bones were young, growing, and partly cartilaginous. There is also osseous ankylosis of the bodies, articular processes, and laminae of the axis and third cervical vertebra to one another. Cardowny was a professional athlete, who used to exhibit himself at fairs, etc., carrying weights (such as a ladder with a person standing on it) balanced on his head.

SERIES 6.

DISEASES OF JOINTS.

SECTION 1. THE JOINTS OF THE LIMBS.

I. CONGENITAL DEFECTS AND MALFORMATIONS, . . .	—
II. CHANGES DUE TO CONDITIONS AFFECTING THE NUTRITION OF JOINTS,	—
III. CHANGES DUE TO INFLAMMATORY DISEASES.	
<i>Suppurative Arthritis.</i>	1
<i>Septic Arthritis secondary to Wounds,</i>	2-6
<i>Tubercular Arthritis—</i>	
<i>Knee-joint,</i>	7-22
<i>Hip-joint,</i>	23-29
<i>Ankle-joint,</i>	30
<i>Shoulder-joint,</i>	31
<i>Elbow-joint,</i>	32-40
<i>Other Joints—Fingers and Toes.</i>	
<i>Ankyloses of Doubtful Origin,</i>	41-42
<i>Gouty Arthritis,</i>	43-49
<i>Arthritis Deformans—</i>	
<i>Lower Limb,</i>	50-71
<i>Upper Limb,</i>	72-75
IV. TUMOURS OF THE JOINTS,	—

SECTION 2. THE VERTEBRAL COLUMN.

I. CONGENITAL DEFECTS AND MALFORMATIONS, . . .	—
--	---

See before No. 76

II. CHANGES DUE TO CONDITIONS AFFECTING THE
NUTRITION.*Lateral Curvature of the Spine,* 76-83

III. CHANGES DUE TO INFLAMMATORY DISEASES.

Tubercular Disease of the Spine, 84-93*Arthritis Deformans of the Spine,* 94-100*Ankyloses of Spine and Sacro-iliac Articulation,* . . . 101-110

IV. TUMOURS AFFECTING THE SPINE, —

COMPARATIVE PATHOLOGY SPECIMENS OF DISEASES OF
BONE, 111-113

SECTION 1. THE JOINTS OF THE LIMBS.

I. ABNORMALITIES IN GROWTH AND DEVELOPMENT.

Specimens wanted.

II. CHANGES PRODUCED BY ALTERATIONS IN THE NUTRITION OF
JOINTS, *e.g.* OLD AGE AND NERVOUS AFFECTIONS.

Specimens wanted.

III. INFLAMMATORY DISEASES OF THE JOINTS.

(a) *Inflammation associated with Pus-forming Organisms.*(A) WHERE THE ORGANISMS HAVE REACHED THE BONE OR SYNOVIAL
MEMBRANE THROUGH THE CIRCULATION, *e.g.* AFTER GON-
ORRHOEA, ENTERIC FEVER, ETC.

Specimens wanted.

**6.1. Suppurative Inflammation of the Knee-joint secondary
to Acute Suppurative Osteomyelitis of Femur.
Obliteration of Joint. Ankylosis. *Hunterian.***Left femur and tibia, probably from a grave, illustrating the above.
The two bones are firmly ankylosed by a great mass of cancellous

tissue. The whole shaft, especially the lower half, of the femur is thickened in consequence of old standing osteomyelitis. In the popliteal space is a cloaca, 7 cm. long by 2 cm. wide, leading into a large sequestrum cavity which extends down to the head of the tibia. This appears to have been produced by acute suppurative osteomyelitis, which has extended into the knee-joint and destroyed it. When the advancing stage was over, healing has resulted in complete bony ankylosis of femur, tibia, and patella, which last has been broken away. The tibia is displaced somewhat to the outside of and behind the femur. There is a considerable bend outwards, and a slight one forwards. A very strong ankylosis, and in fairly serviceable position. See also No. 5.65.

(B) WHERE THE ORGANISMS HAVE GAINED ACCESS DIRECTLY THROUGH WOUNDS.

6.2. Acute Septic Arthritis of the Ankle-joint and Osteomyelitis of the Tibia, consequent on Compound Fracture.

Hunterian. LL. 12.

Section of the lower end of the tibia, soft parts dissected off to the periosteum, showing the above. Injected red. There has been a fracture of the tibia about the epiphysial line, which has evidently gone septic. The lower end of the upper fragment is seen to be necrosed and undergoing separation; the limits of the sequestrum in the cut surface are marked with bristles. The point of the fragment is sawn off, showing what seems to have been a fissure leading into the ankle-joint, by which, doubtless, the septic organisms gained access to it. The fissure is filled with a mass of soft vascular tissue, which microscopic examination shows to be granulations. The articulation seems to have been completely disorganized; its cavity is lined by ragged fibrous-looking granulation tissue. Compare also No. 6.4. (MS. Notes, J.H.T., p. 19.)

6.3. Acute Septic Arthritis of the Ankle-joint secondary to Compound Fracture of the Tibia.

Hunterian. LL. 47.

The other half of the lower fragment of the tibia, from which the preceding specimen was taken, showing the same circumstances.

6.4. Acute Septic Arthritis of the Ankle-joint secondary to Compound Fracture. *Hunterian. LL. 15.*

Astragalus belonging to the preceding specimens, injected red, showing that almost all the articular cartilage has been destroyed, as if melted away, leaving the bone bare. In the posterior part of the articular surface the disease has advanced further; the bone is eroded and carious, and covered with a layer of granulation tissue corresponding to that on the lower end of the tibia. This presents a rather fibrous appearance, indicating that it had been growing for some time; its further organization would have produced obliteration of the joint cavity, and eventually ankylosis. The astragalocalcaneoid joint has also been infected; it shows similar appearances. Compare No. 5.112, Ankylosis after Septic Arthritis secondary to Compound Fracture.

6.5. Acute Septic Arthritis of the Ankle-joint. Destruction of the Cartilages. *Hunterian. LL. 46 (?).*

Anterior portion of the lower third of right leg divided longitudinally, showing the above. Coarsely injected red. The specimen appears to be the end of a stump, probably of an amputation below the astragalus, from which the flaps have sloughed. The lower surface of the soft parts looks as if it had been a raw surface—partly sloughing, partly granulating. The ends of several tendons are visible in it. The articular surfaces are completely denuded of cartilage, but not otherwise diseased; probably the result of septic arthritis following the operation.

6.6. Acute Septic Arthritis of the Ankle-joint. Destruction of the Cartilages. *Hunterian. LL. 45.*

Posterior section of the preceding, with the astragalus removed, showing the articular surfaces of the tibia and fibula denuded of cartilage.

(b) Diseases of the Joints and Bones due to the Tubercle Bacillus.

To render this series anything like representative, a large number of specimens, illustrating various stages of the diseases, are required. Those in the collection are few, and mostly dry bones without any

history; consequently, not quite certainly tubercular. The knee-joint has been taken first, as it was the one least badly represented; also because specimens of it are most readily obtained; and because, from its size and structure, it serves particularly well to illustrate the effects of the disease upon the joints generally.

(A) WHERE DESTRUCTIVE CHANGES WERE IN PROGRESS.

6.7. Tubercular Arthritis. Knee-joint. *Hunterian. LL. 49.*

Lower end of right femur dissected out, illustrating the above. The articular cartilage is thick and opaque, and in several places raised from the bone; apparently sloughing. At one point of the outer condyle it is quite destroyed, and the bone laid bare.

6.8. Tubercular Arthritis. Knee-joint. *Hunterian. LL. 23b.*

A slice of the head of the tibia injected red, and the superficial soft parts dissected off. The greater part of the articular cartilage is quite destroyed, and its place taken by granulations. The bone in parts is bare and carious. An advanced stage in the destruction of the joint by tubercular disease.

6.9. Tubercular Arthritis. Knee-joint. *Hunterian. LL. 23c.*

A patella dissected out, showing the above. The cartilage is eroded, and the bone on the articular surface and round the edges is carious.

6.10. Tubercular Arthritis. Knee-joint. *Jeffray Collection.*

Right knee-joint, probably tubercular, laid open, and all the soft parts dissected off down to the periosteum, to show the articular surfaces of the femur, tibia, and patella. Illustrates chiefly the destruction of the articular cartilages.

Dry Specimens illustrating the Changes in the Bones.

6.11. Tubercular Arthritis. Knee-joint. Changes in the Bones. *Hunterian.*

Head of tibia macerated and dried, illustrating the above. The cartilage has been removed by disease or maceration, revealing in

the head of the bone seven rounded cavities, which, during life, were doubtless tubercular foci. Probably the disease, in this case, was primarily in the bone. The cavities appear not to extend deeper than the epiphysis. From an adult.

6. 11a. Tubercular Arthritis. Knee-joint. Changes in the Bones. *Hunterian.*

Head of left tibia macerated and dried, showing the above. The articular surfaces are worn, irregular, and rarefied—a condition of caries. In the internal condyle there is also a sequestrum with the groove of separation nearly complete all round. Its surface is eburnated. Compare No. 6. 13. Around the articular head and down the shaft there has been some periosteal new-formation of bone, probably due to the joint having become infected by pyogenic organisms through sinuses left by the opening of the tubercular abscesses.

6. 12. Tubercular Arthritis. Knee-joint. Changes in the Bones. *Hunterian.*

Lower end of femur macerated and dried, showing changes similar to those in the preceding—partly tubercular, partly septic.

6. 13. Tubercular Arthritis. Knee-joint. Changes in the Bones. Eburnated Sequestra. *Hunterian.*

Lower end of right femur macerated and dried, illustrating the above. The specimen shows erosion and a number of small rounded cavities, probably tubercular foci, in the osseous articular surface. There are also several sequestra, one measuring fully 3 cm. by 2 cm., situated in the midst of the cancellous bone of the condyles and nearly separated by absorption of the layers of bone around them. The surfaces turned towards the joint are extremely dense and polished, in parts almost like porcelain—eburnated. They extend some little way into the condyle, and their deeper portions seem also somewhat condensed. They are supposed to be produced by a necrosis following on cutting-off of the blood supply by a gradually advancing osteosclerosis. Compare under Arthritis Deformans, Nos. 6. 52, *et seq.*

6.14. Tubercular Arthritis. Knee-joint. Changes in the Bones. *Hunterian.*

Head of left tibia macerated, illustrating the above. The head of the bone is scooped out into a ragged cavity, partly surrounded by an irregular shell representing the original wall. This, where it has not been destroyed, is somewhat condensed. The excavation has passed the epiphysial line and communicated with the medullary cavity, which is now full of adipocere. There are also a couple of small, partly eburnated, sequestra in the outer condyle, nearly detached.

(B) SPECIMENS ILLUSTRATING THE PROCESSES OF NATURAL CURE.

6.15. Tubercular Arthritis. Ankylosis. Early Stage. Knee-joint. *Hunterian. LL. 25.*

"A longitudinal section through the joint of the knee, to show incipient ankylosis, from white swelling probably." The internal condyles of the femur and tuberosity of the tibia are firmly ankylosed, the inner half of the cavity of the joint apparently completely obliterated. Whether the union is osseous or only fibrous cannot be determined in the present state of the specimen. Between the outer condyle and tuberosity the central part of the joint is seen to be still unobliterated; but the cartilages are thinned, ulcerated in some parts, and in others covered with fine threads of fibrous tissue, as if they had been united, but were torn apart in the preparation of the specimen. The bones preserve their normal positions relative to one another. The surfaces of the semi-lunar fibro-cartilages are roughened, and in places covered with fibrous tissue.

6.16. Tubercular Arthritis. Knee-joint. Ankylosis in Semi-flexed Position. Atrophy of the Bones.

Hunterian.

Portions of the left femur, tibia and fibula, and the patella partly macerated and dried; some of the ligaments preserved. From a young subject. No history, but almost certainly tubercular—quite typical lesions. There is osseous ankylosis between comparatively small areas of the centres of both inner and outer condyles of femur and tuberosities of the tibia, and of the patella

to the outer condyle of the femur. The position of the bones is that of semi-flexion, with a certain amount also of inversion and pathological dislocation backwards of the tibia and fibula. There has been considerable erosion of the epiphyses, and also tubercular foci in the cancellous heads of the diaphyses, close to the epiphysial lines. Some of these foci, in both femur and tibia, have apparently been in communication with the joint. The bones, as a whole, are light and unduly porous—a condition of atrophy.

**6.17. Tubercular Arthritis. Knee-joint. Ankylosis in
Bad Position.** *Hunterian.*

Portions of femur, tibia, and patella, probably from a grave, illustrating the above. Probably tubercular complicated by septic disease. The three bones are firmly ankylosed by bone, the cancellous tissue, for the most part, continuous from the one to the other; in parts, a trace of the dense articular plates remains. As in the preceding, the ankylosis is most advanced opposite the centres of the condyles, and there is a space where ankylosis has not occurred between them, corresponding to the attachments of the fibro-cartilages. The patella is fused with the outer condyle of the femur. The tibia is dislocated outwards and backwards, and everted to a very considerable degree. There is slight flexion. From the point of view of utility of the limb, an unsatisfactory position.

**6.18. Tubercular Arthritis. Knee-joint. Ankylosis with
Marked Flexion and Eversion of the Leg: Bad
Position.** *Hunterian.*

Left femur and tibia, probably from a grave, illustrating the above. From an adult. The specimen shows the usual position assumed by a tubercular knee-joint which has been allowed to go on to the natural cure by ankylosis, without proper support or operation. The leg is considerably flexed; the tibia dislocated backwards and outwards, and very markedly everted. The ankylosis is more advanced than in the preceding. The position of the crucial ligaments, as usual, is marked by an open space. The irregularities of the bones are rounded off, showing the disease to have been of very old standing. The head and neck of the femur are set at a very open angle to the shaft; probably to compensate for the deformity.

**6. 19. Tubercular Arthritis. Knee-joint. Ankylosis in
Bad Position.** *Hunterian.*

Left femur and tibia, probably from a grave, illustrating the above. The limb has been flexed almost to a right angle. As in the preceding, the dislocation backwards and eversion of the tibia are very marked.

**6. 20. Tubercular Arthritis. Knee-joint. Ankylosis in
Bad Position. Marked Flexion.** *Hunterian.*

Right femur and tibia, probably from a grave, illustrating the above. The leg has been flexed more than a right angle. The bones are smoothed off, and the space between the condyles filled up with bone, showing that it is an ankylosis of very old standing. There is a pick mark on the inner side of the femur.

**6. 21. Tubercular Arthritis. Knee-joint. Deformity of
Ends of Bones. Interlocking. Fixation in Flexed
Position.** *Hunterian.*

Lower end of the femur and tibia of left side macerated and dried, showing the above. From a young subject. The articular surfaces of the knee have been destroyed, and the heads of the bones fantastically excavated. The hollows and projections in the back of the condyles of the femur and top of the head of the tibia have then fallen into one another, and now interlock. The bones are rather condensed, as if there had been a certain amount of repair in the way of osteosclerosis, with perhaps a little new-formation, increasing the interlocking. There has been flexion, dislocation behind the femur, and marked eversion of the tibia.

**6. 22. Distortion of Lower End of Femur. Tubercular (?)
Osteo-arthritis.** *Hunterian.*

A left femur macerated and dried. The lower end is decidedly increased in width, and its articular surface strangely distorted. The surface for the patella and between the condyles is destroyed, and deeply excavated back to the intercondyloid notch. Into the top of the excavation open a couple of holes, like cloacae passing into the shaft. The articular surfaces of the condyles are roughened, flattened, and slightly lipped round the edges in a manner suggestive

of arthritis deformans. The bone as a whole is condensed, and roughened by inflammatory new-formation on its surface. The deep erosion of the cancellous head is somewhat similar to that seen in the preceding. It is probably from either an old tubercular or septic arthritis. Movement was probably possible, but impaired. The shaft also shows a rickety inward curve, and the neck is set at an unusually open angle.

HIP-JOINT—(A) WHERE THE DISEASE HAS BEEN ADVANCING.

6.23. Tubercular Arthritis. Hip-joint. Primary Disease apparently Caries in the Head of the Femur.

Hunterian.

Head and upper portion of the shaft of a left femur macerated and dried. The bone is rarefied to a very striking degree, and also shows a number of irregular cavities in the back of the neck and great trochanter. The walls of these are scooped out in rounded bays, and several of them are situated just at the edge of the articular head, and burrowing in under the cartilage. Altogether the appearances are very suggestive of tubercular disease in a fairly early and rapidly advancing condition.

6.24. Tubercular Arthritis. Hip-joint. Articular Head separated at Epiphysial Line and discharged through Abscess. Ankylosis at Hip and Knee.

Presented by Dr. Rankine of Carlisle, 1877.

The head of a femur separated through the epiphysial line, and thrown off as a sequestrum. There is some erosion of its articular surface, and also underneath it along the epiphysial line. The following is the history given along with it: "Discharged from abscess at the upper part of thigh. The person lived many years. The bones were turned out at a subsequent period, and the shaft of the thigh bone was found fused to the outside of the ilium. The knee was ankylosed so that the pelvis, thigh bone, and bone of the leg formed one piece."

6.25. Tubercular Arthritis. Hip-joint. Extension through Floor of Acetabulum into Pelvis.

Hunterian.

Right innominate bone macerated and dried, illustrating the above. Probably tubercular. The disease has been located in the

bone under the acetabulum, and there is now a series of intercommunicating cavities, of roughly globular shape, opening very freely into the acetabulum in and behind the fossa for the ligamentum teres, and into the pelvis. The ascending ramus of the ischium and pubis is destroyed, and there is a small round cavity in the body of the pubis, probably another focus of the disease, which seems to have been invading the symphysis pubis. The disease was here probably primarily in the bone.

6.26. Tubercular Arthritis. Hip-joint. Excavation round Acetabulum. Intra-pelvic Bulging. *Hunterian.*

Left innominate bone macerated and dried, illustrating the above. The acetabulum is extensively and irregularly enlarged, and deepened by caries of its sides and floor, and by a decided bulging of the internal dense shell of the innominate bone into the pelvis. The symphysis pubis seems also to have been the seat of disease, which has destroyed the articular surface and a considerable part of the body of the pubic bone. There is also a deep, smooth-floored hollow on the inside of the blade of the ilium, perhaps the seat of a similar disease long healed.

6.27. Tubercular (?) Arthritis with Septic Complication. Hip-joint. *Hunterian.*

Right innominate bone macerated and dried, illustrating the above. The floor and edges, especially the posterior, of the acetabulum are markedly rarefied and eroded. The cavity as a whole is wider and shallower than normal. There has been some formation of periosteal new bone around the acetabulum and on the pelvic surface of the ilium, probably the result of septic osteitis consequent on the formation of sinuses and their infection with pyogenic organisms.

(B) SHOWING THE NATURAL CURE OF THE DISEASE.

6.28. Tubercular Arthritis. Hip-joint. Cure by Ankylosis. *Hunterian.*

Parts of the innominate bone and the femur, from a grave, illustrating the above. The ilium and femur form one piece. A wedge has been cut out, from above and behind, well down into

the base of the acetabulum and the head of the bone, to show the nature of the ankylosis. The bond of union is a mass of cancellous bone, fully 6 cm. in diameter, fairly smooth on the outside, and evidently very old. The cancellated bone of the femur and os innominatum are continuous into one another without a trace remaining of the line of union. The specimen is figured, but without the wedge cut out of it, in Cheselden's *Osteographia*, Plate XLVII., fig. 1, as an "Ankylosis of the os innominatum and os femoris; as communicated to me by Mr. Westbrook." No further history.

6. 29. Tubercular Arthritis. Hip-joint. Cure by Ankylosis. *Hunterian.*

Portion of the innominate bone and femur, from a grave, illustrating the above. Like the preceding specimen, a wedge has been removed so as to show the interior of the ankylosis. The fusion of the cancellated tissues is complete. A thin line of denser bone marks the line of union. In the midst of the cancellous bone is a cavity, probably medullary. Clearly the disease had been long extinct.

ANKLE-JOINT.

6. 30. Tubercular Arthritis. Ankle-joint. Caries of the Astragalus. *Presented by Dr. Rankine of Carlisle.*

Lower end of tibia and fibula and the astragalus macerated and dried, illustrating the above. The ends of the bones show an eroded carious condition. The astragalus is particularly light and spongy. There is some periosteal new-formation on the sides of the bones, probably indicative of septic complications. The fibula shows an old healed fracture near the lower end.

UPPER LIMB—SHOULDER-JOINT.

6. 31. Caries of the Glenoid Cavity of the Scapula. Tubercular (?). *Hunterian. LL. 31.*

Portion of the right scapula cleaned and in spirit, stained greenish. "Glenoid cavity of scapula—carious." The greater part of the articular surface is covered by dense fibrous tissue cut across as if there had been fibrous ankylosis. The disease was still

active in the centre of the facet, where the bone is eroded and rarefied. Probably old tubercular disease.

ELBOW-JOINT—(A) WHERE THE DISEASE HAS BEEN ADVANCING.

6. 32. Tubercular Arthritis. Elbow-joint. Advanced Stage of Destruction. *Hunterian. LL. 51.*

Ends of humerus, radius, and ulna dissected, in spirit, illustrating the above. Formerly described as follows: "The Elbow Joint, where the cartilage has been removed from the os brachii and from the head of the radius, and where the cartilage has not only been removed from the sigmoid cavities of ulna, but the shape considerably altered by long-continued ulceration." The case has probably been an ordinary tubercular elbow, with abscesses and septic infection. The joint is disorganized, the cartilages have sloughed, and the bones are carious. In the radial head of the humerus is an eburnated sequestrum.

6. 33. Tubercular Arthritis. Advanced. Elbow-joint. *Hunterian.*

Right ulna macerated and dried, illustrating the above. The greater sigmoid cavity is deepened and widened by irregular ulceration of the bone after the cartilages had been destroyed. The lesser sigmoid cavity has also been involved. Probably tubercular. There has been some new-formation of bone and condensation round about the edges—probably the result of a secondary septic infection.

6. 34. Tubercular (?) Arthritis. Elbow-Joint. Changes in the Bones. *Hunterian.*

Part of left ulna macerated and dried, illustrating the above. Both sigmoid cavities have been denuded of cartilage, and the bone considerably eroded. The osseous remains of the articular surfaces and the head of the bone around the joint have afterwards been the subject of condensing osteitis and periosteal new-formation. Probably tubercular disease of old standing, and complicated by septic infection.

6.35. Tubercular Arthritis. Elbow-joint. Changes in the Bones. *Hunterian.*

Lower portion of a right humerus macerated and dried, illustrating the above. The dense plate forming the face of the articulation is extensively eaten away and perforated with little circular holes. There are also several rounded cavities, about the size of peas, underneath it, which were probably tubercular centres. There is a considerable periosteal incrustation on the epicondyles and shaft, doubtless due to secondary septic osteitis.

(B) SPECIMENS SHOWING THE NATURAL CURE OF THE DISEASE.

6.36. Tubercular Arthritis. Elbow-joint. Natural Cure by Ankylosis. Good Position. *Hunterian.*

Humerus and ulna, probably from a grave, solidly ankylosed to one another at an open angle, about 135 degrees, and in good line, *i.e.* with a slight bend inwards at the elbow. The line of union is not traceable, except behind along the edge of the olecranon. The radius is absent; it had not been ankylosed to the other two. The articular surface for it on the ulna has not been materially altered; that on the humerus is reduced to a flattened circular table, corresponding with the shape of the top of the head of the radius. This shape of articular surface probably allowed of movements of rotation, which would be all that would be allowed by the circumstances of the other two bones. From the smoothness and absence of thickening of the bones at the seat of ankylosis, it has evidently been a very old affection, and probably free from septic complications.

6.37. Tubercular Arthritis. Elbow-joint. Natural Cure by Ankylosis. Good Position. *Hunterian.*

Humerus and ulna, probably from a grave, illustrating the above. The position is similar to that in the preceding, and the radius is absent, not having participated in the ankylosis. The ends of the bones and the shafts in the vicinity of the joint are considerably enlarged. The surface of the bone is of dense texture and fairly smooth, showing that the disease had long been extinct. The articular surface for the radius is rougher than in the preceding, but otherwise similar. The thickening was doubtless due to the

disease having destroyed the joint very extensively, and perhaps to long-standing septic osteitis about it before ankylosis and healing resulted.

6.38. Tubercular Arthritis. Elbow-joint. Natural Cure by Ankylosis. Good Position. *Hunterian.*

Humerus and ulna, probably from a grave. The position is very much the same as in the two preceding specimens. Evidently a very old ankylosis. A portion of the bone has been sawn off on the inner side to show the nature of the ankylosis. The line of the edge of the olecranon is traceable on the exterior, but internally there is not a sign that the bones were ever distinct—the cancellous tissue of the two is absolutely continuous.

6.39. Tubercular Arthritis. Elbow. Natural Cure by Ankylosis. Bad Position. *Hunterian.*

Humerus and ulna, probably from a grave, illustrating the above. They are united at slightly less than a right angle. The radius has been free, but probably fixed by fibrous adhesion, as the articular facet for it is very imperfectly formed. A very old ankylosis.

6.40. Tubercular Arthritis. Elbow. Natural Cure by Ankylosis. Bad Position. *Hunterian.*

Humerus and portion of an ulna, from a grave, illustrating the above. The ulna is almost at right angles to the humerus, but turned outwards, and also dislocated to its *outside*, and fused with the *internal* condyle and epicondyle. The radius seems to have been ankylosed to the ulna, but it has been broken away. An old ankylosis, the lines of union hardly traceable.

(c) Ankyloses of Doubtful Origin.

6.41. Ankylosis of Tarsal and Metatarsal Bones.

Hunterian.

The specimen, which has probably been obtained from a grave, consists of all the tarsal bones and the first metatarsal and bases of the other four, the shafts having been broken off. They are all fused

together into a mass of spongy bone, the cancellous tissue, where the surfaces of the specimen are broken, appearing to be continuous from one to the other—a line of slightly closer bone indicating the former lines of separation. Externally, the boundaries of the several bones are roughly indicated by the fact that the ankyloses are not continuous, but there are gaps where it has not taken place. These gaps correspond to ligaments between the bones, while the points of fusion correspond with the synovial cavities. For example, there is a tunnel running obliquely through the foot, between the astragalus and os calcis, which clearly represents the interosseous ligament: before and behind, where the bones are normally separated by articular cavities, they are now completely fused together. In like manner, there is a hole from dorsum to sole between the scaphoid and the cuboid, another between the bases of the first and second metatarsals, and several smaller ones in various places—practically all of which correspond to interosseous ligaments, while the points of fusion correspond sufficiently accurately with the distribution of the various synovial membranes. On the dorsum, where the ligaments are comparatively thin, the lines of the articulations are marked on the surface only by shallow grooves or not at all; whereas in the sole, where they are very thick and strong, and dip in between the bones to a considerable extent, the lines of separation are both deep and wide. Apparently, therefore, there has been no ossification of the ligaments. On the inner side, opposite the articulation of the astragalus and scaphoid, the new cancellous bone has been rotted away to some depth, revealing a narrow cavity in the centre—the obliteration of the joint having been incomplete except towards the edges. Between the astragalus and cuboid is a similar cavity also in the centre of the joint. The surface of the old bones and of the new bridges between them, where still preserved, is curiously uniform in texture and appearance. It is a thin, fairly dense shell with smooth surface, pierced with numerous fine pores. The appearance resembles that of the surface of an old piece of masonry, through which water has long trickled, and covered stone and mortar alike with a stalactitic crust which more or less conceals the joins. Parts of the articular plate of the upper surface of the astragalus are preserved. They are decidedly irregular, and perforated by numerous small holes, as if eaten away by granulations. It is interesting to compare this specimen with those of Ankylosis of the Knee-joint, probably tubercular, Nos. 6.16–20, in which the same condition of ankylosis across the synovial cavity, while the ligaments have not

been ossified, is shown ; also to contrast it with the specimens Nos. 6.101-103 and 6.111, where the disease has been of the chronic inflammatory and senile degenerative type, and the ankylosis of the vertebrae is due chiefly to ossification of the ligaments. Its history is unknown, and so also is the cause of the disease. From what has been mentioned above, it appears most probable that it was some acute process of arthritis and osteitis, such as tubercular or septic disease, or a combination of the two.

6.42. Ankylosis of Radius, Carpus, and Metacarpals.

Hunterian.

Left radius, carpal bones, and metacarpals of the four fingers, probably from a grave, showing the above. The pisiform bone alone of the carpals is absent. They are fused together into a solid mass of cancellated bone with a fairly dense smooth outer shell, in which the lines of junctions of the several bones are not traceable, showing that the condition has been of very old standing.

The ulna, first metacarpal, and pisiform have not shared in the ankylosis. The articular surfaces for them are fairly smooth, but, especially the second, distinctly increased in extent by osseous new-formation round their edges, after the manner of arthritis deformans. The surfaces of the distal ends of the metacarpals show slight traces of a similar condition. The hand has been fixed in a position of over-extension, to an angle of almost 40 degrees behind the straight line of the arm, and the carpus is decidedly displaced forwards.

(d) *Gouty Arthritis.*

6.43. Gouty Arthritis.

Hunterian. LL. 26.

"A finger from a gouty hand ; a joint opened and bent on itself, to show the cartilages eroded a little." There is a slight degree of erosion and thinning around their edges.

6.44. Gouty Arthritis. Chalky Deposit.

Hunterian. LL. 27a.

A similar finger, showing "the joint invested everywhere with a thin layer of chalk." The cartilage has a dull creamy appearance,

very different from the normal. It is slightly eroded at one or two points. The chalky layer is urate of soda deposited in the superficial stratum of cartilage. See under No. 6. 48.

6. 45. Gouty Arthritis. Ulceration of Bone and Cartilage.

Hunterian. LL. 29a.

A similar finger. The cartilages are extensively ulcerated. In addition, an ulcerative process has very considerably eroded the cancellous bone around the edges and underneath the articular plates.

6. 46. Gouty Arthritis. Urate of Soda Deposit.

Hunterian. LL. 29b.

A gouty thumb, where there has been an advanced condition of destruction of the cartilages and excavation of the bone below the articular head at the base of the first phalanx. As a result there has been ankylosis; and when the joint was opened, the eroded bone has broken. Between the remains of the cartilages and in the granulations in the fracture is seen "the chalk accumulated about the joint in considerable quantity."

6. 47. Gouty Arthritis. Ankle-joint. *Hunterian. LL. 43.*

"The ankle-joint covered with a stratum of chalk in many places; the cartilage may be seen shining through." There is quite a thick layer over the cartilage of what microscopic examination of a portion of the next specimen shows to be fine crystals of urate of soda. There is some ulceration of the cartilages around the edges.

6. 48. Gouty Arthritis. Urate of Soda Deposit.

Hunterian. LL. 44.

"Some of the joints of the tarsus, the chalky stratum not being so thick." Some thin slices cut from one of the surfaces showed the cartilage to be covered with a layer of bunches of minute acicular crystals of urate of soda having a very slight yellowish tinge. They seemed to be entangled with the superficial layer of the cartilage. In a second slice taken from below the first there were none. (MS. Notes, J.H.T., p. 11.) There is some thinning and ulceration

of the cartilage round the edges. The creamy rough appearance, so different from the normal transparency and brightness of the cartilages, is very striking.

6. 49. Gouty Arthritis.

Hunterian. LL. 44a.

Some joints of the tarsus opened, similar to the preceding. The chalky deposit thicker and apparently deeper in the cartilage.

(d) *Arthritis Deformans.* (Synonyms: *Chronic Rheumatic Arthritis, Rheumatoid Arthritis, Chronic Osteo-arthritis.*)

The knee-joint is taken first, as of it alone are there specimens showing the early stages of the disease.

6. 50. Arthritis Deformans of the Knee-joint. Early Stage.

Hunterian. LL. 23a.

Right knee-joint laid open, showing the above. There is slight osseous new-formation around the edges of the articular surfaces. This presents the typical appearance—thin lips of bone covered by what seem to be extensions of the articular cartilage; the new surface, however, has not the same smoothness and regularity as the old; Billroth's description, "like tallow drippings," hits off their appearance exactly. The cartilage itself over several considerable areas is opened out as if by maceration and teasing, showing its vertical fibres separated from one another, and appearing like the pile of velvet. This in some parts has been decidedly rubbed down, but not to the extent of exposing the bone.

6. 51. Arthritis Deformans(?) of the Knee-joint. Erosion of Cartilage. Wearing down of the Exposed Bone.

Right knee-joint opened, showing the above. There are none of the characteristic osseous outgrowths in this specimen; the cartilage is very widely eroded and destroyed, and there is considerable ulceration of the synovial membranes round about, so that the specimen is possibly not the result of arthritis deformans, but of some more acute process. On the other hand, the bone is worn down in the usual way, and scored in the direction of the move-

ments of the joint, showing that the disease has been sufficiently chronic to allow of movements. The condition of the exposed bone is one of osteoporosis, and contrasts well with the succeeding specimen. Microscopic examination gave negative result, the tissue being too much degenerated.

6.52. Arthritis Deformans of the Knee-joint. Advanced.

Hunterian. LL. 23.

This specimen shows a much more advanced stage of the disease. The cartilage is destroyed over a large part of the articular surfaces of the femur and patella. The bare bone is scored in the direction of movement of the joint; and where the pressure is severest, it is condensed and polished like porcelain, a condition called eburnation. Parts of this eburnated surface are perforated by small round holes, some containing soft tissue, but most empty. From behind, the semi-lunar cartilages can be seen to exist; but from the front, they are concealed by a layer of soft yellow matter, apparently inspissated synovia, so that their shape cannot be made out. The osseous outgrowths round the edges of the articular surfaces are much larger than in No. 6.50. The thin cartilaginous covering has been ulcerated off most of them. The articular surfaces retain their normal shape. This is wrongly described in the old catalogue as bones from a "white swelling."

6.53. Arthritis Deformans of the Knee-joint.

Hunterian. LL. 19.

Left patella dissected out, illustrating the above. There is a transverse line of fracture across it near one end, in consequence of which it has been described in the old catalogue as a fracture of the patella. It is really a fairly advanced stage of arthritis deformans, the eburnation, scoring in the line of movement, and osseous outgrowths being quite typical. The fracture is a detachment of an extra-large plate of these and of the edge of the old bone, from which they were growing.

6.54. Foreign Bodies from the Knee-joint. Arthritis Deformans (?).

Hunterian. LL. 25a.

"The cartilage which covered one condyle of the femur, with the appearance of cicatrix in the middle; two loose smooth thick carti-

laminous and bony bodies are hung to it by the same thread. These lay loose in the cavity of the joint, but had originally lain against this middle portion of cartilage." The joint is not in the collection. It may have been a case of arthritis deformans, in which such bodies are common, or it may have been a simple chronic arthritis.

6.55. Arthritis Deformans of the Knee-joint. Slight.

Hunterian.

Right femur macerated and dried, illustrating the above. The specimen shows scoring and eburnation of the internal condyle, and considerable osseous outgrowths around the edges, more particularly of this condyle. There is practically no deformity of the articular surfaces, and the movements must have been fairly free.

6.56. Arthritis Deformans of the Knee-joint. Very Advanced.

Hunterian.

Lower half of left femur and upper half of corresponding tibia macerated and dried, illustrating the above. The specimen shows a very advanced condition of the disease. The articular surfaces are much altered in shape by destruction of the articular cartilages, and destruction or conversion into bone of the semilunar cartilages, and osseous outgrowths around and upon them. The femoral surface, which now articulates with the tibia, is a rough somewhat flattened one, occupying the parts of the condyles, which look downwards and slightly backwards. These are cut off from the hindermost parts of the condyles and from the patellar surface by lines of bony outgrowths. The head of the tibia presents a correspondingly rough flat surface. There is a certain degree of interlocking between the bones, which must have interfered with movement almost as much as actual ankylosis would have. The tibia is displaced outwards and rotated, so that a line along its anterior edge would pass clear to the outside of the head of the femur. This displacement is compensated for by broadening of the ends of the bones—the extension in the case of the femur being mostly outwards, in the case of the tibia mostly inwards. There is a sort of facet on the outer side of the femur, just at the level of and encroaching on the articular surface for the patella, showing that the latter had been dislocated outwards, and had lain upon this instead of in its proper position. There must have been a

degree of genu valgum, with considerable eversion of the foot. There is considerable thickening and roughening of the surfaces of the shafts of both bones by chronic periostitis; the lines of attachment of various muscles and fasciae in particular show osseous outgrowths.

6. 57. Arthritis Deformans producing Ankylosis.

Hunterian.

Upper end of right tibia and fibula macerated and dried, showing the above. The knee-joint has not been much affected, but there are a few of the osseous outgrowths round the articular surface. There is a cavity in the inner side of the head of the tibia just under the joint, but not communicating with it. The tibio-fibular articulation is very strongly ankylosed. There are some little outgrowths around the ankylosis, which point to its having been produced actually by arthritis deformans.

6. 58. Arthritis Deformans of Knee, Ankle, and Upper Tibio-Fibular Joints. Ankylosis of Last.

Hunterian.

Right tibia and fibula macerated and dried, showing the above. Around all the joints the usual extensions of the articular surfaces are well developed, and, in addition, there are very striking projections, corresponding to the attachment of various muscles, ligaments, fasciae, and interosseous membrane. There is no evidence of loss of the cartilages and friction of the bones. The upper tibio-fibular articulation is ankylosed much as in the preceding. The ossifications are more irregular and more related to the ligamentous structures than in any of the preceding specimens.

6. 59. Arthritis Deformans (?) of the Ankle-joint.

Hunterian.

Left tibia and fibula macerated and dried, illustrating the above. There is very little new-formation of bone, and that is not typical, but there is marked alteration in the shape of the articulation. The lower end of the fibula shows a shallow concave surface looking downwards and slightly inwards, as if it had rested on the top instead of the side of the astragalus, and the inner part of the

tibial surface has also not been in contact with its opponent. Perhaps not arthritis deformans, but an old fracture of the tip of the fibula and dislocation outwards. Both bones show traces of periostitis about the middle of their shafts, which has an appearance very suggestive of syphilis.

6.60. Arthritis Deformans of the Ankle. *Hunterian.*

Right tibia macerated and dried, showing the above. The lower end of the bone shows some periostitic new-formation on the sides, and also characteristic outgrowths round the articular surface, which is also very rough, irregular, slightly eburnated, and full of small holes.

6.61. Arthritis Deformans of the Ankle. Early Stage.
Hunterian. LL. 16.

Lower end of tibia and fibula, soft parts dissected away, showing the articular surfaces covered with cartilage, which is very much worn down, and scored in the direction of flexion and extension. It seems also to be opened out into fibrillae set perpendicular to the articular plate.

For examples of changes similar to Arthritis Deformans of the Ankle-joint associated with Fracture, see specimens Nos. 3. 80, 3. 83, 3. 91, and 3. 95.

6.62. Arthritis Deformans of the Hip-joint. *Hunterian.*

Portion of left femur macerated and dried, illustrating the above. The head of the femur is rendered somewhat conical in shape by an overgrowth of bone of the usual type around the edges, forming, as it were, an extension of the articular surface, and making a sort of collar round the neck, in places fully 1 cm. wide. There is a similar outgrowth around the fossa for the insertion of the ligamentum teres. On its upper surface the head is decidedly worn down, slightly eburnated, and scored with numerous fine lines, from the direction of which it would appear that the movements on the pelvis have been limited and were chiefly abduction and adduction.

6. 63. Arthritis Deformans of the Hip-joint. *Hunterian.*

Right femur macerated and dried, illustrating the above. There is a collar of new bone round the neck, as in the preceding; but there is much more alteration in the shape of the head, which is eburnated and rubbed down on the top, where it has been most pressed upon. The eburnated portion is full of fine holes leading down into the cancelli. Where there has been no friction, the bone is eroded in an irregular manner, as if by the action of granulations. The neck and upper third of the shaft of the bone show considerable periostitic thickening. The knee shows the typical outgrowths of arthritis deformans around the edges of the articular surface.

6. 64. Arthritis Deformans of the Hip-joint. *Hunterian.*

Left femur macerated and dried, illustrating the above. The shape of the head is altered, as in No. 6. 62, by osseous outgrowths round the neck and fossa for the ligamentum teres. The articular surface is very dense and smooth, and shows a friction area over the upper and anterior part of the head round about one-third of its circumference from back to front, looking as if a thin slice had been pared off with a sharp knife and the raw surface polished. The knee, linea aspera, and great trochanter also show characteristic osseous outgrowths.

6. 65. Arthritis Deformans of the Knee and Hip.*Hunterian.*

Right femur macerated and dried, illustrating the above. The head is very little altered, showing only slight osseous outgrowths about the edge of the articular surface and insertion of the ligamentum teres. The trochanters and shaft of the bone, especially along the linea aspera, and the knee-joint, all present evidence of the disease in the shape of osseous outgrowths.

6. 66. Arthritis Deformans of the Hip-joint. *Hunterian.*

Upper half of the left femur macerated and dried, illustrating the above. There is a wide and thick osseous collar about the neck, and the pit for the ligamentum teres is quite filled up. The head of the bone is rubbed down on its upper and posterior surface, and full of irregular holes leading into the cancellous tissue.

6. 67. Advanced Arthritis Deformans of the Hip-joint.*Hunterian.*

Right femur, probably from a grave, illustrating the above. There is a porous and polished bearing surface on the upper and anterior portion of the head, which seems to be considerably rubbed down. The rest of it is covered by a layer, about 5 mm. thick, of cancellated bone, which, from its porosity and friability, is evidently of recent origin. This also extends from its edges below and behind in a pretty deep collar. The shape of the head is materially altered, and its size increased. There is a flat elevation of bone, 6.5 cm. long by 1.8 cm. broad by about 5 mm. thick, on the front of the femur about the middle—an exostosis in the origin of the crureus.

6. 68. Advanced Arthritis Deformans of the Hip-joint.*Hunterian.*

Left femur and os innominatum macerated and dried, illustrating the above. The specimen shows a very striking deformity. The head of the femur is widened on the one hand by new growth round its edges, and flattened on the other hand by wearing down of its inner and upper surfaces. Consequently, the head and neck together are considerably shortened. The greatest amount of new-formation, and that which has suffered least from friction, has been in a backward direction, and also downwards and outwards. It reaches to within 1 cm. of the top of the great trochanter. The head is now an ovoid mass with its apex directed downwards, inwards, and backwards, and showing a roughly-turned bearing surface set almost at right angles to the axis of the bone. This is rough, and eburnated in places. The scores corresponding to the lines of movement are partly obliterated by a newer formation of bone. To receive this peculiarly-shaped head, the acetabulum has grown considerably upwards on the ilium by osseous additions to its upper border. Compare next specimen and No. 6. 79. The apex of the head passes down into a deep fossa, which occupies the position of that in which the ligamentum teres was formerly inserted; the bottom of this fossa is a plate of new bone. The cotyloid notch is also filled up by a plate of bone which is continuous with the preceding, the two forming a complete floor to the acetabulum. From below and behind, a deep hole runs in under this floor, which represents the cotyloid notch and fossa for the ligamentum teres, but is quite cut off from the acetabulum by bone; one minute foramen persists which may

have served to transmit the blood-vessels to the interior of the joint. When the head of the femur is placed in the acetabulum, they fit accurately to one another, and allow of fairly easy movement through a limited angle, at the ends of which the joint locks.

6. 69. Advanced Arthritis Deformans of the Hip. Alterations in Shape of the Head of Femur and Acetabulum. *Hunterian.*

Right femur and innominate bone macerated and dried. The head of the femur closely resembles that of the last specimen in shape. It is fairly rough, but eburnated over a considerable area, which looks upwards and inwards. The acetabulum has extended slightly up on the ilium, but its upper edge has at the same time atrophied, so that it is very shallow. The cotyloid notch and fossa for the ligamentum teres make a hollow nearly as large as the acetabulum, and freely communicating with it. Into this notch, which is not bridged over, passes the downward and backward prolongation of the head of the femur when they are placed in apposition. Compare with the preceding. Above the acetabulum there are numerous small periostitic outgrowths.

6. 70. Advanced Arthritis Deformans of the Hip-joint.

Hunterian.

Left innominate bone and part of the femur, probably from a grave, illustrating the above. The head of the femur is greatly expanded and of a flattened ovoid shape, its longest diameter running from before backwards and downwards. The greater part of it appears to be composed of new bone, formed chiefly round the posterior and lower, less round the upper, and hardly at all round the anterior border. The original head seems to have been worn down to the neck; consequently the neck seems to be greatly shortened. Nearly the whole surface looking inwards and upwards is of dense polished bone perforated by numerous round holes leading inward to the cancelli of the head. This enlarged articular head was received into a wide shallow depression—partly worn in the outside of the ilium below the inferior curved line and outside of the anterior inferior spine, partly formed of irregular new bone thrown out in front of the spine. No trace of the edges of the old acetabulum remains.

The old cotyloid notch and fossa for the ligamentum teres form a triangular pit below and scarcely demarcated from the lower part of the new acetabulum.

6.71. Arthritis Deformans of the Hip-joint. *Hunterian.*

Left innominate bone, probably from a grave, illustrating the above. The acetabulum is somewhat deepened, and the upper part of its floor scored and eburnated. There are also considerable masses of irregular new-formed bone, which was beginning to extend over the fossa for the ligamentum teres; compare No. 6.79, under Lateral Curvature of the Spine. There are also some periostitic nodules round the edges of the bone; there are several round holes in the shell with wider excavation of the cancellous tissue, which were possibly the seat of secondary carcinomata in the medulla.

For Arthritis Deformans of the Hip-joint associated with Intra-capsular Fracture, see Nos. 3.45 and 3.46.

6.72. Arthritis Deformans of the Elbow. Advanced. *Hunterian.*

Right humerus, radius, and ulna macerated and dried, illustrating the above. All the articular surfaces are greatly altered in shape. The head of the radius is of an ovoid shape, flattened and eburnated in front. It is bent backwards just above the bicipital tubercle. The greater sigmoid cavity of the ulna is increased in depth and width, the osseous outgrowths being particularly large around the coronoid process. The articular surfaces of the humerus are altered correspondingly. The flat eburnated surface for the radius is towards the front. The movements of the joint, to judge by the way the bones fit to one another, were very limited. Extension beyond the point of semi-flexion must have been impossible on account of the interlocking.

6.73. Arthritis Deformans of the Elbow. Advanced. *Hunterian.*

Right humerus, radius, and ulna macerated and dried, illustrating the above. The articular surfaces are much altered; the sigmoid cavity of the ulna in this case is very shallow, as if flattened out.

The head of the radius presents a wide, slightly convex quadrilateral surface looking inwards and backwards. It is porous and eburnated, and plays on a slightly concave, eburnated surface on the front of the lower end of the humerus. The surface for the ulna on the latter bone is carried up the shaft over the coronoid depression, corresponding with the wide shallow surface on the ulna. Movement must have been very limited, with the joint pretty nearly fixed at a right angle.

6.74. Arthritis Deformans of the Elbow.

Hunterian.

Left humerus macerated and dried, illustrating the above. The ulnar surface of the articular end is carried up the front over the coronoid depression. The radial is very rough. There is a good deal of osteophytic extension round the edges.

6.75. Arthritis Deformans of the Elbow.

Hunterian.

Left ulna and radius macerated and dried, illustrating the above. The articular surfaces of the ulna are irregular and greatly increased in area. The head of the radius is still fairly circular; on its inner surface it is deepened by a collar of bone corresponding with the enlarged lesser sigmoid cavity of the ulna.

MALFORMATIONS AND DISEASES OF THE VERTEBRAL COLUMN.

I. ABNORMALITIES IN GROWTH AND DEVELOPMENT.

See Series 22, Diseases of the Nervous System, under Spina Bifida, Nos. 14 to 25; and Series 50, Monsters, Nos. 76, *et seq.*

II. CHANGES PRODUCED BY CONDITIONS AFFECTING THE NUTRITION.

(a) *Senile Changes.*

Specimens wanted.

For changes due to Arthritis Deformans and allied conditions, see Nos. 6. 94 to 6. 113.

(b) *Lateral Curvature of the Spine.*

6.76. Lateral Curvature of the Spine.

Hunterian.

An entire vertebral column macerated, dried, and articulated, showing the above. There is a very considerable curve, with the convexity to the right, extending from the third dorsal to the second lumbar vertebra. There is slight rotation of the vertebrae about the middle of the curve, carrying their bodies towards the convexity.

6.77. Severe Lateral Curvature of the Spine.

Hunterian.

The vertebral column, except the cervical portion, with the skeleton of the thorax and pelvis; the soft parts, with the exception of the ligaments, cleaned off, probably after partial maceration, and dried. The specimen shows a very strong curve, with the convexity to the right, extending from the second to the tenth dorsal, where it passes into a still stronger curve of the last two dorsal and all the lumbar vertebrae, with the convexity to the left. In both curves the rotation of the vertebrae towards the convexity is well marked. In the lumbar, one or two of the bodies are distorted, as if crushed down on the concave side of the curve. The ribs are approximated to one another, and share in the curve—the outer surface of the left series anterior to the angles showing a concavity, while the right series is abnormally convex; the angles are narrowed on the right, and flattened out on the left. The pelvis (female) is well shaped.

6.78. Lateral Curvature of the Spine.

Hunterian.

A vertebral column partially macerated, cleaned to the ligaments, and dried, showing a double curvature; convexity to the left, in the upper dorsal; to the right and decidedly backwards, in the lower dorsal and lumbar region. The latter is much more pronounced. The bodies in both are rotated, as usual, towards the convexity, and distorted as if crushed on the concave side. This is very marked at the sharpest curve, the first and second lumbar vertebrae. Around the edges of the articular surfaces of the articular processes, and articulations of the ribs on the bodies and transverse processes, there are osseous outgrowths as in arthritis deformans. These

extend in irregular lips around the joints—in many cases very large and interlocking firmly, but nowhere going the length of ankylosis and fusion. Some of the articular surfaces for the ribs show a dense eburnated surface pitted with round holes leading into the cancelli. There are also osseous outgrowths from the edges of several of the vertebral bodies.

6.79. Lateral Curvature of the Spine. Ankylosis. Arthritis Deformans of the Hip-joint. *Hunterian.*

Lower dorsal and lumbar portions of a vertebral column, with the sacrum and pelvis, from a woman, the ligaments preserved, dried, illustrating the above. There is a very pronounced curve, with the convexity to the left, from the eighth dorsal to the last lumbar vertebra. The bodies are very markedly rotated towards the convexity, the first four lumbar distorted in the usual way on the concave side, and the last lumbar on the convex side, by its sharing in the curvature and being crushed down upon the sacrum. There has also been slight curvature with rotation of the bodies towards the right in the mid-dorsal region. There are large outgrowths of dense bone from the edges of the vertebrae—in many cases bridging over the intervertebral discs, and interlocking. There is also very marked arthritis deformans of the joints of the articular processes. In neither situation is there actual bony ankylosis. The right acetabulum also shows the effects of the same disease in a marked degree. It is enlarged and deepened by osseous additions round its edges. A thick plate has also extended a considerable way across the cotyloid notch, and also over the fossa for the ligamentum teres, almost shutting it off from the acetabulum. A considerable area of the upper and posterior floor of the acetabulum is eburnated and polished. Compare Nos. 6.68, 69, 70, and 71.

6.80. Lateral Curvature of the Spine. Ankylosis.

Hunterian.

A vertebral column, the sacrum absent, macerated, dried, and articulated, showing the above. The column is straight, or very nearly so, down to the seventh dorsal vertebra, when it takes a sudden bend to the left. This is confined almost entirely to the seventh, eighth, ninth, and tenth dorsal vertebrae, which are notably reduced in depth on their left sides. They are also firmly ankylosed

by masses of dense bone bridging over the intervertebral spaces for a width of 2.5 to 3 cm. on the same side. Below the twelfth dorsal vertebra the column sweeps round into another and more open curve in the opposite direction, *i.e.* with its convexity directed towards the left. The rotation of the vertebrae towards the convexity is well marked, especially in the lower curve. The arthritic outgrowths round some of the articulations of the articular processes are very large; in one or two there is actual ankylosis.

6.81. Severe Lateral Curvature of the Spine. *Hunterian.*

A vertebral column from the third cervical to the fourth lumbar vertebrae, with the upper nine ribs of the right and the sixth to the twelfth ribs of the left side, partially macerated and cleaned and dried. It is partly held together by the remains of the ligaments, partly articulated. There is a very severe degree of curvature of the column from the second dorsal to the second lumbar with the convexity towards the right, and, in addition, a considerable stoop forwards. The vertical depth of the chest has been very greatly decreased. The ribs on the right are not markedly approximated to one another, but they droop down more than in the normal condition, and are sharply curved at the angles; the front of the bodies at the convexity of the spine comes within about 3 cm. of them about opposite the middle of the shafts. On the left, in the hollow of the curve, the ribs are so crushed down on one another that articulations have been developed between them a very little outside the transverse processes: the angles are smoothed out, the whole ribs have abnormally little curve, and the ends of them droop downwards to a very marked degree, just as on the right side. The rotation of the vertebrae is very striking.

6.82. Severe Lateral Curvature of the Spine. *Hunterian.*

Vertebral column, pelvis, and a number of the ribs of a young woman, pretty completely macerated, cleaned, and dried. The ligaments having been too much destroyed, it has rather gone to pieces. The epiphyses of the iliac crests are, to a considerable extent, cartilaginous. There is a curvature extending from the first dorsal to the third lumbar with the convexity to the right, and some stooping forwards; it is very similar to the preceding, but worse. The vertebral bodies at the convexity of the curve—eighth, ninth, and tenth dorsal—have been in contact with the ribs, and have been

about one-third worn away ; the ribs which have caused this absorption are themselves considerably worn on their inner surfaces. The ribs on this side are not unduly curved at the angles, but droop down, and are rather straightened in the shafts. The ribs on the other side are crushed together, articulations having formed between them as in the preceding. Their curves are reduced, and even reversed in parts. The pelvis is well formed.

6. 83. Severe Lateral Curvature of the Spine. Ankylosis of Vertebrae and Ribs. *Hunterian.*

Six dorsal vertebrae with a couple of ribs, probably a graveyard fragment, from a case of lateral curvature similar to the preceding. The convexity of the curve is to the left. The six vertebrae are ankylosed into one piece chiefly by fusion of the articular processes and laminae. The spinous processes remain free, and the bodies are only united here and there by small outgrowths from the edges. The two ribs lie close together, and are strongly ankylosed to the sides of the bodies, to the transverse processes, and to one another opposite the transverse processes, and through an articulation which had formed between them a little outside that point.

III. INFLAMMATORY DISEASES OF THE SPINE.

(a) *Tubercular Disease of the Vertebrae.*

6. 84. Tubercular Disease of the Vertebrae. Angular Curvature. *Hunterian. EE. 57.*

“Portion of the Spine from Lowe’s Child, where caustics had been applied ineffectually for incurvation ; the ulceration of the body of the vertebra had gone in as far as the spinal marrow itself.” The bodies of three vertebrae have been partially, and of two others between them totally, destroyed by the tubercular disease. A moderate amount of collapse and angular curvature, “Pott’s Curvature,” has resulted.

6. 85. Tubercular Disease of the Cervical Vertebrae. Retropharyngeal Abscess. Collapse. Paraplegia. *Hunterian. EE. 45.*

“A section through an incurvated portion of spine, about the uppermost vertebrae of the neck, from a child twelve years old ;

died paralytic, arms, etc.; spinal marrow pressed on by the angle of incurvation; in other places the vertebrae carious, and spinal marrow bare." The bodies of the vertebrae, from about the fourth cervical to the second dorsal, have been totally destroyed, and their place taken by a tubercular abscess, which has extended forwards, making a considerable cavity, which lay in front of the upper cervical vertebrae, doubtless bulging into the pharynx. Collapse of the column has occurred, and the cord has been nipped in the upper dorsal region between the upstanding column of vertebral bodies below and the arches of the destroyed vertebrae above. The disease has extended up and down between the dura mater and the vertebral bodies as high as the specimen extends (about the axis), and down to the eighth dorsal vertebra.

6. 86. Extensive Tubercular Disease of the Vertebrae.
Angular Curvature. *Hunterian. LL. 34.*

"The Vertebrae of the Back," fifth dorsal to second lumbar; "with the head of the ribs from a scrophulous child; the bodies of almost all the vertebrae are bare and eroded before; the intervertebral substances and cartilages themselves in many parts destroyed; almost the whole of the bodies of the two middlemost vertebrae gone, the spinal marrow appearing bare behind; the cartilages of the heads of almost all the ribs eroded. From a child in Saint George's Hospital." The bodies of the eleventh and twelfth dorsal vertebrae seem to have been the primary seat of the disease, as they are most destroyed. At this point there has also been a certain amount of collapse with a corresponding slight angular curvature. Behind, two of the spinous processes project to an extent which must have been quite appreciable during life.

6. 87. Tubercular Disease of the Vertebrae. *Hunterian.*

The last dorsal and the lumbar vertebrae and sacrum macerated, dried, and articulated. The adjacent surfaces of the bodies of the first and second lumbar vertebrae have been irregularly eroded and excavated, probably by tubercular disease. The destruction of the bodies is most advanced in front. The disease has also eaten its way through the bone into the vertebral canal. The front of the twelfth dorsal and third lumbar vertebrae also show some erosion. Probably there was a degree of collapse, which has been remedied by the articulator.

**6. 88. Tubercular Disease of the Vertebrae. Collapse.
Angular Curvature.** *Hunterian.*

A vertebral column with portions of all the ribs, cleaned and dried, united by the remains of the ligaments, illustrating the above. There has been destruction, more or less complete, of the bodies of the vertebrae from the seventh dorsal to the first lumbar, most complete in front. A very extensive collapse has ensued, as was common in the days when efficient means of supporting the diseased column were not so universally employed as they are now. The laminae and articular processes have been ankylosed by bone. There is a sharp but evenly rounded curve behind. In front, the upper dorsal and lower lumbar vertebrae meet at a very sharp angle, the anterior surface of the body of the eighth dorsal resting on and having partly ankylosed with the anterior surface of the first lumbar.

**6. 89. Tubercular Disease of the Vertebrae. Angular
Curvature. Ankylosis.** *Hunterian.*

Left half of vertebral column from the fourth dorsal to the tip of the coccyx, with the fifth to the tenth left ribs and scapula, partly macerated, cleaned, and dried, illustrating the above. There has been almost complete destruction of the vertebral bodies from the fifth dorsal to the first lumbar, followed by collapse and a certain amount of ankylosis. The bones are from a young subject. They are all very light, and widely cancellated. The ankylosis is altogether in the articular processes and laminae. Disease was probably still active.

**6. 90. Tubercular Disease of the Vertebrae. Angular
Curvature. Ankylosis.** *Hunterian.*

Left half of the vertebral column from the axis to the twelfth dorsal, with the scapula, clavicle, ribs (first to tenth), and half of the sternum, of a young subject, partly macerated, cleaned, and dried, showing the above. The disease has affected the bodies from the sixth to the twelfth, chiefly in front. Collapse has followed. The ribs are huddled close together. There is firm ankylosis between the laminae and articular processes, and to a less degree between the remains of the bodies of the affected vertebrae.

6. 91. Tubercular (?) Disease of the Vertebrae. Cure with Angular Curvature and Ankylosis. *Hunterian.*

Last two dorsal and first two lumbar vertebrae macerated and dried, showing the above. There has been considerable destruction of the bodies of the last dorsal and first lumbar, evidently chiefly of the adjacent surfaces, as in No. 6.87, followed by collapse, cure of the disease, and complete fusion of the remains of the two bodies. There is also ankylosis between the articular processes and arches of these two vertebrae. The other two are quite free. There is a decided curvature.

6. 92. Deformity of the Aorta associated with Angular Curvature of the Spine. *Hunterian. B. 18.*

"The aorta about the middle of the spine in a girl who had a very great incurvation of the spine from behind forwards. The aorta had adapted itself to that incurvation, and still shows the angle at which the spine was bent, which is very nearly a right angle."

6. 93. Ankylosis of the Cervical Vertebrae and Occiput, probably after Tubercular Disease. *Hunterian.*

Lower part of a skull, with the first three cervical vertebrae, macerated and dried, showing the above. The three vertebral bodies and the basi-occipital are completely fused into one piece, the former lines of articulation being quite untraceable in front. The laminae and articular processes are also ankylosed. The nature of the original disease is, of course, uncertain, but there is present a certain degree of distortion of the vertebrae in the way of collapse upon one another, which suggests that it was tubercular.

(b) Changes in the Vertebrae due to Arthritis Deformans and Allied Conditions.

6. 94. Arthritis Deformans of Spine. *Hunterian.*

The dorsal and lumbar vertebrae macerated, dried, and articulated, illustrating the above. The bodies of several of the dorsal vertebrae show osseous outgrowths from their edges bridging over the spaces formerly occupied by the intervertebral discs. On the right side of

the eighth, ninth, and tenth, these outgrowths are of considerable size, fully 3 cm. wide, projecting about 1 cm., and interlocking by their sinuous edges. The tenth and eleventh are ankylosed by a thick plate of bone, evidently formed of outgrowths of the same nature, which have fused with one another. The facets for the ribs on the sides of the bodies and on the transverse processes are lipped round their edges. The articular processes here and there show slight traces of the same lesion. Compare Nos. 6.77 to 6.82, under Lateral Curvature of the Spine.

6. 95. Arthritis Deformans of the Spine.

Hunterian.

Six lower dorsal and first lumbar vertebrae macerated, dried, and articulated, showing the above. The specimen shows processes of dense bone projecting from the edges of the vertebral bodies, and interlocking with one another. The articular processes and facets for the ribs are slightly affected also.

6. 96. Arthritis Deformans of the Spine.

Hunterian.

Four dorsal and two lumbar vertebrae macerated, dried, and articulated, showing abundant outgrowths from the edges of the bodies, as in the preceding.

6. 97. Arthritis Deformans of the Spine. Section of Ankylosed Vertebrae.

Hunterian.

Two dorsal vertebrae macerated and dried, showing the above. They are ankylosed by a bridge of bone about 1.5 cm. wide, which has grown across the space for the intervertebral disc on the right side. The bodies have been sawn in two vertically to show the structure of the bridge of new bone, which is of ivory-like density and hardness.

6. 98. Arthritis Deformans of Spine associated with Lateral Curvature.

Hunterian.

Ten dorsal vertebrae, probably from a grave, showing the above. There is slight lateral curvature. On the concavity at the point of greatest curvature there are considerable osseous outgrowths similar to those seen in the preceding. In one case they have produced ankylosis.

6.99. Arthritis Deformans of the Spine. Ankylosis.*Hunterian.*

Two lower dorsal vertebrae, probably from a grave, united by osseous outgrowths from their edges on each side. On the right they have ankylosed; on the left they interlock by sinuous edges.

6.100. Arthritis Deformans of the Spine. Ankylosis.*Hunterian.*

Portion of two lower vertebrae, graveyard fragment, showing the above; similar to the preceding, but more advanced.

6.101. Ankylosis of Entire Vertebral Column, Costo-vertebral and First Costo-sternal Articulations, and Sacro-iliac Synchondroses. Arthritis Ossificans (?).*Hunterian.*

The entire vertebral column from the atlas to the coccyx, with the first ribs and manubrium sterni, and seventh to tenth ribs of the right, and fifth to twelfth ribs of the left side, probably from a grave. The vertebrae from the atlas to the last lumbar are ankylosed into a single piece—partly by extensive bony outgrowths from the edges of the bodies similar to those in the preceding specimen, partly by ossification of various ligaments, and ankylosis of a few of the articular processes. There is a decided increase of the normal curve of the lower cervical and upper dorsal regions of the spine; the other curves are about normal. The anterior common ligaments are extensively ossified. These along with the outgrowths from the edges of the bodies enclose the intervertebral discs in a ring of bone, preventing their condition being made out except in a few cases where the ring is incomplete. At these points the space is seen to be empty, narrowed a little perhaps, but showing no trace of ossification across it. From behind, the posterior common ligament for a great part of its extent and the transverse ligament of the atlas can be seen to be ossified. The odontoid process of the axis is ankylosed to the anterior arch of the atlas. In the dorsal region the ligamenta subflava and interspinous ligaments, and the capsular and other ligaments of the ribs, are all ossified. The cavities of one or two of the costo-vertebral joints, which, having been broken or cut, show in section, are not at all obliterated by bone;

the ossification which has produced the ankylosis is in the ligamentous structures around them; these joints are consequently thickened. The two first ribs are very firmly ankylosed to the sternum by similar thick masses of bone surrounding the joints. Part of the cartilages of the eighth, ninth, and tenth ribs are preserved; they are sheathed with bone, and also show some ossifications in their interior. The sterno-clavicular joints are very much deformed by osseous growths around them; the right also shows eburnation of part of its articular surface, such as is seen in arthritis deformans. The intersternal joint is cased with bone growing around its edges; its articular surface has remains of cartilage on it, and there has been no attempt at ossification across it. The sacrum is not ankylosed to the lumbar vertebrae, but there are considerable osseous outgrowths from the edges of its upper surface. The coccyx is ankylosed to it. Both sacro-iliac synchondroses have been firmly ankylosed. The ossa innominata have been sawn off, and the right one forms the next specimen; it was particularly firmly ankylosed to the sacrum. The left was less firmly ankylosed; it is not now in the collection. The greater part of the changes in this and the succeeding specimen are clearly not those of arthritis deformans, but rather of the rare disease described as arthritis ossificans or universal bony ankylosis. Unfortunately, the history of the specimen is unknown.

6. 102. Ankylosis of Sacro-iliac Synchondrosis, Ossifications around Acetabulum and in the Attachments of Muscles.

Hunterian.

The right innominate bone and part of the lateral mass of the sacrum belonging to the preceding specimen. The ilium and sacrum are firmly ankylosed by a thick plate of very dense bone over the top and front of the joint, and by some ossification between the surfaces. There are also osseous outgrowths in the position of the attachments of muscles round the crest of the ilium, on the anterior inferior spine, and above the acetabulum where the rectus femoris arises, along the tuberosity of the ischium, ilio-pectineal line, and on the front of the body of the pubis. The whole circle of the cotyloid and transverse ligaments round the edges of the acetabulum is also ossified. The hip appears not to have been ankylosed. There is no eburnation or scoring of the articular surfaces, as in arthritis deformans.

6.103. Ankyloses of the Vertebral Column. Ossification of Ligaments. Ankylosis of the Costo-vertebral Articulations. *Hunterian.*

Eight dorsal vertebrae with portions of three ribs attached, probably from a grave. The specimen shows a condition very similar to that described in No. 6.101. The vertebrae are ankylosed into one piece by dense osseous outgrowths from the edges of the bodies and by ossification of the anterior ligament, which on the upper three is completely replaced by bone, and of the inter-spinous ligament. The latter is replaced by a bar of bone about 6 mm. in diameter. Portions of three ribs are fused with the bodies of the vertebrae by thick sheaths of dense bone around the joints; the joint cavities can be seen in two of them not to be obliterated. The inter-vertebral spaces are decidedly narrowed—especially the upper four. There is a slight increase of the normal curvature forwards, as in the preceding.

6.104. Ankylosis of Costo-vertebral Articulation.

Hunterian.

Part of a dorsal vertebra and rib, probably a graveyard fragment, showing a condition of the costo-vertebral joint very like that in Nos. 6.101 and 6.103. The lower of the two vertebrae with which the head of the rib articulated is absent. It had been ankylosed to the one which remains. There had been no ankylosis at the costo-transverse joint. Nearly the whole joint cavity between the head and the remaining vertebra is open, though in part the surfaces are roughened by new bone. The ankylosis is by a mass of cancellous bone over the front of the joint, the cancelli of which are continuous with those of the rib, but separated by a line of dense bone from those of the vertebral body.

6.105. Ankylosis of Vertebrae.

Hunterian.

Four dorsal vertebrae, probably from a graveyard, showing the above. The bodies are united by thin plates of cancellous bone bridging the intervertebral spaces in front, and several of the articular processes are ankylosed to one another by plates of bone over the front of the joints. There is no fusion of the articular surfaces.

6.106. Ankylosis of Vertebrae and Costo-vertebral Articulation.*Hunterian.*

Four upper dorsal vertebrae and part of a rib, from a grave, showing the above. The fragment is very rotten, doubtless long buried. The vertebrae are ankylosed, partly by plates between the edges of the bodies, partly by fusion of the cancellous tissues by ossification through the intervertebral discs. The bond of union is all cancellous bone. A section has been made of the rib into the transverse process and body of the vertebra. The cancellous tissues of the three are continuous, a thin line of slightly denser tissue marking the seats of the obliterated joints.

6.107. Ankylosis of Sacro-iliac Articulation.*Hunterian.*

An entire male pelvis, probably from a grave, showing firm ankylosis between the left ilium and the sacrum by a thick plate of dense new bone bridging over the whole upper border of the joint for a width of 6 cm. There are also bony outgrowths from the edges of the upper surface of the body of the sacrum and along the iliac crests, and ossifications of the cotyloid ligaments of the hip-joints.

6.108. Ankylosis of Sacro-iliac Articulation.*Hunterian.*

Sacrum and left innominate bone from a grave, showing the above; similar to the preceding. The right joint has also been ankylosed by a thick bridge of new bone over the top.

6.109. Ankylosis of Sacro-iliac Articulation.*Hunterian.*

Sacrum and right ilium, a very rotten graveyard fragment, showing ankylosis by a plate of new bone across the front and part of the top of the sacro-iliac joint.

6.110. Ankylosis of Sacro-iliac Articulation.*Hunterian.*

Right innominate bone and part of the lateral mass of the sacrum, from a grave, united by plates of new bone all round the articular surface, and by fusion, not quite complete, of the cancellous tissues across the joint.

COMPARATIVE PATHOLOGY.

6.111. Ankylosis of the Spine of an Old Horse.

Presented by Professor Young.

Ten vertebrae, lumbar and dorsal, of an old horse, macerated and dried. They are welded together into one rigid mass, in a manner similar to the preceding human vertebrae, 6.101, *et seq.* As in those there are plates rising from the edges of the bodies and bridging over the intervertebral spaces, and ossification of the anterior common ligaments. The laminae are also extensively fused together by ossification of the ligaments between them. There does not appear to be ankylosis across the articulations between the vertebral bodies. The spinous processes are imperfect. The animal was a quarry horse at Luss, Dumbartonshire, N.B., and had for years carried heavy loads of stone on its back.

6.112. Ankylosis of the Spine of an Old Horse.

Presented by Professor Young.

Four lumbar vertebrae from the same horse. They are united by ossification around the articular processes and between the arches, and by three thick, rather narrow plates of dense bone, each uniting two of the bodies; these last are situated alternately on either side of the spine close to the transverse processes.

6.113. Ankylosis of the Spine of an Old Horse.

Presented by Professor Young.

Two dorsal vertebrae from the same animal, united only by a bridge of bone on the side of one of the joints of the articular processes.

SERIES 7.

STRUCTURE AND ARRANGEMENT OF MUSCLES AND TENDONS, SYNOVIAL SHEATHS, BURSAE, FASCIAE, AND CONNECTIVE TISSUE.

(a) Muscle and Tendon.

7.1. Relations of the Muscles and other Structures in a Limb.

Hunterian. H. 1.

"A transverse section of the arm of a child across the belly of the flexor biceps cubiti. The blood was washed out of the muscles by repeated injections of water from the artery, which, returning by the veins, entirely emptied the vessels of their natural fluids. The muscles now appear equally white with the bone or skin." A bristle marks the brachial artery with the median nerve beside it.

7.2. Muscular Fibres.

Hunterian. H. 2.

"A piece of boiled beef macerated in water, principally at one end. It shows that a muscle is composed of larger packets of fibres, these again of smaller, and these last of barely visible fibres."

7.3. Muscular Fibres.

Hunterian. H. 3.

"A piece of boiled ham treated in the same way. Many of the fibres are as fine as the threads of a spider's web, and probably are the constituent or smallest muscular fibres."

7.4. The Blood-vessels and the Relations of Muscle and Tendon.

Hunterian. H. 4.

Diaphragm of a child, injected red, dried, and mounted in turpentine, illustrating the above. The muscle is so finely injected as to seem "composed entirely of vessels."

7.5. The Blood-vessels and the Relations of Muscle and Tendon. *Hunterian. H. 5.*

"Diaphragm from a child of larger size, injected red, but with coarse injection; is of course less minute, but more distinct:" *i.e.* it shows more clearly the arrangement of the blood-vessels. Compare next specimen. The supply of blood to the muscle is much richer than to the tendon. Mounted in turpentine.

7.6. The Blood-vessels of Muscle. *Hunterian. H. 6.*

"A longitudinal section of a rectilineal muscle very minutely injected; the arteries run chiefly in the direction of the muscular fibres." Compare the preceding. Mounted in turpentine.

7.7. The Blood-vessels and the Relations of Muscle and Tendon. *Hunterian. H. 7.*

Gastrocnemius and tendo Achillis "from a child," injected red, dried, and mounted in turpentine, showing the above.

7.8. The Structure of Tendon. *Hunterian. H. 8.*

"A tendo Achillis to show the white silvery appearance of tendon. The fibres are all longitudinal, and parallel to one another."

7.9. Arrangement of the Flexor Tendons in the Fingers.

Hunterian. H. 9.

A finger dissected and the tendon-sheath opened in its whole length, showing the splitting of the flexor sublimis digitorum (*perforatus*), and the passage through it of the tendon of the flexor profundus (*perforans*).

7.10. The Tendon Sheath in the Fingers. *Hunterian. H. 10.*

A finger dissected, showing the above. "The ligamentary sheath removed only where thinnest." Note the broad strong bands opposite the first and second phalanges, and the narrow strong band opposite the interphalangeal joint with the thin areas above and below it, corresponding to the folds of the skin.

7.11. The Blood-vessels of Tendon. *Hunterian. H. 11.*

"A tendo Achillis injected red, showing few vessels compared with the muscle." Dried and mounted in turpentine.

7.12. Relative Vascularity of Muscle and Tendon.*Hunterian. H. 11a.*

"A portion of the soleus, with the tendo Achillis, injected red; in some parts considerably vascular, but the transparent portion, compared with the muscular, little vascular." Dried and mounted in turpentine.

7.13. Insertion of Muscle into Skin. *Hunterian. H. 18.*

The palmaris brevis and portion of skin dissected and in spirit, illustrating the above.

7.14. Arrangement of Intercostal Muscles. *Hunterian.*

Portions of the ribs and intercostal muscles of a small animal, in spirit, showing the crossing of the different layers.

7.15. Contraction of Involuntary Muscle.*Hunterian. H. 12.*

"A bladder from a hanged woman, removed as found contracted in the dead body, to show that muscular fibres can contract more than one-third of their greatest length."

(b) *The Connective Tissues: Areolar, Adipose, etc.*

The following specimens are some of those used by William Hunter to illustrate a paper, entitled "Remarks on the Cellular Membrane and some of its Diseases," *Med. Obs. and Inq.*, Vol. II., p. 37 (anno 1764). The principal points which Hunter wished to remark upon as being under dispute or misunderstood by his contemporaries were the following: (1) That it was not, as Baron Haller believed, "the inorganic basis of all our organized and vascular solids," but that "all its visible parts are of a vascular texture so as to have circulation and life in them, and to be capable

of increase and decay in every part"; (2) that the fat was lodged in vesicles of its own, not in the interstices of the areolar tissue; (3) demonstration of the sweat ducts, proving that sweating is not a mere filtration of fluid through the interstices of the skin, but a proper secretion. The views expressed there, so far as they go, show his usual accuracy.

7.16. Structure of Areolar Tissue.

Hunterian. F. 2.

Portion of the areolar tissue of the scrotum inflated, dried, and mounted in turpentine.

7.17. Structure of Areolar (Connective) Tissues.

Hunterian. F. 3.

"One-half of the scrotum of a child; the cellular membrane (areolar or connective tissue) was distended from oedema; in this state it was hardened in spirits and then divided. There is no appearance in any of the foregoing preparations of regular cells; the tissue seems rather to consist of very fine laminae of a white cotton-like colour, interwoven so as to form a kind of sponge, all the parts of which are seen to communicate with one another from the enlarged size of the parts thus distended. The cellular membrane appears very ductile, and of course must allow of parts moving easily on one another."

7.18. The Interstices of the Areolar Tissues.

Hunterian. F. —.

A portion of areolar tissue, probably scrotum, which has had its interstices distended with mercury, and, after hardening, been split open. The size of the spaces is exaggerated by the mode of preparation.

7.19. The Septum of the Scrotum and its Blood-vessels.

Hunterian. F. 17.

Part of the scrotum of a child, injected red, dried, and mounted in turpentine, showing the above.

7.20. The Blood-vessels of the Skin and Subcutaneous Areolar Tissue. *Hunterian. F. 4.*

"A portion of the cutis injected red; its inside, as well as the cut edges, shows the cellular and adipose membrane exceedingly vascular." Dried and mounted in turpentine.

7.21. Deposition of Fat in the Omentum. *Hunterian. F. 12.*

"The stomach, omentum, a portion of the transverse arch of the colon with the mesocolon, the spleen, and pancreas of a child, injected red. The transverse arch of the colon, etc., are allowed to fall lower than their natural situation, in order to stretch the omentum, and then show the first depositions of the fat along the sides of the blood-vessels of the omentum."

7.22. Deposition of Fat in the Omentum. *Hunterian. F. 13.*

Portion of the omentum of a child, injected red, stretched on blue paper, showing the deposition of fat along the course of the blood-vessels.

7.23. Adipose Tissue from the Sperm Whale.

Hunterian. F. 15.

"A large portion of adipose membrane from the spermaceti whale. The oil does not appear globular, but seems to be contained in large fluid portions in irregular cells, like those of cellular membrane." William Hunter recognized that the cells in which fat was lodged were special cavities into which it was secreted, not merely the interstices of the areolar tissue, as many of his contemporaries supposed. *Vide* Introductory Note, before No. 7.16.

7.24. Adipose Tissue from the Sperm Whale.

Hunterian. F. 15a.

Similar to the preceding.

For New-formation of Connective Tissue, see Series 36, Injuries and Diseases of the Intestines and Peritoneum, Nos. 40-48; and for Sweat Ducts, see Series 27, Skin, Nos. 47-49.

SERIES 8.

INJURIES AND DISEASES OF MUSCLES, TENDONS, SYNOVIAL SHEATHS, BURSAE, FASCIAE, AND CONNECTIVE TISSUES.

I. INJURIES,	—
II. CONGENITAL DEFECTS AND MALFORMATIONS,	—
III. CHANGES DUE TO CONDITIONS AFFECTING THE NUTRITION.	
<i>Hypertrophy of Muscle</i> ,	1
<i>Hyaline Degeneration of Muscle</i> ,	2-4
<i>Ossifications in Muscles and Tendons</i> ,	5-8
IV. CHANGES DUE TO INFLAMMATORY DISEASES,	—
V. TUMOURS,	—

8.1. Hypertrophy of Muscle to overcome Increased Resistance. *Hunterian. H. 14.*

“A portion of the bladder from a calculous patient, thickened to half an inch in its muscular coat.”

8.2. Hyaline Degeneration of Muscle. *Hunterian. H. 16a.*

“Portion of the belly of gastrocnemius from an adult male subject. The other muscles of that leg and of the other leg were perfectly red. This was as white as it now appears, *i.e.* as white as the muscular fibres of a skate. The great veins running through the muscle had their cavities plugged with coagulated laminated blood as in varicose veins. This disease was supposed palsy of the muscles; cause not known, perhaps frequent cramps, some blow, or accidental destruction of the nerves leading to it, though no external marks appeared.”

8. 3. Hyaline Degeneration of Muscle. *Hunterian. H. 17.*

Another portion of gastrocnemius from the same case as the preceding. "The muscular fibres as white as those of the covering tendon, and at some little distance not to be distinguished."

8. 4. Hyaline Degeneration of Muscle. *Hunterian. H. 17a.*

Another portion of the same. "The coagulated blood in the veins well seen." Partly macerated to separate the fibres.

8. 5. Ossifications in Muscles. *Hunterian. H. 20.*

"Small portions of muscles with very large ossifications in them, a circumstance universal in this body (dissecting room)."

8. 6. Ossification of Tendon of Adductor Magnus.

Hunterian.

Right femur macerated and dried, showing a spine of bone, 3.5 cm. long and 6 mm. in diameter, rising from the top of the inner tuberosity of the femur in the position of the adductor tubercle. It is composed of cancellous tissue, with a thin outer shell of dense smooth bone. Its upper end is broken, so that it does not include all of the original outgrowth. Compare Nos. 5.168 and 5.169, Exostoses.

8. 7. Ossification of the Tendinous Arch of the Adductor Magnus.

Hunterian.

Left femur macerated and dried, showing on the posterior surface, just internal to the inner ridge of the linea aspera, a process of bone about 1.5 cm. long by about 1 cm. broad at its base in the vertical line and about 5 mm. in the transverse, of triangular shape, with an elongated rather hooked apex. It projects inwards, and is curved with its concavity on the anterior surface and the hooked end pointing downwards. From its base a flat outgrowth of bone, about 1 cm. wide by from 2 to 4 mm. high, extends about 3 cm. down the shaft. The hooked process is rather higher up on the shaft than the arch for the femoral vessels usually is, but very near their line, and its shape certainly suggests that it was formed in the arch through which they pass from the inside of the thigh to the popliteal space.

SERIES 9.

MALFORMATIONS, DEFORMITIES, INJURIES, AND DISEASES OF LIMBS AS A WHOLE.

I. CONGENITAL DEFECTS AND MALFORMATIONS.	
<i>Supernumerary Fingers and Toes,</i>	1-4
<i>Congenitally Malformed Limbs, Talipes, etc.,</i>	5-9
II. DEFORMITIES WHICH ARE NOT CONGENITAL,	—
III. INJURIES,	—
IV. DISEASES AFFECTING WHOLE LIMBS,	—
V. RESULTS OF OPERATION.	
<i>Stumps after Amputation,</i>	11-18

I. CONGENITAL MALFORMATIONS OF THE LIMBS.

See also in Series 50, Monsters.

(a) *Supernumerary Fingers and Toes.*

9.1. Supernumerary Finger. *Hunterian. MM. 35.*

"The forearm and hand from a child at birth. There are six fingers instead of five, the sixth one growing out of the little one." The specimen shows a fairly common type of this condition, viz. a small finger, consisting of a terminal phalanx and nail, and part of a second phalanx, attached to the outside of the first phalanx of the little finger.

9.2. Supernumerary Finger.*Hunterian. MM. 36.*

The forearm and hand of a child at birth, showing a similar malformation.

9.3. Supernumerary Toe : Sheep.*From Dr. Allen Thomson's Collection.*

Left fore foot of a sheep, with a supernumerary toe growing from its inner side just above the dew claw.

9.4. Supernumerary Toes : Pig.*From Dr. Allen Thomson's Collection.*

Foot of a pig with six digits. The four ordinary digits of a normal foot are recognizable, and alongside them are two extra digits parallel to the normal foot, and nearly as long and nearly as stout as the normal middle digits.

(b) *Congenitally Malformed Limbs, Talipes, etc.*

9.5. Defective Development of the Feet : Peropus.*Hunterian. MM. 26.*

Right foot and leg of a child at birth, injected red, illustrating the above. The foot is shortened and rounded, and, the sole being more affected than the back, the toes are turned downwards; the foot is in the position of talipes varus. The toes are represented by tubercles on the end of the foot towards its plantar aspect: the first and second are fairly large; the other three hardly at all raised above the surrounding skin. There are no nails.

9.6. Defective Development of the Feet : Peropus.*Hunterian. MM. 27.*

The neighbour of the preceding; similar. Hung upside down to show the sole. In this, the left foot, the toes are better formed, and have nails; but they are very small, and lie on the under surface huddled together and pointing towards the heel, the actual end of the foot being broad and round. The foot is more shortened than the right. There is a small mark like a cicatrix on the end of it.

9.7. Lizard with Double-Ended Tail.

A large lizard showing the above. One of the points continues the line of the tail; the other strikes off to the left at an angle of about 45 degrees. The former is thicker but shorter, being only 2.5 cm. long, while the latter is fully 3.5 cm.

9.8. Talipes Varus.

Hunterian. MM. 46.

Left leg and foot "of a child at birth, injected red and stripped of its cuticle to show the club foot." The foot is inverted and turned up, so that the inner edge looks directly upwards and the sole inwards and backwards, the plane of it being parallel to the long axis of the leg. The next specimen shows the condition of the bones in a similar case.

9.9. Talipes Varus.

Hunterian. MM. 47.

"The skeleton of a similar foot." Right foot and leg of a child at birth, the soft parts carefully removed from the bones. Probably the neighbour of the preceding. The foot, as in it, is turned upon its own axis and strongly inverted, so that the inner edge looks directly upwards, and the sole inwards and backwards. The tarsal bones, as a whole, have an abnormal shape, there being a general twisting of them inwards. The astragalus is the one most affected; its upper articular surface bears the normal relation to the tibia and fibula, but the neck and head are bent and also twisted inwards, with elongation of the outer edge and slight shortening of the inner edge. The lower end of the fibula is carried forwards slightly. The anterior part of the tarsus is also bent, apparently with compression of the scaphoid and cuneiform bones, and an increase of the normal slope (backwards from within out) of the line of the heads of the metatarsals. All these alterations have their share in the production of the deformity, which is of congenital origin.

II. DEFORMITIES WHICH ARE NOT CONGENITAL, *e.g.* CONTRACTIONS AFTER BURNS, FLAT FOOT, ETC.

Specimens wanted.

III. INJURIES OF LIMBS, ETC., *e.g.* CRUSHED HANDS, ETC.

Specimens wanted.

IV. DISEASES AFFECTING WHOLE LIMBS, *e.g.* CELLULITIS, GANGRENE, ETC.

Specimens wanted.

9.10. Swelling of Hand from Obstruction of the Lymphatics.

A very much swollen hand which had been amputated at the wrist, from a small person, showing the above. There is a deep incision in the palm from the base of the first finger almost to the wrist. The swelling does not affect the whole hand; it is very great in the ball of the thumb and adjacent half, or thereabouts, of the palm, the corresponding area of the back of the hand, and the index and middle fingers. These last are enormously swollen, especially in the upper two phalanges, and pressed widely apart. The thumb and other two fingers and the outer edge of the hand are hardly at all swollen, contrasting strongly with the rest. The swelling is not sharply defined. So far as can be seen in the cut surface of the wrist, it did not extend above the hand. On refreshing the edge of the cut, the tissue from the periosteum right up to the skin was found to consist of a network of fibrous-looking tissue, its meshes filled with glancing brown material. It cut easily. To the naked eye it looks like a tumour. Microscopic examination of a large section showed only the normal constituents of the palm of the hand—skin, glands, blood-vessels, fat, areolar tissue, dense fibrous tissue, nerve, and here and there muscle fibres. No evidence of inflammation; no leucocytes in the tissues. The vessels contain fairly well-preserved blood, with rather an excess of leucocytes. The contents of the spaces were masses of hyaline matter of a yellowish colour and lumpy, along with some finer granular debris; no cellular elements. The walls of the spaces resembled those of veins, but without muscular coat—most probably distended lymphatics filled with coagulated lymph much altered by time and spirit. The meshes of the areolar tissue are full of fibrin. Apparently a case of oedema due to obstruction of the lymphatics. The history of the specimen is unknown, and the cause of the condition cannot be made out by examination.

V. RESULTS OF OPERATION.

*Stumps after Amputations.***9.11. Section of Bone from a Stump.** *Hunterian. LL. 9.*

Decalcified, dried, and mounted in turpentine. Formerly described as "a longitudinal section of callus injected very red." The lower end is swollen out into a rounded knob of cancellous bone new formed around the sawn end. There is a considerable number of blood-vessels in it. At one side there is a whitish, nearly avascular portion, apparently a sequestrum. The amputating saw-cut in this specimen has been transverse. Contrast specimens Nos. 9.15 to 9.18, in which it has been oblique.

9.12. Section of Bone from a Stump. *Hunterian. LL. 11.*

Another section of the same.

9.13. Bone from a Stump. *Hunterian.*

A portion of the shaft of a femur macerated and dried. The end of the old shaft is rounded off and covered with a mass of new-formed bone, which materially increases its breadth. The medullary cavity is not well closed. Probably the limb was not properly healed.

9.14. Bone from an Old Healed Stump of the Leg.*Hunterian.*

The head and a small portion of the shaft of a tibia, from a stump, after amputation a little below the knee. The saw-cut has been transverse. The corners are well rounded off. There is a little irregularity of the new bone over the end. Macerated and dried.

9.15. Bone from an Old Stump. *Hunterian.*

A portion of the shaft of a long bone, femur apparently, macerated and dried. The edges are bevelled off, especially in front, and the medullary cavity sealed with a thin plate of bone. This plate is dense as if old, but it is incomplete, there being a small perforation in the centre. The end is not appreciably enlarged. The saw-cut

seems to have been slightly oblique from before and above downwards and backwards.

9.16. Bone from an Old Stump.

Hunterian.

A portion of the shaft of a femur macerated and dried. The end of the bone is quite smooth and rather narrower than the shaft higher up. There is a slight extension of it backwards by new bone. The medullary cavity is closed with dense bone. The saw-cut has been oblique. Compare No. 9.14.

9.17. Bones from an Old Stump of the Leg. Atrophy, probably from Disuse.

Hunterian.

Upper portion, about one-third, of right tibia and fibula, probably from a grave. The edges of the bones are bevelled off all round. They are capped by some new-formed bone, which ankyloses them to one another. The shape of the extremity is conical. The bones are extremely thin and light. Evidently from a very old amputation. There is a little periosteal new bone on the shaft of the tibia ; also a pick mark.

9.18. Bone from an Ulcerated Stump.

Hunterian.

Portion, about 7 cm. long, of tibia and fibula, macerated and dried, illustrating the above. The bones are ankylosed in the same way as the preceding. The ends are slightly expanded, and present a flat eroded surface, which appears to have formed the base of an ulcer. The shafts of the bones above are roughened by periosteal new-formation. They are also extremely porous and light. Apparently a re-amputation from an ulcerating inflamed stump. The saw-cut has passed in a direction from before backwards and slightly downwards. Compare the preceding specimens, which nearly all show an oblique direction of the saw-cut.

For Septic Diseases of Stumps, see Series 6, Nos. 93-100 and 107-110 ; and for Amputation Neuromata, Series 22, No. 29.

SERIES 10.

THE BLOOD AND THE ANATOMY OF THE HEART AND BLOOD-VESSELS.

<i>The Blood,</i>	1-7
<i>Dissections of Foetuses, showing the Relations of the</i>	
<i>Abdominal and Thoracic Viscera,</i>	8-17
<i>Dissections of the Heart,</i>	18-30
<i>The Foetal Heart,</i>	31-38
<i>Nerves of the Heart,</i>	39
<i>Structure of Arteries,</i>	41-50
<i>Structure of Veins,</i>	51-54
<i>The Vasa Vasorum,</i>	55

(a) *The Blood.*

(A) CLOTTING OF THE BLOOD.

10.1. Blood Clot, Post-mortem.

Hunterian. A. 6.

“The right ventricle of the heart laid open, with a portion of the beginning of the pulmonary artery, to show the lymph coagulated even between the muscular fasciculi, and filling up nearly the whole cavity of the ventricle as well as the pulmonary artery. The shape of the semi-lunar valve is finely moulded in the lymph.” “Coagulable Lymph” was the term applied by the Hunters and their contemporaries to the coagulable part of the blood now called fibrin.

10.2. Post-mortem Blood Clot.

Hunterian. S. 58.

A portion of the right ventricle of the heart, containing a very large blood clot, which has formed after death.

10.3. Fibrin obtained by stirring Fresh Blood with a Stick. *Hunterian. A. 2.*

"Coagulable lymph obtained by stirring fresh-drawn blood with a stick, and washed and steeped in water to remove the red globules, and appearing laminated, fibrous, and of a white colour."

10.4. Fibrin from an Aneurism (Stratified Thrombus).

Hunterian. A. 9a.

"Coagulated laminated blood from an aneurism." The stagnation of the blood in the sac of the aneurism favours coagulation, and fibrin is deposited in layers on its walls.

10.5. Post-mortem Blood Clot from Pulmonary Artery.

Hunterian. A. 3.

Blood clot "from the pulmonary artery in the human subject. It appears to have coagulated after death by its bearing the marks of the semi-lunar valves. It branches as the trunk of that artery does, and shows also the manner of its ramifying through the lungs for some little way."

10.6. Post-mortem Blood Clot of the Pulmonary Artery.

Hunterian. A. 5.

Similar to the preceding, but not so perfect.

10.7. Post-mortem Blood Clot from the Pulmonary Artery : Elephant. *Hunterian. A. 7.*

"Differing from the human only in superior size and whiteness." Probably from only one lung, as there is no print of the semi-lunar valves.

(b) The Relations of the Thoracic and Abdominal Viscera.

10.8. The Viscera in a Male Child at Birth, from before.

Hunterian. S. 1.

"A male child at birth, but still-born, injected from the umbilical cord; the anterior parietes of the thorax and abdomen are removed

to show the viscera of both cavities in their situation, from before." The succeeding specimens show the relations and relative sizes of the viscera at earlier dates. In this specimen the thymus and heart are considerably overlapped by the lungs, although these have not been expanded by respiration. The heart is enveloped in the pericardium. The liver is larger in proportion than it is in the adult, but much less so than at an earlier period. The testicles are in the scrotum.

10.9. The Viscera in a Female Child "at Birth," from behind. *Hunterian. S. 2.*

The posterior parietes have been removed to give a back view of the contents of both cavities. The relations of the aorta and its great branches to the oesophagus and trachea above and the rectum below are very well displayed. Injected with vermilion.

10.10. The Viscera in a Male Foetus "at Seven Months," from before. *Hunterian. S. 3.*

Similar to No. 10.9. The appearance of the lungs suggests that the foetus had breathed. The bladder is seen opened from above, and on each side of it are the testicles, not yet descended into the scrotum.

10.11. The Viscera of a Child, from before. *Hunterian. S. 3c.*

Similar to the preceding. The thymus gland is very large and distinct. Behind is seen the sac of a spina bifida laid open.

10.12. The Thoracic Viscera and the Liver of a Child at Birth. *Hunterian. S. 6.*

The child was probably still-born. The lungs are injected with tallow, the systemic arteries red. The spine is left to preserve the relations of the parts, and a portion of the right lung has been removed to show the thymus gland and right auricle of the heart.

10.13. "The Contents of the Thorax of a Child at Birth: Still-born." *Hunterian. S. 7.*

The spine has been removed to show the descending aorta embedded in the areolar tissue of the posterior mediastinum; the

oesophagus is laid open at its upper part; the larynx and trachea are seen in front of it. Injected red.

10.14. "The Contents of the Thorax and Abdomen from a Foetus at Three Months." *Hunterian. S. 10.*

"Intended principally to show that the auricles are larger in proportion than in the adult, and that the right and left auricles touch one another before, and quite surround the upper anterior parts of both ventricles; the lungs are also at a greater distance before, and leave the heart quite exposed, on the right particularly. The thymus is now smaller in proportion to the heart than afterwards." The liver is very large. A bristle is passed between the umbilical arteries and the bladder. Behind, the testicles and gubernacula are seen just below the kidneys.

10.15. "The Contents of the Thorax and Abdomen of a Foetus at Three Months." *Hunterian. S. 10a.*

The heart is raised to show the diaphragm, with the pericardium lying on it. The spine and pelvis have not been removed, and they are beautifully dissected. The pelvis is very small, and all the organs lie above its cavity. In proportion to the other viscera the liver is enormous.

Comparative Anatomy Specimens.

10.16. The Thoracic and Abdominal Viscera: Calf.

Hunterian. S. 3b.

A young foetal calf ("slink calf") dissected like the preceding to show the relations of the viscera. The lungs are small and solid, the animal never having breathed. The thymus, liver, and stomach are very large.

10.17. The Thoracic Viscera of a Mammalian Foetus.

Hunterian. S. —

Not described in the old catalogue. The spine has been removed to show the descending aorta. The lungs, as in the preceding, are very small.

*(c) The Anatomy of the Heart.***10. 18. Heart dissected to show the Cavities and Valves.***Hunterian. S. 12.*

The heart of an adult man ("Hoquet") injected red, hardened in spirit, and afterwards dissected, to show the above. The auricles have been removed at the auriculo-ventricular groove, and the aorta and pulmonary artery cut off short to exhibit the four valves of the heart, viz.: the tricuspid and mitral preventing the return of the blood from the ventricles into the right and left auricles respectively; and the sigmoid or semi-lunar valves of the aorta and pulmonary artery preventing the return of the blood from the arteries into the ventricles. The walls of the ventricles have also been cut away to show their internal fasciculated structure and the chordae tendineae and muscoli papillares of the mitral and tricuspid valves. The left ventricle is recognized by the greater thickness of its muscular wall. The coronary arteries, supplying blood to the heart, are seen rising from the aorta a little way above the semi-lunar valves.

10. 19. Dissection of the Heart "of a Boy about Twelve Years old."*Hunterian. S. 13.*

"Filled with size, hardened in spirit, and then cut open and the size removed to show the internal structure of the auricles and ventricles with the exit of the great vessels."

10. 20. The Heart of an Adult Man: Dissected.*Hunterian. S. 13a.*

Similar to No. 15; but the auricles have been very carefully dissected, and only part cut away, so as to preserve their outlines and their relations to the great vessels. The cavities of the ventricles are exhibited as in the preceding specimen.

*Comparative Anatomy Specimens.***10. 21. Heart of Bird.***Hunterian.*

No description. It is of a type similar to the mammalian heart, having two auricles and two completely separate ventricular cavities. The ventricles are laid open, and bristles placed in the aorta and pulmonary artery. The auricles are intact.

10. 22. Heart of Turtle.*Hunterian. S. 24.*

Dissection in the style of No. 10.18, illustrating the anatomy of the above. It consists of two distinct auricles, of both of which the greater part has been cut away (compare next specimen), and a "kind of single ventricle" imperfectly divided into two chambers by an interventricular septum, which is incomplete towards the auricular end. The veins enter the auricles towards their dorsal aspect: the venae cavae, entering the right, are marked by blunt quills; the pulmonary veins, entering the left, by sharp quills. The part of the ventricular portion which corresponds to the left ventricle of the human heart is recognized by the great thickness of its muscular walls; it lies dorsal to the part which corresponds to the right ventricle. The ends of all the quills in the veins lie to the dorsal side of the incomplete septum. Three large vessels rise from the ventricles, of which the anterior, distinguished by bifurcating about 3 cm. from its origin, is the pulmonary artery; it rises from the right ventricle by an orifice guarded by two semi-lunar valves. Close behind, and rather to the right of it, rise the two other vessels which are the right and left arches of the aorta. The left lies next to the pulmonary artery; its orifice has only two semi-lunar valves; it lies almost directly above the septum, and seems to rise as much from the right as from the left ventricle; the right arch has three valves, rises above the left ventricle, and gives origin to the carotid and subclavian arteries. The muscle of the ventricles presents a very open fasciculated appearance.

10. 23. Heart of Chelonian.*Hunterian. S. 24c.*

A heart very similar to the preceding (not described), less dissected, showing the two large globular auricles and the shape of the ventricle. Injected red.

THE VALVES OF THE HEART.

10. 24. The Aortic and Mitral Valves.*Hunterian. S. 35.*

Dissection of the above, showing their relations and the muscoli papillares and chordae tendineae of the mitral.

10.25. Columna Carnea, "from a Bullock."*Hunterian. S. 36.*

The columnae carnae are muscular processes passing from point to point of the inside of the ventricle, and giving it the fasciculated appearance mentioned in the description of No. 10.18. This one passed "between the two sides of the right ventricle." "The foramina Thebesii on the column injected with mercury, and communicating with the coronary veins."

10.26. The Aortic and Pulmonic Valves. *Hunterian. B. 6.*

"The beginning of the aorta and pulmonary artery hardened in spirit in their distended state, whilst the blood is supposed to be attempting to get back into the heart. The preparation shows the loose edges of the sigmoid valves (semi-lunar) when in contact with another, almost totally shutting up the passage." The orifices of the coronary arteries are seen just above the valves of the aorta.

10.27. The Aortic and Pulmonic Valves, from below.*Jeffray Collection.*

Roots of the above filled with injection, and the auriculo-ventricular septum. The edges of the three semi-lunar valves are tightly pressed together, forming a thoroughly competent valve. The sinuses of Valsalva above the valves are well brought out by the distention with the injecting fluid.

10.28. The Aortic Valve, from below. *Hunterian. B. 6a.*

The root of the aorta distended with spirit till hard and dissected, showing the meeting of the three semi-lunar valves. It is known to be the aorta by the origins of the two coronary arteries.

10.29. Semi-lunar Valves of the Aorta. *Hunterian. B. 6b.*

The root of the aorta, with part of the wall removed to show the semi-lunar valve opposite and the small fibrous nodule in the middle of its edge, called globulus Arantianus or corpus Arantii.

10. 30. The Vena Cava Inferior and Right Auricle.*Hunterian. S. 25.*

About 10 cm. of the vena cava inferior and the right auricle dissected to show the orifices of the hepatic veins and the valve of Eustachius, which is a sharp crescentic ridge forming the lower margin of the entrance to the auricle; also the fasciculated inner surface of the auricle.

FOETAL AND INFANTILE HEARTS, ILLUSTRATING THE PECULIARITIES
OF THE ORGAN DURING INTRA-UTERINE LIFE.

10. 31. The Eustachian Valve, from a Child.*Hunterian. S. 27.*

A portion of the right auricle and inferior vena cava, showing the size and prominence of the above valve, which, in the foetus, directs the blood through the foramen ovale into the left auricle—"putting on the appearance of Brussels lace as delineated by Eustachius."

10. 32. Foetal Heart showing the Foramen Ovale.*Hunterian. S. 29.*

"The heart of a child injected red, both auricles removed, the septum remaining, and the foramen ovale seen from either side; the ventricles also opened to show the septum thin at one place"—the undefended area of the interventricular septum. Compare No. 10.33. From the right ventricle, recognizable by its thin walls, rises the pulmonary artery dividing into two branches; the lower passes on and divides again to supply the two lungs. The upper, running into the arch of the aorta, is called the ductus arteriosus; it carries into the general circulation, in the foetus, part of the blood which, in the adult, goes to the lungs. The innominate and right carotid and subclavian arteries are seen rising from the arch of the aorta before it receives the ductus arteriosus, so that the blood from that passage is all sent into the descending aorta, and thus to the lower limbs and placenta.

10. 33. The Heart of a "Foetus at Seven Months."*Hunterian. S. 29a.*

The auricles and ventricles partly dissected away to show the interior of all the cavities, and "the foramen ovale covered with

a Brussels lace-like membrane, which is loose only at the upper edge, and so placed that the blood of the right ventricle only can pass it, that of the left shutting it close." In this specimen is seen a defect of the interventricular septum in the usual situation; which is mentioned in the old catalogue as "a not hitherto described foramen ovale between the right and left ventricles just in the upper edge of the septum, where it appears thin and transparent in No. 29" (now No. 10.32). See under Development of the Heart, Series 51, No. 23.

10.34. The Heart of a Foetus.

Hunterian. S. 30.

Not injected; otherwise similar to No. 10.33. The valve of the foramen ovale is fairly thick, and is free in the upper and posterior quarter of its circumference.

10.35. Foetal Heart showing the Foramen Ovale.

Hunterian. S. 31.

Uninjected. The auricles removed; the ventricles intact. "The valve of the foramen ovale appears as transparent as spider's web nearly."

10.36. Foramen Ovale patent in an Adult.

Hunterian. S. 32.

"The septum auriculorum from an adult, showing foramen ovale open and a goose quill in the passage."

10.37. Foramen Ovale patent in an Adult.

Hunterian. S. 33.

The septum auriculorum "from an adult," showing the above as a small aperture at the upper part of the fossa ovalis.

10.38. Foramen Ovale patent in an Adult.

Jeffray Collection, No. 612.

Septum auriculorum, showing the above. The opening is in the upper part of the fossa ovalis, and is about 5 mm. in diameter; a rod is passed through it.

10.39. Nerves of the Heart.*Hunterian. S. 47a.*

"A heart, injected green, suspended by its nerves."

(d) *The Structure of the Arteries.*

10.40. The Three Coats of Arteries. Aorta.*Hunterian. B. 11.*

Dissection of a portion of the aorta to show the three coats of the arteries, viz.: (1) external fibrous, partly white, partly elastic tissue, the fibres interlacing in all directions (tunica adventitia); (2) the middle coat, muscular in the arteries, but principally elastic in the aorta (tunica media); (3) the inner coat, composed of the yellow elastic membrane of Henle, a thin fibrous layer, and endothelium (tunica intima).

10.41. The Coats of Arteries. Aorta.*Jeffray Collection.*

Dissection of a portion of the aorta, similar to the preceding.

10.42. The Coats of Arteries. Aorta.*Hunterian. B. 30a.*

Dissection of the aorta, similar to the preceding.

10.43. The Tunica Intima. Aorta.*Hunterian. B. 10.*

"A section of the aorta above the diaphragm turned inside out, and the thin inner coat (tunica intima), transparent and without fibres, peeled off and hanging down."

10.44. The Muscular Contractility of Arteries.*Hunterian. B. 30a.*

"Two portions of the same artery"; prepared to illustrate the above. "The uppermost one in the contracted state, as in an animal bled to death; the other in the natural dilated condition." In the former the cavity is almost obliterated; in the latter it is about 6 mm. in diameter.

Comparative Anatomy Specimens.

10.45. The Coats of the Arteries. Aorta. Ox.*Hunterian. S. 12a.*

A portion of the aorta of an ox dissected to show the above.

10. 46. Aorta of Elephant.*Hunterian. S. 13.*

A section of the aorta of an elephant to give an idea of its size and the thickness of its walls—about 1 cm.

10. 47. Arch of Aorta and Great Vessels. Elephant.*Hunterian. B. 1.*

The specimen, which is not described in the old catalogue, consists of a portion of the aorta and origins of the great vessels of a large animal—from the resemblance of the specimen in size and texture to the preceding probably an elephant.

10. 48. Aorta of Turtle.*Hunterian. B. 16.*

Portion of the above slit open to show the fasciculated internal layer of the muscular coat.

ABNORMAL ORIGIN OF ARTERIES.

10. 49. The Coeliac Axis and Superior Mesenteric arising by a Common Trunk.*Hunterian. B. 34.***10. 50. The Coeliac Axis and Superior Mesenteric arising by a Common Trunk.***Hunterian. B. 35.**(e) Anatomy of the Veins.***10. 51. The Three Coats of Veins. Vena Cava Inverted.***Hunterian. C. 9.*

Preparation of the vena cava to show that the veins have three coats like the arteries, only thinner. The internal coat very much resembles that of an artery; the middle coat is muscular, but the arrangement of its fibres is not so regular as in the arteries; the external, in contact with the glass tube on which it is stretched, is coarser than the middle and entirely fibrous. The fibrous element predominates, there being less need of contractility than in the arteries.

10.52. The Valves of the Veins. *Hunterian. C. 11.*

A vein slit open, showing a pair of valves resembling somewhat the semi-lunar valves of the aorta, only smaller.

10.53. The Valves of the Veins. Horse. *Hunterian. C. 12.*

There are three cusps instead of two, as in the human subject; in other respects similar.

10.54. The Valves of the Veins. Horse. *Hunterian. C. 13.*

A large vein inverted, and the valves stuffed with cotton. The three sets are about 6·5 cm. distant from one another.

10.55. The Vasa Vasorum. Aorta. *Hunterian. B. 15a.*

A portion of the aorta of a child, injected red, slit open, dried, and mounted in turpentine to render it transparent, showing a number of vasa vasorum—the blood-vessels of the blood-vessels.

SERIES 11.

INJURIES AND DISEASES OF THE HEART, PERICARDIUM, AND BLOOD-VESSELS.

SECTION I. THE HEART AND PERICARDIUM.

I. CONGENITAL DEFECTS AND MALFORMATIONS OF HEART AND VESSELS,	1
II. INJURIES,	2
III. CHANGES DUE TO CONDITIONS AFFECTING THE NUTRITION. <i>Aneurism and Spontaneous Rupture,</i>	3-4
IV. CHANGES DUE TO INFLAMMATORY DISEASE. <i>Pericarditis,</i>	5-17
<i>Endocarditis,</i>	18-21
V. TUMOURS OF THE HEART,	—

SECTION II. ARTERIES AND VEINS.

II. CHANGES DUE TO INJURY OR OPERATION. <i>Division and the Results of Ligature,</i>	22-23
<i>Traumatic Aneurism,</i>	24-25
III. and IV. CHANGES DUE TO CONDITIONS AFFECTING THE NUTRITION, AND DEGENERATIVE AND INFLAM- MATORY AFFECTIONS. <i>Atheroma,</i>	26-35
<i>Calcareous Infiltration,</i>	36-37
<i>Aneurisms,</i>	38-76
<i>Phlebitis,</i>	77
<i>Thrombosis of Veins,</i>	78
<i>Varix; Haemorrhoids,</i>	79-81
V. TUMOURS OF BLOOD-VESSELS,	82

SECTION I. THE HEART.

I. CONGENITAL MALFORMATIONS.

11.1. Increased Number of the Semi-lunar Valves.*Hunterian. B. 7.*

"The beginning of the pulmonary artery slit open, showing four sigmoid valves instead of three."

II. INJURIES OF THE HEART.

11.2. Wound of the Heart.*Hunterian. S. 68.*

"The carpenter's heart, who, in dovetailing a piece of wood, ran the chisel through the septum ventriculorum, and died suddenly." The chisel has entered the heart near the apex of the right ventricle close to the interventricular sulcus, and run through the edge of the cavity of the right into the cavity of the left ventricle, transfixing one of the muscoli papillares. A piece of wood indicates the course of the tool, and a second smaller piece is passed into the right ventricle to show that it also had been entered.

III. CHANGES DUE TO CONDITIONS AFFECTING THE NUTRITION OF THE HEART.

*(a) Aneurism and Spontaneous Rupture of the Heart.***11.3. Localized Dilatation or Aneurism of the Left Ventricle. Fibrous Transformation of Muscle.***Hunterian. KK. 31.*

"A portion of the left ventricle of the heart dilated at the apex into a bag large enough to hold a common pear. From the dissecting room." At the seat of dilatation the wall of the ventricle is very much thinned, and scarcely a trace of muscular fibre is to be seen in the cut surface—clearly a case of fibrous transformation. The condition of the coronary arteries could not be made out. There is a pericardial adhesion at the apex of the bag, which has probably had something to do with the production of the aneurism. (Matthew Baillie's *Engravings*, Fasc. I., Pl. III., fig. 1.)

11.4. Rupture of the Heart. Spontaneous.*Hunterian. S. 55.*

"A portion of the right ventricle of the heart of an old man who married his maid, and died suddenly the first night after; the ventricle appears ruptured large enough to admit one's thumb." The seat of the rupture is just at the apex. The heart is loaded with fat on the outside; the muscle is extremely brittle, which may, however, be the result of the long immersion in spirit. Microscopic examination for the same reason gives no definite information. (MS. Notes, J.H.T., p. 36.) The muscle at the point of rupture is fairly thick for a right ventricle.

IV. CHANGES DUE TO INFLAMMATORY DISEASE.

*(a) Pericarditis.***11.5. Acute Pericarditis.* Fibrinous Exudation on the Pericardium.***Hunterian. S. 29.*

"The right ventricle of the heart of an adult who died in Westminster Hospital, covered externally with a very thick crust of coagulated lymph." The shaggy appearance of the fibrinous crust is very characteristic. (Matthew Baillie's *Engravings*, Fasc. I., Pl. I., fig. 2.)

11.6. Acute Pericarditis. Fibrinous Exudation on the Parietal Pericardium.*Hunterian. S. 62.*

Similar to the preceding.

11.7. Acute Pericarditis.*Hunterian. S. 70.*

Similar to the preceding.

11.8. Acute Pericarditis.*Hunterian. S. 71.*

Similar to the preceding.

11.9. Acute Pericarditis.*Hunterian. S. 71a.*

Similar to the preceding.

11.10. Acute Pericarditis.*Hunterian. S. 72.*

Similar to the preceding.

11.11. Acute Pericarditis. Commencing Organization in the Fibrinous Exudation.*Hunterian. S. 75.*

The fibrinous crust has been peeled up from the surface of the left ventricle of the heart. The specimen has been injected blue, and innumerable blue points on the deep surface of the crust show where blood-vessels and other organizing elements had begun to sprout into the fibrin from the pericardial tissues. "The coronary arteries were injected, and the inflammatory crust afterwards peeled off and turned up, in which vessels injected are distinctly seen in many places, proving the living principle of this lymph or blood." (Description of S. 73 in. MS. Catalogue.)

11.12. Acute Pericarditis. Commencing Organization in the Fibrinous Exudation.*Hunterian. S. 74.*

A portion of the auricle of the same heart as the preceding.

11.13. Acute Pericarditis. Commencing Organization in the Fibrinous Exudation.*Hunterian. S. 76.*

Injected red; similar to No. 11.11. The deep layer of the crust shows red points—the new-formed blood-vessels. Some of the injection also appears on the free surface of the fibrinous crust; on examination with a lens, this appears to be in small blood-vessels, although this part of the crust must have been of very recent formation.

11.14. Acute Pericarditis. Organization proceeding in the Crust.*Hunterian. S. 63.*

The heart is highly injected red; and where the fibrinous crust is turned down, its deeper layer, still adhering to the ventricle, and also the deep surface of the freed layer show areas of injection and even distinct blood-vessels in one or two places. There is a distinct reddish colour on the face of the crust, which, as in previous specimen, is due to the presence of the vermilion injection

in fine vessels. The cut edges also show the injection to extend pretty well all through the crust. At the same time, some of the red colour of the free surface may be due to loose vermilion, which might readily be extravasated from the delicate new-formed vessels. The cardiac muscle is beautifully injected, and appears highly vascular. (Matthew Baillie's *Engravings*, Fasc. I., Pl. I., fig. 3.)

11. 15. Old Acute Pericarditis. Fibrous Adhesions. Thickening and Opacity of the Pericardium.

Hunterian. S. 67.

"A heart turned out of its pericardium; there was universal adhesion from inflammation, as appears by the ragged surfaces of both heart and pericardium, which naturally are smooth." The rough honeycombed appearance seen in the preceding specimens is visible only at one or two points; the pericardium, both visceral and parietal, is left thickened and opaque, and studded with fibrous tags, which were adhesions between the two surfaces.

11. 16. Old Pericardial Adhesion. Phthisis Pulmonalis with Excavation, Sloughing of the Pleura, Pleurisy, probably Pneumothorax.

Hunterian. S. 59.

"The apex of the heart adhering to the pericardium, and this last to the pleura lining the chest, by a broad adhesion which admitted of the heart's motion. A portion of the lung adjoining shows the patient to have been phthisical. Their outer surface is much covered with coagulated lymph." Over the seat of the pericardial adhesion there is a very thick loose mass of fibrin on the pleura. Below, the fibrinous exudation gets thinner and finally ceases, and below the fibrin-covered area the pleura has been perforated in two places—the upper perforation measures 2 cm. long by 6 mm. broad; of the lower, only part remains. The perforations lead directly into phthisical cavities, and probably their formation gave rise to pneumothorax; the pericarditis possibly was tubercular. Microscopic examination failed to give any information. (MS. Notes, J.H.T., p. 57.)

11. 17. Ossification (Calcification ?) of the Pericardium.*Presented by Professor Young, 1897.*

The root of the aorta and the auriculo-ventricular septa, with the circle of pericardium around them, dried and mounted in turpentine, showing the above. There is a ring, varying in breadth from 1 cm. to 4 cm., of calcareous plates surrounding the heart about the line of junction of the auricles with the ventricles. "Adherent pericardium of nine years' standing."

*(b) Endocarditis.***11. 18. Acute Endocarditis. Aneurism and Rupture of the Aortic Valves.***Hunterian. S. 56.*

"A portion of the left ventricle of the heart, with the aorta slit open to show one of the semi-lunar valves ruptured." The posterior semi-lunar valve is thickened, and bulged in the direction of the ventricle. A ragged gap with irregular edges, coated with fibrin, traverses the middle of the aneurismal bulging, only the free edge of the valve being left intact. The disease is limited to this one curtain. The edge which has escaped rupture appears to be sound, as if the disease had stopped short of the narrow strip which is beyond the line of contact of the three curtains in closure of the valve. (Matthew Baillie's *Engravings*, Fasc. I., Pl. II., fig. 2.)

11. 19. Chronic Endocarditis. Shortening and Calcification of the Mitral Valve.*Hunterian. S. 65.*

A small piece of the left ventricle and mitral valve. The valve is crumpled up, and there is an irregular calcareous mass in its under surface, which is exposed by turning up the chordae tendineae.

11. 20. Chronic Endocarditis. Very Large Calcareous Nodule in the Mitral Valve. Shortening of the Curtains.*Hunterian. S. 66.*

"A very large ossification in the substance of the heart round the mouth of the left ventricle; from a fat woman, in whom the arteries of the uterus and brain were also ossified." The

mitral valve is quite disorganized, and must have been incompetent. There are a few calcareous patches in the semi-lunar valves of the aorta. (Matthew Baillie's *Engravings*, Fasc. I., Pl. II., No. 4.)

11. 21. Chronic Endocarditis. Funnel-shaped Deformity of the Mitral Valve. *Dr. Allen Thomson's Collection.*

The mitral curtains and chordae tendineae are fused together into a funnel-like diaphragm, and the orifice contracted to a small oval hole less than 1 cm. in its largest diameter; there are also one or two minute holes beside the main passage. From above, several projecting vegetations are seen on the surface of the valve.

SECTION II. THE ARTERIES.

I. CONGENITAL DEFECTS AND MALFORMATIONS.

Specimens wanted. See Nos. 10.36 to 38.

II. CHANGES RESULTING FROM INJURIES OF ARTERIES.

(a) The Results of Ligature.

11. 22. "The Femoral Artery after Amputation." Obliteration by Ligature. *Hunterian. A. 13b.*

Both artery and vein are tied in the old style—with several threads of ordinary twine, which were probably waxed, though no trace of wax remains now. The artery is laid open, and is seen to be filled with blood-clot up to the first branch. It is also somewhat contracted. Compare No. 11.51, Aneurism showing Obstruction of Artery by Atheroma.

11. 23. Femoral Artery after Amputation. Changes after Obliteration by Ligature. *Hunterian. A. 13c.*

The ligatures have separated, doubtless by suppuration, and have been removed, leaving the ends of the vessels matted together and completely occluded by fibrous tissue. The clot, as

in the preceding specimen, extends up to just below a branch, and the artery has contracted closely upon it.

(b) *Traumatic Aneurism.*

11.24. Fracture of the Femur. Traumatic Aneurism of the Femoral Artery in "Hunter's Canal."

Jeffray Collection (?).

The specimen consists of the lower two-thirds of the left femur, with some of the soft parts, injected red. The fracture has occurred in the middle third, with a slight obliquity outwards and forwards, and the lower fragment has been carried strongly outwards and drawn up, so that there is about 6 cm. of riding; its end is covered with fibrous tissue. To the inside of this and crossing it obliquely lie the femoral artery and vein, marked—the former with a piece of whale-bone, the latter with a piece of wood. The artery is seen to communicate, by an irregular opening nearly 1 cm. in diameter, with a sac (opened and kept open by two pieces of whale-bone), having fairly thick fibrous walls lined with fibrin, into which, opposite the tear in the artery, projects the sharp end of the upper fragment, now partly covered with soft tissue of a fibrous character, probably granulations. The cavity of the aneurism extends in between the fragments so as to appear at the other side, forming two somewhat globular sacs united by an oval aperture measuring 2.5 by 1.5 cm. The inner sac has been about 8 cm. in diameter transversely, and rather larger vertically; the outer about the same size. The tendon and arch of the adductor magnus muscle have been preserved, and the tear in the artery is seen to have occurred just above and in front of it, just before the vessels pass from Hunter's canal into the popliteal space, and at a rather lower level than the fracture. There is no history of this case, nor even a number on the jar.

11.25. Lambert's Operation for Traumatic Aneurism.

Hunterian. A. 15.

"The carotid of an ass, on which Lambert's operation for aneurism had been performed, obliterated at the place of puncture by means of the coagulated lymph plugging it up." Lambert's operation was applied to the treatment of traumatic aneurism, especially that at the

bend of the elbow due to wounding the brachial artery in the operation of blood-letting. It consisted in cutting down on the vessel, passing a hare-lip pin through the lips of the wound in it, and bringing them together with a ligature twisted round the ends of the pin, as for hare-lip. (*Med. Obs. and Inq.*, Vol. II., p. 360.)

III. and IV. CHANGES ASSOCIATED WITH CONDITIONS AFFECTING THE NUTRITION, AND WITH INFLAMMATORY AND DEGENERATIVE DISEASE OF THE ARTERIES.

William Hunter recognized two diseases of the arteries: a softening and opacity of the inner coat and an "ossification," which two conditions he regarded as closely allied. It is clear from his descriptions and specimens, that these diseases included atheroma, calcareous infiltration of atheromatous patches, and also calcareous infiltration of the middle coats of the arteries, but he did not recognize the difference between the two last-named conditions. The following specimens were formerly described as ossification of arteries; but, to avoid confusion, they are now all described as atheroma, showing its different stages, or as calcareous infiltration of the middle coat.

(a) *Atheroma.*

11.26. Atheroma of the Aorta. Slight. Opacity and Thickening of the Intima. *Hunterian. B. 20.*

"The three coats of a section of the aorta. The inner coat is in most places opaque, and, as it were, clouded, showing the beginning of ossification." The outer coat is dissected upwards, the middle downwards. The intima, with some fibres of the media in the middle, shows the above conditions. See note on Dr. Hunter's views of diseases of the arteries.

11.27. Slight Atheroma of the Aorta. *Hunterian. B. 37.*

The beginning of the aorta, with the inner coat of the artery a little thickened above the valves.

11. 28. Atheroma of the Aorta with Calcareous Infiltration of the Patches.

Hunterian. B. 25.

Portions of the abdominal aorta slit open to show the above. The brown patches indicate the calcareous plates. The vessel is generally atheromatous.

11. 29. Atheroma of the Aorta with Calcareous Infiltration.

Hunterian. B. 26.

More advanced. The tunica intima has given way over and around many of the calcareous plates, which project bare into cavity of the vessel. They are most numerous around the mouths of the branches—coeliac axis, renal arteries, etc.—and at the bifurcation into the iliac arteries.

11. 30. Atheroma of the Aorta with Calcareous Infiltration.

Hunterian. B. 27.

The calcareous plates are larger and thicker, and seemingly naked towards the cavity of the artery.

11. 31. Advanced Atheroma of the Aorta and Iliac Arteries. Thickening and Deformity of the Vessels.

Hunterian. B. 15 (?).

The aorta is highly atheromatous. The iliac arteries are also highly atheromatous—their walls irregular and thickened. They have been very roughly and irregularly laid open, and the different coats a good deal torn from each other.

11. 32. Atheroma. Separation of the Tunica Intima.

Hunterian. B. 30b.

“A portion of diseased artery, there appearing in some places to be small ossifications, and a separation of the internal coat.”

11. 33. Atheroma with Calcareous Infiltration. The Intima dissected down.

Hunterian. B. 29.

“A section of an ossified calcareous aorta slit open, showing a thin membrane turned down between the bony calcareous matter and the cavity of the vessel.” At the upper part of the specimen the whole

intima is turned down from the muscle, and in it is seen the whole of one patch of atheroma and part of a second. The rest of the second patch adheres to the muscular layer, which, at this point, is evidently being involved in the disease. Below this is a large atheromatous patch infiltrated with lime salts, and from it the inner lamina of the tunica intima has been turned down. The rupture of the inner lamina over a calcareous plate and consequent exposure of its rough surface to the blood stream is a frequent cause of thrombosis. Compare No. 11.35, where thrombosis appears to be the result of a severe degree of atheroma.

11.34. Large Atheromatous Patch in the Aorta. Thrombosis.

Hunterian. B. 28.

Not described in the old catalogue. The first part of the aorta, with its valves, laid open, showing two atheromatous patches in the stage of thickening of the intima. The largest measures 3 by 2.2 cm., and stands out fully 3 mm.; the centre of it presents a cicatricial appearance, and there is a thin deposit of fibrin round its edges. The valves, though they have been injured in preparation, are of normal texture, with the exception of one or two small opaque spots about their attachments.

11.35. Thrombosis of the Popliteal Artery. Atheroma. Gangrene.

Hunterian. A. 11.

"The posterior tibial artery from a mortified leg, impervious from the column of coagulated blood which blocks it up." The artery is very highly atheromatous; its walls are thickened and irregular from the presence of calcareous nodules, several of which are of considerable size and project into the lumen of the vessel. The middle coat at these places is practically destroyed. About 1.5 cm. above the bifurcation into anterior and posterior tibial the artery is considerably dilated, and is filled with a very firm and dark thrombus adherent to the wall. Below this, the vessel is small, and filled with a small and soft coagulum which extends into the branches. Above the dilatation the vessel is filled for a considerable distance with clot, which is soft except where adhering to the walls. Thrombosis due to the atheromatous condition of the vessel has, by obstructing the circulation, been the cause of the gangrene. The dilated portion of the vessel was probably the starting-point of the thrombosis.

(b) *Calcareous Infiltration of Arteries.*

11. 36. Calcareous Infiltration of Arteries. *Hunterian. B. 21.*

"An artery slit open, showing a number of ossifications (calcifications) of a purple colour." The vessel is about the size of the femoral. The calcareous plates involve the whole thickness of the vessel wall, and there are no definite atheromatous patches. It is the other condition, viz. calcareous infiltration of the middle coat, and the plates extend from the loose tunica externa to the tunica intima, and even project naked into the lumen of the vessel.

11. 37. Calcareous Infiltration of Arteries. *Hunterian. B. 22a.*

A similar specimen dried and mounted in turpentine.

(c) *Aneurism.*

**11. 38. "Aneurismal Dilatation of the Aorta." Atheroma.
Contraction of the Valves.** *Hunterian. B. 36.*

A portion of the aorta slightly dilated and atheromatous. The patches present a cicatricial appearance. The aortic valves are thickened and contracted, so that in life the valve was probably incompetent.

**11. 39. Dilatation of the Abdominal Aorta. Atheroma.
Cicatricial Appearance.** *Hunterian. KK. 11.*

"A portion of the descending aorta slit open to show the inner surface becoming aneurismal, irregular, and fasciculated." (Matthew Baillie's *Engravings*, Fasc. I., Pl. IV., fig. 3.)

**11. 40. Dilatation of the Aorta and Innominate Artery.
Atheroma with Calcareous Infiltration.**

Jeffray Collection.

The arch of the aorta laid open, showing atheroma very general and advanced in the first part and less marked beyond the origin of the left subclavian. There are two or three atheromatous ulcers and numerous calcified patches, some of the plates projecting through

the intima. The innominate and left carotid rise by a common trunk, which is highly atheromatous, and dilated for about 3 cm. from its origin.

11. 41. Globular Aneurism of the Root of the Aorta, pressing on the Pulmonary Artery. *Hunterian. KK. 1.*

"The adult human heart. An aneurism about the size of a large cherry is seen opened in the trunk of the aorta, just as it arises out of the left ventricle." The aneurism communicates with the aorta by an orifice, 6 mm. in diameter, about 3 cm. above the valves. It lies between the auricular appendage of the right auricle and the pulmonary artery, and presses on the latter so as to bulge it inwards, but there is no perforation. The aorta is atheromatous and considerably thickened. There is a small stratified thrombus in the sac. "Case, Mr. Adair's patient" (unknown).

11. 42. Aneurisms of the Ascending Aorta and Arch. Rupture into the Pericardium and Chest.

Hunterian. S. 57.

"The aorta ascendens slit open to show its inner surface formed into aneurismal sacs of the size of a small walnut. One of these had burst, and the patient died of internal haemorrhage into the cavity of the chest as well as the pericardium." The first of the sacs, probably the one which burst (though both had been opened in preparation), opens just above the valves by an oval aperture about 2 cm. in its longest diameter. The second, not so large or so globular, is situated in the concavity of the arch just about the beginning of the aorta descendens. The aorta is slightly atheromatous; the valves are healthy.

11. 43. Double Aneurism of the Aorta. *Hunterian. KK. 4.*

"An aneurism of the aorta ascendens, about the size of a child's head at birth, cut open: a small aneurismal sac unopened is seen below the great one, size of a gooseberry." Both aneurisms are on the convexity of the aorta before the origin of the great vessels, and communicate with it by small openings. The greater part of the sac of the large one has been cut away. The aorta is atheromatous and dilated generally.

11.44. Aneurism of the Aorta.*Hunterian. KK. 2.*

"The trunk of the aorta, from an adult; aorta ascendens seen aneurismal about the middle of its arch; the sack equal to a child's head at birth; the upper side full of lamellated, firmly coagulated blood; the upper contained fluid blood, and is now empty." Besides the large saccular aneurism, the aorta presents a fusiform dilatation, about 6 cm. in diameter, extending from the valves to the origin of the innominate artery. From the front of this dilatation, about 3 cm. from the origin of the innominate, the globular aneurism rises by a round orifice about 2 cm. in diameter. The aorta is highly atheromatous, with numerous calcareous plates. There is no coagulation in the fusiform dilatation, and the orifices of the large vessels are clear.

11.45. Aneurism perforating the Chest Wall.*Hunterian. KK. 3.*

"The anterior half of the same sac (the preceding specimen) adhering to the sternum and cartilages of four true ribs." The sternum and second and third right ribs are eroded, and the aneurism passes out in the second interspace and forms an oval sac on the outside, 7 cm. by 4 cm. by fully 1 cm., with thick walls, and filled with laminated coagulum. Where the aneurism has encountered bone, the sac, as usual, has atrophied, till at last the bone lay bare to the blood, and the edges of the sac are firmly united with the periosteum.

11.46. Aneurism of the Aorta.*Hunterian. KK. 2a.*

"An aneurism of the arch of the aorta about the size of an orange: the two carotids are separated two inches from each other by the distension of the bag behind; an opening has been made, showing coagulated blood." The thrombus can be seen from the orifice of the aorta, almost completely obstructing it, and completely filling the aneurism. The sac rises from the arch of the aorta in such a way that the whole of the great vessels are more or less affected at their origins. The right carotid and subclavian rise close together from the apex of the sac, rather to the right side, as if it were partly an aneurism of the innominate. They have been cut open, and are both very nearly if not quite obstructed by a mass of laminated clot which lies across their mouths, but hardly at all

extends into them. The left carotid and vertebral arteries are stretched over the sac and are patent, though the thrombus can be seen almost covering their origins. The left subclavian rises from the aorta, just clear of the sac. (Matthew Baillie's *Engravings*, Fasc. I., Pl. III., No. 2.)

11. 47. Penetration of the Chest by Aneurism. Erosion of the Ribs.

Hunterian. KK. 5.

"The anterior half of an aneurism, with a portion of the ribs and sternum. It appears larger than No. 3 (No. 11.45), and to have continued longer, for the ribs are in some places totally obliterated." The perforation is through the first and second right intercostal spaces, the second rib being almost totally destroyed, and the first and third ribs and the sternum considerably eroded. The internal sac is 11 cm. in diameter, and the outer fully as large; the aperture between them 9 cm. by 3 cm. below, and rather less above, the second rib. At the edges the sac is firmly united with the periosteum.

11. 48. Laminated Thrombus ejected from an Aneurism after Penetration of Chest and Sloughing of Skin.

Hunterian. S. 3a.

The corresponding aneurism is lost. The case is fully described by William Hunter: "The History of an Aneurysm of the Aorta, with Some Remarks on Aneurysms in General" (*Med. Obs. and Inq.*, Vol. I., p. 323). The patient, a staymaker, aet. 39, attributed the disease to a strain at his work while weak after an illness, nine months before the appearance of the external swelling—about three years before his death. The symptoms were at first uneasiness in the chest; later, pain in the region where the swelling afterwards appeared, darting into the right shoulder; teasing cough, "great anxiety and labour in his chest, and difficulty in breathing." When first seen, he had an oblong swelling between the costal cartilages of the second and third ribs of the right side, 2 inches by 1½ inches by ½ an inch high. The skin was not discoloured. The tumour was hard; could be made nearly to disappear on pressure, but with a good deal of pain and oppression. There was a strong pulsation synchronous with the heart. The pulse was regular; for some months it was wanting in the left arm and temple,

returning later; but in this side it remained always weaker than in the right. Some months before his death the skin began to be discoloured and oedematous, and about six weeks before his death a blister formed and burst. Finally, an area about the size of a shilling died about a fortnight before his death and began to separate; and blood began to ooze from the fissure around the edges of the slough. "The day before he died it was seen that the slough adhered to a large plug of blood-clot, which served as a plug to the orifice. Next morning there was pretty severe hæmorrhage, which was arrested by pressure. A few hours later he was seized with coughing; and, on trying to turn himself in bed, the plug started out with such force as to strike against the foot of the bed, and he died instantly. From the illustration the aneurism is seen to have been a large fusiform one of the whole arch, with a projecting sac in front which pierced the chest, and behind, it pressed on and eroded the bodies of the vertebrae. The edges of the sac adhered strongly to the periosteum. There were "many small ossifications" in the wall of the vessel (*i.e.* atheroma with calcareous infiltration). It had also almost penetrated the trachea. A dark mark on the thrombus indicates the point at which the slough adhered to it.

11. 49. Perforation of the Sternum by Aneurism.

Hunterian.

Dried preparation of part of the ribs, sternum, and intercostal muscles, showing a large hole—irregularly circular in shape, and measuring about 6 cm. in diameter—through the sternum, which is almost divided just below the junction of the manubrium and gladiolus. The second and third costal cartilages are very slightly eroded, and have been pressed aside so that the end of the third rests on the fourth, and that again on the fifth. This may have belonged to the same case as the preceding, but there is no plate of the sternum and ribs, and the description is not full enough to identify it absolutely. As to such lesions of the bones as appear in this specimen, William Hunter wrote (*loc. cit.*, pp. 344 and 348): "The injury that happened to the sternum and vertebrae in the above case was different from a common caries; for in such cases, where there is loss of substance in a bone, there is something analogous either to ulceration or mortification. But in this case the appearance was rather as if the blood had insensibly

dissolved and washed away the substance of the bone, making the greatest havock in the softest parts of the bone, as we see in stones of unequal texture that have long been washed by a dropping or a stream of water." As to the remarkable resisting powers of cartilage in such circumstances (compare No. 11.58), he says: "Of all animal substances gristle, perhaps, is the least affected by pressure in the living body. This seems probable from the known structure and uses of the joints, but was particularly evinced by the above case. The constant pressure of the sternum had destroyed the coats of the artery, the periosteum, the bone, the muscles, the tendons, the cellular membrane, the skin, in short, everything that was in its way, except the cartilaginous parts of the ribs."

11.50. Large Aneurism of the Innominate Artery.

Hunterian. KK. 7.

"A portion of the arch of the aorta, with a very large aneurism in the right subclavian; one half of the sac full of concentric lamellae of firm blood—the other empty as having contained either fluid or half-coagulated blood." The specimen consists of half of the aneurism ("the smaller most anterior half") and laminated coagulum. The aorta is above, the specimen being hung upside down. Between the old firm thrombus and the wall is a layer of soft recent blood-clot; the centre of the coagulum is also soft, though stratified: the wall of the sac seems to be lined by a thin firm lamina of white thrombus, on which the recent clot is deposited.

11.51. Aneurism of the Aorta. Atheroma with Calcareous Infiltration. Obliteration of the Left Carotid.

Hunterian. B. 28a.

"A portion of the trunk of the aorta internally much ossified and aneurismal. The trunk of the right carotid and subclavian is nearly an inch distant, at its origin, from that of the left carotid, whose origin is covered with the ossification internally, and the artery shrunk and obliterated. The ossification goes right round the artery, and is an inch broad, and apparently thick and strong." A very extreme degree of atheroma with calcareous infiltration. The aneurismal dilatation is not great. The specimen

illustrates the tendency of atheroma to obstruct the branches of arteries at their origin; also the contraction of an artery into a fibrous cord, which occurs after obliteration by any cause. Compare Nos. 11.22 and 11.23, Obliteration of Arteries by Ligature.

11.52. Large Aneurism of the Arch of the Aorta.

Dr. Allen Thomson's Collection.

The specimen consists of the heart, trachea and thyroid gland, oesophagus, aorta with a large aneurism rising from its arch, and parts of the left first rib and left lung. The ascending aorta, the origin of which can hardly be seen from the outside for the sac pressing on the heart, enters into the bottom of it by a somewhat oblique aperture, and about 5 cm. to the left of this the descending aorta passes out. The large vessels all arise from the sac—the innominate and left carotid at such acute angles that they must have been considerably obstructed. The vena cava superior is seen stretched over the top of the lower division of the sac. The sac is constricted in its upper third, and the portion of rib which remains shows that the larger, lower sac, measuring 15 cm. broad by 11 cm. deep by 12 cm. high, lay in the thorax, and the smaller, measuring 7 by 7 by 6 cm., lay in the neck, reaching up to the lower border of the thyroid gland. The trachea and oesophagus are pushed to the side, but are not adherent to the sac. The walls of the aneurism are thick, and lined with laminated coagulum. The heart is hypertrophied, and, to judge by the way the aneurism presses down on it, must have been considerably displaced downwards and to the left. There was a large gap in the front of the upper division of the sac through which it had been stuffed; whether rupture had occurred or not it was impossible to determine. The anterior wall of the sac has been cut away to show the interior. It is an expansion of fully three inches of the aorta in an upward and forward direction.

11.53. Aneurism of the Aorta projecting into the Lung. Rupture into Bronchus.

Dr. Allen Thomson's Collection.

The heart, aorta, bifurcation of the trachea, and part of the upper lobe of the left lung, the aorta opened from behind. From

the top of the arch an aneurism, about the size of a tangerine orange, rises and projects upwards and outwards into the upper lobe of the left lung, which is considerably compressed. The lung containing the sac and the bronchus of the lobe are laid open, and a black rod passed from the sac through one of the smaller bronchi into the main bronchus shows the manner in which the case terminated. The branch of the bronchus actually opened is quite a small one. Beside this aneurism, and communicating with it by a hole in the partition between them, rises another aneurism which separates the two carotids and presses on their origins; it communicates freely with the aorta. This aneurism is partly filled with firm coagulum; the one which burst contains only a few flakes of soft fibrin.

11.54. Aneurism of the Descending Aorta.

Hunterian. KK. 8.

"A section of the superior portion of the aorta from its origin out of the heart to its passage through the diaphragm. Just as it passes the root of the lungs it dilates into an aneurismal sac capable of containing one's fist. The orifice leading from the aorta into this cavity is about one half inch (12 mm.) long and one inch (25 mm.) broad, making an oval; it had formed a bed for itself in the posterior side of both lobes of the lungs, and was at first sight mistaken for a vomica (phthisical cavity) by the pupils (case unknown)."

11.55. Aneurism of the Descending Aorta.

Hunterian. KK. 9.

The other half of the preceding specimen, with a portion of the lungs still adhering. It contains a thin lining of fibrin.

11.56. Portion of a Dissecting Aneurism of the Abdominal Aorta.

Hunterian. KK. 14.

"The whole aorta descendens aneurismal, and divided into two longitudinal portions; its diameter every way about three inches (about 7.5 cm.), especially about the middle; it became less going downwards. From the dissecting room." The specimen consists of the lesser portion of the aneurism. The tunica intima

has split away from the tunica media, and the space between them is occupied by coagulum. The intima forms a delicate lining to the clot, and is torn in several places. There are numerous calcareous plates on the surface of the tunica media. There has been a rupture, with formation of a false aneurism outside, at the point indicated by the bristle.

11. 57. Aneurism of the Descending Aorta.

Hunterian. KK. 33.

"The greater part of the aorta, where there had been an aneurism near the coeliac artery; there is an opening behind with a small quantity of coagulum. The bag seems to have been cut away. (Case, I believe, Dr. Cooper's)." This reference could not be traced. The orifice of the aneurism measures about 2 cm. by 8 mm., is right at the back of the artery, and is decidedly above the level mentioned; it is in the thoracic aorta. Compare next specimen.

11. 58. Erosion of the Vertebrae by Aneurism.

Hunterian. KK. 34.

"Four dorsal vertebrae, where the bodies have been absorbed from the pressure of an aneurism, and even the canal of the spinal marrow laid bare; the intervertebral substance is entire, being less liable to be affected by pressure. This, I believe, belongs to the aneurism of the last number." The vertebrae are between the fifth and tenth—probably sixth to ninth dorsal. As the sac of the last specimen is wanting, it is impossible to decide absolutely whether they correspond; but an aneurism, rising as the previous specimen does, from the back of the aorta would press on the vertebral column in just such a manner as to produce the condition shown here. The specimen illustrates very strikingly the power of resistance to pressure which cartilage and inter-articular fibro-cartilages possess. The surface of the eroded bone is unusually porous. It would have been interesting to know the extent to which the spinal cord had been affected by the pressure of the aneurism upon it through the gap in the spinal canal. William Hunter in his paper on aneurisms in *Med. Obs. and Inq.*, Vol. I., p. 323, speaks of aneurism invading the vertebral canal, and causing even fatal compression of the spinal cord. Compare No. 11.49.

11. 59. Erosion of the Vertebrae by Aneurism. *Hunterian.*

Dry specimen of the upper dorsal vertebrae (2nd to 9th), illustrating the above; the erosion not so deep as in the preceding specimen. The bone presents a fairly dense surface. The cartilages have shrunk so much in drying that it is impossible to say what has been their condition; the cancellous bone of the bodies of the vertebrae has suffered more than the solid articular plates. The erosion affects the 3rd, 4th, 5th, and 6th dorsal vertebrae.

11. 60. Aneurism of the Descending Aorta. Rupture. Extravasation into the Retro-peritoneal Tissue of the Abdomen. *Hunterian. KK. 10.*

The anterior half of the sac of an aneurism of the aorta descendens, about the size of an orange, situated just above the diaphragm, which was depressed by the tumour, extending to within 1 cm. of the origin of the coeliac axis. The sac was round in shape, and partly filled with firm laminated coagulum. The posterior section is amissing; it pressed on and eroded the 2nd, 3rd, and 4th lumbar vertebrae, which lay bare in the cavity of the aneurism. Rupture occurred close to the bone at the lower border of the erosion, and the blood passed down under the arch of the diaphragm, and lay in a mass, four or five pounds in weight, on the right side of the vertebral column. It also passed between the layers of the mesentery and omentum, so that the viscera presented the appearance of an almost "universal mortification." Patient's symptoms consisted of praecordial oppression, slight cough, laborious respiration, and severe pain in the back. There was visible pulsation in the epigastrium, even the sternum rising and falling synchronously with the heart; the legs and scrotum were oedematous. He died suddenly on raising himself in bed. The abdomen was found full of ascitic fluid. It is mentioned that the last rib on the right side was eroded, but at this point extravasation was prevented by firm adhesion between the sac and the periosteum. "Case, Mr. Bayford's, published." (*Med. Obs. and Inq.*, Vol. III., p. 14, with plate.)

11. 61. Aneurism of the Innominate Artery.*Hunterian. KK. 10a.*

From the same subject as the preceding specimen. It forms a globular sac about the size of a walnut, with a round mouth,

about 1 cm. in diameter, springing from the lower surface of the innominate just about its bifurcation. The sac is fairly thick, and is lined with firm laminated thrombus.

11. 62. Stratified Coagulum from the preceding Aneurism.

Hunterian. KK. 10b.

Aneurisms of the Arteries of the Limbs.

11. 63. Aneurism of the Femoral Artery.

Hunterian. KK. 32.

An aneurism apparently in the femoral artery, which appears to have been opened rather irregularly. The cavity has been filled with rather soft blood-clot, and there is a good deal of blood-clot outside it, as if there had been rupture and extravasation into the tissues. Two bougies have been put into the artery, above and below the aneurism. There is a smaller aneurism about the size of a hazel-nut, almost 4 inches below, which is filled with blood-clot.

11. 64. Aneurism of the Femoral Artery. *Hunterian. KK. 20.*

"A very large aneurism in the thigh, in the middle of the femoral artery; the artery above and below the orifice slit open to show that everywhere else it is sound." The transverse markings are too prominent, as if calcareous infiltration were present in the middle coat. The orifice is oval, 2.6 by 3 cm., and leads into an aneurism of the whole calibre of the artery, as big as a walnut; the sac of the large aneurism has been cut away, all except a small piece to the right of the orifice, but the succeeding specimen shows it to have been very large. The artery is quite as sound close to the aneurism as it is at some distance from it.

11. 65. Large Coagulum from the preceding Aneurism.

Hunterian. KK. 21.

A section of a firm stratified thrombus, formed in concentric lamellae, and much larger than a child's head at birth, showing the size of the preceding aneurism.

11. 66. Aneurism of the "Posterior Tibial Artery."*Hunterian. KK. 24.*

"An aneurism in the opposite leg of the same man to whom the preceding aneurism of the femoral belonged." (No. 11. 65.) The posterior tibial nerve is seen stretched over the sac. The sac is fully 10 cm. in diameter, filled with laminated coagulum, and it is pushing through between the tibia and fibula, which do not seem to have been pressed apart, though it is impossible now to determine this point. Both are eroded; the sac is very loosely adherent and thin round the edges of the erosion. The tibia has grown out into a ridge in front of the erosion on its inner surface. A portion of the femoral artery slit open is stitched to the tibia; the manner in which the vessels communicated with the aneurism cannot now be seen, but the anterior tibial rises just above the sac, and passes through between the bones, which proves this to be an aneurism of the posterior tibial.

11. 67. Aneurism of the Popliteal Artery.*Hunterian. KK. 24a.*

The lower end of the femur and upper ends of the tibia and fibula, with an aneurism of the popliteal artery, seated just above the knee-joint, and pressing between the condyles of the femur. The sac, which is thick and fibrous, and contains some stratified blood-clot, has been split open laterally, and the posterior half, with the artery, turned inwards. The artery, in which a bougie has been placed, communicates with the aneurism by an oval orifice, measuring 15 by 5 mm. On the other side the artery is seen to be dilated in a fusiform manner, and it has been opened behind to show the interior of this dilatation. "Case amputated, Bartholomew's Hospital; Mr. Pott's; died."

*Laminated Coagula from Aneurisms.***11. 68. Laminated Coagulum from Aneurism. Dissected.***Hunterian. KK. 16.*

Formed in distinct broad laminae easily separated from one another.

11. 69. Laminated Coagulum from Aneurism. Partly dissected.

Hunterian. KK. 18.

The clot is firmer than the last, but the laminae are easily separable. (Matthew Baillie's *Engravings*, Fasc. I., Pl. IV., fig. 1.)

11. 70. Laminated Coagulum from Aneurism.

Hunterian. KK. 19.

11. 71. Laminated Coagulum from Aneurism.

Hunterian. KK. 30.

Dense and firm, but has been partly dissected into its original laminae.

11. 72. Old Laminated Coagulum from Aneurism.

Hunterian. KK. 23.

Very dense and fleshy, but showing distinctly that it has been formed in concentric lamellae.

11. 73. Old Laminated Coagulum from Aneurism.

Hunterian. KK. 22.

11. 74. Laminated Coagulum from Aneurism.

Hunterian. KK. 26.

The outer layers are very dense, but inside some of the clot has a more recent appearance. Besides the usual white thrombus there are some brown streaks, which indicate that the red corpuscles have been included in the coagulation.

11. 75. Laminated Coagulum from an Aneurism.

Hunterian. KK. 25.

Part of the sac is included in the specimen, and at the lower part of the section the thrombus is very intimately united with it, as if organization were proceeding in its outer layers.

11.76. Mixed Coagulum from Aneurism. *Hunterian. KK. 35.*

A fairly recent clot, showing numerous laminae of fibrin of the customary white colour, and also masses of looser roughly-stratified brown thrombus, which is recent clot with inclusion of a considerable proportion of the red corpuscles.

*Diseases of the Veins.***11.77. Inflammation of the Veins. Phlebitis after Bleeding.**
Hunterian. C. 17.

"A portion of the median basilic slit open, from a patient who died in the London Hospital from the inflammation of the vein after bleeding. A crust of coagulated lymph is seen lining the vein."

11.78. Old Thrombus from Vein. *Hunterian. A. 10.*

"Coagulated laminated blood from the popliteal vein of an elephant, externally smooth, of pyriform shape, about the size of one's thumb; and internally, as appears from the section, made up of concentric laminae. When found it was of considerable hardness and seemed of long standing." Such thrombi are common in veins, and usually occur about the valves.

11.79. Haemorrhoids and Fistula in Perinaeo.*Hunterian. R. 60.*

"The anus from an adult body in the dissecting room; shows also the perinaeum; round the verge of the anus some piles are opened, and appear to be varicose veins on the little valvulae within the anus (folds of the mucous membrane) elongated. Two bristles also point out two fistulous orifices leading to an ulcerating cavity on the fore part of the rectum and diverging towards each tuberosity of the ischium."

11.80. External Haemorrhoids.*Hunterian. R. 60a.*

The anus showing a number of the above unopened.

- 11.81. Anus turned inside out to show small Projections of the Mucous Membrane like Incipient Haemorrhoids.**

Hunterian. R. 60b.

V. TUMOURS OF THE BLOOD-VESSELS.

- 11.82. Angioma of the Skin. Naevus.** *Hunterian. C. 19.*

Not described in old catalogue. A portion of skin, subcutaneous tissue, and muscle, the skin dissected away in the centre, showing a number of rounded bodies like hemp seeds, which in section are seen to be thin-walled blood-vessels filled with clot, and microscopic examination reveals the typical structure of an angioma. The tumour seems to have occupied the whole thickness of the skin and subcutaneous tissue. (MS. Notes, J.H.T., p. 33.)

SERIES 12.

ANATOMY OF THE LYMPHATIC SYSTEM.

<i>Lymphatic Vessels and Glands in general,</i>	1-16
<i>The Thoracic Duct,</i>	17-21
<i>The Lymphatics of the Limbs,</i>	22-25
<i>Genital Organs,</i>	26-34
<i>Heart,</i>	35-36
<i>Lungs,</i>	37-44
<i>Liver,</i>	45-53
<i>Spleen,</i>	54-57
<i>Stomach,</i>	58-65
<i>The Lymphatics of the Intestines—</i>	
<i>Human and Mammalian,</i>	66-92
<i>In the Turtle,</i>	93-111
<i>In Fish,</i>	112-122

The following 122 specimens comprise the two old series D. Absorbent System, and QQ. Absorbents Particularly. In the old catalogue the specimens were not arranged in any definite order in either series. It has therefore been deemed better to put them all into one series, and arrange them systematically to illustrate, first, some points in the anatomy of lymphatic vessels and glands in general, which can be seen with the naked eye or with simple magnifying glasses; and, second, the distribution of these vessels in the various organs of the body in man and animals. A large proportion of the specimens is taken from the lower animals; these have been placed, according to the particular part of the body from which they came, along with those from the same part of the human body, this arrangement being considered more instructive than making separate human and comparative series would be. As a

demonstration of the whole lymphatic system, or even of William Hunter's knowledge of it, the series is, of course, very far from being complete; still it should be of very great value to students by calling their attention to a most important system, of which, from special methods (and these, too, little practised now) being required for its demonstration, they as a rule see very little, and which in consequence they are apt to neglect and regard as unimportant. The historical interest of the specimens is also very great, on account of the part they played in the investigations of the lymphatic system by William Hunter and his famous assistants, John Hunter, Hewson, and Cruikshanks, whose work on this system is discussed in the historical introduction to the catalogue.

I. SPECIMENS ILLUSTRATING THE STRUCTURE OF LYMPHATIC
VESSELS AND GLANDS IN GENERAL.

12.1. A Large Lymphatic Vessel. *Hunterian. D. 43.*

A portion of the thoracic duct, "from the adult human subject," injected with mercury and mounted in turpentine. The upper third of the specimen is black from having lain only partly immersed in the mounting fluid. Below this point there is a dilatation of the vessel, indicating the presence of a valve. The sinuses into which these vessels, like the veins, are dilated above the valves, and the lines of attachment of the valves, can be clearly made out. A number of little tubercles project from the vessel, which, "examined with a glass, are evidently formed by valves where a vessel had been entering in." These valves prevent the escape of the mercury, as, in life, they prevented the regurgitation of lymph.

12.2. Lymphatic Vessels showing Valves. *Hunterian. D. 37.*

Portions of two lymphatic vessels injected with mercury and mounted in turpentine on a black card. "Their most depending extremities show two pairs of valves preventing the quicksilver from escaping." Looking into the ends of the vessels, the two pouches of the valve are clearly seen, distended with mercury, in shape somewhat like a cloven hoof. They are of the type of semi-lunar valves, as in the veins; compare Nos. 12.9 and 12.10.

12.3. Lymphatic Vessel. *Hunterian. D. 30.*

Not described in the old catalogue. It has been injected with mercury, but has broken and the mercury has fallen out. The

beaded appearance characteristic of these vessels, which is produced by the numerous valves, is very well shown. In turpentine.

12.4. Lymphatic Vessel.

Hunterian. QQ. 15.

A lymphatic vessel in the mesentery (lacteal) dividing into several branches and entering a gland. The beaded appearance at the valves is very distinct. They are not so numerous as in the last specimen, and are placed at irregular intervals. Injected with mercury. From "a dropsical body."

12.5. Lymphatic Vessels. Lacteals.

Hunterian. D. 66.

"Some absorbents, injected with mercury on the intestine of the Neel Ghaw" (Nylgau). They are very large, and the valves very numerous and distinct. Mounted on glass in turpentine.

12.6. Lymphatic Vessel.

Hunterian. D. 27.

"From the unimpregnated uterus of an ass." Injected with mercury and mounted in turpentine. The mercury now fallen out.

12.7. Lymphatic Vessels and Gland.

Jeffray Collection.

Four long lymphatic vessels injected with mercury and mounted on a white card in turpentine, showing the characteristic beaded appearance and the manner of branching and entering a gland. The valves are set at very various intervals.

12.8. Structure of Lymphatic Vessels. Thoracic Duct of Horse.

Hunterian. D. 34.

"A portion of the thoracic duct from a horse, stretched on a glass cylinder and inverted; by this means it was separated into two coats—an internal smooth floating one like that of the arteries; an external fibrous and consequently muscular one, the fibres in all directions, but principally circular";—the latter includes the tunica media or muscular coat and the tunica externa or fibrous coat.

12.9. Structure of Lymphatic Vessels. Thoracic Duct of Horse. Valves.

Hunterian. D. 29.

A portion of the duct with two valves, the lines of attachment of which to the walls are clearly traceable from the outside. At the

upper end, through a window cut in the side of the vessel, is seen the crescentic free edge of a valve. The duct is about 1 cm. in diameter. "It was injected with spirit of wine, in consequence of which it now retains its rounded figure."

12.10. Valves of the Lymphatics. Thoracic Duct of Horse.

Hunterian. D. 45a.

"The thoracic duct of a horse inverted, and then filled with red injection"; a single pair of valves near its lower end indicated by bristles. They appear as thin crescentic membranes stretched out on the inner coat of the vessel, the concave edge of the crescent representing the free edge of the valve. The attachment runs up about 1 cm. above the bottom of the cavity of the valve, which is shown by the bristle introduced into it. Compare Nos. 10.52 to 10.54, Valves of Veins.

12.11. Lymphatic Gland.

Hunterian. D. 47.

"An absorbent (lymphatic) gland from a child's neck"; the arteries are injected red. The gland has been laid open; in the section it appears fleshy and exceedingly vascular.

12.12. Lymphatic Gland. The Lymph Spaces exaggerated by Injection with Mercury and Drying. Horse.

Hunterian. D. 58.

"An absorbent gland from near the spleen of a horse." "The absorbents (lymphatics) entering the gland and the absorbents which pass out were all filled with quicksilver by one injection. After the gland had been dried a year, it was divided longitudinally, and the mercury escaped." Intended to show the cells of the gland. The adenoid tissue has all dried up, and the gland now consists of spaces, separated by thin partitions, freely intercommunicating. Gives a very rough demonstration of the cells or lymph spaces, which lie between the trabeculae and the adenoid tissue.

12.13. Lymphatic Vessel and Glands.

Hunterian. D. 51.

A large lymphatic ("absorbent") vessel injected with mercury, entering and leaving a gland. The gland substance has almost

entirely disappeared in drying, so that it looks like a bunch of lymphatic vessels. "The substance of the gland is so little perceptible, that it looks as if the vessel subdivided and reunited only, without the least intervention of the fleshy substance." Compare No. 12. 11. In turpentine.

12. 14. Lymphatic Vessel and Glands. *Hunterian. D. 56.*

Two lymphatic glands injected with mercury, showing the afferent lymphatic breaking up and entering the gland at several points and the efferent vessel leaving it, also by several branches. In turpentine.

12. 15. Lymphatic Vessels and Glands. *Hunterian. D. 56a.*

Similar to the preceding. In turpentine. See specimens Nos. 12. 4 and 12. 7, and numerous specimens later in the series, for illustrations of the relation of the afferent and efferent vessels to the glands, *e.g.* Nos. 12. 23 and 12. 24.

12. 16. Vasa Vasorum of the Lymphatics.

Hunterian. D. 41.

"An absorbent which had formerly been filled with mercury and dried, now cut open to show the valves in the manner of Ruysch." It has been taken from a finely injected subject, and shows some minute arteries running in its wall longitudinally and connected by transverse branches. In turpentine.

II. THE DESCRIPTIVE ANATOMY OF THE LYMPHATIC SYSTEM
OF VESSELS AND GLANDS.

(a) *The Thoracic Ducts.*

12. 17. The Thoracic Duct.

Hunterian. QQ. 74.

"One of the largest and most perfect thoracic ducts perhaps ever injected (1770). It is filled with quicksilver; is about sixteen inches long; in many places larger than a goose quill, smaller about

the middle, where for an inch or two it is double, forming an island ; it begins by three trunks—one from each leg and one from the mesentery ; the largest trunk lies under the aorta, a little above its bifurcation into the iliacs—and is as thick as one's little finger ; this trunk belongs to the left leg ; the trunk from the right is smaller, but appears previously to have united with the last lower down ; that from the mesentery is nearly as large as a goose quill ; the duct also enlarges above the middle, and splits into several branches before it terminates in the angle between the left jugular and subclavian veins : these veins are filled with green wax, which appears evidently to have been prevented from entering the duct by a pair of valves at the mouth of the duct, so that the quicksilver of the duct terminates in a wedge-like edge passing between the distended valves." The mercury has escaped from parts of the specimen.

12.18. The Centre of the Lymphatic System: Thoracic Duct, Right Lymphatic Ducts, and Lymphatics of the Thorax from behind. *Hunterian. D. 59.*

The lymphatics have all been injected with mercury, but it has fallen out of a number of them. The specimen is rather complicated : in the centre lies a portion of the arch of the aorta with the innominate artery running up to the right, and the left carotid to the left ; the left subclavian has been cut away. Below, in the middle line, is the oesophagus with a quill passed through it : to the right and left are the two bronchi laid open just as they divide into their branches. The thoracic duct, of very large size and now empty of mercury, is seen coming up from the abdomen ; and, after receiving the lymphatics of the left lung and two large branches (which cross behind the oesophagus) from the right lung, runs up to join the left subclavian along with lymphatics from the heart and left upper limb and side of head and neck. The lymphatics from the right lung and most of those from the heart pass up—partly in what looks like a broad plexus of small vessels, but is probably injected glands, partly by a couple of fairly large vessels—to join the lymphatics of the right upper limb and side of head and neck, and terminate in the right subclavian vein as the right lymphatic duct (or ducts, as there are several here). There is only a small piece of each subclavian and jugular vein, and it is laid open. Mounted in turpentine on white paper.

12. 19. Thoracic Duct terminating in the Right Subclavian Vein. *Hunterian. QQ. 75.*

"The spine of a child at birth, arteries injected red ; along the spine is seen the thoracic duct injected with quicksilver and terminating in the right subclavian instead of the left. The tallowy injection thrown into the arteries and veins had got into the thoracic duct, having dropped the colour. This was melted out in hot water, and quicksilver thrown into the duct in its stead." In turpentine.

12. 20. The Thoracic Duct in the Cat. *Hunterian. QQ. 76.*

"The thoracic duct in the cat, filled with quicksilver, lying on the spine and terminating both in right and left subclavians, but chiefly in the left. It appears triple all the way instead of single as in men : the valves in that branch which goes towards the right are exceedingly distinct and numerous." In turpentine.

(b) The Lymphatics of the Limbs.

12. 21. Lymphatics of the Foot. *Hunterian. QQ. 1.*

"The great toe of the right foot, with the metatarsal and tarsal bones in the same line ; the external integuments are removed ; the tendons of the tibialis anticus and extensor pollicis longus are exposed ; on the outside of the first bone of the great toe appear some absorbents filled with mercury ; these run up with the afore-said tendons over the ankle-joint to get upon the foreside of the tibia and inside of the thigh, as will be seen in No. 1. of the dry preparations." The dry preparations are unfortunately not in the collection now.

12. 22. The Superficial Lymphatics of the Leg: Inguinal Glands and Vessels. *Hunterian. D. 53.*

"A number of absorbent glands from the groin, with the absorbents passing in and out." The specimen shows seven or eight lymphatic glands, of various sizes, connected by a plexus of vessels, injected with mercury and mounted on black paper ; in turpentine. The vessels present the characteristic beaded appearance. The afferent vessel breaks up into a number of small branches which enter the gland at several different points, and the efferent simi-

larly rises by several branches which almost at once unite into one vessel. The glands look as if made up of globules of mercury enclosed in minute vesicles, an appearance due to the overdistension of the lymphatic spaces and the shrinkage of the fleshy adenoid tissue in drying.

12. 23. The Lymphatic Vessels and Glands "of the Groin."

Hunterian. D. 54.

Six or seven lymphatic glands and their vessels injected with mercury, similar to the preceding. In turpentine. The lymph spaces of the glands less completely injected.

12. 24. The Lymphatic Vessels and Glands of the Groin.

Hunterian. D. 52.

"Eight or nine of the glands of the absorbents in the groin from the adult female subject; they are injected with quicksilver to great minuteness. The absorbents of the surrounding cellular membrane are even injected and passing into the glands. In some of these last, the mercury appears like a number of pin heads, showing the existence and size of the cells of the gland; in others, the vast numbers of smaller absorbents of the size of the finest human hair, covering the external surface of the gland, prevent us from seeing the cells which lie under them, and give the idea of the glands being a congeries of vessels—only some of these glands communicate not only with the glands lying before them, but with those of each side by collateral absorbents. The inguinal artery, though not injected, is seen running through the middle of this cluster of glands." Some of the lymphatic vessels pass before and some behind the artery, showing that the glands belong, partly at least, to the deep inguinal set. The specimen had at some time been placed in spirit. An attempt to make it fit for turpentine again was only partially successful, as the mercury sweated out so much that drying was stopped before it was complete. (J.H.T., 1896.)

12. 25. The Deep Lymphatics of the Lower Limb, accompanying the Femoral Artery.

Hunterian. QQ. 2.

"The femoral artery, or that part of it which reaches from the groin to the ham; on its outside clings an absorbent, the

trunk of the deep-seated ones of the leg; it is filled with mercury, in some places almost as large as a goose quill, is sometimes double, sometimes triple, but higher up becomes single; it appears now very tortuous, as if much longer than the artery, but the artery is much shortened from its elasticity." This vessel terminates in the deep inguinal or internal iliac glands, which do not appear in the specimen. Several little projections show where it received small tributaries.

(c) *The Lymphatics of the Genital Organs.*

12.26. The Lymphatics of the Testicle. *Hunterian. D. 26a.*

A testicle and spermatic cord mounted on mica; the epididymis contains a mass of small lymphatics, which unite into five large vessels, running up the cord for about 20 cm. They are of various lengths, owing to the specimen having partly broken down and been remounted.

12.27. The Lymphatics of the Testicle. *Hunterian. QQ. 3.*

The lymphatics of the testicle were usually demonstrated by injecting mercury into the body of the organ, from which it could only escape by the lymphatics (*via* the epididymis and spermatic cord), owing to the strong enveloping tunica albuginea. This specimen, however, was prepared by injecting the vas deferens and tubules till some of them ruptured, when the mercury was extravasated into the stroma of the gland, and found its way out by the usual path. The lymphatics of the testicle, as might be expected from its abdominal origin, go up to the lumbar glands, which, however, are not shown in the specimen. In turpentine on blue paper.

12.28. The Lymphatics of the Testicle. *Hunterian. QQ. 4.*

Similar to the preceding. In turpentine on mica.

12.29. The Lymphatics of the Testicle. *Hunterian. QQ. 5.*

Similar to No. 12.27. In turpentine on red paper.

12. 30. The Lymphatics of the Testicle. *Hunterian. QQ. 9.*

A testicle with one side removed; there is no mercury among the tubules; in the cord there are a number of lymphatics, filled with mercury, gradually uniting into two fairly large vessels.

12. 31. The Lymphatics of the Testicle. *Hunterian. QQ. 6.*

The epididymis injected with mercury, which has passed through the testicle by rupturing some of the tubules and filled a large lymphatic on the spermatic cord. At several points slices have been taken off the cord, allowing the mercury to escape, and parts of the vessel are now seen as empty spaces.

12. 32. The Lymphatics of the Testicle. Bear.*Hunterian. QQ. 8.*

Like the preceding specimens, it has been prepared by injecting the vas deferens till rupture of some tubules occurred, and the mercury, extravasated within the tunica albuginea, found its way out by the lymphatics. The pampiniform plexus of veins has been dilated with air before drying. In turpentine on mica.

12. 33. The Lymphatics of the Uterus in the Gravid Condition. *Hunterian. D. 25.*

"A section of the gravid uterus at the ninth month." The lymphatics of the uterus run down along the course of the hypogastric artery to about the level of the cervix, pass out by the broad ligament to the glands on the internal iliac artery, and up to the lumbar glands. In the unimpregnated uterus they are very small, but in the gravid state, as the specimen shows, they become very large; they are probably overdistended with mercury in this specimen.

12. 34. The Lymphatics of the Uterus. Superficial Set.*Jeffray Collection (?).*

There is neither history nor description of the specimen; but, from its shape and by microscopic examination, it has been determined to be uterus. There is a plexus of vessels, of various sizes, but mostly small, running just under the peritoneum, and converging

towards some larger vessels about the cervix (upper end of the specimen as it hangs). The direction in which the vessels run can be made out by examination of the valves, even without the aid of a magnifying glass.

(d) *The Lymphatics of the Heart.*

12. 35. The Lymphatics of the Heart. *Hunterian. QQ. 73.*

A small portion of the human heart; the lymphatics running in the subpericardial areolar tissue minutely injected with mercury. The main vessel to which they are seen to converge accompanies the coronary artery, of which the cut end is seen in the upper edge of the specimen.

12. 36. The Lymphatics of the Heart. *Hunterian. QQ. 71.*

"The human heart, with the absorbents of the right and left ventricles injected with quicksilver; the trunk from the right ventricle goes over the arch of the aorta on the forepart, passes between the two carotids, and gets into glands between the trachea and the arch of the aorta; the trunk of the left ventricle passes under the pulmonary artery, behind the arch of the aorta, to the same glands, and thence large vessels go either to the right or left subclavians, having joined the absorbents of the lungs." The main lymphatic of the left ventricle is cut away after passing between the branches of the pulmonary artery, the glands having been removed. The lymphatics of the ventricles are seen to converge to the courses of the coronary arteries. (This specimen is marked QQ. 75 on the jar, but there is another 75 to which the description corresponds; this specimen corresponds exactly with the description of QQ. 71.) In turpentine.

(e) *The Lymphatics of the Lungs.*

12. 37. The Superficial Lymphatics of the Lungs.

Hunterian. D. 21.

A thin slice of the outside of one of the lungs, showing the subpleural lymphatics injected with quicksilver. They form a fairly regular network, the course of the large vessels corresponding with the interlobular connective tissue underlying the pleura.

12. 38. The Superficial Lymphatics of the Lungs.*Hunterian. D. 21a.*

Similar to the preceding, but more minutely injected, the lymphatic vessels forming a very close network in the subpleural connective tissue. In turpentine.

12. 39. The Lymphatics of the Lungs, Superficial and Deep.*Hunterian. QQ. 13.*

A slice of the outer surface of the human lungs, with the lymphatics injected with mercury, as in the last two specimens; the cut surface also shows several of the deep lymphatics which accompany the blood-vessels and bronchi.

12. 40. The Lymphatics of the Lungs and Bronchial Glands.*Hunterian. QQ. 65.*

The specimen shows a network of superficial lymphatics, and a few of the deep ones accompanying the bronchi, converging to the root of the lung and passing into the bronchial lymphatic glands. Injected with mercury.

12. 41. The Superficial Lymphatics of the Lungs.*Hunterian. QQ. 68.*

"Lobe of the lung of a child at birth," covered with a network of lymphatics, injected with mercury. The arteries have been injected red. The lobulation of the lung is very distinct, and the lymphatic trunks run in the interlobular connective tissue.

12. 42. The Lymphatics of the Lungs. Lioness.*Hunterian. D. 33.*

The specimen shows several lymphatics in the subpleural tissue, injected with mercury, running towards the root of the lung. "A portion of the lungs of a lioness which died in the Tower, and had haemorrhage from the mouth and intestines; the absorbents were full of blood, which in the great trunks was coagulated and prevented the mercury thrown in by the smaller branches from getting on. So that the orifices of the absorbents may be visible in the microscope, since they admitted particles of the blood which

are so." It would reach them by extravasation into their radicles, the spaces of the areolar tissue. See under No. 12. 105.

12. 43. The Superficial Lymphatics of the Lungs. Porpoise.

Hunterian. QQ. 69.

The arteries are injected red, the lymphatics with mercury. There is not a network as in the human subject, but long vessels run towards the root of the lung, anastomosing freely in the earlier part of their course. In turpentine on white paper.

12. 44. The Lymphatics of the Lungs. Turtle.

Hunterian. QQ. 70.

The lymphatics, injected with mercury, are seen forming a very regular network in the subpleural tissue. In turpentine on red paper.

12. 45. The Lymphatics of the Lungs. Turtle.

Hunterian. D. 12.

A large slice of the exterior of the lung injected with mercury, the superficial lymphatics, as in the previous specimen, forming a fairly regular network; only the larger vessels injected. In turpentine, supported by a sheet of very thin wood. Not described in the old catalogue, but on the foot of the jar is cut, "Lymphatics Lungs Turtle."

(f) The Lymphatics of the Liver.

12. 46. The Superficial Lymphatics of the Liver.

Hunterian. D. 20.

A portion of the upper surface of the liver injected red by the arteries, showing the superficial lymphatics injected with mercury, forming a close arborescent plexus below the peritoneal covering of the organ. The larger trunks are seen running off into one of the ligaments on their way to the lymphatic glands. "The preparation appears natural, as the vessels are not dried."

12. 47. The Superficial Lymphatics of the Liver.*Hunterian. D. 26.*

A portion of the upper surface of the liver, showing a number of minute lymphatics in the subperitoneal connective tissue ending in a very large vessel. Injected with mercury.

12. 48. The Superficial Lymphatics of the Liver passing through the Diaphragm.*Hunterian. QQ. 59.*

A portion of the left lobe of the liver, from a boy 12 years old, injected red by the arteries. The lymphatics of the upper surface, injected with mercury and very numerous, are passing along to the left lateral ligament to perforate the diaphragm, by a portion of which the preparation hangs on one side. The trunks then either pass forwards along the pericardium to the anterior mediastinal glands, or backwards along the crus of the diaphragm to the thoracic duct. (While the wording has been altered for the sake of clearness, this description is, in substance, exactly the same as the original in the old catalogue.)

12. 49. The Superficial Lymphatics of the Liver. Upper Surface.*Hunterian. QQ. 61.*

A portion of the upper surface of the right lobe of the liver of the same subject as the preceding. The lymphatics (forming a very fine plexus) run in two diverging sets, each of which converges into two or three vessels of moderate size which pass through the diaphragm, and joining with those from the left lobe pass forwards along the pericardium to the anterior mediastinal glands, or backwards along the crus of the diaphragm to the thoracic duct. (Slightly altered from the old catalogue for the sake of clearness.)

12. 50. The Superficial Lymphatics of the Upper Surface of the Liver.*Hunterian. QQ. 62.*

Another portion of the upper surface of the right lobe, showing numerous lymphatic vessels running over the suspensory (falciform or longitudinal) ligament to join the vessels described in the last two specimens.

12. 51. The Superficial and Deep Lymphatics of the Liver.

Hunterian. QQ. 60.

Portion of the liver of an adult, the arteries injected red, showing part of the subperitoneal system of lymphatics and also some of the deep lymphatics accompanying the portal vessels, through the walls of which the mercury, with which they are injected, shines out distinctly. These lymphatics, along with those from the under surface of the liver, pass to some of the glands about the portal fissure of the liver and lesser curvature of the stomach, and thence pass to the thoracic duct below the diaphragm.

12. 52. The Superficial Lymphatics of the Liver. —

(History unknown; it looks like a Hunterian specimen.) A large slice of the liver, with the superficial lymphatics finely injected with mercury.

12. 53. The Lymphatics of the Gall Bladder.

Hunterian. D. 18.

"A gall bladder, with a small portion of the liver, showing some absorbent vessels running along the surface of the gall bladder and terminating in some absorbent glands situated on the trunk of the vena portarum." They join the deep lymphatics which accompany the portal vein. Injected with mercury and mounted in turpentine.

(g) The Lymphatics of the Spleen.

There are no specimens showing the lymphatics of the spleen in the human subject; the following from animals serve as illustrations:

12. 54. The Superficial Lymphatics of the Spleen. Bullock.

Hunterian. D. 38.

A portion of the external surface of the spleen of a bullock, with the lymphatics injected with mercury, which has fallen out of many of them. They are running in the subperitoneal tissue, and go to glands situated on the splenic vessels. In^d turpentine.

12. 55. The Superficial Lymphatics of the Spleen. Bullock.*Hunterian. D. 38a.*

A portion of the outer surface of the spleen; the vessels are exceedingly numerous, and have been greatly distended with mercury, but most of them are now empty and tending to collapse.

12. 56. The Superficial Lymphatics of the Spleen. Calf.*Hunterian. QQ. 64.*

A large thin slice of the upper surface of the spleen, showing a very abundant supply of lymphatics which are very irregular in size, probably from the force used in injection.

12. 57. The Lymphatics of the Spleen. Turtle.*Hunterian. QQ. 66.*

Three-quarters of the spleen, which is of a globular shape, flattened slightly on one side, the arteries injected red, the veins black, and the lymphatics with mercury. Only the superficial lymphatics are shown, none being apparent in the cut surface.

(h) The Lymphatics of the Stomach.

There are no specimens from the human subject, but the following illustrate them in a mammal (ass), a reptile, and fish.

12. 58. The Lymphatics of the Stomach. Ass.*Hunterian. QQ. 49.*

A portion of the stomach of an ass, showing a number of large lymphatics, injected with mercury, running in the sub-peritoneal connective tissue.

12. 59. The Lymphatics of the Stomach. Turtle.*Hunterian. QQ. 52.*

A portion of the stomach injected, the arteries red, the veins black, and the lymphatics with mercury. The superficial lymphatics accompany the arteries, one on each side, anastomosing

across them here and there. In addition, there is visible, through the transparent muscular wall, a system of lymphatic spaces connected with one another by finer channels; some of these are in the mucous coat, as they appear plainly from the inside; others, which are as indistinct from the one side as from the other, probably in the submucous areolar tissue. A beautiful preparation.

12.60. The Lymphatics of the Stomach. Skate.

Hunterian. QQ. 53.

The lymphatics on the stomach itself are not injected, but the fringe of omentum hanging from the lower curvature is traversed by numerous lymphatic vessels injected with mercury.

12.61. The Lymphatics of the Stomach. Skate.

Hunterian. QQ. 54.

The specimen consists of a portion of the wall of the stomach near one of its orifices, the serous surface outwards. The turpentine in which it is mounted gives it a transparency like horn, rendering visible two plexuses of lymphatics—(1) superficial, running in the subserous connective tissue; and (2) deep, visible from the mucous as well as from the serous surface, running in the submucous connective tissue and communicating with the former. In the wall of the viscus are also to be seen numbers of parasitic nematodes lying in the submucous connective tissue (as was determined when the specimen was being remounted).

12.62. The Lymphatics of the Stomach. Skate.

Hunterian. QQ. 55.

The whole stomach injected, the arteries red, the lymphatics with mercury, dried, and varnished. It is very black, and a great deal of mercury has escaped, and is sweating out at all points still. Shows that the lymphatics run round the viscus like the arteries and veins.

12.63. The Lymphatics of the Stomach. Skate.

Hunterian. QQ. 56.

Similar to No. 12.61, but includes the whole girth of the organ (a small one). There is an abundant network of super-

ficial vessels, and a few large ones, running a circular course in the deeper tissues, can also be traced. In turpentine.

12.64. The Lymphatics of the Stomach. Conger Eel.

Hunterian. QQ. 57.

The stomach of the conger eel, with part of one side cut out, injected, the arteries red, the lymphatics with mercury. The lymphatics are very numerous and regularly arranged, the larger trunks running round the organ along with the arteries and disappearing in the loose omental tissue at the curvatures, where, in mammals, there would be lymphatic glands, which, however, do not exist in fish.

12.65. The Lymphatics of the Stomach. Conger Eel.

Hunterian. QQ. 58.

A small piece, similar to the preceding.

(i) *The Lymphatics of the Intestines: Lacteals and Mesenteric Glands.*

12.66. "The whole Mesentery from an Adult Human Subject," showing the Lymphatic Glands.

Hunterian. D. 48.

"The peritoneum of one side is removed to show the glands of the absorbents." The mesenteric artery is seen branching soon after it enters the mesentery. About these first branchings lies an inner circle of glands, and nearer the intestinal border lie more glands, mostly of smaller size. The distal edge of the mesentery is very much corrugated to give space for the attachment of the intestines.

12.67. "The whole Mesentery of a Child at Birth."

Hunterian. D. 48a.

The arteries injected red, the veins black, and the specimen mounted on mica. It forms almost a complete circle; the sector which is occupied only by a thin sheet of tissue is its base, where it is attached over the spine and receives the mesenteric

vessels. The glands are arranged, as in the preceding, in an inner and an outer circle, between the branches of the artery "to the number of 50 or 60," and the edge is greatly plicated to increase its circumference.

12. 68. The Lymphatics of the Intestine. Lacteals.

Hunterian. D. 2b.

A portion of the small intestine slit open along its mesenteric attachment, stripped of peritoneum, and mounted on blue glass. "The veins are injected black," "and the lacteals, filled with coagulated chyle," which is of a white colour, are seen accompanying them, frequently two to each vein.

12. 69. The Lymphatics of the Intestines. Lacteals.

Hunterian. D. 2c.

A portion of the intestines with part of its mesentery, treated in the same way as the preceding, but the blood-vessels not injected. A number of the lacteals, filled with coagulated chyle, are particularly well seen crossing the mesentery to enter a small lymphatic gland. The column of white chyle presents interruptions due to the valves, but the absence of distension prevents the beaded appearance which is seen in those injected with mercury—the appearance here is more natural.

12. 70. Lacteals and Mesenteric Glands. *Hunterian. D. 47a.*

A portion of the intestine and mesentery, the arteries injected red. Numerous lymphatic vessels filled with coagulated chyle are seen, running in the course of the blood-vessels, to enter lymphatic glands; they show the characteristic interruptions where the valves intersect the column of chyle.

12. 71. The Lymphatics of the Intestine and Lymphatic Glands. *Hunterian. D. 9.*

A similar preparation, but the lacteals injected with mercury, the valves showing very well. "A piece of jejunum, the arteries and veins injected red, from a lady."

12. 72. The Lymphatics of the Intestines and the Mesenteric Glands.

Hunterian. D. 49.

"A small portion of the jejunum and mesentery of a child, the arteries injected red, the lacteals filled with coagulated chyle, to show the glands of the absorbents, at some distance from the upper side of the intestine, clustered and large."

12. 73. The Lymphatics of the Intestines and Mesenteric Glands.

Hunterian. D. 49a.

Similar to the preceding.

12. 74. The Lymphatics of the Intestine and Mesenteric Glands.

Hunterian. D. 50.

"A portion of the colon and mesocolon from the same child, to show the glands of the absorbents, close to the intestine nearly, small and scattered."

12. 75. A Lymphatic Gland and Lymphatic Vessels.

Hunterian. D. 35.

Not described. There are four vessels filled with mercury, terminating in a large gland. In turpentine.

12. 76. The Lymphatics of the Intestine. Lacteals.

Hunterian. QQ. 17.

A portion of the intestine injected red by the arteries, showing four lacteals injected with mercury. In turpentine.

12. 77. The Lymphatics of the Intestine and Mesenteric Glands.

Hunterian. QQ. 14.

A larger portion of the intestine, similar to the preceding, in turpentine, showing a lymphatic dividing, and the two branches going to different glands.

12. 78. The Lymphatics of the Intestine. *Hunterian. QQ. 12.*

A portion of the intestine with mesentery, showing the lacteals injected with mercury, passing to the mesenteric glands.

12.79. The Lymphatics of the Intestines.*Hunterian. QQ. 11.*

A portion of the intestine with the mesentery, showing several lacteals injected with mercury, terminating in mesenteric (lymphatic) glands. The lymphatics divide and reunite on the mesentery. The mercury has escaped from several of the lacteals on the intestine. In turpentine.

12.80. The Lymphatics of the Intestines. Lacteals.*Hunterian. QQ. 16.*

"Absorbent rising out of the human intestine, filled with mercury and exceeding small: the mesentery was cancerous; and the obstruction made, perhaps, the smallest vessels visible."

*The Comparative Anatomy of the Lacteals.***12.81. The Lymphatics of the Intestines. Antelope.***Hunterian. D. 2.*

"A portion of the small intestines and mesentery of an antelope, in which the absorbents are still preserved in the state they were found in the dead body, *i.e.* full of their own chyle. The arteries and veins both injected red." The lymphatics are seen to end in a large lymphatic gland in the centre of the specimen.

12.82. The Lymphatics of the Intestine. Antelope.*Hunterian. QQ. 21.*

The arteries not injected, otherwise similar to the preceding, the lacteals appearing to be injected white from being filled with coagulated chyle.

12.83. The Lymphatics of the Intestine and Mesenteric Glands. Kitten.*Hunterian. D. 59b.*

"A portion of intestine and mesentery from the kitten, showing, in the course of the arteries and veins, small lacteal vessels and small oval bodies, most probably absorbent glands." On blue paper.

12. 84. The Lymphatics of the Intestines and Mesenteric Glands. Kitten.*Hunterian. D. 59c.*

A portion of the intestine and mesentery, stretched on blue glass, similar to the preceding. There is a good deal of fat along the course of the vessels, which hides the lymphatics, but at numerous points little yellowish bodies stand out from the fat, which are the lymphatic glands. They are very small, in proportion to the viscera, compared with the same structures in the human subject.

12. 85. The Mesenteric Glands. Kitten.*Hunterian. QQ. 22.*

A portion of the mesentery of the kitten, showing the lacteals terminating in a mass of glands at the root, called the "Pancreas Aselli." Injected with mercury and mounted in turpentine.

12. 86. The Lymphatics of the Intestine. Lacteals. Porpoise.*Hunterian. D. 22.*

A portion of the intestine and mesentery of the porpoise, the arteries injected red, the lymphatics with mercury. The arteries run across the mesentery in large trunks, branching only near the intestine; there are lymphatics accompanying these arteries, and also others running separate courses across the spaces between the blood-vessels to some large lymphatic glands about the root of the mesentery.

12. 87. The Lymphatics of the Intestine. Lacteals. Porpoise.*Hunterian. QQ. 36.*

A portion of the intestine and mesentery injected, the arteries red, the lymphatics with mercury, dried and mounted on blue paper.

12. 88. The Lymphatics of the Intestine. Lacteals. Horse.*Hunterian. QQ. 18.*

A small portion of the intestine of the horse, with the superficial and a few deep lymphatics very finely injected with mercury. In turpentine.

12. 89. The Lymphatics of the Intestine. Lacteals. Horse.
Hunterian. QQ. 20.

A portion of small intestine (formerly mounted on wood), showing the superficial lymphatics injected with mercury.

12. 90. The Lymphatics of the Intestine. Lacteals. Ass.
Hunterian. QQ. 19.

"A portion of the ass's intestine slit open and hanging lengthways," the arteries injected red. Shows a number of longitudinal and circular lymphatic vessels injected with mercury; the former belong to the superficial set beneath the peritoneum, the latter to the deeper set, apparently in the inner (circular) muscular coat.

12. 91. The Lymphatics of the Intestine. Lacteals. Ass.
Hunterian. QQ. 19b.

A portion of the intestine of the ass laid open, the arteries injected red, and some lymphatics with mercury. The latter belong mostly to the superficial set, and run longitudinally; a few of the circular set are seen shining through from the deeper tissues. Compare the preceding.

12. 92. The Lymphatics of the Large Intestine. Lacteals. Ass.
Hunterian. QQ. 23.

A portion of the "large intestine" and mesentery of the ass, dried and varnished. The arteries are injected red, and a few of the lymphatics with mercury.

THE LYMPHATICS OF THE INTESTINES IN THE TURTLE.

12. 93. The Superficial Lymphatics of the Small Intestine and Mesentery. Lacteals. Turtle.

Hunterian. D. 4.

"A portion of the small intestine and mesentery of the turtle, the arteries first injected red, the veins next blue, and the absorbents (lymphatics) last of all with mercury." Numerous lymphatic vessels are seen running in the subperitoneal connective tissue of the gut, and in the mesentery. They accompany the blood-vessels, generally one on each side of the artery, and

anastomose freely. The colours are rather faded. The bowel is filled with plaster of Paris.

12.94. The Lymphatics of the Small Intestine. Lacteals. Turtle. *Hunterian. QQ. 24.*

A portion of the intestine laid open, with the arteries injected red, the veins black, and the lymphatics with mercury. As in the last specimen, the lymphatics are seen accompanying the blood-vessels—the artery in the middle, two venae comites, one on each side, and outside these a lymphatic vessel on each side. Inside the intestine a few lymphatics are also visible in the villi of the mucous membrane.

12.95. The Lymphatics of the Intestine and Mesentery. Lacteals. Turtle. *Hunterian. QQ. 25.*

A portion of the intestine with mesentery, injected like the preceding, but not opened. The bowel in this and the five succeeding specimens is filled with plaster of Paris.

12.96. The Lymphatics of the Intestine and Mesentery. Lacteals. Turtle. *Hunterian. QQ. 26.*

A portion of the intestine with mesentery, the arteries injected red, the veins black, and the lymphatics with mercury. The latter are very well injected, by Hewson's method of forcing the valves (see under No. 12.106); and the superficial set is seen running, chiefly in a longitudinal direction, in the sub-peritoneal connective tissue, and between the fibres of the outer (longitudinal) layer of muscle. "In the middle of the mesentery the smaller absorbents form a very intricate plexus or network resembling a sort of gland, and probably doing the same office as absorbent (lymphatic) glands in the mesenteries of other animals." There are no lymphatic glands in reptiles and fish, and the spleen is very small.

12.97. The Lymphatics of the Intestine and Mesentery. Lacteals. Turtle. *Hunterian. QQ. 26a.*

This specimen was not numbered, but it is very similar to the preceding, and is probably QQ. 26a, which was supposed to be amissing.

12.98. The Lymphatics of the Intestine and Mesentery.
Turtle. *Hunterian. QQ. 27.*

A portion of the small intestine and mesentery, similar to the preceding.

12.99. The Lymphatics of the Intestine and Mesentery.
Turtle. *Hunterian. QQ. 28.*

A portion of the intestine and mesentery of the turtle, the lymphatics alone injected, with mercury, and running to great minuteness on both.

12.100. The Lymphatics of the Intestine and Mesentery.
Turtle. *Hunterian.*

Similar to the preceding.

12.101. The Deep Lymphatics of the Intestine. Turtle.
Hunterian. QQ. 32.

A portion of the small intestine laid open, showing a number of the deep lymphatics in the submucous connective tissue, and a few also in the mucous membrane itself, injected with mercury. Compare No. 12.105.

12.102. The Deep Lymphatics of the Intestine. Turtle.
Hunterian. QQ. 33.

Similar to the preceding.

12.103. The Lymphatics of the Intestine. Superficial and Deep. Turtle. *Hunterian. QQ. 34.*

A piece of the small intestine of the turtle laid open. On the outside are shown the fine longitudinal vessels of the subperitoneal tissue, and a few of the deeper ones shining through from the muscular layer. From the inside are seen a number of the lymphatics of the submucous and mucous coats. "Two bristles pointing to something like valves in the extremity of the absorbent branches." They are not valves, but probably the ampullula of a villus overdistended with the mercury. Compare No. 12.105.

12.104. The Lymphatic Vessels of the Villi. Intestine of Turtle.*Hunterian. QQ. 50.*

A small portion of the intestine of the turtle, showing a number of fine lymphatics in the longitudinal ridges, which in this animal represent the villi, injected with mercury. This effect is obtained by pressing the mercury in the submucous spaces (which are so well shown in the specimens mounted in turpentine), when some of the metal as a rule manages to escape into the vessels of the villi, as described by Hewson. See under No. 12.106.

12.105. The Lymphatics of the Intestine. Lacteals. Turtle.*Hunterian. D. 30.*

"A portion of the small intestine from the turtle, the arteries injected red, the veins black, and the absorbents with quicksilver. The quicksilver is seen on the internal surface of the intestine in vessels just discernible to the naked eye; in the microscope they make a very large beautiful serpentine appearance, but nothing like orifice was evident." Hewson believed that he had detected orifices closed by valves on the surface of the mucous membrane, which were the commencement of the lacteals of the villi. William Hunter appears always to have had some doubt as to the existence of such orifices. See Historical Introduction.

12.106. The Lymphatics of the Intestine. Superficial and Deep. Turtle.*Hunterian. D. 14.*

"A portion of the small intestine and mesentery of the turtle. The arteries were injected red, the veins black, and the absorbents with mercury, and the intestine dried without distending its natural cavity; so that what in the overdistended intestine seemed extravasations are here seen regularly cylindrical vessels, and give a grand idea of the extent of the absorbent system in this animal." Contrast No. 12.108. The specimens in this and the succeeding section of the series were mostly prepared by Hewson. The following account of them is taken from Hewson's *Works*, p. 149. "In this animal I have been so fortunate as to force the valves, and to inject the lacteals from their trunks to their branches, so as to fill them all around with quicksilver, in several parts

of the intestine. In these experiments I observed that the quicksilver was often stopped by the valves where the lacteals run upon the mesentery, or where they are just leaving the intestine; but when those valves were forced, and the quicksilver had once got upon the surface of the gut, it generally ran forward without seeming to meet with any obstacle. The lacteals anastomose upon the intestines, so that the quicksilver, which has got in upon them by one vessel, in general, returns by another at some distance. The larger lacteals, which run upon the intestines, accompany the blood-vessels; but the smaller lacteals neither accompany those vessels nor pass in the same direction, but run longitudinally upon the gut, and dip down through the muscular coat into the cellular or nervous, as it has been called, which in this animal is very thin in comparison to what it is in the human subject. So far I have traced those vessels to my satisfaction; but what becomes of them after they have got to the cellular coat is not so easy to determine: in five or six different experiments which I have made, the mercury passed from the lacteals into the cells between the muscular coat and the internal, and spread from cell to cell very uniformly over a great part of the intestine, although but little force had been used, and although there was nothing like extravasation in any other part of the intestine. Upon inverting the intestine, after thus filling the lacteals, the mercury, on being pressed, was in many parts driven into small vessels upon the internal coat, or villous, as it is called. From whence it would seem that this cellular network was a part of the lymphatic system in this animal. It might indeed be supposed to be mere extravasation, but that it is rather a part of the lymphatic system appears from the following considerations: first, from the regularity in the size of the cells; secondly, from the little force used in the experiment, and from there being nothing like this appearance in the cellular membrane between the peritoneal and the muscular coat, where extravasations were as likely to happen; thirdly, from my having been able, after inverting the intestine, to press the quicksilver from the cells into the very small vessels upon the internal coat. But I must confess these facts would not be sufficient to determine whether these cells were or were not a part of the system, did not the analogy of the same part in fish clearly prove it. For in the cod, instead of the cellular network, as in the turtle, there is a network of vessels (of which a

description shall be given in the next chapter), so that I have now no doubt but that those cells are parts of the lymphatic system, and that the small absorbent vessels of the internal coat pour their fluid into this network, from which it is conveyed by the larger lacteals." Compare No. 12.112, Lacteals of Turbot.

12.107. Lymphatics of the Intestine. Superficial and Deep. Turtle. *Hunterian. D. 14a.*

A similar preparation to the preceding. The intestine is distended, and the lymphatics are even more finely injected, the mercury in the spaces of the submucosa making a glittering sheet of metal intersected by dark lines, which are the remains of the areolar tissue compressed by the mercury and shrunk by drying. In turpentine. For mode of preparation, see No. 12.106.

12.108. The Superficial and Deep Lymphatics of the Intestine. Turtle. *Hunterian. QQ. 29.*

A portion of the small intestine injected like the preceding by forcing the valves with mercury. The lymphatic spaces between the muscular and mucous coats are not so much distended as in the two preceding specimens. See No. 12.106.

12.109. The Lymphatics of the Intestine. Superficial and Deep. Turtle. *Hunterian. QQ. 30.*

A portion of the small intestine prepared in the same way as No. 12.106, both sets of lymphatic vessels of the intestine and those of the mesentery very finely injected. Veins and arteries injected black. In turpentine.

12.110. The Lymphatics of the Intestine. The Deep Set from within. Turtle. *Hunterian. QQ. 31.*

A piece of small intestine prepared in the same way as No. 12.106, and inverted, showing the lymph spaces between the muscular and mucous coats distended in a manner which suggests extravasation, but is not, the vessels not being ruptured. See under No. 12.106. In turpentine.

12.111. The Lymphatics of the Intestine. Superficial and Deep. Turtle.*Hunterian. QQ. 35.*

A portion of the intestine prepared in the same way as No. 12.106, and opened, showing the deep lymph spaces from the inside; the arteries injected red, the veins black, and the absorbents with mercury. In turpentine.

THE LYMPHATICS OF THE INTESTINES IN FISHES.

12.112. The Lymphatics of the Intestine. Turbot.*Hunterian. QQ. 38.*

A portion of the intestine of the turbot injected with mercury, as described by Hewson, from branch to trunk; "these vessels in fish either have no valves or the valves readily give way, for it is an easy matter to fill them contrary to the course of the lymph." The deep plexus of vessels is seen in the lower part of the specimen. "The lacteals of the cod (and I presume in most other fish) are remarkable for having a beautiful network of vessels between the muscular and villous coat of the intestines. This network may be filled from the lacteals on the mesentery with the least force imaginable. If mercury be injected into this network at one part, it spreads over the intestine, the communications in the network being very numerous; if the intestine be inverted and the mercury squeezed, it is easily driven into the small vessels of the villi of the internal coat." As to this network, "it is made up of cylindrical vessels, and is not cellular as in the turtle, and therefore not in the least like an extravasation; and in fish the vessels on the internal coat are larger than in the turtle." Compare No. 12.106. (*Hewson's Works*, p. 155.)

12.113. The Lymphatics of the Intestine. Cod.*Hunterian. QQ. 39.*

A small portion of the intestine and mesentery, the arteries injected red, the lymphatics with mercury. In turpentine. Most of the mercury has fallen out. As in the reptiles and amphibia, there are no lymphatic glands. (*Hewson's Works*, p. 154.)

12.114. The Lymphatics of the Intestine. Turbot.*Hunterian. D. 32.*

A portion of the intestine laid open, the arteries injected red, the lymphatics with mercury. A number of very large vessels, having a twisted varicose appearance, are seen running in the ridges, which take the place of villi. Some of these vessels probably belong to the deep set in the submucous tissue; others, however, seem to lie in the mucous membrane itself. Compare next specimen.

12.115. The Lymphatics of the Intestine. Turbot.*Hunterian. QQ. 46.*

A portion of the intestine laid open, the lymphatics of the villi, or rather folds which represent the villi in this animal, finely injected with mercury. They form a fine network of vessels running in the very edges of the villi. These vessels were injected by inverting the intestine after the deep lymphatics had been filled in the usual way, and pressing it, whereby the mercury is forced into them. (Hewson's *Works*, p. 155.)

12.116. The Lymphatics of the Intestine. Turbot.*Hunterian. QQ. 48.*

Similar to the preceding.

12.117. The Lymphatics of the Intestine. Turbot.*Hunterian. QQ. 42.*

"A piece of the opened intestine of the turbot, the arteries injected to great minuteness with size and vermilion." A few lymphatics, filled with mercury, are seen in the edges of the villi and in the subperitoneal connective tissue.

12.118. The Lymphatics of the Intestine. Cod.*Hunterian. QQ. 43.*

A piece of intestine laid open, the arteries injected red, the lymphatics with mercury. The mucous membrane has no ridges like those of the turbot's intestine, but is smooth, and, with a

lens, shows a finely honey-combed appearance. The deep lymphatics shine dimly through from the submucous connective tissue, and on the surface of the mucous membrane ramifies a plexus of very fine vessels, which probably are the ultimate lacteals of the villi, distended by the injection.

12.119. The Lymphatics of the Intestine. Cod.

Hunterian. QQ. 44.

A piece of intestine laid open, similar to the preceding, but dried, and mounted in turpentine.

12.120. The Lymphatics of the Intestine. Cod.

Hunterian. QQ. 45.

Similar to No. 12.118, but the lymphatics not so well injected; it shows the pitted surface of the intestine very well.

12.121. The Lymphatics of the Spiral Intestine of the Skate.

Hunterian. QQ. 51.

The intestine of the skate, with a window cut in the wall at three places to show the spiral valve; injected, the arteries red, the veins black, and the lymphatics with mercury, from trunk to branch by forcing the valves. The lymphatics of the superficial set are most clearly seen, forming a fine plexus ramifying along with the larger blood-vessels. Some deep lymphatics of large size, and running a circular course along with the blood-vessels, shine out less distinctly from the inner muscular, or from the submucous coat—it is impossible from the examination of the specimen to say exactly which.

12.122. The Lymphatic System of a Fish, demonstrated in a Haddock.

Hunterian. QQ. 53a.

The anterior two-thirds of a haddock dissected so as to show the base of the skull, orbits, and viscera. The arteries are injected red, the lymphatics yellow, but the yellow has faded. The two large lateral lymphatics, and a few small ones among the viscera, and the receptaculum chyli (seen near the stomach) still show

the yellow colour. It is described by Hewson as having been prepared by injecting through the ventral lymphatic, which is easily found in the skin, just ahead of the anus; the valves, he states, are either very weak and give way very readily, or do not exist, and therefore the whole lymphatic system is readily filled from this one vessel. (Hewson's *Works*, p. 153.) The specimen is figured in *Phil. Trans.*, Vol. LIX., but the illustration is not reproduced in the collected works.

SERIES 13.

INJURIES AND DISEASES OF LYMPHATIC VESSELS AND GLANDS.

I. CONGENITAL DEFECTS AND MALFORMATIONS.

Specimens wanted.

II. RESULTS OF INJURY.

Specimens wanted.

III. CONDITIONS DUE TO CHANGES, LOCAL AND GENERAL, AFFECTING THE NUTRITION.

13.1. Lymphangiectasis. Dilatation of the Lymphatic Vessels.

Hunterian. D. 67.

A portion of the intestine and mesentery injected green. "Some absorbent vessels filled with chyle, which appears to have been hindered in its progress by an enlarged absorbent gland." The obstructed gland is very much enlarged, and the vessels are considerably distended. See also No. 9.18, Oedema of the Hand from Obstruction of the Lymphatics.

IV. INFLAMMATORY DISEASES.

13.2. Tuberculosis of the Lymphatic Glands. Axilla.

Hunterian. D. 64.

A portion of skin from the axilla, with the deeper tissues, showing two large tubercular lymphatic glands. ("Suppurated

scrophulous glands.") The condition is advanced, almost the whole of the glands having necrosed, and passed into the condition of caseation. Calcareous infiltration has also occurred in several of the caseous masses.

13.3. Tuberculosis of the Bronchial Lymphatic Glands.

Hunterian. D. 65.

"The same disease in the glands, surrounding the root of the lungs." A large mass of lymphatic glands about the roots of the lungs and bifurcation of the trachea, showing tubercular disease secondary to phthisis pulmonalis. The glands show the three stages: viz. active growing tubercles, caseation, and calcareous infiltration of the caseous masses. "In the centre of the glands are seen ossifications, or a something between that and petrification, to the size frequently of a small hazel nut. These sometimes are coughed up in pulmonary consumption, and demonstrate it scrophula falling on the lungs (compare this with 63 in Lungs)," Nos. 18.25-18.38.

13.4. Tubercular Lymphatic Glands.

Hunterian. D. 61a.

Not described in the old catalogue. Section of a mass of greatly enlarged lymphatic glands, presenting a fleshy surface with small patches of yellow, apparently caseous patches, scattered over it. On microscopic examination the section is found to be composed chiefly of hyaline material, which is probably amyloid, though it does not stain satisfactorily. The tissue is fairly tough and firm. A few tubercles and patches of caseous necrosis are recognizable. (MS. Notes, J.H.T., p. 39.)

V. TUMOURS AFFECTING THE LYMPHATIC GLANDS.

13.5. Carcinomatous Infiltration of Lymphatic Gland.

Hunterian. D. 61.

A section of a mass of enlarged lumbar glands, illustrating the above condition. The glands are very much enlarged, the mass measuring 10 by 7 cm., some of them being as large as chestnuts; they are fairly soft, tough, and homogeneous in section. A large vein, probably one of the iliacs, is embedded in one side of the specimen. "From Mr. H. (Hoquet), who had a scrophulous

testicle extirpated three or four mos. before. He had a similar tumour on his head, and several such on the inside of the ribs." The history goes against the diagnosis of tubercular (scrofulous) disease, and in favour of carcinoma, and microscopic examination shows that the glands are the seat of secondary carcinomatous infiltration. (MS. Notes, J.H.T., p. 38.) For the primary tumour, see No. 43.62, Carcinoma of the Testicle.

13.6. Carcinomatous Infiltration of Lymphatic Glands.
Necrosis.

Hunterian. D. 62.

A mass of enlarged lymphatic glands, which microscopic examination shows to be infiltrated with carcinoma, which has undergone necrosis in parts. The necrosed parts show faint indications of cellular structure, but no nuclear staining. "From the inside of the pelvis of a woman who had died after labour, and who had the child extracted with the blunt hook; the narrowness of the pelvis, preventing the delivery, was owing to this schirrous mass." (MS. Notes, J.H.T., p. 40.)

SERIES 14.

ANATOMY OF GLANDS.

<i>Vascularity of Glands,</i>	1-4
<i>Ducts,</i>	5-9
<i>Intestinal Glands,</i>	10
<i>Shape of Glands,</i>	11-14

The specimens in this series were intended by William Hunter to illustrate some of the characters of glands in general—their various shapes, their ducts, and their high vascularity. Glands are also illustrated more fully in various of the other series. William Hunter's views regarding secretion are alluded to in the Historical Introduction.

(a) Specimens illustrating their Vascularity.

14.1. The Vascularity of Glands. Human Liver.

Hunterian. G. 4.

A slice of the liver injected red so highly as to appear as if entirely made up of vessels; illustrating the high vascularity of glands.

14.2. The Vascularity of the Spleen.

Hunterian. G. 5.

The structure and functions of the spleen being quite unknown in William Hunter's time, it was classed with the glands simply because its flesh ("parenchyma") was soft and highly vascular. The specimen is injected red and teased to show "the extremities of the arteries terminating in groups of very minute short branches named penicilli."

14.3. The Vascularity of Glands. Kidney. Malpighian Bodies. *Hunterian. G. 7.*

"A slice of the surface of a kidney so minutely injected (red), that the coloured size thrown in by the artery returned by the ureter. The cryptae (Malpighian bodies) of anatomists here appear to be either convolutions of the extreme branches of the artery, or if they are bags to be entirely covered with the convolutions of the artery. The small branches are broken, but the cryptae (Malpighian bodies) are very evident." Mounted on mica in turpentine.

14.4. The Vascularity of Glands. Kidney.

Hunterian. X. 28.

Section of the cortex of a kidney injected red to illustrate the high vascularity of secretory organs.

(b) *Ducts.*

14.5. Excretory Ducts. Tubuli Uriniferi. Kidney. Horse. *Hunterian. G. 10.*

A portion of the kidney of the horse, with the uriniferous tubules injected red from the pelvis; as an example "of the most simple kind of excretory duct." "They are exceedingly distinct at their terminations, and two or three of them are seen uniting to form a larger one before they reach the pelvis. This sufficiently distinguishes them from arteries and veins. The injection has not run far enough to fill the cryptae." A magnifying glass is almost necessary for the appreciation of these points.

14.6. Excretory Duct. Submaxillary Gland.

Hunterian. GG. 14a.

The excretory duct of the submaxillary gland, its whole length preserved, injected with mercury, showing its branches and the lobulated structure of the gland. In turpentine.

14.7. Excretory Duct. Submaxillary Gland.

Hunterian. G. 27.

Similar to the preceding. In turpentine.

14. 8. Excretory Ducts. Vaginal Glands. Ass.*Hunterian. G. 21.*

Two "Lacunae" from the vagina of an ass; the duct is large enough to admit a fine probe, and rises by a number of fine branches from the different lobules of the gland. In turpentine.

14. 9. The Mucous Glands of the Tongue.*Hunterian. G. 11.*

The base of the tongue, showing a number of round elevated bodies, with a round orifice on the top, which are mucous glands. The secretion is poured into the cup-like follicle by numbers of minute ducts.

*(c) Intestinal Glands.***14. 10. Intestinal Glands and Lymph Follicles.***Hunterian. G. 12.*

The caput caecum, part of colon, and termination of the ileum of a foetus injected red, laid open, showing the highly vascular glandular mucous membrane of the intestines, and also the lymph follicles formerly called "solitary glands." These are not glandular, but masses of adenoid tissue like the cell-masses of lymphatic glands, tonsil, root of tongue, and the Peyer's patches of the small intestine, for which see Series 31 and 35.

*(d) The Different Forms of Glands.***14. 11. "Globulated Glands." Kidney of Cat.***Hunterian. G. 23.*

A section of a kidney of a cat, injected red, as an example of a gland which shows no trace of lobulation. William Hunter regarded the external form as not at all an essential character of secreting organs, and illustrated this by showing the different forms assumed by the kidneys in different animals. Compare Series 40, Kidney, Comparative Anatomy Specimens.

14. 12. Human Foetal Kidney. Conglobate Gland.*Hunterian. G. 24.*

As an example of a similar gland which shows a tendency to lobulation; highly vascular.

14. 13. Kidney of Porpoise. Conglomerated Gland.*Hunterian. G. 25.*

As an example of complete division into lobules of a similar gland. The uriniferous tubules open not into a pelvis, but into an excretory duct of the type of that of a salivary gland. Compare No. 14.6.

14. 14. Submaxillary Gland. Human.*Hunterian. G. 26.*

As an example of a conglomerated gland in which the lobulation is less complete.

SERIES 15.

ANATOMY OF THE SPLEEN.

15. 1. The Spleen and Pancreas of a Child. *Hunterian. V. 1.*

"The spleen and pancreas of a child, the artery injected red, the vein yellow"; it shows the shape of the spleen, which has three sides—a large convex one, in contact with the diaphragm, and two concave; of the latter, the narrower, looking inwards, rests on the left kidney; the other is applied to the greater end of the stomach and splenic flexure of the colon. Near the ridge between the two last, on the anterior surface, is a vertical fissure (the hilum) at which enter the blood-vessels and nerves. "The vessels running to the spleen lie in a groove in the upper edge of the pancreas."

15. 2. The Vascularity of the Spleen. Foetus.

Hunterian. V. 2.

"The spleen of a foetus minutely injected red to show that it is exceedingly vascular."

15. 3. The Arteries of the Spleen. Child. *Hunterian. V. 3.*

"The spleen of a little child, injected red and macerated in water; shows its floating vessels very minute in the style of Ruysch."

15. 4. The Vessels and Reticular Framework of the Spleen.

Hunterian. V. 3a.

The spleen of a child, injected red and macerated in water, to show the trabeculae and blood-vessels, the arteries terminating

in bunches (penicilli) of fine vessels which open into the sinuses of the pulp. Compare Nos. 15.5 and 15.10.

15.5. The Trabeculae and Blood-vessels of the Spleen.

Hunterian. V. 4.

"The spleen of an adult (rather small), the arteries injected red, and the capsule removed, macerated in water." The pulp has been pressed out and washed away, leaving only the tough fibrous sponge-like framework and the blood-vessels, which are seen dividing into bunches (penicilli) of fine arterioles floating free in the spirit.

15.6. The Blood-vessels of the Spleen.

Hunterian. V. 4a.

The spleen "of a child," highly injected red, macerated; the trabeculae and the blood-vessels in them finely unravelled; the branching of the arteries beautifully displayed. A magnifying glass is required to see it properly.

Comparative Anatomy Specimens.

15.7. The Trabecular Framework and Blood-vessels of the Spleen.

Hunterian. V. 6.

The spleen of a calf, with the capsule removed off one side, macerated in water so as to remove all the pulp. It shows the trabeculae and the course and distribution of the larger blood-vessels. A few Malpighian bodies can be seen on the arteries.

15.8. The Trabecular Framework and Blood-vessels of the Spleen.

Hunterian. V. 7.

A similar specimen, but injected red by the artery, which enables the trabeculae to be distinguished from the blood-vessels, and shows the tufts (penicilli or pencils) of fine vessels into which each artery divides. The Malpighian bodies on the arteries can occasionally be detected.

15.9. The Trabeculae, Arteries, and Malpighian Bodies of the Spleen.

Hunterian. V. 8.

A similar preparation, but with the whole capsule removed. The masses of adenoid tissue in the sheaths of the arteries, called

Malpighian bodies, appear as small grey granules, like mustard seeds; they are especially numerous in the lower part of the specimen. The injection is not so bright as in the preceding, and there is a deposit from the spirit, in fine white granules, on the points of some of the arteries, which spoils its appearance.

15.10. Spleen Inflated by the Vein and Dried.

Hunterian. V. 10.

"Spleen of the antelope, inflated from the veins." "To show that the trunk of the veins opens into cells, like the trachea in the lungs." This specimen gives a very rough demonstration of the sinuses of the spleen pulp, in which the blood, circulating very slowly, is brought into intimate relation with the cellular pulp. The sinuses are, of course, of microscopic size; they are enormously exaggerated by the mode of preparation. They are irregular spaces intervening between the properly formed arteries and veins; the blood is not extravasated; the sinuses have no communication with the lymphatics, which are never filled by injection of the arteries or veins unless rupture of some vessel occur.

15.11. The Splenic Artery and Vein. Turtle.

Hunterian. V. 12.

The spleen of a turtle injected, the arteries red, the veins yellow; the former are much smaller than the latter.

15.12. The Vascularity of the Spleen. Turtle.

Hunterian. V. 13.

A section of the spleen of a turtle, "injected red by both arteries and veins; the injection has got amongst the reticular substance, and makes it appear one uniform mass of injection," *i.e.* the sinuses of the pulp have been filled from the blood-vessels.

15.13. The Vascularity of the Spleen. Turtle.

Hunterian. V. 13a.

Similar to the preceding.

SERIES 16.

INJURIES AND DISEASES OF THE SPLEEN.

I. CONGENITAL MALFORMATIONS.

Specimens wanted.

II. INJURIES OF THE SPLEEN.

Specimens wanted.

III. CHANGES DUE TO ALTERATIONS OF NUTRITION AND OTHER OBSCURE CAUSES.

16.1. Chronic Hypertrophy of the Spleen.

Hunterian. V. 15.

A very large human spleen, history unknown, illustrating the above. The general shape of the viscus is preserved, though its size is six or seven times the normal. The texture of the splenic tissue is not much altered from the normal; the capsule is thickened, and there are numerous shreds of fibrous tissue (adhesions) on it. Probably malarial.

16.2. Chronic Hypertrophy of the Spleen.

Hunterian. V. 18.

An enlarged spleen of very solid texture. Microscopic examination gives very little information, except that it is not amyloid. Apparently chronic enlargement with marked congestion. (MS. Notes, J.H.T., p. 44.) Probably malarial.

16.3. Chronic Hypertrophy of the Spleen.*Hunterian. RR. 381.*

A much enlarged spleen, history unknown, of very dense consistence, tough, and with the capsule somewhat wrinkled, illustrating an advanced state of the above. Probably malarial.

16.4. Fibroma of the Spleen.*Hunterian. V. 15a.*

This specimen is figured in Baillie's *Engravings*, Fasc. VI., Pl. I., fig. 1, as an example of a soft "cartilaginous" change in the coat of the spleen, which is often met in old people. It is also somewhat shrunken, being from an old man. Microscopic examination of one of the nodules shows it to consist of very dense fibrous tissue; the cut surface to the naked eye is exactly like cartilage. (MS. Notes, J.H.T., p. 43.)

IV. CHANGES DUE TO INFLAMMATORY DISEASES.

16.5. Tuberculosis of the Spleen.*Hunterian. V. 16.*

"A portion of the spleen from a consumptive child, in which there is the same appearance of tubercles as in the lungs."

16.6. Tuberculosis of the Spleen.*Hunterian. V. 17.*

"Ditto from an adult, injected red, in which the tubercles are still larger; they seem to be serophulous suppurations of the cellular part."

V. TUMOURS OF THE SPLEEN.

Specimens wanted.

SERIES 17.

ANATOMY OF THE RESPIRATORY SYSTEM.

<i>The Nose and Pharynx,</i>	1-13
<i>The Larynx, Trachea, and Bronchi,</i>	14-30
<i>Comparative Anatomy of the Larynx and Trachea,</i>	31-38
<i>The Lungs,</i>	39-48
<i>The Comparative Anatomy of the Lungs,</i>	49-57
<i>The Ultimate Air Vesicles (Mammals),</i>	58-67
<i>The Lungs of Birds,</i>	68
<i>The Lungs of Reptiles,</i>	69-73
<i>The Lungs of the Frog,</i>	74
<i>The Respiratory Apparatus of Fish,</i>	75-76

SECTION I. THE AIR PASSAGES.

(a) *The Nose and Pharynx.*

17.1. The Cartilages of the Nose. *Hunterian. GG. 1.*

The cartilaginous portion of the septum, with the superior and inferior alar cartilages dissected. Attached to the posterior angle of each inferior alar cartilage is a small triangular sesamoid cartilage.

17.2. The Septum of the Nose. *Hunterian. GG. 3.*

A median section of the face and base of skull, showing the entire nasal septum, with the vertical plate of the ethmoid, and parts of the nasal, frontal, and sphenoid bones above; and part of the hard and soft palate and the uvula below; injected red.

Shows the shape and relations of the nasal septum. The bony portion, as usual, is deflected—in this case to the left; the mucous membrane appears highly vascular. Behind the septum, just below the division (cartilaginous still) of the basi-sphenoid from the basilar process of the occipital bone, is seen a section of the post-nasal adenoid tissue, called, by Dr. Hunter, the "third tonsil." It is highly vascular. See also Nos. 17.8 and 9 and 21.50.

17.3. The Nasal Septum.

Hunterian. GG. 3a.

A similar specimen, but not extending so far back; finely injected red, and in turpentine. The septum is remarkably straight.

17.4. The Nasal Fossae and their Connections.

Hunterian. GG. 2.

An antero-posterior vertical section of the head, comprising parts of the frontal, ethmoid, sphenoid, occipital, and superior maxillary bones; exhibiting, on the one side, the right nasal fossa, and, on the other, the antrum of Highmore; also showing their relations to the orbit, cavity of the cranium, and mouth. Part of the inferior turbinate bone has been dissected away to show the nasal duct marked by a cannula passed down from the orbit. The middle turbinate has also been partly removed to show a bristle passed from the middle meatus into the antrum; from the outside it will be noticed how high this opening is placed. The frontal sinus and ethmoid cells are also opened. The red injection gives an idea of the vascularity of the mucous membrane (Schneiderian membrane) of the nose. About 7 mm. behind the inferior turbinate bone is seen the orifice of the Eustachian tube, overhung by a fold of mucous membrane, above which is seen a part of the pharyngeal or third tonsil. It is evident how readily enlargement of this tissue might interfere with the orifice of the tube; compare the following specimens.

17.5. The Nasal Passages and their Connections.

Hunterian. GG. 4.

The section of the left side corresponding to the previous specimen; the antrum opened as in the preceding, but the tur-

binat bones untouched, showing the shape and relations of the lower, middle, and superior meatus, and the Eustachian tube, sphenoidal and frontal sinuses. A bristle is placed in the nasal duct, but on the inside it is hidden by the inferior turbinate bone.

17.6. The Nasal Fossae, Orbit, and Antrum.

Hunterian. GG. 5.

A similar section in a young subject, including rather more of the orbit and superior maxilla. The cavity of the lachrymal sac is seen with a bristle passed down into the nasal duct, and appearing in the inferior meatus. There are also bristles in the Eustachian tube, and passed from the superior meatus into the orifice of the ethmoid cells below the superior turbinate bone. Finely injected red.

17.7. The Nasal Septum and Naso-pharyngeal Space.

Hunterian. GG. 6.

The rest of the same face, showing the nasal septum beautifully injected red, and the posterior orifice of the left nostril. On the outside is seen the follicle of the wisdom tooth, with the crown of the tooth in it, close to the antrum. Only the first molar is through the gum. Bristles are passed through the nasal duct and Eustachian tube. The antrum is opened externally.

17.8. The Nasal Fossae and Adjacent Structures.

Hunterian. GG. 42.

A horizontal section just above the floor of the nose, showing the nasal fossae and naso-pharynx from below. The lateral masses of the face also have been cut away along the line of the molar teeth, laying open the antra and orbits. The Eustachian tubes, nasal ducts, and orifices of the antra are marked with bristles. The specimen was intended to show "a follicular surface at the attachment of the pharynx to the basis of the skull, in the middle space between the mouths of the Eustachian tubes and directly behind the upper end of the vomer. Dr. Hunter calls this the third tonsil." Compare No. 17.2. In addition it shows relations of the nose and pharynx to the base of the skull, the length of the roots of the canine teeth, the nasal septum, and the thickness

of the Schneiderian membrane; and the inferior turbinate bones. Compare Section of Head, No. 21.50. Highly injected red.

17.9. The Nasal Fossae and Adjacent Structures.

Hunterian. GG. 43.

A similar section, a little higher up, and with the lateral masses remaining. The cavity of the nose is clearer than in the preceding, and the mucous membrane smoother. The antra are opened from below, and bristles placed in their nasal orifices. The nasal ducts can be clearly seen opening into the inferior meatus well forward. Two other bristles occupy the Eustachian tubes. From above, the anterior ethmoid cells being opened, a bristle is passed by the orifice of the right one into the middle meatus, appearing at the front of the nose. Another bristle passed from the left frontal sinus by the infundibulum into the middle meatus appears at the back of the nose. The pharyngeal tonsil is smaller, and presents a foliated appearance.

17.10. The Cavities of the Nose.

Hunterian. GG. 7.

A transverse vertical section of the nose in the line of the anterior bicuspid teeth, showing sections of the middle and inferior turbinate bones and the nasal passages. Bristles passed from before show how high the cavity of the nose extends. Shows also the thickness of the mucous membrane. Injected red.

17.11. The Cavities of the Nose.

Hunterian. GG. 10.

A similar section showing the same structures; the mucous membrane over both turbinates and the lower part of the septum on the right side is considerably thickened. Bristles indicate the openings of the nasal ducts into the inferior meatus, and of the infundibula into the middle meatus. The frontal sinuses are opened from above. Injected red.

17.12. The Cavities of the Nose.

Dr. Allen Thomson's Collection.

The middle region of the nose of a young subject removed by vertical transverse section in front of the first milk molars and a

little behind the end of the nasal septum, showing the nasal fossae from before and behind. Bristles are passed from behind into the superior meatus, and that in the left projects in front, the section having cut away its blind anterior end. Bristles also pass on each side by the vidian canal, and by the foramen for the pharyngeal branch of Meckel's ganglion, from the spheno-maxillary fossa to appear on the cut surface of the basi-sphenoid. The nasal mucous membrane is about the natural healthy thickness. The septum is remarkably straight.

17.13. The Cavities of the Nose.

Hunterian. GG. 9.

Vertical tranverse section of the nose and roof of the mouth, including about 2 cm. of the middle region of the nose; the left second molar remaining indicates the position of the section. The posterior halves of the orbits are included, and the antra are freely opened in front. The mucous membrane on the right turbinate bones and right side of the septum is somewhat hypertrophied. The septum is deflected to the left.

(b) *The Larynx, Trachea and Bronchi.*

17.14. The Naso-pharynx and Orifice of the Larynx.

Hunterian. GG. 45.

The larynx, tongue, pharynx, soft palate, and pillars of the fauces, with the pharynx opened behind to give a view of the relations of the last four to the epiglottis and larynx. The uvula is turned forward, and the epiglottis rather pressed down. The soft parts have been cleared away from the outside of the hyoid bone and cartilages of the larynx. The relations of these structures are also well shown in No. 21.50, which see.

17.15. The Naso-pharynx and Orifice of the Larynx.

Hunterian. GG. 46.

A similar specimen injected red. The uvula and soft palate are pressed down in front of the epiglottis, quite shutting off the respiratory passages from the mouth. The epiglottis is erect, and the orifice of the larynx open. The thyroid gland is dissected clear in front. Compare No. 21.50.

17.16. The Rima Glottidis.*Hunterian. GG. 48.*

The larynx hung horizontally, so that it can be looked into from either end. From above (considering it in the natural position) the false cords, with the openings of the sacculi laryngis, appear somewhat indistinctly; below them the true cords, whiter and less dull, form the boundaries of the narrow chink—the rima glottidis. From below is seen the wide round cavity of the trachea narrowing to the rima glottidis. The cords are in about the middle position—between that of full separation, as in free breathing, and that of approximation, as for phonation.

17.17. The Framework of the Vocal and Respiratory Passages.*Hunterian. T. 12.*

The hyoid bone, epiglottis, thyroid, cricoid and arytenoid cartilages, and the trachea and bronchi for a little way into the lungs, partly macerated and cleaned. "A beautiful preparation: the branches of the bronchial artery are seen on the lower part; before, the trachea is principally cartilaginous; behind, membranous."

17.18. The Vocal and Respiratory Passages and the Oesophagus.*Hunterian. T. 13.*

A dissection of the same parts not so completely cleaned, "with the oesophagus and pharynx hardened in spirits in its natural situation."

17.19. The Hyoid Bone and Cartilages of the Larynx.*Hunterian. T. 15.*

"The larynx from an adult, with the os hyoides: in a fore view are seen the epiglottis above, next the os hyoides, then the thyroid cartilage, and lowest the narrow part of the cricoid. Behind the principal objects are the arytenoid cartilages standing on the basis of the cricoid," with the minute cartilages of Santorini on their apices. The epiglottis is deeply pitted for the reception of mucous glands.

17.20. The Hyoid Bone and Thyroid and Cricoid Cartilages.*Hunterian. T. 16.*

Similar to the preceding, "from a child," the epiglottis and arytenoid cartilages wanting.

17.21. The Cricoid and Arytenoid Cartilages.*Hunterian. T. 17.*

These parts form the framework of the inferior and posterior part of the larynx. "All these preparations of larynx were macerated in water till the muscles and blood were perfectly dissolved and washed away." The ligaments and the bone and cartilages are the only parts left.

17.22. The Muscles of the Larynx.*Hunterian. GG. 50.*

A dissection of the larynx, showing the muscles from the outside. On the left side the thyro-hyoid and crico-thyroid. On the right side the ala of the thyroid cartilage is removed to show the deeper muscles, viz. the lateral and posterior crico-arytenoid and the thyro-arytenoid muscles, indicated by bristles passed beneath them. Only the origin of the arytenoideus muscle is to be seen, as the larynx has been split open behind to show its interior. A piece of the left false vocal cord has been cut out and turned up to show the cavity of the sacculus laryngis.

17.23. The Cavity of the Larynx.*Hunterian. T. 18a.*

The larynx cut open from behind to show the above. The sacculi laryngis are propped open by pieces of wood. The mucous membrane of the trachea is pitted with the orifices of the ducts of the mucous glands.

17.24. The Cavity of the Larynx.*Hunterian. T. 18.*

The larynx laid open from before to show the above.

17.25. The Tongue and Cavity of the Larynx.*Hunterian. GG. 49.*

The tongue and the larynx laid open from behind, highly injected red, showing their relations. On the under surface of the tongue the ranine branch of the left lingual artery is dissected out. Compare No. 21.50.

17.26. The Trachea.*Hunterian. GG. 51.*

The larynx and trachea down to its bifurcation opened behind, showing the structure—rings of cartilage connected by elastic soft

tissue—and the mucous membrane pitted with the ducts of the mucous glands. "It is narrowest at the glottis and widest just below that."

17.27. The Structure of the Trachea. *Hunterian. T. 22.*

A portion of the trachea, the anterior part removed, a ring being left complete at top and bottom, to show the cartilages in section and the soft parts consisting of mucous membrane and elastic ligaments and muscle. The muscular layer cannot be distinguished. From behind, the line of the ends of the cartilages can be seen on either side, and the soft flexible muscular and elastic part which completes the posterior wall of the tube.

17.28. A Ring of the Trachea. *Hunterian. T. 23.*

Showing the anterior three-fourths of the tube supported and kept open by cartilage, the posterior fourth soft and flexible to accommodate itself to the passage of food down the oesophagus, with which it is in contact.

17.29. The Bifurcation of the Trachea. *Hunterian. T. 24.*

A preparation similar to No. 17.27 to show the division into right and left bronchus, and the arrangement of the cartilages at that place.

17.30. The Bifurcation of the Trachea. *Hunterian. T. 73.*

This specimen was formerly catalogued as "Mr. H.'s trachea slit open to show the internal surface inflamed," but, as usual, the colour has been completely removed by the spirit in which it is mounted.

Comparative Anatomy of the Larynx and Trachea.

17.31. The Tongue, Larynx, Trachea, Oesophagus, and Thymus Gland of a Calf. *Hunterian. GG. 46a.*

17.32. The Larynx of the Porpoise. *Hunterian. T. 20.*

17.33. The Larynx of the Turtle. *Hunterian. T. 21.***17.34. Part of the Trachea. Horse.** *Hunterian. T. 26.*

The cartilaginous rings go right round, and even overlap, but are connected behind only by soft parts, mostly loose fibrous tissue. Probably the overlapping is due to shrinking in the spirit. Compare the succeeding.

17.35. Tracheal Rings. Ass. *Hunterian. T. 27.*

The cartilages, as in the preceding, pass right round, the ends almost overlapping.

17.36. The Structure of the Trachea. Horse.
Hunterian. T. 28.

"A portion of the trachea as it gets more into the lung. The cartilages are replaced by membranous or ligamentous substance; the muscular fibres inside also appear longitudinal." Injected red and in turpentine.

17.37. The Structure of the Trachea. Turtle.
Hunterian. T. 29.

The cartilages form complete rings of oval shape.

17.38. Arteries of the Trachea. Calf. *Hunterian. T. 34e.*

A portion of the trachea of a foetal calf, injected red, laid flat, dried and mounted in turpentine. A small artery runs along both edges of each cartilaginous ring, with another between on the membrane, and an abundance of minute cross branches.

(c) *The Lungs.*

17.39. The Pleura. *Hunterian. T. 11.*

A portion of the investing serous sac of the lungs—parietal layer of the pleura—stripped from the chest wall. Injected red, dried, varnished, and mounted on blue paper. It appears highly vascular from the number of vessels running in its deeper layers.

17.40. The Lungs of a Foetus.*Hunterian. T. 6.*

The trachea and lungs of a foetus, injected red, showing the division into lobes; the right into three—upper, middle, and lower; the left into two—upper and lower. They are convex on the back and outside, adapted to the hollows by the sides of the spine and the ribs, and terminate in front in sharp edges which overlap the heart. The left shows a bay in its anterior edge where the heart is left uncovered. They are highly vascular and lobulated, the lobules being kept together by the interlobular connective tissue and the pleura. They are much solidier, and the edges much sharper than after respiration has taken place. The relations of the lungs to the other thoracic viscera is much better seen in the dissections of the foetus, Nos. 10.8-10.14.

17.41. The Lungs of a "Foetus."*Hunterian. T. 7.*

A similar preparation with a portion of the heart.

17.42. The Left Lung of a "Child 3 or 4 years old."*Hunterian. T. 8.*

Injected red.

17.43. The Investing Membrane of the Lungs. The Pleura.*Hunterian. T. 9.*

The left lung "of a child at birth, highly injected red, the pleura turned down to render it visible." Small fragments only turned down.

17.44. Lung of a Still-born Child.*Hunterian. T. 83.*

A portion of a lobe of the lungs "of a stillborn child," injected, arteries red, veins black, trachea and bronchi yellow. The red predominates, the yellow, as usual, having faded.

17.45. Lung of a "Still-born Child."*Hunterian. T. 64.*

Similar to the preceding.

17.46. Lung of a "Still-born Child."*Hunterian. T. 65.*

Similar to the preceding.

17.47. Lung of a "Child at Birth." *Hunterian. T. 63a.*

Injected red to great minuteness.

17.48. Lung of a "Foetus." *Hunterian. T. 65a.*

Injected red by the arteries, black by the veins.

Comparative Anatomy of the Lungs.

(A) MAMMALS.

17.49. The Trachea and Bronchi. Calf. *Hunterian. T. 31.*

"The trachea with its branches in the calf after the surrounding parenchyma had been destroyed by maceration in water; what is now visible is not materially different from the ramification of an artery or vein."

17.50. The Bronchi and their Branches. Calf. *Hunterian. T. 32.*

Similar to the preceding, but injected with red wax, the colour of which has now faded. "At the extremities of the smallest branches appear small grains; these are a congeries of cells as will presently appear." See Nos. 17.58 to 17.67.

17.51. The Lobules of the Lungs. Calf. *Hunterian. T. 33.*

Partly macerated and the pleura stripped off, and the lobules separated from one another.

17.52. The Lobules of the Lungs. Calf. *Hunterian. T. 33a.*

Similar to the preceding, but rather more macerated, and dissected.

17.53. The Lobules of the Lungs. Calf. *Hunterian. T. 33b.*

Similar to the preceding, but injected red, and the lobules not so finely divided.

17.54. The Bronchial Artery. Calf. *Hunterian. T. 34.*

The lungs of a foetal calf macerated and cleaned till only the bronchi and its branches remain. The bronchial artery was injected red, and its branches are now visible running on the walls of the bronchi.

17.55. The Bronchial Artery. Calf. *Hunterian. T. 34c.*

"A portion of the bronchi near the surface of the lungs in a slink calf, after maceration; the branches of the bronchial artery curling along those of the trachea are extremely beautiful."

17.56. The Bronchial Artery and Nerves of the Lungs. Calf. *Hunterian. T. 34d.*

A similar preparation, with the nerves preserved and indicated by bristles. They are seen accompanying the branches of the bronchial artery.

17.57. The Bronchi and Bronchial Artery. Mammal. *Hunterian.*

A portion of the lung of some mammal, injected red by the pulmonary artery, slightly macerated, and the bronchus and its branches partly cleared. Branches of the bronchial artery, also injected red, are seen running on the bronchus.

17.58. The Ultimate Air Vesicles. Antelope. *Hunterian.*

On the jar is scratched "T. 31, antelope," but there is no description corresponding. The specimen consists of a small piece of lung into which mercury has been run through the trachea, then dried and mounted in turpentine. The mercury has flowed into the ultimate air vesicles rather overdistending them. Where the edge of the lung is thin and transparent, the relation of the air vesicles to the bronchioles can be seen, each bronchiole terminating in a little cluster of vesicles. Compare succeeding specimen.

17.59. The Ultimate Air Vesicles. Antelope.*Hunterian. T. 52.*

A portion of lung injected with mercury by the trachea, like the preceding. These two specimens are placed first in this part of the series, because in the old catalogue it is stated that "the air cells are like those in the human lungs." The human specimens have unfortunately disappeared from the collection. In turpentine.

17.60. The Ultimate Air Vesicles. Calf. *Hunterian. T. 54.*

Similar to the preceding. The air vesicles are very small. In turpentine.

17.61. The Ultimate Air Vesicles. Lion. *Hunterian. T. 47.*

A portion of the lung, the pulmonary artery injected red, and mercury run in by the trachea, as in the preceding. The air cells are much larger than in the human subject. In turpentine.

17.62. The Ultimate Air Vesicles. Lion. *Hunterian. T. 48.*

Similar to the preceding. In turpentine.

17.63. The Ultimate Air Vesicles. Tiger. *Hunterian. T. 49.*

A portion of the lung injected with mercury, and mounted in turpentine. The air cells even larger than in the lion's lung.

17.64. The Ultimate Air Vesicles. Cat. *Hunterian. T. 55.*

A portion of the lung injected with mercury by the trachea; in turpentine. The air cells very large for the size of the animal.

17.65. The Ultimate Air Vesicles. Cat. *Hunterian. T. 56.*

Similar to the preceding. In turpentine.

17.66. The Ultimate Air Vesicles. Porpoise.*Hunterian. T. 45.*

The thin edge of the lung of the porpoise, the trachea injected with mercury, rendered transparent by being mounted in turpentine.

17.67. The Ultimate Air Vesicles. Porpoise.*Hunterian. T. 46.*

Similar to the preceding. In turpentine.

(B) BIRDS.

17.68. The Lungs of the Pigeon.*Hunterian. T. 10.*

The trachea and lungs of a pigeon, with the outer layer dissected off in places, showing the cavities of the air vesicles. Bristles are placed in the orifices of the air passages leading from the bronchi to the cavities of the bones and the air spaces of the abdomen.

(C) REPTILES.

17.69. The Lung of the Turtle.*Hunterian. T. 36.*

"One half of the lung of the turtle, after the pulmonary artery had been injected red, and to great minuteness. In this preparation the trachea and its branches are divided longitudinally, and the whole organ seems to be a cellular network or sponge; on the posterior side some absorbents are filled with mercury, but do not appear unless held between you and the light, from the thickness and opacity of the pleura."

17.70. The Lung of the Turtle.*Hunterian. T. 39.*

Not described. A large lung with part of the trachea, probably of the turtle; the outer layer partly removed to show the air vesicles. The pulmonary artery injected red.

17.71. The Lung of the Turtle.*Hunterian. T. 37.*

Both halves of the lung of a young turtle, injected red, dried, split, and mounted in turpentine, showing its spongy structure and the thick pleura.

17.72. The Lung of the Turtle.*Hunterian. T. 38.*

A small portion, similar to the preceding. In turpentine. The jar also contains a coil of intestine, injected red.

17.73. The Lung of the Turtle. *Hunterian. T. 41.*

A small portion uninjected, "slit open to look on the network of cells."

(D) AMPHIBIA.

17.74. The Lungs of the Frog. *Hunterian. T. 35.*

Injected red, dried, cut open and mounted in turpentine. "Each lung is a bladder, which on the inside is formed into cells like a honeycomb." These are of very various sizes, the smallest being little bigger than pin points. "It gives the most simple idea of lungs."

(E) THE RESPIRATORY APPARATUS OF FISH.

17.75. The Gills of the Codfish. *Hunterian. T. 66a.*

Injected red to great minuteness, showing their high vascularity.

17.76. The Gills of the Codfish. *Hunterian. T. 66b.*

A small piece, similar to the preceding.

SERIES 18.

INJURIES AND DISEASES OF THE RESPIRATORY ORGANS.

SECTION I. THE AIR PASSAGES.

I. CONGENITAL DEFECTS AND MALFORMATIONS.	
<i>Harelip and Cleft Palate,</i>	1-10
II. INJURIES,	11
III. CHANGES DUE TO CONDITIONS AFFECTING THE NUTRITION.	
<i>Atrophy of the Nasal Mucous Membrane,</i>	12
IV. CHANGES DUE TO INFLAMMATORY DISEASE.	
<i>Syphilis of the Nose,</i>	13
<i>Thrush of the Larynx,</i>	14
<i>Diphtheria,</i>	15-16
V. TUMOURS,	17-18

SECTION II. THE LUNGS AND PLEURAE.

I. CONGENITAL DEFECTS AND MALFORMATIONS.	—
II. INJURIES,	—
III. CHANGES DUE TO CONDITIONS AFFECTING THE NUTRITION.	
<i>Collapse of the Lung,</i>	19
<i>Haemorrhagic Infarction,</i>	20

IV. CHANGES DUE TO INFLAMMATORY DISEASE.

<i>Pleurisy,</i>	21-23
<i>Casts of the Bronchi,</i>	24
<i>Tuberculosis,</i>	25-38
<i>Empyema,</i>	34-36

V. TUMOURS,	39-40
-------------	-------

SECTION I. THE AIR PASSAGES.

I. CONGENITAL DEFECTS AND MALFORMATIONS.

18.1. Cleft Palate in a "Foetus at Three Months."*Hunterian. GG. 56.*

The head of a foetus, showing a cleft of the soft palate, which might later in the natural course of development have united. As William Hunter says in the old catalogue, "it shows that the soft, as well as the hard, palate is originally fissured, and that the two halves grow together afterwards. Accounts for the frequency of harelip."

18.2. Cleft of Soft Palate and Uvula. *Hunterian. GG. 59.*

The face of a child injected red, the upper part of the head removed so as to show the roof of the mouth and pharynx, from above and behind. The soft palate is cleft up to the septum nasi, and the uvula is double, that on the right being slightly the larger.

18.3. Cleft of Soft Palate and Uvula.*Dr. Allen Thomson's Collection.*

Similar condition to the preceding, seen from behind. The two halves of the uvula fall together, so that it appears as if there were simply a perforation of the soft palate in front of them.

18.4. Incomplete Cleft Palate.*Hunterian. GG. 60.*

The face of a child injected red, the cheeks cut away and the mouth widely opened, to show a cleft of the soft and part of the hard palate. There is only one uvula--on the right side. About

1 cm. of the base of the vomer can be seen in the median line, showing the extent to which the hard palate had failed to unite with it.

18.5. Incomplete Cleft Palate.

Hunterian. GG. 61.

A similar preparation from an older child. The failure to unite is more extensive, including about half of the hard as well as the soft palate. The septum nasi also appears defective, only a ridge on the roof of the naso-pharynx being seen through the cleft. The tongue has almost got behind the palate.

18.6. Cleft Palate and Single Harelip.

Dr. Allen Thomson's Collection.

The head of a very young foetus, showing the above. The defect is on the left side entirely, the right half of the palate and the vomer having united completely. The cleft involves lip and palate from back to front.

18.7. Single Harelip and Cleft Palate.

The head of a child injected red, showing a very wide single harelip, extending into the right nostril. There is a cleft palate, but it is not well shown, the parts being all in their natural position.

18.8. Harelip and Cleft Palate. Anencephalia.

Hunterian. GG. 62.

The head of an anencephalic foetus, injected red, opened behind to show the cavity of the cranium, and the cheeks split from the corners of the mouth to show the palate. The cleft extends from the back to the front, where the two sides seem to meet, and the harelip does not extend quite into the nose; the exact condition is, however, obscured by disease or decomposition having partly destroyed the nose and the edges of the lips and gums. In the roof of the mouth the edge of the palate is seen on either side separated from a well-formed septum nasi by only a narrow fissure. The uvula is double.

18.9. Double Harelip and Cleft Palate.*Hunterian. GG. 63.*

The anterior half of the head of a child, the brain removed, and the mouth slit towards each ear. The uvula is double, and the hard palate has failed to unite with the vomer on both sides; the premaxilla has united with the maxillary processes, but only by a narrow strip of soft tissue, and it projects considerably, and is turned upwards. The harelip is double and extends into the nostril on either side of the premaxilla.

18.10. Double Harelip and Cleft Palate.*Dr. Allen Thomson's Collection.*

The head of a child, the mouth slit back to the ears to show the above. An extreme degree of the condition, there being hardly any palate. The base of the vomer, considerably expanded, forms a sort of roof to the mouth. The premaxilla, carried on the end of the vomer, projects in the usual way below the point of the nose.

II. INJURIES OF THE AIR PASSAGES.

18.11. Wound of the Air Passages. Cut Throat.*Hunterian. GG. 50a.*

"The hyoid bone, larynx, and portion of trachea with pharynx, from a man who cut his own throat, and was recovering, but died from some other accident (Bengal)." The wound has cut across the thyro-hyoid membrane, dividing the epiglottis about its middle. The relations of the parts are very much altered. The skin has grown deeply in, and has united with the mucous membrane, so that a permanent opening into the trachea would probably have remained. Two bristles mark the outer corners of the wound. Two other bristles show the halves of the hyoid bone, which has been divided to show the interior of the larynx. The upper part of the epiglottis is drawn up to one side, and is attached to the left half of the bone. The glottis seems to be swollen and narrowed. A wound in this position readily opens the larynx, but it is not, as a rule, immediately fatal, as it fails to reach the great vessels.

III. CHANGES IN THE AIR PASSAGES DUE TO ALTERATIONS OF NUTRITION.

18.12. Atrophy of the Nasal Mucous Membrane.

Dr. Allen Thomson's Collection.

There is no history of the specimen, which consists of a section of the base of the skull, showing the outer wall of the right nostril, which illustrates the above condition. The lower turbinate bone is small, and the middle and upper have quite disappeared. Bristles are placed in the orifices of the Eustachian tube and antrum.

IV. INFLAMMATORY DISEASES OF THE AIR PASSAGES.

18.13. Syphilis of the Nose. Destruction of Septum.

Hunterian. LL. 58.

"Ulceration and thickening in Schneider's membrane, from the lues venerea. (Patient in Westminster Hospital.)" The specimen shows the left portion of the nose, including the septum; the other part is lost. "The septum narium, about the middle and lower part, gone before and behind, excepting one pillar about the middle; the disease was getting better, and the (mucous) membranes (of the two sides of the septum) had united at the anterior and posterior edges. The mouths of the Eustachian tubes were much thickened." The turbinate bones have also been destroyed. The external parts of the nose are not preserved.

18.14. "Thrush" affecting the Larynx. *Hunterian. GG. 45b.*

Tongue with larynx, trachea, and bronchi laid open. "In a child who died of thrush, five years old. (Dr. Garthshore?)" There is a small patch like a piece of false membrane on the left vocal cord, and two others below it. Possibly in the fresh state it was a spot of thrush fungus. "Tongue furred, right bronchus obstructed by enlargement of the bronchial glands."

18.15. Diphtheria affecting the Trachea. *Hunterian. T. 70.*

The trachea and beginning of the bronchi "of a child who died of croup or cynanche stridulosa"; laid open. "The pos-

terior half is turned down to show the coagulable lymph (diphtheritic exudation), plugging up the trachea entirely," and extending even into the bronchi.

**18.16. Diphtheritic Exudation from the Trachea. Ex-
pectorated.** *Hunterian. T. 72.*

"Two pieces of coagulable lymph putting on the appearance of tubes coughed up from the lungs"—two pieces of false membrane forming tubular casts of the trachea and beginning of the bronchi. Compare No. 18.24, Fibrinous Casts of the Bronchi. Figured in Matthew Baillie's *Engravings*, Fasc. II., Pl. II., fig. 2.

V. TUMOURS OF THE RESPIRATORY PASSAGES.

18.17. Mucous Polypi of the Nose. *Hunterian. GG. 55a.*

"The right side of the face, cavity of the nose seen on the one side, and antrum of Highmore laid open on the other. Two polypi are seen hanging in the cavity of the nose, under os turbinatum superius (middle turbinate bone), and covering the passage into the antrum. The membrane of the antrum is thickened into a similar substance, as if the polypous disposition had spread over its whole extent." The mucous membrane of the lower turbinate is also thickened and oedematous.

18.18. Carcinoma of the Larynx. *Jeffray Collection, 104.*

A note on the jar says, "Larynx, destroyed by ulceration. The voice was rendered hoarse and deglutition difficult, leading to a suspicion of stricture of the oesophagus." The specimen hangs by the mucous membrane of the root of the tongue. The ulceration is confined to the inside of the larynx; the epiglottis is completely, and the false cords partly destroyed; the true cords are unaffected except at their posterior ends, where there is some thickening of the mucous membrane. Microscopic examination unsatisfactory: appears to be a carcinoma. (MS. Notes, J.H.T., p. 59.)

SECTION II. LUNGS.

I. CONGENITAL DEFECTS AND MALFORMATIONS.

Specimens wanted.

II. INJURIES TO THE LUNGS.

Specimens wanted.

III. CHANGES DUE TO ALTERATIONS OF NUTRITION AND
VARIOUS LOCAL CAUSES.**18. 19. Consolidated Lung.**

Hunterian. T. 86.

"A portion of the lung consolidated into a mass like the liver, where, of course, the air-cells were nearly obliterated. From a woman in the dissecting room." The lung retains a certain degree of the natural spongy texture; the consolidation does not appear to be pneumonic, but rather what would result from compression by pleuritic effusion, or collapse from obstruction of a bronchus. Microscopic examination gave doubtful result, but favoured the idea that the condition was pneumonia at an early stage. (MS. Notes, J.H.T., p. 58.)

18. 20. Haemorrhagic Infarction of the Lung.

Dr. Allen Thomson's Collection.

This specimen, of which there is no history, consists of a portion of a lobe of the lung, showing a large haemorrhagic infarction. It is of a deep brown colour, of triangular shape, its base at the surface of the lung corresponding with the area of distribution of a branch of the pulmonary artery. At its apex the artery is seen laid open; it is filled with soft blood-clot, and white thrombus adhering firmly to its walls and completely obstructing it.

IV. ALTERATIONS DUE TO INFLAMMATORY DISEASES.

18. 21. Fibrinous Exudation of Pleurisy. *Hunterian. T. 75a.*

"A portion of the lungs from a patient who had general inflammation of the thorax, the lungs are encrusted both on the side

next the heart and on that next the ribs with thick coagulable lymph" (fibrinous exudation). The lung tissue is somewhat compressed.

18.22. Fibrous Adhesions of the Pleura. *Hunterian. F. 8.*

"Portions of two distinct lobes of the lungs, united by an adhesion in consequence of inflammation." The lobes, as the result of a pleurisy, have been glued together by fibrin, which has been organized and replaced by a band of vascular fibrous tissue. The blood-vessels are rendered visible by injection with vermilion.

18.23. Fibrous Adhesions of the Pleura. *Hunterian. F. 11.*

Similar to the preceding, stretched on a piece of lead.

18.24. Fibrinous Casts of the Bronchi. Expectorated.

Hunterian. T. 69.

"Coughed up from the lungs." The origin of such casts is obscure.

Tuberculosis of the Lungs: Phthisis Pulmonalis.

18.25. Miliary Tubercles in the Lungs. *Hunterian. T. 78a.*

"A portion of the lungs, on the surface of which the small beginnings of tubercles are seen; some of them are certainly cheesy, like the scrofulous absorbent glands." (Compare Nos. 13.2 to 13.4, Tuberculosis of Lymphatic Glands.) The pleura has been cut away over the tubercles, which are very small and few in number.

18.26. Miliary Tubercles in the Lungs. *Hunterian. T. 79.*

"A small slice of lung, showing abundance of small tubercles. The lymphatics on the outside of the lung injected with mercury."

18.27. Miliary Tubercles in the Lungs. Pneumonic Consolidation.

Hunterian. T. 80.

"A large portion of tubercles, universal, and making the lungs as solid as a piece of liver." There are numerous minute tubercles

scattered through the lung, which have nowhere undergone caseation. They are recognized from the surrounding tissue, which appears to be consolidated by some process of the nature of pneumonia, by their more homogeneous and solid appearance and slightly deeper brown colour. In the lower part of the specimen there is a haemorrhage. There are a few minute flakes of fibrin on the pleura. The larger blood-vessels are injected red.

18. 28. Tuberculosis of the Lungs. Phthisis Pulmonalis.
Stage of Caseation. *Hunterian. T. 81.*

A section of lung crowded from top to bottom with caseating tubercles, here and there showing signs of breaking down, and a few small cavities. The pleura is covered with fibrin—a secondary pleurisy.

18. 29. Tuberculosis of the Lungs. Phthisis Pulmonalis.
Formation of Cavity. *Hunterian. T. 81a.*

A small portion of lung with numerous caseous tubercles, and breaking down into a large ragged cavity.

18. 30. Tuberculosis of the Lungs. Phthisis Pulmonalis.
Hunterian. T. 78b.

“A large branch of the trachea cut open, which communicated with a collection of pus near the lower part of the lungs.” A mass of caseating tubercles is also seen near the root of the lung. Most of the surrounding pulmonary tissue appears healthy.

18. 31. Tuberculosis of the Lungs. Cavities. “Empyema.”
Hunterian. T. 76.

A portion of the outer surface of one of the lungs, with parts of the adjacent ribs, injected red, showing the above. There are a number of cavities, mostly very near the surface of the lung. Sloughing of the pleura had occurred over two of these, leaving oval perforations (about 10 mm. by 5 mm.), and leading to empyema, probably with pneumothorax. The lower part of the lung is covered by a thick exudation, which had become partly organized (as is shown by the presence of injected blood-vessels), and firmly united

the parietal with the visceral pleura. This has probably been a salutary measure for the patient, both in the way of preventing an earlier rupture of the pleura over other cavities and in the way of limiting the effects of the rupture which did occur.

18.32. Phthisis Pulmonalis. Cavities. Empyema.

Dr. Allen Thomson's Collection.

A lung from a phthisical patient, greatly compressed, and covered with fibrinous exudation, which is thickest on the outer surface. A bristle passed from the outer surface through a small round aperture enters a small cavity, which is in free communication with a bronchus.

18.33. Phthisis Pulmonalis. Cavities. Pneumothorax.

Dr. Allen Thomson's Collection.

A portion of the lung, laid open, showing several cavities, one of which has opened into the pleura, the aperture being indicated by a piece of wood. The lung is extensively affected with tuberculosis, and the pleural surface covered with fibrinous exudation of varying thickness.

18.34. Phthisis Pulmonalis. Empyema. *Hunterian. T. 77.*

"A portion of the lungs on the outside of the pericardium near the diaphragm. The patient died of empyema, and the matter was beginning to ulcerate the external surface of the lungs in the places marked by bristles." ("Patient of Mr. Neilson and Dr. Watson, Lincoln's Inn Fields.")

18.35. Fibrinous Exudation on the Pleura. Empyema.

Hunterian. T. 75.

A portion of the above, "from a patient who died of the empyema."

18.36. Empyema opening externally. *Hunterian. T. 82.*

The specimen, of which there is no history, consists of the sternum, left costal cartilages, and parts of the clavicle and upper nine ribs.

The suppurative process inside the chest has ulcerated through the first, second, third, and fourth intercostal spaces, about 2 to 5 cm. from the sternal border, and spread on the outside of the chest, forming a large abscess or abscesses. Parts of the sternum and of five upper costal cartilages and ribs are denuded of periosteum and deeply eroded. There is no necrosis of bone or cartilage, the erosion having nowhere extended right round the rib.

18.37. Phthisical Cavity ulcerating into the Oesophagus.

Hunterian. T. 84.

"A portion of the trachea and oesophagus, from a consumptive child, injected for blood-vessels in spring, 1778; the lungs were exceedingly ulcerated, and a cavity thus formed in the lungs has made its way also into the oesophagus behind them, destroying its anterior part for more than two inches (5 cm.)."

18.38. Calcareous Plates on the Pleura.

Hunterian.

This specimen was not numbered, but was identified by its resemblance to a figure in Matthew Baillie's *Engravings*, Fasc. II., Pl. III., fig. 2, where it is described as an "ossification of the pleura."

V. TUMOURS OF THE LUNGS.

18.39. Sarcoma in the Lungs. Secondary. *Hunterian. T. 83.*

The specimen is described in the old catalogue, and figured in Matthew Baillie's *Engravings*, Fasc. II., Pl. V., figs. 1 and 2, as "tubercles in the lungs of the size of walnuts, truly scrophulous, but it is the pulpy scrophulous tumour, not the cheesy one." Very uncommon, and "of its tendency to run to suppuration nothing is known." "This patient lost both limbs from similar tumours on them, and, at the time he died, had his left arm in the same situation, though the absorbent glands were not affected (Mr. Watson's patient, Westminster Hospital)." Microscopic examination proves them to be spindle-celled sarcomata. The history is very characteristic of sarcoma, and illustrates its tendency to become disseminated by way of the blood-vessels to the lungs and other parts of the body. (MS. Notes, J.H.T., p. 3.)

18.40. Carcinoma in the Thorax.*Hunterian. T. 85.*

A mass about the size of an orange, formerly described as "portions of the left lobe of the lung, with a scrophulous tumour as big as a child's head at birth, which compressed them so that no air passed into them; the tumour was painful, and killed the patient (Dr. J. Jebbs, Westminster)." Microscopic examination shows it to be a carcinoma. (MS. Notes, J.H.T., p. 3.)

SERIES 19.

THE THYROID AND THYMUS GLANDS AND SUPRARENAL CAPSULE.

<i>Thyroid Gland</i> ,	1-3
<i>Thymus Gland</i> ,	4
<i>Suprarenal Capsule</i> ,	5-14

19.1. The Thyroid Gland.

Hunterian. GG. 52.

Dissection of the thyroid gland and larynx "of a woman," to show the former *in situ*. The two lobes lie on the sides of the thyroid cartilage and trachea, united by the isthmus, which crosses the trachea just below the cricoid cartilage. The narrow process of gland running up from the isthmus towards the hyoid bone is a remnant of the diverticulum of the pharynx, from which the gland was developed. Its other end is seen at the root of the tongue as the foramen caecum (see Series 31). The remains of this structure occasionally give rise to cysts in the middle line of the neck. It is usually described as the obliterated duct of the thyroid gland.

19.2. The Thyroid Gland of a Child.

Hunterian. GG. 53.

Similar to the preceding. Also shows the median process extending upwards from the isthmus. Injected red. Appears to be extremely vascular.

19.3. The Thyroid Gland. Adult.

Hunterian. GG. 53a.

Similar to the preceding, but larger; injected red. No trace of the obliterated duct.

19.4. The Thymus Gland.

Hunterian. S. 78.

"A thymus gland, rather of large size." In the child it is large, but dwindles after the second year, and by puberty has almost disappeared. It occupies the lower part of the neck and the superior mediastinum. See Nos. 10.8 to 10.14, Dissections of the Foetus.

19.5. The Kidney and Suprarenal Capsule of a "Child at Birth."

Hunterian. X. 65.

Injected red. The suprarenal is "about half the bulk of the kidney, and sits like a helmet on the upper end of it, and appears to be exceedingly vascular."

19.6. The Kidney and Suprarenal Capsule.

Hunterian. X. 66.

Similar to the preceding; more finely injected.

19.7. The Kidney and Suprarenal Capsule. "From a Foetus at Six Months."

Hunterian. X. 67.

The suprarenal capsule is larger in proportion to the kidney than at birth; the kidney becomes larger in proportion as growth advances.

19.8. The Kidney and Suprarenal Capsule. "From a Child at Birth."

Hunterian. X. 68.

Section of the above, highly injected red, showing the internal structure. It appears highly vascular.

19.9. The Kidney and Suprarenal Capsule.

Hunterian. X. 69.

The other half of the preceding.

19.10. The Suprarenal Capsule of a Child.

Hunterian. X. 70.

Coarsely injected red. It is divided transversely; shows that it consists of two slightly different tissues arranged as cortex and medulla.

19.11. Section of Adult Suprarenal Capsule.

Hunterian. X. 71.

A slice of the above injected red.

Comparative Anatomy of the Suprarenal Capsule.

19.12. Suprarenal Capsule. Elephant. *Hunterian. X. 72.*

"One half of the renal capsule of the Queen's elephant." It has three lobes, and appears to be composed of two substances arranged as cortex and medulla, as in the human subject.

19.13. Suprarenal Capsule. Elephant. *Hunterian. X. 73a.*

A tranverse section of a lobe of the above, showing the division into cortex and medulla. The medulla is riddled with blood-vessels.

19.14. Suprarenal Capsule. Elephant. *Hunterian. X. 73b.*

Similar to the preceding.

SERIES 20.

DISEASES OF THE THYROID AND THYMUS GLANDS AND SUPRARENAL CAPSULE.

(a) *Thyroid Gland.*

20.1. "Bronchocele." Goitre.

Hunterian. GG. 52c.

A specimen of simple hypertrophy of the thyroid gland, with cystic development. (MS. Notes, J.H.T., p. 56.) Figured in Matthew Baillie's *Engravings*, Fasc. II., Pl. I., figs. 1 and 2.

20.2. Malignant Adenoma of the Thyroid Gland. Secondary Infection of Lymphatic Glands.

Hunterian. GG. 52a.

The larynx and trachea and the thyroid gland much enlarged. The enlargement is rather irregular and lobulated, and affects the left side more than the right. There are also a number of greatly enlarged lymphatic glands. In section the tumour presents a mixed appearance, parts having the structure of the thyroid gland undergoing cystic change, while the other parts are of a lighter colour and homogeneous without any cystic development. Parts also appear to be breaking down. Microscopic examination—the structure is that of normal thyroid gland, but in the homogeneous areas the acini are mostly of small size, lined with a few cells of typical thyroid epithelium, and with a very small lumen; here and there they are dilated and filled with colloid material. The section of an affected lymphatic gland shows a structure similar to this last; the loculi are regular, mostly small, but some dilated and filled with colloid material; it is as if the gland were being infiltrated with young thyroid gland tissue. (MS. Notes, J.H.T., p. 55.) "From a patient who died in St. George's Hospital, London."

20.3. Carcinoma of the Thyroid Gland growing into the Trachea.*Hunterian. T. 67.*

The anterior part of the tumour (posterior lost), with the anterior half of the larynx and trachea, the arch of the aorta, and the origins of the great vessels. The whole thyroid gland is affected, but the enlargement is chiefly in the right lobe, which extends from about the middle of the thyroid cartilage to near the bifurcation of the trachea, a distance of 11 cm. In the middle line, resting on the aorta and pressing aside the great vessels, is a mass of enlarged lymphatic glands. In section the tumour appears glandular, but solid, and, except at one or two points, without the dilated loculi full of colloid matter characteristic of the normal thyroid. For a distance of about 5 cm., beginning just below the cricoid cartilage, the tumour has grown through the walls of the trachea, and projects into it in irregular granulation-like projections, considerably narrowing its calibre. On microscopic examination it is found to be a highly cellular carcinoma. (MS. Notes, J.H.T., p. 4.) The thyroid and cricoid cartilages are ossified. "The disease was of one year's standing, and killed the patient." It "occasioned a sense of almost constant suffocation." ("Holbum, Mr. Neilson's patient.")

*(b) Diseases of the Suprarenal Capsules.***20.4. Congenital Smallness of the Suprarenal Capsules. Anencephalic Foetus.***Hunterian. X. 70a.*

"Capsulae from a monster without brain, exceedingly small compared with their kidneys; on one side there appears to be fat only, in place of renal capsula." Compare next specimen.

20.5. Congenital Smallness of the Suprarenal Capsule. Anencephalic Foetus.*Hunterian. X. 70b.*

The other kidney and capsule from the same case; apparently this is the capsule "which appears to be only fat."

20.6. Congenital Smallness of the Suprarenal Capsule. Anencephalic Foetus.*Hunterian. X. 70c.*

Similar preparation from another anencephalic monster. Suprarenal capsule "small, but not wanting."

SERIES 21.

ANATOMY OF THE NERVOUS SYSTEM.

<i>The Spinal Cord and its Membranes,</i>	1-11
<i>The Brain and its Membranes,</i>	12-51
<i>The Dura Mater,</i>	12-19
<i>The Pia Mater,</i>	20-27
<i>The Arachnoid,</i>	28
<i>The Medulla Oblongata and Pons Varolii,</i>	29-36
<i>The Cerebrum,</i>	37-39
<i>The Blood-vessels of Cerebral Cortex,</i>	40
<i>The Base of the Brain,</i>	41
<i>The Cerebellum,</i>	42-48
<i>Head Sections,</i>	49-51
<i>The Cranial Nerves,</i>	52-58
<i>The Peripheral Nerves,</i>	59-65
<i>Comparative Anatomy of the Nervous System,</i>	66-76

(a) *The Spinal Cord and its Membranes.*

21.1. The Spinal Cord and Lower Part of the Brain.

Hunterian (?).

The whole spinal cord with the medulla oblongata, pons Varolii, and part of the cerebellum, the larger vessels injected red, to give a general view of the cord, the nerve roots, and the membranes. The dura mater is left on the posterior surface; in front it is removed, showing the arachnoid with the vessels of the pia mater and the anterior roots of the nerves shining through it.

21.2. The Spinal Cord and its Membranes. Upper Half.*Hunterian. E. 15.*

The upper half of the spinal cord "from an adult human subject," the dura mater opened behind and turned aside, showing the fine transparent arachnoid loosely enveloping the cord. It is separated from the dura mater by a space, the subdural space, except where the nerves, passing out, take with them a sheath from it, which unites with the inner surface of the dura mater. The roots of the nerves are seen rising by an anterior and posterior plane of fibres from the antero- and postero-lateral sulci of the cord. In front the dura mater is seen passing out upon the nerves as their outer sheaths; shows also the spinal ganglia formed by the nerves after perforating the dura mater.

21.3. The Spinal Cord and its Membranes. Lower Half.*Hunterian. E. 16.*

The lower half of the same cord with the dura mater opened in front and turned aside, showing the arachnoid membrane and the conical termination of the cord, and the roots of the lumbar and sacral nerves running for some distance within the membranes, forming a bunch of cords of graduated lengths called, from their resemblance to a horse's tail, cauda equina. The arachnoid forms a loose sac enveloping the bunch of nerves, just as in the upper part it envelops the cord, and extending nearly to the bottom of the sac of dura mater, uniting with it only where a nerve passes out.

21.4. The Spinal Cord and its Membranes. The Pia Mater.*Hunterian. EE. 42.*

The upper half of the spinal cord, the dura mater laid open behind, and the arachnoid dissected away through the fine areolar tissue of the sub-arachnoid space to show the pia mater, an opaque white membrane closely enveloping the cord. The bristles are introduced to exhibit the connections between the pia and the dura mater along the sides of the cord called ligamenta denticulata.

21.5. The Cauda Equina and Filum Terminale.*Hunterian. EE. 43.*

The lower half of the preceding spinal cord, the dura mater slit open and turned back; the arachnoid is dissected away

and bristles put under the upper and lower ends of the filum terminale.

21.6. The Spinal Cord, Membranes, and Blood-vessels.

Hunterian. E. 16a.

The vertebral column "of a child," the bodies and spinous processes removed, and the lateral masses drawn somewhat apart to show the above. The arteries are injected red. The dura mater is left behind and removed in front, and its cavity is seen to extend down to the top of the sacrum. The cervical and lumbar enlargements, the anterior roots of the nerves and their passage through the dura mater to the intervertebral foramina, the termination of the cord about the level of the first lumbar vertebra, and the cauda equina are well displayed. The anterior spinal artery is seen running a serpentine course along the pia mater opposite the anterior median fissure. Rising above from the vertebral arteries, and reinforced by branches from the intercostals and lumbar, especially those of the left side, it forms an anastomosis the whole length of the cord.

21.7. The Pia Mater and Arteries of the Spinal Cord.

Hunterian. E. 16b.

The spinal cord "of a child," the dura mater removed, the arteries injected red. At the top are seen the vertebral arteries uniting to form the basilar, and from one of these rises the upper part of the anterior spinal. In turpentine.

21.8. The Blood-vessels of the Spinal Cord.

Hunterian. E. 17.

The spinal cord "of a child," age not stated, the dura mater removed before and behind, but not at the sides. The arteries are injected red, the veins blue. The plexus of veins which lies between the dura mater and the periosteum of the vertebrae is seen on the dura mater about the roots of the nerves. On the cord the veins accompany the arteries.

21.9. The Arteries of the Spinal Cord.

Hunterian. E. 18.

The spinal cord "of a child," the arteries alone injected, the dura mater opened before and behind to show the above.

21.10. The Arteries of the Spinal Cord. *Hunterian. EE. 39a.*

The pons Varolii, medulla oblongata, and upper part of the spinal cord, the arteries injected red, showing the vertebral arteries giving off the anterior spinal arteries, which ramify in the pia mater, anastomosing with branches of the intercostals entering along the anterior roots of the nerves; showing also the origins of the posterior meningeal and cerebellar arteries.

21.11. The Arteries of the Spinal Cord. *Hunterian. EE. 44.*

"A foetal medulla spinalis, finely injected red, dura matral coat removed except on the sides." The spinal cord is proportionately longer, and the cauda equina shorter than in the specimens from older subjects.

*(b) The Brain and its Membranes.**(A) THE MEMBRANES.***21.12. The Dura Mater of the Upper Surface of the Brain.***Hunterian. E. 4.*

The dura mater of the upper surface of the brain injected red, showing the branches of the middle meningeal artery. The dura mater of the brain differs from that of the spinal cord in being also the periosteum of the neighbouring bone. It is much more vascular than that of the spinal cord, but most of its vessels go to the bones of the cranium. It is also split to form venous sinuses, which carry off the blood from the brain, and communicate with the veins of the diploe. See Nos. 21.14 to 21.16.

**21.13. The Dura Mater of the Upper Surface of the Brain.
The Falx Cerebri.***Hunterian. E. 4a.*

A similar preparation, but better spread out, to show also the internal surface and the falx cerebri.

21.14. The Dura Mater and Longitudinal Sinus.*Hunterian. E. 4b.*

The upper half of the dura mater dried and varnished, and the superior longitudinal sinus and a number of veins entering it

filled with red wax. The veins appear to enter the sinus obliquely and in a direction contrary to that of the flow of blood in it.

21.15. The Dura Mater in situ. The Falx Cerebri and Longitudinal Sinus. *Hunterian. E. 6.*

The vault of the cranium "of a child," with the dura mater still adhering, showing the falx cerebri and the superior longitudinal sinus and some of the veins entering it injected red. The inferior longitudinal sinus runs in the lower edge of the falx, but is not injected.

21.16. The Superior Longitudinal Sinus. *Hunterian. EE. 12.*

The sinus is laid open from above, "to show the bridles or frena, which pass from side to side to prevent overdistension."

21.17. The Dura Mater. Pacchionian Bodies.

Hunterian. EE. 12b.

"A portion of the dura mater, the longitudinal sinus laid open, and two bristles in veins, showing that these veins open into the sinus against the current of the blood; also round bodies in clusters, the supposed glands of Pacchionus." These are not glands, but hypertrophied villi of the arachnoid, which have grown through the dura mater and lie in little depressions of the bone, especially along the edges of the lateral sinus.

21.18. The Dura Mater.

Hunterian. EE. 12a.

The arteries are injected red to considerable minuteness. Numerous branches to the bones project on the outer surface; the inner surface is smooth, glistening, and avascular like tendon.

21.19. The Dura Mater.

Hunterian. EE. 12c.

A similar portion, "the arteries and veins full of their own blood. Coagulated by vinegar." Completely decolourized by spirit.

21.20. The Pia Mater.

Hunterian. E. 7.

A portion of the pia mater from the upper surface of the cerebrum, uninjected, showing the outer surface smooth and

shining; the inner, prolonged into fringes which dip into the sulci of the brain, is shaggy with the ends of innumerable blood-vessels, which enter the substance of the brain.

21. 21. The Vascularity of the Pia Mater. *Hunterian. EE. 5.*

A portion of the pia mater from the upper surface of the cerebrum, "the pia mater injected red; the injection has returned by the veins colourless: the processes on its under surface, which pass between the convolutions of the brain, are seen exceedingly vascular." This specimen is figured in Professor Macewen's *Pyogenic Diseases of the Brain and Spinal Cord*, fig. 24, p. 48, to illustrate "the vascularity of the pia mater and its intimate connections with the cerebral tissue."

21. 22. The Vascularity of the Pia Mater. *Hunterian. E. 8.*

Similar to the preceding, but paler in colour. The particles of vermilion have been too coarse to pass the finer vessels, the injection basis (tallow) accordingly appears white in the veins.

21. 23. The Vascularity of the Pia Mater. *Hunterian. EE. 6.*

Similar to No. 20.

21. 24. The Vascularity of the Pia Mater. *Hunterian. E. 8a.*

A similar portion of the pia mater, less finely injected red by the arteries; the vermilion has been dropped in the capillaries, and the tallow which formed the basis of the injection has returned by the veins, which appear injected white.

21. 25. The Pia Mater. *Hunterian. E. 9.*

A portion of the above, the arteries and veins both injected white, showing the vascular fringes.

21. 26. The Pia Mater of the Cerebellum. *Hunterian. E. 18.*

The vertebral and basilar arteries, and the pia mater of the medulla oblongata and inferior surface of the cerebellum, injected

red. It forms fringes projecting into the sulci, and is highly vascular. The arachnoid is seen floating loosely over the pia mater about the medulla oblongata, the subarachnoid space being of considerable extent in that region. Compare No. 21.28.

21.27. The Blood-vessels of the Cerebellum.

Hunterian. EE. 17.

The cerebellum of a child injected red, showing the above; "half dried and put afterwards into spirits." "It gives a fine idea of the great vascularity of cerebellum."

21.28. The Arachnoid Membrane.

Hunterian. EE. 9a.

The medulla oblongata of an adult turned upside down to show the "loose floating" arachnoid membrane. It is suspended by the vertebral arteries, which were divided close inside the dura mater. The arachnoid is not so distinct elsewhere as here; over the cerebral hemispheres it is hardly distinguishable.

(B) THE BRAIN.

21.29. The Medulla Oblongata, Pons Varolii, and Fourth Ventricle.

Hunterian. EE. 21.

A portion of the medulla oblongata and pons Varolii, all the membranes and origins of the nerves and the roof of the fourth ventricle removed. In front are seen the anterior median fissure with the anterior pyramids and olivary bodies. The decussating fibres of the anterior pyramids lie too deep in the fissure to be seen without separating its borders. At the sides of the pons are seen the peduncles of the cerebellum cut short; and behind, the lozenge-shaped fourth ventricle is laid open, showing the posterior median fissure and the fasciculi teretes forming its floor; it is bounded at its upper end by the cut edge of the valve of Vieussens, which formed its roof, and the superior peduncles of the cerebellum ending in the corpora quadrigemina; below, by the posterior pyramids, in the angle between which is the portion of the floor of the ventricle called the calamus scriptorius, with the central canal of the spinal cord opening at its point.

21. 30. The Medulla Oblongata, Pons Varolii, and Fourth Ventricle. *Hunterian. EE. 24.*

Similar to the preceding, but more dissected. There is not so much of the medulla; the olivary bodies are clearer.

21. 31. The Medulla Oblongata, Pons Varolii, and Fourth Ventricle. *Hunterian. EE. 20a.*

Similar to No. 21.27, but including also the crura cerebri. In front of the pons are seen the two corpora albicantia, formed by the doubling of the anterior crura of the fornix. On the floor of the fourth ventricle bristles are placed under the striae acusticae—bundles of fibres which join the auditory nerves. A cut has also been made between the corpora quadrigemina opening the iter a tertio ad quartum ventriculum or aqueduct of Sylvius.

21. 32. The Medulla Oblongata. *Hunterian. EE. 23.*

A portion of the above, to show the olivary bodies and anterior pyramids.

21. 33. The Medulla Oblongata of a Child.

Hunterian. EE. 23a.

Similar to No. 21.27, from a child of five months, showing the olivary bodies and columns of the cord very distinctly.

21. 34. The Medulla Oblongata, Pons Varolii, and Crura Cerebri. *Hunterian. EE. 22.*

The above, with the pia mater, basilar artery, and nerve roots *in situ*, showing their general relations; the fourth ventricle, aqueduct of Sylvius, and third ventricle laid open. The basilar artery lies on the pons Varolii. A little above the pons are seen the corpora albicantia, indicated by a bristle.

21. 35. The Medulla Oblongata and Crura of the Cerebrum and Cerebellum. *Hunterian. EE. 20.*

Dissection showing the above. Part of the cerebellum is left, but the cerebrum is cut away in front of the corpora quadrigemina, which are also cut away on the right side. A bristle is passed

from the third ventricle through the aqueduct of Sylvius into the fourth ventricle, terminating at the point of the calamus scriptorius. A transverse bristle marks the position of the valve of Vieussens, and a third passes under the posterior commissure into the third ventricle. Below, the pons has been cut away, and the surface shows strands of fibres passing up into the crura to go on to the brain. Between the crura lie the roots of the third pair of nerves, and further forward (*i.e.* above, as the specimen hangs) the corpora albicantia, with the orifice of the infundibulum between them and the chiasma or commissure of the optic nerve in front (above). The pituitary body has been cut off from the lower end of the infundibulum.

21.36. The Medulla Oblongata and Mesencephalon.

Hunterian. EE. 22a.

A dissection of the basal and middle region of the brain to show their general relations; the lower surface showing the medulla, pons, and crura cerebri et cerebelli; the upper, the central parts of the cerebellum covering the fourth ventricle, and the corpora quadrigemina and crura cerebri.

21.37. The Whole Brain and Meninges. *Hunterian. E. 3.*

"The whole of the adult human brain. The arteries are injected red, and the blood in the veins is fixed by coagulation in a strong solution of alum and water." It is hung by the dura mater of the right hemisphere and the falx cerebri, the rest of the dura being removed to show the pia mater and the convolutions of the cortex of the cerebrum. On the under surface are seen the medulla oblongata, pons Varolii, cerebellum, the vertebral arteries uniting into the basilar, the carotid arteries and the roots of the nerves, and the Sylvian fissure separating the temporo-sphenoidal lobe from the frontal and parietal lobes. Compare Model of Brain, No. 51.21.

21.38. The Cerebral Convolutions and Sulci.

Hunterian. E. 10.

A portion of the upper surface of the brain, the pia mater removed, and the convolutions a little separated to show the depth of the sulci.

21.39. The Sulci of the Cerebrum. *Hunterian. E. 11.*

A portion of the cerebrum, showing the processes of pia mater dipping down into the sulci; injected, the arteries red, the veins blue.

21.40. The Blood-vessels of the Cerebral Cortex. *Hunterian. E. 12.*

A portion of the cerebrum with its pia mater; the arteries injected red, the veins white with the returning injection, showing the small size and abundance of the nutrient arteries of the cortex. "Shows it exceedingly vascular."

21.41. The Base of the Brain. *Hunterian. EE. 60.*

The base of the brain cleared of membranes to show the origins of the cranial nerves. The pituitary body hangs by the infundibulum, just behind and below the optic chiasma. On the right side the olfactory bulb and the root of the fourth (pathetic), and conjoined roots of the seventh (facial) and eighth (auditory) nerves are indicated by bristles, and on the left, the root of the fifth (trifacial), and the roots of the ninth (glosso-pharyngeal), tenth (pneumogastric), and eleventh (spinal accessory) all three together, and (anterior to the last) that of the twelfth (hypoglossal) are marked with knotted threads. The greater part of the cerebral hemisphere has been removed, laying open the lateral ventricles.

21.42. A Section of the Cerebellum. *Hunterian. EE. 16.*

The specimen hangs by one of the peduncles or crura, and is intended to show the arrangement of the grey and white matter. The sulci are deeper and more regular than in the cerebrum. Beneath the crus, and to its outer side, is seen a small lobule called the flocculus, with a shred of pia mater adhering. The upper surface is readily distinguished by its flatness.

21.43. A Section of the Cerebellum. *Hunterian. E. 13.*

Similar to the preceding, but the plane of section a little further from the median surface, so as to show the central mass of grey matter called corpus dentatum.

21.44. The Cerebellum.*Hunterian. E. 13a.*

A similar portion of cerebellum, slightly macerated to separate the convolutions.

21.45. The Corpus Dentatum of the Cerebellum.*Hunterian. EE. 16a.*

"A section of the cerebellum of a man who had long been mad, and died so. The appearance in the centre of the medullary part, which resembles the section of a supra-renal capsule, was thought to be at first peculiar, but by comparing it with others, it appears to be common though unnoticed." It is the central grey mass of the cerebellum called corpus dentatum.

21.46. The Corpus Dentatum of the Cerebellum.*Hunterian. EE. 16b.*

Another portion of the same.

21.47. The Nutrient Vessels of the Cerebellum.*Hunterian. EE. 19.*

A section of the cerebellum of a very young child, finely injected red. The vessels entering the cerebellar tissue, like those entering the cerebral tissue, are very small. The centre appears very vascular.

21.48. The Nutrient Vessels of the Cerebellum.*Hunterian. E. 14.*

A similar specimen dried and mounted in spirit.

21.49. Sagittal Section of the Head of a Young Woman.*Hunterian. EE. 33.*

The right half of the head, the section slightly oblique, and passing just to the left of the falx cerebri and nasal septum, showing the layers of the scalp, bones of cranium, contents of cranial cavity, and the cavities of the nose, mouth, pharynx, oesophagus, larynx, and trachea. The structures shown are indicated in detail in the accompanying diagram. The mode of preparation of the specimen is unknown, but some means, such

as injecting the vessels with alcohol, must have been used to harden the internal structure before it was cut, as there is no shrinking of the cranial contents, and the relations of the various parts are preserved with remarkable accuracy. It is injected with vermilion, which in a large measure compensates for the decolourizing action of the spirit in which it is mounted.

FIGURE I.—SAGITTAL SECTION OF THE HEAD.

A.C. The Anterior Commissure. *C.Cal.* The Corpus Callosum in section. *C.Q.* The Corpora Quadrigemina. *Cbl.* The Cerebellum, separated from the Occipital Lobe of the Cerebrum by the Tentorium Cerebelli. *Cr.Cr.* Anterior and posterior sections of the Cricoid Cartilage. *Ep.* The Epiglottis. *Fa.Cer.* The Falx Cerebri. *For.* The Fornix, with a fringe of Velum Interpositum floating out below it. *Fr.Si.* The Frontal Sinus. *Gy.For.* Part of Gyrus Fornicatus. *Hy.* The Hyoid Bone. *L.Oc.* The Occipital Lobe of the Cerebrum. *Lar.* The Larynx. *Med.Ob.S.* The Upper Part of the Medulla Oblongata. *Med.Ob.I.* The lower part of the same. *N.Ph.* The Naso-pharynx. *Nas.Sep.* The Nasal Septum. *Oes.* The Oesophagus. *O.C.* The Optic Chiasma. *Op.Th.* Indicates the position of the Optic Thalami. *P.B.* The Pituitary Body. *P.G.* The Pineal Gland. *P.Var.* The Pons Varolii. *Pal.H. and Pal.S.* Hard and Soft Palate; the former shows the root of an incisor tooth in section. *Phar.* The Pharynx. *Sep.Luc.* The Septum Lucidum with an oval portion in the centre removed. *Si.* The Superior Longitudinal Sinus in the upper edge of the Falx. *Sp.C.* The Spinal Cord. *T.* The Tongue. *Th.Cart.* The Thyroid Cartilage. *Th.Gl.* The Isthmus of the Thyroid Gland. *Tr.* The Trachea. The bones of the skull and vertebral column are identified by the shading of their cancellous parts.

21. 50. Sagittal Section of the Head of a Young Woman.

Hunterian. EE. 34.

Left half of the same head as the preceding. From the obliquity of the section, the posterior part of the falx remains with this half, and a thin slice has been removed from the anterior part of the inner surface of the cerebral hemisphere. In the cut surface the cortex and medulla are distinguished by the

difference in vascularity shown by the different depth to which the injection has coloured the two layers. The diagram of the preceding specimen acts as a guide to this also. The absence of the nasal septum allows the turbinate bones of the nose to be seen.

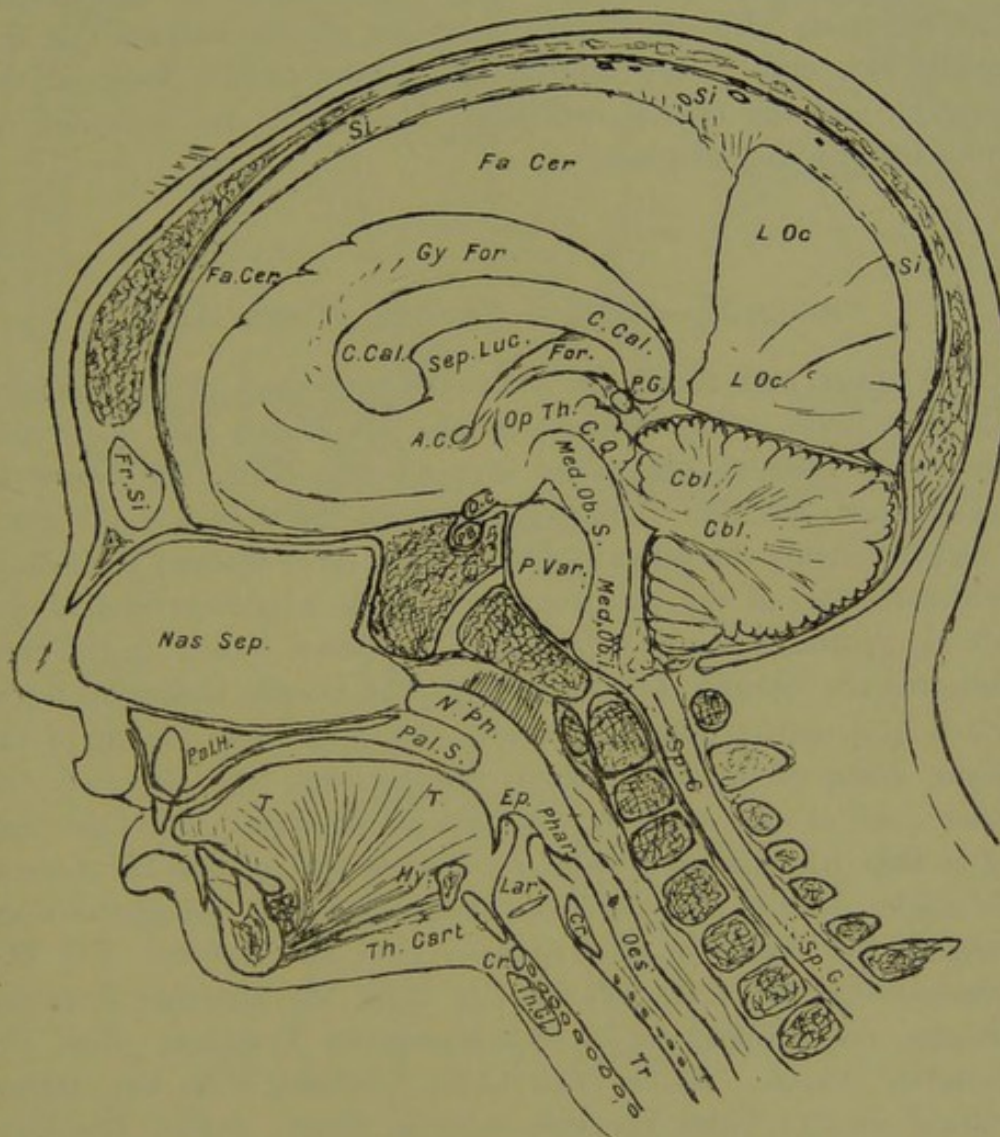


FIGURE I.—Sagittal Section of the Head. (No. 21.49.)

**21.51. Anterior Half of the Head of a Young Woman;
Coronal Section of the Head.** *Hunterian. EE. 35.*

Injected red and hardened *in situ* before cutting, probably by the same method as the preceding, but not so successfully, as there has been some shrinking of the nervous tissues. The plane of the section, which is not quite transverse, passes from a little

behind the bregma above down to and through the base of the skull, so as to divide the right external auditory meatus, but to pass in front of the left. After passing through the base of the skull the plane of the section changes so as to slope backwards in the line of the pharynx, which is laid open, showing the naso-pharynx, palate, base of tongue, and orifice of the larynx. The specimen also shows the relations of the external to the middle ear, and of the middle ear to the middle fossa of the cranium, and the cranial contents. The details are indicated on the accompanying diagram.

FIGURE II.—CORONAL SECTION OF THE HEAD.

The upper part shows the scalp, the bony vault of the cranium, and the brain. The outline of the brain and the sulci, with fringes of vascular pia mater dipping into them, are drawn in heavy lines; the fine lines, curving round the points of the sulci, indicate roughly the passage from cortex (grey matter) to medulla (white matter) of the cerebrum. *C.* in the neighbourhood of the left ear indicates the Carotid Canal in section. *C.Ar.* in the neck indicates the Carotid Artery. *C.Cal.* The Corpus Callosum, below which is a narrow triangular space—the Transverse Fissure of the Brain, occupied by the Velum Interpositum. On the left the outer half of the wing of this space, separated from the rest by a thin white septum—the Fornix—is part of the left Lateral Ventricle. *C.Stri.* The Corpora Striata. *Ep.* The Epiglottis overhanging the Orifice of the Larynx. *Fau.* The Fauces. *I.C.* The Internal Capsules. *M.Aud.* On the right, the External Auditory Meatus, closed internally by the Membrana Tympani. *Nar.* The Posterior Nares. *Op.Th.* The Optic Thalami, with the narrow vertical slit-like Third Ventricle between them. *P.Var.* The Pons Varolii in section near its anterior surface. *Pal.* The Soft Palate and Uvula. *Phar.* The anterior wall of the Pharynx. *Si.* The Superior Longitudinal Sinus cut transversely; the three lines passing from its angles represent Dura Mater and Falx Cerebri. *Syl.F.* On either side is placed between two of the branches of the posterior limb of the Sylvian Fissure. *T.* On the right, the Tympanum, in which parts of the ossicles are seen. *X.* On the left, is placed between the Cochlea and part of the Tympanum.

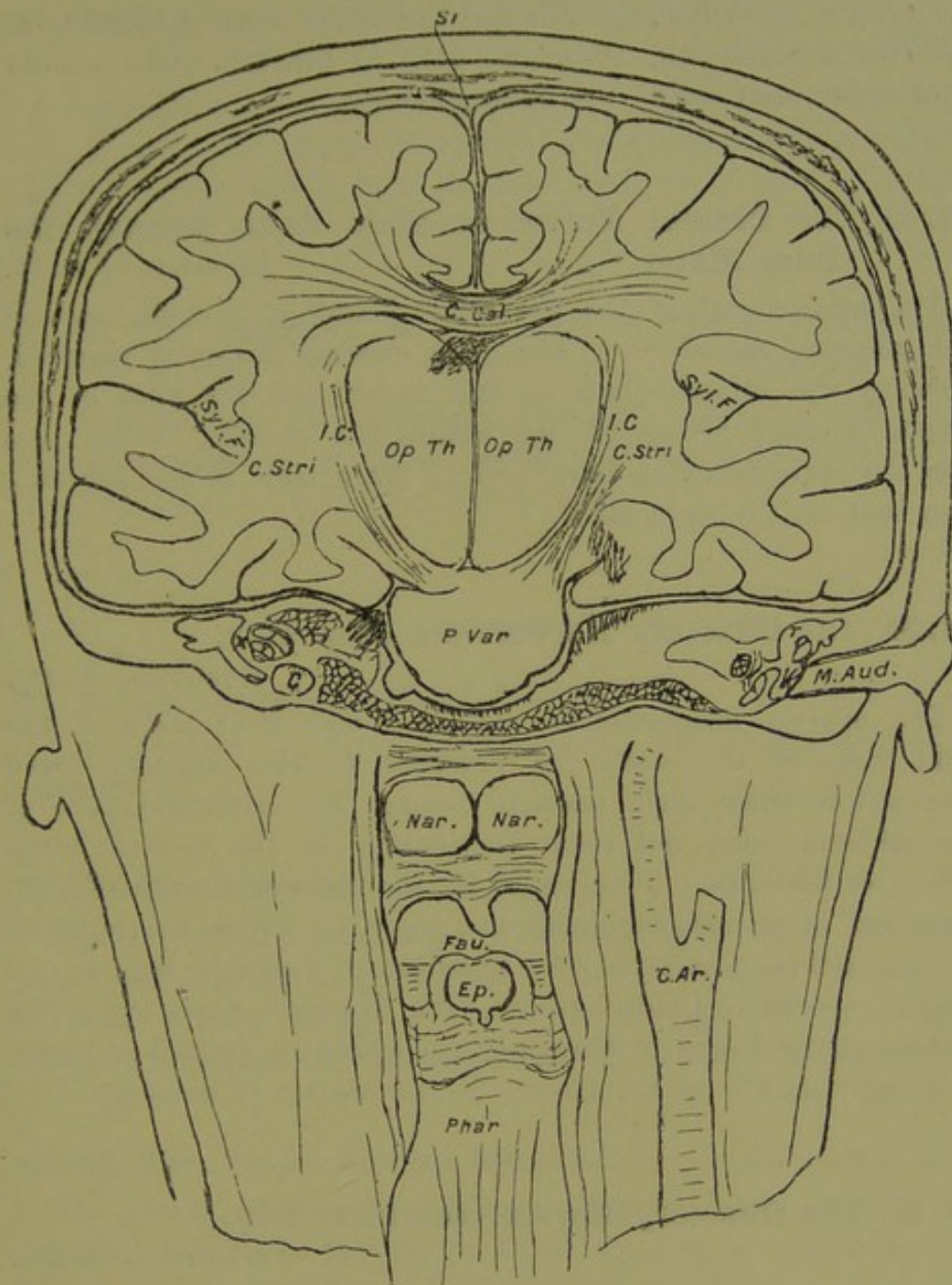


FIGURE II.—Coronal Section of the Head. (No. 21. 51.)

(c) *The Cranial Nerves.***21.52. The Cranial Nerves at their Exits through the Dura Mater.***Hunterian. EE. 13a.*

The middle portion of the skull of a child from the foramen magnum to the frontal bone, injected red, showing the above. The nerves are all indicated by bristles—nine pairs (according to

the system of Willis), the 7th and 8th being marked together as the 7th, and the 9th, 10th, and 11th as the 8th. The carotid arteries are seen beside the optic chiasma.

21.53. The Cranial Nerves at their Exits through the Dura Mater.

Hunterian. EE. 15.

The greater part of the base of the skull of a child, injected red, showing the above. The optic chiasma has been removed, showing the infundibulum in the centre and the ends of the carotid arteries giving off the ophthalmic arteries, which pass into the optic foramina below and to the outside of the nerves—seen best on the right side.

21.54. The Olfactory Nerves—the First Pair.

Hunterian. E. 23c.

The mucous membrane of the outer and inner walls of the right fossa of the nose, the branches of the olfactory nerve dissected to show their passage through the cribriform plate of the ethmoid bone and their distribution in the mucous membrane of the nose. (The shape of the inferior turbinate bone, preserved in its mucous membrane, gives the key to the relations of the different parts of the specimen.) Probably this is the original specimen alluded to in John Hunter's paper "On the Nerves of the Organ of Smelling," published in *Animal Oeconomy*, as being "shown by Dr. Hunter in his courses of anatomy."

21.55. The Olfactory Nerves—the First Pair.

Hunterian. E. 23e.

Part of the mucous membrane of the upper region of the nasal fossae, the branches of the olfactory nerves dissected to show their distribution.

21.56. The Optic Nerves. Decussation.

Hunterian. E. 30.

The optic chiasma, the nerves partially dissected, showing their fibres, some of which appear to decussate. The union of the two nerves in the chiasma is connected with the performance of co-ordinated actions of the two eyes.

21.57. The Sixth Nerve. Abductor of the Eye.*Hunterian. E. 26a.*

A portion of the carotid artery just as it enters the skull, with a portion of the sixth nerve ("motor externus") crossing it and receiving branches from the carotid plexus of the sympathetic ("intercostal").

21.58. The Ganglion of the Root of the Pneumogastric Nerve.*Hunterian. E. 27.*

"A portion of the intercostal and par vagum" (sympathetic and pneumogastric or vagus nerve), showing a ganglion on its root like those of the spinal nerve roots.

*(d) The Peripheral Nerves.***21.59. The Blood-vessels of Nerves.***Hunterian. E. 23.*

Two portions of nerve, injected red, dried and mounted in turpentine.

21.60. The Blood-vessels of Nerves.*Hunterian. E. 23a.*

Similar to the preceding. "Injected with coarse injection, dried and mounted in turpentine on blue paper." "It shows that the arteries of the nerves are very large, and run lengthways in the centre or on the outside of the nerve commonly."

21.61. The Cauda Equina Dissected.*Hunterian. E. 25.*

The cauda equina of a child, its nerves dissected as far as possible into their constituent fibres to give a rough idea of the compound structure of a nerve stem.

21.62. The Cauda Equina Dissected.*Hunterian. E. 25a.*

Similar to the preceding.

21.63. Nerve Stems. The Brachial Plexus.*Hunterian. E. 32.*

Showing a very complex intercommunication between the different nerves.

21. 64. The Branching of Nerves. The Gangliform Expansion of the Median. *Hunterian. E. 26a.*

A portion of the median nerve, with its gangliform expansion "under the annular ligament of the wrist."

21. 65. The Semi-lunar Ganglion of the Sympathetic System. *Hunterian. E. 28.*

The left semi-lunar ganglion lying on the side of the aorta between the coeliac axis and the renal artery.

Comparative Anatomy of the Nervous System.

21. 66. Nerve of Elephant. *Hunterian. E. 22.*

A section of a very large nerve from an elephant, showing it to be made up of a number of nerve bundles.

21. 67. Nerve of Elephant. *Hunterian. E. 23.*

Another portion of the same nerve, partly cut in a longitudinal direction to show the fibres running parallel to one another, bound together with connective tissue.

21. 68. Sympathetic Nerves on Mesenteric Artery. Horse. *Hunterian. E. 33.*

"The superior mesenteric artery of a horse, injected green, showing nerves forming a network on its external coat; this network is termed a plexus."

21. 69. Brain of Turtle. *Hunterian. EE. 37.*

Injected red. The cavities laid open.

21. 70. Brain of Turtle. *Hunterian. EE. 37a.*

21. 71. Brain of Turtle. *Hunterian. EE. 13c.*

The whole brain with a considerable portion of the cranium, upper jaw, and olfactory bulbs.

21.72. Brain of Codfish.

Hunterian. E. 31a.

Dissection of the above, with the base of the skull and part of the spinal cord, to show "that the optic nerves do not blend, as in the human subject, but actually decussate each other." The ear is also opened, showing the ossicle.

21.73. The Olfactory Organ of a Skate. *Hunterian. E. 23b.*

Dissection of the "olfactory nerve from a thornback," showing the large olfactory bulb, with the nerves rising from it "like the feet of a caterpillar," and being distributed on a mucous membrane, plicated into a vast number of lamellae, "resembling in some degree the gills of a fish," which may be compared to the reduplications of the turbinate bones in the mammalia—"corresponding to the human turbinated bones of the nose."

21.74. The Olfactory Organ of the Skate.

Hunterian. GG. 64.

The same part as the preceding, but more fully dissected, so as to show the sac in which lie the lamellae, and their arrangement inside it.

21.75. The Vertebral Column and Spinal Nerves of a Skate.

Hunterian. E. 16b.

A portion of the spine of a skate, dissected to show that it is cartilaginous; and that the anterior and posterior nerve-roots leave by different apertures, and have no ganglia, and unite outside the canal.

21.76. The Nervous System of a Snail.

Hunterian. E. 37.

Dissection showing the above.

SERIES 22.

INJURIES AND DISEASES OF THE NERVOUS SYSTEM.

SECTION I. THE BRAIN AND ITS MENINGES.

I. CONGENITAL DEFECTS AND MALFORMATIONS, . . .	—
II. INJURIES,	—
III. CHANGES DUE TO CONDITIONS, LOCAL OR GENERAL, AFFECTING THE NUTRITION.	
<i>Cerebral Haemorrhage, Embolism, and Thrombosis,</i> . . .	1-2
IV. CHANGES DUE TO INFLAMMATORY DISEASE.	
<i>Pachymeningitis Haemorrhagica,</i>	3-4
<i>Meningitis,</i>	5-6
<i>Tuberculosis and Syphilis,</i>	7-9
V. TUMOURS,	10-13

SECTION II. THE SPINAL CORD AND ITS MENINGES.

I. CONGENITAL DEFECTS AND MALFORMATIONS.	
<i>Spina Bifida,</i>	14-25
II. INJURIES,	—
III. CHANGES DUE TO CONDITIONS AFFECTING THE NUTRI- TION,	—
IV. CHANGES DUE TO INFLAMMATORY DISEASE, . . .	—
V. TUMOURS,	26

SECTION III. THE NERVES.

I. CONGENITAL DEFECTS AND MALFORMATIONS, . . .	—
II. INJURIES.	
<i>Healing of Nerves and Amputation Neuromata,</i> . . .	27-32
III. CHANGES DUE TO CONDITIONS AFFECTING THE NUTRI- TION,	—
IV. CHANGES DUE TO INFLAMMATORY DISEASE.	
<i>Suppuration round Nerves,</i>	33-34
V. TUMOURS,	—

SECTION I. THE BRAIN AND ITS MENINGES.

I. CONGENITAL MALFORMATIONS.

See Series 50, Monsters.

II. INJURIES OF THE BRAIN.

Specimens wanted.

III. CEREBRAL HAEMORRHAGE, EMBOLISM, AND THROMBOSIS.

22.1. Cerebral Haemorrhage. Apoplexy.

Hunterian. EE. 32b.

"A portion of the corpus striatum and thalamus opticus of one side; a coagulum of blood as large as the end of one's finger is seen in the centre of the corpus striatum; there was a coagulum as large as an orange in another part." The colour of the clot has been removed by the spirit. See next specimen for history of case.

22.2. Atheroma of the Cerebral Arteries.

Hunterian. EE. 32a.

"The basilar and carotid arteries within the skull, spread on blue paper to show universal ossification (atheroma with calcareous

infiltration), from a gentleman (Mr. Clive) who died apoplectic." "From the same subject as the last." Illustrates a condition frequently found in cases of cerebral haemorrhage.

IV. CHANGES DUE TO INFLAMMATORY DISEASE.

(a) *Chronic Inflammatory Conditions and Pyogenic Diseases.*

22.3. Pacchymeningitis Haemorrhagica. *Hunterian. EE. 25.*

"The dura mater from a patient who died in Chelsea Hospital, having long had St. Vitus's Dance (Chorea)." A thick membrane has been formed between the dura mater and the pia mater, adhering to the former except where it has been turned down. It covered only one hemisphere of the cerebrum. Compare next specimen.

22.4. Pacchymeningitis Haemorrhagica.

Hunterian. EE. 25a.

"Dura mater from a child of six years old; had the symptoms of worms and hydrocephalus; there is an adventitious membrane evidently from extravasated coagulated blood, and which explains No. 25 (the preceding specimen)." "There had once been inflammation of the dura mater, and of the lining membranes of the ventricles, constituting the first stage of hydrocephalus; the consequence was water in the ventricles to a considerable amount. (Dr. Saunder's case.)" (MSS. lost.) Microscopic examination shows the characteristic appearances of pacchymeningitis haemorrhagica, viz. a layer of blood-clot between two layers of connective tissue, the blood lying in spaces among thin fibrous septa not lined by endothelium. (MS. Notes, J.H.T., p. 47.)

22.5. Bony Spicules in the Dura Mater. Acute Mania.

Dr. Allen Thomson's Collection.

A portion of the dura mater with the falx cerebri, from a case of acute mania, showing a number of spicules of bone—projecting from the inner surface of the dura mater near the falx on both sides.

22.6. "Diseased Brain."*Hunterian. EE. 29.*

"A portion of diseased brain to show inflammation of the cortical substance. (Case unknown, dissecting-room.)"

*(b) Tuberculosis and Syphilis of the Brain.***22.7. Tubercular Nodules of the Brain.** *Hunterian. EE. 26a.*

"Five tubercles strung upon a thread; they are hard and of the scrofulous kind; found in the brain of a child injected for blood-vessels—the largest as big as a walnut, the smallest like a very large pea." Microscopic examination shows that, like most of the specimens described as "scrofulous" in the former catalogue, they are tubercular neoplasms, and consist of tubercles and caseous material, with a good deal of firm fibrous tissue. (MS. Notes, J.H.T., p. 48.)

22.8. Tubercular Growth in the Pons Varolii.*Hunterian. EE. 30.*

Part of the medulla, crura cerebelli, and crura cerebri, and the pons Varolii, which has been sliced parallel to the medulla, and the under portion turned up. The whole of the pons is occupied by the new growth, consisting of strands of firm tissue, with friable breaking-down material between, and a capsule similar in texture to the firm strands. On microscopic examination the supposed capsule is found to be the remains of the lower layers of the pons; the rest consists of bands of recent tubercles, with caseous material between them. Formerly described as "Suppuration of the tuberculum annulare, producing palsy of the upper extremities with some hydrocephalic symptoms, and killing in about two months." ("Dr. Cooper's case wrote out and drawn.") (MS. Notes, J.H.T., p. 49.)

22.9. Gumma of the Pia Mater.*Hunterian. EE. 25a.*

The new growth consists of a sort of membrane adherent to the dura mater, and replacing the pia mater, with a number of nodules of irregular size and shape, which must have lain in hollows on the surface of the brain. It is injected red, and the vessels of the dura mater and fringes of pia mater are seen to

be abundant, but very few vessels enter the new growth. On microscopic examination it is found to consist of round masses, apparently of cellular tissue more or less necrosed, separated by strands of fibrous tissue traversed by a few large blood-vessels—a gumma. (MS. Notes, J.H.T., p. 46.)

V. TUMOURS OF THE BRAIN AND MENINGES.

22.10. Fibroma of the Dura Mater.

Hunterian.

Not described. The dura mater of the vault of the cranium and the falx cerebri. Close to the falx a round tumour between 2 and 3 cm. in diameter, attached to the dura mater by a narrow base, projects inwards upon the brain. It is hard, and on microscopic examination is found to be a fibroma. (MS. Notes, J.H.T., p. 54.)

22.11. Psammoma of the Choroid Plexuses.

Hunterian. EE. 31.

“Plexus choroides of either side, with some hard nodules in them. (Case unknown.)” They are composed of fibrous tissue, with round grains of sand, like miniature calculi, embedded in it, and numerous blood-vessels. (MS. Notes, J.H.T., p. 51.)

22.12. Psammoma of the Choroid Plexuses.

Hunterian. EE. 32.

The choroid plexuses of the lateral ventricles, showing a pair of round nodules similar to the last, but larger. “From a woman who died mad.” (MS. Notes, J.H.T., p. 52.)

22.13. Tumour of the Brain, involving the Lateral Sinus.

Hunterian. EE. 28.

“Inflammation and suppuration with ulcer in the posterior part of the posterior (occipital) lobus cerebri; the dura mater near the lateral sinus was corroded, and the sinus nearly dissected round.” The sinus is opened; it is occupied by a blood-clot. The bulk of the tumour is inside the dura mater, but has infiltrated it, and appears on the outside also. On microscopic examination the

section shows the dura mater with a great deal of blood in masses intersected by strands of fibrous tissue, and masses of very cellular tissue, apparently spindle-celled sarcoma, on both sides of it; badly preserved. (MS. Notes, J.H.T., p. 50.) "(Mrs. Bell's case); died suddenly: there were other tumours externally on the (skull?); suspected venereal disease. (Case wrote out.)" (MS. not found.)

SECTION II. THE SPINAL CORD AND ITS MENINGES.

I. CONGENITAL DEFECTS AND MALFORMATIONS.

22. 14. Spina Bifida.

Hunterian. EE. 48.

Three lumbar vertebrae, sacrum, and coccyx of a foetus cleaned, showing the condition of the vertebral column in spina bifida. The arches are deficient, leaving an oval gap extending from the third lumbar spine down to the lowest arch of the sacrum. The opening in the vertebral canal is, however, often much less extensive.

22. 15. Spina Bifida. Meningocele.

Hunterian. EE. 47.

The lower part of the trunk of a female child, the viscera removed, showing a fairly large spina bifida, which was opened from behind by Professor Cleland (1884), and the spinal cord and lumbar nerves displayed by removal of the bodies of the vertebrae. In the account of it, which he has given in "The Treatment of Spina Bifida," by James Morton, M.D., it is stated that the sac was entirely covered with skin. This is somewhat thinner over the top than on the sides of the tumour. In the interior the sac shows, between the fourth and fifth lumbar vertebrae, a depression, in which is seen, covered by the lining membrane, the lower end of the cord and some nerve roots, while to the right of these is a communication with the arachnoid (subdural) space. In front is seen a well-formed cord, with the nerve roots of the lumbar and sacral plexuses coming off from it. The cord terminates on a level with the top of the gap. The lumbar nerves pass out horizontally, or nearly so, from the cord. The sacral nerves are small. They slope downwards in the usual way, forming a very short and imperfect sort of cauda equina. The tumour is clearly a meningocele. It is entirely behind the spinal cord and nerves.

22. 16. Spina Bifida. Meningocele. *Hunterian. EE. 49a.*

The lower region of the spinal column with the soft parts, showing a spina bifida in the sacral region, laid open from behind. The spinal cord is attached to the base of the tumour, not having been retracted in the normal manner, as the growth of the bones outstripped that of the cord. The cavity of the tumour shows, "on the deep side, a slight linear depression," by which it communicates with the subdural space by a small aperture. The base to the right of this is dissected away, showing a large gap in the vertebral arches, like in No. 22. 14, and the "sacral nerves lying normally, and rising from a level above the linear depression." They run straight from the cord nearly horizontally to their foramina, without entering the tumour sac. The quotations are from the above-mentioned paper by Professor Cleland, in Morton, "On Spina Bifida."

22. 17. Spina Bifida. Meningo-myelocele.*Hunterian. EE. 49.*

Lower part of the trunk of a foetus, part of the vertebrae and sac removed to show its interior. The cord passes out, by a gap opposite the meeting of the 4th and 5th lumbar vertebrae, into the sac, and is attached to its apex, which is drawn down and puckered into a shape like the umbilicus. The central part of the surface of the tumour is a soft tissue, which is not skin. In the centre of this is a narrow foramen leading into the cord; marked with a bristle.

22. 18. Spina Bifida. Meningo-myelocele.*Hunterian. EE. 49b.*

The lower part of the vertebral column and adjacent soft parts of a foetus, showing a spina bifida dissected. The gap in the vertebral arches extends from the top to the bottom of the sacrum. The spinal cord passes out to the apex of the tumour, which is umbilicated at that point. A considerable area round the umbilication is not skin. A bristle is passed from it into the central canal of the cord. The spinal nerves rise from the apex of the sac, and traverse its cavity to their foramina. Compare succeeding specimens.

22.19. Spina Bifida. Meningo-myelocele.*Hunterian. EE. 50.*

Lumbar and sacral portions of the vertebral column of a child with adjacent soft parts, showing a spina bifida laid open. The sac is fully larger than a walnut. A considerable area of its apex is composed of soft membrane, continuous with the skin. The whole length of the arches of the sacrum, as in the preceding, is widely open. The end of the spinal cord passes out across the cavity of the tumour to the membranous area, from which the nerve roots spring and recross it to their foramina. As described by Professor Cleland, "the right and left roots occupy a complete mesial septum, which broadens at the deep part, where the roots deviate to their respective sides." In the mesial line, towards the upper part of the membranous area, is a little foramen, into which a fine bristle was passed for a considerable distance up the spinal cord—the central canal of the cord. The cavity of the sac is clearly the subdural space; the effusion "has been poured only into the right and left halves of the space behind the nerve roots, while the anterior space, the situation for which is within the septum, has remained undeveloped."

22.20. Spina Bifida. Meningo-myelocele.*Hunterian. EE. 51.*

The left half of the lower part of a foetus, showing the above in section. Injected red. The external tumour is very small. It is situated over the sacrum; most of its wall is membranous, and the membrane is decidedly vascular. The cord becomes very small some distance above the tumour, but it runs out into the sac in the usual way; and from the membranous area the nerves rise and run forwards and upwards across its cavity to their foramina.

22.21. Spina Bifida. Meningo-myelocele.*Hunterian. EE. 55.*

Part of the trunk of a foetus, showing a spina bifida of considerable size situated over the lower lumbar and upper sacral vertebrae. The greater part of the sac is a thin, soft, translucent membrane, continuous with the skin. The spinal cord, decidedly reduced in size, passes out to the apex of the sac, which is dimpled, the dimple being the mouth of a sinus which can be traced for about an inch into the cord—marked with a bristle. The nerves are seen very distinctly passing from the membranous wall across the cavity to their foramina

of exit. The lining of the sac is evidently continuous with the dura mater, and the cavity is an expansion of the subdural space.

22.22. Spina Bifida. Meningo-myelocele.

Hunterian. EE. 56.

"A spina bifida, very large, as one's fist nearly; the outward part of the sac beginning to ulcerate: the bag would have burst and killed the patient soon." The tumour has a trilobate appearance, due to two grooves passing over it in a longitudinal direction. The two lateral lobes to right and left are covered by skin; the median lobe, about 3 cm. wide, is covered by soft membrane of the usual kind. The lateral regions have been opened, showing that the cord passes out of a small gap about the level of the first and second lumbar vertebrae, and runs out in the membranous area of the sac; the grooves correspond to the two lines of nerves, passing back across the sac to the invertebral foramina. They form a pair of series, with a considerable space between. At the upper part of the membranous area is the ulceration referred to above, which opens into a locule large enough to admit the tip of the little finger, which, as Professor Cleland has pointed out, "is continued down from the interior of the cord, forming an elongated syringocele" (see No. 22.15 for reference). This throws much light upon the nature of the little foramina seen in Nos. 22.17 to 22.21.

22.23. Spina Bifida. Meningo-myelocele. —

History unknown. The trunk of a child injected red, the anterior parietes and viscera removed. A large thin-walled spina bifida in the lower lumbar region has been laid open by a crucial incision, and the bodies of the vertebrae removed in front, showing the relations of the nerves to the sac and lumbar and sacral plexuses. The spinal cord, marked by a bristle placed behind it, passes out into the sac, and runs up a short way on its wall, spreading out and giving off the nerves, which can be traced across the cavity into the lumbar and sacral plexuses. These are well-formed, and arranged in the normal manner. The filum terminale (redder than the nerve cords) is seen passing across the sac, to disappear again in the lower edge of the mouth of the sac, beyond which it cannot be traced.

22.24. Spina Bifida. Syringocele. *Hunterian. EE. 52.*

The right half of the lower part of the trunk of a foetus, injected red, showing the above. The spina bifida has been divided into two fairly equal portions (see also next specimen.) From behind there is very little tumour; only a somewhat elevated ring of skin surrounding a diamond-shaped area about 2 cm. long by 1.5 cm. wide, the floor of which, considerably below the level of the ring of skin, consists of soft vascular membrane. In section, this soft membrane is seen to be the outer wall of a cavity, which, before the section was made, was enclosed all round by a similar soft tissue. The cavity in this, and perhaps more distinctly in the succeeding, is traceable up the centre of the spinal cord—clearly a syringocele. The anterior wall of the syringocele is separated from the bodies of the vertebrae by a space—a slight distension of the subdural (arachnoid) space—across which the nerves are seen passing from the cord to the intervertebral foramina. The lumbar and sacral plexuses are dissected, and are seen to be fully developed, and arranged quite in the normal manner. There is a tuft of hair at the lower edge of the raised ring of skin.

22.25. Spina Bifida. Syringocele. *Hunterian. EE. 53.*

The other half of the preceding. The anterior wall of the sac of the syringocele is pushed back by bristles to show the nerve roots.

II. INJURIES OF THE SPINAL CORD.

Specimens wanted.

III. CHANGES DUE TO CONDITIONS AFFECTING THE NUTRITION
AND VARIOUS LOCAL CAUSES: HAEMORRHAGE, ETC.

Specimens wanted.

IV. CHANGES DUE TO INFLAMMATORY DISEASE.

Specimens wanted.

V. TUMOURS OF THE SPINAL CORD AND ITS MENINGES.

22. 26. Sarcoma Infiltrating the Dura Mater of the Spinal Cord. Haemorrhage. *Hunterian. EE. 46.*

"A portion of adult spinal marrow, with a tumour, size of a large filbert, adhering: the cause of palsy of the lower extremities (Dr. Knox)." The reference could not be traced. The tumour is outside the dura mater and adhering to it. It is encapsuled in fibrous tissue (derived apparently from the connective tissue between the dura mater and the periosteum). It is very ragged, and probably most of the proper tumour tissue has been washed away in the preparation of the specimen. On microscopic examination of a slice taken from the outer surface of the growth, it is found to have a distinct fibrous capsule (just inside which a large haemorrhage has occurred), and to consist of masses of round and oval nuclei with very little trace of cell protoplasm or intercellular tissue, separated by strands of fibrous tissue similar to the capsule. It is a sarcoma infiltrating the dura mater of the spinal cord. (MS. Notes, J.H.T., p. 43.)

SECTION III. THE NERVES.

I. CONGENITAL DEFECTS AND MALFORMATIONS.

Specimens wanted.

II. CHANGES THE RESULT OF INJURY.

22. 27. Healing of Nerves after Amputation.

Hunterian. E. 35.

A nerve from a stump, swollen into a rounded knob above where a ligature has been tied round it. Below the ligature the end of the nerve shows an "elongation from new matter added; this new matter shows granulation of nerve." Injected red.

22. 28. Healing of Nerves after Amputation.

Hunterian. E. 36.

A nerve from a stump, showing its end swollen into a rounded knob and quite healed. Injected red.

22. 29. Amputation Neuromata from a Stump of the Arm.*Hunterian. E. 41a.*

An artery and vein and three nerves, showing the ends of the last swollen out into rounded knobs three or four times the diameter of the nerves.

22. 30. Healing of Nerves in their Course.*Hunterian. E. 38.*

The larynx, trachea, carotid arteries, and "par vagum" (pneumogastric) and "intercostal" (sympathetic) nerves of a dog. The nerves were divided, and are seen to have united again, "the dog recovering in proportion as the union proceeded." There is a considerable swelling of the right nerve at the point of union; the left presents two small oval swellings at a distance of about 1 cm., the gap being filled by a cord much thinner than the original nerve.

This specimen was identified by Dr. Robert Kennedy. It is figured, and the experiments with which it was related are described, in *Philosophical Transactions*, 1796, Part I, p. 177, under the title, "Experiments on the Nerves, particularly in their reproduction," by Wm. Cruikshanks. He states that the par vagum and intercostal or sympathetic in the dog adhere so closely to one another in the neck that they were divided as if only one nerve. The nerves on the right side were first divided; the chief symptoms produced were inflammation of the right eye and respiratory difficulties. In a few days the dog had improved greatly, and at the end of three weeks "had perfectly recovered." The nerves on the left side were then divided, and the same symptoms appeared as after the first operation. In a fortnight "he was nearly as well as before the operations." He was then killed for examination. "The viscera were to all appearance sound"; "the divided nerves of the right side were firmly united, having their extremities covered with a kind of callous substance." "The nerves of the left side were also perfectly united," but the regenerated nerves were smaller than the original, and "did not seem fibrous like original nerves." The experiments seemed, he thought, to prove completely the "circumstance of regeneration of nerves." The experiments were performed, and the account of them was read to the Royal Society as early as

1779, but was not admitted to the transactions at that time. Their importance was realized some 15 years later.

22. 31. Healing of Nerves in their Course. Dog.

Hunterian. E. 40.

The heart, carotids, and pneumogastric nerves of a dog which had been subjected to the same experiments as the preceding. The nerves are considerably swollen at the points of union. Injected red. "Considerable arteries run in the direction of the nerves towards the divided ends."

22. 32. Healing of Nerve, incomplete. Dog.

Hunterian. E. 41.

"The sciatic nerve of a dog, which had been divided fourteen days before he died; the nerve is swelled at the place of division, had not yet united, but was granulating; a glass ball is attached to keep it steady."

III. CHANGES DUE TO CONDITIONS AFFECTING THE NUTRITION.

Specimens wanted.

IV. CHANGES DUE TO INFLAMMATORY DISEASE.

22. 33. Suppuration round a Nerve—the Nerve Unaffected.

Hunterian. E. 34.

"An abscess between the integuments and the abdominal muscles above the groin; one of the lumbar nerves is seen passing through the abscess unaltered; a bristle likewise shows where the abscess burst." Illustrates the resisting powers of nerves against suppuration around them, which is due to the thickness of the sheath and to the fact that the lymphatics of nerves are not in free communication with those of the surrounding tissues.

2.34. Ulceration of Nerve. Amputation.*Hunterian. E. 42.*

"The popliteal artery with sciatic nerve, both eroded from an ulcer after amputation (suppuration), in which there was constant pain. The nerve is more than three parts of its thickness eroded. The artery had bled a little, but above the place where it burst is seen plugged with an exceedingly firm coagulum of blood." Illustrates the converse of the preceding, viz. that when suppuration does get into a nerve from a wound of the sheath, it affects it in much the same way as other parts. The artery is split, and one part turned down showing its interior.

V. TUMOURS OF NERVES.

Specimens wanted.

SERIES 23.

ANATOMY OF THE EYE AND ITS APPENDAGES.

<i>The Eyelids and Lachrymal Apparatus,</i>	1-10
<i>The Cornea, Sclerotic, Choroid, and Iris,</i>	11-34
<i>The Membrana Pupillaris,</i>	35-38
<i>The Pigmented Tissues of the Eye,</i>	39-42
<i>The Optic Nerve, Retina, and Humours,</i>	43-54
<i>The Ciliary Nerves,</i>	55
<i>Comparative Anatomy of the Eye,</i>	56-89
<i>The Appendages,</i>	56-59
<i>The Eye in Mammals,</i>	60-78
<i>In Birds,</i>	79-80
<i>In Reptiles,</i>	81-87
<i>In Fish,</i>	88-89

I. THE APPENDAGES OF THE EYE.

23.1. The Left Eyebrow and Eyelids. *Hunterian. FF. 2.*

The above injected red, the eyelids closed, showing the eyelashes, and on the inside the conjunctival sac.

23.2. The Eyelids. The Puncta Lachrymalia.

Hunterian. FF. 3.

The right eyelids injected red, showing the conjunctiva very vascular. Bristles are placed in the puncta lachrymalia (the orifices of the lachrymal ducts leading to the lachrymal sac and nasal duct).

23.3. The Eyelids.

Hunterian. FF. 4.

Similar to No. 23.1, mounted in turpentine.

23.4. The Eyelids. The Conjunctiva.

Hunterian. FF. 5.

The left eyeball and eyelids of a child, injected red. The lids are everted, and turned back over the eyeball to show the cavity of the conjunctiva, which forms a continuous membrane over the inside of the eyelids and front of the eyeball, and passes into the orifices of the ducts of the lachrymal gland and puncta lachrymalia. The part lining the eyelids is very vascular, and covered with papillae ("villi"), which become greatly enlarged in granular ophthalmia; the other part, covering the ball, is transparent, and over the cornea quite avascular. The "villi" (papillae) are visible with the naked eye, but are better to be looked for with a lens.

23.5. The Tarsal Cartilage and Ligament.

Hunterian. FF. 8.

An eyelid dissected to show the above; the eyelashes *in situ*, and one of the puncta lachrymalia marked with a bristle.

23.6. The Eyelids. Tarsal (Meibomian) Glands.

Hunterian. FF. 9.

Two pairs of eyelids injected red. The upper pair inverted, showing the orifices of the ducts of the Meibomian glands, between 30 and 40 in number, in a line along the inner edge of each eyelid—in the same line as the puncta lachrymalia.

23.7. The Ducts of the Lachrymal Gland and the Meibomian Glands.

Hunterian. FF. 12.

A pair of eyelids, the inner canthus divided to allow them to be laid flat. Bristles are placed in two of the ducts of the lachrymal gland, near the outer canthus in the upper lid. The Meibomian glands appear faintly through the conjunctiva as yellowish streaks. The secretion is coagulated in droplets, in the orifices of the ducts of a number of them.

23.8. The Conjunctiva, Puncta Lachrymalia, and Meibomian Glands.

Hunterian. FF. 15.

The left eyebrow and eyelids injected red. The secretion of the Meibomian glands is coagulated in the orifices of their ducts in little droplets; "the puncta lachrymalia very well seen towards the inner angle, with bristles in them."

23.9. The Conjunctiva and Puncta Lachrymalia.

Hunterian. FF. 16.

"The left eyelids beautifully injected from a young subject." The eyelids and conjunctiva complete over the cornea; the outer canthus divided, and the eyelids half inverted, to enable the inner canthus, with the puncta lachrymalia or orifices of the lachrymal ducts, to be shown.

23.10. The Conjunctiva and Puncta Lachrymalia.

Hunterian. FF. 17.

A similar preparation stretched on a glass globe the size of the eyeball, dried and mounted in turpentine.

II. THE EYEBALL.

(a) *The Cornea, Sclerotic, Choroid, and Iris.*

23.11. Horizontal Section of the Eyeball.

Hunterian. FF. 18a.

One half of an eyeball coarsely injected, and the humours and retina removed, showing the shape of the eyeball and its two outer coats. The external, consisting of the sclerotic and cornea, is thick and firm to maintain the shape of the organ and to protect the delicate structures within; the latter also modified in the way of transparency for purposes of vision. Lining the interior of this is the middle or vascular coat—the choroid, continued in front as the iris, which hangs like a diaphragm in the anterior chamber, corresponding in size with the cornea. From the point of entrance of the optic nerve hangs the central artery of the inner coat or retina—the proper visual layer of the eyeball.

23.12. The Arteries of the Eye. —

The optic nerve, back of eyeball, and adjacent soft tissues injected red, dried and mounted in turpentine, showing the branches of the ophthalmic artery going to the eye.

23.13. The Sclerotic and Choroid Coats of the Eye.

Hunterian. FF. 19.

An eyeball with the sclerotic divided all round and turned up, showing the choroid. The arteries are injected red, the veins white. The latter, from the manner of their distribution, are called the vasa vorticosa. The arteries, on the other hand, run nearly straight from back to front of the ball.

23.14. The Arteries of the Choroid.

Hunterian.

An eye hung by the optic nerve, the ophthalmic artery and veins injected red. The sclerotic for the most part is dissected off, showing the choroid with its arteries and veins finely injected. The former are recognized by their straight course round the ball from back to front, the latter by their vorticose arrangement.

23.15. The Blood-vessels of the Choroid.

Hunterian. FF. 20.

The sclerotic, choroid, and iris of an eyeball injected red, dried and mounted in turpentine, showing that the choroid is the vascular layer of the eyeball. There are very few vessels in the sclerotic, and none in the cornea.

23.16. The Anterior Chamber of the Eye, the Ciliary Body and the Iris.

Hunterian. FF. 23.

An eye with part of the cornea and sclerotic turned up, showing the above, and the relations of the choroid, iris, and crystalline lens. The anterior chamber is the space, containing the aqueous humour, which lies between the cornea and the front of the crystalline body or lens; theoretically it is divided, as by a diaphragm, by the iris, which, however, really lies in close contact with the lens, though not attached to it. Through the pupil is seen the central portion of the lens. The white ring round the iris

is the ciliary muscle, behind which are seen the ciliary processes of the choroid, deeply pigmented, their serrated posterior edge corresponding with the anterior border of the retina. A number of the ciliary nerves are seen running in the choroid to be distributed to the ciliary body and iris.

23.17. The Choroid, Iris, Ciliary Body and Lens, in situ.

Hunterian. FF. 23b.

An eyeball dissected like the preceding. "One half of sclerotica turned up, in an otherwise entire eyeball, to show choroid in its uninjected state continued into iris; the former appears of a dark brown from the nigrum pigmentum underneath, the latter of a blue and white intermixed; the vessels of the choroid are evidently continued into the iris."

23.18. The Choroid, Iris, Ciliary Body and Lens, in situ.

Hunterian. FF. 23d.

Similar to the preceding.

23.19. The Sclerotic, Choroid, and Ciliary Processes from behind.

Hunterian. FF. 23aa.

An eyeball divided transversely, and the vitreous humour and lens removed, showing the above. There is unusually little pigment about the ciliary processes and iris of this specimen.

23.20. The Greater Arterial Circle of the Iris.

Hunterian. FF. 24.

"The anterior half of sclerotica with cornea from an injected eye; extravasation frequently takes place where the choroid ends and the iris begins; the red circle seen on this inverted coat shows that boundary."

23.21. The Arteries of the Choroid.

Hunterian. FF. 25.

A similar preparation, the posterior half inverted, showing the arteries of the choroid coarsely injected red.

23.22. The Arteries of the Choroid and Iris.*Hunterian. FF. 26.*

A section of the optic nerve and eyeball, the vitreous humour, lens, and retina removed, showing the ciliary arteries in the above very minutely injected.

23.23. The Arteries of the Choroid.*Hunterian. FF. 27a.*

Posterior half of an eyeball injected red, showing the above making a fine network. The entrance of the optic nerve is distinguished by the absence of vessels.

23.24. The Choroid and Iris.*Hunterian. FF. 27c.*

Half of the above from an injected eye, hung by the optic nerve, showing the arteries injected red, the veins white.

23.25. The Veins of the Choroid.*Hunterian. FF. 28.*

"An eyeball, sclerotica partly removed, to look on the choroid from without. The veins are the principal objects, injected white and forming the vasa vorticosa of Steno. The arteries are injected red, but less successfully. A very fine preparation." The arrangement of the veins, coming to the choroid about the transverse equator of the eyeball, and being immediately distributed on it in vortices of small branches, is very beautifully displayed.

23.26. The Arteries and Veins of the Choroid and Iris.*Hunterian. FF. 29.*

An eyeball, with the sclerotic and cornea completely removed, showing the above; arteries injected red, veins white. The former are seen running in nearly parallel wavy lines from behind forwards. The latter as described in the preceding.

23.27. The Arteries of the Iris.*Hunterian. FF. 30.*

An eyeball, the anterior part of the sclerotic and the cornea removed, showing the choroid and iris finely injected red, "and very vascular."

23.28. The Arteries of the Ciliary Processes and Iris.*Hunterian. FF. 30a.*

Part of the choroid and the iris injected red, dried and mounted on a card in turpentine, showing the vessels of the choroid continued into the iris. Round the junction of choroid and iris is seen the greater vascular circle of the iris. On right and left it is joined by a larger vessel, the long ciliary arteries, which enter the back of the globe and run forwards along each side between the sclerotic and the choroid, and pass directly into the vascular circle by an upper and a lower branch.

23.29. The Arteries of the Choroid and Iris.*Hunterian. FF. 31.*

Similar to No. 23.27. The injection has turned brown.

23.30. The Arteries of the Choroid.*Hunterian. FF. 34.*

A portion of the posterior part of the eye; also a choroid and iris, the sclerotic completely removed, finely injected red.

23.31. The Iris.*Hunterian. FF. 37.*

An eyeball with the optic nerve of a child, the cornea removed, showing the iris finely injected red. With a lens the arteries can be seen running from the outer border inwards and forming a very close anastomosis round the pupillary edge of the iris—lesser arterial circle of the iris. It appears very vascular. Compare No. 23.28.

23.32. The Choroid and Ciliary Processes.*Hunterian. FF. 40.*

An eyeball coarsely injected red and divided transversely, the vitreous humour and lens removed and the outer coats inverted, showing the arteries of the choroid injected, but the injection not reaching the ciliary processes, which are seen as a circle of triangular folds of the choroid projecting inwards at its junction with the iris.

23.33. The Choroid and Ciliary Processes, and Arteries of the Iris.*Hunterian. FF. 41.*

A similar preparation, but the halves not inverted. The injection is finer, and shows the ciliary processes to be exceedingly vascular.

Also, on looking through the iris at the light, the serpentine radial arteries and the lesser arterial circle near the pupillary edge show very clearly. A beautiful preparation of these vessels.

23.34. The Choroid and Iris Inverted. Ciliary Processes.

Hunterian. FF. 42.

The whole choroid and iris finely injected and inverted, showing the ciliary processes projecting outwards and slightly separated from one another. Rather crushed.

(b) Structures which exist in the Foetus but disappear later.

23.35. The Capsulo-pupillary Membrane.

Hunterian. FF. 49.

The eye "of a foetus about seven months," injected red; the cornea is removed, showing a fine vascular membrane occupying the pupil, called also "membrana pupillaris." This is the anterior layer of the capsule of the crystalline lens. It receives blood-vessels from the iris and from a branch of the central artery of the retina, which runs forward to the back of the lens in the axis of the globe. The whole tunic along with its vessels usually disappears before birth.

23.36. The Capsulo-pupillary Membrane.

Hunterian. FF. 49a.

Iris "with membrana pupillae from a human foetus," injected red, dried and mounted in turpentine on green paper, showing the vessels of the iris passing into the membrana, and forming a rich plexus converging towards the centre.

23.37. The Capsulo-pupillary Membrane.

Hunterian. FF. 51.

The anterior part of a choroid, with the iris and the membrana pupillae, injected red. "The membrana pupillaris (capsulo-pupillary membrane) is very distinct, and also a little torn in the centre." On holding it between the light and the eye, the fine plexus of blood-vessels in it appears very distinct and beautiful.

23. 38. The Capsulo-pupillary Membrane.*Hunterian. FF. 58.*

The anterior part of the choroid and iris injected red, dried and mounted in turpentine, showing the above very beautifully. Quite perfect. (Not described in the old catalogue.)

(c) *The Pigmented Tissues of the Eye.*

23. 39. The Pigmented Layers of the Sclerotic and Choroid.*Hunterian. FF. 64.*

An eyeball, the sclerotic divided all round—part removed, part inverted—showing the membrana fusca lining its inner surface, and on the choroid the membrana suprachoroidea (with which it is intimately connected), being the pigmented layers of the sclerotic and choroid respectively. There is more pigment than usual. The veins of the choroid are injected white.

23. 40. Section of the Eye showing the Pigment Layers.*Hunterian. FF. 62.*

An eyeball divided longitudinally, showing the above. The pigmentation is not so deep as in the preceding. There is very little in the sclerotic and exterior of the choroid. On the inside of the choroid is a layer of pigment belonging to the pigmented hexagonal-celled layer of the retina, which usually, as in this specimen, adheres to the choroid in a dissection, but belongs developmentally and physiologically to the retina. The optic nerve in section is seen to be continuous with the retina; the relation of the inner parts is distorted by the shrinking of the vitreous humour.

23. 41. The Pigment of the Ciliary Processes and Iris.*Hunterian. FF. 65.*

Anterior portion of an eye, showing the above. The pigment has been removed from the greater part of the iris. The pigment lining the back of the iris is seen continuous with that of the ciliary processes and retina.

23.42. The Eye of a Negro. Pigmentation.*Hunterian. FF. 64a.*

The eye of a negro divided longitudinally, and the vitreous humour, lens, and retina removed to show the depth of the pigmentation both within and without the choroid.

(d) *The Optic Nerve, Retina, and Humours of the Eye.*

23.43. The Optic Nerve and Retina. *Hunterian. FF. 66.*

A longitudinal section of the eye, the vitreous humour removed, showing the optic nerve continuous with the retina; the latter, a good deal torn, can be traced forward as a thin yellowish membrane nearly to the ciliary processes, where it becomes thin and indistinct.

23.44. The Retina. The Optic Disc. *Hunterian. FF. 67.*

The posterior part of an eyeball which has been divided transversely, the vitreous humour removed, showing the retina with the optic nerve entrance a little to the inside of the eye, making a little cup (the optic disc) of a somewhat yellower colour than the surrounding parts. About 2 mm. to the outside (to the right, looking at the specimen as it hangs), on the same level, is seen a faint yellowish spot, which is the macula lutea—the visual centre of the eye.

23.45. The Retina and Humours of the Eye.*Hunterian. FF. 68.*

An eyeball, with the sclerotic, choroid, and pigmented layer removed, showing the retina enclosing the vitreous humour. The ciliary processes and cornea are also preserved. There is great distortion from shrinking of the vitreous humour by the spirit, and considerable tearing of the retina.

23.46. The Central Artery of the Retina.*Hunterian. FF. 73.*

The posterior portion of an eyeball and the optic nerve finely injected red, the vitreous humour removed. The branches of the central artery with the remains of the retina hang from the point of entrance of the optic nerve. The choroid is very finely injected.

23.47. The Central Artery of the Retina. *Hunterian.*

Similar to the preceding, the vitreous body and lens lying on the bottom of the jar.

23.48. The Crystalline Lens in situ. *Hunterian. FF. 80.*

A longitudinal section of the optic nerve and eye, showing the lens *in situ*, with the iris in front of it dividing the space between it and the cornea into the anterior and posterior chambers; at its circumference are the ciliary processes, and behind, the remains of the vitreous humour, retina, and optic nerve; also the choroid continuous with the iris.

23.49. The Crystalline Lens in situ, from behind.

Hunterian. FF. 81.

The anterior half of an eyeball, the vitreous removed, leaving its sheath (the delicate hyaloid membrane), and showing the lens with the ciliary processes resting on its circumference and slightly overlapping it, also the anterior edge of the retina—the “ora serrata.”

23.50. The Crystalline Lens in situ, from before.

Hunterian. FF. 82.

An eyeball, the cornea and iris removed, showing the lens *in situ*, with the ciliary processes resting on its circumference.

23.51. The Crystalline Lens in situ, from behind.

Hunterian. FF. 83.

Similar to No. 23.49.

23.52. The Lens and Ciliary Processes. *Hunterian. FF. 84.*

A portion of an eye, showing the above, dissected out.

23.53. The Lens and Ciliary Processes. *Hunterian. FF. 85.*

The above dissected out and mounted on a card; posterior view. Very deeply pigmented.

23.54. Arteries of the Crystalline Lens of a Foetus.*Hunterian. FF. 93a.*

Two crystalline lenses "from a human foetus," their capsules injected red, mounted on blue cards. This vascular membrane is what is shown in Nos. 23.35-23.38 as the pupillary or capsulo-pupillary membrane.

23.55. The Lenticular Ganglion and Ciliary Nerves.*Hunterian. FF. 21a.*

"The Globe of the Eye with the Optic Nerve; suspended by the lenticular ganglion and its fibrils, which appear, to the number of six or seven, perforating the sclerotic on their way to the iris itself."

III. COMPARATIVE ANATOMY OF THE EYE.

*(a) The Appendages of the Eye.***23.56. The Lachrymal Gland and its Duct. Sheep.***Hunterian. FF. 13.*

The upper eyelid and the lachrymal gland from a sheep, its duct injected with mercury, dried and mounted in turpentine, showing the branching of the duct. Also a number of the tarsal glands.

23.57. The Lachrymal Gland. Goose. *Hunterian. FF. 13aa.*

The eyelids and lachrymal gland, the duct injected with mercury which has passed in and filled even the acini, dried and mounted in turpentine. "The secretion of the gland is ropy" (mucous).

23.58. The Eyelids and Lachrymal Gland. Turtle.*Hunterian. FF. 14.*

Injected red by the arteries. The gland is of the conglomerate form; there is a single duct with a brown bristle placed in it, and in its branches are black bristles. A fold of villous conjunctival tissue, the membrana nictitans, is seen inside the eyelids; both it and the gland appear highly vascular. "The secretion of this gland is ropy and not like tears."

23.59. The Eyelids and Lachrymal Gland. Turtle.*Hunterian. FF. 13b.*

Similar to the preceding, but the duct injected with mercury; dried and mounted in turpentine.

(b) *The Eye.*

(A) MAMMALS.

23.60. Eye of Rabbit.*Hunterian. FF. 60a.*

An eyeball divided transversely, the vitreous humour, lens, and retina removed, dried and mounted in turpentine, showing the sclerotic, cornea, choroid, and iris. "It is from a white rabbit," and there is accordingly very little pigment.

23.61. Eye of Rabbit.*Hunterian. FF. 72f (1).*

A similar eyeball divided longitudinally, showing the same as the preceding, and also the remains of the retina hanging from the optic nerve. The pigment very scanty.

23.62. Eye of Rabbit.*Hunterian. FF. 72f (2).*

A similar eyeball divided transversely, and the rear portion hanging down. Vitreous and crystalline lens removed.

23.63. Eye of Whale.*Hunterian. FF. 10a.*

Divided transversely, showing the enormously thick sclerotic. The vitreous and lens removed; the pupil is oval.

23.64. Eye of Sea Cow (Sirenia).*Hunterian. FF. 27d.*

Divided transversely, and the vitreous humour and lens removed. The anterior part of the choroid, ciliary processes, and iris are deeply pigmented; the posterior part is of a bright greyish-white colour. Compare the Eye of the Nylgau, No. 23.66, and the Eye of the Calf, No. 23.70.

23. 65. Eye of Sea Cow (Sirenia). *Hunterian. FF. 27e.*

A similar specimen, but the pigment is almost completely wanting.

23. 66. Eye of "Neel Ghaw" (Nylgau). *Hunterian. FF. 79.*

Divided transversely, and the humours and retina removed. The internal surface of the choroid is of an iridescent white colour—a structure called tapetum lucidum, which collects the light and enables animals to see in the dark. There is pigment in the outer layers of the choroid and in the ciliary processes and iris.

23. 67. Eye of Bullock. *Hunterian. FF. 48.*

Injected red, and the anterior part of the sclerotic and the cornea removed, showing the arteries of the choroid and iris beautifully injected. The ciliary nerves are also displayed on the outside of the choroid. The shape of the pupil is a long oblong rounded at the corners.

23. 68. Eye of Bullock. The Choroid and Ciliary Processes. *Hunterian. FF. 43.*

The anterior half of the eye, vitreous and lens removed, showing the arteries of the choroid and ciliary processes finely injected.

23. 69. The Choroid, Ciliary Processes, and Iris. Bullock. *Hunterian. FF. 46.*

The sclerotic, choroid, and iris of a bullock's eye inverted, and hanging by the optic nerve; the arteries injected red. The ciliary processes appear to be highly vascular.

23. 70. Eye of Calf. *Hunterian. FF. 69a.*

The outer coats dissected from one another, showing the ciliary processes, the iridescent tapetum lucidum, and the remains of the retina and retinal vessels hanging from the optic nerve.

23.71. The Capsulo-pupillary Membrane. Calf.*Hunterian. FF. 49c.*

"The eye of a foetal calf near its time." The half of its outer coats removed, showing the vitreous humour and crystalline lens, the relations somewhat distorted by shrinkage of the former. Shows the capsulo-pupillary membrane, finely injected red, enveloping the lens and receiving numerous vessels from the arteries of the iris.

23.72. The Retina. Central Artery Injected. Ox.*Hunterian. FF. 70.*

The eye of an ox, injected red, opened, inverted, and hung by the vitreous humour and lens, which are attached to the retina and choroid by the ciliary processes; showing the retina somewhat ragged, but with the branches of the central artery very well injected.

23.73. The Crystalline Lens. Calf.*Hunterian. FF. 93b.*

The vessels of the capsule injected black; mounted on white paper. The vessels are seen mostly round the sides of the lens, and are not visible on the front of it.

23.74. The Crystalline Lens. Calf.*Hunterian. FF. 93c.*

Similar to the preceding, but not mounted on a card; "the vessels which were going to the membrana pupillae left loose and floating all round its edge."

23.75. The Crystalline Lens. Calf.*Hunterian. FF. 93d.*

Similar to the preceding. The capsule is well injected over the back of the lens, and shows a fair number of vessels; in front none are visible.

23.76. The Crystalline Lens. Calf.*Hunterian. FF. 97.*

"Suspended with a glass bubble, with a portion of the membrana pupillaris before; here it seems almost evident that membrana pupillaris and the posterior part of the crystalline capsule are one

and the same membrane, as a portion of the membrana pupillaris is here left on"; together they form the capsule of the lens.

23.77. The Iris and Crystalline Lens. Lamb.

Hunterian. FF. 101.

The crystalline lens, iris, and cornea dissected out. Shows also a portion of the membrana pupillae.

23.78. The Crystalline Lens. Elephant. *Hunterian. FF. 90.*

"Not nearly so large as in the Neel Ghaw or Ox."

(B) BIRDS.

23.79. The Eyelids and Eye. Turkey. *Hunterian. FF. 80a.*

Opened transversely, the posterior parts turned down and the vitreous removed, showing the internal structure. The remains of the retina are seen as a thick whitish membrane attached to the optic nerve. From the optic nerve downwards and forwards, for about a quarter of the circumference, stretches a line of straight processes, of unequal lengths, peculiar to birds, called the pecten ("musculus serratus"). The fissure through which they enter the eye is the remains of the choroidal fold, which sometimes persists in part, giving rise to the condition called coloboma iridis. The specimen also shows the vascular choroid coat, the ciliary processes, lens, sclerotic, and eyelids, which have no eyelashes.

23.80. Eye of Turkey.

Hunterian. FF. 80b.

A similar preparation without the eyelids, the lens removed to show the iris and pupil. The pecten is well displayed.

(C) REPTILES.

23.81. Eye of Chameleon.

Hunterian. FF. 72c.

Divided transversely, and the sclerotic and humours removed. The cornea is very convex and small in proportion to the size of the globe.

23.82. Eye of Chameleon.*Hunterian. FF. 49k.*

Not described. The sclerotic is very thick; doubtless a provision against injury from the great prominence of the organ.

23.83. Eye and Eyelids of Turtle.*Hunterian. FF. 72a.*

The ball is divided transversely, and the posterior half turned down, and the humours and retina removed, showing a remarkably thick and hard sclerotic and a very deeply pigmented choroid. Inside the eyelids is a thin fold, the third eyelid or membrana nictitans.

23.84. Eye and Eyelids of Turtle.*Hunterian. FF. 72b.*

Similar to the preceding, but hung so as to show better the anterior parts of the eyeball.

23.85. Eye of Turtle.*Hunterian. FF. 72bb.*

Similar to the preceding, but without the eyelids.

23.86. The Iris and Ciliary Processes. Eye of Turtle.*Hunterian. FF. 47.*

Anterior portion of the eye of a turtle, showing the above finely injected red.

23.87. The Retina. Eye of Turtle. *Hunterian. FF. 72a (2).*

Posterior portion of eyeball, showing the optic nerve continuous with the retina. The branches of the central artery injected red. Behind the retina is the shining tapetum lucidum.

(D) FISH.

23.88. Eye of Codfish.*Hunterian. FF. 71.*

Divided transversely, and the humours and lens removed. The retina ends in a very sharp regular line, and shows a cleft which

corresponds with the pecten seen in the bird's eye, being the remains of the choroidal fissure. There is a remarkable absence of pigment; all the internal tissues are bright and shining to collect as much light as possible.

23. 89. Eye of Pike.

Hunterian. FF. 72d.

Divided transversely. The internal structures have shrunk very much. There is considerably more pigment than in the cod's eye, but most of the structures present the same shiny appearance.

SERIES 24.

INJURIES AND DISEASES OF THE EYE AND ITS APPENDAGES.

24.1. Human (?) Eye with Oval Pupil. *Hunterian. FF. 105.*

An eye injected red, and part of the cornea and sclerotic raised to show the above malformation. The pupil is oval horizontally. It appears to be a human eye. Not described.

24.2. "A Diseased Eye." *Hunterian. FF. 103.*

"A diseased eye; the retina looks as if collapsed all round, forming a solid mass, continued from the optic nerve, and there is no appearance of humours. (Case unknown)."

24.3. The Muscles of a Blind Eye. *Hunterian. FF. 104.*

"The eyelids of a man who was blind of an eye; the muscles are adhering to the eyelids themselves, or to a kind of shrunk tunica sclerotica; the optic nerve apparently sound."

SERIES 25.

ANATOMY OF THE EAR.

<i>The External Ear,</i>	1-8
<i>The Middle and Internal Ear,</i>	9-26
<i>Human Foetal Ears,</i>	27-30
<i>Comparative Anatomy,</i>	31-45

I. THE EXTERNAL EAR.

25.1. The External Ear or Pinna. *Hunterian. HH. 3.*

Uninjected, showing the shape of the pinna and its various eminences and fossae as follows: First, the large central hollow or concha from which the external auditory meatus opens. In front and overhanging this is a conical prominence—the tragus—below and behind which, and separated from it by a little hollow, is another eminence—the antitragus—with the lobule hanging below. The larger upper part of the ear is bounded by a ridge called helix, inside which is the fossa of the helix, separating it from a broader rounded eminence called antihelix, which spreads out above into two limbs, enclosing a space called fossa of the antihelix or triangular fossa.

25.2. The External Ear or Pinna. *Hunterian. HH. 4.*

Injected red and the cuticle removed.

25.3. The External Ear or Pinna. *Hunterian. HH. 4a.*

Similar to the preceding.

25.4. The Cartilage of the Pinna. *Hunterian. HH. 2.*

A thin plate of yellow fibro-cartilage of the same shape as the pinna, and showing the same fossae and prominences in front and the same reversed behind. It also extends into the external auditory meatus, forming the cartilaginous portion of it: "Giving the permanent shape with flexibility to the external ear."

25.5. The Pinna of a Right Ear, unusually Large and Flat. *Hunterian. HH. 3b.*

There is almost no helix, and the tragus and antitragus are badly formed. The cuticle has been removed. The tragus and antitragus are covered with long hairs.

25.6. The Pinna of a Left Ear, unusually Large and Flat. *Hunterian. HH. 3b.*

The neighbour of the preceding.

25.7. The External Ear of a Negro. Right. *Hunterian. HH. 3c.*

It is small, well-shaped, thick and round, and by no means deeply coloured—possibly partly decolourized by long immersion in spirit.

25.8. The External Ear of a Negro. Left. *Hunterian. HH. 6a.*

Similar to the preceding.

II. SECTIONS AND DISSECTIONS OF THE EAR.

25.9. Dissection to give "a General Idea of the Whole Organ of Hearing." *Hunterian. HH. 1.*

The left temporal bone, with the external ear and Eustachian tube, hung in the natural position; the squamous portion and upper part of the petrous removed by a saw-cut passing inwards from above and behind the external ear obliquely downwards

and forwards, so as to give a view of the mastoid antrum, tympanic cavity, vestibule, cochlea, and internal meatus with the auditory nerve. The anterior wall of the external auditory meatus, tympanic cavity, and Eustachian tube are also cut away, leaving the tympanic ring and membrane and the ossicles. Bristles are placed between the incus and malleus, in the Eustachian tube, and in the vestibule. The carotid canal is also marked by a tied bristle. The preparation is also well seen through the top of the jar.

25.10. Vertical Transverse Section of the Ear, from behind.

Hunterian. HH. 7.

The left temporal bone and external ear of an adult divided in a plane passing through the external auditory meatus rather behind its centre and not quite transverse to the head, the inner end being a little further forward than the outer. This specimen, the anterior half, shows the external auditory meatus curved upwards about its middle and closed internally by the *membrana tympani*, which is placed obliquely with its upper edge considerably overhanging the lower. Just outside the membrane the meatus bends forwards, and dips down into the little hollow in which foreign bodies so often lodge. The tympanic cavity is divided just behind the stapes, which appears with its head articulating with the long process of the incus and its base in the *fenestra ovalis*. Above the tympanum and inner part of the meatus, separated from them by a narrow bridge of bone, is the passage from the tympanic cavity into the mastoid antrum. Through it is seen the upper end of the malleus. The foramen with the bristle in it, in the inner and lower part of the above-mentioned bridge of bone, is the aqueduct of Fallopius containing the facial nerve, and the orifice above it is a section of the external semicircular canal. The roof of the tympanum (*tegmen tympani*) is thin and translucent, and there is also no great thickness of bone between the cavity of the antro-tympanic passage and the external auditory meatus. Of the internal ear is seen the anterior half of the vestibule with the *fenestra ovalis*, which is closed by the base of the stapes, the anterior orifice of the external (horizontal) semicircular canal, and the passage into the cochlea. The internal meatus, with the nerves torn away, is seen just anterior to the plane of section.

25.11. Vertical Transverse Section of the Ear, from before.*Hunterian. HH. 8.*

The posterior half of the preceding. It shows the posterior wall of the external auditory meatus pitted with the ducts of the ceruminous glands. A shred of the membrana tympani demarcates the meatus from the tympanic cavity. Above is seen the mastoid antrum, separated from the middle fossa of the skull by a thin plate of bone continuous with the tegmen tympani. In the mass of bone between the tympanic cavity below and the orifice of the antrum above are seen, as in the preceding, the Fallopian canal, marked with a bristle, and the external semicircular canal, in section, about 2 mm. above it. Rather above and internal to the tympanum lies the posterior half of the vestibule, with the orifices of the semicircular canals indicated by bristles. Internal to the tympanic cavity is seen the bulb of the jugular vein in the jugular fossa, with the orifice of the sigmoid sinus leading out of it posteriorly. The bulb extends outwards and upwards behind the tympanic cavity, separated from it by a plate of bone about 1 mm. in thickness. The sigmoid groove, ending in the jugular fossa, is seen on the posterior side of the specimen. Below, and internal to the lobule of the pinna, appears a mass of parotid gland bounded internally by the styloid process.

25.12. Vertical Transverse Section of the Left Ear, from behind.*Hunterian. HH. 10.*

The left temporal bone and external ear divided in a vertical plane about 3 mm. further forward than the preceding, and, like it, slanting a little forwards. The membrana tympani is seen in section with the handle of the malleus attached to its internal surface. The body of the malleus shows the articular surface for the incus; and the tendon of the tensor tympani muscle, attached to its long process, is seen rising from a conical projection of the inner wall of the tympanum. Above this is seen a gap in the tegmen, the hiatus Fallopii, which transmits the great superficial petrosal nerve, a branch of the facial. Inwards lies the cochlea cut obliquely.

25.13. Transverse Vertical Section of the Ear, from before.*Hunterian. HH. 9.*

The posterior half of the preceding, showing the remainder

of the external meatus and membrana tympani, and the posterior parts of the tympanic cavity. The incus is gone, but the stapes, with its base in the fenestra ovalis, is seen from the opposite side compared with No. 25.11. The vestibule is not opened, but the passage from it into the cochlea is marked by a bristle, and another is passed from above into it by one of the semicircular canals. The facial nerve, cut across, is seen in the Fallopiian canal, running in the inner wall of the tympanum just above the fenestra ovalis. The auditory nerve in section is also seen at the base of the cochlea. The antro-tympanic orifice is at a considerably higher level than the tympanic cavity. Injected red. The parotid gland is well shown up by the injection.

25.14. Horizontal Sections of the Ear. *Hunterian. HH. 11.*

The right temporal bone, most of the squamous portion cut away, and external ear divided transversely just above the floor of the external auditory meatus, the lower portion hanging down. It shows the external meatus, the membrana tympani, and the lower portion of the tympanic cavity. The side of the preparation also shows the sigmoid groove in relation to the mastoid process.

25.15. Horizontal Sections of the Ear. *Hunterian. HH. 11a.*

The left temporal bone and external ear divided horizontally a shade higher than the preceding, showing the same points. Injected red.

25.16. Horizontal Sections of the Ear. *Hunterian. HH. 16.*

The left temporal bone and external ear divided horizontally about the middle of the external auditory meatus, the upper half hanging down. In the lower section bristles have been placed in the fenestra ovalis showing the vestibule, from which another bristle is passed into the canal leading to the scala vestibuli of the cochlea. The ossicles have been removed. The upper section shows the attics of the tympanum and mastoid antrum, a bristle indicating the passage between them. Bristles are also placed in two of the semicircular canals. The internal meatus is also seen in both sections with the nerves removed; a small portion of two turns of the cochlea lies in

front and to the outside of it. The sigmoid sinus, partly opened, is indicated in the lower by a long white bristle.

25.17. The Membrana Tympani. *Hunterian. HH. 14.*

The whole organ of hearing, except the external ear and meatus, "of a foetus," injected red, showing principally the membrana tympani concave externally, with the handle of the malleus shining through it. The incus is also seen, but less distinctly. From the inner side the three ossicles are visible, the articulation between the incus and the stapes is unfortunately broken. Dried and mounted in turpentine.

25.18. The Membrana Tympani. *Hunterian. HH. 16.*

The tympanic ring, ossicles, and adjacent parts of the temporal bone injected red; the ring divided and the membrana tympani split into two layers continuous respectively with the skin and the mucous membrane of the tympanic cavity. Both layers are evidently vascular. The specimen hangs by the very much shrivelled-up external ear. Mounted in turpentine.

25.19. The Ossicles of the Ear. *Hunterian.*

A complete set mounted dry on a black card, the incus above, the stapes in the middle, and the malleus below.

25.20. The Ossicles of the Ear. *Hunterian.*

Several sets of ossicles mounted in different positions on blue paper to show the shape of the bones. Only one of the mallei is complete, the long process (processus gracilis) of the others having been broken. (HH. 22?)

25.21. The Auditory Ossicles in situ. *Hunterian. HH. 17.*

The middle and internal ear "of a child at birth" dissected, the membrana tympani removed to show the above, and also the "musculus externus mallei" (laxator tympani of Soemmering or anterior ligament of the malleus) sticking out above the tympanic ring; the cochlea, vestibule, and vertical semicircular canal also displayed.

25. 22. The Membrana Tympani and Ossicles of the Ear.*Hunterian. HH. 9.*

Three views of the incus, malleus, and membrana tympani from within, dried and mounted on blue paper. They show the handle of the malleus attached to the membrana which is convex internally, and the incus behind it with its short process attached to the posterior wall of the tympanum.

25. 23. Dissection of the Middle and Internal Ear.*Hunterian. HH. 21.*

"The whole organ of hearing from an adult," left side, suspended by the apex of the petrous portion of the temporal bone, showing the tympanic cavity and internal ear laid open from above. The three ossicles are seen *in situ*; a bristle which obscures the malleus indicates the chorda tympani nerve emerging from between the incus and the malleus. The mastoid antrum is also unroofed, and a bristle placed in the descending portion of the Fallopian canal shows the position of the facial nerve relative to the antrum and antro-tympanic passage. The rest of the aqueduct (canal) of Fallopius has been removed to show the stapes, its head articulated with the processus orbicularis which caps the long process of the incus, and its base, supported on its diverging crura, fitted into the fenestra ovalis (the upper wall of which has been removed). Attached to the posterior side of the neck of the stapes is the minute tendon of the stapedius muscle rising out of a conical projection of the posterior wall of the tympanum called the pyramid. The cochlea is here seen exceedingly well; it "was uncovered by a lucky stroke of a hammer and chisel." The meatus auditorius internus is split, and shows the auditory nerve dividing into three branches, one (the largest) going to the cochlea, the other two to the vestibule and semicircular canals.

25. 24. The Middle and Internal Ear. *Hunterian. HH. 22.*

A nearly similar preparation, also left side, but injected red, and all of the osseous portion of the external auditory meatus except the tympanic ring bearing the membrane removed. A bristle passed between the ossicles from the outer side marks the chorda tympani. The Eustachian tube is laid open from the anterior end of the tympanum to the naso-pharynx, and above it, marked by a thick yellow bristle, is the tensor tympani muscle with its tendon, which

can be traced to its attachment on the inner surface of the malleus at the root of the handle (manubrium). External to this is seen the first part of the long process (gracilis) running forward under cover of the tympanic ring. The auditory nerve with its artery, the cochlea, and the vestibule are seen as in the preceding; also the stapes, disconnected from the incus and with a bristle behind it indicating the pyramid and stapedius tendon. The petrous portion, in which the auditory apparatus is imbedded, appears very dense compared with the rest of the temporal bone.

25. 25. The Middle and Internal Ear and Facial Nerve.

J.H.T. 1896.

Dissection of a left temporal bone, showing the auditory and facial nerves in the internal meatus. The latter, above the former, runs out into the geniculate ganglion, from which the great superficial petrosal branch (marked with a bristle) and a small twig to the tensor tympani muscle are seen arising. It then bends sharply back, and is traced in its canal as far as a point above the fenestra ovalis. The former nerve is seen running into the base of the cochlea. The apex of the petrous bone has been broken off showing the cochlea in section, and the knee of the carotid canal and its relation to the cochlea and Eustachian tube. The facial nerve is seen emerging below from the stylo-mastoid foramen, marked with a coarse bristle.

25. 26. The Cochlea.

Hunterian. HH. 49.

Four different views of the cochlea mounted dry on blue paper. The right-hand upper one shows the cochlea from above; the upper left-hand one the cochlea, vestibulum, and semicircular canals from below and inside (?). The middle, a larger dissection, shows the cochlea, vestibule, and mastoid cells from below. ("From a young subject.")

III. SPECIMENS OF THE ORGAN OF HEARING IN THE
HUMAN FOETUS.

25. 27. "The Whole Organ of Hearing from a Foetus."

Hunterian. HH. 13.

The left temporal bone and external ear, the external meatus dissected, showing its length and the membrana tympani; also the apex of the petrous bone removed, showing the cochlea in section.

25.28. The Ear of a Foetus.*Hunterian. HH. 27.*

Not described. The left temporal bone of a foetus, the external ear and membrana tympani removed, injected red. From the outside the ossicles are seen with the chorda tympani nerve passing between the incus and the malleus. Three structures of a bright red colour are attached to the malleus, viz. the external ligament behind, the anterior ligament in front enveloping the processus gracilis, and the tensor tympani muscle below and internal to it. A bristle indicates the tendon of stapedius, also red, emerging from the pyramid. The masto-squamosal suture is well marked. On the inside the petro-squamosal suture is seen open, and the gap of the hiatus Fallopii and the fossa subarcuata, which lies just behind the internal meatus, are very large. Above the petro-squamosal suture is a foramen for the transmission of a branch of the posterior auricular vein.

25.29. The Left Temporal Bone of a Child at Birth.*Hunterian. HH. 14.*

Macerated, cleaned, and mounted dry on blue paper. There are three bristles passed from without into the tympanum, the uppermost pointing to the canal of the tensor tympani muscle, the second to the fenestra ovalis, and the lowermost to the fenestra rotunda, the promontory lying between the last two. The bristle which crosses the tympanum rests with its posterior end on the ridge of the aqueduct of Fallopius, and passes out in front by the Eustachian tube, to the inside of which is seen the carotid canal. The fifth bristle is placed in the lower orifice of the aqueduct of Fallopius. The masto-squamosal suture is crossed by a few bridges of bone, but is mostly open.

25.30. The Left Temporal Bone of a "Child at Birth."*Hunterian. HH. 8.*

Macerated, cleaned, separated into squamous and petro-mastoid portions, and mounted dry on blue paper. The tympanic ring is attached to the squamous portion, the line of union marked by a bristle. The other portion shows the inner wall of the tympanic cavity, the prominent objects being the fenestra ovalis with the ridge of the aqueduct of Fallopius above it, the promontory with the fenestra rotunda almost hidden below it, and the mastoid

antrum and antro-tympanic passage (opened from the outside) above and behind the tympanum.

IV. COMPARATIVE ANATOMY OF THE EAR.

(A) MAMMALS.

25.31. Ear of Guinea-Pig.

Hunterian. HH. 25.

"Membrana tympani, with malleus, vestibulum, and cochlea, from the guinea pig. The cochlea is transparent, and the gyrations may be distinctly seen through its parietes; it resembles a species of small Oriental pyramidal shell." Best seen when held up against the light.

25.32. Auditory Ossicles of Dog, Sheep, Monkey, and Calf.

Hunterian. HH. 31.

"They are three in number as in men. The malleus is a little different in its shape; the others come very near the human. Those of the monkey most like the human."

(B) BIRDS.

25.33. The Head of a Pheasant, showing the Ears Dissected.

Hunterian. HH. 23.

"The head of a pheasant, the organ of hearing exposed on both sides; the meatus externus is about half an inch in length, and runs obliquely backwards and inwards. At the bottom of this passage in all birds are two rows of glands resembling the human sublingual glands, with a number of orifices; these are certainly the glandulae ceruminosae. The membrana tympani is convex externally, and turned obliquely backwards and outwards; its under edge is more inwards, and its upper edge of course more outwards; there is but one ossiculum, which is rather a kind of stapes; by one end it shuts up the fenestra ovalis, and at the other it joins a cartilage in the same line with itself, but which at the membrana tympani is bent nearly at right angles to the stapes, and attached to the posterior side of the circle or ellipse in which the membrana tympani is fixed. There are three canals

corresponding to the semicircular canals in man, and a fourth corresponding to the cochlea. That this last is meant to be cochlea is evident from its having a different entrance, which however is also ovalis, and not rotunda as in men." The cartilage alluded to as resting on the membrana tympani represents the incus and malleus.

(C) REPTILES.

25.34. The Vestibule and Semicircular Canals of a Turtle.

Hunterian. HH. 26.

The auditory nerve is attached to the vestibule.

25.35. Head of Lizard, showing the Ear.

Hunterian. HH. 36.

The membrana tympani is seen almost flush with the skin, there being a very short external auditory meatus. It is situated very far back on the head, and almost in the same line as the mouth.

25.36. Head of Lizard, showing the Ear.

Hunterian. HH. 37.

The cranium laid open and the brain removed, showing the cavity of the ear and the Eustachian tubes.

25.37. Head of Lizard, showing the Ear.

Hunterian. HH. 38.

Similar to the preceding, from a different kind of lizard.

(D) FISH.

25.38. The Semicircular Canals. Codfish.

Hunterian. HH. 33.

The left auditory organ of a codfish dissected, showing the labyrinth, consisting of a very large vestibule containing a large white boat-shaped otolith, and three semicircular canals—one horizontal, the other two vertical—and set at about right angles to one another. They are bulbed at one end like in the mammal. The auditory nerve is visible on the inner side and ramifying over the vestibule and canals.

25.39. The Auditory Organ of the Codfish.*Hunterian. HH. 34.*

The labyrinth fully dissected out, showing the vestibule and semicircular canals. In front of the vestibule is a small bulb, which is the representative of the cochlea.

25.40. The Auditory Organ of the "Kingston" or Angel-fish.*Hunterian. HH. 28.*

Part of the cranium, which is cartilaginous, dissected, showing the large vestibule opened and containing some "black sand"—otoliths; there are three semicircular canals bulbed at one end, and bristles indicate a pair of nerves entering two of these bulbs. Inside the cranial cavity the corresponding nerve roots are visible. (Squalus Squatina. Monk-fish.)

25.41. The Auditory Organ of the Angel-fish.*Hunterian. HH. 27 (?)*

Labelled HH.25, but does not correspond to description; probably HH.27, which is amissing. It resembles the preceding. A bristle is placed in the meatus auditorius externus.

25.42. The Auditory Organ of the "Kingston" or Angel-fish.*Hunterian. HH. 29.*

Similar to No. 25.40, but smaller.

25.43. The Auditory Nerve of the "Kingston" or Angel-fish.*Hunterian. HH. 30.*

"Before it enters the vestibulum, like a diverging cone of rays."

25.44. The Auditory Organ of the Thornback Skate.*Hunterian. HH. 32.*

"The entrance of the nerves into the bulbs of the canals is remarkably distinct; vestibulum is filled with a tremulous jelly, which coagulates like the crystalline of the eye in spirits. The canals are accidentally demonstrated to be tubes, from some particles of the coagulable jelly having got into them in inflating the vestibulum." The organ as a whole is very similar to the preceding.

SERIES 26.

INJURIES AND DISEASES OF THE EAR.

26.1. Perforation of the Membrana Tympani.

Hunterian. HH. 16a.

"Perforated Naturally," is stated in the old catalogue, but it is much more probable that it is a case of perforation due to catarrh of the middle ear. It is situated just in front of the lower end of the manubrium; the membrane does not appear to be thickened. A piece of blue paper is placed on the tympanic cavity, and a bristle in the perforation.

26.2. Carcinoma of the Middle Ear.

Jeffray Collection.

The left temporal bone and external ear divided by vertical transverse section through the external auditory meatus, showing a tumour filling up the tympanic cavity, destroying the tegmen tympani, involving the dura mater over it and projecting into the middle fossa of the skull; also appearing in the external auditory meatus and behind the ear (the pinna being decidedly pushed out from the side of the head), and in the carotid canal. The sides of the inner half of the meatus externus are infiltrated by tumour, and rough, presenting the appearance of a malignant ulcer. No trace of the membrana tympani remains. The bony walls of the tympanic cavity have been destroyed more or less on all sides, but the precise extent to which the inner wall and internal ear is involved does not appear. The growth has no distinct boundary. It is a rounded irregular mass, measuring about 5 cm. in its vertical and transverse diameters, and about 3 cm. from back to front. Below, it is continuous with the parotid gland, and appears to be infiltrating it. A bristle is passed through the

carotid canal, and another bristle close to it indicates the tensor tympani muscle. The Eustachian tube could not be made out, but a little below the canal of the tensor tympani is seen a process of tumour tissue which is probably occupying it. On microscopic examination the tumour presents the structure of an epithelioma, consisting of irregular processes of epithelial cells, with numerous epithelial nests (laminated capsules) in them. The specimen gives no clear indication of the source from which the growth has sprung; but the condition of the inner part of the meatus externus, and the fact that it belongs to a class of tumour which grows from stratified epithelium, point to its having arisen from the inner part of the meatus externus, and to have burrowed inwards. (MS. Notes, J.H.T., p. 62.)

SERIES 27.

ANATOMY OF THE SKIN, EPIDERMAL APPENDAGES, AND THE SUBCUTANEOUS AREOLAR AND ADI- POSE TISSUES.

<i>The Skin and Subcutaneous Tissues ; Blood-vessels,</i>	1-12
<i>The Epidermis,</i>	13-18 and 31-36
<i>The Pigmented Layers,</i>	19-25
<i>The Relations of Skin and Mucous Membrane,</i>	26-30
<i>Hairs and Nails,</i>	37-43
<i>The Glands of the Skin,</i>	44-49
<i>The Cutis Vera,</i>	50-52
<i>Comparative Anatomy of the Skin and Appendages,</i>	54-66

27.1. A Child's Head injected red and with Glass Eyes, showing the Natural Appearance of the Skin.

Hunterian. II. 1.

"A child's head injected red, cuticle not removed. Glass eyes ; remarkably beautiful ; it looks as if it were alive ; about three or four years of age ; the skin of the face most natural." The back of the head and brain are removed, showing the dura mater and the roots of the cranial nerves.

27.2. Skin and Subcutaneous Tissues from a Negro.

Hunterian. II. 2.

A portion of the whole thickness of the skin with the subcutaneous adipose tissue, showing the thickness of the integumentary structures. The adipose tissue is removed from the upper part, showing the inside of the cutis vera, which is a dense firm layer

of white fibrous tissue similar to the loose white fibrous tissue which constitutes the areolar basis of the adipose tissue; it is this part of the skin which when tanned constitutes leather.

27.3. Skin and Subcutaneous Tissue. Negro.

Hunterian. II. 3.

Similar to the preceding.

27.4. The Blood-vessels of the Skin and Subcutaneous Tissues.

A small piece of skin injected red, dried and mounted in turpentine, showing the above.

27.5. The Blood-vessels of the Skin and Subcutaneous Tissues.

Hunterian. II. 32 (?)

A small piece of skin injected red, and the epidermis removed, showing the blood-vessels. Inferior to the preceding.

27.6. The Skin. The Epidermis removed "to show Pores."

Hunterian. II. 1a.

"The left forearm and hand of a girl about twelve years of age," showing the above.

27.7. The Blood-vessels of the Skin.

Hunterian. II. 5.

The lower part of a face, the arteries minutely injected red, and the cuticle removed. To the naked eye the whole thing appears of a uniform red, and the pores of the skin are distinctly, and the papillae fairly, visible. The larger vessels appear as streaks of a pink colour. With a lens there is seen to be a beautiful network of vessels around the pores and in the papillae. The papillae are most evident on the lips and mucous membrane of the mouth. The cuticle, which has been removed, has no blood-vessels. Compare No. 27. 18.

27.8. The Blood-vessels of the Skin.

Hunterian. II. 6.

A similar preparation from a child about ten years of age, very finely injected red. ("Dr. Nichols.")

27.9. The Blood-vessels of the Skin. *Hunterian. II. 7.*

"The left hand of a young woman, minutely injected red and stripped of its cuticle." It is of a beautiful red colour, and appears highly vascular, but not so vascular as the preceding specimens of the face. The palm of the hand, especially near the tip of the fingers, and the beds of the nails are redder than the back. The tissues of the wrist are seen in section beautifully injected.

27.10. The Blood-vessels of the Skin. *Hunterian. II. 7a.*

Another left hand (much larger) injected red, showing the same as the preceding.

27.11. The Blood-vessels of the Skin. *Hunterian. II. 8.*

"The foot of the same subject" (left) injected red, and the cuticle removed; similar to the preceding, and apparently equally vascular. The cut surface at the ankle shows the relative vascularity of the internal tissues; the cartilage and tendons appear quite avascular.

27.12. The Blood-vessels of the Skin. *Hunterian. II. 8a.*

Right foot injected red, similar to the preceding.

*The Epidermis or Cuticle.***27.13. The Epidermis or Cuticle.** *Hunterian. II. 9.*

A portion of the cuticle of the sole of the foot nearly an eighth of an inch (3 mm.) thick. It is marked by parallel ridges running across the foot, crossed at fairly regular intervals by minute furrows. These ridges, after running a short distance, bend and join one another at an acute angle. The outer surface is covered with a horny layer which is desquamating, but shows the ridges very distinctly. In the centre of each ridge is a dotted line due to the mouths of the sweat ducts, which open all along the crests of the ridges in the transverse furrows. The inner surface shows furrows corresponding to the ridges, separated by narrow ridges corresponding to the furrows of the outer surface, and in each furrow a slight line broken at regular intervals by transverse ridges and dots which, as in the outer surface, represent sweat ducts.

The cut edge shows the correspondence of the ridges and furrows, and here and there it is possible to trace a sweat duct. The three strata of the epidermis—rete mucosum or Malpighii inside, horny layer outside, and a yellowish line between, which is the stratum lucidum—can be seen even with the naked eye.

27.14. The Epidermis or Cuticle. *Hunterian. II. 9a.*

Another portion of the cuticle of the sole of the foot, similar to the preceding.

27.15. The Papillae of the Cutis Vera. *Hunterian. II. 9aa.*

A portion of the heel injected red and blue, and the cuticle removed, showing its surface divided by ranges of papillae into ridges and furrows which fit into the furrows and ridges of the deep surface of the epidermis. The colour is rather faded.

27.16. The Horny Layer of the Epidermis.

Hunterian. II. 9b.

"A portion of the sole of the foot where the cuticle is divided into two layers"—the outer, the horny layer, being raised.

27.17. The Epidermis or Cuticle. *Hunterian. II. 13.*

A portion of thin hairy skin "from a white person," the cuticle raised largely, and the rete mucosum only in part; the brownness of the skin seems to depend on the rete mucosum, for under it the skin is of the purest white.

27.18. The Avascularity of the Epidermis or Cuticle.

Hunterian. II. 14a.

A portion of the skin injected red, and the cuticle raised and turned down, showing its avascularity. Mounted on blue paper.

27.19. Skin of Negro, showing the Pigmentation of the Epidermis. *Hunterian. II. 16a.*

A portion of the skin of a negro, the epidermis raised and turned down, showing that the black pigment is contained in the epidermis, the cutis vera being pure white.

27.20. Skin of Negro, showing Pigmentation.*Hunterian. II. 16e.*

The epidermis removed, except from the lower part; the cutis vera white with a yellowish tinge, the epidermis brown.

27.21. The Pigmentation of the Layers of the Epidermis. Negro.*Hunterian. II. 16b.*

A portion of the skin, with the epidermis turned down and divided at its free edge into two layers, the inner of which—the rete mucosum—is more deeply pigmented than the outer or horny layer.

27.22. The Pigmentation of the Different Layers of the Epidermis. Negro.*Hunterian. II. 17.*

A portion of epidermis of a brown colour, the deeper layer scraped away in the centre, showing the clear and less deeply pigmented horny layer.

27.23. The Pigmentation of the Epidermis.*Hunterian. II. 16f.*

A portion of the skin of a negro, the cuticle dissected off to varying depths to show the disposition of the pigment.

27.24. The Rete Mucosum of the Epidermis.*Hunterian. II. 16d.*

A portion of the skin of a negro, the outer layer of the epidermis raised and turned down, leaving the deep layer, which is seen to be deeply pigmented.

27.25. The Thickness of the Epidermis.*Hunterian. II. 27.*

A portion of the cuticle from the foot "of a negro," showing the difference in thickness on the side and back and on the sole.

Specimens showing Modifications of the Skin and its Relation to Mucous Membrane in Various Situations.

27.26. Skin and Mucous Membrane on the Lip.

Hunterian. II. 19.

The upper lip of a negro showing the transition from skin to mucous membrane, the thick skin ceasing abruptly at the edge of the lip, and the pigmented cuticle continued to the inside becoming gradually lighter; the mucous membrane is quite white.

27.27. Skin and Mucous Membrane in Nose and Lip.

Hunterian. II. 20.

One side of the nose and lip "of a negro," of light colour, showing the pigmentation extending about 6 mm. within the nostril. The lining of the nostril preserves its skin character for about 3 mm. inwards, and is covered with short stiff hairs called vibrissae; beyond the line of these its character changes to that of mucous membrane, but the pigmentation continues a little farther.

27.28. The Skin of the External Auditory Meatus.

Hunterian. II. 20a.

The meatus is lined with skin covered in the outer part with hairs, and containing glands. In the osseous part of the tube the skin is thin and hairless and closely adherent to the bone, and the cuticle is continuous over the membrana tympani. Compare Series 25, Ear.

27.29. Skin and Conjunctiva.

Hunterian. II. 18.

The eyelids, bristles in the puncta lachrymalia, showing the thin skin free from fat on the outside terminating at the line of the eyelashes in the clear shining conjunctival mucous membrane.

27.30. The Skin of the Penis. Negro. *Hunterian. II. 21a.*

The penis of a negro, the corpora cavernosa and spongiosa injected with wax, showing the characters of the above. The

skin is fine and free from hairs, and over the glans it assumes the character of the mucous membrane, but preserves its dark colour up to and even a little way into the orifice of the meatus urinarius.

The Cuticle or Epidermis.

27.31. The Entire Cuticle of a Child's Hand.

Hunterian. II. 28.

Removed entire by maceration; hit [as pulled off like a glove, is of a very white colour, and the nails have come with it—a proof of their epidermal nature. This was called a “Cheirotheca” in the old catalogue.

27.32. The Cuticular Sheath of a Child's Foot, Inverted.

Jeffray Collection.

A similar preparation from the anterior part of a child's foot, inverted, showing the roots of the nails continuous with the epidermis.

27.33. The Entire Cuticle of a Child's Foot.

Hunterian. II. 29.

A “podotheca” in the same style as No. 31. The outer layer is raised into minute vesicles, which are clear and like sudamina on the back; on the sole the epidermis over them is thick and dry. There is no history of the specimen.

27.34. The Ridges and Furrows of the Cuticle.

Hunterian. II. 30.

A great toe injected red, the cuticle of the back stripped off, and that of the sole left hanging, showing the ridges converging to a centre about the middle of the end phalanx.

27.35. The Ridges and Furrows of the Cuticle.

Hunterian. II. 31.

A portion of the cuticle from the under side of the great toe, showing as the preceding.

27. 36. Epidermis Stretched by a Tumour.*Hunterian. II. 31a.*

"A portion of the cuticle from an exostosis of the thigh in which the limb was become as thick as the trunk of the body; the intention was to discover pores open at both ends, but they were not visible this way; the hairs in consequence of the distension are removed at a greater distance (from one another) than they were originally." *Vide* Cruikshank, "Experiments on the Insensible Perspiration of the Human Body," 8vo. (pamphlet), London, 1795.

*Epidermal Appendages.***27. 37. Epidermal Appendages. Nails and Hairs.***Hunterian. II. 31b.*

A portion of the cuticle from the upper side of the foot, showing the relation of the nails and roots of the hairs to the epidermis; also the short processes of epidermis which dip into the pores and between the papillae of the cutis vera. The cuticle is desquamating in large scales. Compare next specimen.

27. 38. Epidermal Appendages. Hairs. Desquamation of the Cuticle.*Hunterian. II. 31c.*

A portion of the skin of the back of the foot, showing the roots of a number of hairs and the cuticle desquamating in large scales. The cuticle is normally shed in very fine, almost invisible, dust; the condition here resembles that which is seen on a limb that has been covered by a dressing or bandage for a long time—the epidermis being protected is able to form flakes of considerable size, which become loose, and are shed as such.

27. 39. Epidermal Appendages. Nails. *Hunterian. II. 35.*

The cuticle of the great toe with the nail, inverted, showing the nail continuous with the cuticle as if only a continuation of it. The root of the nail runs under it loose for about 6 mm. * The root of the nail is white, and the papillae of the cutis vera project into it irregularly; in front, the body of the nail is yellow and horny, and marked with regular longitudinal ridges,

into the furrows between which project the highly vascular processes of the cutis vera. The base of the nail is called the matrix or quick; an idea of its vascularity, compared with the rest of the true skin, may be obtained from specimens Nos. 9-12 of this series.

27.40. Epidermal Appendages. Nails. *Hunterian. II. 35a.*

The cuticle and nail of the great toe macerated and pulled off like the finger of a glove, the cuticle dissected away at one side to show the root of the nail and its connection with the cuticle.

27.41. Epidermal Appendages. The Hairs of the Head.

Hunterian. II. 36.

A portion of the scalp of a European injected red, the hair seen in side view cut somewhat obliquely. The roots of the hairs extend right through the epidermis and corium into the subcutaneous tissue; a projection of the corium is carried down with the root of the hair, forming the dermal sheath of the hair follicle, which encloses the hair bulb, which is an epidermal structure.

27.42. The Hairs of the Head.

Hunterian. II. 37.

A portion of the scalp uninjected, the subcutaneous tissue scraped away from part of the specimen, showing the ends of the hair follicles. The roots of the hairs are also well seen in section embedded in the yellow fat. The lower part of the specimen is covered internally by a portion of the occipito-frontalis tendon, which lies a little deeper than the roots of the hair.

27.43. The Woolly Hair of a Negro.

Hunterian. II. 37a.

A portion of the scalp of a negro showing the above.

The Glands of the Skin.

27.44. The Sebaceous Glands of the Nipple.

Hunterian. II. 11b.

The nipple of a man, showing a number of little tubercles round it, on the tops of which open the ducts of sebaceous glands.

27.45. The Sebaceous Glands of the Axilla.*Hunterian. II. 12.*

A portion of skin from the axilla with the thick subcutaneous adipose tissue, which at one part is scraped off, showing a number of sebaceous glands (odoriferous) about the size of hemp seeds immediately under the cutis vera. There is a number of short rather coarse hairs.

27.46. The Sebaceous Glands and Hair of the Axilla of a Negro.*Hunterian. II. 12a.*

A similar preparation from the axilla of a negro. The hair, as on the scalp, is woolly.

27.47. The Ducts of the Sweat Glands. *Hunterian. II. 32.*

A portion of the skin of the sole of the foot injected, and the cuticle half peeled off after scalding or maceration, to show small filaments "as fine as the most delicate threads of a spider's web" passing between the cutis and the epidermis, which are the ducts of the sudoriparous or sweat glands. This and the succeeding specimen are described and figured in William Hunter's paper in *Med. Obs. and Inq.*, Vol. II., p. 17, and Pl. I., fig. 1, entitled "The History of an Emphysema," to which are added some "remarks on the Cellular Membrane and some of its diseases," by William Hunter, M.D., from p. 52 of which the above quotation is made.

27.48. The Sweat Ducts.*Hunterian. II. 33.*

Similar to the preceding. *Ibid.*, Pl. I., fig. 2.

27.49. The Sweat Ducts.*Hunterian. II. 33a.*

A similar specimen but uninjected, and the skin and cuticle not so much pulled asunder.

*The Structure of the Cutis Vera.***27.50. The Papillary Layer of the Cutis Vera.***Hunterian. II. 52c.*

A portion of skin from the arm, injected red, the cuticle removed, and some shreds of thin membrane, evidently vascular, turned

down and floating. This is the papillary layer of the cutis vera separated by dissection, and the surface left is rough and irregular, there being no natural separation like that between the cuticle and cutis, which yields to maceration or scalding. The preparation shows the vascularity of the papillary layer to be greater than that of the subjacent layer of the cutis vera. Cruikshank believed this to be another naturally distinct layer of the skin, though not so distinct as epidermis and cutis vera. *Vide* "Experiments on the Insensible Perspiration," London, 1795.

27.51. The Papillary Layer of the Cutis Vera.

Hunterian. II. 53.

A similar preparation but uninjected, from a negro.

27.52. The Cutis Vera.

Hunterian. II. 54.

Portion of the skin of a negro to show the cutis vera after the papillary layer has been dissected away; it is rough and fibrous like the cut surface of leather—it is raw human leather.

27.53. The Cutis Vera.

Hunterian. II. 56.

A portion of the skin showing the cutis vera torn without maceration into three layers, the outer the most dense. The separation is quite artificial.

Comparative Anatomy of the Integuments.

27.54. Skin of Elephant. Tanned.

Hunterian. II. 47.

A small portion of the above, the epidermis turned down and now fallen away entirely. It is seen to send prolongations into the sweat ducts, which are of considerable size, and marked with bristles which are passed in a considerable distance. The cutis vera is about 2.2 cm. thick, and is raised into small papillae, which fit into corresponding hollows of the cuticle; a magnifying glass is almost necessary to see them.

27.55. Skin of Elephant. Tanned.

Hunterian. II. 48.

Another portion of the same—elephant leather.

27.56. Skin of Elephant. Tanned. *Hunterian. II. 49.*

Similar to the preceding.

27.57. Skin of Whale. *Hunterian. II. 10.*

A portion, apparently, of the edge of one of the fins, composed chiefly of fibrous tissue with two pieces of cartilage visible in the upper cut surface. The epidermis is turned down, showing the cutis vera covered with long papillae. The horny layer is partly separated from the deeper tissue of the epidermis. It shows very prettily the spaces into which fit the papillae of the cutis vera.

THE STRUCTURE OF HOOFS.

27.58. The Foot of the Horse. *Hunterian. II. 8.*

A horse's foot injected red, the hoof removed by long maceration in water, showing the vascular surface of the underlying skin. The sole, which corresponds to the pad of the finger, is beset with long villi; this part is called the "frog" of the hoof. The outer surfaces of the foot correspond to the part of the finger (or toe) which bears the nail, and the cutis is there thrown into long ridges similar to those under the human nail.

27.59. The Foot of the Horse. *Hunterian. II. 8aa.*

A portion of the epidermal part of the horse's foot, the ragged and dirty parts cut away, showing the thick epidermis of the sole or frog corresponding to the skin of the sole of the human toe; and round the outside, and extending into the sole behind, the hoof proper, a greatly developed nail about 12 mm. thick, with the marks of the shoe nails in it.

27.60. The Foot of a "Slink Calf." *Hunterian. II. 8b.*

Beautifully injected red and the epidermal part removed by maceration, showing the vascular bed of the hoof.

27.61. The Foot of a "Slink Calf." *Hunterian. II. 8c.*

Similar to the preceding. A "slink" calf is a foetal or newly born calf.

27.62. The Foot of a Foetal Calf. *Hunterian. II. 8d.*

Similar to the preceding, but from a much younger animal, the hoof in part left on.

27.63. The Hoof of a Calf. *Hunterian. N. 107d.*

Posterior section of the foot of a young "slink calf" (foetal calf) finely injected red, showing the vascular parts of the foot and the avascular horny hoof.

27.64. The Hoof of a Calf. *Hunterian. N. 107e.*

Anterior section of the same or a similar specimen.

27.65. The Hoof of a "Slink Calf." *Hunterian. II. 35c.*

One hoof of the above removed by maceration, showing the nail and the thick epidermis of the sole. The epidermis projects a long way beyond the nail, not having been worn down by use.

27.66. Modifications of the Epidermis. Scales. Leg of Turkey. *Hunterian. II. 34.*

The tarsus and foot of a turkey, showing the cuticle converted into thick strong scales for the purpose of protection.

SERIES 28.

INJURIES AND DISEASES OF THE SKIN AND APPENDAGES.

<i>Healing Wounds,</i>	1-6
<i>Tattooing,</i>	7-9
<i>Small-pox Eruption,</i>	10-11
<i>Tumours,</i>	12-16

I. DEFECTS IN THE DEVELOPMENT OF THE SKIN AND APPENDAGES.

Specimens wanted.

II. INJURIES OF THE SKIN : TATTOOING, ETC.

Healing of Wounds in the Skin.

28.1. An Ulcer. Injected.

Hunterian. II. 26a.

"The cutis of a stump injected after amputation." The specimen shows the end of a stump, with an oval ulcerated surface, 5 cm. by 3 cm., injected red. The epidermis has been removed. The ulcer shows the thick edge of the old skin, with a bluish line of new-formed cicatricial tissue internal to it, where the epidermis had been shooting in over the granulating surface. A large part of the granulating surface is gone, and the rest is mostly dull yellowish red in colour, as if not very vascular, and there is a slough in the centre of it. The new-formed cutis at the healing edge is of a bluish tinge, with red streaks, and where it joins the raw surface has a red,

highly vascular appearance ; here and there the granulating surface appears bright red also. The deep surface of the specimen is highly injected and of a bright red colour.

28.2. Cicatrix of an Ulcer. Negro. *Hunterian. II. 25.*

"A portion of skin with a large cicatrix, from a negro." The cuticle is turned down, showing the cicatricial contracted new skin, which is wrinkled, but is whiter, thinner, and of smoother appearance than the old skin from the absence of hairs and the pores connected with the sweat glands. The cuticle corresponding to the cicatrix is distinctly thinner and lighter in colour than the normal cuticle, owing to the rete mucosum, which contains the greater part of the pigment, not being regenerated over the surface of a wound. Compare next specimen.

28.3. Cicatrix of an Ulcer. Negro. *Hunterian. II. 25a.*

"A portion of the skin from the top of the shoulder of a negro," showing the above. It is a dull white mark, much lighter than the surrounding tissue, "as if the rete mucosum had not been regenerated, or were no longer of a black colour." Compare the preceding.

28.4. Cicatrix of an Ulcer. White Man.

Hunterian. II. 26.

A portion of skin injected red, showing a healed ulcer. The cuticle, which is very thin, is raised in part, showing the new-formed cicatricial tissue fairly vascular.

28.5. Cicatricial Condition of the Skin from Overdistension.

Hunterian. II. 43.

"A portion of skin from the belly of a woman who had borne children ; it is full of marks like cicatrices, as if in the distension some new skin had been inserted or formed in different parts, which is whiter and thinner than the originally formed skin."

28. 6. Inclusion of a Foreign Body in the Subcutaneous Tissue.*Hunterian. II. 38.*

"A portion of scalp from an adult ; on the outside is seen a long cicatrix ; and on the inside, a lock of hair which had been driven in at the time of receiving the wound, and continued there for years probably, without irritating."

28. 7. Tattooing.*Hunterian. II. 22.*

"Two portions of skin from a sailor's arms ; on one side is represented, in gunpowder and some red powder, the crucifixion ; on the other, his mistress' name, with some love emblems. From both the cuticle is turned down to show that this kind of painting could not be effaced, but with the destruction of the cutis." The pigment has healed in, in the same manner as the lock of hair in the preceding.

28. 8. Tattooing.*Hunterian. II. 23.*

"A small portion of cutis, with G.W. and 1745 done in the same way as the former," showing, as before, that the pigment is deposited in the true skin.

28. 9. Tattooing.*Hunterian. II. 24.*

"A portion of cutis, with I.S. done in the same way ; (the horny epidermis turned down) rete mucosum left on to show that the characters are under it."

III. CHANGES DUE TO CONDITIONS AFFECTING THE NUTRITION (*e.g.* GLOSSY SKIN).

Specimens wanted.

IV. CHANGES DUE TO INFLAMMATORY DISEASES.

28. 10. The Skin in Small-pox.*Hunterian. II. 40.*

A portion of skin injected red, showing a number of small-pox pustules in a fairly advanced stage. The umbilication is well marked.

28.11. The Skin in Small-pox.*Hunterian. II. 41.*

A small portion of skin injected red, "the heads (of the pustules) removed to show the bottom extremely vascular and red, the slough having just thrown off."

28.12. The Skin in Small-pox.*Hunterian. II. 50.*

Similar to the preceding.

V. TUMOURS OF THE SKIN AND ITS APPENDAGES.**28.13. Dermoid Cyst from the Leg of a Sheep.***Hunterian. II. 39.*

"A cyst from a sheep's leg." A long spindle-shaped cyst, with fairly thick walls, covered internally with fine hair. It is filled with balls of tightly compressed hair, "which had grown from its surface, shed, and accumulated gradually."

28.14. Tumour at the Edge of the Nail of the Great Toe.*Hunterian. II. 35b.*

A left great toe, the cuticle and nail removed, showing a tumour "about the size of a shelled almond," growing out from the inner edge of the bed of the nail. No history. On microscopic examination of a small slice from the under part of the side next the nail, nothing was found but normal skin and subcutaneous tissue. A section of the base would be necessary to determine its nature. It is not malignant. Probably it is an ungual exostosis, covered by a good deal of soft tissue. See next specimen for the nail and cuticle. (MS. Notes, J.H.T., p. 78.)

28.15. The Cuticle and Nail from the preceding Tumour.*Hunterian. II. 35a.*

The nail is thickened, deformed, and has lost its natural shining surface. A mass of thick irregular epidermis, which covered the tumour, has fallen away, and is hung to the lower end of the cuticular sheath.

28. 16. Sarcoma of the Back.*Hunterian. II. 63.*

A tumour, about 7 cm. in diameter and 3 cm. thick, of irregularly round shape, and somewhat lobulated, with an oval piece of skin, which has been excised with it. On section, the tumour looks like gland, with a good deal of fibrous tissue, and on microscopic examination is found to be a sarcoma, with a very well developed stroma. The cells have to a very large extent atrophied. Formerly described as "a tumour, which Dr. Hunter formerly extirpated from between the scapulae in a man; it looks glandular; the disease recurred, proved cancerous, and killed." (MS. Notes, J.H.T., p. 41.)

END OF VOL. I.

1899



