

**An improved method of the radical operation for carcinoma of the breast /
by Willy Meyer.**

Contributors

Meyer, Willy, 1858-1932.
Royal College of Surgeons of England

Publication/Creation

New York, NY : Trow, 1894.

Persistent URL

<https://wellcomecollection.org/works/pm5xcug3>

Provider

Royal College of Surgeons

License and attribution

This material has been provided by This material has been provided by The Royal College of Surgeons of England. The original may be consulted at The Royal College of Surgeons of England. where the originals may be consulted. This work has been identified as being free of known restrictions under copyright law, including all related and neighbouring rights and is being made available under the Creative Commons, Public Domain Mark.

You can copy, modify, distribute and perform the work, even for commercial purposes, without asking permission.



Wellcome Collection
183 Euston Road
London NW1 2BE UK
T +44 (0)20 7611 8722
E library@wellcomecollection.org
<https://wellcomecollection.org>





AN IMPROVED METHOD

OF THE

16.


Radical Operation for Carcinoma
of the Breast

BY

WILLY MEYER, M.D.

PROFESSOR OF SURGERY AT THE NEW YORK POST-GRADUATE MEDICAL SCHOOL AND
HOSPITAL; ATTENDING SURGEON TO THE GERMAN AND NEW YORK
SKIN AND CANCER HOSPITALS; CONSULTING SURGEON
TO THE NEW YORK INFIRMARY

Reprinted from the MEDICAL RECORD, *December 15, 1894*



NEW YORK

TROW DIRECTORY, PRINTING AND BOOKBINDING CO.

201-213 EAST TWELFTH STREET

1894




AN IMPROVED METHOD
OF THE
Radical Operation for Carcinoma
of the Breast


BY
WILLY MEYER, M.D.

PROFESSOR OF SURGERY AT THE NEW YORK POST-GRADUATE MEDICAL SCHOOL AND
HOSPITAL; ATTENDING SURGEON TO THE GERMAN AND NEW YORK
SKIN AND CANCER HOSPITALS; CONSULTING SURGEON
TO THE NEW YORK INFIRMARY

Reprinted from the MEDICAL RECORD, *December 15, 1894*



NEW YORK
TROW DIRECTORY, PRINTING AND BOOKBINDING CO.
201-213 EAST TWELFTH STREET
1894





AN IMPROVED METHOD OF THE RADICAL OPERATION FOR CARCINOMA OF THE BREAST.¹

SINCE Heidenhain has shown that in a great number of cases of cancer of the breast the pectoralis major muscle is also involved by the disease, and that, if left in place, the growth is more liable to recur,² it has become, I believe, the duty of the surgeon always to remove this muscle with the breast and the axillary contents. Only, if carried out according to this plan, the operation should be called radical.

According to well-known methods the surgeon generally first removes the breast with the axillary contents. If he believes in doing in every instance as radical work as feasible in fighting this treacherous disease, he will then cut out the pectoralis major muscle from its origin to its insertion.³ It means no serious addition to the operative procedure, but rather still more radical work, also to extirpate the pectoralis minor muscle at the same time. It enables the operator to remove the loose connective tissue and fat under this muscle, which is often diseased.

Within the last three years I have operated, according

¹ Read before the Section on Surgery of the New York Academy of Medicine, November 12, 1894.

² Lothar Heidenhain: Ueber die Ursachen der localen Krebsrecidive nach Amputation Mammæ. Verhandlungen der deutschen Gesellschaft für Chirurgie, Berlin, 1889, and von Langenbeck's Archiv für klin. Chir., 1889, vol. xxxix., p. 97.

³ Heidenhain believes that it might be best to remove the strip of periosteum of clavicle and sternum, to which the muscle is attached, with the latter. Before making this addition to the operation, I, personally, should rather wait and see whether future observations prove that by leaving in place the respective pieces of periosteum a regional recurrence is favored.

to this plan, on six female patients, and found by increasing experience, with reference to the technique :

1. That the extirpation of the pectoral muscles, carried out in this way, means an addition of about fifteen to twenty minutes to the operation, including ligatures.

2. That it saves blood and time to first cut off the insertion of the muscles on the humerus and coracoid process, and then to reflect the muscles downward. The arteriæ perforantes being on the stretch, can then be well seen and caught with the forceps close to the intercostal muscles, before being divided. If we pursue the reverse method, viz., cut off the origin of the muscle on ribs and sternum first, and then turn up the same toward the humerus, these arteries often tear near the intercostal muscles and the ribs. It is then difficult to catch and ligate the bleeding points.¹

The parasitic theory of the etiology of cancer is yet unproved. On the other hand, inoculation of small pieces of cancerous tissue into the peritoneal cavities of animals has been successful. A cancer of the same type developed in such a spot. Clinical observations also make it highly probable that small particles of cancer-tissue, if entering hitherto healthy tissue, can there produce the same growth. Kraske gives a *résumé* of the special literature on this subject, and relates two very interesting cases in this respect.² He found in two cases of ulcerating cancer of the rectum, where the tumor could just be reached with the finger, low down immediately above the sphincter muscle, secondary small cancerous

¹ The arteriæ perforantes are branches of the intercostal arteries. They are of tolerably large size. After having traversed the intercostal muscles, which they supply with blood, they enter and feed (besides the serratus anticus major muscle and a portion of the abdominal muscles) the pectoralis major muscle and the mammary gland. Heidenhain emphasizes the fact that these arteries and their ramifications are accompanied by cancerous lymphatics above the fascia of the pectoralis major muscle. He therefore advises to divide the vessels "within" the latter. It is, in my opinion, a still better plan to divide them "underneath" the muscle, just above the intercostal muscles.

² Centralblatt für Chirurgie, p. 801, 1880.

nodules of the type which was represented by the main growth. In both patients a healthy strip of mucous membrane, of at least 10 ctm. length, was interposed between the original and, as he explains it, the secondary tumors. He believes that the latter originated from the proliferation of the living epithelial cells which had severed their connection with the primary carcinoma, and had then been implanted in the lower portion of the rectal mucous membrane. Small tears in the latter, made by the examining finger or instruments, the hyperæmia and catarrhal condition of the lower end of the rectum always present in these cases, will favor the development of the inoculated particles.

With reference to the breast, the unavoidable handling of the tumor by the operator's hands and the assistants' hooks has been considered harmful, and called upon to explain the distressingly low percentage of cures after the operation. It has been assumed that during these manipulations cancer-cells, or, if we accept to-day the theory of the parasitic origin, the parasites themselves, might be pressed into the lymphatics and thus disseminate the disease through the body.¹ It has therefore been proposed to attack the axillary cavity first, clean out its contents before severing their connection with the breast, and then to remove the breast and axillary contents together.² This procedure may be of some importance. Yet there are multiple other lymphatic vessels, which are not touched by the knife in such an operation, and which can carry away infectious material in different directions, thus, for instance, to the opposite side, to the supra-clavicular region, etc. (It is, of course, understood, that in cases of long standing these regions may have become

¹ A. G. Gerster, on the Surgical Dissemination of Cancer, New York Medical Journal, February 28, 1885.—It has been my personal misfortune to have had among the patients on whom I removed a cancer of the breast, quite a number in whom there was no regional recurrence of the disease, but who died within one year and a half after the operation, helpless, almost paralyzed, and with great pains, from metastatic growths in the spinal column.

² Gerster : Loc. cit.

infected before an operation for the removal of the cancer of the breast is undertaken.) As Dr. Gerster wrote me the other day, the result, as far as recurrence is concerned, has not been improved by this procedure. This fact is a matter of course, since we know that the fascia of the pectoralis major muscle and this muscle itself, as well as the loose fatty tissue below the same and below the pectoralis minor muscle, so often are the seat of cancer. And this, not very rarely, in cases where the tumor is yet comparatively small and the breast freely movable over the underlying tissues.

The most harm is surely done during the manipulations with the knife, the hooks, and the hands "within the operating field itself," as long as we work "within" and not "outside of" the diseased area. During the operation lymphatic vessels between breast and fascia, those of the pectoralis major muscle, between and below the pectoral muscles, in the axillary, sub- and infra-clavicular fat, all more or less filled with epithelial cells, are compressed, cut, and torn. Their contents enter the fresh wound. Direct local infection of hitherto healthy tissue by cancer is liable to take place. I believe that especially the primary tearing off or preparing the breast tumor with the knife from the subjacent fascia of the pectoralis major muscle, or from the superficial layer of its fibres, if the tumor be adherent to the fascia—as it has been the general custom of operators up to date—may at times directly infect the large fresh wound with microscopical elements of cancerous tissue. It has been shown that just the fascia of the pectoralis major muscle and the superficial layer of fibres of the latter, often contain a very large number of microscopical cancerous deposits.

By first excising the breast with the axillary glands and then extirpating the muscles, the latter procedure forming the second part of the operation, we also increase the loss of blood. Many vessels are cut—and have to be tied—twice.

In view of these considerations I have thought that

in order to avoid local or remote infection, also to save loss of blood, and still to be as complete in the work as possible, that the following might be an improvement: *Not* to excise the breast tumor in connection with the axillary contents first, and *then* to remove the pectoral muscles and clean out the sub- and infra-clavicular space ;

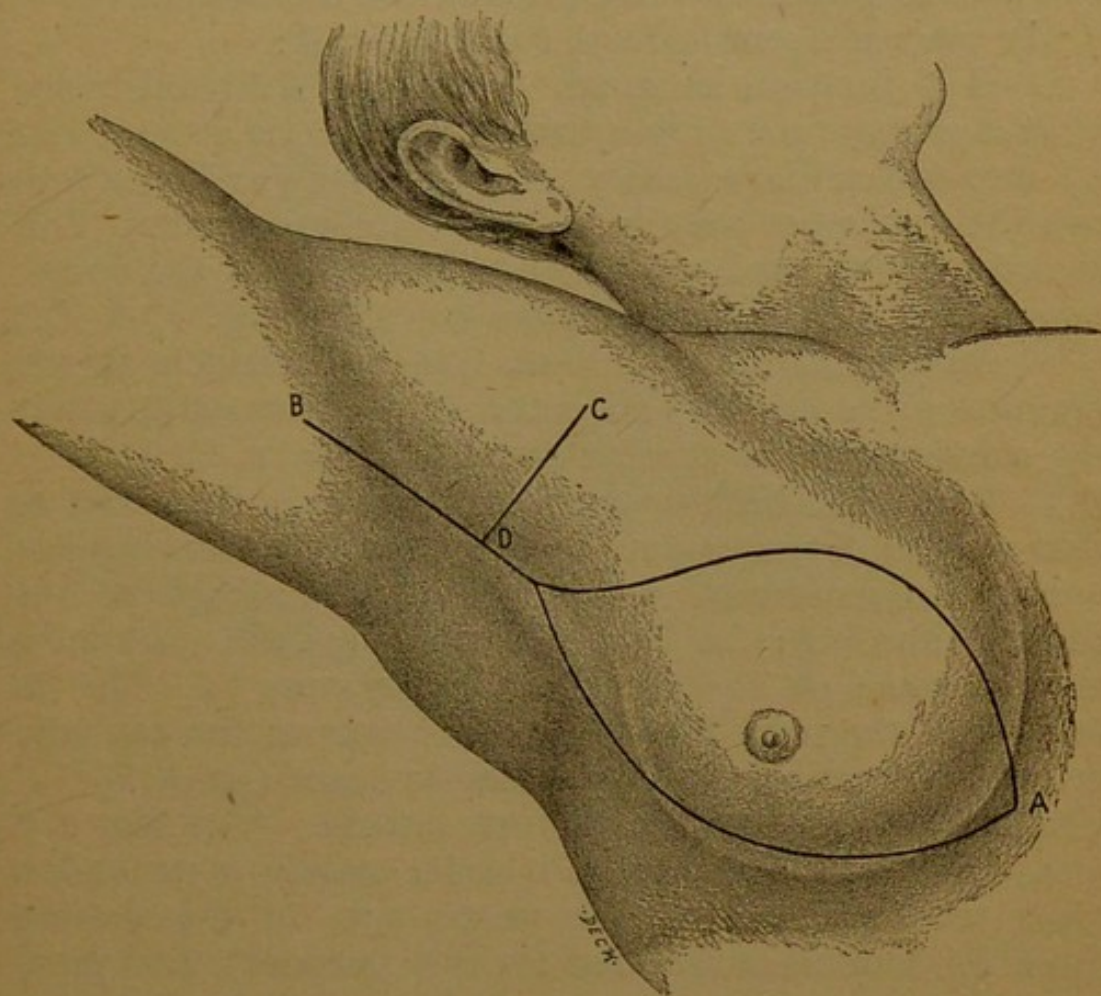


FIG. 1.

but “*to extirpate the breast, the contents of the axillary and of the sub- and infra-clavicular region, and the pectoral muscles, in one mass.*” In other words, I thought I would try and let the knife never enter the infected area (cancer), but work “*everywhere*” around the latter in healthy tissue, of course as far as this may be feasible in such cases.

For this purpose the operator must first come down to

landmarks, when reflecting back the flaps of skin, before attacking the seat of the cancer proper. These landmarks, as I mapped them out, would be : *a.* Above : cephalic vein and clavicle. *b.* Outward : The tendon of the pectoralis major muscle on the humerus. *c.* Below : the border of the latissimus dorsi muscle. *d.* Inward : The sternal extremity of the clavicle and the sternum itself.

My plan of operation was the following :

1. Skin incision as usual, embracing a liberal piece of skin around the nipple, which incision is at once run up into the axillary cavity, about an inch and a half to two inches farther than in the ordinary operation. This in order more easily to reach the tendon of the pectoralis major muscle on the humerus. (See Fig. 1, A, B.)

2. Additional skin incision from the clavicle at the junction of its middle and outer thirds downward, meeting the first wound at right angles. (Fig. 1, C, D.)

3. Reflection backward of the three skin flaps with as thin a layer of the underlying fat as possible, leaving just enough so as not to endanger a future necrosis of the flaps,¹ exposing : *a.* The insertion of the pectoralis major muscle on the clavicle and sternum. *b.* The insertion of the same muscle on the humerus, the cephalic vein in Mohrenheim's sub-clavicular space (guide !). *c.* The border of the latissimus dorsi muscle. (See Fig. 2.)²

4. Division of the pectoralis major muscle in its tendon close to the humerus (the raised arm of the patient must be somewhat lowered for this purpose), and preparation of the same downward (Fig. 2) to its insertion on the clavicle. Here it is cut off at once down to the sternal extremity of the bone, in order to thoroughly expose the contents of the axillary cavity and the infra- and sub-clavicular region. During this time an assistant

¹ Further experience must show how much fat must be left attached to the skin. It means, no doubt, a better prognosis, with reference to recurrence, to say : "the less the better," or, "none whatever."

² This plate has been drawn by the artist without his having witnessed the operation. He was obliged to work guided only by my explanations.

exerts some traction on the breast, to put the tissues on the stretch.

5. Preparation and excision of the sub clavicular, infra-clavicular, and axillary fat, glands and lymphatics, with the knife, beginning over the bundle of nerves and vessels high up in the cavity, and continuing this procedure from the lower border of the sub-clavian and axil-

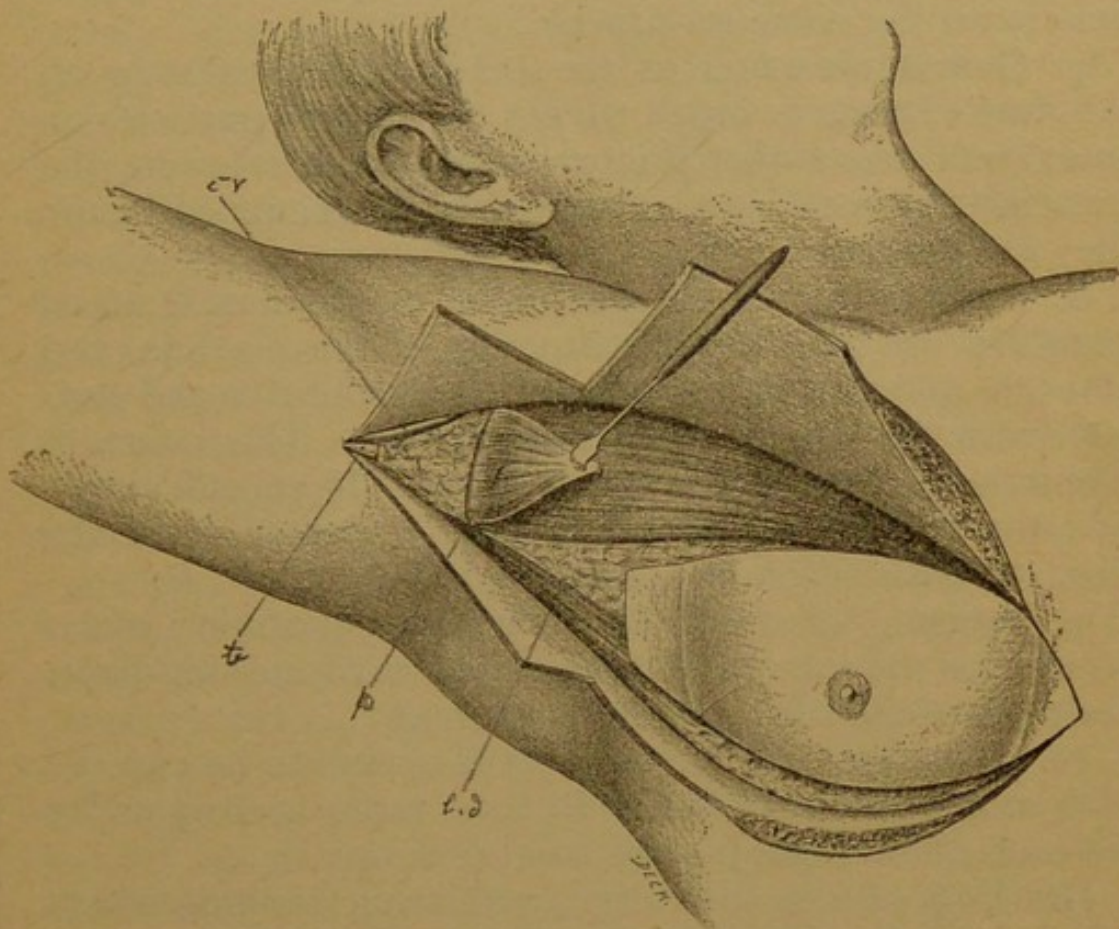


FIG. 2.—*p*, Pectoralis major muscle; *t*, tendon pectoralis major muscle; *c, v*, cephalic vein; *l, a*, latissimus dorsi muscle.

lary vein downward. As soon as freed, these contents, having been divided on the outer side from the fat in the upper part of the sulcus bicipitalis of the arm, are raised and cut out from the outer side inward. This means, beginning from the border of the latissimus dorsi muscle. This excision is continued, including the fat on the sub-scapularis and teres major muscles, until the

chest-wall, viz., ribs, intercostal, and part of the serratus anticus major muscles, are plainly before us, and until the "lower" surface of the pectoral muscles is reached. Fat with glands and lymphatics are nowhere cut into, but remain in one piece and attached to the outer lower border of the pectoral muscles in their normal anatomical relation.

6. Division of the tendon of the pectoralis minor muscle on the coracoid process.

7. Gentle elevation of the breast and muscles by an assistant's hands in order to put the blood-vessels which enter and leave the pectoralis major muscle on the stretch. As mentioned above, they are clamped before they are divided.

8. Amputation of the pectoralis major muscle at its insertion on the sternal extremity of the clavicle, and of both muscles at their insertion on the ribs and sternum with the knife close to these bones. This insertion forms the pedicle of the whole mass. If cut off alongside the sternum after having been separated from the ribs, the extirpation of the cancer is finished.

9. Suturing of the wound as far as possible; plate-sutures for the sake of better coaptation of the skin-flaps, drainage of the axillary cavity as usual.

10. Dressing; the large defect is always to be covered with rubber tissue in order to favor rapid healing under the moist blood-clot; good compression.

Grafting of the resulting granulating wound, which will follow the removal of a liberal piece of skin, may be done in about eight or ten days without narcosis, ethyl-chloride being used for anæsthetizing the area of the arm or thigh, from which the grafts are taken. The granulating surface need not be scraped for this purpose.¹

¹ Julius Schnitzler u. Karl Ewald: Zur Technik der Hauttransplantation nach Thiersch, Centralblatt für Chirurgie, 1894, No. 7, page 148. According to my experience, immediate grafting on the very uneven basis of the fresh defect is not advisable.

On September 19, 1894, I had my first opportunity to operate according to this plan.

Mrs. F. O——, aged thirty-seven. Slowly increasing tumor of the left breast since eighteen months. It never ached, and thus made the patient neglect to consult a doctor. Examination on September 15th showed a tumor of goose-egg's size in the centre of the breast. Nipple not retracted. Axillary glands hard and infiltrated. September 19th operation as just described, with the exception of omitting the additional incision from the clavicle downward. One upper flap only and one lower one were thus formed. This was a mistake. It somewhat impeded the easy reach of the attachment of the muscle on the clavicle. I should advise always to make this incision, especially in fat patients. I had done so, in fact, in my former cases, in which I first cut away breast and axillary contents, and then the muscles. The operation was not difficult. Only when preparing from the edge of the latissimus dorsi muscle inward and upward, in order to reach the chest-wall and the pectoral muscles (from below), I found it somewhat inconvenient in comparison with the former method of operating, to have the great mass of tissue above. Clever assistants will here be of great help. Temperature never rose above 100° F. First dressing changed on the sixth day; primary union throughout; drainage-tube removed; patient out of bed. To-day arm freely movable. The specimen which I hand around will show nicely, how radically the operation has been done. The whole mass is in one piece. The microscope substantiated the diagnosis of cancer.

As seen in this, as well as in my former cases, where I extirpated the pectoralis major muscle entirely, the loss of the latter never interfered with the motion of the arm. On the contrary, the patients were able to sooner move the arm in all directions than I have seen if the muscles be not or only partially removed. The strong

inner (clavicular) portion of the deltoid is fully able to adduct the arm. Some patients complained of a tight sensation over the chest, they "felt their ribs exposed." This annoyance was soon, however, overcome. In order to avoid stiffness in the shoulder-joint, the patients should be ordered to begin with active and passive motions after the first change of dressing, viz., between the eighth till tenth day after the operation.

I am, of course, fully aware that also this most radical method of operation will not prevent recurrence of the growth "in loco," nor metastases in remote parts, especially not, if the patients be subjected to the operation in an advanced stage of the disease. Yet I venture to consider it a step in trying still further to reduce the chances of probably infecting the fresh wound and the entire system with cancer by our work "during" the operation; also to do as complete work as possible.

In this view I thought it permissible to communicate this method to the Surgical Section, having so far had only one personal practical experience.

Mr. President and Gentlemen, the idea of removing the carcinoma of the breast in this way was conceived by me last winter. By a peculiar coincidence not one case of carcinoma of the breast came under my care since then until September, even not during a four-months' service at the German Hospital. This paper was written in the latter part of September. It was announced to the Secretary of the Surgical Section at about October 20th. Before doing so, I had very carefully perused the newest literature, especially the elaborate articles on the subject by Dennis, Weir, and Bull, in order to ascertain whether others had removed a cancer of the breast in the way just described. I did not find this procedure mentioned. Now, ten days ago, on November 2d, the November issue of the *Annals of*

Surgery has come into my hands.⁷ In this issue Dr. William S. Halsted, of the Johns Hopkins Hospital, has published a brilliant article upon the results of operations for the cure of cancer of the breast, performed by him at the Johns Hopkins Hospital from June, 1889, to January, 1894, in which he recommends practically the same way of operating just proposed by me, viz., the removal of the breast, fat, and glands of the axillary cavity and infra-clavicular region "in one mass." He thinks it advisable to explore and clean out also the supra-clavicular region in almost every operable case.¹ He has operated in this way on most of the fifty patients whose histories are recorded. As will be seen by comparison, our methods differ in some respects. I shall mention those which seem to me to be of some importance.

Halsted surrounds the base of the breast with an incision, and reflects a triangular flap of skin downward and outward.

I first reflect back three flaps of skin, two upper ones and one lower one, so far, until I reach the landmarks mentioned above, namely: the tendon of the pectoralis major muscle, the cephalic vein, the clavicle and sternum, the border of the latissimus dorsi muscle.

Halsted's third step of the operation reads: "The costal insertions of the pectoralis major muscle are severed, and the splitting of the muscle, usually between its clavicular and costal portions, is begun, and continued to a point about opposite the scalenus tubercle on the clavicle." The sixth step reads: "The splitting of the muscle is continued out to the humerus, and the part of the muscle to be removed is now cut through close to its

¹ This is, no doubt, a very wise addition. I shall certainly add this point to my plan of operating laid down above, in every case coming under my care. By lengthening the additional incision as proposed by me (Fig. 1, C, D.) upward above the clavicle, this operation can be easily and rapidly done. Of course, we shall clean out the supra-clavicular space thoroughly, by removing the fat with glands and lymphatics also "in one piece."

humeral attachments ;” and the eighth to tenth : “ The lower outer border of the minor muscle having been passed and clearly exposed, this muscle is divided at right angles to its fibres, and at a point a little below its middle.” “ The tissue, more or less rich in lymphatics and often cancerous, over the minor muscle near its coracoid insertion, is divided as far out as possible, and then reflected inward in order to liberate or to prepare for the reflection upward of this part of the minor muscle.” “ The upper, outer portion of the minor muscle is drawn upward with a broad, sharp retractor. This liberates the retractor which until now has been holding back the clavicular portion of the pectoralis major muscle.”

In the manner as I have planned and performed the operation, the belly of the pectoralis major muscle, as well as that of the minor, is not touched at all. To repeat briefly what has been said above : I first cut off the humeral attachment of the pectoralis major muscle, prepare its upper border free from the cephalic vein, and detach it with the knife close to the clavicle. Then the muscle is turned downward and inward, until the tendon of the pectoralis minor muscle can be cut off from the coracoid process. Later—that means after the tissue over the bundle of vessels and nerves high up in the axilla, and after the axillary, sub- and infra-clavicular fat, glands, and lymphatics have been carefully prepared in the well-known manner, “ but *left in their original anatomical relation to the breast and to the muscles*”¹—both muscles are raised and cut away from above downward and inward.

Further : Halsted turns the mass over to the outer side and cuts it off on the base of the skin-flap, which had been primarily formed and reflected outward. This I believe will be more convenient for the operator.

As my procedure follows the direction of the fibres of

¹ The lower outer border of the minor muscle is thus not clearly exposed, but remains attached to the axillary fat.

the pectoral muscles from above downward, the mass must be turned upward and inward first, when preparing from the axilla, and then inward. A clever assistant will be easily able to hold it out of the way. When the pedicle, the sterno-costal insertion of the pectoralis major muscle, is reached, a few strokes with a sharp knife complete the operation.

Further experience must show whether Halsted's or my plan of operating deserves preference.

I personally should prefer the operation as proposed above and carried out by me. It seems to me to be more anatomical than that of Halsted. It also is, I trust, still more radical, since in every instance the entire pectoralis major muscle (and the minor) will be removed. I think, this is absolutely necessary, in order to do radical work. Heidenhain specially states, that he considers a muscle, which has been invaded by cancer, suspicious from its origin to its insertion. "Not a fibre of the muscle should be left behind." On this ground I should also prefer to abstain from all splitting of the pectoralis major muscle between its different portions. By *not* working within the belly of the muscle whatsoever, we shall, no doubt, be best guarded against infection of the fresh wound with cancer, and against regional recurrence.

The nucleus of the operation, however, is the following rule: "Lift *all* the tissue, that may be diseased, and often will be found on microscopical examination to be diseased *throughout*, out of its bed *in one piece*."

That this kind of radical operation will be "the" operation for the extirpation of carcinoma of the breast, there can be no doubt. It is proved by Halsted's unprecedented percentage of cures. He so far records cure in ninety-four per cent. of his cases, including the cases operated up to February, 1894, a number which has never been reached by a surgeon before.

I venture to hope that, by absolutely and continuously working everywhere around the seat of disease, by never

trespassing on the belly of the muscles, and always removing the latter completely, this extremely gratifying result might be also secured by others.

Thus will then, at last, it is to be hoped, also this terrible foe of suffering mankind, this dread especially of the female sex, become oftener silenced and made more submissive to the surgeon's knife, provided the operation is done early, before remote parts of the system have become infected.



