

The progress of cystoscopy in the last three years / by Willy Meyer.

Contributors

Meyer, Willy, 1858-1932.
Royal College of Surgeons of England

Publication/Creation

[Place of publication not identified] : [publisher not identified], [1892]

Persistent URL

<https://wellcomecollection.org/works/xq7zwf5x>

Provider

Royal College of Surgeons

License and attribution

This material has been provided by This material has been provided by The Royal College of Surgeons of England. The original may be consulted at The Royal College of Surgeons of England. where the originals may be consulted. This work has been identified as being free of known restrictions under copyright law, including all related and neighbouring rights and is being made available under the Creative Commons, Public Domain Mark.

You can copy, modify, distribute and perform the work, even for commercial purposes, without asking permission.



Wellcome Collection
183 Euston Road
London NW1 2BE UK
T +44 (0)20 7611 8722
E library@wellcomecollection.org
<https://wellcomecollection.org>





15.

The Progress of Cystoscopy
in the Last Three Years.


BY


WILLY MEYER, M. D.,

Attending Surgeon to the German and New York
Skin and Cancer Hospitals.


REPRINTED FROM

The New York Medical Journal
for January 30, 1892.





*Reprinted from the New York Medical Journal
for January 30, 1892.*



THE PROGRESS OF CYSTOSCOPY IN THE LAST THREE YEARS.*

BY WILLY MEYER, M. D.,

ATTENDING SURGEON TO
THE GERMAN AND NEW YORK SKIN AND CANCER HOSPITALS.

THREE years ago Dr. Max Nitze, of Berlin, the inventor of the cystoscope, in his well-known essay, *Contribution to Endoscopy of the Male Bladder*,† stated that we could now, with the help of the cystoscope in its handy and improved shape, establish a strict differential diagnosis between the diseases of the bladder. He further said: "Having seen with the cystoscope that the bladder is healthy, and that the morbid process therefore involves the upper urinary passages, most probably the kidneys, it is tempting to put the question whether we shall be able to prove with the cystoscope which kidney or which pelvis of the kidney is diseased. Either we could attempt to push a thin catheter under the guide of our eyes into the orifice of the ureters, to draw the urine directly from each kidney separately, or we might be able to observe with the cystoscope out of

* Read in part before the Medical Society of the State of New York at its eighty-fifth annual meeting, Albany, February 3, 1891.

† V. Langenbeck's *Archiv f. klin. Chirurgie*, vol. xxxvi, p. 661.

which ureter the blood escaped in a case of hæmaturia," or, I may add, pus or purulent urine in a case of pyelitis or suppurating kidney.

It was obvious from the beginning that Nitze's statement would be sustained by all who practiced cystoscopy—namely, that our knowledge as well as the diagnosis of *bladder* diseases would just as rapidly widen, clear up, and improve with the help of the new cystoscope as our knowledge of laryngeal diseases, for instance, did after the invention and introduction of the laryngoscope. But would Nitze's hope also be realized, or could it be realized, in regard to *kidney* troubles? Might we hope to be able to use his cystoscope as at least one means of observing the "character" of the urine in its direct descent from each kidney?

Reviewing the literature on cystoscopy which has appeared since 1887, and the results of my own work in this line, covering now (December, 1891) a period of nearly four years, we can unhesitatingly answer this question in the affirmative.

Before treating of the progress in the diagnosis and treatment of "kidney" diseases with the help of the cystoscope—the special object of my paper—any further, I will try to give a short review of the development of cystoscopy in general, with reference to the construction of additional instruments, made in accordance with the principles laid down by Nitze, and to its influence upon the diagnosis, prognosis, and treatment of diseases of the bladder.

I. INSTRUMENTS.

After three years' careful trial and comparison of the two chief cystoscopes which have been in the market—viz., that of Dr. Max Nitze, manufactured by Paul Hartwig, of Berlin (*Markgrafenstrasse*, 79), and that of Mr. Joseph Leiter, the well-known instrument-maker of Vienna, manu-

factured by himself (*Mariannengasse*, 11)—I must slightly alter my remark, made a few years ago,* that I “prefer” Nitze’s instrument. It is true, I still mostly use it, because I have become accustomed to it, and because it seems to me that the picture, as seen through its prism and lenses, is more stereoscopic.† I also believe that, in order to avoid diagnostic errors, it is better to train one’s eyes exclusively on one instrument. After experience has been acquired, it is immaterial which instrument is used. And since Leiter has slightly altered the pattern of his instrument in accordance with the suggestion of Hurry Fenwick, of London, he has secured the essential advantages of Nitze’s cystoscope and eliminated the former disadvantages of his own. || Leiter’s instrument is now most highly finished and perfectly reliable. ‡ “The length of the beak is reduced to less than an inch. § The elbow is well rounded; the length of the shaft is seven inches and a half. The ocular end is fitted with a rotatory plate, carrying the binding screws, while, instead of the Nitze slot-key, a small screw upon the face of the plate forms a more convenient switch.” ¶ In the

* Author. A Contribution to the Surgery of the Bladder. *New York Med. Jour.*, Feb. 23, 1889.

† That others are of the same opinion is shown by the following passage in a recent treatise by Cecil-Kent Austin, entitled *Sur le diagnostic précoce des néoplasmes de la vessie et du rein au moyen du cystoscope*, Paris, 1890: “Je ferai remarquer en passant que les images perçues au moyen de l’instrument de Berlin m’ont paru plus nettes, plus satisfaisantes que celles que donne l’instrument viennois.”

‡ In the new one, which is in my possession, the beak still measures an inch.

§ This alteration, as it appears, was first employed by Leiter in the old Nitze-Leiter instrument. *Neue Beleuchtungsapparate mit Zuhilfenahme des elektrischen Lichtes. Nachtrag zu den von Josef Leiter verfassten Catalogen*, 1890, p. 1.

|| I should say here that Nitze demands that Leiter’s cystoscope which is practically the same as Nitze’s, be called the Nitze cystoscope manufactured by Leiter.

Leiter instrument of 1887 the beak was nearly half an inch longer, the elbow presented an angle, the shaft was too short, and the battery wires had to be fastened in the binding screws, which were immovable upon the instrument, and thus would twist around it, if the latter was turned around its longitudinal axis in the bladder. The only difference, then, which still exists between the two German instruments, apart from the arrangement of the mignon lamp, is in the telescope. That of Nitze slightly magnifies; that of Leiter slightly diminishes. The lenses in Nitze's instrument also give a more perspective picture, to my eyes at least, and cover a larger field—*i. e.*, the observer's eye will perceive with one glance a larger area.*

The drawbacks alleged against Nitze's cystoscope are: †

1. A somewhat less brilliant light.

It is true, that of Leiter is brighter, because the still longer beak carries a larger, less delicate, and more powerful incandescent lamp. Still, the light as thrown from the Nitze mignon-lamp, if tested as to its strength previous to the introduction of the instrument (what always should be done), will be found entirely satisfactory in every case. Where we can not see with it for special reasons, we shall most probably also not succeed with the other.

2. The silver tip, the carbon filament of which has given out or has been destroyed, has to be sent to Berlin for put-

* Take Nitze's instrument in one hand, turn its prism to the window, and hold the palmar side of the slightly flexed fingers of the other hand at a distance of about two inches from it; then look through the telescope: you will see at once the fifth to second fingers and a part of the ulnar side of the thumb. Do the same with Leiter's cystoscope: you will see only two fingers and a half.

† Cf. E. Hurry Fenwick. *The Electric Illumination of the Bladder and Urethra*, second edition. London: J. and A. Churchill, 1889, pp. 36 and 43.

ting in a new incandescent lamp, whereas Leiter has made the cystoscopist independent.

This is now easier arranged for cystoscopists on this side of the ocean, who work with Nitze's cystoscope, as I have induced the W. F. Ford Surgical Instrument Company, 315 Fifth Avenue, New York city, to carry a number of silver tips in stock. Useless tips will there be exchanged for new ones, which fit upon the instrument. (Difference of price here and in Berlin, 50 cents.) I should add, although it is self-understood, that it will be necessary to have a number of these tips, all armed with the carbon filament, constantly on hand, just as the order sent to Leiter should include six reserve lamps. The price of the latter is, however, one fifth of that of the silver tip of Nitze's cystoscope. The difference of the two instruments in this respect is therefore merely a pecuniary one. To *replace* a burned-out incandescent lamp by a new one does not require a moment longer in Nitze's cystoscope—nay (if such a simple, though important, manipulation is to be compared at all), is even still simpler than in Leiter's. But there is—

3. Another disadvantage, which became manifest to me in the course of the last year, since I have been in possession of three different Nitze cystoscopes. It is that the screw of the different tips in stock will sometimes be found not to fit exactly on the thread at the lower end of the shaft. Thus the screw of the tips now and then overruns the limit of screwing or does not reach it at all. The surface of the lamp then points to another direction than the prism, and the tip is simply useless. It will, however, be seen at once that this is no drawback to the instrument proper, but a mistake which can be remedied at once by a greater accuracy of the instrument-maker. It is to be hoped that Mr. Hartwig will yield to the cystoscopists' urgent requests and pay better attention in the future to this slight but impor-

tant defect, explained to him at length. The screw-thread of each cystoscope ought to be manufactured *accurately alike*, and the tips, before being sent away, carefully fitted on a standard instrument at Berlin. The arrangement as now made here in New York also dispenses with this annoyance. In cities where a similar arrangement is not or can not be made, the cystoscopist will soon have his small stock of fitting tips, and must insist upon having put new incandescent lamps into these very same tips. I should not omit to state here that, after some experience and with proper care and a good battery, the same tip can be used for nearly a year and perhaps still longer.*

In his first essay, and later also in his *Text-book on Cys-*

* Still I have to mention—

1. To constantly have Nitze's instrument in good working order, it is absolutely necessary to keep clean and dry the two circular grooves at the upper end of the instrument, as well as the concave surface of the rotatory handle, which, when attached to these grooves, conveys the current from the battery to the instrument. This refers especially to the irrigating cystoscope.

2. The slot key, which, under management of the thumb, serves for opening and breaking the circuit, may work rather easily after some time. The light then will be less brilliant. A simple turn of the screw which holds the key in place will correct this difficulty.

3. If the cystoscope turns too easily in the handle, it will be found useful to leave the left hand at the upper end of the cystoscope, the so-called "funnel," during the examination, while pressing the handle with the other hand tightly against it.

4. If the lamp of a new tip does not burn at once when the current passes its filament, a slight straightening of the little cork-screw-like silver wire at the basis of the tip, before the latter is screwed on, will often be found sufficient to get a bright light.

5. The small bubbles of air which often arise with a peculiar noise from the junction of shaft and tip in Nitze's instrument are caused by the decomposition of the water by the electric current. If a bit of wax is smeared upon the lower groove of the screw at the tip, previous to its being adjusted, this can always be avoided.

toscopy,* Nitze recommended three different cystoscopes for a thorough inspection of the entire inner surface of the bladder.

Cystoscope No. 1, which carries the lamp and prism at its concave side (the latter at the junction of beak and shaft), represents the main instrument, "the" cystoscope.

Cystoscope No. 2, for the inspection of the fundus: The lamp on the concave side; the window at the end of the shaft, through which the observer looks with the telescope; of course, no prism.

Cystoscope No. 3, for illumination of the internal orifice of the urethra and its immediate neighborhood: The lamp and prism on the concave side of the beak, which latter is about half an inch longer than in the others, and bent in nearly a right angle to the shaft. A small mirror, situated at the convexity of the curve inside the tube, reflects the picture which is thrown into the telescope from the reflecting plane of the prism. I have tried this instrument in a number of cases, and can state that the picture seen with it is utterly indistinct. It is to be hoped that it will soon be improved. Although we are able to diagnosticate the hypertrophy of the prostate "in the picture" with No. 1, yet a thorough inspection of the internal urethral orifice and its surroundings under electric illumination would be very valuable in a number of cases.

In regard to cystoscope No. 2 I can only repeat what I said two years ago: † that it is unnecessary to buy it. I have always succeeded in inspecting the fundus and trigonum, together with the mouth of the ureters, by simply turning No. 1 180° and depressing the handle, even in cases with hypertrophy of the prostate. The inconvenience to the patient

* Wiesbaden, 1889. Verlag von J. F. Bergmann.

† *Loc. cit.*, p. 203.

is slight. Nitze himself advised me, when I saw him at the International Congress at Berlin, to exchange my No. 2 for a longer No. 1, which would prove very useful in cases of hypertrophy of the prostate, where the urethra is materially lengthened. I did so, and can say that I am very thankful to Dr. Nitze for this kind advice. The long shaft will be found of advantage in many instances.

As a third instrument I procured the new irrigating cystoscope of Nitze, which permits of changing the fluid in the bladder without being removed itself.* It contains two small tubes in its shaft, which is thus increased in size to 25 gauge, French. (The size of the beak is 22, as in the others.) The one tube ends just in front of the prism with three small holes side by side. It carries fresh water into the bladder. The water, thrown in with the help of a hand syringe, passes with considerable force over the surface of the prism, thus washing it and removing blood coagula or pus shreds which so frequently settle there and render a successful cystoscopy impossible. This is a very clever arrangement. The other tube ends, or rather begins, with a single oval-shaped opening at one side of the lower end of the shaft; through it the water passes out of the bladder. Both tubes are carried to either side of the upper end of the instrument, and their current can there be shut off by a small stop-cock. Both these stop-cocks are attached below the funnel to a metal ring, which also carries the handle with the slot-key. They thus remain steady in the hand of the observer while the shaft can be turned around its longitudinal axis. The irriga-

* *Centralblatt f. Chirurgie*, 1889, p. 949. Nitze had two irrigating cystoscopes made—a "simple" and a "more complicated" one. The former, oval in shape, only permits of throwing more water into the bladder; the latter, which is round, enables us to really change the water. Only the latter is to be recommended.

tion can be effected without regard to the turning of the shaft. To put the whole into working order, rubber tubes are attached and tied on the end of the two tubes. It will be found of advantage to have the one which carries the water out of the bladder cut so long as to hang into a basin under the table. If the water is changed and the examination continued—which will frequently be of great importance—an assistant or the patient must pump the water in. This latter manipulation is best done intermittently by sudden brief pressures on the handle of the syringe. A fountain syringe can also be used. Of course, this arrangement does not enable us to flush the viscus or wash it out in the ordinary sense. Still, I have found this irrigation sufficient and of the greatest value in clearing up an obscure bladder trouble as well as in the diagnosis of renal disease, pyuria, and hæmaturia. In examining the bladder of patients who suffer from such troubles, the originally transparent medium becomes rapidly and suddenly turbid and the outlook is at once clouded by a dense fog; nothing can be distinguished. I succeeded, in one of these cases where I had to perform nephrectomy for pyonephrosis and cystic degeneration, and therefore wanted to determine the condition and excretory power of the remaining kidney, in establishing the fact, just after fresh water had been thrown into the bladder, that the urine descending from the other kidney was clear (cf. Case III, nephrectomy). In another troublesome case also I could make out only with the help of the irrigating cystoscope that the large amount of pus which always turned the injected water murky in a few seconds was ejected from one ureteral orifice only (cf. Case I, nephrotomy). In fact, I should prefer to use the irrigating cystoscope mostly were it not that, on account of the increased size of the shaft, its use is only practicable when the urethra is of a certain dimension.

In vesical hæmaturia, where the blood more easily coagulates, the irrigating cystoscope of the present size will often be of little or no use, as the blood-clots generally block at once the canal which carries the water out of the bladder. Fresh water is then pushed into the vesical cavity, but the turbid fluid can not get out.* If a tumor is to be examined and it does not bleed during the examination, the instrument will also prove valuable in determining the insertion of the growth. The jet of water propelled across the prism and beak will make a pedunculated growth swing, while it leaves the sessile growth undisturbed. (The same result can be obtained in using cystoscope No. 1, by pressing with one hand in sudden short shocks on the epicystic region.)

The irrigating cystoscope will be also found of advantage in cases where papillomatous growths, inserted around the internal urethral orifice, cover lamp and prism of the instrument as soon as it has entered the bladder, and thus render an examination impossible. The field of vision then appears dark. These growths can be easily pushed aside by the forcibly injected fluid, and will then be suddenly seen in bright illumination, swaying in the fluid. Concrements and foreign bodies lying in the pouch behind an hypertrophied prostate gland, and not to be detected there by the examining eye, may sometimes be thrown by the water out of the recessus, and thus diagnosticated. Lastly, it is worth mentioning that the irrigating cystoscope enables us to view the bladder in different degrees of distention. In a certain number of cases the ureteral openings can be seen only by this means. (Nitze, *loc. cit.*)

Having thus carefully compared and tried the cysto-

* The instrument could be made more useful by increasing the caliber of the tubes and thus, of course, also, of the cystoscope up to No. 30 and more. A female urethra will always, and the male urethra in a few instances or after meatotomy, admit that number.

scopes of Nitze and Leiter, I am ready to say that it is difficult to give proper advice as to which of the two had best be bought by the beginner, as both instruments are equally worthy of being in the hands of everybody who practices electric illumination of the bladder. But, whereas Nitze has given us three useful cystoscopes (according to pattern No. 1), and whereas I deem it of pre-eminent importance, in order to avoid mistakes, to stick to one pattern in the beginning, I prefer to advise the beginner to buy the Berlin instruments. I, personally, have so far gladly incurred the slight annoyance of sending my few burned-out reserve tips to Berlin for repair once in a year. The pleasure of being enabled to work with the three cystoscopes has amply rewarded me. Still, I also often find advantage in using Leiter's elegant instrument in its new shape.

The very newest instrument of this class, which has just been made known to the profession in a preliminary communication, is the *operating cystoscope*, invented by Nitze, and constructed by P. Hartwig, of Berlin (*Centrbl. f. Chirurgie*, No. 51, 1891, p. 993). A cutting forceps is attached, by a peculiar mechanism, to the lower circumference of a cylindrical tube. Its two blades carry at their end a small, sharp scoop. They are opened and closed by a lever, which moves in a longitudinal slit at the upper end of the same tube. The whole is slipped on the shaft of the ordinary cystoscope No. 1, and can be moved on it, downward and upward (see Fig. 1 and Fig. 2).

A few more mechanisms of a similar pattern have been designed for intravesical topical treatment.

To enable one to disinfect these different instruments, and also to make the armamentarium which is needed for intravesical surgery as simple and comparatively cheap as possible, the funnel of the cystoscope has been made movable. It can be screwed on or off the shaft. Thus we can

use the same *cystoscope* for all the manipulations, and only need a number of the cylindrical tubes, which carry the

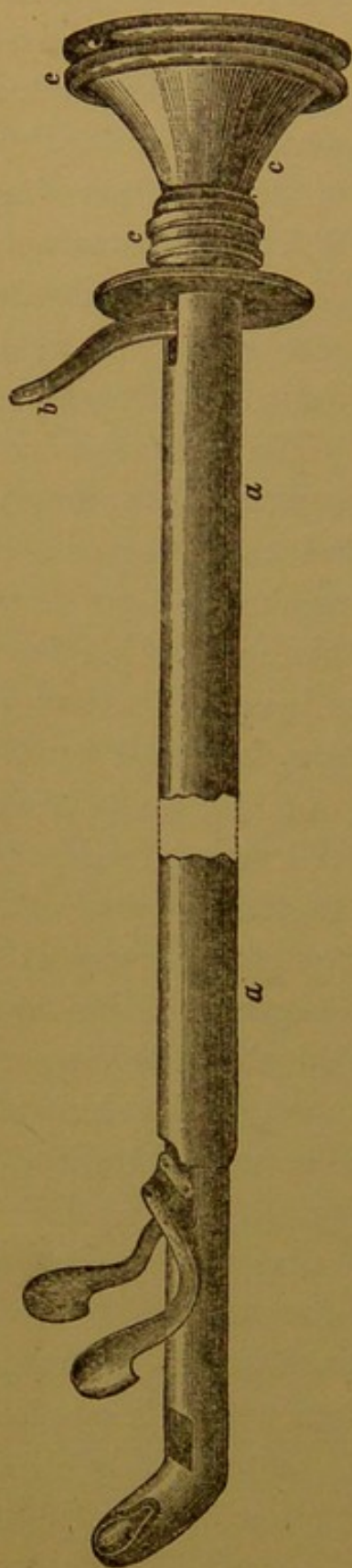


FIG. 1.

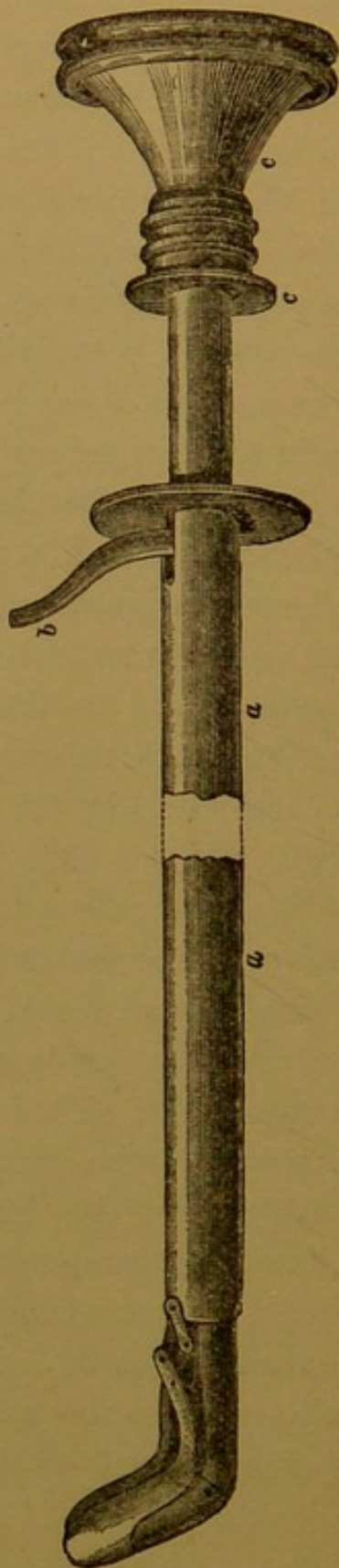


FIG. 2.

proper mechanism. The cystoscope for this kind of work has, besides the movable funnel, a smaller caliber and a longer shaft than the ordinary No. 1. The instrument armed with the forceps has the size of an evacuator as used in litholapaxy; if armed with the other mechanisms, it corresponds to about Nos. 21 to 23 of the French gauge.

Before introducing the operating cystoscope the cylindrical tube, Fig. 2, *a*, is shifted down toward the prism and the forceps, for instance, closed by pressing the lever, *b*, upward. The two blades then surround the beak in such a manner as to form one solid body with it. (The arrangement of the other mechanisms is similar to this.) The instrument will now easily pass a urethra which is not too narrow. As soon as it has entered the bladder the tube is slipped back toward the funnel of the cystoscope (Fig. 1), the light is turned on, the forceps, etc., opened, and everything is ready for work. In looking through the telescope, the motion of the two blades of the forceps or of the cold or red-hot wire of the snare-écraseur can be thoroughly observed and controlled by our eyes.

Thus, an immense progress has again been made. The cystoscope, which hitherto could only be used for diagnostic purposes, is now ready for local intravesical treatment. With the same, if not with more, precision than, for instance, in laryngoscopy, we can make topical application with certain drugs in the bladder without bringing them in contact with other spots of the vesical mucous membrane; we can cauterize (with the galvano-cautery) ulcers and flat tumors,* can tear off pedunculated growths with the for-

* Of course this can not be done if the bladder is filled with water. For such purposes it has to be expanded by air. As Nitze's lamp is situated in the extreme end of the beak, it can burn in the open air for about two to three minutes without spoiling the prism. I presume Nitze intends to proceed in this manner. He promises, in his preliminary article, to give soon full particulars in a more elaborate essay.

ceps, can seize and extract foreign bodies, small stones, or the fragments of larger ones, which have been previously crushed. And all this under the direct guidance of our eyes. Indeed, the medical profession, as well as a great portion of suffering mankind, owe thanks to Dr. Nitze for the many brilliant gifts he has bestowed upon them.

In the last three years a few more varieties of the same mechanical principle have been advanced. I will mention these for the sake of completeness :

1. *Hurry Fenwick's Modification of the Leiter Instrument*.^{*}—Part of it has been mentioned above. A further modification is the perforation of the silver cap by three small holes on the side opposite the pane of rock-crystal which covers the oval window. This is done "to allow of a free current of water to surround the lamp, whereby the hood is kept perfectly cold." In hæmaturia the non-perforated hood has to be slipped on. Fenwick adds in a foot-note: "I break more lamps in the long run, but incur less risk of burning the mucous membrane." In buying a Leiter cystoscope it will be certainly advisable to also order a perforated cap, which is, no doubt, a pretty and sensible improvement, as the larger mignon lamp, situated in the middle of the beak and covered by the rock-crystal pane, heats the entire cap. When in use, the urine or water in the bladder carries off this heat as fast as it is formed, its temperature not being perceptibly raised, even if the lamp is burned for an hour in the bladder. But as soon as it comes in contact with the sensitive mucous membrane of the bladder wall, the patient invariably has a burning sensation. It will be readily understood that a longer unintentional contact, for instance, during narcosis, may really burn the mucous membrane.

The short-beaked Nitze cystoscope carries the incandes-

^{*} Fenwick, *loc. cit.*, p. 43.

cent lamp in the tip *uncovered* in direct contact with the surrounding medium. It presents the perforated hood in a peculiar original form. Its lamp does not heat by far as much. In a large number of cystoscopies, with or without anæsthesia, I have so far never had a mishap. The touch of the bladder-wall with Nitze's cystoscope also creates a slight burning sensation.

2. *The Irrigating Cystoscope of Berkeley Hill*.—Hill proposed* to add two small tubes to the lower aspect of the instrument through which irrigation is easily made. The tubes do not greatly increase the caliber.† Nitze's irrigating cystoscope, which carries the tubes inside, seems to offer better advantages.

3. *The "Improved" Incandescent-lamp Cystoscope of Whitehead, Manchester*.‡—The Leiter pattern of 40 French gauge (instead of the usual 22 French); the window of observation and incandescent lamp present double the size, thus increasing the field of vision as well as the brilliancy of light. It is introduced through a median incision in the membranous urethra.

Such an application of the instrument directly annuls the special advantage of cystoscopy—namely, "that it affords a visual diagnosis without a cutting operation." It

* Irrigation of the Bladder in Cystoscopy. *Lancet*, London, 1889, i, 169.

† In a valuable essay of Alexander Stein, New York—Some Points in the Differential Diagnosis of Bladder and Kidney Affections—which appeared in the *Journal of Cutaneous and Genito-urinary Diseases*, 1888, p. 370, I find this passage: "In hæmaturia the injected fluid soon loses its transparency, so that we can see but indistinctly or not at all. I think this latter can be remedied by soldering an oval tube to the bottom of the cystoscope, which would reach to the curve, so that the bladder could be irrigated and refilled without removing the instrument."

‡ *British Medical Journal*, April 7, 1888, p. 768.

may, however, be useful and valuable in the female, where the urethra can be easily dilated to No. 40 French.*

4. *Brunner's Modification of the Leiter Pattern for sounding the Bladder and Catheterism of the Ureters under the Guidance of the Eye.*†—Cystoscope No. 2, of No. 28 French, which carries a separate small channel on the convex side of the shaft. This channel terminates just below the window and can also be used for changing the water in the bladder. It is occluded by a mandrel, when the instrument is introduced. The mandrel later is extracted and replaced by a minute English catheter or an elastic metal sound. Brunner thus succeeded in pushing the catheter into each ureter of a female patient exposed by the light, but failed to do the same in the male. He has had no opportunity to continue his trials in this direction. When the catheter or sound is in the ureter, the instrument itself may be slipped back over it. Perhaps also topical treatment of the bladder could be instituted with this help.

5. *Messrs. F. A. Reichardt & Co., surgical instrument makers, New York city*, have tried to manufacture a cystoscope according to a modified Berlin pattern, which latter bears no international patent. They have, however, not yet succeeded in accomplishing the difficult and expensive task. The instrument which I have inspected at their store was very unsatisfactory in many respects.

6. *The French Cystoscope of Boisseau Du Rocher, of Paris*,‡ is manufactured by Collin, Maison Charrière, of

* At Hurry Fenwick's suggestion, Leiter has made a larger cystoscope of 40 French, to be used exclusively for the female bladder. Its shaft is three inches shorter than in the ordinary cystoscope.

† Leiter. *Neue Beleuchtungsapparate mit Zuhilfenahme des elektrischen Lichtes*. Wien, 1889, p. 9.

‡ Presented by me with the following remarks to the Surgical Section of the New York Academy of Medicine, March 9, 1891.

Paris. In July, 1885, the first report was made about it to the Académie des sciences. But the instrument was not used by others until last year, when Boisseau du Rocher described it at length in an article which appeared in the *Annales des maladies des organes génito-urinaires*, février, 1890.* He called his instrument "*mégaloscope*," and the method of examination for which it was to be resorted to, "*mégaloscopie vésicale*." The doctor maintains that his "*mégaloscope*" is an entirely new design; that its pattern originated with him independently from those which are already in the market.

To settle this question from the start, it must be said that Boisseau Du Rocher's cystoscope is in its principle nothing else than an elongated ordinary cystoscope of the Leiter pattern No. 2, which is used for an easy inspection of the fundus of the bladder.

In comparison with the latter, the specially striking new features of the Paris instrument are:

A longer beak; a longer telescope, which causes the length of the instrument and in its peculiarities greatly enlarges the spot coming into view; an additional combination of pipes for irrigating the bladder and also for passing the telescope, or passing instruments for catheterism of the ureters.

But the principles in accordance with which the *mégaloscope* has been constructed are, of course, and had necessarily to be, the same as those brought out in the Nitze-Leiter original cystoscope—viz., the introduction of the light itself into the cavity which is to be examined, and an optic apparatus which magnifies and enlarges the object. The priority of these two devices, which, combined, effected the immense recorded progress in cystoscopy, is due to Nitze

* See also W. v. Vragassy. Das "Megaloskop" des Dr. Boisseau du Rocher in Paris. *Wiener med. Presse*, 1888, pp. 51 and 90.

beyond a doubt. Any new cystoscopes or endoscopes can only be variations of this original idea.

Further, the medical profession should not accept a new name for Boisseau Du Rocher's instrument and for that which can be done with it. We talk of a laryngoscope and laryngoscopy, of an ophthalmoscope and ophthalmoscopy. We should only have different patterns of a "cystoscope," and one name for the practice created by it—"cystoscopy."

The probable advantages of the Paris instrument, in comparison to the Berlin or Vienna one, as far as I have been able to see them, are the following:

1. That, on account of the length of its telescope, it is six to seven inches longer, and the face of the observer is therefore farther removed from the genitals than is possible in using the other cystoscopes. (But, on account of the great length, a slight motion of the handle will result in a by far greater one of the beak, which thus will often touch the wall of the bladder.)

2. That we can perceive with one glance a larger area and see everything in the same upright position as our eyes would see it without the telescope. (The latter is also experienced in using the Nitze or Leiter pattern No. 2.)

3. That the pipes which run alongside and inside of the lower aspect of the shaft enable us to wash out the bladder before, and apply permanent irrigation during, the cystoscopic examination. There is a wider canal in the center of the instrument for passing the telescope. It is filled out by a steel mandrel while the instrument is introduced into the bladder. If we make use of this canal for irrigation, the viscus can be very thoroughly flushed.

4. That the larger one of the small pipes can be utilized for passing instruments of minute caliber for catheterism of the ureters.*

* Cf. the Brunner modification

5. That the telescope is introduced after the whole instrument has passed the urethral canal—*i. e.*, is in the bladder. The objective lens can thus never be dimmed by an adherent mucous or pus shred or a small blood-coagulum.*

6. That the instrument can be sterilized by boiling water, the cement which is used for fastening the rock-crystal pane in the window of the beak, etc., being such as to stand a great heat. The other cystoscopes can not be boiled. They are disinfected by wiping them very carefully and thoroughly with gauze dipped in a three- to five-per-cent. solution of carbolic acid.

Now, has the French cystoscope also drawbacks as an offset to these advantages? Yes, and very serious ones.

1. We can not inspect the whole inner surface of the bladder with this cystoscope, which, besides, is quite clumsy and not at all as easy to handle as that of Nitze or Leiter.

Boisseau Du Rocher finds an objection to Nitze's instrument on account of the latter's advice† to make five exact motions with the cystoscope in the bladder in order to bring into sight every spot of its interior with mathematical exactness. With his own, when introduced into the bladder, the whole fundus, the posterior wall, and a portion of the upper and the two lateral walls come at once into view, without turning or moving the instrument. (In trying to obtain this result we shall, however, get a kind of bird's-eye view.) But to examine the anterior portion of

* Cf. Nitze's irrigating cystoscope. If we make it a rule always to inject some glycerin into the posterior portion of the urethra with the help of a Nélaton catheter right after a careful irrigation of the anterior portion of the urethra, of the neck of the bladder, and of the latter organ itself, and right before introducing the cystoscope, we certainly shall quite rarely meet with this annoying occurrence when using the ordinary cystoscope.

† Cf. Nitze's *Text-book on Cystoscopy*, pp. 93-99.

the vertex with the Paris cystoscope, the examining person would nearly have to sit on the floor, and even then the result might not be satisfactory. Therefore two instruments become necessary.

2. The caliber of the shaft is No. 27 of the French scale, that of the beak No. 23. The increase of the size of the shaft is caused by the pipes for irrigation. It is to be mentioned, though, that they are situated at the lower aspect of the shaft, and thus give the tube a conical shape (cf. Brunner's modification). The top of this cone corresponds with the lower circumference of the urethra, which can be stretched. (The size of Nitze's and Leiter's cystoscope is No. 22, that of Nitze's irrigating cystoscope, the shape of which is round, No. 25.)

3. The beak is very long—half an inch longer than that of Leiter's, and twice as long as that of Nitze's cystoscope.

4. The angle at the junction of the beak and shaft is 130° and abrupt; in the other two instruments only 145° and well rounded.

5. The lumen of the two pipes used for irrigation and passing catheters for catheterizing the ureters is extremely small. There is at present no catheter in the market, in this city at least, small enough for this purpose.

6. There is no key or screw to make and break the electric circuit. We always have to put in or unscrew one of the conducting wires for this purpose.

7. It is difficult to thoroughly cleanse the inner surface of the objective lens of the telescope. This lens can not be detached from the tube, but has to be reached by a long conductor which holds at its end a piece of maple-marrow.

I have not, so far, succeeded in removing some particles of dust from the inner surface of this lens. A compliance with this need by the manufacturer would mean an improvement of the telescope.

8. The spherical aberration of the lenses of the telescope.

9. A constant dripping of water out of the upper end of the instrument during examination. The intravesical pressure constantly forces the water alongside the telescope, which does not snugly occlude the lumen of the central canal.

So far I have got the impression that the French cystoscope will not as easily come into general use as that of Nitze and Leiter. It decidedly has a few important new features, which will make it desirable for the cystoscopist to be in possession of it. But until the defects mentioned above shall have been remedied,* we certainly shall always need the additional use of one of the two other cystoscopes in the market if we want to be ready to thoroughly perform a cystoscopic examination in cases where this method can be applied.

In closing this section, a tabulated comparison of the size of the different parts of the three cystoscopes which attract special interest may perhaps be welcome. (See next page.)

In regard to the batteries, a great variety is now at our disposal. Hartwig & Leiter sell a battery with the cystoscope which fully answers the purpose.† The fluid is a mixture of pure chromic acid (to be ordered of Messrs. Churchman & Co., Philadelphia), sulphuric acid, and water. (Formula for Hartwig's battery: Chromic acid, 375; sulphuric acid, 300; water, 3,000. For Leiter's: Chromic

* According to a remark of Dr. W. K. Otis, of this city, in the discussion on Dr. L. B. Bangs's paper—Cases illustrating some Difficulties in the Use of the Cystoscope (Section in General Surgery of the New York Academy of Medicine, meeting of November 9, 1891)—this gentleman is at present engaged in improving Rocher's instrument.

† For description, see Nitze's *Text-book*, p. 62; Leiter, *Catalogue*, 1889, pp. 13–17.

Cystoscope.	Size, French gau. c.	Length of entire instrument, measured from outer brim of funnel to tip of beak, in a straight line.		Length of shaft, measured from outer brim of funnel to junction with beak.		Length of that part of the instrument which alone comes into consideration with reference to length of urethra—namely, from inner brim of funnel to lower border of prism.		Length of beak.		Size of angle between shaft and beak.
		Inches.	Centim.	Inches.	Centim.	Inches.	Centim.	Inches.	Centim.	
Nitze. { No. 1, long..... Irrigating cystoscope Leiter, No. 1..... Boisseau du Rocher.....	22	10 $\frac{1}{6}$	25 $\frac{1}{2}$	9 $\frac{1}{2}$	24	8 $\frac{1}{3}$	21	3 $\frac{3}{4}$	2	145° (Rounded.)
	22	11 $\frac{1}{6}$	28 $\frac{1}{4}$	10 $\frac{1}{2}$	26 $\frac{1}{2}$	9 $\frac{1}{3}$	23 $\frac{3}{4}$	3 $\frac{3}{4}$	2	"
	25	11 $\frac{1}{6}$	28 $\frac{1}{4}$	10 $\frac{1}{2}$	26 $\frac{1}{2}$	8 $\frac{3}{4}$	22 $\frac{1}{4}$	3 $\frac{3}{4}$	2	"
	22	9 $\frac{5}{6}$	25	9	23	7 $\frac{1}{3}$	18 $\frac{3}{4}$	1	2 $\frac{1}{2}$	"
	{ Shaft = 27 Beak = 23	16 $\frac{2}{3}$	42 $\frac{1}{2}$	16	41	8 $\frac{3}{4}$	22 $\frac{1}{4}$	1 $\frac{1}{2}$	3 $\frac{3}{4}$	130° (Abrupt.)
		(With telescope.)		(With telescope.)		(From entrance of tubes for irrigation to vertex of angle between shaft and beak, at its concave side.)		

acid, 500; sulphuric acid, 375; water, 3,000.) The two original Leiter batteries, with hard-rubber cells, are not to be recommended, as they will surely crack and leak after a short while. The repair of such a crack is troublesome and always unreliable. Since last year the cells have been made of glass. Thus a very annoying disadvantage is at last eliminated. Fenwick uses a battery supplied by Schall (London),* and is pleased with it. He wants a rheostat. For cystoscopists on this side of the ocean I would recommend the cheap and easily manageable, portable, small six-celled battery of the Galvano-Faradic Manufacturing Co., New York city. Not to destroy with it the incandescent lamp at once, the elements must be screwed very slowly and carefully into the fluid until the light is bright. In all these batteries there is no rheostat attached. I so far have never seemed to be in actual need of the latter. In a nearly four years' practice in cystoscopy the number of lamps destroyed by me is a very small one. Still, its presence in a battery will be welcome. A very fine storage battery, Gibson's (three different sizes),† is sold by the W. F. Ford Surgical Instrument Co. It contains four large cells and has a rheostat. Its lighting power is ample.‡ It can be arranged to permit of endoscopic and galvano-caustic work

* *Loc. cit.*, pp. 46, 47.

† Size I weighs about fifty pounds, and has a capacity of fifty amp. hours; size II, about forty pounds, capacity thirty amp. hours; size III, about thirty pounds, capacity fifteen amp. hours.

‡ The Nitze mignon-lamp requires more electro-motive force (9 to 10 volts) than that of Leiter's cystoscope and urethroscope (6 volts), because its filament is finer, and consequently offers more resistance to the current. The maximum force of the Gibson four-cell storage battery is eight volts and a fifth. The Ford Co. is now constructing a six-cell storage battery which lights the Nitze lamp also to brilliancy. Its price and weight are of course slightly higher. The manufacturer of the Nitze lamp should build it eight volts or less. This can easily be done.

at the same time, which will be found especially convenient in urethroscopy. Recharging once in two to six months; * in spite of its price, I should advise its purchase by a cystoscopist who lives in a great city.

I still have to call attention to the various attempts which have been made in regard to *fixing the picture* as seen with the cystoscope by *clay or wax modeling, colored drawings, and photography*.

Fenwick, the originator of the first-mentioned method, † has proved, by the very pretty pictures in his work, how nicely and thoroughly the various pathological conditions of the interior of the living bladder, especially of tumors, if modeled in some plastic material, wax or clay, and then photographed, may be recorded and demonstrated to others who could not attend the examination.

E. Burckhardt very lately gave us a fine collection of colored drawings of bladder images in health and disease; ‡ every one of them was observed by himself and drawn at once with the cystoscope in position. The *Atlas* will especially be useful to the beginner, and explain to him many a picture which was seen but could not be at once identified.

Instantaneous photography, "the *ne plus ultra* of cystoscopic delineation (Fenwick)," is still in its infancy. Nitze has theoretically laid out an interesting method of best getting a small negative, and then magnifying it. Want of

* This is, of course, a disadvantage, as it makes us dependent upon the electrician. In houses that are connected with the street electric light system, charging can be done at home.

† Clay and Wax Modeling of the Living Urinary Bladder under Electric Light, *British Medical Journal*, January 5, 1889; and The Electric Illumination, etc., *loc. cit.*, p. 88.

‡ *Atlas der Cystoskopie, mit 24 Tafeln in Farbendruck*: Basel, 1891. See, also, the few excellent colored drawings at the end of Nitze's handbook.

time has not permitted him to make practical experiments.* Géza von Antal, † by his assistant, B. Hermann, published the photographic picture of the cystoscopic appearance of a black hair-pin in a female bladder. It is, however, utterly indistinct.

Fenwick (in connection with Mr. Pearson-Cooper, of the London Camera Club) has succeeded in obtaining good negatives of artificial growths both in the dummy and the dead bladder. But the negatives of the living bladder were too indistinct. A number of certain mechanical obstacles have so far formed an almost insuperable barrier to such a method being successful and practical.

In view of the rapid strides of modern technique, it is to be hoped that these obstacles will soon be overcome and that we shall then be enabled to "graphically record the many new and interesting clinical facts which the electric cystoscope is constantly revealing."

As it seems, this hope has meanwhile already been fulfilled. (See Ueber Photographie innerer Körperhöhlen, insbesondere der Harnblase und des Magens, by Dr. Robert Kutner. *Deutsche med. Wochenschrift*, Berlin, No. 48, November 26, 1891, p. 1311. Kutner is a former assistant of Nitze.)

II. CYSTOSCOPY WITH REFERENCE TO DISEASES OF THE BLADDER.

To give an accurate account of everything of interest that has so far been seen in the bladder and published is a difficult task and one of no intrinsic value. The literature on cystoscopy, which has appeared mostly within the last three years, is already very large. Nitze's so often men-

* *Text-book*, p. 325.

† *Internationales Ctrbl. für Physiologie u. Pathologie der Harn- u. Sexualorgane*, Bd. i, Heft i, p. 18.

tioned fundamental and instructive *Text-book on Cystoscopy*, Hurry Fenwick's valuable, lucid, and extremely interesting work, *The Electric Illumination of the Bladder and Urethra*, as well as also many other articles bearing on the same subject, written by different men, fully cover the ground. The appearance of these writings within the very last years renders an attempt in this direction at my hands a work of supererogation. The manifold brilliant results as enumerated in this part of medical literature demonstrate how often and sometimes easily an exact diagnosis of a previously obscure urinary disease can be and has been established with electric illumination of the bladder. These results fully sustain Nitze's original statements and predictions in every particular—namely, that the present electric illumination of the bladder gives us the means of establishing a strict differential diagnosis between the various forms of catarrh of the bladder—acute,* chronic, hæmorrhagic, diphtheritic; that it is easy to see with it ulcerations, to demonstrate diverticula, to find and localize foreign bodies; that it seems almost unnecessary to mention how plainly we can now see stones, make out their number, size, shape, and mobility, and percuss them with the beak of the instrument; how encysted stones, too, will not escape the examining eye; that especially the diagnosis of tumors of the bladder is now easy and can be made early.

It is obvious how strongly this exact diagnosis at once reflects upon prognosis,† indication, and treatment. Not infrequently an unnecessary operation can thus be avoided.

* In cases of acute catarrh the use of the cystoscope is, of course just as much to be prohibited as that of a catheter or sound.

† Fenwick believes he has seen and found a peculiar condition of the vesical mucous membrane which he calls "precancerous." *The Elect. Illum.*, etc., p. 153; also *Brit. Med. Journal*, September 22, and October 13, 1888.

Certainly it has been sufficiently established that if any doubt exists of the diagnosis in a case of vesical disease and the three cardinal conditions which enable a cystoscopic examination to be made * are fulfilled, it is the duty of the attending physician to submit his patient as early as possible to this ocular inspection. This on the same ground as he would look with the help of a mirror at the interior of the larynx, eye, nose, or ear in their respective disorders.

A few cases of my own, each representing a different chapter of vesical disease, selected from a large number of interesting cystoscopies, perhaps deserve to be briefly reported in this place. In every one of them (the one sub *a* alone excepted) the cystoscopic diagnosis was verified in the subsequent operative interference. I shall omit cases illustrating the various forms of catarrh (localized and general) and the hypertrophy of the lateral lobes of the prostate, although they were frequently met with.

a. Tuberculous Ulceration.—Mr. H. C. E., aged forty-five years, married, came to me for examination through the courtesy of Dr. L. G. N. Denslow, of St. Paul, in April, 1890.† Twelve years ago first pain in glans penis, which in the following ten years often gave rise to trouble. Two years and a half ago first appearance of blood and mucus in urine, with increased pains in glans. November, 1889, a large, painful swelling in the right lumbar region, which had formed under considerable rise of temperature, nearly disappeared after the passage of a large

* 1. The caliber and shape of the urethra must permit of passing the cystoscope into the bladder. 2. There must be sufficient capacity of the bladder (average = 5 ounces). 3. The fluid in the bladder must be transparent, at least during the time of examination (cf. irrigating cystoscope). See author on Cystoscopy and the New Cystoscope of Nitze and Leiter, with a Demonstration of the Same, *N. Y. Med. Journal*, April 21, 1888, p. 429.

† Cf. the author's review of Nitze's *Text-book on Cystoscopy*, *Annals of Surgery*, June, 1890.

quantity of pus with the urine. One month later last hæmaturia at the end of micturition. Present condition: Greatly reduced man; pains in glans penis if bladder is full. Urinates every two hours day and night. No tenesmus, no stoppage. Right kidney palpable, slightly painful on pressure. Urine only slightly turbid; contains a large amount of tubercle bacilli in every microscopical specimen. Cystoscopy (Nitze's cystoscope, No. 1): Immediately above the swollen mouth of the right ureter and its elevation of mucous membrane an ulcerated spot of about the size of two silver dollars appears. Purplish-red, broad elevations (evidently the inflamed fibers of the detrusor muscle) cross each other in different directions. Small particles of snowy, shining mucus, adherent to their surface, float in the fluid. The depressions between these elevations are of a lighter hue, also covered with mucous flakes. In between them numerous very small and larger sessile growths of grayish coloring are plainly visible, a few about as large as a pin's head, undoubtedly *miliary tubercles*. On one spot a small rhomboid-shaped, dark-red (hæmorrhagic) spot can be seen. The entire other inner surface of the bladder is perfectly normal, of grayish-white color, rather anæmic, corresponding with the condition of the patient.* As I was informed by Dr. D. some time ago, the right kidney was lately removed, with great

* It has to be stated that the cystoscopic picture of a tuberculous *infiltration* has not yet been established. A failure in making the diagnosis of tuberculous non-ulcerative cystitis with the cystoscope before the suprapubic incision is resorted to for clearing up the obscure trouble is no reproach to this mode of examination. If tubercle bacilli have been found in the urine *before* cystoscopy is tried—and they will be by far easier found, even in a relatively clear urine and if present in a very minute quantity, by the centrifugal method of Stenbeck, modified by v. Frisch (Zur Diagnose der tuberkulösen Erkrankungen der Urogenitalsystems, *Internat. klin. Rundschau*, 1891, Nos. 28–30)—a localized hyperæmic spot of the vesical mucous membrane seen through the cystoscope has to be diagnosticated as being most probably one of tuberculous character (tuberculous infiltration). It is to be hoped that such cases, if made out in this manner, will henceforth be published in detail.

benefit in regard to the patient's general condition. It had been converted into a large pus-sac.

b. Diverticulum.—Mr. J. P., aged sixty-four, had come under my care in the summer of 1888 on account of an intense catarrh of the bladder, due to hypertrophy of the prostate of long standing. Urine of foetid smell, voided every few minutes. Cystoscopy (Leiter, No. 1). Mucous membrane of dark-grayish appearance, nearly black. Shreds of mucus and necrotic tissue adherent to the wall, floating in the injected water. No diagnosis made. Subsequent examination of urine showed a far advanced diabetes which so far had not been diagnosticated. Strict antidiabetic regimen brought comparatively quick relief. Cystoscopic (probable) diagnosis then advanced: diabetic superficial gangrene of the mucous membrane of the bladder.* About one year later cystoscopy (Nitze, No. 1) was again performed: All symptoms of chronic catarrh, *vessie à colonnes*; a little outward of the mouth of the left ureter a large, dark spot of about a five-cent piece is seen. Its lining mucous membrane is wrinkled. The light of the cystoscope is then turned off and the tip, posted right in front of this spot, gently pushed forward. It evidently enters a cavity but touches no concrement. Diagnosis: diverticulum. Operative interference for the hypertrophy of the prostate is not proposed, as patient is satisfied with the use of the catheter. Strict antidiabetic regimen. Two years later patient has to catheterize himself every fifteen to twenty minutes; constant pain, fever, seven per cent. sugar. Epicystotomy becomes imperative and shows a large diverticulum at the diagnosticated spot filled with phosphatic *débris*.

c. Foreign Bodies.—B. v. P., aged forty-one, was admitted to the German Hospital on May 22, 1888.† He had always been a healthy man up to three years ago, when left renal colic with hæmaturia had first appeared. The latter had been intermittent since then. Frequently the first drops were mixed with blood during micturition; then the urine was clear. Now and then he passed pure blood. According to the advice of one of

* Author, *N. Y. Med. Journal*, February 23, 1889, p. 203.

† *N. Y. Med. Journal*, 1889, p. 198.

the gentlemen whom he had consulted abroad, he had for a long time had his bladder flushed daily with a mild solution of permanganate of potassium. Two months before entering the hospital a severe catarrh of the bladder had set in. With great strain small particles of a semi-solid substance had now and then been voided through the urethra. Frequent stoppage of flow of urine; great pains; morphine habit. On examination, the searcher did not strike stone. Urine, muddy and of alkaline reaction, contains three per cent. albumin. Under the microscope: red blood-corpuscles, pus and mucus, no casts. A tumor of about two fists' size with a smooth surface, evidently belonging to the left kidney (tumor or pyonephrotic stone-kidney?), can be palpated in the left hypochondrium of the anæsthetized patient. Cystoscopy under chloroform (Nitze, No. 1): As soon as the instrument had entered the bladder and the light had been turned on, I saw a few (six to eight) curiously shaped more or less flat curved bodies of black color, covered with whitish deposits of phosphates. Stirred up by the outflowing streams of urine from the ureters, they constantly tumbled over each other and were thrown against the beak. No click, however, was noticed; their consistence was soft. Besides these bodies there was no stone, no tumor, only evidence of catarrh.

To establish a diagnosis with reference to the nature of these bodies from this cystoscopic picture was entirely impossible. None of those present had ever seen anything like them. The most probable supposition seemed to be that of coagulated blood, which had descended from the left kidney. Still the semi-solid condition and peculiar shape of the bodies remained unexplained. Nevertheless the result of cystoscopy was highly satisfactory. The cause of all the *vesical* trouble had been found. No searcher, no bimanual palpation could ever have accomplished anything like it. When the bladder was incised—above the pubes—about eight bodies of various size could be easily extracted. They were of a semi-solid, black substance, flexible, and covered with phosphatic deposits, just as they were made out through the cystoscope. Chemical analysis showed that they consisted of sixty per cent. fibrin and forty per cent. permanganate of potassium.

d. Stones.—CASE I.—Mr. D., fifty-three years old,* merchant, for several years troubled with chronic gastritis, was seized with pain in the glans penis and in his left lumbar region in the fall of 1886. After three days the pain left him and did not return until a year later, September, 1887, when he developed symptoms of stone in the bladder. Neither hæmaturia nor stoppage of the flow of urine had ever been present. A thorough examination with the searcher repeatedly performed at that time by a very able surgeon failed to detect stone, and the patient was therefore put on suitable internal medication. But as his condition got steadily worse, his family physician courteously sent him to me for cystoscopy June 11, 1888. The patient's bladder being extremely irritable, and examination with the searcher having been accompanied and followed before by great agony, I yielded to the patient's urgent request and immediately introduced the cystoscope (Leiter, No. 1). Having turned the instrument 180°, thus directing the prism toward the fundus of the bladder, I saw at the first glance in brightest illumination an oval-shaped, brownish body covered with white spots (evidently phosphatic deposits) of the size of an almond, lying in the pouch behind the enlarged prostate. It threw a distinct shadow upon the opposite wall of the bladder. I then turned off the light and touched the body with the tip of the instrument. I got an unmistakable click. The bladder otherwise presented symptoms of catarrh. The ureteral openings emitted a clear and transparent fluid. No further special attention was paid to the character of the jets of urine coming from the ureters at that time, as no symptoms indicated a diseased kidney.

Suprapubic lithotomy was performed and the stone easily removed. It presented the characteristics as seen with the cystoscope.

CASE II.—Mr. X., always healthy, is suddenly unable to urinate. A doctor tries to introduce a soft-rubber catheter, but does not succeed. When I saw the patient in consultation my perforated sound struck a hard substance just at the neck of the bladder, which slipped back into the viscus. Nearly two quarts of urine were voided. The patient then was all right. Three

* *N. Y. Med. Journal*, 1889, p. 199.

days later retention for a second time set in, and was again relieved by catheterization. I was convinced that there was a small stone in the bladder, but was unsuccessful in striking it with the searcher. The cystoscope (Nitze, No. 1), of course, gave at once evidence of a small, uneven concrement, about half an inch long, not unlike a small dried bean. I proposed to try and aspirate it with Otis's evacuator. Meanwhile the stone again blocked the urethral canal, but, with the help of a sudden forcible strain, was expelled, to the greatest delight of the patient. Its characteristics were found as stated in my letter to the colleague.

e. Hypertrophy of the Median Lobe of the Prostate.—X., aged seventy, relies entirely upon catheter, which has frequently to be passed. Passage attended by difficulty and pain. Two strictures—one in the anterior, the other in the posterior portion of the urethra—had been divulsed about a year before, and then the bladder carefully washed for some time. Urine was clear—no blood, no pus, no albumin, no casts; great local distress. Cystoscopy (Nitze, No. 1, long): In introducing the instrument its handle had to be pressed far down before the beak enters the bladder. A slightly hypertrophied third lobe, of about half to three quarters the size of the third phalanx of the middle finger, is easily diagnosticated; the bladder presents a *vessie à colonnes* in a most beautiful manner. Soon afterward suprapubic cystotomy was performed by another surgeon. The third lobe was found as diagnosticated, and pinched off with the rongeur.

f. Tumors.—Out of a greater number of these cases I cite the following two, which may serve as paradigms:

CASE I.—Mr. X., aged fifty-three years,* was seen by me in consultation on March 20, 1890. For six months he had nearly continuously passed bloody urine without submitting to a close examination. He had suffered from frequent forcible micturition and intermittent pain in the glans; otherwise he had felt comfortably. Repeated careful chemical and microscopical examination

* Cf. *Annals of Surgery*, l. c.

only showed red blood-corpuscles and mucous cells, never a particle of a new growth. Bimanual palpation was very difficult, and also promised no result on account of the patient's great corpulence and marked hypertrophy of the prostate. I therefore immediately resorted to cystoscopy. As a hypodermic of morphine, with local cocaine anæsthesia, did not quiet the irritable bladder, the patient was narcotized. Now I saw in brightest illumination a round sessile growth with an uneven surface, not unlike a large round strawberry, on the left wall of the bladder, about an inch above the mouth of the left ureter. I very plainly observed that blood was oozing out of its surface. The other portion of the interior of the bladder appeared to be healthy; there were symptoms of a slight catarrh.

Diagnosis.—Cancerous sessile tumor of the bladder.

Suprapubic cystotomy, March 25, 1890 (performed as usual in Trendelenburg's posture). Growth, on the spot localized before, presented all the characteristics as formerly diagnosed with the cystoscope. It was, with the adjacent parts of the wall of the bladder, cut out with the knife by an ellipsoid incision. The base was then carefully burned with Paquelin's thermo-cautery. Uninterrupted recovery. No recurrence till date.

CASE II.—Mr. J. B., aged forty-eight years, had been in perfect health up to May, 1889. At that time he had a sudden and causeless attack of hæmaturia, which ceased as suddenly after forty-eight hours, but only to return after a few weeks. The bleeding then became intermittent, appearing first about every one, two, or four months, later in as many weeks. Pain in glans and frequency of micturition also were experienced. January, 1890, retention caused by clots. The catheter brought relief, but started catarrh. The patient had consulted different doctors, but only irrigation had been advised. One colleague proposed suprapubic incision without having strictly diagnosed the case. Cystoscopy on May 12, 1890 (Nitze, No. 1); five ounces thrown in. On turning the beak to the left side and slightly directing the prism toward the floor, a large, cock's-comb-like, pinkish-red tumor is at once detected. Deep, irregular furrows divide the surface into larger and smaller, un-

even, and lobulated areas, which bleed when touched with the beak of the instrument. The growth is planted on a thick and succulent base, a little outside of the left ureteral orifice, and embraces an area of at least a silver dollar. Illuminated by the electric light—the peaks and plateaus in brightest sunshine, the many irregular wounded valleys, out of which a few trickling streams of blood slowly find their way, in dark shade—the appearance of the whole succulent, erect, and pulsating growth was picturesque in the extreme. Nearer to the fundus and the median line a second smaller tumor is seen about as large as a cherry. The interposed portion, as well as the whole of the interior of the bladder, appears healthy.

Diagnosis.—Cancer of the bladder, still extirpable.

When the bladder had been opened above the pubes, the condition corresponded exactly to my cystoscopic diagnosis, which I had before explained to the gentlemen who kindly assisted me during the operation. The large tumor was shelled out in healthy tissue with Paquelin's thermo-cautery knife. Two large spurting arteries which entered the base of the growth and fed it were ligated with medium-sized silk, as catgut seemed unreliable and the bladder was to be drained. They could be easily tied, as they had been torn about an inch above the inner bladder surface. The smaller cancer was cut out with the knife and its insertion carefully burned. Tamponade with iodoform gauze; drainage for twelve days. Quick recovery. Seven months later I had to extract a longitudinal small stone from the patient's urethra. Nucleus: a silk ligature! Seven weeks later the patient again called on me on account of great distress and hæmaturia. On introducing the cystoscope I saw in the fundus a stone, of at least almond-size, covered with mucus and phosphates, and in the upper inner angle of the flat, whitish, shining scar (the result of the former operation) a small, stalked recurrent growth, of cauliflower shape, overhanging the mouth of the ureter and swaying at every eddying rush of the ureteral streams.

In view of this complication, I proposed and performed suprapubic cystotomy for a second time. The stone was easily removed (its nucleus was the other silk ligature), and the bleed-

ing spot, where the recurring tumor had been inserted, thoroughly burned. To-day patient is doing well. (This case will soon be published *in extenso*.)

Before closing this section I ought to say that the cystoscopic diagnosis in bladder diseases is not at all always so easily made. First of all, it must be borne in mind that this ocular inspection can not be applied in every case, and that, if it can be resorted to, it requires *in praxi* a great deal of patience and, to avoid mistakes, also experience. The three cardinal conditions which alone guarantee a successful examination should be carefully investigated *before* the instrument is introduced. If one of them can not be fulfilled, a failure may be expected. Although I am well aware that we may be able to make a correct diagnosis, after some experience at least, with only from three to four ounces of water in the bladder, still I have made it a point—and I would especially give this advice to the beginner—always to try and have five ounces thrown in. We know, from Nitze's investigations, that this amount just expands all the folds and grooves of the intravesical surface. The only exception from this rule I make is in cases of supposed tumor of the bladder with obstinate hæmaturia, but without a marked vesical catarrh. Here the cystoscope is introduced as soon as the bleeding has ceased, and probably a sufficient amount of urine is in the bladder. Washing will frequently start the hæmorrhage again. (If we wish to increase the capacity of the bladder, we must inject the fluid forcibly with the syringe, and not use the irrigator; and even then we may sometimes be unsuccessful.) Only in this way, by training our eyes to inspect the surface of the properly and more or less always equally expanded viscus, can we hope to learn by and by how to avoid the many pitfalls which await the cystoscopist. If the surface of the prostate begins to bleed at the slightest touch of a solid instrument, I at once try to

examine with the irrigating cystoscope and have the nurse throw water in while the beak passes the posterior urethra and neck of the bladder.

We also have to pay attention to the magnifying power of the Nitze telescope as well as to the fact that the nearer the prism the larger the object. If after a careful examination and deliberation there is still doubt with reference to explaining and identifying the image observed, a second cystoscopy should be insisted upon.

Lastly, the cystoscopist should accustom himself, especially in cases which he sees in consultation, first to obtain a thorough history, then to make a general examination, especially with reference to tuberculosis, to carefully analyze the urine, to palpate the lumbar region of each side, the testicles, and the prostate, and test the caliber of the urethra. The operator should always start with the case as if he did not yet possess the cystoscope to enable him to view the interior of the bladder. He should push his means of diagnosis as far as possible by rational signs and examination of the urine. But the first instrument he then takes in hand should be not the sound, but the cystoscope. Only when a stone in the bladder is strongly suspected should the sound be used first.

Here are a few examples, for the beginner as well as for him who uses the cystoscope without a previous general examination, as just explained, and also possibly fails to read the literature beforehand and thus benefit by the experience of others :

He will easily take the taggy shreds of necrotic tissue, hanging at the edge of a tuberculous ulcer and floating in the fluid, for a polypus, without at all noting the ulcer, especially if the prism is brought close to it (the experienced and careful examiner has probably found before tuberculosis of the testicles, or an enlarged kidney, or tubercle

bacilli in the urine, or such a detritus under the microscope which will lead him to suspect the existence of an ulcer and thus make him look out for it); he will take the prolapse of the ureter for a sessile growth (but if the prism is carried near by, this growth is entirely transparent, and on careful inspection it will be seen that out of one spot of its perfectly round and smooth surface a whirl of urine will suddenly be expelled).

He will take an incrusted growth for a stone (a touch with the beak will quickly dispel any doubt); a deposit of coagulated blood around one of the ureteral cones will perhaps puzzle him (the experienced will take it as a hint at hæmaturia of renal origin, most probably on the same side), as will also the picture of the enlarged median lobe of the prostate.

Success will not be with him if the just injected clear fluid turns murky at once after a long-continued irrigation, or is found to be so as soon as the cystoscope has entered the bladder. (The experienced man at once suspects kidney trouble, will exchange the ordinary for the irrigating cystoscope, and watch, after a quick glance at the interior of the bladder, the ureteral orifices. Most probably pains or the already palpated swelling in one lumbar region will guide him on which side to look first.)

Of course an infiltrated spot in the wall of a bladder which can not be properly distended, or greatly hypertrophied and easily bleeding rugæ in a case of localized chronic catarrh, will also easily mislead the well-trained eye and induce one to diagnose a tumor where the suprapubic incision will merely show infiltration. Also many other mistakes may occur. But they will become rarer with increasing experience; and if, nevertheless, they still occur, the physician may console

himself with the reflection that mistakes occur just as often and as easily in the other and older branches of surgical diagnosis.

III. CYSTOSCOPY WITH REFERENCE TO DISEASES OF THE KIDNEY.

Nitze, Fenwick, Goldschmidt, Poirier, Tuffier, Janet, and many others have published interesting cases where negative vesical evidence gave a positive diagnosis of renal disease and where cystoscopy not only proved the formerly obscure trouble to be of renal origin, but gave the means for exactly locating the lesion and distinguishing which kidney is diseased or whether both are affected.

Under ordinary circumstances it is not difficult to determine whether the urine propelled from the ureteral cones is clear, murky (purulent), or bloody. We simply have to place our prism just opposite and comparatively close to the mouth of the ureter, and then carefully watch. Some experience and patience, a quiet hand, and close attention are all that is needed. But, as mentioned above, this task at once grows more difficult if the injected clear water rapidly becomes turbid. The inspection can then only be effected by means of the irrigating cystoscope.

CASE I. *Pyuria; Cystoscopy; Nephrotomy; Nephrectomy; Recovery.*—Mrs. X., aged forty-five years, had noticed since several years that her urine was now and then cloudy; had also occasionally experienced some pain in her left side. The latter was attributed to a fall the patient had received while out sleigh-riding in the country twenty years ago. Otherwise she had always been in apparently good health. At the middle of June this year she was suddenly taken very sick with high, continuous fever, enlarged spleen, and general symptoms, which were suspicious of typhoid. But a tumor was palpated in the left lumbar region, and the urine contained pus. The gentleman

who had been consulted proposed cystoscopy, and I was called in to perform it. After a short irrigation the water returned clear. Quickly the elements of the battery were screwed down into the acid, the full strength of the current allowable for getting a bright light determined, and the circuit broken. The catheter, corked, had been left in the bladder meanwhile. In extracting it then a few drops of water escaped, perfectly turbid. Of course only renal trouble could have done that. Again the fluid in the bladder was changed and the irrigating cystoscope introduced. One glance in bright illumination, showing a healthy bladder; and a dense fog suddenly came up and threw a heavy veil over the whole landscape. Now the irrigating cystoscope was put at work. The prism was turned to the left and the murky fluid allowed to run off, while the hand-syringe threw in short jets of clear water. The fog lifted, and I clearly perceived the left ureteral opening, and out of it nearly at the same moment a forcible eruption of a snowy-white, milky fluid. Spurting forward into the medium, which was contained in the bladder, in the shape of a fire-sheaf, the first rather thick mass at once dispersed and was dissolved into myriads of minutest snow-flakes, which slowly came down and at once put a stop to all further examination. The manoeuvre was now repeated on the same side and the diagnosis of suppurating kidney clearly established. The very frequently descending jets, which always are pathognomonic of an irritative process in the pelvis of the respective kidney, could be attributed to the coexisting pyelitis or the presence of a stone in the pelvis. Of course the urine of the right kidney was now analyzed in the same manner. It was clear.* A few days later I performed nephrotomy and found a pyonephrotic kidney with a large stone in the greatly enlarged

* I want to state here that even with the able help of the irrigating cystoscope it is extremely difficult, if not in many cases impossible, to make out a urine which is only very slightly turbid or which is clear and contains long shreds of tissue, as I have seen it in one case. Generally a certain amount of turbidity is required before it becomes visually apparent and perceptible. Bimanual palpation of the suspected diseased organ or pressing it will frequently help in making the cystoscopic diagnosis of renal pyuria.

pelvis. Only the debilitated condition of the patient prevented me from removing the diseased organ at once. Primary nephrectomy seemed to me to be fully justified in view of the cystoscopic result, and would have spared the patient a second operation. The kidney was, however, left in and drained, with the intention of extirpating it as soon as the lady's health would permit it. Nephrectomy was done by me four months later, on account of an annoyingly running renal fistula. To-day the patient is cured.

A number of patients with intermittent abundant hæmaturia have been under my care in whom the cystoscope demonstrated a perfectly healthy bladder. In only one of them have I been so lucky as to make the examination just at the time of the bleeding, and I then saw a red, rapidly propelled whirl crossing the prism, and slowly mix with the transparent water, slightly coloring the same. None of the patients, who just happened to be examined at the bloodless period, reappeared at the time of the next hæmaturia as ordered. Perhaps they were unable to come. The one in whom I had diagnosticated unilateral renal hæmaturia—which, according to the symptoms, was evidently caused by a new growth—declined the proposed operation. She died after an abundant hæmorrhage not long afterward. A few cases of this kind are published by Nitze, Fenwick, and others.

But the transparency, color, and frequency of the descending jets of urine are not the only points which have to be observed and noted in exploring the bladder with the electric light. We are able to still further analyze and specify *the character* of the whirls as they can be seen jetting from the ureters.

The history of a few more cases of renal disease, which lately occurred in my own practice, will well illustrate this.

CASE II.—*Cystoscopy ; Suprapubic Lithotomy ; Cystoscopy ; Nephrolithotomy ; Recovery* (the continuation of a case previously mentioned in this paper).* On the 10th of March, 1891, Mr. D., of whom I had lost sight since the summer of 1888, again called upon me, a sick man. His stomach was entirely out of order. Every few days he vomited great masses of sticky mucus, and was only able to do so by first drinking a tumbler of very strong salt water. Cathartics were freely used. Entire loss of appetite. He had been for this trouble under a physician's care, who was, however, unable to improve his condition in spite of constant careful attendance. The doctor diagnosticated "nephrolithiasis on the left side" and sent the patient to me for operation. The history further revealed that not long after the suprapubic wound had definitely closed an attack of epididymitis on the right side had twice set in. The urine had never entirely cleared up. Last summer (1890) the left testicle became suddenly inflamed. At the same time, the former dull and constant pain in his left lumbar region, which had now and then troubled him during the entire last year, became more marked. For three days the urine was mixed with blood. A similar attack occurred in January, 1891. At present he had a constant pain and he was obliged to get up twice during the night to pass water. In the daytime he urinated about every four to five hours.

Cystoscopy (cocaine): Mucous membrane of the bladder comparatively healthy. No scar as a result of the operation visible. Prostate large, easily bleeding. Right ureter is pumping at regular, though rather short, intervals; ejects clear fluid. The whirlings propelled from the *left* ureteral opening are by far less frequent and last nearly as long as three of the opposite side combined. This phenomenon can be noticed with so much greater precision as the urine of the corresponding kidney is slightly turbid. No renal hæmaturia at present.

Considering all these facts, I diagnosticated "a stone in the

* Read before the Section in Genito-urinary Surgery of the New York Academy of Medicine, November 12, 1891, the patient being present.

pelvis of the left kidney large enough to partially block the upper ureteral opening." Taking this conclusion as correct, it was evident that the urine had to gather in greater quantity and had to distend the pelvis of the kidney more than ordinary before finding or rather making its outlet on one or more spots alongside the necessarily irregular surface of the stone. And this again explained best the curious character of the jets as observed at the left ureteral cone. Taking further into account that the patient had noticed his very first pain in the left lumbar region as early as 1886, and that I had to remove a stone from the bladder two years later, my diagnosis was well founded that nephrolithiasis had been the primary and constantly persistent trouble in this case. No doubt a small piece of the renal calculus had been broken off as early as 1886 and carried down to the bladder, and had there formed the nucleus of the stone which was removed by me in 1888. Was the other kidney healthy? I did not venture to answer this question on the ground of the cystoscopic result. Certainly the abnormal rapidity of the jets was suspicious and pointed to an irritation in the pelvis of the right kidney. But the answer to this question was less important, as only nephrotomy on the left side seemed to be indicated.

I told the patient my diagnosis, and also my hope of being able to help him by operative interference. But, to confirm what I had just seen, I asked for a second cystoscopic examination. The patient at once agreed. When he returned for this purpose, he reported that in walking home from my office the other day he had felt a sharp pain in his right side. This had at first frightened him very much. But, as the pain had not reappeared, he felt easier now. The second cystoscopic examination fully corroborated the result of the first one.

Nephrotomy was proposed and accepted. On May 5th, this year, I made the lumbar incision. A large stone, entering the ureter for some distance, was felt as soon as I was down on the kidney. The pelvis was transfixed with two silk threads which afterward served as holders, and then incised between them in the length of fully an inch and a half. To extract the stone in one mass proved to be impossible. I broke it with my fingers

by pressing upon the upper portion of the ureter from outside. Then I was able to pull the two pieces out with an ordinary dressing forceps, the larger upper portion from the pelvis of the kidney and the more slender lower one from the ureter. The whole stone presented a perfect cast of the enlarged pelvis of the kidney and the upper part of the ureter. Its lower pole was flattened, in a shape not unlike the mouthpiece of a flute. It is in all two inches long (see Fig. 3). Now I pushed a long thin rubber bougie down the ureter, and then a small-sized soft-rubber catheter cut off at its end, through which I flushed a syringeful of warm boric water into the bladder. The ureteral canal evidently was free. Still I carefully palpated with a curved steel sound the interior of the kidney from the pelvis upward. No other concrement was found.

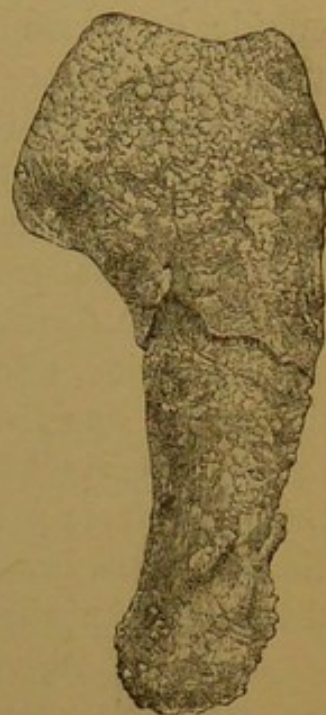

FIG. 3.

Meanwhile great care had been taken not to tear the cut surfaces of the pelvis of the kidney by pulling too hard on the silk threads which held it apart, as such a tear generally produces urinary fistula. Now the wound of the pelvis was closed with six catgut stitches, which did not include the mucous membrane, and the wound loosely packed with iodoform gauze. A small-sized short drainage-tube led down to the sewn-up wound in the pelvis of the kidney. The outer wound was closed with silkworm-gut threads which were only loosely tied.

The patient made an uninterrupted recovery. He never was feverish. Gauze and drainage-tube were removed after forty-eight hours. Leakage never set in. The wounds healed by primary union throughout. The patient left the hospital with the wound firmly closed on May 21st, sixteen days after the operation.

When I saw him again he reported that, four days after having returned to his home in Brooklyn, he was suddenly seized with a very intense renal colic on the right side—that is, the

side opposite to the diseased kidney—which lasted six hours. The pain was so severe that the attending physician had to administer chloroform for a full hour. When the pain began to subside, he passed about ten ounces of urine at two times inside of an hour. Since that accident he was free from pain. Only the stomach was still troublesome. He soon left for the country, where he spent the summer. Lately a throat specialist has burned his nose and throat, which, according to the patient's statement, has greatly improved the still slightly rebellious stomach. A fortnight ago he passed, after some pain in his left lumbar region, two round, semi-solid masses, each of a bean's size. This was from the side operated on. To-day he appears hale and hearty, fully able to attend to his business. He is entirely free from pain and trouble. His urine at present is clear. He, of course, has to remain under observation on account of the probable nephrolithiasis on the right side.

CASE III. *Suppurating Floating Kidney ; Nephrotomy ; subsequent Cystoscopy ; Nephrectomy ; Recovery.*—Mrs. X., forty-five years old, came under my care in July, 1887. Two months previous she had been operated upon for an inflammation which had set up in the left (floating) kidney. The lumbar incision had revealed a cystic degeneration of the organ, the cysts being filled with clear, transparent fluid or pus, or a mixture of both. A number of cysts were opened, and communication established between as many as could be reached with Paquelin's thermocautery. The pelvis of the kidney was not opened. The wound had healed well up to two small sinuses, which remained in the scar and gave a continuous exit to a small or larger amount of sero-pus. The patient was greatly benefited by the operation. For more than two years she felt comfortable and enjoyed life; only at the time of menstruation she suffered from more or less intense bladder tenesmus. But after a while this symptom ceased to be limited to the menstrual periods and became nearly constant. It increased in such a degree of severity and frequency, in spite of manifold and persevering trials to fight it, that life was a misery, and the question came up, Could the patient still be improved by operative interference? Of course, this question had been frequently considered at length before, but it was always re-

jected in view of the clinical fact that cystic degeneration of the kidney very rarely is a unilateral disease. Usually both organs are involved.* Cystic degeneration is therefore rather a contra-indication to nephrectomy. And indeed in this case the lower pole of the right kidney was palpable in the right hypochondrium. But could this enlargement of the organ not be just as well due to compensatory hypertrophy, in view of the constantly diminishing size of the left one, which had always been easily palpable in the slim patient? If we could know that the right kidney had already assumed the work of the other, or that the secretion of urine from the left diseased organ was insignificant in comparison with that of its fellow, the patient could only be benefited by the removal of this nearly useless cystic mass, provided that she stood the operation. That the greatest amount of pain and trouble was dependent upon the presence of the left kidney could be proved by vaginal palpation of the ureters. The left ureter presented a cord as thick as a thumb, the slightest compression of which created at once an urgent and painful desire to urinate; the right one was perceptible merely to the normal degree. Pressure upon it did not irritate the bladder.

Active treatment, however, became imperative when in November, 1890, chills, followed by high though short-lasting fever, repeatedly set in, apparently due to progressive ureteritis. To determine the exact condition of the right kidney it was, of course, very tempting to compress the left ureter, or even drain it for some time from the vagina. Either of the procedures, however, would have required narcosis, which, if possible, had to be avoided.

* Cf. O. Riegner. Exstirpation einer wandernden Cystenniere. *Deutsche med. Wochenschr.*, 1888, No. 3.—Clark. Case of Cystic Kidney in which Nephrectomy was performed. *Glasgow Medical Journal*, 1889, p. 177.—Newman. A Case of Cystic Disease of the Kidney diagnosed during Life. *Ibid.*, 1889, p. 255.—C. A. Ewald. Ein Fall von totaler cystöser Degeneration beider Nieren beim Erwachsenen nebst Bemerkungen zur Klinik dieser Erkrankung. *Berlin. klin. Woch.*, 1892, No. 1.

I now resorted to cystoscopy and saw the following condition: Catarrh of the bladder, minutest and larger blood-vessels injected. The place where the orifice of the left ureter should be seen presented a succulent and curiously folded growth—viz., the swollen and inflamed fold of mucous membrane belonging to and surrounding the ureteral opening, the whole mass resembling a large lamp-shade. Still looking at the picture with interest and trying to find the mouth of the ureter, I suddenly noticed a jet of fluid, mixed with smaller and larger yellow flakes and shreds, which came from a somewhat retracted spot, a little to the left from the top of the mass. This exactly recalled the appearance of an eruption of a volcano, as drawn by the pencil of the artist. A few minutes later a long thread of thick, yellow pus was slowly making its way out of the same opening into the bladder. It took some time before I found the other, rather rounded, ureteral opening, a portion of normal though deeply injected mucous membrane, about three quarters of an inch in length, being interposed between it and the swelling just described. At this moment I had to stop the examination, which was made under local cocaine anæsthesia, as the weak patient felt rather tired. A short time later the bladder was again illuminated, this time with the intention to determine, if possible, the character of the jets descending from the *right* kidney. The ureteral orifice was quickly found and carefully watched. This orifice was pushed forward and retracted alternately, as we see it normally with each jet of urine thrown into the bladder. The regularity and frequency of this intermittent movement markedly contrasted with the slow and irregular working done on the other side. It struck me whether this symptom might not be used in finding out the exact amount of work done by each kidney. So I asked the assisting nurse to look at the watch and carefully count the time between my saying "Now," which marked each jet. I noted a passage of every twelve, fifteen, twenty, twenty five seconds on the right side, while on the other only every four, six, eight minutes, the period of the emission of the jet besides covering a somewhat longer time on the right than on the left side. Meanwhile the water had become muddy. It was easily

changed, as I performed the examination with the irrigating cystoscope, and now I also perceived that the urine of the right kidney was clear.

What conclusion could I draw from these facts? I believed this: that the right kidney was doing from twelve to sixteen times as much work as the left one.* Was I therefore justified in pronouncing the right kidney healthy? I did not venture to make such a definite diagnosis, especially in view of the frequent bilateral affection in cystic degeneration of the kidneys. The urine might be at times transparent, while at others turbid. Only often-repeated cystoscopy might possibly have cleared up this part of the diagnosis.

But to diagnosticate health or disease of the right kidney was not the main question. The question really was: "Would the work of the right kidney be sufficient if the left had been removed?" That it would be so seemed to be amply proved by the cystoscopic examination, and if it did, the diseased organ, which caused the repeated weakening attacks of ureteritis and septic fever, was a burden to the organism and could and should be removed.

On these grounds a favorable prognosis was made in regard to nephrectomy in its future results, provided the immediate effects of the operation were well borne.

I therefore performed the operation, and the specimen thus obtained showed that only the lower third of the organ contained secreting tissue and that the upper two thirds consisted of cysts, smaller and larger in size, more or less communicating. In one of them there was a very small round stone. The whole organ was greatly diminished in size.

In the first twenty-four hours after the operation urine was scarce on account of the loss of blood. From the second day on the daily average quantity was thirty to forty ounces. The former chills and fever ceased at once. The patient made an uninterrupted recovery, and is so far greatly benefited by the operation.

* I think this is the first time that this kind of observation has ever been used for determining the work done by each kidney, and that its correctness was afterward proved by the specimen obtained.

CASE IV. *Left Suppurating Kidney; Cystoscopy; Nephrectomy; Recovery.*—Mrs. P. M., aged forty-eight years, was sent to me from Collinsville, Conn. Her father had died of phthisis. She had had eleven children, of whom seven were still living. For fourteen years the urine had been muddy and of offensive smell. Tenesmus changing in severity toward and after the end of micturition. Two years ago pains in the left lumbar and hypochondriac region appeared; the urine became of a milky color, and had lately contained small particles of coagulated blood. It was voided ten to twelve times in the day-time and at least four times during the night. The patient had continuously lost flesh and felt very weak. December 18, 1890, examination: On deep pressure below the border of the left false ribs, a hard, not very large, mass can be palpated, which is rather immovable, painful to the touch, and of apparently smooth surface. Vaginal exploration reveals a thickened left ureter, which, if compressed, is quite painful and creates the desire to urinate. On the left side of Douglas's *cul-de-sac* an enlarged, painful, immovable swelling (probably the ovary); urine of neutral reaction; smells very offensively; two thirds of volume sediment; shows pus and mucous cells, a few red blood-corpuscles, micro-organisms of great variety, crystals of oxalic acid and ammonium phosphates; detritus; one-per-cent. albumin in the filtered specimen.

Could this evidently suppurating left kidney still be removed? Did it still partake in the secretion of urine? Were both kidneys diseased?

Cystoscopy under cocaine: Mucous membrane of the bladder hyperæmic, and around the left ureteral orifice papillomatous in appearance. Out of the latter a very long, worm-like, under the electric illumination snow-white, shining thread of thick pus of the size of a thin pencil is very languidly making its way at short intervals. No jet whatever. The pus evidently was very viscid, as the long strings settle and curl in the bladder fundus—a very characteristic picture, which was also plainly noticed by a number of gentlemen present. It took some time before the medium became muddy. The right ureteral orifice was occupied by a round red growth of the size of

a cherry. On putting the prism quite close to it, it appeared transparent. It consisted of mucous membrane (prolapse of the ureter). Out of its left (median) side jets of seemingly clear urine were thrown at short intervals.

Cystoscopic diagnosis: "Left suppurating kidney. Its secreting tissue entirely gone. Right kidney already does double duty for its destroyed fellow. Some irritation in the pelvis of the right kidney."

On account of this cystoscopic diagnosis I proposed nephrectomy. The operation was done by me at the German Hospital, December 29, 1890. It was found that the whole greatly enlarged left kidney was sclerosed and did not present a bit of normal secreting tissue. It contained many cavities communicating with its pelvis. A large ramified stone entered a number of them. After the operation the amount of urine never varied except in the first twenty-four hours. The patient made an uninterrupted recovery up to the thirty-ninth day, when she was suddenly seized with intense right renal colic and abundant hæmaturia. After five days of serious, nearly hopeless, illness she passed a stone (an excellent *demonstratio ad oculos* of the pathognomonic correctness of prolapse of the ureter). From that moment on she was again well and remained well. To-day she is perfectly healthy; her urine absolutely clear.

These cases present the most interesting ones in which I have resorted to endoscopic examination of the bladder for the purpose of diagnosing disease of the kidneys. The last two cases especially are, I believe, of so much more value as not only did cystoscopy enable me to establish the indication for nephrectomy and to make the prognosis that this operation would most probably not interfere with the patient's general condition, apart from its possible immediate consequences, but the specimen proved in each case the correctness of the different important points thus made out.

The catheterism of the ureters, with the help of still improved cystoscopic instruments, will, I trust, soon be an

extremely important and never-to-be-omitted factor in cystoscopy for renal disease. Its results will greatly reflect upon and vastly increase the value, correctness, and exhaustiveness of such a cystoscopic diagnosis. The catheterism of the ureters in this way will easily, simply, and happily solve the problem on which many an ingenious mind worked in vain, or at least without general and recognized success—namely, the bloodless, separate collection and analyzation of the secretion of each kidney.

The only non-operative method which formerly could be applied to localize and diagnosticate a kidney trouble in the male,* where a large swelling or growth in one of the hypochondriac regions did not at once show where to search for it, was by compression of the ureter. The attempts at solving this task have been very ingenious, but have not been generally adopted in practice.† Axel Iversen,‡ therefore, proposed to open the bladder above the pubes and then to catheterize each ureter separately. Fully appreciating the great value of this mode of procedure, and not looking at suprapubic cystotomy as being a dangerous

* In the female our non-operative diagnostic means in this respect have been more ample, however difficult to practice, for a number of years. Cf. G. Simon. Ueber die Methoden, die weibliche Urinblase zugänglich zu machen u. über die Sondirung der Harnleiter beim Weibe. Volkmann's *Klin. Vorträge*, No. 88.—Lewers, *Lancet*, 1886, November 13th.—K. Pawlik. Ueber Harnleitersondirung beim Weibe u. ihre praktische Verwendung. *Wiener med. Presse*, 1886, Nos. 44–51.

† Tuchmann, Ueber ein neues Mittel zur Diagnose der Blasen- u. Nierenkrankheiten, *Wiener med. Wochenschr.*, 1874, Nos. 31 and 32.—Ueber den künstlichen Verschluss u. über die Sondirung des Harnleiters, *Deutsche Zeitschr. f. Chirurgie*, Bd. vi, p. 560.—O. Silbermann, Ueber eine neue Methode der temporären Harnleiterverschliessung u. ihre diagnostische Verwerthung für die Krankheiten des uropoëtischen Systems, *Berl. klin. Wochenschr.*, 1883, No. 34.

‡ Beitrag zur Katheterisation der Ureteren bei dem Manne. *Centralblatt f. Chirurgie*, 1888, No. 16, p. 281.

operation, I am perfectly convinced that cystoscopy will ere long make it just as superfluous and unnecessary, in the majority of cases at least, as it has already made Sir Henry Thompson's digital exploration of the bladder in most instances.

Of course, I do not want to be understood as if I thought that all exploratory operations would now become obsolete. It is obvious that there will still be a number of cases where obstacles will render the ocular inspection of the bladder and of the descending jets of urine impracticable; where an insufficient capacity of the bladder, purulent or bloody urine will make the electric illumination of the bladder resultless; where, I may add, the ureters can not be catheterized, because their orifices can not be found or approached. In such cases we, of course, have to operate for diagnostic purposes. But these cases will henceforth be exceptions and their number will still lessen with the advance of this endoscopic branch, with the increased dexterity and experience of the cystoscopist, and with the additional construction of a really useful cystoscope for catheterism of the ureters.

In closing my remarks I offer the following conclusions:

1. In all obscure reno-bladder diseases cystoscopy has to be practiced, if necessary repeatedly, before operative interference for diagnostic purposes is resorted to.

2. There are a number of causes which make cystoscopy impracticable.

3. Cystoscopy is an easy and harmless examination; but its successful employment requires experience.

4. It should be performed as a *dernier ressort* after all other well-known means for making a diagnosis have been exhausted.

5. If properly applied, cystoscopy will generally clear up an obscure disease of the bladder.

6. In most cases we can determine, with the help of electric illumination of the bladder, whether we have to deal with a disease of the bladder or of the kidneys.

7. We can thus find out whether there are two working kidneys, also whether only one of the two kidneys is diseased or both.

8. We shall most probably soon be able, perhaps, in the greatest majority of cases, after sufficient personal practical experience and with the help of proper cystoscopic instruments designed for this purpose, to catheterize the ureters and thus gather in a bloodless manner the urine from each kidney separately.

9. We can make out in certain cases by observing *the character* of the jets of urine, especially by *timing their frequency and duration* at the ureteral orifices, whether the other kidney is doing the work for the one which is diseased.

10. These facts will tend to make superfluous, in the majority of cases at least, a preliminary suprapubic or perineal incision for diagnostic purposes, as well as a nephrotomy performed for determining the action of the other (not diseased) kidney. They greatly widen and strengthen our means for making the indication and prognosis of nephrectomy.

11. With the aid of Nitze's newest instrument, the operating cystoscope, we may look forward to being able to carry on intravesical treatment under the direct guidance of our eyes.

The following is a partial list of the literature of the subject since 1887 : *

Antal, Géza von. *Spezielle chirurgische Pathologie und Therapie der Harnröhre und Harnblase*. Stuttgart, 1888.—Diag-

* Cf. E. Hurry Fenwick, *l. c.*, and Cecil Kent Austin, *l. c.*, Literature Index.

nostik der Harnblasenaffektionen. Cystoskop. Bilder. *Wien. med. Pr.*, xxviii, 49, p. 1688.

Bangs, L. B. Cases illustrating Some Difficulties in the Use of the Cystoscope. Report, *New York Med. Journal*, January 9, 1892, p. 51; *Med. Record*, January 2, 1892, p. 24.

Barling, G. The Electric Cystoscope and the Method of using it. With Notes of Cases. *Birmingham Med. Review*, 1889, pp. 257-270.

Boisseau du Rocher. De la mégaloscopie. *Comptes-rendus de l'Académie des sciences*, vol. ci, 1885, p. 329.—Mégaloscopie vésicale. *Annales des maladies des organes génitaux-urinaires*, 1890, p. 65.

Broca, A. De la cystoscopie ou endoscopie vésicale. *Gaz. hebdomadaire*, 15 mars, 1889.—De l'endoscopie vésicale ou cystoscopie. *Annales des maladies des org. gén.-ur.*, 1889, p. 166.

Brokaw, A. V. L. Cystoscopic Explorations. *International Journal of Surgery*, New York, 1889, ii, pp. 5-7.

Burckhardt, E. Endoskopische Befunde und endoskopische Therapie bei den Krankheiten der Harnröhre und der Blase. *Beiträge zur klinischen Chirurgie*, Band v, pp. 1 and 261.—Ueber Endoskopie. *Korrespondenzblatt für schweizer Aerzte*, xix, p. 755.—*Atlas der Cystoskopie*. Basel, 1891.

Clarke, W. B. Obscure Affections of the Bladder and Diagnosis by Means of the Cystoscope. *Brit. Med. Journal*, 1890, No. 1,555, p. 893.

Cruise. On Irrigation of the Bladder in Cystoscopy. *Lancet*, London, 1889, p. 372.

Davis. Epicystic Surgical Fistula for Cystoscopic Exploration, Intra-vesical Treatment, and Drainage. *Jour. of the Am. Med. Assoc.*, 1889, p. 685-688.

Desnos, E. *Traité élémentaire des maladies des voies urinaires*. Paris, 1890, p. 445.

Dittel, von. Ueber Fremdkörper in der Harnblase. *Wiener klinische Wochenschrift*, 1891, No. 12.

Fenwick, E. Hurry. Electric Illumination of the Male Bladder by Means of the New Incandescent Lamp-cystoscope. *Brit. Med. Journal*, February 4, 1888.—The Value of Electric Illumination of the Urinary Bladder (the Nitze Method) in the

Diagnosis of Obscure Vesical Disease. *Brit. Med. Jour.*, April 14, 1888.—The Value of Inspecting the Orifices of the Ureters by Electric Light in the Diagnosis of Symptomless Hæmaturia and Pyuria. *Brit. Med. Jour.*, June 16, 1888.—The Bloodless Method of removing Vesical Growths controlled by Electric Illumination. *Brit. Med. Jour.*, September 22, 1888.—The Prognostic Power of the Electric Cystoscope. *Brit. Med. Jour.*, October 13, 1888.—Clay and Wax Modeling of the Living Urinary Bladder under Electric Light. *Brit. Med. Jour.*, 1889, i, 13.—Fifteen Months' Experience of Electric Illumination of the Bladder in the Diagnosis of Obscure Vesical Disease. *Brit. Med. Jour.*, 1889, i, 989, 1053.—Precancerous Conditions of the Mucous Membrane of the Bladder Recognizable by Electric Light. *Brit. Med. Jour.*, July 6, 1889, ii, p. 13.—*Electric Illumination of the Bladder and Urethra*. Second edition. London, 1889: J. & A. Churchill.—The Influence of Electric Illumination of the Bladder upon our Knowledge and Treatment of Urinary Disease (abstract). *Brit. Med. Jour.*, 1890, p. 894, No. 1,555.

Goldschmidt, H. Ueber den praktischen Wert der Nitzeschen Cystoskopie. *Therap. Monatshefte*, iii, 10, p. 442, und *Allgem. med. Centralzeitung*, 1889, p. 2303.

Gruenfeld, J. Eine vereinfachte Methode zur Demonstration endoskopischer Bilder. *Allgem. Wiener med. Zeitung*, 1888, p. 375.—Cystoscopy in General. *Medical Press*, 1889, p. 670.—Ueber Cystoskopie im Allgemeinen und Blasentumoren im Besonderen. *Wiener klin. Woch.*, Band ii, 21, p. 423.—Endoskopische Untersuchung der Blase. *Wiener med. Blätter*, 1889, xii, 328.

Guyon, J. C. Félix. *Leçons cliniques sur les affections chirurgicales de la vessie et de la prostate*. Paris, 1888.—*Verhandlungen des 3. französischen Chirurgenkongresses*. Paris, 12–17. März 1888.—Endoscopie pour tumeur vesicale. *Gaz. hebdomadaire*, 26 avril, 1889.—Diagnostic des tumeurs de la vessie. *Gaz. médicale*, 27 juillet, 1889.—Néoplasmes de la vessie, diagnostic et indications opératoires. *Annales des maladies des org. gén.-ur.*, 1889, p. 449.—Diagnostic précoce des tumeurs malignes du rein. *Annales des mal. des org. gén.-ur.*, 1890, p. 329.—Diagnostic des

tumeurs vésicales, hématurie et endoscopie, *Bull. méd.*, Apr. 22; *Ann. des mal. des org. gén.-urin.*, 1891, p. 431.

Harrison, R. Remarks on Endoscopy with the Electric Light. *Lancet*, May 26, 1888.

Helferich. Ueber die praktische Bedeutung der modernen Cystoskopie. *Münch. med. Woch.*, 1890, p. 1.

Hermann, B. Eine Haarnadel in der Harnblase. *Internationales Centralblatt für Physiologie und Pathologie der Harn- und Sexualorgane*. Band i, Heft 1, p. 18.

Hill, B. Irrigation of the Bladder in Cystoscopy. *Lancet*, 1889, vol. i, p. 169.—Some Affections of the Genito-urinary Organs. *Brit. Med. Jour.*, June 22 to July 6, 1889.

Kaufmann, C. Cystoskopischer Nachweis eines Katheterstücks in der männlichen Harnblase. *Korrespondenzblatt für schweizer Aerzte*, 1889, p. 375.

Kutner, Rob. Ueber Photographie innerer Körperhöhlen, insbesondere der Harnblase und des Magens. *Deutsche med. Woch.*, No. 48, Nov. 26, 1891, p. 1311.

Leiter, J. Neue Beleuchtungsapparate. Wien, 1889.

Linhardt. Zur Endoskopie. *Archiv für Derm. und Syphilis*, Band xxi, p. 519.

Malherbe. De la cystoscopie. *Progr. méd.*, 1891, Nos. 1, 2.

Meyer, Willy. On Cystoscopy and the New Cystoscope of Nitze and Leiter, with a Demonstration of the Same. *New York Med. Journal*, April 21, 1888.—A Contribution to the Surgery of the Bladder. *New York Med. Jour.*, Feb. 23, 1889.—Review of Nitze's Text-book on Cystoscopy (with Remarks). *Annals of Surgery*, June, 1890.

Newell, O. K. Diagnosis of Tumors of the Bladder and Stone with the Cystoscope. *Boston Med. and Surg. Journal*, 1889, p. 381.—The Diagnosis of Vesical Tumor by the Cystoscope. *Med. Record*, vol. xxxiii, p. 596.—The Endoscopic Instruments of Leiter, of Vienna, and the Present Development of Endoscopy. *Boston Med. and Surg. Journal*, cxvii, 528–530.

Newman. Lectures on Surgical Diseases of the Kidney. 1888, p. 415.

Nitze, M. Beiträge zur Endoskopie der männlichen Harnblase. 1887. Langenbeck's *Archiv*, xxxvi, Heft 3, p. 661.—*Lehrbuch der Cystoskopie*. Wiesbaden: J. F. Bergman, 1889.—Das Irrigations-Cystoskop. *Centralblatt für Chirurgie*, 1889, p. 945.—Das Operationscystoskop. Vorläufige Mitteilung. *Centralblatt für Chirurgie*, No. 51, December 19, 1891.—Sur le chirurgie intra-vésicale. *Ann. des mal. des org. génit.-urin.*, Dec., 1891.

Otis, F. N. Papillomatous Tumor of the Bladder demonstrated by Means of Leiter's Electro-Cystoscope. *Med. Record*, May 18, 1888.

Otis, W. K. Recent Improvement in Endoscopic Apparatus. *Med. Record*, xxxiv, p. 658.

Poirier. Cathétérisme des uretères. *Annales des mal. des org. gén.-ur.*, 1889, p. 625.

Raymond, P. L'Endoscopie à Vienne. *Annales des mal. des org. gén.-ur.*, 1888, p. 776.

Rivière. L'Endoscopie à Vienne et à Paris. *Progrès médical*, 1888, 12 mai.

A Cystoscope. *The Sei-I-Kwai Medical Journal*, Tôkyô, vol. viii, No. 1, 1889.

Southam. On Endoscopy in Tumors of the Bladder. *Lancet*, 1889, p. 729.

Stein, Alexander W. Some Points in the Differential Diagnosis of Bladder and Kidney Affections. *Journal of Cutaneous and Genito-urinary Diseases*, 1888, p. 370.

Stelzner. Mitteilung eines durch Operation geheilten Falles von grossem Blasentumor und Demonstration des neuesten Blasenbeleuchtungsapparats. *Jahresberichte der Gesellschaft für Chirurgie und Heilkunde in Dresden*, 1889, p. 58.

Tuffier et Janet. Endoscopie vésicale appliquée à l'extraction des corps étrangers. *Annales des mal. des org. gén.-ur.*, 1889, p. 126.

Ultzmann und Schustler. Die Krankheiten der Harnblase. *Deutsche Chirurgie*. Billroth und Lücke, Wien, 1890.

Verhoogen, J. De l'endoscopie de l'urèthre et de la cystoscopie. *Journ. de méd., chir. et pharmacol.* Bruxelles, 1889, p. 161.

Vragassy, W. von. Das Megaloskop des Dr. Boisseau du Rocher in Paris. *Wiener med. Presse*, 1888, Nos. 3, 4.

Wallace, D. Electric Cystoscopy. *Edin. Med. Journal*, February, 1890.—Cystoscopy, etc. *Edinb. Med. Jour.*, Oct., 1891, p. 324.

Whitehead, W. A New Incandescent-lamp Cystoscope. *Brit. Med. Journal*, April 7, 1888.

ASTOR LENOX TILDEN FOUNDATION

500 N. 5TH ST. NEW YORK, N. Y.







