

A case of Graves' disease with scleroderma and a positive Wassermann reaction, treated with Salvarsan / by H.F.L. Ziegel.

Contributors

Ziegel, Hermann Fred Lange, 1876-
Royal College of Surgeons of England

Publication/Creation

New York, NY : William Wood, 1913.

Persistent URL

<https://wellcomecollection.org/works/vrzxj2ch>

Provider

Royal College of Surgeons

License and attribution

This material has been provided by This material has been provided by The Royal College of Surgeons of England. The original may be consulted at The Royal College of Surgeons of England. where the originals may be consulted. Conditions of use: it is possible this item is protected by copyright and/or related rights. You are free to use this item in any way that is permitted by the copyright and related rights legislation that applies to your use. For other uses you need to obtain permission from the rights-holder(s).



Wellcome Collection
183 Euston Road
London NW1 2BE UK
T +44 (0)20 7611 8722
E library@wellcomecollection.org
<https://wellcomecollection.org>

11.

A CASE OF GRAVES' DISEASE
WITH SCLERODERMA AND A
POSITIVE WASSERMANN
REACTION, TREATED WITH
SALVARSAN.

BY

H. F. L. ZIEGEL, M.D.,
NEW YORK.

REPRINTED FROM


THE

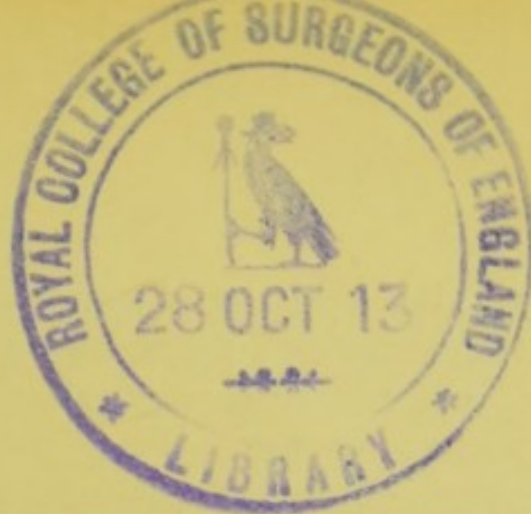
MEDICAL RECORD

June 21, 1913.

WILLIAM WOOD & COMPANY
NEW YORK







A CASE OF GRAVES' DISEASE WITH
SCLERODERMA AND A POSITIVE
WASSERMANN REACTION, TREAT-
ED WITH SALVARSAN.*

By H. F. L. ZIEGEL, M.D.,

NEW YORK. .

MRS. J. A., 28 years of age, has had no serious previous illness except malaria in Italy when she was 9 years old. Her menstruation started at 13. At the age of 15 she married. Her first child died of meningitis in infancy. Her second child, a boy 7 years of age, is healthy; in him the Wassermann was negative one year ago. Her husband gives no history or clinical evidence of syphilis; in him the Wassermann was negative in 1911. Four years ago she again became pregnant but aborted at the second month. Since then her menstruation has been regular, moderate, painless, of three days' duration, and without marked moulimina.

The patient first came under my observation in August, 1911. She had been nervous since a child, but no swelling in the neck had been noticed till Dr. Howard Fox, who four months previously had seen her at the Skin and Cancer Hospital, called her attention to this swelling. For two years pre-

*Report read and case presented in the Section on Medicine, New York Academy of Medicine, May 20, 1913.

viously (so she said in August, 1911) she had been more nervous and there had also been cardiac palpitation on exertion, visual disturbance, and difficulty in swallowing. Five months previously a lump was noticed on the external aspect of the left arm just beneath the shoulder. Later other hard areas appeared on the arm, behind the shoulder, on the anterior aspect of the elbow, and on the upper forearm. There was no pain, but occasional slight pruritus. She slept and ate well and did not feel weak. Defecation and urination were normal. The patient came complaining of the annoyance due to the hardness and discoloration of the skin, which had been increasing rapidly, also of "nervousness," headaches, visual disturbance, difficulty in swallowing, and cardiac palpitation on exertion.

Physical examination made in August, 1911 (some of the negative findings being omitted), showed considerable uniform swelling of the thyroid gland, moderate exophthalmos, presence of Graefe's and Mœbius' signs, pulse frequency of 96° to 100°. No marked tremor. Extending from below the left cubital fossa upwards to the point of the shoulder, on the outer and front aspects of the left upper arm, and over the left scapula in the region of the spine, was a hardened condition of the skin, nodular in areas. The affected skin was discolored and furrowed, and in the central portions apparently longest involved it was slightly scaly. In some areas there was hard edema; here the skin could not be pinched up; it did not pit on pressure. Where most affected it was attached to the deeper tissues. The infiltration merged into the surrounding apparently normal skin. The color resembled somewhat that of ivory. There was no sclero-

dactylie, the skin of the lower forearm, hand, and fingers not being involved. The pupils reacted normally. Drs. Martin Cohen and Mulcahey made ophthalmoscopic examinations and found the fundus normal. There was slight general enlargement of the lymph nodes. The breasts were negative. The patient's weight was 149 pounds. The blood was negative as to anemia; the leucocytes numbered 9,000, with a slight relative increase of the mononuclear cells. The urine was negative.

August 18, 1911: the Noguchi modification of the Wassermann reaction performed at the Rockefeller Institute was positive. The Wassermann reaction performed by Dr. J. J. Hertz was positive. August 24: Salvarsan, 0.5 gram suspended in 3 c.c. of iodipin, was injected into the right sacrospinal muscle. On the following day the pain was slight at the site of injection, the pulse was 100, the rectal temperature was 100° F., and apparently no ill effects followed the treatment. August 29: Tumors of the skin softer. At the periphery of the areas where there is hard edema normal skin is replacing the hard patches. September 5: Further replacement by normal skin of sclerodermatous areas, especially those on the forearm and in the scapular region. Gaining in weight—now 150 pounds.

September 6, 1911: Repetition of salvarsan treatment; 0.5 gram of arsenobenzol in iodipin suspension injected into the left sacrospinal muscle. Though there was no constitutional reaction, the pain at the site of injection was very severe, and ever since then the patient has refused all injections. September 14: Further gain in weight, which is now 153½ pounds. The size of the thyroid gland has steadily diminished and the pulse

has continuously become less rapid since the first salvarsan injection. To-day the pulse frequency is 80. The second injection of salvarsan was not immediately followed by marked changes in the skin condition as was the first treatment. The urine is negative. Arsenous acid, 1/30 grain, and sajodin, 5 grains, were started t.i.d. October 19: Wassermann negative (Dr. Hertz). The luetin test performed ten days ago is negative. November 20: Slow but steady replacement of hard patches by normal skin. The patient says she is much less nervous than formerly. The pulse rate is now 76. The thyroid swelling has diminished markedly since the salvarsan treatment. December 18, 1911: Further improvement in the skin condition. As to the nodules beneath the spine of the scapula, many have gone entirely and the remaining ones are softer and more movable. The forearm and cubital fossa are now entirely free of the skin lesions. The patient no longer complains of headaches and is less nervous. Pulse 76. Weight 156 pounds.

The patient unfortunately refuses an intravenous injection of salvarsan, also another intramuscular injection, though further salvarsan treatment was strongly urged. February 12, 1912: There has been little change during the past two months in the skin condition; it is now about one-third of its extent when first seen a year and a half ago; the tumors beneath the skin are not nearly as numerous as originally and those that remain are softer. Weight $160\frac{3}{4}$ pounds. Pulse 72. May 6, 1912: Continuous improvement in the general condition. Weight now 164 pounds. Pulse 72. The patient has been getting Fowler's solution, 10 minims, t.i.d. December 20, 1912: During the past seven months there has been no marked increase nor diminution in


the extent of the morphea. Pulse 76. Arsenic internally continued, now in the form of the Dürckheimer Maxquelle water, 1 dram, t.i.d., p.c. April 1, 1913: There is noted some further improvement in the skin condition, which is now less than one-third of its extent when first seen by the writer. Bands of normal skin are extending into the affected areas, causing the latter to appear as islands. Most of the nodules disappeared after the salvarsan injections one year and a half ago, and those that remain are softer and smaller than originally. The patient absolutely refuses any more injections. The weight is now 179 pounds, *i.e.* a gain of 30 pounds since salvarsan was first given. The pulse frequency is 68. There is now very little swelling of the thyroid. Since the salvarsan treatment there has been no recurrence of the headaches, "nervousness," cardiac palpitation, and difficulty in swallowing. April 7, 1913: The luetin test has again been negative. Dr. Howard Fox and the New York Board of Health found the Wassermann negative.


Summary and Conclusions.—In a married woman 28 years of age with Graves' disease complicated with the circumscribed form of scleroderma or morphea the Wassermann reaction was positive. There was no history or clinical evidence of syphilis. In a son 7 years of age and in the husband the Wassermann was negative. Since two intramuscular injections of salvarsan of 0.5 gram each were given one year and nine months ago the Wassermann has been negative; moreover, the treatment with arsenobenzol was followed by a gain of 30 pounds in weight, by considerable diminution in the thyroid swelling, by disappearance of the nervous symptoms and the tachycardia, and by marked improvement in the skin condition. Most of the no-


dules in the skin disappeared, those that remain are softer and smaller, and the scleroderma is now less than one-third of its extent when first seen; the skin on the upper forearm, in the cubital fossa and the scapular region, which regions were originally involved, is now apparently normal. Unfortunately there was considerable pain caused by the second intramuscular injection, and ever since then further treatment with salvarsan has been refused, though an intravenous injection was advised; instead arsenic in various forms has been given by mouth.

From an experience limited to one case it would surely not be justifiable to draw conclusions as to the therapeutic value of salvarsan in the conditions described. Moreover, a rational interpretation of the changes that have taken place would have to be based partly upon answers to the following questions: Did this patient possibly have latent syphilis, despite the absence of anamnestic and clinical evidence of the disease, and were the favorable changes and the negative Wassermann due to the antiluetic effect of the salvarsan? Did the arsenic have a direct remedial influence on the Graves' disease and the scleroderma? Or did the improvement occur spontaneously and coincidentally, *after* rather than *because* of the arsenic therapy? Certain it is, however, that the administration of salvarsan and other forms of arsenic was followed by negative Wassermann reactions, by marked improvement in the scleroderma and by symptomatic cure of the Graves' disease.

8 WEST EIGHTY-SIXTH STREET.







A COMPOSITE FAC-SIMILE

MEDICAL RECORD

A Weekly Journal of Medicine and Surgery

WILLIAM WOOD AND COMPANY, Publishers, 51 FIFTH AVENUE, NEW YORK

\$5.00 Per Annum.

PUBLISHED AT NEW YORK EVERY SATURDAY

Single Copies, 15c

ORIGINAL ARTICLES.

Radium for the Treatment of Cancer and Leukemia. By William J. Morton, M.D., New York.
Cutaneous Tuberculin Vaccination in the Diagnosis of Tuberculosis. By William J. Butler, M.D., Chicago.
Prevention of Death During Anesthesia by Chloroform and Ether. By Robert Heyburn, A.M., M.D., Washington, D.C.
What Shall We Do with the Advanced Cancer of the Large Bowel? By R. C. Coffey, M.D., Portland, Ore.
Sustentation of the Canal Zone. By Colonel William C. Gergan, M.D.
Vaginal Implantation of Adenocarcinoma of the Uterus. Blood Metastasis in Recurrent Carcinoma. By Geo. W. Kaan, M.D., Boston, Mass.
Relation of Accidents to Functional Nervous Diseases and Psychoses. Medico-legal Considerations. By Alfred Gerber, M.D., Philadelphia, Pa.
Diseases of the Gastrointestinal Tract on the Borderland between Surgery and Internal Medicine. By John C. Hemmeter, M.D., Ph.D., L.L.B., Baltimore, Md.
The Organic Factor in High Blood Pressure. By Alexander Hale, M.A., M.D., Owen, London.
Primary Melanosis of the Palate: Nasopharyngeal Flap of Recent Sarcomatous Origin. By J. N. Roy, M.D., Montreal, Canada.

EDITORIALS.

Contradictory Advice to Consumptives. The Army Canteen. The Dangerous Effects of Ether and Chloroform. Preventive Medicine. A Case of Hymen Labor.

EDITORIAL NOTES.

The Causation of Appendicitis. To Accelerate the Course of Labor. The Period of Infection in Typhoid Fever. Asphyctic Operating. The Technique of Spinal Anesthesia. The Infection of Scarlet Fever. The Effect of Athletic Contests on the Health. Treatment of Constipation by Abstinence from Meat. The New Tuberculin Reactions. Early Mercury Treatment and Syphilitic Nervous Diseases.

NEWS OF THE WEEK.

Against Chloroform in Michigan—"Out-look for the Future"—Typhoid Investigation in Trenton—Codification of Regulations of the Chicago Health Department—Study of Speech Defects—Vaccination Rule Sustained in Chicago—Confederation of Students' Societies—Makos Doctors His Victims—Physicians' Building for Cleveland—Druggist Convicted—The Nicholas Senn Estate.

CORRESPONDENCE.

Our London Letter. Our Paris Letter. Our Berlin Letter. Our Letter from the Philippines. Our Letter from Copenhagen.

PROGRESS OF MEDICAL SCIENCE.

Achondroplasia and Laparotomy—Trypsin in the Treatment of Malignant Tumors—Varicose Veins, Their Treatment by Multiple Short Incisions—Arteriosclerosis—Upper Respiratory Obstruction and Oral Deformity. Subacute Polymyositis—Dementia Praecox. Mutual Relations of Upper-Air Tract, Jaws and Teeth—The Diagnosis of Appendicitis—Cerebral Anesthesia in Cerebrospinal Meningitis. The Value of Vaccine Therapy to the General Practitioner in the Treatment of Bacterial Diseases.

BOOK REVIEWS.

American Practice of Surgery. A Complete System of the Science and Art of Surgery, by Representative Surgeons of the United States and Canada. Editors: Joseph D. Bryant, M.D., and Albert H. Buck, M.D. Complete in eight volumes.
The Medical and Surgical Knowledge of William Shakespeare. With Explanatory Notes. By John W. Wainwright, M.D.
A Textbook of the Practice of Medicine. For Students and Practitioners. By James Macgregor French, M.D. Third Revised Edition. 131 Illustrations. It Being Full-page Plates in Text and Colours.
Manuel de Gynécologie pratique. Par J. Barrois. Préface de M. L. O.
Medical Jurisprudence, Forensic Medicine, and Toxicology. By E. A. Wittich, A.M., M.D., Professor of Chemistry, Physics, and Toxicology in Cornell University.
Manual of Hygiene and Sanitation. By Robert M. M. Fourth Edition. Enlarged and Thoroughly Revised. Illustrated with Ninety-three Engravings.

SOCIETY REPORTS.

Medical Society of the State of New York. General Meeting. Southern Surgical and Gynecological Association. American Medical Association. Section on Practice of Medicine. Joint Meeting with Section on Pharmacology and Therapeutics. American Laryngological Association. American Public Health Association. Sixth International Dermatology Congress. New York Academy of Medicine. Section on Pediatrics. Section on Surgery. Section on Obstetrics and Gynecology. Section on Medicine. Mississippi Valley Medical Association. Medical Section. American Therapeutic Society. Philadelphia County Medical Society. Western Surgical and Gynecological Association. American Gastroenterological Association. New York Psychiatric Society. British Medical Association. Section of Tropical Diseases.

STATE MEDICAL LICENSING BOARDS.

State Board Examination Questions, University of the State of New York. Answers to State Board Examination Questions, University of the State of New York. State Board Examination Questions, Illinois State Board of Health. Answers to State Board Examination Questions, Illinois State Board of Health. Bulletin of Approaching Examinations.

SURGICAL SUGGESTIONS.

Circumcision—Methods Against Fleas—Urethral Hemorrhage—Strangulated Hernia—Health Report. Dermato-Venerel Don'ts—Burns—Tuberculosis—Peritonitis—Skin Grafting.

THERAPEUTIC HINTS.

Sweating Hands or Feet—Influenza—Alcohol Abuse—Pneumonia—Paraphimosis—Catarrhs Pharyngitis.

NEW INSTRUMENTS.

A New Stethoscope. By Dunlap F. Pondstew, M.D., Boston, Mass. A New Bone Drill and Bone Wrench. By Carl Beck, M.D., New York.

MEDICAL ITEMS.

Contagious Diseases, Weekly Statement—Health Reports. DIRECTORY OF NATIONAL AND STATE MEDICAL SOCIETIES.

JUST PUBLISHED

TEXT-BOOK OF ANATOMY

By D. J. CUNNINGHAM, F.R.S.

THIRD EDITION

Royal Octavo, 1467 pages; 936 Wood Engravings of which 406 are in two or more colors. Muslin, \$6.00 net; Half Morocco, \$7.50 net.

URGENT SURGERY

By FÉLIX LEJARS. Translated by WILLIAM S. DICKIE, F.R.C.S.

FROM THE SIXTH FRENCH EDITION

Two volumes, large octavo. Vol. One, 631 pages. Illustrated by 458 engravings, in black and colors, and by ten full-page plates. Muslin, the set, \$14.00 net; Half Morocco, \$16.00 net.

WILLIAM WOOD AND COMPANY, Medical Publishers
Copyright, 1910, by William Wood and Company.

51 Fifth Avenue, New York
Entered at the Post-Office at New York as Second-Class Matter.

