

Smith's cataract operation : a descriptive and illustrated article written during a visit to Smith's Clinic at Jullundur, Punjab, India / by Derrick T. Vail.

Contributors

Vail, Derrick Tilton, 1898-
Royal College of Surgeons of England

Publication/Creation

[London] : [The Lancet], [1911]

Persistent URL

<https://wellcomecollection.org/works/jsnk6pan>

Provider

Royal College of Surgeons

License and attribution

This material has been provided by This material has been provided by The Royal College of Surgeons of England. The original may be consulted at The Royal College of Surgeons of England. where the originals may be consulted. Conditions of use: it is possible this item is protected by copyright and/or related rights. You are free to use this item in any way that is permitted by the copyright and related rights legislation that applies to your use. For other uses you need to obtain permission from the rights-holder(s).



Wellcome Collection
183 Euston Road
London NW1 2BE UK
T +44 (0)20 7611 8722
E library@wellcomecollection.org
<https://wellcomecollection.org>


P. 6 10

With Compliments of
the Author.

3

THE SMITH CATARACT OPERATION

DERRICK T. VAIL, M.D.



SMITH'S CATARACT OPERATION

A Descriptive and Illustrated Article Written
During a Visit to Smith's Clinic at
Jullundur, Punjab, India.

BY

DERRICK T. VAIL, M.D.,

CINCINNATI.



Reprinted from THE LANCET-CLINIC, January 7, 1911.

INTRODUCTORY.

There is a growing interest on the part of the ophthalmologists of America in the operation of extraction of cataract in its capsule, for all are agreed that the argument is sound, viz., that the capsule and a certain amount of lens matter left behind in many cases are the source of vexation, trouble or even disaster.

The author of the following pages only endeavors to report Smith's operation as done by Smith himself, and to give a brief account of his own experience and observation while attending Smith's clinic in India. He offers no improvements or modifications, taking it for granted that the reader desires first to know exactly how Smith operates. The only claim he desires to make is that the description is full and accurate. The sketches were mostly made at the side of the operating-table, during October and November, 1909, and are published with Col. Smith's kind approval.

For a detailed account of the original work of Smith in India and the arguments favoring his operation, the reader is referred to Smith's own book on "The Treatment of Cataract," published by Thacker, Spink & Co., Calcutta, Ind., 1910.

D. T. VAIL,
24 E. Eighth St., Cincinnati, O.

December, 1910.



SMITH'S CATARACT OPERATION.

A DESCRIPTIVE AND ILLUSTRATED ARTICLE WRITTEN DURING A VISIT
TO SMITH'S CLINIC, AT JULLUNDUR, PUNJAB, INDIA.*

BY DERRICK T. VAIL, M.D.,
CINCINNATI.

WHEN Smith arrives at the Victoria Memorial Hospital at Jullundur, at about eleven o'clock any morning, there will be from fifty to over one hundred native Hindus and Mohammedans waiting for him. They are a sorry lot to behold, for aside from the infirmities which various forms of blindness have brought upon them, they appear miserably poor and wretched. Many have come to Jullundur from their far distant homes, and have brought all their worldly goods in small bundles, which they carry on their heads or under their arms. The blind are almost invariably accompanied by members of their families, and they are huddled together like a flock of sheep on the veranda or in the open court near the door entering the operating-room. Usually within thirty minutes the entire lot has been examined and assorted in groups, the male cataract cases in one group, the female cases in another, the iridectomy cases in a third, and they all are permitted to squat Hindu-fashion in the large operating-room. The trichiasis or ectropion cases to be operated on are grouped in the adjoining or smaller operating-room along with all other kinds of surgical cases—cancers, abscesses, amputations, laparotomies, stones in the bladder, strictures, etc. It is an unusual sight to see one man examine and assort over one hundred patients in less than an hour. Approximately over one-fourth are turned away with the statement "*Noor ban a-wallah*," which means "nothing can be done for you." This sad group represents all forms of hopeless cases, from total and incurable blindness to hopeless cripples and imbeciles.

It is manifest that either eye-patients are rushed to the operating-table without a suitable examination or else Smith has unusual diagnostic ability, for how can he diagnose operable and inoperable cataract cases at the rate of two a minute, when we know that it takes the most expert from five to ten minutes at least to examine a single case and decide such an important matter? With such a large amount of work coming in daily, it is imperative that no time be wasted. The patients are examined by daylight inspection. No time is frittered away with getting the history of the case or with a general examination. The eye speaks for itself, and if there is a chronic disease present, it too speaks for itself.

* Presented to the Chicago Ophthalmological Society and read by invitation at its weekly meeting, December 19, 1910.

THE EXAMINATION.

Smith stands at the door with his back to the light, which falls full in the patient's face as he approaches him. A glance by an expert will tell "a sea of troubles." Trachoma, pannus, trichiasis, glaucoma, macula cornea, iritis, phthisis bulbi, ulcers, new growths, tear sac trouble, etc., are all at once spotted. The cases of cataract, which interest us most, are selected with ease, for Smith acts on the principle that there

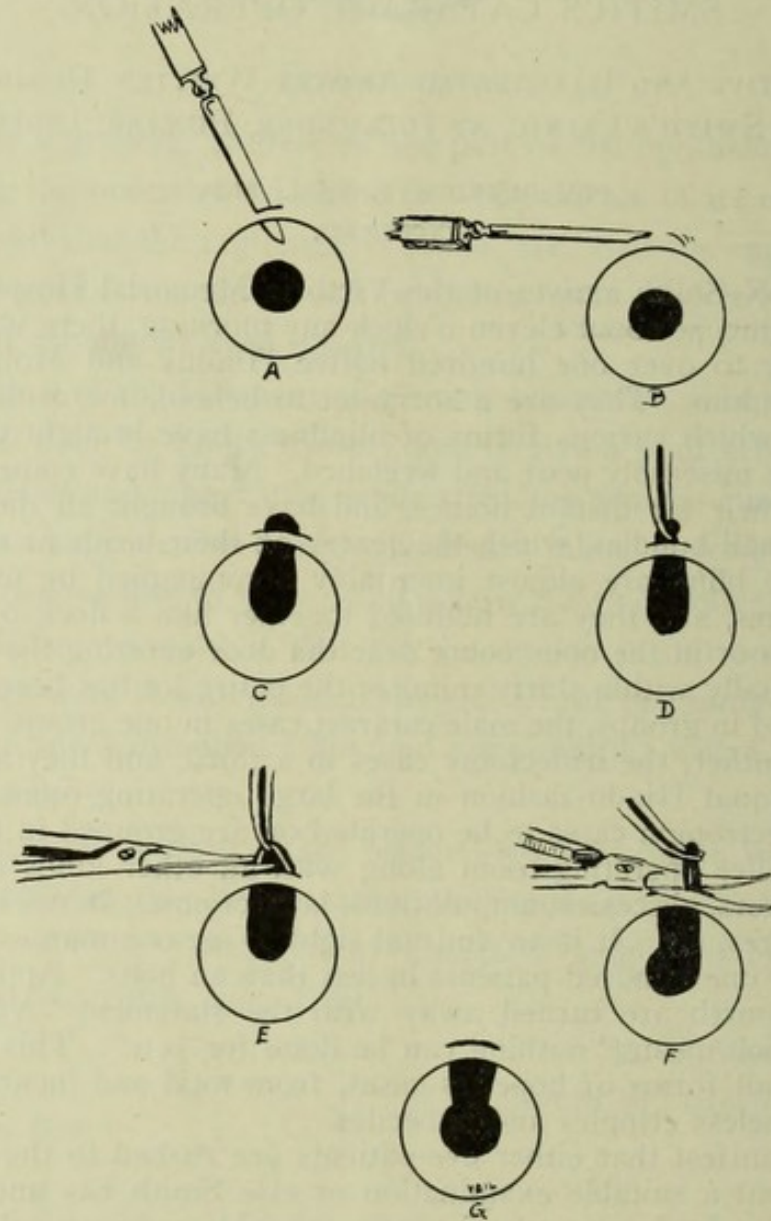


FIG. 1.—Showing Smith's method of doing iridectomy for glaucoma. A, the point of the knife is entered; B, the handle is lowered till the edge of the knife finds the extreme angle of the cornea; C, iris presents spontaneously or after pressure at the upper edge of the wound; D, iris grasped with forceps; E, iris cut half off; F, iridectomy completed; G, result.

is no complication to cataract which does not express itself in some way plainly to be seen at a glance in a good direct light. If the pupil is a little larger than it should be, it suggests glaucoma simplex or retinitis pigmentosa (of which there is an enormous amount in the Punjab). The taking of the tension will decide which, and an inquiry

into the presence of night blindness will confirm the opinion. If the pupil is too small and the chamber deep, it suggests a couched or dislocated lens or an opium pupil. If the pupil *does not readily respond*, it is immediately spotted as a complicated case that, no matter if cataract is present, will not go to the operating-table until the trouble is differentiated. If there is pericorneal deep injection or superficial conjunctival congestion, the presence of chronic cyclitis or chronic dacryocystitis is at once suspected, but if the eye is clean and good at a glance, the pupil responding quickly to the light, and things look good, the case is immediately passed as an uncomplicated case and will be operated upon the same day. Many of the complicated cases will go to the operating-table, for such complications as a run-out trachoma, pterygium, macula cornea, opium pupil or even dislocated or couched lens, need not give the operator any special concern. Smith is exceedingly watchful for glaucoma. It would be to my notion as hard for any kind of a glaucoma case to pass Smith and go to the operating-

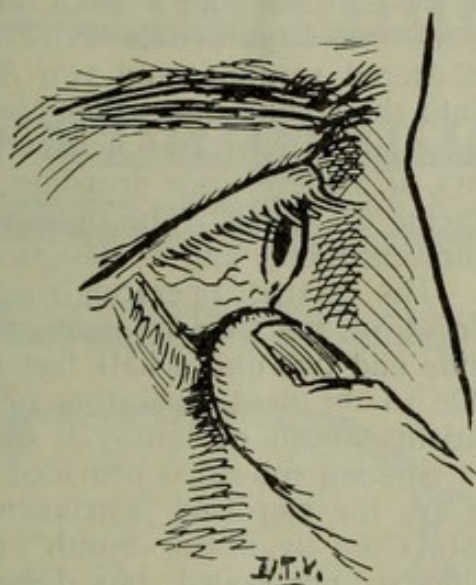


FIG. 2.—Showing Smith's manner of "taking the tension." The lower lid is depressed by the tip of the forefinger and the eyeball is gently pushed to determine the tension.

table for cataract as it would be for a small boy to steal his way into the circus. He will do iridectomies (Fig. 1) on those which give a history of pain in the brow or temple, but will not usually under any ordinary circumstances attempt to extract the cataract, and if, owing to the stress of circumstances, he does undertake the cataract, he does so with great misgivings as to the result. What he fears most in these cases is expulsive hemorrhage from the choroid. The ordinary way of taking the tension through the eyelids, by having the patient look slightly down, is not used at all by Smith. He much prefers to apply the pulp of the forefinger directly to the exposed eyeball in the region of the ora serrata. (Fig. 2). This is done without any cocaine drops, of course, and is entirely painless. He can thus tell the tension with exquisite nicety, and the patient is not spoken to or directed to do anything. In all of Smith's operations and examinations he leaves the patient's equation entirely out of consideration. In examination he relies solely on the evidence of his own senses; in operations he sets

aside the spasms and straining efforts by acts and tricks which, while very simple, are never for a moment violated; that is the patient is rarely trusted or requested to "hold still" or to "look down" or to "not squeeze." They generally lie quietly, and as long as they remain so no request is made of them. His technique when properly carried out will usually set aside any impending or actual damage any one can do by ordinary resistance. I shall describe fully what those measures are when I come to the technique of the operation.

THE OPERATING-ROOMS AT THE VICTORIA MEMORIAL HOSPITAL
AT JULLUNDUR.

There are three operating-rooms in the hospital with marble slab floors, marble wainscot and white painted walls. There are two on the ground floor and one on the second story. The larger of the downstairs rooms is used for cataract and iridectomy operations. It is a room perhaps forty feet long and twenty-five feet wide, having a large double window on its western side and a small double window on its northern side. There are two large double doors on the southern side leading out to the cloistered veranda, and two double doors on the eastern side leading into the second or smaller operating-room, which is about forty feet long and fifteen feet wide. In this room is the cabinet for instruments, also shelves for dressings, solutions, etc., and one double window facing the north. The upstairs operating-room is over the cataract operating-room, and is designed for gynecological and obstetrical work. The cataract operating-room has three operating-tables, arranged to utilize the western light. These tables are six feet long, two feet wide and two and a half feet high. Smith passes quickly from one table to the next, operating in rotation, while the assistants prepare patients ahead of him. A small, round, marble-top iron table, on easy running rollers, is provided for the instrument-pan, and in this pan are the sterilized instruments described in my article on "Instruments Used by Major Smith" (Fig. 3), all except the Graefe knife, which is not boiled, but dipped in pure carbolic solution. There is another square-top glass table between two of the operating-tables, on which is a square pan containing 1-20 carbolic solution, in which are kept immersed a number of instruments that are only occasionally used—"emergency instruments." They are cataract knives (two), Tyrell hook, Daviel spoon, cystotome, spatula, extra iris forceps and iris scissors, medicine dropper and fixation forceps, and whatever else may be of use at special occasions. On this table is a wide-mouth bottle, containing 1 per cent. formalin solution, glycerinized, for preserving the unbroken lens after extraction, also a smaller bottle of alcohol, in which are kept the straight scissors for trimming the lashes, and a one-ounce bottle of saturated solution of carbolic acid for one-minute immersion of the blade of the Graefe knife just before using. A roll of dry cotton and roller gauze bandages, immersed in 1-2,000 bichloride, are also kept on the second or lower shelf of this table. Suspended from the ceiling are two five-gallon glass gravity douches, with outlet below, from which emerge half-inch rubber hose used in flushing the eye. These large douche-bottles are filled each morning with 1-2,000 bichloride solution warmed. There is no nozzle attached to the rubber hose to direct the stream in

the eye; the full stream is used, but there is a good cut-off of the ordinary kind (Fig. A). Smith rarely uses a sponge for any of his surgical operations. He uses this flushing device in his major operations on the body as well as for cataract work. He usually begins his operations on the cataract cases first, putting off the iridectomies and other surgical cases until after all the cataract cases are finished. Three cases are selected by the operating-room assistant at random, and are placed on these operating-tables. Their eyelids and brows are wiped with a pad wet in 1-2,000 bichloride, and two or three drops of 5 per cent. solution of sterile cocaine dropped in each eye only once. In the meantime the operating assistant, Nur Ilali, a native Moham-medan, who is not a medical man or even a trained nurse in the ordinary acceptance of that term (but nevertheless a skilled assistant of the first order), has selected the two sets of instruments and seen that

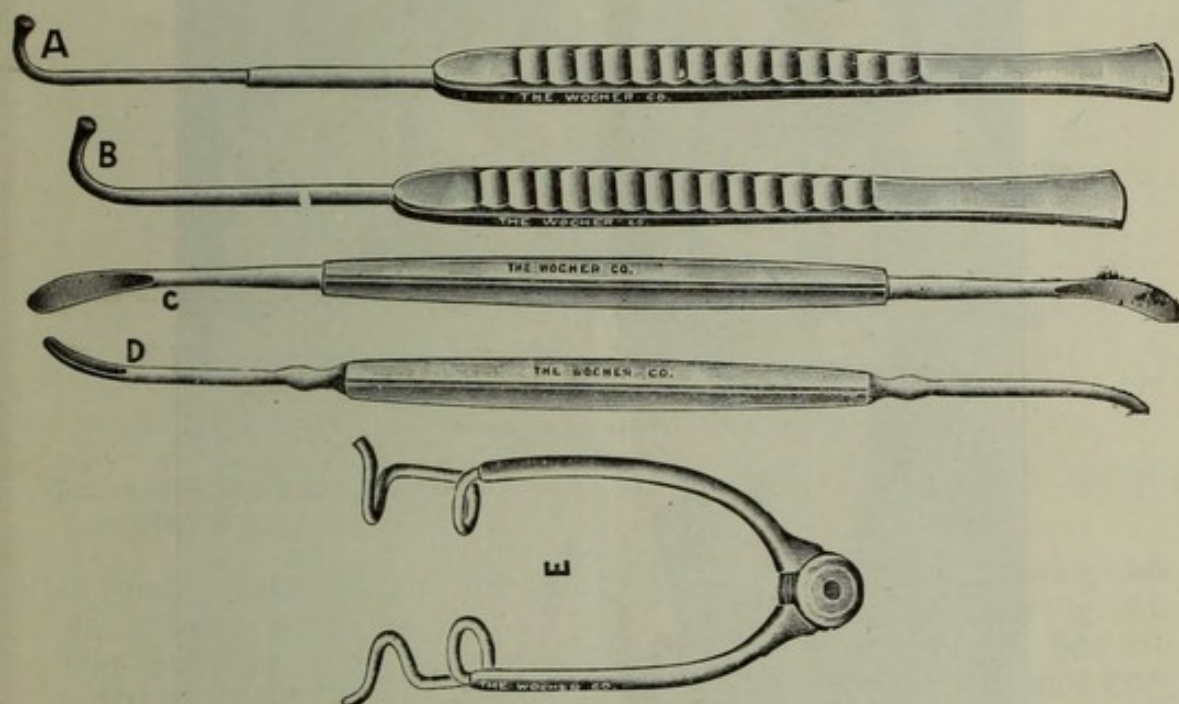


FIG. 3.—Smith's cataract instruments. A, the lens hook; B, the lid hook; C, the double spoon or lens spatula; D, the iris repositor; E, the "Jullundur" speculum.

everything is in working order. The sterilizer consists of a hand-made square copper boiler, designed to contain the operating tray of instruments, and it is filled half full of warm water containing a little bicarbonate of soda to "soften" the water, and a good alcohol lamp is placed underneath. A lid covers the pan, and soon the solution is boiling. It is kept boiling during the entire time operations are going on, and when one set of instruments is taken out in its tray the other is put in the boiling water. The tray which contains the instruments is perforated at the bottom, to let the water quickly through, and the two handles on the ends are mounted with wood to make it handy for holding. This perforated tray is transferred from the sterilizer to another pan containing 1-40 carbolic solution, which cools the instruments and renders them ready for use at once.

Smith always subjects the eyes to a scrutinizing examination *while*

the patient is lying down awaiting his turn. Examination while the patient is recumbent will reveal conditions that may be masked by the upright position, *e.g.*, iridodonesis, soft tension, etc. This examination is more thorough and careful than the entrance examination, for he will not operate until he has satisfied himself that the *pupil is normal and active*, or at least he will not operate without knowing positively what the behavior of the pupil is. He will not deny any patient even a small chance. I have seen him operate on cases that I certainly would have refused, and I have seen success reward his courage in many such cases. But he does not go about it haphazardly; he carefully satisfies himself in every case on the three following points:

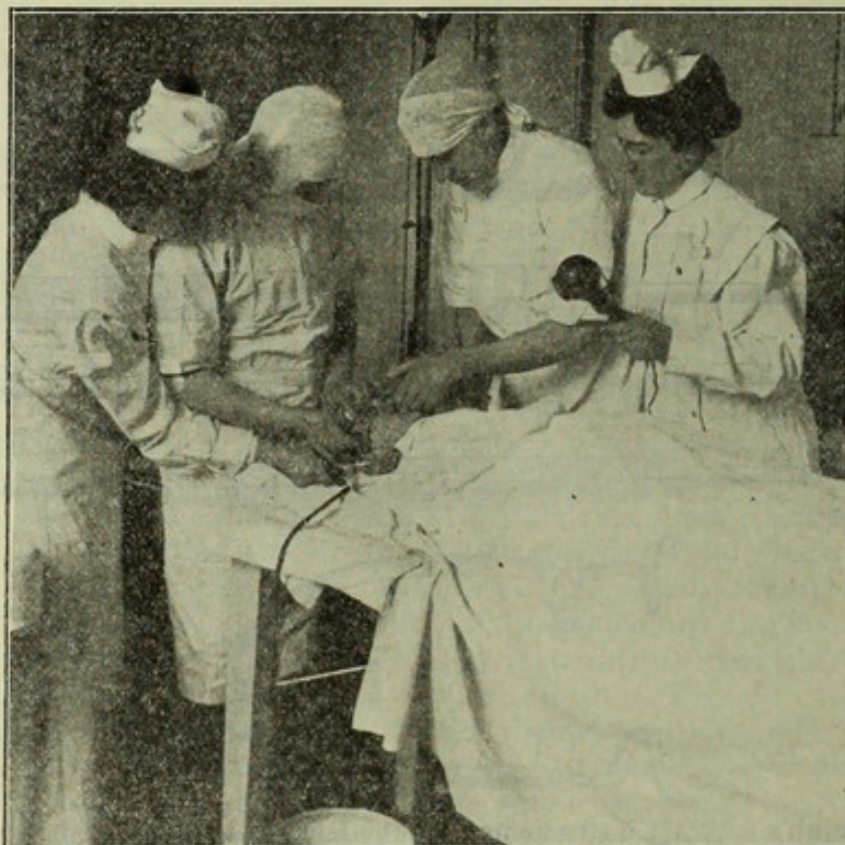


FIG. A.—Operating scene, showing operator exposing the cul-de-sac by lifting the speculum with his right hand and retracting the eyebrow with his left, while the assistant sends a stream of bichloride solution into the exposed sac with a forcible gravity douche.

(a) is it a cataract? (b) What kind of a cataract? (c) Any complications?

He told me that in reporting his statistics where he had 8 per cent. vitreous losses, he *counted all cases*, counted the complicated and desperate cases along with the uncomplicated ones. He also said that he had done and can do a hundred uncomplicated or selected cases in succession without a single loss of vitreous, and repeat it oftentimes in the next hundred, and that his percentage of vitreous escapes in *uncomplicated selected cases is less than 2 per cent*. This I believe to be true, and I have every reason to believe it. The light is always ordinary daylight, which falls through the large window directly in the patient's face, and obliquely under the upper lid when it is raised

off the ball with the lid hook. It is most important that a thoroughly good view of the upper fornix is thus obtained, for the most important field of the entire operation lies quite under the upper lid and within the very fornix itself, and so the best light must be in this upper pouch.

PREPARING THE FIELD OF OPERATION.

Everything being in readiness, the operator takes his first position at the head of the patient, no matter which eye is to be operated upon, and the assistant stands to the left. He trims the lashes of the upper lid for about one-third of the distance from the outer corner, in order that the blade of the knife shall not become contaminated as it passes into the eye, at the same time leaving the central lashes uncut for convenience in grasping and raising the lid during or after the operation or at the time of subsequent dressing. The "Jullundur speculum" (Figs. 3 and 4) is introduced. Smith insists that he has tried

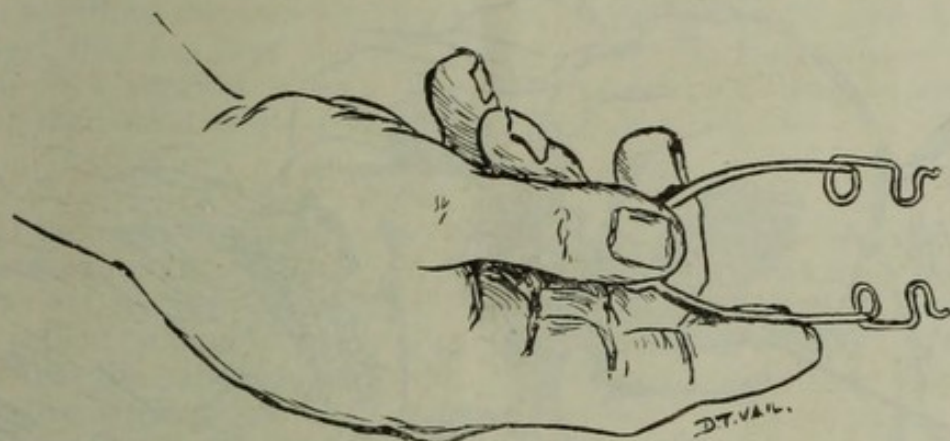


FIG. 4.—Showing the way Smith holds the speculum in introducing it and removing it also.

all kinds of specula, and has found defects in them all excepting this one pattern, which he regards to be a perfect instrument (Fig. 4). The speculum being introduced and in proper position, the lids are raised off the eyeball by the speculum held at its outer or temple portion in such a way that the speculum and lids are bodily and *en masse* lifted off the eyeball (Fig. 5); then, by seizing the eyebrow by the fingertips of the unoccupied hand, the brow is firmly slid upward on its bony background. This maneuver obliterates all the folds of conjunctiva at the upper fornix and converts the collapsed conjunctival sac into a wide-open, smooth pouch, without a single pocket, ruga or fold, so that you may look into it and see for yourself that the entire conjunctival sac is open like an empty sack would be after it is inflated. This area, the most important of the eye, is now thoroughly exposed for flushing with the 1-2,000 bichloride douche, and as the half-inch current with a three-foot drop is sent with a swirling force into the sac, the field gets a thorough scouring out. There is no other method which will be so effective and yet so free from mechanical insult as this. The reflection fold cannot be cleansed by any other means that I know of. Certainly the usual method of turning a ribbon-like stream through a flat nozzle under the upper lid while it approximates the globe, or the various undine and medicine-dropper methods in

vogue, will not unfold the multiple rugæ there, and the eye is not scoured clean of its débris, foreign or infectious matter that lies hidden within these ample folds. By placing the speculum (which has a wide space for the lid to lie between, and a deep reflection to go up under the lid) in place, and forcibly *retracting the entire brow*, to overcome the corrugator supercilii, you certainly do unfold all the wrinkles of the upper fornix, and can, by douching, clean it out without injuring the tissues. Smith states that the warm salt solution or saturated boracic solution would probably do as well as this 1-2,000 bichloride, but he has used the latter in over 20,000 cases, with such re-

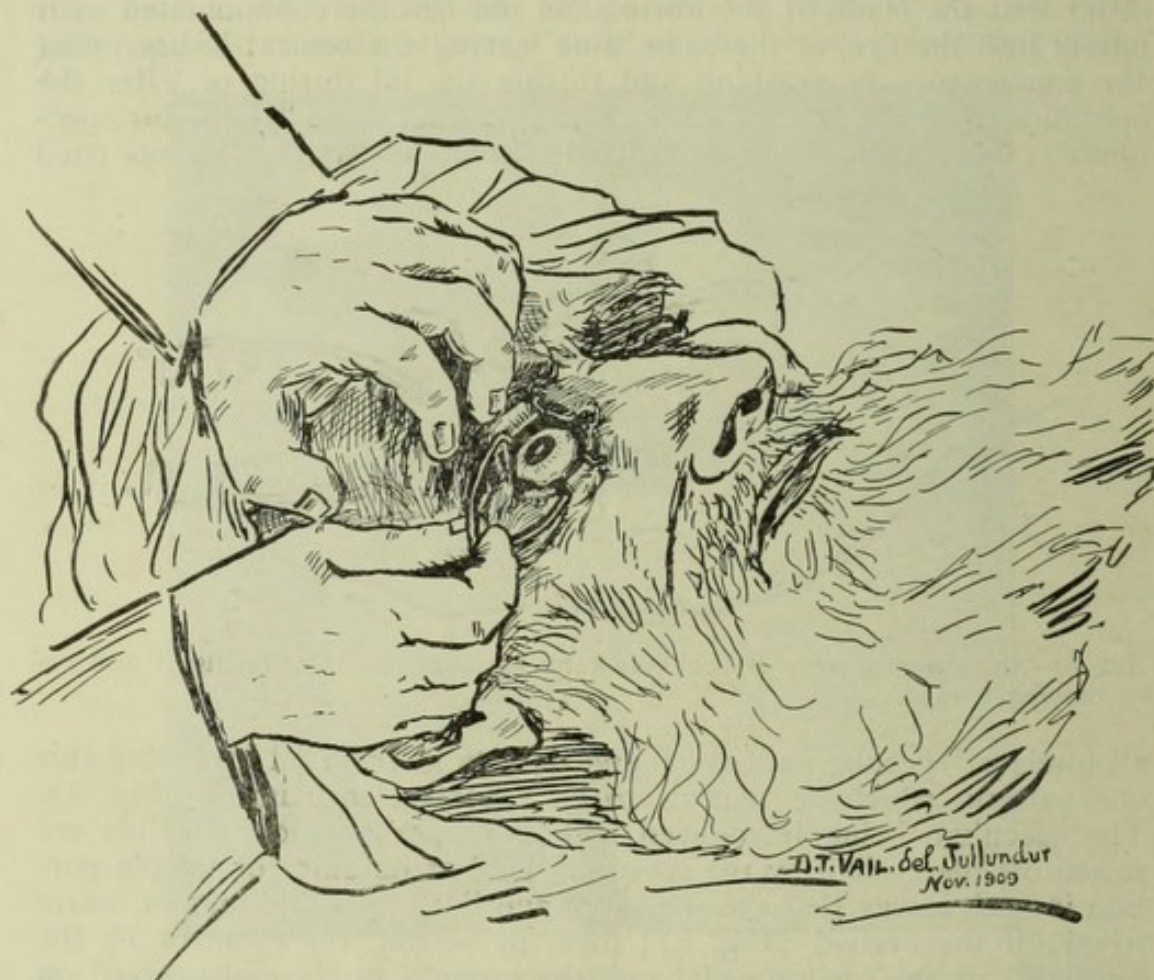

FIG. 5.—Showing how the fornices are fully exposed by lifting the lids away from the eyeball while the left hand retracts the brow. The douche stream can now reach every pocket and fold, and surgical cleansing is thus achieved.

sults as regards post-operative infection that prove the soundness of the reasoning and justify the proceeding. In over 1,000 extractions that I saw at Jullundur there occurred but two cases of panophthalmitis, and they could be proven to occur from other causes. In 350 extractions of my own there occurred no case of post-operative infection. So far as I know, this method of sterilizing the cul-de-sac is entirely Smith's own, and it is a valuable contribution to ophthalmic surgery, whether cataract in the capsule, out of the capsule, iridectomy, paracentesis or any other operation on or in the eyeball is to be done.

The next maneuver is emptying the conjunctival sac of the solution which naturally gravitates into the depressions. Most operators

would use a sterile cotton sponge for taking up the fluid left in the corner of the eye and the lower cul-de-sac. In my own work I am always careful to wipe out the fold of the plica, the caruncle, the puncta and the entire inner canthus with a squeezed-out cotton sponge, but Smith merely depresses the speculum to its first position, tilts the patient's head slightly to the temple side and applies his thumb or finger close to the outer canthus (but not touching the conjunctiva or lid margin), and thus "draws off" the excess of fluid by capillary attraction. In the present description I am endeavoring to tell how Smith does his operation. I take it that the reader wants to know "Smith's method" of doing the entire operation, since it has been claimed by some that he does nothing original or that has not been done by many before his time. The finger capillary sponge, whether good or bad, is one of "Smith's own" tricks, as far as I know. Smith pays the highest respect to the ocular tissues and will not so much as touch the eye with anything that is under the slightest suspicion, even with a cotton pledget that has been handled with fingers that may or may not be clean in a surgical sense. The inner canthus receives no attention other than what is given it by the "flood-gate" douche.

MAKING THE INCISION.

If the right eye is to be operated upon, he stands at the head of the patient and cuts with his right hand, cutting upward toward himself; if the left eye is to be operated upon, he takes his stand to the left of the patient and cuts away upward from himself (Fig. B). He argues that the patient is entitled to the surgeon's best hand; that ambidexterity is spectacular and practiced for effect. His personality spurns anything that looks like affectation; he does what he thinks is right, and claims a just reason for his choice of methods, and that reason is always on the side of the patient's welfare. But he does not insist on doing the section exclusively with the right hand. He says, "Do it any way you like, just so you do it right."

The philosophy of the section Smith advocates is ably exploited in McKechnie's article "On the Incision," read before the Bombay Medical Congress in February, 1909. In brief, it is that the section which is at right angles to the corneal layers throughout the entire line of cut, is the correct one to make. Other points which Smith claims in favor of the section which he makes are: (1) The section being purely corneal, there is no hemorrhage to annoy operator; (2) the section being at right angles to the cornea throughout, there are no thin, knife-like edges to curl, retract or override—the wound apposition is perfect; (3) the best union is primary union, which is only achieved by perfect approximation; (4) there being perfect coaptation of the wound, layer for layer and epithelium for epithelium, there is a minimum degree of astigmatism, and the scar is a mere line which in time can scarcely be seen; (5) the section being mostly completed in a clean forward sweep of the knife, there are no minute ridges and gutters, which always occur with the sawing section; (6) the absence of these gutters and ridges, which could be counted like the saw cuts on a log, favors union by primary healing, thus avoiding interstitial exudation, cellular proliferation to fill vacant places and delayed healing. He maintains that the cleanest possible eye, after the most rigid sterilizing process, will

only remain clean for approximately three days, and that if there is unusual irritation in the wound from ragged or saw-cuts, overlapping and curled edges, unnecessary reaction, to say the least, is the result, and that if the section has been rightly done, according to his observation and experience, in three or four days' time the wound, to all purposes and intents, is sealed and healed, thus safeguarding the eye from secondary disaster. My own observation regarding these points is that Smith's contentions along this line are thoroughly sound. Certainly the healing among his cases is prompt and after-troubles remarkably scarce. Whether due to the nature of the cut or the absence of excessive manipulation through the wound and bruising of its edges, incident to his

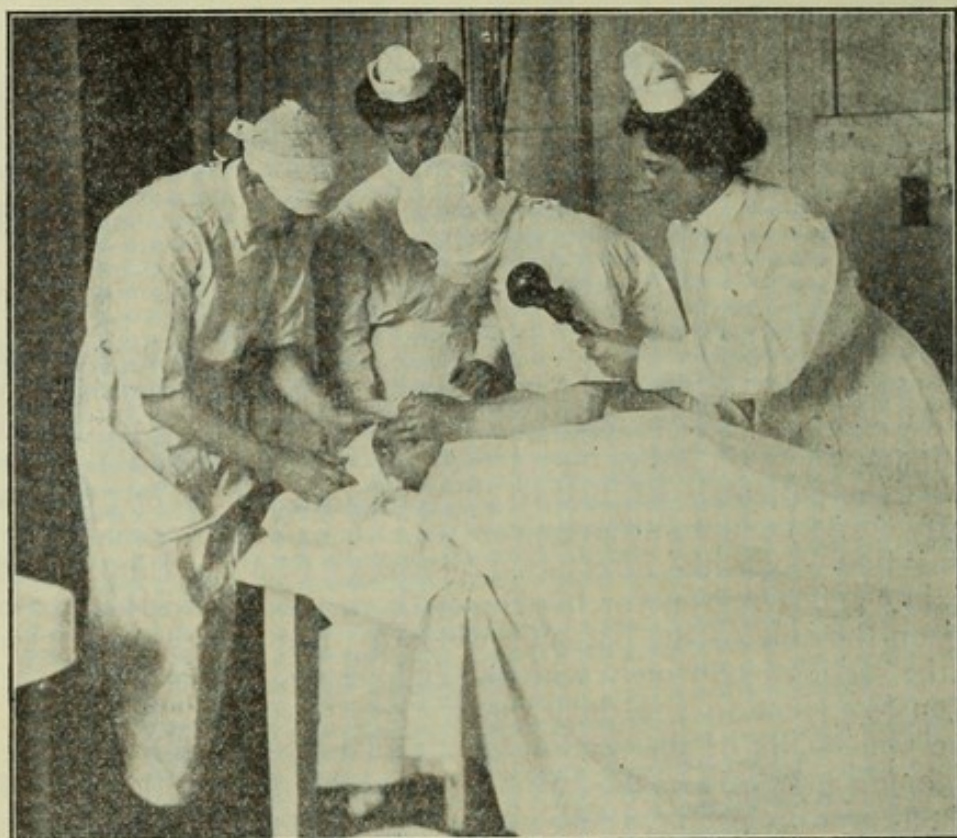


FIG. B.—Operating scene, showing the position the operator assumes in making the incision on the left eye. The left hand steadies the eyeball with the fixation forceps, while the assistant, standing at the head of the patient, retracts the eyebrow with the thumb of the left hand to prevent squeezing.

method of extracting the lens in its capsule, or the total absence of tags of capsule, there being no capsule left in the eye, I cannot state. At any rate, it is remarkable how quickly and well the incision heals in Smith's clinic.

Having turned the patient's head slightly away from the side operated on, and grasped the conjunctiva with the ordinary fixation forceps (without a catch) in the fingers of the left hand (Fig. 6), giving it in most instances a quarter turn to fold the grasped conjunctiva slightly around the grasping end of the forceps, thus affording better anchorage, *he lightly holds the Graefe knife* (narrow, short blade), slightly back of the middle (Figs. 7, 8, 9, 10), letting the handle rest as lightly as a feather between the thumb of his right hand and the tip

of the index finger and side of the tip of the middle finger, resting the tip of his little finger against the temple near or on the zygoma, taking care with the forceps to pull the eye and steady it slightly divergently, or at least in the middle (not the least convergently), and holding the knife so that the *edge will be turned away from the plane of the iris about fifteen to thirty degrees*; in other words, the edge turned in an exact line with the intended cut, he slowly and steadily passes the point through the *limbus* at or near the horizontal meridian of the cornea without raising or lowering the handle, and *employing only finger move-*

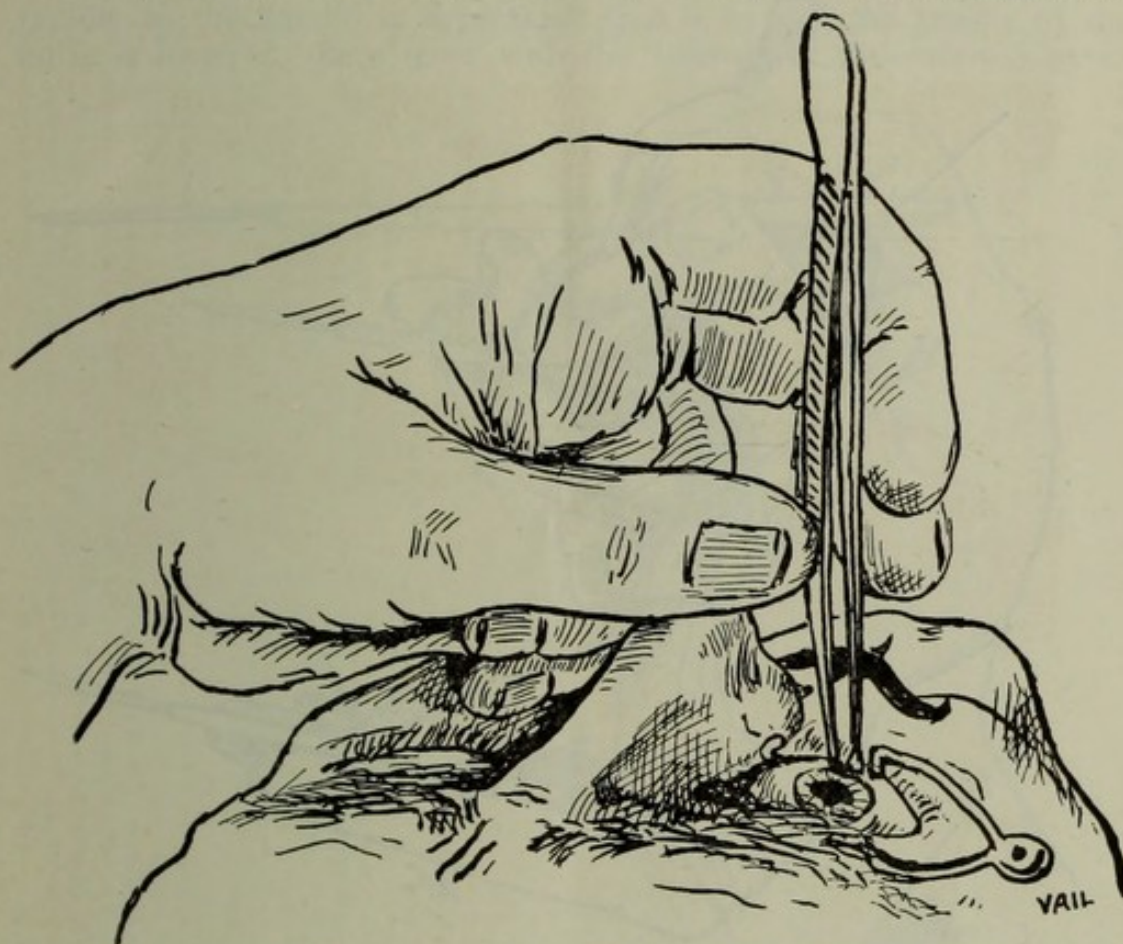


FIG. 6.—Showing the position of the left hand steadying the patient's face, at the same time grasping the conjunctiva below the cornea for sectioning the right eye.

ment, thus passing the point of the knife into the anterior chamber near the angle of the cornea and rather close to the root of the iris, the back of the knife being on a perfect parallel plane with the iris; he then passes the blade across the anterior chamber very slowly, but headed for the exact spot where he intends the point to emerge through the cornea at the limbus, at a place corresponding to the point of entrance (Fig. 12 A). In demonstrating the passage of the knife through the anterior chamber and the selection of the point of emergence, he often pauses to allow you to note exactly how it is done, and calls your attention to the edge of the knife, which is directed forward from fifteen to thirty degrees, a feat that in many hands would be accompanied with a certain leakage of aqueous and riding forward of the iris, but by his method no aqueous leaks out, and, as I just said, he

will often pause for a considerable time while demonstrating the relative position of things. The reason why the aqueous does not run out for Smith is because of two things: (1) The knife has been used as a *puncturing instrument*, not a cutting one; (2) the extreme lightness with which he holds the knife does not permit either normal or abnormal tremor to be conveyed to the blade of the instrument, and as the knife blade exactly fills the puncture it has made, and as the knife is

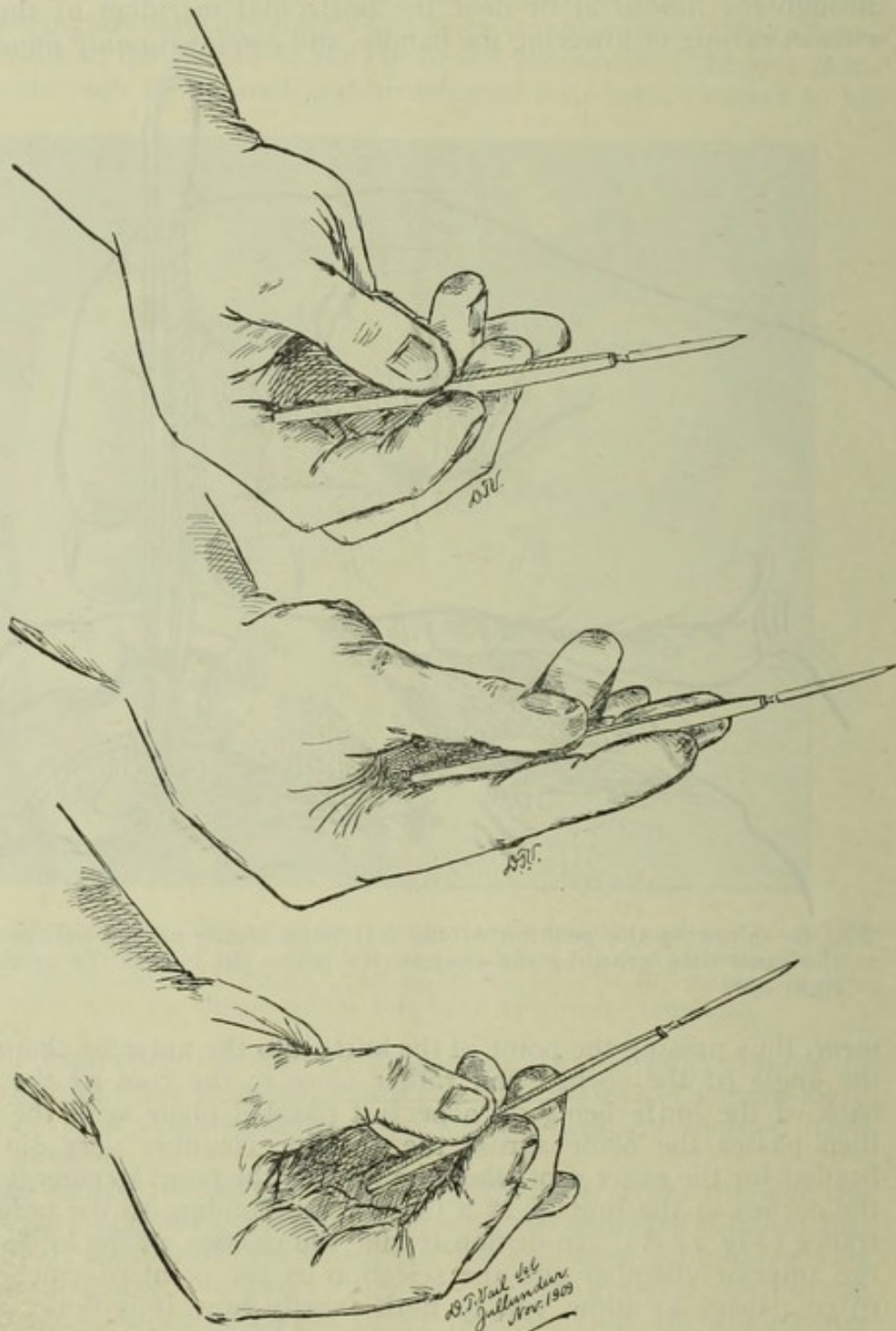


FIG. 7.—Posed by Smith to illustrate how he holds the knife in doing the section of the right eye. 1, Knife is held very lightly. 2, Fingers are straightened out when section is half made. 3, End of handle disappears in the hollow of his hand as section is completed. No arm movement is used.

not converted into a lever at any stage of the transfixion, no aqueous can escape. If you hold your knife "with a grip like a crowbar," as Smith says, you cannot make the puncture and carry the blade across to the other side, *no matter how steady you are*, without escape of more or less aqueous.

As soon as the point of the knife peeps through the limbus at its emergent point, and one can always tell that it is about to emerge, he naturally grasps the handle a little tighter, and the real section begins without a moment's delay (Fig 12 B). The blade is not advanced as rapidly as the handle is *depressed*; that is to say, the handle of the knife is lowered like a lever with the fulcrum at the *entering* punc-

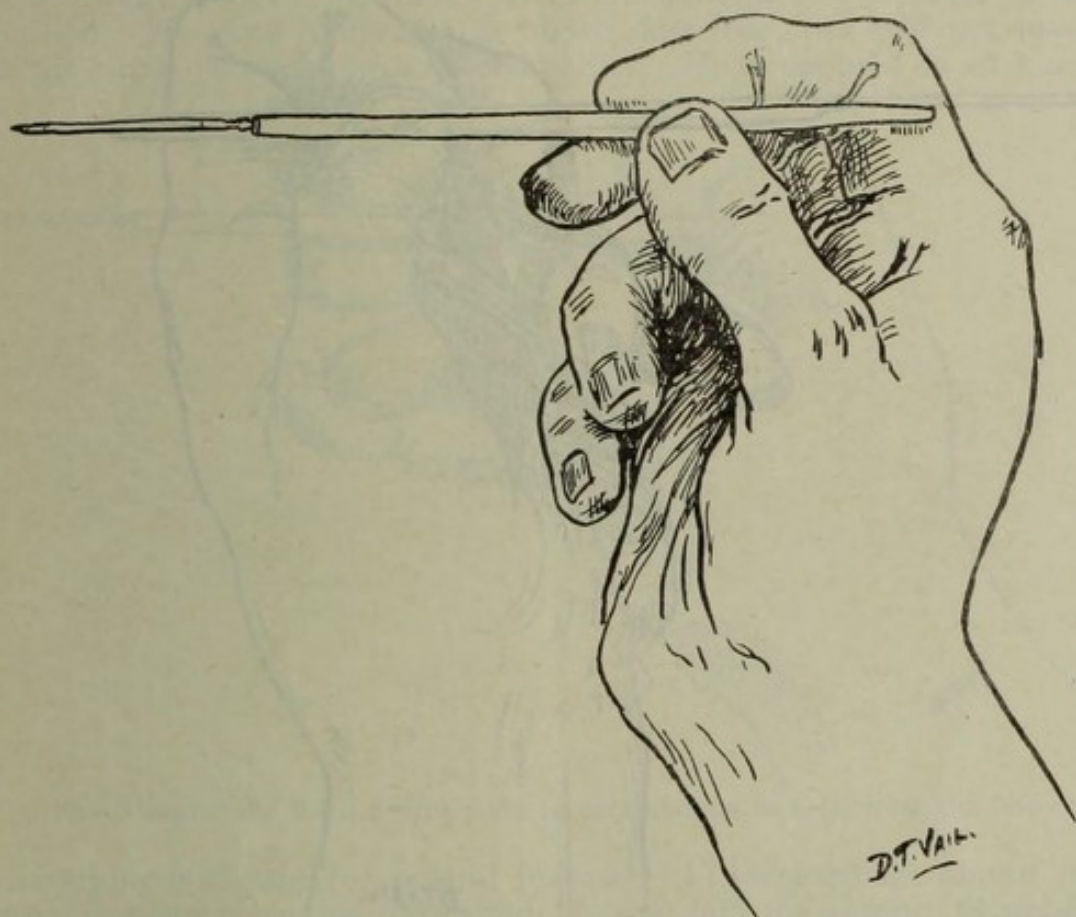


FIG. 8.—Showing the first position of the fingers in sectioning the left eye, grasping the knife handle lightly a little back of its middle.

ture, and the pointed end of the blade is made to ascend, at the same time being slightly advanced. Thus the cutting of the cornea is on the nasal side nearly to the summit before the temple side of the cut is begun (Fig. 12 C). The section may now be completed with a return stroke, cutting the temple side by raising the handle as the blade is withdrawn (Fig. 12 D). During the finishing of the section the cutting edge of the knife is turned nearly at right angles to the cornea, carefully avoiding conjunctival flaps (Fig. 12 D). The only part where the conjunctiva is cut at all is at the point of entrance and emergence of the knife. The summit of the cut is about 2 or 3 mm. below the limbus above, well in the corneal tissue, and often just opposite the halfway line between the pupil margin and the periphery of the iris

above. The line of cut represents a perfect arch or curve (Fig. 11), being somewhat less curved than the corneal rim. As the point of the knife is advanced and raised in the act of cutting the nasal half of the incision, it is directed *over the bridge of the nose* at the lower place corresponding to the suture between the nasal and frontal bones, thus permitting the blade to be driven home to its shank without the point encountering any opposition against the side of the nose. Smith prefers a short, very thin and very sharp knife, and will in perhaps one-third of the cases make the entire incision with one forward stroke of the knife (Fig. 13 A). In about one-third of the cases, owing to the

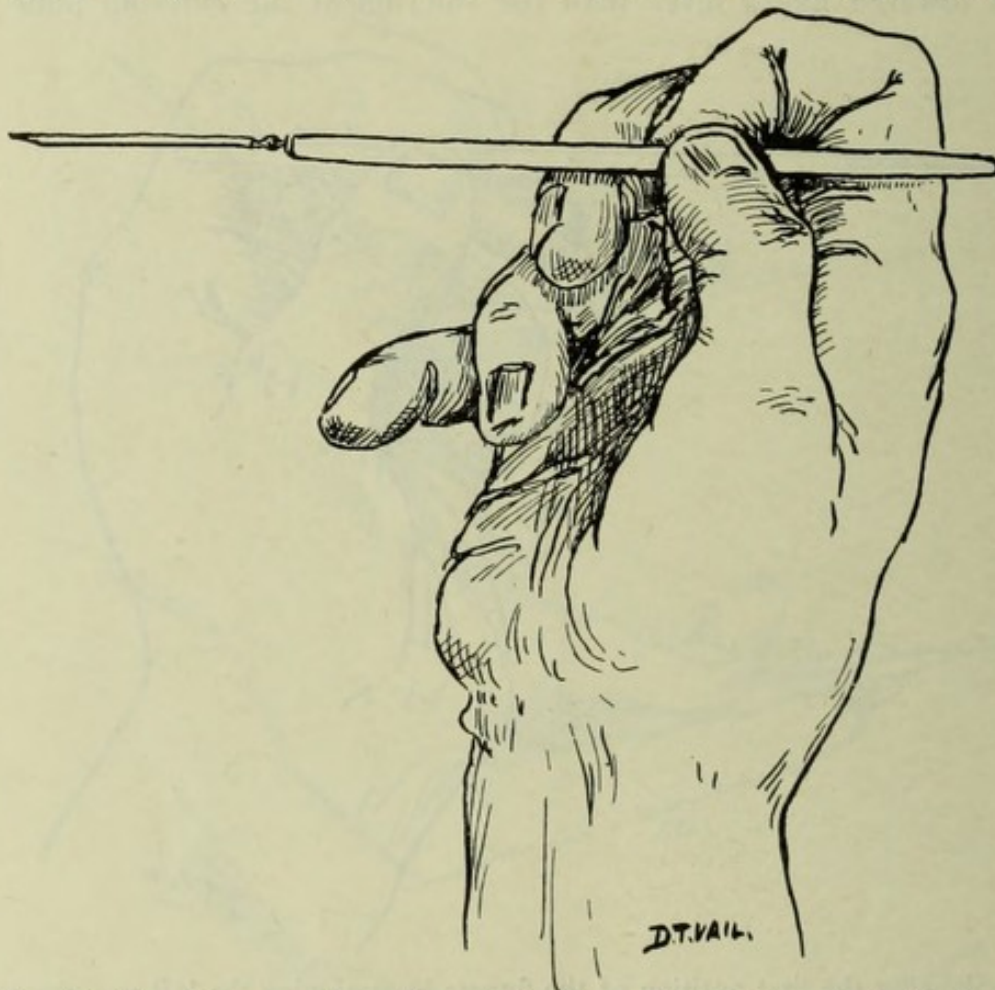


FIG. 9.—Showing second position of the fingers in holding the knife for sectioning the left eye. Edge of knife is upward and turned away from the operator, who stands to patient's left. The section is made by finger movements only.

knife not being of exquisite sharpness, or because of a deep-set eye or abnormally high bridge, or for other reasons, only about one-third of the incision can be made on the forward stroke, and the remaining two-thirds of the incision is completed by the knife's heel *while the handle is being raised* (Fig. 13 B). In a few cases of unusually deep-set eyes and small palpebral fissures, the point of the knife cannot be advanced much beyond its emerging point, and in these cases nearly the entire incision is made (just as effectively) by raising the handle of the knife and using the blade as a lever of the second class with the fulcrum at the counter-puncture (Fig. 13 B). It is a pleasing and beautiful thing

to see with what ease these otherwise troublesome cases are thus sectioned. At no time and in no case will there be a sawing cut. The cornea is not sawed through; it is cut with a clean incision, as you would cut a loaf of butter with a sharp knife. Thus there are no minute ridges recording the number of strokes backwards and forwards, such as are made when sectioning as I formerly did in my own practice and have seen done in many clinics. This incision I have dwelt on at length and minutely, as I believe that it is of paramount importance in insuring perfect coaptation, rapid healing and a minimum of traumatism. The fate of an eye may depend on the smoothness of the cut alone, and if so, Smith's method of cutting the cornea, which I have since learned is a Panas' incision, is without doubt the best. Smith does not lay much stress on the nature or location of the incision. He does it himself as above described, but will not insist on his pupils doing it one way or another. He is opposed to all kinds

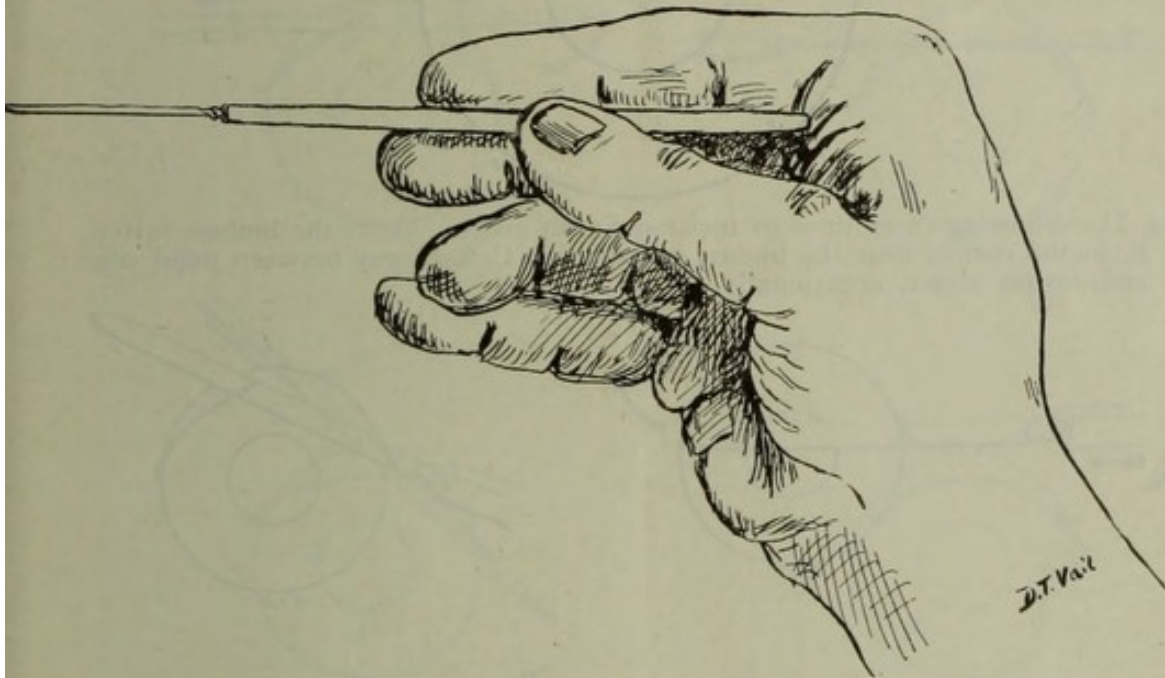


FIG. 10.—Showing the third position the fingers assume in sectioning the left eye.

of conjunctival flaps for several reasons: (1) Hemorrhage almost invariably takes place, the blood finds its way into the anterior chamber, thus annoying the operator, not to speak of the manipulations, irrigations and instrumentation it entails; (2) inversion of the flap in the anterior chamber or lips of the wound, which is objectionable at any stage of the operation, for it carries mucus, dead cells and tags into the wound, and necessitates manipulation and instrumentation, not to speak of the danger of infection of mild or severe grades to delay healing; (3) greater astigmatism results as compared with the purely corneal section he makes; (4) the section is too far back for the primary safety of the eye; vitreous loss is more imminent at every stage of the operation where the section is well back in the endeavor to make a flap; (5) chronic irido-cyclitis and more or less permanent disaster occurs among some cases where limbus incisions and conjunctival flaps are made, but in the truly corneal section that he advocates such disaster is most rare.

Aside from the above arguments and others of like nature, the fact exists that in delivery of the lens in its capsule an apron of conjunctiva hanging to the upper lip of the cornea after it is cut bothers the operator and interferes with his manipulations. It is of paramount importance *not to make the section too small in any cataract operation,*

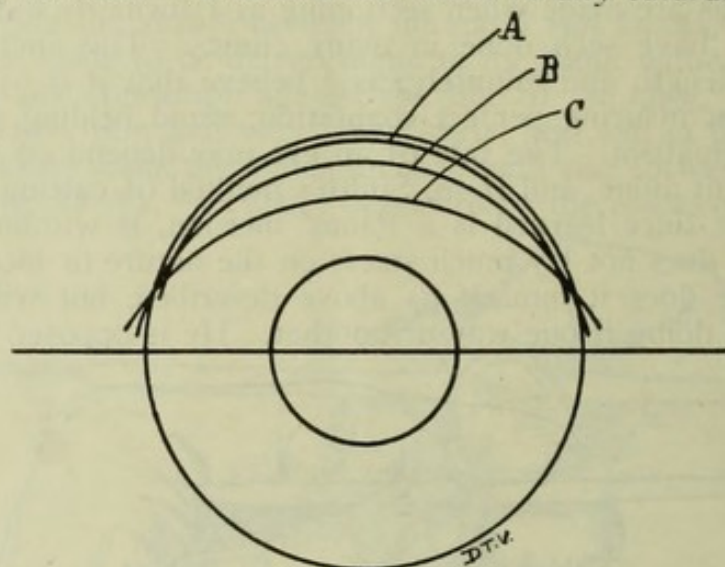


FIG. 11.—Showing three lines of incision Smith makes. A, at the limbus, rarely; B, in the cornea near the limbus, commonly; C, half way between pupil edge and cornea above, occasionally.

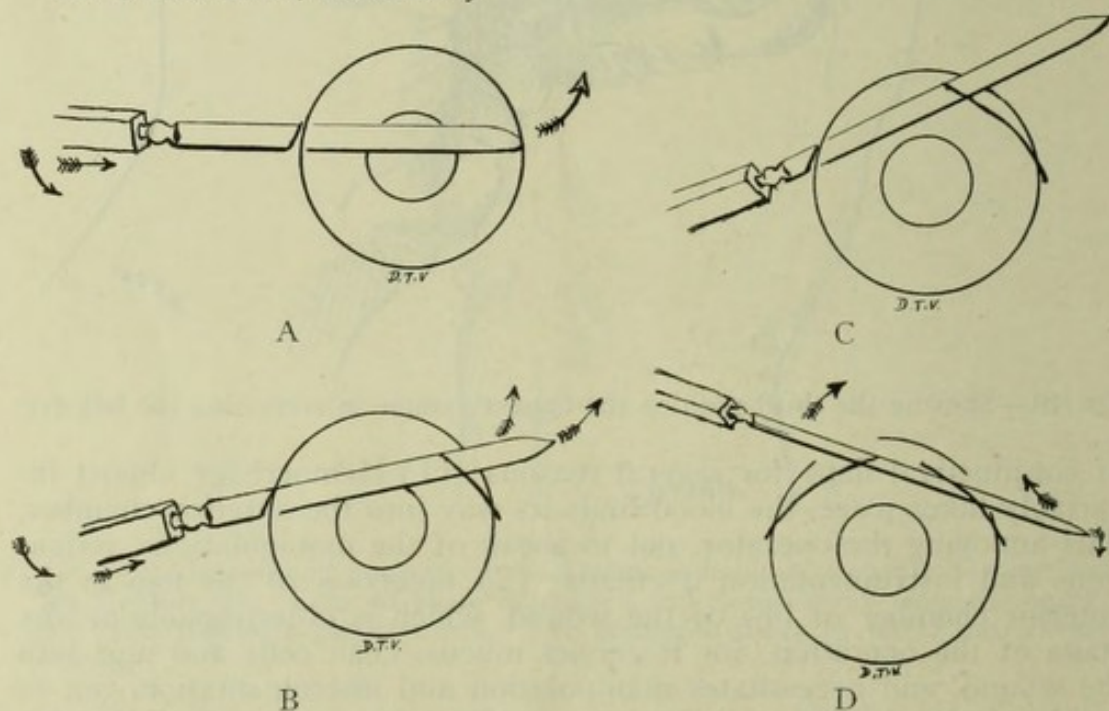


FIG. 12.—A, showing points of entrance and emergence; B, cutting on the nasal side; C, cutting to the summit of the cornea, blade in to the hilt; D, finishing incision by raising the handle on the return stroke.

and since in the radical extraction the nucleus, cortex and capsule are all extracted *in toto* and *en masse*, the incision *should be full sized*. If it is small, a dextrous operator, who knows all the arts and tricks of accouching the lens in its capsule, will perhaps be able to succeed in most instances anyway, but there is employed more manipulation, more

traumatism and delay than is needed if the section be large enough. A section too large is better than one too small, but the objections of slightly increased danger of vitreous escape and the increased care necessary in the after-treatment and nursing are to be avoided if possible. These cases seem to go on to healing and recovery quite as well as the ones where the section was of smaller size. The size of the incision is not indicated by the line of the cut that you see on the cornea, but is the size of the opening on the *inside, concave surface* of the cornea. The proper size, according to Smith, is slightly less than one-half as measured by noting the half-circle of pupil below the blade of the knife when it is passing across the anterior chamber and before the point emerges. Always look to the pupil before making the counter-puncture to see that you are making the cut neither too large nor too

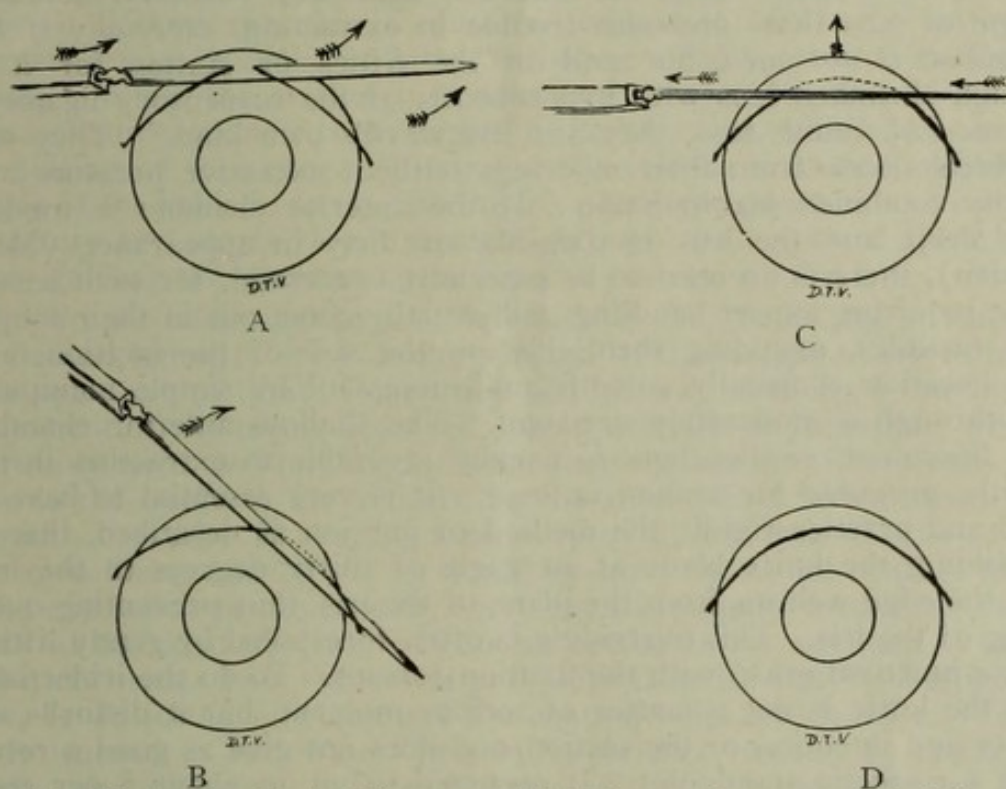


FIG. 13.—Illustrating the incision as modified in certain cases. A, incision completed in one forward stroke; B, incision made by the heel of the knife blade in case of deep-set eyes, by raising the handle to a complete quadrant swing; C, incision in case of riding over the knife blade of the iris; edge well forward; note the indications the arrows make; D, the result of all kinds if technique employed is the same.

small. It will be remembered that, although the point of entrance and emergence of the knife in the cornea is at the horizontal meridian, the cut itself is considerably within the cornea; thus the section is not so large as if the cut had been made at the periphery. Cataracts differ enormously in size. In my collection of lenses I find specimens very thin, small and shrunk, so they will not measure over 7 mm. in diameter and 2 or 3 mm. in thickness, and many which are very large and nearly globular, measuring 9 mm. in diameter and 6 or 7 mm. in thickness. These cataracts should be diagnosed while still in the eye, so that some notion of the size of the incision to make may be previously had. The diagnosis of the kind of cataract is made by taking into consid-

eration (a) the age of the cataract; a *thoroughly ripe* cataract that has existed in a completely ripe state longer than two years is apt to be shrunken; (b) the color of the cataract, whether blank white (almost chalky), homogeneous-white (soap-like), flocculent white or whitish. The chalk-white lens is apt to be quite small, the homogeneous (Morgagnian) may be larger and globular, but will pass like an hour-glass through a smaller incision than some other kinds. The flocculent white is always full-sized (tumescent), and the cataract with some live cortex is the normal-sized lens or the sclerosed small-sized lens. In effect the blank-white, small, shrunken lens is to be likened to the flat discoid pearl; the homogeneous to the round white onyx; the flocculent to the opal, and the immature to the cloudy amber. (c) *The depth of the anterior chamber*, taking into consideration the above colorings and effects. The blank-white, old cataract, with *deep chamber*, indicates a type of lens that forebodes trouble in extracting, *especially if the individual is not aged*, but still in the fifties or sixties, for it is a tough shrunken lens with hyperfibrosis of the suspensory ligament, and, as Col. Smith says, they are "the devil's own kind." They will not break loose from their moorings without excessive pressure and usually combined manipulation. If the anterior chamber is moderately deep, and the lens is soap-like or dirty in appearance (Morgagnian), there is no need to be especially concerned, for such lenses, while requiring expert handling, will usually come out in their toughened capsules, moulding themselves to the size of the incision, and the operation is usually smooth and successful by simple manipulation through a moderately-sized cut. The shallow anterior chamber with flocculent, swollen lens, is usually favorable to extraction in the capsule, *provided the section is large*. It is very essential to have in mind and practice rigidly the method of incision as described, that is, by holding the knife blade at an angle of thirty degrees to the iris, with the edge well up from the plane of the iris, thus preventing overriding of the iris. This overriding is often forestalled by gently lifting the conjunctival grasp with the fixation forceps. To do the iridectomy with the knife is not a matter of serious moment, but it disturbs the beauty and intention of the section, and does not give as good a result from a cosmetic standpoint. It occurred to me in about 5 per cent. of my own cases done at Jullundur, and is sometimes unavoidable by any method that I know of. The normal anterior chamber with immature cataract calls for a full-sized section, neither larger nor smaller than our rule calls for.

During the section, the assistant, who stands to the left of the patient's head if the right eye, or at the head of the patient if the left is being operated upon, must always hold up the brow firmly but without causing pain, by his thumb or fingers, and with the palm of his hand on the patient's forehead, thus keeping the corrugator under strict control to prevent disaster from squeezing. In three cases out of over a thousand done at Jullundur during my stay there, the patients made a sudden squeezing effort just as the section was completed, and the lens rolled out of the eye accompanied with a threatening show of vitreous. In two of these cases no vitreous escaped, but in one some was lost. This is always an accident that takes the operator by surprise, but if the brow is properly held by the assistant no harm is usu-

ally done. In such cases one has to forego the iridectomy and be satisfied with replacing the updrawn pupil and curled iris the best he can. The iris repositor can be used if the blunt hook is inserted, and the eyelid held in the manner soon to be described. An operator can usually tell when a squeezing effort is about to be made, by a certain drawn expression of the face, and in such cases it can be avoided if he will let go with his fixation forceps a moment *before* completing the section and finish the cut very slowly and deliberately with the edge of the knife, cutting out at right angles to the cornea, the assistant attending to the brow in the meantime.

There are those who have said that Smith's method of operating contributes nothing new to the surgery for cataract, that all his steps are those which have been done by various operators from time immemorial. I think that this is an untrue statement, for, so far as my observation goes, there is nothing "orthodox" that he does from start to finish. While the section just described is what Smith himself calls the LeBrun section, it is performed in Smith's way, without any sawing or slitting of the cornea. Owing to the oblique manner he holds the blade of the knife in relation to the iris plane, the puncture and counter-puncture are nearly if not straight through the layers of the cornea, thus gaining the greatest space for the passage of the lens.

I do not wish to pose as a defender of Col. Smith; he is well able to defend himself; nor is it the purpose of this article to try to proselyte operators to Smith's operation and his way of doing it, but a mere statement of the points observed during my visit at Jullundur, which I carefully write and publish for what they are worth. Every man must decide the question for himself, but he should first be informed what Smith's operation is like, the true story of it, and then dispose of it to his own liking and belief. I would be sorry to see all oculists undertake extraction in the capsule, sorry for the patients as well as for the bulk of the operators, for it is not an operation for any man to undertake, no matter how successful and skillful he is, until he has learned *how to do it* and how to meet the contingencies which arise. This is only learned in two ways—first by experience, second by taking lessons. Smith learned it by experience afforded by thousands of cases, having the one idea in mind always to do it in the best and safest way. Some have done five or six so-called "Smith's operations," and reported their results; others have done forty or more, and the results which they got by thus "trying" the operation justify their adverse attitude toward it. The operation is not jugglery that has to be learned like tricks done by sleight of hand, but there are acts and methods to learn entirely different from those employed in the old method, and which any experienced operator, who has good surgical instinct combined with good co-ordination of touch, good judgment and good eyesight, may learn after he has done many under the guidance and teaching of a good instructor. I am sure none of us will spurn "taking instruction" to achieve any surgical operation which is worth the learning, but it is hard to get the present generation of experienced men to undertake such instruction unless it can be shown by actual results that the operation is worthy of a high place as a surgical procedure. This attitude is perfectly just and well taken, and thus Smith's opera-

tion is still on trial. Personally, I believe in it, but I had to see Smith do it in his own clinic before I was convinced.

THE IRIDECTOMY.

The *iridectomy* is the next step of the operation. The operator holds the iris forceps (of the design described in my article on "Instruments Used," see *Ohio State Medical Journal*, January, 1910),

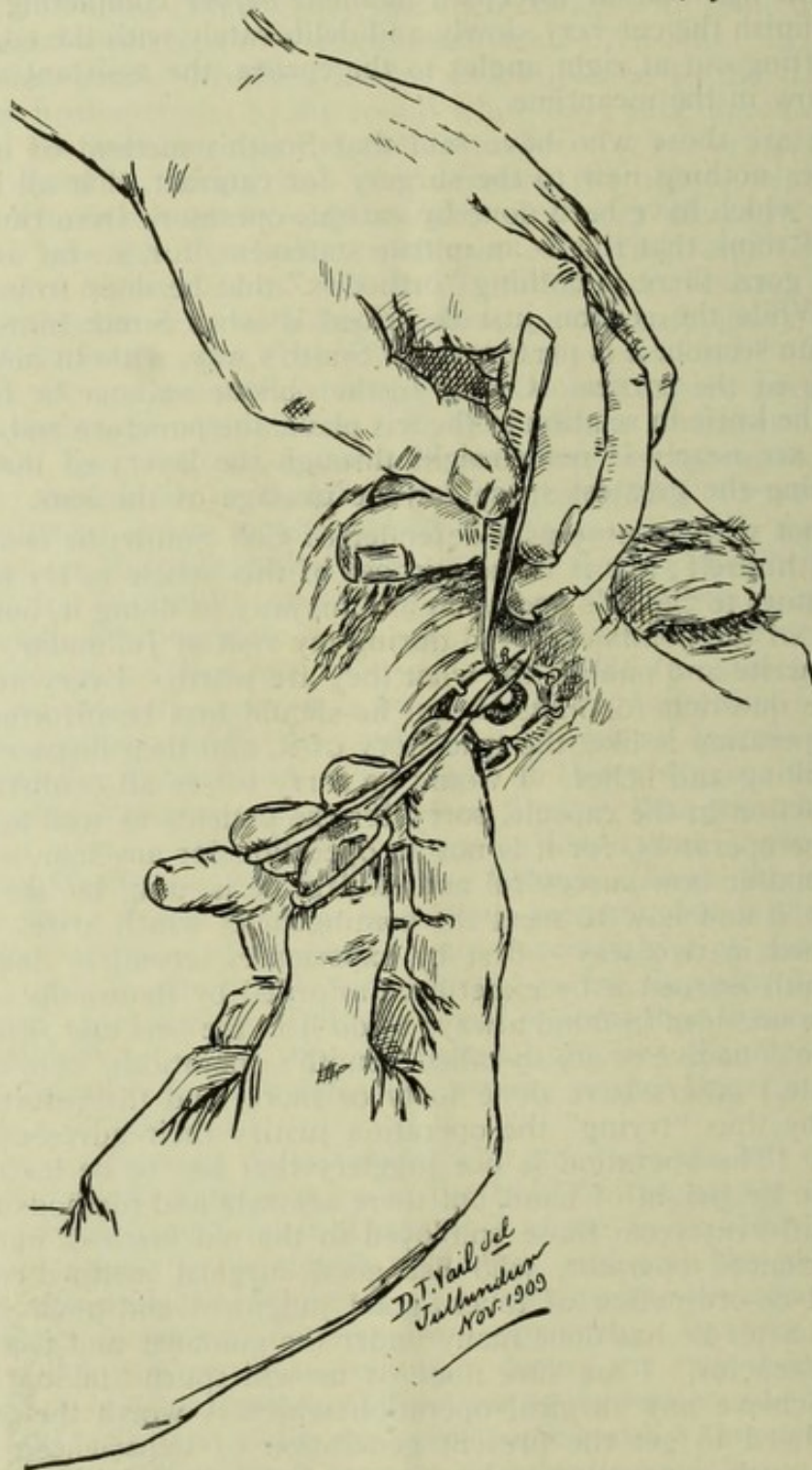

FIG. 14.—Posed by Smith to illustrate his method of holding the instruments in doing the iridectomy. Note how the brow is held by the last two fingers of the left hand.

in a *vertical manner* between the thumb and first two fingers of the left hand, the remaining two fingers *being used to hold up the brow* to overcome contraction of the corrugator supercilii (Fig. 14), the grasping ends of the forceps being turned exactly to the right or *parallel to the line of incision*. The assistant always holds the eye down and steadies it in a favorable position by means of the fixation forceps held in the left hand (Fig. C, p. 26). This is necessary in pursuing Smith's technique, which leaves out any instruction or request to the patient, and as the patient naturally directs his eye straight ahead or upwards, the assistant will take his hold on the conjunctiva where the operator had in doing the section, and will gently and slowly rotate the eye downward without pushing against it in the slightest. The operator holds the scissors (of ordinary pattern, curved on the flat) in his right hand, with the very tip of his thumb in one ring of the scissors and the tip of his third or ring finger in the other ring of the

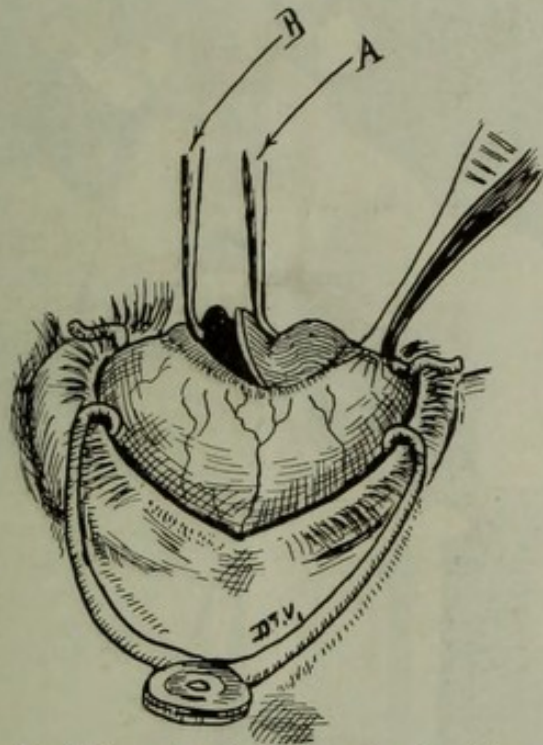


FIG. 15.—Illustrating Smith's method of grasping the iris to perform iridectomy. B, A, blades of the iris forceps; B held stationary, A gliding upward over the depressed cornea to cause iris to present in the wound, where it is grasped and cut off. The assistant holds the eye with fixation forceps.

scissors, the middle finger resting on the shank near the ring, and the forefinger well down near the rivet of the scissors to steady it and to control the action of the blades in cutting. The palm of the hand holding the scissors is turned upwards like a cup (Fig. 14), and the closed points of the scissors are held close to the incision, while the little finger is resting on the zygoma or temple if it is in the right eye, but if it is in the left eye the scissors are rested on the bridge of the nose curved side up.

The operator being in perfect readiness in regard to all these things, opens the iris forceps and places the end nearer him just within the edge of the sclerotic side of the wound or against the upper edge of the cut and farther end of the forceps well down on the cornea to a

point corresponding to the upper margin of the pupil, the forceps being held exactly vertically to the iris (Fig. 15). The upper blade of the forceps is made to remain in its position while the lower blade is closed toward it, at the same time slightly depressing the cornea and causing the iris to bulge upward in the wound, where it is grasped, withdrawn with a slight turn of the end of the forceps to point toward the patient's feet and cut off. In the act of advancing the scissors to do the iridectomy, the blades are opened *quite widely*, and the cutting is done very slowly and deliberately, not with the point of the scissors, but with the cutting blades well back from the point. As the scissors are made to cut, they are held in such a way that the neatest and closest apposition of the cutting edges takes place, thus avoiding "chewing" or bruising the iris in the cutting and insuring a clean cut. The cutting

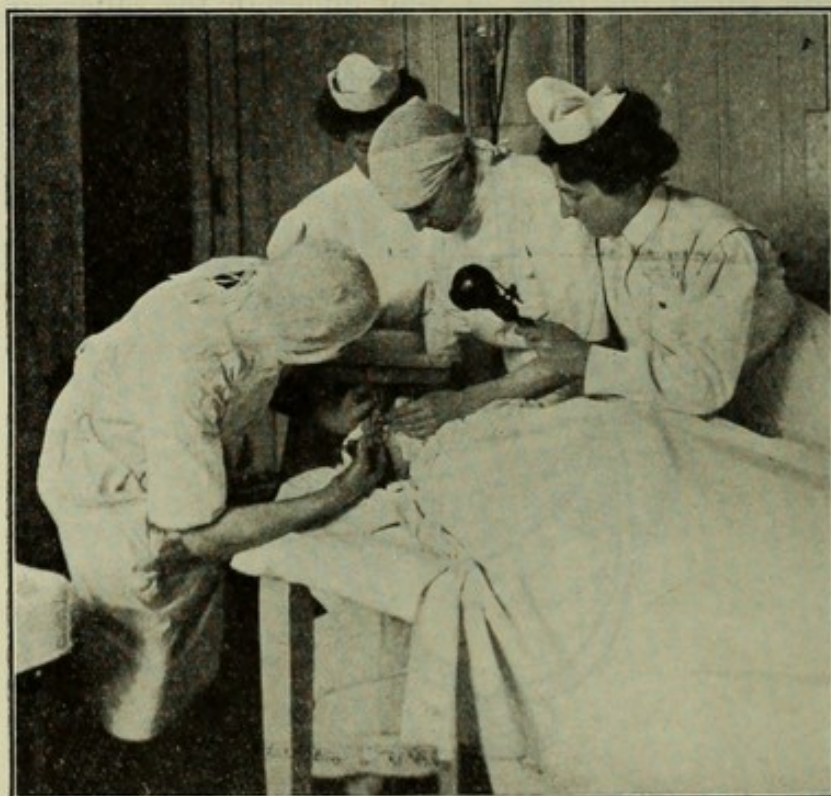

FIG. C.—Operating scene, illustrating the iridectomy step of the operation. The assistant steadies the eye with the fixation forceps. The operator holds the brow with the last two fingers of his left hand, at the same time having perfect control of the iris forceps. The right hand holds the scissors according to Smith's method.

is done in a line with the corneal incision, care being taken *not to do a large iridectomy*. Very often when the eye is pulled down, the iris bulges from the lips of the wound, and it is then picked up carefully and incised in the manner described.

The advantages claimed for this method of doing the iridectomy are: (1) The ends of the forceps are not introduced into the aqueous chamber; (2) the ends of the forceps as they close to grasp the iris are directed toward the space above the lens, thus safeguarding against pinching or wounding the capsule. In the usual methods the blades of the forceps are introduced into the eye with the ends directed

toward the feet of the patient, and the iris is pinched up by pressing the forceps backwards with the lens for a background, the iris lying between, thus jeopardizing the capsule, which in radical extraction is extremely important not to wound; (3) the method of holding the forceps permits the operator to have and to keep full control of the brow with his ring and little finger, so that the patient cannot frown or squeeze up his eye, a matter of great importance.

Smith will not use DeWecker's, Liebrecht's or any of the other specially devised scissors, not because he does not approve of them—he does approve of them—but because of their expense and the cost of keeping them in good repair.

He performs during the spring and fall seasons on an average perhaps twenty-five cataracts a day, or one hundred and seventy-five a

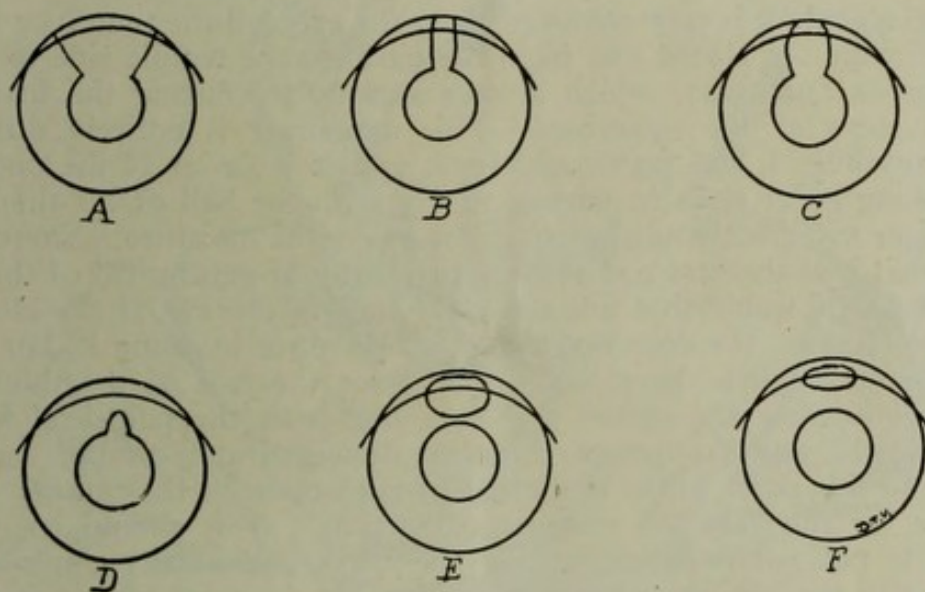


FIG. 16.—Showing different results in attempting iridectomy. A, too wide; B, too narrow; C, correct; D, incomplete, the sphincter alone has been cut; E, a large buttonhole with a bridge of tissue at the pupil margin—no heed is taken of this; F, small buttonhole done intentionally for the purpose of leaving a round pupil.

week, and the cost of maintaining perfectly-cutting DeWecker's scissors would be an item in itself. Moreover, by his method of holding the scissors, they may become exceedingly dull and very rickety, but still will cut with perfect success. The scissors with which he operated when I was there had been used perhaps thousands of times for cataracts and iridectomies; at any rate, they were positively so loose in the joint that by reversing the cutting act the blades could be made to gape at least a quarter of an inch, and still when used as above described they cut well in his hands. He states that if for any reason DeWecker's scissors should "act up" and not cut, there is no chance for the operator to overcome the defect by any act or trick of his own, but that he would simply have to be satisfied with chewing off the iris the best he could, whereas with his dull and rickety scissors, held and used in the manner he does, the operator has complete compensation for the dullness and looseness of his scissors in the manner he uses them, thus insuring a good cut at all times.

In perhaps one-third of the cases it was impossible to compel the iris to come up in the wound by his method of grasping with the iris forceps, and after two or three unsuccessful attempts he would then go in the wound with the forceps and grasp the iris in the usual way. In one of my own cases I demonstrated the wisdom of his method, for on introducing the forceps within the eye, I pinched the capsule and tore it very slightly, thus rendering extracting in the capsule in that case impossible. The lens was delivered with the capsule left behind, and it was necessary to introduce forceps within the eye after delivery to secure the capsule, a maneuver which in that case was successful just the same, but every additional step or manipulation adds that much greater risk to the success of the operation.

PREPARATIONS FOR THE NEXT STEP.

The speculum is now removed from the eye and the thumb or finger used to wipe the closed eye from the nasal to the temple side to rid it of aqueous and tears, which always accumulate during the first and second steps of the operation. This maneuver is entirely different from anything I had previously seen, and it looks as if the operator was taking great risks in wiping an eye with the ball of his thumb or forefinger sufficiently hard to strip the eye of its moisture. Smith contends that it is the best and most natural way of getting rid of the several drops of water that are always found in the eye at the close of the iridectomy. He does not use much pressure in doing it, but sufficient to accomplish the result. He passes the ball of the thumb or forefinger across the closed eye in a line with the palpebral fissure quite slowly, and the moisture is thus delivered at the outer canthus.

Up to this point in the operation of extraction of the cataract in its capsule, or the "radical cataract extraction," as it should be called, Smith is not particular regarding the ways and means employed to accomplish the various steps. He states, "It does not matter so much how you do the incision and the iridectomy, just so you do them well;" although he maintains that the methods above described, the results of years of experience and much thought, are the very best ones. From this point on he insists that the extraction must be accomplished according to set rules and routine conduct, strictly according to the method he has found and proven to be the best. Not a single principle or rule must be violated.

The following are a few of the rules laid down which must be followed to insure success from this time on to the completion of the operation:

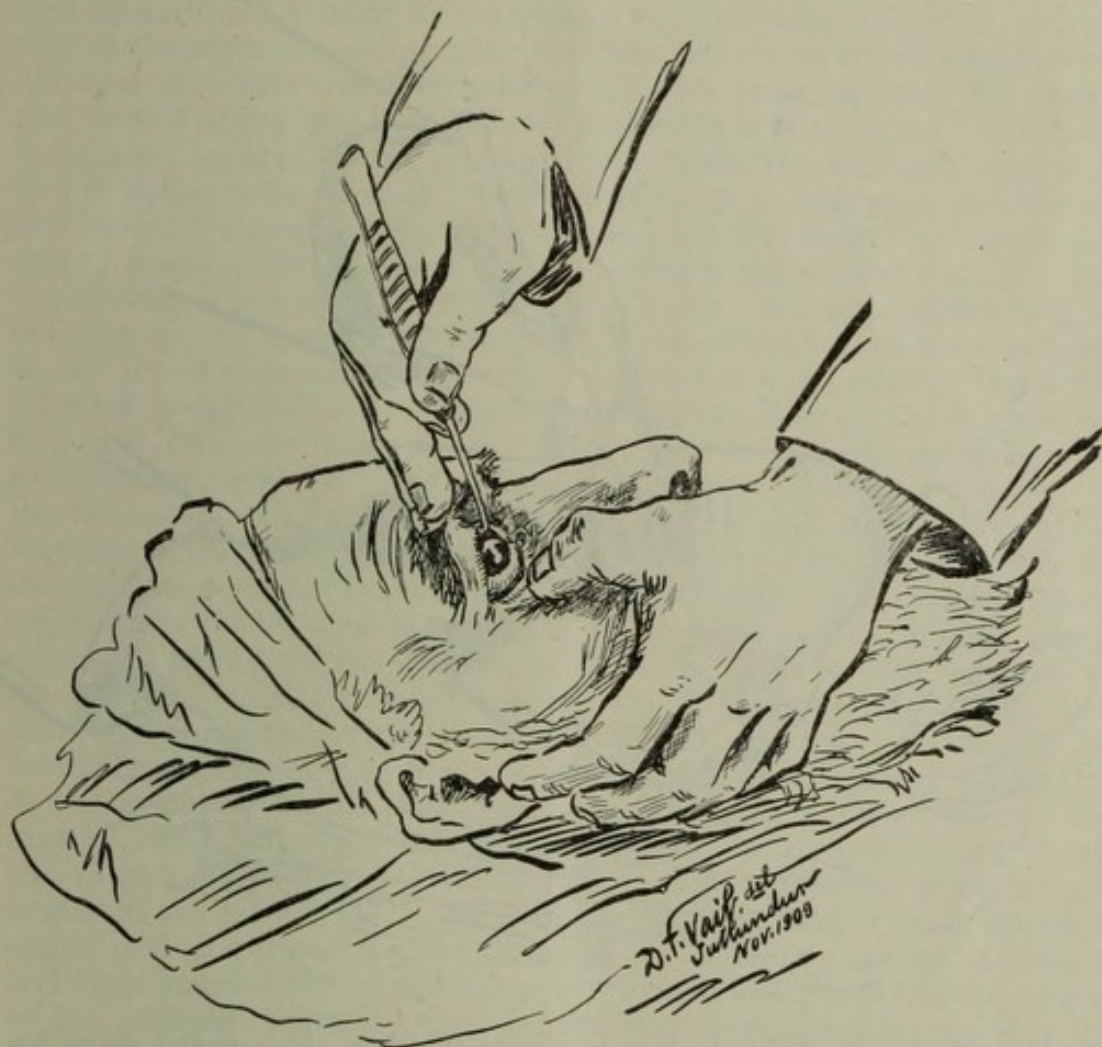
1. Do not touch the eye with an instrument which is not above suspicion as regards its being absolutely sterile; if the working end of the instrument touches anything by accident, or if it is accidentally held where the breath of the patient's nostrils will blow across it, it is at once to be cast aside as being dangerous.

2. Do not use the same instrument over again without resterilizing especially if the wound is to be entered.

3. Do not begin to express the lens until the assistant has proper control of the eyelid and brow (soon to be described).

4. Stand in proper relation to your field, so that you will have a perfect view of the wound and the fornix. In order to do this, one has

5. Do not say a word to the patient at any time as long as he is



quiet, and attend strictly to your own business. The assistant should know what to do without instruction.

7. The assistant must watch his part of the performance and just the moment that vitreous shows a disposition to present, shift his lines

of traction in the proper way to prevent any possible weight of cul-de-sac or lids against the eyeball. There is a way to do this (Fig. 18), and it is very effective in favoring the suctioning or gravitation back of the vitreous in such cases of imminent loss, where it looks as if a large mass of vitreous would surely escape. These cases were fortunately of rare occurrence, but sufficiently frequent to cause the opera-

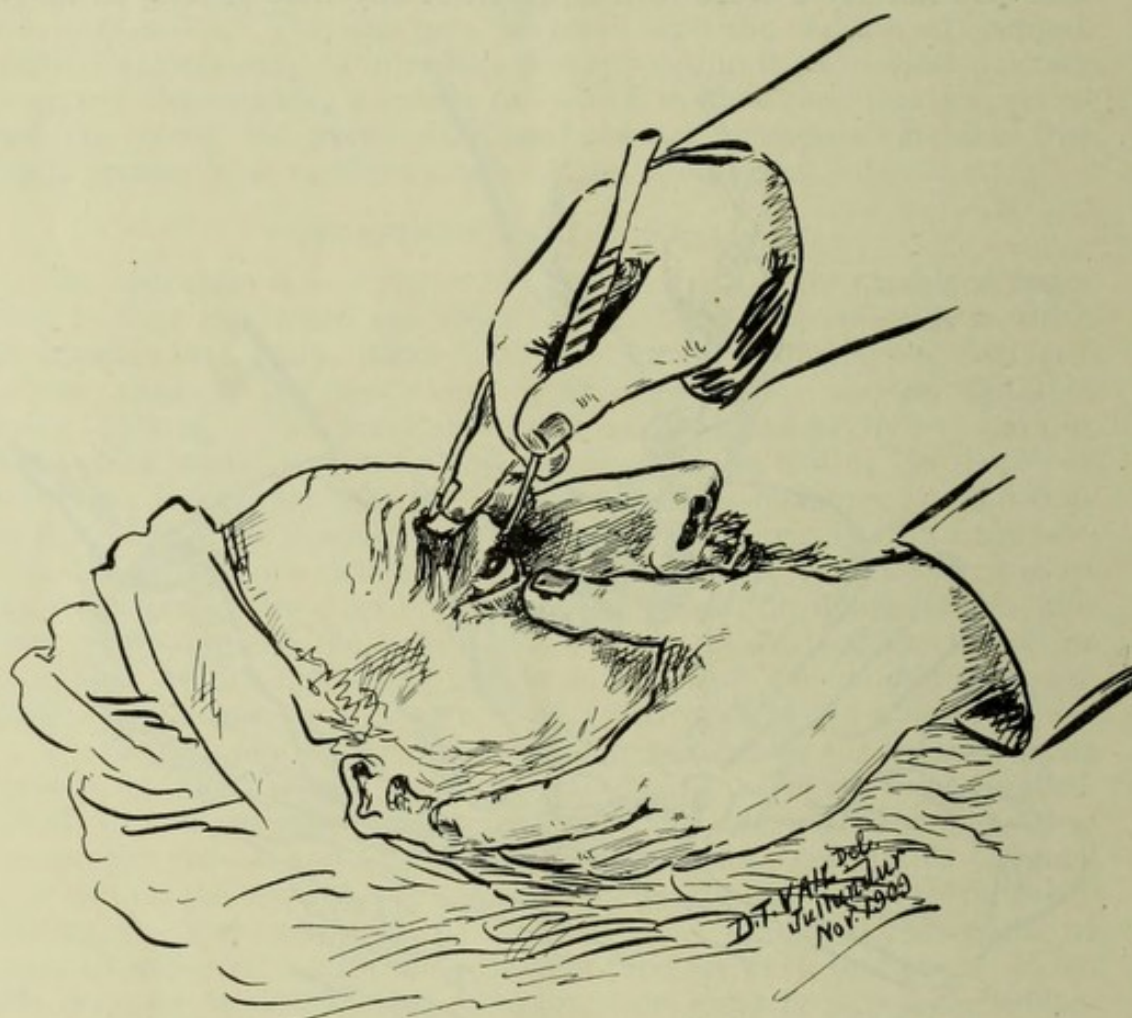


FIG. 18.—Companion sketch to Fig. 17, illustrating how the assistant shifts his position in case of vitreous loss actual or imminent. The proximal end of the lid hook is shifted toward the patient's feet, while the hook end is more forcibly holding up the tissues of the cul-de-sac. The thumb of the left hand is straightened out to afford room for the operator to continue.

tor and assistant to keep the possibility in mind in *any case*, and be prepared to act concertedly to thwart any imminent disaster that may threaten.

THE ASSISTANT.

The assistant, standing in his place to the left of the patient (either eye), holds the lid hook in a vertical manner in his right hand, with the thumb on the flat side of the handle near the junction of the handle to the shank, the curved end being directed away from him. The fingers assume their natural positions on the other side of the handle and shank, as shown in the accompanying sketch (Fig. 17), the forefinger being rather straight in its grasp and the remaining

fingers straightened out and low on the shank or obliquely across the shank. The thumb nail thus faces the patient's feet and the elbow is held high (Fig. E). The assistant has a good view of his own field of labor, since he is on the left side of the operator and patient and can see and watch every move in the field of operation. The last two fingers (ring and little fingers) are straightened out perfectly straight and stiff, their tips caught up under the hairy eyebrow and lifting it well up on the forehead to overpower any frowning effort or contraction of the corrugator supercilii. Let any one try to frown and squeeze his own eye while forcibly holding his own brow up with his finger, and he will appreciate how utterly impossible it is to do so. The brow being now secured by the assistant, who holds the lid hook somewhat like a writer who, writing "back hand" with a stub pen, would hold his pen if his finger nails would glide over the paper, he directs his pressure away from himself and up towards the patient's scalp. The lower lid is depressed with the thumb of his left hand, affording an opening for the operator to proceed with the blunt end of the lens hook in the act of expressing the lens. I learned it was better to insert the lid hook under the lid at the outer canthus in either eye, as it gives the best and quickest hold, at the same time there being no danger of touching the eyeball. The technique of holding the upper eyelid on the lid hook is awkward at first, and quite difficult to master without repeated effort, but when mastered it is easy, natural and graceful, and all the movements are under perfect control. The assistant having slid the lid hook well under the upper tarsus at its middle, gently raises the eyelid off the eyeball, at the same time forcibly pushing up the eyebrow with his extended ring and little finger tips (Fig. 19). During this maneuver the thumb of the left hand is forcibly and effectually depressing the lower eyelid, either with a small pledget of dry cotton between his thumb and the lid or without, as the case demands. The palm of his left hand lies on the patient's right cheek, the fingers spread and extended, assuming a natural grasp at the angles of the jaw (Fig. 17), if it is the right eye that is being operated on, or over the lower part of the nose and obliquely across the mouth and right cheek if it be the left eye. I have described these attitudes of the assistant minutely, as I regard it of great importance that the assistant assume no other position, and that he may clearly know what the correct attitude is. (Fig. E). I played the rôle of assistant in a large number of cases, and will say that while it is at first awkward, one soon catches the trick and it becomes a pleasure to assist. You soon learn that you have perfect control of the eye, and you feel ready to meet any emergency that may arise. The part the assistant plays is certainly a most important one, and no man would dare to operate without previously instructing his assistant regarding the above points. Any one who has handled eyes at all can learn in a few minutes how to do the work of an assistant if he will closely heed the above instruction. (Figs. D and E).

EXPRESSING THE LENS.

The operator now takes the double spoon in the fingers of his left hand and the lens hook in his right. The former is passed under the assistant's right arm, and the wrist and hand assume a natural position

of rest, awaiting any demand that may arise, while the hand lies lightly on the patient's nose or left cheek, depending on which eye is being operated on. The lens hook is held in about the same way as the Graefe knife, that is, very lightly, with the little finger resting on the zygoma or temple and the bulbous end of the hook directed upward toward the incision, while the curved end is laid flat against the lower part of the cornea, half of the short right angle end being on the cornea and half on the ciliary. This is the first position of the hook in the lower half of the vertical meridian of the cornea, with the bulbous end of the hook at a point *a little below the margin of the pupil*, or half way between the lower margin of the pupil and the lower periphery of the iris. The idea is to make pressure with the end of the hook

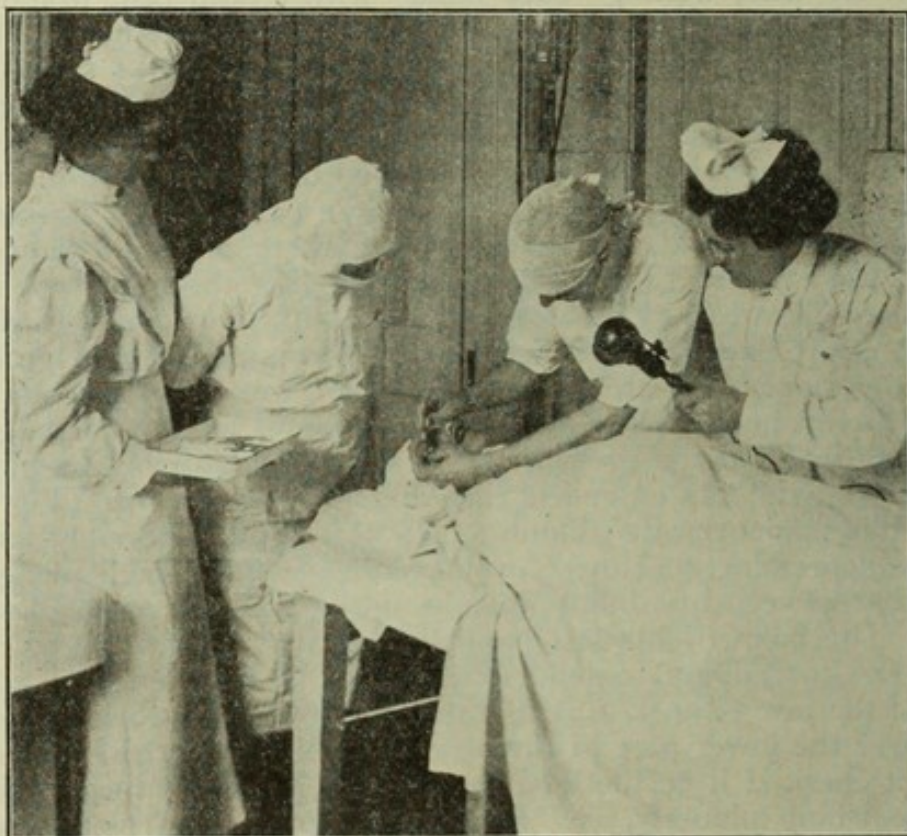


FIG. D.—Operating scene, illustrating the *wrong way* to hold the upper lid on the lid hook. The right forearm is too low. There is not room enough for the operator to pass his left arm and wrist under in approaching the eye with the double spoon held in the left hand.

held obliquely in relation to the cornea and, turning the hook slightly on its long axis, force the bulbous tip in the lower circumlental space. (Fig. 20).

There are two kinds of delivery to consider, and this seems to be the proper place to discuss them. One is the *upright delivery*; that is, the lens is born with the upper edge coming through the incision first. In a series of ninety-nine cases observed by me before I began operating my series, when I took careful notes of all that transpired, there were seventy-five upright deliveries. The other class is the so-called "tumblers," where the lens turns within the eye and comes out with the lower edge first—a sort of "podalic version" of the lens. In

the series of ninety-nine cases referred to there were twenty-four "tumblers." I noted two kinds of tumblers, one in which there was a completed quarter somersault of the lens within the eye, the other where the lens showed no disposition to turn, but on continued or slightly increased pressure it gave a sudden start and tumbled at the moment of birth. It seemed to be Smith's endeavor to make all the cases tumble that would do so, the following being his argument in his own words: "Tumblers should be dislocated below first, because if you prevent tumbling and force them up straight, they detach above and come half out, being hard to follow up." In nearly every instance he would tell beforehand whether the case was one where the "tumbling" technique should be employed. His choice of technique is based

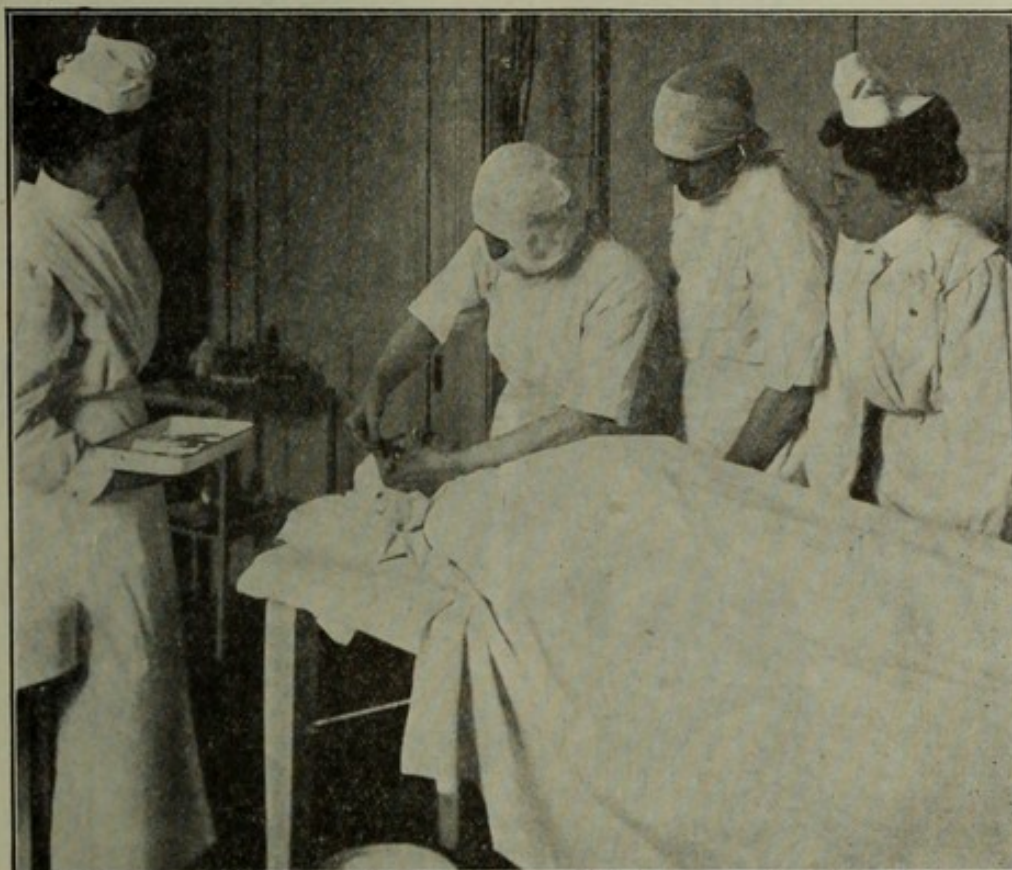


FIG. E.—Operating scene, illustrating the correct pose of the assistant in controlling the upper lid on the lid hook. The hook is about to be inserted. The elbow is held high to allow room for the operator to approach the eye with his left hand holding the double lens spoon.

on the kind of cataract which exists in a given case. By referring to the above description of the kinds of cataract, it will be observed that we have shrunken (discoid), Morgagnian (baggy), tumescent (swollen) and immature cataracts to deal with. The only kind which lends itself to the tumbling act, and tumblers are always favorable for success, is the tumescent or ripe cataract. They usually come out beautifully, but success depends largely upon the size of the incision. If it is too small they will give some trouble, as the capsule is apt to burst at the moment of delivery; if the incision is exactly right in size, they will roll out most beautifully and easily.

TECHNIQUE OF DELIVERY OF THE TUMBLER CLASS.

Having decided that the case is to be a tumbler, the following is the mode of procedure with the lens hook. The hook is laid quite flatly across the ciliary, nearly one-half being on the cornea at the lower part of the vertical meridian, the tip about 3 mm. from the corneal rim, or midway between the lower rim of the pupil and the lower periphery of

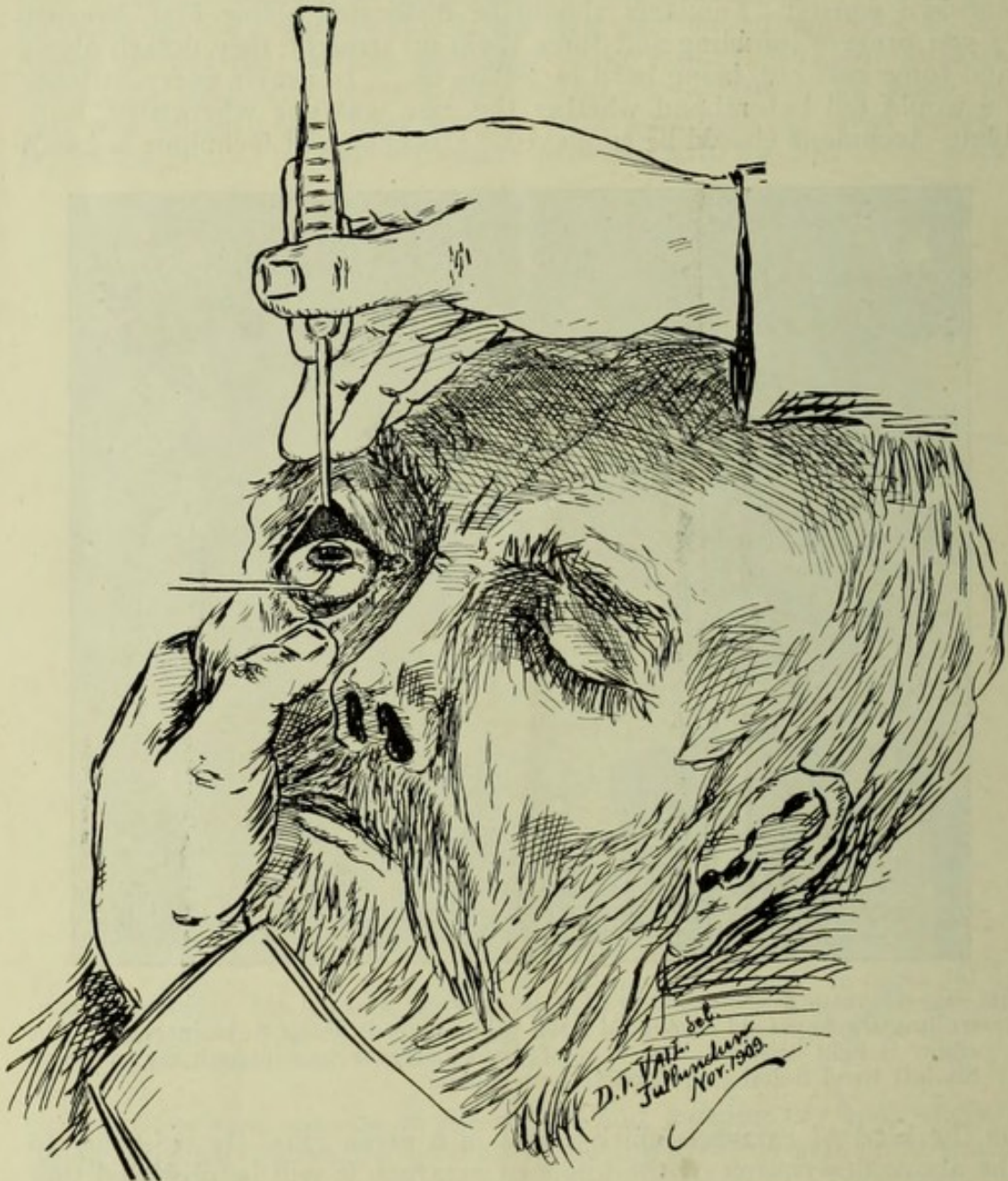


FIG. 19.—General view of the operation, showing the position of the assistant's hands. Note that the fingers of the right hand are holding up the eyebrow, thus avoiding the squeezing effort.

the iris. In operating on the left eye the shank of the hook is *steadied on the bridge of the nose*. Pressure is now made by *rotating the handle*, making about one-eighth of a turn and impinging the blunt end of the hook in the circumlental space below, forcing it quite deeply into the

narrow space (Fig. 21, E). Thus the *ciliary ridge* can be plainly felt like a welt under the hook, and with that for a hold the pressure is shifted directly *toward the patient's feet*, being careful not to let the end of the hook slip off the ridge. If it does slip off (which it will in the hands of a beginner), no harm results, as a new hold can be taken, but in an expert's hand the muscular sense is so well developed that the hook will not slip off the ridge. Thus the eye is dragged downwards and the cornea is wrinkled in a V shape; at the same time there is a marked gaping of the wound. The pull or traction, while being made boldly downwards toward the patient's feet, is at the same time intelligently directed deeper at the tip of the hook toward the optic nerve, thus impinging the hook more deeply under the lens and dimpling the vitreous below the lens. Under these circumstances the lens can do but one thing, and that is to turn with the lower edge next to the cornea and the front surface of the lens at right angles to the gaping wound, the upper rim of the lens having recessed backwards against the ciliary ridge above (Fig. 21, F). Thus everything is favorable to suc-

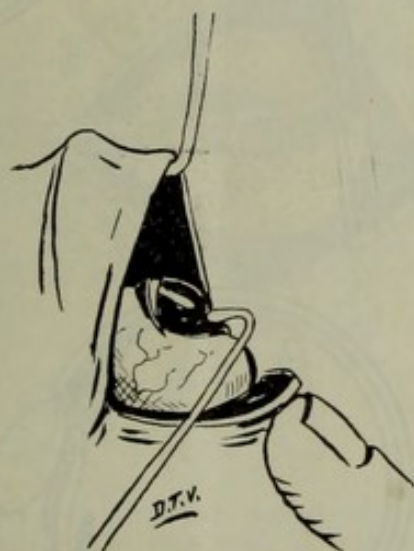

FIG. 20.—Showing side view and illustrating where the pressure is applied with the olive end of the "strabismus" hook. The wound is just beginning to gape. The upper lid is held on the lid hook.

cessful turning and extraction, as the lens entirely blocks the wound and the vitreous has no possible crack or space to come forward. As soon as the lens is half turned and there is every sign that it is coming along nicely, the pressure toward the feet is abandoned and the blunt end of the hook is made to ascend to *follow it up* (Fig. 21, F), keeping the cornea hugging it below and at the same time choking off any space that may form above from faulty technique. The lower part of the lens now comes out of the wound and the *cornea is tucked well under it* by upward gentle undersliding of the hook, until you suddenly feel that the background is quite soft (minus tension). (Fig. 21, G.) This accomplishes two advantages: (1) The cornea being tucked under the lens, the latter cannot settle back in the eye when you withdraw the hook. (2) There is no space for the vitreous to show. The hook is now removed from under the lens and its curved arm is gently insinuated around the *left* side of the lens preparatory to gently raking it

away in a line with the wound (Fig. 22), for the suspensory ligament above has not been ruptured by this technique and the lens is still tethered by its upper ligaments. You must be very careful at this point not to lay the hook flatwise on the eyeball, as you would suppose, for if you do so the blunt end, which you cannot see, as it is behind the lens hidden from sight, is apt to bury into the wound, and if so the lens cannot be rolled away, for in that case the lens hook is in the vitreous,

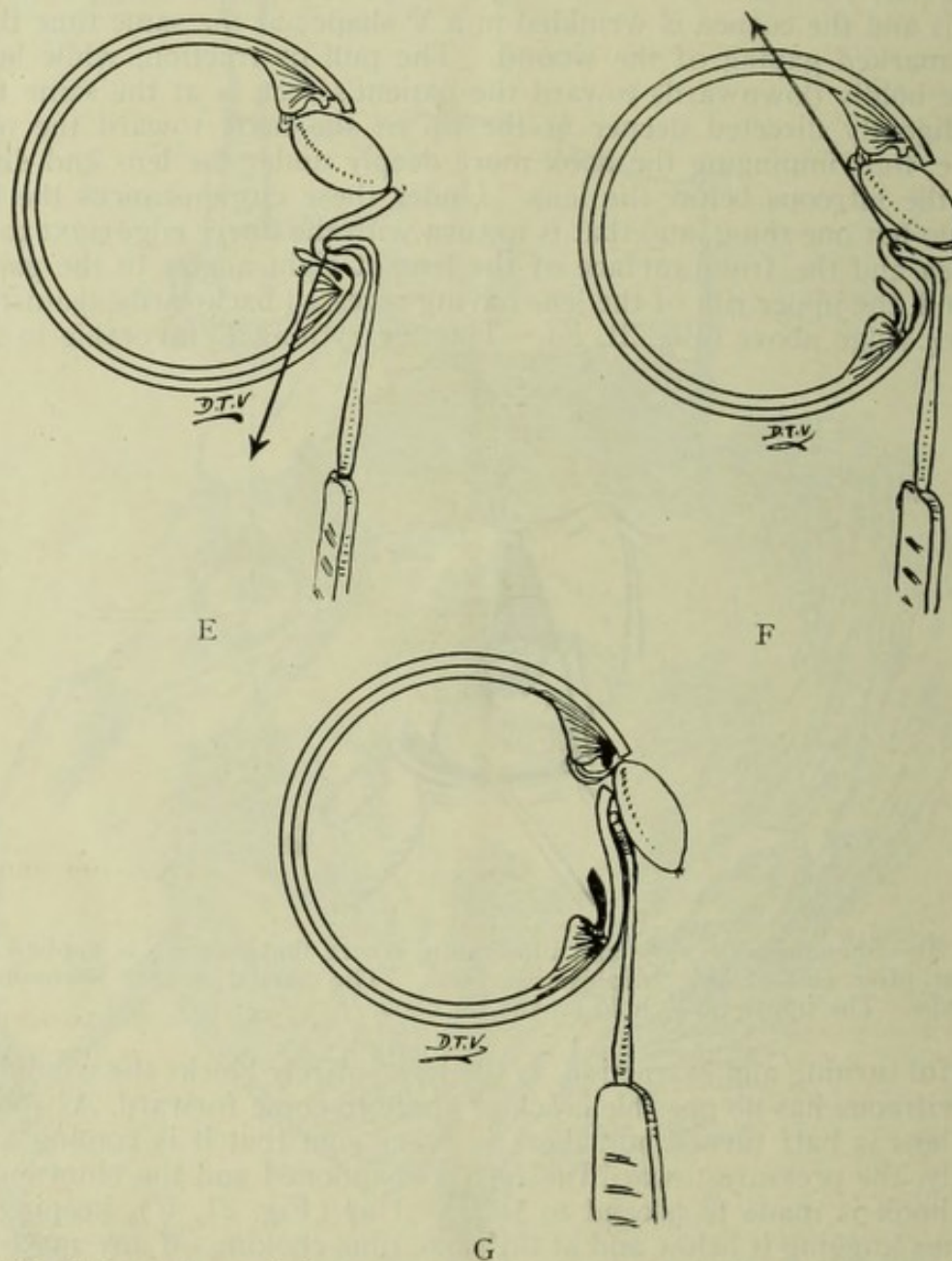


FIG. 21.—Illustrating technique to employ in case of "tumblers." E, the pull has been downward toward patient's feet; F, the pressure is now up toward patient's head; G, the cornea is now tucked behind the lens, which was delivered lower edge first and is still attached above.

a manifestly faulty position. You must direct the end of the hook at a distant angle *upwards* away from the eyeball, at the same time sinking its *elbow* into the crack of the incision. This is a little trick that spells success, and if gentle deep pressure is made as the elbow of

the hook glides between the lens and the wound, the cataract is made to separate from its attachments and the wound is "ironed" in perfect apposition. Smith has a dextrous way of nudging the lens out of the eye with the lens hook after it is completely detached and lies in the conjunctival sac, but I found the curved spoon handy at this stage for receiving the lens on its hollow paddle-like blade and lifting it out. The capsule is so friable it will stand no violence whatever, for it is impossible to use it roughly by any means without bursting it, an objectionable feature even after delivery, for it is surprising how easily it is lost in the conjunctival sac.

Thus, in the case of "tumblers," there are three distinct lines of pressure employed: (1) backward towards the optic nerve, with rotary

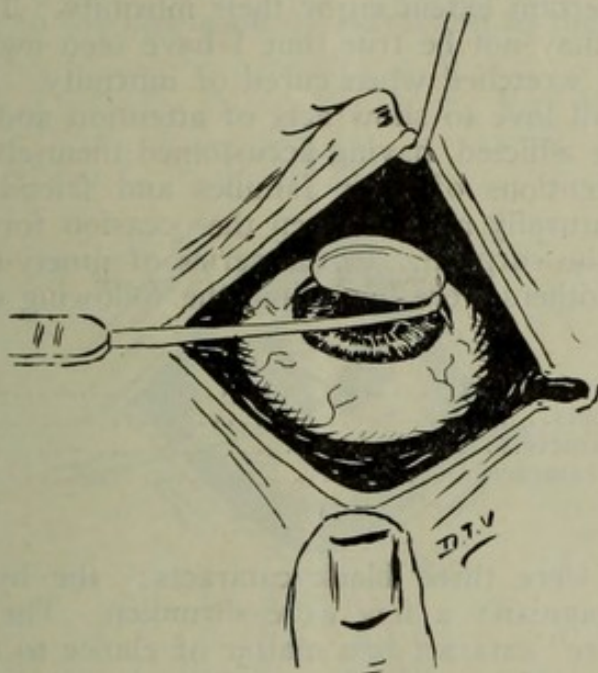


FIG. 22.—Showing lens born and lying just outside the incision, but still held by a few fibers of the zonule. The lens hook is being used to drag it away, at the same time the elbow of the hook will "iron out" the lips of the wound and seal it.

action of the shaft; (2) steady downward pull toward the feet of the patient at right angles to the first pressure; (3) gentle upward and rather deep pressure as the lens turns to come, thus allowing no space to form for vitreous to present. These different lines of pressure are never abrupt in shifting from one to the other.

The shrunken, simple, mature Morgagnian and immature cataracts are not favorable to turning in delivery for the following reasons: (1) Shrunken are too small and flat and the suspensory ligaments are very tough. (2) Morgagnian have very friable suspensory ligaments, as a rule, and the moment pressure is made on the first position described, the upper edge of such cataracts usually present in the wound. (3) Immature cataracts are more rigid than tumescent, and are not molded as they move, and are pressed against like the tumescent ripe kind, which have a pultaceous cortical layer, and there are apt to occur fissures for the presentation of vitreous. The presentation of vitreous at any stage of cataract in the capsule delivery calls for a sudden aban-

doning of all attempts to delivery in the normal way, and demands that the operator take to other entirely different methods of technique, soon to be described.

The majority of cataracts which are operated on at Jullundur are mature, some of them being tumblers; next in frequency are immature, and last hypermatures. The ratio is roughly stated as follows: Mature cataract, 50 per cent.; immature, 35 per cent.; hypermature, 15 per cent. But there is no doubt that there are a great many more immature cataracts in the world to-day than any other and all other kinds. They do not come to the surgeon for manifest reasons. Such cases naturally put off coming from dread of operation as long as they can see. This is especially true of the lower and poorer classes, many of whom to a certain extent enjoy their infirmity. This is an unkind statement, and may not be true, but I have seen many people happy in infirmity and wretched when cured of infirmity. Everybody pities the blind; we all love to show acts of attention and kindness to the afflicted, and the afflicted, having accustomed themselves to the tender mercies and attentions of their families and friends, soon grow to liking it, and naturally miss it when the occasion for such tenderness is removed by the surgeon. In the series of ninety-nine cases which I studied while others were operating, the following classification was noted by me:

Cataracts not classified.....	10
Mature cataracts.....	48
Immature cataracts.....	23
Hypermature cataracts	18
	<hr/>
	99

In this list were three black cataracts; the hypermature were nearly all Morgagnian; a few were shrunken. The classification of forms of "mature" cataract is a matter of choice to a certain extent; many of them would be called hypermature by others, and some even Morgagnian.

THE TECHNIQUE OF DELIVERY OF THE UPRIGHT CASES

(averaging 75 per cent.), is somewhat different from that of the "tumbler" class. In any one of them one may try the first pressure described, with the hope that they will tumble, but a stiff lens will show no desire to turn, and the pressure toward the feet with the blunt end of the hook caught over the ciliary ridge should be abandoned after a single effort.

The end of the hook is laid at an angle of about forty-five degrees on the pressure-spot, corresponding to the lower edge of the lens (Fig. 24, A) The pressure is made deeply and steadily back toward the optic nerve, neither upwards nor downwards in the slightest degree, *straight back toward the depths of the eye*. This tilts the upper edge of the lens in the wound, and the cornea does not wrinkle in a V-shape so much as in the case of tumblers, when the instrument is hooked over the ciliary ridge. The operator, seeing the upper edge of the lens presenting, continues his pressure(Fig. 24, B), but not pressing hard, holding the edge of the hook steadily at the deepest point, at the same time gently edging the pressure upwards; this he will almost

unconsciously and naturally do. Thus the lens starts from its fossa, and if the pressure is nicely graduated to meet the exact onward movement of the lens, it can be made to glide nicely out of the wound. The suspensory ligament first ruptures above, and one must know that and keep it in mind, as to forget it or be not aware of the fact, and continuing the deep backward pressure, there will a crack appear behind the lens, in which vitreous will surely show and the thin hyaloid burst (Fig. 26, K). Knowing that the lens is torn loose from its upper attachments one will naturally so adjust his pressure as to keep the lens exactly in all the space of the gaping wound, to afford no avenue for vitreous to show. If you section a lens in one of its diameters and look at the cut surface, you will observe that the contour of one half is that of a modified cone like a Bishop's mitre. This conformation is favorable to the operation of extraction in the capsule, as this

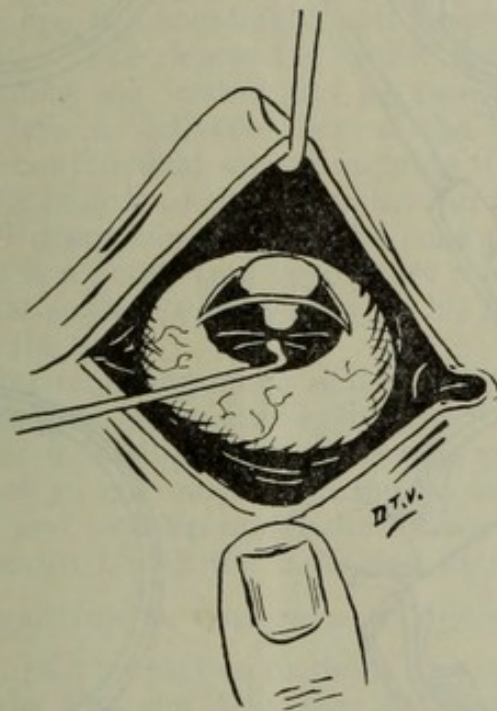


FIG. 23.—Showing front view of the delivery in case of "upright" lens. Note that the pressure will soon be shifted upwards to drive out the lens and to tuck the cornea behind it.

oncoming lens, having just presented with its upper edge in the wound, is like a wedge which will exactly fill the space of the wound, *if the pressure below is rightly and intelligently used*. Taking advantage of these facts insures success in the majority of this class of cases. As the lens rides out of the wound, the deep pressure is rapidly lessened and is shifted to the right angle upwards, thus driving the lens on out and at the same time tucking the cornea under and behind it to get the edges of the wound in approximation and prevent settling back of the lens when the manipulation has ceased (Fig. 24, D). It is manifest that as soon as the greatest convexity of the lens is born, the cone tapers off to a point and there is no demand for any further deep pressure, but great demand for the upward undertucking act. In performing the last act in the delivery of the lens, it is necessary to gradually lay the hook quite flat or nearly so with the cornea, and at

the same time use only the tip for a pressing point, and that very lightly, too. While pressing the opened eyeball to force out a cataract, one can *see* the pressure, but so soft is the eye that he can scarcely feel that he is pressing. As the lens is half or two-thirds out, it will probably fall down with its upper edge toward the feet of the patient

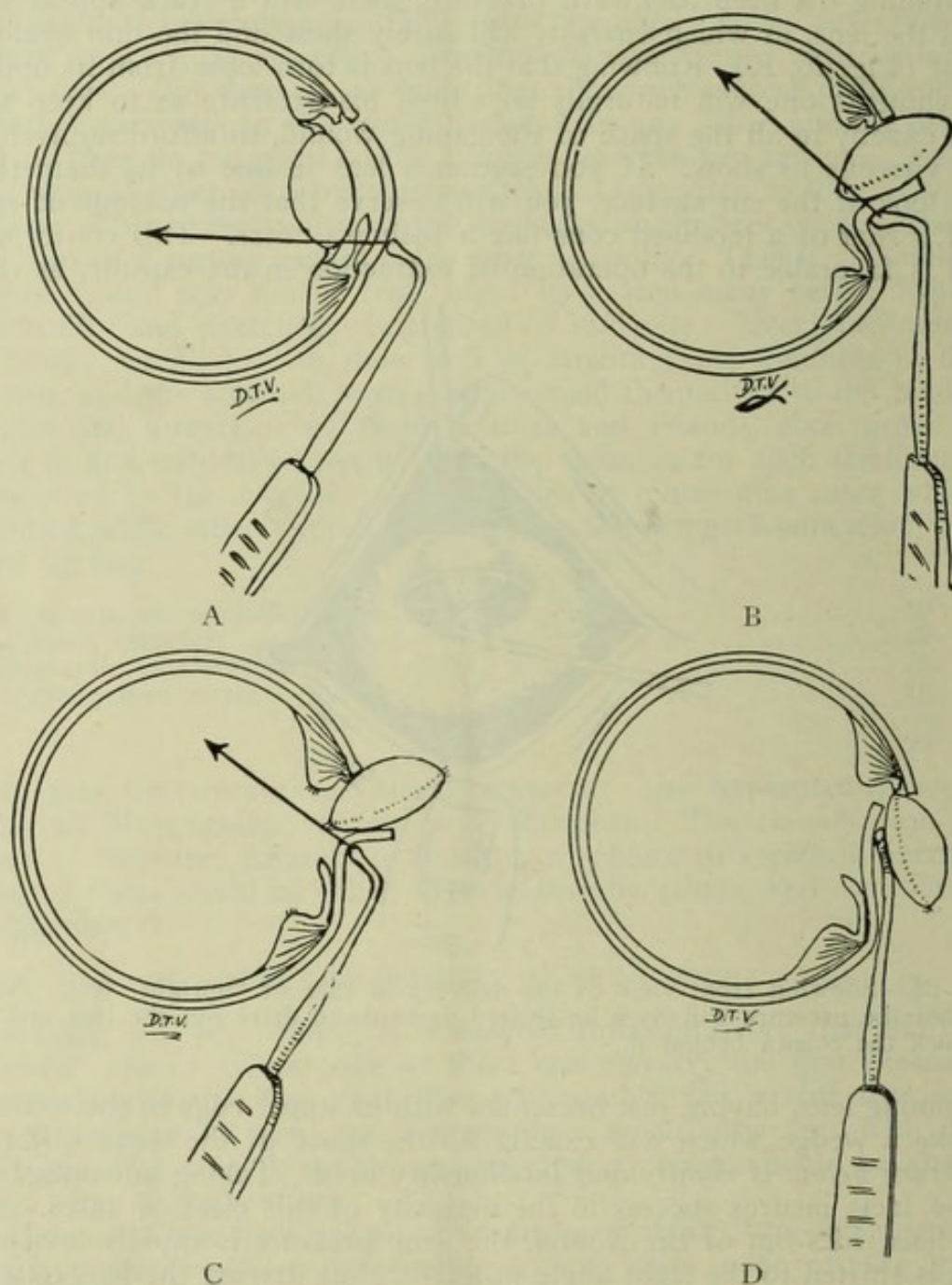


FIG. 24.—A, showing where the pressure is about to be made; B, following the detached lens out of the eye; C, tucking the cornea behind the lens about to be born; D, lens born, cornea tucked behind it. The spear indicates the direction to make pressure.

on the outside of the cornea (Fig. 24, D), but the lower one-half or one-third is turned upwards, and will lie in the space of the wound even after the cornea is tucked home. In such cases the cornea is always cupped (concaved) by the weight of the lens, but if the tucking

has been *rightly done* and *completely done*, it will not slip back in the eye, although it looks as if it surely would. The attachments are all severed, with the exception perhaps of some of the fibers of the zonula corresponding to the horizontal meridian of the lens. To deliver such a lens it is necessary to use the hook as described in the last act of the tumbler class—that is, use it gently as a golf-stick (mid-iron) would be used for raking a golf ball that is floating on the water, only it is very necessary to always have in mind that unless the end of the hook is turned away from the wound at an angle of about forty-five degrees upward, so that the elbow of the hook will sink under the lens in a line with the wound, and *rather deeply, too*, the point of the hook may enter the wound. That the pressure of the elbow of the hook is rather deeply made in the slow, steady and gentle stroke in the act of raking the lens out of the wound, is proven by the sight and not by the sense of touch, for the eye is exceedingly soft under such circumstances and cannot be felt. The depression which the elbow makes in the softened eyeball along the wound can be seen like the hollow of a wave. Thus the lens is delivered out of the wound, and is either pushed out of the conjunctival sac by nudging it along, or else gently forced over into the hollow of the spoon held in the left hand. Sometimes the lens will disappear up over the summit of the eyeball into the fornix. There is a good-sized open space there, for the assistant's work is to keep that space opened widely by his method of holding the eyelid away from the ball.

It is not a matter requiring much skill to get the lens down and out of the eye if it has gone up in this space, but it is hard to *see* where it lies, and go after it intelligently, and not go groping around in the dark for it. To see it, one must often lay his head quite low toward the patient's chest and look up under the lid for the lost lens. When seen, it is easily secured with the hook and extricated.

EXTRACTION BY COMBINED MANIPULATION.

It will be noted that in the two methods of extraction last described (that of turning the lens and delivering the lens upright), the entire delivery in either case was effected by means of intelligent pressure on the eyeball by the hook, unaided by any other instrument. A certain number of cases in a series will present some difficulties, which in order to overcome one must employ combined manipulation, or in other words, call upon the spoon in the left hand to assist in causing the lens to move. This emergency will rarely or never arise in the case of tumblers. They come out by means of pressure with the blunt lens-hook unassisted. But there are cases of upright presentation in which, to get the lens to start and move out of the incision, it is necessary or wise to apply a little pressure on the eyeball near the point where the lens-hook is making its pressure, in order to steady the vitreous or increase the tension of it in this way. In the series of ninety-nine cases referred to, it was necessary to use combined pressure to effect delivery in sixteen cases, which is about the average percentage. In making deep backward pressure with the hook, one can tell when he has reached the limit of tolerance by the sense of touch aided by the eyesight. He instinctively knows that to press harder is to invite rupture of the hyaloid behind the upper margin of

the lens. Smith will often avoid employing the spoon as an adjunct by a trick of turning the hook flatwise on the ciliary, while keeping up the same pressure with the end of the hook. This added area of pressure on the vitreous body will suffice to cause the lens to loosen its moorings above, and delivery will be effected in a normal way, but I found that it was not easy to keep up the *same pressure* with the end of the hook and turn it flatwise at the same time. There are niceties in every operation which the long-experienced hand will assume, and this is one of them. I found that it suited the purpose

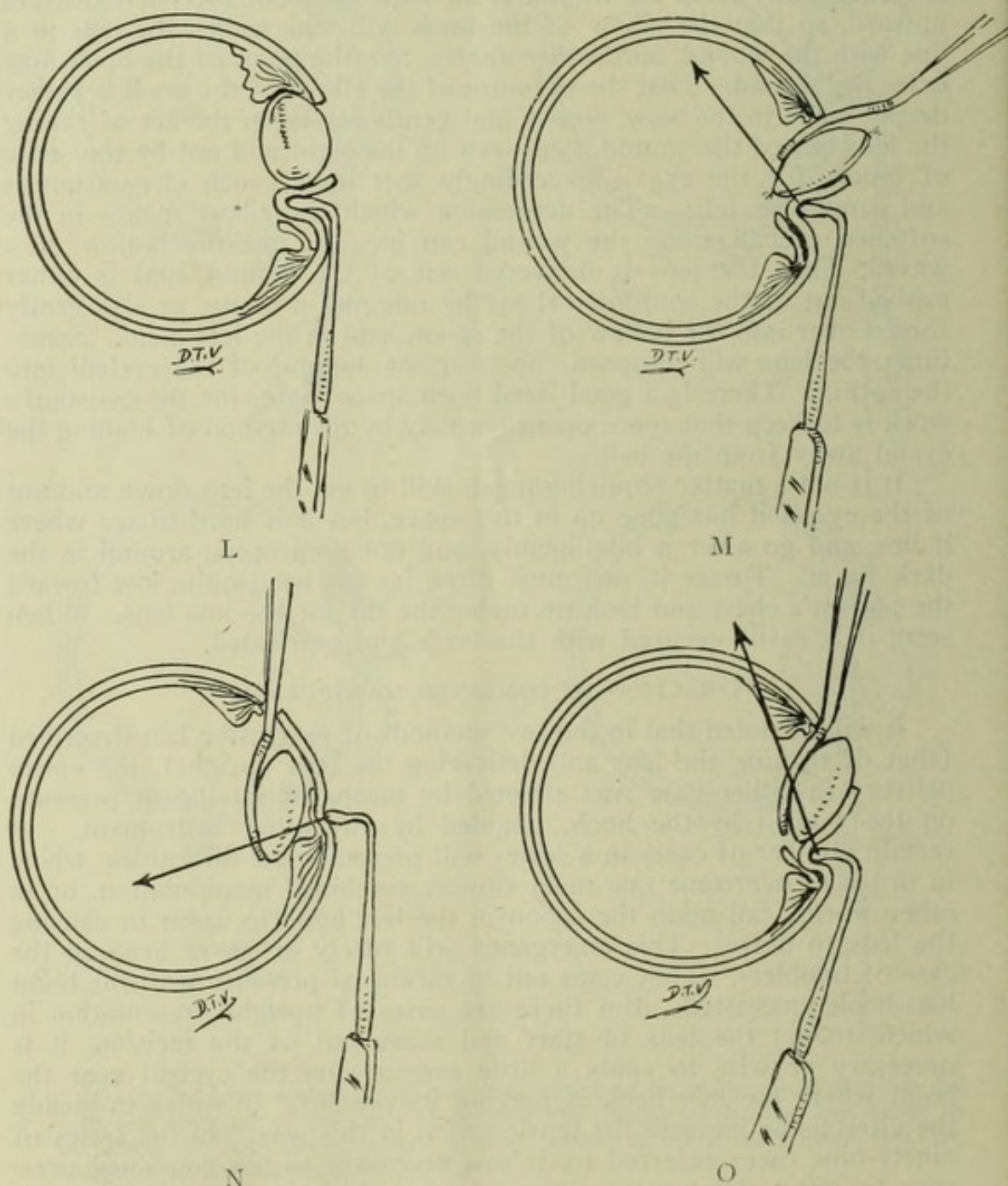


FIG. 25.—Illustrating "jammed lens" and spoon deliveries. L, lens is jammed and cannot be delivered without another start and a change of technique; M, spoon held just in the wound to sustain the vitreous; N, spoon placed low in the eye behind the lens; O, using the spoon as an inclined plane and driving the lens out of the eye.

better in my hands to employ the end of the spoon placed vertically anywhere on the eyeball near the lower edge of the cornea, thus increasing the *vis a tergo*, or forward push of the vitreous on the back of the lens. It is pleasing and somewhat surprising to note how readily the lens responds to this added pressure, and it gratifies one

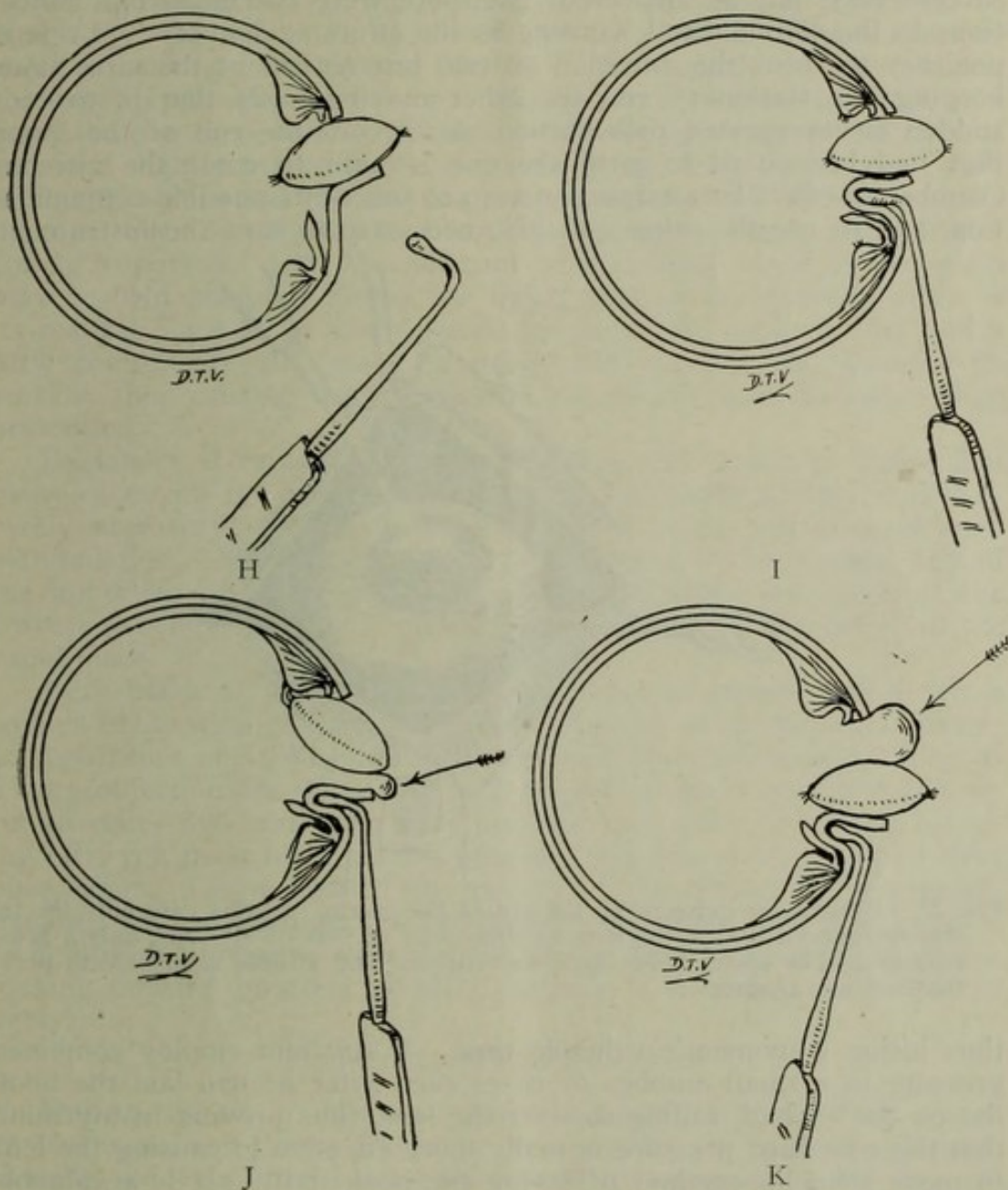


FIG. 26.—Illustrating some things that will happen. H, the pressure is taken off before the cornea is tucked behind the lens; I, the incision is too small, lens cannot be born without dangerous pressure, use combined pressure or enlarge the wound; J, too much downward traction in trying to make a "tumbler" tumbler, and the vitreous presents below—upward pressure will close the gap; K, similar to J, but the presentation is above, calling for spoon assistance.

who is expecting trouble on account of the immobility of the lens and its apparent stubbornness in moving, to see it start on its way toward the opening at such a crisis. One must remember that the *hook pressure must be kept up*, not increased or diminished, while a

gentle push is given to the eyeball with the spoon in the left hand, and just as soon as the lens starts to move, the spoon pressure must be stopped at once and the instrument removed from the eye. I remarked to Smith that I thought all beginners should be taught the combined pressure first, as it simplifies the technique and renders success easy, but he answered that there were two important objections to the second hand working in the effort at delivery: (1) It is not easy to focus the attention on two instruments at the same time, keeping one stationary and the other moving; (2) that in case of sudden or unexpected presentation of vitreous the end of the spoon that had been used to push the eye is unfit to enter the vitreous chamber to effect lens extraction, on account of its possible contamination, and to use the other end it is necessary to turn the instrument,

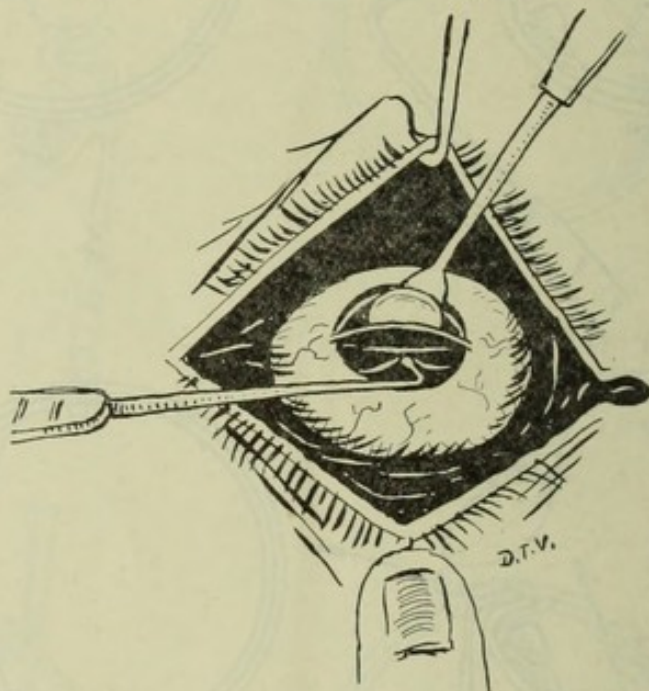


FIG. 27.—Illustrating delivery by the aid of the spoon. In this case only the tip was introduced behind the lens, as there was no loss of vitreous, only a presentation. The spoon holds back the vitreous and affords a surface to press the lens out against.

thus losing a moment's valuable time. I saw him employ combined pressure in a small number of cases even after he had laid the hook flat on the eyeball, failing to start the lens, thus proving in my mind that the combined pressure is really more effective in causing the lens to move than his method of laying the hook flatly. It is a valuable point to know and to employ, namely, that simple pressure failing to start the lens, combined pressure by means of the spoon in the left hand can be safely and successfully employed.

There is another form of combined pressure which is occasionally employed, though rarely. In some cases the lens will neither turn nor will it tilt and present its upper edge in the wound. Perhaps owing to faulty technique, it is allowed to move in a vertical direction out of its bed, and the upper edge passes under the overhanging edge of the cut sclero-cornea and refuses to budge by any reasonable pressure from below (Fig. 25, L). You can always tell that this is the

trouble by two observations: (1) The lens is stuck and refuses to move; (2) there is a well-marked bulging of the sclerotic near the cornea. In some of such cases to release the pressure entirely and start over again will cause the lens to tilt and present in the wound, but usually the lens goes back to its former faulty position, wedged behind the upper lip of the wound, from which place it refuses to budge even by moderate combined pressure below. There are two ways of causing it to tilt and present in the wound: (1) By placing the *edge of the spoon on the sclerotic above*, about two or three mm. from the cornea or five or six mm. above the upper lip of the corneal incision, slightly releasing the pressure below with the corneal hook to compel and permit the lens to present properly. It requires a nicety of adjustment of pressure to effect this maneuver, but it is the proper course to pursue. (2) The *flat* convex or concave blade of the spoon may be held obliquely across the upper part of the eyeball, which is its natural place to go when passed up under the upper eyelid, and a little counter-pressure made to steady the vitreous and increase its tension, thus causing the imprisoned lens to tilt with its upper edge presenting.

Beginners at radical cataract extraction will be apt to judge that many cases call for combined pressure. As a matter of fact, it is very rarely necessary; not over 16 per cent. of cases will demand such manipulation. Most all the lenses which seem to be wedged behind the upper lip of the wound will present and come out nicely if the correct pressure is applied with the hook on the cornea below in the usual place.

Very often at first I found things going so slowly that I felt a sudden exhaustion of hand, or at least the loss of the muscular sense; at such times one also loses judgment and fine discernment. This is a very objectionable thing, and will happen to every operator at first. Smith states that your own hand and eye soon grow tired, and, knowing this, you must make all the progress you can as soon as you have once begun. I soon learned the wisdom of this advice, and was rarely troubled with exhaustion and incertitude after that. The way to do is to apply your pressure with the end of the hook, and go right ahead, making onward progress steadily, without a moment's hesitation or delay.

SPOON DELIVERY OF THE LENS.

During the act of delivery, even when everything portends a successful issue, and things are going on smoothly, the hyaloid will occasionally suddenly burst behind the lens at its upper edge, and you will realize quicker than thought that the vitreous and not the lens is about to be born. In some other cases the vitreous and not the lens will present without bursting in the gape in the cornea. In still others (very rarely) the vitreous will show or burst below the lens which is turning (Fig. 26, J). These are emergencies that call for speedy and cool conduct on the part of the operator, for it is quite possible, in fact, certain, that by proper action by the surgeon the lens can be taken out in its capsule without the loss of a particle of vitreous, or at most only a slight amount.

In the series of ninety-nine operations done by others (not by

Smith), which I carefully wrote up as we went along, I noted that spoon delivery of the lens was employed in six cases, that is, it was necessary to introduce the lens spoon within the vitreous chamber behind the lens in six cases out of ninety-nine in order to get the lens out. Of these six cases, there were four in which no vitreous was lost; in the remaining two there was slight loss, one from below the lens, the other from above.

The spoon delivery of the lens as employed by Smith is another great contribution to cataract surgery, and without it attempted radical extraction would hardly be justifiable, in my judgment. With it the

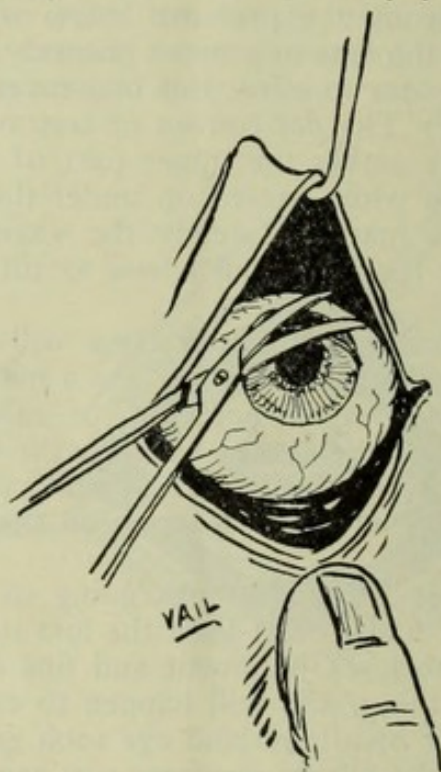


FIG. 28.—Showing how Smith trims off the vitreous in cases where there has been escape, and where a string of vitreous still hangs in the wound. The scissors are sharp. One snip is used after the blades are carefully placed to engage the vitreous.

operation is robbed of its terrors, for even if things go wrongly, and the vitreous presents or bursts before the lens comes, it is not a difficult matter, *provided the spoon and lens hook are rightly used*, to make the operation as good a success as if simple delivery had been effected.

Under no circumstances should the spoon of Smith or any other pattern be used for raking out the lens. It is to be used as a little paddle to *keep the vitreous back*, and is gently slid behind the lens and held quietly in *one fixed place* (Fig. 27), all the work of extraction being done by the lens-hook pressing the cornea against the lens and the lens against the spoon up an inclined plane (Fig. 25, M). The tendency of beginners is to use the lens-hook to rake cut the lens like a poker is used to rake chestnuts out of the hot ashes. This is the *wrong way* to use it; the right way is as follows: The vitreous having "shown" or "burst," all pressure on the eyeball is immediately stopped. The assistant shifts his line of traction with the lid-hook, so that he

no longer holds the lid off the eyeball in a vertical manner, but more obliquely downwards and away from the ball, for by tractioning the lid with a pull downwards a little, towards the patient's feet, he thus relieves the eyeball of every vestige of weight and pressure of the extra-ocular tissues (Fig. 18). The patient is now directed to look slightly downwards, if he will (if not, it does not matter much), and a little pressure is applied to the cornea below the lens. This causes the wound to gape enough to allow room to pass the spoon gently within the vitreous chamber, not vertically, but a little obliquely, as that is the natural way the spoon enters the wound. If there has been only a "presentation" of vitreous, it is only necessary to introduce the tip of the spoon to hold back the vitreous while the lens is forced up and out, a thing quite easy to accomplish (Fig. 27). If there has been a bursting of the hyaloid, with the loss of a little (or more) of vitreous, or even a considerable loss, the spoon is made to pass quite within the vitreous chamber behind the lens, and of course close to it in a plane parallel, as nearly as one can judge, with the posterior surface of the lens (Fig. 25, N). The spoon is then held perfectly still (no traction or forward pull), and the lens forced up and out by means of the hook on the cornea, using the *spoon as a gliding surface purely and simply*. One can soon acquire this technique. I did not do it well the first time I tried it, but after that had no trouble in carrying out the principle.

What do we do in the so-called Graefe extraction when the vitreous bursts and begins to flow? We either make continued pressure on the eye, using the escaping vitreous for a background, and it is a race between the lens and the vitreous, or else we pass a lens-hook with teeth or corrugations on its concave surface, or a tooth-instrument like a cystotome, to drag it out or snag it out; in the meantime there is more or less collapse of the globe from vitreous loss, from either the pressure of the expressing spoon, the traction of the lens-spoon or the squeezing and frowning of the patient, or all of these forces combined. In Smith's method we have a means of handling these cases with every assurance that there will be a *minimum loss, if any*, and operators who employ any method of extraction, be it Graefe's or any other, will do well to look into Col. Smith's method of holding the eyelid on the hook, the eyebrow up with the fingers, and the flat curved spoon as an inclined plane to force the lens out against. If vitreous hangs out of the wound, it is trimmed off with curved-on-the-flat scissors, as shown in Fig. 28.

BURSTING OF THE CAPSULE.

Bursting of the capsule is an accident due to faulty technique. It occurred twelve times in the series of ninety-nine cases referred to. It may occur in one of four ways:

1. *The incision too small.* (a) This is the usual cause of rupturing of the capsule, and is a thing which will occur occasionally in the hands of the best operator. We cannot always estimate the size of the lens, and are sometimes surprised to find a large lens when we expected to encounter a small one. The incision may be smaller than we intended it to be, owing to some accident, like pricking the iris with the point of the knife as we pass across in making the puncture and counter-puncture, in which case we are apt to let some aqueous escape

when endeavoring to release the knife point, and after that we cannot pass the knife point into the angle of the cornea in making the counter-puncture, but are apt to come out well into the cornea, thus making the incision smaller than we had intended.

(b) In making the puncture, we are apt to hold the knife with the flat of the blade parallel to the plane of the iris, instead of at an angle with cutting edge forward, and in so doing we slice the layers of the cornea and enter the anterior chamber too far toward the center. The size of the incision is not the outside of the corneal cut, but the *inside*, and in completing an incision started in this way we are apt to make it smaller than it appears to be or than we intended it to be.

(c) We may complete a section well begun by cutting out of the cornea lower down from the upper edge than we had intended, thus making a small incision.

(d) Then, too, we may for some reason make the puncture and counter-puncture too high, cutting relatively only one-third of the corneal periphery.

There are some chances of compensating a bad beginning in making the incision, if we recognize the fault at once. For instance, if the




FIG. 29.—The left hand sketch shows that by holding the knife so the edge will be turned away from the iris the cut at the point of emergence (arrow) will be entirely in the cornea, while the right hand figure shows that by holding the blade flat on a plane with the iris the knife will emerge quite far from the cornea (see arrow) in the conjunctival area near the plica. Free bleeding will result.

point of the knife should prick the iris, it is usually best not to attempt to release the point, but go right ahead as if things were as we had intended; if the cornea is sliced making the puncture, the counter-puncture can be made either a little lower than the rule calls for or a little further into the angle of the cornea. In doing the latter it is well to tilt the edge forward in order to avoid the knife coming out in the region of the plica (Fig. 29). Cutting well back is nearly always followed by profuse hemorrhage, either from the conjunctival vessels or the canal of Schlemm. If the knife has cut its way out too far down in the cornea, the wound may be enlarged by using a pair of scissors, which should always be at hand ready for such an emergency. If the puncture and counter-puncture are slightly too high, we may either cut our way out quite in the limbus, or enlarge one angle of the cut, as above described.

2. In raking the delivered lens away from its final attachments above, the blunt lens hook may wound the fragile capsule and burst it. This is not a matter of any serious moment, as the lens is quite out of the eye and the nucleus and cortex are not left behind. The empty sack in which the lens reposed lies in the lips of the wound and may easily be secured in the manner soon to be described. One must bear in mind the extreme friability of the capsule and at no time touch it

with the blunt end of the hook. It is not necessary at any stage of the operation or in any emergency to do so. The beginner is apt to forget this until he has had his experience with it, after which he will respect the principle and avoid touching the lens with the end of the hook. One may rupture the capsule by not turning the end of the hook upwards away from the wound as he begins to rake away the delivered lens. In forgetting to do this, the end of the hook becomes engaged in the wound and there is some danger of wounding the capsule.

3. In passing the knife through the anterior chamber, the point may prick the lens; this occurred once in my own hands. It is an almost imperceptible incident when it occurs, and may be quite overlooked. No matter how minute the pricking of the capsule has been, the contents will tear their way out and the capsule be left in the aqueous chamber.

4. In doing the iridectomy, especially in the "old way," one is apt to pinch up the capsule in grasping the iris, thus tearing or wounding it, so that it is left behind when the lens is forced out. This likewise happened to me and was almost imperceptible.

SECURING THE CAPSULE.

Col. Smith is radically opposed to leaving the capsule behind. He states that he would rather lose one-third of the vitreous than leave the capsule behind, that the patient has a far better chance of having

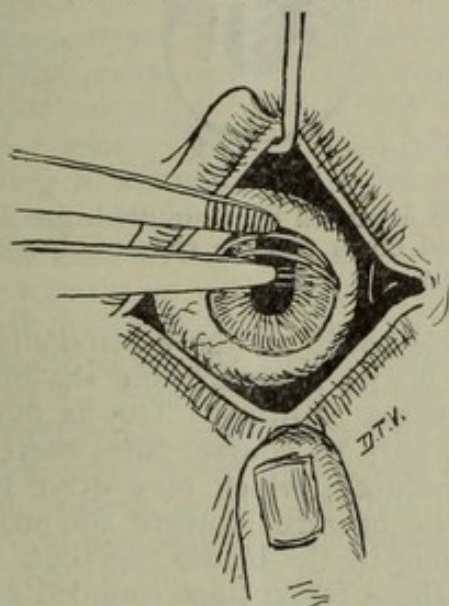


FIG. 30.—Showing method of grasping the ruptured capsule which hangs partly out of the wound. The upper blade of the dissecting forceps is held fixed at the scleral edge of the wound, while the lower blade depresses the cornea slightly in order to coax the ruptured capsule to present within the grasp of the forceps.

a good permanent result in the case of vitreous escape than when the capsule remains within the eye.

I take the series of ninety-nine cases as representing about the results that will occur to any experienced oculist who begins this work, as they were done by four or five expert oculists who were studying the operation under Smith. Later on his results will be far better.

In the series of ninety-nine cases referred to, there were twelve where the capsule burst and three where Smith was not able to secure it. What the results were in these three cases I am unable to state, as it was impossible to follow them up on account of the immense amount of other more important work. But one would think that such cases ought to do as well or nearly as well as cases do with the ordinary extraction, where the capsule is left behind as a routine practice. One thing is certain, it is never absorbed; on the contrary, it usually thickens and becomes apparently calcified after a long time, as was proven in the cases of couched lens operation done many months before, where the capsule had been wounded by the lens coucher and the soft cortex had absorbed, leaving nucleus and a complete capsule of astonishing thickness.

There are two methods Smith employs in securing the capsule (the assistant still holding the lid on the hook and retracting the brow): (1) By the use of a rather large pair of good dissecting forceps, which are corrugated on the approximating surface and which surfaces perfectly fit each other. (Fig. 30.) He has a way of working the blades by a series of half closing strokes with one end of the forceps above the wound and against it and the other well down on the cornea,

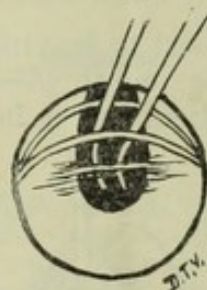


FIG. 31.—Entering the eye in search of a ruptured capsule left behind. The leaf of the cornea is turned down and the ends of the forceps made to go back deeply after the capsule.

causing the lower blade to do all the excursions. There is a little pressure made as the blades approach and the lips of the wound will present with the cut edges showing. This is due to the dimpling of the eye, which is very soft, of course; thus there is a sort of milking or stripping effect produced, which may drive the half detached or nearly detached capsule upwards toward the wound, where it is secured by a firm pinching of the blades together. Of course, the very ends of the blades of these forceps are rounded and present no jagged edges to wound or scratch the cornea. This maneuver will succeed in about two-thirds of the cases. It will succeed in all cases where the capsule was burst after the lens was born. (2) Failing in this method, he takes the iris forceps, which, it will be remembered, has a single good-sized tooth in the very end and corrugations well back on the curved elbow on the approximating surfaces, and introduces it flatwise and closed until the end is well down toward the lower margin of the pupil. (Fig. 31). Then he raises the proximal end of the forceps and holds it quite vertically; in fact, the upper end a little tipped toward the feet and the *corneal flap held down* so that the wound gaps open quite widely; he then dives backward toward the

depths of the patellar fossa with the blades expanded to the proper width and makes one slow and gentle, but firm and steady closing of the forceps with the end seemingly in the vitreous. He is remarkably clever at this trick, and I have seen him drag many capsules from the fossa of the vitreous on the first attempt. In over a thousand or twelve hundred cataract cases which our experience at Jullundur afforded, there must have been upwards of fifty such cases, and Smith would go after the capsule himself in every case where it had been left within the eye, I believe. Thus I had a good chance to observe the method at close range.

In order to get at such an eye, it is best to have the patient look slightly downwards. It cannot be done if he looks high up, but if he looks straight ahead it is not difficult, and Smith would only request them to look down in the former cases. Vitreous will not present or escape when the patient looks down to the very limit, *provided the lower lid is fully retracted*.

REPLACING THE CUT EDGES OF THE IRIS.

Like in nearly every other phase of cataract extraction, Smith has his own original way of dealing with the edges of the cut iris. This part of his technique interested me greatly, for according to my reasoning the fate of Smith's method of extraction depends as much on the replacement of the pupil in relation to the center of the cornea and the replacing of the edges, angles and upper apron of the cut iris so that there will be no entanglements, adhesions, infoldings, hernias or pupil distortions, as upon the comparative visual results. I shall first tell how Smith goes about replacing the iris and then relate the results according to my observations. In the first place, having seen him replace the iris according to his own method many times, I determined to try it his way for myself. I soon learned the technique, for it is not difficult to do, but hard to describe, and after doing over fifty on my own account till I could do it thoroughly well, I requested him to replace the iris in all my cases after that, as I wanted especially to study the results. Smith is willing and anxious that honest observers subject his methods to the most scrutinizing test, and did not object in the least to my inquisitiveness in that regard. I had heard great objections to Smith's operation raised by eminent oculists I had met and talked with at various places, on the grounds that a drawn-up pupil, very wide coloboma and adhesions in the angles of the corneal wound were the invariable results, and I made up my mind that so far as I personally was concerned, I would not undertake to do Smith's operation on my private cases if these things *were necessary and could not be avoided*. I was satisfied before I went to India that the lens could be nicely and safely extracted in the capsule, for I had done it myself to my own satisfaction, even with faulty technique, and I knew that Smith had many arts and tricks which his vast experience had enabled him to acquire, which would surely add safety and success in the more troublesome cases as well as the easy ones.

But were drawn-up, distorted pupils with incarcerated iris at the angles *necessary results* of his method? We all will agree that a patient can see as well out of one clear pupil as another, no matter what the shape may be, but nearly all are taught that incarcerations at

the angles and lips of the wound are a menace to the future of an eye. On the other hand, we will all agree that we have seen anterior synechia and incarcerations in our own cataract cases, which existed for many years without a single incident happening to show that they were at all dreadful.

The assistant continuing to hold the eyelids in the manner described, the patient is allowed to direct his eye in any direction he pleases. The cornea is usually collapsed. The proper lifting away of the eyelid and periocular tissues by the lid hook in the hand of the assistant takes off all lateral weight and the cornea sinks in with the flap side of the cornea lying quite deep in the vitreous, and the upper lip of the wound projecting like an eave and showing its clean-cut edge. The passage outward of the lens has widened the coloboma and caused the angles to be folded unto themselves fan-like; there are

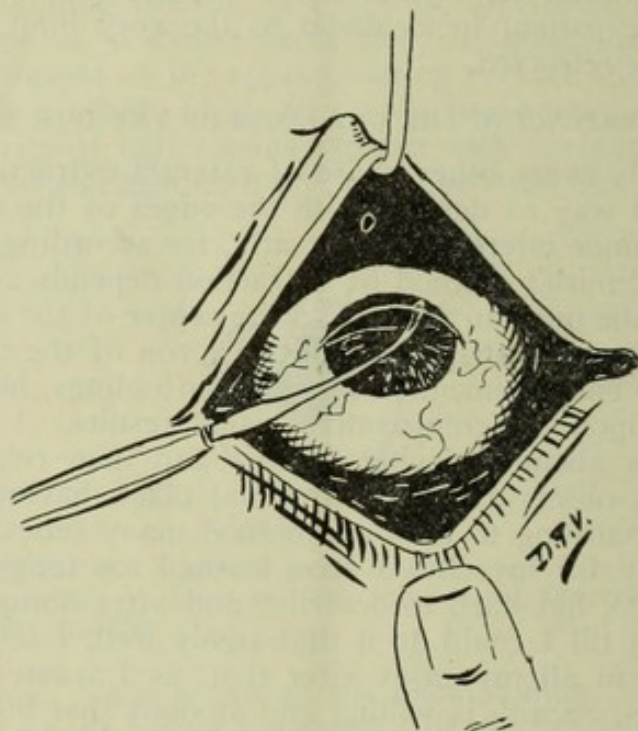


FIG. 32.—Illustrating Smith's way of separating the root of the cut iris from the shelf of the incision. The iris spatula is gently passed from one end of the incision to the other.

incarcerations or not, as the case may be, at the angles of the incision. The iridectomy has cut the sphincter and a part of the down-hanging iris above, but has left a small ruffle or apron which the parturient lens has jammed tightly against the posterior surface of the upper or overhanging eave, where it usually clings throughout the extent of the incision. The pupil is thus drawn up and the iris seems suspended like a hammock tied with the opposite ends in each angle of the incision. The operator looks under the eyelid by tilting his head toward his right shoulder. The eyelid held up by the assistant causes plenty of space like that produced by an open gable of an unfinished house, where one may look in under the rafters and roof. With the iris repositor pointed toward the summit of the eye, the spatula held at right angles to the cut projecting upper lip of the wound and somewhat vertical to it (Fig. 32), Smith gently separates the contact be-

tween the iris apron and the over-shelving scleral wound, passing the end of the instrument quite to the ciliary body, and, entering the wound at one extreme angle, tucking back the fold caught there, passing lightly but well under the shelf along the back surface to the other angle, where he likewise releases the adhesions, and going over the ground again carefully and very lightly, he will declare the operation finished. The assistant now removes the lid hook, gently replacing the lids to the globe. As soon as the weight of the eyelids and tissues are allowed to return to the globe, the corneal flap springs up in perfect adaptation to its upper edge. This technique, properly carried out, will leave the eye free from incarcerations of all kinds in, I would judge, 95 per cent. of the cases.

Smith pursued this technique in 99 per cent. of cases, but did not always employ the same instrument for doing it. He states that any clean instrument that is curved on the end, like the closed iris forceps or the lens hook, will answer quite well in his hands, although he

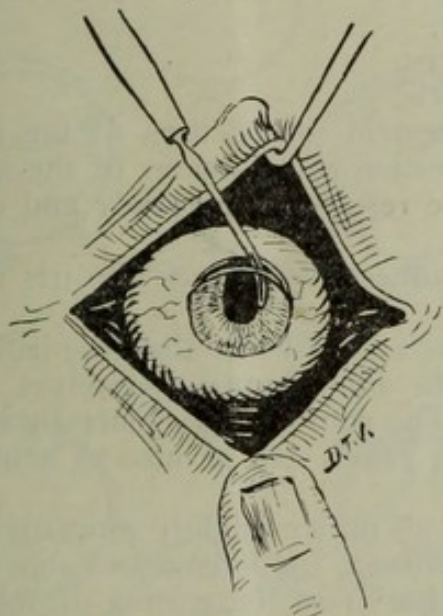


FIG. 33.—Showing how Smith replaced the iris at the angles where it had been caught.

prefers the grooved iris spatula, which is slightly pointed but blunt. (Fig. 3, D.)

The dressing is so simple that it can be described in a few words. A little yellow oxide of mercury ointment, 1 per cent. or 2 per cent., is lightly smeared along the lashes by a salve applicator; a small square of gauze torn from a bandage wet in 1:2000 bichloride solution is placed over each eye, a small bit of loose cotton is torn from the roll and laid on the square of gauze, and a wet gauze bandage is applied in figure of 8 fashion by a single turn for each eye and one for the forehead. The patient is carried on a litter made by using the canvas strip on which he had lain while on the table, poles being passed along the sides and held apart by iron bars with a ring in each end to slide over the end of the poles, and thus taken to his bed, where he is cared for by the native expert M.D., Dr. Diwanali, assistant surgeon in charge.

The entire time consumed in the actual operation from the moment

the speculum is introduced until the final dressing is applied is very often only a minute or two, five minutes is the exception; thus the eye is subjected to minimum exposure and instrumentation.

The "toilette" of the wound amounts to replacing the edges of the cut iris. There being no remains of cortical matter and no tags of capsule, the amount of manipulation and instrumentation after the iris is replaced is *nil*. No attention is paid to mucus or blood clots, as a rule. There is no flap of conjunctiva to replace. Thus the operation is completed soon after the lens is out. There is a complete omission of the capsulotomy step, and the operation is otherwise shortened by the time of lens delivery as well as in the preliminary cleansing of the eye for operation.

The natural and necessary steps Smith employs are the following, not counting cocainization:

1. Introduction of speculum and douching the eye.
2. The incision.
3. The iridectomy.
4. The lens delivery.
5. Replacing the iris.

I took great interest in the position of the pupil, the size of the coloboma and the question of adhesions of the angles of the cut iris. The following are the results of my study and observations on these points.

1. There are no adhesions between the iris and cornea excepting in rare instances.

2. The coloboma is a little wider than the iridectomy, showing that the iris edges must be folded unto themselves. The key-hole pupil was the exception. The contour was generally oval or U-shaped. So far as looks go these pupils are as nice to behold as the key-hole pupils.

3. The pupils are all drawn slightly upwards—not from adhesions between the iris and cornea, for I remarked above that adhesions were the rare exceptions—but from the curling or folding of the iris unto itself, I thought.

Smith's method is the only one that I know of which takes into consideration the adhesions between the apron of the cut iris and the shelving wound. All other methods of replacement are directed toward the cut vertical sides of the coloboma and are done with a view of setting the pupil low again, for in the old operation the pupil is drawn up after extraction and needs to be replaced quite as much as in Smith's operation.

I had done extraction in the capsule before I set out for India, having previously observed Greene, of Dayton, Ohio, operate many times in the Soldiers' Home Hospital, and it was through his kindness and enthusiasm that I was led to undertake this work. In those operations I did previously to my trip to India I always replaced the iris, unfolding its wrinkled sides and resetting the pupil low with perfect ease and success, employing the well-known and universally practiced method.

REGARDING VITREOUS LOSS.

While in England, I met Professor Fuchs and asked his opinion regarding the Smith operation. He said, "I do not like the loss of vit-

reous," and it is the general opinion the world over that the per cent. of vitreous loss, in the hands of those who have tried extraction in the capsule by what they thought was Smith's technique and honestly believed was Smith's method, was so high that Smith's own statement regarding his percentage of vitreous loss (8 per cent.) was either charged up to enthusiasm or to dishonesty. I am now in possession of the facts regarding the percentage of vitreous loss, having kept careful tally myself of over 500 cases done by eight different operators at Jullundur, seven of whom were visitors, and the actual percentage does not exceed 7 per cent., counting all kinds of cases. If you eliminate the complicated cases, glaucoma, juveniles, dislocated lenses, etc., the percentage is not over 5 per cent. My own results were consid-

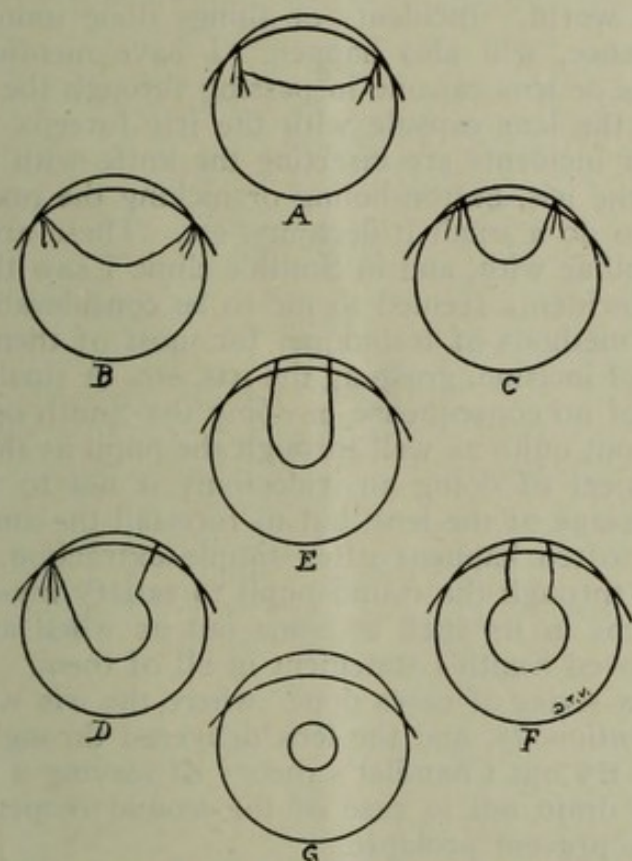


FIG. 34.—Showing some good and bad results. A, vitreous has escaped and iris is caught in the angles of the wound; B, angles of coloboma folded and caught in the wound should be liberated; C, faulty replacement, incarceration still present; D, one angle only is replaced; E and F, good result; G, no iridectomy has been done.

erably better than 5 per cent.—in fact, exactly 2 per cent.—but my cases were all uncomplicated, and I had Smith there to pilot me. As for the *amount of vitreous loss*, there were in over a thousand extractions only five or six where the amount exceeded one-third (estimated), and only ten or fifteen where the amount lost equaled one-third. In over 90 per cent. of the cases where vitreous was lost there was merely "a drop," certainly a *very small amount*. More would have been lost in every case if the eyelid and brow had not been properly held. I saw quite a number of cases "pop" just as the lens let go its fastenings, and an alarming amount of vitreous well up into the wound,

but the control of the eyelid and brow, the cessation of pressure with the hook, aided by the gravity of the vitreous, caused it to retract usually *in toto* back into the eye as if suctioned. I could not notice any difference in the after-behavior of the cases that had lost vitreous and those which had lost none, and I am brought to believe that by Smith's method a large amount of vitreous loss is practically impossible and a small amount of no consequence whatever. I think "vitreous escape" is not in the argument to be used against Smith's technique.

ACCIDENTS AND INCIDENTS. *

That "accidents will happen in the best-regulated families" is an old adage and can be applied to any operation done by the greatest experts of the world. Incidents or things done unintentionally, but of no consequence, will also happen. I have mentioned a few, as pricking the iris or lens capsule in passing through the aqueous chamber, wounding the lens capsule with the iris forceps in grasping the iris, etc. Other incidents are inserting the knife with the edge downwards, slicing the iris, button-holing or nicking the margin of the iris in attempting to do a small iridectomy, etc. These are things all operators are familiar with, and in Smith's clinic I saw them all, but the percentage of incidents seemed to me to be considerably smaller than with the older methods of technique, for most of them are overcome by his method of incision, grasping the iris, etc. A small button hole or a large one is of no consequence in doing the Smith operation, for the lens will come out quite as well through the pupil as through the coloboma. The object of doing an iridectomy is not to furnish a pathway for the passage of the lens, but to forestall the annoying prolapse of iris that so often happens after simple extraction. I did five or six extractions through the round pupil to satisfy myself that it is as easy for the lens in its shell to come out as when an iridectomy is done, and I proved Smith's statement in all of them.

There was a series of cases done where the iris was button-holed at the root *intentionally*, and the lens delivered through the pupil, the object being to try out Chandler's theory of leaving a button hole for the aqueous to drain out in case of the wound reopening during the healing stage to prevent prolapse.

Accidents and complications that I observed, taken from over a thousand cases, are the following:

1. Expulsive hemorrhage from the choroid at the completion of the operation (glaucoma), two cases.
2. Lenses lost in the vitreous through faulty technique, two cases.
3. Panophthalmitis, two cases.
4. Excessive loss of vitreous, a few cases (five or six).
5. Severe iridocyclitis, three or four cases.
6. Delayed healing, perhaps a dozen cases.

In a few cases where dense maculae corneae existed, involving the upper half or two-thirds of the cornea, downward extraction was done by Smith according to his method. In one or two cases the lens was delivered through an oblique incision. The entire technique is the same as in upward extraction, but the movements are reversed, of course, and the operator has to adapt himself to the new lines of pressure and resistance. The deliveries are as easily performed and

the results so far as prognosis is concerned are as good as in the upward extraction.

Smith's operation for cataract has its greatest sphere of usefulness in the cases of slowly ripening or immature cataract. It is no longer necessary for the patient to wait till he is blind and infirm from cataract. He may have his cataracts removed whenever he feels the handicap of failing sight, for the results in immature cases are uniformly good and lasting. It is also true that immature cataracts are more easily extracted by Smith's method than any other kind, and the chances of success are far better in these cases than by the old operation.

The first part of the paper is devoted to a general discussion of the problem of the origin of life. It is shown that the problem is one of the most important and interesting in the history of science. The author discusses the various theories of the origin of life, and shows that the most probable one is the theory of spontaneous generation. This theory is based on the fact that life is everywhere, and that it is not possible to explain its origin by any other theory.

The second part of the paper is devoted to a detailed discussion of the theory of spontaneous generation. The author shows that this theory is based on the fact that life is everywhere, and that it is not possible to explain its origin by any other theory. He also shows that the theory of spontaneous generation is based on the fact that life is everywhere, and that it is not possible to explain its origin by any other theory. The author also shows that the theory of spontaneous generation is based on the fact that life is everywhere, and that it is not possible to explain its origin by any other theory.

The third part of the paper is devoted to a detailed discussion of the theory of spontaneous generation. The author shows that this theory is based on the fact that life is everywhere, and that it is not possible to explain its origin by any other theory. He also shows that the theory of spontaneous generation is based on the fact that life is everywhere, and that it is not possible to explain its origin by any other theory. The author also shows that the theory of spontaneous generation is based on the fact that life is everywhere, and that it is not possible to explain its origin by any other theory.

The fourth part of the paper is devoted to a detailed discussion of the theory of spontaneous generation. The author shows that this theory is based on the fact that life is everywhere, and that it is not possible to explain its origin by any other theory. He also shows that the theory of spontaneous generation is based on the fact that life is everywhere, and that it is not possible to explain its origin by any other theory. The author also shows that the theory of spontaneous generation is based on the fact that life is everywhere, and that it is not possible to explain its origin by any other theory.

The fifth part of the paper is devoted to a detailed discussion of the theory of spontaneous generation. The author shows that this theory is based on the fact that life is everywhere, and that it is not possible to explain its origin by any other theory. He also shows that the theory of spontaneous generation is based on the fact that life is everywhere, and that it is not possible to explain its origin by any other theory. The author also shows that the theory of spontaneous generation is based on the fact that life is everywhere, and that it is not possible to explain its origin by any other theory.

