

The preputial or odoriferous glands of man / by Arthur Keith and Arthur Shillitoe.

Contributors

Keith, Arthur, Sir, 1866-1955.

Shillitoe, Arthur.

Royal College of Surgeons of England

Publication/Creation

London : Lancet, 1904.

Persistent URL

<https://wellcomecollection.org/works/h3atpmsx>

Provider

Royal College of Surgeons

License and attribution

This material has been provided by This material has been provided by The Royal College of Surgeons of England. The original may be consulted at The Royal College of Surgeons of England. where the originals may be consulted. Conditions of use: it is possible this item is protected by copyright and/or related rights. You are free to use this item in any way that is permitted by the copyright and related rights legislation that applies to your use. For other uses you need to obtain permission from the rights-holder(s).



Wellcome Collection
183 Euston Road
London NW1 2BE UK
T +44 (0)20 7611 8722
E library@wellcomecollection.org
<https://wellcomecollection.org>

3

THE PREPUTIAL OR ODORIFEROUS GLANDS OF MAN

BY

ARTHUR KEITH, M.D. ABERD., F.R.C.S. ENG.,

LECTURER ON ANATOMY, LONDON HOSPITAL MEDICAL COLLEGE

AND

ARTHUR SHILLITOE, M.B. CANTAB., F.R.C.S. ENG.

SURGEON TO OUT-PATIENTS, LONDON LOCK HOSPITAL

Reprinted from THE LANCET, January 16, 1904.

Digitized by the Internet Archive
in 2016

<https://archive.org/details/b22472885>

THE PREPUTIAL OR ODORIFEROUS GLANDS OF MAN.

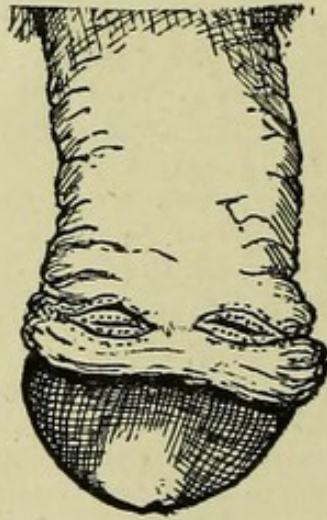
IN a considerable proportion of males in whom some slight degree of hypospadias is present certain curious and symmetrical markings are to be seen on each dorso-lateral aspect of the prepuce. These markings, which are represented in Fig. 1, consist of two or more crescentic reddish lines which meet above at a dorsal angle or fornix and below towards the frænum of the prepuce at a ventral fornix. They may be styled from their shape and appearance "preputial ocelli." In the oval area between the reddish lines are elevated folds on which may be seen minute openings and frequently the short stumps of hairs. An occasion arose which gave us an opportunity of examining microscopical sections through one of these preputial ocelli. We found it studded with large, wide-mouthed sebaceous glands. A reference to literature gave us no clue as to their nature; all text-books agree in stating that the skin of the distal two-thirds is destitute both of hairs and sebaceous glands. From the regularity of their form and the frequency of their occurrence in conjunction with hypospadias (they were well marked in the last nine cases of hypospadias with hooded prepuce examined at the Lock Hospital) we had no doubt that these markings were neither accidental nor pathological but were probably remnants of some structure or organ of which we were ignorant.

The first real clue as to the nature of these preputial ocelli was obtained from the examination of the foreskins of rodents. On the prepuce of developing rats and mice,¹ long before that structure has risen into a fold to cover the glans, a circular area of epithelium grows downwards into the subcutaneous tissue of the penis and in the course of development forms a compound sebaceous gland quite as large as a sultana raisin. When the foreskin rises into a fold

¹ Mr. C. B. Lockwood very kindly placed his splendid embryological collection at my disposal.—A. K.

the duct of the preputial gland opens just inside the free margin of the foreskin. Its secretion gives rise to a peculiar odour. This gland in mice and rats is evidently formed by the submergence of an area of sebaceous glands. In the pig a preputial gland is formed in the same manner. In the rabbit there is a series of sebaceous glands round the margin of the vulval orifice, but one of them in a recess behind the fold that represents the prepuce is especially large and secretes a substance with a characteristic odour. In the cat and in most members of that tribe the sebaceous gland which secretes the sexual odoriferous substance is derived

FIG. 1.



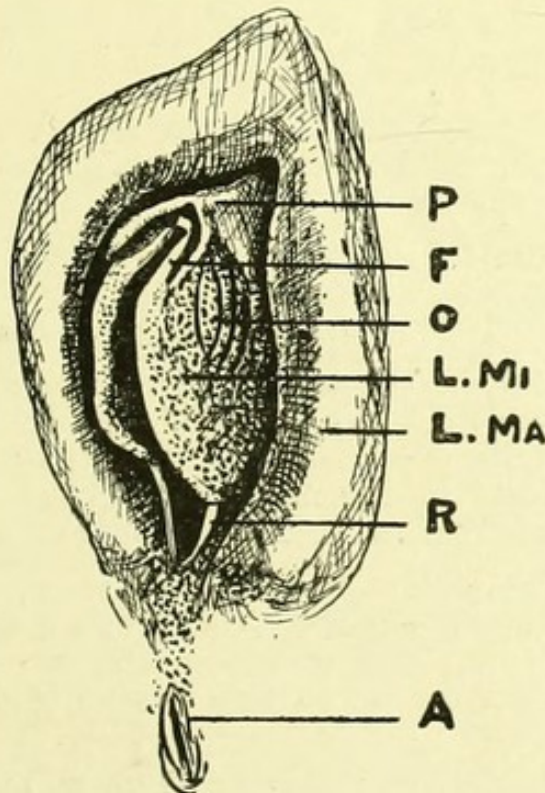
Dorsal aspect of a penis in a case of hypospadias, showing the ocelli on the prepuce.

from the circumanal and not from the circumvulval series, and lies inside the margin of the anus. A more extended research showed that throughout the mammalia, and to this law man is no exception, there is a fringe of specialised sebaceous glands surrounding the anal and urogenital apertures, which are functionally odoriferous glands and are connected with the sexual system. With castration, be these glands round the anus or round the urogenital openings, they cease to secrete their characteristic substances.

At first our search for the preputial glands in primates, animals much more nearly allied to man than those above cited, was disappointing; an examination of human embryos

at all stages of development was also, at first, without result, because we did not know where or what to look for. The first real evidence we found of them was in certain South American apes and it was not in the males, but in the prepuce of the clitoris of the females that we came across the same markings and structures as we found in the prepuces of hypospadiac man. The skin of the penis in apes and anthropoids is covered with hair and ordinary sebaceous

FIG. 2.



Vulva of a human foetus in the seventh month. The area is faintly stippled in which sebaceous glands are found. P, Prepuce. F, Frænum. O, Ocellus. L.MI, Labium minus. L.MA, Labium majus. R, Retinaculum. A, Anus.

glands. We ought to have recognised that the correlation of the ocelli with hypospadias indicated that the condition was to be sought for in the female—for hypospadias is undoubtedly a partial inheritance of a female condition.

On turning to the condition on the prepuce of the female these ocelli, sometimes poorly marked, but frequently very distinct, were always to be seen (Fig. 2). On the lateral

aspect of the prepuce, in the neighbourhood of the frænum preputii, an area of large sebaceous glands was constantly found on microscopical examination, although to the naked eye they may appear to be absent. They do not occur on the dorsal aspect of the prepuce or on the skin along the dorsal aspect of the clitoris. Dr. Robert Keith found them to occur on both aspects of the labia minora, an especial group being situated at each side of the clitoris in the depression between the prepuce and the labium majus. They vary greatly in development in different women. The inner aspect of the labia majora is studded with them. In a series of cases kindly inspected for us by Mr. Charles Gibbs at the Lock Hospital the following conditions were observed.

CASE 1.—The patient was a quadroon, married, aged 28 years. There was a well-marked preputial fold but no evidence of glands.

CASE 2.—The patient was single, aged 20 years. The prepuce and anterior extremities of the nymphæ were united into a ridge. There was no evidence of glands.

CASE 3.—The patient was married, and aged 38 years. The prepuce was well marked, the clitoris being small. The upper part of the vestibule beneath the clitoris showed two small blind holes in the mid-line, which represented the lacuna magna. There was no evidence of sebaceous glands.

CASE 4.—The patient was aged 22 years, single. There was a rudimentary clitoris. The prepuce and crura were represented by a slight elevation on each side, with a depression in the centre. There was no evidence of sebaceous glands.

CASE 5.—The patient was aged 23 years, married. There was a large clitoris; the crura and prepuce were well marked; no evidence of sebaceous glands was present.

CASE 6.—The patient was aged 24 years, married. The clitoris was well marked, the crura passing down into the nymphæ. There were a slight ridge under the pink mucous membrane and a hooded well-marked prepuce. Under the lens the appearance was like a ridge of sebaceous glands.

CASE 7.—There were two distinct rows of glands, six in the external, four in the internal row in the angle between the prepuce and the labium majus; all the genitalia were more greasy-looking than usual.

CASE 8.—The patient was single, aged 22 years. In the angle between the prepuce and the labium majus were four well-marked glands on the left, not so obvious on the right.

CASE 9.—The patient was married, aged 24 years. The nymphæ were covered with sebaceous glands which extended to the prepuce. On the left side was a row similar to that in Cases 7 and 8. The whole genitalia were very greasy.

CASE 10.—There was no evidence of sebaceous glands.

CASE 11.—The patient was a German, married. The sebaceous glands in the angles between the labium majus and the prepuce were continuous with those of the nymphæ.

CASE 12.—The patient was a half caste negress, single, aged 29 years. She had a well-marked prepuce and clitoris. There was a large number of sebaceous glands on the nymphæ, extending to the edge of the prepuce; none were present on the prepuce.

CASE 13.—The patient was a blonde. There was no pigmentation about the vulva. No sebaceous glands could be seen. In brunettes they are better marked.

CASE 14.—The clitoris, prepuce, crura, and anterior extremity of nymphæ were united into a curved ridge. There were one or two depressions in the vestibule like the orifices of glands.

CASE 15.—There was a pale pink mucous membrane. No sebaceous glands could be seen.

CASE 16.—The same conditions were present as in Case 15.

CASE 17.—The patient was single. Sebaceous glands were present in the angle between the labium majus and the prepuce but none on the prepuce. The genitalia were very greasy.

CASE 18.—The patient was married. There were sebaceous glands extending up to the clitoris.

CASE 19.—The patient was married. The prepuce was well marked; there were no sebaceous glands.

CASE 20.—The patient was single and aged 21 years. The sebaceous glands were well marked in the angle between the labium majus and the prepuce, also on the prepuce.

CASE 21.—The patient was single. There were well-marked sebaceous glands from the hair of the mons Veneris to the prepuce. These were huge and arranged in parallel rows. She had an atrophied uterus and her breasts were wasted. One ovary was removed five years ago.

CASE 22.—There were a large prepuce and clitoris, with smegma. No sebaceous glands were to be seen on the prepuce.

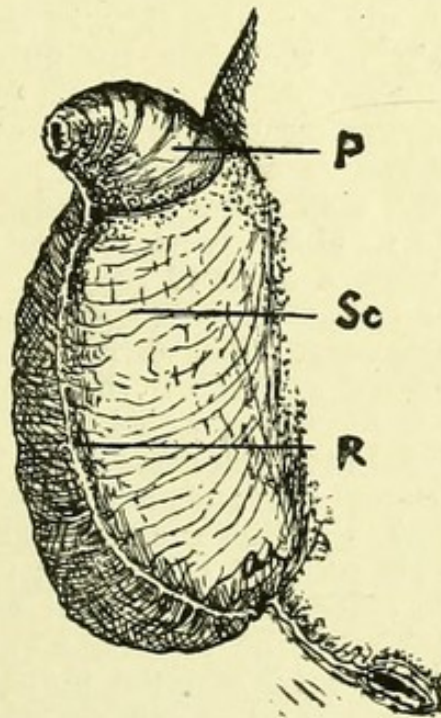
CASE 23.—The patient was single and aged 22 years. There was a well-marked bunch of sebaceous glands extending to the prepuce.

In the male department out of 504 cases examined during the months of July and September, 47 cases, or 1 in 10·7, were found to have abnormally placed meatus. 13 of these showed two or more openings through which the urine was passed. Since the end of May we have seen nine cases as depicted in Fig. 1. One of the nine showed two well-marked ridges extending from the ventral fornices, downwards, to be lost behind the misplaced meatus urinarius.

With this knowledge of the distribution of the sebaceous glands in the female to guide us we found that there was constantly present in the skin of the penis a series of glands beginning in the ventro-lateral aspect of the prepuce (see Fig. 3) and stretching backwards along the ventral aspect on each side of the raphé and ending in the ordinary sebaceous glands at the root of the penis and base of the scrotum. This gave us a clue to certain vexed points concerning the homology of the labia minora in the male. In the male these folds grow together on the ventral (perineal) aspect of the penis; the series of sebaceous glands on the ventral aspect represents the glands of the labia minora in the female. The retinacula of the labia minora, shown in Fig. 2, are the only parts which directly assist in forming the floor of the male urethra. Thus the conclusion we were led to concerning the nature of the preputial ocelli, found in cases of hypospadias, is that they are, like the condition of hypospadias itself, inherited from the female. In the same manner the male inherits the nipple and breasts and the rudiments of a vagina and uterus, and further, that the circumvulval or odoriferous glands of man are similar in nature to the corresponding glands of mammals, but in him they are developed in the female and only represented as rudiments in the male.

In the course of this research we failed to find any trace of Tyson's glands which have been described in every text-book of anatomy published since Tyson's time. To quote from the last edition of Quain's Anatomy : "Numerous sebaceous glands are collected round the cervix of the penis and corona glandis ; they are named the glands of Tyson or glandulæ odoriferæ, their secretion having a peculiar odour." It shows the strength of the faith of anatomists that they have for

FIG. 3.



Side view of the penis and scrotum of a child at full time. The area is faintly stippled in which sebaceous glands are found. P, Penis. Sc, Scrotum. R, Raphé.

nearly two centuries described glands which have not, and never had, an existence. Further, there is no written evidence that Tyson ever described or observed such.

On turning to a paper by Professor Tandler and Dr. Paul Dömény² we found that a number of leading continental investigators had denied their existence from time to time

² Wiener Klinische Wochenschrift, 1898, p. 555.

during the last 20 years ; they, however, had failed to find sebaceous glands in the prepuce as well as in the corona of the glans or the neck of the penis. They describe, however, a number of cysts in the neighbourhood of the frænum preputii.

Whence, then, comes the smegma which is found beneath the prepuce ? It certainly is not secreted by glands. Before discussing its origin it is necessary to turn to the development and nature of the prepuce. Rather more than two years ago Dr. D. Berry Hart published in the *Journal of Anatomy and Physiology* an excellent paper dealing with the morphology of the human urino-genital tract. In that paper he set forth quite a new view of the development of the prepuce. Up to the time he published his paper everyone regarded the epithelium which joins the prepuce to the glans penis as having been buried there by the growth of the prepuce forwards over the glans. He, on the other hand, regarded the epithelium as a solid ingrowth, which starting from the neighbourhood of the meatus urinarius, shelled off, as it were, a layer of skin to form the prepuce. One of us accepted that view and gave it prominence in a text-book on embryology. But on investigating the matter we found that the old account is the correct one—namely, that the prepuce is formed as a fold that rises up and grows forward like a hood over the glans. As the prepuce grows forward three changes occur : (1) a new epithelium is formed on its deep surface, the lining cells arising from the epithelium covering the neck of the penis ; (2) deep ingrowths of epithelium take place during the last month of foetal life into the free margin of the prepuce which is thus thrown into folds (if this process is arrested phimosis is the result) ; and (3) that in the lateral aspects of the penis ridges of epithelium grow into the prepuce and give rise to folds. In cases of hypospadias in the male, and as a normal process in the female, these ingrowths are few in number and limited in extent. It is these ingrowths which give rise to the red lines seen in the preputial ocelli. The epithelium which covers the neck of the penis and lines the prepuce is of a peculiar nature. It is clearly allied in structure and nature to the epithelium which forms the sebaceous glands. When the cells desquamate they are transformed not as are the cells of the skin into a corneous substance but into a substance closely allied to sebum—smegma.

The skin of the penis of man is peculiar in being destitute of hairs. In that man differs from every other primate. This

we believe is due to the fact that the skin on the dorsum of the human penis is, comparatively speaking, an insertion or new growth that separates the prepuce from the skin over the symphysis pubis. The origin of the dorsal skin of the penis characterised by the absence of hairs and sebaceous glands may be related to the posture in which connexion is effected in man.

