

**The morbid anatomy of periodontal disease / By J.F. Colyer, L.R.C.P. Lond.,
M.R.C.S., Eng., L.D.S.**

Contributors

Colyer, Frank, 1866-1954
Royal College of Surgeons of England

Publication/Creation

[London :] : C. Ash, 1914.

Persistent URL

<https://wellcomecollection.org/works/sm8wcedt>

Provider

Royal College of Surgeons

License and attribution

This material has been provided by The Royal College of Surgeons of England. The original may be consulted at The Royal College of Surgeons of England.

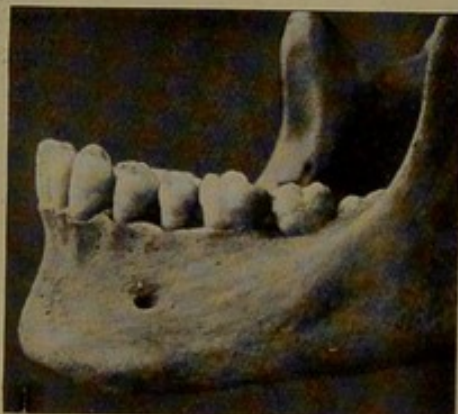
Conditions of use: it is possible this item is protected by copyright and/or related rights. You are free to use this item in any way that is permitted by the copyright and related rights legislation that applies to your use. For other uses you need to obtain permission from the rights-holder(s).

THE MORBID ANATOMY OF PERIODONTAL DISEASE.*

By J. F. COLYER, L.R.C.P. Lond., M.R.C.S. Eng., L.D.S.

THE odontological collection in the Museum of the Royal College of Surgeons of England contains an excellent, probably unique, series of specimens illustrating the morbid anatomy of

FIG. 1.



Mandible of female, aged 22, with an alveolar process which may be regarded as normal.

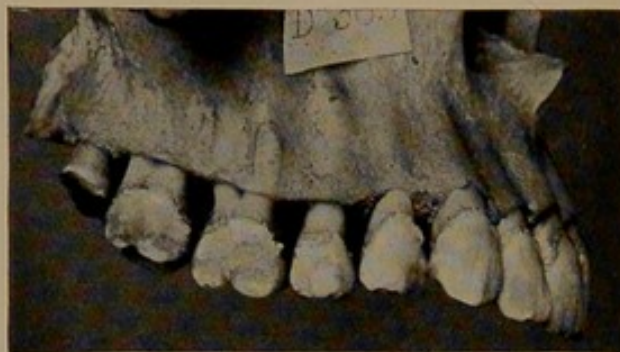periodontal disease. The specimens include examples of the disease in man as well as in the lower animals, the value of the collection being enhanced by the fact that all stages of the disease are illustrated. The object of this paper is briefly to describe the more instructive specimens in the collection.

* A museum demonstration given at the Royal College of Surgeons of England on November 6th, 1912, with additional matter and illustrations.

and palatal aspects. This stage is shown in Fig. 5. The points to be noted are:—

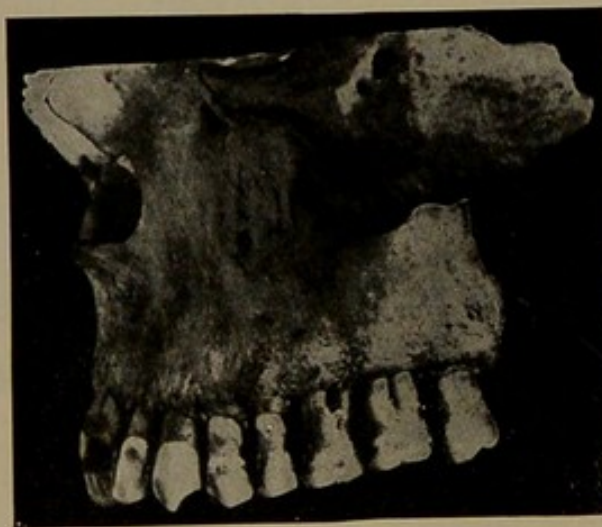(1) The small destruction of bone around the front teeth compared with that around the premolars and molars ; and

FIG. 5.



Maxilla in which the destruction of the bone has advanced beyond the stage shown in Fig. 3.

FIG. 6.



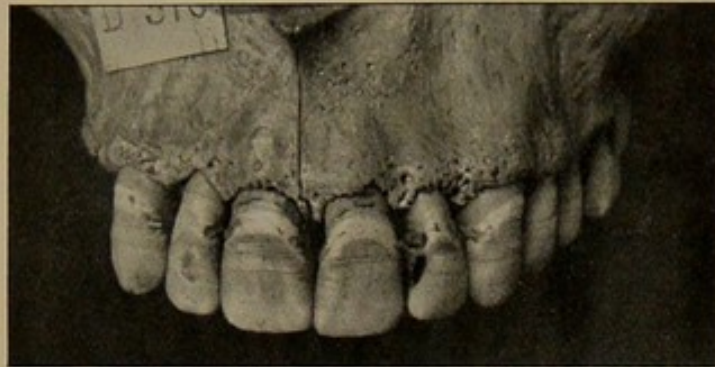
Maxilla showing considerable destruction of the alveolar process.

(2) The greater loss of tissue around the molars compared to that around the premolars.

A further stage of the disease is shown in Fig. 6. The bone has disappeared to the extent of exposing about half of the roots

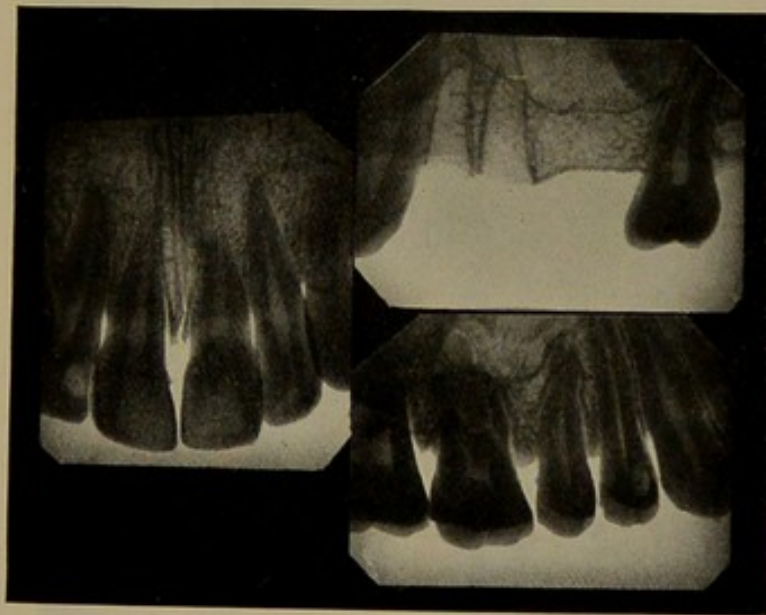
of the incisors and two-thirds of the roots of the molars. Around the canine and premolars the bone destruction is less advanced.

FIG. 7.



Specimen in which the disease probably commenced around the incisors.

FIG. 8.



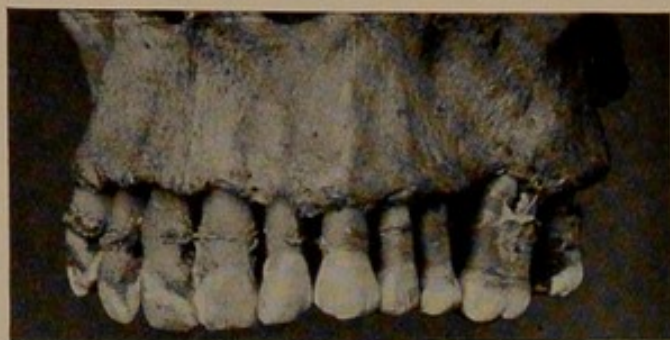Skiagrams of specimen shown in Fig. 7.

The extent of the bone lesion and the resistance of the tissue between the central incisors is clearly shown.

A specimen in which the disease probably commenced around the incisor teeth is shown in Fig. 7. There is a loss of bone

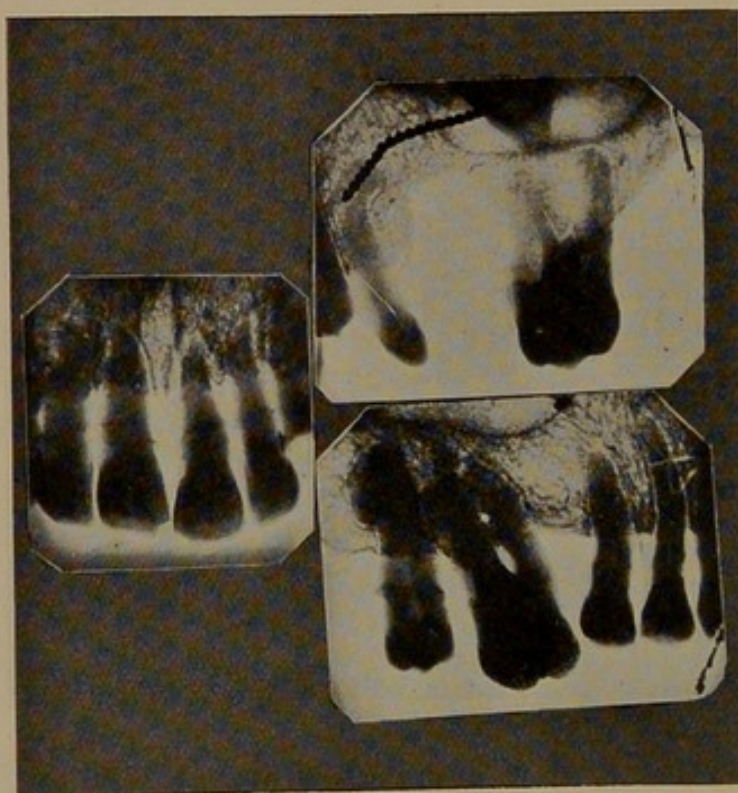
between the teeth, and the roots on the labial aspects are uncovered. The margin of the bone shows the pitted, irregular

FIG. 9.



This specimen from a male, aged 30, shows the morbid anatomy of an advanced case.

FIG. 10.



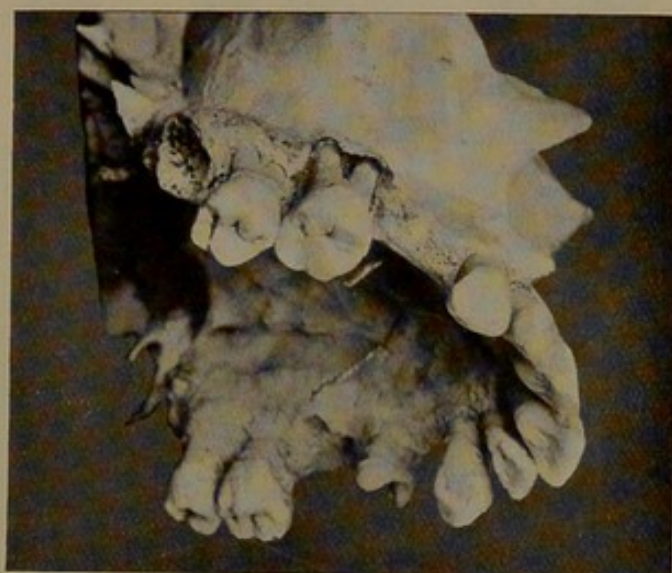Skiagrams of Fig. 9.

appearance characteristic of rarefying osteitis. It will be observed that there has been less destruction of bone between the central

incisors than between the other front teeth. An examination of the specimen shows that the destruction of bone is more advanced around the incisors than the molar teeth. The skiagrams (Fig. 8) bring out clearly the extent of the bone lesion and also the resistance of the tissue between the central incisors.

The specimen shown in Fig. 9 from a male, aged 30, shows in an excellent way the morbid anatomy of an advanced case. The bone around the incisors has almost disappeared, and the molar

FIG. 11.

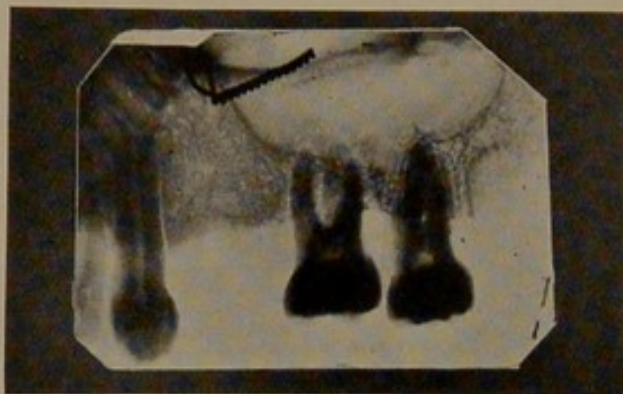


Maxilla showing cup-shaped absorption of the bone around the right first molar.

teeth are uncovered to near their apices. Cup-like spaces around the teeth are evident, this appearance being due to the fact that the bone bordering the tooth disappears first. The appearance of the bone shows that there has been a marked rarefying osteitis. Nodular deposits of calculus are present on the teeth, and it will be observed that these are, in the case of the incisors, canines, and premolars, well away from the margin of the bone. The skiagrams of this specimen are shown in Fig. 10. The cup-shaped absorption of the socket is well seen in the right first molar of the specimen illustrated in Fig. 11. Around the second molar the

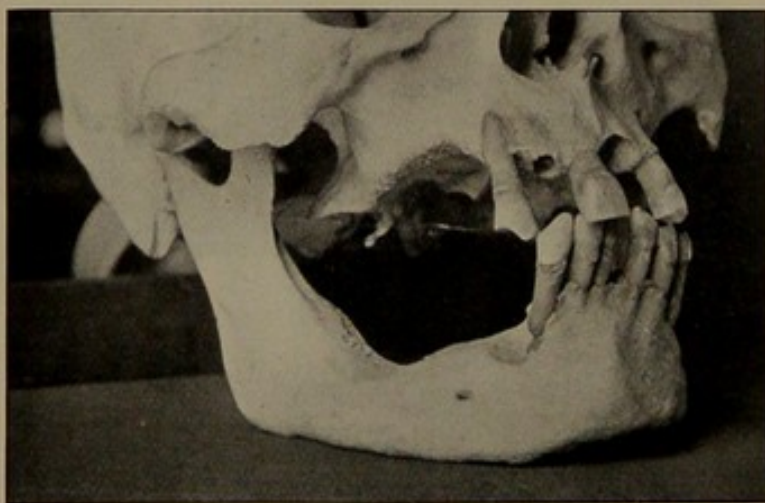
destruction of the bone has been of a more chronic type, the cup-shaped absorption being absent. The skiagram of these teeth (Fig. 12) shows a very distinct difference. Around the roots of

FIG. 12.



This skiagram of the first and second molars in Fig. 11 shows the different degrees of bone destruction around these teeth.

FIG. 13.



Shows a final stage of the disease; the teeth have fallen out owing to the extreme loss of the surrounding bone.

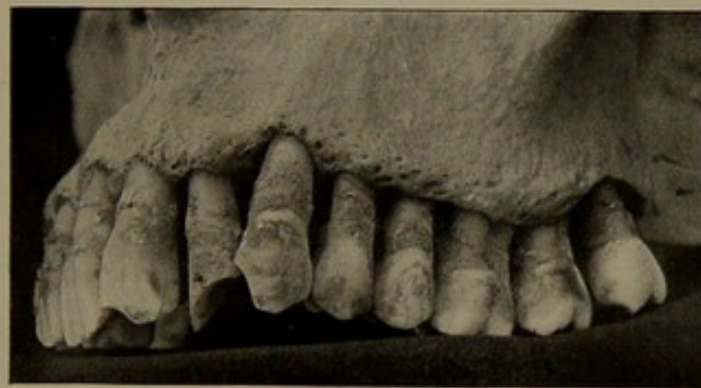
the first molar there is a definite clear area and an absence of the dense layer which marks the outline of the normal socket. The bone around the tooth shows definite signs of rarefying osteitis. The bone bordering the roots of the second molar still retains the

dense appearance, and indicates that the rarefying process has not spread deep into the bone around this tooth.

The final stage of the disease is reached by the teeth falling out owing to the extreme loss of the surrounding bone. An excellent example is shown in Fig. 13. The premolars and molars have been lost and the alveolar process has entirely disappeared—a condition in the living subject represented by an absence of “ridges.” The mandibular canine in this specimen shows, in a graphic manner, how the final loss of the tooth is brought about.

In specimens where the teeth show marked attrition the outer

FIG. 14.



A specimen in which the bone shows marked reaction.

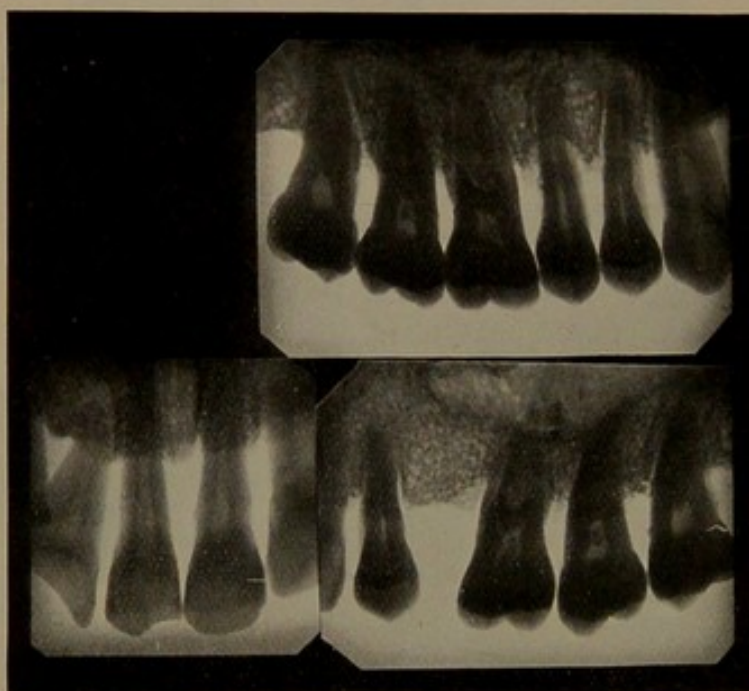Note the thickened margin of the alveolar process.

aspect of the alveolar process is often thickened and the rarefaction of the bone is limited to the alveolar margins. A case of this type is shown in Fig. 14. The skiagrams of this specimen (Fig. 15) show that the rarefying process is, to a great extent, limited to the surface, and has not spread deep into the sockets. Compare the skiagraph appearance of the bone around the incisors with that around the incisors shown in Fig. 10. The marked attrition of the teeth in this type of case suggests that the function of mastication has been efficiently performed, with the result that the bone around the teeth has been kept well nourished with a

plentiful flow of blood, and is thus more easily able to react to injury.

A more marked example of thickening of the bone is shown in Fig. 16. The position of the calculus in its relation to the margin of the bone is sufficient evidence that well-defined pockets existed around the teeth. The surface of the bone around the tooth shows signs of a rarefying osteitis, but there is no cup-like

FIG. 15.



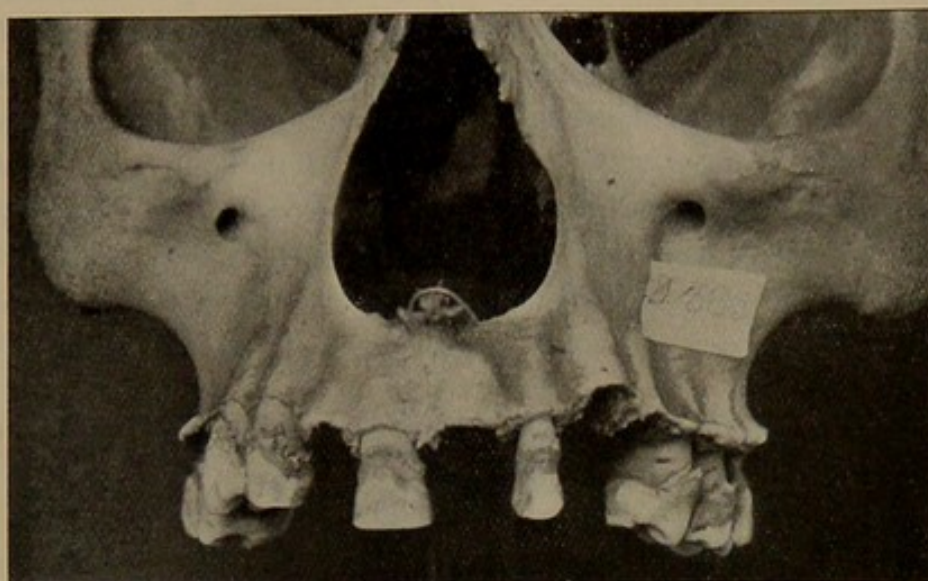
These skiagraphs of Fig. 14 show that the rarefaction of bone is to a great extent limited to the surface.

absorption of the bone. Beyond the surface the bone is thickened, indicating a "sclerosing" inflammation. This specimen shows a well-formed arch and teeth well worn by mastication, suggesting good functional activity.

An example of the formation of nodular masses of bone is shown in Fig. 17.

There is a type of case met with in practice in which the destruction of the bone has progressed to a far greater extent on

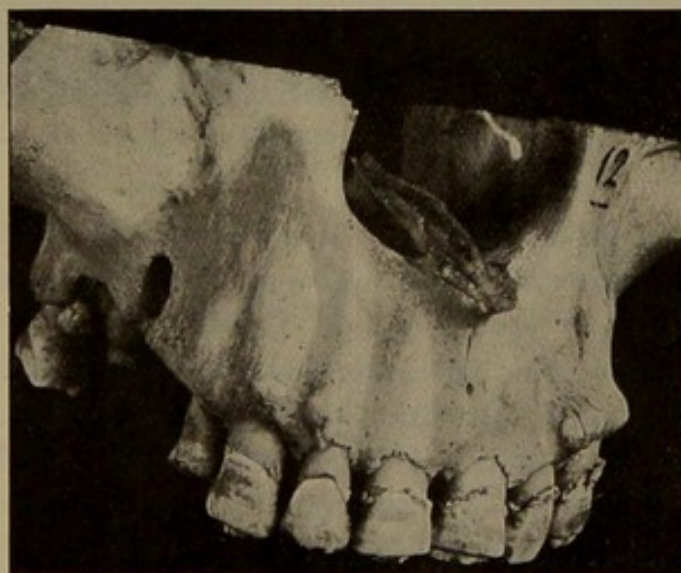FIG. 16.



A specimen from a very chronic case showing considerable thickening of the margin of the bone.

the labial and palatal aspects of the teeth compared to the approximal. In many of these patients the gum margin is but little above the neck of the tooth, and a probe inserted between

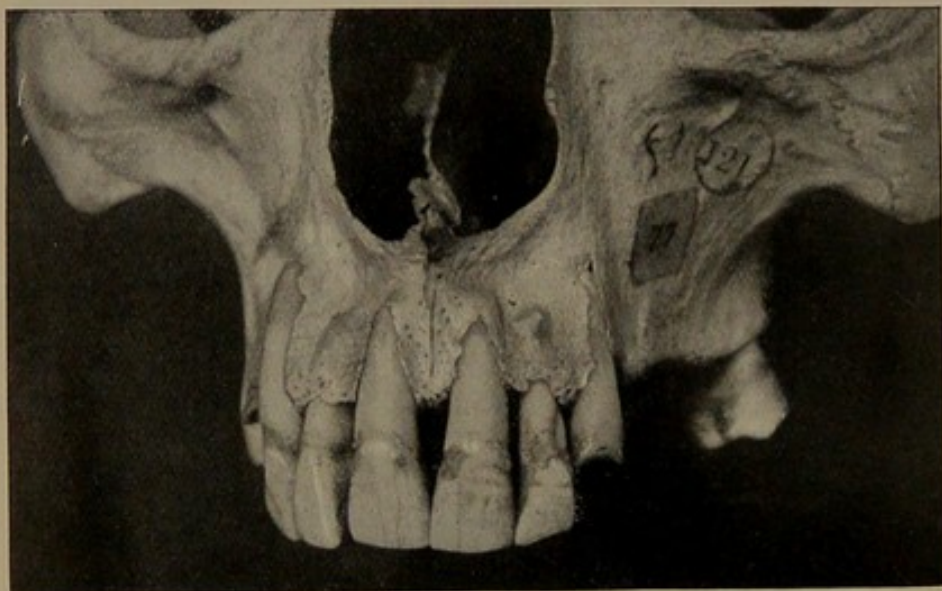
FIG. 17.



A specimen showing the formation of nodular masses on the outside of the alveolar process.

the gum and tooth will be found to pass almost up to the end of the root. This condition is generally seen in the anterior teeth, and often in patients presenting the condition where the teeth are unduly prominent. A specimen illustrating the morbid anatomy of this type of case is shown in Fig. 18. The bone on the labial aspects of the right canine and central incisor has completely disappeared; the left central incisor and canine are only covered by bone in the neighbourhood of the apex. Note in this specimen

FIG. 18.



In this specimen the bone destruction is most marked on the anterior aspects of the teeth.

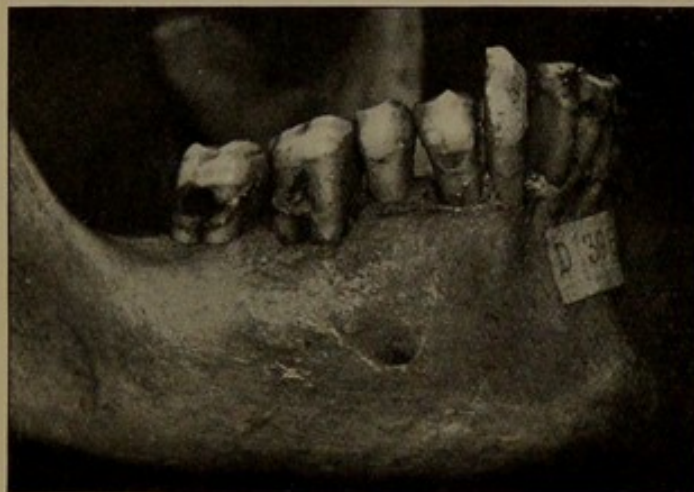the deposit of calculus around the necks of the teeth and the freedom from calculus of the remaining exposed portion of the roots.

If we examine this specimen from the point of view of the position of the teeth in relation to the bone, we shall notice that the arch of the teeth is decidedly narrow and that the general direction of the teeth is too vertical. In the normal the slope of the upper teeth is outwards; that is to say, the crowns occupy the arch of a larger circle than the roots. In the specimen under consideration the crowns slope slightly inwards and occupy a

smaller circle than the roots. In the normal arrangement the strain in mastication tends to force the roots towards the body of the bone, which is well able to resist, and there is no undue pressure on the outer alveolar plate. In the specimen shown in Fig. 18 the direction of the teeth would seem to lead to undue strain on the outer alveolar plate, and this, combined with, in all probability, a deficiency of "power of reaction," leads to a thinning of the bone. The result is that this weak area in the alveolar process rapidly succumbs to toxic processes.

This want of development of the alveolar process around

FIG. 19.



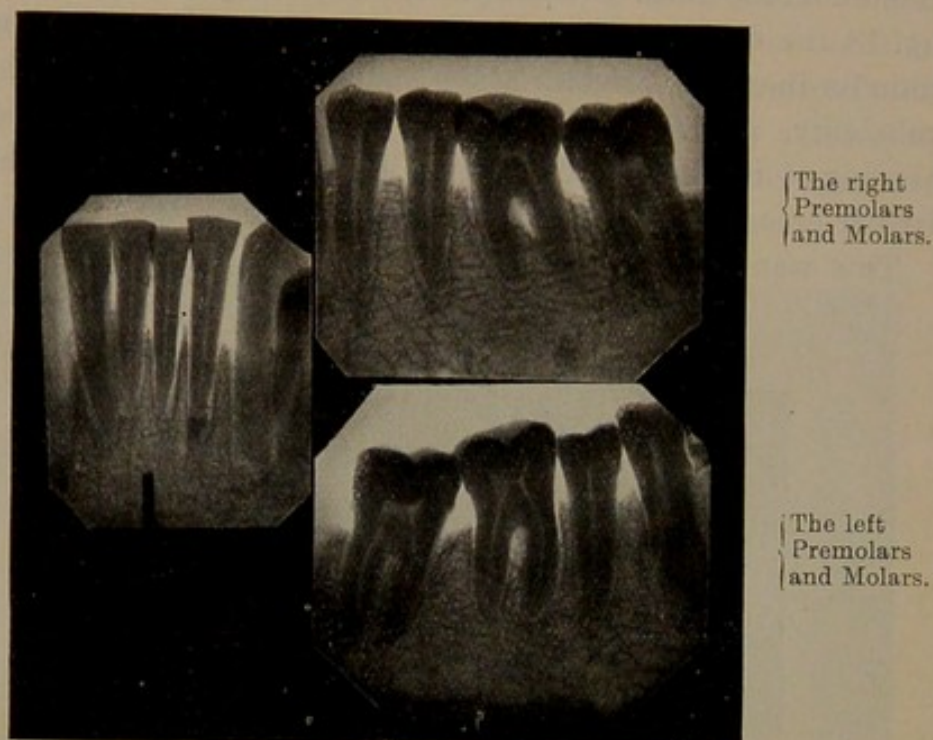
Mandible from an advanced case.

individual teeth is of constant occurrence, and whatever may be the correct explanation of the condition, it is only reasonable to think that such tooth sockets must naturally be lowered in their resistance to pathological processes.

A point worthy of notice is the difference in the spread of the disease in the maxilla compared with that in the mandible, and this is especially marked in the region of the molars (Figs. 19 and 20). This limitation of area of the bone destruction in the mandible is of interest, and is to be accounted for by the different nature of the osseous tissues in these two bones. In the maxilla the bone is

of a much more cancellous character than that in the mandible. This difference in the spread of the disease in bones of different

FIG. 20.



Skiagrams of the specimen shown in Fig. 18.

FIG. 21.



Teeth from a case associated with multiple arthritis.

density is, as we shall subsequently see, well brought out in considering the disease in the lower animals.

The series of specimens just described indicates that the bone lesion is a progressive rarefying osteitis which commences at the

margin of the tooth socket and eventually destroys the bone until the tooth is shed owing to the loss of its attachments.

THE TEETH.

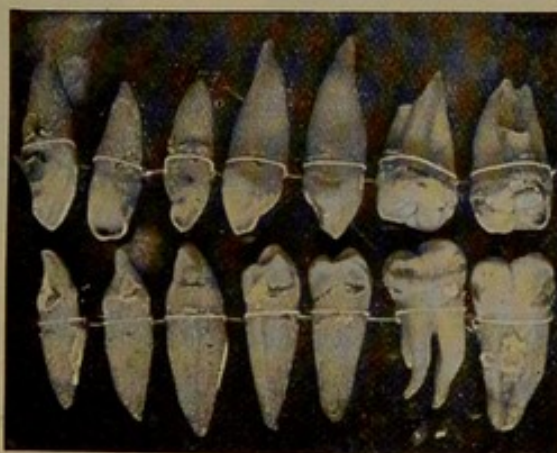
The teeth exhibit definite changes. The hard tissue shows absorption, and the periodontal membrane is thickened—indications of a chronic inflammatory process. Teeth removed from a series

FIG. 22.



Teeth from an advanced case which had been treated for two years with vaccine.

FIG. 23.



Teeth showing changes at apical portions.

of cases are shown in Figs. 21, 22, and 23. The teeth illustrated in Fig. 21 were from a man, aged about 34, who was a mouth-breather and was suffering from mucous colitis. One year previously he had an attack of arthritis involving several of the large joints. The roots of the teeth showed signs of rapid absorption. The condition of the teeth may be taken as an index of

the amount of rarefying osteitis. Let me explain this point more fully. Absorption of the hard tissues around the apex of the tooth indicates the presence of periodontitis. You cannot have periodontitis without pathological changes in the adjacent bony tissue. The more rapid the absorption of the tooth the more extensive will be the rarefying osteitis, and the greater the degree

FIG. 24.

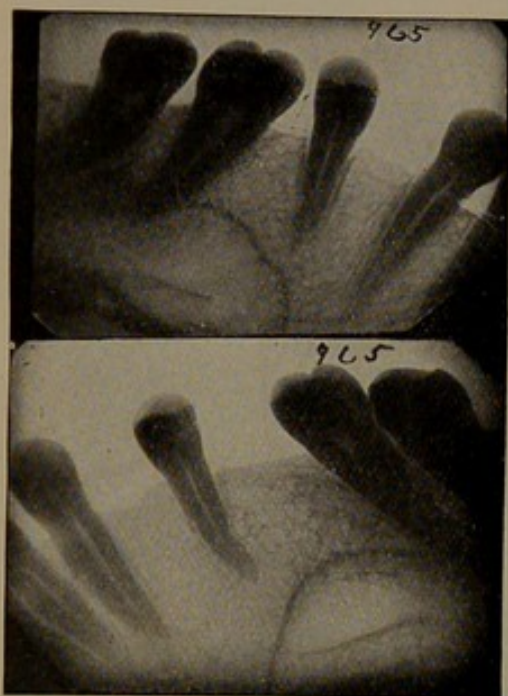
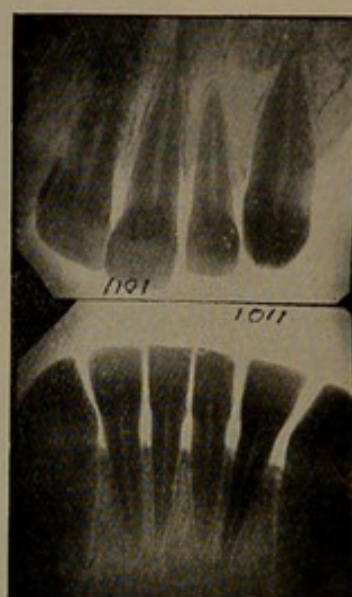


FIG. 25.



Skiagraphs of the case shown in Fig. 23.

of rarefying osteitis the greater will be the liability to direct infection of the tissues.

The molar teeth frequently show large masses of adventitious tissue in the cleft between the roots, indicating extensive loss of osseous tissue at these points. The specimens shown in Fig. 22 are very good examples of the condition of the teeth from cases exhibiting deep pockets and profuse suppuration. For two years treatment by vaccines had been tried, but the patient, who was suffering from marked septic poisoning, continued to "run down hill." The removal of the affected teeth, fourteen in number, brought about a rapid improvement in health.

An examination of teeth removed from certain cases of periodontal disease indicates that with the formation of a pocket around the tooth pathological changes commence around the apex of the tooth. This is well demonstrated in the teeth shown in Fig. 23. In this case there was a persistent gingivitis, but as far as could be ascertained neither the pockets nor the bone destruction were very extensive (Figs. 24 and 25). The teeth on removal showed that around the apices there had been active trouble, as evidenced by the absorption of the tooth tissue which had occurred. This condition can be explained as follows:—From the septic focus around the neck of the tooth absorption of toxins or organisms takes place through the periodontal membrane, probably by lymphatics. The material absorbed is held up, as it were, in the tissues around the apex. In other words, there is probably a natural defence at this part of the tooth to prevent the organisms and toxins, etc.; the tissues around the apex naturally react to injury—that is to say, the phenomena of inflammation appear. The formation of these septic foci around the apices of the teeth has, so far as I know, not been recognised, but it is clear that it is an important factor to be reckoned with in considering treatment.

The teeth in many cases are very brittle. Mr. J. G. Turner,* in drawing attention to this curious fragility of the teeth, suggested that the nutrition of the dentine was probably affected by toxins absorbed *via* the cementum. I have subjected a series of teeth from cases of periodontal disease to staining in borax carmine, and have come to the conclusion that the change that occurs in the tooth is an increase in the calcification of the soft parts of the dentine and cementum. The toxins injure the tooth tissues, with the result that, like other tissues in the body, they react. The reaction takes the form of an increased calcification of the soft contents of the dentinal tubes and cemental lacunæ, with the result of an increase in brittleness.

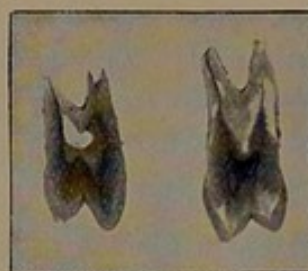
* Proc. Roy. Soc. Med. (Odonto. Sec.), May 25, 1908.

This view is supported by an examination of the teeth themselves. If held up to the light, they seem to be more translucent than in the normal, the translucency being most marked about the apex. If teeth showing this condition are immersed for six to eight weeks in borax carmine, this translucent area refuses to stain to the same extent as the remainder of the tooth, and this suggests

FIG. 26.

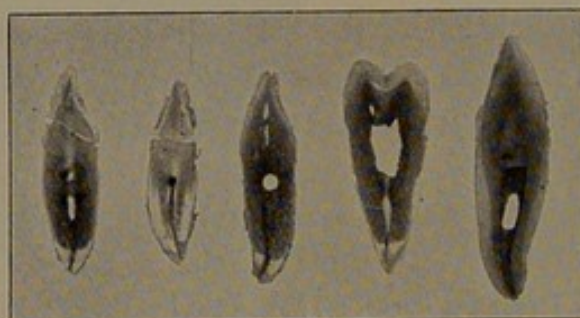


FIG. 27.



Teeth from cases of periodontal disease showing translucent areas.

FIG. 28.



Teeth from a case of periodontal disease showing translucent areas.

that the soft tissue normally present has undergone calcification. Sections of teeth from three cases of periodontal diseases are shown in Figs. 26 to 28.

II.—THE DISEASE AS SEEN IN ANIMALS.

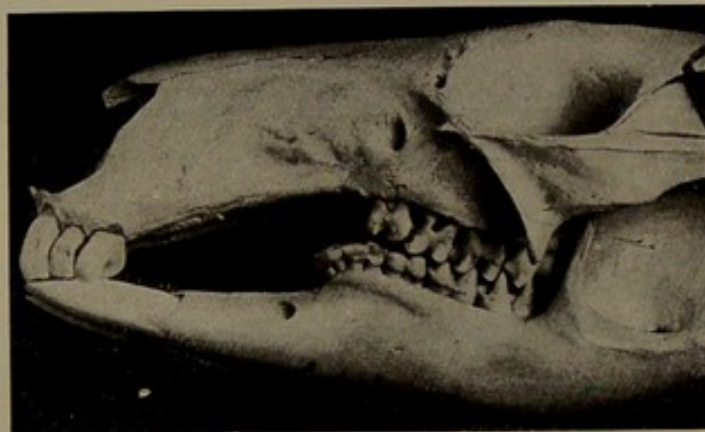
Periodontal disease is of frequent occurrence in horses, in cats and dogs, and in wild animals that have been kept in captivity. A study of the disease in these animals is most

instructive, and throws considerable light on the etiology and pathology of this serious affection. For convenience we may consider this section under two headings: (a) wild animals and (b) domestic animals.

(a) WILD ANIMALS.

The odontological section in the Museum of the Royal College of Surgeons of England contains a unique collection of skulls showing the disease in a wide range of animals. There are examples in rodents, marsupials, herbivora, monkeys, edentata,

FIG. 29.



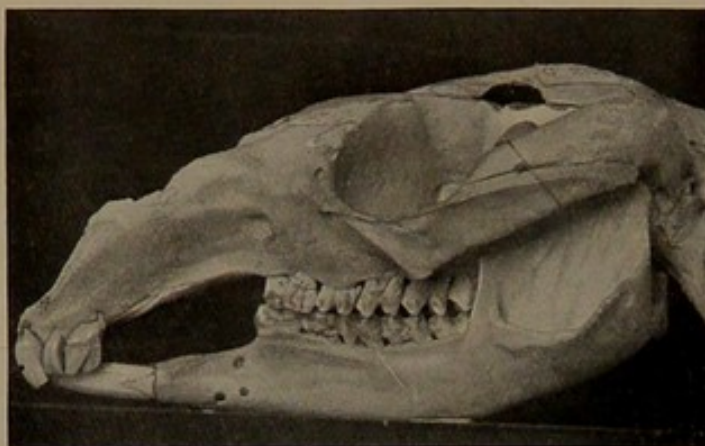
Macropus bennetti (Bennett's Wallaby), showing an early stage of periodontal disease. The loss of bone is more marked in the maxilla than in the mandible.

and the small and large carnivora. As the first example of the disease in wild animals we may take a series of four specimens showing various stages of the disease in the kangaroo and its allies. An early stage is to be seen in a Bennett's wallaby (*Macropus bennetti*) (Fig. 29).

In the maxilla the septa between the anterior teeth have been partially destroyed, and in the region of the first molars the bone shows signs of rarefying osteitis. A more advanced stage can be seen in the skull of a brush-tailed kangaroo (*Petrogale penicellata*) (Fig. 30) in the same collection. The disease

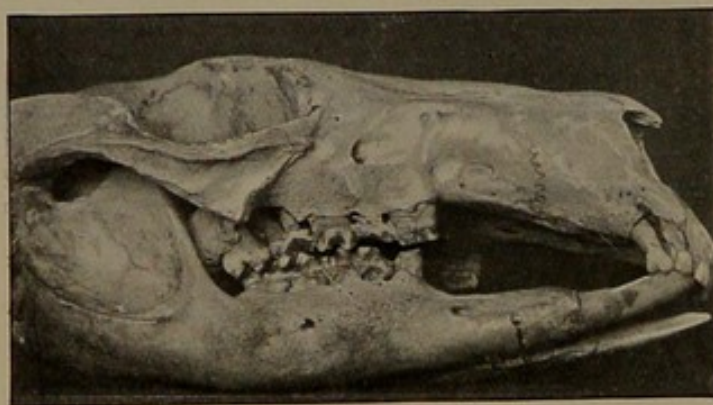
here is more generally distributed, the mandibular teeth being more affected than in the preceding specimens. A slight deposit of calculus is present on the teeth. A skull of macropus (species

FIG. 30.



Petrogale penicellata (Brush-tailed Kangaroo). In this specimen the disease is more advanced than in specimen Fig. 29.

FIG. 31.

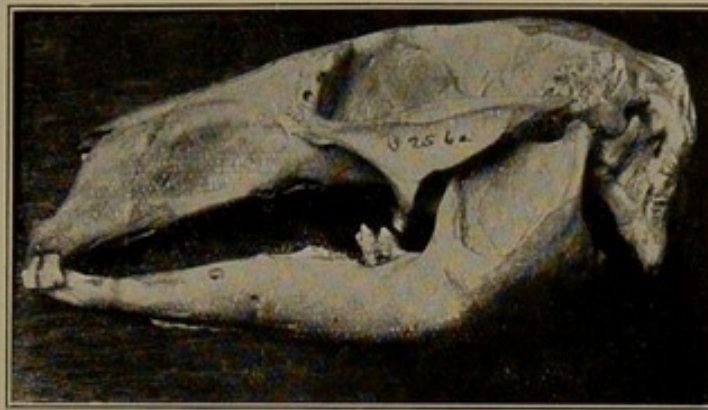


Macropus. Species unnamed. In this specimen the disease is well advanced, more especially in the region of the maxillary molars.

unnamed) (Fig. 31) takes us a stage further. Here the bone has been extensively destroyed in the neighbourhood of the right maxillary third molar; the bone shows plenty of signs of rarefying osteitis, while in the mandible there is a marked

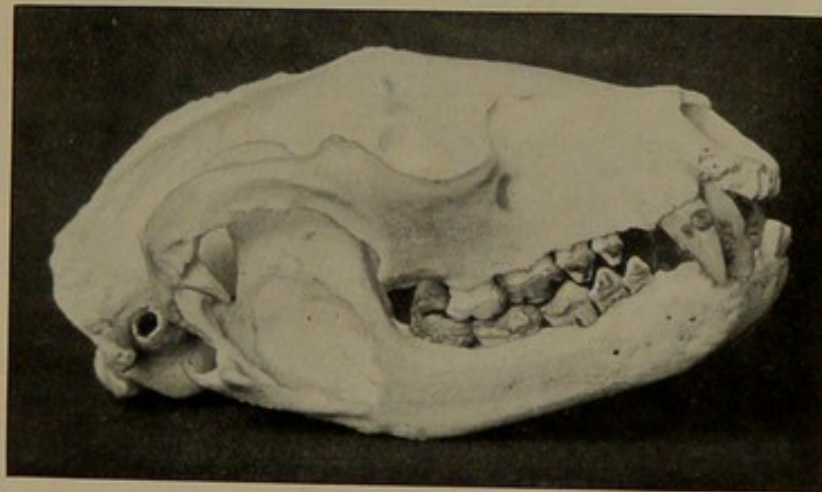
thickening of the bone in connection with the right first molar. Lastly, there is the left half of the skull and mandible of a kangaroo, in which all the molars have been lost with the

FIG. 32.



Macropus. Species unnamed. The majority of the teeth have been lost from the disease.

FIG. 33.



Procyon cancrivorus (Crab-eating Raccoon). An early stage of the disease.

exception of one in the maxilla and one in the mandible (Fig. 32). The bone around both these has been extensively destroyed.

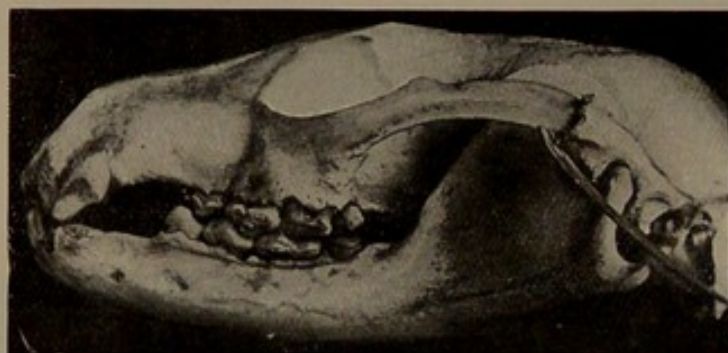
In the carnivora a similar gradational series can be traced, the point of interest being that the disease tends to spread more

rapidly in the maxilla than the mandible, owing probably to the less dense character of the former bone.

In Fig. 33 we have an early stage of the disease in a crab-eating raccoon (*Procyon cancrivorus*). The septa between the premolars and molars have been destroyed and pockets have been formed.

The next specimen, a masked paradoxure (*Paradoxurus larvatus*), China (Fig. 34), shows a further stage. The destruction of the bone around the maxillary molars is more marked and there are definite signs of rarefying osteitis. In the mandible

FIG. 34.



Paradoxurus larvatus (Masked Paradoxure). In this specimen the destruction of the bone in the maxilla compared with that in the mandible is well marked.

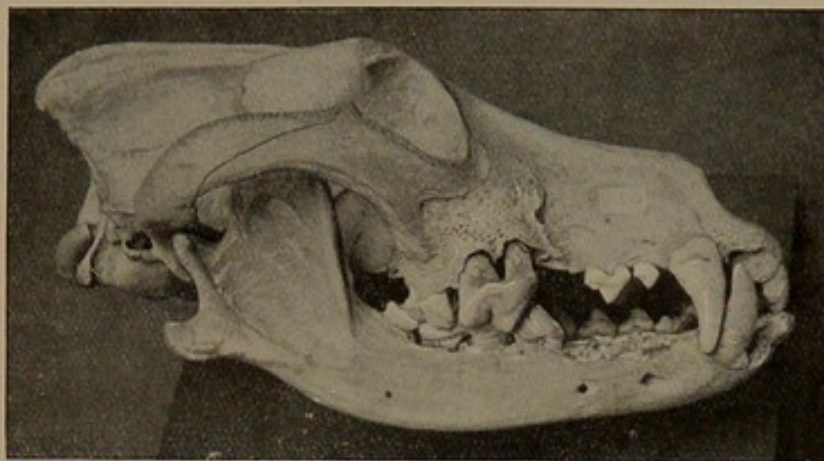
the disease is not so advanced, and the outer aspect of the bone does not show signs of rarefying osteitis.

A further step in the destruction of the tooth socket is shown in Fig. 35, an example of the disease in the common wolf (*Canis lupus*). Here the bone around the maxillary fourth premolar has almost disappeared. The cup-like absorption of the socket is well seen, and the spread of infection into the bone demonstrated by the large area of rarefying osteitis. In the mandible the disease is not so advanced, and here again, as in the specimen of the paradoxure, the outer layer of bone of the mandible does not show signs of rarefying osteitis.

The final stage in the destruction of the socket is admirably

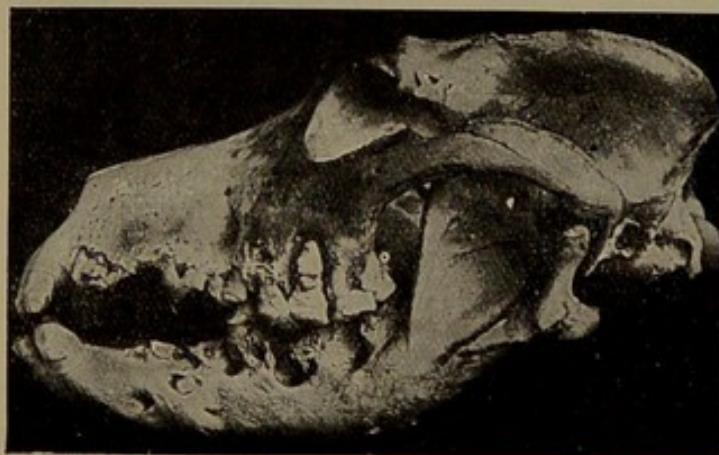
shown in Fig. 36, the skull of a spotted hyena (*Hyæna crocuta*). Many of the teeth have been lost, but the first molar is just held

FIG. 35.



Canis lupus (The Common Wolf). This specimen shows very clearly the "cup-like" absorption of the bone around the maxillary fourth premolar.

FIG. 36.



Hyæna crocuta (Spotted Hyena). An advanced stage of the disease.

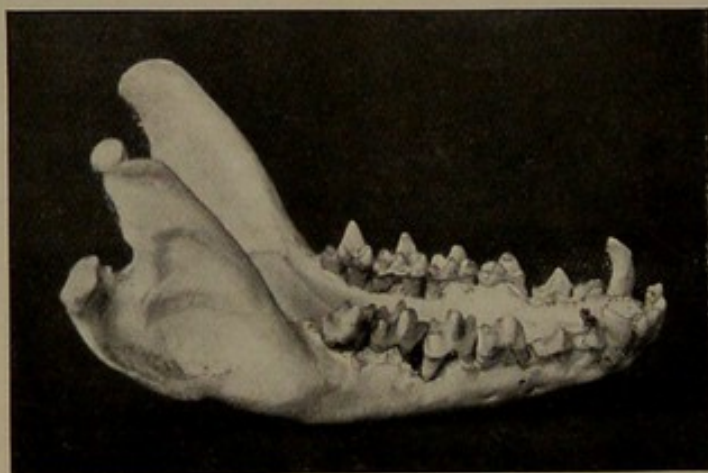
in position by a thin lacework of bone. This animal was in the Zoological Gardens only about nineteen months.

Amongst the small carnivora there are four examples in suricates (*Suricata tetradactyla*). The mandible would seem to be

more affected than the maxilla, and it is possible that this is due to the shape and arrangement of the teeth in this animal. In the mandible the molars are often slightly crowded, and the shape of the teeth assists in the lodgment of food. In Fig. 37 is depicted the mandible of one of these animals. The slightly irregular setting of the premolars and molars is seen in addition to extensive destruction of the alveolar process, the disease being more marked in the region of the molars than the premolars, and the absorption of the bone greater between the teeth than on the buccal and lingual aspects.

The collection contains several excellent examples in the

FIG. 37.

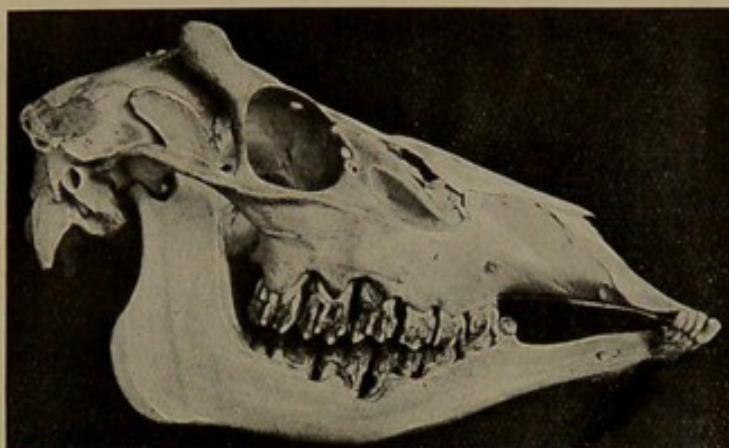


Suricata tetradactyla (Suricate). Mandible showing the slightly irregular arrangement of the molars and premolars.

herbivora. The skull shown in Fig. 38 is that of a Panolia deer (*Cervus eldi*). The alveolar process has been extensively destroyed, more especially in the neighbourhood of the first molars. The more rapid disappearance of the bone between the teeth compared with that in the buccal aspects is very marked. A point to be noted is the comparative absence of rarefying osteitis of the outer alveolar plates. The disease in the maxilla has not involved an extensive area of bone as noticed in studying the disease in the carnivora. This point is of interest when we

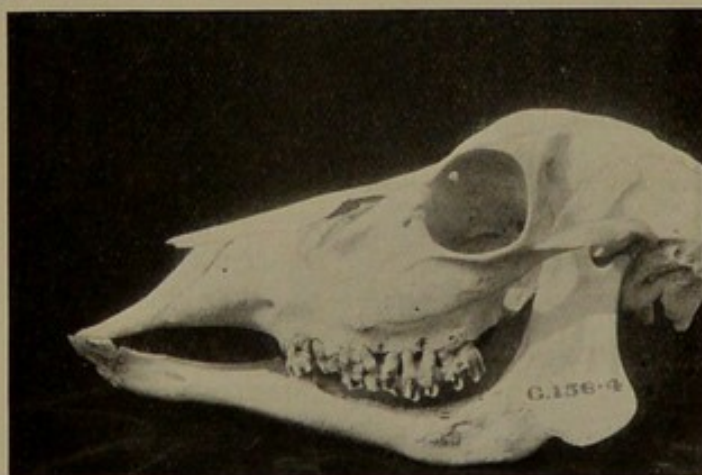consider the comparative density of the bone of the maxilla in the carnivora and herbivora. In the former the tissue is not so dense, and there is a greater proportion of cancellous bone

FIG. 38.



Cervus eldii (Panolia Deer). The destruction of the bone is most marked in the region of the first molars.

FIG. 39.



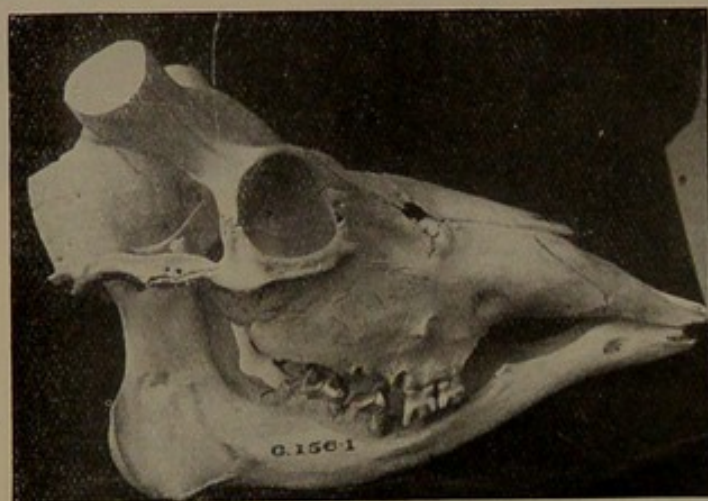
Antelope. Species unnamed. In this specimen the mandibular teeth have been lost through the disease.

compared to the herbivora. The degree of density of the bone would therefore seem to bear a relationship to the rapidity of spread of the disease. Another point of interest in the skull of

this deer is that the destruction of tissue is most marked in the region bearing the main brunt of mastication. In the recent state the spaces formed between the teeth are choked up with fodder. This condition is seen in the skull of a Nagar antelope (*Cervicapra redunca*) preserved as a moist specimen.

A more advanced stage in an antelope is seen in Fig. 39. Here the bone around the roots of the maxillary teeth has almost disappeared, so that the teeth retain their position in quite a precarious manner. The lower teeth in this specimen have been

FIG. 40.



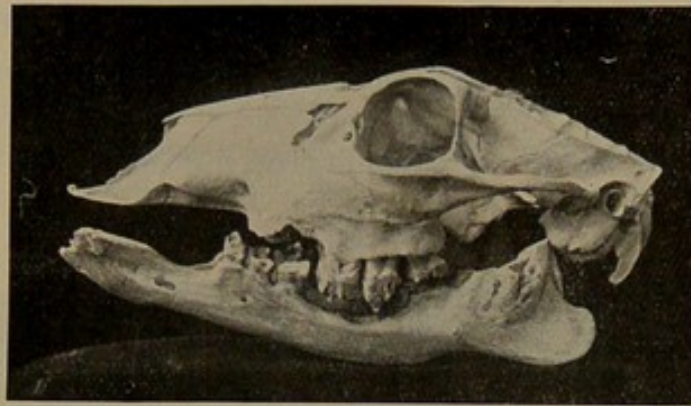
Cervus schomburgki (Schomburgk's Deer). An advanced stage of the disease.

lost through the disease. There is another specimen showing an advanced stage of the disease in a Schomburgk's deer (*Cervus schomburgki*) (Fig. 40). This specimen and the preceding one serve to emphasise the limitation of the infection of the bone in the herbivora. In both animals, although the disease was present in an aggravated form, the bone was but slightly affected beyond that in the immediate neighbourhood of the teeth.

In two specimens the infection in connection with the mandibular teeth has spread to the body of the bone and has resulted in extensive necrosis of the coronoid process. An excellent

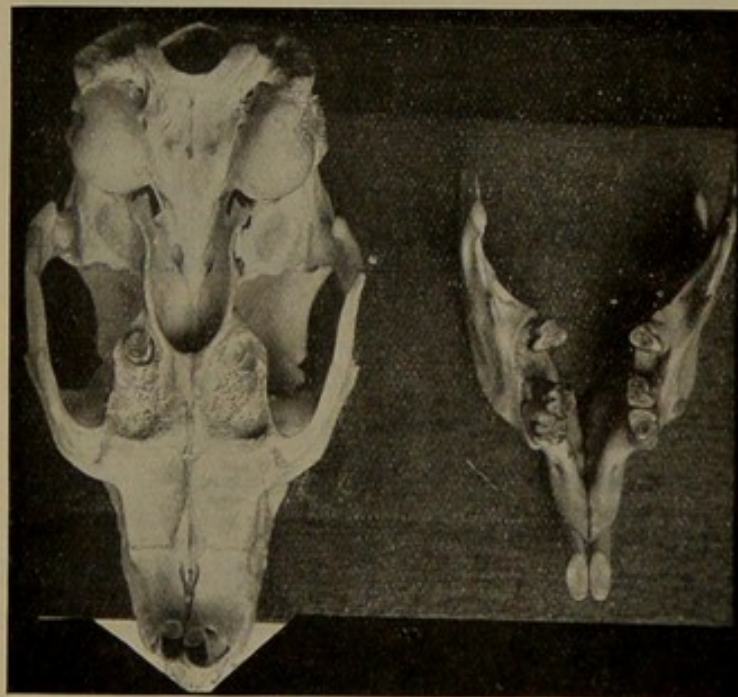
example of this is shown in Fig. 41, the mandible of a deer. This tendency to excessive suppuration in the body of the bone may be due to the shape of the teeth in herbivora. They are of

FIG. 41.



Cervus. Species unnamed. In this specimen there has been suppuration in the body of the mandible from infection around the teeth.

FIG. 42.

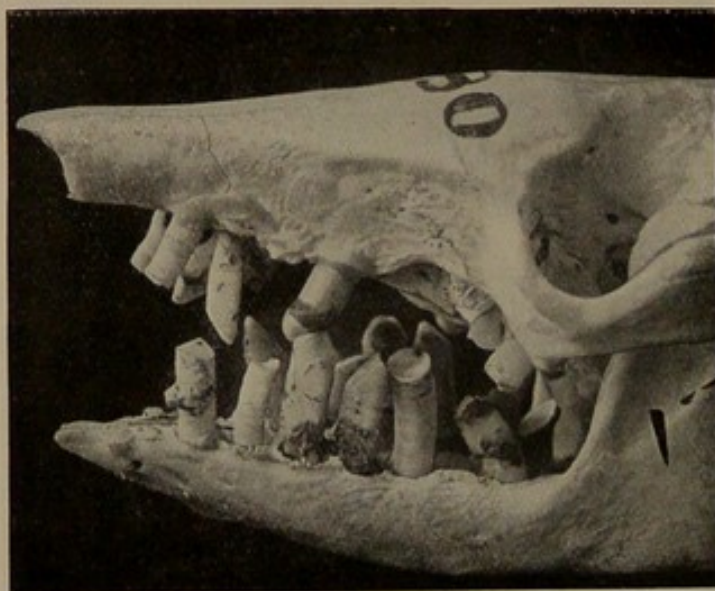


The skull of an Agouti, showing loss of teeth from periodontal disease.

the hypsodont type, and the alveolar process is dense in character; the result is that infection is very liable to track along the direction of least resistance—in other words, the periodontal membrane. By this means it is conveyed deep into the substance of the bone and thence spreads rapidly in the cancellous tissue, the spread to the coronoid process and not to the condyle being again accounted for by the former offering a direction of least resistance.

Of rodents, there are examples of the disease in an agouti

FIG. 43.



Dasypus villosus (Hairy Armadillo). An advanced stage of the disease.

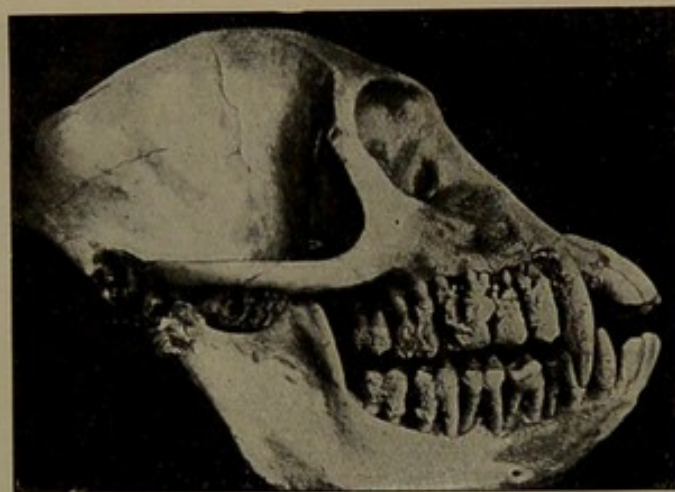
(Fig. 42), a marmot, and a porcupine. The specimens show the condition in which the loss of alveolar process is nearly complete, and the teeth that remain are quite loose.

Fig. 43 shows that even the armadillos cannot claim immunity. The picture represents the skull of a hairy armadillo (*Dasypus villosus*), La Plata, and it will be noticed that the disease is advanced, several of the maxillary teeth having been lost.

In the monkeys there is a specimen of a vervet monkey (*Cercopethecus lalandii*). This skull was first described by Sir J. Bland Sutton in the *Transactions of the Odontological Society*. (The condition of the teeth and jaws is admirably shown in Fig. 44.)

The outer alveolar process has been destroyed so as to expose the teeth to their apices: the destruction, however, of the inner plate is not so severe. The teeth themselves are smothered with salivary calculus, a pretty clear indication that the function

FIG. 44.



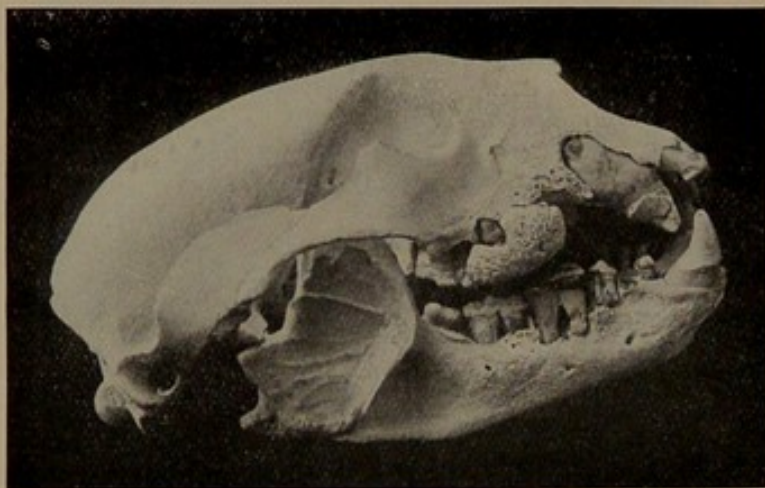
Cercopethecus lalandii (Vervet Monkey). In this specimen the disease is more marked on the right than on the left side. On the right side the alveolar process is almost entirely destroyed.

of mastication was in abeyance on this side and that the whole surface was one large stagnation area. The teeth on the left side of the animal are but slightly affected. It is difficult to ascertain from an examination of the skull why the disease was principally localised to the right side; it is possible that an injury to one or more of the teeth on this side may have rendered them tender to mastication, and the result was lodgment of food or the formation of a stagnation area.

That an injury does determine the onset of the disease is

well exemplified in the skull of a spectacled bear (*Ursus ornatus*) from the Andes of Peru. This animal was in the Zoological Society's Gardens for nearly fourteen years, and at its death the right side of the mouth presented the condition shown in Fig. 45. The teeth that remain are but slightly fixed to the bone and are well coated with salivary calculus, a large mass being adherent to the buccal aspect of the maxillary right molar. The teeth on the left side show an early stage of the disease. The interesting feature of the specimen is that the pulp chamber

FIG. 45.



Ursus ornatus (Spectacled Bear). The disease in this specimen probably followed on injury to the right maxillary canine.

of the right maxillary canine has been exposed by attrition or fracture, and the pulp has died; it is more than possible that the trouble to the canine determined the severity of the disease on the right side by creating a tender area, and so interfering with the functional activity of the teeth on that side of the mouth.

The wild animals in the collection which show the disease have all been kept in captivity with the exception of two specimens, namely, two female gorillas. In the skulls of one of these the septa between several of the back teeth have been destroyed, the most marked space being between the mandibular

second and third molars. In the other specimen several of the teeth in the mandible have been lost from definite periodontal disease. I do not know the history of these skulls, but inasmuch as the gorilla is so seldom kept in captivity there is every possibility that the specimens referred to above are from animals in the wild state.

(b) DOMESTIC ANIMALS.

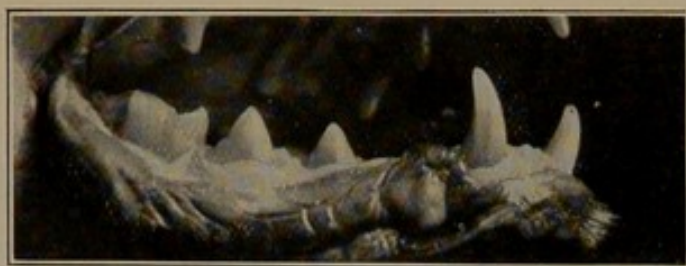
Of domestic animals the cat, the dog, and the horse are most liable to be affected.

Cats.—In cats the disease is frequently met with in those pet animals whose diet, instead of consisting of raw meat, is rather drawn from that class of food which has a natural tendency to stick around the teeth. Cats of the lower class whose diet more nearly approaches their natural food are practically free from the disease. Mr. H. Gray, who is an authority on diseases of cats and dogs, informs me that the starting point of the periodontal trouble is the region of the maxillary fourth premolar. This tooth, owing to its shape, is liable to retain the food more easily than the anterior premolars, which are more sectorial in type. The changes in the bone are similar to those already described in man and wild animals. In order to appreciate the extent of damage to the soft tissues it will perhaps be useful to study the normal. In Fig. 46 are depicted the gums of a normal cat. The gingival margin shelves gradually away from the tooth, and is of a normal pink colour. Contrast this with the mouth of the animal shown in Fig. 47. The margins of the gums are thickened, deeply congested, and before being prepared as a moist specimen a discharge could be freely expelled from the spaces around the teeth. This animal, although quite young, had already lost teeth from the disease.

Dogs.—From the dogs we are able to obtain some instructive data about the disease. In the short-muzzled breeds, such as the pug and the bull dog, the start of the disease is usually around the mandibular incisors, the maxillary incisors becoming subse-

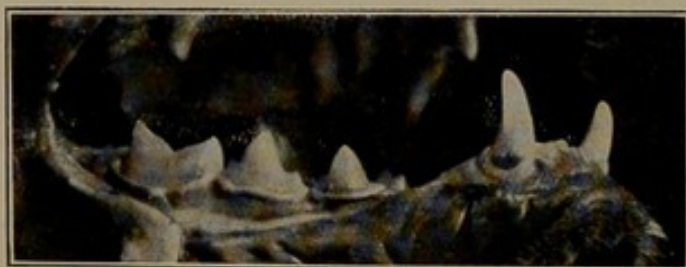
quently involved (Fig. 48).* This fact is of interest when we remember that the lower teeth in these breeds are constantly exposed and escape to a great extent the cleansing action of the lip. It is easy to realise that food of a sticky type is almost certain to lodge about them. The upper incisors, although functionless as far as mastication is concerned, are to a certain

FIG. 46



Felis domestica (Cat). Appearance of normal gums.

FIG. 47.

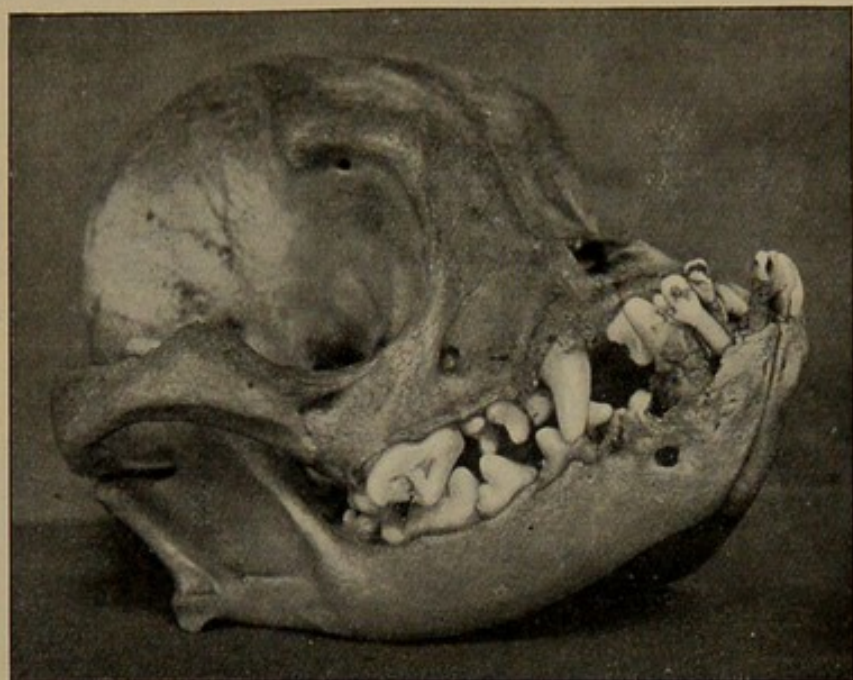


Felis domestica (Cat). The gums show a marginal gingivitis.

degree cleansed by the play of the upper lip across them, and this is probably the reason why they withstand longer than the lower teeth. Towards the back of the mouth a favourite starting-point of the disease is the region of the second and third premolars. In the short-muzzled breeds these teeth are often placed obliquely to the line of the arch, and are so crowded as to form excellent nooks

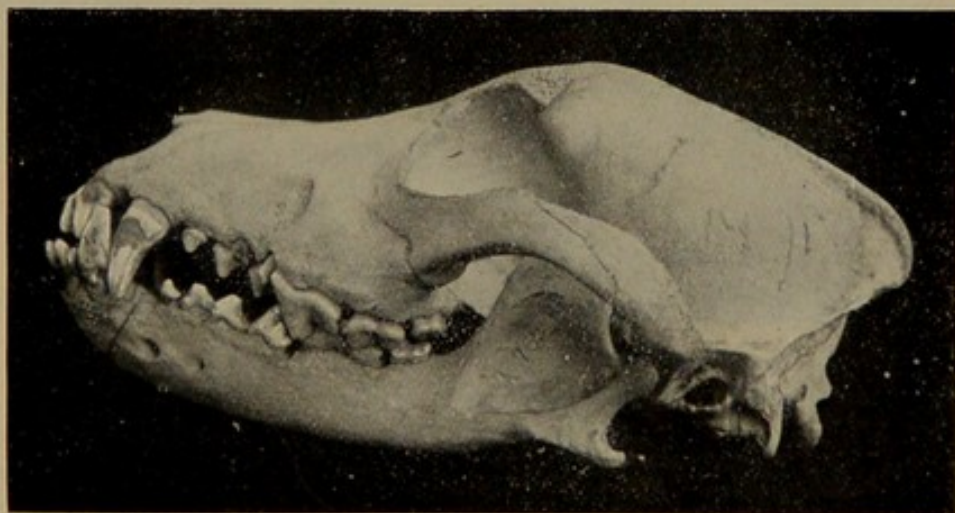
* The skull of a pug dog. The disease is well established in the mandibular incisors and canines, the remaining teeth being comparatively free from trouble.

FIG. 48.



Canis familiaris (Pug Dog). The disease is limited to the mandibular incisors, which are functionless teeth.

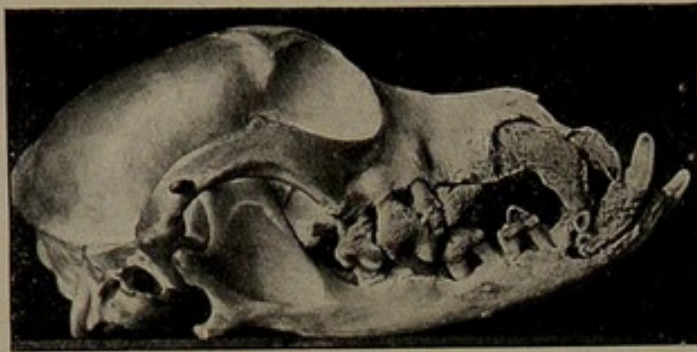
FIG. 49.



Canis familiaris (Irish Terrier). In this specimen the disease commenced in the molar region. The destruction of the bone between the molars is well marked.

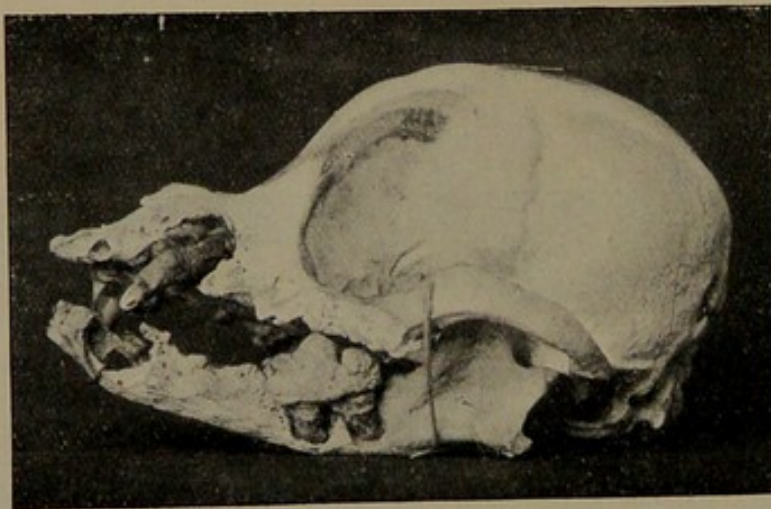
for the lodgment of food. In the long-muzzled breeds the disease usually starts between the premolar and molars (Fig. 49), a favourite site being the angle formed between the last premolar

FIG. 50.



Canis familiaris (variety unnamed). An advanced stage. The disease commenced around the mandibular incisors.

FIG. 51.

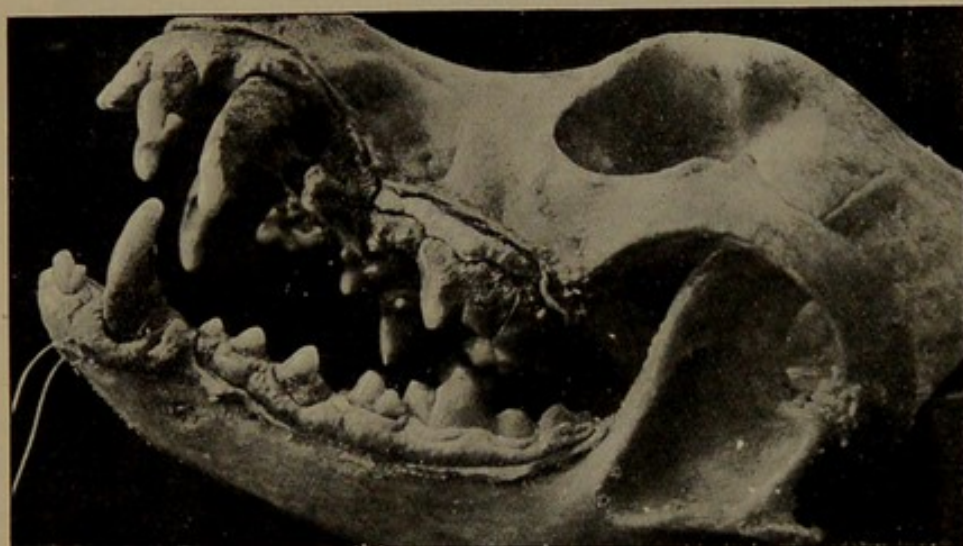


Canis familiaris (Maltese Terrier). An advanced stage in a "Society pet."

and the first molar on the palatine aspect. From these early beginnings the disease can be traced through all stages to the final loss of the teeth from complete destruction of the alveolar process. Two specimens illustrating the progress of this disease

are shown in Figs. 50 and 51. In the first specimen (Fig. 50) several of the incisors have dropped out; the roots of the premolars and the maxillary molars are exposed almost to their apices, and the buccal aspects are loaded with calculus. The mandibular molars have shown the most resistance, due possibly to the nature of the bone around these teeth. In the second specimen (Fig. 51) we have a most advanced stage. It is the skull of a thoroughbred Maltese terrier, an animal which had been a treasured pet of a Society dame.

FIG. 52.



Canis familiaris (variety unnamed). This specimen shows the condition of the soft parts in a well-marked example of the disease.

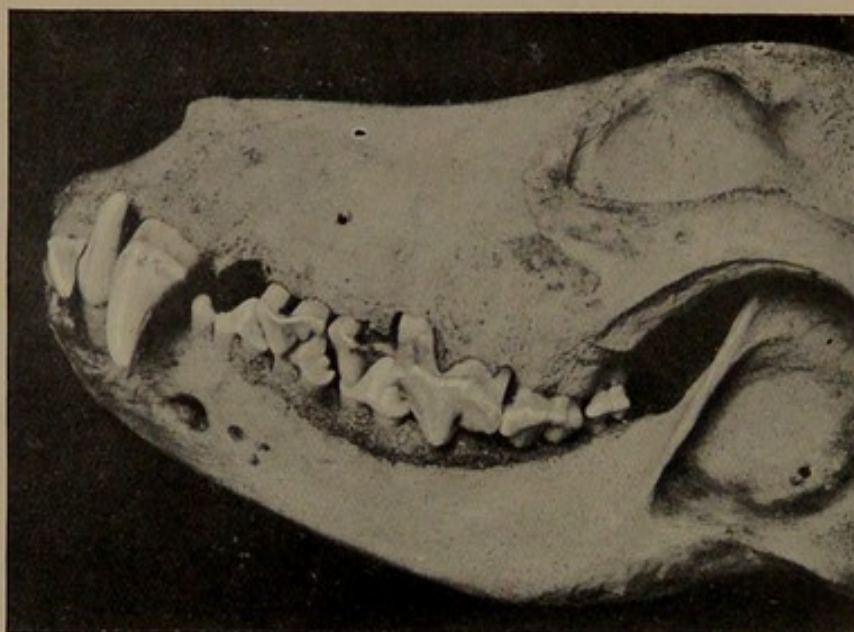
An idea of the condition of the soft tissues in the dog showing advanced periodontal disease may be gathered from the skull shown in Fig. 52.

In the collection of dogs there is another specimen to which reference must be made, because it demonstrates nicely the varying degree of involvement of the bone in the maxilla and the mandible. It is the left half of the skull and mandible of a large dog. Five out of the six incisors have been lost. In the maxilla the bone around the premolars and molars shows definite signs of

rarefying osteitis, while in the mandible the margin of the alveolar process shows considerable thickening (Fig. 53).

Horse.—The most instructive lesson in the animal kingdom is to be found in the horse, for one can follow quite easily every stage from the initial lesion to the advanced suppurative condition. How prevalent the disease is in town horses may be gathered from the fact that out of 484 skulls examined in the recent state no less than 166, or rather more than one-third, showed more or

FIG. 53.



Canis familiaris (variety unnamed). In this specimen the destruction of the bone is more advanced in the maxilla than in the mandible. In the mandible the bone shows distinct signs of "reaction to injury."

less injury of the periodontal membrane, ranging from a slight destruction of the gingival margin to the most aggravated type of the disease. If the normal mouth of the horse is examined, the muco-periosteum will be noticed to fit snugly into the interproximal spaces. The first sign of trouble is the destruction of the muco-periosteum at this place, with the result that a triangular space is formed. In these spaces one may find a grain of corn, a little chaffed hay, or other material. At this stage the

muco-periosteum appears to be only slightly inflamed. The space gradually increases in size and the periodontal membrane becomes more and more involved, and with the increase in the size of the spaces there is a greater accumulation of *débris*. The muco-periosteum becomes thickened, and there is a profuse muco-purulent discharge around the teeth, the breath being extremely offensive. With the advance of the trouble the teeth tend to separate and the food wedges between the teeth, the destruction of the bone continues, the teeth loosen, the infection spreads in the maxilla to the antrum, setting up suppuration, and in the mandible causing an abscess in the bone. The mandible is much more liable to attack than the maxilla, and as far as my observations go spaces are seen rather more between the anterior premolars than the molars; but this point must be noticed, that the spaces formed between the premolars do not seem to set up the same amount of trouble as those found towards the back of the mouth. In the maxilla, spaces seem to occur with the greater frequency towards the back of the series, and usually start on the buccal aspects of the teeth. As a result of the spaces the teeth become painful to pressure, and the function of mastication is interfered with, leading in many cases to marked irregular wear of the teeth. In some cases only one or two spaces are seen; in others huge gaps occur between nearly all the teeth. The bone destruction is invariably most marked in the regions which bear the brunt of mastication.

The following illustrations show the various stages of the disease as seen in the horse.

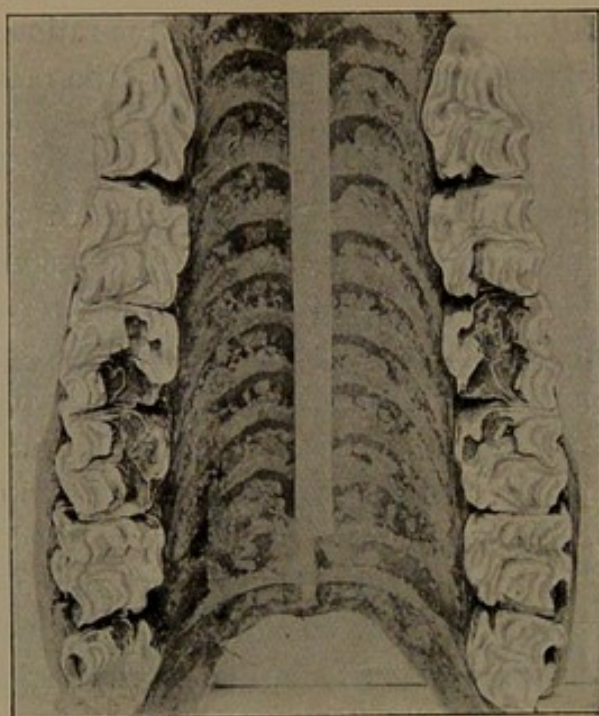
The earliest stage is shown in Fig. 54. It is the maxillæ of a horse affected with caries, the specimen having been prepared with the muco-periosteum in position. The initial lesion of the muco-periosteum is seen between the last two molars on the right-hand side of the picture and the second and third premolars on the left-hand side.

The next stage is shown in Fig. 55. The loss of bone on the inner aspect of the teeth is well marked, the interproximal spaces

being most affected. A further development is illustrated in Fig. 56. The bone destruction has progressed to such an extent that the first molar is quite loose and is being extruded from its socket. Here, as in the preceding specimen, the interproximal spaces are most affected.

The formation of spaces between the teeth is shown in Fig. 57, and the next specimen (Fig. 58) gives a good idea of the

FIG. 54.



Equus caballus (Horse). A specimen with the muco-periosteum of the palate in place. The teeth are carious. The first stage of periodontal disease is shown in the slight destruction of the muco-periosteum between the last two molars on the right-hand side of the illustration.


condition of many of these spaces when seen in the recent state. They are crammed full with fodder and other material.

The effect of the food packing on the soft tissues is well shown in Fig. 59. It is a portion of a mandible prepared with part of the muco-periosteum *in situ*. The infection from the space between the fourth premolar and the first molar has

spread to the body of the bone and has led to the formation of an abscess.

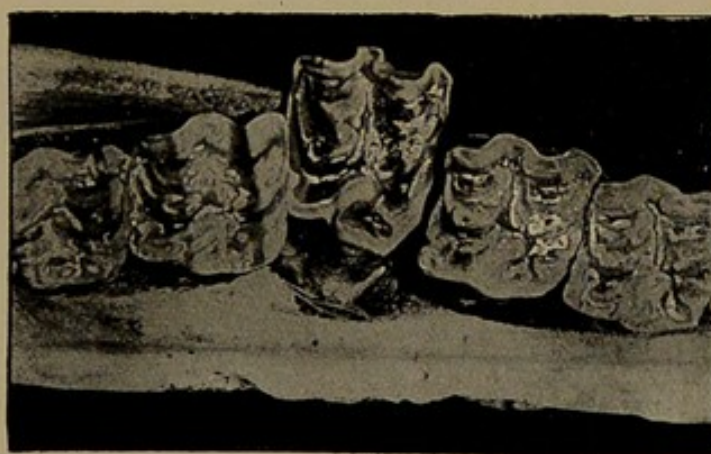Another preparation illustrating the infection of the body of the bone from the spaces between the teeth is shown in Fig. 60.

FIG. 55.



Equus caballus (Horse). An early stage of the bone destruction.

FIG. 56.



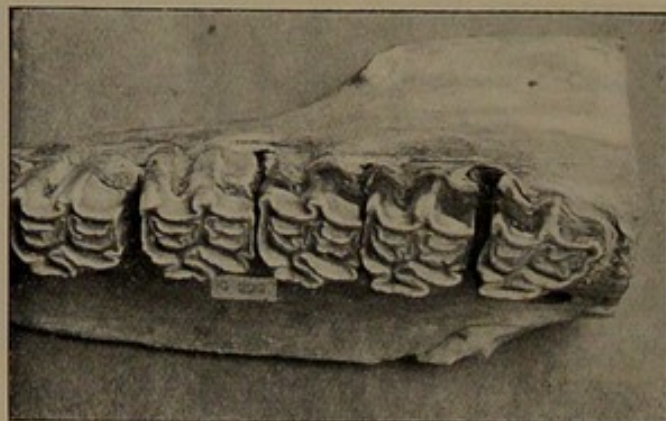
Equus caballus (Horse). The bone destruction has advanced sufficiently to loosen the attachment of the first molar.

The spaces are filled with fodder; there has been suppuration in the body of the bone and considerable thickening of the outer layer of the bone.

Finally, we have the specimens shown in Figs. 61 and 62. I had an opportunity of seeing the animal when alive. The

mouth was pouring with pus, a foetid discharge was flowing from the nostrils, and on opening the mouth the sulcus between the cheeks and teeth was clogged with food. The animal was killed and the head prepared partly as a moist specimen and

FIG. 57.



Equus caballus (Horse). Showing spaces found between the teeth.

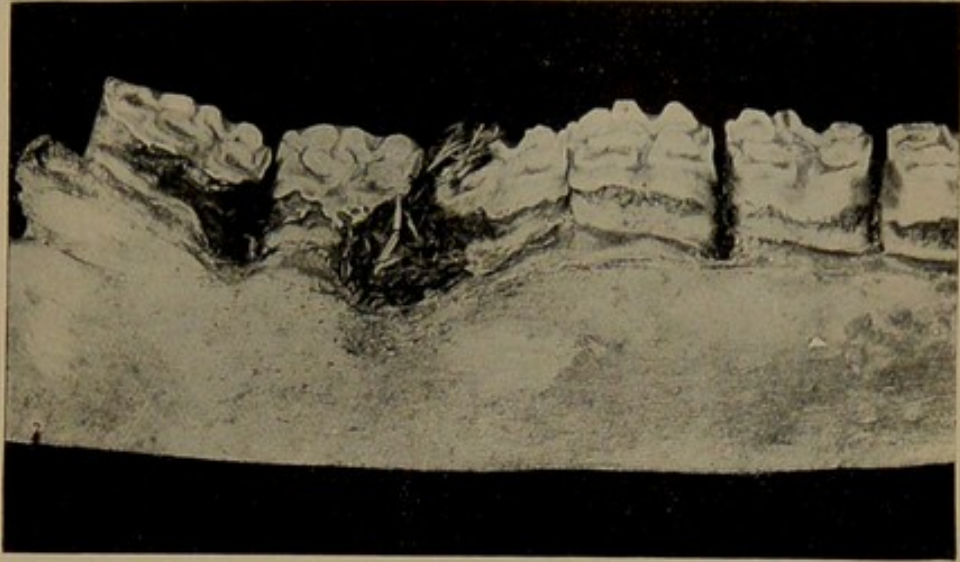
FIG. 58.



Equus caballus (Horse). Shows the condition of the soft tissues from the food packing.

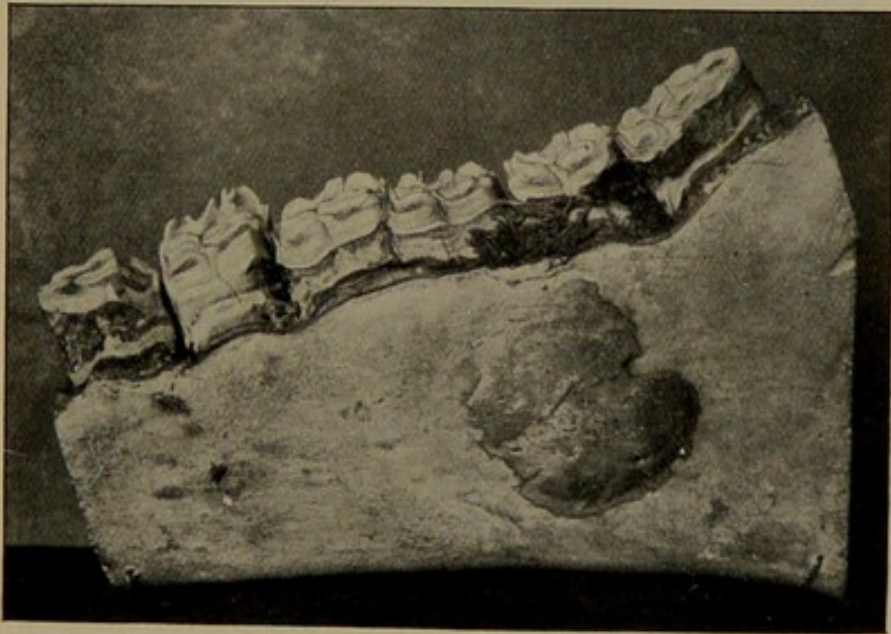
partly as a dry specimen. Fig. 61 shows the right maxilla. The premolars and molars are carious. The margin of the gum is thickened and detached from the bone. There is a huge space between the second and third molars, which communicates with the antrum, the lining membrane of this cavity being thickened

FIG. 59.



Equus caballus (Horse). Shows the spaces filled with fodder.

FIG. 60.



Equus caballus (Horse). From a well-marked case of periodontal disease in which there has been suppuration in the body of the bone.

E

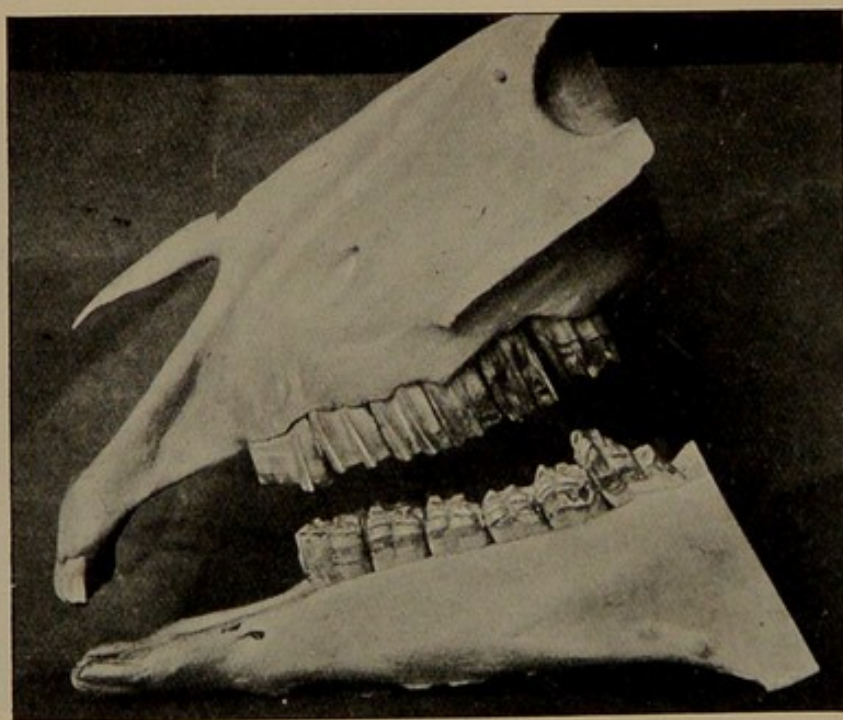
and inflamed. The left half of the skull and the mandible (shown in Fig. 62) give a good idea of the bone lesions. Several of the teeth, both in the maxilla and mandible, are carious, the

FIG. 61.



Equus caballus (Horse). From an advanced case. A director is placed in a sinus leading to the antrum.

FIG. 62.



Equus caballus (Horse). The left maxilla and mandible from the same case as shown in Fig. 61.

alveolar process has been extensively absorbed, the greatest loss of tissue being in the region of the two last maxillary molars. The space between these teeth communicates with the antrum. The buccal aspects of the posterior teeth show signs of caries, due, no doubt, to the lodgment of food in the buccal sulcus. It would have been difficult to realise that such an extreme condition had its earliest beginning in a slight injury to the muco-periosteum had we not had the opportunity of following the disease in the horse through the progressive stages as shown in Figs. 54 to 60.

The conclusions to be drawn from the examinations of the specimens are :—

(1) That the bone lesion is a progressive rarefying osteitis commencing at the margin of the alveolar process.

(2) That the disease is purely local in origin, and has its immediate cause in the formation of stagnation areas around the teeth.

(3) That the varying density of the bone influences the rate of destruction.

I have to thank the proprietors of *The Lancet* and the Council of the Royal Society of Medicine for the loan of several of the blocks illustrating this communication.

The first of these is the fact that the personality is not a static entity, but a dynamic one. It is constantly changing and developing, and its development is influenced by a variety of factors, including heredity, environment, and experience. The second factor is the fact that the personality is not a unitary entity, but a complex one. It is composed of many different parts, each of which has its own characteristics and functions. The third factor is the fact that the personality is not a fixed entity, but a flexible one. It is capable of adapting to a wide range of circumstances and situations, and its behavior is often determined by the specific context in which it is operating.

- (1) That the personality is a dynamic entity, constantly changing and developing.
- (2) That the personality is a complex entity, composed of many different parts, each with its own characteristics and functions.
- (3) That the personality is a flexible entity, capable of adapting to a wide range of circumstances and situations.