

**Angioma pigmentosum et atrophicum, Taylor : melanosis lenticularis progressiva, Pick, liodermia cum melanosi et telangiectasia, Neisser, xeroderma pigmentosum, Kaposi, dermatosis kaposi, Vidal / by James C. White.**

### **Contributors**

White, James C. 1833-1916.  
Royal College of Surgeons of England

### **Publication/Creation**

New York : William Wood, 1885.

### **Persistent URL**

<https://wellcomecollection.org/works/fybn2xpj>

### **Provider**

Royal College of Surgeons

### **License and attribution**

This material has been provided by This material has been provided by The Royal College of Surgeons of England. The original may be consulted at The Royal College of Surgeons of England. where the originals may be consulted. This work has been identified as being free of known restrictions under copyright law, including all related and neighbouring rights and is being made available under the Creative Commons, Public Domain Mark.

You can copy, modify, distribute and perform the work, even for commercial purposes, without asking permission.

**wellcome  
collection**

Wellcome Collection  
183 Euston Road  
London NW1 2BE UK  
T +44 (0)20 7611 8722  
E [library@wellcomecollection.org](mailto:library@wellcomecollection.org)  
<https://wellcomecollection.org>

19

# ANGIOMA PIGMENTOSUM ET ATROPHICUM.

BY

JAMES C. WHITE, M.D.,


PROFESSOR OF DERMATOLOGY IN HARVARD UNIVERSITY.

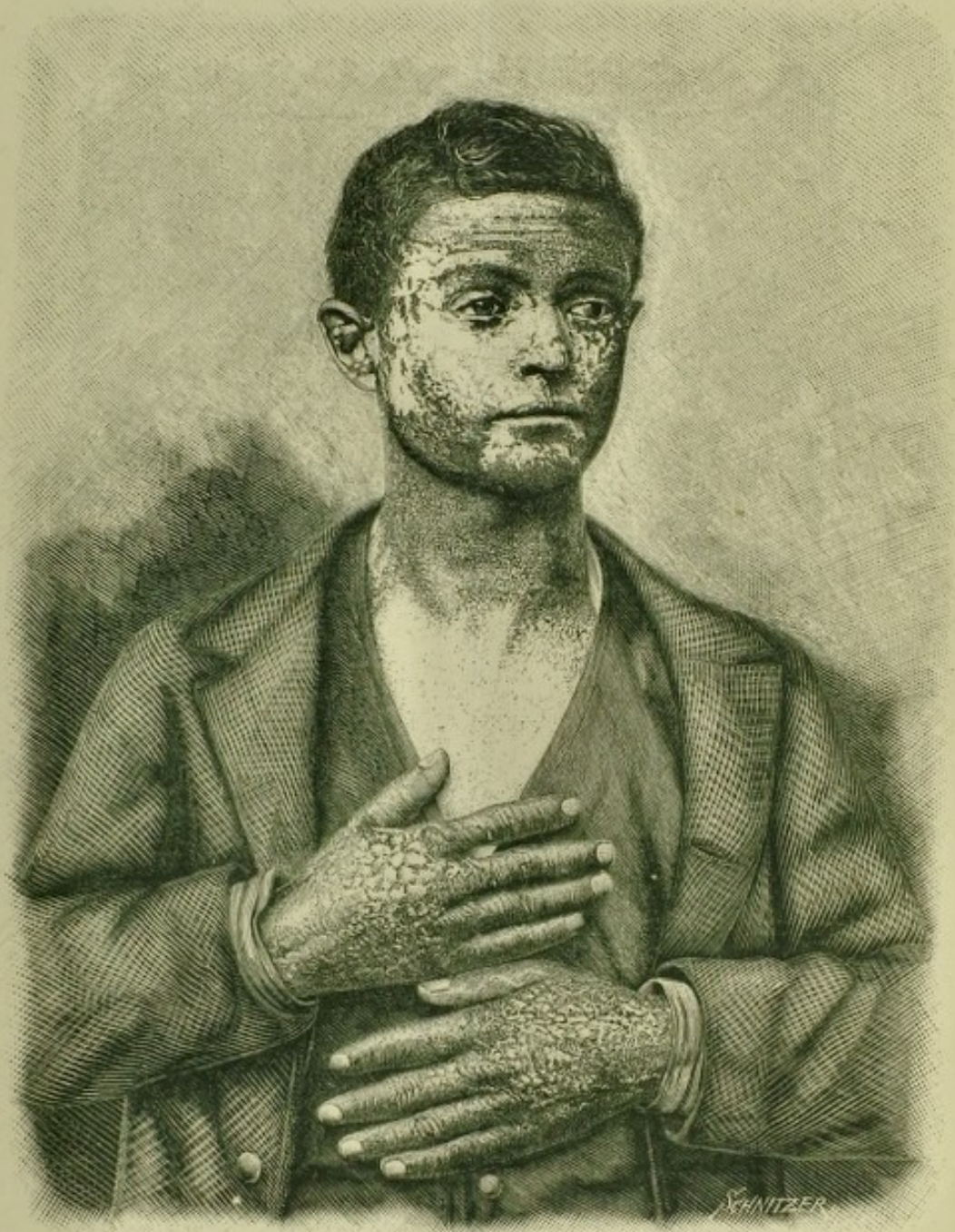
---

*Reprinted from the* JOURNAL OF CUTANEOUS AND VENEREAL DISEASES, *Vol. III.,*  
*December, 1885.*


---

NEW YORK  
WILLIAM WOOD & COMPANY  
1885





Dr. White's case of Xeroderma Pigmentosum.



ANGIOMA PIGMENTOSUM ET ATROPHICUM, *TAYLOR*.  
MELANOSIS LENTICULARIS PROGRESSIVA, *PICK*.  
LIODERMIA CUM MELANOSI ET TELANGIECTASIA, *NEISSER*.  
XERODERMA PIGMENTOSUM, *KAPOSI*.  
DERMATOSIS KAPOSI, *VIDAL*.<sup>1</sup>

BY

JAMES C. WHITE, M.D.,

Professor of Dermatology in Harvard University.

IT is my purpose to present a brief account of two cases of this disease which have lately come under my observation. This peculiar affection, characterized by so many and so striking pathological processes, has been so ably studied of late by such competent observers as Neisser, Vidal, and Pick, and its appearances so well pictured by the latter two, that little remains for me but to add this report of additional cases to the lists published by them.

The cases occur in a family of Russian Polish Jews. The parents have lived in Russia, England, New York, and Boston. The mother is a healthy-looking woman, stout, of fair complexion, dark-brown hair and eyes. She says that she has always been well. The father, by the wife's report, is a blond with light hair and eyes. No such disease has occurred previously in either family to their knowledge.

The boy Louis came to the Massachusetts General Hospital Out-patient Department, July 27, 1885. He was asked if there were other cases in the family, and on the statement that a little brother had the

<sup>1</sup> Read at meeting of Amer. Derm. Association, Aug. 26, 1885.

same disease, he was told to come on the following day with him and the mother. The mother gives an account of her children as follows:

1st child, girl. Died at age of 12 of fever. Skin unchanged.

2d child, boy, æt. 17. Case 1.

3d child, girl, æt. 15. Skin unchanged, eyes and hair black, has few freckles.

4th child, boy, æt. 11. Skin unchanged, eyes blue, hair brown.

5th child, boy, æt. 5. Skin unchanged, eyes and hair black, skin deep olive.

6th child, boy, æt. 3. Case 2.

7th child, girl, æt. 1½. Skin unchanged, eyes blue, hair brown.

This condition of the family was confirmed by a subsequent inspection.

CASE I.—Louis Berrick, æt. 17. The mother first noticed a change in the skin before the child was two years old, and while they were living in Poland. A few freckles, as they were then supposed to be, appeared upon the face and later upon the hands, which increased in numbers up to the age of six, when the family emigrated to England, leaving Louis behind. He was not seen by the mother again until two years ago, an interval of nine years, when he joined the family in Boston. At that time the melanoderma was nearly as marked as at present, but the leucoderma was just beginning to develop, and has been steadily increasing in area since then. When the telangiectasic condition appeared is not known, but the mother thinks that it was as noticeable when he rejoined the family as now.

The patient as an infant was well developed and always healthy. As a boy he continued to have good health, but has grown slowly, and is now not larger than a boy of twelve years. The muscular tissue is firm, and the genitals, although small, are well developed. The hair-growth about them is scanty, but upon the scalp it is very thick and of an intense blackness. The eyes are also very black. It is impossible to determine with certainty the natural color of the skin, so universally has it become affected by the disease.

*Present appearances: Melanosis.*—The forehead, cheeks, lower face, and neck are of a very dark brown, apparently uniform in tint, but on close inspection small darker spots are seen to cover the parts very thickly, resembling strongly the skin of a badly freckled dark mulatto. The tint of the whole trunk is as dark as that of a dark Spaniard, and superimposed there is a dense spattering of a still darker hue, least noticeable over the central abdominal region, but nowhere absent. The scrotum is very black, and the penis and glans present sparse, but very dark spots. The arms, particularly the extensor surfaces, are very thickly pattered, and the hands are very deeply colored and bespotted, some of the blotches here being of an intense blackness. The nails present a

natural appearance, and the palms are unspotted. The thighs, like the trunk, are of a lighter tint and more sparsely freckled, but one of them presents upon its inner surface an almond-shaped blotch of the deepest black, slightly elevated, smooth, and sparingly covered with a hair-growth of considerable length. The lower legs are very dark and thickly occupied by blotches of larger size and blacker color than elsewhere. The mucous membrane within the mouth and larynx (carefully examined by Dr. Langmaid) is free from melanosis.

*Atrophic or leucodermic condition.*—On the right side of the face, occupying at least one-half of its surface, is a sharply defined area entirely without pigment. Similar areas are seen upon the other cheek, the forehead, and about the mouth. The surface of these parts is smooth, and has a stretched, glistening appearance. In places the skin thus affected has a pinkish hue, and the deep veins are readily seen within it. The integument here is apparently thinned, and resembles superficial scar tissue. The ears are very thin, but show no loss of cutaneous pigment. They resemble tanned sheepskin. No leucodermic patches, but a few minute white dots are seen upon other parts of the body. The striking contrast between the white areas upon the face and the intense blackness from which it is so abruptly separated, gives it an indescribable appearance. The sensibility of the atrophic districts, tested by Dr. James J. Putnam, is decidedly impaired. Touching them with the end of a string was unrecognized by the patient, although the prick of a pin was appreciated. The sweat glands are less active in the leucodermic areas.

*Telangiectasis.*—Over the central parts of the face there are numerous bright-red, slightly elevated spots, varying in size from a large pin's head to a small pea. They are most noticeable and abundant in the leucodermic patches, on the lips, and about the edges of the eyelids. Within the lids near the edge are two angiomatous new-growths, more elevated than those of the integument. A few of the red spots are seen upon the ears and the backs of the hands, but they are not very conspicuous. Several greatly enlarged vascular twigs are also noticeable upon the face, especially upon the alæ of the nose. On very close inspection, a few minute red points may be discovered over the general surface.

The vascular hypertrophy cannot be represented in the accompanying woodcut.

CASE II.—Iza, a well-grown boy, 3 years old. He was born in New York. When he was 18 months old, his mother for the first time noticed a few light-colored freckles upon the face, which largely disappeared during the following winter. Since then the present appearances have been gradually developing. The hair is rather dark brown, the eyes are black. The tint of the skin is Brunette. The mother says



hat the eyes of both these children are very weak, during the summer especially. Those of Iza appear very sensitive when directed towards the window. The mental condition of both seems to be normal. The face is universally covered with small, deep-brown freckle-like spots on a general brownish ground. A few of them are deep black. The spots are so small and thickly distributed that at a little distance the face looks as if deeply and uniformly tanned. In some parts they are slightly thickened and rough to the touch, as patches of keratosis senilis. The backs of the hands and wrists are uniformly covered with innumerable, very small, faintly brown spots. Elsewhere the skin is of its natural color. There are no leucodermic patches and no telangiectasis.

Of the correctness of the diagnosis in these cases there could be no question at the first glance to one familiar with the descriptions of the affection. Three of the distinct pathological processes which characterize it are present in the oldest patient in a marked degree: the melanosis, the vascular new-growths, and the superficial atrophy of the skin. There is lacking only the almost constant, final transformation into carcinoma. In the second case, seen in the near beginning of the disease, we have only one condition present, namely, the pigmentation. From a careful study of this in its inception, and of the parts last affected in Case I., I conclude that the disease begins, or at least has begun in them, with an excessive formation of pigment in the shape of minute points; that these points enlarge and take forms in no way to be distinguished individually from ordinary freckles. They appear to be evanescent at this stage, like the latter, and affect, like them, parts most exposed to light; that is to say, the melanoderma begins to manifest itself upon parts of the skin naturally prone to just such irregular pigmentation in childhood. It occurs, too, with just the same absence of all unusual subjective or objective precedent or apparently causative phenomena, as in lentigo. In these cases, there had been no exceptional exposure to sun or visible hyperæmia before the beginning of the melanosis. Gradually the lenticular spots multiply until large surfaces are entirely occupied by them, but never so as to form uniform areas of considerable extent, as in other forms of melanoderma, the skin always appearing spotted or blotched with well-marked lentiginous shapes. They advance slowly and regularly, too, from the face, hands, and feet towards the central parts of the general surface, thus allowing an easy study of the course of development of this feature of the disease. It is probable that several years, certainly two, may pass, and no other manifestation of the disease present itself. Case II. shows that within two years from its start, the pigment cells may increase so much faster than they are removed by the natural process of desquamation that they may heap themselves up and form marked elevations, and that a verrucous,

papillary hypertrophy may develop beneath such pigmentary keratoses within the same period. In Case I., on the other hand, we have the disease in progress for fifteen years without any such accumulation of pigment cells or papillary hypertrophy; but only a single, small, flat, somewhat elevated *nævus pigmentosus et pilosus* of uncertain duration as an indication of advanced pigment change.

How early the telangiectasis appeared in Case I. cannot be ascertained. It is now most apparent in the part longest the seat of the melanoderma, viz., the face. It is nowhere present upon parts last affected, nor has it yet developed in Case II. after eighteen months of melanosis. These observations led me to the belief that it is a secondary condition, certainly not necessarily the initial process, nor even coincident in some cases. It is by far most developed in Case I. in the areas of atrophied skin, as if developed there anew, as in some cicatrices, or, at least, as if left behind unaffected by the atrophic process. Telangiectasis is not a common sequence of melanoderma in any of the many other forms of the latter, nor are the ordinary, superficial, vascular new-growths of the skin, the enlarged vascular twigs, the "spider cancers" ever followed by pigmentation. The two processes seem, therefore, to have no real pathological association. I exclude from this class of phenomena, of course, the melanoderma which may follow diffused hyperæmia of all grades.

In this connection, however, I must appropriately refer to a case which came under my observation two years ago for a very brief period. It was a woman, 28 years old, who, five years previously, during pregnancy, noticed the development upon her face of numerous telangiectases, or red spots, as she called them, which disappeared largely after confinement. The following year she again became pregnant, and the "spots" re-appeared and remained. She believed that they had been increasing in number since then, but that some of them had vanished and had left behind them brown spots; at all events, brown spots had been appearing in a very conspicuous manner. The forehead and upper face, especially in the vicinity of the eyes, were very thickly occupied by linear and lentiginous-shaped, discrete telangiectases of a very brilliant hue. Interspersed with them were numerous freckle-like pigment spots of all shades, varying from a light buff almost to black. They were also thinly scattered over the cheeks and upon the sides of the neck. The patient had never before exhibited freckles. I could see no evidence of a transformation of a telangiectasic spot into melanosis, or *vice versa*. They appeared entirely independent of each other in position and development. There were no atrophic areas. The appearances as a whole were very striking, and I was in doubt whether to regard them as an exceptional instance of the disease we are considering or not.

Neither in these cases do I observe anything which shows the transformation of an individual pigment spot into a telangiectasis, or *vice versa*, nor is there any necessity of such a presupposition. Both processes are very common ones in themselves, and, as already stated, have ordinarily no such relationship or even association. The new-growth of blood-vessels certainly underlies that of pigment, and in my cases is certainly subsequent to it. The two processes may be regarded as no more closely allied than associated or coincidental features of a strongly marked pathological condition of the skin.

Nor can the date of the beginning of the atrophy in Case I. be ascertained. It occupies considerable areas, and has without doubt been in progress for several years. The atrophy embraces a large part of the thickness of the integument, as shown by the thinning of the alæ of the nose and of the ears—parts which permit the loss of tissue to be readily estimated. I should judge that the papillary layer with the underlying superior plexus of vessels at least had wholly disappeared, and that the glandular structures had also mostly perished. The follicular openings were no longer apparent. The relation of this atrophy to the two processes above described is to me incomprehensible. We know that some forms of abnormal pigmentation of the skin are capable of self-involution, that others involve the tissue in which they are deposited in exceptionally rapid destructive processes, that others have an intimate association with carcinomatous disease, and that in some varieties or instances of morphœa we do have the close combination of melano-derma, vascular hypertrophy, and atrophy of the skin also, but the observation of these facts affords no satisfactory explanation of their occurrence. The *atrophia cutis* must be ranked as step three in the history of the disease.

That two more processes are likely to be developed in the future of Case I. is more than probable, viz., hypertrophy of the epithelial and papillary layers, and later a transformation of the same into epithelioma. This has been the sequence of tissue-change in so large a proportion of the thirty-three authentic cases thus far tabulated by nine observers, and embracing only individuals of a dozen families, more or less, that this grave prognosis can hardly be avoided in so well-marked an example of the affection.

I have but a word to add concerning the title of the disease. From my limited opportunity of study, I consider that recommended by Dr. Taylor, and adopted by our Association, *angioma pigmentosum et atrophicum*, as ill chosen in some respects, for I cannot regard the *angioma* as first in importance of pathological significance, or deserving priority as the initial lesion. The term *melanosis* seems to me in these respects to deserve precedence. The additional terms *lenticularis* and *progressiva*

of Pick are significant, but for descriptive titles not sufficiently comprehensive. We should go further, if we would thus completely define it, and add *telangiectodes* and *atrophica*. It is to be regretted that some single name, arbitrarily selected, if need be, should not be adopted for a disease so remarkable in its complex and exceptional diversity of tissue-change and protracted progression.

Faint, illegible text at the top of the page, possibly bleed-through from the reverse side.