

Four cases of echinococci in the female pelvis / by W.A. Freund and James R. Chadwick.

Contributors

Freund, W. A. 1833-1918.
Chadwick, James R. 1844-1905.
Royal College of Surgeons of England

Publication/Creation

[New York?] : [publisher not identified], 1875.

Persistent URL

<https://wellcomecollection.org/works/c3abzfm9>

Provider

Royal College of Surgeons

License and attribution

This material has been provided by This material has been provided by The Royal College of Surgeons of England. The original may be consulted at The Royal College of Surgeons of England. where the originals may be consulted. This work has been identified as being free of known restrictions under copyright law, including all related and neighbouring rights and is being made available under the Creative Commons, Public Domain Mark.

You can copy, modify, distribute and perform the work, even for commercial purposes, without asking permission.



Wellcome Collection
183 Euston Road
London NW1 2BE UK
T +44 (0)20 7611 8722
E library@wellcomecollection.org
<https://wellcomecollection.org>



3

FOUR CASES OF ECHINOCOCCI IN THE FEMALE PELVIS.¹

By W. A. FREUND, M.D., of Breslau, Prussia,

AND

JAMES R. CHADWICK, M.D., of Boston, Mass.

IN Klob's Treatise on the Pathological Anatomy of the Female Sexual Organs we find only two organs mentioned as the seats of this entozoon—the ovaries and the uterus. Inasmuch as the presence of echinococci in the ovaries is not satisfactorily established by him, and we are not in position to confirm or refute his opinions, we will pass them by without comment.² On the other hand, a more careful examination into the statements made by him and other authors about echinococci of the uterus will not prove devoid of interest.

On page 195 Klob makes the following assertions: "Many descriptions have been given of hydatids in the womb, all of which properly relate to hydatid moles; a mistake between the two has undoubtedly been made in these instances. The only fully authenticated case is, in my opinion, that of an acephalocystic vesicle in the uterus reported by Rokitansky." A search for this case in the latest edition (1861) of this author's treatise on pathological anatomy will prove futile; but possessors of the old edition of 1842 may deem themselves more than usually fortunate, for it rarely happens that old editions are fuller than the more recent ones. We will quote the passages, bearing upon our theme, from the two editions:

"Cystic formations are extremely rare in the uterus; not a single instance has yet occurred here (Vienna), and *but one instance of acephalocystic vesicles in the uterus has come under my personal observation.*" Edition of 1843, III., p. 538.

"Echinococci have been observed (in the uterus) in a few rare cases with perforation of the cyst and extravasation of the

¹ From JOURNAL OF OBSTETRICS, February, 1875.

² O. Petit reports the only known case of echinococci in the ovary. Observations, Pathol. Anat., 19-22, Tab. III., 7-11.

vesicles into the internal organs, or their discharge through the vagina (Hislop) or into the peritoneal cavity (Wilton)." Edition of 1861, III., p. 500.

What inferences are to be drawn from a comparison of these two paragraphs? Have we not a right to conclude, from the entire absence of details in the earlier and the complete omission of this "fully authenticated" case in the last edition, that Rokitansky has become dissatisfied with the scientific accuracy of his old observation, and virtually retracts his former statement.

Turning now to Hislop's¹ cases, they are related briefly as follows: The first was that of a girl, 17 years of age, who had been ill for six months; her catamenia, till then regular, had ceased; in their place she had had an occasional discharge of an offensive bloody fluid. As her condition aroused suspicions of pregnancy, she was examined. The hymen was found intact, the os uteri somewhat patulous, and within the womb a mass, that felt soft to the touch. As all signs of pregnancy were wanting, an ineffectual attempt was made to expel the mass from the uterus by means of ergot. A catheter was finally introduced into the organ, causing the expulsion of a large quantity of bloody serum and purulent masses of very offensive odor. Pains set in during the night, and after repeated doses of ergot the woman gave birth to a filamentous mass filled with numerous large hydatids. She made a perfect recovery, married subsequently, and had children.

A second, quite similar case, was that of a woman 26 years old, the mother of several children. She suffered for some time from constant bloody discharges and pain in the back and thighs. She would not admit the possibility of pregnancy. As various styptics failed to arrest the hemorrhages, and her condition did not improve, the os uteri, which was fully closed, was dilated by means of a sponge-tent, a hand inserted, and a soft mass severed from its attachment to the uterine mucous membrane. The administration of an infusion of ergot, gallic acid, and a good diet, soon restored the patient to health. The mass expelled was likewise filamentous and contained many hydatids.

¹ P. B. Hislop, Details of Three Cases of Hydatids of the Uterus, with Remarks, *Monthly Journal of Medicine*, April, p. 326.

The third patient was a woman, 48 years old, who, after a ride in an omnibus, had a severe flooding and uterine contractions. The os uteri gradually dilated, but this act not being followed by the expulsion of the tumor, owing to its broad attachment, the latter was extracted with the hand. In spite of several subsequent hemorrhages the patient gradually recovered.

Hislop gives no data in the reports of these cases, which can satisfy us that he was correct in calling these cysts true hydatids, and not hydatid moles. A woman's statement that she cannot be pregnant, and even the presence of a hymen, have so often proved fallacious guides in the diagnosis of pregnancy that they have but little weight. In addition, we are not told that any search was made with the microscope for hooks or vesicles in the fluid—the only perfectly reliable tests of echinococci. On the other hand, the masses are represented as being *filamentous*, and as attached to the uterine walls, not buried in them, as true hydatids would probably have been. These facts constrain us to agree with Van Will,¹ Veit,² Haussmann,³ and Klob,⁴ in refusing to recognize them as cases of true hydatids. This opinion is strengthened when we reflect upon the improbability of three cases occurring in the practice of one physician, when the most experienced pathologists have never met with a single instance.

Wilton's case is less vague, but here again we have not the convincing proofs that might have been adduced. The first symptoms were metrorrhagiæ of twenty-four hours duration, occurring after weekly intermissions and labor-like pains that gradually increased in intensity until a fluid was expelled in spurts. After the lapse of three months the patient died suddenly with symptoms of internal hemorrhage. At the autopsy Wilton found in the upper part of the uterine walls a considerable mass of hydatid cysts, a part of which projected freely into the cavity of the womb, and a part formed irregular elevations on the outer surface of the organ; a perforation at one point here had led to a fatal hemorrhage into the peritoneal cavity.

¹ Canstatt's Jahresbericht, IV., p. 230, 1851.

² G. Veit, Krankheiten der weiblichen Geschlechtsorgane. Erlangen, 1867.

³ D. Haussmann, Die Parasiten der weiblichen Geschlechtsorgane, Berlin, 1870.

⁴ Loc. cit., p. 195.

If this was an instance of true hydatids it disproves Davaine's¹ statement about the peritoneum, though he was undoubtedly correct in discarding the old and especially the French observations of echinococci evacuated from the female sexual organs. "Nous ne connaissons point d'exemple de kyste hydatide ouverte spontanément dans la cavité du péritoine ou du vagin, ni dans celle de l'utérus."

The only other case that we have been able to find recorded in medical literature is that given by Graily Hewitt.² The woman was married, but not living with her husband; she had been in the habit of eating much pork and veal. For eight or nine years the left side of the abdomen had been swollen and occasionally painful, but had not increased greatly in size. On March 22, 1870, grape-like masses came away from the vagina. No hemorrhage. The uterus was enlarged posteriorly, and was about the size of a gravid uterus at the second or third month. The cavity was large enough to contain an orange; its surface presented irregularities. The vesicles that were expelled were distinctly separable from each other. They contained an albuminous fluid rich in sodic chloride. The microscope showed the lamellar structure of the membranes and the echinococci-heads studded with hooklets. She was discharged well.

This is the first perfectly authentic case on record in which true hydatids have been found in the uterus. Our first case belongs to the same category.

CASE I.—*Echinococci in the posterior wall of the uterus. Incision with evacuation of hydatid vesicles. New colonies in the pelvic cellular tissue. Spontaneous perforation into the bladder and rectum.* (Figs. 1 and 2.)

Mrs. S., 57 years of age, presented herself on August 22d, 1870, and gave the following history: Menstruation began in twentieth year, had always been scanty; she was married when twenty-five, and had remained sterile. Menses ceased several months ago. Hardness in lower part of abdomen. Has suffered much for past six years from difficulty of micturition and defecation, as well as a sense of weight in the abdomen. For several weeks the retention of urine and fæces has been

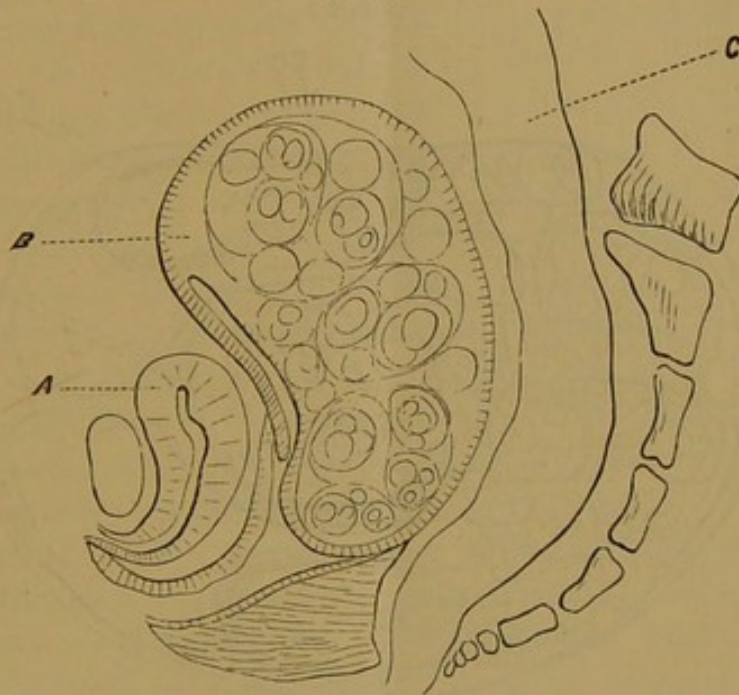
¹ *Traité des Entozaires et des maladies vermineuses de l'homme et des animaux domestiques*, Paris, 1860, p. 756.

² *Obstetrical Transactions*, Vol. XII., 237.

nearly complete. Only produces dejections by means of large enemata passed very high up through a long tube.

Examination gave the following results: The bladder was distended so as to rise three inches above the pubes, and was displaced somewhat to the right. To the left of the bladder in the inguinal region was a smooth elastic tumor. The vagina was reduced to two-thirds of its normal length by an elastic

Fig. 1.



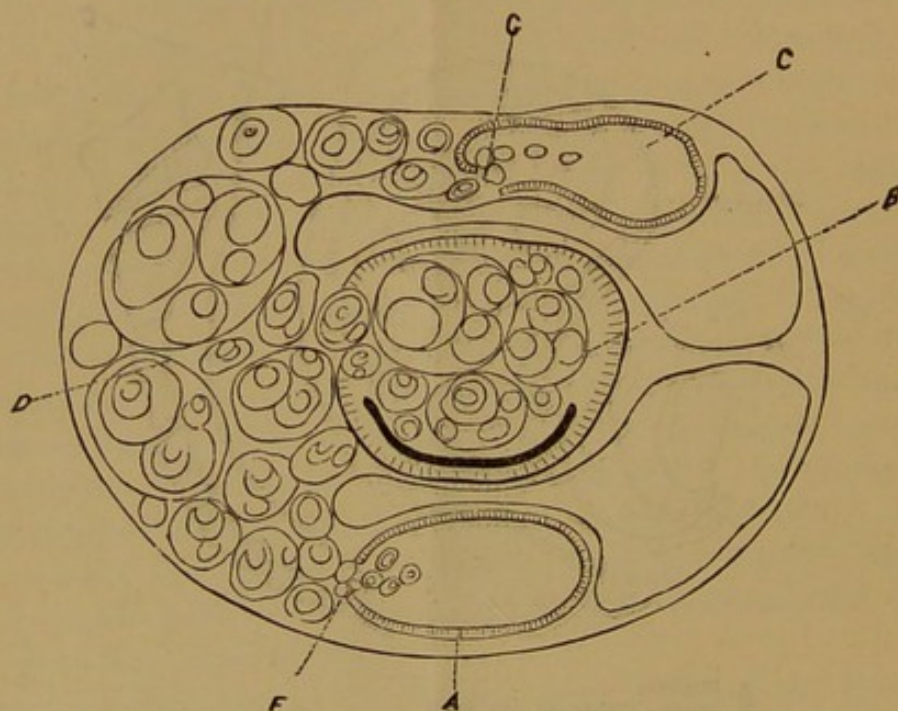
A. Bladder.
B. Uterus, Echin, in post. wall.
C. Rectum.

tumor that completely filled the small pelvis. Upon passing the catheter to evacuate the bladder, we found that the urethra was greatly elongated, as happens with retroflexion of the pregnant uterus. A great quantity of thick urine was drawn off. The tumor was clearly recognized as belonging to the posterior wall of the womb, for it could be traced into the posterior lip of the os, which was completely drawn out. The external os appeared as a narrow transverse cleft, bounded posteriorly by the tumor and anteriorly by the very attenuated anterior lip. By the bimanual examination the uterus was found to correspond in size with the pregnant organ at the third month. The sound entered five inches, and showed that the anterior wall was extremely thin throughout its whole

extent. Sims' speculum brought only the surface of the tumor into view, the os being pressed forward against the symphysis pubis. Upon these data we diagnosticated a cystic tumor in the posterior wall of the uterus, and thought it a fibro-myoma with a secondary cyst.

On August 25th, in order to relieve the retention of urine and fæces, as well as to aid our diagnosis, we introduced a

Fig. 2.



- A. Bladder.
- B. Uterus, Echin. in post wall.
- C. Rectum.
- D. Echin. colonies in cellular tissue, perforating the bladder at F, and the rectum at G.

trocar into the tumor very near to the os. As a clear watery fluid gushed from the canula, we at once enlarged the opening with a bistoury; a great amount of fluid escaped, containing numerous vesicles varying in size from a pea to a cherry. The posterior wall did not collapse as much as might have been anticipated from the amount of fluid evacuated; it felt thick and rough. We would emphasize this point as suggesting a likelihood of the parent vesicle being located in the uterine wall. The fluid was limpid, contained no sediment, and only traces of albumen. A more exact chemical examination was superfluous, because the microscope told the tale. With

it structureless stratified membranes, scolices and separate echinococci-hooks were seen.

During the week subsequent to the operation a thick greenish fluid, containing shreds and flakes of membrane, escaped from the incision. From this date until Nov. 11th we lost sight of our patient. She then related that immediately after reaching home she had been taken with high fever and symptoms of gastro-enteritis, accompanied by a profuse discharge of very offensive fluid from the vagina. Her general health was very good. Micturition and defecation were few. The nodular and enlarged uterus was moderately anteverted; the posterior wall still much thicker than the anterior, but in the right side of the anterior wall we were able to feel irregularities and round hard nodules. Precisely similar nodules were felt behind and to the right of the womb; the bladder was firmly adherent to this mass, whereas on the left side it was freely movable with the catheter and distensible. With the speculum the anterior lip was seen to have become much thicker than before, and presented many degenerated follicles. The posterior lip was rough and of a gray color.

In April, 1871, the woman again appeared with new complaints. She had a constant desire to urinate, and when successful had much strangury. She exhibited many vesicles which had passed with her urine. A large catheter brought away a little thick urine filled with vesicles and shreds of membrane. The woman reported that similar membranes, together with pus, had often been discharged from the vagina, after severe tenesmus. A firm infiltration of the cellular tissue to the right and behind the womb was made out; in this the cervix was embedded. The discharge through the bladder ceased about the middle of May.

In October, 1872, the woman brought vesicles which she had passed from the rectum. She had had several profuse hemorrhages from the vagina. The uterus was more firmly held than before by the parametric infiltration, which then half enveloped the rectum with an unyielding arch, yet the mucous membrane of the rectum was only attached to the underlying tissues at one point; no perforation could be discovered. Through the speculum the vaginal portion was seen to be very broad; the anterior lip differed completely from the posterior;

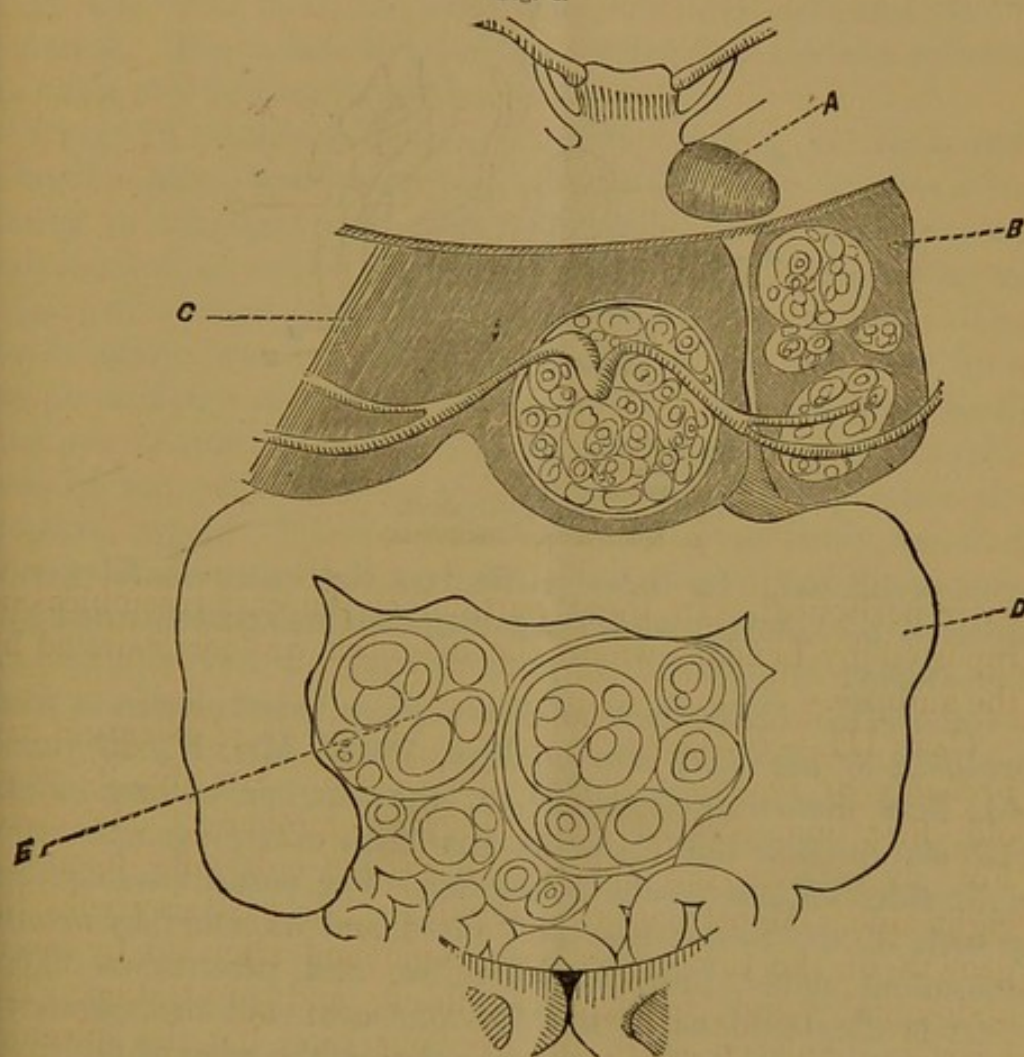
it surrounded the latter like a half-moon, and was only one-third as thick. Its appearance was peculiar. The surface was smooth, the mucous membrane seemingly intact; its external border was of carmine-red color, the rest of brick-red with brighter radiating stripes; in the spaces between these latter yellow points, varying in size from a millet-seed to a pea, were scattered. The posterior lip looked like a complete vaginal portion; it was grayish, rough, and irregular. The yellow points in the anterior lip proved not to be vesicles but only ovula Nabothi.

Remarks.—The chief interest of this case rests upon the unquestionable presence of echinococci in the parenchyma of the uterus. That this site of the vesicles was primary is more than we can assert, for, at the same time that we found them in the womb, we likewise discovered indications of them in the surrounding tissues. They may have been first developed in the uterine walls, or have penetrated into them from the cellular tissue or even from the peritoneal cavity. In the latter alternative, the case would be analogous to those in which the same entozoon has been known to pass from the pericardium into the substance of the heart; according to the best pathologists it is never developed primarily in the last-named organ. Our case is at any rate a new proof that echinococci may exist in the parenchyma of the uterus.

CASE II.—*Echinococci in the liver, spleen, great omentum and pelvic cellular tissue.* (Figs. 3 and 4)—Miss J., 22 years old, began to menstruate when 15, and has always been regular. Has been in poor health for three years. The abdomen has been gradually swelling in its upper and middle parts. Lately catamenia more scanty, and frequent desire to urinate. Is much emaciated; left thorax is somewhat distended; the heart is pushed upward and to the right; the apex is in the second intercostal space. Beneath the heart is the spleen, greatly enlarged and extending downwards to the edge of the ribs. The liver extends from the fourth rib to two inches below the thorax. The womb is pushed down towards the pubes. By percussion a portion of the stomach can be made out, projecting from beneath the spleen. The ascending, transverse and descending colon can be distinctly traced around a tumor, whose

surface is broken up by smooth prominences. The tumor reaches to the symphysis pubis and gives the most perfect hydatid tremor upon percussion. The vagina is very much

*Fig. 3.

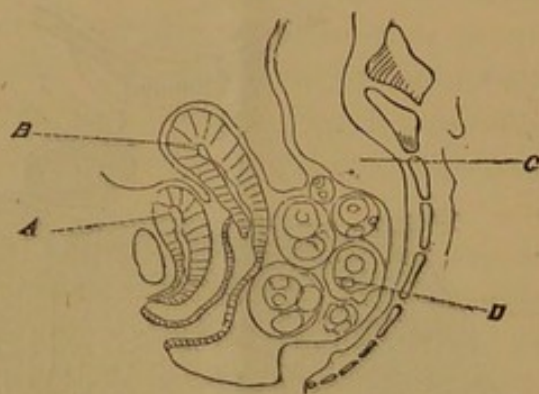


- A. Heart.
- B. Spleen.
- C. Liver, Echinococci in left lobe.
- D. Colon.
- E. Omentum, Echinococci.

compressed, and the uterus is held firmly against the pubes by an elastic tumor, which projects from the right side of the small pelvis toward the middle. The rectum is pushed over to the right and is somewhat constricted, yet defecation has not been impeded. Puncture of the tumor per vaginam revealed all the characteristics of echinococci; after its evacuation small round tumors were still to be felt behind the womb. The cyst evacuated, and those still remaining in the pelvis are

unmistakably situated in the extra-peritoneal cellular tissue of the pelvis; we may likewise assume that the hydatids composing the abdominal tumor are in the omentum and equally

Fig. 4.



- A. Bladder.
- B. Uterus.
- C. Rectum.
- D. Echinococci, subperitoneal.

extra-peritoneal. In these particulars the case resembles one reported by Lendat,¹ where the diagnosis was corroborated by the autopsy.

CASE III.—*Echinococci of liver, spleen, great omentum and probably of the right ovary.*—May, 1868. Mrs. K., 25 years old, first menstruated when 15, the mother of one child. For six months the abdomen has been enlarging upon the right side. Menstruation is regular. For past six weeks the growth of the tumor has been rapid and attended by severe abdominal pains, fever, great thirst, and prostration. The heart is displaced as in the previous case, but the spleen is even larger and projects two inches below the edge of the ribs. The liver extends from the third rib to three inches below the margin of the ribs; the left lobe is chiefly enlarged, and forms a very prominent tumor, which gives the hydatid tremor; the ensiform cartilage is forced outwards. The colon here also encompasses a mass of hydatids in the omentum, which impart the characteristic tremor. This tumor is separated from the symphysis pubis by convolutions of the intestines. The uterus is easily grasped bimanually, and is anteverted. Obliquely behind it is a small cystic tumor resembling in every respect an ovarian tumor. For the purpose of relieving the dyspnœa, the

¹ Gazette Médicale de Paris, No. 27, 1856.

cyst in the left lobe of the liver was punctured with a trocar three times at intervals of three weeks. It discharged the usual contents of an hydatid cyst; the last time the fluid was purulent and the cavity did not now refill. The tumor of the omentum was treated in the same way, but was not completely emptied. The woman then felt so comfortable that she refused to allow any further interference.

CASE IV.—*Echinococci, of hepatic origin, in Douglass' Pouch.*—Mrs. R., 55 years old, presented herself because of a tumor in the right side of her abdomen. She could give no information as to the manner of its growth. The abdominal organs all seemed healthy until we reached the genitals. The senile uterus was pushed forwards and to the left side by a tumor as large as a child's head at birth; it was rough, hard, and not fluctuating, and seemed to be adherent to the posterior wall of the womb, and not to be connected with any other abdominal organ. The woman's sufferings arose from repeated attacks of circumscribed peritonitis in the vicinity of the tumor; these were relieved, and she passed from our care. By a lucky chance, however, we were present at the autopsy of this patient, who had died of some intercurrent affection. We found a firm tumor in the spot designated: it was adherent to the uterus, and at first appeared to have no connection with the other organs; but a careful search was rewarded by the discovery of a band, a foot long, and as fine as a thread, running to the right lobe of the liver. The tumor consisted of a dead echinococcus cyst filled with an immense number of secondary vesicles. The connecting-band and the deep yellow color of the membranes point, with a strong show of probability, at the liver as the original site of the cyst. It had developed in the substance of the liver, gradually protruded from its surface, became pediculated, and hanging down into the pelvis, formed adhesions there. The case was suited to deceive the most skilled diagnostician.

According to Virchow, echinococci develop in the lymphatic vessels. Every cavity containing a parent cyst has two walls, one belonging to the organ and one to the animal. The membranes of the cyst, when discharged, always roll up inside out, exciting a doubt among the ignorant as to whether the animals do not grow on the outside. If there is any roughness

on one side of the membrane, it is safe to conclude that this is the inner surface. The irregularities are not, as a rule, young animals, but only pathological appearances common to old age. On section, the membrane is seen to consist of many strata, arranged with the greatest possible regularity. Each principal layer is divided into many thinner ones. Much the same, though less regular an appearance, is seen in a common fibrinous coagulum which has been formed by successive deposits. Acetic acid, however, caused the layers of fibrine to swell and the stratification to disappear. No such effect is produced upon the echinococcus membrane.

A sediment is commonly found at the bottom of the cyst, consisting principally of egg-shaped formations of carbonate of lime, as deposited in the body of the animal. They only appear in old animals, and their number increases with age. These are of great value in the diagnosis, but are not absolute.

The hooklets are like young hyoid bones in shape, and are the surest indications of the entozoon when it is no longer present. One hook and a few lime formations are sufficient for a diagnosis. The cysticercus has similar but much larger hooks, and likewise lime deposits.

