

Large cystic myoma of uterus of over twelve years' duration removed by enucleation : recovery : with notes on cystic 'fibroids' / by Alban Doran.

Contributors

Doran, Alban H. G. 1849-1927.
Royal College of Surgeons of England

Publication/Creation

London : Printed by Adlard and Son, 1894.

Persistent URL

<https://wellcomecollection.org/works/zmjahuhz>

Provider

Royal College of Surgeons


License and attribution

This material has been provided by This material has been provided by The Royal College of Surgeons of England. The original may be consulted at The Royal College of Surgeons of England. where the originals may be consulted. This work has been identified as being free of known restrictions under copyright law, including all related and neighbouring rights and is being made available under the Creative Commons, Public Domain Mark.

You can copy, modify, distribute and perform the work, even for commercial purposes, without asking permission.



Wellcome Collection
183 Euston Road
London NW1 2BE UK
T +44 (0)20 7611 8722
E library@wellcomecollection.org
<https://wellcomecollection.org>



LARGE CYSTIC MYOMA OF UTERUS

OF OVER TWELVE YEARS' DURATION REMOVED
BY ENUCLEATION; RECOVERY.

WITH NOTES ON CYSTIC "FIBROIDS."

BY

ALBAN DORAN, F.R.C.S.,

SURGEON TO THE SAMARITAN FREE HOSPITAL




Read May 23rd, 1893.

[*From Vol. LXXVI of the 'Medico-Chirurgical Transactions,' published by the Royal Medical and Chirurgical Society of London.*]

LONDON:

PRINTED BY ADLARD AND SON,
BARTHOLOMEW CLOSE, E.C., AND 20, HANOVER SQUARE, W.

1894.



LARGE CYSTIC MYOMA OF UTERUS

OF OVER TWELVE YEARS' DURATION REMOVED BY ENUCLEATION; RECOVERY.

WITH NOTES ON CYSTIC "FIBROIDS."

BY

ALBAN DORAN, F.R.C.S.,
SURGEON TO THE SAMARITAN FREE HOSPITAL.

Received January 25th—Read May 23rd, 1893.

E. R—, æt. 47, was admitted into my ward in the Samaritan Hospital on June 16th, 1892, suffering from a large abdominal tumour.

She was the mother of six children, the youngest being ten years old. About twelve or fourteen years ago she noticed a swelling in the right iliac fossa. In 1882 she consulted Dr. Ilott of Bromley, who sent her to me. There was a swelling on the right side of the uterus, feeling more like a dilated tube than a fibroid. Unfortunately the original full notes have not been preserved. I saw her frequently for two months till she ceased to attend, owing to the illness of her husband. She nursed him for over two years, then he died, and she worked hard in a laundry until the spring of 1891, when she was laid up

for a week with severe pains in the abdomen and lumbar region. The abdomen was then much distended. She could no longer work in the laundry, but was able to sit up and ply her needle till admission, when her health was failing rapidly.

She was rather tall and somewhat emaciated. She lay on her back in bed, feeling uneasy when sitting up or lying on one side. The abdomen was extremely distended, especially towards the left; the superficial veins were dilated, the integuments free from œdema. The girth at the umbilical level was $44\frac{1}{2}$ inches; the distance from the ensiform cartilage to the umbilicus 11 inches; from the umbilicus to the symphysis pubis $14\frac{1}{2}$ inches. The distension was due to a tumour which reached to and pushed forward the ensiform cartilage. There was resonance in the left loin, but not in the right. The lower part of the tumour was very prominent and fluctuated separately from the rest, from which it appeared to be divided by a deep groove. Over the upper and lateral parts was distinct fluctuation.

On vaginal examination the cervix could be felt rather high up and far back in the pelvis. The sound passed three inches forward and to the right; it could be moved somewhat forwards, but in no other direction. The tumour descended into Douglas's pouch and the left fornix, and on the other hand extended anteriorly downwards in front of the sound. A mucous polypus, about one inch in length, projected from the os.

The period, regular till a year before admission, had not been seen for six months. The average daily excretion of urine, independent of what passed during defæcation, was 35 ounces during the first week in hospital, the sp. gr. 1020. There was a trace of albumen. The temperature was normal; the pulse 100, hard, small volume.

The diagnosis was very uncertain; there had been no menorrhagia, and I have seen many large ovarian tumours of ten or twelve years' standing present similar features, physical and clinical. Hence some of my colleagues,

as well as myself, were inclined to consider that the tumour was ovarian, although before beginning the operation I expressed doubts, owing to the long history of a tumour.

As the bulk of the fluid caused great distress, I tapped the lower part of the tumour with the aspirator on June 20th, but only 6 pts. 17 oz. of a yellow, serous, imperfectly-coagulable fluid escaped. On tapping the upper part nothing came away excepting a little blood. I will presently return to this question of paracentesis. Though so little was removed good results followed in this case. The patient ate and drank better and felt in better spirits.

Five days later, June 25th, 1892, I operated, assisted by Mr. Butler-Smythe. I made a long incision ending four or five inches above the pubes, lest the bladder should be wounded. The surface of the prominent lower part of the tumour was exposed. It was pale, but not bright and shiny as in an ordinary ovarian cyst free from complications. The trocar was introduced, and twenty-five pints of orange-red fluid escaped. I was repeatedly obliged to introduce my hand into the tumour in order to tear off and clear away masses of broken-down tissue. On passing my hand upwards I was able to make sure that the upper tumour (which fluctuated separately) was continuous with the lower. I enlarged the incision, and then found that the cæcum and vermiform appendix lay on the surface of the tumour high up to the right, close to the liver. A tedious enucleation had to be undertaken, for the cæcum was not merely adherent, but lay on the peritoneum, which invested the tumour, forming a capsule. The elastic ligature was passed round the root of the entire mass. The uterus, containing several interstitial fibroids, was discovered, displaced to the left. The right and left appendages ran over the tumour, which had pushed up the pelvic and iliac portions of the peritoneum on the right side, hence displacing the cæcum. The catheter was then passed by Mr. Malcolm, who was present, but the fundus of the bladder did not rise high. The right round ligament looked like a ureter. It was not only stretched to the

extent of about six inches, but also much hypertrophied. It ran over the capsule round the right side of the tumour, and behind it to its normal insertion on the uterus. I passed the *serre-nœud* above the elastic ligature, then introduced two pins and cut the entire tumour away. The cæcum and appendix lay close to the *serre-nœud* wire. The elastic ligature was removed. I carefully sewed the parietal peritoneum to the serous lining of the stump on the proximal side of the wire. The rest of the wound was closed in the usual way with silkworm-gut sutures.

Even when removed, the relations of the tumour to the natural structures which had to be sacrificed with it were not to be detected at a glance. I have endeavoured to make the matter clear by the annexed sketch.

The fundus (*f*), distinguishable by its relation to the tubes, lay level with the surface of the tumour. It measured over 3 inches between the origins of the tubes. From its posterior aspect rose an interstitial fibroid (*a*), becoming subperitoneal, about $2\frac{1}{2}$ inches in diameter at the base and 2 inches in vertical measurement. To its left was a smaller fibroid (*b*), growing from the left side of the uterus, and beginning to burrow between the layers of the broad ligament. The corresponding round ligament (*l. r. l.*) seemed, as it were, to spring from the smaller fibroid. The left Fallopian tube (*l. F. t.*), unobstructed, was elongated, measuring over 4 inches. Both layers of the mesosalpinx, that is the broad ligament above the level of the ovary, were in normal apposition, except close to the uterus, where they were parted to a certain extent by the smaller fibroid, *b*. That fibroid had burrowed into the broad ligament below the level of the mesosalpinx. The left ovary was atrophied and very flat, as the small fibroids *a* and *b* had jammed it against the bony pelvis. It contained two small atrophied follicles. The ovarian ligament was one inch long and very thin.

The relation of the small fibroids to the normal parts

on the left of the middle line is instructive, as it explains the relations of the great tumour that had developed on the right side. Had *a* and *b* grown as large as that tumour, the posterior reflection of the pelvic peritoneum would have been pushed upwards to the left hypochondrium, carrying with it the large intestine. The left

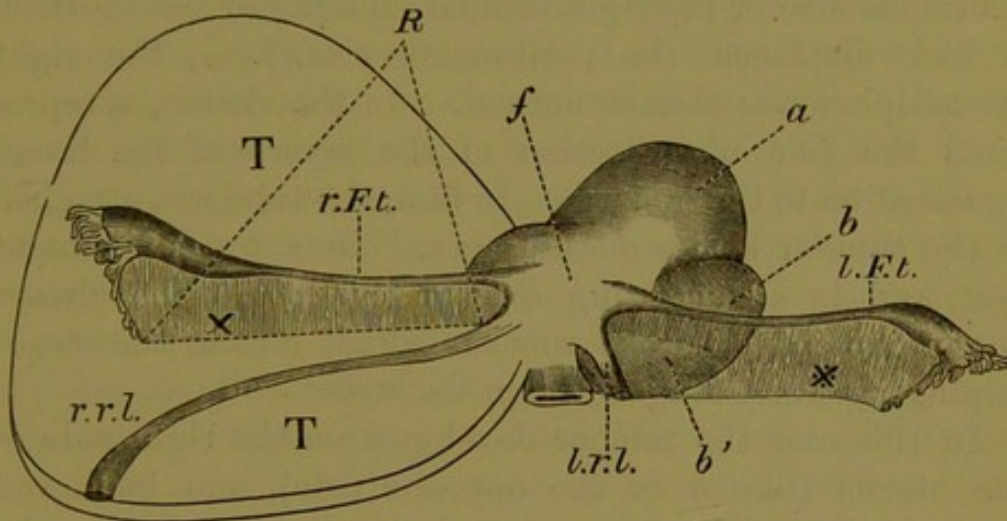


Diagram showing the parts removed with the cystic fibroid tumour.—
T. Portion of surface of tumour. *r. F. t.* Right Fallopian tube.
x. Position of right ovary behind broad ligament. *R.* Line of reflection
of broad ligament on to surface of tumour. *r. r. l.* Right round liga-
ment, greatly elongated. *f.* Fundus uteri. *a.* Small fibroid. *b b'.*
Another small fibroid, beginning to open up the broad ligament below
mesosalpinx. *l. r. l.* Left round ligament. *l. F. t.* Left Fallopian
tube. ***. Position of left ovary behind broad ligament.

round ligament would have been greatly stretched by that portion of the tumour which pressed forward. There was no cystic degeneration in the fibroids on the left side; that change, so marked on the right side, must have greatly aided in displacing peritoneal relations.

The front of the fundus passed on to the right or main tumour. The right round ligament (*r. r. l.*) measured 9 inches as it lay on the serous capsule torn off the tumour. The uterine cavity lay entirely behind the tumour, and measured 3 inches vertically.¹

¹ This measurement is of little value, as it is impossible to make sure how much of the uterus, above the cervix, remains behind.

The relations of the right tube and ovary were remarkable. The Fallopian tube (*r. F. t.*) was $5\frac{1}{2}$ inches long and unobstructed; the right ovary $3\frac{1}{4}$ inches long, and $\frac{1}{2}$ inch in vertical measurement. It bore an oval cystic cavity full of recent clot, and one inch in long diameter. The ovarian ligament was only half an inch long. The noteworthy feature was that, notwithstanding the enormous size of the right tumour, and the extent to which it had displaced the peritoneum elsewhere, the right mesosalpinx was almost normal. In the sketch, *r* represents the line of reflection of the layers of the broad ligament on to the tumour. In fact, the tube was attached to the tumour by its mesosalpinx. In a broad ligament cyst, and in a burrowing ovarian cyst, the tube always lies in contact with the tumour which effaces the mesosalpinx by burrowing between its layers.

In this case the tumour developed on the right side of the uterus (like *b* on the opposite side), and burrowed between the layers of the right broad ligament below the level of the mesosalpinx, finally dissecting up and distending the pelvic peritoneum, stretching the round ligament in front, and carrying upwards the cæcum. The distending and stretching of the peritoneum must have prevailed over the dissecting-up process, else the tumour would have lain against the parietes entirely in front of the parietal peritoneum, or else against the aorta and posterior boundaries of the abdomen behind the posterior reflection of the peritoneum. As it was, a deep peritoneal pouch lay between the tumour and the structures in front of and behind it. Stretching (with hypertrophy, of course) of the peritoneum is seen in broad ligament cysts which may be of great size, although the relations of the peritoneum around them remain absolutely unchanged. Here it is the mesosalpinx alone, normally a very small peritoneal fold, that undergoes so much distension. In my case the tumour stretched the peritoneum forming the broad ligament below the level of the ovary, and also stretched part of the peri-

toneal lining of the right iliac fossa. As usual, when it began to stretch, it ceased to dissect up and displace any more peritoneum.

The solid part of the tumour weighed 10 lbs. 6 oz.; the fluid amounted to 25 pints. Hence, including the 6 pints 17 oz. removed five days previously, the patient was relieved of about 42 lbs. of solid and fluid material. The tumour itself was divided into two parts by an hour-glass constriction. Each part consisted of a main cavity, communicating with the same in the other half, as I mentioned in describing the operation, and bounded by a solid wall which varied in thickness from one eighth of an inch to over two inches. The solid matter was throughout, wherever cut into, a spongy tissue, as in soft uterine fibroids. It was full of cavities, which gave it a bullous appearance on section. A piece, where this appearance was most distinct, was preserved for microscopic examination. From these solid walls much broken-down material projected into the cavity. Beyond what had been torn down in the course of the operation, there were masses of pedunculated bodies, two or three inches long, apparently fibrinous. They may represent changes in old coagula, such as are seen in hydroceles and bursal sacs. Mr. Targett made several sections of the "bullous" tissue,¹ described above, in the laboratories of the College of Surgeons. The tissue consisted of loose bundles of almost pure plain muscle-fibres in a colourless matrix; there were spaces which bore no lining. Hence the histology of the tumour throws no light on its origin. I

¹ Since this paper was prepared, M. Maurice Cazin examined a cystic fibroid which M. Segond had removed by operation; it was found attached to the fundus by a broad pedicle. The greater part of the cystic structure was due to œdematous softening; but near the surface of the tumour were minute cysts, not larger than millet-seeds, which were found to be lined with cylindrical epithelium. The uterine mucous membrane, though so far from the periphery of the tumour, seemed to M. Cazin to be the only possible source of origin of these epithelial cysts. Possibly, in my own case, the bullous structures might have originally been lined with epithelium which had become shed through a degenerative process.

believe that the cavities which appeared like bullæ on section might have been developed from lymphatic vessels. The endothelial lining of these vessels in morbid growths is not easy to detect by the microscope.

In the after-treatment of the case the stump gave me some trouble, as, notwithstanding every precaution, dressing with absorbent gauze, tannin, and iodoform, there was a considerable amount of sloughing below the level of the wire during the second week. The sloughy tissues were gradually trimmed away, and by the seventeenth day the wound was clean and granulated freely. It was packed with iodoform-gauze, and washed out daily with red lotion. The patient was discharged on August 9th.

When I saw her last, on April 28th, 1893, she was in excellent health and had gained flesh. The cicatrix, deeply puckered, was firm and healthy; there was no indication of any hernial protrusion. It is remarkable that a slight "show" of blood occasionally issued from the vagina, though the appendages had been entirely removed, and the greater part of the uterus amputated, the stump undergoing extensive destructive changes during convalescence. The show is probably due to the small mucous polypus.

I did not remove the mucous polypus, as it gave no trouble; there was neither discharge nor hæmorrhage. I know of a case where a polypus of this kind was twisted off, a large uterine fibroid existing. The removal of the fibroid was to have taken place a few days later, but the "minor" operation killed the patient.¹

It cannot be said that the pathology of fibro-cystic myoma of the uterus is thoroughly known. According to some authorities the cysts are formed by breaking down of myomatous tissue through œdema or fatty degeneration, but the manner in which this breaking down begins has been explained on different hypotheses. Certain pathologists believe that the cysts are originally developed from dilated vessels or blood-sinuses. Others

¹ See my 'Handbook of Gynæcological Operations,' p. 315.

maintain that they represent obstructed lymph-channels. In the later stages all these changes may be detected, but the initial lesion cannot then be determined.

Virchow distinguishes a myxo-myoma from simple œdema. Yet may not the latter be the cause of myxomatous degeneration? Œdema and softening, Gusserow admits, may result from changes during pregnancy. As damage to the nutrition of a solid "fibroid" during parturition may cause its delivery (if submucous) or suppuration or gangrene, so similar damage may set up cystic changes. My patient had borne children since the tumour had grown large enough to attract her attention. The disappearance of myoma during pregnancy may be explained, Gusserow suggests, in the same manner. W. Müller, among recent writers, does not reject œdema, but his views on lymphangiectasis will presently be considered. The myxomatous degeneration and the condition resembling "molluscum fibrosum" of Virchow, which have been observed by Bland Sutton and others in specimens examined under the microscope, no doubt exist in the solid matter around fibro-cysts, but these authorities do not prove that they cause the cysts to develop.

Dr. Friedrich Uter has prepared one of the most recent monographs on the development of cysts by breaking down of tissue. He and Dr. Schaumberg detected areas of necrosed myomatous tissue. He describes the appearances with great care. The specimens were from a case of fibroid impacted in the pelvis. The patient suffered from severe local symptoms with peritonitis and fever. But the "fibroid" apparently contained but one cyst, "about the size of a cherry;" it was almost filled by a piece of necrosed tissue which was attached by a pedicle to the bounding wall. That wall was irregular and bore no epithelium. No myxomatous degeneration was noted. Numerous small circumscribed deep red patches were seen scattered over the cut surface of the solid matter, and these, Dr. Uter believes, represented the origin of the cyst. But impacted fibroid is an extreme condition,

and there is no evidence that in my case or in many other cases of cystic fibroid impaction ever occurred. Dr. Uter admits the existence of other forms of cystic uterine tumour.

The theory that the cysts develop from pre-existing cavities must now be considered. When no epithelial lining is detected in a large or even a small cyst it does not follow that the cyst arose from a tissue devoid of epithelium. Indeed, the two structures, blood-vessel or lymph-channel, whence it is said the cysts arise, bear endo- not epi-thelium, and endothelium does not readily adapt itself to the progressive changes which epithelium undergoes in adenoma and more malignant growths.

Virchow's myoma telangiectodes is a distinct form, at least anatomically, though pathologically the distinction is less marked, and clinically there is none at all. So thinks Gusserow, who compares the cavernous tissue to the corpus cavernosum penis, and notes that the tumour often increases perceptibly in size at the menstrual period. This change is often seen in solid fibroids. He notes Leopold's case where the cystic cavities were full of blood. This appearance is not seen, as a rule, in the majority of fibroids with large cysts.

The evidence that Virchow's and Leopold's tumours represent a distinct and rare class seems strong though not conclusive. On the other hand, there is good reason to believe that a large proportion of cysts in fibroids are in origin lymphangiectases. Pozzi speaks of their endothelial lining as distinctive, but I have already noted that there is no evidence that the endothelium may not disappear when the cyst grows large. W. Müller, who has examined numerous myomata with large, medium, and minute cysts, believes that lymphangiectasis is far more common than is usually supposed. Many cases have never been submitted to microscopic examination. Simple œdema must be distinguished from vesicular œdema ("blasige Œdem"—Virchow) the latter being due to dilated lymph-channels. There are, Dr. Müller ob-

serves, evident intermediate stages between the two forms, representing incipient lymphangiectasis. He insists that a tumour of this kind is in no sense a lymphangioma.

I am strongly inclined to agree with Dr. Müller, for I know from long clinical experience that in large fibroids there is evidence of great obstruction to the lymphatics. Large yellow bubbles are often seen in the broad ligaments during operation, whilst enormously dilated lymphatics run over omentum adherent to the fibroid. The bubbles are thin-walled spaces (lacunar cysts of Verneuil), and lymph drains from them after the removal of the tumour, so that they disappear. In these cases I have traced dilated lymphatics entering the fibroid.

The fluid in the cysts bears the characters of lymph. It is rarely like the altered blood seen in old hydroceles and in the loculi of ovarian cysts. Moreover, when real blood is found in a cyst in a "fibroid," it may have escaped from ruptured vessels in the degenerate cyst-wall; it does not prove that the cyst was originally a blood-vessel. As a rule, says Gusserow, the fluid is pale yellow and coagulates imperfectly. Heer, it is true, found that in only eleven out of seventy cases did this spontaneous coagulation take place. Keith, in his first case, notes how the red serous fluid turned into a jelly in the course of the operation. In my own case the fluid might well have originated from lymphatics, without any admixture with blood.

There is reason to suppose that treatment by electricity may at least encourage cystic degeneration of "fibroids." Dr. Bache Emmet removed a large cystic fibroid, with the uterus entire, from a woman aged forty. Ten years before operation it was as large as an egg. Eight years later it was about the size of a uterus at term. It was treated by galvano-puncture, powerful currents being employed. There was temporary relief, then in a year menorrhagia set in, and the tumour increased greatly in size. Milder galvanic currents, without puncture, were used in vain, so the tumour was removed. Dr. Harry Sims, in

reference to Dr. Bache Emmet's case, observes that in one case upon which he had operated he found that no reduction followed the electrical treatment. The tumour was honeycombed throughout by large disintegrated masses. Mr. Knowsley Thornton observed cystic degeneration in a case where the abdominal wall was freely scarred by previous "Apostoli's treatment." In these cases necrosis, as described by Uter, possibly occurred. In none is there distinct proof that the electrical treatment actually caused the cysts to develop.

From pathology we will now pass to diagnosis. Many writers testify that cystic fibroids are often first detected in the course of an intended "ovariotomy." This had happened to experienced authorities such as Keith. In Case 1 "no very careful examination was made, for now I never doubted that the tumour was ovarian." In Case 5 "a single, almost momentary examination, was made, and the opinion given was that there was no doubt that the tumour was ovarian." In Dr. Keith's remarkable case (36) he hesitated, for given reasons, between "uterine fibrous cyst" and "some undescribed form of retro-peritoneal tumour." Case 40, still more extraordinary, was mistaken by two distinguished Italian professors for an ovarian tumour, but Dr. Keith made a correct diagnosis.

Gusserow relates a case in Spiegelberg's practice, where a cystic fibroid was tapped by mistake, being taken for an ovarian cyst. In Cushing's case, "the tumour when exposed looked like a multilocular ovarian cyst." In my case, though the surface of the cyst was not bright and shiny, as in a multilocular ovarian tumour free from adhesions and inflammatory or degenerative changes, it was not unlike many such tumours subject to these complications. The reddish capsule of a broad ligament cyst resembles uterine tissue. In cases of my own, and also in others under the care of my colleagues, I have seen the surface of a uterine fibroid appear white and shiny when exposed. Thornton, McMurty of Louisville, Kollock. and Henry Byford relate remarkable errors of diagnosis.

In several of the cases above quoted, as in many others where cystic fibroid of the uterus was taken for an ovarian cyst, the tumour was pedunculated. Hence the uterus moved freely from it, and hence it is very natural that it was mistaken for an ovarian tumour. Sir Spencer Wells notices errors of this kind in his well-known writings. Gusserow observes that cystic fibroids are said to grow quickly, whilst ovarian cysts grow slowly, "but numerous exceptions on both sides are sufficient to show that this point of diagnosis is unsafe." All observers of any experience will agree with him. Ovarian cysts often increase rapidly; on the other hand, when the vessels of the pedicle become gradually obliterated, they not rarely remain stationary (whether large or small) for many years. Some uterine cystic fibroids grow rapidly; some, as in my case, increase slowly.

The catamenial history is often misleading; menorrhagia may be present when the cyst is ovarian, and cystic fibroids are seldom associated with that condition. In my case no "show" had been seen for six months, yet there was a mucous polypus, which often keeps up hæmorrhage. The menopause is frequently deferred till fifty or later in patients subject to fibroid of the uterus.

The fluid found in large cystic fibroids has been described. It is certainly different from the characteristic glairy fluid which fills the cavities of multilocular ovarian tumours or the watery contents of broad ligament cysts. But tapping is dangerous, and not to be advocated in doubtful cases as a means of diagnosis. Again, fluids in cysts may undergo many changes which alter their appearance and puzzle the observer. Large ovarian cysts not rarely contain a lymph-like, pale yellow fluid.

The relations of cystic uterine fibroids are often puzzling. I have just referred to the close resemblance of pedunculated cystic fibroids to pedunculated ovarian cysts, as far as physical signs can guide us. Both these tumours may, on the other hand, be sessile. Diagnosis then becomes particularly difficult. The uterus in both cases

appears more or less intimately connected with the tumour. The sound may fail to settle the difficulty. The uterine cavity is not always enlarged in cystic fibroid disease, whilst in cases of large sessile ovarian tumours it may be elongated. Of course careful employment of the sound for ascertaining whether the uterine cavity lies in front of the tumour or behind it is necessary for diagnosis. It must not, however, be forgotten that the sound is a dangerous instrument in many cases of uterine disease, especially cystic fibroid. Thus in Spiegelberg's case, already quoted, where the cyst was tapped by mistake, the patient died of septicæmia from suppuration of the tumour due to perforation of the uterus by the sound. On two occasions that instrument was made to pass $6\frac{3}{4}$ inches into the mass.

Dr. Lediard, of Carlisle, relates an interesting case of "fibro-cystic myoma of the uterus," where the patient was admitted into hospital for free hæmorrhage and vomiting. The sound passed 4 inches into the uterus. The symptoms continued, and a month after admission the temperature rose to 103.6° . Nine days later the sound was passed both into the uterus and the bladder; no bad symptoms followed, but at the end of a week the sound was introduced into the uterus and the bladder examined as before. There was evidence of decomposing retained discharge. On the following day the patient was restless, hot, and sick. Symptoms of septicæmia set in. The patient died on the ninth day after the last sounding. There was no trace of abrasion within the uterus, but no examination of the veins was made. The lungs were oedematous and congested; the kidneys contained millet-seed collections of pus. Dr. Lediard gravely suspected the sound as the cause of the fatal result. Dr. Gervis, when the case was read before the Obstetrical Society, expressed his fear that Dr. Lediard was not alone in his experience of the occasional mischief which followed the most careful use of the sound. A very slight abrasion might be followed by absorption if any septic products

were at hand. I have known death to occur within a few hours after careful passage of the sound in a case of malignant tumour of the ovary. The penetrative power of the sound, in some cases where the uterus is apparently healthy, is well known. Little harm is done in such cases, but, as the above records show, it is quite otherwise when a cystic fibroid exists.

In short, diagnosis between cystic uterine fibroid and ovarian cyst is sometimes barely possible, and two of the favourite methods of diagnosis—tapping and the sound—are neither sure nor safe.

Whilst some cystic uterine fibroids have been taken for ovarian tumours, others have been taken for solid uterine fibroids. When the walls of the tumour are thick this error is natural, for fluctuation is often obscure or absent. A soft, œdematous, solid fibroid often gives to the hand a sense of fluctuation. Sudden increase of growth is a frequent symptom when cystic degeneration of a solid fibroid has set in, but it is not invariably seen. In my case the increase was very slow and very uniform. The presence or absence of menorrhagia is in no way reliable as a symptom. Pedunculated cystic fibroids do not cause menorrhagia, but they may be complicated by small sub-mucous growths or mucous polypi, and then there will be more or less bloody discharge.

I have mentioned that a mucous polypus grew from the cervix in this case. Matthews Duncan notes that "a fibroid often induces the growth of mucous polypi of the body or of the neck of the womb, and these aggravate and prolong hæmorrhage." How a fibroid can "induce" this new growth he does not explain. In my case, as already noted, the polypus neither caused hæmorrhage nor deferred the menopause.

The consideration of the treatment of cystic fibroid is a matter of high importance. The presence of cysts is a distinct complication, and when the tumour is mainly a single large cyst, as in my case, an operation is often needed, the more especially as the tumour does not tend

to atrophy at the menopause, and the pressure-effects increase in severity.

When the nature of the disease is almost certain, I doubt that any surgeon would recommend tapping. In cases of ovarian cysts, where there is a great amount of fluid with marked dyspnoea, the patient being old, tapping is sometimes advisable. The sudden removal of a great quantity of fluid during operation may cause serious pulmonary complications—a gravematter when from other causes there is much shock. Hence tapping before operation allows the patient time to recover the perfect use of her lungs and improve digestion, whereby she is the more fit for ovariectomy. In my own experience excellent results have followed this practice. In my case of cystic fibroid this improvement actually took place. Yet had I been more certain, I should not have tapped. Experience shows that in cystic uterine fibroid the practice is very dangerous. Gusserow remarks that, according to Leopold and Fehling ten out of eleven cases of systematic tapping proved fatal. The rigidity of the uterine cysts allows of the entrance of air, and large vessels or very vascular layers of tissue are often wounded. Not rarely the trocar is hard to drive into the cavity of the cyst, and only a few drops of bloody fluid escape. The soft, oedematous, breaking-down tissue bordering on the cyst may be pushed forwards and obstruct the cannula. In Dr. Keith's first case, when the tumour was already exposed at the operation, "there was a difficulty in getting in the trocar. The cyst was quite thin, but it required a very strong effort to push in the instrument." In Case 5, during operation, much force was required to pierce the tumour, and then nothing but a little blood escaped. Should the tumour be a very soft, solid uterine "fibroid," which often feels cystic, tapping would involve great dangers.

An exploratory incision is but a step towards operation. In my own case, as in many others, the mere exposure of the tumour by no means settled the diagnosis. This subject, the appearance of the cyst-wall, has, however,

been already discussed. In Sir Spencer Wells's case, performed at Dublin in 1864, the nature of the cyst was not evident at a glance even after exposure and tapping. The tumour must be manually explored with great caution, so that its relations may be determined.

There can be no doubt that, other conditions being the same, the removal of the tumour is more justifiable and more necessary when it is cystic than when it is solid. Some of the reasons for this opinion have already been given. Gusserow shows, from the collected evidence of earlier workers, that the duration of cystic fibroids is relatively short, the longest period being ten years, whilst in many cases death occurred within a few months. It is not possible to determine how long the tumour had become cystic in my case. Suppuration through thrombosis in their substance or neighbourhood is frequent. The rapidity of growth, and tendency to suppuration and to increase instead of diminish at the menopause, all suggest that an operation is needed.

When the tumour is pedunculated, as is so frequently the case, its removal is not very difficult. The pedicle is harder to secure than that of an ovarian tumour. The ligature may slip, and the *serre-nœud* involves sloughing which may extend into the uterus or give rise to troublesome hæmorrhage. When the cyst burrows under or behind the parietal peritoneum, or in front of it, the difficulties of the operation are great, as my case proved. The complications may be very intricate, too varied and complex for any description here in detail. Fuller information will be found in the writings of Sir Spencer Wells, Keith, Pozzi, and others. To the special difficulties arising from displacement of peritoneum may be added those not rare in cases of solid "fibroid"—such as vascular adhesions and difficulty in making a pedicle. In a case where Dr. Cushing successfully operated, the patient, aged fifty, suffered severely from dyspnœa owing to the bulk of the tumour. She had to be made to sit crosswise on the table. As the tumour was rolled out

the veins, relieved from pressure, began to distend, and syncope threatened to come on; she was placed in the ordinary recumbent posture and the operation completed. Other operators have experienced great trouble owing to rents in the peritoneum, which required union by suture, unless the edges of the serous membrane could not be brought together, and then the raw surface required drainage.

The uterine tissue is often œdematous and otherwise degenerate. Hence the stump requires very careful dressing, and in spite of all precautions may, as in my case, cause much trouble during the after-treatment. Perhaps firm packing with absorbent gauze, frequently changed, is the best kind of dressing. It is of particular importance that the peritoneum be well united by sutures to the stump on the proximal side of the serre-nœud wire. This practice prevents retraction of the stump into the peritoneal cavity, an accident always serious in hysterectomy, and especially dangerous when the remains of the amputated uterus are soft and bulky, as in cystic fibroid disease, so that the sloughing process may extend some distance below the level of the wire.

REFERENCES.

- Byford, Henry*.—‘Amer. Journ. Obstet.,’ 1889, p. 965.
Cazin, Maurice.—“Fibro-myome kystique de l’Utérus,” ‘Bulletins de la Soc. Anatom. de Paris,’ March, 1893, pt. 9, p. 232.
Cushing.—“Degeneration of Uterine Fibroids,” ‘Boston Med. and Surg. Journ.,’ vol. cxxii, 1890, pp. 315—321.
Duncan, J. Matthews.—‘Clinical Lectures on the Diseases of Women,’ Lecture “On the Terminations of Uterine Fibroids.”
Emmet, Dr. Bache.—“A Large Uterine Fibroma showing Cystic Degeneration, possibly the Result of

Galvanic Treatment," 'Amer. Journ. Obstet.,' 1892, p. 251.

Gusserow.—"Die Neubildungen des Uterus," Billroth u. Luecke, 'Deutsche Chirurgie,' pt. 57, 1885. (Includes references to Heer, Leopold, Spiegelberg, and Virchow.)

Keith.—'Contributions to the Surgical Treatment of Tumours of the Abdomen,' pt. 1, 1885.

Kollock, Cornelius.—"Fibro-cystic Myoma and Ovarian Cystoma," 'Trans. Amer. Gynæc. Soc.,' vol. xiii, 1888, p. 471.

Lediard.—"Fibro-cystic Myoma of Uterus; Septicæmia," 'Trans. Obstet. Soc.,' xxvi, 1884, p. 193.

McMurty.—'Amer. Journ. Obstet.,' 1892, p. 819.

Müller, W.—"Beitrag zur Kenntniss der Cystoiden Uterustumoren," 'Archiv f. Gynäk.,' vol. xxx, 1887, p. 249.

Pozzi.—'Traité de Gynécologie clinique et opératoire,' 2me édition, 1892.

Thornton, J. Knowsley.—"Two Uterine Fibro-cysts," 'Trans. Obstet. Soc.,' vol. xxxi, p. 199.

Uter and Schaumberg.—"Zur Genese der Fibro-cystischen Geschwulste," 'Centralbl. f. Gynäk.,' 1892, p. 541.

Wells, Sir T. Spencer, Bart.—'On Ovarian and Uterine Tumours,' 1882.

Breus Centralbl. f. d. medicin. Wissenschaften
 no 29 1894—very important—cysts lined with ciliated epithelium, which to Bruns's dict.
 (For report of the discussion on this paper, see 'Proceedings of the Royal Medical and Chirurgical Society,' New Series, vol. v, p. 114.)

1. The first of these is the fact that the
the second is the fact that the
the third is the fact that the
the fourth is the fact that the
the fifth is the fact that the
the sixth is the fact that the
the seventh is the fact that the
the eighth is the fact that the
the ninth is the fact that the
the tenth is the fact that the
the eleventh is the fact that the
the twelfth is the fact that the
the thirteenth is the fact that the
the fourteenth is the fact that the
the fifteenth is the fact that the
the sixteenth is the fact that the
the seventeenth is the fact that the
the eighteenth is the fact that the
the nineteenth is the fact that the
the twentieth is the fact that the
the twenty-first is the fact that the
the twenty-second is the fact that the
the twenty-third is the fact that the
the twenty-fourth is the fact that the
the twenty-fifth is the fact that the
the twenty-sixth is the fact that the
the twenty-seventh is the fact that the
the twenty-eighth is the fact that the
the twenty-ninth is the fact that the
the thirtieth is the fact that the
the thirty-first is the fact that the
the thirty-second is the fact that the
the thirty-third is the fact that the
the thirty-fourth is the fact that the
the thirty-fifth is the fact that the
the thirty-sixth is the fact that the
the thirty-seventh is the fact that the
the thirty-eighth is the fact that the
the thirty-ninth is the fact that the
the fortieth is the fact that the
the forty-first is the fact that the
the forty-second is the fact that the
the forty-third is the fact that the
the forty-fourth is the fact that the
the forty-fifth is the fact that the
the forty-sixth is the fact that the
the forty-seventh is the fact that the
the forty-eighth is the fact that the
the forty-ninth is the fact that the
the fiftieth is the fact that the
the fifty-first is the fact that the
the fifty-second is the fact that the
the fifty-third is the fact that the
the fifty-fourth is the fact that the
the fifty-fifth is the fact that the
the fifty-sixth is the fact that the
the fifty-seventh is the fact that the
the fifty-eighth is the fact that the
the fifty-ninth is the fact that the
the sixtieth is the fact that the
the sixty-first is the fact that the
the sixty-second is the fact that the
the sixty-third is the fact that the
the sixty-fourth is the fact that the
the sixty-fifth is the fact that the
the sixty-sixth is the fact that the
the sixty-seventh is the fact that the
the sixty-eighth is the fact that the
the sixty-ninth is the fact that the
the seventieth is the fact that the
the seventy-first is the fact that the
the seventy-second is the fact that the
the seventy-third is the fact that the
the seventy-fourth is the fact that the
the seventy-fifth is the fact that the
the seventy-sixth is the fact that the
the seventy-seventh is the fact that the
the seventy-eighth is the fact that the
the seventy-ninth is the fact that the
the eightieth is the fact that the
the eighty-first is the fact that the
the eighty-second is the fact that the
the eighty-third is the fact that the
the eighty-fourth is the fact that the
the eighty-fifth is the fact that the
the eighty-sixth is the fact that the
the eighty-seventh is the fact that the
the eighty-eighth is the fact that the
the eighty-ninth is the fact that the
the ninetieth is the fact that the
the ninety-first is the fact that the
the ninety-second is the fact that the
the ninety-third is the fact that the
the ninety-fourth is the fact that the
the ninety-fifth is the fact that the
the ninety-sixth is the fact that the
the ninety-seventh is the fact that the
the ninety-eighth is the fact that the
the ninety-ninth is the fact that the
the hundredth is the fact that the