

**The journal of anatomy and physiology : normal and pathological. Vol. XV.
[Pt. 4] / conducted by G.M. Humphry [and others].**

Contributors

Harris, Vincent Dormer, 1851-1931.
Doran, Alban H. G. 1849-1927.
Royal College of Surgeons of England

Publication/Creation

London : Macmillan, 1881.

Persistent URL

<https://wellcomecollection.org/works/yzscghw8>

Provider

Royal College of Surgeons

License and attribution

This material has been provided by This material has been provided by The Royal College of Surgeons of England. The original may be consulted at The Royal College of Surgeons of England. where the originals may be consulted. This work has been identified as being free of known restrictions under copyright law, including all related and neighbouring rights and is being made available under the Creative Commons, Public Domain Mark.

You can copy, modify, distribute and perform the work, even for commercial purposes, without asking permission.



Wellcome Collection
183 Euston Road
London NW1 2BE UK
T +44 (0)20 7611 8722
E library@wellcomecollection.org
<https://wellcomecollection.org>

THE
JOURNAL OF ANATOMY AND PHYSIOLOGY
NORMAL AND PATHOLOGICAL.

CONDUCTED BY

G. M. HUMPHRY, M.D., F.R.S.,

PROFESSOR OF ANATOMY IN THE UNIVERSITY OF CAMBRIDGE;

W. TURNER, M.B., F.R.S.,

PROFESSOR OF ANATOMY IN THE UNIVERSITY OF EDINBURGH;

J. G. M'KENDRICK, M.D., F.R.S.E.,

PROFESSOR OF THE INSTITUTES OF MEDICINE IN THE UNIVERSITY OF GLASGOW;

C. CREIGHTON, M.D.,

DEMONSTRATOR OF ANATOMY IN THE UNIVERSITY OF CAMBRIDGE.

Vol. XVI. Part I. will appear in October.

The *Journal* is intended chiefly for original contributions in ANATOMY (Human and Comparative), PHYSIOLOGY, and PATHOLOGY; it contains also CRITICAL and HISTORICAL ANALYSES, EXTRACTS, REVIEWS and NOTICES OF BOOKS, &c.

It appears Quarterly in October, January, April, and July. Price 6s. each part, or 20s. a year, post free 21s. paid in advance.

Authors will receive 25 copies of their communications *gratis*.

MACMILLAN & Co.
LONDON AND CAMBRIDGE.

THE
JOURNAL OF ANATOMY AND PHYSIOLOGY
NORMAL AND PATHOLOGICAL

EDITED BY

G. M. HUMPHREY, M.D., F.R.S.

PROFESSOR OF ANATOMY IN THE UNIVERSITY OF CAMBRIDGE

W. TURNER, M.D., F.R.S.

PROFESSOR OF PHYSIOLOGY IN THE UNIVERSITY OF CAMBRIDGE

J. G. MITCHELL, M.D., F.R.S.

PROFESSOR OF THE THEORY OF MEDICINE IN THE UNIVERSITY OF CAMBRIDGE

C. GORDON, M.D.

PROFESSOR OF PHYSIOLOGY IN THE UNIVERSITY OF CAMBRIDGE

Vol. XVI, Part I, will appear in October.

The Journal is included chiefly for original contributions
in Anatomy, Physiology and Comparative Zoology, and
Embryology; it contains also Clinical and Historical
Anatomy, Neurology, Geriatrics and Medicine as far as
it applies directly to the above, January, April and July.
It is the only part of the Journal published in
October.
Subscribers will receive 25 copies of their subscription gratis.

W. A. G. M. I. L. A. N. & C.

10, MARK LANE, LONDON, E.C.

THE
JOURNAL
OF
ANATOMY AND PHYSIOLOGY
NORMAL AND PATHOLOGICAL.

CONDUCTED BY

G. M. HUMPHRY, M.D., F.R.S.,
PROFESSOR OF ANATOMY IN THE UNIVERSITY OF CAMBRIDGE;


WM. TURNER, M.B., F.R.S.,
PROFESSOR OF ANATOMY IN THE UNIVERSITY OF EDINBURGH;

J. G. M'KENDRICK, M.D., F.R.S.E.,
PROFESSOR OF THE INSTITUTES OF MEDICINE IN THE UNIVERSITY OF GLASGOW;

AND

C. CREIGHTON, M.D.,
DEMONSTRATOR OF ANATOMY IN THE UNIVERSITY OF CAMBRIDGE.

VOL. XV.



WITH TWENTY-SEVEN PLATES AND NUMEROUS WOODCUTS.

MACMILLAN AND CO.,
London and Cambridge:
1881.

THE
JOURNAL

OF

ANATOMY AND PHYSIOLOGY

NORMAL AND PATHOLOGICAL

EDITED BY

G. M. HUGHES, M.D., F.R.S.

PROFESSOR OF ANATOMY IN THE UNIVERSITY OF EDINBURGH

AND

ASSISTANT PROFESSOR OF ANATOMY IN THE UNIVERSITY OF EDINBURGH

NEILL AND COMPANY, EDINBURGH,

GOVERNMENT BOOK AND LAW PRINTERS FOR SCOTLAND.

AND

G. G. GORDON, M.D.,

PROFESSOR OF ANATOMY IN THE UNIVERSITY OF EDINBURGH

VOL. XL

WITH TWENTY-SEVEN PLATES AND NUMEROUS ILLUSTRATIONS

MACHILLAN AND CO.

Printed and Published by

1881



CONTENTS.

<i>FIRST PART—OCTOBER 1880.</i>	PAGE
AN INFECTIVE FORM OF TUBERCULOSIS IN MAN IDENTICAL WITH BOVINE TUBERCULOSIS. By C. CREIGHTON, M.D. (Plates I.-VI.)	1
TERTIARY OCCIPITAL CONDYLE. By WILLIAM ALLEN, M.D. (Plate VII.)	60
SOME POINTS IN THE HISTOLOGY OF CIRRHOSIS OF THE LIVER. By J. DRESCHFELD, M.D., M.R.C.P. Lond. (Plate VIII.)	69
A CONTRIBUTION TO THE PATHOLOGICAL ANATOMY OF LEAD-PARALYSIS. By SIEGMUND MORITZ, M.D., L.R.C.P. (Plate IX.)	78
VASCULAR LESIONS IN HYDROPHOBIA AND IN OTHER DISEASES CHARACTERISED BY CEREBRAL EXCITEMENT. By GEORGE S. MIDDLETON, M.A., M.B. (Plate X.)	88
AN ETHER PERCOLATOR, FOR USE IN PHYSIOLOGICAL OR PATHOLOGICAL LABORATORIES. By DONALD MACPHAIL, M.B. (Plate XI.)	105
THE COMPARATIVE VALUE OF CHLOROFORM AND ETHIDENE DICHLORIDE AS ANÆSTHETIC AGENTS. By DAVID NEWMAN, M.B.	110
OBSERVATIONS ON THE TEMPERATURE OF THE HEALTHY HUMAN BODY IN VARIOUS CLIMATES. By ROBERT PINKERTON, M.B. (Glasgow). (Plate XII.)	118
THE LYMPHATICS OF CARTILAGE OR OF THE PERICHONDRIUM. By GEORGE HOGGAN, M.B. (Edin.), and FRANCES ELIZABETH HOGGAN, M.D. (Zurich), M.K.Q.C.P. (Plate XIII.)	121
A PALATINE BRANCH FROM THE MIDDLE MENINGEAL ARTERY. By R. J. ANDERSON, M.D.	136
MUSCULAR ANOMALIES. By J. F. KNOTT	139

SECOND PART—JANUARY 1881.		PAGE
THE BONES, ARTICULATIONS, AND MUSCLES OF THE RUDIMENTARY HIND-LIMB OF THE GREENLAND RIGHT-WHALE (<i>Balaena mysticetus</i>). By JOHN STRUTHERS, M.D. (Plates XIV.—XVII.).....		141
AN INFECTIVE FORM OF TUBERCULOSIS IN MAN IDENTICAL WITH BOVINE TUBERCULOSIS. By C. CREIGHTON, M.D.		177
CASE OF MEDULLARY NEUROMA OF THE BRAIN. By WILLIAM OSLER, M.D., M.R.C.P. Lond. (Plate XVIII.)		217
DISSECTION OF THE GENITO-URINARY ORGANS IN A CASE OF FISSURE OF THE ABDOMINAL WALLS. By ALBAN DORAN, F.R.C.S. (Plate XIX.).....		226
DESCRIPTION OF A POLYGRAPH (with Figure). By DAVID NEWMAN, M.B.		235
REMARKS ON THE MECHANISM OF THE SECRETION OF SWEAT. By C. HANDFIELD JONES, M.B. Cantab., F.R.S.....		238
ANOMALOUS GROWTH BEARING PILOSE SKIN IN THE PHARYNX OF A YOUNG WOMAN. By P. S. ABRAHAM, M.A., B.Sc., F.R.C.S.I. (With Figure.)		244
THE HISTOLOGY OF GRANULAR KIDNEY (with Figure). By ROBERT SAUNDBY, M.D., Edin.....		249
NOTES ON TWO CASES OF CEREBELLAR DISEASE. By THOMAS OLIVER, M.D.		252
SOME OBSERVATIONS ON THE COLOURING MATTER OF JELLY FISHES. By Professor M'KENDRICK.....		261
THE NERVES OF THE HIND-LIMB OF THE THYLACINE (<i>Thylacinus Harrisii</i> or <i>Cynocephalus</i>) AND CUSCUS (<i>Phalangista maculata</i>). By D. J. CUNNINGHAM, M.D.		265
PULSE DICROTISM. By WM. JAS. FLEMING, M.D.....		278
ANATOMICAL NOTICES.....		292

THIRD PART—APRIL 1881.

THE BONES, ARTICULATIONS, AND MUSCLES OF THE RUDIMENTARY HIND-LIMB OF THE GREENLAND RIGHT-WHALE (<i>Balaena mysticetus</i>). By JOHN STRUTHERS, M.D.....	301
THE STRIDULATING APPARATUS OF CALLOMYSTAX GAGATA. By ALFRED C. HADDON, B.A. (Plate XX.)	322
THE STERNUM AS AN INDEX OF SEX AND AGE. By THOMAS DWIGHT, M.D., Boston, U.S.A.....	327

	PAGE
THE MECHANISM OF COSTAL RESPIRATION. By JOHN M. HOBSON, M.D. (With Figures.).....	331
THE MEMBRANA PROPRIA OF THE MAMMARY GLAND. By C. W. MANSELL MOULLIN, M.A., M.D. Oxon., F.R.C.S. (With Figures.).....	346
DOUBLE AND TREBLE STAINING OF MICROSCOPIC SPECIMENS. By WILLIAM STIRLING, M.D., Sc.D., F.R.S.E.....	349
THE COMPARATIVE ANATOMY OF THE LYMPHATICS OF THE MAMMALIAN URINARY BLADDER. By GEORGE HOGGAN, M.B. (Edin.), and FRANCES ELIZABETH HOGGAN, M.D. (Zurich), M.K.Q.C.P. (Ireland). (Plate XXI.).....	355
NOTES ON A DISSECTION OF A CASE OF EPISPADIAS. By R. J. ANDERSON, M.D.....	378
THE MORPHOLOGY OF THE MUSCLES OF THE TONGUE AND PHARYNX. By R. J. ANDERSON, M.D.....	382
THE SO-CALLED MOVEMENTS OF PRONATION AND SUPINATION IN THE HIND- LIMB OF CERTAIN MARSUPIALS. By ALFRED H. YOUNG, M.B., F.R.C.S.	392
A CONTRIBUTION TO THE PATHOLOGICAL ANATOMY OF PNEUMONOKONIOSIS (<i>Chalicosis pulmonum</i>). By THOMAS HARRIS. (Plate XXII.).....	395
THE HISTOLOGY OF SOME OF THE RARER FORMS OF MALIGNANT BONE TUMOURS. By ROBERT MAGUIRE, M.R.C.S.....	405
THE MORBID HISTOLOGY OF THE LIVER IN ACUTE YELLOW ATROPHY. By Professor J. DRESCHFELD.....	422
THE RELATIONSHIP BETWEEN THE MUSCLE AND ITS CONTRACTION. By J. THEODORE CASH, M.D. (With Figures.).....	431
ANATOMICAL NOTICES.....	446

FOURTH PART—JULY 1881.

THE OVARY IN INCIPIENT CYSTIC DISEASE. By VINCENT D. HARRIS, M.D., and ALBAN DORAN, F.R.C.S. (Plate XXIII.).....	453
ANATOMY OF THE KOALA (<i>Phascolarctos cinereus</i>). By A. H. YOUNG, M.B., F.R.C.S.....	466
THE LYMPHATICS OF THE PANCREAS. By GEORGE HOGGAN, M.B., and FRANCES ELIZABETH HOGGAN, M.D. (Plate XXIV.).....	475

	PAGE
CASE OF PRIMARY CANCER OF THE FEMUR. By ROBERT MAGUIRE, M.R.C.S. (Plate XXV.).....	496
CASE OF CHRONIC LOBAR PNEUMONIA. By THOMAS HARRIS.....	502
A CONTRIBUTION TO THE PATHOLOGICAL ANATOMY OF PRIMARY LATERAL SCLEROSIS (SCLEROSIS OF THE PYRAMIDAL TRACTS). By J. DRESCH- FELD, M.D., M.R.C.P. (Plate XXVI.).....	510
THE FORM AND PROPORTIONS OF A FETAL INDIAN ELEPHANT. By Professor TURNER, M.B., F.R.S. (Plate XXVII.).....	519
THE FEMORAL ARTERY IN APES. By J. MACDONALD BROWN, M.B.....	523
THE BRAIN AND NERVOUS SYSTEM: A SUMMARY AND A REVIEW. By ROBERT GARNER, F.L.S., F.R.C.S.....	536
INDEX.....	580

4

Journal of Anatomy and Physiology.

THE OVARY IN INCIPIENT CYSTIC DISEASE. By
VINCENT D. HARRIS, M.D., Lond., *Demonstrator of Physiology and late Casualty Physician, St Bartholomew's Hospital ;*
and ALBAN DORAN, F.R.C.S., *Surgeon to Out-Patients, Samaritan Free Hospital, Pathological Assistant to the Museum, Royal College of Surgeons of England.* (PLATE XXIII.)

WE, the authors of this paper, desire to take advantage of certain opportunities which we have enjoyed of studying incipient cystic disease of the ovary in its earlier stages. In the Samaritan Free Hospital the operation of ovariectomy is performed seventy to eighty times every year. In over one-eighth of the cases the operators, Dr Bantock and Mr Knowsley Thornton, find, that, after the removal of a large ovarian cyst, the opposite ovary presents such distinct symptoms of early cystic disease, that they remove it, knowing that otherwise a second operation will almost assuredly be necessary at no very distant date. A large number of such ovaries have been collected, and their appearances, when fresh, carefully described ; the history of the patients, and notes as to the absence or regularity of the menstrual functions, together with records of abortion, parturition, or sterility, have also been preserved. The ovaries, within a few hours after removal, were placed within a half per cent. solution of chromic acid mixed with equal parts of methylated spirit. When sufficiently hardened, sections were prepared from them by means of Williams' freezing microtome. These sections were stained in logwood solution, and then mounted. Lastly, all have been since examined minutely by both of us, and separate notes carefully compared. The following observations are the result of this combination of study.

In the first place, we determined to divest ourselves of all preconceived opinions on the subject, before examining the sections; a task not so very difficult when it is remembered that previous theories neutralise each other by being so completely contradictory. Cystic disease of the ovary has been asserted to originate from the Graafian follicles, from the corpora lutea, from the ovarian stroma by a degenerative softening, from certain morbid, tubular, epithelial structures, and lastly from changes in the large blood-vessels in the tissue of the hilum. Most of the pathologists who trace the cysts to one of the above elements, admit the possibility of their origin from one or more of the others, a point on which we strongly insist. It would be tedious to quote all the authorities who hold each of these different opinions; they are named in most works on general pathology, but we shall have to refer to the researches of some of the more recent observers, in the course of the paper.

We have also been careful to select, for minute description, ovaries which were in all cases the fellows of others in an advanced stage of cystic disease; in all cases under 3 inches in diameter, but distinctly cystic; and in all cases showing more evidence of incipient symmetrical disease than the mere presence of simply over-distended Graafian follicles—evidence which many would consider to be valueless. We have examined cysts 4 or 5 inches in diameter, but the appearances in their stroma or cyst-walls might be due to secondary changes, and might give deceptive notions on the actual origin of the main and the smaller cysts. We have also examined ovaries apparently unaffected, in cases where their fellows have been the seat of large cystic tumours, and have noticed appearances very similar to other changes noted in ovaries more evidently morbid; these appearances will be described. In fact, we have chosen for description ovaries in as early, but at the same time, as evident a condition of cystic disease as could be procured, such specimens being most suited for the purpose. In all cases the disease in the opposite ovary has been the commonest multilocular form; dermoid cysts and tumours traced to a supposed parovarian origin have been put aside for the present. Yet these, unless it could be shown that all ovarian cysts spring either from a dermoid or a parovarian source, which is improbable,

prove that cysts in connection with the ovary may have more than one origin.

The first specimens worthy of attention are sections from the right ovary of R. C., aged 23, a single woman, from whom a large cystic tumour of the left ovary was removed by Dr Bantock in July 1880. The opposite ovary was distinctly enlarged and cystic, and therefore it was deemed advisable to remove it. The patient had menstruated regularly; the last period was ten days before operation, and there was no history of ovaritis nor dysmenorrhœa.

This ovary weighed three-quarters of an ounce. Its surface was, in parts, deeply puckered; the margins of the puckering were elevated and tubercular in parts. Close under the tunica albuginea was one large cyst containing a drachm of clear, pale yellow albuminous fluid; its cavity had a thick, highly vascular living membrane bearing perfectly flat endothelium, well displayed by nitrate of silver staining. Besides this cyst, numerous thin-walled cysts were laid open on cutting into the stroma; two contained fluid blood. No corpora lutea in any stage could be detected.

On examining the stained sections we found no changes in the germinal epithelium, which, as in most adult ovaries, was very indistinct. At the puckered depressions, the free surface of the ovary with its epithelium ran far, like a gulf or sea-loch, into the stroma, but did not bear the least resemblance to the cystic bodies presently to be described. This we noted, as at first we were reminded of Malassez and De Sinety's *enfouissements pathologiques*. Such structures may exist, and be the origin of cysts in ovaries where they are found, but here the depressions of the surface and the cystic bodies proved absolutely different in structure.

The stroma of the parenchyma consisted of the usual fusiform cells, rather closer together than in a normal ovary. The division of the "albuginea" or fibrous tissue beneath the germinal epithelium into an outer and inner longitudinal (fig. 1, *a* and *c*), and a middle circular layer (*b*) as recognised by Henle and Klein, was very distinct. The fibres of the middle layer, cut across, appeared as a series of round points, like nuclei, and caused this layer to look like a collection of epithelial cells,

traversed by longitudinal bands. These points, however, were very much smaller than the nuclei of certain epithelioid bodies admitted to exist in the ovarian stroma. The resemblance of transversely cut fibres to epithelium will be shown to be of great importance, when we come to consider the cysts.

Graafian follicles were entirely absent in the stroma, which was occupied throughout, from the hilum to immediately under the tunica albuginea, with large cavities bounded by very distinct and very thick walls (fig. 1, *d*). None of these cavities were absolutely spherical, some were triangular, others trapezoidal; the commonest form was like to the outline of a dumb-bell or an hour-glass. The cavities were, in some instances, filled with blood-corpuscles. At the first glance these cavities bear a strong resemblance to corpora lutea, an impression dispelled by careful examination. Under a $\frac{1}{2}$ inch objective a few small specks can be seen distributed over the middle of the thick coat of one of the cavities (fig. 1, *f*). On examining any part of the wall with an $\frac{1}{8}$ inch power, abundant, plain muscular fibres could be detected (fig. 2, *e*); mixed up with them are bodies (*b*) which at first appear to be epithelium, but on comparing them with the round points, above described, in the circular layer of the albuginea, they were found to be identical. In short, they are fibres cut across. Close to the cavity three or four groups of fibres, also cut across, were discovered (fig 1, *e*). These, too, at first gave a false impression, and reminded us of the vestigial epithelium found in normal ovaries. But we noted that the cells of such epithelium are much larger. To return to the examination of the wall of the cavity, its innermost or free margin showed a very distinct single layer of endothelium (fig. 2, *a*). The nature of the cavity at once became clear—it was a blood-vessel, with the transverse and circular muscular fibres of the middle coat and the endothelium of the tunica intima so distinct that, if the specimen had not been an ovary, no observer would have remained one moment in doubt about these appearances. We further examined the walls of arteries of the normal size in other parts of the same section, and also the vessels in preparations from healthy adult ovaries. In both, the walls were identical in nature, though inferior in thickness and development, to those of the cavities.

These cavities were still better seen in sections from a slightly enlarged ovary, fellow to a great multilocular tumour removed in June 1880 by Mr Spencer Wells. Their walls were not quite so thick as in the ovary from Dr Bantock's case, and a few very large cavities could be seen, the walls of which were even thinner, yet still bore traces of longitudinal and circular fibres. In short, this specimen threw a light on the fate of the enlarged vessels or arterioles, as, strictly speaking, we must call them; they were destined to dilate, to become obstructed in parts, and to develop into cystic cavities between the points of obstruction. Plugging of the narrower cavities we found to be very frequent. In this ovary the entire surface was deeply puckered, but none of the depressions of the tunica albuginea, not even those that ran one-eighth of an inch into the stroma, showed any signs of becoming cystic by closure at the surface and dilatation deeper down; nor could any morbid process of cell-proliferation be traced from the epithelium lining the deepest processes of the albuginea towards the stroma, which was perfectly healthy around these depressions. Lastly, there was neither resemblance nor communication between the depressions of the tunic and the cavities formed by dilated vessels.

We examined many more ovaries, but found totally different appearances in several that were as surely in a state of incipient cystic disease as the two already described, and, like them, had been removed from patients in whom the opposite ovaries had become large multilocular cysts. Whilst those already discussed showed morbid appearances mostly in their vessels, these gave evidence of abnormal changes commencing in the Graafian follicles, or rather in what were follicles. We say this, because in no case could we trace disease from simple distension of a normal follicle, with changes in its wall, nor even from the corpora lutea of pregnancy and menstruation. Disease, in all cases, appeared to have started from the follicles that had undergone involution without ever having taken part in the active processes for which they are functionally destined; but of the myriads of follicles that exist in an infant's ovary, the greater proportion are, of necessity, bound to degenerate in this manner.

Dalton,¹ Beigel,² Slavjansky,³ and others, have minutely described these degenerate follicles.

On July 15, 1880, Dr Bantock removed a large multilocular cyst of the right ovary from a robust young married woman, aged 28, whom we will briefly term "Case 2." She had been married nearly two years, and not having menstruated for several months, was believed to be pregnant. The left ovary was clearly in a state of incipient cystic degeneration, and was therefore removed. It measured $2\frac{3}{4}$ inches in its long diameter, and weighed 360 grains. Examined fresh, the surface was but little puckered; on section it appeared full of thin-walled cysts containing highly albuminous fluid. These cysts were simply Graafian follicles bearing perfect ova. Between these follicles the stroma was abundant, pale, and succulent.

On microscopic examination no morbid changes could be detected in the tunica albuginea. The stroma consisted of the normal spindle-shaped cells, not closely packed, but freely distributed as in a healthy child's or young girl's ovary. This we noted to counteract any hasty conclusions that cirrhotic changes in the stroma may prevent the follicles from bursting, and allow them to slowly develop into large cysts. There were plenty of cysts but no cirrhosis. In fact, the loose stroma was overabundant, and bore large numbers of degenerate follicles (by this term we imply such as have never taken a share in pregnancy nor menstruation). Some were reduced to a mere cloudy sinuous band, no longer forming a complete chain; the tissue partly included by this band was looser than elsewhere, yet not undergoing any kind of degeneration. Most of these follicles formed fusiform bodies composed of radiating cloudy tubes, or rather bands, bearing traces of degenerate nuclei. In the centre were broken-down masses of pigment. The tubes were, externally, very sharply bordered by the surrounding stroma, which, however, sent in filiform processes of elongated and nucleated cells (see fig. 3).

¹ "Report on the Corpus Luteum," *Trans. Amer. Gynecological Soc.* vol. ii. 1877.

² "Zur Naturgeschichte des Corpus Luteum," *Archiv. f. Gynäkologie*, vol. xiii. 1878.

³ "Zur normalen und Pathologischen Histologie des Graaf'schen Bläschens des Menschen," *Virchow's Archiv.* vol. li. 1870.

We will pass, without comment, to another case of suspected symmetrical disease. On June 1, 1880, Dr Bantock removed a multilocular cyst of the left ovary from a single woman, aged 25, who had menstruated regularly until operation. In this third case the right ovary was enlarged and distinctly in a state of incipient cystic degeneration, its surface was covered with flakes of lymph, probably the result of tapping, performed a few weeks previously, to relieve the great distension of the opposite cystic ovary. The patient never appeared to be subject to any form of dysmenorrhœa.

This ovary weighed over half an ounce; its surface, when freed from the inflammatory deposit, appeared in general smooth, but presented a few puckered depressions. The interior contained follicles from $\frac{1}{20}$ to nearly $\frac{1}{4}$ inch diameter, but no corpora lutea of menstruation; ova were found in the fluid of most of the distended follicles. On section, for the microscope, the stroma appeared perfectly normal; the large spindle-cells were arranged in all directions, and lay at wide intervals from each other. The germinal epithelium of the tunica albuginea was normal, and no morbid involutions of the cells into the stroma could be detected. The distended follicles showed no morbid changes. But opaque bodies, some $\frac{1}{10}$ inch in diameter, lay in the stroma. On close examination, these bodies proved to show a morbid form of involution of follicles that had never been ruptured, as in the last described specimen, only here the differentiation from normal involution was more advanced.

In fig. 4, the appearance of the largest of these bodies is sketched, as seen under a 2-inch power. The stroma is condensed to a slight extent around the body, and sends numerous delicate ingrowths between the opaque, tube-like masses of which the body is essentially made up. These masses differ in no way, except in arrangement and in their increased development, instead of effacement, from the altered epithelium of an unburst follicle in cases of normal involution. In fig. 5, a portion of the centre of the body is shown as seen under a $\frac{1}{4}$ -inch objective. This higher power demonstrates what cannot be seen under a lower object glass, and this is the fact that the ingrowths from the stroma are not lost in the midst of the opaque masses, not ending as little flaps or pennons, but on the

contrary, form a wide and complete meshwork, enclosing spaces. Let it be remembered that it is a section and not a solid that is being inspected, and then we must conclude that the spaces enclosed by a border of spindle cells, continuous with the stroma of the ovary, are really cavities, and there is no reason to doubt that most of these cavities are more or less completely closed, or at least, can become so. In fact, we seem to see a very evident method of cyst-formation, and, what is more, this formation is multilocular from its very origin. The tube-like bodies cut off as loops in these spaces or cavities, being mucoid in appearance, would account for the mucoid contents always observed in the smallest cysts that can be found among the immense cystic cavities of a large tumour of the ovary, as in the fellow to this specimen. Such cysts may lie alongside of true Graafian follicles, which may exceed them in size, and be clearly in a state of true evolution or normal involution. In the denser strands of stromal ingrowth, in this specimen, large vessels can be detected. These cannot but indicate free nutrition of the morbid structure, a nutrition which must maintain and develop the entire abnormal fabric to an indefinite extent, which is the case, if, as the authors of this paper believe, these bodies now under consideration represent one of the origins of multilocular ovarian cysts.

In all the slightly enlarged ovaries removed, since the above described specimens were examined, from cases of cystic disease of the opposite ovary, we have found one of the two appearances already discussed—namely, an abnormal condition of certain vessels in the stroma, or else some differentiation in the involution of unruptured follicles. The first case showed the vascular change, the third demonstrated the follicular changes to perfection; the second was a less active form of the same kind of degeneration, the mucoid degeneration of the follicles being associated with less abundant and less active ingrowths from the stroma. In one ovary, 2 inches long, 1 ounce in weight, and fellow to a large multilocular cyst removed from a woman, aged 29, by Dr Bantock, a similar, yet not identical, method of cyst-formation from unruptured follicles could be distinguished. In this ovary was one corpus luteum representing very recent menstruation, its surface showing a small aperture whence blood leaked during removal, at the operation. Some true

normal follicles lay in the stroma of this fourth case (fig. 6, *a*), but deeper in the ovarian tissue lay bodies from $\frac{1}{10}$ to $\frac{1}{6}$ of an inch in diameter, appearing to the naked eye like mucoid masses. Under a pocket-lens they assumed the appearance shown in fig. 6, *b* and *c*, being cavities with boundaries not uniformly distinct, and with transparent, hazy contents, broken-down in the middle either from actual degeneration, or in the process of preparation. Under a No. 8 Hartnack objective the hazy contents appeared to consist of large branched cells (fig. 7), the processes from each cell freely uniting with others from neighbouring cells. In fact, we have here a myxomatous change. At the border of each of these morbid bodies a strong objective showed the close relation between the branched cells and the surrounding stroma (fig. 8). The processes of the cells joined certain fine fibres in the stroma. Besides, the stroma itself sent ingrowths among the branched cells, and here again the same relation between the stroma and the processes of the cells could be seen; indeed the sketch (fig. 8) is actually from such an ingrowth. In the midst of the ingrowths some faint traces of branched cells were visible. This would lead us to suspect that the myxomatous changes arose from the ingrowths, the branched cells either springing from them, or developing and perishing with them. This is, in fact, more probable than that such changes should begin in the practically dead or degenerate, hazy, tube-like tissue which represents the relics of the membrana propria of a follicle in unruptured follicles undergoing normal involution.

Such are the appearances which we have observed in ovaries, all the fellows of large multilocular cysts, and all so distinctly enlarged and so abnormal in appearance as to afford the strongest presumptive evidence that they were in a state of incipient cystic degeneration. We have rejected all cases where we believed that simple congestion of the ovary, due to recent menstruation, explained some slight enlargement, as well as all ovaries with marked cirrhosis of the stroma; and, mindful of the researches of Dalton, Beigel, Slavjansky, Patenko, and earlier authorities, we have been careful to watch the process of normal involution of follicles after menstruation and impregnation, so as not to confound natural with morbid appearances. We strongly

insist on the great necessity of gaining an accurate knowledge of the nature of every normal change in the follicle, as seen under the microscope, including, above all things, the natural involution of unruptured Graafian follicles. Equally important is it that the student of ovarian pathology should thoroughly distinguish dilated vessels from cysts, and not confound a bundle of the spindle-shaped cells of the stroma or of the circular coat of the vessels, when cut transversely, for a collection of round cells with distinct central nuclei. To gain an accurate knowledge of the corpus luteum and the changes in the follicles, requires much time and experience. To make the mistake about transversely cut fibres is more easy than one would at first suppose.

The numerous theses, monographs, and shorter papers on the true origin of ovarian cysts, that have appeared within the last few years, are too well known for even brief quotation. Roughly speaking, we have the Graafian-follicle dilatation theory, the colloid degeneration of stroma theory, the dilated vessel theory, and the special tube theory. We think it more advisable to summarise our own conclusions than to quote other researches at length.

1. There is strong evidence that multilocular cystic disease of the ovary may arise from two totally different ovarian elements.

2. Cysts may arise from partial dilatation and partial obstruction of enlarged and thickened blood-vessels, as Noeggerath maintains,¹ and we think, as he does, that many errors have arisen from imperfect knowledge of the appearance of blood-vessels in the ovarian stroma.

3. Cysts more frequently appear to originate in changes in those Graafian follicles that undergo involution without having ever ruptured; this includes a large majority of the follicles, when we remember the vast number found in the ovary at birth, and bear in mind that involution of many follicles takes place between birth and puberty.

4. The morbid changes which replace normal involution of the follicle are an active ingrowth from the stroma, and a long persistence of the cloudy tube-like bodies that represent the remains of the membrana propria of the follicle. These two

¹ "The Diseases of Blood-Vessels of the Ovary in relation to the Genesis of Ovarian Cysts."—*Amer. Journ. of Obstetrics, &c.*, vol. xiii., 1880.

processes sometimes proceed at an equal rate, sometimes irregularly.

5. When the relics of the membrana propria are slow to disappear, and the stroma slowly sends ingrowths amongst these relics, we find the cystic bodies described as seen in the fourth case, containing myxoma-cells partly, at least, connected with the ingrowths. Such delicate tissue, made up of these cells, must soon break down as the cyst becomes larger.

6. When the process of ingrowth of stroma into the follicle, during involution, is particularly active, the ingrowths interlace and rapidly form cystic spaces, including portions of the cloudy relics of the membrana propria, giving the appearances seen in the third case.

7. On the other hand the stroma may show little or no tendency to develop ingrowths, but the relics of the membrana propria may break down very slowly, and end, not in simple effacement and incorporation with the stroma, but in slowly breaking down, as in the second case. This must necessarily end in the formation of a cyst full of a colloid or semi-fluid material, the completely broken down granulosa, &c.; previous theories on colloid degeneration of the stroma itself may be based on the overlooking of the intra-follicular origin of the colloid collections. In all cases of myxomatous or colloid changes, or simple rarefaction of tissue, we found full evidence that those changes were in degenerate follicles and never free in the stroma.

8. All these changes in the degenerating membrana propria and the tissue surrounding the follicle, begin as exaggerations of the normal process of involution, which is never a mere disintegration and degeneration of the follicle. Slavjansky, in the work we have quoted, gives accurate drawings of the normal process. Patenko traces these abnormal changes to sclerosis of the follicle-wall, under different conditions.¹

9. These changes in the follicle do not appear due to inflammation; indeed, in old inflamed ovaries the atrophy of the follicles appears to be quicker and more complete than in healthy ovaries, so that no trace of them is left, excepting certain granular masses.

¹ In Virchow's *Archiv.*, May 1881, he demonstrates the manner in which this process ends in the formation, not of cysts, but "corpora fibrosa."

10. The manner in which the young cyst first becomes invested with its characteristic epithelium is obscure. We found that the "germinal epithelium" of the tunica albuginea and the cells of the granulosa of normal follicles never invaded the ovarian stroma, and the epithelial relics of the Wolffian tubes, that are usually found loose about the stroma, were never in close relation to any of the bodies we have described. In the case of the dilated vessels, the endothelium must be the most natural starting-point of the epithelial lining of cysts derived from such vessels. Remembering the changes in the mucous membrane of a prolapsed vagina, the endothelium may, we can conceive, alter its character when the nature of the free space on which it borders has become completely altered. Should the theory of Cripps¹ be even partly correct, that nuclei in lymphoid or connective tissue may gather protoplasm around them till they form real epithelioid bodies lining spaces deeply situated in solid structures, we could readily account for the origin of the epithelial lining of any cyst. We do not profess to accept as positive that observer's theory, that the nuclei in the sub-mucous tissue of the rectum are normally the parents of the columnar epithelium of the mucous membrane, although microscopical evidence tends to support it; his other opinion, expressed above, that such nuclei may become epithelioid, is far more probable. An area in any tissue, with such nuclei, breaks down—the nuclei bordering on the broken-down region must be placed at once in different circumstances to their normal state, deep in tissue and away from any free surface. We do not find such nuclei on free surfaces; we do find epithelium. In other words we see no difficulty in supposing that the epithelial lining of ovarian cysts is probably developed from nuclear elements in the bodies above described. It seems, on mere reasoning, less far-fetched to assert that this epithelial lining is derived from pre-existing epithelium. To this we reply that, on actual observation, detecting incipient cystic cavities and also healthy epithelium on the tunica albuginea, in the follicles, and, as embryonic relics in the stroma, often in one single section, we find no connection between the cavities and any of these three normal epithelial elements. We must not conclude that

¹ *Cancer of the Rectum*. See particularly Pl. III. fig. 1, in that work.

when the mucoid contents of the imperfectly involved follicles have broken down to their utmost, the cellular elements immediately adjacent to the resulting semi-fluid material, simply assume the epithelial type. Only as long as the source whence normal epithelium is renewed remains obscure, so long must this question remain unsettled.

INCIPIENT CYSTIC DISEASE OF THE OVARY.

(PLATE XXIII.)

From Drawings by A. DORAN.

Fig. 1. Section of the smaller ovary of Case 1 (R. C., aged 23) $\times 40$:—*a* and *c*, outer and inner longitudinal layers of the albuginea; *b*, the middle layer, with the circular fibres cut across transversely—the fibres are arranged in bundles intersected by fibres running in a different direction; *d*, a large, thick-walled vessel, its lumen is partly filled with corpuscles; *e*, fibres of the deeper part of the ovarian stroma, cut transversely, as in *b*; *f*, circular fibres of *d*. No trace remains of the normal follicular structure of the ovary.

Fig. 2. A segment of the wall of the vessel *d*, fig. 1, $\times 400$:—*a*, endothelium; *b*, circular fibres of the muscular coat, cut transversely; *c*, longitudinal fibres; *d*, a few fibres (strictly, elongated cells) of the stroma, some cut transversely.

Fig. 3. A section of the smaller ovary of Case 2, as seen under a 2-inch objective. It shows a very large degenerate follicle presenting appearances but slightly different from the normal condition, but the ingrowths from the surrounding stroma and the breaking down of the central portion are made distinct. The stroma abounded with these bodies, as well as with normally degenerating follicles.

Fig. 4. One of the bodies from the ovary of Case 3 (2-inch objective). It differs considerably from fig. 3, the ingrowths of the stroma are very active.

Fig. 5. The central portion of the same body, $\times 210$. The stromal ingrowths here may be seen to have penetrated very completely, forming spaces—which in the actual solid condition of the part would be cystic cavities—cutting off and enclosing some of the original substance of the body, which is a follicle undergoing abnormal changes in its involution. A portion of a small vessel lies in the stromal ingrowth, to the left.

Fig. 6. Portion of the ovary from Case 4, as seen under a pocket-lens:—*a*, a normal follicle; *b*, *c*, follicles in an abnormal state of involution, they contain a transparent material, partly broken down in the centre.

Fig. 7. A part of this material from *b*, fig. 6, $\times 400$; it consists of cells of the variety observed in myxomata.

Fig. 8. A stromal ingrowth into *b*, fig. 6, $\times 400$; its fibres are connected with *a*, branched cells composing the material shown in fig. 7.

ANATOMY OF THE KOALA (*Phascolarctos Cinereus*).

By A. H. YOUNG, M.B., F.R.C.S., *late Assistant-Lecturer on Anatomy, The Owens College, Manchester.*

IN a former communication to this *Journal*¹ I directed attention to the genito-urinary organs of the Koala, in so far as these related to the male.

The principal features of anatomical interest which more especially refer to the remaining visceral arrangements are already more or less well known, mainly through an excellent description of them which was read by Mr Martin² in 1836, before the Zoological Society of London.

Nevertheless, I found, when engaged in the dissection of three well-preserved specimens of *Phascolarctos*, that there were still some few points which, so far as I have been able to ascertain, seem to have been overlooked hitherto. These it appeared advisable to record, whilst at the same time I am enabled in many respects to confirm the observations of Mr Martin.

Mouth.—The lips are well developed—a slight vertical cleft marks the upper one. The muzzle is smooth, but covered with fine downy hairs. As in marsupials generally, the mucous membrane of the hard palate is marked by a series of well-defined transverse ridges. Eight in number, the ridges are most strongly marked anteriorly; those posteriorly situated present a finely serrated free margin. The soft palate is remarkably long. It extends backwards for a distance of $3\frac{1}{2}$ inches,³ and reaches as far as the thyroid cartilage; on its upper surface the mucous membrane is raised into a longitudinal mesial ridge. There is no *uvula*; on the contrary, the posterior margin of the soft palate presents a deep cleft in the middle line, into which the projecting larynx may be received, and thus a direct passage between the upper aperture of the larynx and the nasal chambers be more or less shut off from that of the mouth and pharynx.⁴ This arrangement, by means of which the larynx of the foetus is

¹ On the Male Generative Organs of the Koala, *Journ. of Anat. and Phys.*, vol. xiii. p. 305.

² Notes on the Anatomy of the Koala, *Proc. Zool. Soc.*, 1836.

³ This, and the succeeding measurements are taken from the smallest of the specimens examined, the total length of which is $20\frac{1}{2}$ inches.

⁴ Art. "Marsupialia," *Todd's Cyclopædia*, vol. iii. p. 326.

guarded during the passage of milk down to the stomach, is not however so complete in the Koala as in the Kangaroo. The inner surface of each cheek presents a well-marked buccal pouch. This extends in the direction of the eye, and lies between the cheek and upper jaw, its opening into the mouth being wide and elongated. The anterior margin of the pouch is on a level with the canine tooth, and is formed by a fold of mucous membrane which passes to the intermaxillary bone; the posterior margin, which is opposite the hinder border of the premolar, is formed by a fold of mucous membrane which separates the pouch from the cavity of the cheek. Immediately behind the buccal pouch, and at a point corresponding to the interval, between the two anterior molars, is the opening of the parotid duct.

Salivary Glands.—Of the salivary glands, the parotid is exceedingly large. In the neck there are numerous small isolated and detached portions. There is a well-marked sub-maxillary gland, but I was not able to distinguish a separate sublingual. A small gland, sub-zygomatic in position, rested upon the buccinator.

Tongue.—The tongue is very similar to that of the Kangaroo. Posteriorly it is thick, but anteriorly it becomes thinner, and assumes a spatulate character. The base is constricted, and the posterior extremity appears prominent and projects backwards into the pharynx. Small filiform papillæ of a simple character cover the greater part of the dorsal surface and margins; interspersed among these are numerous fungiform papillæ of a whitish colour. These are most plentifully distributed along the free margins and tip of the organ. A single isolated circumvallate papilla is situated mesially half an inch in front of the posterior projecting margin of the tongue.

Professor Owen¹ describes also "a single large fossulate papilla" in the Kangaroo. In the single specimen of this animal, however, which I have had an opportunity of examining, I found three such papilla arranged as in dendorlagus, &c.

Teeth.—Dental formula—

$$i \begin{array}{r} 3-3 \\ 1-1 \end{array} \quad c \begin{array}{r} 1-1 \\ 0-0 \end{array} \quad p.m. \begin{array}{r} 1-1 \\ 1-1 \end{array} \quad m \begin{array}{r} 4-4 \\ 4-4 \end{array} \quad \text{total, } 30$$

¹ *Anat. of Vert.*, vol. iii. p. 191.

Of the upper incisors the posterior one on each side is small. The upper canine also is small; it is situated just behind the premaxillary suture, and occupies an isolated position in the space between the incisor teeth and the premolar. There is a similar interval between the lower incisor and premolar. These spaces in the Koala are never occupied by functionless free molars, such as exist in the Phalangers.¹ The molars are quadrituberculate. In certain respects, therefore, the dental formula of the Koala differs from that of the Wombat, and approaches rather to the Kangaroo. From the Kangaroo the Koala differs in the presence of canines in the upper jaw, and from the Wombat in this and also in the presence of posterior incisors in the same jaw. In its dentition the Koala agrees very closely with the Phalangers, differing from them only in the absence of a few inconstant and functionless premolars which exist in *Phalagistidæ*. For this reason Latreille assigns to Koala a position next to the Phalangers.²

Pharynx is tubular; its calibre but slightly exceeds that of the œsophagus, with which it becomes continuous. From the root of the tongue to the cricoid cartilage it measures between 3 and 4 inches, and for almost its whole extent it is divided into an upper and a lower channel by the greatly elongated soft palate.

The œsophagus extends from the pharynx, and, passing between the muscular fibres derived from the crura of the diaphragm, terminates immediately after it enters the abdomen, at the lesser curvature of the stomach, about 1 inch from its cardiac end.

Stomach is simple in character; in none of my specimens did it present the contraction described by Martin³ as dividing it into two parts. This viscus is of an elongated ovoid form, narrowing slightly towards its pyloric extremity. Its surfaces are directed forwards and backwards, and its curvatures upwards and downwards (*i.e.*, dorsad and ventrad) respectively. A well-marked thickening of the coats of the stomach, together with a constriction, indicates the position of the pylorus.

¹ Owen, *Anat. of Vert.*, vol. iii. p. 291.

² Owen "On the Dentition of the Koala," *Proc. Zool. Soc.*, 1838, p. 154.

³ *Proc. Zool. Soc.*, 1836, p. 110.

The mucous membrane is smooth, with the exception of that portion which occupies the cardiac end of the stomach; this is thrown into longitudinal rugæ. As in the Wombat¹ (and Beaver), a large conglomerate gastric gland exists. It is situated, as in these animals, on the smaller curvature of the stomach, close to the œsophageal opening. The glandular patch is somewhat circular in form, and presents numerous large oval apertures, at the bottom of which are smaller depressions irregularly disposed.

Small Intestine—measures 8 feet in length, the duodenum is slightly dilated at its commencement, the remainder of the gut is of uniform calibre; when flattened it measures half an inch across. The mucous membrane is smooth throughout. The circular muscular fibres of the walls are strong, and arranged in bundles, which give a transversely striated appearance to the walls of this part of the alimentary canal.

Large Intestine and Cæcum.—On opening the cavity of the abdomen the great intestine, with its cæcal appendage, entirely concealed such abdominal viscera as were situated posterior to the stomach. Martin describes rightly the cæcum as turning spirally on itself.²

The large intestine itself, from the cæcal orifice to anus, measures 9 feet 10 inches; its diameter at its commencement and for 3 feet onwards is $2\frac{1}{2}$ inches, but thereafter it dwindles to the size of the small intestine, and so remains to its termination.

Cæcum is of enormous length, being indeed more than three times the total length of the animal itself, and more than half the length of the great intestine.

In the specimen, from which all dimensional data are taken, the cæcum measures 5 feet 3 inches (the specimen itself, as noted before, being 1 foot $8\frac{1}{2}$ inches from snout to end of rudimentary tail), whilst in another of the koalas, which itself measures 2 feet $2\frac{1}{2}$ inches, the length of the cæcum is 7 feet.

At its commencement the diameter of the cæcum equals that of the broadest part of the great intestine; from this there is a gradual and progressive diminution down to a somewhat bluntly

¹ Home, *Phil. Trans.* Lond. 1808, p. 312, plate ix.

² *Loc. cit.* p. 111.

pointed extremity. The whole of the cæcum, together with the upper part of the colon, is regularly sacculated.

The mucous membrane of the large intestine and cæcum is disposed in parallel longitudinal laminae, some of which measure half an inch in depth; they project into the interior, and their arrangement is well seen in a transverse section of the gut.

This longitudinal lamination of the mucous membrane disappears in the narrow part of the great intestine, but reappears in the rectum, which is longitudinally corrugated. Ileo-cæcal orifice is circular and prominent; from its circumference laminae of the mucous membrane radiate, most of which become continuous with the longitudinal laminae just described. Upon each side of the ileo-cæcal valve an irregular, somewhat circular, glandular patch, in the centre of which are numerous glandular sacculi of large size, is situated.

ABDOMINAL GLANDS.

Liver.—The liver presents the maximum marsupial tendency to subdivision into numerous lobes. According to Owen, no less than thirty to forty of these latter may be distinguished.

Following the method of description adopted by Professor Flower,¹ the liver of Koala consists of right and left segments, the division being well marked by the attachment of the suspensory ligament, which indicates the position of the umbilical fissure. The left segment is divided into lateral and central lobes by the left lateral fissure; and a corresponding division into lateral and central lobes, by means of a lateral fissure, exists also on the right side.

A deep fissure for the gall bladder divides the right central lobe into almost equal parts. There is a well-defined Spigelian, as well as a caudate lobe. Both right and left segments present fissured margins, and on the right side numerous secondary lobes are thus differentiated.

The gall bladder measures 3 inches in length, and its fundus projects considerably beyond the ventral margin of the liver. Its general form is ovate rather than pyramidal, the base being the broadest and the fundus the narrowest part. The duct of the gall bladder unites with the hepatic duct close to the liver,

¹ *Med. Times and Gazette*, vol. i. 1872, p. 293.

and the resulting duct, after receiving that of the pancreas, opens into the duodenum 2 inches below the pylorus.

The internal surface of the gall bladder is quite smooth.

Pancreas measures $4\frac{1}{2}$ inches in length, and, as in other marsupials, is enlarged at its splenic extremity; gradually narrowing, it reaches to the duodenum, and by a small duct opens into the "ductus communis."

Spleen consists of two parts, united by an isthmus. One portion, the larger, is broad and of an irregular quadrilateral form; the other is small and tongue-like. The total length is 3 inches.

GENITO-URINARY ORGANS.

Those in the male¹ have already been described at some length in a previous communication. Of the three specimens which came into my possession, one was a female; but, unfortunately, it had been somewhat injured in the region of the pelvis and lower part of the abdomen, so that I am not able to speak with certainty as to the anatomy of its pelvic viscera. So far as I could ascertain, however, the principal features appear to be as follows:—Kidneys, ureters, and bladder, are just as in the male. Urogenital canal measures 2 inches in length; its mucous membrane is thrown into longitudinal rugæ. The external orifice of this canal is enclosed, along with that of the rectum, in a common sphincter cloacæ.

GENERATIVE SYSTEM.

Ovaries.—Each ovary is oval and sub-compressed. It equals in size, and somewhat resembles, in outline, a French bean; its surface is slightly lobulated. Each is contained in a well-marked pavilion furnished by the broad ligament.

The Fallopian tubes are slender, and somewhat spirally arranged; not nearly to such a marked extent, however, as Owen figures in *Didelphys dorsigera*. Each Fallopian tube opens into its corresponding uterus.

Each uterus measures 2 inches from fundus to os tinæ. The lining membrane is soft; smooth and velvety near the fundus, it becomes arranged in longitudinal rugæ inferiorly. The

¹ *Journ. of Anat. and Phys.* vol. xiii. p. 305.

rugæ converge towards the os, and the margins of the latter have in consequence a slightly serrated appearance.

The walls of the uteri become thicker near the ora uteri, which are distinct and well marked.

Vaginæ.—Traced from its opening into the uro-genital canal, the vagina of each side ascends upwards and slightly outwards, then expanding receives the orifice of the corresponding uterus, and next descends united to its fellow of the opposite side to form a central "cul-de-sac," which descends towards the uro-genital canal, but does not communicate with it.

The culs-de-sac of opposite sides are united by their mesial walls, and these blended together form a septum between the two. In Koala, as in the Phalangers, Kangaroos, and Wombat,¹ the septum is imperfect above, and so permits a communication between the vagina of opposite sides. The septum also presents a small oval opening a little distance lower down. In the *Dasyurus viverrinus* and in *Didelphys Virginiana*, the septum dividing the mesial culs-de-sac is complete, and the two walls can be separated from each other,² whilst in *Didelphys dorsigera* the vaginæ are still more distinct from each other.

The partial union of the opposite vaginæ in Koala, Phalangers, &c., is somewhat interesting, as it apparently indicates a tendency to the complete coalescence of the Müllerian ducts to form the single vagina of the placental mammal.

In the Koala each vagina proper is about one-half the diameter of the uterus. Its mucous membrane, in common with that of the cul-de-sac, is smooth, but it becomes rugose near its inferior termination. The uro-genital canal has already been referred to.

Two muscles, corresponding exactly to the retractores penis in the male,² spring from the sacrum, and terminate upon each side of the urethro-sexual canal, near its external orifice.

Sphincter cloacæ encloses both the anus and uro-genital orifice. Anteriorly a few fibres are attached to the symphysis pubis.

Mammary glands are two in number. I was only able to distinguish a single nipple to each gland.

A well-defined compressor of the mammary gland (*ilio-marsupialis*—Cuvier) springs from the ilium, winds round the

¹ Owen, art. "Marsupialia," *Todd's Cyclop.* vol. iii. p. 316.

² *Journ. of Anat. and Phys.* vol. xiii. p. 312.

marsupial bone, and expanding passes to the mammary gland beneath the pouch.

Professor Owen¹ considers that the chief function of the marsupial bone is to add the power of the pulley to the compressor of the mammary gland, and to effect the requisite change in the course of the contractile fibres of the muscle.

In the conformation and arrangement of the generative organs the female Koala is typically marsupial in character. Relatively large, the ovaries are not quite so smooth as those of the Kangaroo, whilst they contrast strongly with the botryoidal form and large size of the ovaries of the Wombat. But it is in respect of the vaginal portions of the female generative organs that the greatest variations take place; the extent to which these are observable in the various marsupial genera differs materially.

In the possession of two true vaginae, the Koala agrees with all other marsupials; in the further complication of these vaginae by mesial culs-de-sac it agrees with most, the *Didelphys dorsigera*² forming an exception to this rule.

Inasmuch as in Koala the mesial culs-de-sac communicate with each other through an imperfect septum, it is allied to the Phalangiers and Kangaroos, but differs from the Opossums, *Dasyurus*, and probably also from the Wombat.⁴

In the comparative shortness and straight character of the true vaginae, and the relatively larger development of the mesial culs-de-sac, the female organs of Koala approach somewhat to the condition met with in the Kangaroo Rat⁵ (*Hypsiprymnus murinus*).

Comparing the visceral anatomy of Koala with that of other marsupials, it is at once seen that, although in its dentitional characters it closely resembles the Kangaroos, yet it contrasts strongly with these latter in the possession of a simply arranged stomach, which is provided with a special glandular apparatus. The cæcum of the Koala also exceeds in size that of the Kangaroo,

¹ *Anat. of Vert.* vol. iii. p. 769.

² *Todd's Cyclop.* art. "Marsupalia," vol. iii. p. 313, fig. 137.

³ *Cyclop.* 316.

⁴ *Todd's Cyclop.* vol. iii. p. 316, art. "Marsupalia." See also "Notes on Anatomy of the Wombat," *Proc. Zool. Soc. Lond.* 1836, p. 52.

⁵ Owen, *Anat. of Vert.* vol. iii. p. 683.

which, however, is characterised "with all the Poepagans" by the possession of a long cæcum.

A simple stomach, uncomplicated with sacculi, exists amongst sarcophagous, entomophagous, and carpophagous marsupials. In this respect koala agrees with them, rather than with the poepagans; but inasmuch as its stomach is provided with a conglomerate glandular apparatus, it differs from them, and resembles the rhizophagous (Wombat), in which the stomach is almost identical.

The very long cæcum possessed by Koala is also a characterising feature in the allied Phalangers. Shorter, but still elongated, are the cæca of the entomophagous and poepagous tribes; very short is the cæcum in rhizophagous (Wombat), whilst it is entirely wanting in sarcophagous marsupials.

Summarising, it appears that Koala only differs in its visceral anatomy from other Phalangers by the existence of its special gastric glandular apparatus, closely resembling the Wombat (*Phascolomys Wombat*) in this respect, but differing widely from this animal in the possession of a long cæcum, and in the absence of a vermiform appendix. In Koala, moreover, there is no enlarged sacculus, simulating a second cæcum such as Owen describes as being present in the Wombat.¹

March, 1881.

NOTE.—*June 15.* Since correcting the proof sheets of the above, I have, through the courtesy of the author, received a copy of Mr W. A. Forbes's paper on "Some Points in the Anatomy of the Koala" (*Proc. Zool. Soc.*, 1881). Mr Forbes, who had the advantage of dissecting a fresh specimen, describes the vaginal *culs-de-sac* as quite distinct and free, there being no communication between them. This condition he regards as a characteristic feature of *Phascolarctinæ*. Mr Forbes gives also an admirable description of the Brain, Heart and main vessels, and of the Lungs.

¹ Notes on the Anatomy of the Wombat, *Proc. Zool. Soc.* 1836, p. 50.

ON THE LYMPHATICS OF THE PANCREAS. By GEORGE HOGGAN, M.B. (Edin.), and FRANCES ELIZABETH HOGGAN, M.D. (Zurich), M.K.Q.C.P. (Ireland). (PLATE XXIV.)

ALTHOUGH the pancreas is an organ which, from its position, is in a manner practically removed from all surgical interference, and in which it is almost hopeless to expect that a knowledge of the course of its lymphatics will enable us to detect clinically in the living subject the course of any disease specially involving the lymphatic system, nevertheless the lymphatic system in the pancreas possesses special interest for two reasons. In the first place, except that efferent lymphatics have been seen to emerge from the organ, nothing whatever seems to be known of its intrinsic lymphatics at the present day, and it appears to have enjoyed almost unique immunity from the rash and vague guesses which compiling anatomists have so liberally made regarding other more accessible organs like the bladder and uterus. In the second place, the pancreas may be taken as the type of the racemose glands throughout the body, such as the salivary and lachrymal glands, in none of which, to our knowledge, has any attempt ever been made to discover the existence or arrangement of the lymphatic system. The result of any satisfactory investigation into the lymphatics of the pancreas may therefore be held, from the similarity of the general anatomical structure of these glands, to be equally applicable to them all. Our ignorance in this respect is probably due partly to the comparative massiveness of these glands, and partly to the fact that they are so embedded in or surrounded by other tissue, that it would be difficult, in the event of any lymphatics being found in their immediate neighbourhood, to decide whether they belonged to the gland itself or to the contiguous tissues. At first sight, it would appear that their massiveness would render the glands unsuitable for imbibition by silver solution, which we hold to be the only trustworthy method at the present day; but there appears to be no reason why investigators should not have attempted investigations by the injection method, as

has been done in the case of the liver, kidney, ovary, and even the spleen; for anyone who did not hesitate to investigate the latter organ by means of the injection method, and to publish the results thereof, ought not to have hesitated afterwards to undertake a similar investigation on any other organ in the body. As, however, the investigation by means of coloured injections of the organs referred to has, even when undertaken by illustrious investigators, only saddled anatomical science with a burden of error which we shall afterwards illustrate in this paper, it may be considered fortunate that no similar attempts have been made or succeeded on the pancreas and other racemose glands. Thus, our task will be narrowed to giving the facts as we find them, and there will be no alleged facts, already enjoying the advantage of possession of anatomical minds, to disprove.

The pancreas is an organ to the study of which the advantages of comparative anatomy are peculiarly applicable. Although in man and the larger mammals it is a massive, solid organ, yet in some of the smaller mammals, the rodents for example, it is, we believe, the unique example of a naturally dissociated large racemose gland, which can be investigated not merely by silver and staining fluids for its lymphatics, but also for the rest of its component tissues, all of which can be suitably prepared without injury to the gland as a whole, and made perfectly transparent under the microscope. In the rodents, more especially and conveniently in rats, mice, and rabbits, the pancreas is spread out upon the mesentery like a fruit tree on a wall, the branches being represented by the various ducts, of which the terminal twigs continually anastomose, and the leaves being represented by lobules of acini of the gland, thin enough, after staining, to be rendered perfectly transparent for microscopical investigation. In fact, here we have an almost perfect natural dissociation of the gland substance, so that the development, as well as the relation of all the component tissues in the adult, can be perfectly studied, not only in the gland itself, but in their approaches to it, in the clear, transparent, gelatinous matrix of the mesentery, which intervenes between the lobes of the gland.

The manipulation necessary for investigating these structures is extremely simple. Only one apparatus, the histological rings

invented by us, is absolutely necessary. In the case of the rabbit, which we have found to be the most advantageous, the rings ought to be about $1\frac{1}{2}$ inch in diameter; this will generally be found large enough to include the whole of the pancreas. Immediately after the animal has been killed, the abdomen is opened widely in the mesial line. The omentum and the greater part of the small and large intestine are laid over to the right, so as to expose the duodenum and its mesenteric attachment. On the anterior surface of the mesentery, with the arborescent pancreas spread like an espalier upon it, there will be observed another portion of the intestine, with its mesentery lying like a loop adherent to the duodenal mesentery, midway between the root and the attachment of the mesentery to the duodenum. Holding the duodenal portion of the intestine firm with one pair of forceps, the other portion may be gently torn or separated from it, so as to leave the pancreas supporting mesentery intact; but at the same time the act of separating the two mesenteries will have left what may be called the anterior surface (in the natural position) of the pancreas denuded of endothelium, and specially suitable for imbibition of silver solution. The attached intestine may now be lifted up and its mesentery kept distended, while the lower ring is placed upon its anterior or denuded surface, and the upper ring jammed upon it from the opposite uninjured surface. The tambourine thus formed may then be excised with scissors from its connection to the spine and the intestine, and one or both surfaces of the membrane as it is now stretched upon the rings may have a 1 per cent. solution of silver poured quickly on and off, when after a short exposure it may be well washed with ordinary water. This preparation must afterwards undergo excessive exposure as compared with other tissues, in order to bring its lymphatics into view. Moreover, as it is generally advisable to stain the whole membrane with hæmatoxylin, so as to show the nuclei of the cells, it is well to expose it even to what may appear an injurious extent, as the process of staining seems subsequently to remove the brown tint to a large extent. The logwood-staining fluid is to be filtered upon it in the usual way, and when found sufficiently stained the membrane is well washed and clarified with alcohol and oil of cloves.

All this time it must be understood that the mesentery forming the membrane stretched between the rings has been touched by nothing except the different fluids. Shortly after clarification the membrane may be excised as a disc, and although thin as gossamer, it will retain its evenly spread out condition, so that if it be found suitable it may be at once mounted as a permanent preparation in varnish, without a wrinkle in its whole extent and without any injury to its surface. Between, however, its being subjected to the silver solution and its permanent preservation as a preparation, two or three days may require to elapse, during which it may be examined, when convenient, for the development of the image of the lymphatics. It will generally be found that the lymphatics are best seen, or only seen, on the inner (the originally denuded) surface of the tambourine membrane, as on the outer surface the serous endothelium of the peritoneum remains uninjured and well shown by its silver markings, while at the same time the endothelial cells interfere with our success, by preventing the silver solution from penetrating to a sufficient depth to demonstrate the lymphatics on that surface of the gland.

There is about the lymphatics in this tissue the peculiarity that they require a comparatively high power in order to be recognised. A power of from 250 to 400 diameters should be used, and the crenated edges of the lymphatic endothelium must be the only permissible mark of recognition. The crenated edge of the endothelium of the lymphatics in this region, for some reason as yet inexplicable to us, appears to be specially well marked, as seen in figs. 4 and 8. In figs. 4 and 8, every one of the cells was outlined by the camera lucida, and the crenation there renders their recognition absolutely certain. When the lobules of the gland have been deeply stained, the lymphatics lying upon them will be recognised easily, even under a low power, by being of a much lighter blue or purple tint upon the dark purple background, in consequence, apparently, of the endothelium of the double lymphatic wall having protected the gland cells beneath them from the imbibition of the logwood staining fluid, the crenated lines being, however, previously sought for as a test of identification. Before we proceed to the description of these lymphatics, let us first give a *resumé* of the

opinions hitherto held, and held at the present day, with reference to the lymphatics of the pancreas.

Many of our best known workers who have made personal investigation into the general lymphatic system, do not even refer to the pancreas. Of these Teichmann is a notable example. Of those observers who do mention it, Cruikshanks appears to have been the earliest, and of its lymphatics, he says, at page 166 of his work on the lymphatics: "That the pancreas has lymphatics, I am well assured. I have seen them on a great many occasions rising out of the pancreas and joining the splenic plexus." Haller did not believe that the pancreas had any lymphatics, and he pointed out that the pancreas, in which other authors had previously asserted they were to be seen, was not the true pancreas but the mesenteric glands. Mascagni, at page 50 of his great work, says: "The lymphatics which come out of the pancreas follow the course of its blood-vessels, and enter the glands to which the splenic lymphatics pass, but have no connection with those of the liver or intestine." Cruveilhier, at page 491 of the 3d edition of his *Anatomie Descriptive*, says: "The lymphatics of the pancreas are not well known; it is probable that they enter the glands nearest to them." In *Quain's Anatomy*, 8th ed. vol. ii. p. 397, we are merely told that "its lymphatics terminate in the lumbar vessels and glands," and, in vol. i. p. 511, that "lymphatics emerge from the pancreas at different points, and join those derived from the spleen." Frey, at p. 491 of his *Histology*, 3d ed., says that "the lymphatics of the pancreas are numerous, but they require more minute investigation." Finally, we come to Sappey, who appears to be the latest investigator and author who has referred to these lymphatics. In his *Anatomie Descriptive*, published in 1870, p. 831, he states: "Their investigation is very difficult; nevertheless I have twice succeeded in injecting them. They come out of the pancreas at different parts of the superior border of the organ, and join the glands near the coeliac artery." In short, it will be seen by our extracts that, although several investigators have seen lymphatics extrinsic to the pancreas, not one has seen them within the organ, or pretends to describe, or even hint at, their probable relationship to the component tissues of the gland.

When we have placed before us what appears to be a thoroughly successful specimen of a pancreas of one of the rodents, prepared according to the method we have described, in order to demonstrate its lymphatics, we must carefully bear in mind that there is one source of error to be eliminated from our search. As the pancreas is spread out upon the mesentery, we naturally have near it, and sometimes upon or within it, the main efferent lymphatics, or lacteals, passing from the intestine to the receptaculum chyli. These, at first sight, might be taken to represent the lymphatics of the pancreas, and we, ourselves, were, at the beginning of this research, partly led astray by the presence of these lymphatics, which often lie in the line of the main chains of pancreatic lobules. Having, however, been made aware of this source of error, it is easy practically to eliminate it from interfering with the special lymphatics of this research. The efferent lymphatics or lacteals in question can always be recognised by means of their straight and regular course. Although formed by the junction of smaller branches on the side of the intestine, and even by the extrinsic efferent lymphatics of the pancreas, they remain of regular calibre, with valves at regular intervals, and as they grow larger by the junction of other channels, strengthening elements in the shape of smooth muscle-cells get applied to them externally, isolated and scanty at first, but forming a very respectable coat sometimes before they reach the receptaculum chyli. In most cases, the greater part of their course lies within the transparent gelatinous matrix of the mesentery, where they may be seen to receive efferent lymphatic branches from the pancreatic lobules. In the smaller rodents, like mice and rats, this elimination is much more difficult to make, but in the rabbit, from which we chiefly took the special material for this research, there is no difficulty whatever in making it. In figs. 2 and 5, for example, it scarcely requires the foregoing caution to enable us to state that the irregular and erratic lymphatics seen passing up through the axis of the chain of lobules are certainly not the efferent lacteals, but the efferent lymphatics of the pancreas itself, receiving tributaries from various parts of the surfaces of the individual lobules.

Although, physiologically, we have here, as elsewhere, only

two divisions, namely, the collecting and the efferent lymphatics, yet for the sake of anatomical description we must divide the latter category into two subdivisions, and this too independently of the efferent lymphatics, or lacteals proper, of the intestinal canal, which we have just eliminated from consideration. No one can find much difficulty in differentiating the broad network of vessels almost destitute of valves which form the collecting lymphatics proper of the organ, as shown in figs. 1 and 3, from the irregular lines or loops of valved lymphatics which lie in the axis of the lines of pancreatic lobes, and intertwine with the blood-vessels and pancreatic ducts in that locality, as seen in figs. 2 and 5, giving off branches, at nearly right angles to the efferent stream, which pass round or between the lobules to join the groups of collecting lymphatics on the opposite side of the lobes, as seen in figs. 2 and 6. These lymphatics we speak of as intrinsic efferent lymphatics, and they, with their collecting lymphatics, form the special lymphatics of the pancreas, of whose existence, condition, or relationships nothing has hitherto been known, or even suspected. While, however, the main efferent lymphatic stream seems to pass down in the axis of the chain of pancreatic lobes, we observe, as we follow it under the microscope, that comparatively large lymphatics pass off at frequent intervals from the chain of lobes and its intrinsic efferent lymphatics, and turning backwards wend their way through the mesentery, either to join the receptaculum chyli, or, as is most frequently the case, they join after a longer or shorter course one of the great efferent lacteals from the intestine, passing through the mesentery on its way to the receptaculum chyli. The lymphatics alluded to correspond to the vessels referred to by the writers we have quoted, and, although lying within the same field of the microscope with the other vessels, and, so to speak, within the area of the pancreas, we speak of them as the extrinsic lymphatics of the pancreas. The relation of such a lymphatic to the intrinsic efferent lymphatics is seen at *c*, fig. 5. After leaving the lymphatics seen in the axis of the lobes in that drawing, the extrinsic efferent trunk remains of regular size, and no longer forms loops or anastomosing branches. We have not drawn the straight efferent lacteals we referred to as sources of error, as to do so

would be unnecessary for this research, they being too well-known to histologists to require special delineation for comparison. In fact, purely efferent lymphatics, anywhere throughout the body, although they may form anastomoses and networks, as, for example, on the upper surface of the diaphragm, seldom break up into irregular-sized loops and meandering channels intertwining with the blood-vessels, such as are seen in fig. 5.

The course of the intrinsic efferent lymphatics, as seen in figs. 2 and 5, follows pretty closely the course of development of the organ. Beginning as a bud from the duodenal orifice, this gland in the rodents divides primarily into two divisions, and these subsequently into many other divisions, which diverge from the orifice like the ribs of an unfolded fan. As they elongate, these ribs not only give out branch ribs, in the same general direction of divergence, but they also give off branches which pass from one chain to another at every variety of angle to the general plane of divergence. In all this development, it must be understood that the formation of the chains of lobules is preceded by the formation of the duct beyond the ultimate point of lobule formation. This is very well shown in the cross chains, where the whole duct, formed of lozenge-shaped cells, is often formed before a single lobule is developed upon it, and the first evidence of lobules as buds composed of five or six cells, forming an embryo acinus, can be observed, and the whole subsequent course of development exactly studied.

In some such cases the development of collecting lymphatics for the future chain of lobules can also be watched, and this gives us a satisfactory conception of the progress of the lymphatic arrangement for this special organ. Tracing the lymphatics back from the head of the pancreas, we find them passing, as we have stated, in the general axis of the head or primary chain of lobules, either as one or more channels forming irregular dilatations or loops, intertwining with the blood-vessels and duct, sometimes passing on one side, sometimes on the other, of the root or attachment of the lobules to the duct, as seen in the figures. From what we have already stated, it will not be supposed that, because the whole lymphatic arrangement of the pancreas develops backwards from the head of the

pancreas, like the ducts of the gland, as if parallel and *pari passu* with these ducts, the lymph stream passes wholly down those lymphatics, as the pancreatic juice itself passes wholly along the gland ducts towards the main opening into the duodenum. At various intervals in the course of the development peripherally of the axial intrinsic lymphatics, the extrinsic branches pass off often at right angles to the chain of lobules, as at *c*, fig. 5, and these, turning backwards, take a course as already stated, towards the receptaculum chyli, or join some of the efferent lacteals passing thereto from the intestine. These branches drain off the greater part of the lymph before it has run far along the axial chain. In figs. 7 and 8, from the developing pancreas of a young rat, we have an example of the development peripherally of an axial chain of lymphatics. At *i*, fig. 7, is seen a cul-de-sac offshoot that probably will finally become one of the extrinsic efferents we have alluded to, which will drain off part of the lymph from the axial lymphatic lying upon the chain of lobules, and which is developing peripherally at the cul-de-sac *h*, fig. 7, shown under a higher power in fig. 8.

As the main duct of the chain divides dichotomously, or gives off connecting branches to other tracts, the lymphatic vessel or vessels, as in fig. 5, likewise send an offshoot in the same direction, until the whole pancreatic espalier is provided with a chain of lymphatics along each branch.

In the smaller rodents, like mice, the lymphatic system is seldom seen to get beyond this stage, but in the rabbit we have a further development of special collecting lymphatics connected with the intrinsic efferents by branches passing off at nearly a right angle to the main chain of axial lymphatics. Several of those special collecting branches are seen in fig. 2; and fig. 6 shows one of them under a moderately high power. At *a* we see the branch ending as a cul-de-sac applied flatly to the mass of the lobule *en face*, this being the manner in which many of the branches end as collecting lymphatics; while *b'* and *b'* in the same figure represent branches which pass between the lobules to join more complicated plexuses on the opposite surface, similar to those seen in fig. 1, and which latter embrace the lobule in the same manner as the paper nautilus grasps its shell.

From the position of the intrinsic efferent lymphatics, and the manner in which they intertwine with the vessels and ducts of the organ in the axis of the chain of lobes, they may be described in relation to the individual lobes as lying in the hilus of each, or upon the hilus surface of the lobe; but in that position there is the clearest evidence that they never pass into the substance proper of the lobe. On the contrary, when we trace the branches given off from them, as seen in figs. 2, 3, and 6, we find them either terminating as a flat cul-de-sac on the same hilus surface, or passing between the primary lobules (not acini) which constitute a lobe, and emerging on the opposite surface from similar clefts or interstices between lobules, and joining or forming a collecting plexus of lymphatics on that surface. In this respect the lymphatic arrangements upon an individual lobe, such as is seen in figs. 1 and 3, even although that lobe be almost microscopical in size, are identical with the lymphatic arrangements which obtain on such massive organs as the kidney and spleen in the larger mammals, the efferent lymphatics being found at or passing to the hilus, and the collecting lymphatics at the opposite point in the periphery of the lobe, the whole lymphatic arrangement being, as we have so often insisted, merely a peripheral drainage system of vessels, and that drainage system of such comparatively little importance that it is often altogether unrepresented or absent, and is therefore evidently not of primary necessity.

We have already stated that in the pancreas of such a small animal as the mouse, the collecting lymphatics proper are generally absent, the intrinsic efferent lymphatics fulfilling the necessary function, but in these animals, and in innumerable instances in our preparations even of the rabbit's pancreas, large lobes, and even groups of lobes, are seen to be unprovided with any lymphatic vessels whatsoever. In the cases referred to the lobe or group may have developed upon or from one of the cross branches of the pancreatic duct at nearly the middle of the length of the duct, being separated from the rest of the secreting structure of the organ. It is easy there to examine the duct and accompanying blood-vessels on either side of the group of lobes, and to ascertain that no lymphatic accompanies them, and that therefore that isolated lobe or

group of lobes is unprovided with any lymphatics, which consequently cannot be an indispensable adjunct to these tissues. This, indeed, is only a narrow demonstration of a much wider principle, which becomes very evident when a comparative study of the lymphatics is made in many classes and sizes of animals, where in one class we find an organ destitute of lymphatics, which in another class (generally a larger one) is plentifully provided with them.

The collecting plexus of lymphatics, even where best developed upon the pancreas, as in fig. 3, presents features common to the same structures in many other organs in the body. The plexus found there might have been equally found upon or drawn from the sub-epithelial plexus of the intestinal canal (minus the culs-de-sac of the villous portion), from the greater curvature of the kidney and spleen (in the horse), from the lower surface of the diaphragmatic musculature, from the peritoneal surface of the transversalis abdominis, from the perichondrium or from the supra-pubic plexus in the mouse, and from numerous other localities in the body. In fact, there is a remarkable simplicity and similarity in the lymphatics throughout the body; differences can scarcely be said to exist, but only modifications in a general plan, of which the connecting links are always evident and easy of understanding. The innumerable specially descriptive names applied to various portions of vessels of the system—the Lymph-röhrchen, spalten, räume, the sinus, canaliculi, lymphatic sheaths, vasa serosa, &c.—are in most cases the outcome of fertile brains and clumsy injections, which have made artificially the cavities described as parts of a natural system, as we shall show in the course of this paper.

The relation of the collecting lymphatics to the other elements in the pancreatic lobes is extremely simple, and is shown in fig. 4. Huge drains, whose walls are formed by dovetailing tiles, lie upon the cellular structure of the lobe, and receive any excess of fluid that may ooze into them. No branched cells are to be detected in connection with them. This might be said to be due to the difficulty of detecting them upon the rather opaque cellular mass on which the lymphatics lie. But in fig. 8 there is no such inconvenience; the cul-de-sac there is evidently a purely collecting lymphatic. In the clear gelatinous matrix

the finest granule could be detected. The pyrogallate staining has also been applied so intensely that every nuclear or protoplasmic element in the vicinity of the lymphatic is made clearly and abundantly evident, but there is no trace of any minute channel beyond the walls of the cul-de-sac; in short, there is distinct evidence that the mythical vasa serosa or lymph-canalicular system of branched cells cannot have any existence there.

It often happens that branches of the lymphatics are observed leaving the close proximity of the lobule, and passing off for a short distance and again returning to it, lying in the interval within the clear gelatinous matrix of the mesentery; and, as in such conditions a deep staining can be applied to its nuclei, we can form a satisfactory opinion as to the mode of development. This explains the projection of the cul-de-sac of the developing lymphatic in fig. 8. In such cases we generally find blood capillaries accompanying the growing lymphatic, as shown in figs. 7 and 8, as if these capillaries were the pioneers of the lymphatics. There is, of course, no relation between the development of the lymphatics and the development of the blood capillaries, the latter being formed of the terminal attachment and hollowing out of terminal cells, while the former has several endothelial cells in its periphery at its termination while undergoing development or extension, so that extension takes place by the interposition of new or wandering cells between the crenated margin of the lymphatic endothelium. These cells, by their growth and broadening out into lymphatic endothelium, serve to prolong the cavity of the developing lymphatic peripherally. This process can be followed by examining a series of terminal projecting culs-de-sac in developing lymphatics, similar to those in fig. 7. In fact, the development of the lymphatics resembles the growth of a capillary into a larger blood-vessel by the interposition of cells between the existing cells of its previously formed walls.

When we trace a lymphatic, or chain of lymphatics, along the axis of a chain of lobules until we reach what may be called its extreme peripheral termination, upon the last lobule of the chain, we generally find it terminate in a cul-de-sac, as in fig. 6, *a*, like a club-shaped finger-tip upon the thickest part of the

lobule, the axis of both being parallel to each other. Although, however, the tip or point of the cul-de-sac is actually broader than the channel behind it, there is never any attempt to send off small channels such as one might conceive the ultimate lymphatic radicle to resemble.

We have already stated that, owing to the protection given by the double endothelial wall of the lymphatic to the mass of the glandular tissue beneath it, the silver solution has not been permitted to permeate the mass at such points, and the excessive exposure to light which we previously urged as a necessity, while it renders the less protected surface of the glandular tissue of a dark brown colour, leaves the places covered by the lymphatics of a light blue tint, due purely to the staining of the logwood fluid. This is so well marked that there is no difficulty in recognising the course and shape of such lymphatics with powers much too low to recognise the crenated endothelium, which is alone the guarantee of a lymphatic.

In addition to the light blue images which mark the lymphatics, many other small light blue spaces may be observed upon the mass of the lobule that might be taken to be points of cul-de-sac of lymphatics penetrating the organ, and as evidence of complete permeation of the lobule by branches of the lymphatic system, such as exist almost unanimously in theory, but never in fact. When such isolated light blue patches are examined by a high power, more than sufficient to show with beautiful clearness the crenated edges of the contiguous lymphatics, it will be observed, in the first place, that such spaces possess no crenated lines which would argue the presence of a lining of lymphatic endothelium. Further examination will show that those spaces represent the crevices between the contiguous ultimate lobules, or even acini, of the gland. When in the living condition the silver solution was momentarily applied to the tissues, these lobules or acini being close together prevented the silver solution from penetrating between them and staining them. The subsequent extended exposure to hæmatoxylin allowed, however, that staining fluid to colour all the elements of a light purple tint. When, subsequently, the tissues were dishydrated by alcohol and essential oil a certain amount of contraction took place, more or less, but unequally, in the

different elementary tissues, so that the acinus, or lobule, shrinking from the contiguous acini, or lobules, left often a distinct interval or crevice, easily recognisable under the microscope.

The clearly demonstrated existence of such spaces leads us to one of the gravest considerations in connection with the whole anatomy and physiology of the lymphatic system, as built upon the results of comparatively late researches made by the most distinguished histologists of Germany in particular, and the arguments which we are about to bring forward ought to have the effect of destroying all confidence in the correctness of the results arrived at by those observers, pending further investigation. That spaces, crevices, or cavities, such as we have described, actually exist within our preparations, admits of no manner of doubt, by simple microscopic observation; and it is equally evident that, were the canula of an injecting syringe plunged at random into the solid mass of the gland, such cavities would certainly be the first to be filled by the injected fluid, and the cavities thus injected would be described as being parts of the lymphatic arrangement of the organ; for the injection method shows only the casts of cavities, whether natural or artificial, and offers no guarantee like the crenated endothelium to stamp the characters of the lymphatic system. Probably, in such an injection, some lymphatic channel would also be opened into and injected, and this would lead to the filling and distention of the efferent-valved lymphatics extrinsic to the organ, which would seem to confirm the relation of such cavities to the lymphatic system, but in reality would only confirm a gross but almost universal error. We have long been aware of this error in a large number of researches into the lymphatic system by means of coloured injections, we having, by long study of the system by means of the silver method, acquired an almost indefinable consciousness of what is and what is not a lymphatic in such injections; but it is only lately that we have been able to explain the cause of it, and ultimately to reproduce at will a demonstration of the process in operation under the microscope, a process which we propose to describe.

What we have said of the production of the blue spaces or cavities in the pancreas is equally an explanation of the cause of error, or rather of the existence of the spaces in other tissue

and organs, which probably do not exist during life. The application of what are known as hardening or fixing fluids, produces a certain almost imperceptible change in the volumes of the different elemental tissues of the body. The amount of this change, however, varies considerably in different elements, as, for example, between the protoplasmic element, or cells, and the gelatinous matrix which binds the cells together in groups. In consequence of this, when a tissue formed of these different elements is exposed to the same hardening fluid, whether alcohol, chromates, or Müller's fluid, the differential contraction in the volume of each respectively, causes, so to speak, a shrinking of the one element away from the other. In the pancreatic tissue under consideration, we saw that either the cell-formed acini or lobules shrink away from the gelatinous matrix, or from each other, so that spaces are left where formerly the tissues were in apposition. Such spaces are not, however, found only between the acini or between the acini and the gelatinous matrix of the mesentery, in which the gland-tissue lies more or less embedded, but also around the blood-vessels, ducts, and even the lymphatic vessels themselves. When a tissue has been prepared by fixing or hardening fluids (and we generally find the observers we shall afterwards allude to recommending this preliminary hardening as indispensable for a successful injection of the lymphatics), the consequence is that the cavities thus artificially formed are the first injected, and they are afterwards described as the lymphatics of the part. Now for the demonstration of the fact.

If we take the pancreatic tissue under consideration, stretch it firmly upon our histological rings, and apply the silver solution so as to demonstrate the locality and cells of the lymphatic vessels and gland acini, stain it slightly with hæmatoxylin so as to show the exact character of all the tissues, wash it and dehydrate with alcohol in the usual way, and clarify with oil of cloves, naturally enough the thin gelatinous membrane of the mesentery will be more quickly clarified than the smaller and outlying lobules of the gland which follow next in order. (We shall suppose that clarification is effected by pouring a few drops of oil of cloves on a sheet of glass upon which the reversed tambourine is placed, and gently heated from time to time),

The large lobules forming thick masses of acini, are the last to yield, and require slight heating from time to time, to complete the process ; but when that process is all but complete, it is stopped while only a shade of haziness remains in the centre of the larger lobules, which are generally those nearest the head of the gland. The all but completely clarified disc must now be excised, and a bed of very thick varnish (or balsam) having been prepared for it on a slide, it is deposited thereon, a sufficient quantity of the same thick varnish placed upon the tissue, and the cover-glass applied and pressed down. If, now, the preparation be gently heated, a minute quantity of vapour will become developed from the centre of the incompletely clarified lobules, and from the centre of the axial group of blood-vessels, ducts, and lymphatics. The slide may now be placed under the microscope, and the whole process observed step by step. The vapour is noticed extending by little jumps, passing upwards along the outsides of the vessels as an immense beautifully branched air-bubble, whose ramifications appear black by the transmitted light of the microscope mirror. From the group of axial vessels it passes on to the periphery of the lobule, sending on its black slender processes, as at fig. 9, so as to form a network between the acini in the mass of the lobule and upon its surface, filling, especially, the very light blue spaces we have been considering some pages back. It does not travel within the lymphatic trunks and blood-vessels, but so completely surrounds or ensheaths them externally as to demonstrate satisfactorily, even to the most sceptical observer, the mistake of the whole hypothesis of lymphatic sheaths of blood-vessels, nerves, &c., upon which so many fabulous theories stand at the present day, in medical science. Here we have an exact reproduction of the errors existing in numerous researches on the lymphatics of organs, which can be watched, step by step, under the microscope.

These appearances are, however, not permanent, but may disappear in from a few hours to a few days, according to the amount of moisture left in the preparation after clarification and embedding in thick varnish. The more complete the vapour injection the more confused the image of the whole gland becomes, in consequence of the closeness of the vapour

injected network, and the irregular refraction of light, which adds to the confused appearances. On this account it is difficult to draw, even by the camera lucida, and as, moreover, the most correct drawing given by us would still be liable to suspicion of unconscious deception, we were fortunate in getting our friend Mr Fowke, of the British Medical Association, to photograph directly under the microscope, a preparation of pseudo-lymphatics such as we have described, and we think it well worthy of being represented in fig. 9, copied direct from the microscopic photograph by the lithographer. The photograph was taken a few hours after the preparation had been made, and the latter now shows no trace of the former vapour injection, which has become absorbed by the varnish. It will be understood that a satisfactory demonstration can only be obtained from an uninjured tissue; an ordinary cut section would not reproduce it, and one may vary infinitely the kinds of tissue experimented upon. The muscular abdominal wall of a mouse shows this process in action very well. In it the vapour passes around and between the muscular fibres of each layer, and thus, with the three layers of the transversalis, external and internal oblique, we have the lines of vapour lying across each other according to the direction of the fibres in each layer. In the walls of the urinary and gall bladders, the vapour injection follows the direction of the felted bundles of smooth-muscle fibres, so as to give an exact reproduction of certain drawings of the lymphatics in similar tissues.

Before passing from this question, let us offer a few examples of the errors we have referred to, which may be examined in proof of what we have advanced. In Ludwig and Zwarykin's paper on the lymphatics of the dog's kidney, figs. 15 and 16 reproduce the errors we have described, fig. 15 by injection, and fig. 16 as the natural result of an amazing preliminary process of rendering the kidney artificially œdematous by ligature of the ureter during life, leading naturally to the grotesque and grossly erroneous appearances described as lymphatics. In Tomsa's paper on the lymphatics of the spleen, all the nine figures are drawings equally erroneous. In Macgillivray's paper on the lymphatics of the liver, figs. 7 and 10 reproduce the erroneous artificial injections seen round the vessels of our preparations of

the pancreas; figs. 1, 3, and 9 are also errors. Of Leopold's paper on the lymphatics of the uterus, fig. 8 is entirely wrong. It does not show a single lymphatic, and fig. 7, while it shows the lymphatics correctly in its lower half, shows a large number of what he calls lymphspalten, lymphrohren, &c., which have actually no existence. As that figure is probably a section from one of the uteri on plate i., we may take the whole of the figures in that plate to be equally erroneous.

In an article on the structure of the uterus, in the *Medicinskt Archiv* of Stockholm, for 1867, Lindgren gives in fig. 2, plate iv., what he considers to be a view under a high power of the main lymphatics of the mucosa of the neck of the uterus, with lymphatic radicles proceeding from them. The two lymphatics lie parallel to each other, and between them lie a large number of branched cells in a transparent matrix. The blue injection fills the two lymphatics, and branches off from them along the spaces in which lie the so-called branched cells of the connective tissue. The drawing bears the stamp of honesty, as a reproduction of the appearances seen, and, taking these appearances as they stand, they form a complete demonstration of the theory that the radicles of the lymphatics are the cavities surrounding, or in which lie, the cells of the connective tissue. But the whole thing is a deception. The great blue cavities, shown as lymphatics, are not lymphatics, which have everywhere complete walls formed of endothelium, unlike the spaces seen in Lindgren's drawing, and the cells separated from their matrix, by means of contraction of their substance, have allowed a certain amount of the blue fluid to penetrate between them from the large spaces. We have referred at some length to this example, on account of its value as an instance of the artificial cavities we have described. This list might be greatly extended, but the examples we have quoted may serve to show the serious character of the errors which at the present day are accepted as facts.¹ It will

¹ While the present paper was in the hands of the printer, an article remarkably illustrative of the mistakes we deprecate has appeared in English. It is a research by Dr E. Klein on the lymphatics of the skin, and appears in the report of the medical officer to the Local Government Board. This research is illustrated by twenty coloured plates, seventeen of these being of the lymphatics of the skin of the Mammalia. In our opinion not one of the latter represents the lymphatic system. Nothing could be more beautiful than the manner in which the coloured injection has followed the course or sheaths of the blood-vessels, breaking up into small branches as they break up, exactly as in the deceptive

be, however, understood that all researches into the lymphatic system by the injection method are not equally fallacious. The plates in Teichmann's splendid work on the lymphatics, and Ludwig and Schweigger Seidel's drawings of the lymphatics of tendon and aponeurosis may be instanced as examples of apparently absolutely correct injections.

The general lessons taught by the existence of the errors we have pointed out are:—(1) the lymphatic system of the solid organs, which have only, as yet, been investigated by the injection method, may be considered practically unknown, and the former opinions erroneous; (2) the results obtained by the injection method ought never to be depended upon, except where they have been confirmed by the silver method.

It has been a great misfortune that the method of silver imbibition or injection should have succeeded to the methods of injection by mercury and coloured masses, as, had the order been reversed, there cannot be much doubt that at the present day little would have remained unknown of the lymphatic system. Unfortunately, silver solution can only be applied to surfaces, but the injection method may still prove a valuable auxiliary in showing the connection between lymphatics on opposite surfaces, when once these have been previously demonstrated by silver, so as to avoid the risk of future mistakes, in injecting non-lymphatic cavities.

At the present day, there is no reliable method for investigating the lymphatics of the pancreas, where the organ forms a solid mass, any more than in the case of any other special solid organ. If the injection method were to be used, or had ever been used, in that organ, it would only reproduce the erroneous and misleading appearances seen in fig. 9, and we are glad to have had the opportunity of demonstrating what the cause and character of those appearances would be before they had obtained a footing as recognised facts in anatomy, as is already the case with process described by us, but in a fashion never found in the lymphatic system. In this way Dr Klein not only demonstrates lymphatics within the papillæ, where normally they never exist, but, by forcing the injection between the epidermic cells, he demonstrates lymphatic radicles in the sweat glands and hair follicles. In the text Dr Klein criticises in a not unfriendly manner the methods employed by us in a similar research, but it appears that he wrote either before or in ignorance of the existence of our extended and illustrated article on the lymphatics of the skin published two years and a half ago in the *Journal de l'Anatomie*. We only regret, in the interest of scientific truth, that we find occasion to answer his criticisms by such a wholesale condemnation of the method which has led astray so distinguished an histologist as Dr Klein.

the lymphatics of the other organs we have specially referred to. Although it may have appeared wandering from the special subject of this paper to have referred to them, yet the causes and examples of these errors are so general, and easily explicable, that we thought we could do no better, when showing the source of the errors, than give crucial examples in point from accepted researches of the most capable and renowned investigators in this department of research.

The results that we have obtained from the pancreas of rodents, in regard to the lymphatic system, can be easily and correctly applied to the solid pancreas of the larger mammals, and also to the large racemose glands throughout the body, by supposing the dispersed lobules compressed together in a mass. The following conclusions may therefore be taken as generally applicable throughout the series:—

1. *Accompanying the axial arrangement of blood-vessels and pancreatic ducts, one or more irregular efferent lymphatics will be found intertwining with the other vessels, and forming at times a network around these.*

2. *These efferent lymphatics are largest where the other vessels and ducts are largest, and they divide dichotomously with these vessels, as they pass to subordinate lobules of the glands.*

3. *As the lymphatics approach the individual lobules, they lie on the hilus surface, and give off branches which spread over each lobule on its external or peripheral aspect, and terminate either as broadened out cul-de-sac terminations, or in the general form of loops or meshes.*

4. *When (hypothetically) a racemose gland is surrounded by other tissues, the main efferent lymphatics pass directly from the gland to the surrounding tissues, instead of passing to the termination of the main duct of the gland.*

5. *In the pancreas, although the great chains of axial intrinsic efferent lymphatics tend towards the opening of the main duct, little of the lymph within them reaches that point, being drawn off from the axial lymphatics by extrinsic efferent branches passing off at nearly right angles from them. These pass either backwards along the mesentery to join the receptaculum chyli, in rodents, or at the superior border, to join the lymphatics lying along the splenic artery in man and the larger mammals, as described by Sappey and others.*

DESCRIPTION OF PLATE XXIV.

Drawings made by the aid of the Camera Lucida.

Fig. 1. View, under very low power, of several groups of collecting lymphatics, *a, a*, in the pancreas of the rabbit; *b*, small portion of intrinsic efferent lymphatics; *d, d*, lobes of pancreas; *e, e*, vessels and nerves passing through mesentery, $\frac{1}{8}$.

Fig. 2. View, under similar power, of the intrinsic efferent lymphatics in the pancreas of the rabbit, $\frac{1}{8}$.

Fig. 3. Enlarged view of a portion of the group of collecting lymphatics seen in the centre of fig. 1; *f, f*, points where the collecting plexus becomes continuous with the efferent lymphatics on the opposite side of the lobe. Only the lobules and acini are shown in this drawing, $\frac{1}{100}$.

Fig. 4. Greatly magnified view of a portion of fig. 3, showing the pancreatic cells, *g*, forming acini, the capillaries *e*, and their relation to the lymphatic *a*, $\frac{1}{300}$.

Fig. 5. Group of intrinsic efferent lymphatics from the pancreas of the rabbit, showing an extrinsic lymphatic *c*, passing off from the intrinsic efferent group to join the efferent lacteals lying within the mesentery, $\frac{1}{18}$.

Fig. 6. Enlarged view of a portion of intrinsic efferent lymphatics, breaking up into branches which pass between the pancreatic lobules to join the collecting lymphatics on opposite surface of lobe. At *c* is an efferent lacteal lying upon the lobe, into which the intrinsic efferent branch *b* subsequently opens, $\frac{1}{100}$.

Fig. 7. Lymphatic in course of development upon the pancreas of a young rat. The cul-de-sac termination *h* appears to be the peripheral extension of the lymphatic, while the cul-de-sac *i* appears to be the prolongation backwards of what will become an extrinsic efferent lymphatic, $\frac{1}{80}$.

Fig. 8. Greatly magnified view of the cul-de-sac *h* in fig. 7, showing its relation to the wandering cells *l, l*, blood capillaries *e, e*, and nuclei of peritoneal endothelium *m, m*. The cells *l, l*, are the so-called fixed branched cells of the connective tissue, which have no connection with the lymphatic, $\frac{1}{200}$.

Fig. 9. Pseudo-lymphatics, as they appear in the pancreas of a mouse, the dark-coloured ramifications being merely artificially and intentionally made channels, filled with air or vapour, which by refraction appears 'black'. This view was photographed direct from the preparation under the microscope, by Mr Francis Fowke; *d*, pancreatic lobules; *j*, pseudo-lymphatic branches; *k*, main channel, $\frac{1}{100}$.

In the above figures the following letters apply equally throughout; *a*, collecting lymphatics; *b*, intrinsic efferent lymphatics; *c*, extrinsic efferent lymphatics; *d*, pancreatic lobes; *e*, vessels and nerves; *f*, junction of efferent with collecting lymphatics.

Figs. 7 and 8 are from preparations stained with silver and pyrogallate of iron; all the others are stained by silver, gold, and hæmatoxylin.

7

CASE OF PRIMARY CANCER OF THE FEMUR.

By ROBERT MAGUIRE, M.R.C.S. (PLATE XXV.)

(From the Pathological Laboratory of the Owens College.)

AMONG the malignant tumours which primarily attack bony tissue, the sarcomata occupy the most prominent position, and have been shown to form by far the greater number of those growths which, until very recent times, were known as cancers of bone. Modern science, by unravelling the confusion which existed between the two great types of malignant tumours, has, indeed, shown that the carcinoma, in its primary form, is one of the rarest of bone tumours, but many eminent pathologists would go farther than this. Believing that cancer cells are invariably the descendants of pre-existing epithelial cells, according to the theory of Thiersch and Waldeyer, they assert that it is impossible for carcinoma to occur primarily in a non-epithelial structure, or in an organ developed from the meso-blastic layer of the embryo. Since, then, bone belongs to this class of structure, it would be impossible for primary cancer to be found there. But, although it must be admitted that they are of rare occurrence, many cases of cancer occurring in meso-blastic structures have been described; and while, in the present paper, I have reported a case of carcinoma of bone which I have myself examined, I have also endeavoured to collect the recorded cases of bone cancer which were of primary nature.

The specimen I examined was taken from a patient who was an inmate of the Manchester Royal Infirmary, and I am indebted to Dr Dreschfeld for permission to make use of the tumour, and for his kind assistance in the examination. The clinical history, briefly stated, was the following:—The patient had first noticed a swelling of the right thigh, which increased in size, and in a little while he complained of some difficulty of breathing, and swelling of the arms. On admission there was found oedema of both arms, and of the right leg, and there was a little dulness under the first rib of the right side. There was diagnosed a primary tumour of the femur and a secondary

tumour in the thorax, pressing on the superior vena cava. This diagnosis was confirmed *post mortem*, when, after a careful examination, there were found the tumour of the thigh described below, and in the chest some enlarged lymphatic glands which had become matted together and had pressed on the vena cava superior.

The tumour of the thigh occupied the inner side of the neck and upper part of the shaft of the right femur, and appeared as a globular mass, reaching from the base of the head of the bone downwards for about $4\frac{1}{2}$ inches. On section it was seen that the tumour was very friable, and contained numerous cavities. It apparently grew from the external portions of the bone, and was covered by a thick layer of fibrous tissue, continuous with the periosteum.

Sections made after decalcification showed that the tumour consisted, in its most perfectly developed part, of large alveoli communicating with each other, filled with cells, and their walls formed by a fibro-nuclear tissue (see fig. 1). The cells contained in the alveolus were of an epithelioid character, each containing one round nucleus with nucleoli, and a somewhat large amount of granular protoplasm. At the circumference of the alveoli the cells were more closely packed than elsewhere, and assumed somewhat of a columnar character, but in the centre of the alveolus they become rounder and a little smaller; no interstitial tissue was seen between the individual cells. The stroma consisted of fibrous tissue, with spindle and round cells, and in some places giant cells were found, but these were only seen in those parts of the stroma near the normal bone. Blood-vessels were not abundant in the stroma, but, when present, had their normal structure. Masses of old blood-pigment were also found in the stroma. It was evident, then, that the tumour was a true cancer. The epithelial character of the cells, the absence of intercellular matrix and of embryonic elements in the walls of the blood-vessels, the distinct alveolar arrangement of the cells, and marked separation of stroma and alveolar contents, distinguished it from an alveolar sarcoma with which it could possibly be confounded.

The development of the tumour was very interesting. The periosteum as it approached the tumour became infiltrated with round cells, which increased in quantity the farther the tissue

was traced into the region of the tumour. The periosteum was thus found to be connected with the stroma of the cancer. The bone itself was in some parts in process of absorption, and in others the bone corpuscles were in a state of proliferation, but I could not satisfactorily trace any connection between them and the cells of the stroma. These cells, as the alveoli were approached, increased in size, and assumed the characters of the intra-alveolar cells, so that it would appear, from some portions of the sections, that the intra-alveolar cancer cells were produced from the round cells of the stroma. So far, this would very much correspond with the description given by Cornil and Ranvier of the origin of cancer in bone. They describe first, inflammation of the bone, which gives rise to a mass of embryonic cells. This they call the stage of hesitation, for these cells may again develop true bony tissue, giving rise to sclerosis of bone. But if there should be a determination to cancer, then some of these cells form fibrous tissue, which encloses some of their fellows, and these latter, increasing in quantity, develop into cancer cells, while the fibrous tissue forms the alveoli.

But in the present tumour another possible source of the cancer cells appeared. I have mentioned that in the stroma a quantity of giant cells were found. Now these in some places could be seen to break up into several smaller cells by their nuclei surrounding themselves each with a separate mass of protoplasm. There was thus produced a mass of cells which could, it is true, be observed in many cases to become continuous with the other cells of the stroma; but in some parts, and this was best seen where a giant cell was situated near an alveolus, the various cells produced by the splitting up of the giant cell had the same characters as the intra-alveolar cells, and thus the space originally occupied by the giant cell became a cancer alveolus (see fig. 2).

The diseased lymphatic glands in the chest presented, on examination, the ordinary appearance of cancer. The cancer cells were more uniform; the stroma showed no giant cells.

In the above case a careful examination was made of the epithelial surfaces of the body, and there could be no doubt that any possible primary growth on such surfaces was not overlooked. We have, then, in the body only two cancerous masses.

If we assume, as the history of the case seemed to declare, that the cancer of the femur was primary, and that of the lymphatic glands secondary, the case is quite incompatible with the theory of Thiersch and Waldeyer. Professor Butlin, in his recently published lectures, says that the discovery of an alveolar structure in a bone tumour should at once suggest a doubt of its primary nature. But if, in the present case, we doubt the primary nature of the bone affection, we must assume that it was secondary to the disease in the glands, and we have, nevertheless, to do with a mesoblastic structure. Such a view would, however, agree either with Köster's theory of the origin of cancer from lymphatics, or with that of Ranvier, who believes that it develops from endothelium. The case might also be explained, but in a much less satisfactory manner, by the application of the so-called "atypical" theory, it being supposed that during embryonic life a few epithelial cells had become imbedded in the mesoblast, these having lain dormant for a long time, but having suddenly increased in quantity and formed the cancerous tumour described.

I will now mention some reported cases of cancer of bone in which the affection appeared to be primary.

In vol. xix. of the *Pathological Transactions* there is an account of a primary tumour of the lower jaw removed by Mr Christopher Heath, and this, when examined by the Committee of Morbid Growths of the Pathological Society, was declared to be encephaloid cancer. The patient died from recurrence.

In vol. xxii. of the *Pathological Transactions* is an extremely interesting case reported by Dr Moxon, in which cancer of the colloid variety occurred primarily in several bones, and secondary growths were found in the glands.

In the *St Bartholomew's Reports* for 1879, Mr Walsham reports two cases of primary cancer, one in the humerus the other in the femur.

Mr Norton (*Lancet*, Nov. 9, 1878) records a case of primary cancer of vertebræ and sacrum. At the *post mortem*, cancerous disease was found in the right ileum, the mesenteric and lumbar glands, the kidneys, and thorax. No detailed account of the microscopic examination is given.

In the same volume of the *Lancet*, and also in the *Pathological*

Transactions for that year, there is a case by Dr Braidwood of unilateral cancer affecting the left ileum, left mesenteric glands, and certain of the bones of the skull. The rectum was not removed, but was probably healthy.

During the discussion of the above case at the Pathological Society, Dr Sturge mentioned a case of cancer of the ileum, with secondary deposits in the lungs and petrous bone, in which the rectum was healthy.

Mr Pridgin Teale (*British Medical Journal*, July 23, 1870) reports a case of cancer of the femur, with secondary nodules in the lungs. No details of the microscopic examination are given.

Mr T. Holmes (*British Medical Journal*, 1880, vol. ii.) reports, for Dr Lightfoot, a case of malignant sub-periosteal tumour of the femur which was removed by amputation, and the patient recovered. The tumour was examined by a pathologist in Edinburgh and declared to be cancerous.

In the *Glasgow Medical Journal*, vol. xiii., a case is reported in which Mr M'Leod removed a tumour of the humerus, which was examined by Dr Coats and found to be carcinoma. There was also a family history of cancer. In this case also the patient recovered, and thus absolute proof of the primary nature of the disease, by examination of all the epithelial surfaces, was not obtainable, but this may safely be assumed from the clinical features of the case.

Dr Busch (*Berliner Klinisch. Wochenschrift*, 1877, p. 178) records a case of cystic epithelioma of the inferior maxilla, in which there was no affection of the mucous membrane of the mouth. He explained the case by the "atypical" theory, and said that this was the third case of the kind which he had examined.

In the following cases I have not had access to the original papers, and can only quote them from the Year Books, &c.

Schott (*Dissertat.* Giessen, and mentioned in *Virch. Archiv.* vol. xxxiv.) describes three cases of primary cancer in bones, in one of which the cancer was multiple, and after some time secondary nodules were found in the mamma.

Sudhoff (*Dissert.* Erlangen, and reviewed in *Virchow and Hirsch. Jahresbericht*, 1875, vol. ii.) gives a case of cancer in several vertebræ, the spinal cord being free; metastatic tumours

being found in the liver, and in the sternum, and other bones. The tumour resembled glandular cancer.

Witt (*Virchow and Hirsch. Jahresbericht*, 1871, vol. ii.) describes two cases of primary cancer occurring in multiple form in the bones.

Doutrelepont (*Sitzungs. d. Med. Rhein. Gesellschaft, zu Bonn*, 1879, p. 415) reports a case of spontaneous fracture of a femur in which two carcinomatous tumours were found.

Violettes (Montpellier, 1879)—epithelioma of the upper jaw.

Staples (*Minnesota Med. Soc. St Paul*, 1879)—medullary cancer of the humerus.

Allen (*Austral. Med. Journal*, Melbourne, 1880)—cancer of the os innominatum.

Cornil and Ranvier, in their *Text-Book of Pathology*, assert that they have examined many cases of primary bone cancer. Wilks and Moxon also state their belief in its occurrence.

The figures accompanying this paper were drawn by Dr Young, Pathological Registrar of the Manchester Infirmary, whose kindness I wish gratefully to acknowledge.

8

ON A CASE OF CHRONIC LOBAR PNEUMONIA. By
THOMAS HARRIS, *Student of Medicine at the Owens College.*

(From the Pathological Laboratory of the Owens College.)

AMONGST the chronic forms of lung disease those comprised under the term of fibroid phthisis occupy a special class, and present, both clinically and pathologically, special features of their own. A glance at the different treatises and text-books will at once show that under this term several separate affections are included, which have only a few points in common, such as, for instance, the limitation of the process to one side in most cases, the excessive induration and retraction of the lung tissue, the dilatation of the bronchi, and the excessive thickening of the pleura, whilst in the fundamental process which leads to these appearances they differ; thus, whilst some authors apply the term of fibroid phthisis as synonymous with chronic interstitial pneumonia, and separate altogether from phthisis, others include under this head different forms of chronic phthisis (with or without tubercles) having only the considerable fibroid induration of the lung tissue as the common factor.

M. Charcot, in his lectures before the Faculté de Médecine, reported in *Revue Mensuelle*, 1878, attempted to bring some order where, until now, so much confusion prevailed. Seeing with others that we have to do here with the terminal stage of different forms of an inflammatory process, having its starting-point within the lung alveoli, or in the interalveolar tissue, or in the pleura, he includes them all in the class of "chronic pneumonia," of which he distinguishes three groups:—

The Chronic Lobar or Chronic Croupous Pneumonia.

The Chronic Lobular Pneumonia.

The Pleurogenic Phthisis.

As the first of these three forms is of great rarity, I beg to be permitted to report a case which had been under the care of Dr Dreschfeld at the Manchester Infirmary, and to whom I am indebted for considerable assistance in compiling the present paper.

The case clinically presented most of the features of chronic

pleurisy with retraction, whilst pathologically it proved to be a case of chronic lobar pneumonia of the lower left lobe, with subsequent interstitial pneumonia of both upper and lower lobe. The examination of the lungs presented some other points of more than ordinary interest, some of which I may mention at once, namely,—the change of the exudation within the alveoli into fully formed fibrous tissue; the presence of a good deal of interstitial deposit, which caused excessive *contraction* of the larger bronchi instead of dilatation, as is usually the case; and the presence of typical tubercle elements in the affected part of the lung, though to the naked eye this showed neither caseation nor cavitation, and the other healthy lung and the rest of the organs were perfectly free from any tuberculous deposits.

The clinical history of the case is briefly this:—

John T., æt. 65, admitted Jan. 10, 1879, had an acute attack of inflammation of the lung (according to his account) fifteen months before admission, ever since which he had been troubled with cough and expectoration.

The physical examination showed retraction of left side of thorax, with a drawing inwards and downwards of the lower ribs, and a corresponding curvature of the spine (which symptoms, according to Walshe, only occur in pleurisy with retraction); the apex beat of the heart visible in sixth intercostal space in the left axillary line; chest movements of left side were very deficient; percussion of left side gave dulness both in front and behind, except in infraclavicular region, where percussion note was slightly tympanitic; fremitus absent from left side, except in infraclavicular region, where it was increased; breath sounds absent over the whole of the dull region. In the infraclavicular region there was heard tubular breathing, with ægophony on patient speaking.

The right side of the chest showed nothing, but compensative emphysema, together with bronchitis. The sputum was profuse, thick, tenacious, contained neither blood nor elastic fibres. The temperature normal; pulse 60, slightly jerky; all other organs normal.

The case resembled thus in every particular a case of chronic pleurisy with retraction.

The physical symptoms as regards the lungs remained the same.

during the further progress; there was never any hæmoptysis, never any signs of bronchiectasis.

A fortnight after admission there supervened acute pericarditis, giving rise to loud friction sounds, but not to any increase of cardiac dulness, nor was it accompanied by any pyrexia; soon after there came on swelling of the left leg from thrombosis of the left femoral vein; swelling of the left arm also supervened. The œdema gradually subsided, but the general condition of the patient became rapidly worse from an asystolic condition of his heart, and he died on Feb. 16th. Throughout the whole duration of the case the temperature had been normal or subnormal. The urine normal in quantity, of average specific gravity, was always found free from albumin.

The *post-mortem* examination showed, besides the lung affection to be immediately described, adhesions of recent date between heart and pericardium, dilatation of right side of heart, thrombi in left femoral and subclavian veins, infarcts in the spleen, and commencing cirrhosis of the liver.

As regards the lungs, the right was found the seat of bronchitis, emphysema, and congestion of the lower parts, otherwise it showed no changes. The left lung was found retracted, so as to leave the heart, which had been pushed considerably to the left, uncovered to a great extent; the lung was firmly united to both costal pleura and diaphragm, so that it could only be removed with great difficulty. A longitudinal section through the whole lung showed the lower lobe to be one solid, uniform, firm mass devoid of air, its cut surface smooth and not granular, the colour of the section varied; some parts, especially near the periphery, were reddish, others had a greyish appearance, whilst in other places there appeared smaller yellowish spots of softened and altered lung tissue. Firm white fibrous tracts intersected the lung, some of them passing inwards from the thickened pleura which surrounded the lungs; others, and these by far the stronger tracts, surrounding the larger bronchi and blood-vessels, and increasing in thickness towards the hilus, where the main bronchus and the pulmonary vessels were completely encircled by the fibrous tissue; the bronchus being thereby very much diminished in its lumen, so as scarcely to allow a crow quill to pass; the pulmonary artery, besides being

narrowed, had its walls drawn into folds by the surrounding tissue in the fashion of a lady's work basket. The bronchi throughout the lobe had their lumina diminished in size, and everywhere surrounded by firm white fibrous tissue, in which small masses of pigment were seen, otherwise this lobe was singularly free from pigment, and only showed small thin wavy black lines near the smallest bronchi and at the circumference of the lung.

The upper lobe presented a totally different appearance; it was very much diminished in size, could be cut only with great difficulty, and its cut surface consisted of firm, slate-coloured, fibrous masses, separated by irregular cavities filled with detritus; it had much more the appearance of the lung in Corrigan's cirrhosis. Most of its bronchi dilated.

The pleura formed a thick firm capsule of more than $\frac{1}{4}$ inch in thickness surrounding both upper and lower lobe. At the root of the lung were found enlarged, highly pigmented, glands, imbedded in fibrous tissue.

On microscopic examination the upper lobe was found to consist chiefly of fibrous tissue, with excessive masses of granular pigment; in many places no alveolar structure could be made out; in other places, especially near the circumference, a firm, fibrous, thickened, interalveolar tissue was seen surrounding smaller alveolar spaces, and these were filled with flattened epithelium, taking the logwood staining well. But for the pigmented stroma these parts looked very much like an epitheliomatous growth. The change of the lung epithelium to the flattened epithelium, however, is seen in many cases of chronic pneumonia and phthisis, and it has been recently described by many observers (Friedländer, Charcot, Martin). In no part of the upper lobe were there seen any tubercles; the cavities seemed to form irregular ulcers, communicating with bronchi, the detritus which was found in them consisting of granular debris.

The lower lobe, microscopically examined, showed a different and more varied appearance. In many places, especially near the periphery of the lung, were seen patches which showed typical croupous pneumonia, the alveoli still filled with fibrine, small cells, and few red blood corpuscles, the interalveolar tissue, however, thickened and composed of young embryonic

elements. In other parts of the lung the alveolar arrangement had completely disappeared, and was replaced by a more or less fully formed fibrous tissue, with round cellular elements, which took the staining well.

In some parts this uniform fibrous tissue showed a compressed bronchus and artery in its centre, and masses of pigment surrounding these canals, and was, therefore, evidently a chronic peribronchitis; in other parts, however, no such canals could be seen, while, on the other hand, the arrangement of the fibrous tissue resembled more in its outline the lung alveoli. A portion of this young fibrous tissue, no doubt, was nothing more than increased interalveolar tissue; another part, however, seemed to have its origin from within the alveoli, and transitional stages were seen, which showed the correctness of the view, for between the stage of croupous exudation and that of complete organisation, a gradual change from one to another could be observed, different parts showing the various stages of the process of the transformation of the inflammatory products within the alveoli into fibrous tissue. Thus in some regions the alveolar wall was seen somewhat thickened, while within the alveoli existed a mass of cells, chiefly of the round variety, and with these some little fibrine was still perceptible. In other parts, and apparently as a later stage of the same process, the cellular contents of the alveoli become more numerous and closely packed, and, at the same time, their nuclei became distinctly oval, while the fibrine was no longer to be seen.

In many parts the intraalveolar mass could not be distinguished from the alveolar boundary, and its separate origin from this proved, but in others this was most distinct and evident, a fibrillated nucleated tissue being contained within the alveoli, and quite separate and distinguishable from the alveolar wall. The intraalveolar fibrous tissue was found to contain capillaries, and in some places these seemed directly to proceed from the capillaries in the alveolar walls. On comparing the several transitional stages, it seemed more than likely that the exudation cells within the alveoli were chiefly concerned in this organisation, while the endothelial lining cells of the alveoli had little or no share in the process, a view which has also been adopted by other observers (Coupland, Marchand).

The spots, which to the naked eye appeared softer and more friable, were found, microscopically, to have the structure of tubercle, and consisted of a granular, not easily stained, centre, in and immediately around which giant cells, with many nuclei, were visible, and a peripheric part, consisting chiefly of small round cells, closely packed, and easily stained, with a small amount of fibrillar matrix.

These small tuberculous masses were very abundant; they were often seen also in parts, which, to the naked eye, presented no signs of softening. Their relation to the different lung structures could not be made out; they were, however, only found in those parts where the pneumonic process had reached the last stage of organisation, and where the fibrous masses of the latter seemed to pass gradually into the small celled growth at the periphery of the tubercle.

The epitheliomatous appearance described above as seen in the upper lobe was nowhere seen in the lower lobe.

As regards the condition of the bronchi, many sections exhibited large tracts of fibrous tissue, with the lumen of the bronchus in the centre contracted, but not otherwise altered; in the lumen of the larger bronchi, firm plugs were found, consisting of fibrine and granular masses.

It will be seen from the description, that this case, which during life resembled a case of pleurisy with retractions (for there was retraction of the left side of the thorax, drawing in of the lower ribs, displacement of the heart towards the left, and the dulness on percussion, absence of fremitus and of breath sounds owing to the obstruction and contraction of the bronchi), is a case of chronic lobar pneumonia.

The patient's history gives evidence of an acute febrile attack sixteen months before his death, and the examination of the lung shows large tracts yet in a state of red and grey hepatisation. It is not uncommon to find true croupous inflammation in cases of chronic phthisis, never, however, are these found in such large and connected tracts as in this case; we have further to notice that the affection is confined to one lobe, and occupies the whole of that lobe, which could scarcely be the case if the process was any other than lobar pneumonia.

Seeing then that the primary affection was an acute pneumonia,

or rather pleuro-pneumonia, we have here the rare occurrence of the pneumonic intraalveolar exudation undergoing organisation, and becoming fully formed fibrous tissue. This termination is one which has only recently been made the object of closer study; it is noticed by Green, Goodhart, and more recently by Coupland (*Path. Trans.* 1879, p. 224), who describes a case somewhat similar to the one which is the subject of this paper, and in which the same intraalveolar changes could be followed.

Marchand (*Virch. Arch.* vol. lxxxii. p. 317), describes the same changes in several cases of acute croupous pneumonia, and believes, also, that the exudation cells are the elements from which the fibrous tissue is formed, a view which is also held by Coupland (whose paper seems to have escaped Marchand's notice), and to which the appearances seen in the above case give a strong support.

Besides the lobar pneumonia, we have to notice in our case a very considerable amount of interstitial pneumonia, in the form of excessive tracts of fibrous tissue, surrounding the bronchi and blood-vessels, and found also in the interalveolar spaces. Some of these bands proceeded inwards from the pleura, by far the greater portion, however, developed primarily in the interstitial tissue and around the bronchi, where it was found much more abundantly than at the periphery of the lung.

The contraction of the bronchial tubes described above is a most unusual symptom. Charcot had already drawn attention to the fact, that in chronic lobar pneumonia the bronchi are not dilated, and in Coupland's case they were but little dilated. This is, however, not invariably so, as was pointed out by Wilson Fox (*Reynold's Syst. Med.* vol. iii. art. "Ch. Pneumonia"). The absence of dilatation in these cases is probably due to the intra-alveolar deposit, rendering the lung impervious to air, and being in itself, by virtue of its organisation, the cause of the retraction of the lung.

Two other points remain to be noticed, the want of pigmentation and the presence of tubercles in the affected lower lobe. As to the first of these two points, I think it is easily explained when we consider, that from the first the lung alveoli were the seat of an exudation, and that subsequently the bronchi became

contracted; very little pigment could thus reach the alveoli, and still less could be deposited in the interstitial tissue, as it would have to traverse the organised alveolar contents. As for the presence of tubercles, this, no doubt, is a very rare complication. From their position there can be no doubt that they were of later date than the pneumonia, and were implanted upon the fully formed organisation; that they bore some relation to the affected part is shown by their limitation to the pneumonic lobe, the rest of the organism remaining free. As for the upper left lobe its condition is interesting when compared with the lower lobe. It was contracted, consisted simply of firm black fibrous bands, with large irregular cavities, which, in a few places, could be seen connected with bronchi. The bronchi, except near the lower and inner part of the lung, were found dilated. It was thus a typical specimen of chronic interstitial pneumonia, and differed from the lower lobe in the absence of intraalveolar organisation, in the presence of large masses of pigment, in the presence of dilated bronchi, and in the presence of a peculiar epithelium in some of the lung alveoli, a condition which Dr Dreschfeld found in another case of chronic interstitial pneumonia, and which will be the subject of a separate communication.

From the above description, I think it becomes clear that we had here first a pneumonia or pleuro-pneumonia of the lower lobe, and that afterwards both lobes became affected with an interstitial fibrous growth, and a gradual chronic thickening and infiltration of the pleura.

The peculiar physical symptoms seen during life, the dilatation of the right side of the heart, and the formation of thrombi in the veins, are easily explained and require no comment.

23 FEB 1909
9

A CONTRIBUTION TO THE PATHOLOGICAL ANATOMY
OF PRIMARY LATERAL SCLEROSIS (SCLEROSIS
OF THE PYRAMIDAL TRACTS). By J. DRESCHFELD,
M.D., M.R.C.P., *Professor of Pathology, Owens College.*
(PLATE XXVI.).

SEVERAL years have now elapsed since Erb and Charcot described, the former under the head of "Spastic Spinal Paralysis," the latter under the title of "Tabes Dorsal Spasmodique," a special form of chronic spinal disease, chiefly characterised by a gradually progressive paresis (advancing from below upwards), accompanied by muscular rigidity, contractures, and increased tendon reflexes. The clinical features of this group of symptoms, especially the spastic gait, "are so well marked" that the disease is easily recognised, and it was soon found that the spastic spinal paralysis is by no means a rare affection, that it may occur in very young children, and that in some cases it proves amenable to treatment. The clinical symptoms being thus very precise, it became an important question whether they were due to a distinct and idiopathic disease of the spinal cord, or merely the outcome of other and various affections. From the symptoms, both Charcot and Erb believed the disease to be due to a "symmetrical progressive sclerosis of the lateral columns from below upwards, especially in their posterior parts." These theoretical considerations have, however, so far not been verified by the results of the *post-mortem* examinations on cases which, during life, presented more or less the typical symptoms of primary lateral sclerosis, and several observers, notably amongst whom Leyden (*Berl. Klin. Woch.* 1878, No. 48), began to doubt the independent existence of such a disease.

Amongst a number of cases with the typical symptoms of lateral sclerosis, which my friend and colleague Dr Morgan had under his care in the Manchester Infirmary, and some of which he described in the *British Medical Journal*, January 29, 1881, there was one which ended fatally, and where the spinal cord showed such characteristic lesions in support of Charcot and

Erb's views, that I beg to be permitted to describe in detail the lesions found in that case, especially as the short report I appended to Dr Morgan's paper is brief and incomplete.

The clinical history of the case is given by Dr Morgan in his paper already quoted; and it showed paralysis of the lower extremities, with marked contractures, increased tendon reflexes (of both upper and lower extremities), absence of any sensory or trophic disturbances, of any bladder troubles, or any brain symptoms. The patient died from a thrombosis of the femoral vein, followed by pyrexia and septicæmic symptoms.

The *post-mortem* examination, conducted by Mr Hodgson, then resident house physician, showed a soft purulent thrombus in the left femoral vein, small deposits in the lungs, great fluidity of blood, slight ecchymoses on pericardium, enlarged softened spleen, swelling of the solitary follicles and Peyer's patches in the intestines.

The brain, medulla, and spinal cord were examined by me at the time with the necessary care.

The brain and its coverings showed no lesions whatever. The dura mater normal, its veins not immoderately filled with blood. There were a few Pacchionian granulations. The pia mater normal; neither thickened nor abnormally vascular. The brain itself of normal size, colour, and consistence. Numerous sections through the brain displaying the motor area of the cortex, the internal capsule, and the adjacent parts at each side showed no naked-eye changes; the ventricles were not dilated; the peduncles normal. Sections through the pons and medulla showed these parts normal, both as regards consistence, colour, and vascularity.

As regards the spinal cord, its membranes were found of normal thickness and vascularity; no adhesions. The cord itself showed to the naked eye no changes except slight softening in the lowest dorsal region. Sections made through the cord, at small distances from each other, showed to the naked eye no abnormality.

The spinal cord and medulla, with portions of the pons and brain, were put in bichromate solution for microscopic examination; when sufficiently hard, sections through the cord showed already to the naked eye one light-coloured patch in each lateral column; this patch was particularly well marked in the

dorsal region, and became less marked in the cervical and lumbar regions.

The microscopic examination of sections stained in carmine showed again the portions of brain and medulla which were examined to be free from any changes, with the exception of the anterior pyramid in the lowest portion of the medulla, which showed an increase of the neuroglia and the presence of a great many Deiter's cells. Some of the axis cylinders swollen and some atrophied.

The upper cervical, and some of the region of the cervical enlargement, showed a small sclerotic patch close to the posterior horns, extending forward, but not reaching the anterior horns, and extending but little outward in each lateral column. The direct pyramidal tract in each half at this region took the staining better than the rest of the anterior column, and showed an increase of the neuroglia.

The lesion in the lateral columns became much more pronounced in the lower portion of the cervical enlargement. Here the sclerotic patch occupied almost entirely the lateral pyramidal tract, and also the direct pyramidal tract on each side (see fig. 1). In the lateral tract the sclerotic patch was in close relation to the posterior horn; receding from it as it passed forward anteriorly it did not extend to the anterior grey matter, and externally it did not reach the external border of the white matter. The direct cerebellar fibres were therefore perfectly free from disease, so were the posterior columns; Burdach's as well as Goll's tract. As for the grey matter no pathological lesion could be detected in this part of the spinal cord either in the anterior or posterior horns.

In the upper dorsal region the lesions were the same. The large motor ganglia cells showed perhaps some more pigment than is ordinarily found; some of the cells also seemed separated from their processes, and the central group of cells had fewer cells than is usually found here. But beyond these changes no further lesions could be observed in the grey matter. As for the sclerosis in the pyramidal tracts, it occupied exactly the same position as in the cervical, but extended a little further laterally in the lateral columns. The sclerotic patch in the left lateral column extended somewhat further outward than

in the right (during life the left leg was found to be more affected than the right).

In the lower dorsal region, whilst the lesions in the lateral columns were very pronounced, and occupied the same extent as in the upper dorsal, the sclerosis of the direct pyramidal fibres was still indicated by increase in Deiter's cells and neuroglia generally. The grey matter showed here marked atrophy and pigmentation of some of the cells of the central and antero-lateral groups, whilst the internal group and the postero-lateral group, and also the cells in the vesicular column of Clarke were normal (see fig. 2).

In the softened part of the cord which occupied the lower and part of the lowest dorsal region the cord was a little out of shape, the anterior horns being pushed slightly backwards and outwards, and thus causing the posterior horns and the lateral columns to assume a slightly crescentic form on each side. Microscopically it is clearly seen that this appearance is simply due to pressure and not due to any disease, for the sclerotic patches in each lateral column appear with great distinctness, whilst the rest of the white matter is normal, and the grey matter presents the same changes of the cells as in the dorsal region just described.

In the lumbar region the sclerosis occupied a triangular patch, bounded internally again by the posterior horn and deviating a little from it as it passed forward, whilst externally it came up close to the periphery to the cord; it did not reach so far anteriorly as in the dorsal or cervical region. No other part of the white matter was affected. As for the grey matter, the internal group, the postero-lateral group, and the vesicular column of Clarke were normal. The rest of the cell groups were in some places scarcely visible, in other parts they were found, but while some were still normal, and showed their processes, others were atrophied, shrunk, without nuclei, often highly pigmented (fig. 3). The neuroglia of the grey substance in the regions where the ganglia cells were found affected showed the presence of a quantity of granular matter. The blood-vessels, however, were not found affected.

The sclerotic portion in the lateral columns, when examined with a high power, showed engorgement of the blood-vessels,

increased thickness of their walls, and perivascular deposits of small cells. The neuroglia showed excessive increase of Deiter's cells, numerous oval and round nuclei, which took the staining well, and a quantity of fine fibrillæ. The nerve fibres had in some places quite disappeared, in other places they were simply reduced to axis cylinders, which were either atrophied or hypertrophied. In the anterior pyramidal tract, throughout the cord, the lesions were of less intense character, the blood-vessels especially showing no change. In those parts of the cervical region where the lesions were so very limited, the changes were equally confined to the neuroglia, the nerve fibres showing few changes beyond a swelling of their axis cylinders.

From the above description it will be seen that we had here to do with a distinct systemic lesion affecting the whole of the pyramidal tract in the lumbar and dorsal and lowest cervical region, and part of the pyramidal tract in the upper cervical regions, extending slightly into the anterior pyramids of the medulla. Beyond an atrophy of the ganglia cells in certain groups of cells in the anterior horns in the lumbar and lower dorsal regions, the rest of the cord was found perfectly normal. As for the changes in the ganglia cells, I cannot help looking upon these as secondary to the sclerosis of the pyramidal tract, for they are absent in those parts of the cord where the sclerosis is in a less advanced stage; there is also the absence of any alteration in the blood-vessels in the grey matter, which would scarcely be missed, if the disease originated primarily in the grey matter—a fact which I again recently had occasion to notice in a case of amyotrophic lateral sclerosis which had been under the care of my colleague Dr Leech; further, the appearance of the affected cells themselves, showing nearly all the different degrees of atrophy, and lastly, the distribution of the atrophy. It will be seen that the cell groups which remain intact are the internal and postero-lateral groups, while the central and antero-lateral groups were found affected. Now, in those cases of old hemiplegia with contractures, in which, after years, the ganglia cells in that half of the cord which is the seat of the descending sclerosis undergo atrophy, the distribution seems, according to Pitres (*Arch. de Phip. Norm. et Path.* 1876, p. 664) and Brissaud (*Récherches sur la Contracture*, p. 179)

somewhat similar—in Brissaud's case the postero-lateral group was also much affected—and there can be no doubt that in those cases the affection of the ganglia cells is purely secondary to the sclerosis.

It will be argued that in cases of cerebral hemiplegia with contractures the changes in the ganglia cells appear only very late in the course of the paralysis, and are associated with muscular atrophy and diminution in the rigidity of the paralysed limb. It must, however, be considered that in those cases the affection of the pyramidal tract is itself only a secondary degeneration, and follows soon after the onset of the primary lesion, while in the above case the sclerosis of the lateral columns is the primary disease, and therefore most likely, as such, sooner followed by secondary degeneration in the grey matter than in hemiplegic cases. If, in the above case, there was no atrophy of the muscles noticed during life, and no diminution in the rigidity of the limbs, the explanation may be found in the fact that the atrophy of the cells had, after all, not reached a very considerable degree; and many a normal ganglion cell was found amongst a group of atrophied ones. Nor is it at all a generally established fact that the resolution in the contracted limb and the atrophy of the ganglia cells go hand in hand. In the case of amyotrophic sclerosis above alluded to the contractures persisted to the end, and the corresponding regions of the cord showed most marked and most extensive lesions in the ganglia cells of the anterior horns. In further support of the view I have taken, I can cite a case of transverse myelitis of the dorsal region, with secondary descending sclerosis in the lower dorsal and lumbar region, and where, besides the lateral pyramidal tracts, the anterior grey matter was also affected, and affected in a degree similar to the above case.

If, lastly, we compare the appearance of the anterior horns in this case with the appearances seen in cases of undoubted primary disease of the grey matter, such as infantile paralysis, amyotrophic lateral sclerosis, we see most marked differences; or in those affections whole groups of cells have disappeared, the neuroglia shows marked alterations, and the blood-vessels engorged and thickened; none of these changes are seen here.

That the affection in our case is not only "systemic," but also progressive from below upwards, is seen on comparing and following upwards the lesion in the several regions of the spinal cord. Though, during life, the upper extremities showed nothing abnormal, beyond increased tendon reflexes, there are found after death distinct signs of sclerosis, though very limited, occupying the pyramidal tracts in the cervical region. Now, in three cases which I have lately had under observation, all of which seemed typical examples of spastic spinal paralysis, as yet in an early stage, the patients were not conscious of any affection of their upper limbs, nor seemed there to be any loss of power or rigidity in the arms, and yet, in all three cases the tendon reflexes in the wrist, forearm, and arm, were markedly increased; and the presence of this symptom seems to me to be of some importance from a diagnostic point of view, and may still further assist us to distinguish the *primary sclerosis of the pyramidal tract*—as the disease may, I think, now rightly be called—from other nervous affections, which may for a time present similar symptoms but be due to a variety of lesions, all, however, having perhaps this in common, that the pyramidal tract in some portion of its course is implicated either directly or indirectly by the lesion.

In conclusion, I beg to thank my friend, Mr A. H. Young, for the drawings which accompany this paper, which were made from specimens submitted to him, and which show at a glance, and correctly, the lesions observed in this case.

A P P E N D I X.

The object of the foregoing paper was simply to record the lesions of a case of primary lateral sclerosis, and to show that the group of symptoms observed in our case was due to an idiopathic symmetrical sclerosis of the pyramidal tracts of the spinal cord, wherefore I have proposed to call the affection "primary sclerosis of the pyramidal tracts." It may be not uninteresting briefly to refer to the other cases on record in which the diagnosis during life was not verified by the *post-mortem* appearances. Without entering at all into a discussion of the clinical features of the disease as foreign to the purposes for which this journal was established, it will be readily seen that many varied affections of both brain and spinal cord may give rise to some of the symptoms of this disease, especially to the "spastic gait," but that the onset and the course of the disease, and the presence of other

symptoms on the careful analysis of the case, may assist much in our differential diagnosis.

The first *post-mortem* account of a reputed case of primary lateral sclerosis we owe to Charcot (Bétau, *Etude sur le tabes dorsal spasmodique*, Paris, 1876). The case turned out to be a case of disseminated sclerosis. It is, however, remarked by Charcot (*Leçons sur les localisations*, 2^m fasc. p. 369) that in this case there were present besides the characteristic symptoms also vertigo and tremors, which, taken into account in a second case observed by Charcot, enabled him during life rightly to diagnose disseminated sclerosis, which diagnosis was confirmed after death.

The second case is reported by von Stofella (*Wien. Med. Wochensch.* 1878, Nos. 21, 22, 24). The affection is here stated to occupy the two lateral columns in their posterior portion, in the dorsal and lumbar regions, extending laterally from the posterior horns to the pia mater. The spinal cord was not examined microscopically, and no mention is made of the condition of the brain and medulla. It is thus doubtful whether the case was one of primary lateral sclerosis.

Schulz (*Deutsch. Arch. f. Klin. Med.* vol. xxiii. p. 346) gives the *post-mortem* examination of two cases, the clinical history of which are contained in *Arch. f. Heilk.*, vol. xviii.

In the first case a gliomatous tumor was found in the medulla, extending into the anterior pyramids. The spinal cord showed typical lateral sclerosis a little more extensive on the right than on the left side. The rest of the white matter and the grey matter was in a normal condition. In this case the sclerosis was secondary and not primary, and the symptoms, as relating to the cord observed during life, in harmony with the lesion found. Much more remarkable is the absence of any bulbar paralysis as the tumor reached up to the calamus scriptorius.

In the second case the spastic symptoms were only of short duration. Symptoms pointing to a cerebral tumor at the base of the brain came on. A small sarcomatous tumor was found between the pons and the crus cerebelli ad pontem. There was besides distension of the ventricles of the brain. The spinal cord showed no changes. The case merely shows that spastic symptoms may be present in brain-affections. The presence of cerebral symptoms in most cases would, however, prevent an error in the diagnosis.

Schulz gives a third case. The symptoms commenced here in both upper and lower extremities at the same time; there was also vertigo present. The *post-mortem* examination showed the presence of chronic hydrocephalus, the spinal cord showed no changes. In a more recent paper (*Centrbl. f. Nerven.* 1880, p. 376), Schulz expresses the opinion that the hydrocephalus caused irritation of the lateral tracts.

Hallopeau (*Des paralyses bulbaires*, Paris, 1875), describes a case where *post-mortem* a tumor was found in the medulla and secondary degeneration of the lateral columns of the cord.

Strümpell (*Arch. f. Psychiatrie*, vol. x. p. 676) gives the account of two cases.

In the first case the spastic symptoms were very marked. There was, however, present retention of urine and hyperæsthesia of the lower extremities. The *post-mortem* examination showed the case to be one of myelitis of the upper dorsal region, with secondary degenerations extending both upwards and downwards, including also the direct cerebellar tracts which were found affected both above and below the seat of lesion.

The second case ran much more the course of lateral sclerosis. The autopsy showed sclerosis of the lateral pyramidal tracts and of the direct cerebellar tracts, caused probably by a hydromyelus which was found to extend throughout the spinal cord.

A. Friedenreich (*Centrbl. f. Nervenl.* 1880, p. 213), a case, where, besides the spastic symptoms, there were symptoms relating to the brain and medulla. The brain showed numerous blood points, the medulla and spinal cord showed multiple patches of sclerosis with hypertrophy of the neuroglia, whilst in other places the parts were softened with complete destruction of the nervous tissue. The patches had a very irregular distribution.

Schulz (*Centralbl. f. Nervenl.* 1880, p. 369) gives additional two cases. In the first there were, besides the symptoms of spastic paralysis, disturbances of sensibility and affection of the bladder. The autopsy showed the case to be due to a myelitis caused by pachymeningitis. To the naked eye there seemed to be no degeneration of the lateral tracts. No microscopic examination was made.

In the second case there was also considerable loss of sensibility, which went on to complete insensibility in the lower extremities. The case was one of transverse myelitis with secondary combined sclerosis of the lateral and posterior columns.

Aufrecht (*Deutsch. Med. Woch.* No. 18, 1880). I have only had access to the review of Aufrecht's case in the *Centralbl. f. Nervenl.*, p. 239. According to this account the symptoms were not quite typical at the onset, though during the course of the disease they were better developed. There was complete paralysis with contractures and increased tendon reflexes. Towards the close of life, bladder and rectum became paralysed and the tendon reflexes disappeared. The *post-mortem* examination showed changes in the lateral columns in the lumbar and dorsal regions. The ganglia cells in the anterior horns were profoundly affected.

A review of the above given cases shows that where the spastic symptoms are observed we may infer that the pyramidal tracts are involved. That these symptoms may remain the chief symptoms for some time, but that when the affection involves other tracts, some new group of symptoms appear, such as disturbances of sensibility, affection of the bladder, &c. The cases given only show that primary sclerosis of the pyramidal tracts is a much rarer affection than was at first supposed; but that it does exist as an independent disease has, I think, been proved by our own case.



10

THE FORM AND PROPORTIONS OF A FŒTAL INDIAN ELEPHANT. By Professor TURNER, M.B., F.R.S. (Plate XXVII).

IN the stores of the Anatomical Museum of the University of Edinburgh is the fœtus of an Indian elephant, which was acquired many years ago from the late Mr John Arthur. No history is attached to the specimen. As several anatomists have of late years investigated the anatomy of this animal, and as this *Journal* has been the means of communicating several of these investigations, a figure of this specimen, with some account of its form and proportions, may be of interest to our readers. Albert Seda did, indeed, before the middle of the last century, figure¹ and give a short description of the fœtus of the African elephant, but, so far as I know, that of the Indian elephant has not previously been figured.

The abdominal and pelvic viscera, together with the lumbar and sacral spine, had unfortunately been removed by an incision made along the dorsal mesial line, so that the shape of the posterior part of the body was affected. The umbilicus had been torn off, but the sheath of the penis was preserved. The head, anterior part of the trunk, and anterior and posterior limbs, were in good order.

The following dimensions were taken :—

From base of trunk along curve of back	
to hinder end of body, . . .	21½ inches.
Length of trunk, . . .	8 „
Length of lower lip, . . .	2¾ „
Height at shoulder, . . .	15½ „
Circumference of fore foot, . . .	5 „
Length of eye slit, . . .	½ inch.

The circumference of the foot was only about one-third of the height of the animal at this stage of development, and not one-half, as is stated to be the rule in the well-grown elephant.

¹ Locupletissimi rerum naturalium Thesauri accurata descriptio, vol. i. tab. cxi. fig. 1, Amstel. 1734.

The fore arm was slightly flexed on the upper arm, and the fore foot was somewhat flexed on the fore arm, and it was not possible fully to extend the fore limb. The hind foot was flexed slightly forwards, so that the heel was prominent.

The cuticle was dark brown, and where it was shed the cutis had a dull yellowish tint. The general surface of the skin was without hairs, but short delicate hairs were present in the following localities:—the outer surface of the lower lip; the skin of the trunk, especially about and within the nostrils; the external auditory meatus; and the upper border of the tragus.

The auricle of the ear was $3\frac{3}{4}$ inches high, and $3\frac{5}{8}$ inches in antero-posterior diameter. It was thin and flattened, especially at the edges, and triangular or spear-shaped, with the apex directed backwards to the shoulder. The meatus was no larger than would admit a small catheter, and was guarded in front by a large tragus.

There were no eyebrows, and the lids were without eyelashes. A large third eyelid was present.

The surface of the trunk was marked by transverse constrictions. The median process at the free end of the trunk was distinct. The columella was situated $\frac{1}{4}$ inch within the orifice.

The cheeks were distensible. The lower lip was prolonged forwards to a point in front of the mandible. The upper lip was not quite so well developed as the lower, but was prolonged forwards to the base of the trunk. The mucous surface of the palate was traversed by feeble transverse ridges, and the free surface of the membrane between these ridges was thickly studded with short papillæ. The inner surface of the cheek was also papillated, especially in a line parallel and close to the upper and lower gums. In the presence of ridges on the palate, and of papillæ on both cheeks and palate, this animal differed from the African elephant described by Mr W. A. Forbes. The orifice of the parotid duct was seen on the inner surface of the cheek. The gums were smooth, and not perforated by the teeth.

The tongue was pointed in front, and could be drawn forwards as far as the pointed tip of the lower lip. $1\frac{1}{8}$ inch of the tongue was situated in front of the frænum linguæ. Numerous papillæ were scattered over the dorsum of the tongue, and at its posterior

parts two well-developed circumvallate papillæ were at each side of the mesial line. At each margin of the tongue several short transversely arranged slit-like furrows of the mucous membrane were seen, resembling the arrangement described by Mayer¹ in the Indian, and by W. A. Forbes² in the African elephant. The folds of mucous membrane between these furrows were not unlike in their position, but shorter than, the so-called papillæ foliatæ, so well seen in the tongue of the rabbit, or in the human tongue in front of the attachment of the palato-glossal fold of mucous membrane. As the papillæ foliatæ in the human and rabbit's tongue contain the gustatory bulbs, and are associated with the sense of taste, for which reason I have named them gustatory lamellæ,³ it is not improbable that if these folds in the elephant's tongue were examined microscopically in a fresh specimen, gustatory bodies would be discovered in them. The mucous membrane of each fold between the furrows had one or two sharp papillæ projecting from it, and a distinct series of similar papillæ was prolonged forwards towards the tip of the tongue in a line with the furrows.

A single large leaf-like papilla projected from each side of the frænum linguæ, where it was attached to the under surface of the tongue. It is probable they were connected with the mouths of the ducts of Wharton, although I did not detect the orifices.

A pair of very small foramina, admitting only a very fine probe, opened at the anterior border of the mucous membrane, covering the hard palate. These were Jacobson's canals, and on pressing the mucous membrane a little fluid oozed out through these openings. Where each upper lip became continuous with the gum covering the pre-maxillary bone a row of five small openings was seen. Each led into a shallow cul-de-sac, and was probably the orifice of a mucous follicle.

The posterior buccal orifice was almost circular, and only $\frac{4}{10}$ ths inch in diameter. There was no uvula.

Five nails were developed on each fore foot, but only four on the hind foot, for the rudimentary great toe had no nail.

¹ *Nov. Act. Akad. Cæs. Leop.* xxii. 1847.

² *Proc. Zool. Soc. Lond.* May 6, 1879.

³ *Introduction to Human Anatomy*, part i. 1875.

Mr Carse, in his interesting memoir on the *Manners, Habits, and Natural History of the Elephant*,¹ states that the young animal at the time of birth seldom exceeds 34 inches in height, though on one occasion a young male stood 35½ inches high. The young animal, a female, recently described by Dr Chapman,² was 30 inches high when born, and measured from the base of the trunk to the root of the tail 35 inches. From these measurements it would seem that the specimen described in this communication was only about a half-grown foetus.

For the drawing from which the lithographic plate has been reduced I am indebted to my assistant, Arthur Thomson, M.B.

¹ *Philosophical Transactions*, 1799.

² *Journal of Acad. Nat. Sciences of Philadelphia*, viii. 1880.

11

28 FEB 1

THE FEMORAL ARTERY IN APES. By J. MACDONALD
BROWN, M.B., *Demonstrator of Anatomy, The Owens College
Manchester.*

ABOUT a year ago, through the kindness of Professor Morrison Watson, I had an opportunity afforded me of making a careful dissection of a female chimpanzee (*Anthropopithecus troglodytes*). While pursuing my investigation I was much struck by the peculiar distribution of the arteries to the leg and foot, as well as by the extreme scantiness of the literature on the subject. I therefore resolved to endeavour to ascertain as far as possible what condition existed in the rest of the quadrumana. During the past winter session I have dissected five different species, viz., *Cercopithecus Campbelli*, Waterh.; the white-crowned mangabey (*Cercocebus Æthiops*, Linn.); the dog-faced baboon (*Cynocephalus porcarius*, Bodd.); the sphinx-monkey (*Cynocephalus Sphinx*, Linn.); and the common drill (*Cynocephalus leucophæus*, Desm.). Of the first and last named monkeys I dissected two, and in all of them, to insure accuracy of detail, both legs were examined, but the differences noted were so trivial as to render it unnecessary that they should be mentioned. In order to obtain a fine injection, a mixture of size and vermilion was employed.

It is my intention in this paper to give a brief account of the distribution of the femoral artery and its branches in these monkeys, to note the condition of the arteries in the anthropoids, and to compare these with each other.

The arrangement of the apes is in accordance with the classification adopted by the Zoological Society of London in their "List of Animals."

With regard to the literature of the subject in addition to original memoirs, I have consulted the systematic works on comparative anatomy of Cuvier, Stannius, Meckel, Carus, Owen, Huxley, Vrolik, Wagner, &c., &c.; but in none of the latter, with the exception of Meckel, did I find more than the most general statements about the arteries. It seemed to me, therefore, that a brief but systematic account of the femoral artery, and the modifications which it undergoes in these

monkeys, might, if recorded, prove of some interest. To the memoirs, as well as to Meckel's observations, I shall have occasion to refer to subsequently.

I. *Cercopithecus Campbelli*, Waterh. (Campbell's Monkey).—In this monkey the femoral artery resembled very closely that of man, both as regards its relations and distribution. The profunda was somewhat rudimentary, but gave off both circumflex arteries, and, winding as in man behind the femoral trunk, supplied two perforating branches. The highest perforating artery was derived from the internal circumflex. About the middle of the thigh the femoral divided into two trunks, of which the outer—which was also the larger—passed between the insertions of the adductores magnus and longus, while the inner one occupied the usual position of the anastomotic in the human subject. This latter, which might be named the “great saphenous artery,” gave off in the thigh a few muscular twigs, and an articular branch to the knee-joint in the same position as, but relatively smaller than, that in man. The artery then passed downwards, lying upon the insertion of the gracilis, the inner head of the gastrocnemius, and for a short distance upon the origin of the flexor longus digitorum. In the above course it lay along the posterior border of the sartorius muscle, and was accompanied by the long saphenous nerve. It then crossed the shin obliquely, and divided upon it into two branches, an external and an internal. Just above this bifurcation it gave off a slender branch, which ran downwards along the posterior border of the bone, and ended over the inner ankle in small anastomotic branches. This branch, we shall find, is the representative of the posterior saphenous artery in other apes, *e.g.*, the baboon. The internal artery passed downwards towards the dorsum pedis, lying upon the tibia, and in front of the ankle-joint and anterior annular ligament. It supplied the hallux and first interspace. The more external division, which was the larger, crossed the tibia, and lay in front of the ankle-joint but beneath the annular ligament. In the dorsum it divided into two branches, the larger of which ran forwards in the second interspace and entered the sole. Between it and the lesser branch an arch was formed, from which branches to $3\frac{1}{2}$ toes were supplied.

About 1 inch above the ankle the artery gave off an anastomotic branch to the anterior peroneal.

The popliteal divided as in man into the anterior and posterior tibial trunks.

The *Anterior Tibial* was very small indeed, and ended by anastomosing with arteries at the ankle. Having given off an articular to the knee it supplied the tibial and fibular muscles mainly by two branches.

The *Posterior Tibial* was much as in man. The peroneal had the ordinary distribution. In the sole, however, the plantar trunks derived from the posterior tibial were extremely small, the arch being principally formed by the perforating saphenous. The digital and perforating branches call for no remark.

II. *White Crowned Mangabey* (*Cercocebus Ethiops*, Linn.).—In its dissection the first peculiarity worthy of remark was that the circumflex arteries came off from the femoral trunk, otherwise they were much as in man. There was no profunda femoris, but the perforating arteries (three in number) were derived, the superior from the internal circumflex, the lower two from the femoral. The latter vessel divided, as in the cercopithique, into two trunks, of which the external one (great saphenous) was somewhat smaller than the other. Rather above the middle of the leg the great saphenous bifurcated into two branches, anterior and posterior. The posterior was the smaller of the two, and passed downwards, lying upon the flexor digitorum longus, then entered the superficial aspect of sole running behind the internal maleolus. There it gave off numerous calcanean and anastomotic twigs, and divided just behind the tarso-metatarsal articulation into two branches, external and internal. These supplied the skin richly, and anastomosed anteriorly with deeper arteries.

The *Anterior Saphenous Artery* ran obliquely across the shin, and very soon divided into two branches while yet on its surface. The more internal of these in its course lay upon the tibia, and crossed the front of the ankle-joint, lying beneath the anterior annular ligament, then upon the tarsus and tendon of the tibialis anticus muscle, being crossed by the innermost belly of the extensor brevis digitorum, which was so distinct from the

rest of the muscle as almost to appear a separate one. The artery then ran in the second interspace (upon the dorsal interosseous muscle), and leaving it about the anterior third passed through to the sole. In its course it supplied the inner aspect of the foot, and by two large branches the first and second interspaces. In the sole it formed the plantar arch by anastomosing on the outer side of the foot with the external superficial plantar artery already referred to. In addition, it received communicating branches from dorsal arteries. From the convexity of the arch were given off three branches, which were distributed as in man to the outer $3\frac{1}{2}$ toes. The hallux and half of the second toe were mainly supplied by the dorsal artery.

The external branch in its course lay upon the tibia, and in front of the ankle-joint, then in the furrow of the astragalus. It ran to the outer aspect of the tarsus, being crossed by the tendon of the tibialis anticus muscle. After having given off articular, malleolar (both sides of foot), and tarsal branches, it divided into two over the base of the 4th metatarsal bone, which arteries supplied the outer two interspaces. Just above the inferior tibio-fibular articulation it gave off a branch, which, running outwards, anastomosed with the anterior perforating from the posterior tibial artery.

The *Anterior Tibial* was of a fair size. It gave off a recurrent articular (as in man), also muscular branches, and then about the upper third of the leg divided into two trunks, which ran downwards towards the ankle. These were simply muscular, but anastomosed with branches about the ankle, as well as with several twigs from the posterior tibial, which perforated the interosseous membrane at various parts.

The *Posterior Tibial* was relatively a large artery with a distribution and course very similar to that found in man. It terminated, however, in small branches about the ankle, and was not prolonged into the sole. In its course it gave off several twigs which pierced the membrane, and anastomosed as above described. Its peroneal branch was as in man, except that it was smaller than usual. It gave off perforating and malleolar branches.

III. *Dog-Faced Baboon* (*Cynocephalus porcarius*, Bodd.).—

The description of the femoral artery in the mangabey would almost serve for that in the baboon, and indeed for the other monkeys yet to be described. So that I shall content myself with enumerating the salient points, and contrasting any little differences which may exist.

The femoral artery gave off no profunda trunk. The circumflex arteries, external and internal, arose from the femoral itself. The perforating branches were three in number, and were derived, as in the mangabey, from the internal circumflex and femoral arteries.

The *Great Saphenous* artery equalled in size the continuation of the femoral trunk. It gave off branches to the vasti muscles and a large anterior articular one. While crossing the insertion of the semitendinosus it divided into two branches, the anterior and posterior saphenous arteries.

The *Posterior Saphenous* was the lesser of the two, and ran along the posterior border of the shin, lying upon the soleus and flexor longus digitorum muscles. After having given off numerous twigs to the internal malleolus, it passed beneath the internal annular ligament and entered the sole. As it did so it was crossed by the muscles from the calcaneum to the hallux. It then gave off tarsal and metatarsal branches, and divided into external and internal plantar arteries. These were, however, very small, and anastomosed with branches from the plantar arch. The internal plantar supplied both sides of the hallux and the inner aspect of the second toe.

The *Anterior Saphenous* artery had a similar course and relations to that described in the mangabey. In its passage towards the ankle it was crossed by the two tibiales antici and by the extensor longus hallucis muscles. About 2 inches above the ankle-joint it gave off a large branch, which ran almost transversely outwards and after supplying malleolar and articular branches anastomosed with the anterior peroneal. The artery continued forwards beneath the anterior annular ligament, and gave off two large branches, one on either side, just after it had emerged from under the annular ligament. The main trunk was continued forwards in the second interspace as in the mangabey. The external branch supplied malleolar and tarsal twigs, and ended in branches to both sides of the fourth

and fifth, and to the outer aspect of the third toe. The internal artery supplied both sides of the hallux and the inner aspect of the second toe. The remaining branches for the supply of the dorsal aspect of the toes were derived from the main trunk just before it left the dorsum pedis. The plantar arch was formed in a most curious manner. Two large arteries perforated the second interspace (of which the anterior was the larger), the one just at its posterior limit, the other in the usual position. The posterior one ran almost transversely outwards across the metatarsal bases to the outer aspect of the sole, then forwards, and united with the anterior branch, thus forming the arch, which lay just behind the heads of the metatarsal bones. A small branch connected the two perforating arteries immediately after they had entered the sole, so that in the present case an arterial circle existed. As in the mangabey, the arch supplied branches to $3\frac{1}{2}$ toes, the hallux and inner half of the second digit mainly receiving blood-supply from the dorsal branches.

The *Anterior Tibial* artery had similar relations and disposition to those in the mangabey. Its muscular branches were more extensive and numerous. It terminated on the anterior aspect of the ankle-joint by anastomosing with the anterior saphenous artery. One or two twigs from it could be traced to the joint itself.

The *Posterior Tibial* had the usual relations, and supplied the same arteries as in the human subject. The only differences which existed seemed to be that its muscular branches were larger, and that the peroneal artery came off at a lower level and was relatively small. The peroneal gave off no anterior branch, and its communicating one was of diminutive size. The posterior tibial artery terminated by piercing the interosseous membrane in the position usually occupied by the anterior peroneal, and none of its branches could be traced into the sole. A very extensive anastomosis existed at the back of the ankle-joint and over the malleoli.

IV. *Sphinx Monkey* (*Cynocephalus Sphinx*, Linn.)—The femoral artery was much as described in the preceding apes. There was no profunda femoris, its place being taken by branches from the main trunk as in the former cases.

The *Great Saphenous* was almost precisely as in the last monkey. Its posterior division was identical in relations, &c. with that of the mangabey, except that about 1 inch above the ankle it gave off a branch, which, running outwards on the posterior aspect of tibia, took the place of the anterior peroneal. The *Anterior Saphenous* had the same relations and branches as in the cercopithique. Its internal division supplied the first interspace and pierced the sole, anastomosing there with the plantar arch. The external artery gave off an anastomotic above the ankle, and was distributed to the dorsum as in Campbell's monkey. It entered the sole through the second interosseous space.

The *Anterior Tibial* supplied articular and muscular branches, but could not be traced as far as the ankle. It anastomosed freely, however, with two branches from the posterior tibial, which pierced the interosseous membrane at varying heights.

The *Posterior Tibial* was relatively small. It seemed to be like the last, chiefly a muscular trunk. There was no distinct peroneal, properly so called, but its fibular branches much exceeded its tibial ones in size. The artery terminated near the ankle by anastomosing with the perforating saphenous.

The plantar arch was formed by that artery which, coming through the second interspace, anastomosed with the external plantar from the posterior saphenous artery. The digital and other remaining branches were as in the mangabey and baboon.

V. Common Drill (*Cynocephalus Leucophæus*, Desm.).—The femoral was distributed as in the last case, there being no profunda artery.

The *Great Saphenous* was as in the baboon and sphinx. Its posterior division had the usual course, and ended in small anastomotic branches about the inner ankle. The anterior saphenous artery did not divide into two trunks in the leg as was the case in the cercopithique, mangabey, and sphinx; but, as in the baboon, was a single unbranched trunk giving off only small muscular twigs, and an anastomotic branch to join that from the posterior tibial. Several small branches were distributed to the tarsus and metatarsus, &c., then the artery entered the sole through the second interspace, in which also it gave off a pos-

terior perforating, so that really it communicated with the plantar arteries by two channels.

The *Anterior Tibial* was a small vessel, which, after piercing the membrane, gave off several ascending and articular arteries, and divided then into two trunks, external and internal, both of which were distributed to the muscles. One branch from its internal part seemed to anastomose with the anterior saphenous. As in the sphinx, several branches from the posterior tibial pierced the interosseous membrane at various points, and inosculated with branches from the anterior.

The *Posterior Tibial* was much as in man, except that the plantar arteries were relatively small. There was no distinct peroneal artery, but as in the baboon the anterior peroneal came from the posterior tibial itself.

VI. *Spider Monkey (Ateles)*.—Professor Humphry¹ describes the anastomotic artery in *ateles* as dividing into three branches. Of these, one took the place of the anterior tibial and supplied the foot, a second supplied the hallux, and the third replaced the posterior tibial in lower part, and supplied the plantar arteries. The posterior tibial itself was small, and terminated at the outer ankle.

I propose now to describe the arterial supply of the posterior extremity in the anthropoids (*Simiidae*). Of these I have only dissected the chimpanzee, so that for my description of the femoral artery in the gorilla, orang, and gibbon, I must refer to the accounts given by other anatomists.

(I.) *Gorilla (Trogodytes gorilla)*.—Dr Chapman of Philadelphia² states that "the only peculiarity about the vessels of the lower extremity, was that of the femoral artery giving off in the middle of its course a good-sized vessel, which accompanied the long saphenous nerve, and ran to the inner aspect of the foot."

He considers it possible that the condition might have been an anomalous one, but that it existed on both sides. He proposes to call it the "long saphenous artery." The plantar arteries were as in man.

¹ *Journ. of Anat. and Phys.* vol. i.

² *Proc. Ac. Nat. Sci. Phil.* part iii. pp. 391, 392, 1878.

The above is the only account of the femoral trunk in the gorilla which I have been able to find.

(II.) *Chimpanzee* (*Anthropopithecus troglodytes*, Gm.)—As previously stated, I made a careful dissection, about a year ago, of a female chimpanzee. In it the femoral trunk was very similar to that in man. The profunda was present, although somewhat small, and gave off the circumflexes and perforating branches just as in man. About an inch above the opening in the adductor magnus the femoral gave off a large trunk, which, running at first almost in the same axis as the main artery, afterwards wound round to the front of the tibia. Above the knee it supplied articular and muscular branches, but until it had entered the dorsum pedis it was unbranched. It crossed the tendons of the tibialis anticus, extensor longus hallucis, and the inner one of the extensor brevis, and disappeared between the two heads of the first dorsal interosseous muscle.

The *Anterior Tibial* was as in man until it reached the ankle, when, instead of running forwards as the dorsalis pedis, it divided into two branches. Of these, the external supplied the tarsus and metatarsus, while the internal split into two parts, of which one passed round into the sole, the other anastomosed with the saphenous artery.

The *Posterior Tibial* was as in man, except that relatively it was rather smaller. In the sole, the saphenous divided into two parts, one running forwards to supply the inner toes and internal aspect of the foot, the other, passing backwards and outwards, formed, with the external plantar artery, the plantar arch, from which branches to the outer toes were given off. Humphry states¹ that in his chimpanzee, on the right side, the anastomotic supplied only the interval between the hallux and index, the rest of the lower part of the limb being supplied by the posterior tibial, which, in its course, gave off perforating branches to the muscles in front. On the left side the artery was small, and did not extend beyond the middle of the leg, the last perforating branch of the posterior tibial taking the distribution of the anterior tibial in man.

Chapman² found the anterior tibial extremely small, "the long saphenous" replacing it.

¹ *Journ. of Anat. and Phys.* vol. i.

² *Proc. Ac. Nat. Sci. Phil.* part i. p. 56, 1879.

Vrolik describes ¹ the arterial condition in the leg as identical with that in man.

(III.) *Orang-Outang* (*Simia satyrus*, Linn.)—Chapman ² here also describes the "long saphenous" artery, with a similar distribution to that in the gorilla and chimpanzee.

(IV.) I have been unable to find any description of the femoral in the genus *Hylobates*.

If we carefully consider the foregoing arterial conditions, we cannot but be struck with the remarkable gradation that is displayed by them. In order the more succinctly to demonstrate this, let me summarize the leading arteries and the modifications which they undergo.

1. *Profunda Femoris*.—This vessel, absent in the drill, sphinx, baboon, and mangabey, is present, although rudimentary, in the cercopithique and chimpanzee. In the latter it has a disposition similar to that in man, although relatively somewhat smaller.

2. *External Circumflex*.—In the first four monkeys this vessel is derived from the femoral itself; in the cercopithique it almost arises in common with the rudimentary profunda; while in the chimpanzee it is given off by the latter artery.

3. *Internal Circumflex*.—This branch, like the last, arises from the femoral in the first four monkeys, but is derived from the profunda in the cercopithique and chimpanzee.

4. *Perforatings*.—These, in the drill, sphinx, baboon, and mangabey, are furnished by the internal circumflex and femoral; in the cercopithique by the internal circumflex and profunda; and in the chimpanzee by the profunda alone.

5. *Great Saphenous*.—This vessel equals the femoral in size in the drill, sphinx, and baboon; is rather less than it in the mangabey, while in the cercopithique and chimpanzee it is considerably smaller. In all it gives off muscular and articular branches.

6. *Posterior Saphenous*.—This artery is almost identical in calibre with the anterior saphenous in the sphinx; is much

¹ *Recherches d'Anat. sur le Chimpanzé*, 1841.

² *Proc. Ac. Nat. Sci. Phil.* 1880.

smaller than it in the drill, baboon, and mangabey, and extremely slender in the cercopithique. It is absent in the chimpanzee. The artery terminates over the inner ankle in the drill and cercopithique; it supplies the anterior peroneal and rudimentary plantars in the sphinx, while it ends in small plantars vessels in the baboon and mangabey.

7. *Anterior Saphenous*.—This is an unbranched vessel in the drill, baboon, and chimpanzee, and in the two former supplies the place of the anterior peroneal. In the other monkeys it divides into two trunks, external and internal, of which the former supplies the plantar arch in the sphinx and cercopithique while the latter does so in the mangabey.

8. *Anterior Tibial*.—In the sphinx, and probably also in the drill, this artery is extremely small, and does not extend so far down as the ankle. It is small, and anastomoses with arteries at the ankle in the baboon, mangabey, and cercopithique. In the chimpanzee, until the vessel reaches the ankle it is similar to that in man, but, unlike his, it terminates on the dorsum pedis in tarsal and metatarsal branches.

9. *Posterior Tibial*.—In the sphinx this artery is small, and ends in muscular twigs near the ankle. In the baboon its distribution is rather more extensive, and in it the vessel terminates by assuming the place of the anterior peroneal. In the mangabey it reaches but ends at the ankle. In the drill it supplies the anterior peroneal, and ends in the sole by dividing into rudimentary plantars. The artery in the cercopithique has a very similar distribution to that found in man; the plantars are, however, proportionately much smaller. In the chimpanzee it is similar to that in man.

10. *Plantar Arch*.—This is entirely derived from the saphenous arteries in the sphinx, baboon, and mangabey; chiefly from them in the drill and cercopithique, while in the chimpanzee it is mainly formed by the posterior tibial artery.

The absence or modification of the profunda femoris in these apes has not, to my knowledge, been hitherto noted. We find in the lower monkeys that the muscles of the thigh are supplied by branches from the femoral itself, and it is only, indeed, when we reach the cercopithique that a

special muscular trunk (*profunda*) is provided. Meckel describes¹ the femoral artery in the *quadrumana* as dividing, near the crural arch, into two branches, which he names the anterior and posterior crural. He states that the posterior is a muscular branch to the calf, while the anterior, partly muscular, passes to the *dorsum pedis*, thence into the sole. He says it is probable that this early division of the femoral is an indication of the breaking-up of this artery into a number of branches, constituting, by their interlacement, a vascular plexus, of the disposition of which some species, more or less related, offer examples. He describes the femoral artery in the *cebus* as dividing into two branches, a superficial muscular, and a deep which supplies the anterior and posterior tibials. Of these, the anterior, which is also the smaller, descends to the *dorsum*, while the posterior supplies the sole.

It seems to me that, in the first description, Meckel refers to the great saphenous vessel when he speaks of the anterior crural, and in the *cebus* his deep division probably represents it.

Nunn² states that in monkeys, while the anterior tibial is limited to the leg, the anastomotie (saphenous) passes to the foot.

Humphry³ says that the anastomotie (great saphenous) is usually large in apes; accompanies the saphenous vein to the ankle, and supplies, to a greater or less extent, the district which, in man, is supplied by the anterior tibial, and even that by the posterior tibial. He further seeks to account for this peculiar distribution by assuming that it probably has relation to the outward bend of the knee and inward direction of the hallux in these animals, which conditions render the course along the inner side of the knee and leg the shortest and straightest to the region of the hallux.

Be this as it may, we have presented to us in the monkeys before described, a striking series of changes in the area and extent of distribution of this artery. Beginning with the *ateles*, *sphinx*, *baboon*, and *mangabey*, we find it in these supplying

¹ *Comparative Anatomy*, vol. ix.

² *Observations on the Arteries of Limbs*, 1864.

³ *Journ. Anat. and Phys.* vol. i.

both dorsal and plantar aspects of the foot, thus replacing, in position and function, the tibial vessels, which are here, comparatively speaking, rudimentary. In the drill, also, the foot has a similar arterial supply, but in it rudimentary plantars from the posterior tibial are also present.

As we ascend the series, even the cercopithique resembles the last as regards the distribution of this artery to the foot, although the tibial plantars are relatively somewhat larger.

It is only, indeed, when we reach the *Simiidae* that we find the supply of the sole to be chiefly derived from the posterior tibial. In these animals, also, there is a further approximation towards the condition in the human subject, in that the anterior tibial supplies part of the dorsum.

As regards the anterior tibial, I am inclined to think that its size and extent have been somewhat under-estimated. It is generally described as being very rudimentary, if, indeed, its presence is not altogether overlooked. Now, of the six apes I dissected, in three it could be traced to the ankle, while in the chimpanzee it even supplied part of the dorsum pedis.

In the quadrumana, therefore, the tibial arteries are, as a rule, rudimentary, or, at least, chiefly muscular to the leg, while the duty of supplying the foot with blood is relegated to a special artery, possibly, according to Humphry's theory, because, from the construction and position of the parts of the limb, a more direct course to the foot is required than that afforded by the tibial vessels.

Humphry¹ and Cruveilhier² compare the anterior tibial to the radial artery. Nunn, again, states that the great saphenous (anastomotic) is the analogue of the radial, but, considering the extensive distribution of the former in all the monkeys I have described (with the exception of the *Simiidae*), we cannot but infer that in these, as in the ateles described by Humphry, the saphenous is the analogue of the radial and ulnar arteries combined.

¹ *Observations on Limbs of Vert. Animals*, 1860.

² *Descriptive Anatomy*, p. 758.

28 FEB 1912 12

THE BRAIN AND NERVOUS SYSTEM: A SUMMARY AND
A REVIEW. By ROBERT GARNER, F.L.S., F.R.C.S.

IN investigating the brain, the crown and summit of animal organization, enthroned in which is located that *receptive faculty* as regards the external world, ministered to by vital conductors, or nerves, the medium between the two, of a *centripetal* nature, and also that *initiatory power* of reacting the exterior through similar channels, but these *centrifugal*—in studying this organ we cannot adopt such means solely as are adopted by anatomists in the investigation of any other organ, for we have but an imperfect notion of the way in which its functions, including that mysterious one, the reciprocal action and reaction of mind and matter, are performed. We may become familiar with its morphology, or rather with the mere topography of its components, a part of anatomy, however, difficult enough to master, and we may examine its finer structure with the microscope in each locality within its boundaries, but though a few results will seem probable enough, yet there will be too few to satisfy the mind, and we shall be led to seek for further conclusions from other facts, physiological or pathological, or at least indirect in their nature. Thus in man we endeavour to appreciate the greater or less development of the organ, or its parts, according to age, sex, race, and individual, for these circumstances imply differences in faculties, and, presuming as we may that the last will be accompanied by concomitant differences in organisation, we are led to hope that herein we may find some inlet to the arriving at ideas respecting the true meaning of the brain. Thus, again, we trace the gradual complication of the nervous system upwards from the lowest to the highest animal, especially in the vertebrate series, and as regards the brain, especially in such Mammalia as have convoluted cerebral lobes. Finding the advent of any new part, or the enlargement, or diminution of any constant part, to correspond with any new faculty, or the greater or less development of any function, we hope to draw important conclusions from the same. And lastly, for similar reasons, we trace up the morphology of the human brain through its gradual development from the embryo state.

Till a comparatively recent date, the convolutions of the human brain, which we may fairly conclude from several considerations to be the portion of our bodily structure most intimately connected with our mental functions, have been given up by the anatomist and draughtsman as an indefinite congeries of the fortuitous enteroid windings of the organ in question—a *mighty maze without a plan*—no convolution having a distinct function, which probably is to some extent the case, but more than this, it has often been supposed that the cerebral faculties are so diffused through the brain as a whole that, excepting distinct functions as regards the cortical and medullary strata, any

portion according to its extent may perform different actions ; and that one faculty or its manifestation is never confined to a single convolution or tract of medullary and consequently transmitting matter.

Such are the views advocated more or less by Brown-Séquard. Recently good service has been done by closer study of these convolutions, and by the record of the same being more accurately registered by drawing, engraving, and photography, so that now the observer's attention can be fixed to any part of the brain surface by verbal definition. Indeed, an accurate cast of the brain itself may be taken : *we* let the brain fall from the skull into a hardening solution of bi-chloride of mercury, the strength about 6 ounces of the salt to the half gallon of water, making a fluid of about 1038 sp. gr., or the same as the brain itself, in which it consequently remains suspended in mid-fluid, without pressure on any of its surfaces, and becoming hard and solid, without the contraction which takes place when spirit is used.

All arrangements of the cerebral convolutions at present are probably somewhat arbitrary and unphysiological, telling us too little of the action or supposed action of the organ and its parts, or at anyrate they have little foundation on the internal structure or development. It is true that a few anatomists have attempted more—Foville for instance, and Mr Swan in his later work. Perhaps it may be said that both works are very faulty, yet they appear to take account—the first of the brain's formative converging and diverging fasciæ, and of its commissural structures, the latter point enforced more recently by the observations of Dr Broadbent¹ and others—the second attempting an arrangement of the convolutions or rather of their fibrous basis, the cerebrum ovale, and lower cerebral peduncles, as these are composed of afferent or efferent, sensory or motor, tracts, and as the influence conveyed by the latter is flexor or extensor, or with regard to the convolutions which are the centres of respiratory, voluntary and involuntary, or psychical impulse.

A preliminary matter may be adverted to, treated by Professor Turner and by the author of this paper in the *Journal of the British Association*, 1862 ; it is a point which has as much a practical as a physiological import.² We may perfectly know the disposition of the brain-windings as they are called, yet be puzzled to attribute them to the particular localities of the skull to which they appertain when we view it from without or from within. This skull is more than a mere protective covering, but a fused development of several of the

¹ This gentleman considers some convolutions to have no connection with either the crus or corpus callosum, but only with other convolutions which have, and to the first he attributes the higher faculties. To the organs of sense are due on the one hand *impressions*, to the thalami crude *sensations*, and to the marginal convolutions *perceptions* administering to the first class of convolutions, where perceptions are compared and the will initiates reflex functions as the *motor*, performed through the convolutions of the second class and the corpus striatum, and also *speech* itself through the appropriate convolution.—See Lectures in the *British Med. Journal*, 1876. See also the paper of an earlier date 1870. *Journ. of Mental Science*.

² The author's papers are in the *Reports of the British Association*, 1860, 1861, 1862, 1863, 1869, 1870, 1876.

individual segments of the jointed carpentry of the body, and that the segmental nature of the skull is not to be disregarded is evinced in the tacit division of the cerebrum into corresponding segments, and in the nomenclature transferred to the brain from the bony case which protects it. By perforating the skull at a few points along the lines of the sutures, and marking the cerebrum at the corresponding points, by introducing a particle of vermilion by means of a grooved needle, it will be well seen where the brain and its bony covering correspond; and if a cast of the former is made, this may be permanently shown by introducing pins, head first, into the brain at the points marked, which will be drawn out with the moulds and afterwards left imbedded in the final cast, the result being not devoid of interest. The fissure of Rolando, ascending a good way from the upper margin of the fissure of Sylvius obliquely backwards to the summit of the brain, but terminating more forwards or backwards according to the greater development of the posterior or anterior convolutions, has been commonly held to separate the frontal from the parietal division of the brain, but it is thought by others, and we think properly, that the less marked line of sulci, the ascending ramus of the Sylvian fissure, under the coronal suture, is the true line of separation between the frontal and parietal convolutions, though the bases of the frontal convolutions, and the anterior of the two convolutions bordering the fissure of Rolando, from which the frontal certainly spring, are situated behind the coronal line. This fissure or line of sulci of the ascending ramus appears to exist independently of any special adaptation for the lodgement of arteries, and corresponds sufficiently with the inner parietal, or upper branch of the calloso-marginal sulcus, for both together to form a line of demarcation across this part of the brain; but a question may be, is there any physiological significance in this division, or indeed of the better-marked fissure of Rolando? This last fissure attains the middle line a little before the præcuneus. The basis of the frontal convolution seems to be annectent communications of the frontal perceptive portion of the brain with the parietal motor, forming a triangular surface, marked by a corresponding impression in the interior of the skull. Taking this view then, the frontal lobe is separated from the parietal, not by the fissure of Rolando, but rather by the ascending ramus of the Sylvian fissure, and within the longitudinal fissure by the ascension to the edge of the upper margin of the hemisphere of the sulcus or rather of a branch of it, separating the gyrus fornicatus (here girdling the corpus callosum) from the marginal; it is more or less marked in man, and situated at the end of the anterior third of the brain-margin near the junction of the coronal and sagittal sutures—better marked in animals, corresponding to a crucial fissure on the upper surface of the brain, showing in them the extension backwards of the frontal lobes, most in the higher and more intelligent, least in the lower and more obtuse species. Of these frontal convolutions, progressively added or inserted as we ascend in the animal series between the more external and posterior convolutions, we may suppose the internal one to have some relation to smell, for the crest-like tracts of this part of the brain figured by Foville are seen to

originate from the olfactory region, and ascend within the longitudinal fissure, and it may also be significant that the convolutions here are often marked by the dark colour of their arachnoid in some animals, the sheep for instance, as are their olfactory tracts and bulbs, as well as the Schneiderian membrane : of the middle frontal convolution we can say less, it may be a light centre, of the external one we must instance the theory of Broca as a matter not to be dismissed so dubiously. The occipital lobe of the brain is well separated from the parietal within the longitudinal fissure by the internal parieto-occipital sulcus, and externally not quite so obviously by sulci running in the line of the lambdoidal suture. It has the calcarine sulcus within the longitudinal fissure marking the situation of the posterior horn of the ventricle, and the upper triangular portion is called the cuneus. Thus the occipital lobe corresponds to that plate of the occipital often called the interparietal bone, sometimes even in man a distinct bone, connected by suture at the lower part to the occipital. The posterior half of the parietal lobe lying within the longitudinal fissure consists of a quadrilateral lobule so-named (or *præcuneus*), and before this, separated by the ascension to the superior edge of the cerebrum of the fissure (calloso-marginal) lying between the gyrus fornicatus and the margin, are the convolutions more or less separated from the inner surface of the true frontal lobe. All these convolutions within the upper portion of the longitudinal fissure have their formative fibres more or less springing from the front before the anterior bent portion or genu of the corpus callosum, in a crested fashion, owing to the mode of the original development of the brain. On the outer and lower margin of the hemispheres, or of the occipito-temporal portion, at one-third of its length from behind, is the termination of the external occipito-parietal sulcus, presenting a depression which marks the division of the temporal and parietal lobes, considerable vessels ascending here upwards and backwards, within the cranium ; in this place arises the upper edge of the petrous bone, and externally the squamous suture here becomes more crenate over the mastoid process. The tuberosity of the third frontal convolution lies within the frontal bone just above its junction with the great wing of the sphenoid. The suture between the parietal and sphenoidal, when it exists, lies a little higher up over the fissure of Sylvius ; in fact, it is directed almost in the same line as the squamous suture itself, which last marks the line of the Sylvian fissure, or sometimes rather of the superior temporal gyrus. This sphenotemporal or inferior lobe of the brain corresponds outwardly to the squamous process of the temporal and great wing of the sphenoid, its apex might be reached from the back and external part of the orbit, a thin plate of bone only there intervening. Of course the olfactory tracts and bulbs, so little developed in man, correspond with the ethmoid, and the grey perforated space of the brain behind corresponds to the body of the sphenoid ; the cerebellum is covered by no portion of the parietal, but only by the mastoid portion of the temporal and the occipital.

The Sylvian fissure is the principal inlet by which the outer convex surface of the brain receives its arteries, and it is by its being little or

strongly marked a measure of the straight antero-posterior direction of the convolutions, or of their being more or less arched and doubled upon themselves. Foville describes the fibres from the spinal cord and crus as directed by, or following in some measure, the direction of the low convolutions (*operti*) of the insula situated within the fissure, and, in a fan-like fashion, forming its marginal convolutions on the one hand, being in themselves one perfect system not to be divided, and on the other, constituting a second inner set of convolutions circling the great longitudinal margin of the brain. According to this view convolutions on the exterior of the brain are arranged in two circles, or parts of circles, and with a third internal one to be described, all terminating and connected about the locus perforatus or anterior centre of the inner ganglionic matter of the brain. The third circle is the gyrus fornicatus, continued in a clasping fashion all around the corpus callosum, and of the same medullary appearance, and then along the inner margin of the temporo-sphenoidal lobe as the hippocampal, and finally the uncinat convolution; having behind a connection with the occipital part of the brain, and indeed excentrically with all the other convolutions; it also surrounds the peduncle of the brain, and its two extremities merge between the point of the temporal lobe and the external gyrus belonging to the frontals, with the locus perforatus, and notably with the point of origin of the convolutions of the island of Reil, as well as with the hippocampus, analogous indeed to the arrangement of the two preceding circles. Without this, on the inner surface of the temporal lobe, are gyri, lingualis, and fusiformis, having relation to the descending cornu, separated by the collateral fissure. On the outer surface of the brain are many important gyri and sulci—the frontal bounded in the way described—ascending parietal, separated by the fissure of Rolando; other parietal gyri above the extremity of the Sylvian fissure, called the supra-marginal and angular convolutions, also the posterior parietal, continuous with the præcuneus internally, and having externally the inter-parietal fissure. There are three parallel gyri running along the temporal lobes, and lastly, supra-orbital convolutions, which, however, will not be dwelt upon here. The uncinat fasciculi form a notable connection between the frontal and temporal lobes.

Professor Turner points out that the parietal prominence corresponds pretty commonly to the supra-marginal gyrus; and further, that some latitude must be allowed in describing the lambdoidal and squamous sutures as corresponding exactly with the parieto-occipital and Sylvian fissures.

There seems a somewhat analogous communication between the parietal and occipital gyri behind, as is described between the parietal and frontal before; but the occipital lobe is commonly more precisely marked off, the communicating or annectent gyri in the quadrumana are more or less covered from view. In these last animals the posterior lobe is ample, and such seems a quadrumanous rather than a human character. Yet in man, though it is smaller relatively, it has a more convoluted surface; and gyri, which can only be reckoned as annectent or occipito-parietal bridges, form a considerable

portion of the parietal part of the brain. As to the above peculiarity the question arises—What is the relation of the extra development?

How far the external divisions, and, moreover, the lobules and gyri are of significance, that is, how far they correspond to internal structure, and are appropriated exclusively to particular functions, is a serious question in every sense. Turner's description of the convolutions, as well as that of Ecker, are valuable as a kind of first survey of a region more intimately to be investigated, though Meynert speaks lightly of such arrangements—advocating a longitudinal though a somewhat interrupted one. A scientific arrangement should show us the connections of the convolutions with the ganglionic centres and the fasciæ of the crus; this task, attempted by Foville, has been especially undertaken by Mr Swan, whose dissections at anyrate speak for themselves in the College of Surgeons, as do the engravings of his later work, though the descriptions are as usual with him very obscure.¹ He appropriates the region lying upon each side of the longitudinal fissure (so far as extend according to his idea the diverging fibres of the corpus callosum, and which receives no fasciæ from the crus) to the mental faculties; but its posterior portions, and indeed those of the whole brain, appertain to sensation. Consequently, to this, the corpus callosum is not a general commissure, but belongs only to the medial part of the brain; herein Mr Swan agrees in some measure with Foville, who makes it to be continuous only with the formative fibres ascending from the crura; more laterally external to this median region exists another equally longitudinal, the intercedent region appertaining in front to smell, further back mostly to the cranial and spinal motor nerves, then to sight, and finally behind, at the very summit of the cerebrum, constituting the cerebral representative of involuntary or respiratory power, so far as we suppose it has a cerebral representative. The involuntary convolutions at the summit of the brain is represented by the club-shaped mass seen in a longitudinal section of the medulla oblongata; above, in its passage upwards, this seems especially related to the grey matter within the third ventricle, the tract ascending through a kind of ring in the thalamus. The further continuation backwards of the region becomes, like the previous median region, sensory. As the eye, face, head, &c., are supplied with other nerves, according to Swan, the motor tracts from this region might perhaps have been considered by him involuntary, or may be of passion, or emotion. Another region, external motor, appropriates the remainder of the convex surface of the brain, subdivided into three other layers, of which that one nearest the longitudinal sulcus appertains mostly to the flexors, and also to the muscles of inspiration; that one occupying the margin, the extensors and expiration, whilst an intermediate layer gives a second set of motor nerve-fibres, as mentioned above, to the eyes, face, tongue, neck, &c. Of these three layers also, he considers the posterior parts to be sensory. With this location of sensation in the posterior portion of the cerebrum, and its connection with the thalamus, more especially

¹ Plates of the brain, 1853.

united as the last is with the same function, many physiologists will concur.

With respect more especially to the continuation of the above tracts from the cerebral surface through the crus, a little more must be said ; and in this, perhaps, his industry and anatomical skill serve him in better stead than his great suppositions apparent in the last paragraph. Between the olfactory convolution, situated in the front of the second or intercedent region, and the optic much further back, beginning from behind, we may particularise a surface descending hence by its tract to the first or front segment of the crus, and to the third, oculomotor nerve ; from the succeeding surface nervous tracts descend for both the upper and lower extremities through the second, third and fourth segments of the crus ; then the centre for the face, mouth, tongue, &c. sends a tract descending through the fifth segment of the crus and posterior layer of the pons, agreeing in this more or less with the nature and origin of the corresponding nerves themselves. The most anterior tracts of the intercedent region of the brain diverge outwards towards the most posterior tracts of the crusta, while the gyrus just mentioned in front of, and in connection with, the visual, has been understood to send forward its tract to give off the third nerve in front of the crus.

But these last parts, the face, &c., are, as observed before, also provided by purely voluntary motor nerves derived from tracts in a different part of the brain-surface, though the two strands coalesce in the crus. The centre for these is more at the antero-exterior part of the hemisphere, but intermediate between the extensor and flexor series of gyri ; the corresponding nerves are for muscles having no antagonists, and either attached or inserted into fixed bones. These strands have already been mentioned as united to those from the intercedent region, the same applies in the case of the third nerve. The strands also descending from the last intercedent region, and going to the extremities, are united to the strands of the more voluntary flexor (inner), and extensor (outer) centres, from the outer margin of the brain.

Among the inner flexor foci is one governing to a certain extent inspiration, situated, however, more forwards than its antagonist, among the outer extensor foci, governing expiration ; but both their pedicles descend together towards the restiform columns, and consequently towards the grey respiratory foci of the medulla oblongata, the ratio of this being ostensible enough.

Then, with regard to the flexor and extensor convolutions for the extremities, an inner and outer series, the upper extremities have their united efferent band, joined also by the corresponding band from the intercedent region, forming the fourth segment of the crus outside of the anterior pyramid. Next, with respect to the lower extremities, the combined efferent extensor and flexor strands, together with the corresponding intercedent one, form the third segment of the crus, and the middle part of the anterior pyramid ; the strands to the lower extremities and spine are also connected with what Swan terms the extensor and flexor crescentic belts. These belts appear to answer to what has been termed by others the *ansa* or *substantia perforata*.

At the posterior extremity of the outer portion of the brain are the two last foci (flexor and extensor) of the spine, and it is these two portions of the layers that form respectively the flexor and the extensor crescentic belt; the former in front, circling also the anterior commissure, and forming the second segment of the crus tending to the fissure of the spinal cord, being joined also by the extensor belt. More precisely the penultimate flexor focus forms a larger portion, the ultimate a smaller one, of the flexor belt, passing with the extensor, as just said, to the second segment of the crus.

How far does the above rather complicated account correspond to nature? Swan comes to the conclusion that the motor convolutions send down their efferent strands uninterruptedly through the internal and external striated bodies to the spinal cord, which is not generally admitted. Another objection, we think, is stronger, that the convolutions towards the external margin of the brain must have some relation to, and morphological modification by, the island of Reil, yet he makes no account of it as so modifying them; indeed, it is impossible to localise most of his convolutionary foci, well as the artist has delineated his dissections. The arrangement may be nearer to the truth as regards the ruminants and pachydermata, whose brains are included in Mr Swan's dissections, brains in which the convolutions have a more precisely longitudinal arrangement than in man, with little reflection on themselves, and with the Sylvian fissure and island of Reil scarcely indicated. The reverse takes place in man, these longitudinal convolutions being probably infringed upon before and behind by other lobules, the frontal and occipital. From this consideration the parietal convolutions arising from above the fissure may be supposed to be continuous with those below, or the temporal.

It may be thought that more attention is here bestowed on Mr Swan's book than it is entitled to, yet it probably will be found to be by no means devoid of truth, nor altogether at variance with modern *localisations*.

In estimating, or endeavouring to estimate, the relative development of the brain and its physiological and physical functions, the comparative size of the organ may be considered, modified, as it is, according to age, sex, race, or by congenital disease, and we may ascertain this variation by weighing the brain itself *post-mortem*, or by measurement of the skull in its diameter or capacity. But what would probably throw more light on our problem would be, as Huschke has particularly set himself to do, to ascertain by direct cerebral weighing or measurement, or by a comparison of the capacity of the regions of the skull, the relative development of the different lobes of the brain in the above conditions, age, sex, &c.

It was shown by Wagner, as by others since, that the brain and cranium will be large in an individual of large build. The Chinese giant "Ching," not many years since exhibited, had a head too large for any European's hat to fit; but this increased size mostly depends on the mere carpentry of the skull, and fortunately does not apply to simply *tall* persons, for here a heavy cranium would be out of place, and probably in them a small cranium, or a long or high narrow one

is generally seen. Andamanese, Bushmen, and Veddahs, are small in stature, yet have a small head; whilst the little Laps and Eskimaux have a large one, it has been thought, from a morbid state. All these out-driven races seem somewhat undeveloped or degenerated. The brain is commonly the largest at from thirty to forty years of age, but it may increase even after that age, and it has been said especially in negroes. It is often large at seven or eight years of age, probably from a semi-morbid state. The frontal tuberosities are often prominent in such subjects, causing what Foville terms, the *ventricular* brain case. I have found it difficult, taking school children, especially boys, to form an opinion of their mental capacity from mere craniometry. At birth the human brain may be from one-third to one-fourth its full size, or more; 13 or 14 oz. in weight. As compared with the body, it grows very rapidly the first year or two, but afterwards the latter surpasses it in this respect. It by no means wastes *pari passu* with the body, as seen in disease as phthisis.¹ A very emaciated child of six months of age, weighing but 6 lbs. within a small fraction, had a brain weighing 1 lb. within an equally trifling fraction. In old age the brain decreases, and corresponding compensation of the size of the skull is probably made by the increase of the ventricular fluid, the thickening of the skull, the sinking of the parietal bones, and perhaps by the increased size of the glandulæ Pacchioni.² A large brain in adults would appear, from Wagner's tables, to conduce to longevity. As might be supposed, the brains of idiots are often much smaller than the average, whilst the average is exceeded in the cleverest men—thus the brains of both Byron and Cuvier were in great excess.

The European man is considered to have a broader, higher, and more prominent os frontis than the other sex, though with regard to the two last particulars (that is, comparatively), this may be doubted. Man has, however, without a doubt, a larger frontal superficies. In woman the parietal bones are somewhat of the child's type, and predominate when compared with the others; the skull, upon the whole, is more lozenge-shaped. Some women, however, have not a parietal projection, but their skull is round or oval. Woman's occipital region, and especially the occipital squamous process, called also the interparietal bone, are full but smooth. The squamous portion of the temporal bone is small in woman; this is not the case with the alæ majores of the sphenoid, which are large. In the negro, &c., the alæ do not always articulate with the parietals, but are cut off by the junction of the frontal with the temporal, or by intercalated plates of bone. The ascending convolutions of the female brain are less inclined, the central fork more anterior, the frontal lobes shorter, and the corpus callosum corresponding. The hinder convolutions are more developed, also the thalami predominate in her; but in man the corpora striata

¹ In one instance of this disease there appeared to be atrophy of the convolutions confined to the temporal lobes.

² In an old woman upwards of ninety years old the brain was very healthy, but the sulci between the convolutions were generally enlarged, with much effusion under the arachnoid. The dura mater was opaque and like parchment, and the skull very thick and spongy.

both external and internal ; in her sentiment, perhaps, in him volition, being prominent.¹

The skull of woman compared with that of man is small, small even when the comparative weight of the body is alone estimated, exclusive of sex. The average weight of brain, according to Parchappe, is 1368 grammes, or about 3 lbs. Eng. in man ; 1206 grammes, about 2 lbs. 1 oz. Eng. in woman. According to Flower, man's skull cavity as to woman's is as 1000 to 856. According to Tiedemann, the average male brain is 3 lbs. 10 oz. the female, 3 lbs. 5 oz. Huschke gives for the male skull capacity 1772 grammes, about 3 lbs. 14 oz. ; the female, 1590 grammes, about 3 lbs. 8 oz. ; brain tissue, 1424 grammes, about 3 lbs. 2 oz. male ; 1272 grammes, about 2 lbs. 13 oz. female. He says that man's skull reaches one-fifth or one-sixth greater inner capacity than woman's, others think not so much as that difference by one-half (man's brain to woman's as 10 to 9), whilst in some races the inequality between the sexes seems less ; thus the European man much exceeds the corresponding female. The negro is commonly a good deal below the European man, whilst the negress not unfrequently appears to approach the European woman. According to Huschke, old women decrease in brain weight less than old men.

The above figures are perhaps somewhat unsatisfactory. The eminent surgeon Dupuytren had a brain agreeing more than that of Byron or Cuvier with the rest of his fellow men, it being 1436 grammes, or 3 lbs. 2 oz. Careful observations on the weight of the brain, distinguishing sex and nationality, and as belonging to the mentally advanced and cultivated individual, or the reverse, are still a desideratum. Errors seem to have originated from the difference of the weights adopted, and in measuring the skull capacity from the different allowances deducted for the membranes, &c., also from the material used in measuring. We have many tables drawn up in asylums, infirmaries, and workhouses. Dr Crichton-Browne's figures are—male, 1334 grammes ; female, 1198 grammes. Dr Thuraum's figures are rather less. The above numbers refer to cases of all sorts, the mental disease being of a wasting nature or not, and the weights are somewhat below what ought to be called the human average. Dr Crichton-Browne says, in acute cases of mental alienation, the weight was about 6 per cent. greater, and considers that more like the average weight in sane people. Dr Boyd makes the brain of the inmates of workhouses not to weigh more than the mentally alienated, which we may believe, from the mental character of many of the inmates, as so great a cause of pauperism is mental weakness.

There being generally a relation between the brain and the skull which contains it, and besides as we must obtain from the examination of the skull alone whatever light on psychology or brain-function can be learnt from the study of the encephalon in many of the races of mankind, craniometry becomes of interest to us. Of course the brain

¹ Wagner figures a female brain in opposition to that of Fuchs of the opposite sex ; the former is certainly narrow in front, and the frontal convolutions much simpler. Yet in this last respect, if he had made other comparisons, the result would have been different.

and skull vary according to race ; the savage man will on the average have a small brain, the advanced man, at least if the doctrines of development in contradistinction to that of primitive distinctness of race hold good, a more amplified one and corresponding skull ; more than this, the average bodily size of the races varies, and, as already said, the largest men will as a general rule, with some exceptions, have the largest brain, at least the largest skull ; in almost all races, however, large skulls occur. The uncultivated portion of the Irish have less cerebral development than their more advanced countrymen who are far from deficient, often macrocephalic.¹

Huschke found the German skull to be large. Morton also found the Teutonic cranium large, that of many Peruvians, Negroes, Hottentots, Hindoos, American Indians, and Australians, of small proportions. The smallest skull Mr Flower has found belonged to a Cingalese (Veddah). According to Dr Davis we may assign 92·1 cubic inches of skull capacity to European races, 89·7 to the Oceanic races, 88·7 to the Asiatic races, 86·2 to the African races, 81·7 to the Australians, 87·5 to the American races. It is believed, though not quite proved, that the Chinese come below the European (*Brit. Med. Journal*, May 31, 1879.) The skull of the lower races is sometimes rather thick and heavy than capacious. Dr Davis in his *Thesaurus* gave the mean cubic capacity of the English skull as only 90·9, but thinks that size too small, many of his English skulls having been collected for phrenological purposes. According to Meigs the English skull has the large cubic capacity of 96, representing a nett weight of brain of about 3 lbs. 11 oz. Size of brain, however, scarcely appears to be altogether either a national or a race character, but liable to vary both from the organisation and habits of the individual.² The modern English skull, according to Davis, has a circumference measuring 20·1 inches; anterior posterior, diameter 7·2 in.; transverse, diameter 5·6 in.; proportion of breadth to length, 78. The corresponding amount obtained by measuring the heads of four Welshmen from a remote village in Caernarvonshire I found to be 21·9 inches in circumference; anterior posterior, 7·2; transverse, 5·4; breadth to length, 80.

As already observed, it would be more interesting could we exactly estimate the relative size of the different cerebral lobes, ascertained either by measurement or weight of the brain itself, or measurement of its bony case.

The following deductions are principally from Huschke, who appears to have paid most attention to this point.

¹ Whilst the Peruvians are well known to have a small capacity Mr Flower gives a very large one to the less civilized Chinooks, who, however, if we may judge by their productions, are not deficient in aptitude. The Kaffirs, too, have a skull of large capacity. In a Negro of the more advanced type, though the skull was narrow and thick, but elevated, the brain was developed to the British average, and weighed 49 oz.

² After all it must be conceded that in estimating brain capacity richness of the convolutions and of their grey cortex takes precedence over mere size. This may be seen by an inspection of Wagner's Plates, as in the figure of the brain of the celebrated Gauss, less in size but much richer than the brains of other known individuals that he figures,—than that of Dirichlet for instance.

The frontal and interparietal regions are the parts of the skull having the greatest post-natal expansion comparatively, the first trebling its superficies during childhood and manhood. The parietals attain their full size earlier. Europeans have, as a rule, skulls which are not less in length from the forehead to the occipital tuberosity than 7 inches, but a few Europeans, where height of skull more predominates, as Finns and Turks, as well as many Asiatics, and Eastern Islanders where both height and breadth preponderate, do not attain that length. Length (dolicocephalism) is more especially characteristic of Africans (and Papuans), though not absolutely, but on comparing length with breadth, for in them it scarcely exceeds the length of even some European females, owing to the generally greater size of the European skull. Sometimes the skull, and consequently its contents, undergoes an elongation either from artificial moulding or an unusual closing or synostosis of the sutures. Such a deformation would mathematically lessen capacity, unless compensated for by some expansion elsewhere, but it is doubtful what is the exact effect on the physique and morale of the brain, though probably it is a perversion. The modern European and Caucasian skull exceeds in breadth (brachycephalic) and especially in frontal breadth. Some Oceanic races, and some American Indians also, are brachycephalic. Parietal breadth is less perhaps an Asiatic characteristic than frontal, whilst, as observed before, narrowness of skull is an African, or rather Negro, Australian, and Andamanese trait. The transverse diameter, however, may preponderate, and *vice versa*, even in the same families—nay, of twins one may present brachycephalic and the other dolicocephalic characters.

But taking the comparative development of the different regions of the skull into consideration, we might also seek for conclusions by measuring the longitudinal arch of the skull, from the root of the nose to the posterior margin of the occipital foramen, and compare the frontal, parietal, interparietal, and occipital portions of the line with each other, or with a line taken over the arch transversely. The frontal portion of the longitudinal arched line will appear, when compared with the parietal, long in many females; this is generally a perfection, but it extends a good way back without being really longer in many Africans, and the internal cavity formed in such skulls is shallow, and therefore the Negro's frontal lobes are sometimes poor in this respect and at the sides; the reverse is a European characteristic, mere height, however (unless it is frontal), is not altogether European but rather Asiatic, and it is seen in the Eskimaux and Siamese.¹ The parietal line must be short where the frontal predominates; the occipital portion of the same longitudinal arched line is short in the lower races, either from an excess of the parietal portion or from a backward position of the occipital foramen. With respect to the occipital transverse diameter between the most remote points of the lambdoidal suture it is least exceeded by the transverse line between the parietal prominences in the narrow skull of the male African; females have in

¹ Professor Flower has lately ascertained that some Fijian skulls are the longest and narrowest of any known.—*Nature*, July 8, 1880.

some races a parietal excess. The parietal breadth also predominates over the occipital progressively in Asiatics, Eskimaux, Europeans, Australians, and Oceanic races. The Eskimaux, however, have *in toto* very narrow though very high skulls. The European exceeds the African in all the above measures as follows:—frontal by $\frac{3}{10}$ of an inch, parietal by $\frac{6}{10}$, occipital, $\frac{2}{10}$ ths.

The cerebellum, both in man and animals, is very small at birth—from one-sixth to one-eleventh of the weight of the cerebrum; it increases much at an early age, becoming seven or eight times the size it was at birth. At birth I found it in one case only one-twentieth of the weight of the whole brain. It has been found large in many criminals and lunatics; castration appears to prevent its full development, and this seems more determined by the muscular growth of the body. Huschke makes it at birth as $6\frac{1}{2}$ to $93\frac{1}{2}$, at walking time, $13\frac{1}{2}$ to $86\frac{1}{2}$. The cerebellum, as a whole, decreases less than the cerebrum in old age; however, its vermiform process is considered to be prominent in middle life, and in the female, whose cerebellum is fairly developed, but with no excess as Gall supposed. The cerebellum is long in the Negro as is the skull, but probably *in toto* smaller than in the European. It is said to be well developed in the French, corresponding to their natural grace and dexterity; in fact, comparatively better developed than is the cerebrum.

It varies much in man, and scarcely appears to have any purely intellectual significance; the accompanying cerebrum it is said may be small when itself is large, yet it decidedly militates against these views, that when either cerebral lobe is wasted the opposite cerebellar lobe is so likewise.

We observed at the commencement of this paper that light may possibly be thrown on the physiology of the nervous system by a study of it as it gradually develops itself, or rather as it is found developed in the different groups of animals, beginning at the lowest and ascending to the highest. Nerves render impressions made in a distant part to a common centre, as in ordinary sensation; or connect these sensations with a distant part to produce muscular action, as in sneezing; or convey the impetus for motion from the centre to the circumference, as in common voluntary movements; or connect two motile parts in unison, as the external and internal respiratory muscles; or intimate to one part the organic state of another, as takes place between the stomach and the heart. Besides nerves or nerve fibres we have also nerve cells, the especial quality of which is an advance on that which every cell of the body has, capability of impression culminating in a cerebral cell in sensation and motility; the corresponding quality of the nerve fibre is conductivity, more elaborated and more capable of isolation than is any other similar conductor. Motion is a function of muscle, not of nerve. Perhaps nerve granules are another important constituent of the nervous system.¹

¹ In an address by F. M. Balfour, F.R.S., delivered in Section D. of the British Association, 1880, is an interesting resumé of what has been done in this subject by Von Baer, Romanes, the Brothers Hertwig, &c.

It does not appear that a nervous system, including both nerves and ganglia, is requisite to animals for them to perform any of their functions in the simplest form, feeling, motility, or nutrition; at least, we see no proof of its existence in such cases any more than in a portion of protoplasm, of contractile fibre, or in a cell. Neither ganglia nor nerves are clearly seen in the irritable actinia, though certainly the nature of its tissues is such as must render their demonstration difficult, and so in the asterias or star-fish. The former, when we irritate a single tentacle, gradually draws them all in one after the other, but irritated at the sessile-disk draws in all of them at once, and this certainly answers to Spix's account of the basal ganglia and communicating nerves. The common actinia has also ocelli-like organs in a row around the mouth. In the star-fish, as in the acephala, nerves with sense organs, visual or auditory, are now generally admitted. In other animals the nervous system may consist of little more than an internuncial or combining single cord, as in a sipunculus, or of a single ganglion between the orifices of an ascidia as it appears to us.

In higher animals the varied organs must be connected by nerves. There must be a sensorium commune, and this must be united with the ganglia whence motile impetus proceeds, necessitating a combination of nerve cells and of commissural connections, also constituting the centre of the animal's individuality. But a separated muscle contracts when irritated by simply pricking its fibres, whilst on the other hand, a worm moves and writhes when divided, but it is only the front half containing the cephalic ganglia that progresses.¹ In the last case we see the start of that development through which the encephalon becomes the seat of intelligence, the brain the organ of mind, or in other words the medium through which the exterior world acts by means of sensation on the animal, and the animal by motor impulse on the exterior. The brain and nerves, as a whole, present in all animals a resemblance of the whole form, as indeed may be said of the vascular system or of the skeleton; but in the nervous system, its functions being higher, individuality more especially lies. In articulated animals each ring of the body is more or less the copy of the other, and so with the ganglia and nerves, those of the head, however, being the ganglia to which the special nerves are mostly directed, whilst the following are either incited from it through the longitudinal cords, or are excito-motor with a double set of nerves to correspond, and others differently disposed to regulate the rhythmical movements of one articulation with another. Throughout molluscous animals ganglia of threefold nature are developed, sensitive, motor, and respiratory, and in addition others regulating organic or nutritive life; for the molluscous nerves and ganglia by no means correspond in the whole with the ganglionic nerves of organic life in higher animals. The molluscous nervous system corresponds, though widely different in arrangement, to the cerebro-spinal, and both have an appended organic nervous system.

¹ This agrees with Mr Wood's examination of the functions of the nervous system in the cray-fish.

The higher mollusca have a cerebrum above the mouth, and the ganglia below it still in connection with the mouth answer to the medulla, though very different in localisation, owing to the different situation of the locomotive system, and to its conforming to the molluscan characteristic, the annular arrangement of the ganglia around the mouth, the morphology widely differing from the vertebrate, and, therefore, the disposition of the nervous system. In the cuttle-fish (*Sepia*) the cephalic ganglion at the upper part receives olfactory and optic tracts from olfactory and optic lobes; the lower part gives off nerves to the locomotive arms at the front, and has also tracts from the olfactory or gustatory ganglia, and from the upper cerebral; the back portion also gives off motile nerves, but they are all connected with swimming, which is intimately in unison with respiration; it is also connected with the auditory sacs, as the functions are in the nervous system of higher animals. From the very posterior extremity long gangliated visceral and branchial vagi nerves are given off, also two columns analogous to a spinal cord, one portion purely motor to the side fin, the other with a stellate ganglion giving off nerves to the more sensitive sac. These two latter nerves are intimately connected with fine visceral nerves, the centre of which is a large gastric ganglion, and one, two, or more small ganglia near the commencement of the oesophagus.

The fish, especially adapted by its form, its large but simple mass of muscle, and its swimming bladder, to progress and float in the water, needs no large brain to animate its organs, acting as its nervous system does in an automatic or reflex manner, guided however by the cerebral nerves of sensation. Hence the diminutive size of the brain and cerebellum, appearing to be little more than a continuance of the spinal cord. In the osseous fishes, of which the cod is a good instance, the front ganglia may be called the hemispheres analogous with the olfactory portion of the mammalian cerebrum; however, in front of these are the true olfactory bulbs often at a considerable advance, connected by an olfactory tract, at other times sessile. Further back are the optic lobes, hollow within, and presenting on the floor certain elevations likened by Fritsch to the corpora quadrigemina; there are also appearances of thalami if not of corpora striata, and indeed these parts seem homologous with the ganglia mentioned, roofed in by a portion of the basal mammalian brain. An opening in the floor of the cavity leads down to the pituitary body, and backwards to a fourth ventricle, and the fourth nerve arises behind, sufficiently showing what these ganglia are, though the hemispheres are not consolidated with them. Behind we see a simple tongue-shaped cerebellum, without side processes, in the cod, but in other species, where locomotive, or respiratory, or electrical organs are more developed, garnished with sides lobules, as in rays, sharks, &c. Generally spinal impetus suffices for locomotion, olfactory, optic, or acoustic sensations, guiding—the cerebellum directing the different systems of muscles as far as they require it, be they respiratory or locomotive, and most in the skate and shark.

The skate and shark have no swimming bladder, hence their large

brain and cerebellum are more in requisition perhaps for swimming than in most fishes; there is a commissure also between the right and left trigemini and facial nerves, also supplementary gyri at the side of the fourth ventricle, belonging perhaps to the trigemini.

In the reptiles there is not the above incertitude respecting the parts of the between- or mid- brain; there is great ascent of general development, and distinct hemispheres with striated bodies. Remarkable upon the whole for their sluggish or simple movements, they are nevertheless like the fish (at least the lowest reptiles, the batrachia), independent of the cerebrum, for motor impetus, powerful as that is; neither is the cerebellum much developed, and their movements upon the whole require little separating or inhibitory action. The movements of the frog are remarkably combined, it leaps and swims, but does not walk as the toad, with its larger cerebellum; in the frog it is but a commissure, its spinal cord thick and long, with a ventricle all down, whilst in the toad the spinal cord is shorter. The frog leaps or swims when the cerebrum is removed. In the higher orders there may be more cerebral action, and both cerebrum and cerebellum are more developed, yet even in these their sluggish and statue-like position is very remarkable, though at times they are more active.

Leaving these cold-blooded and slow respiring creatures, we have a much larger development and importance of the nervous system in birds, though upon decapitation they appear for a short time to flap their wings consentaneously, but unlike the frog can accomplish no regular locomotive action, though if the cerebral lobes simply are removed they can.

The bird has a large brain as we might suppose from its diversified faculties, the seat of volition and of sensory perception, but, however, with less of the tactile, for the latter must be small in the bird; the corpora striata (motor) are amply developed, the thalami (sensory) less so. The impulse for flying seems to descend through the spinal-cord, the cerebellum exerting but a combining action, the wings generally in unison. The legs seem more automatic, and this dependent on spinal reflex action; the cord supplying the legs has the corpus rhomboidum, a superadded ventricle with grey ganglionic matter. The bird rests or sleeps standing on its legs, or even on one, the feet also the only part of the body free from feathers and adapted for bodily sensation. The cerebellum is primarily developed in its central portion (vermiform process), indicating that its action is on the mid-trunk where the great muscles moving the limbs originate; whereas, perhaps, where side lobes are developed we may appropriate these to limbs. Some birds progress by hopping, others by true walking, and the cerebellum is probably modified accordingly as to its side lobes; in the Mammalia a similar principle may exist, both the middle and side lobes of the cerebellum being regular or irregular as the locomotion is uniform or not so. The optic lobes or bigemini (answering to the corpora quadrigemini) are placed forwards and not behind the cerebrum, corresponding apparently to the almost absence of thalami. The olfactory lobe is not much developed, smell being a weaker guide to birds than sight. The corpus callosum is not developed, and the

cerebral lobes are consequently not united though in apposition; the anterior commissure is present; the intraventricular parts, except the corpus striatum, less defined.

Amongst the Mammalia, the monotremata as well as the marsupialia, are peculiar in their brain, as well as in other organs, showing a great difference between them and other Mammalia, difficult to explain, except from their being of a different epoch as to their appearance, constituting a distinct mammalian kingdom rather than an order. The great commissure (the corpus callosum) is very small, and the third ventricle situated between the thalami comes into view when the hemispheres are drawn aside, roofed in, however, by the fornix. This, connected in front with the parts at the inner origin of the olfactory nerve, diverges backwards and downwards, and so to the hippocampal and vast olfactory tract, forming the frame of the hilum where the crus enters. The brain, especially in the echidna must be an olfactory organ *par excellence*. In both the echidna and the ornithorynchus the frontal portion of the cerebrum is small, the bulk being the parietal portion probably sentient; yet the muscular strength of the former species is said to be enormous when dug out of its retreat.

It is curious that whilst the ornithorynchus has the cerebrum smooth like that of a bird, the echidna has many transverse deep sulci behind, a difference not generally seen in species of the same order, therefore the two animals have more than generic difference. The spinal cord is massive, giving auto-motive power, regulated however by an equally developed cerebellum, which has in the ornithorynchus side floccs lodged in cavities of the temporal bone. We may conclude that both animals are somewhat stupid not over active, sensori- rather than ideo-motor; the olfactory and tactile organs, and especially the fifth nerve amply developed, the posterior corpora quadrigemina small. In other Australian animals, as the kangaroo, the anterior part of the brain is very narrow, the hind part broad. In numerous Mammalia (the lissencephala of Owen) the brain is devoid of convolutions, so that there is nothing except comparison of size in fore and aft brain to enable us to draw any conclusion as to the function of the main regions of the brain—that is as to the seat or situation. As a rule sulci are not necessary to shelter the small vessels of small brains, and consequently they have them not. Yet, if the small animal belong to a class, the brain character of which is to be convoluted, it in this case will probably conform to the family type. Large brains must have a better mechanical provision for the distribution of the arteries, but the arrangement depends for its *raison d'être* not entirely in the vascular distribution itself, but in the physiological morphology of the organ.

With respect to the small smooth-brained animals, they are often not wanting in intelligence. For instance, the squirrel is very observant and quick in its movements, with the faculty of construction, and foresight of hoarding, and using its fore-feet as hands; still more, with respect to other Rodents and Insectivora. A difference may be seen in them in the shape of the brain; for instance, when we compare the broad fronted cerebrum of the constructive beaver with the same part

so narrow in front in the rabbit. These brains differ in the comparative development of the nervous centres of smell.

The volant bats have a small cerebrum, but a comparatively large cerebellum. The timid hare has a portion of the cerebellum surrounded by the semicircular canals—a provision probably frequent in timid animals. The mole has the organ of sight very imperfect; the eye is a light—not an object-organ, with little trace of optic nerve or tract and ill-developed inferior corpora quadrigemina. Its olfactory and auditory nerves are on the contrary highly developed, as are the hippocampi.¹ Prof. Turner describes the brain of an armadillo (exemplary of the Edentata) as not devoid of sulci, at least sufficient to mark out into three divisions the cerebrum—the anterior being the olfactory bulbs, with their large tracks running backwards—behind this in front and at the sides a gross portion also running to the posterior of the brain, and forming with the preceding track the temporal lobe, whilst above and behind is a superincumbent portion, being in shape as it were an epitome of the cerebrum itself; the corpus callosum is not much developed (*Journ. of Anat. and Phys.* 1867).

Some difficulty is experienced in comparing the lobes and convolutions of the brain of the remaining Mammalia, and especially with that of man. It may be premised that some similitude exists between the arrangement of the cerebrum with that of the spinal cord—that a cross section of both presents parts of somewhat the same import, and relatively similarly situated. In a section of the cord we have a central cavity, more or less obliterated however—an anterior motor strand with anterior grey cornua, represented in the brain by the crus and the corpora striata, lateral or middle strands traced by Swan upwards to the vertex of the brain, and posterior sensory tracts having in the cord the posterior cornua and substantia gelatinosa represented in the cerebrum by the strands more especially connected with the thalami, and going to the posterior part of the cerebrum, or rather the middle and the outside of the hinder half.

An anterior cerebral region we have apparently in all Mammalia, embracing perhaps gyri which appertain to intelligence and volition, and which are connected with the gyri initiatory of movement and probably especially with the movements of the hand and anterior extremities. There is reason to believe in the existence of a cerebral focus of respiratory action in the mid-brain, but more especially of sensation—the tegmentum of the medulla expands into the thalami in all these animals, and so into parietal and temporal lobes, but in the primates there is a distinct hinder portion or occipital lobe—large in quadrumana but less convoluted than in man—and this lobe appears ill marked in other Mammalia. In accordance with our suppositions this lobe may probably have relation to the hind rather than

¹ In the *Zoological Transactions* are the accounts of the examination of the brain of several rare animals, as the manatee, rhinoceros, hippopotamus, hunting dog, &c., by the late Dr Garrod. Professor Flower has given the description of the bush dog, which appears somewhat transitional between that of the *Canidae* and the *Felidae*.

the front of the body, also more especially to sensation; thus it is seen principally in animals with hind hands and prehensile tails, and in man, where the hind extremities can in no wise be compared to the little sensitive clawed or hoofed hind legs of Carnivora or Herbivora. Dr Ferrier's experiments, however, do not agree with these views.

This occipital lobe is scarcely seen in the last orders mentioned, though certain outputs of the posterior convolutions may be considered as incipient occipital lobes; such are the internal longitudinal convolutions lying on the falx of Ruminants, brought apparently by a species of supination to the exterior, towards the back part of the cerebrum, and often corresponding to the lengthened portion of the occipital bone, called the interparietal or supra-occipital.

In the Ruminants (ox or sheep) and Solipedes (horse) we find the brain large and convoluted, agreeing with the size of the body, the convolutions longitudinal in their arrangement, without being much bent round the island of Reil. A crucial line above, over the inner edge of both hemispheres, is traceable downwards to the callosomarginal sulcus, and seems to show where the anterior lobes end, marking a good sized frontal lobule, the line answering, I think, not to the fissure of Rolando, but rather to the præcentral ascending oblique fissure of man, found, however, not behind, but before the coronal suture, which is far back in horned animals. Another matter besides degree of intelligence should perhaps be here borne in mind, the development of the frontal bone from the presence of the horns, which may account in some measure for the stupid sheep equalling the sagacious dog in size of anterior lobe, but here again we must allow for the difference of the mode of life and amount of education. The olfactory tract is greatly developed, but the temporo-sphenoidal prominence is small.

There are three long parietal convolutions on each side in Ruminants, besides the superior convolutions supposed to represent the occipito-parietal. In front the division of the longitudinal convolutions is less distinct; they are here gathered into one set on each side—the olfactory and orbital portion. The sheep may be said to have two double parietal convolutions on each side, and one internal (occipital), the latter terminating in front at the crucial or rather V-shaped descending sulcus, the parietals run into a mass of frontal and supra-orbital gyri. Below is a lower parietal or Sylvian convolution, and the hippocampal eminence runs up behind into the crested convolution, and into that which we suppose to be occipital.

Supplementary to the last brains may be classed those of the Cetacea—large and much convoluted; the disposition of the convolutions more or less longitudinal; the large brain development somewhat accounted for, as the brain tissue is of a light and perhaps coarse development, as we see in the bones of the animals: the same hydrostatic principle evident in the head of the spermaceti whale.¹ The

¹ The brain of the white whale is well figured in the *Journ. of Anat. and Phys.* 1879, by H. C. Major. The sulci in the Ungulata have been systematically described by Krueg (*Nature*, 1878). Mr Galton has described the brain of the manatee, Sumatran rhinoceros, and several other interesting animals.

olfactory nerves so highly developed in Ruminants, are actually absent in most Cetacea, other nerves, as the fifth, seventh, and eighth, supplying those parts for respiratory purposes which in most Mammalia are partly subservient to smell.

The parietal bones in the Cetacea do not meet in the middle line of the skull above, and the convolutions here seem rather to correspond to the parieto-occipital than to parietal.

The brain of the Ruminant does not differ very much from that of the boar, which may be said to have two double, or four single side convolutions passing from before to behind, with the Sylvian fissure more evident. The olfactory portion is well marked, inserted between the anterior lobules. The upper convolution sends a process downwards into the longitudinal fissure, behind the crucial or V-shaped sulcus, and further back a process reflected into the parieto-occipital; the lower convolution bends around the fissure of Sylvius.

The remarkable antero-posterior direction of convolutions which we see in Ruminants (though the posterior parietal extremities have a tendency to diverge, apparently to form posterior or parieto-occipital lobes) no longer exists in the Carnivora—at least, though the parietal convolutions may be straight, still their extremities bend round an antecedent Sylvian fissure. This is well seen in the dog, the wolf, or the bear; in this the carnivorous animal resembles man, in whom the brain is also bent on itself as it were. These convolutions may be said to be about four in number, with a tendency to divide behind, and so form the occipito-parietal lobe, ill-developed however, as is the supra-occipital bone above.

In front the upper convolution bends around the anterior (olfactory) gyri, marked off by the crucial fissure from the rest of the frontal and orbital lobes, having more of the cerebrum before it in the dog than in the cat or even the fox, the cat's brain looking as it were cut off before, the fox's sharp, the dog's broader. In the latter, four arched supra-Sylvian convolutions bend down before and behind, in front bordering the olfactory lobe, at the back forming the temporal prominence, and also by a division seeming to provide for an occipital lobule. An upper marginal tract of the longitudinal fissure seems more connected with the frontal convolutions than the curved or arched gyri. The dog's brain is not nearly so large as that of the wolf; education does not appear to have had the effect of much increasing it, that is, if we suppose it true that the dog is a reclaimed and civilised wolf. Large dogs have not a proportional enlargement of the brain, nor is that of small dogs correspondingly less. The arched convolutions may differ in proportional size according to species: the upper temporal gyrus is large in the spaniel, small in the bull-dog, its anterior bend less in the spaniel. The fissure of Sylvius is directed more backwards, and the cerebrum elongated in the greyhound, foxhound, and Newfoundland dog. The frontal lobe seems large in the spaniel, but also in the bull-dog.

In the brain of man we have a vast enlargement of the cerebral convolutions, but probably the occipital lobes are larger in the Simiæ in proportion to the size of the cerebrum, but in man much more

convoluted.¹ The anterior lobes are much expanded at the sides; a central lobule here starts from the orbital surface and runs backwards somewhat further than the coronal suture, the inner surface of the parietal bones more or less marked, as already mentioned, from the vessels which go upwards, following the sulcus, which ascends from the anterior part of the Sylvian fissure, forming the division between the frontal and parietal portion of the brain, though the præcentral sulcus further back is mostly considered to mark this boundary; the debateable land is seen above to be of the shape of a broad halberd or fleur-de-lis; at one or the other boundary is the upper end of the superior frontal convolution, and below on each side is a middle and inferior one. Behind the first oblique ascending convolution, and its anterior sulcus, bridged across by the inosculations from the frontal lobes, is a second oblique ascending parietal convolution, having before it the fissure of Rolando, and behind this there is sometimes a third similar convolution and sulcus, the latter making part of the posterior parietal sulcus. This last sulcus divides the remaining upper parietal portion of the brain into two sets of lobules, of which the inner (upper parietal lobule) is quadrilateral in form with the parieto-occipital fissure behind, and with its fellow, together with the gyrus behind the fissure of Rolando, forming a bat-shaped region in this part of the brain surface; the other set is behind the termination of the Sylvian fissure, and has been called the inferior parietal, touching upon the angular and marginal gyri of others, and here the supra-Sylvian convolutions probably are bending round the top of the Sylvian fissure, as in the carnivorous animal. Further back is the occipital lobe, more or less separated by a fissure on the outer surface, more evidently within, and this fissure is crossed by bridging connections from the parietal and temporal convolutions. Dr Foville was the first to point out the peculiarities of that great circular convolution, called limbic by Broca, otherwise the gyrus fornicatus, bordering the cerebral inlet, and surrounding the peduncle. It may be followed up from that grey commissure connected with the olfactory and optic nerves, and at the base of the brain—the locus perforatus—it mounts up along the inner surface of the hemisphere over the corpus callosum, the white internal fibres also ascending in a crested fashion—the convolution expands into the quadrangular lobule or præcuneus, corresponding pretty well to the posterior parietal lobule above—hence the limbic rim is continued downwards, and then forwards, receiving tracts, as it were, from the occipital and temporal lobes connected with the dentate lobule, hippocampus, and uncinate gyrus, and so again to the locus perforatus. This forms the great olfactory circle, and indeed the frontal lobe, in many animals, where smell is far more developed than in man. We need not enumerate the divisions in the outer or inner surface of the occipital lobe, but the longitudinal or calcarine fissure

¹ A high function is allotted to the occipital lobes by Hughlings Jackson, and other clinical observers, though Ferrier allots to them the organic and nutritive functions. The latter gentleman, however, with Prof. Yeo, now finds that upon extirpation of both occipital lobes and both angular gyri *vision* is quite destroyed.

of the last indicates the situation of the hippocampus minor in the posterior horn of the ventricle, a feature of the primates. Professor Dalton, of New York, entertains ideas similar to the author's regarding the doubling on themselves of the lateral parietal and temporal convolutions (*Brain*, July 1880). The upper temporal varies in calibre, &c.

The production of defined movements in the limbs, &c., by irritation of the surface of the brain, in opposition to the experiments of older physiologists, as well as modern, of Flourens, Magendie, Vulpian, &c., anticipated by the opinions of Hughlings Jackson, has been announced by Fritsch and Hitzig in 1870, and by Ferrier in 1873. Modern experiments of stimulating the surface of the brain by electricity, cautery, or ablation, do not militate against what we have said, at least generally speaking. The anterior parts of the hemispheres do not respond to stimulation, and we should suppose they would not do so if they are the regions, as we should opine, more intimately concerned in psychical functions. On operating on the convolutions further back various muscles are caused to act; to speak roughly, those connected with the sense of smell, with sight, with the hands or fore extremities, and with the head; further back still the muscles moving the hind legs and tail. The whole of this portion of the brain is especially connected with the corpora striata, generally believed to be of motor function. The rest of the brain is more connected with the thalami which, as generally inferred, relate to sensation. In this latter region no response, generally speaking, takes place upon stimulation, with the exception of a few spots, as the angular gyrus which seems connected with sight, the temporal infra-marginal convolution (hearing), the hippocampus (smell, taste, &c.). These last movements appear to be reflex, the parts stimulated being the termini of visual, &c., centripetal sensation, producing the corresponding movements by influencing motile centres, elsewhere situated and connected with the striate bodies and not the thalami. Neither does stimulation appear to affect the occipito-parietal lobes as motor foci. Ferrier upon the whole considers them as recipients of sensation of the visceral organs, which theory is perhaps very disputable, as may be concluded from what has already been said.

Unlike the vascular system there is little in the nervous to demonstrate the mode of mechanism by which it performs its functions—a vessel in some measure tells us what is its use by its plain disposition; a nerve or ganglion tells us nothing of the sort at any rate indubitably. The phenomena of reflex action indicated by Prochaska, and formulated by Marshall Hall, have been in more recent days elucidated in their extensive bearings. Some have supposed them to be purposive and intelligent, which kind of functions we can hardly attribute to the spinal cord.

Beginning synthetically with the spinal cord and its functions—besides conveying nervous impulse, as both motor and sensory, to and fro between the brain and the body, it has actions solely dependent on itself, reflex actions, and from the disposition of its grey matter like a cross with a surrounding circle of the spinal nerve-tissue, the longi-

tudinal tracts, internal ganglionic cells, and their communicating fibres, there appears no difficulty in understanding its various spinal reflex action without any participation of the brain. There are other nervous actions more independent of the nervous centres than even spinal reflex action: thus it is with the sympathetic nervous system of organic life, connected however with the spinal nerves, but for what purpose seems doubtful, probably to carry upwards and downwards reciprocating nervous influence; the ganglionic seats of organic life having organic motor power and being recipients of organic sensation and the cause of their reflexion, yet susceptible of stimulation or inhibition from the animal nerves of the medulla itself, as in the case of the sphincters, the uterus, the diaphragm, and muscles of respiration generally. It is worth while to consider the different degrees of voluntary impulse exercised over motor function. The actions of the uterus, bladder, bowels, and vesiculæ seminales are independent of cerebral action; yet of these the last responds in answer to special sensations; the three first organs when aided by the voluntary or semi-voluntary action of the organs themselves, but especially by the diaphragm and intercostals. These actions themselves are the subjects of sensation, not different from the ordinary as far as the cerebrum is concerned and influenced by its ordinary reflexed motor action. Swallowing is involuntary when reflex action is produced in the shape of the projected morsel. The heart's action is quite involuntary though it may be influenced by emotion, and so that of the larynx. Vomiting, sneezing, and coughing are accomplished by the aid of semi-voluntary muscles, whose action if resisted at length becomes involuntary. Hiccough, gaping, sighing, and laughing are spasmodic actions of the same class of muscles. None of these are under the control of the cerebrum, though it may influence them in some cases. Over and above these various nervous actions, dependent on the spinal cord, or at least on parts below the cerebrum, there are others which are undoubtedly more in unison with the brain, such as impressions of sight, smell, hearing, general sensation, and pain, afferent or leading up to the encephalon, and, on the other hand, movements of various kinds brought about by impressions transferred from the encephalon to the muscles. At first sight it might appear that this afferent and efferent impetus might be accomplished by very simple means, like the to and fro conductors of a galvanic apparatus, but the requirements are not so simple.

In the first place, omitting at present the subject of nervous decussation, the brain, like the other animal organs of the body, is double, yet commonly acts as one, the body duplex the mind one; each stage of the nervous system therefore is united by commissures, even the so-called cerebral nerves themselves. The nerves of sense likewise appear to communicate with different receptive regions: (1) with the higher region of intellect; (2) with the sensorium—the optic tract, for instance, is connected with grey matter at its commencement, and then proceeds to more distant ganglia; (3) it sometimes appears necessary for the good of the being that they should have a connection also with the seat of involuntary or automatic impulse. Seeing necessitates

certain muscular movements, partly voluntary and partly involuntary, but acting in curious unison as to the two eyes.

The transmission of pain upwards seems a very simple mechanism, though there is a wide divergence of opinion as to its precise route, and whether the same channel as that of the ordinary sense of touch or of heat and cold conveys it; also, as to the precise course of that sense of muscular tension and relaxation which must be necessary to guide the body in its various movements. Many of these last impressions may be carried upwards so as to form perceptions or impressions at the summit of the cerebro-spinal system, or may stop half way. Thus in a reverie we may walk, step safely, and balance our bodies without thinking that we are walking. In this case that sense of contact necessary for balancing the body, and of the muscular exertion must stop somewhere short of the sensorium, and be reflected in the nerves at lower levels than where they are influenced by the will or ideas.

Then, again, in any voluntary movement produced by contractions of a certain set of muscles it is not the mind that selects the suitable muscles, at least after the movements have become associated by repetition. It seems to will the *effort*, rather than the *mode* of action by which the effort is to be produced. There must be here, besides the unconscious experience, some physical arrangement, we suppose, of the cerebellum.

The true structure of the brain is likely to be elucidated by a study of its embryological growth, and also of that of its bony case; Messrs Huxley and Flower especially having paid attention to the latter. As regards the embryological growth of the brain, its early phases and their external appearances are well figured by Tiedemann, and more recently by Reichert; but it appears to the writer that Mr Callender has more efficiently investigated its very early stages.¹ In the new born infant the two characteristics most apparent are, I think, the comparative smallness of the cerebellum, and the want of convolutions at the front of the brain, corresponding perhaps to the little developed movements and mental faculties. Mr Callender gives to the embryonic brain in its early stage three consecutive formative vesicles, but we would rather take Professor Owen's view of there being four, rhin-pros-mes- and ep-encephalon. Upon the doctrine of the skull being in reality a series of highly developed vertebræ, their number of course must correspond, and also the cranial nerves ought to be in accordance, though this latter point seems rather a difficult subject. Excluding the nerves of special sense, we would divide the first branch of the fifth into a nasal and ocular division, making with its second branch three nerves of ordinary sensation, while its third branch is a mixed nerve, sensational and motor. The deficient motor power in the upper branches of the fifth, is with respect to the eye supplied by the fourth nerve, apparently especially allied with expression, &c., and the third and sixth pairs, of which those, given off above the cerebellum, appear not to be subject to its functions of controlling, inhibitory, separating,

¹ Lectures in *British Medical Journal*, 1874.

&c.; the seventh nerve, most conveniently from its course, supplies motor power to the parts of the head and face, as regards which the fifth nerve is deficient. We omit the respiratory nerves, peculiar, like the nerves of sense in many respects. Mr Callender, in his accounts of the brain of the very early embryo, takes two parts, the pituitary body and the pineal body, one fixed at the anterior termination of the notochord, and the other at the internal tuberosity of the occipital bone, and compares them with the structures at the lower termination of the spinal cord, the gland of Luschka, &c. With the above two glands so called, the upper one of which at this early stage exists superficially behind the anterior vesicle, the growth of the brain convolutions is particularly connected. At an early stage the formative spinal cord is seen to consist of two portions or rather two pairs of columns, the posterior form the vermiform centre of the cerebellum, its lobes vegetating afterwards from the sides, and move forwards the corpora quadrigemina, whilst the anterior pair more directly take their course towards the pituitary. The four columns are connected together before they diverge. The insertion of the nerves at this early stage agrees with what is generally taught. It may be said that the posterior columns go to form the thalami, while another portion of these columns on each side is destined to the medullary portion of the hemisphere. The anterior columns, directed as above mentioned, rise up from before and below the thalami to form the internal and external folds of the hemispheres upon the anterior cerebral vesicle, the corpora quadrigemina being the middle and the cerebellum the posterior vesicles. The internal folds, in an embryo of eight or ten weeks, appear running lengthwise from the front of the brain; later on the upper fold turns down and unites with the lower one (which is the gyrus fornicatus) forming a cavity, which, however, is not the lateral ventricle, but becomes solidified. Like these gyri, the corpus callosum, formed by the coalition of two folds from each side, also gradually extends backwards. A little later we can make out, on this inner surface of the brain, the well-known features of the adult brain, the quadrate lobule rising obliquely backwards from the gyrus fornicatus, and further back the occipital lobe with its calcarine fissure. Mr Callender considers the left convolutions to be the earliest in development, though Dr Crichton Brown finds from his weighings that the right hemisphere in the adult is the larger. On the external surface of the brain, at about the same period of growth or soon after, the surface is marked by regular fan-like folds; the fissure of Rolando seems indicated, but the folds can hardly be identified with those of the adult brain. The embryonic brain now unfolds, thickens, and extends behind and downward; consequently the anterior and posterior horns of the ventricles are formed, the latter by the wrapping over of the crowded posterior folds. The bends in the brain and its pedicle also disappear, the cerebellum becomes covered, and the pineal gland is removed from the occipital surface accompanying the lowered quadrigemina to where the membranes enter the ventricles, at the transverse Sylvian fissure, which membranes are well described by Mr Callender. In the *Journal of Anatomy and Physiology* of 1874, this portion

of anatomy is elucidated in the editors' report of a paper by Key and Retzius. "By these investigations and by the former papers of the authors it is demonstrated that a continuous serous system pervades the entire nervous system from the ventricles of the brain, the sub-arachnoid spaces, and the sheaths of the vessels in the brain and spinal cord, to the extreme ramifications of the peripheral nervous system."

In consequence of the above-mentioned crowding and puckering of the folds at the hind extremity of the hemispheres this portion of the brain necessarily becomes twisted on itself, at first outwards, then downwards, and finally inwards, forming the spheno-temporal lobe, having within the hippocampal gyrus and hippocampus itself, which is a gyrus tucked inwards into the continuation of the Sylvian fissure, entering here what are called the inferior horns of the ventricles, the same crowding, accounting in a similar way for the lesser hippocampus in the posterior horn.

We think the formation of the brain may be illustrated so :—Take a fan and mark on the outer ribs, one-third upwards, two spots to indicate the pineal and pituitary ; when expanded suppose the posterior extremity bent down outwardly towards the spot indicating the pituitary gland ; the posterior edge will represent the hippocampal gyrus, and the folds situated nearest this edge the supra-tentorial surface. By such a curve, too, the extremities of the gyrus fornicatus and the longitudinal margin of the hemisphere, to which we may add the fornix, are approximated towards the grey matter near the pituitary gland, much as Foville teaches, the posterior curve of the corpus callosum not extending so far back.

The intrinsic structure of the nervous system is still imperfectly known notwithstanding many labours. The course of the fibres or medullary matter, and the disposition and differences of the grey matter, have been investigated with the aid of the microscope and of transverse (Querschnitte) and longitudinal sections (Durchschnitte) by Reichert, Luys, Gerlach, Meynert, &c. of whose writings we avail ourselves. The last anatomist, as well as Kölliker, Arndt, and also Beale, Cleland, Clarke, and others, more recently have endeavoured to make out the disposition of the cells and their processes and nuclei. It may perhaps be said that large pyriform or fusiform cells abound in motor parts ; smaller or vesicular ones, sometimes aggregated into glomeruli, in the sensory parts.

Professor Turner, in *Journal of Anatomy and Physiology*, 1879, and Dr Dodds. *id.* 1878, give reports embracing an account of what has been done on this point with regard to the nature of the nervous cells, and the latter, in addition, shows the feasibility of supposing that direct and uninterrupted fibres exist between the spinal cord and the convolutions.

There is a paper in the first number of *Brain* by Mr Lewis, on the "Comparative Structure of the Cortex," showing that there is a distinction of motor sites in the brain convolutions, situated principally before the fissure of Rolando, marked by clusters or nests of great ganglionic cells ; it is becoming evident that the forms, disposition, and many or few processes, &c., of the

cerebral cells have a relation to brain function. Meynert gives the different types for most parts of the brain; these are, with respect to the convolutions—(1) a common or five-laminated type of the cortex of the convolutions of the vault of the hemispheres; (2) the type of the occipital apex; (3) the type of the Sylvian fissure; (4) the type of the cornu ammonis; (5) the type of the bulbus olfactorius.

In divisions 2, 3 and 4 the general type may be varied, or its constituents re-arranged, constituting in 2 a poorer formation. In 3 and 4 the large pyramidal or fusiform cells abound in their proper layers; but in 5, the formation of the olfactory bulb or lobe, called the olfactory nerve in man, we have small nuclear-like cells abounding, the true olfactory nerves extending to a stratum glomerulosum on the surface of the bulb, which last has been considered analogous to the retina; and indeed the nervous attachments at the base of the olfactory lobe may be arranged analogously with the optic tract, the connection of the olfactory with the fibres of the anterior commissure forming an olfactory chiasma, for which, however, there appears no reason in regard to smell. A structure of corresponding cells is seen in the neighbouring extremity of the corpus striatum; but *in toto* this olfactory region presents in man but a rudiment of what it is in many animals.

The posterior cornua of grey matter in the spinal cord do not abound in the groups of large cells seen in the anterior cornua; it is probable that with these anterior large cells the motor-roots of the spinal nerves are connected through the *nerve* processes of Deiters, whilst the same cells give off *protoplasmic* processes, through which their union with the descending motor strands of the cord is effected. The arrangement appears different in the posterior cornua. The sensory nerve-roots, instead of combining with large cells, pass in part through the *substantia gelatinosa*, immediately dividing into a fine nerve plexus, which also extends further forward in the cornua—in part traverse the posterior columns before helping to form the above plexus. This plexus is here endowed principally with nerve-cells of smaller size than those of the anterior cornua. Vertical fibres ascend within the grey matter of the posterior cornua, and also through the posterior columns, the existence of which, and of the anterior and posterior commissures before and behind the central canal, certainly admits of a belief in both an ascending cerebral and cerebellar communication, and also of decussed or commissural paths administering to reflex or combined action. The grey substance and its ascending fibres might be assigned (in accordance with Brown-Séquard's experiments) to cerebral afference, the posterior columns to cerebellar. The former would also appear to convey the sensations of temperature and of pain, whilst the latter (perhaps solely) pertain to muscular sense.

In reflex spinal action the muscles contract in a somewhat orderly manner even in the new-born infant, where no experience or practice can be supposed; hence it might appear that within the cord itself some arrangement exists co-ordinating the flexors in contradistinction to the extensors, or rather flexion in opposition to extension; and the further question arises—whether, as the extensors answer most to dorsal

nerves, there is an arrangement for the bipartition of the anterior spinal strands? and whether minor portions of the motor fibres for the dorsal part of the body go backwards in the cord itself and join the posterior roots? as some anatomists believe, which roots therefore must be both sensory and motile, as far as the posterior part of the organism is concerned. It however is not a view we take, and fortunately does not trench upon our explication of the mode of connection between the supposed motile action of the brain and its peduncle above the pons. Deiters, Clarke, Luys, and others, maintain that fasciæ decuss and cross over in the region of the pyramids *towards* the posterior roots of the opposite spinal nerve. At this point it may be inquired—Are the inter-spinal ganglia in any degree distributors of motor nerves? or are they solely commissures of the anterior and dorsal, and other connecting sensitive nerve branches? which last we should suppose to be the fact, a synæsthesia being so effected; a reversed distributive action being facilitated in the motor nerves, as far as mechanical arrangement goes, by a plexus, the axillary for instance.

Theory might induce us to assimilate the slender columns on the dorsum of the spinal cord, which appear to terminate with the cord itself, and of which there is an intimate commissure within the dorsal fissure, with the two slender columns, which may be distinguished below the pyramids and down the cord in front, intimately united like the preceding within the anterior fissure. If the dorsal appertain to the extension of the trunk the ventral columns would to its flexion—the muscles concerned in both escape being affected in paralysis.

The arrangement for the nervous supply, dorsal and ventral, takes place at the roots of the nerves rather than in the medulla. The number of spinal nerves constituting the plexus supplying a limb has a relation to the number of the distal divisions of the limb throughout the animal series; also, it may be added, that the nervous roots forming the extensors, are upon the whole, the more anterior as regards the body.

Dr Broadbent does not admit separate conductors to the brain for pain, temperature, &c., and makes a proposition expressing that “the spinal cord is capable of co-ordinating—*i.e.*, of combining—for orderly, purposive, or adapted action, all movements guided by cutaneous impressions,” and its three chief functions are the balancing of the body when standing or walking, the bi-lateral association of nerves, and the crossed association of the anterior with the posterior extremities; but in man the spinal function must be often superseded by cerebral or cerebellar influence. With respect to spinal conduction a paper by Dr Rutherford in the *Journal of Anatomy and Physiology* for 1873 may be consulted.

Clarke describes a column of cells found especially in the dorsal region of the grey matter, and rather behind the central canal, peculiar from the absence of any evident nervous processes, but in which Gerlach traces strands outwards and backwards towards the posterior spinal roots, which we might perhaps connect with the lateral or respiratory system.

Dr Ross, in the *Medical Times and Gazette*, October 27, 1877, examines the structure, in the infant of a month old, of the spinal

cord; it then consists of the central grey matter, and two anterior and two posterior bundles at the sides at the roots of the nerves; other bundles are added on each side, two pyramidal ones both together forming one of the pyramids; a variable number of fibres from each pyramid pass directly down the cord close to the anterior fissure; the larger portion decussate with those of the opposite side proceeding backwards and forwards. A fifth bundle occupies a lateral surface of the cord and connects the cells of Clarke's column with the cerebellum. The sixth system is a wedged-shaped bundle lying between the posterior nerve roots and the posterior fissure, ending above in the slender columns. Dr Preston studies the cord in the same way; and, after Flechsig, makes out seven tracts on each side; these are, in the order of their formation—(1) fundamental tract of anterior column; (2) fasciculus cuneatus (Burdach); (3) anterior mixed tract of lateral column; (4) lateral bordering layer of grey substance; (5) Goll's column; (6) direct cerebellar tract; (7) pyramidal tracts. The first four are commissural between different portions of the cord; the three last, increasing in size from below upwards, serve to connect the cord with the brain—the pyramidal tracts with the cerebrum and basal ganglia, the cerebellar tracts with the cerebellum, and Goll's column with the medulla oblongata (J. Crichton-Browne in *Brain*).

Upon the whole it would appear that the spinal cord is not, *per se*, an independent organ, as Volkmann surmised, its fibrous strands increasing as they ascend, and the grey matter alone where the great nerves are given off. On the contrary, it is as it were the highway of nervous conveyance between the brain and the nerves of the periphery. Still it has some independent power, automatic, and of nervous reflexion; but whether these two powers are attributable to distinct cells, those without and those with nervous processes, is only matter of theory.

The sub-pyramidal decussation, in contradistinction to an inter-pyramidal one of finer fibres, appears to account for the crossed action of the cord as far as motor influence is concerned; it is a question, however, how far down the cord a true decussation takes place. If the decussation is total at the pyramids without any lower down, as taught by Meynert and Hirschfeld, then division of one lateral half of the spinal column in the living animal in any part much below the medulla oblongata, ought to produce total paralysis on the same side, but not on the other, though Brown-Séquard says there is some of the latter, as there might be, if Foville and Valentin are correct in supposing, a true decussation all down the spinal cord. Apparently the lower and inner parts of the pyramids decussate and go backwards, while the outer portions join the descending olivary tracts, and form the anterior columns; the posterior slender columns would also appear to descend a good way, though this is rather in opposition to certain views of their formation: the main posterior columns, where the extremities of the nerves are received, and the restiform bands, appear to us continuous.

Brown-Séquard's experiment of dividing the internal grey substance of the cord seems to show that ordinary sensation is conveyed upwards

through the inner substance of the cord in its opposite side. Subjects with great congenital atrophy of one side of the body have the opposite side of the brain atrophied, but with regard to the lobes of the cerebellum, that one on the side of the atrophy in the body is wasted ; it follows from this, that if the posterior columns are the conveyors upwards of any kind of impression, as the muscular sense, there can be no *spinal* decussation of these columns.

In cases where a limb has been long amputated, the posterior roots of the spinal nerves, the grey matter of the cord, and especially its posterior columns, as far as the medulla oblongata, are atrophied (Dr Dickinson, *Journ. Anat. and Phys.* 1868). Dr Dreschfeld also has shown that this atrophy affects the cells of the posterior horns, from desuetude we presume (*id.* 1880).

Supposing that the status of the muscles is rendered to the cerebellum by the posterior columns and restiform tracts, or rather, perhaps, their internal portions, the cerebellum appears sufficiently rich in organisation to receive complicated impressions, to separate, analyse, and distribute, as well as to combine and co-ordinate, this being accomplished by it through its anterior peduncles and the pons, by its disturbing momentum ; the cerebrum willing an action, but the cerebellum subservient, ruling elaborate movements which, in this, become more involuntary in nature. We do not, however, mean to exclude purely cerebral voluntary motor power, or the reverse, inhibitory influence ; hence the necessity for an afferent sensory as well as an efferent motor tract through the crus, between the spinal cord and the cerebrum, the former independent of the loop of the cerebellum ; the internal grey matter might be the medium, or rather the fasciculi, running upwards beneath the fourth ventricle (the posterior longitudinal spinal fasciculi of the tegmentum), though, we should add, that, according to some physiologists, the motor nerves themselves can telegraph upwards the state of the muscles which they supply, or that it can be estimated centrally, from the motor power required. We cannot think, as we understand Luys to say, that the cerebellum receives no afferent strands, and that it is an automaton having three processes or exits of power, or what he terms a trilogy of independent motor impulse, giving it higher powers than the cerebrum itself ; we cannot see how it can act at all without receptive influence ; it could not govern even the involuntary movements, whereas it seems to influence even the voluntary initiated by the cerebrum ; probably it is placed in connection with the cerebrum by some constituent of the tegmentum or upper peduncle. Its vast foliated expansion must have relation to some great function, and it appears likely to that of the numerous muscles concerned in locomotion, &c. There is no crossed action in the cerebellum itself, but only through the medium of the pons, because it is certain that the right or left cerebellar lobe corresponds to the left or right cerebral crus.¹

¹ The theory advocated of the function of the cerebellum seems fairly supported by the anatomy, but it is also corroborated by the experiments of division of its brachia, which have been long known, and the effects of which on locomotion have not been nullified.

According to Meynert, there is a connection between the cerebellum and corpus striatum—the latter part has cells of two distinct kinds, of which one kind forms a loop with the cerebellum through the crusta, substantia nigra, and pons, the crusta diminishing much in size at this part. This, probably, is afferent as regards the cerebellum, being a *processus cerebri ad cerebellum*.

Of the action of the cerebellum other theories, besides the one favoured here, have been advanced—as Ferrier's: that it governs the movements, but only as influenced by vision. The special character of its cortical nervous corpuscles may be found to have a bearing on the question; certain of the outer cells appear to be recipient, while other larger cells, those of Purkinje, arranged in regular series through the inner cortical layer, appear to have both exterior processes, which Meynert connects with the brachia to the pons, and centrally direct solitary processes connected with the lower peduncles. These cells may well be considered as constituting a commissure between its brachial and peduncular systems.

Dr Tuke, in contravention to there being any psychical or physical indication during life, in consonance with theories which are held by most physiologists respecting the cerebellum and co-ordination through the same, instances several cases of atrophy or destruction of the cerebellar hemispheres without such indications (*Journ. of Anat. and Phys.* 1873).¹

We are disposed to accept Ferrier's theory in part, and that vision subserves the cerebellum from above as the muscular sense does from below—vision through the tegmentum, in which case the particular element of the tegmentum concerned must be afferent to the cerebellum and not to the cerebrum; this particular element is probably the valve of Vieussens.

Broadbent says—"The cerebellum co-ordinates movements guided by vision (or other senses, as smell in the mole for instance), or combines the general movements of the body rendered necessary by special actions ordered by volition." Drs Howden and Brockman give instances analogous to the one of Van der Kolk; in the latter case, the right cerebral hemisphere, the crus cerebri, the corpus albicans, and optic nerve, were atrophied; whilst the left cerebellar hemisphere was correspondingly wasted (*Journ. of Anat. and Phys.* 1875-76).

¹ In the following case, a want of power of co-ordination attended disease of the cerebellum. The patient, a girl of fifteen, had from her childhood been subject to deafness and headache. Since a kind of fit, seven weeks back, she has had a slight hesitation in speaking, and the right arm and leg are both deficient in sensation and motion, the right leg being very slightly dragged. "When she walks it is with the head steadily fixed, and the eyes looking straight at the ground before her. If desired to lift her eyes from the ground her gait becomes unsteady, and she appears unable to regulate her course." The *post-mortem* showed that the brain substance was generally soft, and the ventricles filled with serous fluid. On coming to the cerebellum, a cyst was found in the right hemisphere containing laudable pus in large quantity. The auditory nerve was especially soft. See also a case reported by Dr Ferrier in *British Medical Journal*, December 11, 1880.

The disposition of the formative and efferent bands of the cerebellum is pretty well understood in their broad features, but much relating to it has not been worked out; its lower peduncle is composed of two parts, and the inner part enters into relation with the roof nuclei, discovered by Stilling, situated below the central lobule of the superior vermiform process; the two inner parts also decussate and then become related to the posterior medullary velum, the flocculus, and auditory nerve. We presume that this lower posterior peduncle in part may mediate or immediately ascend to the cerebrum. The superior peduncle of the cerebellum has its insertion or origin within the dentate nucleus of the cerebellum, differing in this from the other two peduncles. It is rather bold, what some might be inclined to do, to assign the flocculi, which, in some of the lower animals are surrounded by the semicircular canals, to the nerve of hearing. Perhaps, in regard to the lateral lobes and central vermiform body of the cerebellum, the first may have most relation with the limbs, the last with the trunk of the body.

Of the so-called respiratory tract in the medulla oblongata and top of the spinal cord, little of a precise nature can be said; we do not see that respiration requires other than nerves of a motor and sensory function, or of a mixed nature, as we may suppose the acknowledged respiratory nerves to be from their intermediate origin, yet do they appear remarkable in being interwoven with other nerves at their roots, and for the special latticed or retiform structure of the part of the bulb where they arise, interlaced as it is with numerous fibres arcuatæ, and effacing the ordinary disposition of the medulla.

Little definite being evident respecting the respiratory focus in the medulla oblongata from the anatomy, perhaps we may infer more from physiology and pathology. Both respiratory feeling (*besoin de respirer*) and respiratory movements, though seated primarily in the region of the medulla oblongata, are not entirely withdrawn from cerebral influence; hence, when the brain is oppressed the breathing becomes impeded. Swan especially, shows how this connection is effected anatomically. Sentiment likewise, as well as speech, is connected with respiration. On the other hand, in infants, certain spasmodic respiratory states, laryngismus or pertussis, so far as the latter is simply a spasmodic disease, become more urgent by inordinate cerebral or cerebellar action, or from an ill-matured state of the instinctive respiratory process. The great importance of the respiratory function is somewhat contrasted with the smallness of its medullary centre; and the nerves here given off seem rather superadded than of the ordinary spinal type, they all make their exit from the interior of the skull above the point of origin of some of their roots. Respiratory muscles may in addition be otherwise supplied, as those of the face, tongue, throat, and chest. The fifth nerve, the portio dura, the vagus, the glosso-pharyngeal, the hypoglossal, and the spinal accessory are all more or less connected with the respiratory reticulated region, and must be united in many sympathetic actions.

With such a function as we attribute to the cerebellum, the sense of hearing may be well allied. It is subservient to all the movements

of animals, and in man especially, to movements of a higher kind, indeed, in him it is intimately connected with his higher sentiments, and hence must be transferred upwards through the central grey substance probably, or in some other unknown manner. Meynert teaches that the auditory nuclei have no structural connection otherwise than with the cerebellum; at the same time he admits the feasibility of considering the upper cerebellar peduncles to include auditory tracts analogous to the optic; some, however, would sooner fix upon the valve of Vieussens thereto.

Higher up the great divisions of the peduncle of the brain become defined as an anterior motor (*crusta*) and a posterior sensory (*tegmentum*) portion. We presume that the posterior spinal columns are continued upwards into the restiform bodies, which they help to form, as these latter do the cerebellum, being the bearers to it of the status of the muscular actions, in contradistinction to common tactile sensation, conveyed upwards by the internal grey substance or the fasciculi above mentioned. The cuneate and slender columns at the back of the oblongata may take part in this, connected as they are below with the posterior columns, and indeed formed, as they are considered to be, by the crossing over of the arcuate fibres of the restiform, threading the bulb, and connected moreover with the olives, each restiform forming or helping to form the cuneate and slender columns on the opposite side (?); it is not possible, however, to trace these last upwards through the fourth ventricle.

The posterior longitudinal fasciculi seen on the floor of the fourth ventricle are continuous below with the posterior sensory spinal elements, and above go under the corpora quadrigemina to the third ventricle, the loop and Sylvian fissure: in the middle line of the ventricle below, however, the anterior motor columns ascend and project as the round fasciculi or *eminentiæ teretes*. The olivary bodies give another element to the crus above—the fillet; these olivary bodies have already been mentioned as united below with the outer undecussated fasciculi of the pyramids to form the median portion of the anterior spinal columns, as well figured in Hirschfeld's plate.

This fillet, connected above with the quadrigemina, also giving fasciæ more forwards (possibly a commissural respiratory cord) is seen, when we tear down through the locus niger, the tegmentum from the crusta, to merge into the olivary bodies as just said.

The above fillet, in part together with the respiratory tract, Swan carried upwards through the ring of his involuntary or middle tract to the summit of the cerebrum; but in itself it may be considered as a *processus inter corp. quad et medullam*.

Above the pons, of which each side half consists of the strands from the cerebral hemisphere of the same side, but interlaced by loops from the cerebellar peduncle of the opposite side, we may say the crus of the brain commences, but here fortified by pigmented cells (*locus niger*) which cease below. The anterior part of this crus or brain peduncle (*crusta*) seems simple enough in its arrangement, the outside bands, however, trending to an early crossing inwards. Swan's idea of the arrangement of the bands has been mentioned. Meynert teaches,

moreover, that the external and posterior part of the crusta receives strands from that portion of the cerebrum which we have considered to belong to its sensorial function, the temporal and parieto-occipital lobes, &c., and that these external fibres, more or less connected perhaps with the optic tract, cross over the other bands, and so, but through the upper or finer pyramidal decussation, trend towards the back part of the spinal cord. He considers them exceptional to the general motor function of the crusta, in opposition to that of the tegmentum which must be in the main sensory. There are other interlaced and inflected fasciæ in the crusta as those from the external corpus striatum in relation below with the third nerves and nates; fasciæ from the internal corpus striatum, &c.

Whilst the structure of the crusta or motor part of the brain-peduncle is tolerably evident, the intimate composition of the tegmentum or sensory portion is a more difficult study. Broadly speaking the latter has strands which are principally afferent of sensation to the cerebrum, though certain of them may transmit sense-impressions downwards. The principal connections above are the thalami and the cerebral convolutions, or the latter through the corpora quadrigemina and their brachia; below, the connections are the cerebellum, the medulla oblongata, and spinal cord. The internal grey matter around the central canal is no doubt one of the tracts by which sensation is conveyed upwards, trending to the intraventricular grey matter, and connected in front with the tuber cinereum, corpora albicantia, pituitary, and pineal bodies.

Foville places in apposition with these last the anterior terminations of the sensory and middle tracts, reflected outwards in the quadrilateral grey space to the points of the temporal lobes: we would not, however, separate these from the crescentic arches of Swan, or the substantia innominata.

Through the posterior tegmental portion of the crus, and in the direction of, but beneath, the corpora quadrigemina, ascend the posterior sensory tracts of the cord, so far as they have not been exhausted, or if they have been so exhausted, which hardly seems the case, they are yet virtually continued upwards through the grey substance, longitudinal fasciculi, and the cuneate and slender columns, which the restiform columns or inferior peduncles of the cerebellum have, according to Meynert, helped to form; and there are other bands which are constituents of the tegmentum. These are *in toto* the upper peduncles of the cerebellum, the valve of Vieussens, the posterior longitudinal fasciculi, the inner grey ganglionic matter, the fillet, the corpora quadrigemina, and also fibres interlacing with the anterior crusta. The posterior stratum of the pons would appear to belong to the tegmentum, and might be referred, as Meynert suggests, to the sensory and olfactory region about the caput of the corpus striatum above. Our view, however, of the functions of these constituents is in brief the following: the upper peduncles, crossing above, are afferent upwards, connecting the cerebellar lobes with the opposite cerebral; the longitudinal fasciæ convey upwards from the medulla to the cerebrum together with the central grey substance; the fillet and quadri-

gemina are respiratory, and the latter, moreover, especially connected with the cerebral nerves of sense and motion; probably the valve of Vieussens conveys from the cerebellum to the quadrigemina, or perhaps *vice versa* for the most part.

Kölliker makes the elements of the medulla oblongata to be as follows, and thus connected with the medulla spinalis:—

The anterior columns of the cord form or join the—

Pyramids (outer part).

Olivary columns (contributing to the peduncles of the cerebellum and constituting also the)

Fillet (and tegmental fasciæ).

The lateral columns constitute the—

Lateral fasciculi (contributing to the restiform bodies and tegmentum).

The decussation of the pyramids.

The eminentiæ teretes.

The posterior columns constitute the—

Fasciculi graciles (going to the tegmentum).

Fasciculi cuneati (to the peduncle of the cerebellum) and tegmentum.

The region of the corpora quadrigemina is formed of different elements and cells; their ganglionic parts, situated above the iter or communication between the third and fourth ventricle, and covered by medullary fibres direct from the cortex of the posterior part of the cerebrum, are enclosed below by another tegmental lamina; their capsules thus formed decussating in the middle line, give origin to the *processus corp. quad. ad cerebellum*, or valve of Vieussens; anterior to the iter or aqueduct lies that portion of the tegmentum seen below at the region of the lamina perforata posterior, and below this on each side is the crusta.

The true decussation of the tegmentum is other than the above decussation of the capsules, it is of the upper peduncles of the cerebellum below the corpora quadrigemina. Within and above is the aqueduct with the posterior longitudinal fasciculi at the sides and floor, also descending roots of the fifth nerve, rich in vesicular ganglionic cells; originating from the mid-fasciculi are roots of the oculo-motor nerves marked by large ganglionic cells, decussating and derived above, however, from the lenticular nucleus *via* the loop or collar or deep stratum of the so-called ansa and crusta. The superior peduncles of the cerebellum or *processus cerebelli ad cerebrum* after their decussation are in opposition to the lemniscus or superior lamina of the fillet.

The superior peduncles form the so-called red nuclei, the two fellow parts decussating behind the nates, as said before, between the posterior longitudinal fasciculi and the layer of the fillet, the tegmental fascicles from the spinal cord being pressed outwards. They are more prominent below than above, forming the lateral wall of the fourth ventricle, inclosing the valve of Vieussens from the corpora quadrigemina, and unite also the vermiform lobe of the cerebellum with the fillet. The above red nuclei on the one side are connected with the

thalami and corona radiata; on the other, as just said, with the superior peduncles, *i.e.*, the processus cerebelli ad cerebrum.

The antero-lateral part of the tegmentum interweaves with the descending root nuclei of the fifth nerve, forming a kind of upper interlaced or latticed region (analogous to that of the medulla oblongata).

The entry and exit of the elements of the crus into the cerebrum is not absolutely a simple matter; the substantia innominata or ansa peduncularis of Gratiolet (being probably the crescentic arches of Swan) is a disposition of the constituents of the crura, near where they are crossed by the optic tract; one of its components, the loop, belongs to the crusta, and is formed by the fasciculi of the lenticular nucleus of the corpus striatum; the next is a ganglionic expansion, formed by the posterior longitudinal fasciculus from the tegmentum, and expanding above into the external capsule of the lenticular nucleus and Sylvian floor; another is the inferior peduncle of the thalamus connected with the cortex of the Sylvian fissure and the temporal lobe; the fourth constitutes the temporal portion of its zonal or encircling stratum. The connection of the tegmentum by the posterior longitudinal fasciculi and their laminae of the ansa with the island and capsule of the lenticular ganglia of the corpus striatum is not, like that of the crusta by its loop or collar, effected through the means of the laminae medullares of the latter; which last, centrifugally it may be supposed, conveys motor impressions to the lower oculomotor nerves.

The tegmentum, as far as the thalamus is concerned, is connected with it, with decussation or not, at various points—the posterior commissure, its medullary laminae, the peduncular ganglion of the pineal, and by the distinct ganglia situated below the thalami called the red nuclei, which are connected behind with the anterior peduncles of the cerebellum.

With the tegmental system the optic tract is in union through the corpora quadrigemina, and also through the virtual prolongation of the tegmentum through the grey substance of the ventricles. Here it comes in relation with the basal optic ganglion near the chiasma, and also with the anterior distribution of the fornix. The union of the optic tract with the tegmentum is specially effected by the corpus geniculatum externum, in a peculiar structure¹ consisting of alternate

¹ A not uncommon form of transient hemiopia seems due to the structure of this body; it is described by Dr Airey, and an abstract of his paper is given in *Scientific Opinion* for 1870, but the present writer may describe the affection as for some years it has occurred to himself, after close study, unusual exertion, &c. It is often attended with headache, and the attack, from beginning to end, may last half-an-hour. It commences with the appearance of a small cloud a little above and to the right of the field of vision. At this spot a few scattered lines and angles appear, and gradually a line of bastions or zigzag, such as we see in Norman architecture, takes a circular or oval form, but incomplete below. It is luminous and presents a peculiar waving motion; after enlarging, it disappears by becoming shorter; occasionally the circle is intersected by a second further inwards. It is equally present whether the eyes are open or closed, more luminous in the latter case; any partial pressure on the globe of the eye produces no change; but the spectrum is affected by pressure on the carotid.

layers of white and grey substance; the tract is then in connection with the inner corpus geniculatum, with the nates and testes, the cerebellum, and in the lowest vertebrata with the cord.

The sensorium appears to be informed of the movements, as modified by cerebellar action, through the upper peduncles or processus cerebelli ad cerebrum. In this region, too, together with the tracts above enumerated, is the connection of the optic tracts with their motive adjuncts or ganglia, and hence is conveyed upwards the intimation which muscular action of the optic motor nerves adds to the mere sensation of the retina.¹ These motores oculorum nerves have no connection with the cerebellum, at least the principal ones, the third pair, and consequently the action of its fellows, is less separable than those of a nerve given off below the cerebellum as the sixth, and therefore must be antagonized by a nerve pair, of which either right or left can be separately excited. In the mole the optic nerve seems only a light—not an object organ, and in the parasitic and sessile cyclopterus it has no other connection with the cerebrum than a slight one with the grey matter before the pituitary body—its further insertion in other animals in the geniculata and quadrigemina and connection with muscular nerves gives further powers of sight; and further still, its connection in the higher animals with the thalami and through them with the cortex of the brain.

The recognised origins of the so-called cranial mixed or motor nerves are such as to admit earlier or later of an union, either commissural or decussated, but generally speaking no further tract upwards to the cerebrum can be assigned to them, though it can with respect to the third and fourth nerve *via* the lenticular nucleus.

Smell in man may be principally connected with the grey substance at the base of the brain, and with the amygdala (Luys); in most Mammalia the more highly developed nerves run further back through the spheno-temporal lobe and hippocampus, as well as through the gyrus fornicatus, so that such brains have been termed olfactory. The olfactory lobe or tract, at first evidently in union with the internal and external olfactory convolutions, is connected by a medullary tract to the perforated and internal grey substance and so to the fornix; its internal or medial connection is also the anterior extremity of the gyrus forni-

¹ That the fourth nerve is liable to paralysis would appear from the following:—A collier has complained of double vision and headache for six months. They came on gradually, he at first noticing a waving of the candle in the pit. The eyes ached much when used. The peculiarity is seen chiefly when he looks upwards or at a face before him. This peculiarity is a rotation of the eye on its antero-posterior axis when looking at an object. The pupils contract as usual. The rotation is inwards and downwards, that is, from the temple over the cheek towards the nose, the action would seem to be produced from the inferior oblique muscle having lost the effect of its antagonist, the superior. The crossing of these nerves is in the valve of Vieussens external to the point of origin.

Ptoxis is often a prelude of brain affection, as is also defect of nervous power in the hypoglossal nerve. In the latter case the major affection may be in abeyance for years, the former in one case continued six months, eye everted, pupil somewhat dilated, articulation also somewhat affected; apoplexy and paralysis then came on; the tongue was put out, directed to the right, which was the side paralysed.

catus, together with some minor bandelettes belonging to the corpus callosum, septum lucidum, &c.

Hearing is more especially united with the cerebellar centre of locomotion, which, when uncontrolled by the cerebrum, it is so concerned in directing, and secondly with the conscious cerebral centre by means of the grey matter of the cerebral cavity, or the valve of Vieussens it may be.

Taste apparently is only perceived through the glosso-pharyngeal, and the rationale of its centre seems much as is the case with the nerve of hearing. Thus the sense nerves are inserted in various ways immediately or mediately into the cerebrum or its ganglia. Yet if taste is inherent in the glosso-pharyngeal, as might be inferred from the parts supplied by that nerve being precisely the seat of taste, it seems strange that taste and smell, so closely allied in their nature, should be so far separated in their cerebral centres. We might from this last consideration be disposed to assign taste to the gustatory nerve, were it not from experiment showing that the true gustatory surface (of the tongue and palate) is supplied by the glosso-pharyngeal directly or indirectly, and besides, the latter nerve has most relation with the pharynx, as its name implies, so intimately concerned in the act of swallowing.

With the olivary tracts or fillet, according to Solly, the fourth nerve, the motor root of the fifth, the sixth, the portio-dura, and the ninth nerves, are attached; but the so-called origin of the cerebral nerves would be a matter for a volume rather than an essay like this. All the cerebral nerves except the first four are in relation at their origin or insertion with certain nuclei of sensory or motor cells situated principally in the fourth ventricle, and amenable to the demonstration of transverse sections, chemical and colouring re-agents, and the use of the microscope. Hence the importance of the ventricular floor. These nuclei have been so studied at this point by Stilling, Clarke, Dean, Meynert, &c. The account given by Meynert is ample enough as far as the subject is understood, and we must refer to him. Physiology and anatomy do not appear to differ in this point; the fifth nerve has, as has long been known, several places for its deep insertion. The abducens oculi we have already said to be influenced by the cerebellar action according to our theory, but it is also considered to be connected above with the corpora quadrigemina, and it is synenergetic with the third nerve. The facial, considered by Winslow from its large distribution to be a smaller sympathetic, has numerous points of origin; the auditory nerve cannot fairly be traced to the cerebrum, but appertains rather to the cerebellum, so necessary as hearing is a guide to movements.¹ The three respiratory nerves Meynert arranges as a lateral system of mixed function, in relation to the reticular structure of the medulla oblongata, a structure which appears to account in some degree for the numerous liaisons which there must be of nerve roots at

¹ The auditory nerve includes a softer and less fibrous portion, and this it derives from the cochlea, which is most developed in the highest vertebrata, birds, and Mammalia and it is this portion which theory would lead us to attach to the cerebrum.

this locality. As to the separate and special functions of the three nerves constituting the eighth, it may perhaps be said that experimental physiology has not thrown unmixed light upon them; the spinal accessory is no doubt, as its name expresses, a motor adjuvant to the pneumo-gastric, whilst the glosso-pharyngeal, with its jugular ganglion, seems as clearly sensitive distributed to the internal ear, palate, tongue, and upper pharynx. The pneumo-gastric, called the middle sympathetic by Winslow, receiving through its ganglion branches from the adjacent petrous ganglion of the last, and conjoined with the accessory in the ganglion or plexus of the trunk, must be considered a mixed nerve, but principally motor, but sometimes inhibitory of motion. Its supply to the larynx is, as is well known, very noteworthy. The hypo-glossal has evidently a motor, and like the other motor nerves is crossed at its roots. As the nerve of speech it should be, as it is, connected with the trunk of the ganglion of the great nerve of respiration; it also, as is well known, supplies the muscles connected with the tongue, and is reinforced from the cervical nerves through the descendens noni, &c.

Supplementary to the above, it should be said that Stilling's nerve nuclei are principally situated on the lozenge or rhomboid-shaped floor of the fourth ventricle as follows:—Considering the space itself as marked above by the convergence of the superior peduncles, and below by the divergence of the fasciculi graciles, divided also by the median furrow, and crossed in the middle by the striæ medullares of the auditory nerves. At the upper angle are the eminentiæ teretes, and without these appear the fossæ cæruleæ caused by cell clusters belonging to the sensory roots of the fifth nerve. Lower down is the auditory nucleus, and below this that of the glossopharyngeus. In the middle line are the nuclei of the facial and sixth pair. In the lower portion of the space is the grey nucleus on each side common to the vagus and accessory nerves, and in the middle line the emitteretes and the nuclei of the hypoglossal.

The small motor root of the fifth nerve in connection with one set of its sensory roots is derived perhaps from the vicinity of the aqueduct, and other sensitive roots from the nates, and others again ascend from the corpora gelatinosa of the medulla; the nerve also seems influenced by the cerebellum. Meynert makes the sixth nerve to be connected with the pyramidal decussation, and so of the facial nerve, the latter trending to different points of origin—descending, plane, and ascending. The nuclei of the auditory nerve are by no means simple though, as already said, no higher connection than the cerebellum is shown. The hypoglossal corresponds much with the sixth nerve in a motor origin and in its decussation. According to Schröder v. d. Kolk this nerve's origin is connected with the olivary body.

Dr Ferrier's experiments give a cerebral centre to the three nerves of smell, taste, and hearing in the hippocampal lobe. In this case, might not the fornix be the conductor of the posteriorly received sensations of taste and hearing from the central grey matter?

The fifth nerve appears to be the double-rooted spinal nerve of the head, if it be not the union of three, if not four, nerves analogous to spinal

ones, motor roots being only furnished to the last division ; the rest of the face and head being supplied by the seventh and cervical motor nerves in addition to the fifth. A rationale, which may assign each division of the fifth to an especial cranial vertebra, seems difficult to discover. Valentin treats upon this point in the *Nevrologie*. This seventh, or facial nerve, does not answer to a regular spinal nerve, or to either portion of one ; it is *par excellence* a nerve of expression and of respiratory movement of the face, especially attached likewise to the internal ear and petrosal bone, the last being intercalated, and not of the regular vertebrate series. It is remarkable whilst in its bony canal for its connections with Meckel's and the otic ganglia, probably conveying motor power to nerves of the palate and internal ear, also for its communication through the chorda tympani with the sub-maxillary ganglia. This last nervous chord, with the three ganglion, may be considered as belonging to the sympathetic system, as also may the ophthalmic ganglion, a distributive or reflex function being also attached to them ; and all the cerebral nerves, except those of pure sense, intimately connected with this sympathetic system. What the seventh is to the face, motor, yet of respiration and expression, the fourth nerve is to the eyeball.

The individuality, as far as sensation and perception are concerned, must be largely maintained by the continuity or solidarity of the grey ganglionic substance lining the whole cavity of the central nervous organs ; not ignoring, however, the connection of one portion of the apparatus of organic life with another as maintained by the ganglionic sympathetic nerve, the heart with the lungs, or the stomach with the bowels or heart. Certain terminal and denuded grey surfaces in the brain and spinal medulla as the pituitary body, pineal gland, and filum terminale have been suspected to be in relation especially to the central grey matter, the former to sympathise in disordered action of the organic nerves. It might also be opined that the appendages in question may be sensitive to impressions upon the nervous organs themselves, as a whole, as from succussion, shock, &c. This central grey nerve matter may be the seat of pain, or at anyrate of that general bodily feeling of *malaise* or exhilaration which may be our misery or comfort, to say nothing of more dangerous hyper-æsthesia.¹

Dr Ferrier is disposed to connect the corpora quadrigemina with equilibration, locomotion, and emotional respiratory expression. The corpora quadrigemina have a variation as to size in relation to vision ;

¹ In tetanus, according to J. Lockhart Clarke, the seat of lesion is the grey substance in the cord (see his paper in vol. xlviii. of the *Med. Chir. Trans.*) associated with a morbid condition of some of the peripheral nerves ; two of Clarke's cases occurred under the notice of the writer of this. In another case of injury of the left thumb and index finger, the nerve going to the back of the thumb was much enlarged, the same nerve in the forearm injected, as was also the brain and spinal cord. In hydrophobia we might suppose the morbid action is directed to different strands in the cord, &c., sensory rather than motor, of which nature (sensory) the symptoms seem in the main to be. It appears remarkable that tetanus never occurs from the operations of dentistry, probably from the character of the nerves injured. In paralysis there is also dilatation of the central cavity of the cord and wasting of the strand concomitant with that of the muscles.

it may be inquired whether this relation holds with respect to both upper and lower pairs, or only to the lower, with which the optic tracts seem more especially connected, or whether they have any relation to the musculature of the eyes. Comparative anatomy ought to throw some light on this subject; it is not certain that any sense is in special relation to the upper pair, though they may have anatomical connection with those roots, which, in part, run backwards through the internal capsule, and form the anterior peduncle of the thalamus; the corpora quadrigemina exist well developed in many Cetacea, in which an olfactory organ scarcely exists at least under an unmodified form. The mole has the lower bodies small, whilst the hippocampi are large, and so in the monotremata. They are comparatively moderate in man, the upper ones largest in Rodents and Herbivora the lower in Carnivora. Through the adjacent bands the sensory afferent bands of the cerebrum must ascend to the thalami and cortical substance, communicating likewise with the lenticular part of the corpus striatum.

The connection of the thalami with the medulla of the cerebrum is well seen by placing the brain on its upper surface, and exposing the roof of the ventricle in its full extent, removing the hippocampal convolution of the sphenotemporal lobe. They are, on the other hand, certainly continuous with the corpora quadrigemina and the sensory strands, thus constituting a great centre, initiating movements by reflexion even directly without the exercise of volition (sensori-motor) being in immediate connection with the motor corpora striata; hence it is hard to refrain from movements if the feelings predominate though the will may disapprove.

It is the thalami which principally supply or receive the medullary strands of the middle temporal and occipital regions of the brain, a few excepted, which have a more immediate course behind to the crus; they (the thalami) are connected with the frontal lobes by their anterior peduncles. They also derive an inferior peduncle from the Sylvian fissure and temporal lobe, the third stratum of the collar or ansa; in this way also the external lamina or zonula layer is formed. The afferent strands of formation are the corpora quadrigemina and tegmentum, the latter ascending from the periphery. The fornix contributes also to the thalamus by its ascending and descending crura, connected also with the ventricular grey matter, stria cornea, and corpora mamillaria, &c. Of course the connecting fibres forming the above-mentioned anterior peduncle must run in a different direction through the internal capsule from those derived from the central medullary fibres of the cerebrum. The upper peduncle of the thalamus is derived from the ascending pillar of the fornix and gyrus fornicatus; the thalamus also is connected by its corresponding surface with the parietal, temporal, and occipital lobes.

The corpora striata, ventricular, and extra-ventricular are as clearly connected with the efferent locomotive strands of the crus as the thalami are with their afferent sensory strands.

In many cases the ventricular corpus striatum is continued posteriorly by its attenuated extremity along the inferior horn, præflexed on itself.

With respect to the inter-communication of the corpora striata and thalami, Luys connects the tegmentum, belonging to the sensory system, with the concentric septa of the external striata by means of fibres running beneath the thalami *via* his superior olivary bodies or red nuclei. He also connects the front of the thalamus with the corpus striatum by means of certain fibres bent upon themselves, which he calls cortico-striate, deriving them at their origin from the cerebral convolutions. Meynert connects the thalamus with the corpus striatum by means of the anterior peduncle of the former. But it would appear that there is a closer union of the thalamus and the corpus striatum accounting for sensori-motor action. There is the interlacement that takes place through the convolutions and deep substance of the island; besides there is a more direct commixture between the thalamus and the internal corpus striatum, as well as the external corpus striatum.

The origin of a large portion of the cerebral convolutions, the posterior, middle, and inferior, from the medullary strands connected with the thalami is pretty certain; and correspondingly the reception by the corpora striata of the medullary strands arising from the greater portion of the anterior convolutions—sensation and perception appertaining to the former, voluntary or even unconscious ideo-motor impulse arising in the latter. It may be seen by ablation of the convolutions bordering the island of Reil that the extent of the latter corresponds with the extent of the corpora striata and thalami, and that the lenticular portion of the corpus is in apposition behind with the thalamus. But many anatomists, as Kölliker, deny the uninterrupted descent of locomotive medullary fibres of the brain through the corpora striata.

Dr Broadbent makes the convolutions which are connected with the crus to have each one, both motor and sensory fibres, distributed together through the internal capsule so called; and besides each one, callosal fibres.

Meynert is of opinion that the corpus striatum, and also the thalamus, are connected with almost all parts of the hemisphere—the former, however, more especially with the anterior lobes, and the latter with the posterior; and therefore that every convolution is not destitute of both motory and sensory fibres. That there are direct fibres from the medulla spinalis to the convolutions is inferred by Huguenin and others, and it has been seen that degenerations of the cord have had corresponding lesions in the convolutions, but not in the just mentioned ganglia. These lesions, concomitant with paralysis, or congenital deficiencies, or defects of development, such as the original want of a hand or defect in an organ of sense, often furnish additional corroboration of the doctrine of cerebral localisation.

It must be added, moreover, that Dr Broadbent, whilst he says there is an uninterrupted passage of the crus into the convolutions in part, makes the corpora striata most intimately connected with the crus, the thalami, on the contrary, with the convolutions; and observes “anatomical structure does not lead us to expect that there will be a distinct sensory and motor region of convolutions.”

Dr Broadbent further denies that all convolutions are connected with either the corpora striata or thalami. For instance, the lateral convolutions situated between the longitudinal or marginal, and those surrounding the island, though upon transverse sections of the brain these appear to give off fibres descending to the crus. It is evident, however, that the convolutions are bound together by longitudinal commissural bands. The convolutions on the internal surface within the longitudinal fissure are evidently so connected, as shown by their crested disposition, and so well figured by Foville. The commissural fibres, including the important series of arcuate fibres connecting the gyri together, are perhaps as extensive as those of a radiate disposition.

But, contrary to what Foville supposes, the corpus callosum is not a portion of the divergent crura bending inwards and forming a kind of enclosure to the ventricles, nor, as Swan teaches, a commissure of the inner margin of the hemispheres. It is seen upon sections of the hemispheres to arise from almost all parts of them, the anterior commissure helping, however, to connect the temporal lobes and corpora striata in a transverse way; whilst the fornix, with its accessory bandelettes, unites the hippocampi and temporal tuberosities in a longitudinal manner to the grey matter within the ventricles, and at the base of the brain about the optic chiasma—in fact, it seems to belong to the system of the corpus callosum, and to the intercerebral septum.

Perhaps this general review of the subject may point out to some extent what is the truth in this difficult piece of anatomy and physiology; but there are many points which await further elucidation, even the course and connection of the principal cerebral strands, which must be all-important factors as regards function.

The motor portion of the cerebrum, as determined by experiments, corresponds pretty well with the parts which are shown by the anatomy as probably connected with the crusta, and to have that function. In this front part of the brain, however, are parts not having a motor function. Nerve roots from the first nerve join the anterior commissure, and so go to the temporal lobe, and thence to that more posterior part of the brain which, with its centre (the thalamus), appears to appertain to sensation. These last ganglia also receive other fibres from the frontal lobe and head of the corpora striata, as already said.

Of course, as might be expected, numerous objections have been made to the doctrine of localisation—as unavoidable diffusion of the currents, the excitability of the action *solely* by the electrical irritation, and on the supposition insisted on by Brown-Séquard, that the brain acts *en masse*, and that its motor power is not differentiated in any particular localities of it. This physiologist also calls in inhibitory action to account for the phenomena, of which last theory Dr Dodds observes that, while it “has little to support it in fact, its adoption lands us in hopeless difficulties.” Schiff and other physiologists, totally contrary to Ferrier, believe all the convolutions to be sensory, and the contractions to take place from the transference of impulse to

the lower ganglia. The latter may be the case sometimes, and the convolutions irritated not the *pons et origo* of the motion, influenced by the will in the normal state. They may be in some cases sensori-motor, or connected with more distant convolutions, the latter receiving impressions from the organs of sense. Extirpation, &c. of convolutions strengthens the doctrine of localisation, though the loss of motion is liable to be recovered from, especially in the lower animals, and in this case it appears to us that Ferrier's view is very probable—that the actions regained are of a different kind, more automatic, and the result of the action of lower centres. The phenomena of aphasia, according to Broca's view, remarkably confirm the doctrine of localisation; and, moreover, show that the left hemisphere takes the lead, almost without exception, in initiating the movements necessary to speech. Therefore, it happens that we need only walk the wards of an hospital or asylum to see the very general association of aphasia with right hemiplegia.

Dr D. J. Cunningham records a case in which a large subarachnoid cyst “corresponded to the position of the following convolutions:—(1) The ascending parietal; (2) the supramarginal, or the convolution of the parietal eminence; (3) the angular; (4) the posterior portion of the superior temporo-sphenoidal convolution.” The patient was peculiarly affected with a general hypertrophy, but “he had no symptom whatever of paralysis or paresis.”—*Journ. of Anat. and Phys.*, 1879.

Dr Carmichael, in the same journal for 1880, relates two cases of lesion of the temporo-sphenoidal lobe without any indications of loss of special sense.

I should expect that in cases where the left external frontal lobule is solely diseased that there will be aphasia and right hemiplegia during life; but they also undoubtedly occur with extensive disease of the left island of Reil, the left hemisphere, &c., while the frontal lobules remain healthy or nearly so; but this from faculties being injured which are requisite in speech.



INDEX.

A.

- Abdominal Wall, Fissure of, 226.
Abraham, P. S., on Pilose Growth in Pharynx, 244.
Acute Yellow Atrophy of Liver, 422.
Allen, W., on Occipital Tertiary Condyle, 60.
Anderson, R. J., Arterial Anomalies, 136; on Epispadias, 378; on Muscles of Tongue and Pharynx, 382.
Anomalies, Arterial, 136; Nervous, 295; Osseous, 60, 292; Muscular, 139, 293; 296.
Apes, Femoral Artery in, 523.
Artery, Femoral in Apes, 523.

B.

- Balæna Mysticetus, Hind-Limb of, 141, 301.
Biceps Flexor Cruris, Variety of, 296.
Bladder, Urinary, Lymphatics of, 355.
Bone, Malignant Tumours of, 405, 496.
Bovine Tuberculosis, 1, 177.
Brain, Neuroma of, 217; Cerebellar Disease, 252.
Brain and Nervous System: a Summary and a Review, 536.
Brown, J. M., on Malformation of Feet, 448; on Femoral Artery in Apes, 523.

C.

- Cancer, Primary of Femur, 496.
Callomystax gagata, Stridulating Apparatus of, 322.
Cartilage, Lymphatics of, 121.
Cash, J. Th., on Muscle and its Contraction, 431.
Cerebellar Disease, 252.
Chalicosis Pulmonum, 395.
Chapman, H. C., on Placenta and Genital Apparatus of Elephant, 330.
Chloroform as an Anæsthetic, 110.

- Cirrhosis of Liver, 69.
Climate and Temperature of Human Body, 118.
Colouring Matter of Jelly Fishes, 261.
Condyle, Occipital Tertiary, 60.
Costal Respiration, Mechanism of, 331.
Creighton, C., on Tuberculosis, 1, 177.
Cunningham, D. J., on Nerves of Hind-Limb of Thylacine and Cuscus, 265.
Cuscus, Nerves of Hind-Limb of, 265.
Cystic Disease of Ovary, 453.

D.

- Dicrotism, Pulse, 278.
Dislocation, Congenital, 452.
Doran, Alban, on Genito-Urinary Organs in Fissure of Abdominal Wall, 226.
Doran and Harris on Cystic Disease of Ovary, 453.
Dreschfeld, J., on Cirrhosis of Liver, 69; on Acute Yellow Atrophy of Liver, 422; on Primary Lateral Sclerosis, 510.
Dwight, Thos., on Sternum as Index of Sex and Age, 327.

E.

- Elephant, Placenta and Generative Apparatus of, 330; Form and Proportions of Foetal Indian, 519.
Elephant, Foetal Indian, 519.
Epispadias, 378.
Ether Percolator, 105.
Ethidene Dichloride as an Anæsthetic, 110.

F.

- Feet, Malformation of, 448.
Femur, Primary Cancer of, 496.
Femoral Artery in Apes, 523.
Femur, Dislocation of head of, 452.
Fissure of Abdominal Walls, 226.
Fleming, W. J., on Pulse Dicrotism, 278.
Foetal Indian Elephant, 519.

G.

- Garner, Robt., Summary and Review on Brain and Nervous System, 536.
 Genito-Urinary Organs, 226, 378.
 Glands, Liver, 69, 422; Sweat, 238; Kidney, 249; Mammary, 346.
 Greenland Right-Whale, Hind-Limb of, 141, 301.
 Granular Kidney, 249

H.

- Haddon, A. C., on Stridulating Apparatus of *Callomystax gagata*, 322.
 Halliburton, W. D., on Abnormal Biceps Flexor Cruris, 296.
 Harris, Thos., on Pneumonokoniosis, 395; Chronic Lobar Pneumonia, 502.
 Harris and Doran on Cystic Disease of Ovary, 453.
 Hind Limb, Pronation and Supination in, 392.
 Hind Limb of *Balæna Mysticetus*, 141, 301; Nerves of, in *Thylacine* and *Cuscus*, 265.
 Hobson, J. M., on Mechanism of Costal Respiration, 331.
 Hoggan, Lymphatics of Cartilage and Perichondrium, 121; of Urinary Bladder, 355; of Pancreas, 475.
 Human Body, Temperature of, 118.
 Hydrophobia, Vascular Lesions in, 88.

I.

- Infective Tuberculosis, 1, 177.

J.

- Jelly Fishes, Colouring Matter of, 261.
 Jones, Handfield C., on Mechanism of Secretion of Sweat, 238.

K.

- Kidney, Granular, 249.
 Koala, Anatomy of, 466.
 Knott, F. G., on Muscular Anomalies, 139.

L.

- Lead Paralysis, Anatomy of, 78.
 Liver, Cirrhosis of, 69; Atrophy of, 422.
 Lymphatics of Cartilage and Perichondrium, 121; of Urinary Bladder, 355; of Pancreas, 475.
 Lobar Pneumonia, 502.

M.

- Macphail, Donald, on Ether Percolator, 105.

- Maguire, Robt., on Malignant Bone Tumours, 405; Primary Cancer of Femur, 496.
 Malignant Bone Tumours, 405, 496.
 Malformations, 226, 378, 446.
 Mammary Gland, *Membrana propria* of, 346.
 Man, Tuberculosis in, 1, 177.
 Marsupials, 265, 392.
 Mechanism of Costal Respiration, 331.
 Medullary Neuroma of Brain, 217.
Membrana propria of Mammary Gland, 346.
 Microscopic Specimens, Staining of, 349.
 Middleton, G. S., on Vascular Lesions in Hydrophobia, 88.
 M'Kendrick, Prof., on Colouring Matter of Jelly Fishes, 261.
 Moritz, S., on Lead Paralysis, 68.
 Moullin, W. M., on *Membrana propria* of Mammary Gland, 346.
 Muscular Anomalies, 139, 293, 296.
 Muscle and its Contraction, 431.
 Muscles of Tongue and Pharynx, 382.

N.

- Nerves of *Thylacine* and *Cuscus*, 265.
 Nerve Fibres, Structure of, 446.
 Neuroma of Brain, 217.
 Newman, David, on Comparative Value of Chloroform and Ethidene Dichloride as Anaesthetics, 110; Polygraph, 235.

O.

- Occipital Tertiary Condyle, 60.
 Oliver, Thos., on Cerebellar Disease, 252.
 Osler, Wm., on Medullary Neuroma of Brain, 217.
 Ovary, Cystic Disease of, 453.

P.

- Palate, Soft, Absence of, 295.
 Palatine Branch from Middle Meningeal Artery, 136.
 Pancreas, Lymphatics of, 475.
 Paralysis Lead, Anatomy of, 78.
 Percolator, Ether, 105.
 Perichondrium, Lymphatics of, 121.
 Pharynx, Growth-bearing Pilose Skin in, 244.
 Pharynx, Muscles of, 382.
Phascolarctos cinereus, 466.
 Pilose Growth in Pharynx, 244.
 Pinkerton, Robt., on Temperature and Climate, 118.
 Placenta and Generative Apparatus of Elephant, 300.
 Pneumonia, Chronic Lobar, 502.
 Pneumonokoniosis, 395.
 Polygraph, 235.
 Primary Lateral Sclerosis, 510.
 Pronation, 392.
 Pulse Dicrotism, 278.

R.

Respiration, Costal, 331.

S.

Saundby, Robt., on Granular Kidney, 249.

Secretion of Sweat, Mechanism of, 238.

Sclerosis, Primary Lateral, 510.

Shepherd, F. J., on Congenital Dislocation of Head of Femur, 452; on Anatomical Variations, 292.

Soft Palate, Absence of, 295.

Staining of Microscopic Specimens, 349.

Sternum as Index of Sex and Age, 327.

Stirling, Prof., on Staining of Microscopic Specimens, 349; Structure of Nerve Fibres, 446.

Stridulating Apparatus, 322.

Struthers, Prof., on Rudimentary Hind-Limb of Greenland Right-Whale, 141, 301.

Supination, 392.

Sweat, Mechanism of Secretion of, 238.

T.

Temperature of Human Body, 118.

Tertiary Occipital Condyle, 60.

Thylacine, Nerves of Hind-Limb of, 265.

Tongue, Muscles of, 382.

Tuberculosis, 1, 177.

Tumours of Bone, Malignant, 405, 496.

Turner, Prof., Abstract of Chapman's

Memoir of Placenta of Elephant, 330;

On Form and Proportions of Fœtal

Indian Elephant, 519.

U.

Urino-Genital Organs, 226.

V.

Vascular Lesions in Hydrophobia, 88.

Variations, Anatomical, 136, 139, 292 296.

W.

Whale, Greenland, Hind-Limb of, 141, 301.

Y.

Young, A. J., on Pronation and Supination, 392; On Anatomy of Koala, 466.

Fig. 1.

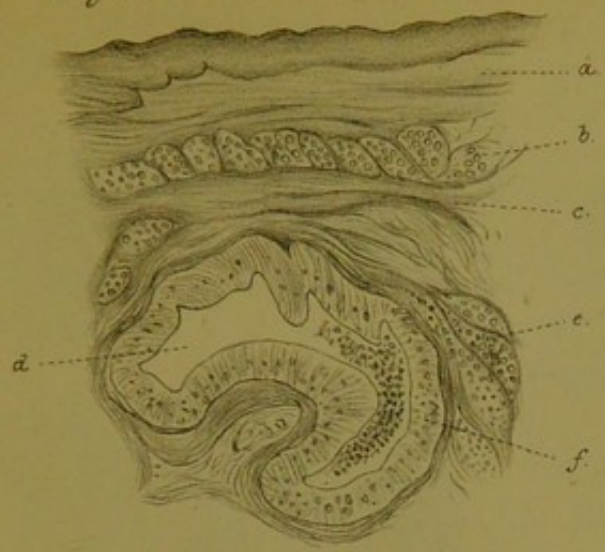


Fig. 3.

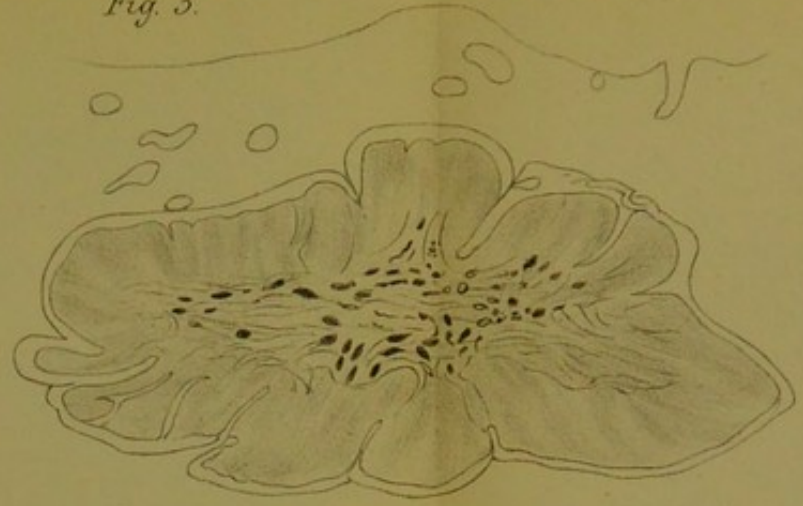


Fig. 2.

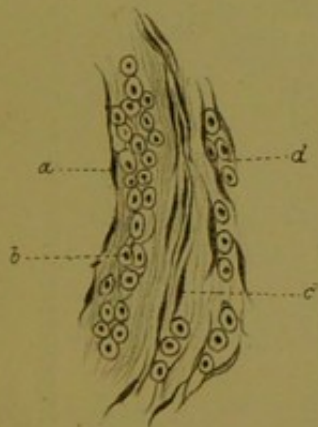


Fig. 4.

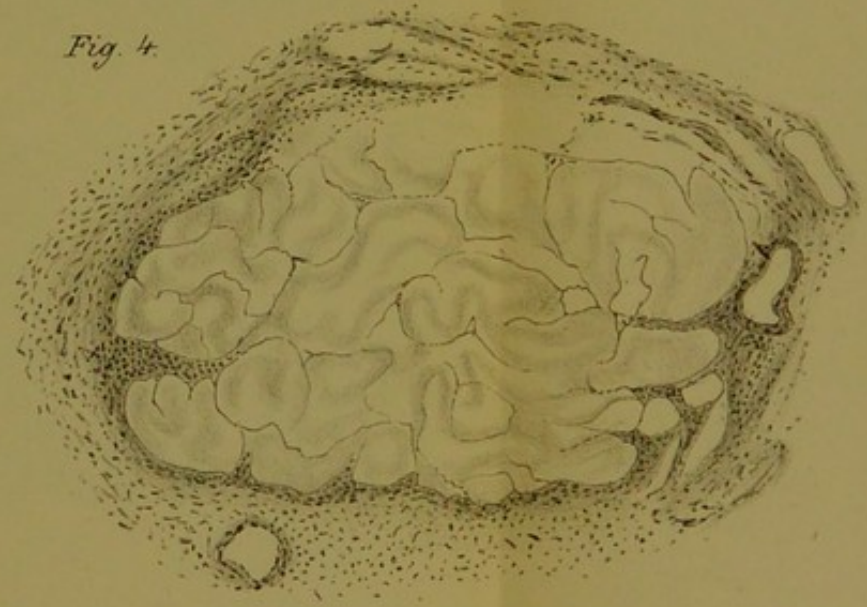


Fig. 5.

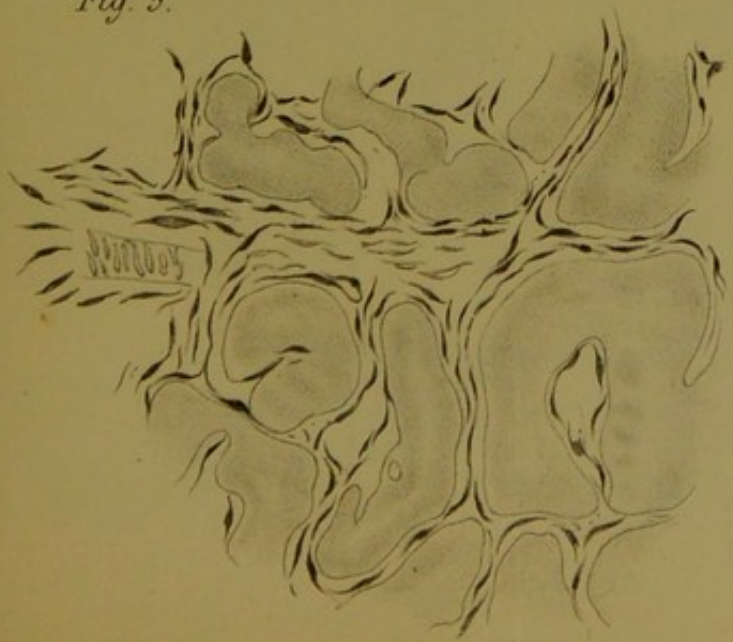

Fig. 6.

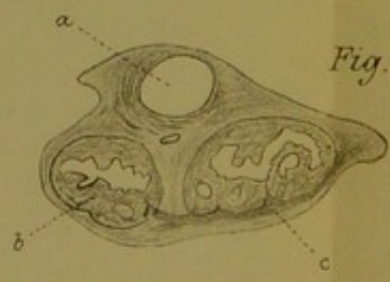
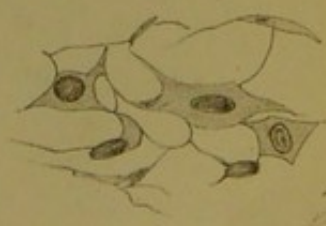


Fig. 8.

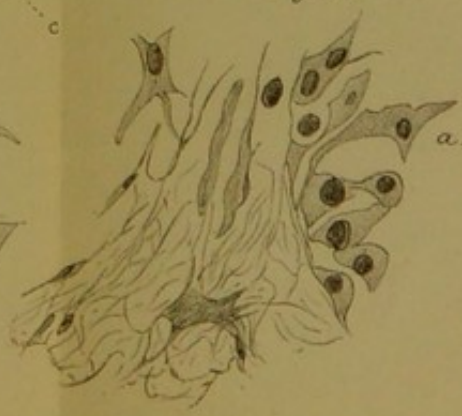

Fig. 7.






Fig. 1.

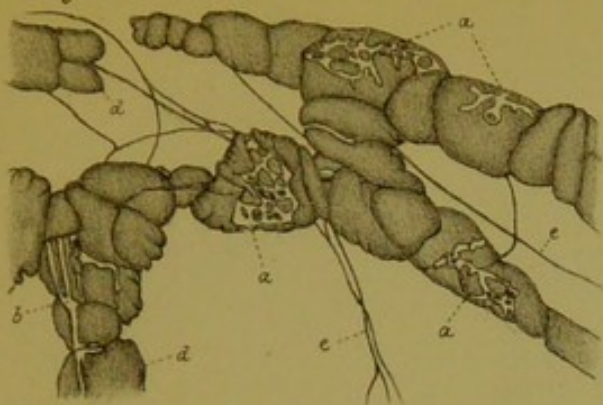


Fig. 2.

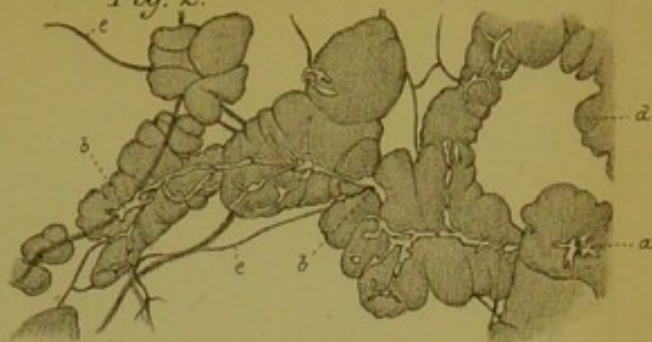

Fig. 3.

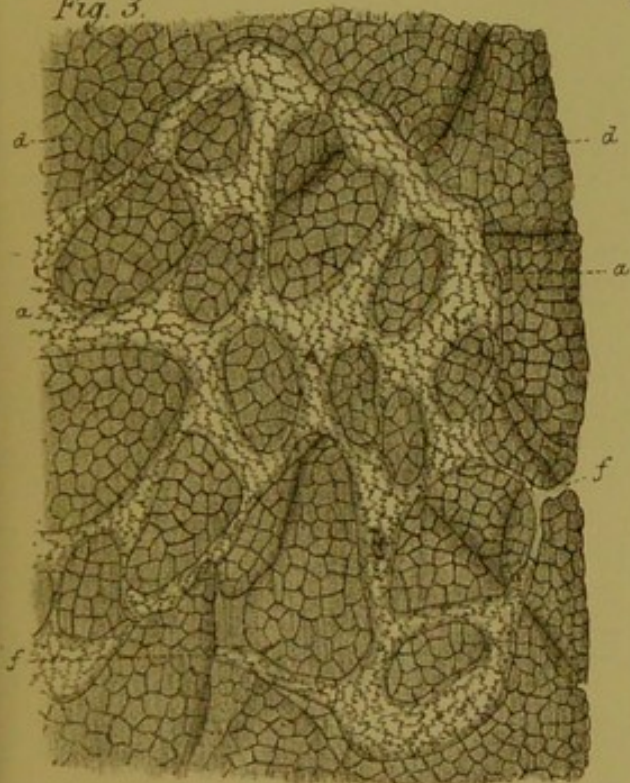


Fig. 5.

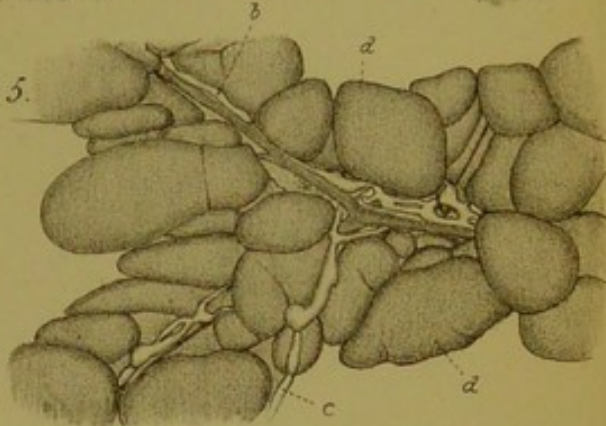


Fig. 6.

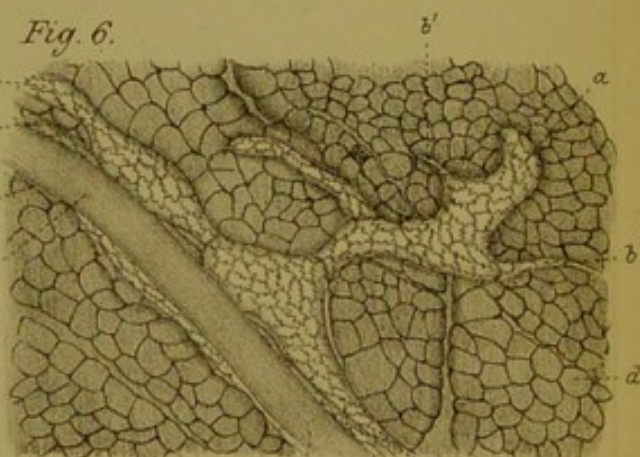


Fig. 4.

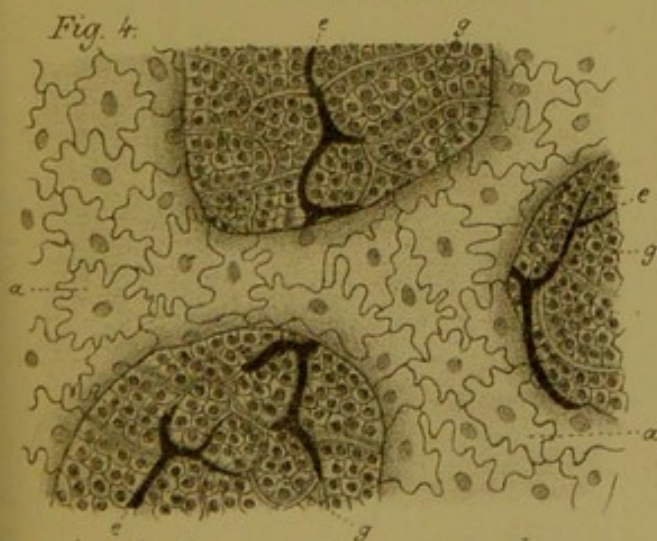


Fig. 8.

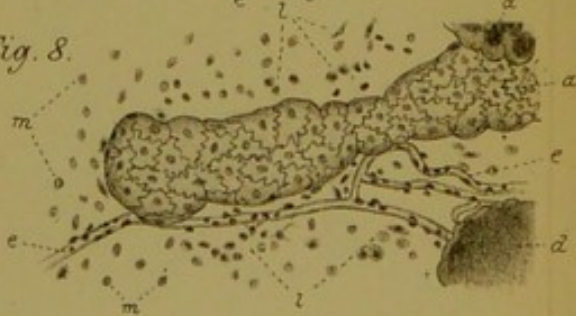

Fig. 9.

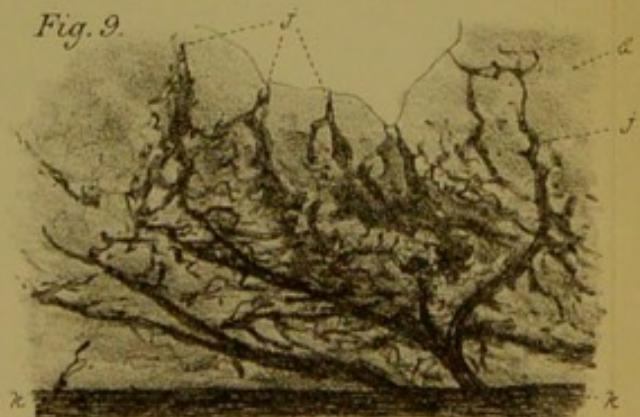

Fig. 7.

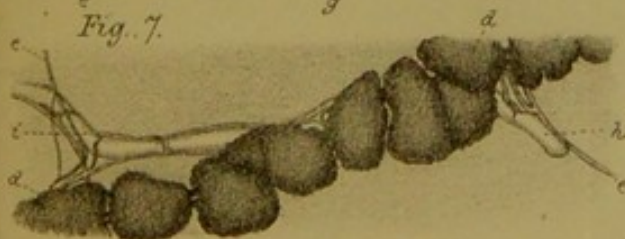



Fig. 1.

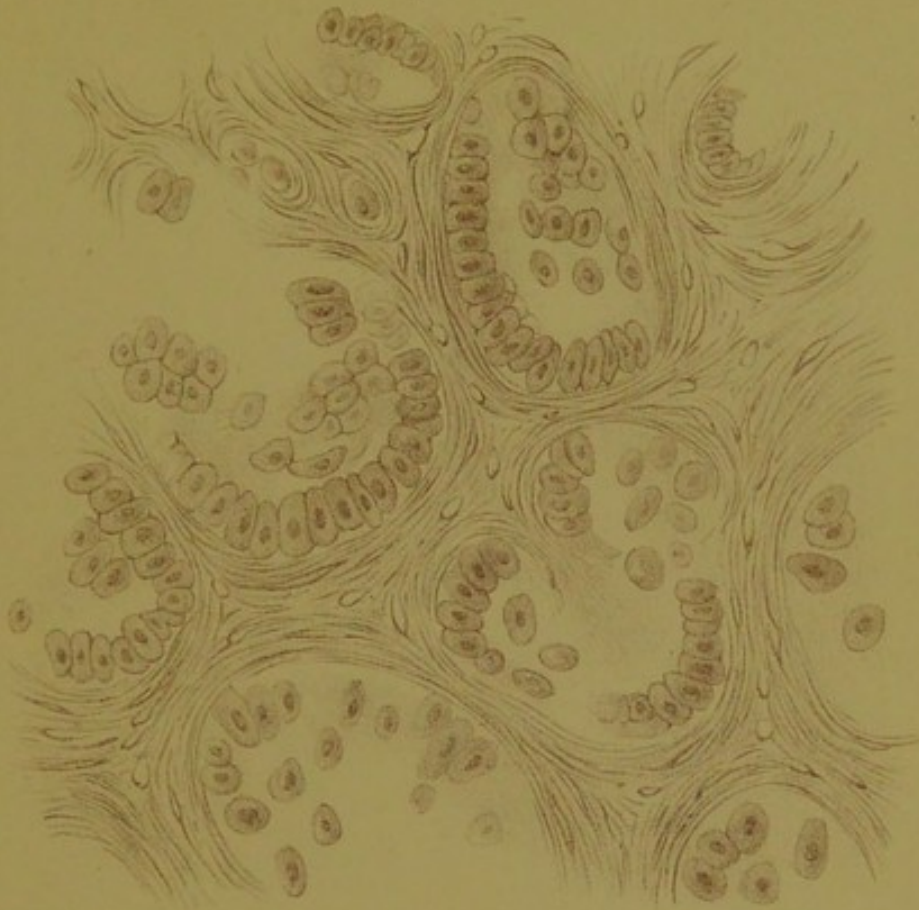

Fig. 2.





