

A case of tumor of the brain / by Theo. W. Fisher.

Contributors

Fisher, Theodore W. 1837-1914.
Royal College of Surgeons of England

Publication/Creation

[Baltimore] : [Utica State Hospital Press], 1885.

Persistent URL

<https://wellcomecollection.org/works/zthcrd4p>

Provider

Royal College of Surgeons

License and attribution

This material has been provided by This material has been provided by The Royal College of Surgeons of England. The original may be consulted at The Royal College of Surgeons of England. where the originals may be consulted. This work has been identified as being free of known restrictions under copyright law, including all related and neighbouring rights and is being made available under the Creative Commons, Public Domain Mark.

You can copy, modify, distribute and perform the work, even for commercial purposes, without asking permission.

**wellcome
collection**

Wellcome Collection
183 Euston Road
London NW1 2BE UK
T +44 (0)20 7611 8722
E library@wellcomecollection.org
<https://wellcomecollection.org>

Compliments of
T. W. F.


12

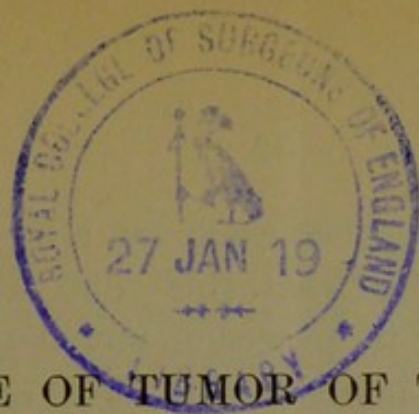
A CASE OF
TUMOR OF THE BRAIN.

By THEO. W. FISHER, M. D.,
Superintendent Boston Lunatic Hospital.

[From the *American Journal of Insanity*, for January, 1885.]







A CASE OF TUMOR OF THE BRAIN.*

BY THEO. W. FISHER, M. D.,
Superintendent Boston Lunatic Hospital.

F. H. C., born in Boston, single, clerk, aged twenty-four, was admitted to the Boston Lunatic Hospital, February 15, 1884. The record further states that he was a Protestant, with a good high school education, naturally cheerful, and very conscientious, with no bad habits of any kind known to his friends. His father, who is living, was a moderate drinker. His mother died of phthisis. Nothing is known of his father's family by our informant. No heredity except phthisis on mother's side. One maternal aunt died of apoplexy, and one maternal uncle died of Bright's disease. His mother died when he was ten years old, but is said to have been in consumption when he was born.

Patient is said to have had epileptic attacks at five years of age and after. He had a small head, and was a delicate boy. Left school at seventeen, and has been a clerk in the same store for seven years. Of late years has had headaches. One year ago, February, 1883, he had neuralgia in the left side of head and temple. The pain was not constant, but lasted five weeks, and was accompanied with vomiting. There

* Read before the Association of Medical Superintendents of American Institutions for the Insane, at Philadelphia, May 15, 1884.

was no fever, though it came on after a cold. Dr. Wadsworth saw him from this time till the last of July with reference to his vision, and the record he has kindly furnished is inserted here.

February 18, 1883. Never troubled with eyes till lately, though has not thought them strong. Three or four weeks ago, while at work, noticed blur, and soon double vision when he looked up at any one. This was just after a severe cold, which had left neuralgia through temples and in eyes chiefly. The neuralgia was worse at night, and three times had caused vomiting; the last time ten days ago. Neuralgia continued till a week ago, when it almost entirely disappeared under treatment. Double vision has continued; not observed all the time; may look at something and see single, then again double; it is observed chiefly when he looks off at a level. Not at work last two weeks. Never had syphilis or rheumatism. There is slight conjunctivitis and blepharitis. No apparent loss of movements of eyes. There is vertical diplopia of small amount when the eyes are turned to the right, horizontally and upward, not in other directions. The upper image is that of the right eye. Eyes externally normal; pupils rather large, react well enough; vision normal, $\frac{1}{10}$; accommodation good; fundus normal, R. and L. Pot. iod. gr. v., t. d. Zinci sulph. gr. $\frac{1}{2}$, Aq. $\frac{3}{4}$ i, Coll. Ung. zinci oxyd.

22d. Neuralgia waked him at 3 A. M. on 20th, disturbed his sleep the rest of the night, and continued through yesterday; none to-day. Double vision as on 18th. Quin. sulph. gr. ii, q. d. Exercise.

25th. Neuralgia again 5 A. M. to-day, not so severe as on 20th, but caused retching and vomiting small amount of greenish fluid. Now, 1 P. M., has a dull feeling in forehead. Digestion good, dejections regular, appetite fair. Double vision as before, except that once there was while testing it some lateral separation of images when eyes turned up and to right, and vertical diplopia when turned upward. Quin. gr. xii to-day, xvi to-morrow.

27th. Pain all day yesterday; did not sleep till one this morning; waked at 7, but slept till 11. Pain not so severe as before. No vomiting; less now. Quin. 24 grains during day.

March 1. No pain 2 days. Ears buzzed after 24 grs., and only 16 yesterday and to-day.

5th. Since the 1st a pretty continuous "sort of pain" through temples or in back of head, not in eyes so much. Since last even-

ing pain in back of neck when moves quickly. Double images as before. Some acne from iod. Omit P. I.

11th. Occasionally slight headache in top of head. Otherwise felt well. Double vision observed less. I find it as before. He now sees a little better with 0.5 cylinder before each eye. May go to work. Drop quin. gradually.

18th. Has been writing, but not done full work. Double vision has troubled him rather more. Diplopia about as before, only sometimes slight vertical doubling also when eyes turned to left. When looking across the room he can correct the diplopia by tipping his head a little toward the right shoulder. The diplopia is not always precisely the same, though nearly so. Has had no headache. Taken exercise, and feels generally well. Quin. gr. ii, t. d. for a week.

25th. Yesterday morning and this morning slight neuralgia, not enough to wake him. The diplopia in general about the same, but varies a little. There is now, and has been before, some difficulty in turning the eyes much upward. A prism of 2° base up and out before the right eye corrects the diplopia, and this, together with 0.5 cylinders for each eye, is ordered to be worn constantly.

April 15th. Only obtained glasses to-day, and finds they relieve the diplopia.

29th. Has had no double vision since wearing glasses. "Cold" the past week. Did well till two days ago, when he began to have some "grumbling" in eyes, yesterday more and in forehead, and waked early this morning by pain and vomited. Now after being in open air feels better. Quin. gr. ii, morning, noon and night and vi at bed-time.

July 12th. Wore glasses constantly without diplopia till two or three weeks ago, then began to notice double vision in the street; this was noticed more and more, and four days ago found he could see better without the glasses. The last two or three days has left off the glasses part of the time while at work, and thought he could do better without them. For a month he has noticed that while dressing in the morning without the glasses he could see better and better. He now has double vision with the glasses looking across the room, not without them; double vision with glasses to right, not to left. There is at 18' without glasses, vertical diplopia of small amount when the eyes are turned strongly to the left at all heights, also, very little, when the eyes turned to the right and down. There is the same difficulty in turning the eyes upward that was noticed in March. Drop the prism.

26th. Been working steadily. Few days ago began to have a little smarting of eyes, and for one or two days a little neuralgia; relieved by Q. S. ii. morning and night. Now vision for distance improved by weak concave glass (slight spasm of accommodation) $\frac{1}{10}$. Fundus normal, as before.

In August became nervous and disturbed in mind. Thought his work was not properly done. He had for a year had scruples about the propriety of his attending communion at the church to which he belonged. Felt himself unworthy for some cause, real or imaginary. He was advised to take a vacation, and sailed for the Azores. On his way out the pain in his head returned, and he lost control of his movements on one or two occasions. Threw the medicine glass from him by an involuntary movement of his right hand. His food looked indistinct on his plate, as he could not focus it properly. Returned at once on arrival at the Azores. In September, while near the Bermudas, felt better because of the hot weather. Arrived in Boston October 6th, where his sight failed more rapidly. He had headache, but no nausea. He had black specks before his eyes and carried his head backward in order to see. Sight of left eye failed first, and by December he was blind.

During the fall he became childish, but had no delusions. Occasionally thought he heard strange voices in the room. When walking went to the left without knowing it. Once fell backwards to the left. Deafness came on slowly after November. February 12th, 1884, lost consciousness, and his thumbs and hands were turned in. The attack came on without trembling, and lasted forty-five minutes. He was red at first and then pale. His right arm is said to have been powerless before the attack. He was more stupid after the attack, and swallowed with difficulty. He

had once before fallen out of bed injuring his knees and chin, and did not seem to feel the hurt. His right patellar reflex was increased and the left diminished. He had no headache during the winter, and was at no time depressed or violent, but simply stupid.

The preceding account was given by Dr. Ida D. Clapp, homeopathist, who had him in charge both before and after his visit to the Azores. Dr. J. Heber Smith, homeopathist, was called by her in consultation several times. He was also seen by Dr. A. N. Blodgett, in August. Application was made for his admission to the Massachusetts General Hospital, February 14th, and Dr. James J. Putman examined him with reference to that application. Dr. Putman kindly lent me his notes from which such facts are taken as have not been previously noted. He says:

The pupils were usually dilated and slow to react. There was some diplopia, and in order to overcome it, the head had to be thrown back so that the eyes were in the position of looking downwards. This manner of carrying his head was retained till near his death. There was slight ptosis of the left eyelid, and Dr. Clapp thought the color of the iris changed from grey to green. After his return from the Azores some difficulty in swallowing and a loss of power in his right hand were noticed. He began to be childish, and lost all initiative, all interest in things, and his power of attention seemed to be gradually snuffed out. The neuralgia ceased about two weeks after his return, and did not come back. There was no more vomiting, and he slept well. Was able to pass and control his urine. Sight of left eye began to fail in September, and hearing soon after. It was hard to say whether deafness was primary or only dependent on his mental condition, because he would respond to his sister's voice when not much raised, when he failed to hear a strange voice, though much louder. Could understand some words and not others. Felt impelled to the left in walking as early as September. The gait was reeling. Fell back and to the left once or twice. Hands unsteady. No great loss of sensibility, though mental condition made it hard to determine its extent. There was nystagmus and strabismus. The skin was dry and scaly.

Application was refused on account of his mental condition.

The patient was examined by Dr. Smith and Dr. George F. Jelly for commitment to an insane hospital. The certificate, on which he was received at the Boston Lunatic Hospital, states that he had an epileptic seizure February 12th, that he is "dazed and demented, and unable to give intelligible answers to questions. He can not walk without assistance, and when walking and even sitting still his body sways to the left. There is total inability to stand alone. He is blind and quite deaf. All his symptoms indicate impairment of the brain, and perhaps a new growth there." The causes assigned are "over-work and self-abuse." The latter cause was alleged, I believe, on the strength of observations made during his sickness in bed, and may have been a symptom rather than a cause.

The following examination was made and recorded by Dr. Philip C. Knapp, Jr., hospital interne, on February 15th, the day of his admission:

Circumference* of head 55 cm. One external auditory meatus to another, 34.8 cm. Root of nose to occipital protuberance, 35.3 cm.; long diameter, 18.8 cm.; biparietal diameter, 14.6 cm.; bitemporal diameter, 13.3. Pupils were small before being dilated by atropine. Right internal strabismus present. The right eye not moving outward beyond medium line. Lies perfectly impassive, and does not seem to see anything. Objects can be brought down very closely to his eyes without making him wink, unless he feels the wind from large objects. Winks on irritating the conjunctiva or margins of lids. Moves face and eyes a little. Nystagmus noticed. With ophthalmoscope double optic neuritis observed. Yawns naturally, but will not protrude tongue. Tongue moves naturally in mouth when jaws are forced open. No response to irritating face. Resists opening his mouth with both hands, using the right most powerfully. Makes no response to

*These dimensions are fully up to the normal averages given by Kraft-Ebing.

any cutaneous irritation, but moves eyes and face a little as if disturbed when anterior nares are irritated. Arms being raised in the air, they are held in position for a minute or two. The right being held up longer; this phenomenon was not present on later trial. Examination of chest and abdomen negative. Abdominal, epigastric, cremaster, gluteal and plantar reflexes normal; costal reflex slight; triceps very slight; no patellar or ankle clonus; patellar reflex very faint in left knee, exaggerated in right; slight front tap contraction right. Temperature, 97.9° ; pulse, 64; respiration, normal.

The hospital records state that the patient on admission took supper, but seemed to swallow solids with difficulty. Passed urine naturally.

February 16. Lies with his eyes open and pays no attention to anything. After shouting in his ear he once said in a natural voice, "Did you speak? I can't hear a word you say." Swallows with difficulty. Liquid diet ordered to be given with great care. Patellar reflex nearly alike on both sides. No front tap contraction. Evening—Pulse, 90; respiration, 30; coarse râles in trachea since taking beef-tea at supper.

February 17. Lies with head thrown back to the left. Hurts him to straighten it. Strabismus is not apparent as he lies. Uses his hands a little. Uses urinal when placed in position. Soils the bed; bloody sputum on pillow. Pulse, 124; respiration, 24. Evening—Pulse, 100; respiration, 31; temperature, 101° .

February 18. Slept but little. Pulse, 120; respiration, 28; temperature, 103. Loud moist râles over front chest on expiration. Evening—Face dusky; tracheal râles. Pulse, 120; respiration, 32; temperature, $103\frac{1}{2}^{\circ}$.

February 19. Pulse 108; respiration, 25; temperature, $99\frac{1}{2}^{\circ}$. Evening—Pulse, 120; respiration, 30 to 40; at times much obstructed by mucus in trachea; temperature, 103.2° . Swallows fairly.

February 20. Lies with his head turned to left. Pressure over cervical vertebra, on attempting to move head seems to cause pain. Feet in marked plantar flexion. Some contracture of gastrocnemius preventing full dorsal flexion. Slight contracture of muscles of back of thigh. Respiration rapid, with tracheal râles obscuring chest sounds. Strabismus and nystagmus persist. Temperature, 102.9° ; pulse, 116; respiration, 36. Evening—Right eye injected. Pulse at 9.40, 144, respiration, 44; temperature, 103° .

February 21. Pulse, 114; respiration, 30; temperature, $99\frac{1}{2}^{\circ}$. Evening—Dying. Pulse almost gone. Left external strabismus.

February 22. Still alive. Swallowed a little brandy. Pulse, 136; respiration, 56; temperature, 100.5° . Right external strabismus. Died at 10.30 P. M.

by Dr W. W. Gannett

Record of autopsy on F. H. C., February 23, 1884. Autopsy 16 hours after death. Body small, poorly developed, somewhat emaciated, lividity of dependent portions. Rigor mortis present. Skull measured ant. post. 17.7 cm., trans. 13.9 cm. Calvaria measured in thickness $1\frac{1}{2}$ mm., with the exception of the longitudinal sinus, where it measured 5 mm. Inner portions of the calvaria showed an irregular surface of a dark, bluish color, inner table being everywhere absorbed and diploë exposed. Longitudinal sinus contained a small amount of partly coagulated blood. External surface of the dura showed marked vascularity and a somewhat ragged surface. Inner portions showed nothing remarkable. Brain completely filled the cavity of the skull and weighed 1,605 gm. Pia rather pale and dry. Convolutions flattened. Sulci obliterated. Vessels at the base and in the fissure of Sylvius showed nothing remarkable. Lateral ventricles contained each by estimate 75 c.c. clear fluid. Ependyma everywhere smooth and shining. Choroid plexuses pale. Region of the corpora quadrigemina, and the pineal gland occupied by a globular, soft, reddish grey mass measuring 30 mm. in all its diameters. It extended to, but apparently did not involve the corpora geniculata. Over it lay the velum interpositum, and the venae galeni much stretched. On section, the tumor showed the same reddish-grey basis-

substance with numerous red specks and streaks, evidently blood-vessels. To the left of the middle, sagittal line of the tumor were three or four pearly-white bodies, varying in size from a large pin's head to a filbert-meat, showing a concentric laminated structure. No trace of the pineal gland or anterior corpora quadrigemina could be made out. Of the posterior corpora quadrigemina only a layer about 2 mm. thick remained on the posterior surface of the tumor.

The fourth ventricle showed nothing remarkable. Brain substance in general firm. Cortex of the usual thickness, good color, white substance showed nothing remarkable. Section of the basal ganglia, pons, medulla and cerebellum showed nothing worthy of note. Between the periosteum of the canal and the dura extending from the foramen magnum along the cervical cord was a considerable amount of dark, firmly coagulated adherent clot, otherwise the cord and membranes showed nothing of note. Diaphragm, 3d intercostal space on the right; 4th intercostal space on the left. Pericardium contained fluid enough to moisten the surfaces. Heart small. Right ventricle and auricle distended with dark fluid blood. Left ventricle contracted and empty. Aortic and pulmonary valves sufficient. Mitral admitted the tips of 3, the tricuspid the tips of 4 fingers. Valves, cavities and muscular substance not remarkable. Pleural surfaces free from adhesions. Left lung partially retracted, pale and crepitant. Upper lobe dark in color. Over the lower lobe numerous nodules the size of peas could be felt externally. On section the surface showed numerous reddish-grey granular nodules. Bronchial mucous membrane reddened, injected and covered with a layer of bloody mucus. Pleural surface of right lower lobe covered with a layer of thin, fibrinous false membrane. Lower lobe non-retracting and non-crepitant. Section showed a reddish-grey granular surface. Lobular region being well marked. Bronchial mucous membrane as in left lung. Spleen, kidneys and liver showed nothing remarkable beyond smallness of size. Intestine showed nothing of note beyond a tarry contents of the small intestine. Nothing remarkable about mucous membrane. Aorta thin and elastic.

DIAGNOSIS.

Diffuse atrophy of skull.

Chronic internal hydrocephalus.

Tumor of velum interpositum (vascular sarcoma).

Hæmorrhage into the space between dura and periosteum of vertebral canal.

Acute fibrinous pleurisy.

Acute bronchitis with broncho-pneumonia hypoplastic aorta.

Microscopic examination of the tumor showed varying appearances. In parts it was made up wholly of very numerous small round cells, imbedded in a delicate connective-tissue mesh, and abundantly supplied with blood vessels.

Other parts showed a distinct alveolar structure, the spaces being filled with nests of medium-sized, irregular, rather plump cells. In patches these cells were seen lying, flattened against one another in clumps.

The pearly nodules were made up of pale, glistening, thin, homogeneous scales concentrically arranged.

Diagnosis of tumor, vascular sarcoma with cholesteatomatous portions, growing probably from the velum interpositum.

Microscopic Examination of Brain and Cord.—Nothing abnormal was observed in the brain beyond the fact that the vessels contained rather more blood, and that the perivascular spaces were somewhat wider than usual.

Cord, Cervical Region.—The perivascular spaces wide, were filled with a finely granular material, an appearance characteristic of albuminoid fluids when acted on by a hardening agent.

Dorsal Region.—Marked dilatation of central canal, the epithelial lining being intact. The perivascular spaces widely distended, and filled with a similar, finely granular material.

The appearances of sections of the lumbar region were similar to those of the dorsal region.

<i>Symptoms in the Order of their Occurrence.</i>	<i>Probable Causes or Corresponding Lesions.</i>
Neurotic constitution, delicate health and epilepsy at five.	Phthisis in mother at time of birth.
Vascular sarcoma at age of twenty-three from velum interpositum.	Cause unknown, unless cerebral congestions from over-work or other causes.
Left hemicrania.	Irritation of nucleus of fifth nerve.
Vomiting.	Irritation of pneumogastric branch of eighth nerve.
Diplopia.	Paralysis of third, fourth or sixth nerves.
Slight ptosis on left.	Paresis of third nerve.
Dilated pupils.	Paresis of ciliary branch of third nerve.
Deep-seated pain in parietal and occipital regions.	Commencing intracranial pressure.
Inability to turn eyes upward.	Paresis of third and fourth nerves.

<i>Symptoms in the order of their Occurrence.</i>	<i>Probable Causes or Corresponding Lesions.</i>
Spasm of accommodation.	Irritation of ciliary branch of third nerve.
Loss of mental initiative.	Pressure on cortex from internal hydrocephalus.
Lost of control of right hand on taking a cup.	Reflex phenomenon due to loss of control of the centers of motor inhibition.
Loss of sight, first of left eye then of right.	Pressure of tumor on part of optic tract in the corpora quadrigemina, or pressure of plexus in third vent. on optic chiasm.
Strabismus of changing character.	Paresis of third or fourth nerves.
Nystagmus.	Tremor of muscles from innervation of third, fourth and sixth nerves.
Dementia.	Intracranial pressure on cortex.
Hallucinations or illusions of hearing.	Irritation of auditory nerve nucleus in floor of fourth vent.
Gait reeling, with tendency to turn or fall to the left.	Vertigo from irritation or paresis of nerve (7th) supplying the semicircular canals?
Deafness, if primary.	Pressure on auditory nerve nucleus.
If secondary.	Pressure on cortex.
Diminished sensibility to pain.	Pressure on cord and medulla or cortex.
Loss of strength in hands and unsteadiness.	Paresis from intracranial pressure.
Unconsciousness.	Pressure on cortex.
Spasms of thumbs and hands.	Irritation of Ferrier's center for hands.
Dysphagia.	Second branch of eighth nerve.
Inability to stand.	Paresis from pressure.
Right patellar reflex increased, left diminished.	Inhibitory center in left hemisphere weakened more than the opposite one.
Skin dry and scaly.	Malnutrition from deficient innervation.
Double optic neuritis.	Choked discs from passage of fluid from arachnoid cavity between outer and inner sheaths of optic nerve.
Pain on straightening head and tenderness over cervical vertebra.	Pressure of clot on cervical cord.
Turning of head back and to left.	Semiconscious effort to relieve pain.
Plantar contraction on both sides.	Pressure on cervical cord by clot, or on medulla by hydrocephalus.

Tumors of the brain are of such comparative infrequency, and cause such a variety of complex

symptoms that they are always worthy of study. New light is thrown upon cerebral function by almost every case. Although presenting psychical derangement in from one-third to one-half of all cases they are not often met with in hospitals for the insane. In the case in question the residence in hospital was so short and the dementia so excessive that some of the usual tests for impaired motion and sensibility could not be applied.

Tumors of the brain may be of three kinds: new formations, vascular tumors, and parasitic growths. According to Ross ("The Diseases of the Nervous System," London, 1882), they are twice as frequent among men as among women. Tubercle is the most common form met with, especially in youth, and in the present case, in view of the phthisical heredity, tubercular tumor might have been anticipated. There was no history of syphilis and no reason to suspect the presence of a syphilitic growth, which may occur at any age. Cancer of the brain is most frequent in persons over fifty years of age. The other forms of tumor are of accidental occurrence, and can not be predicated from any observed diathesis. I will name them simply to refresh my own memory and yours. Glioma, hard and soft, fibro-glioma, glio-sarcoma, hyperplasia of the pineal gland, myxoma, carcinoma, cholesteoma, papilloma of the pia, sarcoma, lipoma, psammomum, osteoma, cystic growths and angioma. The preceding are new formations to which must be added aneurisms and parasitic growths, the latter of two kinds, viz.: cysticercus and echinococcus. With such a variety of forms any attempt to determine before death the kind of tumor present must be guess-work.

Tumor of the brain must be regarded both as an irritative and a destroying lesion, consequently pain, spasm, paresis and sympathetic organic disorder may be expected. The most constant symptoms are pain in the head, vertigo, neuralgia, sensory and motor derangement of cranial nerves, affections of the special senses, vomiting, dysphagia, polyphagia, polyuria or saccharine urine. When internal hydrocephalus occurs as in the present case from pressure on the vena galeni or softening from pressure on the arteries, general paresis or general motor and sensory disturbance with psychical disorder occurs. The latter may be purely emotional and of the hysterical form, masking for a time all other symptoms. Ten years ago, or more, I had a case in which for several weeks hysteria seemed to be the more reasonable diagnosis. I was supported in this view by the late Dr. Calvin Ellis. Although the possibility of tumor was admitted, no positive evidence was obtained until optic neuritis was discovered by Dr. Hasket Derby.

The excitement may become maniacal when the irritation or hyperæmia is excessive. There are often outbursts of passion and fury, and there may be hallucinations or delusions, the latter sometimes of the grand type simulating those of general paresis. None of these conditions were present in the case before us, but instead, mild depression and self-depreciation, loss of mental grip and initiative, followed by a gradual extinction of the mind. The increasing pressure from within upon the cortex, which is shown by the absorption of the inner table of the bones of the skull slowly snuffed out its functions as with a leaden extinguisher.

Diagnosis is sometimes difficult between tumor of the brain and apoplexy, chronic softening, abscess, atrophy and hypertrophy. A careful analysis of symptoms extending over a period of weeks or months

will prevent mistake in most cases. Optic neuritis, which is a valuable aid to diagnosis, may be delayed so as to afford no assistance, but should be looked for frequently. In the case before us it was not present the first six months, and its discovery was not reported, if made, until the patient came to the hospital. The diagnosis of tumor had however been made without it by several physicians. The cause of this symptom has been in dispute. It was formerly supposed that the hyperæmia and swelling of the optic nerve which caused the appearance known as choked disc was due to intracranial pressure on the ophthalmic vein. Prof. Schweigger ("Hand-book of Ophthalmology," 1878), of Berlin, admits that these phenomena are caused by a stasis of blood, but thinks intraocular pressure insufficient on anatomical grounds to account for it. A swelling of the nerve itself would be a sufficient and more reasonable cause. He presents the views of Schwalbe, Manz, Schmidt and others, that choked disc is due to an accumulation of arachnoidal fluid between the inner and out nerve sheaths, retained there by intracranial pressure. Although he does not fully endorse this view, it is the generally accepted one. I believe, with most authorities, optic neuritis is not pathognomonic of brain tumor, as it may exist independently of it, and cerebral tumors may exist without it.

There is little to be said regarding prognosis and treatment. The former is always unfavorable except in case of syphilitic tumors, which may disappear under appropriate treatment. In any case treatment by large doses of iodide of potassium is warranted as an experimental measure. In the case in hand it was not used, except in five grain doses, as far as I am informed.



