

## **Cases of athetosis / by Francis Warner.**

### **Contributors**

Warner, Francis, 1847-1926.  
Doran, Alban H. G. 1849-1927  
Royal College of Surgeons of England

### **Publication/Creation**

London : Printed by William Clowes and Sons, [1880?]

### **Persistent URL**

<https://wellcomecollection.org/works/ne58wfyx>

### **Provider**

Royal College of Surgeons

### **License and attribution**


This material has been provided by This material has been provided by The Royal College of Surgeons of England. The original may be consulted at The Royal College of Surgeons of England. where the originals may be consulted. This work has been identified as being free of known restrictions under copyright law, including all related and neighbouring rights and is being made available under the Creative Commons, Public Domain Mark.

You can copy, modify, distribute and perform the work, even for commercial purposes, without asking permission.




Wellcome Collection  
183 Euston Road  
London NW1 2BE UK  
T +44 (0)20 7611 8722  
E [library@wellcomecollection.org](mailto:library@wellcomecollection.org)  
<https://wellcomecollection.org>









20/ \*

## CASES OF ATHETOSIS.

BY FRANCIS WARNER, M.D., LOND., M.R.C.P.

*Assistant Physician to the London Hospital, and to the East London Hospital for Children.*

THESE cases came under notice at the East London Hospital for Children.

### *Athetosis with Epilepsy.*

CASE I.—Alice T., aged 13 years, was brought under my observation in January, 1880, complaining of a swelling in the axilla. This proved to be glandular, and soon subsided. The mother also complained that the left arm had been useless since she was six months old, that she was liable to fits, and rather stupid.

The girl was of fair stature, rather pale and thin, and of weak intellectual power. She could walk, assist her mother in the house, and answer questions, but was very dull and apathetic.

When seen, the following description was taken: *The left upper extremity* is almost useless for most voluntary purposes on account of the condition of the hand. If told to put her hand to her mouth, or to the back of her head, the hand gets there, being moved slowly and awkwardly by the action of the muscles moving the shoulder and elbow, but though flexion and extension of the elbow be sufficiently voluntary to perform such acts, involuntary movements of pronation occur, while the hand is being moved up to the mouth. All through the time of the general movement of this limb, it is obvious that there is much perfectly involuntary movement of the wrist, often causing marked flexion, or affecting independent digits.

As to the condition of the hand, the description was taken while the forearm was gently supported by the mother, the wrist being left perfectly free. It was then noted: The wrist droops, the metacarpus hanging straight down, but frequently supernated rather quickly, but not in a jerky manner, the hand then passes slowly back to its former position, the series of movements being repeated. Flexion and extension of the wrist through a few degrees are nearly constant movements.



The movements of the fingers are almost incessant, the primary and quickest movements being flexor, followed by slower extension. The movements are slower than the jerks of chorea, and more deliberate, and looking like gesticulations; they are purposeless and gliding in kind.

The fingers are constantly going through grotesque movements, sometimes crossing one another, sometimes one is extended, while the others are flexed; there are no adductor and abductor twitches, such as are usually seen in chorea; the thumb is mostly turned in on the palm, but is often also extended. These finger movements appear utterly purposeless, looking as if the tendons were merely pulling upon dead fingers, as an automaton pulled by strings, or like the movements of a boneless limb, such as an elephant's trunk or an anemone's tentacle. The metacarpal bones are rather contracted together by the arching of the palm of the hand, giving it a narrow appearance.

The muscles of the forearm are neither hypertrophied nor atrophied. The heart and lungs were normal.

The following was the history of the patient.

She appeared healthy at birth: was suckled thirteen months.

When six months old, and while in apparently good health, she was taken suddenly in a fit, "as if choking, and wanting to be sick," there was some struggling, and the head was hot; the mother says that only the left arm and leg worked, and that the mouth was drawn to the left. After this fit she lay for three or four days quite helpless. There was no recurrence of fits for some months, then a second similar attack occurred, which was followed, after an interval, by a third paroxysm, each lasting about eight hours. There were in all three attacks during the first two years. There have been no fits from infancy till lately. The left arm has never been healthy since the first fit. The mother cannot say when the movements of the arm were first noticed, but they have certainly lasted many years, probably from infancy. It seems that she had some little use of the hand until the occurrence of the recent slight fits.

During the previous six or eight months epilepsy had returned, two or three slight fits having occurred each month, they set in suddenly, with loss of consciousness.

In the attack she would bite, look strange, and be powerless and stupid after them. Since the onset of the fits she has had less muscular power and more involuntary movements of the left hand as described.

The *patient* is the eldest of a family of six children, four of whom are living, delicate children, but with no nervous symptoms. One child died in infancy of bronchitis.



The mother has had one miscarriage.

The *father*, aged 40, never had fits. He is now a teetotaller, because he finds that if he takes liquor it makes his head bad. Before the birth of this child he used to drink a good deal, and suffered from it. His mother was liable to fits for many years, falling, struggling, and biting her tongue. Her sister is insane.

The *mother*, aged 34, is liable to hysterical fits, not biting her tongue: she has two sisters, one aged 30, liable to epileptic fits, biting her tongue; the other 22, strong and well.

The patient was under treatment for one month. She took bromide of potassium, and the recurrent fits to a great extent subsided; the girl looked brighter, and the athetosis movements became lessened in degree.

As to causation, the early occurrence of fits in the child, and the inheritance of a tendency to brain disease on both sides of the family, point to heredity as the principal factor in producing disease. The purposeless, involuntary, and gliding character of the movements of the upper extremity were characteristic of athetosis.

*Athetosis associated with Chronic Hydrocephalus.*

CASE II.—Thomas P., first seen, May 7, 1879. The mother complained of the large size of his head, that he could not stand, or sit up, or hold up his head; that he rolled his eyes about very much, and could not use his right hand.

He was then 1 year and 10 months old, obviously hydrocephalic, with a head measuring in circumference 23 inches, and from ear to ear over vertex  $12\frac{1}{2}$  inches; eyes much depressed, so that usually a portion of the pupil was hidden. The bones of the calvarium were thin and spread out or expanded. The anterior fontanelle was nearly closed. There were no signs of rickets; he had sixteen teeth. There was no otorrhœa. His general health was good, and no disease was detected in any organ but the brain. The condition of the right upper extremity especially attracted attention; the following description is compiled from notes taken on various occasions.

The limb was useless for any purposive movements; there was no voluntary power over the hand, and but little over the shoulder and elbow. When a flower was held up to the child, he looked at it and made a noise, evidently indicating his pleasure, then moved his left hand to the flower, took hold of it, and tried to put it to his mouth. He could not take the flower with his right hand.

The wrist was frequently kept half flexed, while the fingers



were extended and flexed generally all together, in a slow and rhythmical manner. Pronation and supination were not common; the movements of the wrists were usually confined to flexion and extension of the fingers as described.

The hand was moved when pricked. There was no difference between the similar measurements in the two arms, but there was some rigidity of the right arm. The right leg was weak, but presented no athetosis. The child's birth was effected by instruments, and then it was noticed that the head was long and soft at the back. Convulsions occurred the day after birth, then no more till he was four months old, when he was strongly convulsed for four hours and greatly exhausted, but after a day or two he seemed as well as before. At eight or nine months old "he began to feel his feet," then his head was noted as enlarging, and he was frequently slightly convulsed. The mother is sure that before nine months old he could use his right hand, holding a crust in it, and that this power was gradually lost.

The child is still under observation (July 1880); no marked change has occurred except a few fits in June.

Here the condition of the limb was associated with brain disease and convulsions. The movements occurred in a paralysed arm, and were more limited in extent than in Case I.

*Double Athetosis not associated with Epilepsy.*

CASE III.—Eliza R., aged  $4\frac{1}{2}$  years, came under observation May 13, 1880. She was a playful, intelligent, pleasing little girl, good and well-behaved, and soon became a general favourite. Her general health was good, and development appeared good in all particulars, but for the athetosis she was well nourished. Her habits were clean, there was no slobbering, and no paralysis, and she never had fits.

The child was unable to stand or do anything for herself on account of the movements of the hands and feet, associated with which there was no doubt some want of muscular power. The muscular condition of the head and face appeared natural. There appeared to be a fair amount of voluntary power over the shoulders and elbows, so that she could hold a doll to her. When told to take hold of a toy she brings her hand to it, but is unable to open the fingers so as to clasp it; all through the time of this effort the fingers are in constant movement. When the object is placed in her hand, she clutches it and is unable to drop it.

Supporting the left upper extremity free from the trunk by holding the humerus, it was possible to observe the following movements succeeding in a rhythmical manner.



The wrist was frequently bent backwards, and sometimes abducted. The thumb was mostly bent in on the palm, turned in under the index finger. The fingers were frequently extended at the metacarpo-phalangeal joints, remaining flexed at the inter-phalangeal joints. The greatest power of extension seemed to be in the index finger. In getting the hand near an object, it moved about much before it came in contact with the object, and then could not grasp it on account of the condition of the fingers. The fingers were usually kept flexed; she could not spread them voluntarily. When the child is played with, her fingers spread open spontaneously, as also when attention is specially drawn to the other hand. When one's finger is slipped into her hand, her fingers grasp it, and cannot let it go unless the fingers happen to open of themselves. When she makes an effort and puts her legs out of bed to show her feet, the involuntary movements of the hands and fingers are increased, and movements of pronation and supination are noticeable.

The toes of both feet are continually being flexed and extended, but these movements are less in degree, and less characteristic in kind than those of the hands. She can kick her legs about in bed, but cannot walk.

The eyes and special senses are normal, and general sensation is good. Heart and lungs healthy.

The movements are very strange and purposeless, in kind they have more resemblance to voluntary movements than is usual in athetosis, and less of the gliding, successive-rhythmical character.

During sleep the hands are usually quiet.

This condition of the child appeared to have existed from birth. There were no signs of progressive disease.

The family were quite healthy.

CASE IV.—The following case should probably be classed as one of Athetosis of the face associated with *petit mal*.

John Clark came under my observation, May 1878; he was then 12 years of age. The complaint made was that his hands twitched, his face worked much, and that at times he was quite silly.

He was a well-grown lad, of good complexion; his features presented a constrained appearance, and there was much movement of the face. The right hand twitched, but not violently. As he stood up there was some irregular muscular twitching all over the body. He spoke well, and was not himself conscious of the twitching of the face.

The movements of the face were very striking, and were carefully observed. They were principally confined to the



parts about the eyes, nostrils and mouth, i.e. not affecting the forehead.

In July, when he was an in-patient at the East London Children's Hospital, I took the following description: Face: complexion somewhat anæmic, mucous membranes a little pale, not markedly so. There is considerable movement of the muscles of the face; he frequently closes his eye, next draws up the angle of the mouth on the same side, then contracts his eyebrows (corrugators), next he elevates them. He appears quite unaware that he is making grimaces. The inner portion of the occipito-fontales (grief muscles) frequently contracts in excess of other portions of these muscles; no movements of the hair or scalp seen.

The orbicularis oculi is frequently contracted, as indicated by the furrows around the eye, and the movements of the lower lid, while at the same time the eye is sufficiently open to allow of the pupil being distinctly seen (coincident of the orbicularis and levator palpebræ?).

The eyes are much moved in a restless manner, and are frequently turned upwards when the eyelids are being closed. There is never any strabismus. Fundus oculi normal. The tongue is protruded at request, and kept out, and there is much irregular movement of its muscular structure.

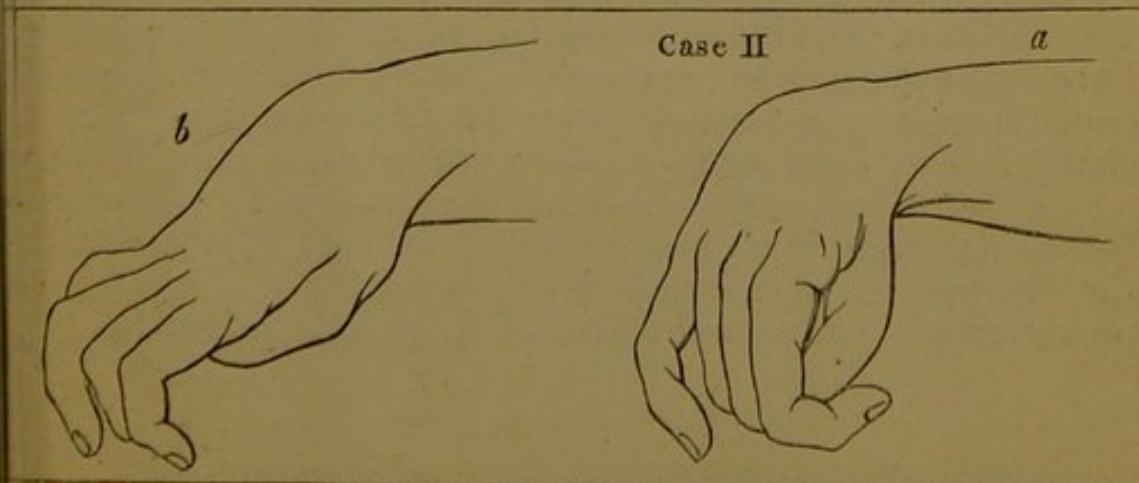
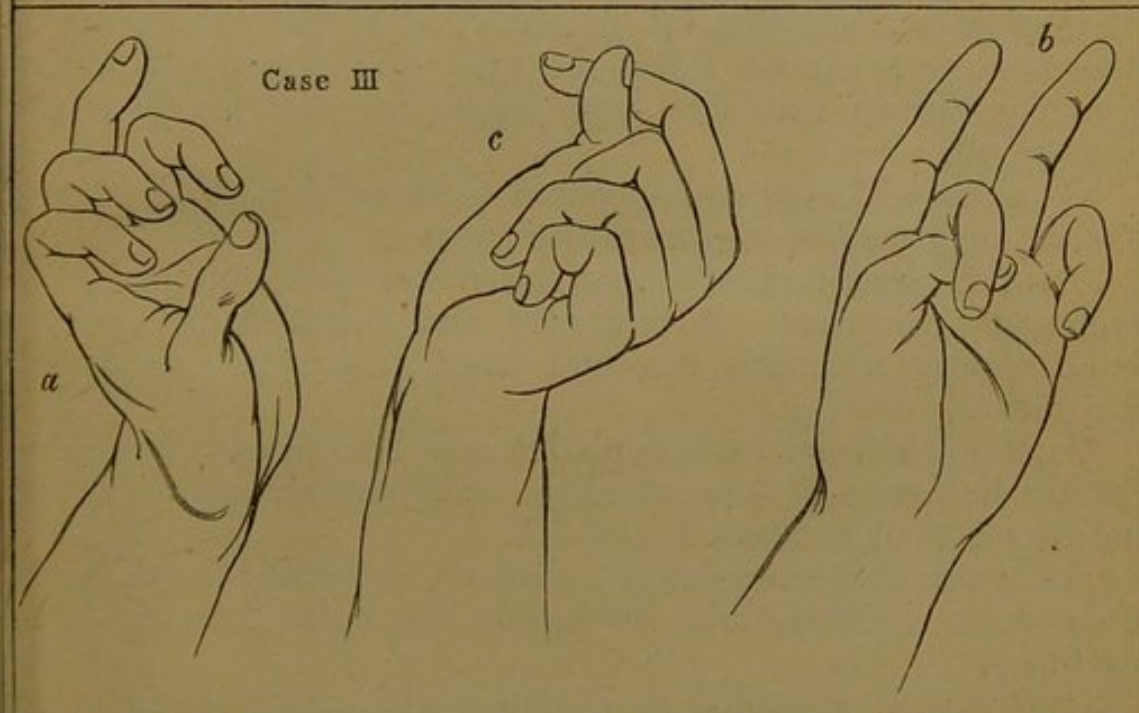
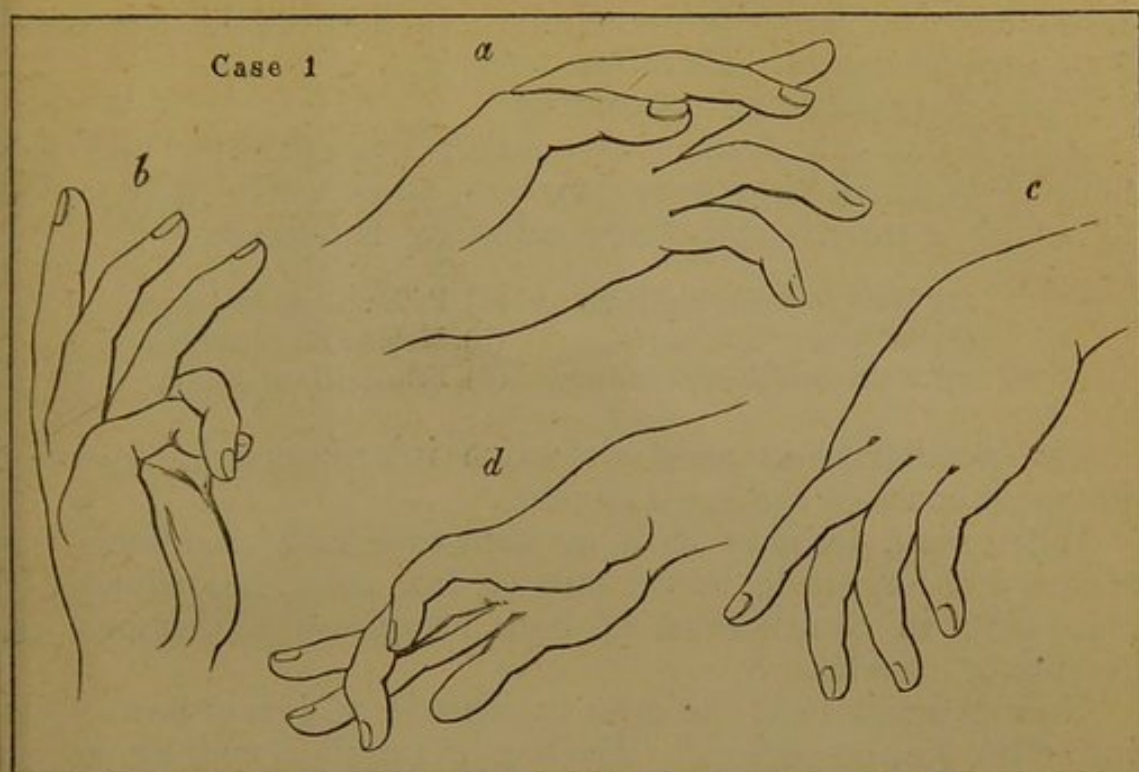
As the patient stands upright with his heels together, there is scarcely any movement of the body. When he holds out his hands, and spreads his fingers, they are kept steady, but very slight adductor-abductor movements and almost inappreciable flexor-extensor movements of the fingers are seen; there are also slight movements of the toes. He walks well, with a steady gait, but slight irregular swaying movement of the head.

His heart and lungs appeared normal.

The following was the history of the case. He had always been strong and well till a year and a half or two years previous to my seeing him. He never had convulsions; he went to school when five years old, was bright and intelligent, and did as well as other boys till the autumn of 1876; never any complaint of pain till this time. About that date it was noticed that he made contortions of his face, and frequently nodded his head; then later on the fingers of the right hand began to work. After some months it was noticed that his manner was changed, he became forgetful and vacant—at times as if silly.

When sent on errands he went to wrong shops. He appeared at times to lose himself. One day he was found in the middle of the road at a distance from home, and could not say how he came there or where he lived. He became a tiresome boy, and at times passionate. If beaten he became worse, as







if he had lost his reason entirely. In hospital he conversed well, and no mental failure was noticed.

Sleep was sound and refreshing.

As to the inheritance, the father and mother, and the families of which they were members, appeared healthy. The following is the account of the collateral members:—

- |                                 |                            |
|---------------------------------|----------------------------|
| (1) Male 25 years, healthy.     | (4) Patient, age 12 years. |
| (2) Male 22     "      "        | (5) Male 9, very healthy.  |
| (3) 5 children died in infancy. | (6) Female 7, not strong.  |

The possibility of some defective inheritance is the only probable cause of the boy's illness.

When seen, January 1879, he went to school, was much less absent and forgetful; movements of face were less, principally consisting in contractions of both occipito-frontales muscles. No fits or attacks.

Now (August 1880) he goes to school; seldom or never falls into "the lost condition." His face is peculiar, and somewhat impassionless, but without pathological movement except in the forehead. As he talks, the skin of the forehead is frequently thrown into fine long transverse wrinkles by a slow movement.

*Remarks.*—These cases appeared to be worth putting forward for the opportunity of contrasting them.

CASE I. presented athetosis associated with epilepsy, as is commonly the case. It increased and subsided in severity concurrently with the fits, and there was some mental impairment.

CASE II. showed hydrocephalus and hemiplegia, associated with athetosis and some rigidity. The movements were less in degree than in Cases I. and III.

CASE III. presented double athetosis, or double hemikinesis. The cause existed from birth, and the child was free from epilepsy.

CASE IV. is classified as athetosis with some reserve; but the persistent rhythmic contractions of the facial muscles, the long continuance of the movements, and general steadiness of gait, suggest a greater alliance to this condition than to chorea. The cases agree in the purposeless, gliding character of the movements which affected principally the upper extremity, and were most marked in the digits, and in the flexor-extensor movements of the wrist, less marked in pronation-supination, and least in the elbow and shoulder.



