

Improved method of treating club-foot / by Alex. Ogston.

Contributors

Ogston, Alexander, 1844-1929.
Royal College of Surgeons of England

Publication/Creation

Edinburgh : Oliver and Boyd, 1878.

Persistent URL

<https://wellcomecollection.org/works/h9t4pbs6>

Provider

Royal College of Surgeons


License and attribution

This material has been provided by This material has been provided by The Royal College of Surgeons of England. The original may be consulted at The Royal College of Surgeons of England. where the originals may be consulted. This work has been identified as being free of known restrictions under copyright law, including all related and neighbouring rights and is being made available under the Creative Commons, Public Domain Mark.

You can copy, modify, distribute and perform the work, even for commercial purposes, without asking permission.



Wellcome Collection
183 Euston Road
London NW1 2BE UK
T +44 (0)20 7611 8722
E library@wellcomecollection.org
<https://wellcomecollection.org>





25.

Improved Method of Treating

Club-foot.

by

Alex. Ogston.



Edinburgh Med. Journ. 1878



IMPROVED METHOD

OF


TREATING CLUB-FOOT.

BY

ALEX. OGSTON., M.D.,


SURGEON TO THE ABERDEEN ROYAL INFIRMARY.

(Reprinted from the Edinburgh Medical Journal for December 1878.)



EDINBURGH: OLIVER AND BOYD, TWEEDDALE COURT.

MDCCCLXXVIII.





IMPROVED METHOD OF TREATING CLUB-FOOT.

THE treatment of congenital club-foot (*Talipes Equino-varus*) is one of the most difficult, tedious, and disappointing undertakings in the whole range of surgery.

The array of mechanical appliances that have been invented and recommended for it, and the number and variety of plans in favour with the various orthopædic surgeons, sufficiently point out that no perfect, easy, and universally applicable method has as yet been devised. The truth of this is soon borne sharply home on all those who have to undertake the direction and management of these deformities. The young surgeon, starting with the idea that the difficulties in the way are neither very serious nor important, commences his connexion with them with a confidence and hopefulness that are very soon rudely shaken. He finds that, after all his most carefully-planned and skilfully-performed tenotomies, carried out according to the advice of the ablest and most experienced writers on the subject, much, and the most difficult of all, remains to be done. He uses one method after another, tries one splint or apparatus after another, employs all the various caliverts and boots that have been recommended, improves on these, or devises new ones for himself, and, as his cases become numerous and his experience extensive, comes at last to the conclusion that we are yet far, very far indeed, from having attained to anything like a satisfactory solution of the problem, how to cure club-foot.

One great truth, often overlooked, is at the foundation of most of the disappointments experienced. The pernicious doctrine, that ordinary congenital club-foot depends on paralysis or contraction of certain muscles and fasciæ, is still tolerated in the profession, and believed in by the laity. Consequently, a cure, or at least a marked improvement is too confidently expected to result from the operation of subcutaneous division of these structures; and teno-

tomy occupies the most prominent place in the minds of those interested in the progress of the case. But, in truth, division of resisting structures is one of the smallest and least weighty factors.

If we consider for a moment the true pathology of club-foot, we find ourselves in a better position to estimate the difficulties to be overcome and to give a correct prognosis as to the time and trouble that its cure necessitates. In an infant born with the deformity there exists, properly speaking, neither paralysis nor contraction. The whole limb is distorted, and every structure in it contributes its relative share towards producing the deformity. The skin of the foot and leg, if taken off and stuffed, will assume the clubbed form. The muscles, the tendons, the fasciæ, the very vessels and nerves, are all altered in length to suit the deformed foot and leg, but no trace of disease, nor of paralysis or contraction, exists in them. If we were to take away all the muscles, fasciæ, vessels, and nerves, the bones and ligaments would still exhibit the distorted shape characteristic of the disease; and if, after removing all the ligaments, we were to articulate to each other the cartilaginous bones that remained, we could do so only in the deformed position. Hence it has to be borne in mind that *every structure in the limb, without any exception, contributes its share towards keeping up the malformation, and has to receive its share of the treatment.* Certain it is that some tissues, especially the tendo Achillis, require to be cut by the surgeon, because they, from their powerful structure, resist any other means at his command to restore them to the length they must have ere the limb can be brought into a normal posture; but their division is no essential part of the proper plan of cure, and is resorted to only as a convenience, as an adjunct, often a very necessary one, to the treatment. The treatment proper consists in fulfilling the indication of gradually bringing the limb into the right form, and adapting the means of cure so as to fulfil the indication of a gradual moulding of bones, ligaments, muscles, fasciæ, nerves, vessels, and skin, into a form that shall approximate, as far as possible, to that of a sound leg and foot. Whosoever treats club-foot on any other plan treats it mistakenly and unscientifically.

It is unnecessary here to discuss the question whether club-foot is a result of intrauterine pressure on the foot, or of a non-development of the limb through its failing to go through the normal process of unrolling which, in the fœtus, proceeds downwards along the whole lower extremity and, from the posture it occupies in the earlier periods of intrauterine life, brings it into the position normal to the mature infant. The grounds on which such a question can be finally decided are not yet sufficiently known; but, so far as regards what has already been said, it is of little moment which explanation is the true one. But it is high time that the obsolete and misleading views regarding paralysis and contraction, so far as they refer to the ordinary typical con-

genital club-foot, were banished from our surgical lectures and text-books.

Putting aside the question of tenotomy, which is simply an adjunct to all methods of treatment, it may be correctly said that the cure can be obtained only by a gradual rectification of the position of the limb. At that, accordingly, all proper methods aim, and some attain it in one way, others in another, but all, without exception, have their weak points and drawbacks.

Well-constructed orthopædic apparatus is of very great value, and can achieve signal triumphs in this disease. But it has its dark as well as its bright side. Its expense puts it beyond the reach of the poorer classes and the poorer institutions to which they bring their deformed children. Thousands of parents and hundreds of charitable institutions cannot afford to procure the necessary mechanism to apply to these distorted feet, not to mention replacing it by new apparatus as the child outgrows that originally applied. Most of the untreated and uncured club-feet among the poorer ranks owe their condition to the impossibility of procuring the money required for the proper apparatus.

No treatment by bandaging to splints and afterwards using lacing boots will bear comparison with that by apparatus. The foot, it is true, can be considerably improved, but the final results will not for a moment bear comparison. Hence this plan of treatment is pursued, as a rule, only amongst the very poorest class of patients.

Rectification by elastic traction, as recommended by Barwell, does not by any means excel the treatment by orthopædic apparatus, if it even comes up to it; and it is so closely allied to it, that it may be said to be a mere modification of it with no special advantages to recommend it.

Gradual rectification by plaster of Paris bandages—a method we owe to our German brethren—is, on the contrary, capable of simplifying and cheapening, to an important extent, the cure of the disease, and putting a really reliable and satisfactory method within the reach of even the poorest. I have employed it for a considerable time, and have been led to make some modifications in the manner of employing it that seem to me to add greatly to its simplicity and success.

This paper, therefore, is designed to bring before the profession the mode of employing it which, I believe, amongst the poor at least, deserves to take the preference over all other methods of treatment.

In undertaking the cure of club-foot, it is absolutely necessary to be impressed with the fact that, although the position of the limb can be rectified to a great and satisfactory degree by a few months of treatment, there will in every case, or almost every case, remain traces of the disease, slight tendencies of the foot to assume its original perverse directions, which require for years, generally up to the age of puberty, a careful watching on the part of the

parents, or an occasional visit to the surgeon who directs the treatment, and that these tendencies cannot be safely let out of sight until the advancing intelligence of the patient, and his increasing regard for his personal appearance render him fitted to watch himself over his faulty limb. It is of the utmost moment, and indeed the only way by which the confidence and co-operation of the parents of the patient can be secured and retained during the necessary series of years, that the amount of improvement to be obtained, the difficulties and disappointments to be overcome, and the tendencies to relapse that may be met with, be all carefully explained to them before the cure be undertaken at all. They ought to be invariably made acquainted with the difficulties of the undertaking they are entering upon, and should learn both its bright and its dark sides. It is necessary that it should be expressly, and with a considerable degree of formality said to them, that the surgical part of the treatment may require a good many months, perhaps a couple of years; that after that is finished they themselves will have to be constantly on the watch for the reappearance of malpositions; that they must not be disappointed or discouraged should such occur, but have them promptly attended to; and that a tendency to inversion of the front part of the foot will never quite disappear until the child has arrived at the age of puberty.

Inasmuch as all structures of the foot are concerned in the production of club-foot, it stands to reason that the earlier the cure is undertaken after the birth of the child, the softer and less rigid will they be, and the easier will be the cure. But it is not wise to commence the cure in the first few months of life. The child at that epoch requires frequent bathing, has not acquired habits of cleanliness, and perhaps has a more vulnerable skin, so that it is not easy to keep the plaster appliances clean and dry. The best age to commence treatment is from six to nine months, at which time it will be found that the tissues are not appreciably more firm or resistant than at birth, while there is, on the other hand, the great advantage that by the time the foot is rectified the child will be beginning to walk, and the movements of standing and progression will materially aid in maintaining the improved position.

The treatment by plaster bandaging is exercised on the principle of putting the foot into as good a position as it can be made to assume, fixing it by plaster in that position till it has become natural to it; then taking off the plaster, rectifying the position still more, and again fixing it in the improved position, and so on until the foot is straight. The plan of treatment recommended in this paper has nothing new in principle, since it is merely a carrying out of this idea. But it is the way in which it is carried out that is claimed as being advantageous. It is usually recommended by those who employ the plaster treatment, to place the sole of the foot against a flat surface, press it as straight as possible, then apply

the plaster bandages and allow them to set ; or to pull the foot into as good a position as may be, and hold it firm until the bandages have been applied and become hard. Both these plans I have tried and given up as not sufficiently answering their intended purpose, and have adopted that which is now about to be described as better suited to effect what is desired.

Before entering on a minute description of the treatment which yields such good results, there are *three* preliminary subjects that require a short consideration.

In the *first* place, I would point out, that, even in an infant under chloroform, the clubbed-foot, when moved by the hand or other means into the best position it can be made to assume, resumes immediately on the removal of the force its original malposition, because the tissues spring back into the place that has become habitual to them. But it is possible, by a few minutes of firm manipulation, to tire out or exhaust the resiliency of the structures, so that the foot does not spring back—or rather has less tendency to spring back—but remains on the contrary in a considerably improved posture. For manipulating so as to effect this there is nothing equal to the hand of the surgeon, by which the amount of resistance, the point of resistance, and the direction of the resistance, can be so accurately gauged and overcome. If the clubbed-foot of a child under chloroform be grasped by the two hands of the operator and steadily and firmly unfolded, the projecting points which ought not to project (such as the calcaneocuboid joint) being firmly pushed inwards by the thumbs, and the toes and front part of the foot unfolded and coaxed outwards by the fingers, a certain improvement of the position is first obtained ; then strong resistance is met with in the attempt at still further rectification, as the bones, ligaments, and fasciæ, all the firmer structures in fact, refuse further to give way. But if, disregarding their resistance, the force be continued, and even augmented, not by fits and starts, but steadily and inexorably, not with reckless force, but with a watchful yet determined persistence in the proper direction, the foot is brought into a position much more nearly normal than might have been considered possible ; the bones, ligaments, and other resisting tissues, thanks to their yielding properties at so early an age, are moulded or forced into a comparatively normal situation without any signs of rending or fracture being observable, and their powers of resistance seemingly exhausted, remain in the new position with so little tendency to spring back, that the slightest support enables them to be kept there until the plaster bandages have been applied. Ten minutes steady moulding in this manner are more than sufficient in every case to obtain in a child of nine or twelve months of age a most pronounced and decided amelioration of the pre-existing deformities. It is scarcely needful to say, that the force must never be so wildly and recklessly applied as to produce fracture or dislocation, nor

continued to too great an extent in the endeavour to obtain too much at one sitting, but that, a decided rectification once obtained, further attempts should be reserved for the next sitting. The merest minimum of practice is requisite to enable the surgeon to feel how much can safely be gained at each sitting.

This force, so applied, must evidently act by overstretching the soft parts, and probably by slight bending or even infraction (similar to greenstick fracture) of the bones, but it is never followed by any swelling, inflammation, extravasation, or other marked reaction, and does not pain the child after it has awakened from the anæsthesia. I may add that fracture or dislocation is very difficult to produce in so young a child, and need never be dreaded if even reasonable caution be preserved.

In the *second* place, I would add my testimony to the truth of that which has been already well and sufficiently pointed out by others, that the foot must be unfolded before the heel is brought down. It is not quite correct to say that club-foot is a combination of the equinus position, where the heel is drawn up, with the varus position, where the foot is inverted, and that the adjective equino-varus expresses the deformity. The deformity is far too complicated to be thus satisfactorily defined, for it affects even the knee-joint, appears markedly in the leg, and reaches in the foot such a degree of complicated twisting that no word or name can adequately express the state of affairs. Still, on the whole, so far as concerns the foot and ankle alone, the term "equino-varus" is *an approximation* to the truth, and, so far as the treatment goes, it is well to retain the term, helping as it does to indicate that there are two main sets of deformities to be overcome.

In the treatment, the foot must always be unfolded and the varus position rectified, before by the bringing down of the heel the equinus position is interfered with, for the fixation of the heel by the tendo Achillis is an immense assistance, giving an additional prop to work on in unfolding the anterior part of the foot.

In the *third* place, I would remark that division of anything save the tendo Achillis is rarely required. The fashion of promiscuous division of all the main tendons around the ankle cannot be too strongly condemned. It must be remembered that such tendons as possess synovial sheaths cannot be divided without the certainty, or next to certainty, that they will never reunite,—a fact often experimentally proved and never refuted, and that is yet not sufficiently appreciated or known. Although a foot may serve passably well for locomotion after division of a number of its tendons, that is no reason for running a muck against them, under the delusion that they are the offending agents in the disease. It is quite an erroneous and unjustifiable line of treatment to divide the peronei, the tibialis anticus, the tibialis posticus, or the flexor longus digitorum, each of which possesses a synovial sheath around its tendon. Their division is never necessary, is of no assistance in the treatment, and is merely

a relic of the time, now gone by, when the pathology of the disease was thought to consist of paralysis of some muscles and contraction of others. In trying to cure the deformed foot it is quite a mistake to divide tendons according to any fixed plan or rule; the only wise course is to wait until, during the progress of the foot towards rectification, it becomes evident that some structure is offering a real and invincible resistance to the means employed, and then of course that structure, whatever it be, must be divided. It will invariably be found that in infants the tendo Achillis is the only tendon requiring division, and that at the very utmost in addition to this the plantar fascia may now and then have to be cut in the way recommended by Buchanan of Glasgow.

Having now exhausted the preliminary considerations necessary to prevent any misunderstanding, we come to describe the procedure which it is my object to recommend.

The child, we will suppose, has arrived at about the age of six or nine months, and the parents have had clearly explained to them the possibilities and the difficulties of the case.

The child has all clothing removed from its lower limbs, and is laid upon a small table of the ordinary height, so that the operator can finish his work without the fatigue of prolonged and considerable stooping. A pillow is placed under its head, and chloroform is administered. Children bear chloroform well, and its administration is most desirable, as it renders the limbs passive and quiet during the rectification and bandaging. The chloroform need not be deeply given, but it must be administered sufficiently to prevent the child moving during the application of the bandages. The operator grasps, say, the right foot with both hands, back upwards, holding the ankle joint and heel in his left hand, and the front part of the foot in his right hand, with both thumbs pressing on the outer edge of the sole, opposite Chopart's articulation, just below the thin scar-like patch of skin usually present on the most prominent part of the dorsum of the foot. Maintaining steady pressure with his thumbs, he now strives by a deliberate, gradually and cautiously increased force, exerted by his hand, to abduct, evert, and pronate the foot, so as to bring it into as natural a position as possible, but without any attempt whatever to bring down the heel. At first the foot yields readily, but soon ceases to move as desired, and the operator becomes conscious that greater force will be needed to effect his object. Renewing his grasp, if this has been rendered insecure by the improved position of the foot and wrinkling of the loose skin on the outer part of the dorsum of the foot, he continues his task by applying, with the same steadiness and caution, an increased force, in exactly the same manner as before. The force is slowly increased, with every now and then, if there seems to be any danger of fracturing the bones, intermissions of half a minute or so, during which it is merely kept up, and not further increased, until the resistance of

the foot being by degrees overcome, it unfolds from its perverse position, and has not the same strong tendency as formerly to spring back again. After as much advance has been made as seems prudent, the hands are removed, and the foot, if the manipulation has been well managed, lies passive and improved in posture, flaccid, and with considerably diminished tendency to return to its old vicious shape. There are no marks of its having suffered from the proceeding; there are no signs of fracture, contusion, or even abrasion, but the foot appears simply more normal in shape.

When this has been achieved the operator next proceeds to fix it with plaster of Paris in its new posture. It is bandaged from the roots of the toes to the insertion of the ligamentum patellæ with a single thickness of flannel bandage, one and a half inches in breadth and four feet long.

To retain the foot in the position most nearly approaching that of the normal foot, two strips of adhesive lead plaster are used, each of them eighteen inches long by one-third of an inch broad. One of these is made into a loop, applied to the foot over the ball of the great toe, and, guided by the hand of an assistant, pulls the foot outwards, or rather retains it by moderate traction in the favourable posture gained by the manipulation already described (see Figure 1). The second strip is likewise made into a loop, passed round the foot over the ankle and heel at the exact spot that seems most advantageous in each case, and forms a resisting force to the traction exercised by the former loop, by drawing the ankle inwards, or rather preventing its being drawn outwards. The assistant who holds these two stands on the right side of the pelvis of the patient with his face to the child's feet, and uses the toe strap with his right and the ankle strap with his left hand. In this manner he avoids interference with the operator, who now proceeds to put on the plaster bandages. A strip of "book muslin," one and three-quarter inches broad and five feet long, with plaster of Paris well rubbed into its meshes and loosely rolled up, is dipped for a few seconds into water until it is well soaked, then wrung firmly to expel the superfluous water, and wound round the foot and leg, beginning at the toes. It should not be drawn tight, but simply laid on outside the flannel bandage and loops of strapping where the latter are in contact with the limb, and it should be brought once or twice between the limbs of the straps where they leave the foot to proceed to the hands of the assistant holding them. The toes should be left uncovered. After the plaster bandage is in position, about a heaped breakfast-cupful of dry plaster of Paris is made into thin, nearly fluid, paste by adding the required quantity of water and stirring with a spoon, a common iron kitchen spoon serving this purpose best. With the spoon the paste is spread on the foot and leg, first along their upper surfaces, then along their sides, and finally

Edinburgh Medical Journal

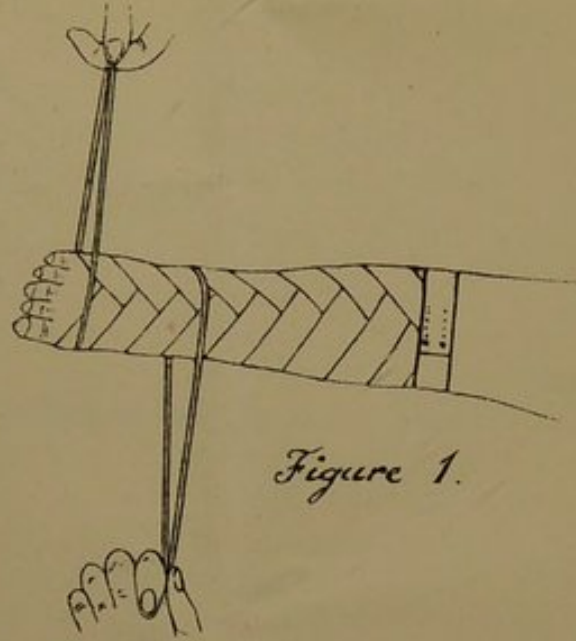


Figure 1.

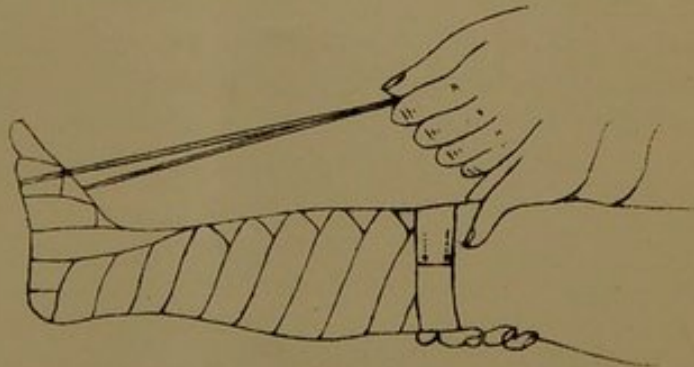


Figure 2.

Ogston on Club-foot



down the back of the leg, over the heel, and on the sole to the roots of the toes, care being taken to insert a sufficient quantity between the limbs of the two straps and carefully spread it out there, so that the bandage may not be weak at these points. The layer of plaster thus applied to the foot and limb should be a quarter of an inch thick, not exceeding three-eighths of an inch at most. It need not be very carefully smoothed on its surface by the spoon or hands of the operator; it is better to lay on outside it without any delay another muslin plaster bandage, which renders the exterior smooth and neat, and adds greatly to its strength and power of resisting injury. For this purpose, while the plaster is being laid on the limb with a spoon, another muslin bandage, similarly prepared to the first, should be soaking in water, and as soon as the plaster is spread on the limb, and while it is yet soft, the second bandage is wrung out and laid on outside the plaster layer in the same manner as the former one had been applied, with the same care to bring it once or twice between the limbs of the loops of strapping. When this last bandage has been put on, any plaster paste remaining over may be used to rub on its exterior and make everything smooth and neat. By the time all this has been done the plaster will have begun to set, and as soon as it is firm enough not to yield or crack when the straps are relaxed, these should have their ends cut off close to the plaster, and the places where they have emerged be smoothed over with a touch of the plaster paste.

The limb is now finished, the toes alone remaining uncovered, so that they may show by their temperature and colour whether the bandage has been by accident too tightly applied around the limb. If reasonable care is taken not to pull the inner muslin bandage too tight, this occurrence never happens, and the toes remain pink and warm. Should they be slightly bluish and cold, the bandage may still be left on, as that is a condition that will in all probability pass off in a few hours and cause neither pain nor trouble. But if they be found deep purple and quite cold, the bandage is certainly very badly applied, and must come off at once. I have never once, however, seen a bandage require to be removed for this or any other similar cause.

The other foot, the left one in the case we have supposed, is next treated in a precisely similar manner, the hands of the operator who manipulates and of the assistant who holds the straps, being of course reversed, and the straps being also reversed, as is self-evidently necessary.

The whole of the above treatment can be readily carried out in half an hour, or, with a little practice, in even less time. The chloroform is stopped, and the child, when it awakes, shows signs of neither pain nor uneasiness, so soothing is the firm, equable support of the plaster of Paris bandage. I have never seen the treatment followed by more than a very slight uneasiness of the

child for the first twenty-four hours, and that was probably due to the effects of the chloroform, or to the feeling of weight of the bandages.

The plaster bandages, if well applied, will easily last for six weeks, and for that period they should be left undisturbed. So far as I have been able to judge, no advantage is to be gained by renewing them at shorter intervals. The foot requires some time to become habituated to its rectified position, and, active as the processes of life and repair are in infants, they seem to need a period of about this duration to make the new position normal and habitual to the foot. The parents are therefore instructed to remove the plaster bandages two days before the expiry of the six weeks. They are best removed by cutting or scraping them through with a stout knife, and as their removal requires a good deal of time and trouble, it is best that the parents be instructed to undertake it themselves. The limb ought then to be well washed to remove the rough epidermis that has collected on the skin, and, when seen on the expiry of the six weeks, the foot, having been free for two days, shows by the position it has assumed the degree of improvement really attained by the treatment. A few slight abrasions, not amounting to complete removal of the epidermis, are generally seen in the form of red lines about the ankle. These offer no contra-indication to a renewal of the treatment. The child is again anæsthetised, and, by the same manipulation and bandages, the foot is still further rectified. Every six weeks a fresh rectification is obtained until the foot has lost all tendency to adduction and inversion, and even become somewhat abducted at Chopart's joint.

It is absolutely necessary not to begin to bring down the heel, *i.e.*, cure the equinus position, until the varus position has completely gone, and even been replaced, as stated above, by a slight abduction. For the foot will in time again become a little abducted, hence the wisdom of curing the varus deformity as fundamentally as possible. In slighter cases three or four bandagings suffice to effect this; in the worst cases six or eight may be required.

Once the varus position has disappeared the tendo Achillis must be cut. It is no use trying to avoid its division. The heel will not come down without it. It is indeed easy by the plaster treatment to produce dorsal flexion of the foot and bring the toes up, but this is effected by a yielding of Chopart's joint, the heel remaining unchanged in position, and the sole becoming convex instead of concave. Hence, in commencing the second part of the treatment, the cure of the equinus position, it is wise, at the very outset, to divide the tendo Achillis. On the subcutaneous division of this structure I have nothing special to say, save in favour of effecting reposition of the foot immediately after it, as saving time and being unattended with any disadvantage.

Accordingly, in undertaking the second part of the cure of club-foot, the correction of the equinus position, the first act is to perform, under chloroform, tenotomy of the tendo Achillis in the usual way, then after having washed the leg with carbolic water, to apply a pad of antiseptic gauze over the small wound, and retain it there with the hand during the manipulations that immediately follow. There is no harm whatever in rectifying the plantar flexion of the foot at the ankle-joint to a considerable extent immediately the tendon is cut, and the operator should therefore proceed at once with the following manœuvre. In the case of the right foot the leg is grasped just below its middle by the surgeon's left hand, back upwards, the fingers of this hand retaining the gauze pad in position over the tenotomy wound. The palm of the right hand is placed against the sole of the foot, the fingers and thumb closing on its dorsal surface, and the toes are steadily raised, so as to produce dorsal flexion of the foot, until the resisting structures are tired out and yield, just as in the forcible rectification of the varus posture. It is well, however, not to press matters too far in the sitting of which the tenotomy forms the commencement, but to wait for next sitting to wield the manipulation with its full power. After reasonable rectification has been obtained, a flannel bandage is applied as before, and serves to retain the gauze pad over the tenotomy wound, and the limb is fixed in the improved posture so that the plaster may be put on. This is done as follows:—

An assistant, standing on the right side of the child, obtains complete command over its knee-joint by placing the palm of his right hand on its outer side, and grasping the articulation with his thumb closed over the patella, and the fingers crossing behind over the popliteal space, and resting on the head of the tibia behind so as to push it forwards, thus keeping the extremity firmly extended at the knee-joint. Only a single loop of plaster is thus required, and is crossed over the sole of the foot just at the balls of the toes, while its ends, meeting together above the dorsum of the foot, are held in the assistant's left hand, and serve to draw the toes and front part of the foot upwards, and fix them in the desired position (see Fig. 2). The plaster of Paris bandages and paste are now put on exactly as before, and the limbs of the plaster loop cut off. The opposite limb is then submitted to the same treatment. When six weeks have elapsed the bandage is removed, the foot is further rectified, a new bandage is put on, and the process is repeated until a good form and position have been acquired by the foot, a thing generally obtainable by at most three or four repetitions of the proceeding. It is then put into a lacing boot and the child is allowed to walk.

Even then, however, it is well to be suspicious of a club-foot, and emphatically to repeat to the parents before dismissing them that tendencies towards relapse are far from improbable, especially

in the direction of adduction of the front part of the foot at Chopart's joint. It has been recommended to advise the mother of every child whose treatment for club-foot has been finished, to sit down with the child once every day and carefully flex the front part of the foot upwards on the leg, following this by a firm and decided adduction of the foot at Chopart's joint, so as to aid in keeping the heel down and the toes outwards. This apparently sensible advice I have never found to be productive of any benefit, since few, if any, mothers will use sufficient force to render the proceeding of any real avail. But it should be well impressed on those who have the charge of the children, that they should return to the surgeon on any serious symptoms of relapse setting in. If a relapse occur, it must be treated in the way already detailed, according as it is the varus or equinus position which is returning. If varus, the manipulations and bandages for that; if equinus, a repetition, if required, of the tenotomy of the tendo Achillis, followed immediately by the manipulations and bandaging for that. But if the cure have been thoroughly completed in the first instance, and no gross error in the management of the child have been subsequently committed by the parents, a relapse is not to be expected.

This concludes the description of the cheap and simple treatment which I would recommend in club-foot. It is, as already stated, not new, for plaster of Paris is used by many on a similar plan, and with success. But the manipulative straightening of the foot which I was led to devise while trying the ordinary plans is of great assistance in shortening the treatment and making it more exact and satisfactory. When mentioning above the number of times the bandages have to be renewed, the maximum number that has hitherto been found needful in the worst cases has been stated, but, generally speaking, fewer are required.

Nor is this method claimed as being without defects. At present we know of no method free from defects, but that which is here recommended is as free from them as any I know, and is the only one which seems to me able to compete with the treatment by orthopædic apparatus. Moreover, I believe I am speaking within the mark in saying, that the results obtained by it are in no way inferior to those obtained by apparatus in point either of completeness of rectification or of the time required to effect it.

Simple and effectual as it is, it deserves a trial in the hands of those who have to treat clubbed-feet amongst the poorer classes.

