

Gritti's supra-condyloid amputation of the thigh / by Robert F. Weir.

Contributors

Weir, Robert F. 1838-1927.
Royal College of Surgeons of England

Publication/Creation

Syracuse, N.Y. : Truair, Smith & Bruce, printers and binders, 1879.

Persistent URL

<https://wellcomecollection.org/works/p4jap59q>

Provider

Royal College of Surgeons

License and attribution

This material has been provided by This material has been provided by The Royal College of Surgeons of England. The original may be consulted at The Royal College of Surgeons of England. where the originals may be consulted. This work has been identified as being free of known restrictions under copyright law, including all related and neighbouring rights and is being made available under the Creative Commons, Public Domain Mark.

You can copy, modify, distribute and perform the work, even for commercial purposes, without asking permission.



Wellcome Collection
183 Euston Road
London NW1 2BE UK
T +44 (0)20 7611 8722
E library@wellcomecollection.org
<https://wellcomecollection.org>

25.

GRITTI'S
SUPRA-CONDYLOID AMPUTATION
OF THE THIGH.


BY

ROBERT F. WEIR, M. D.,

SURGEON TO THE NEW YORK AND ROOSEVELT HOSPITALS.

*With the Compliments
of R. F. Weir*

READ BEFORE THE MEDICAL SOCIETY OF THE STATE OF
NEW YORK, FEBRUARY 3, 1879.



SYRACUSE, N. Y. :
TRUAIR, SMITH & BRUCE, PRINTERS AND BINDERS.
1879.


525

GRITTI'S
SUPRA-CONDYLOID AMPUTATION
OF THE THIGH.

BY

ROBERT F. WEIR, M. D.,

SURGEON TO THE NEW YORK AND ROOSEVELT HOSPITALS.



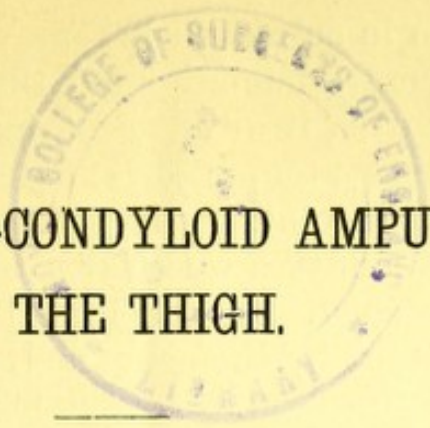
READ BEFORE THE MEDICAL SOCIETY OF THE STATE OF
NEW YORK, FEBRUARY 5, 1879.

SYRACUSE, N. Y. :
TRUAIR, SMITH & BRUCE, PRINTERS AND BINDERS.
1879.



Digitized by the Internet Archive
in 2015

<https://archive.org/details/b22453519>



GRITTI'S SUPRA-CONDYLOID AMPUTATION OF THE THIGH.

BY ROBERT F. WEIR, M. D., OF NEW YORK.

SURGEON TO THE NEW YORK AND ROOSEVELT HOSPITALS.

The advantages that have led to the general favor with which amputation at the knee-joint is at present regarded are, as stated by Velpeau and others :

1. The safety of the operation—on the accepted dictum that for every inch nearer the trunk the greater is the danger.

2. The capacity afforded by the expanded end of the femur to sustain the weight of the body or to bear the pressure of an artificial limb, and thus to meet the requirements of both the rich and the poor man ; in contradistinction to the fact that in amputations through the thigh the support of the body is of necessity placed at or near the tuberosity of the ischium. With this goes the removal of the cicatrix from the face to the posterior aspect of the stump ; and

- 3d. The preservation of the natural motions of the limb, by reason mainly of the non-interference with the attachment of the adductor muscles.

As this excellent amputation became more and more accepted, and chiefly in this country by the efforts of Dr. Markoe, of the New York Hospital, certain minor points were also determined, one of which is, that now-a-days in its performance, the surgeon does not deem it necessary to remove the encrusting cartilage from the femur, but covers it at once by his flap, knowing that in the majority of instances he will have no trouble resulting, and that, even should necrosis and exfoliation of it occur, it will be but to a limited extent, and without much detriment to the healing process. The experience of the earlier performers of disarticulation at the knee-

joint, who also in many cases removed at the same time a slice of the femur, demonstrated that by the section of the condyles but little, if any, additional risk to life was encountered; for Brinton, in his exhaustive paper on "Amputation at the Knee-joint,"* gives the mortality as 28.12 per cent. when the condyles were sawn off, and 27.84 when they were left untouched. In the knee-joint amputations however, whether done by the usual method of the long anterior and short posterior flap, or by the use of the lateral flaps of Rossi and Stephen Smith,† the line of incision, in order to cover the expanded end of the femur, necessarily descends quite a distance on the leg—in the first method fully a hand's breadth below the patella, and by the second to a point even lower.

Hence, the natural endeavor of surgeons has been to devise or practice a mode of amputation that would preserve as far as possible the good points of the knee-joint amputation, and at the same time admit of a smaller flap; or, in other words, would allow of the benefits of a disarticulation in conditions that would otherwise necessitate amputation higher up through the thigh. Two such methods have, in consequence, been made known to the profession; and, though chronologically the latest in this respect, yet, in reference to the actual data of its first performance (1846), as well as to the fact that it is already well known to both American and English surgeons, the procedure of Mr. Henry D. Carden, of Worcester, England, first deserves attention. Mr. Carden‡ proposed in 1864 an amputation of the thigh through the condyles, covering the sawn femur by a long anterior flap.

The operation consists (see No. 2 in diagram) in reflecting a rounded or semi-oval flap of skin and fat from the front of the joint, dividing everything else straight down to the bone, and sawing the bone slightly above the plane of the muscles, thus forming a flat-faced stump, with a bonnet of integument to fall over it. The operation is simple, and is performed easily in two ways: the operator, standing on the right side of the limb, seizes it between his left forefinger and thumb at

*Am. Jour. Med. Sciences, April, 1868.

†Ibid.; Jan., 1870.

‡Br. Med. Jour. April 16, 1864.

the spots selected for the base of the flap; enters the point of his knife close to his finger, bringing it round through skin and fat, below the patella,* to the spot pressed by his thumb; then, turning the edge downward at a right angle with the line of the limb, he passes it through to the spot where it first entered, cutting outward through everything behind the bone. The flap is then reflected, and the remainder of the soft parts divided straight down to the bone; the muscles are then slightly cleared upward, and the saw is applied. “ . . . Or the flap may be reflected first, and the knee examined, particularly if the operator be undecided between resection and amputation. In amputating through the condyles, the patella is drawn down by flexing the knee to a right angle before dividing the soft parts in front of the bone; or, if that be inconvenient, the patella may be reflected downward.”†

Carden, in his paper, presented 31 cases wherein this operation had been performed through the femoral condyles, of which four were for primary injuries, with 1 death, or 5 deaths in all. His method, he also shows, is of use in other limbs, and he gives 32 instances of its varied applicability.

This is an admirable method, and has met with the commendation of surgeons both here and abroad. Syme says that the safety of it mainly depends upon the dense bone and medullary texture not being concerned, and states, moreover, that Lister drew his attention to this circumstance. He also adds that the resulting stumps in his seven cases were comfortable and serviceable.

Lister and Spence have both somewhat modified Carden's operation, in making the anterior flap to consist, instead of integument alone, of a certain amount of muscular tissue cut from above the patella (which in all of these condylloid amputations hitherto spoken of is sacrificed), and also in having a short posterior flap. Mr. Spence carries the section of the femur well up in the shaft beyond the condyles. In his words,‡ it is done as follows: “supposing that the right thigh is to be amputated, the surgeon, standing on the inner side of the limb, (so as to be able to grasp the distal por-

**i. e.*, to level of tuberosity of the tibia. See Carden's paper.

†Stimson: *Manual Operative Surgery*, p. 127.

‡Spence's *Surgery*, Vol. II., p. 750.

tion of the bone when sawing,) inserts his knife deeply pretty far back on the outside of the thigh, and about three inches above the patella. He then carries the knife downward through the skin and fascia to a level with the lower edge of the patella, and, after cutting with a gentle curve across the front of the limb, he carries the incision up the inside of the thigh to a point opposite the place where he commenced it. While he is making the incision, his assistant retracts the skin and fascia, and when by a few touches with the knife the muscular tissue of the thigh is exposed, the surgeon cuts obliquely through it to the bone, so as to dissect up the flap from the femur; then, applying the edge of his knife to the soft parts on the posterior aspect of the limb, at least two inches lower than the level of the base of his flap, he cuts them with a sweep obliquely to the bone. The assistant next retracts the soft parts, while the surgeon clears the bone for nearly two inches with a circular movement of the point of his knife; the femur then, being elevated so as to project it fully, is sawn through close to the soft parts, immediately above its condyloid portion. . . . The flap folds over the face of the stump, and is then adjusted and retained by sutures."

Lister's modification consists in making a transverse cut across the leg on a level with the tubercle of the tibia, the extremity of the incision being prolonged obliquely downward for half an inch, (13 mm.) so as to obviate subsequent notching. The knife is then passed beneath the limb, and a slightly convex short skin-flap marked by joining the two oblique cuts. The limb being now raised, this posterior flap is to be reflected together with the integument of the knee, as in a circular amputation, until the hamstring tendons are exposed, when they are to be divided by a circular sweep, passing also above the patella and through the muscle on the front of the thigh. The saw is to be applied immediately above the articular cartilage of the knee, and the condyles divided.*

The second method for accomplishing a supra-condyloid amputation of the thigh, and the one to the consideration of which this paper is mainly devoted, is that suggested by the Italian surgeon, Dr. Rocco Gritti, of Milan, in 1857. Deriv-

* Heath: Operative Surgery, part v., Pl. 19, p. 122.

ing the idea from Pirogoff's amputation at the ankle-joint, Gritti proposed not only to cut through the condyles, but also to remove the cartilaginous surface of the patella by a saw, and then to apply it to the end of the femur in order to obtain bony union between these two surfaces. He had, at the time he published this brochure, not done the operation, which remained untried in his own land until 1866, when it was performed by Melchiorj, of Salò; but in Russia it was favorably received, and was first performed, it is said, by Sawostitzki,* early in 1862, and subsequently by other surgeons of that country and of Germany. But Neudorfert† claims that he performed the same operation in 1859, as an original idea.

Sédillot attributes the operation to the ingenuity of Szymanowski,‡ who, in 1860, published an account of the method of its performance; but this distinguished surgeon (alas! too early cut off) had only worked out the operation on the cadaver. During the military campaigns that ensued in the next few years, this operation was employed a number of times, but with unsatisfactory results, (in several cases, indeed, it was done for injuries that now would be thought sufficient to call for a higher amputation.)

In America, during our late civil war, a somewhat similar operation was resorted to by Dr. J. W. S. Gouley,§ at the time an assistant surgeon in the U. S. Army, on a soldier who had been wounded at Fredericksburg, December 13, 1862, by a musket-ball, which entered the outer condyle of the femur, and escaping posteriorly in the middle of the lower third of the thigh, left the bone much comminuted at its exit. The limb was amputated the next day, at one and seven-sixteenth inches (37 mm.) (as determined by subsequent measurement) from the articular surface of the condyles, and the sawn surface of the patella applied to the femur. Sloughing came on in the stump with concurrent secondary hemorrhage, which necessitated reamputation on the ninth day. The patient died four days later. The interesting specimen of this operation, believed by the able operator to be original,

* St. Petersburg Med. Zeitschr., Bd. VIII., No. 1.

† Neudorfer, Handbuch der Kriegschirurgie, 1864.

‡ Prager Vierteljahrschr., Vol. I., p. 78.

§ Boston Med. and Surg. Journal, Feb. 26, 1863.

is preserved in the Army Medical Museum at Washington, D. C., and is numbered 536.

In 1870, Gritti's operation became better known to the English-speaking part of our profession, by means of a paper read before the Medico-Chirurgical Society of London, by Mr. William Stokes,* of Dublin, under the title of "Supra-Condylloid Amputation of the Thigh." Up to this time it had been performed, besides the surgeons already mentioned, by Wahl, Michenewski, Hofnoki, Linhart, Simon, Szymanowski, Pairkt, Spanner, Wagner, Fuxs, Schuh, Beck, Middeldorpf, and a number of others on the continent, and once in England by Mr. Rivington,† in 1864.

Mr. Stokes set forth the advantage of the operation in an extremely clear manner, and presented two cases in which he had most satisfactorily used it, and subsequently in other papers‡ contributed the results of his further experience in this amputation, together with that of his surgical brethren.

He, however, stated that his method differed from that of Gritti's, in that: 1st. The femoral section is made in all cases at least half an inch (13 mm.) (sometimes as high as three-quarters of an inch) (19 mm) above the antero-superior edge of the condyloid cartilage, (and, therefore, higher up than suggested by Gritti.)

2d. That in all cases the cartilaginous surface of the patella is removed.

3d. That the flap is oval and not rectangular.

4th. That there is a posterior flap fully one-third the length of the anterior flap.

In the two latter points Mr. Stokes is undoubtedly right, and the shape of his flap is probably an improvement on the original one of Gritti, inasmuch as this change permits a covering of the bone with the least sacrifice of the length of the limb. Indeed, Stokes himself elsewhere admits the advisability of even giving more length than this to the posterior flap. In respect, however, to the first two points upon which he bases his claim to an improvement on Gritti's amputation,

* Trans. Med.-Chir. Soc., Vol. 53.

† London Hosp. Reports, Vol. II., p. 395.

‡ Dub. Journ. Med. Sciences, December, 1872, and August, 1875.

and which is being generally known by his name, I must, in justice to the Italian surgeon, ask attention to an extract from Gritti's paper on this subject.* For it is evident from Mr. Stokes's words that he has not been able to obtain access to this article, or to that of Melchiorj† (whom he credits with the performance of the operation in 1851;) and it will be seen by this, too, that Gritti had thoroughly worked out the details of the operation proposed by him, and that he had fairly covered the points claimed by Mr. Stokes in his paper.

Under the heading of "Rules to observe," Gritti says: "1s. The operator in making his flap must take the precaution to remove all the adipose tissue that lies under the ligamentum patellæ in such a manner as to do as little violence as possible to what is left of the ligament. 2d. That care must be taken to remove entirely all the cartilage covering the internal surface of the patella, because this bone presents on this side a vertical elevation; the cartilage is sometimes not completely sawn off, and this is especially so at the side. Hence, if accidentally a small part of the patella remains covered by cartilage, it is necessary to cut it out with a knife so as to reach the bony structure. 3d. The section of the femur ought to be made at the line of junction of the epiphysis with the shaft, which corresponds anteriorly where the articulating cartilage ceases to cover the bone, or the section must be made considerably higher up in the shaft. If the section take place in a plane lower than the superior margin of the patella, it is impossible to turn this bone down on the sawn face of the femur, and so the operator would find himself in no less a dilemma than a surgeon would be, who, following Pirogoff in amputating the foot, should saw the heel too far forward or the malleoli too low down. Whenever this happens in an operation another layer of the femur must be removed until the point indicated is reached."

As to how high up one can divide the femoral condyles and

* Rocco Gritti: Dell' amputazione del femore al terzo inferiore e della disarticolazione del ginocchio. Valore relativa di cadanna cell' indicazione di un novo metodo denominato amputazione del femore ai condilli con lembo patellare, Milano, 1857.

† Giovanni Melchiorj: Caso de amputazione sopra condilodea del femore col metodo del Doct. Rocco Gritti. Milano, 1867. From this it will also be seen that the title of the operation is the same as that chosen by Mr. Stokes, as distinctive of his operation.

still preserve a vascular spongy tissue to oppose a similar one on the patella, the researches of Michenewski* in 1866 are confirmed by those of Stokes. According to the former observer, the medullary cavity of the femur is in the child 20 mm. from the bottom of the condyles, and in the adult 45 mm.; and by Stokes's measurements, more accurately made, as a repetition by myself has shown, the distance is in the majority of cases in the adult about three-fourths of an inch (19 mm.) above the articular junction on the anterior surface of the bone. Lücke has, however, observed, when amputating for knee-joint disease, that from osteoporosis the medullary canal is apt to reach lower down than in health.

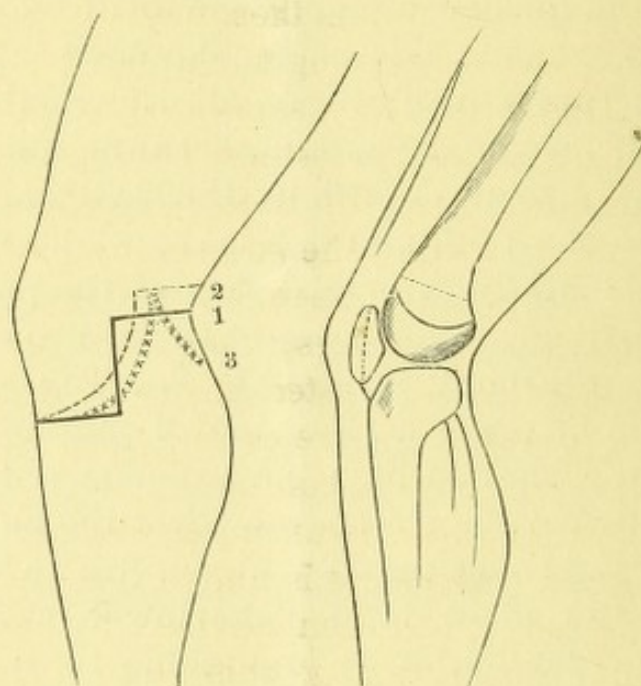


FIG. 1.†

FIG. 2.†

- 1. Gritti's Incision.
 2. Carden's "
 * * * * * 3. Stokes's "

The operative procedure evolved by Gritti, and resorted to by most of the German and Russian surgeons, is as follows:

†“The incision of the integuments (see No. 1 in diagram), beginning at the upper edge of the head of the fibula is continued transversely across the leg, about one inch below the lower border of the patella, to internal tuberosity of the tibia. From extremities of this incision a vertical cut is made

*Wahl: St. Petersburg. med. Zeitschr., Vol., XI., 1866.

†Cut furnished by Medical Record.

‡Gritti: Op. cit., p. 16 et seq.

upward, on each side of the limb, to the level of the middle of the patella. Then the flap thus outlined is dissected up to the posterior edge of the patella; the joint is opened by cutting through the ligamentum patellæ close to the bone. The flap is then turned back without disarticulating at the joint, as I did in my first trials on the cadaver, and, . . . a segment of the patella, about two lines in thickness, is taken from its internal surface by means of a little bow-shaped saw.* This is done in the following manner: the left hand is used to hold the patella firmly by means of a napkin to prevent slipping, and with the right, after exposing the cartilaginous junction at the edges, the section is made with the saw. The posterior flap is then made by an incision direct to the bone, and connecting the upper extremities of the lateral cuts. This flap is then separated from the femur for a short distance, and the periosteum having been cut through with an amputating-saw, the limb is removed. The operation is ended, after ligating the vessels, by placing the sawn bone surfaces together, and securing the edges of the flaps by several interrupted sutures; these are strengthened by several strips of adhesive plaster, disposed in such a manner as to exert a moderate pressure on the patella, just sufficient to maintain the two bones in contact."

Inasmuch as after this operation, as well as after disarticulation at the knee, an abscess is apt to form in the remaining synovial cul-de-sac, it has been advised by Szymanowski to dissect this out; but in reality this step is inadvisable, except when Gritti's operation is resorted to for a disease of the joint itself. To avoid the occurrence of such a collection of pus, it is only necessary, as personal experience has proven, to cut across the synovial ligaments that stretch out from the patella, and to insert a drainage-tube on each side to the top of this pouch, in addition to the usual tube passed across the stump.

Stokes,† in his paper, made the following modification of the flaps: "An incision was made with a strong scalpel, beginning one inch (25 mm.) above the external condyle, and carried merely through the integument downward and forward to the tubercle of the tibia, and then carried upward and backward

*Szymanowski recommended later the small metacarpal saw, now generally used.

†Op. cit., pp. 181-2.

to a corresponding point on the inner side of the thigh (see No. 3 in diagram). The knife was then closely applied to the edge of the integuments, the deeper structures were separated, and the flap containing the patella rapidly dissected back to a point as high as where the incisions were originally commenced. The posterior flap, at least one-third in length of the anterior flap (subsequently he advised it to be even longer), was then made, the first incision, or that through the skin, being so curved that the convexity should look backward. The deeper structures were then divided with an ordinary amputation-knife, and the rest of the posterior flap completed by the instrument. A transverse section of the femur was then made, commencing half an inch (13 mm.) above the commencement of the antero-superior edge of the condyloid articular cartilage. The removal of the articular surface of the patella constituted the last stage of the operation, and was not attended with any difficulty." "This section," he says further, "is most rapidly accomplished with one of Langenbeck's fine section-saws."

Heath* recommends that an assistant should, until the saw has made for itself a sufficiently deep groove, hold the patella firm by grasping it transversely with a lion forceps.

I beg now to present two cases in which I employed this method of amputation, and to state that it was in accordance with the directions of Stokes that the second operation was performed.

CASE 1.—*Epithelioma of the Leg—Gritti's Supra-condyloid Amputation of the Thigh—Recovery.*

P. C., aged thirty-two, was admitted into the Roosevelt Hospital, November 19, 1876, for caries of the lower portion of the tibia of many years' duration. The diseased bone was gouged out with apparent benefit, but subsequently, about January, 1877, the granulations became sluggish and hard, and eventually took on an epitheliomatous appearance, which condition was confirmed by a microscopical examination.

The disease gradually extended, with its usual symptoms, until the posterior border of the tibia became involved, and a false point of motion ensued. Upon the patient's consent-

* Op. cit.

ing to the amputation proposed, the limb was removed, May 14th, under the carbolic spray. It was intended to have removed the limb at the knee-joint, but, owing to the cloud of carbolic mist (it being the first amputation performed by me under Lister's method,) the posterior flap was cut too short to properly cover the femur. When this was ascertained, the femoral condyles were sawn off about half an inch (13 mm.) above the articulating surface,* and the patella deprived of its cartilage by a flat cutting-forceps. This done, the synovial ligaments on each side of the patella were divided to allow the egress of the secretions from the synovial pouch above. After the arrest of the hemorrhage by catgut ligatures and the insertion of the drainage-tubes, the wound was closed by sutures, and the protective and other antiseptic dressings applied. Nearly complete union by first intention occurred, and the patient was out of bed by the eleventh day, and was discharged from the hospital June 19th. The stump was excellent in shape, with the patella united to the face of the femur, and capable of bearing the strongest pressure, both gradual and sudden, without giving rise to the least pain. He has since worn an artificial limb with ease and comfort. The movements of the thigh were preserved to an unusual degree.†

In the second case the result was not so favorable, for the patella slipped from its position, and rode on the anterior surface of the femur, just above the end of the bone, where it afterwards became fixed by fibrous adhesions. I was not then acquainted with the procedure of Sawostitzki,‡ who

* Recently the same mishap, occurring to Mr. Bryant, of Guy's Hospital, London, was remedied in the same way, *i. e.*, by the performance of Gritti's operation; see *Lancet*, Jan. 4, 1879.

† I have, since the reading of this paper, received the following letter:

BRIDGEPORT, Ct., Feb. 9, 1879.

MY DEAR WEIR:—I regret exceedingly that I forgot to see Cook for you immediately upon my return from New York, but as soon as I remembered your request I hastened to see him.

He has fitted up for himself a stiff leg, which he likes better than the one jointed at the foot. He has no trouble from the amputation whatever, either at the extremity of the stump or elsewhere. His weight has increased from 170 to 202 pounds (77 to 91½ kilograms.)

For my edification he danced the "Pinafore" hornpipe without crutch or cane—"Not an ache or a pain;" he says I shall tell you. When you are here he wants to see you.

Yours Truly,

GEO. L. PORTER.

‡ *Moskovs. Med. Gazeta*, 1862. Vol. V.

fastened the patella to the femur by a steel pin thrust through the anterior flap; nor with the suggestion of Shiffer* (1867,) to fasten the remains of the ligamentum patellæ to the femur by means of sutures of wire or silk, but preferably of catgut (Stokes, 1872.) When it was ascertained that the patella was not likely to hold its place, it was my intention to divide the quadriceps tendon (as was done at the time of operation by Szymanowski in 1863,) but the amount of inflammation that supervened decided against interference.

CASE 2.—*Epithelioma of the Leg—Gritti's Amputation—Slipping of the Patella—Recovery.*

T. M., aged fifty-four, was admitted to the Roosevelt Hospital, June 6, 1877, with an epithelioma of the left leg of nine months' duration, which had attacked an extensive cicatrix, the result of an injury in early life. The ulcer, at the date of his admission, was some two and a half inches in diameter; pain severe. Slight enlargement of inguinal glands. Amputation June 21st. It was determined to avoid disarticulation at the knee, as the flaps would of necessity encroach upon some of the old, though yet unaffected, cicatricial tissues. Hence a supra-condyloid amputation was done by a long anterior and short posterior flap (after the plan of Stokes,) removing the limb at the joint after cutting through the ligamentum patellæ, and subsequently sawing off the condyles a little more than half an inch (13 mm.) above the line of the cartilage, and also dividing the bony surface of the patella by cutting-forceps, which had acted well in the previous case. Considerable oozing of blood followed, due probably to the Esmarch's bandage; but after arresting this as far as practicable by ligation of all visible bleeding-points, drainage-tubes were inserted into the synovial pouch, which had been laid open, and the wound duly closed. Sponges wrung out of a 1 to 20 carbolic solution were compressed over the end of the stump, and over these the usual antiseptic dressings were applied. Considerable muscular twitchings occurred, and on redressing the stump the next day the patella was found to have slipped up on the front of the femur. The antiseptic dressings, by their bulk, neutralized all the attempts to replace the patella by bandaging the thigh

* Schmidt's Jahrbüch., Vol. 136.

from above downwards, and on the fourth day the odor, with swelling running up the outer and posterior aspect of the thigh, showed that the antiseptic dressing had failed. This swelling ran along the divided external hamstring,* and by introducing a director to its full length, and cutting down upon its end, a counter-opening was made which permitted the track to be thoroughly washed out with a 1 to 20 carbolic solution, as was also the stump. By the next day all inflammatory symptoms had subsided, the odor had disappeared, and thereafter the patient did well, most of the stump healing by granulation. He was discharged from the hospital September 4th, with a very serviceable stump, capable of bearing a considerable amount of pressure, but not so much as in the previous case.

In endeavoring to appreciate the real value of this method of amputation, I have been able to collect up to the present time some eighty-three cases in which it has been resorted to. Of these, 7 occurred in military surgery,† with only one recovery. I have thought it advisable, for obvious reasons (one of which has already been mentioned), to leave these out of the list, as they are too few for statistical purposes, and to consider only the 76 remaining cases. The mortality of these is only 22, or 28.94 per cent., comparing in this respect very favorably with that met with in knee-joint amputations, in which it is, as before stated, between 27 and 28 per cent. while the statistics of the Surgeon-General's office show that in military surgery the mortality is 50 per cent.

The question of mortality after amputations has, however, since the use of carbolic acid, drainage, rest, etc., been so much altered that such figures are now misleading. An amputation, such as the one under consideration, should, under the antiseptic treatment, have a death-rate of not more than 5 to 10 per cent.‡ Of more importance at present is, therefore, the efficiency of a limb after Gritti's amputation. Bearing strongly on this point is the fact that out of forty-four cases, where the condition of the stump is

* This extension of inflammation along the sheaths of tendons after knee-joint amputations, though spoken of by German surgeons, has only, so far as I am aware of, been alluded to in the vernacular, by Brinton, of Philadelphia.

† Lucke, 4 cases and 1 recovery; Beck, 3 cases, all died.

‡ Results of Antiseptic Surgery, N. Y. Med. Journal, Dec., 1877, and Jan., 1878.

stated, in fourteen it is mentioned that a good or excellent stump resulted, in twenty-two it is explicitly stated that the patella had united to the femur, and in eight only it is noted that the patella had slipped up on the femur. In three cases, Richardson's, Szymanowski's, and Pairkt's—and probably there have been others, for the details of many of the operations are very imperfect—there was a primary division of the quadriceps tendon resorted to, which in two of them not only left the patella safely *in situ* against the sawn femur, but also in one it is remarked that it was attended by no loss of power in the limb. These facts must certainly outweigh the theoretical objections that have been raised against the operation, such as :

1st. That the patella normally is a sensitive bone, and is only called upon to bear the weight of the body in such short acts as kneeling in prayer, and hence is unfit to be placed at the end of a stump. Szymanowski advised relative to this point, and to obviate the risks of inflammation that might arise from the patella in its new position, that the pre-patella bursa should be removed. It need only be said that all these objections have been proved by experience so far to be chimerical.

2d. That the patella cannot be held in its new position. Again experience refutes this: in thirty-six instances out of forty-four the patella did not slip, and the aim of the operation was entirely accomplished. With the aid of sutures, or by tenotomy in obstinate cases, the failures can still further be lessened; or should it occur, all the advantages that accrue to a Carden's amputation will still belong to the stump. This point in favor of Gritti's operation has been made by several of the writers on this subject, and is, in my mind, a strong one in its support.

The testimony of those who have practiced the operation is decidedly in its favor. Wheelhouse,* of Leeds, considers "the supra-condyloid amputation to possess advantages which render it decidedly superior to any other known method. In no instance has the patella slipped from its position; in all a good cushion covered with well organized skin, and a limb (or rather stump) endowed with more than

* Dub. Jour. Med. Sciences, August, 1875.

usual freedom of movement, has been the result." Jessop,* another English surgeon, says that "the supra-condylod amputation fully maintains its repute here (Leeds). Whenever a suitable case presents itself, I prefer it to Carden's."

Stokes† states that, "of the amputations in the neighborhood of the knee, the supra condylod amputation undoubtedly affords the most satisfactory results, and more important than all, is the operation of its kind, which is attended with the minimum of risk to the patient's life.

Schuh,‡ who had in 1864 then operated twice by this method, remarks that a stump is formed whose cicatrix is situated posteriorly and above, and is not exposed to pressure, while the patella, which is the main point of support at the end of the stump, bears pressure exceedingly well. Linhart,§ who resorted to this amputation five or six times, says that the stump after Gritti's amputation is far preferable to the one remaining after amputation through the lower third of the thigh (Bruns's or Carden's,) because, when the patella is united to the femur, the patient can use the false limb soon after amputation of the leg. Lucke,|| who had but one successful case** out of four in military surgery, recommends the operation as a worthy one, notwithstanding his want of success.

It is now only necessary to briefly indicate in what cases the operation is suitable. Although Gritti himself, with some other surgeons, deemed the amputation one that would supplant that made through the knee-joint, yet time has not yet, and in all probability never will confirm such views. It has *not* been the purpose of this article to indicate such a claim, but only to present the supra-condylod amputation of the thigh, with a patella flap, as a substitute in many instances for that of Carden, or for an amputation higher up in the thigh. The applicability of Gritti's amputation has

* Idem.

† Dub. Jour. Med. Sciences, August, 1875.

‡ Wien. med. Wochenschr., Vol. XIV., 1864.

§ Wien. med. Presse, 1865, pp. 4-61.

|| Schmidt's Jahrbucher, Vol. 124, p. 270.

** The injury in two of his cases consisted of a fracture of the femoral condyle, with lodgment of the bullet; and in another the joint was also involved, and in the fourth it is not clearly stated.

already been alluded to in the earlier portion of this paper, and it is only necessary therefore to express the indications for its use somewhat more in detail. It can be resorted to evidently in cases of extensive caries or necrosis of the bones of the leg, and particularly of the head of the tibia; in compound fractures, or severe lacerations, etc., demanding amputation; for tumors condemning the limb—wherein, in all these conditions, a sufficiently ample covering cannot be obtained for a disarticulation. A reference to the annexed table of cases of Gritti's amputation, which has been collected from all available sources, will show still better the range of its applicability. For gunshot wounds or compound fractures involving the condyles of the femur, its practicability is yet undetermined, and time will probably record an adverse judgment against it in such cases. For diseases of the knee-joint it affords a better operation, in my judgment, than disarticulation, which has lately been revived. When Gritti's amputation is resorted to for a chronic arthritis, it is necessary to carry out Szymanowski's plan of dissecting out the synovial pouch, so that, with the bone sections, the joint is entirely extirpated.

In conclusion, I beg to say that the results of the investigation of so many cases of this operation have only confirmed the satisfactory impression that a single case of complete success gives rise to, and it is believed that further experience will only reiterate the good reports that have lately been made of this amputation by Dittel, Stokes, Wheelhouse, Teale, Albert, Melchiorj, and others.

GRITT'S SUPRA-CONDYLOID AMPUTATIONS OF THE THIGH.

Surgeon.	No. of amputations.	For what disease or injury.	Died.	Cause.	Recovered.	Remarks.	Reference.
Neudorfer 1839.	1	?	1	Handbuch der Kriegschirurgie, 1864.
Sawostitzki 1862	1	Compound fracture of leg three inches from knee-joint.	1	Patella drawn up; stump a very good one.	St. Petersburg med. Zeitschr., VIII., 1, 1861.
Szymanowski 1853.	1	Gunshot wound of leg.	1	Gangrene.	Tenotomy of quadriceps; bursa removed; patella in place.	Prag., VIII., 1, 1861.
"	1	Elephantiasis.	1	Good stump.	Idem.
"	1	Secondary to a Pirogoff.	1	Tuberculous.	Patella in position; bony union; no tenotomy.	Idem.
"	1	Malformed limb.	1	Pyæmia.	No tenotomy; bursa extirpated.	Idem.
Wahl 1863.	1	Elephantiasis of right leg.	1	Patella adherent to femur; good stump.	St. Petersburg med. Zeitschr., VIII., 1, 1864.
"	1	Compound fracture of leg.	1	Pyæmia.	Idem.
Linhart 1864.	5	Necrosis of tibia (1); others not stated.	3	2	One patella adherent; in one it was not, but not drawn up; but in both it was as sensitive as in normal position.	Operationslehre, 1867.
Rivington 1864.	1	Compound fracture of leg.	1	Pyæmia.	London Hospital Reports, Vol. II.
Simon 1864.	1	Pseudo-arthritis.	1	Good stump.	Deutsche Klinik, 1866, Nos. [29, 34]
"	1	Osteomyelitis, etc.	1	Pyæmia.	Patella retracted.	Idem.
Wagner 1864.	1	Chronic ulceration of leg.	1	Patella slipped up.	Schmidt's Jahrbucher., Vol. CXXIV., p. 270.
Schuh 1864.	1	Medullary cancer of leg.	1	?	Wien. med. Wochenschr., Vol. XIV., 1864.
Steinlechner 1864.	1	?	1	Good stump; can bear any amount of pressure.	Alleg. med. chir. Zeits., 1864, p. 12.
Michenewski 1864.	1	Gangrenous ulcers.	1	Patella united to femur.	St. Petersburg med. Zeitschr., XI., 1866.
"	1	Compound fracture of leg; gangrene.	1	Septicæmia.	Patella in situ; bursa extirpated.	Idem.
Melchior 1866.	1	Compound fracture of leg.	1	Hæmorrhage.	Patella in situ and firm.	Idem.
"	1	Gunshot fracture of leg.	1	Patella firmly united.	Annali universali di medic. a, p. 398, 1867.
"	1	Gunshot wound of knee-joint, and injury to popliteal artery and vein.	1	Good stump, could bear full weight of body on it.	Annali. nuov. di med., 1874.
Park 1866.	1	Necrosis of tibia.	1	Bursa extirpated, and tenotomy.	Allg. Militair Ztg., I., 1866.
Spanner 1866.	1	?	1	?	Idem., No. 14, 1867.
Hotokl 1866.	1	Compound fracture of leg.	1	Pyæmia.	Bony union, progressing.	Wien. med. Presse, IX., 3, 48.
Fuchs 1866.	1	Gangrene of leg.	1	Patella in situ, and united to femur by fibrous tissue.	Archiv. f. klin. Chirurg., VIII., 1866.
Wolf 1866.	2	?	2	(1) Hæmorrhage.	?	Berl. klin. Wochenschr., No. 40, 1866.
"	1	Compound fracture of upper end of tibia.	1	(1) Pyæmia.	Patella slipped up.	Schmidt's Jahrb., Vol. CXXCVI., 1867.

GRITT'S SUPRA-CONDYLOID AMPUTATIONS OF THE THIGH.—CONTINUED.

Surgeon.	No. of amputations.	Surgeon.	Died.	Cause.	Recovered.	Remarks.	Reference.
Stokes	10	Necrosis or caries of leg (3) compound fracture (1), disease of knee-joint, (1), others not stated.	1	9	In all the recoveries there were good stumps, and patella had not slipped and had united to the femur.	Guy's Hosp. Reports, Vol. XXIII., 1878; Med. Chir. Trans., Vol. LIII.; Dub. Journal Med. Sciences, 1872-73.
Jessop	5	?	1	4	Three had good stumps, no slipping of patella; one patella slipped up, one died, but not from the amputation.	Dub. Journ. Med. Sciences, Dec., 1872.
Teale	2	?	2	Good stumps.	Idem.
Wheelhouse	4	?	4	No slipping; union of patella to femur; in all a good cushion.	Archiv. f. klin. Chirurg., XV., 1873.
Bryck	1	Cancer of leg.	1	Patella united to femur; good result every way.	Idem.
Denzel	1	?	1	Re-amputation required.	Dub. Journ. Med. Sciences, 1871, p. 280.
Richardson	1	?	1	Tenotomy of quadriceps; patella united to femur; pressure well borne.	Schmidt's Jahrb., Vol. CLXVII., 1873.
Adelman	1	?	1	Resection of condyles required by swelling of stump.	Idem.
Mazzoni	1	Giant-cell sarcoma of leg.	1	Septicæmia.	...	Septicæmia attributed to use of Esmarch's bandage.	Idem.
Berger	1	Chronic disease of knee-joint.	1	Tubercular meningitis.	...	Had fungous arthritis of stump; synovial sac not dissected out.	Idem, Vol. CLXXI., 1876.
Dittel	8	?	8	Extirpates whole synovial sac and supra-patella bursa, and uses a special bandage to keep patella in situ; all had good stumps.	Wien. med. Wochens., No. 37, 1877.
Romanowsky	1	Compound fracture of leg, with extensive laceration of soft parts.	1	Good stump; skin over it callous.	Centralbl. f. Chirurg., No. 14, 1874.
Albert	1	Cancer of tibia.	1	Good stumps; bony union between patella and femur.	Wien. med. Presse, No. 33, 1877.
Jacobson	1	Sarcoma of leg.	1	Idem.
.....	1	Compound fracture of leg, with contusion about knee.	1	Idem.
.....	1	Compound fracture of leg; gangrene.	1	Idem.
.....	1	Recurrent erysipelas and necrosis.	1	Idem.
Stimson, L. A.	1	Sarcoma of calf of leg.	1	All good stumps; patella united to femur.	Guy's Hospital Reports, Vol. XXIII., 1878.
Bryant	1	Necrosis of tibia, involving knee-joint.	1	Femur sawn ½ inch above articular cartilage; patella slipped up; cleatrix well behind face of stump.	Communicated by the operator.
Weir	2	Epithelioma of leg.	2	Good solid stump; can bear weight of body on it, patella united to femur.	Lancet, January 4, 1877.
.....	Good stumps; in one, patella slipped; in other, capable of bearing great pressure.	Now reported.
76		22		54			