

**I. Fracture of the greater tuberosity of the humerus, with dislocation of the humerus into the axilla : immediate reduction of dislocation, on seventh day nailing of fragment of tuberosity in place. II. Fracture at the anatomical neck of the humerus and dislocation of the head into the axilla, with fracture of the shaft : difficult removal of head of humerus / by William Williams Keen.**

**Contributors**

Keen, William W. 1837-1932.  
Royal College of Surgeons of England

**Publication/Creation**

Philadelphia, Pa. : J.B. Lippincott, 1907.

**Persistent URL**

<https://wellcomecollection.org/works/x7ge7wbg>

**Provider**

Royal College of Surgeons

**License and attribution**

This material has been provided by This material has been provided by The Royal College of Surgeons of England. The original may be consulted at The Royal College of Surgeons of England. where the originals may be consulted. Conditions of use: it is possible this item is protected by copyright and/or related rights. You are free to use this item in any way that is permitted by the copyright and related rights legislation that applies to your use. For other uses you need to obtain permission from the rights-holder(s).



Wellcome Collection  
183 Euston Road  
London NW1 2BE UK  
T +44 (0)20 7611 8722  
E [library@wellcomecollection.org](mailto:library@wellcomecollection.org)  
<https://wellcomecollection.org>

# ANNALS OF SURGERY

A Monthly Review of Surgical Science and Practice.


Edited by LEWIS STEPHEN PILCHER, M.D., LL.D., of New York.  
With the Collaboration of  
J. WILLIAM WHITE, Ph.D., M.D., of Philadelphia. SIR WILLIAM MACEWEN, M.D., LL.D., of Glasgow.  
W. H. A. JACOBSON, M.Ch., of London.

## TABLE OF CONTENTS

ORIGINAL MEMBERS.	
I. The Surgical Treatment of Facial Paralysis by Nerve Anastomosis. By Horatio Cushing, M.D. . . . .	41
II. On the Possibility of Operating Safely on Certain Forms of Facial Paralysis. By Lewis Steffen Pilcher, M.D. . . . .	86
III. Intracranial Neurectomy. By Howard D. Cotton, M.D. . . . .	87
IV. The Surgery of the Lower Limbs. By Hugh M. Young, M.D. . . . .	101
V. Contribution to the Solution of Perforated Peptic Ulcers. By Jonathan M. Swainwright, M.D. . . . .	101
VI. Ruptured Crucial Ligaments and their Repair by Operation. By A. W. Allen, M.D., and J. A. C. . . . .	101
VII. A Case of End-to-End Anastomosis of the Posterior Artery for Gunshot Injury. By Alexander Hugh Ferguson, M.D., F.R.C.S. . . . .	170
VIII. The Successful Removal of a Large Embolus of the Chest Wall, Involving the Diaphragm. By J. C. Jones, M.D., M.C. . . . .	176
IX. Hemorrhagic Nephritis from a Surgical Abscess. By Charles Greener Coe, M.D. . . . .	181
X. Chronic Intestinal Pseudo-tuberculosis. By Lewis Whittaker Allen, M.D. . . . .	181
XI. Tuberculosis of the Peritoneal, Splenic, and Other Lymph Nodes secondary to Foot Wounds. By Charles A. Dwyer, M.D. . . . .	181
XII. Contribution to the Literature of Old Intractable Dislocations of the Shoulder-joint. By A. P. Jones, M.D. . . . .	179
XIII. An Old Trigonum dorsale by the Albuginea Sac. By Henry Perkins Murray, M.D. . . . .	181
XIV. An Anomalous Tendon. By Edward M. Gilchrist, M.D. . . . .	176
XV. A New Oesophageic Trophic. By W. Arthur Ripston, M.D. . . . .	179

TRANSACTIONS OF THE NEW YORK SURGICAL SOCIETY.	
Special Meeting, January 9, 1907 . . . . .	173
TRANSACTIONS OF THE CHICAGO SURGICAL SOCIETY.	
Special Meeting, February 6, 1907 . . . . .	176
REVIEWS OF BOOKS.	
Alcock, J. and W. E. Carter and Other Authors of the Manual of Surgery. By Richard A. Fisher. Text-Book of Anatomy. Secretary and Assistant, Compendium des Operations and Verbandhefte. . . . .	170
CORRESPONDENCE.	
"Exclusion of Aerial Rays of Light during Operation for General Peritonitis." A Trial as to Whether the Carbon Arc Light forms a Perfect System in the Repair of . . . . .	170

Published Monthly by J. B. LIPPINCOTT COMPANY, Philadelphia, Pa.  
Solely Retailers: Cassell & Co., Limited, AMSTERDAM; O. G. Sauer & Co., ST. LOUIS, Mo.  
Price in United States, \$3.00 a Year in Advance. Single Number, 30 Cents.  
Price in Great Britain and Australasia, Single Number, Two Shillings.  
One Guinea a Year in Advance.



P. 29

14.

- I. FRACTURE OF THE GREATER TUBEROSITY OF THE HUMERUS, WITH DISLOCATION OF THE HUMERUS INTO THE AXILLA. IMMEDIATE REDUCTION OF DISLOCATION. ON SEVENTH DAY NAILING OF FRAGMENT OF TUBEROSITY IN PLACE.\*
- II. FRACTURE AT THE ANATOMICAL NECK OF THE HUMERUS AND DISLOCATION OF THE HEAD INTO THE AXILLA, WITH FRACTURE OF THE SHAFT. DIFFICULT REMOVAL OF HEAD OF HUMERUS.\*

BY WILLIAM WILLIAMS KEEN, M.D.,  
OF PHILADELPHIA.

Professor of Surgery, Jefferson Medical College

\* Read before the Philadelphia Academy of Surgery, March 4, 1907

REPRINTED FROM ANNALS OF SURGERY FOR JUNE, 1907





- I. FRACTURE OF THE GREATER TUBEROSITY OF THE HUMERUS, WITH DISLOCATION OF THE HUMERUS INTO THE AXILLA. IMMEDIATE REDUCTION OF DISLOCATION. ON SEVENTH DAY NAILING OF FRAGMENT OF TUBEROSITY IN PLACE.\*
- II. FRACTURE AT THE ANATOMICAL NECK OF THE HUMERUS AND DISLOCATION OF THE HEAD INTO THE AXILLA, WITH FRACTURE OF THE SHAFT. DIFFICULT REMOVAL OF HEAD OF HUMERUS.\*

BY WILLIAM WILLIAMS KEEN, M.D.,

OF PHILADELPHIA.

Professor of Surgery, Jefferson Medical College.

I.

E. F. K., æt. fifty-nine, first consulted me January 29, 1907. Three days before, on January 26, in getting off a trolley car on the ice-covered street, he slipped and fell, striking his left shoulder,—he rather thinks upon the point of the shoulder, though he is not certain of this. He also thinks that when he found himself about to fall he threw up both arms violently in the air, as would be very natural, but he is also not quite sure of this.

The moment the accident occurred he felt great pain about the head of the humerus, and the whole arm was useless; he was scarcely able even to move his fingers. He was taken to the Pennsylvania Hospital. Here he was attended by Dr. William Drayton of the resident staff, and I owe to him and to Dr. Montgomery, the skiagrapher, the early history of the case and the skiagraph. A dislocation into the axilla was diagnosed and was reduced under ether. No crepitus was felt until after reduction of the dislocation. An X-ray picture was then taken, which showed a fracture of the greater tuberosity (Fig. 1). The arm felt much better after the dislocation was reduced. No bruise existed about the shoulder to show the point of impact when he fell. When he came out of the ether, the arm was so bandaged to his body that he was unable to move it in any direc-

\* Read before the Philadelphia Academy of Surgery, March 4, 1907.

tion and hence whatever disability may have resulted from the fracture of the greater tuberosity cannot be definitely stated, as no opportunity for muscular movement had existed. He left the hospital the same day.

When he saw me, three days after the accident, I found the arm securely bandaged with a shoulder-cap splint and he was very comfortable. Examination of the excellent X-ray picture showed that the greater tuberosity was broken off in a triangular fragment, the base being uppermost and the apex extending about to the surgical neck. The fragment was drawn upward and backward so that it lay between the spine of the scapula and the head of the humerus. Evidently, if it remained there, it would be a serious bar to abduction of the arm to or beyond the horizontal, and probably also to other movements, and external rotation of the arm would be impaired or lost. I, therefore, took him to the Jefferson Hospital and had Dr. George W. Spencer and Dr. W. F. Manges try different positions of the arm, to see if any of them approximated the humerus to the fragment in such a way as to restore their proper relation, for it was clear that the fragment could neither be brought to its normal position by manipulation nor held there by any suitable dressing.

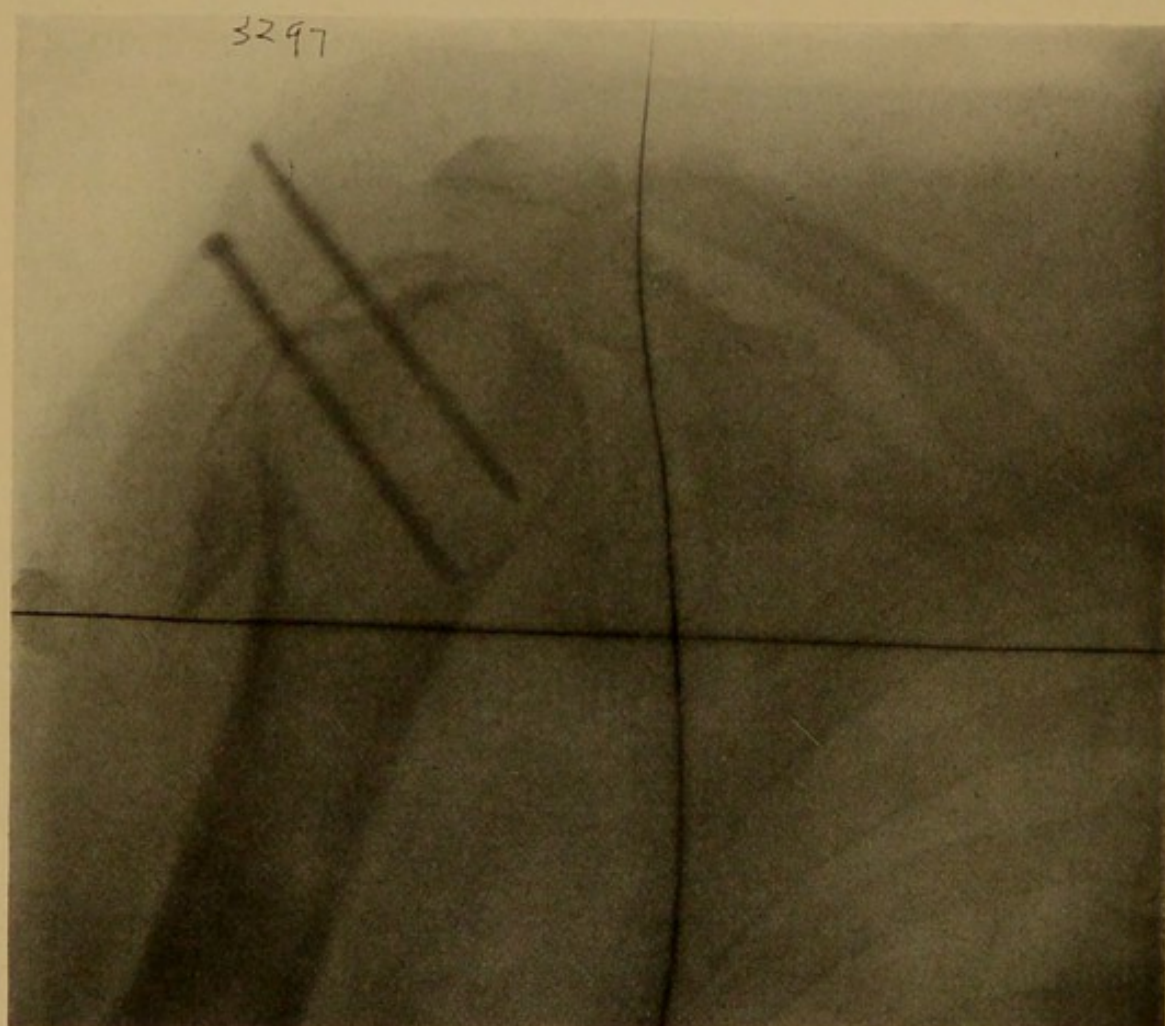
Several attempts were made to effect this purpose by elevation of the arm and external rotation with retention of the arm in place by plaster dressing and in other positions, but all were failures. I, therefore, determined to operate by exposing the parts, drawing the fragment of the tuberosity into place and holding it there by wire nails. Though at that time I knew of no case thus operated upon, it seemed to me both rational and reasonable to do so.

*Operation, February 2, 1907.*—I made a vertical incision a little in front of the middle of the acromion directly down through deltoid to the bone, separating the fibres of the deltoid as far as possible rather than cutting them. As soon as I reached the bone, I detected the anterior edge of the bony fragment lying at the posterior margin of the wound. Carrying my examining finger under the anterior edge of the wound, I found the rough, raw surface from which the tuberosity had been torn away at a considerable distance from the anterior margin of the wound. The fragment torn away from the humerus was separated from it by about 5 to 6 cm., and lay posteriorly between the head of the

FIG. 1.

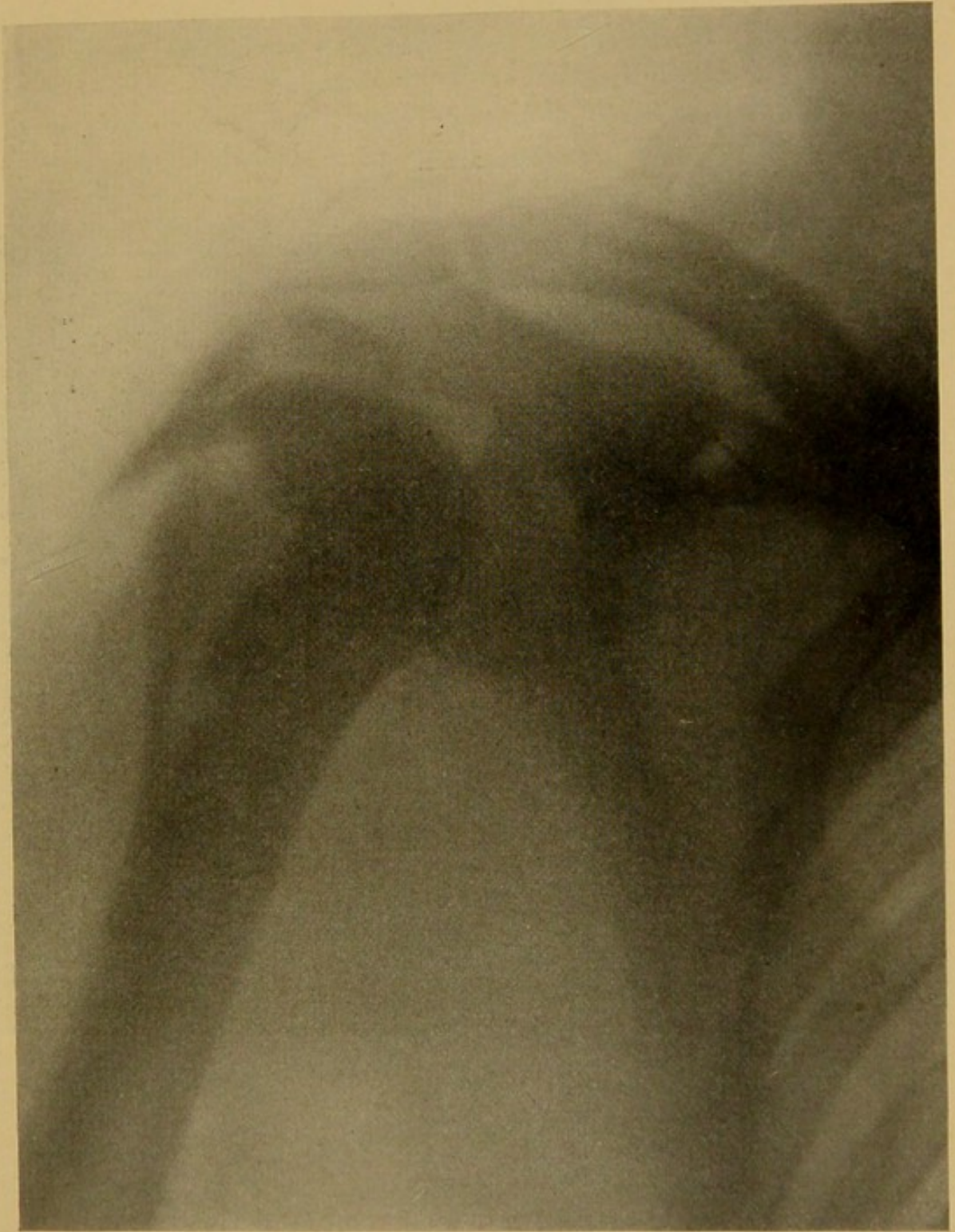

FIG. 2.



bone and the acromion and spine of the scapula. Evidently no union other than perhaps a very poor fibrous union could ever take place between the normal surface of the bone and the capsular ligament and the raw surface of the fragment. Moreover, the position of the fragment would interfere with the usefulness of the arm, for whenever the arm was raised, this ectopic piece of bone would be a sort of wedge between the acromion and spine and the head of the humerus. An assistant, therefore, rotated the humerus externally as far as possible. This brought the posterior edge of the raw surface of the bone to the anterior edge of my incision. I was able then to expose this raw surface by strongly retracting the anterior edge and next to draw forward and downward the fragment of bone so that I brought it nearly into its normal position. It was impossible to get it absolutely into its former place. I found the best means to replace the torn fragment of bone was by seizing the tissues around it with the Allis "tissue forceps." These practically resemble the one-prong tongue forceps, the opposite blade being a simple curved notch rather than the broad surface of the tongue forceps.

Holding the fragment in position, I drilled two holes in it and nailed the fragment in place by means of two wire nails 7.5 cm. in length and about 2 mm. in diameter. These were long enough to allow the head of the nail to protrude beyond the skin. A large portion of the nail, of course, was outside the bone, corresponding to the thickness of the deltoid, the fat and the skin (Fig. 2).

The wound was then entirely closed, excepting where the nails protruded, and at the lower angle where I inserted a small bit of gauze for a temporary drain, especially because there was considerable grumous blood accumulated at site of fracture.

His highest temperature was 100° degrees, and he made a perfectly uneventful recovery. One nail was removed without difficulty at the end of two weeks and the other at the end of the third week. The wound left by the nails healed quickly. Passive motion and massage were begun at the end of four weeks.

#### REMARKS.

Until very recently fracture of the tuberculum majus of the humerus has been believed to be very rare. In the statistics of Gurlt, covering one hundred years, he records but 46



examples found in literature and in museums. Usually the fracture accompanies dislocation. Gurlt found only 4 cases of fracture unaccompanied with dislocation, and even one of these was not free from doubt.

The systematic use of the X-rays, however, has entirely disproved this notion and has shown that, on the contrary, it is a not uncommon fracture. I have asked several skiagraphers in Philadelphia as to their experience, with the following results:

Dr. Manges of the Jefferson Hospital has only had one case; Dr. Kassabian has seen 4 in about 800 fractures; Dr. Leonard has no exact record, but recalls 2 of the great tuberosity alone, and at least 6 cases with other associated fractures; Dr. Pfahler of the Medico-Chirurgical Hospital in 84 cases found 7 such fractures with no other lesion, and 3 cases of this fracture associated with dislocation; Dr. Frederic Montgomery of the Pennsylvania Hospital, in 75 cases of injury of the upper end of the humerus has found 3 cases of this fracture including the present case; Dr. Pancoast, at the Hospital of the University of Pennsylvania, writes as follows: "In looking over the skiagraphs I have made of fractures of the upper part of the humerus, I found 6 cases of fracture of the great tuberosity, which seem to belong in a class by themselves. In one of them there is also an incomplete fracture of the surgical neck, and in another, either an incomplete or an impacted fracture of the surgical neck. In this last case, no fracture whatever was diagnosed clinically. The other 4 cases were purely uncomplicated. In addition to these cases, I found 3 with fracture of the anatomical neck and the tuberosity, and 4 with fracture of the surgical neck and the tuberosity. In all these 7 cases, as in the first 5, the tuberosity is a separate fragment by itself.

"The fragment representing the tuberosity varied in size from a thin scale of bone to the entire tuberosity and part of the neck below it.

"In 1 case only, out of the 12, am I certain that a clinical diagnosis of fracture of the tuberosity was made prior to the

skiagraphic examination, but such a diagnosis could hardly have been expected in the seven distinctly complicated cases."

These six observers have, therefore, seen at least 21 uncomplicated cases and 18 more with other associated lesions, all, presumably, within about four or five years. Through their courtesy, I was able to show 23 of these 39 skiagraphs.

Before the X-rays were used, the lesion was generally diagnosticated as a severe "contusion" or "bruise" of the shoulder, which often permanently disabled the arm to a greater or less extent. Now we know that the condition is more frequent and the consequences much more serious than has been believed.

FIG. 3.

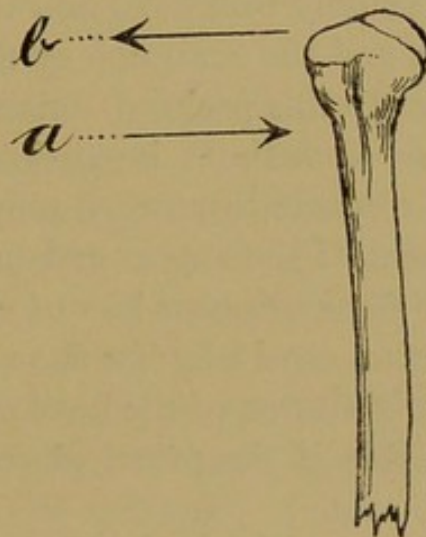


Diagram to show the opposite direction of the two forces acting on the head of the right humerus. *a*, direction in which the bone is forced in the dislocation; *b*, direction in which the muscles act either in suddenly throwing up the arms to prevent the fall or in the involuntary endeavor to prevent the dislocation.

Whether the cause is always the direct result of a fall or blow on the shoulder, or whether it may result from muscular contraction alone, is disputed. Doubtless both of them act together, the dislocation acting in one direction (inward) and the sudden contraction of the muscles in the opposite direction (outward) (Fig. 3). In the present case the blow dislocated the humerus, but the sudden and violent elevation of the arms to prevent his fall might well have produced the fracture in a man of fifty-nine, even if there had been no fall.

The pathology of the lesion has been well ascertained by the findings at operation and by the extraordinary good fortune of Jössel, who in 1880 reported the facts ascertained by the dissection of 9 cases of habitual dislocation of the shoulder. He found the supra- and infra-spinati torn loose, retracted and in fatty degeneration, part of the capsule was torn loose and the head of the humerus was in contact with the deltoid and the acromion. Of 8 cases of old dislocation operated on by Kocher, in 6 the tuberculum majus was torn off. Last year Perthes reported 10 cases of luxation of the shoulder, in 6 of which there was either a fracture of the tuberosity or the muscles were torn loose from the bone.

The results of such a fracture are a displacement of the fractured fragment usually backward and upward between the head of the humerus and the acromion or the outer end of the spine of the scapula. In this position, union of the fragment is often improbable and sometimes impossible. The fragment, if of any size, is an obstacle to upward movement of the arm. The loss of attachment of the supra- and infra-spinati and the teres minor involves diminution or loss of external rotation of the arm, and, as Perthes especially has shown, permits repeated and finally habitual dislocation of the head of the humerus. In fact, in his opinion this is the principal reason why habitual dislocation occurs.

Formerly the diagnosis was in most cases only presumptive until the advent of the X-rays. In fat persons especially it was often impossible to make a diagnosis if this fracture was associated with other fractures or with dislocation. The contour of the shoulder, in a minor degree, however, resembles a dislocation, as shown by the prominence of the acromion and a furrow below this prominence. The head of the bone may be broader than normal; if the fractured fragment is of any size, a groove can sometimes be felt between it and the head of the bone; crepitus may be felt but sometimes is absent, especially while the dislocation is unreduced, as in the present case, and it will usually be impossible to lift the arm above the horizontal—even passively—and external rotation is lost or les-

ened. The deltoid is sometimes atrophied as a result of injury to the circumflex nerve.

As long ago as 1886, Bardenhauer suggested suture as a means of treatment; but it seems not to have been done till 1898 by W. Müller. The latter surgeon excised an oval portion of the capsule of the joint and sutured the muscular attachment by advancement (Vornähung) of the external rotators. In 1904 Perthes operated on 2 cases by means of double-pointed, U-shaped nails. Both of his cases were ancient fractures, one being operated on over three years and the other five years after the accident. He made the posterior incision of Kocher for excision of head of the humerus, in one case chiselling a part of the spine and the acromion (which were wired later), and turning downward and forward a large deltoid flap. In both the results were good.

My own case is, I believe, the first in which a primary operation has been done. I made a vertical incision, seized and drew downward and forward the fractured piece, and, after external rotation of the arm, nailed the fragment as nearly as possible in place by two disinfected wire nails which were afterwards removed.

I should have delayed publishing the case until I could report the final result, but that a long absence in the immediate future prevents my waiting. Every indication points to a speedy and satisfactory result, as there is little ankylosis of the joint. Passive motion has just been begun.

#### BIBLIOGRAPHY.

- Bardenhauer. Verletz. Oberrn Extrem., 1886, 418.  
 Deuerlich. Inaug. Dissert., Göttingen, 1874.  
 Gurlt. Knochenbrüche, 1862, ii, 655.  
 Hilton. Guy's Hospital Reports, 1847, second series, vol. v.  
 Jones. Brit. Med. J., 1906, i, 1385.  
 Jössel. Deutsch. Zeit. Chir., 1874, iv, 124 and 1880, xiii, 167.  
 Kocher. Deutsch. Zeit. Chir., 1890, xxx, 423.  
 Müller (Francke). Deutsch. Zeit. Chir., 1898, xlvi, 403, Case 18.  
 Nieszytka. Deutsch. Zeit. Chir., 1906, lxxxii, 147.  
 Perthes. Deutsch. Zeit. Chir., 1906, lxxxv, 199.  
 Reuss. Arch. klin. Chir., 1866, vii, 150.  
 Wohlgemuth. Verhandl. Deutsch. Gesell. Chir., 1900, xxix, 375.  
 Other references will be found in Nieszytka's paper.

## II.

CASPER K., æt. sixty, first consulted me December 23, 1905, with Dr. A. P. Hull of Montgomery, Pa., to whom I owe the following history:

On November 18, 1905, he fell from the top of a wagon of fodder about 10 feet, falling on his feet. The fodder followed, fell upon him and threw him forward. He fell, striking on his right shoulder. He was helped up and walked to his brother's house about 100 feet away.

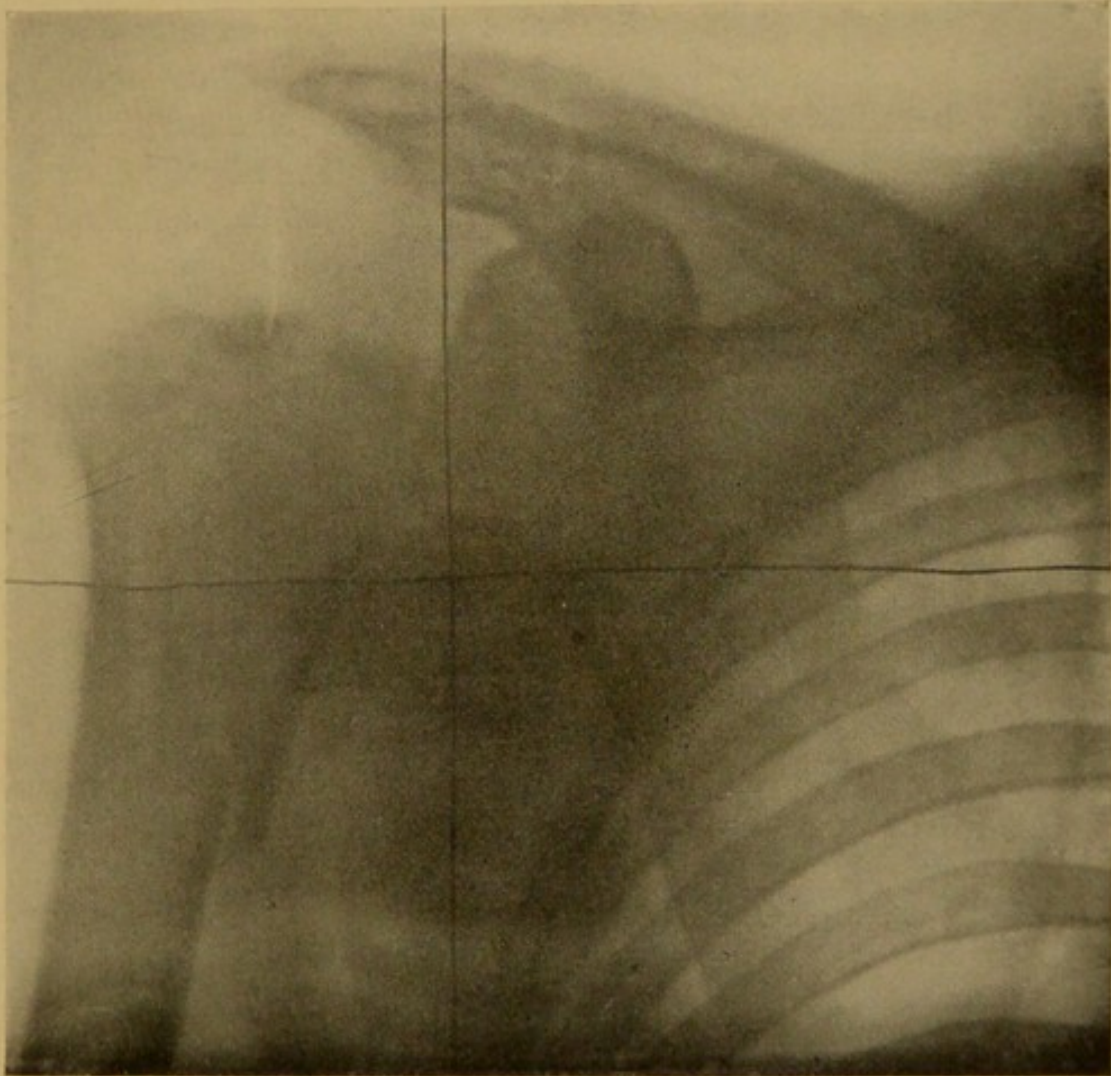
Dr. Hull saw him two hours later and found a subcoracoid dislocation. Under chloroform this was reduced and the forearm put in a sling. At the end of three weeks, as he had not called as directed, the doctor went to see him and found that the dislocation had been reproduced; he also discovered crepitus on moving the arm. The patient states that he has had pain ever since the accident. He has slept poorly, though occasionally he has had a good night. He has had to lie with extra pillows propping him up most of the time since the accident. His appetite is fair, bowels in fair condition. He has worn a sling most of the time.

*On examination* I saw clearly a marked fulness under the coracoid, like a subcoracoid dislocation, but there was no outstanding elbow, nor any change in the axis of the upper arm in relation to the body. The acromion was very prominent; a hollow existed below it; there was flatness over the muscles of the shoulder posteriorly and fulness in front under the coracoid. On attempting to rotate the arm, crepitus was easily elicited, but as movement was very painful, I decided to wait till I could get an X-ray picture of the arm. The arm was greatly swollen, especially over the forearm, there being less and less swelling from the elbow up toward the shoulder. The entire arm from shoulder to elbow was also still very much discolored from the effused blood.

December 26.—On examining the X-ray picture (Fig. 4) I found that there was a fracture exactly through the anatomical neck and that this fragment was dislocated inward under the coracoid process. In addition to this there was a vertical fracture from the upper end of the shaft downward to the surgical neck.

*Operation*, December 27.—I first made an incision from the coracoid process down nearly to the insertion of the deltoid. I

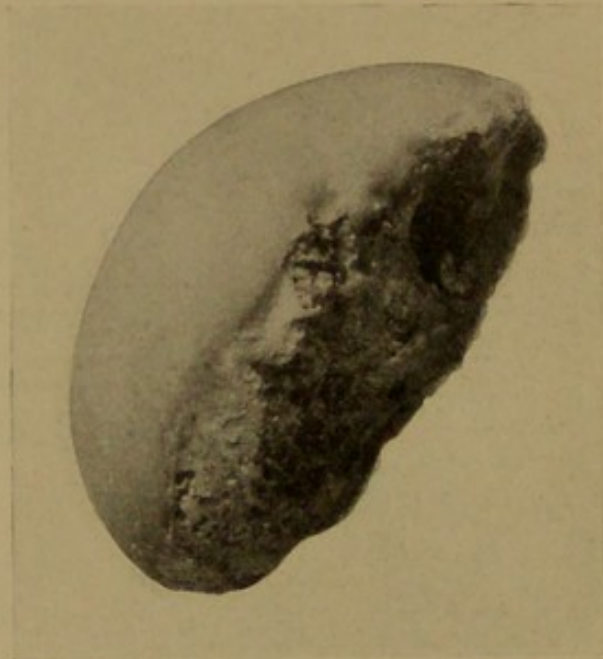FIG. 4



Fracture-dislocation of shoulder. Fracture of anatomical neck and shaft of humerus.  
Dislocation of head into axilla.



FIG. 5.



Fracture of anatomical neck of humerus (Keen).

separated the fibres of the deltoid, watching carefully for the circumflex nerve and the long tendon of the biceps. I did not at any time see the circumflex nerve. The tendon of the biceps was dislocated inward from its groove and the capsule of the shoulder joint opened. On inserting the finger, I found that the upper end of the humerus was almost entirely smooth and it was, of course, utterly hopeless to obtain union even if I had succeeded in replacing the dislocated head of the humerus or if it had any reliable blood supply. A considerable amount of fluid, black blood, evidently effused at the time of the accident, was liberated from the tissues. On dissecting toward the inner side, so as to lay bare the dislocated head of the humerus, I found it lying so much to the inside of my incision that it was evidently much more accessible by a separate incision. This started from just below the insertion of the tendon of the great pectoral in a direct line toward the sterno-clavicular articulation, reaching to a point below the middle of the clavicle. I separated the fibres of the great pectoral by blunt dissection and finally found the head of the bone with its fractured surface looking toward the middle line and the articular surface toward the humerus,—*i.e.*, completely rotated. It was very adherent, but gradually I was able to loosen it and finally to pry it up very slowly and carefully, lest I should either do harm to the nerves or to the axillary vessels which lay immediately in contact with it. By combined prying upward and traction by means of a large sequesterum forceps, I finally dislodged the head entirely (Fig. 5). Very deep in the wound a vessel immediately began to bleed very copiously: I was able, fortunately, instantly to put a finger of the left hand upon it and arrest the hæmorrhage. It was so deep, however, that it was impossible to ligate it through the existing incision. Accordingly, I divided completely the great pectoral tendon about 3 cm. from the humerus. This gave me wide access to the axilla and I was able finally to seize the bleeding vessel, which would have been otherwise inaccessible. The vessel was double ligated as it was bleeding from both directions. A few other small vessels required ligation. The parts were then irrigated with salt solution and the tendon of the great pectoral overlapped and sutured with twenty-day chromicized catgut. The long head of the biceps was replaced and sutured in place with catgut. A drain was placed in each wound, that in the second



incision going deeply into the axilla, and the wounds were closed. The arm was placed next the chest, the forearm flexed in front of the chest with a pad in the axilla and a Velpeau bandage applied.

On the evening of the day of operation his temperature rose to 101 degrees, but by the second day it was down to the normal and so remained. He went home on January 7, eleven days after the operation.

Dr. Hull writes me, February 1, 1907: "He can raise his arm to two-thirds of the normal height; the wasting of the muscles of the shoulder is disappearing with use and he can use the arm right well in digging, etc."

Fracture of the anatomical neck of the humerus is an extremely rare injury. Stimson<sup>1</sup> states that the only reported specimens of fresh fracture without dislocation or additional fracture through the tuberosities are those of Boyer and Spence. The cases of fractures associated with dislocation are more numerous, yet even they are so rare that Stimson himself "had seen only one case in which the diagnosis seemed probable," and a second undoubted case. Hamilton<sup>2</sup> also in his very large experience in fractures saw only one case. The present is the only case that I have ever seen.

This fracture may be either intra- or extra-capsular. "It is probable, since bony union is not denied to this fracture (*i.e.*, intra-capsular fracture), that the line of separation is not always, or generally, perhaps, completely within the insertion of the ligament, but that it is in some degree extra-articular if not extra-capsular. If it is entirely intra-articular, no doubt union of the fragments can never take place and necrosis with suppuration must ensue, demanding, at a period not very remote, an operation for the removal of the fragments, the same as in compound fractures. Gibson, however, thinks that the fragment occasionally remains, being gradually absorbed and changed in figure."<sup>3</sup>

In this particular case the specimen I think shows that the fracture was wholly intra-articular. In addition to this the head of the bone was not only not displaced within the cap-

sular ligament, but was thrust wholly outside of it, far into the axilla. Impaction of the upper fragment into the lower is not uncommon, as in fact would be natural from the force necessary to break off such a limited rounded fragment. If there is impaction, union, of course, may take place.

The last edition of Stimson's work was published only a few years after the X-rays were discovered and before their general use. Hence he makes no reference to their use in such cases. These rays have made perfectly possible correct diagnoses of fractures about the shoulder joint, such as the present case and the other one that I report this evening, a fracture of the greater tuberosity. Before the discovery of Röntgen, such cases were always obscure. In Stimson's next edition, without doubt, certainty will take the place of presumption in the diagnosis.

In the present case fracture of the anatomical neck was associated with dislocation and complete rotation of the fragment and also with a longitudinal fracture of a sharp fragment from the inner side of the shaft as far down as the surgical neck. When the head is in place, crepitus can often be elicited. Had the lesion been limited to fracture and dislocation of the head, no crepitus would have been felt. Undoubtedly, the crepitus felt at the time of my examination, almost six weeks after the injury occurred, was between the fragment fractured from the shaft of the bone and the shaft itself, for the skiagraph shows that the fractured and dislocated head could not have produced the crepitus. That this second fractured fragment should not have been united with the bone at so distant a time and yet, as the later history shows, never have undergone necrosis or caused any trouble is both surprising and gratifying. Union, of course, took place later.

The acromion is usually much more pronounced than normal, but it is not so prominent, nor is the furrow under it so well marked as in a subcoracoid dislocation. The skiagraph shows well the very great distance between the upper end of the shaft and the acromion, although, as will be observed, the shaft is evidently pulled upward (to the mid-point of the

glenoid cavity) by the action of the muscles and the arm is shortened by so much. Unfortunately, I did not make any measurements of the comparative length of the two arms.

When it is not dislocated the fractured head of the bone can usually be felt within the capsular ligament and its abnormal mobility determined. When it is dislocated into the axilla, as in my own case, it can also be felt as a marked abnormal prominence either directly below, or below and external to the coracoid. If the head is not displaced outside of the capsule, it is usually displaced with reference to the shaft of the bone, so that the upper end of the bone is considerably broadened.

After all, the Röntgen rays serve the best purpose and I think are an absolutely reliable means of diagnosis. It is precisely in these obscure lesions that the X-rays help us the most.

The usefulness of the patient's arm at the present time is quite as much as one ought to expect from so serious and complicated a case and especially one that had been neglected by the patient for so long.

#### REFERENCES.

- <sup>1</sup> Fractures and Dislocations, third edition, 1900, 216.
- <sup>2</sup> Fractures and Dislocations, sixth edition, 1880, 234.
- <sup>3</sup> Hamilton, *ibid.*