

The positive and negative diagnosis of gastric cancer by means of serial röntgenography / Lewis Gregory Cole.

Contributors

Cole, Lewis Gregory, 1874-1954.
Royal College of Surgeons of England

Publication/Creation

New York : [A.R. Elliott], 1914.

Persistent URL

<https://wellcomecollection.org/works/h8jeg5zg>

Provider

Royal College of Surgeons

License and attribution

This material has been provided by This material has been provided by The Royal College of Surgeons of England. The original may be consulted at The Royal College of Surgeons of England. where the originals may be consulted. Conditions of use: it is possible this item is protected by copyright and/or related rights. You are free to use this item in any way that is permitted by the copyright and related rights legislation that applies to your use. For other uses you need to obtain permission from the rights-holder(s).



Wellcome Collection
183 Euston Road
London NW1 2BE UK
T +44 (0)20 7611 8722
E library@wellcomecollection.org
<https://wellcomecollection.org>

2.c.5

9


The Positive and Negative Diagnosis of Gastric Cancer by Means of Serial Röntgenography

LEWIS GREGORY COLE, M.D.

Professor of Radiology, Cornell University Medical College
NEW YORK



*Reprinted from the New York Medical Journal
February 14, 1914.*



THE POSITIVE AND NEGATIVE DIAG-
NOSIS OF GASTRIC CANCER BY
MEANS OF SERIAL ROENT-
GENOGRAPHY.

BY LEWIS GREGORY COLE, M. D.,

Professor of Röntgenology, Cornell University Medical College.
New York,

The value of an early positive diagnosis of gastric cancer is evidenced by Mayo's recent statement¹ that thirty-six per cent. of gastric carcinomas have been cured by surgical procedure. His further statement that an early diagnosis can be made only by surgical exploration is paradoxical, as it eliminates the possibility of such diagnosis in the majority of cases, because patients will not usually submit to a laparotomy until they have definite or severe symptoms, and such symptoms do not generally occur until the process has passed beyond the incipient stage.

The negative or positive diagnosis of gastric carcinoma may be made with as great a degree of accuracy by serial röntgenography as by exploratory laparotomy, as a study of 616 cases has shown. Moreover, this examination may be made without risk to the patient. Therefore patients presenting very slight symptoms would welcome such an examination, while absolutely refusing an exploratory operation.

The more extensive growths may be detected readily by röntgenoscopy (fluoroscopy) or by two or three röntgenograms. But the negative or positive diagnosis of small, indurated ulcers or early carcinomas necessitates a careful study of several series of röntgenograms, made with the patient in both the prone and erect postures, and at various intervals after the ingestion of barium and buttermilk. The author is not content with less than forty röntgenograms, and frequently makes

¹Meeting of the A. M. A., Minneapolis, 1913.

seventy or eighty, which are set up where they may be studied individually and collectively, and superimposed for comparison. If expedient, they are reduced in size and reproduced cinematographically. The examination is necessarily an expensive one, but like surgery it may be placed within the means of all patients. The technic of serial röntgenography has been described in previous communications, and may be omitted here.

The röntgenological diagnosis of new growth of the stomach described herein is based on permanent, constant deformities in the gastric wall, which interfere with the systole and diastole of the stomach, and the progression pylorusward of the peristalsis. These lesions may be detected at practically any stage of development, and in many cases they may be differentiated with a reasonable degree of certainty. In this communication carcinoma, adenoma, myoma, sarcoma, and indurated ulcer will be regarded as gastric cancer, because the surgical indications for all of them are the same, and one can be differentiated from the other only by a careful microscopical examination of the specimen after its removal. In many instances the surgeon does not know whether he has cured a case of cancer or prevented one until he receives his pathological report. Such growths should therefore be considered malignant until proved otherwise.

Syphilis of the stomach sometimes resembles cancer so closely that it would be a wise precaution to have the Wassermann test made in every case to eliminate the possibility of confusion. There are, however, röntgenological findings which have enabled me to make the diagnosis of gastric syphilis in cases where I had not suspected such a condition; and the subsequent history and Wassermann reaction have corroborated my diagnosis.

The röntgenographic appearance of carcinoma of the gastric wall depends upon the nature and form of the growth. Where a large rounded mass projects into the stomach it prevents the bismuth from filling this portion of the lumen. The area of involvement is constant in size, shape, and position. (Figs. 2 and 4.) If the growth occupies the body or fundus of the stomach, obstruction and gastric retention do not result.

Multiple nodular growths, reaching out like peninsulas and islands into the normal tissue, present a peculiar appearance of fingerprints. (Figs. 5 and 18.) They are likely to occur on the posterior wall, and cause an obstruction. (Fig. 5.) Victims of this type of cancer are singularly free from symptoms.

If the growth is annular, progressing in the form of a cone, the stomach has the appearance of a funnel, drawn out toward its apex in a small constricted lumen, containing bismuth, sometimes converging to the point of complete obliteration. (Fig. 8.) The cone or floor of the funnel may be filled and emptied during each gastric cycle by the peristalsis of the normal portion of the stomach. The peristaltic contractions cease abruptly in their progress pylorusward when they reach the involved area. A wormeaten appearance with overhanging edges sometimes indicates the line of invasion. (Fig. 19.) The constricted lumen remains constant in size, shape, and position, and is devoid of rugæ, which are present in normal tissue, and which are exaggerated in cases of adhesions and pylorospasm.

The sclerotic or scirrhus type of cancer (Figs. 13 and 14) may involve large areas of the wall of the stomach without protruding into its lumen. In such cases the position of the stomach is usually high, and frequently there is an area of immobility on the lesser curvature. The most notable characteristic is the absence of peristaltic contractions, or an attempt at peristalsis, which produces unusually broad waves, showing a lack of pliability of the affected tissue. The point to observe in these cases is that when the serial plates are matched over each other the contour and detail of the involved area is exactly the same in all the röntgenograms.

Extensive inoperable tumors may occur in the pars media without causing any obstruction or dilatation. In such cases the stomach usually evacuates itself with abnormal rapidity. In cases of extensive carcinoma, involving the entire pars pylorica and pars media, inefficient peristalsis may prevent the gastric dilatation, which one would ordinarily expect. If the growth involves the pylorus and diminishes its lumen, gastric dilatation and stasis of food occur early. (Fig. 20.)

Small, round, punched out ulcers of the pars pylorica frequently have the röntgenological appearance of duodenal ulcers, the pathology of which has been described by Moynihan and Codman. (Figs. 17A and 17B.) In such cases surgery is undoubtedly indicated. Whether the lesion is malignant or nonmalignant can be positively determined only by microscopical examination of the specimen.

Röntgenologically, tumors of the stomach may be grouped into two classes, inoperable and operable, according to their size, location, and state of mobility. Unfortunately many cases come under the first or inoperable group, because the symptoms of incipient cancer are often so mild that the patient does not consult a physician, or if he does seek medical advice, the physician watches the case, perhaps carefully, until classical symptoms of cancer appear. The röntgenological findings in nearly all such instances have shown tumors which were beyond the stage for satisfactory removal. Even in advanced cases, the röntgenological examination is of great value. One can determine the location and extent of the tumor, whether a gastroenterostomy is necessary, and if it is necessary, whether enough healthy gastric wall remains to make the operation possible, and whether a posterior gastrointestinal anastomosis is possible, or whether an anterior gastroenterostomy must be resorted to. In the great majority of inoperable cases surgical procedure, particularly exploratory operation, is thus rendered unnecessary, and the patient is saved the inconvenience, expense, and suffering of an operation. This in itself would justify a most careful röntgenological examination.

Most of the early carcinomas and indurated ulcers considered here have been found in the practice of a few of those physicians who have all doubtful cases examined röntgenologically. By such procedure, and only by such procedure, can malignant gastric lesions be detected in their incipency. These few physicians reap the reward for their confidence in röntgenological examination by making use of an early and accurate diagnosis, for which they themselves get the credit, so far as the patient is concerned.

A study of a number of cases, classified as above,

will best illustrate the value of this method of diagnosis. The röntgenological findings and diagnosis are extracts from the original reports. But the question of the advisability of surgical procedure has been considered in the light of the subsequent clinical histories or surgical findings, and the conclusions following the descriptions of the cases, are drawn from a retrospective study of the entire series of cases in all their aspects.

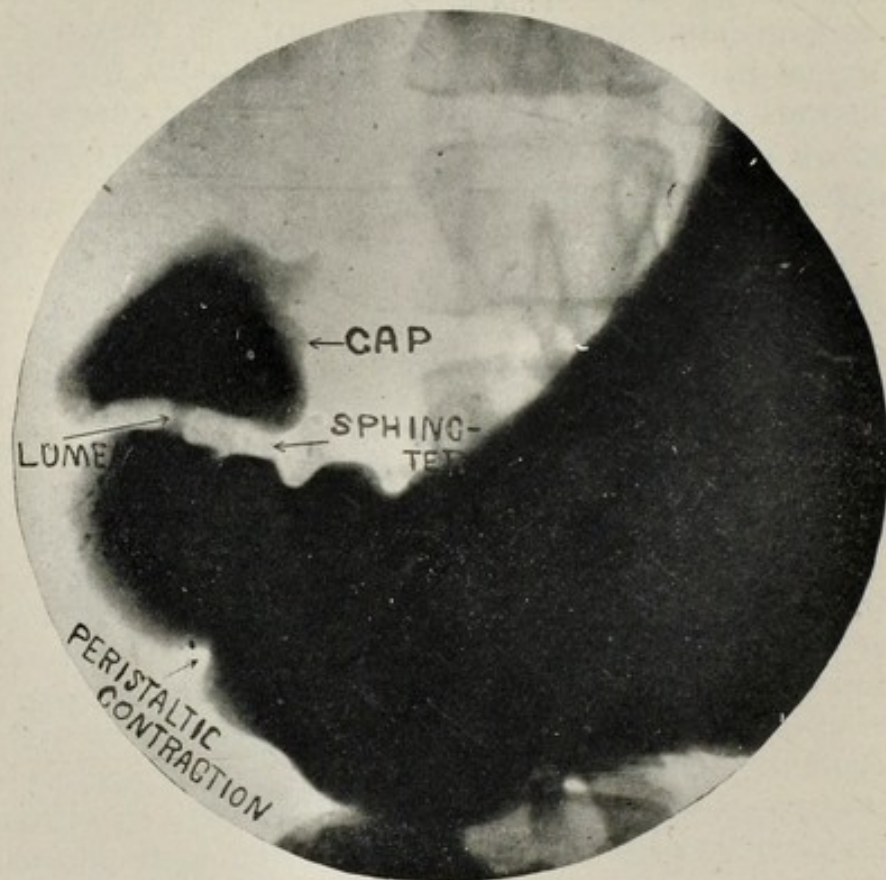


FIG. 1.—Showing uninvolved stomach, pyloric sphincter, and cap (Case I).

CASE I. Referred by Dr. William Van Valzah Hayes. *Röntgenological findings and diagnosis* (Fig. 1): The gastric lumen expanded and contracted uniformly, exhibiting the three cycle type of unobstructed peristalsis. The cap was well filled and corresponded perfectly in size and contour with the terminal portion of the pars pylorica. The space of three sixteenths inch, dividing the cap from the stomach, showed the smooth, clear cut outlines of a normal pyloric sphincter, except for the slight fold on the lesser curvature, a finding which has so frequently proved of no pathological significance, that it may be considered of congenital origin. The lumen of the pyloric sphincter was centrally located with respect to both its gastric and duodenal surfaces.

Conclusions: This roentgenogram is introduced to illustrate an uninvolved stomach, pyloric sphincter, and cap, with which the pathological findings herein reported may be compared.

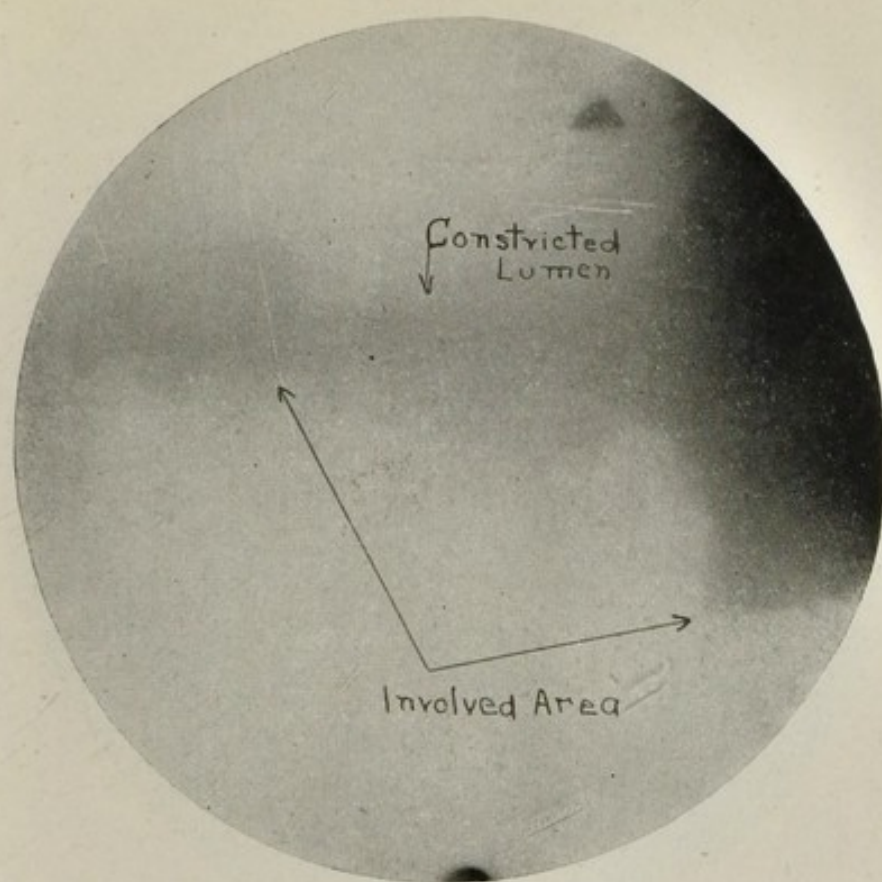


FIG. 2.—Showing constant area of involvement; growth probably carcinomatous (Case II).

EXTENSIVE GROWTHS, ONE LARGE TUMOR.

CASE II. Referred by Dr. William Van Valzah Hayes. The patient was a woman in robust health, with few gastric symptoms, and none of the classical symptoms of carcinoma. There was no gastric retention.

Röntgenological findings and diagnosis (Fig. 2): A great mass occupied the pyloric end of the greater curvature, projecting into the gastric lumen so that it was reduced to about one half inch in diameter. The röntgenologic diagnosis was extensive growth of the stomach, probably carcinoma.

Surgical findings: The surgeon found an immense growth, as large as two fists. Half of it involved the lumen of the viscus, and the other half extended beyond the normal contour of the stomach wall. Unfortunately the operation was unsuccessful, and the patient died.

Conclusions: The tumor was obviously too extensive to offer a good opportunity for removal, and as there was no obstruction, gastroenterostomy was not indicated. In cases of this sort, unnecessary operation may be prevented by a röntgenographic examination, and the patient may live for some time without severe symptoms.

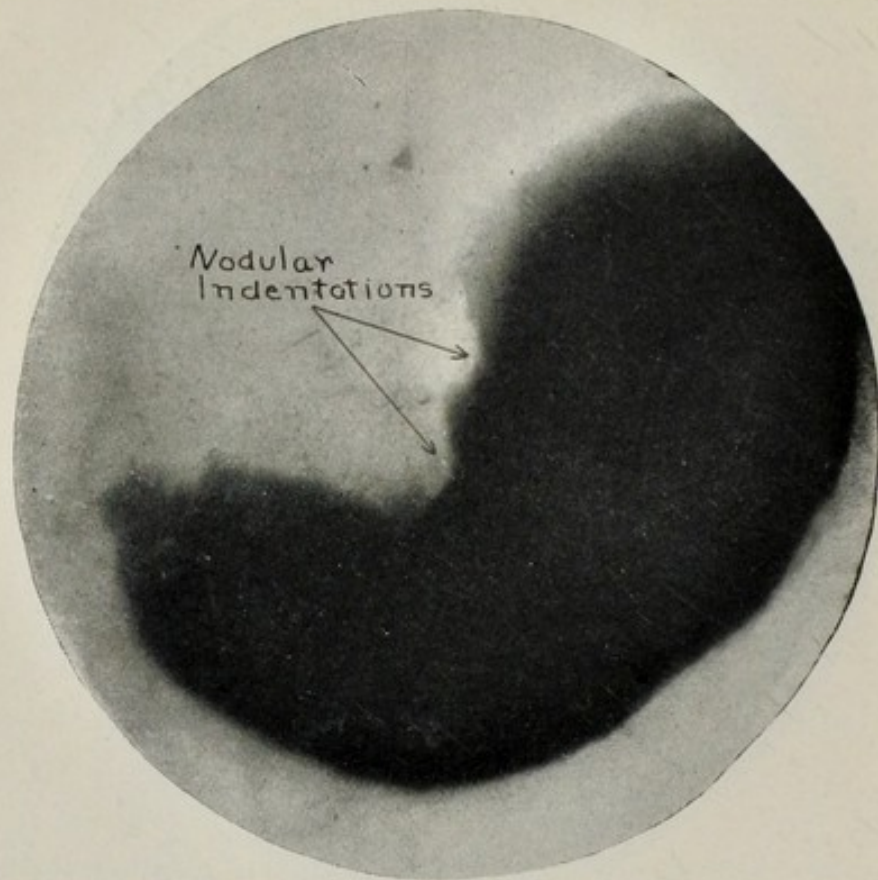


FIG. 3.—Showing fingerprint appearance; probably a malignant growth.

CASE III. Referred by Dr. W. Gilman Thompson. The general health of this patient was good. His gastric symptoms, which had been present for four years, were attacks of pain in the left side, occurring every few days and lasting several hours, loss of appetite, and a reduction in weight of twenty pounds in six weeks.

Röntgenological findings and diagnosis (Fig. 3): Two indentations presented on the lesser curvature, about three inches from the pylorus, resembling peristaltic contractions, except that their position and size were constant. Their failure to relax and contract, and to move pylorus-ward during the gastric cycle, and the fact that their contour presented slight indentations suggested a malignant nodular growth. The patient refused operation and died within six months.

Conclusions: The location of the tumor rather than its size rendered this case unfavorable for removal. It offered the surgical difficulties encountered in Case XVI. As there was no evidence of pyloric obstruction or gastric retention, a palliative gastroenterostomy was not indicated.

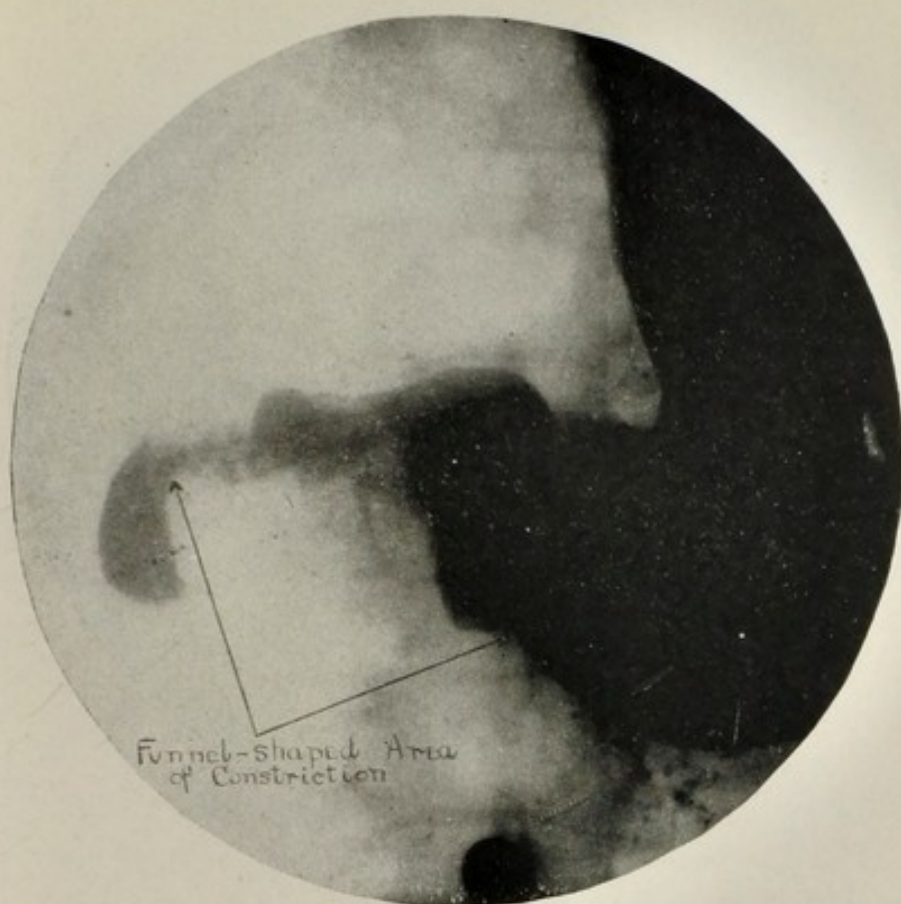


FIG. 4.—Area of involvement constant in size, shape, and position. Nature of this growth dubious (Case IV).

CASE IV. Referred by Dr. William Seamans Bainbridge. An exploratory laparotomy had been performed on this patient by a Philadelphia surgeon, who found an "inoperable cancer of the stomach." No specimen was taken. It was prophesied that the patient would die in six weeks. Several months later the patient was still living and the symptoms were no more severe. Röntgenography was employed to determine why the surgeon's prophecy had not been fulfilled.

Röntgenological findings and diagnosis (Fig. 4): The lumen of the pars pylorica was constricted in funnel shape to one quarter inch in diameter at the narrowest point. The posterior wall of the greater curvature was distorted for a space of three inches from the pyloric sphincter and indented by two constant nodules. The lesser curvature appeared to be involved only slightly.

Conclusions: The lumen of the stomach was patent. The interesting question is—was the growth benign or malignant?

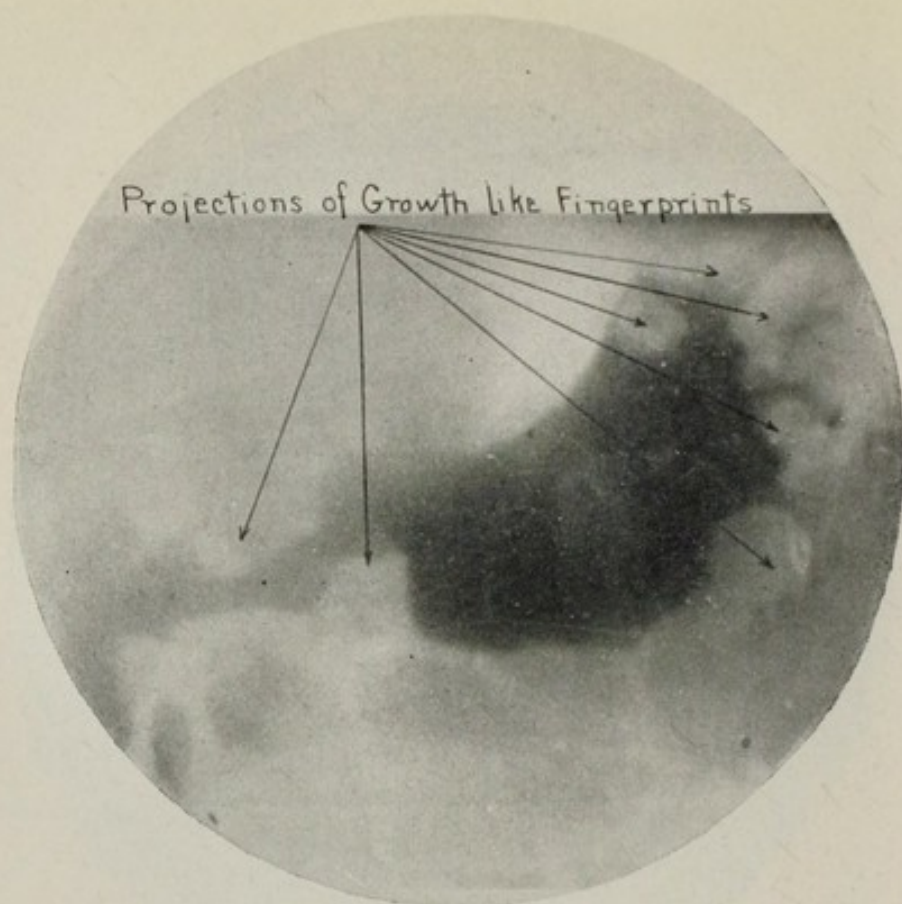


FIG. 5.—Another fingerprint appearance on posterior wall.
Inoperable carcinoma (Case V).

EXTENSIVE NODULAR GROWTHS.

CASE V. Referred by Dr. Alexander Lambert. The patient's only gastric symptom was eructation of gas.

Röntgenological findings and diagnosis (Fig. 5): This case was referred with colonic symptoms, but I followed the procedure, which I have since adopted as a routine, i. e., a complete gastrointestinal examination. An inoperable carcinoma was thus revealed, where there was not the slightest suspicion of such a condition. The whole gastric lumen was distorted and constricted. It was considered impossible that so extensive a growth should cause no symptoms.

Surgical findings: Surgery relieved the colonic symptoms and confirmed the röntgenological diagnosis. Symptoms of gastric carcinoma did not appear until several months later.

Conclusions: There was no röntgenological indication for operation on the stomach, as the growth was too extensive for removal, and a gastroenterostomy was unnecessary. A posterior gastroenterostomy would have been impossible. The röntgenographical examination of the colon showed that the patient's symptoms were due to adhesions of the first portion of the transverse colon, entirely independent of the gastric carcinoma.

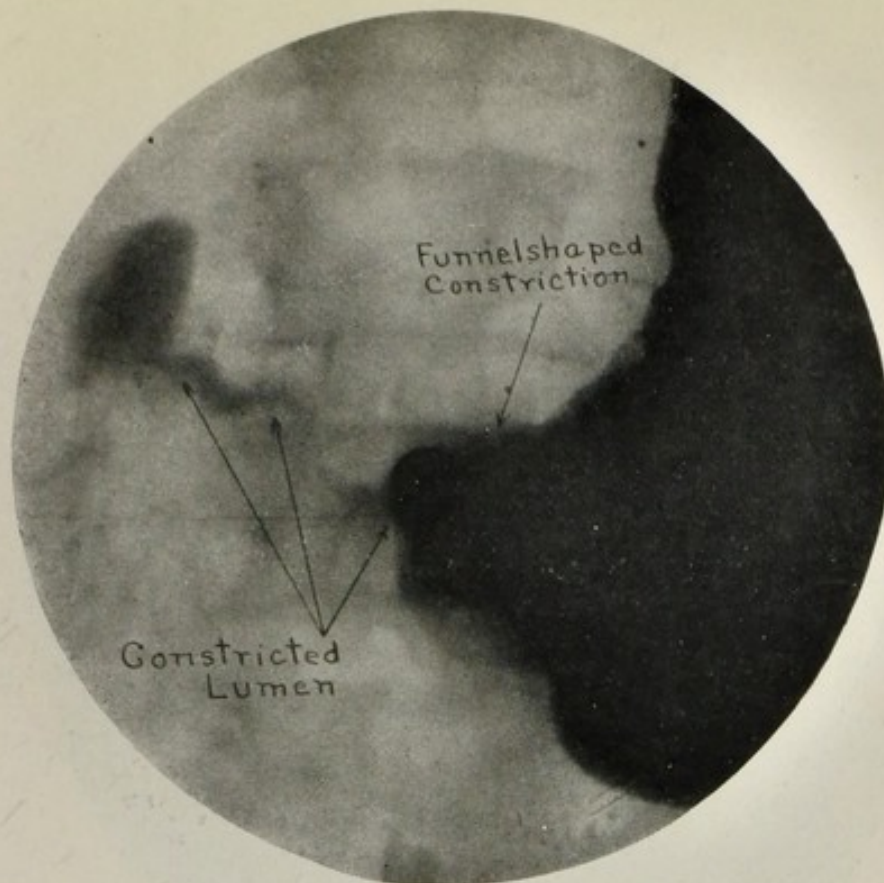


FIG. 6.—Indurated ulcers of stomach and duodenum; malignancy not established.

CASE VI. Referred by Dr. Max Einhorn. *Röntgenological findings and diagnosis* (Fig. 6): The röntgenological report, made at the time of the examination, read: "From a study of the plates one is justified in making a diagnosis of new growth of the pyloric end of the stomach, the lumen being almost completely obstructed for a distance of 2.5 or 3 inches."

Surgical findings kindly reported by Dr. William H. Mayo: "Patient had two ulcers, one in the stomach and one in the duodenum. The ulcer in the stomach was indurated and adherent to the pancreas. There was marked obstruction. There was a peculiar soft tumor four or five inches from the origin of the jejunum, rendering an anterior gastroenterostomy necessary. The ulcer in the stomach was almost continuous with the one in the duodenum. While a good many glands were found to be involved, we were unable to positively establish malignancy. There were also many nodules in the liver, apparently secondary to the original growth in the stomach."

Conclusions: Here was an indurated ulcer of the stomach, with extensive adhesions to the pancreas and much glandular involvement, and a nodular growth on the liver, yet malignancy was not established by an exploratory laparotomy at a clinic where there was every facility for making a diagnosis by such means. Why should the röntgenologist be expected to differentiate between malignant and nonmalignant tumors of the stomach if malignancy cannot be established by exploratory operation and pathological examination?

The extensive involvement of the pars pylorica and pars media, with adhesions to the pancreas, which the röntgenograms demonstrated, was another good reason for not doing a posterior gastroenterostomy.

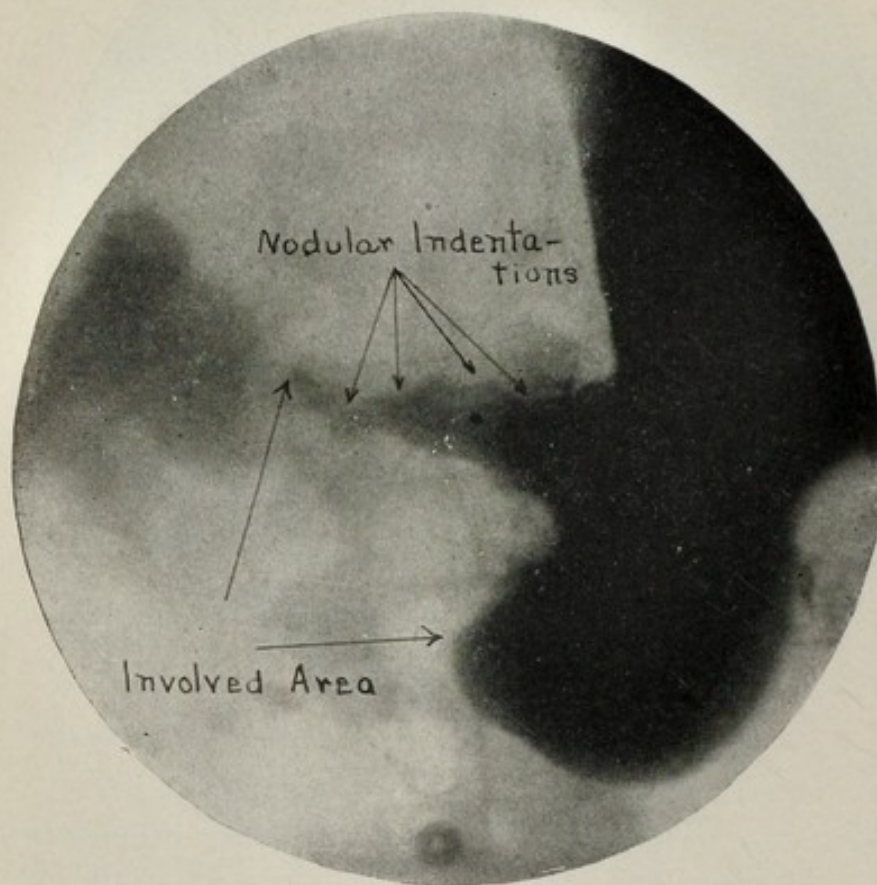


FIG. 7.—Adenocarcinoma of pylorus (Case VII).

EXTENSIVE ANNULAR GROWTHS.

CASE VII. Referred by Dr. Maurice H. Gross. *Röntgenological findings and diagnosis* (Fig. 7): An annular growth occupied the pars pylorica, leaving a remnant of lumen about one half inch in diameter along the lesser curvature. Its outline, devoid of peristalsis, presented constant nodular deformities on both curvatures, and justified a diagnosis of malignancy.

Surgical findings, by Dr. A. A. Berg: "A pylorectomy and gastroenterostomy for adenocarcinoma of the pylorus were performed."

Conclusions: This is the most extensive of the growths herein described for which pylorectomy has been performed successfully. Doctor Berg writes that the patient is free from symptoms seventeen months after the operation.

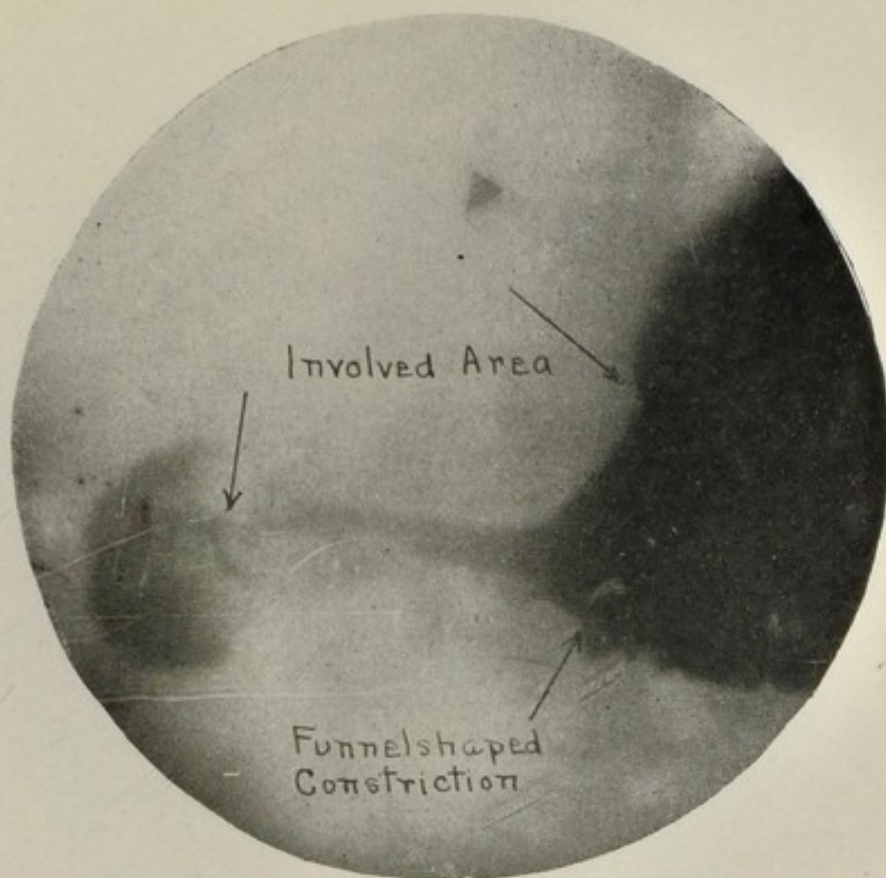


FIG. 8.—Funnel appearance, verging to obliteration. Extensive annular carcinoma (Case VIII).

CASE VIII. Referred by Dr. Max Einhorn. *Röntgenological findings and diagnosis* (Fig. 8): The lumen of the pars pylorica and pars media was constricted to a diameter of one quarter inch, expanding in funnel shape where it joined the apparently uninvolved cardiac region. The lesion was diagnosed as an extensive annular carcinoma, requiring immediate surgical procedure.

Subsequent history: Five months after the röntgenological examination the patient wrote that his condition was somewhat improved, and that he was going to the mountains of Arizona to recuperate. Three months later, after having lost nine months of valuable time, he was operated upon, and the röntgenological diagnosis was confirmed, unfortunately too late even for a gastroenterostomy.

Conclusions: Lack of cooperation between the patient, his physician, and the röntgenologist deprived this man of the valuable information derived from the examination. A proper demonstration of the röntgenograms would have proved to him beyond any question of doubt the conditions which existed.

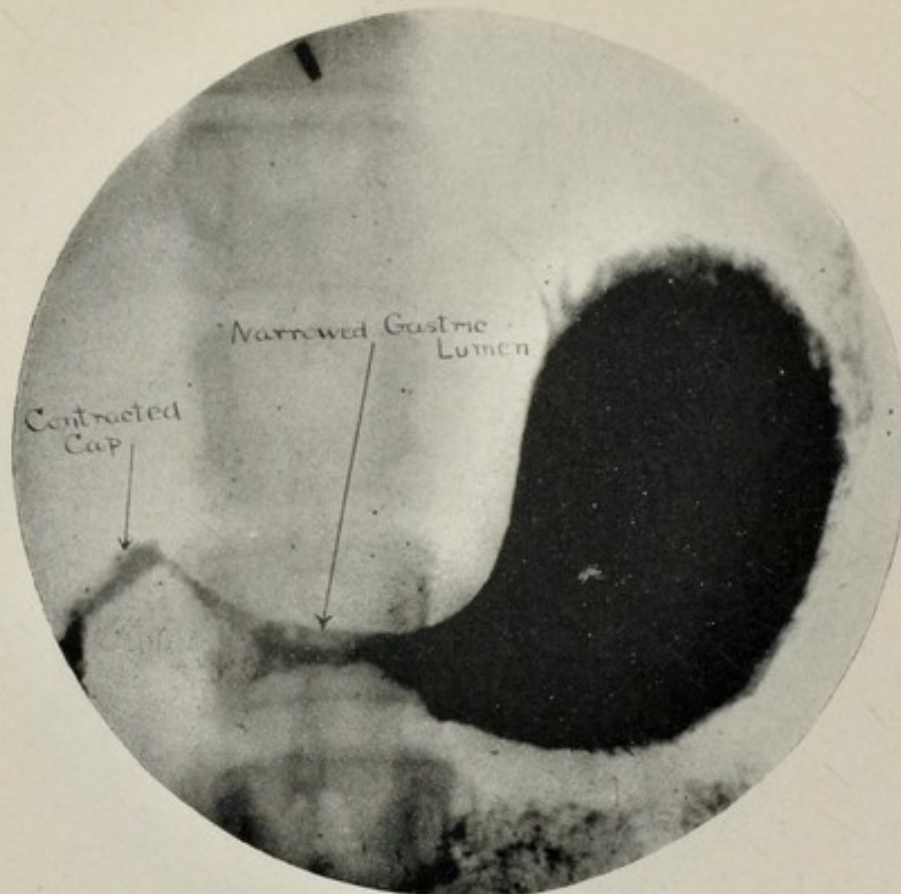


FIG. 9.—Extensive inoperable carcinoma (Case IX).

CASE IX. Referred by Dr. William Van Valzah Hayes and Dr. Theodore Bailey. The patient was a woman, aged forty-four years, who had had a poor digestion, and constipation for thirty years. For a year she had complained of constant belching and entire lack of appetite. In three months she had lost thirty pounds. A month previous there had been a slight hematemesis.

Röntgenological findings and diagnosis (Fig. 9): The lumen of the stomach, from the cap to the pars media, was constricted to one quarter inch in diameter by a growth, which apparently extended also posteriorly along the lesser curvature up toward the cardia. It was diagnosed as an inoperable carcinoma.

Surgical findings: The surgeon found a carcinoma so extensive that an anterior gastroenterostomy could not be performed.

Conclusions: The growth was so extensive that it was not advisable to attempt even an anterior gastroenterostomy. The lumen of the stomach was of sufficient size to allow fluids and semisolids to pass into the duodenum, but as the digestive function of the stomach was entirely destroyed, carbohydrates and predigested proteids constituted the proper diet.

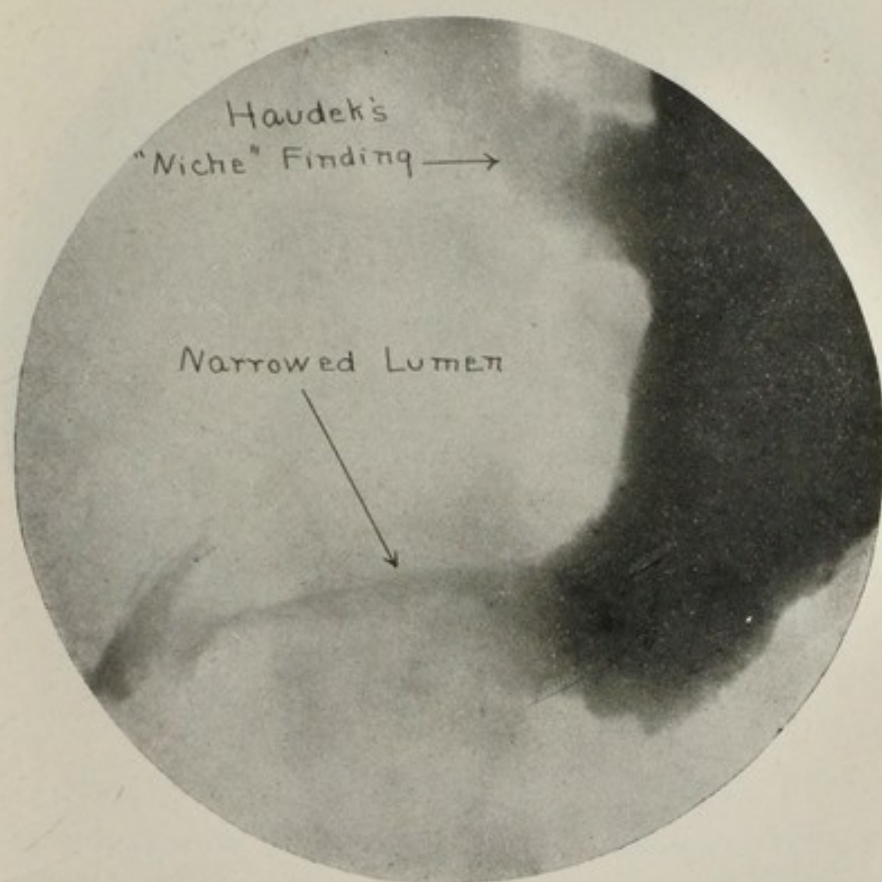


FIG. 10.—Growth similar to that shown in Fig. 9 (Case X).

CASE X. Referred by Dr. John Douglas. *Röntgenological findings and diagnosis* (Fig. 10): The greater and lesser curvatures, from the cap to the fundus, were denticulated by the inroads of a growth, which so diminished the lumen that it tapered out to a mere point at the pyloric sphincter. On the lesser curvature near the fundus a small bismuth shadow projected from the adjacent mass, as if in a pocket, resembling Haudek's "niche" findings for perforating ulcer. In this instance the phenomenon accompanied an extensive malignant growth.

Conclusions: As the growth was similar to the one just described, which proved too extensive to provide space even for an anterior gastroenterostomy, I advised against operation.

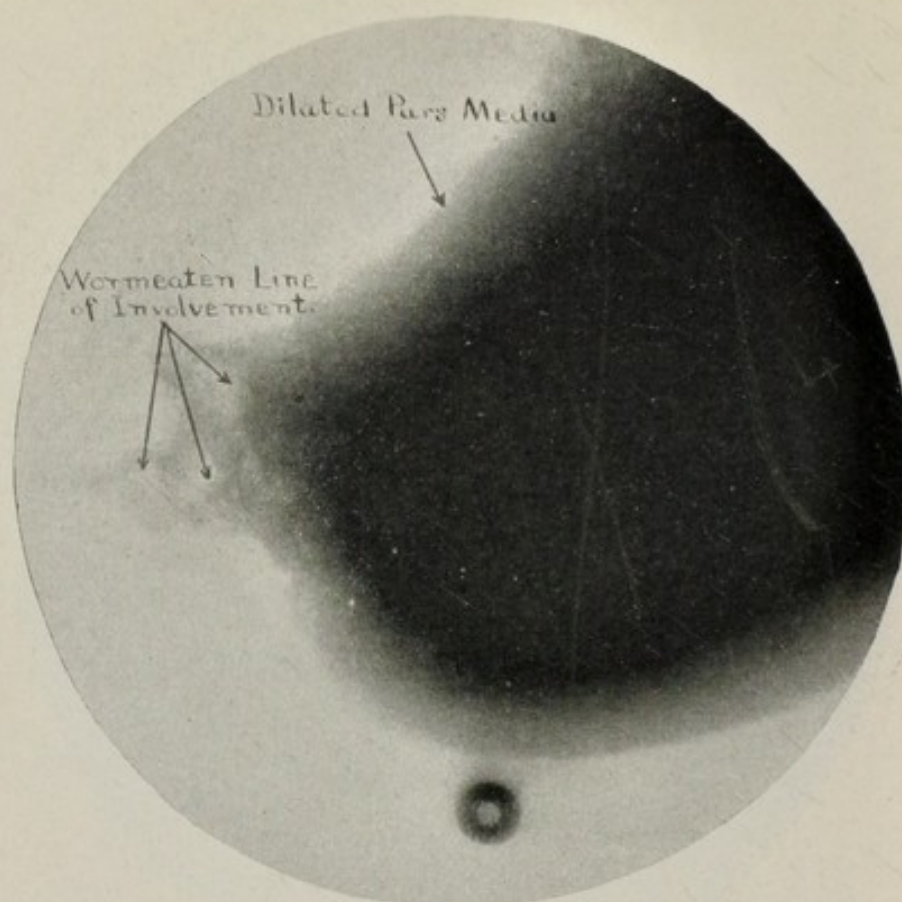


FIG. 11.—Carcinoma of pylorus, relieved by gastroenterostomy (Case XI).

CASE XI. Referred by Dr. Carlyle E. Sutphen, Jr. *Röntgenological findings and diagnosis* (Fig. 11): The röntgenograms showed the typical nodular indentations with wormeaten edges, which are characteristic of carcinoma. The lumen of the pars pylorica was so narrowed as to cause pyloric obstruction and dilatation of the stomach.

Surgical findings, by Dr. Carlyle E. Sutphen, Jr.: Carcinoma of the pylorus, involving the greater omentum and transverse colon, causing almost complete obstruction. As a posterior gastroenterostomy was impossible, an anterior gastroenterostomy was performed. This afforded only temporary relief.

Conclusions: Unfortunately this is but one of the many cases which are submitted to the röntgenologist for diagnosis too late for permanent surgical relief, and after the growth has become so extensive that it is impossible to determine whether it originated in one wall or was annular at its incipency.

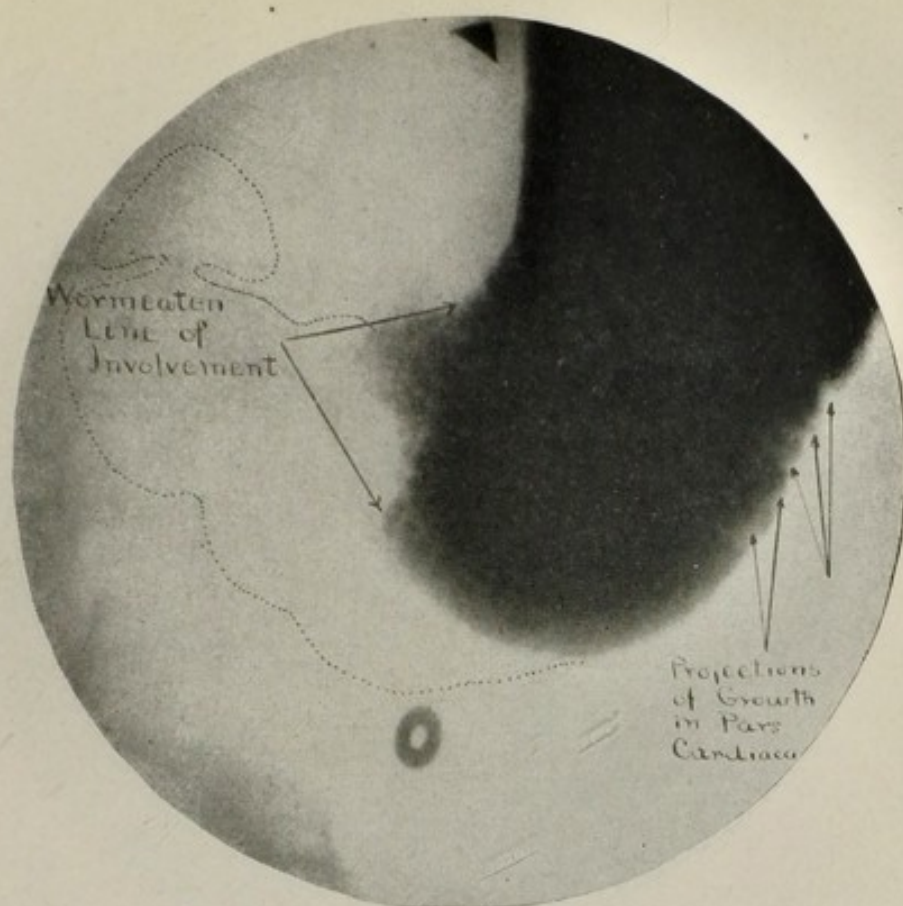


FIG. 12.—Extensive carcinoma, involving lesser curvature and gastrohepatic omentum (Case XII).

CASE XII. Referred by Dr. William Van Valzah Hayes. *Röntgenological findings and diagnosis* (Fig. 12): The pyloric portion of the stomach was almost completely occluded by a carcinoma as far back as the pars cardiaca, the greater and lesser curvatures of which showed a wormeaten contour.

Surgical findings, by Dr. John Wyeth and Dr. J. Prescott Grant: "An extensive carcinoma, involving most of the lesser curvature and gastrohepatic omentum; also much of the greater curvature. It was difficult to find space for a gastroenterostomy."

Conclusions: The growth was altogether too extensive to offer any hope of removal. The interesting point to determine was whether or not to attempt a gastroenterostomy. The small amount of normal tissue, which the röntgenograms defined with remarkable accuracy, as operation proved, would lead me in the future to urge against any attempt at surgical treatment, even a gastroenterostomy. Deaths immediately following operations immeasurably increase the percentage of mortality from surgical procedure. Such fatalities prevent many patients from consenting to an operation which would mean their salvation.

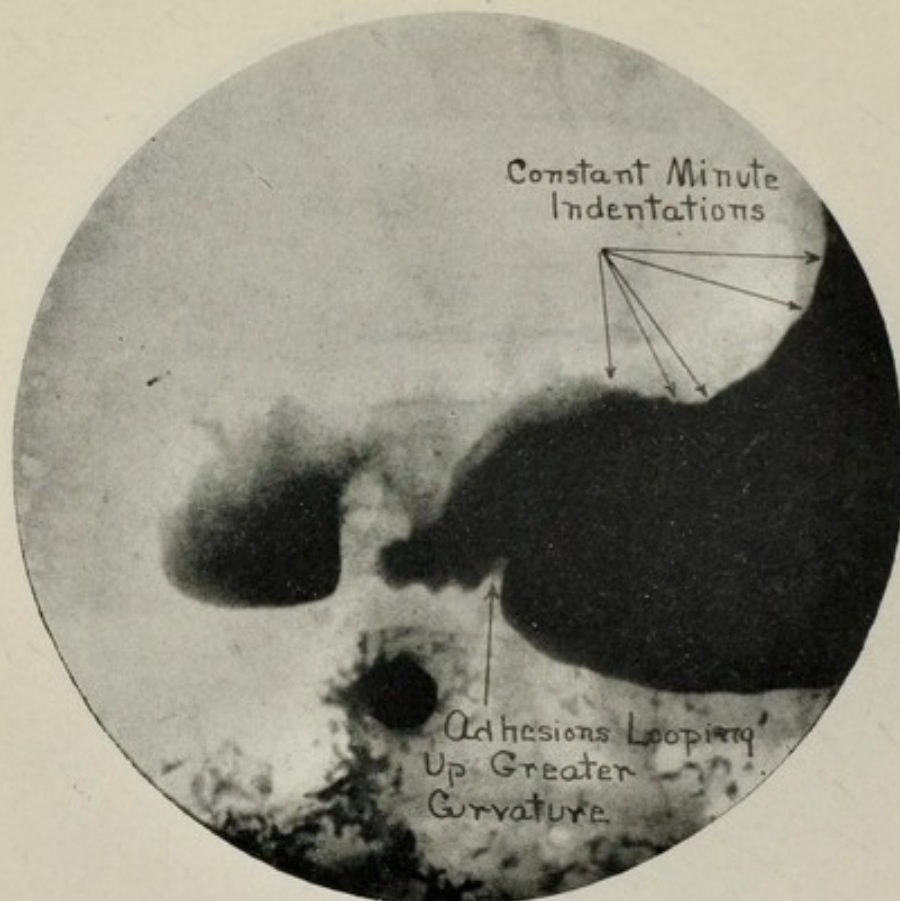


FIG. 13.—Sclerotic type of cancer; inoperable (Case XIII).

SCLEROTIC GROWTHS.

CASE XIII. Referred by Dr. Frederick M. Johnson, Jr. The patient was a man, aged thirty-six years. His symptoms were of six months' duration, increasing markedly for two months. He complained of pain in the epigastrium and right hypochondrium, radiating through to the back, occurring fifteen to twenty minutes after eating, and especially at night. There was marked heartburn, and at times regurgitation. He had lost thirty pounds in two months.

Röntgenological findings and diagnosis (Fig. 13): Constant minute indentations along the lesser curvature indicated an inoperable carcinoma. Adhesions looped up a portion of the greater curvature of the pars pylorica.

Conclusions: The deformity of the cap and the permanent fold in the greater curvature, one inch from the sphincter, distract one's attention from the permanent, slight irregularities along the lesser curvature, where peristalsis was absent. They can be detected only by matching the roentgenograms over each other or reproducing them cinematographically. I could not conscientiously urge surgical procedure, and the patient refused operation.

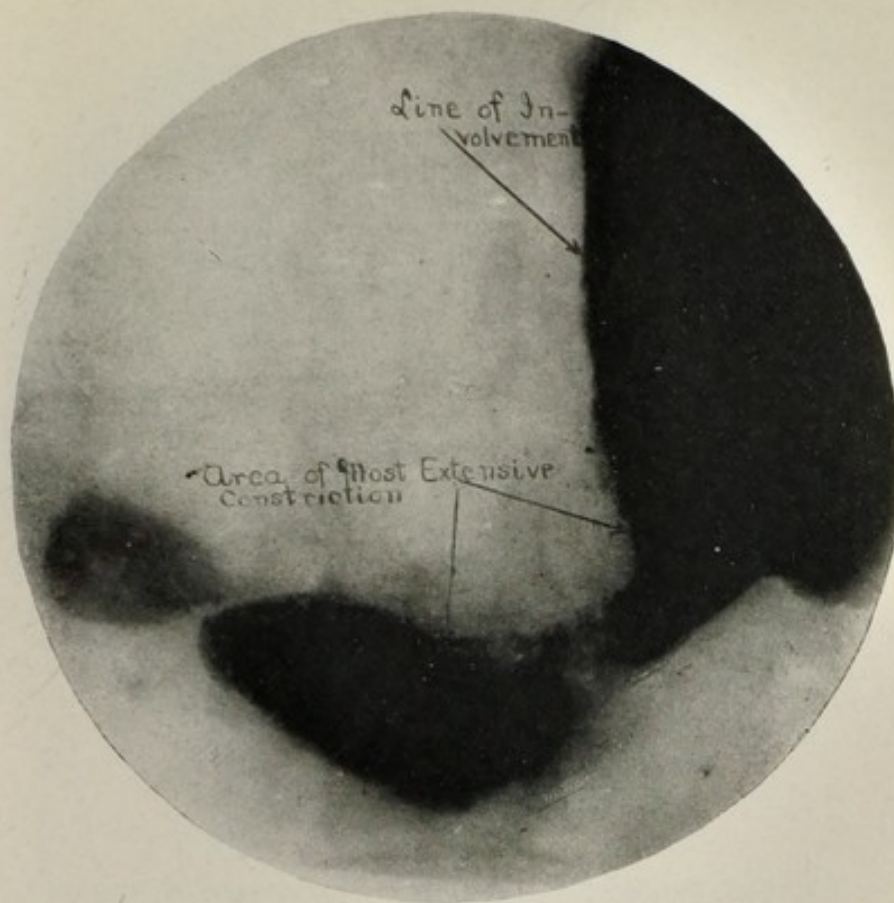


FIG. 14.—Sclerotic cancer involving a large area; inoperable.

CASE XIV. Referred by Dr. James D. Miller. The patient was a woman, aged fifty-nine years. For about two years she had been vomiting every day or two after meals, and upon arising in the morning. Hematemesis occurred several times. There were pain and distention over the whole abdomen. She complained of constant belching and regurgitation of liquid. There was a loss of about thirty pounds in six months. On three occasions her trouble had been diagnosed as gallstones.

Röntgenological findings and diagnosis (Fig. 14): The lumen of the stomach was constricted from the pyloric sphincter to the pars cardiaca, the greater and lesser curvatures being about equally involved. The lesion was most extensive at the pars media. The affected area was devoid of rugæ and wormeaten in appearance.

Conclusions: The sclerotic involvement of the pars media was too extensive to make its removal possible, and as the size of the lumen was adequate, a gastroenterostomy was not indicated. Indeed it is doubtful if a gastroenterostomy could have been performed.

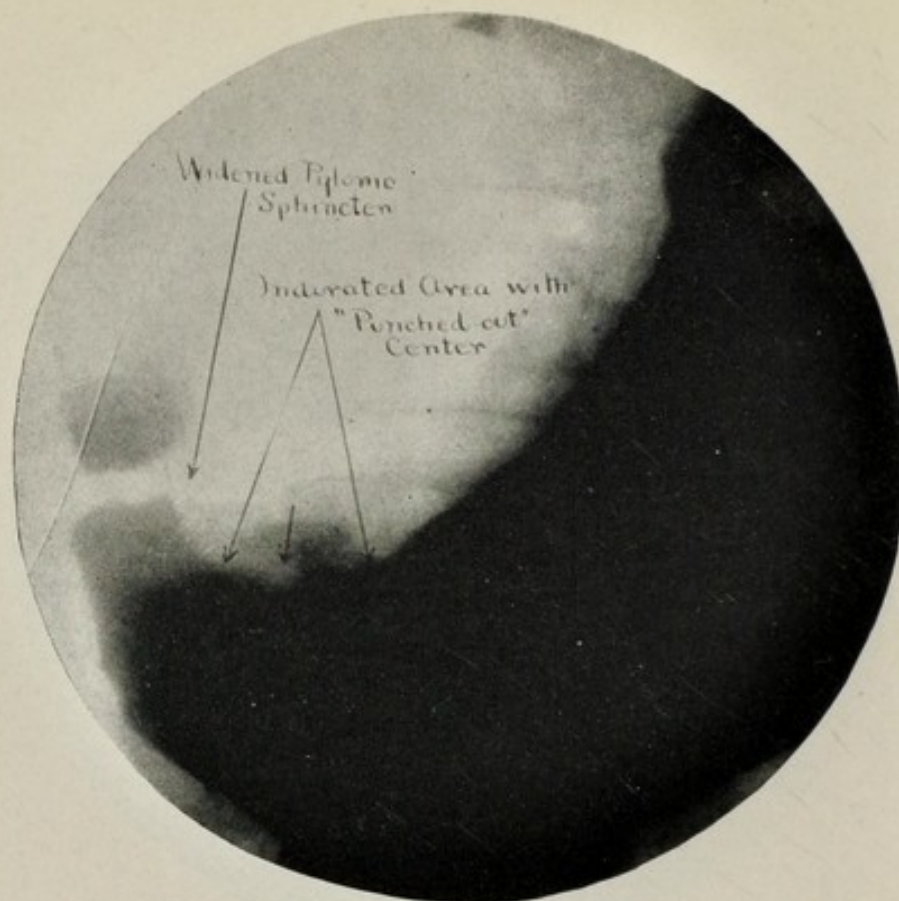


FIG. 15.—Indurated gastric ulcer; no signs of malignancy (Case XV).

LOCALIZED AREAS OF INDURATION.

CASE XV. Referred by Dr. C. G. Haven. The patient, a man, aged fifty-three years, stated that for three months he had had moderate pain or distress after eating. This was his only symptom, except frequent hiccoughing.

Röntgenological findings and diagnosis (Fig. 15): The röntgenograms revealed an area of infiltration for about two inches along the lesser curvature. Its depressed centre corresponded to descriptions of the "saddle" ulcer. Immediate surgical procedure was advised.

Surgical findings, by Dr. Charles H. Peck: Operation revealed an indurated gastric ulcer, but it was impossible to determine whether the lesion was a simple ulcer with indurated edges or an ulcer with carcinomatous degeneration at the base. A microscopical examination of the specimen showed no evidence of malignancy.

Conclusions: Neither the attending physician nor the surgeon found sufficient clinical evidence of any abdominal lesion to warrant an operation. But the röntgenological evidence was sufficiently definite to justify surgery, even in the absence of clinical evidence.

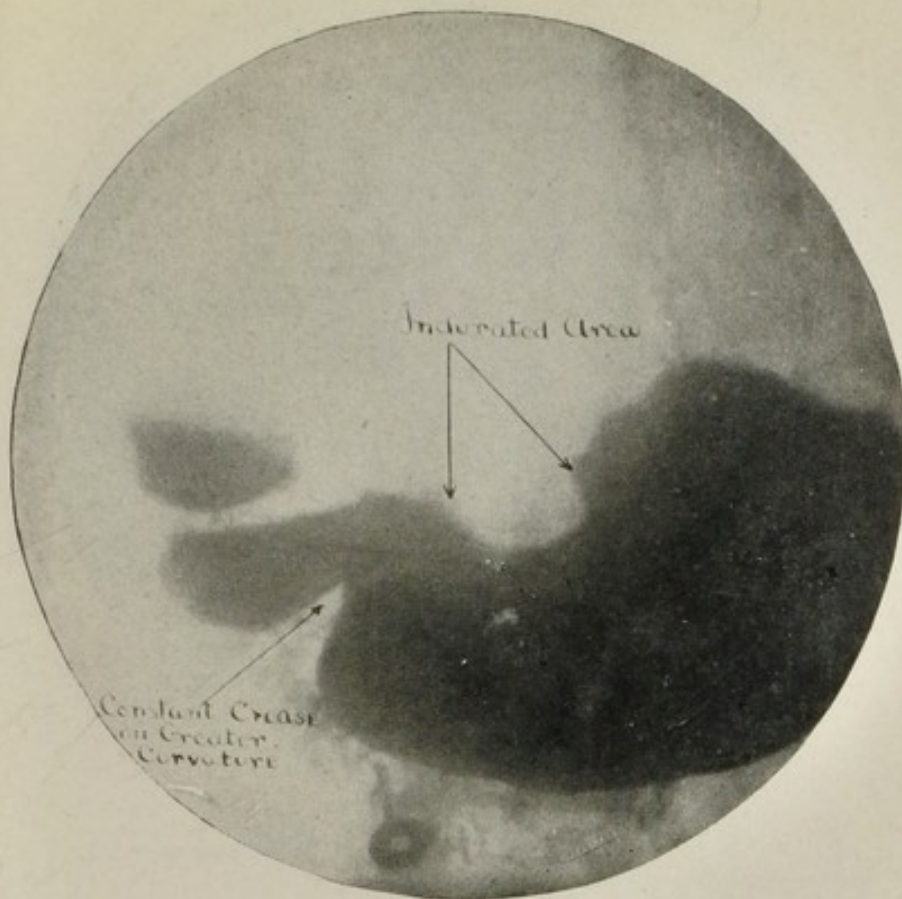


FIG. 16.—Indurated ulcer, probably malignant (Case XVI).

CASE XVI. Referred by Dr. William Van Valzah Hayes. The patient was a woman, aged forty-six years. She complained of nausea, vomiting, and pain and soreness in the epigastrium. She had lost twenty-six pounds in five months.

Röntgenological findings and diagnosis (Fig. 16): The deep constant sulcus on the lesser curvature was diagnosed as an area of induration, requiring immediate surgical procedure, because, although it resembled a broad peristaltic contraction, it did not relax with diastole nor progress pylorusward.

Surgical findings, by Dr. William A. Downes: Indurated ulcer, believed to be malignant, about two inches in diameter, on the lesser curvature. It extended so far up toward the cardia that complete excision was not done, but a posterior gastroenterostomy was performed.

Conclusions: Note the constant crease on the greater curvature, and its absence on the lesser curvature, as in Case XIV. The interesting factor was that, although the tumor was only moderate in size, its location rendered its removal inadvisable. No section was taken for microscopical examination.

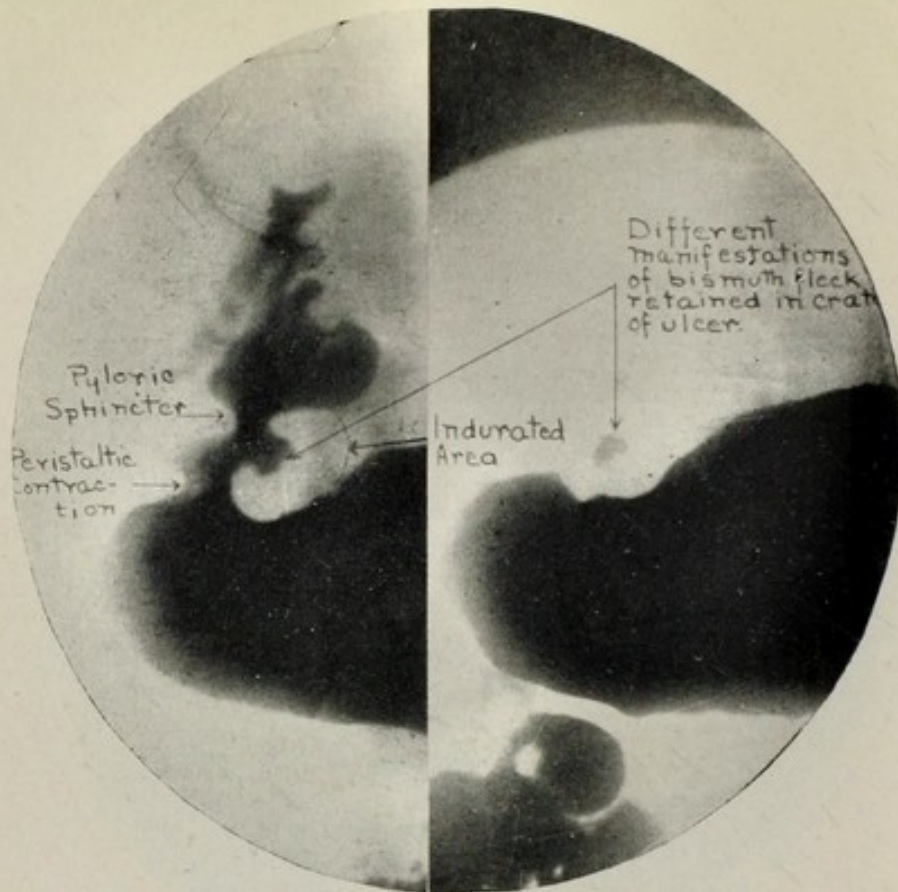


FIG. 17A.—Growth resembling duodenal ulcer, but of undetermined malignancy (Case XVII).

FIG. 17B.—Same as 17A.

CASE XVII. Referred by Dr. George Emerson Brewer. For three years the patient had experienced a raw, burning hunger pain in the epigastrium about two hours after eating.

Röntgenological findings and diagnosis (Figs. 17-A and 17-B): The pyloric sphincter was three times the normal thickness on both curvatures. On the lesser curvature a persistent bismuth fleck corresponded in size and shape with the crater of an ulcer (Fig. 17-B). The lumen of the sphincter entered the cap anteriorly. The cap, although somewhat irregular, was less involved than the stomach. The findings corresponded with Moynihan's and Codman's descriptions of postpyloric duodenal ulcer, and yet the ulcer lay nearer the gastric than the duodenal surface of the sphincter, so it might be classed as either postpyloric or prepyloric.

Surgical findings, by Dr. George Emerson Brewer: The ulcer was discovered in the first portion of the duodenum on its anterior surface, just beyond the pylorus. The pylorus was thickened and covered with adhesions, old and new.

Conclusions: This case demonstrates that the small, round perforating ulcers of the pars pylorica and the slight induration surrounding them give unmistakable röntgenological findings, indicating the size and extent of the lesion. Only a microscopical examination of the specimen can determine the question of malignancy.

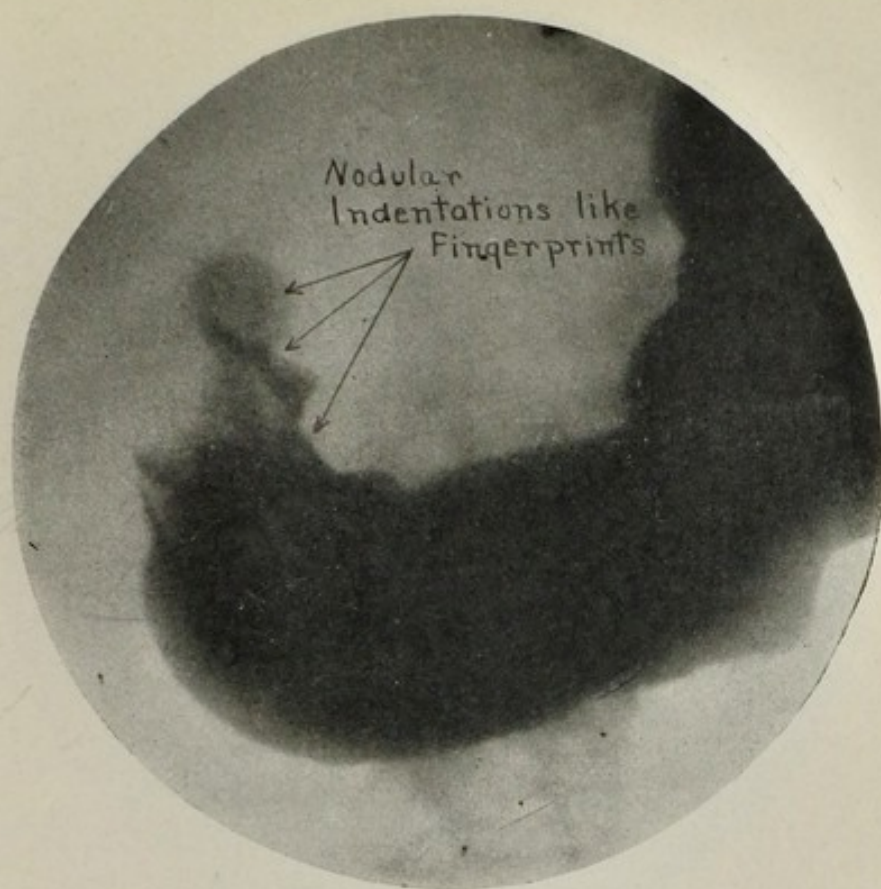


FIG. 18.—Third view of fingerprint appearance; multiple carcinoma (Case XVIII).

SMALL NODULAR GROWTHS.

CASE XVIII. Referred by Dr. James D. Nisbet with a clinical history of gastric ulcer or carcinoma.

Roentgenologic findings and diagnosis (Fig. 18): Three indentations like fingerprints were observed near the pylorus. This group of nodules and the wormeaten character of the adjacent region formed a typical picture of multiple carcinoma.

Subsequent history: Owing to the age and physical condition of the patient, surgery was not resorted to, although the nature and extent of the lesion was fully recognized by Dr. Nisbet. The patient improved under his regulation of diet and medical treatment for about eight months, and then rapidly grew worse, and died fourteen months after the Roentgenographic examination of carcinoma of the stomach.

During the period of her improvement under Dr. Nisbet's care, another gastro-enterologist, whom the patient consulted, stated that he found no evidence of new growth.

Conclusions: In this case we knew that a malignant lesion was present. Nevertheless careful diet and medical treatment so masked the incipient growth that another gastro-enterologist failed to recognize it. As the same circumstances might occur in the early stages of any gastric carcinoma, they indicate the necessity of a Roentgenographic examination of patients presenting slight gastric symptoms, even though they are relieved by medical treatment.

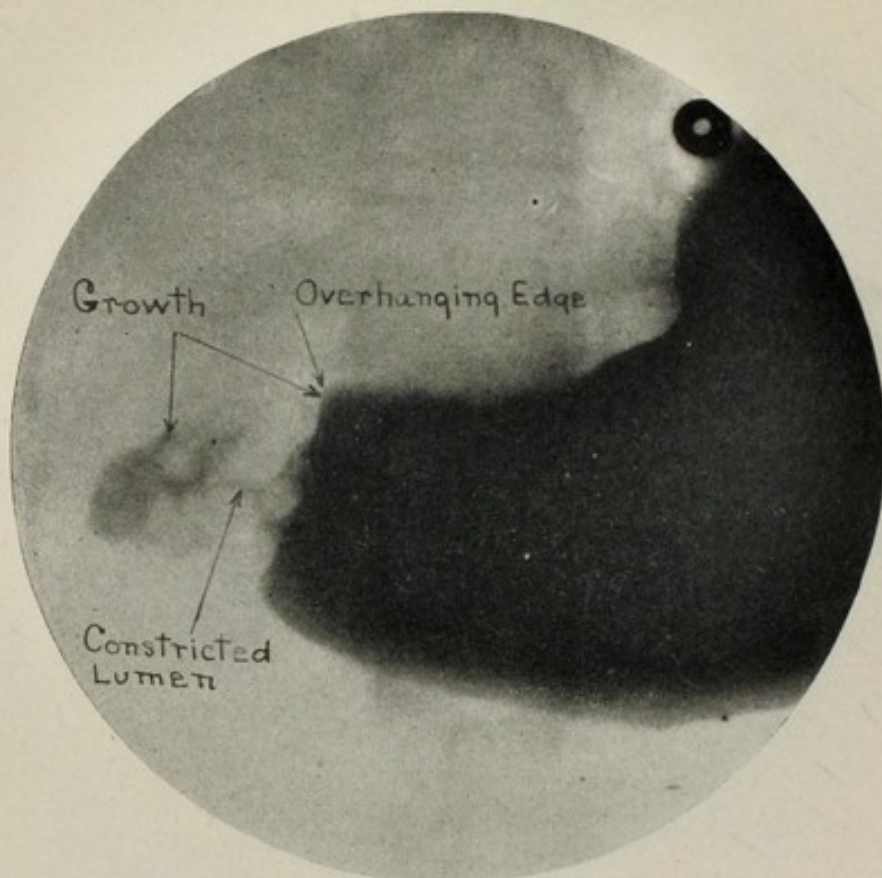


FIG. 19.—Showing wormeaten effect. Annular carcinoma of pylorus (Case XIX).

SMALL ANNULAR GROWTHS.

CASE XIX. Referred by Dr. William Van Valzah Hayes. The patient was a middle aged woman, whose principal symptoms were gastric retention and loss of weight and strength.

Röntgenological findings and diagnosis (Fig. 19): The röntgenograms presented a typical picture of annular carcinoma of the pylorus, the lumen of which was constricted to one eighth inch in diameter, widening out in funnel shape at both ends where the uninvolved region adjoined. The conical areas had a wormeaten appearance.

Surgical findings, by Dr. Oliver C. Smith: A gastroenterostomy was safely performed, but the patient's condition did not justify a gastrectomy. A small growth was found, without glandular involvement, which the surgeon considered benign. However, the patient failed to gain strength and weight and the surgeon expressed the opinion that the röntgenological diagnosis was probably correct. Death ensued about two and one half years later.

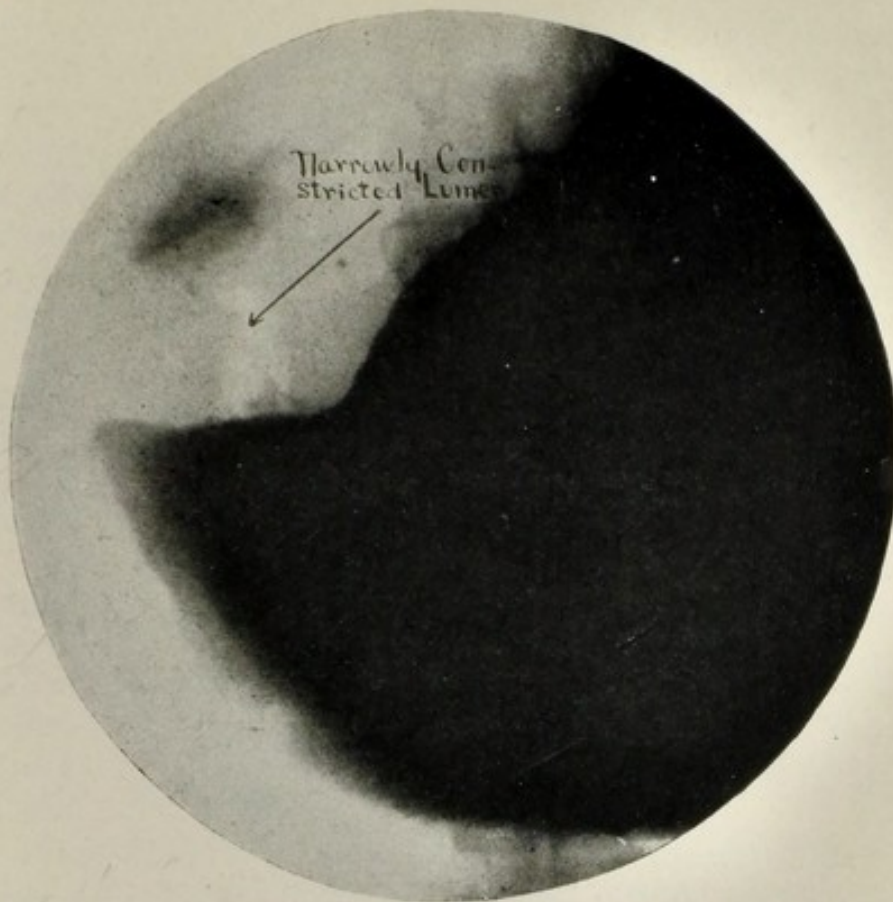


FIG. 20.—Malignant growth involving pylorus and constricting lumen.

CASE XX. Referred by Dr. William Francis Honan. *Röntgenological findings and diagnosis* (Fig. 20): An annular growth circumscribed the pars pylorica, constricting the lumen for one and one quarter inch to so narrow a passage that only a hairline of bismuth was visible. As a result the stomach was immensely dilated. Successful removal of the growth was deemed possible, on account of its location, and prompt surgical interference was recommended.

Surgical findings, by Dr. William Francis Honan, agreed with the röntgenologist's even to the exact measurement of the tumor. He described it as "a malignant growth at the pylorus about one and one quarter inch wide." The patient was so emaciated from inanition that he did not recover from the operation.

Conclusions: This case was kept under careful observation for six weeks, and because of a practically normal gastric secretion the possibility of gastric carcinoma was dismissed. Röntgenologically the growth was one that offered an exceptional opportunity for removal.

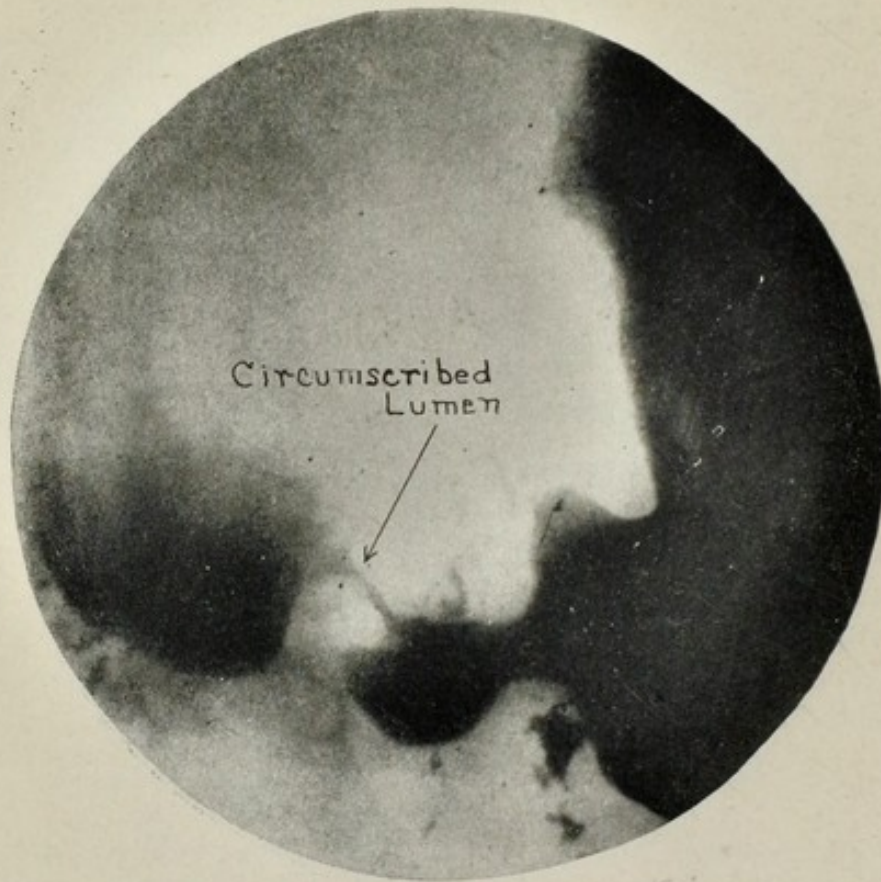

FIG. 21.— Gastric carcinoma (Case XXI).

CASE XXI. Referred by Dr. George Emerson Brewer. The patient presented the classical symptoms of gastric carcinoma.

Röntgenological findings and diagnosis (Fig. 21): An annular growth confined the pars pylorica. It was more extensive on the lesser than on the greater curvature and involved the anterior more than the posterior aspect. The lumen of this region was reduced to one eighth inch in diameter and presented an identical contour in all the röntgenograms of the series. Immediate surgery was recommended.

Surgical findings, by Dr. George Emerson Brewer: Operation proved that the röntgenological findings were entirely correct.

Conclusions: This carcinoma had escaped detection by plain röntgenography, when only two or three röntgenograms had been made. But when a large series of plates were studied individually and collectively, and matched over each other, there was no question of the presence of a growth requiring surgical procedure.

These few cases have been selected from a large number to illustrate various types of gastric carcinoma. While many of those omitted are of equal interest from a röntgenological and clinical standpoint, little would be gained by showing analogous cases.

A negative or positive diagnosis of gastric cancer has been made in each of the 616 cases examined by means of serial röntgenography, and in not a single case (to my knowledge),² where I have made a negative diagnosis of gastric cancer or indurated gastric ulcer, has surgery or autopsy proved the existence of such lesion, nor has surgery or autopsy failed to reveal a definite organic lesion, requiring surgical procedure, in any case, where a positive diagnosis of carcinoma or indurated ulcer has been made.

Six hundred and sixteen cases have been examined by serial röntgenography. Ninety-seven cases have been operated in. In ninety-four of the cases the röntgenological diagnosis was proved absolutely correct. In three cases the surgical findings were more or less at variance with the röntgenological findings.²

As evidence of the accuracy of this method these statistics are so remarkable as to appear almost incredible. It may be that some surgeons have failed to report errors, but such is not likely to be the case.³

Gastric cancer at any stage of development or indurated gastric ulcer may be detected by the use of serial röntgenography with as great a degree of accuracy as renal calculi or bone fractures may be detected by plain röntgenography. The time has come when a surgeon has no more right to operate on a chronic gastroduodenal lesion without a thorough röntgenological examination than he has to operate for a kidney stone or to treat a fracture without an x ray examination.

103 PARK AVENUE.

²In one case I made a diagnosis of adhesions from gastric ulcer with a possibility of a malignant base, and surgery showed that the lesion was due to cholecystitis with gallstones. In two cases the future clinical history indicated that the patients died of carcinoma. Upon further study of the röntgenograms of one of these cases, unquestionable evidence of malignancy presents at the cardia just on the edge of the plate. In the other case it is simply a question of röntgenological evidence versus clinical evidence.

³If the reader knows of any positive or negative diagnosis of gastric carcinoma, made by the author, which has since been disproved by surgery or autopsy, a report of it would be greatly appreciated.

