

**Congenital obliteration (or congenital atresia) of bile-ducts with hepatic cirrhosis / by F. Parkes Weber and G. Dorner.**

**Contributors**

Weber, Frederick Parkes, 1863-1962.

Dorner, G.

Royal College of Surgeons of England

**Publication/Creation**

London : Adlard & Son, [1911]

**Persistent URL**

<https://wellcomecollection.org/works/hs76v974>

**Provider**

Royal College of Surgeons

**License and attribution**

This material has been provided by This material has been provided by The Royal College of Surgeons of England. The original may be consulted at The Royal College of Surgeons of England. where the originals may be consulted. Conditions of use: it is possible this item is protected by copyright and/or related rights. You are free to use this item in any way that is permitted by the copyright and related rights legislation that applies to your use. For other uses you need to obtain permission from the rights-holder(s).



Wellcome Collection  
183 Euston Road  
London NW1 2BE UK  
T +44 (0)20 7611 8722  
E [library@wellcomecollection.org](mailto:library@wellcomecollection.org)  
<https://wellcomecollection.org>

10

THE BRITISH JOURNAL  
OF  
CHILDREN'S  
DISEASES.

REPRINT

PRINTED AND PUBLISHED BY ADLARD & SON,  
BARTHOLOMEW CLOSE, LONDON, E.C.

23.


CONGENITAL OBLITERATION (OR CONGENITAL  
ATRESIA) OF BILE-DUCTS WITH  
HEPATIC CIRRHOSIS.

By F. PARKES WEBER, M.D., F.R.C.P.,  
Physician to the German Hospital, London ;

AND

G. DORNER, M.D.,  
House Physician to the German Hospital.









## CONGENITAL OBLITERATION (OR CONGENITAL ATRESIA) OF BILE-DUCTS WITH HEPATIC CIRRHOSIS.\*

By F. PARKES WEBER, M.D., F.R.C.P.,  
*Physician to the German Hospital, London; and*

G. DORNER, M.D.,  
*House Physician to the German Hospital.*

THE child, Doris S—, when admitted to the German Hospital on July the 4th, 1910, was four months old, well formed and not emaciated (body-weight  $11\frac{1}{4}$  lb. on July the 5th), but rather deeply jaundiced, and showing considerable firm enlargement of both the liver and the spleen; the lower borders of these organs were about half-way between the costal margin and the umbilicus. At that time and until the child's death no bile entered the intestine, for the fæces ("acholic") were white and free from urobilin (stercobilin), whereas the urine always contained bile-pigment and gave Gmelin's reaction for bilirubin, though (by the ordinary tests) it was always free from urobilin and urobilinogen. This would not have been the case had any bile been entering the intestine, since the evidence obtained from experimental work and from clinical and necropsy records is now quite sufficient to prove that when urobilin and urobilinogen are present in the urine there must be some bile (whether from the liver or artificially introduced from without) entering the alimentary canal, whereas if urobilin and urobilinogen are always absent from the urine (and fæces) no bile can be finding its way into the alimentary canal.†

The history given was that the jaundice had been noticed *soon after birth*. We have no information in regard to the colour of the meconium (and the early fæces). At birth the child seems to have had a bullous eruption, from which it recovered under medical treatment in the course of two months. No evidence was obtained

\* A paper read at the Royal Society of Medicine (Section for Disease in Children), November the 25th, 1910.

† See Friedrich Müller, 'Ueber Icterus,' 1892; also A. E. Garrod and Gowland Hopkins, 'Journ. of Physiol.,' Cambridge, 1896, vol. xx, p. 112.



## 2 CONGENITAL OBLITERATION OF BILE-DUCTS.

of syphilis in the parents, who were both young, the patient being their first child. The absence of inherited syphilis in the case was further confirmed by Wassermann's sero-reaction, which was kindly tried (July, 1910) by Dr. H. R. Dean, at the Lister Institute, with negative result.

### SUBSEQUENT COURSE OF THE CASE IN THE HOSPITAL.

The case was at first under the care of Dr. Fürth, but later on, owing to his absence on a holiday, was kindly handed over by him to Dr. Weber. The general condition varied somewhat from time to time. Ordinarily, the child seemed free from pain and happy and took her food. Occasionally there was slight fever. The urine was free from albumin until the end, when it contained a trace.

A blood-count made on July the 15th gave the following result: Red cells 6,080,000 in the cubic millimetre of blood; white cells 8700 in the cubic millimetre of blood; hæmoglobin 122 per cent. The differential count of 500 white cells (which was kindly made by Dr. A. E. Boycott) gave: Neutrophile polymorphonuclears 51 per cent.; lymphocytes 39.4 per cent.; large hyalines 5 per cent.; eosinophiles 4.6 per cent. No mast-cells were seen. The red cells appeared normal. The blood-serum obviously contained bile-pigment. It may be worth mentioning that the red blood-corpuscles, tested with regard to their resistance to hæmolysis (July the 14th), by being added to graduated hypotonic aqueous solutions of sodium chloride, appeared to be rather less resistant to hæmolysis than the red corpuscles from healthy persons, though the resistance of the red corpuscles in cases of obstructive jaundice (both in adults and children) towards hypotonic saline solutions is often somewhat greater than in ordinary healthy subjects. In the present case very slight hæmolysis occurred when the washed red cells were added to an aqueous solution of 0.63 per cent. sodium chloride, and hæmolysis was complete with a solution of 0.45 per cent.; whereas by the same method in normal blood Dr. Dorner finds that hæmolysis usually only commences with a solution of about 0.45 per cent.

At the end of July the jaundice was very deep and there was a dusky pigmentation of the skin in addition to the jaundice; there was some ascites. The child was not markedly emaciated, and took her food fairly well, though she sometimes vomited part of it out again. The body-weight at the end of August was 13½ lb. By the commencement of September the ascites had decidedly increased, and on September the 6th, 350 c.c. of clear, bilious ascitic fluid was



removed by paracentesis abdominis. The ascitic fluid was of specific gravity 1012 and contained rather more than 3 per mille albumin; it gave a negative reaction to Rivalta's test\*—that is to say, a drop of the fluid, when allowed to fall into a glass containing very slightly acidified water, did not produce a smoky-looking cloud like a drop of any inflammatory serous effusion invariably does. Afterwards the child had diarrhoea and vomiting. On September the 8th the child looked rather emaciated and there were slight bronchitic signs. In the evening she had fever (102° F.) and slight convulsions, and died at 9 p.m. (September the 8th), when a little over six months of age.

#### NECROPSY.

The *liver* (weight 9 oz.) was of green colour, finely cirrhotic, and had a slightly granular surface, with a little patchy peri-hepatic thickening of the capsule. The gall-bladder was found contracted (with thick walls), and containing only a little transparent, colourless slimy fluid. The cystic duct, the distal part of the hepatic duct and the common bile-duct (choledochus) were represented by connective-tissue cords (see diagram); that representing the common bile-duct apparently disappeared altogether before it reached the duodenum. The proximal part of the hepatic duct (up to the site of obliteration of the channel) and its right and left trunks (coming respectively from the right and left lobes of the liver) were moderately dilated and contained green inspissated bile. The *pancreas* appeared normal and the opening of the pancreatic duct into the duodenum at the "biliary papilla" was apparently pervious; at all events, a fine probe could be passed from the duodenum into a duct opening at the "biliary papilla."

The *brain* (weight 20½ oz.) appeared normal and its substance (and the cerebro-spinal fluid, we think) was not jaundiced. There was some broncho-pneumonia. The heart (weight 1 oz.) showed nothing of importance. There was no ascites. In regard to the alimentary canal it may be remarked that the intestines seemed considerably too thick for the age of the child. The *spleen* (weight 2½ oz.) was enlarged, of rather firm consistence, and there were

\* This test to distinguish between inflammatory and passive serous effusions was described by Rivalta in 1895; see F. Rivalta, 'Riforma med.,' Napoli, 1895, vol. xi, p. 242; also R. Lauter, 'Comptes rend. hebdomadaires de la Soc. de Biologie,' Paris, 1909, vol. lxxvii, pp. 223, 385, 827. In confirmation of Rivalta's conclusions we have found, as far as our observations go, that a drop of inflammatory effusion always gives rise to a smoky cloud.



patches of perisplenic thickening of the capsule. The kidneys (weight together  $2\frac{1}{2}$  oz.), the supra-renal glands, and the thymus, showed nothing special. The bone-marrow in the shaft of the right humerus, which was opened, was quite red. The mesenteric lymphatic glands were enlarged and some of them reddish on section. There were many enlarged red lymphatic glands along the spinal column. No congenital malformation was found anywhere in the body except that described in connection with the bile-ducts.

#### MICROSCOPICAL EXAMINATION.

The *liver* showed a uniform cirrhotic change of interlobular ("monolobular," better "unilobular") distribution, with considerable

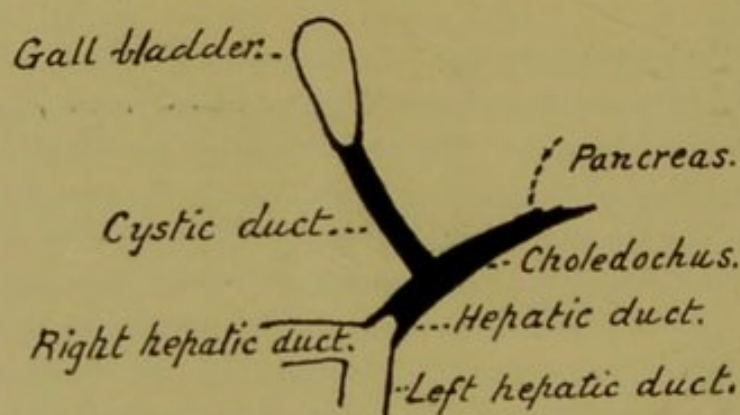


Diagram to show which of the extra-hepatic biliary ducts were represented by solid cords.

interlobular increase of biliary vessels. Many of these small bile-ducts in the connective tissue between the lobules, as well as many of the minute intra-lobular biliary channels, were plugged with inspissated bile. In fact, the microscopic picture was a typical one of so-called "biliary cirrhosis," such as has been experimentally produced, through ligature of bile-ducts in animals, by Charcot and Gombault,\* D. Gerhardt,† D. Nasse,‡ Vaughan Harley and Barratt,§ and others. A similar biliary cirrhotic change in the liver (though in a less typically unilobular form) has been sometimes found in necropsies on patients who have suffered from chronic obstructive jaundice due to gall-stones, etc.||

\* Charcot and Gombault, 'Arch. de Physiol.,' 1876, second series, vol. iii, p. 272.

† D. Gerhardt, 'Arch. f. Exper. Path. und Pharm.,' 1892, vol. xxx, p. 1.

‡ D. Nasse, 'Arch. f. klin. Chirurgie,' 1894, vol. xlviii, p. 885.

§ Vaughan Harley and W. Barratt, 'Journ. of Path.,' 1901, vol. vii, p. 203.

|| For a review of this whole subject see F. Parkes Weber, "On Biliary Cirrhosis of the Liver, with and without Cholelithiasis," 'Trans. Path. Soc., Lond.,' 1903, vol. liv,



The *spleen* showed an increase in the thickness of the capsule and the fibrous trabeculæ—that is to say, an increase in the fibrous supporting framework of the organ. The large size of the organ was doubtless partly due to increase of the pulp-tissue, which was decidedly in excess as compared with the lymphadenoid tissue of which the Malpighian corpuscles are composed. Dr. J. C. G. Ledingham, whom we must here thank for his kindness in looking through most of the sections from the case with us, points out that a marked feature of the spleen is that there are a great number of plasma-cells in the neighbourhood of the large trabeculæ and walls of the blood-vessels\*; many of the plasma-cells are being enclosed in the cytoplasm of phagocytic endothelial cells.

The sections of pancreas, kidney, heart-muscle and intestine showed nothing special. The most interesting part of the microscopical examination was that of the extra-hepatic bile-ducts, and of the connective-tissue cords representing them.

Sections of the wall of the *gall-bladder* showed that it was thickened, and that it was very rich in connective tissue and blood-vessels of a peculiar kind. These blood-vessels consisted almost entirely of endothelial cells, and reminded one of the embryonic type of blood-vessels met with so conspicuously in some forms of cutaneous nævus (*hæmangioma hypertrophicum*, *hæmangio-endothelioma*). Many of the vessels in question might be described as endothelial cells arranged in more or less thick columns, with empty channels. In some columns, indeed, there was no obvious lumen.

The microscopical examination of the *proximal portion of the hepatic bile-duct* (the portion which contained inspissated bile) disclosed a remarkable condition. The walls were very rich in connective tissue and in the "endothelial" type of young blood-vessels which has just been described. The hepatic duct was lined by inspissated bile; no epithelial layer could be made out. But its lumen, in addition to the inspissated bile, contained a good deal of loose connective tissue, containing blood-vessels, similar to the loose connective tissue which replaces a blood-clot in the interior of a blood-vessel, when organisation and vascularisation of the thrombus has occurred. It seems probable that the plug of in-

pp. 103-135. This paper contains numerous references to the literature of the subject.

\* Sections of the spleen from a previous case of "Congenital Obliteration of Bile-Ducts," described by F. P. Weber in 'Proc. Roy. Soc. Med.,' 1909, vol. ii (Section for Disease in Children), p. 231, were examined by Dr. Ledingham. He found there likewise "plasma-cells in large numbers arranged round the sheaths of the vessels or indiscriminately among the pulp-cells."



spissated bile in the interior of the hepatic bile-duct in our present case has been dealt with by Nature in the same way in which Nature usually deals with a thrombus blocking a blood-vessel, namely, that it has been treated as a foreign body, and has been partially removed by a process of organisation and vascularisation.

Our sections of the *common bile-duct* (*choledochus*), or rather, of the connective-tissue cord which represented it, showed on microscopical examination no trace of any lumen at all. They merely showed connective tissue very rich in the "endothelial" or embryonic type of young blood-vessels previously described. Quite possibly, therefore, the cord representing this part of the *choledochus* never had any channel at any time (see later on, under "Remarks"). It is worth mentioning also that in some of our microscopical sections of this region we cut across two veins of ordinary type, which showed patches of thickening and calcification of the elastic layer immediately external to their endothelial lining.

#### REMARKS.

The present case differs from the case of congenital obliteration of bile-ducts previously described by Dr. Weber (May, 1909)\* in that in the previous case the obstruction to the entry of bile into the intestine was not always complete, whereas in the present case, as we have already pointed out, no bile could have entered the intestine whilst the child was in the hospital. Nevertheless, the patient in the present case lived to six months of age—one month longer than the first child did. In the present case it seems difficult to account for the supposed absence of jaundice at birth.

The chief points of interest are those connected with the examination of the extra-hepatic biliary channels. The almost complete absence of evidence of active inflammation, both in the pervious ducts and in the impervious ducts (or rather, cords), makes it seem highly probable that the disease in the present case is to be regarded as primarily an error of development in the bile-ducts, with secondary biliary cirrhosis of the liver as a result of obstruction to the bile-flow. This corresponds with the views recently expressed both by R. S. Lavenson† and by John Thomson.‡ As

\* F. P. Weber, 'Proc. Roy. Soc. Med.,' 1909, vol. ii, Section for Disease in Children, p. 231.

† R. S. Lavenson, 'Proc. Path. Soc. Philadelphia,' 1907, and 'Journ. Med. Research,' Boston, 1908, vol. xviii, p. 61.

‡ John Thomson, Allbutt and Rolleston's 'System of Medicine,' second edition, London, vol. iv, Part I, pp. 103-108.



already mentioned, it seems, indeed, in the present case quite likely that the connective-tissue cord representing part of the common bile-duct (choledochus) never contained a lumen at any time. This would fit in with the teaching that the bile-ducts are originally solid cords, "Remak's fibres," which subsequently become hollowed out to form channels. According to this view, the so-called congenital "obliteration" of bile-ducts would really be due not to obliteration, but to failure of formation of the lumen in some portion of the extra-hepatic biliary tract, and the condition, as Lavenson points out, would be better termed "congenital atresia" of bile-ducts.\*

Probably the only operation which could have been performed was the establishment of a biliary fistula, as suggested by M. Hirschberg† and J. Rotter,‡ by boring a hole (*e. g.* with a Paquelin's cautery) into the substance of the liver ("hepatostomy"), endeavouring in that way to drain away the bile by opening up one or more large intra-hepatic bile-ducts. This method was tried by Dr. Michels in the case of an adult with chronic jaundice due to primary carcinomatous obstruction at the junction of the two hepatic bile-ducts, and the case was described by him and Dr. Weber in the 'Medico-Chirurgical Transactions' for 1905.§ But there is great difficulty in keeping a biliary fistula of this kind ("hepatostomy") open for a long time, and it is unlikely that the child in the present case would have benefitted from such an operation. In regard to the question of operation in the rare cases of supposed congenital stenosis of bile-ducts in older children and adults a real indication seems to be the presence of a distinct tumour (bile-retention cyst) accompanied by chronic obstructive jaundice (Victor Veau||). An interesting case of obliteration of the common bile-duct (choledochus), acquired in early life, was that of a girl, aged 19 years, who had suffered from obliterative jaundice for sixteen years before Sir F. Treves¶ performed the operation of cholecyst-enterostomy.

In regard to *diagnosis*, cases of ordinary "icterus neonatorum" can be recognised by the early clearing up of the jaundice, whereas in the present class of cases the jaundice gradually deepens, although the degree of jaundice in some cases varies from time to time.

\* R. S. Lavenson, *loc. cit.*

† M. Hirschberg, "Die Behandlung schwerer Lebererkrankungen durch die Anlegung einer Leber-Gallengangsfistel," 'Berl. Klinik,' 1902, vol. xv, Part 172.

‡ See H. Scheuer, 'Berl. klin. Wochenschr.,' 1902, vol. xxxix, p. 138.

§ Weber and Michels, 'Med.-Chir. Trans.,' London, 1905, vol. lxxxviii, p. 247.

|| V. Veau, 'Bull. de la Soc. de Péd. de Paris,' 1910, vol. xii, p. 289.

¶ Treves, 'Practitioner,' London, 1899, vol. lxii, p. 18.



Cases of what may be termed "familial icterus gravis neonatorum,"\* which have been shown not to be connected with congenital obliteration of bile-ducts, and are apparently not necessarily connected with sepsis or inherited syphilis, have to be distinguished. Their pathology is still imperfectly known, but they have been shown not to be connected with congenital obliteration of bile-ducts, and, though the spleen is probably generally enlarged, the liver shows no constant changes, and the fæces are not always, if ever, "acholic." Moreover, in some of these there has been "Kernicterus" of the brain, and it is possible that the cerebro-spinal fluid obtained by lumbar puncture would contain bile-pigment, which it does not contain in most jaundice cases.†

Infective jaundice in newly born children, connected with umbilical phlebitis, etc., may be distinguished by the local and constitutional signs of infection. The "pericellular" (better, "intra-lobular" or "intercellular") hepatic cirrhosis of inherited syphilis is not usually accompanied by jaundice, but cases of jaundice in children apparently due to syphilitic stenosis of bile-ducts have been recorded by Beck‡ and H. D. Rolleston.§ From such syphilitic cases the cases of congenital obliteration of bile-ducts (like our present one) may be distinguished by the absence of the ordinary signs of inherited syphilis and by a negative Wassermann's sero-reaction for syphilis (the reaction was negative in our present case).

The gradual deepening of the jaundice in cases of congenital obliteration of bile-ducts, the enlargement of the liver as well as of the spleen, and (above all) the definite clinical evidence that the jaundice is obstructive, distinguish these cases from cases of congenital acholuric (so-called "hæmolytic") jaundice with splenomegaly.||

\* See especially J. Pfannenstiel, "Ueber den habituellen Ikterus gravis der Neugeborenen," 'Münch. med. Wochenschr.,' 1908, vol. lv, p. 2169; and Nahm's paper on the same subject, *ibid.*, 1909, vol. lvi, p. 139. See also H. D. Rolleston, "Recurring Jaundice in Four Successive Pregnancies and Fatal Jaundice in Three Successive Infants," 'Brit. Med. Journ.,' 1910, vol. i, p. 864. Pfannenstiel and Rolleston give references to several published series of cases which fall into the group of "familial icterus gravis neonatorum."

† See, however, an exception to this rule in the case of an adult recorded by Mosny and A. Javal, 'Bull. de la Soc. Méd. des Hôpitaux de Paris,' 1909, third series, vol. xxviii, p. 280.

‡ Beck, 'Prager med. Wochenschr.,' 1884, vol. ix, pp. 257, 266, 284. See also the references to the literature of the subject given by Lavenson, *loc. cit.*

§ H. D. Rolleston, 'Brit. Med. Journ.,' 1907, vol. ii, p. 947.

|| For the literature on this subject see F. P. Weber and G. Dorner, "Four Cases of Congenital Acholuric Jaundice in One Family," 'Lancet,' London, 1910, vol. i, pp. 227-232.

In regard to *further investigation* on the subject of so-called "congenital obliteration" of the bile-ducts. What is chiefly needed is obviously very careful microscopical examination, in all cases, of the bile-ducts, and the connective-tissue cords representing the bile-ducts, especially in the neighbourhood of the termination of the lumen. Information of this kind would likewise be very valuable in the rare cases of chronic obstructive jaundice supposed to be due to stenosis of the choledochus, of congenital origin or dating from the first years of life.\*

\* See the papers by Treves and by Veau already referred to, *loc. cit.*



