

**Endo-aneurysmorrhaphy (Matas) in the treatment of traumatic aneurysm of the femoral artery / by J.M. Elder.**

**Contributors**

Elder, John Munro, 1859-  
Royal College of Surgeons of England

**Publication/Creation**

[Philadelphia, Pa.] : [J.B. Lippincott], 1908.

**Persistent URL**

<https://wellcomecollection.org/works/kjm5nrgq>

**Provider**

Royal College of Surgeons

**License and attribution**

This material has been provided by This material has been provided by The Royal College of Surgeons of England. The original may be consulted at The Royal College of Surgeons of England. where the originals may be consulted. Conditions of use: it is possible this item is protected by copyright and/or related rights. You are free to use this item in any way that is permitted by the copyright and related rights legislation that applies to your use. For other uses you need to obtain permission from the rights-holder(s).



Wellcome Collection  
183 Euston Road  
London NW1 2BE UK  
T +44 (0)20 7611 8722  
E [library@wellcomecollection.org](mailto:library@wellcomecollection.org)  
<https://wellcomecollection.org>

REPRINTED FROM  
**ANNALS OF SURGERY**

FEBRUARY, 1908.

**ENDO-ANEURYSMORRHAPHY (MATAS) IN THE  
TREATMENT OF TRAUMATIC ANEURYSM  
OF THE FEMORAL ARTERY.**

BY J. M. ELDER, M.D.,

OF MONTREAL.

SINCE the publication of Matas' second article<sup>1</sup> on the subject of repairing wounds of blood vessels by suture, a good deal of work, experimental and clinical, has been done to test his contention that ruptured arteries could be repaired in much the same way as injuries of other hollow viscera, and, under proper conditions, with as good functional results.

In the ANNALS OF SURGERY for September, 1907, there appeared a most interesting symposium on "The Surgery of the Vascular System" by several prominent American surgeons, and as the subject of this communication is very similar to some of the cases therein cited, I have thought it would be well to publish it while the interest in the subject was still fresh in the minds of your readers.

*History* (Montreal General Hospital, No. 1278, S. series, 1907).—In July, 1907, a healthy lad of ten years struck his right leg against the sharp nozzle of an oil can, causing a small punctured wound just above and to the inner side of the popliteal space. The nozzle was at once withdrawn and the wound bled freely, but not furiously. The family physician, Dr. D. K. Cowley, of Granby, Quebec, saw the case and found that he could pass a probe into the wound upward, backward, and inward for a distance of two inches. The end of the probe would then be close to the position of the femoral artery in Hunter's canal. The wound was irrigated and a dry dressing applied, and it healed apparently without incident, the lad appearing to be quite well ten days after the accident.

<sup>1</sup> ANNALS OF SURGERY, February, 1903.



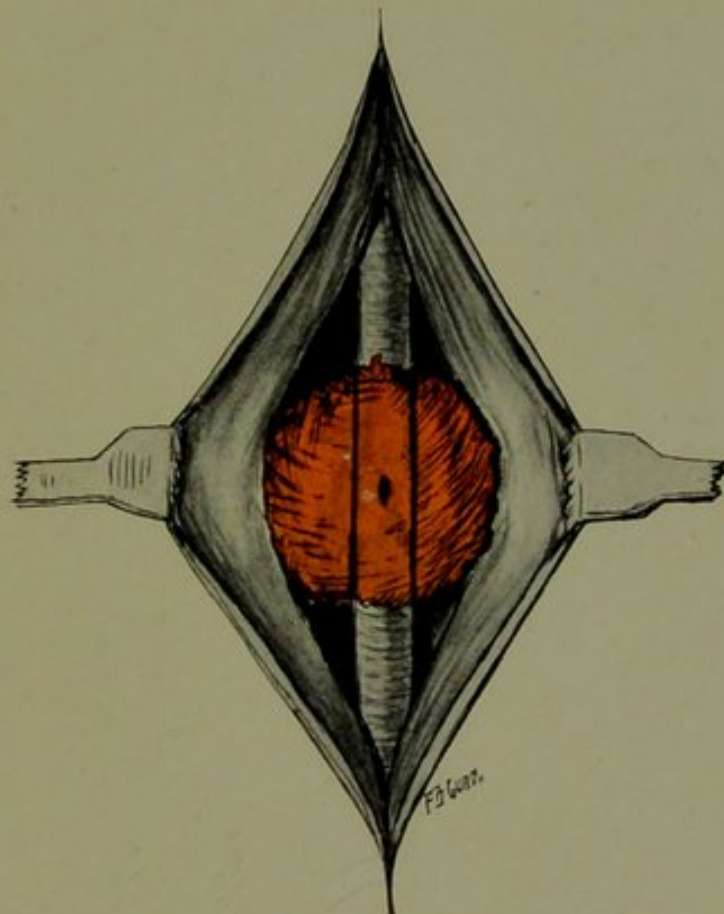
About one month later he began to complain of pain in the knee and soreness at the site of injury. His physician again examined the limb and found a tumor about the size of a Tangerine orange, situated under the scar of the former wound. The tumor was very tense and resistant (non-fluctuating) and no pulsation could be detected in it, but the stethoscope revealed a well-marked systolic bruit when placed lightly over it. The case was watched for eleven days, and it was noticed that the tumor increased rapidly in size and became softer and more fluctuating. The pain in the knee also grew steadily more severe and the lad could not extend the knee joint.

*On admission* to the hospital on September 11th the patient lay on the right side with right knee semi-flexed and supported on a pillow. The pulse was 84, temperature 100° F. A well-marked tumor was visible along the inner and posterior aspect of the right thigh at upper level of popliteal space. Examination confirmed the facts above noted by the family physician, and in addition there was noted much diminished pulsation in the right posterior tibial artery but no other signs of circulatory disturbance; there was local tenderness and heat over the tumor but no redness. Leucocyte count, 13,500.

*A diagnosis* of aneurysm was made and operation was carried out next day.

*Operation.*—A vertical incision, three inches long, was made over the tumor, and we at once came down upon a fluctuating swelling about the size of a Florida orange. A director introduced through the capsule showed the contents of this cyst (for such it evidently was) to be dark blood. An Esmarch was applied to the thigh higher up and all bleeding controlled. The contents of the sac, consisting of thick, dark blood-clot, were then turned out, the quantity being about four ounces. The cyst wall, or sac, was evidently composed of connective tissue only, and upon swabbing the interior the artery was seen lying at the bottom of the sac, and in the vessel wall was an oval opening measuring  $\frac{1}{2} \times \frac{1}{4}$  cm. (Fig. I). Bright red blood spurted through this opening when the tension of the Esmarch was relieved. As soon as the parts were quite dry (as Matas insists upon) this opening was closed by three sutures of fine silk, a small, round, curved needle being used and care being taken to include the intima in the sutures (Fig. II). The pressure of

FIG. 1.

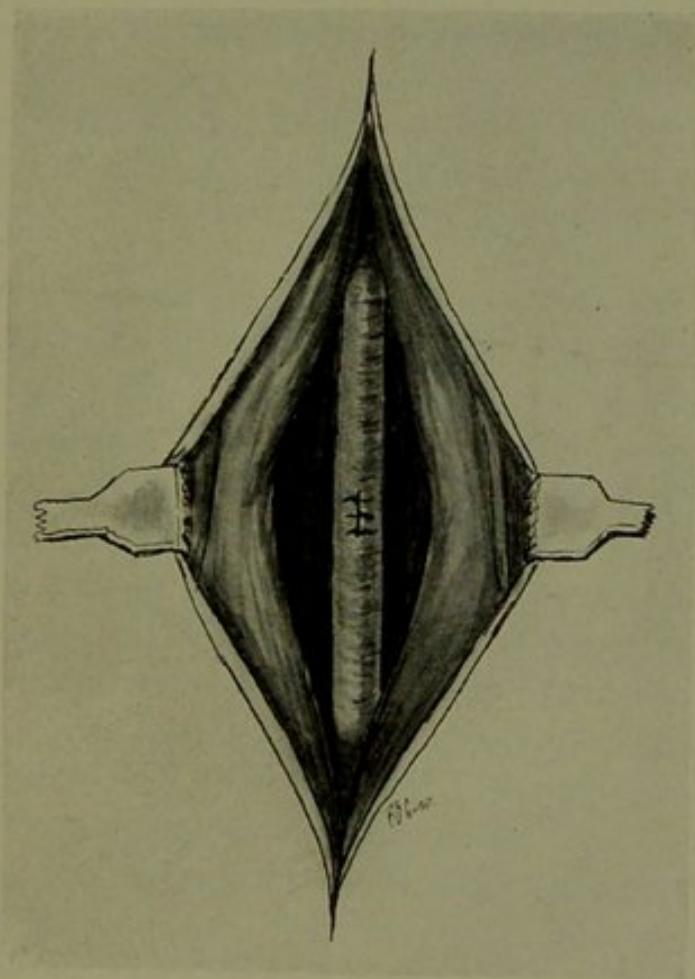


Showing sac of traumatic aneurysm, with opening in the femoral artery.





FIG. 2.



Artery sutured.



the Esmarch was then taken off and the pulsations of the artery watched for a few minutes, in order to make sure that the sutures were sufficient to control all hemorrhage. The lining of the sac was irrigated with sterile water and a cigarette drain with iodoform gauze inserted down to the artery, after which the wound was closed.

The drain was removed in forty-eight hours, there being no oozing, and there followed without incident primary union of the wound. The patient left the hospital nine days after operation though still forbidden to use the limb for two weeks. There was then equal pulsation in the two tibials with no pain or swelling anywhere. Dr. Cowley has since written me that the boy is as well as ever and has absolutely no disability in the limb.

In this case one had evidently to deal with a sacciform aneurysm—really a false aneurysm, inasmuch as the sac did not consist of dilated vessel wall, but of the perivascular connective tissue. The continued stretching of this tissue would cause the pain complained of. It is likely that at the time of the accident the nozzle of the oil can had not actually pierced the wall of the artery, but had struck it with sufficient force to cause subsequent necrosis, and hence rupture of the vessel and formation of the sacciform aneurysm. As Matas, and others, point out, this is the most favorable form of aneurysm to treat by this method of suture, as one has only to close the opening to leave the vessel intact. In the fusiform (true) aneurysm, the sac would also need to be sutured or obliterated in some way, and could not be neglected as was practically done in this case.

The operation is certainly, both in its rationale and its results, much preferable to the risks of the ligature, which could always be resorted to should the suture fail.



THE HISTORY OF THE  
CITY OF BOSTON  
FROM THE FIRST SETTLEMENT  
TO THE PRESENT TIME  
IN TWO VOLUMES  
BY NATHANIEL BENTLEY  
VOL. I.  
BOSTON: PUBLISHED BY  
J. B. BENTLEY, 1822.