

The importance of the X-ray in the treatment of fractures / by James P. Warbasse.

Contributors

Warbasse, James Peter, 1866-1957.
Royal College of Surgeons of England

Publication/Creation

[Brooklyn] : [publisher not identified], 1909.

Persistent URL

<https://wellcomecollection.org/works/rw3jqg24>

Provider

Royal College of Surgeons

License and attribution

This material has been provided by This material has been provided by The Royal College of Surgeons of England. The original may be consulted at The Royal College of Surgeons of England. where the originals may be consulted. Conditions of use: it is possible this item is protected by copyright and/or related rights. You are free to use this item in any way that is permitted by the copyright and related rights legislation that applies to your use. For other uses you need to obtain permission from the rights-holder(s).

10
10

The Importance of the X-Ray

IN THE

Treatment of Fractures


10

BY
JAMES P. WARBASSE, M.D.

BROOKLYN - NEW YORK



REPRINTED FROM
LONG ISLAND MEDICAL JOURNAL
FEBRUARY, 1909





THE IMPORTANCE OF THE X-RAY IN THE TREATMENT OF FRACTURES.

By JAMES P. WARBASSE, M.D.

Surgeon to the German Hospital and to the Seney M. E. Hospital.

BROOKLYN-NEW YORK.

THE X-ray has long been esteemed as an aid in the diagnosis of fractures; but its importance has become so great and its use turned to such practical ends that we must think of it as an aid in the treatment of fractures as well as a help in diagnosis. At the time of the advent of the X-ray the diagnosis and treatment of simple fractures was making but little advance. Since the introduction of the X-ray more progress has been made in the treatment of these fractures than had been accomplished in a hundred years before. We were once wont to think that by palpation, mensuration, and imagination we could divine the character of a fracture and the relations of the fragments, but we now know that we are often mistaken. We often spoke of perfect reposition when the reposition was far from perfect. We secured good functional results, and assumed that our diagnoses were correct. Now with the light of the X-ray thrown upon the subject we find that a perfect reposition in fractures of the long bones is not often obtained; but still perfect restoration of function is the rule.

These facts teach several lessons. In the first place, we have learned that manipulating a fracture through its covering of skin, muscles, fascia, nerves, and vessels, makes the operation an obscure one, and that we should not have in mind the reducing

a fracture in the living body in the same sense that we think of fitting together the broken fragments of a bone outside of the body or as we think of joining together the ends of a broken stick. The conditions are so utterly different that they are scarcely comparable. Still we have always made the public think that they are about the same thing. A patient with a broken leg gets a good functional result, and he thinks the reason that he has good use of his leg is because a perfect piece of joining was done; still if he had been allowed to see an X-ray picture of the position of the fragments before consolidation had taken place he would have been filled with misgivings as to the outcome. The best results, of course, demand accurate reposition of fragments; but restoration of function, to all appearances as good as normal, is usually accomplished without securing perfect reposition.

We demand of the carpenter that he join two fragments of wood with mathematical accuracy; but that is because it is dead material which he has plainly exposed to view and in the manipulation of which he encounters no obstacles. But suppose that we give him a piece of stick which is enclosed in the middle of a coat sleeve filled with rubber elastic attached to its whole circumference, he would declare a good job to be im-

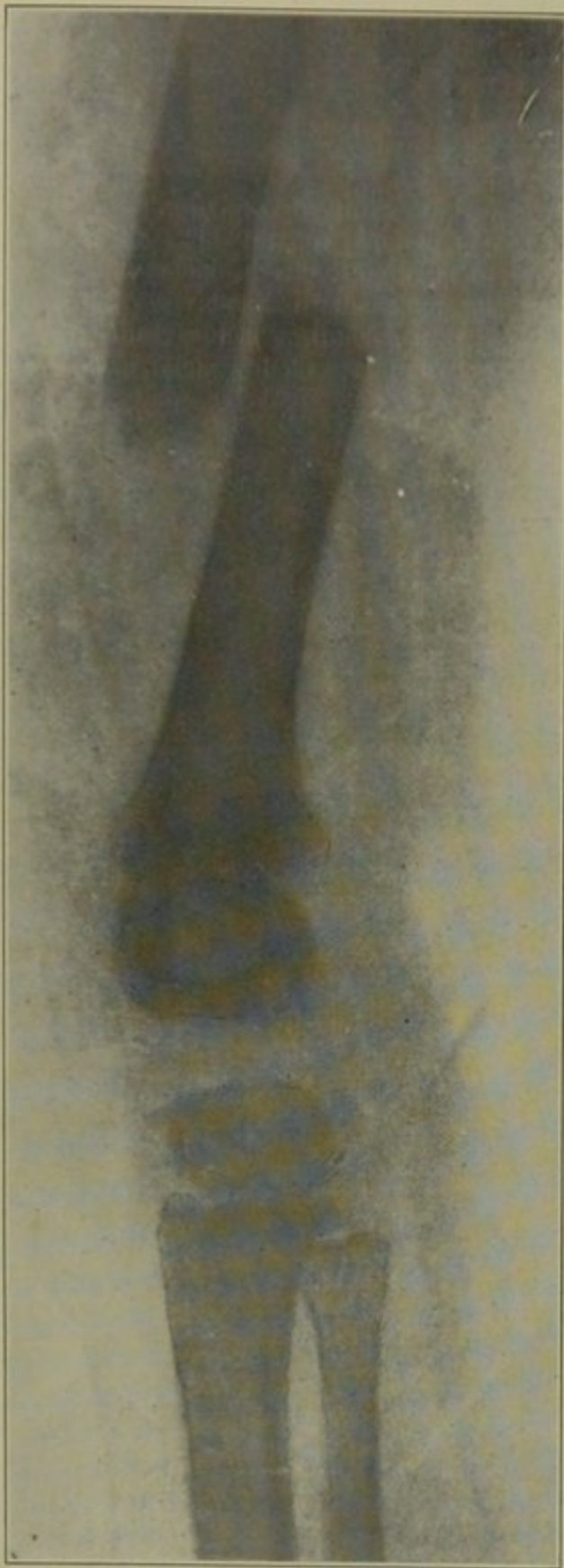


FIG. 1—Transverse fracture of femur in child, aged 8. This fracture required 50 pounds of traction combined with anesthesia to overcome the overriding. In the adult this is a rare fracture; and in a strong man it is practically incorrigible without operation.

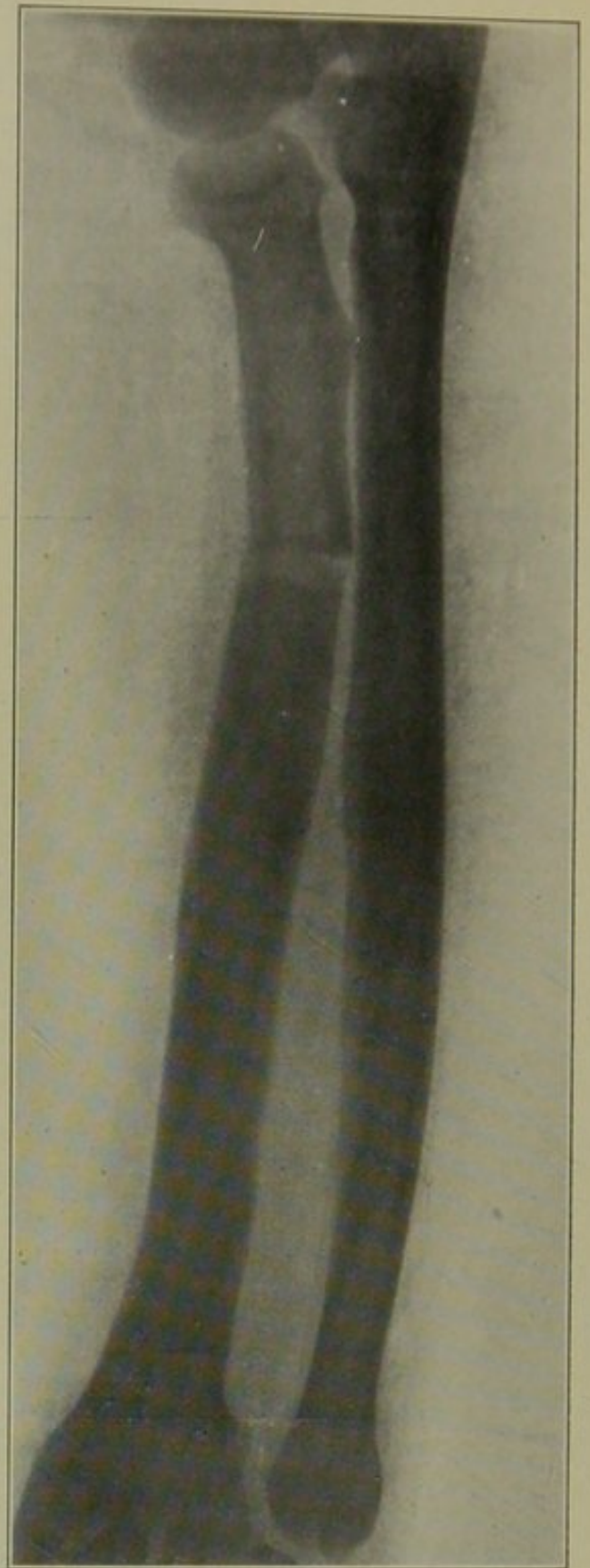


FIG. 4—Fracture of the upper end of the radius, presumably well corrected, but actually in bad position.

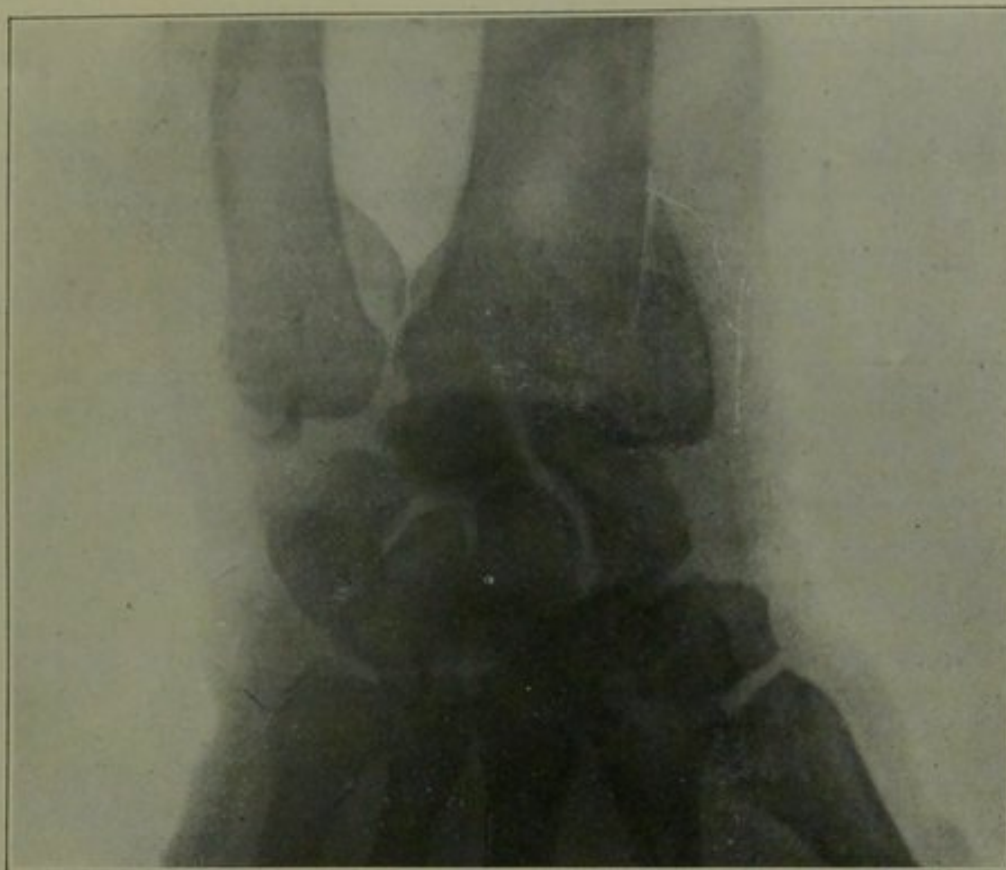


FIG. 2—Longitudinal fracture of lower end of radius. Ligaments intact. Undiagnosable except by means of the X-ray.

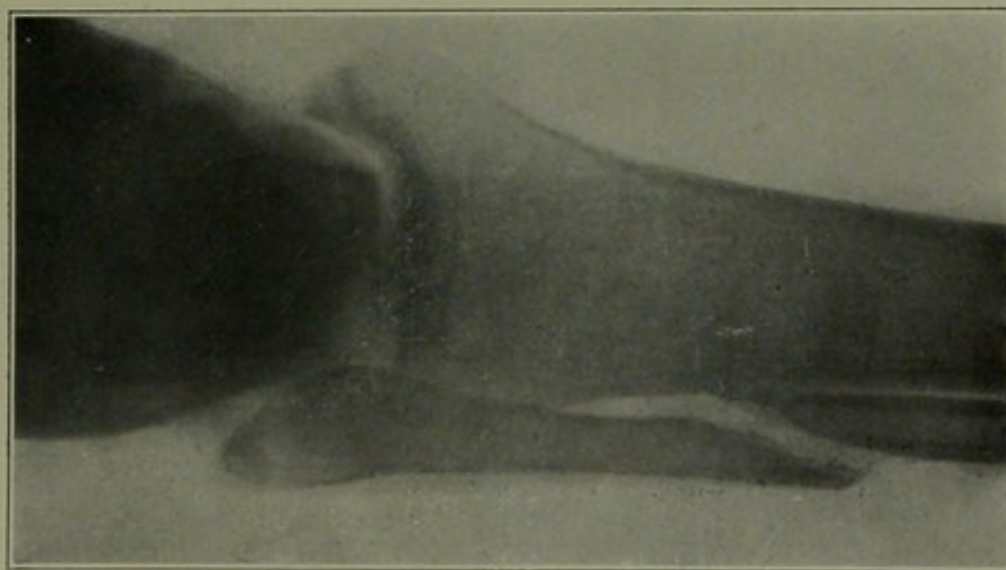


FIG. 3—H. W., 121107. Fracture of fibula by direct violence. Presumed to be in good position. This separation could only be discovered by the X-ray. The outward displacement of the lower fragment can be corrected by eversion of the foot and a little pressure. The inward displacement of the upper fragment is incorrigible except by operation.

possible. Yet this approximates the condition present in fractures of the shaft of the humerus or femur. It is a common experience, when we have put up a fracture of the humerus, and think that it is in satisfactory apposition, and have the X-ray show us that there is lateral displacement equal to half of the diameter of the bone.

fracture in the adult is practically never reduced. The fragments unite side by side. Immediately after the injury, blood and serum are poured out into the surrounding muscles and fascia, reducing their elasticity, and the nerves of the muscles are irritated by these products, so that the soft structures cannot be brought down to their former length if overriding

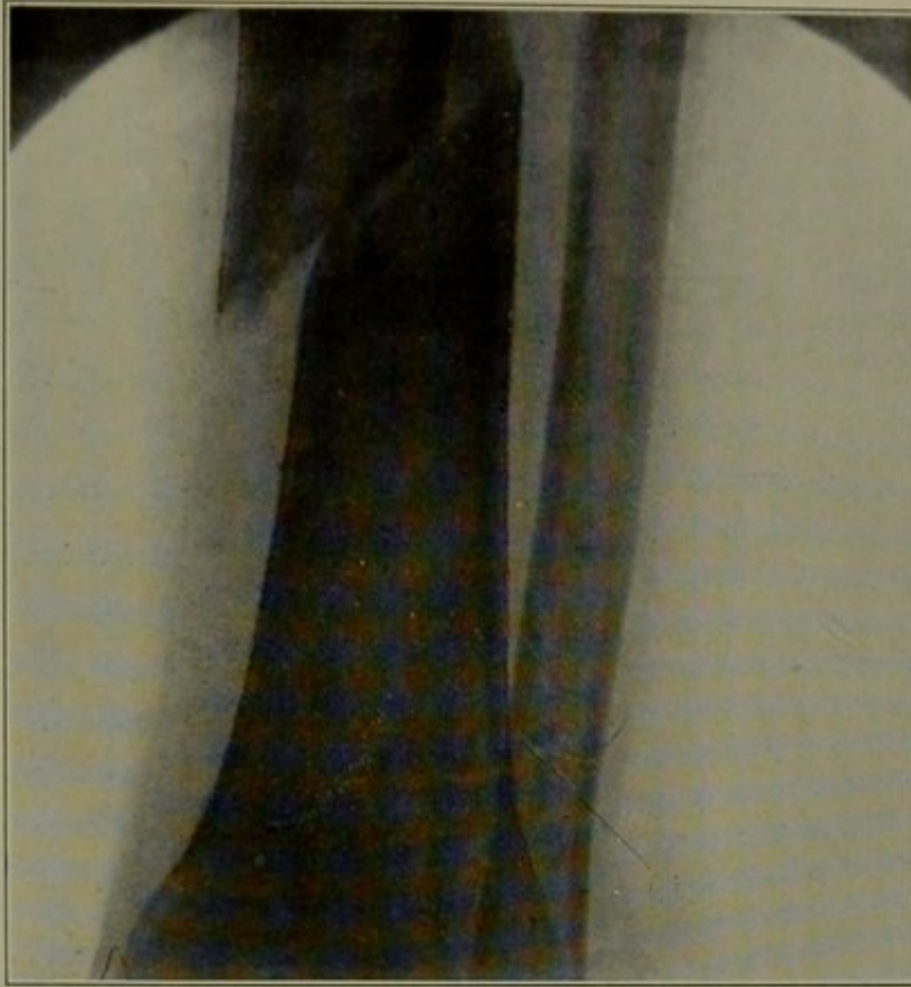


FIG. 6—G. B., 411108. Fracture of lower end of tibia. But slight displacement palpable.

The old ideal in the treatment of fractures of the shaft of the femur used to be to reduce as much as possible the inevitable shortening. It is rarely completely overcome. We now know that the apposition in this fracture can only be made perfect by open operation, and even then only with much difficulty. Fortunately most fractures of the femur are oblique, and the longitudinal overriding does not necessitate much lateral displacement. The less common transverse

has once taken place. Our text-books speak of ten pounds of traction being indicated, when correction could not be accomplished with fifty or a hundred pounds (Fig. 1). I can never speak of fracture of the thigh without emphasizing the necessity of early traction. These cases should not be permitted to lie in bed with the long side splint of the ambulance surgeon until it suits the convenience of somebody to put on the extension apparatus. The case is an emergency case

until the greatest tolerable extension can be applied; and it is most important that that be done immediately.

One of the things the X-ray is doing for patients with this fracture is that it is saving them the damage, incidental to the increasing of effusion, caused by diagnostic manipulations. If it is possible to get an X-ray picture of a broken thigh, the best interests of the patient are served by the immediate application of immobilizing splints and extension and making the refinements of diagnosis by means of the X-ray. A well organized hospital should have facilities for wheeling a patient's bed to the X-ray room and taking two pictures, at two different planes, without disturbing the splints or traction. The less motion of the fragments that occurs from the moment of fracture the less will be the infiltration and hardening of the elastic soft tissues and the more easily will shortening be overcome.

In the study of the typical fractures of the lower end of the radius the X-ray has added but little to what was already known. The importance of complete reduction, the natural tendency of the fracture to remain reduced even without splints, and the imperative necessity for allowing free motion of the finger tendons from the first, have all been well understood. There are, however, certain fractures of this region which were practically undiscovered until the X-ray threw its light upon them. Such a fracture is shown in Fig. 2. Here is a fracture which eluded the most careful examination.

Fractures of the lower end of the humerus, I have shown in a recent paper* often defy satisfactory reposition except by the help of the X-ray.

Fracture of the clavicle is so easily accessible to touch and inspection that its treatment remains unchanged. Fracture of the fibula is commonly associated with inward displacement of the lower end of the upper frag-

ment which is entirely out of reach (Fig. 3). The position of the fragments in fracture of the shaft of the radius and ulna can not be satisfactorily determined without the X-ray, as is shown in Fig. 4. Before Roentgen's discovery was applied, fractures of the tibia were put up presumably in perfect apposition, and good results were secured; but now

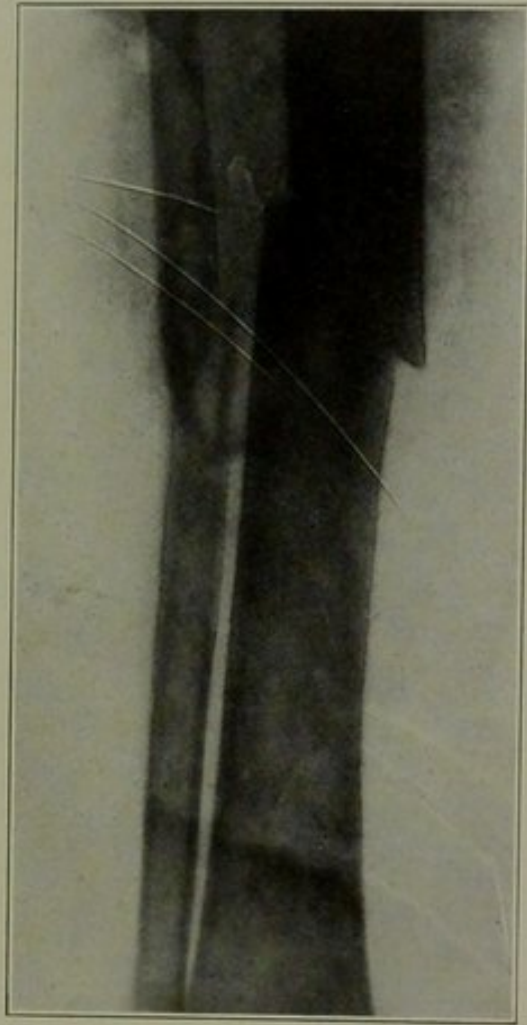


FIG. 7—M. M., 22v07. Fracture of tibia and fibula, presumed to be in good position. Observe lateral displacement, angular displacement, and shortening.

we observe that they are rarely in perfect position; indeed, in the majority of cases perfect position can be secured only with much pains and difficulty and often only by open operation. Figures 6, 7, and 8 illustrate this point. Because of the fact that the public has been taught to expect perfect joining at the surgeon's hands just as at the carpenter's hands, these plates would furnish damaging evidence in a malpractice suit.

* Medical Record, New York, 1909.

The series of pictures, Figs. 9, 10, and 11, show the value of X-ray examination in the treatment of separation of the lower epiphysis of the femur. Figs. 12 and 13 show a transverse fracture of the patella which could not be determined except by the X-ray. No treatment but rest of the knee and of the quadriceps extensor was required in this

displacement the old idea still prevails in many minds, that, if certain traction or manipulations are made and the bone ends brought into approximately normal relations they slip back into place as a dislocation does under the same conditions. The X-ray has shown us that this is not the case, but that perfect apposition, while sometimes secured is by no

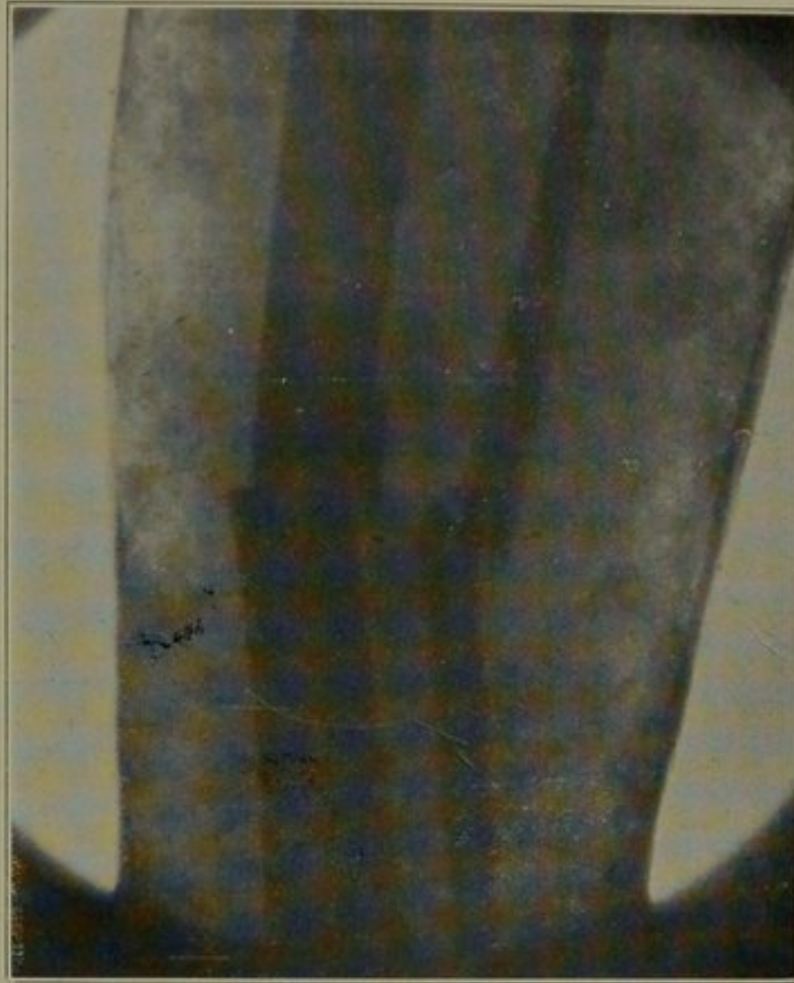


FIG. 8—A. K., 23v07. Fracture of tibia and fibula. In plaster case. Presumed by an experienced and competent surgeon to be in good position.

case, but had the nature of the lesion not been discovered and the patient been allowed about, the chances are strong that he would soon have returned with a typical fracture with a palpable separation. In transverse fracture of the extreme upper end of the humerus, satisfactory reduction, on account of the heavy upper arm and shoulder muscles, can only be determined by the X-ray.

In thinking of these fractures with

means the rule. I could show pictures illustrating that it is possible to get perfect apposition; but the object of this paper is to show that it is possible to think that we have perfect apposition when in reality we have not. Still the functional results have been good in these cases with which I am familiar which have healed with mechanically imperfect reposition. At the same time it must not be assumed that we are to be

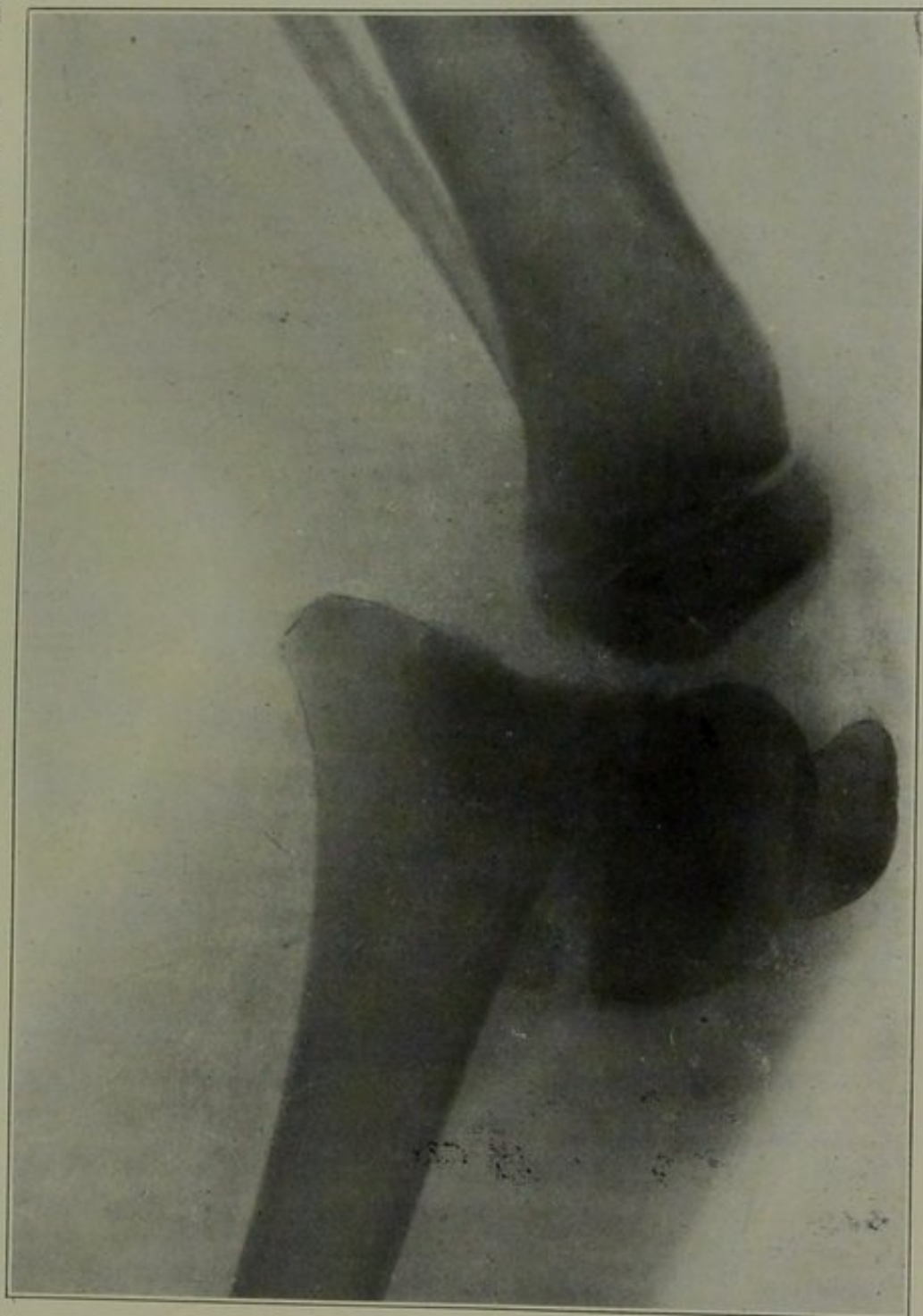


FIG. 9.—J. A., 8694, 2311106. Boy, aged 12. Separation of lower epiphysis of the femur. Observe epiphysis lying at right angle on the front of shaft. This is easily palpable under general anesthesia.

satisfied with even good functional results and bad joining if good joining is possible. In all surgical operations, whether in the operative treatment of a tumor, an hernia, or in the manipulation treatment of a fracture, the aim of the surgeon should be to restore the parts to their normal relations. The scarcely noticeable limp, due to a slightly shortened leg, may

undoubtedly are, are predetermined by the degree as well as by the presence of the traumatic abnormality.

I can not close this paper without emphasizing the desirability of the early and complete reduction and immobilization of all fractures. In the ordinary simple fractures of the tibia and fibula I have always advocated immediate encasement in the plaster

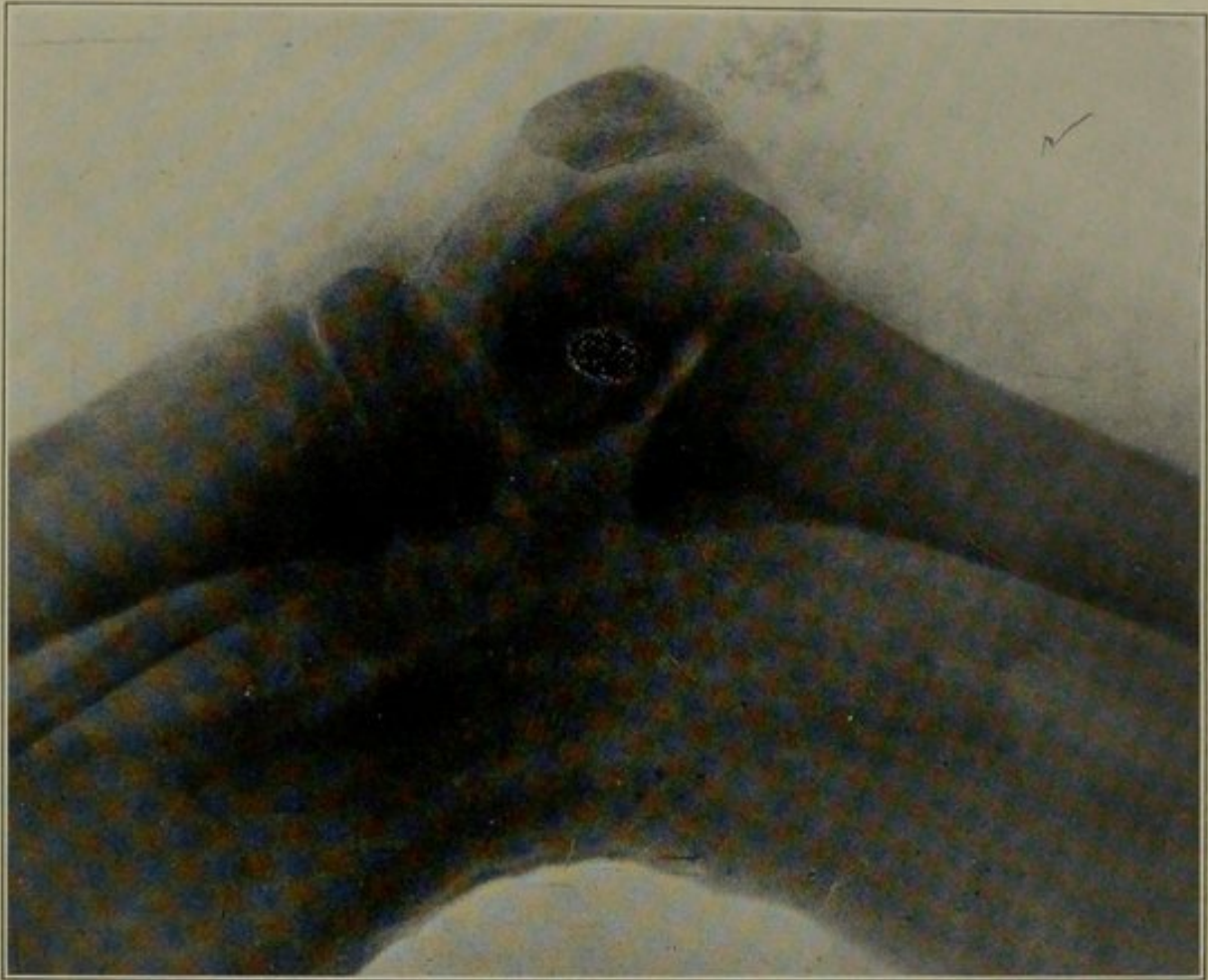


FIG. 10—J. A., 8694. Separation of lower epiphysis of femur. In plaster case, after anesthetization and apparent correction by the sense of feeling. Observe anterior displacement of epiphysis.

be the determining cause of other disease; the "rheumatism," occurring in a leg that has been broken, is often but an expression of pressure upon a nerve by a hump of bone slightly out of place; local circulatory obstruction, with its train of symptoms, may be due to the same cause; and osteitis and sarcoma, occurring at the site of fracture, if due to traumatic abnormalities of the bone, as they

splint with only a cotton stocking between the skin and the plaster. If such fractures can be immobilized early, swelling amounts to but little. A final cardinal point is that, after its reduction and immobilization, such fractures should be free from pain. Opiates are contraindicated. A fracture that is painful is wrong; and should not be concealed by a splint.

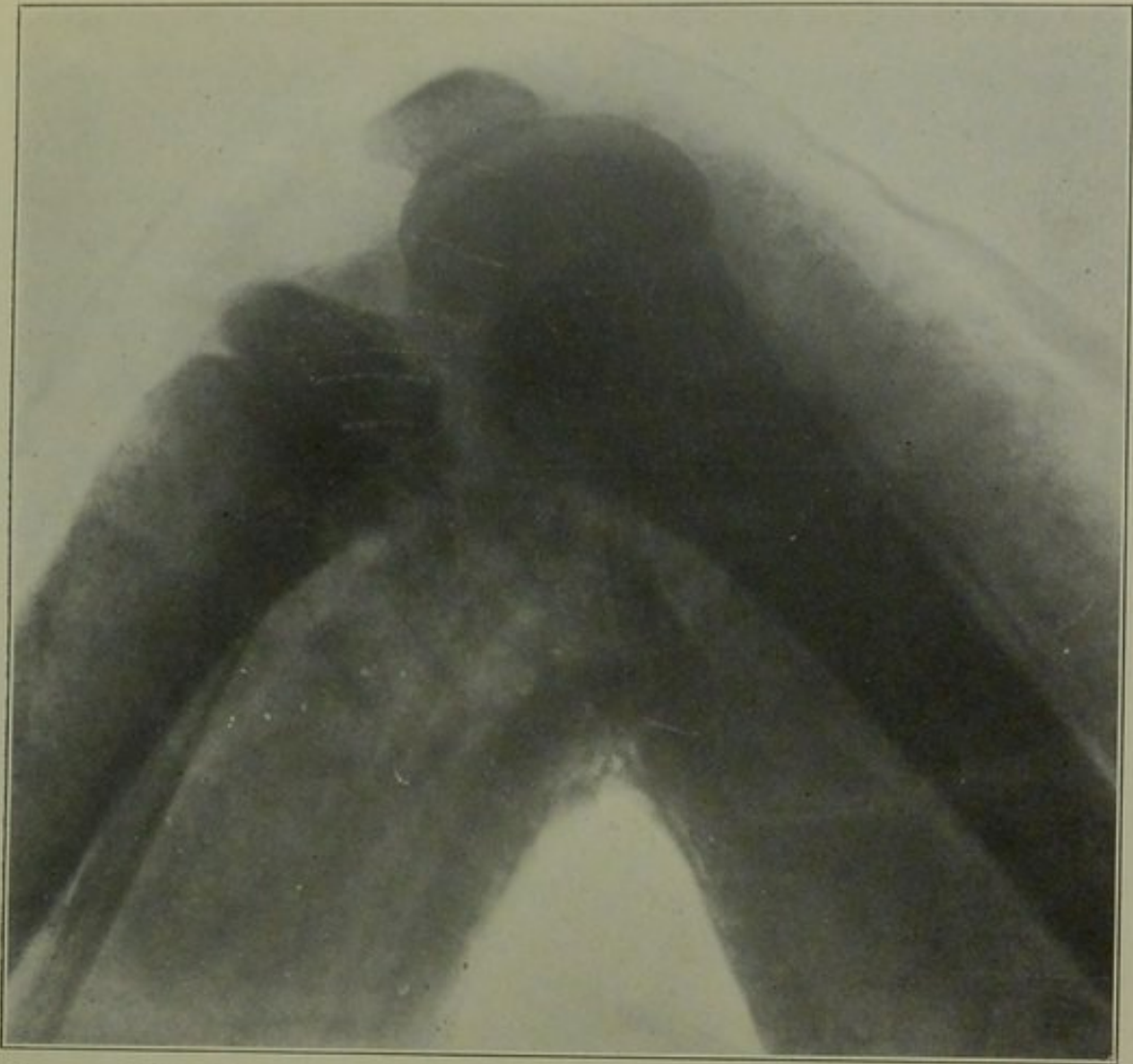


FIG. 11—J. A., 8694. Separation of lower epiphysis of femur. In plaster case, after further anesthetization and extreme flexion. Position perfect.

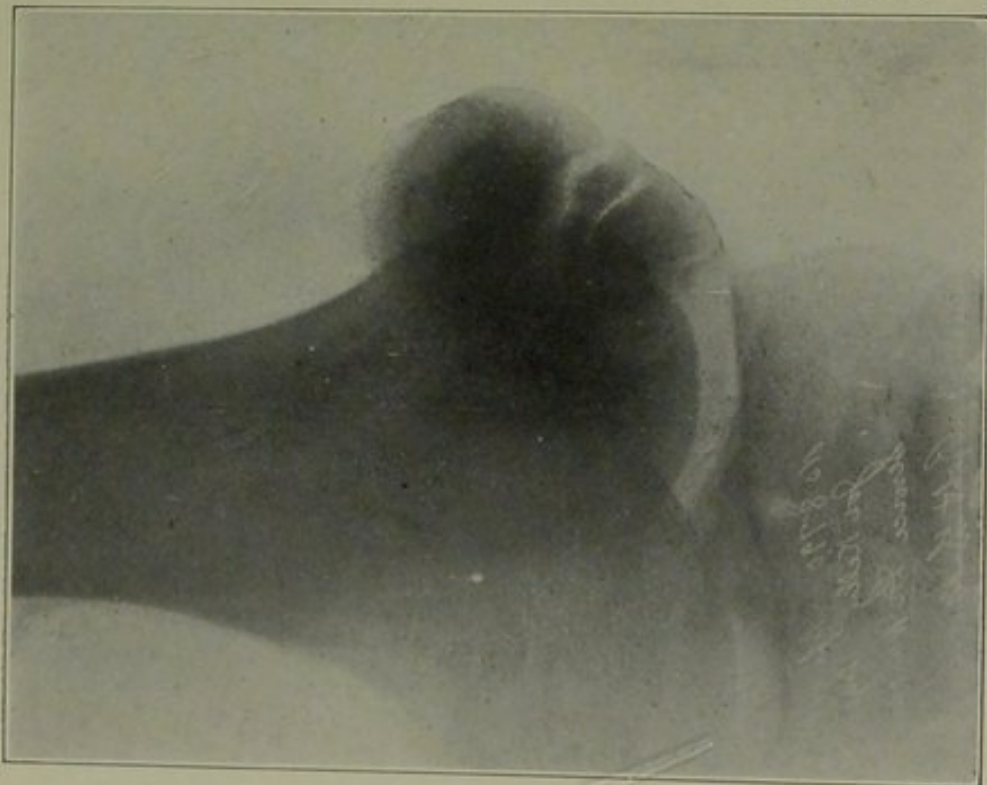


FIG. 12—J. K., 8791. Fracture of the patella with slight separation.

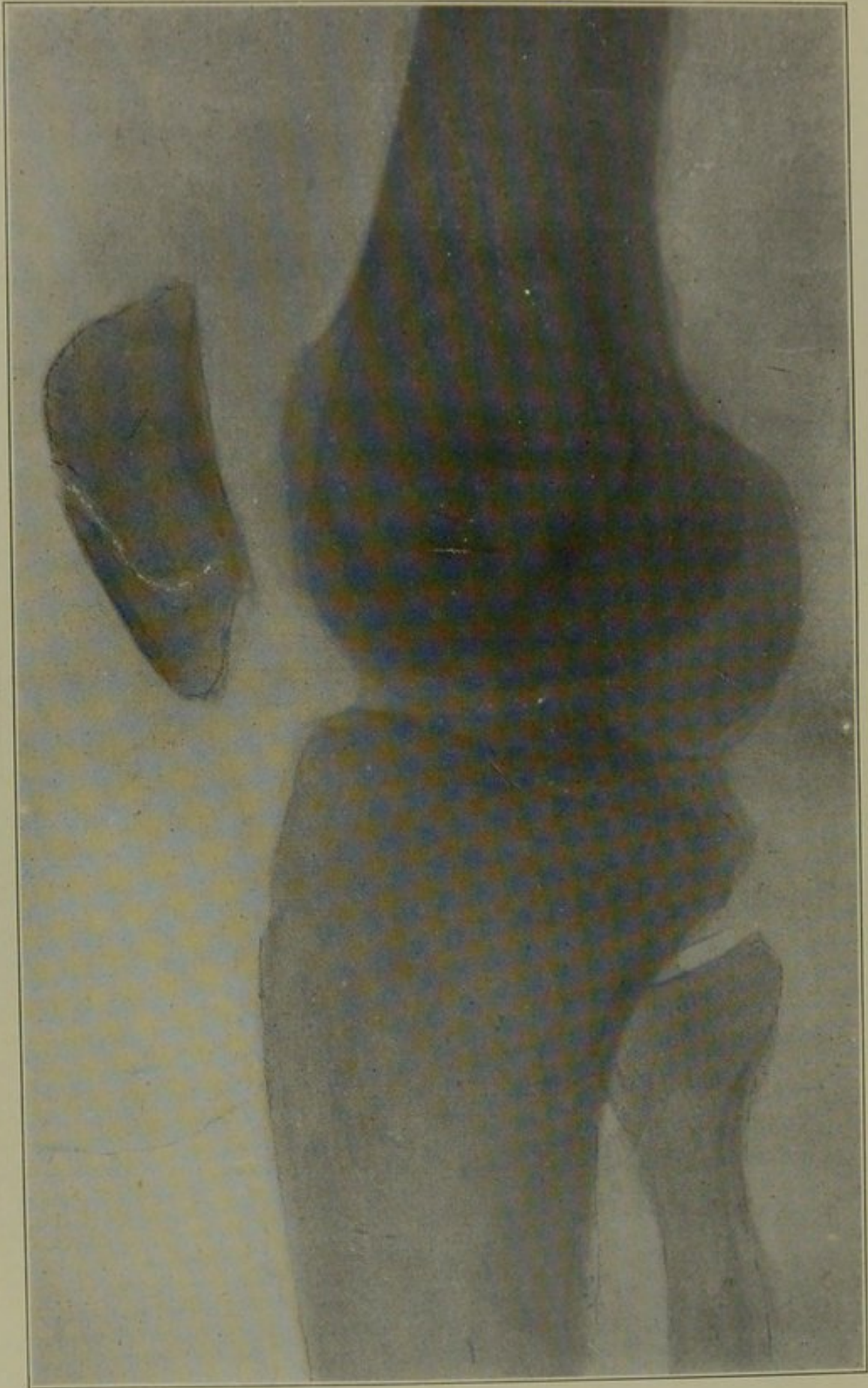


FIG. 13—J. K., 8791. Fracture of the patella with slight separation. This picture shows the obliquity of the fracture.

Discussion.

DR. J. P. WARBASSE agreed that it is a mistake to apply a routine treatment to all fractures. Each fracture is peculiar and each patient is peculiar, and, indeed, each surgeon is peculiar.

As to the interpretation of X-ray pictures, much study and skill are necessary; and there are a good many errors due to failure to interpret correctly these shadows.

Dr. Bristow has alluded to the treatment of fractures of the elbow; but he has advocated a routine treatment. He has made the statement that fractures of the condyles are best treated by extreme flexion. That is laying down a rule, which is a dangerous thing to do. If Dr. Bristow had seen some of the pictures of elbow fractures, which the speaker had presented at the Kings County Society last winter, he was sure he would not have made this statement, for he showed pictures of fractures of the condyles, in which flexion did not remedy but made the condition worse. He had showed pictures of fractures of the condyles, in which extension corrected the deformity, when it could neither be corrected by flexion or manipulation; and, furthermore, he had showed a picture in which correction could not be accomplished under an anesthetic by either flexion or extension and required operative treatment. That extreme flexion is the most generally available treatment for these fractures is well said, but to lay it down as a rule is decidedly bad practice.

Concerning extension in fractures of the thigh, the only point he would make is that in applying it, no traction should be made upon the ligaments of the knee-joint. To put up a fracture of the thigh in a man the leg from the toes to the knee-joint should be covered by a stocking or bandage, so that the adhesive strips are not applied to the skin below the ligaments of the knee-joint.

There are cases of fracture of the femur which cannot be corrected by

extension. It does not make any difference whether 30, 40 or 250 pounds are used. It sometimes happens that the sharp point of the oblique end of a fragment becomes engaged in the fascia or muscle and cannot be corrected by traction or manipulation, and a perfect apposition is secured only by operation. These are the cases which result in delayed or non-union and often compel operation.

The inequality of the legs shown by Wight, we are familiar with. The measuring of the legs to determine whether there is shortening or not, he thought of little importance compared with the X-ray picture. We may find that we have satisfactory measurements, but we may have a spicule of bone engaged in the muscle which will absolutely hinder a good result.

That Sands first applied the method of treatment he had advocated (immediate application of plaster with no padding), he was not inclined to accept. Sands, he believed, advocated the immediate correction and dressing of fractures of the lower extremities in plaster, but it was his practice to apply a large amount of cotton; and with the amount of cotton that was used in those days a satisfactory immobilization was not secured. If we secure absolute immobilization we will not have the swelling which has always been expected.

The use of opiates for relieving pain in fractures after a splint is applied, he desired to condemn as pernicious practice. The only way to make a patient comfortable is to reduce the fracture and put on a proper splint. To use opiates is deceiving oneself and the patient too, and delaying the correction of the cause of pain.

The ambulatory treatment of fractures is a subject occupying attention at the present time. Much was to be said in its favor and considerable against it. Time would not permit its discussion.

As to the case referred to by Dr. Bacon, the man with delirium tremens: by all means his deformity should be corrected. The speaker

believes that if there is anything conducive to delirium tremens, aside from the bad previous habits of the patient, it is the presence of periosteal nerve irritation. When the pain is due to an unreduced fracture, he believes the patient is more apt to develop delirium tremens as a result of the constant nerve irritation, than if he was given a momentary pain and the fracture corrected, or the operation done under anesthesia. The very important indication in delirium tremens is to remove all sources of irritation.

As to Colles' fracture, he disagreed with much that was said. That all Colles' fractures are impacted he believed is not correct. Many slip back easily into place. That an anesthetic is indicated in all cases, he did not concur in; and he did not believe there was a man who practices giving an anesthetic in all cases however

strongly he may advise others to do it. It is not necessary in even the majority of cases. It is not a difficult thing ordinarily to put a Colles' fracture back. We should always tell these patients that the chances of shortening in the injured bone are very great; and they may see later by the prominence at the lower end of the ulna that the forewarning was justified. But this is an accident which the surgeon cannot prevent.

In Potts' fracture, to give all these patients a general anesthetic, as has been recommended by a previous speaker, as a routine measure, is not indicated. The rule is to make a little overcorrection, which throws the upper end of the lower fragment out where it belongs. Occasionally these cases do require a general anesthetic, but he did not believe it necessary in all cases, nor should we lay it down as a routine treatment.