

The hymen : anatomically, medico-legally and historically considered / by E.S. M'Kee.

Contributors

McKee, Edward S.
Royal College of Surgeons of England

Publication/Creation

[Cincinnati] : [publisher not identified], 1908.

Persistent URL

<https://wellcomecollection.org/works/wxesk7j5>

Provider


Royal College of Surgeons

License and attribution

This material has been provided by This material has been provided by The Royal College of Surgeons of England. The original may be consulted at The Royal College of Surgeons of England. where the originals may be consulted. Conditions of use: it is possible this item is protected by copyright and/or related rights. You are free to use this item in any way that is permitted by the copyright and related rights legislation that applies to your use. For other uses you need to obtain permission from the rights-holder(s).



Wellcome Collection
183 Euston Road
London NW1 2BE UK
T +44 (0)20 7611 8722
E library@wellcomecollection.org
<https://wellcomecollection.org>



17.

Anatomically, Medico-Legally and Historically Considered.

BY E. S. M'KEE, M. D.,
CINCINNATI.

FORWORD.

Twenty-three years ago it was the writer's privilege to read a paper before the Academy of Medicine on the hymen. This was widely quoted by the medical journals, in Sajous' Annual of the Universal Medical Sciences, and Prof. A. Martin, then of Berlin, later of Griefswald, quoted two pages from the paper in his Text-Book on Diseases of Women, second American edition. Dr. David DeBeck, then of Cincinnati, now of Seattle, was the artist who assisted me in my first paper, and Dr. R. W. Thomas, of Cincinnati, made the beautiful water colors which are shown to-night. I am sorry to say that a number of those which are not shown were loaned to physicians and it was impossible to get them back. Their appreciation of art was in excess of their ideas of *meum et tuum*. Dr. W. W. Seely was presiding when I read twenty-three years ago, and Dr. W. H. Wenning was Secretary.

In "23" years one ought to skidoo,
And when I have done that's just what I'll do.

Hymen is from the son of Apollo and Urania, the god of marriage. The Latins speak of it as *membrana virginitalis*; the Germans, *scheide klappe*, *jungfern hautschen*, *jungfern schloeslein*, *jungfern schatz*. The Italians speak of the *camisca del onore*, and the Germans of the *chrenhemde*, referring to the blood-stained night-garment which shows the rupture of the hymen in *primis nuptiis*. The French called the hymen *capule* or *cypris*, which latter term we often find in the writings of Fontaine. The word *chaperone*, which we hear everyday, first meant the head-dress worn in France by the doctors and bachelors of arts. Later it referred to an old woman who watched young girls, and then the significance of guardian of virginity.

The hymen, though frail, is no doubt the strongest *signum anatomicum de virgo intacta*.

The scarcity of the hymen is often commented upon, many physicians having told me that they never saw one. There are probably many more hymens than we know of, yet they are often found wanting. Unlike Kentucky whisky, they do not improve with great age, for Shakespeare has said: "The longer kept the less worth." The ancient Greeks termed their furies "eternal virgins." Hieronymous said: "*Difficilis res virginitas idioque rara*." Though the hymen as a sign of innocence and virtue may be laughed at by some, who never saw it, it is doubtless the best we have, by far, and should be honored with due consideration.

Of the principal varieties of the hymen, their varied powers of resistance might be mentioned, weakest first, in the following order: Cribiform, semilunar, horseshoe, annular, bi-lobate, imperforate. The comparative resistance of these forms is a matter of medico-legal importance.

THE DEVELOPMENT OF THE HYMEN.

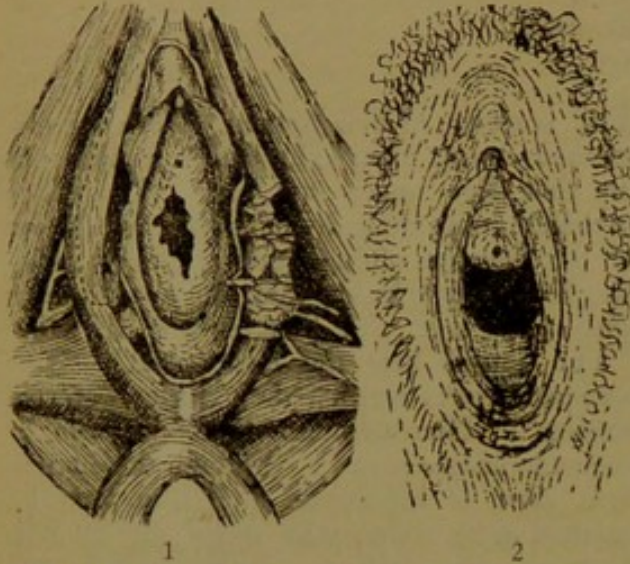
The following theories have been advanced: The hymen is the product of the sinus urino-genitalis; it is the product of the Muellerian ducts and the sinus urino-genitalis; it is the product of the Muellerian ducts; it is the product of the Wolfian ducts.

We must consider the various forms of the hymen. The annular hymen is found in two forms. First, we have a membrane which has the same width or breadth in all directions, in the center of which there is a circular opening having smooth borders. In the second form of annular hymen the borders are slightly indented on the upper part while the remainder of the border of the opening is smooth. There are also forms rather transitional, tending toward the crescentic. There are found congenital slits of the hymen. They are important, because they completely change the general aspect.

There is a hymen consisting of several lobes with rounded borders here and there

* Read before the Academy of Medicine of Cincinnati, December 16, 1907.

slightly fringed which can be readily depressed backwards. A hymen bipartus, or septus, or bridge-shaped hymen, is an orifice divided into equal parts by a narrow band of mucous membrane running from above downward. Congenital hyperplasia is, according to Luschka, the cause of the hymen fibrinatus. There are two forms of hymen which allow the penetration of large bodies



1. Anatomy of the hymen and surrounding tissues.
2. The hymen semilunaris, crescentic, or normal hymen.

without rupture—congenital slits and elastic membrane.

ANATOMY OF THE HYMEN.

This is a membrane situated at the juncture of the vulva and the vagina, partially closing the entrance to the latter. Authorities give the hymen as occurring in the ape, bitch, bear, donkey, hyena, giraffe, horse, cow and pig, besides the human female. Macroscopically the hymen appears as a semilunar fold. Next most frequent to the crescentic form is the annular variety, in which the hymeneal opening is circular in shape. The thickness and consistence of the hymen vary widely; in one the structure is as delicate as a spider's web, in the other a dense ligamentous membrane.

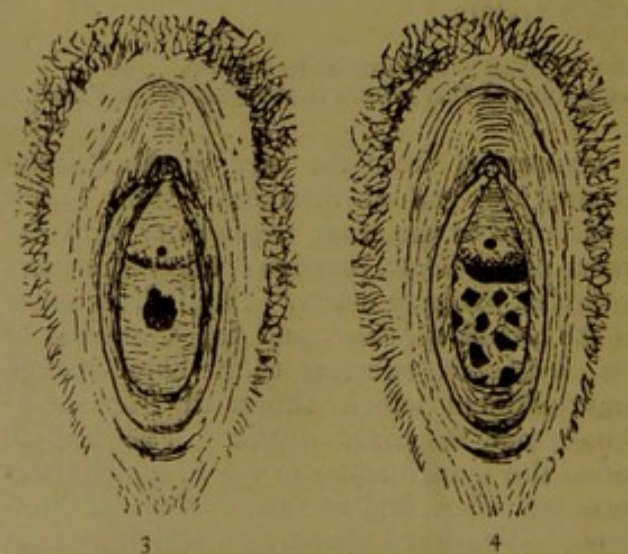
The hymen is composed of dense connective tissue covered on either side by epithelium. The epithelium is the usual multilayered pavement type. The connective tissue in the hymen of the fetus, new-born and adult is dense, with numerous nuclei. In the amount of nuclei, as well as in the density of fibres, the hymen is readily distinguished from the vulva. The blood supply is rather rich. A gradual increase of both the number and thickness of the elastic fibres takes place throughout the existence of

the membrane. Smooth muscular fibres have been repeatedly found in the normal hymen, though their presence is not the rule. In atresia, congenital or acquired, smooth muscular fibres are found with great uniformity. It has always been found very difficult to demonstrate the nerve supply of the hymen, and most authorities have failed in this, though some few report having done so. Experiments have shown that if the patient's attention is diverted the hymen can be pierced or pinched without pain, and that it is not sensitive to heat and cold. The pain in defloration is probably not due to the laceration of the hymen in most cases, but rather to the forcible dilatation of the entrance to the vagina. The elasticity of the hymen is in some instances so great that intercourse, or even parturition, may occur without rupturing it. As a rule, however, it is ruptured by the first coition. Healing is accompanied by a considerable formation of elastic and connective tissue.

ANOMALIES OF THE HYMEN.

Hymen Denticulatus.—A frequent form, consisting of a number of tooth-shaped indentations, which are frequently limited to the smooth inner border, especially the anterior surface. Frequently mistaken for ruptured hymen. To differentiate, note the uniform softness of the borders and the absence of cicatrization.

Hymen Fibrinatus.—The border of the hymen is fringed as shown by the microscope



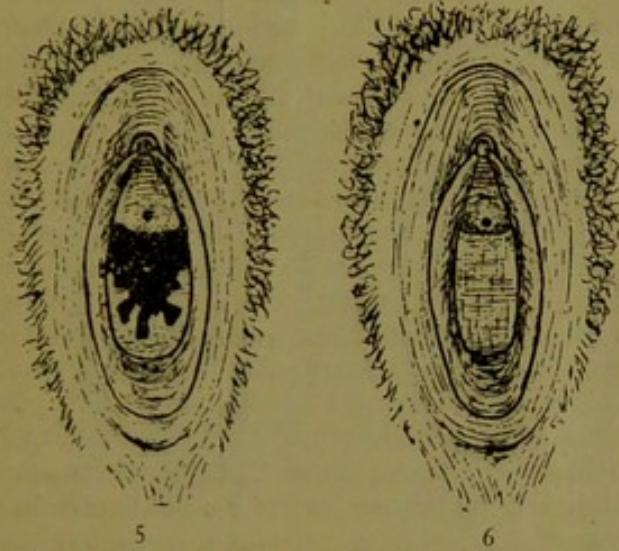3. The hymen circularis, or annular, with small central opening.
4. The hymen cribriformis, sieve-like, containing many holes like a water pot.

to be due to a development of the papillæ. The fimbriæ are not limited to the border of the hymen, but are spread over its surface, and at times over the labia minora. This is

a diagnostic point from violent rupture. In some the fimbriæ extend over the labia majora.

Hymen Infundibuliformis.—This variety is firmly attached at its base to the vagina, but its free borders are pushed in cone-shaped. This form often escapes rupture on sexual intercourse, being pushed up and stretched by the male organ.

Hymen Multiplex.—Two hymens, one above the other, duplex, have been several



5. The hymen fimbriatus, similar to the fringe-like appendages of the ostium abdominale of the tubæ Fallopiæ. This form is the most important in a forensic point of view, as it may be taken for the normal hymen which has been torn.
6. The hymen imperforatus. This is a frequent cause for surgical interference on account of the retentio mensium dependent upon it. It may obstruct the penetration of the male organ.

times reported. Friso has reported a case where four hymens existed, one above another, each having a central opening.

Hymen Septus.—The hymeneal opening is subdivided, usually vertically, the band being usually thick inferiorly or posteriorly and thinning out anteriorly. The band, if not central, is usually deflected from the right anteriorly to the left posteriorly, and the opening on the left is larger and higher. This anomaly is closely connected with the fetal obliquity of Mueller's ducts. The hymen subseptus is one in which there are two projections, which, however, do not meet.

Hymen Cribriformis.—This variety contains perforations, probably two to ten.

Absence of the Hymen.—This, though reported, is so rare that men of enormous experience have failed to notice it congenitally absent.

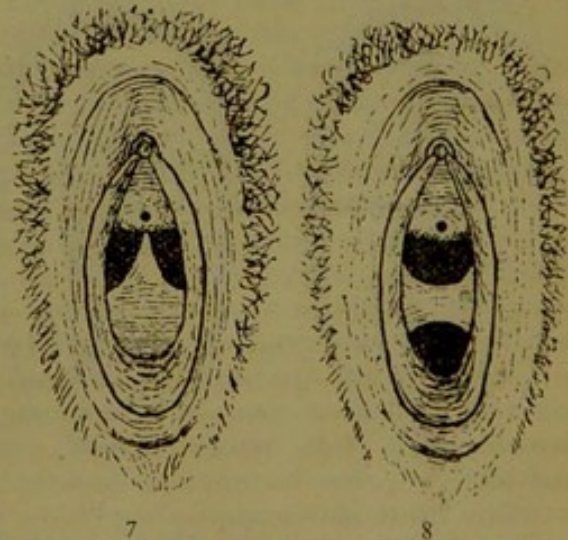
Abnormal Site of Hymen.—Cases are reported of higher and lower situations of the hymen. The higher is possible, but the

lower is more probably membranous occlusions of the vulva or adhesions of the labia. Turnipseed thought the hymen was situated higher in the negress, which does not seem proven.

The Male Hymen.—Leuckart pointed out in 1852 that the vesicula prostatica represents not only the uterus, but also the vagina of the female, and it occurred to Shattock that an analogue of the hymen might be found in the adult male at the spot where the prostatic vesicle opens into the urethra. He accordingly made dissections and found that the termination of the male vesicula, as viewed on opening the prostatic urethra on its anterior wall, consists of two projecting opposed longitudinal lips, forming a miniature hymen. It is in fact this male hymen which constitutes the eminence of the verumontanum. This homology is an extremely interesting scientific fact.

HOW TO EXAMINE FOR THE HYMEN.

The author has found a very careful way to examine a virgin with hymen intact and not lacerate it, as follows: If examining with the left index finger stand to the patient's left side about opposite the umbilicus, and if

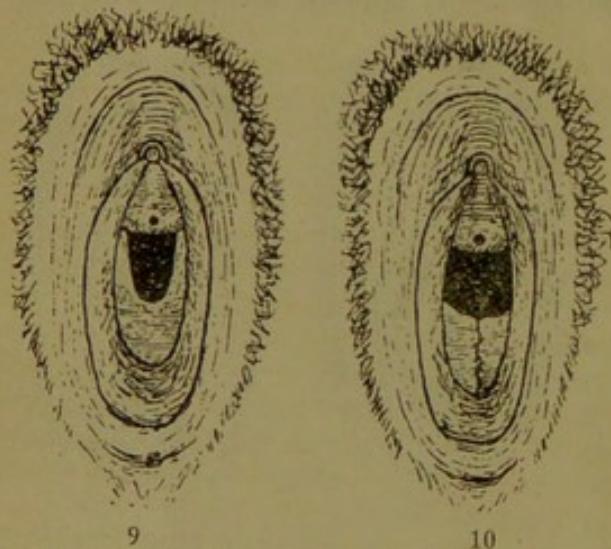

7. In rare instances the opening of the hymen is found divided by a perpendicular bridge into two parts. This strip of tissue passes from the concave border of the hymen to the meatus urinarius where it is fast.
8. In some instances there is a variety in which there exists an upper or anterior and a lower or posterior opening with simply a band lying transversely across the vagina. In rare cases we also find a second hymen existing above the first.

using the right index finger stand on the patient's right side. The patient in the dorsal position, the finger, well lubricated, is passed with the palmar surface creeping down over the surface of the clitoris and bulb of the urethra, telling the patient at the same time to bear down as if at stool. This latter

downward pressure will depress the inferior border of the hymen and retract the whole membrane and enlarge the hymeneal opening, so that in most cases the index finger in that position can be introduced and a fairly careful examination made without tearing the hymen

Another method is this: An ordinary soft red rubber catheter is taken and over its point for about one inch or one and a half inches there is placed an ordinary india rubber condom, which is tightly bound onto the stem of the catheter by a few turns of thread. There is thus improvised an instrument closely resembling one which used to be employed for arresting hemorrhage in cases of epistaxis, the armed catheter being placed in the nose at the point to plug the nostrils. This arrangement is gently passed into the vagina; the point is then expanded either by inflation or by injecting a small quantity of warm water; this done, the catheter is clamped. There now is inside the hymen what may be termed a miniature Champetier de Ribes bag, and by making very gentle traction on the catheter the hymen is put slightly on the stretch and bulged from within. In this way



9. The horseshoe hymen. 10. The bilobate hymen.

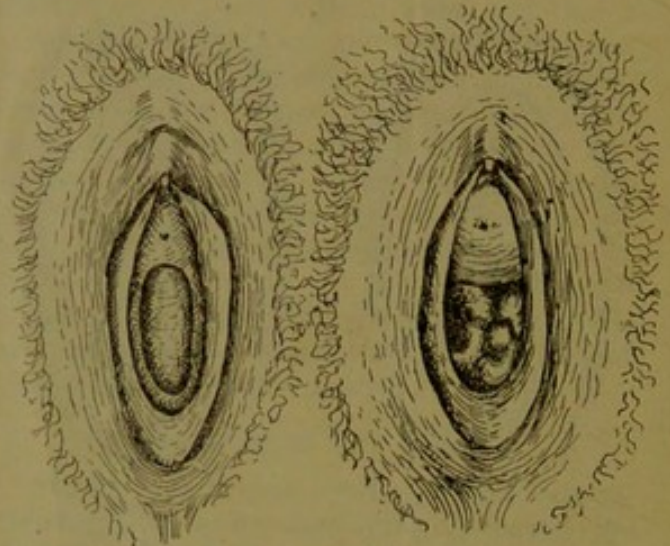
the whole hymeneal margin is fully exposed to view, so that any interruption in its integrity is at once detected, however slight it may be. In very young girls this method will be found particularly useful, as in them the hymen is very inaccessible.

THE HYMEN MEDICO-LEGALLY.

Magnum est crimen
Perrumpere virginis hymen.

Truly great is the crime of the unlawful destruction of the hymen. The punishment in most States and countries seems to fit the crime. The old Mosaic law was death if

the maid was engaged, and marriage and a fine paid the father of the girl and no chance for a divorce if the maid was not betrothed. There was a difference in the punishment if the rape was in the city or country, reasoning that in the city she could cry out and get help and therefore the crime was on her part greater. Among the Athenians, Romans, old French and English and in many of the United States the crime was punishable with death. In Texas it is still a capital crime.



11. Hymen imperforatus with hematokolpos.
12. Sculptured hymen.

The Manx in ye olden time brought the criminal into the market place. His victim was then given a whip, a sword and a ring. His punishment lay entirely in her hands. She could either kill, whip or marry him. Among the savages of the Figi Islands the bride of the son of a chief, if found without her hymen, had her own skull crushed in by a club in the hands of her father or brother.

Rupture of the hymen otherwise than by sexual intercourse may occur through the examining finger or the instruments of the careless gynecologist, masturbation, flooding, the passage of a tumor from within, the passage of various foreign bodies by accident or design. Hyrtle reports a case where a woman was sawing wood and a passing wagon threw her onto the saw, running the handle into the vagina and rupturing the hymen. The author of this paper was called in consultation in the case of a fifteen-year-old girl who, while walking a paling fence, fell astride it and a paling passed into the vagina, rupturing the hymen and doing much other damage.

There is a curious belief extant among the ignorant that connection with a virgin will cure venereal disease. The presence of

venereal disease in the victim appearing at the proper time has served to convict a number when this means was taken to cure the disease.

The diagnosis of rupture of the hymen in its medico-legal sense permits a great display of tact on the part of the examining physician. To differentiate between moral and mechanical rupture is sometimes so difficult as to be almost impossible.

The persistence of the hymen during sexual intercourse and even after labor is explained as follows: There are certain women in whom the hymen is relaxed and very dilatable, and in these cases, if there is no great disproportion between the male and female organs, the penis may readily penetrate the vagina without rupturing the hymen. The opening of the hymen is generally at the superior portion of the vulva, rarely central. Sometimes we have a double hymen, being divided by a longitudinal or transverse band. Here, if the hymen is dilatable and lax, it is simply pushed up at the first sexual act, then yields and penetration follows without rupture. In some cases the hymen yields gradually, so that penetration is only attained after weeks or months, the hymen being gradually dilated. In some cases the penis simply invaginates the hymen, copulation taking place in a vulva-vaginal sac of variable depth, according to the elasticity of the hymen and the vigor of the male organ. In some intromission does not occur, the semen being deposited upon the vulva and impregnation follows.

Issues of the gravest import, the loss of life, liberty and what is to some much greater than either of these, the loss of character and reputation, frequently hang upon the evidence of the medical man. It is a fact which we cannot deny that this evidence is sometimes founded upon the most superficial knowledge and careless and cursory examination, either clinical or pathological. While we should by no means shield the guilty, we should protect at all hazards the innocent. How often have we noticed that confident self-assurance in the witness-box concerning matters which require special experience to enable one to attempt a solution! This is often noticed in cases of disputed chastity or attempts at abortion, or the pathological proofs of mechanical violence or other means said to have been used to empty the uterus.

Varieties of the hymen of medico-legal interest include what might be termed the folding hymen. It is of normal appearance and structure, but of peculiarly yielding na-

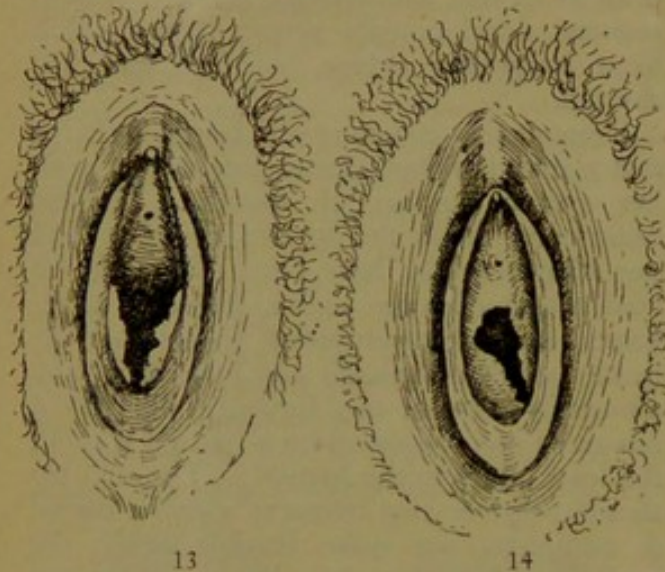
ture, readily admitting the entrance of an ordinary vaginal dilator or a fair-sized speculum. During the passage of these instruments it folds back against the vaginal wall and returns quite intact on their removal.

Given an instance where a woman has been recently married and where some difficulty occurs on attempting intercourse on account of resistance and feigned pain on her part, we sometimes find the following: On examination a complete hymen is found, but of the folding type. An opinion has been given that the woman is intact. Subsequent developments prove that she has lived irregularly before marriage and had aborted.

Suppose that a young girl brings a charge that a man has had sexual intercourse with her over a number of months. Medical examination finds the hymen complete and says that it would have been impossible, at least continued over such a length of time. Expert medical examination shows that the hymen yields completely and folds back, and ultimately without any force or difficulty a fair-sized conical speculum is passed without the least injury to the hymen. The opinion should be given that frequent coition, partial or complete, was quite feasible under the conditions, but that the chastity of the girl was not impugned. Cases occur in women who have been married a number of years, not having conceived, where the speculum is passed without difficulty, the membrane simply folding back in tubular form as the speculum is pushed back into the vagina, returning again to its natural position on the removal of the instrument. In fact, pessaries may be introduced into some of these vaginæ without rupturing the hymen. It is important to remember that it has been pretty clearly shown that the *carunculæ mytriformes* are formed only by child-bearing and not by lacerations from sexual intercourse. Mere vulvar intercourse is constantly occurring, and it leaves no evidence behind it. The law does not define in what penetration consists. Many of the cases which have been related of pregnancy having occurred with an almost imperforate hymen are but examples of conception following these half-completed acts of coition. It is just these unusual occurrences which, arising suddenly, without warning, throw men off their guard, and we find them giving an opinion wrongly on which so much depends.

Double hymen, according to Hart, is due to the permanent non-coalescence of the Wolfian bulbs, and not of the ducts of Mueller. This author has advanced a new

view as to the development of the vagina and hymen. Until the third month of fetal life the vagina is formed by the coalesced Muellerian ducts, ending blindly at their lower ends; there is no lower aperture, no hymen. In the beginning of the third month proliferation of the epithelium lining the lower ends of the Wolfian ducts takes place, forming what he calls the Wolfian bulbs; the peripheral cells are active, the central ones become less active, and become arranged in layers of squamous cells, resem-



13. Hymen semilunaris ruptured.
14. Hymen annularis ruptured.

bling the structure of vaginal epithelium at full time or in the adult state. The hymeneal opening is brought about by the epithelial involution from the uro-genital sinus meeting the distended Wolfian bulbs.

Different hymens tear differently. The direction and manner of the tear depends on the shape and position of the hymen and the amount of force used. The semilunar usually tears in the mid line posteriorly, the annular hymen tears in several different flaps; a resistant hymen with small opening tears usually at its base and floats like a sail in the entrance to the harbor. Ordinarily we find the remnants of the annular hymen in four flaps.

It has been claimed by some that the rupture of the hymen from masturbation can be easily differentiated from that by sexual intercourse. The signs of masturbation are hyperdevelopment, multiple folding and excessive pigmentation of the genitals which correspond to the masturbating hand. Slight rupture of the hymen occurs usually on one side, that of the masturbating hand, and at this point adherence of the hymen to the labia minora by cicatricial tissue often results at the point of rupture. We may have the

evidences of masturbation and criminal assault both present at the same time, and in a by far greater number of cases the medical expert can swear to nothing beyond "penetration by some blunt instrument."

THE SIGNIFICANCE OF THE HYMEN INTACTUS IN MEDICAL JURISPRUDENCE.

When we reflect that the condition of the hymen is often the only evidence by which a differentiation between rape and assault with intent to commit rape can be made, it is easy to see the importance of this integrity in a case which has come to trial. Some authors quote as many as a hundred or more cases of hymen remaining intact up to the time of delivery. Prostitutes have been found with intact hymens, having made their living for many years by sexual intercourse. The writer well remembers one such case in his practice. Cases are reported where the hymen is still intact after labor and even after repeated labors. This goes to show that a very large body may pass through a lax annular hymen without causing a rupture. Verdicts have been given against men for adultery and rape when the women were found to have the hymen intact. When it is known that conception may take place with the hymen intact juries are loth to accord it much standing as a sign of virginity.

THE HYMEN ABROAD.

Among some Asiatic tribes *virgo intacta* has no charms for aspiring husbands. They consider the matter strictly business, and prefer a widow to a virgin, as she has no hindrances to coition and is a better housewife. He who has a widowed daughter can realize twice as much on her second marriage as on her first. It was Chaucer who said:

"If twenty crowns for thy lip so red,
What would I give for thy maidenhead?"

Yet the ancient Egyptians considered it a useless obstruction and cut it away. Athanasius says that the Phoenicians turned the bride over to a favorite slave to have her relieved of her virginity. Tiberius promulgated a law that no virgin should be hung. She must first be relieved of her hymen by the hangman. There are numerous instances among the ancients where they were weak-backed and demoralized enough to consider the hymen only a hindrance to sexual intercourse, and have it removed by priests or little ivory idols. In the Figi Islands, when a young man has arrived at the age when he is to assume the

duties of a chief he selects the daughter of another chief as his bride. The two tribes then assemble at the market place to witness the test of virginity. After the tribes have formed a circle the bride is led in and divested of all her clothing. She then walks slowly and tremblingly before the multitude and seats herself on the snow white sheet and awaits the coming of the groom. He arrives promptly, and with a serious countenance and blood in his eye, seats himself on the sheet, opposite the bride. He then inserts two fingers into the bride's vagina, withdraws them, and holds them up high, while the bride and her tribe wait anxiously to see the few drops of blood which fall on the white sheet. The sight of the blood is the signal for shouts of joy on the part of the bride's tribe, for both her honor and that of her tribe is now proven, and congratulations are in order. Among those people so much importance is placed upon the presence of the hymen that in case it is not found the girl is put to death. Among civilized people, if there is any country where more hymens are found *pro mille* than in America, it is that country from which so many Americans originate—the Emerald Isle.

THE RESTORATION OF THE HYMEN.

This is not so much a myth as some might think. Indeed, it is not a great many years ago when a late Cincinnati physician advertised to restore the hymen, "thus often saving embarrassment." He was elected to the Board of Health. Once, when business was dull, the rent was due, while under the influence of methylthionia hydrochloridum for splanchnic neurasthenia, the writer composed the following lines:

A maiden forsaken
A true love may get,
But a hymen once broken
Can never be set.

Now, this sounds very proper, but the author thinks it is not absolutely true. He has seen freshly lacerated hymens which

could have been repaired with a good result. He has no doubt that where the hymen is entirely obliterated a plastic operation could be done which would fool any man but a medical man, and maybe some of them. This, however, should be kept dark.

THE CARUNCULÆ MYRTIFORMES.

Quod figuram habeant Baccharum Myrti.
According to Schröder, these are caused by childbirth ensuing upon the rupture of the hymen. They are the contracted remains of the lacerated hymen made more prominent by the stretching and the ruptures of ensuing childbirth. Immediately after coition there are present bloody lips, and on the site of these usually are found the carunculæ myrtiformes. Sometimes there are three elevations, at other times but two, or even one. At times they become hypertrophied so as to require surgical interference. It is possible that the elastic tissue plays a rôle in the formation of the caruncles, as they are more frequent at the base of the hymen, and when the latter is torn they tend to contract it into the little bulbs near the base. If the hymen at childbirth is torn deeply into a number of small pieces, each piece retracts owing to the more powerful action of the radial fibres. For some time thereafter one is able to pull each caruncle to its original length, but after long standing atrophy results largely through the retraction of these fibres and faulty circulation. Copious hymeneal hemorrhage occurring after coition is generally due to the extension of the lacerations into adjacent parts.

From a German gynecologicum hystero-poeticum called "*der Kleine Scanzoni*," we select the following epitaph to be placed on these tombstone-like last sad remains of the hymen:

"So Mancher suchte sie im Dunkeln
Und fand statt ihrer nur Karunkeln."

19 W. 7th St.

