

Retinitis pigmentosa without the characteristic pigmentation : a report of two cases / by George M. Gould.

Contributors

Gould, George Milbrey, 1848-1922.
Royal College of Surgeons of England

Publication/Creation

[St. Louis, Mo.] : [Jones H. Parker], 1897.

Persistent URL

<https://wellcomecollection.org/works/s4z9vkj7>

Provider

Royal College of Surgeons

License and attribution

This material has been provided by This material has been provided by The Royal College of Surgeons of England. The original may be consulted at The Royal College of Surgeons of England. where the originals may be consulted. This work has been identified as being free of known restrictions under copyright law, including all related and neighbouring rights and is being made available under the Creative Commons, Public Domain Mark.

You can copy, modify, distribute and perform the work, even for commercial purposes, without asking permission.



Wellcome Collection
183 Euston Road
London NW1 2BE UK
T +44 (0)20 7611 8722
E library@wellcomecollection.org
<https://wellcomecollection.org>


14
RETINITIS PIGMENTOSA WITHOUT THE CHARAC-
TERISTIC PIGMENTATION.—A REPORT
OF TWO CASES.

BY GEORGE M. GOULD, A. M., M. D.

PHILADELPHIA, PA.

[Illustrated].

REPRINTED FROM
ANNALS OF OPHTHALMOLOGY, Vol. VI., No. 4,
October, 1897.



RETINITIS PIGMENTOSA WITHOUT THE CHARACTERISTIC PIGMENTATION.—A REPORT OF TWO CASES.

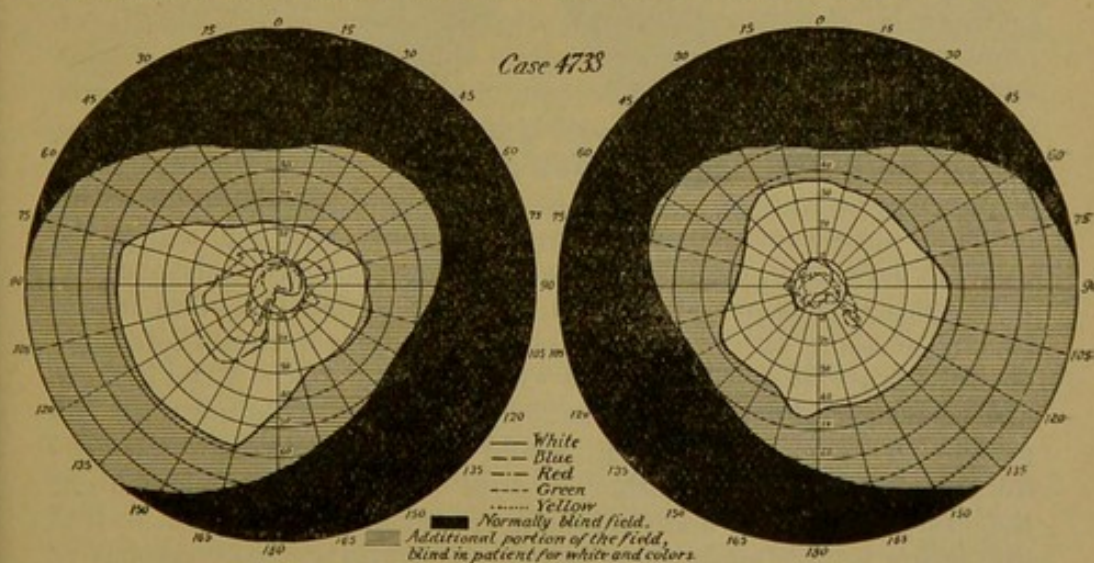
BY GEORGE M. GOULD, A. M., M. D.

PHILADELPHIA, PA.

(Illustrated.)

So far as I have been able to learn, only five cases probably like those I shall describe, have been reported, and the reports of these contain no charts of the visual fields for colors, while two are without the fields for white, as well as without other important details. My cases are as follows:

CASE 4733.—A young lady of 26, a typewriter (and a very expert one) by profession, presented herself on May 1, 1897, complaining of headaches and obscure ocular and cerebral symptoms, apparently



due to eye strain. Under mydriasis I found her error of refraction to be:

R. — Sph. 0.37 — Cyl. 0.24 ax. 180 = $20/20$.

L. — Cyl. 0.37 ax. 180 = $20/30$.

There was no considerable muscle-imbalance.

The ophthalmoscopic examination was negative, *i. e.*, there was no pathologic tissue-change detected in the fundus. I did not suspect anything wrong and therefore did not make inquiries as to symptoms which were, at a later date, elicited by questioning. I prescribed spectacles for near-work.

I am sorry that lack of space compels the insertion of illustrations too small to bring out clearly the distinctions between the different fields.

At a subsequent visit, in conducting the patient out of the office, I noticed a certain doubtfulness of stepping in the darker hallway, a sort of groping motion of the hands and feet that, had I been more busy, or tired, less alert-minded, might have escaped my attention. Inquiry at once brought out the fact that for three years she had had difficulty in walking at night, and by further questioning, her brothers and sisters confirmed the statement. They had frequently noticed her indecision and stumbling. By tests, I found what I think is a significant sign or hint of the limitation of the visual field; the necessity of bowing the head well downward in darkened halls or at night, in walking over rough places, or in beginning the ascent or descent of unfamiliar stairs. This device is required to bring the images from the periphery to the more central portions of the retina. I show herewith carefully made perimetric charts, enlarged by my friend, Dr. Pyle, of the girl's visual fields, setting forth the extreme peripheries of the same for white, red, blue, green and yellow. These charts tell the story perfectly. The white fields are about half the normal extent, those for the remaining colors are very small, extremely irregular in outline and in relative order.

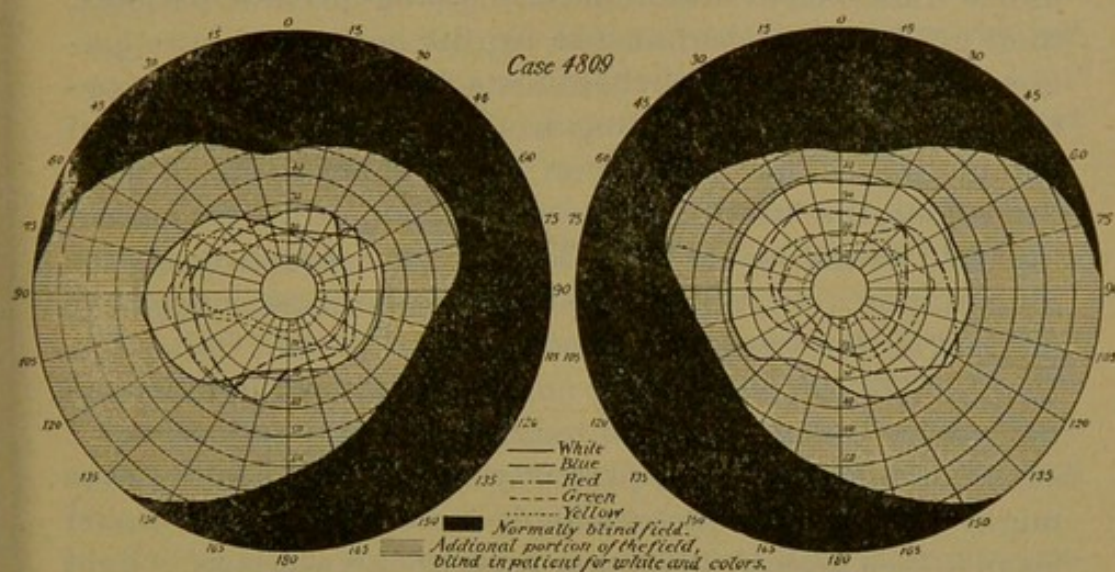
With aroused attention I now most carefully examined the ophthalmoscopic details of the periphery of the retina. They were such as to have been passed over in routine work, but with not a little difficulty I could now detect numberless obscure tiny dots, brownish or blackish, similar to those of a stippled engraving, closely strewn about the periphery; sometimes they seemingly tended to a streamer-like or strand-like arrangement, but not in the faintest degree suggestive of the appearance of typical retinitis pigmentosa; in no part of the fundus were there any pigment-heapings whatever, and all the vessels were without the least abnormal pigmentation. This punctate appearance, or microscopic stippling, was confined to the extreme periphery, ceasing gradually as one approached the equator.

The patient was not color-blind, although across the blind indentations of some of the color fields certain tints were not detectible until the traveler overlapped the white fixation-spot. Even if there had been central color blindness for these colors, I do not think the patient, with both eyes open, would have failed to distinguish the tints accurately enough, either because of one field supplementing the other, or by the unconscious device of indirect fixation, so that the image would fall on some retinal tissue still normally responsive to the stimulus. It is interesting to note that in approaching the center of fixation, the red and blue travelers were for 5° or 10° perceived as pink, or spotted, before the true tint was detected. Other parachromatisms were found in charting the fields. Of especial interest is the fact of the little island of preserved blue-response in the southeast portion of the right field, separated from the central field by 10° or 15° of space insensitive to the color. Into this island a sharp angle of peninsular red extends.

The discovery of the true nature of the foregoing case, of course, moved me to secure examinations of this patient's relations, and I was able to do so in the cases of two brothers, one sister, and their mother. In one brother, and in the mother, inquiry, refraction, and ophthalmoscopic examination were negative, except that in the sister, there was an almost indistinguishable stippling of the retinal

periphery, similar to that in her sister, but less distinct. The perimeter, however, showed normal fields. The pathologic process was either incipient, or had been checked prior to any involvement of the distinctive retinal function—and this was at least a suggestive fact to be borne in mind in the future. In one brother, however, I had the scientific delight of finding another case like that of the affected sister—a typical case of what, lacking a better name, we must at present paradoxically call retinitis pigmentosa, without the characteristic pigment.

CASE 4809.—This patient, a brother of the patient whose case I have just described, is a strong, healthy business man, 29 years old, who, with the exception of night blindness, had never suspected



anything abnormal as regards his eyes or vision, besides his ametropic error, measuring

R. — Sph. 0.25 — Cyl. 1.25 ax. 180° = 20/30.

L. — “ 0.75 — “ 1.50 “ 180° = 20/30?

He had, however, to bow his head to see the ground or floor at night, and his brothers and sisters, as well as himself, had been aware that for ten years he stumbled, or was abnormally undecided and bothered in walking at night or in dimly lighted rooms. Even with perfect correcting lenses, it is noticed that his 20-foot amblyopia is greater than the sister, although his visual fields are far less abnormal and limited. He had the same stippling as the sister, at the periphery of the retina, but like her, there was not a pigment-cluster or line so large as the smallest pinhead in the entire fundus. As in the sister's case the vessels, disc, etc., were not abnormal. Both being blondes, the choroidal vessels were somewhat clearly visible. I show you the fields for white and the four principal colors, from which you will see their precise delimitations.

Your own scientific and dramatic satisfaction can hardly equal that of mine in learning that, although the father of these children was free from the symptoms of the disease in question, *his* father, that is, the paternal grandfather of the two patients, had all his life, decided and complete night blindness, and went entirely blind, not probably from cataract, at the age of 70. When I asked the mother

concerning the symptoms, she remembers that her husband's father had to bow his head very low, when in doubt, to see the ground, stairs, etc. I am most sorry to add, that this man is now dead, and that no oculist ever examined his eyes. Whether his disease was with or without the characteristic pigmentation, must remain a regrettable mystery. Under the circumstances, there cannot be the slightest doubt that it was one or the other. The knowledge would help to determine two important questions, that relating to heredity, and that as to the essential identity of the disease.

I regret very much that it was impossible for me to measure the variation of central and peripheral acuteness under diminished illumination. Being private patients, their good will was exhausted by the perimetric examinations, and I judged that these tests were of far more importance than those pertaining to the intensity of the retinal stimulation. There can be no doubt that, as in all such conditions, the law of greater contraction of the fields, and lessened acuity would have followed the lowering of the illumination. In this connection, of the most suggestive interest is the case of Atwood (Royal Lond. Oph. Hos. Rep., 1895), in which with normal fields for full illumination, there was contraction under lowered illumination. I suspect, however, that perfectly normal and healthy eyes might exhibit this phenomenon more or less. It would seem to be a logical deduction from the known laws of light and sensation. If this is true, the initial stages of retinitis pigmentosa without pigmentation might naturally exhibit a disproportionately greater reduction, both in acuity and contraction.

A Brief Review of the Literature.*

Nothing better illustrates the importance of a proper definition and use of words, than that pertaining to the words hemeralopia and nyctalopia. For years I have been advising their utter disuse on account of the confusion sure to result if each writer does not distinctly state what he means whenever he employs them. But until I attempted to collate the literature on this subject, I never suspected the extent of misfortune connected with the term "hemeralopia." In the first place, and in any case, it denotes but a symptom, and may be a consequence of very diverse and manifold causes and conditions. The same author will sometimes use it in the most contradictory senses, or

*I am under obligations to my friends, Dr. Wendell Reber and Dr. W. L. Pyle, of Philadelphia, for valuable and kind assistance in collecting the reports reviewed.

one author will use it to denote one symptom or disease, while another will understand the reverse. Nobody defines the word, and yet by the reports of cases one finds it to mean amblyopia, night-blindness, day-blindness, photophobia, and a multitude of other symptoms. One finds that it may be caused by exposure to bright light, electric light, snow, etc., or may be due to myopia, or to any form of local ocular disease; it may be the result of deprivation of food, or the consequence of a hundred systemic diseases; it may be transient and curable, functional or organic, chronic or congenital; it may be anything or nothing. Great is hemeralopia of the Germans! I have never yet found anyone who could define the word, and I am quite sure it is beyond the power of the finite mind. Let it be anathematized, world without end!

In endeavoring to digest the literature, I have been forced to exclude several classes of cases as not like those I report. These cases are as follows:

1. All such as were acute or functional, whatever may have been the cause. The disease of my patients was chronic and perhaps congenital. With such cases those have no analogy which were plainly due to a temporary cause, and that recovered under treatment and rest.

2. Diseases due to light-traumatism, such as from over-exposure or over-stimulation by bright light, snow, etc.

3. Diseases certainly or possibly due to such local ocular affections, as malignant myopia, optic-nerve disease, choroiditis, retinitis, xerosis of the conjunctiva, keratitis, etc., or to reflex ocular neuroses.

4. Affections the result of systemic diseases, as e.g., anemia, drug-intoxication, fevers, digestive malfunction, deprivation of food, etc.

5. Cases in which the reports were self-contradictory as, for example, those of hereditary congenital night-blindness, in which the visual fields were reported "normal," or in which the patient saw better by night than by day. They surely had no pathology at all like that of my cases.

I have also been forced to put aside cases reported as "hemeralopia," but the reports of which, with all the intellect and sympathy I was able to command, were utterly unintelligible to me. It is possible that among these there may have been some belonging to the same class as my own. But were it so, it must be added, that the omission

from the reports of the all-important light-fields and color-fields, with other details, must make any use of or deductions from them quite impossible. I may also add, that many writers seemed at first to offer tempting riches, but when I found that the "hemeralope" saw better by night than in the day, that he had central scotomata, that there was no limitation of the fields, or, *mirabile dictu!* that no ophthalmoscopic examination was made, plainly nothing more was to be done.

Most of the text books have none, or only a passing allusion to the subject. There is no reference to it in Gowers, Michel, McNamara, Roosa, Carter and Frost, Hart-ridge, Wolf, Jones, Juler or Stellwag. The first case in point of time that I have been able to find of this disease upon which one may rely, is that of Perrin (*Annal d'oc.*, 1875, p. 234—published also in Hocquard's These.). The patient was a soldier of 21, who is described as afflicted with congenital "hemeralopia." This instance was plainly not so pure a case as mine, as there was "a single oval point of pigment along a vein" in the upper part of the fundus of the right eye, and in the left eye "two or three small grains of isolated pigment, stellate in shape." There was said to be great limitation of the field (for white), but no exact perimetric examinations were made, a fact especially regrettable as to colors. "Integrity of the color-sense" is reported. There is also no evidence that the (difficult) examination of the periphery of the retina was carried out with the ophthalmoscope and the results carefully set down. The man died soon after of scarlet fever, and the great value of the otherwise faulty report consists in the very valuable histologic post mortem examination of the retinæ.

The next case reported is that of Huidiez; his article is entitled *Retinite Pigmentaire sans pigment visible a l'ophthalmoscope*, (*Ann. d'oc.*, 1877, p. 211). The patient was a girl child of 8, afflicted with night-blindness from earliest infancy. The author says central vision was good, the fields for white narrowed, and also for colors. No pigment existed along the vessels, but there were traces of slight pigmentary infiltration at the periphery. Here again no charts of the fields, even for white, are given.

Alvarado, in an article entitled *Un Caso de Retinitis pigmentaria sin pigmentation de la Retina visible con el ophthalmoscopia*, (*Rev. de Cien. Med.*, 1882, VIII, p. 269,)

had a patient who was a healthy laboring man of 32, with gradual unaccountable loss of vision. "With strong bi-concave lenses, he could read letters No. XL. of de Wecker's scale at $3\frac{1}{2}$ meters." With one eye fixed on some small object on the wall, he could not see small bits of colored paper passed before his eyes in different directions, except at a very few centimeters from the fixed point. If these were placed in front of the eyes, they were distinguished though with some difficulty, this being less so (*mas sensible*) when he tried to distinguish light and dark shades. With oblique vision, at the posterior pole of the crystalline, was seen a star-shaped opacity, of 7 branches in the left eye, and 6 in the right. Proceeding to ophthalmoscopic examination, I was astonished to find the fundus completely clear and limpid, without the slightest trace of obscurity at any point of the retina. Thinking I had made an error in diagnosis, I re-examined the patient, who only confirmed the previous history; with the ophthalmoscope nothing was found beyond a fundus of intense orange color, the pupil standing out perfectly white with well defined borders, the vessels standing out clearly, the retinal vessels, especially the arteries, being quite atrophied. This last did not indicate anything, since the patient could see, and although the clear outline of the *venæ vorticosæ* might indicate alterations of the epithelium of the choroid, yet this last not being rare in perfectly normal eyes, I could only arrive at the diagnosis of pigmentary retinitis, minus one of its principal symptoms—pigmentation of the retina visible with the ophthalmoscope. With the exception of this last, no other characteristic symptoms were lacking."

The entire report arouses many doubts and questions. The crude tests of the field, without the perimeter, make us pause, the existence of cataract complicates, and yet, notwithstanding this, "the fundus completely clear and limpid without the slightest trace of obscurity at any point of the retina," seems an impossibility, and makes us doubt any accuracy in the report; the failure to say a word about night-blindness makes the last sentence quoted very indefinite, to say the least; the high myopia and rough indefinite diagnosis of the same, complicates our doubt and heightens our skepticism; and, finally, the "fundus of intense orange color" makes us wonder if there was not systemic leucocythemia present. On the whole, I think we must exclude the report, as being of any value, in future statistics and investigations.

In one of Darier's cases (*Archiv. d'oph.*, 1887, Vol. 7, p. 170,) of anomalous retinitis pigmentosa, there were but few typical pigmentary stars, and another had only two or three small black points along the vessels, and peculiar macular changes. One other of his cases, that of a boy of 18, may have been like mine, but the lack of the all-necessary fields and other details, as well as the general indefiniteness of the report, together with certain retinal and macular changes suggestive of a different disease, make me feel very doubtful about it. It cannot be too strongly urged that, especially in these incipient cases, if they may so be called, there need not be, and if uncomplicated, there should not be any great retinal, macular, vascular, or discharges. The visual field, Darier says, was reduced to central vision. In returning from school in winter, the patient had great difficulty in walking. The reports lead one to infer that the author does not use a mydriatic, and so there is a doubt left in our minds, although he says that in no part of the periphery were there any pigmentary spots. It seems from the pathology of the disease, that were the field limited, there must necessarily be the ophthalmoscopic showing of stippling or of some form of pigment infiltration. As to this case, not a word is said about night-blindness, though we may suppose it to have been present. However, when we find another observer reporting a case purporting to be retinitis pigmentosa without pigment, and yet in which the patient saw better by night, our skepticism is likely to become dominant. I have grave doubts if Darier's case belongs to the class under discussion.

Morton (*Transac. Oph. Soc. U. K.*, 1893, p. 147,) has reported two cases, evidently like those I have described. Many male members of the family of these two patients were night-blind for several generations. No abnormal pigmentations of the fundi was found. The fields were much contracted and irregularly so for white, but I am sorry the color-fields are not reported.

Nettleship, *Transac. Oph. Soc.*, U. K., Vol. VII, 1887, p. 301,) reports four cases of permanent partial night-blindness, with unusual ophthalmoscopic changes. These changes were of two types: 1. Minute, discrete, opaque white dots, apparently deposits on the choroid and retina, separated by comparatively wide spaces of healthy choroid. The spots were round or oblong, not glistening, the

majority free from pigment, though with some black bordering. 2. Irregular distribution of pigmented epithelium of a mottled or stippled appearance, but not of the reticulated patterns of retinitis pigmentosa. Twilight blindness had always existed in all. It is to be noticed that in one of the four cases there was no contraction of the field, and no mention is made of contraction in the other three cases.

Galezowski (*Recherches Ophthalmoscopiques*, 1863,) described a case with typical symptoms in which the pigmentation was characteristic, but less in amount and extent than usual.

Hoch's case (*Klin. Monatsbl. f. Aug.* 1875, p. 58,) was an atypic but most decidedly pigmented case, and that of Magnus and Jacobson (*ibid.*, 1888, p. 202,) was the same. In the latter, the intense pigment-changes are shown in a chromo-lithographic plate. Germaix's case (*Ann. d'oc.*, 1893, p. 276,) occurred in a child of 11 during an attack of variola, but without ophthalmoscopic examination, and is, moreover, evidently not to be included in this category. In Cowell's case (*Trans. Oph. Soc.*, United King., Vol. 2, p. 58,) sight began failing at 14, and there was at the time of examination only a perception of light. "The pigment accumulations were much fewer than normal, and only sparingly stellate."

Leber (Ueber anomale Formen der Retinitis Pigmentosa, *Arch. Ophthal.*, 1871, XVII., Abth. 1, p. 314,) makes his class 2 consist of cases of "Retinitis Pigmentosa mit typischen Séhstorung mit anomalen Augenspiegelbefund," and his sub-class A, "die wohlbekannte retinitis pigmentosa ohne Pigment," which through many intermediate forms passes into the typical. Leber's expression, *wohlbekannt*, well-known, made me gasp for breath at first, until I came later to the sentence wherein he says that, in the ophthalmoscopic examination of these cases, "in spite of the failure of the pigment, the pigmentation is sufficiently characteristic to make the diagnosis clear." Cases without the characteristic amount of pigmentation, but with decided typical pigmentation, are necessarily not of the class under discussion. This quite shuts his cases out of our consideration, and when we find given no perimetric charts, no records of amblyopia or ametropia, no specific data of night-blindness, no precise statements as to the amount and kind of pigment-deposits, nor of other ophthalmoscopic findings, we are compelled to omit the re-

ports as of helpful value to us. Moreover, of the three cases to which he vaguely alludes, without the mention of the typical symptoms, he speaks of one seeing better by night than by day, a fact that absolutely puts it out of our classification.

Pettlesohn (*Centralb. f. prakt. Augen.*, Bd. XII, p. 206,) quotes Donders and Schweigger (*v. Graefe's Arch.*, Vol. 1,) who pointed out, even so early, that contracted fields, night-blindness, and decline of the central visual acuity could exist independent of pigment-change in the retina and claimed that the two affections are identical. Donders observed that, "according to his idea, the pigment-changes were secondary and other than causative." Schweigger describes the visual failure in such cases to an affection more of the percipient than of the conducting portion of the visual apparatus. Leber lays stress on the fact that the essential character of the affection is not the pigment-change, but is really a coincident interstitial hypertrophy of the retinal elements. But, says Pettlesohn, Leber's cases, as observed by Schweigger, may belong to the so-called cerebral amauroses; namely, all presented visual failure and contracted fields even in earliest childhood.

He further says (and this was in 1888), "I have not yet seen a case reported in which their existed coincidently all the classic signs of ret. pig. without a pigmented fundus." He then details the following case seen in Hirschberg's clinic:

A 21-year-old lithographer complained that for two years his vision had been rather indistinct, and he was never sure of himself after dark. Investigation revealed that a 30-year-old cousin was similarly affected, although there was no consanguinity. The patient's sisters had perfectly good eyes.

O. D. — 2 *S.* — 2 *Cyl. ax. 180° = 20/20.*

O. S. — 4 *S.* — 2 *Cyl. ax. 180° = 20/20.*

At noonday, with good illumination, there was no contraction of the field, although with diminished illumination it shrank to within 10° of the fixation-point. There was no pigment to be found in the fundus, or if any, there were only the smallest flecks to be seen in the periphery. Three years later the patient returned for change of glasses, when the fundus was found studded with the characteris-

tic stellate heapings of pigment, and even with perfect illumination there was a contraction of the field. Vision was unchanged. In the meantime (between 1885 and 1888) two younger sisters were said to be becoming affected in like manner although, unfortunately, could not be examined.

Pettlesohn says in conclusion: "We can now positively state what has long been thought probable, 'that retinitis pigmentosa sine pigment,' is identical with, and is only an early transitional stage of typical retinitis pigmentosa."

This conclusion seems quite convincing, though it by no means proves that there may not be stationary cases of retinitis pigmentosa without pigmentation. My patients seem to be examples, as no ingravescence has been noted in late years.

We are thus limited to five cases upon which we may rely as probably like, or similar to my own, one each of Perrin and Huidiez and two of Morton and one of Pettlesohn. It must not be forgotten, however, that in the reports of neither case are given some highly important details. No fields of vision for colors were taken by any with the perimeter, and Morton and Pettlesohn alone give the fields for white; the existence, or not, of central amblyopia is often not stated; the refraction is not specified, and there is a lingering doubt if the ophthalmoscopic examinations were made with the iris paralyzed—a prerequisite of accurate, and even then often difficult, examination of the extreme periphery of the retina. Moreover, in Perrin's case, there was some slight pigmentation and what existed was characteristic of the common retinitis pigmentosa. It will be noticed that, as Leber writing in 1871, had not before him the report of a single case to justify his "wohlbekannte retinitis pigmentosa ohne Pigment," the expression according to his own contradiction, was meaningless, and its use was theoretically devised in the interests of classification and, perhaps, of prophecy, certainly not of history.

Wells (*Diseases of the Eye*, p. 529, Ed. of 1883,) alludes to Schweigger who, he says, noticed night-blindness and contraction of the field (only for white of course) "before the appearance of any pigment in the retina; but in all cases there was a marked contraction of the retinal arteries, whilst the older brothers and sisters had retinitis pigmentosa. He also observed this, in some rare instances,

in older persons (between the ages of 40 and 50) who suffered from all the symptoms of retinitis pigmentosa, *e. g.*, "hemeralopia" from torpor of the retina, great contraction of the visual field, without any trace of pigmentation of the retina, or any other symptom except contraction of the arteries and paleness of the disc. In similar cases, von Graefe has subsequently found a deposit of pigment in the retina."

I have been unable to find Schweigger's printed words of a date prior to Wells, but in Schweigger's *Vorlesungen*, etc., (1890, p. 143,) there is an allusion to the histologic findings of certain cases which "ophthalmoscopically gave no indication of pigmentation." Graefe and Saemisch (1877, Band. 5, Th. 5, p. 641,) say that the pigment in retinitis pigmentosa "may be entirely wanting," but with "fine points and dots, a fine brown or black punctation upon a light ground at times pale yellow, more rarely yellowish-white spots alternating with dark." Swanzy says the pigment is, in some cases, "quite absent;" de Schweinitz, that cases occur with "the usual subjective symptoms, but without the accumulation of pigment;" Fuchs speaks of the existence of cases "without pigment," and "not necessarily associated with the presence of pigment;" Berry's words are, "not so very rare to find no pigmentary changes of the characteristic form." References to the subject by other authors are still more vague or uncertain, and are hardly worthy of quotation.

As to Consanguinity, Heredity, Etc.

In my cases there was no relationship in the ancestors, so far back as I could learn; not even the grandparents were cousins. In typical retinitis pigmentosa, consanguinity, according to de Wecker, exists in 33 per cent., and Liebreich says the percentage may be as high as 50. In Huideiz's case, the maternal grandparents were cousins, and one first cousin of the maternal grandmother, born of first cousins and aged 55, was congenitally night-blind.

My cases were almost surely examples of heredity, and in the typical disease it is estimated to exist in 33 per cent.

As to sex, in the typical disease, about 70 per cent. of cases are males.

A small proportion of patients are also afflicted with deafness.

I may observe parenthetically, that in both of my patients, there is a peculiar quivering and tremor of the fingers when the hands are held loosely extended. I have never seen anything like it; it is present in the normal brother and sister, is most intense in Case 4733, somewhat less so in the man, Case 4809. I do not know that it has any correlated significance, nor what is its cause. All are otherwise healthy, hard working people. This tremulousness, the mother informs me, was very noticeable in her husband, and existed all his life, although he had no night-blindness. In the case of the girl, (Case 4733,) there is also the slightest possible tremor of the eye-ground when she is tired, or has been subjected to long examination. It could hardly be called nystagmic in character.

Pathology.

In the typical disease, the histo-pathology is well understood. De Wecker calls it a retinal cirrhosis; others call it a sclerosis; the essential process consists in a hyperplasia of the cellular tissue of the pigment-layer with infiltration of its own pigment, *i. e.*, of that of its epithelial layer. Poncet's report in Perrin's case was as follows:

"The equatorial portion of the retina was sown with small pigment heaps, the principal flecks being somewhat irregular, between which was a general pigmentation more firm. It did not exist along the vessels, but was localized in the external granular layer. The reason that the pigmentation was not typical or stellate is, that this is due to the fact where the process is complete, the pigment is deposited along the sheaths of the vessels; but as vessels do not exist in the external layer, and, as in this case, the pigment did not pass beyond the external layer, it did not take the stellate form. The limitation of the field was in direct proportion to the pathologic pigment-change of the periphery. This process had its inception in the polygonal layer of the choroid." In Huidiez's case the same result was found, the pigment not having passed beyond the external granular layer of the retina.

In the articles on "Amblyopia" and "Amaurosis," in de Wecker and Landolt's *Traite complet*, Nuel divides nyctamblyopia into two classes, the congenital or hereditary, and the acquired. From the first class must be excluded the observations made in preophthalmoscopic days,

and the author inclines to view the balance as cases of *retinite pigmentaire larvee*, either stationary or progressive, different cases showing all intermediate stages of nearly absent or typical pigmentation up to the characteristic retinitis pigmentosa.

Assuming, then, that my cases were pathologically and essentially of the same nature as those of Perrin and Huidiez, we have as the nature of the tissue-change a morbid cirrhotic process existing in the pigment layer of the retinal periphery, whereby the pigment infiltrates the retina in discrete punctate particles, but the infiltration is checked at the external granular layer, not, however, before having injured the retinal structure so as to destroy its functions as an intermediate of light sensation and color sensation. At this point the discrete pigment-infiltration becomes ophthalmoscopically visible as a half hidden punctate stippling. If the infiltration-process proceeds to its full extent, the pigment becomes heaped in large moss-like masses, and extends along the course of the obliterated capillaries, giving the typical picture of the completed and characteristic retinitis pigmentosa.

What starts the morbid process into existence, whether it is congenital or not, what checks it, if it is checked, what is its rate of progress, if progressive—these are questions that remain to be answered. Therapeutics is also inconceivable. It should be added, that we may feel absolutely assured that the morbid process is not confined to the retinal periphery; the limitations and irregularities of the color-fields of my cases clearly demonstrate that the whole retina is affected, and as my charts show, irregularly so. The limitations are relatively not concentric. But the microscope as yet fails to tell us of the infinitely small local changes that interfere with the responses to certain colors, permit them to others, while still not too extensive to prevent the general reaction to white. The indication is, that color-response is interfered with by a slighter degree of the infiltration-process than that occurring at the periphery, and one that so far has escaped the microscope. The explanation of color-sensation may result from a closer attention by the microscopist to the difference in tissue change between the periphery and the central part of the field, both in these cases and in normal retinae. More microscope and less theory, might lessen the work of the eternal theory-makers as to the nature of color-reactions.

It is evolutionally of interest to suggest that the mechanism of normal reaction to certain colors has developed later in the biologic process, and that the peripheral reaction was established subsequent to the central; hence, according to well known atavistic laws, the more unstable later acquirement of certain color-reactions, and of all sensation at the periphery of the retina, are the first or more frequent to fail in congenital exceptions, and in acquired diseases. A proof of this is the very fact of the differences in extent of the normal color-fields, the greater amount and the more constant of the colors having relatively the more extended retinal reactions, white, of course, exceeding all.

Not to wander too far afield, and into glimpsed by-paths, I have a fancy that these five cases illustrate a phase or grade of disease, of which the albinotic eye is an extreme type. It would be almost if not absolutely impossible to prove, but I wonder if the albino has not greatly contracted fields, and if the nystagmus is not a device, partly to find a less exhausted and more sensitive portion of the retina, but also by this means to get images of lateral objects on the central and reacting portion of the retina, without motion of the head. Of significance is the fact, that the nystagmic movements are lateral, not vertical. However this may be, it is highly desirable that there should be a scientific study of the chromogenesis of normal and pathologic pigmentation, including perhaps, therapeutics. Some one, let us hope, will some day learn the cause and, hence, the prophylaxis and cure of albinism—and what a benefactor he will be!

Returning to our subject, I would conclude by a suggestion that these cases of non-pigmented, peripheral retinal atrophy are possibly more numerous than we suspect. Both of my cases had passed through the unsuspecting hands of other good oculists—and with no discredit to them, surely. Argon was discovered only a year or two ago. Habit and a sensitive nervous organization enable such patients to circumvent and compensate for their partial night-blindness, at least to forget it, and unless the oculist draws them out by questioning, they would not volunteer the recital of the subjective symptoms. The perimeter alone tells of the objective symptom, and on a busy day the making of ten perimetric charts of one patient, is a task we are none too anxious to undertake.

I would finally suggest:

1. Inquire of every office patient, if he sees as well at night as other people; watch for the "bowed-head sign."

2. Test every patient (it takes but an instant) with finger movements at 90 degrees to the patient's temporal sides.

3. In doubt, test the extent of the field at least for white, with the perimeter.

4. If there is a narrowed field, carefully examine (under mydriasis) the periphery of the retina, as to its pigmentation.

5. If a case is found, report it, and besides the usual history and data, give also carefully made perimetric charts for white and the four principal colors; record also, the central acuity of form, and the exact (mydriatic) error of refraction.


The important facts to determine, are:

(a) Is the disease progressive?


(b) If so, is it the incipient stage of what later becomes typical retinitis pigmentosa? Typical cases in brothers and sisters, or inherited from an ancestor with the typical disease, would greatly help to determine this.

(c) What is the pathology of the abnormal color-fields?

(d) What is the etiology of the disease?



ANNALS OF OPHTHALMOLOGY



A Practical Journal of

OPHTHALMOLOGY,

EDITED BY

CASEY A. WOOD, M. D., CHICAGO.
CHARLES H. MAY, M. D., NEW YORK.
WENDELL REBER, M. D., PHILADELPHIA.
H. V. WÜRDEMAN, M. D., MILWAUKEE.
ALBERT B. HALE, M. D., CHICAGO.
GEORGE M. GOULD, M. D., PHILADELPHIA.

ISSUED ON THE LAST OF JANUARY, APRIL,
JULY AND OCTOBER.

The Volume for 1897 Contains Over 860 Pages of Reading
Matter, Fully Illustrated.

SUBSCRIPTION PRICE, *Per Annum*, - - - \$4.00
SINGLE COPIES, - - - - - 1.25

Sample copies will be furnished for 75c. each,

ANNALS OF OTOLOGY, RHINOLOGY AND LARYNGOLOGY, \$3.00, OR BOTH
TO THE SAME PARTY, \$5.00.

October number for 1896, containing 413 pages of Ophthalmology
and Otology furnished for 50 cts. until the supply is exhausted. This
is a first-class number, the regular price being \$1.50.

Address Subscriptions to

JONES H. PARKER, Publisher,

108 North Fourth Street, St. Louis, Mo.
