

Two cases of generalized blastomycosis / C. Christensen and Ludvig Hektoen.

Contributors

Christensen, C.
Hektoen, Ludvig, 1863-1951.
Royal College of Surgeons of England

Publication/Creation

Chicago : Press of the American Medical Association, 1906.

Persistent URL

<https://wellcomecollection.org/works/jkee57hy>

Provider

Royal College of Surgeons

License and attribution

This material has been provided by This material has been provided by The Royal College of Surgeons of England. The original may be consulted at The Royal College of Surgeons of England. where the originals may be consulted. The copyright of this item has not been evaluated. Please refer to the original publisher/creator of this item for more information. You are free to use this item in any way that is permitted by the copyright and related rights legislation that applies to your use. See rightsstatements.org for more information.

2 c. 3

3

Two Cases of Generalized Blastomycosis.

C. CHRISTENSEN, M.D.

LA CROSSE, WIS.

AND

LUDVIG HEKTOEN, M.D.


CHICAGO.




*Reprinted from The Journal of the American Medical Association,
July 28, 1906, Vol. xlvii, pp. 247-252.*

CHICAGO:

PRESS OF THE AMERICAN MEDICAL ASSOCIATION,
ONE HUNDRED AND THREE DEARBORN AVENUE,
1906.





TWO CASES OF GENERALIZED BLASTOMYCOSIS.

C. CHRISTENSEN, M.D.
LA CROSSE, WIS.

AND
LUDVIG HEKTOEN, M.D.
CHICAGO.

In neither of the cases of disseminated blastomycosis here reported is the course of the disease completed. Both patients, however, have passed out of our hands and it is extremely doubtful whether either will come again under our observation. We, therefore, place the two cases on record now and principally because certain facts noted in connection with them appear to us to add something to our knowledge of the clinical course, especially in the earlier stages of this interesting disease. It is not necessary at this time to review in detail the facts observed in connection with the previously recorded cases. That is done satisfactorily in the recent reports by Bassoe,¹ by Eisendrath and Ormsby,² and, so far as the closely related "coccidioidal granuloma" in California is concerned, by Ophüls.³

REPORT OF CASE 1.

Summary.—Man, aged 28, farmer in northeastern Iowa, was taken with acute fever in November, 1904, lasting one week. At the end of the second week numerous spots and lumps had formed on the face, head, neck, hands, forearms, lower extremities and back. Some of these lesions subsided, others grew into larger and smaller ulcers and abscesses, most of which refused to heal. There was some loss in weight. On admission to hospital, Jan. 10, 1906, 60 lesions of the skin and subcutaneous tissue were recognized, most of them being superficial ulcers and scars. Blastomycetes were present in

1. Jour. Infect. Dis., 1906, iii, p. 91.
2. Jour. A. M. A., 1905, xlv, p. 1045.
3. Ibid., p. 1291.

pure culture in contents of abscesses and in sections of the ulcers. Some pulmonary signs, but no blastomycetes or tubercle bacilli were demonstrable in the sputum. There was considerable general and marked local improvement. He left the hospital April 6, 1906.

Patient.—R. K. U., born near Decorah, Iowa, twenty-eight years ago, entered La Crosse Lutheran Hospital Jan. 10, 1906.

Previous History.—His father's mother and one brother died of consumption after preceding pleurisy. As a child he had measles; otherwise he was healthy. For the last five years he has been a milk peddler, besides helping on the farm.

Present Illness.—In November, 1904, he was taken suddenly ill with headache, chills, pain in back and limbs, "as if he had taken cold." He felt feverish for a week, but did not stay in bed. At the end of the second week he observed that red spots or lumps from 1 to 2 cm. in diameter had broken out on the face, on the head and neck, hands and forearms, on the lower extremities and a few on the back of his body. The six or seven eruptions on the scalp reached in a few days the size of large hazel nuts, then broke, discharged considerable matter, dried up and healed in about two weeks.

The other spots or lumps started to grow with different rapidity, some quite early, others being apparently stationary for from five to six months. In a month some reached a diameter of from 2 to 4 cm., with an elevation of say 2 mm. over the surrounding skin; then they commenced to form crusts and disappeared gradually, leaving a more or less brown depression in the skin. Others formed elevations of reddish-blue color; matter would discharge itself through many pinhole openings, ultimately leaving a red granular, easily bleeding and very tender ulcer. Several of the smaller ones of this suppurating kind healed also in about three or four months, leaving the same atrophic skin as landmark.

The healing began always in the center. The larger ones reached a size of from 4 to 7 cm., and showed no tendency to permanent improvement.

Course of the Disease.—In June, 1905, after he had participated in the spring work on the farm, some of the spots on both legs and on the right foot, which had been nearly stationary since the primary eruption in 1904, began to grow rapidly and soon made it difficult for him to move about. Several abscesses formed; the first ones, in both submaxillary regions, were opened in July, one the "size of a fist" in the left supraclavicular region in October, two smaller ones on the flexor side of the left wrist and one as large as an egg over the right ulna a little below the olecranon in November, 1905.

In October and November, 1905, there was great improvement. All ulcers, especially on the lower extremities, diminished rapidly, secretion ceased, the surface flattened, glisten-

ing scales seemed to substitute granulations, tenderness disappeared, and he again moved about very freely, "perhaps too much."

In December, 1905, he became worse, all the apparently healing ulcers breaking up almost simultaneously, and he was again forced to stay in bed most of the time. In the face, where the eruptions were very numerous, the growth was slow

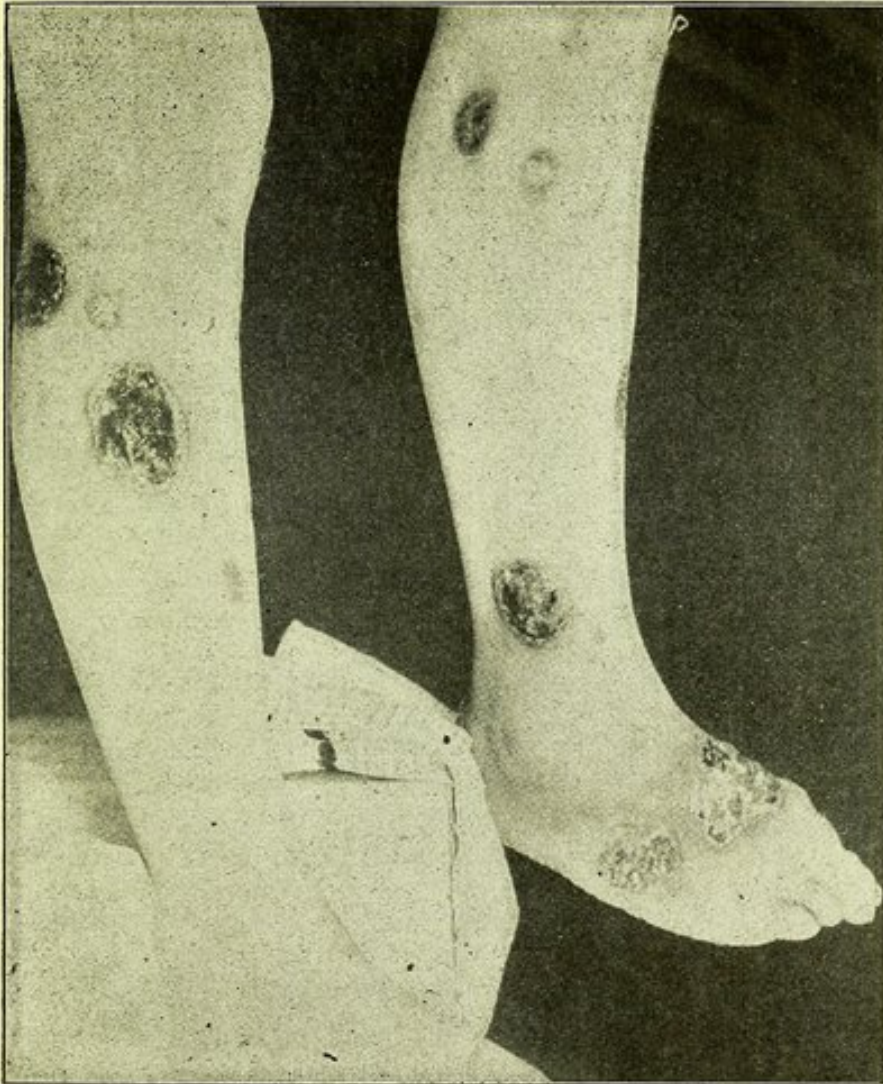

Fig. 1.—Showing lesions in skin over lower extremities in Case 1.

and the granulations not so luxurious; only a few smaller ones suppurated, leaving scars on the chin and cheeks.

The patient claims that no new spots have formed since the first eruption in November, 1904, and that consequently all infiltrations or ulcerations have developed from pre-existing lesions.

With the exception of pain, especially on the changing of bandages, and the necessity of staying in bed, his general condition has been fair. Appetite has been good as a rule,

but still he has decreased in weight from 174 to 145 pounds. He had no chills nor night sweats, but some cough with slimy expectoration the last three weeks. The patient knows of no similar case in his neighborhood.

Present Condition.—There are 52 superficial skin lesions, including 16 scars and 8 deeper processes, either cutaneous

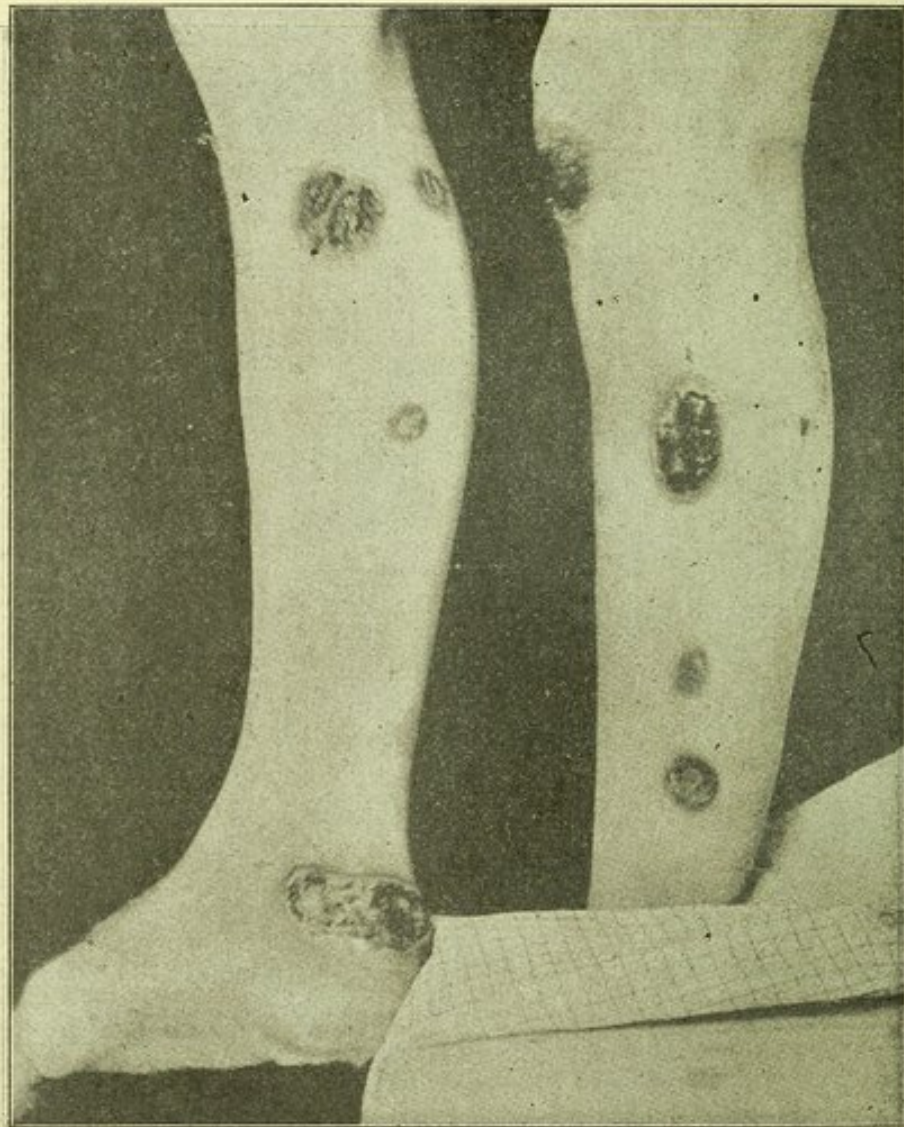

Fig. 2.—Lesions in skin of lower extremities in Case 1.

infiltrations or subfascial abscesses, only one of which has healed. Of the eruptions on the scalp no trace is to be seen, as growth of hair is even all over. In the face eleven eruptions can be recognized, three of which have healed, leaving rather deep but not wide depressions. Except some smaller ones on tip and wing of nose, the larger areas seem to be healing; their margins are still, however, elevated, bluish in color, partly covered with a smeary crust, on removal of which small bleeding points are seen. The margins slant

toward the center, which is covered more or less with whitish scales, the color being more like that of normal skin. The eruption on the glabella, adjoining eyebrows and nose makes the man look older than he is and gives at first sight an appearance not unlike a leper. An ulcer on the right temple has everted the external angle of the eyelids. One area covers the left half of the upper lip, left angle of the mouth and extends into the left nostril. On the back of the neck are two smaller, suppurating lesions and one scar.

On his back are three ulcers from 1 to 3 cm. in size, slightly elevated, covered with white scales; of these he is not aware. In the lumbar region are scars after two small ulcers, which did not annoy him any.

In the right submaxillary region is a small red scar from an opened abscess. In the left submaxillary region is an area of red infiltrated, undermined skin, where pus can be pressed out through several openings. In the left supraclavicular region is a fistulous opening, through which pus discharges freely.

On the dorsum of both hands are several large ulcerating surfaces, elevated about 5 mm. above the surrounding healthy skin. They consist of papillomatous granulations within an infiltrated, bluish-red wall, about 1 cm. wide, and partly covered with brownish, tallow-like crusts. On one finger are two slightly elevated areas with white dry scales.

On the volar aspect of the left wrist are two separate infiltrations in the skin with fistulous openings.

On the extensor side of the right arm below the elbow joint, is a small, deep, granulating ulcer, leading into a cavity under the fascia for about 4 cm.; no denuded bone is found. On the extensor side of the left arm, a little above the wrist, is a fluctuating tumor, approximately 6 cm. in diameter, over which the skin is freely movable and of normal color.

On the right thigh are seen four brownish scars or depressions from 2 to 4 cm. in diameter. On the right leg is one scar and two ulcers from 4 to 5 cm. in size. On the dorsum of the right foot are two areas, one 5x3 cm. and one 6x7 cm.; above the right heel is one 2.5x7 cm. In the left inguinal region is a subcutaneous abscess with a red, infiltrated, fistulous covering. On the left thigh are three scars and two suppurating ulcerations, on the left leg six scars and four ulcerations. (Figs. 1 and 2.) All lesions on the lower extremities look more active, the secretion is more profuse, and the odor very offensive. They are also extremely painful to the touch.

Over both lungs a few bronchial râles are heard and over a small area over the fourth rib in the papillary line there is fine creptitation. No blastomycetes or tubercle bacilli were found in the sputum. There are no enlarged lymph glands and the urine is normal.

Demonstration of Blastomycetes and Microscopic Examination.—There was no difficulty in recognizing blastomycetes in the form of characteristic, large double-contoured, occasionally budding bodies, in the unstained smears of the pus diluted with salt solution. No forms showing endogenous sporulation were seen.

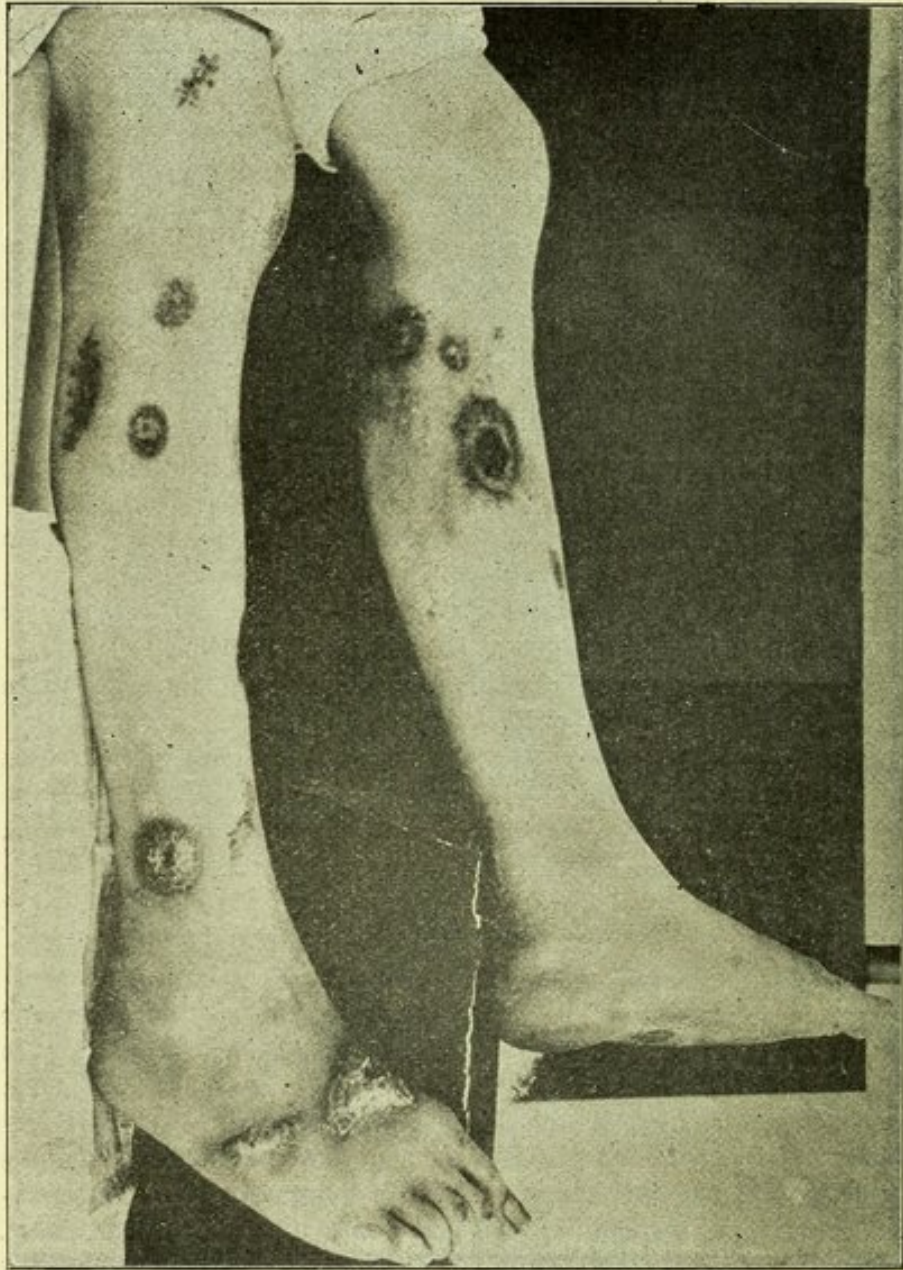


Fig. 3.—Scars in skin of lower extremities after ulcers have healed in Case 1.

Rather liberal quantities of pus from unbroken abscesses, secured as carefully as possible to prevent contamination, were smeared on numerous agar slants (plain, glycerin, glucose), and after several days' incubation about 40 per cent. of the tubes showed pure growths of blastomycetes, the rest

of the tubes being sterile. The number of colonies in the different tubes varied greatly, some tubes giving only one or two colonies, others a dozen or more. The colonies began as small, delicate, raised points that slowly grew into wrinkled masses, which eventually sent offshoots into the air and down into the depths of the medium. The organism belongs to the hyphomycetoid subgroup of Ricketts,⁴ and its cultural characteristics are being studied further.

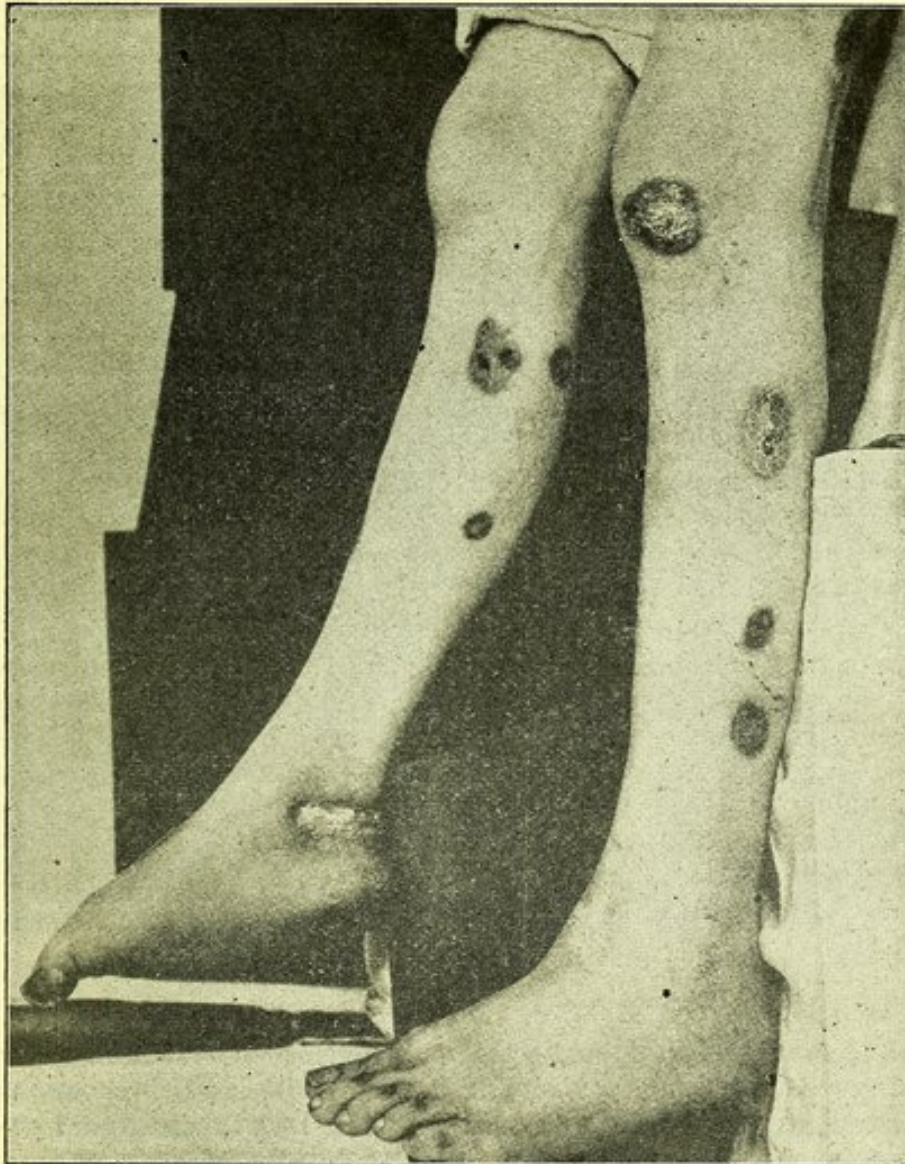


Fig. 4.—Scars in skin of lower extremities in Case 1 after ulcers had healed.

In sections of abscess walls and of cutaneous ulcers, blastomycetes were found quite easily, generally free, surrounded by leucocytes, sometimes within giant cells. The ulcers

4. "Oidiomycosis (Blastomycosis) of the Skin and Its Fungi." Jour. Med. Research, 1902, vol. vi, p. 374.

present the structure characteristic of blastomycetic dermatitis—marked epithelial hyperplasia, inflammatory infiltration with giant cells here and there, and miliary abscesses. Tubercle bacilli or typical tubercles were not found.

Treatment and Further Course of Disease.—At first the treatment consisted in administration of potassium iodid, beginning with 4 grams and increasing the dose to 8 grams a day, besides local applications of different antiseptic solutions; boric acid, copper sulphate, silver nitrate and corrosive sublimate.

After several weeks' hesitation and refusal, he was persuaded to have the ulcers and abscesses curetted, which was done Feb. 14, 1906. The whole granulating surface of every surface was removed in one mass, leaving a perfectly smooth, freely bleeding, not very deep defect in the skin; no further curetting was necessary except of the margins.

After a while there commenced to form in the ulcers new granulation tissue, epidermization took place from the edges and eventually complete healing resulted, the healed areas being dark red in color, covered with scales, and (in distinction to the spontaneously healed foci), their center was more elevated than their margins. (Figs. 3 and 4.)

The deeper abscesses were curetted and counter-drained, but they have shown less tendency to heal, although secretion has diminished in all of them, especially during the last four weeks.

From March 16 to April 6 four injections were given of blastomycetic vaccine prepared by Dr. Ricketts from cultures of the organisms isolated from the patient, but of course no conclusions can be drawn as to the effect of the vaccine. The first injection was succeeded by a rise in the leucocyte count of 4,600, but the succeeding injections had no definitely recognizable immediate effect either on the leucocytes or on the temperature, which always fluctuated between 98 and 101.

The patient left the hospital April 6, 1906. Most of the lesions had healed and he could walk without inconvenience.

REPORT OF CASE 2.

Summary.—Norwegian, aged 58, farmer in Wisconsin for many years, became acutely ill Jan. 23, 1905, and three weeks later a large abscess had formed in the left lumbo-dorsal region.

Somewhat later, a similar attack occurred, and before long a swelling appeared in the left forearm and on the thighs and right forearm eruptions that formed raised granulating areas that would heal partially and break open again. In October, 1905, an abscess formed in the right arm and more recently in the left arm. Blastomycetes were found in the pus and tissues of the ulcers. Excision and curettement of lesions was performed, in addition to general treatment.

There were cough and expectoration—tubercle bacilli, but no blastomycetes were found in the sputum.

Patient.—C. O. Q. entered La Crosse Lutheran Hospital Feb. 21, 1906.

Previous History.—He was born in Norway fifty-eight years ago and has been in America thirty-eight years; for the past twenty-seven years he has been farming in Wisconsin. There is much tuberculosis in his family. He has been a dipsomaniac for many years, but has always been healthy.

Present Illness.—Jan. 25, 1905, he was suddenly taken ill

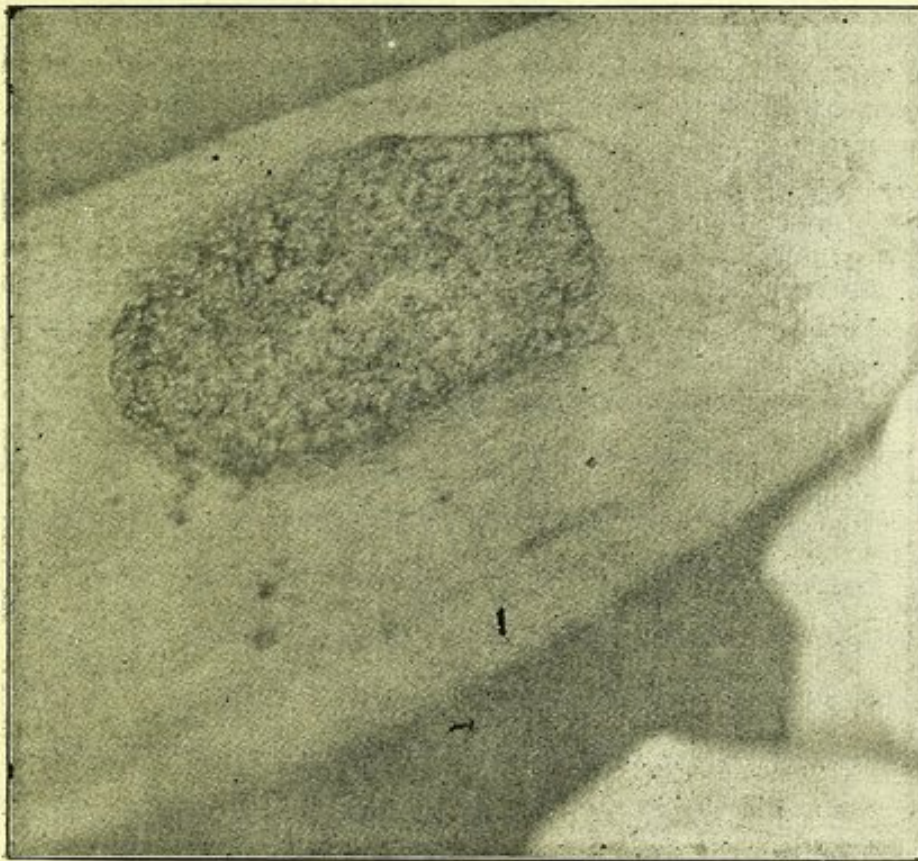


Fig. 5.—Ulcer on right thigh in Case 2.

with chills, headache, pain in the left chest and general malaise. There developed a large swelling in the left lumbo-dorsal region, and three weeks after onset an abscess surrounding eleventh and twelfth ribs and extending into the paranephritic tissue was opened and the eleventh and twelfth ribs were resected. Three weeks later, when recovering from the operation, he claims to have had another attack of chills and general debility. Soon after he detected a swelling under the skin in the middle of the left forearm on the extensor side. This has varied a little in size, has never been larger than an almond and never painful.

In the middle of May an eruption "like a ringworm" appeared on the outside of the middle of the right thigh. A little later he noticed a similar affection on the extensor side of the right forearm and one over the left trochanter. These eruptions began as red spots, 2 cm. in diameter, and increased gradually in size, became elevated over the surrounding skin, assumed a granular surface, and a crust of peculiar offensive odor formed. The eruption on the left hip ceased to grow, when it—in about two months—had reached its present size of 3x4 cm. and has always been covered more or less with dry crust. The eruptions on the right arm and thigh grew more rapidly, became more elevated, the granulations larger and more tender, the discharge more abundant and the surrounding wall higher. Several times during the autumn it appeared as if these two large ulcers would heal as the granulations would disappear, first in the middle, and in a short time the whole surface would become covered with red smooth skin, almost to the margins, which, however, were still elevated and not participating in the healing process. In a few days the ulcers would break out again and the same high granulations with the same offensive secretion would form. The patient used boric acid compresses and no internal medication.

Course of Disease.—During October, 1905, the right arm above the elbow began to swell and be painful. For over two months he suffered very much and lost in flesh. The mobility of the elbow joint decreased somewhat during that time. In the first part of January, 1906, this swelling was incised and a large amount of pus evacuated with instant relief. The opening has been discharging ever since, but there is pain only on attempting to straighten the arm.

Lately he has observed two swellings on the left forearm, the smaller one near the elbow in front, the other 6 cm. above the elbow on the back of the arm; both are a little painful to pressure.

Since May, 1905, when he recovered from the operation, he has been in fairly good health, and although he has not been able to work, he has not regarded himself as sick except for the inconvenience of the ulcerations and the pain during November and December, 1905, before the abscess on the right arm was opened. He claims that he has gained some lately. He has not been aware of any fever of late. Appetite has been good and the natural functions in order. Lately he has been coughing considerably.

Present Condition.—The patient looks old, with sunken cheeks, grayish color of skin, pale lips and conjunctivæ. Height 5 feet 6 inches, weight 110 lbs.

In the left lumbo-dorsal region is a scar 12 cm. long; the twelfth rib and the greater part of the eleventh are missing.

and whenever he speaks or coughs the integument bulges out.

The swelling on the left arm (which is the second lesion in order of appearance) is about 4 cm. long, 2 cm. wide and 1 cm. high; the skin over it is of normal color and freely movable; the mass seems to be attached to the deeper layer of muscles, is slightly fluctuating, and somewhat painful to pressure.

On the same arm are the two swellings, which recently made their appearance, the one right above the elbow has the size of an almond, the other, as large as a hen's egg, is situated 6 cm. above the elbow; it seems to be attached to the triceps, with which it moves. This last one has grown very rapidly in size. Both are soft, fluctuating.

The first "ringworm-like" eruption on the right thigh has now developed to an ulcer 10 cm. long and 5 cm. wide. (Fig. 5.) It is surrounded by an infiltration that forms a wall or margin about 1 cm. wide and 7 mm. high, a little undulated, of bluish-red color, partly covered with light brown sebum-like crust, on removal of which fine openings are seen. This wall or margin surrounds an uneven granulomatous or papillomatous surface. The granulations bleed easily and are very tender to the touch. Some of them form slender papillæ.

The eruption on the left hip, which the patient claims has been stationary for at least seven months, is only slightly elevated over the surrounding skin, and covered with a brown crust; the whole area has a more warty appearance.

The lesion on the right forearm is the largest, being 13 cm. long and 7 cm. wide. (Fig. 6.) It differs from the eruption on the right thigh in that a healing process has commenced in its central part, where the granulations are substituted by thin skin, which looks quite healthy, when the crust is removed.

On the same arm is an abscess, opening 5 cm. above the external condyle. The whole lower extremity of the humerus is very thickened. Above the internal condyle is a soft fluctuating swelling, covered with red infiltrated skin, but it does not communicate with the former opening.

No enlarged lymphatic glands are to be found anywhere.

There are bronchial râles over both lungs. No tubercle bacilli or blastomycetes were found in the sputum on entrance. The urine contains no albumin nor sugar.

Demonstration of Blastomycetes and Microscopic Examination.—Blastomycetes were found in the unstained smears of the pus from an unopened abscess. No other micro-organisms were found in stained preparations. Smears of the pus on agar slants gave pure cultures in about one-half the tubes. This organism also proved to belong to the hyphomycetoid group of Ricketts. Blastomycetes were demonstrated also in

the sections of the extirpated ulcers and in the walls of abscesses. The ulcers were typically blastomycetic in structure. Typical tubercles with caseation were not observed.

Treatment and Further Course of Disease.—The deeper abscesses were either curetted or excised. The area over the left hip was excised. In these instances healing resulted. The lesion on the right thigh was excised and grafted, but only some of the grafts took and the wound healed by granulation tissue. The area on the right arm was curetted, leaving an island of healthy looking skin in the center. Four days later this area was studded with yellow points as large as pin heads; one per cent. solution of copper sulphate was applied in the form of compresses and healthy granulations soon sprang up and healing has since progressed from the margins. During his stay in the hospital he was given potassium iodid

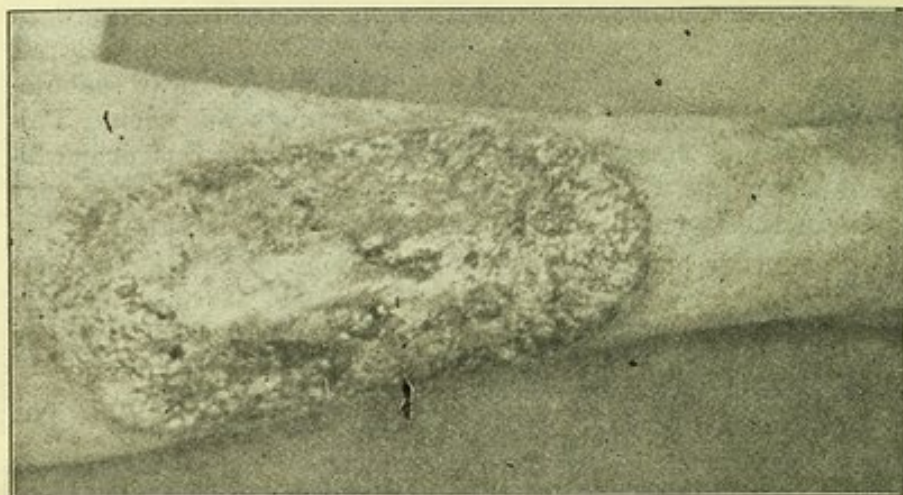


Fig. 6.—Ulcer on right forearm in Case 2.

up to six grams daily. He also received four injections of blastomycetic vaccine prepared from organisms cultivated from his own lesions, but whether it had any influence on the rapid healing of the local lesions can not be stated.

During the last two weeks or so of his hospital sojourn the cough and expectoration increased and eventually tubercle bacilli were found in the sputum, but no blastomycetes.

The temperature ran from 98 in the morning to 100 and 101 in the evening. He left the hospital April 6, 1906.

REMARKS.

1. *Mode of Invasion.*—In these two cases the dissemination of the blastomycetic infection appears to have taken place quite suddenly and without the presence of any chronic, external lesion that might be regarded as

the primary localization. In Case 1 the onset is like that of an acute general infectious disease, numerous separate lesions developing simultaneously in the skin and subcutaneous tissue directly on the heels of a general febrile reaction. In Case 2 the onset is also definite, but here the localization of the infection seems to have taken place in the deeper tissues before the subcutaneous invasion. Of course, the question whether or not the pararenal abscess, which formed soon after the first general reaction, really was of blastomycetic nature probably never can be decided, because the pus was not examined. At all events, other foci had formed already, or did form soon after, of the blastomycetic nature of which there can be no question.

The actual portal of entry of the infecting organism in these cases is, of course, largely a matter of conjecture. In Case 1 the history points to the lungs. In most of the previously reported instances of systemic blastomycosis the lungs are regarded as the point of primary attack. The hypothesis that blastomycosis may result from aërial infection might well form the basis for experiments to determine (a) whether the organisms in question are conveyed easily in air currents when dry, (b) whether they retain their vitality and infectiousness after drying, and (c) whether they are carried in minute droplets of sputum in which we know they may occur in pulmonary blastomycosis (Eisendrath and Ormsby, Bassoe). In this way some knowledge might be obtained as to the danger of established cases of blastomycosis as sources of further infection.

In the majority of instances of systemic blastomycosis (and coccidioidal granuloma) the involvement of the integument has been marked. The organisms seem to have a special predilection for the skin which may be an important avenue for escape perhaps to new hosts. As yet we know nothing of the occurrence of pathogenic blastomycetes or oidiomycetes in nature and consequently we do not know whether the cases of blastomycosis that are being recognized with increasing frequency, particularly in this part of the world, are the result of infection with facultative parasites or facultative saprophytes, but so far as the mechanisms for

continued parasitic existence are concerned the organisms of blastomycosis would appear to have reached a high degree of parasitic adaptation.

The frequent development of typical blastomycetic ulcers (dermatitis) in the course of generalized blastomycosis suggests that even more or less isolated, cutaneous, blastomycetic lesions may develop as the result of infection by way of the blood current and not necessarily always, as seems quite natural, from direct implantation from without. This possibility should, we believe, receive particular attention in those cases in which the lesion is located on parts of the body, e. g., the back, not ordinarily exposed to external infection. The fact that blastomycotic foci sometimes undergo spontaneous healing (illustrated especially well in our Case 1) may make it difficult to trace the sequence of events in a given case.

Treatment.—As yet no effective treatment for systemic blastomycosis has been discovered. Judging from the literature the problems of the nature of the finer reactions to blastomycotic infection and the formation of specific antibodies have received but little attention. The character of the lesions of blastomycosis—the accumulation of leucocytes, the formation of giant cells, and the phagocytosis of blastomycetes—indicates that this is an infection in which phagocytosis is an important means of defense and of healing. Certain preliminary test-tube experiments showed that phagocytosis of blastomycetes is favored by the presence of normal serum, and the idea arose that it might be possible to stimulate the greater formation, in cases of blastomycosis, of the body that promotes phagocytosis (opsonin), as well as of other antibodies, by the injection of blastomycetic substances in readily absorbable form. It was thought that the resistant character of the micro-organisms coupled with their enclosure in cellular exudate and granulation tissue possibly prevents the absorption in proper quantities of the substances necessary to call forth strong immunizing reactions. Hence, in order to hasten, if possible, the reactions that favor healing, we injected in each of our cases a sterile blastomycetic vaccine prepared by Dr. H. T. Ricketts of the correspond-

ing organism. This procedure is based directly on the principles underlying A. E. Wright's method for the treatment of infections by vaccines composed of corresponding bacteria. Unfortunately the patients left the hospital at a time when no conclusion of value could be drawn as to the results of the vaccine. Work is at present in progress to develop certain methods whereby the effect of the blastomycotic vaccines may be estimated *in vitro*, in the hope that it may be possible to furnish some guidance to the treatment.

