

The operative treatment of cancer of the breast : with an analysis of a series of one hundred consecutive cases / by J. Collins Warren ; (assisted by Walter B. Odiorne and William F. Whitney).

Contributors

Warren, John Collins, 1842-1927.
Odiorne, Walter B.
Whitney, William F. 1850-1921.
Tweedy, John, 1849-1924
Royal College of Surgeons of England

Publication/Creation

[Philadelphia, Pa.] : [J.B. Lippincott], 1904.

Persistent URL

<https://wellcomecollection.org/works/cu26gx22>

Provider

Royal College of Surgeons

License and attribution

This material has been provided by This material has been provided by The Royal College of Surgeons of England. The original may be consulted at The Royal College of Surgeons of England. where the originals may be consulted. The copyright of this item has not been evaluated. Please refer to the original publisher/creator of this item for more information. You are free to use this item in any way that is permitted by the copyright and related rights legislation that applies to your use. See rightsstatements.org for more information.



Wellcome Collection
183 Euston Road
London NW1 2BE UK
T +44 (0)20 7611 8722
E library@wellcomecollection.org
<https://wellcomecollection.org>

ANNALS OF SURGERY

A Monthly Review of Surgical Science and Practice.

Edited by LEWIS STEPHEN FOLGER, M.D., LL.D., of New York.

With the Collaboration of

WILLIAM WHITE, Ph.D., M.D., 312 WILLIAM MACKENY, M.D., LL.D.,
OF PHILADELPHIA.

W. H. A. JACOBSON, M.Ch.,
OF LONDON.

TABLE OF CONTENTS

ORIGINAL MEMOIRS	
I. The Surgical Treatment of Facial Paralysis by Nerve Anastomosis. By ALBERT VOLKBY, M.D.	561
II. On the Feasibility of Operative Relief of Various Forms of Facial Paralysis. By LEWIS STEPHEN FOLGER, M.D.	567
III. Unconvergent Strabismus. By ALBERT D. COOPER, M.D.	582
IV. The Surgery of the Lower Uvula. By WILLIAM H. FRANK, M.D.	588
V. Contributions to the Surgery of Perineal Hemorrhoids. By JACQUES M. BRUNSWICK, M.D.	592
VI. Extended Circular Ligaments and their Significance in Carcinoma. By A. W. HOWE, M.D., F.R.C.S.	598
VII. A Case of Endothelial Epithelioma of the Forearm Artery for Quiescent Type. By ALBERTO RIGGI, Professor, M.D., CAP.	602
VIII. The Radical Removal of a Large Epithelioma of the Chest Wall, involving the Diaphragm. By C. ALLEN, Jr., M.D.	606
IX. Multiple Epithelioma from a Surgical Neoplasm. By CHARLES CLARENCE COOPER, M.D.	610
X. Clinical Anatomico-Pathological. By LEWIS STEPHEN FOLGER, M.D.	614
XI. Tuberculosis of the Esophagus, together with Other Lesions, sometimes associated with the Lung. Report of a Case. By CHARLES H. COOPER, M.D.	618
XII. Contribution to the Literature of Old Intra-uterine Protrusions of the Uterine Neck. By A. F. JONES, M.D.	622
XIII. An Old Trochanter detached by the Kluge's Forceps. By ALBERTO RIGGI, M.D.	626
XIV. An Anomalous Tricuspid. By EDWARD W. GILBERT, M.D.	629
XV. A New Ovarianian Trochanter. By W. JACQUES PEYRON, M.D.	633

TRANSACTIONS OF THE NEW YORK SURGICAL SOCIETY.	
Minutes Meeting, January 20, 1903	637
TRANSACTIONS OF THE CHICAGO SURGICAL SOCIETY.	
Minutes Meeting, February 6, 1903	643
REVIEWS OF BOOKS.	
Frederic J. and M. E. Carter and Other Authors: "A Practical Treatise of Anatomy, Laboratory and Microscopic, Comparative and Experimental."	647
CORRESPONDENCE.	
Exhibition of Article Rays of Light during Operations for Cancer of the Breast.	651
A Trial of a Machine for Carrying Glass Slides in a Patient's Bag.	655
Notes	659

Published Monthly by J. B. LIPPINCOTT COMPANY, Philadelphia, Pa.
 Great Britain: Cassell & Co., Limited, Amersham; Cassell, Mackenzie & Co., London.
 Price in United States, \$4.00 a Year in Advance. Single Number, 30 Cents.
 Price in Great Britain and Australia, Single Number, Two Shillings.
 One Guinea a Year in Advance.

Printed at the Press Office in Philadelphia, and authorized for transmission through the mails at second-class matter. Copyright, 1903, by J. B. Lippincott Company, 490 Broadway, New York.


20.

Compliments of
 J. Collins Warren, M. D.
 68 Beacon Street,
 Boston, Mass.

THE OPERATIVE TREATMENT OF CANCER OF THE BREAST

BY J. COLLINS WARREN, M.D., HON. F.R.C.S. (ENG.),
 Boston, Mass.

Reprinted from Annals of Surgery, December, 1904



THE OPERATIVE TREATMENT OF CANCER OF THE BREAST.

WITH AN ANALYSIS OF A SERIES OF ONE HUNDRED CONSECUTIVE CASES.

BY J. COLLINS WARREN, M.D., HON. F.R.C.S. (ENG.),

OF BOSTON, MASS.,

Professor of Surgery in Harvard University.

(Assisted by WALTER B. ODIORNE, M.D., and WILLIAM F. WHITNEY, M.D.)

THE new method of operating upon the breast for cancer has now been in use for a sufficient length of time to enable even the most critical observers to obtain a satisfactory estimate of its value.

The reports which have been received from time to time by various writers fail usually to give as complete and convincing details as to the relief or curability of cancer by this operation as the professional public would like to obtain.

With this end in view therefore, the writer has collected a series of 100 consecutive cases of cancer of the breast, taken from his hospital and private practice, in which at least three years have elapsed from the time of operation.

These cases have all stood the test of careful microscopic examination,—in the large majority of the cases by one observer (Dr. W. F. Whitney),—and their subsequent history has been relentlessly followed up by Dr. Walter B. Odiorne. The returns are therefore so far complete that the writer is able to give end results bearing upon all important points of interest in connection with this operation.

This group represents an average set of cases such as the surgeon would consent to operate upon with hope of benefit, if not of cure, to the patient. There has been no attempt to select favorable cases, only those cases being rejected where it was manifestly impossible mechanically to remove the disease with the knife. The results may therefore be said to give us

an idea of what we may expect to accomplish under the usual conditions of surgical practice. A careful analysis of the different types and stages of the disease shows also what we have a right to hope for under more favorable conditions.

During the period embraced by this series, which covers nearly two decades, the operation has undergone many radical changes; but even in the earliest cases the scope of the operation was a sufficient departure from old methods to bring them within the pale of modern work. The ever-increasing improvement in technique and diagnosis and the education of medical men to recognize the importance of early surgical interference will justify the hope that still more encouraging results may eventually be obtained than are shown in this article. It is now my custom, in all cases of tumor of the breast, in which there is uncertainty as to the nature of the growth, to explore the gland through the so-called Thomas incision, and thus arrive at the earliest possible diagnosis.

Etiology.—There are some interesting facts brought out under this head, particularly those bearing upon the origin of the disease in pre-existing lesions of the breast. There were five cases in which it was evident that cancer had developed as a secondary process in either a cyst wall or in that chronic inflammatory condition of the gland tissue which is the accompaniment of cystic degeneration. In three other cases, not in this series, I have also observed the changes of cyst into cancer. One of these cases I saw nearly two years before operation was finally performed, and cancer was then found growing in the cyst wall.

All but one of the five cases in this series are reported as "cures." In another case cancer was found growing in a small fibroma, about the size of a horse-chestnut, which had existed for over twenty years. Such experience is strong testimony in favor of the early operation of non-malignant tumors of the breast. Still more marked is the influence of true inflammation, whether arising from sepsis or trauma. There was a history of abscess in six cases and a history of some kind of blow in sixteen cases. Adding these cases together, we

find the existence of a pre-existing lesion of some kind in twenty-eight cases. There was a family history of cancer in eighteen cases. The age of the patients is definitely known in ninety-nine cases, and the following table shows the disease to be most commonly observed in the sixth decade.

Age of Patients at Time of the Appearance of the Disease.—One case observed between the age of 20 to 29 years (inclusive); 14 cases between 30 to 39 years; 28 cases between 40 to 49 years; 36 cases between 50 to 59 years; 15 cases between 60 to 69 years; 5 cases between 70 to 79 years.

The average age of those cases cured by operation was 52.9 years. The youngest cured was thirty-one years old and the oldest seventy-three years old.

Diagnosis.—The pathological diagnosis was made in the great majority of cases by one individual, and the terms used, therefore, have a distinctly comparative value. "Medullary cancer" was the report in forty cases; "cancer" in twenty-six; scirrhus in twenty-eight; adenocarcinoma in three; colloid cancer in two, and Paget's disease in one. A careful record in duplicate was kept of the diagnosis of the case in every operation performed at the Massachusetts General Hospital, and a similar system was carried out at each operation in private practice. A pathologist is present at each operation, and a provisional diagnosis is made by the microscope at the time. A report is made also of the condition of the lymph-glands removed, and dissection is continued until the report comes back that the last gland removed was not infected. If the disease approaches too near the healthy border of the structures removed, the operator is immediately advised of the condition. This system has been carried out in nearly every case, and the writer has found it of the greatest assistance in making an intelligent dissection of the parts involved. Of late, microscopic sections of the specimens have been preserved, and it has thus been possible to make a new study of certain cases, those in which a cure has been effected being of special interest.

One most valuable feature of this system, that is, of having a trained pathologist at the operating-table, is the pos-

sibility of thus saving all breasts in which the growth is not malignant. In this way, and by means of the Thomas incision, the mammary gland may be inspected from behind, benign morbid growths removed, and the organ restored to its original contour. The writer has devised an operation for this purpose, which he proposes to describe at length in another article as "Plastic resection of the mammary gland."

Prognosis.—Of these 100 cases there are twenty-six that can be regarded as cured, that is, the patients are either alive now (free from recurrence) or have died from other causes than cancer at a time three years or more after the operation or after the removal of recurrent growths. These cases are Nos. 1, 2, 3, 4, 5, 9, 14, 19, 20, 35, 38, 39, 42, 44, 54, 59, 60, 64, 66, 76, 77, 79, 81, 93, 97, 98.

Two of these cases had recurrences,—one in the axilla and one in the pectoral region. The former appeared five years and the latter nine years after operation. These nodules were removed, one fifteen years ago and one ten years, and both patients are alive and well at the present time.

Seven of the twenty-six cases have died of causes other than cancer, there having been no recurrence in any case at periods from four to fourteen years after the operation. These cases have been subjected to searching inquiry, and the writer is satisfied that death was in no case due to cancer.

Cause of Death in "Cured" Cases.

- CASE 2.—Apoplexy, 10 years after operation.
 CASE 5.—Cholera, 6 years after operation.
 CASE 9.—Pulmonary hæmorrhage, 14 years after operation.
 CASE 20.—Grippe, 13 years after operation.
 CASE 42.—Pneumonia, 10 years after operation.
 CASE 60.—Apoplexy, 8 years after operation.
 CASE 77.—Pneumonia (myxœdema), 4 years after operation.

In addition to these cases there are four patients, who are alive and well without further recurrence, in whom recurrent

nodules have been removed. These cases will be referred to more at length under the head of "recurrence."

We have therefore at the present time twenty-three cases that are alive and well and seven that have died of other causes than cancer,—a total of thirty out of 100 cases, or nearly one-third.

Of the remaining nineteen cases in which the patient is alive and well without recurrence over three years after operation,

	I	is	alive	and	well	20	years	after	operation.
	I	"	"	"	"	19	"	"	"
	I	"	"	"	"	18	"	"	"
	I	"	"	"	"	14	"	"	"
	I	"	"	"	"	11	"	"	"
	2	are	"	"	"	10	"	"	"
	2	"	"	"	"	8	"	"	"
	3	"	"	"	"	7	"	"	"
	5	"	"	"	"	5	"	"	"
	I	is	"	"	"	4	"	"	"
	I	"	"	"	"	3	"	"	"

It will be observed that the majority of living "cures," twelve out of nineteen, range on this list from five to ten years after operation,—there being only five living over ten years after operation.

This small number is to be accounted for by the average age of the patients, fifty-three years, as those who have survived the operation ten years are always liable to the susceptibilities of elderly people, as the table of deaths from "other causes" shows. Recurrence, as will be seen lower down, has played no part in the mortality of the more mature cases, for in no case has a recurrence been seen after a period varying eight to nine years after the operation.

The pathological status of the cases cured is interesting, and a study of this point is suggestive as valuable aid to the prognosis in any given case. In two cases the diagnosis was "colloid cancer;" in six cases "cancer;" in twelve cases "scirrhous;" in three cases "medullary cancer;" in one case Paget's disease, and in two cases adenocarcinoma.

If we compare these figures with the total number of each variety of cancer, we find that in colloid cancer and in Paget's disease there were 100 per cent. cures.

In adenocarcinoma 66 per cent. cures; in scirrhus 43; in cancer 23, and in medullary cancer only 7 per cent. cures.

Thus it appears that the most favorable diagnosis is that of colloid or of Paget's disease of the nipple, and that adenocarcinoma comes next. These, however, are unfortunately rare forms of the disease. "Scirrhus" and "cancer" together constitute more than half the cases, and the percentage of cures in these two varieties combined is about 33. If, however, we combine all the varieties except "medullary," we have sixty cases with twenty-three cures, or 40 per cent. Unfortunately, the remaining forty cases, being medullary, have the small percentage of 7 in the list of cures.

The following table gives a summary of these percentages:

Percentage of Cures in Each Variety of Cancer.

Disease.	No.	Cures.	Percentage.
Colloid	2	2	100
Cancer	26	6	23
Scirrhus	28	12	43
Medullary	40	3	7
Paget's disease	1	1	100
Adenocarcinoma	3	2	66
	100	26	

Disease.	No.	Cures.	Percentage.
Non-medullary	60	23	38

Clinical Stages of the Disease.—The clinical course of the disease may be divided into three stages, which are sufficiently well marked from one another for the purposes of classification.

The first stage includes all cases in which the disease still remains practically in the condition in which it was when first discovered by the patient. This is characterized by the pres-

ence of a lump in the breast from one to two inches in diameter, and usually one or more perceptibly enlarged glands in the axilla.

As the figures show, this is of several months' duration, though it may last for several (three to four) years.

The second stage marks the beginning of the period of visible activity in the growth. The nodule which has remained for months quiescent begins gradually to increase in size, the skin to become adherent, and the glands to show themselves more plainly in the axilla. The patient now, for the first time alarmed, seeks advice. This accounts for the very large number of cases operated upon in this stage (between one-third and one-half of the total number). In the third stage are included all cases which have advanced beyond the immediate neighborhood of the primary focus, and have involved adjacent regions, either by direct extension or by metastasis. In such a category should be placed all cases which involve the whole breast or tissues contiguous to the mammary gland—such as the muscle, the skin, elsewhere than in direct contact with the growth, or the fasciæ—as well as the various metastases. Spreading of the infection to glands above the clavicle would alone constitute a condition necessary to place the disease in this class, even though the primary focus had changed but slightly.

Analyzing the cases on this basis, we find forty-five in the first stage of the disease at the time of operation. The number of cases cured in this class was nineteen. Thus it would appear that when the disease was operated upon promptly, we have as a result a percentage of cures as high as 42 per cent. But looking more closely into the duration of the disease before operation, we find that, of the forty-five cases of this class, in three only was it a question of weeks, and in these three cases there were no "cures." In twenty-eight cases the disease had existed from one to ten months, and here there were ten "cures." On the other hand, of the fourteen cases in which the disease had lasted over a year there were eight "cures." In one case the duration of the disease is not stated. We must

infer, therefore, that, although promptitude is all-important in surgical intervention, much depends upon the degree of malignancy of the growth.

Still, it is a consolation to know that we find cures even in the late stages of the disease, for in the second stage we have thirty-five cases with six "cures," showing that when the disease was operated upon in its second stage we had 17 per cent. cures.

There were nineteen cases that may be said to have been in the third stage with one cure, No. 81 (see below), or 5 per cent.

Summarizing these data, we have the following table:

Stage.	No. of Cases.	Cures.	Per Cent.
1	45	19	42
2	35	6	17
3	18	1	5

There were two cases in which death resulted from the operation, and which are therefore not included in this list.

Adherence of the Skin.—As the determination of a first or second stage is one which might vary with different diagnosticians, the forecast of any individual case could not always be so easy to determine by the aid of the above figures as by a consideration of the prognosis in the case of some very characteristic lesion, such as the adherence of the superjacent skin.

There were twenty-three cases in which the skin was adherent to the growth; of these

- 6 died within a year after operation;
- 5 died 1 to 2 years after operation;
- 1 died 2 to 3 years after operation;
- 4 died 3 to 4 years after operation;
- 1 died 5½ years after operation;
- 2 recurrences, 4 years after operation (now alive and well);
- 4 cures, 13, 10, 6, and 4 years after operation.

There are in this series about 17 per cent. cures. We may therefore say that adhesion of the skin diminishes by one-third the chances of cure. It should, however, be said that 26 per cent., or over one-quarter, of these cases are alive and well at the present time.

Axillary Infection.—In seventy-two cases enlarged glands were felt in the axilla. In seventeen cases there was no axillary involvement. In eleven cases no record was made. Of the seventeen cases in which there was no infection of the axillary glands eleven are cures,—that is, cures were effected in 64 per cent. of the cases in which no glands were felt.

Among the twenty-six recorded cures there are twelve cases in which there is a record of enlarged glands being felt in the axilla. In eleven cases no glands were felt, and in three no record is made.

Of the above seventy-two cases in which enlarged glands are recorded as present, there were eight in which glands were also felt above the clavicle. One of these cases died of the operation. Six died of recurrence, but lived on an average 19.8 months after the operation. One individual lived nearly three years after the operation. One is living with recent recurrence eight years after operation (Case 55). In all these cases a very thorough dissection of the posterior cervical triangle was made, but no permanent cure has been obtained.

ANALYSIS OF CASES CURED BY THE OPERATION.

A brief comment on each case cured is given below in order to bring out any peculiarities which may be recognized as contributing to the favorable result.*

*The terms used to designate the different types of cancer can be briefly explained as follows: Under scirrhus are classified those in which the connective tissue markedly exceeds the epithelial cells; under medullary, those in which the reverse is the case; under cancer, those where they are about equal. The adjuncts plexiform and adeno describe peculiarities in the arrangement of the epithelial cells. Illustrations of small (scirrhus) and large (medullary) plexiform adenocarcinoma are given in the microphotograph plate, Figs. 1 and 2.—(W. F. W.)

CASE 1.—This was a case of colloid cancer which had already existed three years and seven months previous to the operation; an enlarged gland was removed from the axilla five years after the operation. She is now alive and well sixteen years after the last operation.

CASE 2.—The diagnosis given in this case was "cancer." The duration of the tumor was uncertain. The patient was sixty years of age, and had a tumor the size of a walnut in the inner hemisphere; no infected glands were found in the axilla. It was probably what now would be considered a case of adenocarcinoma. The patient died of apoplexy at the age of seventy. She was stout and of plethoric habit. There had been no sign of recurrence.

CASE 3.—This was a typical scirrhus in a woman forty years of age. Duration of tumor one year. No glands were felt in the axilla, but one very small nodule was found after removal of the axillary contents. She is alive and well to-day, nineteen years after the operation.

CASE 4.—This patient was sixty years of age, and the tumor had been observed two months at the time of operation in 1885. The tumor was the size of a hen's egg and was in the upper inner quadrant. In 1894 a cancerous nodule was removed from the pectoral region, below and outside scar. She has been seen within a year; that is, ten years since the last operation, and is alive and well without recurrence. In this case microscopic examination showed masses of large epithelial cells in a stroma of connective tissue. "Cancer."

CASE 5.—A case of "cancer" in a woman sixty-five years of age. Duration of tumor, two months. There was considerable glandular infection, and I regarded the prognosis at the time as unfavorable. She died in mid-summer, six years later, at the age of seventy-one, of "sporadic cholera," and never had any sign of recurrence.

CASE 9.—The patient was thirty-eight years of age, the duration of the tumor six months, and the diagnosis was "scirrhus." The growth in the breast was the size of a walnut, and there was one infected gland in the axilla. She was examined repeatedly by me, and no sign of local recurrence was found. She was reported by her physician to have died of pulmonary hæmorrhage fourteen years after operation, and that this in his opinion had no relation whatever to a recurrence of the original disease. Micro-

scopic examination. "A dense retracting mass showing small nests of epithelial cells in the midst of firm connective-tissue stroma. The scraping from the gland showed an occasional epithelial cell."

CASE 14.—This was a woman fifty years of age with a tumor of six months' duration. It proved to be a case of cancer developing and spreading from the walls of a cyst. The patient was last heard from five years after the operation, and was alive and well at that time.

The following is Dr. Whitney's report:

"The whole gland is replaced by a dense white tissue in which were several cavities, the largest as big as a robin's egg. These were lined with a smooth membrane and had evidently contained fluid. On microscopic examination the basis of the growth was found to be composed of a dense fibrous tissue. In this were embedded the altered glandular elements. In places the ducts were dilated, evidently the origin of the large cysts seen in gross. Here and there the acini of the gland were reduced in size and the cells smaller as if undergoing atrophy. In other places the cells had proliferated, and extended widely from their original place in a plexiform net-work into the surrounding tissue. In places the lines of cells appeared to follow the lymphatics; here and there a compound granular cell, and in general, a decided tendency to fatty degeneration.

"The growth seems to be a diffuse interstitial fibroma in which the gland elements are now beginning to proliferate actively (commencing cancer)."

CASE 19.—The patient was fifty-one years old; the disease had existed seven months. The microscopical diagnosis was "cancer," and the glands in the axilla were found non-infected. The patient is alive and well thirteen years after operation. The nodule when examined was the size of a walnut in the upper outer quadrant deep in the substance of the breast. The cut surface was marked by yellowish opaque lines and dots. Under the microscope there was a dense connective-tissue stroma with relatively small masses of cortical epithelium in the spaces. The glands were enlarged, but in the one examined there was no distinct nodule of new growth.

CASE 20.—Fifty-two years of age; duration of disease, twenty months. The mass is described in the report as the size

of a small orange in the upper inner quadrant; glands in the axilla involved. She died of "grippe" thirteen years after operation. Pathological report. "A large, dense nodule deep in the breast with a radiating appearance, and the surface marked by yellow opaque lines and dots. Microscopic examination showed masses of cubical gland cells deep in the connective tissue. Cancer."

CASE 35.—Sixty years of age. Duration, thirteen months. Hard tumor size of hen's egg movable on muscle; skin adherent. A chain of glands running high up was found in the axilla at operation. The diagnosis was "cancer." Alive and well eleven years after operation. Microscopic examination. "A large nodule extending quite through the thickness of the breast, showing masses of epithelial cells in a stroma of vascularized connective tissue. The axillary glands were infected with a growth of similar character."

CASE 38.—Thirty-five years of age. Duration of growth, five years. Tumor size of goose-egg. Diagnosis, "cancer." Alive and well eleven years after operation. Microscopic examination. "Nodule size of an egg in the periphery of the breast and adherent to it, but not to the skin. The section surface was grayish, slightly translucent, and thickly covered with small, opaque, yellow spots from the size of a pin's point to a pin's head. This on microscopic examination was found to be made up of solid masses of epithelial cells lying in a connective-tissue net-work." Axillary glands were infiltrated with a similar growth.

CASE 39.—Fifty years of age. The duration was known very accurately in this case, as patient (whose mother had died of cancer) had been warned to be on the lookout at same age. The operation was performed within the month. Two small nodules the size of a pea were found in the breast, and one gland about one-third of the size in the axilla. The diagnosis was "scirrhous." Alive and well eleven years after operation.

CASE 42.—Sixty years of age. Disease of two years' duration. Nodule in skin on axillary border over upper and outer quadrant; a few glands felt in the axilla. Died of pneumonia ten years after operation. This type has been described by me as "cancer of the axillary border;" (*Boston Medical and Surgical Journal*, November 12, 19, 1896, and January 21, 1897; Inter-

national Text-Book of Surgery, Vol. ii, p. 280; Hektoen, Text-Book of Pathology, p. 1089;) and if untreated runs the typical course of cancer of the breast. In this respect it resembles closely Paget's disease of the nipple.

CASE 44.—Fifty-three years of age. Duration, three months. Mass size of walnut; no glands felt. Diagnosis, "scirrhus." Alive and well ten years after operation. No swelling or restriction in the use of arm (a frequent report in reply to questions on this point in other cases). Pathological report. "A very small, dense, retracting nodule just beneath nipple, containing masses of epithelial cells in a dense connective-tissue net-work."

CASE 54.—Forty-five years of age. Duration, five months. This was an excellent example of cancer originating in an involution cyst. The following is Dr. Whitney's report: "The tumor was a large, diffused mass more or less opaque, dotted with yellow lines in the midst of a fibrous, thickened gland with numerous cysts small in size. Microscopic examination showed the growth to be made up of small, solid masses of epithelial cells in the midst of a connective-tissue stroma. The axillary lymph glands were slightly enlarged, but as far as could be determined were not invaded by the disease. The diagnosis is a scirrhus cancer originating in a diffuse fibroma of the breast with retention cysts."

CASE 59.—Forty-nine years of age. Duration not stated. There was a small, dense, fibrous retracting nodule the size of the tip of the finger deep in the breast tissue. Microscopic examination showed masses of rather small, irregular epithelial cells separated by a dense stroma of fibrous tissue. The axillary glands were infiltrated with a similar growth, but those at the highest point of the tissue removed both in front and behind the great vessels were normal. The diagnosis is "scirrhus."

The patient is alive and well nine years after operation.

CASE 60.—Sixty-six years of age. Duration, three years. Diagnosis, "atrophying scirrhus." Small gland felt in axilla. Died of paralysis eight years after operation, at age of seventy-four. During the intervening period had frequently reported, and was known to have been perfectly well.

CASE 64.—Sixty-three years of age. Duration, seven months. Mass size of lemon in upper outer quadrant. No glands felt in axilla. Pathological report. "Nodule fibrous and infiltrated with

relatively large areas of opaque puriform-looking material in the substance. The microscope showed masses of epithelial cells, large and irregular, undergoing a rapid fatty degeneration, separated by a stroma of connective tissue. Neither by the eye nor by the microscope was there any evidence of a new growth in the glands." "Medullary cancer."

CASE 66.—Fifty-eight years of age. Duration, six months. Diagnosis, "medullary cancer." Nodule in upper inner quadrant, size of horse-chestnut; few slightly involved axillary glands. (Recent study of the specimen by Dr. Whitney shows a pseudo-alveolar formation; no infiltration of surrounding tissues; no invasion of lymph nodes. Diagnosis, adenomedullary type.) (Fig. 1.)

CASE 76.—Fifty-one years of age. Duration, ten months. There was a mass the size of a walnut in the upper inner quadrant occupying the entire thickness of the mammary gland and a small nodule in the pectoral muscle. The axillary glands were not implicated. A recent study of the specimen by Dr. Whitney classifies it as an adenoscirrhous. (Fig. 2.) "The growth was composed of masses of small epithelial cells in a close plexiform arrangement in places, with a distinct gland-like arrangement about a central opening. These could be followed in the connective tissue between large and small bundles of muscular fibres."

CASE 77.—This patient was seventy-three years of age and had myxœdema. The wound healed slowly, but without sepsis. She died of croupous pneumonia four years after the operation. Microscopically, there were small alveoli close together, the same condition in the lymph-glands. Diagnosis, adenoscirrhous. There was a hard nodule about three centimetres in diameter, beneath a retracted nipple, in a large breast.

CASE 79.—Sixty-five years of age. Duration, two years. Colloid cancer originating from an involution cyst. No glands felt. "Retention cysts with mucous degeneration of the stroma of cancer, which was of the small plexiform scirrhous type."


CASE 81.—Forty-six years of age. Duration, twenty months. "Medullary cancer with cystic degeneration." Tumor was a large nodule about six centimetres in diameter close to the nipple and adherent to the skin, which was reddened. The centre of the nodule was occupied by a cystic cavity about three centimetres in diameter. The aspect of the surface was grayish and

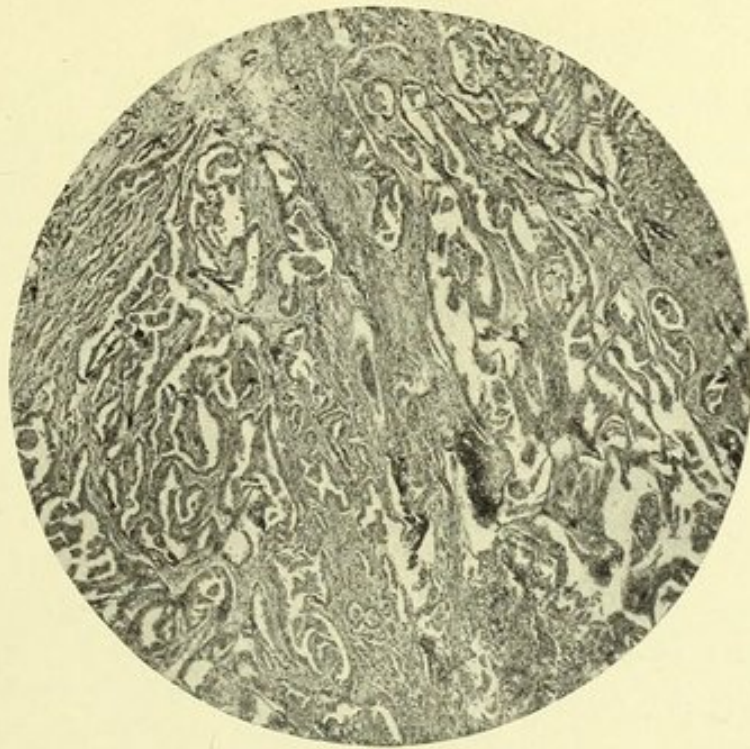

FIG. 1.—Large plexiform adenocarcinoma ("adenomedullary"). Case No. 66.

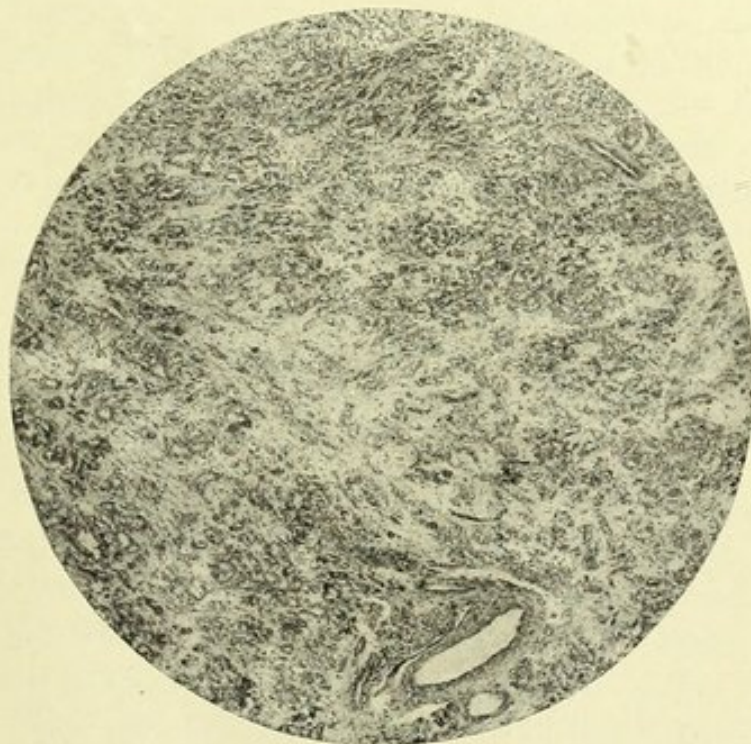

FIG. 2.—Small plexiform adenocarcinoma ("adenoscirrhous"). Case No. 76.



medullary. Microscopically there were large, solid masses of epithelial cells separated only by bands of fibrous tissue. These cells had a marked tendency to softening, and in places were only left intact in close proximity to the vessels. In other places the cells had apparently grown into and filled small cystic cavities (of which there were numerous ones in the immediate vicinity of the growth), making a coarse plexiform arrangement. Everywhere in the gland tissue there was a slight tendency to proliferation of the epithelium. There were eight or ten lymph nodes in the specimen, many of which were infected, but the node from the highest point in the axilla as well as those above the clavicle did not show any infection.

CASE 93.—Thirty-one years of age. Duration, eight weeks. Mass size of plum under nipple. Nipple retracted. No glands felt. Small plexiform adenoscirrhous. (Fig. 2.) Lymph nodes the same. Diagnosis, adenocarcinoma.

CASE 97.—Sixty-three years of age. Duration, two years. There are several small nodules varying from one centimetre to three centimetres in diameter in the mammary gland. One of these in the line of a cicatrix of an old abscess many years before. There was a tendency to form dense fibrous tissue in all these nodules. In the axillary fat one rather large and two small exceedingly hard lymph nodes were found. Under the microscope the main growth was made up of small, solid masses of epithelial cells, separated in places by a meshwork of dense fibrous tissue of varying thickness. In places this could be seen extending along the outside of the smaller ducts.

CASE 98.—Forty-four years of age. Duration, nine years. Diagnosis, Paget's disease. No axillary involvement. The downward growth from the rete could be distinctly followed microscopically.

A study of these cases seems to show in the majority some peculiarity throwing light upon the favorable issue. Nearly one-half were typical scirrhous (see list above). Several (four) originated from involution cysts. In another case my early diagnosis (three days) seemed to contribute to the favorable result. The case of Paget's disease and those which I have termed "cancer of the axillary border," where the disease also begins superficially and spreads ultimately into the mammary

tissue, seem also examples of a favorable type; yet there is one of this latter type in the list of deaths with metastases in the spinal column, showing it to be a true "cancer of the breast." That youth is not always a sign of unfavorable prognosis, Case 9 is proof, the age of the patient being thirty-eight years.

It is encouraging to see several distinctly unfavorable types of the disease in this list of cures, such as Case 5, about which I was at the time of operation quite despondent; Case 35, where the skin was adherent to the growth; and Cases 66 and 81, which were examples of medullary cancer.

In a recent study of the specimens of several of the above cases, Dr. Whitney finds two which are of a distinctly unfavorable type. In Case 81 all the marks of a rapidly growing cancer were present. In Case 77, although of a more fibrous type, with relatively small cells in small plexuses, still, the axillary infection was very marked, and many small vessels in the surrounding fat tissue were filled solidly with cells. Whether these were small veins or lymphatics with thickened walls was hard to determine; in either case it added to the gravity of the prognosis, as, when once the disease is in the veins, metastases in distinct organs are rarely absent.

Recurrence.—The date of death is known in sixty-one of the cases in which death from recurrence occurred. In these sixty-one cases the average duration of life after operation was two years and one month.

In fifty-two cases the date of appearance of recurrence is noted. The average space of time was one year and ten months after operation.

This series includes Cases 1 and 4, in which there were late recurrences, but which are now in the list of cures, and Cases 55, 56, 74, 84, 89, 92, and 94. These patients are now either living with recurrence or have had recurrent growths removed within three years.

Excluding these nine cases, there are left forty-three cases in which death occurred from recurrence, the date of the recurrence being known. It averaged in these forty-three cases one year and two months after operation. In the nine cases

(two cures and seven living, with history of more or less recent recurrences), the average duration of time was much longer, being five years and five months after operation.

Of the sixty-one cases in which death occurred from recurrence of the disease, 7 died before 6 months, 8 between 6 months and 1 year, 22 between 1 year and 2 years, 12 between 2 years and 3 years, 5 between 3 years and 4 years, 2 between 4 years and 5 years, 2 between 5 years and 6 years, 1 between 6 years and 7 years, 1 between 7 years and 8 years, 1 between 8 years and 9 years.

The greatest mortality is at the period ranging from eighteen months to three years after operation.

Of the sixty-one cases, it will be seen that there are twelve, or 19 per cent., which have died after the three-year limit. After a period of five years has elapsed the percentage is as low as 8, and it is not until nine years have elapsed that no deaths are found in the list. These figures show that the three-year limit does not by any means constitute an infallible test of cure.

Returning now to the nine living cases in which there is a history of recurrence, we find two that are "cured," having gone respectively sixteen and ten years since the last operation. The following is a brief statement of the peculiarities of the remaining seven cases.

CASE 55 (aged fifty-six years at time of operation) is now alive at time of writing, with symptoms of recurrence in shape of pleurisy and enlargement of the upper end of the sternum and a nodule in the pectoral region, all having appeared within a year, that is, eight years after the operation (January, 1895). This was a case of medullary cancer originating from a cyst with axillary and supraclavicular infection. At the operation the clavicle was divided and the cervical region thoroughly dissected. I had regarded this case until now as the only "cure" in cases where the supraclavicular glands had been found involved.

CASE 56.—This patient, forty-five years of age and suffering from scirrhus, had a "recurrence" in the other breast almost eight years after the operation. The breast was removed by a surgeon

in Shanghai, and she is now alive and well, about a year and a half after the second operation. Was this to be regarded as a recurrence or as a new infection?

CASE 74 (fifty-six years of age) was a medullary cancer taken early and while the growth was small. An operation was performed in Tokio by a Japanese surgeon on account of the appearance of the disease in the opposite breast, nearly five years later. There was no recurrence in the first operation scar. At last accounts she was failing.

CASE 84.—This was a case of scirrhus with infection of the axillary glands in a woman forty-seven years of age. The operation was performed in April, 1899. A nodule was removed in August, 1902, from the pectoral region, and a section of the second rib was removed in January, 1903. Since then there has been no sign of disease.

CASE 89.—Sixty years of age. Duration, one year. Mass size of egg in lower outer quadrant; two areas of infected skin size of three-cent piece below and inside nipple. No glands. Operation, October, 1899. Small nodule removed from pectoral region by Dr. Odiorne in October, 1903. Alive and well at present time. Disease, scirrhus.

CASE 92.—Sixty-one years of age. Duration, eighteen months. Mass size of egg in upper outer quadrant. No glands. Operation, November, 1899. Nodule removed from scar in pectoral region by Dr. W. B. Odiorne in July, 1903.

CASE 94.—Patient, thirty-six years of age. Duration, two and a half years. Mass size of walnut in scar of an incomplete operation seven months before. Adherent to ribs. Diagnosis, adenocarcinoma. No recurrence for three years, when disease reappeared in cicatrix. No secondary operation has been performed.

It will be seen that four of these cases are alive and well at the present time, but as none of them has gone through a period of more than eighteen months since the last operation, they cannot be regarded as cured.

They are all cases, however, which furnish ample justification of the operation performed, for in two cases there was a respite of eight years from disease, and in one of five years; and one of these patients is alive and well nine years after her

first operation. Another is now alive and apparently well five years after her first operation in spite of two recurrences.

In two of these cases the disease reappeared in the opposite breast. This locality of recurrence, if we consider it a recurrence, was found in eight cases of the entire 100 cases, but in only one other beside the two mentioned was there an independent development of the disease in the opposite breast, there being no sign of a return in the operation scar. The comparatively frequent association of disease in the opposite breast with recurrence in the side originally affected, as shown in Cases 26, 27, 69, 90, and in Case 40, where both breasts were affected simultaneously, makes it seem highly probable that these are not examples of so-called "new infections," but that the breast must be regarded as in the same category with the brain, the uterus, and other distant regions such as the bones of the inferior extremity, which, although not in the direct track of the disease, occasionally become infected.

Palliative Operations.—There are fourteen cases in which the disease may be considered to have advanced so far that a radical cure could not be expected; but these cases were all given a chance, as the new operation might give a long respite, if not an occasional cure, such as we have seen in one case at least in the third stage of the disease reported above. (Case 81.)

These cases may be briefly noticed to show their general character. In Case 6 the skin was involved, and there were roselike outgrowths, and the glands in the axilla were the size of a lemon. Recurrence, however, did not take place until two and one-half years after operation, and the patient lived nearly three years.

CASE 7.—Brawny infiltration of breast with pregnancy; death three months later.

CASE 13.—Tumor size of cocoanut. Skin adherent; death in six months.

CASE 18.—Tumor size of an apple, with glands above clavicle. Recurrence in eleven months; death two years after operation.

CASE 24.—Tumor size of orange; skin adherent and ulcerated; the glands are adherent to the axillary vessels. Death eighteen months later.

CASE 30.—The disease involved the whole breast; offensive ulceration; the axilla was filled with infected glands; but the patient lived over eight years. At the autopsy, the lungs, pleura, chest wall, liver, and long bones were found involved.

CASE 32.—General involvement of breast. Orange skin. Death in six months.

CASE 61.—Puerperal cancerous mastitis. Death in three months.

CASE 67.—Primary nodule adherent to skin and muscle. Nodules in skin. Glands in axilla. Death in fourteen months.

CASE 73.—Whole breast involved and enlarged glands above clavicle. Died of pulmonary embolism five days after operation.

CASE 75.—Tumor size of cocoanut. Axillary glands could not all be removed. Died in fourteen months.

CASE 85.—Could not all be removed; died within the year.

CASE 90.—Orange-skin breast. Glands above clavicle. The patient lived nearly three years, for two of which she enjoyed excellent health.

CASE 94.—Operation for recurrent disease following an incomplete operation seven months before. Adherent to ribs. Adenocarcinoma. Recurrence three years later.

I think it is fair to assume that in none of these cases had the surgeon any right to give hope of cure, and yet one lived two years, three lived three years, and one died eight years after operation. In this latter case there was an offensive ulceration from which she was entirely relieved, the patient dying of internal metastases (Case 30).

Such a case as this is an encouragement to the surgeon to attempt relief under most discouraging circumstances.

Situation.—A record of the situation of the disease has been kept in seventy-four cases, as follows: Upper outer quadrant, 17; centre of breast, 12; upper hemisphere, 10; lower outer quadrant, 8; upper inner quadrant, 7; whole breast, 7; outer hemisphere, 7; lower hemisphere, 3; lower inner quadrant, 1; inner hemisphere, 1; axillary border, 1.

The disease was more frequently observed in the upper hemisphere than in the lower; in the outer hemisphere than in the inner hemisphere; and in the upper outer quadrant than in any other quadrant.

Looking over the list of cures with reference to the situation of the growth, we find an accurate statement in eighteen only. Among these, in five the growth was somewhere in the inner hemisphere, in four somewhere in the outer hemisphere, in five somewhere in the upper hemisphere, and in three in the central region of the breast.

Inasmuch as only nine cases are stated definitely to have been in the inner half of the gland, it is evident that the percentage of cures is much higher in this hemisphere than in the outer.

Duration of Disease.—Although we have stated elsewhere that the percentage of cures is much higher when the disease is operated upon in its early stages, a study of the duration of the disease before operation does not appear to bear out this view. The average duration of the disease in the 100 cases was 11.8 months before treatment, but the average duration in the twenty-six cured cases was 12.3 months. Here we find a longer interval had elapsed before operation in the successful cases; this can probably be explained by the supposition that the disease in these cases was of a milder character and remained for a longer time in the primary stage.

Retraction of the nipple was recorded in twenty-two cases.

Operation.—The operation which was performed in the first fifty cases consisted in a removal of the breast and pectoral fascia and a dissection of the axilla. In the second fifty the "completed" operation, as it is now understood, was performed, both pectoral muscles being removed, the clavicular portion of the pectoralis major being left behind, and the posterior cervical triangle frequently dissected. Lately, it has been my habit to omit the dissection of the triangle in case microscopic examination of the higher axillary glands shows that the limit of infection has been reached.

It may be worth noting at this point that the results of

operation in these two series of fifty cases show a slightly greater number of cures where the lesser operation had been performed. In the first fifty there were fourteen cures, and in the second fifty only twelve.

This was due to the fact that Cases 1, 2, 3, 4, and 5 were all cures; but, allowing for this unusually fortunate series of consecutive cures, we do not find any striking differences in the results of the two methods.

In the greater portion of the second series the method known as the Halsted operation was conscientiously followed. Latterly, however, *i.e.*, during the past year, I have adopted the method given below, and find it one that I can recommend as both safe and thorough. Safe, because—following as it does anatomical lines—the vessels are divided at their point of origin at the beginning of the deep dissection, and hæmorrhage is thus controlled without unduly prolonging the operation, while the greater portion of the wound is not exposed until the close of the operation. Thorough, because it permits of a free exposure and dissection of the axilla up to the point of the disappearance of the axillary plexus of lymphatic glands beneath the clavicle before the mass to be removed has been dislodged from its attachments and allowed to interfere with the anatomical relations of the parts.

An "anatomical operation" for cancer should of course only be so far permitted in that it facilitates the freest possible removal of the diseased parts. It should always be remembered that the indications are in cancer to stamp out the disease. All other considerations which enter into so many other operations should be disregarded, with the single exception of the safety of life. Anatomy and æsthetics should always play a secondary rôle. This having been conceded, there is still much that can be done to make the operation less exhausting and disfiguring than some of the "completed methods." It should be said here, however, that the modern operation, as now performed by the most conscientious surgeons, is always to be preferred to the feeble imitations that one often sees, even at the present time, in hospital practice.

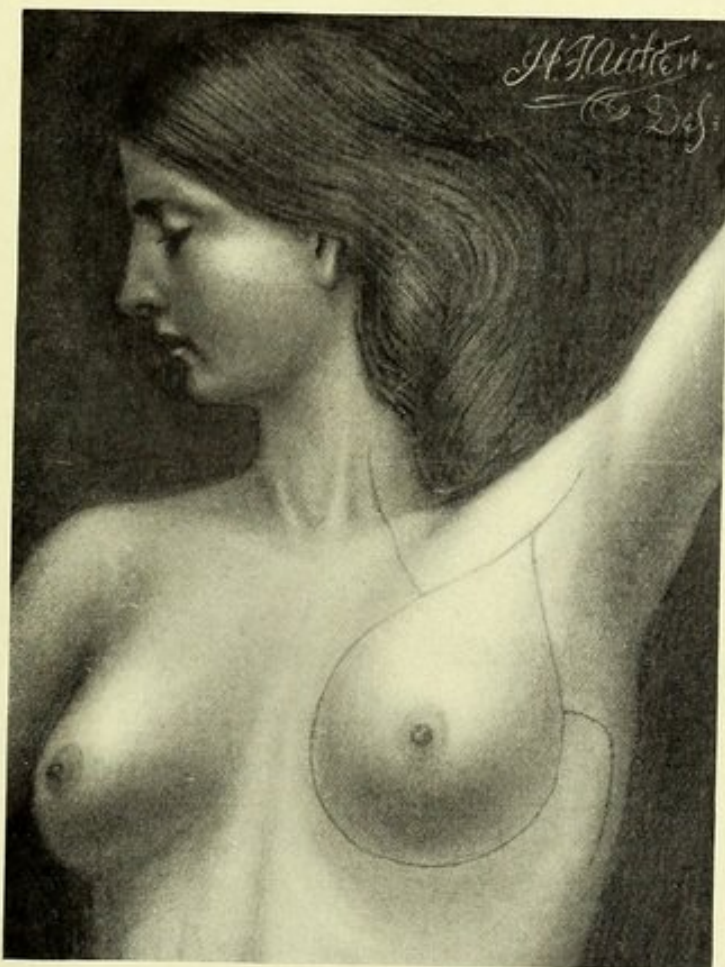


FIG. 3 shows the amount of skin included in the racket-shaped incision; also the flap which is diminished in appearance by perspective.

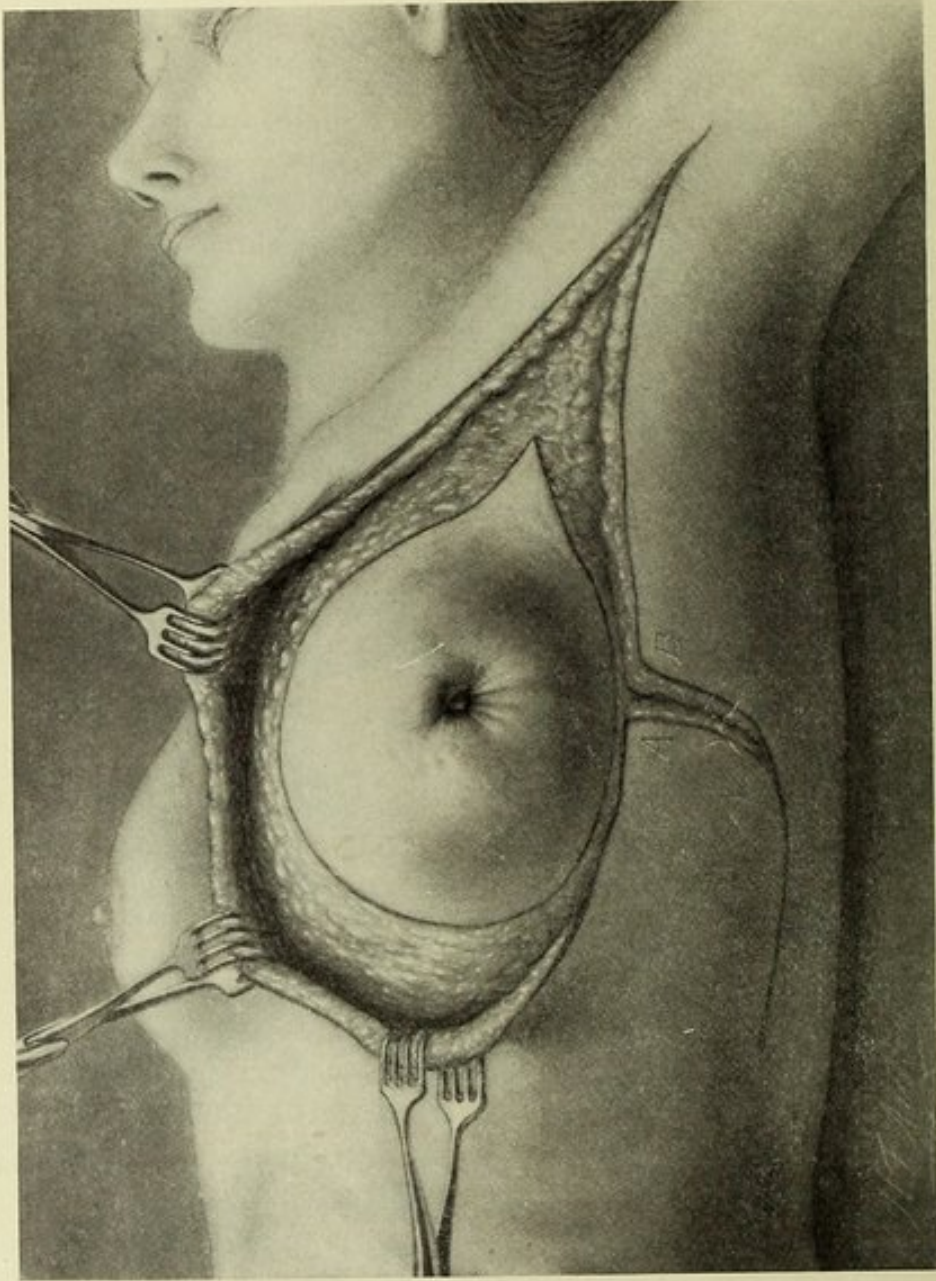


FIG. 4.—Preliminary dissection of the integuments in all directions, leaving a pyramidal mass of tissues to be removed, of which the primary nodule is the apex.

The steps of the operation, as I have performed it, are as follows:

An incision is made from the anterior and outer margin of the axilla running a little above its upper border and the line of insertion of the pectoralis major muscle around the lower border of the breast to a point on the boundary line of the inner and lower quadrant. If there is serious doubt as to the malignant nature of the growth, the breast can be lifted up from below by carrying the dissection of the last half of this incision more deeply, and exploring the mammary gland on its posterior surface. Otherwise a second incision is made beginning at the middle of the anterior axillary fold, gradually diverging from the first incision as it approaches the breast and, sweeping around the upper and inner margin of the organ, meets the first incision at its terminal point. This may be called the preliminary racket-shaped incision. (Fig. 3.) The operator should not tie himself down too rigidly to these landmarks, but the circle should be described around the primary nodule, as nearly as may be, as a central point.

Before proceeding to the second step of the operation, a flap should be marked out on the outer side of the pectoral region. To do this, the knife divides the skin above the middle of the first incision, *i.e.*, on the outer edge of the wound, on a line drawn first at right angles to said incision and gradually sweeping round until it becomes parallel to it and terminates at a point a little below the level of the lower margin of the wound. (Figs. 3 and 4.) This flap is intended to be turned into the lower portion of the wound. Formerly, I made two such flaps, one above and one below, but now find the method of closing in the wound described below to be preferable. The present flap is therefore made longer than the one described in my earlier operations.

In case there is infection of the cervical region, an additional incision should be made from the middle of the upper half of incision number two along the posterior border of the sternomastoid muscle to expose the clavicle and the posterior cervical triangle. This incision, if necessary, is, however, not to be made until a later stage of the operation.

The second step of the operation is the dissection of the integuments freely on all sides, the axilla included, from the subjacent adipose tissue. The axillary skin and the flap are thus dissected off on the outer and lower side of the wound, and the dissection on the median line is carried well over the margin of the sternum. (Fig. 4.)

Above this superficial dissection should be carried up so as to expose the clavicle. When the skin is reflected back on all sides, a cone with a broad base is exposed, the apex of which is the nipple, and which is composed of the breast, the pectoral muscle, and the surrounding adipose tissue. (Fig. 5.) The removal of these structures *en masse* constitutes the third stage of the operation. This is done from without inward in a direction exactly opposite to that carried out in the Halsted operation, so that the entire mass to be removed is thrown towards the median line.

Beginning with the humeral insertion of the pectoralis major muscle, the forefinger of the left hand of the operator is slipped under the edge of the muscle from above downward and the muscle is divided a short distance from its insertion. (Fig. 5.) The proximal end of the muscle is seized by hooks and pulled in the direction of its origin, while its fibres are separated from those in immediate contact with the clavicle. An assistant while holding the hooks gently draws the breast with the other hand in the direction of the epigastrium. A few touches of the point of the knife expose the insertion of the pectoralis minor muscle. The finger is now hooked under this insertion and the muscle divided. (Fig. 6.) When the assistant retracts the breast in the direction already indicated, the axillary region is freely exposed, and the thin fascia overlying the vessels being divided, the larger vessels are readily identified. In this way the dissection of the axilla can be carried out with great precision, and the origin of all the large branches can be secured with the ligature. (Fig. 7.)

Too great care cannot be taken in this dissection, and the various processes of adipose tissue must be sought for and turned back upon the mass to be removed. As the main branches are

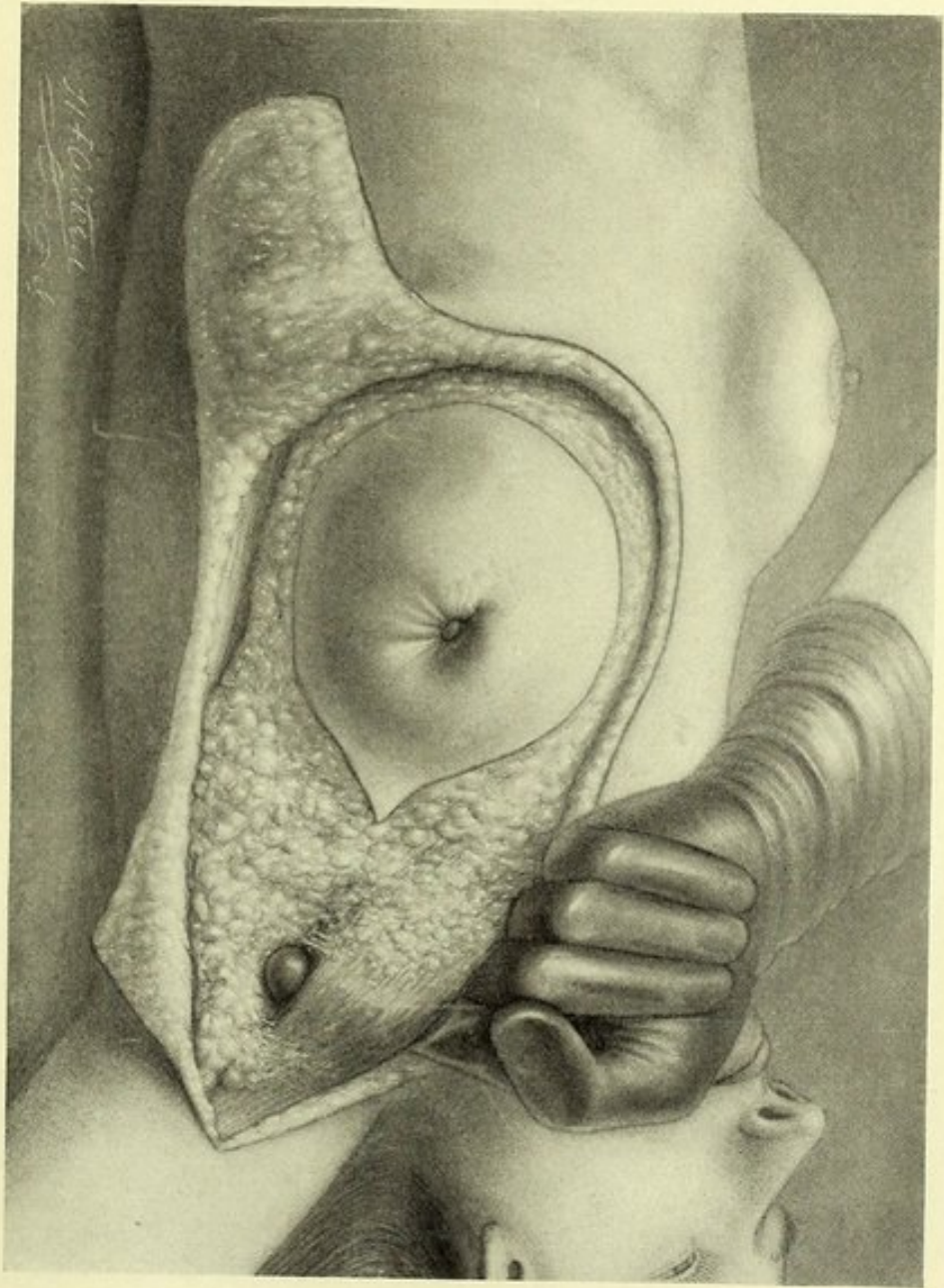


FIG. 5.—Exposure of the insertion of the pectoralis major. The knife is about to divide the muscle at this point. The latissimus dorsi is also exposed, showing the limit of the dissection outward.

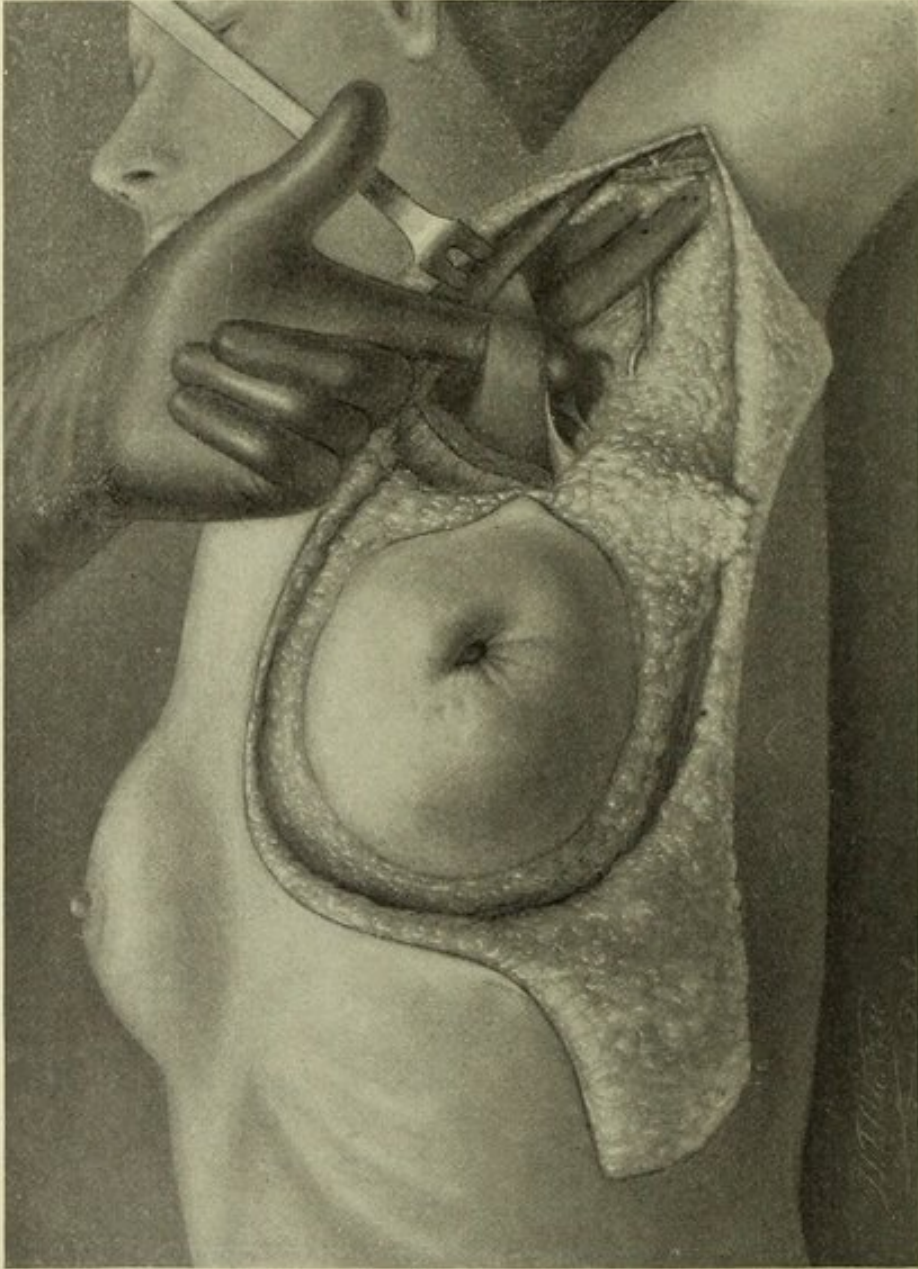


FIG. 6.—Division of the insertion of the pectoralis minor muscle.

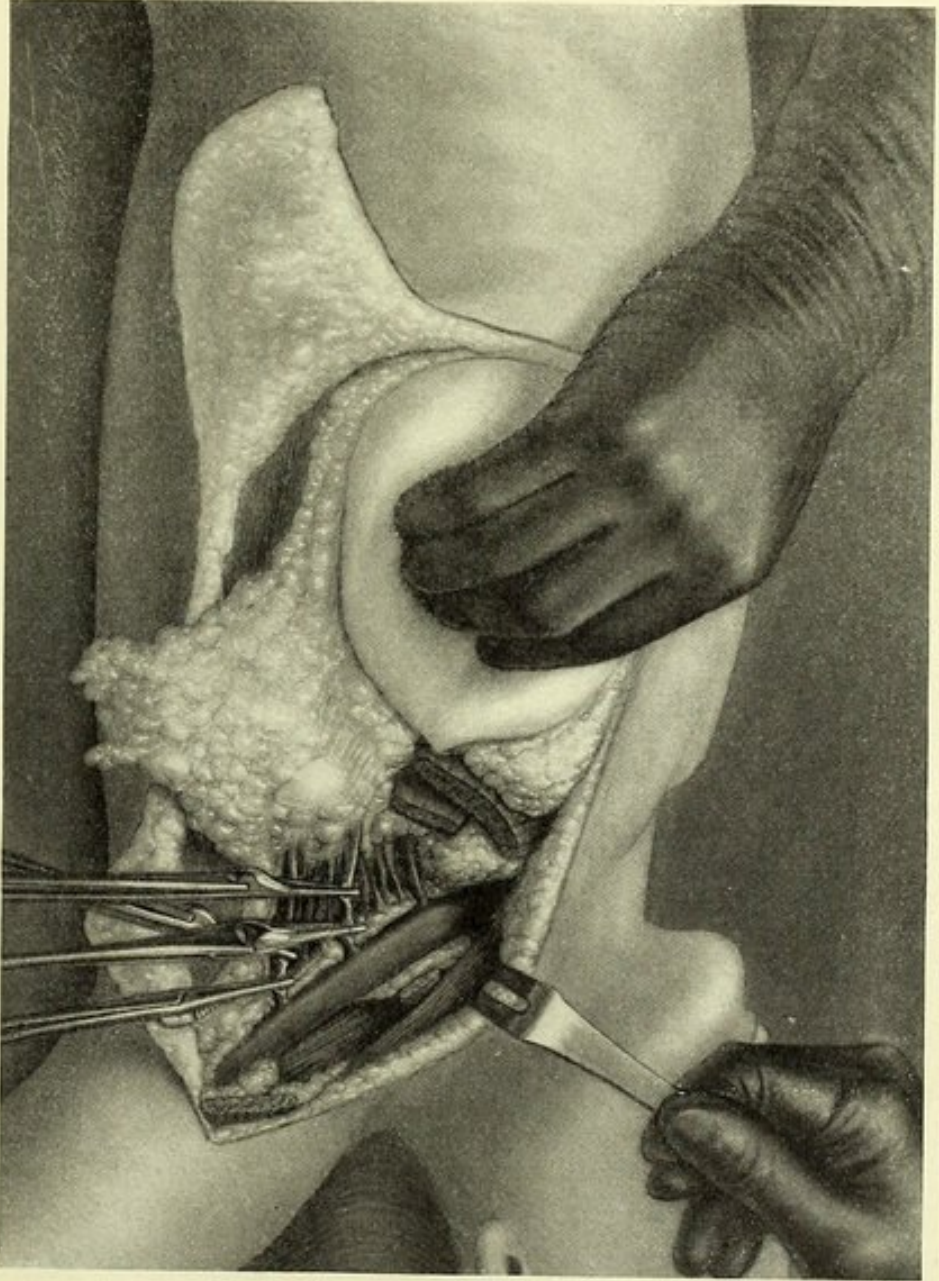


FIG. 7.—The divided muscles permit the retraction downward and inward of the breast and axillary contents and enable the operator to expose freely the axilla and to tie the main branches at their origin.

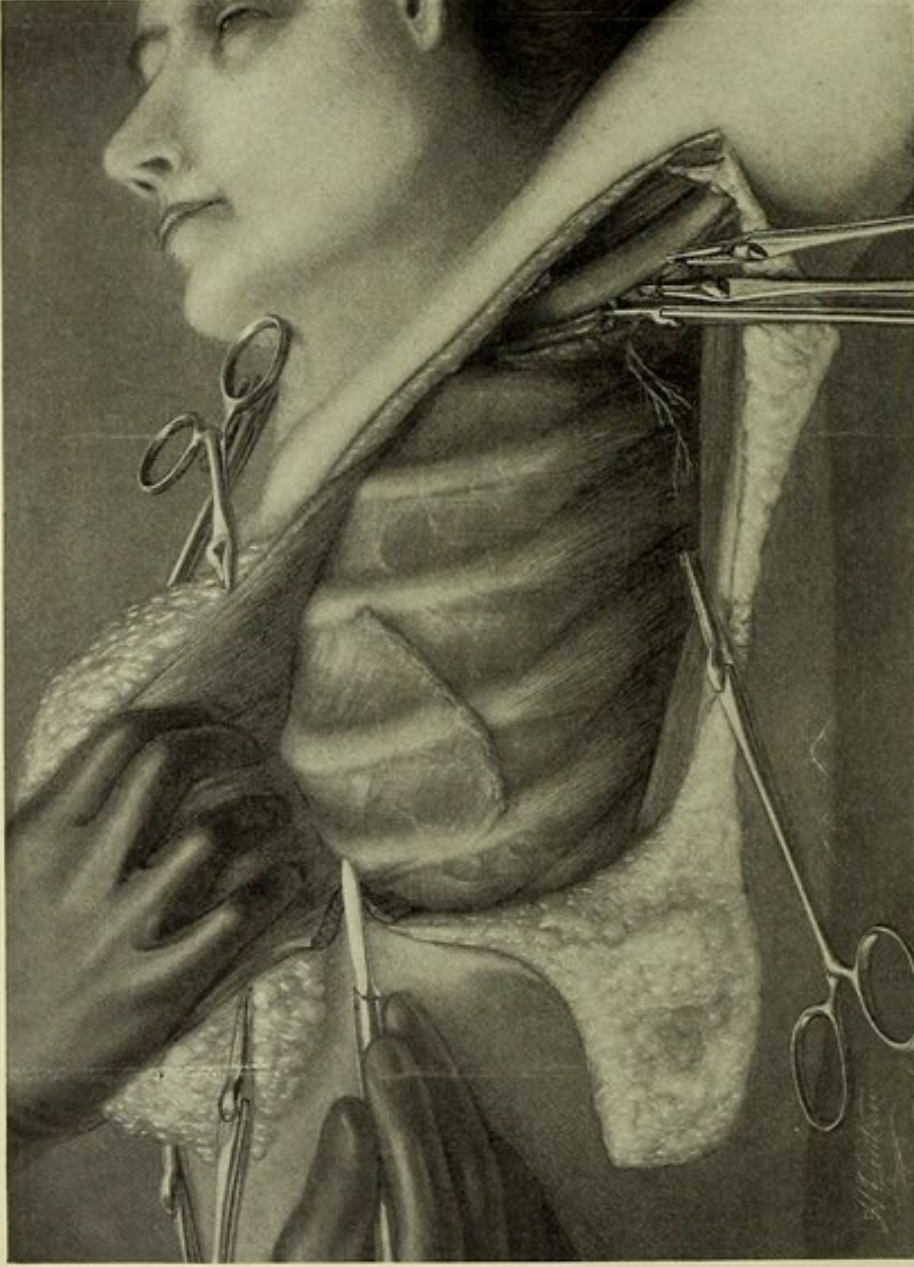

FIG. 8.—The mass to be removed has been reflected towards the median line; the origin of the pectoralis minor has been divided and the origin of the pectoralis major is being divided as the final step in the operation. The large wound is thus uncovered only at the last moment.

divided, the dissection can be carried both inward and outward with more freedom, thus allowing the breast to slide gradually inward and downward.

As the dissection of the axilla approaches the clavicle, care must be taken not to cut through the superjacent fat that has been exposed by the earlier dissection, but to reflect it back in every direction towards the centre of the mass, so that the upper edge of the origin of the pectoralis major at the sternal margin is clearly identified. As the dissection proceeds downward and outward in the axilla the adipose tissue must not be divided until the knife can come down upon the latissimus dorsi muscle. (Figs. 5 and 6.) The greatest care must be taken not to separate any of the tissues from the included lymphatic glands or to cut into them. No attempt should be made to save vessels or nerves in the axilla, but the great plexuses must of course be treated without roughness, and there is no necessity for wounding them. Division of the axillary vein has been found necessary in only one instance, and the patient suffered no great inconvenience; but operations in which such radical measures are necessary can be looked upon only as palliative, the disease being advanced too far to admit of a radical cure. At least this is my experience. A slight wound of the axillary vein is easily controlled by catching up the bleeding point with blunt forceps and passing a fine silk ligature around it.

A few sweeps of the knife separate the mass from the latissimus dorsi muscle. The breast is now seized by the operator and rapidly dissected off the thoracic wall from without inward. The origin of the pectoralis minor is first divided, and the final act of the operation consists in severing the origin of the pectoralis major while the breast and attached tissue are firmly held away from the sternal margin. (Fig. 8.)

The time occupied with these three stages of the operation should not exceed forty minutes, and usually thirty minutes are sufficient.

The hæmostatic forceps are now disentangled and each vessel tied with fine silk. I find this material on the whole most satisfactory for the operation, and have experienced no incon-

venience from ligature sinuses. Silk seems to be readily disintegrated and absorbed in this region. Meanwhile the specimen has been handed to a pathologist, and the condition of the peripheral portions carefully investigated. Particular attention should be paid to the most distant glands, and if the report comes back that those near the vessels as they run under the clavicle are infected, the posterior cervical triangle should be exposed. The incision to be made for this purpose has already been described.

After cutting through the deep layer of the superficial fascia of the neck, the posterior border of the sternomastoid is pulled inward and the omohyoid is lifted upward. A thin fascia then presents itself, under which lies a pad of adipose tissue, in which one or more lymphatic glands are found. It is this group which is continuous with those in the upper axillary region and which is first to become infected. (Fig. 9.)

At one time I made this dissection a routine feature of the operation, but, after finding them in the great majority of cases non-infected, I reserve this dissection for those cases only in which there are well-marked indications.

The pad of adipose tissue should be freed as much as possible by blunt dissection, and all bleeding points carefully secured as the operation proceeds.

When the region has been properly cleaned out, it is possible to make the forefingers of each hand come in contact with one another beneath the clavicle. In a few cases I have divided this bone, but do not find that any additional advantage can be gained by this procedure.

I have referred above to a case where this bone was divided in order to remove glands above the clavicle. (Case 55.)

The patient is now slowly succumbing to the disease, eight to nine years after the operation, with infection of the sternum and pleura; but there is no return in the cervical region. Such cases go far to show the very serious prognosis that must be given when the cervical triangle has been invaded.

The closure of the wound in this operation has always been a difficult problem, since it has been decided that the whole in-

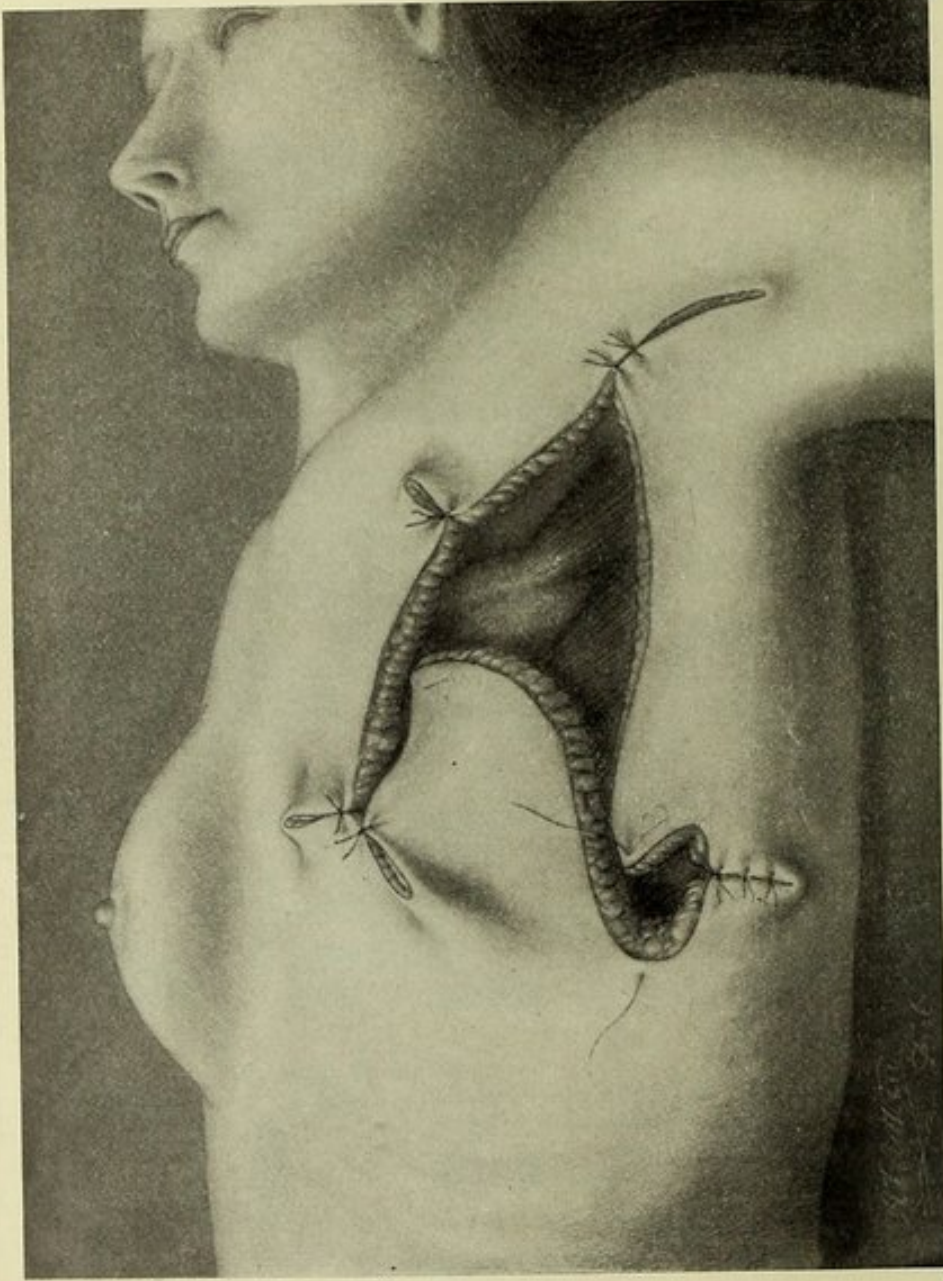


FIG. 10.—Mode of closing the wound. *A*. The flap has been turned in and caught with one suture. It is gradually being pushed into position by peripheral sutures. *B* shows how the upper half of the outer edge of the wound is slid under the lower half or flap. Note the shortening of the long axis of the wound by the stitching on the inner border.

tegument of the breast should be included between the incisions. Any method which permits of an easy approximation of the edges of the wound is out of date.

The method of grafting adds materially to the length of the operation and leaves a most unsightly scar. The removal of the breast is at best a demoralizing ordeal to most patients, and every effort should be made to procure as rapid healing and as little unsightly a cicatrix as possible.

So far as the scar itself is concerned, this difficulty is overcome by dissecting the opposite breast away from its attachments to the pectoral muscles and sliding it over to the median line, thus closing the wound without tension. The result is one, however, which produces a deformity of outline which is hardly likely to make this method popular with patients.

The lower portion of the wound is the part where the edges are the most difficult to approximate. The free loosening up of the skin enables the upper portions to come easily together.

The flap made at the outer side of the wound is about the size of the human hand, and when first turned in seems to be totally inadequate for the purpose. To draw upon this flap is to endanger its vitality. For this reason I begin suturing on the outskirts of the wound at four different points, viz., at each end and on each side. A few stitches should be taken at the axillary and at the sternal ends of the wound first. The flap is then turned in (Fig. 10) and held in place by a temporary stitch, while it is gradually *pushed* up into place from below by sutures firmly girding together the edges of the skin to which the flap was originally attached. Thus it gradually comes about that the point *B*, which was originally in contact with point *A*, is rolled in underneath the flap and forces it into position. Sutures should all be superficial, as deep sutures cut and do not give the skin included by them a chance to stretch. In order to enable the edges to come together easily, it should not be forgotten that it is necessary to dissect up the skin for a considerable distance in every direction. This is what the first stage of the operation attempts to accomplish, while it at the same time makes the operation all the more radical. In stout patients the

cavity of the wound is easily closed, but the problem is more difficult in thin individuals. Experience only will enable the operator to determine how much tension can be put upon the flap in inserting the final stitches. In doubtful cases there is no objection to leaving them untied, as the opening thus left serves admirably for drainage. In many cases this opening can be closed by secondary suture a few days later, or it may be allowed to heal by granulation. A small graft may be used to facilitate the process, and I have occasionally resorted to this plan, but rarely find that the granulating wounds are sufficiently large to make such a method desirable.

Fig. 11 shows the wound as finally closed, one or two sutures remaining untied indicate that these are the last to be tied. The position of the drainage gauze—a short and small wick—is indicated. The wound should be dressed at the end of twenty-four hours, and the wick should then be removed.

Mortality.—In this series of 100 cases there have been two deaths from the operation. One was from acute septic infection, due apparently to the fact that the patient had been put in the bed previously occupied by a case of erysipelas. The second case was one of pulmonary embolism caused by allowing the patient to sit up too soon and move about too freely after the operation. Since this experience, I have been in the habit of keeping patients in the recumbent position for one week after the operation, thus allowing time for any thrombus that may have formed to become firmly attached to the vessel wall.

A final word about cancerous infection during the operation. Whether or not there is a possibility of such an occurrence does not seem to me to be fully determined by any data now in our possession. There are, however, some very suggestive experiences familiar to all where exploratory incisions have apparently led to an extension of the disease.

It is my habit to act upon the supposition that such danger exists, and throughout the operation to attempt to keep the parts exposed protected as much as possible by gauze packing. The operation which I have described has this advantage, that nine-tenths of the wound is not exposed, or in fact touched by an

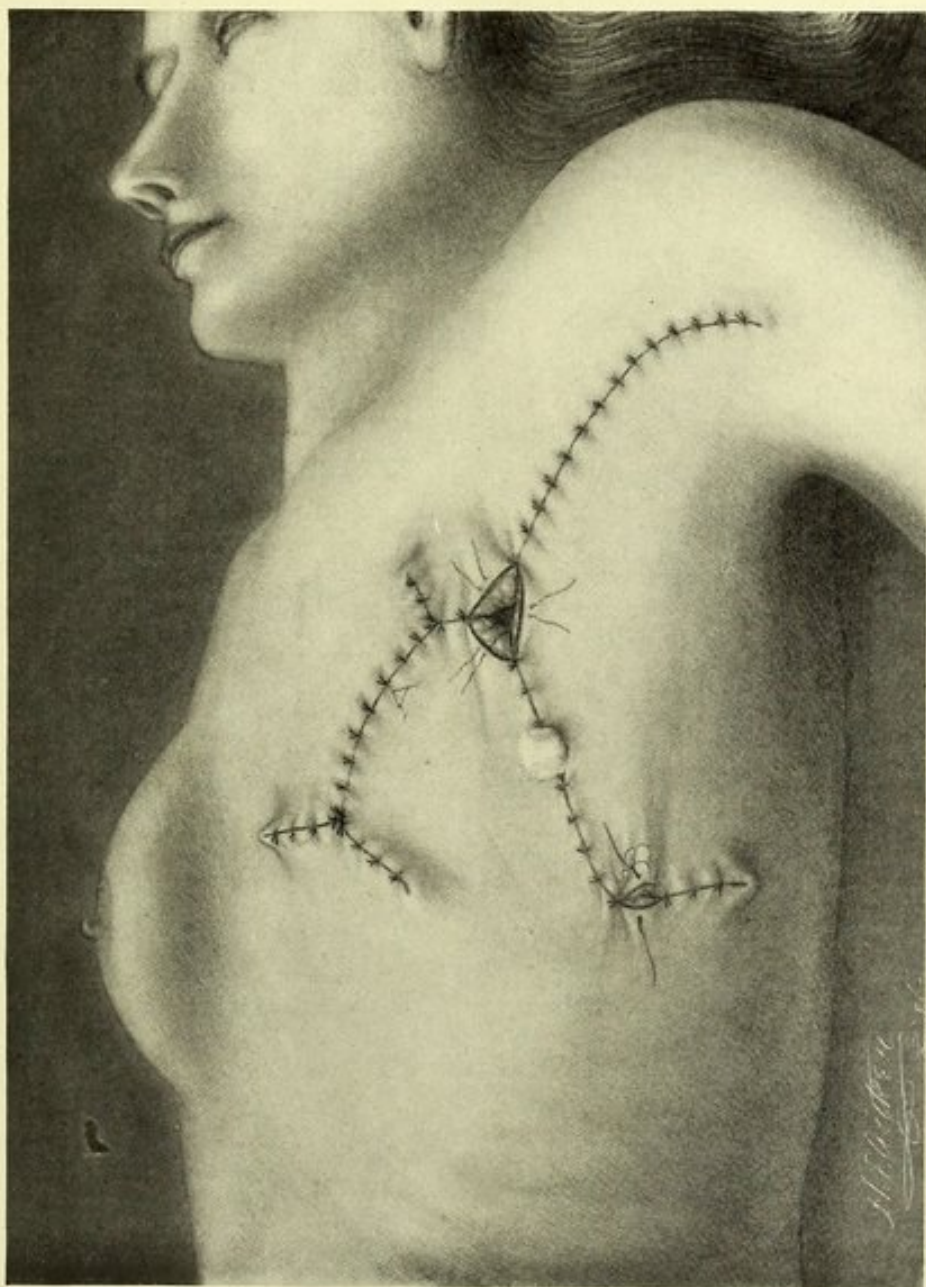



FIG. 11.—Final adjustment of the flap. Note the relative positions of *A* and *B*. The final sutures are still to be tied. Note the position of the gauze drain, which is left in twenty-four hours.



instrument, until the close of the operation, presenting, therefore, much less danger of such infection than wounds that may have been wide open for hours.

In exploratory incisions such as I have described, instruments should be changed, and the wound leading to the disease temporarily closed by suture or packed with gauze, so as to protect the operation wound as thoroughly as it is possible to do under the circumstances.*

* A portion of this series, consisting of seventy-two cases, was published in the *Boston Medical and Surgical Journal*, August 25, 1898. Two new cases have since been inserted in this list, *i.e.*, No. 20, a "cure," and No. 30, a late recurrence. Twenty-six new cases have been added. Some details as to the history of the cases can be found in this article. With the slight changes above mentioned, the numbers correspond.

CHAPTER I

The first part of the book is devoted to a general survey of the subject. It is divided into two main sections, the first of which deals with the history of the subject, and the second with its present state. The author begins by pointing out the importance of the subject, and then proceeds to give a brief account of its development from the earliest times to the present day. He then discusses the various methods which have been employed in the study of the subject, and finally gives a summary of the results which have been attained.

The second part of the book is devoted to a detailed examination of the subject. It is divided into three main sections, the first of which deals with the theory of the subject, the second with its practical applications, and the third with its future prospects. The author begins by pointing out the importance of the subject, and then proceeds to give a detailed account of its theory and practice. He then discusses the various methods which have been employed in the study of the subject, and finally gives a summary of the results which have been attained.