

Four cases of bi-temporal hemianopsia / by A. Hill Griffith.

Contributors

Griffith, A. Hill.
Tweedy, John, 1849-1924
Royal College of Surgeons of England

Publication/Creation

Manchester : John Heywood, 1887.

Persistent URL

<https://wellcomecollection.org/works/eus9w7b9>

Provider

Royal College of Surgeons

License and attribution

This material has been provided by This material has been provided by The Royal College of Surgeons of England. The original may be consulted at The Royal College of Surgeons of England. where the originals may be consulted. This work has been identified as being free of known restrictions under copyright law, including all related and neighbouring rights and is being made available under the Creative Commons, Public Domain Mark.

You can copy, modify, distribute and perform the work, even for commercial purposes, without asking permission.



Wellcome Collection
183 Euston Road
London NW1 2BE UK
T +44 (0)20 7611 8722
E library@wellcomecollection.org
<https://wellcomecollection.org>

10.


With kind regards

FOUR CASES
OF
BI-TEMPORAL HEMIANOPSIA.

BY
A. HILL GRIFFITH, M.D.,
Assistant-Surgeon, Manchester Royal Eye Hospital.



REPRINTED FROM THE "MEDICAL CHRONICLE," JANUARY, 1887.



FOUR CASES OF BI-TEMPORAL HEMIANOPSIA.

BY

A. HILL GRIFFITH, M.D.,

Assistant-Surgeon, Manchester Royal Eye Hospital.

REPRINTED FROM THE "MEDICAL CHRONICLE," JANUARY, 1887.

JOHN HEYWOOD,
DEANSGATE AND RIDGEFIELD, MANCHESTER;
AND 11, PATERNOSTER BUILDINGS,
LONDON.
1887.



FOUR CASES OF BI-TEMPORAL HEMIANOPSIA.

THIS form of hemianopsia is caused by interference with the fibres of the optic nerves supplying the nasal side of each retina, and when the defect occurs in the field of *each* eye, as in the cases I am about to describe, we can have no hesitation in locating the intracranial disease at the optic chiasma where these fibres cross, and hence we may term this the localising form of hemianopsia, in contradistinction to the homonymous variety in which the exact position of the lesion can seldom be diagnosed, and then only by the presence of other signs. Central vision is always impaired from the first, and often seriously so; whereas in the homonymous form it is very seldom much reduced, and is usually normal. The bad sight, and characteristic defect in the visual field, may be the only symptoms present, but we may also have paralyses of eye muscles and loss of smell, from pressure on the oculo-motor and olfactory nerves; and total amaurosis of one or both eyes is common from secondary atrophy of the optic nerves. Among the general conditions noted in some of these cases have been deposit of fat, polyuria, increase of the amount of urine passed, glycosuria, and great thirst. Cessation of menstruation has been several times observed. In regard to the relative frequency of temporal hemianopsia, Mauthner's estimate is about 1 per cent of all cases of hemianopsia, Forster's 23 per cent, and my own experience, 4 in 27, about 11 per cent, so that we see that it is a comparatively rare form. Wilbrand has collected and reviewed the symptoms of all the cases published up to the date of his paper,¹ 32 cases in all; and the same writer in a later paper² refers to other five later cases. Berry,³ in a very interesting paper, to which I beg to acknowledge my indebtedness, records two cases, and refers to one new case by Niden, not included in the list of those I have referred to. Ross⁴ records a very interesting and most typical case, and at the Manchester Medical Society, December, 1883, showed a case complicated with paralysis of eye muscles; lastly, McHardy⁵ and Hansell,⁶ of Philadelphia, each records a case. These, along with my own four cases bring the total up to 48; but a large number of the cases collected by

¹ "Ueber Hemianopsie und ihr Verhältniss, zur topischen Diagnose des Gehirnkrankeiten," 1881.

² "Ophthalmatrische Beiträge zur Diagnostik der Gehirnkrankeiten," 1884.

³ "Temporal Hemianopia, with two cases."—*Ophth. Review*, June, 1884.

⁴ "Diseases of the Nervous System, 1883, Vol. II., p. 583.

⁵ *Trans. Ophth. Socy.*, 1881.

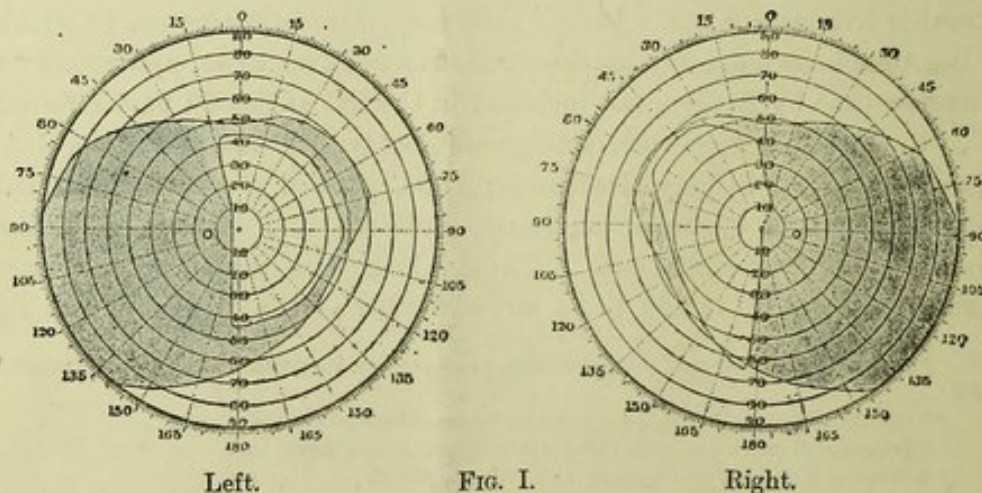
⁶ Noticed in Knapp's "Archives of Ophthal," Vol. XIII.

Wilbrand are, as Berry points out, far from conclusive as to their chiasmal origin, some of them showing total amaurosis of one eye with ill-defined temporal defect of the other eye, a condition noted by Gowers¹ in an undoubted case of primary atrophy in locomotor ataxy.

Wilbrand has tabulated twelve cases in which a post-mortem examination revealed the cause of the pressure on the chiasma. In six a tumour was found, in one a tubercular nodule, in two a gumma, in one a cyst, in one periostitis, and in one meningitis. Besides these, we have a fracture of the body of the sphenoid in one of Nieden's cases, a sarcoma of the dura mater covering the body of the sphenoid in Ross's first case, and a tubercular nodule in his second case. In McHardy's case was found a reddish tumour, probably syphilitic, involving the chiasma and tracts. Silcock, at a meeting of the Ophthalmological Society, December 10th, 1883, showed a sarcomatous tumour springing from the pituitary fossa and compressing the chiasma. In this case, as far as could be ascertained, there had been no impairment of vision.

Before describing my cases, I wish to say I am indebted to the courtesy of Dr. Little for Cases 1 and 3, and to Dr. Glascott for Case 4. Case 2 I saw in consultation with Dr. Livy, of Bolton.

Case 1.—Peter Eaton, collier, aged 30, married, was seen for the first time on December 28th, 1883. He complained of failure of sight for three months, which had come on about three days after a blow on the back of the head. He did not fall, but was only slightly stunned for a moment, and there was no bleeding from the ear. With the right eye he saw No. 19 Jäger, and with the left eye No. 16. The fundi were normal, charts of the visual fields were also normal, and there was no central colour scotoma. The patient is a strong, stout, healthy man, and never had syphilis or any venereal disease. He was ordered strychnine. In February, 1884, the charts were again traced and found normal. In March, right 4 and $\frac{6}{15}$, a very great improvement in three months. Left, 16 as before. In July the strychnine was changed for iodide of potassium in ten grain doses. In October the vision of each eye was as at last examination, but the fields of vision now showed the characteristic defects (Fig. I.). In

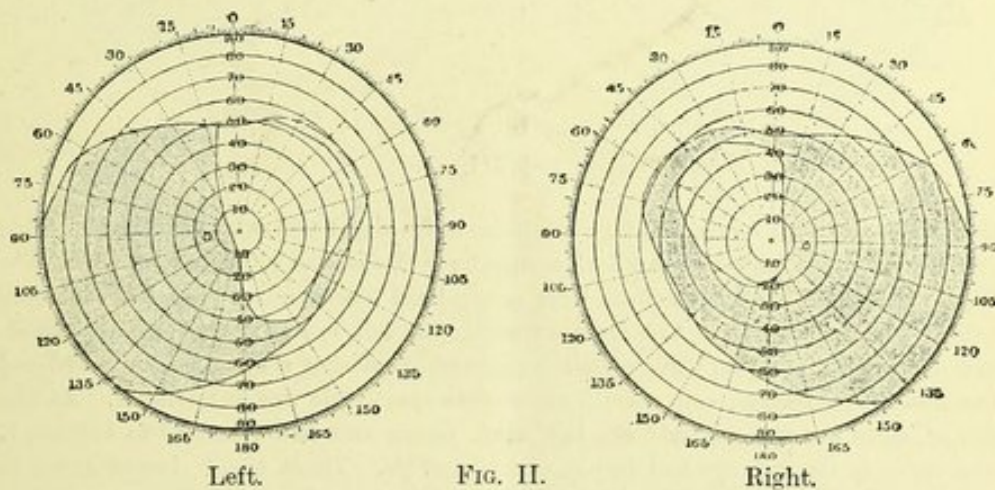


¹ "Medical Ophthalmoscopy," 2nd Edition, Case 55.

November, it is noted that the pupils react to light, whichever way reflected into the eyes. In December, twelve months from date of first visit, the vision remains as before. He was ordered pil. hydrarg. gr. ii. along with the iodide. In June, 1885, right 16, left 20, and when I saw him next time in January, 1886, he told me he had been in bed for three weeks with severe pain in the head and vomiting. He looked ill, pale, pasty, and bloated. Urine normal, as it had been found on several previous examinations. There was only perception of light with each eye. Mercurial inunction was afterwards tried, but with no beneficial result. The left eye lost even perception of light, and the right retained only perception at the nasal side. Both optic discs became pale, the retinal vessels retaining their normal calibre. Both pupils retained the power of contracting to light so long as any perception of light remained, and the left pupil only lost this property when all perception of light had vanished.

It is important to notice in this case that the bad sight preceded by nearly nine months the defects in the fields, for, of course, the diagnosis could not be made in the absence of such defects. Dr. Ross, who saw the case, believed that the blow had caused fracture of the body of the sphenoid, with subsequent exudation pressing on the chiasma.

Case 2. James T—, bootmaker, aged 33, married, was seen by me in January, 1886. Right, 19, left 16, fundi normal, but perhaps the right disc was a little paler than left. The charts of the visual fields are depicted in Fig. II. The sight had

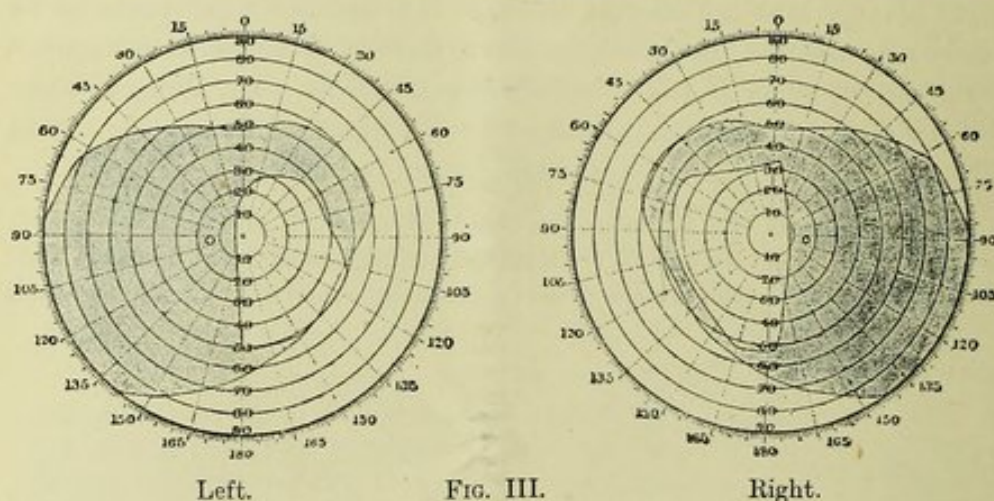


been failing for two years. Patient is a good deal stouter than he used to be; has been married eight years, has two children, and wife is again pregnant; heart sounds are normal, and there is no staggering gait. Urine was examined by Dr. Livy, and found normal; there was no increased urination. At the expiry of eleven months the vision, state of the fundi, and visual fields was unchanged.

The case is remarkable for the entire absence of other symptoms than the bad sight and defects in the fields, and for the stationary character of these symptoms, and on this account I am of opinion that the growth is an osseous one connected with the body of the sphenoid.

Case 3. Miss P., aged 33, single, nurse, was first seen by me on February 9th, 1886, and the result of the examination was—right eye $\frac{6}{30}$, left, $\frac{6}{30}$; fundi normal, pupils active. H. under 2 D.; loss of temporal side of field in each eye, with some restriction of nasal halves, doubtful impairment of cutaneous sensibility on left side,

dyschromatopsia in right eye, loss of sense of smell in left nostril, taste not affected. The symptoms appeared nine months ago, when engaged in nursing a "head case," she could not lift her eyelids, and she suffered from diplopia and also a good deal of pain in head; she has not been able to read for eight months, and is afraid of crossing the streets. Menstruation ceased five years ago, and has not returned; she has been getting stout for the last few years; the gait is not affected. The pupils were dilated, and a thorough examination made, but nothing abnormal was found except a circle of white opaque striæ at the periphery of each lens, a condition which, I believe, is physiological, and have seen other examples of the same condition. No improvement of vision was obtained by correcting the slight hypermetropia present. February 23rd, a tracing of the fields was taken, and showed well-marked bitemporal hemianopsia (Fig. III). There is slight left ovarian tenderness, and the patient tells me



that about the time menstruation ceased, she had a slight yellowish vaginal discharge, and she was examined by a medical man, who said she had ulceration of the womb. With the right eye she calls white light green, light blue is called grey, but pinks are named correctly; the colour perception with the left eye is normal. This examination was performed on three different visits with a similar result. She was ordered bromide of potassium, and shortly afterwards the iodide was substituted. At the end of seven months she said she felt much better and had returned to her work. The vision in the left eye had improved to 2 and $\frac{6}{4}$. There is still loss of smell in the left nostril; she complained for the first time to me of a noise like a wave in her head, but I could detect no sound with the stethoscope. The urine was examined twice and found to be normal.

On the first examination of this patient I was inclined to regard the nature of the case as hysterical, for the first tracing of the visual fields was not unlike general peripheral contraction, and the mode of onset, temporary ptosis, left anosmia, and dulness of cutaneous sensibility were all consistent with the diagnosis. On the other hand the impairment of colour perception was on the right side, and on taking the fields the second time there could be no doubt the contraction was due to pressure on the chiasma, for I am not aware that any well marked persistent case has been shown to be functional in its nature. A case of rapid amblyopia, with partial loss of the temporal sides of the fields, has

been recorded by me.¹ The symptoms came on during a heavy drinking bout in a previously temperate woman, and disappeared in a few days of abstinence from alcohol. Cessation of menstruation, which occurred in Case 3, is also noted in one of Berry's cases, and the latter author, in his paper, refers to four other cases in which this happened.

Case 4.—David Bennett, aged 31, married, a collier, was seen for the first time in July, 1885. The history I elicited was that twenty days ago, when working in the pit at 12 midnight, the left eye went suddenly dim, and it has gone gradually since then, so that there is not even perception of light, and the pupil only reacts through the right eye. With a -5D he has vision equal to $\frac{2}{5}$ with the right eye. The fundi are normal, and there appears slight myopia in the right eye, but rotatory nystagmus comes on and prevents a thorough ophthalmoscopic examination. Patient has always had good health, and never had any venereal disease; he complains, however, of suffering from "rheumatism in the head" for the last six weeks. There is a double aortic rough bruit, with very visible epigastric pulsation. I examined him a month after and found no change. At the end of three months the left eye was as before, but the vision in the right eye had sunk to $\frac{6}{60}$, and was not improved by glasses; the fundi were normal. An examination of the field of the right eye revealed a very unusual and interesting change (see Fig. IV.), a sharply defined tem-




FIG. IV.—Right.

The limits of the field for blue is indicated by the line — — —, field for red by — . . . —, and for green by - - - - -.

poral defect for red and green, while the temporal field for white and blue remained normal. I showed the chart to Dr. Ross, who considered it showed the invasion of the nasal side of the right optic nerve. Smell was not affected. In six months from this date I found the field of the right eye again normal in every respect, and vision was also normal. With the left eye, which at last examination was quite blind, he could pick out letters in 20 Jäger. The field of the left eye shows well marked hemianopsia (Fig. V.) He confused pinks and light greens together, and both these colours appeared rather like a blue; blue and red are correctly named; the colour perception in the right eye is normal. The right disc is certainly hyperæmic, the redness invading the physiological cup; the left disc by comparison is pale, but is of a good colour all the same. The nystagmus has now quite gone, even when a prolonged examination is made. The last examination was made on November 17th,

¹ "The Field of Vision,"—*Med. Chron.*, Nov. 1885, p. 9.

1886, and showed distinct pallor of the left optic disc, vision 16 Jäger, temporal defect in field as before ; pinks and greens are still confused, and appear like blue. The right eye is normal in every respect, each pupil reacts separately to light, but the left only slightly.




FIG. V.—Left.

I certainly did not suspect the chiasmal nature of this case till the temporal achromatopsia appeared in the right eye, and the diagnosis was further confirmed by the defect in the left field afterwards appearing. The nystagmus was in all probability simply that often found in colliers, and its complete disappearance on ceasing pit work rather favours this idea.