

History of a case of recurring sarcomatous tumour of the orbit in a child, extirpated for the third time, and ultimately causing the death of the patient / by Thomas Hay.

Contributors

Hay, Thomas.
Tweedy, John, 1849-1924
Royal College of Surgeons of England

Publication/Creation

Philadelphia : Lindsay & Blakiston, 1877.

Persistent URL

<https://wellcomecollection.org/works/ktehcad8>

Provider

Royal College of Surgeons

License and attribution

This material has been provided by This material has been provided by The Royal College of Surgeons of England. The original may be consulted at The Royal College of Surgeons of England. where the originals may be consulted. This work has been identified as being free of known restrictions under copyright law, including all related and neighbouring rights and is being made available under the Creative Commons, Public Domain Mark.

You can copy, modify, distribute and perform the work, even for commercial purposes, without asking permission.



Wellcome Collection
183 Euston Road
London NW1 2BE UK
T +44 (0)20 7611 8722
E library@wellcomecollection.org
<https://wellcomecollection.org>

HISTORY OF A CASE 5
OF
RECURRING SARCOMATOUS TUMOR


OF THE ORBIT IN A CHILD,
EXTIRPATED FOR THE THIRD TIME,
AND
ULTIMATELY CAUSING THE DEATH OF THE PATIENT.

BY
18 DEC
THOMAS HAY, M.D.,
OF PHILADELPHIA, PA.



*Reprinted from the Report of the Fifth International Ophthalmological Congress,
held in New York, September, 1876.*

PHILADELPHIA:
LINDSAY & BLAKISTON.
1877.





HISTORY OF A CASE OF
RECURRING SARCOMATOUS TUMOR.

BY THOMAS HAY, M.D., PHILADELPHIA.

THE subject of this case, a boy, H. C., not six years old, was brought to me July 10, 1874, pale and worn, with an orbital tumor of the left side, projecting from the orbit upward above the supra-orbital arch, downward below the nose, and encroaching on the one side upon the nose, and on the other upon the temple and cheek.

The history of the case dates back to January, 1873, when the child was four years and four months old, at which time the first tumor appeared, growing, apparently, from the supra-orbital plate. The child had always been strong and hearty previously, and had been regarded as a healthy boy till the appearance of this neoplastic growth. He was born of healthy and strong parents; both are now living. His brother, the only other child, is well, and no evidence of hered-

itary transmission of disease can be traced to either branch of the family of mother or father. The father is an inebriate.

In November, 1872, fourteen months prior to the appearance of the first growth, the child tripped on a board, and falling, struck himself across the root of the nose upon the hearth of a cook-stove. The skin was not broken by the fall, but it caused a large transverse indentation, and a swelled and bruised appearance, which lasted a week or ten days. The accident was not attended with suffering, and no special injury could be detected. The mother, however, attributes the origin of the tumor to the effect of the fall.

The tumor grew slowly, and the child's health continued good for six months after its first appearance, when his health began to fail, and the tumor grew more rapidly, but it had caused no pain till within about three weeks before its first removal, which operation was performed by Dr. James W. Kerr, of York, Penn., in August, 1873, seven months after its first appearance. At this period the growth was not large, and, though the eyeball was somewhat displaced in a forward and downward direction, the sight was good.

The operation was performed by cutting across the upper eyelid, and extracting through the in-

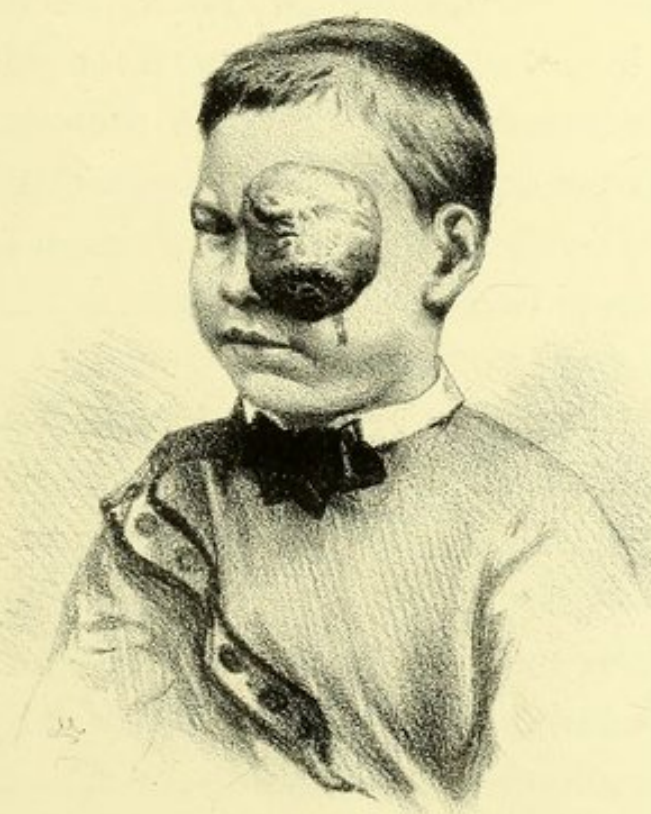cision. The parts healed up kindly in about three weeks, and all pain had disappeared, but it was followed by complete ptosis. The boy's health improved, and it was thought he was cured. But the tumor reappeared *in loco* in November, 1873, ten months after the appearance of the first one, and three months after its removal. Its growth was more rapid than the first, and the tumor soon pressed the eyeball outward and caused it to become prominent.

In February, 1874, six months after the first operation, and three months from the date of its second appearance, it was again removed by the same gentleman, the eyeball being left *in situ*, by making the incision through the cicatrix of the former one.


The growth at the time of its second removal was hardly one-third the size of the third growth (*See Plate I*). About a month prior to the second operation, pain in the tumor was noticed, and from that time it is supposed the sight in the eye was lost. The pain was severe, and caused loss of rest, and the child became emaciated. Touching the tumor seemed to increase the sufferer's agony, and at night he would lie on his face with his head supported by his hands to protect the eye from contact with the bedclothes. The sec-

ond operation was not followed by a good result. The parts remained swollen and painful, the tumor reappearing almost simultaneously with its removal. Taking on new growth, it increased rapidly in size, and the patient's sufferings continuing, he became greatly reduced and emaciated. Till in May following—for three months—the pain was terrible. After that period it subsided somewhat, and in June it was very much less severe and less constant. The eyeball then having been entirely covered in by the tumor, it was no longer visible, nor could it be detected. The incision of the second operation never healed, and the edges of the wound were separated by the growing tumor, and near the inner angle a lobular mass the size of a marble protruded.

When the child came under my notice emaciation was marked, and he was restless and fretful, and had very little appetite, and was evidently declining in health, although his general condition was better than it had been. He suffered much less from pain than heretofore, and to this may be attributed his improved state of health. After prescribing iron, arsenic, and cod-liver oil, I left the patient to see me again in a month. His general improvement under the treatment was decidedly marked, and his condition was so much better that



This Plate represents the appearance of the Child and Tumor
at the time of the operation.




I concluded to operate. *Plate I* is a correct and fair picture of the appearance of the child and the tumor at the time of operating, the picture having been taken the same day. The upper black and rough surface in the picture is the site of the old incision, and the protruding mass above referred to; the one below is the palpebral aperture widely separated, nothing being visible in the latter but an inflamed, ulcerated, and thickened membrane, from which, as well as the opening above, there is a constant discharge and oozing of thin pus. The intervening part covering the tumor is healthy but very much stretched and thinned integument.

August 10, 1874, one year and a half after the appearance of the first tumor, and six months after the date of the second operation, assisted by my friend Dr. E. W. Meisenhelder, Mr. A. M. Stout, my medical student, and others who were present, with the patient thoroughly anæsthetized, I operated at York, Penn., removing the tumor and remains of the eyeball by dividing the tissues between the palpebral aperture—without enlarging the space at the outer canthus—down to the growth, and with the finger and handle of the scalpel enucleated the tumor, separating and taking away with it a large surface of periosteum from the supra-orbital plate to which it was

attached in an antero-posterior direction. By compressing the mass as I gradually withdrew it, its escape was easy. Separation at the base of the orbit was made with the knife, and subsequently every particle of the morbid mass was removed. The normal tissues within the orbit were not invaded by the disease, and were perfectly healthy, and the surface of the bone from which the periosteum was removed was thoroughly sound. As the tumor grew it embraced the muscles and flattened the eyeball, which latter had a position on the lower and inner side of the orbital cavity. Solid nitrate of silver was thoroughly applied, and a tampon of charpie, saturated with the solution of the persulphate of iron, was introduced and allowed to remain forty-eight hours. Very little bleeding followed the operation, and none upon the removal of the tampon. There was no suffering afterward, and, under the use of opiates, stimulants, and good diet, he speedily recovered, and two months after the operation the patient presented the appearance as represented in *Plate II*. The operation was severe, and prolonged and hazardous from the effects of the anæsthetic. The anæsthetic chiefly used was one part of chloroform to three of ether by weight. From its use collapse



The appearance of the Child two months after
the operation.



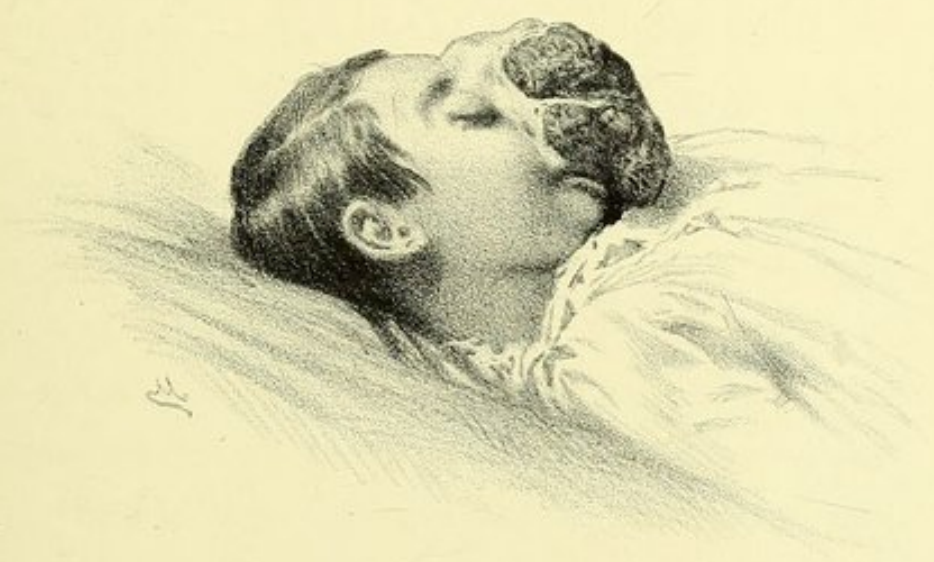occurred three times, and at each the operation was suspended, and I was obliged to resort to artificial means to resuscitate the patient. The third time the collapse proved almost fatal. After he revived I finished the operation, using ether as the anæsthetic. Its influence was thoroughly satisfactory, and no further delay or inconvenience followed.

For the character and minute structure of the tumor I am indebted to my friend Dr. Joseph G. Richardson, of Philadelphia, who made an examination of the specimen for me. I append an extract from his letter :

“Thin sections, cut from the most prominent nodule of that orbital tumor you left with me, when properly stained, exhibited large numbers of spindle-shaped, oval, and rounded cells (with moderate sized nuclei), imbedded in a well-formed fibrous stroma, which was everywhere intercellular, and separated each cell-element from its neighbors. This structure of elongated cells, isolated by an all-pervading intercellular substance, indicates, of course, that the growth is a *sarcoma fusocellulare*, and probably belongs to the group of recurrent fibroids of Paget. In regard to prognosis, since the neoplasm is positively not a carcinoma, I should give my opinion that, while liable, it is not very likely to return after thorough extirpation. Moreover that, should recurrence take place, another, and if possible, even more radical removal of the tumor would be advisable, since we might even then hope for a complete cure.”

It is but just to mention that Dr. Richardson was without the history of the case when he made the examination, and he only knew that the specimen was a tumor which had been removed from the orbital cavity of a child.

Everything progressed well with the little patient, and all his friends thought he was thoroughly cured till their anxiety and fears were aroused by the appearance of a swelling of the lower lid of the same eye, which was first noticed about three months after my operation—in November, 1874. This time the growth was alarmingly rapid, and terribly destructive, and ended the life of the little sufferer in May, 1875, nine months after my operation, and two years and four months from the appearance of the first tumor. *Post-Mortem* examination could not be had, but the accompanying picture (*Plate III*), which was taken after death and sent to me, gives a correct idea of the size of the mass, and the terribly distressing condition the little sufferer must have been in. The black part of the picture shows a surface of ulcerated, bleeding, fetid fungosity.



The appearance of the Child after death showing the
condition of the new growth.

