

Acute pemphigus : a contribution to the aetiology of the acute bullous eruptions / by George Pernet and William Bulloch.

Contributors

Pernet, George.
Bulloch, William, 1868-1941.
Tweedy, John, 1849-1924
Royal College of Surgeons of England

Publication/Creation

[London] : [publisher not identified], [1896?]

Persistent URL

<https://wellcomecollection.org/works/njab52ky>

Provider

Royal College of Surgeons

License and attribution

This material has been provided by This material has been provided by The Royal College of Surgeons of England. The original may be consulted at The Royal College of Surgeons of England. where the originals may be consulted. This work has been identified as being free of known restrictions under copyright law, including all related and neighbouring rights and is being made available under the Creative Commons, Public Domain Mark.

You can copy, modify, distribute and perform the work, even for commercial purposes, without asking permission.



Wellcome Collection
183 Euston Road
London NW1 2BE UK
T +44 (0)20 7611 8722
E library@wellcomecollection.org
<https://wellcomecollection.org>

(16.)

With Guy Romet's Compliments



ACUTE PEMPHIGUS:

A CONTRIBUTION TO

THE ÆTIOLOGY OF THE ACUTE BULLOUS ERUPTIONS.

By GEORGE PERNET, L.R.C.P. LOND., M.R.C.S. ENG.,

AND

WILLIAM BULLOCH, M.D. ABERD.,

Bacteriologist in the British Institute of Preventive Medicine.

INTRODUCTORY REMARKS.

It is not necessary in this place to insist on the complexity of the subject of Pemphigus; nor would it serve any useful purpose to enter into a lengthy historical discussion of the various phases through which it has passed.

In submitting the present paper to dermatologists, our object is to show that there is an acute bullous eruption (Acute Pemphigus) which affects butchers, that infection takes place through a wound, and that it is probably due to a specific micro-organism. Further, that, apart from butchers, the condition may arise in a similar way in those handling animals or animal products.

The subject will be treated in three parts. I. Clinical. II. Bacteriology and Morbid Anatomy. III. General Conclusions.

PART I.—CLINICAL.

BY GEORGE PERNET.

The first case described is the one which came under our own observation. It is followed by seven other cases.

CASE I.*—A. E. H., a journeyman butcher, æt. 32, was admitted as an emergency case to the skin ward, University College Hospital, on the evening of March 2nd, 1895. At 7 P.M. on that day his temperature was 104.4°. I first saw the patient on March 4, about 11 A.M., and found him in a very serious condition. He was able, however, to give a connected account of his illness.

History of Present Illness.—About three months and three weeks before his admission he noticed a tiny gathering on the right little finger. It did not trouble him, and remained the same for three months. Nothing was done to it. On February 8th a large blister suddenly formed round the lesion on the little finger. It was exactly the same as the blisters now seen on his body. It was raised quite half an inch above the level of the skin. The blister corresponded to the area of roughened skin, which can still be seen about the site of the original lesion. The next day, February 9th, he came to the Surgical Out-patients' Department of the Hospital, when the blister was treated like an ordinary whitlow. It was opened,† and fomented until February 11th. An ointment was then applied, and on the 16th the finger was practically well. On the following day, February 17th, the patient began to break out all over the body, the eruption beginning about the neck, behind the ears, on the back and scalp, in the groins and on the knees. He felt very bad, as if he were going to die, and complained of shivering, back-ache, and pains all over. The bowels and micturition remained normal. On the 28th, blisters appeared on the tongue, lips, ears, and forehead. On March 1st the eyelids were affected. Blisters appeared on his hands and feet after his admission to Hospital. He attributed the original lesion on the little finger to a small wound inflicted in the course of his occupation.

The Eruption.—The patient on admission had been dressed with boracic acid ointment, but as the smell was extremely offensive, the dressings were carefully and rapidly changed. While this was proceeding I was able to make the following notes:—The whole of the back is a sheet of reddened, blistered skin, laterally bounded by sinuous borders, with a very few islets of healthy skin about the sides of the thorax. Beyond its limits there are discrete old lesions produced by the bullous eruption, spreading thence down the arms and thighs. About the upper part of the back there are raw areas here and there; lower down, and especially about the buttocks, to below the gluteal folds, the skin is quite raw, and bleeds readily when the dressings are removed.

On the back of the thighs there are numerous old lesions and broken-down bullæ. In front, the groins are also quite raw, in a band-like manner, and the area of denuded skin reaches round to the back. The scrotum is not affected; nor is the penis as far as can be seen (long phimotic prepuce and copious smegma). The inguinal glands are not enlarged. The thighs in front present discrete hæmorrhagic lesions about one-eighth of an inch in diameter; these are somewhat oval in shape. The front of the left knee is much more affected than the right, but the flexures of both are raw. The anterior lower third of the legs and the dorsal surface of the feet present recent bullæ, with slight areola.

Between the toes, on both sides, except between the fourth and fifth, the skin is denuded of epithelium. The soles are free, but the skin is somewhat thickened. There are some old discrete lesions and subsiding and broken-down bullæ on the calves.

* This case is published in abstract in this Journal, p. 120, Vol. VII., 1895.

† The dresser states the contents were clear.

On the arms there are also old discrete lesions. The inner surface of the left arm on the flexor aspect is raw. There are fresh and subsiding bullæ on the flexor surfaces of the forearms. The palms are free, as far as can be seen, but the skin is hard and horny. The left hand is a dull red to the end of the fingers on the palmar surface; on the dorsum the redness affects the thumb and index-finger only. This red area is well-defined and somewhat raised. The same hand also

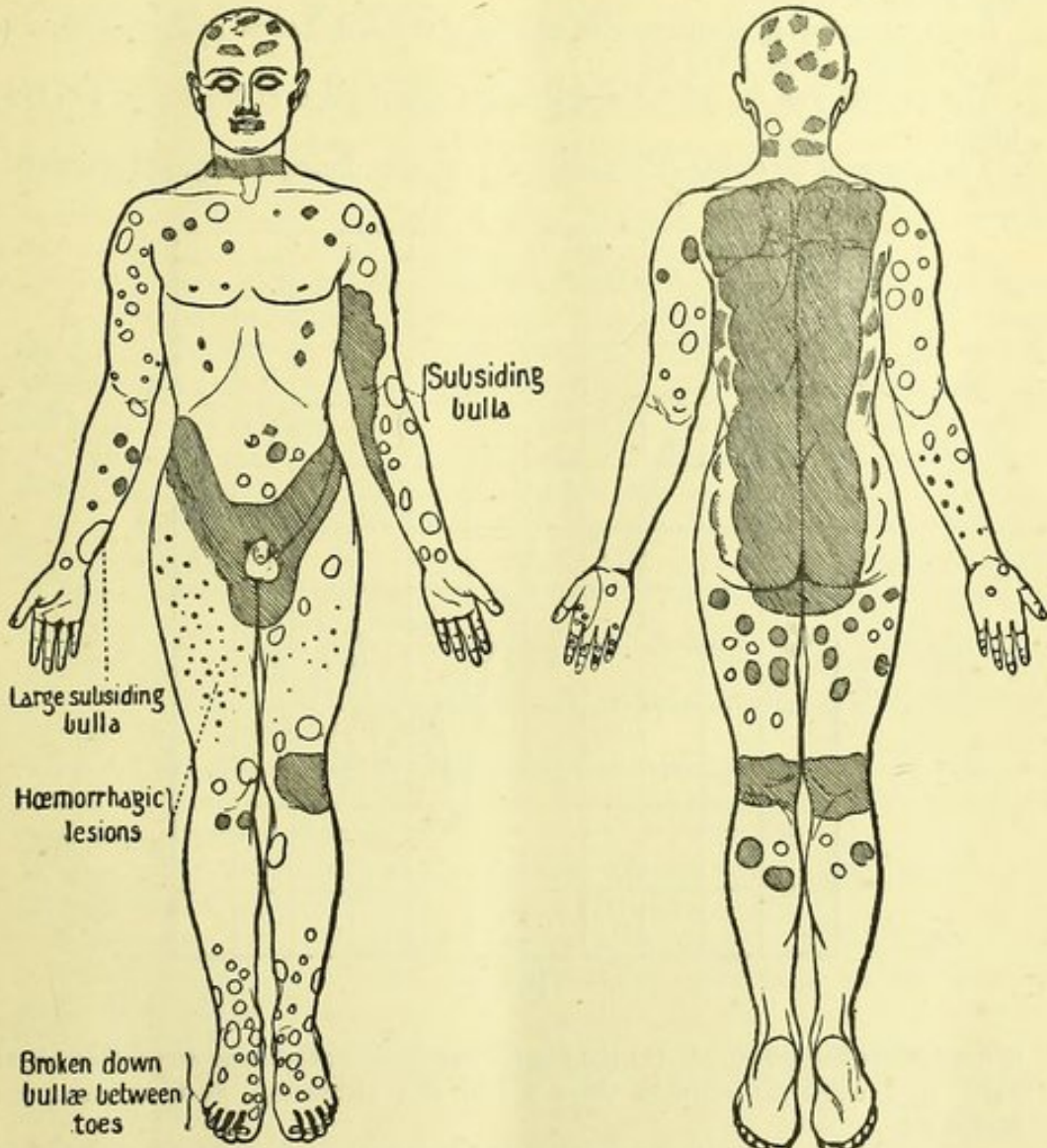


FIG. 1.

FIG. 2.

presents recent bullæ on the dorsal surfaces of the fingers. The site of the original wound on the right little finger is occupied by a small hard, horny nodule.

The neck is raw, as the result of bullæ which have broken down. There are blood-crusts about the lips, nostrils, ears, and eyes. Also raw areas on the forehead and about the inner canthus of the eye. There is a purulent discharge from the eyes, and the lids have a tendency to stick together. The conjunctivæ are injected.

Rusty, viscid saliva issues from the mouth, and is got rid of with difficulty by the patient. The mouth cannot be opened to any extent, and the tongue can be but slightly protruded. The scalp has been crusted; there are remains of old lesions about it.

The bullæ vary in size from a small split pea to a hen's egg. The smaller are tense, with clear serous contents; the larger are flaccid and subsiding, with sero-purulent contents.

The accompanying diagrams give an idea of the distribution and appearance of the eruption. (Figs. 1 and 2.)

The patient was too ill for a systematic examination of his lungs, &c., to be made.

The Course of the Case.—The patient was delirious during the night of March 4th,

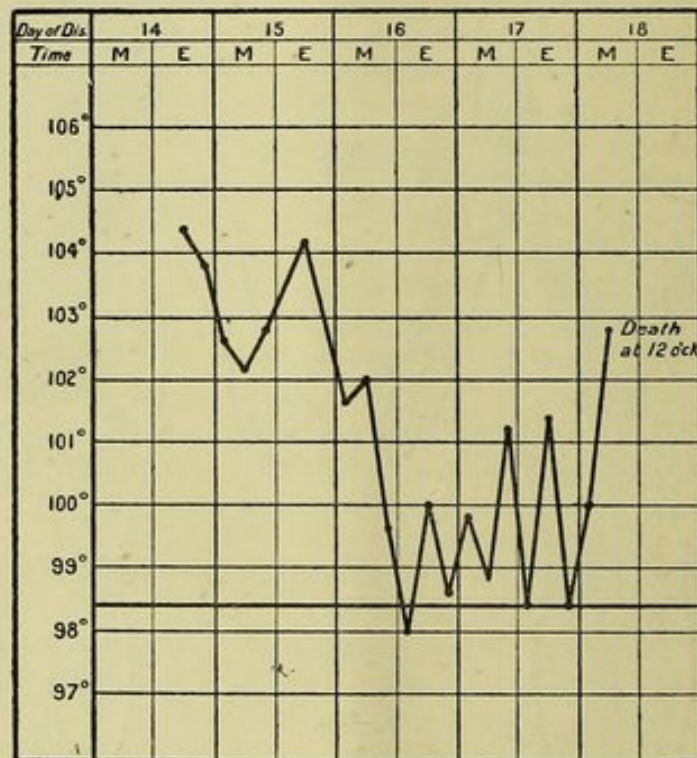


FIG. 3.

and sedatives had no effect. On the 5th he was weaker; the pulse very feeble, about 142. That night he vomited three times, and ultimately died at noon on March 6th.

Temperature.—It fluctuated between 104.8° (7 P.M., 3rd March) and 98° (3 and 11 P.M. on the day before death). (Fig. 3.)

Urine.—The urine was twice examined, viz., on March 4th and 5th. It was acid, 1.024–1.026 s.g., presented a trace of albumen, but no sugar and no blood.

Motions were normal, and no blood was noticed in them.

Treatment (general).—The patient was made as comfortable as possible on a water-bed. He was ordered an effervescing quinine mixture, and his strength was kept up with milk, fresh eggs, and brandy.

Local.—His mouth was frequently swabbed out; and the eyes were kept clean with

boracic acid lotion. The large bullæ were opened. Boracic acid ointment dressings, then carbolic oil, 1 in 40, were changed as frequently as the condition of the patient would allow.

P.M.—I took the opportunity of examining the skin lesions, before proceeding with the actual autopsy.

The back, from the nucha to below the gluteal folds, was raw, presenting here and there epithelial sloughs. At the upper part, the raw surface extended from shoulder to shoulder, the width diminishing from above downwards, and corresponding to the parts in contact with the bed in the dorsal decubitus. Beyond the limits of this raw surface there were discrete lesions spreading round the body towards the ventral surface. The flexures of the knees were raw, to the extent of $3\frac{1}{2}$ by $2\frac{1}{2}$ inches. The elbows were also denuded. The palms were thickened, also the soles of the feet, but to a lesser extent. No trace of an eruption could be seen on these parts.

There were no traces of lesions on the ocular conjunctivæ. The internal surfaces of the lips were ulcerated, and there were traces of old lesions on the hard palate. On the penis there were two small superficial ulcerations from $\frac{1}{12}$ th to $\frac{1}{8}$ th inch in diameter about the corona and glans respectively. No enlarged glands could be felt at the elbow and in the axilla on the right side, that is on the same side as the original wound on the little finger. On the legs and feet there were some recent, tense bullæ, from about $\frac{1}{4}$ to $\frac{1}{2}$ inch in diameter, with clear contents.

As to the post-mortem examination itself, the following notes were taken:—Twenty-two hours after death, rigor mortis well marked (weather cold and damp). Body well-nourished, of medium but good build. One inch and a half of fat on abdominal wall. A quantity of fat about omentum.

Heart and Pericardium.—About half an ounce of fluid in pericardium. Weight of heart, $11\frac{1}{2}$ oz. Partially decolorized clot in left ventricle. Slight atheroma of aorta, and slight thickening of aortic valves.

Lungs.—Slight band of adhesion about right lung. Left lung, no adhesion. No fluid in pleuræ. Both lungs crepitant all over. Congestion in lower lobe of both lungs. No consolidation.

Liver is not obviously enlarged. Surface, smooth. On section, pale, lobules distinct, surrounded by fatty area. Weight, 4lbs. 4ozs.

Spleen.—5ozs. Apparently slightly enlarged, pultaceous, of light red colour.

Kidneys.—Together, $11\frac{1}{2}$ ozs. Capsules, slightly adherent. On section, pale, rather firm. Slight fibrosis.

Brain.—Superficial congestion. Base, normal. On section, normal.

Intestines.—Two portions, about one foot each in length of ileum, are congested. No ulceration anywhere.

Bladder.—Healthy. Contains a small quantity of urine.

Urethra.—Normal.

Taking all the facts of the case into consideration, I came to the conclusion that there was a causal connection between the wound on the little finger, and the subsequent eruption and fatal termination. It was to confirm and support my hypothesis that I determined to look up the literature of Pemphigus. I have been able to collect five very

similar cases, in three of which there is a history of a preceding wound; and also two other cases of acute fatal bullous eruptions occurring in butchers.

I will, in the first place, refer to those cases that most resembled my own.

Case II.—Under Burrows,¹ at St. Bartholomew's Hospital. A young butcher was admitted on April 8th, 1886.

History.—Five weeks previously, whilst cutting a fresh sheep's head, the knife slipped and cut the patient's left thumb.

He remembered that the sheep's lung was full of "white knobs." He remained quite well (with the exception of the thumb being incised, and subsequently discharging) until April 5th, without any symptoms of fever. He then noticed a spot upon his lip, which looked like a scald. Then a discharge from the eyes came on, but no headache and no shivering; and the spots gradually increased about his face and hands, till the disease had the appearance that it presented on admission.

The Eruption.—On April 8th, when admitted, his condition was as follows:—On his face, more especially about the skin, was a crop of small bullæ about the size of split peas. There were also similar spots on the mucous lining of the lip, as well as on the edge of the tongue, and on the soft palate and uvula. There was also a purulent discharge from the left eyelids. On the back of the hands there were some red elevated spots commencing to be papular. There were also many red elevated spots about his abdomen and back, and the upper part of his thighs.

When Burrows saw the patient on the following morning, April 9th, his expression was anxious; face flushed; eyes suffused, with a purulent discharge from the inner canthus of the left eye, and the outer canthus of the right. There was also a purulent discharge from the right nostril. About his face, below the chin, there was an abundant crop of bullæ, which seemed to have become more pustular in character since the previous day. They were also increased in size, some being larger than a fourpenny-piece. Around each of the bullæ the cutis seemed inflamed. A few were now observed about the hairy scalp. The eruption was seen about the hands, wrists, extending up the inner aspect of the forearms. There was a similar eruption in the iliac regions, inner aspect of the thighs, on the scrotum and penis, and upon the back; also upon each foot, about the ankle and along the tarsus. Some of these bullæ were very minute, and others larger, about the size of split peas. The eruption was apparently confined to the finer parts of the skin. Where the cuticle was thickened—on the outer aspect of the arm and thigh, the palms of the hands, and the soles of the feet—it was absent.

The wound of the thumb was open and discharging.

With regard to the patient's general condition constitutional disturbance was much less than might have been expected. Breathing easy. Slight cough and sore throat. Skin hot and dry. Tongue coated on the dorsum, the edges presenting an appearance of having small pimples upon them. Appetite fair. No sickness, no headache, and no thirst. Constipation. Urine free.

¹ George Burrows, "Clinical Lecture on a Vesicular Disease Contracted from Sheep."—*Medical Times and Gazette*, 1856, Vol. I. p. 589.

On the following morning, April 10th, the constitutional disturbance was greater than on the previous day. Expression anxious. The pulse, 108, sharp and compressible. Appetite began to fail. Great thirst. No headache. Bowels opened, hard motion. Urine free. Some sore-throat. Slight cough and scanty mucous expectoration.

As to the eruption, the lesions on mucous lining of mouth and lips had the appearance of being covered with patches of sloughs. The numerous bullæ on the face had begun to dry up. On the inner aspect of the upper extremities the bullæ and vesicles were so closely aggregated as to have become completely confluent. The skin looked as if it had been scalded with boiling water. The eruption had increased about the trunk, the axillæ and back, the iliac regions, the inner part of the thighs, and the scrotum. Some of the spots on the thorax, which were more numerous, contained fluid.

Some of the lesions had ruptured, and were copiously discharging. The eruption was also more abundant on the lower extremities, ankle-joints, and over the insteps.

Course of Illness.—Fresh bullæ appeared for sixteen days after admission. As long as fresh vesicles and bullæ made their appearance, the same constitutional disturbance existed as has been noticed. The vesicles were clear and transparent for two or three days, then became opaque, shrivelled up, or burst, if subjected to friction or pressure. They left sores or crusts, which when detached left red spots behind.

The patient's condition gradually improved. A week later, that is about four weeks from beginning of the eruption, the disease as a disease had entirely ceased, but he was emaciated, pallid, and exhausted.

Treatment.—Locally fine hair- or starch-powder was dusted on the parts affected, which gave great comfort. Borax and honey, diluted in warm water, was used for the mouth.

General.—Beef-tea, milk, por wine, arrowroot. A mixture containing Liq. Cinchonæ $\mathfrak{m}\text{xv}$. and Pot. Chloras gr. xv. was given every four hours.

CASE III.—When describing the above case, Burrows² refers to a precisely similar case, which came under his observation in 1854. The patient, a young man employed as a shopman at a butcher's, had been engaged skinning, cutting up and dressing sheep's-heads, and had wounded himself. He was admitted to Bartholomew's in the month of March, and presented over the surface of his body an eruption precisely similar to the one just described. He was in a more advanced stage of disease, and died about a fortnight after admission. The body was not examined.

CASE IV.³—H. M., a butcher, æt. 33, was admitted to the Hôpital St. Louis, under Lailler,⁴ on June 24, 1869.

History.—The patient works eighteen hours a day slaughtering cattle. Alcoholic. No history of syphilis.

Unhealed and freely suppurating wound of the right thumb for two months. On

² *Loc. cit.* p. 590, column 2.

³ This case I have found since my paper on "The Etiology of Acute Pemphigus" was published in *Brit. Med. Journ.*, Vol. ii. 1895, p. 1554.

⁴ NODET, "Contribution à l'étude des éruptions pemphigoides aiguës chez l'adulte." Paris, 1880. Observation inédite, communiquée par M. Lailler, p. 88.

June 21st the patient pricked his left middle finger with a bone; this wound also freely suppurated, the epidermis becoming detached, without the preceding formation of a bulla. At 7 P.M., on June 21st, about twenty rounded bullæ appeared on the inner parts of the thighs. This was followed by headache and pain during the night, and in the morning the patient vomited. On the 22nd and 23rd there were pain, headache, and shivering; and the sweating of the feet, usually abundant, was suppressed. On the morning of the 23rd the eruption became general, the bullæ on the thighs rupturing, with copious and fetid discharge.

The Eruption.—He was admitted to the hospital on June 24th: eruption on inner parts of the thighs and on the right index-finger. Sleeplessness and vomiting. Bullæ on the tongue, and also one on the soft palate. No enlarged glands.

On the 28th the eruption had increased on the inner parts of the thighs, on the back and scalp. The bullæ were large, without areola. Subsiding bullæ on the tongue, the uvula and gums.

The patient was better on June 30th, but on July 1st a fresh crop of bullæ appeared. Confluent eruption: back, scalp, inner parts of thighs.

July 5th.—A general erythematous eruption was noticed. By the 15th of the same month the patient was well. The discoloration of the skin following the bullæ lasted fifteen months before they completely disappeared.

Treatment.—General: One *Pilule de Lutz* is mentioned as having been given (? Opiat de Lutz: sulphur and honey). Local: Lycopodium powder and tannin.

CASE V.⁵—François B., a journeyman tripe-butcher, æt. 17, under Horand, at the Antiquaille Hospital, Lyons (1872).

History.—The patient has never had any venereal disease. He is a teetotaler. Nothing in the family history.

He cannot assign any cause to his present illness. Lately he has worked harder than usual, and suffered slightly from diarrhœa. No malaise on the day preceding the eruption, which began on the morning of August 21st, when on waking he noticed small bullæ on the fingers and toes. Some of these were ruptured when the patient washed himself, leaving superficial ulcerations. He went to work as usual. During the day fresh bullæ appeared on the forehead, and during the night the eruption attacked the forearms.

The Eruption and Course of Illness.—Admitted to the hospital on August 22nd. The eruption was discrete. Bullæ, the largest not exceeding a small pea in size, on forehead, lips, forearms, fingers and toes. The patient was slightly feverish, and there was some watering of the eyes.

During the night the eruption became general, and on the morning of August 23rd, bullæ were distributed over the whole of the body. They ranged from a pin's-head to an almond in size. Their contents were serous and pale yellow; some were umbilicated, others presented an areola. Between the toes and fingers, where the bullæ had broken down, there were superficial greyish ulcerations, and the discharge from them was fetid and sanious. On the back and abdomen there were erythematous patches: first stage of the eruption. Conjunctivæ injected. Pulse, 64. Temperature, A.M., 38°; P.M., 37·8°.

When seen on the 24th the bullæ had considerably increased in size, especially

⁵ HORAND, "Note pour servir à l'histoire du Pemphigus aigu fébrile," *Ann. de Derm. et de Syph.*, Vol. IV., 1872-73, p. 402.

on the forearms, where some of them were as large as a small egg. Vesicles on tongue, right anterior pillar, and mucous lining of lips. Deglutition painful. Diarrhœa. Pulse, 70. Temperature, A.M., 38°; P.M., 38·2°.

August 25.—Fresh bullæ on limbs, abdomen, and back. Deglutition more and more painful. The constitutional symptoms are practically unchanged.

Temp. A.M. 38°. P.M. 39·2°.

August 26.—On the abdomen the bullæ have increased in size, as if blisters had been applied. On the left thigh there were several small bullæ of a violet colour; two others, of the size of a hazel-nut, were turbid and yellow in the lowest parts, whilst the fluid above this was clear and serous.

Pulse 88. Temp. A.M. 38·2°. P.M. 39·2°.

By the 27th, the number of hæmorrhagic bullæ had increased, but they were only present on the thighs, and no larger than a large pea. The older and larger bullæ were breaking down, and the discharge from them was fetid. There were extensive excoriations on the back and buttocks, rendering movements very painful. The urine is red, turbid, and only a small quantity is passed.

Pulse A.M. 88. P.M. 112. Temp. A.M. 39°. P.M. 39°.

On the 28th, the hæmorrhagic bullæ were subsiding. No fresh crop. Deglutition very painful. Fever, continuous. The patient weaker and weaker.

Pulse 120. Temp. A.M. 39·4°. P.M. 39·8°.

August 29th.—Much worse. Pain due to excoriations intense. The patient could scarcely make himself understood. The mouth filled with thick secretion. Suppuration free and fetid. The patient looked as if he had been burnt.

Pulse 120. Temp. A.M. 39·2°. P.M. 40·2°.

August 30.—Patient quite collapsed. Respiration rapid. Face covered with profuse sweat. Pulse small, weak, and rapid. The day before, he fainted for a short time after an attempt to shift his position, and he had a very restless night.

Pulse 130. Temp. 40·4°. The patient died at 12 o'clock.

Treatment.—General: At first aconite was exhibited, but when the temperature went up quinine was given.

Local: Dressed with an ointment containing sub-acetate of lead and laudanum (Cérat de Goulard laudanisé).

Post-mortem: Thorax.—No fluid in pleuræ or pericardium. Some old lesions of lungs. Heart normal. Slight congestion at bases of lungs.

Abdomen.—Peritoneum: nil. Intestines distended, normal in appearance. Nothing found in the intestines. The liver is very large, red, friable, and fatty; the right lobe especially apparently engorged. Kidneys slightly congested. Spleen healthy.

Nervous system not examined.

CASE VI.⁶—Louis R., æt. 17, a journeyman pork-butcher under Vidal at St. Louis (1881).

History.—Father healthy, mother suffers from rheumatism. As a child the patient was healthy. He has lived in Egypt, where he suffered from ophthalmia,

⁶ PAUL GIBIER, "La Bactérie du Pemphigus. Recherches sur l'Étiologie de la fièvre pemphigoïde (pemphigus aigu, fièvre bulleuse. *Ann. de Derm. et de Syph.*, T. iii., 2^e Série, 1882, p. 104.

also from " Nile Boils " (boutons du Nil) which have left scars on his face. Has never had any other eruption.

Previous to his illness, he had freely partaken of pork-butcher's meat. During the whole of previous summer he suffered from pruritus, affecting the whole of the body. No malaise, no feverishness.

The eruption of which he complains commenced on August 14th, the trunk, face, and root of limbs being affected.

The Eruption.—When admitted, on August 18, there was a general pemphigus eruption, the bullæ ranging in size from a millet-seed to a bean. Small bullæ on the right eyelids. Bullæ on the face, neck, chest (but fewer); in the axillæ (confluent), on the buttocks, penis, thighs (few). A few bullæ on the legs. None on the feet. Vesicles and confluent bullæ about a recent scar over the metacarpophalangeal joint of the left middle finger.

The bullæ contain a clear, pale yellow fluid. No inflammatory areola.

While he was being examined the patient complained of noises in the ears and dizziness. For three minutes he could not distinguish light. He was ultimately able to return to his bed in the ward. Temp. 37·8°.

August 19.—Eyelids sticking together. On getting up in the afternoon: noises in the ears and dizziness.

August 21.—An abundant crop of large tense bullæ all over the body, with exception of feet. On the abdomen and arms the bullæ became confluent. Patient has not slept.

August 22.—A fresh crop of bullæ; a few on the abdomen as large as a walnut. Half an hour after opening the bullæ on the abdomen fresh ones made their appearance. These were tense, but not quite so large.

August 23.—Fresh bullæ. One on the nose as large as a large almond-shell.

August 24.—Epistaxis lasting more than half an hour. Vomited several times. Scarcely any normal skin can be seen. Temp. 40°. Sub-delirium. Fetid odour.

August 25.—Temp. 40·5°. No fresh bullæ. Patient in greater pain. Great thirst.

August 26.—Small crop of bullæ on thighs.

August 27.—Typhoid condition. Adynamia. Hæmorrhagic bullæ in different parts, especially on buttocks and knees.

August 28.—Very weak. Temp. 38°. Pulse 120. Breath and smell from body very fetid. No fresh bullæ.

August 29.—Collapsed. Quiet delirium.

August 30.—(Gibier gave up charge of patient to Brocq.) Pulse 120. Respiration 40. The eruption distinctly hæmorrhagic. Diarrhœa. Tongue slightly dry. Red lymphatic lines about the bullæ on lower limbs. Erysipelatous redness of forehead.

August 31.—Death.

Temperature.—The lowest temperature was 37·6° (August 21), and the highest 40·5° (August 25), falling to 39° (August 29).

Urine.—A notable quantity of albumen found on August 20, also on 21st and 25th, less on 26th, and only a slight ring of albumen on 27th August.

Post-mortem.—Thirty-six hours after death.

Blood.—Diffluent, and saturating all the tissues.

Brain.—Punctiform hæmorrhages in the white substance, otherwise nil.

Spinal Cord.—Nothing to be seen.

Skin.—The bullæ are no longer visible.

Lungs.—Congested at the bases.

Heart.—Nil.

Kidneys.—Capsule easily removed. Healthy (?).

Alimentary Canal.—Sub-mucous ecchymoses of the stomach, and especially of the large intestine.

The two following cases may be added to the above :—

CASE VII. (Moissenet's).⁷ An alcoholic pork-butcher, who succumbed in twenty-four hours. No details.

CASE VIII. (Henning's).⁸

The patient, a weaver, æt. 30, did the slaughtering for the village, as no butcher lived in the place. Alcoholic. The patient had been suffering for eight days from an eruption when first seen by Henning. There was an epidemic of measles of a benign type at the time.

The Eruption and Course of the Illness.—The man's condition is described by the author as one of *fürchterlicher Pemphigus*. Bullæ of various sizes and shapes were present on the hairy scalp, the nucha, the chest and back, the abdomen and thighs.

The skin between the bullæ was in places of a deep brown. The greater number of the bullæ contained dark yellow, stinking pus, and most of them were the size of a walnut. Where they had burst, the excoriated surfaces left behind were black and gangrenous; this was well seen on the back and buttocks, which also presented thick crusts here and there. The discharge gave rise to severe burning pain, where it came into contact with the skin. The patient could scarcely speak, and movement gave rise to convulsions. There was severe headache, and the eyes, mouth, and nostrils were inflamed.

Besides this the man complained of great thirst. The pulse was small, quick, and flickering. Diarrhœa and pain on swallowing. From the mouth and nose issued a bloody, frothy mucus. The stench was unbearable.

The patient died the following night.

Treatment (general).—Tamarind whey as a drink. Concentrated infusion of cinchona with sulphuric acid.

Locally.—The attending surgeon to apply decoction of oak bark in sour whey.

Moreover, fumigations of vinegar were to be employed, and the windows and doors of the room to be opened every half-hour (the hygienic conditions were horrible). When possible clysters of cinchona bark boiled in whey to be administered.

COMPARISON OF CASES, I.—VIII.

Occupation.—All the patients were butchers, and actively engaged in their work as journeymen, with the exception of Case VII., where

⁷ Vide HORAND, *loc. cit.*

⁸ HENNING, "Geschichte eines Pemphigus der am zehnten Tag tödlich war," *Journ. d. prakt. Arzneykunde u. Wundarzneykunde*, 1813, Bd. XXXVI., Stück III., p. 89.

no details, further than the fact that the patient was a butcher, are given.

Age.—They were young adults, from between 17 to 33 years of age (again, with the exception of Case VII. : no details).

History of a Wound.—In four cases (I., II., III., IV.) there is a distinct history of a wound of the fingers, inflicted in the course of work.

Further, in Case VI., a recent scar of the hand was noticed. In the remaining cases no wound is mentioned, but it is needless to point out that injuries to the hands must be frequent in butchers, especially in journeymen, who have the rough work to do.

Mortality.—The disease was rapidly fatal in six of the eight cases.

Duration of Fatal Cases :—

Case	I.	...	about 17 days after first appearance of the eruption.			
"	III.	...	14	"	"	"
"	V.	...	10	"	"	"
"	VI.	...	18	"	"	"
"	VII.	...	24 hours	"	"	"
"	VIII.	...	10 days	"	"	"

Previous History.—In three cases (IV., VII. and VIII.) there is a history of *Alcohol*. Two of these patients died in 24 hours and about 8 days respectively. One recovered. But it will be noted that the patient in Case V. was a teetotaller, and he died. *Syphilis* was excluded in two cases (IV. and V.) ; and no reference is made to it in the other cases. As far as Case I. is concerned, there was no evidence of it, although I looked for some on account of the long duration of the wound on the little finger.

Prodromal and Constitutional Symptoms.—Usually nothing was noticed before the eruption had made its appearance, and the constitutional disturbance then corresponded with the course of the eruption, being more evident as the skin became more involved. Burrows (1856) states (Case II.) that the constitutional symptoms were much less than might have been expected, but the temperature is not recorded (it was in the days before the clinical thermometer). This is mentioned, because in Case I. the patient, although he was extremely ill, was able to give a connected account of his illness, which was corroborated by the clerk to the case, who had attended

to him when he came to the out-patients' department, and confirmed by a reference to the out-patients' case book.

Temperature.—In Case I. the highest temperature was 104.8° (7 P.M. on the day after admission), the lowest 98° (on 3rd day). Just before death it went up again to 102.8° (5th day in hospital). The highest points reached in Cases V. and VI. were 40.4° (104.7°) and 40.5° (104.9°) respectively.

Urine.—In Case I. a trace of albumen was noted. Albumen was present in larger quantities in Case VI.

Treatment.—Quinine or bark was exhibited in all the cases where treatment is mentioned (Cases I., II., V., and VIII.), one of these cases recovered (II.).

In Case IV. *Pilules de Lutz** were administered. The patient recovered.

The original wound.—It is interesting to note that in three cases, where details are forthcoming (I., II., and IV.), a wound had been inflicted 3 months, 5 weeks, and 2 months respectively, before the appearance of the eruption. In Case I. it remained as a "tiny gathering"; in II. and IV. the wound continued to discharge up to the time of the cutaneous outbreak. In Case I. what appears to have been the first bulla arose on the site of the original wound. Mr. Chandler, the dresser, is quite sure the contents were clear when he opened and treated it as a whitlow in the out-patients' department. In Case IV., where the patient, besides the 2 months' old suppurating wound, had also pricked another finger with a bone, it is noted that the epidermis became detached about the wound, but without previous formation of a bulla. In Case VI. there were vesicles and confluent bullæ about a recent scar of hand.

Although the actual position of the wound probably plays no part in the matter, it may be noted that the right little finger (Case I.), the left thumb (Case II.), and the right thumb (Case IV.), were the fingers affected.

This leads us to the consideration of:—

Incubation.—The period of incubation is probably a long one. Of course it is impossible to say whether the wounds were infected at the time they were inflicted, or at a subsequent period, between that time and the appearance of the eruption. The second wound

* ? *Opiat de Lutz*.

mentioned in connection with Case IV. was inflicted on the same day that the first bullæ appeared; but when the case is compared with the others, it is more likely that the original wound was the source of the trouble.

The Eruption.—In all the cases the eruption rapidly became general. Where the cases are described more or less fully there was a great similarity about the distribution. The horrible fœtor emanating from the patients is frequently insisted upon. The palms and soles were not affected in Cases I., II., and probably III. (Burrows states it was exactly like Case II.). In Case VI., again, there were no bullæ on the feet.

In some of the cases (II., and no doubt III.: Burrows's cases), some of the lesions were vesicles, but as the bullæ are described as increasing in size, the vesicles were probably early stages. The bullæ varied in size: small split peas to a hen's egg (Case I.), split pea, fourpenny-piece (Case II.), pin's head to a small egg (Case V.), millet-seed to a walnut (Case VI.). Sometimes an areola is described as surrounding the bullæ; in other cases an areola was present, but not constant. Again, it is noted in Case VI. that there was no areola.

In Cases I. and V. there were hæmorrhagic lesions on the thighs, and in Case VI. hæmorrhagic bullæ were present on the buttocks and knees.

The bullæ were sometimes preceded by erythematous patches.

The mouth, palate, eyes, nostrils, were almost always more or less affected; and in Case VI. there was also epistaxis.

In Cases I. to VI., the bullæ appeared in crops during the course of the illness.

It was noted in two cases (I. and IV.) that the glands were not enlarged.

A *post-mortem* examination was made in three cases (I., V., and VI.). In two the liver was not normal: enlarged and slightly fatty (Case I.), and very large, friable, and fatty (Case V.—that is the teetotaller). In Case I. the ilium was congested, in parts; and in Case VI. there were sub-mucous ecchymoses in the stomach, and large intestine. The kidneys were practically normal, to the naked eye, in the two cases in which albumen was found (Cases I. and VI.).

Hygienic Conditions.—In Case VIII. they were extremely defective.

Case I. lived in artisans' dwellings. The disease does not appear to have any relation to hygienic surroundings, or it would be more frequent.

Season.—March (Cases I. and III.), April (II.), June (Case IV.), August (V. and VI). The cases are too few to draw any conclusion on this point.

Cases Apart from Butchers.

CASE IX.—A tanner, æt. 50, under Dr. G. N. Pitt,⁹ at Guy's Hospital. Health good until October, 1887, when the patient poisoned his left little finger: ill three weeks. Five weeks later poisoned his left thumb: ill three weeks. Next, he noticed small vesicles on the arms, neck, and thighs. They disappeared, and he resumed his work for three weeks. On December 27, 1887, he noticed fresh vesicles on the perinæum, penis, and thighs. He was admitted to Guy's Hospital, January 3, 1888, and died on the 10th of same month. Dr. Pitt describes the case as one of Pemphigus malignus. It was very much like my own (Case I.), but not so extensive.

Duration.—Fourteen days.

Post-mortem.—Practically nothing.

No history of *Syphilis*.

Treatment.—Liq. Arsenicalis.

CASE X.—Published by E. Ballard.¹⁰ On August 16, a man, æt. 21, whilst administering a physic-ball to a horse, was bitten on the dorsum of the right hand, over metacarpal bone of index-finger, blood flowing from the wound. The same day he milked some cows suffering from a bullous eruption on the udders and teats. About a week after a bleb appeared at the bitten spot, and a few blebs of a similar kind appeared on the skin just around it. In the course of another week, or later, when the first blebs were fading, a large crop of similar lesions appeared about the dorsal surfaces of the hands. A few also appeared on the knees, legs, and buttocks. The patient then felt very ill. There was much inflammatory swelling, vomiting (it is said) of some bloody matter, and fever; but never any rigors.

He consulted a medical man on September 6, when a fresh crop of bullæ appeared on the face and neck, and a few on the hairy scalp. The face became swollen, and the eyes closed. The mouth and throat also presented blebs; bloody matter flowed from the nose. The *urine* looked as if it contained blood, as it was very red, but it was not examined.

From September 29th to October 2nd he vomited a good deal, and could keep nothing down. On October 1st he passed two fetid stools, apparently melænic.

Dr. Ballard saw him on October 8th for the first time. He was then convalescent. Several of the blebs on the arms were flat and shrivelling, others were

⁹ PITT, "Pemphigus malignus," *Path. Trans.*, 1889, vol. xl, p. 303.

¹⁰ BALLARD, "Notes of a case of Pemphigus, in which the disease was contracted by inoculation from an eruption upon the teats of a cow," *Med. Times and Gaz.*, 1871, Vol. I., p. 5.

covered with blood-crusts. In some parts the situation of the blebs was occupied by superficial sores or excoriations, cracked and bleeding. Nothing in mouth nor throat.

The *urine* contained no albumen. No fever. A fortnight later the patient was out and about again.

These two cases are very interesting, and corroborate the view that severe acute bullous eruptions may arise from infection through a wound.

In Case X. the disease was contracted by inoculation from the teats of cows suffering from a bullous eruption. In this place it should be mentioned that bullous eruptions have been observed in cattle and horses. Seaman¹¹ mentions a case of pemphigus in a bullock, resembling pemphigus in man. Seaman saw the case on the day (May 14th) the animal fell ill, and he noticed bullæ or bladders, from a small nut to a fowl's egg in size. The animal was very ill at the time. Excoriations and loss of hair followed.

Loiset¹² observed a "Pemphigus enzootie" in cows, near Lille, during September and October, 1887. There were no febrile symptoms. It is stated that a woman, with an excoriation, presented bullæ similar to those seen on the cows, on the right hand, arms and breast.

Gibier,¹³ with Bouley, observed two horses with acute pemphigus. Hoffmann¹⁴ has seen acute fatal pemphigus in a horse.

Bullous eruptions are also said to have been observed in dogs¹⁵ and in pigs.¹⁶

Case X. is further interesting from the fact that the first sign of the eruption was a bleb, which appeared at the bitten spot, a point already insisted on when referring to the cases in butchers, especially Case I.; but the period of *incubation* was shorter (one week).

As to the period of incubation in the tanner (Case IX.), it is diffi-

¹¹ *The Veterinarian*, 1852, p. 262.

¹² *Journ. de Méd. Vét.*, 1858. Cited by Falke in *Schmidt's Jahrbücher*, 1860, Vol. CV., p. 342.

¹³ *Recueil de Méd. Vét.*, 1882, Vol. II., Série 6, p. 480.

¹⁴ HOFFMANN, *Tierärztliche Chirurgie für prakt. Tierärzte u. Studierende*, 1892, II., p. 490.

¹⁵ *Vide* GIBIER, *loc. cit.*

¹⁶ WINKLER, cited by Friedberger und Fröhner, "Lehrb. d. spec. Path. und Therap. d. Haustiere," 1892, I., p. 412.

cult to say precisely when infection took place. But variations must be allowed for (idiosyncrasy of patient, state of health, variations in the virulence of the micro-organism, time of year), as in other diseases due to infectious germs.

As also confirming the views put forward in the introductory remarks, the following cases may be adduced:—

CASE XI.—Under Dr. Bleibtreu,¹⁷ of Cologne. A female servant, æt. 20, of strong constitution. The eruption commenced on June 1st, 1893; admitted to hospital on June 8th. She was sent in as a varicella case. On admission a subcutaneous whitlow was noticed round the nail of the right index-finger. Bleibtreu suggested that it may have arisen from a suppurating bulla.

Diagnosed on June 10th as acute pemphigus.

Death on June 27th.

Duration.—Twenty-seven days from commencement of eruption.

Treatment.—Quinine.

Urine contained albumen.

Post-mortem.—Inflammatory condition of large and small intestines. Otherwise practically nothing.

The superficial whitlow noticed in this case may have been a bulla developing on a wound, as in some of the preceding cases. In Case I. the ileum was congested; in this case there was inflammation of the large and small intestines.

CASE XII.—Under Dr. Southey¹⁸ (1875). A general servant, æt. 19, came to the hospital on October 28th for a sore on the side of the hand, which commenced as a blister (carpal end of metacarpal of right little finger). It had been cauterized. She first felt very poorly (ill) on November 15th, when eruption appeared. Blebs on the dorsal and palmar aspects of the hands. None on the soles. She recovered.

From the description it resembled generally my case (I.).

The urine contained some organic compound or colouring matter, which decomposed nitric acid.

Treatment.—Baths. Nutrient enemata. Carbolic oil dressings. These left off for plain olive oil, Carron oil, linseed poultices. Some of the larger bullæ were pricked, and Arg. nitras, gr. ii. ad. ʒi., injected (according to Graves's plan). All these were beneficial.

Here, again, we have the history of a sore on the hand, which commenced as a blister.

The treatment is mentioned at some length because baths, &c.,

¹⁷ BLEIBTREU, "Beitrag zur Kenntniss des Pemphigus Acutus," *Berliner klin. Wochensh.*, 1893, p. 671.

¹⁸ SOUTHEY, "Acute Pemphigus," *Clin. Soc. Trans.*, Vol. VIII., p. 179.

proved beneficial. In Case I. baths would have been tried had not the patient been in so hopeless a condition from the first. Still, where there is every convenience, baths should be tried.

CASE XIII.—Under Dr. S. Coupland.¹⁹ A hard-worked woman, æt. 45. On admission to the Middlesex Hospital it was noticed she had a *whitlow* at the base of the right thumb-nail. She first noticed a blister had formed on her nose. The patient recovered.

Urine.—No albumen.

Treatment.—Arsenic.

CASE XIV.—Under Dr. Barthel.²⁰ A man-cook, æt. 47, alcoholic. On February 17: Rigor, feverish headache. On February 19, vesicles on the back, inner part of thighs, &c. On February 21, scalp affected. The chorion is exposed in inguinal regions and perinæum. The bullæ vary from a walnut to a small orange in size (thirty or forty bullæ). No bullæ on palms or soles; none on face. A slight areola observed round bullæ. Patient recovered and returned to work on March 16.

Temp.—Never above 40°.

Treatment.—Quinine, port wine, ice-bag to head, &c.

As in most of the cases the palms and soles were free.

CASE XV.—A married barmaid, æt. 23, under Dr. West,²¹ at St. Bartholomew's. The patient was bitten on the right thumb by a dog a month before admission. A week after the bite small spots like blisters appeared on the back of the right hand. This was followed by others on the arms, legs, and trunk. No bullæ on buttocks, groins, or back. She was discharged a month after admission.

Urine.—Normal.

Temp.—100°.

Treatment.—Arsenic. Daily bath, &c.

This case is mentioned because it followed a bite of a dog. It was not a severe case.

CASE XVI.—Fagge²² has recorded a case of bullous eruption following the bite of a pony on the right upper arm. The patient, a woman, æt. 45, was admitted to Guy's Hospital on September 22, 1869. The bite on the front of the arm healed, but on the back it remained indolent and painful, and after the lapse of a month spread as a raw sore. A month or more later (two months before admission) vesicles and papules appeared on the hands and arms, commencing on the little

¹⁹ "Case of Acute Pemphigus—Recovery." (From Notes by Mr. C. R. Tyrrell), *Med. Times and Gazette*, 1879, II., p. 99.

²⁰ BARTHEL, "Ein Fall von Pemphigus Acutus," *St. Petersburger med. Wochenschr.*, 1876, No. 14, p. 4.

²¹ WEST, "Case of Acute Pemphigus." *St. Barth. Hosp. Rep.*, 1886, XXII., p. 227.

²² Fagge, "Remarks on Certain Cutaneous Affections; with Cases."—*Guy's Hosp. Rep.*, 1870., 3 s., XV., p. 335.

finger of left hand. The chin and the feet were next affected. The patient quickly recovered under *Liq. Arsenicalis* m. iii. ter die.

The urine, S. G. 1·009, was slightly precipitable by heat and nitric acid, and there were granular casts.

CASE XVII.—Under Dr. Penrose,²³ at St. George's. A kitchen-maid, æt. 22. She was first seen as an out-patient on October 26, 1893, for sore-throat, and was treated outside until November 14, when she was admitted as an in-patient.

She first noticed blebs on November 13, on forearms and front of both knees. She got rapidly worse on November 22, and died on the 29th.

Duration.—Seventeen days.

Urine.—No albumen on admission.

Post-mortem.—Slight congestion about duodenum.

There is no mention of a wound. It may be asked whether the sore-throat was the first symptom of infection; or did infection take place through the throat?

Reviewing the Cases (IX. to XVII.), and omitting the cases of the barmaid (Case XV.) and of the pony-bite (Case XVI.), the occupation of the patients brought them into contact with animals or animal products (tanner, milker, servants, house-wife, man-cook).

Whitlows were present in two cases; in two there were sores of the hand or fingers; in three there was a history of a bite, and, in one of them, subsequent inoculation from cows.

Three cases were rapidly fatal.

Whether the micro-organism may be introduced into the stomach and thus give rise to the disease remains to be shown.²⁴

I have to thank Dr. H. Radcliffe-Crocker for kindly allowing me to make use of Case I., which was admitted to the Skin Ward of University College Hospital under his care.

²³ PENROSE, "A case of Acute Pemphigus in a young adult female, &c." *Lancet*, 1894, Vol. I., p. 265.

²⁴ J. W. ANDERSON, of Jamaica. "Note of a fatal case of Acute Pemphigus and Gangrene following a meal of Putrid Conger."—*Lancet*, 1873, I., p. 875.

PART II.—BACTERIOLOGY AND HISTO-PATHOLOGY.

BY WILLIAM BULLOCH.

MANY observers have recorded observations of the presence of bacteria in the different forms of bullous eruptions, but only those observations which have been made since the introduction of Koch's methods possess value for the present time. That the contents of the bullæ in cases of *Pemphigus neonatorum* are inoculable was long ago demonstrated by Scharlau,¹ Röser,² Colrat,³ and Vidal.⁴ More recently Almquist⁵ and others have demonstrated the same fact. Röser was the first to describe the occurrence of micrococci in the vesicular contents, an observation confirmed by Birch-Hirschfeld;⁶ Gibier,⁷ however, was the first to describe these microbes in detail. He found them in the form of short chains of cocci, the individual cocci being 2.5μ in diameter, and the chains varying from 2–20 μ . His experiments on the inoculability of the contents of the bullæ were, however, attended with negative results. In an epidemic of pemphigus occurring in young children Colrat (*loc. cit.*) found large numbers of diplococci in the vesicles. The inoculation of these into the skin of rabbits' ears produced an excoriation (*décollement*) of the epidermis, with slight induration of the subcutaneous tissues, in which again similar diplococci were found. In a broncho-pneumonia following *Pemphigus acutus*, Sahli⁸ found cocci, and he regarded these as having probably entered the blood from the original cutaneous lesions.

From the vesicles of a typical case of *Pemphigus acutus*, Demme⁹ isolated in pure culture a diplococcus which he thought was the specific cause of the disease. Morphologically it resembled the gonococcus, although $\frac{1}{2}$ – $\frac{2}{3}$ larger. Characteristic colonies were obtained on blood serum at a temperature of 35–37° C. Inoculations were

¹ SCHARLAU, "Casper's Wochenschr. f. d. ges. Heilk.," 1841, p. 187.

² RÖSER, *Thèse de Paris*, 1876.

³ COLRAT, *Revue de Méd.*, 1884, XII., p. 935.

⁴ VIDAL, *Compt. rend. Soc. de Biol.*, 1876–77, 6 Ser., III., p. 235.

⁵ ALMQUIST, *Zeitschr. f. Hyg.*, 1891, X., p. 253.

⁶ BIRCH-HIRSCHFELD, Quoted by Weyl in *v. Ziemssen's Handb. d. Hautkrankheiten*, 1883.

⁷ GIBIER, *Gaz. d. Hôp.*, 1881, No. 124, and *Annal. de Derm. et de Syphilog.*, 1882, III., p. 101.

⁸ SAHLI, *Correspond. Blatt. f. Schweiz. Aerzte*, 1884.

⁹ DEMME, "Verhandl. d. Congresses f. inn. Med.," Wiesb., 1886, p. 336.

made on guinea-pigs, rabbits, cats, dogs, and pigeons, with either the vesicular contents or diluted pure cultures. No positive results were obtained from subcutaneous inoculations, but 2 c.c. of bouillon cultures inoculated into the pleural cavity in eight guinea-pigs caused death in five, from marasmus and broncho-pneumonia. In the pneumonic patches the cocci were again found, and in pure cultures exhibited their characteristic appearance for several generations.

In a case of *Pemphigus chronicus*, Dähnhardt¹⁰ found diplococci which he regarded as identical with Demme's "diplococcus of acute pemphigus," and he was accordingly inclined to doubt the specificity of Demme's coccus as the cause of acute pemphigus. He further raised the important question as to whether chronic pemphigus includes a number of different conditions, some infectious, others not.

From microscopic examination only, Zechmeister¹¹ believed he saw Demme's cocci in the contents of the bullæ in a small epidemic of *Pemphigus neonatorum* under his observation.

In a case of *Pemphigus acutus* in a child three weeks old Strelitz¹² found by culture methods two different organisms, the one growing as a golden yellow mass on the media, the other as a milky white; the former corresponded in several respects to the coccus of Demme, the latter was evidently entirely different, although both were cocci slowly liquefying gelatine.

In a series of nine cases of *Pemphigus neonatorum*, Almquist (*loc. cit.*) isolated a micro-organism closely allied to if not identical with *Staphylococcus pyogenes aureus*. The inoculation of the cultures on the skin of human subjects are, however, stated to have produced typical pemphigus vesicles in two days.

In 1892 Strelitz¹³ recorded a case in which he had again found two different varieties of micrococci as described by him in his previous communication. Inoculation of the yellow cultures on the arm produced pemphigus vesicles within thirty hours.

The most important confirmation of Demme's work has been made by Bleibtreu¹⁴ from the examination of a case of *Pemphigus acutus* in a young adult. The cultures made by Claessen corre-

¹⁰ DÄHNHARDT, *Deutsche med. Wochenschr.*, 1887, No. 32, p. 711.

¹¹ ZECHMEISTER, *Münch. med. Wochenschr.*, 1887, p. 737.

¹² STRELITZ, *Archiv. f. Kinderheilkunde*, 1890, XI., p. 7.

¹³ STRELITZ, *Archiv. f. Kinderheilkunde*, 1893, XV., p. 101.

¹⁴ BLEIBTREU, *Berlin Klin. Wochenschr.*, 1893, XXX., pp. 671 and 704.

sponded closely to the description given by Demme. Inoculation of a three days' old culture produced in a young pig redness locally, but no vesicular formation.

Others have found in cases of pemphigus, pyogenic cocci, *e.g.*, *Staphylococcus pyogenes aureus* (Felsenthal),¹⁵ *Streptococcus* (Babes),¹⁶ while rapidly fatal cases are on record, where, after careful bacteriological examination, no micro-organisms could be found (Lenhartz).¹⁷

In the fatal case recorded by Pernet a careful examination was made bacteriologically and pathologico-anatomically, with the following results:—

The remains of the primary cutaneous lesion on the right little finger, together with pieces of skin, with bullæ in different stages of development, were fixed and hardened, and embedded in paraffin. The staining reagents used were Ehrlich's hæmatoxylin, carmine; Loeffler's blue, and the Gram-Weigert stain.

Anatomy of the primary lesion: Epidermis.—The cells of the much thickened horny layer were separated from each other and loosely attached to the *rete mucosum*. At one point on the surface there was a slight depression, containing the remains of a brownly pigmented scab of indefinite structure. In the *stratum corneum* at the side of the scab were several large masses of pigment of a sepia-brown colour. The cells of the *rete mucosum* did not appear to be much altered, although in some the nuclei seemed shrunken and irregular.

Cutis.—The papillæ were flattened and irregular in shape. In some the vessels were distended, and throughout the papillæ there was a marked infiltration of granulation cells, which in places were aggregated into masses. The deeper layers of the *cutis* were also infiltrated with small round cells, gradually diminishing towards the depth, although well-marked around the sweat-glands. The whole appearances were those of a chronic inflammatory process.

Sections stained by Loeffler's blue and the Gram-Weigert process did not show the presence of any micro-organisms.

Anatomy of the Bullæ: Epidermis.—At each side of the bullæ the epidermis appeared to be normal, except that at the immediate edge

¹⁵ FELSENTHAL, *Archiv. f. Kinderheilkunde*, 1892, XIV., p. 15.

¹⁶ BABES, "Internat. Atlas of Rare Skin Diseases," 1893, I., p. 15.

¹⁷ LENHARTZ, *Berliner klin. Wochensch.*, 1882, XIX., p. 696.

many of the *rete* cells had very cloudy protoplasm, and the nuclei were swollen and did not stain well. At the extreme margins of the bullæ the epidermic layers were split, so that the *stratum corneum*, *stratum lucidum*, and *stratum granulosum*, formed the roof, the remaining layers forming the floor in part, but it gradually thinned off, so that along the greater part of the floor it was absent, its place being taken by a layer of condensed non-papillated fibrous tissue.

The cells forming the roof were not markedly altered, although a few lining the vesicles seemed to be necrosed.

Contents of the Bullæ.—1. A distinct fibrinous network, most dense along the roof, was distributed throughout the cavity of the bullæ. In the thickest parts of the meshwork some of the cells of the *rete* were entangled. Their contour was irregular, protoplasm very granular, and their nuclei badly stained. From these cells a distinct radiating fibrinous network was seen. In some of the older bullæ the network had become broken down, its place being taken by masses of irregularly-sized granules staining badly by Weigert's fibrin stain.

2. Some of the *rete* cells, singly or in groups of five or six, were lying free in the bullæ, while others were attached in masses to the *stratum granulosum* on the roof.

3. Small round cells with large, deeply-stained nuclei were present in numbers.

4. Red blood-corpuscles were also observed, but sparsely distributed.

5. Micrococci could be seen in sections stained by the Gram-Weigert process. They were mostly in the form of diplococci, resembling those found in the cultures to be afterwards described; we are, however, unable to say with certainty whether they were identical with these or not.

Bacteriological Examination.—An unruptured bulla was punctured by a heated and sterile Pasteur's pipette, and a drop of the fluid was inoculated on the surface of a tube of sloped agar. In twenty-four hours, at the temperature of 37.5° C., a number of minute, circular, greyish-white colonies had made their appearance. Plate cultivations and microscopic examination showed that only one species of organism was present—a pure culture. From the original agar culture subcultures were made on different nutrient media. In peptonized slightly alkaline bouillon growth took place rapidly. In six hours

there was diffuse cloudiness, and by the end of twenty-four hours a deposit occurred on the bottom of the tubes, leaving the rest of the fluid comparatively clear. No membrane formed on the surface of the medium.

On sloped agar the colonies at the end of six hours were in the form of small whitish specks. By the end of twenty-four hours they were of the size of a pin's head. Further growth then took place by the shooting out of club-shaped processes from the periphery of the colony, so that in three to four days the whole colony had a rosette-like aspect, exactly as described and figured by Demme.

On straight agar growth occurred along the whole track of the needle in the form of small lenticular-like colonies, while upon the free surface the growth resembled that on sloped agar.

On blood-serum the colonies were less characteristic, the peripheral club-shaped expansions not being so clearly defined.

On glycerinized potatoes at incubation temperature a glistening mother-of-pearl-like coating was formed on the surface.

On gelatine at ordinary temperature a faint growth was observed after a week, but no marked liquefaction took place.

Under conditions of anærobiosis growths were obtained in liquid and solid media. On agar small whitish colonies were formed.

Microscopic Examination.—The microscopic examination of the cultures, liquid and solid, showed that the micro-organism was a coccus, and occurred almost exclusively as a diplococcus, resembling the gonococcus, but somewhat larger. The two opposing surfaces were distinctly flattened, while the remaining surfaces were segments of a circle. The diplococci stained well by Gram's method and its various modifications. They were also well stained by all hydro-alcoholic aniline stains.

Experimental.—A guinea-pig, weighing 300 grammes, received .5 c.c. of the first bouillon culture under the skin, previously shaved and disinfected. On the following day distinct redness was visible, but no vesicular formation followed. After six days an inoculation of 1 c.c. of bouillon culture was made into the pleural cavity. Rapid breathing and rise of temperature followed, and the animal gradually sank with marasmus and dyspnoea, dying on the seventh day after inoculation.

Post-mortem.—Slight pleurisy on the side of inoculation. Conges-

tion of the lungs, with patches of broncho-pneumonia disseminated in both lungs. Kidneys congested, with hæmorrhages in the cortex. Spleen enlarged and congested. Slight peritoneal effusion.

Microscopic examination showed that in the broncho-pneumonic patches there was desquamation of the alveolar epithelium, and minute extravasations of blood. In some of the patches a distinct fibrinous network was visible in sections stained by Weigert's method. Diplococci resembling those of the cultures were also seen, some lying free, others within desquamated cells, while a few were visible in the interalveolar septa. In the kidney desquamation of the epithelium had taken place in the convoluted tubules. In the glomeruli also an exudation was observed between the capillary tuft and the capsule of Bowman. No diplococci could, however, be found in the kidney, nor in the liver or spleen.

From the pneumonic patches the diplococci were cultivated in bouillon, and at the end of twelve hours 1 c.c. was inoculated under the skin of a guinea-pig weighing 400 grammes. Next day distinct redness was visible, and the epidermis was raised up by an exudation. At the site of the inoculation necrosis of the skin followed, and the part sloughed out, leaving an ulcer. The animal subsequently wasted, dying on the seventh day after inoculation.

From the ulcer large numbers of diplococci were demonstrated microscopically. Inoculation on agar also yielded characteristic colonies in pure culture.

Microscopic examination of the local lesion (after fixing and embedding) showed the presence of a dense infiltration of round cells into the skin. The epithelium was necrotic and the vessels dilated. Large numbers of diplococci were found, some free, others enclosed in cells. In both lungs pneumonic patches containing diplococci were seen. The spleen was hyperplastic and congested.

The repetition of these experiments some time later was attended with incomplete results, probably from the fact that the organism, grown from generation to generation in artificial nutrient media, had lost its chief pathogenic properties.

PART III.—CONCLUSIONS.

The cases brought forward in support of the views expressed in the introductory remarks* are, we think, sufficiently convincing to allow of the following conclusions being arrived at, viz. :—

1. There is a group of rare cases of acute bullous eruption, accompanied by severe constitutional symptoms, and generally terminating fatally, which affects butchers.

2. The disease follows a wound of the hands or fingers.

3. It is probably due to a micro-organism.

4. The same ætiological factors are probably at work in another group of very similar cases, in which the patients are brought into contact with animals or dead portions of animals.

This is supported by the *Bacteriological* results, although the number of animals used was too small to found any definite conclusions upon. We believe, however, that we were dealing with the micro-organism originally described by Demme, and later by Claessen. That the organism is the cause of acute pemphigus we cannot assert with certainty. In our case the diplococcus was found in pure culture in a young unruptured tense bulla. It may have been there from the first, or it may have entered later as a secondary contamination. We are inclined to regard the former possibility as the most probable, in so far as we were unable to refer the coccus to any of the species known to be normal inhabitants of the skin. The coccus found by us was certainly neither the staphylococcus nor the streptococcus. Further, it was evidently pathogenic for guinea-pigs, although not markedly so. From the fact that apparently the same micro-organism has been found in three cases of acute pemphigus (Demme, Bleibtreu, Pernet)—a very rare disease—we are inclined to believe that it has a distinct relation to that disease, especially as we have been unable to identify its presence elsewhere.†

N.B.—Our paper had been in type for some time when the interesting report on two cases of Acute Pemphigus, under the care of Dr. Whipham at St. George's Hospital, was published in the *Lancet*

* See also G. Pernet, "The Ætiology of Acute Pemphigus," Brit. Med. Assoc. Meeting (section of Dermatology), July–August, 1895.

† We may mention that in a chronic bullous eruption in a child, examined by us, no diplococci were found, although several micro-organisms were present.

(May 2, 1896, p. 1219). The conclusions arrived at by us derive much support from Dr. Whipham's clinical observations and Dr. Russell Wells's bacteriological examination. We have had an opportunity of comparing the cultures obtained by Dr. Wells and find that as regards morphology, staining reactions and appearances in various media, they are in perfect harmony with the organism isolated by us.

14

Faint, illegible text, possibly bleed-through from the reverse side of the page.