

**A case of interilio-abdominal amputation for sarcoma of the ilium, and a synopsis of previously recorded cases : being a report of two clinical lectures delivered at the Jefferson Medical College Hospital, with supplementary remarks / by William W. Keen and J. Chalmers Da Costa.**

### **Contributors**

Keen, William W. 1837-1932.

Da Costa, J. Chalmers 1863-1933.

Royal College of Surgeons of England

### **Publication/Creation**

Philadelphia, Pa. : J.B. Lippincott, 1904.

### **Persistent URL**

<https://wellcomecollection.org/works/dp3n2gwy>

### **Provider**

Royal College of Surgeons

### **License and attribution**

This material has been provided by This material has been provided by The Royal College of Surgeons of England. The original may be consulted at The Royal College of Surgeons of England. where the originals may be consulted. The copyright of this item has not been evaluated. Please refer to the original publisher/creator of this item for more information. You are free to use this item in any way that is permitted by the copyright and related rights legislation that applies to your use.

See [rightsstatements.org](https://rightsstatements.org) for more information.



Wellcome Collection  
183 Euston Road  
London NW1 2BE UK  
T +44 (0)20 7611 8722  
E [library@wellcomecollection.org](mailto:library@wellcomecollection.org)  
<https://wellcomecollection.org>

(17)

---

CASE OF INTERILIO-ABDOMINAL AMPUTATION  
FOR SARCOMA OF THE ILIUM, AND A SYNOPSIS  
OF PREVIOUSLY RECORDED CASES

WITH A REPORT OF TWO CLINICAL LECTURES DELIVERED AT THE JEFFERSON  
MEDICAL COLLEGE HOSPITAL, WITH SUPPLEMENTARY REMARKS

BY WILLIAM W. KEEN, M.D., LL.D., F.R.C.S. (HON.)

AND

J. CHALMERS DA COSTA, M.D.

Professors of the Principles of Surgery and of Clinical Surgery in the Jefferson  
Medical College of Philadelphia

*Reprinted from International Clinics, Vol. IV., Thirteenth Series.*

---

Copyright, 1904, by J. B. LIPPINCOTT COMPANY, Philadelphia, Pa.



THE UNIVERSITY OF CHICAGO  
LIBRARY

1891

1892


1893

1894

1895

1896





# A CASE OF INTERILIO-ABDOMINAL AMPUTATION FOR SARCOMA OF THE ILIUM, AND A SYNOPSIS OF PREVIOUSLY RECORDED CASES

BEING A REPORT OF TWO CLINICAL LECTURES DELIVERED AT THE JEFFERSON  
MEDICAL COLLEGE HOSPITAL, WITH SUPPLEMENTARY REMARKS

BY WILLIAM W. KEEN, M.D., LL.D., F.R.C.S. (HON.)

AND

J. CHALMERS DA COSTA, M.D.

Professors of the Principles of Surgery and of Clinical Surgery in the Jefferson  
Medical College of Philadelphia

---

## HISTORY AND DIAGNOSIS OF THE CASE BY DR. DA COSTA

GENTLEMEN: The patient I now present to you is a white man 42 years of age, an Austrian by birth, and a machinist by occupation, who was admitted to the Jefferson Medical College Hospital yesterday, February 27, 1903. His family history is entirely negative. He has had the ordinary diseases of childhood, and during four or five months in his fifteenth year he suffered with chorea. Eight years ago he was for many months the victim of chronic lead-poisoning. He has never had syphilis. Seven months ago, while walking on a wet pavement, he slipped and fell; but in his descent he grasped a fence, and thus avoided striking the ground. His left leg was forcibly thrown over his right, but he did not strike his left side at all. He says he heard a cracking sound, and felt something give way in the region of the left hip. He experienced very sharp pain about the left hip and the left iliac crest. He quickly regained the erect posture; and, although he felt some soreness, he went to the shop and worked all day. The day after the accident the pain was so severe that he remained in the house; but the following day he went to work again, in spite of the fact that some



soreness still remained. During the next few days the pain completely disappeared. Two months after the accident, that is, five months ago, he discovered a lump the size of a walnut below and external to the crest of the left ilium, and a little posterior to the anterior superior iliac spine. It was hard and immovable, but neither painful nor tender. It increased in size rather rapidly, and three months ago had attained the dimensions of a large orange. At this time it became somewhat tender and very painful, the pain being worse at night and in cold or damp weather.

An examination at the present time discloses an accentuation of the second sound of the heart at the aortic area, but no cardiac murmur; normal lungs and a normal temperature. The urine is acid, has a specific gravity of 1020, and contains 1.3 per cent. of urea, a one-sixth moist layer of albumin, a few granular and many hyaline casts, but no sugar. Examination of his blood shows the following: Erythrocytes 4,370,000, leukocytes 9400, hemoglobin 78 per cent., color index 0.89, finely granular oxyphiles 75 per cent., coarsely granular oxyphiles 1 per cent., small lymphocytes 20 per cent., and large lymphocytes 4 per cent.

You can all see distinctly a large, somewhat irregularly hemispherical, bulging mass, the size of two fists, situated external to the crest and posterior to the anterior superior spine of the left ilium (Figs. 1 and 2). It measures 25 cm. transversely, and is elevated 7.5 cm. above the level of the skin. The semicircumference of the pelvis on the right side is 42.5 cm., on the left side 50 cm. The skin is not discolored, but several large-sized veins may be seen. Neither the leg nor the thigh is swollen, but there are some varicose veins below the left knee. The skin over the tumor is not edematous, is no warmer than the adjacent surface of the body, and is freely movable.

The tumor is smooth, slightly irregular in contour, and absolutely immovable, being firmly attached to the ilium, but not involving the femur. On palpation, the growth is found to pass over the crest and into the pelvis, quite a large mass occupying the venter of the ilium. Anteriorly, the tumor reaches within 5 cm. of the pubic spine; posteriorly, to a line prolonged from the posterior border of the great trochanter. Below, it reaches the level of the great trochanter. The edges are definite, and distinctly outlined from the surrounding tissue; and there is no evidence of local dissemination,



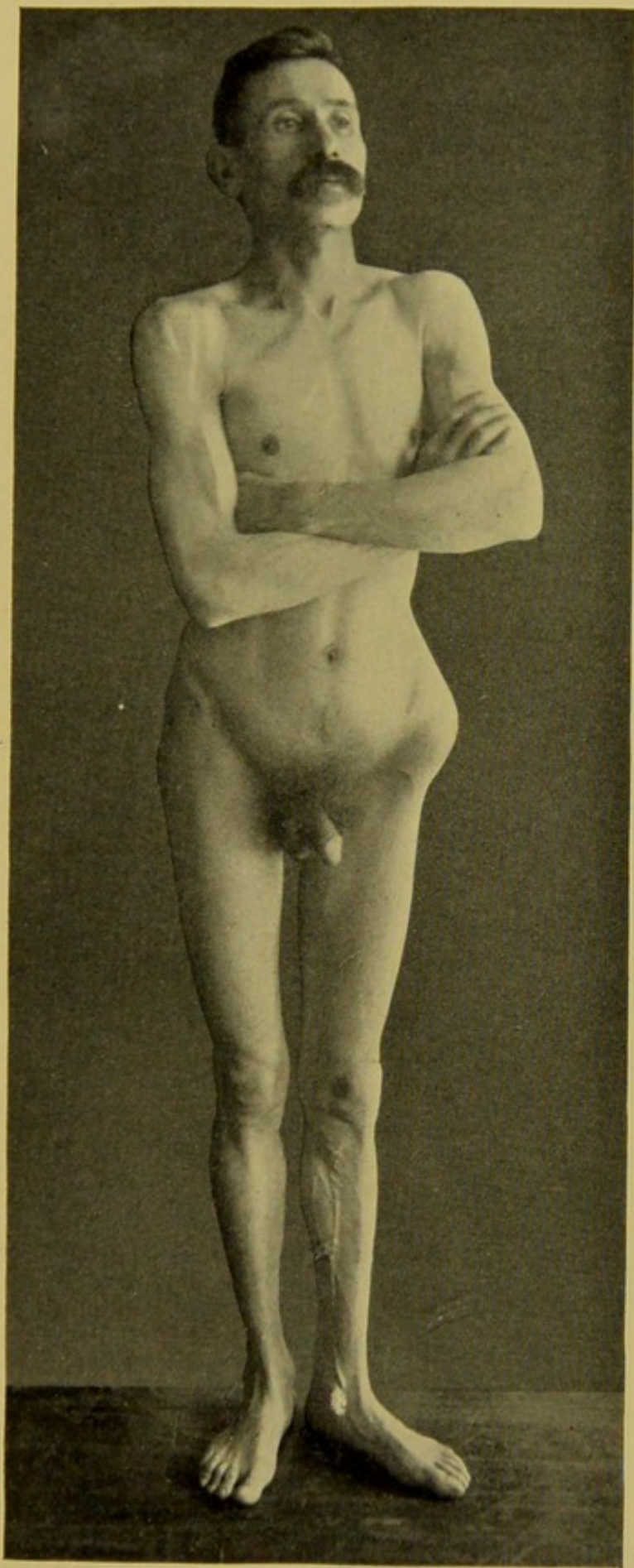


FIG. 1.—Tumor viewed from the front.

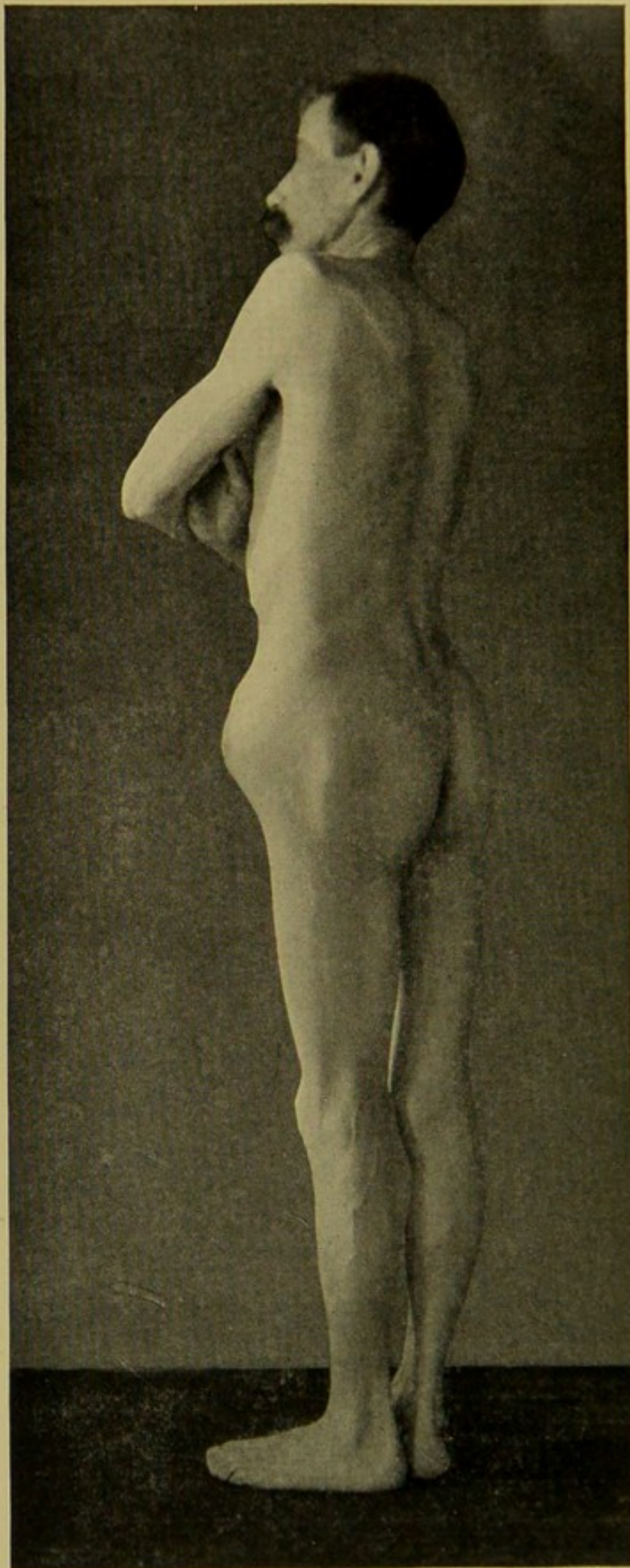


FIG. 2.—Tumor viewed from the rear.



except an enlarged gland that can be felt in Scarpa's triangle. The tumor is also rather soft. It has a somewhat elastic feel, and here and there are distinct soft spots; but nowhere is fluctuation obtainable, and nowhere is calcification or ossification evident.

The mass is somewhat tender on pressure and is constantly painful. The pain is not limited to the growth, but is diffused over the growth, to the buttock of the same side, and to the left thigh; that is to say, it corresponds to the distribution of the iliac branch of the iliohypogastric nerve, the lateral cutaneous branch of the last dorsal nerve, and the anterior crural nerve. This pain is due, therefore, to pressure upon these nerves.

We are not dealing with a growth that has begun within the diploe of the ilium and has then broken through the osseous structure. The tumor lies on the ilium, and does not arise from the interior of that bone. Where the mass exists, the outline of the bone is covered and hidden; but everywhere else it is perfectly normal. The tumor evidently arises from the periosteum. No enlarged glands can be detected within the false pelvis.

With what condition are we dealing? Remember the history and the results of examination: A man, 42 years old, had a fall; wrenched, but did not bruise, the region affected; was confined to the house but one day; two months later, discovered a tumor the size of a walnut, which in five months grew to the great size you see; a tumor which is generally somewhat soft and in places very soft, perfectly immovable, and not attached to the skin; which is tender, causes pain from pressure on nerves, and is not associated with fever or with any evidence of constitutional involvement.

Is the condition inflammatory? Clearly not. The duration rules out an acute inflammation; and, besides, the part lacks the heat, the discoloration, and the soft, brawny, or edematous swelling that passes insensibly into the surrounding parts. We note, also, that there is no elevation of temperature. The distinct outline of the swelling, the great size, and the somewhat irregular contour prove that it is not a chronic inflammation; and, further, the pain is not in the bone, but is obviously due to the compression of nerve-trunks.

Are we dealing with an area of hyperplastic tuberculosis? Surely not. There is no evidence that this mass originates from the bone itself, and there is not a sign of the extensive caseation and



softening near the center that would be inevitable in so extensive a tuberculous mass. Long before this, such an area, if tuberculous, would have broken down into a tuberculous "abscess," as the result of coagulation necrosis and fatty degeneration.

Neither is the tumor the result of syphilitic periostitis. It is quite true that tumor-like formations may thus be produced; but the margins of such growths, in their early stages, are generally indefinite in outline. A growth of that sort is also somewhat doughy to the touch, is often tender, and gives rise to pain, particularly at night. Such a condition is called a syphilitic node. Nodes are usually multiple, and rarely attain any large size. I have often seen gummas of large size, especially in the subcutaneous tissues; but such a gumma softens, and resembles a tuberculous "abscess" more than a solid tumor. Besides, the skin over it soon becomes adherent, discolored, and ulcerated. This man denies a history of syphilis; but such a denial is, of course, not conclusive. The facts that I have cited, and also the entire absence of all other signs of syphilis, are, however, sufficient to rule this condition out of consideration.

The distinct outline of the mass, its solidity, and the deformity that it has produced show that we are dealing with a genuine tumor; and the history and the examination prove that the tumor springs from the periosteum. The periosteum is a connective tissue, and the tumors that spring from it are of the connective-tissue type; hence, this is a connective-tissue tumor and not an epithelial growth.

Is it innocent or malignant? Let me review the commoner innocent tumors. It is not a periosteal fibroma; for such a tumor grows very slowly, never attains any considerable size, and is extremely hard and more or less movable.

It is not a periosteal lipoma. Such growths are among the rarities of clinical experience, although J. Bland Sutton has collected nine of them from literature. Lipomas are soft and grow very slowly.

It is not a chondroma springing from the bone. The bone is not expanded; and an osseous chondroma would be certain to expand the bone, a shell of bone always being detectable on the surface of such a growth.

It is not a periosteal chondroma. These growths are very rare after puberty; although later in life chondromas are not unusual



in other tissues. A periosteal chondroma is markedly lobulated; often possesses a partial shell of bone, which may disappear when the growth has attained a large size; is very hard in some spots, from calcification or ossification; and is soft and fluctuating in other places, from cyst-formation. There is no pain and no tenderness; and, whereas the growth may be extremely large, it takes years to become so. Chondromas, also, are often multiple. The diagnosis of chondroma has, of course, been suggested by the history of injury; for half of all the cases are so produced.

It is not an osteoma. An osteoma is of bony hardness and grows very slowly; and the growth ceases before the tumor can become large. An osteoma causes neither pain nor tenderness, and such growths are often multiple.

It is needless even to consider the other innocent connective-tissue tumors, such as, angioma, lymphangioma, lymphoma, myoma, and neuroma. Thus, by the process of exclusion we come to the decision that we are not dealing with an innocent connective-tissue tumor, but that the growth is a malignant connective-tissue tumor; in other words, that it is a sarcoma springing from the periosteum. The very rapid growth of the mass is, in itself, enough to have driven us to this conclusion. Bone is the most common seat of sarcoma, and periosteal sarcoma is by no means rare.

The tumor before us is not myeloid or giant-cell. A giant-cell sarcoma is apt to rise within the bone. It expands, thins, and breaks through the bony structure. It is soft and frequently cystic. It does not ossify; and after it has broken through the bone, it is usually the seat of pulsation and of bruit. Such phenomena are absent in the case before us.

A spindle-cell sarcoma usually springs from the periosteum; and this growth may possibly be in part spindle-celled. In most spindle-cell sarcomas of the periosteum more or less ossification occurs; but in some, the growth remains somewhat soft and no ossification takes place. A spindle-cell sarcoma usually causes pain and tenderness; is somewhat firmer than a round-cell tumor, and grows much more rapidly than a myeloid sarcoma, but not so rapidly as a round-cell growth.

A round-cell sarcoma neither calcifies nor ossifies; grows very rapidly around the bone, and involves adjacent connective tissues; is soft; and is softer in some places than in others, the very soft



spots marking degeneration. It soon produces infection of adjacent tissues, and at a comparatively early period causes general infection. This is one of the most malignant of all tumors, and is the form of growth which I believe is present in this patient.

What part did the injury play in causing the tumor? Had there been a distinct bruise, we should have attached great importance to it; for a contusion is the frequent antecedent of a sarcoma. It may be that, by a sudden or violent movement, the patient injured the periosteum through muscular traction; and such an injury might be causative quite as well as a contusion. Another supposition is that the tumor had already begun; and that the man injured the region of the tumor or lacerated the muscular fibers around it, rapid growth having followed the injury. It is impossible to say whether the injury caused the sarcoma, or whether it simply hastened the growth of an existing tumor.

In order to confirm the diagnosis, I now introduce, with every aseptic care, a tubular exploring needle, entering it into one of the softest spots. The point moves with considerable freedom, although not with as much ease as it would if it had entered an abscess cavity. Only blood flows out. I cover the puncture with collodion, send the patient out, and will have the skiagrapher take an x-ray picture. [As this threw no new light upon the case, it is not reproduced.]

Can we do anything for this poor fellow? If we let him alone, death is inevitable and will come soon; and in order to reach it, he must travel a weary road of pain, sleeplessness, exhaustion, ulceration, and hemorrhage. If it were a giant-cell sarcoma, there might be some hope that, if we could remove the tumor and also a part of the ilium, the patient would be benefited; but in a round-cell, or even in a spindle-cell sarcoma, the growth is so disseminated locally that such a procedure would be worse than useless. A chance, and the only chance, is afforded by an operation of the most formidable nature,—an operation that consists in the removal of the entire lower extremity and a large portion of the pelvis. It has been several times performed with success in Europe; but it has not, I believe, been attempted in this country.<sup>1</sup> Professor Keen has been much interested in this operation of late, and has performed it on

---

<sup>1</sup> Later this was found to be an error. See table of cases, page 8.



the dead body several times. Professor Keen, Professor Hearn, and I will hold a consultation; and if we decide that such an operation is justifiable, and if the patient, after having had it fully explained to him, is willing, it will be done before you in this arena next week.

#### CLINICAL REMARKS BEFORE THE OPERATION BY DR. KEEN

GENTLEMEN: I must first of all acknowledge the kindness and courtesy of my friend and distinguished colleague, Professor Da Costa, in insisting upon my doing the operation with his assistance, in spite of my wishing to assist him, as the patient is his.

The sole reason for such an extensive operation is that the growth is above the hip-joint, and therefore an amputation at the hip-joint will not remove the tumor.

HISTORY OF THE OPERATION.—The *history of the operation* briefly is as follows: Berg, of Stockholm, then assistant to Billroth,<sup>1</sup> states that Billroth did the operation for the first time in 1891.<sup>2</sup> The patient only survived a few hours, and the case was never published. Even in the hands of so distinguished a master as Billroth, you observe the tendency to publish our successful cases and hide our unsuccessful ones.

The first formal publication on the subject was by Jaboulay,<sup>3</sup> after whom the operation is sometimes named. The operation, of course, was suggested by the now well-established operation of removal of the entire upper extremity including the scapula and clavicle. The name which Jaboulay suggested, using the analogue of that by which the former is usually known, is the one now generally adopted. Removal of the entire upper extremity, including the scapula and clavicle, is usually called the "interscapulo-thoracic" amputation or disarticulation, as the case may be. For the similar operation on the lower extremity, Jaboulay proposed "interilio-abdominal" disarticulation. In case any of the innominate bone is left, it would, of course, not be, strictly speaking, a disarticulation but an amputation. In the following table I have gathered all the cases which have been reported, together with the results:

<sup>1</sup> Savariaud, Rev. de Chir., 1902, xxvi, 350.

<sup>2</sup> Others state that it was done in 1889.

<sup>3</sup> Lyon Médicale, 1894, p. 507.



## CASES OF INTERILIO-ABDOMINAL DISARTICULATION OR AMPUTATION FOR SARCOMA AND TUBERCULOSIS.

No.	Year.	Operator.	Result.	Remarks.	Reference.
1.	{1889 or 1891}	Billroth.	Died.	After a few hours.	Savariaud, <i>Rev. de Chir.</i> , Sept., 1902, 350.
2.	1894	Jaboulay.	Died.	Next day.	<i>Lyon Méd.</i> , 1894, 507.
3.	1895	Cacciopoli.	Died.	3 hours.	<i>Rif. Med.</i> , 1894, Nos. 69 and 70; <i>Cbl. Chir.</i> , 1894, 988; <i>Therap. Gaz.</i> , Feb., 1895, 84.
4.	1895	Gayet.	Died.	1 hour.	<i>La Provinc. Med.</i> , 1894, No. 35.
5.	1895	Girard.	Recovery.	.....	<i>Rev. de Chir.</i> , 1895, 952.
6.	1897	Girard.	Recovery.	.....	<i>Rev. de Chir.</i> , 1898, 1141.
7.	1899	Faure.	Died.	Operation abandoned on account of hemorrhage.	Savariaud, <i>loc. cit.</i>
8.	1899	Freeman. <sup>1</sup>	Recovery.	.....	<i>Annals of Surgery</i> , 1901, xxxiii. 318.
9.	1900	Nanu.	Recovery.	Ligature applied to common iliac. Died on 20th day from gangrene extending to the other leg from occlusion of the other common iliac.	<i>Rev. de Chir.</i> , 1900, 427.
10.	1900	Salistcheff.	Recovery.	.....	<i>Arch. f. klin. Chir.</i> , 1900, lx. 57.
11.	1901	Savariaud.	Died.	2 to 3 hours.	<i>Rev. de Chir.</i> , 1902, xxvi. 345.
12.	1901	Gallet.	Died.	1 hour.	<i>Journal de Chir. et Annales Soc. Chir.</i> , Belge, 1901, vol. ix. 569.
13.	1902	Morestin.	Died.	9 hours.	<i>Bull. et Mém. Soc. Anat.</i> , Paris, 1902, lxxvii., 6 Ser., No. 8, 795, and <i>Arch. Gén.</i> , 1903, July 7, No. 27, vol. xcii. 1665.
14.	1903	Keen and Da Costa.	Died.	33 hours.	This paper.
15.	?	Kadjan.	Died.	.....	Kocher's <i>Chir. Oper.-Lehre</i> , 4th ed., 1902, 603, and <i>Laitop. Russk. Chir.</i> , St. Petersburg, 1900, v. 657.
16.	?	Kocher.	Died.	.....	Kocher's <i>Chir. Oper.-Lehre</i> , 4th ed., 1902, 603.
FOR TUBERCULOSIS.					
17.	1895	Girard.	Died.	50 minutes.	<i>Rev. de Chir.</i> , 1898, 1141.
18.	1897	Bardenheuer.	Recovery.	.....	<i>Verhandlung. Deutsch. Gesellsch. Chir.</i> , 1897, xxvi. 1, 130, and Wolf, <i>Ctl. Chir.</i> , 1897, 185.
19.	1900	Gallet.	Died.	6 hours.	<i>Journal de Chir. et Annales Soc. Chir.</i> , Belge, 1901, vol. ix. 569.

<sup>1</sup> I have included Freeman's case in the table because, though technically it was not an interilio-abdominal amputation, as so much of the bone was left, yet



You will observe, therefore, that of the 19 cases of which the termination is known, there are only 5 recoveries: Bardenheuer 1, Salistcheff 1, Freeman 1, and Girard 2. The case of Nanu ought, in my opinion, however, to be regarded as practically a recovery. Ligation of the common iliac was practised, and the proximal thrombus extended into the opposite iliac or into the aorta itself, causing gangrene of the other leg. Evidently the patient had weathered all the danger of the operation proper, in view of the fact that he survived twenty days.

OPERATIVE TECHNIC.—(1) *Preliminary Precautions*.—The patient is in good general condition after six days' rest in bed; were he not, I should wait for a few days, to prepare him for so severe an ordeal. Professors Da Costa and Hearn have kindly consented to assist me.

In order to combat the necessary shock, I have had the patient's right leg wrapped in cotton and flannel and covered with a sterilized sheet; the body above the umbilicus is similarly protected, and he lies upon a hot-water bed, which, of course, must not be too hot. I have also had the opposite (right) arm sterilized, and as soon as I begin the operation, Dr. Heineberg, the house surgeon, will expose a vein at the bend of the elbow, and will begin infusion of normal salt solution, administering as much of it as the exigencies of the case will demand. I shall use the Esmarch bandage from the toes up to the middle of the thigh, below the tumor; but I shall not do it until after I have exposed and tied the iliac vessels, up to which time there will be virtually no loss of blood. My reason for deferring it is simply to avoid any possible increase in the size of either the iliac arteries or especially the veins which might increase the difficulty of the ligation. As soon as these vessels are surrounded by the ligature, I shall apply the Esmarch bandage, in order to save to the patient as much of the blood as possible in the extremity to be amputated.

(2) *Ligation of the Vessels*.—The next step will be the ligation of the internal iliac artery. I shall reach this by an incision begin-

---

virtually it was equivalent to such an operation. At the time of Professor Da Costa's remarks and at my operation, neither of us remembered Freeman's operation. As soon as I discovered it, I wrote to Dr. Freeman, and he courteously sent me a drawing (Fig. 10) showing how much of the pelvis he removed.



ning above the middle of Poupart's ligament, parallel with the ligament and extending some distance beyond the anterior superior spine. Then I shall strip up the peritoneum, and usually, you know, the ureter, which crosses at the bifurcation of the common iliac, is fortunately so much more adherent to the peritoneum than to the vessels, that it is lifted out of harm's way by this procedure. I shall not tie the internal iliac vein, not only because of the difficulty of its ligation, but, even if it is not tied, the hemorrhage from its radical veins will not be serious. Of course it would be very easy to ligate the external iliac artery and vein; but I think it wiser in this case, in order to prevent, if possible, gangrene of the long internal flap, that the femoral artery and vein should be tied as low as possible in the flap. Ligation of the common iliac is not, in my opinion, advisable, though it has been adopted by Kocher and others.

(3) *Formation of the Flaps.*—Five different methods of forming the flaps have been used. In the present case I am forced to use still another method.

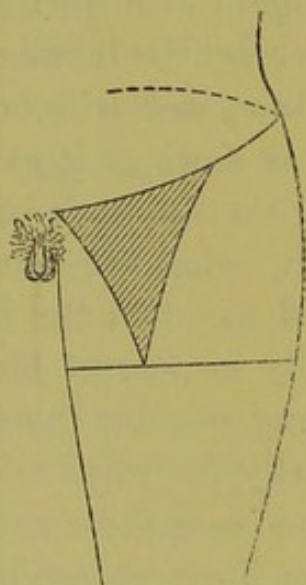


FIG. 3.—Jaboulay's method.

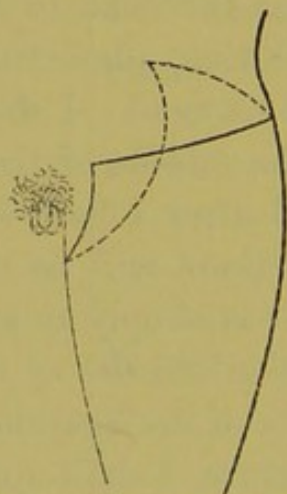


FIG. 4.—Girard's method.

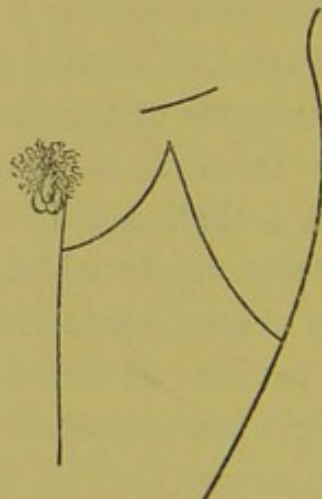

FIG. 5.—Bardenheuer's method.

(a) The original one of Jaboulay (Fig. 3) was by means of a circular incision around the thigh at the junction of the upper and middle thirds. From the anterior portion of this a V-incision was made, one branch passing inward to the spine of the pubes, the other outward toward the anterior superior spine of the ilium and continued parallel with the crest of the ilium to the posterior superior spine.



(b) The method of Girard by means of anterior and posterior flaps (Fig. 4), the first incision going from the spine of the pubes to the anterior superior spine, and passing onward to the posterior superior spine. He joined the two ends of his first incision by another passing from the spine of the pubes along the inner border of the thigh to the posterior superior spine. I have rehearsed the operation six times on the cadaver. The first time I adopted the method of Girard, and my flap was wholly insufficient to cover the stump.

(c) The method of Bardenheuer (Fig. 5), who makes very simple internal and external lateral flaps, with an independent incision for the ligation of the arteries.

(d) The method of Salistcheff, a racquet incision (Fig. 6). This begins below the twelfth rib, and passes by the anterior superior spine of the ilium to Poupart's ligament, which it follows to the spine of the pubes. Through this incision the vessels are secured. A second incision sweeps around the buttock and thigh.

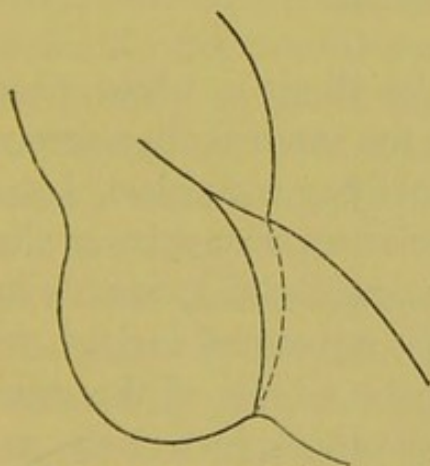


FIG. 6.—Salistcheff's method.

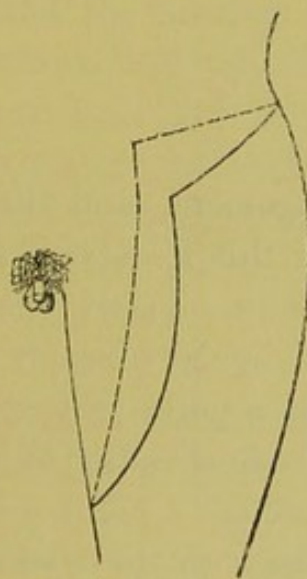


FIG. 7.—Savariaud's method.

(e) The method of Savariaud (Fig. 7), with a long internal flap. This internal flap begins at the middle of Poupart's ligament, descends to a little above the middle of the thigh, sweeps backward and reaches the posterior superior spine. On the cadaver I found that a flap so made would only cover in the stump with difficulty. Besides this, as in the present case the position of the tumor makes it undesirable to use any of the tissues on the outer side of the thigh,



it is imperative that my internal flap should be sufficient. Of course I recognize the advantage of two short flaps rather than one long one on account of the danger of gangrene in the latter case. But I hope by securing the femoral vessels low down in the flap to avoid this. In these cases we have to "cut our coat according to our cloth." Accordingly, I shall modify Savariaud's method as follows:

(f) Method of the authors (Fig. 8). My first incision shall be from the spine of the pubes, 2 cm. above and parallel with Pou-

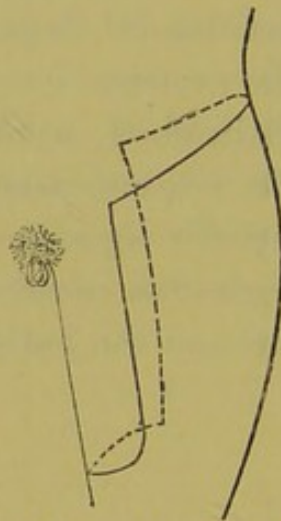


FIG. 8.—Authors' method.

part's ligament, and the crest of the ilium to about its middle. Through this incision I shall secure the internal iliac artery extra-peritoneally. Later, when the internal flap is finished, I shall continue this incision nearly to the posterior superior spine of the ilium.

From a point just external to the middle of Poupart's ligament (in order to save the femoral vessels), my second incision will pass downward to a point a little below the middle of the thigh, then horizontally to the median line of the thigh posteriorly, and then upward to the posterior end of the first incision, *i.e.*, a little external to the posterior superior spine of the ilium. On the cadaver I found that this flap would be ample to cover in the stump, and would prevent a hernia of the intestines, which are left without any support by the removal of so large a portion of the bony pelvis. As an additional means of preventing a hernia if the ileopsoas muscle is not involved in the tumor, I shall cut it long enough to turn it up and attach it to the abdominal flap.

(4) *Division of the Muscles inserted into the Crest of the*



*Ilium.*—This will be the next step in the operation. The first incision parallel with Poupart's ligament will be continued nearly to the posterior superior spine, and all the muscles divided down to the peritoneum, which will be preserved intact. This is followed by the separation of the psoas magnus and iliacus internus from the inner surface of the ilium. This step must necessarily vary considerably in accordance with the degree to which the tumor has encroached upon these two muscles. If they are involved in the tumor, they must be entirely sacrificed, of course.

(5) *Removal of the Bone.*—I shall divide the horizontal and the descending rami of the pubes and not separate the bone at the symphysis. If the body of the pubes is removed, the firmness of the support given to the abdominal viscera by the rectus abdominis muscle is lost. By dividing the horizontal ramus, the body of the pubes and the attachment of the rectus are preserved. Moreover, the descending ramus of the pubes should be divided at a point below the attachment of the corpus cavernosum, so that, if the patient recovers, his sexual power may not be impaired. Not only are the loss of the support of the rectus and the possible impairment of the patient's sexual power important, but the increased hemorrhage, especially from the corpus cavernosum, and the greater time required by the dissection of the rectus, the corpus cavernosum, and at the symphysis, is a serious increase of danger in an operation already involving the greatest peril. Every minute counts. Not an extra moment should be consumed unless the benefit is real and well worth the time.

Bardenheuer first amputates at the hip-joint and then removes the pelvic bone. I, however, do not think this advisable.<sup>1</sup> The patient necessarily must lose some additional blood, and, as has just been observed, and is of more importance, it needlessly prolongs the operation. Moreover, if the ilium is to be disarticulated, the leg can be flexed so that the heel rests upon the table, and the leg then forms an excellent lever in disarticulating the ilium. In the present case, however, instead of disarticulating the ilium, which has been the usual course, I shall saw from the crest of the ilium into the sacrosciatic notch. This saves a great deal of time, for the disarticulation is difficult and tedious, and I do not believe that the

---

<sup>1</sup> See pages 19, 20 for a modification of my views as to this point.



very small portion of the ilium that is left, any more than the small portion of the pubes that is left, practically increases the danger (Fig. 9). Moreover, if it is necessary, and the condition

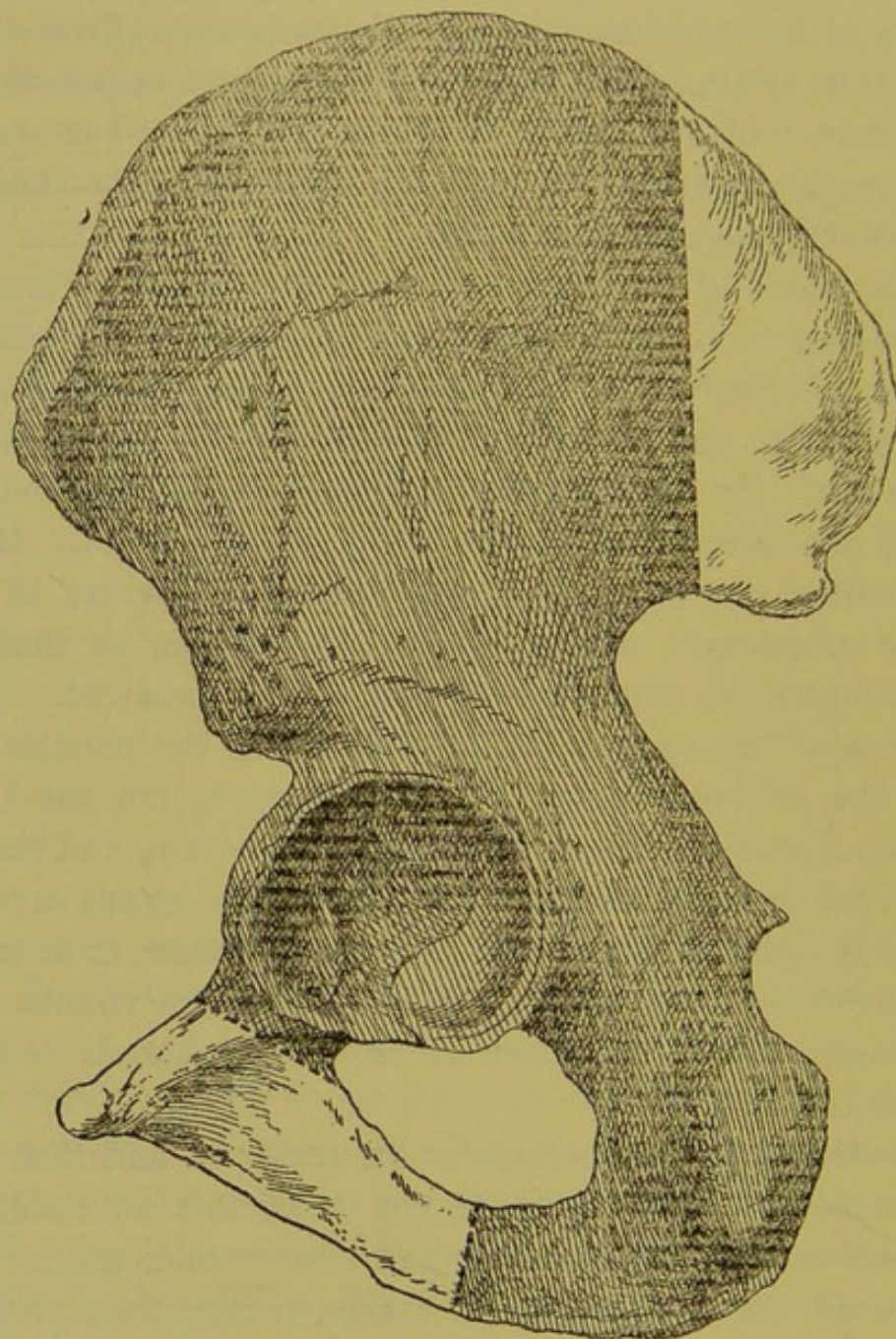


FIG. 9.—Authors' case. The shaded portion of the bone was removed.

of the patient is such as to allow it, the small fragment of the ilium that has been left can be more expeditiously removed later after the extremity has been completely severed from the body. Theoretically, of course, the entire innominate bone should be removed. Practically, I think it does not increase the danger to leave these portions of it.

The flaps will then be trimmed if necessary; the sutures inserted



by the chief assistant as well as by the surgeon in order to save time; suitable drainage tubes will be inserted; an ample dressing applied; and all the usual necessary means used to combat shock, promote reaction, and secure recovery. The operation is the most extensive one in all the realm of surgery. Its mortality has been very great (73.68 per cent.). With time, no doubt, this will fall to a more reasonable percentage, and the operation take its place as one rarely necessary, but in these rare cases entirely justifiable.

#### DESCRIPTION OF THE OPERATION AND THE LATER HISTORY OF THE CASE BY DR. KEEN

Operation, March 4, 1903. I first made a small incision into the tumor, and in the judgment of Professors Hearn and Da Costa and of Professor Coplin, who kindly was present to give me the aid of his pathological knowledge, it was an osteosarcoma. This incision was closed by sutures. In the course of the operation Dr. Heineberg injected two pints and one-half of warm salt solution into the veins. Very largely, as a result of the various measures described above, the patient suffered but little shock.

I did not apply the Esmarch bandage to the left leg until after I had secured the internal iliac, as I thought that it might possibly make the operation a little more difficult by damming up the blood. As a result of my experience in this case, I think it is a matter of indifference whether it is done before or after the ligation. I then made the first incision as described, and carried this incision nearly to the middle of the crest of the ilium. I had no difficulty in stripping back the peritoneum and with it the ureter, and the exposure not only of the external iliac artery and vein, but of the internal and the common, was all that could be desired. I ligated the internal iliac artery with a double ligature of silk. I did not ligate the vein not only on account of the difficulty of reaching it and the possibility of wounding it, but because I did not think it needful to do so. The result proved that I was right, as the veins in the postero-external tissues gave me virtually little or no trouble. Two or three enlarged glands that lay in connection with the external iliac vessels just within Poupart's ligament were removed. I then made the long internal flap as described above, and with a chain-saw sawed through the horizontal ramus of the pubic bone, being careful to avoid the obturator vessels. I attempted to lay bare the descending ramus of



the pubes, but found it so deep and difficult of access that I deferred this to a later stage of the operation. The psoas and a part of the iliacus internus muscle were then divided. In doing so, I was very careful to divide them well up toward the crest of the ilium far away from the tumor, which formed a protuberance on the inner aspect of the ilium half as large as a fist.

Next the patient was turned over on his right side, and the remaining muscles attached to the crest of the ilium were divided nearly to the posterior superior spine.

The long internal flap was then completed by an incision from the posterior end of the first incision to the end of the short circular cut at the mid-thigh, the muscles were separated from the tuber ischii, and the descending ramus of the pubes exposed and readily divided by a straight saw. Next, by the same straight saw I divided the ilium from the crest to the great sciatic notch (Fig. 9). This line stood in relation to the posterior part of the ilium as the chord to an arc. The center of this chord was 5 cm. in front of the posterior superior spine. I was then able to separate the entire lower extremity and the innominate bone from the rest of the body by dividing a few portions of muscular and other tissue which still held it. When I had removed it, I found that a considerable portion of the sacral surface of the sacro-iliac articulation was exposed. I then tied a few bleeding vessels and approximated the flaps. I first united the muscles of the two flaps to the muscles of the anterior abdominal wall by buried sutures, and only at one point was there much tension. I then united the skin by interrupted silkworm gut and inserted two drainage tubes, one passing from along the postero-external surface and another in the neighborhood of the vessels through the anterior surface, but away from the inner margin.

The entire operation took an hour and a half. It would not take more than an hour and a quarter, or possibly not much over an hour, with the experience that I now have had and the changes in the method which I would recommend.

Immediately after the operation, the patient's temperature was 101.4° F., but fell to the normal by 6 P.M. (4 hours). By 5 A.M. the next day it was 102° F., but was again normal by 9 A.M., and so continued till 3 P.M., when it rose suddenly to 101° F. In three hours it was again normal. Four hours after the operation the dressings were changed and again six hours later. He complained of but little



pain, and retained all his food. His kidneys only secreted 7 ounces of urine in the 33 hours after the operation. Enemas of hot salt solution were administered by the rectum, local heat was applied to the kidneys in addition to the internal remedies, which were partly diuretic. He reacted from the operation quite well, and was never nauseated. His pulse was from 130 to 140, of fair volume but little tension. His pulse, however, began to fail in spite of the use of strychnin, atropin, and adrenalin with occasional small doses of digitalis. At 4 A.M. of the morning after the operation, 14 hours after operation, the nurse noticed a putrid odor. When the dressing was changed, it was found that already the tissues over the buttock, supplied by the internal iliac artery and its branches, had become gangrenous over an area 10 by 12.5 cm. in extent.

He gradually sank, and died at 10.40 P.M., 33 hours after operation.

#### SUPPLEMENTARY REMARKS

The precautions against shock have already been detailed. After operation, his temperature, instead of being much below the normal as would have been expected, was 101.4° F. His general condition as to pulse, skin, etc., was encouraging, and I had fair hopes of his recovery.

I did not ligate the external iliac artery or vein, but on the contrary tied the femoral and the deep femoral and several of their branches toward the extremity of my internal flap. This I think was a mistake. It consumed a good deal of time by requiring the ligation of a number of branches; it cost the patient a moderate loss of blood, and I do not think that the lessened risk of gangrene of the internal flap compensated for this loss of time and loss of blood. In another case I should carry my incision external to the femoral vessels until I reached a point just below the origin of the deep femoral; then by securing the two vessels I should be spared much time and considerable loss of blood. The flap could then be prolonged to the required length. Indeed, Morestin advises against the prior ligation of any of the iliacs,—common, internal, or external.

The two points where I divided the bone internally were, I think, wisely selected. The division of the horizontal ramus of the pubes rather than a disarticulation of the symphysis certainly is very much better for the reasons given above. Fortunately, I had



both a Gigli and a chain-saw ready, and when the Gigli saw, which I first used, broke after two or three strokes, I used the chain-saw.

The flap that I made was just sufficient comfortably to cover and support the abdominal contents.

Before doing the operation, I had rehearsed the various methods upon the cadaver; and it was most fortunate that I did so, for the first time that I did the operation on the cadaver I found that I did not have nearly enough flap to cover in the wound. Accordingly, I modified the procedure as indicated.

I presume there might be as much difference of opinion upon my deciding to leave a portion of the ilium as upon any other point. I did this deliberately for several reasons.

In rehearsing the operation six times upon the cadaver, I found that the disarticulation at the sacro-iliac joint was the most troublesome and tedious part of the operation. I therefore saved a great deal of time, some blood, and a considerable amount of shock to my patient by sawing the bone at this point and leaving a portion of it instead of disarticulating it. Inasmuch as I was quite far away from the tumor, and as, until after its careful dissection, I was not in a position to say positively to what extent it had invaded the bone, I felt that it would not be injudicious to leave this small distant portion of the ilium just as I left the body of the pubes. Freeman, in his case (Fig. 10), left about half of the innominate bone, and yet sixteen months after operation there was no recurrence. Inasmuch as the disease has recurred in the internal organs, after removal of the entire ilium, as in Girard's operation, I scarcely think that there will be much added danger in leaving a small portion of the ilium. The much less time required by leaving it, compensates, I think, by the certainly diminished immediate danger for the possible remoter danger of recurrence in the portion of the bone that is left. Even should it be determined to remove this portion of the bone, I think upon the whole it might be more easily and more quickly accomplished by sawing the bone through in this way, and then disarticulating the small remaining portion of the ilium.

The patient's death was due to two causes: (1) Almost complete suppression of urine, and (2) very unexpected gangrene of the parts supplied by the internal iliac artery. While I should not have been surprised had the gangrene occurred in the long internal flap,



its appearance posteriorly was wholly unexpected, and so far as I can see wholly unavoidable.

Morestin, in a later paper,<sup>1</sup> published since our operation, proposes to modify the operation as follows: A. In tuberculous cases, first to amputate at the hip-joint, and at a later period to resect as

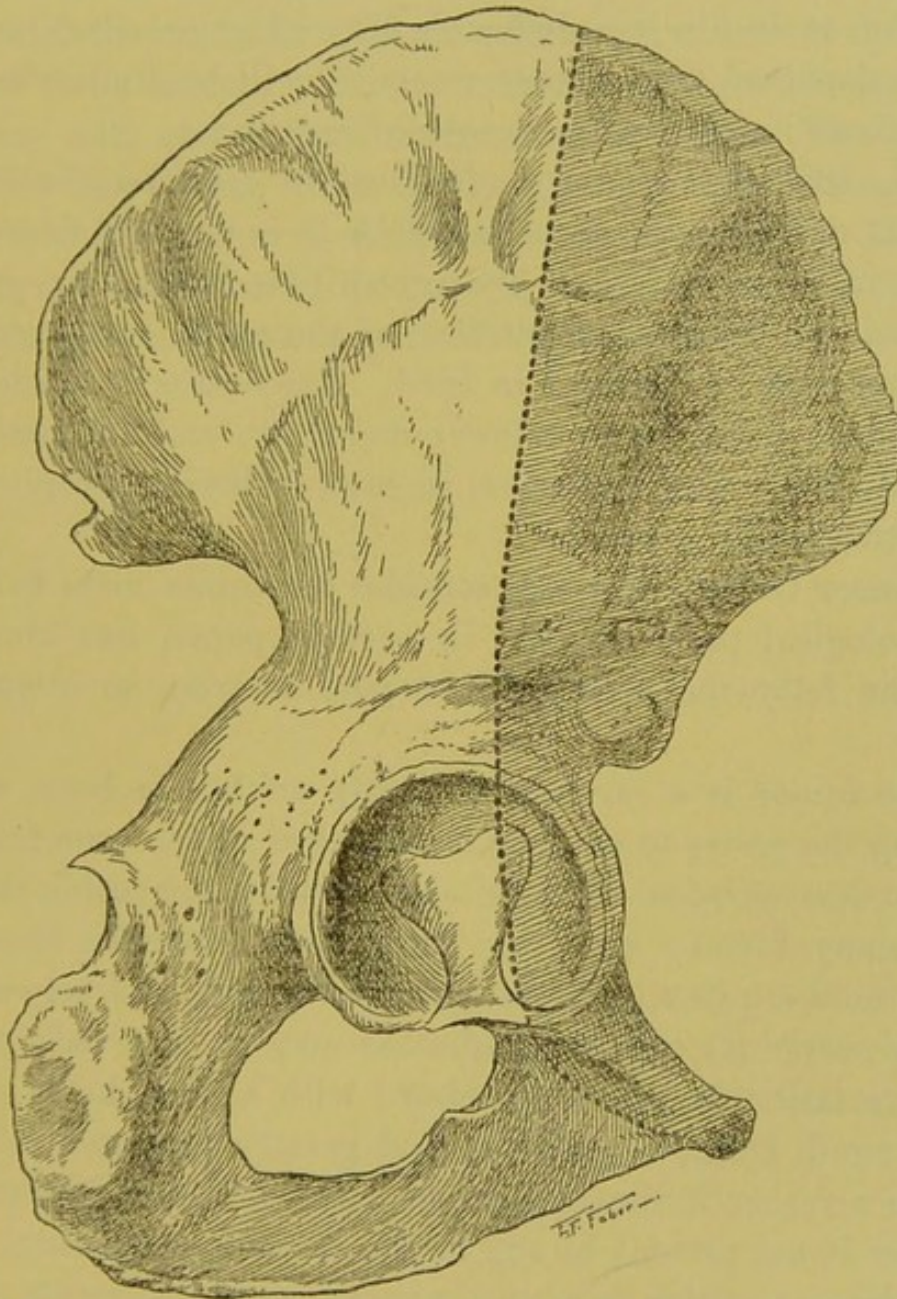


FIG. 10.—Freeman's case. The unshaded portion of the bone was removed.

much as is necessary of the innominate bone, thus doing the operation in two stages. B. Obviously the operation cannot be done in two stages in sarcoma. He proposes, therefore, to amputate at the hip-joint, and then, instead of disarticulating the ilium and the

<sup>1</sup> Arch. Gén., July 7, 1903, p. 1665.



pubes, to leave the body of the pubes, and, if possible, the tuber ischii, and to saw the ilium in the manner which I adopted in this case. He advises against any preliminary ligation of the iliacs—common, internal, or external. Mature reflection and my experience in this case lead me to concur with Morestin, at least in the disarticulation at the hip and sawing the bone. Bardenheuer advocates an amputation at the hip-joint before dealing with the innominate bone. I believe that thus the primary mortality will be diminished materially without increasing the danger of recurrence.

I am, however, still more inclined to abandon the interilio-abdominal operation in cases in which it is possible to substitute resection of more or less of the innominate bone, even up to its entire removal, without amputation of the entire lower extremity, as was first done by Kocher,<sup>1</sup> in 1884. The results in Kocher's and Roux's hands have shown a lower mortality, and the patient can stand and walk. Only, however, in cases of limited neoplasms will this substitution be possible.

Professor Coplin, who will consider the tumor more fully from the pathological point of view in another paper, has kindly furnished the following pathological report in order to complete the case.

"The tumor is a sarcoma evidently arising in bone, and still possessing the power to produce more or less atypic bone fragments, hence, an osteosarcoma. The cellular elements composing the tumor are of many forms; some are large with relatively conspicuous nuclei, others are small, almost lymphoid in size, and between these extremes nearly all possible gradations may be observed; the noteworthy variation in size is associated with a remarkable polymorphism, round, irregular, spindle, and greatly elongated cells being mixed in a rather indiscriminate manner. Pigment production by the tumor is not present in any of the sections examined; the contained pigment, which is scanty, appears to be the result of hemolysis of extravasated blood which is fairly abundant throughout the sections. The architecture of the tumor is such as to enable us to extend and render more accurate the diagnosis of sarcoma; it is alveolar,—an alveolar osteosarcoma. The arrangement of the cells within the alveoli—surrounding central spaces, some of which con-

<sup>1</sup> Chirurgische Operationslehre, 4te Aufl., p. 531, 1902.



tain blood or the detritus resulting from blood disintegration, while in other areas the spaces are quite free—is typically that of the endotheliomata. That some of the spaces correspond to blood-vessels and others to lymph-vessels would allow the neoplasm to be called a hemangio-endothelioma in the one instance, and a lymphangio-endothelioma in the other. There is, so far as I am aware, no objection to the recognition of the association of two of the accepted forms of endothelioma. The metastases found further support the belief that both types of endothelioma are present. The lymphatic extensions have arisen from the lymphangio-endotheliomatous elements, and such a tumor should manifest, sooner or later, wide-spread hematogenous diffusion of the growth, through dissemination by the hemangio-endotheliomatous part of the neoplasm.”



The first part of the book is devoted to a general history of the United States from the discovery of the continent to the present time. The second part is devoted to a detailed history of the United States from the discovery of the continent to the present time. The third part is devoted to a detailed history of the United States from the discovery of the continent to the present time. The fourth part is devoted to a detailed history of the United States from the discovery of the continent to the present time. The fifth part is devoted to a detailed history of the United States from the discovery of the continent to the present time. The sixth part is devoted to a detailed history of the United States from the discovery of the continent to the present time. The seventh part is devoted to a detailed history of the United States from the discovery of the continent to the present time. The eighth part is devoted to a detailed history of the United States from the discovery of the continent to the present time. The ninth part is devoted to a detailed history of the United States from the discovery of the continent to the present time. The tenth part is devoted to a detailed history of the United States from the discovery of the continent to the present time.

The first part of the book is devoted to a general history of the United States from the discovery of the continent to the present time. The second part is devoted to a detailed history of the United States from the discovery of the continent to the present time. The third part is devoted to a detailed history of the United States from the discovery of the continent to the present time. The fourth part is devoted to a detailed history of the United States from the discovery of the continent to the present time. The fifth part is devoted to a detailed history of the United States from the discovery of the continent to the present time. The sixth part is devoted to a detailed history of the United States from the discovery of the continent to the present time. The seventh part is devoted to a detailed history of the United States from the discovery of the continent to the present time. The eighth part is devoted to a detailed history of the United States from the discovery of the continent to the present time. The ninth part is devoted to a detailed history of the United States from the discovery of the continent to the present time. The tenth part is devoted to a detailed history of the United States from the discovery of the continent to the present time.