

## **Illustrations of plastic operations.**

### **Contributors**

Maccormac, William, Sir, 1836-1901.  
Anderson, William, 1842-1900  
Royal College of Surgeons of England

### **Publication/Creation**

[London?] : [publisher not identified], [1888?]

### **Persistent URL**

<https://wellcomecollection.org/works/z5y6pvzg>

### **Provider**

Royal College of Surgeons

### **License and attribution**

This material has been provided by This material has been provided by The Royal College of Surgeons of England. The original may be consulted at The Royal College of Surgeons of England. where the originals may be consulted. This work has been identified as being free of known restrictions under copyright law, including all related and neighbouring rights and is being made available under the Creative Commons, Public Domain Mark.

You can copy, modify, distribute and perform the work, even for commercial purposes, without asking permission.



Wellcome Collection  
183 Euston Road  
London NW1 2BE UK  
T +44 (0)20 7611 8722  
E [library@wellcomecollection.org](mailto:library@wellcomecollection.org)  
<https://wellcomecollection.org>

9

Dr. R. M. G. J. Wm

ILLUSTRATIONS OF PLASTIC  
OPERATIONS.

(3)

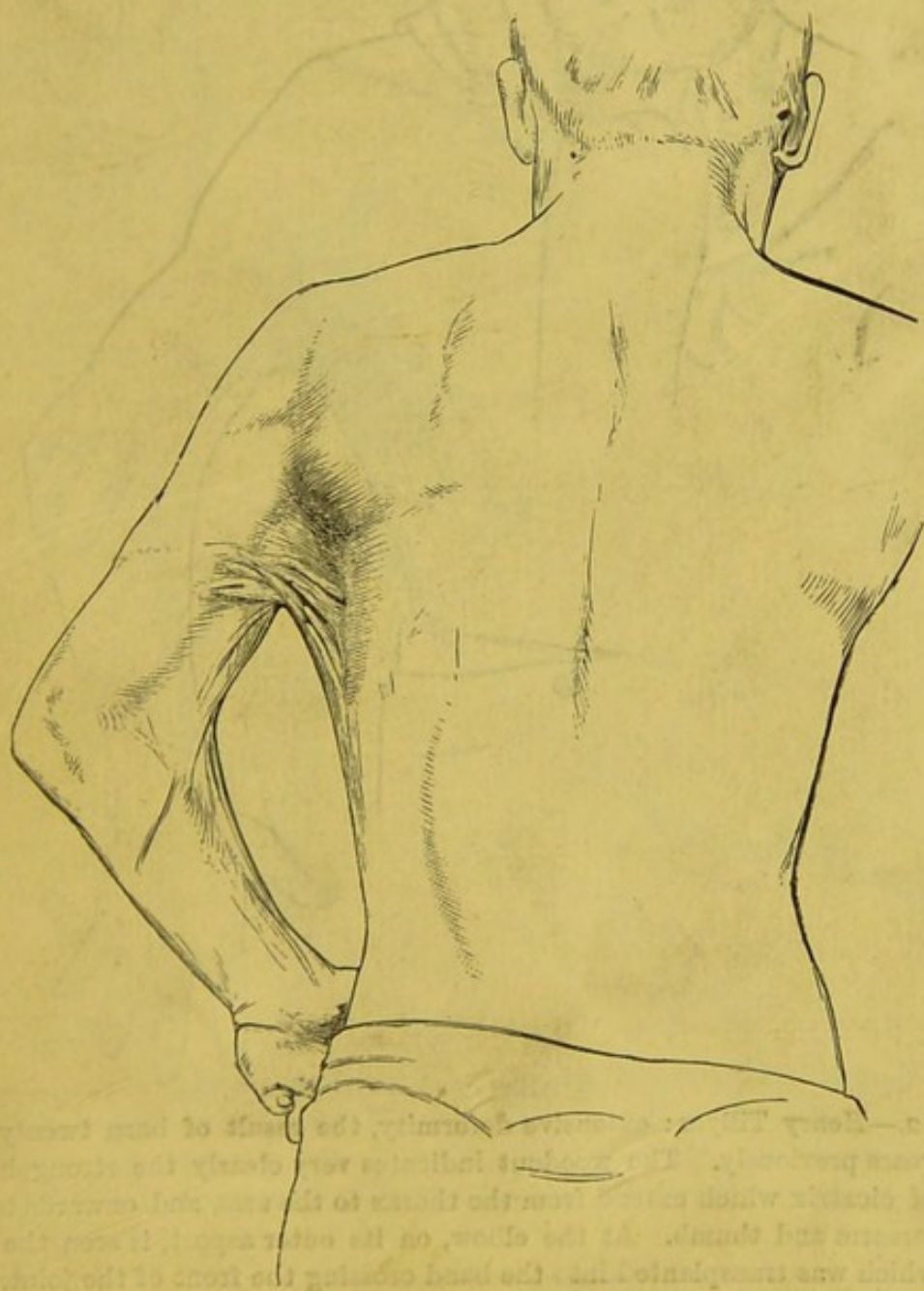


FIG. 1.—Henry Tillyer: extensive deformity the result of burn twenty-five years previously. Posterior view of the cicatricial webs binding the arm to the thorax and hindering extension at the elbow-joint.

A

[after 1888 - see fig. 7.]

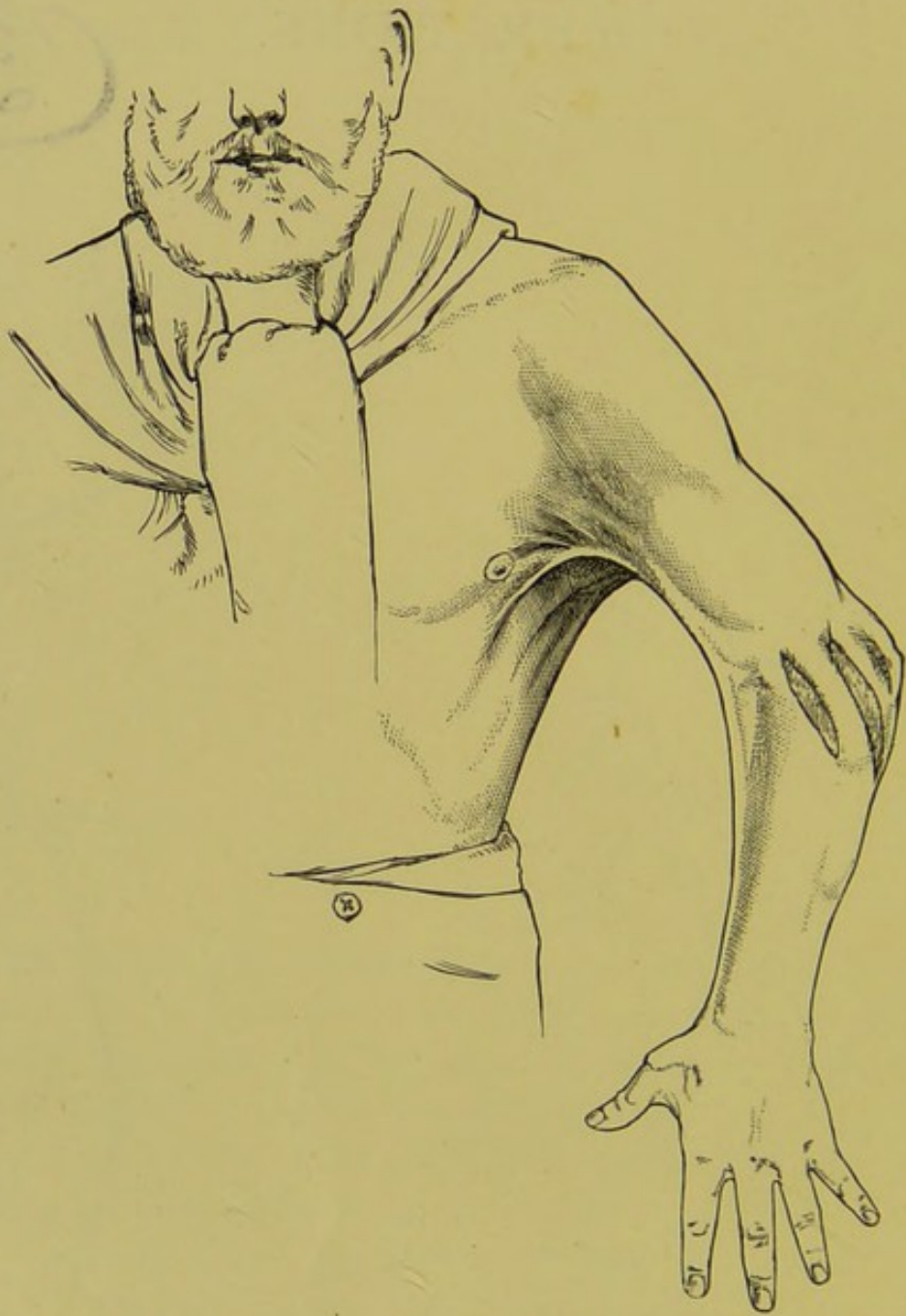

FIG. 2.—Henry Tillyer: extensive deformity, the result of burn twenty-five years previously. The woodcut indicates very clearly the strong bands of cicatrix which extend from the thorax to the arm, and onwards to the forearm and thumb. At the elbow, on its outer aspect, is seen the flap which was transplanted into the band crossing the front of the joint.



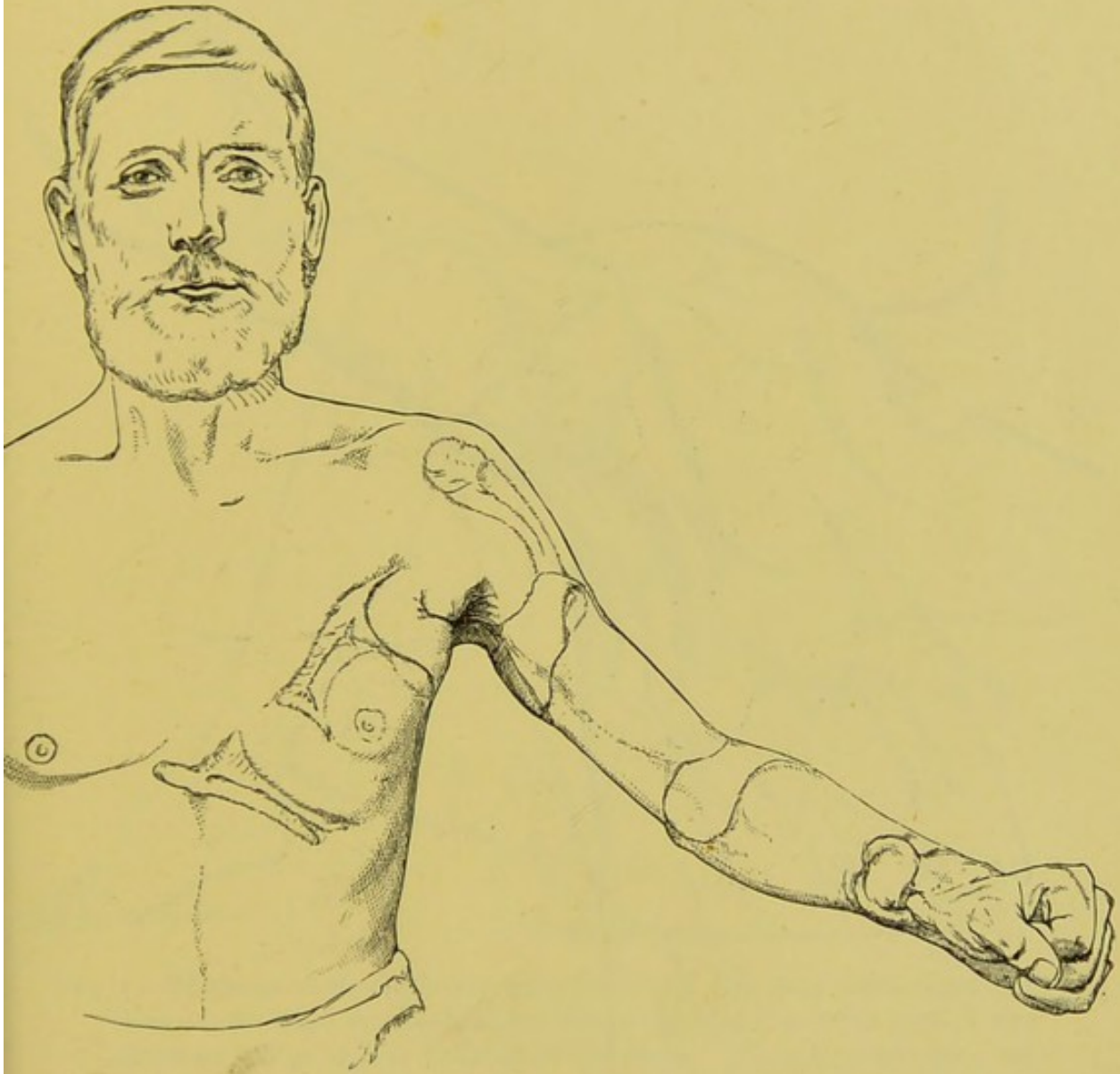


FIG. 3.—Henry Tillyer : In the woodcut the final result of the various operations performed is delineated. The flaps inserted at the wrist, the elbow and across the axilla may be distinctly traced, and thus the full power of extension possessed by the man is seen. The woodcuts are taken from photographs.

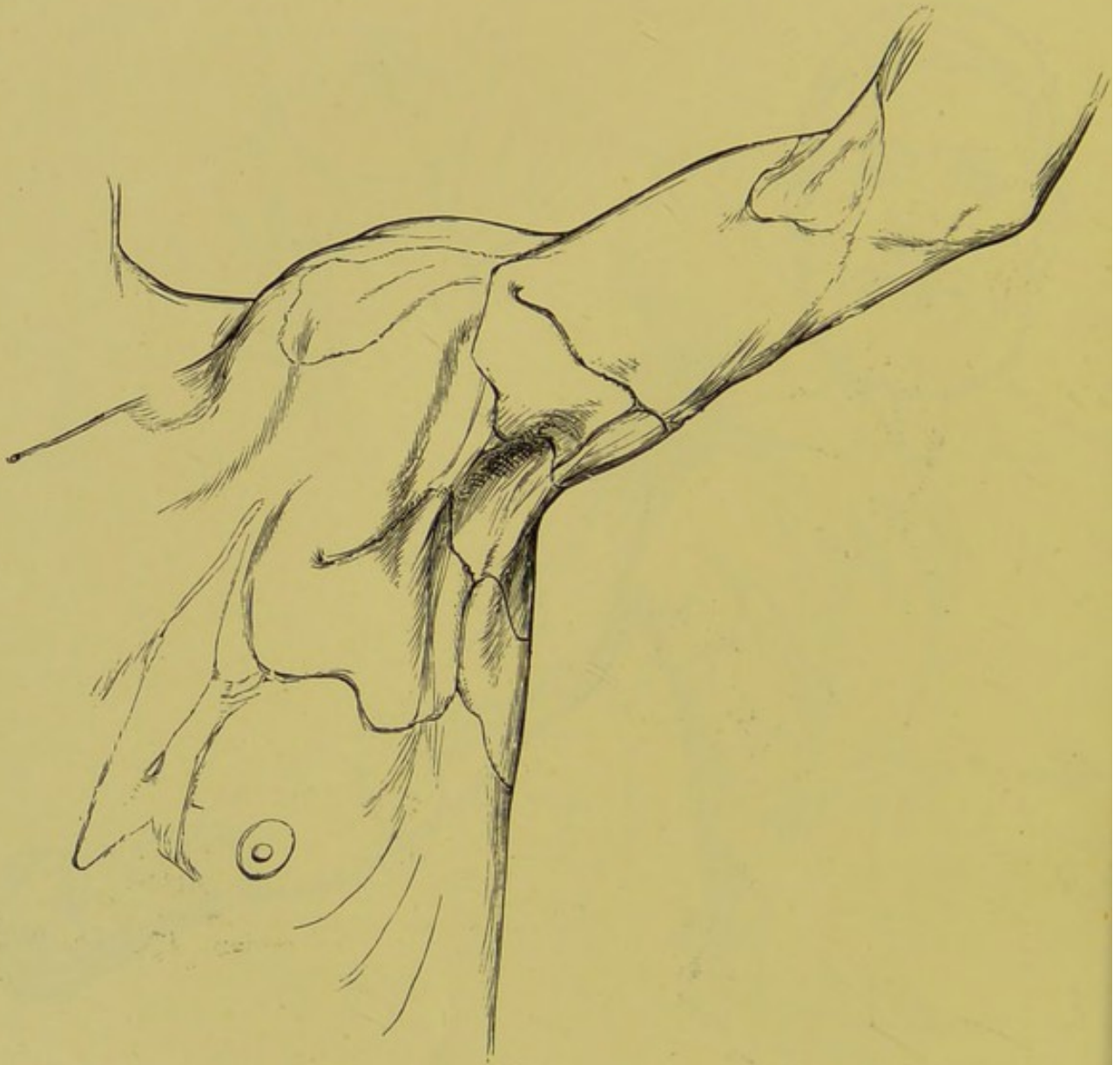


FIG. 4.—Henry Tillyer : case of extensive deformity the result of burn. This woodcut shows the great amount of stretching which has taken place in the axillary and elbow-joint flaps and very complete manner in which the arm can be abducted and the forearm extended.

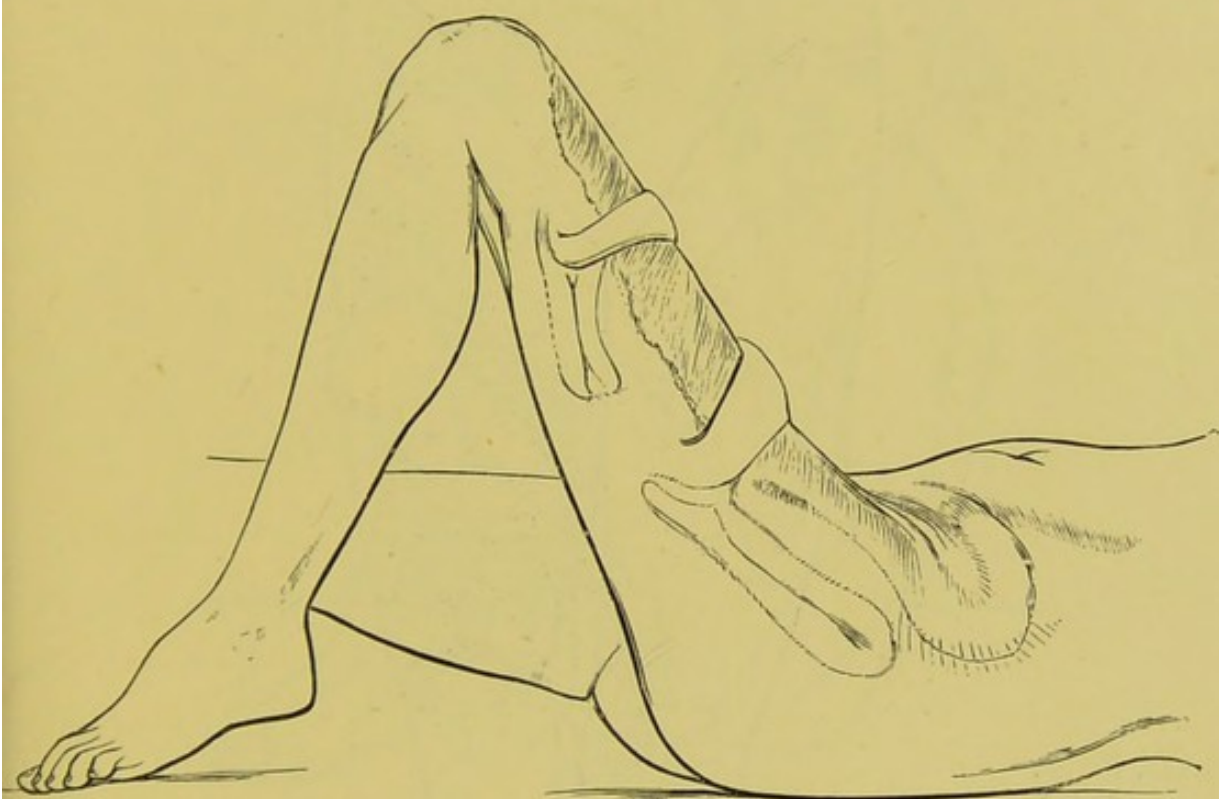


FIG. 5.—Diagrams to illustrate the implantation of four flaps taken from the sides of the thigh in an extensive cicatrix covering the lower part of the abdomen, the groin and the front of the thigh. When the operation was complete, the limb could be fully extended. Previously, it was permanently flexed both at the hip- and knee-joints.



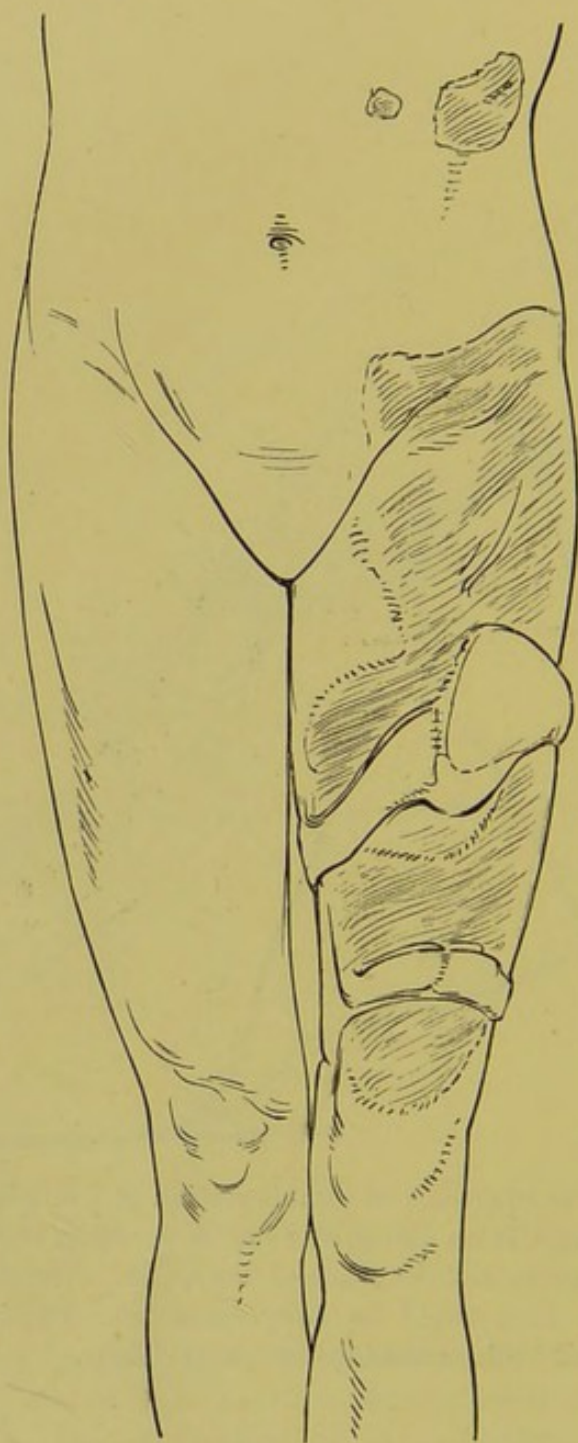


FIG. 6.—This drawing, taken from life, illustrates the fully extended position of the limb as the result of the operation.

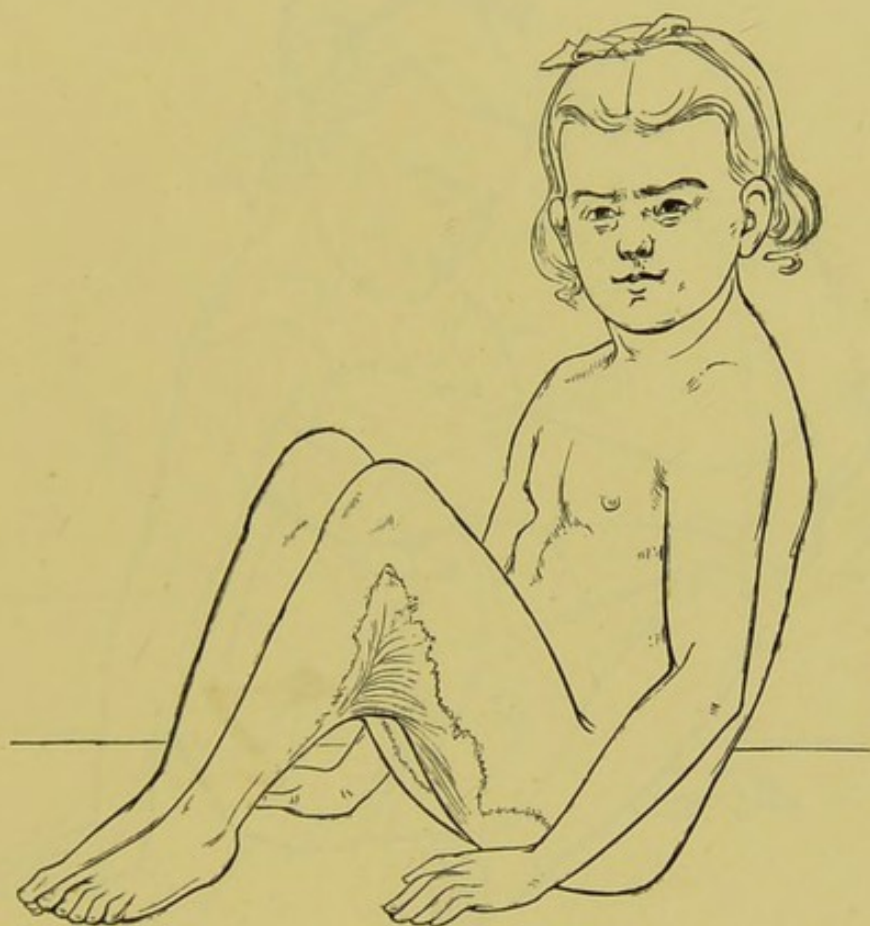


FIG. 7.—Extensive cicatrices the result of severe burn. Involving the posterior surface of both lower limbs, wholly hindering extension of the legs and completely crippling the child, the cicatricial tissue and the bands in the ham were first divided, and a bridge-flap taken from the thorax was implanted.—VON HACKER, "Lang. Archiv," vol. xxxvii. p. 91.

1888



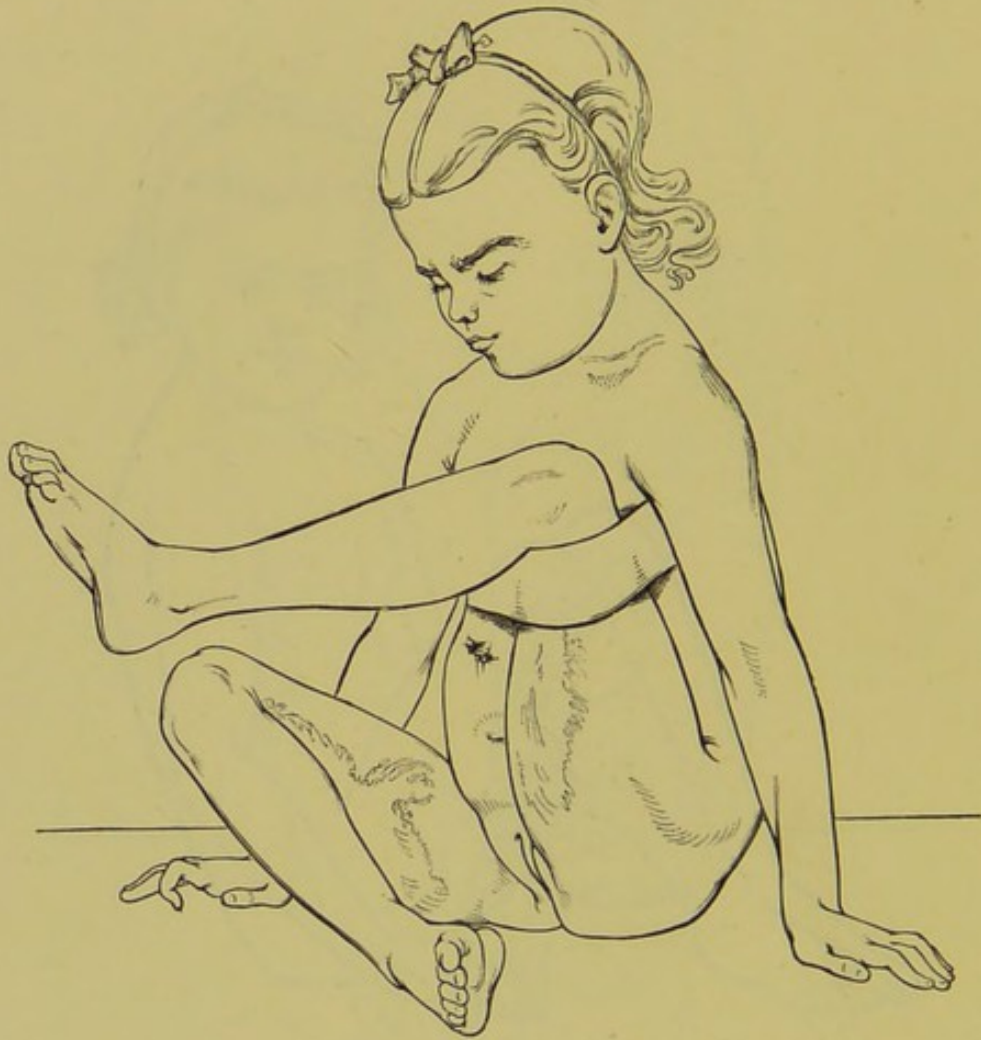

FIG. 8.—Position of the limb after it had been passed beneath the thoracic flap. When perfectly adherent the flap was detached from the thorax first at one side and then at the other, and after the operation was completed as regards one limb, the other was operated upon with like success. Sound union took place, and the child had perfect control over the limbs, which could be fully extended, enabling her to stand upright and walk with ease. —VON HACKER.




FIG. 9.—Diagram to illustrate how a bridge of skin may be raised from the thigh and immediately utilized to implant in a cicatricial contraction at the fold of the elbow.

In a case of very extensive burn involving the greater part of the arm and forearm, producing much cicatricial contraction and permanent flexion at the elbow-joint, a flap was in this manner transferred from the thigh to the elbow. The cicatrix was first divided, taking care not to injure the deeper structures. The flap was then raised from the thigh and left attached at each extremity, the arm being passed underneath. The flap was then fastened by suture to the margins of the gap across the front of the elbow. The position in which the limbs were subsequently fixed by plaster-of-Paris is indicated in the diagram. The bridge of tissue was subsequently divided first at one extremity, and then, after a sufficient interval, at the other.





FIG. 10.—Diagram to illustrate the mode of transference of a flap from the arm on one side to the back of the wrist or forearm of the opposite limb.

This woodcut shows how a flap may be readily transplanted from one arm to the other.

In a very similar way the flap might be taken from the lateral aspect of the thorax and the hand and wrist of the affected side passed beneath it for the needful distance. The steps subsequently adopted would be similar to those in the preceeding case.



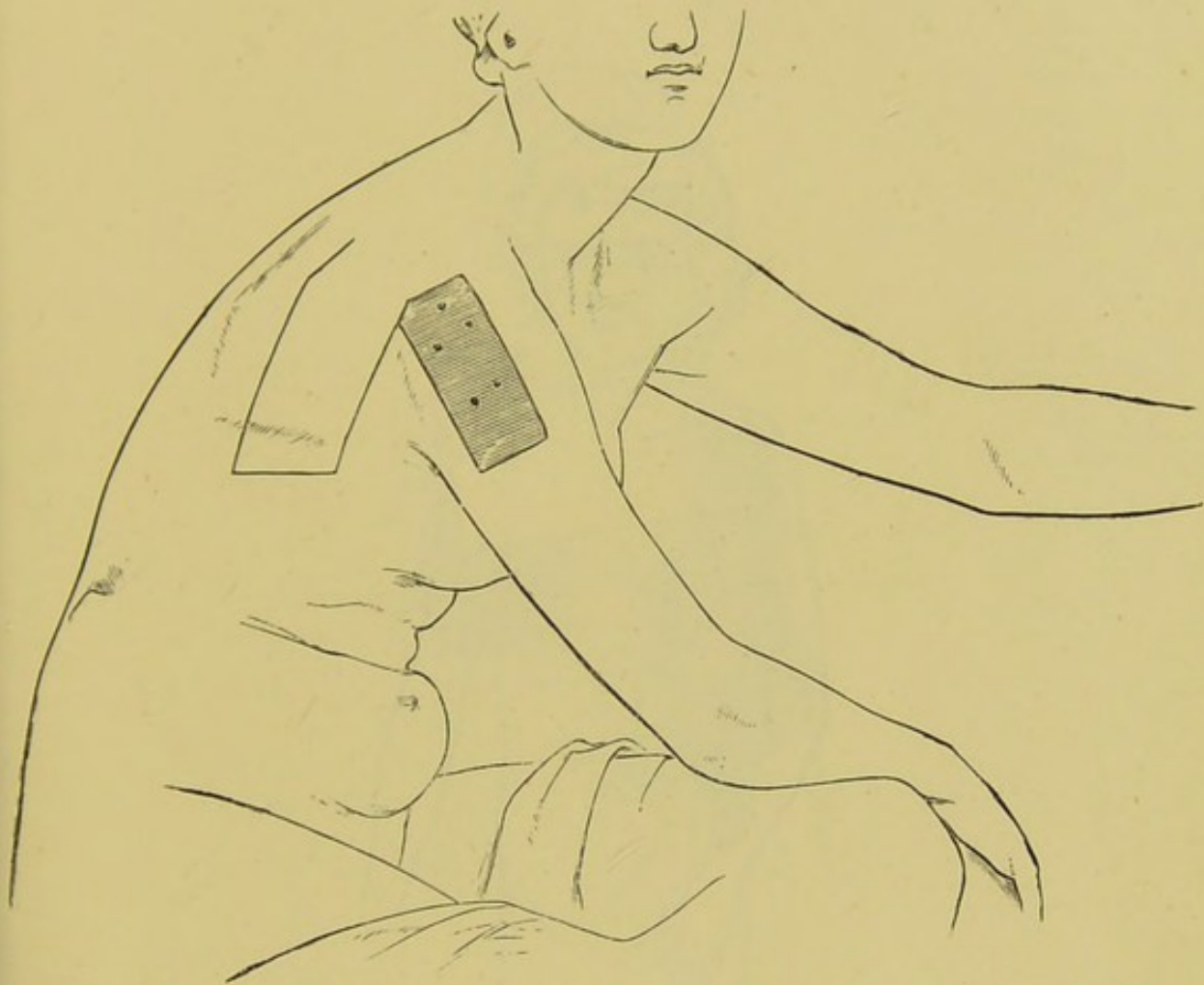


FIG. 11.—Position and shape of the flap transplanted to cover an ulcerated surface on the shoulder complicated with sinuses which would not heal under ordinary treatment. The result was most satisfactory. Lupoid and other forms of ulceration have been treated in a similar way by Langenbeck and others, with remarkably good results.—“Lang. Archiv,” vol. xxxi. p. 586.

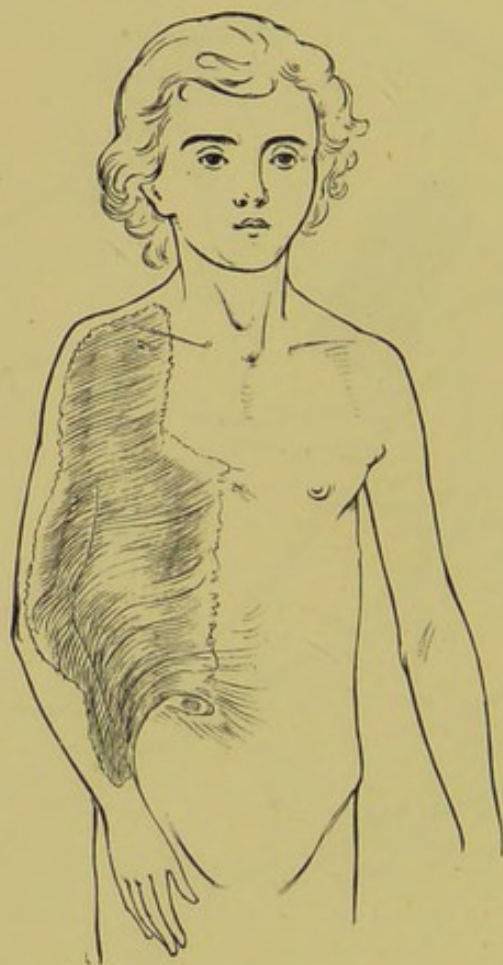

FIG. 12.—Extensive burn of arm and chest. The adhesions have fastened the arm and forearm to the side of the thorax.

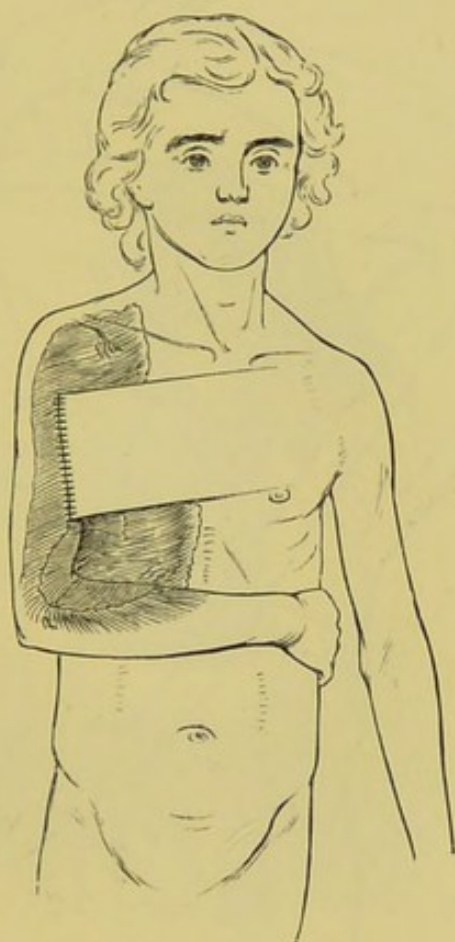


FIG. 13.—A large flap was made from the chest wall, quadrangular in shape. Left attached at one extremity, the other was sutured to a wound made in the cicatrix. When union had taken place the flap was detached from the thorax, the cicatricial bands divided, and the flap made to adhere to the raw surface thus formed upon the axillary surface of the arm.



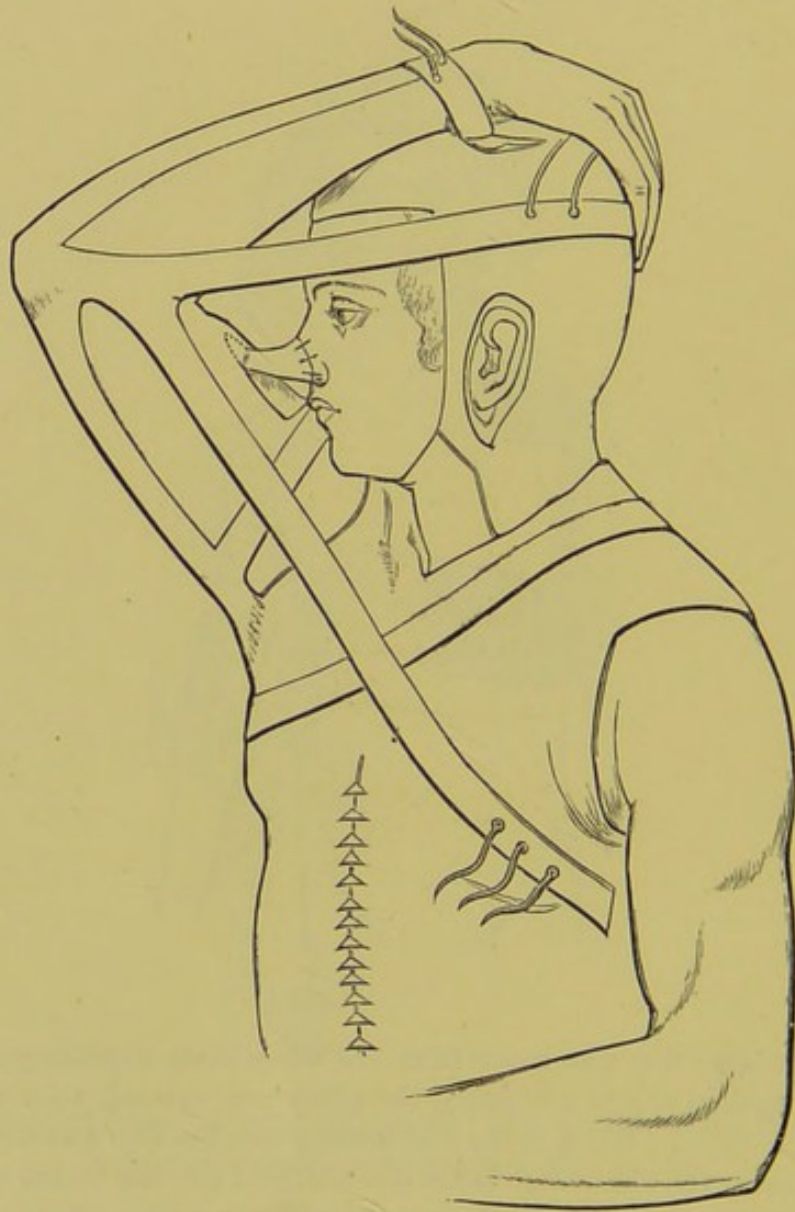


FIG. 14.—Straps and jacket used by Taliacotius for fixing the arm to the head, in order to allow the flap taken from the arm to adhere to the face in its new position.



FIG. 15.—Modification of the Taliaacotian jacket which I found answer its purpose perfectly in the cases in which I used it.

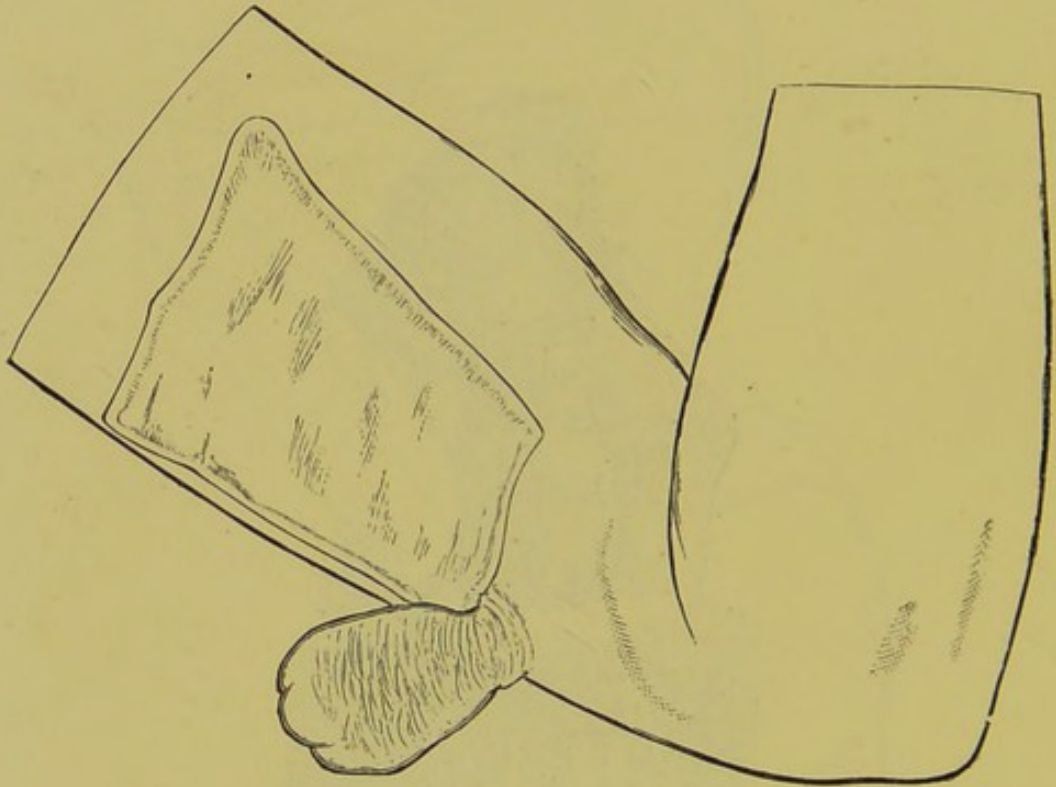


FIG. 16.—Flap of skin cut from the arm for the purpose of transplanting, to form the new nose, after the Taliacotian method.

The size of the original flap is indicated on the already cicatrized arm. The portion destined to form the new nose is still attached by a thick pedicle, and by contraction and trimming has been made to assume the required shape, and is now ready to be applied to the face.—GRAEFE, Berlin, 1818.



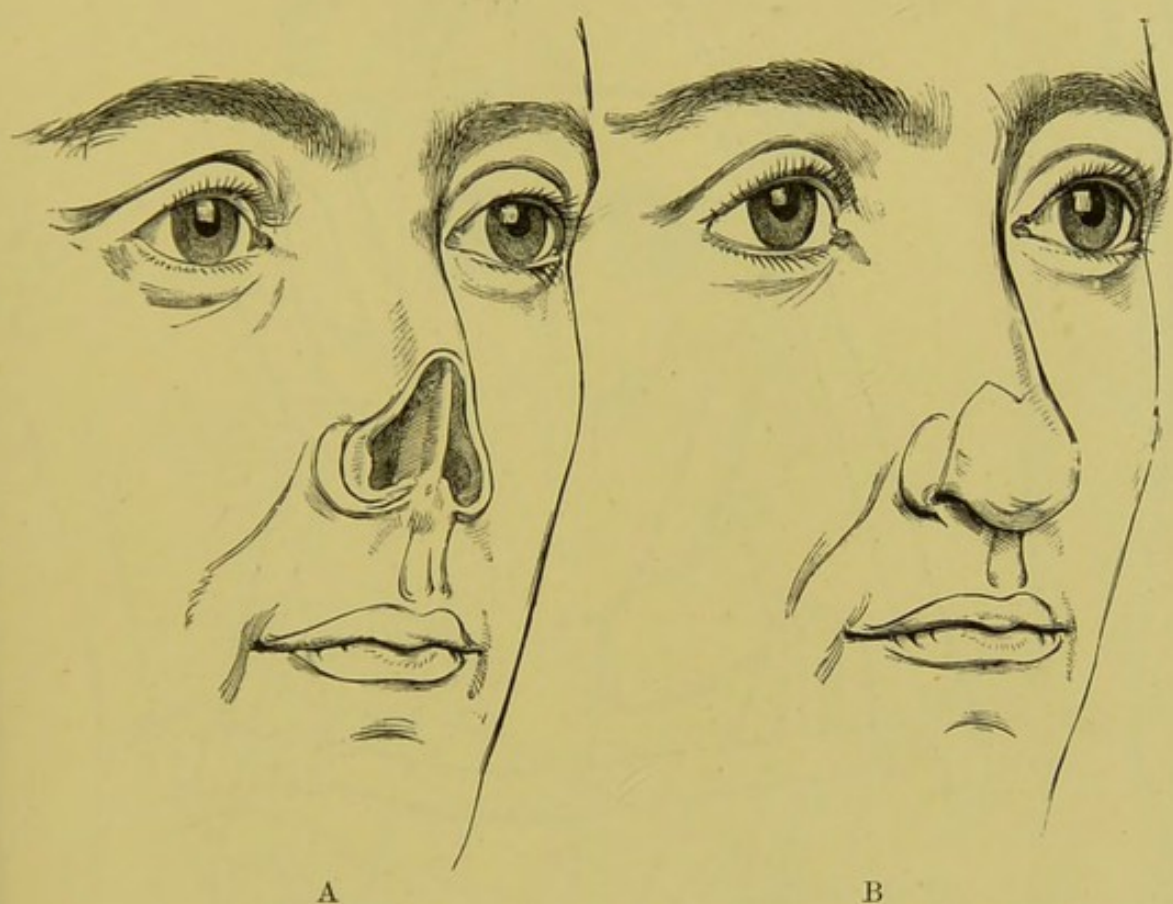


FIG. 17.—A represents the condition of a young man of 28, who had lost the end of his nose by a sabre cut. Graefe operated upon him by the Italian method.

B gives the result of the operation.—C. F. GRAEFE, "De Rhinoplastice," Berlin, 1818.

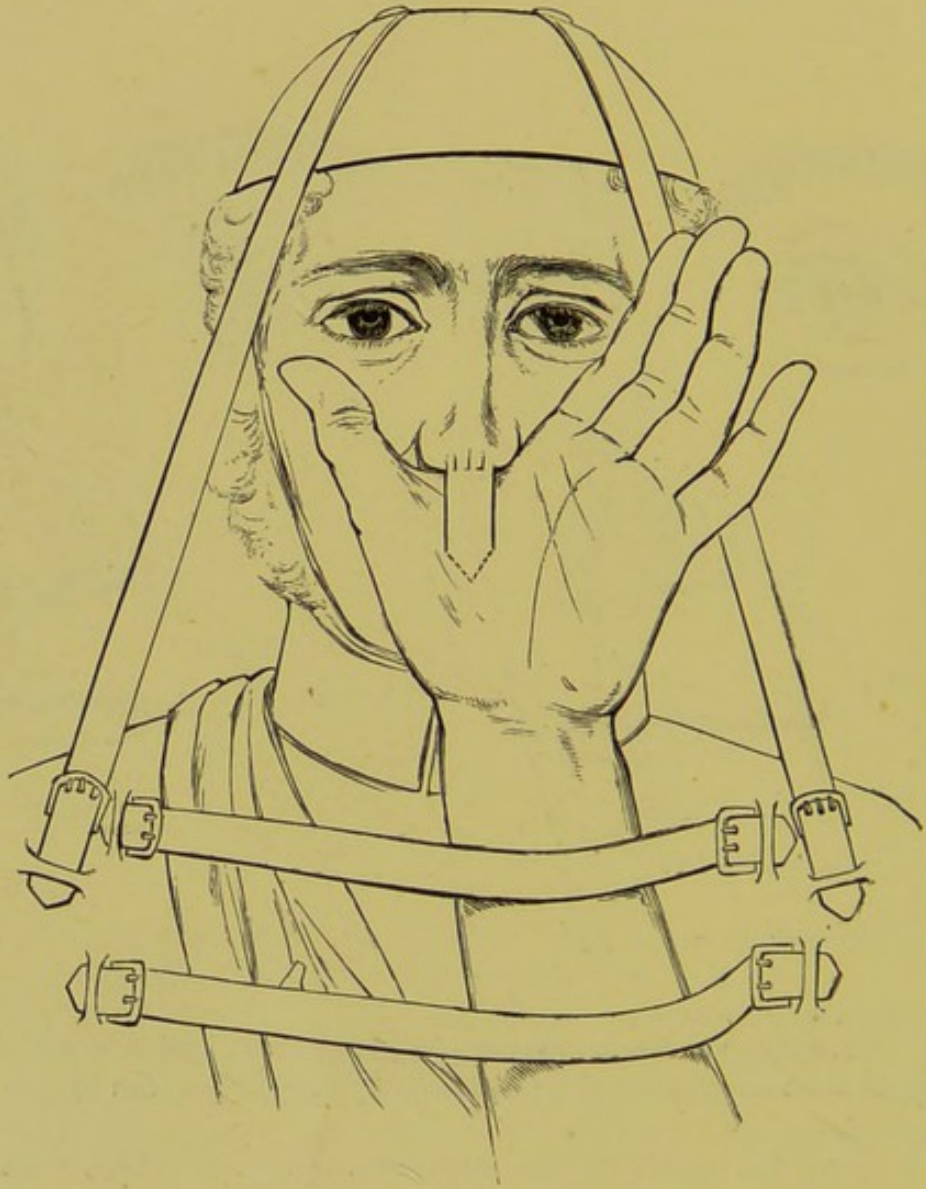

FIG. 18.—Method suggested by Roux in order to form a new septum nasi by means of transplantation from the palm of the hand.

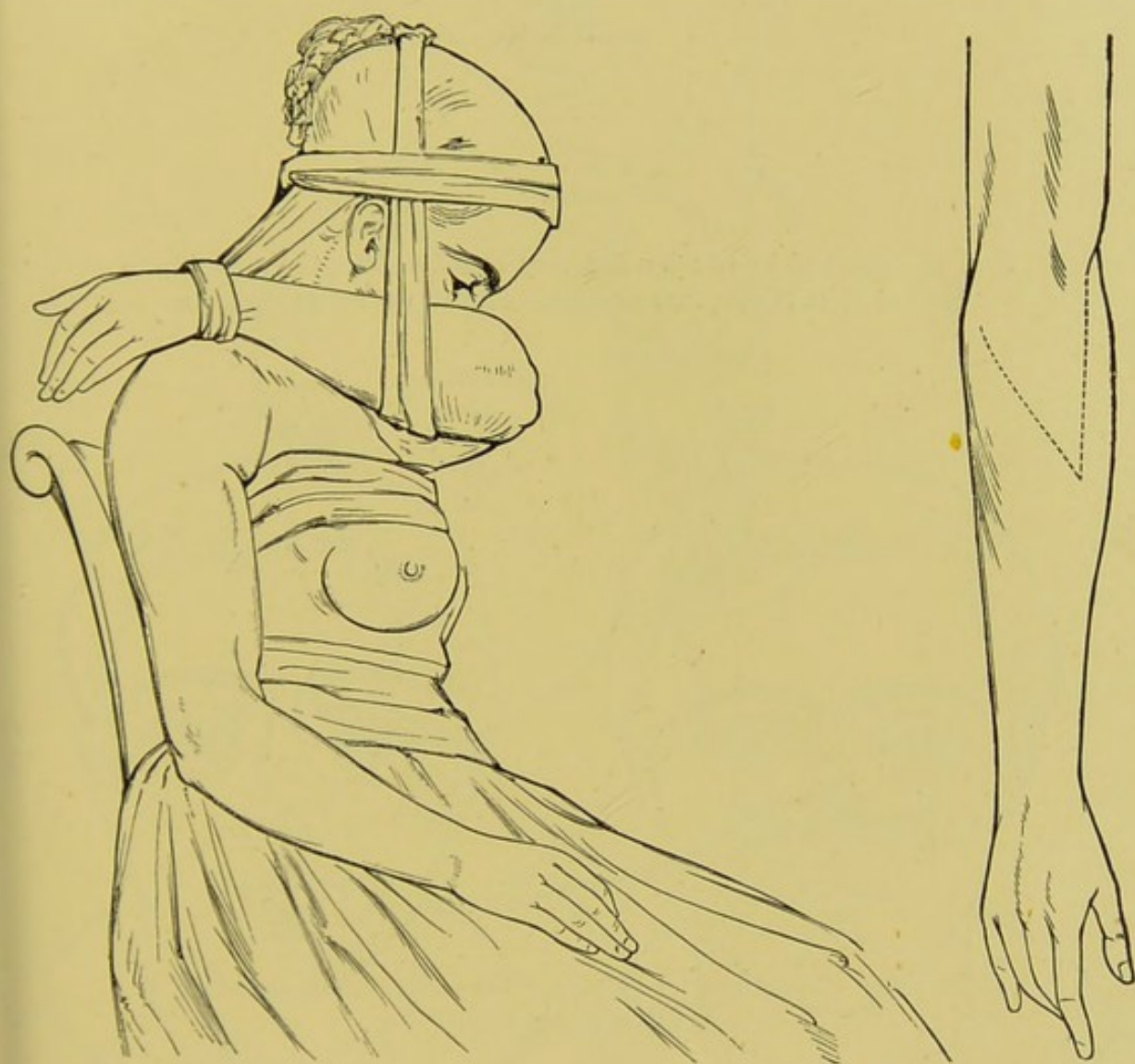


FIG. 19.—Diagram to show the immediate transference of a flap of skin from the arm to remedy a defect in the nose. Upon the arm is marked out the triangular flap employed in this case.



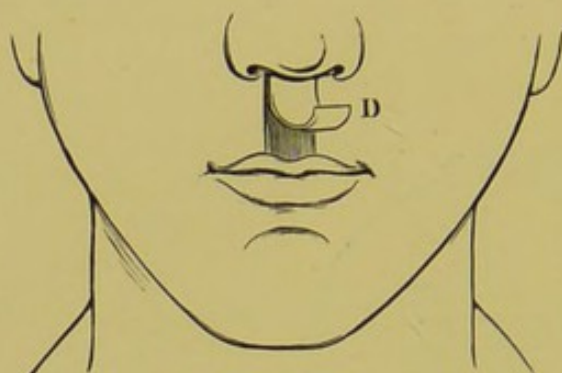


FIG. 20.—Method by which a flap may be taken from the upper lip to help to form the septum narium.—SERRE OF MONTPELLIER.

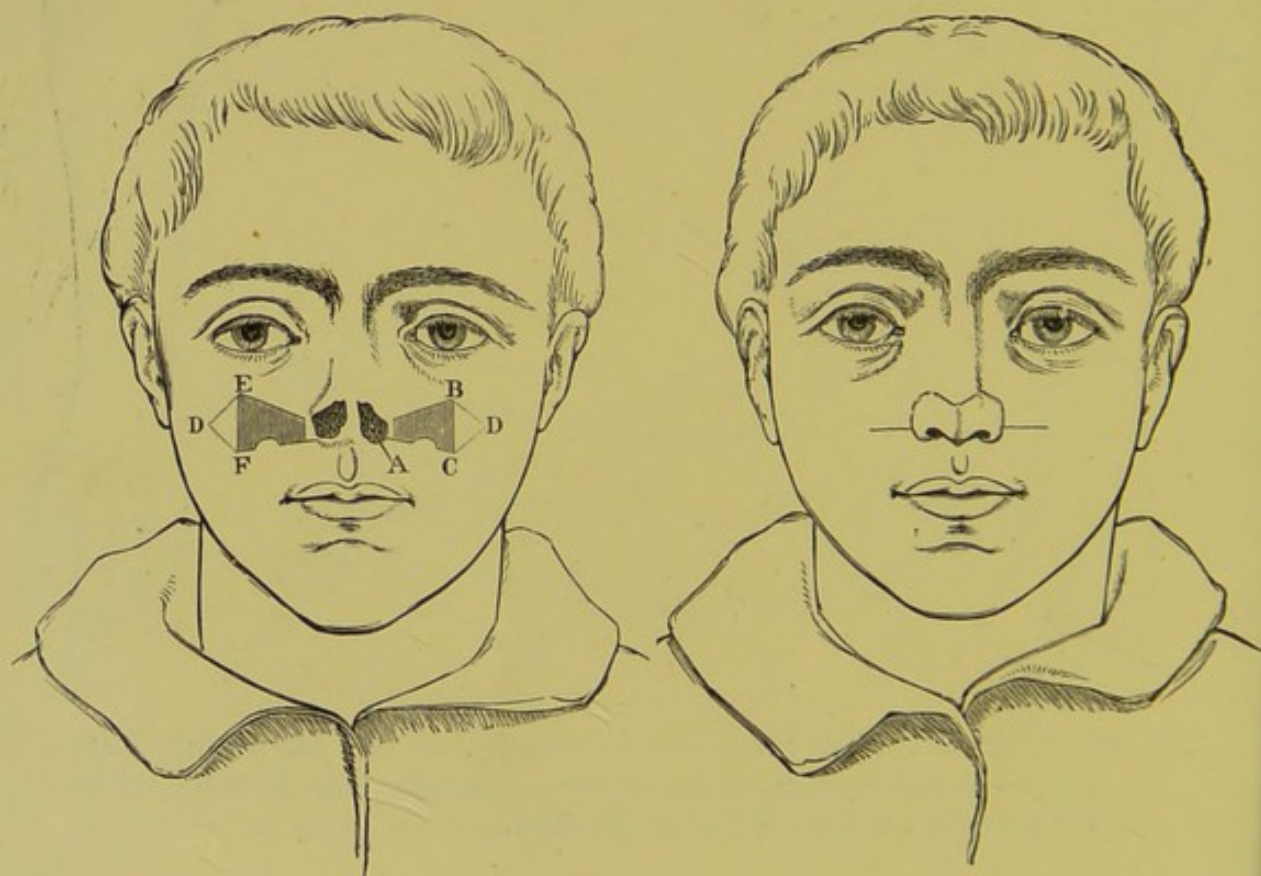
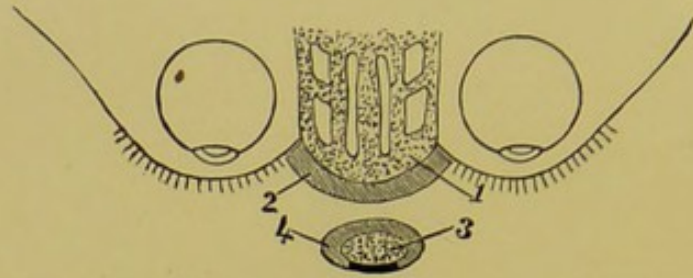


FIG. 21.—Suggestion as to the manner of forming from the cheeks, a new extremity for the end of the nose.—SERRE OF MONTPELLIER.



FIG. 22.—Manner of utilizing a flap taken from the cheek to remedy an ectropion.



Method of forming a new bony bridge for the nose.

FIG. 23.—Transverse section made on the level of the angles of the eyelids.

- (1) Bony skeleton of the nose.
- (2) Cutaneous covering of the bridge.
- (3) Transposed flap of bone from the forehead.
- (4) Cutaneous covering of the flap. The dark line anteriorly represents the cicatrised surface covering the transplanted bone.

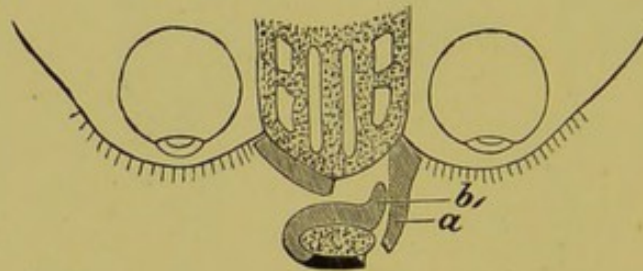


FIG. 24.—Method of forming the flaps for the completion of the lateral walls of the nose.

- (a) External flap composed of skin taken from the old nasal bridge.
- (b) Internal flap dissected off the transplanted flap of bone, periosteum, and skin.

The raw surfaces will lie in contact with one another and presently unite.

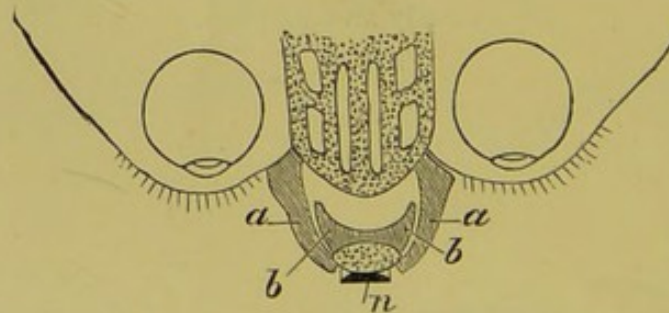


FIG. 25.—Both lateral aspects of the nose are in this diagram seen completed.

- (a a) Flap detached from old nose.
- (b b) Flaps detached from transplant.
- (n) Cicatrix formed over the new nasal bridge.

ISRAEL, "Lang. Archiv," 1887.



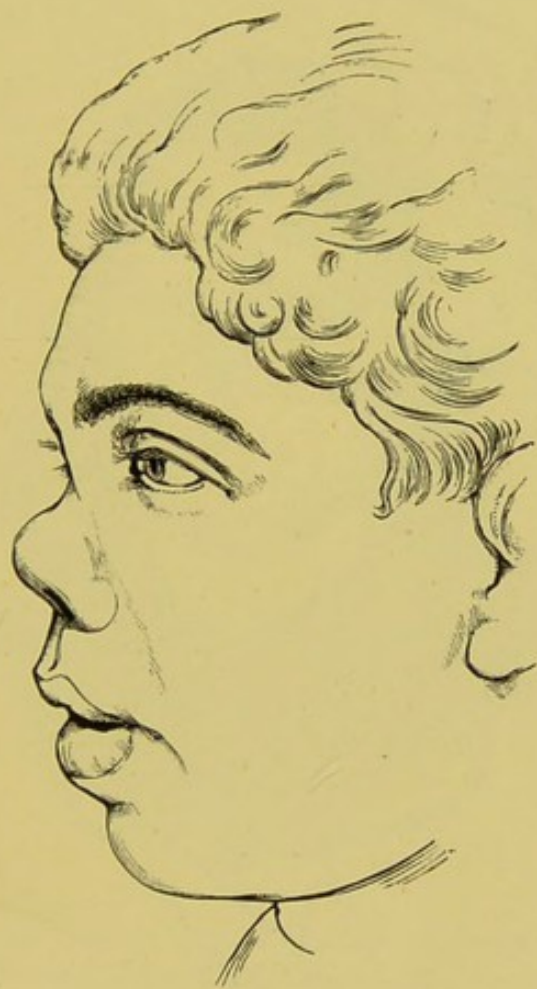

FIG. 26.—This woodcut refers to the condition of the patient before operation.  
The bridge of the nose has fallen in as a consequence of syphilitic  
necrosis.



FIG. 27.—This woodcut shows that the operation illustrated in figs. 23, 24, 25, is capable of securing an admirable result.—ISRAEL, "Lang. Archiv," ii. 1887.

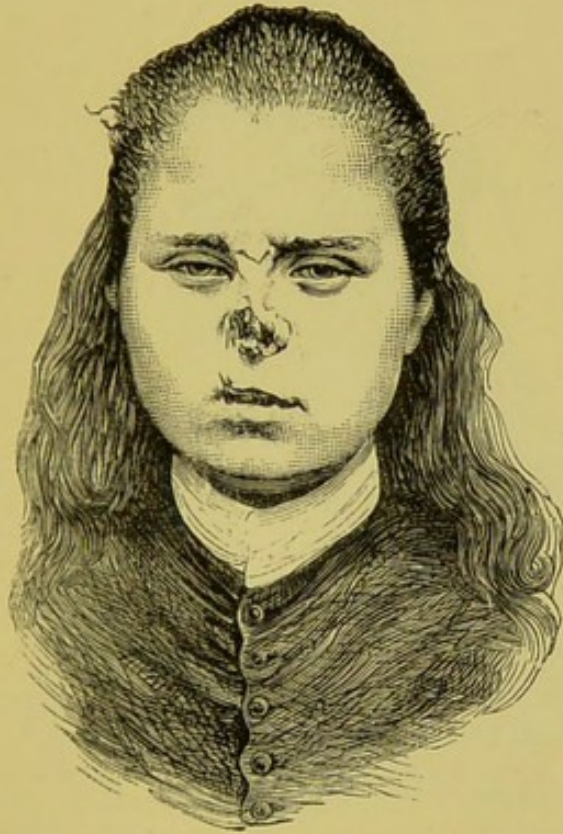

FIG. 28.—The appearances here shown are from a photograph of a girl sixteen years of age, whose nose partially sloughed as the result of an injection of perntrate-of-iron solution for the cure of a naevus, when the girl was two months old. The tip of the nose and the two alæ are lost and the deformity produced is most unsightly.





FIG. 29.—From a photograph taken four weeks after the completion of the operation. The new nose is large, but the flap subsequently contracted sufficiently to prevent the condition being noticeable to a casual observer.



FIG. 30.—Shows the instrument applied which was used to maintain the flap taken from the arm in exact apposition with the face, modified from the original apparatus of Taliacotius. It answered the purpose very completely. The flap was taken from the inside of the left arm, and for twenty-one days remained attached at both extremities till it became thick and vascular. It was then divided at its lower extremity and cut into proper shape. It became thoroughly united in its new position in two weeks, when the apparatus was removed.

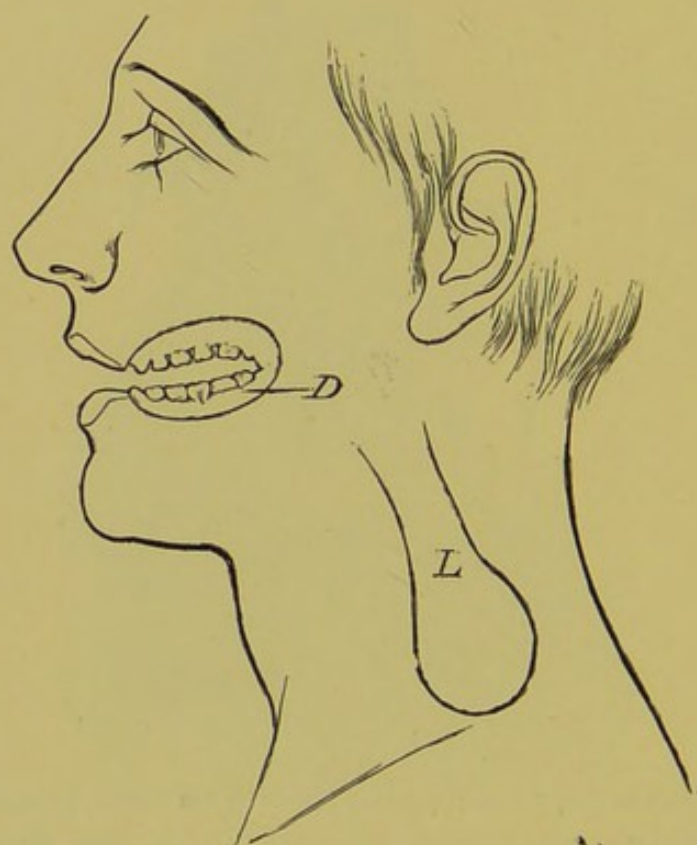


FIG. 31.—In the woodcut D represents the area of a defect left in the cheek after the removal of an extensive epithelioma in an elderly woman. L shows in position and outline the flap which was taken to fill the gap.—ISRAEL, "Lang. Archiv," ii. 1887.



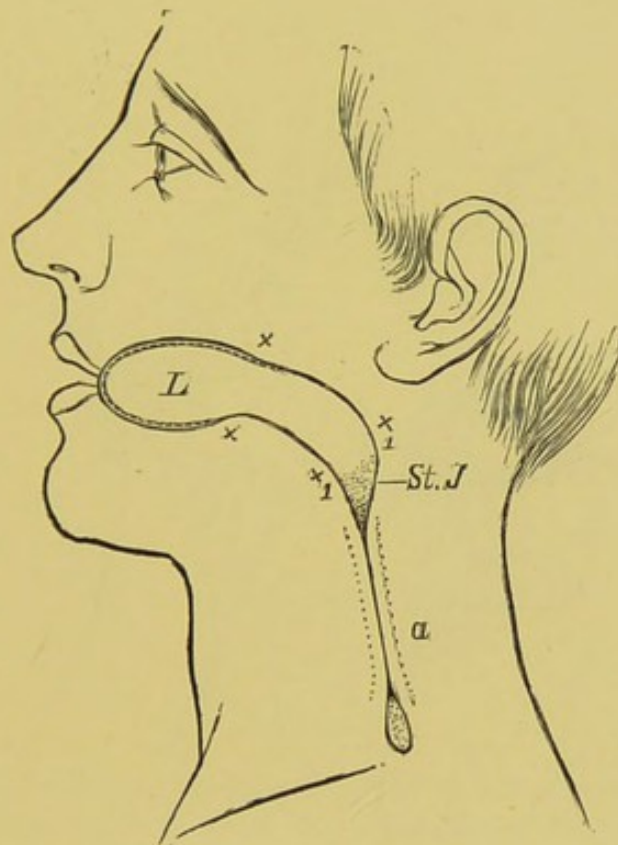


FIG. 32.—The flap *L* has been turned upwards into its new position in the cheek, and the edges of the skin are sutured to the mucous membrane. Between  $\begin{smallmatrix} \times \times \\ \times \times \end{smallmatrix}$  there is a bridge of tissue freely movable over the surface underneath. *a*, wound caused by the transference of the flap, united by suture. *St. J.*, from pedunculated attachment of the transplanted flap, which is quite free from any attachment to the skin underneath.—ISRAEL, "Lang. Archiv," 1887.

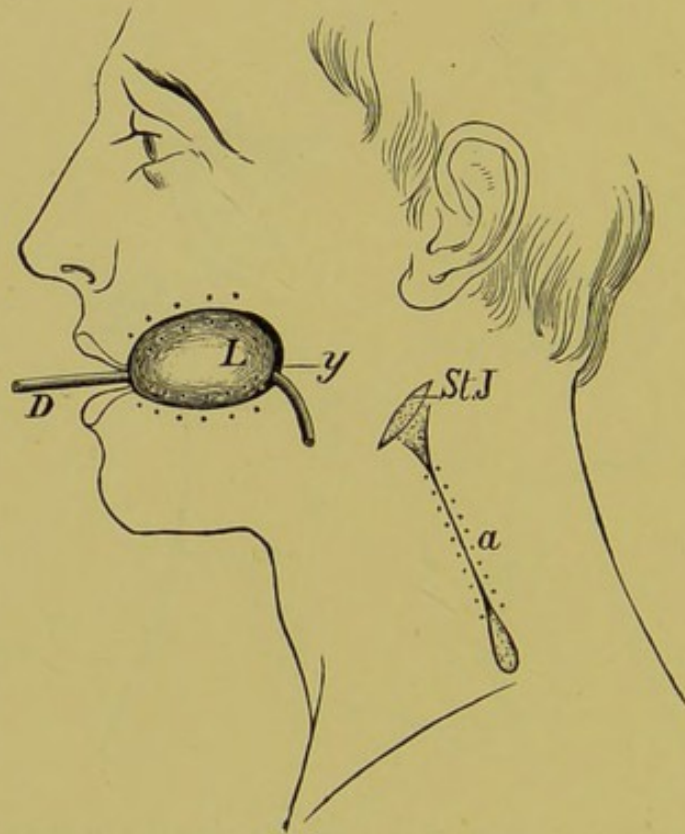


FIG. 33.—The flap *L* has been separated at the attachment of its pedicle at *St. J.* The posterior half has been turned forwards and fills the gap in the cheek to which it is attached by suture. *y*, at this point there is an interval between the flap and the posterior margin of the gap in the cheek. *D*, drainage tube.—ISRAEL, "Lang. Archiv," ii. 1887.

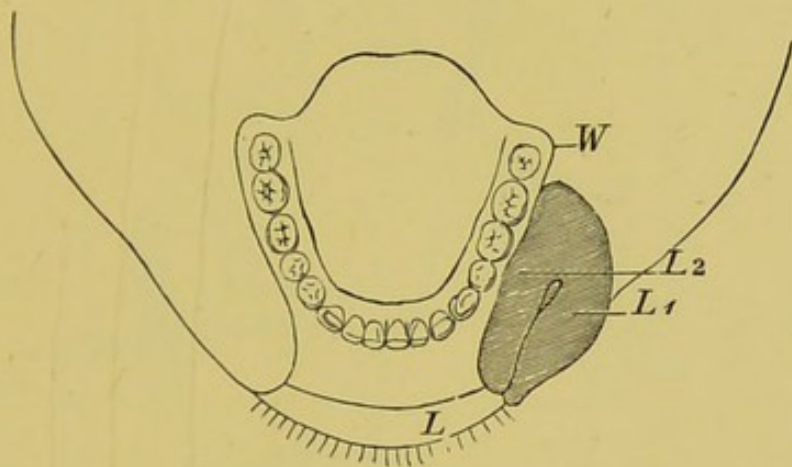


FIG. 34.—Transverse section through the cheek at a level with the angle of the mouth, showing the final result, and condition of the parts. *L* Mucous membrane of the lip. *L*<sub>1</sub> External layer of the transplant. *L*<sub>2</sub> Internal layer of the transplant. *W*, Lining mucous membrane of the cheek.—ISRAEL, "Lang. Archiv," 1887.



## MEDIATE TRANSPLANTATION.

Series of operations performed by Dr. Shrady, of New York. The woodcuts illustrate his method of mediate transplantation. A flap taken from the arm is first caused to unite firmly with the fore-finger. The flap is then detached from the arm and applied to the defect in the cheek which it is desired to fill up; and when it has soundly healed in its new position the finger is detached, and the operation completed.



FIG. 35.—Mode of formation of the flap on the arm. The arms are placed in a convenient position for purposes of measurement both of the size and position of the flap to be taken from the arm. Immobilization is subsequently effected by plaster-of-Paris bandages.

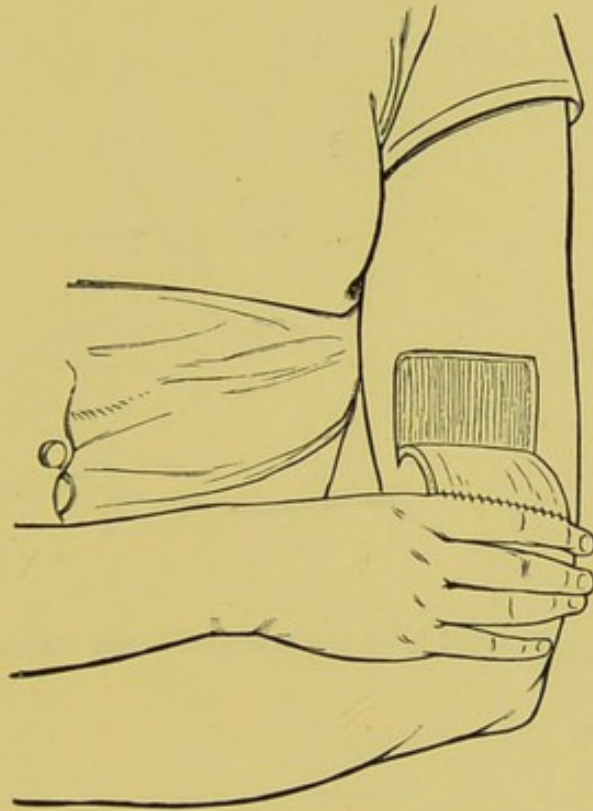


FIG. 36.—The flap is now in position attached to the forefinger, the deeper surface externally, and the arms are firmly bound together by means of plaster-of-Paris bandages.

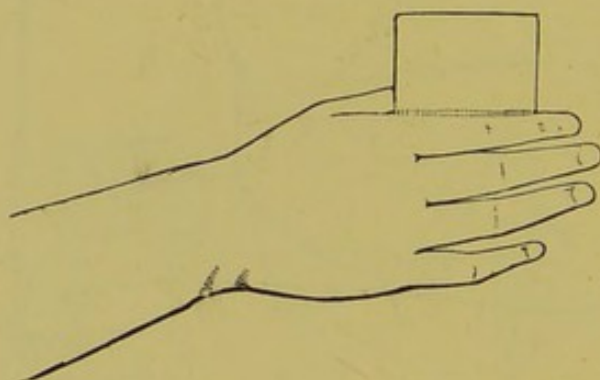


FIG. 37.—The flap separated from the arm and firmly united to the forefinger.



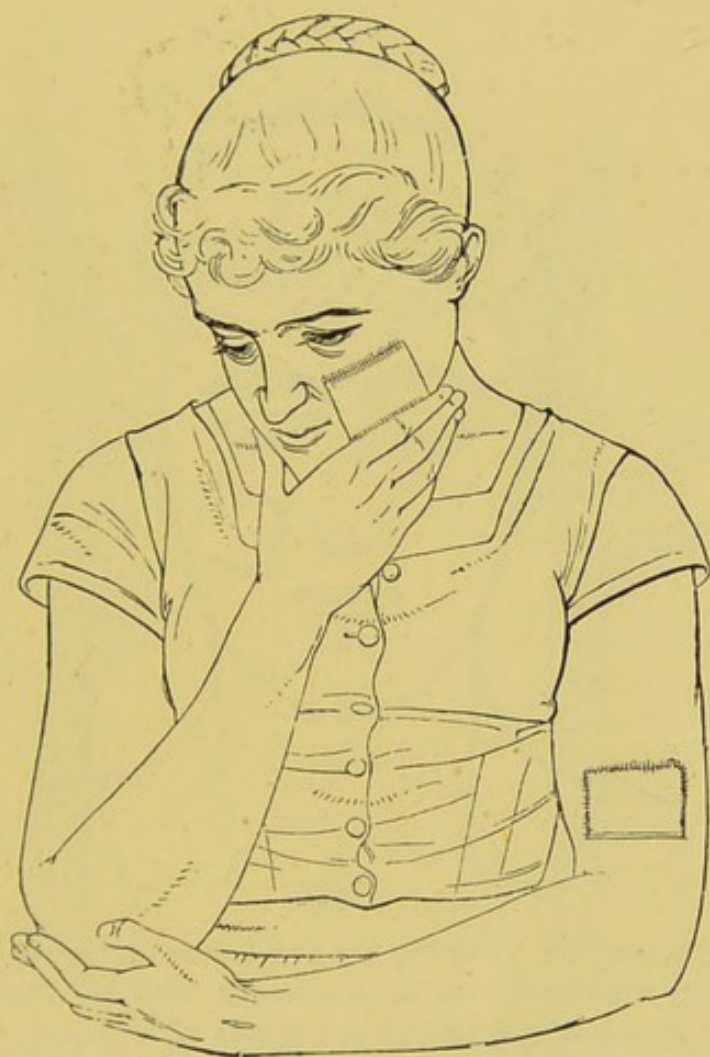

FIG. 38.—Flap, whilst remaining attached to the forefinger, is represented in position and sutured to the gap in the cheek to which it subsequently adhered. Patient was confined in that position by plaster-of-Paris bandages applied to the head, shoulder, and elbow.

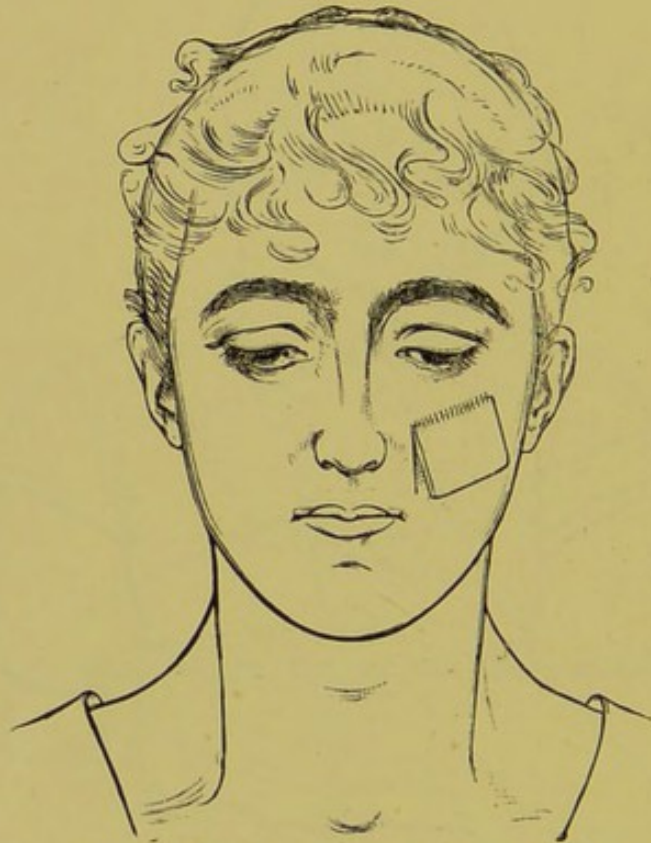

FIG. 39.—Flap in position. The flap has now become adherent to the cheek, and is finally separated from its connection with the finger, which has been thus successfully employed as a means of transport of the flap of skin from the arm to the face.

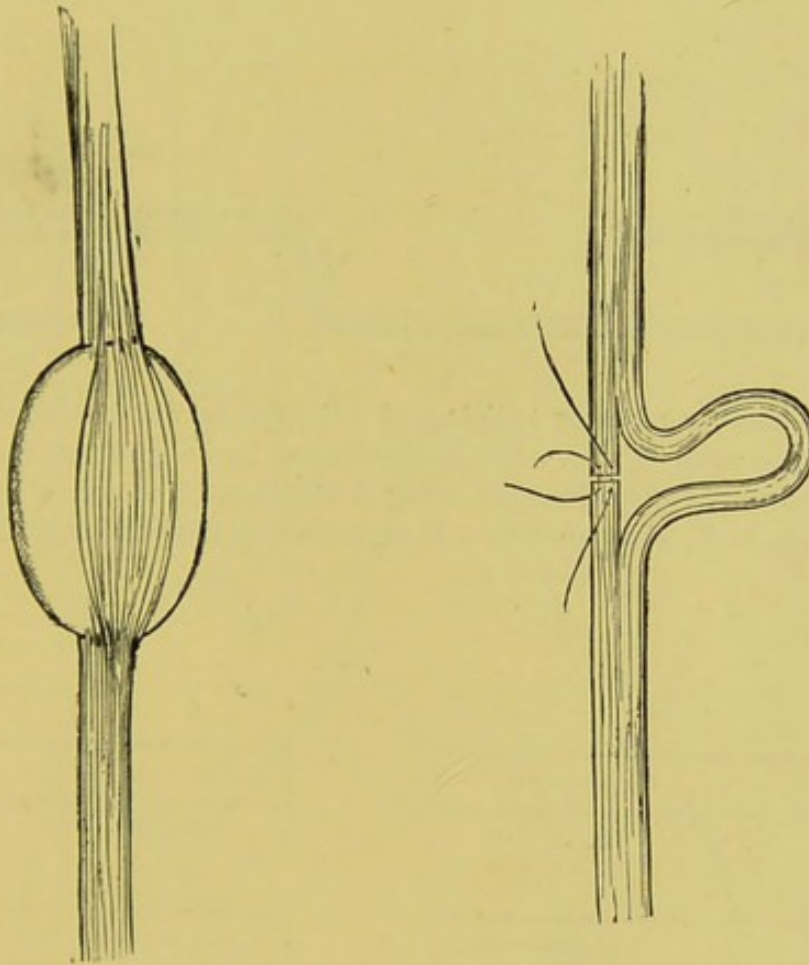


FIG. 40.—Neuroma of the median nerve. Half the thickness of the nerve passed through the tumour, the other half over it being spread out upon the surface of the growth, The excision of the tumour was effected after the portion of nerve which crossed it had been carefully dissected off. The cut ends of the portion which was removed were sutured after stretching the nerve sufficiently to bring them together without tension. The undivided portion formed a loop.



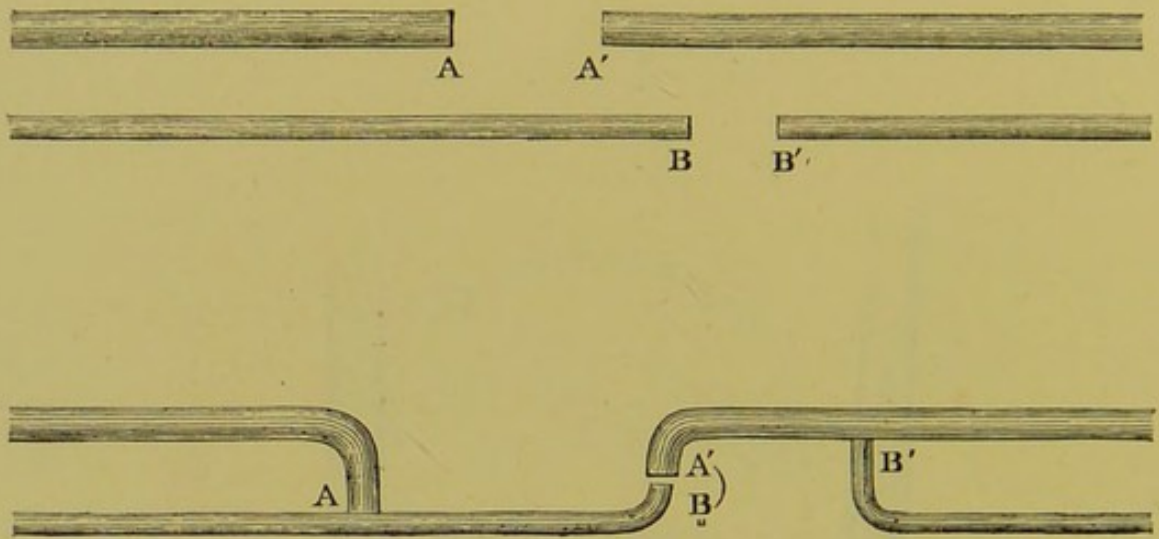


FIG. 41.—Manner of cross splicing of adjacent nerves divided at different levels in such a way, and also separated by so great an interval, that their proper ends cannot be sutured together. The end A' is united by sutures to B; subsequently A is engrafted on B and B' engrafted on A'.

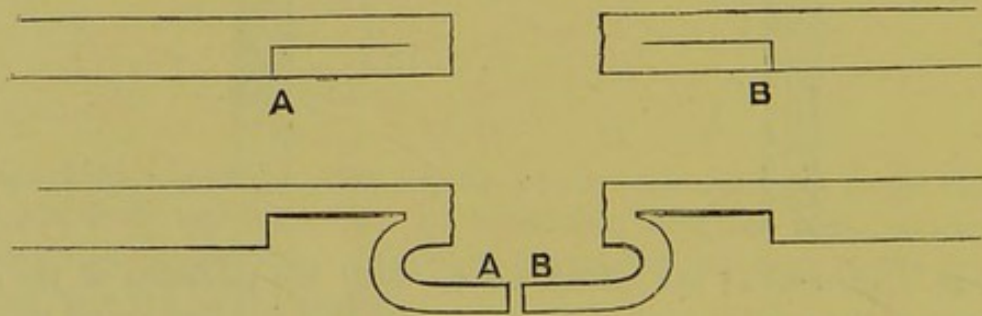


FIG. 42.—Manner of splicing a divided nerve whose ends are so far separated that they cannot be brought together and sutured in the usual way.

A flap of nerve may be taken either from both ends or from only one end, and turned down and united as seen at *A B*, according to the degree of the separating distance between the ends which may require to be bridged over.

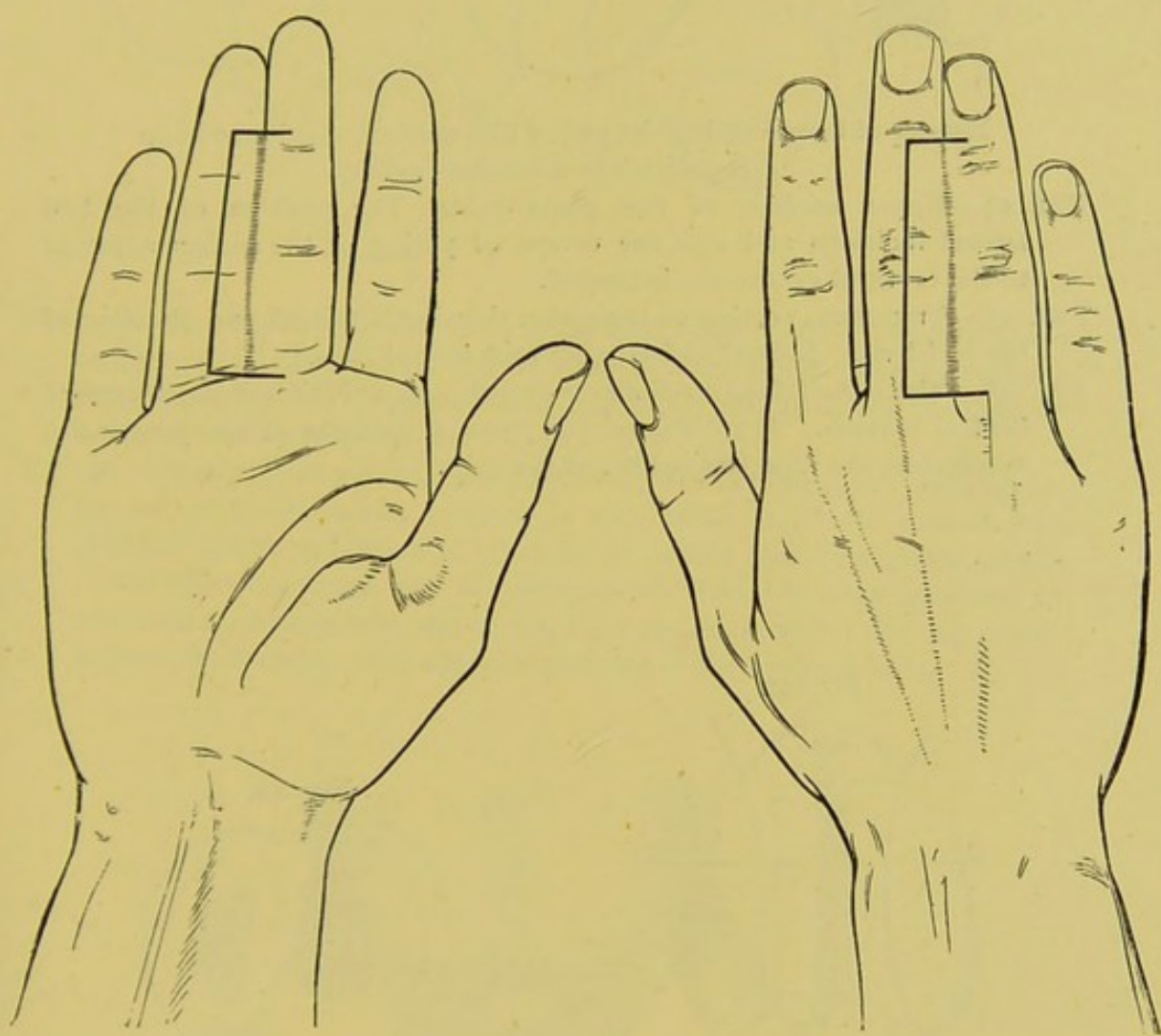


FIG. 43.—Method of forming flaps, well calculated to release the parts and ensure a good result in a case of webbed fingers.



FIG. 44.

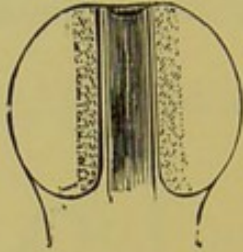

FIG. 45

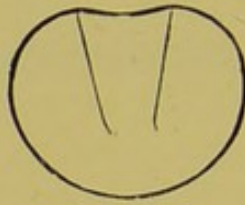
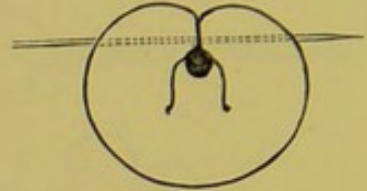


FIG. 46.



Manner of transforming the gutter like mucous membrane in an epispadias into a tubular urethra.

FIG. 44.—Upper surface of the glans penis. The position of the two lateral incisions and also the extent of paring of the surface adjacent to the urethral groove are indicated.

FIG. 45.—Transverse section of the glans, showing the depth and direction of the incisions. Lateral incisions forming lateral flaps.

FIG. 46.—The lateral flaps are drawn forwards and united over the depressed central portion. A rubber tube or piece of catheter of the proper size determines the form and calibre of the tube.

FIG. 47.

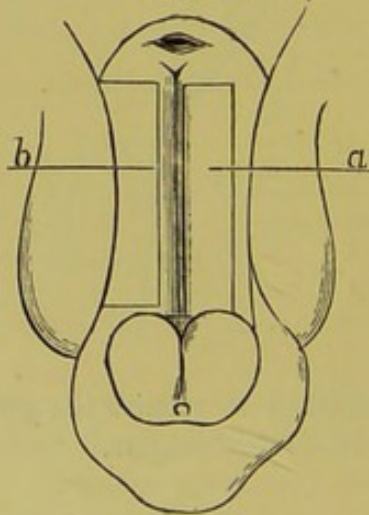


FIG. 48.

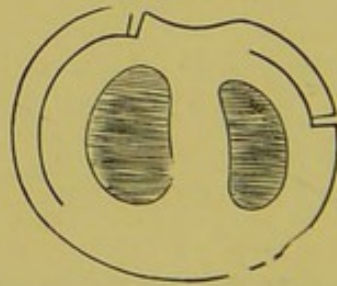


FIG. 47.—Shows the position and quadrangular form of the flaps made from the skin and subcutaneous tissue of the penis which are employed to form a representative of the urethra.

FIG. 48.—Cross section, indicating the width of the flaps.



FIG. 49.

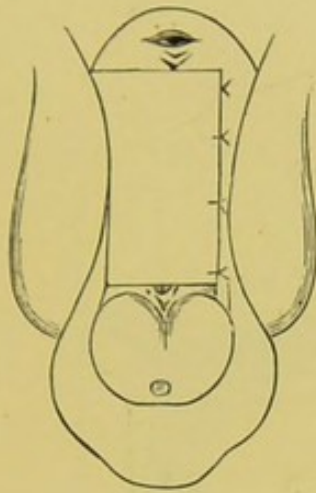


FIG. 50.

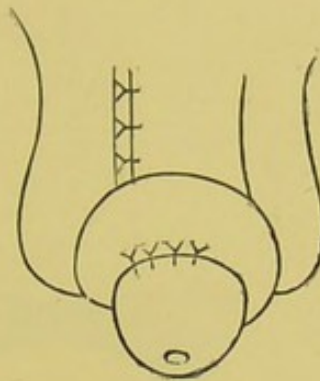


FIG. 49.—The flaps turned over and fastened by suture. The cutaneous surface of the flap (a) fig. 47, is applied towards the mucous surface. The flap (b) fig. 47, is superimposed by sliding, and both are fastened by suture in their new positions.

FIG. 50.—To close the small triangular interval between the penile and glandular part of the tube, the prepuce is split, lifted upon the dorsum, and attached above and below after suitable paring, and by another simple plastic operation a flap may be transplanted from the neighbourhood to close the aperture above, and to unite the lower margin of the flap covering the extroversion with the proximal end of the urethral tube.

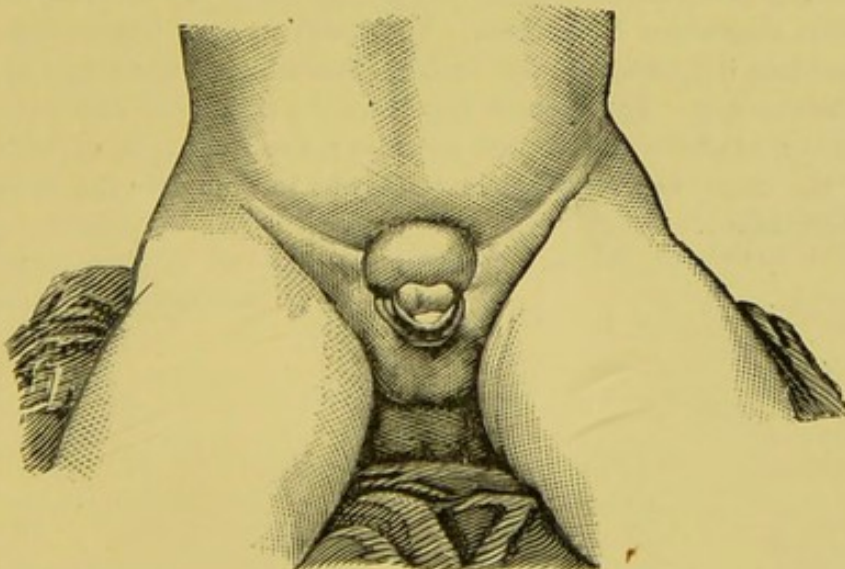


FIG. 51.—Woodcut copied from a case illustrating the usual form of *Extroversio vesicæ*.

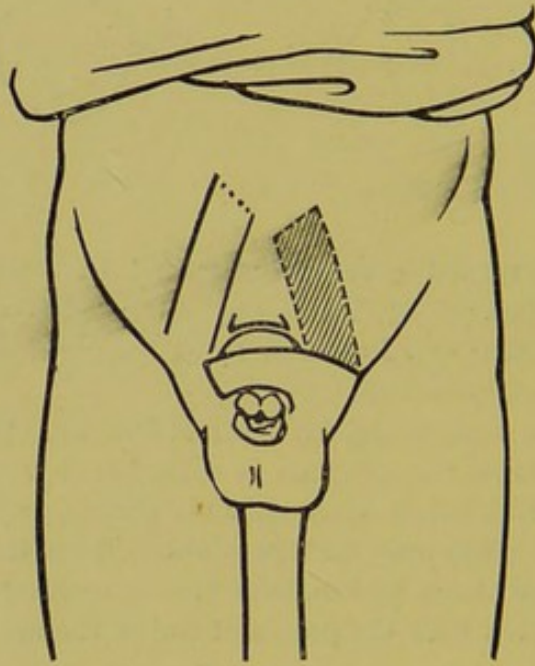


FIG. 52.—The position and outline of the flaps employed to cover the exposed mucous membrane is marked. The lower or first formed flap has been turned into its place, and the surface from which it was removed indicated by the shading. The second flap is on the right side and will presently be detached above and turned down to cover the upper exposed portion, and the small superior flap is employed to complete the closure of the bladder above.

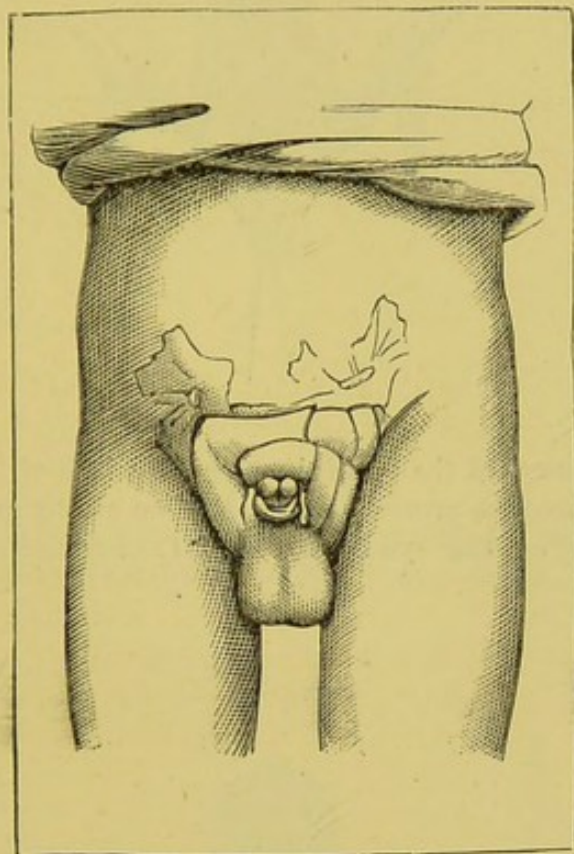


FIG. 53.—Result obtained. I hear from this patient about once a year, and he is very grateful for the relief afforded by the operation.—THIERSCH'S method of operation.



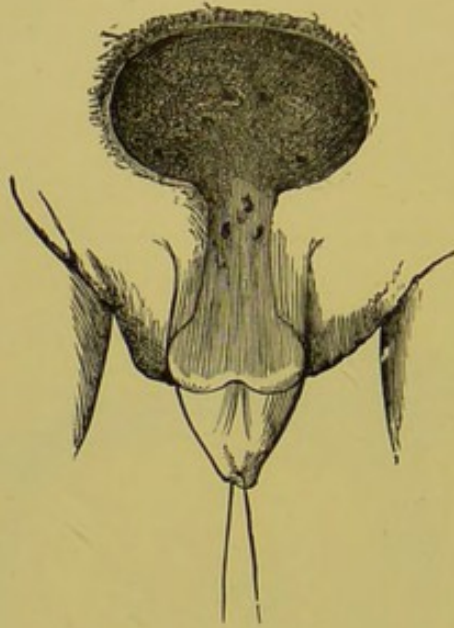


FIG. 54.—Appearances of the parts showing the width of the exposed surface of mucous membrane previous to the division of the sacro-iliac ligaments and diastasis of the synchondroses.—TRENDLENBURG'S method of operation.

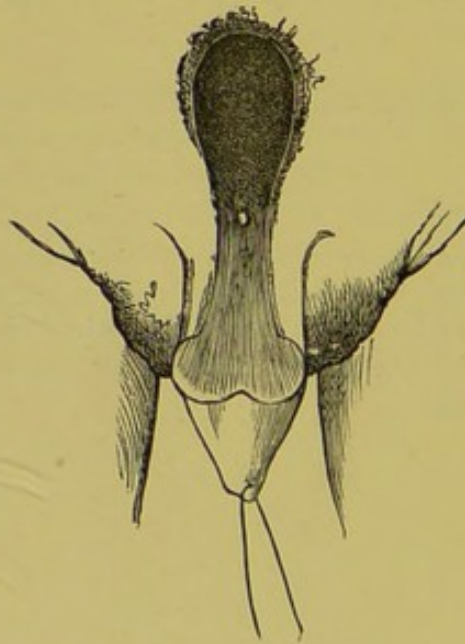


FIG. 55.—Appearance of the vesical cleft after the division of the synchondroses and consequent approximation of the pubic bones.—TRENDLENBURG'S operation, "Langenbeck's Archiv," 1886.

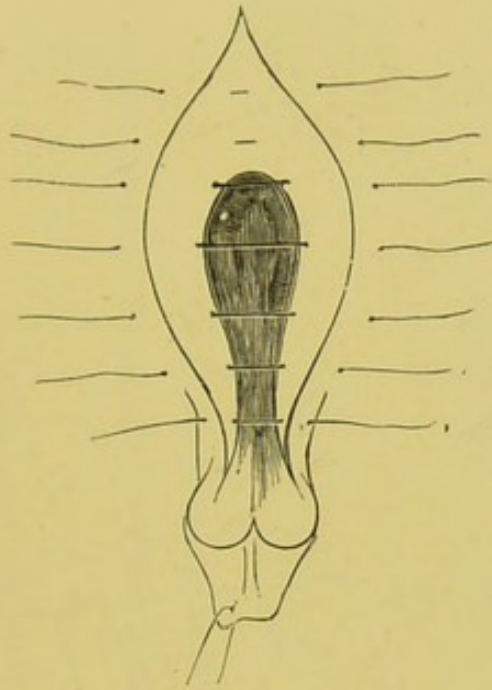


FIG. 56.—Manner in which the margins of the cleft are pared. Introduction of sutures.—TRENDELENBURG, "Lang. Archiv," 1886.

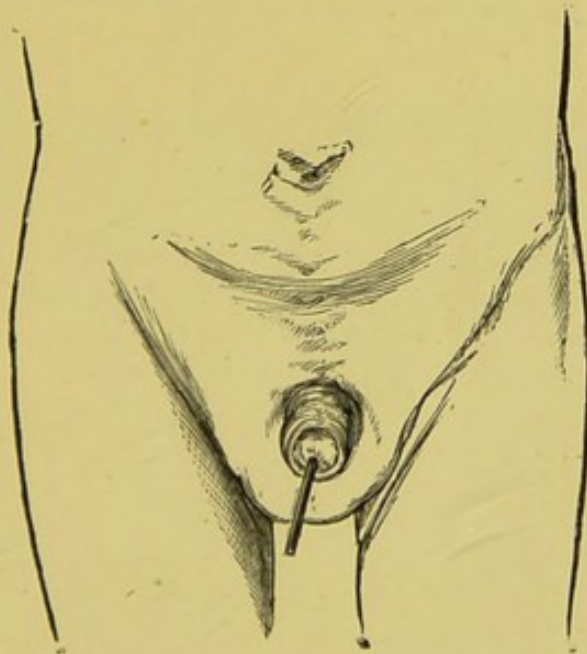


FIG. 57.—Completed operation. The margins of the cleft have firmly united in the middle line and a new urethra has been formed. All fistulae have closed.—TRENDELENBURG, "Lang. Archiv," iii. 1886.

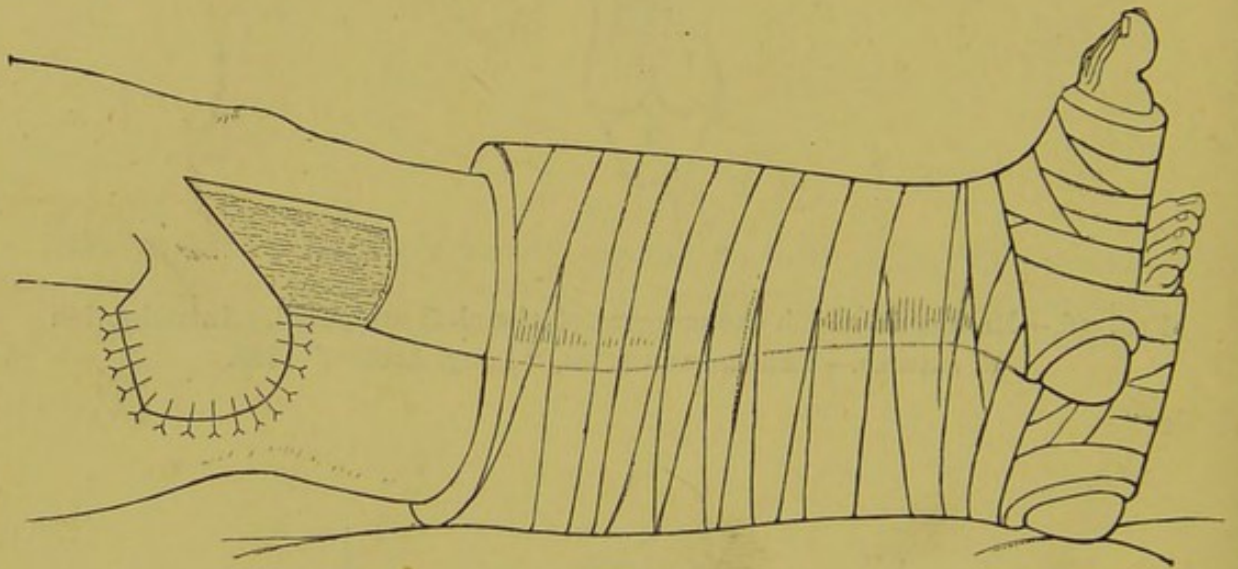


FIG. 58.—Manner of applying plaster-of-Paris bandages to immobilise the limbs for purposes of flap transplantation. Each limb is first bandaged separately, and then the two are bandaged together.