

An unreported case of primary cancer of the Fallopian tubes in 1847 : with notes on primary tubal cancer / by Alban Doran.

Contributors

Doran, Alban H. G. 1849-1927.

Renaud, F. 1819-1904.

Royal College of Surgeons of England

Publication/Creation

London : Printed by Adlard and Son, 1896.

Persistent URL

<https://wellcomecollection.org/works/mgpstcuq>

Provider

Royal College of Surgeons

License and attribution

This material has been provided by This material has been provided by The Royal College of Surgeons of England. The original may be consulted at The Royal College of Surgeons of England. where the originals may be consulted. This work has been identified as being free of known restrictions under copyright law, including all related and neighbouring rights and is being made available under the Creative Commons, Public Domain Mark.

You can copy, modify, distribute and perform the work, even for commercial purposes, without asking permission.



Wellcome Collection
183 Euston Road
London NW1 2BE UK
T +44 (0)20 7611 8722
E library@wellcomecollection.org
<https://wellcomecollection.org>

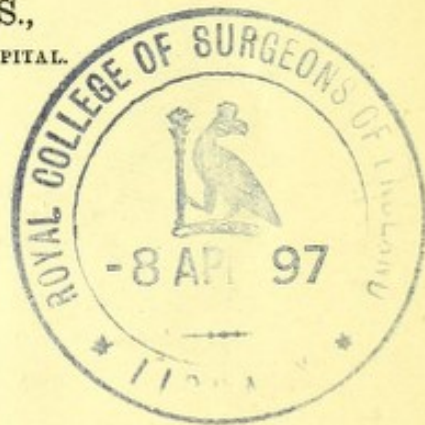
Tracts 1350.

(1)

AN UNREPORTED CASE
OF
PRIMARY CANCER OF THE FALLOPIAN
TUBES IN 1847,
WITH NOTES ON PRIMARY TUBAL CANCER.

BY
ALBAN DORAN, F.R.C.S.,
SURGEON TO THE SAMARITAN FREE HOSPITAL.

Read October 7th, 1896.




[*From Volume XXXVIII of the 'Transactions of the Obstetrical Society of London.'*]

LONDON:
PRINTED BY ADLARD AND SON,
BARTHOLOMEW CLOSE, E.C.
1896.



Digitized by the Internet Archive
in 2015

<https://archive.org/details/b22395155>



AN UNREPORTED CASE OF PRIMARY CANCER
OF THE FALLOPIAN TUBES IN 1847, WITH
NOTES ON PRIMARY TUBAL CANCER.

By ALBAN DORAN, F.R.C.S.,

SURGEON TO THE SAMARITAN FREE HOSPITAL.

(*Abstract.*)

IN a MS. atlas of pathological drawings recently presented to the library of the College of Surgeons by Dr. Renaud of Manchester, is a drawing of a case of cancer of the tubes and ovaries, dated November, 1847. The uterus was free, it appears, from malignant disease. The further history has been lost. The drawing represents the disease as far advanced in one tube, whilst the ovaries remain small. This is the condition found in primary cancer of the tubes described within the last ten years. Mr. Doran notes a source of fallacy. The large tube may be a hydrosalpinx into which cancer has extended from a relatively small ovary, as in Winter and Fabricius's cases. Orthmann has published a useful summary of cases of cancer of the tube related by the older writers of this century. Many observers, instead of analysing each case on its merits, seem to have worked with the fixed idea that cancer of the tube must always be secondary. Recent investigations by Orthmann, the author, and others tend to prove that primary cancer is more frequent in the tube than is commonly supposed.

In the course of some investigations on tubal cancer, the result of which is published in Drs. Allbutt and Playfair's 'System of Gynæcology,' my attention was turned by Dr. Cullingworth to an unrecorded case of singular interest.

Dr. Renaud, now consulting physician to the Manchester Royal Infirmary, recently presented to the library of the

Royal College of Surgeons of England a fine MS. atlas of pathological drawings in two volumes. The author's painstaking observations extend from 1837 to 1888, or over half a century. Some of the drawings were used for an instructive article in the 'Journal of Medical Science' in 1845.* The greater part of the atlas, including the original of the sketch now exhibited, remains unpublished.† The writing under the original sketch is "*Vide Case 21, p. 124: medullary cancer of right and left oviducts, also of right and left ovaries, uterus free from all ordinary evidences of malignant disease. Case, Mary Rigby, November 16th, 1847; F(rank) R(enaud).*"

In reply to inquiries last summer (1896), Dr. Renaud informed me that the case was possibly recorded in the 'London Medical Gazette' about 1847, amongst brief reports of the Manchester Pathological Society. We have both looked through several volumes of the 'Gazette,' and failed to find the desired information. There are several notes on uterine cancer in 1846-8, one of considerable length. The specimen was probably exhibited at the Society, but not reported in the 'Gazette.' Dr. Renaud remembers nothing further about the case, nor can he explain the meaning of "Case 21, p. 124." It refers to some lost MSS., and not to the newspaper above mentioned.

The first undoubtedly genuine case of primary cancer of the tube was published by Orthmann in 1888.‡ His report includes an instructive summary of cases of cancer of the tube described by older writers. Sanger and Barth,§ referring to this summary, justly remark that the accuracy of many of the older writers is problematical.

* "The Human Female Ovary with reference to Corpora Lutea, both True and False," 'London and Edinburgh Monthly Journal of Medical Science,' vol. v (1845), p. 589.

† I must thank Dr. Renaud and the President and Librarian of the College of Surgeons for permission to make this copy.

‡ "Ueber Carcinoma Tubæ," 'Zeitschrift für Geburtshülfe,' vol. xv, p. 212.

§ Martin's 'Krankheiten der Eileiter,' art. "Neubildungen," p. 252.

Renaud's case, for reasons which I have made clear, escaped the notice of Orthmann, Snger, and Barth. I agree with the opinion of the latter writers just quoted; I may point out, however, that I have examined Dr. Renaud's drawing, and am also among the few who have had an opportunity of examining thoroughly a case of primary cancer of the tube. Let it be observed that in Renaud's drawing, which gives every indication of artistic ability, the right tube is clearly dilated and filled with new growth, displayed by an orifice cut in the tubal wall. The ovaries are quite small, and almost hidden by the enlarged tubes, and Renaud reports them as cancerous. This relative proportion of tube and ovary is precisely what is seen in primary tubal cancer. We see a big tube or tubes filled with new growth, and a small ovary or ovaries healthy or becoming cancerous. In the second case ever published of primary tubal cancer, where the patient was observed so closely by Dr. Amand Routh and myself, this condition was well marked.*

On the other hand, in primary cancer of the ovary infecting the tube we see a large ovary with a small tube. The walls of the tube show deposit growing from without inwards, and its canal may be normal without dilatation. Snger and Barth figure† a typical case of this kind.

Thus the way to distinguish primary cancer of the tube is seldom difficult. A source of fallacy exists when a hydrosalpinx lies on a cancerous ovary. A few patches of malignant growth inside the tube in such a case must not mislead the observer; Klob was not deceived by this condition. Fabricius recently reported a typical case. The patient was forty; a free bloody discharge had existed for several months. This symptom is observed in primary tubal cancer. There was a small cystic cancerous tumour of the ovary, and a large hydrosalpinx which contained masses of cancerous substance floating free in its lumen.

* 'Trans. Obstet. Soc.,' vol. xxx, 1888, p. 194, 'Trans. Path. Soc.,' vol. xxxix, p. 208; vol. xl, p. 221.

† Loc. cit., fig. 53, p. 275.

This substance had entered the tube through a perforation communicating with the diseased ovary. Judging from the drawings and report in the original paper, there seemed to be no evidence of cancer of the tube itself.* Winter describes a similar case.† A hydrosalpinx lay in contact with a cancerous ovary, and a pedunculated cancerous mass projected into the cavity of the tube.

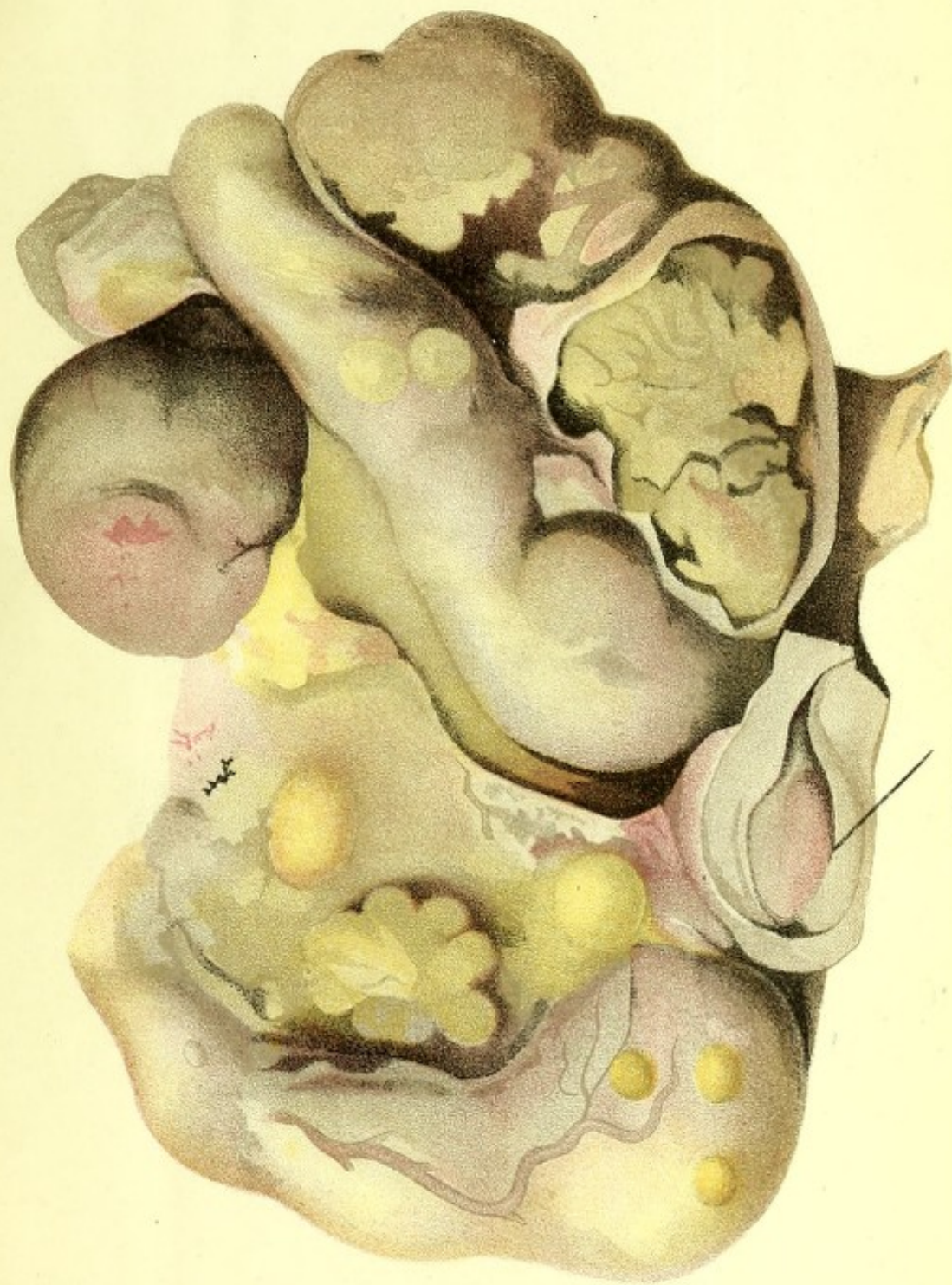I am inclined to agree with Orthmann in believing that some of the older observers did actually detect primary tubal disease, though the cases which he quotes are of little value in the absence of microscopical reports, and most of them seem rather instances of extension of cancer from the uterus. Since Orthmann wrote his report some twenty cases of primary cancer of the tube have been published, and the appearances of the disease are now no longer unfamiliar. Thus Schröder and others erred in asserting that malignant disease in the tube was never primary. Such assertions are certain to lead to error. Let it be understood that we must examine a specimen of tumour of the tube with the sole intent of getting at the truth, and not to prove that it cannot be primary or cannot be secondary. The fact remains, however, that primary disease is not unknown. The subject demands, I admit, much further investigation. I believe that in not a few cases of malignant pelvic growths, too advanced for operation or for precise pathological definition, the disease began in the tube. I refer especially to cases where the growth, though advanced, hardly rises out of the pelvis, and the uterus is free. In primary ovarian cancer the tumour usually rises high in the abdomen.

* "Perforation eines malignem Ovarialtumor in die Tube," 'Wiener klin. Wochenschrift,' vol. ix, 1896, pp. 59 and 74.

† 'Centralblatt f. Gynäkologie,' 1887, p. 497.

CANCER OF TUBES.

(After a drawing of Dr. RENAUD's, 1847).



CERVIX UTERI.

