

**On a series of cases of cancer of the mouth and fauces / by Stanley Boyd and W. H. Unwin.**

**Contributors**

Boyd, James Stanley Newton, 1856-1916.

Unwin, William Howard, 1871-1945.

Royal College of Surgeons of England

**Publication/Creation**

London : The Practitioner, 1904.

**Persistent URL**

<https://wellcomecollection.org/works/zktun3x6>

**Provider**

Royal College of Surgeons

**License and attribution**

This material has been provided by This material has been provided by The Royal College of Surgeons of England. The original may be consulted at The Royal College of Surgeons of England. where the originals may be consulted. The copyright of this item has not been evaluated. Please refer to the original publisher/creator of this item for more information. You are free to use this item in any way that is permitted by the copyright and related rights legislation that applies to your use. See [rightsstatements.org](https://rightsstatements.org) for more information.

From "THE PRACTITIONER" for March, 1904.

ON A SERIES OF CASES OF CANCER OF THE  
MOUTH AND FAUCES.

By STANLEY BOYD, M.B., F.R.C.S.,

*Surgeon to the Charing Cross Hospital, and to the Hospital for Consumption and  
Diseases of the Chest; and*


W. H. UNWIN, M.D., F.R.C.S.

*Late Demonstrator of Anatomy, Charing Cross Hospital.*



"THE PRACTITIONER," LIMITED,  
30, HOLBORN, LONDON, E.C.

L O N D O N :  
PRINTED BY EYRE AND SPOTTISWOODE,  
HIS MAJESTY'S PRINTERS,  
EAST HARDING STREET, E.C.



## ON A SERIES OF CASES OF CANCER OF THE MOUTH AND FAUCES.

By STANLEY BOYD, M.B., F.R.C.S.,

*Surgeon to the Charing Cross Hospital, and to the Hospital for Consumption and Diseases of the Chest; and*

W. H. UNWIN, M.D., F.R.C.S.,

*Late Demonstrator of Anatomy, Charing Cross Hospital.*

IN the May number, 1903, of THE PRACTITIONER, we gave an account of our cases of cancer of the tongue and its frænum during the twelve years 1891-1902 inclusive: to complete our contribution to the subject to which that number was devoted, we now record our cases of cancer occurring elsewhere in the mouth. Before doing so, however, we must note that since May, 1903, No. 24 of the tongue-cases, then regarded as free from cancer, has been found to have inoperable recurrence in the cheek.

As in our first paper, so here, we give a full account of our cases, in chronological order, in an appended table, reference to which is necessary to follow our remarks.

### EPITHELIOMA OF THE INNER SURFACE OF THE CHEEK.

In two cases (Nos. 2 and 7), both men, a considerable area in front of the wisdom-tooth was affected. Treatment consisted in dividing the skin of the cheek backwards from the angle of the mouth sufficiently to expose the whole growth, which was then excised, together with all the tissues deep to the skin. In both cases long immunity has resulted—in No. 2, four years and eight months up till July, 1903, but the amount of leucoplakia upon both cheeks indicated danger. He has not been seen since. In No. 7, three years after the first operation, an epithelioma of the lower lip appeared and increased rapidly, so that in October, 1903 (6 weeks), most of the left half of

[Continued on page 8.]



## EPITHELIOMA OF

No.	Sex.	Age.	Duration.	General Condition.	Local Condition.	Glands.
1. 1893, Nov.	F.	58	4 months slight pain in swallowing and lump inside. 3 weeks lump below jaw.	?	$\frac{3}{4}$ in. ulcer far back on right cheek adherent to toothless lower alveolus and root of coronoid process, not reaching maxilla.	"Half-walnut" mass fixed to jaw: small gland over edge of sterno-mastoid.
2. 1898, Nov.	M.	40	4 months sore mouth and white spot inside right cheek. 3 months carious right upper molar removed.	Good.	Ulcer on right cheek $1\frac{1}{2}$ in. back from angle of mouth and $\frac{3}{4}$ in. down from upper fornix; marked leucoplakia behind it; skin normal.	No note. "Some of those removed" were infected (microsc.).
3. 1899, Dec.	M.	63	2 years "wart" inside cheek. Slow growth till 6 months ago. 6 weeks lump at angle. Teeth all lost 15 years.	Good.	Growth inside left cheek from 1 in. from angle of mouth nearly to anterior pillar, adherent to coronoid process; it slightly involves hard palate and thence passes down to lower alveolus in molar region, involving inner surface of jaw more and more as it is traced back towards angle. Cheek swollen from molars down to angle of jaw near which a bit of skin is involved.	Several large submaxillary glands.
4. 1899, Dec.	F.	38	5 months soreness about left lower jaw.	Good.	Three months ago was operated on by another surgeon through a curved cut over left angle of jaw; neither bone nor glands touched. Now sinus in centre of scar; gape somewhat limited; left lower jaw toothless. Ulcer from bicuspid region up on to front of coronoid process, just involving floor of mouth, but not that of outer sulcus. Beneath unchanged mucosa of cheek, a 1 in. long oval mass continuous with ulcer and jaw.	An adherent submaxillary mass. No glands in parotid or upper carotid region.
5. 1900, July.	M.	62	? Attributed to 8 years' irritation by broken molar. Recently skin involved and burst through. One week—glands below jaw.	Losing flesh.	Cheek swollen, red, infiltrated, discharging "pus." Large mass occupies inner surface from outer surface of upper almost to lower alveolus, and from $\frac{1}{4}$ in. behind angle of mouth to edge of coronoid. Fixed to maxilla and malar (?). Total mass "half orange," $1\frac{1}{2}$ in. diameter.	No note.
6. 1900, Aug.	F.	57	2 months—lump inside. 6 weeks pain.	Fat.	No teeth. Ulcer on right lower molar alveolus, nearly reaching coronoid, involving cheek slightly behind and filling up outer sulcus; not reaching inner side of alveolus. Hardness felt through cheek.	No note.
— Dec.	—	—	1 month	—	No present state in notes	—

## GUM AND CHEEK.

Operation.	Recurrences.	Result.
Glands felt removed: large mass burst into wound. Mouth gagged open, ulcer outlined with knife and clipped out with scissors. Access unsatisfactory.	—	Lost sight of.
Kocher's cut; limb along sternomastoid prolonged down to $1\frac{1}{2}$ in.: all glands in this area removed. Cheek divided $1\frac{1}{2}$ in. back from angle of mouth: Growth circumscribed and removed with all tissues of cheek except skin. Skin and mucosa saturated, leaving $1\frac{1}{2}$ gap in latter.	—	July, 1903 ( $4\frac{3}{4}$ years). Gape normal, fine scar on cheek. Marked leucoplakia of both cheeks, especially along line of bite. On right a small firm white "wart" at one point of scar. This was removed. There was no downgrowth of epithelium: only round-celled infiltration deep to the epithelium mass.
Submaxillary cut. Submaxillary and upper carotid glands removed. Involved skin circumscribed. Lip and chin divided and left cheek reflected, except infected skin and mucosa. Left jaw sawn well in front of growth and removed by exarticulation, together with growth on cheek, alveolus, and hard palate. Some bits of bone came away later.	—	March, 1903 ( $3\frac{1}{4}$ years). In excellent health. Quite free from recurrence. Chin deviates very little and whisker conceals depression over left jaw. Mouth open fully. No notching of lip. Jan., 1904 (4 years, 1 month), quite well.
To excise sinus it was necessary to use old scar and to extend thence along lower edge of jaw, instead of using Kocher's cut. Submaxillary mass (salivary and lymph-glands matted) removed with parts of digastric, mylohyoid and periosteum of jaw: gland burst and flooded wound: sponged with 1:20 carbolic. Nothing felt in upper carotid region. Lip and chin split; cheek turned back; sinus and mass cut out; jaw removed from canine level to line from root of coronoid to angle, and then whole front of coronoid split off vertically with bone forceps. Incision noted as "very inconvenient."	In 2 months (December, 1900) recurrence began near angle of mouth and has extended to upper lip, across midline of lower and far back in cheek. Large mass beneath left sternomastoid and some on right side. Deformity due to operation marked. Chin fell over to left, scar was rather striking, lower lip centrally notched.	Inoperable recurrence; its commencement near the angle of the mouth, which was not near the primary disease, was hard to explain.
Kocher's cut. Submental, submaxillary and upper carotid glands, from digastric to thyroid cartilage removed. Growth circumscribed outside and inside—removed, being elevated from surface of maxilla. Hole left in cheek after suturing.	—	Died on 65th—"septic bronchitis." Large foetid cavity at left apex. Temperature always intermittent. Nothing found in chest on 46th.
Kocher's cut. Submaxillary and upper carotid glands removed—one of latter was large. Cheek slit back 1 in. from angle, growth outlined and removed. $\frac{1}{2}$ in. in depth of exposed alveolus and coronoid removed with forceps and chisel. Mucosa sewn together.	In $2\frac{1}{2}$ months precoronoid ulcer.	—
Ulcer removed with a bit of tongue towards which it tended; apparently no bone.	—	March, 1903 ( $2\frac{1}{4}$ years), quite well. Mouth seems to open fully. January, 1904 (3 years, 1 month), quite well.



## CANCER OF THE MOUTH AND FAUCES.

No.	Sex.	Age.	Duration.	General Condition.	Local Condition.	Glands.
7. 1900, Aug.	M.	43	6 weeks' pain.	Good.	Growth inside left cheek $1\frac{1}{2}$ in. by $1\frac{1}{4}$ in., raised $\frac{1}{2}$ in. Reaches from angle, where it involves upper lip to second molar. Neither sulcus involved.	A filbert-sized submaxillary.
— 1903, Oct.	—	—	6 weeks' growth in lower lip.	—	Rapidly growing epithelioma of lower lip. Most of left half of lip affected, but left edge of ulcer separated from old scar by $\frac{1}{2}$ in. Apparently unconnected with original growth.	—
8. 1900, Aug.	M.	60	12 weeks or less.	Strong : fat.	Ulcer ( $1\frac{1}{2}$ in. by 1 in.) inside left cheek, extending from $\frac{1}{4}$ in. from coronoid process forward to bicuspid region; upwards it rises above level of crowns of teeth, downwards obliterates sulcus, and occupies base of coronoid. Base adherent.	One left submaxillary, size of filbert.
— 1900, Feb.	—	—	—	—	Only slight separation of incisors possible. Dense cicatricial bond between jaws in molar region. Behind this, ulceration seen with dental mirror.	No note.
9. 1901, July.	M.	50	2 months' pain about lower right third molar. Tooth removed : did not heal.	Strong : fat.	Right cheek swollen. Ulcer from socket of third lower molar 1 in. up coronoid process; in on to tuberosity of maxilla and slightly on to soft palate; down and in across sulcus just on to side of tongue; out on to cheek where ulcer is deepest and seems to burrow into and under masseter.	No glands felt.
10. 1901, Nov.	M.	56	3 weeks' neuralgia in left face; difficulty in opening jaw, and sore on roof of mouth.	Very emaciated; out of all proportion to local disease.	Can separate incisors $\frac{3}{4}$ in. Ulcer on posterior end of left upper alveolar process, extending on to cheek and on to soft palate. No sign of infection of antrum.	None felt.
11. 1902, May.	M.	52	2 months' swelling inside left cheek. 3 weeks' limited movement.	Strong : fat.	Left cheek full. Gape under 1 in. Hard ulcer on left cheek, spreading on to upper alveolar process, soft palate, coronoid process.	One; left submaxillary. Fulness beneath upper end of sternomastoid. (Of these, first only infected.)

Operation.	Recurrences.	Result.
Left submaxillary region cleared. Cheek-skin divided over growth from angle of mouth backwards, skin raised. Growth with bit of upper lip and $\frac{1}{4}$ in. margin removed. Sutured, mucosa also where possible.	—	August, 1903 (3 years), quite well. Good gape, but cheek a little tight near angle.
Right submaxillary region cleared, also submental. Lip-growth removed through V-shaped incision. Glands not affected (microscope).	See next line - - -	January, 1904, quite well. No sign of recurrence of first growth (3 years, 5 months) or of second.
Kocher's cut. Submaxillary glands (3) removed. Also numerous glands deep to digastric and upper end of sternomastoid. Cheek divided from angle of mouth back to growth: ulcer outlined with $\frac{1}{4}$ in. margin, dissected from cheek, elevated from jaw and coronoid. Zinc chloride applied, wounds sutured.	In February, 1901 (6 months), neuralgia, attributed to upper molar, almost ever since operation (see next line).	—
Cheek divided along old scar to 1 in. in front of posterior edge of ramus. Ulcer found from near lower on to upper alveolus and soft palate, and from coronoid process to back of scar; and removed, muscle and fat external to it being cut away freely, the coronoid and alveolar processes being divided with a chisel. Healed well.	Recurrence - - -	Death in July 1901.
Kocher's cut. Submaxillary salivary gland removed, and lingual tied; no lymph-glands. These found to be all high up under cover of jaw adherent to growth in floor of mouth. Bidigital palpation further showed a rounded mass in posterior third of right base of tongue—from rather behind level of third molar, almost to epiglottis and quite up to midline. The surface of tongue was involved only where seen. Lip and chin divided in midline. Cheek flaps turned back. Ulcer outlined on cheek, maxilla and palate; dissected up from mandible with some temporal bone not bared by growth, but surface gouged away. A good wedge of jaw removed, having base on alveolar process (around infected third molar socket) and apex on free border. Ulcer in floor, adherent sub-maxillary glands and mass in base of tongue were cut away, the left side being freely trepanned upon. Margin none too wide at many spots. Operation over 2 hours; no shock; upon 4th.	Recurrence took place in the cheek, but date could not be fixed. It was diffuse and inoperable. Ultimately it ulcerated through a long sinus into neck and involved many cervical glands which broke down; it invaded right face up to nose and parotid glands; broke down; masseter was infiltrated to origin; right ear became deaf. The hard and soft palate, cheek, and floor of mouth became involved, and the tongue so swollen that it filled the mouth.	November, 1902. Died.
Thinking the antrum was probably invaded or that part of maxilla would have to be removed to obtain access to growth behind it, the cheek was turned back from maxilla, ulcer outlined and removed with subjacent bone and part of inferior pterygoid. Antrum opened; healthy. On 45th no recurrence; jaws becoming fixed.	—	Died August, 1902 (9 months); cause uncertain. In May he was very thin and pale, and could not separate teeth at all. Esmarch's wedge and resection of jaw $\frac{3}{4}$ in. separation possible. Marked general improvement. On return home jaws again became fixed.
Kocher's cut; submaxillary and upper carotid regions cleared (4 small glands), and glands along 11th nerve removed. Lower lip and chin split; cheek reflected; wedge removed at angle of jaw to give access, and prevent closure of jaws. Growth removed with $\frac{1}{4}$ in. to $\frac{1}{2}$ in. margin, elevated from maxilla, palate, internal pterygoid, and coronoid processes.	Inflammatory swelling of cheek lasted many weeks; small sequestrum separated and sinus healed. December, 1902, well, and seemed free from recurrence; able to eat well; bite not quite true; scar in lip too plain. March, 1903, recurrence in base of tongue, and soft palate, spreading back to naso-pharynx.	Inoperable recurrence.



## HARD AND

No.	Sex.	Age.	Duration.	General Condition.	Local Condition.	Glands.
12. 1897, June.	M.	47	4 months' painful ulcer on palate. Constant ache. No syphilis. Much tubercle on mother's side. Teeth sound.	Very strong and healthy.	On right palate opposite second and third molars; ulcers, size of sixpenny piece; base level with edge, which is not thickened or irregular. A smaller sore beginning behind this. Did not look at all like epithelioma (tubercular?)	None.
— Oct.	—	—	—	—	October 4. Half-inch ulcer opposite third molar, extending slightly on to soft palate and out on to mucosa in front of coronoid. Neither tender nor painful. Curettings from operation in June were now examined—epithelioma.	None.
— Nov. 28	—	—	—	—	—	None.
13. 1899, May.	M.	68	4 months' "sore throat."	Some loss of strength.	Ulcer size of shilling, on left soft palate, base of uvula and upper third of posterior pillar.	None felt.

## LEFT LOWER GUM AND

14. 1901, Feb	M.	57	9 weeks' loosening of left teeth.	Has been losing flesh.	Ulcerated swelling on gum from front of second lower left molar to symphysis. On right, quite distinct from above, two or three small warty ulcers on mucosa of jaw, internal to bicuspid, and an indurated mass in floor beneath sublingual fold, adherent to surrounding parts. [N.B.—We became aware of these lesions on the right side only during the operation.]	Left sub-maxillary; none along sterno-mastoid.
---------------------	----	----	-----------------------------------	------------------------	--	--

## TONSIL AND

1. 898, May	M.	63	6 months pain.	Good.	Typical ulcer (2×1 cm.) along right anterior pillar, extending on to palate and tongue slightly. Not infiltrating deeply.	A few hard upper carotid on both sides.
2. 1899, Jan.	M.	56	2 months stiffness of jaw and earache.	Good. Has lost flesh and strength.	Ulcer on right tonsil, both pillars and mucosa in front of coronoid process from maxilla to mandible.	Right upper carotid ("plum-stone") a few small and soft, along posterior edge of sterno-mastoid in upper half.

## SOFT PALATE.

Operation.	Recurrences.	Result.
Curetted; bone left bare, but smooth and hard. Iodoformed. Healed quickly.	About September 20; recurrence <i>in loco</i> .	—
Ulcer circumscribed, first and second upper molars drawn, subjacent alveolar process, lower end of pterygoid process and bit of bony palate removed with chisel and mallet. Antrum slightly opened. Normal.	The wound did not heal. In November, 1897, cocaine and excision of fragment from centre — pure epithelium and a "nest." Movement of jaw impaired.	—
Second upper bicuspid removed for access; free and deep excision.	Recurrence <i>in loco</i> ; stiffness of jaw. Extension along palato-maxillary canal and among pterygoids diagnosed; temporary resection or removal of maxilla, to obtain access, suggested.	Recurrence; further operation declined; death.
All affected parts cut away freely - - -	—	Lost sight of.

## RIGHT FLOOR OF MOUTH.

Left Kocher's cut. Submental and submaxillary region cleared, also upper carotid. Several apparently healthy glands beneath sternomastoid removed. Mesial division of lip and chin, reflection of left cheek to masseter; jaw sawn behind and to right of epitheloid and removed after division of mylohyoid and mucosa. Growth on right side now found and removed; mucosa on inner side of jaw being elevated with the small ulcers. But it had extended into sockets of bicuspid teeth; these were freely gouged to avoid complete resection of arch.	—	May, 1901. Doing well. No recurrence. Left ramus markedly flexed, but not causing inconvenience. Portion of chin left not much displaced. Gape $1\frac{1}{2}$ in. March, 1903. Letter of enquiry returned marked "Deceased."
--	---	--

## FAUCES.

Cut from below ear to cricoid: fat and glands stripped upwards from vessels and well outside them—some enlarged glands beneath digastric. Right cheek split from angle to masseter. Growth excised cleanly with $\frac{1}{4}$ in. margin—outside red area on tongue and palate—and removed with superior constrictor and tissue outside it. Recovery and healing good.	December, 1898. Recurrence in glands on right side of neck; removed January, 1899. August, 1899. Large inoperable recurrence in glands of left anterior and posterior triangles.	Inoperable recurrence. Died December 23, 1899. P.M. No growth found other than that in left anterior and posterior triangles, involving the great vessels.
Kocher's cut and extension along sternomastoid: complete clearing of submaxillary, subparotid (2 large glands), upper carotid regions, of carotid sheath down to cricoid (3 or 4 small glands) and of posterior triangle, along 11th nerve (3 or 4 small). Right ramus of jaw removed. Growth cut away freely, including the tonsil with both pillars, neighbouring mucosa, and much of both pterygoids; almost whole wound gauze-drained.	—	Death on 10th day: cause? Did well up to 8th, on which night he became delirious and refused food. On 9th temp. $97^{\circ}$ , pulse 104, respiration 22. Some discharge bagging in front of submaxillary wound. P.M. Removal complete: viscera normal. Brain oedematous: many arachnoid adhesions.



No.	Sex.	Age.	Duration.	General Condition.	Local Condition.	Glands.
3. 1899, Feb.	M.	56	10 weeks difficulty in swallowing: sore throat; slight earache. Thin patient.	Good. Some loss of flesh.	Ulcer of right half of soft palate, uvula, anterior pillar, mucosa over lower jaw behind last molar.	One large right sub-maxillary gland.
4. 1899, May.	M.	52	2 months lump in neck. 6 weeks slight pain in swallowing.	Emaciated.	Mouth normal. Glottis normal. Epiglottis drawn to left; puriform fluid seen, and a hard edge felt on its left side.	Hard mass below left angle of jaw, adherent to deep structures, including ala of thyroid cartilage near superior cornu.

the lip was affected, but the left edge of the ulcer was still separated from the scar of the first operation by  $\frac{1}{8}$ th inch. The lip-growth appeared to be unconnected with the original cheek-growth. In both these cases the cheek-scar was but little visible, and the gape was surprisingly good.

In one case, No. 5, the epithelioma had been allowed to perforate the skin, and to form a mass in the cheek, of the size of half a small orange, fixed above to bone. As it seemed possible to remove all disease and to close the gap later by a plastic operation, excision was done, the patient dying in 65 days of septic bronchitis. During 36 hours previous to operation this patient's temperature varied between 98·8 and 99·4; but nothing amiss was found in his lungs then or as late as the 46th day.

In two women (Nos. 1 and 6) the cheek and lower alveolar process were involved. No. 1 was much the more serious of the two as regards both local and glandular disease. The primary growth was removed with scissors through the gagged-open mouth—a most unsatisfactory method—and the gland-operation was much too limited. She has not been traced. In No. 6 a fairly wide gland-operation was performed, and



Operation.	Recurrences.	Result.
Kocher's cut. Submaxillary and upper carotid regions cleared. Cheek split to masseter: most of palate, anterior pillar, mucosa on jaw behind last molar (drawn), and bit of tongue hard by were removed. [It was noted that mouth could not be fully opened under C.H.Cl <sub>2</sub> (from unrecognised infiltration of muscles?); lighting and access were unsatisfactory.]	In March, 1899 (1 month), a small recurrence over coronoid process was removed and bone deep to it was nibbled away. In May, 1899 (3 months), a similar recurrence, with inability to separate jaws: cheek split again, ulcer removed, bone deep to it chiselled and cut away with forceps.	Recurrence in fauces and neck. Death on March 9, 1900.
Long cut down sternomastoid and another forwards to midline below hyoid: triangular flaps reflected. These were removed: glands over parotid; large gland-mass and superjacent parotid, large adherent piece of sternomastoid, and long piece of internal jugular. Also glands along 11th nerve. Pharynx opened by transverse cut through middle constrictor. Notes state only that part of left pharyngeal wall, great cornu of hyoid, and upper part of left ala of thyroid cartilage with thyrohyoid membrane were removed. Pharynx closed: neck-wound closed above, gauze-drained below. Little shock: all seemed well on 5th.	—	Death on 5th from asphyxia from inspired blood. P.M. Internal carotid had burst at root: coats very thin and transparent round the hole. No trace of growth except perhaps at a spot outside arytaeno-epiglottid fold. Much inspired blood in lungs.

access was obtained to the primary growth by splitting the cheek. Within three months she was thought to have a slight recurrence, but this seems doubtful; there is no microscopic note, and the operation performed would probably have been unsuccessful. She remains (three years) in excellent health, and the deformity of the scar is slight. The gape is good, the vertical involvement of the cheek having been limited.

In No. 8, a man, the local condition was probably very similar to that in the first of the two preceding cases (No. 1), whilst infection of glands was apparently less serious, and was dealt with by a Kocher's operation. Removal of the primary growth was effected through the split cheek, a rugine being used to detach it from the alveolar and coronoid processes to which its base adhered. After six months it was found that the teeth could only just be separated—a result very different from that noted in the preceding cases, in which the epithelioma lay entirely in front of the last molar. A history of persistent "neuralgia" roused grave suspicions of recurrence, and with a dental mirror an ulcer could be obscurely seen behind a short vertical cicatricial band which held the jaws together. A free

removal of the recurrence, coupled, this time, with a chiselling off of the surfaces of the coronoid alveolar processes, resulted in further failure and ultimate death.

The next posterior cheek-case (No. 11) which came under treatment was rendered graver than the last by swelling of the cheek and extension to the upper gum, the soft palate, and the mucosa over the coronoid process. After the usual Kocher's gland-operation, access to the primary growth was obtained by splitting the lip and chin in the midline, and turning back the cheek and submaxillary flaps. To anticipate cicatricial stenosis and increase access, a wedge of jaw was removed from the angle (primary Esmarch's operation), its apex being formed by the coronoid process where it was covered by the epithelioma. The ulcer was then clipped out with a good margin, the rugine being used to separate its base from the maxilla and hamular process. Some of the temporal tendon was involved, and was removed. Great swelling of the cheek resulted from this operation and persisted for many weeks, slowly subsiding. After seven months all seemed satisfactory ; but three months later a rapidly-spreading and inoperable local recurrence was present.

The last case of this group (No. 10) probably began about the tuberosity of the left upper jaw. When seen, after only three weeks' suffering, he was so thin and ill-looking as to raise the suspicion of advanced malignant disease. His friends said he always looked "like that." Only an ulcer of moderate size, spreading on to the cheek and soft palate from the tuberosity of the maxilla as a centre, was found. Thinking it probable that the antrum was invaded and that limitation of movement of the mandible ( $\frac{3}{4}$ -inch gape) was due to infiltration of muscles behind the maxilla, access to the growth was obtained in this case by reflection of the cheek from the maxilla ; no deep extension of the disease was found, and it was thought at the time that a better view would have been obtained, and greater facility for working behind the maxilla afforded, by reflection of the cheek from the lower rather than from the upper jaw. As the wound healed, the jaw became fixed ; but until six months had passed without obvious recurrence, it was thought undesirable to



yield to the man's earnest entreaty for an Esmarch's operation. After this, he improved markedly for a short time; then the jaw again became fixed, and he died at home—presumably of recurrence.

We turn back now to a case (No. 3), which occurred in 1899, of such distribution and extent as to require removal of the angle and ramus of the mandible. There can be no question as to the freedom of access which this affords; but we cannot base any conclusion upon the satisfactory result in this one case, especially as the history seems to point to a more chronic form of cancer than was present in Nos. 7 and 10. A "wart" had appeared on the inner surface of the cheek two years earlier, and had grown slowly for 18 months, more rapidly for the last 6 months, the skin at the angle of the jaw becoming infiltrated during the last 6 weeks. When seen, an epithelioma extended from one inch behind the angle of the mouth nearly to the anterior faucial pillar, and from the edge of the hard palate posteriorly down to the lower alveolus in the molar region; thence it passed downwards and backwards adhering more and more closely to the inner surface of the mandible, and infiltrated the skin just beyond its angle. The submaxillary glands were markedly affected. A submaxillary incision was planned to circumscribe the involved skin and to allow removal of the submaxillary and upper carotid glands. Then the lower lip and chin were divided in the midline and the cheek was reflected, so as to leave the growth behind. The jaw was sawn in front of the point at which the growth came into contact with it, and the ramus was removed by disarticulation with the whole growth adherent to it. In March, 1903, (3½ years) this patient was in excellent health and free from obvious recurrence. There was no median notch in the lower lip; the chin deviated but little; the depression over the left angle was concealed by whisker, and the mouth opened fully. He said that he had been at home three months before he discovered that he had lost a piece of his jaw! This absence of marked deformity seems to be exceptional after removal of the ramus, and our experience is insufficient to enable us to explain it in this instance.



In January, 1904 (4 years, 1 month), this patient reported himself as being quite well.

Perhaps this is the best place to refer to the case of a woman (No. 4) with recurrent disease of which the exact primary seat is unknown to us. We think it may have been the cheek low down and far back. She had been operated upon by another surgeon through a curved incision round the angle of the jaw, no bone or glands (apparently) being removed. She had, when seen 3 months later, a sinus in the centre of the scar. An ulcer occupied the left lower alveolus from the bicuspid region to well up on the coronoid process; it just involved the floor of the mouth, but the floor of the sulcus outside escaped. Beneath the normal mucosa here, however, was an almond-sized mass attached to the jaw. A considerable submaxillary mass adhered to the jaw. This patient was most anxious to avoid deformity, and was with difficulty persuaded to allow any operation. It was clearly necessary to excise the sinus, and this, together with the presence of a very obvious scar, obliged us to use the line of the old incision, and to prolong it forwards along the edges of the jaw to the midline—in the position of the old-fashioned incision for excision of half the mandible. It was exceedingly awkward for a submaxillary gland operation, and the upper carotid region was not cleared. It was hoped that the lower edge of the mandible might be saved: so the adherent submaxillary mass was separated from the bone with a rugine. It brought away the periosteum with it and burst, flooding the wound with its contents; 5-per-cent. carbolic, the strongest antiseptic at hand, was used to wipe out the wound. It was now plain that the whole depth of the mandible must be sacrificed. To this end the cheek-skin was raised from the submucous mass, and the bone sawn in front of the disease, an endeavour being made to avoid splitting the lip and chin; but without doing this it was impossible to deal satisfactorily with the floor of the mouth. So ultimately the cheek was turned back, the jaw was again divided through the angle, and the anterior half of the coronoid process with its temporal fibres was split off with bone-forceps and removed. As usual, the patient suffered for placing restrictions upon the freedom of the surgeon. Every step which would have been



taken had there been no request to consider was enforced by the conditions found, and was taken—too late to be of full advantage to the patient—after a good deal of work had been done in the dark. Recurrence was early and at a spot difficult to account for, viz., in the lower lip near the angle, where an indurated sinus, half an inch long, formed and whence extension in all directions occurred. Possibly the sinus was longer than a probe seemed to indicate, and really started from the wounded area.

It is difficult to group these cases ; but we have one more (No. 9) which seems to have its closest affinities with cancers starting far back in the cheek. After two months' treatment with lotions for a sore and pain about the right lower wisdom-tooth, the tooth was removed ; and as the pain continued and the socket did not heal, further treatment was sought. The right cheek was greatly swollen, and on its inner surface, far back, was a deep ulcer, which seemed to burrow beneath the masseter. It spread across the jaw into the socket of the last molar, across floor of mouth, and just on to the side of tongue, upwards and backwards for an inch along the coronoid process, and thence inwards on to the tuberosity of the maxilla and slightly on to the palate. No glands were felt, but the patient was fat. Examination under anæsthesia during the operation revealed a mass of disease in the base of the tongue, which, had it been discovered earlier, would probably have turned the balance against any operation. This being the case, it will be sufficient to refer to the table for details, and to note here only that inoperable recurrence was the result, followed by death in 17 months.

We have now dealt with 10 primary cases of epithelioma originating, or seeming to originate, on the inner surface of the cheek. The two last are open to considerable doubt in this respect. Seven occurred in men and three in women. The average age was 52, the extremes being 38 (F.) and 63. All were operated upon : one died of septic broncho-pneumonia ; four remain free from recurrence at 4 years and 8 months, 4 years and 1 month, 3 years and 1 month, and 3 years and 5 months. Of these the first has not been heard of since July, 1903, to which time the above period is reckoned, and the



last returned 3 years after the first operation with an epithelioma of the lower lip, apparently quite unconnected with his original cheek-growth. He is now (January, 1904) free from further recurrence. In one, the result is unknown, but recurrence seems highly probable; in four there was inoperable recurrence. One of these was almost, if not quite, unsuitable for operation. On the other hand only one of the four cases remaining sound was an extensive posterior case.

In two the anterior part of the cheek was alone affected, and it would seem from the result that in such the removal of the submaxillary and upper carotid glands (from beneath the digastric down to the bifurcation), together with the free removal of the growth through a wound in the skin of the cheek, will be satisfactory both as regards life and function.

In the remaining eight cases the posterior part of the cheek, opposite to and behind the molar teeth, was the seat of disease. In all some parts other than the cheek were involved. A free gland-operation is of course essential, and it would seem that the removal of the submaxillary and upper carotid glands down to the level of the bifurcation of the carotid is sufficient, when no glands or only submaxillary glands can be felt enlarged. With regard to the removal of the primary growth in this region, attempts to do so through the mouth (one case) may be condemned as most unsatisfactory. Splitting the cheek back to the masseter improves access, but is not wholly satisfactory even in a simple case, such as No. 6; and where the growth is believed to infiltrate the structures beneath its base (*e.g.*, coronoid, masseter, temporal), we think it is decidedly better to divide the lip and chin in the midline and to turn the cheek freely back. It is true that this sometimes, and in spite of perfect apposition and alignment of parts, leaves a central notch in the lip and an obvious skin-scar (No. 4); but a long cut through the cheek may also be very deforming. It will probably be wise, therefore, to reflect the cheek and thus obtain good access to even apparently slight epitheliomata situated in the region of the coronoid process. This operation allows satisfactory removal of any bone with which the growth may come into close relation, and it is well to excise the bone and growth in one piece. When extension of the growth to



the floor of the mouth, tongue, or fauces requires it, it is easy to divide the jaw at any point which will afford convenient access by dragging the gap open ; or to remove a part or the whole of the ramus, either on account of involvement or to obtain a clearer view. Whenever it is fairly certain that cicatricial closure of the jaws will result from the operation and the jaw has to be divided, it seems to us an advantage to remove at once such a wedge as will ensure permanent mobility of the jaw : for, thus, access is certainly improved and the patient does not go through a period of inability to masticate with resulting discontent and loss of flesh and strength. If, however, it is not necessary to divide the jaw for access, we are doubtful whether an Esmarch's operation should be done at the time of the primary operation, with the object of warding off cicatricial closure, as it seems to us that the probability of septic necrosis of the cut surfaces of the jaw is greater at this time than later, when the mouth has healed. On the other hand, we are of opinion that, when necessary, excision of a wedge of jaw in front of the scar should not be too long withheld—until, for example, the surgeon is satisfied that early recurrence will not take place. In one case (No. 10) we adopted this course to the great dissatisfaction and, as we believe, detriment of the patient. The operation, done with a chain or Gigli's saw, is a slight one, and may well be performed without regard to recurrence.

In addition to the ten primary cases, there was one in whom the growth was recurrent when first seen. In her case treatment was somewhat hampered by restrictions, and the result was inoperable recurrence.

#### HARD PALATE.

We must next refer shortly to single cases, fully stated in the table. No. 12 began as a small, constantly-painful ulcer on the hard palate in the immediate neighbourhood of the posterior palatine canal. Its appearance was very unlike that of an epithelioma, which the microscope again and again showed it to be. There was never, whilst under our observation, much to be seen in the mouth ; but after fairly wide removals of what was visible, the recurrences appeared at a spot which seemed to indicate that the new growth had

penetrated deeply along the posterior palatine canal. The probability of extension in this direction was recognised, and two attempts were made to get above it. More could not have been done, working through the gagged-open mouth; so the case suggests that in November, if not in October, permission to obtain freer access to the region behind the maxilla should have been sought. This patient wandered about seeing many first-rate surgeons: some declined to believe in the epithelioma, and he took their advice. In March, 1898, he wrote that the "place" felt healed, but his jaw was fixed. He wasted steadily and died some months later.

#### SOFT PALATE.

We have had one case (No. 13) of epithelioma of the soft palate, which was freely excised. The man cannot be traced.

#### GUM AND FLOOR OF MOUTH.

The chief point of interest about No. 14 is that two distinct epitheliomata were present in the mouth. The man came complaining of a sore upon the left side of his mouth, which was recognised as a fairly extensive epithelioma of the left lower alveolar margin, and an operation for its removal was undertaken. Late in the progress of this, an epithelioma of the right floor of the mouth was found, extending into the sockets of the lower bicuspid. This extension was not very thoroughly treated. Enquiry about this patient has enabled us to discover only that, two years after the operation, he was dead.

#### THE FAUCES.

In four cases an epithelioma affected the fauces, or the region included between the soft palate and the arytaeno-epiglottic fold, above and below, and between the anterior and posterior pillars of the fauces from before backwards. The extent of the primary and of the glandular growths varied as shown in the table. No. 1 was apparently slight in both respects, though he gave a longer history (six months) of trouble than any of the others. In Nos. 2 and 3, especially the former, both primary and glandular growths were serious; and



in No. 4 a small primary growth outside the arytaeno-epiglottic fold had given rise to a very serious gland-mass which involved the sternomastoid and vessels. In all cases a free gland-operation was done, special attention being paid to the glands deep to the parotid and digastric, to those along the jugular vein, at least as low as the cricoid, and to those along the spinal accessory nerve. The primary growth was approached twice (Nos. 1 and 3) through the split cheek, and in No. 3 it was specially noted that both lighting and access were unsatisfactory. In No. 2 good access was obtained by removal of the ramus of the jaw; and in No. 4 the low situation of the growth required the removal from the neck-wound of part of the side-wall of the pharynx, together with the great cornu of the hyoid and the upper part of the left ala of the thyroid cartilage.

The results have been extremely discouraging. Two patients (Nos. 2 and 4) died directly from the operation. In No. 2 even the post-mortem examination did not make clear the cause of death; presumably it was some form of septicæmia. No. 4 died on the fifth day from rupture of the internal carotid at its root, where it was somewhat dilated, and its coats around the perforation were very thin. It is noted that "the common, external, and internal carotids were closely cleaned in part;" probably the cleaning was too close at the point of rupture, though some inclined to the view that sponging of the wound with strong chloride-of-zinc solution was responsible. Early and inoperable recurrence followed in No. 3. In No. 1 there is some reason to hope that the primary growth was eradicated, as it did not recur in the  $1\frac{3}{4}$  years which the man lived after its removal. Possibly the infection of glands on the same side as the primary growth had been successfully dealt with, as there was no further recurrence in 11 months. Infection of the left glands was not anticipated: the recurrence was inoperable when first seen.

With regard to the question of access to the primary growth, if this be situate upon the tonsil or palatine arches, our small experience would lead us entirely to distrust removal through the split cheek, and to prefer division of the jaw in front of the ramus followed by separation of the fragments; and, should there still be insufficient room for free work under guidance of sight, more or less of the ramus should be



excised. When thus opened up, the region is one in which it is possible to remove a good deal of tissue without trenching too closely on the more or less essential vessels and nerves. This will be evident upon reference to Fig. 1, drawn from a subject in which the right half of the mandible had been removed, and to Fig. 2, a horizontal section at the level of the teeth, after a drawing in Cunningham's *Text-book of Anatomy*.

When the primary growth lies low in the region under consideration, it can be readily dealt with through the side-wall of the pharynx below the jaw.

That the operation upon glands must be free is obvious. In the case of tonsillar and palatine cancers the upper carotid

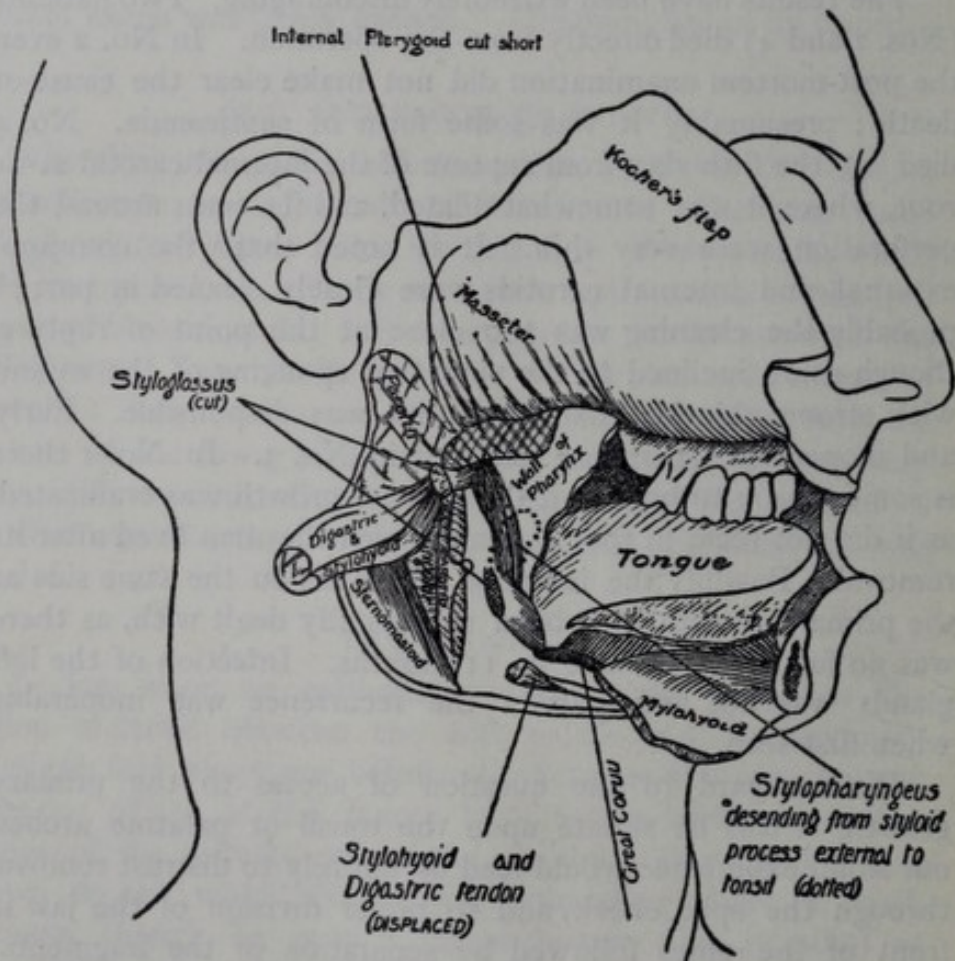


Fig. 1.

glands, deep to the digastric, are probably the first to be infected, and then those lower along the great vessels and those passing back along the spinal accessory into the posterior

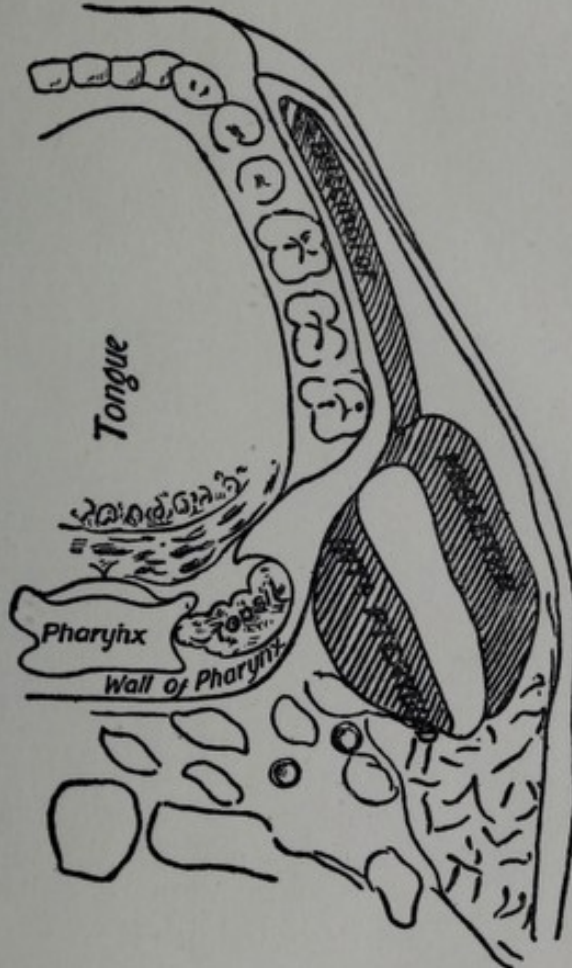


Fig. 2.

triangle. Case No. 3, however, shows that the submaxillary group may not be neglected.

