

Cases of deformity of various kinds, successfully treated by plastic operations / by Thomas D. Mütter.

Contributors

Mütter, Thomas Dent, 1811-1859.
Royal College of Surgeons of England

Publication/Creation

Philadelphia : Merrihew and Thompson, printers, 1844.

Persistent URL

<https://wellcomecollection.org/works/mng7dekz>

Provider

Royal College of Surgeons

License and attribution

This material has been provided by This material has been provided by The Royal College of Surgeons of England. The original may be consulted at The Royal College of Surgeons of England. where the originals may be consulted. This work has been identified as being free of known restrictions under copyright law, including all related and neighbouring rights and is being made available under the Creative Commons, Public Domain Mark.

You can copy, modify, distribute and perform the work, even for commercial purposes, without asking permission.

Fig. 1.



Fig. 2.

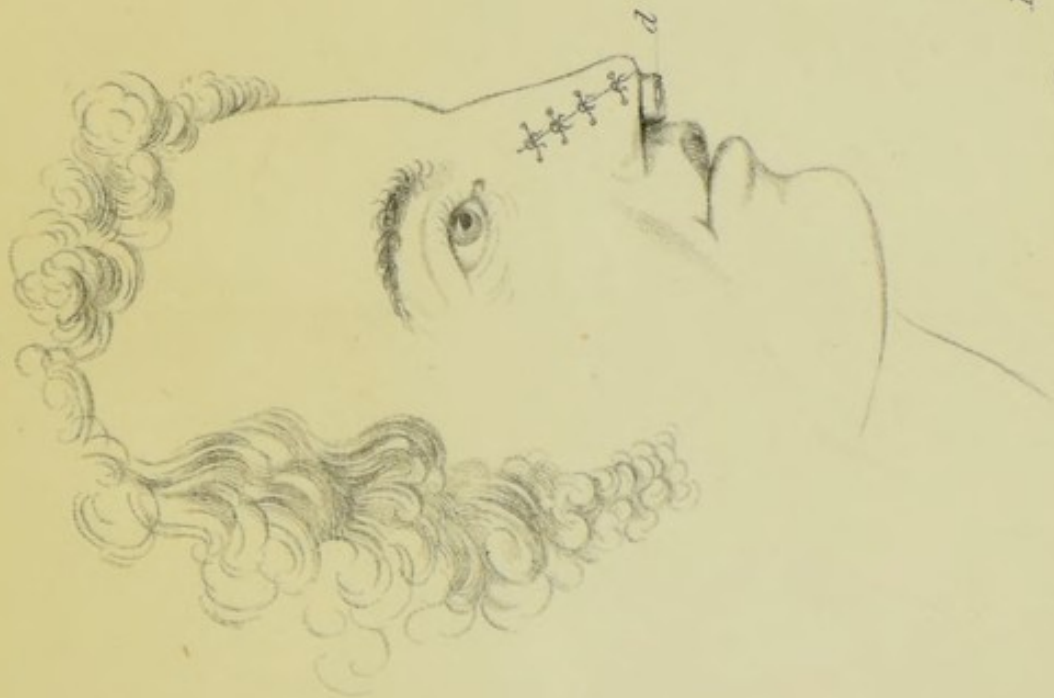

Fig. 3.



Fig. 4.





Digitized by the Internet Archive
in 2015

<https://archive.org/details/b22386634>

Fig. 2.

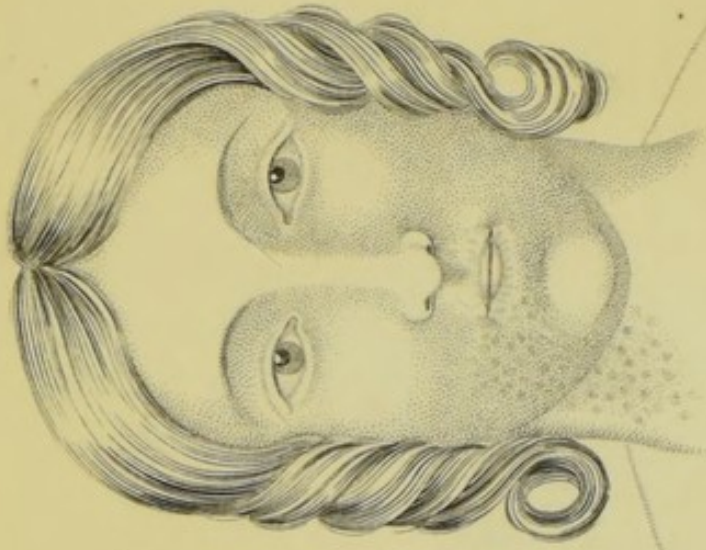


Fig. 1.

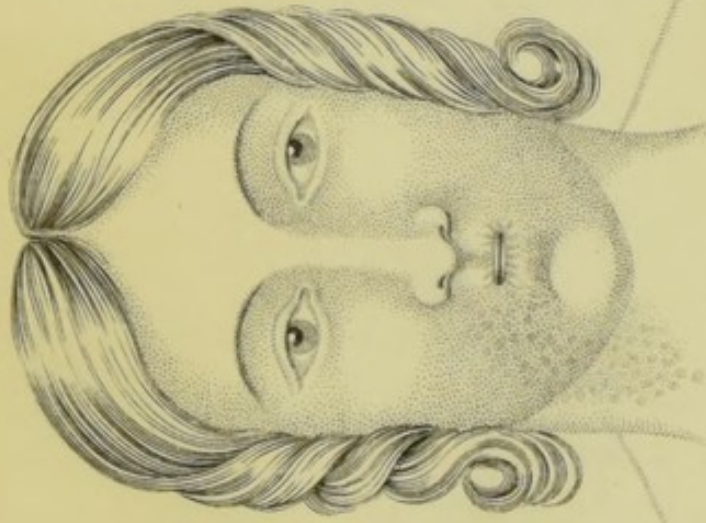

Fig. 1.



50. 14.

C A S E S

OF

DEFORMITY OF VARIOUS KINDS,

SUCCESSFULLY TREATED


BY

PLASTIC OPERATIONS.

BY

THOMAS D. MÜTTER, M.D.,

PROFESSOR OF SURGERY IN JEFFERSON MEDICAL COLLEGE, PHYSICIAN TO THE
INSITUATION FOR THE DEAF AND DUMB, PHILADELPHIA; CORRESPONDING
MEMBER OF THE "NATIONAL INSTITUTE," AT WASHINGTON; COR-
RESPONDING MEMBER OF THE NEW YORK MEDICAL SOCIETY;
HONORARY MEMBER OF THE PHILADELPHIA MEDICAL
SOCIETY; FELLOW OF THE COLLEGE OF PHYSI-
CIANS, PHILADELPHIA; MEMBER OF THE
ACADEMY OF NATURAL SCIENCES,
PHILADELPHIA, &c. &c.



PHILADELPHIA:

MERRIHEW AND THOMPSON, PRINTERS,
No. 7 Carter's Alley.

.....
1844.

MEMORIALS OF VARIOUS CASES

SUCCESSFULLY TREATED

BY THE

PLASTIC OPERATIONS

BY J. B. M. M. D.

OF THE

OF THE

OF THE

OF THE

OF THE

RHINOPLASTIC OPERATION.

ABOUT the 1st of October, 1837, I was requested by Professor Jackson to visit, in consultation, a gentleman from the South, who had had the misfortune to lose a considerable portion of the right half of his nose.

Without entering into a history of the case, which would have but little bearing upon the operation to be described, I shall proceed at once to state the character of the deformity, and the means employed to accomplish its cure.

Upon reference to *Pl. I., Fig. 1*, it will be seen that the whole of the right ala, as well as the adjacent soft parts, as high up as the os nasum of the same side, are wanting. As a consequence of this loss, an opening half an inch in its *perpendicular* diameter, and about three-quarters of an inch in its *transverse*, at the widest part, and of the shape represented in the sketch, was established. The margins of this opening were thin and callous, while the neighbouring tissues, to the distance of two or three lines, were much paler and firmer than natural, owing to the deposit of lymph, during the period of inflammation to which they had recently been subjected.

The septum nasi, the os nasi, and the Schneiderian membrane were perfectly sound. The face was rather full, and

its integuments healthy, with here and there a small cicatrice, the result of previous local inflammation.

As the deformity was striking, and as the deficiency of nostril on one side modified the voice, so as to render it rather disagreeable, the patient determined to submit to any operation that promised success. His general health, though delicate for some years past, is at the present moment excellent; while his age, (28,) and temperament, (sanguine,) rendered our prognosis, respecting the results of an operation, very favourable.

Upon an attentive examination of the deformity, it was determined to attempt its relief by an operation differing essentially from those proposed by the surgeons who have devoted their attention particularly to the autoplasmic department of surgery. The details of this operation I shall now present. It was performed on the 6th of October, at 12 o'clock, in the presence of Drs. Jackson, T. Harris, J. Randolph, J. R. Barton, P. B. Goddard, and Langley.

The patient was seated with the organ to be operated upon exposed to a good light, while his head was slightly thrown back, and supported by Dr. Randolph. Seating myself in front, I commenced the operation by making, with a small sized convex edged bistoury, an incision extending from a few lines above the *superior* border of the orifice, to a short distance *below* its inferior, and directed *downwards* and *outwards*. (See *Pl. I., Fig. 1, a.*) It did not penetrate to the bone, but was sufficiently profound to allow a flap about *three* lines in thickness to be readily detached. Upon reference to the plate, it will be found that this incision was completely on the *outside* of the cicatrice, a portion of which was subsequently removed in order to prevent its hardened edges from irritating the raw surface of the flap, which was to be placed immediately upon it.

One or two small arteries were cut across, but the hemorrhage from them was arrested by pressure, until the *second* incision was made. This commenced at the *terminal* extremity of the first, *and extended horizontally outwards*

about an inch. (See *Pl. I., Fig. 1, b.*) A *triangular* flap was thus marked out, and immediately detached from the subjacent bone, by dissecting with the edge of the knife held nearly parallel to the surface of the cheek. In the execution of this part of the operation, two or three arteries of some size were necessarily cut across, and required the application of the ligature.

The *third* incision, which extended from the *initial* extremity of the *first* to the point of the nose, (See *Pl. I., Fig. 1, c.*) was made with a pair of strong straight scissors, these being preferred to the scalpel, in consequence of this margin of the orifice being, to a certain extent, loose and unsupported. The triangular piece of cicatrice included between the superior extremities of the first and third incisions, was then removed with the scalpel and forceps; and the sharp margin of the inferior portion of the opening also pared off, for reasons already stated.

The hemorrhage having been arrested, and the parts properly sponged, the next step of the operation was undertaken. This consisted in the approximation of the first and third incisions, and the application of such measures as were calculated to retain the flap in its proper position. From the free dissection, and the yielding character of the subcutaneous cellular tissue of the cheek, no difficulty was experienced in placing the edges in contact; and in order to insure their perfect and close approximation, *four* stitches of the *interrupted* suture made with saddlers' silk, waxed and doubled, were passed, (see *Pl. I., Fig. 2.*) In addition, two or three small adhesive strips were applied to the spaces between the sutures.

Finally, in order to prevent adhesion between the *flap* and raw surface beneath it, and to give a better shape to the former, a small roll of soft lint, well oiled, was introduced into the *new nostril.* (See *Pl. I., Fig. 2, d.*)

The patient bore the operation, which was necessarily tedious and painful, with remarkable firmness. He was ordered tinct. opii. gtt. xxx.: to be kept perfectly quiet, and to lie

with his *head elevated*. The temperature of the room to be 50° Fahrenheit.

October 6th, afternoon. Four hours after the operation we paid our patient a visit, and found, with much satisfaction, that he had passed a very comfortable time. The temperature of the flap was a little *above* that of the rest of the body, but this increase of temperature was not accompanied by *pain*. The pulse was a little excited, but the reaction could scarcely be considered *febrile*. Strict injunctions were left with the assistants relative to the *position* of the patient during the night.

7th. Passed a good night; complains of a little *stiffness* and *soreness* in the parts. The flap was still somewhat *warmer* than natural, though its *colour* was not deepened. Slight oozing of a bloody serum from the lower part of the wound; pulse natural; tongue coated with *white*; bowels costive; slight thirst and anorexia; ordered ol. ricini ℥j., to be followed, if necessary, by a laxative injection: *diet*, iced lemonade, barley water, or tea and toast; room to be kept *quiet* and *cool*, and in case of fever's occurring, spts. ether nit. ℥j., to be given in a little cool sweetened water.

8th. Slept well; flap more painful, and slightly erysipelalous; discharge of bloody serum more copious; pulse *natural*; tongue cleaner; appetite better, and less thirst; medicine had operated freely; ordered the flap to be bathed with tepid mucilage of medul. sassafras; diet, &c., the same as yesterday.

9th. Pretty much as yesterday; flap still slightly erysipelalous, but *less painful*; continue same treatment.

10th. At 12 to-day, in the presence of the consulting surgeons, the dressings were removed; *union by the first intention* has taken place throughout, and is sufficiently firm to bear the removal of the sutures; granulations have sprouted from the lower margin of the flap, and extend some lines below the tip of the nose. Healthy pus was discharged in considerable quantity upon the removal of the plug from the nostril; flap appears much as it did at the previous visit;

tongue clean; bowels open; no thirst; pulse natural; reapplied adhesive strips and plug; ordered poultice of cort. ulm. americ. to the nose; diet, &c., as before.

11th. Slept well; flap wears a much more healthy aspect, slight inflammation, however, still remains; discharge of pus from beneath the dressings; no *pain* or *stiffness* in the parts; pulse natural; secretions normal, &c.; continue same treatment. The antiphlogistic system was pursued for the period of two weeks, the treatment varying only in some minor points from day to day. During this period, the ligatures of the arteries were discharged, one of them ulcerating through the flap, but it occasioned no inconvenience of any kind. About the commencement of the *third* week, it was determined to remove the granulations from the lower margin of the flap, and at the same time give it a proper curve. This was accordingly done, by means of a pair of strong curved scissors.

In consequence of the contraction of the flap, the septum nasi was caused to incline to one side, which deformity was made very evident by the removal of the granulations.

In order to remedy this, the *line of union between the base of the flap and the cheek* was divided, cutting from within with a small scalpel held parallel to the surface of the cheek, to the extent of three or four lines.

The plug was then increased in size, and introduced into the nostril, while a wide adhesive strip was carried from the tip of the nose across the cheek on the sound side, and attached just in front of the ear, in order to incline the septum in this direction as much as possible.

No bad consequences resulted from this operation, and the antiphlogistic system, to a certain extent, was still pursued for a couple of weeks longer. The patient's diet, however, had been somewhat improved, and he had also been allowed to move about the house. The use of the strap across the cheek was discontinued, in consequence of its invariably producing irritation of the skin. It moreover exerted but little influence in straightening the septum. The plug, during

this period, had been gradually increased in size, with the view of *distending* the nostril, as well as to give it a proper "*set*," and the granulations within, which were very luxuriant, touched twice a day with a weak solution of the nit. argent. or creosote, and occasionally with solid caustic; at the end of the sixth week from the day of the first operation, it was determined to execute the "third step" in the treatment. This consisted in the division of the skin and cellular tissue at the base of the flap in a *semi-circular* direction, the convexity of the curve looking outwards. The object of this incision was to give the peculiar rounded margin of an original ala; to diminish the fulness of the cheek where the natural depression should exist, which depression had of necessity been destroyed by the tension of the flap, and to permit a return to the perpendicular position of the deviated septum nasi. The incision was made with a small scalpel, and extended to the depth of three lines. In order to prevent union of its margins, a small roll of oiled lint was introduced into the cut, and a strip of adhesive plaster applied to the tip of the nose, and fastened on the cheek of the sound side. (See *Pl. I., Fig. 3, a*, for shape of incision.) The patient was ordered to confine himself to his room, and to reduce his diet.

On the third day the dressings were removed, and it was found that the margins of the incision were nearly cicatrized and beautifully rounded off.

The same dressing was reapplied, and the plug intended for both incision and nostril increased in diameter. No change of importance was made in the dressing, or in the subsequent general treatment, except that the patient was allowed to return to a more generous diet, and to take exercise in the open air. At the expiration of the eighth week, the nose presented the appearance exhibited in *Pl. I., Fig. 3*. The contraction of the granulations had caused the margin of the flap to be rounded off, and the cicatrice resulting from the union of the first and third incisions, which was originally located nearly upon the dorsum nasi, to descend nearly to the cheek. This

has occurred, which may not be until after a week or two, the slip is again raised by incision, and cut off close to the adherent flap. The wound in the ridge of the nose is then united by suture."—*Practical Surgery*, p. 233. London: 1837.

It is evident that in all these plans, a wound of greater or less extent must be made in the *cheek* or *forehead*, the cicatrice of which gives rise to considerable deformity. But in addition to the inevitable occurrence of deformity, another objection of much moment presents itself against the *first* and *last*.

Every one familiar with operations is aware, that when a part is *twisted*, or caused to deviate from its *natural* direction, to such an extent as to occasion an *impediment* to a *free circulation* of blood through it, *gangrene* is *very often*, though *not invariably*, the result. Hence the great difficulty in the rhinoplastic operations, where a flap is taken from the forehead or cheek, and *torsion* resorted to.

In the operation I have performed, both of these difficulties are done away with. There is no *scar* on the face, or at most one scarcely perceptible, and no *torsion* of the flap being required, union by the *first intention* is almost "a thing of certainty." The free supply of blood to the flap is also another circumstance in its favour.

Such is the laxity of the cellular tissue of the cheek, that no difficulty whatever is experienced in the approximation of the parts. The only *objection* to this operation is, that unless the *incisions* are carried *outwards* sufficiently far, the subsequent *contraction* of the flap may cause a deviation of the septum nasi; but this can scarcely be termed an *objection*, inasmuch as it is always subject to remedy.

It is, I am aware, *unsafe*, if not *unwise*, to attempt the establishment of an operation as a "*standard*," upon the successful termination of a *single* trial; but so clear is the *principle*, so *simple each step*, and so *satisfactory* the *termination* of the one in whose favour I am enlisted, that I think I may with perfect security recommend it to the favourable notice of the profession.

The objection to taking a flap from the *cheek*, as advised by Mr. Liston, is the production of a *scar* of some magnitude.

One or two interesting physiological points connected with autoplasmic operations in general, and which are still "matters of dispute," deserve a passing notice.

It is stated by Lisfranc, Blandin, and others, that in all cases of "Autoplasty," there exists, for some weeks after the operation, a *perversion of sensibility* in the flap; or, in other words, that an impression made upon the flap (such as the prick of a pin, for example,) is not referred by the patient to the point of its reception, but to the part from which the flap has been removed. Dieffenbach contends that this is altogether a mistake, and remarks that, "in all his experience (which has been most ample,) nothing of the kind has ever been met with." Liston and others state, that "perversion of sensibility is not by any means so common an occurrence as many assert," though it may occasionally happen. In the case just recorded, there certainly did exist, for a few days only, however, something like it; for example, a fly resting upon the *nose*, caused the patient to brush his cheek, &c. But here the nervous communication between the parts was so *direct* and *extensive*, that we are at no loss to account for the phenomenon.

Another statement made by most writers upon the subject is, that when the flap has been taken from a part naturally covered with hair, the hair-bulbs in the transplanted parts, either dry up, or secrete a very *fine, silky, and light coloured down*, altogether different from the original hair. *Jobert* denies this assertion, and says that the hair, though somewhat lighter in colour, nevertheless continues to grow as luxuriantly as before.

In my case, the flap extended into the bearded portion of the upper lip, and *two months* after the operation, this beard *continued to grow*; whether or not it has since disappeared I am unable to say.

In all cases of successful rhinoplasty, the granulating sur-

latter change was a very favourable circumstance, as it produced a depression in the exact spot at which it was required, in order to give a proper expression to the face. Had it not taken place, there would have remained *a sort of inclined plane* from the bridge of the nose to the outer portion of the cheek. At the expiration of the ninth week, my patient returned home with scarcely a vestige of his deformity remaining. There existed a slight deviation of the septum, but this was perceptible only on close examination, and in all probability will gradually diminish as the tissues of the cheek regain their original elasticity. There was also a slight discharge of mucus and pus from the nostril, owing to a few of the granulations being still uncicatrized.

The nostril itself is perfectly open, and its orifice nearly of the shape of its fellow.

The flap presents the usual colour of the skin of the face, and is so firm that the patient unhesitatingly made use of it in the ordinary operation of cleansing the emunctory. In short, as was remarked by one of the attendants, "so perfect is the cure, that no one would ever imagine that an operation had been performed upon the organ." The voice is also rendered natural.

Remarks. By those familiar with the divisions of modern "*Autoplasty*," the operation just detailed will readily be recognised as belonging to that in which the loss of original tissue is supplied by *sliding a portion of neighbouring integuments over the deformity, (operation par glissement du lambeau.)* For the *principle*, the profession is indebted to Celsus.

In cases similar to that of my patient, there cannot be a doubt of the vast superiority of this operation over all others hitherto performed, and the wonder is, that it has never, so far as I am able to learn, been earlier resorted to. Dieffenbach, Graëfe, Labat, Dupuytren, Blandin, Liston, and every other authority, ancient as well as modern, that I have consulted, make no mention of such an operation for *such a case*. The *principle*, it is true, has been applied to other cases of

deformity; for example, a fistula of the male urethra was cured by Alliot, by "*sliding* a portion of sound skin over the opening, and then uniting it by sutures to the surrounding parts." Chopart, Roux, Roux de Saint Maximin, Lisfranc, Velpeau, Blandin, and others, have also made use of it in a variety of cases, but more especially in ulcers of the *cheek* or *lips*.

The mode of relieving the deformity created by the loss of one ala nasi, has heretofore consisted in the section of a flap from the cheek, the *pedicle* of which rests on the *margin* of the *wound*. *Torsion* is resorted to, and the *flap* attached to the septum, &c., by suture or strap. Another plan, practised especially by *Liston*, and the English generally, has recently been published. This consists in the section of a flap of the form represented in *Pl. I., Fig. 4*; and is altogether a better operation than the one usually performed. There is here no *twisting* of the pedicle; "The coaptation of the flap is consequently more exact, the supply of blood more free, and the vitality of the part less endangered."

A, Form of flap on cheek; B, the slip of attachment. It is evident that by simply bringing A into a straight line with B, the flap may be placed in apposition, without any twisting of the attachment; the acute angle between the two being entirely removed by the change.

Another operation for this deformity, where the cheek is *spare* and *shrunk*, has been successfully performed by Liston. The flap is taken from the forehead.

"This is done," observes Mr. Liston, "in the same way as for restoration of the whole nose; but a variation is expedient when the organ is of unusual length. Then the long and narrow connecting slip, if treated in the ordinary way, would be so indifferently nourished, and so ill supported, that the vitality of the transplanted part would be endangered. To obviate this, a deep incision is made along the ridge of the nose, continuous with the wound in the forehead, at that side to which the twist is to be made. This longitudinal incision is, by a little dissection with the point of the knife, widened sufficiently to contain the connecting slip from the forehead; and, into the groove so formed, the slip is laid and retained, until firm union of the whole flap has taken place. When this

He then attempted to dilate it, by first making an incision of about six lines in length, extending from each angle of the mouth, in an outward and nearly horizontal direction, and afterwards introducing the tents to prevent the lips of the wounds from uniting. This appeared at first to be productive of some good, but in a short time they cicatrized and contracted, and the patient remained in as uncomfortable a condition as before.

Finding himself foiled in both attempts, he determined to visit Philadelphia for the purpose of consultation. She was accordingly brought on, and became a patient of mine. When I first saw her nearly a year had elapsed since the occurrence of the accident. Her appearance at this time was very singular. Firm and dense cicatrices nearly surrounded the mouth, but were most marked on the lower lip, and about the angles; while the orifice of this cavity was barely large enough to admit the point of the finger, and presented an oval form. The cicatrices of the incisions made by her father, were also very apparent at each angle. (See *fig. 1.*) Her general health was perfect, and it was only on account of the deformity and difficulty of taking food that the operation was requested. Her speech was not much affected, although some of the labial sounds were imperfectly pronounced. The lining membrane of the mouth was perfectly normal.

From the history of the case, I concluded at once that it would be utterly useless to attempt a cure by the repetition of the measures already employed, and which are the ones usually had recourse to. I therefore proposed the operation recently devised for such cases by the celebrated Dieffenbach, and, her father consenting, it was accordingly performed on the 28th of November, 1836.

The patient was seated in a low chair, with her head supported by her father, and exposed to a good light. Following the directions of Dieffenbach, I then introduced the extremity of the fore finger of my left hand into the mouth, and placed it under the left labial angle, which, by this means, was ren-

dered prominent and sufficiently firm to permit the second step of the operation to be readily executed.

This is accomplished by the introduction of one blade of a pair of narrow, straight scissors into the substance of the cheek, between the mucous membrane and the other tissues, and a little above the commissure. The blade is then slowly pushed from before backwards, separating as it passes along the mucous membrane from the muscles and integuments until its point reaches the spot at which we wish to locate the new angle of the lips; the blades are then closed, and the parts included between them cut squarely and smoothly at a single stroke. The first incision being completed, the scissors were withdrawn, and a second one, parallel and similar to the first, made in the lower lip; the distance between the two being about three lines. These incisions were then united at their posterior termination by a small crescentic section.

By these cuts, it is evident that a small strip of muscle and integument was insulated from the surrounding parts, and it only remained to separate it from the buccal mucous membrane, which was easily done by a single stroke of the scissors.

The second step of the operation being thus finished on the left side, similar incisions were performed on the right.

Looking at the lines traced out in *fig. 1*, which shew the course of the incisions on each side, it will be seen that two wounds, each about three lines wide and six long, the floors of which were formed by the mucous membrane of the mouth, had been made. The next steps of the operation, and by far the most difficult of the whole, were the division into equal portions of the mucous membranes, the eversion of the flaps, and their attachment to the edges of the incisions just made, as well as to the red pellicle of each margin of the lips.

To divide the membrane equally, I separated the jaws of the child as much as possible, by which measure the former was put upon the stretch, and kept sufficiently firm to bear

face of the flap becomes in time converted into *mucous membrane*, and enjoys to a certain extent the function of this membrane in an original organ; the *sensibility* is not, however, as acute; in my case, this change has been fully accomplished. Within the last few days I have received a most gratifying letter from my patient, a brief extract from which I introduce; it bears date four months after the operation.

“Dear Sir,—After a very pleasant trip in fine weather, and some intentional delay on the road, I arrived home in safety about a fortnight since. I suffered no injury from travelling. Since my arrival, I am pleased to say to you, that the wound on my face has *entirely* healed, both *inside* and *outside* the new formed ala. The new skin, internally, is *entirely sound* and *healthy*, and all swelling has subsided. The scar on the face is hardly observable, and the adjacent parts have accommodated themselves, as well as I could expect, under all the circumstances, to the altered condition of the nose and cheek. The nostril appears natural, but not quite large enough; and there seems to be a disposition in the part still farther to contract, though I hope it may eventually be overcome.”

“N. B. My general health is very good, and I am as actively engaged in business as ever.”

I have no doubt whatever, but that in course of a few months, all “*tendency to contraction*” will be overcome.

STOMATOPLASTIC OPERATION.

THE following interesting case came under my charge the latter part of November, 1836. The individual affected was the daughter of a highly respectable practitioner of medicine residing in South Carolina, and, at the time the accident productive of the deformity occurred, about 11 years of age. Her general health has always been perfect, though her temperament is a strongly marked lymphatic.

In the commencement of the winter of 1835, while at play with her companions, she was by some means or other thrust against a heated stove, by which her hands, arms, neck, and the lower part of her face, were severely burned.

Her wounds were treated in a most judicious manner by her father; but, in spite of all his efforts, those about the mouth cicatrized with so much contraction, that the entrance into this cavity was almost obliterated. As soon as the tenderness of the part was somewhat diminished, he commenced a course of treatment calculated to restore this orifice to its natural size. He first began by introducing sponge tents, which were allowed fully to distend themselves; but, after repeated attempts with them, by which he caused the child much suffering, without materially benefitting her, they were abandoned.

the operation of the scissors. The incisions in the membrane did not extend so far as those made in the muscles and skin, but stopped about three lines from the union of the latter. This was done in order to make the outer portion of this tissue adapt itself accurately to the new commissure. The flaps were then brought out, reflected over the margins of the wounds, and firmly attached to them by means of the twisted suture, the needles used being very short and fine. (It should be recollected that the membrane must be first attached to the commissure, by which measure we secure the proper adaptation of the flaps to the other parts.)

Every thing having been properly adjusted, a common roller bandage was applied, as in cases of fracture of the lower jaw, in order to prevent any derangement of the wounds. The patient was then placed in bed with her head elevated, and, as she had, just before the operation, eaten freely of some light food, ordered to take no nourishment of any kind until the next visit, and to be perfectly silent.

Nov. 29th. Passed a good night; slept well; no fever; and complains of no pain; parts merely a little sore; needles all in place; writes that she is hungry. Ordered thin oat meal gruel as diet, which, as well as her drink, is to be given with a small teaspoon.

30th. Quite as well as yesterday; every thing in place; bowels costive. Ordered an injection of white soap and water; diet as before.

31st. Complains of stiffness in the wounds, but no pain; dressings all secure; injection had operated well; pulse natural. Ordered chicken soup for diet.

Dec. 1st. The bandage was removed, and the first dressing commenced. The sutures, which had been closely bound down to the parts by blood, were carefully softened with warm water and cut away. As soon as they were removed, and the parts properly dried, the most gratifying exhibition of the success of the operation was afforded. On both sides, union between the everted mucous membrane and the margins of

the wounds had taken place nearly throughout, and the *new lips* presented an appearance almost natural. Some of the needles were then removed, but as there appeared to be a feebleness in the adhesion at some points, the needles passing through them were allowed to remain, and a thread cast loosely around them. The bandage around the head was also reapplied.

2d. Second dressing, parts all firm and healthy; the remaining needles were now removed, and the bandage only reapplied, which was done to prevent talking; no pain in the part, and the patient in fine spirits. Ordered bowels to be opened with an injection, and the diet to be more nutritious, but still liquid.

Nothing remarkable occurred in the subsequent treatment. All dressings were taken off on the 15th inst., and the child allowed to pursue her ordinary course of life. The mouth presented a very good appearance, though the lips were somewhat thinner than natural, and there was some difficulty in bringing them into close contact, especially at the central portions. I have no doubt, however, but that this defect will soon disappear. (*Fig. 2* represents her eight weeks after the operation.)

Remarks. The annals of modern surgery hardly afford an example of more ingenuity than is exhibited in the design of the operation just detailed. Dieffenbach, whose fame as a rhinoplastic surgeon is just beginning to be appreciated in this country, and whose skill and success fully justify the eulogiums which are now bestowed upon him, having been foiled in several attempts made to relieve cases similar to the above, at last hit upon the beautiful expedient illustrated by the operation. The great difficulty, in all such cases, arises from the constant tendency to contraction manifested by the cicatrice, which occasionally goes on to such an extent that the orifice of the mouth is almost closed. At the first examination of such a deformity, the remedy which seems to promise most success is mechanical dilatation. Unfortunately,

this is productive of but temporary relief, and has never, I believe, effected a permanent cure. Next to this method, comes incision of the commissures. We might naturally expect such a course to be sufficient to effect the end desired, and, in all probability, this would be the case, could we by any means prevent reunion of the edges of our incisions. But this, it would appear from the statements of the best authorities, has hitherto been impossible; for, notwithstanding the introduction of tents, leaves of sheet lead, cerate cloths, &c., between the lips of the wounds, their adhesion, more or less complete, is sure to take place.

The primary indications in the treatment of such cases, then, are, 1st, the division of the commissures; and, 2d, the application of some measure by which the margins of the incisions may be made to cicatrize separately. Aware of the difficulties attendant upon the fulfilment of these indications, it occurred to Dieffenbach that if we could cover these margins with a tissue which would not readily unite with itself, a cure would be accomplished. He accordingly performed the operation which I have just described, and his success was such as to lead to his repetition of it in several cases, in all of which the most happy results were obtained. There can be no doubt relative to the value of this new process, as it is applicable to almost every case of contraction of the natural openings, either congenital or acquired. It is moreover safe, and but slightly painful. The whole operation, when performed on the mouth, may be accomplished in ten or fifteen minutes, and there is little or no hæmorrhage to be apprehended, for the branches of the coronary arteries which are divided are so small that they contract of their own accord, and do not require the ligature.

There is one case, however, in which it would not in all probability succeed, viz. when the buccal mucous membrane itself participates in the lesion. But this complication must be of very rare occurrence, as the injury, in almost every instance, is confined to the outer surface of the surrounding

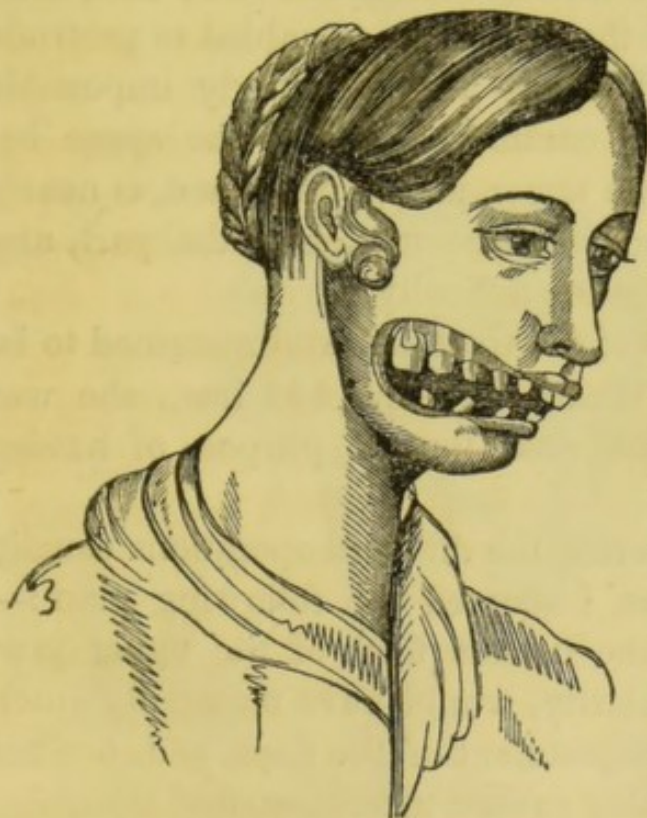
parts. In conclusion, I may remark, that although this is the only case that has come under my immediate observation, the success attending the operation has been such as to lead me to recommend its performance in every instance in which the mucous membrane surrounding the orifice is in a sound condition.

Philadelphia, May, 1837.

EXTENSIVE MELOPLASTIC OPERATION.

IN the month of March, 1842, A. T——, aged 30, of Clearfield county, Pennsylvania, applied to me for the relief of a distressing deformity, occasioned by the abuse of mercury. About six years before I saw her, she had been most severely salivated for a bilious fever; and in consequence of ulceration attacking the right cheek, nearly the whole of this portion of the face was destroyed.

Fig. 1.



The extensive loss of substance is well represented in fig. 1. To conceal the deformity, she has been in the habit of keeping her face "tied up" in a handkerchief; consequently, but little motion being allowed the lower jaw, this partial rest of the organ persevered in for more than six years, has produced a permanent contraction of the masseter muscles on each side, so that scarcely any motion exists in the tempero-max-

illary articulations, and it is impossible to introduce any substance more than the sixteenth of an inch in thickness between the upper and lower jaw. Her speech is of course very much impaired, and all her food is reduced to the smallest possible

bulk, or taken in the shape of liquids. Her general health is excellent.

The first indication in such a case was obviously, to obtain as much motion in the articulations of the lower jaw as possible; and this could only be accomplished by increasing the space between the maxillary bones. To accomplish this, it was deemed best to divide the masseter muscles, (the entire muscle on the left, and what remained of it on the right side,) and then separate the bones by a lever of some kind. Accordingly, on the first Wednesday in March, that being the regular clinical day at the College, she was brought before the class, and the operation performed with a common scalpel, the muscles being divided from *within*, and the edge of the knife carried obliquely downwards and outwards. The wounds were dressed with dry lint, and, on the second day, the lever of Heister was employed to separate the jaws. Each day the screw was turned a thread or two; and, after the lapse of two weeks, the patient was enabled to protrude her tongue without difficulty,—a thing utterly impossible when the treatment was commenced,—and the space between the teeth, when the lower jaw is depressed, is nearly an inch. She has, of course, free motion in the part, and chews her food without much difficulty.

The most difficult part of the treatment still remained to be accomplished; and on Wednesday, the 23d inst., she was again brought before the class, for the purpose of having this put into execution.

After carefully considering the different operations usually performed in such cases, I adopted the following plan:—Having first extracted the useless teeth of the upper jaw, which, from their irregularity, would have materially interfered with the proper adjustment of the flaps, and, besides, by their sharpness, possibly caused ulceration and sloughing of the tissues forced against them, I proceeded to detach the integuments by which the opening in the cheek was surrounded. The edge of the scalpel was directed towards the bone, and the incisions carried sufficiently far to allow the

margins of the wound to be approximated to a considerable degree. This callous margin, formed of the "inodular tissue," was then carefully pared off with a bistoury, in order

Fig. 2:

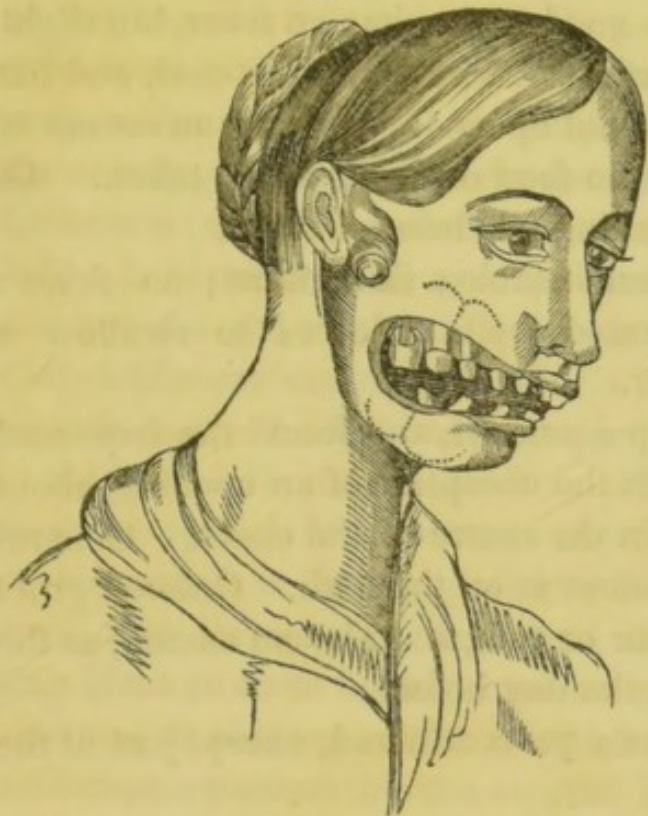
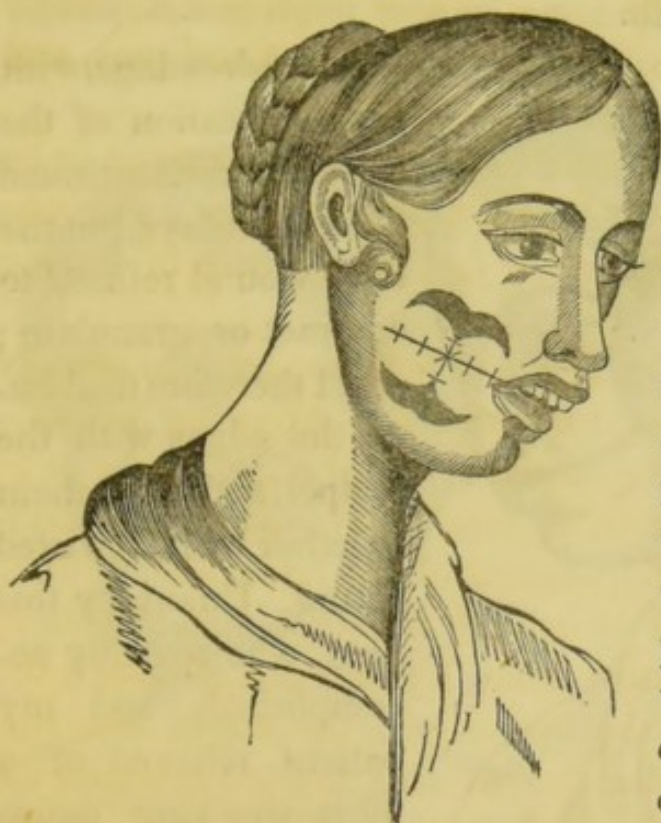


Fig. 3.



to obtain, if possible, union by the "first intention" between the edges of the flaps. An effort was then made to close the wound by sliding the detached integuments, from all sides, towards the centre, but they refused to yield, and it became necessary to make the incisions indicated by the dotted lines in fig. 2. By these incisions, *four flaps* were formed, and detaching them carefully from the subjacent parts, we found no difficulty in uniting them at a line which indicated the longest diameter of the opening. The twisted suture was employed, and the wound presented, after their introduction, the appearance exhibited in fig. 3. To support the whole, one or two straps were passed over the points upon which there was most strain, and over all a thin pledget of patent lint was laid.

and the patient placed in bed. The hemorrhage was comparatively trifling, but few arteries requiring the ligature; and the operation, though painful and tedious, was borne by the patient without a murmur.

24th. Patient passed a good night; has no fever, but slight headache, and warm surface. The wound is cool, and but slightly tumified; bowels not opened. Ordered an enema of salt and water, &c., and no food or drink to be taken. Of course no attempt at speaking has been allowed.

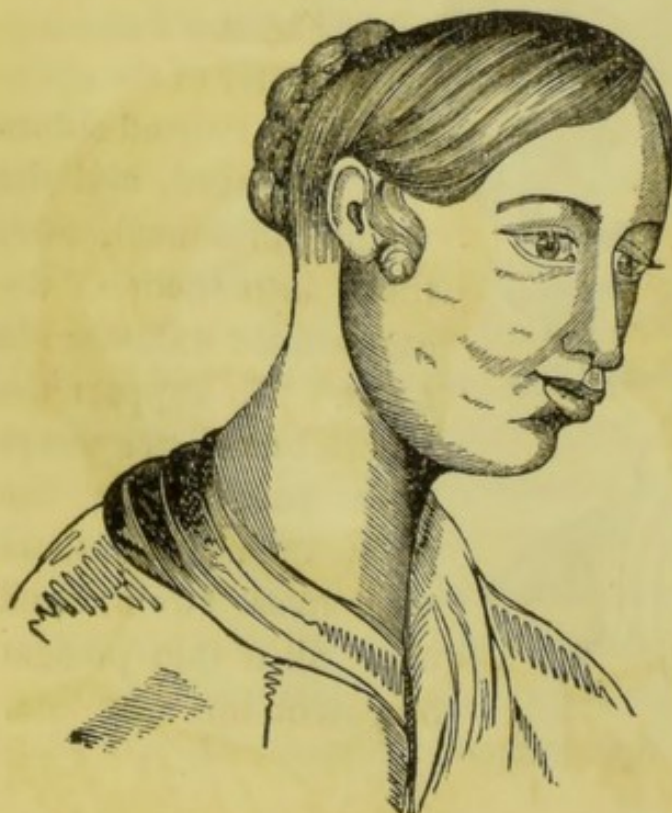25th. Patient more comfortable; skin moist; no fever: thirst; enema had operated well; allowed to swallow a mouthful or two of water.

26th. Removed the top dressings, and found the flaps cool and united perfectly, with the exception of an opening, about the size of a small shot, in the centre of the cheek. General condition of the patient same as on the 25th. Ordered gruel and cool water every hour or two, and also an enema, as the bowels were not opened the day before.

28th. Removed needles; parts adhered, except just at the centre of the wound.

30th. Touched the edges of the orifice with argent. nit., and applied a cerate cloth.

Fig. 4.



Simple dressings, with the application of the caustic, were continued for several days, but the little wound refused to contract or granulate; and I therefore freshened the edges with the scalpel, and drew them together with a twisted suture. Union, by this plan, was speedily accomplished, and my patient relieved of a most shocking deformity. (Fig. 4.)

Remarks.

There is probably no defect, for the removal of which "plastic surgery" is required, more difficult to remedy than an extensive opening in the cheek. On this point, Dieffenbach, Blandin, Roux, Liston, Zies, and, indeed, all surgeons who have directed their attention to this department of surgery, unite in opinion. To Delpech and Lallemand the credit of being the *first* to make an attempt at relieving the deformity is usually rendered; although Franco, in all probability, is better entitled to it. Several operations have been devised for the defect in question; but it must be obvious that, while certain *general* rules of action may be laid down, no one series of details will answer in every case.

Lallemand's Method.—The plan usually resorted to in cases of partial destruction of the cheek, unless the opening is very small, is that proposed by Lallemand. In this operation, after having first freshened the edges of the wound, a flap is taken from the adjacent integument of the neck, *turned upon its entire pedicle*, by which means torsion is obviated, and then attached by the twisted suture to the margins of the wound it is intended to occupy. The accompanying figures, taken from one of my cases, illustrate the steps of this operation better than language can describe them.

Fig. 1.

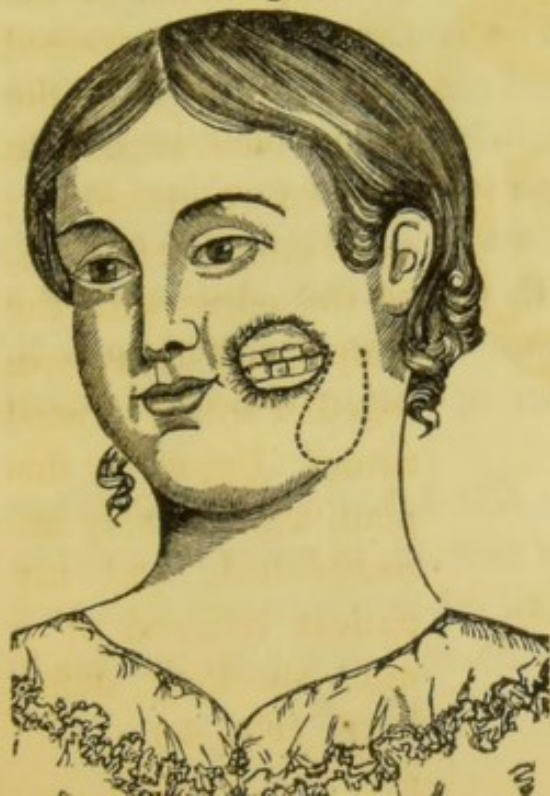
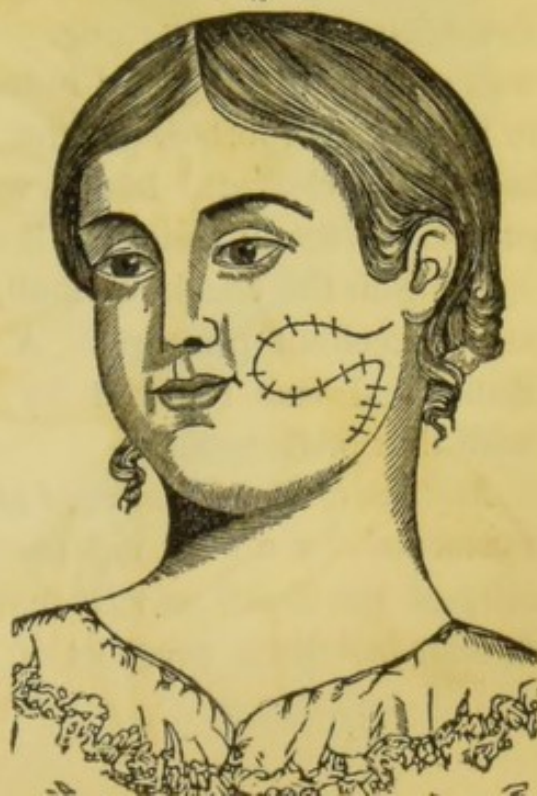
Fig. 2.



In Lallemand's case there was much difficulty experienced, from the restive disposition of the child, but the operation eventuated successfully. From the fact that in this method the base of the flap is subjected to but very slight torsion,—the great obstacle to success in most cases of plastic surgery,—it has found many advocates, and is to be preferred, in my opinion, whenever practicable, to any other.

Dupuytren's Method.—Dupuytren, in cases similar to the above, was in the habit of taking his flap from the most convenient parts, but often *twisted it upon its base, as is done* in some forms of the Rhinoplastic operation; and, according to his statement, with the most perfect success. There is more danger of sloughing, of course, when the flap is subjected to torsion, and, although the method has been followed by successful results, yet it should never be employed when the operation of Lallemand can be carried into effect.

Gensoul's Method.—In a case of most extensive destruction of the cheek, Gensoul, of Lyons, succeeded in relieving the deformity by an operation somewhat different and more simple than those described. After extracting the teeth, which were irregular, and in the way, and freshening the edges of the wound, he detached the integuments from the subjacent parts, above, below, and over the masseter muscle, and then, by sliding the flaps, caused them to unite about the centre of the opening. The success of this operation was most gratifying, and induced me to attempt its execution in the case reported, but the adhesions between the integuments, muscles, and bones, were so firm as to oblige me to prefer the modification of it already described. When the opening in the cheek is small, this operation must answer a most excellent purpose. A similar case occurred to I. N. Roux, and was relieved by an operation almost identical with that of Gensoul.

Method of Prof. Roux, of the Hôtel Dieu.—Prof. Roux has succeeded, by a most ingenious method, in relieving a deformity of the cheek so vast that all other operations appeared to offer but little prospect of success. His plan consists in

procuring the required portion of integument from a distance, and gradually carrying it, by *separate* operations, to the defective spot. By this *migratory process*, as it is termed by Blandin, Roux cured the deformity of a girl who had lost a portion of the left side of the upper lip, the corresponding ala of the nose, and part of the cheek. The flap was taken from the lower lip, and first attached to the upper, and then subsequently transferred to the cheek. The patient was under treatment a year, and submitted to several *severe operations*.

Method of Dieffenbach.—In those cases where the flaps are made to approach each other with difficulty, Dieffenbach, to relieve them from the strain, and thus obviate the danger of separation of the wound after the sutures are withdrawn, has been in the habit of making an incision across the base of the flap, as first advised for *other operations*, in which the parts are too tense, by Thévenin.

In the case from which the following drawings were taken, I adopted the plan of Dieffenbach in part, and with the most decided benefit. After freshening the edges of the wound, I drew them together, and then made the incision indicated by

Fig. 1.

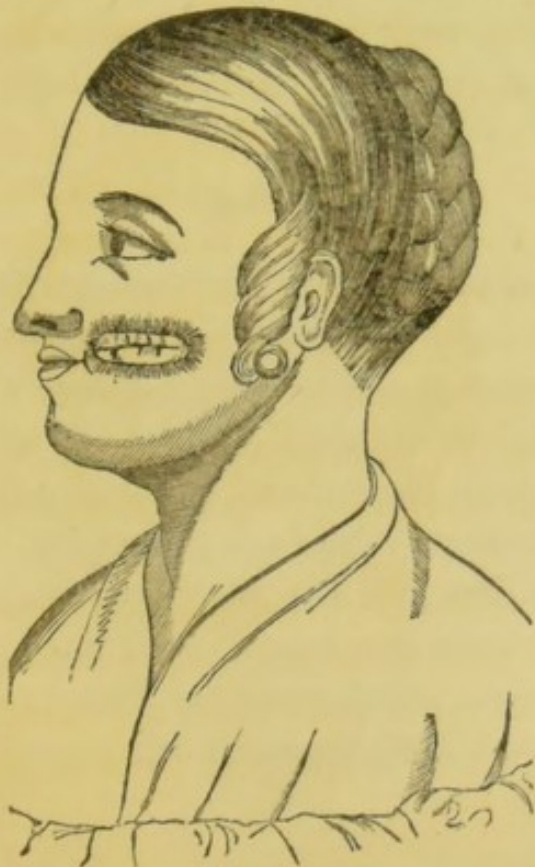
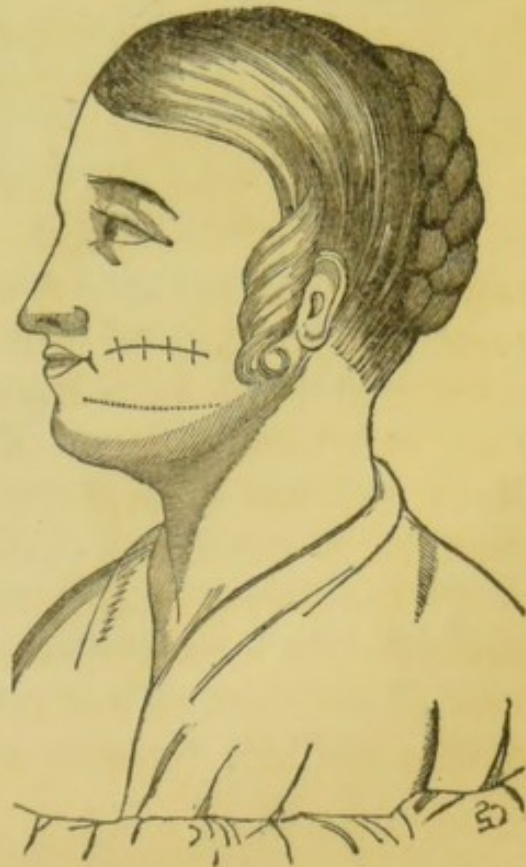
Fig. 2.



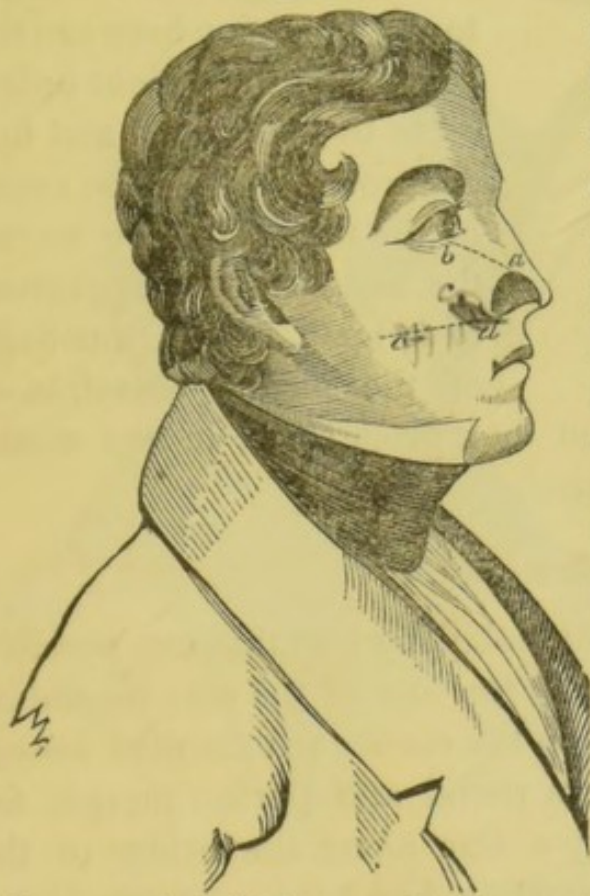
the dotted line in fig. 2, preceding page. All strain was thus taken off the flap ; and, inasmuch as this was attached by its extremities, and could thus be well supplied with blood, I made the cut as soon as the wound in the cheek was closed.

My operation, in the first case, differs in many respects from those just described, although it resembles, somewhat, that of Gensoul ; but future repetition must prove whether or not it is to be preferred.

RHINOPLASTIC OPERATION.

GEORGE DESHER, aged 19, in a fight with a person much stronger than himself, had a large portion of the right ala of

Fig. 1.



the nose *bitten out*. The parts healed kindly, but there remained the deformity exhibited in fig. 1. On a careful examination of the parts, I determined to perform an operation essentially different from those usually employed in similar cases. Accordingly, on the 3d of April he was brought before my class, and the following method of operating put into execution:— Being properly seated, and the head supported by an assistant, I passed, flatwise, a long, thin, narrow, and

sharp-pointed bistoury between the integuments and the subjacent cartilage in the direction of the dotted line *a b*, in fig. 1. When the point of the instrument reached the spot indicated by the letter *b*, I turned the blade upon its *edge*, and divided the cartilage and muscle freely from without, *inwards*. Then disengaging the knife, I passed it, in the same manner, in the direction of the line *d c*, and separated the cartilage from its attachment. These two incisions enabled me to pull the flap, included between them, *downwards* and *forwards*, so as to occupy the space originally occupied by the ala nasi. I next

The correct line d. c. is that made

Fig. 2.



freshened the edge of the flap, and also that along the bridge of the nose, and brought them together by four stitches of the interrupted suture, as is seen in fig. 2. A strip or two of isinglass plaster was placed over the parts; a small pledget of lint introduced into the lower edge of the wound, to prevent union between the edges, and the patient ordered to be kept quiet, and in a cool room; and in the event of the flap being too warm, the assistant was requested to irrigate it with mucilage of the medul. sassafras.—

Union by the first intention took place; and in two weeks my patient was entirely cured.


Remarks.

This operation is unquestionably the best that can possibly be proposed in all cases of *partial* loss of the ala; inasmuch as by it we avoid a scar upon the cheek, an extensive dissection, and, above all, secure a round and perfect margin for the nostril. There is only a line along the bridge of the nose to indicate that an operation had been performed, and the deformity is entirely relieved.

CHEILOPLASTIC OPERATION.

IN the month of January, 1842, I was requested to see I. Lambert, aged about 50, who, for several years, had suffered

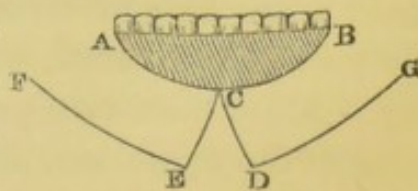
Fig. 1.



from a cancerous affection of the entire lower lip. The appearance of the disease is well represented in fig. 1. The general health of the patient being excellent, the glands in the vicinity apparently perfectly sound, and the season of the year favourable, I determined to attempt at once the removal of the disease, and at the same time restore the lip by a plastic operation. Accordingly, the patient was brought before my class

on the regular clinical day, and the following operation performed.

Having seated him in a favourable position, with his head supported against the chest of an assistant, I proceeded to the removal of the entire diseased mass, by a semi-elliptical incision, which started from the commissure of the mouth on one side, and terminated at a corresponding point on the other. (See diagram, curved line A B.) From the centre of this line two slightly curved incisions, indicated by the lines c D and c E, were carried



downwards and outwards, until they reached the base of the inferior maxillary bone. It is obvious that these incisions were separated from each by a triangular piece of skin, the superior angle of which nearly reached the first incision, A B. Then, from the terminal extremities of the incisions c D, and c E, two others were carried upwards along the base of the lower jaw, until they reached a point opposite the initial and terminal points of the incision A B. Two quadrangular flaps, A C E F, and B C D G, were thus marked out, and immediately detached from the subjacent bone.

The hemorrhage having been arrested, and the patient al-

Fig. 2.



lowed a few minutes of repose, the flaps were raised and placed in the position originally occupied by the lower lip, and then united to each other at the mesial line, and also by their lower thirds to the triangular piece of integument, by means of the twisted suture. By the elevation of these flaps, a raw surface on each side was left to heal by the modelling process, or by granulation. The parts were dressed with

the "tepid water dressing," the patient placed in bed, with his head elevated, and a rigid antiphlogistic system of treatment ordered. Nothing of interest in the subsequent management of the case presented itself; the parts healed kindly, and the patient recovered, without a trace of the disease remaining. More than two years have elapsed since the performance of the operation, and Mr. Lambert is perfectly well, and actively engaged in business.

Remarks.

From the conspicuousness of the organ, its utility in articulation, and also in the prevention of an involuntary and incessant flow of saliva, the lower lip may be considered one of the most important portions of the face. Unfortunately, it is exceedingly prone to diseases of various kinds, especially tumours and ulcers, requiring, for their relief, the loss of either a portion or the whole of the organ involved. It would appear that its importance was long since recognized, and attempts made by the older surgeons to remedy its loss. But it is to our modern brethren, especially Dieffenbach, Liston, Velpeau, Roux, Lisfranc, Dupuytren, Blandin, Blasius, Zies, and Rigaud, that we are indebted for the most valuable information relative to the best modes of curing its diseases, or remedying its destruction.

Velpeau classes all the operations for the restoration of a lip under three general methods: the "*Italian*," "*Indian*," and "*French*"—each one of which comprises a vast number of "special methods," the result of the ingenuity of the operator, and the exigencies of the case. To these general methods, might be added that which Graëfe has designated as the "*German*." Taliacotius, and most of the older surgeons, resorted to the "*Italian*" plan of procedure; while the moderns, almost to a man, prefer some modification of either the *Indian*, *French*, or *German*. It would be worse than useless to enter into a description of all the operations that have been devised, but a brief sketch of the most novel and important may prove both useful and interesting to those not familiar with this department of plastic surgery.

Chopart's Operation.—The operation practised by Chopart consisted in making on each side of the diseased tissue, a perpendicular incision, which extended from the margin of the lip to a point below the base of the lower jaw. Dissecting up the flap inclosed between the incisions, he carefully removed from its upper margin all the affected tissue, either by a *transverse* or *curvilinear* cut. Then, pulling upon

what remained of the flap, he brought its upper edge to the level of the margin of the natural lip, and there retained it by suture, straps, and placing the head of the patient in such a position as to prevent all strain upon the part.

This method, though apparently simple and easy of execution, does not generally answer, in consequence of the subsequent contraction of the tissues. Nevertheless, it is well thought of by Velpeau, Rigaud, and some others. In my own cases, I have been obliged to perform a second operation, similar to that proposed by Thévenin, where the tissues are tight, and refuse to yield readily, viz.: a *transverse incision* about an inch below the free margin of the lip. By doing this, and thus taking off all traction upon what forms the new lip, I have succeeded in making a very good cure.

Horn, or Roonhuysen's Operation.—When the tumour or ulcer to be removed is small, a common V-shaped incision, including the whole mass, is sufficient. The raw edges of the wound are brought together, and treated like a case of common hare-lip; but where the mass is large, this process is sure to diminish the orifice of the mouth, and thus give rise to deformity and inconvenience. To obviate this difficulty, it was proposed by Horn to detach the adjacent parts by free dissection from the maxillary bones, which would of course afford more material for the lip. The only objection to this method is the circumstance that, in many cases, the orifice of the mouth is rendered so small as to be almost useless, besides presenting great deformity.

Operation of Dupuytren.—This, in ordinary cases, was nothing more than cutting away by a semi-elliptical incision all the diseased tissue. Granulations spring up from the margin of the healthy skin, occupy in part the place of the original lip, and conceal to a certain extent the deformity. It is only in mild cases, however, that such a measure could succeed. In more desperate ones, Dupuytren himself resorted to some of the usual methods employed by others.

Celsian Operation.—Celsus, who was in truth one of the the best plastic surgeons that ever lived, proposed, in cases

where great deficiency of tissue existed, to perform the following operation:—Having carefully removed the diseased part by a V-shaped incision, he next divided the tissue remaining *horizontally*, carrying the cuts as far into the cheek on each side as he deemed necessary, after the manner of Horn; but in order to take off the strain from the flaps, he made a *semilunar incision* in the cheek, just beyond the base of each. This enabled him to bring the parts together without difficulty; and the only objection to his operation is the danger of wounding the larger vessels, nerves, and ducts of the cheek, in making the semilunar divisions. This operation is spoken of by Galen, Paulus, and others, and was imitated by Guillemeau and Thévenin, who made *straight* instead of *semilunar* incisions.

Operation of M. Serres.—It sometimes happens that the disease is confined to the integuments or subjacent muscles, leaving the mucous lining of the lip perfectly sound. In such cases, Serres *cuts away only the affected part*, and then *turns the mucous membrane over* the margin of what is subsequently to form the lip. A few stitches are sufficient to hold it in place; and union by the first intention usually occurring, a very natural and useful organ may thus be made. This method, however, will only answer in cases of *superficial* and *recent* disease.

Operation of I. N. Roux.—After removing the affected tissues, and forming suitable flaps of the adjacent parts, M. Roux takes away with the saw or cutting instruments the *prominent centre of the maxillary bones*, so as to make room for the proper and easy adjustment of the integuments intended to replace the organ destroyed. I have never, as yet, met with any instance of a defect that required for its relief the performance of so severe an operation, and am not disposed to advise its employment, inasmuch as I believe *most*, if not *all*, cases may be cured with much less suffering and hazard by operations equally successful in their results. Cambrelin, Thomas, Nichet, and Velpeau, however, have all had recourse to it, and with, according to their reports, decided advantage.

Operation of P. Roux.—Professor Roux, not satisfied with the measures of his namesake, goes so far as to *saw out an inch or more* of the bone, and then by drawing the lateral flaps towards each other, he thus diminishes the *breadth* of that part of the face involved in the disease. Then detaching the flaps, he draws them across the opening in the bone, and the sutures which hold and unite the soft parts are, for the most part, sufficient to hold the bones in their proper places.

Operation of Mr. Morgan.—The operation of Mr. Morgan consists in, *first*, removing the entire lip by a *semilunar incision*, the *concavity* of which is uppermost; and *second*, in making an incision also curvilinear and parallel to, and about an inch or more *below* the first. The skin included between the two is then carefully detached, except at its extremities, and lifted into the place occupied by the diseased lip. Velpeau gives another explanation of this plan of Morgan; but from all I can ascertain, the process, as just described, was the one practised by that gentleman.

Operation of Blasius.—M. Blasius has performed a very simple operation, when the tumour was large; and, according to his statement, with decided success. After removing the diseased mass by a common V-shaped incision, he next divided the integuments along the base of the lower jaw, by two incisions which commenced at the entering angle of the V and extended an inch or more in the direction specified. Lifting the flaps, he made them occupy the place of the original lips. It will be perceived that this plan is somewhat similar to the one employed in the case I have just reported.

Operation of Dieffenbach.—This extraordinary surgeon has, among many other plans for restoring the lip, performed one apparently hazardous and severe, but, nevertheless, according to the reports of others as well as those of Dieffenbach himself, exceedingly useful. The following description is taken from Zeis:—

“Having pared away the useless remains of the former diseased lip, or separated the cicatrised margin, a horizontal

incision, about two inches long, is carried from either angle of the mouth outwards, through the cheeks, so as to throw the mouth widely open. The length of these incisions must be regulated according to the width of the mouth; or, as a general rule, the combined incisions must somewhat exceed in length the breadth of the upper lip. From the outer point of each of these, another incision is next carried obliquely downwards and towards the median line; the section in this case likewise extending through the whole thickness of the cheek. Thus, by means of the first operation for paring the cicatrix, and by the succeeding horizontal and vertical incisions, a flap will be prepared on either side to replace the defective lip; this flap is of a quadrangular form, and maintains a connexion of more than an inch wide with the soft parts covering the tissue of the lower jaw. It may be useful further to separate the mucous membrane at its attachment to the gums, to allow of the more ready traction of the flaps."

The severe injury inflicted on the facial nerve, the large arteries and veins, and possibly the parotid duct, has rendered this operation anything but popular. Yet, as already remarked, it has been performed with success by several, among whom is my colleague, Professor Pancoast.

Operation of Liston.—Any opinion of this truly great surgeon is always deserving the utmost respect and attention, and, although my own observations lead me to a different conclusion in relation to the best mode of restoring a lip, I cannot for a moment hesitate to advise the repetition, whenever practicable, of his method, (a modification of the Indian,) by all who desire experience in this department of our art. It consists in first removing the diseased mass by a horizontal and two perpendicular cuts, or by one curvilinear in shape; and, second, in detaching a flap from the chin and neck, twisting it on its pedicle, placing it in the seat of the original lip, and there retaining it by suture. After adhesion has taken place, the pedicle is divided, and a "wedge-shaped" piece removed, so as to allow the flap to be laid down

smoothly. This method, it is obvious, is frequently applied to the restoration of other parts, and will answer here exceedingly well in many cases; but I prefer the one I have reported, as there is *less scar*, and *less risk of sloughing* of the flaps. Mr. Liston proposed this operation ten years since, but some give the merit of the principle to Lallemand.

The operation reported by myself has been claimed by several, among whom are Dieffenbach, Blasius, Buchanan, and others. I can only say, that I performed it in 1834, and if any surgeon has a prior claim to the merit of its introduction into practice, I am both ready and willing to award to him all the honour that may accrue from its authorship.