

**A case of hydatid cyst of the liver : serious displacement of viscera, operation, death / by R. Lawford Knaggs.**

**Contributors**

Knaggs, Robert Lawford.  
Royal College of Surgeons of England

**Publication/Creation**

[London] : Printed by Adlard and Son, [1890]

**Persistent URL**

<https://wellcomecollection.org/works/jsqw7vqy>

**Provider**

Royal College of Surgeons

**License and attribution**

This material has been provided by This material has been provided by The Royal College of Surgeons of England. The original may be consulted at The Royal College of Surgeons of England. where the originals may be consulted. This work has been identified as being free of known restrictions under copyright law, including all related and neighbouring rights and is being made available under the Creative Commons, Public Domain Mark.

You can copy, modify, distribute and perform the work, even for commercial purposes, without asking permission.



Wellcome Collection  
183 Euston Road  
London NW1 2BE UK  
T +44 (0)20 7611 8722  
E [library@wellcomecollection.org](mailto:library@wellcomecollection.org)  
<https://wellcomecollection.org>






6

with the writer's compliments







*A case of Hydatid Cyst of the Liver: serious displacement of viscera: operation: death.* By R. LAWFORD KNAGGS. *Read April 11, 1890.*

HANNAH S., æt. 36, who was sent to see my father by Dr. Carter, of Raistrick, came under his care in the Huddersfield Infirmary. Two years ago she first noticed a lump in the stomach, which had gradually increased. It had caused her no inconvenience except shortness of breath on exertion. She had had two severe attacks of obstructive jaundice. There were numerous and large varicose veins upon both legs, which began to appear about six years ago. The legs swelled after walking, but they had not been worse since the lump became more prominent. She suffered neither from cough nor from palpitations.

There was a large, tense, globular swelling presenting at the epigastrium, and raising that part with the lower portion of the ensiform cartilage into a rounded eminence, thus giving the patient a peculiar appearance. The whole thorax was pushed up, making her look short-necked and high-chested. The swelling contained fluid, and a thrill could be felt from the epigastrium to the lower ribs on each side behind, and into each loin, but more readily on the right side.

The liver dulness extended in front from the level of the third costal cartilage to the right anterior superior iliac spine. The upper limit of dulness was horizontal until it blended with the cardiac dulness over the left apex, but below, the line extended obliquely from the anterior superior spine upwards and across the abdomen to the left costal margin.

A notch was felt in the liver at the umbilicus, and on the right side of this notch a thick rounded liver edge could be traced till it disappeared behind the iliac crest, close to the anterior superior spine. On the left side the rounded under-surface of a cystic tumour, as large as an ordinary gas globe, could easily be felt. The liver moved slightly with respiration.

The cardiac dulness occupied the first and second costal spaces on the left side, and blended below with the liver dulness; there was visible pulsation over this area, and there was a distinct impact from the closure of some of the valves. The

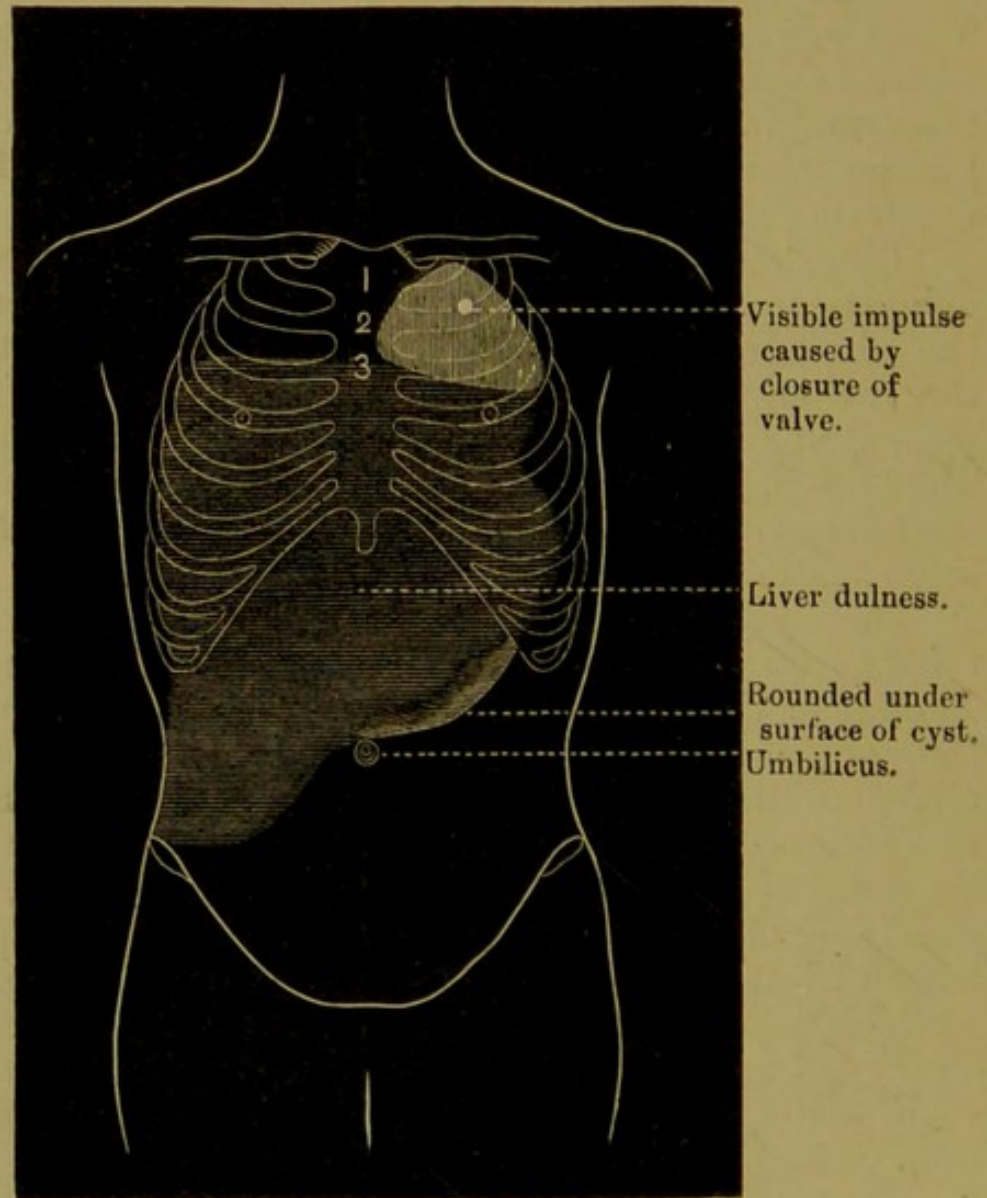


apex was situated between the fourth and fifth ribs in the axilla.

Respiration, compensatory in character, could only be heard at the extreme apex on the left side, and in a triangular space below the breast, where the dulness was not so complete; behind there was harsh crackling down to the base on inspiration, and sucking in of the intercostal spaces.

On the right side respiration could be heard as low as the third rib in front, and to the base behind, but at the extreme base the entry was deficient. There was dulness on both sides behind over the lowest three ribs.

On the right side of the chest were some dilated veins,



but these were not prolonged over the abdomen. There was slight jaundice, and the body was covered with scratch marks.



The urine : sp. gr. 1030 ; no albumen ; loaded with phosphates.

The diagnosis was hydatid cyst of the liver, and it was thought that the remarkable displacement of the heart had been caused by the growth of the cyst subsequent to the formation of adhesions between it and the parietes.

The existence of these adhesions made it doubtful whether, when the cyst was emptied, the viscera would return to their natural place, or remain as they were. In either case danger was to be apprehended : if the viscera resumed their natural positions, from the sudden alteration in the relations of the heart and great vessels ; if they were unable to fall back, from some interference with the circulation due to a twist or kink in the great vessels, which the collapse of the cyst, on which the heart rested, was likely to produce.

The following treatment was adopted :

On April 26, 1889, the cyst was tapped in the median line with a small trocar, and 47½ oz. of thin, clear, limpid fluid were drawn off. The sp. gr. of the fluid was 1008 ; it contained no albumen, and no hooklets were found. The heart's apex did not alter its position. Vomiting began half an hour after the tapping, and continued for eighteen hours, when it ceased. During the day about the normal quantity of urine was passed, and the evening temperature was 99·4°.

On the morning of April 27 there was œdema of the eyelids and across the bridge of the nose, and the pulse could barely be felt. Temp. 100°. Under the free administration of brandy she improved, and at night the œdema had gone ; the pulse was 130 and very feeble, and the temp. 100·8°.

Only 5 oz. of urine were passed during the twenty-four hours, containing a considerable quantity of albumen and bile pigment. The pupils were contracted and the patient was drowsy. The skin was at first hot and dry, but acted freely after a vapour-bath.

On the 28th the pulse was 112 and the temp. 101° ; 19 oz. of urine, containing only a trace of albumen, were passed. Sp. gr. 1020.

On the 29th morning temp. was 98°, evening temp. 103°. Urine increased in quantity.

On the 30th, pulse 80, temp. 99°. Forty ounces of urine were passed, and there was no albumen.

On May 5 she was going on well. The positions of the liver and heart were unaltered. The tumour was much smaller and less tense, and the right superficial epigastric



veins were slightly enlarged. From this date the cyst gradually refilled, and on June 7 the tumour had been for some time as large as before the tapping. On this day the cyst was transfixed with three long hare-lip pins passed through the abdominal wall and marking out a triangular space. The object was to procure adhesion between the cyst wall and the parietes, and the method is highly spoken of by FitzGerald in Heath's *Dictionary of Surgery*. The insertion of the pins was found to be exceedingly difficult, on account of their flexibility and the firmness of the abdominal parietes, and led only to three being employed. They were removed in eight hours, but a smart inflammatory action was set up around them, which, however, in two or three days quite subsided, and the punctures quickly healed.

On June 14 the cyst was tapped with a medium-sized trocar within the triangular space, and 29 oz. of fluid allowed to escape. The cannula was left in and plugged and covered with an antiseptic dressing. The fluid was very different from the first quantity that was removed. It was of a deep yellow-green colour, evidently due to bile, with a sp. gr. of 1011.

It contained masses of flocculent yellow lymph, in which were to be found hooklets and numerous scolices, also pieces of cyst wall, which under the microscope showed the laminated structure.

June 15.—The dressing was saturated, and the bed wet with the fluid that had escaped by the side of the cannula. Thirty-six more ounces of fluid were drawn off, and then the cyst was washed out with boracic lotion by means of a syphon. A quantity of flocculent yellow material and portions of cyst-wall were removed. This was repeated at night. So far the general condition was all that could be wished, and there was no sign of the trouble that followed after the first tapping.

June 16.—The washings were repeated. In the evening there was vomiting, and the temperature rose to 100°. The rising temperature, vomiting, and general febrile symptoms seeming to threaten the commencement of a septic condition, and the frequent obstruction of the cannula by the flocculent masses preventing the satisfactory washing out of the contents, were the reasons which led to the decision to introduce under anæsthesia a large drainage-tube into the cyst to facilitate the more complete evacuation of its solid contents.

June 17.—Under ether the cannula was removed, and an incision made into the cyst upwards from the existing opening.



The cyst was well washed out with boracic lotion, and a large drainage-tube left in; a large quantity of flocculent material escaped. She took the ether well, and the operation seemed well borne. The temperature continued to rise, first to 101°, and finally to 102°. In the evening she was almost pulseless, but there was no œdema of the face, and no albuminuria. She died in the early morning of the next day, eighteen hours after the operation, to all appearances from shock.

*Post-mortem.*—The heart: The apex was in the fourth space in a line with the anterior axillary fold. There was no enlargement, and no adhesions fixing it in its position. The aortic and pulmonary valves were competent, and the mitral admitted two fingers. The left side was contracted.

The stomach was enormously elongated, and adherent at its lesser curvature to the under surface of the cyst. There was slight effusion of blood into the gastro-hepatic omentum.

The liver weighed 7¼ lbs. Its natural shape was completely altered, and the usual landmarks were unrecognisable. It contained an enormous single hydatid cyst, which probably had begun in the left lobe, a small portion of which, about an inch deep, still remained upon its anterior wall.

The cyst had evidently become adherent by its upper surface to the diaphragm over a space as large as the palm of a hand to the right of the median line (the adhesions were old and very tough), and as it grew the liver had been rotated and pushed backwards and downwards, and to the right. The liver had accommodated itself to its new position. There were well-marked grooves upon its surface, corresponding to projections in the parietes. These facts prevented any return to its original position, and its weight would have been sufficient to have kept it where it was. The cyst wall was fully a quarter of an inch thick. The cyst was collapsed, and contained several handfuls of thick green lining membrane, which was quite detached and easily removed.

There was an adhesion to the abdominal wall where the cannula had been retained, but if there had been any produced by the hare-lip pins they had been torn through when the cyst collapsed, and had left no trace.

The collapsed cyst lay under the ribs, and its original situation was taken by the stomach, the cardiac end of which was placed very high up under the left ribs (in the chest). The elongated shape of the stomach had been caused probably by its adaptation to the cyst. There was a flake of recent yellow lymph on the under surface of the cyst. The exposed intes-



tines looked natural, but those coils which had lain in the pelvis were congested and red, had lost their gloss, and with the other pelvic viscera were covered with patches of recent lymph. About a teacupful of serous fluid was in the pelvis.

The heart had been prevented from falling—

1. By the alteration in the shape and position of the liver; and—

2. By the position of the stomach, which its elongated shape and the adhesion to the under surface of the cyst assisted it to retain.

The spleen was much enlarged, and the kidneys were healthy. The base of the right lung was collapsed.

My reason for placing on record this unusual example of hydatid cyst of the liver is to draw attention to the fact that cases will occur in which radical surgical procedures will do more harm than good in consequence of serious alterations in the shape and the positions of the viscera.

The favourite plan of treatment amongst surgeons at the present time is incision and drainage.

In this instance the removal of a portion only of the contents was sufficient to place life in immediate danger, and had incision been employed in the first instance there can be little doubt that the patient would have speedily succumbed—if, indeed, she had been so fortunate as to survive the operation.

It is interesting to note that the evidences of interference with the circulation that occurred after the first tapping were not renewed after the second; the amount removed, however, was a pint less than on the first occasion, and this was followed by oozing alongside the cannula, so that the diminution of the tumour took place very gradually. It is open to criticism whether, after the serious condition that was induced by paracentesis, any further treatment should have been attempted—at any rate until a much longer interval had elapsed.

The operator's intention was to have kept the removal of the contents under control, and whilst emptying the cyst by degrees to have been ready to take alarm at any untoward symptom due to the diminishing size of the tumour, and to have removed the cannula.

The reliance that was placed upon "transfixion of the cyst" was mistaken. Not only did the pins entirely fail in their purpose, but they gave rise to a false feeling of security, in consequence of which the cannula was retained *in situ*, and so permitted an escape of bile-stained fluid contents. This,





by finding its way in part into the peritoneum, was probably the cause of the pelvic peritonitis, and the vomiting and rise of temperature that followed were looked upon as due to changes going on in the cyst contents, and led to the incision and drainage. I would direct attention to the alteration in the character of the hydatid fluid that followed the first tapping, and I should like to ask what influence it would have had upon the cyst if no further treatment had been adopted.

I feel unable to decide the proportionate influence which (a) the shock of the anæsthetic and operation, (b) the complete emptying of the cyst, and (c) the pelvic peritonitis had in determining death. The peritonitis certainly seemed inadequate, and, as far as could be judged from her condition and pulse, the patient seemed to take the anæsthetic and bear the operation well.


On the other hand, it is to be remembered that the cyst had been washed out with a syphon four times before the incision was made, and therefore, though not completely emptied, no very great alteration can have been effected in its size by that operation.











Sheet  
10/10/10







