

**A case of pseudo-lupus vulgaris caused by a blastomyces / by T. Caspar Gilchrist and William Royal Stokes.**

**Contributors**

Gilchrist, T. Caspar 1862-1927.  
Stokes, William Royal.  
Royal College of Surgeons of England

**Publication/Creation**

[New York] : [publisher not identified], [1898]

**Persistent URL**

<https://wellcomecollection.org/works/y36zyena>

**Provider**

Royal College of Surgeons

**License and attribution**

This material has been provided by This material has been provided by The Royal College of Surgeons of England. The original may be consulted at The Royal College of Surgeons of England. where the originals may be consulted. This work has been identified as being free of known restrictions under copyright law, including all related and neighbouring rights and is being made available under the Creative Commons, Public Domain Mark.

You can copy, modify, distribute and perform the work, even for commercial purposes, without asking permission.



Wellcome Collection  
183 Euston Road  
London NW1 2BE UK  
T +44 (0)20 7611 8722  
E [library@wellcomecollection.org](mailto:library@wellcomecollection.org)  
<https://wellcomecollection.org>





(9.)

A CASE OF PSEUDO-LUPUS VULGARIS  
CAUSED BY A BLASTOMYCES


BY

T. CASPAR GILCHRIST, M. R. C. S., AND WILLIAM ROYAL  
STOKES, M. D., BALTIMORE

(FROM THE PATHOLOGICAL LABORATORY OF THE JOHNS HOPKINS UNIVERSITY  
AND HOSPITAL)

FROM  
THE JOURNAL OF EXPERIMENTAL MEDICINE  
VOL. III, No. 1, 1898





## A CASE OF PSEUDO-LUPUS VULGARIS CAUSED BY A BLASTOMYCES.

BY T. CASPAR GILCHRIST, M. R. C. S., AND WILLIAM ROYAL STOKES,  
M. D., BALTIMORE.

*(From the Pathological Laboratory of the Johns Hopkins University and Hospital.)*

### PLATES IV-VIII.

Within the last three years a number of important communications have appeared concerning pathogenic yeasts. Before this period it was generally believed that among the yeast plants there existed none pathogenic for man or animals. The experiments of Bernard, Grohe, Popoff, Falk, and the more recent ones of Neumayer and of Raum, furnished no satisfactory evidence in favor of the possession of infectious properties by the blastomycetes.

In August, 1894, Busse \* published a brief report, followed in April, 1895, by a fuller account of a case interpreted by him as one of chronic pyæmia, in which he found in tissue removed during life and in diseased foci after death, numerous parasitic bodies which he proved to be yeast fungi. These he isolated in pure culture and inoculated successfully into animals. He designated the disease produced by this parasite in man as *saccharomycosis hominis*.

In May, 1894, three months before Busse's first publication, one of us (Gilchrist) exhibited and described before the American Dermatological Association in Washington, microscopical sections from a case of cutaneous disease in Philadelphia under the care of Dr. Duhring, who had excised and sent a piece for microscopical examination. Peculiar parasitic bodies, which were interpreted as plant rather than animal forms, were observed and described. After the appearance of Busse's paper these bodies were recognized as forms of blastomycetes. This case has been fully described and illustrated by Gilchrist under the title of "A Case of Blastomycetic Dermatitis in Man."

\* References to literature will be found at the end of this article.



The most prolific writer upon the subject of pathogenic yeasts since the year 1894 has been Sanfelice, who has obtained from various sources cultures of blastomycetes pathogenic for animals. A systematic experimental investigation of the pathogenic properties upon animals of yeast cultures obtained from various sources has been made also by Rabinowitsch. The Italian investigators especially, of whom, besides Sanfelice, may be mentioned Maffucci and Sirleo, Roncali, Aievoli, Corselli and Frisco, Fermi and Aruch, d'Anna, Binaghi, Secchi, Rossi Doria, Casagrandi and de Simoni, have interested themselves in this subject. Many of these writers, as well as Kahane in Vienna, deal with the question of the parasitic origin of malignant tumors. Although it cannot be doubted that in some instances yeasts have been cultivated from such tumors by Roncali, Corselli and Frisco, and others, we do not consider as thus far successful the efforts to identify the much discussed cell-enclosures in carcinoma and sarcoma with blastomycetes or other genuine parasites.

Of interest are the observations of Tokishige concerning the blastomycetic origin of a farcy-like disease of horses and cattle in Japan, apparently identical with a similar disease in Italy and France likewise referred to blastomycetes by Fermi and Aruch, and also those of Sanfelice concerning so-called epithelioma contagiosum (Bollinger) of fowls, which had been attributed by Rivolta and Delprato to psorosperms, but which Sanfelice believes to be caused by a yeast parasite.

Curtis, in France, has published interesting observations upon a yeast parasite, which he calls *Saccharomyces subcutaneus tumefaciens*, found in a tumor of myxomatous appearance in the thigh of a human being. This he cultivated and inoculated successfully into rats, mice and dogs.

A preliminary account of the case which forms the subject of the present paper was published in the Bulletin of the Johns Hopkins Hospital in July, 1896. Since that time we have had the opportunity of making more extended observations and inoculation experiments, and are, therefore, now in a position to give a full description of the case and the results of our investigations. The patient first came under the care of Professor Halsted of the Johns Hopkins Hospital, by



whose permission one of us (Gilchrist) had the opportunity of examining and studying the case. We take this opportunity of thanking Professor Halsted and also of expressing our indebtedness to Professors Welch and Flexner for their valuable aid and advice in our investigations.

*Clinical History.*—The patient is 33 years of age, married, about 5 feet 9 inches in height, and of a slender but wiry build. He is one of thirteen children, twelve of whom are still living and in good health; one child died when five months old from whooping-cough.

On July 4, 1885, the present eruption is said to have been first noticed at the back of the left ear, just behind the mastoid process, as a pimple which was about as large as a grain of wheat. It was roundish in shape and only slightly raised; the pimple soon became pustular. The eruption began to spread in a linear direction towards the lobe of the ear, but increased in extent very slowly, so that during the succeeding four or five years the length of the patch was only from 3 to 5 cm. As the disease extended the oldest portion gradually healed spontaneously, and a white, slightly hypertrophic scar was produced. The healing process was always only partial and took years for its accomplishment. The linear scar, which is now distinctly visible, is about 4 cm. long and 5 to 6 mm. broad.

After four or five years the disease, which continued to spread very slowly forward, began to involve the cheek, and then gradually extended upwards and downwards, so that seven years after the first appearance of the eruption it had only reached the external canthus of the left eye, after which it continued to travel along the eyelids. The tendency to heal as it progressed was still a characteristic feature of the process, but the scar was now more atrophic, whitish and thin, particularly over the cheek. Besides extending to the eye, the lesion also spread gradually down the left cheek until it reached the left side of the chin. In about nine years the nose was attacked by the growing edge; the bridge was soon crossed and the right eyelids and eyebrow became involved. After this the patient noticed that the growth became more rapid, especially on the forehead and down the right cheek.

About one month after the first lesion was observed there appeared on the back of the right hand, over the middle of the third metacarpal bone, another pimple which soon became pustular and opened spontaneously. This lesion also began to increase slowly; it remained superficial and assumed the same characters as that on the face; it took about four years for it to spread over the whole posterior surface of the hand, from the



knuckles to the wrist, and from the thumb to the inner margin of the hand. The eruption was treated successfully with caustics by the family physician.

Another secondary lesion occurred six months after the first on the right side of the scrotum at the upper portion, and this again, as was stated, had the appearance of a pimple which followed the same course as the others, except that it contained only a little pus; but the characteristic creeping propensities were shown until the area attained to about the size of a silver dollar. This scrotal lesion grew slowly for a year, when it healed spontaneously. No external applications were used.

Still a fourth lesion appeared in the same manner and at about the same time as the scrotal eruption, on the anterior surface of the left thigh and just above the internal condyle. This also spread peripherally for about a year until it formed a patch 5 cm. by 7.5 cm. in size, when it also healed spontaneously without treatment, leaving a slightly raised scar. On the back of the neck, just above the 7th cervical spine, a fifth lesion made its appearance a little later than the one on the thigh and continued to grow for two years, when it also healed spontaneously. The patient says none of the lesions were at all painful. Upon entrance of the patient into the Hospital it was noted that on the face the diseased portion presents a distinct line of demarcation. The upper border, as shown in the photograph (Plate IV), extends from the middle of the right eyebrow sloping upwards and then passes across the forehead to the left side, where it curves down again to a point just outside the external canthus of the left eye. This border, with the exception of a small portion which has apparently healed, consists of a comparatively thin (8 mm. wide), inflammatory, red ulceration, which is superficial and covered with a scanty scab. Along the right eyebrow the characters of the lesion present a somewhat different aspect, showing a firm papillomatous appearance. These papillomatous growths can be separated, and sometimes a minute quantity of pus can be squeezed out from between them. Thin scabs are found partially covering these lesions.

The right border of the facial patch extends from the right eyebrow horizontally outwards to a point within an inch of the ear; it then proceeds downwards and forwards towards the right angle of the mouth, and stops abruptly within 1.5 cm. of this point. The border of the patch then turns slightly upwards and inwards towards the ala of the nose. This right border is about 2.5 cm. broad and presents, especially towards the lower angle, a pronounced papillomatous character, being dry and scabby; where it has encroached on the region of the beard it is pierced by hairs. The largest papillæ, which are all closely aggregated together,



are about the size of large pin-heads; from between these also sometimes a small quantity of pus can be squeezed out. The other portion of this border is covered with a thin scab, on removal of which a superficial ulcerative patch is exposed. The continuation of the lower border extends across the nose to within an inch of the tip as a superficial ulcerative edge.

From the left ala the lesion passes downwards to the left angle of the mouth, whence it extends still further down to the border of the jaw, along which it continues upward to the point of its first commencement. This area also is about 2.5 cm. broad, and again at the lower angle, *i. e.* between the mouth and the border of the jaw, the papillomatous character is well marked and numerous hairs protrude. These enlarged papillæ are raised nearly 6 mm. above the level of the normal skin. The lesion along the lower jaw is much narrower and the ulceration is quite superficial.

The whole area enclosed by this irregular border consists of one continuous atrophic scar which is whiter and thinner than normal skin. The eyelids of both eyes are practically destroyed, so that the patient cannot cover the eyeballs. Around the left eye the patch presents a raw, red, moist, easily bleeding surface, which extends for nearly 3 cm. downward from the lower border of the eye. The right eyelids present similar appearances except that the lower patch is not so extensive. The tears are continually running over these patches, particularly on the left side. The patient says that the disease is not even now particularly painful.

On the back of the right hand is an atrophic thin whitish scar which extends over the whole surface of the dorsum. The scar on the right side of the scrotum is about 3.5 cm. in diameter, is reddish and somewhat contracted, whereas the scar on the left thigh is smooth, thin, very white and not contracted. The lesion which was situated on the back of the neck has left a hypertrophic scar of distinctly keloidal appearance.

There are no enlarged glands. The patient has no cough; the bowels are regular, tongue fairly clean; he says that his general health has always been good. There is no history of syphilis, although the patient's wife had a miscarriage at four months, but no children. The wife's menstrual courses are very irregular. No tuberculous history in the family could be obtained.

Our first impression was that we had to deal with a case of lupus vulgaris, which would, therefore, have made its first appearance at the age of twenty-two years; but the primary lesion of all the patches



presented the same feature, appearing first as a pimple and then as a pustule, followed later by a superficial ulceration spreading, in the majority of the lesions, peripherally. As the disease extended, atrophic and in one lesion hypertrophic scarring had resulted. There was no history of the formation of lupus-nodules nor could any such lesion be found. The papillomatous form of the disease was in many respects suggestive of lupus papillomatosus. Tuberculosis cutis was then thought of and particularly tuberculosis verrucosa cutis (Riehl and Paltauf); but this disease is usually due to frequent contact with decomposing animal matter and our patient had not been exposed to such influences, although clinically various points of resemblance presented themselves between this disease and our case. Tuberculosis verrucosa cutis begins as a papule, which later becomes pustular, and after forming a scab, which falls off, takes on a papillomatous growth. It spreads very slowly peripherally, and on lateral pressure a little pus can be squeezed out from between the papillæ; but the hands, forearms and feet are the only regions of the body where this disease has been found. The history of the lesions in our case, and the fact that they healed spontaneously in three situations, would appear to be clinically almost sufficient to exclude tuberculosis of the skin in any of the usual forms. Scrofuloderma was also considered, but was excluded on the grounds that the lesions in our case practically presented none of the typical features of this disease, nor were there any enlarged glands or constitutional symptoms to support this view.

For purposes of diagnosis three portions were excised, one from the right eyebrow (inner border), one from the right border (papillomatous) of the patch, and the third from the lower end of the left border near the chin. One portion was dropped into 5 per cent. formalin solution, and the other two into 95 per cent. alcohol.

#### PATHOLOGICAL HISTOLOGY.

Unstained sections treated with ordinary liquor potassæ showed the presence of numbers of curious bodies which were doubly contoured and very refractive, whereas the tissue assumed a blurred appearance.

The stained specimens showed a hypertrophy of the epidermis (Plate V, Fig. 1), throughout which numerous well defined miliary abscesses



of various sizes were scattered. Fig. 1, Plate VIII, represents one of the smaller miliary abscesses in the epidermis and contains two parasites. The epidermis was elsewhere considerably infiltrated with polynuclear leucocytes, and irregular masses of detritus covered certain portions of the epidermis. Large collections of granulation cells were massed in the corium, and numerous miliary abscesses (Plate V, Fig. 1, *b*) were also observed in the upper part of this region. A considerable amount of inflammatory material was also distributed throughout the corium, and in a number of sections there was distinct evidence of the formation of tubercle-like nodules (Plate V, Fig. 1, *n*) in the deeper portion of the corium.

Situated in all the miliary abscesses, and also among the granulation cells in the corium, as well as in the pseudo-tubercles, were numbers of doubly contoured, refractive, round and ovoid bodies (Fig. 1, *p*), varying in size from 10 to 20 $\mu$  in diameter. Many of these forms presented buds of various sizes, and a vacuole was often, although not always, discernible. The bodies were usually found singly or in pairs, but they were sometimes arranged in groups. They were more numerous in the miliary abscesses than elsewhere. The contents of the bodies consisted of finely and coarsely granular protoplasm which took up the ordinary stains. Unna's method of staining for mastcells with polychrome methylene blue was employed on some sections and the coarse granules were found to be stained red, whereas the remaining portion of the protoplasm was practically decolorized. This reaction seemed to show that the coarse granules were basophilic.

Mastcells were somewhat numerous, but comparatively few giant cells (Fig. 1, *G*) were scattered throughout the corium; some of the latter enclosed one or more parasites. The contents of all the miliary abscesses (Plate V, Fig. 1, *a*, and Plate VIII, Fig. 1) consisted principally of large numbers of polynuclear leucocytes and nuclear fragments besides the parasites (*p*). Detached epithelial cells were sometimes present in the epidermal miliary abscesses.

Fig. 1, Plate V, represents a section from the cutaneous lesion; in it are seen numerous miliary abscesses (*a*) scattered throughout the hypertrophied epidermis (*e*) and corium (*c*). The section also shows the communication of one of the abscesses with the surface (*s*). Practically the entire epidermis was infiltrated with polynuclear leucocytes. The whole upper half of the corium (*c*) was the seat of acute and chronic inflammatory changes. Two hair follicles (*h*) were seen in the section, but they were essentially normal. The sudoriparous glands were also unaffected, and there did not appear to be any particular relationship between the diseased condition and the appendages of the skin.



Two pseudo-tubercles (*n*) were seen in this section in the lower portion of the corium; these showed at their centres one or more parasites. The pseudo-tubercle was thus made up of one or more organisms in the centre, surrounded by a number of polynuclear leucocytes, around which were three, four or more layers of epithelioid cells, while a large number of mononuclear or lymphoid cells formed the peripheral portion. The pseudo-tubercles were more numerous in the papillomatous or chronic variety of the lesions; whereas in the acute or ulcerative form, miliary abscesses, and consequently more parasites, were present.

In the papillomatous lesions the papillæ were markedly hypertrophied and the mouths of the hair follicles, especially from the region of the beard, showed pronounced hyperkeratosis (*k*). The epidermis itself was not much altered and did not present the miliary abscess-formations. The corium consisted chiefly of large masses of granulation cells with very few of the miliary abscesses situated near the upper portion. Parasites were found in all the abscesses. One could also find now and again an organism among the granulation cells, but here they were not at all numerous; giant cells were present in only small numbers.

Generally speaking every miliary abscess contained one or more parasites (*p*), which were often in a budding stage. No parasites were found enclosed in cells except in a few giant cells which were situated in the deeper portion of the corium.

The organisms were first found and studied with the ordinary hæmatoxylin and eosin stain. Under ordinary circumstances they could always be found in the tissues, but if the sections were at all thick one could easily pass them over. They took the hæmatoxylin stain just about as readily as the cell nuclei, but were more easily decolorized. We found that the most practical method of demonstrating the presence of these organisms in the tissues was to immerse the section in a mixture of equal parts of liquor potassæ and glycerine, when they were at once easily recognized. When we used Unna's polychrome methylene blue stain the organisms were very prettily stained, the capsule and protoplasm being colored blue, whereas the coarse granules were stained red. Methylene blue (aqueous) and eosin also gave good results. With carbolfuchsin and methylene blue the capsule was sometimes stained red and the protoplasm blue.

The organisms were usually round or oval, and their resemblance to the parasites found in Gilchrist's case of blastomycetic dermatitis,



already cited, was very close, although in the latter they were more numerous. The mode of development by budding could be followed out in the sections. In some instances the capsule had given way and the endosporium protruded as a bud (Fig. 12, Plate V), but more often the bud was formed by a pushing out of both endo- and exosporium (Fig. 11, *b*). The bud then grew larger and larger (Plate V, Figs. 3-13) until it reached almost the size of the parent, when the endosporium or protoplasm became divided by a clear space (*s*, Fig. 5). This stage was followed by a folding in of the capsule (*c*, Fig. 7) until the folds met and a separate organism was formed (Fig. 10). Sometimes a second bud was produced before the first had become detached (Figs. 11, 12, 13). A vacuole (see Figs. 2, 4, 6) was more often than not seen in the parasite, but there was much variation both in its size and shape. A few organisms presented rather a curious appearance (see Fig. 8); the section was stained with hæmatoxylin and eosin, but this organism did not stain, and presented, especially its central portion, a very refractive appearance, as if it had undergone some form of degeneration; surrounding the capsule was a delicate, fibrous-like structure of irregular outline. One shown in Fig. 9 also presented a similar appearance as far as the external, fibrous-looking, irregularly shaped coat was concerned, but the central portion stained in the same manner as in the other organisms. Fig. 15 shows also an unusual form where the protoplasm has contracted into a half-moon shape. Sometimes a number of parasites are collected into a group (Fig. 16), which is usually situated in the corium and rarely in an abscess. Plate VIII, Figs. 3, 4, and 5, show varieties of organisms enclosed in giant cells. In Fig. 5, Plate VIII, the vacuole, both in the parent and in the bud, was particularly clear and well marked. Four parasites were found enclosed in a giant cell as shown in Fig. 4; three of them were in various stages of gemmation.

#### CULTURES.

After careful sterilization of the surface of the papillomatous lesions, cultures on plain agar were taken from two places from the pus, which after pressure oozed out from between the growths. Other



similar cultures were taken from the diseased area after removal of the scab, and from one excised portion of the tissue.

Although every possible precaution was taken in order to avoid any contamination, yet the cultures from the tissues contained a profuse growth of pus organisms, and in only one instance a single large colony of the parasites developed. These cocci were not further noticed, as they were not found in the pus and could not have caused the chronic process.

Both of the tubes inoculated with the pus showed in one week a pure growth of the organism about to be described.

*Morphology.*—This was first observed in specimens taken from young colonies from the surface of plain agar, and mounted in salt solution. They may be studied either with the No. 7 Leitz objective or by means of the oil-immersion lens.

The most usual form consists of a large, round, oval, or irregular, highly refractive body, surrounded by a doubly contoured membrane, consisting of an exosporium and an endosporium (Plate VI, Figs. 5, 13; Plate VII, Fig. 1). These bodies contained many refractive granules resembling fat granules, which at times show Brunonian movements, and a number of finer dark granulations. At times one or more large vacuoles can be seen within the protoplasm.

These bodies may be stained while fresh by adding a small amount of an aniline dye to the salt solution. If the precaution be taken to tease out carefully a dry bit of a colony on a cover-slip or slide, and the specimen be then diluted with a drop of salt solution and dried in the air or high above the flame, the organisms can be stained as are ordinary bacteria.

Treated thus with Loeffler's methylene blue or carbolfuchsin, the membrane stains deeply while the protoplasm takes on a lighter stain. The large pseudo-fat granules do not retain the dye, while, on the other hand, the small granulations stain more intensely than any other portion of the cell. At times the finely granular protoplasm does not completely fill the cell, but is separated from the membrane by a clear faintly staining hyaline area. These bodies remain unchanged in pure glacial acetic acid, and in 25 and 50 per cent. hydrochloric acid, but in pure hydrochloric acid they disappear.

Attempts were made to ascertain the chemical nature of the large granules, but they gave no reaction when treated with iodine, and hot



Millon's reagent and ether, although applied twelve times in succession, failed to dissolve them. The membrane also failed to give the cellulose reaction, but the fine black granulations would appear to be albuminous, since on boiling fresh specimens with Millon's reagent they often appear in the protoplasm as brownish-red particles.

The first colonies which were obtained from the original pus cultures consisted almost entirely of budding forms of the parasite (Plate VI, Figs. 4, 5, 6, 7, 17, 18, 19).

*Mode of Growth.*—The development of the parasite was then studied by means of small particles of the growth introduced into a hanging drop culture of gelatine and then allowed to grow (Plate VI).

From the round or oval bodies there occurs a growth of many long branching threads like mycelium, which are divided into shorter hyphæ by intervening fine transverse lines (Plate VI, Fig. 12). The protoplasm of the hyphæ is at first clear (Plate VI, Figs. 17, 18), but later it becomes beset with numerous fine granules or larger refractive bodies resembling oil drops (Plate VI, Fig. 3). In old cultures the protoplasm seems to arrange itself into long or oval hyaline bodies separated one from the other by a clear interval.

The numerous drawings of Plate VI represent many of the varieties which were found in the hanging drop cultures.

After several days, at various points along the sides of the hyphæ a number of knob-like projections (Plate VI, Fig. 15) of the limiting membrane may be seen, which gradually enlarge and at last form full-grown, round cells, or conidia, joined to the mycelium by means of their stems or sterigmata (Figs. 14, 15). These conidia may possess a double contoured membrane, together with fine or coarse granules. They may also become detached from the hyphæ, when they can either repeat the cycle of development just described, or increase by the process of budding and the formation of daughter cells. This latter phenomenon is of interest, since it is the only evidence of increase to be found in the tissues. The growth of the cultures is always accompanied by the formation of envelope and small crystals of oxalate of lime (Plate VI, Fig. 22).

Occasionally, in about the third generation of various cultures, certain colonies appeared to consist chiefly of the budding variety, only short hyphæ being observed here and there (Plate VI, Figs. 17, 18). In old cultures there appeared at times a mycelium which was finer in structure than the usual form observed.

*Appearance of Cultures.*—The organisms grow best on glycerine agar and potato, and develop slowly. In about seven days numerous fine grayish-white colonies appear on the surface, which later become pure white



and show minute prickles, thus resembling a number of minute white chestnut burrs scattered over the medium. They can attain the size of a split pea; they grow about two millimetres above the surface, and, if numerous, form a confluent membrane, suggesting a portion of the skin of a white mouse stretched over the surface of the medium. The growth is always firmly adherent to its substratum, and portions of the latter material are often removed with the colonies.

After the cultures have been passed through several generations of animals the loss of the mycelium causes these masses to appear as moist, flat gelatinous drops spread over the surface of the medium. In clear fluid cultures, for example, with bouillon, the parasite forms a thick interlacing meshwork through the medium, and no individual bodies can be found in the culture fluid.

In plate agar cultures the colonies show under a low magnifying power a granular centre from whose periphery fine ramifying branches grow out.

Colonies also develop readily on plain nutrient gelatine, 20 per cent. beer-wort gelatine, plain agar, 5 per cent. beer-wort agar, bouillon, fluid beer-wort (unfermented beer), Dunham's solution, milk, agar made from infusions of the various organs, Loeffler's blood-serum mixture, and human blood serum. Milk is not coagulated nor acidulated; no indol forms in Dunham's solution, and gelatine is not liquefied. No alcoholic fermentation occurred, nor was the formation of any gas observed after several weeks growth in the fermentation tubes containing glucose, lactose and saccharose bouillon.

Although cultures have been left for several months on apparently dried-up tubes, yet when transferred at the end of this time they grew luxuriantly, and in one case even proved pathogenic after this length of time.

The parasite will not grow as a strict anaerobe. This was proven by making several stab cultures into glycerine agar and covering the surface with melted gelatine. This tube was then placed in a Buchner jar with pyrogallie acid and KOH, and allowed to remain for one month at room temperature. At the end of this time the bodies introduced showed no evidence of increase.

The organisms develop in about one month when subjected to a temperature but slightly above freezing, and grow most favorably at a temperature ranging from 18-36° C. Their maximum temperature for growth is 40° C.

#### INOCULATION OF ANIMALS.

Fresh bits of tissue were introduced subcutaneously into a white mouse and a guinea-pig. The mouse died in 24 hours of a pneumo-



coccus septicæmia. The guinea-pig showed no change although observed for several months. Another guinea-pig was inoculated in the peritoneal cavity with diseased tissue after a laparotomy. After two months the animal was killed, but showed no pathological changes, with the exception of a few necrotic areas in the liver. Cultures, cover-slips and hardened specimens failed to reveal the presence of any parasites or bacteria in the liver, and cultures from the heart's blood and other viscera were negative.

These inoculations are only of negative importance, as they enable us, in conjunction with the facts mentioned above, to exclude tuberculosis.

A number of inoculations were made also with pure cultures of the organism. Four white mice were inoculated at the root of the tail. They survived the inoculation one month and were killed at the end of this time; the autopsy and cultures were negative. Two guinea-pigs inoculated subcutaneously with teased bits of cultures failed to show any reaction during two months, and several similar animals injected hypodermically with teased particles in bouillon gave negative results.

Several attempts were also made to reproduce the disease by implanting pure cultures upon scarified areas, or introducing them into small subcutaneous pockets made in the skin of a dog. These inoculations resulted only in abscesses containing the ordinary pus organisms. The organism was also introduced into the circulation of a rabbit, but when the animal was killed, two months later, the autopsy showed nothing remarkable, and stained hardened specimens of the lung showed these to be normal.

The following inoculation experiments, however, proved successful:

*Exp. 1. Dog 1.* The neck of a small dog was shaved and cleaned; the external jugular vein was exposed by Dr. Flexner, and one cubic centimetre of a suspension of teased colonies from a growth from the original pus was injected in the direction of the circulation. During the next two months the animal became somewhat emaciated and developed a discharge from the nose; at the end of that time it was killed.

*Autopsy.* Left external jugular vein obliterated and changed to a fibrous cord.

*Lungs.* Upon opening the thoracic cavity, both lungs presented a striking picture. Projecting from the entire pleural surfaces of both lungs there were numerous, generally discrete, pea-sized or larger, firm, light yellow nodules, which on section extend for the distance of from 0.5 to 2 centimetres into the lung substance. These areas are yellow, but are dotted here and there with lighter grayish-yellow apparently softer spots, half a pin-head in size. These nodules are round, their



peripheries are sharply marked off from the surrounding healthy lung tissue, and they are of about the consistence of a fresh pea. On section of both lungs numerous similar bodies were found scattered over the surface, but no cavities or caseous areas were seen. The bronchial glands were enlarged, firm, light yellow on section. The other viscera presented nothing of interest.

Bits of the pulmonary nodules and bronchial glands were teased finely and mounted in equal parts of 5 per cent. KOH and glycerine. A large number of the organisms were apparent in both specimens as highly refractive bodies with a well marked doubly contoured membrane; numerous budding varieties were also found. Fresh sections were placed in 10 per cent. formalin, followed by alcohol, and then stained with Stirling's gentian violet solution and decolorized with acetic acid 1-1000 and oil of cloves (Flexner's method). The nodules were then seen to consist of large central areas of necrosis containing an occasional giant cell and many fat drops, and surrounded by a zone of large epithelioid and lymphoid cells. The parasites are for the most part scattered throughout the necrotic area. The membrane stains dark blue, and the protoplasm a lighter blue, but no further differentiation can be made out. From the study of these bodies in fresh sections it is quite evident that there has been an extraordinary increase of them within the lungs, as from 6 to 10 spores often form the nucleus of an entire colony, and not a great number of these colonies were originally injected. No mycelium was present in the tissues.

*Cultures.*—The surface of the lung nodules was sterilized and relatively large portions were then dissected out with sterile instruments and placed on the surface of tubes of human blood-serum, glycerine agar, and beer-wort agar. In one week typical and pure growths occurred from the edges of the portions of tissue introduced, which consisted of bodies morphologically identical with those described above, and which later formed a profuse mycelium as in the cultures from the original case.

*Pathological Histology.* The smaller nodules scattered through the lung tissue consist of large accumulations of round, oval or elongated epithelioid cells and small round lymphoid cells, together with a moderate number of polynuclear leucocytes. These latter often accumulate around or apparently even invade the interior of some of the parasites which are probably dead. The larger and older nodules have undergone coagulative necrosis and in places contain groups of polynuclear leucocytes. Nodules stained for fibrin and glycogen gave negative results. Sections of pieces hardened in Flemming's solution show numerous large or small black fat drops for the most part within the caseous areas, but at



times they are seen in younger nodules, or in large *Staubzellen* on the edges of the diseased tissue. The younger nodules contain a few giant cells which often include a parasite.

The bronchial glands consist of a mass of confluent pseudo-tubercles intermingled with smaller areas of normal lymphoid tissue. These tubercles contain a number of giant cells, leucocytes and parasites, but show very little necrosis.

Both in the connective tissue of the larger bronchi and in the thick fibrous trabeculae of the bronchial glands there are a number of mast-cells present.

*Exp. 2. Dog 2.* The next animal inoculation was made by injecting about two cubic centimetres of a suspension in sterile bouillon made from portions of the teased nodules of the lung of Dog 1 into the external jugular vein of a second dog.

In about two weeks the animal developed a sniffing cough and showed a well marked secretion of pus from the nose. This condition lasted several weeks, but, although the pus was examined microscopically several times, only one body having some resemblance to the parasite was found.

The animal was killed at the end of two months, and the autopsy showed each lung to contain about twelve firm, grayish-yellow, sharply circumscribed, round nodules, varying in size from a pea to a sparrow's egg, with an average diameter of from one to two centimetres. They are apparent as slight elevations over the surface of the pleurae, and also as circumscribed nodules throughout the lung tissue.

The gross appearance of these nodules in the lungs of both dogs much resembles that of metastatic carcinoma. Nothing else of interest was noticed macroscopically.

The lung nodules from Dog 2, when teased and mounted in salt solution, showed a number of round or oval doubly contoured bodies exactly resembling those obtained from the lung of Dog. 1. The bronchial glands contained no organisms.

Pure cultures of the blastomyces were obtained by spreading large portions of the lung nodules over the surface of beer-wort agar.

On microscopic examination these nodules did not show such marked necrotic areas as were observed in the lungs of the first dog, but they here and there exhibited a tubercular formation with giant cells, epithelioid cells and lymphoid cells. It was not an uncommon thing to find a single adult organism apparently situated in the centre of an alveolus, which was filled up with a large collection of epithelioid cells, with a number of polynuclear leucocytes directly surrounding the parasites (Fig. 2, Plate VIII). This picture shows very closely what was sometimes seen in the



tissues of the original case. The general appearances were those of a chronic inflammation, and one would not be likely to regard the lesions as those of a neoplasm. Organisms of the budding form, without mycelium, were found in all the nodules, but not so many apparently dead forms were seen as in the first dog's lung. Giant cells were not numerous; most of those seen contained one or more parasites.

At the periphery of the younger nodules the alveoli showed marked swelling and projection of the epithelial cells, and often in the centre of an alveolus completely filled with epithelial cells one or more of the parasites could be made out. It would appear that this proliferation forms the beginning of the pathological process.

*Exp. 3.* A guinea-pig was inoculated with a suspension made from the lung nodule from Dog 2 into the peritoneal cavity, but an autopsy two months later showed no pathological lesions.

*Exp. 4. Dog 3.* A third dog received also an intravenous injection of about two cubic centimetres of a bouillon suspension from the lung of Dog 2, and at the autopsy two months later the lungs were seen to contain a moderate number of small, grayish pseudo-tubercles, the size of a pin-head. These nodules when teased in salt solution were seen to contain a few of the parasites and many fatty endothelial cells. The lesions were less marked and fewer than in the two previous dogs, showing that the organism was apparently losing its virulence.

*Exp. 5.* A guinea-pig was inoculated in the peritoneal cavity with some finely teased nodules from the lung of Dog 1. In about two weeks the epididymis on both sides became tense, swollen and painful, and later these swellings opened upon the skin surface and discharged a large amount of pus. This, when examined under the microscope, was found to contain a number of large doubly contoured bodies, many of which possessed small budding knobs and daughter cells. The formation of these knobs was also beautifully shown, and consisted in the rupture of the thick, doubly contoured membrane, and the protrusion through this opening of the protoplasm of the cell surrounded by the thin endosporium. These knobs later became invested by an outer membrane, and daughter cells were thus formed. Cover-slips stained for pus cocci gave negative results. The cultures were not contaminated.

These abscesses gradually healed, and at the autopsy, one month after inoculation, nothing was found except the fibrous scars of the pus cavities.

*Exp. 6. Sheep.* The external jugular vein of a sheep was exposed and 2 cc. of a suspension in bouillon of several fine colonies from a pure culture of the organism derived from Dog 1 were injected into the vein



by a sterilized hypodermic syringe. The needle was simply withdrawn and no ligatures were used.

From time to time a thin purulent secretion from the nostrils was noticed, but no parasites were found in the pus. In about five weeks the animal was killed, and both lungs contained a number of gray, semi-translucent, firm nodules, varying in size from a pin-head to a split pea. These nodules contained numbers of doubly contoured bodies, and a pure culture of the organism was obtained on beer-wort agar. Surrounding the nodules was quite a marked belt of young fibrous tissue.

*Exp. 7. Horse.* Many fine colonies from beer-wort agar culture from the lung nodules of Dog 1 were also teased and suspended in bouillon, and 2 cc. of this fluid were injected into the right external jugular vein of a horse, while at the same time a similar quantity was introduced into the subcutaneous tissues of the neck near the seat of the former injection.

In about thirty days there appeared an indurated abscess, the size of an egg, which soon opened superficially, and discharged a thick, creamy, yellow pus. This abscess was situated about midway between the angle of the jaw and the shoulder, on the right side of the neck, just beneath the seat of local inoculation. The skin over this abscess was shaved and sterilized, the abscess was thoroughly opened, and about 10 cc. of pus was collected in a sterile Petri dish. The opening closed in one week.

Cover-slips from this pus showed that it contained large numbers of doubly contoured refractive parasites, together with many eosinophiles, while cultures on beer-wort agar in one week showed a number of elevated gray, irregular membrane-like colonies. These consisted of doubly contoured blastomycetes, developing hyphæ as in cultures previously described. Plate VII represents a number of the varieties which were found in a teased colony and their method of growth. The tendency of the organism to develop by budding was again more pronounced at first, as in the cultures from the pus obtained from the original case. Although several cultures were made, none of the ordinary pus organisms developed, and cover-slips from pus also failed to reveal any such organisms.

At the end of two months the horse was killed and, although the superficial opening of the abscess had healed, yet in the deeper tissues of the neck a thick fibrous capsule was found surrounding a mass of thick yellow pus, which contained numbers of the blastomycetes.

On opening the thorax the pleural surfaces of both lungs showed a moderate number of firm, yellowish, sharply circumscribed nodules, varying in size from a split pea to an almond. Some nodules contained a central pus cavity, while from others pus could be squeezed as from a



sponge. These nodules were seen throughout the cut surface of both lungs. Neither the bronchial nor the cervical glands were affected, and the rest of the organs were normal.

The cultures from the pulmonary nodules became contaminated, but cover-slips from teased nodules contained typical blastomycetes.

*Exp. 8.* A teased nodule was put into the peritoneal cavity of a guinea-pig and the animal was killed in two months. Just beneath the point at which the tissue was introduced, between a loop of intestine posteriorly and the abdominal wall anteriorly, there were many organisms similar to those described above. It was impossible to take any cultures.

*Exp. 9.* A young pig (not guinea-pig) and several mice were inoculated subcutaneously with the pus from the abscess of the horse, but with negative results.

*Exp. 10.* A number of teased colonies from a beer-wort agar culture from the pus from the horse's neck were introduced into the peritoneal cavity of a guinea-pig, and in two months the animal was killed. On opening the abdomen a pea-sized, ovoid, yellow nodule was found enclosed within folds of peritoneum and attached to the testicle by a fibrous, long, thin pedicle. This mass consisted of a thin capsule, including a mass of soft semi-caseous pus, which contained numerous doubly contoured, refractive bodies. Cultures from the pus on blood-serum showed a pure growth of the parasite.

In addition, an attempt was made to produce a lesion in the liver of a guinea-pig by injecting a teased culture suspended in bouillon from the lung of Dog 1 into the mesenteric vein. At the autopsy about eight weeks later the liver was found to be normal, but at the point of entrance of the hypodermic needle a small abscess had developed. This was hardened in alcohol, and when stained was seen to consist of numerous pus cells and a large number of parasites, including many budding forms. Although the pus from the horse's neck was injected subcutaneously into one guinea-pig, and introduced into the peritoneal cavity of a second animal, the results in both cases proved negative.

Speaking generally, the effects produced on animals were the formation of typical pseudo-tubercles with caseation in the lungs of the first dog; in the second dog the necrosis was not so pronounced, although there was some slight caseation, and in the third dog the lesions were less marked and presented more the characters of foci of chronic inflammation. In the horse a local abscess was formed in the neck at the seat of inoculation and pseudo-tubercular nodules were formed in



both lungs. In the sheep the pulmonary lesions were also of a pseudo-tubercular character. In the three guinea-pigs which were successfully inoculated, encysted abscesses were the result, and a much larger number of organisms were contained in them than were injected.

The parasitic organisms in all the lesions presented the same general features and appeared identical in character with those in the patient. No mycelium was ever found in any of the lesions, although such developed in the cultures.

Many staining methods were tried on the diseased tissues from the animals, but the organism could be distinguished and studied well with the ordinary hæmatoxylin and eosin stain if the sections were thin.

If overstained with the hæmatoxylin the parasites would take up this stain, but if the eosin was used in excess they assumed the latter stain by preference. With the carbolfuchsin and aqueous methylene blue, the organism, particularly in the nodules from the lungs, could be made to acquire a double stain, the capsule being red and the protoplasm blue. The same effect could also be produced with eosin and aqueous methylene blue. Although safranin was tried and the organisms took up the stain well, they were less easily found among the surrounding stained cells. Flexner's method of staining with Stirling's gentian violet and decolorizing with acetic acid caused the parasite to stand out very prominently, but did not differentiate the contents of the organism.

#### CLASSIFICATION.

In our preliminary communication we classed our organism as an oidium for the following reasons: the organism did not ferment glucose, saccharose or lactose, and, although it only developed by gemmation in all the tissues, human and animal, yet upon artificial culture media it developed mycelia with the formation of conidia. After consulting Brefeld's writings, and also after a personal conference with Dr. Erwin Smith of Washington, an acknowledged authority in mycology, we were inclined to consider the parasite as an oidium. On further investigation we find that mycologists are not at all certain about the classification of either the yeast fungi or the oidia. We



find that there are a number of wild yeasts which do not ferment sugar and which form mycelium on the usual bacteriological media. In accordance with the prevailing custom in the nomenclature of organisms presenting characters similar to ours, we now prefer to designate the parasite as a blastomyces rather than an oidium.

#### COMPARISON OF OUR ORGANISM WITH THOSE OF PREVIOUS OBSERVERS.

In Busse's case the primary lesion was thought at first to be a sarcoma and the internal lesions resembled those of chronic pyæmia. Gilchrist's case resembled chronic scrofuloderma of the skin, wherein it resembled one variety of the cutaneous lesions of the present case. Corselli and Frisco described their case as one of sarcoma of the mesenteric glands, and Curtis speaks of his case as a tumor of myxomatous appearance of the thigh and loin.

The lesions in our patient differ then from those in all the previous cases with the exception of Gilchrist's case of blastomycetic dermatitis, in that ours simulated lupus vulgaris, and in the inoculated animals presented lesions somewhat resembling tuberculosis with acute and chronic inflammation. Our organism was also distinctly pyogenic both in the original case and in inoculated animals.

The organism in our case, although apparently differing but little from those described in previous human cases, is markedly distinct in its method of growth on media by profuse mycelium and conidia. In all the other cases the growth has been described as being chiefly by gemmation. In her experimental work on blastomycetes Rabinowitsch demonstrated that a number of wild yeasts which were pathogenic in animals did not ferment sugar and formed mycelium. Whether all these parasites have the power of producing different pathogenic pictures according to the organism which they attack, or whether they are varieties of the same species, is a question which is very difficult of solution in the present crude state of our knowledge regarding this class of micro-organisms.

#### COMPARISON OF OUR ORGANISM WITH THE SO-CALLED CANCER PARASITES.

As we have already mentioned, many of the investigators who have reported cases where blastomycetes were believed to be the cause



of pathogenic lesions, have made the assertion that the bodies present in cancerous tissues, which some previous observers had wrongly described as protozoan parasites, are really blastomycetes. Not a few authors have also described many of the lesions which have been produced in animals by inoculation with blastomycetes, as genuine neoplasms, and have adduced these in support of the parasitic origin of malignant tumors. Sanfelice, especially, described the lesions produced in the mammary glands of a bitch and in the comb of a cock as presenting a carcinomatous appearance. Sanfelice, Roncali, Kahane, Binaghi and others have also asserted that the curious bodies which are often found in sarcomatous and epitheliomatous tissues are really blastomycetes, although they have failed to obtain them in cultures and have not succeeded with inoculation experiments. One of us (Gilchrist) has already made comparison between the blastomycetes which he found in his case and the so-called parasites in twenty-three cases of epithelioma of the skin, and demonstrated that there were very few points of resemblance between these forms. He concluded that the evidence appeared to be strongly against the idea that the bodies found in cancer are blastomycetes. We have compared our parasites in this case again with the so-called cancer parasites, and feel still more strongly in favor of the view that the bodies found in cancer are really the result of epithelial degeneration. The same arguments can be presented here against the view that the cancer bodies are blastomycetes, which one of us (Gilchrist \*) advanced in regard to these bodies being considered as protozoa. These are mainly as follows: (1) The so-called cancer parasites found in twenty-three cases of cancer, five of which were of the lip, bear very little resemblance to the blastomycetes either of Gilchrist's case or the present one. (2) They are by no means present in every case of undoubted cancer. (3) They are often found in other diseases, *e. g.* in benign growths of the skin, in tuberculosis cutis, in syphilitic ulcers of the skin, and in other cases. (4) There is an entire absence of uniformity in the appearance of the cancer bodies, those described for one case being often entirely unlike those seen in another. (5) The descriptions given of developmental stages are

\* *Johns Hopkins Hospital Reports*, i.



vague and by no means convincing. (6) Special stains and refined technique are required to bring out many of the so-called cancer parasites, whereas the blastomycetes are demonstrable by all methods and stain readily. (7) The blastomycetic dermatitis of Gilchrist's case and the present one do not approach the clinical or pathological characters of epithelioma, but bear more resemblance to tuberculosis of the skin. (8) No positive results have ever been obtained from the numerous inoculation experiments which have been made. (Roncali has isolated what he calls a blastomyces from an epithelioma, but one can often cultivate many kinds of fungi from superficial epitheliomata.) (9) The ready demonstration of the blastomycetes by liquor potassæ does not apply to the so-called cancer parasites.

The theory of the blastomycetic origin of malignant tumors has also received little support from experimentation. Shattock and Balance made a large number of cultures from malignant tumors upon all of the various culture media, but with negative results. At the suggestion of Dr. Flexner we have also made cultures upon beer-wort agar (the most favorable medium for yeasts) from about ten sarcomata and carcinomata. Our method consisted in sterilizing by heat both sides of a small block of tumor immediately after removal, and then punching out a cylinder with a sterile trochar, teasing the tissue in a sterile Petri dish, and plating the finely divided tumor in beer-wort agar. The plates usually remained sterile, and although an occasional colony developed this never consisted of yeasts. The plates were observed for weeks. The theory of the blastomycetic origin of malignant tumors, we think, needs much more confirmatory evidence before it can be accepted.

#### TREATMENT.

We had intended to place the patient under the influence of ether and curette the cutaneous lesions very thoroughly, and then apply the nitrate of silver stick to the denuded surface. In view of the fact that the parasites were not very numerous and the course of the disease had shown itself to be exceedingly chronic, we considered we had good reasons for supposing that the disease could thus be easily cured, especially since the neighboring lymphatic glands were unaffected. But



the patient was called away from the hospital on account of the serious illness of his wife, and he has remained without treatment up to the present time. We received a letter from him recently, six months after he left the hospital, in which he says that his face and eyelids have almost healed up. The disease, all through its course, has shown a strong inclination to spontaneous cure. The prognosis, in our opinion, therefore, is good.

#### SUMMARY.

The case reported in this article is one of a somewhat extensive cutaneous disease, which occurred in a man, 33 years of age, who gave the following history: The disease first made its appearance, eleven and a half years ago, at the back of the left ear, as a pimple which soon became pustular. The process extended forward very slowly and gradually encroached upon and covered almost the entire face, the central portion of which now presents an atrophic cicatricial condition. Another similar lesion occurred, one month after the primary invasion, on the back of the hand, which healed in about four years, after treatment with caustic. A third lesion appeared on the right side of the scrotum (six months after), which increased in size for a year and then healed spontaneously. A fourth inoculation appeared on the anterior surface of the left thigh just above the internal condyle, and grew for a year, after which it gradually healed spontaneously. A fifth lesion appeared on the back of the neck and also healed spontaneously after growing for a year. The disease when first examined presented many of the features of a lupus vulgaris.

There were no enlarged lymphatic glands and the patient's health had always been good. The family and personal history revealed no syphilitic or tuberculous taint.

Sections from the cutaneous lesions showed the presence of what appeared to be budding blastomycetes. The sections also presented pathological features similar to those seen in the first case recorded by Gilchrist; in many sections almost typical tubercles were found.

The organisms in the tissue are chiefly spherical, unicellular bodies varying from  $10-20\mu$  in diameter, and consist of a doubly contoured membrane, which encloses a fine granular protoplasm with sometimes



a vacuole. Many budding forms in various stages were found; no nucleus could be demonstrated, neither were any mycelium or hyphæ present in the tissues. The parasites were almost always found outside of cells, comparatively few being enclosed in giant cells.

Pure cultures of the organism were obtained directly from the cutaneous lesions in two places from the pus squeezed out from between the papillomatous variety of the lesion. The organism grew on all ordinary media, and especially well on potato and beer-wort agar. The cultures showed both budding forms and a fairly profuse mycelium. Older cultures, carried through many generations, produced sometimes little or no mycelium. The organisms in the cultures were round, ovoid, doubly contoured, refractive bodies, varying in size from about 10 to 20 $\mu$  in diameter. The mycelium was, on rare occasions, of two varieties, very fine and also coarse with sessile buds and conidia.

Dogs, a horse, a sheep and guinea-pigs were successfully inoculated, the most striking results being nodules, grossly simulating tumors, in the lungs. Microscopically these nodules were of a chronic inflammatory nature and contained numerous parasites identical in appearance with those in the patient. In the tissues of none of the animals successfully inoculated was any mycelium found. Since our organism did not ferment sugar and produced in cultures mycelium, it may either belong to the blastomycetes or to the oidia, but in conformity with prevailing nomenclature we regard it as a blastomyces.

We shall term the disease which has been produced by this organism *Blastomycetic Dermatitis*. We give the name *Blastomyces dermatitidis* to the parasite which we have isolated and described in this paper.

In closing we are of the opinion that it would be advisable to examine more carefully all tuberculous lesions of the skin, and especially those of tuberculosis verrucosa cutis, for the presence of blastomycetes. This can be readily and rapidly done by soaking the unstained sections in ordinary liquor potassæ, when the organisms if present will stand out as doubly contoured refractive bodies.



## DESCRIPTION OF PLATES IV-VIII.

## PLATE IV.

Photograph of patient showing the cutaneous lesions of blastomycetic dermatitis.

## PLATE V.

Fig. 1 represents a microscopic section of blastomycetic dermatitis. The epidermis (*e*) is hypertrophied and encloses numerous miliary abscesses (*a*), which contain the parasitic organisms (*p*). In the corium (*c*) miliary abscesses (*b*) are also present as well as pseudo-tubercles (*n*), which enclose parasites (*p*). The corium is filled with masses of granulation-tissue cells and contains a few scattered giant cells (*G*).

Figs. 2-16 represent various forms of the blastomycetic parasite as observed in the tissues of the patient. Various stages of the budding process are shown. The refractive double contours of the enveloping membrane and the protoplasmic contents of the parasite are depicted. The organisms drawn in Figs. 8 and 9 appeared to have an outer irregular fibrous coating. Fig. 16 shows a group of parasites in the corium.

## PLATE VI.

Figs. 1-21 represent various growth-forms as observed in a colony of the blastomyces cultivated in a hanging drop of gelatine on the slide. Figs. 6, 7, 10, budding yeast forms. Figs. 16, 17, 18, beginning development of hyphæ. Other figures show various mycelial developmental forms with conidia. Fig. 22, crystal of calcium oxalate.

## PLATE VII.

Figs. 1-16 represent a number of varieties of the developmental stages of the blastomyces as obtained from a colony from the pus produced in the horse's neck. Fig. 1 is a single round organism with a large clear space in the centre. Direct budding forms are seen in Figs. 2, 4, 14 and 16. A sessile bud on mycelium is shown in Fig. 8. Mycelial threads forming from the organism are seen in Fig. 3, whereas in others the mycelium shows attempts at forming the round or oval form directly in the axis.

## PLATE VIII.

Fig. 1 shows a small miliary abscess situated in the epidermis. It contains two parasites, a number of polynuclear leucocytes, nuclear fragments, and nuclei of detached epithelial cells.

Fig. 2 represents a portion of one of the most recently formed nodules from the lung of the first dog inoculated. The organism is in the centre, a number of polynuclear leucocytes lie between the parasite and the epithelioid cells, and lymphoid cells constitute the peripheral portion.

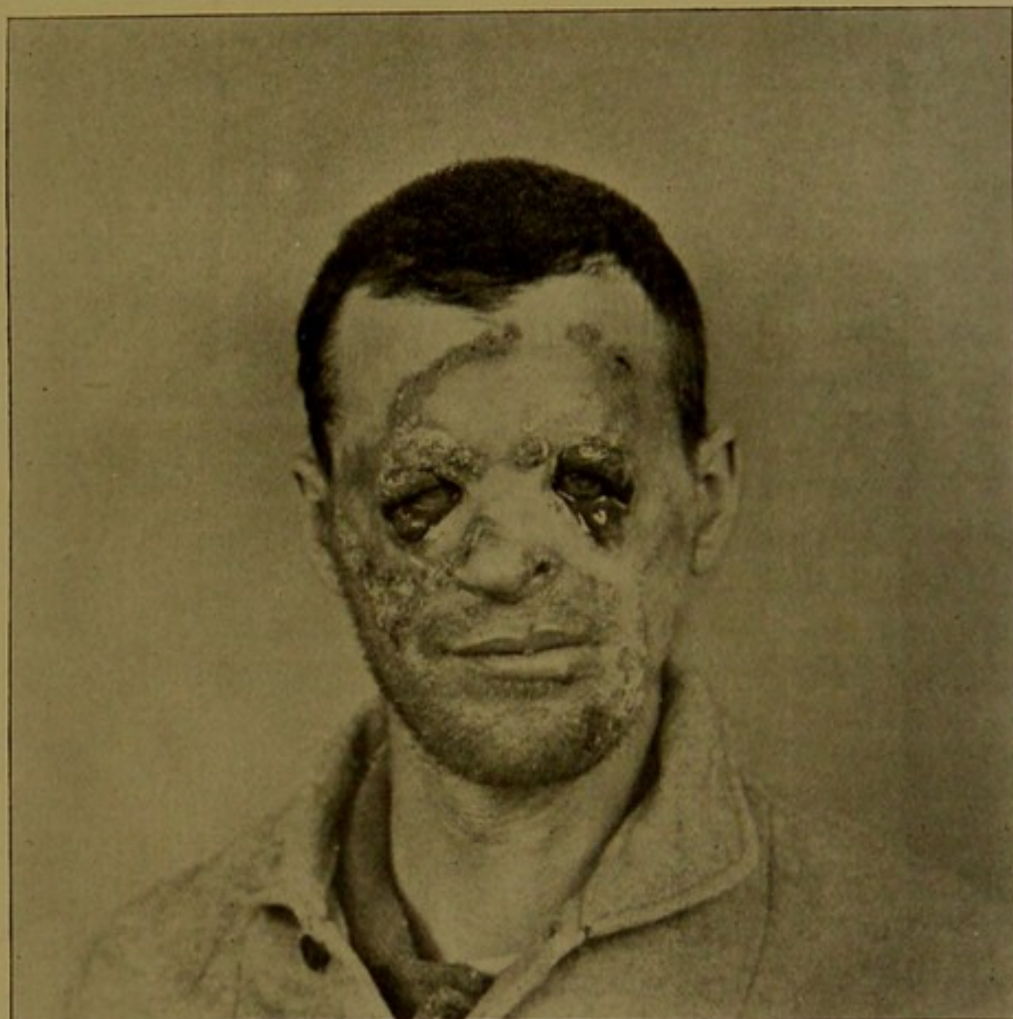
Figs. 3, 4 and 5 show giant cells which were found in the deeper portion of the corium of the patient's cutaneous lesions. The vacuole in the parasite and the budding are well marked in Fig. 5.



## REFERENCES TO LITERATURE.

- Aievoli.—*Il Policlinico*, ii (1895).  
 D'Anna.—*Ibid.*, ii (1895).  
 Binaghi.—*Zeitschr. f. Hyg.*, xxiii (1896).  
 Bollinger.—*Virchow's Archiv*, lviii (1873), 349.  
 Brefeld.—*Landw. Jahrbücher*, iv, and *Botanische Untersuch. üb. Hefenpilze*.  
 Busse.—*Centralbl. f. Bakt.*, xvi (1894), 175; *Virchow's Archiv*, cxl (1895), 23; cxliv (1896), 360; *Die Hefen als Krankheitserreger*, Berlin, 1897.  
 Casagrandi.—*Riforma med.*, 1897, No. 265.  
 Corselli and Frisco.—*Centralbl. f. Bakt.*, xviii (1895), 368.  
 Curtis, F.—*Presse méd.*, 1895, Sept. 28, and *Ann. d. l'Inst. Pasteur*, x (1896), 449.  
 Fermi and Aruch.—*Centralbl. f. Bakt.*, xvii (1895), 593.  
 Gilchrist.—*Duhring's Cutaneous Medicine*, Part I, p. 157, Philadelphia, 1895. *The Johns Hopkins Hospital Reports*, i, 269 and 291.  
 Gilchrist and Stokes.—*Bulletin of the Johns Hopkins Hospital*, July, 1896, No. 64, 129.  
 Kahane.—*Wiener med. Presse*, 1895, No. 14. *Centralbl. f. Bakt.*, xviii (1895), 616.  
 Maffucci and Sirleo.—*Centralbl. f. allg. Path. u. path. Anat.*, vi (1895), 305 and 438.  
 Neumayer.—*Arch. f. Hyg.*, xii (1891), 1.  
 Rabinowitsch.—*Zeitschr. f. Hyg.*, xxi (1896), 11.  
 Raum.—*Ibid.*, x (1891), 1.  
 Rivolta and Delprato.—*L'Ornitopatologia*, Pisa, 1881, p. 269.  
 Roncali.—*Centralbl. f. Bakt.*, xviii (1895), 353 and 432; xx (1896), 481; xxi (1897), 318, 394 and 517.  
 Rossi Doria.—*Il Policlinico*, 1895.  
 Sanfelice.—*Centralbl. f. Bakt.*, xvii (1895), 113 and 625; xviii (1895), 521; xx (1896), 219; *Zeitschr. f. Hyg.*, xxi (1896), 32 and 394; xxii (1896), 171; xxvi (1897), 298.  
 Secchi.—*Monatshefte f. prakt. Dermat.*, 1896, 509.  
 Shattock and Ballance.—*Brit. Med. Jour.*, 1887, ii, 929; 1891, i, 565.  
 de Simoni.—*Centralbl. f. Bakt.*, xxii (1897), 120.  
 Tokishige.—*Centralbl. f. Bakt.*, xix (1896), 105.

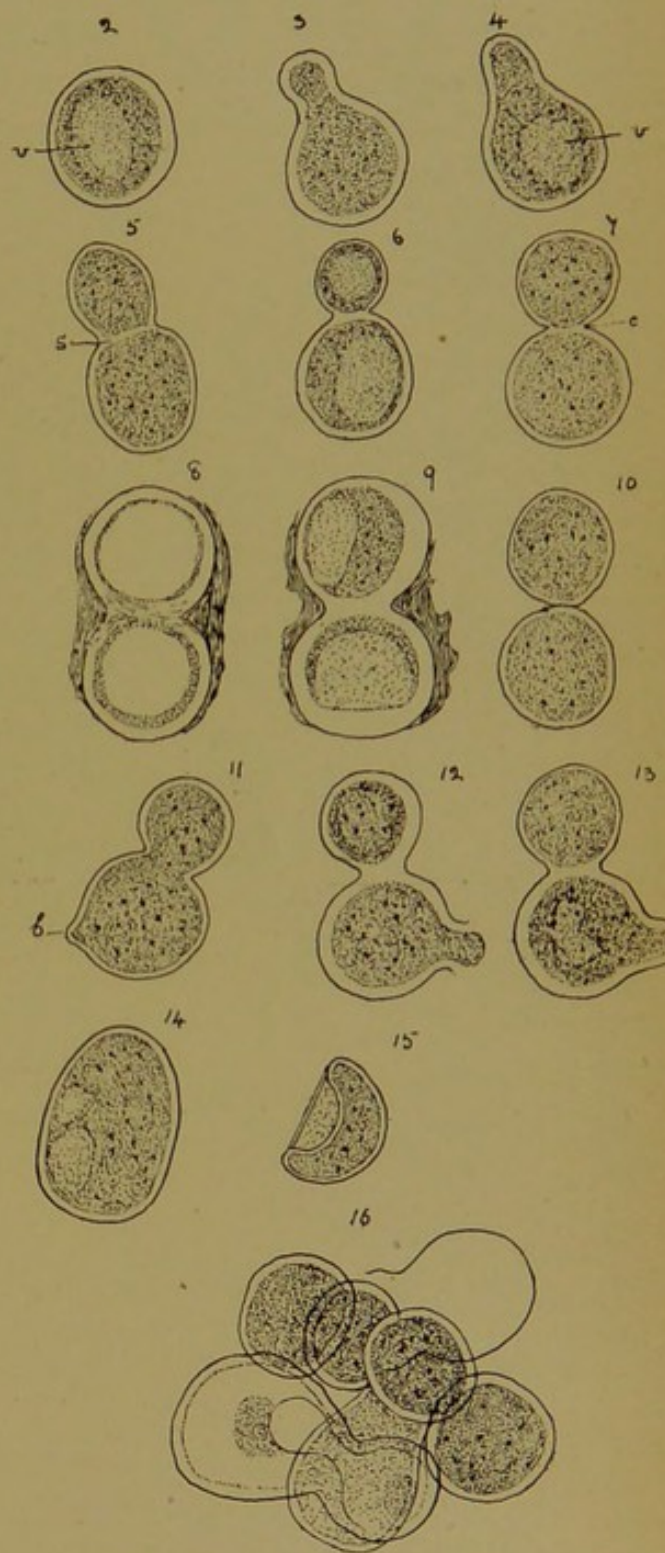
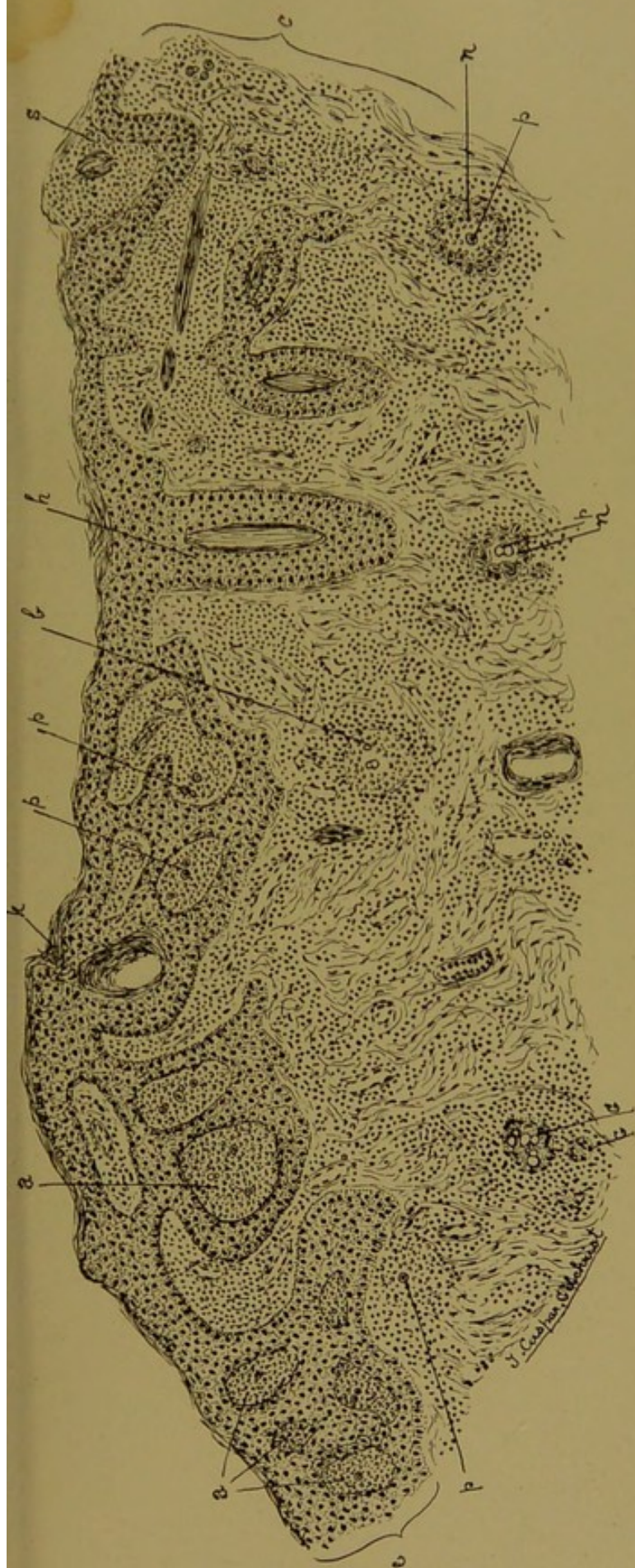








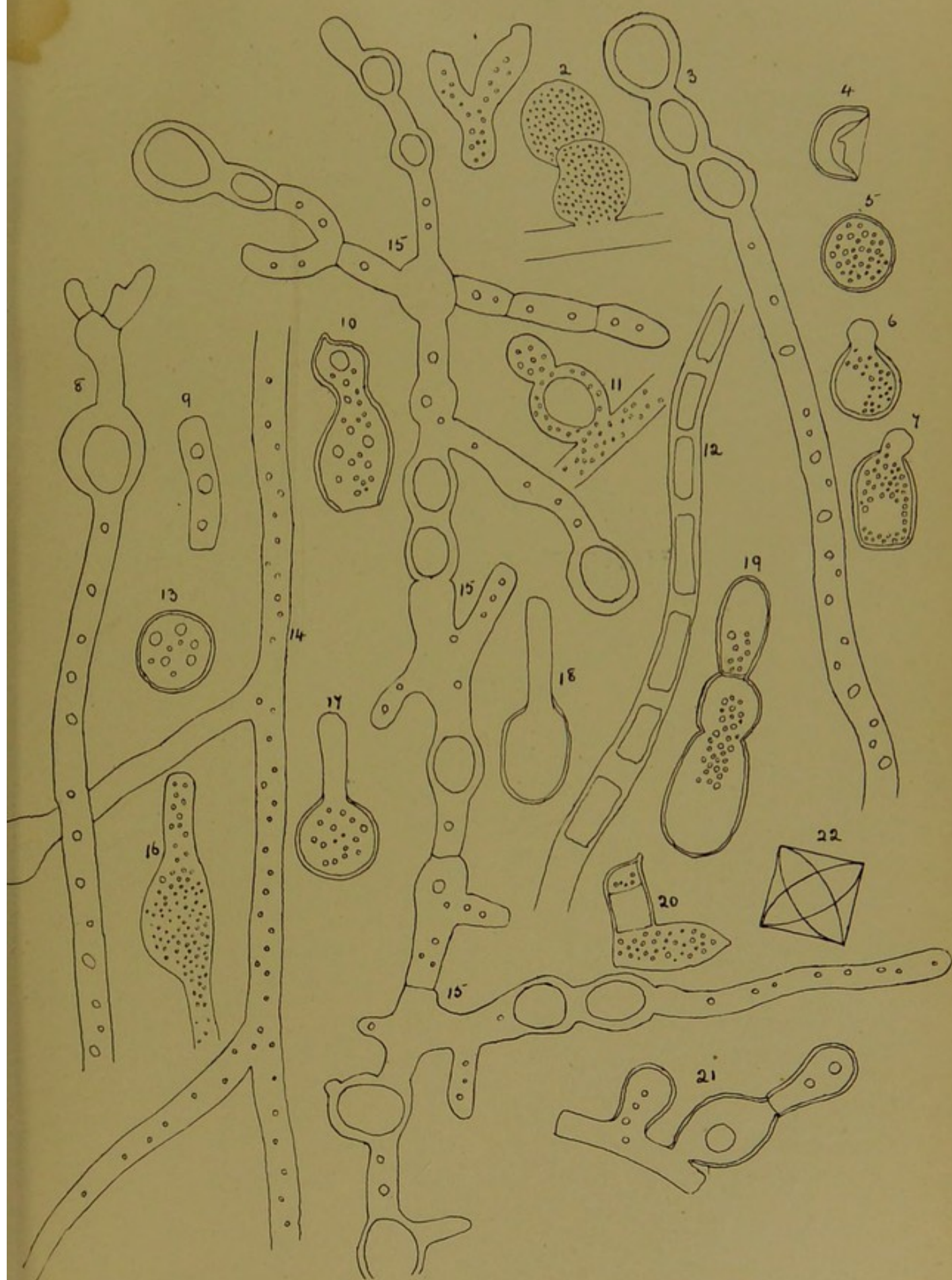








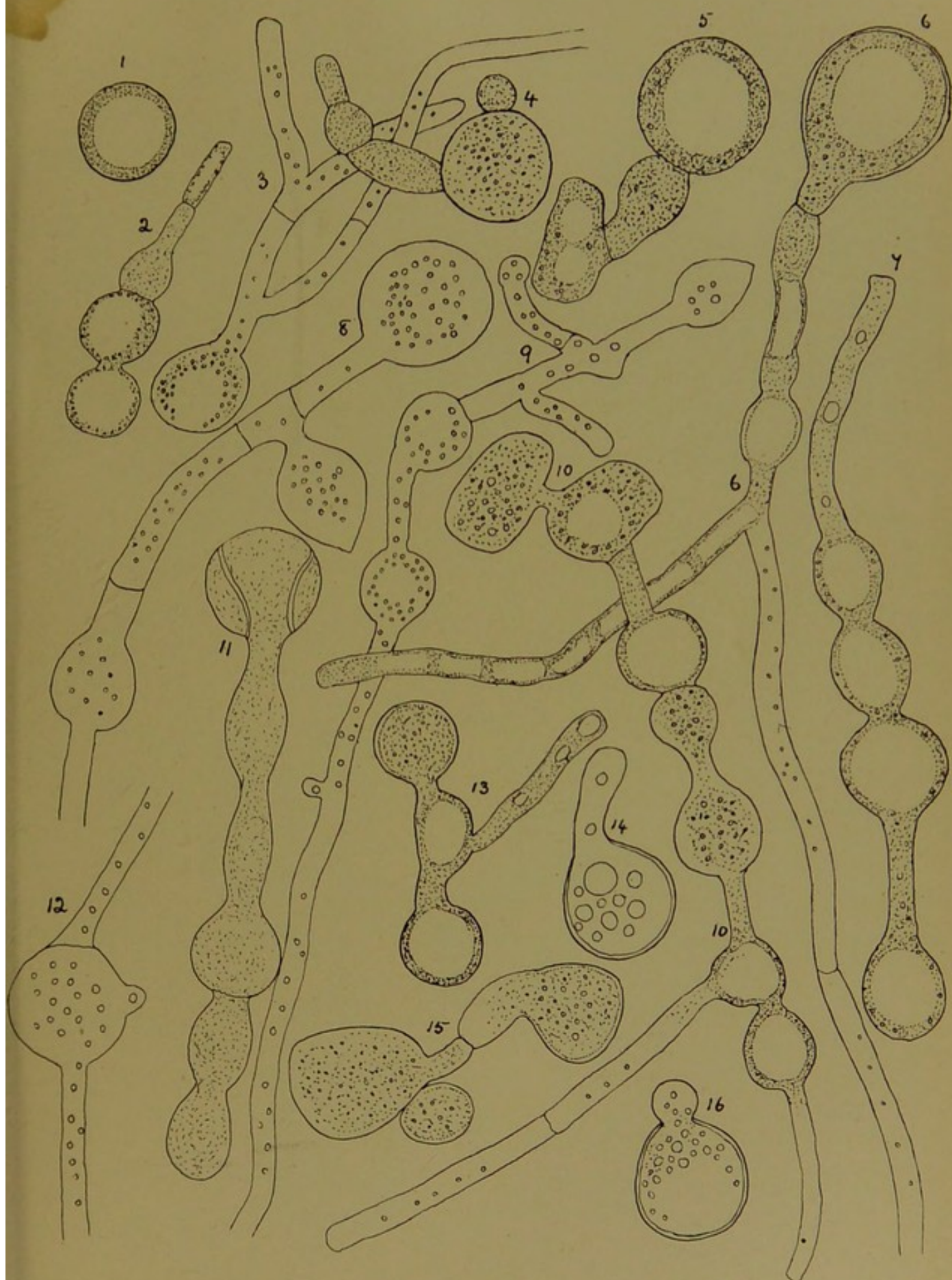










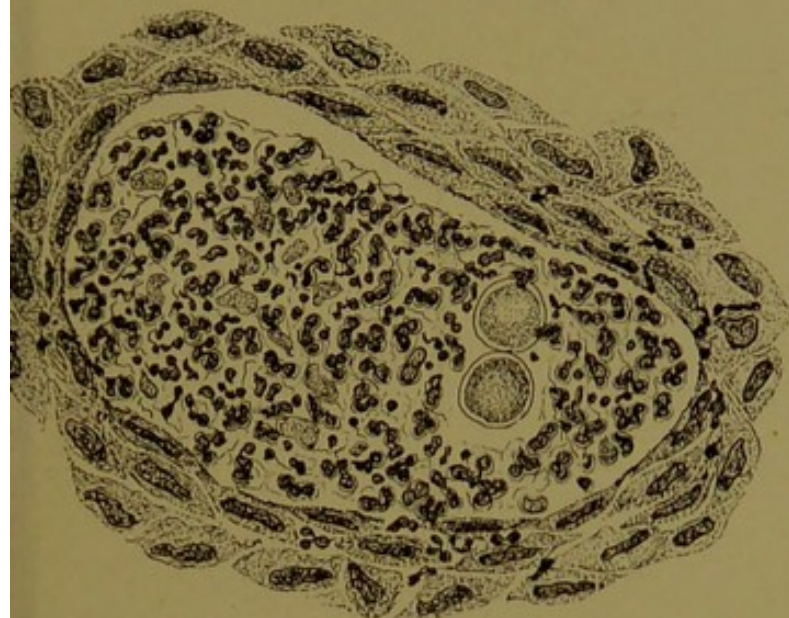



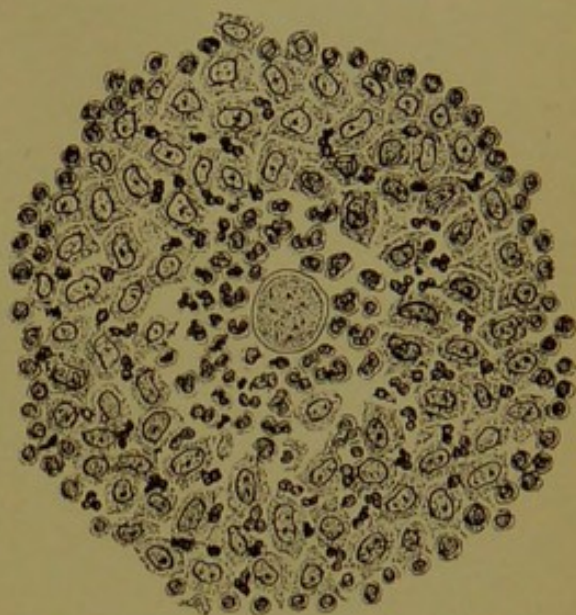




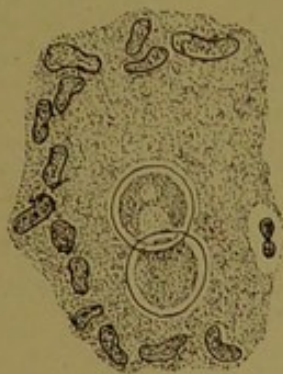
1



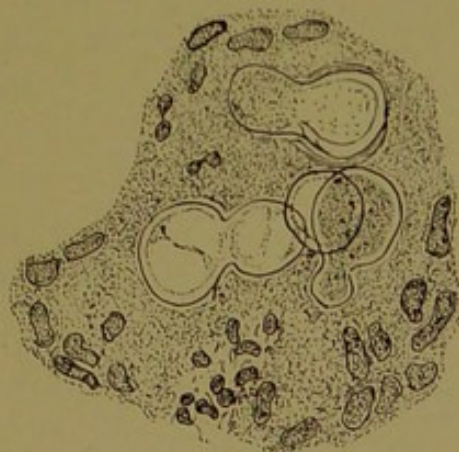2



3



4



5





