

On the surgical treatment of lupus / by William Anderson.

Contributors

Anderson, William, 1842-1900.
Royal College of Surgeons of England

Publication/Creation

London : Printed by Adlard and Son, 1897.

Persistent URL

<https://wellcomecollection.org/works/sxmdxhep>

Provider

Royal College of Surgeons

License and attribution

This material has been provided by This material has been provided by The Royal College of Surgeons of England. The original may be consulted at The Royal College of Surgeons of England. where the originals may be consulted. This work has been identified as being free of known restrictions under copyright law, including all related and neighbouring rights and is being made available under the Creative Commons, Public Domain Mark.

You can copy, modify, distribute and perform the work, even for commercial purposes, without asking permission.




Wellcome Collection
183 Euston Road
London NW1 2BE UK
T +44 (0)20 7611 8722
E library@wellcomecollection.org
<https://wellcomecollection.org>

ON THE 13
SURGICAL TREATMENT OF
LUPUS.

BY

WILLIAM ANDERSON, F.R.C.S.,
SURGEON TO THE HOSPITAL.



Reprinted from Vol. XXV of 'St. Thomas's Hospital Reports.'

LONDON:
PRINTED BY ADLARD AND SON,
BARTHOLOMEW CLOSE, E.C., AND 20 HANOVER SQUARE, W.
1897.



ON THE SURGICAL TREATMENT OF LUPUS.

—
BY WILLIAM ANDERSON, F.R.C.S.,
SURGEON TO THE HOSPITAL.

THERE are few diseases of a chronic type that have brought more disappointment and less success to the physician and surgeon than lupus. Drugs have been found almost powerless for good; the strongest caustics, chemical or thermal, have seldom done more than supplement the ravages of the disease; the growth has been scraped out of its bed by the curette, only to reappear before nature has found time to repair the surgical injury; the knife, timidly used, has had no better result, and bacteriology has only suggested possibilities in the future. Lupus is still as defiant as in the dark ages.

This obstinate resistance against local treatment is a curious problem. The affected tissues show fair evidence of natural reparative force,—in fact, more or less repair almost always goes hand in hand with the destruction; the disease almost invariably confines its ravages to the superficial structures, skin, or mucous membrane, in which it originates; it rarely manifests any of the fatal tendency so conspicuous in the typical malignant growths, to migrate to other parts through the lymph or blood stream; and yet surgery has been able to attain a far greater success in the extirpation of cancer than in that of lupus. Lupus is now recognised as a tuberculous affection, slower in progress and more easy of access than tuberculous disease

of the bones and joints ; but while the surgeon attacks the white swelling or the caries with good hope of a cure, he is thwarted by a patch of lupus no bigger than the palm. The explanation probably is that a bold and skilful surgery is usually exercised in the one case, and only half-hearted measures in the other. While a cancer of the tongue or of the breast, a tuberculous knee or tarsus, has been from the first in the hands of the surgeon, and treated in accordance with the most recent developments of his science, the local treatment of lupus is only just emerging from the mediæval phases. The aim of the surgeon in his treatment of cancer is to remove the whole of the disease, not only the part that is visible to the eye, but that which he knows to exist outside the obvious focus ; the dermatologist is too often content to burn his lupus with caustics, or to scoop out the obvious nodules that yield with such fatal facility to his curette, rarely attempting to deal with the apparently healthy tissues which conceal the bacillary sappers and miners who are at work in advance of the main body. It is the timidity which has respected the infected skin and subcutaneous tissue lying beyond the macroscopic disease that has brought so much disappointment to the operator : the new growth must of course be removed, but with it must go the infecting area beyond, or our labour is lost. This infection has been traced in the skin, or mucous membrane and subjacent tissue bordering the growth, and beneath and even within the fibres of the cicatrix left by the disease or the surgeon, and is always most virulent in the tissues on the spreading side of the growth. Unless these facts are borne in mind the surgical treatment is likely to be of little avail.

The problem of local extirpation is only in course of solution, but even when it is solved the triumph will still remain incomplete. However completely the local disease for which the patient consults us may be removed, the constitutional predispositions remain, and are only to a limited extent under control. Hence we cannot prophesy that a person who has been delivered from a patch of skin tubercle by the skill of the surgeon will not become subject to another outbreak in a near or distant part of the

surface; but we should be able to look forward with fair confidence to the local success of any individual operation, and we can promise an easy victory over any new manifestation that is brought at once under observation, and not fostered by delay and irritated by half-measures. At some future time we may hope that the advance of sanitation will confine the prevalence of the tubercle bacillus within comparatively harmless limits, or that a successful form of preventive inoculation on Jennerian lines may be discovered, and mankind so delivered from its most terrible scourge; but in the meantime we must do our best to improve the materials and methods at our command.

Setting aside the general treatment of lupus, which of course must vary with the special circumstances of each case, the available remedies for the disease may be classified as follows:

1. The internal administration, by injection or otherwise, of materials which are believed to affect specifically the seat of disease through the blood. Under this heading come tuberculin and thyroid extract.

2. Local inoculation with common pyogenic or other organisms, with the object of destroying the tubercle bacillus, and so enabling the diseased tissues to right themselves.

3. Destruction of the affected area by chemical or thermal agents.

4. The use of operative measures either for the direct removal of the disease, as by erosion or excision; or to induce its disappearance indirectly, as by scarification.

To these may perhaps be added hereafter the possibility of transmitting through the affected tissues radiant energies, comparable to the X rays, that may destroy the causative organisms without inflicting serious injury upon the tissues.

The specific measures to which attention has most recently been drawn are two: the Tuberculin of Professor Koch, and the internal administration of Thyroid Extract. Of tuberculin it is only necessary to say that its almost complete disuse must be taken as a verdict, but only as a temporary one. It must not be forgotten that it has been proved possible to storm the tubercle bacilli in their very citadels; and although this may not be safely and effectually

done by tuberculin, even in its newly modified form, the means will sooner or later be perfected, and the result will be one of incalculable magnitude for the benefit of mankind. For the present, however, we can only await a further development of the new researches.

The use of Thyroid Extract stands upon a far less scientific basis, and all that can be said for its results is that they are perhaps better than might have been expected. So far it has been shown that a certain proportion of cases of lupus subjected to favorable hygienic and dietetic conditions, and treated with the extract, may improve up to a certain point. I believe it would be difficult to produce a single example of a complete and lasting cure, but on the other hand I have seen a few cases deteriorate both locally and constitutionally under its influence. That some such remedy, capable of acting specifically upon the growth, may hereafter be discovered is more than possible, but we have no reason to believe that the remedy in question is thyroid extract.

There are yet other agents besides tuberculin to which bacteriological theory has drawn attention, agents locally directed, but yet scarcely coming under the head of surgical treatment. We have had many dreams in recent years of pitting an organism of a manageable nature against another of a more ferocious strain, and there has been some accidental evidence to encourage an experimental application of the idea. It has been noticed from time to time that when a patient suffering from lupus contracts erysipelas, the former disease may undergo a remarkable improvement, or even a temporary cure. We have also seen an erysipelas of the scalp lead to a vigorous new growth of hair upon a head almost denuded of its covering by *seborrhœa sicca*, a disease that all dermatologists now regard as microbic in origin; and huge fibromata of the skin and cellular tissue have almost entirely melted away under the same influence; but there is nearly always the "almost" in the record of a favorable result. It is rarely that the improvement, when it does happen, is more than a passing one; and before we act upon the suggestion of an intentional inoculation of one disease to cure another we must remember that the experiment may prove dangerous as well as inefficacious.

The power of the X rays to destroy certain micro-organisms has opened up a new possibility, and the striking influence exerted by their transit through the integuments in certain individuals is suggestive of a therapeutic use in skin diseases, and particularly in lupus. I am at present, in conjunction with my colleague Dr. Barry Blacker, initiating some experiments to test the question, but it is too early to speak of these yet. We are driven, then, for the present, to treatment of a local character; and here, fortunately, we may show results that have withstood the test of time.

We have the choice of measures which involve a surgical operation, and of those which do not. The physician naturally prefers the latter, and it has been chiefly through his investigations that our resources in the direction of external applications have been so greatly enlarged.

Of the *non-operative* means I shall say little, for the story is so old. We may destroy a patch of lupus by the actual or galvano-cautery, or by caustics either of a selective or of an indiscriminating kind. Of the discriminative caustics, which act by preference upon the unstable lupous growth, while they are resisted by the healthy tissues, arsenic, pyrogalllic acid and salicylic acid may be taken as types. The indiscriminating caustics, which destroy healthy and diseased structures alike, are exemplified by nitrate of silver, chloride of zinc, the mineral acids, and caustic potash. I have employed some of both groups in the milder and more superficial forms of lupus with benefit, and with still greater profit have made use of them as accessories after operation; but as the sole agents in the cure of severe cases I have found them almost uniformly disappointing, and occasionally more than disappointing, for they may irritate a quiescent growth to disastrous activity.

The *operative* measures of scarification, erosion, and excision, all of comparatively recent date, are all of value if boldly and skilfully applied.

Scarification, as perfected by Vidal, does not aim at immediate ablation of the growth. It merely cuts up the morbid tissue into minute segments, apparently leaving the infective organisms to the vengeance of the phagocytes attracted to

the part by the surgical summons. The theory is not very satisfactory, and the results are little more so; but with certain modifications the method may be used with advantage in the more superficial forms of the disease, including lupus erythematosus. When successful it is eminently so, for it leaves a scar that is superior in pliancy, colour, and absence of contraction or hypertrophy, to that which follows any other treatment. The object of the surgeon is to "cross-hatch" the lupous tissue as minutely as possible down to the fibrous bed, a process which requires much experience and delicacy of touch, since a section that falls short of the entire thickness of the new growth will be inefficacious, while one that goes too deep may give rise to troublesome bleeding. The lines should cross in four directions, and should extend about a quarter of an inch outside the apparent area of disease. Various instruments have been recommended for the purpose, but in my experience a common scalpel is the best, as the value of every stroke is appreciated by the finger of the surgeon. In any case the process is painful and sanguinary, and if a large extent of surface is to be dealt with an anæsthetic should be administered.

The "mincing" having been completed, and the bleeding arrested, I have found the immediate application of a 5 per cent. solution of carbolic acid a valuable addendum, and this may be followed by the application of a salicylic ointment, 20 grains to the ounce. By this means large patches have been cured which had resisted all other treatment for years. Scarification, however, is useless for a lupus vulgaris of any great depth, as the nodules will inevitably reappear in a short time, even invading the very centre of the area treated.

Erasion, or scraping, a process initiated by Fischer, of Cologne, is the means at present most in favour with dermatologists. Unlike scarification, it aims at the removal of the cell-growth by a sharp-edged spoon or ring-shaped blade, leaving the defensive wall of fibrous tissue by which the surrounding structures endeavour to circumscribe the spread of the disease. The shape and size of the instrument selected will of course vary with the extent and form of the disease. A small spoon-shaped instrument is suitable

for the little nodules, a larger ring curette for wide areas ; but whatever be the tool, it must be used with energy and judgment. All that is to be done on any individual patch should be completed at one sitting, and if possible the whole area of disease should be attacked at the same time. The edge of the curette must be carried everywhere boldly down to the fibrous bed ; and the growing margins, whether solid or undermined, should be scooped away with especial care. The imperfectly formed cicatricial pellicle which often covers in a part of the disease must never be spared, but must be scraped off, together with the thin layer of cell-growth nearly always found beneath it. A hesitating use of the instrument is worse than useless. Considerable force may and should be employed, and the immediate result will be a gap in the textures that looks far larger than might have been expected from the appearance of the disease before the operation began. The greater part of the new growth will have offered little more resistance to the curette than firm jelly, but as the fibrous bed is approached more force is required, and the difficulty will often be greatest where a thin and deceptive epidermic covering has been thrown over the still unhealed disease.

The process, if efficiently carried out, is even more painful and bloody than that of scarification, and calls for a general anæsthetic. Cocaine and its allies are of little or no service as substitutes for chloroform or ether.

The operation over, the bleeding may be allowed to cease spontaneously, or may be arrested by a styptic powder, such as tannic acid. The wound may finally be dressed with iodoform powder, or covered with a salicylic acid ointment.

The first effects of erosion are remarkable ; the area treated quickly assumes a healthy aspect, new epidermis is formed both marginally and centrally, and the whole sore gives a promise of complete and early repair, that unfortunately is seldom destined to fulfilment. Bye-and-bye, nodules show themselves about the borders of the healing patch ; the area of cicatrization, at first thin, even, and transparent, becomes thickened into unsightly ridges, and assumes an unwholesome, veal-like whiteness, diversified by tiny blood-vessels ; and yet a little later the surgeon has the

annoyance of realising that he must begin afresh. Of course this disappointment is not invariable or absolute, but no surgeon of experience will have the boldness to promise a patient with lupus that erasion will cure the disease.

The reason of the frequent failure of the operation, even in the best hands, is that already given. The curette is arrested by the fibrous floor and wall which apparently limit the new growth on all sides; but unfortunately the limitation is only apparent, for the fibrous tissue that resists the instrument is already invaded, and sooner or later will produce a new crop of the apple-jelly-like material by which the disease signalises its presence. The "keloid" thickening of the new cicatrix is not a mere "hypertrophy" of scar, it is a scar lupus; and new nodules will show themselves not only at the margins, but may appear in the very midst of the seemingly healed surface. To prevent this failure various supplementary measures have been added to the curettage. Caustics of different kinds have been applied after the scraping has been completed, and the knife has been employed in a manner that will be referred to later. In former years I was in the habit of applying caustic potash to the scraped area and about the spreading border immediately after the operation, neutralising the alkali with acetic acid as soon as the required effect was judged complete; the surface was then dusted over with iodoform, which formed with the mingled blood and chemical products an aseptic scab that remained until the healing process was complete. The result was often excellent; but I have since replaced the potash by an ointment of salicylic acid in the proportion of 20 or 30 grains to the ounce of vaseline, with 20 or 30 minims of creasote. Under this cicatrisation goes on with remarkable quickness, and the scar is of a more satisfactory kind. Chloride of zinc paste and many other chemicals have also been used with the same purpose in view—the destruction of germs that might otherwise provoke renewed mischief after the curette had done its work.

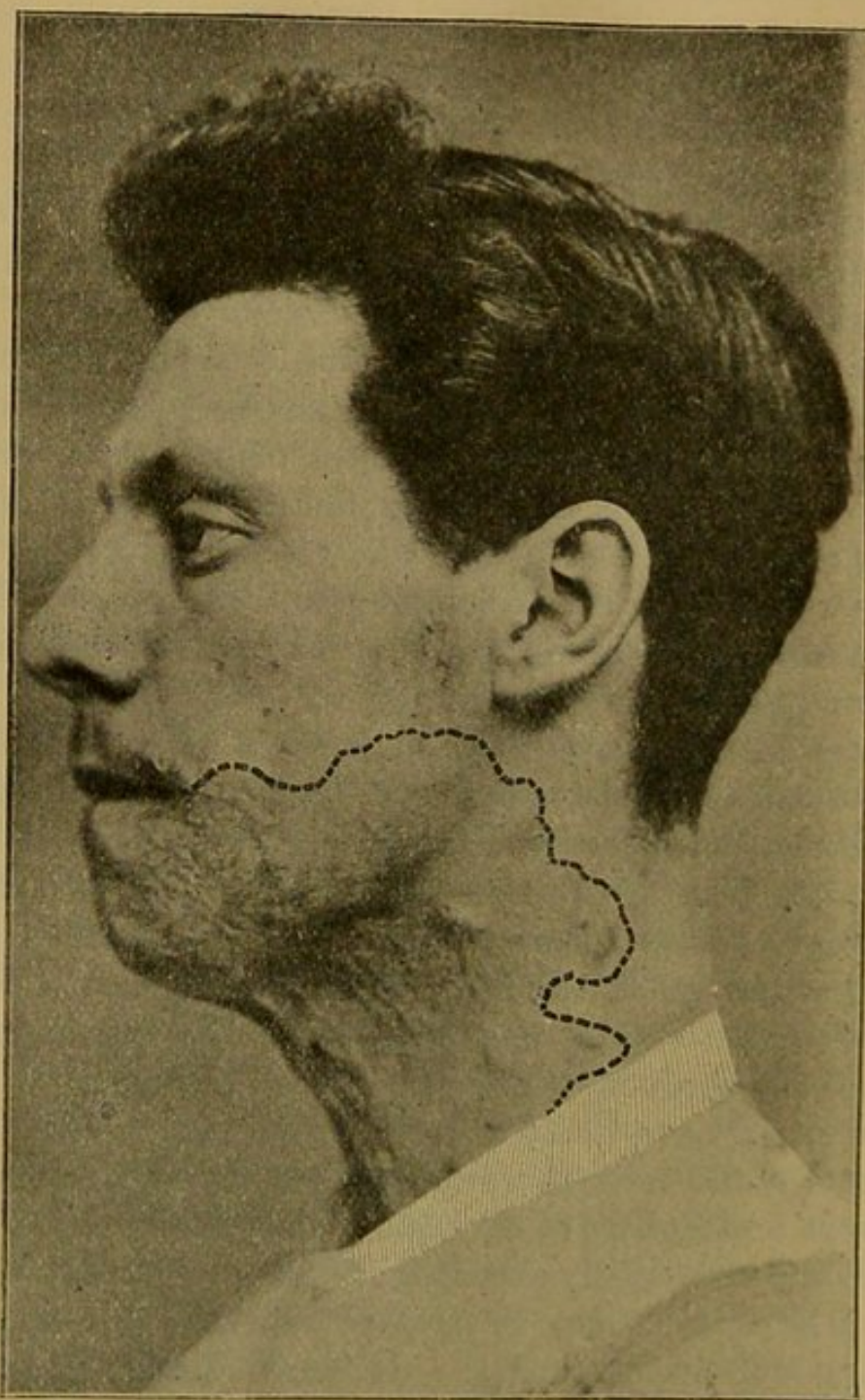
Erasion, then, I believe to be untrustworthy as a sole method, but in association with other surgical resources it is of great value when the area is too large for a more radical treatment. The patient represented in Fig. 1, after having

undergone all kinds of treatment for many years without success, was subjected to erasion followed by the application of caustic potash, and supplemented by the excision of a few marginal recurrences. As a result he is restored to a social life and employment from which he had long been excluded by the repulsive aspect of his disease.

Before quitting the subject of erasion a word may be said as to its diagnostic value. Occasionally lupus may be closely simulated by destructive eruptions dependent upon inherited syphilis, and the so-called "syphilitic lupus" mistaken for the tuberculous disease has been subjected to a good deal of needless local treatment. Should the curette be used, it will be found that the syphilitic tissue, instead of shelling cleanly out of its hollow in the derm like the lupus cell-growth, strongly resists scraping, and conveys so different an impression to the tactile sense that an experienced operator is at once apprised of his mistake.

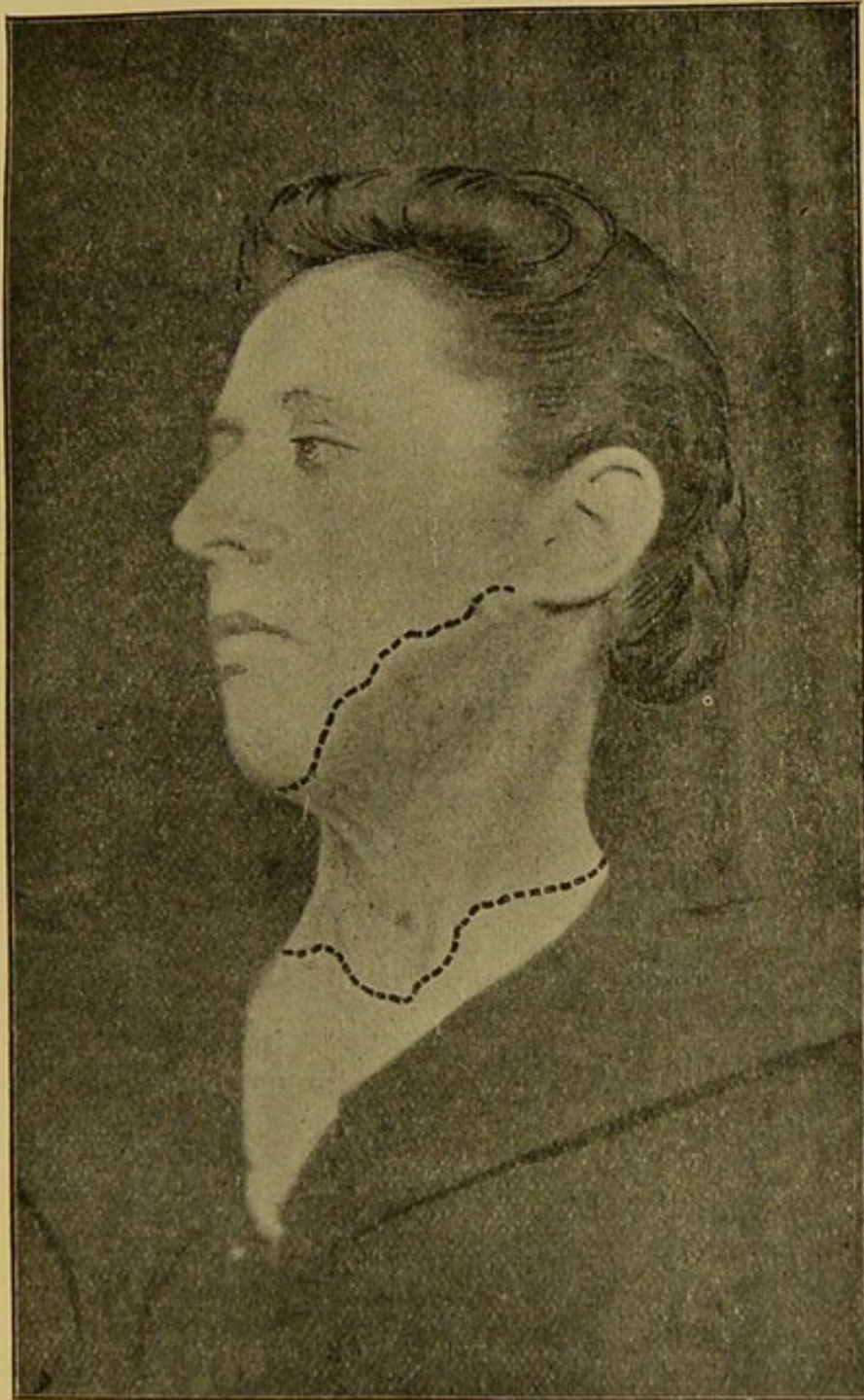Excision in the treatment of lupus has been regarded by most dermatologists either as a last resource or as altogether unjustifiable, but a few have thought differently, and have employed it with great success. During the past fifteen years I have adopted it in all suitable cases, and in these, if it be carried out in the light of modern science, I believe it should be not a final resort but both the alpha and the omega of the surgeon. For patches not exceeding a crown piece in size I have found it by far the most successful, the most speedy, the most thorough, and, in its results, the most permanent and sightly of all plans. The removal is quickly effected, and if properly executed it leaves very little contraction. The wound may be treated in three different ways according to circumstances. If small and conveniently situated it may be closed immediately by suture, leaving a linear cicatrix; if large, or otherwise unsuitable for closure, it may be covered either immediately or after a short interval with an epidermic graft, and the healing process in any case is concluded within a period of two or three weeks. Recurrence is exceptional,—that is recurrence within the cicatrix or at the borders of the excised patch; but should a new focus arise in any part of the body, its existence may be terminated promptly by the same process. Much larger

FIG. 1.



Patient æt. 27. Had suffered from lupus for twenty years, the disease involving the lower part of both cheeks, the lower lip and chin, both sides of the neck down to the clavicle, and the mucous membrane of the lower lip and buccinator region; centre and margin ulcerated. Treated by caustics and curetting on many occasions. In 1892 curetted and cauterised immediately afterwards with potassa fusa at St. Thomas's Hospital with almost complete success. A few marginal recurrent nodules excised in 1894, and one in 1896. Now quite well. Area of original growth indicated in dotted line.

FIG. 2.

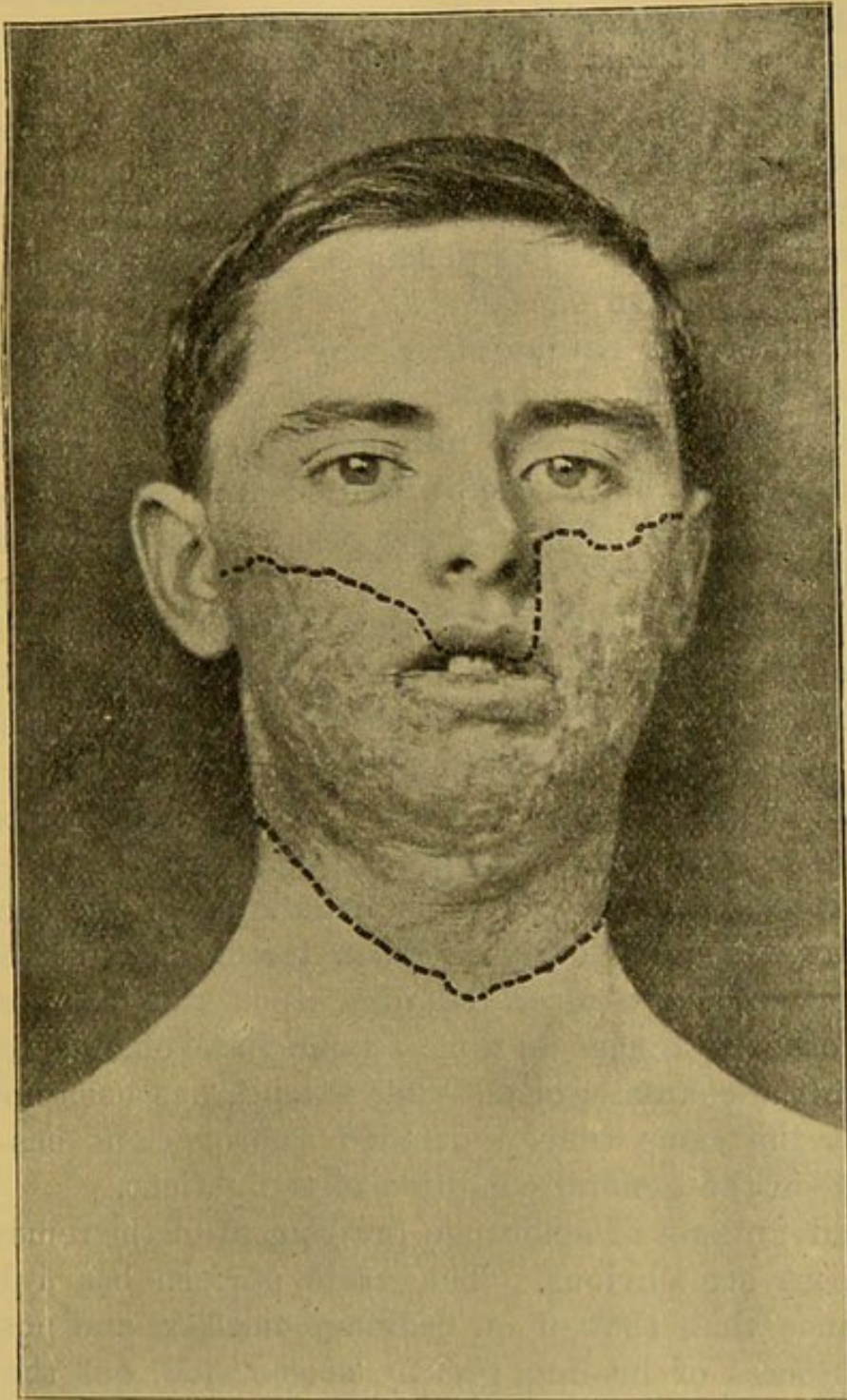


Patient æt. 21. Duration of lupus twelve years. Extent of disease indicated by dotted lines. Margins ulcerated. Cured and cauterised on several occasions without success. In 1894 the largest patch, measuring $2\frac{1}{2}$ inches by 2 inches, was excised, and the keloid ridges were shaved. Small marginal nodules were excised in 1895-6. From a photograph by Mr. Ernest Cobb, Clinical Assistant in the Skin Department, St. Thomas's Hospital.

areas than those named may be treated on the same lines when the surgeon has gained confidence in the method. I have excised patches covering nearly the whole of the cheek, and sometimes extending to the submaxillary region and even the lower portion of the opposite cheek, completing the operation at a single sitting, and without inducing any perceptible shock ; but where these extensive operations are undesirable, I have adopted a plan of excising the growing borders of the disease, vigorously curetting the rest, covering the whole with salicylic ointment until cicatrization is well started, and then using epidermic grafts if necessary. In most of these cases, however, the formation of new epidermis under the salicylic acid is so rapid that little is to be gained by grafting, and the entire process may be left to nature. The patient in Fig. 3 was so treated, and although the scar is less uniform in level than where a complete excision is practised, it is sound and presentable.

The method of the excision is simple. The line of incision is placed (where possible) a third to a half of an inch from the most rapidly spreading edge, but may approach to within a quarter of an inch of the more quiescent parts of the border. On the trunk or limbs the section may be carried down to the deep fascia if the subcutaneous tissue is scanty, or well into a thick layer of fat, and the process is quickly accomplished ; but in the face the removal is much more difficult, and calls for some practical experience. The section here must run into the integumentary covering without exposing the muscles or the branches of the facial nerve, and the depth within these limits must be adjusted to the degree of infiltration of the tissues by the new growth, taking care to remove the whole of the disease and a certain portion of the apparently healthy structure beneath. The bleeding from the skin arteries is very free, but never serious in its results if proper precautions are taken. The surface left after the hæmorrhage is checked is of yellowish colour, from the fat lobules embedded in the connective tissue, and fairly elastic. If now the surgeon believes that his section has passed well below the lupous cell-growth, he may at once proceed to close the wound by suture if possible, or to cover it in by grafts ; but should he be in doubt on this point it will be better to apply

FIG. 3.



Patient et. 22. Disease of fourteen years' duration, involving at time of admission into hospital (1897) both cheeks, lower lip, and chin, the greater portion of the upper lip, and the upper half of the neck; not ulcerating, but spreading actively at margins. Treated by marginal excision, central erosion, and immediate application of salicylic ointment. Rapid cicatrization. No sign of return three months afterwards. From a photograph by Mr. Ernest Cobb.

immediately a layer of salicylic ointment spread on strips of lint over the raw surface, and dress it daily until healthy granulation is established and marginal cicatrisation has commenced. It may then be grafted in the usual manner. On the neck, limbs, and trunk, and occasionally on the face, the raw surface may be covered in partially or completely by gliding portions of detached integument from an adjacent part, or other resources of plastic surgery may be employed, but this is not often necessary.

The number of patches that may be treated by excision is almost unlimited. I have removed at a single sitting as many as thirty-five, of sizes ranging between that of a three-penny piece and that of a crown, from different parts of the body, nearly the whole of the wounds being closed by sutures.

It is a remarkable fact that the removal of the growing edges of an active patch of lupus has a decided influence upon the condition of incipient or indolent areas outside the seat of operation. This is difficult to explain, but it is probable that the ulcerating edge, as a breeding place for bacilli, serves as a focus of infection for other parts of the body. In one case a large patch of incipient lupus of the shoulder disappeared spontaneously within a fortnight after the removal of an active ulcerated area upon the face, and in several other instances an almost immediate change for the better in the character of outlying patches has been noticed, while at the same time a decided improvement has been observed in the general condition of the patient.

The advantages of epidermic grafting after the removal of the disease are obvious. The graft surface has a better appearance than that of an ordinary cicatrix, and not only is the process of healing greatly accelerated, but the contraction incident upon it is much reduced. In any case, however, the contraction is much less than might have been expected, but where the lower eyelid is approached by the operation an ectropion is sometimes inevitable. Should this occur the lid may be subsequently freed, drawn up into position, and the gap filled with an epidermic graft with perfect success.¹

¹ See cases reported by the author in 'Lancet,' 1896, vol. ii.

To sum up, I should advise that every patch of lupus vulgaris be excised if not so large or so located that removal by the knife is inexpedient ; precautions being subsequently taken to guard the patient from recurrence as far as possible by suitable general treatment, and especially by an examination into the sanitary conditions of the house in which the disease was first manifested. In lupus erythematosus, and the erythematous form of lupus vulgaris, linear scarification may be employed and followed by the immediate application of a 5 per cent. solution of carbolic acid and the later use of salicylic ointment (20 or 30 grains to the ounce). In large areas of lupus, especially in the ulcerating stage, excision is sometimes available, but when they are considered unsuitable for this, the spreading edge may be excised in the manner described, the central portion freely scraped, and the whole surface covered with salicylic ointment. The mode of closure of the surgical wound, by suture, by epidermic grafts, or by gliding, will of course be decided by the special conditions of each case.

