

**Puerperal hysterectomy, or, Porro's operation by a new method / by H. Widenham Maunsell.**

**Contributors**

Maunsell, H. Widenham, 1845-1895.  
Bryant, Thomas, 1828-1914  
Royal College of Surgeons of England

**Publication/Creation**

Dunedin : J. Wilkie, 1891.

**Persistent URL**

<https://wellcomecollection.org/works/ud7sh35n>

**Provider**

Royal College of Surgeons

**License and attribution**

This material has been provided by This material has been provided by The Royal College of Surgeons of England. The original may be consulted at The Royal College of Surgeons of England. where the originals may be consulted. This work has been identified as being free of known restrictions under copyright law, including all related and neighbouring rights and is being made available under the Creative Commons, Public Domain Mark.

You can copy, modify, distribute and perform the work, even for commercial purposes, without asking permission.



Wellcome Collection  
183 Euston Road  
London NW1 2BE UK  
T +44 (0)20 7611 8722  
E [library@wellcomecollection.org](mailto:library@wellcomecollection.org)  
<https://wellcomecollection.org>

Reprinted from N.Z. MEDICAL JOURNAL, January 1, 1891.

PUERPERAL  
HYSTERECTOMY;

OR,

PORRO'S OPERATION BY A NEW METHOD.

By H. WIDENHAM MAUNSELL, M.D.,

*Honorary Surgeon, Dunedin Hospital; Lecturer on Surgery in the Otago  
University.*

DUNEDIN:

J. WILKIE & CO., PRINTERS, PUBLISHERS, STATIONERS, &c.

1891.

THE UNIVERSITY OF CHICAGO

PHYSICS DEPARTMENT

REPORT OF THE

COMMISSION ON THE

REVISION OF

THE

UNIVERSITY OF CHICAGO

1962

# PUERPERAL HYSTERECTOMY; OR PORRO'S OPERATION BY A NEW METHOD.

By H. WIDENHAM MAUNSELL, M.D.,

*Honorary Surgeon, Dunedin Hospital; Lecturer on Surgery in the Otago University.*

PORRO, of Pavia, was the first surgeon who successfully amputated the pregnant uterus in a woman—utero-ovarian amputation as a mode of completing Cæsarean section. The operation was performed twelve years ago in the Maternity Hospital of Pavia, on a woman deformed by rickets. Since then the operation has been performed 200 times, with a mortality of nearly 50 per cent.

*Instruments required.*—Strong scalpel, large strong circular amputating knife, two pairs of strong scissors, eighteen pairs of Spencer Wells' artery forceps, two strong slightly-curved needles, on handles; curved surgical needles, suitable sutures and ligatures, specially prepared; yard of strong rubber tubing, for tourniquet; Tait's recent modification of Kœberlé's serre-nœud, with needle for transfixing pedicle; three large flat sponges, the bichloride antiseptic solution, and large quantities of hot water.

In performing laparotomy in the median line, the incision should be lower than for simple Cæsarean section, as the stump of the amputated uterus has to be brought out immediately above the pubes, as in hysterectomy. A sound should be passed into the bladder, and every care taken not to injure it, as it is often dragged up above the pubes in these cases.

## NEW METHOD OF TREATING THE STUMP.

1. The incision should be long enough to permit of the gravid uterus being taken out of the cavity of the abdomen.

2. While an assistant takes charge of the gravid uterus, place a large flat sponge, wrung out of hot water, over the bowels, to keep them warm and out of sight; and rapidly suture up the wound with strong salmon silkworm gut, as far as the neck of the uterus, which is pressed towards the pubic end of the wound by an assistant.

3. Open uterus by longitudinal incision in upper third, and remove child, leaving placenta behind.

4. Apply the rubber tourniquet below the uterus.

5. Pack round with sponges. Make transverse incision through peritoneum, covering the top of the uterus, and rapidly reflect it to within half-an-inch of the rubber tourniquet. If the peritoneum is found to be very adherent to the fundus, make a circular incision all round the upper third of the uterus, and reflect it as above described.

6. Apply Kœberlé's pin and wire ecraseur to the neck of the deperitonised uterus.

7. Amputate the uterus with a large circular amputating knife, leaving a fair stump behind the pin.

8. Apply torsion and ligature to all bleeding points, as the assistant slowly and cautiously removes the rubber tourniquet.

9. Secure the lower end of the laparotomy wound, immediately above the stump, with a strong acupuncture needle.

10. Place a thin layer of iodoform wool under the reflected peritoneum, which is spread out like a saucer round the stump. Secure the edges of the reflected peritoneum loosely to the skin by five or six horse-hair sutures. Dust the peritoneal reflection above and below night and morning with large quantities of iodoform and amorphous boracic acid (1 to 9), so as to keep it thoroughly dry. If treated in this manner, in a few days this *saucer-like* reflection of the peritoneum becomes dry, hard, tough, and aseptic, and drops off in from three to five weeks.


11. Screw up the wire clamp daily. Dress the stump night and morning with a thick layer of iodoform and absorbent wool.

*I have advocated this method of treating the stump in cases of hysterectomy for fibroids. (See N.Z. MEDICAL JOURNAL, September, 1887). As far as I know, this method of treating the stump has never been tried or suggested before. Its advantages may be summed up as follows:—*

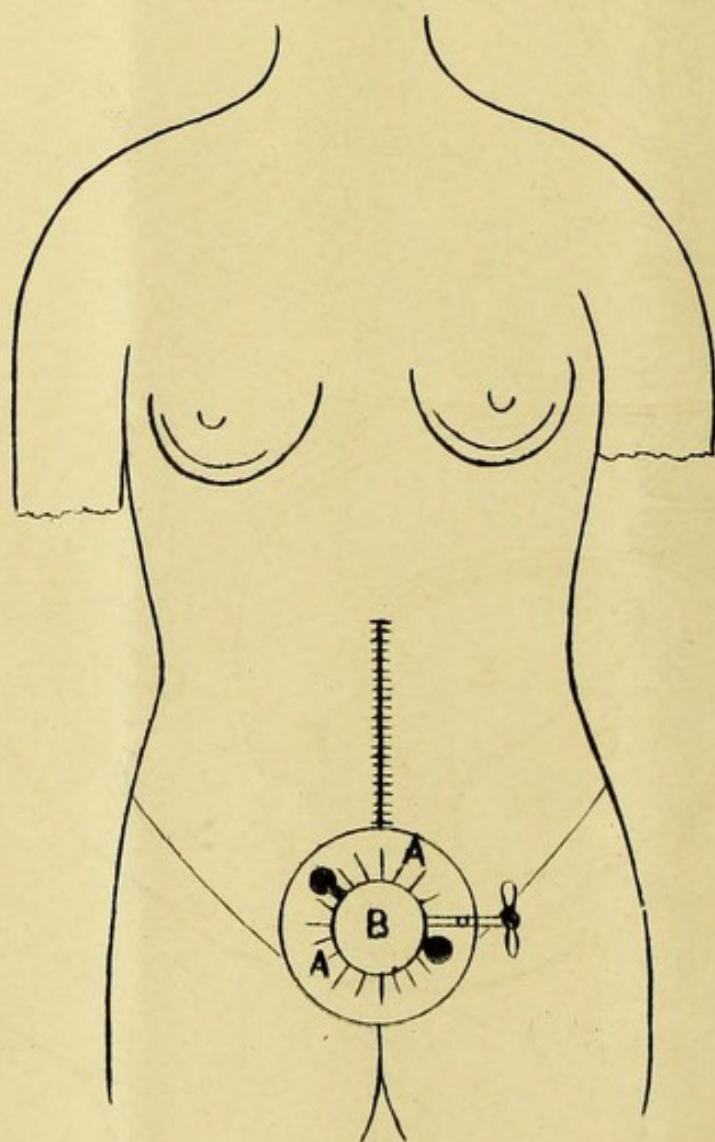
- (A) The bladder and ureters cannot be injured by the ecraseur.
- (B) There is no tension of the peritoneum or broad ligaments.
- (C) The stump cannot retract into the cavity of the peritoneum.
- (D) The stump is effectually shut off from the cavity of the peritoneum; and as it shrinks and sloughs away it is impossible for the matter to drain on to the abdominal wound, or into the cavity of the peritoneum.

#### GODSON'S CLASSIFICATION.

1. True Porro operation—fœtus viable.



PUERPERAL HYSTERECTOMY BY A NEW METHOD.

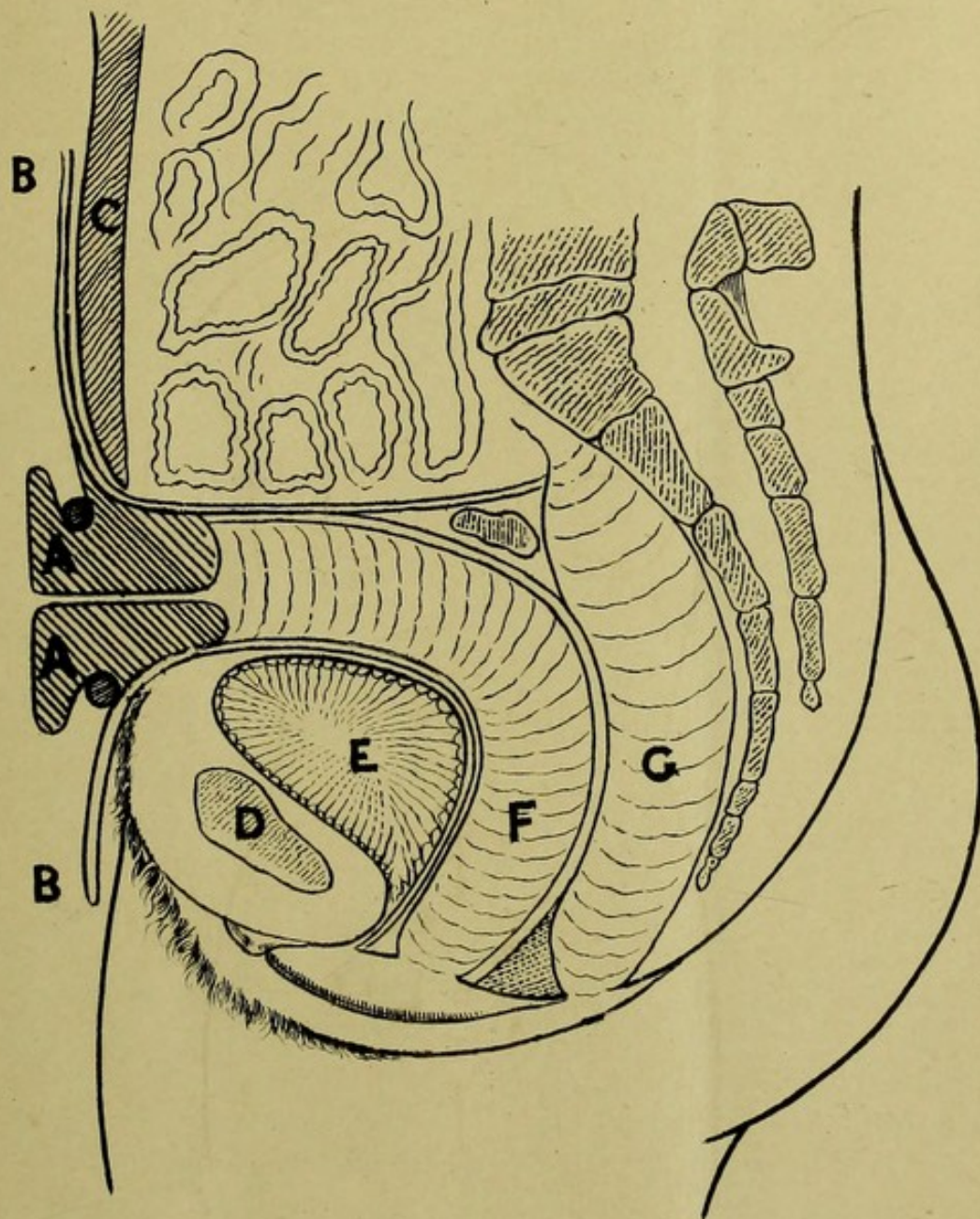


EXTRA PERITONEAL METHOD OF TREATING THE STUMP.

**A A** Saucer-like Reflection of Peritoneum.

**B** Deperitonised Stump with Kœberlé's Pin and Ecraseur.

PUERPERAL HYSTERECTOMY BY A NEW METHOD.




EXTRA PERITONEAL METHOD OF TREATING THE STUMP.

*Vertical Section Shewing*

- A A** Deperitonised Stump Constricted by Ecraseur.  
**B B** Reflected Peritoneum.  
**C** Wound in Abdomen Sewn up to Stump.  
**D** Pubic Bone.    **E** Bladder.    **F** Vagina.    **G** Rectum.





Digitized by the Internet Archive  
in 2015

2. Utero-ovarian amputation performed during pregnancy, before foetus is viable.

3. Laparotomy for removal of foetus from abdominal cavity, followed by amputation of ruptured uterus and ovaries.

The same treatment of the stump applies with equal force to all these conditions.

In puerperal hysterectomy, experience is strongly in favour of the extra-peritoneal method of treating the pedicle. According to Godson's tables, eleven died out of fifteen cases treated by intra-peritoneal methods.

---

Over two years ago the above paper was forwarded to the Gynæcological Section of the Intercolonial Medical Congress of Australasia. To my great annoyance it was refused admission, on the erroneous supposition that it had been previously published in the N.Z. MEDICAL JOURNAL. With the exception of paragraph 4, describing the removal of the child, it is step by step and almost word for word *the same operation that I advocated for the extra peritoneal method of treating the stump in uterine fibromyomata*, published by me in the N.Z. MEDICAL JOURNAL, September, 1887, several copies of which I sent to a number of prominent medical men in the Old Country. Judge my astonishment on finding that all the details of my operation for the surgical treatment of uterine fibromas have been unwittingly appropriated by Dr. Bantock, of London.

Dr. Batchelor, Lecturer on Gynæcology in the Otago University, has kindly drawn my attention to the following extracts from the last May and August numbers of *The British Gynæcological Journal*:—

“Dr. Bantock showed a specimen of soft sarcoma removed from a single woman of 36. A week before the growth of the tumour had been very rapid, and lately had been attended by so much hæmorrhage that it incapacitated her from her work. She was seen by Dr. Ingleby Mackenzie, and was sent on by him to the Samaritan Hospital. This case illustrated a point which had already been under discussion. The line of the peritoneum was very high on the growth, and it was one of those cases in which the pedicle was very short, and if he had treated it in the ordinary way, by putting a *serre-nœud* round including the peritoneum, he would have a very short pedicle with a tremendous drag upon it. Indeed, he would possibly hardly have been able to get the pins through so as to bring them out on the skin. *He therefore adopted the plan which he had lately had several times had occasion to bring before their notice. He first of all put on an elastic ligature, then divided the peritoneum all round, stripping it down to the base of the tumour. Then he secured the ovarian vessels on either side,*

and applied the *serre-nœud* to the raw surface, the tumour being enucleated away down to the level of the internal os. In this way the whole of the pedicle was extra-peritoneal." (Italics are mine.) "These surfaces were stitched together, the pins being put through the raw surface not touching the peritoneum. In that way there was very little drag upon it."

"Dr. Heywood Smith (same journal, page 123), with regard to the first case, asked for a more exact description of the manner of dealing with the peritoneum. Dr. Bantock had spoken of stitching the flaps together, and this was not very clear to him. What he wanted to know was the exact position of the peritoneal edges after the wound was closed.

"Dr. Bantock demonstrated *his* procedure. First he applied a ligature outside the tumour, covered as it was by peritoneum. Then he opened the peritoneal investment and applied the *serre-nœud* at the base of the tumour, this time *inside* the peritoneum. Having removed the tumour, there only remained to stitch together the layer of peritoneum, covering what was the base of the tumour, *i.e.*, the broad ligament, with that lining the parietes."

In the August number of the same journal (page 183) there is the report of a case of the removal of a large uterine myxoma by Dr. W. H. Fenton. The patient died owing to the injury of the ureters in the wire of the *serre-nœud*. At the conclusion of the very interesting paper Dr. Fenton makes the following pertinent remarks (pp. 191 and 192):—

"The first question that arises to me is this: could I in a similar case avoid the same accident of injuring the ureters? It must be remembered that I had a huge tumour with a very thick pedicle. I naturally selected the narrowest part below the ovaries for engaging with the wire, and I thought that the wire at that point was encircling the cervix uteri. I had no idea the pedicle really consisted of a portion of the tumour, apparently growing from the posterior vaginal wall and the vagina itself, and that I was some inches below the os uteri. An inter-abdominal *hysterectomy* performed in such a way would be bound to include both ureters, as they ordinarily pass from behind the cervix uteri to the base of the bladder.

"Dr. F. A. Purcell (p. 194) observed that the method described by Dr. Bantock at their last meeting seemed peculiarly adapted to Dr. Fenton's case. He alluded to the application of an elastic ligature over the base of the tumour before attempting to enucleate. Had that been done the hæmorrhage would have been restrained. Then the capsule might have been divided and stripped down and the *serre-nœud* applied around the base of the tumour, which would have been easy, and the tumour then lifted up out of its cavity. The walls of the tumour would thus form the pedicle, and the application of the *serre-nœud* within the capsule would have had the effect to further

restrain the hæmorrhage. Then the stump could be brought up and fixed to the parietes, after which the elastic ligature should be removed. He thought that if this procedure had been adopted the ureters would undoubtedly have escaped inclusion.

“Dr. Bantock (page 202) demonstrated *his* procedure. First, he applied a ligature outside the tumour, covered as it was by peritoneum. *Then he opened the peritoneal investment and applied the serre-nœud, at the base of the tumour—this time OUTSIDE the peritoneum.* Having removed the tumour there only remained to stitch together the layer of peritoneum, covering what was the base of the tumour, *i.e.*, the broad ligament, with that lining the parietes.”

By the next mail I forward the September (1887) number of the NEW ZEALAND MEDICAL JOURNAL, giving a full description of my method of treating uterine myomas to the President of the British Gynæcological Society. On perusing the above paper I feel certain that Dr. Bantock will abandon all priority to the above method, which I have christened the *deperitonised method* of dealing with the stump of uterine myomas.

