

Club-foot : astragalectomy for relapsed and invertebrate cases : a clinical lecture delivered at the University Hospital / by De Forest Willard.

Contributors

Willard, De Forest, 1846-1910.
Royal College of Surgeons of England

Publication/Creation

Philadelphia, Pa. : J.B. Lippincott, 1902.

Persistent URL


<https://wellcomecollection.org/works/zkfjfm8>

Provider

Royal College of Surgeons

License and attribution

This material has been provided by This material has been provided by The Royal College of Surgeons of England. The original may be consulted at The Royal College of Surgeons of England. where the originals may be consulted. Conditions of use: it is possible this item is protected by copyright and/or related rights. You are free to use this item in any way that is permitted by the copyright and related rights legislation that applies to your use. For other uses you need to obtain permission from the rights-holder(s).



CLUB-FOOT; ASTRAGALECTOMY FOR RELAPSED AND INVETERATE CASES.


A CLINICAL LECTURE DELIVERED AT THE UNIVERSITY HOSPITAL.


BY DE FOREST WILLARD, M.D.,

Clinical Professor of Orthopædic Surgery, University of Pennsylvania; Surgeon, Presbyterian Hospital, Philadelphia.

REPRINTED FROM INTERNATIONAL CLINICS, VOL. III., TWELFTH SERIES.

Copyright, 1902, by J. B. LIPPINCOTT COMPANY, Philadelphia, Pa.





CLUB-FOOT; ASTRAGALECTOMY FOR RELAPSED AND INVETERATE CASES.

A CLINICAL LECTURE DELIVERED AT THE UNIVERSITY HOSPITAL.

BY DE FOREST WILLARD, M.D.,

Clinical Professor of Orthopædic Surgery, University of Pennsylvania; Surgeon, Presbyterian Hospital, Philadelphia.

GENTLEMEN,—I present to you to-day two cases of talipes equinovarus of especially severe grade. The one is a neglected and untreated boy of ten. As you will observe by examination of his foot and from this photograph (Fig. 1) he has, by constant walking, forced his astragalus forward, and so distorted its shape together with that of all his tarsal bones that it is impossible again (as the accompanying skiagraph shows, Fig. 2) to replace this astragalus within the inter-malleolar mortise. The other is a rigid relapsed case which from neglect of manipulation after previous tenotomies and forcible straightening, has again assumed its deformed position, and is steadily growing worse, since each step tends to render all the tarsal bones wedge-shaped and distorted (Figs. 3 and 4).

You have in this clinic so frequently seen the benefit of multiple tenotomies and forcible straightening that I need not say that it is the operation of preference; but every surgeon will meet with a class of cases in which the hinderance to correction lies not in tendons and fascia alone, but also in the bones themselves, and it is of these severe grades only that I shall speak this morning while removing the astragali of these two cases.

Astragalectomy is to be reserved for: (1) Adults with great bony deformity; (2) neglected children of five to fifteen years, who have markedly distorted their tarsi by locomotion; (3) relapsed cases which have resisted the milder forms of operation, or which have been neglected by parents after previous operation; (4) only occasionally, young children in whom from infancy the bones of the foot have been exceedingly rigid and unyielding, and where there

is practically but little motion either at the ankle-joint or in the tarsus. Aside from these varieties, practically all cases can be brought into proper walking position by multiple subcutaneous tenotomies, fasciotomies, and forcible straightening, or by open section of the contracted tissues. Let it be understood that any operation for club-foot should be considered incomplete in which at the time of operation the foot cannot by slight pressure be brought into nearly a normal position, and the foot extended to at least a right angle with the leg. The object of every operation for the relief of talipes should be to place the foot in such position that locomotion shall be secured after the lapse of a few weeks, with the sole of the foot squarely upon the ground and with hyperextension at the ankle-joint, which will enable the patient to walk in the normal position. Unfortunately, other conditions besides those of the foot will modify locomotion; the in-toeing which is so common in these cases is not due alone to the twisting of the foot, but is occasioned also by rotation of the legs upon the thighs, and of the thighs upon the pelvis, the external rotators of the trochanters often being defective.

Astragalectomy is an operation that would never be required if the family practitioner could be brought to the comprehension that the treatment of club-foot should be commenced before the infant is twenty-four hours old,—almost, as has been remarked by one individual, “during the third stage of labor.” It seems strange that any educated physician can wilfully neglect the golden opportunity of moulding such distorted bones during the first three months of life when the osseous structures are soft, and when growth is so rapid that if neglected, irreparable deformity of the bony structures must result. During these months constant manipulation and simple forms of retentive apparatus will accomplish wonders, but all of these milder methods we will discuss at another time. With the definite understanding, then, that bone operations are necessary only in the class of cases already mentioned, I may say that from my experience, after testing all the bony substitutes, astragalectomy is the simplest and the safest operation, and is the one that yields subsequently the most elastic foot. No cancellated bony structure is exposed, the cartilage-covered calcaneum slips easily into the mortise between the malleoli of the tibia and fibula, and excellent rocking motion is secured at the ankle-joint. When

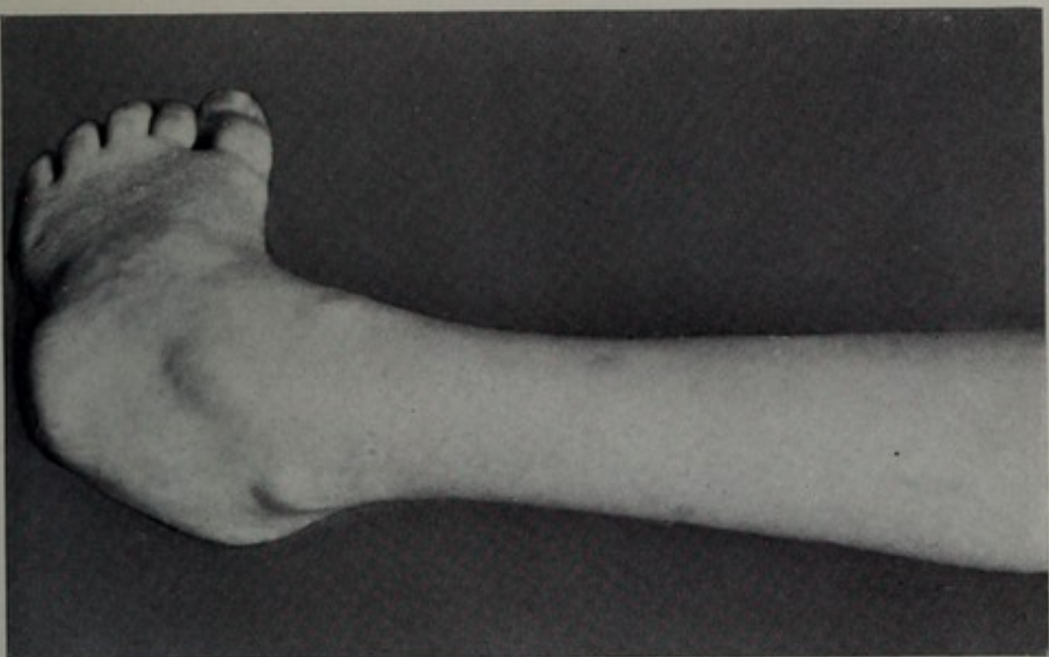


FIG. 1.—Neglected talipes equinovarus: astragalus forced forward.

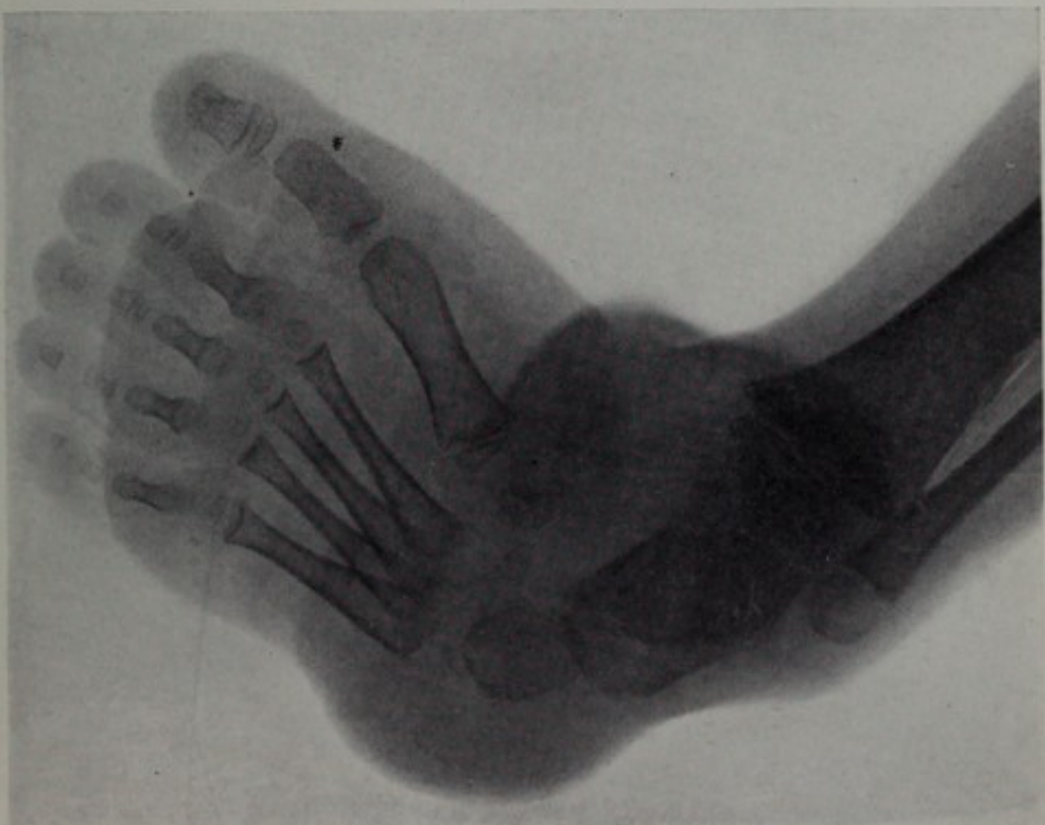

FIG. 2.—Skiagraph showing a distorted astragalus and the tarsal bones misshapen.

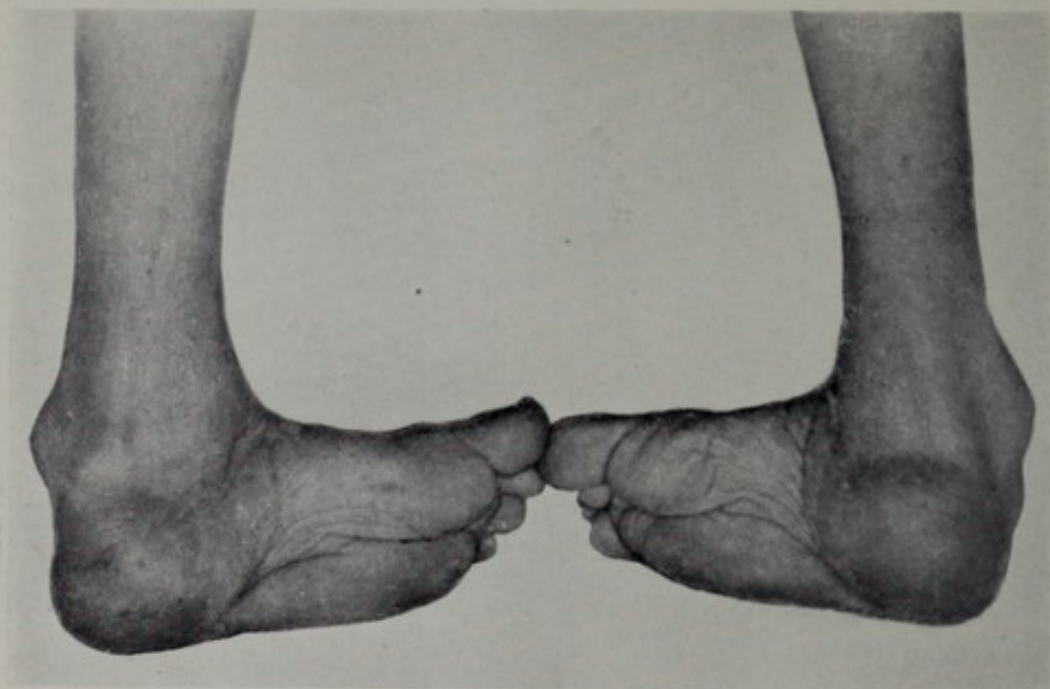


FIG. 3.—Relapsed talipes equinovarus.

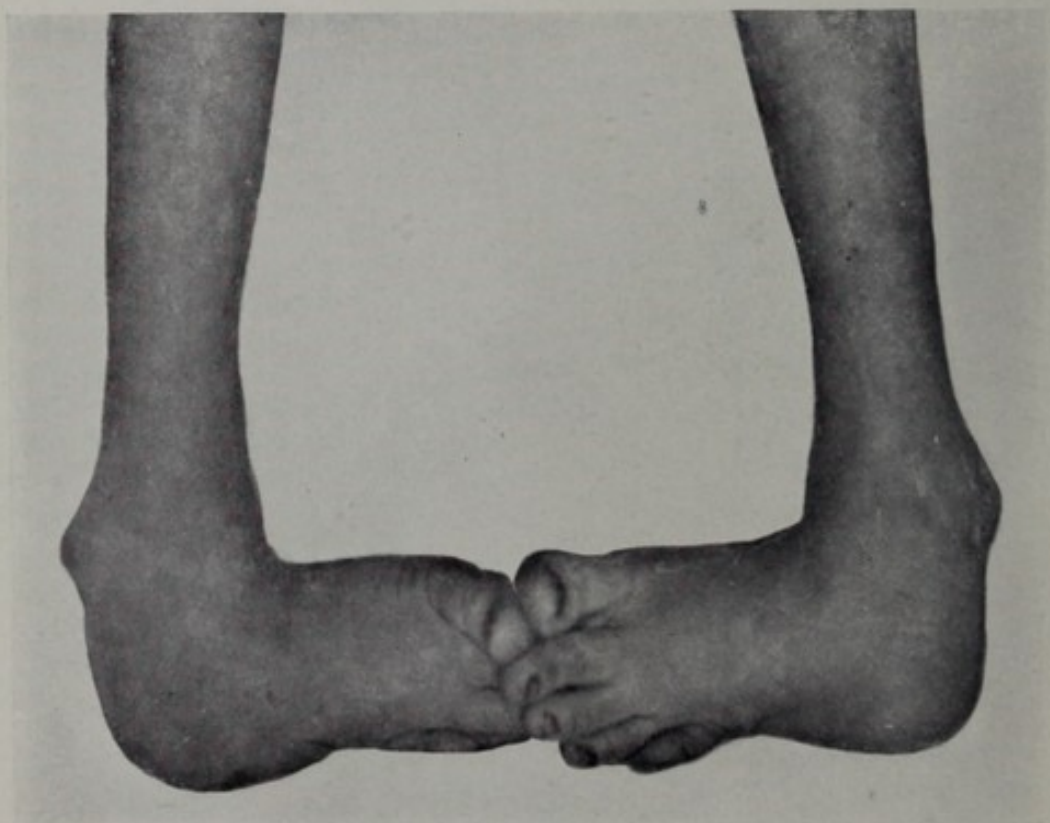


FIG. 4.—Relapsed talipes equinovarus.

both feet are operated on, the slight shortening in stature is unnoticed. The removal of the astragalus alone frequently gives hyperextension beyond the right angle, without any division of the tendo Achillis; room is also afforded for correction of the varus without section of the tibialis posticus and anticus. In my judgment, removal of the astragalus is a decidedly better method than wedge-shaped tarsal excision, or osteotomy of the neck of the bone, or any of the various methods practised. The secret of securing a movable ankle-joint lies in the performing of a thoroughly aseptic section, so that speedy union may be secured, and ankylosis avoided. To prepare for such an operation in an adult with large callosities and bursæ upon the outer side of the foot is a work of days of preparation, lest infection take place. All callosities, corns, etc., must be thoroughly removed by cutting and scraping and the use of washing soda. An excellent plan is to poultice with flaxseed meal for several nights, to soften the horny epidermis; the scraping must then be most vigorous, and the antiseptics made to thoroughly penetrate the skin by wet sublimated gauze applied for several nights, when possible. Rapid healing is so dependent upon cleanliness that time is gained, not lost, by preliminary treatment.

The incision for the removal of the astragalus (as you will note on this boy's foot) commences in front of and a little below the external malleolus, so that the tender scar tissue shall not later be over the tip of the malleolus. The peroneal tendon should be avoided, and as the extensor tendons of the toes are displaced inward, the head of the astragalus can be reached by an incision stopping at the astragalo-scaphoid articulation, just short of these tendons. The distortion of the astragalus is sometimes so great that the error is made of cutting in front of the scaphoid instead of behind it, a mistake which will be recognized by the fact that while both articulations are cup-shaped, in the one case there will be a single bone in front, while in the other there will be three bony facets. By keeping close to the periosteum of the bone upon the dorsum of the foot, wounding of the anterior tibial artery can always be avoided, and the tendons spared. The deformation of the astragalus is often so great that disarticulation becomes difficult, but simple nicks with a knife or scissors will free the bone upon its dorsal and external aspects, after which the internal lateral ligament of the ankle can be reached. When the astragalo-calcaneal ligaments have been

divided, the bone should be seized with a pair of strong forceps by means of which enucleation can be more readily accomplished, especially if an assistant forcibly bends the anterior part of the foot in various directions, as needed. When the bone is soft, care must be taken that it be not crushed in the jaws of the forceps. The twisting of the bone is sometimes so great that after removal it has been unrecognizable even by such a skilled anatomist as Joseph Leidy. When the internal lateral ligament is reached, great care should be exercised lest the posterior tibial artery be wounded. In a few cases of severe grade if the calcaneum is too wide to slip into the mortise of the tibia and fibula, the tip of the latter bone may be cut away, and in exceedingly rare cases a portion of the cuboid may also demand removal.

The Esmarch bandage has such positive disadvantages that I prefer to work without its application, save in exceptional cases. It has sometimes unexpectedly been the cause of paralysis, and nearly always the subsequent oozing interferes with the speedy closure of the wound.

I have already said that the secret of successful treatment depends upon the restoration of the foot to its normal position. Only rarely the tendo Achillis, or the structures upon the side of the foot, will require attention. If any pieces of partially detached cartilage are found in the cavern, they should be dissected out lest they necrose. The wound should then be wiped dry, the skin closed with catgut sutures, and if thorough asepsis has been enforced, a few strands of sterile catgut only are inserted at the angle. If the asepsis has been complete, the surgeon can then encase the foot in gypsum, fix it in proper position, and let it alone for four weeks. A zinc strip should be inserted, and the cast cut throughout its entire length, save for a half inch at the top and bottom as soon as it has hardened. This will save much time, and will also allow for springing open the cast at any time should swelling necessitate, or circulation be impeded. If the toes remain exposed, the condition of the foot can be accurately gauged. At the end of the third week the patient should walk about upon the cast. At the end of the fourth week the cast should be removed, and a proper curative walking apparatus applied so that good ankle motion may be secured. The administration of ether and a little forcible motion at the joint will save the patient pain, and assist in more rapid

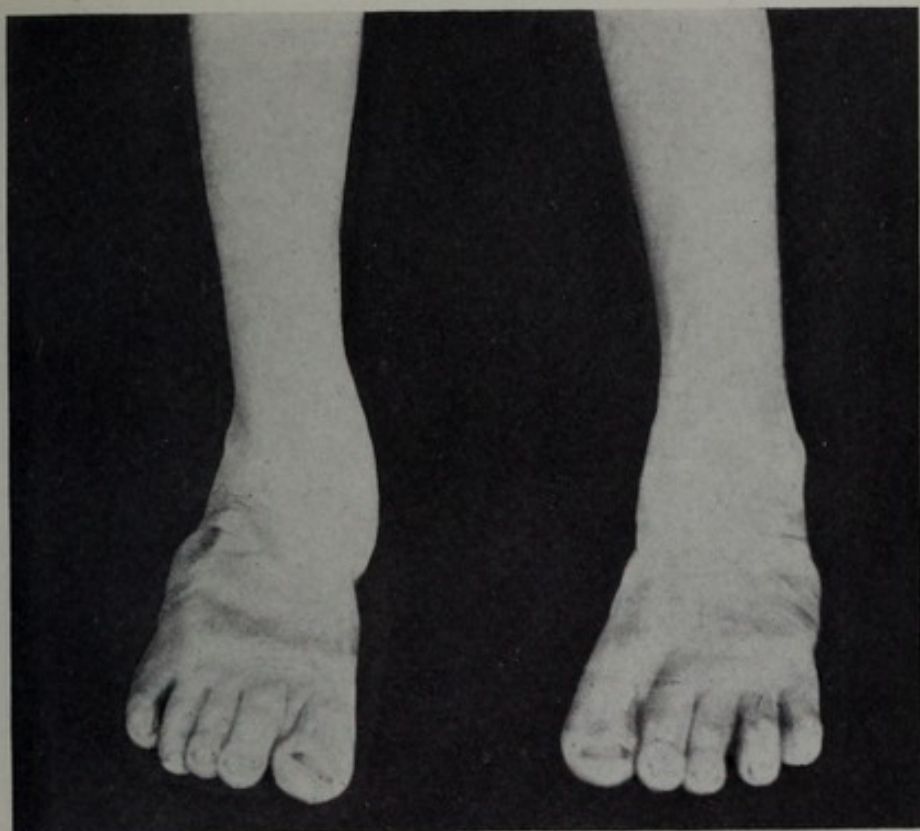

FIG. 5.—Talipes equinovarus; result after astragalectomy.

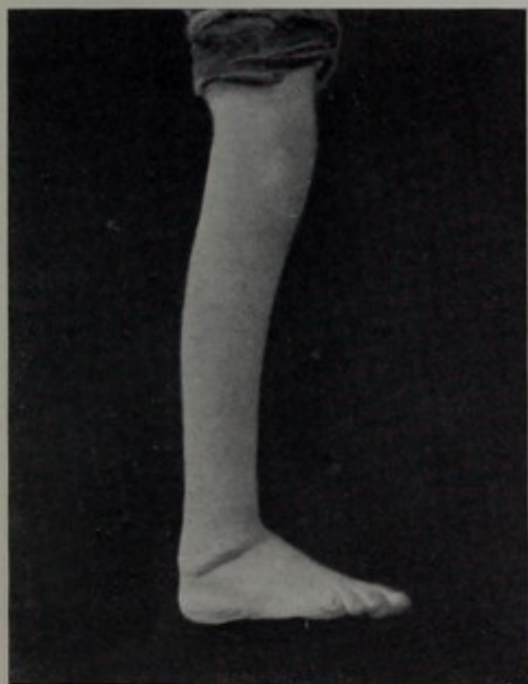

FIG. 6.—Right talipes equinovarus; result after astragalectomy.

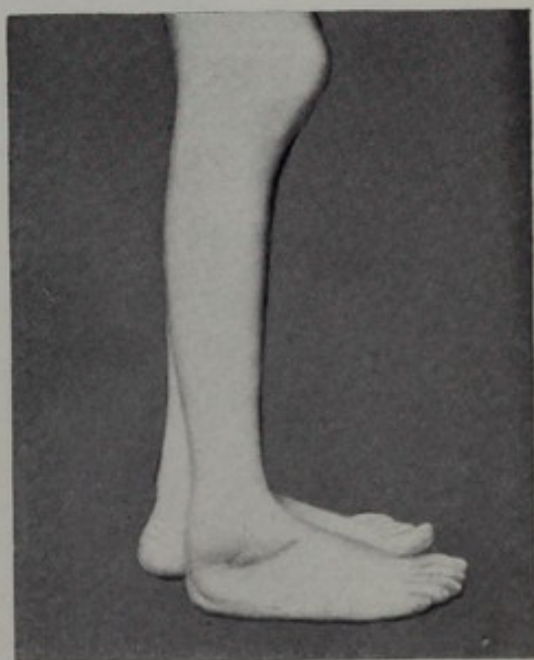


FIG. 7.—Talipes equinovarus; result after astragalectomy.



restoration of function. Manipulation, massage, and voluntary muscular movements should be maintained for many months. In many cases the use of apparatus will be dispensed with in a few months, but not until the tendency to relapse has passed. Too great haste should never be the rule. If you have followed the steps of the operation as demonstrated in these two cases during this hour, you will have fixed in your minds a procedure that will relieve you from the discomfiture of failure in these most troublesome relapsed and rigid cases. A few photographs which I exhibit to illustrate the results of this operation will demonstrate the changes that take place in the appearance of the foot (Figs. 5, 6, and 7), but the best demonstration of its utility will be to show you the walking powers of a few patients upon whom the operation has been performed in the past. They walk squarely upon the soles of their feet, they have good motion at the joints, marked strength in their legs, and a number of them have for years dispensed with all apparatus.

