

**Interstitial or tubo-uterine gestation : with notes on similar cases in the museums of London hospitals / by Alban Doran.**

**Contributors**

Doran, Alban H. G. 1849-1927.  
Royal College of Surgeons of England

**Publication/Creation**

London : Printed by J.E. Adlard, 1883.

**Persistent URL**

<https://wellcomecollection.org/works/n5c3nggk>

**Provider**

Royal College of Surgeons

**License and attribution**

This material has been provided by This material has been provided by The Royal College of Surgeons of England. The original may be consulted at The Royal College of Surgeons of England. where the originals may be consulted. This work has been identified as being free of known restrictions under copyright law, including all related and neighbouring rights and is being made available under the Creative Commons, Public Domain Mark.

You can copy, modify, distribute and perform the work, even for commercial purposes, without asking permission.

**wellcome  
collection**

Wellcome Collection  
183 Euston Road  
London NW1 2BE UK  
T +44 (0)20 7611 8722  
E [library@wellcomecollection.org](mailto:library@wellcomecollection.org)  
<https://wellcomecollection.org>

299  
2

INTERSTITIAL OR TUBO-UTERINE  
GESTATION.

WITH NOTES ON SIMILAR CASES IN THE MUSEUMS  
OF LONDON HOSPITALS

BY

ALBAN DORAN.

Read November 1st, 1882.

[From Volume XXIV of the '*Transactions of the Obstetrical Society  
of London*']

LONDON:

PRINTED BY

J. E. ADLARD, BARTHOLOMEW CLOSE.

1883.



Digitized by the Internet Archive  
in 2015

INTERSTITIAL OR TUBO-UTERINE GESTATION.  
WITH NOTES ON SIMILAR CASES IN THE  
MUSEUMS OF LONDON HOSPITALS.

By ALBAN DORAN.

THIS preparation consists of a uterus and its appendages, showing a cavity on the right side of the fundus, which has ruptured and discharged a foetus and its membranes into the abdominal cavity.

A brief history of the case was published in the 'British Medical Journal,' October 14th, 1882, by Mr. Carr Holstok Roberts, of Kilburn, who has presented the uterus to the museum of the Royal College of Surgeons. In that collection, which possesses a fine series of preparations illustrating tubal gestation, this specimen is, at present, unique.

The patient was a tall and stout married woman, aged 32. Her two only children had been born at the full period, the youngest was fourteen months old, and had been weaned about two months; she had neither menstruated during lactation, nor seen a period since the weaning of her last child. At 10.30 p.m. on October 1st, 1882, she was seized with severe abdominal pains when in bed. Her husband gave her brandy, but without any good effect, he then sent for Mr. Roberts, who found that her abdomen was neither swollen nor tender, although she complained of severe pain. The patient was also suffering from sickness and slight diarrhoea, caused, according to her belief, by some strong pills. The vomit consisted of half digested food and the motions were such as would

be produced by a purgative. The patient's skin was cool and moist, her pulse good, and her respiration and temperature both normal. Sedatives, hot fomentations and linseed poultices to the abdomen were ordered, but at 8 a.m. on October 2nd, Mr. Roberts, when sent for, found her in a state of collapse ; she remained perfectly conscious until 10.30 a.m. when she expired.

When the patient's body was examined after death no external marks of violence were found, the abdominal cavity was filled with nearly six pounds of clot, and five pints of a bloody fluid. Floating in this fluid was a foetus, at about the second month of development, enveloped in its membranes. It measured one inch and a half in length. At the upper part of the uterus a rupture was detected, large enough to admit three fingers. The thoracic and abdominal viscera were normal excepting the heart, which was very flabby and its chambers perfectly empty.

I have since dissected and prepared the uterus. The greater part of its posterior wall has been removed to show more perfectly the relations of the cyst. The uterus is five inches long, from the fundus to the os externum and appears very unsymmetrical, on account of the bulging of the cyst at its right upper corner. The walls are, posteriorly, from a fifth to a quarter of an inch thick, and the cavity is lined with a well-formed decidua.

The right side of the fundus is dilated, and rent asunder by a long ragged aperture, measuring two and a half inches when unstretched. The cavity thus exposed measures one inch and a half vertically, supposing the edges of the rent to be closed, and one inch antero-posteriorly. The walls are very thin along the line of laceration.

Anteriorly, the right round ligament springs from the outer aspect of the exposed cystic cavity which bulges freely, at its lower aspect, into the upper part of the interior of the uterus, at this part its walls are much thicker than above. The inner wall of the cyst, as we may term it, is very rough, resembling, to a certain extent, an auricular appendix. From some of its numerous pits

or depressions hang broken-off tags of chorion, but there is not a trace of a distinct decidua.

The right Fallopian tube passes into the outer and anterior aspect of the walls of the cyst, expanding slightly into a funnel-shaped orifice, which opens into the cavity of the cyst, close to the rent in its walls. A stout bristle, introduced into the tube from without, passes readily into the cavity through the funnel-shaped orifice, which is lined with very smooth mucous membrane. On the outer surface of the portion of the cyst that projects into the uterine cavity is another funnel-shaped aperture with a smooth lining. A bristle has been passed from without, through this opening, into the cavity of the cyst without meeting with the slightest obstruction.\* This sufficiently proves the tubal origin of the cyst, there being no evidence of rupture of the wall of the uterus out of the line of the tube, as it runs through uterine tissue into the uterine cavity. Still less is there any ground for believing in a partially bicornute condition of the uterus.

The right ovary measures  $1\frac{1}{10}$ th inch in length, it is flattened and four follicles are dilated to a maximum of  $\frac{1}{12}$ th inch diameter. It contains a true corpus luteum of triangular form,  $\frac{2}{3}$ ths of an inch in its widest measurement, lying far from the free border of the ovary towards the hilum, having ruptured on one side of the ovary. The left ovary is half an inch in its longest diameter and contains no palpably dilated follicles, the left tube presents no abnormality.

The two sketches which accompany this paper are taken from drawings made by Mr. Sherwin. The first represents the relations of the cyst to the uterine cavity, the second shows the interior of the cyst and the rent in its walls. Before entering into general considerations, it will be advisable to compare this specimen with others that, existing in the metropolis may be conveniently compared with Mr. Roberts' case by members of our Society.

\* This patulous condition of what represents the uterine orifice of the tube has been already observed in similar cases by Peppell, as quoted by Parry.

I could find no specimens of interstitial or tubo-uterine pregnancy in the museums of St. Bartholomew's, St. George's, St. Mary's, Westminster, St. Thomas's, Middlesex, and Charing-Cross Hospitals, nor in the museum of King's College, or in the collection preserved at the Hospital for Women, Soho Square.

In the museums of three medical schools, only, do such specimens exist and I have examined them all, in order to compare them with Mr. Roberts' case. The following brief notes may prove acceptable for convenience of reference.

*Guy's Hospital*, No. 2517<sup>65</sup>.—"The ovum was imbedded in the left horn of the uterus. The cavity is about the size of a horse-chestnut and is quite closed. The uterus is much increased in size, the cavity is filled by an exuberant growth of deciduous membrane closing the Fallopian tubes." Death from rupture occurred at about the second month, the case is recorded in '*Guy's Hospital Reports*,' series ii, vol. iii, p. 272. The cyst is of precisely the same character as in Mr. Roberts' case, but of not half the capacity. The Fallopian tube runs into its outer wall. No communication of the cavity with the interior of the uterus is indicated.

No. 2517<sup>90</sup>. "At the fundus" of the uterus "is a large cyst, formed within its walls, in this the fœtus," which is over four inches in length, "was contained, at its upper part a rent was seen. The cavity is about three inches in diameter and is situated in the uterine walls adjoining the left Fallopian tube." The uterus is lined with a decidua, as in the last specimen; a corpus luteum exists in the corresponding ovary; the case is recorded in '*Guy's Hospital Reports*,' series iii, vol. vi. p. 275. This is a beautiful specimen, the cyst is clearly continuous with the tube, and bulges into the uterine cavity as in Mr. Roberts' case which, in degree of development, as indicated by the clinical history and the size of the cyst, lies midway between the two specimens in *Guy's Hospital*.

*London Hospital*.—The two examples in the museum of

FIG. 1.

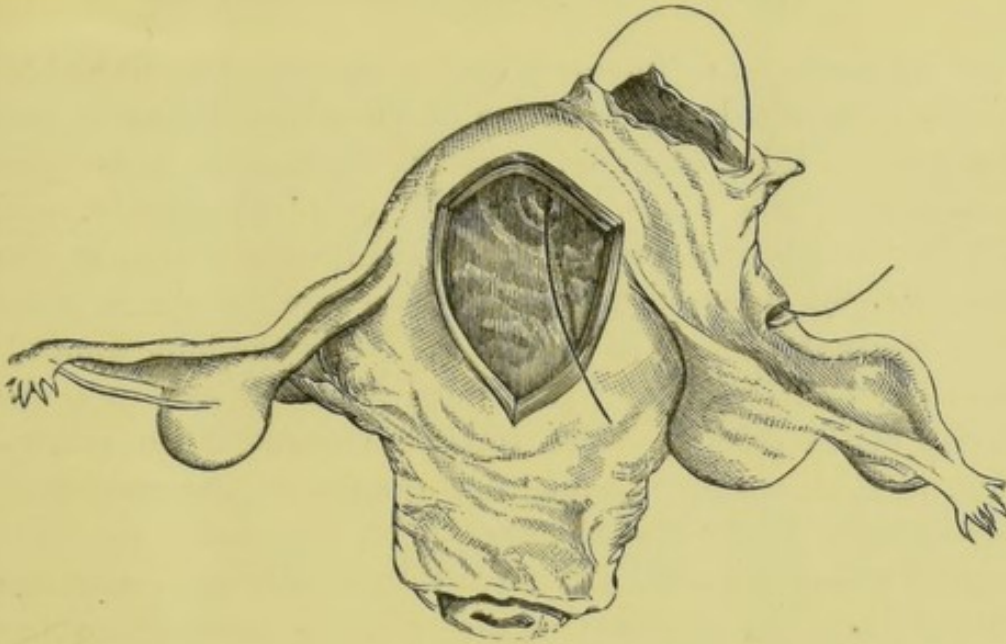
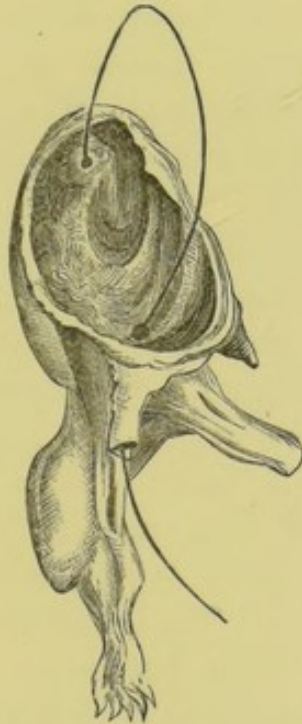


FIG. 2.



MR. C. HOLSTOK ROBERTS' CASE OF TUBO-UTERINE GESTATION. (Mr. Doran's paper.)

FIG. 1.—View of the uterus and its appendages, posteriorly: the greater part of the posterior wall of the uterus has been removed by dissection. The rent in the cyst is seen at the right of the fundus; the lower part of the cyst projects into the uterine cavity. A bristle has been introduced into this projecting portion through an orifice representing the uterine orifice of the tube, and passed through the cavity of the cyst into the tube, which has been divided artificially in its middle third.

FIG. 2.—View of the cavity of the cyst, seen from the right, showing the course of the bristle through its uterine and tubal outlets. The right round ligament of the uterus projects from the lower part of the cyst.



that institution are immortalised in the late Dr. Ramsbotham's 'Principles and Practice of Obstetric Medicine and Surgery.' Unfortunately, neither specimens show the relations of the tubes, uterus and cyst intelligibly. In *Eh* 24 "the bones of a foetus, probably near full time, are seen lodged in a sac behind the uterus, they are as clean as if macerated." "A portion of one of the long bones," says Dr. Ramsbotham, "protruded from the cyst into the cavity of the colon." The further account of the dissection, in that author's work, not quoted in the catalogue, leaves little doubt that the cyst which "occupied the right side of the uterine walls" is truly tubo-uterine. Had the cyst been in the free part of the tube, no matting together of the parts, by adhesions, could have forced it into the uterine walls, but it is unfortunate that the relations of the right Fallopian tube cannot be seen. The specimen might, however, be an example of a hernial pouch in the uterus, such as Dr. Roper has described; to this question I shall presently return.

*Eh* 105 is "a shrivelled foetus of about four months which has escaped through a laceration in the uterine wall, in a case of parietal gestation." The cyst and uterus are included in the specimen. Dr. Ramsbotham most truly observes that the preparation does not display the peculiarities of the case well "having been taken from the body hurriedly and at great disadvantage." By the courtesy of Dr. F. C. Turner I have been enabled to examine this specimen very closely. The lower part of the cervix with the os externum has been cut away, the uterus has been laid open from the fundus to close above the cervix. The cyst has been completely severed from the uterus and sewn on to it by threads passed through their serous lining only. It has no aperture excepting the rent through which the foetus escaped, but, on close scrutiny, the edges of the lower part of this aperture are found to be uterine tissue cut artificially in dissection. Moreover, the tube and the ovarian ligament proceed from the outer aspect of the cyst precisely as from a uterus; the ligament of the ovary never

springs from a true tubal cyst in this manner. The whole aspect of the cyst, from outside, is like the uterus from which it has been severed, and its walls are of pure uterine tissue. Dr. Ramsbotham's description of the dissection leaves little doubt of the true nature of the specimen, the cyst was "formed within the walls of the uterus" and "one tube was attached to the cyst." The same author figures Breschet's case which bears all the appearance of being tubo-uterine.

The museum of *University College* possesses one specimen (3543) labelled "A case of extra-uterine foetation in the substance of the uterus,\* close to the end of the Fallopian tube. Rupture of the ovum at seventh week, hæmorrhage and death in twenty-four hours." The manuscript catalogue describes the specimen as having been taken from the body of a young woman, and the rupture of the cyst was clearly caused by violent exercise. This specimen is well prepared, the cyst is not half an inch in diameter, being smaller than in the specimen 2517<sup>65</sup> at Guy's Hospital. There can be no doubt that the cyst is here a dilatation of the part of the tube that passes through the uterine walls, a bristle has been introduced through the tube into the uterus and it traverses the cyst, concealed by the chorion which lines the inner aspect of that abnormal cavity. The uterus possesses a decidua.

Thus, including the preparation from Mr. Roberts' case there appear to be six examples of so-called interstitial foetation mounted as pathological specimens in London museums. It is most significant that, in all the four where the condition of the affected parts has been intelligibly displayed, the tubal origin of the "interstitial cyst" is self evident.

These notes are intended to be strictly pathological, still they suggest certain obstetrical considerations. "Inter-

\* Dr. Barnes would be thoroughly justified in the use of his term "ectopic gestation" in such a case as this, where the older term reads as an absurdity (see 'Trans. Obst. Soc.,' vol. xxiii, p. 94), but space prevents me from entering into questions of synonyms.

stitial" or tubo-uterine pregnancy is a rare accident, as our London museums prove, for practitioners are never backward in presenting to such collections specimens of extra-uterine gestation, and the numerical richness of a series is facilitated by the fact that sudden death is so frequent an ending of this abnormality of gestation that a necropsy is generally allowed, or even enforced by a coroner. Hence we see a goodly array of the more frequent tubal form in almost every museum; since 1877 I have dissected and mounted no less than four, for the museum of the Royal College of Surgeons alone. The records of our Society's 'Transactions' teem with cases of tubal gestation. Yet notwithstanding the publicity thus given to extra-uterine foetation, only six specimens of the tubo-uterine form can be found in the metropolis. In Parry's standard work, 31 cases of this variety are included in a table of 500 cases of extra-uterine pregnancy; but in that table 230 cases are set down as "doubtful." This ambiguous series, however, must have been mostly made up of cases that were chiefly doubtful as to their originally tubal or "abdominal" character; cases of hopeless matting together of pelvic structures so common in all such disorders when of long standing; but interstitial foetation is less likely to be overlooked and classified among these 230 doubtful cases.

In fact it seldom reaches the stage at which it becomes "doubtful" to a dissector. Interstitial pregnancy generally ends in a "foetal cataclysm," as Dr. Barnes would say, at the second or third month, as in Mr. Roberts' case; hence there is no time for pelvic peritonitis, burying the ovaries in adhesions and contorting the tubes in every possible direction.

This tendency to early rupture of the cyst involves, of necessity, great difficulties in diagnosis, which is practically impossible during the first few weeks.\* In

\* Dr. Gibbes, of South Carolina, distinguished a tumour in a case of tubo-uterine pregnancy, which he took for a fibro-myoma, and De la Faille correctly diagnosed a case from the intense pain caused by pressure on the uterus.—(See Parry, 'Extra-Uterine Pregnancy.')

these days of abdominal surgery a rescue of a case like that of Mr. Roberts, by a very experienced operator may yet be recorded; but the very circumstances under which this accident must occur will seldom bring the patient within timely reach of a surgeon who can manage complicated cases of ovarian and uterine tumours. A purely tubal cyst, even at this early stage, certainly bleeds less rapidly, moreover diagnosis is not so difficult; on the other hand, the soft swelling on the right of the uterus in Mr. Rogers' case could hardly have been detected on palpation, although abdominal section would have revealed its true character. Then, amputation of the uterus above the cervix would have been the sole practicable course.

The tendency to early rupture is clearly due to the thinness of the cyst towards its upper or peritoneal aspect. The lower portion of its walls tend rather to grow thicker, and, supposing that the upper part does not rupture, pregnancy may continue till term. Rokitansky has described such a case, quoted in several works by contemporary writers. I can well understand how the foetus might be born into the uterine cavity, after expulsion from the sac, and then directly, or after an interval, delivered from the uterus "into this breathing world" in the usual manner. Dr. Mundé describes a case\* where he fully believes that such a phenomenon occurred; the patient recovered, so that the precise condition of the parts could never be ascertained.

The cases of suspected hernial embryo-bearing pouches of the uterus, well known to Fellows of the Society, may, in many instances, have been really tubo-uterine cysts, and there is every reason to believe that the former uterine orifice of the tube, in the part of the cyst that projects into the uterine cavity, might become dilated, from various causes, so as to admit a sound or even the forefinger. This orifice might dilate, in the delivery of the foetus into the uterus, as the os externum

\* 'American Journ. Obstet.,' 1879, p. 330. The same remark applies to Dr. Lenox Hodge's case, just published in Parry's work.

dilates in natural labour, but it is more probable that it would be rapidly rent asunder. In the discussion on Dr. Barnes' paper on the so-called "Missed Labour," Mr. Spencer Wells and Dr. Gervis suggested the possibility of some missed labour cases being instances of tubo-uterine pregnancy.\* But the cases quoted in support of this theory were theoretical, in so far as they all recovered, as did Dr. Mundé's patient; besides, the tubo-uterine nature of the pregnancy was based on the fact that the sound had been previously passed into an (apparently) empty uterus, without producing abortion; but this accident does not always follow the introduction of a sound into a normally gravid uterus. On the other hand, Dr. Roper's cases, mentioned by him in the same discussion, appear to have been verified by dissection; that obstetrician believes in hernial pouching of the gravid uterus through rupture of a part of its inner wall.† Should his cases have really been correctly interpreted in this fashion, I am inclined to rank among them the specimen *Eh* 24, in the London Hospital Museum. Still, I suspect that some such cases were tubo-uterine cysts. When developed to a very great size their relation to the Fallopian tube might become confused and constitute a source of fallacy. As to pregnancy in one horn of a double uterus, it has so clearly nothing to do with the specimen I exhibit this evening, that it is unnecessary for me to discuss that subject.

The cause of the arrest of the ovum in the uterine part of the Fallopian tube is not, in Mr. Roberts' case, self-evident. The cavity bearing the foetus appears to be a pure dilatation of the tube; as in most similar cases, there is no evidence that the muscular structure of the uterus itself has been ruptured; hence the unsatisfactory

\* 'Trans. Obst. Soc.,' vol. xxiii, p. 100.

† Since this paper was read, a "Case of Intra-mural Pregnancy Resulting in Missed Labour" has been contributed to the 'British Medical Journal,' (November 18th, 1882) by Mr. C. E. Steel, of Liverpool. In this case "the Fallopian tubes were normal, and opened into the uterus separately from the sac." Thus there can be little doubt of the nature of the sac, which could not possibly have been tubo-uterine.

character of the term "interstitial." Such a rupture would, if it could be proved by dissection, have occurred from some uncertain cause, before the arrest of the ovum, for a very young ovum could hardly burst the tube, whilst, were the tube ruptured in its uterine part already, we can understand how an ovum might be forced into the uterine tissue, instead of into the uterine cavity. The uterine orifice of the tube, that is to say, in this case, the aperture in the lower part of the cyst, is quite patulous, and there are no traces of any polypi obstructing it, as in cases related by Beck, Breslau, and Leopold.\* Yet, although the uterine orifice of the tube was unobstructed at the date of the patient's death, it might very possibly have been obstructed by catarrhal swelling of the mucous membrane some eight weeks earlier, and this would have been sufficient to arrest the ovum. On the other hand, a dilatation or tortuous condition of the uterine part of the tube might have existed before conception, and if so, it is easy to understand how the ovum was arrested in it; Leopold discovered an abnormal and crooked condition of this part of a left tube, in a case where the corresponding portion of the right tube held a foetus. I believe that the truth lies between these two explanations, but that the second is more probable than the first.

\* "Zur Lehre von der Graviditas Interstitialis," 'Archiv. für Gynäkologie,' vol. xiii, heft 3.

