

Case of femoral hernia, containing the caput coecum, and complicated with an irregular obturator artery surrounding and constricting the protrusion, and other cases illustrative of the operation for femoral hernia / by James Spence.

Contributors

Spence, James, 1812-1882.
Royal College of Surgeons of England

Publication/Creation

Edinburgh : Printed by Murray and Gibb, 1855.

Persistent URL

<https://wellcomecollection.org/works/m9jhw889>

Provider

Royal College of Surgeons

License and attribution

This material has been provided by This material has been provided by The Royal College of Surgeons of England. The original may be consulted at The Royal College of Surgeons of England. where the originals may be consulted. This work has been identified as being free of known restrictions under copyright law, including all related and neighbouring rights and is being made available under the Creative Commons, Public Domain Mark.

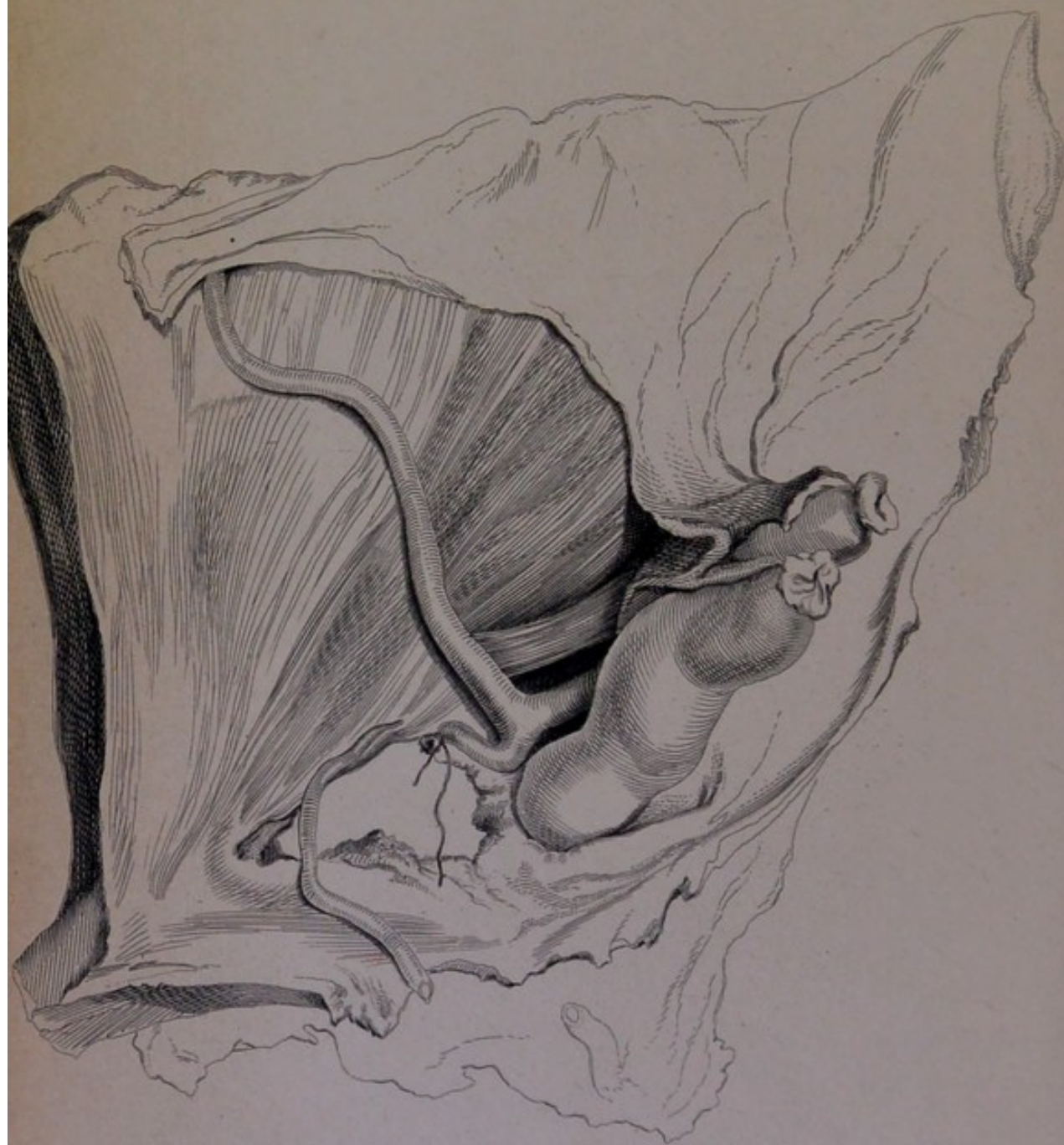
You can copy, modify, distribute and perform the work, even for commercial purposes, without asking permission.



Wellcome Collection
183 Euston Road
London NW1 2BE UK
T +44 (0)20 7611 8722
E library@wellcomecollection.org
<https://wellcomecollection.org>

+
156

57



M^r Spence's case of Hernia.

150
37

15

C A S E

OF

F E M O R A L H E R N I A,

CONTAINING THE

CAPUT CECUM, AND COMPLICATED WITH AN IRREGULAR OBTURATOR
ARTERY SURROUNDING AND CONSTRICTING THE PROTRUSION,

AND

O T H E R C A S E S

ILLUSTRATIVE OF THE

O P E R A T I O N F O R F E M O R A L H E R N I A.

BY

JAMES SPENCE, F.R.C.S.,

LECTURER ON SURGERY,

AND SURGEON TO THE ROYAL INFIRMARY, EDINBURGH.

PRINTED BY MURRAY AND GIBB, EDINBURGH.

MDCCCLV.

[FROM THE MONTHLY JOURNAL OF MEDICINE, JULY 1855.]

CASE OF FEMORAL HERNIA.

IN the history of this case I have purposely been most particular in detailing minutely every point connected with the operation, so that the practice resorted to, the reasons for its adoption, and the remarks which follow, may be perfectly understood.

Archibald H—, æt. 49, the subject of the present communication, had been under treatment in the medical wards of the Infirmary for some time, on account of severe chronic bronchitis, and skin disease. He had suffered from femoral hernia for many years, which he had always hitherto been able to reduce by taxis, although often with considerable difficulty. On the evening of the 17th of March, I was requested by the resident physician to see the patient, as the hernia had come down suddenly about six hours previously, during a fit of coughing, was of larger size than usual, and had resisted the efforts made to reduce it, whilst vomiting, pain and tension in the swelling had supervened. The resident physician informed me that he had tried the taxis as on former occasions, and that failing, it had also been fully tried whilst the patient was under chloroform by one of the resident surgeons, but without success; I learnt, moreover, that the patient had been making constant but unavailing efforts to reduce it himself. I found him vomiting, complaining of pain in the abdomen, and with an anxious expression of countenance. The hernia, which was a femoral one, about the size of an orange, was tense, and painful on pressure. I had him put under the influence of chloroform, and judging from the state of the swelling and the previous efforts for reduction, that it would be better not to persist too much in the taxis, merely made a slight trial, and failing in this, proceeded to operate. I divided the integuments over the hernia, as I usually do, by a T incision, but owing to the depth of the fat, and the bulk of the tumour, converted it into a crucial incision, to gain more room. The superficial fascia having been divided so as to expose the tumour, it was seen to be of a somewhat irregular form on the surface. On drawing the body of the swelling downwards, the falciform edge was seen, with the neck of the hernia very deeply situated. The fasciæ immediately covering the sac were next cautiously cut through, and a small flat director was insinuated *beneath the margin of the falciform edge, which was notched with the bistoury sufficiently to enable me to use the point of my finger, to guide the knife in dividing the deeper constriction.* On pressing my finger upwards, I became sensible of the indistinct pulsation of a vessel close to the constriction, and, therefore, only made a very slight notch upwards and inwards, and another directly upwards, so as to divide the stricture at two points of its circumference. This enabled me to get the point of my finger so far below the crural arch as to push the vessel upwards and divide the arch to a sufficient extent to allow of the reduction of an ordinary hernia. I then scratched through a few fibres lying immediately on the neck of the sac, and attempted reduction

without opening it, but unsuccessfully. I made the less effort to do this, as the hernial contents, as seen through the thin sac, seemed exceedingly dark and tense. I, therefore, opened the sac, and gave vent to a quantity of dark bloody serum, and exposed a portion of intestine (the cœcum), tense, and almost black from ecchymosis. Anxious to avoid, as far as possible, any further pressure on the bowel, I again enlarged the division of the ring sufficiently to enable me to introduce my finger, and also to draw down and examine the portion of intestine immediately above the stricture: I now found the contents of the sac to consist of the cœcum and the lower portion of the ileum; the latter was at once easily reduced, but the cœcum, from its form and connections, could not be so readily returned, and as, on examining it, I found a small portion of its peritoneal and muscular coats had been lacerated by the attempts at taxis, I thought it safest to make a still freer opening by dividing Poupart's ligament completely. With this view the chord was drawn upwards with a blunt hook, and I carefully dissected through the lower part of the tendon of the external oblique in a line corresponding to the centre of the femoral ring. Having fairly divided the superimposed textures, I found that there was still some constriction higher up preventing the gut being returned, and which kept it tense. On passing my finger up, I felt a tight cordlike substance encircling the hernia external to the sac, and recollecting the vessel I had felt pulsating, I at once concluded this must be the irregular obturator, whilst from the bulk, distension and state of the protruded gut, it was equally evident this constricting cord must be divided to permit safe reduction. Accordingly, keeping the finger of my left hand within the sac, as a guide to the constricting vessel, I used the forefinger of my right hand so as to hook it down, and brought it distinctly into view. The vessel was tied with two ligatures, and divided between them, the gut reduced, and the wound dressed and bandaged in the usual way.

I ordered an opiate to be given, and directed leeches to be applied at once, in case any symptoms of peritonitis supervened. Next day the pulse had risen to 120, and there was pain in the abdomen, and vomiting. Fifteen leeches were applied, and a pill, composed of 2 grs. of calomel and $\frac{1}{2}$ gr. of opium, was given every four hours. On the 20th, the abdominal tenderness and the vomiting were less, but as the bowels had not yet been moved, an assafoetida enema was administered, this produced no satisfactory evacuations; a large distending enema on the 21st also failed to open the bowels, a dose of castor oil was therefore given on the evening of the 22d, and, on the morning of the 23d, after another large enema of warm water, a very considerable fœculent evacuation took place, with great relief. On the 24th, his general appearance was better, the pulse had fallen to 100, and the abdominal tenderness now complained of was confined to the lower part of the abdomen, and evidently due to inflammation, and threatened suppuration in the abdominal parietes. He could retain food without vomiting, and was ordered chicken soup and some port wine. He was weaker and restless on the 26th. There was considerable pain and tension at one part of the abdominal parietes, and it was thought advisable to make an incision, in case of purulent matter being confined; but the incision, though carried deeply, did not open any purulent collection. A poultice was directed to be applied. The patient continued much the same till towards the morning of the 27th, when he became worse, sunk rather suddenly, and died at 11 a.m.

Post-mortem Examination.—On opening the abdomen, there were found the marks of acute peritonitis, but in a great measure limited to the right iliac and pelvic regions; lymph was effused upon the surface of the intestines, and there was a small quantity of turbid serum in the pelvis. The cœcum had regained nearly its normal position and appearance, retaining only slight traces of ecchymosis; the abraded part of its peritoneal and muscular coats, however, was as distinct as when first seen during the operation, and no attempts at plastic reparation seemed to have taken place; the lower parts of the ileum

were also free, except a portion about three inches in length, which was thickened, and adherent to the parietal peritoneum in the neighbourhood of the wound.

Before making any further dissection, I inserted a pipe into the right common iliac artery, and threw in some injection to distend the vessels, so as to be able to examine them more carefully afterwards.

On examining the swollen parts of the abdominal parietes, the muscular tissue was found generally thickened, and of a dense brawn-like consistence; whilst the substance of the rectus and oblique muscles was studded with numerous small collections of pus of a dirty grey colour, and which seemed infiltrated into their texture, not escaping readily when the collections were opened. There was also a considerable diffuse abscess in the sub-peritoneal cellular tissue on the right side of the bladder, at some distance from the wound. The parts more immediately concerned in the operation, were removed for further examination.

On careful dissection, I found, as might have been expected from the lapse of time, that the parts were considerably matted by plastic effusion. On dissecting from without, I found the whole of the falciform process, together with the lower border of the tendon of the external oblique, fairly divided, and the spermatic cord and its investments laid bare, leaving even yet, after the contraction consequent on the healing process, a very free opening.

Dissecting from within, I found the epigastric artery of a large size, and the obturator arising from it; this latter vessel was obliterated to some extent, and diminished in size from the effects of the ligature. The ligature on its proximal end had not separated, that on the distal end had; but the injection had entered the distal portion by the anastomosing vessels, so that the course of the artery round the opening through which the hernia passed, can be readily traced in the preparation; a sketch of which is subjoined. It arises from the epigastric before that vessel has ascended on the parietes, creeps slightly upwards on the outer side of the femoral ring, then curves closely around its upper border, and finally descends along its inner side to gain the obturator foramen, so as to encircle the opening at all points available for division with the knife.

I learn from Mr Edwards, one of the demonstrators in the University, that the artery was also irregular on the opposite side,—where the epigastric arose from the common femoral, passed upwards in front of the femoral vein, and, on reaching the abdominal parietes, gave off the obturator so as to surround the upper part of the crural ring; unfortunately, however, the dissection has not been preserved.

Remarks.—This case is, I believe, unique in one respect, being, as far as I can learn, the only one in which the presence of the artery has been ascertained during the operation, and avoided in incising the ordinary seat of constriction; whilst its ligature and division were ultimately necessitated, from the vessel itself being the obstacle to reduction.

But I think it principally worthy of being detailed, as it seems to me to show practically, that, in cases of femoral hernia, where the irregular vessel exists, its presence may be ascertained, and the constricting portion of the crural ring may be sufficiently divided to admit of reduction, without wounding the irregular vessel, if certain precautions be adopted; and, secondly, when complications may necessitate or endanger its division, it shows that the vessel may be tied, and what the plan of procedure in such cases ought to be.

First, then, as to the risk and chance of avoiding injury in ordinary cases of femoral hernia.

I will not enter into anatomical details further than to say that there are three different positions in which we find the obturator artery placed, in relation to the femoral ring, when it arises by a common trunk with the epigastric—viz., 1st, Descending closely applied upon the external iliac vein, to reach the obturator foramen, and hence lying to the outside of, or behind and to the outside of a femoral hernia, and therefore out of all risk of injury during the operation. 2d, Passing down from the epigastric towards the obturator foramen—further removed from the vein, so as to divide the femoral ring into two sections, in which case it might be either pushed aside, or stretched in front of a hernial protrusion, or, as in a case described by the late Mr Allan Burns, have two small hernial protrusions, one on either side of it. 3d, The artery arising from the epigastric passes upwards, then curves round the upper, and descends along the inner margin of the femoral ring to gain the obturator foramen, so as to encircle a hernia passing out at the femoral opening, in all the directions available for incision. It is to this last irregularity I would at present direct attention. As regards the statistics of this form of irregularity, there is considerable discrepancy, some authorities, as Mr Quain, stating it at nearly 1 in 10; Velpeau, 1 in 15; and Monro, 1 in 20 or 25. It is evident, however, that practically, no matter how rare or frequent such an irregularity may be, the surgeon can never predicate in what case he may meet with it, and is therefore bound to act in every case with the same caution as if it might be present.¹

This arterial irregularity, as coincident with a femoral hernia, must be, of course, still more rare, yet there are several such cases on record.

There is a preparation in the Barclayan department of the Museum of the Edinburgh College of Surgeons, showing such a coincidence; and the late Mr Liston had one in his museum.

In at least two cases the artery has been wounded during the operation for strangulated femoral hernia: once in a case operated on by Baron Dupuytren, where its division was only discovered after the patient's death from other causes. The other case occurred to Mr Skey of St Bartholomew's; in it the bleeding was profuse at the time, the lower end of the artery was tied, the upper could not be secured, but bleeding was arrested by other means, for the patient only died some days afterwards, from the effects of a drastic purgative,

¹ Perhaps the practical value of acting on this principle will be best illustrated when I state that, having devoted very considerable attention to the anatomy of femoral hernia, and made more than two hundred special dissections of the region, I never met with the irregular obturator in such a position as to encircle the femoral ring in any of my own dissections, nor in any dissection occurring in the practical rooms under my care, during ten years when I taught anatomy: and the first instance in which I have encountered it was in this case, whilst operating.

given by mistake. Lastly, in a case which occurred to the late Dr Richard Mackenzie, it was found, on the patient's death some weeks after the operation, that the irregular obturator had encircled the neck of the sac, but had escaped division.

Now, these cases show both that the artery has been accidentally cut, and accidentally avoided; but the case I have recorded goes a step further, for it shows that the surgeon, by proceeding cautiously, and feeling with the pulp of his finger, before dividing the constriction formed by the deeper or higher portion of the crural arch, may detect the presence of the irregular vessel, and then, by cautiously notching the constriction, to a very slight extent, at two points of its circumference, he will gain room sufficient to enable him, either with his nail or the point of a small flat director, to push the artery out of the way, while he divides the stricture more fully.

By following this plan, I was enabled to relieve the constriction, so far as to draw down and examine the intestines contained in the sac, and readily to reduce the portion of the ileum, so that, under ordinary circumstances, no further incision would have been necessary, and the vessel would have remained intact.

Of course, if the operator holds the opinion that the whole thickness of the crural arch, including Poupart's ligament, ought to be divided in every case, then the irregular vessel runs a much greater risk, than if he limits his incision to the division of that portion of the arch formed by the convergence of the abdominal fasciæ, below Poupart's ligament, which immediately constricts the sac, and which is all that I have almost ever found it necessary to divide in cases of femoral hernia.

Secondly. The case, however, shows that certain complications, occurring in a femoral hernia where the irregular obturator artery was present, might render it necessary to divide the surrounding textures so freely, for the purpose of reducing the protrusion, that there would be very great risk of wounding the vessel; or that, from the artery tightly surrounding the protrusion, it might absolutely require to be divided, as itself an obstacle to reduction: And this leads us to the consideration of what these complications are, and how such difficulties may be best met and overcome.

Though I have mentioned the irregularity of the obturator artery as being an obvious and serious complication in the case, it was by no means that which gave rise to the greatest difficulty;—indeed, from my remarks under the first head, it may be seen that I hold that, except for the other conditions of the hernia, the irregular vessel would not have given rise to much difficulty, or been in much danger of being wounded.

The real difficulties which complicated the operation were, I think, the bulky and irregular form of the protruded cœcum; its comparatively fixed position, by its peritoneal attachments, near the site of the femoral opening; and its posterior cellular connections, not allowing it to slip back like portions of the floating intestine; and

last, not least, the state of the bowel from the previous attempts at the taxis, forbidding all further pressure or manipulation that could possibly be avoided.

The form and connections of the cœcum always render its reduction slow and gradual, even under more favourable circumstances, where the bowel can safely bear moderate compression, and where the constricting textures have been very freely divided,—as I found in a case of inguinal cœcal hernia, on which I operated some months ago, where there was no limitation to making the incision of the constriction very free indeed; and I have also seen the same difficulty, though to a much less degree, in cases where the sigmoid flexure of the colon formed the contents of inguinal herniæ. In femoral hernia, however, where our incisions must, in general, be much more limited, and, especially, when we have ascertained the presence of an irregular artery round the upper part of the ring, the causes of difficulty I have alluded to become very embarrassing, and require us to adopt great caution in dividing the constricting textures; indeed, it was the eccentric pressure of the bulky distended gut, which brought it into contact with structures which do not ordinarily form the seat of stricture, and in this way the irregular artery, dragged and stretched to the utmost by the distended portion of the cœcum, had come to form a cord-like constriction upon it, requiring division before the bowel could be returned.

As to the plan to be adopted in such cases of femoral hernia, requiring such free incisions to relieve the bowel, I can only say that, after much consideration of this case, I would still proceed to divide the superimposed textures by the same method,—viz., by dissecting cautiously through the lower division of the tendon of the external oblique, and the other textures, down to the peritoneum, in a line corresponding to the centre of the femoral ring, the chord being drawn aside. Thus all danger of wounding the artery accidentally is avoided, and if it be found itself constricting the swelling, it will not be found very difficult to bring it into view and put ligatures upon it.

Indeed, this plan is that which Sir Astley Cooper recommended as safest and best in all cases of large femoral hernia; and, although I cannot think, after some experience in femoral herniæ, that it is either necessary or advisable as a general plan, it will be found the safest in complicated cases requiring more than usually extensive incisions; it is, in fact, a cautious dissection down upon the upper part of the sac, or the parietal peritoneum immediately above, and continuous with it, and if carefully conducted, attended neither with difficulty nor danger.

CASE II.—Christian A., æt. 72, residing in Dalkeith, first noticed a swelling in the groin on the morning of Sunday, 17th September 1854. During the day she was sick and much pained, and in the afternoon felt a strong desire to have motion in the bowels, which was accompanied with severe straining, but without any evacuation. She took some brandy to relieve the colicky pains, and then a dose of castor oil; shortly after which, vomiting commenced, and con-

tinued for some time. At 3 A.M. on Monday, she had another attack of vomiting, which was followed by an interval of comparative ease, until 3 P.M., when the pain and vomiting increased in violence. She sent for Dr Thomson late in the evening, but made no mention of the swelling. A purgative was ordered, and an enema directed to be given.

On Tuesday Dr Thomson found that the vomiting had become more frequent, and that the medicines had not acted; he then examined for, and detected the femoral hernia, and tried to reduce it whilst she was under the influence of chloroform, but did not succeed. In the evening her countenance was anxious, and she was restless, but the pulse not much affected. The vomiting had become feculent.

On Wednesday morning Dr Thomson was told her bowels had been moved, but without any relief, and, on examining the stool, it was evidently from the lower bowel. I saw her with Dr T. about 3 P.M. on Wednesday; her features were sharp; pulse quick and small; abdomen distended; the tumour tense and painful, and the skin over it was of a dusky colour. The matter vomited was evidently feculent, and she had occasional attacks of hiccough. Under these circumstances I made no attempts at reduction, but proceeded to operate after the administration of chloroform. On exposing the sac I found the textures infiltrated with inflammatory exudation, and matted together. The neck of the sac was very tightly constricted, and I required to use great caution in opening it, as there was no fluid between it and the bowel; indeed, they were adhering at some points by recent lymph. The bowel was very dark, of a dull granular appearance, and very tightly constricted. On dividing the stricture I drew down the bowel above it, and finding it of a natural appearance, I reduced the protrusion, and dressed and bandaged the wound in the usual way. Dr Thomson informed me that the urgent symptoms were relieved by the operation, and that the patient speedily recovered.

CASE III.—Mrs W., æt. 64, of spare habit of body, and long subject to dyspepsia, sent for Dr Maine of Gorebridge on the 2d of November 1854, stating that she had been suffering from an attack of pain in the stomach, and had vomited twice. As she was subject to frequent attacks of vomiting, this did not attract special attention, until next morning, when Dr M., finding that she had passed a bad night, that her bowels had not been opened, and that the vomiting had been more frequent, examined for, and detected a femoral hernia.

She had been long aware of the existence of the swelling, but thought it of no consequence, as it used to go away of itself. Dr M. tried reduction by taxis, but without success; and as she had vomited some stercoraceous matter, he gave her an opiate, directed cold to be applied to the swelling, and sent for me to visit the patient. It was late in the evening before I saw her; she was then much exhausted with the vomiting and pain; pulse quick and small; skin covered with cold perspiration, and great pain in the abdomen.

I put her under the influence of chloroform, and exposed the hernia by a T incision. From the severity of the symptoms, and the doubt as to how long the hernia might have been strangulated prior to her applying for medical aid, I determined to open the sac. As there seemed to be a little fluid at the lower part, I pinched up and opened the sac at that point, and exposed a portion of bowel of a very dark colour. On trying to pass my finger, I found the sac connected to the bowel, by old adhesions, over its whole surface, so as to prevent even a thin flat director from being passed at any point, and this adhesion considerably lower than the seat of strangulation; I therefore proceeded to divide the falciform process and lower crural arch fully, so as to open the sac in the femoral canal above the constriction, and then divide it from above downwards. In doing so, when I had divided the textures over the neck of the swelling, it became flaccid, and was so evidently relieved, that I returned the adherent portion of the sac and bowel together.

I did not see the patient again, till she came to town to get a truss fitted; but I am indebted to Dr Maine for the following report of the case:—

She passed the first part of the night very comfortably. Early in the morning she became cold, sick, and uneasy, but no pain in the abdomen; pulse very weak and indistinct. An opiate was given, and a little wine and beef-tea tried occasionally. In the afternoon she was greatly better; pulse much improved. Opiate was repeated at bed-time, and a dose of castor oil directed to be given in the morning, followed by an enema of warm water, if necessary. On the third and fourth days after the operation, she had a little pain and tenderness over the abdomen, with tympanitis, which was relieved by opiates, sinapisms and fomentations to the abdomen, and a turpentine enema. With this exception, she recovered without any bad symptoms. The wound healed rapidly, and she regained a better share of health and strength than before the operation.

CASE IV.—Margaret C., æt. 50, had suffered for many years from prolapsus uteri. She first noticed the rupture about fifteen months before I saw her, and had always been able to put it back when she lay down. On the 4th of January 1855, she was seized with violent pain in the belly, and vomiting, which she attributed to obstinate constipation. The vomiting and pain continued to increase in violence until the morning of the 6th. Dr Middleton was then sent for, and attempted to reduce the hernia, but without success.

At 2 P.M. I visited the patient, and having tried reduction by taxis ineffectually, I proposed an operation. Accordingly, at 4 P.M., I saw her, along with Drs Middleton and Thomson, and proceeded to operate, after chloroform had been administered. On dividing the skin and superficial fascia, a hernial tumour was brought into view, tilted upwards on the abdomen. On drawing down the tumour it was seen to be shaped somewhat like an inverted T. The perpendicular portion or neck descended from below the falciform edge. The outer end of the transverse or lower part had been tilted up, and rested on the abdomen, and the inner end projected over and rested upon the pubic portion of the fascia lata. On dissecting through the fascia propria which invested it, I found that the internal part of the transverse portion was not truly hernial, but a mass of dark congested glands, closely adherent to the inner and lower part of the sac. I then opened the sac, which required some care, as it contained no fluid. The bowel was of a dark purple colour, dull and granular on the surface, with recent lymph effused between it and the sac at different points. On dividing the stricture, I drew down and examined the bowel above it, and finding it healthy, and free from any appearance of ulceration at or above the constricted part, I gently returned the protrusion, and cut away the part of the sac to which the congested glands were adherent; then closed the wound, bandaged the patient in the usual manner, and directed an opiate to be given. Contrary to my expectations, from the state of the constricted bowel, no bad symptoms supervened, and the patient made an excellent recovery.

CASE V.—Mrs D., æt. 55, had been the subject of a large uterine tumour for many years, and had first noticed a swelling on the left groin about seven or eight years ago. This swelling she could reduce at pleasure when it came down, but she had never worn a truss for it. For the last three months she has been suffering much more from it than formerly, and has had frequent attacks of vomiting and constipation, accompanied with great pain in the swelling.

On Friday, April 6th, she was seized with one of these attacks, presenting all the usual symptoms, but with more than usual severity. I was asked by Dr Alexander to visit her on Sunday, April 8th. When I first saw her, she had frequent and severe vomiting, much pain and tenderness over the abdomen generally, and the swelling was hard, tense and extremely painful. Having tried reduction by taxis without success, I directed the turpentine enema which had been already given, to be repeated, and returned, with Drs Alexander and Struthers, at 8 P.M. We then found that no feculent matter had

been brought away by the injections, and that all her symptoms were aggravated. The taxis having again failed, even with the aid of chloroform, I at once proceeded to operate. After dividing the skin, superficial fascia, and a considerable quantity of fat, a small oval tumor was seen, lying about an inch below the falciform process, and enveloped in thin, smooth, and glistening membrane.

On opening this there was found a mass of fat, and on dissecting cautiously through the fat, and removing part of it, I exposed a very dark, rounded swelling, about the size of a small cherry; it felt firm and hard, and on trying to trace it up towards the femoral ring, I could feel no distinct neck.

I divided the falciform process freely, but still failed to detect any swelling continuous with the lower protrusion. I accordingly very carefully pinched up a part of its outer covering, and cut out a small portion of it; then, by means of dissecting forceps, separated it a little more, and exposed a portion of intestine of a very dark purple colour; on gently insinuating a narrow flat hernia director between the gut and the sac, I found that the neck of the protrusion passed obliquely upwards and outwards close along and apparently within the proper sheath of the common femoral vein. The sac was slit up, and the finger introduced to the constriction, which was then divided upwards and inwards with the probe-pointed bistoury. I drew down and examined the bowel. The small knuckle contained in the sac was very dark—almost black; the part above the constriction I found tolerably healthy, but adherent within the abdomen near the outer side of the femoral ring. The protruded part was then easily reduced and the operation completed. No bad consequences followed, and the patient made a rapid recovery.

CASE VI.—On the 29th April last, I was requested by Dr Middleton to visit Mrs B., who was suffering from the descent of a femoral hernia, which had resisted reduction by taxis. I found that the patient, a woman about 80 years of age, had a small femoral hernia on the right side, which she stated had occasionally troubled her for some time past, but was usually readily reduced by pressure; that on the present occasion she had felt it more painful than formerly, and, being unable to reduce it, had applied to Dr Middleton. Dr M. told me that he had tried the taxis, but without making any impression on the tumour, and, as he felt it tense, he did not persevere, especially as vomiting had set in. Her pulse was good, not above 80 in the minute, and there was no great tension of the abdomen. As the integuments over the swelling were red and tender from pressure, I thought it best to apply cold over the tumour; directed her to abstain from all further attempts to reduce it; ordered a distending enema to be given, and made an appointment to see her in about three hours, to try reduction when she was under the influence of chloroform, and if not then successful, to operate. I again visited her with Dr M. at the time appointed, when I found an evident change for the worse; her features sunk and anxious, more pain and tension of the abdomen, frequent vomiting, and a small rapid pulse. The enema had brought away no feculent matter. The tumour, though less tender, owing to cold applications, was still hard and tense. I therefore told her that possibly an operation would be requisite, if we could not return it with the aid of chloroform, but she absolutely refused either to take chloroform, or allow anything to be done, notwithstanding everything we could say to show her the danger she was in. We therefore told her son that we considered the operation as her only chance, and, having obtained his consent, we administered chloroform. I tried the taxis, but the swelling was so evidently tightly constricted, that I did not persevere long, but proceeded to operate. On dividing the constricting textures, external to the sac, I found the hernia still constricted, and therefore opened the sac, which proceeding required much care, as there was no fluid between it and the bowel. The intestine contained in the sac was of a very dark colour, and on dividing the stricture, and drawing down the bowel, I found it deeply indented; it was then reduced, and the patient dressed and placed

in bed. There was scarcely any bleeding during the incisions. An opiate was given. Next day I found she had passed a good night, the vomiting had ceased, and there was no abdominal pain; pulse 86. Her bowels were freely opened next day, and she continued to progress very favourably for the first 18 days after the operation, only very peevish and restless, and complaining of pain on the opposite side. On calling one day, I found her by no means so well, and the wound discharging very freely. On examination, I felt an abscess over the left side of the pelvis, near the left spine of the pubis, from which matter could be pressed towards the wound, but she would scarcely allow me to feel it, far less would she listen to the proposal of opening the abscess. I therefore directed poultices to be applied, and her strength supported by wine and diet. Under this treatment she continued to improve, the abscess opened its way to the surface, over the left side of the pubis, and discharged freely for some time, both there and by the wound; but the discharge gradually decreased, and now (15th June) it is of very small amount, both openings are contracting, and her appetite and general health are good. Aug. 6. She is now quite well.

CASE VII.—Elizabeth C., æt 50, farm-servant, admitted into the Royal Infirmary, Jan. 30, 1855. First noticed a slight swelling in the left groin in October 1854, which gave her little pain or inconvenience, except after unusual exertion, and at times the swelling entirely disappeared. While walking, on Monday, Jan. 29, she felt great pain in the tumour, which was followed by sickness and vomiting, with constipation. Dr Maine of Gorebridge was sent for, who, finding the hernia could not be reduced by taxis, recommended her to my care, in the Royal Infirmary. She was admitted on Tuesday the 30th, when the operation for strangulated femoral hernia was performed, about midnight. The stricture was exposed, and readily divided without opening the sac, and part of the hernia was easily returned; but as there still remained a portion of the contents irreducible, I considered it right to open the sac, to make sure of the state of the portion that remained. This I found to be a round and thickened mass of omentum, adherent to the sac, and removed it by the knife. The wound was dressed in the usual way; no bad consequences followed the operation, and she was dismissed cured, March 7, 1855.

CASE VIII.—Elizabeth L., æt 45, admitted into Hospital April 16, 1855. The patient states, on admission, that she has had a rupture for many years: she could always reduce it easily until eight days ago, when all her attempts to do so failed. On Friday evening, April 13, she felt considerable uneasiness in the belly, with nausea, and took some purgative medicine, which acted pretty freely on the bowels, but without much relief to the abdominal symptoms. The uneasiness and pain increasing, and being unable to return the swelling, she applied on Sunday to Dr Somerville, who, failing to reduce it by taxis, requested me to see her, on Monday, April 16. I found her restless, with anxious expression of countenance, rapid pulse, and great nausea; pain over the abdomen on pressure, and great pain and tenderness over the hernial swelling, which was tense, hard, and, red. I therefore had her sent to the hospital, where I again tried the taxis whilst she was under chloroform, but did not succeed. The operation for strangulated femoral hernia was therefore immediately performed. When the sac was opened, it was found to contain only a piece of tightly strangulated omentum—this being a case, therefore, of purely omental hernia. The strangulated piece of omentum was extremely congested, and almost gangrenous; its recovery being doubtful, I removed it by the knife. The wound was dressed and bandaged in the usual way; an opiate was ordered, and also a mixture, containing hyoscyamus and acetate of ammonia. On the third day after the operation she complained of pain in the right lumbar region, which was removed by leeching. On the fourth day the bowels were moved by injection, for the first time since the operation. Her recovery was complicated, by a pretty severe attack of dysentery, and by frequent bilious diarrhœa, but she is now quite well.

Remarks.—The first five of these cases form a group having some features in common. The patients were all females, debilitated either by old age or by previous disease. The general symptoms present, the length of time these had existed, the tightness of the stricture, the morbid alteration in the constricted portion of bowel in all, and the feculent vomiting and hiccough in some of them—were elements for an unfavourable prognosis; and yet in none of them did any unfavourable symptoms supervene.

In a former series of hernia cases, published in the *Monthly Journal*, I had occasion to contrast different cases, and to remark on the difficulty of prognosis from the appearance of the constricted portion of intestine; but experience leads me to believe, that examination of the state of the bowel immediately above the constriction may form a criterion. If it be of a pale reddish-grey colour, and feel thick and fleshy, the chances are in favour of a successful result, the constricted portion will be likely to recover itself when replaced.

On the other hand, if the bowel above the constriction be of a bright pink colour, appearing thin and as if distended with air, and bedewed with a clammy exudation,—and if there be a large escape of red or dark-coloured serous fluid from the abdomen on dividing the constriction,—the prognosis is most unfavourable, as indicating that peritonitis has commenced, or that structural alteration is proceeding, in and beyond the constricted portion.

The practice of gently drawing down and examining an inch or two of the bowel above the constriction, is advisable, I think, in all cases where we open the sac, both because it ensures that the constriction is fairly removed, and, by allowing the protrusion to be emptied of its contents, renders its reduction more easy; but it is specially necessary where the constriction has been of long duration, for in such cases perforation not unfrequently occurs from half-an-inch to an inch above the constriction. I have in my possession three preparations showing this state in cases of femoral hernia where the patients died without being operated on, and I need hardly remark what would be the result of returning a portion of bowel either actually perforated or about to sphacelate.

Some of the cases narrated also present individual peculiarities deserving attention. Thus, in Mrs W.'s case, we find a condition showing the necessity for constant caution in every case of herniotomy, however simple the case may seem; for here, when the lower part of the sac was opened over the collected fluid, had I, without further examination, attempted to run the bistoury upwards to slit it open, the bowel, from its close adhesion above, would almost certainly have been injured, and this has actually happened in similar cases.

In Margaret C.'s case, the congested lymphatic glands adherent to the sac, and enveloped in the thin, smooth, transparent fascia propria, had very much the appearance of the sac itself. I have met

with several such cases where the deep glands were thus closely adherent to the sac; and in all of them where I had to open the sac, I have pursued the plan I adopted in this case, viz., removing the detached portion of the sac together with the adherent glands; because, in such cases, the dissection necessary to expose the sac has generally so injured the vitality of these structures that they are almost certain to slough, or to lead to tedious suppuration, and so I think it best to obviate such consequences by at once removing what would prove a source of irritation, and I have never seen any reason to regret having done so.

In Mrs D.'s case, there was some little obscurity as to the nature of the swelling, as her history of it was by no means clear. She had for years suffered from a large uterine tumour, and was subject to attacks of vomiting and abdominal pain; and as may be supposed from the condition of the hernial tumour, as seen during the operation, its character was not very distinct. It was possible it might be a glandular swelling connected with the uterine disease; and I confess that, during the operation, when I could not trace the continuity of the small swelling up towards the ring in the usual position, I began to suspect such might prove to be the case, especially as I knew of a very similar case where that had been found concurrent with all the symptoms of strangulated hernia. Still, the rule of practice was clear, and accordingly I proceeded, by careful dissection, to make sure of the nature of the small tumour.

In the case of Mrs B., the abscess which formed subsequent to the operation, though a serious complication in a person at her advanced age, could scarcely be regarded as a consequence of it; for there were no extensive incisions, nor interference with the parts, during the operation, likely to lead to the formation of matter. Besides, it occurred eighteen days after the operation, and on the opposite side of the abdomen; and although it ultimately partly discharged itself by the wound, that was only owing to the pus meeting with less resistance in that direction, and to the patient's obstinacy in not allowing the abscess to be opened.

In opening the sac in Mrs C.'s case, after having reduced a part of its contents, I proceeded upon a principle which I hold as essential to safety in performing the extra-peritoneal operation, viz., that the surgeon should satisfy himself that the sac is fairly emptied of its contents; and that, when any part of the hernia cannot be so reduced, the sac should be opened to make sure of its condition. For whilst I think that, in recent cases, when we can readily reduce the hernial protrusion without opening the sac, it is well to avoid further interference; on the other hand, I do not apprehend so much danger from opening the sac, as some do, and, at all events, it is never to be compared with the risk of leaving any portion of such a hernial protrusion unreduced and unexamined.

Indeed, I think that the dangerous form of peritonitis we meet with in cases of hernia, is most generally antecedent to, rather than

consequent on, the operation; and from all I have seen of *post mortem* examinations of such cases, I believe that it depends upon inflammation arising at the constricted part, and thence diffusing itself generally. I have seen fatal peritonitis, from this cause, follow an operation where a recent femoral hernia was reduced with great ease, without opening the sac; and I have at present a case of inguinal hernia, which bears on this point. When first called to see the man, he was labouring under urgent symptoms, depending on a large scrotal hernia, which had been down for twenty-six hours, and had resisted all efforts to reduce it by taxis. I succeeded in reducing it, however, with the aid of chloroform; but this was followed by an attack of acute peritonitis, requiring leeching, calomel, and opium, etc., to subdue it. A few weeks after, when able to go out, he left off the truss for a short time, and the hernia again came down; urgent symptoms supervened, and, although I saw him early, all my attempts to reduce it by taxis were vain. I was obliged to operate; and naturally fearing a tendency to peritonitis, and also on account of the size of the swelling, I was anxious to avoid opening the sac; but this I found impossible, as the stricture was evidently in the neck of the sac itself. I therefore opened it, and yet the patient, who is now quite well, never had the slightest symptom of peritonitis after the operation.

The case of Mrs L. was one of purely omental hernia, which, as its history shows, had slowly progressed from incarceration and congestion to complete strangulation; and the removal of the all but gangrenous mass of omentum seemed to me the safest proceeding, when I considered the little vitality of the fatty texture and the small chance of its recovering itself, the great risk of gangrene occurring in and spreading from it, and the consequent danger of inflammation of the omentum, and general peritonitis.

In reflecting on the complications met with in such cases as that of Mrs D. and others, narrated in this series, and which I have so frequently met with in cases of femoral hernia, both in my own operations, and seen while assisting other surgeons, it has always seemed to me, that if one thing was more essential than another to the safe performance of herniotomy, it was that the incisions should be so placed as fairly and fully to expose the structures over the neck and upper part of the protrusion at least, and in small herniæ, the whole tumour, whether the sac was to be opened or not, so that the operator might make quite sure of the removal of all constriction, and of the gradual and complete reduction of the contents of the sac; or, in the event of difficulties occurring, that he might be able to judge of the state of parts, and to *see* what he was doing. Accordingly, I have never been able to appreciate the supposed advantages of the plan of operation proposed by Mr Gay, which has for its avowed object the division of the stricture without exposing any part of the protrusion or its proper coverings, by means of a small incision made at some little distance from its upper and inner side,

approaching almost to the principle of subcutaneous division of the stricture.

This plan appears to me the most hap-hazard method that can well be imagined ; and I confess I was greatly surprised to find, from some remarks in a paper by Mr Ward, that surgeons of such experience in herniotomy as those of the London Hospital, should have adopted it. Professor Fergusson, in his "Practical Surgery," likewise eulogizes the plan ; but any one looking at the direction of the incision, as represented in his work and that of Mr Gay in the original memoir, will see there is a difference even in that respect ; and that he does not carry out the more objectionable principles of Mr Gay's method is obvious, I think, from what he says when speaking of the question of not opening the sac in hernia : "In many I have found it answer admirably ; but in others, even after the stricture had been divided, I have, probably from an old and bad habit, felt that, without opening the sac, I could not be satisfied, and have therefore done so, occasionally with advantage, and never, that I could perceive, with any material difference of hazard to the patient." A safer plan, and one requiring more exposure of the hernia than inculcated by Mr Gay.