

Removal of both astragali in a case of severe double talipes / by Edward Lund.

Contributors

Lund, Edward, 1823-1898.
Royal College of Surgeons of England

Publication/Creation

[London] : Printed by T. Richards, 1872.

Persistent URL

<https://wellcomecollection.org/works/nr6q3y4c>

Provider

Royal College of Surgeons

License and attribution

This material has been provided by This material has been provided by The Royal College of Surgeons of England. The original may be consulted at The Royal College of Surgeons of England. where the originals may be consulted. This work has been identified as being free of known restrictions under copyright law, including all related and neighbouring rights and is being made available under the Creative Commons, Public Domain Mark.

You can copy, modify, distribute and perform the work, even for commercial purposes, without asking permission.



Wellcome Collection
183 Euston Road
London NW1 2BE UK
T +44 (0)20 7611 8722
E library@wellcomecollection.org
<https://wellcomecollection.org>

REMOVAL
OF
BOTH ASTRAGALI
IN A CASE OF
SEVERE DOUBLE TALIPES



BY

EDWARD LUND, F.R.C.S.,

Lecturer on Anatomy in the Royal School of Medicine, and Surgeon to the Royal
Infirmary, Manchester.

[Reprinted from the *British Medical Journal*, October 19th, 1872.]

PRINTED BY
T. RICHARDS, 37, GREAT QUEEN STREET.

1872.



REMOVAL OF BOTH ASTRAGALI IN A CASE OF SEVERE DOUBLE TALIPES.*

"FINIS coronat opus" is a motto which may be well applied where the operation we have to describe is novel in character, and therefore one in which it is needful to show cause why it should be performed at all. These remarks are applicable to the details I am about to relate of the removal of both astragali in a case of severe double talipes.

H. W., aged 7 years, a native of Whitchurch, Shropshire, was admitted into the Manchester Royal Infirmary, under my care, for double talipes equino-varus, on January 22nd, 1872. From the history, I learned that he had been born with the deformity ; that, when six months old, he had been placed under the care of an orthopædic surgeon in London, the tendons had been divided, and he remained under treatment four months. He then had an apparatus for the feet, which he wore until he was thirteen months old ; and after this he was provided with boots with irons attached, which he used until very shortly before the time when he first came under my observation. He could at one time move about pretty well ; but, as he lived in the country, no farther attention was given to the case ; no alteration was made in the size or strength of the apparatus, and it no longer controlled the vicious direction of the feet. The child walked upon the external border of each foot ; the toes were turned inwards, almost to the transverse degree ; the heels ceased to touch the ground ; and, very rapidly, whatever improvement in the form of the feet might have resulted from the division of the tendons was entirely lost.

It was very apparent, on an inspection of the deformity, that the bones of each foot had become so crumpled up and faultily placed that the articular surfaces were changed in form, so as to interfere with their

* Read in the Surgical Section at the Annual Meeting of the British Medical Association at Birmingham, August 1872.

intrinsic movements, irrespectively of any limits to these from contraction of the tendons.

I made several attempts to diminish the distortion. The patient was placed under chloroform; and I endeavoured, by manipulation, to break down any adhesions which might exist in the tarsal joints, and restore the position of the bones. But in this I could not succeed to the least degree. I next tried what could be done by long-continued pressure and traction, by using, first, a Scarpa's shoe with screw-action, and then Mr. Tufnell's tinned splint, with leg plaster straps; but in neither plan would the delicate skin of the edges and soles of the feet tolerate the necessary amount of pressure; and I was compelled reluctantly to stay all similar proceedings. It then occurred to me that, one great impediment to the replacement of the tarsal bones being due to a partial dislocation of the head of the astragalus from the cup of the scaphoid, by which an undue adduction of the portion of the foot in front of the medio-tarsal joint had been effected, if I could remove the astragalus, most, if not all, of these obstacles would vanish. And I did not hesitate to indulge in the possibility of such a result, seeing that I had known of cases in which, from injury and compound fracture near the ankle-joint, the astragalus had been completely dislocated and the bone removed—the patient, after a slow recovery, enjoying the use of a very serviceable foot. Such cases are well known to the profession; some of our most distinguished surgeons having specially referred to the urgent propriety of trying to save a foot under such circumstances, rather than condemning it to amputation.

Having duly considered the probable difficulties of the operation, and studied carefully what seemed to me the best mode of performing it, I proceeded to remove the astragalus from each foot by the following method.

On the 17th May last, the little patient being under chloroform, I commenced with the left foot, which was the more deformed. I made a longitudinal incision just over the most projecting part of the head of the astragalus, parallel to the antero-posterior axis of the foot, guiding it between the line of the outermost tendon of the extensor longus digitorum muscle and the tendon of the peroneus tertius. The incision being of sufficient depth, and about an inch and a half in length, I expected at once to come down to the cartilaginous surface of the head of the astragalus; but here I was met by an unexpected difficulty. The dorsal astragalo-scaphoid ligaments which I had divided were so much thickened, so white and firm in structure, and so closely pressed upon

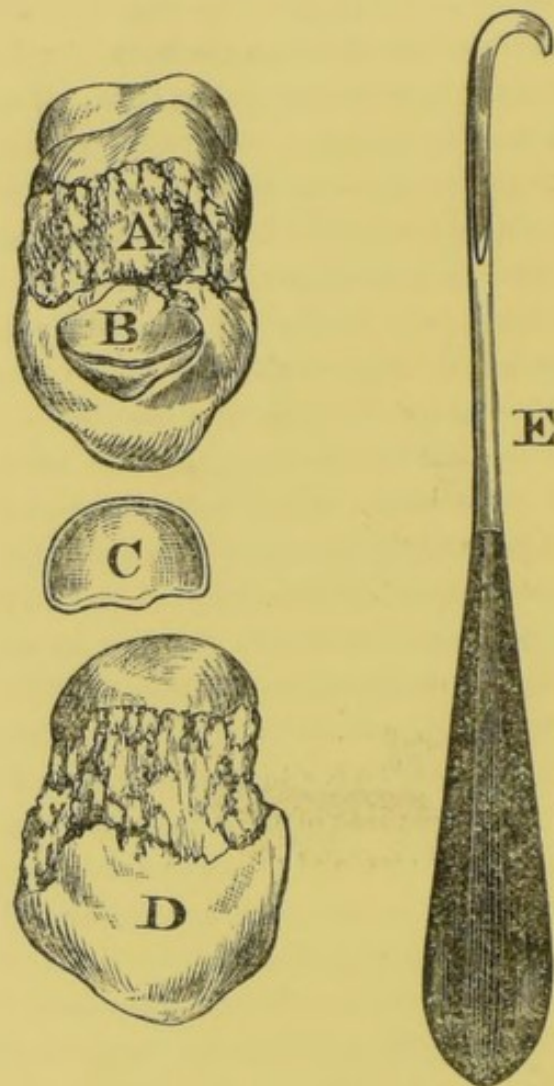
the bone, that it was nearly impossible to be certain whether or not all the fibres were divided and the head of the bone fully exposed ; this, however, being done, I tried with a gouge to raise the bone, while the scaphoid and the front part of the foot were bent backwards ; and, in doing this, I cut off a thin piece of the edge of the cup of the scaphoid — there was so little space between the bones for the passage of the instrument, that it cut into the soft young bone. The same accident occurred when I used the gouge between the external malleolus and the side of the astragalus ; for here, again, from want of space, I detached unwittingly a slice of the inner side of the malleolus, as the preparation will show. Fortunately, I had provided myself with a little instrument, which I here found very useful. It is a small, strong, curved hook, fixed in a stout handle (Fig. E) ; and it has on its concavity a cutting edge, while the edge of the hook is round and blunt.* This hook I used as a lever to raise up the astragalus, and lift it from the bed or socket formed for it by the scaphoid, upper surface of the calcaneo-scaphoid ligament, and the os calcis ; and, passing it round one end of the calcaneo-astragaloid ligament between the bones, by simple traction, I cut through the interosseous band in its whole length. This proved to be the key of the operation ; for, after its division, I could dislodge the astragalus, and, holding it firmly with Sir William Ferguson's lion-forceps, made a few touches with the cutting hook, used first as a wedge between each side of the astragalus and corresponding malleolus to separate the bones, and then as a cutter to divide the bands of the lateral ligaments ; the bone was thus set free and drawn out easily. There was little, if any, impediment from fibres at the back of the astragalus, and none at all, as I had anticipated, from adhesions of the tendon of the flexor longus pollicis to the sheathed groove in the bone ; for, in fact, the groove itself was very shallow, and but poorly developed.

I need not say that, in operating on the right foot, I used only the cutting hook, and not the gouge or chisel, to detach the astragalus from its ligaments ; so that, in this foot, I did not injure the neighbouring bones nor remove any portions of them.

The operation on each foot was conducted, from first to last, in strict accordance with those principles of antiseptic surgery which are well known as Mr. Lister's method. Catgut ligatures were used on two small arteries which were tied—the carbolised wax and resin sutures to

* It is very similar to the guarded cutting hooked knife which I show in the museum collection as useful for the division of internal blind fistulæ.

close the wounds ; these were enveloped in carbolised gauze, and the feet placed on rectangular splints. It could soon be seen what were likely to be the results of the operations. Each foot could be placed



A, is the Left Astragalus, with a piece of the external Malleolus, B, loosely attached to it ; C, the portion of the Scaphoid of the same side ; while D represents the Astragalus of the right side, which was removed entire, and without injury.

immediately, without difficulty, with the plantar surface at a right angle with the back of the leg. The internal border of the foot still presented, although to a far less degree than before the operation, a certain concavity, more in the left than the right foot, suggesting the possibility that this might be caused by some alteration in form or new deposit in or about the calcaneo-cuboid joint, which would not yield sufficiently. This was, as I have said, much less conspicuous in the right foot, where

the internal border could be brought to nearly a straight line from the ball of the great toe to the heel. The same principle of dressing, the same precautions and general treatment, were rigidly pursued throughout the whole progress of the case. No pus was formed; the deep cavity in which the astragalus had rested was slowly filled up by new tissue. The sutures caused no irritation, and held well until the twelfth day, when three were removed from each foot, and, on the fourteenth day, the remaining two. On the thirty-eighth day, it was reported that the wounds were perfectly healed. No constitutional irritation had existed; the child had seemed to be cheerful, slept well, and taken its food naturally. No tendency to inflammation was observed along the line of the tendinous sheaths in the front of the leg, as might have been expected; and the only pain of which the patient complained was in the immediate neighbourhood of the wound during the dressings, when it was necessary to remove the feet from the splints.

On the sixty-first day (July 17th), I began to apply to each foot Mr. Barwell's system of treating talipes; and, by means of elastic bands carefully adjusted, I have sought to imitate the action of the peroneus longus and peroneus brevis muscles, and very slowly and cautiously to abduct the foot and keep the external border well raised. There is at the present time (August 1st) considerable flexing movement in the ankles. The boy can bear just to rest his weight on the feet when slightly assisted, and he slides and creeps about the ward in a half sitting posture very happily. I intend very shortly to have him supplied with a pair of Dr. Sayre's club-foot shoes, which will allow him to walk about, while the same action of the elastic bands can be preserved. This has been done (September 30th). The boy has worn the shoes for nearly a month, and he walks very well without any help.

The only case which I have found recorded in which any of the tarsal bones have been removed so as to assist in correcting the malposition which exists in talipes, is one performed by the late Mr. Solly, and referred to in Mr. Adams's work on *Club-Foot*, in which Mr. Solly removed the cuboid bone, under the idea that this was the key-stone of the arch of which the deformity consisted, and, that being removed, the curled foot might be, as it were, unfolded into a more natural form. But, I believe, the result was not satisfactory; and I hardly think the plan adopted attacked the true centre of the deformity; for talipes varus is, in its very nature, an exaggerated condition of adduction and excessive rotation inwards and upwards of that portion of the foot which is anterior to the medio-tarsal joints. At this articulation,

a partial dislocation occurs, which, when all other efforts to correct it have failed, may be got rid of, in exceptional cases like the present, by excision of the astragalus, as a justifiable operation.

I have had two objects in view in relating this case to day : the one has been to obtain the opinion and sanction of so distinguished a surgical tribunal, as I now address, to the procedure itself, under certain limited conditions ; and the other has been to place on record another instance of the triumphs of antiseptic surgery in the management of operations in the neighbourhood of joints. For I am convinced that whoever will watch, without prejudice, the progress of such a case as this, from the date of the operation until the healing process be fully completed—the entire absence of suppuration, the freedom from constitutional distress, the perfect closure of deep wounds in the most satisfactory manner—must admit that by no other method than by the absolute avoidance of septicity dare we attempt to treat so formidable an operation.
