

Endothelioma of the Gasserian ganglion : two successive resections of the ganglion, first, by the extradural (Hartley-Krause) operation, and secondly, by an intradural operation / clinical report by F.X. Dercum ; surgical report by W.W. Keen ; pathologic report by W.G. Spiller.

Contributors

Dercum, Francis X. 1856-1931.

Keen, William W. 1837-1932.

Spiller, William G. 1863-1940.

Royal College of Surgeons of England

Publication/Creation

[Chicago?] : [publisher not identified], [1900]

Persistent URL

<https://wellcomecollection.org/works/avxeaptc>

Provider

Royal College of Surgeons

License and attribution

This material has been provided by This material has been provided by The Royal College of Surgeons of England. The original may be consulted at The Royal College of Surgeons of England. where the originals may be consulted. Conditions of use: it is possible this item is protected by copyright and/or related rights. You are free to use this item in any way that is permitted by the copyright and related rights legislation that applies to your use. For other uses you need to obtain permission from the rights-holder(s).


5.

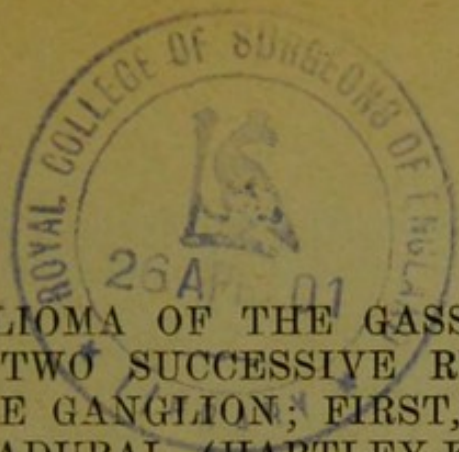
ENDOTHELIOMA OF THE GAS-
SERIAN GANGLION

Two Successive Resections of the Ganglion;
First, by the Extradural (Hartley-Krause)
Operation, and Secondly, by an Intradural
Operation



F. X. DERCUM, A.M., M.D.
W. W. KEEN, M. D., LL.D.
and WM. G. SPILLER, M.D.
Philadelphia





ENDOTHELIOMA OF THE GASSERIAN GANGLION; TWO SUCCESSIVE RESECTIONS OF THE GANGLION; FIRST, BY THE EXTRADURAL (HARTLEY-KRAUSE) OPERATION, AND, SECONDLY, BY AN INTRADURAL OPERATION.*

CLINICAL REPORT BY F. X. DERCUM, A.M., M.D.
PROFESSOR OF NERVOUS AND MENTAL DISEASES, JEFFERSON MEDICAL COLLEGE; NEUROLOGIST TO THE PHILADELPHIA HOSPITAL.

SURGICAL REPORT BY W. W. KEEN, M.D., LL.D.
PROFESSOR OF THE PRINCIPLES OF SURGERY AND OF CLINICAL SURGERY, JEFFERSON MEDICAL COLLEGE, PHILADELPHIA.

PATHOLOGIC REPORT BY W. G. SPILLER, M.D.
PROFESSOR OF DISEASES OF THE NERVOUS SYSTEM IN THE PHILADELPHIA POLYCLINIC.
PHILADELPHIA.

DR. DERCUM'S CLINICAL REPORT.¹

The following case, both because of the rarity of the affection from which the patient suffered and because of the interesting nature of the symptoms, is worthy of record.

Mr. X., a business man, 32 years of age, married, a native of Louisville, Ky., came under my care on Nov. 20, 1899.

Family History.—The father died at 68 years of age, of some affection of the heart. The mother is living and well at 60, also a brother and sister. The family history is negative as regards mental, nervous and other diseases.

Personal History.—The patient was rather delicate as a baby, suffered from various diseases of childhood, had an attack of scarlet fever which resulted in disease of the ears, but in youth he seemed to be rather healthy. Twelve years ago he was said to have had an attack of

*Read in a Symposium on the "Fifth Nerve in its Neurological and Surgical Relations," before the College of Physicians of Philadelphia, April 20, 1900.

¹ Figures 1 and 2 in Dr. Dercum's portion of this paper have been omitted because they were inaccurate.

typhoid fever. Some ten years ago he suffered from a venereal sore which was believed to be syphilitic, and although he never presented any secondary symptoms, he was for some time at Hot Springs, Ark., under treatment. The physician at this place, so we were informed, thought he did not have specific disease. He had also acquired gonorrhoea on two occasions. When 20 or 21 years of age he went into business as a manufacturer and worked very hard, often day and night. He was a man of extremely nervous temperament, and was married in September, 1895. Subsequent to this time he complained greatly of severe shooting pains in his legs, and he occasionally walked with a limp. The pains were regarded as rheumatic, and he suffered from them in two successive winters. He had inflammation of the bowels in 1898 and was ill at this time some six or eight weeks. Subsequently he appeared to be well, very strong and energetic but for over a year past has complained of being tired at night and always wished to retire early. He would sleep heavily and without awakening during the entire night. General weakness became evident about this time and was very marked. At times he would have very severe headaches, especially in the mornings, but they would pass off after he had been up and around for an hour or two.

In February, 1898, he discovered a glandular swelling on the left side of the neck, about the size of an olive. It remained stationary for about eighteen months. Early in the summer of 1899 he began to lose in weight and to be extremely irritable and nervous. Various physicians who were consulted considered the glandular swelling tubercular, except one who thought it syphilitic and advised treatment at Hot Springs. He went there on July 1. About the time of his arrival he began to suffer from very severe pain over the left temple and over the left side of the top of the head. The swelling on the side of the neck also became painful; it had not pained him previously. It now began to grow and grew rapidly until it attained the size of a large egg. The pain in the temple was much worse in the evening and night, the patient not being able to sleep until about 4 or 5 o'clock in the morning. He took the baths and also had mixed treatment for seven weeks, while the swelling was painted with iodine. No relief whatever was obtained

from this treatment. He then consulted Dr. Abbe, of New York, who removed a series of glands, varying in size from an olive down. These glands, as was subsequently learned from Dr. Abbe, were of a gray, even consistence, not unlike tubercle, but entirely without caseation. A microscopic examination was made at the College of Physicians and Surgeons of New York and endothelioma diagnosticated. Dr. Abbe very kindly sent me a section of one of these glands and I had no difficulty in confirming the diagnosis. The pain in the side of the head subsequently assumed the character of trifacial neuralgia and grew steadily worse. He was treated ineffectually with large doses of the iodids and morphia finally had to be resorted to.

On November 1 Dr. Abbe operated on him a second time, now removing the infraorbital division of the fifth nerve. The pain continued, though it appears to have been for a time less marked in the distribution of this branch. His suffering was so great that he was transferred to a sanatorium. Here his treatment was also without relief.

During the period of development of the neuralgia he had some recurrence of the shooting pains in the legs. For two months he had been in the habit, according to his wife, of dropping off to sleep suddenly. For instance, while talking, he would suddenly fall asleep. This condition was for a time quite marked. The wife herself attributed it to the great loss of sleep at night, thinking that he simply fell asleep in this way during the day from sheer exhaustion.

When first seen by me, Nov. 20, 1899, he was evidently suffering greatly from pain in the entire trigeminal distribution of the left side. The suffering was so terrible that he could not at this time be carefully examined. It was only after a certain amount of morphia had been administered on the following day that an examination could be made. Even after $\frac{1}{4}$ grain of morphia the pain was agonizing in character and constant, there being, according to the statement of the patient, not a single instant of relief. His expression, gestures and conduct evinced a degree of pain and suffering greater than I have ever before witnessed. The pain appeared to be most marked in the temple, the eyeball and the tissues about the orbit and the brow, less marked

in the infraorbital distribution and least in the inferior maxillary distribution. The patient constantly kept the left eye covered by his left hand, and maintained a loud and almost ceaseless moaning and groaning. The suffering, as just stated, appeared to be most marked in the orbit and brow, though at times the patient said the greatest pain was present in the teeth of the upper jaw, more especially in the incisors. He often begged piteously for something to be done to the teeth to relieve them. The pain was accompanied by irregular recurring twitching of the zygomatic muscles. Occasionally this twitching also involved the elevators of the upper lip and of the angle of the mouth. Tested for sensation it was found that the entire area of the trigeminal distribution to the face was decidedly hypesthetic. This hypesthesia could readily be demonstrated over the left side of the nose, the left brow and forehead and over the left temple and cheek. It was especially pronounced over an oval patch in the infraorbital distribution. This patch, which appeared to have the infraorbital foramen as its center, was about $1\frac{1}{2}$ inches in its vertical diameter and 1 inch in its transverse. Sensation in the face was everywhere sufficiently preserved for the patient to distinguish between a pin point and the head of a pin. Pressure sensation appeared to be everywhere well preserved. This was also the case with the temperature sense. The superficial pain sense could not be studied accurately as the patient declared all handling of the parts gave him pain. Distinct prickling of the skin, however, gave more decided demonstrations of pain than a mere touch, and there can be no doubt that marked hyperalgesia was present. The conjunctiva was distinctly hypesthetic as compared with the conjunctiva of the opposite eye. The condition of the sense of taste on the left side of the tongue could not be satisfactorily determined. Movements of the tongue and the opening of the mouth so greatly increased the suffering of the patient that no test could be applied with satisfaction. The pain, it should be added, was referred by the patient not only to the surface but also deeply into the tissues.

The patient was excessively weak and, according to his own statements, had lost greatly in weight. He stood with some difficulty and when prevailed on to walk did so with a slightly staggering gait. When tested for

station with feet apposed and with his eyes closed, he evinced a tendency to fall backward. These phenomena impressed me at the time as being rather the symptoms of extreme weakness than those of ataxia. When he was seated, the movements of the arms were tested and no ataxia of these members was revealed. The knee-jerks, however, were both absolutely lost. They could neither be elicited by the ordinary methods nor by efforts at re-enforcement. The general examination failed to reveal any sensory losses whatever, nor was there any sensory retardation. It should be added that the patient also suffered from an old cystitis which occasionally gave rise to considerable pain.

Prof. G. E. de Schweinitz made an examination of both eyes, with the patient in bed, his head and shoulders raised on pillows. The pupillary reflexes were normal. There was no failure in rotation of the eyes and no nystagmus. Each disc was somewhat anemic. There was neither congestion, neuritis nor atrophy. Both retinæ were normal, the retinal circulation also, and fields for white and red. In addition there was present chronic otitis media of the right ear. This was later confirmed by a detailed examination of the ears, made by Dr. Walter J. Freeman, who reported in addition that the membrane of the left ear was decidedly depressed and scarred but could readily be inflated.

The non-paroxysmal character of the neuralgia, its frightful severity and unvarying intensity, the deep-seated temporal pain, the nearly simultaneous involvement of all branches of the trifacial, the hypesthesia in the distribution of the fifth nerve, and the somnolency suggested to me both an organic cause and the Gasserian ganglion as the seat of the disease. Further, the remarkable result of the microscopic examination of the glandular masses, removed from the neck by Dr. Abbe, suggested the existence of a neoplasm within the cranial cavity. It would be extremely difficult to explain the presence of an endothelioma in the lymphatic glands of the neck on other grounds; and it therefore seemed to me a most important point to confirm the diagnosis as to the nature of the tumors removed by Dr. Abbe by a personal examination, and this, thanks to the kindness of the Doctor, I was able to do. On November 23, I called in Prof. W. W. Keen, with a view to a possible

surgical operation directed to the Gasserian ganglion. Dr. Keen carefully examined the patient and was greatly impressed by the character of the pain, which differed, as he expressed it, from that in any case of trigeminal neuralgia he had before seen. On November 25, he was removed to Dr. Keen's private hospital, and on November 27 an operation was performed in which, as the Doctor details, he discovered and removed in large part a tumor occupying the position of the Gasserian ganglion. As far as could be determined, at the time, the foramen rotundum had become both divided and obliterated. Much of the mass back of this and also over the foramen ovale and to some extent posterior to the latter was removed. The fragments of the tumor resembled fibrosarcoma in their microscopic appearance. They were handed to Prof. W. G. Spiller for microscopic examination. It was thought wise to discontinue the operation at this point. The patient promptly rallied, but on resuming consciousness at once complained as bitterly as before of pain. It was also evident that he was delirious, and delirium accompanied by great excitement continued for about ten days, during which it was impossible to make an accurate examination as to the sensory phenomena. He was excessively noisy and loud and almost incessant in his lamentations. Some quiet followed hypodermic injections of morphia, but the periods of relief thus secured were generally short and imperfect.

He made a good surgical recovery from the operation, and the delirium somewhat abated, but the pain continued with undiminished severity. He was examined on December 13 with the very surprising result that no change whatever in the sensory phenomena was observed, except some increase in the hypesthesia. The temple and the cheek were now decidedly more hypesthetic than before. This increased diminution in sensation in the face, could not, however, be claimed for the conjunctiva or for the brow. The patient was still everywhere able to appreciate touch, and he could for the most part distinguish a pin point from a pin head, though occasionally he failed to make this distinction—especially was this true over the oval patch of pronounced hypesthesia in the infra-orbital distribution discovered at the first examination. He could still everywhere readily distinguish between a

hot and a cold spoon, and also between light and deep pressure. An examination of the sense of taste was again without definite result; the patient still complaining bitterly of the pain in his upper teeth and of great distress when any manipulation involving the mouth was attempted. He did say, however, that his food did not taste properly and that the left side of his throat was sore. The left masseter and temporal muscles were completely paralyzed. Some time after the operation a paresis of the left rectus externus was also observed. Prof. G. E. de Schweinitz again examined the eyes and reported a complete paralysis of the left external rectus muscle, but no other changes.

The pain had evidently not been appreciably influenced by the operation. Professor Spiller further reported that he had found only a few ganglion cells in the fragments of the tumor which had been handed him, and after repeated consultations with Dr. Keen and also with Dr. Charles K. Mills, it was decided to again submit the patient to operation. The second operation was performed by Dr. Keen on December 26. The details and extent of this are described by Dr. Keen. Suffice it for me to say that the operation, as far as it was possible to judge, was most thorough and extensive. All accessible portions of the tumor, except that in relation with the cavernous sinus, were removed. In addition part of the inner end of the petrous bone, including the depression normally occupied by the Gasserian ganglion, was chiseled away and the anterior surface of the pons freely exposed.

As before the patient rallied well from the operation, but he again passed into a condition of confusion and delirium. He was as before noisy, and loudly and ceaselessly dwelt on his pain, which seemed to be unabated. As before, it was referred to the orbit and brow and to the upper teeth. It was not until four days elapsed that it was possible to make another sensory examination. It was then found that the increased hypesthesia noted at the first examination now involved the entire trigeminal distribution. It was, however, as before, merely a hypesthesia and not an anesthesia. The patient was still able to appreciate contact, still able to appreciate decided differences in pressure and, what I regarded as extremely remarkable, still able to appre-

ciate differences in temperature. He readily distinguished, and always correctly, between a spoon dipped in hot and another dipped in cold water. The hypesthesia was as before most pronounced in the oval patch in the infraorbital distribution noted at the previous examinations. In this area the patient would at times fail to differentiate between simple contact and pin pricks, but total sensory loss did not exist. The hypesthesia of the left side of the face further was not sharply limited by the middle line, but merely seemed to grow less pronounced as the sound side was approached. For instance, he felt a pin point clearly on the right side of the nose and for some distance after the bridge of the nose had been well crossed over to the left side. This fact was also observed in the lips, the chin and the forehead. At the final examination the conjunctiva appeared to be profoundly hypesthetic but not anesthetic. It was difficult, however, because of the patient's lamentations and excitability, to conduct this portion of the examination satisfactorily. For the same reason and because of the intense pain which the patient was suffering, no attempt was made to study the sense of taste at this time. The above observations, as before, were verified repeatedly.

Subsequently little or no change took place in the patient's condition and his wound having healed by January 9, he left the city for his home, still complaining loudly and constantly of his pain, and still holding his hand over his brow. I have been informed that since his return home the pain has continued, and that he still requires morphia for its relief. The cornea is now absolutely anesthetic. The eye is immovable and blind and there is much difficulty in raising the upper lid. His general health is much improved though he is quite anemic and very thin. Recently another enlarged gland has appeared under the jaw on the left side.

Remarks.—This remarkable case is interesting first because of the persistence of sensation after undoubted extirpation of the Gasserian ganglion, and secondly because of the rarity of tumors involving this structure. The persistence of sensation would perhaps at first sight suggest that the ganglion and its branches had been imperfectly removed, but no one present at the time of the operation could doubt the accuracy of the anatomic verification nor the thoroughness with which the work was done.

Persistence of sensation, however, both after removal of the branches and even after extirpation of the ganglion is not unknown. Dr. John K. Mitchell¹ has reported two most interesting cases, in the first of which portions of the supraorbital and supratrochlear nerves were removed by Dr. Keen. Subsequently some degree of anesthesia was present for touch and pain, but it was noticed that the loss of sensation was less complete than might have been expected and seemed to be absolute only in an oval area at the outer canthus of the eyelids and of the upper lid. In the second patient Dr. Keen resected the supraorbital and the infraorbital nerves. A subsequent examination revealed an even less degree of loss of touch, pain and heat sense than was present in the first case. "Indeed," says Dr. Mitchell, "it could hardly be said that there was more than slight delay or impairment of perception anywhere in the supraorbital, nasal, palpebral or labial branches." When the patient was discharged after the ninth day there was neither slowness nor impairment of sensation for any form of stimulation. "The touch of the finest filament of thread was instantly felt and correctly located everywhere on the cheek, temple, nose, eyelids and upper lip." Dr. Mitchell also reports his findings in a case in which Dr. Keen had removed the Gasserian ganglion: "After the removal of the ganglion the patient's mental condition was such for nine or ten weeks that no study of the sensation could be made but when it became possible there was no absolute anesthesia to be found except between the margins of the wound. The touch sense was everywhere preserved in some degree, the pain sense was but slightly less in degree than before the operation." "The mucous membrane of the lips and cheek of the right side and of the right side of the tongue was also partially anesthetic." On the right side the sense of taste was entirely lost. In explanation of these remarkable findings, Dr. Mitchell suggests the presence of sensory fibers in the facial nerve, and cites the statements of Turner and Ramon y Cajal as to the relations of the facial nucleus to the sensory trigeminal root and to the substantia gelatinosa. He also cites Frankel-Hochwart's results as to the evidence of slight sensory losses present in some cases of paralysis of the facial nerve. The thought also suggests itself to me that in a case like the present, in

which the Gasserian ganglion is slowly and gradually involved, that perhaps a *gradual* substitution of function may take place through the facial nerve.

The persistence of the pain subsequent to the operation is perhaps to be referred to degenerative changes in the sensory root of the fifth nerve, and perhaps also to changes in the cerebrum. The projection of the pain to the surface is analogous to the psychic projection of pain and other sensations beyond the stump of an amputated limb.

To my knowledge but 2 tumors involving the Gasserian ganglion have thus far been reported; 1 by Hagelstam² and one by Trénel.³ In Hagelstam's case, which came to autopsy, there was present a tumor, an endothelioma, of about the size of a walnut, situated in the left, middle cerebral fossa. The dura mater and Gasserian ganglion were completely involved in the growth, which had in part perforated the underlying bone and penetrated into the posterior portion of the nasopharyngeal cavity. During life the patient had complained of constant pain over the entire left half of the face and over this area and for some centimeters upward on the hairy scalp, sensibility both for pain and touch was lost except in the area of distribution of the great auricular nerve. Over the cornea and the conjunctiva the sensibility was diminished. The sense of taste on the anterior third of the tongue to the left of the median line was lost for bitter and acid substances and for salt and sugar. The temporal muscle appears to have been atrophied. No muscular contractions could be elicited by the strongest currents. The masseter muscle felt firm and hard, but could not be made to contract to the faradic current and the jaw could only be separated for one centimeter.

In Trénel's case there was present an angiolithic sarcoma. It had involved and penetrated the peripheral portions of the right Gasserian ganglion. On microscopic examination, the latter, however, still presented nerve-cells of normal aspect. During life there had been present profound hypesthesia if not complete anesthesia of the right side of the face. The patient also presented marked mental depression, was difficult to examine and the limits of the sensory loss could not be accurately determined. No atrophic nor circulatory disturbances were noted in the eye.

Two other cases have been reported in which the Gasserian ganglion, though not directly involved, suffered from the pressure of a tumor. In one of these, reported by Krause,⁴ there was a large cholesteatoma which filled the third ventricle and also involved the adjacent parts, such as the chiasm and sella turcica. The tumor was found to be entirely within the dural sac and there was no involvement of the Gasserian ganglion whatever. The patient had suffered for sixteen years from a persistent and most terrible trigeminal neuralgia. There had never been present headache, giddiness, vomiting, irregularity of the pulse nor any other cerebral symptoms. An examination of the eyes by one of the most distinguished ophthalmologists had also failed to reveal any abnormalities. As he regarded the symptoms sufficient to establish the intracranial seat of the affection, Krause decided to remove the Gasserian ganglion, although peripheral nerve operations had not yet been attempted. The removal was followed by complete relief of pain. However, about two weeks after the operation, headache made its appearance and cerebrospinal fluid began to trickle from the point of drainage. Notwithstanding the insertion of a drainage-tube and other surgical measures, fever set in and the patient died about four weeks after the operation. It is remarkable that in Krause's case nothing could be discovered of the tumor at the time of the operation, but this is no doubt to be explained by the fact of the complete intradural situation of the growth. Krause explains the neuralgia from which the patient suffered by compression of the Gasserian ganglion and its roots. He also considered it probable that the tumor began at the upper edge of the petrous bone; this bone itself was entirely normal.

Another case was reported by Homen,⁵ in which a tumor, an endothelioma of the dura mater, had pressed upon and flattened the Gasserian ganglion and its branches. In this case there had been present toothache in the left upper jaw, intense pain and sensations of cold in the entire left half of the face and complete anesthesia, the latter also involving the forehead, the anterior part of the parietal and the temporal regions. The conjunctiva was entirely without sensation, much injection, somewhat swollen and the reflexes were absent. The cornea was cloudy, with ulceration on its inner edge.

The mucous membrane of the nose and of the left half of the tongue was anesthetic. The patient appeared to be deaf in the left ear. In addition the entire left half of the face was sunken and atrophic and the left angle of the mouth somewhat depressed. In other words, there was in Homen's case, in addition to the neuralgia and anesthesia, a hemifacial atrophy. Although the ganglion itself was not involved in the growth, a microscopic examination of the peripheral portions of the trigeminal nerve revealed a far-advanced degenerative atrophy of all its branches. This was also the case with the roots of the trigeminal nerve.

DR. KEEN'S SURGICAL REPORT.

I first saw Mr. X. with Dr. Dercum on Nov. 23, 1899, and learned his earlier history. The case at once impressed me as different from an ordinary tic douloureux. As my notes taken at the time state, the pain was not that paroxysmal darting one we see in tic, but a severe and constant aching pain. In view of the removal of the submaxillary endothelioma by Dr. Abbe, and of a later resection of the infraorbital nerve, without any relief, I suspected that there was probably an endothelioma within the skull, involving the ganglion, and that any extracranial operation would be useless. After talking the matter over with Dr. Dercum, we decided on operation on the ganglion.

First Operation.—Nov. 27, 1899, the usual Hartley-Krause operation was done. As soon as the dura was exposed it seemed to be more tense than usual. When I separated it from the middle fossa of the skull, as I approached the median line, I found that it became extremely adherent, much more so than I had ever before observed. As a result of this it was extremely difficult to find the foramina rotundum et ovale. As soon as I reached the vicinity of the ganglion I appreciated that there was a hard, not very irregular, mass of considerable size occupying approximately the site of the ganglion. The dura, when lifted from the base of the skull, could be rolled over a mass about as thick as the forefinger, and I was now thoroughly convinced that we had to deal with a new growth. After much trouble I finally found the seat of the foramen rotundum, but instead of the usually large opening, there were two small depressions in the bone, separated by a bony bridge. Whether they

were complete foramina could not be determined, as no probe would pass through these small openings. No trace of the second division passing through these minute foramina could be found. The foramen ovale, however, was found and the third division passing through it, though both the foramen and the nerve were smaller than usual. Partly with the scissors, partly with the gouge, and partly with the Allis dissector, I was able to remove a mass estimated to measure 3.5 by 1.5 cm. I was not able to remove it as an entire mass but piecemeal. It extended from the cavernous sinus, which as far I could judge, formed its inner extremity, to the outer extremity of the foramen ovale. It stopped short of the foramen spinosum, for the middle meningeal was found pulsating and was tied, lest in the removal of the growth I might possibly divide it and be embarrassed by serious hemorrhage. The removal of the mass involved a large opening in the dura, through which a considerable amount of cerebrospinal fluid escaped. I was then confronted with this problem:—in order to remove the inner portion of the tumor, it would be necessary deliberately to open the cavernous sinus. After consultation with Drs. Taylor, Dercum and Spiller, I decided not to do so, on these grounds: If the tumor were malignant, there were unquestionably other remnants left elsewhere by which it would be reproduced and the removal of the wall of the sinus would be useless, and if it were not malignant, the removal of the major portion of the tumor would probably be followed by the disappearance of the remainder. Moreover, the removal of the outer wall of the sinus would have involved, in all probability, destruction of the third and fourth nerves themselves, thus producing an extensive ophthalmoplegia and in addition to this there would have been also a possibility of injury of the sixth nerve and of the carotid artery. The fragments removed were handed to Dr. Spiller. The osteoplastic flap was replaced and the wound closed, a small gauze wick being passed under the posterior superior angle between the bone and the dura, as a drain. The operation lasted nearly 2½ hours. He was placed in bed in a very satisfactory condition.

From the surgical point of view, his physical recovery was all that could be desired. The day following the

operation, his temperature rose to 100 F. With that exception it was never above 99.4 F. The stitches were all removed on the sixth day, the wound being entirely healed. On the third day I removed the stitches by which the eyelids had been closed at the time of operation, and after careful disinfection I placed a Buller shield over the eye. This was removed night and morning and the eye washed with warm boric acid solution. No ocular disturbances followed the operation. The Buller shield was removed after twelve days. The patient left the hospital on the ninth day after operation.

From the mental standpoint, however, things were quite different. The operation was followed by a traumatic insanity, amounting almost to acute delirium, so that the patient had to be watched very carefully lest he do himself or others harm. A part of this I attributed to the withdrawal of his morphin, which was rapidly reduced and by the sixth day was cut off entirely. Various hypnotics were tried and did some good. No reliable examination to determine the sensibility of his face could be made at this time. He, however, complained constantly and bitterly of pain in the head and the left side of his face, especially in the upper teeth. His mental condition, however, gradually improved and by about December 12, the fifteenth day, he was fairly clear. Another complication also was a great deal of vesical pain, the result of stricture, which I dilated with great benefit. As the pain steadily continued and, according to his assertion, was even worse than before, after consultation with Dr. Abbe, it was determined to operate again.

Second Operation.—Dec. 26, 1899, Dr. Abbe was kindly present and, with Dr. Taylor, assisted me in the operation. The former osteoplastic flap was turned down. The bony portion of the flap was in a few minutes caught by a gauze sponge and with but little force was torn loose from the flap. I did not replace it. The dura was then lifted up as at the first operation, and without serious hemorrhage. Dr. Abbe confirmed my observations as to the existence of the foramen ovale and the blocking up of the foramen rotundum. Between the two we found a third opening in the base of the skull, which we judged to be the result of the gouging of the first operation. A moderate blood clot occupied the site

of the former operation and a considerably thickened mass of tissue corresponding to the old tumor could be felt. We then decided to open the dura and attack the tumor from within. This was opened by an incision a little smaller than that in the bone. As soon as the flap of dura was turned down, I noticed on the inner surface of the dura quite a number of small granulations like miliary tubercles. They were about 1 to 2 mm. in diameter, and were apparently clear and translucent. There were one or two doubtful little granulations on the pia, but on the flap of dura turned down, there were, I judge, forty or fifty sprinkled over it. Later some others were seen on the dura lining the base of the skull, but much less numerous than those on the flap. Three of these little granulations were excised and given to Dr. Spiller. The pia was a little clouded along the vessels, but elsewhere was perfectly clear. The brain was now lifted up by a broad brain retractor and a very satisfactory view of the base of the skull obtained. As soon as the site of the Gasserian ganglion was disclosed, I at once saw the opening in the dura, as large as the end of the thumb, caused by the first operation. It was partly filled up by a translucent gelatinous mass which resembled, to the eye, a sarcoma having considerable consistency. Along side of it was a considerable mass of blood clot and débris. All of this was finally gouged out and there was left a cavity so large that an ordinary, round, gauze sponge was easily packed into it. The site of this cavity was the inner end of the petrous bone. The carotid was not seen. The ridge along which runs the superior petrosal sinus had been destroyed by the tumor. I then sought for the pons and, on lifting the brain a little further, there came very readily into view the opening of the tentorium and the pons at a lower level. A considerable amount of cerebrospinal fluid welled up from the spinal canal and mingled with the small amount of blood which escaped. This required constant sponging to keep the operation field clear, but there was no difficulty in determining the facts. The temporosphenoidal lobe was slightly lacerated by my retractor, but not to any notable extent. Having apparently done all that was possible, the dura was closed with continuous catgut suture and the external wound with interrupted silkworm gut suture. A small extradural

gauze wick was introduced as a drain and to arrest the hemorrhage from a small blood-vessel on the surface of the dura. The operation lasted an hour and a quarter, and he suffered very little from the shock. The temperature after the second operation fluctuated a little above and a little below 100 F. The wound healed by first intention, except at the point of drainage, where a little blood and then bloody serum escaped for about ten days. The patient went to his home in Louisville on January 9, the wound being entirely healed.

Following this operation, after two or three days, during which he was rather dull and stupid, there was also very considerable traumatic insanity. This delirium, however, was not as prolonged nor as severe as that which followed the first operation. He had recovered almost entirely from it within a week.

Dr. Walter J. Freeman examined his ears, as he had suffered from aural discharge for a long time, and reported that the left membrane was retracted and scarred, the diminution in the degree of hearing being exaggerated by the collapsed membrane. On the right the membrane was absent and there was free discharge. He has been treated for the discharge from his ears on and off since he was a child. The Doctor reported as follows: "I do not know what efforts have been made to stop the discharge, but where it is long continued I would rather suspect involvement of the bone. The only thing which promises relief is to open the mastoid freely down to the middle ear and remove the diseased bone. I do not, however, think there is any need for operation in his case at present. His hearing was benefited by inflation, but there was no marked increase. Indeed, the condition of his ears is too bad for us to look for any great benefit in this direction."

Remarks.—The present case is the first case of tumor of the Gasserian ganglion reported in the United States, and is, so far as I can learn, the third tumor ever reported. It is the first case that has ever been operated on. The operative technique was very satisfactory and his recovery from both operations of so serious a character most gratifying. The view of the base of the brain at the second operation was the most extensive I have ever seen.

DR. SPILLER'S PATHOLOGIC REPORT.

From the William Pepper Laboratory of Clinical Medicine
(Phoebe A. Hearst Foundation).

The tumor consists of cells forming long columns, or more irregularly-shaped masses, and at some parts a plexiform arrangement of these cells is seen. In some places the tumor cells are very numerous and the nuclei are small and round, so that the growth resembles a round-cell sarcoma in these portions. The cells which

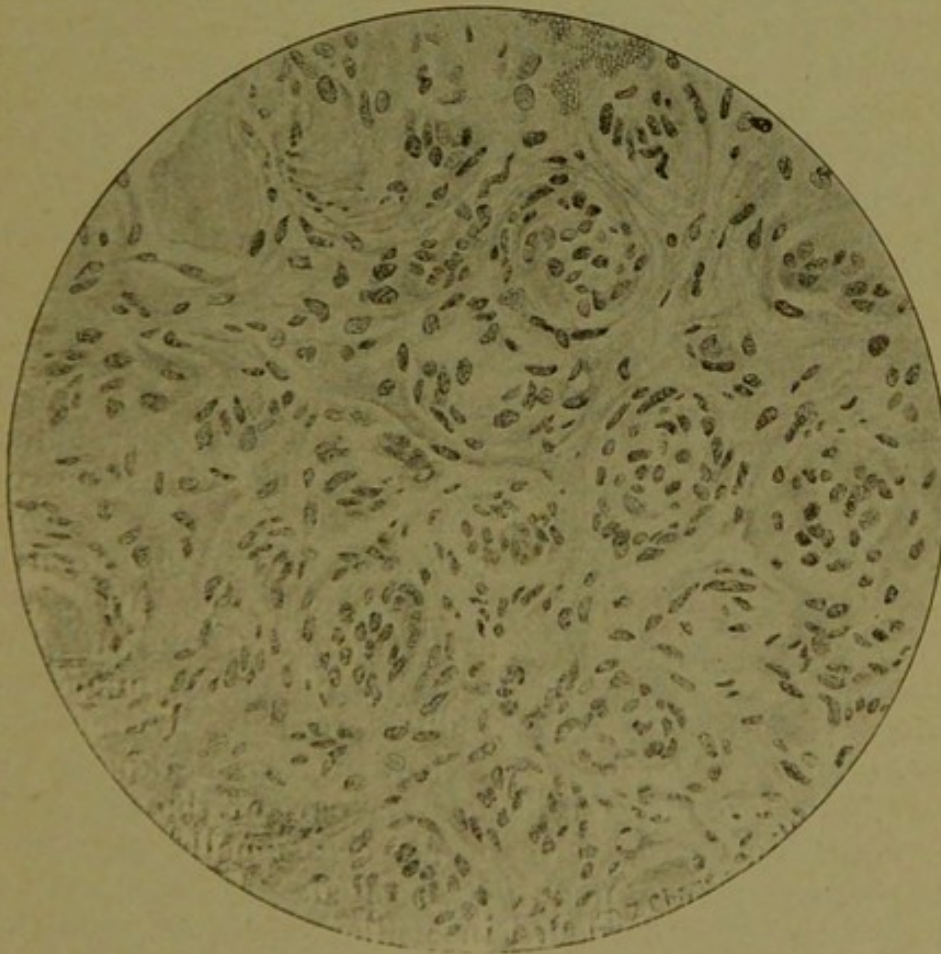


FIG. 3.—Oc. 3. Ob. 7. A portion of the Gasserian ganglion in which the nerve-cells have almost entirely disappeared. A concentric arrangement of the nuclei may be seen in different parts of the field, seeming to indicate that the cells of the capsules have proliferated and filled the spaces left by the destruction of the nerve-cells.

form the long columns have chiefly elongated or oval nuclei, and these stain deeply, but at some parts of the tumor the columns are formed of cells with large oval nuclei which take the stain less intensely. The tumor is, in places, rich in fibrous tissue, and this latter appears to consist in part of empty nerve sheaths, the nuclei of

which have undergone great proliferation. Many of these nuclei are long and narrow, although some are oval. The tumor is not very vascular.

The Gasserian ganglion is invaded by the new growth, although some parts of the ganglion are relatively free from tumor cells. The nerve-cells within the ganglion are not so numerous as in normal ganglia, and this decrease in number is more noticeable at some parts than at others. Some of the nerve-cells are more shriveled than can be explained by the method of hardening (Müller's fluid), and the nuclei of the capsules about some of the nerve-cells are unusually numerous, indeed in some parts the nerve-cells seem to have disappeared while the cells of the capsules have proliferated and filled the spaces left by the destruction of the nerve-cells. (See Fig. 3.) This explanation is suggested by the concentric arrangement of nuclei seen in certain parts of the ganglion.

In certain parts of the tumor a few medullated nerve-fibers are found, but these are greatly degenerated and empty nerve sheaths are more numerous than medullated nerve-fibers. When these apparently medullated nerve-fibers are examined more carefully they are seen to consist of separate blocks of myelin and are therefore greatly degenerated. Professor Keen was able to positively determine the third division of the ganglion, and this division was kept separate from the pieces of tumor removed. Most of the nerve-fibers in this division are destroyed. (See Fig. 4.) Within the tissue known by the presence of nerve-cells to be a part of the ganglion a medullated nerve-fiber can only occasionally be found, and even these are much degenerated. As this portion of the tissue was hardened in Müller's fluid alone, without the addition of formalin, the failure to detect numerous medullated fibers can not be explained by the technique employed.

At the time of the second operation small nodules a little larger than the head of a small pin were found on the inner side of the dura, somewhat resembling miliary tuberculous growths. They were slightly larger than the tubercles usually seen in cases of miliary tuberculosis of the brain, and they grew from the inner surface of the dura and were not in the cerebral pia along the blood-vessels, where miliary tuberculous growths are more com-

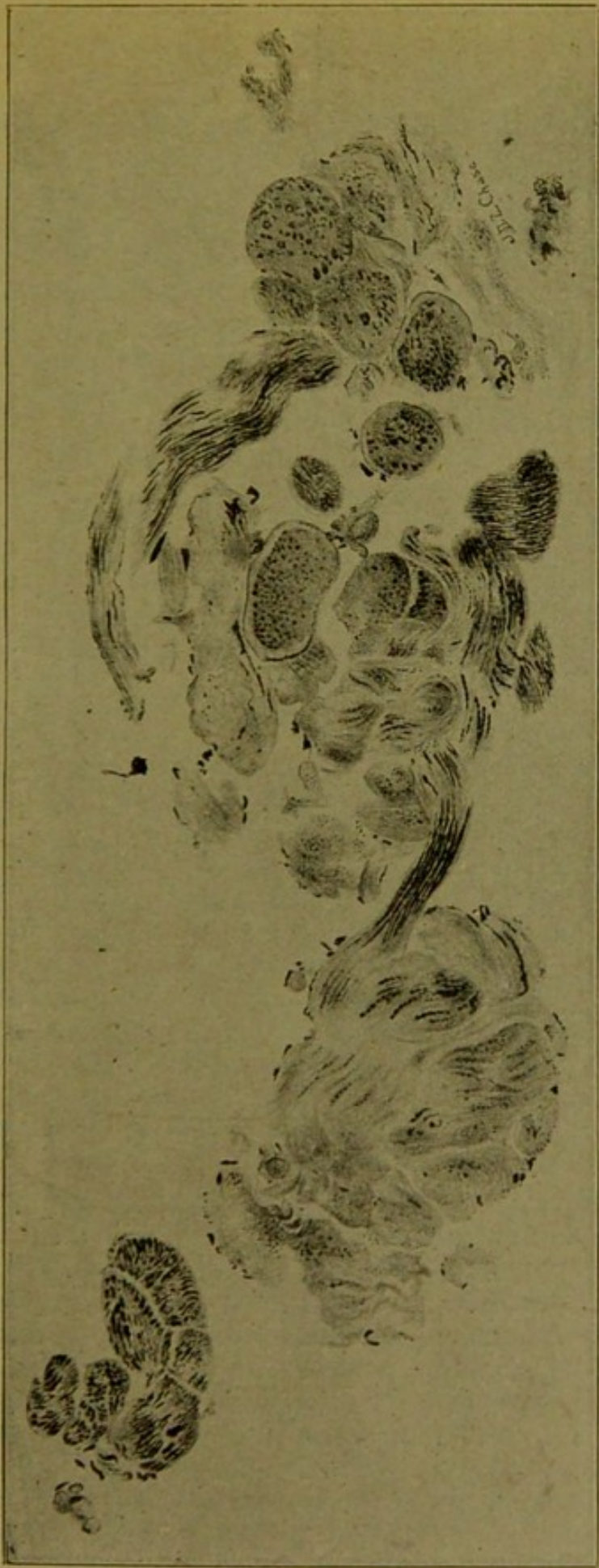

FIG. 4.—The third division of the Gasserian ganglion almost completely degenerated. The black dots and lines indicate the few normal nerve-fibers remaining.

monly found. These minute nodules of the dura seemed to me to be related to the tumor of the Gasserian ganglion, although they were *on the inner side of the dura* and in no direct connection with the large tumor mass. I expected to find that under the microscope they would have the same structure as the large tumor of the ganglion. This proved to be the case, as one of these minute nodules examined is unquestionably an endothelioma well defined from the surrounding tissue of the dura. (See Fig. 5.) A small piece of dura removed with this nodule was also studied. Its inner surface showed accumulations of cells, some with round and some with oval nuclei, and two of these accumulations examined were separated from one another by nearly normal dural tissue.

The microscopic study of the tissue removed by Professor Keen shows that the growth is an endothelioma invading the Gasserian ganglion, destroying many of its nerve-cells and causing almost complete degeneration of the medullary sheaths of the nerve-fibers.

The tumor is unquestionably an endothelioma, although in some parts the structure is not entirely typical of this form of growth. Endothelioma, according to Birch-Hirschfeld,⁶ belongs undoubtedly to the connective-tissue tumors, and in some cases a sharp distinction can not be made between it and sarcoma. When the formation of endothelial cells occurs with proliferation of the stroma, it is doubtful, he thinks, whether such a tumor can be classed with the endotheliomas, and it should more properly be called an endothelsarcoma; when the fibrous tissue is excessive it may be called endothelioma fibrosum.

Ziegler⁷ says that the alveolar, tubular or plexiform arrangement of the endothelioma is very distinct only in the early stage of tumor formation, and that in later stages the proliferation of connective-tissue cells makes the tumor resemble a sarcoma. Endothelioma can not therefore be sharply separated from sarcoma.

The tissue removed from the patient is so typical in many places of endothelioma that the growth may be called an endothelioma, although at parts considerable accumulations of round nuclei are found, and at other parts much fibrous tissue consisting partly of empty

nerve sheaths. In the small nodule removed from the dura the typical structure of endothelioma is seen.

The proliferation in some parts of the ganglion of the nuclei of the cells in the capsules about the nerve-cells is an interesting observation. We might expect these cells to proliferate in an endothelioma of the ganglion. The capsules of the nerve-cells of the spinal ganglion, according to v. Lenhossék⁸—and the same is true of the cells of the Gasserian ganglion—consists of connective

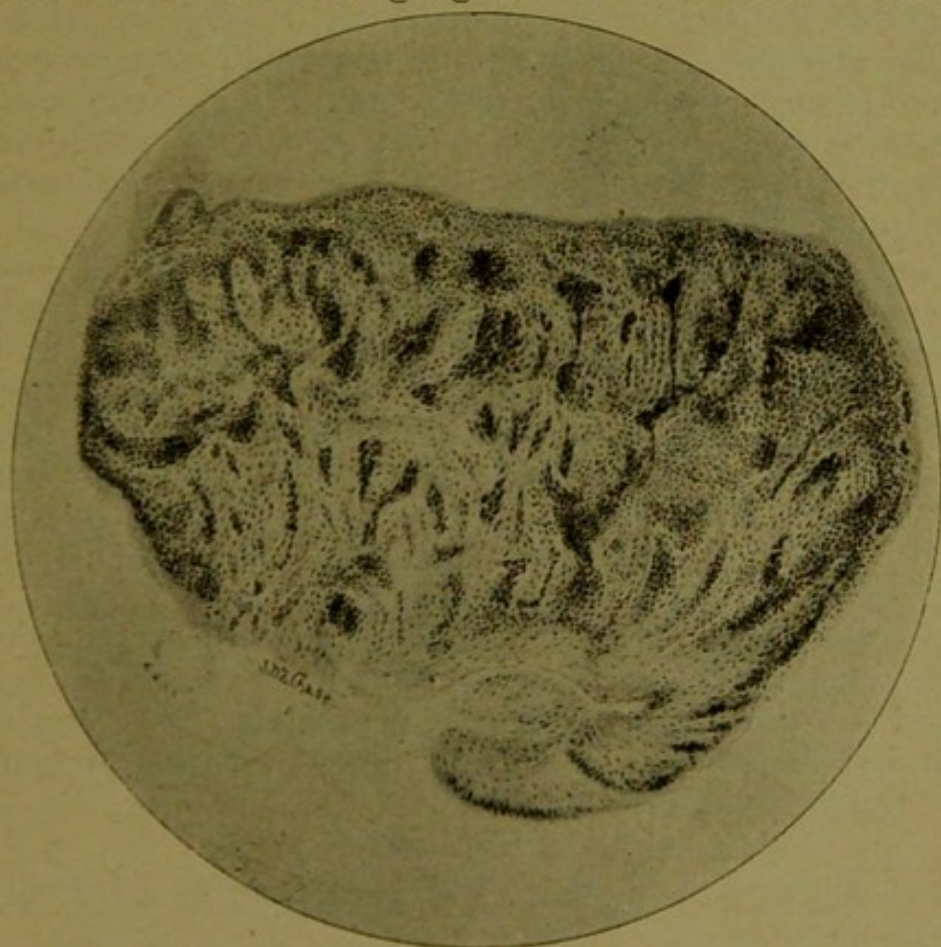


FIG. 5.—One of the miliary endotheliomas on the inner surface of the cerebral dura.

tissue which passes into the sheath of Henle of the axis-cylinder process. This capsule, especially about the larger cells, presents a laminated structure consisting of two or three layers and containing small flat or elongated nuclei. The inner surface of the capsule is lined with one layer of epithelium. In many animals the cells are flattened like endothelial cells, but in man they are quite large and rich in protoplasm and the nuclei are large and round or elliptical. Von Lenhossék at one time believed that a lymph space existed about the cells of the

spinal ganglion, but in his study of ganglia removed from an executed man soon after death and hardened rapidly, he found that a pericellular space does not exist. Whether the cells lining the cell capsule are to be regarded as endothelial or not seems undetermined. Their proliferation in an endothelioma might occur whether the cells resemble endothelium or epithelium.

The great degeneration of nerve-fibers of the fifth nerve and the pressure caused by the tumor explain the intense pain felt by the patient, but it seems surprising that objective sensation in the face could have been so well preserved when the medullated fibers were so greatly degenerated. Axis-cylinders deprived of medullary sheaths may have existed, although such naked axis-cylinders are always difficult to detect.

In two excellent papers on endothelioma that have recently appeared (Kelly,⁹ Sailer¹⁰), in which the literature is carefully considered, no mention is made of miliary endothelioma, and Sailer says that endothelioma of the dura is almost invariably benign and rarely gives rise even to pressure symptoms. Dr. Kelly and Dr. Sailer inform me that in their study of the literature on endothelioma they have found no mention of the occurrence of numerous small endotheliomas. Our case of tumor of the Gasserian ganglion caused what may be regarded as numerous metastatic growths and—even more uncommon—miliary endotheliomas. I have also had a case of endothelioma of the cerebral dura in which pressure symptoms were very marked.

BIBLIOGRAPHY.

1. Mitchell, John K.: *Jour. of Nervous and Mental Dis.*, June, 1898.
2. Hagelstem: *Deutsche Zeitsch. f. Nervenheilkunde*, vol. xiii, Nos. 3 and 4, p. 205.
3. Trénel: *Bulletins et Mém. de la Soc. Anatomique de Paris*, March, 1899, p. 326.
4. Krause: *Die Neuralgie des Trigemini*, p. 101.
5. Homen: *Neurologisches Centralbl.*, 1890, p. 385.
6. Birch-Hirschfeld: *Lehrbuch der Path. Anatomie*.
7. Ziegler: *Lehrbuch der Allgemeinen Pathologie*. Ninth Edition. Vol. i, p. 431.
8. v. Lenhossék. *Arch. f. Psychiatrie*, vol. xxix, No. 2, p. 345.
9. Kelly: *The Philadelphia Monthly Medical Journal*, February, 1899.
10. Sailer: *Contributions from the William Pepper Laboratory of Clinical Medicine*.

REPRINTED FROM

THE JOURNAL OF THE AMERICAN MEDICAL ASSOCIATION

APRIL 28, 1900

