

## **Case of injury to the upper jaw / by John Powell.**

### **Contributors**

Powell, John.  
Royal College of Surgeons of England

### **Publication/Creation**

[London] : [publisher not identified], [1817?]

### **Persistent URL**

<https://wellcomecollection.org/works/y8ekg3rj>

### **Provider**

Royal College of Surgeons

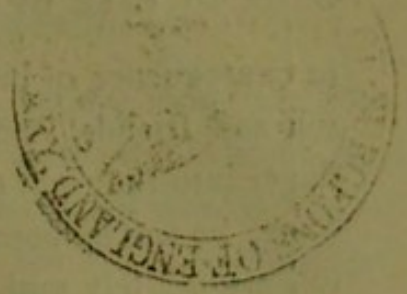
### **License and attribution**

This material has been provided by This material has been provided by The Royal College of Surgeons of England. The original may be consulted at The Royal College of Surgeons of England. where the originals may be consulted. This work has been identified as being free of known restrictions under copyright law, including all related and neighbouring rights and is being made available under the Creative Commons, Public Domain Mark.

You can copy, modify, distribute and perform the work, even for commercial purposes, without asking permission.



Wellcome Collection  
183 Euston Road  
London NW1 2BE UK  
T +44 (0)20 7611 8722  
E [library@wellcomecollection.org](mailto:library@wellcomecollection.org)  
<https://wellcomecollection.org>



C A S E  
OF  
INJURY TO THE UPPER JAW.

BY JOHN POWELL, ESQ.

KEPPEL STREET;

Member of the Royal College of Surgeons.

---

THE object of this communication is to show the great resources of nature in remedying an extensive chasm and deformity therefrom, from the loss of the two first incisor teeth; the alveolar socket; and a portion of the palate.

In the month of August 1806, M. N. then a boy about eleven years of age, was thrown from a horse with great violence upon his head and face; he was stunned by the accident, and upon recovering himself found his mouth much hurt, the two front incisors of the upper jaw knocked out, and a large wound in the under lip through which he could thrust his tongue: he lost a considerable quantity of blood, and was, upon his arrival at home, placed under the care of a surgeon, who attended him for upwards of six weeks, when the external wound was sufficiently healed to admit of his going to school again. During the above period, and afterwards, he had several portions of bone removed from the upper jaw and palate. The breathing through the nostrils was nearly obstructed; and he has subsequently been constantly obliged to sleep with his mouth open. He came to London about fifteen months afterwards; but as the roof of the mouth was well, and the obstruction in the nostrils considered irremediable, it was left to take its own course, until nearly five years had elapsed, when,

in consequence of his breath being extremely offensive to himself and friends, and his fancying that by passing his little finger into the right nostril he could perceive a portion of loose bone, he was induced to apply to a surgeon, who attempted to remove it, but without success; and considering it as an exfoliation, he advised suitable applications, and desisted from further attempts to extract it for some months; but finding all future trials equally unsuccessful, he recommended him patiently to wait until nature had made further progress in detaching what hitherto appeared a considerable portion of the bony palate. The fœtor of his breath became daily more disagreeable, so as frequently, and especially in the summer months, to be almost insupportable to himself and those who came within a few paces of him. In July 1816, he became my patient; when, with some difficulty, and giving him no small degree of pain, I succeeded in removing one of the permanent incisors from the right nostril, somewhat carious. I could also with a probe perceive other carious parts, but they appeared so firmly attached, and the attempt to remove them caused so much pain, that I deemed it more prudent at that time to desist. I have since been deterred two or three times by similar obstacles; but on the 21st of June last, after using considerable force and occasioning much hæmorrhage, I had the satisfaction of bringing away the other incisor from the same situation as the former, and with it every thing unpleasant has disappeared. The teeth are of large size, and appear to have been driven perpendicularly upwards: they completely filled up the right nostril anteriorly, and had forced the septum narium to the left side, so as to obstruct that passage also; though nothing was visible on external examination, except in particularly favourable positions of light; and then only a small portion of carious bone, full an inch and a half from the nasal orifice. The palate of the mouth, &c. has long been well; the two lateral incisors have approximated closely to each other; and the general contour of the jaw has so little appearance of deformity, that no person, except a

surgeon or dentist, would distinguish any defect in it. The cut, through which the tongue was protruded in the under lip, has not quite so favourable an appearance, and there is a horizontal scar nearly the whole length of the lip, with considerable irregularity and prominence at the left angle of the mouth.

He is now twenty-two years of age, and the teeth have remained in their preternatural situation ten years and ten months. He has been occasionally subject to attacks of hemi-crania (and loss of appetite from the offensive discharge and fœtor of the breath), but in other respects he has enjoyed good health. In relating this case, I beg it to be understood, that I have merely mentioned his having been under the care of other surgeons, to account for his bearing so long his uncomfortable situation with such apparent apathy.

Since this case came within my observation, I have advised the removal of irregular teeth in the mouths of females, and have had the pleasure of seeing the cases terminate in a few months to the satisfaction of all parties, although in one or two instances my opinion had been opposed by dentists of the first reputation.

