With the Author's Compliments

16

THE

EXAMINATION OF THE CHEST,

IN

A SERIES OF TABLES.

BY

GEORGE N. EDWARDS, M.D. CANTAB.,

ASSISTANT-PHYSICIAN TO ST. BARTHOLOMEW'S HOSPITAL; PHYSICIAN TO THE CITY OF LONDON HOSPITAL FOR DISEASES OF THE CHEST, VICTORIA PARK.

LONDON:
JOHN CHURCHILL, NEW BURLINGTON STREET.
MDCCCLXII.

E. ADLARD, PRINTER, BARTHOLOMEW CLOSE.

PREFACE.

The following Tables are intended to assist Students in the diagnosis of Diseases of the Chest, by the connection of the various physical signs with their proper value and signification. They were originally drawn up at the suggestion of the late Dr. Baly, who gave me for publication two or three tables used by him in his Lectures, which, with slight alterations, are included in this series. Somewhat similar tables may also be found scattered throughout larger works on the subject. The nomenclature employed is that in general use at St. Bartholomew's Hospital, synonymous terms being printed in italics. The outlines of the engravings are copied from photographs of the skeleton.

GEORGE N. EDWARDS.

Finsbury Square;
March, 1862.

. E. ADLARD

I.—ORDER TO BE OBSERVED IN RECORDING A CASE OF DISEASE OF THE CHEST.

NAME AND AGE OF PATIENT.—

General Appearance.—Condition of Body		Any obvious swelling or deformity.
	Complexion	Colour of lips.
	Posture	
	Respiration	Condition of alæ nasi.
	State of Skin	Any rash (or eruption).
	„ Pulse	Frequency, volume, force, regularity.
	„ Tongue	Whether clean and moist, or the contrary.
	„ Appetite	Nausea and vomiting.
	„ Thirst	
	Rest at night	Delirium, stupor, or otherwise.
	Functions of Brain	Memory, &c.
	State of Bowels	Character of motions.
	Urinary Organs	Reaction of urine, specific gravity, and chemical characters.
	Catamenia	
Complaints of Patient	Pain	Its situation and character, whether increased by exertion, deep inspiration, or pressure.
	Cough	Character and frequency.
	Expectoration	Character, general and microscopical appearance of sputa.
Physical Examination by		Inspection, palpation, measurement, percussion, and auscultation.

History.—Residence, occupation, habits; date and nature of previous ailments; date and early symptoms of present illness; manner and dates of their aggravation; whether any medical treatment has been resorted to; family history.

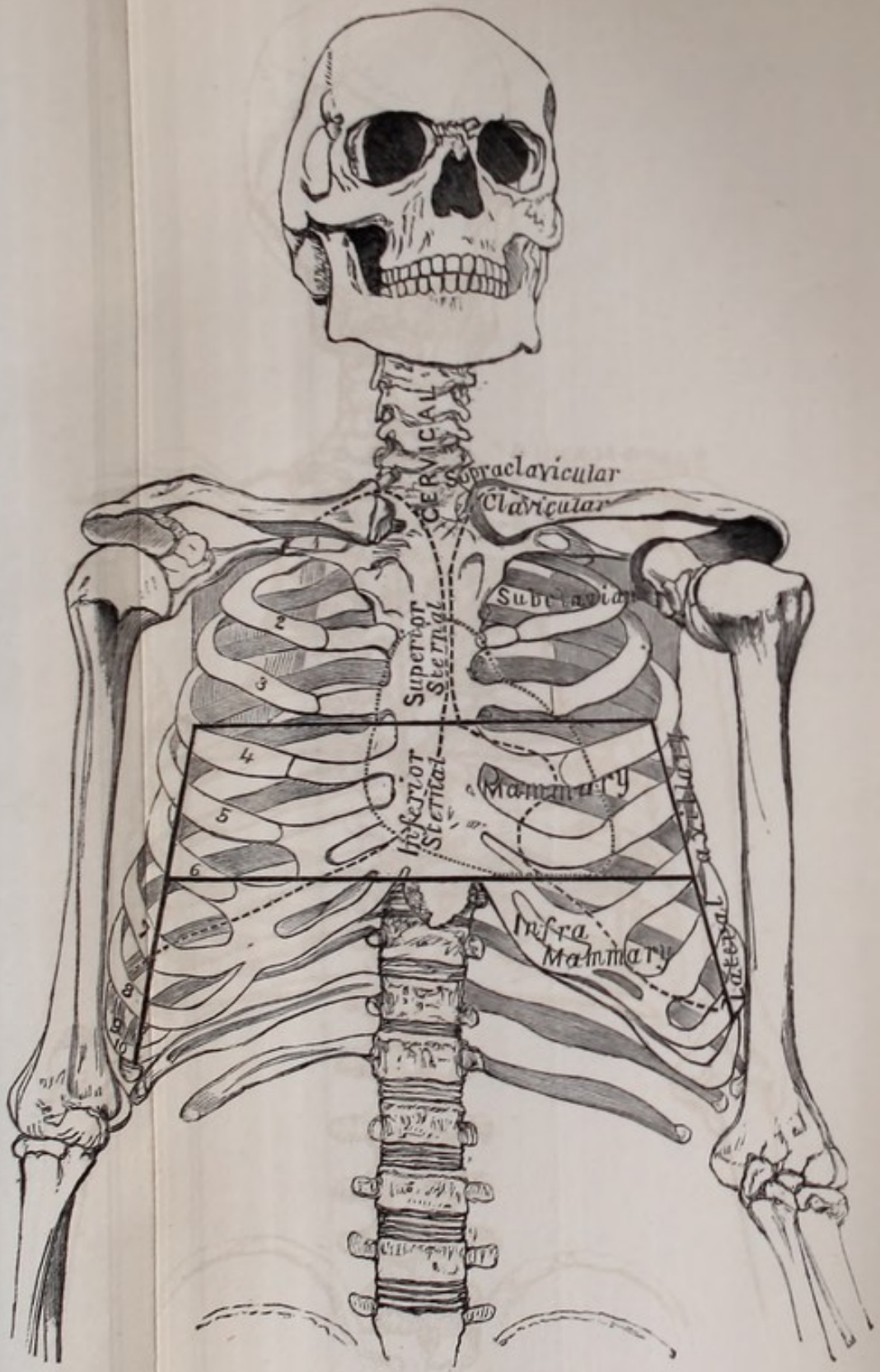
Cervical
Supraclavicular
Clavicular
Subclavian
Superior Sternal
Inferior Sternal
Mammary
Infra Mammary
Lateral
Axillary
2
3
4
5
6
7
8
9
10

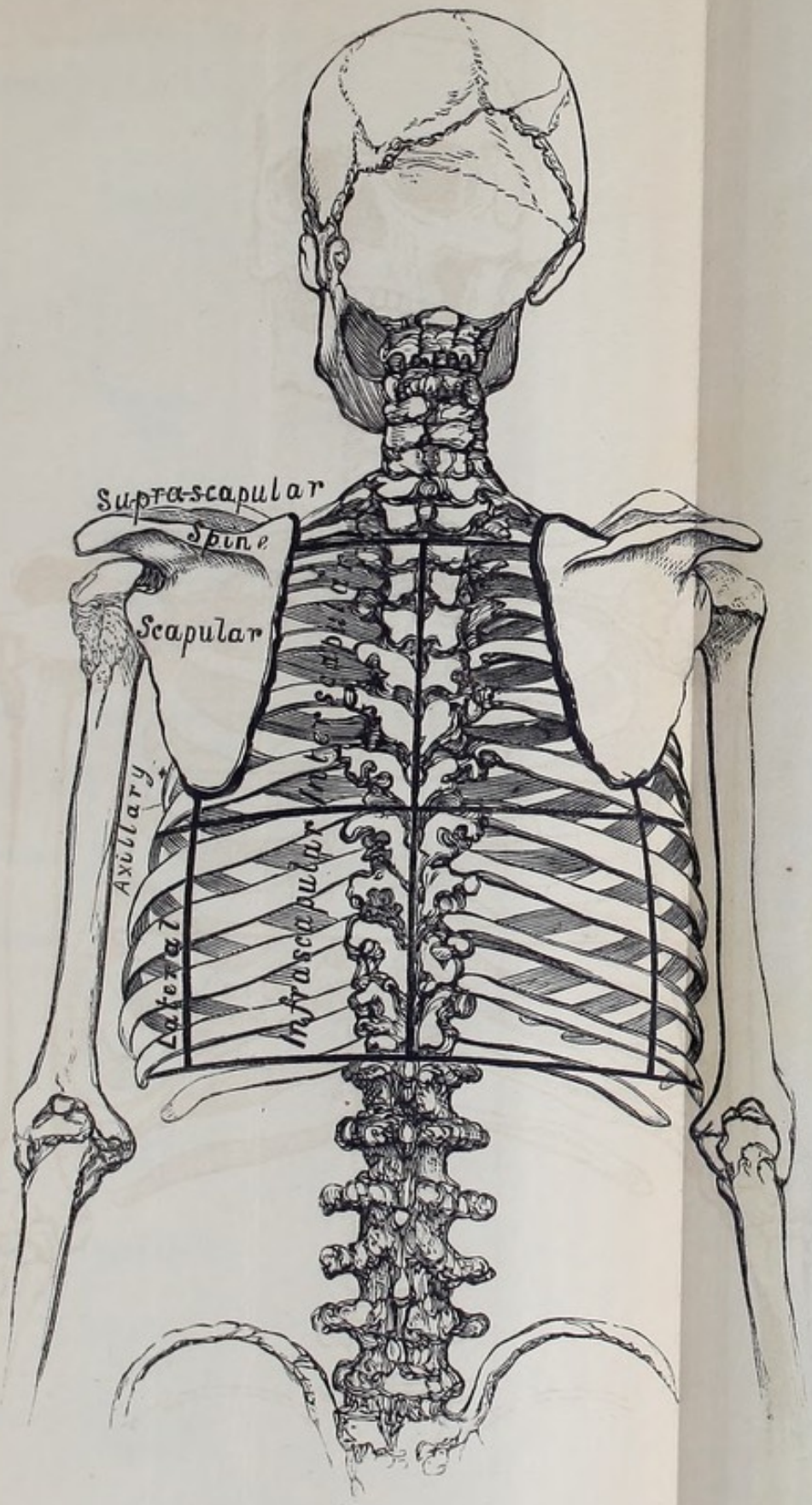
Supra-scapular
Spine
Scapular
Axillary
Lateral
Infra-scapular
Inter-scapular

II.—REGIONS OF THE CHEST.

Region.	*Contents.*	*Resonance on percussion in health.*	*Auscultation in health.*
1. CERVICAL* . .	Larynx and trachea.	...	Tracheal breathing and voice.
2. SUPRA-CLAVICULAR .	Apex of lung.	Clear.	Very pure, vesicular murmur, (scarcely audible); voice scarcely audible.
3. CLAVICULAR . .	Clavicles, and vesicular structure of lung.	Clear.	Pure vesicular murmur and scarcely audible voice, except at the sternal end, where there are bronchial breathing and bronchophony.
4. SUBCLAVIAN . .	Vesicular structure of lung.	Clear.	Pure vesicular murmur and scarcely audible voice. Heart sounds on left side below.
5. MAMMARY . .	Vesicular structure of lung. Heart on left side.	Clear on right side. Dull on left, in greater part of region.	Pure vesicular murmur above. Heart sounds below on left side, and feeble vesicular murmur on right. Voice scarcely audible.
6. INFRA-MAMMARY .	Anterior portion of base of lung. Stomach below on left side, liver on right.	Generally tympanitic on left side; dull on right.	Distant vesicular murmur. Voice scarcely audible.
7. SUPERIOR STERNAL .	Division of trachea, aorta, and great vessels.	Clear.	Bronchial breathing and bronchophony.
8. INFERIOR STERNAL .	Anterior mediastinum above. Stomach below.	Clear above; tympanitic below.	Pure vesicular murmur above, becoming feeble below. Voice scarcely audible.
9. AXILLARY . .	Vesicular structure of lung.	Clear.	Pure vesicular murmur. Voice scarcely audible.
10. LATERAL . . .	Vesicular structure of lung.	Clear above; dull below on right side.	Pure vesicular murmur. Voice scarcely audible.
11. SUPRA-SCAPULAR .	Apex of lung.	Clear.	Pure vesicular murmur. Voice scarcely audible.
12. SCAPULAR . .	Vesicular structure of lung.	Rather less clear.	Pure vesicular murmur. Voice scarcely audible.
13. INTER-SCAPULAR .	Roots of lung, and large bronchi.	Clear.	Bronchial breathing and bronchophony (vesicular, but more tubular than in other regions).
14. INFRA-SCAPULAR .	Base of lung.	Clear.	Very pure, vesicular murmur. Voice scarcely audible.

* This region has been added to those which more properly belong to the chest, on account of its containing part of the respiratory organs.

III.—PHYSICAL EXAMINATION.

Method of examination.	*Shows*	*Instruments used.*
1. INSPECTION . .	Form, symmetry, and capacity of the chest. Outline of sternum, costal cartilages, and spine. Any swelling or deformity. Mode and type of respiration (natural and forced). Comparative size and degree of movement of the two sides. Position of apex of heart.	
2. PALPATION . . (*Application of the Hand.*)	Comparative movement of the two sides. Vibration communicated to the parietes of the chest by the voice (vocal vibration). Force of the heart's impulse. Occasionally certain morbid phenomena, as pleural and pericardial friction.	
3. MENSURATION—		
(*a*) *Of Size* .	Comparative size of the two sides of the chest.	Graduated tape. M. Woillez's cyrtometer.
(*b*) *Of Movement.*	Actual and comparative movement of the chest in respiration.	Dr. Sibson's stethometer. Dr. Quain's ,, Dr. Edwards' chest callipers.
4. PERCUSSION . .	Degree of resonance in various parts of the chest (most valuable in comparative investigations).	Plessor.—A hammer tipped with india rubber. The first and second fingers of the right hand will be found to be the best plessor. Pleximeter.—A thin plate of ivory or bone. The forefinger of the left hand will be found to be the best pleximeter.
5. AUSCULTATION .	Character of respiratory murmur. Abnormal respiratory sounds. Heart sounds. Abnormal cardiac sounds (murmurs).	Stethoscope.—A hollow cylinder of wood, about eight inches long, with a flat piece at one extremity for application to the ear, and the other extremity cone-shaped, for application to the walls of the chest. A modification of the stethoscope, in using which both ears are employed, has been recently invented by Dr. Scott Alison.

PERCUSSION may be—(1) *Immediate.*—Where the chest is struck *directly,* without the interposition of any pleximeter.
(2) *Mediate.*—Where an instrument termed a pleximeter is interposed between the chest and the substance with which the stroke is made. This may be either a thin plate of ivory or bone, or, still better, the first and second finger of the left hand.

AUSCULTATION may be—(1) *Immediate.*—Where the ear is applied directly to the walls of the chest.
(2) *Mediate.*—Where the stethoscope is interposed between the ear and the walls of the chest.

IV.—ABNORMAL RESONANCE ON PERCUSSION.

Resonance.	*Cause.*	*Examples of disease.*
DIMINISHED in various degrees, or altogether ABSENT.	Deficiency of air in the lung beneath the part percussed, or solid or liquid matter between the walls of the chest and the lung containing air.	Pneumonia, first stage. Phthisis; contracted lung, with thickened pleura. Œdema and congestion of lung. Extreme tubercular infiltration. Tumours. Pneumonia, second and third stages. Pleuritic effusion. Intra-thoracic tumours and aneurisms.
INCREASED	Air increased in quantity; or air in pleural cavity.	Emphysema. Tubercular cavity, having thin walls, and situated near the surface.
TYMPANITIC		Pneumothorax. Extreme emphysema.
AMPHORIC	Uncertain.	Upper part of lung compressed by fluid below.
BOX-LIKE		Pneumonia of upper lobe. Cavities.
CRACKED-POT SOUND	Air expelled from cavity by sudden pressure.	Cavity of considerable size, with large bronchus opening into it, mouth of patient being open.

V.—ABNORMAL VOICE SOUNDS.

Sound of voice.	*Cause.*	*Examples of disease.*
FEEBLE OR EXTINCT VOCAL RESONANCE	Primary bronchus obstructed, or non-conducting medium in pleura.	Tumours compressing, or foreign body in, bronchus. Pneumothorax. Hydrothorax. Empyema.
EXAGGERATED VOCAL RESONANCE	Large cavities; diminished distance of large bronchi, from malformation; increased resounding or conducting power.	Dilatation of bronchus. Incipient phthisis.
BRONCHOPHONY . . .	Much increased resounding or conducting power.	Pneumonia, second and third stages. Phthisis, with great consolidation. Dilated bronchi.
ÆGOPHONY	Fluid, in small or moderate quantity, in pleural cavity.	Pleurisy, with effusion.
PECTORILOQUY . . .	Large abnormal cavity, with dense walls.	Phthisis.

VI.—MODIFICATION OF NORMAL RESPIRATORY SOUNDS.

Sound.	*Chief causes.*	*Condition of organs.*	*Examples of disease.*
FEEBLE BREATHING	Various. Air entering the air-cells in diminished quantity and force.	Lung partially solidified, either by increase of solid or fluid within it or by pressure from without.	Emphysema. Incipient phthisis. Bronchitis. Pneumonia, first stage. Pleurisy. Tumours.
EXTINCT BREATHING	Generally the presence of a non-conducting medium between the lung and the walls of the chest.	Lung solidified by pressure upon its surface.	Pleuritic effusion. Tumours.
INTERRUPTED / JERKING BREATHING (*Respiration saccadée* of Laennec)	Air entering feebly; blood strongly impelled into the lung.	Uncertain.	Debility, with palpitation. Incipient phthisis. Spasmodic asthma.
PUERILE / SUPPLEMENTARY BREATHING	Air entering the air-cells with increased rapidity and force.	Healthy.	Disease of opposite lung, or of other parts of the same lung.
EXAGGERATED / COARSE BREATHING	Increased friction in the air-cells and smallest bronchial tubes.	Lung not solidified (sound soft).	Generally consistent with health, and supplementary. Heard in cases of uræmia and other blood-poisoned diseases, and in hysteria and nervous diseases.
		Lung solidified, or bronchial tubes obstructed (harsh sound).	Incipient phthisis.
BLOWING / TUBULAR or BRONCHIAL / CAVERNOUS BREATHING	Friction of air in the large bronchial tubes, or in abnormal cavities of the lung.	Lung only partially solidified (soft sound).	Phthisis. Pneumonia. Tumours.
		Lung solidified or compressed (harsh sound).	Tubercular and other cavities.
AMPHORIC BREATHING	...	...	Pneumothorax. Dilated bronchial tubes. Large cavities.

VII.—ABNORMAL SOUNDS (DRY).

Sound.	*Situation.*	*Causes.*	*Examples of disease.*
SIBILUS . . . . (*Rhonchus sibilans.*)	Lesser bronchial tubes.	Vibration of thick mucus attached to the wall of the tube, or dryness of mucous membrane; not easily removed by cough.	Bronchitis. Emphysema. Asthma.
RHONCHUS . . . (*Rhonchus Sonorans.*)	Larger bronchial tubes.	Vibration of thick mucus in tubes; generally easily removed by cough.	Bronchitis.
PLEURAL FRICTION SOUND CREAKING SOUND .	Layers of pleura.	Movement of opposed surfaces of pleura, roughened by the deposit of lymph or tubercle.	Pleurisy, before effusion has commenced, or after absorption of the fluid.
METALLIC TINKLING	Cavities.	Vibration of air in large cavities, with tense walls and generally some solid contents; or (much more doubtfully)— Falling of a drop of fluid from the upper part of a large cavity, with tense walls. Occasionally produced by the action of the heart upon a tympanitic stomach.	Phthisis, with very large cavities. Pneumothorax.

VIII.—ABNORMAL SOUNDS (MOIST).

Sound.	*Situation.*	*Causes.*	*Examples of disease.*
FINE CREPITATION (Pneumonic) (*Crepitant râle.*)	Air-cells or smallest tubes.	Bursting of air-bubbles in fluid, or, possibly, separation of the adherent walls of the air-cells themselves.	Pneumonia in first stage, and occasionally during resolution.
MEDIUM CREPITATION (*Subcrepitant râle.*)	Bronchial tubes of second and third divisions.	Bursting of air-bubbles in fluid.	Phthisis. Bronchitis. Congestion and œdema of lung. Pulmonary apoplexy.
CLICK (Valvular) .	A small cavity.	Bursting of a single air-bubble. (?)	Phthisis, with softening tubercle.
LARGE CREPITATION (*Mucous râle.*)	Largest tubes and small or moderate-sized cavities.	Bursting of air-bubbles in fluid.	Phthisis in second or commencement of third stage. Bronchitis.
GURGLING . . . } SPLASH ON COUGH }	Large cavities (or number of small cavities).	Bursting of air-bubbles in fluid.	Phthisis in third stage. Abscess of lung.
CHURNING SOUND .	Lung in a state of disorganization.	...	Gangrene of lung.
SPLASH ON SUCCUSSION	Cavity of pleura.	Sudden disturbance of air and fluid existing together in the pleura.	Pneumothorax, with effusion. Very large cavities.

VIII.—ABNORMAL SOUNDS (MOIST).

Sound.	*Situation.*	*Causes.*	*Examples of disease.*
FINE CREPITATION (Pneumonic) (*Crepitant râle.*)	Air-cells or smallest tubes.	Bursting of air-bubbles in fluid, or, possibly, separation of the adherent walls of the air-cells themselves.	Pneumonia in first stage, and occasionally during resolution.
MEDIUM CREPITATION (*Subcrepitant râle.*)	Bronchial tubes of second and third divisions.	Bursting of air-bubbles in fluid.	Phthisis. Bronchitis. Congestion and œdema of lung. Pulmonary apoplexy.
CLICK (Valvular) .	A small cavity.	Bursting of a single air-bubble. (?)	Phthisis, with softening tubercle.
LARGE CREPITATION (*Mucous râle.*)	Largest tubes and small or moderate-sized cavities.	Bursting of air-bubbles in fluid.	Phthisis in second or commencement of third stage. Bronchitis.
GURGLING . . . SPLASH ON COUGH	Large cavities (or number of small cavities).	Bursting of air-bubbles in fluid.	Phthisis in third stage. Abscess of lung.
CHURNING SOUND .	Lung in a state of disorganization.	...	Gangrene of lung.
SPLASH ON SUCCUSSION	Cavity of pleura.	Sudden disturbance of air and fluid existing together in the pleura.	Pneumothorax, with effusion. Very large cavities.

XI.—SOUNDS AND IMPULSE OF HEART.

Sound.	*Character.*	*Situation.*	*Cause.*	*Time.*	*Condition of circulation.**
First Sound . (Systolic)	Dull and prolonged.	Præcordial region. (Beyond it in thin and nervous persons.)	Closure of auriculo-ventricular valves, and perhaps muscular contraction of the ventricles themselves.	One half the whole time of heart's rhythm.	Contraction of ventricles, dilatation of auricles. Closure of auriculo-ventricular valves, openness of arterial valves; propulsion of blood into the arteries. Impulse of the heart, immediately followed by pulse at the wrist.
Second Sound (Diastolic)	Short and clear.	Præcordial region and course of aorta and pulmonary artery.	Sudden closure of the aortic and pulmonary valves.	One quarter of the whole time of heart's rhythm.	Dilatation of both auricles and ventricles. Closure of arterial valves, opening of auriculo-ventricular valves.
Pause . . .	...	...	...	One quarter of the whole time of heart's rhythm.	Completed distension of auricles, followed by their contraction and distension of ventricles. Auriculo-ventricular valves open, arterial valves closed.
Impulse . .	...	Between fifth and sixth ribs on left side, about one and a half or two inches below the nipple.	Contraction of the ventricles, tilting the apex upwards and forwards, and causing it to strike against the walls of the chest.		

* From Dr. Kirkes' 'Physiology.'

XII.—ABNORMAL CARDIAC SOUNDS, OR MURMURS.

Murmur.	*Character*	*Time.*	*Situation.*	*Cause.*	*Concomitant symptoms.*
PERICARDIAL .	Friction.	Double sound, heard in addition to the natural sounds of the heart, and obscuring them, but not taking their place.	Pericardium.	Rubbing together of the opposed surfaces of the pericardium, which have been roughened by the products of inflammation.	Pain in præcordial region, with tenderness on pressure, and palpitation.
ENDOCARDIAL .	Blowing.	Single, taking the place of one of the sounds of the heart; or double, taking the place of both sounds.	Endocardium. Generally one or more of the valvular orifices.	Unusual vibrations communicated to the particles of the blood by obstacles which it meets with in its passage through the heart (organic). (or)	Frequently without any symptoms directly calling attention to the heart; or, with pain, excessive impulse, intermittent or otherwise irregular action, and palpitation.
(1) SYSTOLIC .	...	Taking the place of the first sound of the heart.	...	Unusual vibrations among the particles of the blood, arising from some peculiar state of the blood itself (functional).	
(2) DIASTOLIC .	...	Taking the place of the second sound of the heart.			

XIII.—ENDOCARDIAL MURMURS.

Time.	*Situation and direction.*	*Orifice.*	*Nature.*
SYSTOLIC — 1 .	Heard most distinctly in the situation of the aortic valves, diminishing in intensity towards the apex of the heart. Heard distinctly at the junction of the second rib with the sternum on the right side; scarcely at all in the same situation on the left side.	Aortic.	Obstructive.
,, 2 .	Heard most distinctly in the situation of the pulmonary valves; in other respects the same as those stated above, except that it is distinct on the left and very faint on the right side, at the junction of the second rib with the sternum.	Pulmonary.	Obstructive.
,, 3 .	Heard most distinctly at apex; faint at base; audible posteriorly.	Mitral.	Regurgitant.
,, 4 .	Heard most distinctly to right of apex, but very difficult to distinguish from preceding.	Tricuspid.	Regurgitant.
DIASTOLIC—1 .	Heard most distinctly at base.	Aortic.	Regurgitant.
,, 2 .	Heard most distinctly at apex.	Mitral.	Obstructive.

TABLES OF SOME OF THE PRINCIPAL DISEASES OF THE LUNGS, WITH THEIR SYMPTOMS, PHYSICAL SIGNS, AND APPEARANCES ON DISSECTION.

XIV.—ACUTE BRONCHITIS.

Disease.	*Symptoms.*	*Physical signs.*	*Appearances on dissection.*
ACUTE BRONCHITIS: 1st Stage	Cough, with urgent dyspnœa, but generally without expectoration. Frequent pulse and febrile symptoms.	Resonance on percussion unimpaired. Feeble vesicular murmur, mixed with rhonchus and sibilus.	Congestion of mucous membrane of bronchial tubes, with some degree of swelling and dryness of surface.
2nd Stage .	Cough, with expectoration of frothy, transparent mucus, mixed with air-bubbles of various sizes, and occasionally tinged or streaked with blood. Urgent dyspnœa, often amounting to orthopnœa. Lividity and febrile symptoms increased. Restlessness at night.	Resonance on percussion clear, or only very slightly impaired. Feeble vesicular murmur, mixed with rhonchus, sibilus, and large or medium crepitation.	Lungs do not collapse when the chest is opened. The mucous membrane of the bronchial tubes is still red and swollen, and the tubes filled with frothy, adhesive mucus.
3rd Stage . (Termination favorable)	Gradual remission of the symptoms. Expectoration becomes thick, greenish, and opaque.		
(Unfavorable)	Increase of febrile symptoms. Dyspnœa very urgent, signs of impending suffocation. Profuse cold sweats. Sinking and delirium.		

XV.—CHRONIC BRONCHITIS.

CHRONIC BRONCHITIS	Cough, generally coming on at the approach of winter, with the history of former attacks. Sputa sometimes thin and transparent, at others thick and mucopurulent, either green or yellow. Dyspnœa. Lividity of surface, and in some cases the symptoms resemble those of chronic phthisis, as wasting, with night-sweats and hectic.	Respiration laboured and abdominal. Slightly impaired resonance on percussion, most marked in the lower and posterior portions of the chest. Feeble vesicular murmur, mixed with rhonchus, sibilus, and crepitation.	Lungs generally much congested, presenting a dark, livid hue, with portions collapsed. Bronchial tubes filled with secretion, which may be either thin and transparent or thick, greenish, or puriform. Mucous membrane thickened. Tubes frequently dilated.

Disease.	*Symptoms.*	*Physical signs.*	*Appearances on dissection.*
EMPHYSEMA (Vesicular)	Habitual shortness of breath, with occasional paroxysms of urgent dyspnœa, most frequently supervening on catarrh. Palpitation, and œdema of the ancles. Cough, with or without expectoration of thin, transparent, frothy mucus.	Form of chest peculiar. Sternum projecting forwards. Scapulæ and clavicles raised and ill-defined. Lateral regions of chest prominent and rounded, and intercostal spaces widened. Respiration abdominal. Movement of chest much diminished. Resonance on percussion greatly increased or tympanitic. Feeble inspiration, prolonged respiration; the former wheezing, the latter generally with rhonchus or sibilus. Heart often displaced.	Lungs do not collapse, as usual, when the chest is opened, but, on the contrary, may rise up and bulge out of its cavity. They are pale and anæmic, and do not crepitate when pressed, but feel soft and downy. Lung drier than ordinary. The air-cells are dilated, or several have become one cavity from the rupture of the septa between them. Cells vary from the size of a millet-seed to that of a swan-shot, or larger.
EMPHYSEMA (Interlobular)	Urgent dyspnœa and oppression, generally occurring suddenly after some violent effort, the subcutaneous areolar tissue frequently becoming œdematous.	Percussion tympanitic over the affected part.	Bead-like bubbles of air seen through the pleura, or partitions between the lobules much widened. Sometimes air is found beneath the areolar tissue of the neck.

XVIII.—PNEUMOTHORAX.

PNEUMOTHORAX, TRUE (very rare)	Various, depending on the cause which produces the pneumothorax. Always urgent dyspnœa, with inability to lie on the affected side. Generally, sharp, stabbing pain. Cough and fetid puriform expectoration.	Dilatation of the affected side, with obliteration or bulging of the intercostal spaces. Movement on respiration diminished or absent. Increased elasticity of the walls of the chest. No vocal vibration.	Lung collapsed. Air in pleura, occasionally from the spontaneous evolution of gas, said to be owing to the chemical decomposition of purulent fluid in the pleura.
		Clear, tympanitic resonance on percussion. No true vesicular murmur, but amphoric sounds with inspiration, voice, and cough. Occasionally bronchial breathing along the spine and in inter-scapular region.	
PNEUMOTHORAX (with Effusion)	...	Same as in true pneumothorax, except that percussion is dull in the lower part of the chest, and tympanitic above the level of the fluid. Metallic tinkling and splashing sound on succession are also frequently heard.	Lung collapsed. Air, mixed with fluid, in the pleural cavity, from the bursting of various kinds of abscesses. Mostly arises as a termination of phthisis, a superficial cavity becoming ruptured. May occur in pneumonia, emphysema, or gangrene of the lung, and more rarely in other diseases.

XIX.—PNEUMONIA.

Disease.	*Symptoms.*	*Physical signs.*	*Appearances dissection.*
PNEUMONIA: 1st Stage	Rigors, followed by heat of skin. Increased frequency of pulse. Pain in the side, increased by cough or deep inspiration. Dyspnœa. Cough, at first dry, with rusty sputa about the second or third day. Inability to lie on affected side. Dilating alæ nasi. Herpes about lips. Frontal headache.	Diminished movement of the affected side. Respiration abdominal. Slightly impaired resonance on percussion. Fine (pneumonic) crepitation, most frequently heard at base of lung.	*Lungs.*— Engorged frothy and bl serum. Dark colour extern and on sec Crepitating and heavier sound lung, still floating water. Pul ary tissue sl ly softened.
2nd Stage .	Increased distress and dyspnœa. Respiration and speech panting. Cough more urgent, and sputa still rust-coloured, extremely viscid, and tenacious.	Very slight movement. Vocal vibrations well marked. Dulness on percussion. Bronchial breathing and bronchophony, generally accompanied by some crepitation.	Red externally or mottled granular on surface. E torn, and fluid exudin pressure les bundant tha first stage, thicker, and wards the of this stage coming puru Not crepita and sinking water.
3rd Stage .	Aspect much distressed. Face pale and livid. Great failure of vital powers. Hectic and delirium. Cough continues, and the sputa sometimes remain rust-coloured, at others become absolutely purulent, or dark, thin, and fetid.	Absolute dulness on percussion. Bronchial breathing and bronchophony, frequently with gurgling crepitation where the lung is disorganized.	Reddish-yellow grey. More ten and fri Purulent exudes from cut surface, on pressure. whole lung be reduced pulp-like ma

Disease.	*Symptoms.*	*Physical signs.*	*Appearances on dissection.*
PLEURISY: 1st Stage (Inflammation, without Effusion)	Rigors. Sharp, stabbing pain in the side, increased by deep inspiration or cough, accompanied generally with some tenderness on pressure. Breathing short and hurried. Respiration chiefly abdominal, with inability to lie on the affected side. Cough, without expectoration. Febrile symptoms, often severe.	Diminished movement of affected side. Friction sometimes felt by the hand. Some impairment of resonance on percussion. Feeble and indistinct vesicular murmur, with friction sound heard only during respiration.	Pleura opaque, roughened, and highly vascular, presenting a close network of blood-vessels, with ecchymoses.
PLEURISY: 2nd Stage (with Effusion)	Cough, dyspnœa, sense of weight, and fulness of the affected side. Febrile symptoms. Hectic in empyema. Patient lies towards, not on, the affected side.	Almost total absence of movement of the affected side, which is unduly prominent, the intercostal spaces being obliterated or even bulging. Integuments occasionally œdematous. Vocal vibration absent. Complete dulness on percussion, most marked in the dependent portions of the chest, and sometimes altered by change of posture. Heart pushed over to sound side, and diaphragm pushed down, so that the liver and stomach descend lower into the abdomen than in health. Vesicular murmur almost or quite absent. Frequently bronchial breathing along the spine. Puerile breathing in sound lung. Voice sounds feeble, except when the layer of fluid is thin, when there is ægophony.	Fluid, either serous or purulent, mixed with shreds of creamy lymph, in the cavity of the pleura. Lungs pushed upwards and backwards towards the spine, its surface coated with a layer of lymph of the same kind as that mixed with the fluid. The lung collapsed.
PLEURISY: (Resolution after Effusion)	Gradual diminution of the cough, dyspnœa, and other symptoms. Returning ability of the patient to lie on the sound side. Gradual return of displaced organs to their normal position.	The movement of the chest gradually increases. The dulness on percussion diminishes from above downwards, but the resonance generally remains box-like for a considerable period. There is gradual restoration of the vesicular murmur on the affected side, and, when nearly all the fluid has been absorbed, return of the friction sound for a short time. Diseased side becomes less prominent, after a time flattened, the intercostal spaces being almost obliterated, so that the ribs approximate or nearly touch each other. The spine becomes curved in the dorsal region towards the diseased, in the lumbar towards the healthy, side.	