

Cases in surgery illustrative of a new method in applying the wire ligature in compound fractures of the lower jaw / by Hugh Owen Thomas.

Contributors

Thomas, Hugh Owen, 1834-1891.
Royal College of Surgeons of England

Publication/Creation

London : John Churchill and Sons, 1869.

Persistent URL

<https://wellcomecollection.org/works/j9gmwfbz>

Provider

Royal College of Surgeons

License and attribution

This material has been provided by This material has been provided by The Royal College of Surgeons of England. The original may be consulted at The Royal College of Surgeons of England. where the originals may be consulted. This work has been identified as being free of known restrictions under copyright law, including all related and neighbouring rights and is being made available under the Creative Commons, Public Domain Mark.

You can copy, modify, distribute and perform the work, even for commercial purposes, without asking permission.



Wellcome Collection
183 Euston Road
London NW1 2BE UK
T +44 (0)20 7611 8722
E library@wellcomecollection.org
<https://wellcomecollection.org>

W. H. H. H.
13 *Comp*

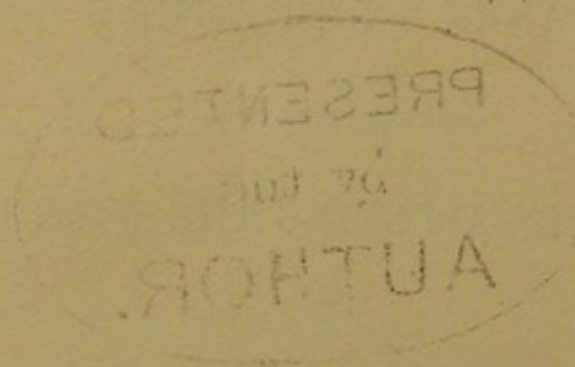
CASES IN SURGERY

ILLUSTRATIVE OF A

METHOD IN APPLYING THE WIRE LIGATURE

IN

COMPOUND FRACTURES OF THE LOWER JAW.



13

CASES IN SURGERY

ILLUSTRATIVE OF A

NEW METHOD IN APPLYING THE WIRE LIGATURE

IN

COMPOUND FRACTURES OF THE LOWER JAW.

PRESENTED
by the
AUTHOR.

BY

HUGH OWEN THOMAS, M.R.C.S.L.



LONDON:

JOHN CHURCHILL AND SONS, NEW BURLINGTON STREET.

MDCCCLXIX.

THE HISTORY OF THE

REIGN OF THE

OF THE

OF THE



CASES IN SURGERY

ILLUSTRATIVE OF A

NEW METHOD IN APPLYING THE WIRE LIGATURE

IN

COMPOUND FRACTURES OF THE LOWER JAW.

IN the following pages I purpose to explain a new method of applying wire ligature in fractures of the lower jaw. Some of the cases here reported have been already communicated to the profession through one of the medical journals, but the mode of operating is now published for the first time. Experience of this method, extending over several years, has shown me that it can be more easily and quickly applied, with less irksomeness to the patient, and I am so convinced of its superiority that I believe it has only to be known to be adopted, and to supersede the complicated and painful appliances hitherto in use.

It is not necessary for me to enter into any of the difficulties of the numerous methods now in practice; the mechanics of this injury have been so well illustrated by Hamilton, Packard, and Heath. I make no claim to originality in the use of wire ligature in fractures of the jaw, as it has been used, though only in exceptional cases, by Dr. Buck, of New York, in 1847; Kinloch, of Charleston, 1859; Hamilton, of New York, 1858; and Dr. Wheelhouse, of Leeds, 1864. In 1863 I operated successfully in a case where a portion of the lower jaw, including two incisor teeth, had been removed by a direct blow from a capstan bar. Since then I have on every occasion practised this plan.

The instruments used are the drill (fig. 3, Pl. I) and its bow (fig. 2), or the steel-rod (fig. 4), covered with india-rubber, to place in the groove A (fig. 3) to drive the drill; the key (fig. 5) for twisting the ends of the wire, a tubular straight needle (fig. 6), and a watchmaker's broach. Fig. 1 is for the purpose of broaching at right angles between the molar teeth. The operation is advo-

cated for compound fractures of the jaw only; and by compound fractures of the lower jaw I mean fractures in which the periosteum and surrounding tissues are lacerated and permitting some degree of primary displacement. Simple fractures seldom require the aid of the surgeon. Having applied in the early part of my practice the wire ligature with the ordinary tie or cross-twist, I could not avoid noticing that, however firm the fracture may be fixed on the day of operating, it becomes relaxed on the second or third day, and that the wire with a cross twist will not bear the strain of several extra turns without breaking. This necessitates a second application at a stage so painful that it is often objected to by the patient. To obviate this difficulty I devised the twist or coiling which is detailed in the following cases, and which enables the surgeon to tighten, as often as he judges the case demands, without pain to the patient and in a few seconds of time.

The drill and bow, as the watchmaker's drill, is the best instrument to use in the hands of

an expert, as it enables the operator to have one hand at liberty to steady the bone, while an assistant works the bow of the drill. An Archimedian drill (used by clockmakers) is more manageable when the operator is not practised in drilling. The wire used should be full 1-24th inch silver, or even stronger.

The first case illustrates one method of applying the wire.

T. S—, while engaged in a street brawl, April 5, 1866, received a blow on the lower jaw. On making an examination the following morning I found a compound fracture of the lower jaw at the symphysis, with great mobility of the fracture. With the patient's consent I prepared to fix the fracture. Having directed an assistant to steady the head and another to evert the lower lip, I passed the drill through the bone on both sides of the fracture at the reflection of the mucous membrane, care being taken not to injure the teeth. Fig. 3, Pl. II, illustrates the mode followed in this case. The silver wire was then

passed through the opening at A. Next, the tubular needle was passed through B, into the open end of which the return end of the wire was introduced. Then the tubular needle was withdrawn, and with it the wire. The use of this needle is to act as a director to the internal opening of the aperture at B, and to obviate a second of delay in searching for the entrance from behind forwards of either openings A and B. Afterwards the end of the wire at A was inserted into the slit of the key (fig. 5, Pl. I) and twisted in three or four coils, the same being repeated with the end of wire at B, until the fracture was fixed. On the fifth day it became slackened and required the use of the key in the coil at A or B—either would do—though it is best to choose the smallest coil for tightening, and to notice first if the cross-piece of the wire A (fig. 5) is well into the slit B (fig. 5). This case required tightening every three or four days. In twenty days the fracture was firm and united. The patient, from the commencement, expressed his ability to masticate, which I did not permit.

Afterwards he informed me that he had disregarded my veto in this respect occasionally. The application in this situation, at or near the symphysis, need not occupy more than three minutes in its performance.

CASE 2.—T. B—, ship carpenter, was struck by a piece of heavy timber on the face, which caused him to fall seventeen feet from a work stage. On examining him, one hour after the accident, I detected a compound fracture of the lower jaw on one side at the situation of the first and second molar teeth, which had been removed by the force of the blow. With one exception I never before witnessed so much mobility in fractures of this part. The remaining teeth were firm *in situ*. Agreeably to my instructions, my assistant exposed the injured portion by drawing aside the cheek, and the third molar tooth was steadied with a piece of wood directed across the mouth from the side opposite to the fracture. Then using, on this occasion, the Archimedian drill, a hole was drilled from without backwards

and inwards across the third molar tooth below the enamel, this tooth being firm in the posterior portion of the fracture. The wire was then passed through the hole in the molar tooth B (fig. 4, Pl. II) from without inwards, and brought forwards between the bicuspid and canine teeth A (fig. 4). As these latter teeth were close set in the anterior fragment of the fracture, the broach was used between them to enable the thick wire ($\frac{1}{24}$ in.), to pass. Finally, the ends of the wire were coiled with the key, an operation which was repeated from time to time as was required. In three weeks there was union; on the fourth week the bone was firm, and the wire removed. The patient was with difficulty restrained from using the jaw in mastication.

In this case the bone was not drilled; but had the bicuspid and canine teeth not been firm, I should have drilled at a point between A and C (fig. 4). A metallic amalgam was easily introduced into the aperture in the third molar with the aid of the steel syringe (fig. 8, Pl. I).

CASE 3.—W. T—, during a street riot, Feb. 18, 1867, was severely injured about the face. On making a careful examination next morning I found a compound fracture of the lower jaw, half an inch to the right side of the symphysis, and also at the left angle of the jaw, accompanied with great swelling of the surrounding tissues, &c. I operated on the fracture at the symphysis, repeating the method as in Case 1. The fracture at the angle was supported with bandage and adhesive plasters. On the fifth day the parts over the injured angle of jaw became the seat of inflammation and abscess, which, combined with an attack of pneumonia on the eighth day, made it impossible to assist the fracture at the angle with mechanical aid. The fracture at the symphysis was tightened at periods, and on the expiration of six weeks it was firmly united, at which time there was no union at the angle. The patient now returned to his native town.

CASE 4.—W. H—, while at work, fell into the dry dock, March 8, 1867, and received a com-

pound fracture of arm, fracture of base of skull, and severe compound fracture of the lower jaw at the symphysis. From the very serious nature of his other injuries I did not think it prudent to interfere with the injured jaw in this case, during the first week. On the 15th of March, the condition of the patient being much improved, the fractured portion of the jaw was separated by an interval of one quarter of an inch, and no aid whatever had been applied. It was now wired by the method followed in Case 1. The treatment was the usual tightening of the coils. There was perfect recovery in four weeks after the operation. This patient made use of the jaw in mastication, abstaining only from flesh.

CASE 5 is illustrated by fig. 2, Pl. II. Capt. T— applied to me on November 11, 1867, to fix a fracture of the lower jaw. The fracture was compound, and situated between the right bicuspid and canine teeth; there was also a fracture of the left ramus, from which I removed, at a later stage, a portion of necrosed bone. To

fix the fracture it was drilled through the anterior fragment at B (fig. 2), and a broach passed between the bicuspid and molar teeth. The wire was then passed through the drill-hole at B, and then backwards and outwards between the molar and bicuspid teeth. The ends were then coiled and tightened with the key, but I could not reduce and fix the displacement until I had removed the canine tooth, which had been displaced and hindered proper adaption of the fracture. The fractured ramus was aided with bandage and plasters. At the expiration of seven weeks the parts were firm and united. On the patient's recovery the gap between the bicuspid and incisor teeth did not exist, nor was there any trace of the site of the removed canine.

CASE 6.—April 16, 1868, J. P— was struck a severe blow on the jaw by a pugilistic acquaintance, with such effect that there resulted a compound fracture of the left side, between the first and second molars, and a simple fracture of the right of the symphysis. The molar teeth at the

site of the fracture were large and firm, which induced me to operate, as illustrated in Fig. 1, Pl. II, by the method C, E, D. Had the simple fracture required any treatment, I should have followed the method represented by A and B (fig. 1). The wire was tightened occasionally. The simple fracture was firm in three weeks. The compound fracture was united at the end of the seventh week.

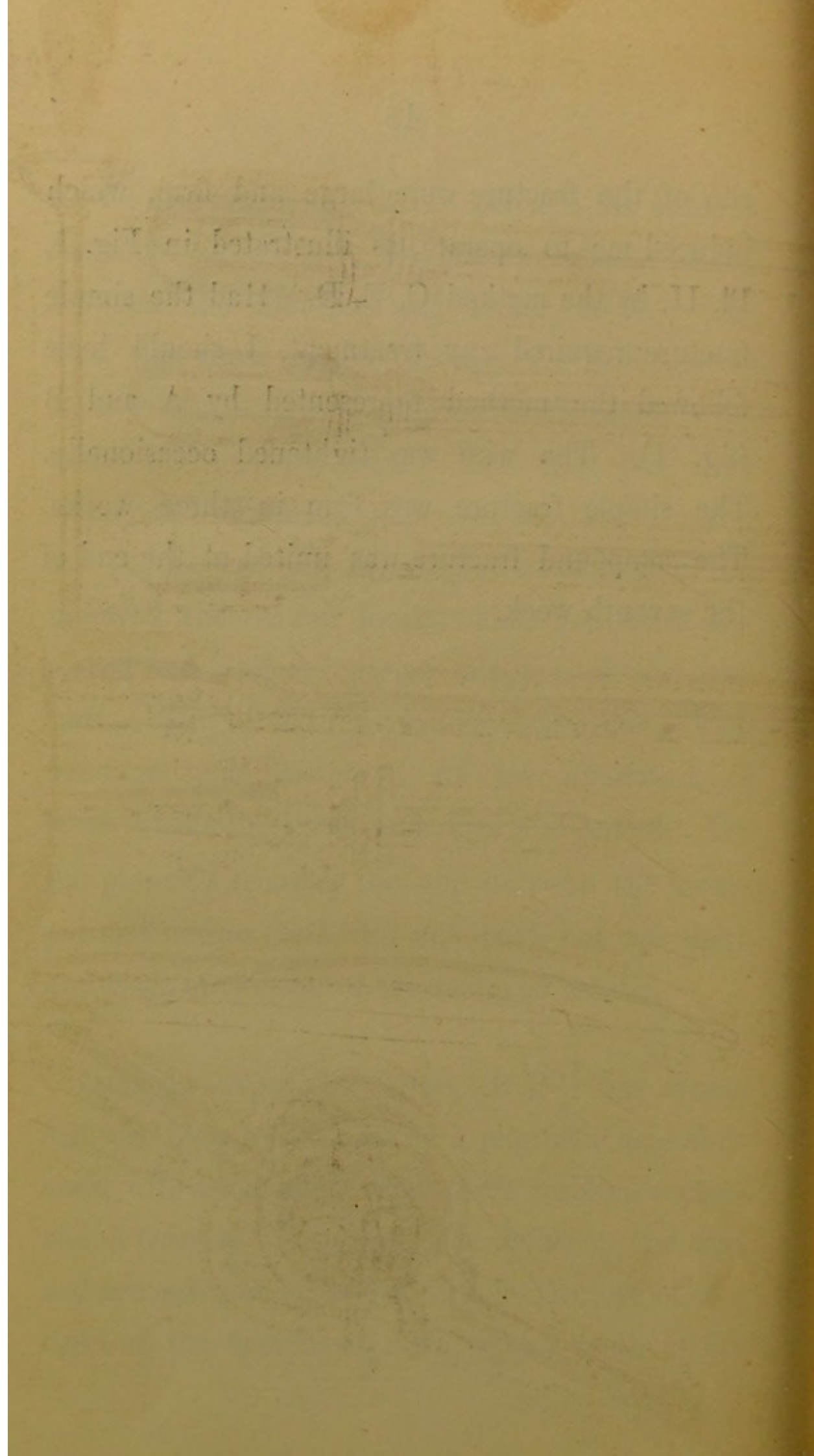
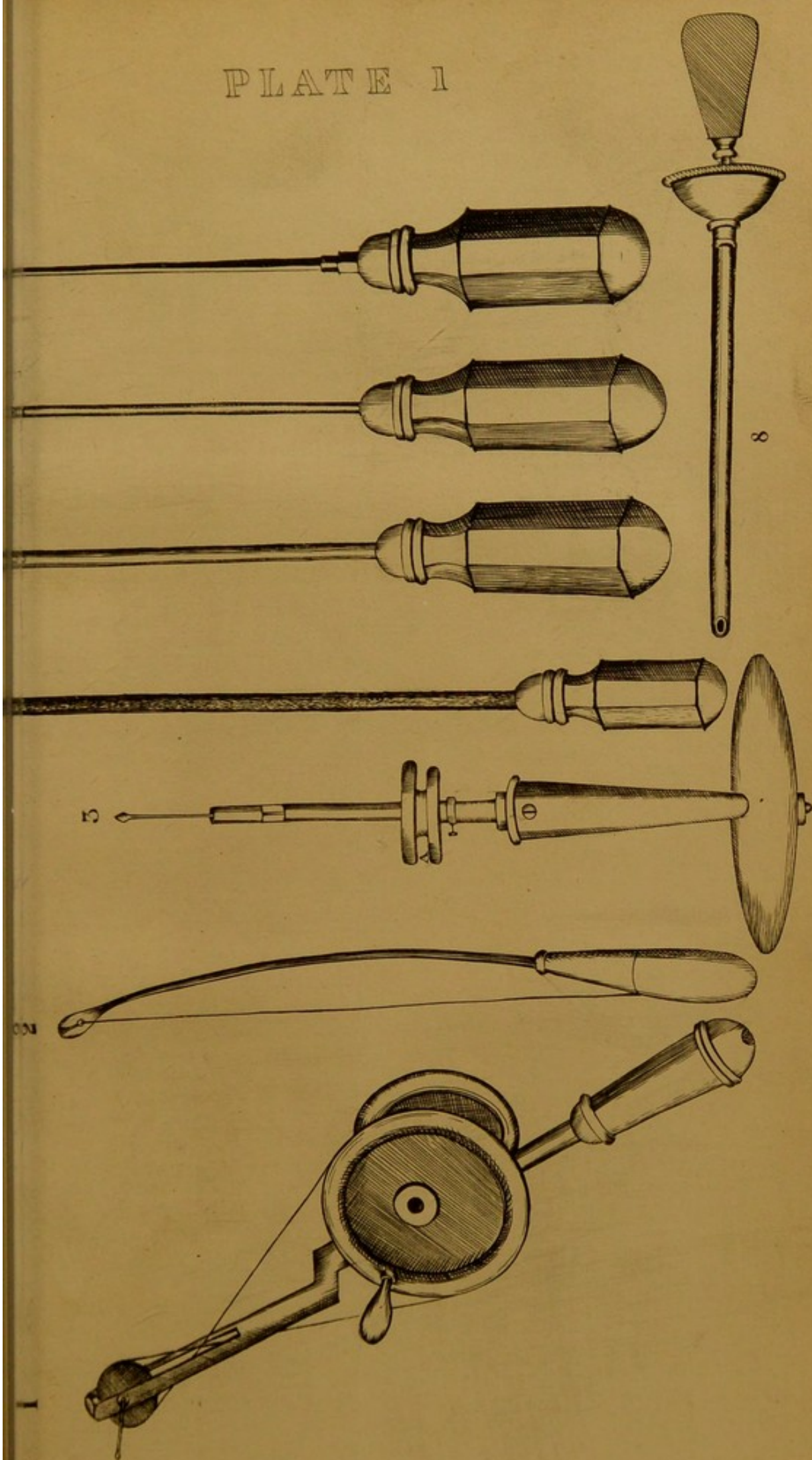


PLATE I



177

178

179

FIG 1

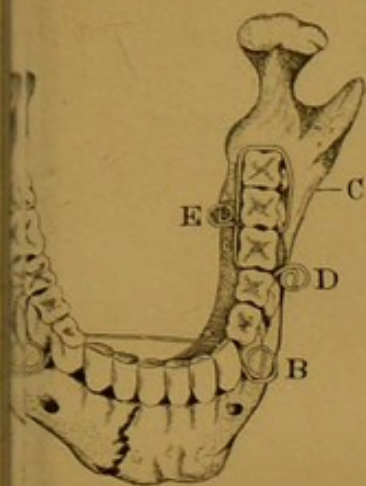


FIG 2

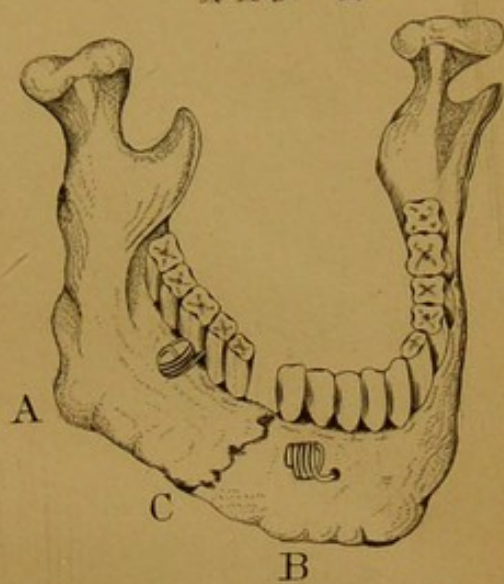


FIG 5

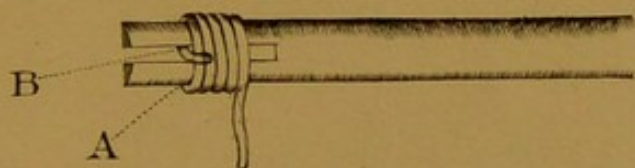


FIG 3

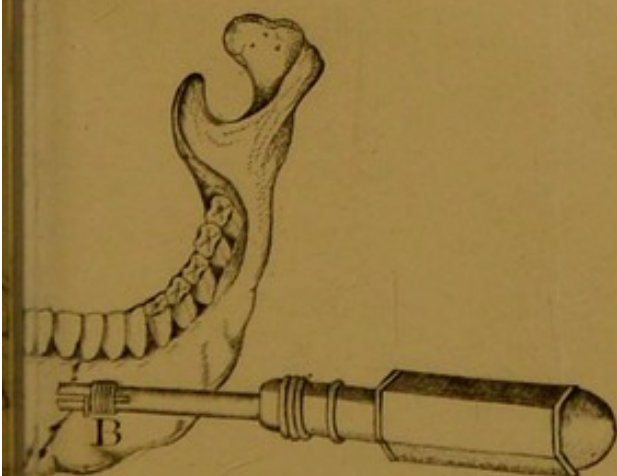

FIG 4

